

BRACHIAL PLEXUS

By Fatima Haider

KGMC

1. ROOTS

Anterior rami of C₅ – C₈ + T₁

2. TRUNKS

Superior Trunk → C₅ + C₆

Middle trunk → C₇

Inferior trunk → C₈ + T₁

3. DIVISIONS

Three anterior divisions by each trunk

Three posterior divisions by each trunk

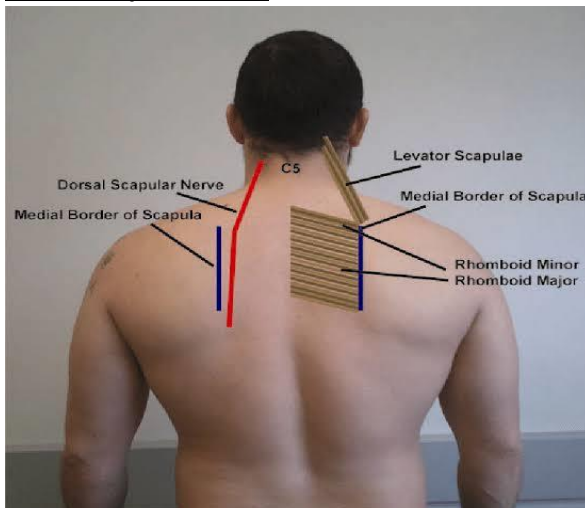
4. CORDS

Locations in relation to 2nd part of axillary artery

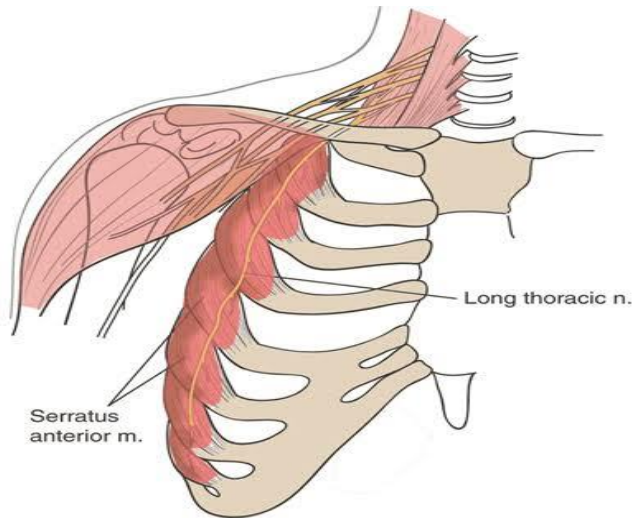
- Lateral cord → anterior divisions of superior and middle trunks (C₅, C₆, C₇)
- Medial Cord → Anterior division of inferior trunk (C₈, T₁)
- Posterior cord → union of all three posterior divisions (C₅-T₁)

BRANCHES OF ROOTS

1. Dorsal scapular nerve

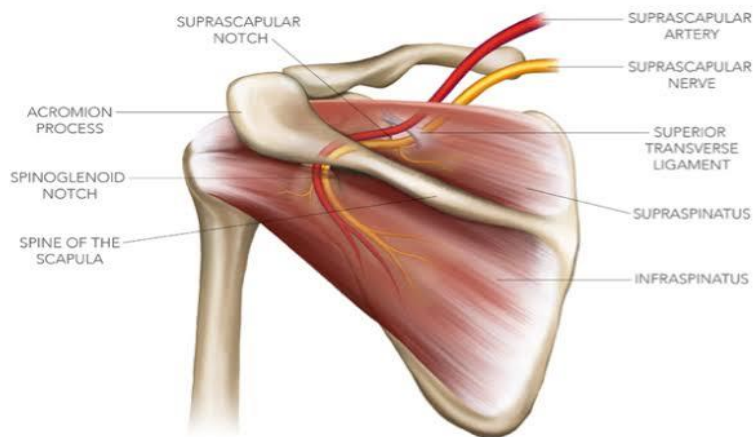


2. Long thoracic nerve



BRANCHES FROM SUPERIOR TRUNK

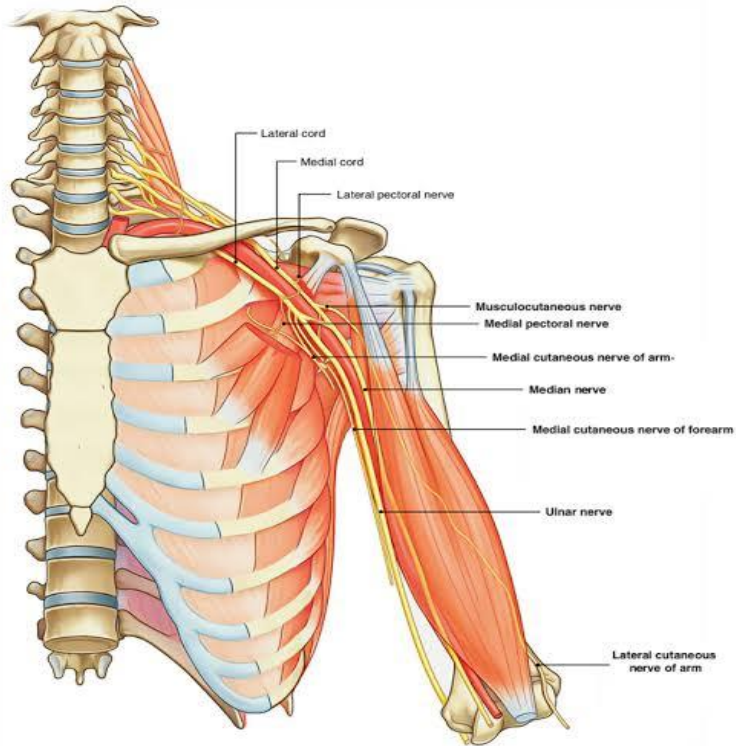
1. Suprascapular nerve



2. Nerve to subclavius muscle

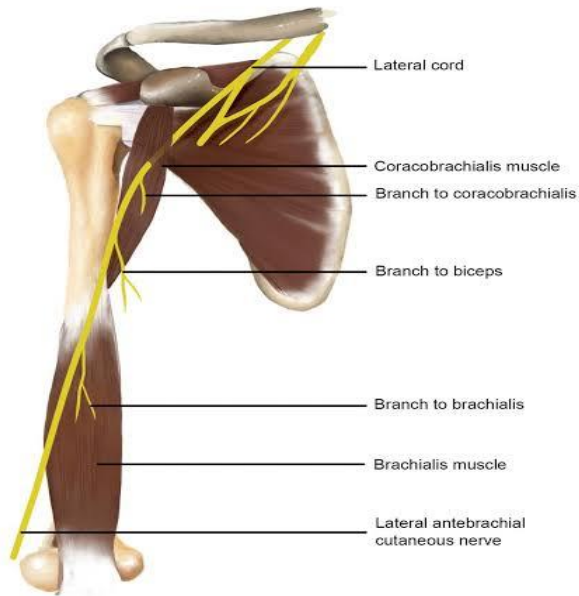
BRANCHES OF LATERAL CORD

1. Lateral pectoral nerve



2. Musculocutaneous nerve

Musculocutaneous Nerve

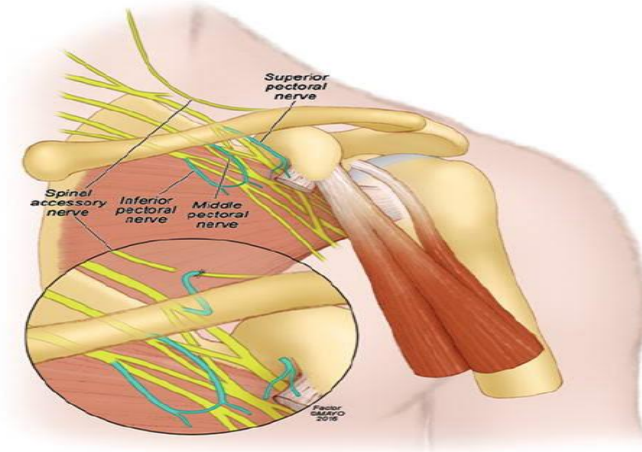


© Lineage

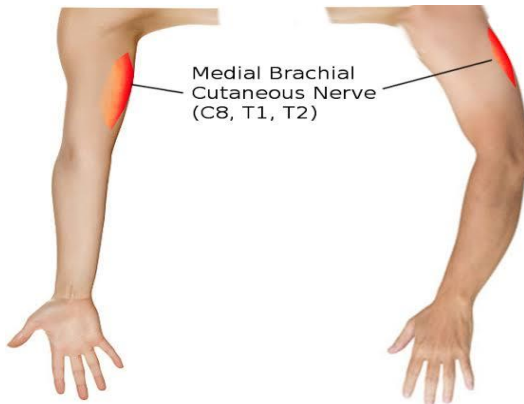
3. Lateral root of median nerve

BRANCHES OF MEDIAL CORD

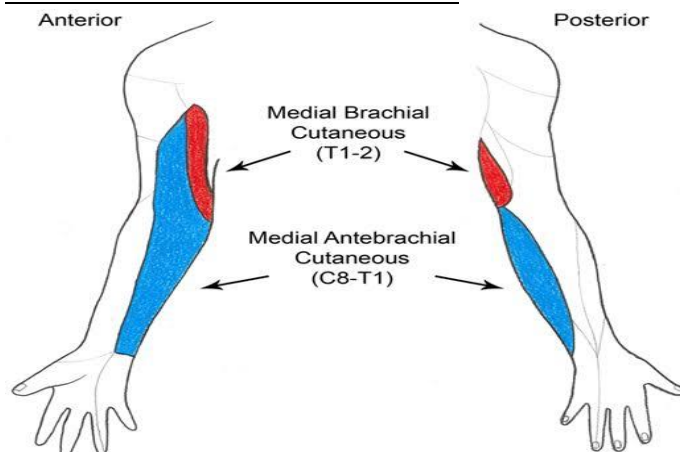
1. Medial pectoral nerve



2. Medial brachial cutaneous nerve

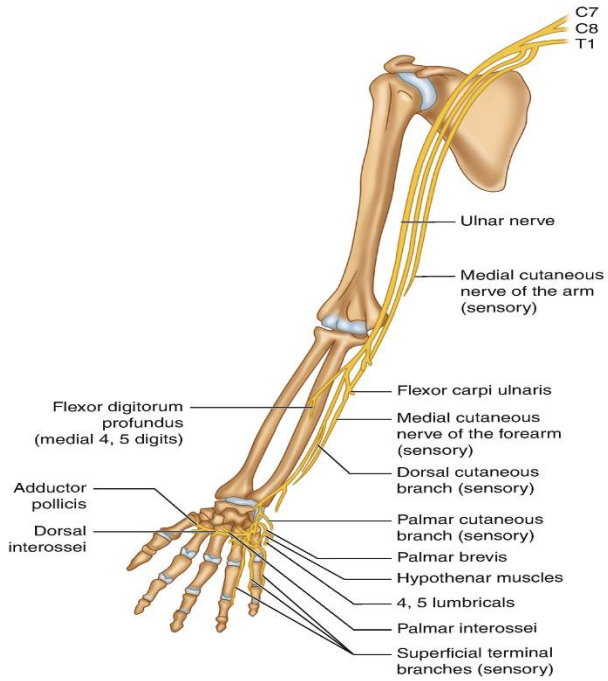


3. Medial antebrachial cutaneous nerve

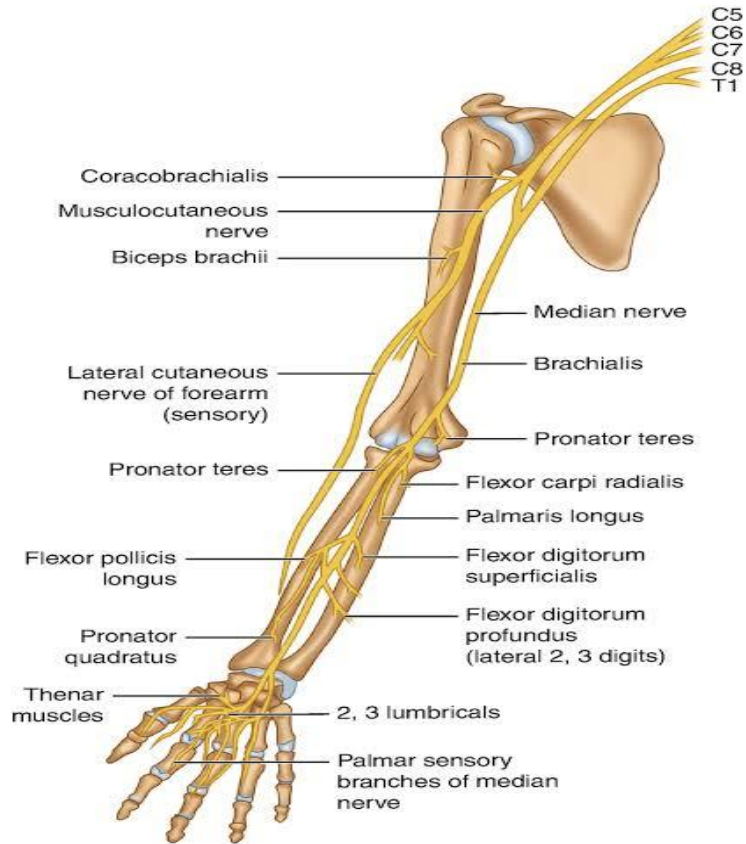


4. Medial root of median nerve

5. Ulnar nerve

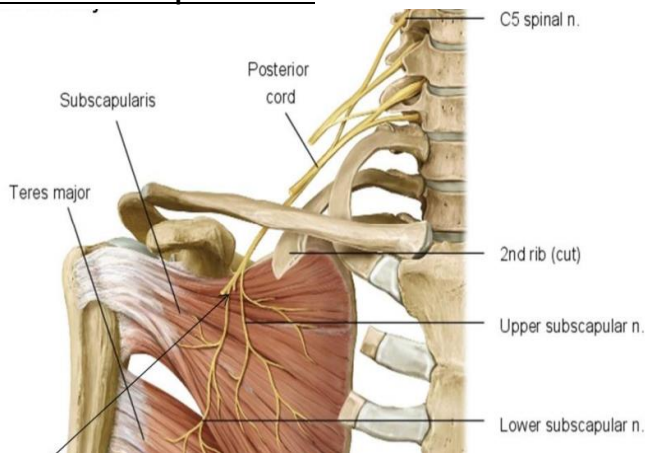


- **MEDIAN NERVE**

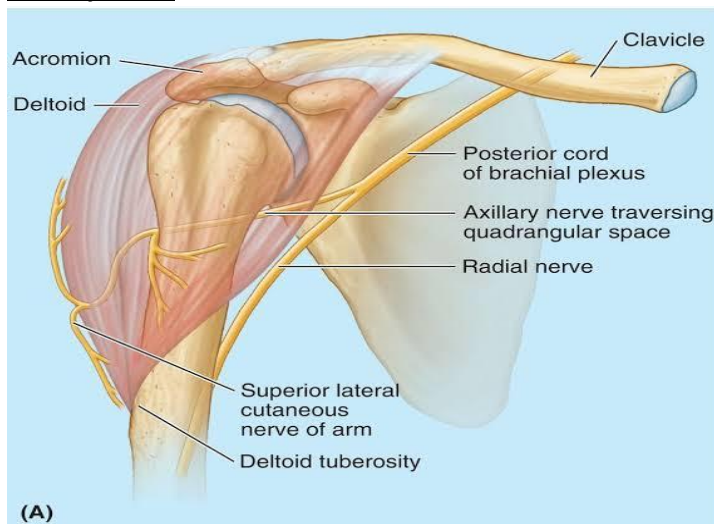


BRANCHES OF POSTERIOR CORD

1. Superior subscapular nerve
2. Inferior subscapular nerve



3. Axillary nerve



4. Radial nerve

