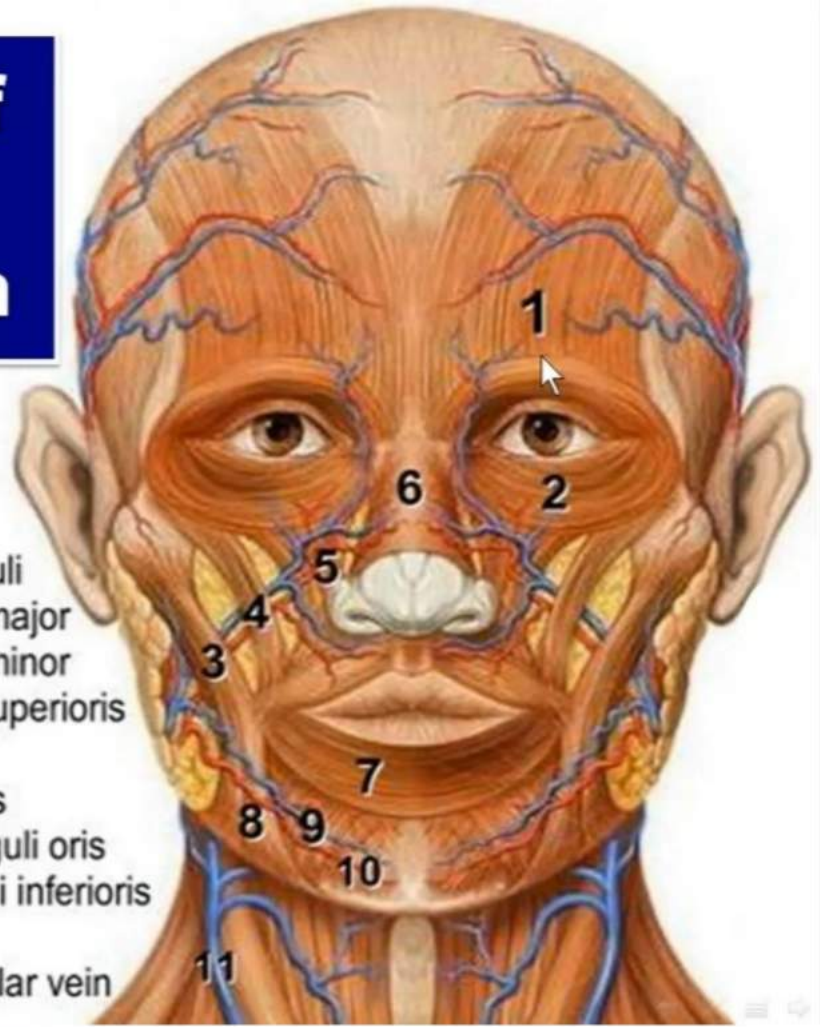


Muscles of Facial Expression

- 1: Frontalis
- 2: Orbicularis oculi
- 3: Zygomaticus major
- 4: Zygomaticus minor
- 5: Levator labii superioris
- 6: Nasalis
- 7: Orbicularis oris
- 8: Depressor anguli oris
- 9: Depressor labii inferioris
- 10: Mentalis
- 11: External jugular vein



OPHTHALMIC NERVE

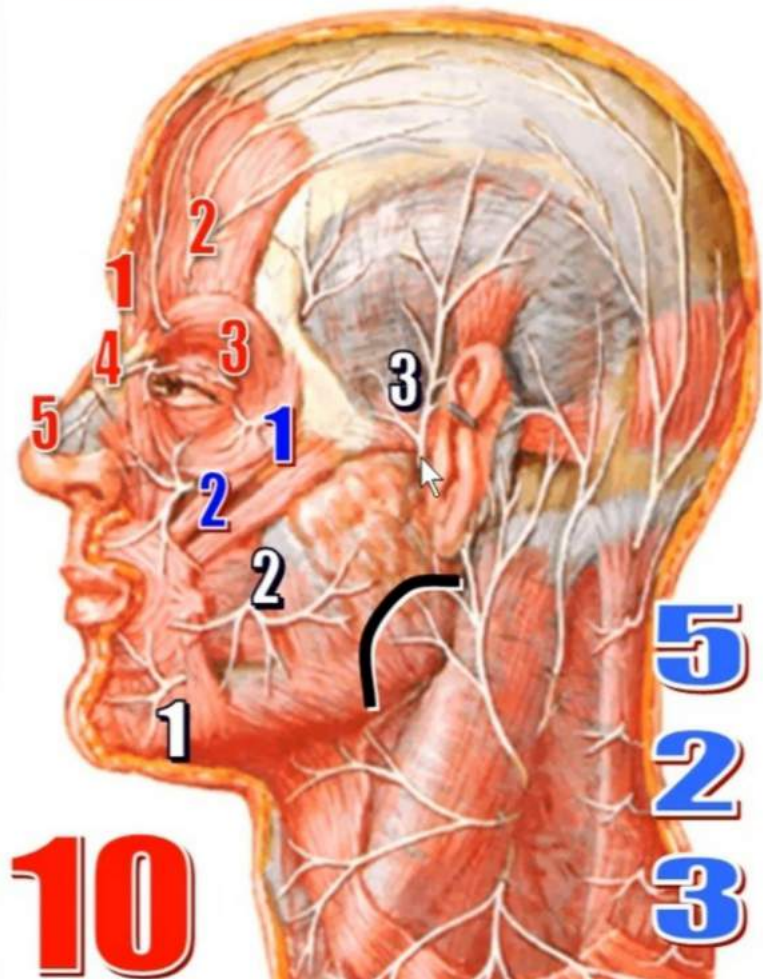
- 1. supratrochlear nerve
- 2. supraorbital nerve
- 3. Lacrimal nerve
- 4. Infratrochlear nerve
- 5. External nasal nerve

MAXILLARY NERVE

- 1. Zygomaticofacial nerve
- 2. Infraorbital nerve:
 - a. palpebral
 - b. nasal
 - c. labial

Mandibular NERVE

- 1. Mental nerve
- 2. Buccal nerve
- 3. Auriculotemporal n



Muscles of Facial Expression

- ☺ Are derived from the 2nd pharyngeal arch
- ☺ Are supplied by the facial nerve

Orbital Muscles

Orbicularis Oculi: 3 parts

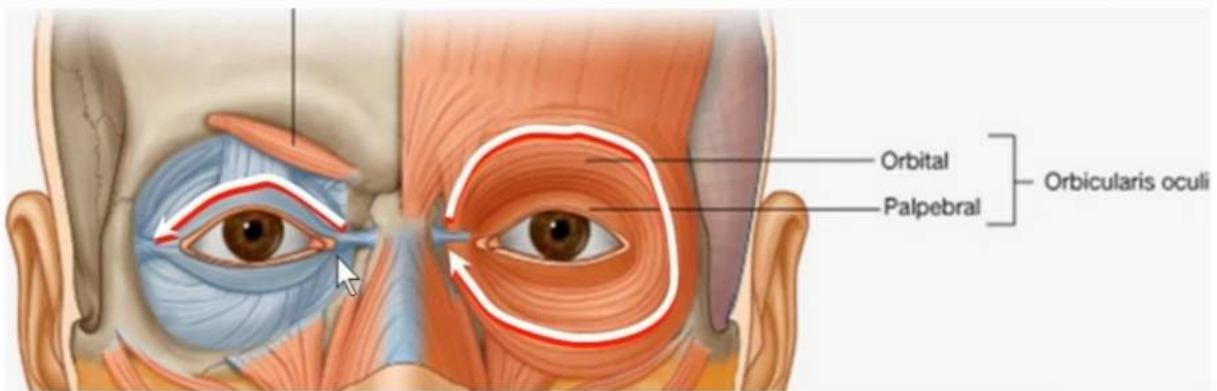
1. **Orbital part:** powerful closure of the eye
2. **Palpebral part:** light closure (blinking)
3. **Lacrimal part:** dilate the lacrimal sac to aspirate tears from the eye

Frontalis: elevate the eyebrow (act of surprise or fear)

Oral Muscles

- **Buccinator**
- **Orbicularis oris**
- **Zygomaticus major:** elevate the angle of the mouth
- **Zygomaticus minor:** elevate the upper lip

Nasal and Auricular Muscles



Orbicularis Oculi: 3 parts

1. **Orbital part:**
 - ♣ surround the orbital margin
 - ♣ from the medial palpebral ligament to the med p lig
 - ♣ powerful closure of the eye
2. **Palpebral part:**
 - ♣ present in the eyelid
 - ♣ from the medial to the lateral palpebral ligament
 - ♣ light closure of the eye (blinking and sleep)
3. **Lacrimal part:**
 - ♣ from the lacrimal bone to the lacrimal sac
 - ♣ dilates the lacrimal sac to aspirate tears

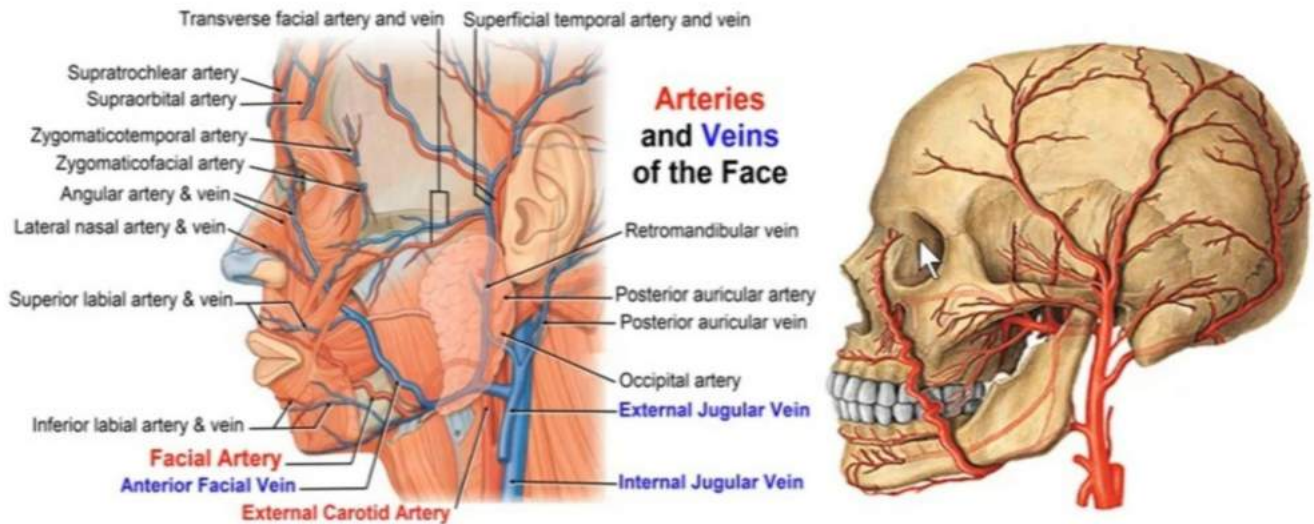
ARTERIAL SUPPLY

1. Facial Artery

2. Superficial Temporal Artery

3. Ophthalmic Artery & Maxillary Artery:

accompany the branches of the trigeminal nerve



Relations of the Buccinator

COVERED BY:

2 Vessels:

1. Facial artery anterior
2. Ant facial vein posterior

2 Fascia:

1. Buccal pad of fat
2. Buccopharyngeal fascia

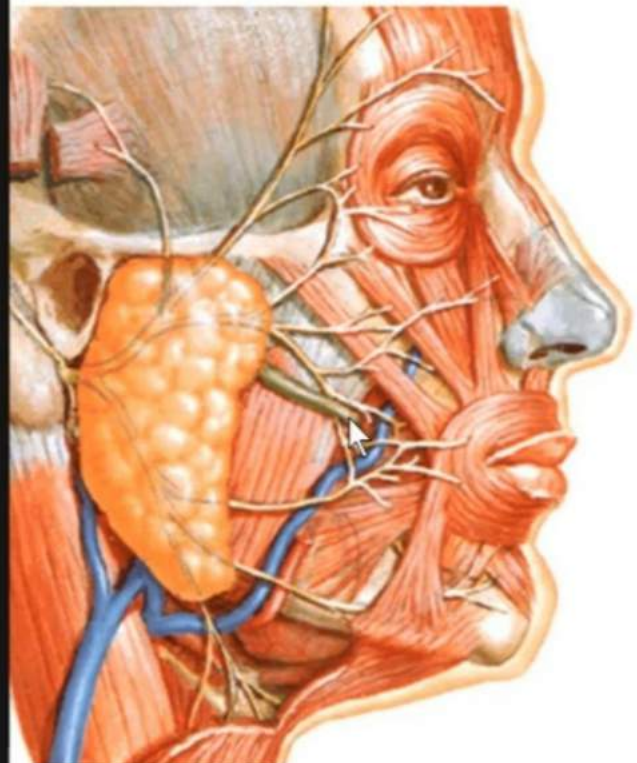
2 Nerves:

1. Buccal branch of VII
2. Buccal branch of mand n

Buccal lymph node

PIERCED BY 2:

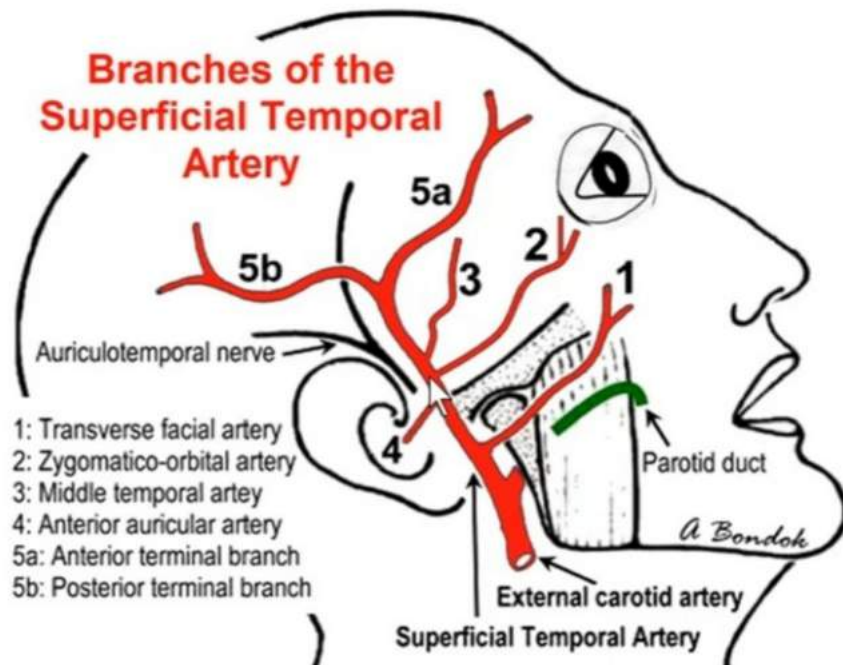
1. Parotid duct
2. Buccal branch of mand n



A R T E R I E S

Superficial Temporal Artery

1. **Transverse facial artery**
2. **Zygomatico-orbital artery**
3. **Middle temporal artery**
4. **Anterior auricular artery**
5. **2 terminal branches: ant & post**

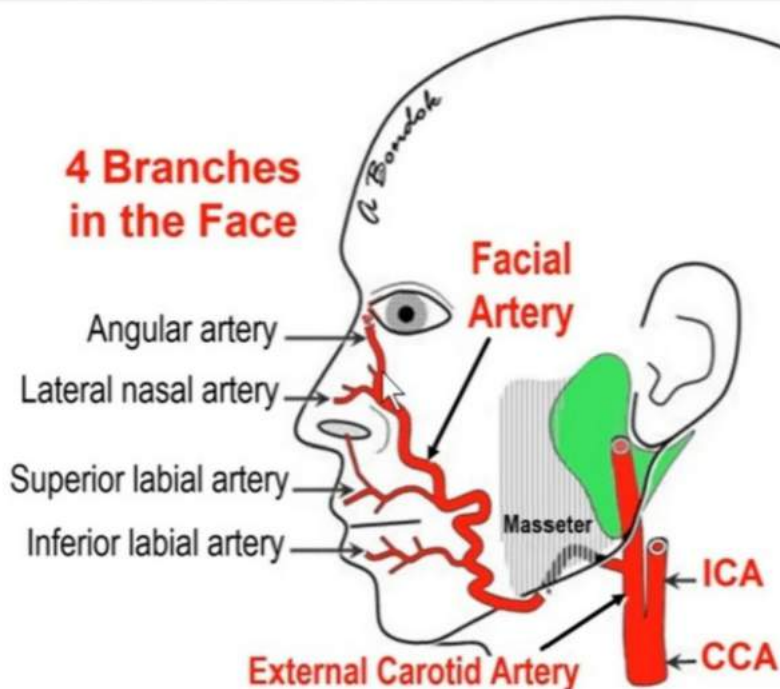


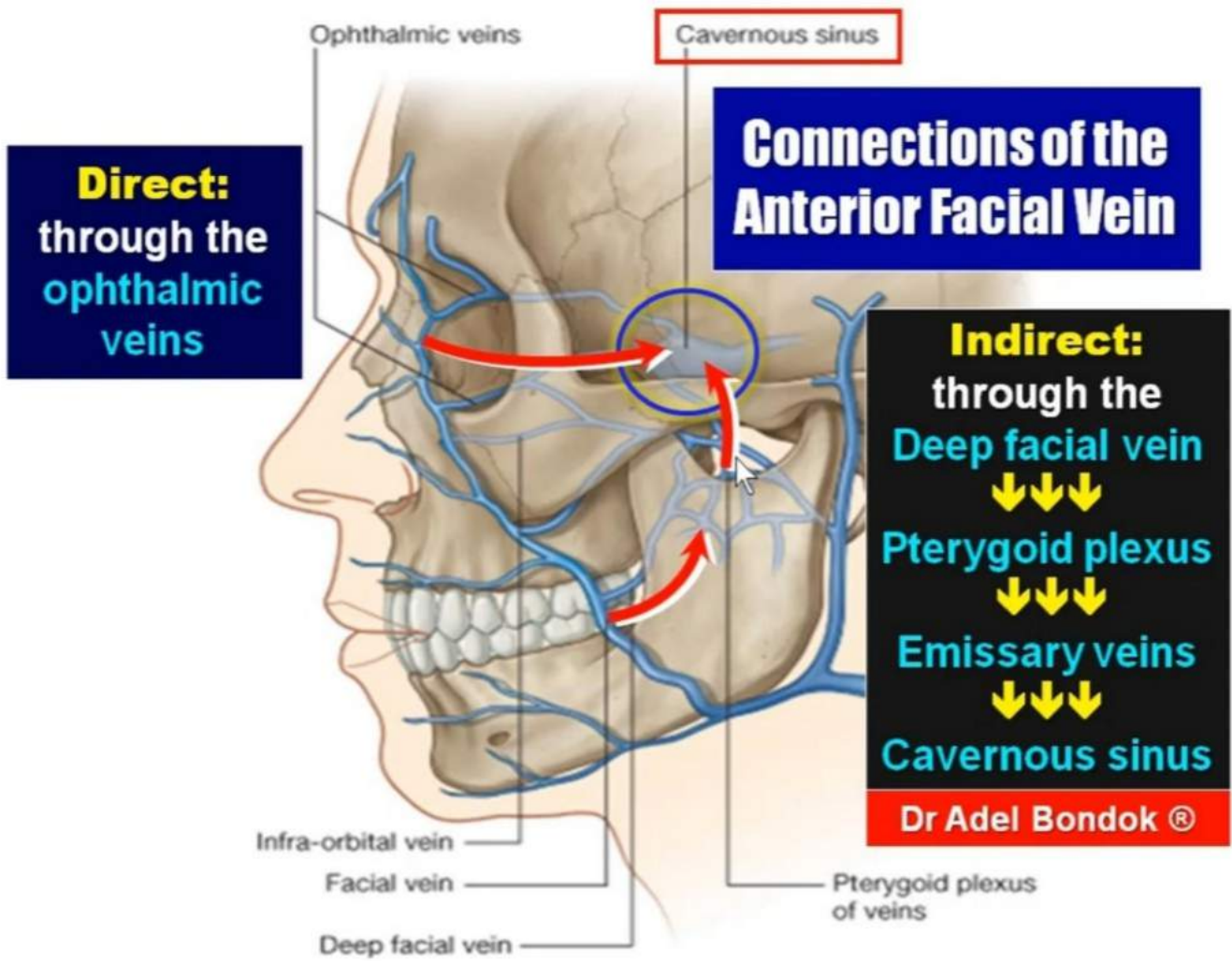
A R T E R I E S

Facial Artery

4 branches in the face

1. **Inferior labial:** lower lip
2. **Superior labial:** upper lip
3. **Lateral nasal:** side of nose
4. **Angular:** terminal branch

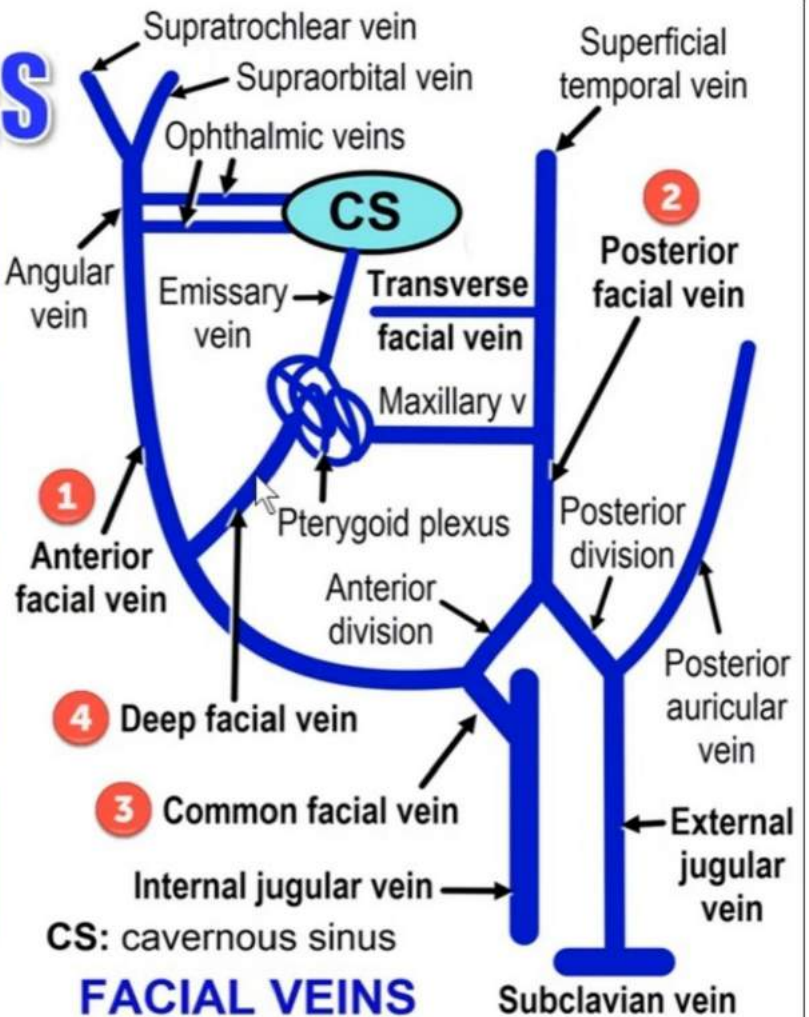




Facial Veins

- 1** Anterior facial vein
- 2** Posterior facial vein
- 3** Common facial vein
- 4** Deep facial vein

Dr Adel Bondok ®



Nerve Supply of the Face

SENSORY

MOTOR



TRIGEMINAL NERVE

FACIAL NERVE

Except the angle of the mandible



OPHTHALMIC NERVE

1. supratrochlear nerve
2. supraorbital nerve
3. Lacrimal nerve
4. Infratrochlear nerve
5. External nasal nerve

MAXILLARY NERVE

1. Zygomaticofacial nerve
2. Infraorbital nerve:
 - a. palpebral
 - b. nasal
 - c. labial

Mandibular NERVE

1. Buccal nerve
2. Mental nerve
3. Auriculotemporal

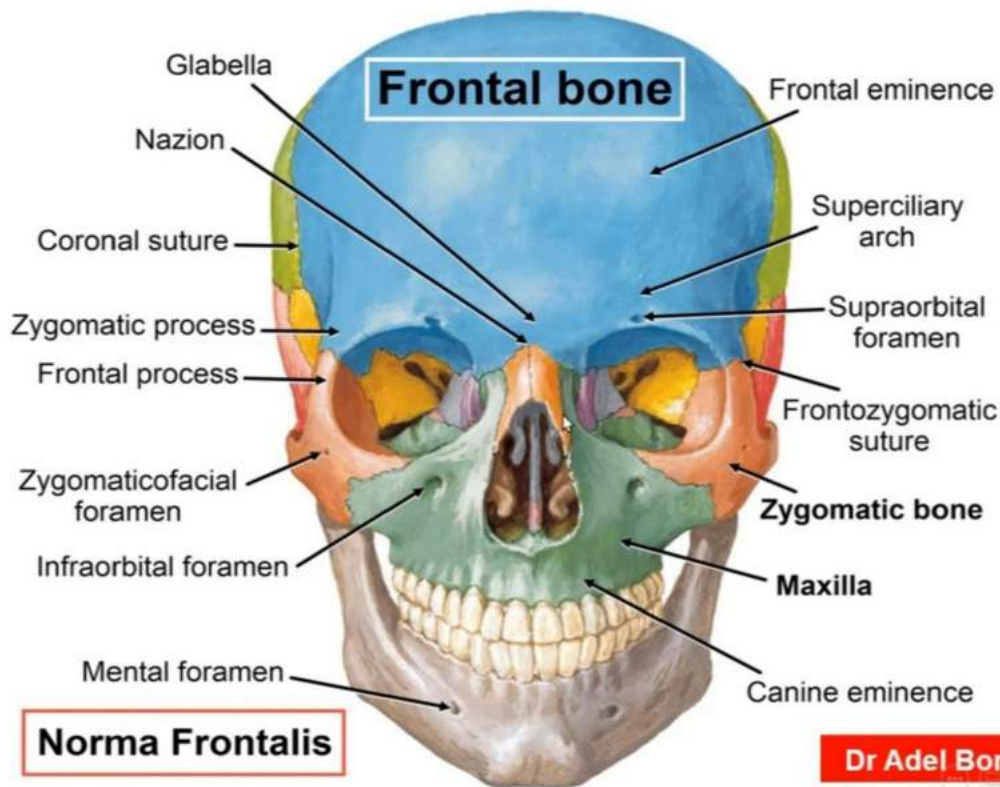
DANGEROUS AREA OF THE FACE

Upper lip, Nose, Eye & Forehead

Clinical Importance

Infection can be transmitted from the dangerous area to the dural sinuses via the ophthalmic veins & the deep facial vein causing meningitis & thrombosis of the dural sinuses





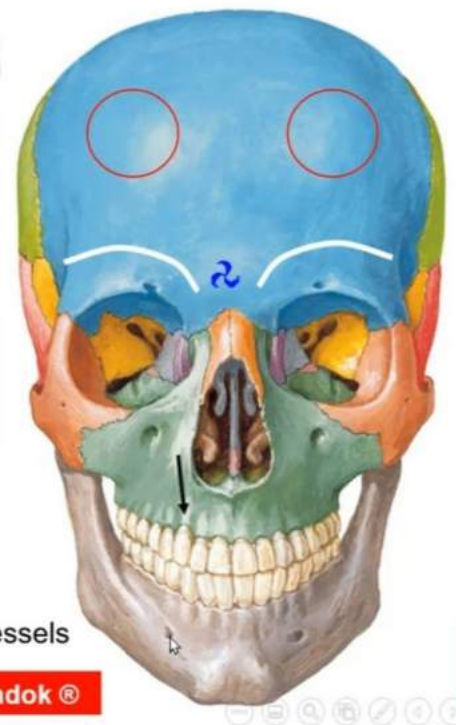
Norma Frontalis

Identify the Bony Landmarks:

1. **Frontal eminence:** center of ossification
2. **Superciliary arch:** above the orbit
3. **Glabella:** elevation between the 2 superciliary arches
4. **Nasion:** depression at the frontonasal suture.
5. **Nasal septum and anterior nasal spine**
6. **Middle and inferior nasal conchae.**
7. **Canine eminence:** formed by root of the canine tooth

Identify the Foramina:

1. **Supraorbital foramen:** supraorbital nerve & vessels
2. **Infraorbital foramen:** infraorbital nerve & vessels
3. **Zygomaticofacial foramen:** zygomaticofacial nerve & vessels
4. **Mental foramen:** mental nerve & vessels



Norma Verticalis Interna

Identify the Bones:

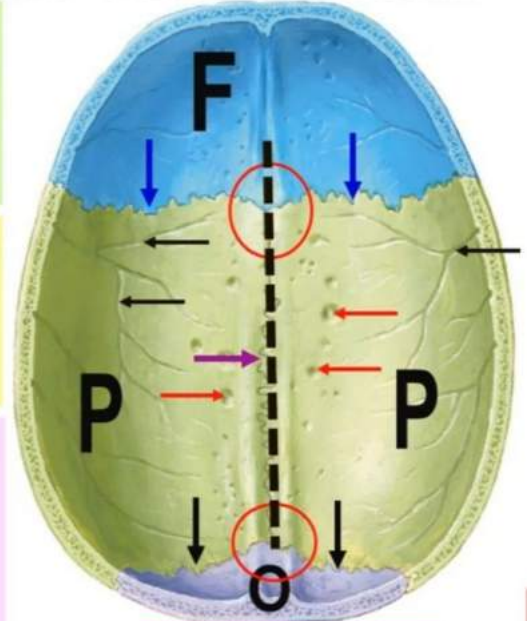
1. **Frontal bone:** anterior part
2. **Occipital bone:** posterior part
3. **Parietal bones:** one on each side

Identify the Sutures:

1. **Coronal suture:** between the frontal & parietal bones
2. **Sagittal suture:** between the 2 parietal bones.
3. **Lambdoid suture:** between occipital & parietal bones

Identify the Bony Landmarks:

1. **Bregma:** meeting of the sagittal & coronal sutures
2. **Lambda:** meeting of the sagittal & lambdoid sutures.
3. **Groove for superior sagittal sinus:** in the middle
4. **Grooves for the middle meningeal vessels**
5. **Granular foveolae:** made by arachnoid granulations



Dr Adel Bondok ®

Norma Verticalis Externa

Identify the Bones:

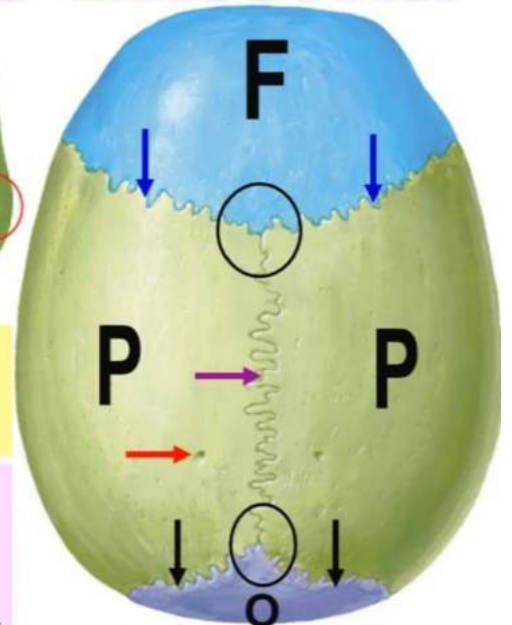
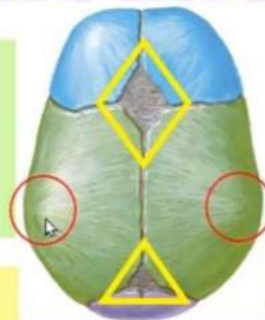
1. **Frontal bone:** anterior part
2. **Occipital bone:** posterior part
3. **Parietal bones:** one on each side

Identify the Sutures:

1. **Coronal suture:** between the frontal & parietal bones
2. **Sagittal suture:** between the 2 parietal bones.
3. **Lambdoid suture:** between occipital & parietal bones

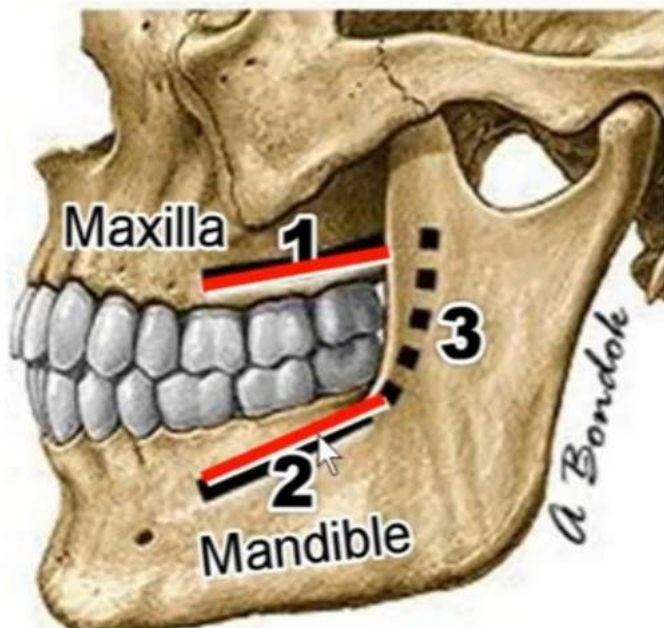
Identify the Bony Landmarks:

1. **Bregma:** meeting of the sagittal & coronal sutures
2. **Lambda:** meeting of the sagittal & lambdoid sutures.
3. **Parietal foramen:** emissary vein between SSS & scalp v
4. **Parietal eminence:** site of the center of ossification.



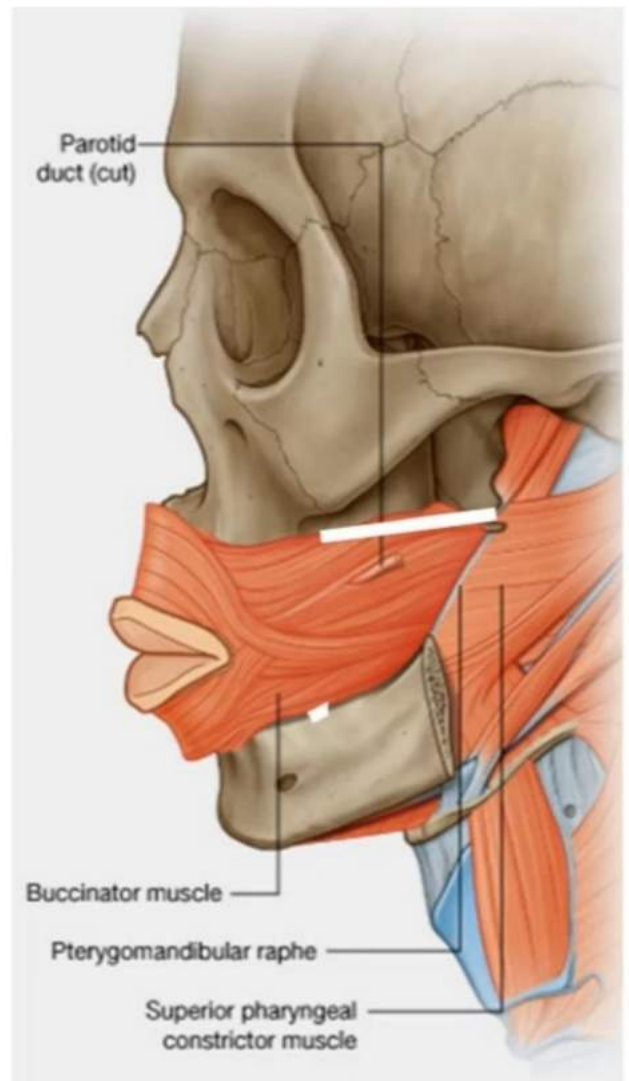
Dr Adel Bondok ®

Buccinator



3: pterygomandibular ligament

Origin of Buccinator



ARTERIAL SUPPLY

5 ARTERIES

2 from the internal carotid artery:

1. **Supratrochlear artery** **ophthalmic artery**
2. **Supraorbital artery** **artery**

3 from the external carotid artery:

1. **Superficial temporal artery**
2. **Posterior auricular artery**
3. **Occipital artery**

ARTERIAL SUPPLY

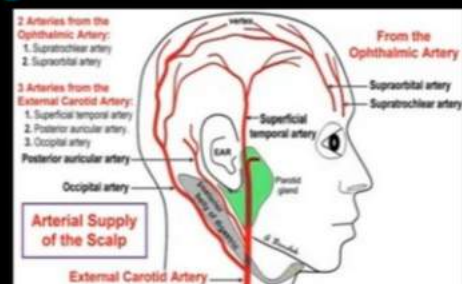
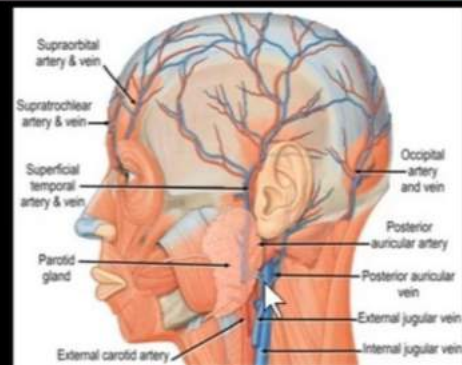
5 ARTERIES

3 in front of the ear:

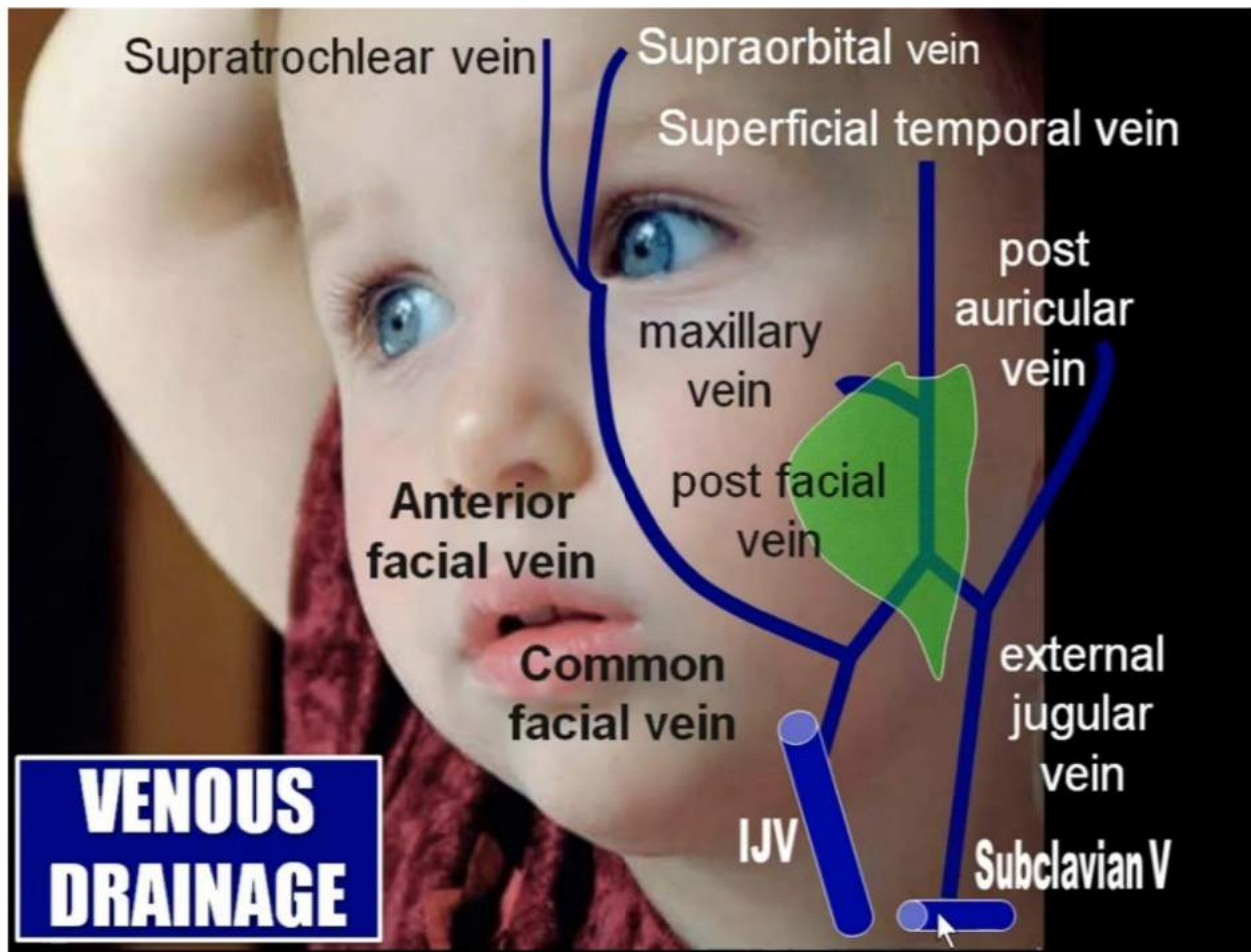
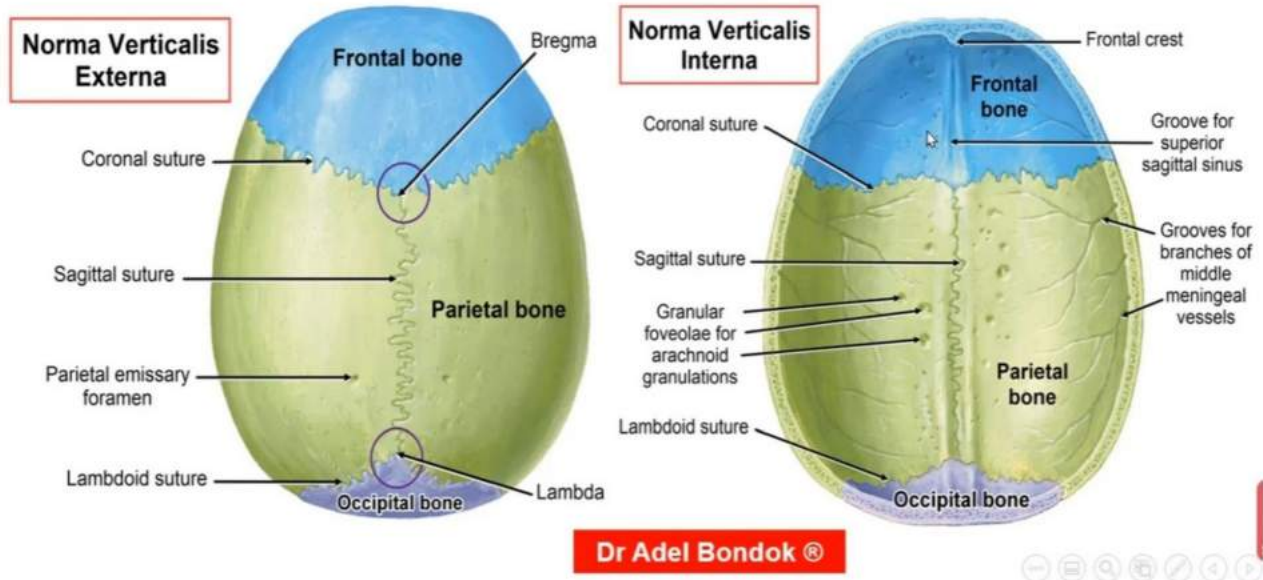
1. **Supratrochlear artery**
2. **Supraorbital artery**
3. **Superficial temporal artery**

2 behind the ear:

1. **Posterior auricular artery**
2. **Occipital artery**



Norma Verticalis

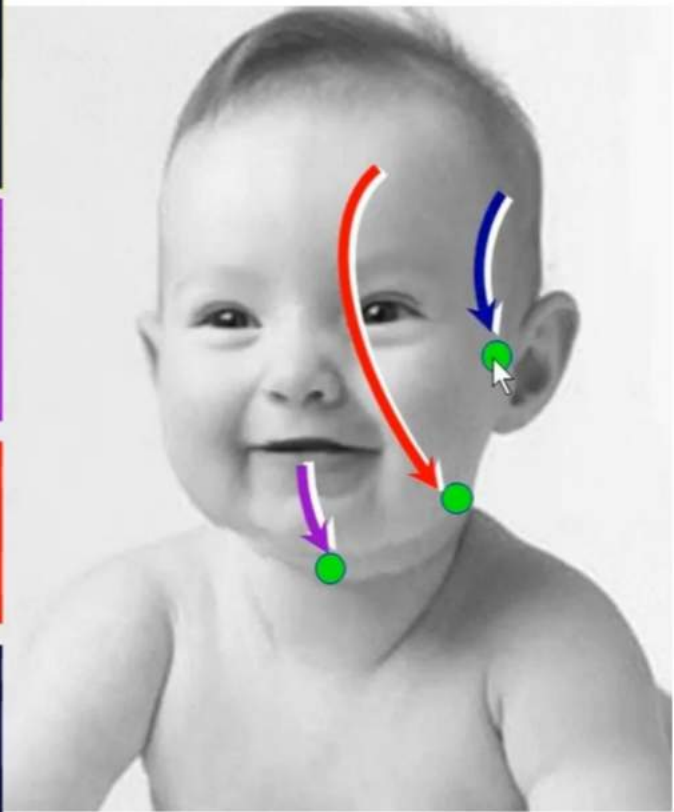


LYMPH DRAINAGE of the FACE

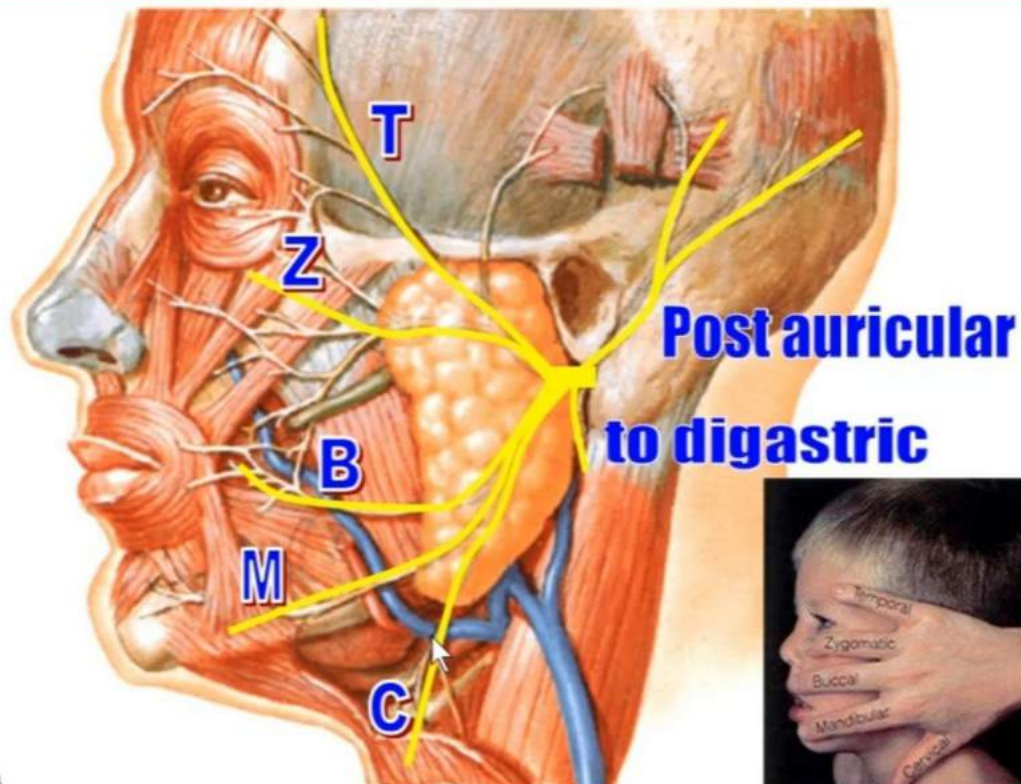
Central Part of the Lower Lip & Chin: submental lymph nodes

Forehead & Anterior Part: submandibular L nodes

Lateral part & Lat part of Eyelids: preauricular L nodes



Facial Nerve Branches



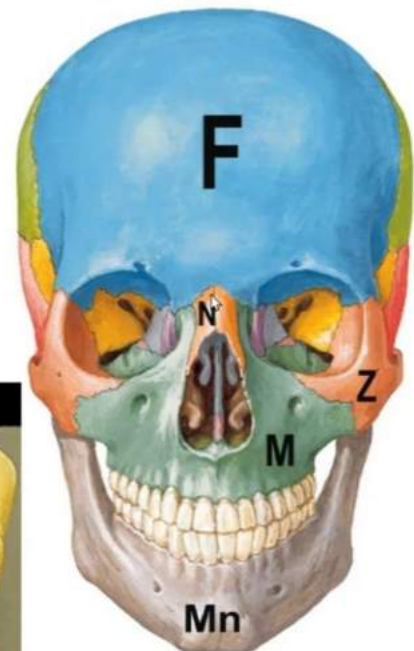
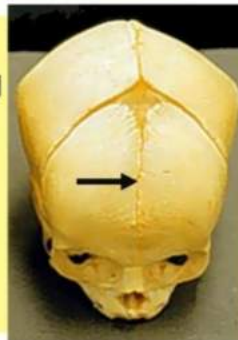Norma Frontalis

Identify the Bones:

1. **Frontal bone:** upper part
2. **Nasal bones:** above the nasal opening
3. **Zygomatic bones:** lateral to the orbital opening
4. **Maxilla:** forming the upper jaw.
5. **Mandible:** forming the lower jaw.

Identify the Sutures:

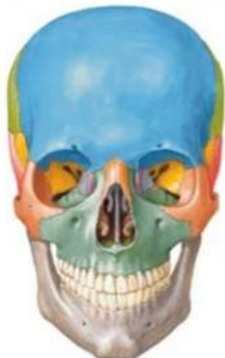1. **Coronal suture:** between frontal & parietal
2. **Metopic suture:** in infant skull between the 2 halves of frontal bone. It **disappears at the age of 2 - 6 years**. The lower part persists in about 8% of adult skulls.
3. **Frontonasal & frontozygomatic suture**
4. **Internasal suture**



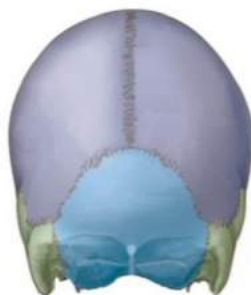Dr Adel Bondok®

Different Aspects of the Skull

Norma Frontalis
From the front



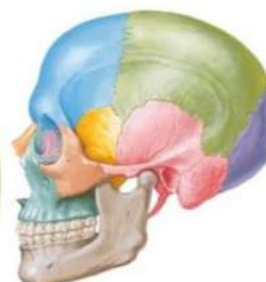Norma Occipitalis
From the back



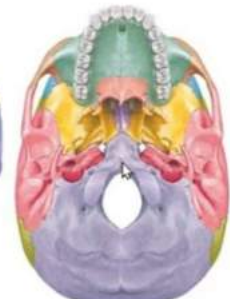
Norma Verticalis
From above



Norma Lateralis
From the side



Norma Basalis
From below



Anterior ethmoidal canal:
anterior ethmoidal nerve & vessels

Posterior ethmoidal canal:
posterior ethmoidal nerve & vessels

Superior orbital fissure: Live **F**ree
To **S**ee **N**o **I**nsult at **A**ll+ **O**V
Lacrimal n, Frontal n, Trochlear n,
Sup division of III n, Nasociliary n,
Inferior division of III n, Abducent n

Flacerum: ICA & deep petrosal n

Internal auditory meatus:

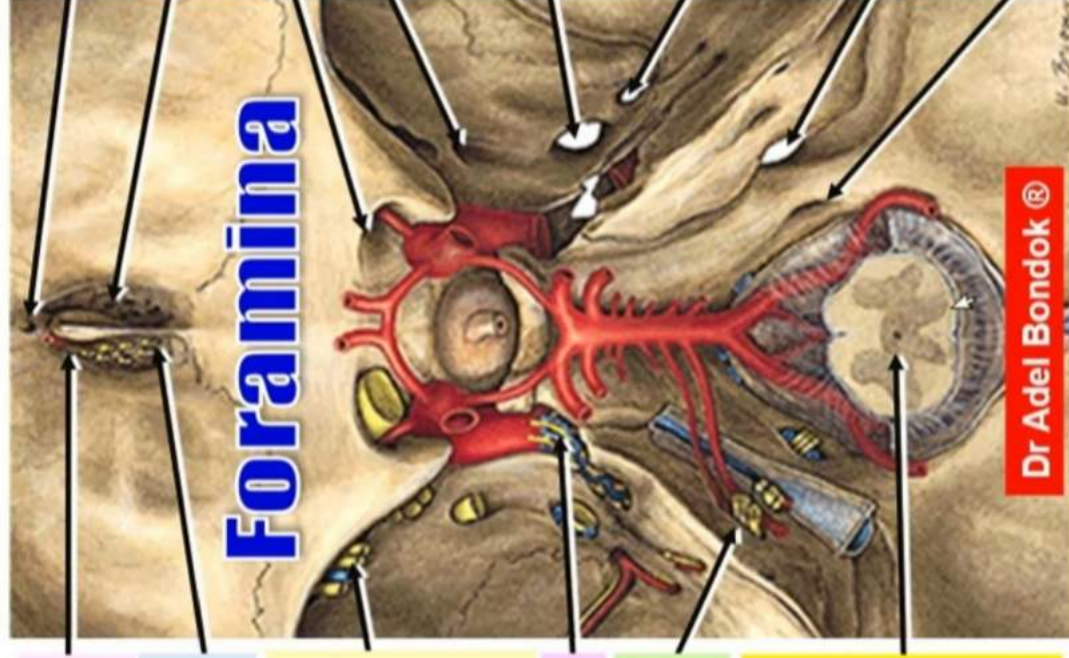
VII n, VIII n & labyrinthine artery

Foramen magnum: 9

3 nervous: medulla to become SC,
spinal accessory n, sympath fibers

3 arteries: 2 vertebral, 1 anterior
spinal & 2 posterior spinal arteries

3 meninges: dura, arachnoid & pia



Foramen cecum: emissary vein
between nasal vein and **SSS**

Cribriform plate : olfactory nerves

Optic canal:

Optic nerve and ophthalmic artery

Foramen rotundum: maxillary n

Foramen ovale: "MALE"

Mandibular nerve, **A**ccessory
meningeal art, **L**esser petrosal n &
Emissary vein of cavernous sinus

Foramen spinosum: middle
meningeal art & nervus spinosus

Jugular foramen: 2 V & 3 N

Anterior: inferior petrosal sinus

Posterior: sigmoid sinus

Middle: IX, X & XI nerves:

Hypoglossal canal: XII nerve

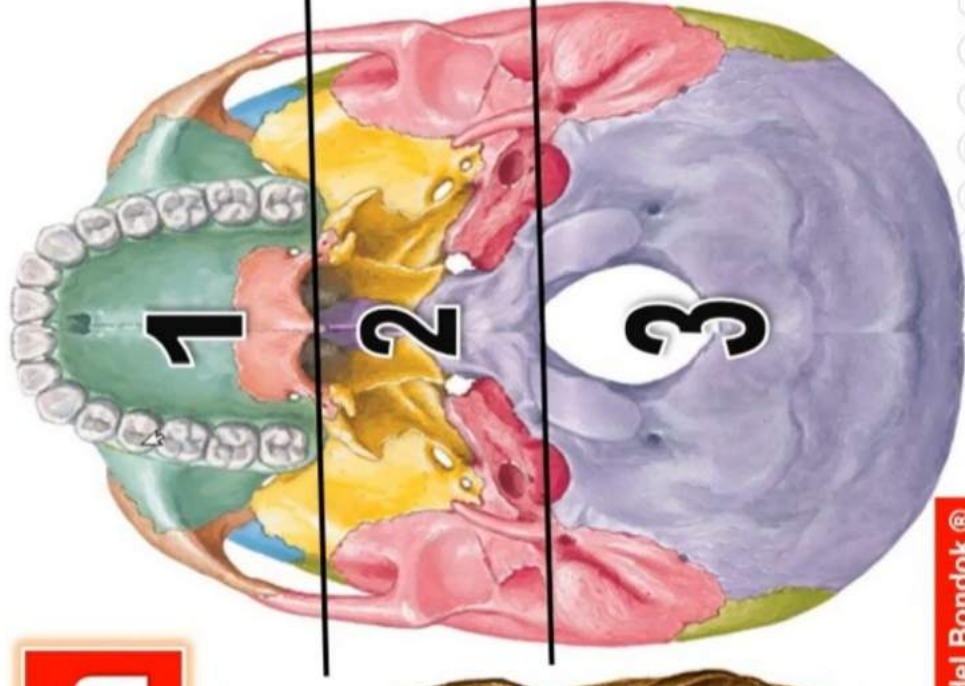
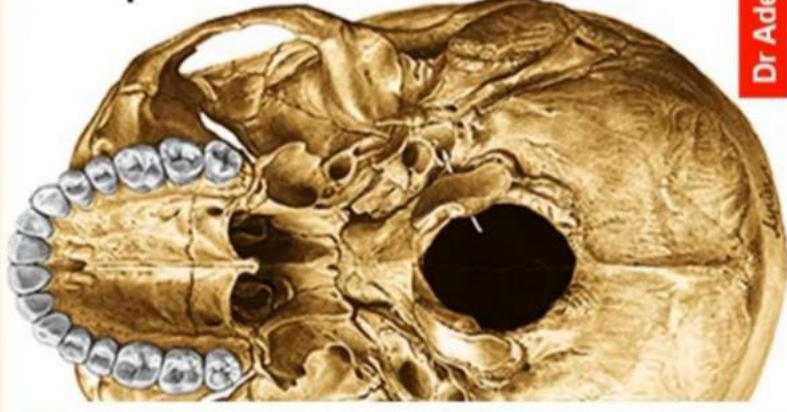
Norma Basalis Externa

Divided into 3 Parts:

1. Anterior Part:
Is the hard palate

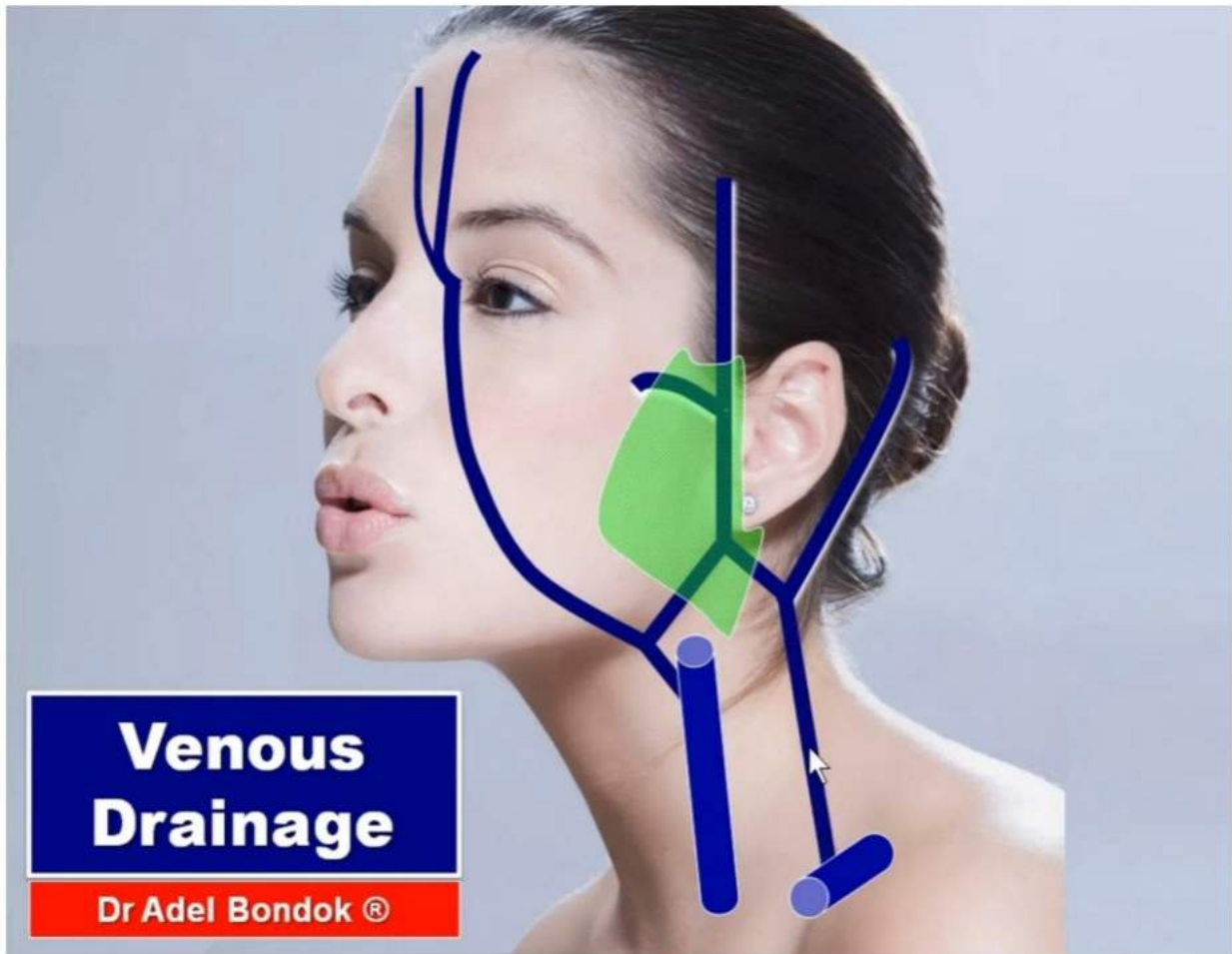
2. Middle Part:
Between the hard palate
and anterior margin of the
foramen magnum

3. Posterior Part:
Behind the anterior margin
of the foramen magnum.
It is the occipital bone and
mastoid process



Dr Adel Bondok ©

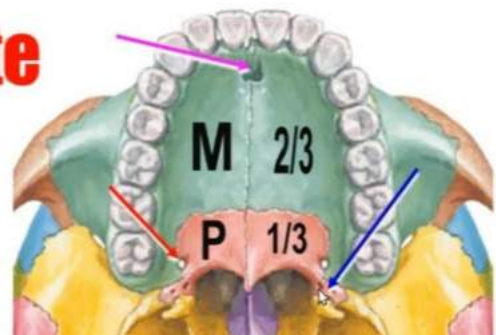




Anterior Part: Hard Palate

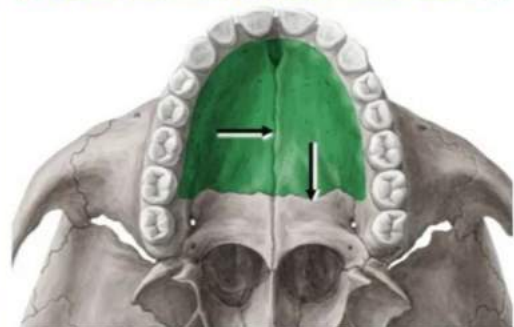
Identify Parts of the Hard Palate:

1. Palatine process of the maxilla: anterior 2/3
2. Palatine bone: posterior 1/3
3. Posterior nasal spine: in the middle of the free posterior border.



Identify the Sutures & Foramina:

1. Median palatine suture: in the midline.
2. Palato-maxillary suture: between the maxilla and the palatine bone.
3. Incisive foramen (fossa): transmits nasopalatine nerve and sphenopalatine vessels.
4. Greater palatine foramen: transmits greater palatine nerve and sphenopalatine vessels
5. Lesser palatine foramina: transmit lesser palatine nerve and vessels



Dr Adel Bondok ©

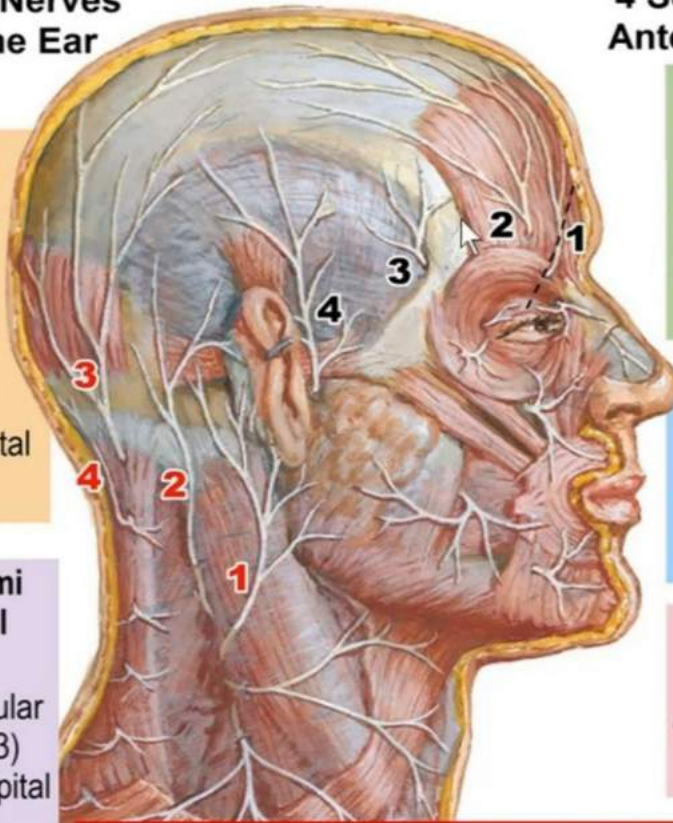
4 Sensory Nerves Behind the Ear

Dorsal Rami of Cervical Nerves

- 3. Greater occipital nerve (C2)
- 4. Third occipital nerve (C3)

Ventral Rami of Cervical Nerves

- 1. Great auricular nerve (C2, 3)
- 2. Lesser occipital nerve (C2)



4 Sensory Nerves Anterior to the Ear

Ophthalmic Nerve

- 1. Supratrochlear nerve
- 2. Supraorbital nerve

Maxillary Nerve

- 3. Zygomatico-temporal nerve

Mandibular Nerve

- 4. Auriculo-temporal nerve

Sensory Nerve Supply

NERVE SUPPLY OF THE SCALP

10 NERVES

5 in front of the ear

↓
4 sensory

TRIGEMINAL NERVE

- 1. supratrochlear n: ophth
- 2. supraorbital n: ophth
- 3. zygomaticotemporal: mx
- 4. auriculotemporal: mn



5 behind the ear

↓
4 sensory

CERVICAL NERVES

- 1. great auricular: C2, 3 VR
- 2. Lesser occipital: C2, VR
- 3. greater occipital: C2, DR
- 4. 3rd occipital: C3, DR

1 motor

1 motor

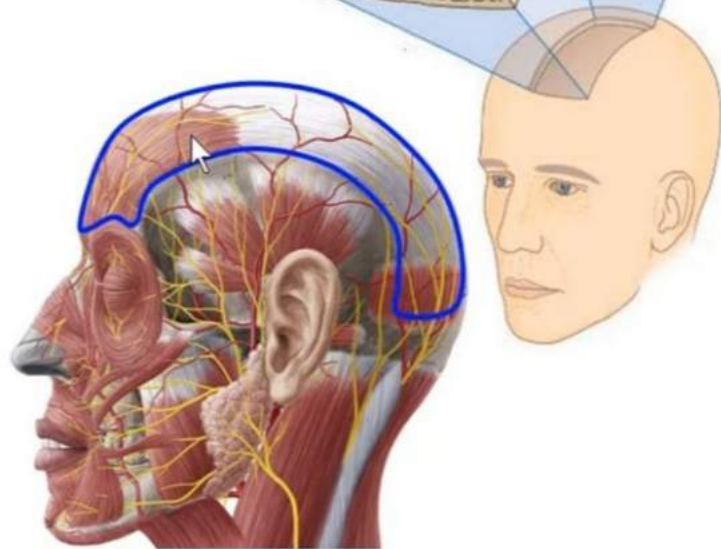
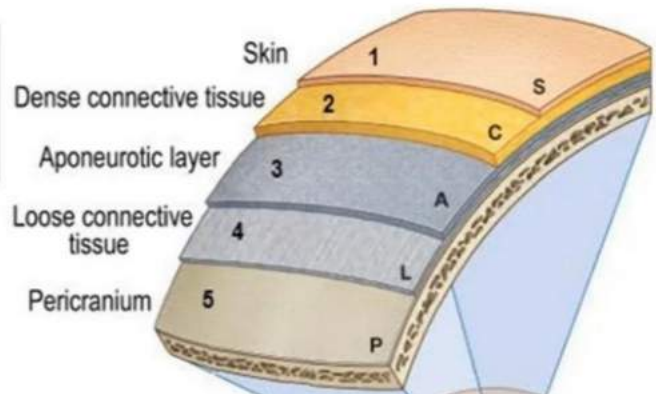
temporal branch ←

FACIAL NERVE

→ post auricular branch

SCALP

1. What is it?
2. Extension
3. Layers:
S C A L P
4. Muscle: O-F

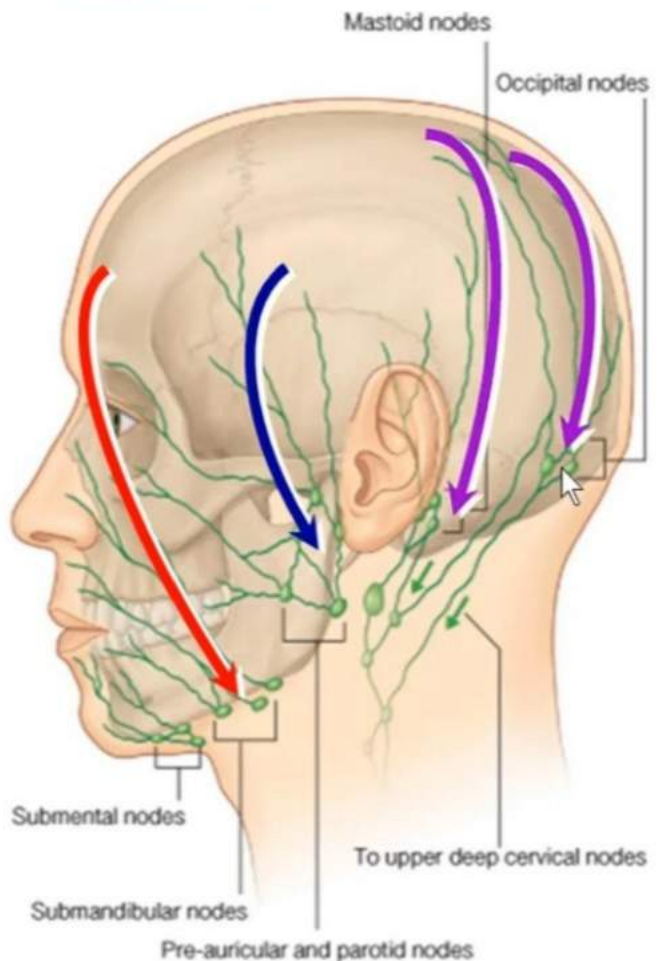


Lymph Drainage of the SCALP

Forehead: to the submandibular L nodes

Lateral part: to the preauricular L nodes

Posterior part: to the mastoid & occipital lymph nodes



SCALENUS ANTERIOR

Anterior Relation

2 Arteries:

1. Suprascapular artery
2. Transverse cervical art

2 Veins:

1. Subclavian Vein
2. Internal jugular vein

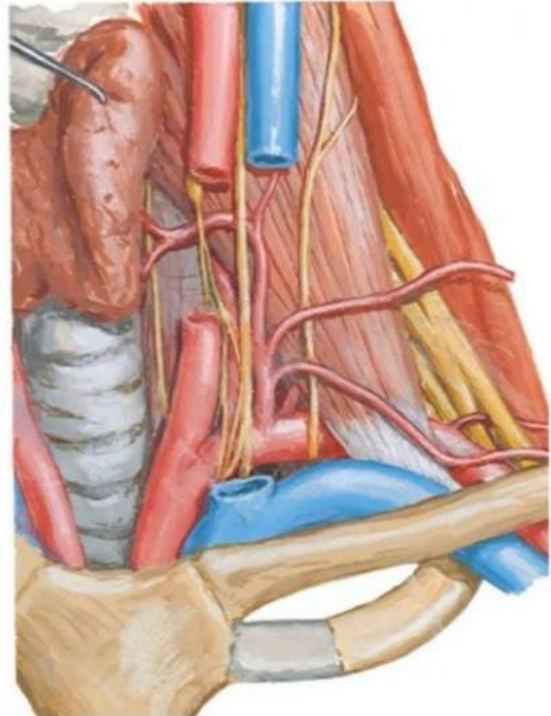
2 Nerves:

1. Phrenic nerve
2. Vagus nerve

2 Muscles:

1. Sternomastoid
2. Tendon of Omohyoid

8



CERVICAL PLEXUS

SITE:

- In front of the scalenus medius
- Deep to the prevertebral fascia

FORMATION:

Ventral rami of upper 4 cervical nerves

BRANCHES:

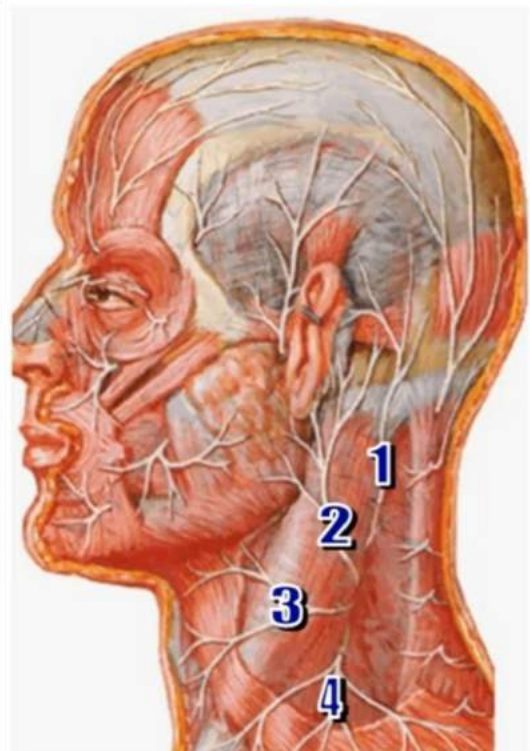
4 Cutaneous Branches:

1. Lesser occipital n: C2
2. Great auricular n: C2, 3
3. Transverse cervical n: C2, 3
4. Supraclavicular n: C3, 4

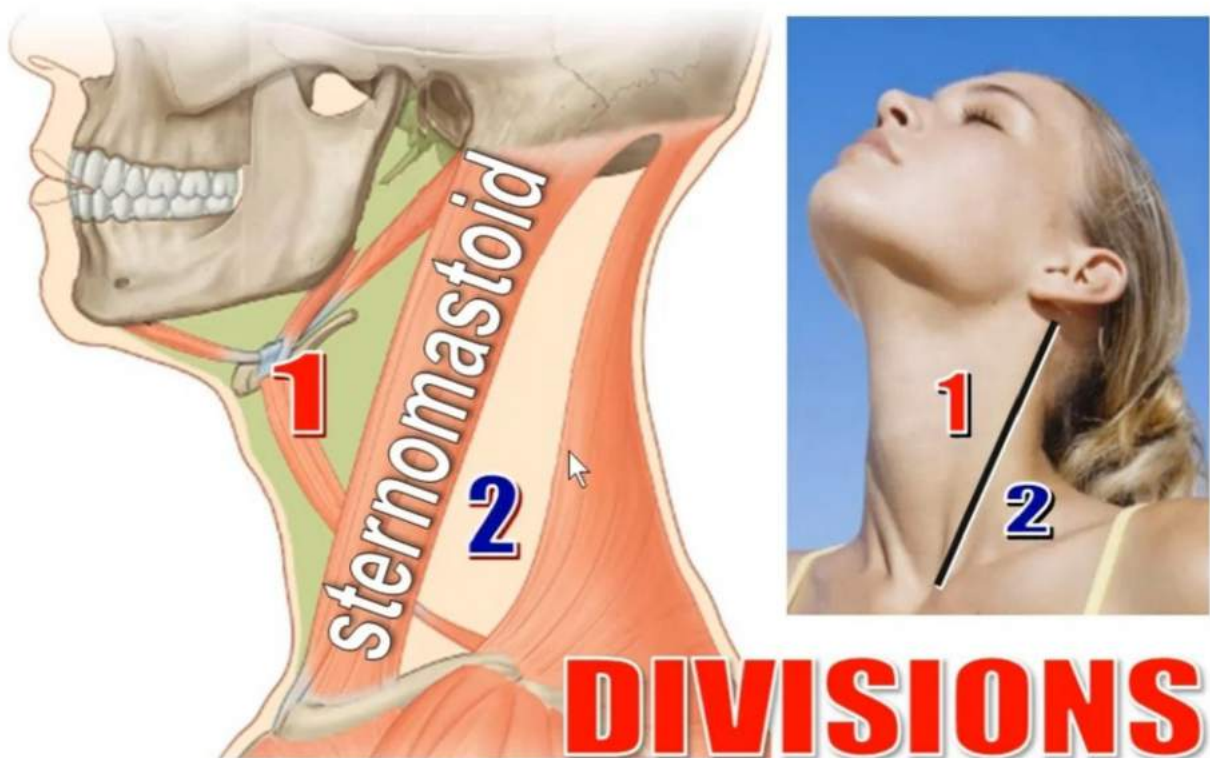
4 Muscular Branches:

1. Sternomastoid: C2 & C3
2. Trapezius & levator scapulae: C3 & C4
3. Scalene muscles
4. Ansa Cervicalis to infrahyoid muscles

Phrenic Nerve: to diaphragm



SIDE OF THE NECK



DIVISIONS

STERNOMASTOID

ORIGIN:

- 1. Sternal head:**
front of the manubrium
- 2. Clavicular head:**
medial 1/3 of the clavicle

INSERTION:

1. Lateral surface of mastoid process
2. Lateral 1/3 of superior nuchal line

NERVE SUPPLY:

1. Spinal accessory nerve
2. C2 & C3: sensory

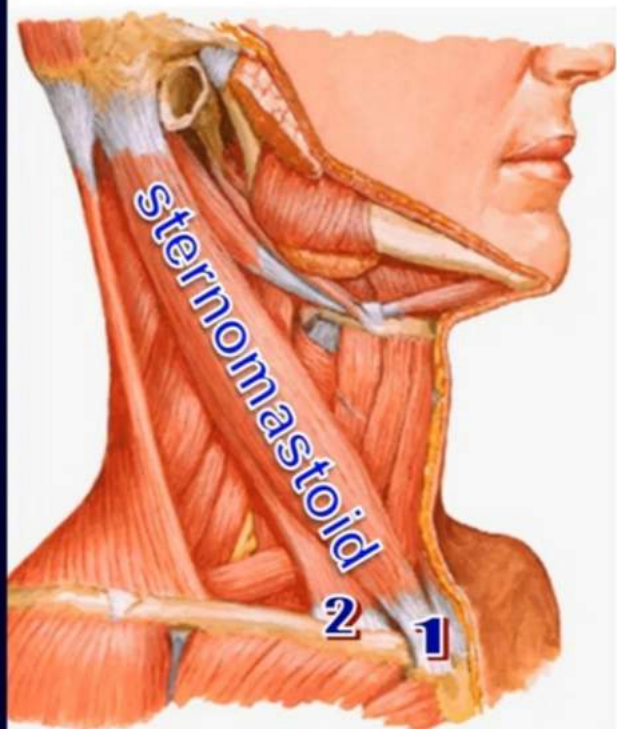
ACTION:

One Muscle:

Rotate the face to the opposite side & Lat flexion of the neck: brings the ear to the tip of the shoulder of the same side

The Two Muscles:

Forward flexion of the neck



Middle Part: Sphenoid & Petrous Temporal Bone

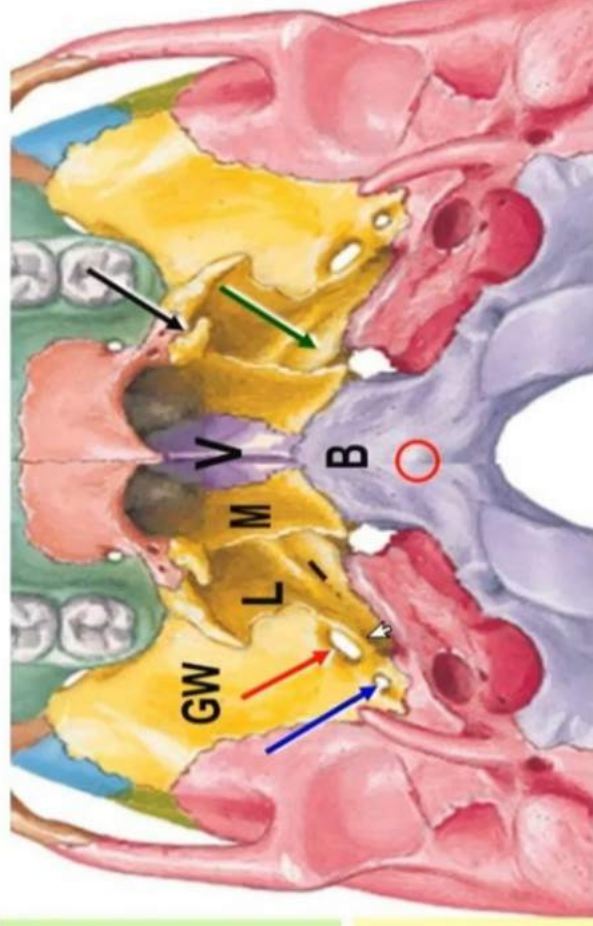
Identify the Bones & Foramina:

In the Midline:

1. The vomer & body of the sphenoid
2. Occipitospheoid suture: ossifies at 25 yrs
3. Basilar part of the occipital bone
4. Pharyngeal tubercle

On Each Side:

1. Medial & lateral pterygoid plates
 - a. Pterygoid fossa: between the 2 pt plates
 - b. Pterygoid hamulus & **scaphoid fossa**
2. Greater wing of the sphenoid: contains:
 - a. **Foramen ovale**: transmits "MALE"
Mandibular nerve, Accessory meningeal art, Lesser petrosal nerve & Emissary vein
 - b. **Foramen spinosum**: middle meningeal artery & nervus spinosus.
3. Groove for auditory tube: behind f ovale



Posterior Part: Occipital Bone & Mastoid Process

Occipital Bone:

Divided by foramen magnum into 3 parts:

1. **Basilar part:** in front of the foramen magnum
2. **Squamous part:** behind the foramen magnum
3. **Condylar part:** 2 occipital condyles

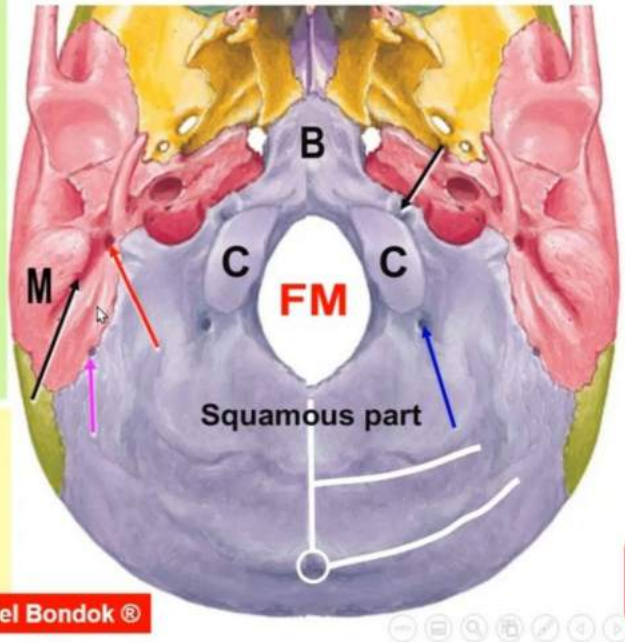
2 Foramina:

1. **Hypoglossal canal:** above the occipital condyle
Transmits the hypoglossal nerve
2. **Posterior condylar canal:** behind the condyle.
Transmits emissary vein between the sigmoid sinus and suboccipital venous plexus.

Mastoid Process:

1. **Mastoid notch:** on the medial side (digastric)
2. **Stylomastoid foramen:** transmits facial nerve & styomastoid art from posterior auricular art
3. **Mastoid foramen:** transmits artery & vein
4. **Groove for the occipital artery**

Dr Adel Bondok ®



Middle Part: Sphenoid & Petrous Temporal Bone

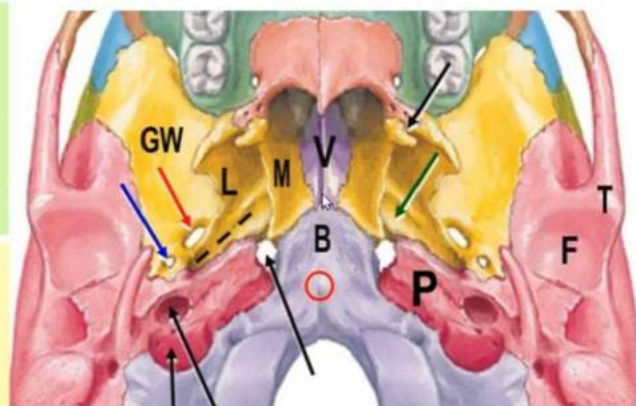
Identify the Bones & Foramina:

In the Midline:

1. The vomer & body of the sphenoid
2. Occipitospheonoid suture: ossifies at 25 yrs
3. Basilar part of the occipital bone
4. Pharyngeal tubercle

On Each Side:

1. Medial & lateral pterygoid plates
 - a. Pterygoid fossa: between the 2 pt plates
 - b. Pterygoid hamulus & scaphoid fossa
2. Greater wing of the sphenoid: contains:
 - a. **Foramen ovale:** transmits "MALE"
Mandibular nerve, Accessory meningeal art, Lesser petrosal nerve & Emissary vein
 - b. **Foramen spinosum:** middle meningeal artery & nervus spinosus.
3. Groove for auditory tube: behind f ovale



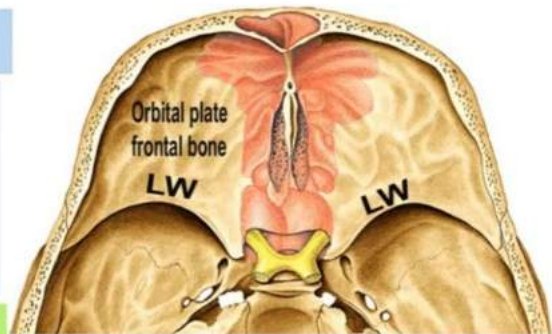
4. Petrous part of temporal bone: showing
 - a. Foramen lacerum: transmits ICA & DPN
 - b. Carotid canal: transmits ICA.
 - c. Jugular foramen
5. Styloid process
6. Articular tubercle & articular fossa

Dr Adel Bondok ®

1. Anterior Cranial Fossa

Identify the Bones & Foramina:

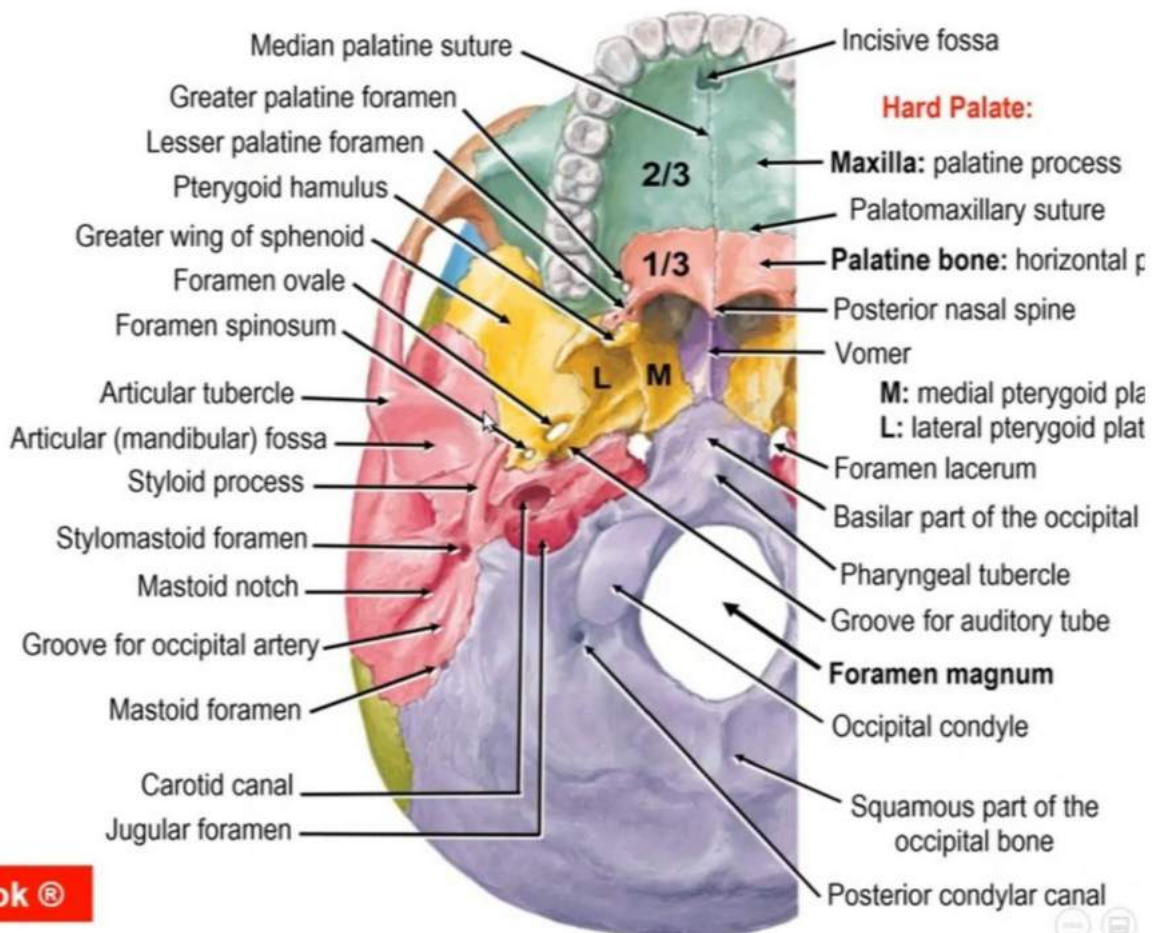
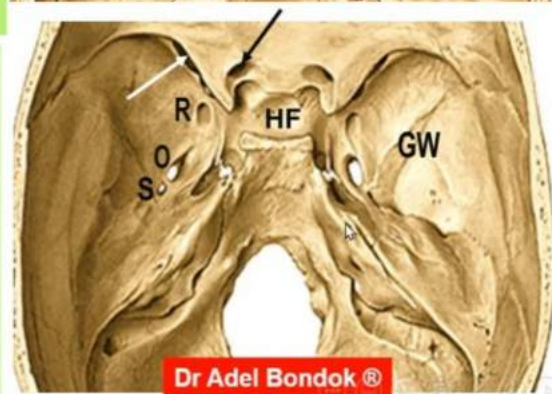1. Frontal crest, foramen cecum & crista galli
2. Cribriform plate of the ethmoid bone
3. Orbital plate of the frontal bone
4. Lesser wing of the sphenoid bone
5. Anterior & posterior ethmoidal canals



2. Middle Cranial Fossa

Identify the Bones & Foramina:

1. Sella turcica: hypophyseal fossa, tuberculum sellae & dorsum sellae.
2. Anterior & posterior clinoid processes
3. Optic canal & sulcus chiasmaticus
4. Greater wing of the sphenoid: contains 3 foramina:
Foramen rotundum, ovale & spinosum
5. Superior orbital fissure
6. Petrous temporal bone: trigeminal ganglion fossa, tegmen tympani, arcuate eminence; foramen lacerum



Anterior wall

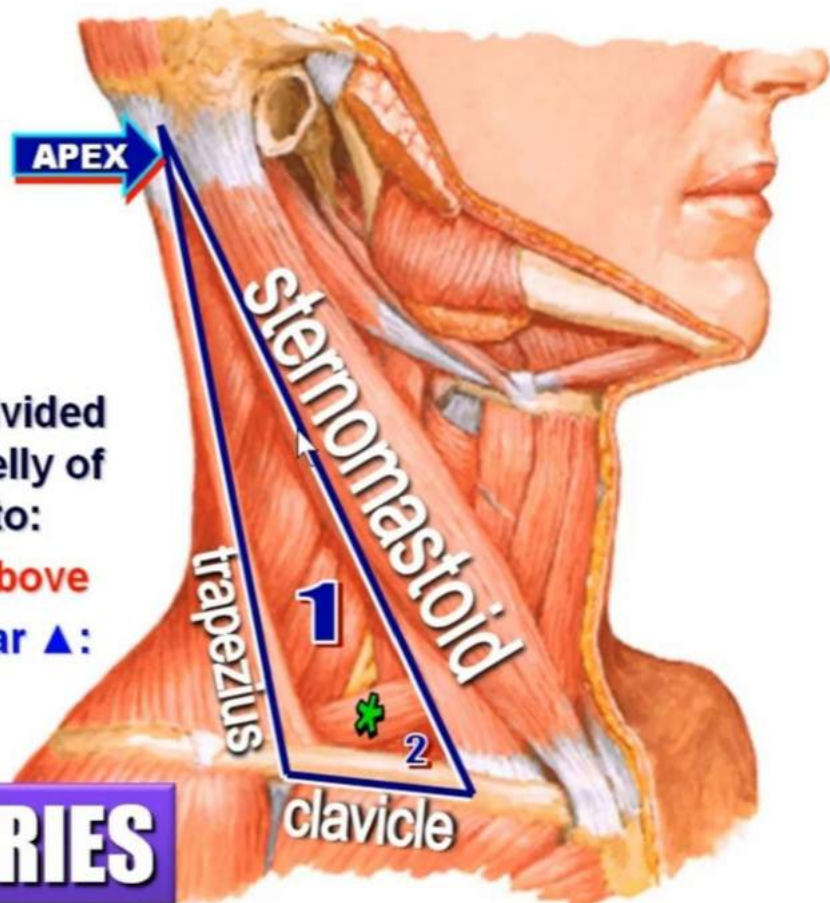
Posterior wall

Apex

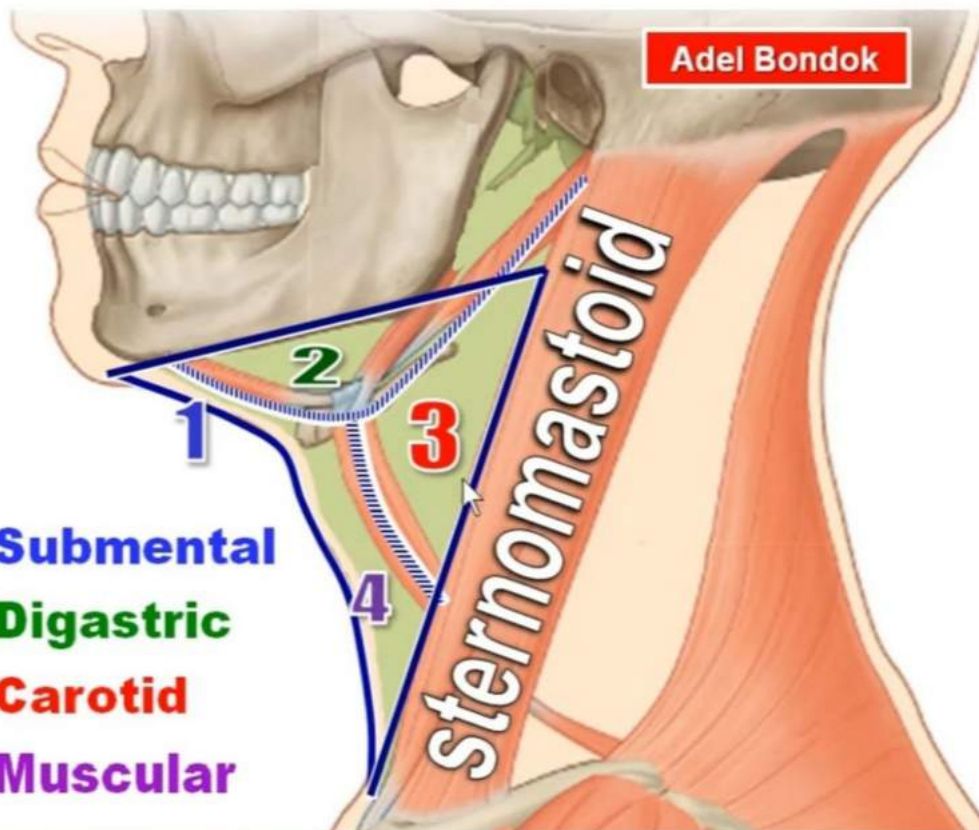
Base

The triangle is divided by the inferior belly of the omohyoid into:

1. Occipital ▲: above
2. Supraclavicular ▲: below



BOUNDARIES



1. Submental
2. Digastric
3. Carotid
4. Muscular

BOUNDARIES & DIVISIONS

ROOF

1. Skin

2. Superficial fascia: contains

a. external jugular vein

b. 4 cutaneous branches
of the cervical plexus

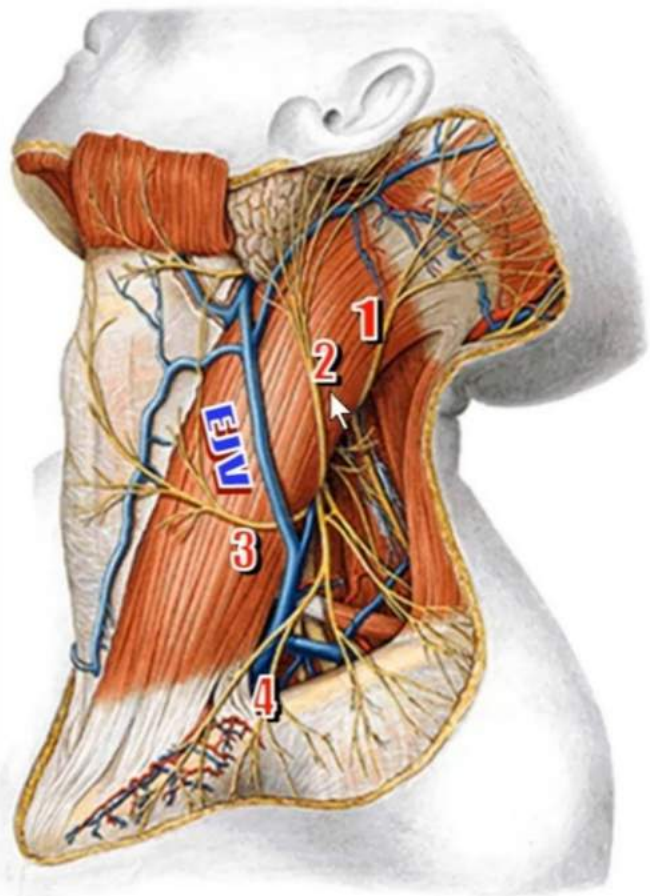
c. platysma

3. Deep fascia: investing layer of deep cervical fascia

pierced by:

a. branches of the cervical
plexus

b. external jugular vein

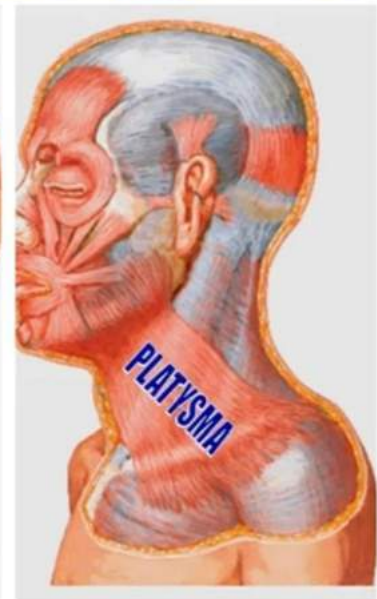
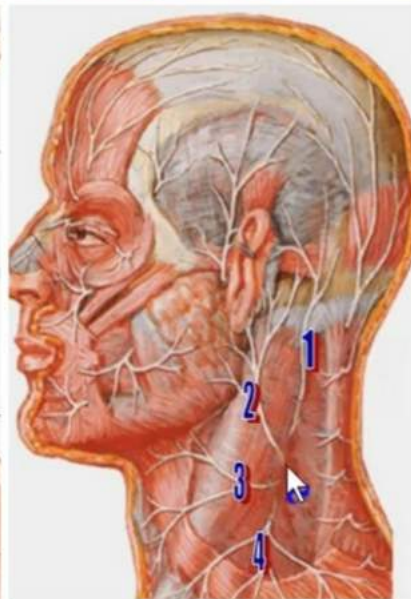
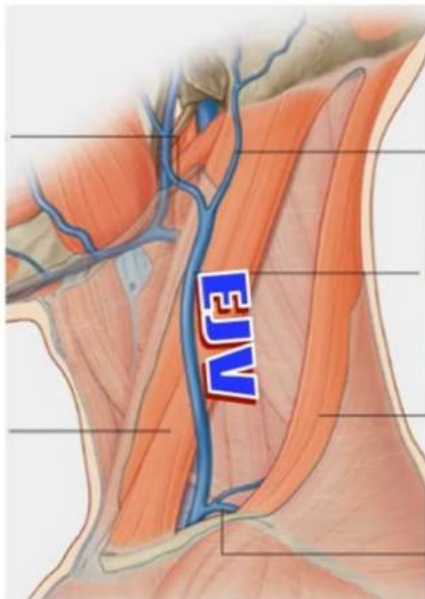

ROOF

1. Skin

2. Superficial fascia: containing external
jugular vein, 4 cutaneous branches of
the cervical plexus and platysma

3. Deep fascia: pierced by branches of the
cervical plexus and external jugular vein



CONTENTS OF POSTERIOR TRIANGLE

Blood Vessels:

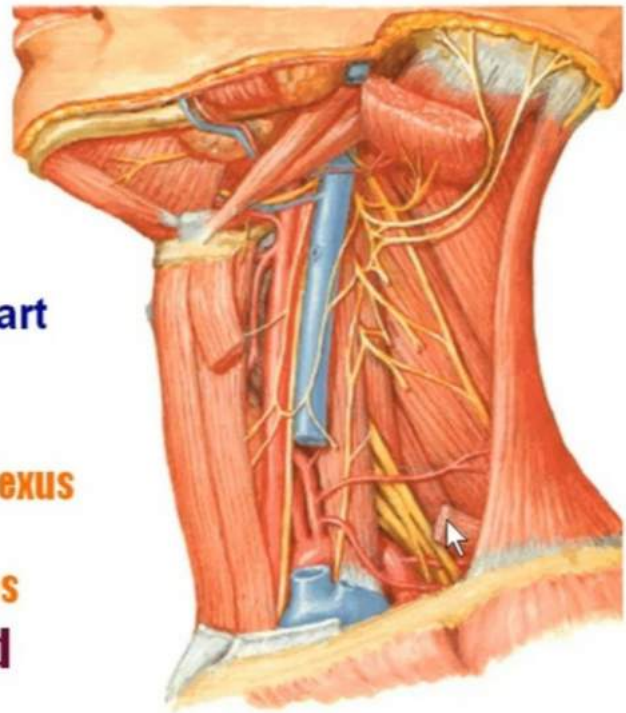
1. 3rd part of subclavian artery
2. Suprascapular artery
3. Transverse cervical artery
4. Occipital artery: at the apex
5. Subclavian vein
6. Ext Jugular Vein: terminal part

Nerves:

1. Spinal accessory nerve
2. Roots & Trunks of Brachial plexus
3. Cervical plexus
4. Dorsal rami of cervical nerves

Muscle: inf belly of omohyoid

Lymph Nodes



FLOOR

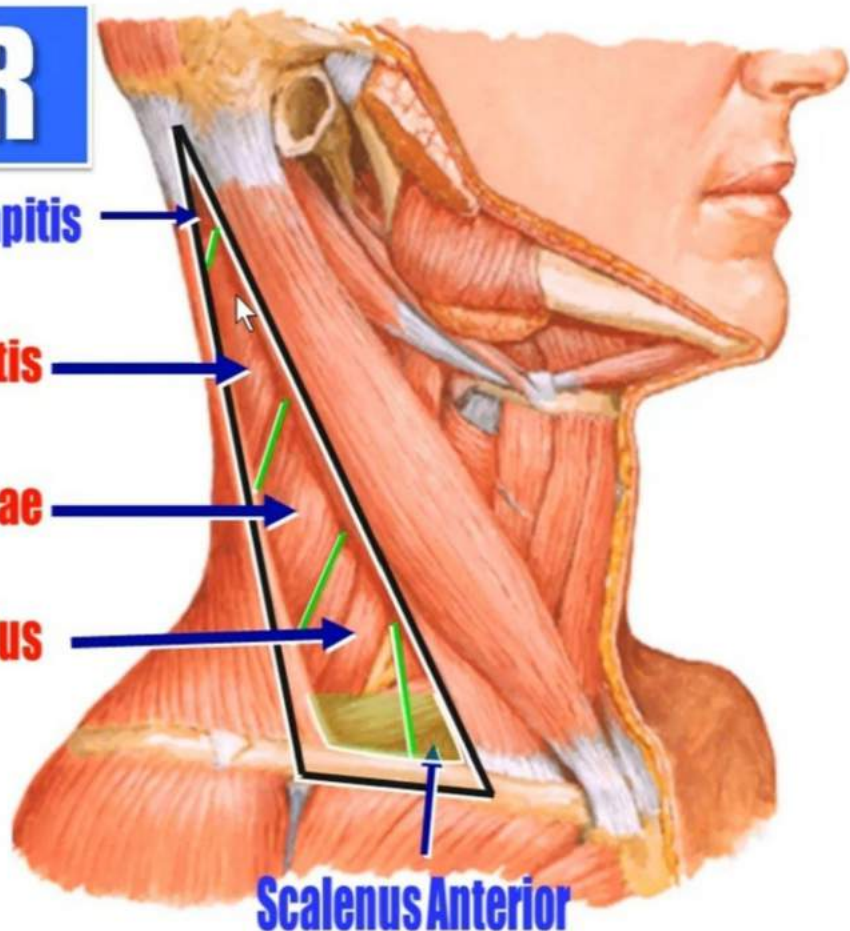
Semispinalis Capitis

Splenius Capitis

Levator Scapulae

Scalenus Medius

The muscles are covered by the prevertebral fascia

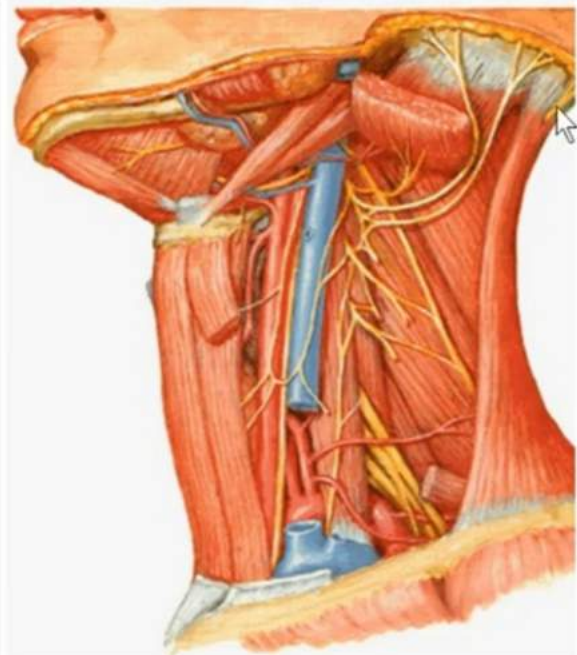

**Spinal
Accessory
Nerve
Supplies
2 Muscles**



NERVES IN POSTERIOR TRIANGLE

- 1. Spinal accessory nerve**
- 2. Roots & Trunks of Brachial plexus**
- 3. Cervical plexus**
- 4. Dorsal rami of cervical nerves:**
 - a. Greater occipital nerve
Dorsal ramus of C2
 - b. 3rd occipital nerve
Dorsal ramus of C3



Relation of the Posterior Belly

DEEP RELATION:

3 Big Vessels: lateral to medial

1. Internal Jugular Vein: lat
2. Internal Carotid Artery
3. External carotid Artery

3 Cranial Nerves: 10, 11, 12

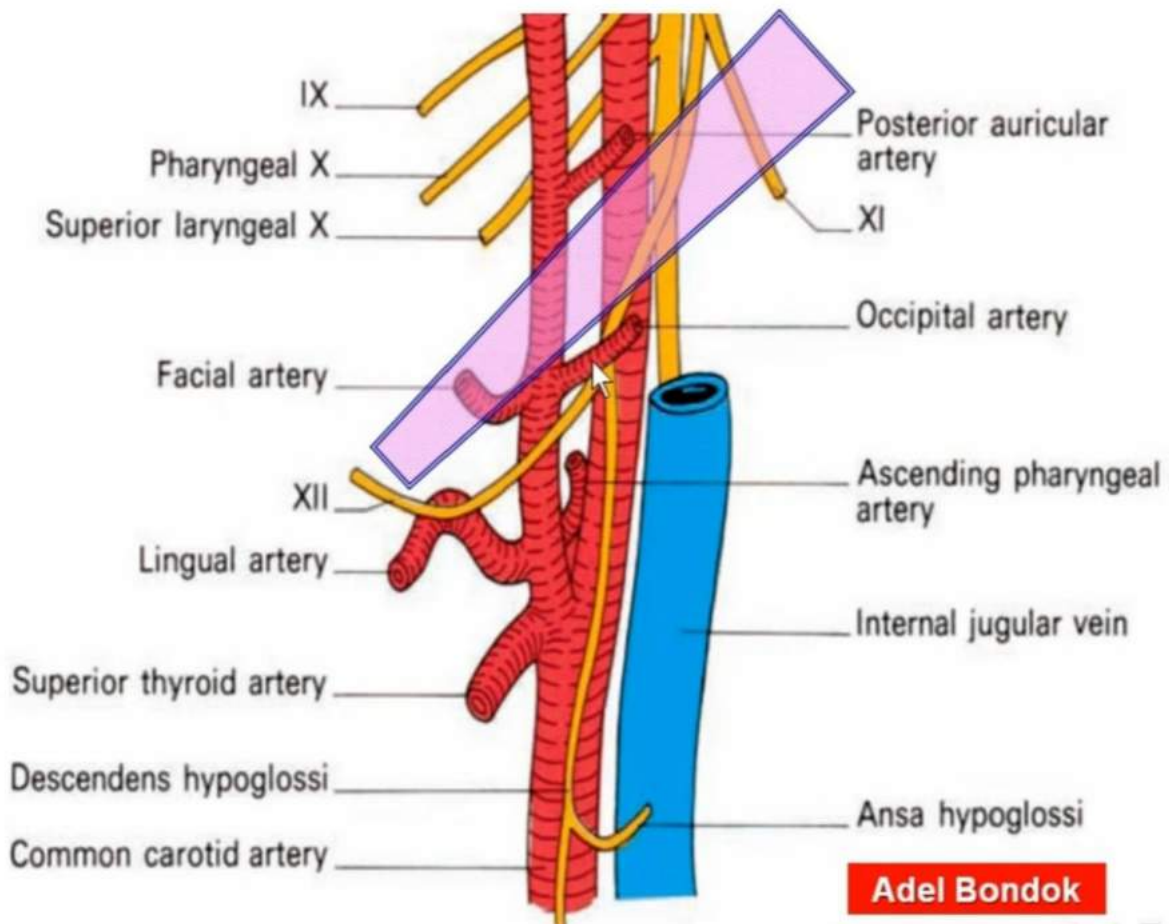
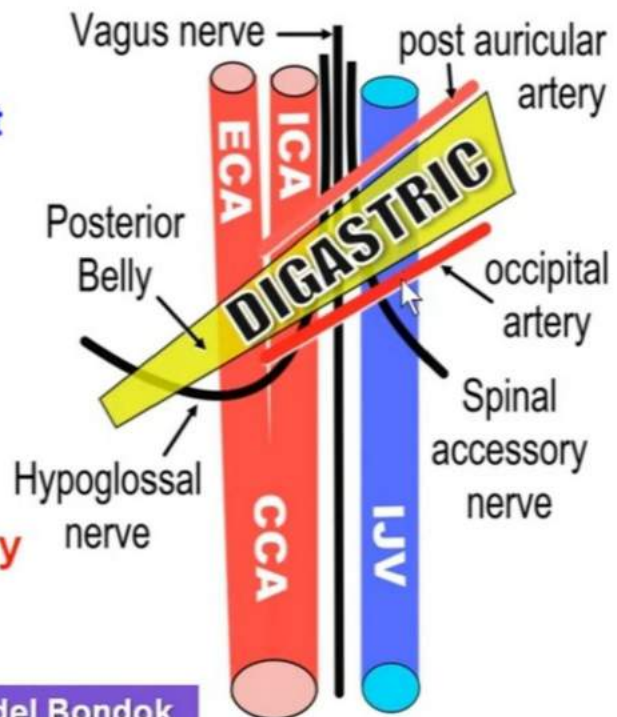
1. Vagus
2. Spinal accessory
3. Hypoglossal nerve

UPPER BORDER:

1. Posterior auricular artery
2. Stylohyoid muscle

LOWER BORDER:

Occipital artery



DIGASTRIC MUSCLE

ORIGIN:

- 1. Anterior belly:**
digastric fossa of the mandible
- 2. Posterior belly:**
mastoid notch

INSERTION:

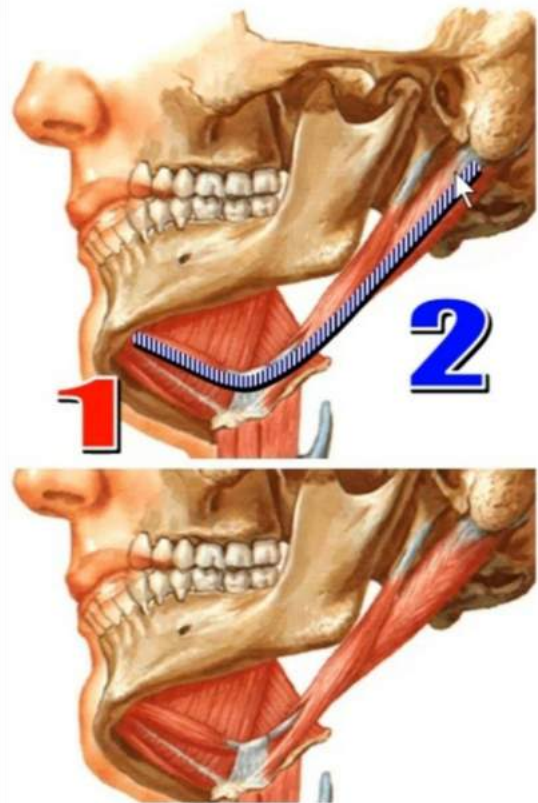
Intermediate tendon attached to the hyoid bone by fibrous loop

NERVE SUPPLY:

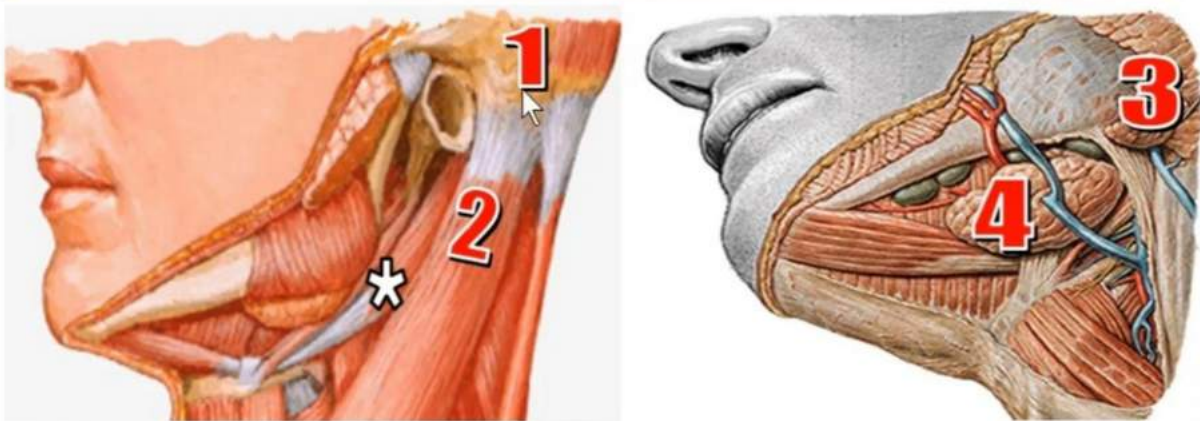- 1. Anterior belly:** nerve to mylohyoid
(developed from the 1st arch)
- 2. Posterior belly:** facial nerve
(developed from the 2nd arch)

ACTION:

- Anterior belly:** depress the mandible
Posterior belly: elevate the hyoid bone during swallowing



Relation of the Posterior Belly

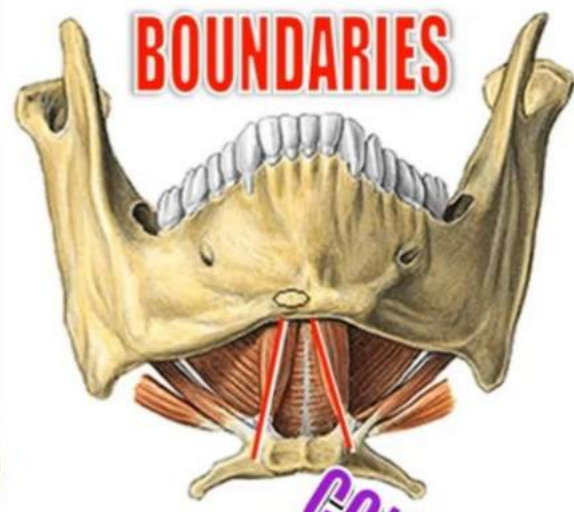
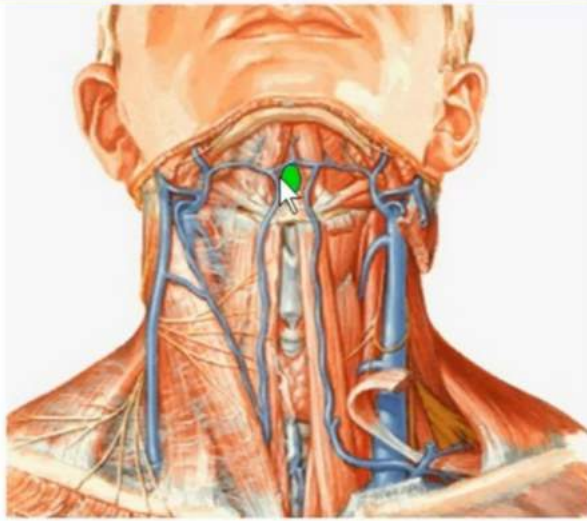


SUPERFICIAL RELATION

- 1. Mastoid process**
- 2. Sternomastoid**
- 3. Parotid gland**
- 4. Submandibular gland**

Adel Bondok

SUBMENTAL TRIANGLE

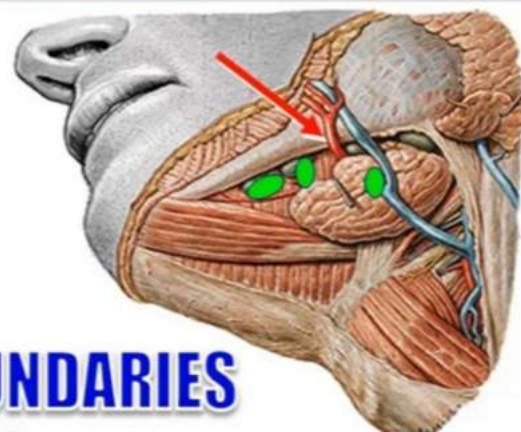
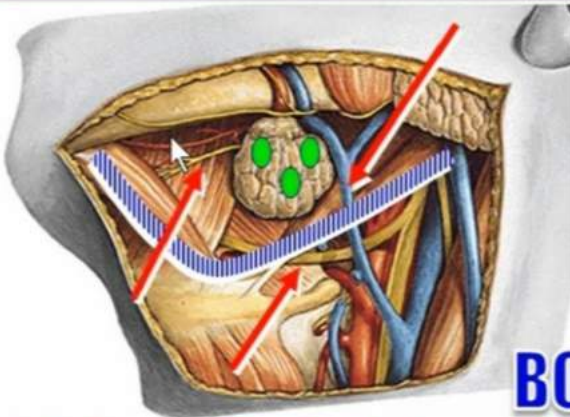


BOUNDARIES

CONTENTS

1. Submental lymph nodes
2. Submental artery: branch from the facial artery
3. Submental veins: form the anterior jugular vein → EJV

DIGASTRIC TRIANGLE



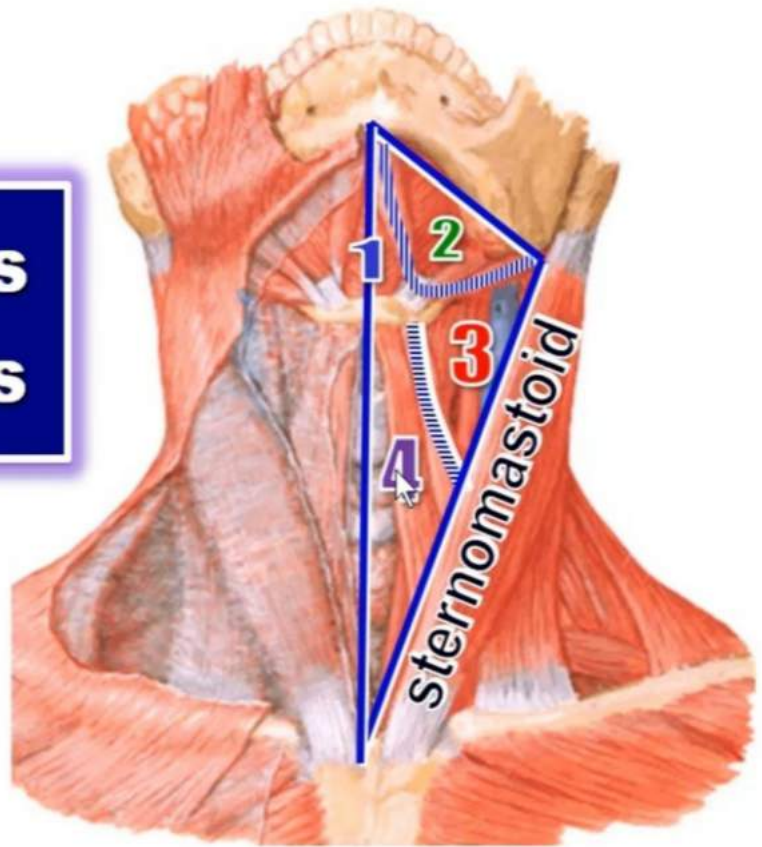
BOUNDARIES

CONTENTS

1. Submandibular Salivary Gland
2. Submandibular lymph nodes
3. Facial artery and its submental branch
4. Common facial vein
5. Hypoglossal nerve
6. Lingual Nerve
7. Nerve to mylohyoid: mylohyoid & ant belly of digastric

Boundaries & Divisions

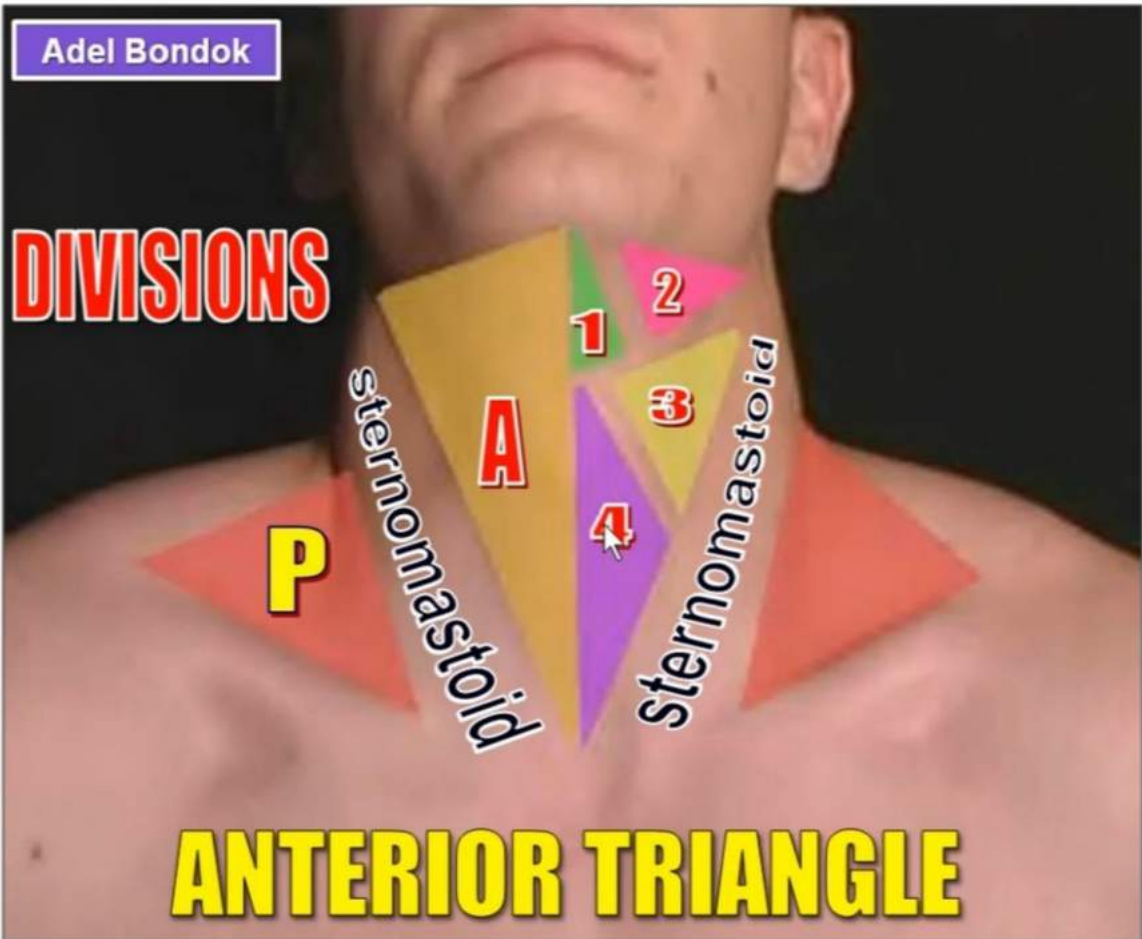
- 1. Submental
- 2. Digastric
- 3. Carotid
- 4. Muscular



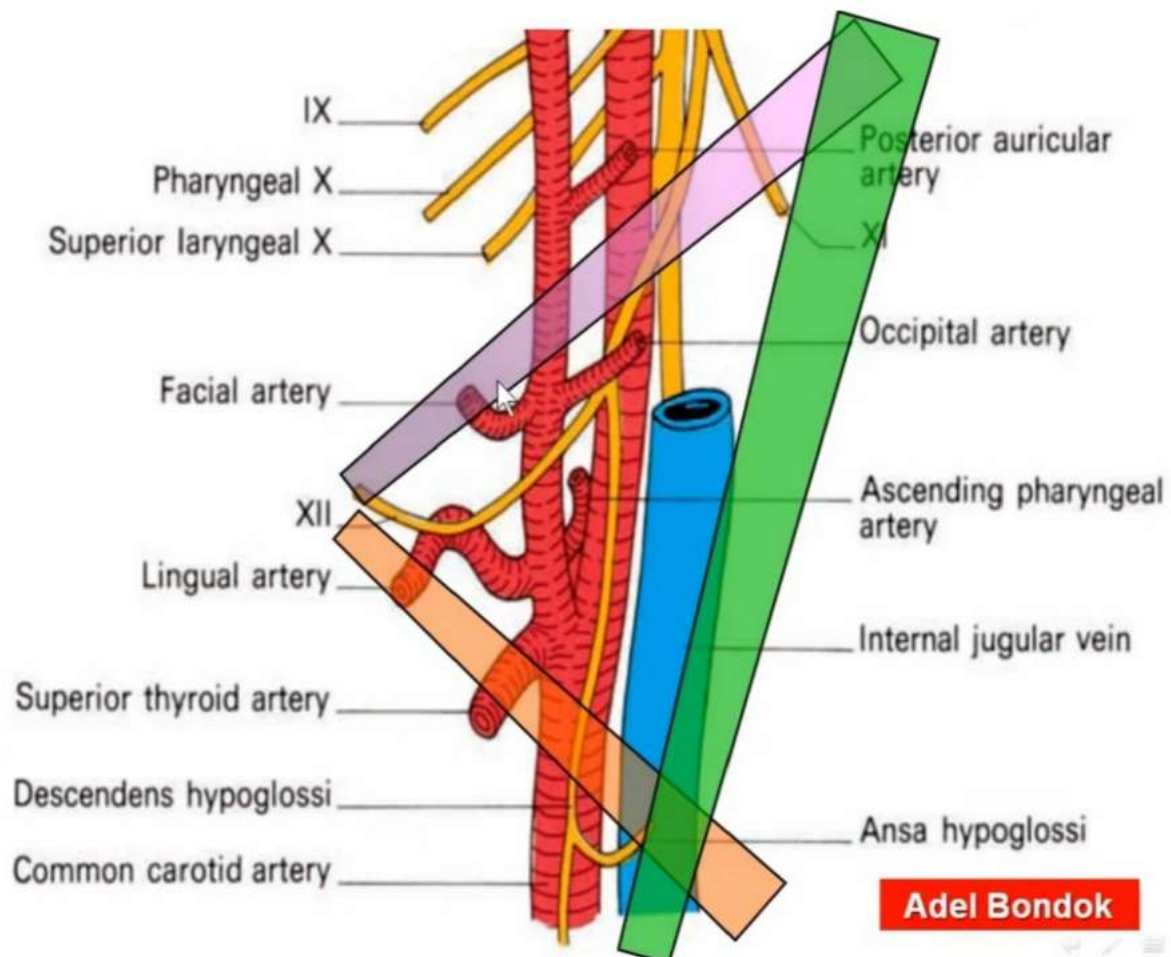
Adel Bondok

Adel Bondok

DIVISIONS



ANTERIOR TRIANGLE



MUSCULAR TRIANGLE

BOUNDARIES CONTENTS

1. 4 Infrahyoid muscles
2. Thyroid gland

4 INFRAHYOID MUSCLES:

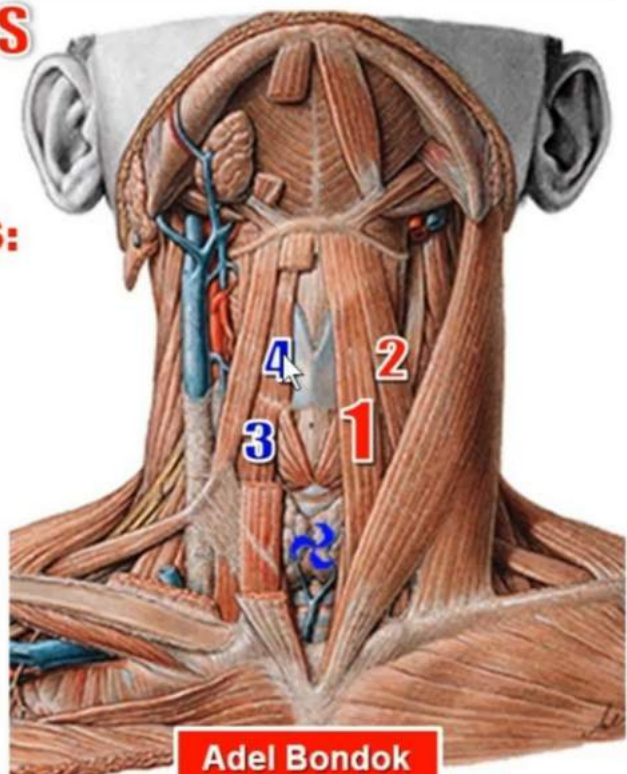
A. Superficial Layer: 2

1. Sternohyoid
2. Omohyoid

B. Deep Layer: 2

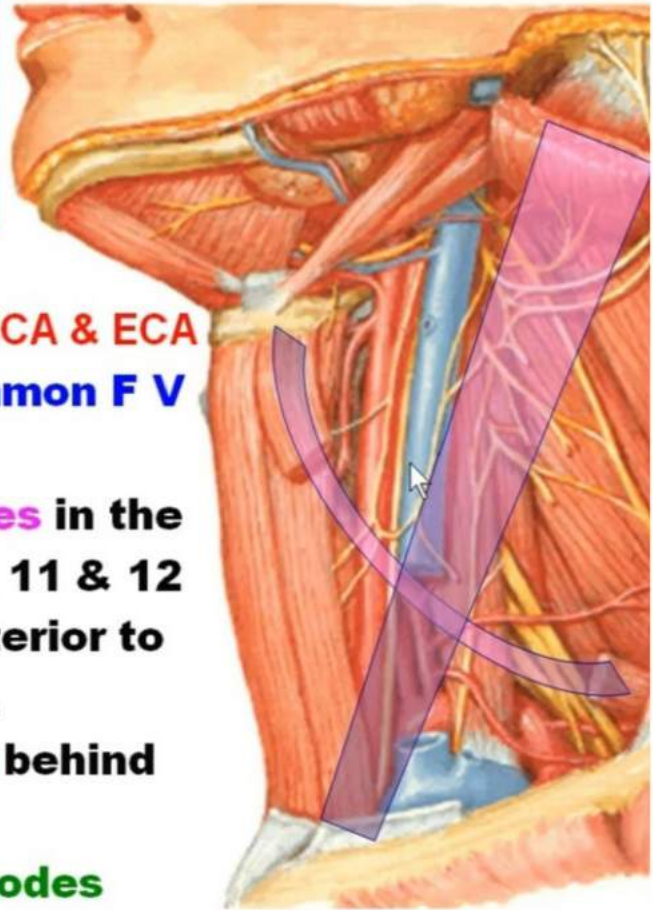
3. Sternothyroid
4. Thyrohyoid

Nerve Supply: all infrahyoid muscles by **ansa cervicalis** except thyrohyoid by **C1** through the **hypoglossal nerve**



CAROTID TRIANGLE

1. Carotid Sheath
2. Carotid arteries: CCA, ICA & ECA
3. Veins: Int Jug V + Common F V
4. Nerves:
 - a. Last 3 cranial nerves in the carotid sheath: 10, 11 & 12
 - b. Ansa cervicalis anterior to the carotid sheath.
 - c. Sympathetic chain behind the carotid sheath
5. Deep cervical lymph nodes



CAROTID SHEATH

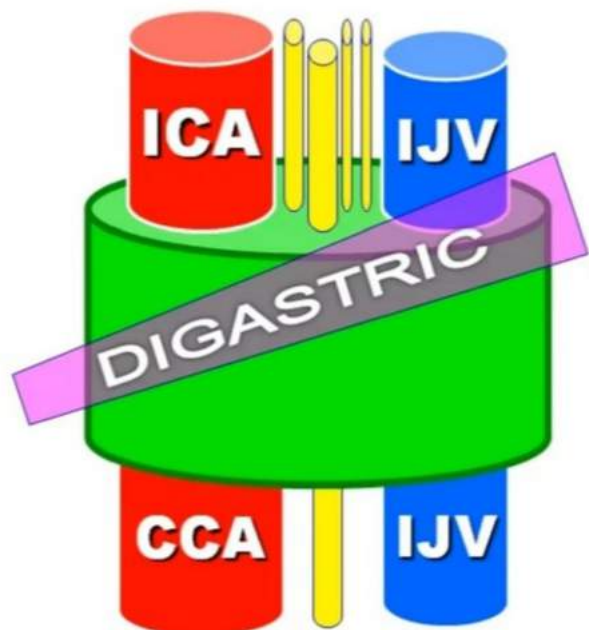
Above Digastric:

- Laterla: Internal Jugular vein
- Medial: Int carotid artery
- Middle: last 4 cranial nerves

Below Digastric:

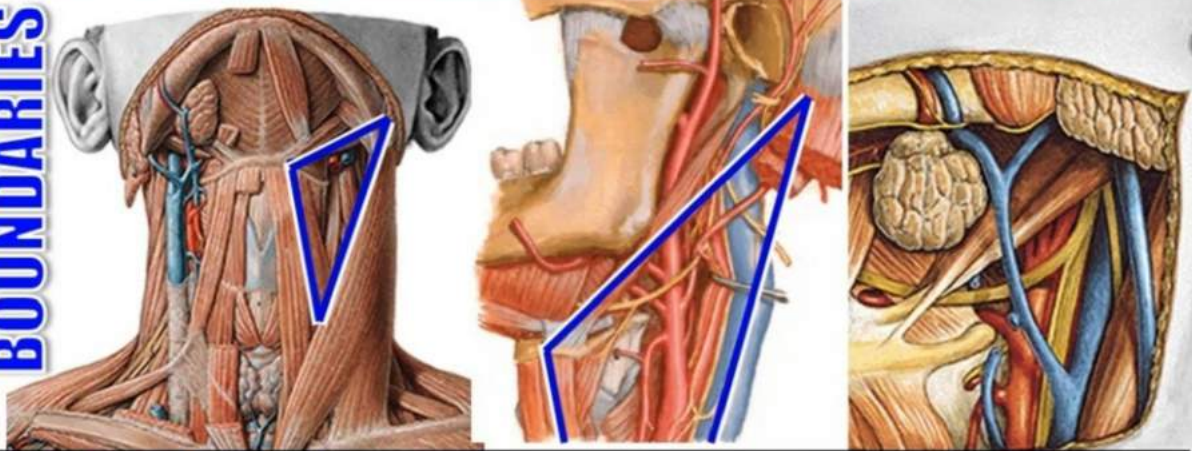
- Laterla: Internal Jugular vein
- Medial: Common carotid artery
- Middle: Vagus

CONTENTS



CAROTID TRIANGLE

BOUNDARIES

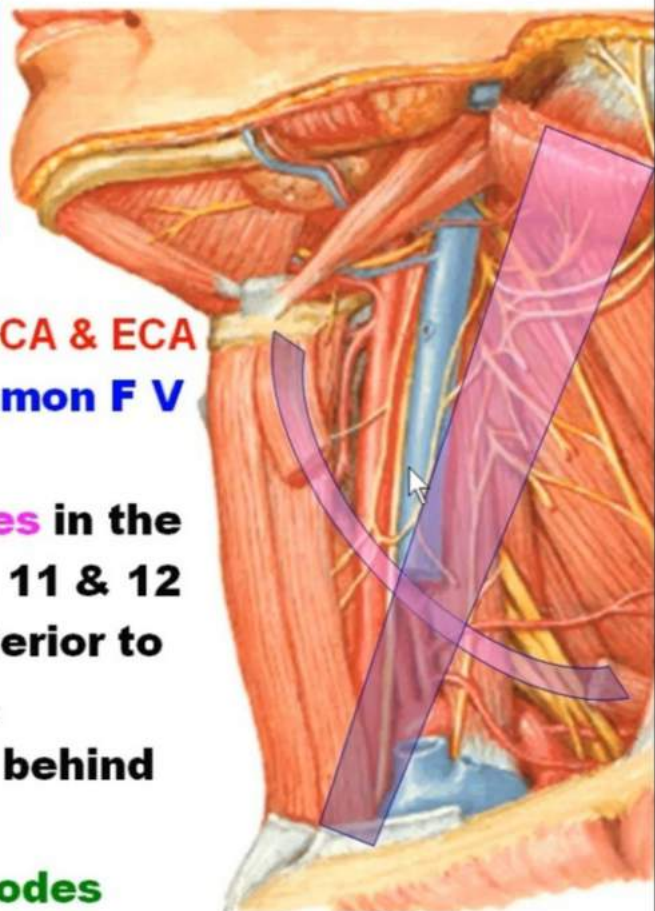


1. Carotid Sheath
2. Carotid arteries: CCA, ICA & ECA and its branches
3. Veins: Internal Jugular V + Common facial vein
4. Nerves:
 - a. Last 3 cranial nerves in the carotid sheath: 10, 11 & 12
 - b. Ansa cervicalis: anterior to the carotid sheath.
 - c. Sympathetic chain: behind the carotid sheath

CONTENTS

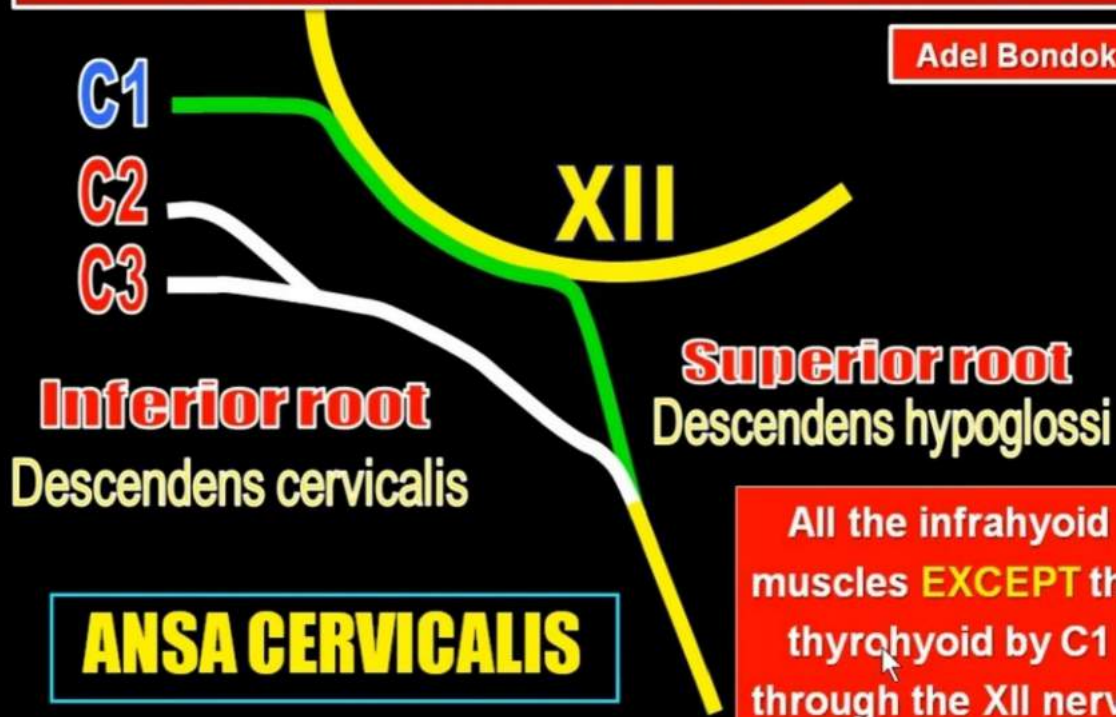
CAROTID TRIANGLE

1. Carotid Sheath
2. Carotid arteries: CCA, ICA & ECA
3. Veins: Int Jug V + Common F V
4. Nerves:
 - a. Last 3 cranial nerves in the carotid sheath: 10, 11 & 12
 - b. Ansa cervicalis anterior to the carotid sheath.
 - c. Sympathetic chain behind the carotid sheath
5. Deep cervical lymph nodes



ANSA CERVICALIS

Adel Bondok



ANSA CERVICALIS

Adel Bondok

Site: in front of the carotid sheath

Formation: C1, 2, 3

a Superior root (descendens hypoglossi):

C1 thru the hypoglossal nerve

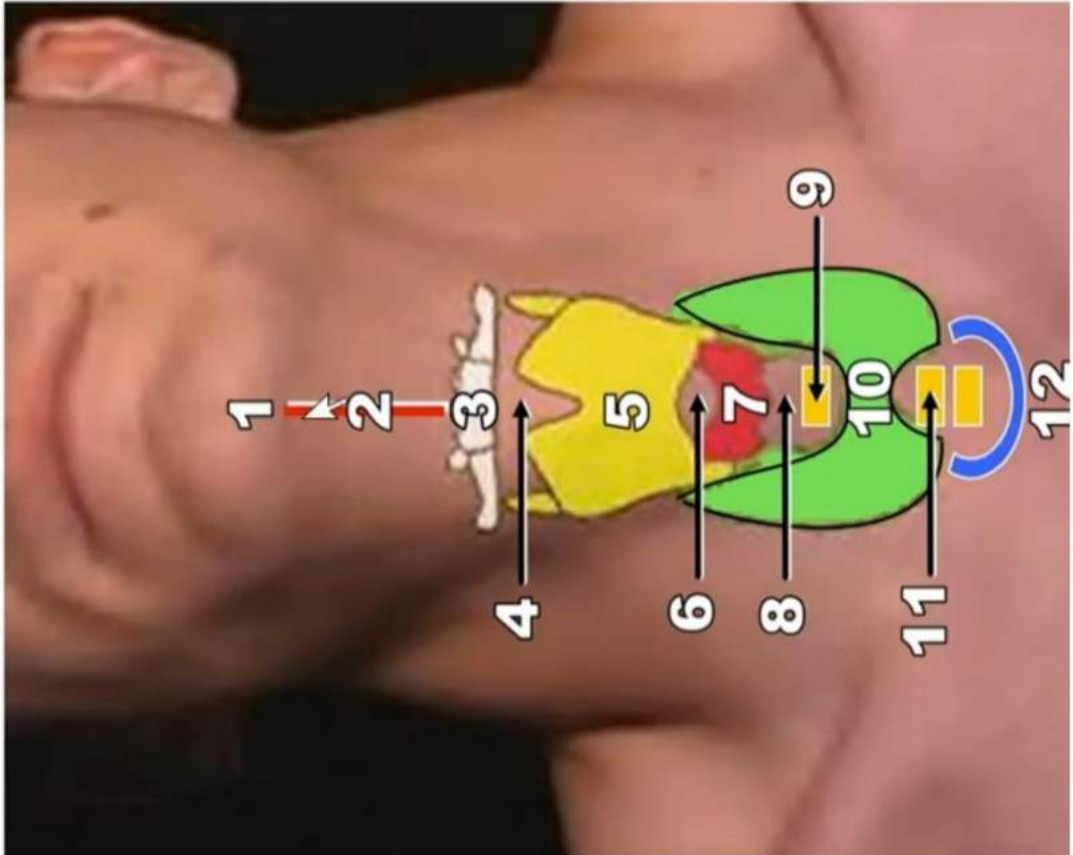
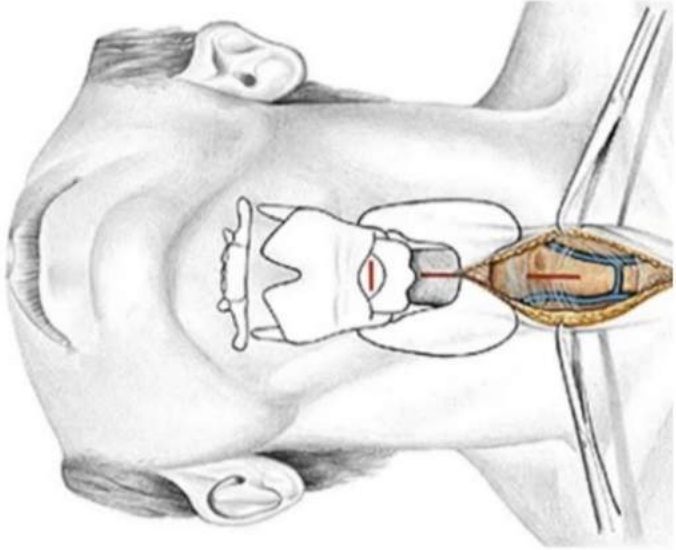
b. Inferior root (descendens cervicalis):

C2 & C3

Distribution:

TO: All the infrahyoid muscles **EXCEPT** the thyrohyoid by **C1** through the **XII** nerve

MIDLINE OF THE NECK



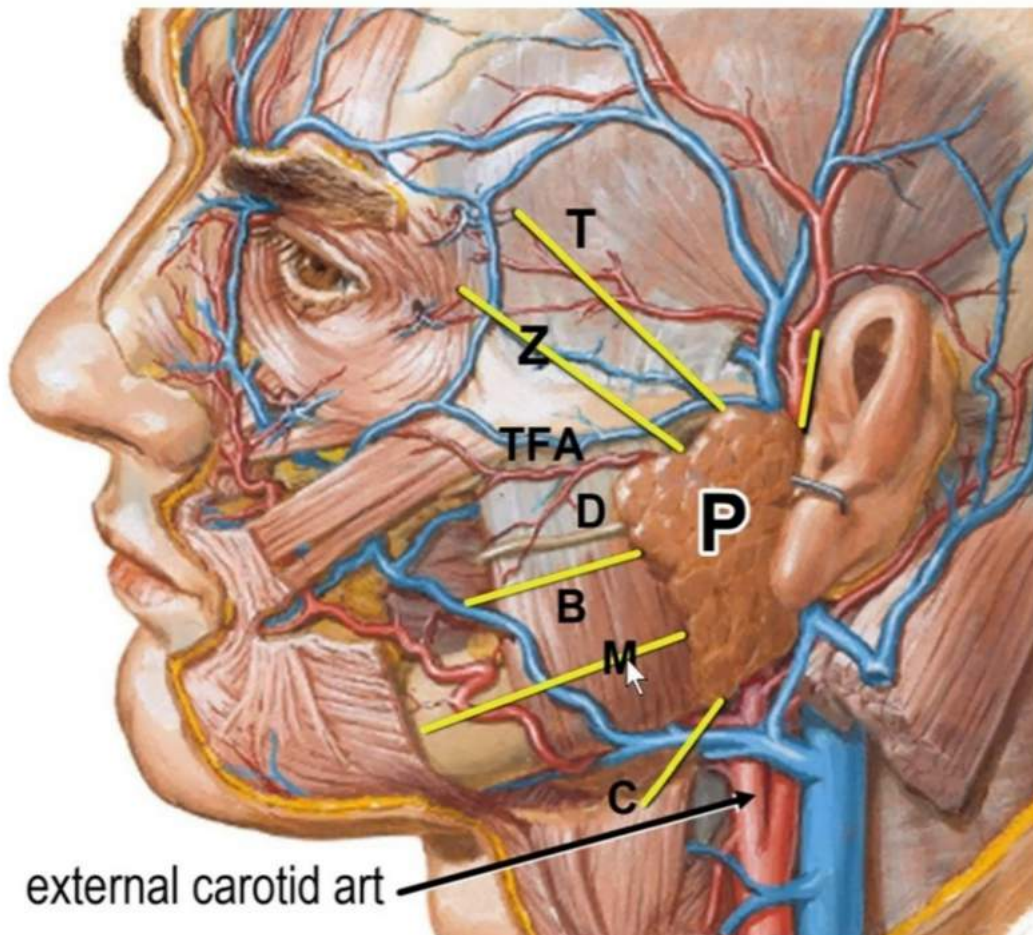
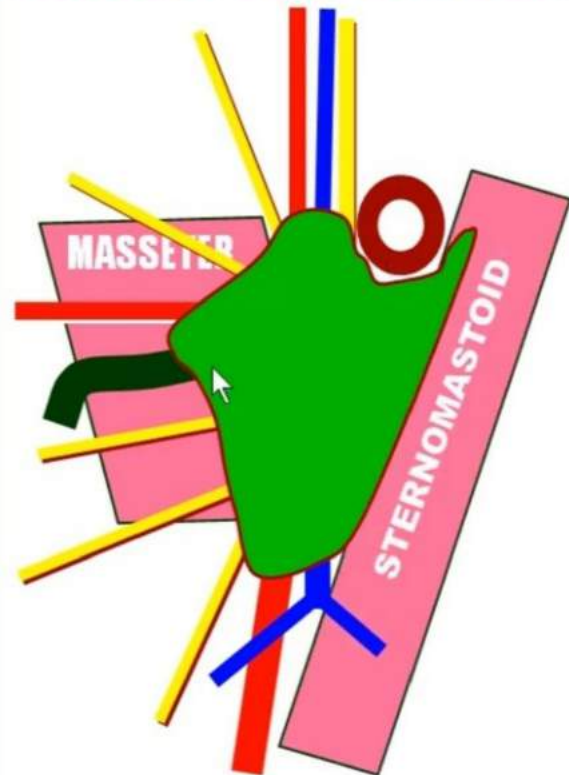
ANTERIOR BORDER

- Overlap the masseter muscle
 - Deep to the anterior border comes out **D, A & 3 nerves**:
1. **Parotid duct**
 2. **Transverse facial artery**
 3. **3 branches from the facial nerve: zygomatic, buccal and mandibular branches**

POSTERIOR BORDER

- Overlap the anterior border of the sternomastoid muscle

ANT & POST BORDER



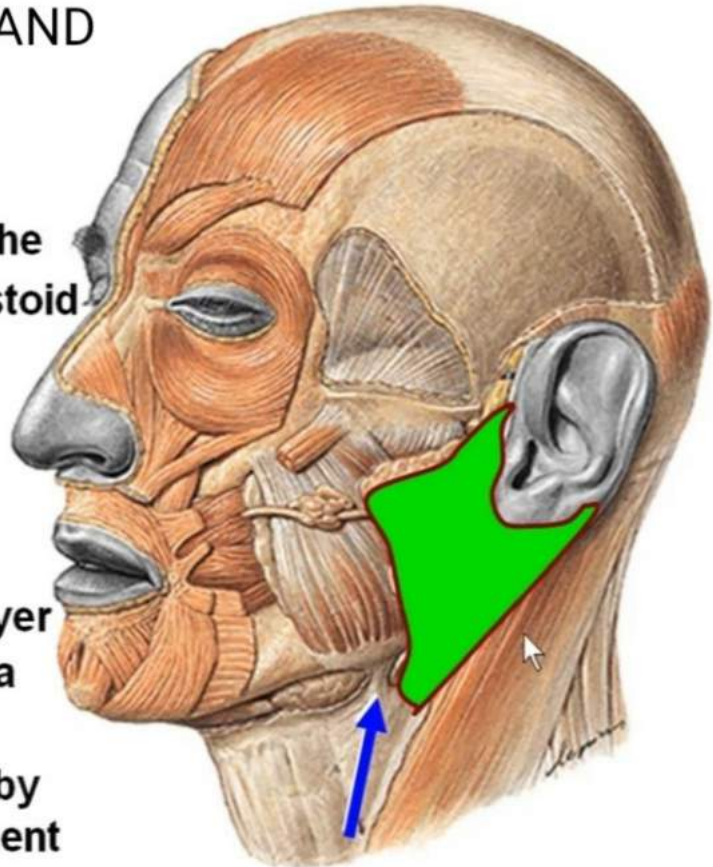
PAROTID GLAND

POSITION:

- ▶ **Between** the angle of the mandible & sternomastoid
- ▶ **Below** the external auditory meatus

CAPSULE:

- ▶ **From** the investing layer of deep cervical fascia
- ▶ **Is separated from** the submandibular gland by stylomandibular ligament



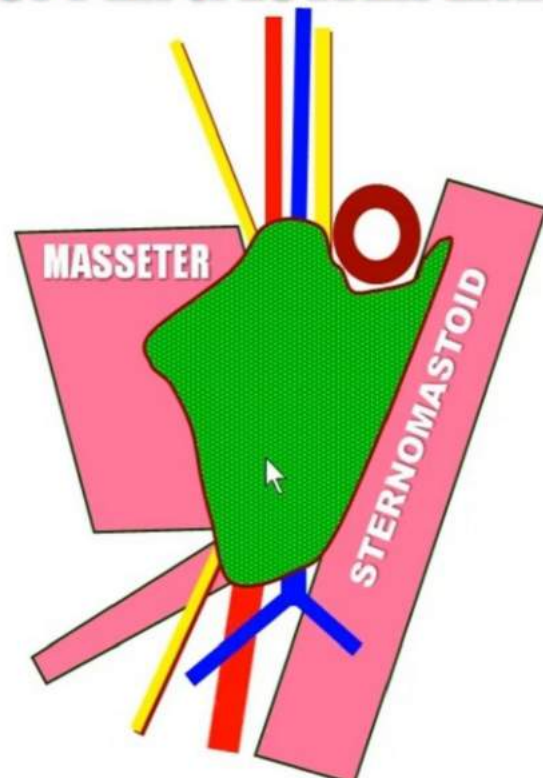
UPPER END:

- Surround the external auditory meatus
- From the upper end comes out **1 A, 1 V & 2 nerves:**
 1. **Superficial temp artery**
 2. **Superficial temporal vein**
 3. **Auriculotemporal nerve**
 4. **Temporal branch of VII nerve**

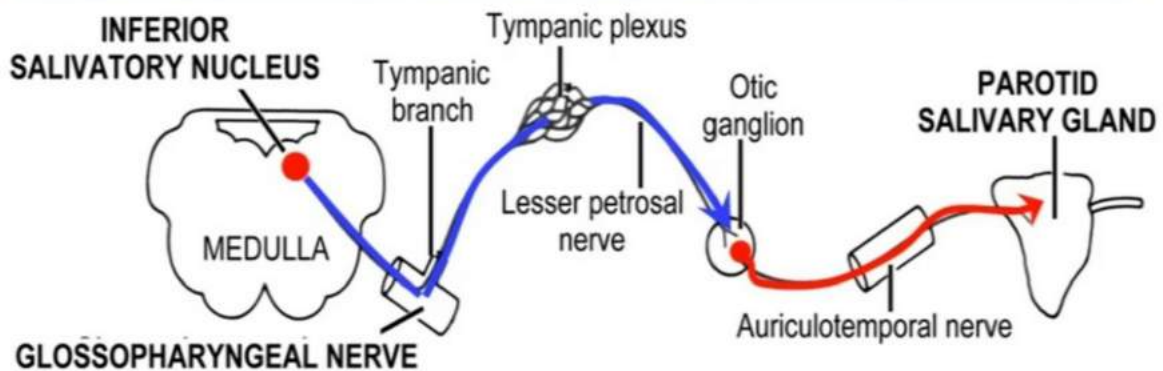
LOWER END:

- Overlap the posterior belly of the digastric
- Related to **N, V & Artery:**
 1. **Cervical branch of VII nerve**
 2. **Retromandibular v or its 2 br**
 3. **External carotid artery**

UPPER & LOWER END



NERVE SUPPLY



1. Sensory:

a. **Capsule:** great auricular nerve

b. **Parenchyma:** auriculotemporal nerve

2. **Parasympathetic:** glossopharyngeal n → lesser petrosal n
→ otic ganglion → reach the gland with the auriculotemporal n

3. **Sympathetic:** plexus around **external carotid artery**

PAROTID DUCT

Length: 5 cm

Begins at the anterior border

Course:

1. **Passes on** the masseter

2. **Pierces:**

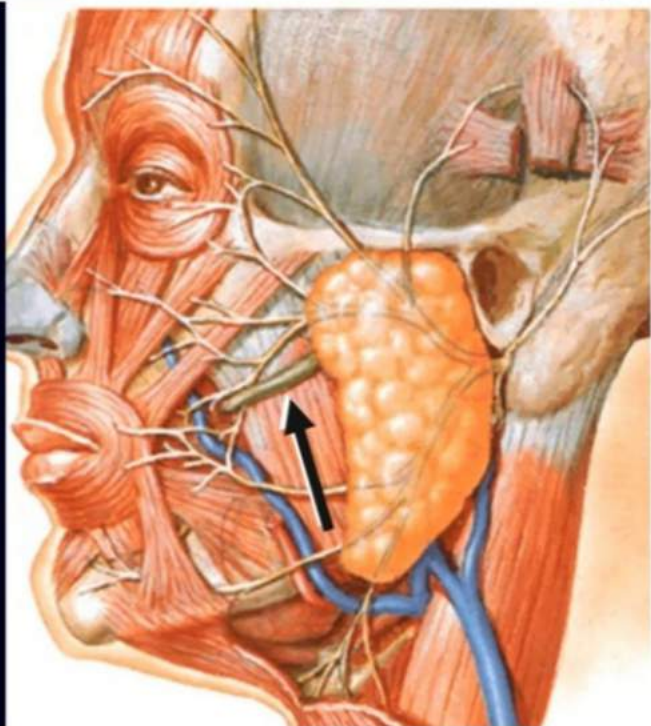
a. **Buccal pad of fat**

b. **Buccopharyngeal fascia**

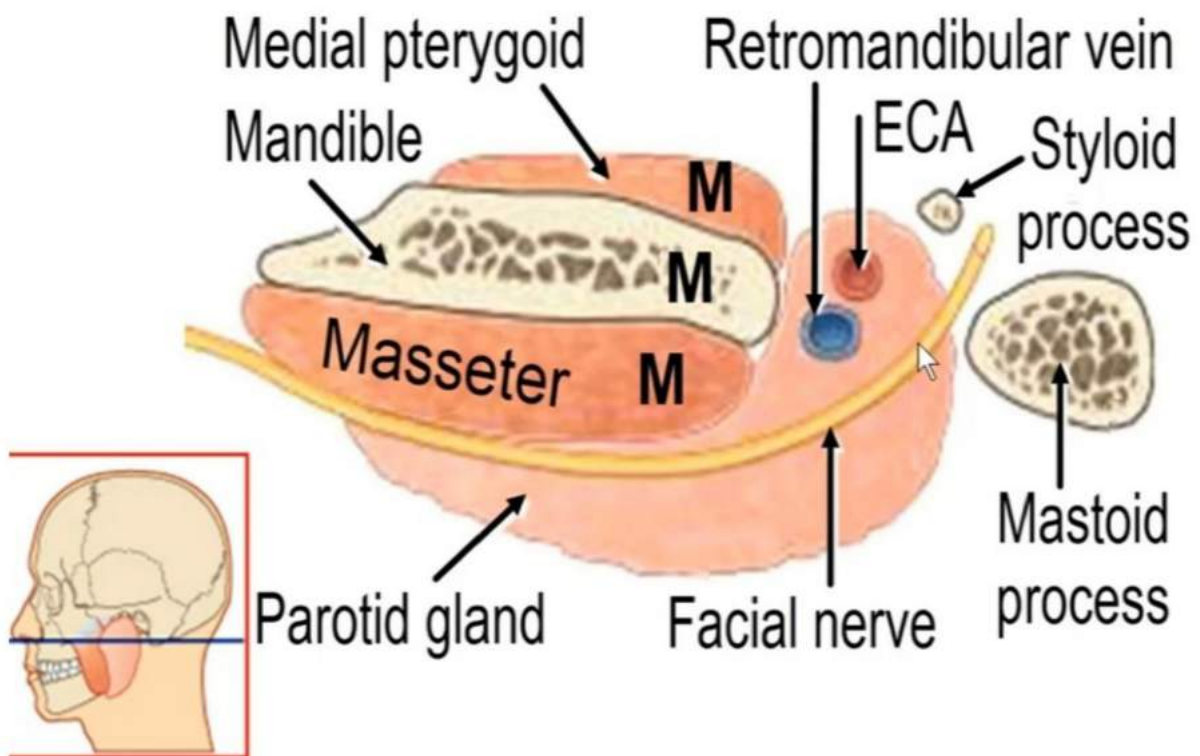
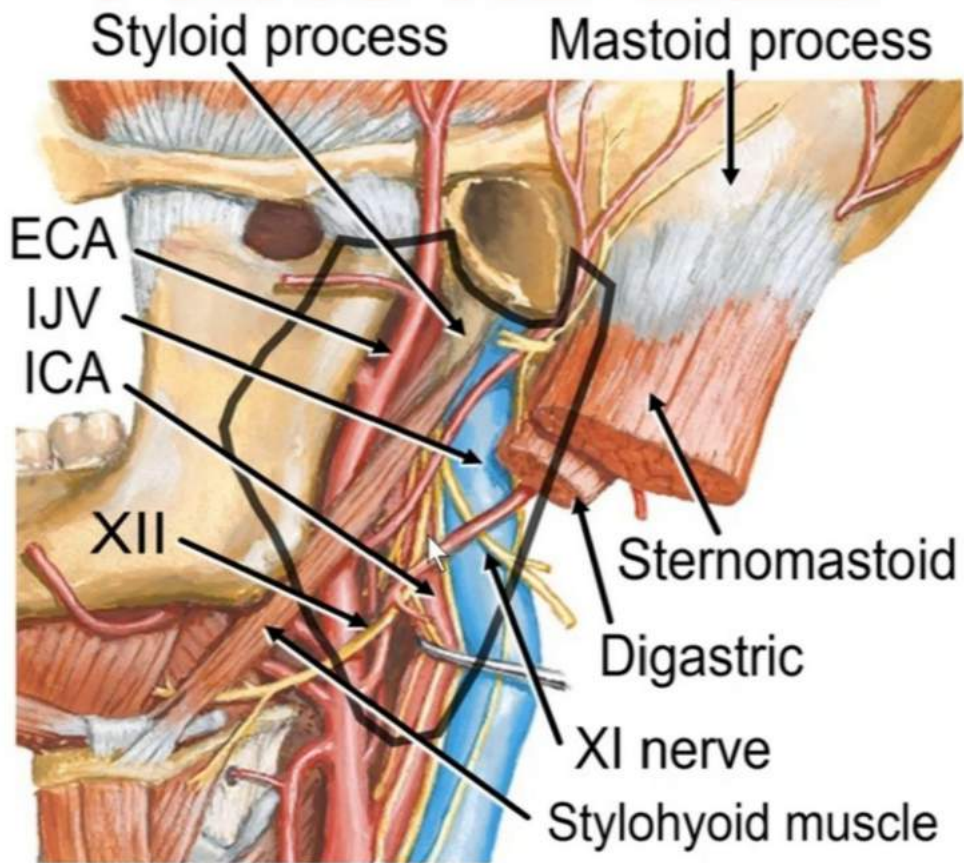
c. **Buccinator**

d. **Mucous membrane**

Termination: vestibule of the mouth opposite the upper 2nd molar tooth



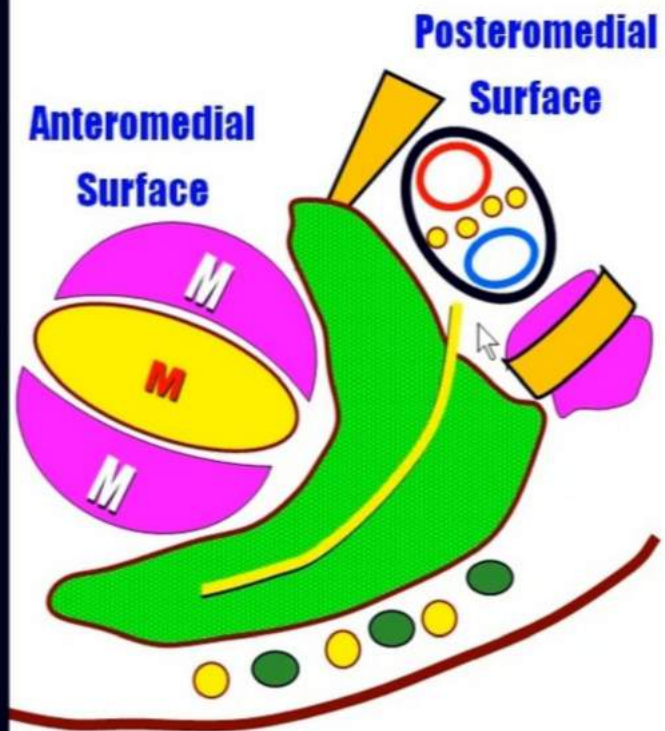
PAROTID BED



Posteromedial Surface (Parotid Bed)

- 1. Mastoid Process and structures attached to it:**
 - a. **Sternomastoid**
 - b. **Post belly of the digastric**
- 2. Styloid Process and structures attached to it:**

5 S: 3 muscles + 2 lig
- 3. Carotid Sheath and its contents: IJV, ICA & last 4 cranial nerves**
- 4. Pierced by the facial nerve**

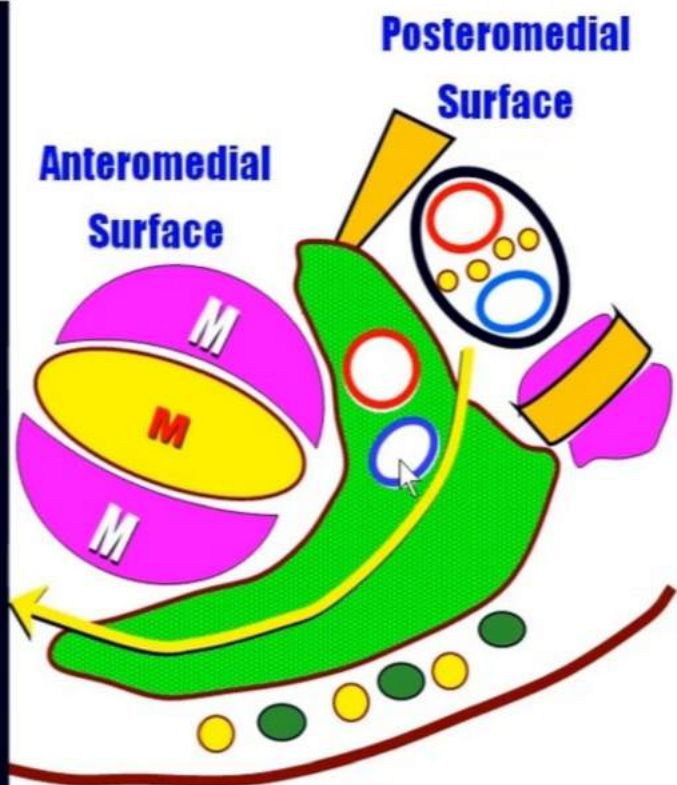


Structures Inside The Parotid Gland

- 1. Facial Nerve:** most superficial
- 2. Retromandibular vein:** in the middle
- 3. External Carotid Art:** the deepest

BLOOD SUPPLY

- 1. AS:** Ext carotid artery
- 2. VD:** retromandibular V



LATERAL SURFACE:

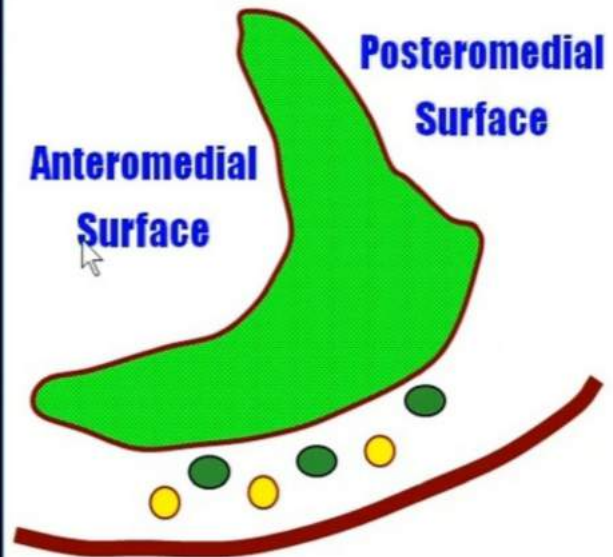
- Skin
- Superficial fascia containing:
 1. Branches of the great auricular nerve
 2. Parotid lymph nodes; preauricular L nodes

MEDIAL SURFACE:

1. Anteromedial Surface
2. Posteromedial Surface

SURFACES

MEDIAL SURFACE



LATERAL SURFACE

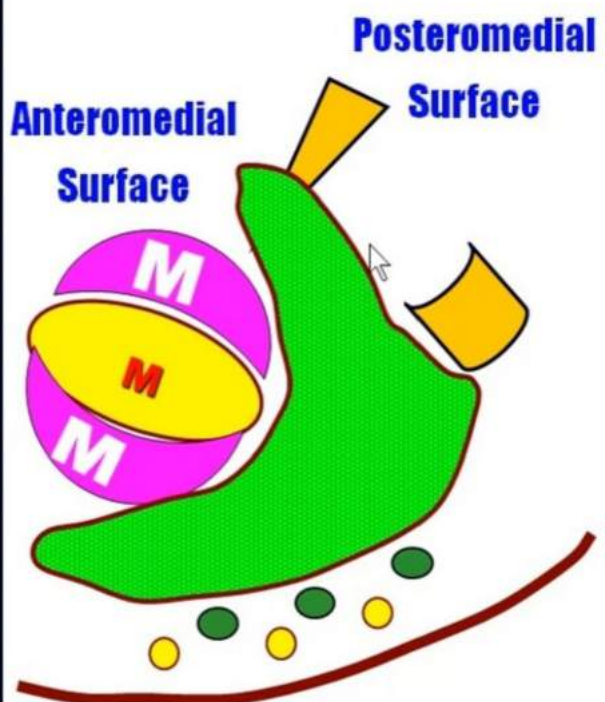
ANTEROMEDIAL SURFACE:

- Surround the angle of the mandible
- Related to 3M:
 1. Masseter muscle
 2. Mandible
 3. Medial pterygoid m

POSTEROMEDIAL SURFACE:

(Parotid Bed)

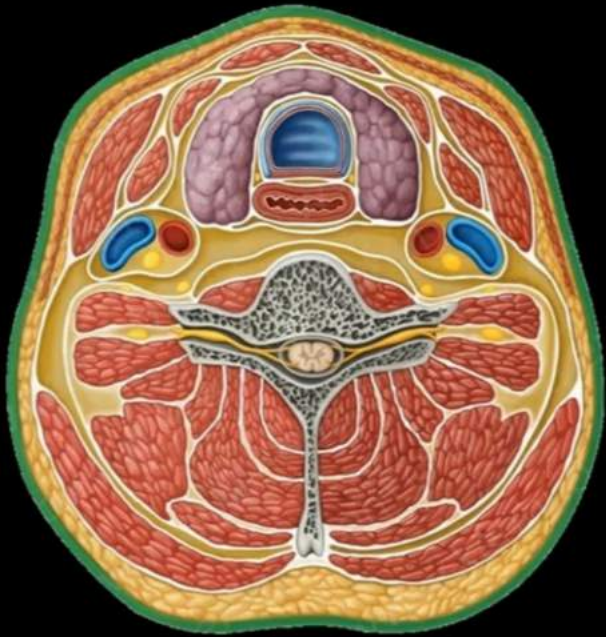
1. Mastoid Process
2. Styloid Process
3. Carotid Sheath



LATERAL SURFACE

SUBSCRIBE

Deep Cervical Fascia

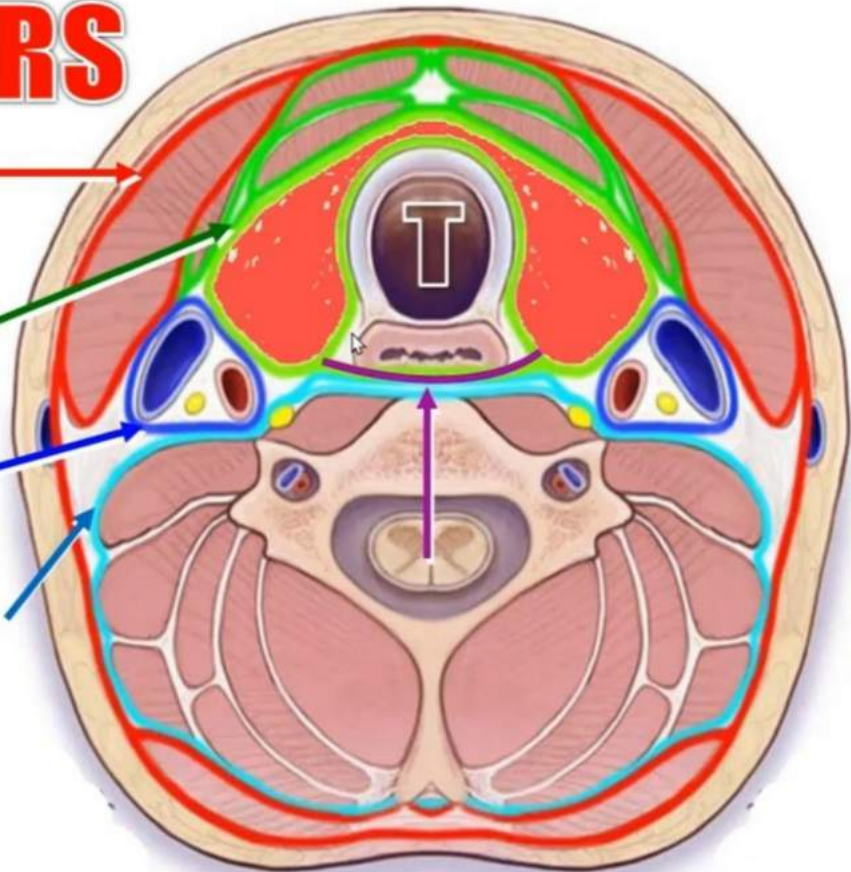


Dr. Adel Bondok

Mansoura University, Egypt

5 LAYERS

1. Investing Layer
2. Pretracheal Fascia
3. Carotid Sheath
4. Prevertebral Fascia
5. Pharyngeal Fascia



SUMMARY

■ **Investing Layer Forms:**

1. Parotid fascia: capsule of parotid gland
2. Capsule of submandibular gland
3. Stylomandibular ligament
3. Roof of the posterior & anterior triangle

■ **Pretracheal Fascia:**

1. Fix the thyroid gland to the trachea
2. Continuous with the fibrous pericardium
3. Surround the strap muscles "infrahyoid"

■ **Prevertebral Fascia Forms:**

1. Floor of the posterior triangle
2. Axillary sheath or axillary fascia

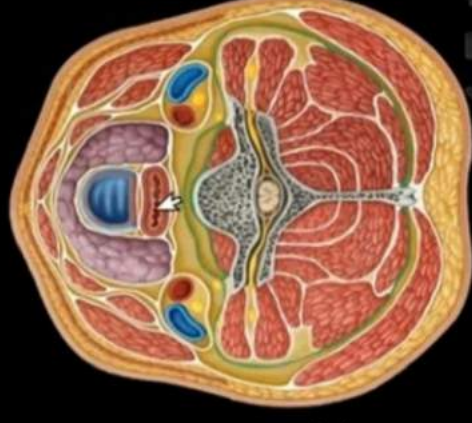
■ **Carotid Sheath Contains:**

1. Internal jugular vein: lateral
2. Common carotid artery medial to lower part
3. Internal carotid artery: medial to upper part
4. Last 4 cranial nerves

Buccopharyngeal Fascia: pierced by parotid duct

Phryngobasilar

Fascia: in the wall of the pharynx



CAROTID SHEATH

UPPER PART:

1. Lateral: **Internal Jugular vein**
2. Medial: **Int carotid artery**
3. Middle: **last 4 cranial nerves**

LOWER PART:

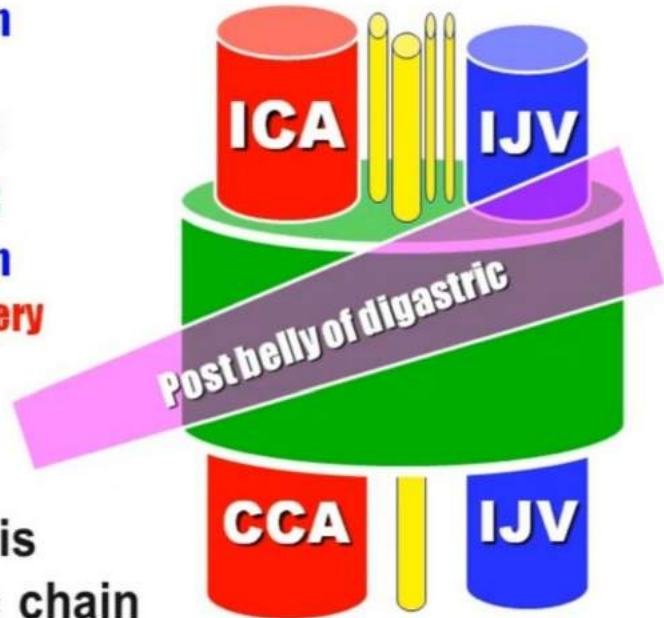
1. Lateral: **Internal Jugular vein**
2. Medial: **Common carotid artery**
3. Middle: **Vagus nerve**

Related to:

Anterior: ansa cervicalis

Posterior: Sympathetic chain

CONTENTS



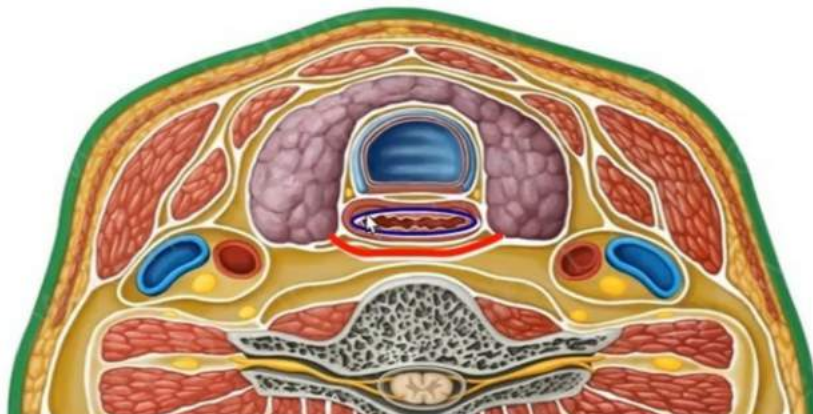
PHARYNGEAL FASCIA: 2

Buccopharyngeal Fascia:

- ☺ Cover the buccinator and the muscles of the pharynx
- ☺ Pierced by the parotid duct

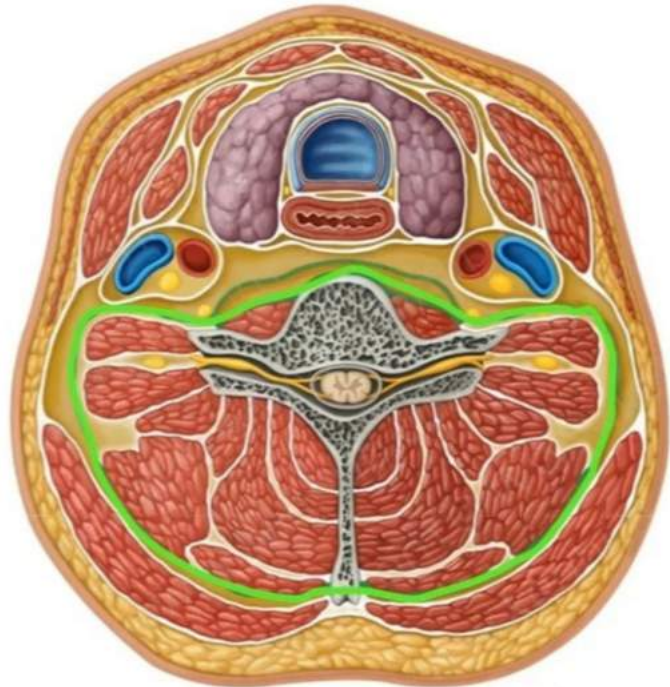
Pharyngo-basilar Fascia:

- ☺ In the wall of the pharynx between the mucous membrane and the muscles of the pharynx



PRETRVERTEBRAL LAYER

- ❑ Covers prevertebral muscles forming the floor of the post triangle
- ❑ Separated from the pharynx by the retropharyngeal space
- ❑ Continues in the axilla as the axillary fascia



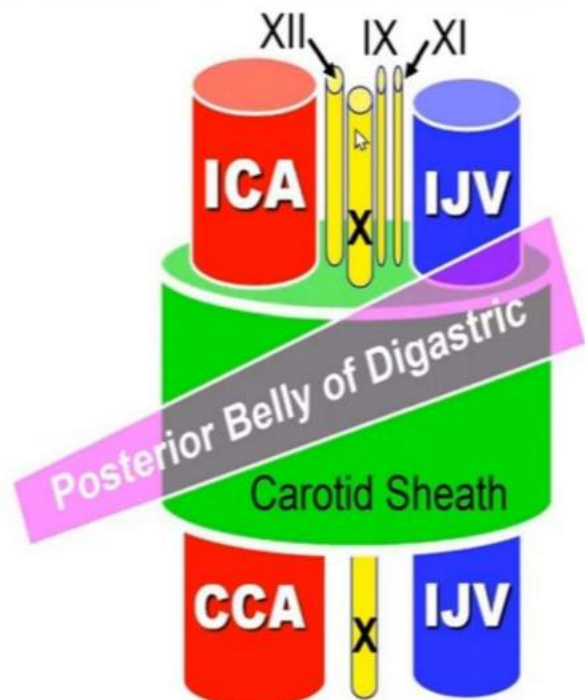
CAROTID SHEATH

It extends from From:

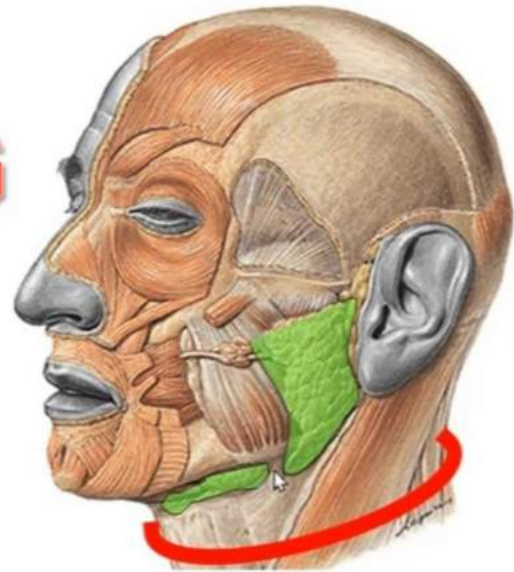
- a. Base of the skull
- b. To the arch of the aorta

CONTENTS:

1. **IJV: lateral**
2. **CCA: medial in the lower part**
3. **ICA: medial in the upper part**
4. **Last 4 cranial nerves in the middle**



INVESTING LAYER

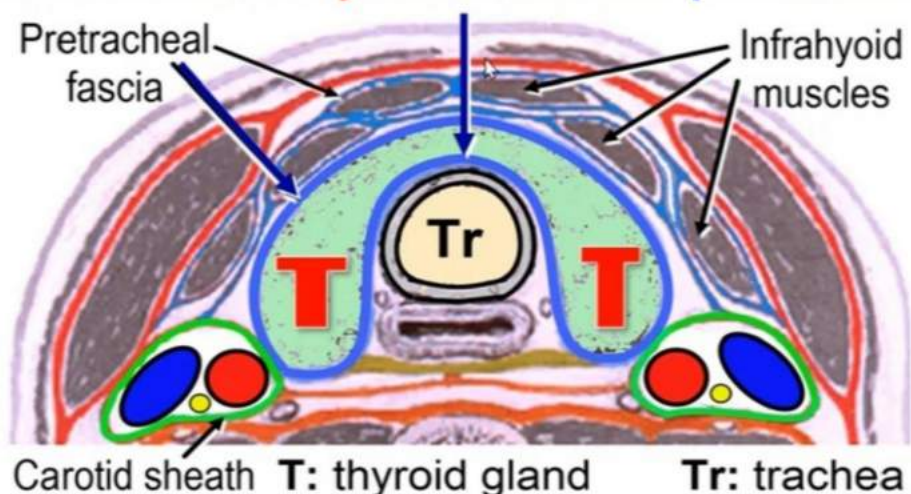


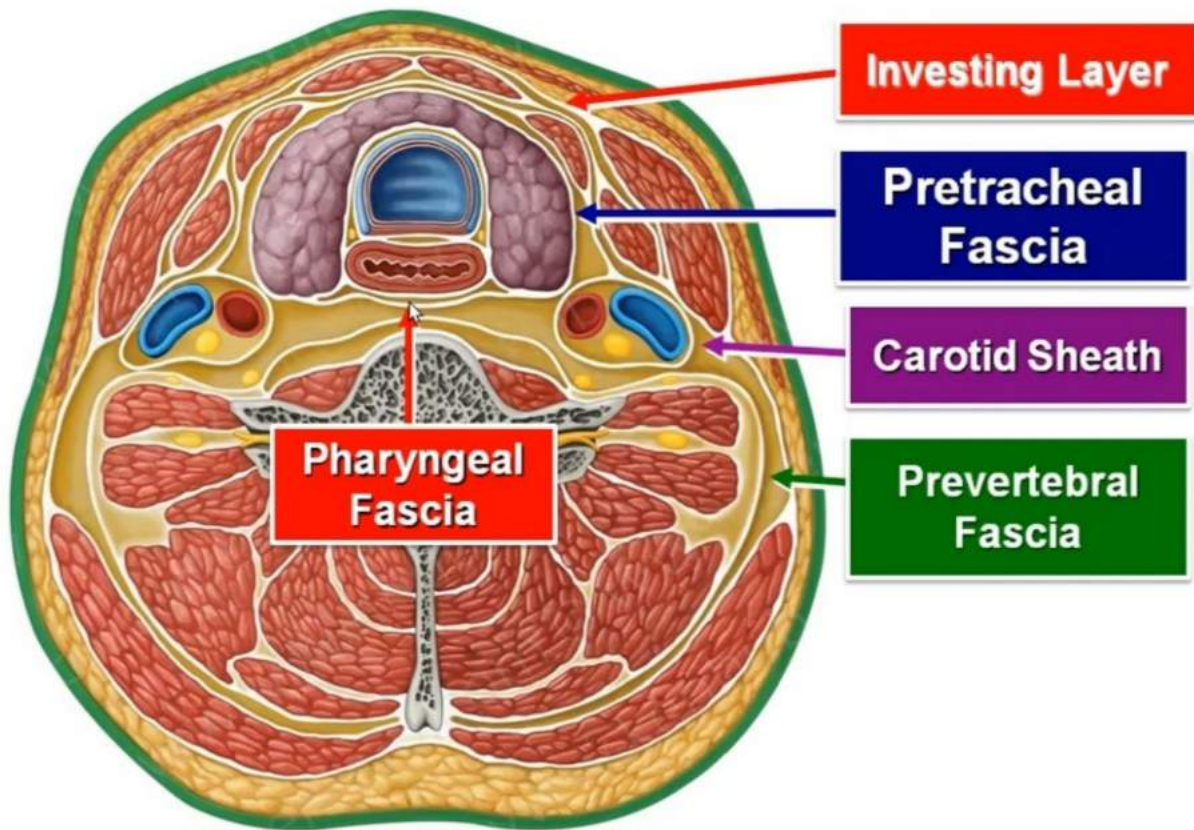
Therefore, it:

1. It surrounds the neck
2. Surrounds (**encloses**) the sternomastoid and trapezius.
3. Forms the **ROOF** of the anterior & posterior triangle.
4. Forms the **capsule** of the paroid gland.
5. Forms the **capsule** of the summandibular gland.
6. Forms the stylomandibular **ligament**.

PRETRACHEAL LAYER

- Covers** the front and sides of the trachea
- Surrounds** the thyroid gland **forming its capsule**.
- Surrounds** the infrahyoid muscles
- Continues inferiorly with the fibrous pericardium**

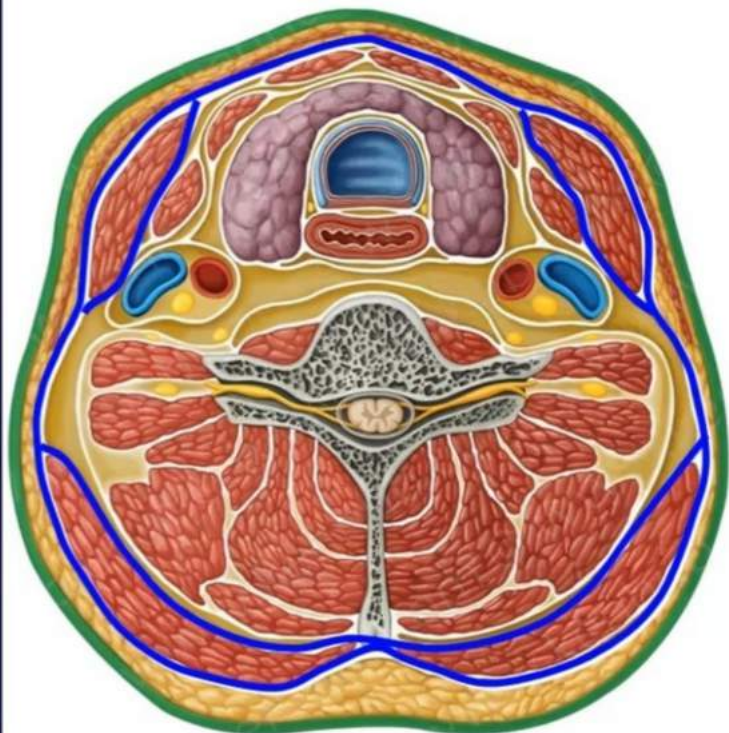




5 LAYERS

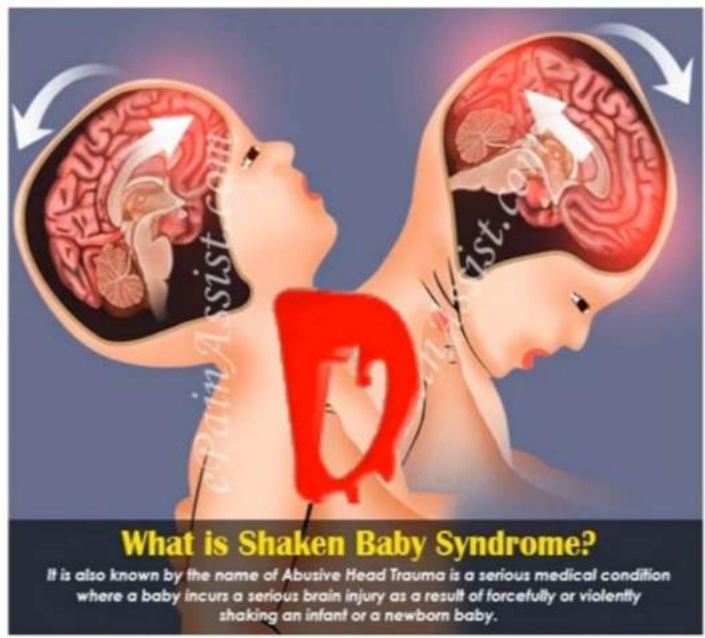
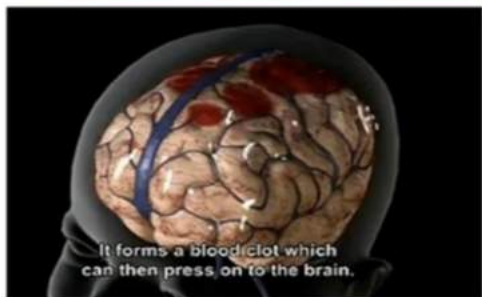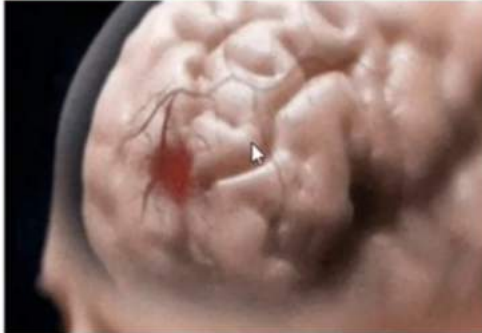INVESTING LAYER

- Surrounds the neck
- Splits to enclose the sternomastoid & trapezius
- Forms the roof of the anterior & post triangle
- Splits to enclose the parotid gland forming its capsule
- Splits to enclose the submandibular gland forming its capsule
- Thickened between the 2 glands to form the stylomandibular lig



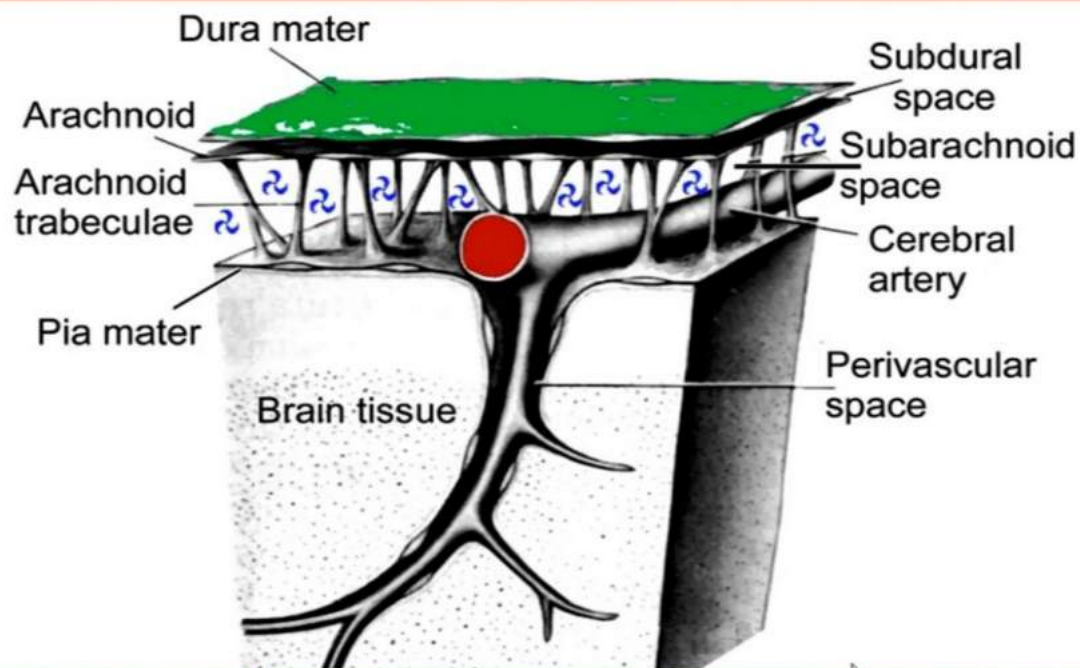
Shaken Baby Syndrome

Never Ever Shake a Baby



SUBDURAL HEMORRHAGE

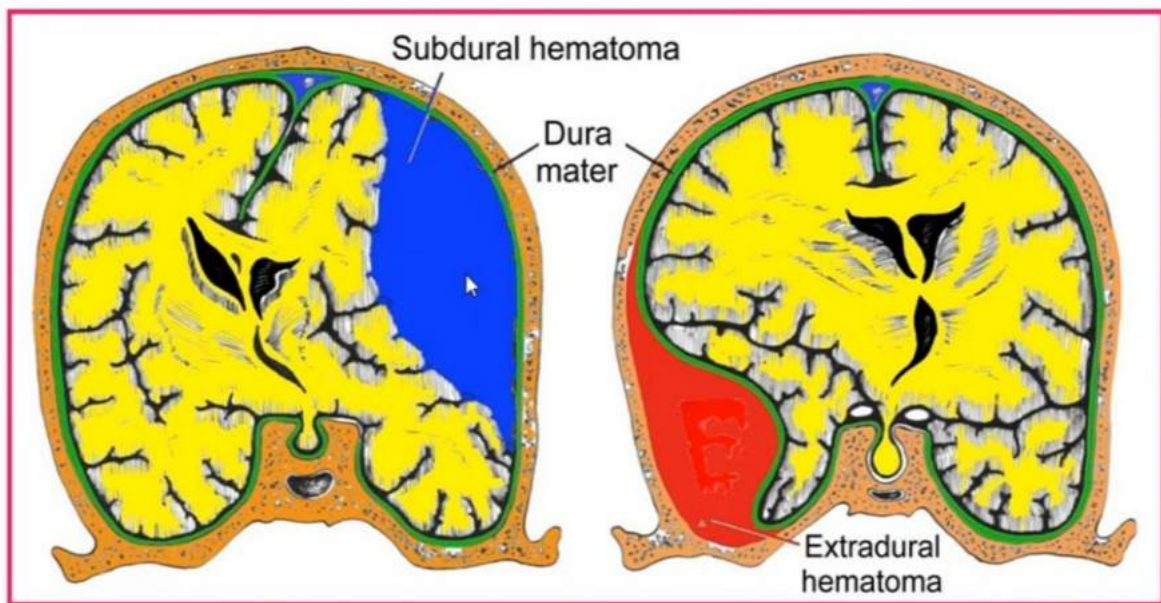
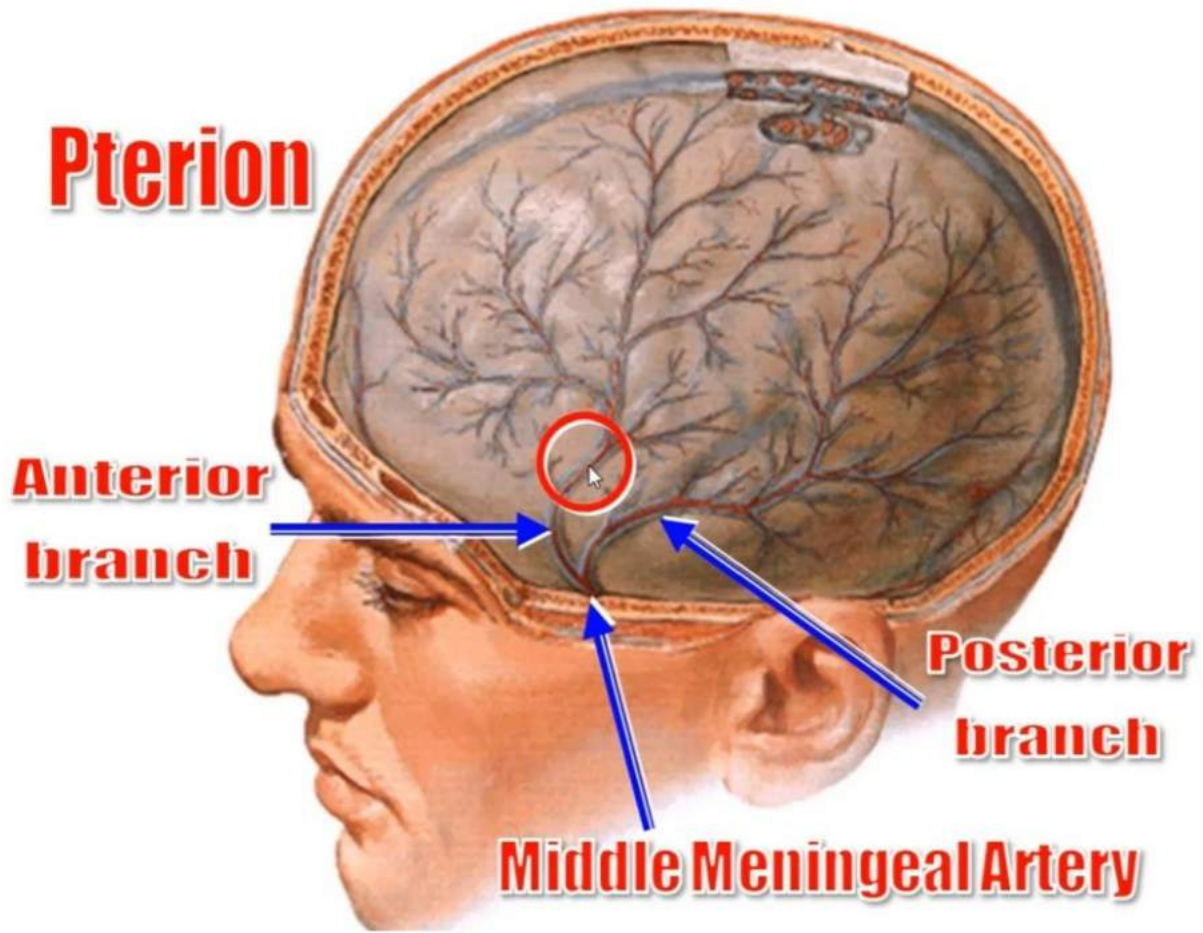
SUBARACHNOID SPACE



SITE

CONTENT

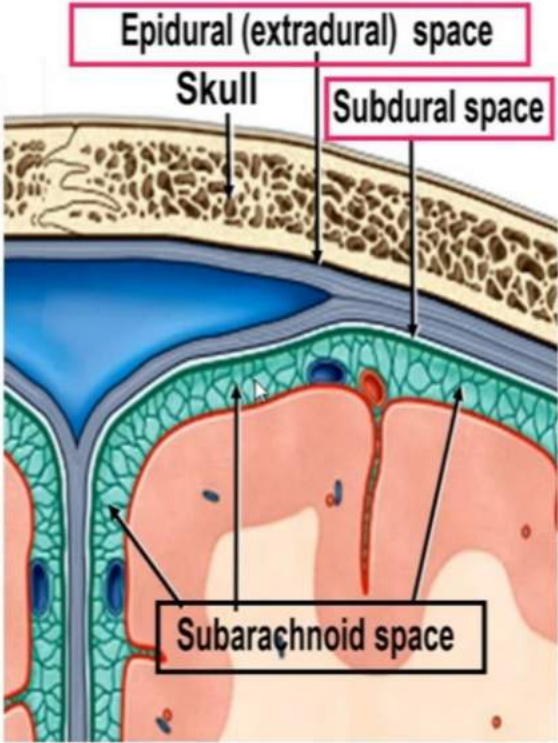
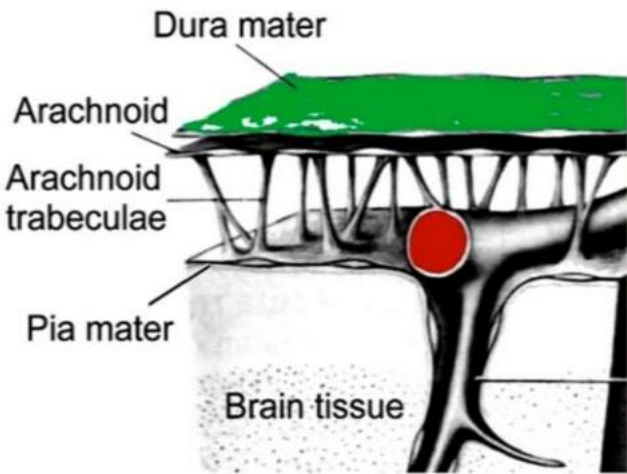
CLINICAL IMP



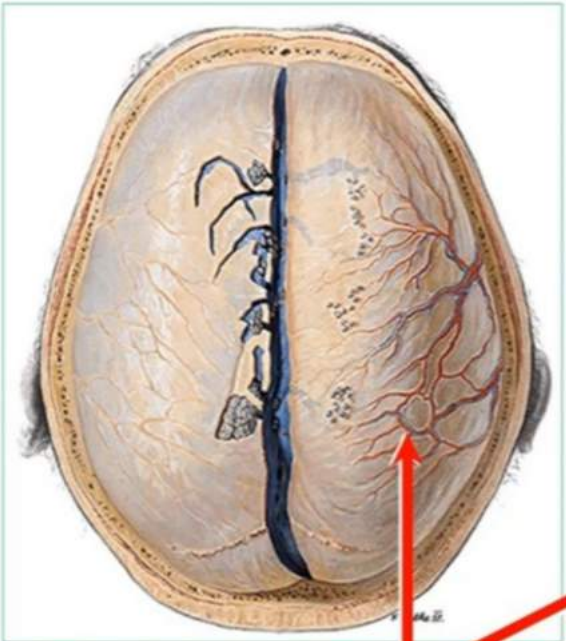**SUBDURAL
HEMORRHAGE**

**EXTRADURAL
HEMORRHAGE**

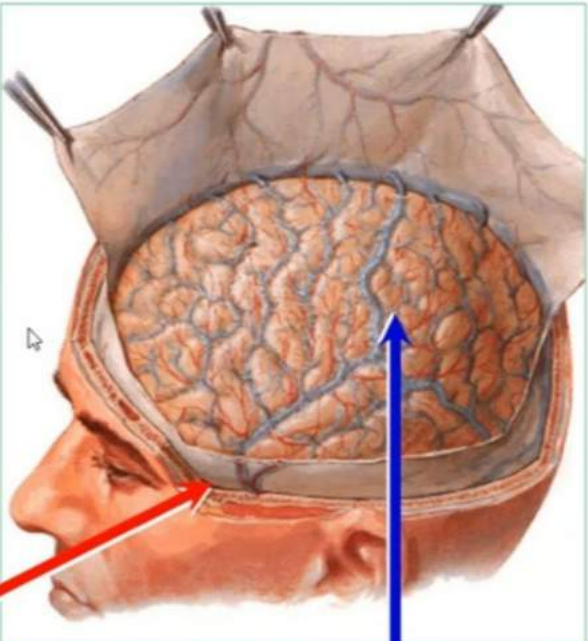
MENINGEAL SPACES



- 1. Extradural or Epidural**
- 2. Subdural**
- 3. Subarachnoid**



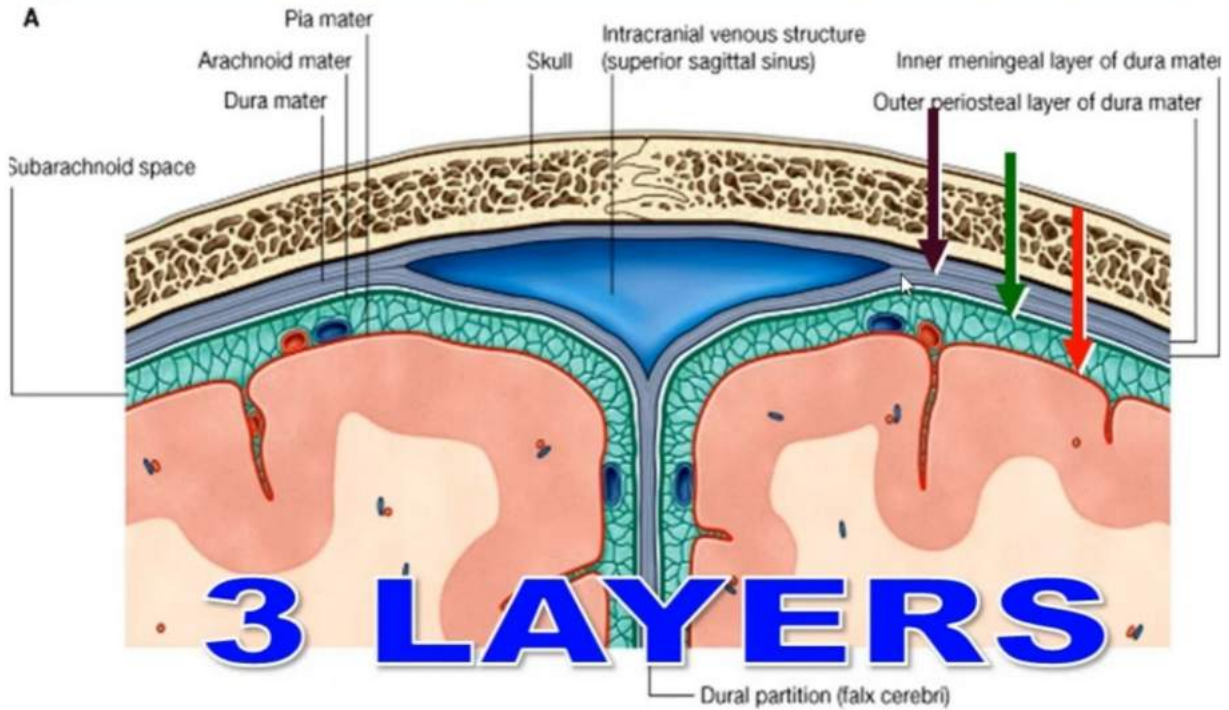
Extradural (Epidural) Space



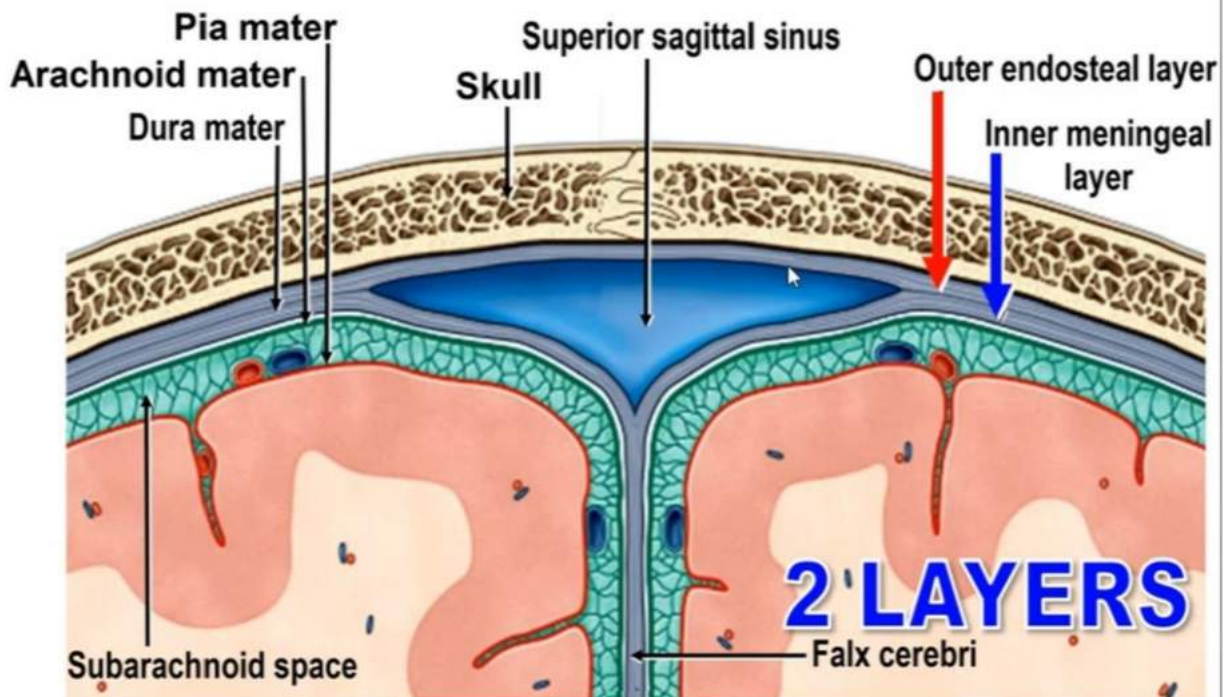
Subdural Space

SITE	CONTENT	CLINICAL IMP
------	---------	--------------

MENINGEAL LAYERS



DURA MATER



CRANIAL MENINGES

1. Dura

2. Arachnoid

3. Pia



MENINGES



1. DURA MATER: outer

2. ARACHNOID : middle

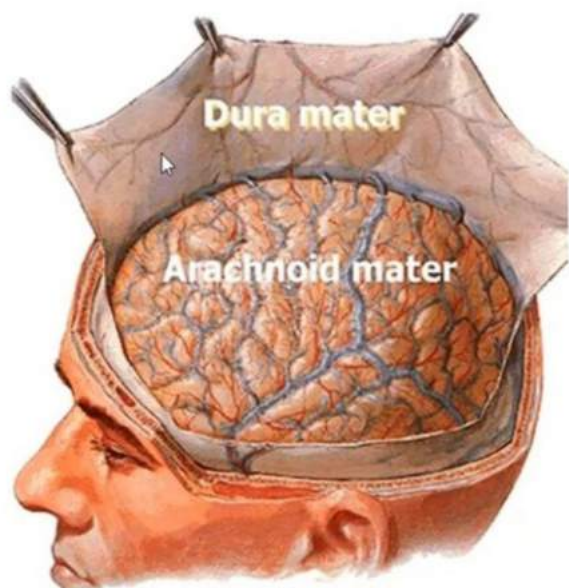
3. PIA MATER: inner

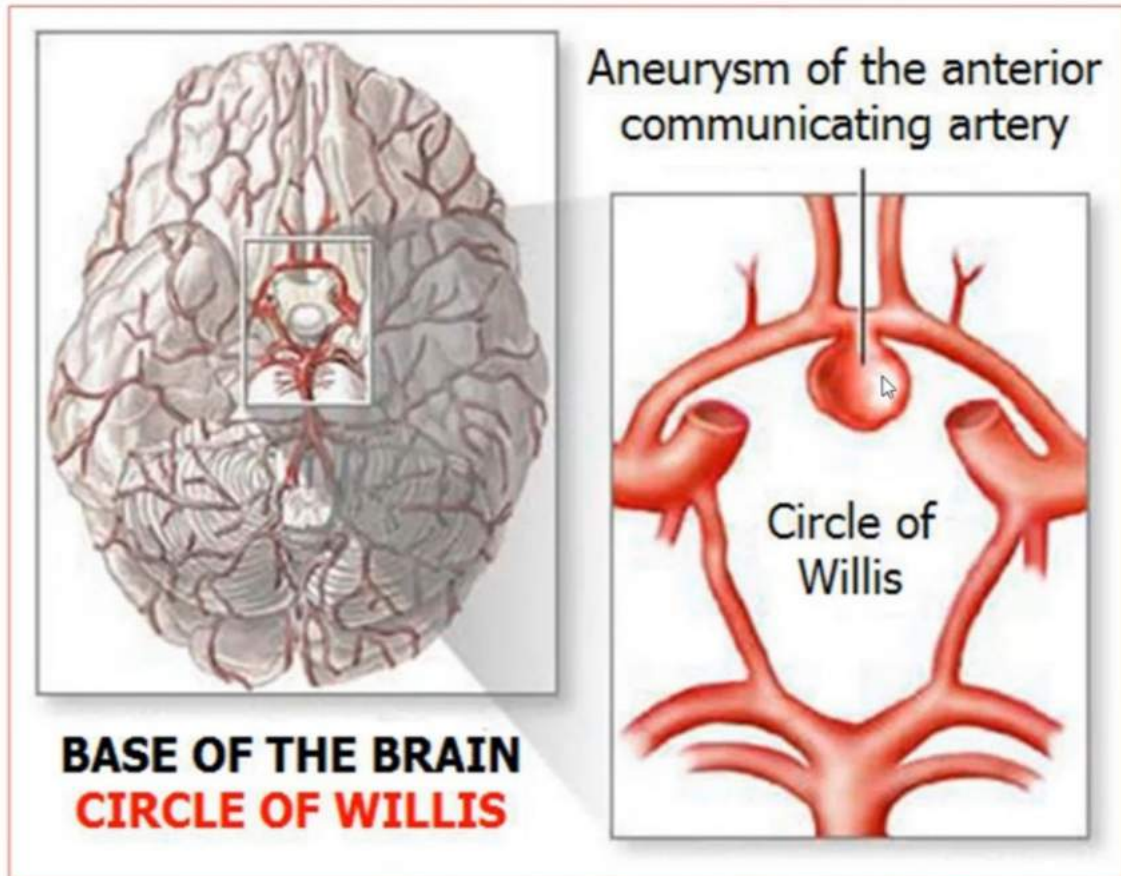
Cranial Dura: 2 layers

a. Outer endosteal

b. Inner meningeal

Spinal Dura: one layer

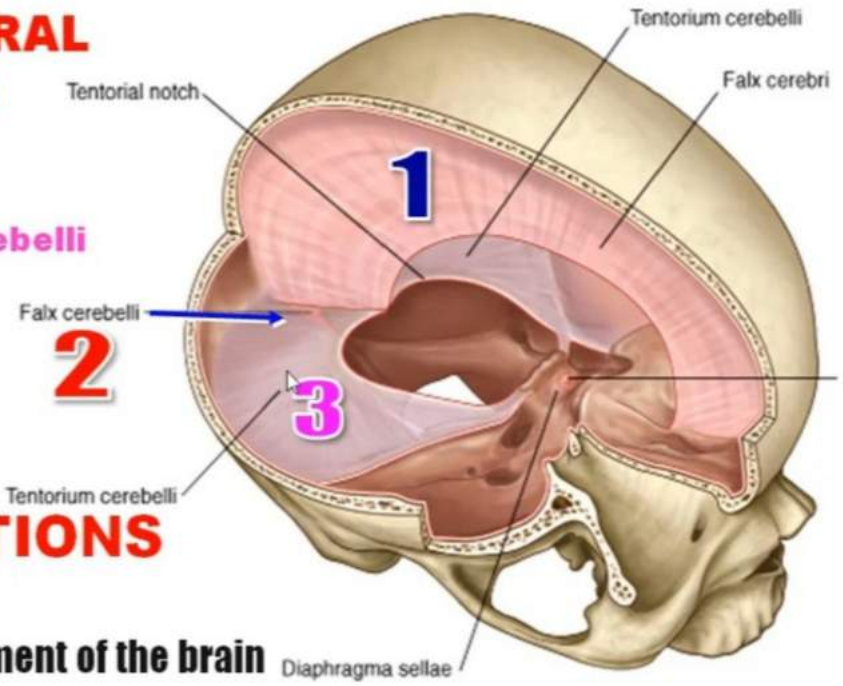




DURAL FOLDS

3 Main DURAL FOLDS

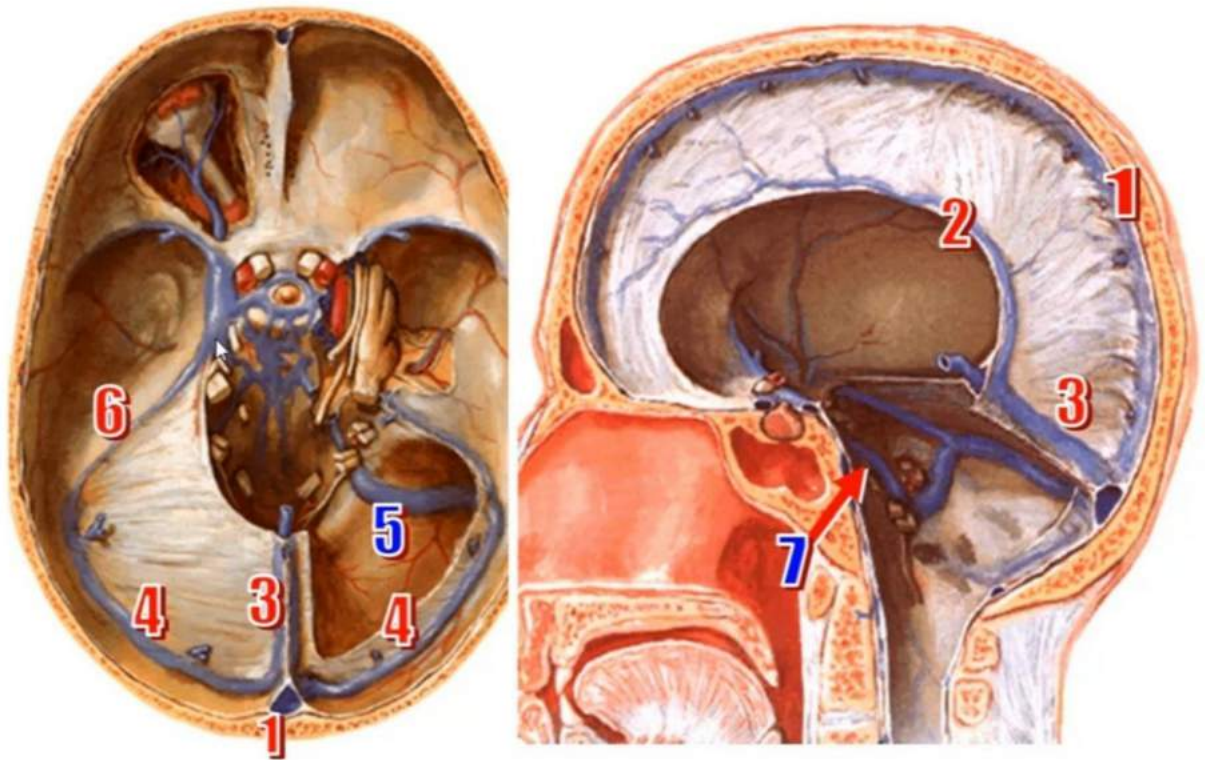
1. Falx Cerebri
2. Falx Cerebelli
3. Tentorium Cerebelli



FUNCTIONS

1. Protect the brain
2. Prevent displacement of the brain
3. Minimize the effect of vibrations

ORIGIN & TERMINATION OF EACH SINUS



CAVERNOUS SINUS

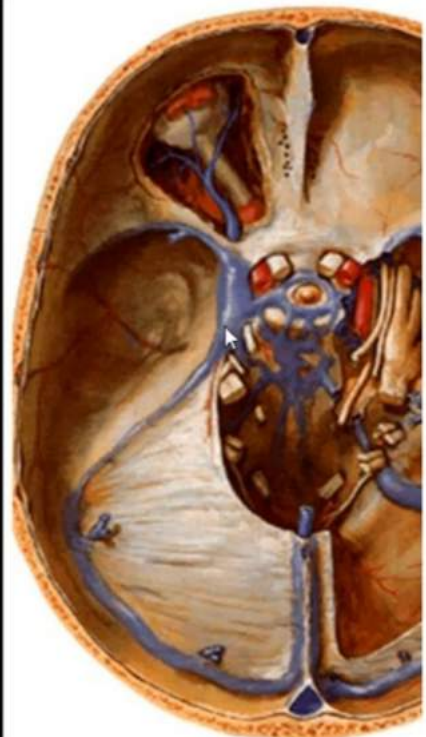
SITE:

TRIBUTARIES:

1. **ANTERIOR END:** ophthalmic veins, central vein of the retina & sphenoparietal sinus
2. **MEDIALY:** 3 intercavernous sinuses
3. **SUPERIORLY:** middle & inferior cerebral veins
4. **INFERIORLY:** emissary veins connecting it with:
a. pterygoid plexus: foramen ovale & lacerum
b. pharyngeal plexus: carotid canal

DRAINAGE: posteriorly to

1. Superior petrosal sinus: to the transverse sinus
2. Inferior petrosal sinus: to the internal jugular V



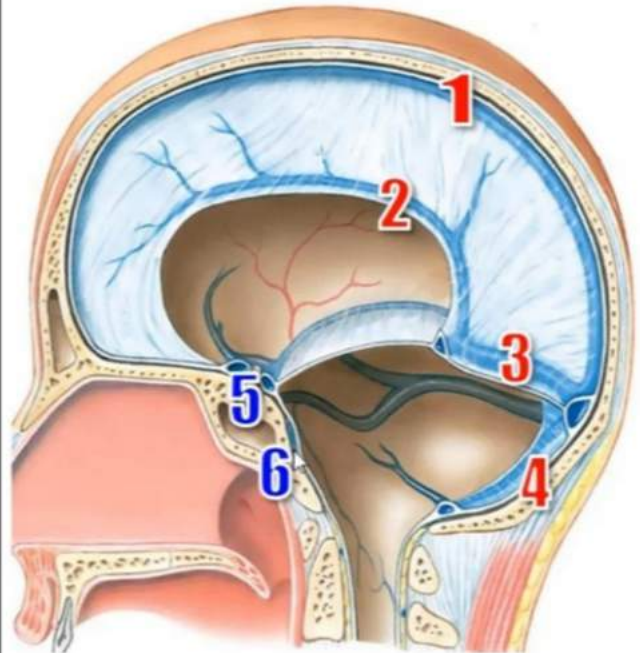
CLASSIFICATION OF SINUSES

6 SINGLE SINUSES & 6 PAIRED SINUSES

6 SINGLE SINUSES

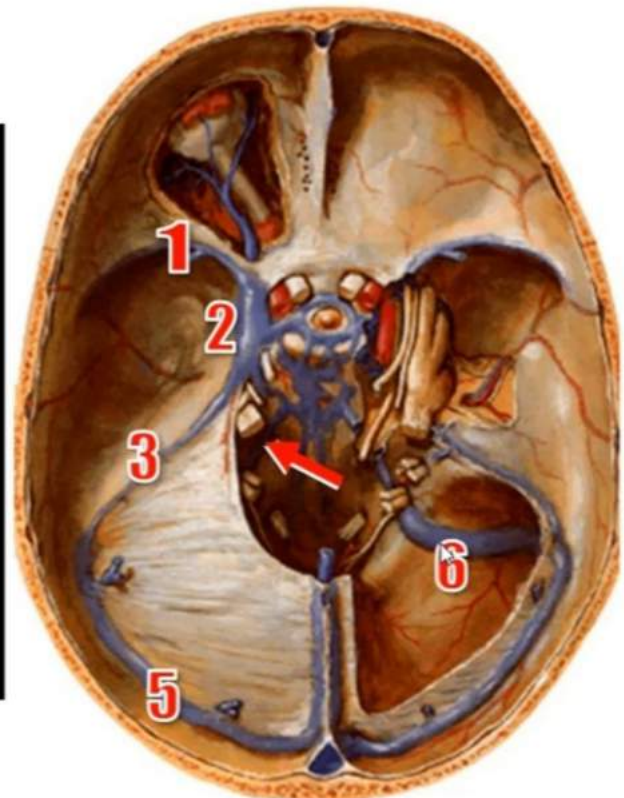
(midline sinuses)

1. Superior Sagittal sinus
2. Inferior Sagittal Sinus
3. Straight Sinus
4. Occipital Sinus
5. Intercavernous Sinuses
6. Basilar Plexus



6 PAIRED SINUSES

1. Sphenoparietal sinus
2. CAVERNOUS SINUS
3. Superior Petrosal Sinus
4. Inferior Petrosal Sinus
5. Transverse Sinus
6. Sigmoid Sinus

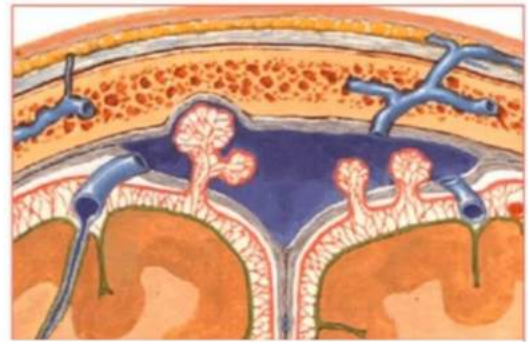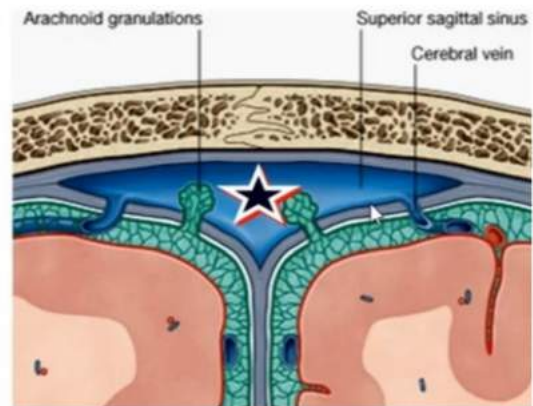


DURAL SINUSES

■ **Are channels** between outer and inner layers of dura

■ **They drain the:**

1. Brain
2. Meninges
3. Skull bones
4. CSF

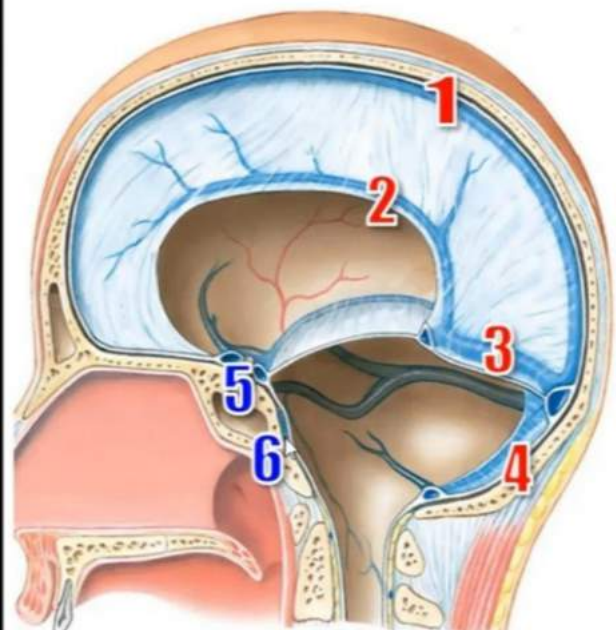


CLASSIFICATION OF SINUSES

6 SINGLE SINUSES & 6 PAIRED SINUSES

6 SINGLE SINUSES (midline sinuses)

1. Superior Sagittal sinus
2. Inferior Sagittal Sinus
3. Straight Sinus
4. Occipital Sinus
5. Intercavernous Sinuses
6. Basilar Plexus



ARTERIAL SUPPLY

- 1. ANTERIOR meningeal arteries:**
from the anterior and posterior ethmoidal branches of the **ophthalmic artery**
- 2. MIDDLE meningeal artery:**
from the 1st part of the **maxillary artery**
- 3. ACCESSORY meningeal artery:**
from the 1st part of the **maxillary artery**
- 4. POSTERIOR meningeal arteries: from**
 - a. Vertebral artery**
 - b. Occipital artery**
 - c. Ascending pharyngeal artery**

4

NERVE SUPPLY

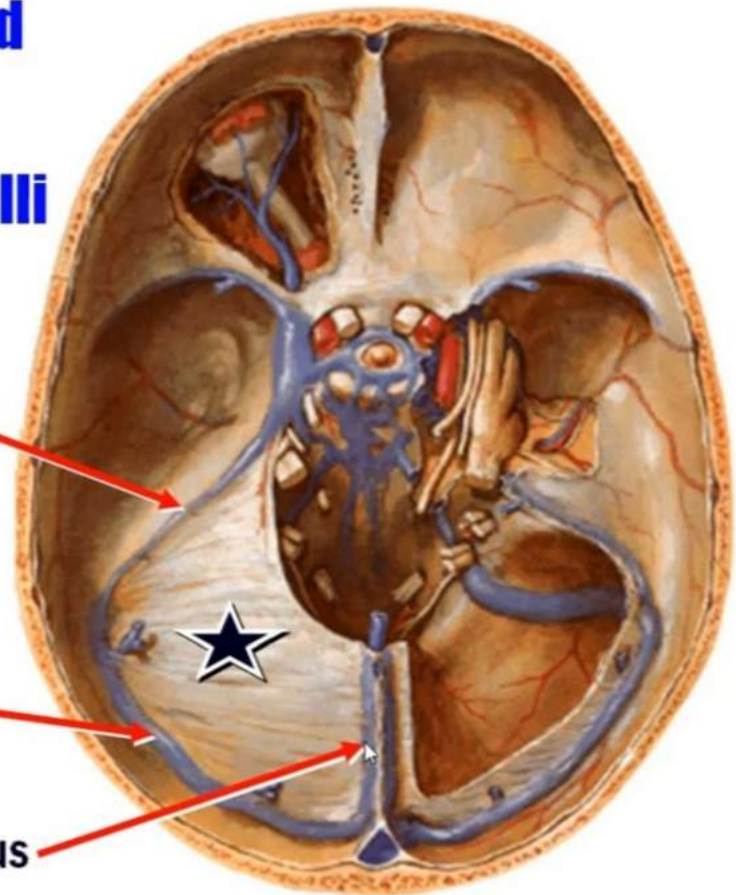
- 1. ANTERIOR CRANIAL FOSSA:**
from the anterior and posterior ethmoidal branches of the **ophthalmic nerve**
- 2. MIDDLE CRANIAL FOSSA:**
from the **maxillary** and **mandibular** nerves
- 3. POSTERIOR CRANIAL FOSSA:**
from the **cervical nerves** through the 9th, 10th & 12th cranial nerves

3 Sinuses Related to the Tentorium Cerebelli

1. Superior petrosal
sinus

2. Transverse sinus

3. Straight sinus



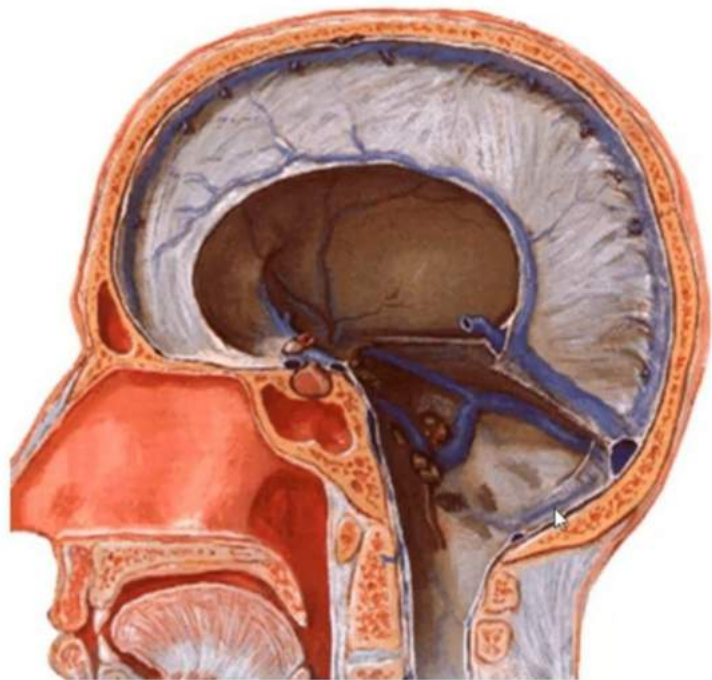
FALX CEREBELLI

SITE:

SHAPE:

RELATED SINUS:

Occipital sinus



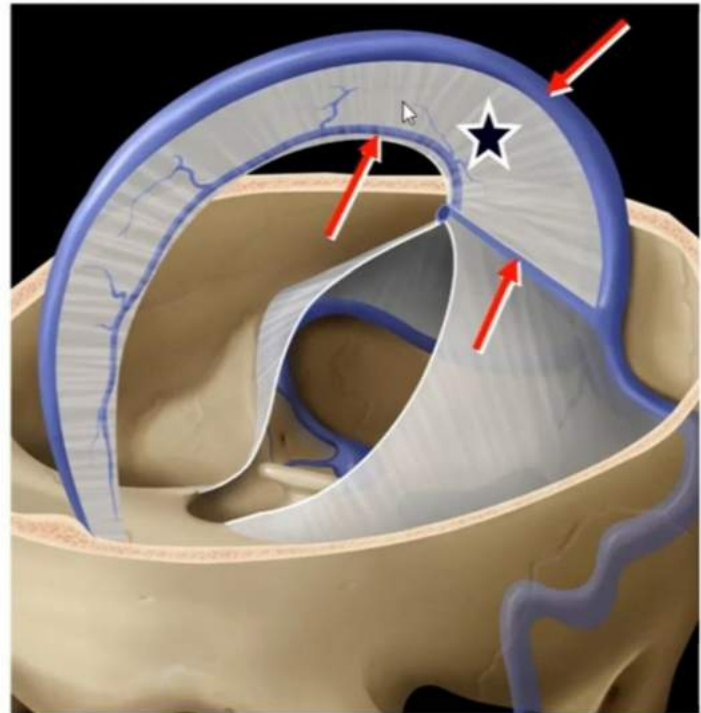
FALX CEREBRI

SITE:

SHAPE:

RELATED SINUSES:

1. Superior sagittal sinus:
upper border
2. Inferior sagittal sinus:
lower border
3. Straight sinus: **base**



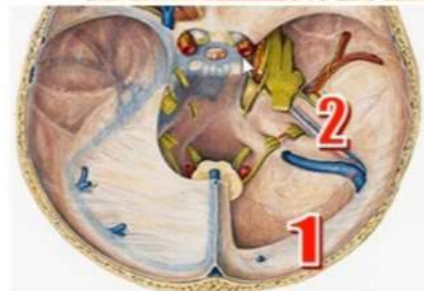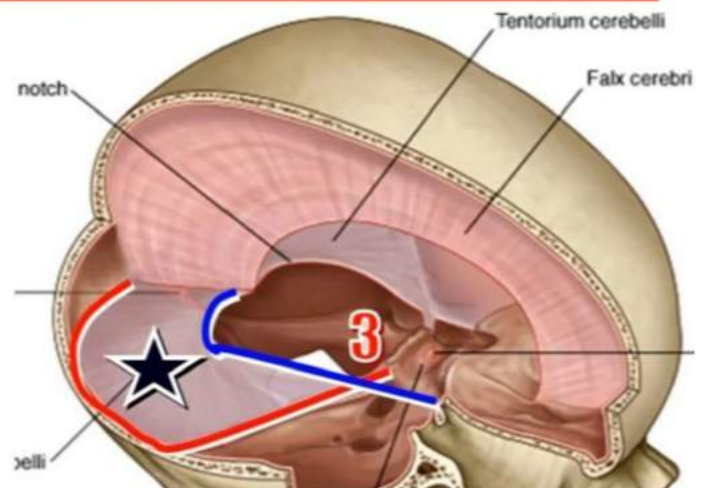
TENTORIUM CEREBELLI

SITE:

SHAPE: tent-like

BORDERS:

- ✿ Free border
- ✿ Attached border



ORBITAL WALLS

ROOF:

- a. Frontal bone
- b. Lesser wing of sphenoid

FLOOR:

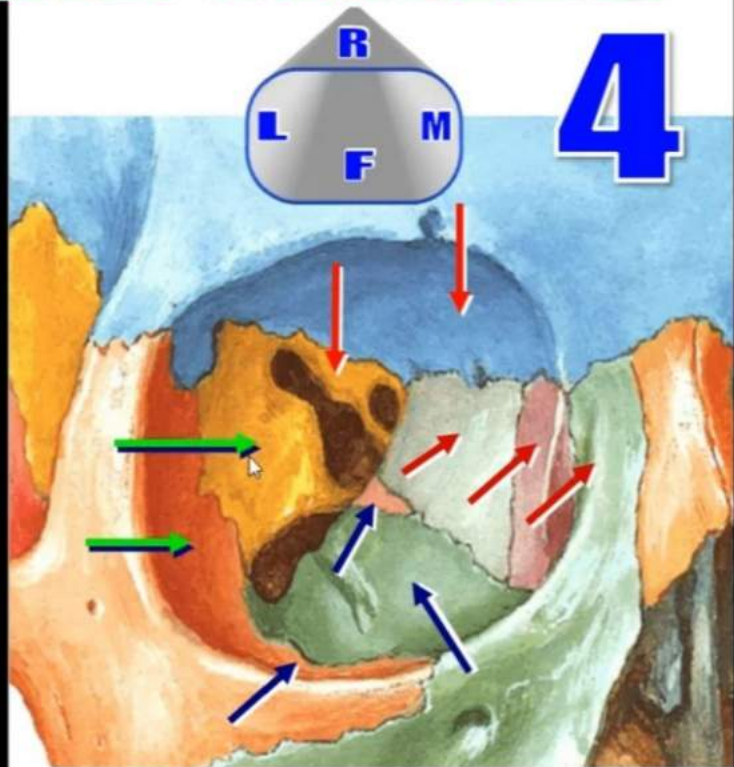
- a. Zygomatic bone
- b. Maxilla
- c. Palatine

MEDIAL WALL:

- a. Maxilla
- b. Lacrimal bone
- c. Ethmoid bone

LATERAL WALL:

- a. Zygomatic bone
- b. Greater wing of sphenoid



ROOF OF THE ORBIT

ROOF

Bones:

- a. Frontal bone
- b. Lesser wing of sphenoid

Features:

- a. lacrimal gland fossa
- b. supraorbital notch / foramen

Related To:

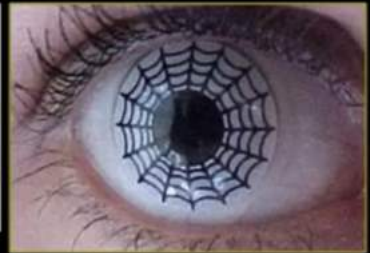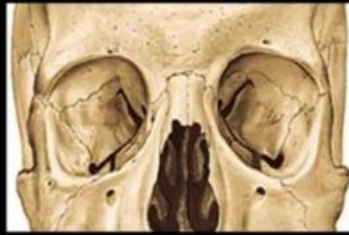Frontal lobe of the brain



THE ORBIT

★ BONY ORBIT:

1. Orbital Margin
2. Walls of the Orbit
3. Foramina and Fissures



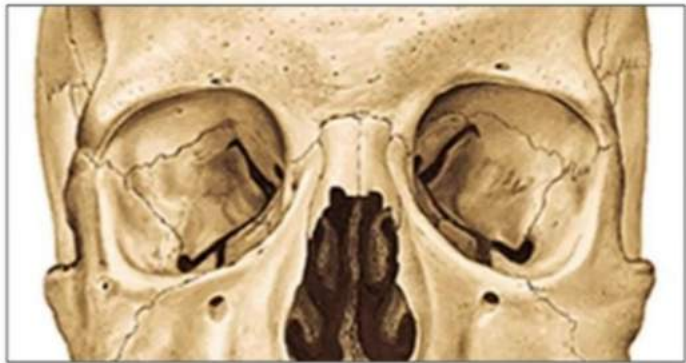
★ EYELIDS:

★ CONTENTS OF THE ORBIT:

1. Eye Ball
2. **Ocular Muscles:** extraocular & intraocular muscles
3. **Nerves:**
 - a. Motor: **3, 4 & 6**
 - b. Sensory: **optic nerve & ophthalmic nerve**
 - c. Autonomic: **sympathetic & parasymp (ciliary ganglion)**
4. **BLOOD VESSELS:**
 - a. **Ophthalmic Artery**
 - b. **Superior & Inferior Ophthalmic Veins**
- ★ 5. **Lacrimal Apparatus**

ORBITAL MARGIN

1. SUPERIOR:
 - a. **Frontal bone**
 - b. **supraorbital foramen**
2. INFERIOR:
 - a. **Zygomatic bone**
 - b. **Maxilla**
3. MEDIAL:
 - a. **Frontal bone**
 - b. **Maxilla**
4. LATERAL:
 - a. **Frontal bone**
 - b. **Zygomatic bone**



RELATIONS OF THE CAVERNOUS SINUS

MEDIALY:

1. **Piuitary gland**
2. **Sphenoidal air sinus**

LATERALLY:

Temporal lobe of the brain

SUPERIORLY:

1. **Internal carotid artery**
2. **Optic chiasma**

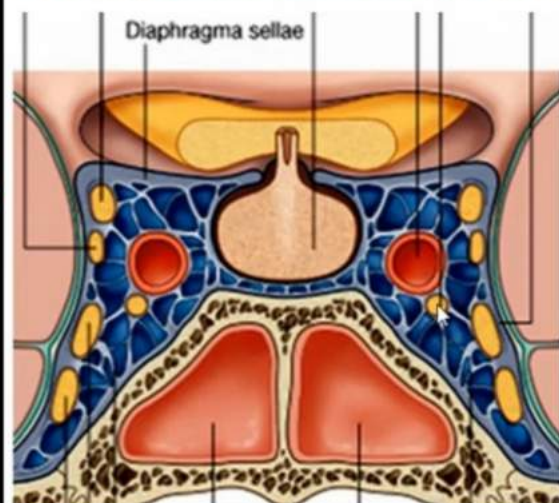
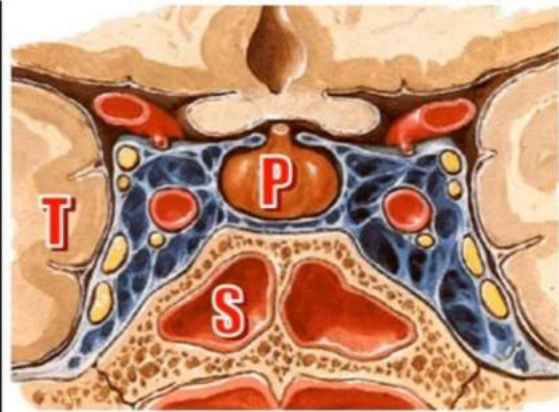
INFERIORLY: **sphenoidal air sinus**

STRUCTURES IN THE LATERAL WALL:

1. **Oculomotor nerve**
 2. **Trochlear nerve**
 3. **Ophthalmic nerve**
 4. **Maxillary nerve**
- 3 - 4 - 5**
OTOM


STRUCTURES INSIDE THE SINUS:

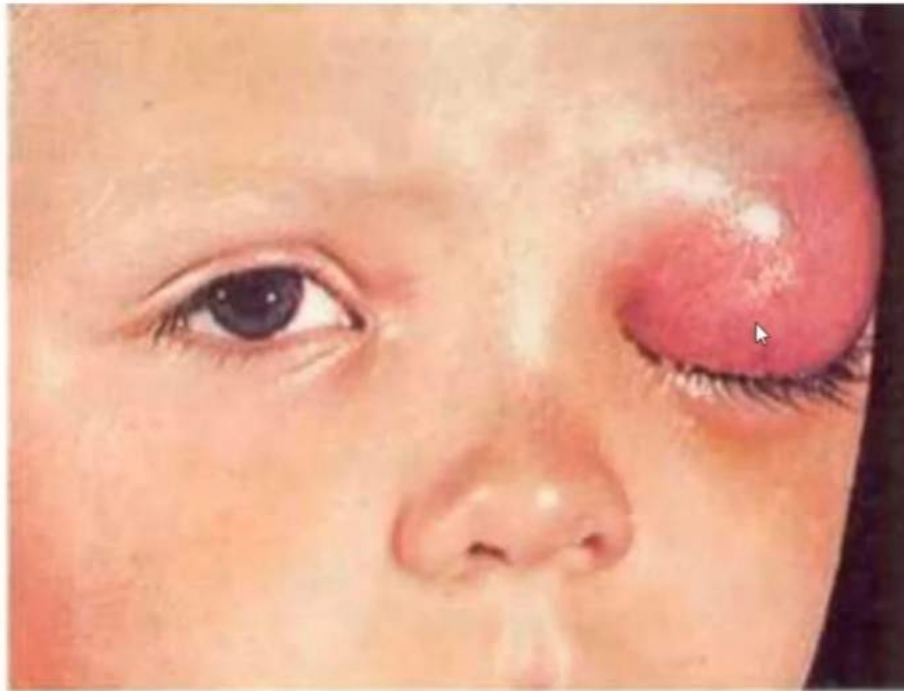1. **Internal carotid artery**
2. **Abducent nerve**



CLINICAL IMPORTANCE

1. Spread of infection from the dangerous area of the face to the cavernous sinus
2. Infection and thrombosis of the cavernous sinus may cause:
 - a. **Blindness** due to interference with the venous drainage of the retina
 - b. **Paralysis** of the oculomotor, trochlear, ophthalmic and abducent nerves

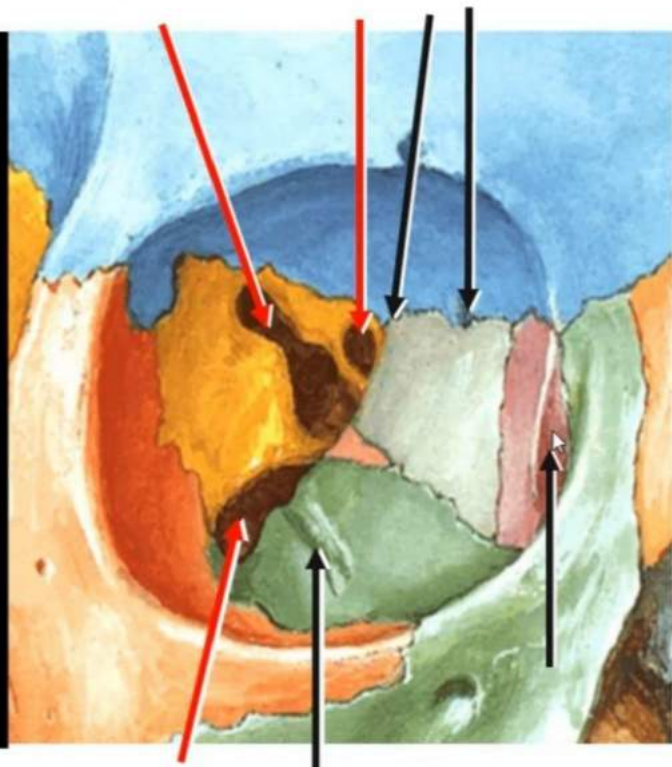




Orbital abscess due to extension of ethmoidal sinusitis

FORAMINA & FISSURES

- 1. Optic canal**
- 2. Superior orbital fissure**
- 3. Inferior orbital fissure**
- 4. Anterior & posterior ethmoidal foramina**
- 5. Infraorbital groove**
- 6. Lacrimal groove for lacrimal sac**

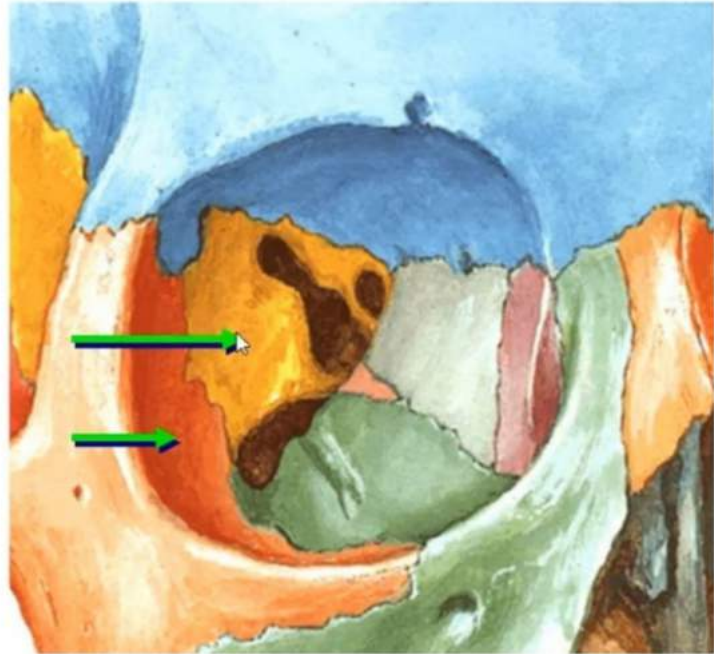


LATERAL WALL

BONES:

a. Zygomatic bone

b. Greater wing of sphenoid



THEREFORE:

1. THE ROOF:

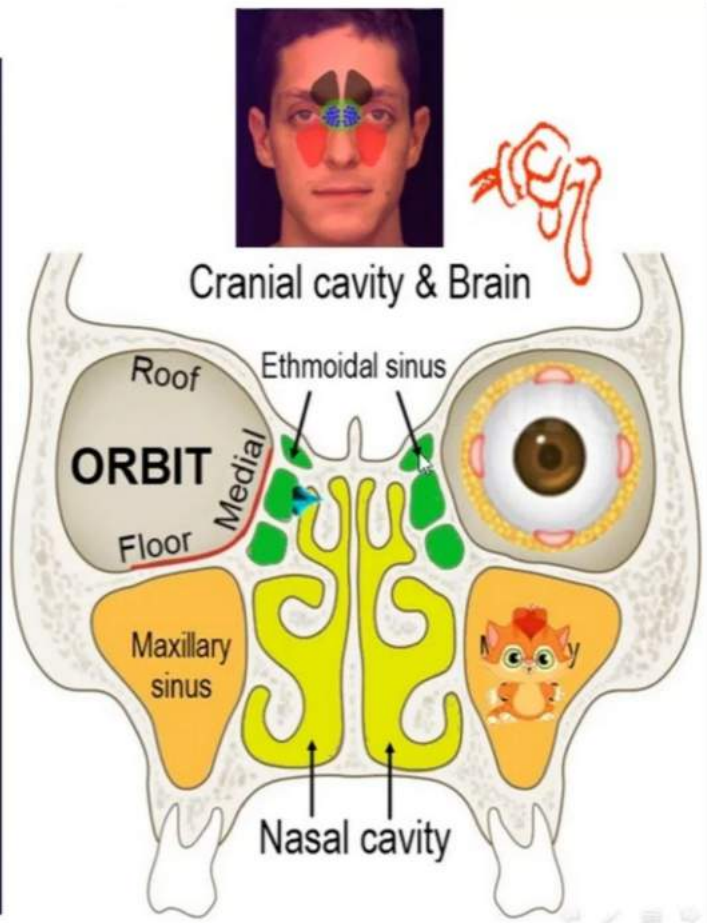
is related to the anterior cranial fossa and the brain

2. THE FLOOR:

is related to the maxillary air sinus

3. THE MEDIAL WALL:

is related to the ethmoidal air sinuses



FLOOR OF THE ORBIT

FLOOR



Bones:

- a. Zygomatic bone
- b. Maxilla
- c. Palatine



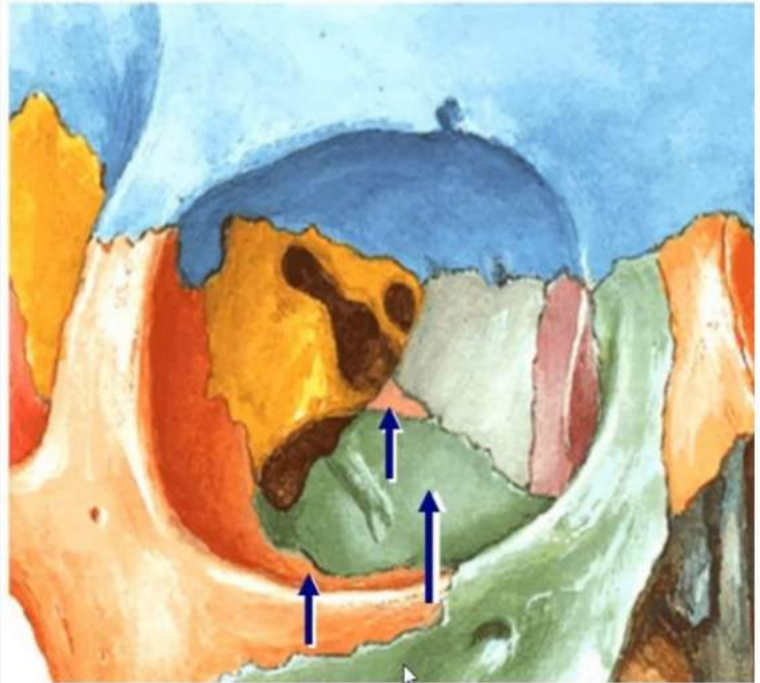
Features:

- a. infraorbital groove
- b. infraorbital canal



Related To:

Maxillary air sinus



MEDIAL WALL

MEDIAL WALL

Bones:

- a. Maxilla
- b. Lacrimal bone
- c. Ethmoid bone

Features:

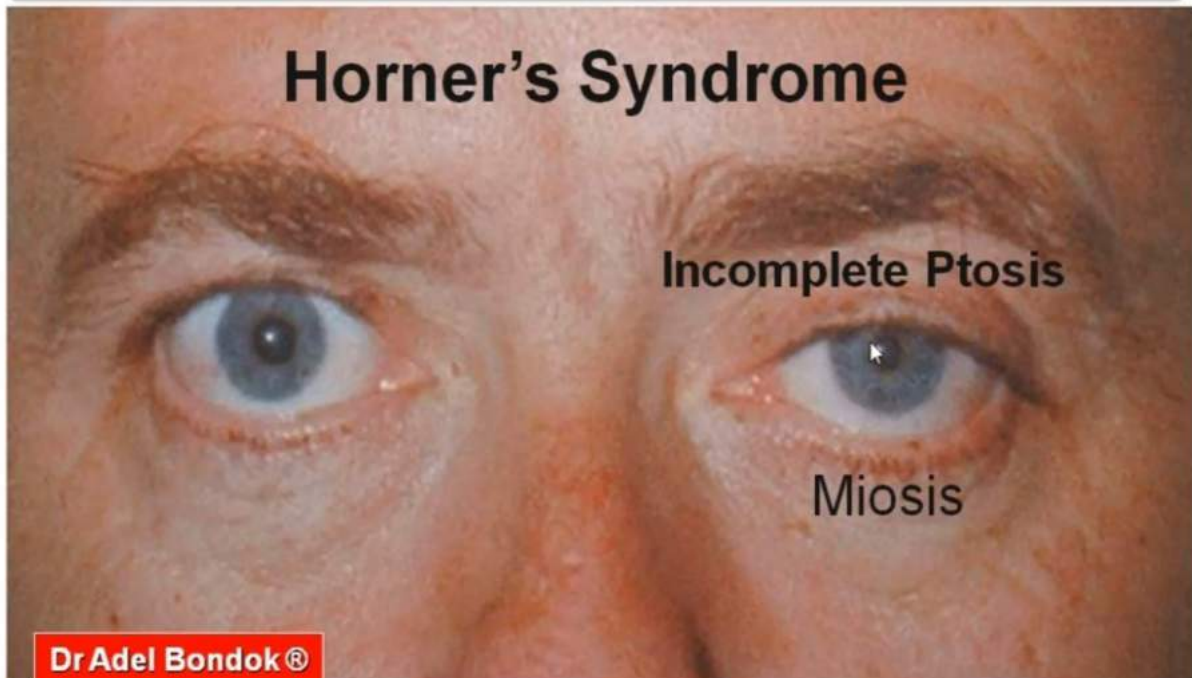
- a. Lacrimal sac fossa
- b. Anterior & Posterior ethmoidal foramina

Related To:

Ethmoid air sinuses



INCOMPLETE PTOSIS: Sympathetic paralysis of Muller's muscle



3 INTRAOCULAR MUSCLES

1. SPHINCTER PUPILLAE

Supplied by the oculomotor nerve

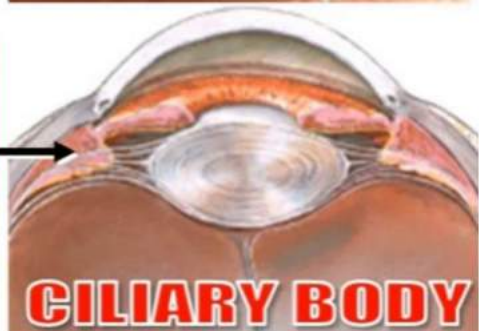
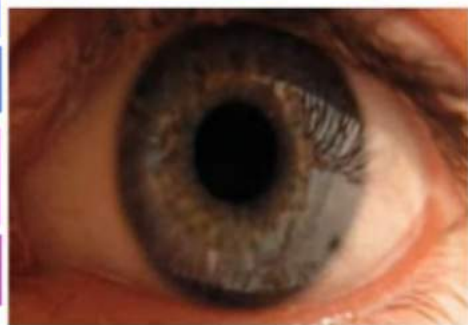2. DILATOR PUPILLAE

Supplied by sympathetic fibers

3. CILIARY MUSCLE For accommodation

Supplied by the oculomotor nerve

PUPIL



Dr Adel Bondok®

EYELID MUSCLES: 2

1. **Orbicularis oculi: for closure**

2. **Levator Palpebrae Superioris:**

Origin: roof of the orbit

Insertion: 2 parts

a. **Voluntary:** into the skin

b. **Involuntary:** Muller's muscle
smooth muscle into the tarsus

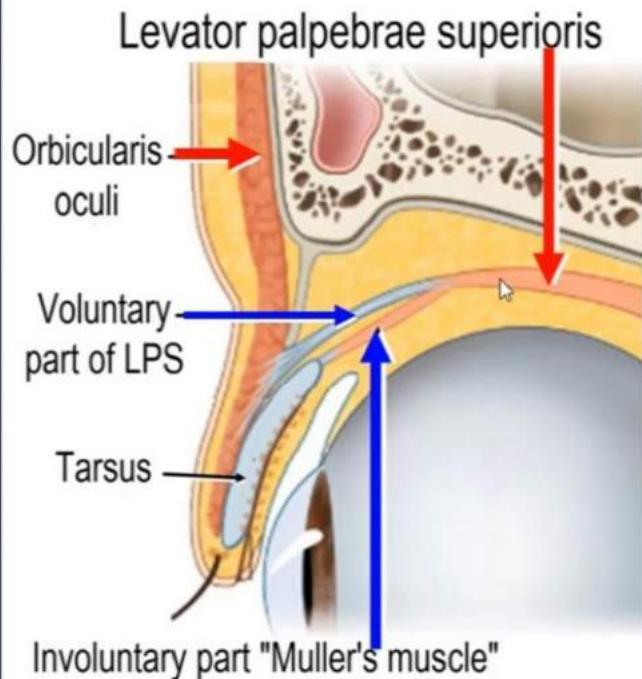
Nerve Supply: 2 parts

a. **Voluntary:** oculomotor nerve

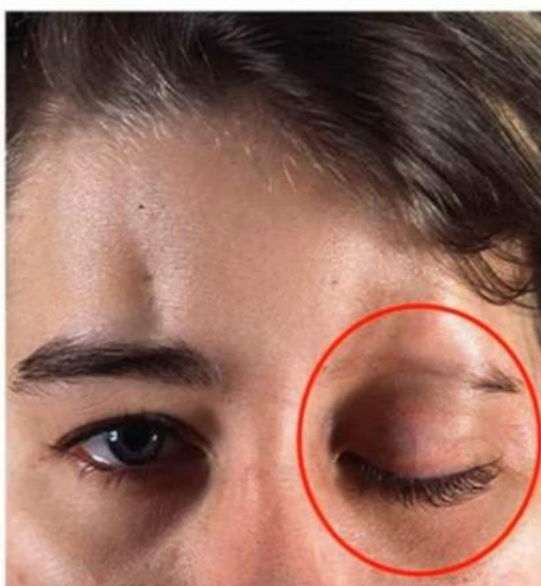b. **Involuntary:** Muller's muscle
sympathetic plexus around ICA.
Reach the muscle with the
oculomotor nerve

Action: elevate the upper eyelid

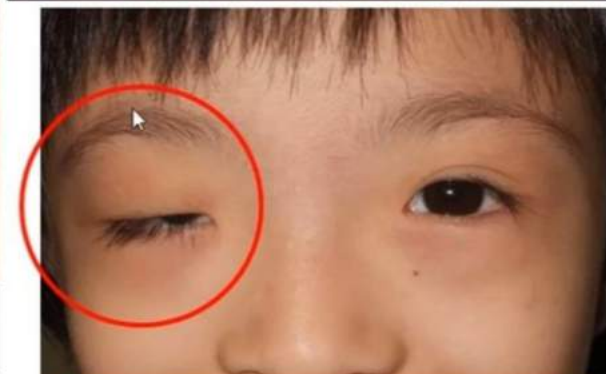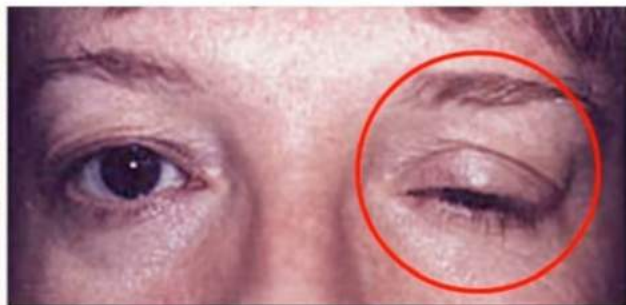Paralysis: ptosis



**COMPLETE PTOSIS: III nerve
paralysis of levator palpebrae superioris**



Left Oculomotor Nerve Paralysis
Complete Ptosis



EYE BALL: 3 LAYERS

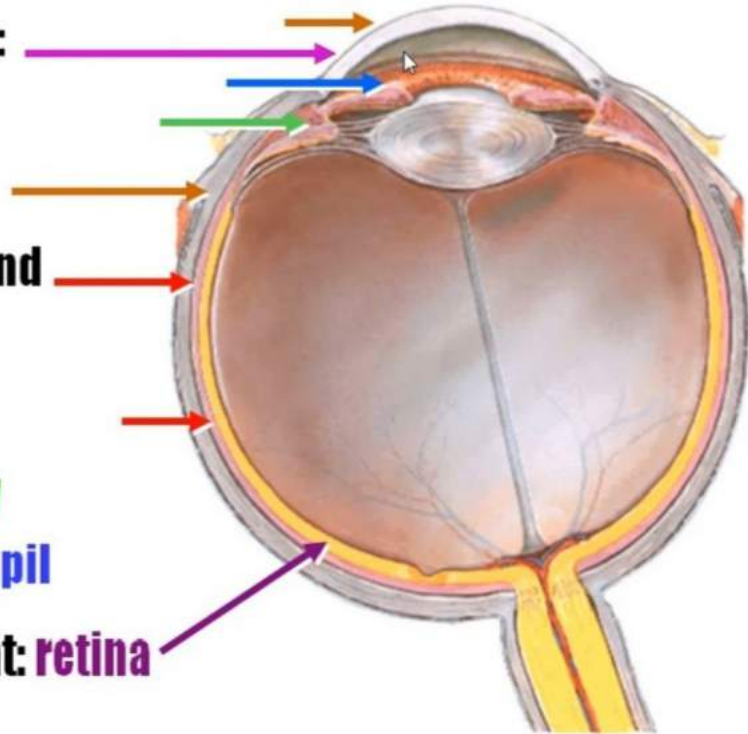
1. Outer Fibrous Coat:

- a. Cornea
- b. Sclera

2. Middle Vascular and Pigmented Coat:

- a. Choroid
- b. Ciliary body
- c. Iris & the pupil

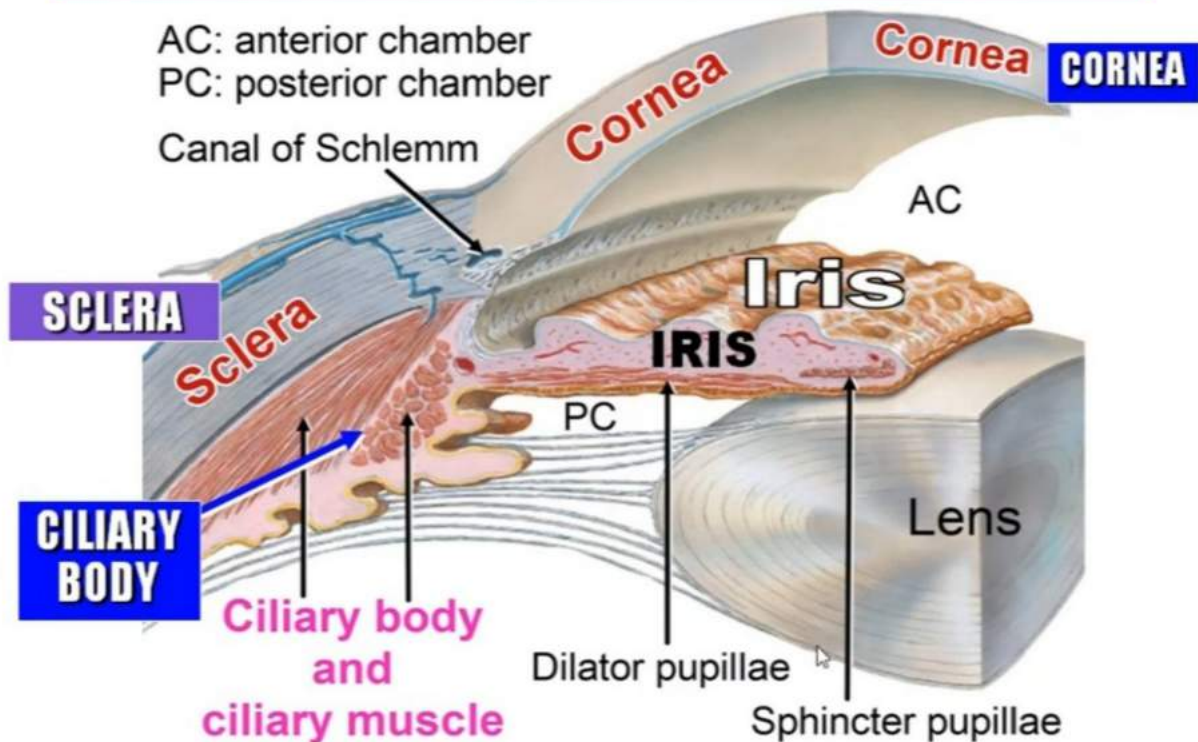
3. Inner Nervous Coat: retina



EYE BALL

AC: anterior chamber
PC: posterior chamber

Canal of Schlemm



Ophthalmic Veins

Live: Lacrimal nerve

Free: Frontal nerve

To: Trochlear nerve

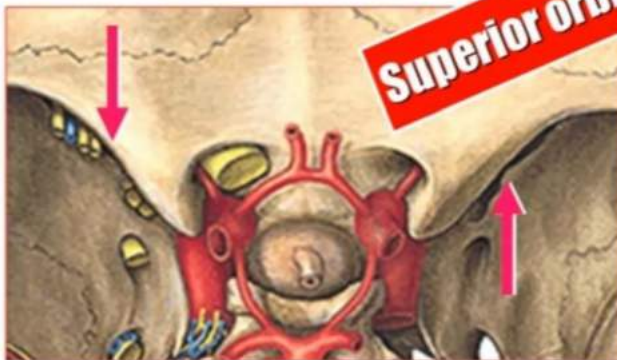See: Sup division of the III nerve

No: Nasociliary nerve

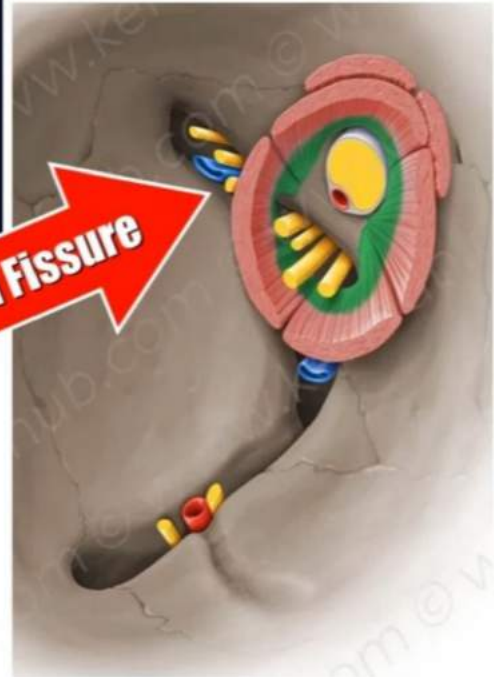Insult: Inf division of III nerve

At all: Abducent nerve

Outside the tendinous ring



Superior orbital Fissure



Superior Orbital Fissure:

Ophthalmic veins

Live: lacrimal nerve

Free: frontal nerve

To: trochlear nerve

Outside the tendinous ring

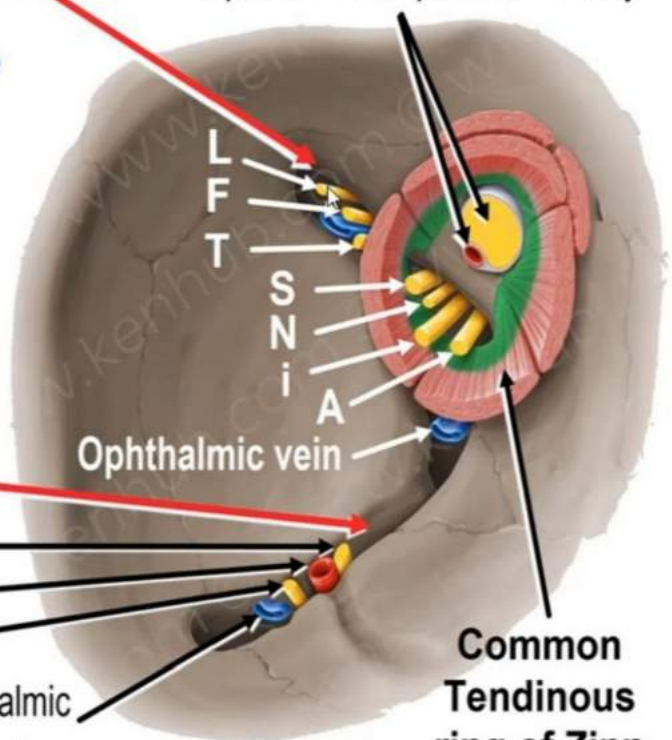
See: superior division of III nerve

No: nasociliary nerve

Insult: inferior division of III nerve

At all: abducent nerve

Optic nerve & ophthalmic artery



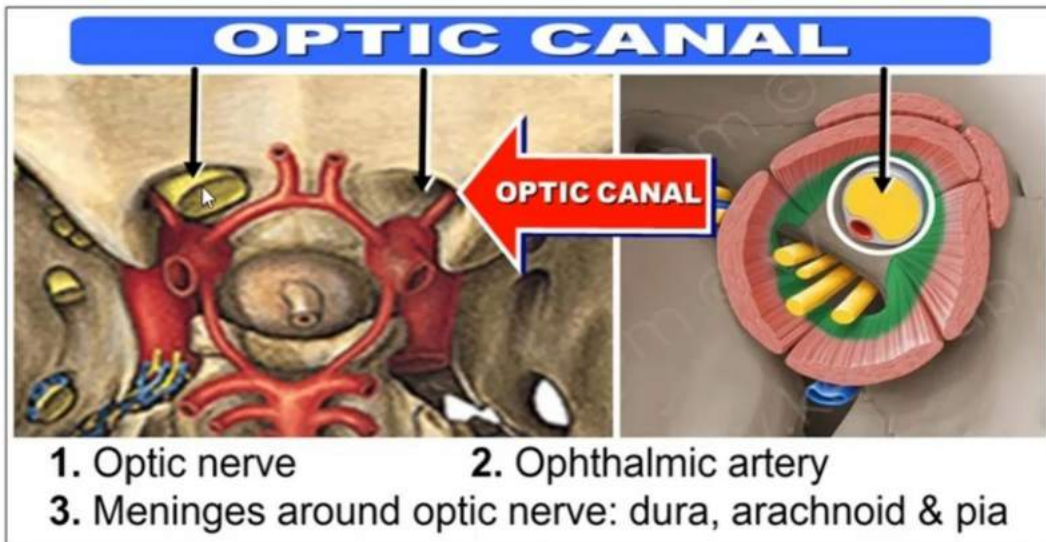
Inferior Orbital Fissure:

1. Maxillary nerve
2. Infraorbital artery
3. Zygomatic nerve
4. Vein between inferior ophthalmic vein and pterygoid venous plexus

Common Tendinous ring of Zinn

OPTIC CANAL

1. Optic Nerve
2. Ophthalmic Artery
3. 3 Meningeal layers around the optic nerve



Ophthalmic Veins

Live: Lacrimal nerve

Free: Frontal nerve

To: Trochlear nerve

See: Sup division of the III nerve

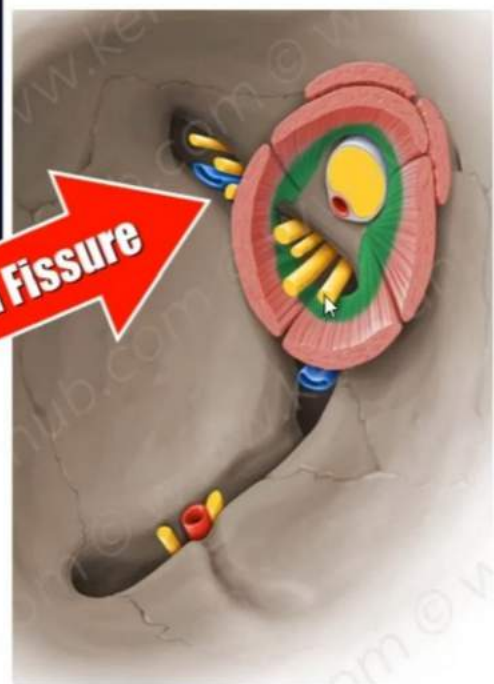
No: Nasociliary nerve

Insult: Inf division of III nerve

At all: Abducent nerve



Superior orbital Fissure



2 OBLIQUE MUSCLES

Dr Adel Bondok®

Origin:

1. **SO:** posterior part of the **roof** of the orbit
2. **IO:** anterior part of the **floor** of the orbit

Insertion:

postero-lateral part of the sclera

1. **SO:** in the upper part
2. **IO:** in the lower part

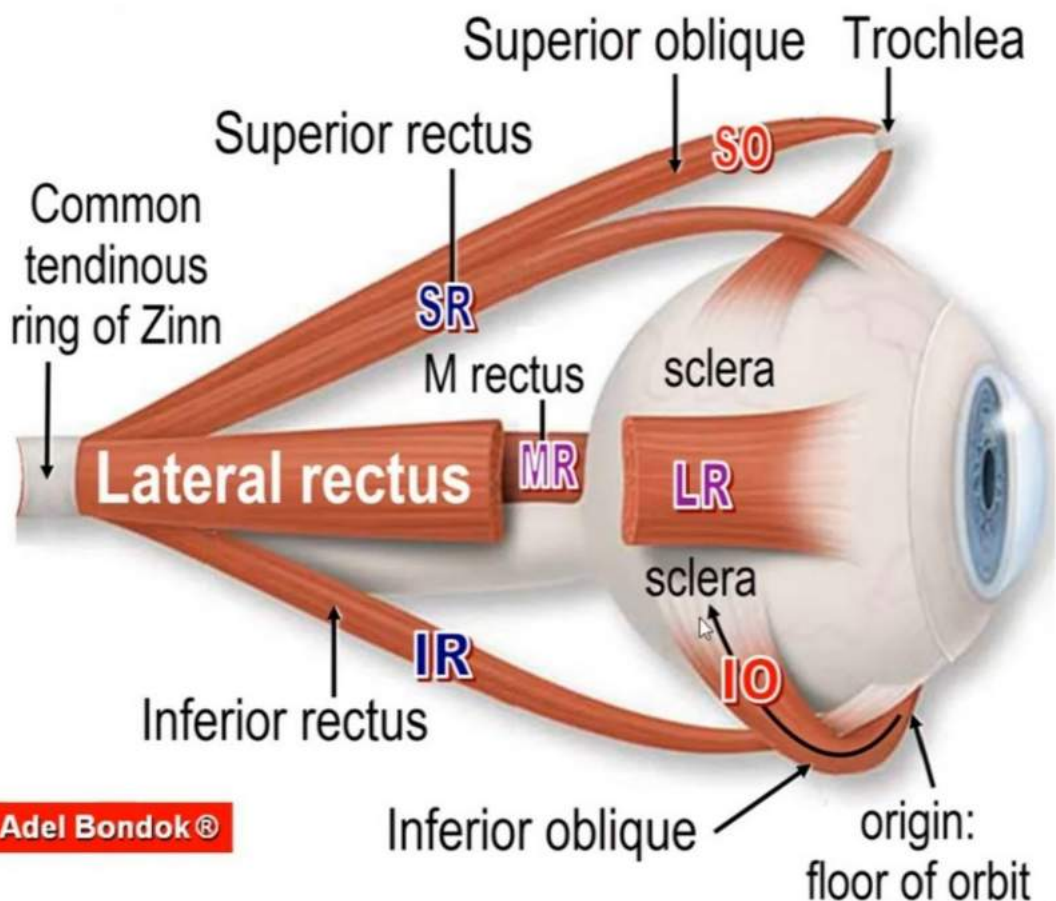
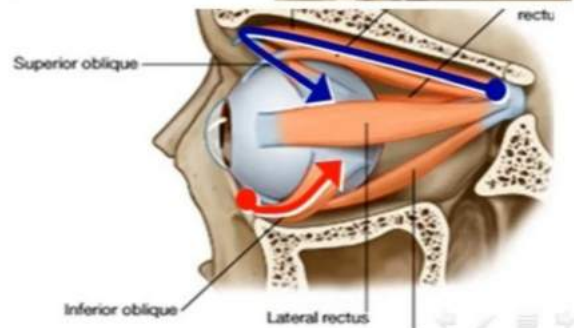
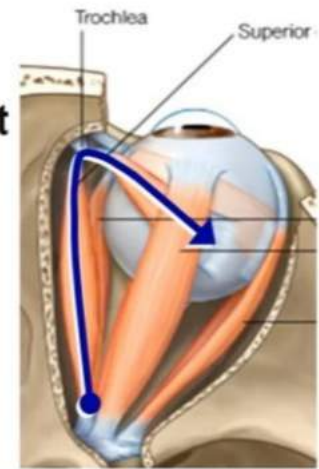
Action:

opposite to their name & to the recti

1. **SO:** depress & abduct
2. **IO:** elevate & abduct

Nerve Supply:

1. **SO:** trochlear nerve
2. **IO:** oculomotor nerve



Dr Adel Bondok®

6 EXTRAOCULAR MUSCLES

4 RECTI & 2 OBLIQUE

4 RECTI MUSCLES

Superior, Inf, Medial & Lateral

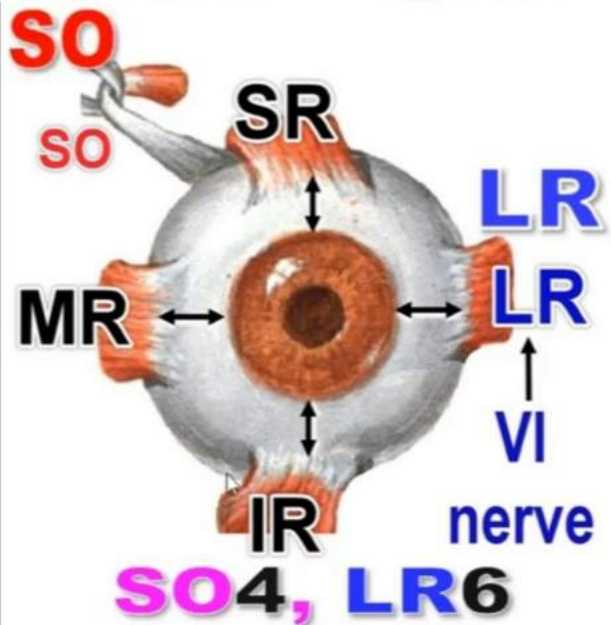
2 OBLIQUE MUSCLES

Superior & Inferior Oblique

NERVE SUPPLY:

All the extraocular muscles are supplied by the oculomotor nerve except:

1. Lateral rectus: by the abducent nerve
2. Superior oblique: by the trochlear nerve



Dr Adel Bondok®

4 RECTI MUSCLES

Common Origin:

Tendinous ring around the optic canal

Insertion:

Sclera 6 mm behind the corneal margin

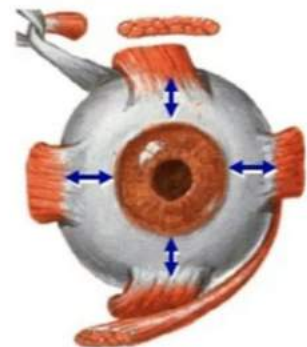
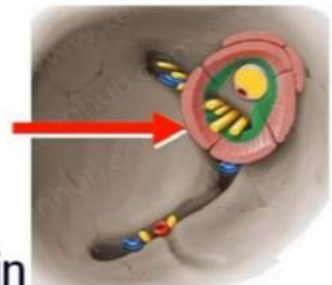Action: according to the name

1. Medial rectus: adduct the eye
2. Lateral rectus: abduct the eye
3. Superior rectus: elevate & adduct
4. Inferior rectus: depress & adduct

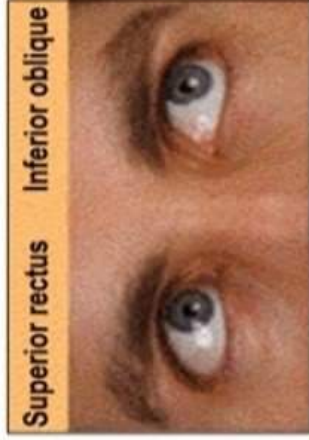
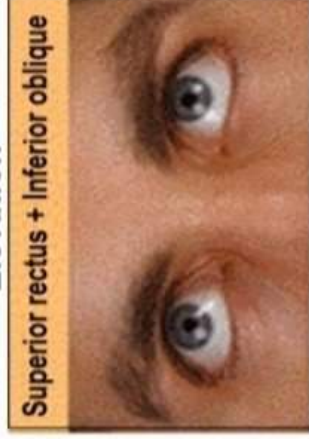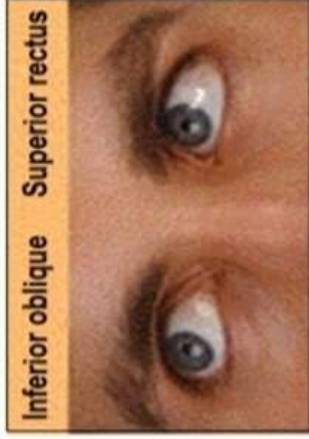NERVE SUPPLY:

All by the oculomotor nerve except the lateral rectus by the abducent nerve

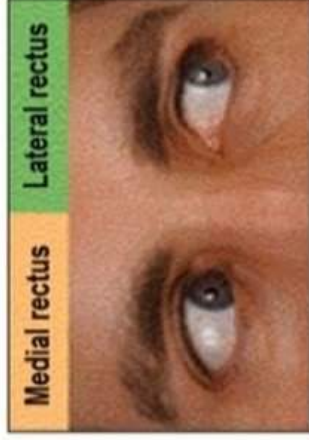
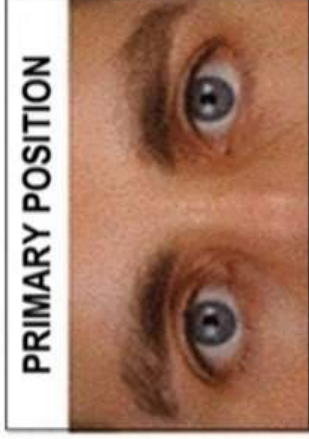
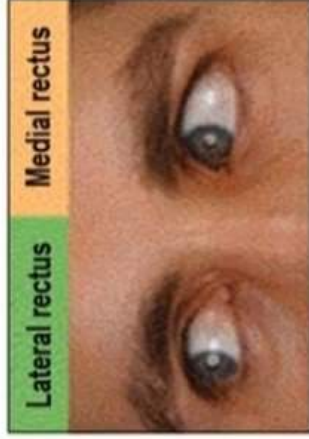
Dr Adel Bondok®



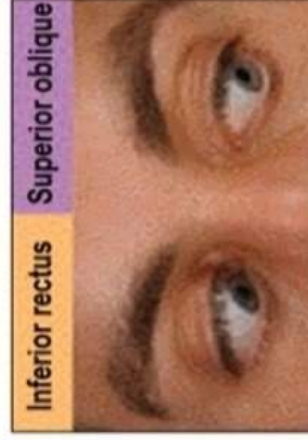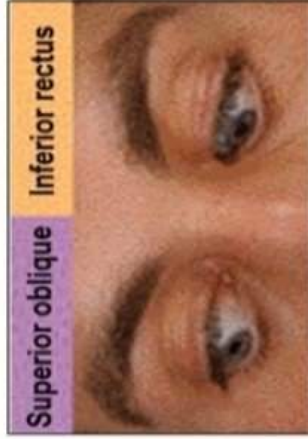Elevation



 III nerve



VI nerve

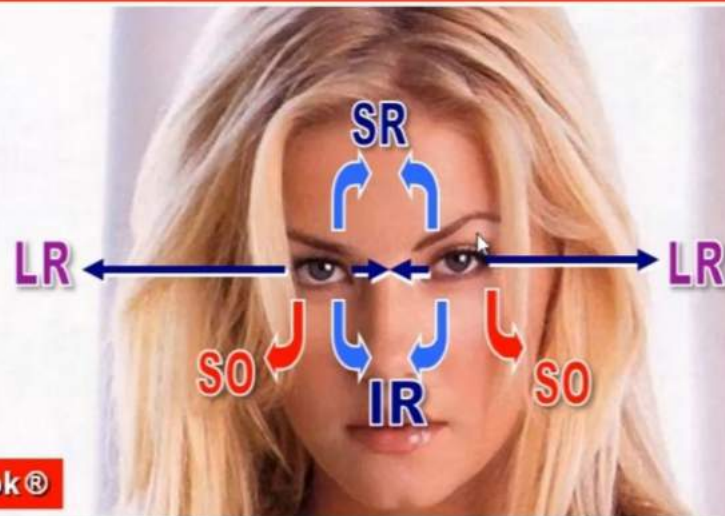


IV nerve

Depression

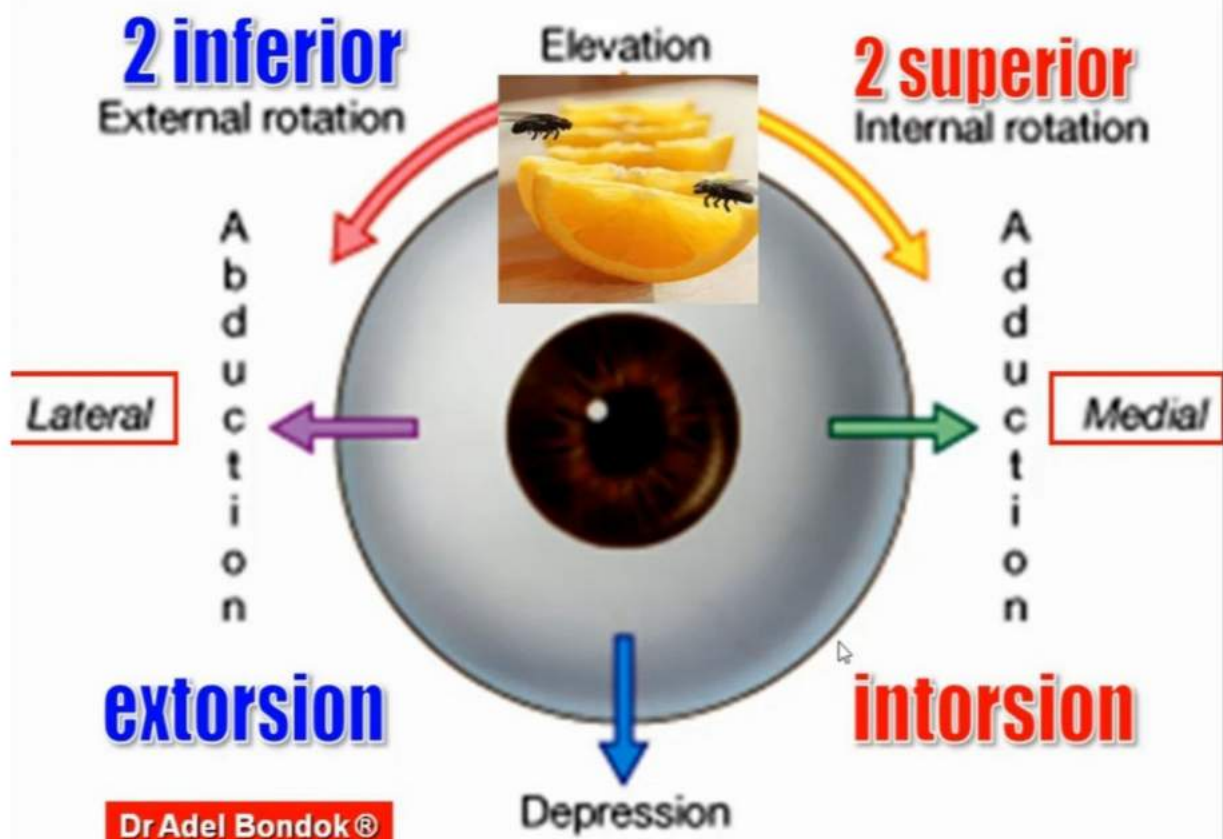
Dr Adel Bondok®

ACTION OF THE EXTRAOCULAR MUSCLES



Dr Adel Bondok®

1. **Medial rectus:** adduct the eye
2. **Lateral rectus:** abduct the eye
3. **Superior rectus:** elevate + adduct
4. **Inferior rectus:** depress + adduct
5. **Superior oblique:** depress + abduct
6. **Inferior oblique:** elevate + abduct



LESIONS

Parinaud's Syndrome

Loss of upward gaze

Lesion in the posterior commissure

May be due to Pinealoma

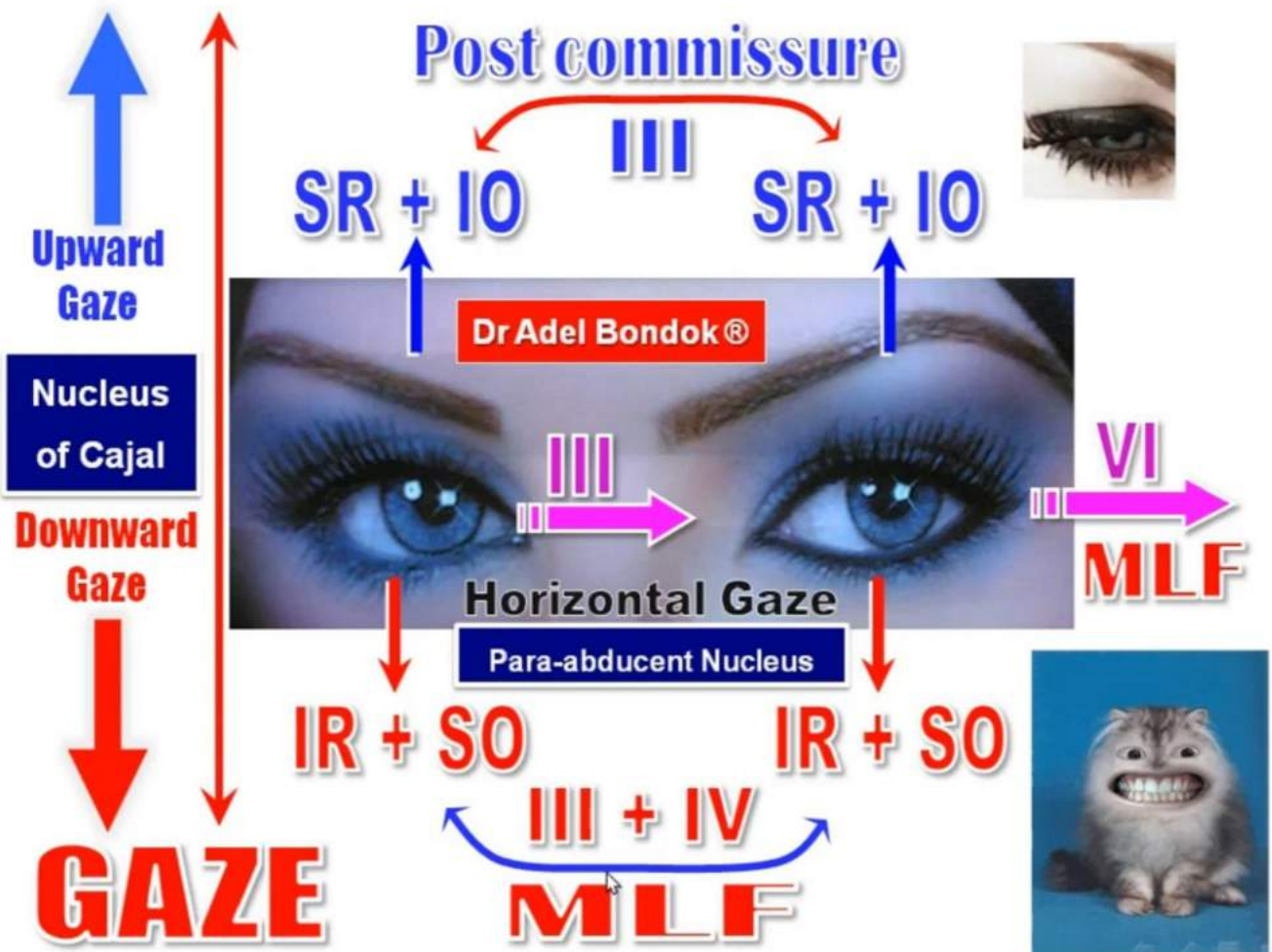Internuclear Ophthalmoplegia

Loss of horizontal or downward gaze

Lesion in the MLF

May be due to MS

Dr Adel Bondok®



Arteries of the Eyelids

1. From the ophthalmic artery:

- a. Supraorbital artery
- b. Supratrochlear artery
- c. Lacrimal artery

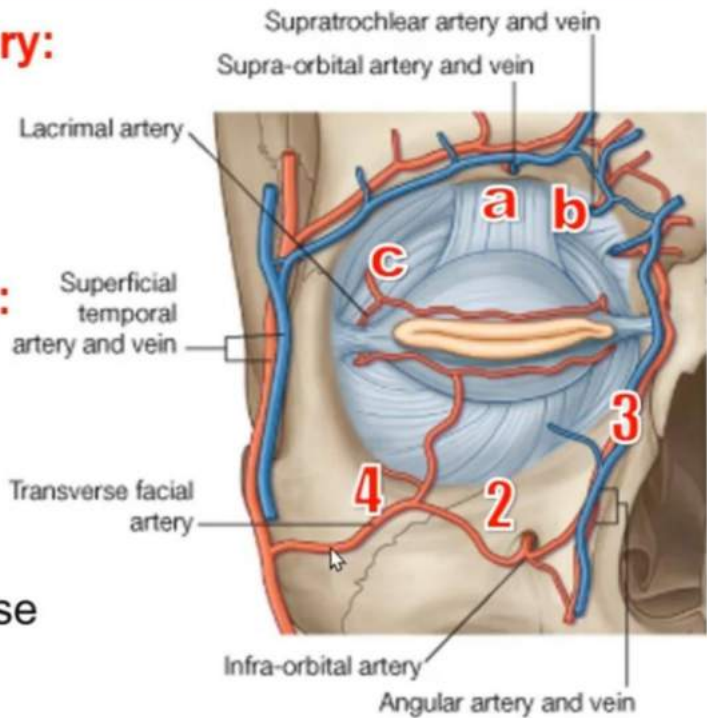
2. From the maxillary artery:

infraorbital artery

3. From the facial artery:

angular artery

4. From the superficial temporal artery: transverse facial artery

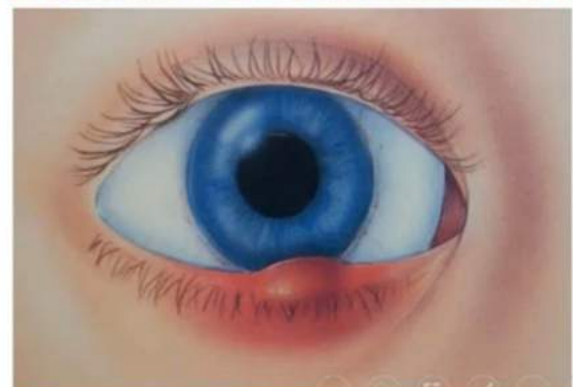
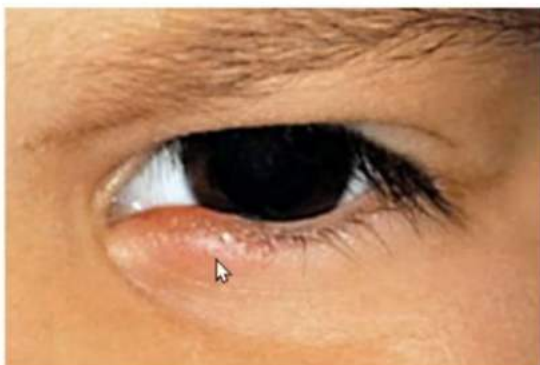
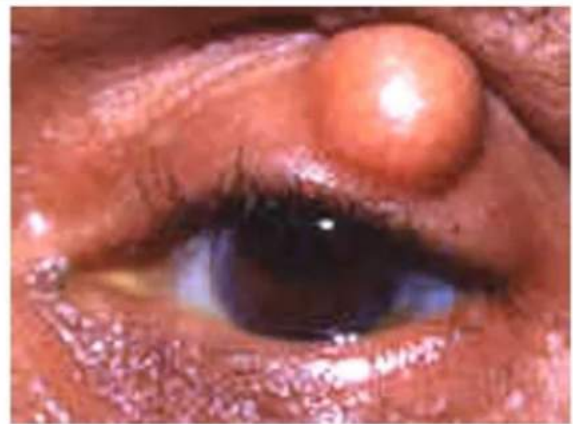From the Surrounding Arteries

Clinical Correlation

1. Chalazion: is due to obstruction of the **duct of Meibomian Gland**

2. Stye: is inflammation of the **skin glands**



Glands of the Eyelids

Glands of the Skin:

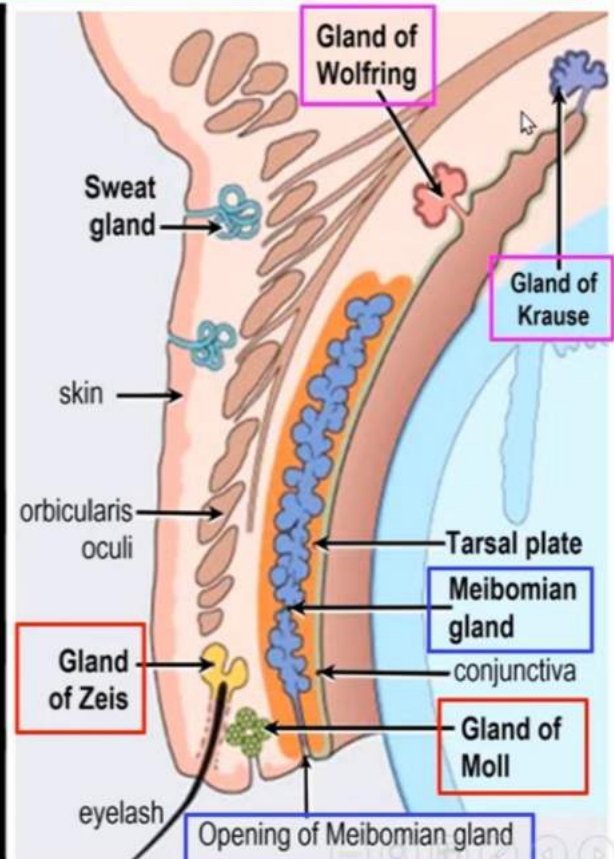
1. **Sebaceous glands of Zeis:** open into hair follicles
2. **Glands of Moll:** modified sweat glands. Open between eyelashes

Tarsal or Meibomian Glands:

Modified sebaceous glands
Open behind the eyelashes

Conjunctival Glands:


1. Goblet cells
2. Accessory lacrimal glands



Nerve Supply of the Eyelids

MOTOR: 3

1. **Orbicularis oculi:**
facial nerve
Lesion: inability to close the eye
2. **Levator palpebrae superioris:** III nerve
Lesion: complete ptosis
3. **Muller's muscle (superior tarsal):**
sympathetic fibers
Lesion: incomplete ptosis



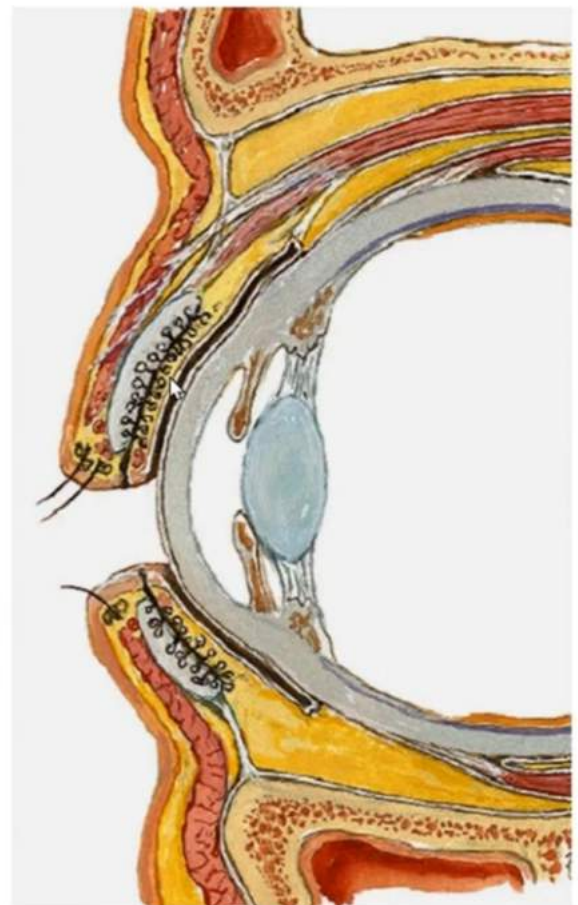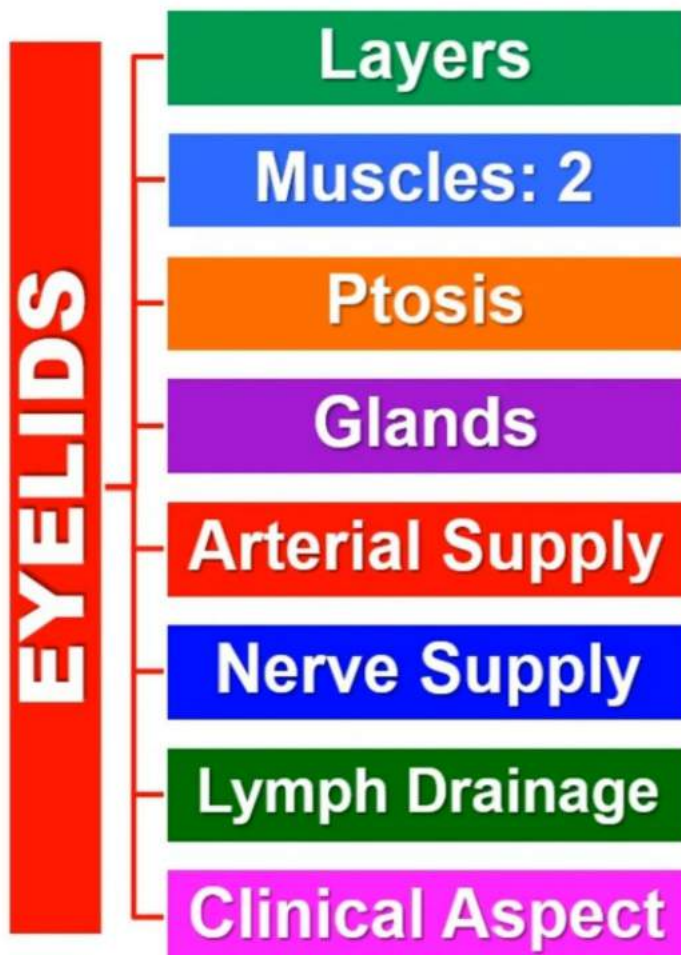
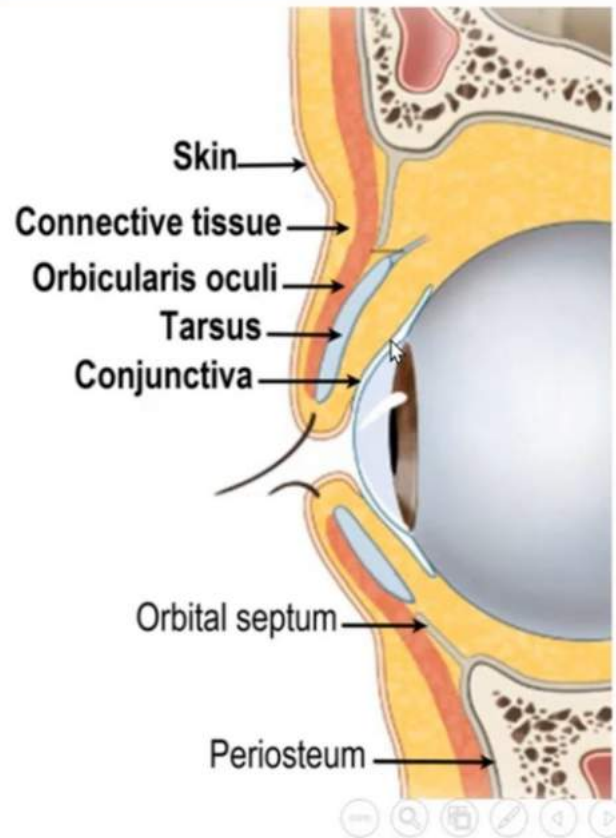
SENSORY

Upper Eyelid
Ophthalmic Nerve

LOWER EYELID
Maxillary Nerve

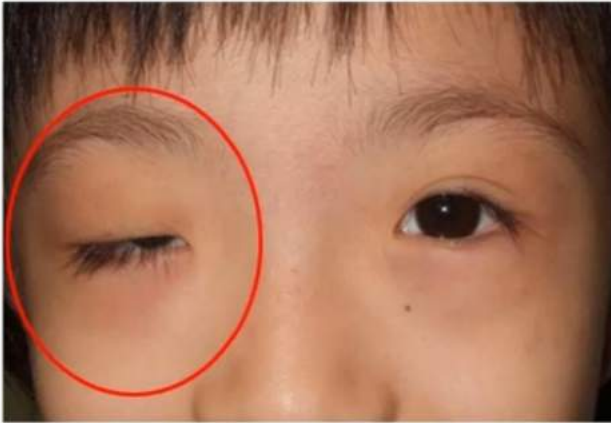Layers of the Eyelids

- 👁️ **Skin**
- 👁️ Thin layer of **connective tissue**
- 👁️ Palpebral part of the **orbicularis oculi muscle**
- 👁️ **Tarsus**: dense fibrous tissue. Receives the insertion of the **levator palpebrae superioris**
- 👁️ **Conjunctiva**: thin membrane covers the back of the eyelid



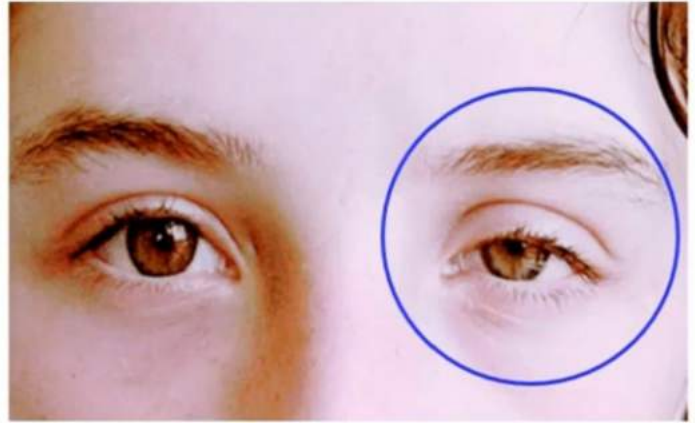
PTOSIS: Drooping of the Upper Eyelid

Complete



Paralysis of the levator palpebrae superioris
(oculomotor nerve)

Incomplete



Paralysis of Muller's muscle (symp fibers)
(Horner's Syndrome)

Eyelid Muscles: 2

1. **Orbicularis oculi:** for closure
2. **Levator palpebrae superioris:**

Origin: roof of the orbit

Insertion: 2 parts

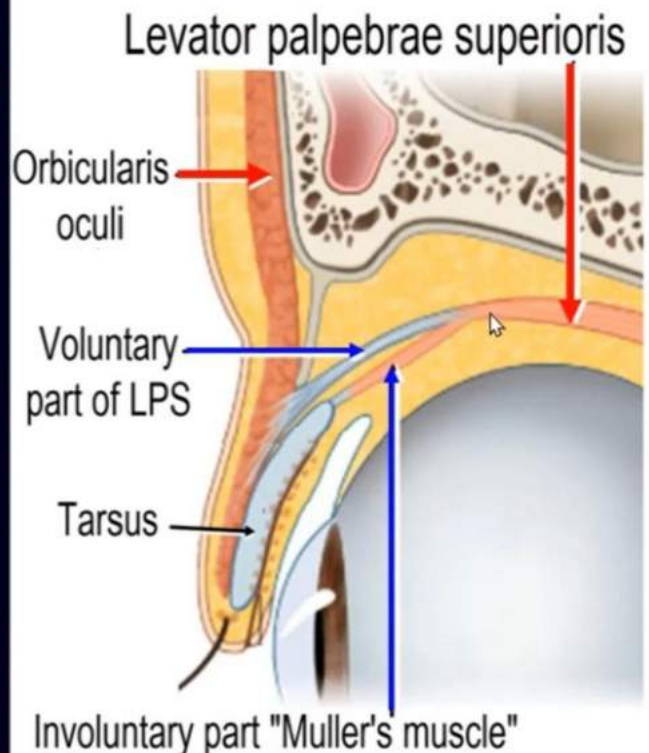
- a. Voluntary: **into the skin**
- b. Involuntary: **Muller's muscle smooth muscle into the tarsus**

Nerve Supply: 2 parts

- a. Voluntary: oculomotor nerve
- b. Involuntary: **Muller's muscle sympathetic plexus around ICA. Reach the muscle with the oculomotor nerve**

Action: elevates the upper eyelid

Paralysis: ptosis (drooping)



Arteries of the Eyelids

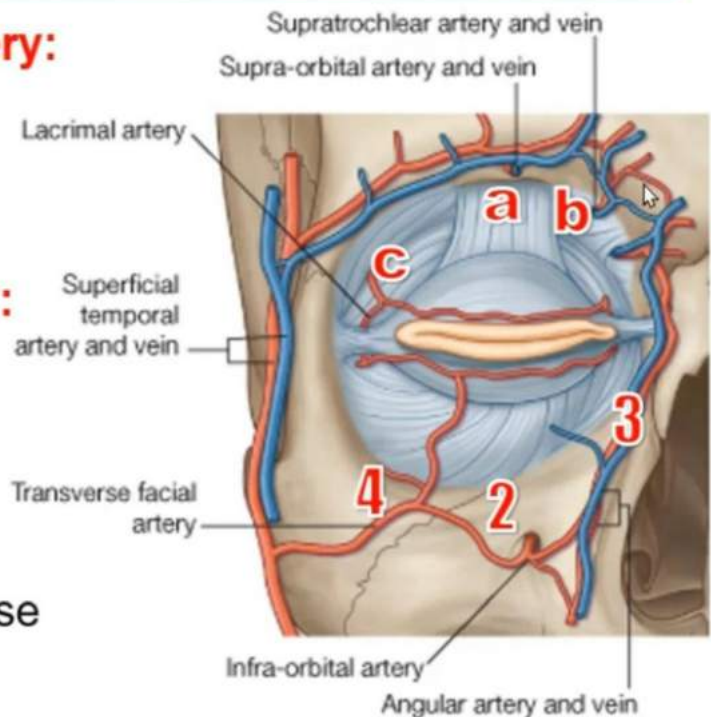
1. From the ophthalmic artery:

- a. Supraorbital artery
- b. Supratrochlear artery
- c. Lacrimal artery

2. From the maxillary artery: infraorbital artery

3. From the facial artery: angular artery

4. From the superficial temporal artery: transverse facial artery



From the Surrounding Arteries

Glands of the Eyelids

Glands of the Skin:

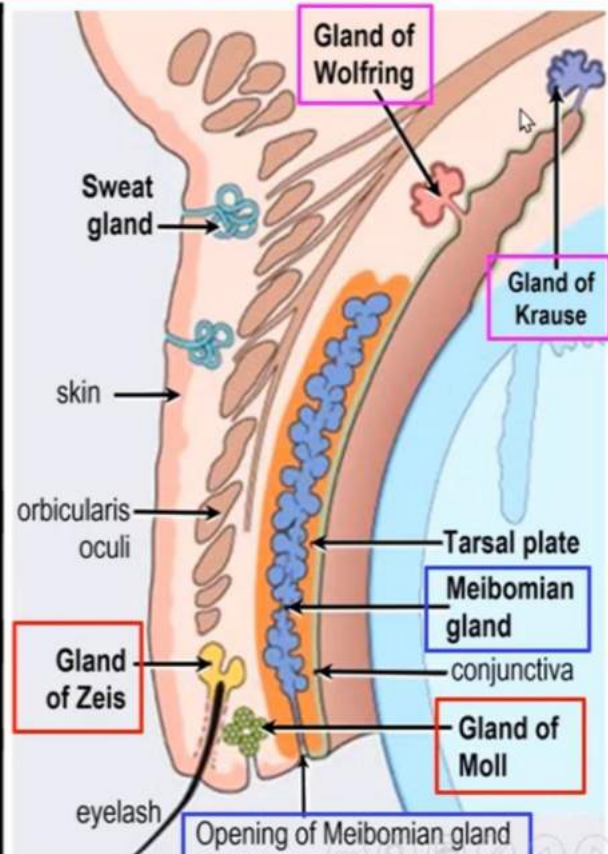
1. **Sebaceous glands of Zeis:**
open into hair follicles
2. **Glands of Moll:** modified sweat glands. **Open** between eyelashes

Tarsal or Meibomian Glands:

- Modified** sebaceous glands
- Open behind** the eyelashes

Conjunctival Glands:

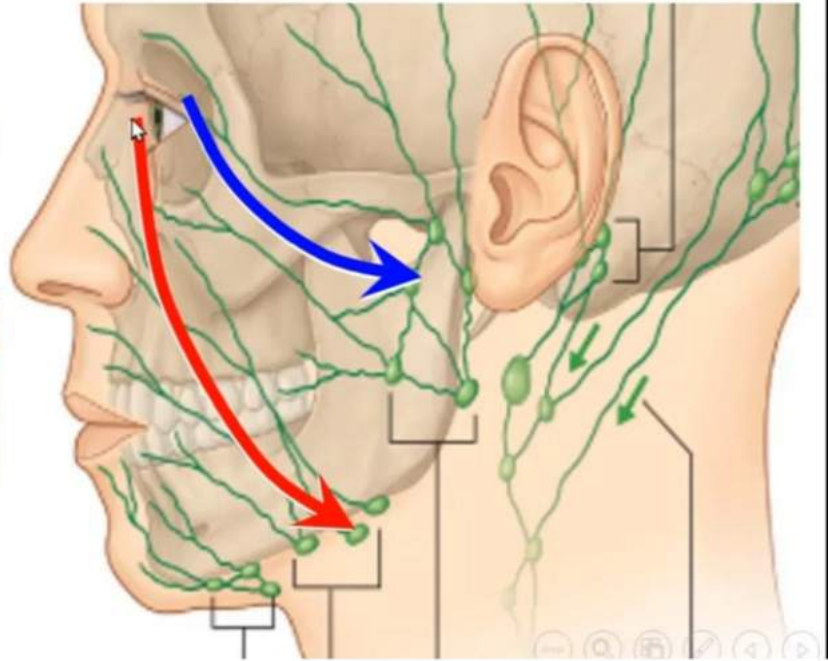
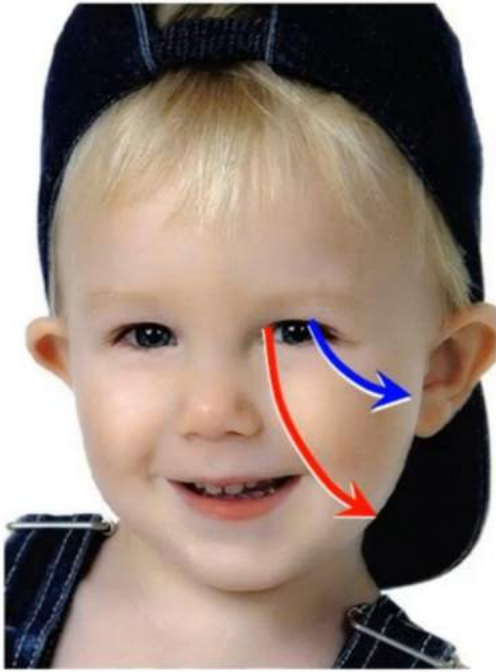1. **Goblet cells**
2. **Accessory lacrimal glands**



Lymph Drainage of the Eyelids

1. Medial Part: submandibular lymph nodes

2. Lateral Part: parotid lymph nodes



Nerve Supply of the Eyelids

MOTOR: 3

SENSORY

1. Orbicularis oculi:

facial nerve

Lesion: inability to close the eye

2. Levator palpebrae superioris: III nerve

Lesion: complete ptosis

3. Muller's muscle (superior tarsal):

sympathetic fibers

Lesion: incomplete ptosis



Upper Eyelid

Ophthalmic Nerve

LOWER EYELID

Maxillary Nerve



Gaze Centers

How the 2 Eyes Move Together

Vertical Gaze

Up and Down

Nucleus of Cajal



Horizontal Gaze

Right and Left

Paraabducent nucl

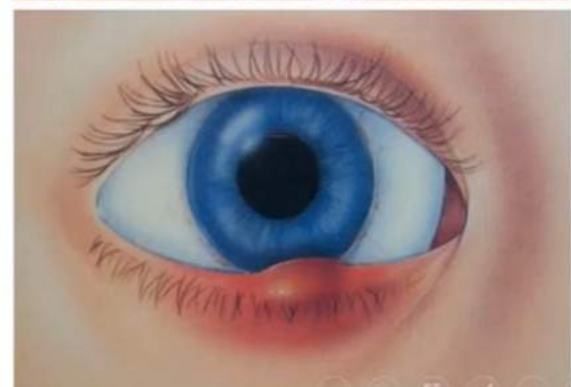
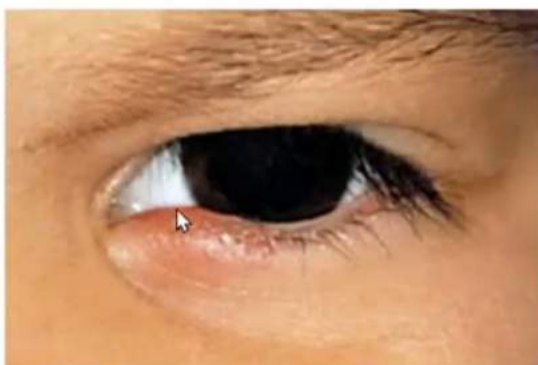
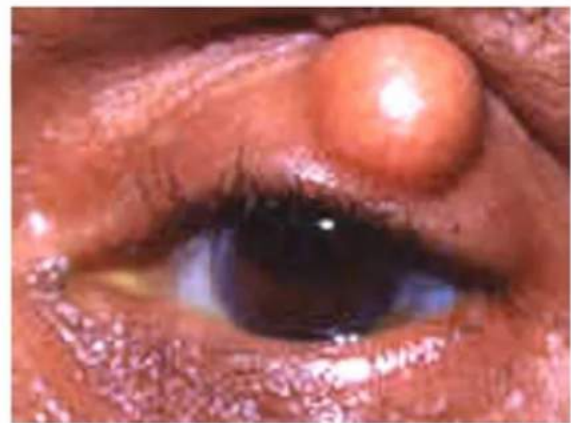Dr Adel Bondok®

Clinical Correlation

1. Chalazion: is due to obstruction of the **duct of Meibomian Gland**

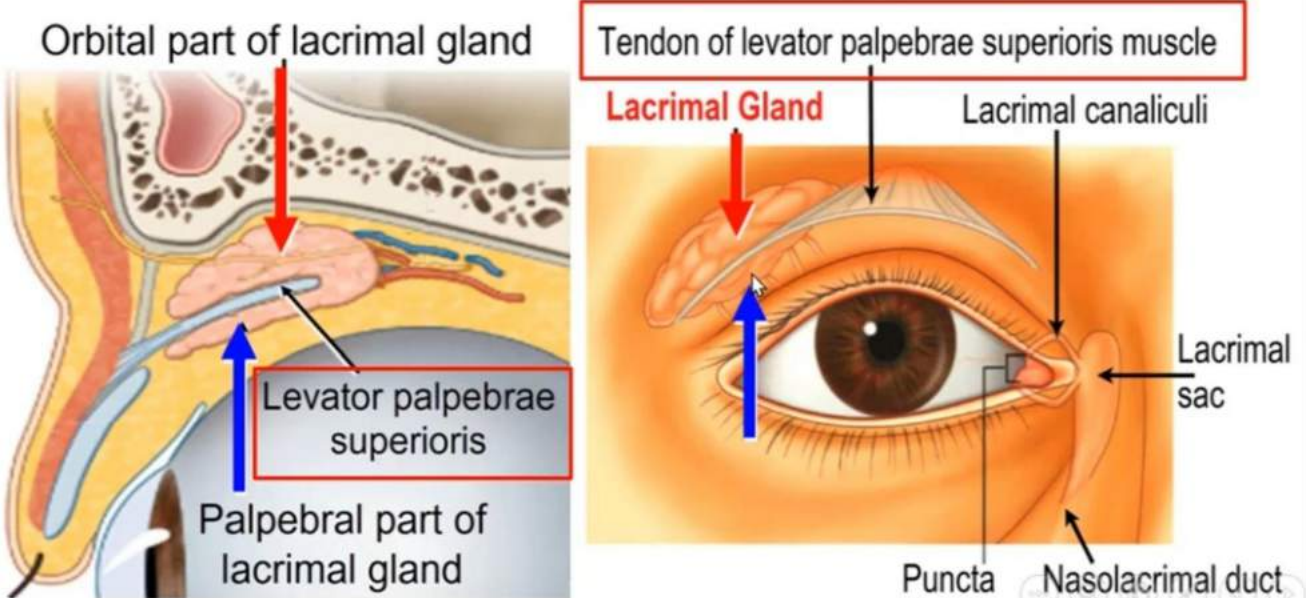
2. Stye: is inflammation of the **skin glands**



Parts of the Lacrimal Gland

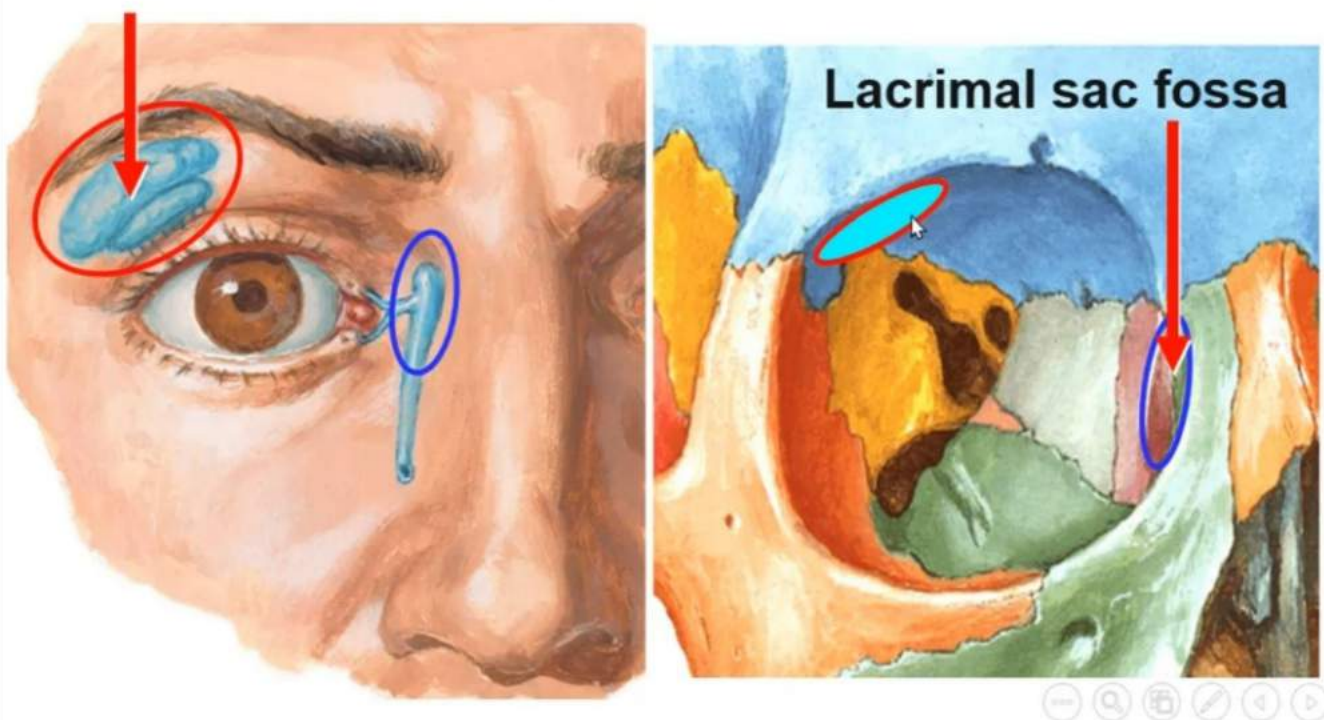
It is divided by the **levator palpebrae superioris** into 2 parts:

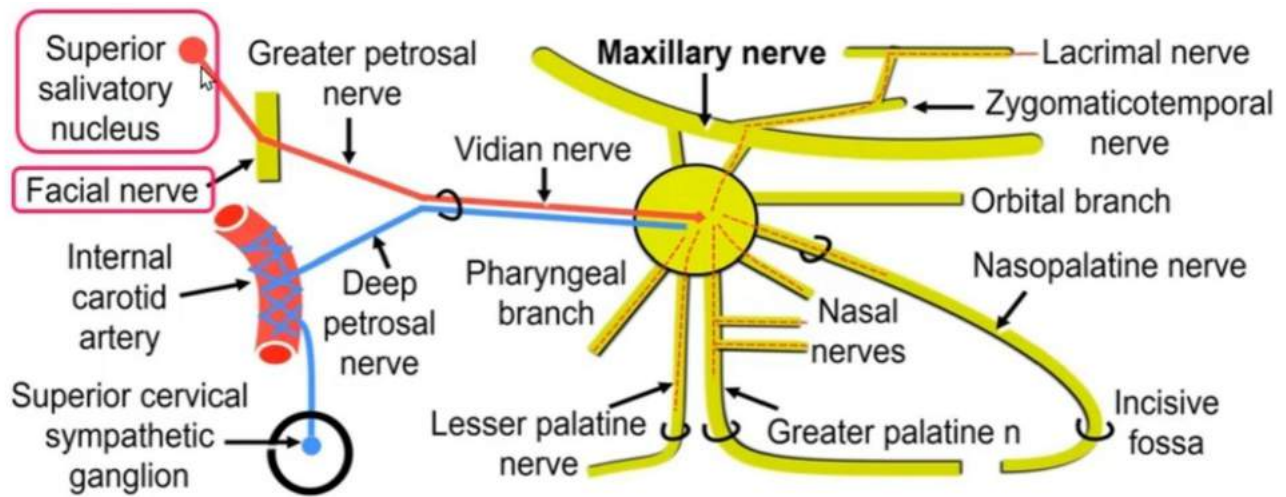
- 1. Large Orbital Part:** in the lacrimal fossa **above** the muscle
- 2. Small Palpebral Part:** in the upper eyelid **below** the muscle



Location of the Lacrimal Gland

In the **lacrimal gland fossa** in the upper lateral part of the roof of the orbit





Parasympathetic Fibers To Lacrimal Gland

superior salivatory nucleus ⇒ facial nerve ⇒ greater superficial petrosal nerve ⇒ join the deep petrosal nerve ⇒ nerve of pterygoid canal ⇒ pterygopalatine (sphenopalatine) ganglion ⇒ maxillary nerve ⇒ zygomatic nerve ⇒ zygomaticotemporal nerve ⇒ lacrimal nerve ⇒ lacrimal gland

LACRIMAL GLAND

Ducts:

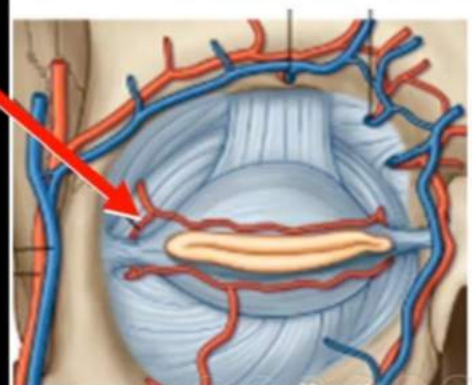
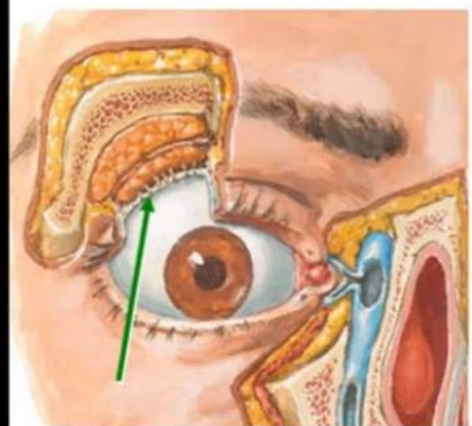
- ❑ about 12 in number
- ❑ open in the superior conjunctival fornix. The fluid is moved medially by blinking and accumulates in the lacrimal lake & drained by the canaliculi.

Arterial Supply:

Lacrimal artery (ophthalmic artery)

Nerve Supply:

1. Sensory: lacrimal n, ophthalmic
2. Parasympathetic: facial nerve
3. Sympathetic: SCSG > deep petrosal n



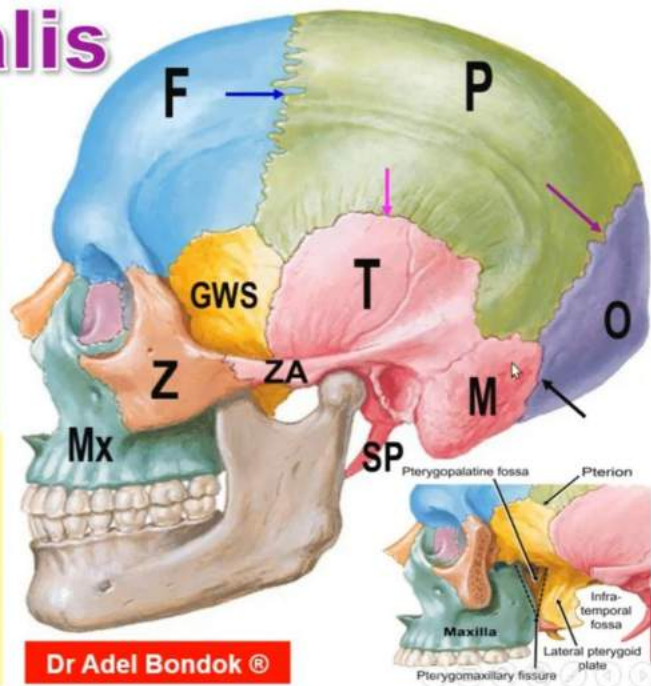
Norma Lateralis

Identify the Bones:

1. Above: frontal, parietal & occipital bone
2. Zygomatic bone & zygomatic arch
3. Greater wing of sphenoid
4. Squamous part of the temporal bone
5. Mastoid process & Styloid process
6. Bones of the face: nasal & maxilla
7. Infratemporal fossa & pterygomaxillary fissure: deep to the ramus of the mandible

Identify the Sutures:

1. Coronal suture
2. Lambdoid suture.
3. Squamosal suture: between parietal & temporal bones
4. Occipitomastoid suture & mastoid foramen
5. Parietomastoid & frontozygomatic sutures



Dr Adel Bondok ®

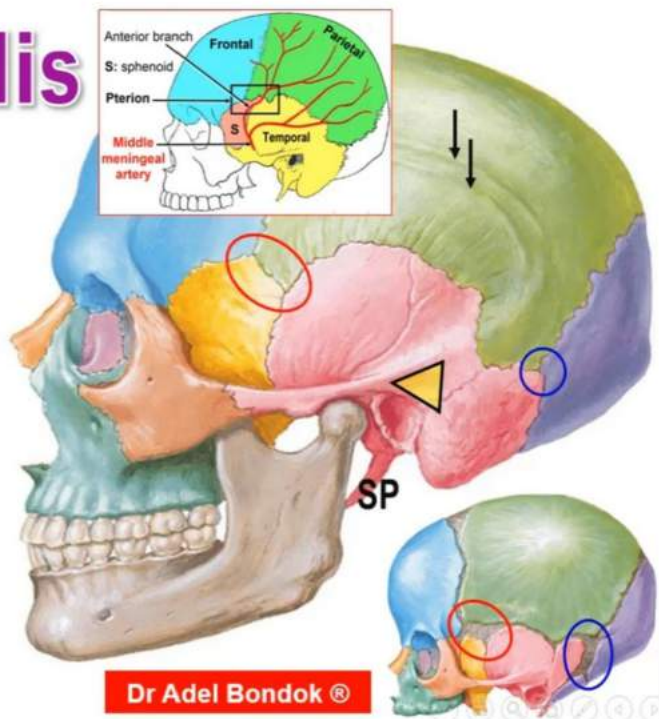
Norma Lateralis

Identify the Bony Landmarks:

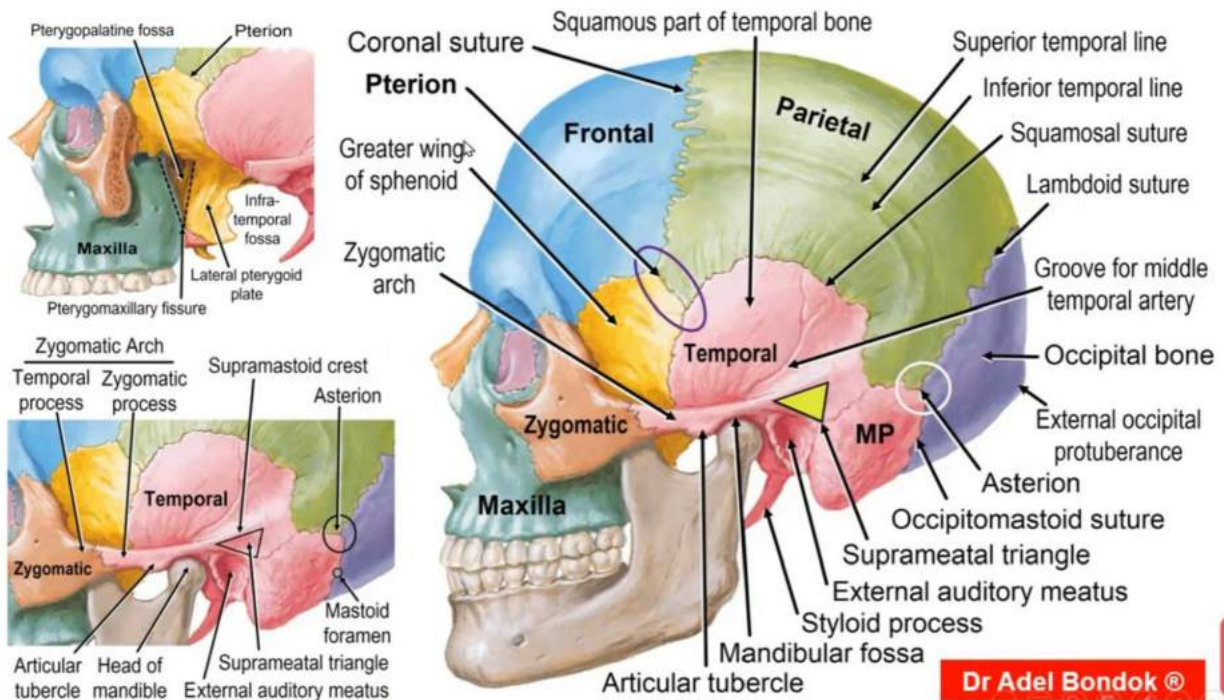
1. Pterion: site of anterolateral fontanelle.
2. Asterion: site of posterolateral fontanelle
3. Superior and inferior temporal lines
4. External auditory meatus
5. Suprameatal triangle
6. Articular tubercle & head of mandible

5 Structures Attached to the Styloid Process: 3 M & 2 L

1. Stylohyoid muscle: by the VII n
2. Styloglossus muscle: by the XII n.
3. Stylopharyngeus muscle: by the IX n
4. Stylohyoid ligament
5. Stylomandibular ligament



Dr Adel Bondok ®



3. Posterior Cranial Fossa

Identify the Bones:

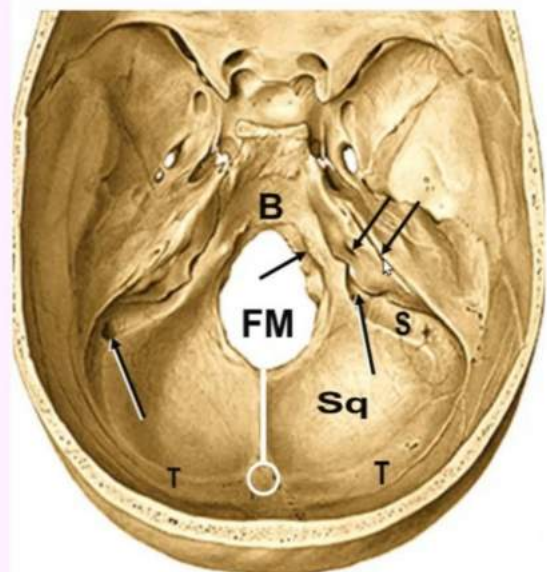
1. Basilar part of the occipital bone
2. Squamous part of the occipital bone
3. Clivus: formed of sphenoid & basilar part of occipital b
4. Internal occipital protuberance
5. Internal occipital crest

Identify the Foramina:

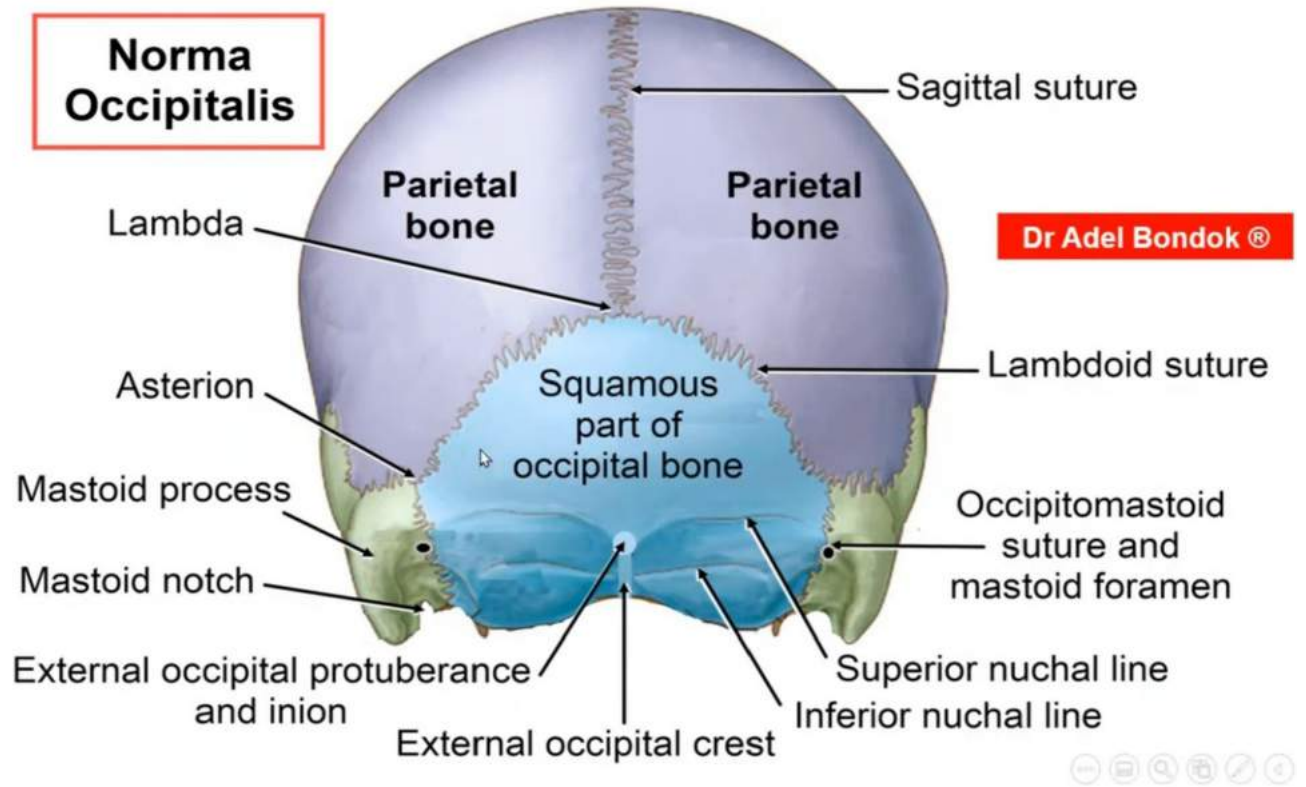
- a. Foramen magnum
- b. Jugular foramen: between occipital & petrous TB
- c. Hypoglossal canal (anterior condylar canal)
- d. Internal auditory meatus
- e. Mastoid foramen: in the groove for sigmoid sinus

Identify the Grooves for dural venous sinuses:

- a. Transverse sinus.
- b. Sigmoid sinus
- c. Superior petrosal sinus



Dr Adel Bondok ®



Norma Occipitalis

Identify the Bones:

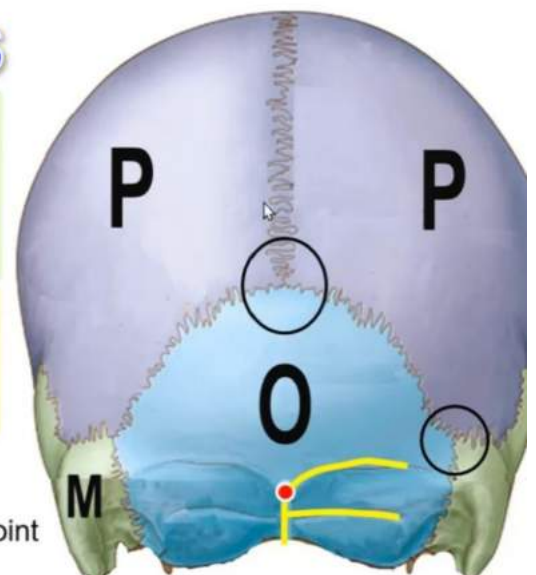
1. Right & left parietal bones
2. Squamous part of the occipital bone
3. Mastoid process

Identify the Sutures:

1. Sagittal suture & Lambdoid suture.
2. Occipito-mastoid & Parieto-mastoid sutures

Identify the Bony Landmarks:

1. External occipital protuberance. Inion is the prominent point
2. External occipital crest
3. Lambda: meeting of the sagittal & lambdoid sutures.
4. Asterion: meeting of 3 bones: parietal, occipital and mastoid bones
5. 3 Nuchal lines: highest, superior & inferior.
6. Mastoid notch (digastric notch)
7. Mastoid foramen: emissary vein & meningeal branch of occipital artery

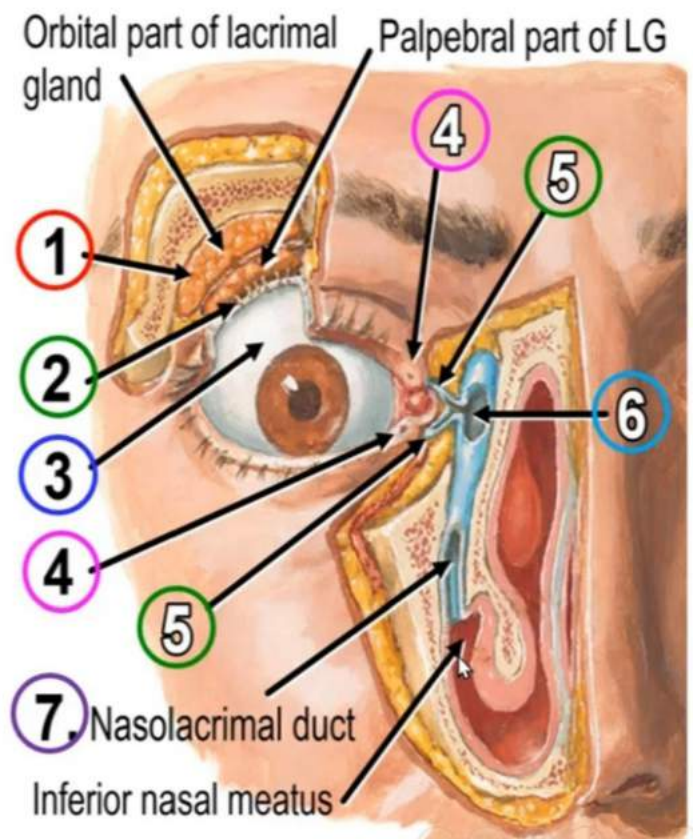


Dr Adel Bondok ®

LACRIMAL APPARATUS

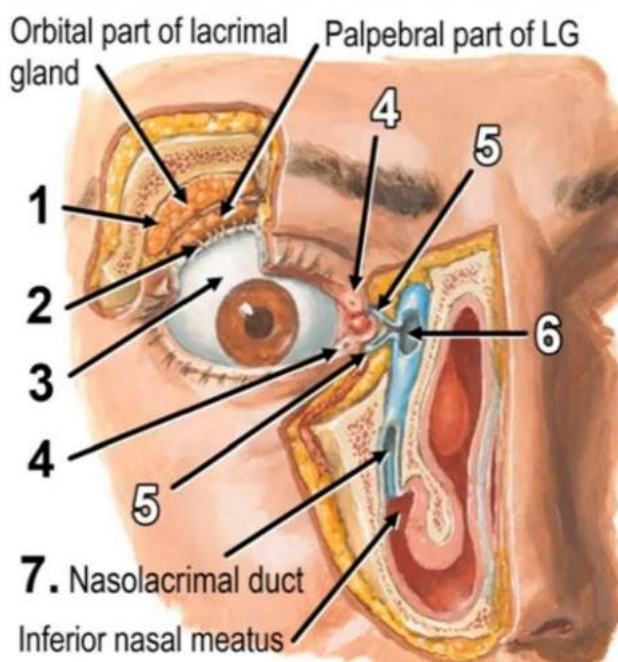
COMPONENTS

1. **Lacrimal Gland**
2. **Lacrimal Ducts: 12**
3. **Conjunctival Sac**
4. **Superior & Inferior Lacrimal Puncta**
5. **Lacrimal Canaliculi**
6. **Lacrimal Sac:** in the lacrimal sac fossa
7. **Nasolacrimal Duct:** opens in the inferior nasal meatus



Lacrimal Apparatus

Components



Lacrimal Gland

Location

Parts: 2

Ducts: 12

Arterial Supply

Nerve Supply

TYMPANIC MEMBRANE

NERVE SUPPLY

1. Outer Surface:

- a. Auriculotemporal nerve (mandibular nerve)
- b. Auricular branch of the vagus

2. Inner surface: tympanic branch of the IX nerve

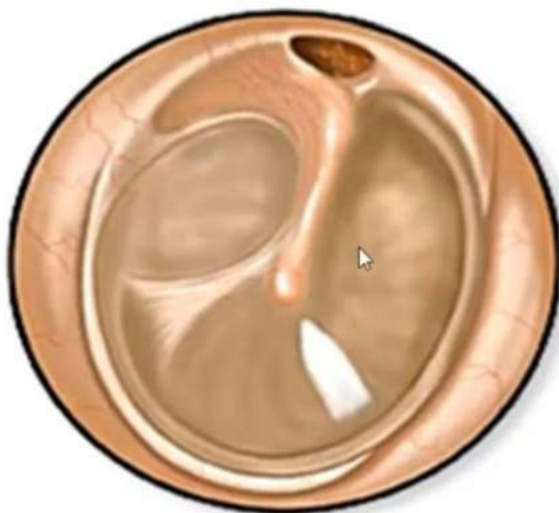ARTERIAL SUPPLY

1st part of the maxillary artery

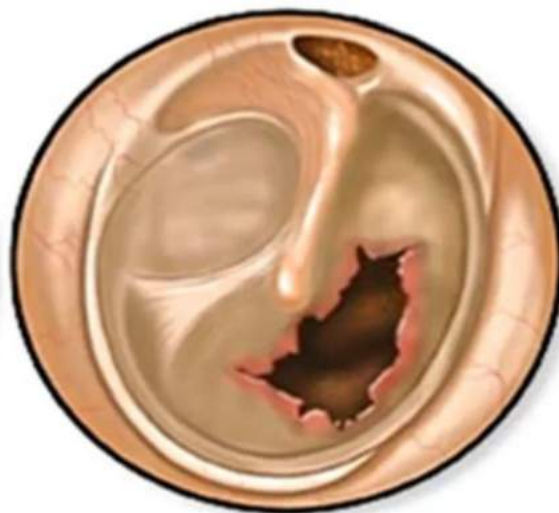1. Outer surface: deep auricular artery

2. Inner surface: anterior tympanic artery

Normal
eardrum



Ruptured
eardrum



LAYERS: 3 layers

1. **Outer concave layer:** skin
2. **Middle layer:** fibrous tissue
3. **Inner layer:** mucous membrane

PARTS: 2 parts

1. **Pars flaccida:** upper 1/6
doesn't have fibrous layer
2. **Pars tensa:** remaining 5/6
The 2 parts are separated by anterior & posterior malleolar folds

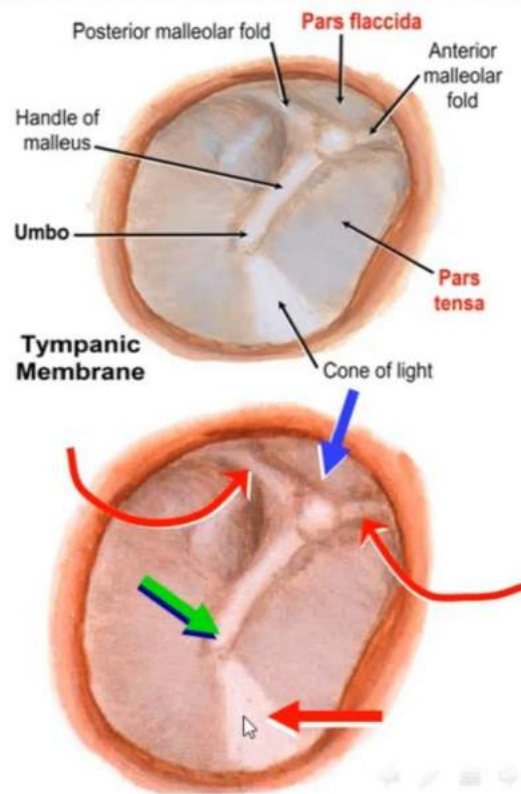
Umbo:

Depression in the center produced by the handle of malleus

Cone of light:

In the anteroinferior quadrant.
It reflects the light of the doctor's mirror

TYMPANIC MEMBRANE



EXTERNAL AUDITORY MEATUS

LENGTH: 2.5 cm

SHAPE: S-shaped

PARTS: 2 parts

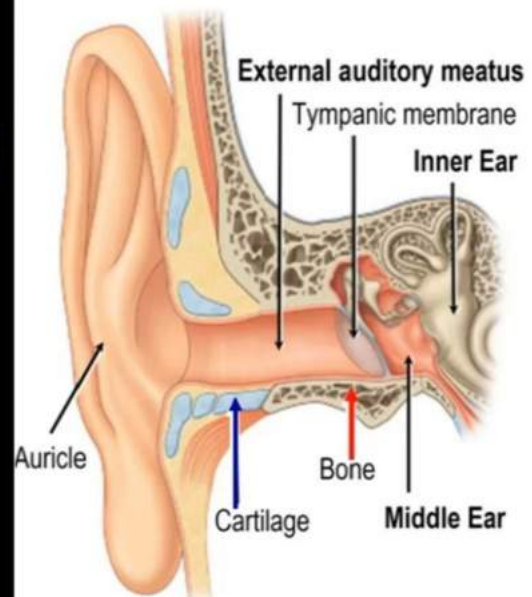
1. **Cartilaginous part:** outer 1/3
contains glands that secrete wax
2. **Bony part:** inner 2/3

NERVE SUPPLY:

1. Auriculotemporal nerve
2. Auricular branch of vagus

ARTERIAL SUPPLY: 3

1. Anterior auricular artery (STA)
2. Posterior auricular artery
3. Deep auricular artery (maxillary)



THE EAR

EXTERNAL EAR:

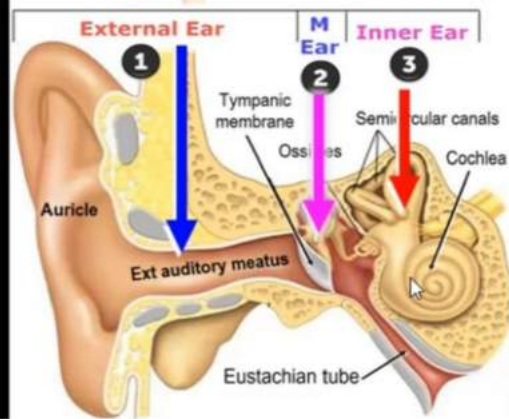
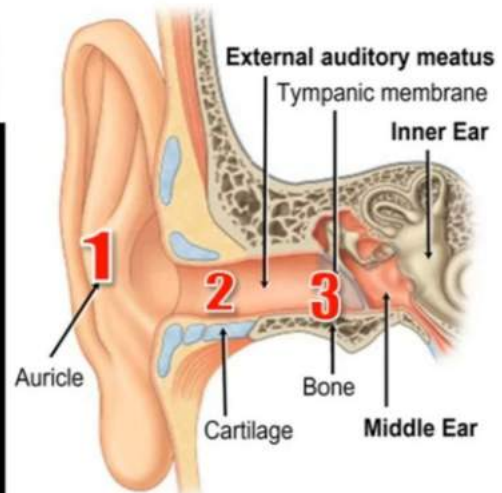
1. Auricle
2. External Auditory Meatus
3. Tympanic Membrane

MIDDLE EAR:

1. Boundaries
2. Contents
3. Eustachian tube

INTERNAL EAR:

1. Bony Labyrinth
2. Membranous Labyrinth



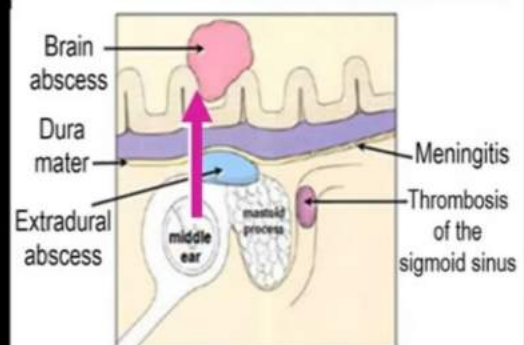
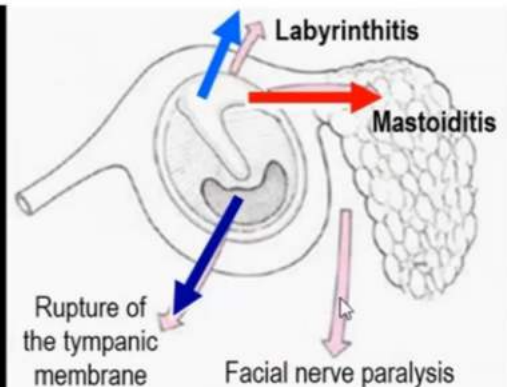
OTITIS MEDIA

DEFINITION:

is inflammation of the middle ear

COMPLICATIONS:

1. Rupture of tympanic membrane may lead to **deafness**
2. Extension to the mastoid process causing **mastoiditis**
3. Extension to the inner ear causing **labyrinthitis**
4. Extension to the cranial cavity causing **meningitis** or **brain abscess**
5. Extension to the facial nerve causing **facial paralysis**



Intracranial Complications of Otitis Media

NERVE SUPPLY

OUTER SURFACE: 4

1. **Auriculotemporal nerve:** upper part
2. **Great auricular nerve:** lower part
3. **Auricular branch of vagus:** concha
4. **Facial nerve:** post auricular branch

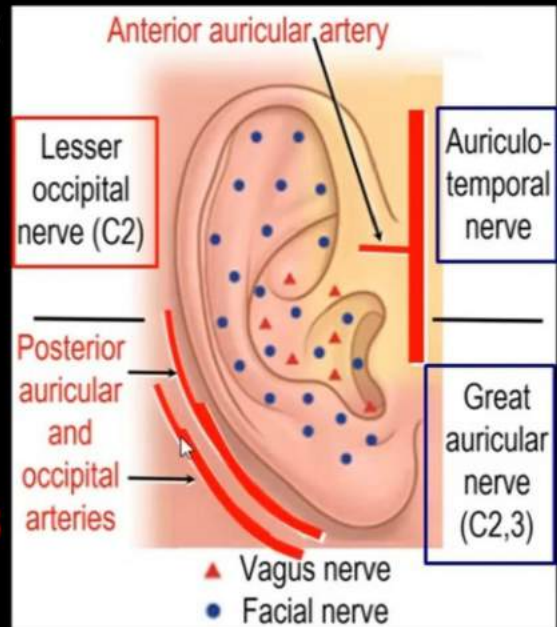
INNER SURFACE: 2

1. **Lesser occipital nerve:** upper part
2. **Great auricular nerve:** lower part

ARTERIAL SUPPLY: 3

1. **Superficial temporal artery**
2. **Posterior auricular & Occipital artery**

THE AURICLE



THE EXTERNAL EAR

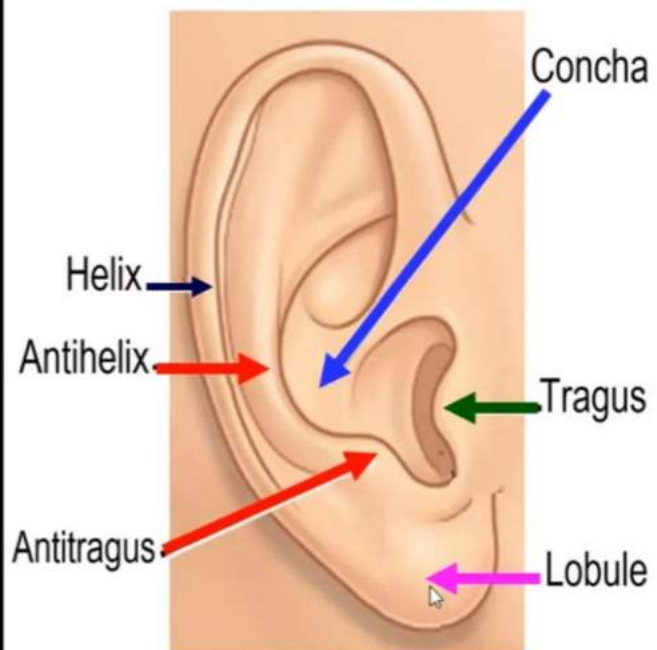
AURICLE

Skeleton:

Elastic cartilage + skin

Parts: 5

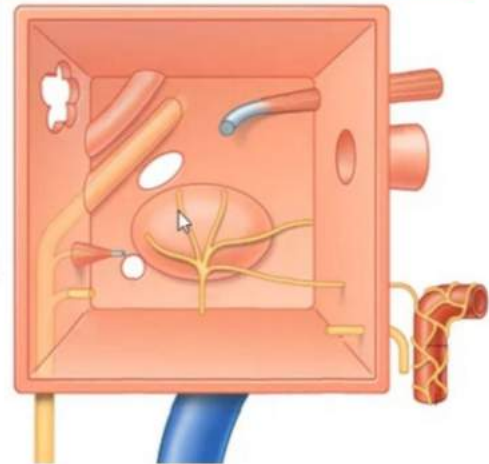
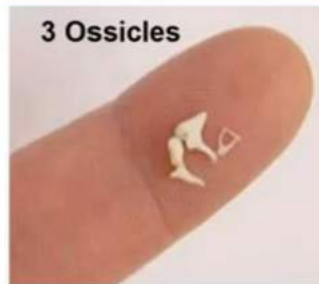1. **Helix**
2. **Antihelix:**
terminates as antitragus
3. **Concha**
4. **Tragus**
5. **Lobule**



CONTENTS OF MIDDLE EAR

3 OSSICLES:

- a. Malleus
- b. Incus
- c. Stapes

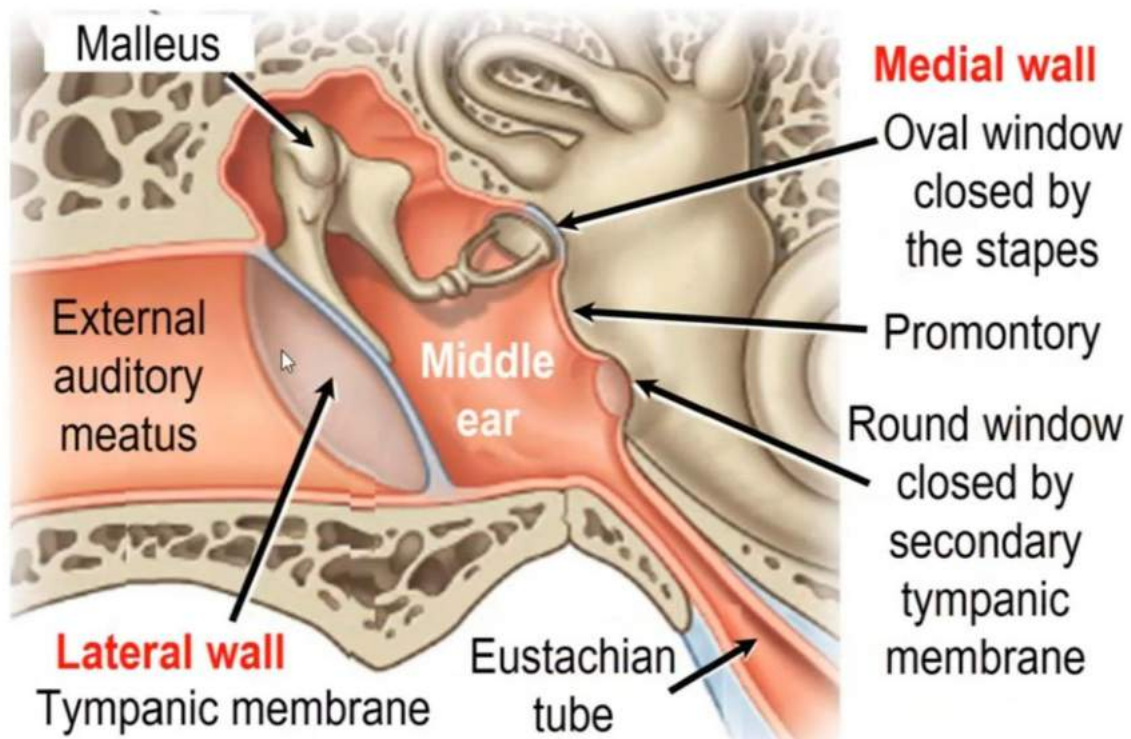


2 MUSCLES:

- a. Tensor tympani
- b. Stapedius

2 NERVES:

- a. Chorda tympani
- b. **TYMPANIC PLEXUS:** on the medial wall. **Formed by:**
 - 1. **Tympanic branch:** of IX nerve
 - 2. **Caroticotympanic nerve:** sympathetic around ICA
 - 3. **Facial nerve:** communicating branch



THE INNER EAR

■ **FORMATION:**

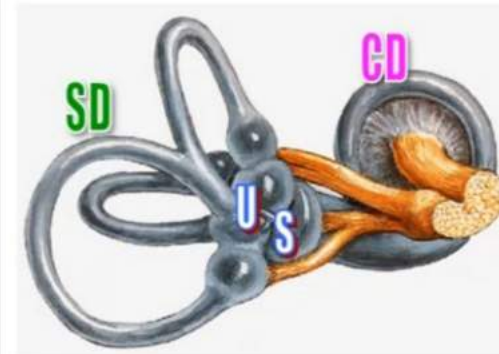
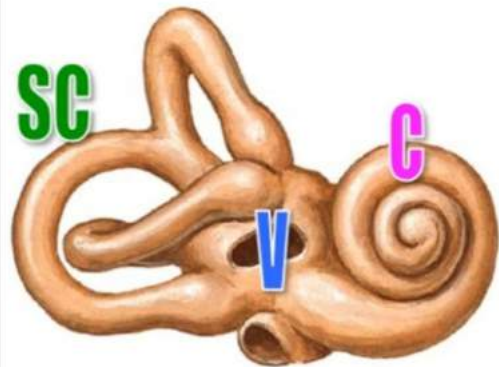
1. **Bony Labyrinth**
2. **Membranous Labyrinth:** inside the bony

BONY LABYRINTH:

- Filled with perilymph
- Formed of 3 parts:
 1. **Cochlea:**
 2. **Vestibule**
 3. **3 Semicircular canals:**
Superior, posterior & lateral

MEMBRANOUS LABYRINTH:

- Filled with endolymph
- Formed of 3 parts:
 1. **Cochlear duct:** contains organ of Corti
 2. **Utricle & Sacculle:** in the vestibule and contain the sensory **macula**
 3. **Semicircular ducts:** in the canals and contain the sensory **crista ampullaris**



EUSTACHIAN TUBE

LENGTH: 4 cm (36 mm)

PARTS:

1. **Cartilaginous part:** ant 2/3
2. **Bony part:** posterior 1/3

CONNECTS:

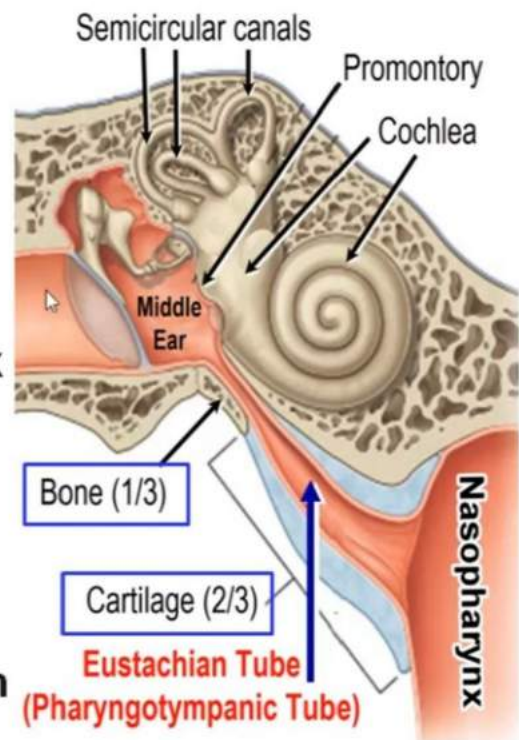
Tympanic cavity with nasopharynx

NERVE SUPPLY:

Tympanic plexus (IX nerve)

FUNCTION:

1. Ventilation of the middle ear
2. Equalizes air pressure on each side of tympanic membrane



THE LARYNX

Skeleton: Cartilages

Membranes & Ligaments:

Laryngeal Inlet:

Laryngeal Cavity:

Muscles:

1. Extrinsic: move the larynx up & down

a. Elevators: suprahyoid muscles

b. Depressors: infrahyoid muscles

2. Intrinsic: act on vocal cord & inlet

a. Move the vocal cord: 4 directions

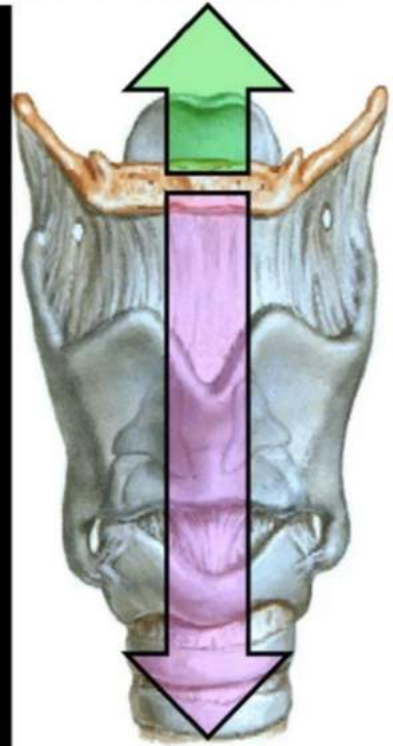b. Close or open the laryngeal inlet

Blood Supply

Nerve Supply

Lymph Drainage

Adel Bondok



Cartilages of the Larynx

3 SINGLE & 3 PAIRED

3 SINGLE

1. Thyroid cartilage

2. Cricoid cartilage

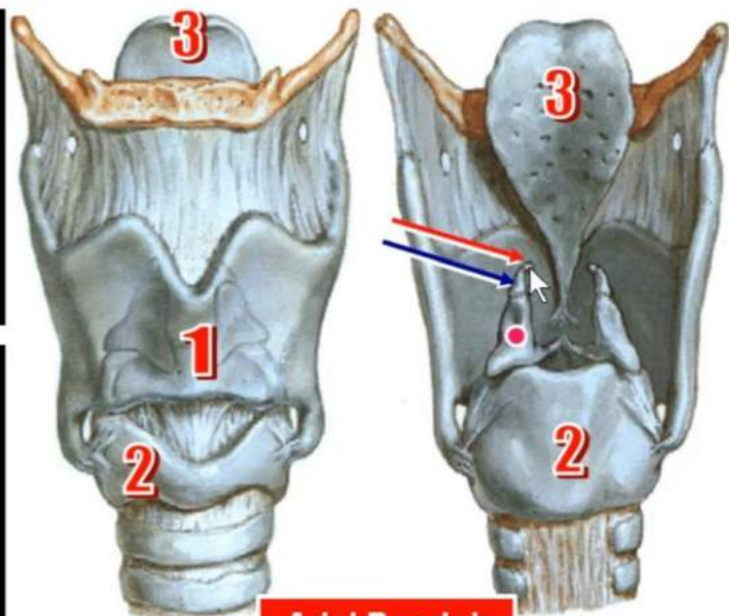
3. Epiglottis

3 PAIRED

1. Arytenoid

2. Corniculate

3. Cuneiform



Adel Bondok

THE EAR

EXTERNAL EAR:

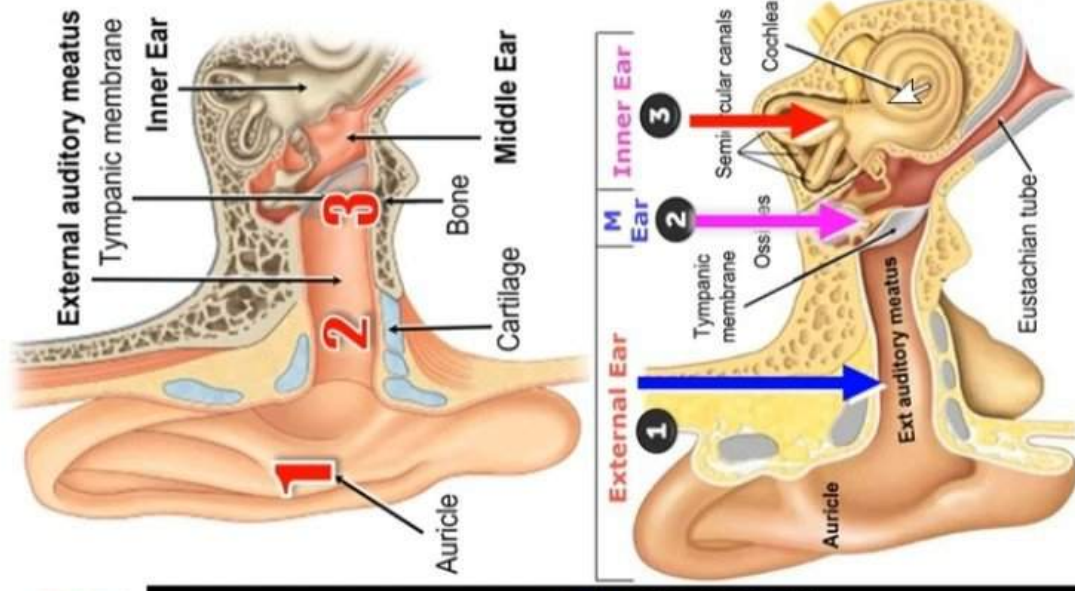
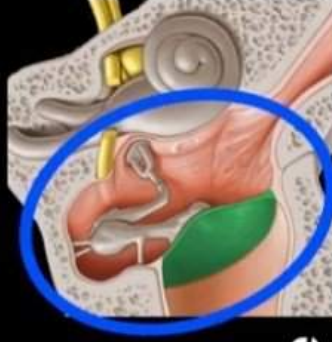1. Auricle
2. External Auditory Meatus
3. Tympanic Membrane

MIDDLE EAR:

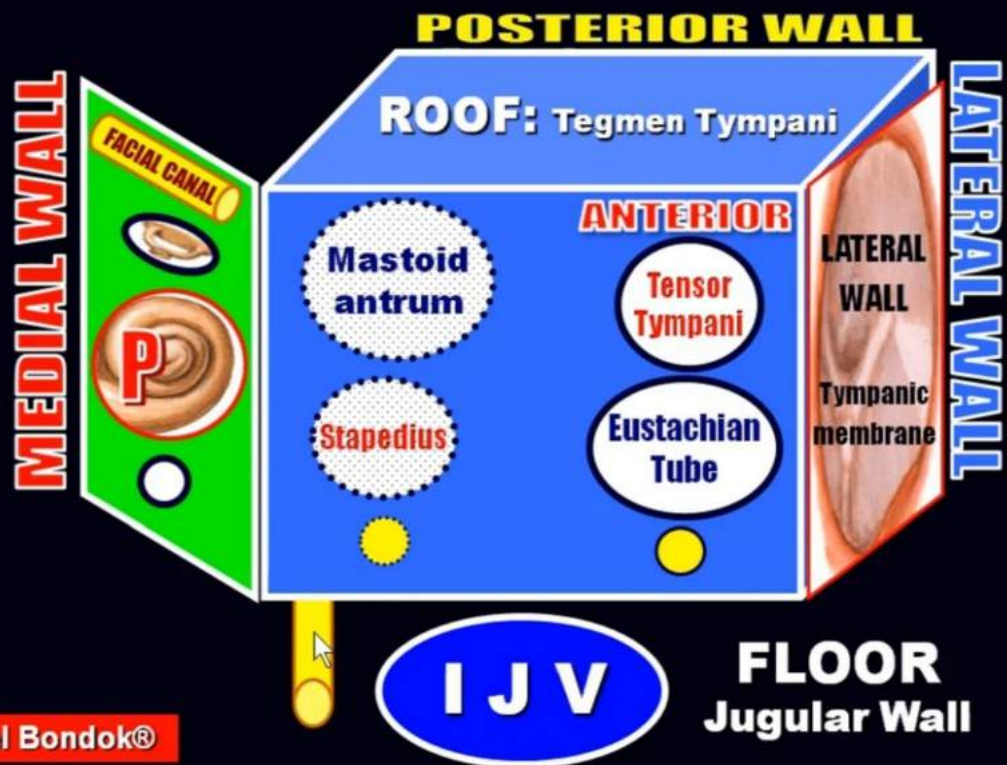1. Boundaries
2. Contents
3. Eustachian tube

INTERNAL EAR:

1. Bony Labyrinth
2. Membranous Labyrinth



THE MIDDLE EAR



Dr Adel Bondok®

ROOF: tegmen tympani
FLOOR: jugular fossa & IJV
LATERAL WALL: tympanic membrane
MEDIAL WALL: P W W N

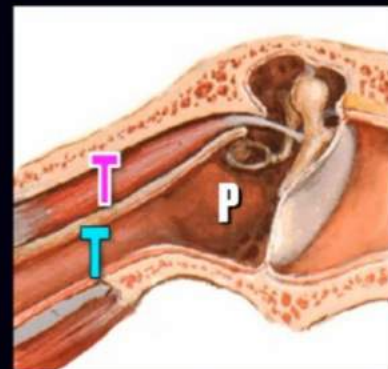
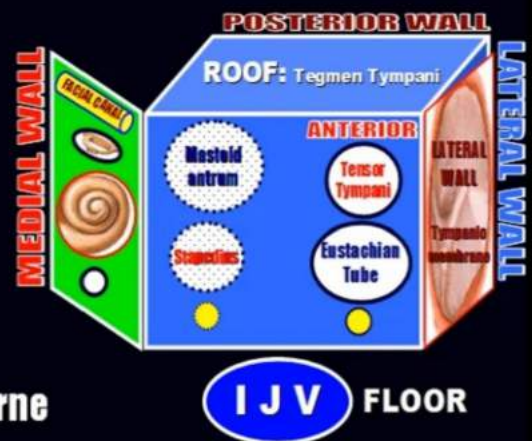1. **Promontory:** by the cochlea
2. **Oval window:** above
Formed by foot of the stapes
3. **Round window:** below
Closed by 2ndry tympanic membrane
4. **Facial canal:** horizontal part

ANTERIOR WALL: T + T + N

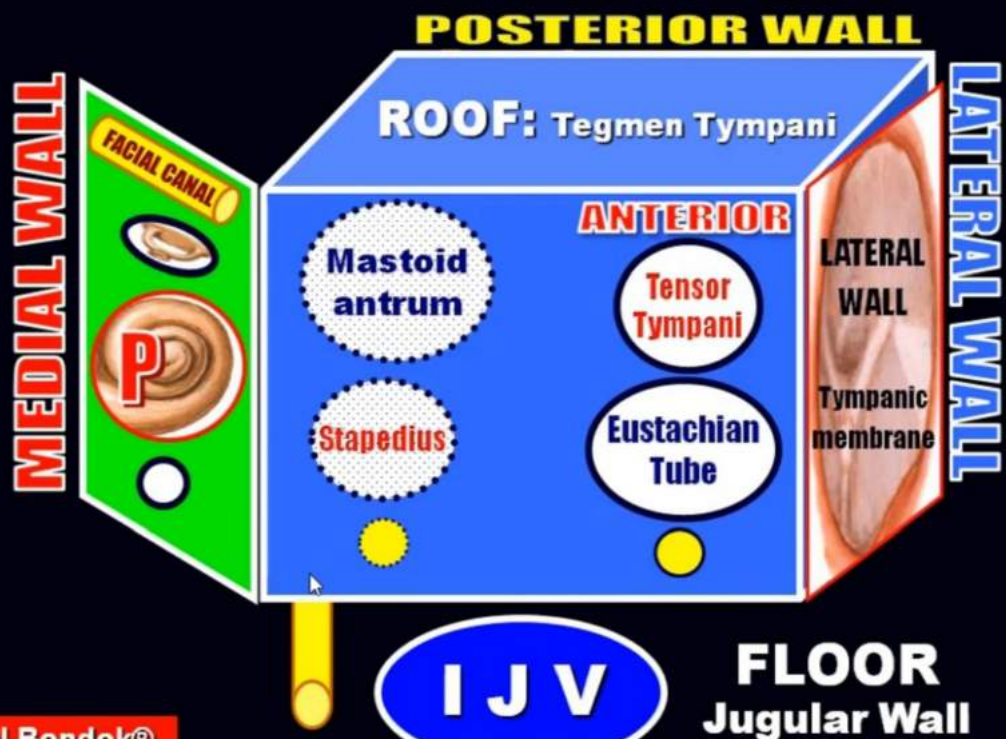
1. **Tendon:** tensor tympani
2. **Tube:** Eustachian tube
3. **Nerve:** chorda tympani

POSTERIOR WALL: T + T + N

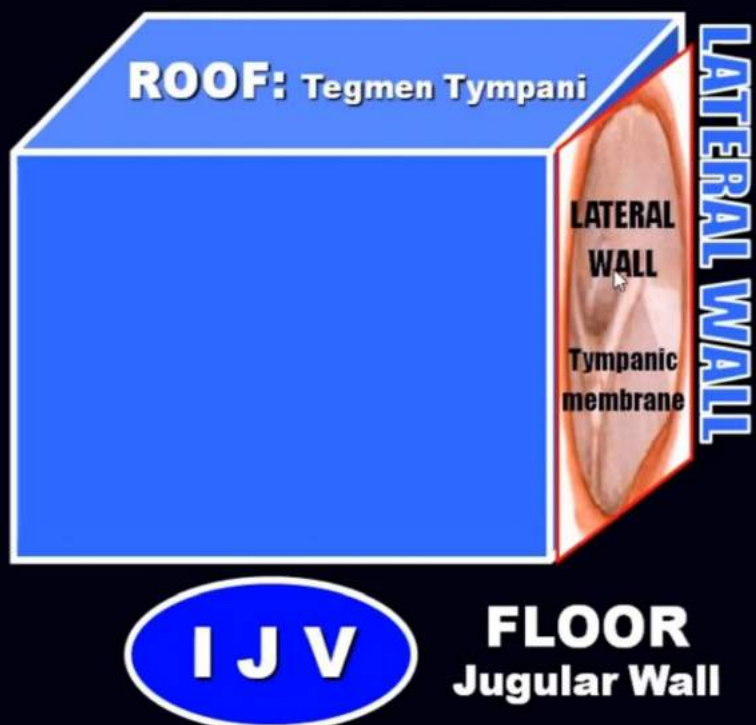
1. **Tendon:** stapedius
2. **Tube:** mastoid antrum
3. **Nerve:** chorda tymph + facial canal Vertical part

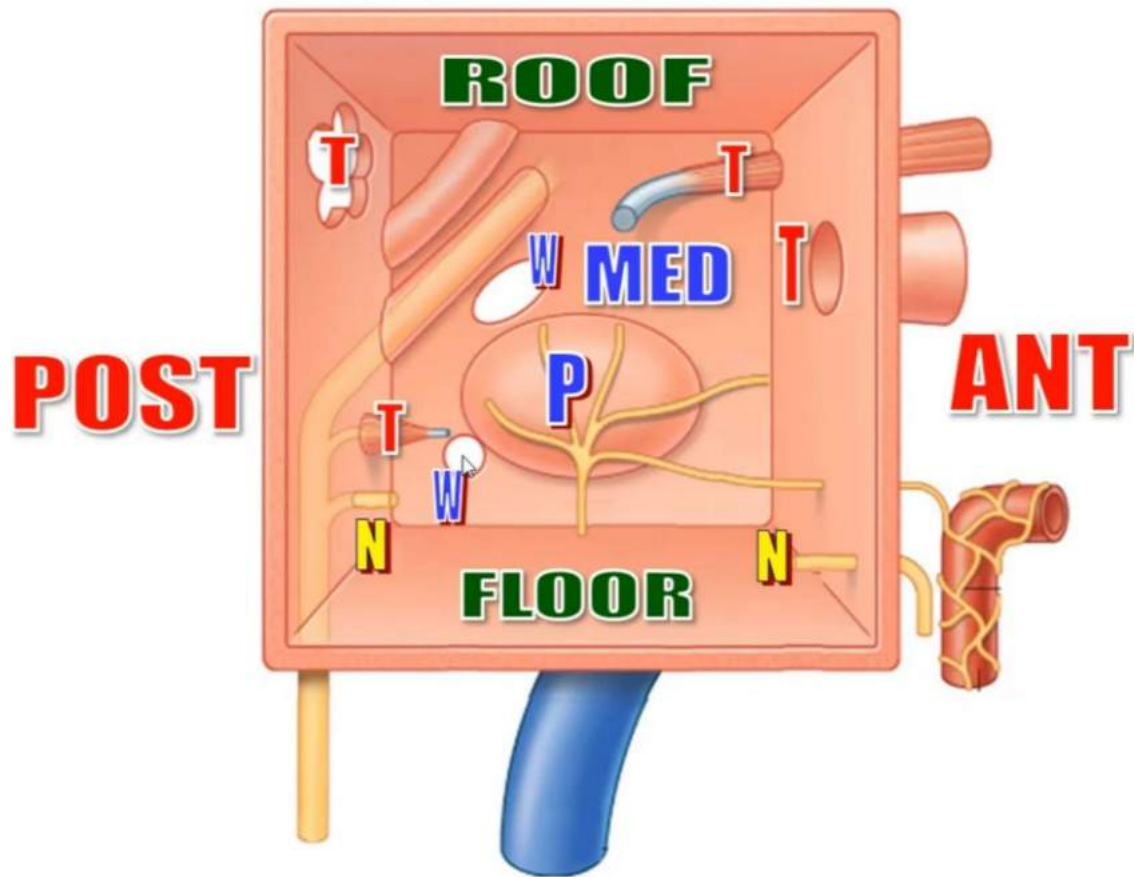


THE MIDDLE EAR



THE MIDDLE EAR





ROOF: tegmen tympani

FLOOR: jugular fossa & IJV

LATERAL WALL: tympan membrane

MEDIAL WALL: P W W N

1. Promontory: by the cochlea

2. Oval window: above

Formed by foot of the stapes

3. Round window: below

Closed by 2ndry tympanic membrane

4. Facial canal: horizontal part

ANTERIOR WALL: T + T + N

1. Tendon: tensor tympani

2. Tube: Eustachian tube

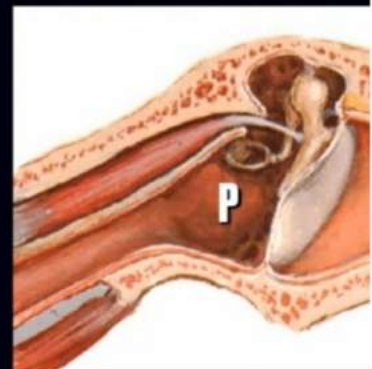
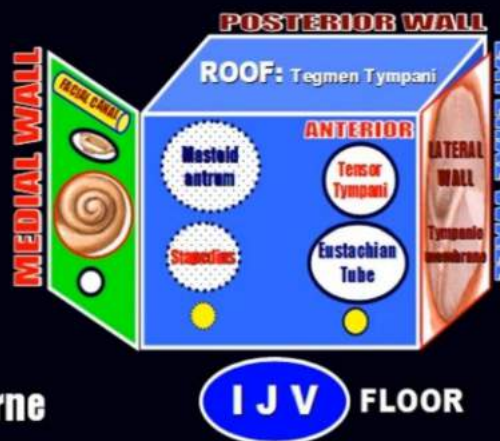3. Nerve: chorda tympani

POSTERIOR WALL: T + T + N

1. Tendon: stapedius

2. Tube: mastoid antrum

3. Nerve: chorda tympani + facial canal Vertical part



Cricoid Cartilage

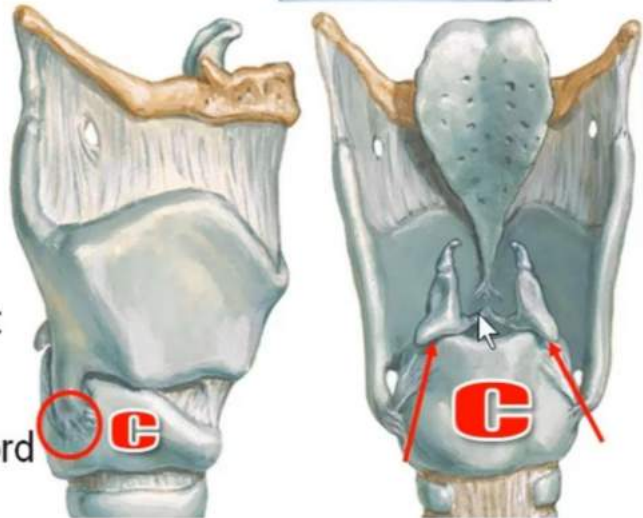
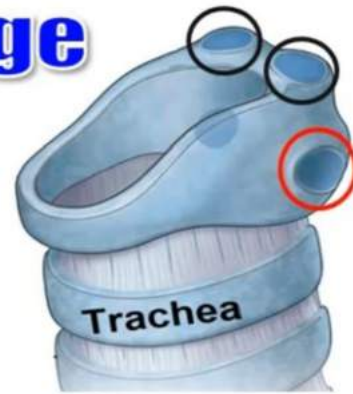- Is **ring-shaped**
- Has narrow **anterior arch** and wide **posterior arch**
- It forms **2 joints**:

1. Cricothyroid joint:

- @ Synovial, hinge
- @ It adjusts the tension of the vocal cord

2. Cricoarytenoid joint:

- @ Synovial, ball and socket
- @ Permits adduction and abduction of the vocal cord



Adel Bondok

Membranes of the Larynx

3 External & 2 Internal

3 External Membranes:

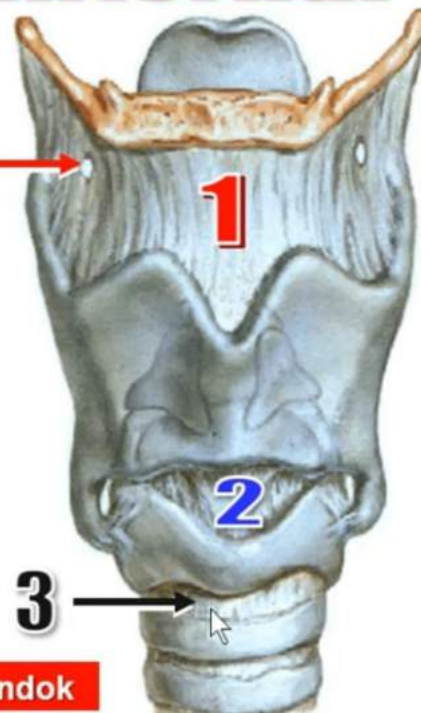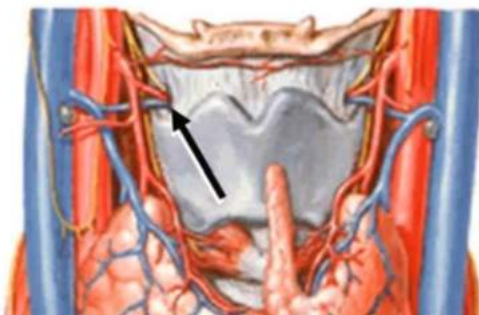
1. Thyrohyoid membrane

Pierced by: 

- Internal laryngeal nerve
- Superior laryngeal artery**

2. Median cricothyroid membrane

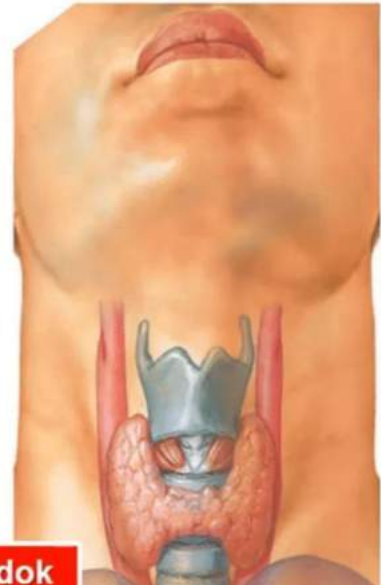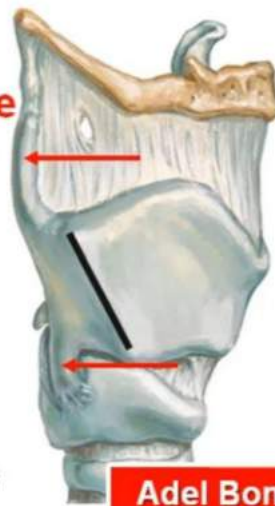
3. Cricotracheal membrane



Adel Bondok

Thyroid Cartilage

- Is the **largest** cartilage of the larynx
- It is formed of **2 laminae**.
- Each lamina has **superior horn** and **inferior horn**
- Has **oblique line** for muscle attachment.
- The upper border forms the **thyroid notch**
- The **laryngeal prominence (Adam's apple)** lies below the thyroid notch
- The **vocal cord is longer** in males than in females **because** the prominence is more projecting in males



Adel Bondok

Arytenoid Cartilage

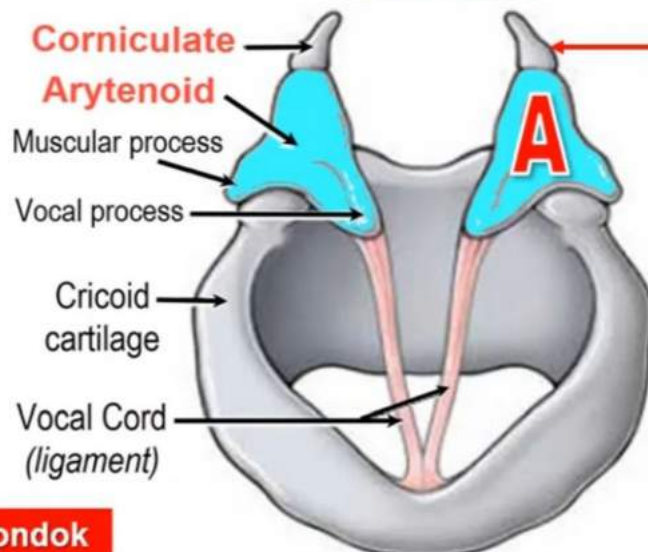
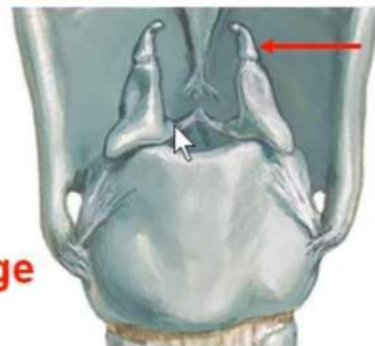- Is **pyramidal** in shape
- **Apex:** related to the **corniculate cartilage**
- Has **2 processes:**

1. Muscular process:

- @ Lateral
- @ Attachment of muscles

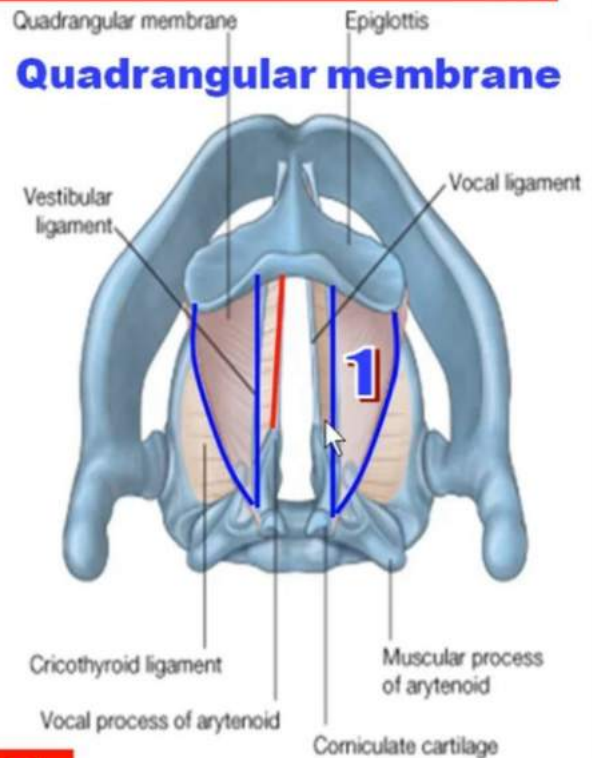
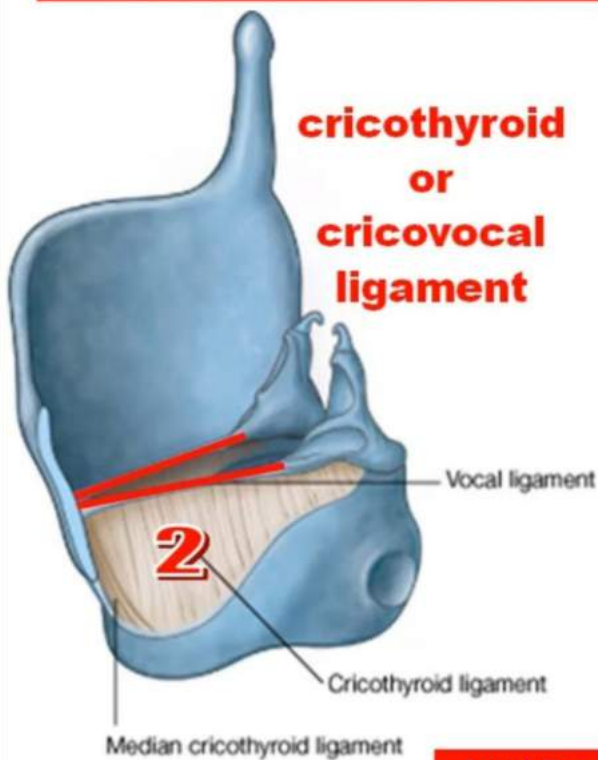
2. Vocal process:

- @ Anterior
- @ Attachment of the vocal cord



Adel Bondok

2 Internal Membranes



Adel Bondok

CAVITY

2 Folds on Each Side:

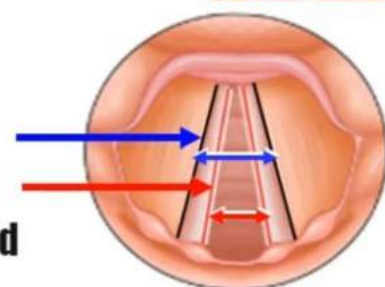
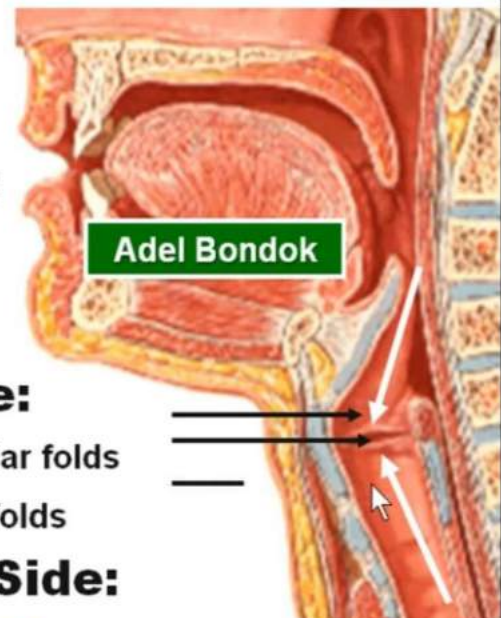
- 1. Vestibular fold:** above
- 2. Vocal fold:** below

2 Spaces in the Midline:

- 1. Rima Vestibuli:** between the vestibular folds
- 2. Rima glottidis:** between the vocal folds

3 Compartments on Each Side:

- 1. Vesibule or Supraglottic space:** above the vestibular fold
- 2. Ventricle:** between the vestibular and vocal folds
- 3. Infraglottic space:** below the vocal fold



2 Internal Membranes

Beneath the mucous membrane: QM: **Quadrangular membrane**

1. Upper part:

quadrangular membrane:

between epiglottis & arytenoid

a. The upper border forms aryepiglottic fold

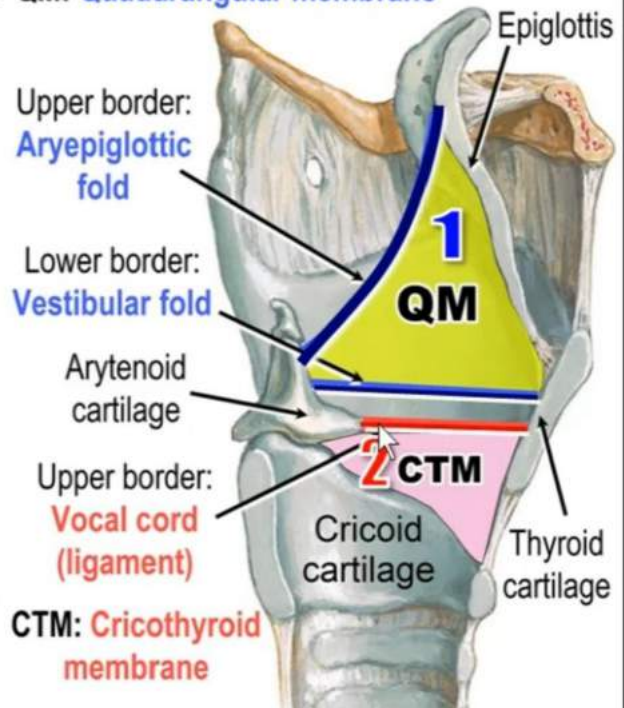
b. The lower border forms vestibular fold

2. Lower part:

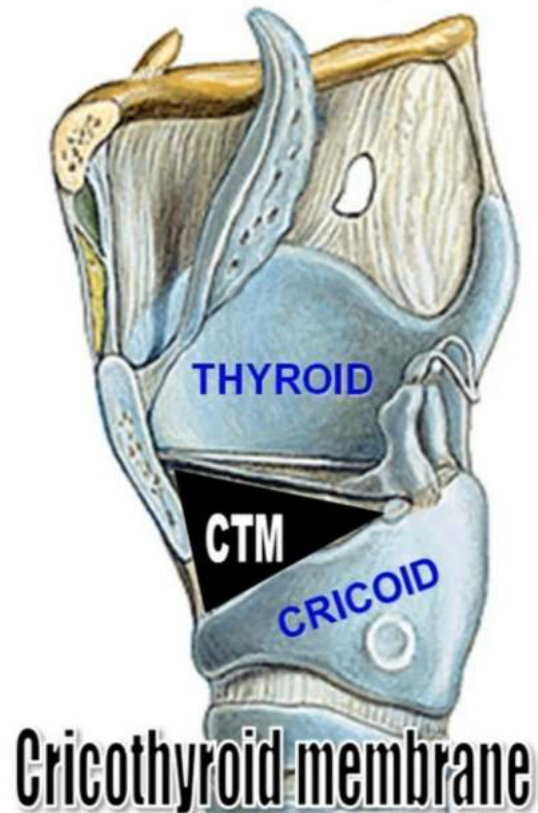
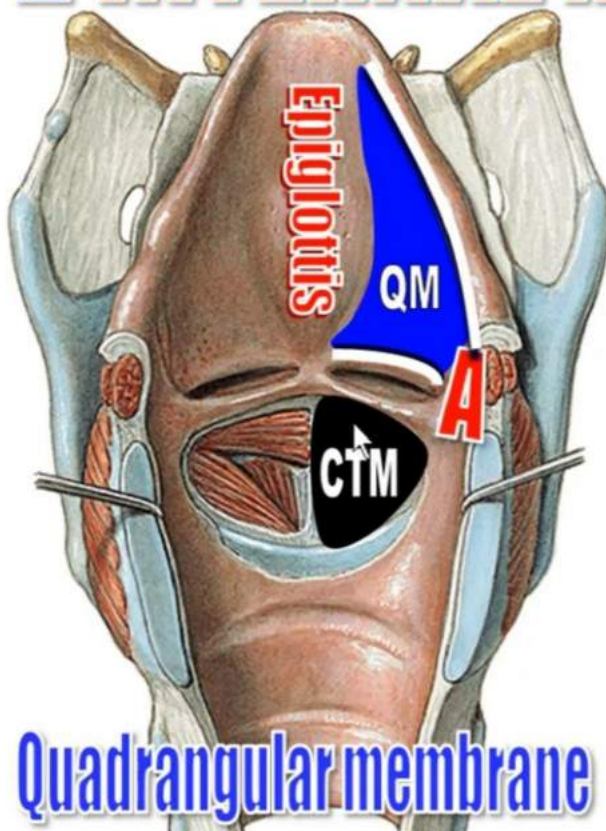
cricothyroid ligament

between cricoid & arytenoid & thyroid cartilage

The upper border forms the vocal cord



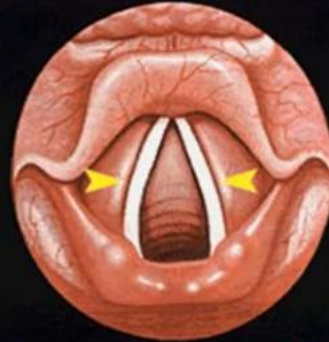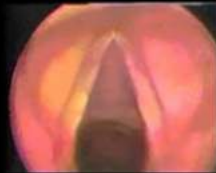
2 INTERNAL MEMBRANES



INTRINSIC MUSCLES

Muscles Acting on the Vocal Cord

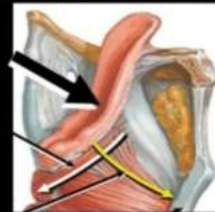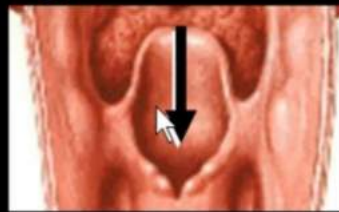
1. Abduct
2. Adduct
3. Tense (elongate)
4. Relax (shorten)



Adel Bondok

Muscles Acting on the Laryngeal Inlet

1. Open
2. Close



EXTRINSIC MUSCLES

Move the Larynx
Up and Down

a. Elevators:

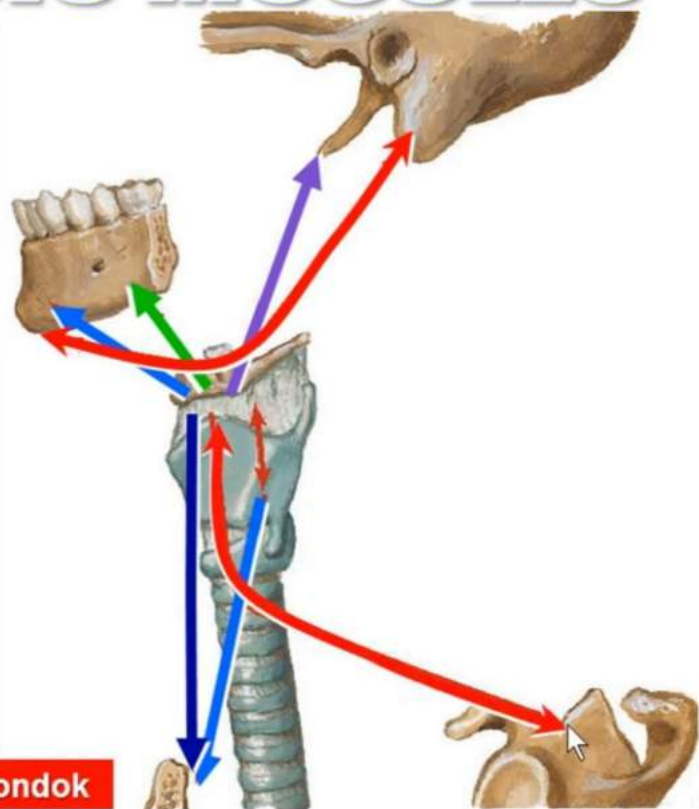
suprahyoid muscles

1. Mylohyoid
2. Geniohyoid
3. Stylohyoid
4. Digastric

b. Depressors:

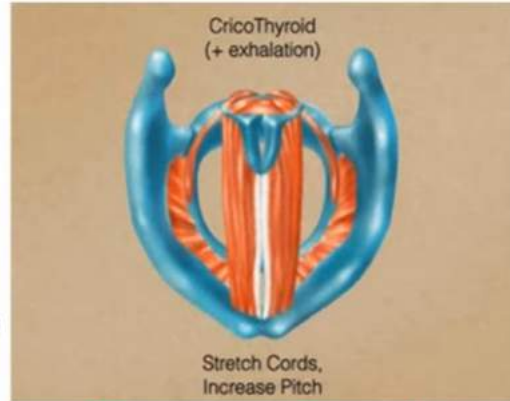
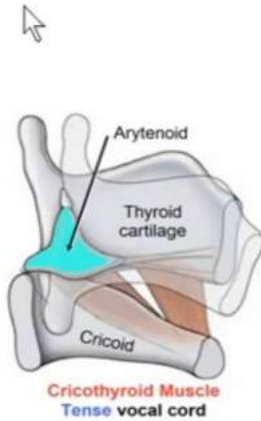
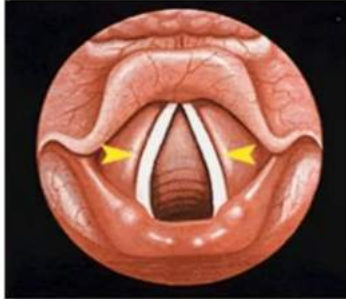
infrahyoid muscles

1. Sternohyoid
2. Sternothyroid
3. Omohyoid



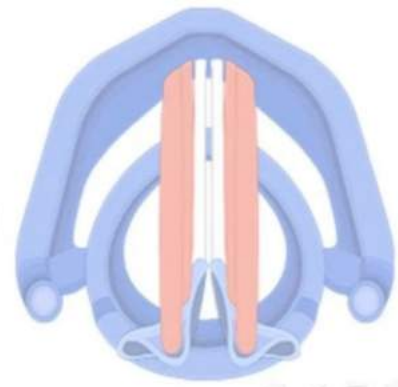
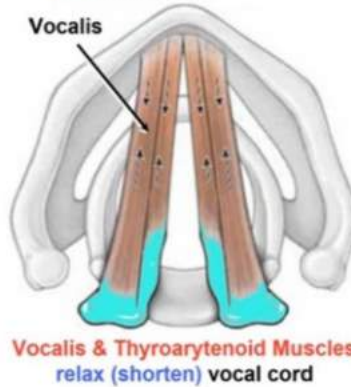
Adel Bondok

Tensor Lengthening

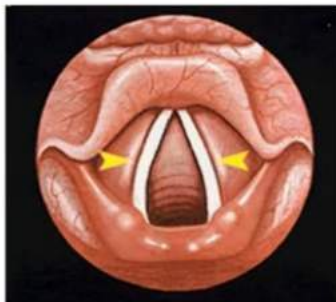

Adel Bondok

Relaxation Shortening

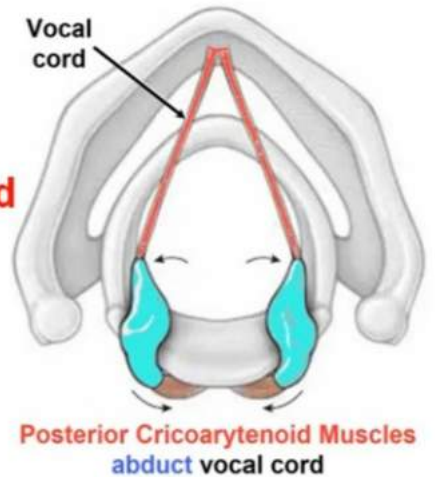


Abduct the Vocal Cord



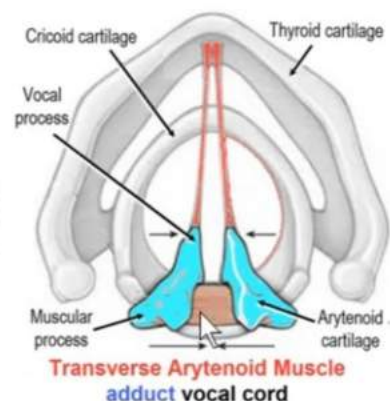
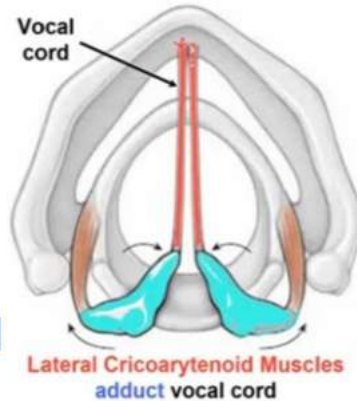
One Muscle:
Post cricoarytenoid
(Muscle of life)

Adel Bondok



Adduct the Vocal Cord

Lat cricoarytenoid
Transverse arytenoid



Muscles Acting on the Laryngeal Inlet

Closure

Aryepiglottic muscle
(Oblique arytenoid)

Opening

Thyroepiglottic muscle

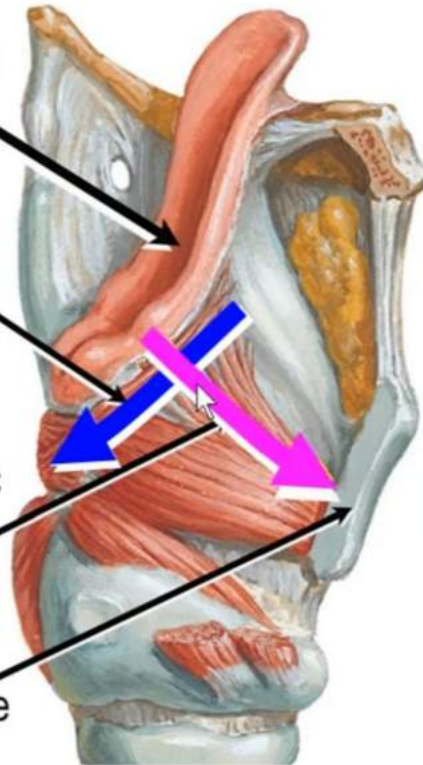
Adel Bondok

Laryngeal Inlet

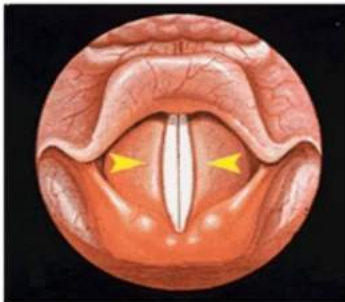Aryepiglottic muscle
(Closing)

Thyroepiglottic muscle
(Opening)

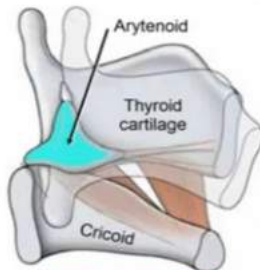
Thyroid cartilage



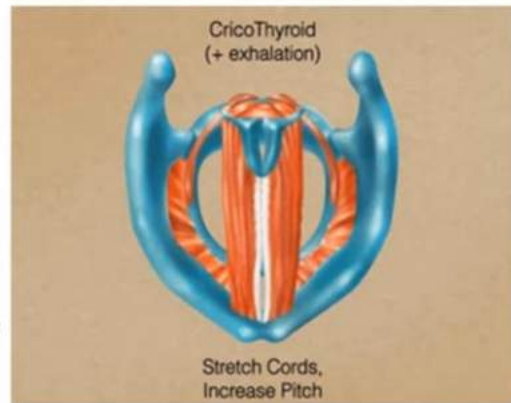
Tensor Lengthening



Cricothyroid
Increase pitch.



Cricothyroid Muscle
Tense vocal cord



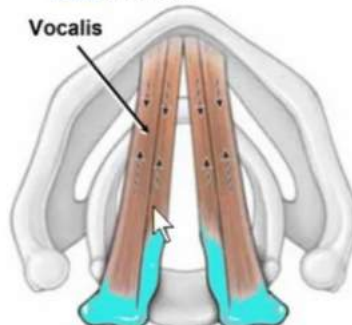
Adel Bondok

Relaxation Shortening

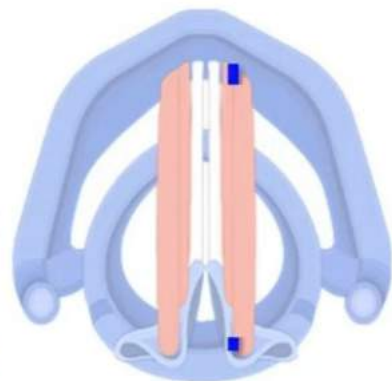
2 Muscles:

Vocalis

Thyro-arytenoid



Vocalis & Thyroarytenoid Muscles
relax (shorten) vocal cord



FUNCTIONS



Respiration



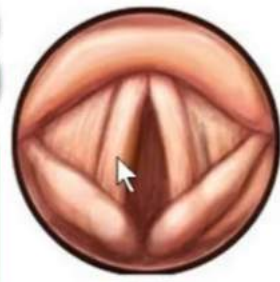
Phonation



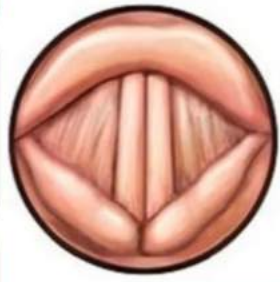
Protection by the epiglottis



Protection by cough reflex



In Inspiration:
the vocal cords are **abducted** to open rima glottidis for air

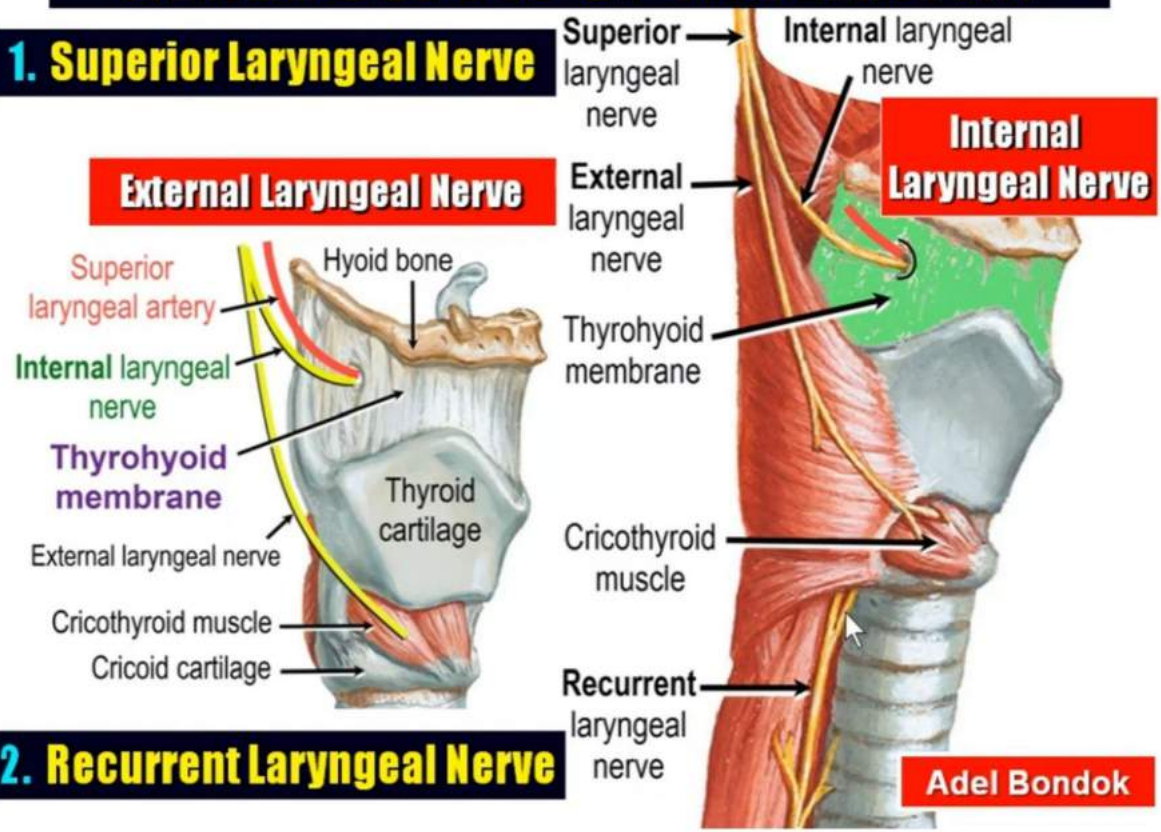


In Phonation:
the vocal cords are **adducted** to force the air between the 2 cords and produce sound



NERVE SUPPLY OF THE LARYNX

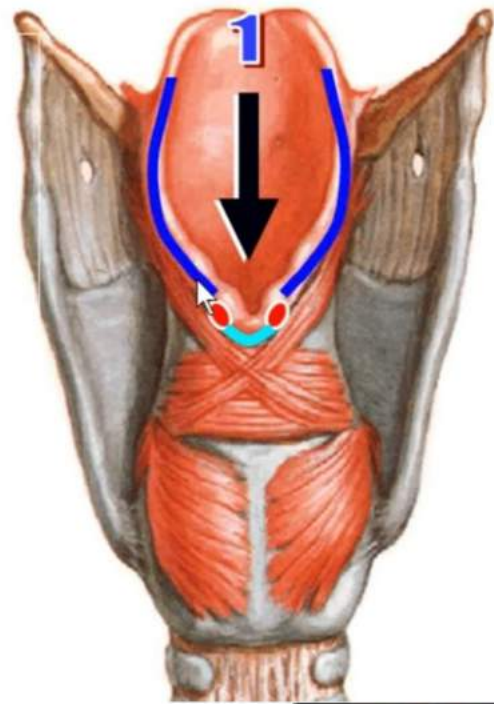
1. Superior Laryngeal Nerve



2. Recurrent Laryngeal Nerve

INLET OF THE LARYNX

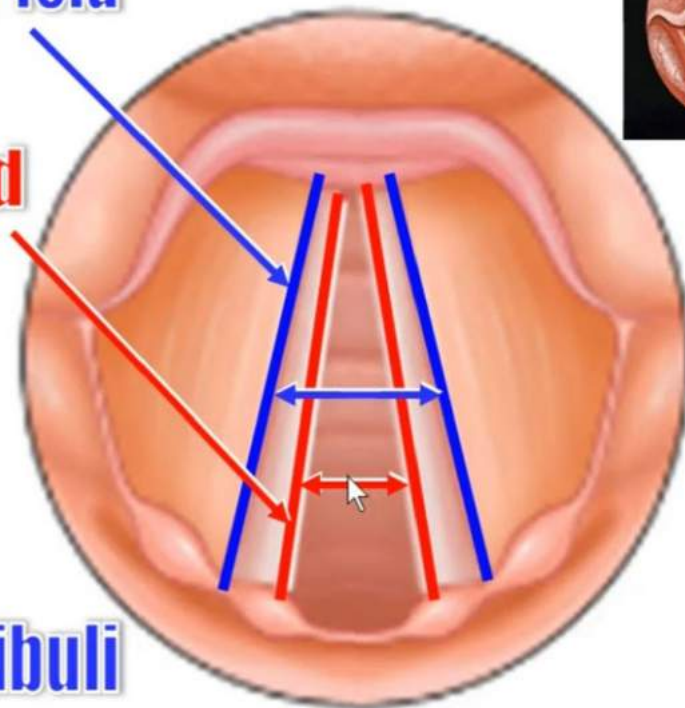
1. **Anterior:** epiglottis
2. **Posterior:** arytenoid & interarytenoid fold
3. **On each side:** aryepiglottic fold



Adel Bondok

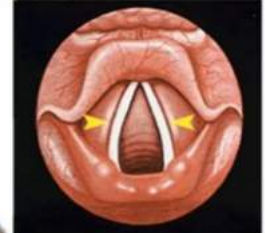Vestibular fold

Vocal fold



Rima vestibuli

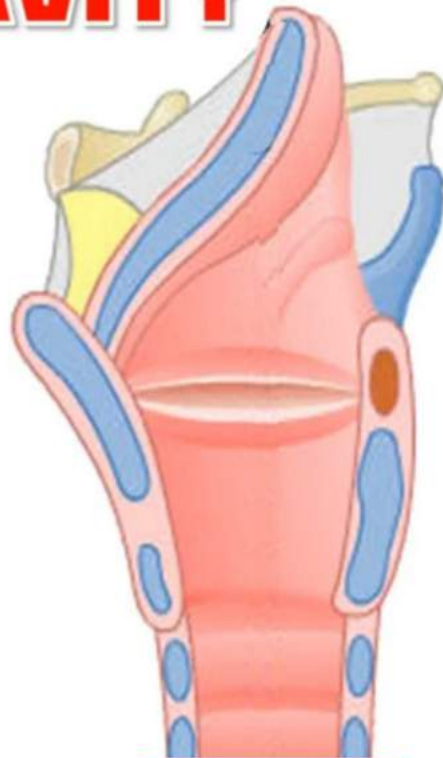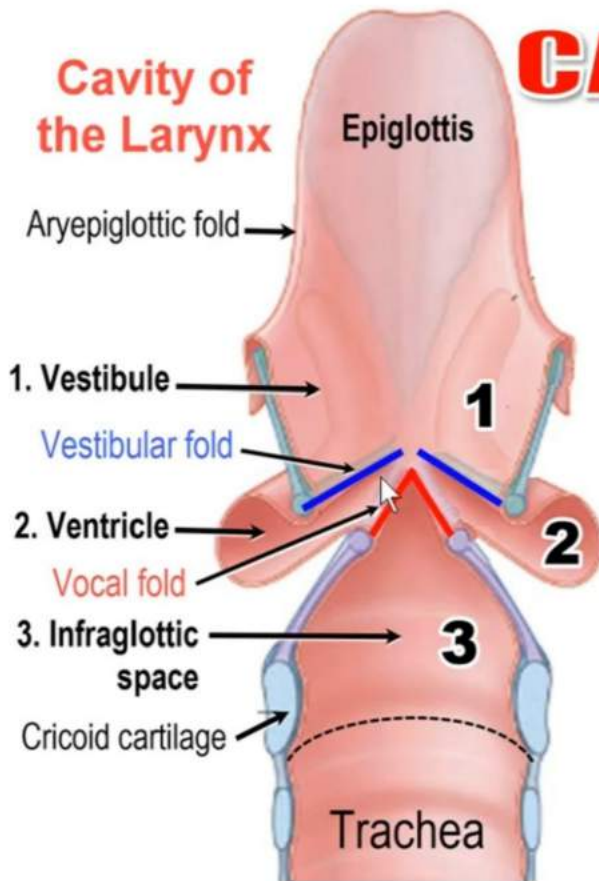
Rima glottidis



Adel Bondok

Cavity of the Larynx

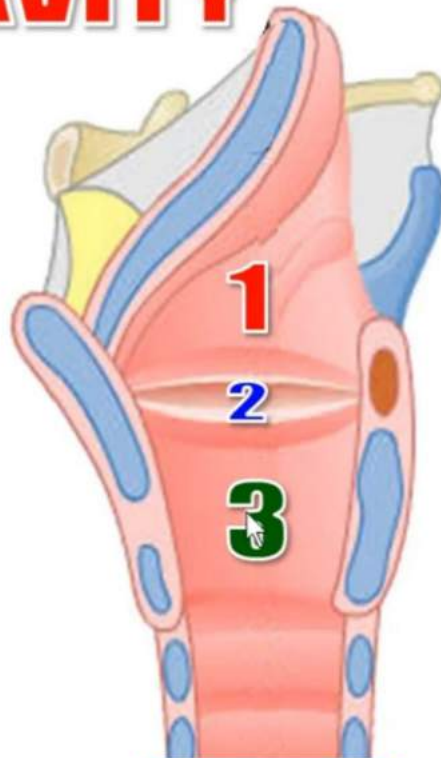
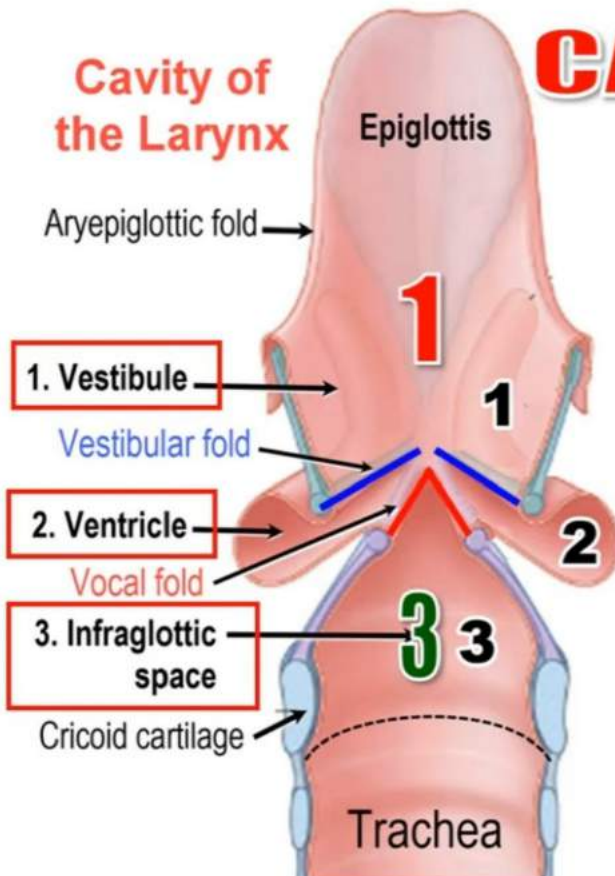
CAVITY



Adel Bondok

Cavity of the Larynx

CAVITY



Adel Bondok

Laryngeal Nerve Paralysis

Causes:

1. Thyroid and parathyroid gland surgery.
2. Lesion in nucleus ambiguus: lateral medullary syndrome

Superior Laryngeal Nerve Lesion

Lead To:

Adel Bondok

1. Paralysis of the Cricothyroid muscle
2. Sensory loss: above the vocal cord

Effect on the Vocal Cord:

Loss of tension → cause shortening of the vocal cord

NERVE SUPPLY: Vagus

MOTOR: vagus n to the intrinsic muscles

1. Cricothyroid muscle: external laryngeal nerve
2. All the other muscles: recurrent laryngeal nerve

SENSORY: Vagus

1. Above the vocal cord:

Internal laryngeal nerve (superior laryngeal nerve)

2. Below the vocal cord:

Recurrent laryngeal nerve

Adel Bondok

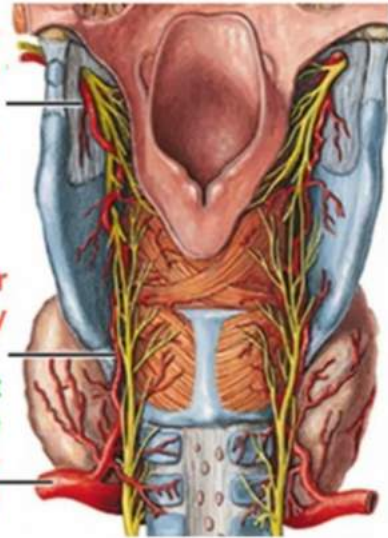
ARTERIAL SUPPLY

1. Superior laryngeal artery: from the superior thyroid artery

Superior laryngeal artery and Internal laryngeal nerve

2. Inferior laryngeal artery: from the inferior thyroid artery

Inferior laryngeal artery and Recurrent laryngeal nerve
Inferior thyroid artery

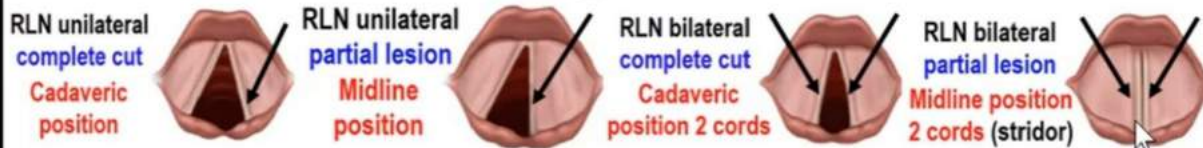

LYMPH DRAINAGE

Adel Bondok

- Upper Part:** upper deep cervical lymph nodes
- Lower Part:** lower deep cervical lymph nodes

Recurrent Laryngeal Nerve Lesion



Lead To:

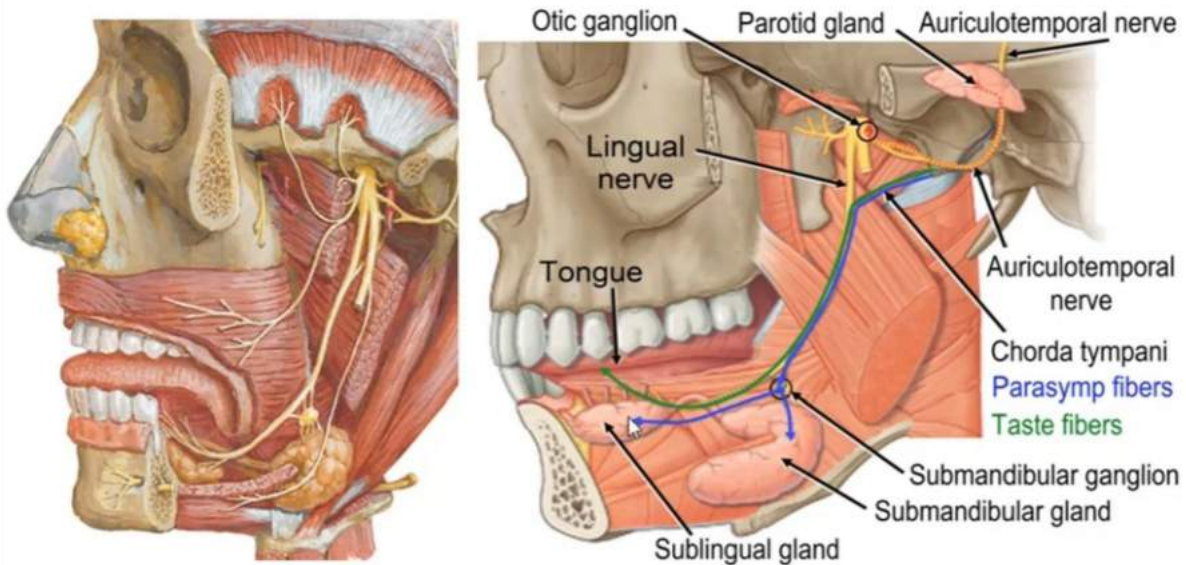
- Unilateral complete cut:** results in paralysis of all muscles of the larynx except the cricothyroid muscle on one side.
- Unilateral Partial crush lesion:** → injury of the peripheral fibers which supply the abductor (posterior cricoarytenoid)

Effect on the Vocal Cord:

- Unilateral complete cut:** the vocal cord assumes midway position between adduction & abduction (cadaveric position).
- Unilateral partial lesion (crushing):** vocal cord assumes the adducted midline position → severe stridor if bilateral
- Bilateral lesion:** as above but on the 2 sides

Nucleus	Nerve	Ganglion	Attached to	Target
Edinger-Westphal	III	Ciliary	Nasociliary nerve	Sphincter pupil Ciliary muscle
Superior salivary	VII	Sphenopalatine	Maxillary nerve	Lacrimal, Nasal, Palatine Glands
Superior salivary	VII	Submandibular	Lingual nerve	Submandibular Sublingual GJ
Inferior salivary	IX	Otic	Mandibular nerve	Parotid Gland
DMN of the Vagus	X	Terminal	Wall of the viscera	Thoracic and abdominal visc

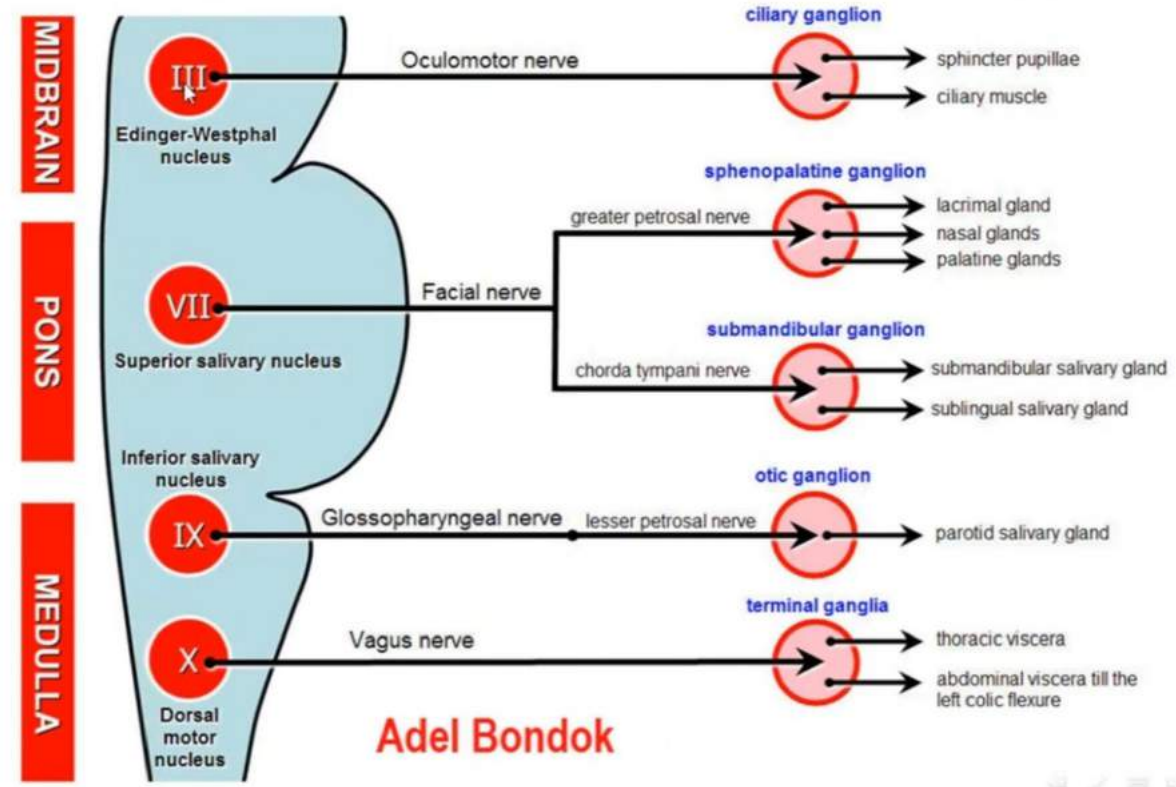
Dr Adel Bondok®



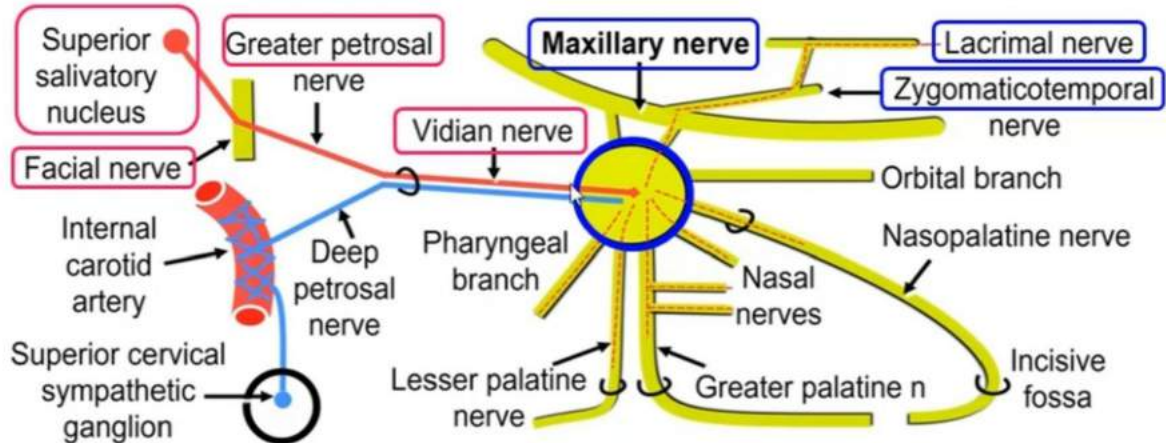
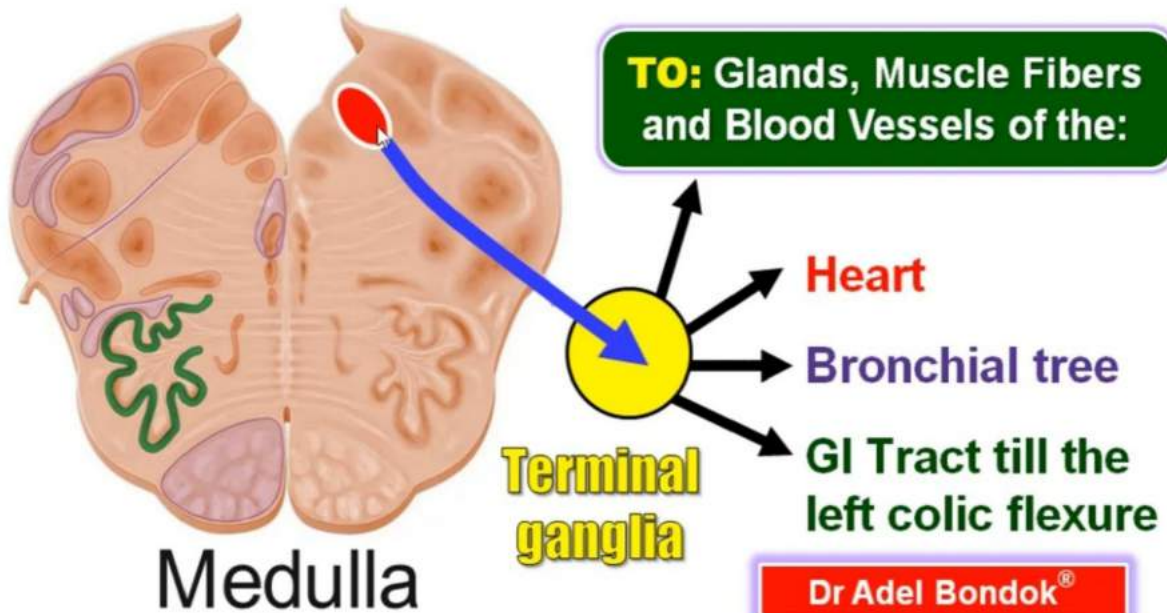
**PARASYMPATHETIC fibers to
SUBMANDIBULAR & SUBLINGUAL GLANDS**

Superior salivatory nucleus ⇨ facial nerve ⇨ chorda tympani ⇨ lingual nerve ⇨ submandibular ganglion ⇨ submandibular and sublingual salivary glands.

Parasympathetic Nuclei & Ganglia



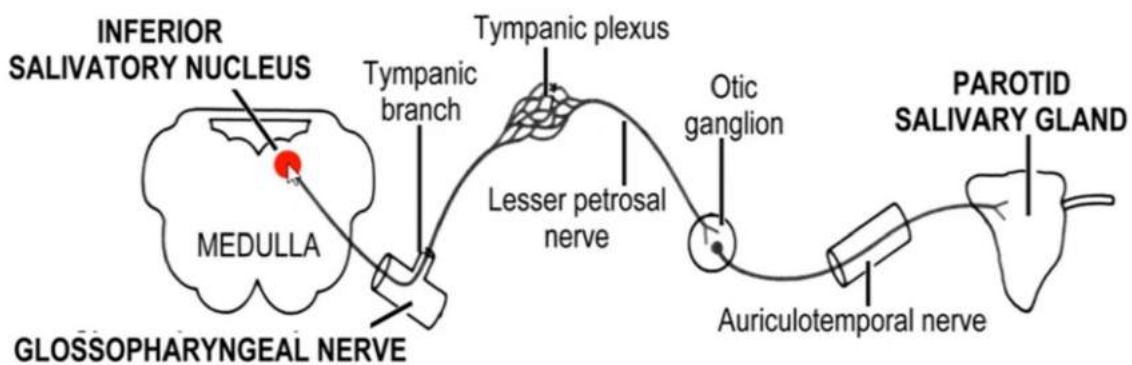
DORSAL MOTOR NUCLEUS of the VAGUS



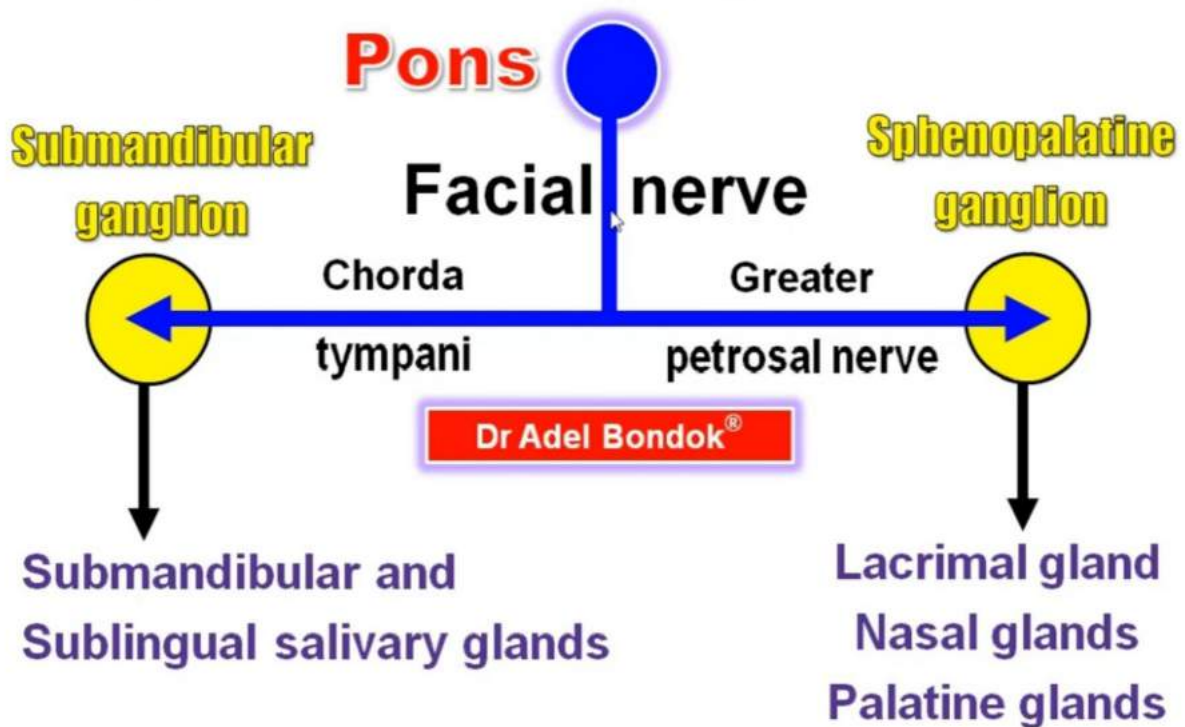
Parasympathetic Fibers To Lacrimal Gland

superior salivatory nucleus ⇒ facial nerve ⇒ greater superficial petrosal nerve ⇒ join the deep petrosal nerve ⇒ nerve of pterygoid canal ⇒ pterygopalatine (sphenopalatine) ganglion ⇒ maxillary nerve ⇒ zygomatic nerve ⇒ zygomaticotemporal nerve ⇒ lacrimal nerve ⇒ lacrimal gland

INFERIOR SALIVARY NUCLEUS: IX Nerve



Superior Salivary Nucleus



4 Parasympathetic Nuclei in the Brainstem

1. **Edinger-Westphal Nucleus:** midbrain

2. **Superior Salivary Nucleus:** pons

3. **Inferior Salivary Nucleus:**

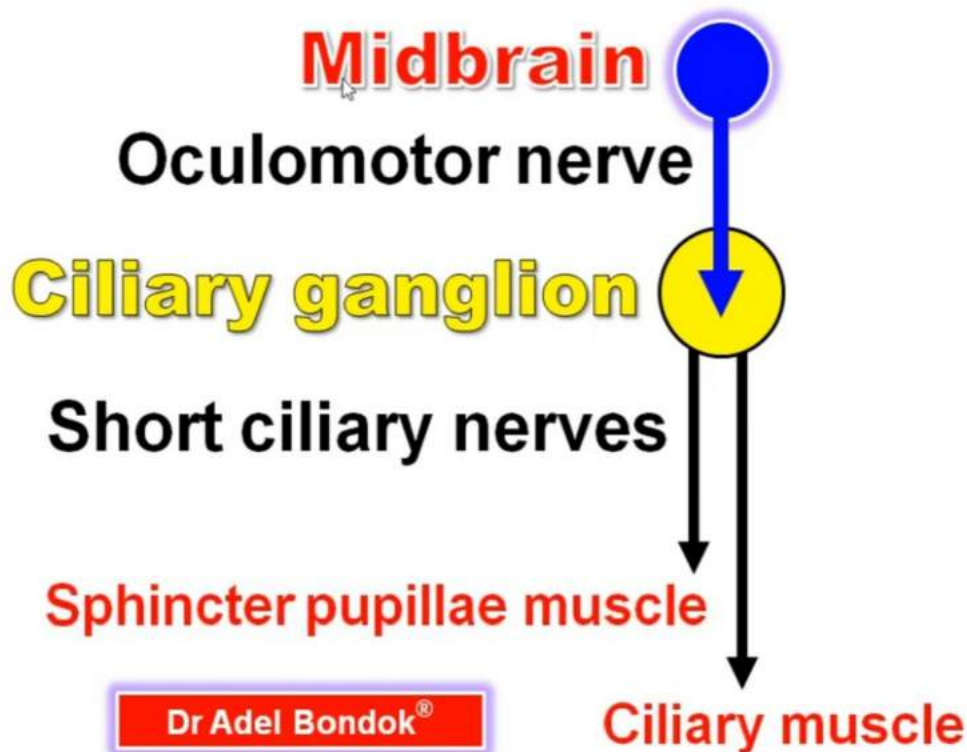
- In the **medulla oblongata**.
- Gives fibers to the **glossopharyngeal nerve**.
- Supplies the parotid gland

4. **Dorsal Motor Nucleus of the Vagus:**

- In the **medulla oblongata**.
- Gives fibers to the **vagus nerve**.
- Supplies the thoracic and abdominal viscera till the left colic flexure.

Dr Adel Bondok®

Edinger-Westphal Nucleus



Dr Adel Bondok®

Midbrain

Edinger-Westphal Nucleus

Pons

Superior Salivary Nucleus

Medulla

Inferior Salivary Nucleus

Dorsal Motor Nucleus of Vagus

4 Parasympathetic Nuclei in the Brainstem

Dr Adel Bondok®

4 Parasympathetic Nuclei in the Brainstem

1. Edinger-Westphal Nucleus:

- In the midbrain.
- Gives fibers to the **oculomotor nerve**.
- Supplies the sphincter pupillae and ciliary muscles

2. Superior Salivary Nucleus:

- In the **pons**.
- Gives fibers to the **facial nerve**.
- Supplies the lacrimal, nasal and palatine glands and the submandibular and sublingual salivary glands

3. Inferior Salivary Nucleus:

4. Dorsal Motor Nucleus of the Vagus:

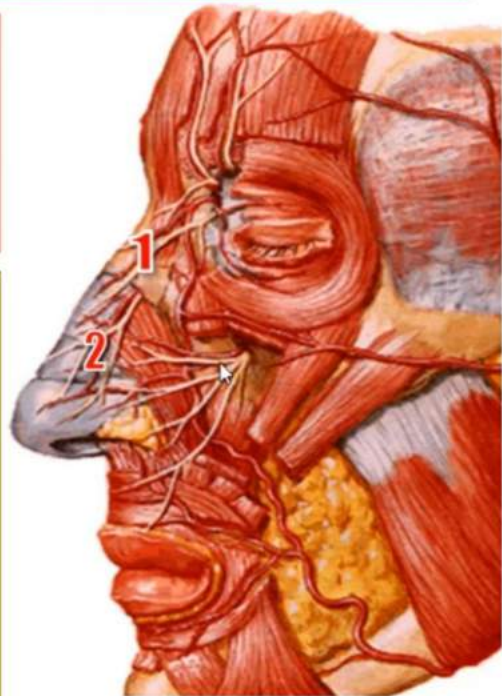
Dr Adel Bondok®

NERVE SUPPLY

1. Skin of the Nose
2. Nasal Septum
3. Lateral Wall

Skin of the Nose:

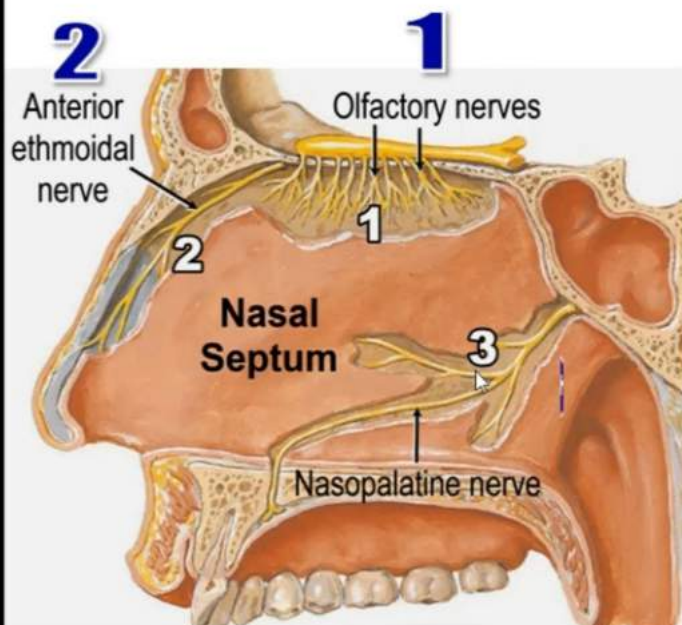
1. Infratrochlear nerve:
ophthalmic nerve
2. External nasal nerve:
ophthalmic nerve
3. Infraorbital nerve:
maxillary nerve



NERVE SUPPLY

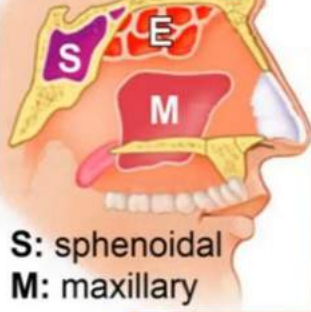
NASAL SEPTUM

1. UPPER PART:
Olfactory nerves
2. ANTERIOR PART:
Anterior ethmoidal ner
from nasociliary nerve
3. Remaining Part:
Nasopalatine nerve
from maxillary nerve.
Carry secretory fibers
to the nasal glands

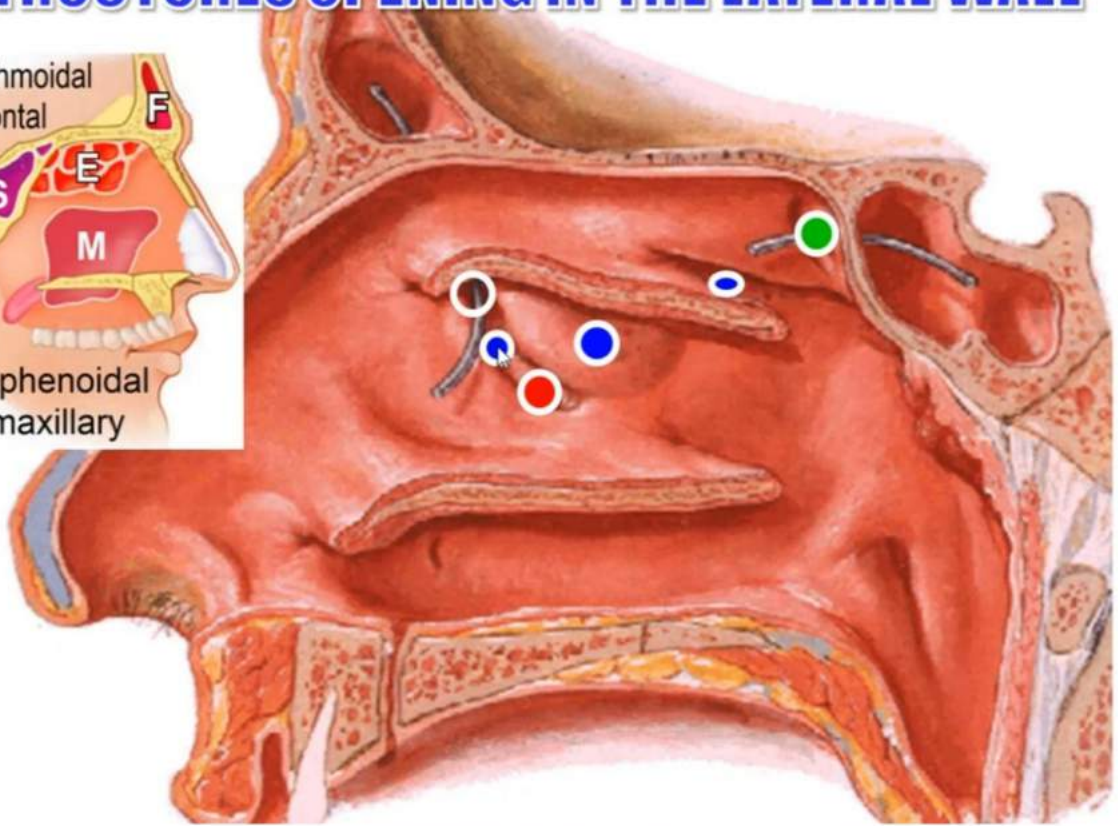


STRUCTURES OPENING IN THE LATERAL WALL

E: ethmoidal
F: frontal



S: sphenoidal
M: maxillary



STRUCTURES OPENING INTO THE LATERAL WALL

1. SPHENOETHMOIDAL RECESS:

Sphenoidal air sinus

2. SUPERIOR MEATUS:

Posterior ethmoidal sinus

3. MIDDLE MEATUS:

A. Middle ethmoidal sinus: Bulla

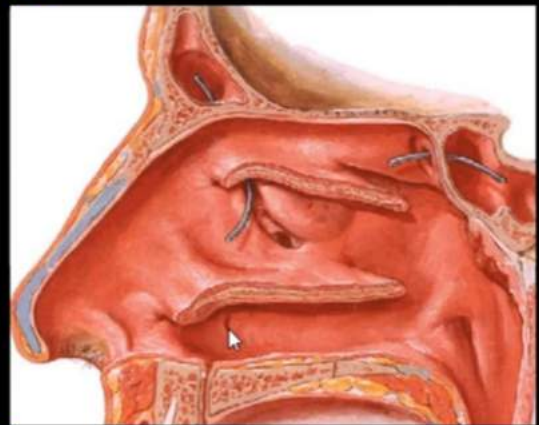
B. Anterior ethmoidal sinus: HS

C. Maxillary sinus: HS

D. Frontal sinus: Infundibulum

4. INFERIOR MEATUS:

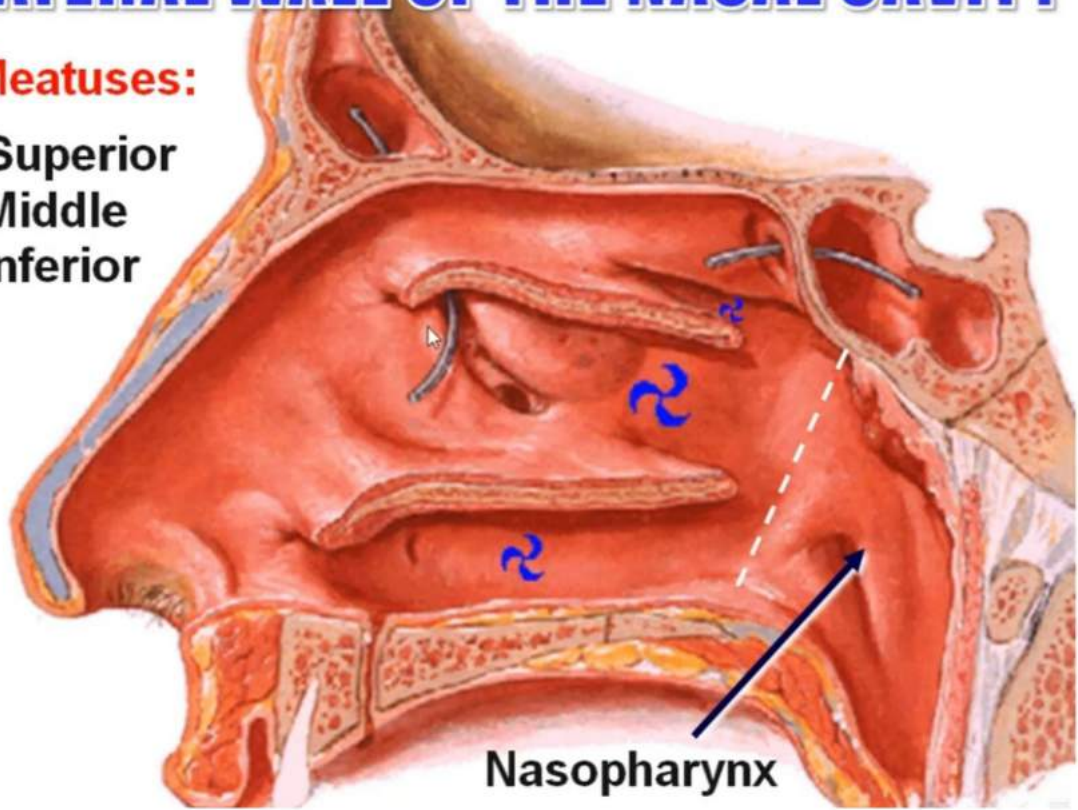
Nasaolacrimonal duct



LATERAL WALL OF THE NASAL CAVITY

3 Meatuses:

1. Superior
2. Middle
3. Inferior

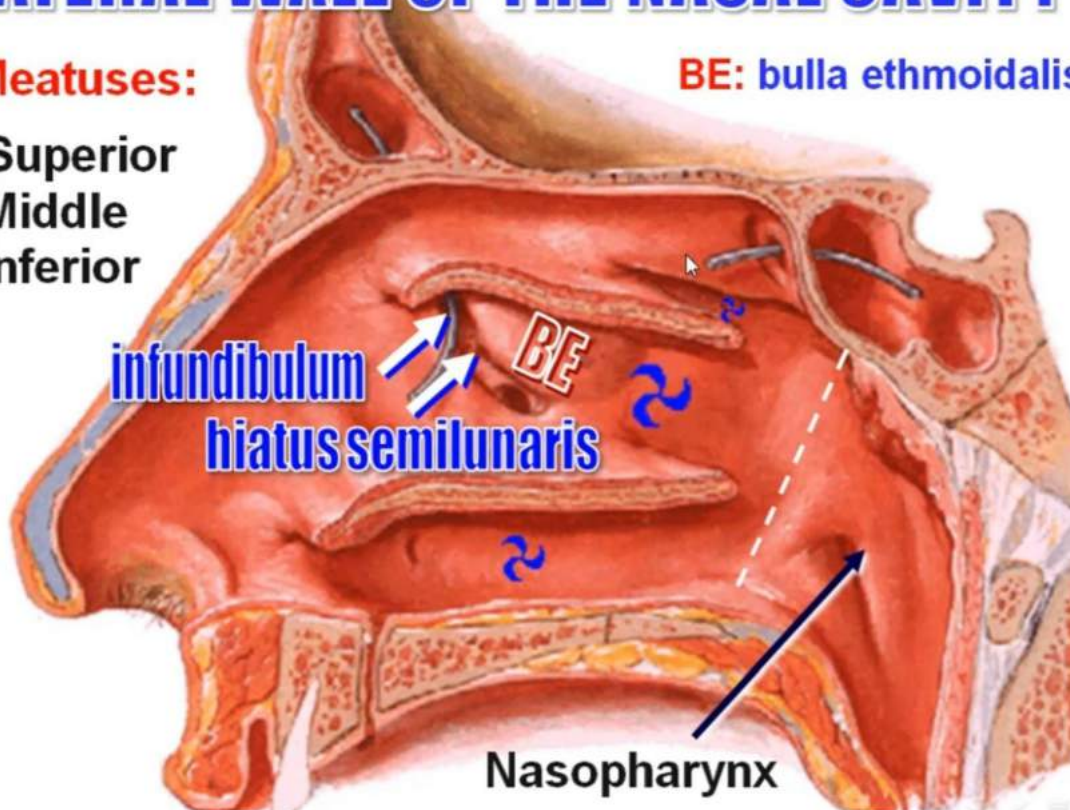


LATERAL WALL OF THE NASAL CAVITY

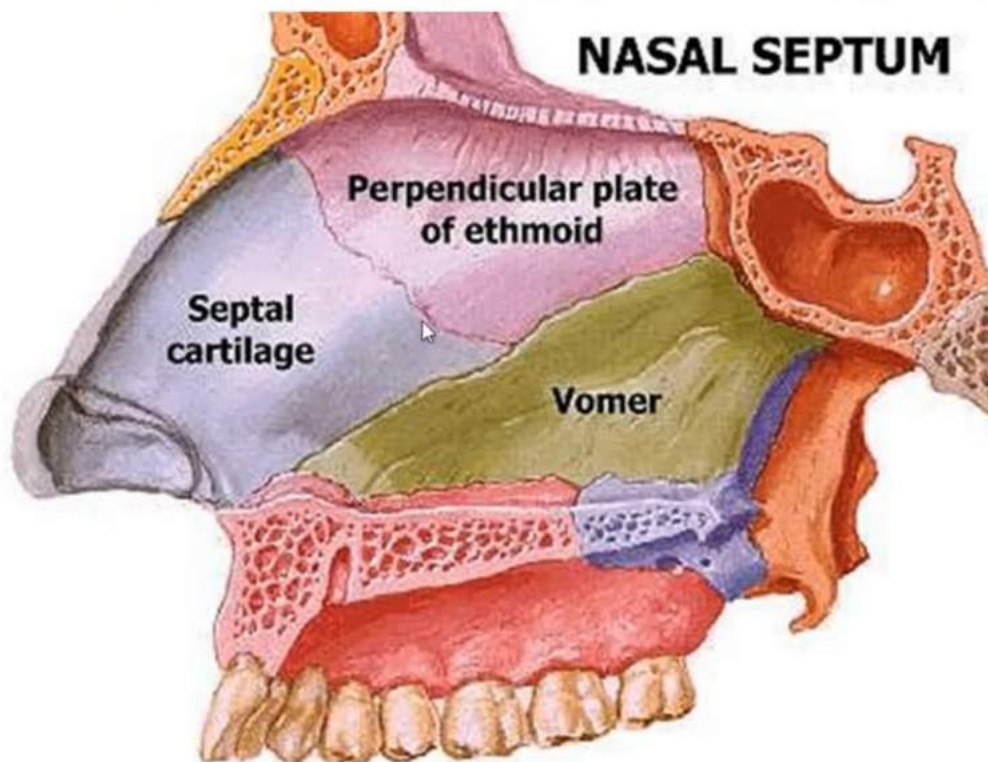
3 Meatuses:

1. Superior
2. Middle
3. Inferior

BE: bulla ethmoidalis



NASAL SEPTUM



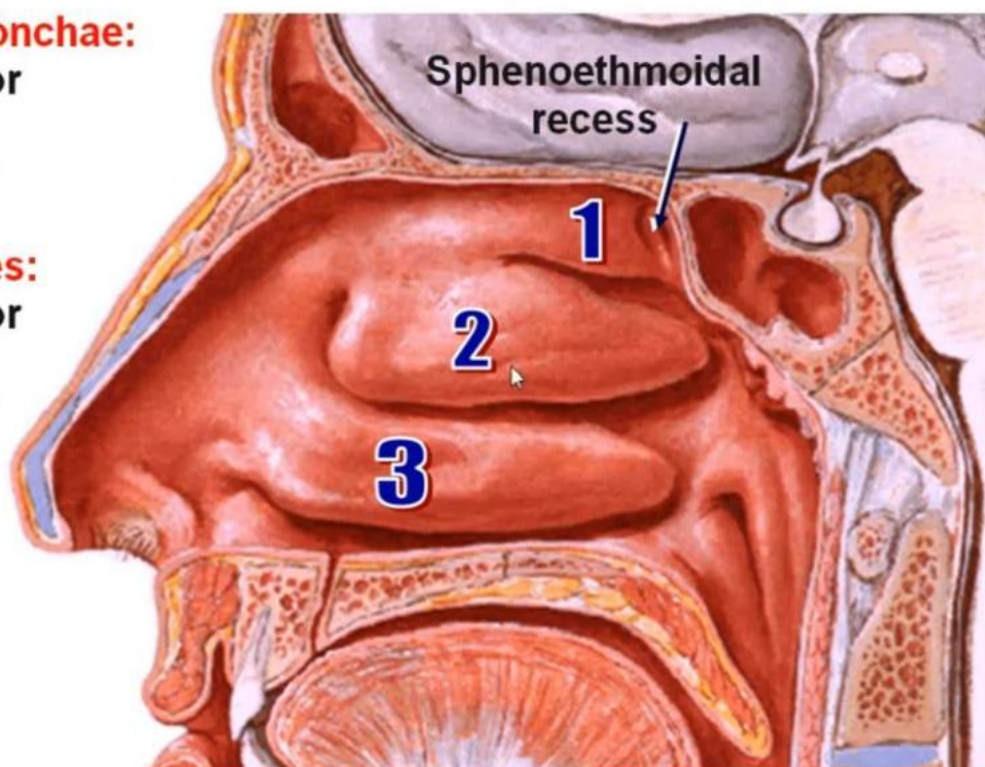
LATERAL WALL OF THE NASAL CAVITY

3 Nasal conchae:

1. Superior
2. Middle
3. Inferior

3 Meatuses:

1. Superior
2. Middle
3. Inferior



NASAL CAVITY



Boundaries:



Structures opening into the lateral wall



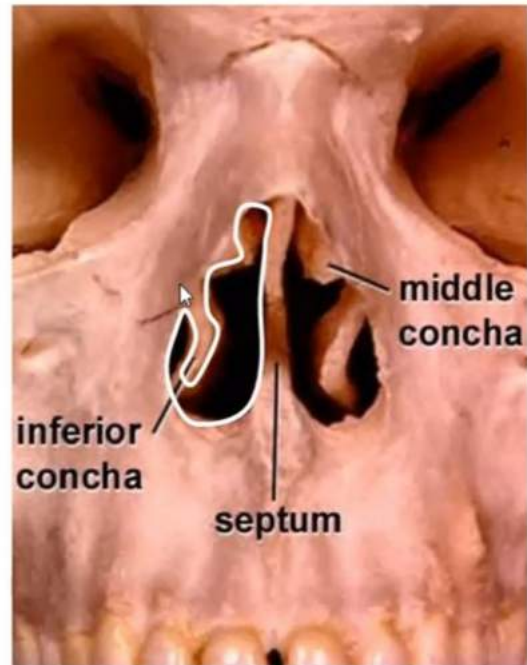
Nerve supply



Arterial supply



Paranasal sinuses



BOUNDARIES OF THE NASAL CAVITY

Roof: Anterior Part

1. Nasal cartilage
2. Nasal bone
3. Frontal bone

Middle Part:

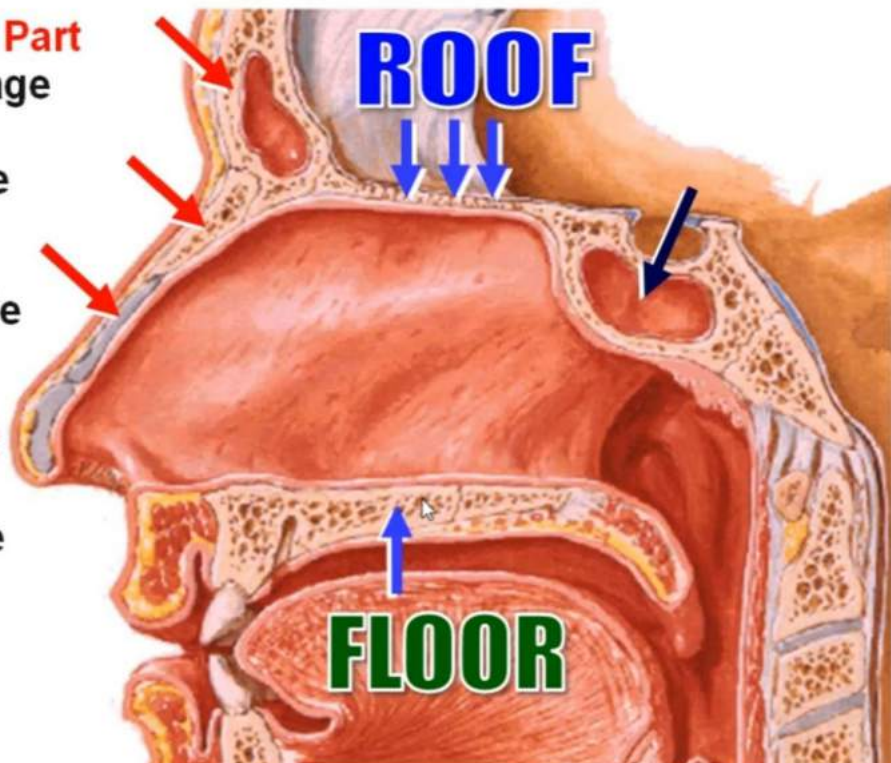
Cribriform plate of ethmoid

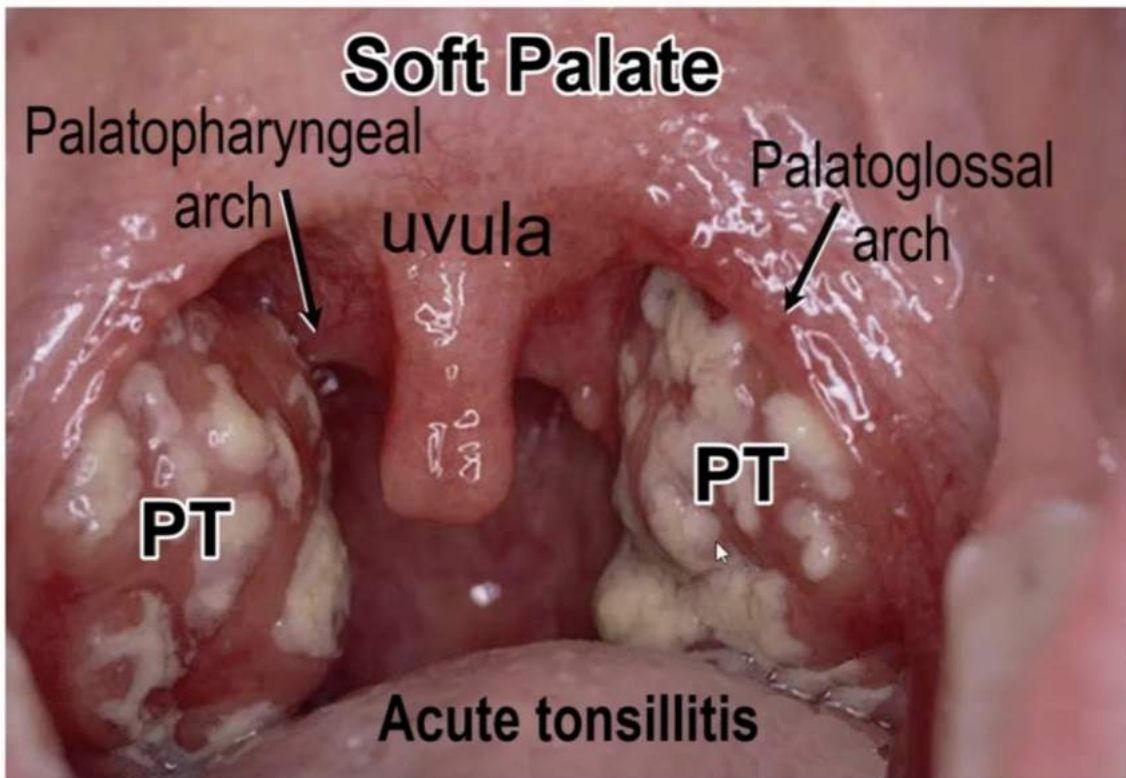
Posterior Part:

Body of the sphenoid bone

Floor:

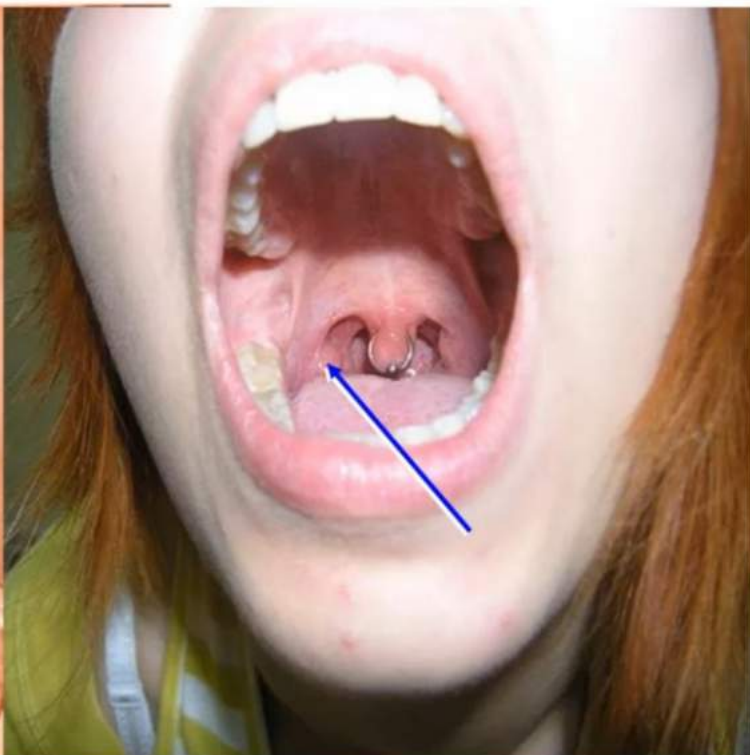
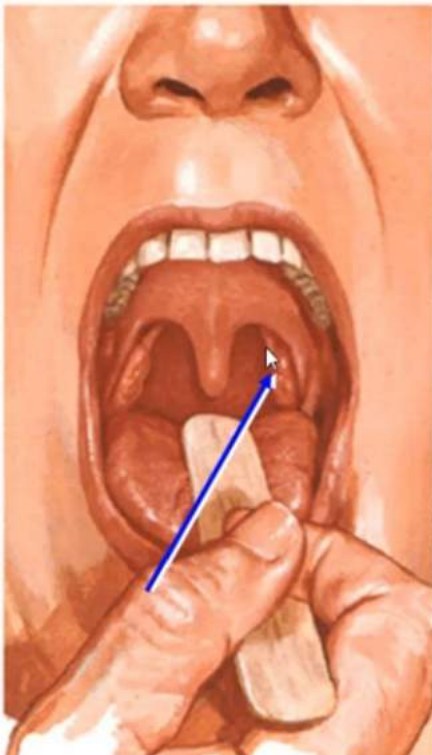Hard palate





Acute Follicular Tonsillitis

EXAMINATION OF THE TONSIL



PALATINE TONSIL

SITE: tonsillar fossa **BOUNDED BY:**

1. **ANTERIOR:** palatoglossal arch
2. **POSTERIOR:** palatopharyngeal arch
3. **FLOOR:** superior constrictor

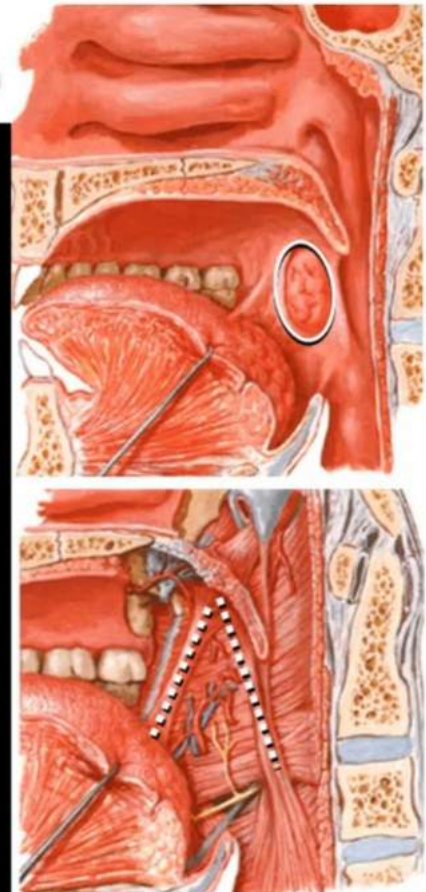
ARTERIAL SUPPLY:

1. **Facial artery:** tonsillar branch. Main supply
2. **Facial artery:** ascending palatine branch
3. **Ascending pharyngeal:** from ECA
4. **Lingual artery:** through dorsal lingual art
5. **Lesser palatine:** from greater palatine art

NERVE SUPPLY: IX & lesser palatine

LYMPH DRAINAGE:

jugulodigastric lymph nodes (upper deep, C)



TONSILLAR FOSSA

Anterior:

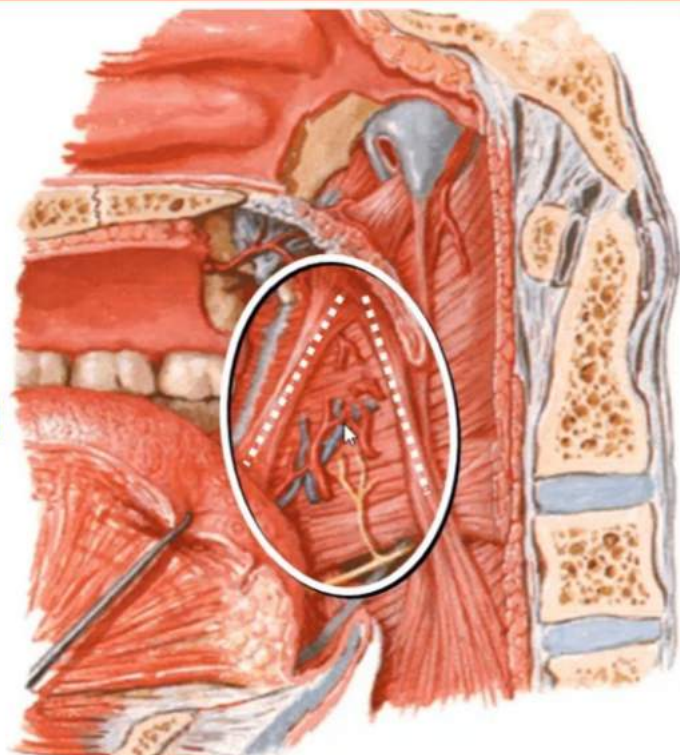
Palatoglossal arch

Posterior:

Palatopharyngeal arch

Floor:

Superior constrictor



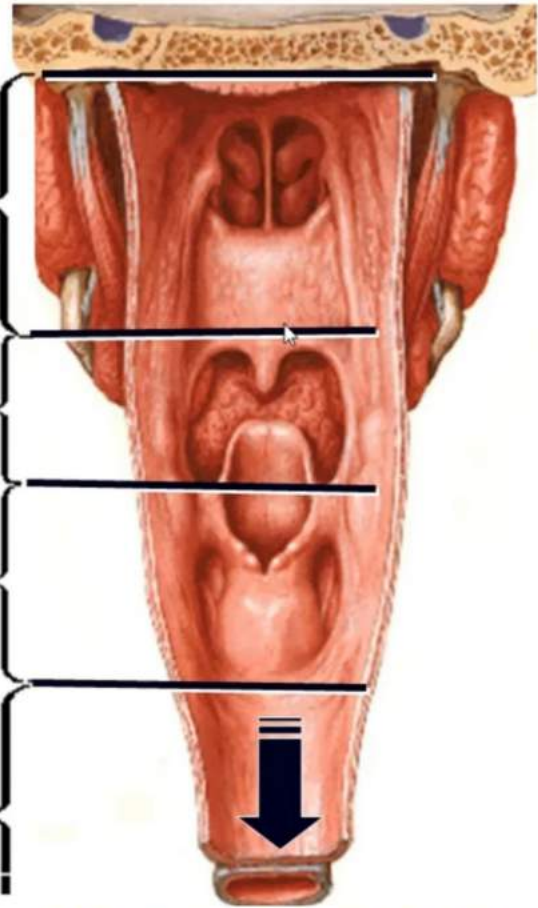
DIVISIONS

NASOPHARYNX

OROPHARYNX

LARYNGOPHARYNX

ESOPHAGUS



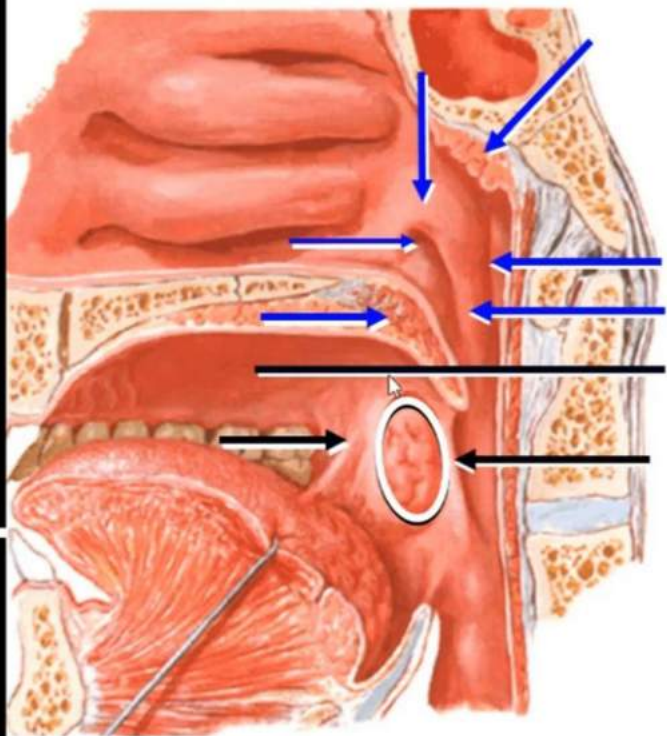
NASOPHARYNX & OROPHARYNX

NASOPHARYNX

- 1. Roof & Post wall:** adenoid (Pharyngeal tonsil)
- 2. Floor:** soft palate
- 3. Anterior:** post nasal orifice
- 4. Lateral Wall: contains**
 - a.** Opening of auditory tube
 - b.** Tubal elevation
 - c.** Salpingopharyngeal fold
 - d.** Pharyngeal recess

OROPHARYNX

- 1. Palatine Tonsil**
- 2. Ant:** Palatoglossal arch
- 3. Post:** Palatopharyngeal arch



THE PHARYNX

Length: 5 inches

Location: in front of upper 6 cervical vert

Extent: from base of the skull to C6

RELATIONS:

1. ANTERIOR: 3 cavities:

nasal, oral, larynx

2. POSTERIOR:

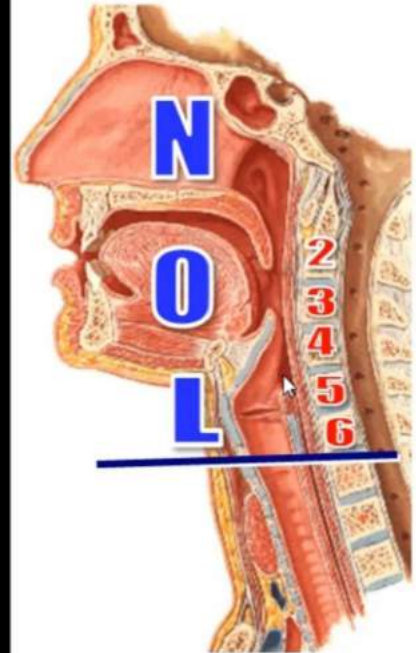
upper 6 cervical vertebrae

DIVISIONS:

1. Nasopharynx

2. Oropharynx

3. Laryngopharynx



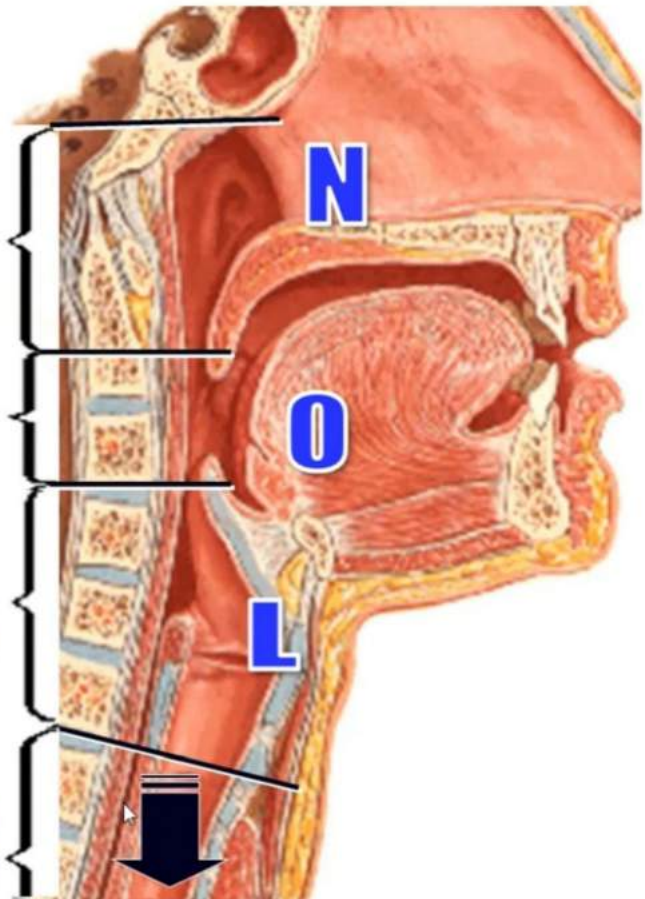
DIVISIONS

NASOPHARYNX

OROPHARYNX

LARYNGOPHARYNX

ESOPHAGUS



Functions of the Sinuses

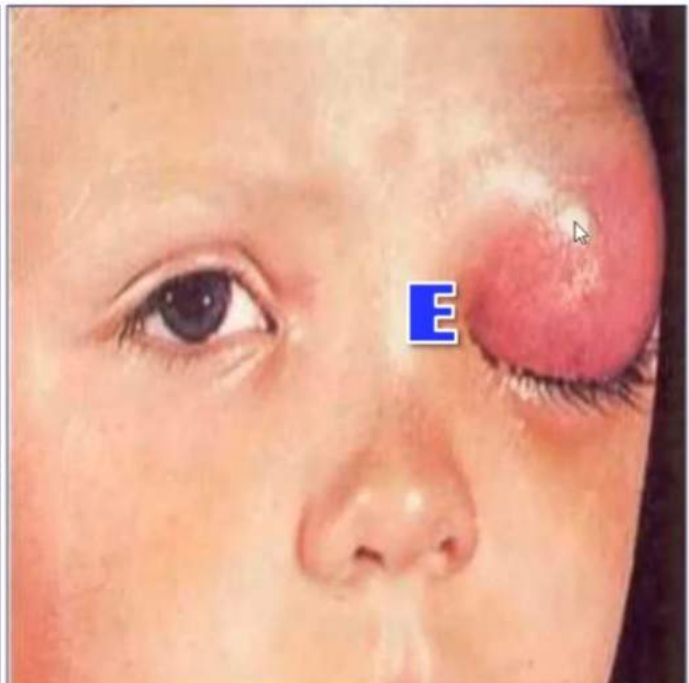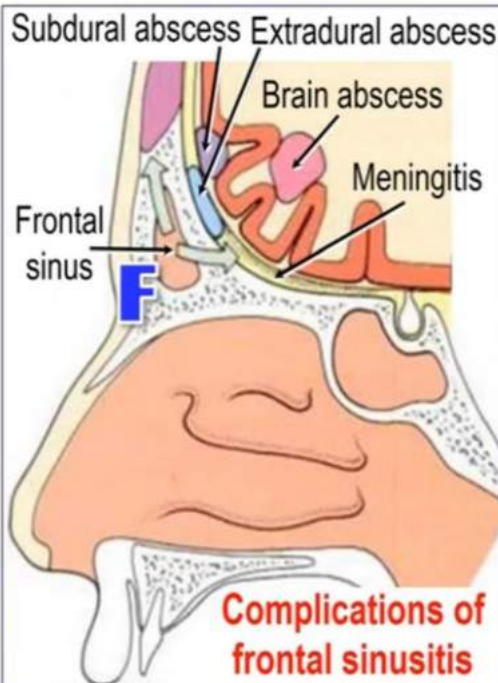
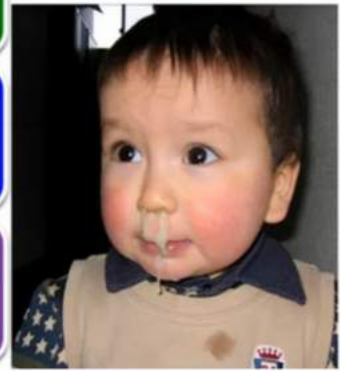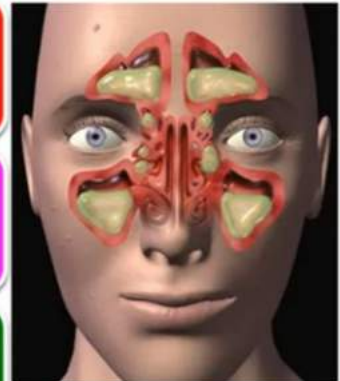Decrease weight of the skull

Make the voice resonant

Increase surface area for the air

Air conditioning of the head

Absorb shocks in face trauma



Brain abscess due to frontal sinusitis

Orbital abscess due to ethmoidal sinusitis

ARTERIAL SUPPLY

1 Anterior ethmoidal artery

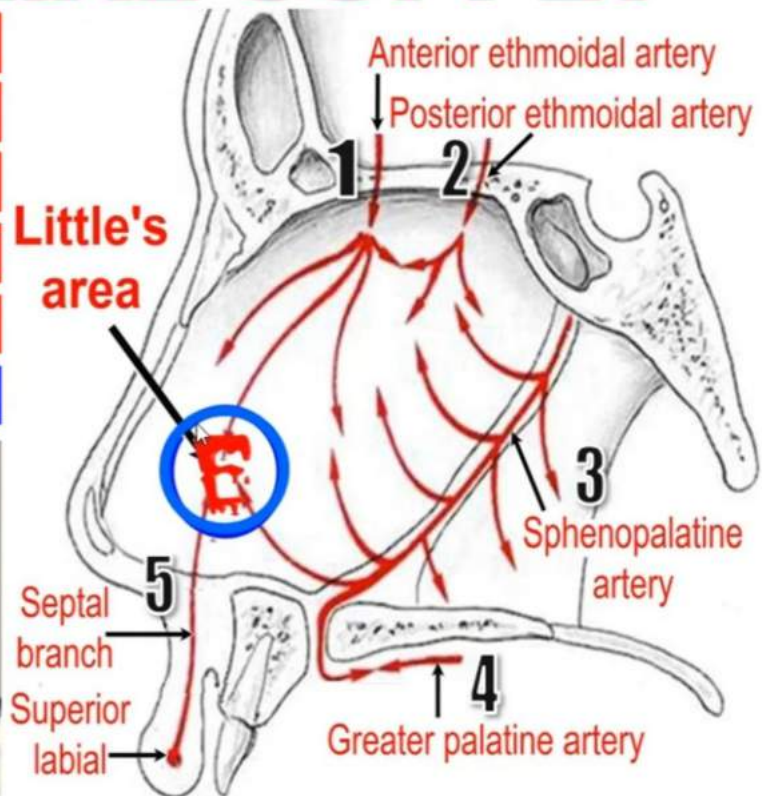
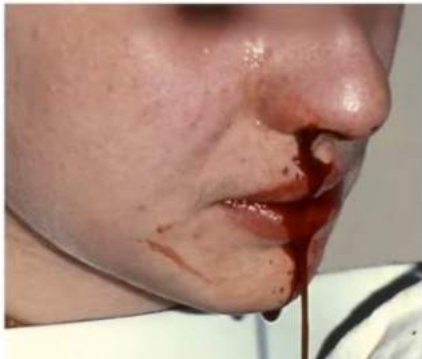2 Posterior ethmoidal artery

3 Sphenopalatine artery

4 Greater palatine artery

5 Septal branch of sup labial

Little's Area of Epistaxis



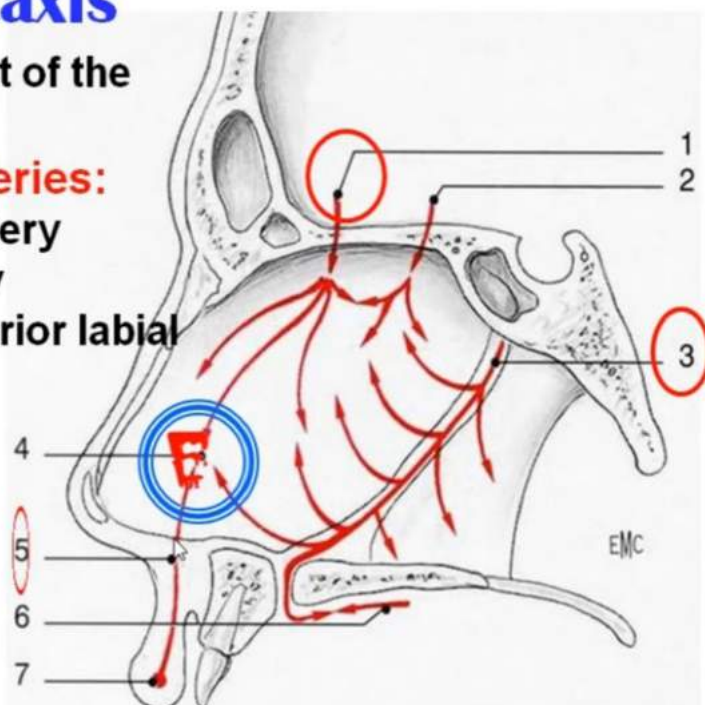
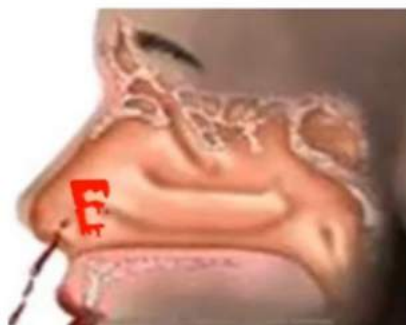LITTLE'S AREA

Area of Epistaxis

Site: antero-inferior part of the nasal septum

Anastomosis of 3 Arteries:

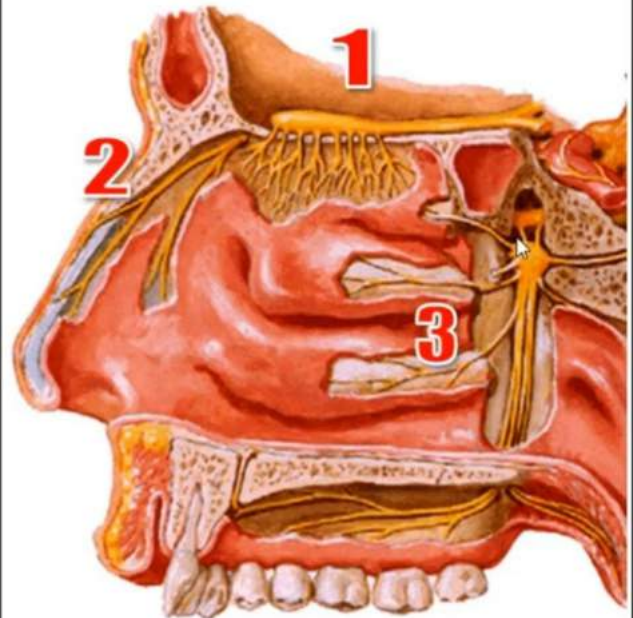
1. Anterior ethmoidal artery
3. Sphenopalatine artery
5. Septal branch of superior labial



NERVE SUPPLY

LATERAL WALL

- 1. UPPER PART:**
Olfactory nerves
- 2. ANTERIOR PART:**
Anterior ethmoidal nerve
from nasociliary nerve
- 3. Remaining Part:**
Nasal branches of the
greater palatine nerve &
sphenopalatine ganglion
Carry secretory fibers
to the nasal glands



ARTERIAL SUPPLY

6 ARTERIES

2 from the OPHTHALMIC artery:

1. Anterior ethmoidal artery
2. Posterior ethmoidal artery

2 from the MAXILLARY artery: 3rd part

1. Sphenopalatine artery: main supply
2. Greater palatine artery

2 from the FACIAL artery:

1. Lateral nasal artery
2. Septal branch of the superior labial artery

LYMPH DRAINAGE

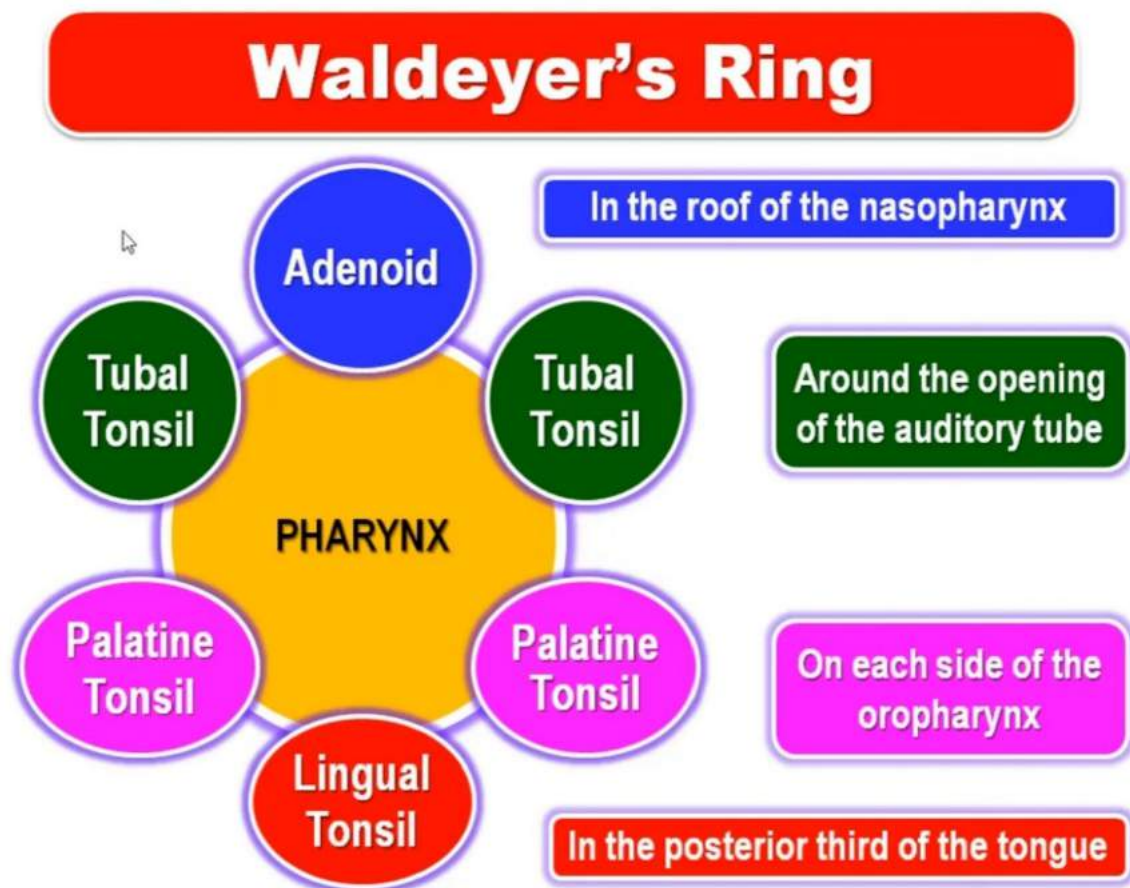
1. Retropharyngeal
2. Deep cervical lymph nodes

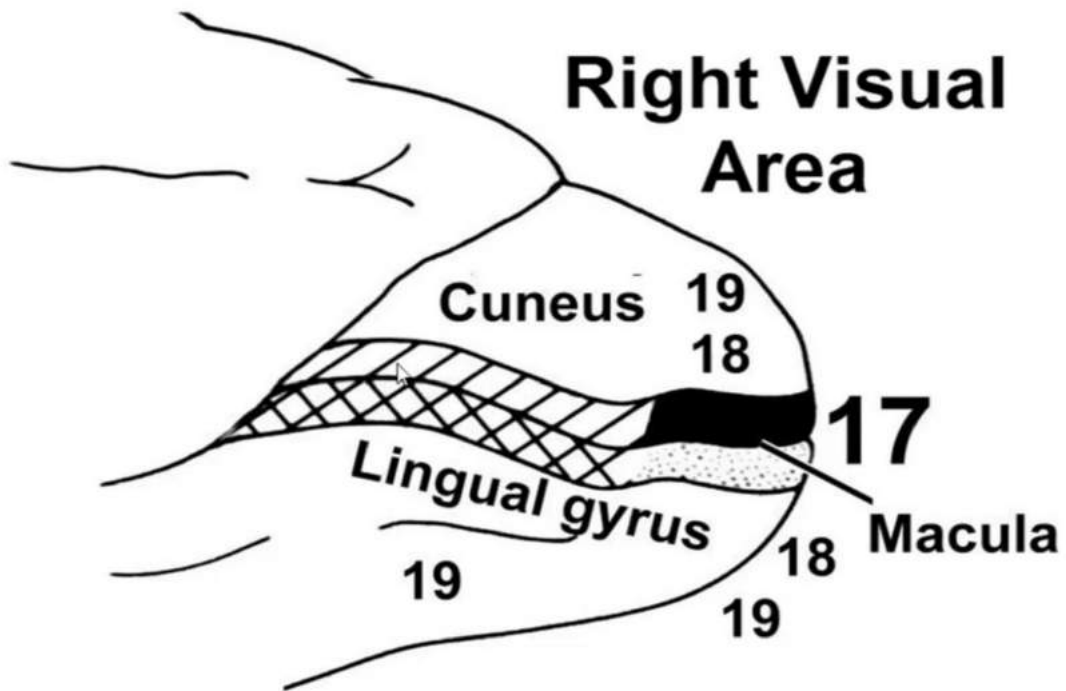
WALDEYER'S RING

A ring of lymphoid tissue around the pharynx

Formed by:

1. Lingual tonsil
2. Palatine tonsil
3. Tubal tonsil
4. Pharyngeal tonsil (**adenoid**)



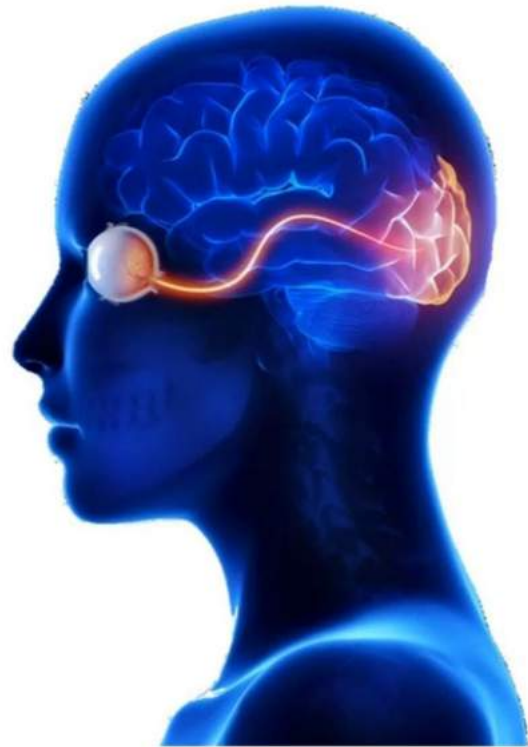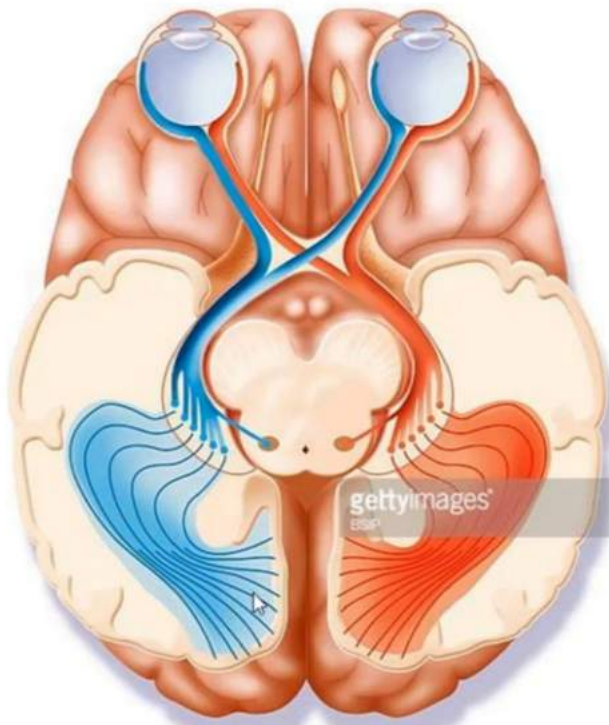


Representation of the Retina and Field of Vision in the Visual Area

LEFT EYE	RIGHT EYE	Description
		Blindness of the ipsilateral eye
		Bitemporal hemianopia
		Binasal hemianopia
		Contralateral homonymous hemianopia
		Cont. homonym. lower quadrantic anopia
		Cont. homonym. upper quadrantic anopia
		Contralateral homonymous hemianopia with macular sparing

TOTAL LESION IN AREA 17

LESIONS



OPTIC NERVE

OPTIC NERVE

Origin: axons of ganglion cells of the retina

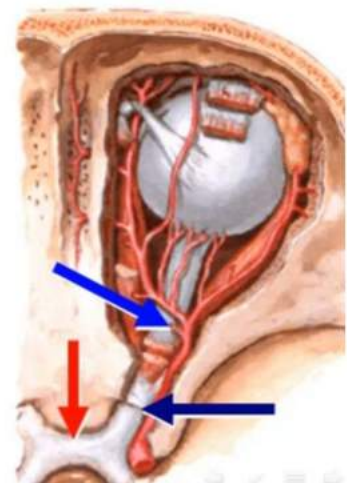
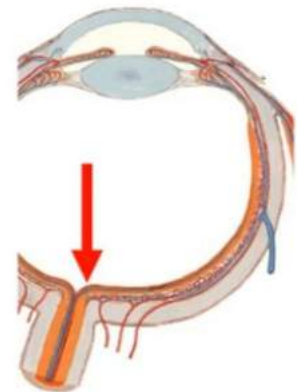
Termination: optic chiasma

Course:

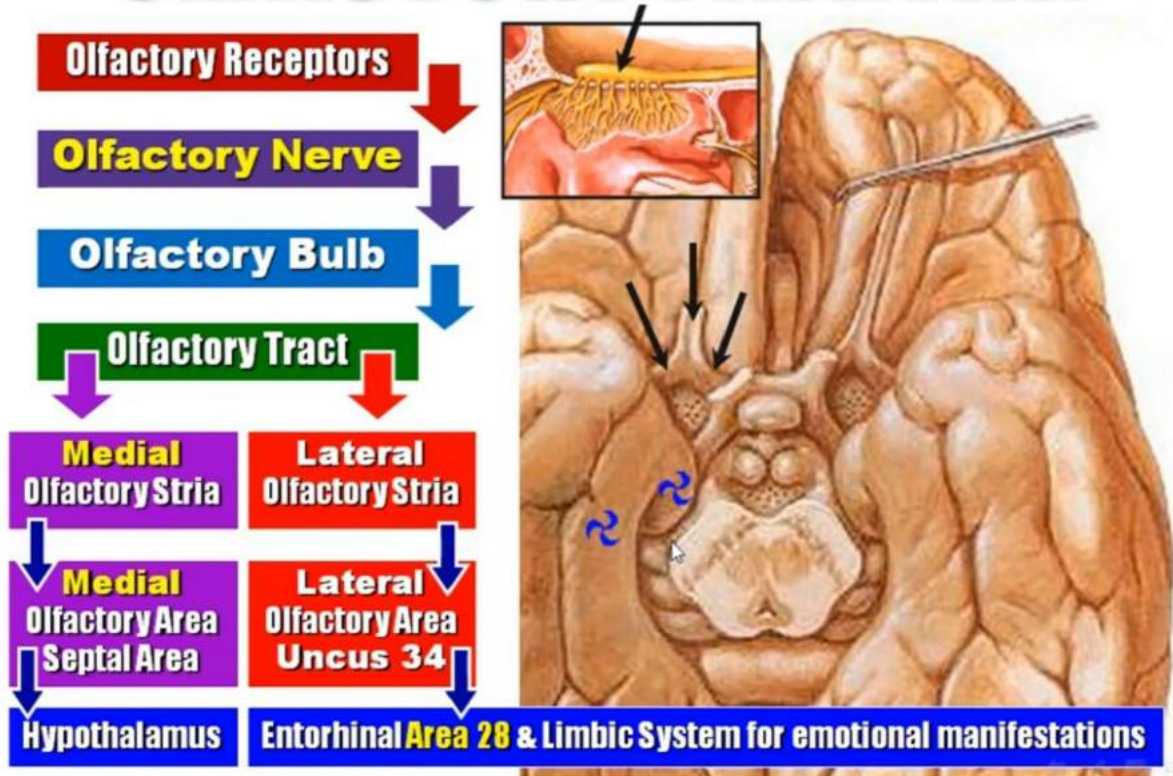
1. Pass through the optic canal
2. Pierced by central retinal artery & vein

3 Differences from peripheral nerves:

1. It is surrounded by meninges & CSF
2. It has glial cells & no Schwann cells
3. It doesn't regenerate after injury.

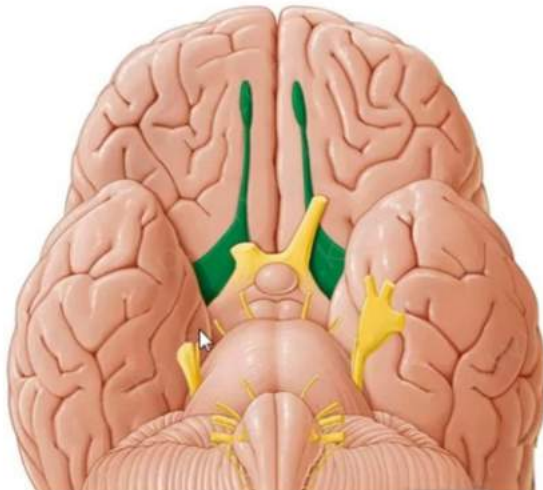

OLFACTORY PATHWAY

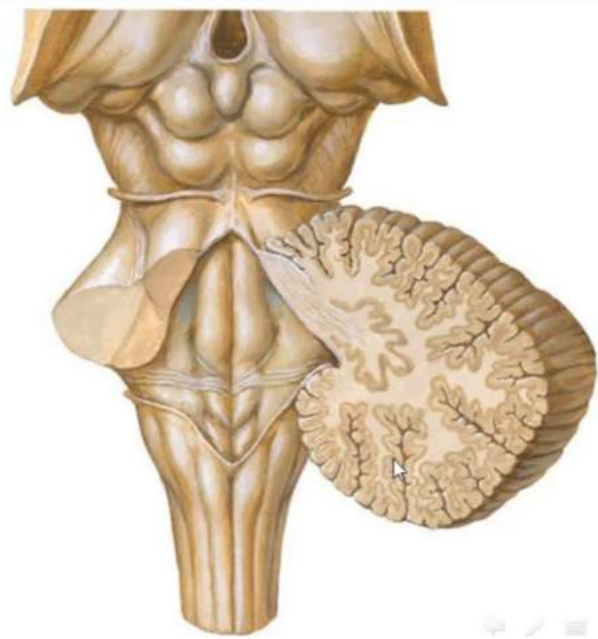
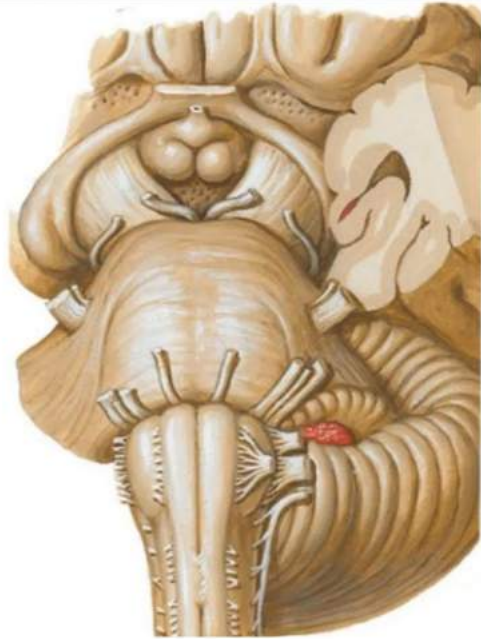

Lesion of the Olfactory Nerve

- 1. Anosmia:** loss of smell
- 2. Olfactory hallucination:** irritative lesion of uncus



EXIT OF THE CRANIAL NERVES FROM THE BRAIN



OLFACTORY NERVE

Origin:

Olfactory receptors

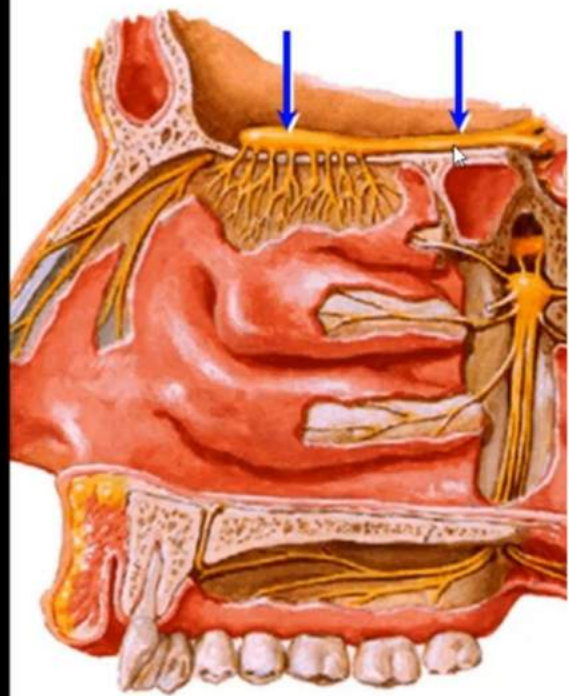
in the roof & upper part of the nasal septum & lateral wall

Exit from the nose:

20 rootlets through the cribriform plate of ethmoid

Termination:

Olfactory bulb
then olfactory tract



CRANIAL NERVES

🤩 **Origin From The Brain**

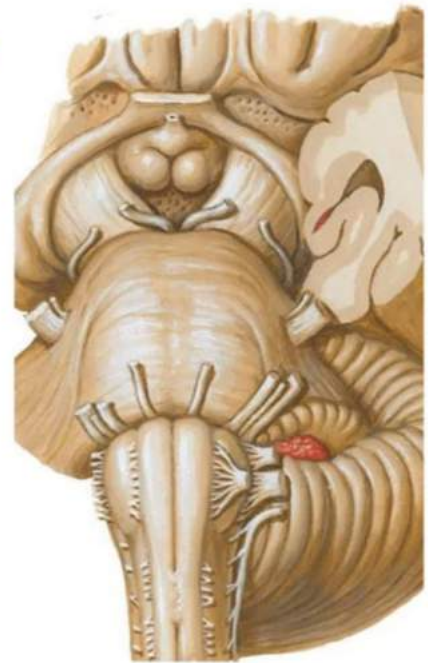🤩 **Exit From The Brain**

🤩 **Exit From The Skull**

🤩 **Brief Course**

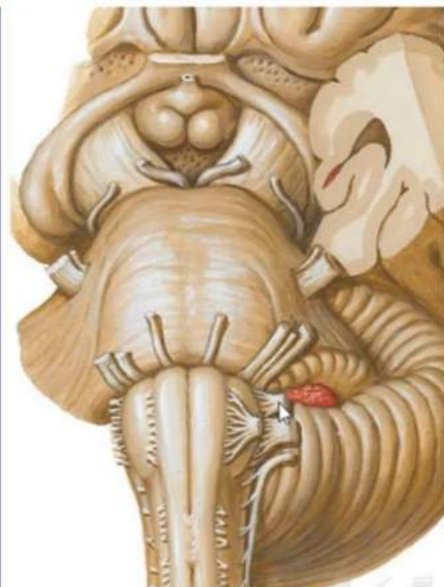🤩 **Distribution**

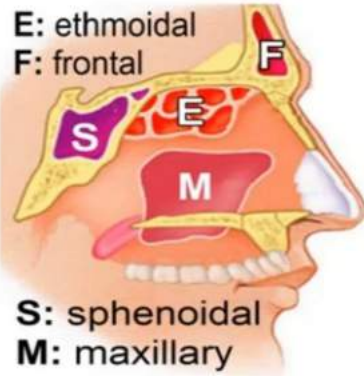
🤩 **Lesion**



ORIGIN OF THE CRANIAL NERVES

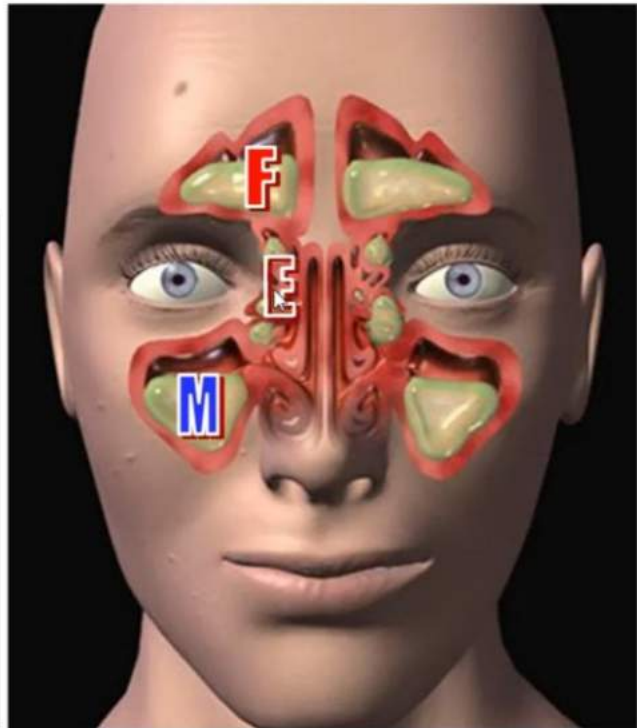
1. **Olfactory N:** from nose
2. **Optic Nerve:** from retina
3. **III & IV:** from midbrain
4. **Middle 4:** from pons
5. **Last 4:** from medulla



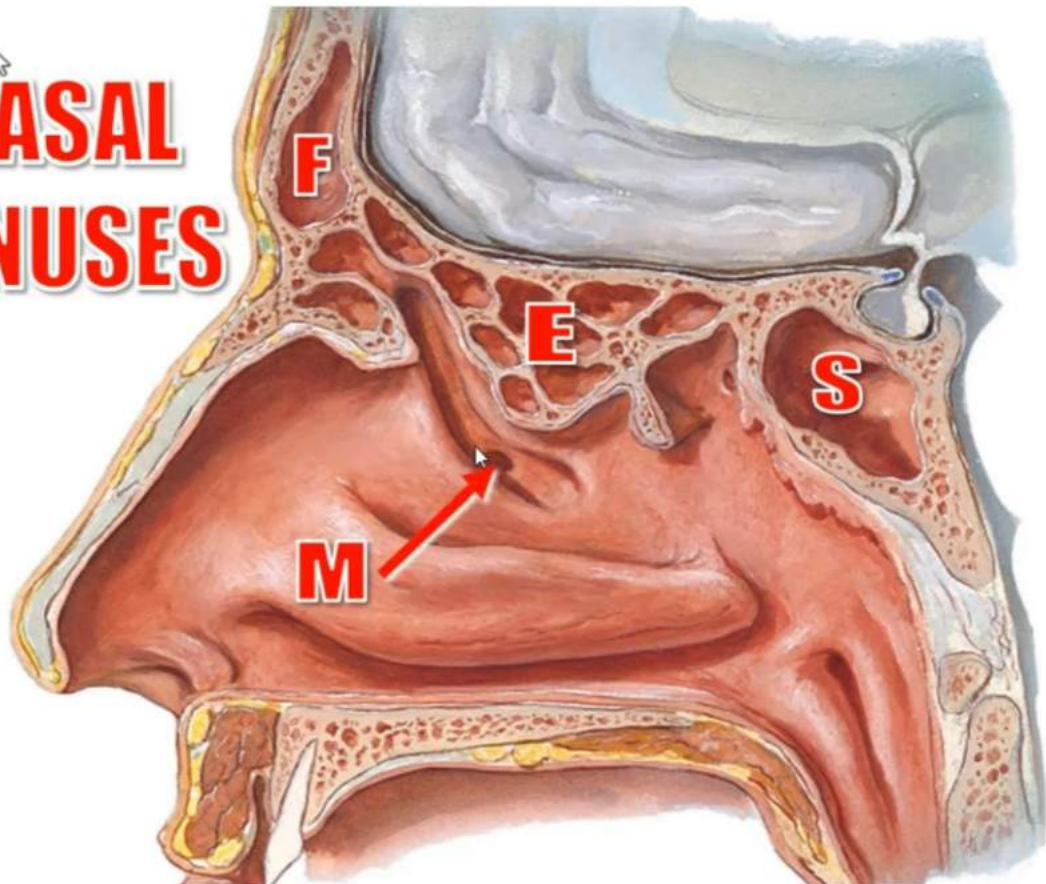


NASAL SINUSES

1. Sphenoidal air sinus
2. Frontal air sinus
3. Maxillary air sinus
4. 3 Ethmoidal sinuses:
 1. Anterior
 2. Middle
 3. Posterior



NASAL SINUSES



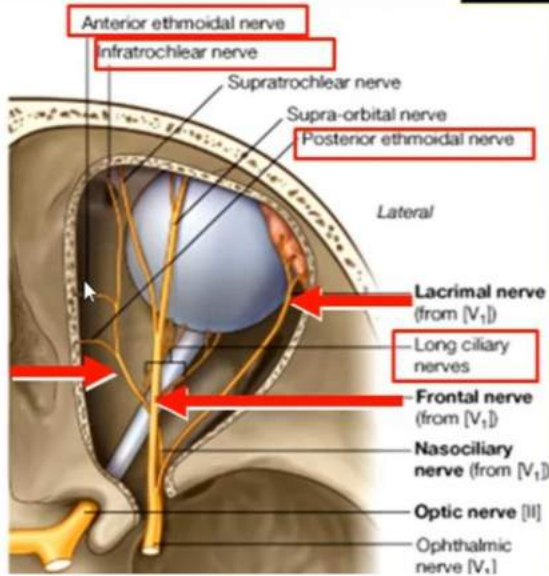
OPHTHALMIC NERVE

LACRIMAL NERVE

1. Lacrimal gland
2. Upper eyelid

FRONTAL NERVE

1. supratrochlear nerve
 2. supraorbital nerve
- Both supply upper eyelid & scalp

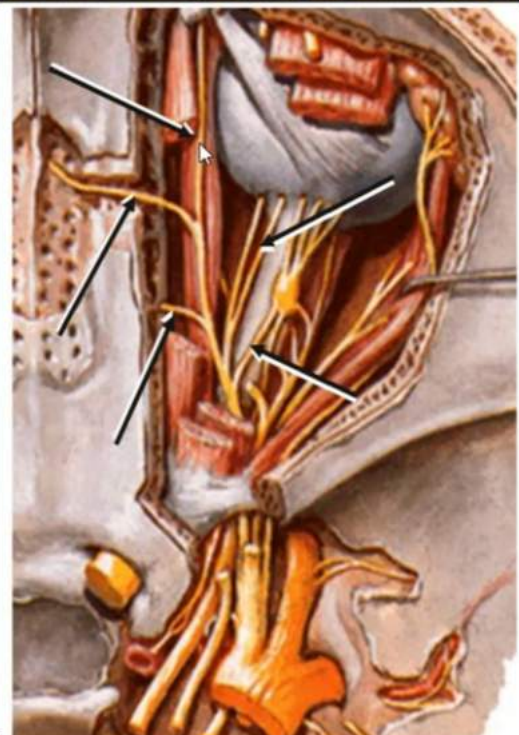


NASOCILIARY NERVE

1. **Sensory root** to ciliary ganglion
2. **Long ciliary nerves:**
 - a. **sympathetic** to dilator pupillae
 - b. **sensory** to the cornea & iris
3. **Posterior ethmoidal nerve:** to sphenoid & ethmoidal sinuses & dura
4. **Anterior ethmoidal nerve:** to the nasal cavity & the dura mater
5. **Infratrochlear nerve**

NASOCILIARY NERVE

1. **Sensory root:**
to the ciliary ganglion
2. **Long ciliary nerves:**
 - a. **sympathetic:**
to the dilator pupillae
 - b. **sensory:**
to the cornea & iris
3. **Posterior ethmoidal nerve:**
to sphenoid & ethmoidal sinuses and dura mater
4. **Anterior ethmoidal nerve:**
to nasal cavity and dura mater
5. **Infratrochlear nerve**



OPHTHALMIC NERVE

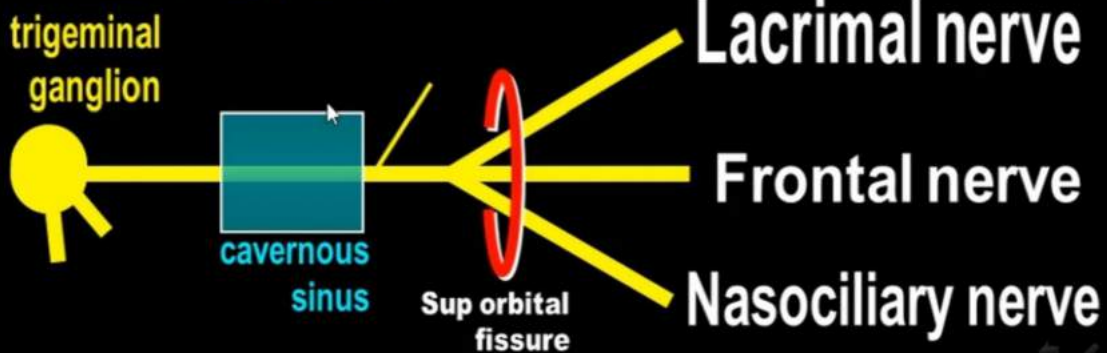
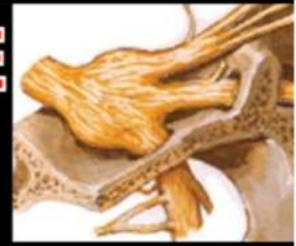ORIGIN: trigeminal ganglion

COURSE:

1. Lateral wall of the cavernous sinus
2. Divides into 3 branches which enter the sup orbital fissure

BRANCHES:

1. Meningeal branch: to the dura
2. Lacrimal nerve: to lacrimal gland
3. Frontal nerve: supratrochlear & supraorbital nerves: to the scalp & upper eyelid
4. Nasociliary nerve



OPHTHALMIC NERVE

Meningeal branch

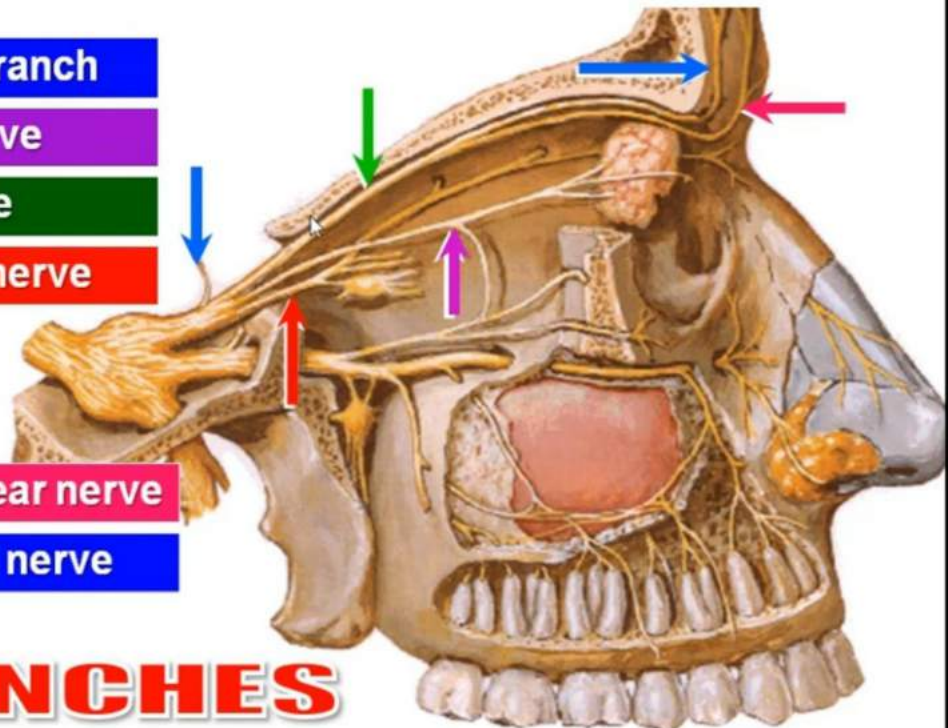
Lacrimal nerve

Frontal nerve

Nasociliary nerve

Supratrochlear nerve

Supraorbital nerve



BRANCHES

TRIGEMINAL NERVE

ORIGIN: 4 NUCLEI

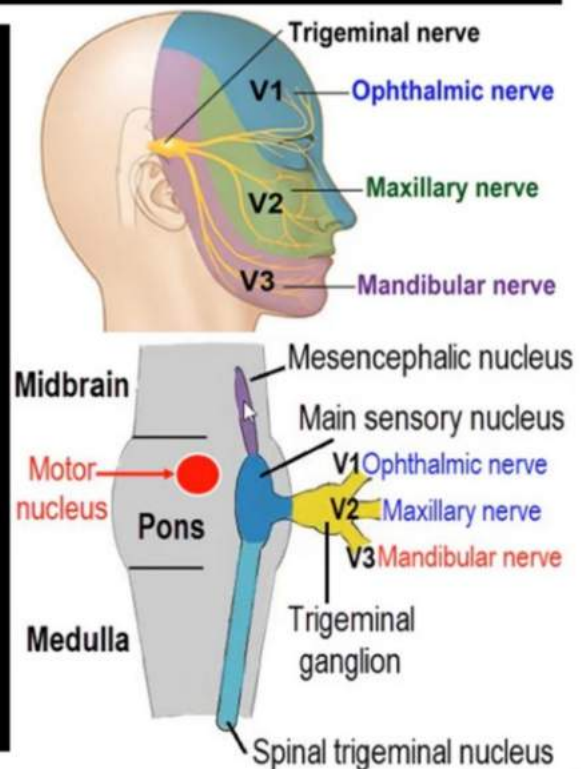
Motor Nucleus: Pons →
to muscles of mastication

3 Sensory Nuclei:

1. Spinal Trig. Nucleus:
→ medulla → pain

2. Main Sensory Nucleus:
→ pons → touch

3. Mesencephalic Nucl: →
midbrain → proprioception

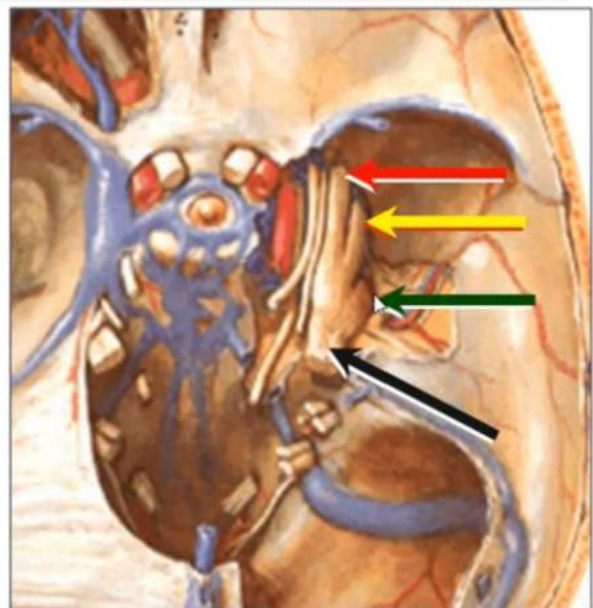


BRANCHES OF THE TRIGEMINAL NERVE

OPTHALMIC NERVE



MAXILLARY NERVE

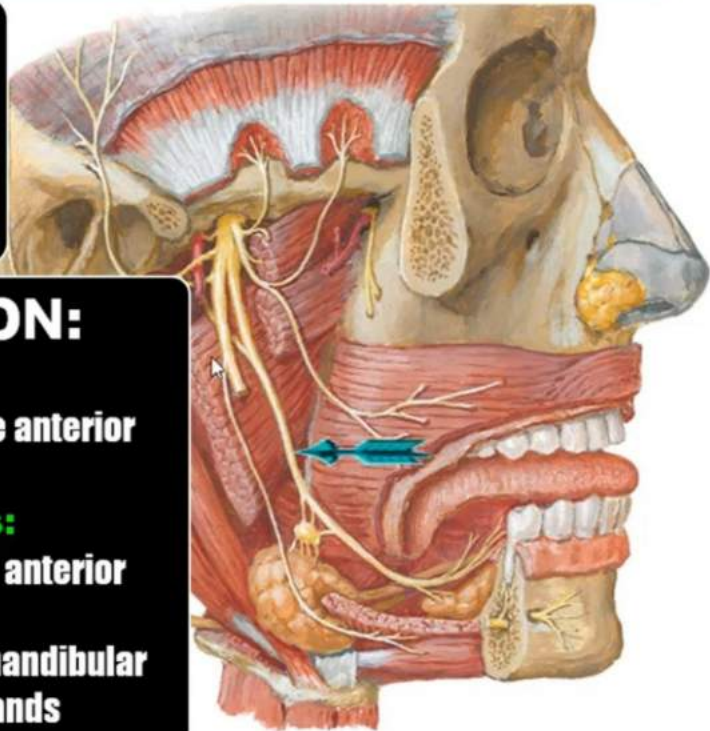
MANDIBULAR NERVE



LINGUAL NERVE

IMPORTANT POINTS:

-  Join the chorda tympani
-  Run below the last molar



DISTRIBUTION:

Lingual Nerve Itself:

General sensation from the anterior 2/3 of the tongue

Chorda Tympani Fibers:

1. Taste sensation from the anterior 2/3 of the tongue
2. Parasymp fibers to submandibular & sublingual salivary glands

SUMMARY

FROM THE TRUNK:

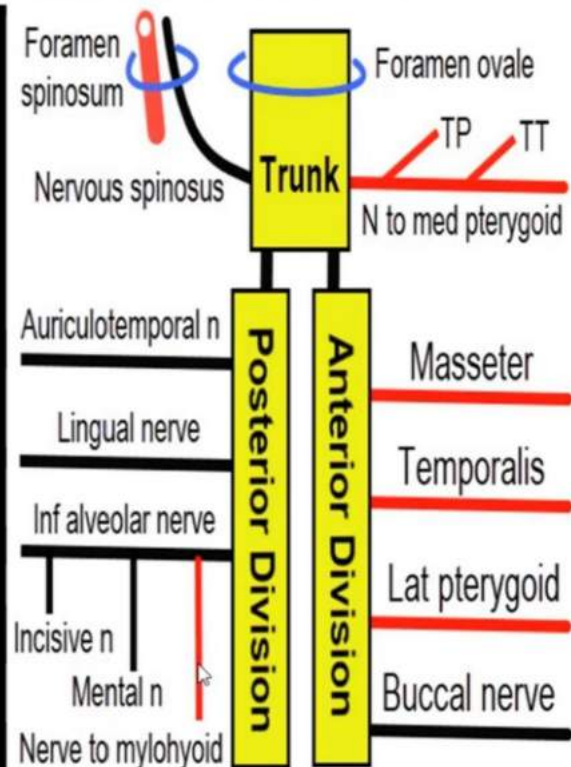
1. Nerve to Medial pterygoid
2. Nervus spinosus: sensory to dura

ANTERIOR DIVISION:

1. Nerve to Masseter
2. Deep temporal: temporalis
3. Pterygoid branches: to Lat ptery
4. Buccal branch: sensory

POSTERIOR DIVISION:

1. Auriculotemporal nerve
2. Lingual nerve
3. Inferior alveolar nerve



AURICULOTEMPORAL NERVE

ORIGIN:

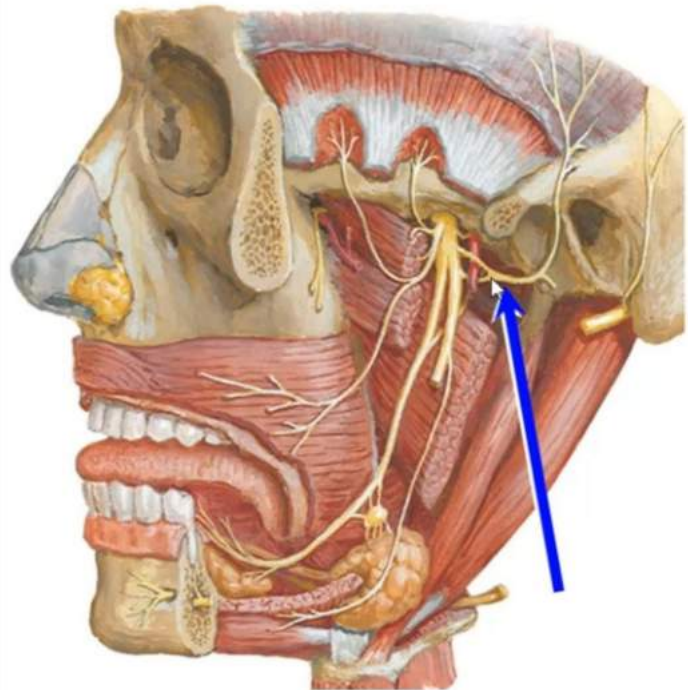
By 2 roots surrounding the middle meningeal art

DISTRIBUTION:

1. Sensory Fibers: to

- a. scalp
- b. Auricle
- c. external auditory m
- d. tympanic membrane
- e. parotid gland.
- f. Temporomandibular J

2. Parasymp Fibers: to the parotid gland

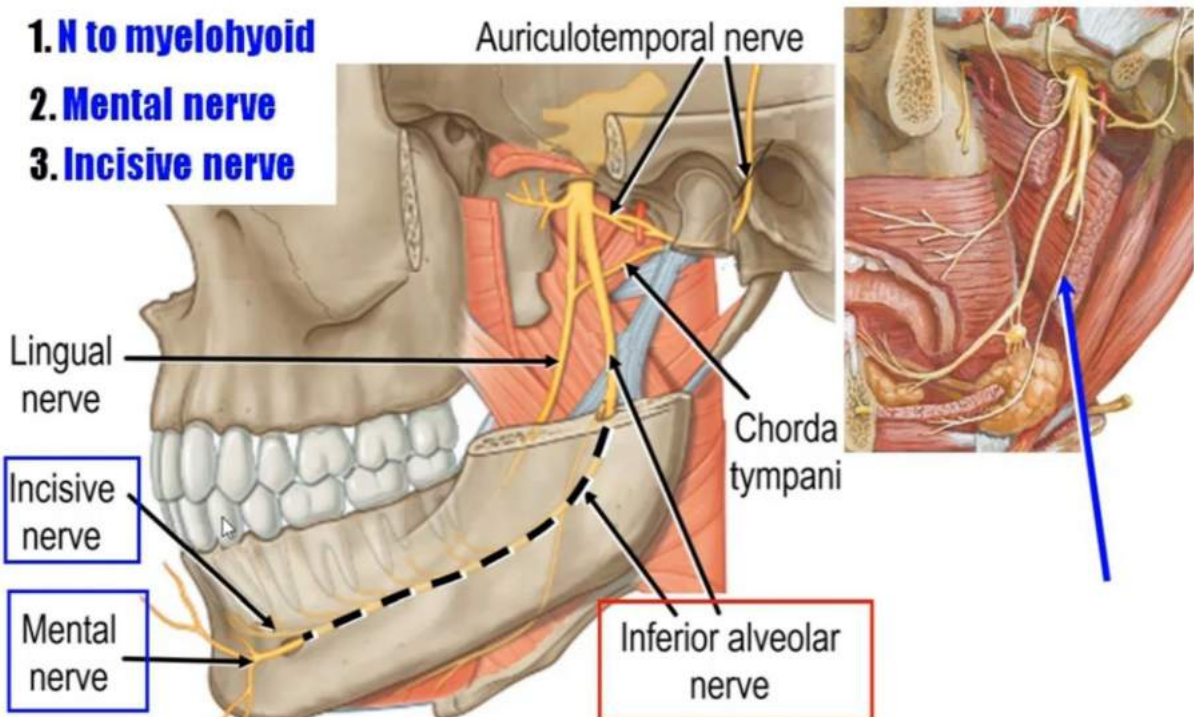


INFERIOR ALVEOLAR NERVE

1. N to myelohyoid

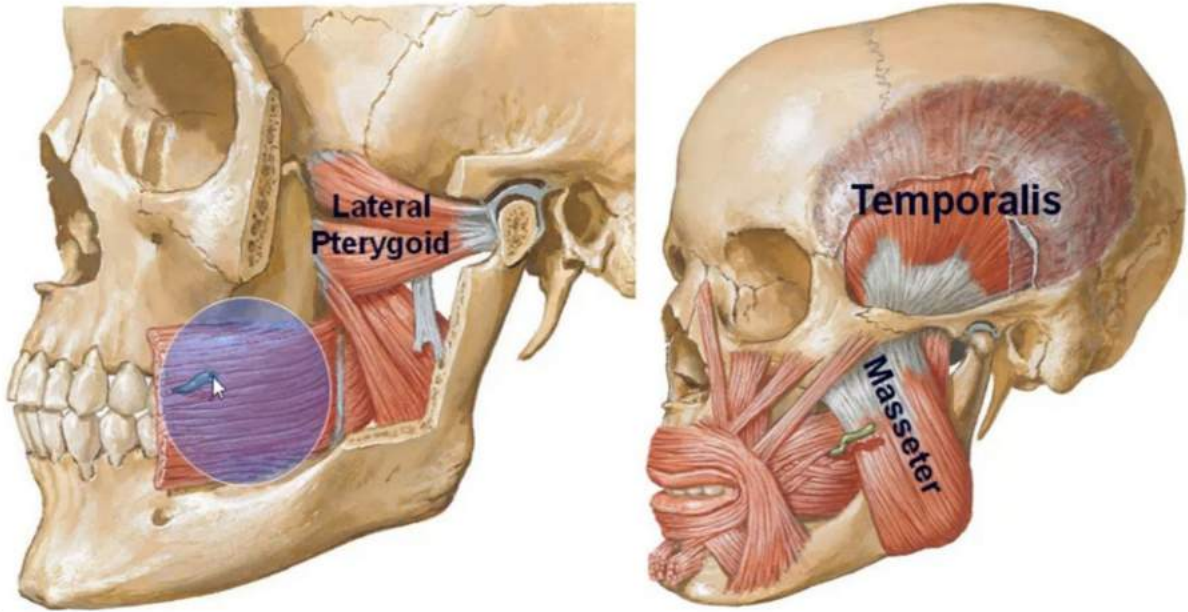
2. Mental nerve

3. Incisive nerve

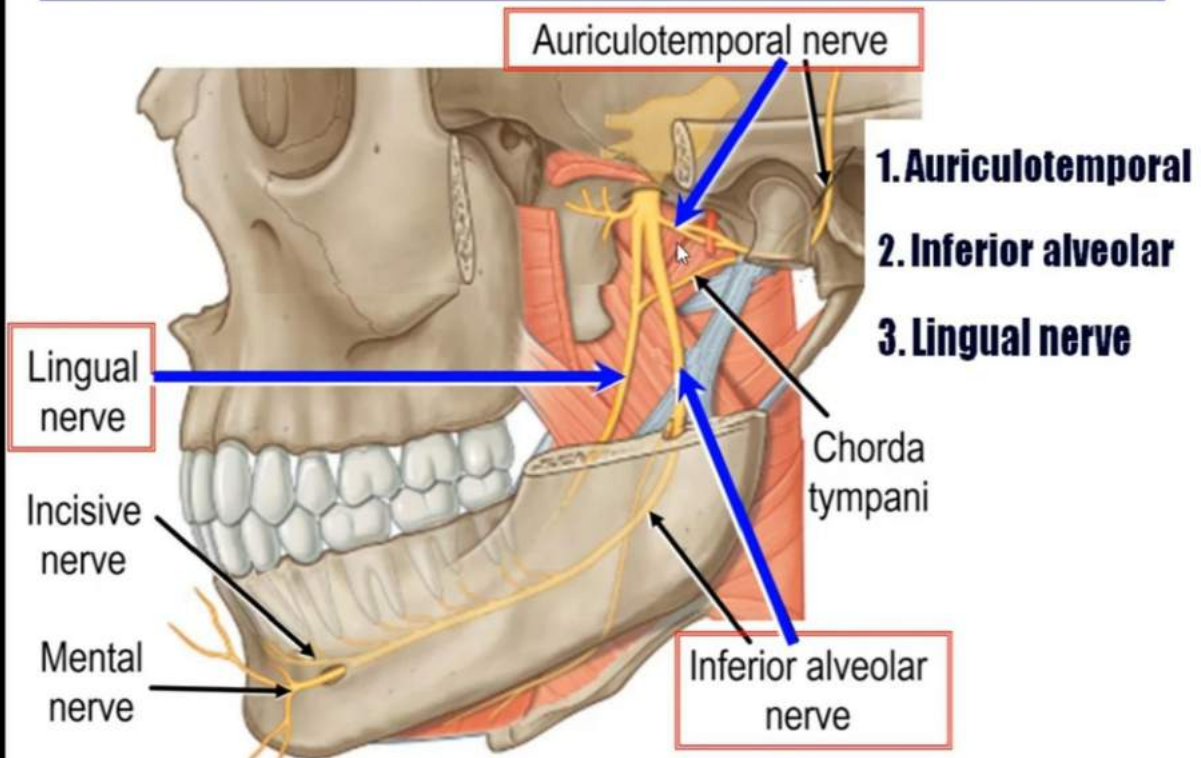


ANTERIOR DIVISION

1. **Muscular:** all muscles of mastication **except** medial pterygoid
2. **Buccal branch:** sensory to skin & mm over the buccinator



POSTERIOR DIVISION: 3



MANDIBULAR NERVE

ORIGIN: by 2 ROOTS:

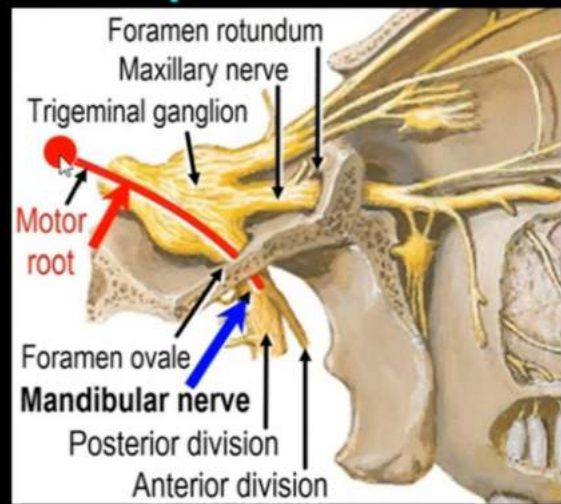
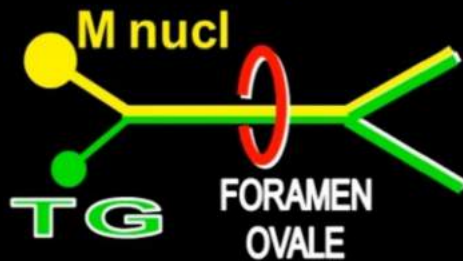
1. **Motor Root:** from the **Motor Nucleus**
2. **Sensory Root:** from the **Trigeminal Ganglion**

COURSE:

1. **Pass thru foramen ovale**
2. **Divides into 2 divisions: anterior and posterior**

BRANCHES:

1. **From the trunk:**
2. **From the anterior division:**
3. **From the posterior division:**



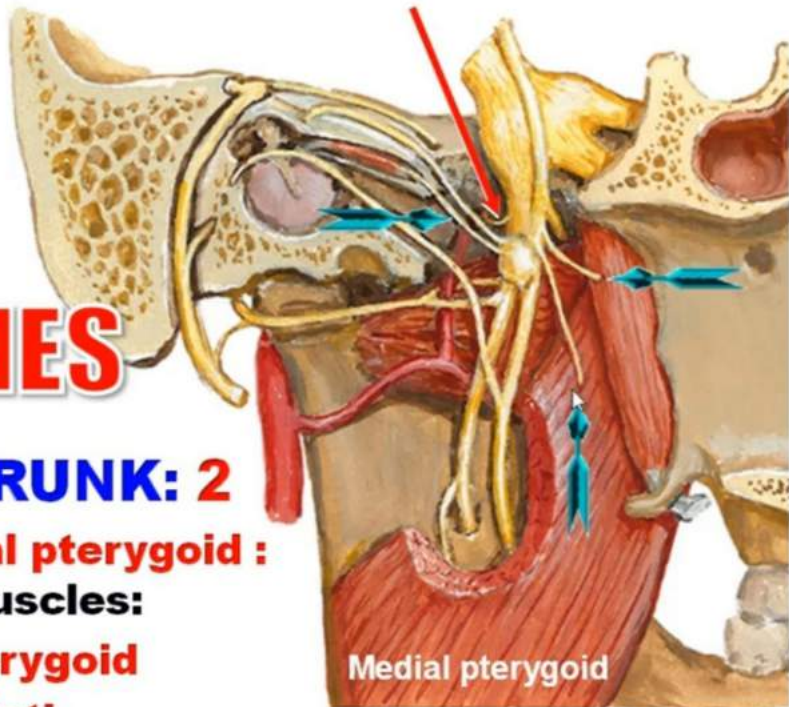
BRANCHES

FROM THE TRUNK: 2

1. Nerve to Medial pterygoid :
it supplies 3 muscles:

- a. **Medial pterygoid**
- b. **Tensor palati**
- c. **Tensor tympani**

2. Nervus spinosus: sensory to the dura



MAXILLARY NERVE COURSE

Foramen rotundum

Pterygopalatine fossa

Pterygomaxillary fissure

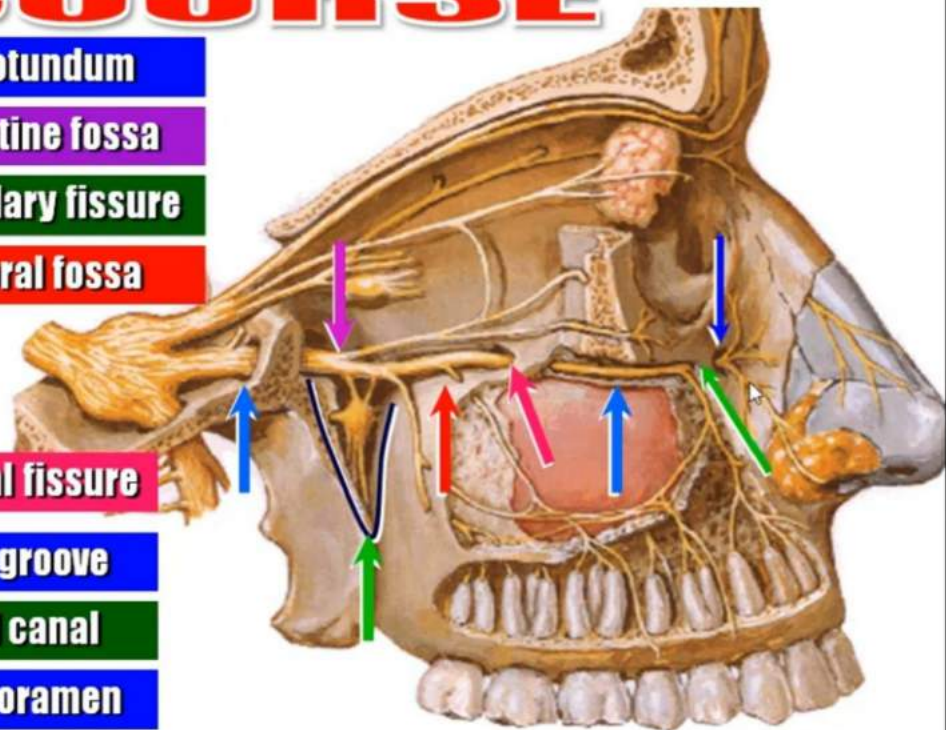
Infratemporal fossa

Inferior orbital fissure

Infraorbital groove

Infraorbital canal

Infraorbital foramen



MAXILLARY NERVE DISTRIBUTION

1. Meningeal branch

2. Ganglionic branches

3. Zygomatic nerve

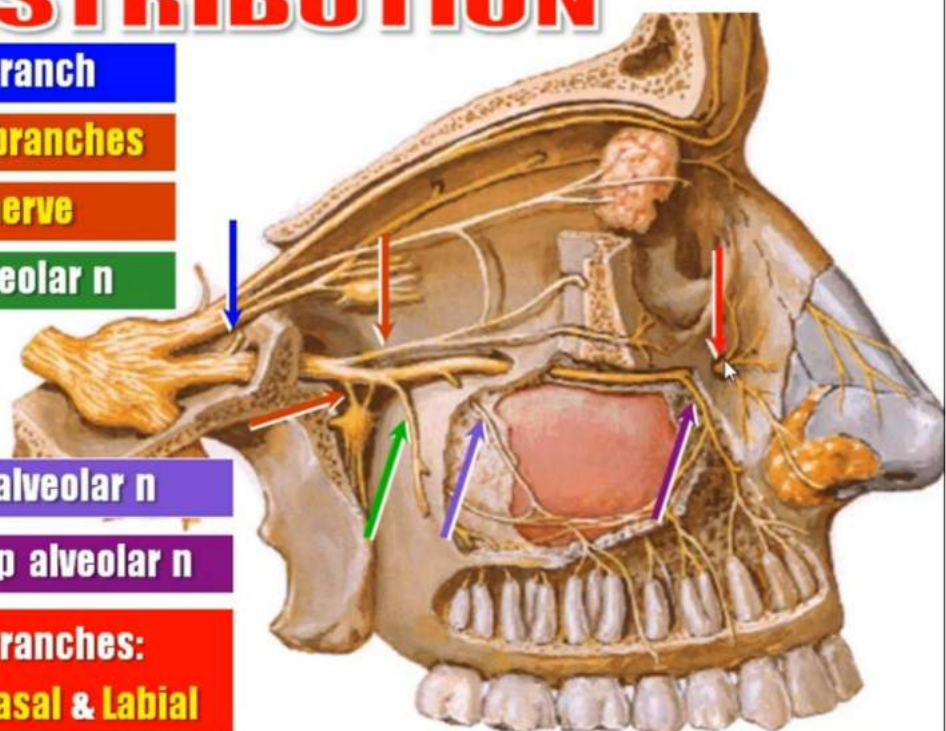
4. Post Sup alveolar n

5. Middle Sup alveolar n

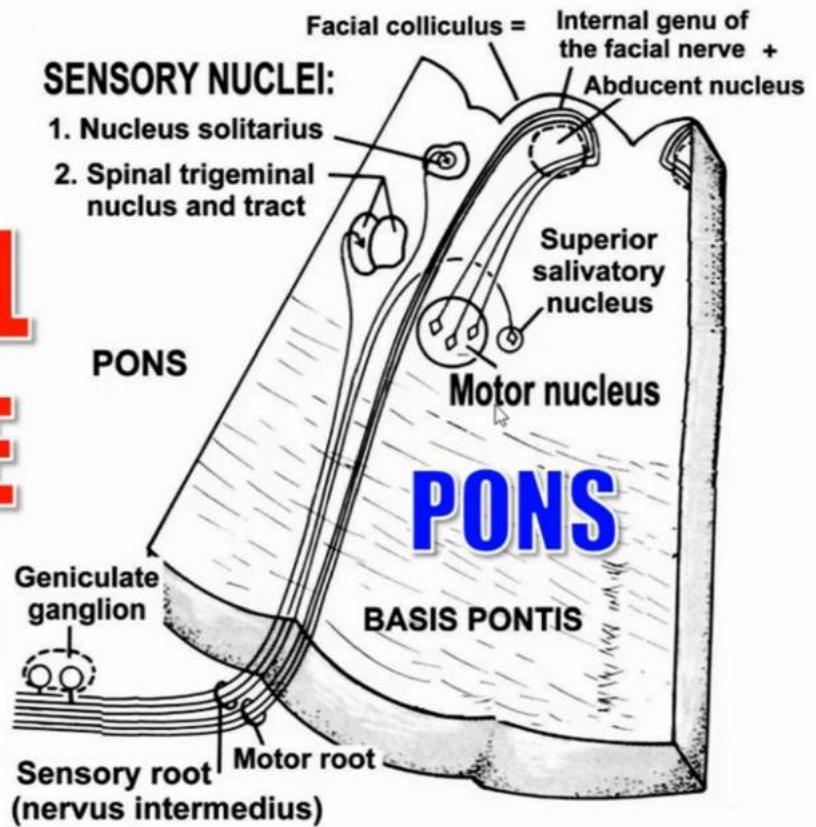
6. Anterior Sup alveolar n

7. 3 Terminal branches:

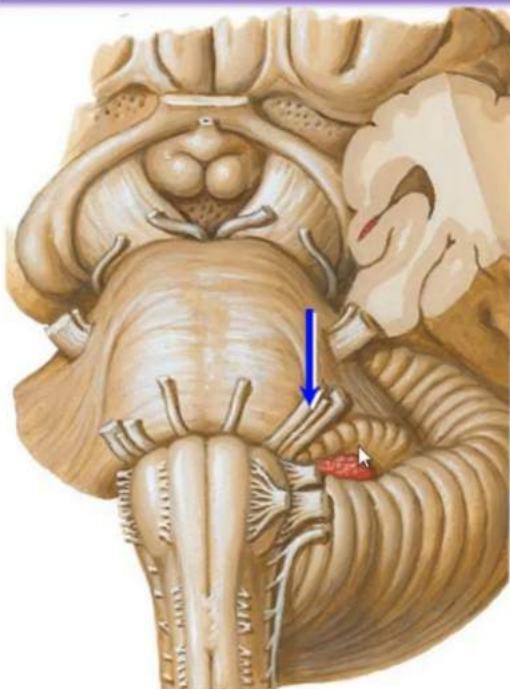
Palpebral, Nasal & Labial



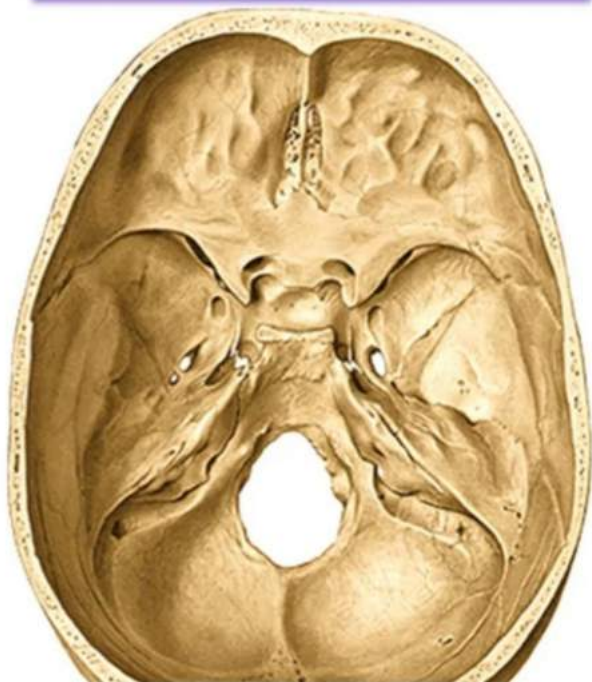
FACIAL NERVE

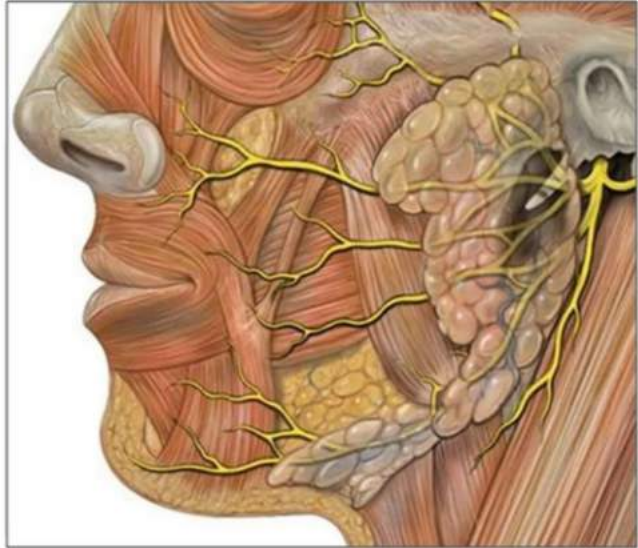


EXIT FROM THE BRAIN



EXIT FROM THE CRANIAL CAVITY





Facial Nerve

Dr Adel Bondok

YouTube Subscribe

FACIAL NERVE



MOTOR NUCLEUS: ⇒ to
muscles of facial expression

PARASYMPATHETIC NUCLEUS:

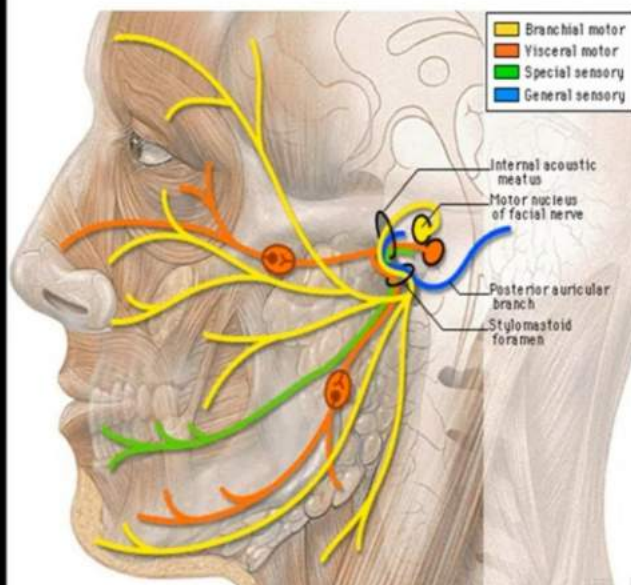
Superior salivary nucleus ⇒
to

1. Submandibular & sublingual glands.
2. Lacrimal, nasal & palatine glands

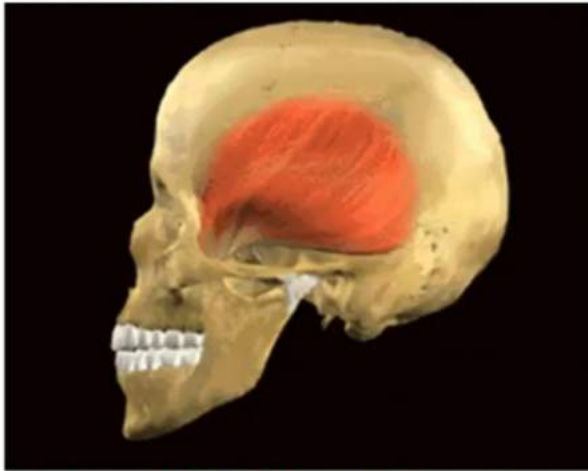2 SENSORY NUCLEI:

1. Solitary nucleus: taste
2. Spinal trigeminal nucleus

DEEP ORIGIN



Trigeminal Nerve Lesion

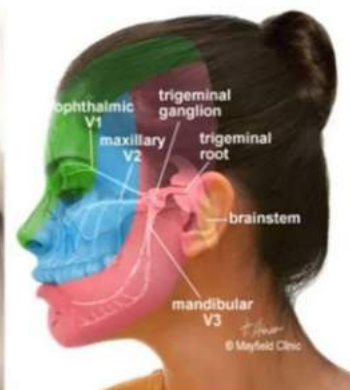
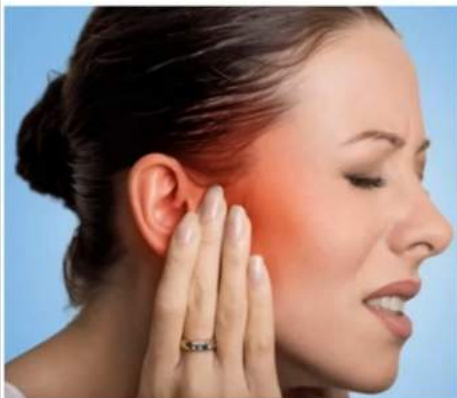
Normal TMJ Closed Overview



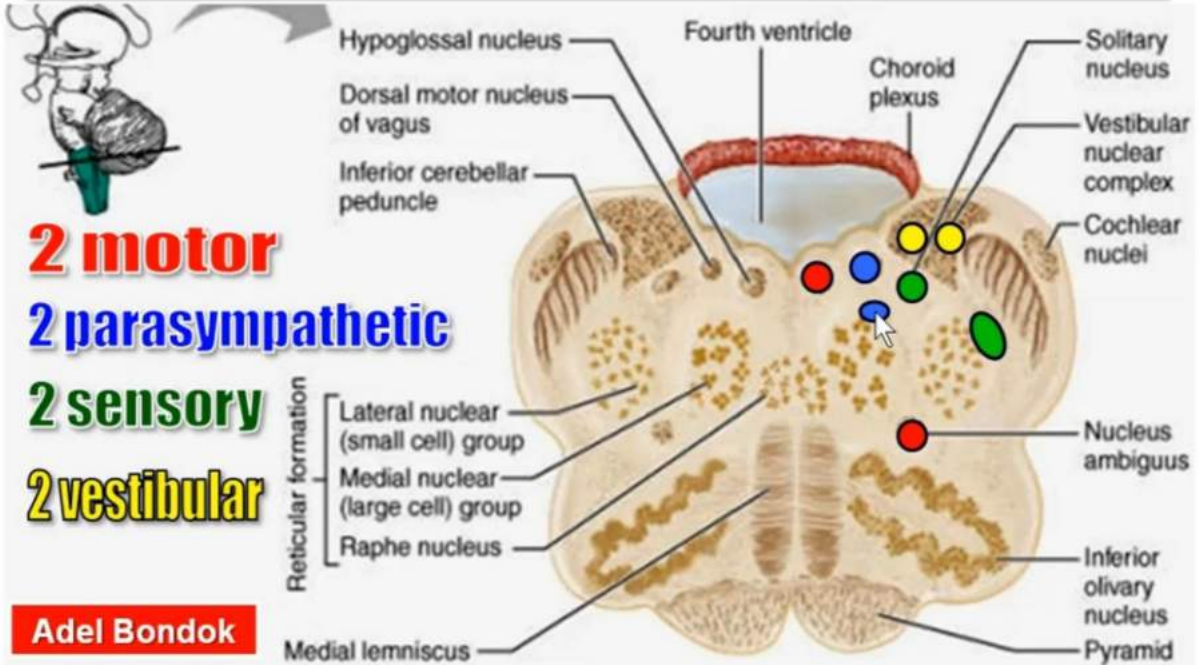
Paralysis of muscles of mastication of the same side
Loss of all sensations on the same side of the face

Trigeminal Neuralgia

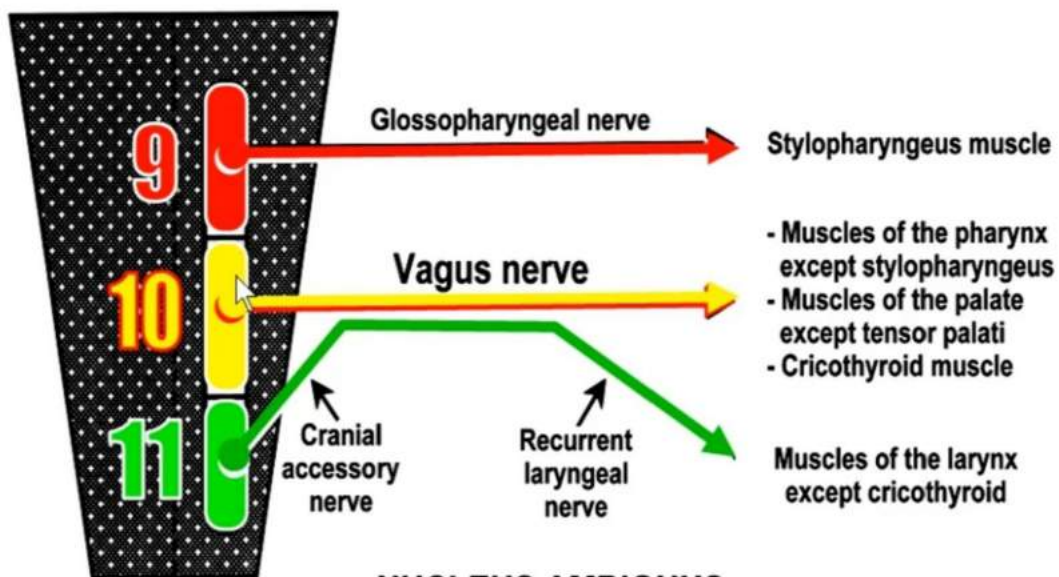


- ❑ Trigeminal neuralgia is a severe pain along the distribution of any branch of the trigeminal nerve
- ❑ It is due to compression or irritation of the trigeminal nerve by a tumor or cyst or blood vessel

IX, X, XI & XII Nerve Nuclei in the Medulla



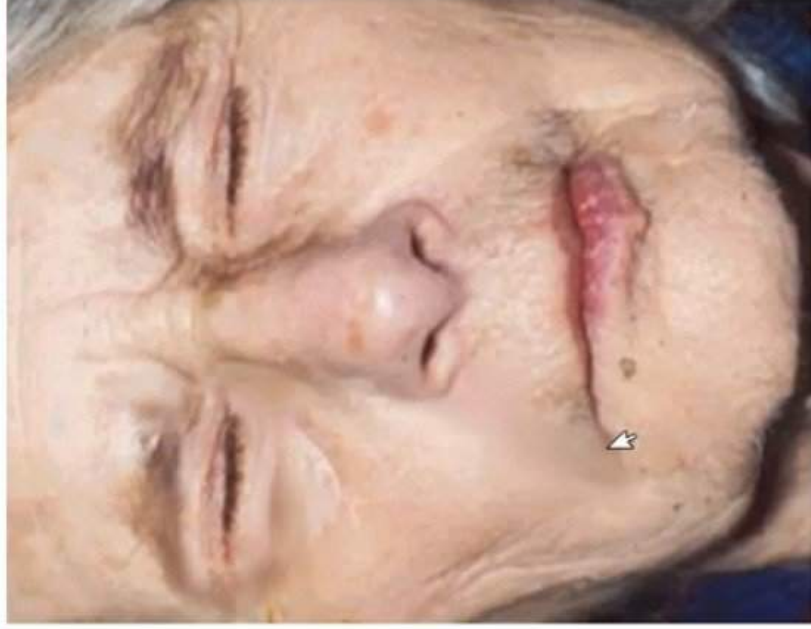NUCLEUS AMBIGUUS



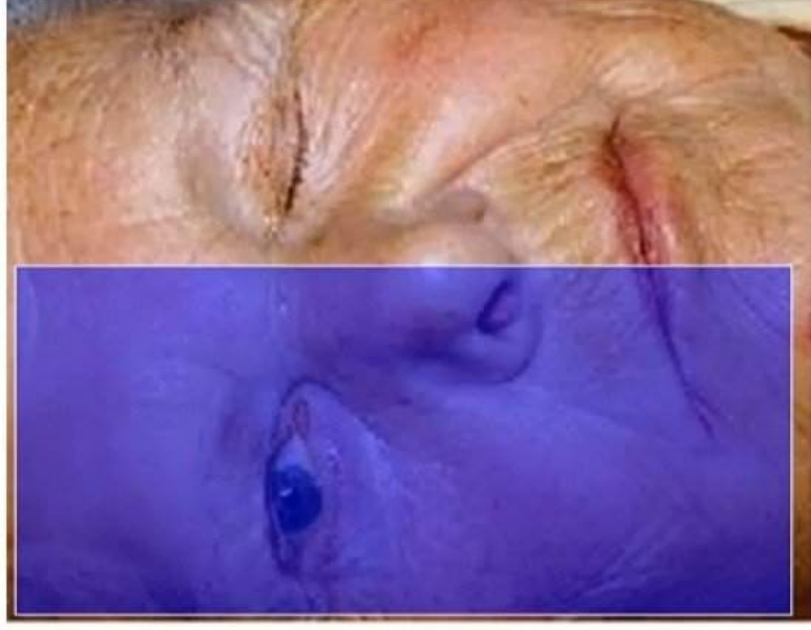NUCLEUS AMBIGUUS
(motor to pharynx, larynx and palate)

Adel Bondok

UMNL & LMNL of the Facial Nerve

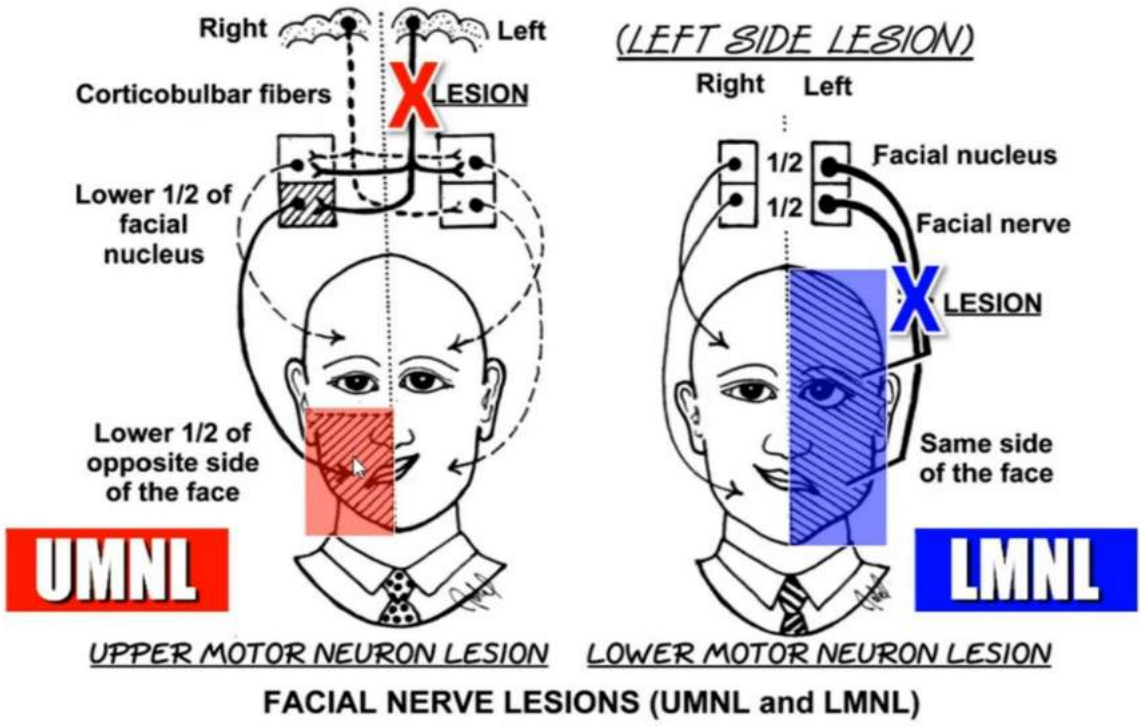


UMNL

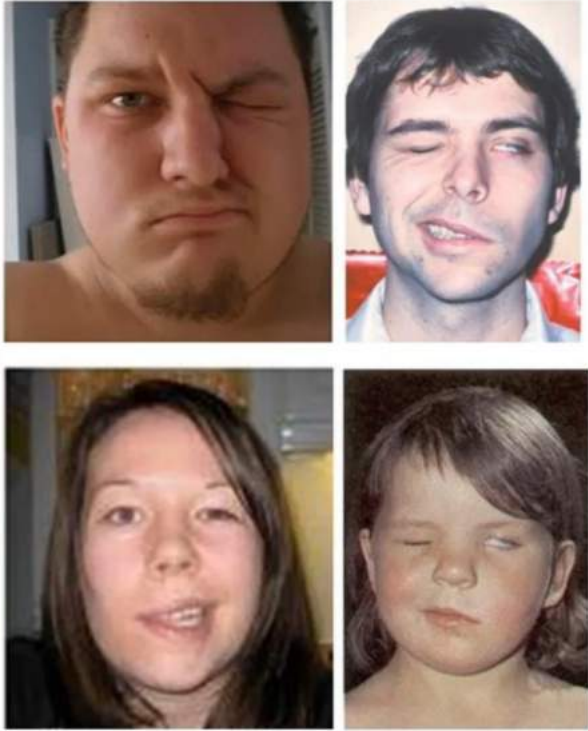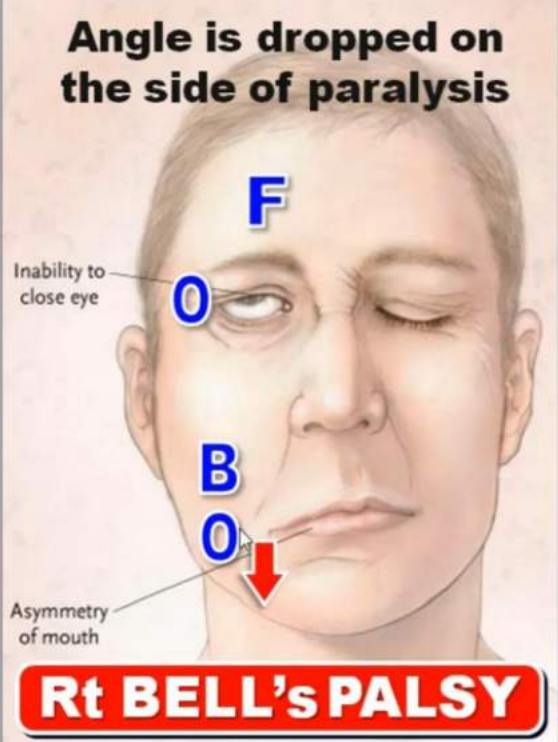


LMNL

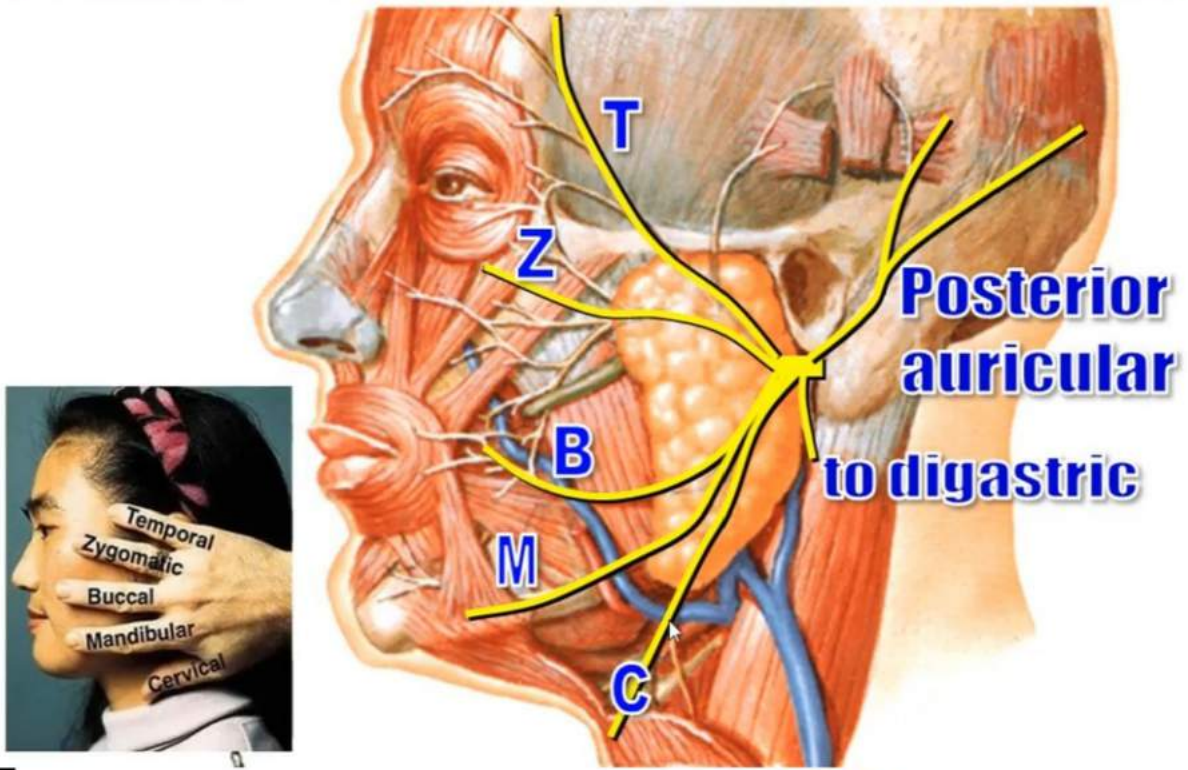
FACIAL NERVE LESIONS



LMNL of FACIAL NERVE



Extracranial Part



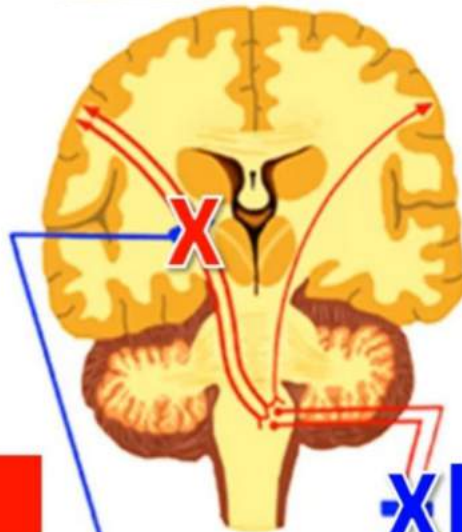
FACIAL NERVE LESIONS

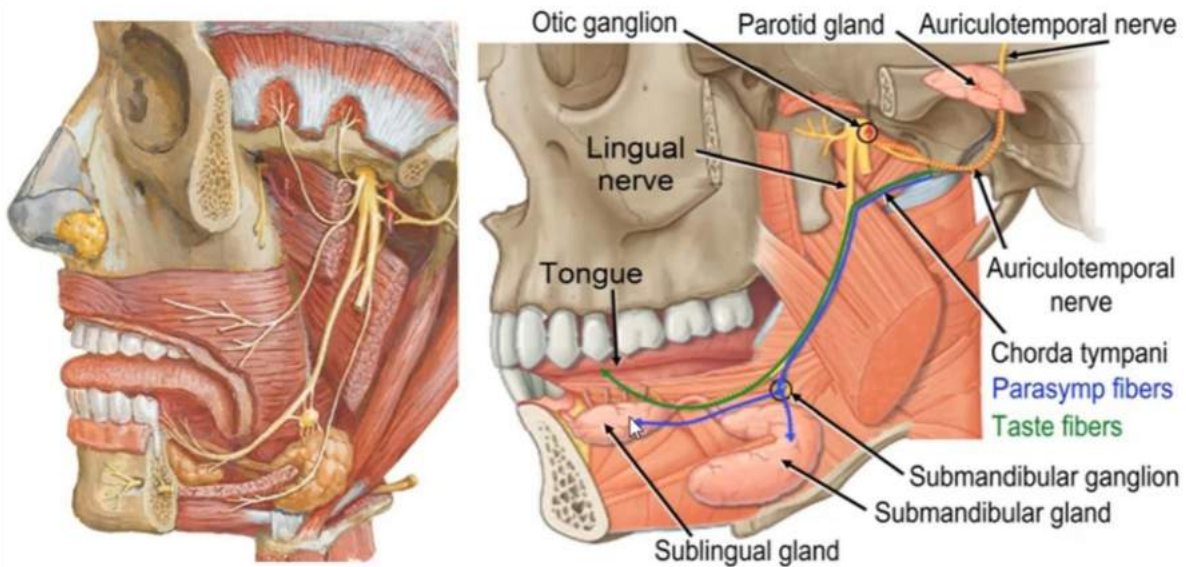
UMNL

Lesion in the corticobulbar tract

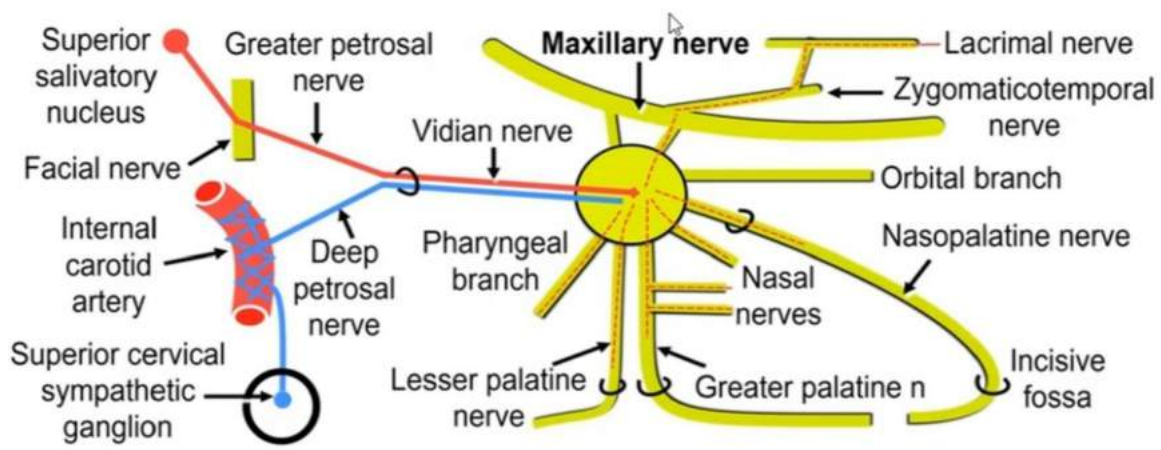
LMNL

Lesion in the nerve





PARASYMPATHETIC fibers to
SUBMANDIBULAR & SUBLINGUAL GLANDS
 Superior salivatory nucleus ⇨ facial nerve ⇨ **chorda tympani** ⇨ **lingual nerve** ⇨ **submandibular ganglion** ⇨ **submandibular and sublingual salivary glands.**



Parasympathetic Fibers To Lacrimal Gland
 superior salivatory nucleus ⇨ facial nerve ⇨ **greater superficial petrosal nerve** ⇨ **join the deep petrosal nerve** ⇨ **nerve of pterygoid canal** ⇨ **pterygopalatine (sphenopalatine) ganglion** ⇨ **maxillary nerve** ⇨ **zygomatic nerve** ⇨ **zygomaticotemporal nerve** ⇨ **lacrimal nerve** ⇨ **lacrimal gland**

COURSE OF THE FACIAL NERVE

Cerebello-Pontine angle

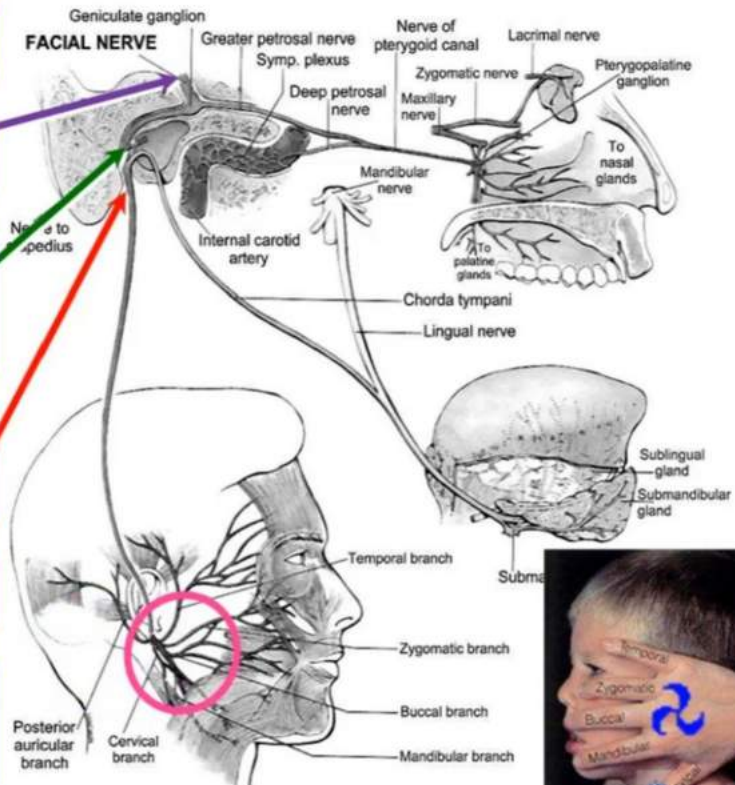
Internal auditory meatus

Facial canal:
medial & posterior
wall of middle ear

**Exits from the
stylomastoid foramen**

Enters Parotid Gland

**Divides into 5
terminal branches**



BRANCHES OF THE FACIAL NERVE

In the Facial Canal

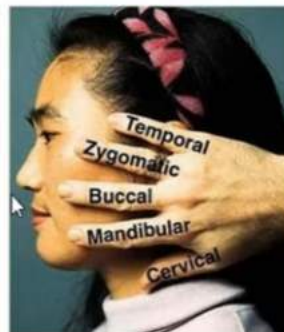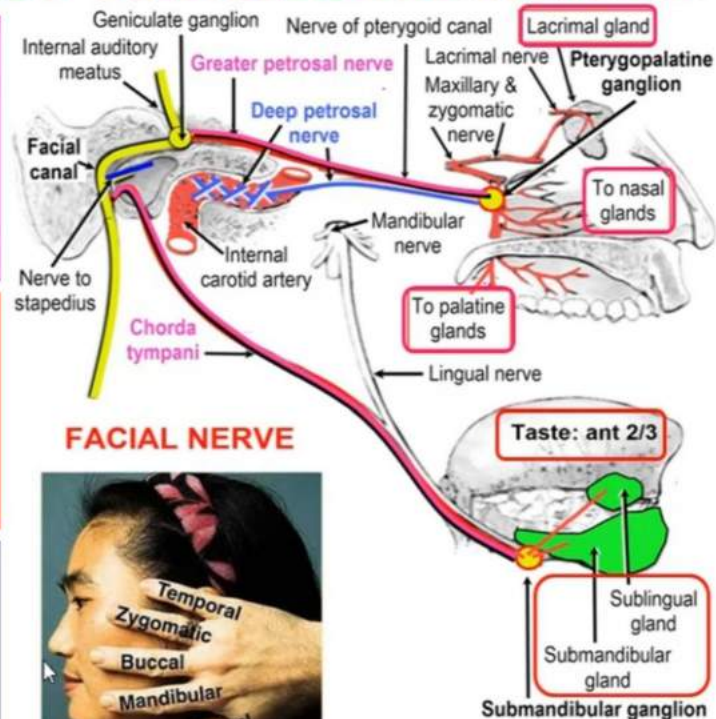
1. Greater Superficial petrosal nerve
2. Nerve to stapedius
3. Chorda tympani

At Stylomastoid Foramen

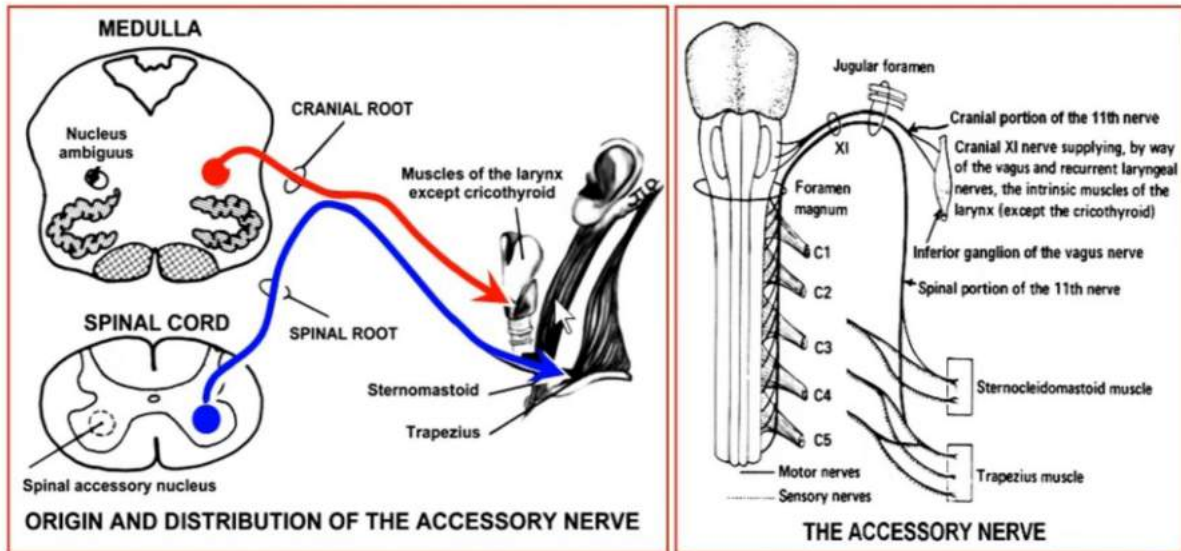
1. Post auricular nerve
2. Nerve to post belly of the digastric

**5 Terminal Branches In
the Face**

- | | |
|-------------|---------------|
| 1. Temporal | 2. Zygomatic |
| 3. Buccal | 4. Mandibular |
| 5. Cervical | |



ACCESSORY NERVE



Adel Bondok

ACCESSORY NERVE LESION



Inability to shrug the shoulder

Adel Bondok

Distribution of the Vagus Nerve

Auricular branch:

- a. Auricle and External auditory meatus
- b. Tympanic membrane

Adel Bondok

Pharyngeal branch:

- a. Muscles of the palate **EXCEPT** tensor palati
- b. Muscles of the pharynx **EXCEPT** stylopharyngeus

Superior Laryngeal nerve: divides into:

- a. External laryngeal nerve: to cricothyroid muscle
- b. Internal laryngeal nerve: mm membrane **above** vocal cord

Recurrent Laryngeal nerve:

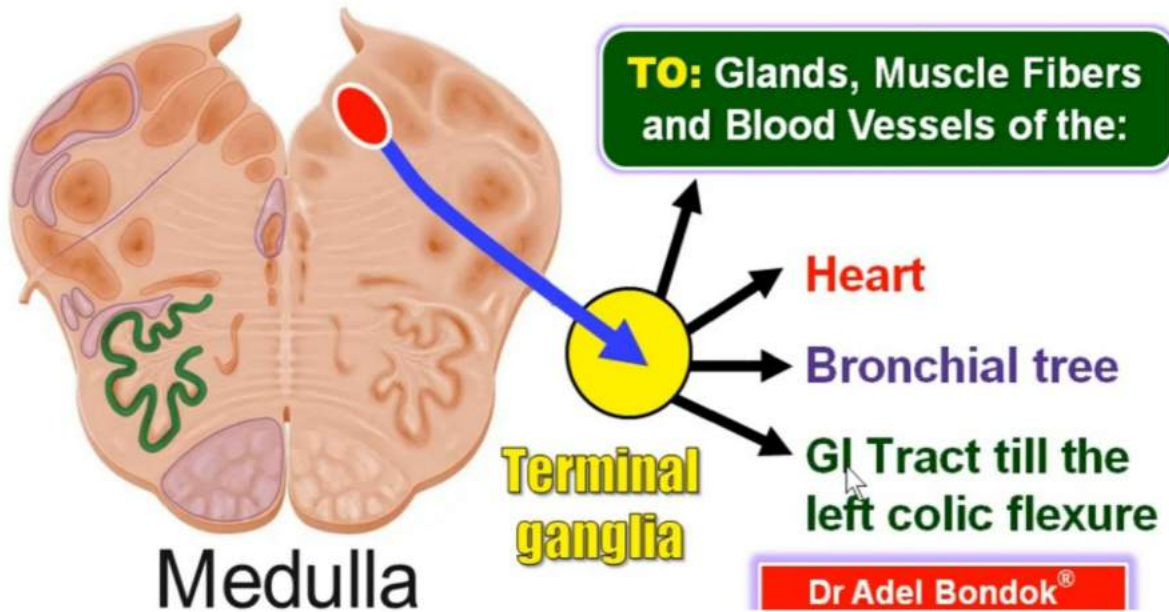
- a. All muscles of the larynx **EXCEPT** cricothyroid.
- b. Mucous membrane **below** vocal cord

LESION OF THE VAGUS NERVE

1. **Dysphagia:** paralysis of muscles of the pharynx
2. **Hoarsness of voice:** paralysis of muscles of the larynx
3. **Regurgitation of food from nose and deviation of the uvula to the normal side:** paralysis of muscles of the palate
4. **Loss of the pharyngeal gag reflex.**
5. **Loss of the cough reflex.**

Adel Bondok

DORSAL MOTOR NUCLEUS of the VAGUS



THE VAGUS NERVE

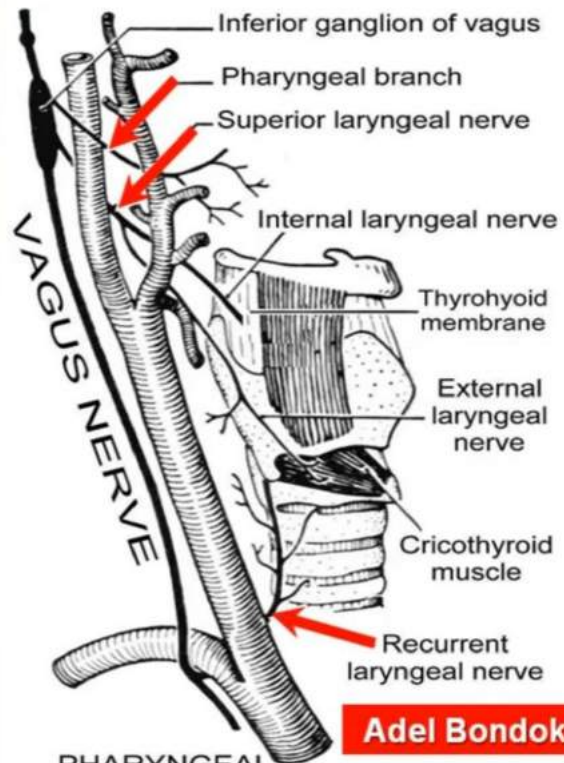
Postolivary fissure

Jugular foramen

Descends in the carotid sheath with IJV, CCA & ICA

BRANCHES:

1. Meningeal Branch
2. Auricular branch
3. Pharyngeal branch
4. Superior Laryngeal nerve
5. Recurrent Laryngeal nerve
6. Cardiac branches



PHARYNGEAL AND LARYNGEAL BRANCHES

The Glossopharyngeal Nerve

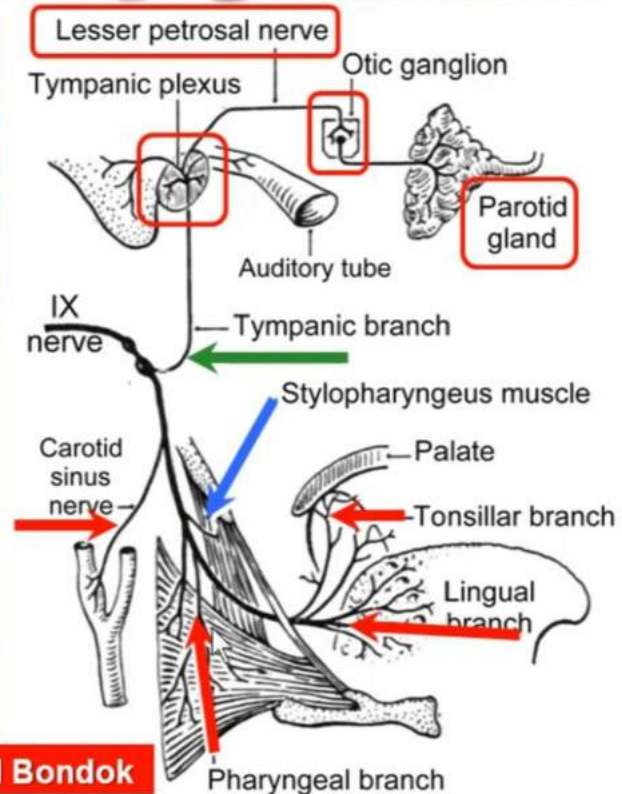
Postolivary fissure

Jugular foramen

Divide into 3 terminal branches

BRANCHES: 3+3

1. **Tympanic Branch:**
2. **Nerve to stylopharyngeus**
3. **Carotid sinus nerve**
4. **3 Terminal Branches:**
 - a. **Tonsillar**
 - b. **Lingual**
 - c. **Pharyngeal**



Adel Bondok

VAGUS NERVE

1. Motor Nucleus:

Adel Bondok

Nucleus ambiguus ⇒ **t0**

1. Muscles of the pharynx **EXCEPT** stylopharyngeus
2. Muscles of the palate **EXCEPT** tensor palati
3. Muscles of the larynx

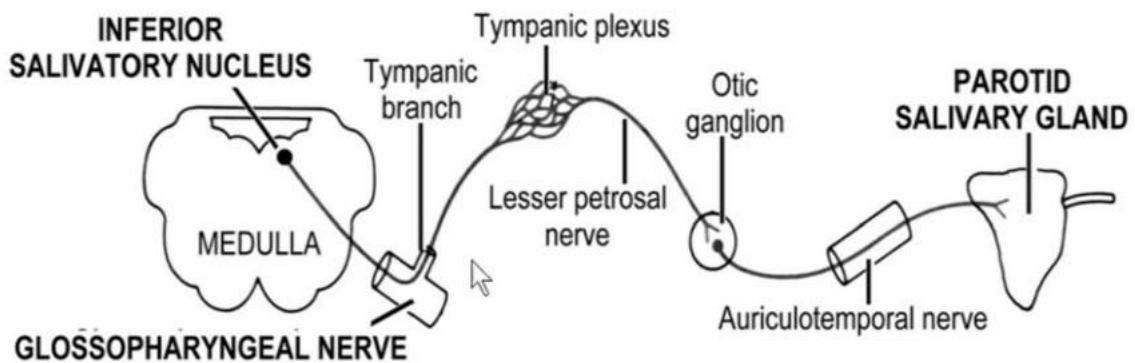
2. Parasympathetic Nucleus:

dorsal motor nucleus ⇒ **abdominal & thoracic viscera**

3. Sensory Nuclei:

1. **Nucleus solitarius:** abdominal & thoracic viscera
2. **Spinal trigeminal nucleus:** external ear

INFERIOR SALIVARY NUCLEUS: IX Nerve



Adel Bondok

Glossopharyngeal Nerve

1. Motor Nucleus:

Adel Bondok

Nucleus ambiguus ⇒ **to stylopharyngeus**

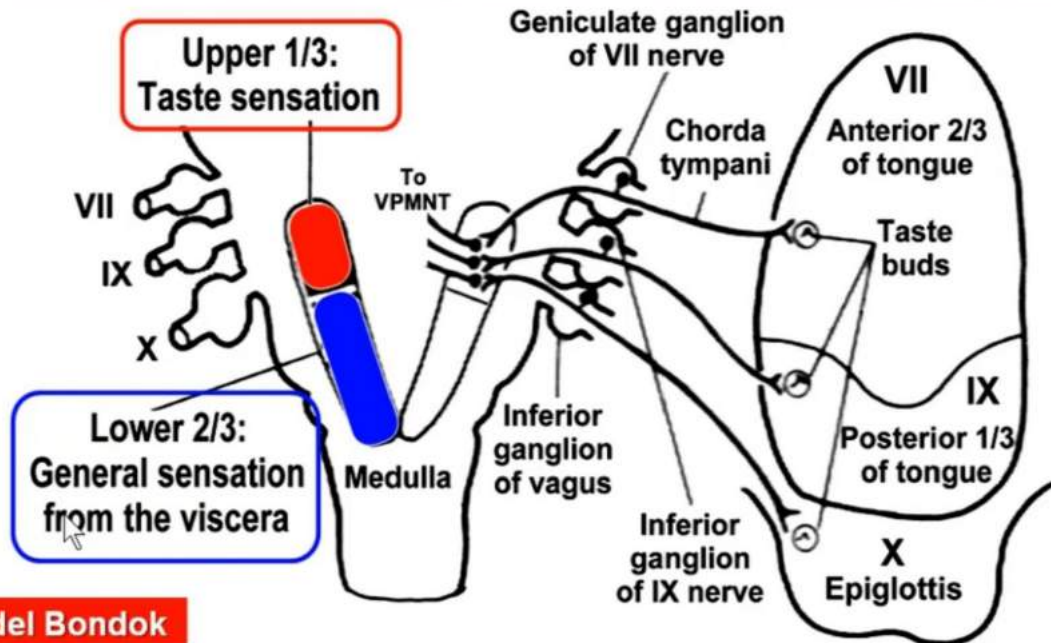
2. Parasympathetic Nucleus:

inferior salivary nucleus ⇒ **parotid gland**

3. Sensory Nucleus:

Nucleus solitarius: posterior 1/3 of tongue, middle ear, Eustachian tube, and palatine tonsil

NUCLEUS SOLITARIUS

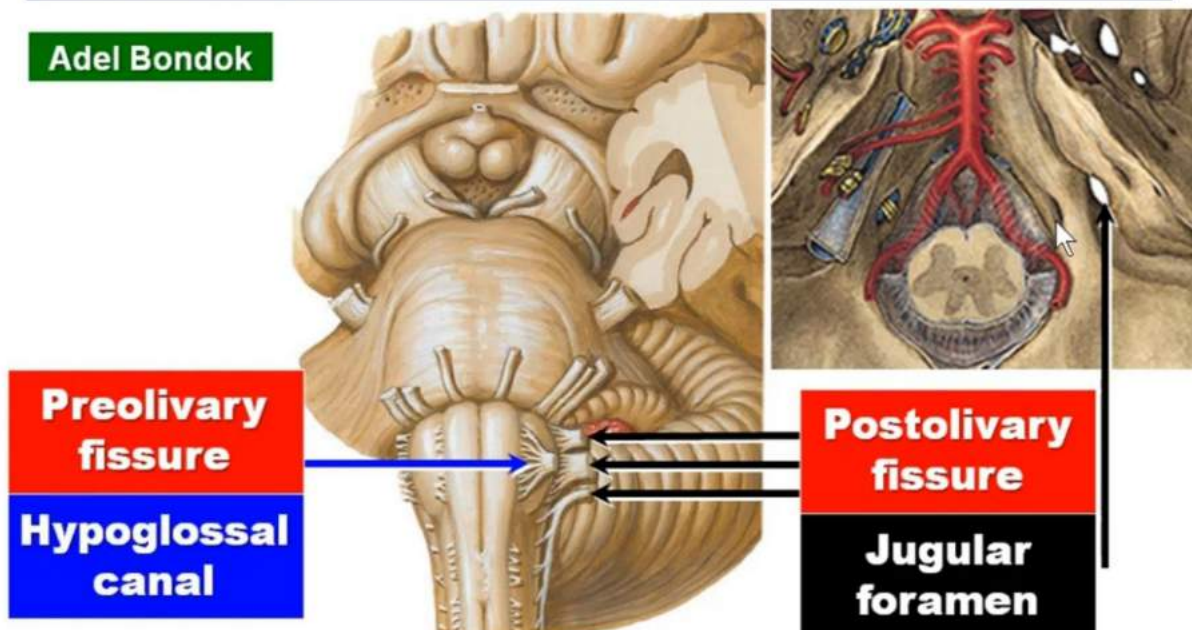


Adel Bondok

NUCLEUS SOLITARIUS AND TASTE SENSATION

IX, X, XI & XII Nerves Exit from the Brain & Skull

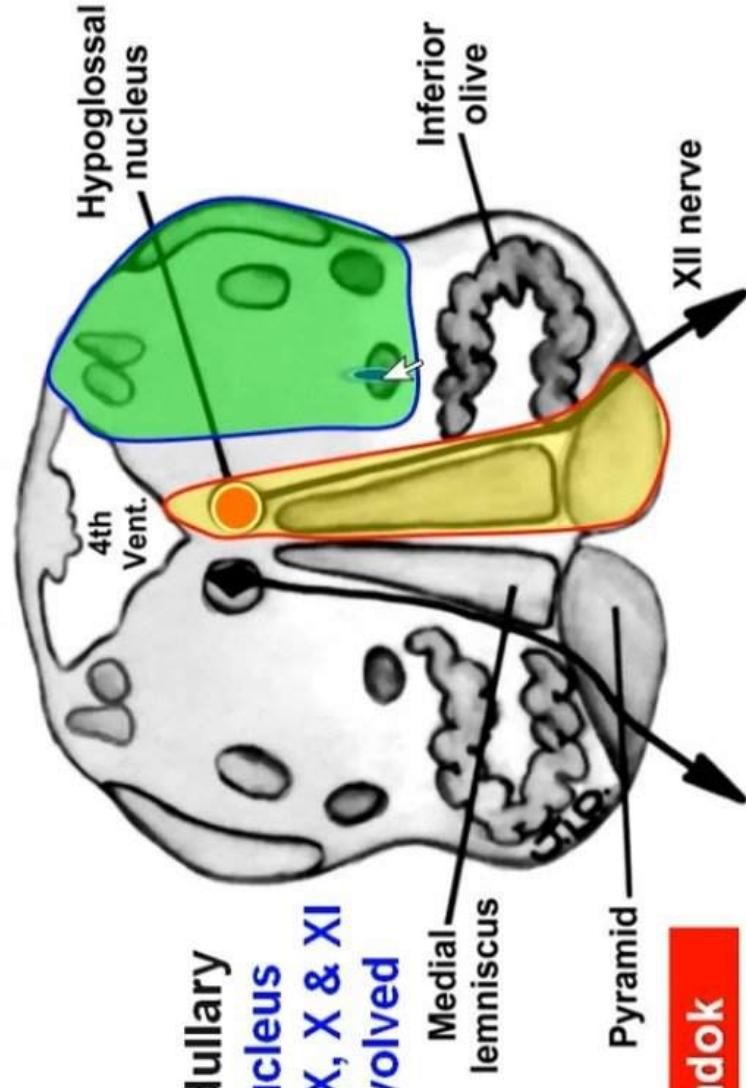
Adel Bondok



Note to Neurologists

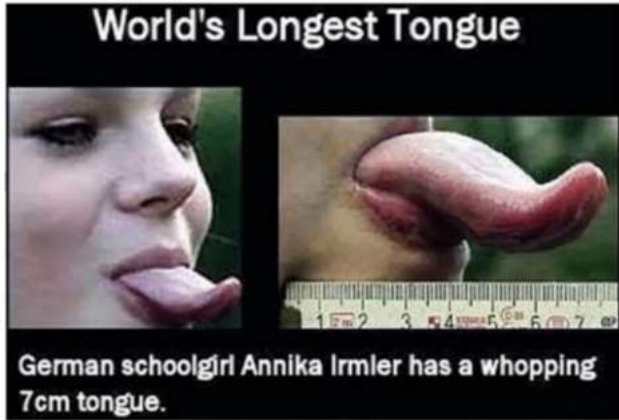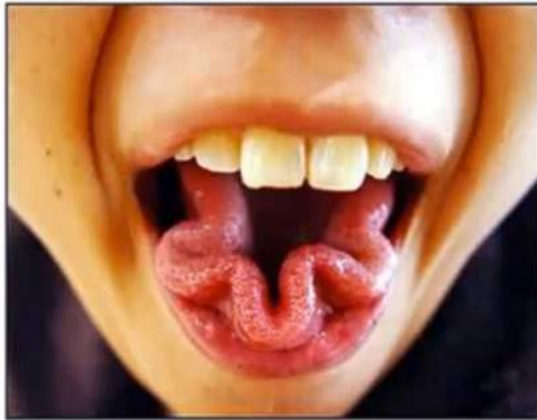In Medial Medullary Syndrome, the XII nucleus & nerve are involved

In Lateral Medullary Syndrome, nucleus IX, X & XI ambiguus & X & XI nerves are involved



Adel Bondok

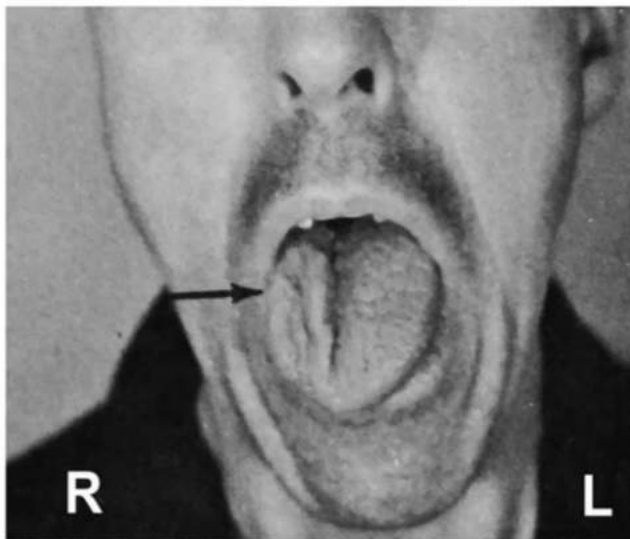
HYPOGLOSSAL NERVE



Supplies **ALL** the muscles of the tongue
EXCEPT palatoglossus muscle

Adel Bondok

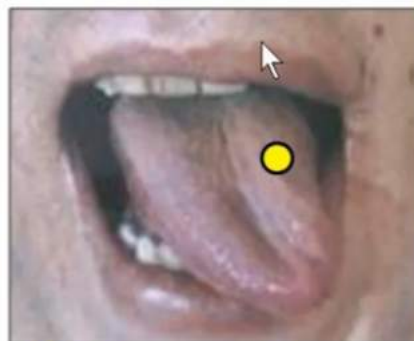
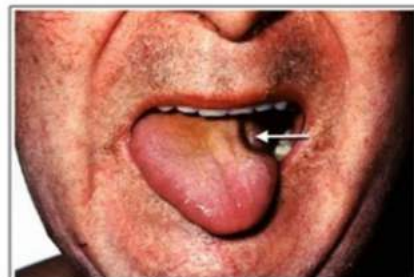HYPOGLOSSAL NERVE LESION



Right Hypoglossal Nerve Paralysis

- Atrophy of the right side of the tongue
- Deviation of the tongue to the right

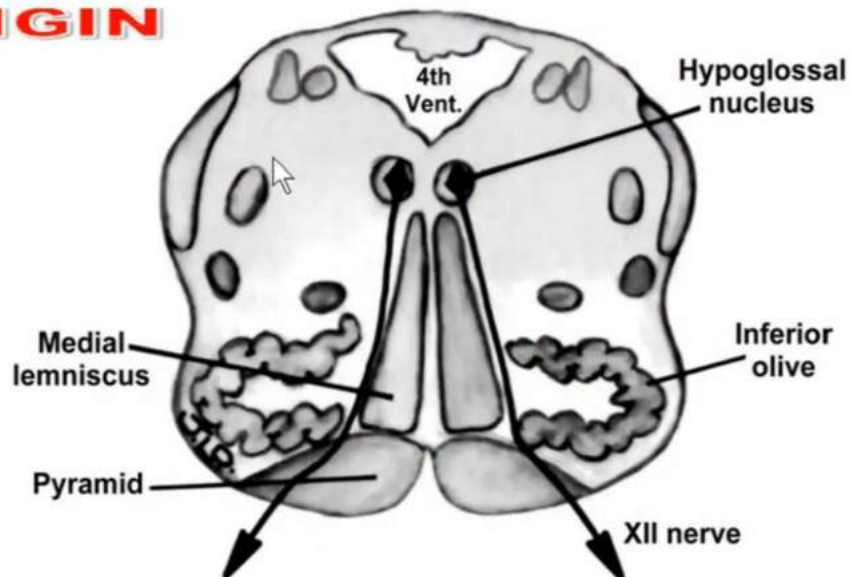
Adel Bondok



Left Hypoglossal Nerve Paralysis

HYPOGLOSSAL NERVE

ORIGIN



ORIGIN OF THE HYPOGLOSSAL NERVE

Adel Bondok

HYPOGLOSSAL NERVE

Exit from the **BRAIN**

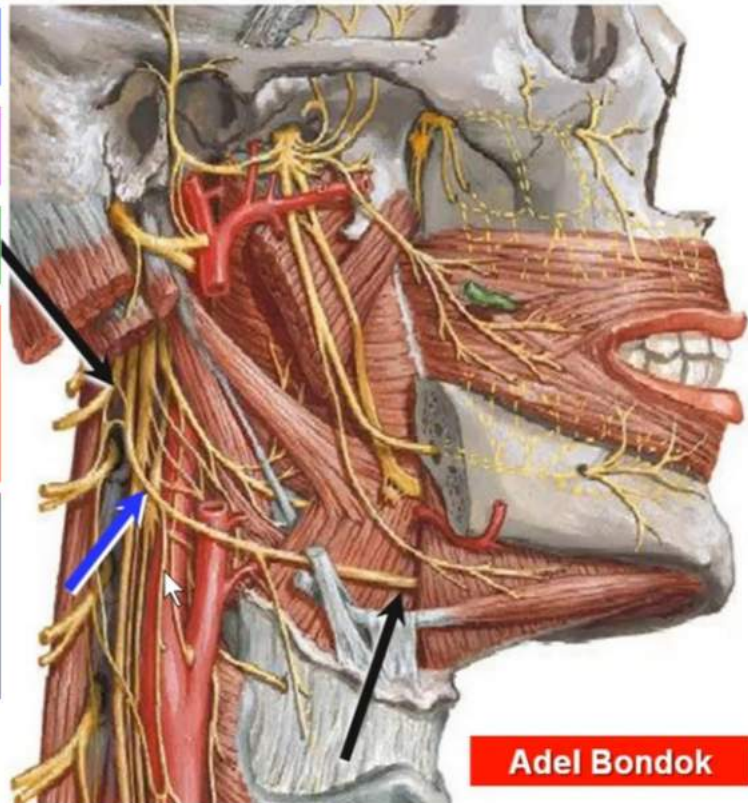
Exit from the **SKULL**

Joined by **C1**

Passes between
hyoglossus and
mylohyoid

BRANCHES:

1. XII nerve itself
2. C1

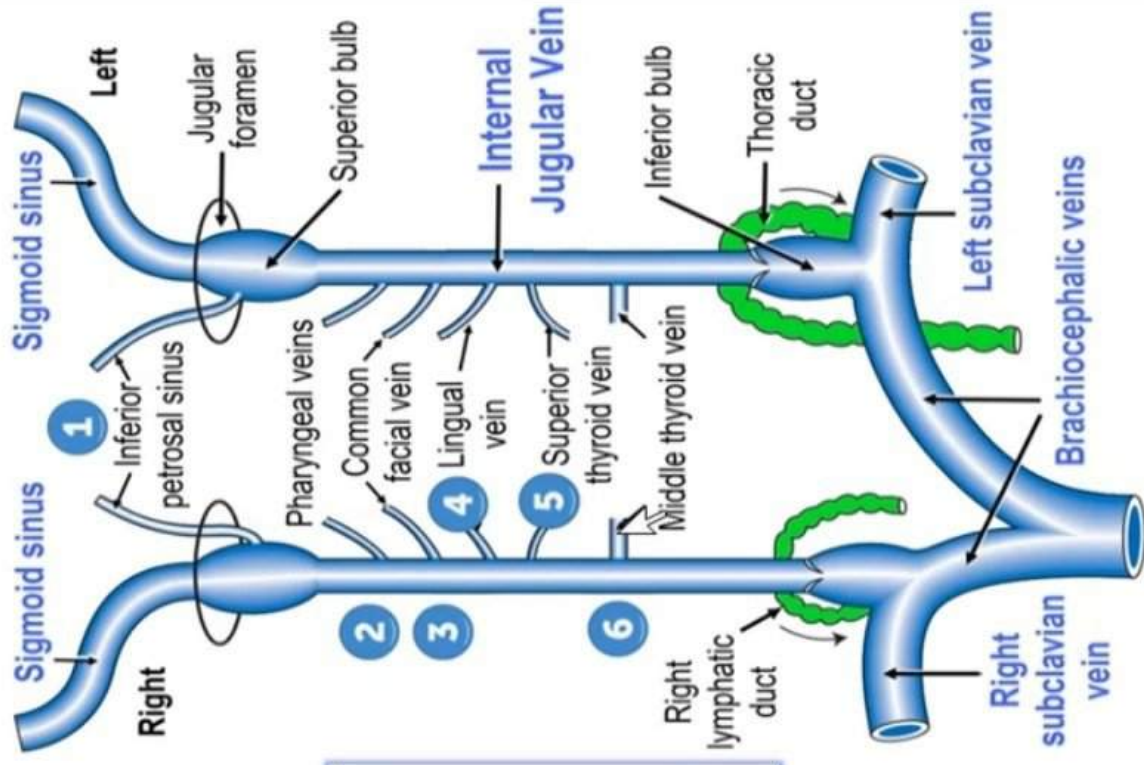


Adel Bondok

TRIBUTARIES

1. Inferior petrosal sinus
2. Pharyngeal veins
3. Common facial vein
4. Lingual vein
5. Superior thyroid vein
6. Middle thyroid vein

! Prefer Common Locations Such as Museums



1st PART: 3

1. Thyrocervical trunk:

- a. Inferior thyroid artery
- b. Transverse cervical art
- c. Suprascapular artery

2. Vertebral artery

3. Internal thoracic art

2nd PART: 1 branch

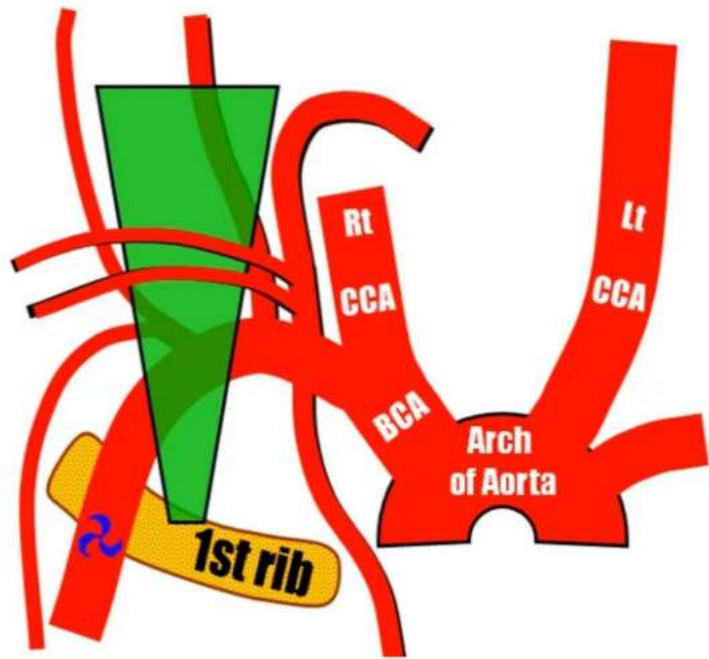
Costocervical Trunk:

- a. Deep cervical artery
- b. Superior intercostal ar

3rd PART: may be 1

Descending scapular art

BRANCHES OF THE SUBCLAVIAN ARTERY



Origin:

continuation of the sigmoid sinus in the jugular foramen

Course:

Inside the carotid sheath lateral to the internal carotid artery then lateral to the common carotid artery.

The upper and lower ends are dilated to form the superior and inferior bulbs, respectively

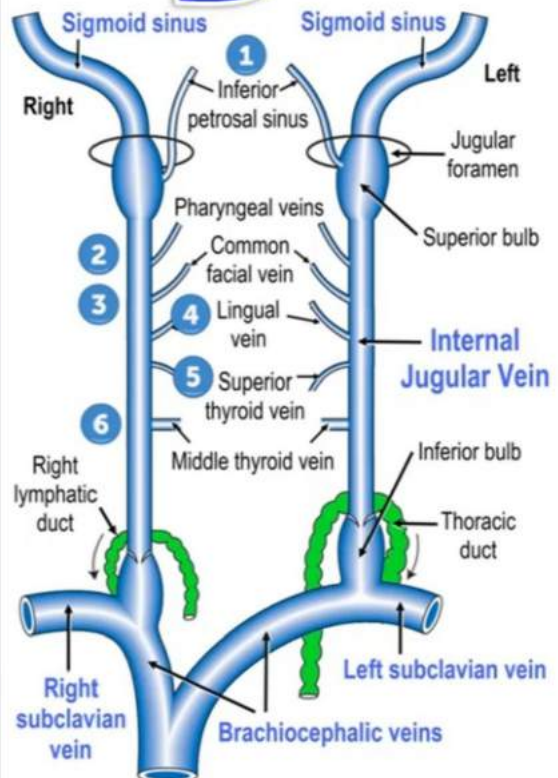
Deep cervical lymph nodes lie along the vein

Termination:

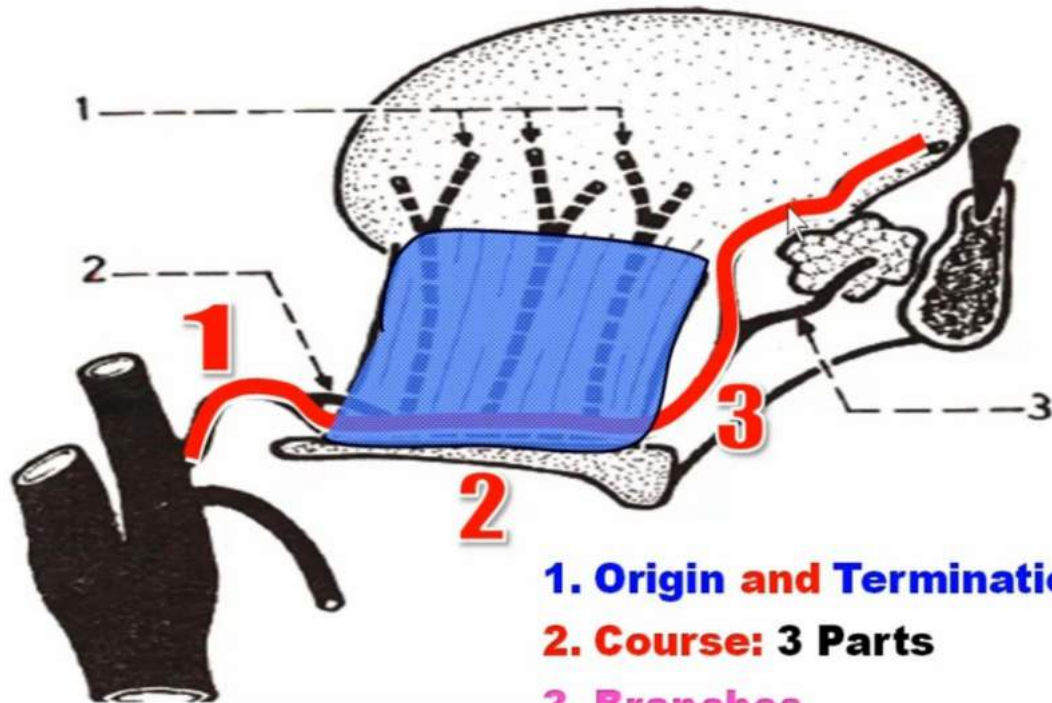
Behind the sternoclavicular joint by joining the subclavian vein to form the brachiocephalic vein

Tributaries:

IJV



LINGUAL ARTERY



SUBCLAVIAN ARTERY

ORIGIN:

1. **Left:** arch of the aorta
2. **Right:** brachiocephalic

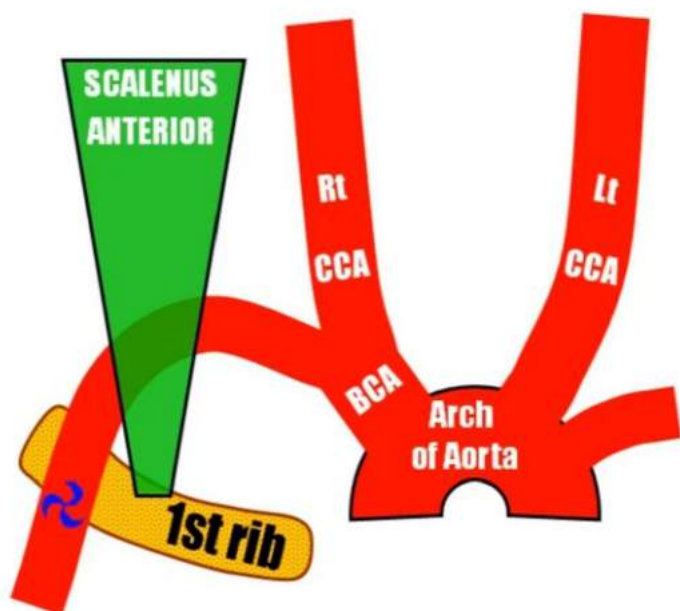
TERMINATION:

Outer border of the 1st rib to continue as Axillary art

COURSE: 3 parts

1. **1st part:** medial
2. **2nd part:** behind
3. **3rd part:** lateral

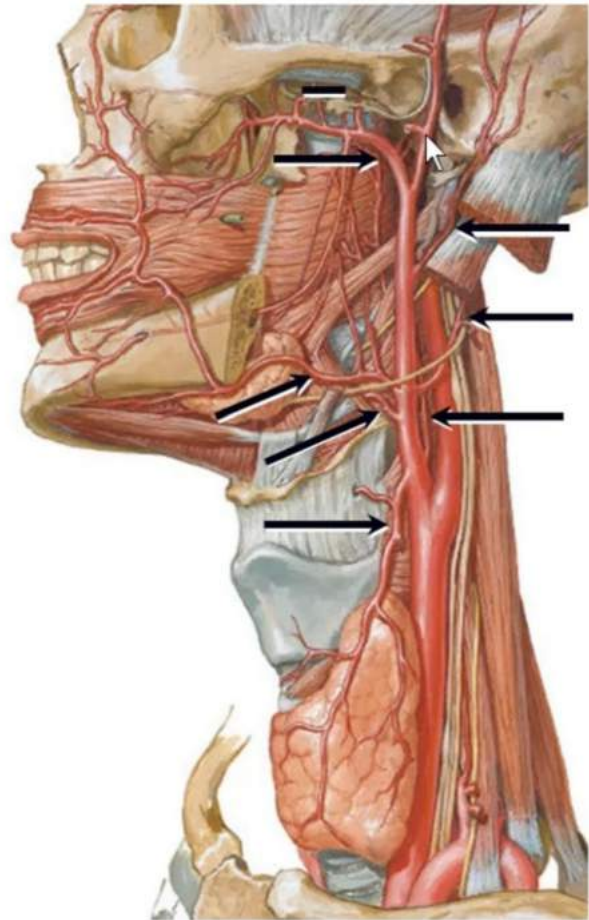
BRANCHES:



BRANCHES OF THE ECA

Some	Superior Thyroid a
American	Ascen Pharyngeal
Ladies	Lingual artery
From	Facial artery
Oklahoma	Occipital artery
Practice	Post Auricular art
Medicine	Maxillary artery
& Surgery	Superfic temporal

Dr Adel Bondok®



Origin: ECA above the lingual art

Termination: as angular artery

BRANCHES: 8 4 + 4

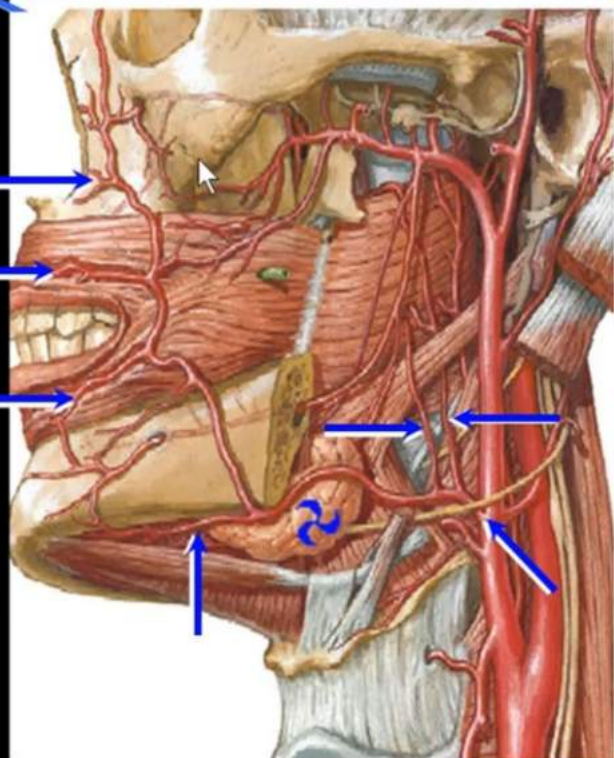
4 in the NECK:

1. Ascending palatine artery
2. Tonsillar artery
3. Glandular branches
4. Submental artery

4 in the FACE:

1. Inferior labial
2. Superior labial
3. Nasal
4. Angular

FACIAL ARTERY



Parotid Gland

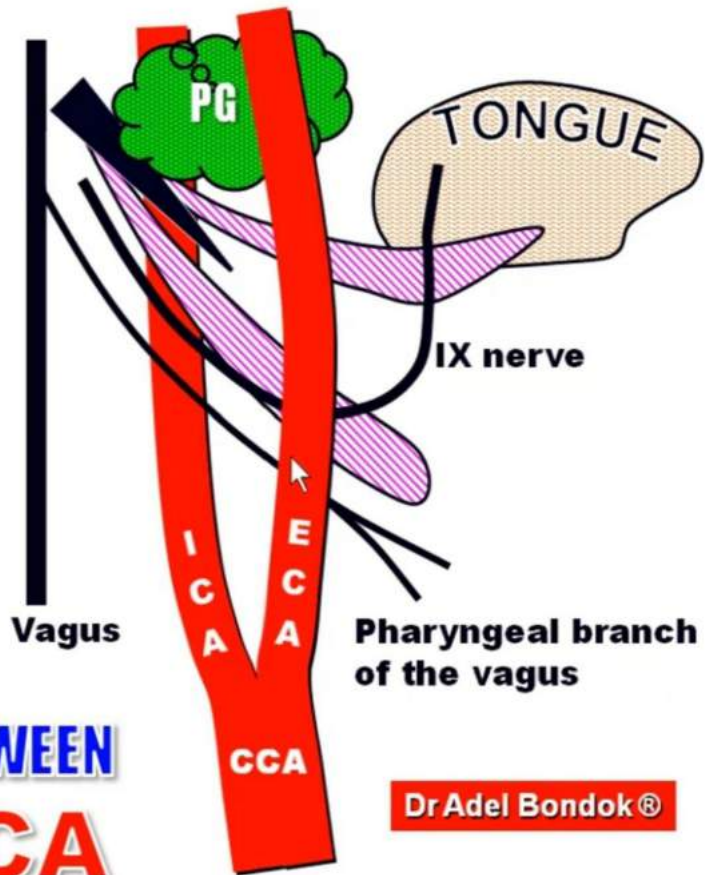
Styloid process

Styloglossus

Stylopharyngeus

Glossopharyngeal nerve

Pharyngeal branch of the vagus

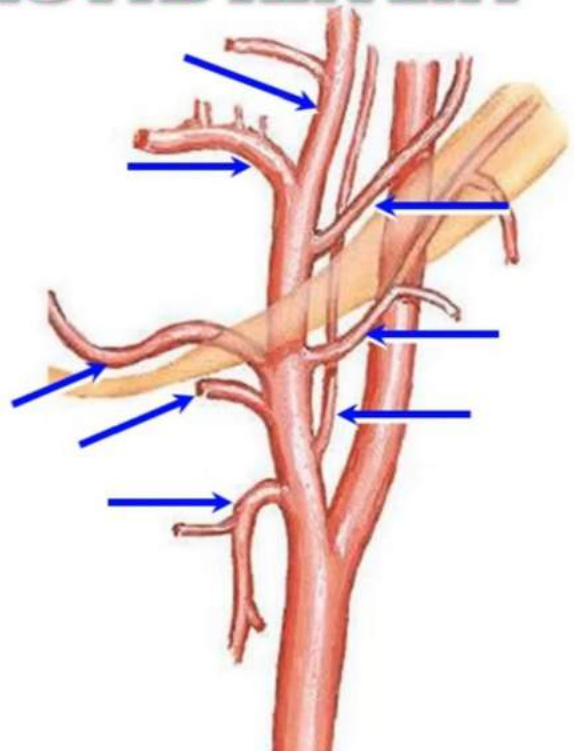


STRUCTURES BETWEEN ECA & ICA

Dr Adel Bondok®

BRANCHES OF THE EXTERNAL CAROTID ARTERY

Some	Sup Thyroid artery
American	Ascen Pharyngeal
Ladies	Lingual artery
From	Facial artery
Oklahoma	Occipital artery
Practice	Post Auricular art
Medicine	Maxillary artery
& Surgery	Superfic temporal



Dr Adel Bondok®

Common Carotid Artery

Origin:

1. **Left:** aortic arch behind the manubrium
2. **Right:** brachiocephalic artery behind the sternoclavicular joint

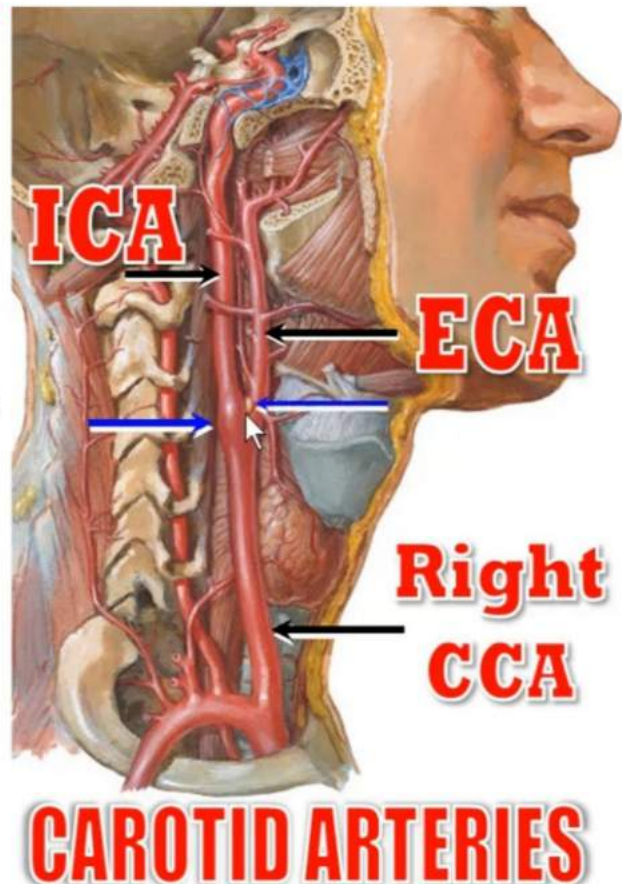
Termination:

Divides into **ECA** & **ICA** at the upper border of thyroid cartilage or disc between **C3** & **C4**

Course:

1. Passes in the carotid sheath
2. The upper end is dilated to form the carotid sinus
3. The upper end is related to the carotid body "chemoreceptor"

Branches: only **ECA** & **ICA**



EXTERNAL CAROTID ARTERY

Origin:

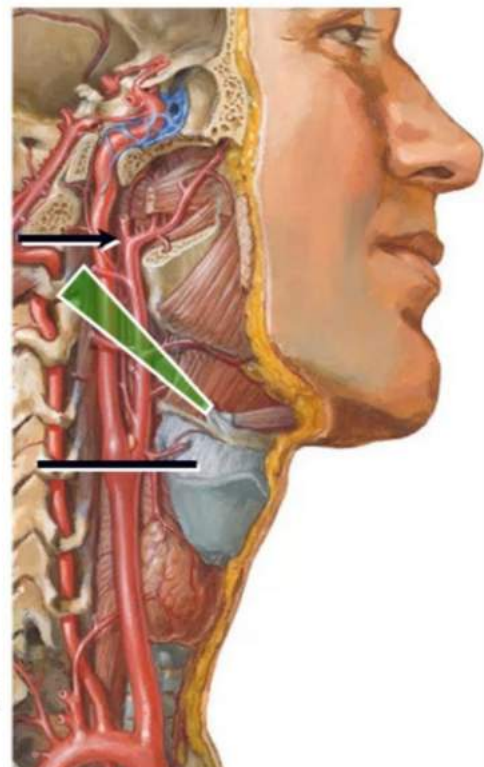
Termination:

Behind the neck of the mandible
Inside the parotid gland by dividing into **2 terminal branches:**
maxillary & superficial temporal arteries

Relations: some points

1. **Outside** the carotid sheath
2. **Deep to** posterior belly of the digastric
3. **Separated from ICA by:**
 - Gland:** parotid gland "deep part"
 - Bone:** styloid process
 - 2 muscles:** styloglossus & stylopharynx
 - 2 Nerves:** IX & pharyngeal branch of X

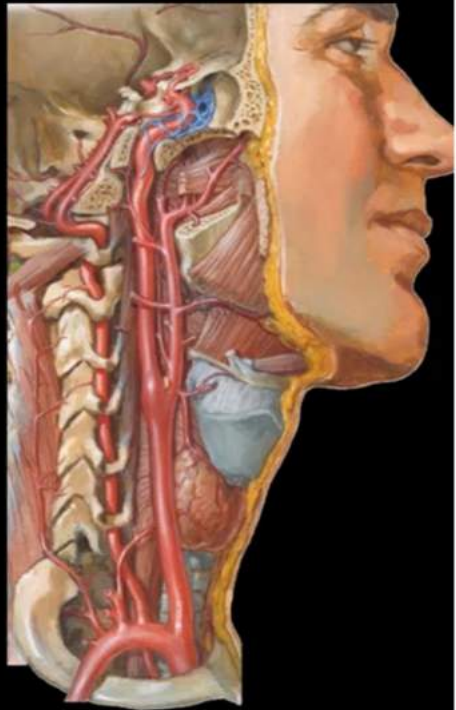
Branches: 8



YouTube **Subscribe**



Arteries and Veins Head & Neck

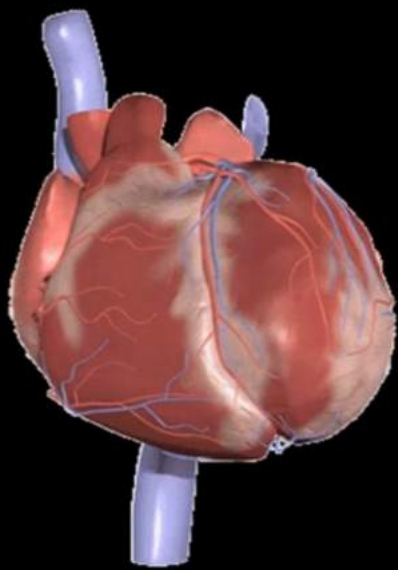


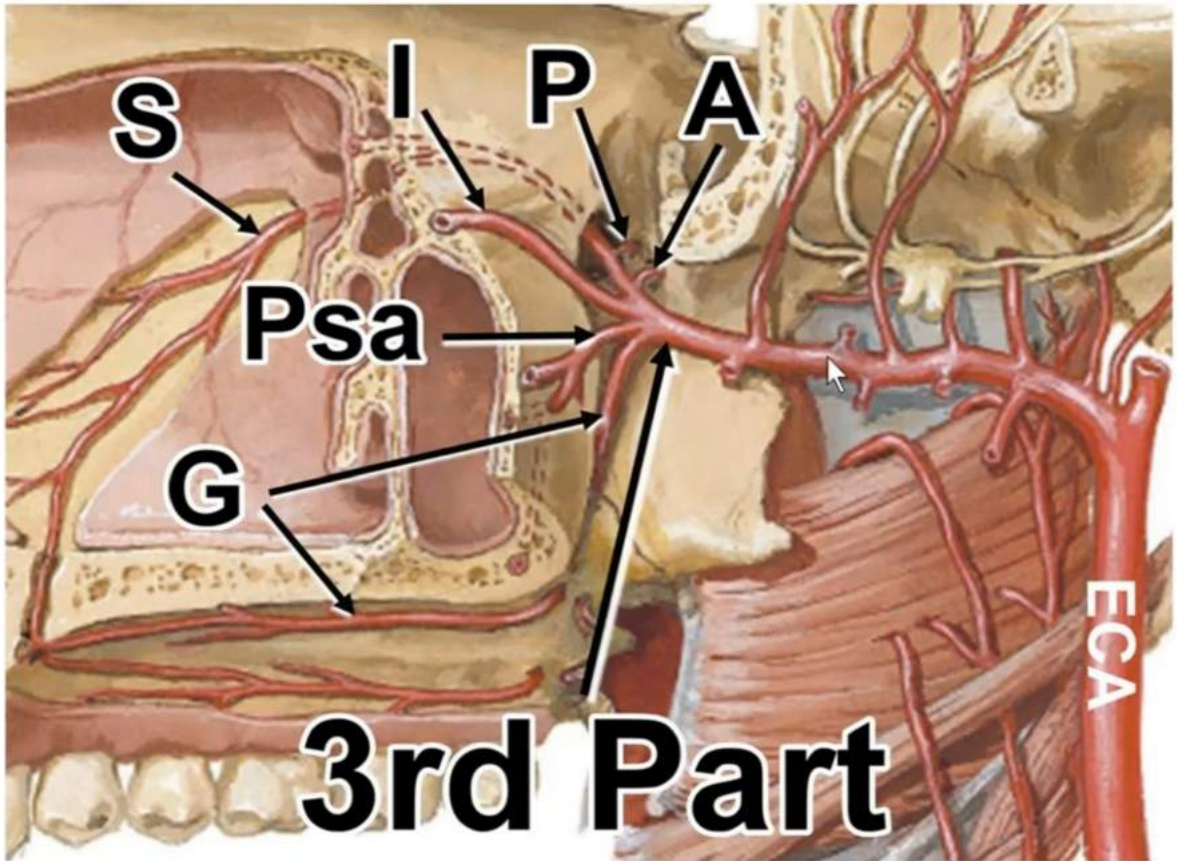
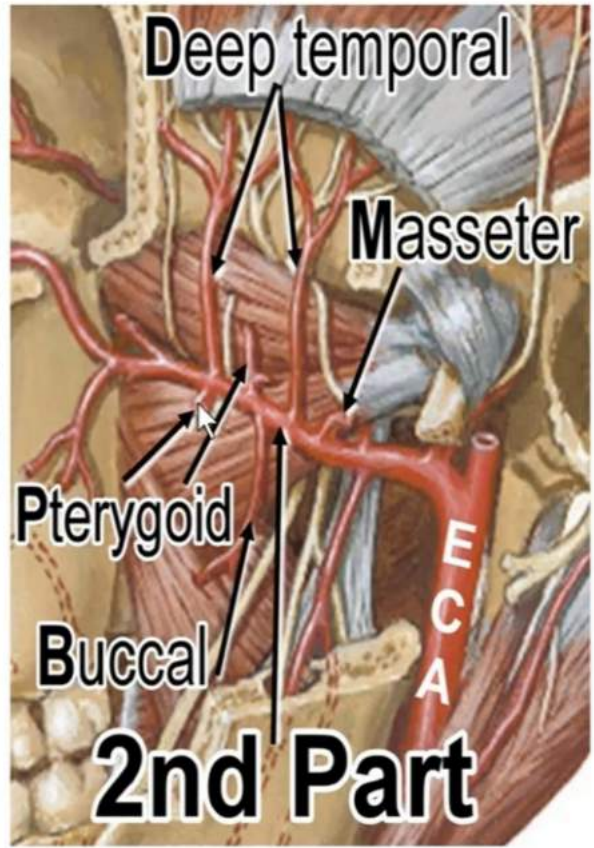
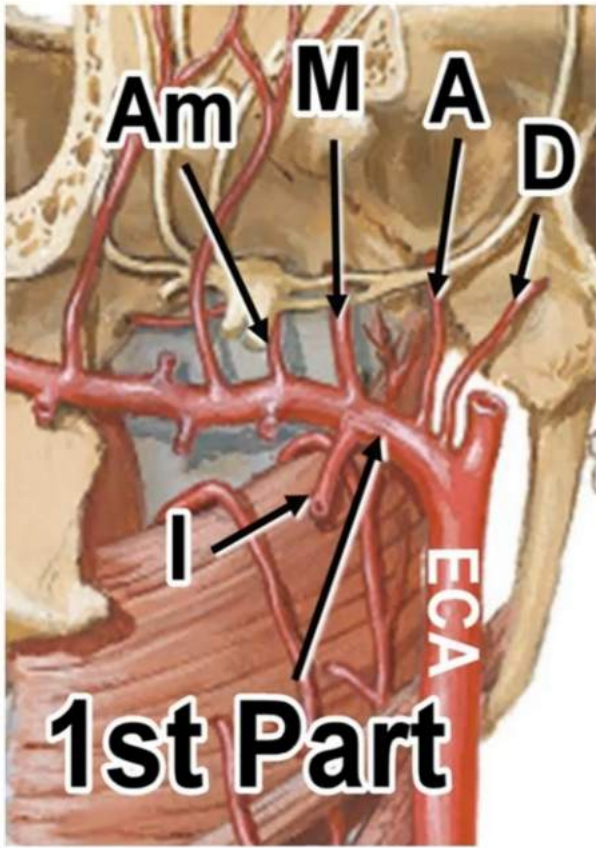
Dr Adel Bondok

BIG VESSELS

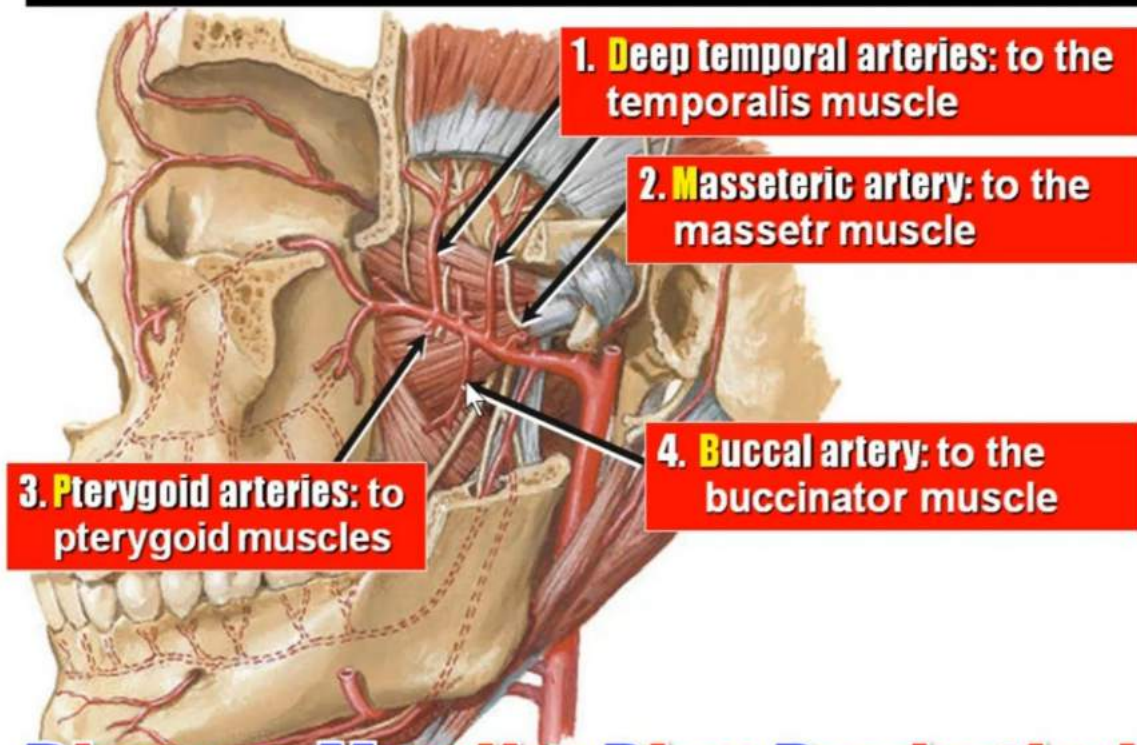
ARTERIES
Carotid Arteries &
Subclavian Artery

VEIN
Internal Jugular Vein



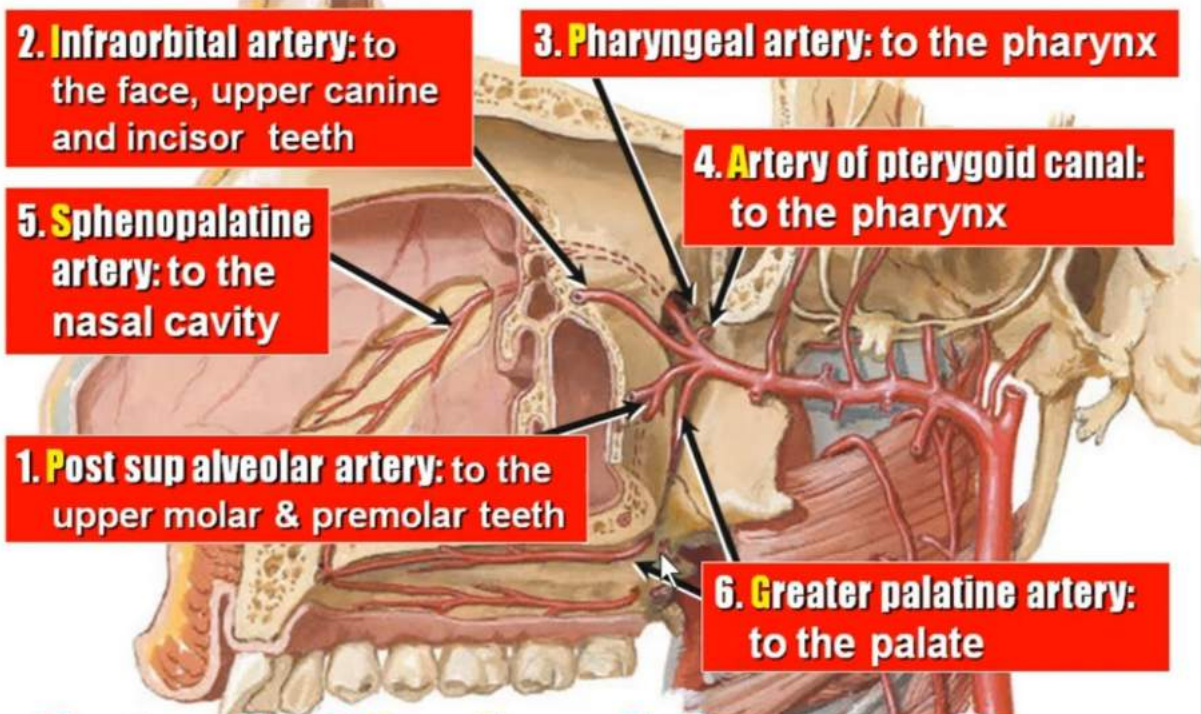


2nd PART: 4 branches “muscular”



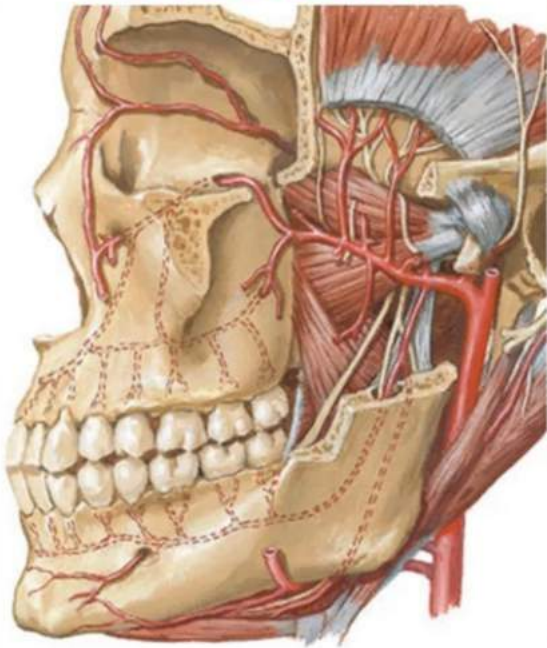
Diana & Monika Play Basketball

3rd PART: 6 branches



Peter Is Playing A Soccer Game

MAXILLARY ARTERY



ORIGIN

One of the 2 terminal branches of the ECA behind the neck of the mandible

TERMINATION

In the pterygopalatine fossa as the sphenopalatine artery

COURSE

Divided into 3 parts by lower head of lateral pterygoid

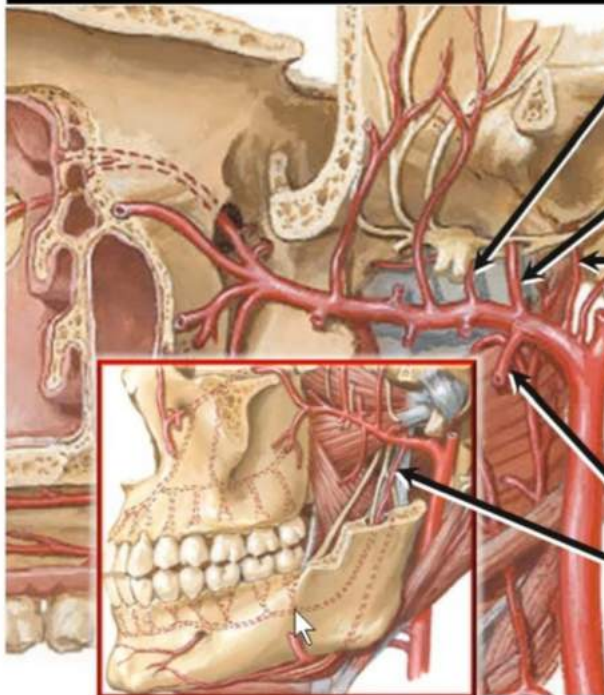
BRANCHES:

1st part: 5

2nd part: 4

3rd part: 6

1st PART: 5 branches



4. Accessory meningeal artery: to dura of middle cranial fossa

3. Middle meningeal artery: to dura of the middle cranial fossa

2. Anterior tympanic artery: to the tympanic cavity

1. Deep auricular artery: to external auditory meatus

5. Inferior alveolar artery: to lower teeth, chin & lower lip

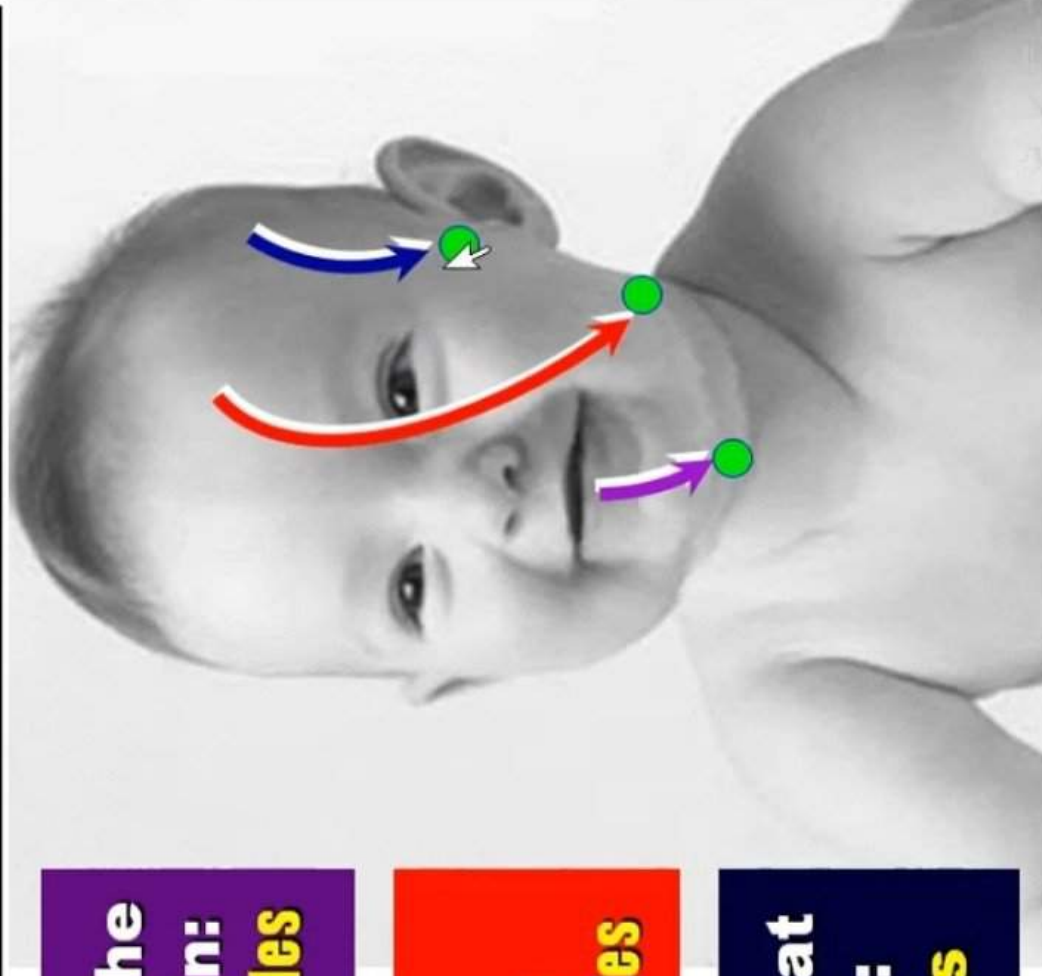
Diana And Monika Are Intelligent

Lymph Drainage of the Face

**Central Part of the
Lower Lip & Chin:
Submental Lymph Nodes**

**Forehead &
Anterior Part:
Submandibular L Nodes**

**Lateral part & Lat
part of Eyelids:
Parotid L Nodes**

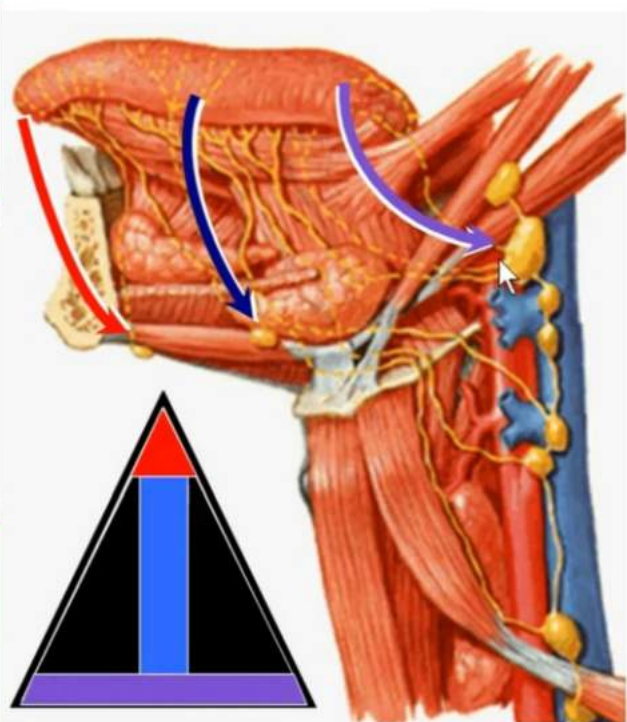


LYMPH DRAINAGE OF THE TONGUE

TIP:
to submental
Lymph nodes

ANTERIOR 2/3:
Submandibular lymph nodes
Central part: bilateral
Peripheral part: unilateral

POSTERIOR 1/3:
upper deep cervical lymph
nodes

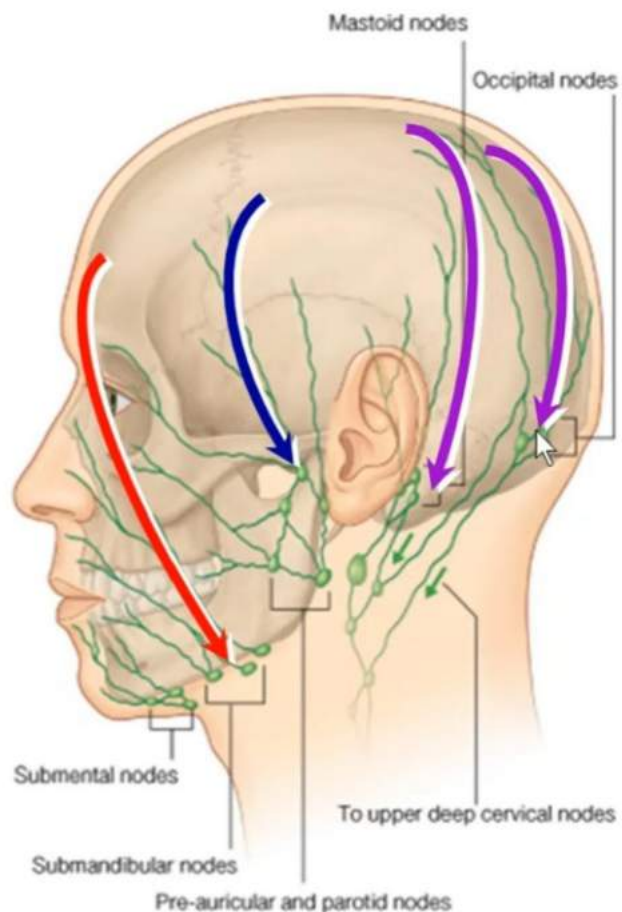


LYMPH DRAINAGE of the SCALP

Forehead: to the
submandibular L nodes

Lateral part: to the
preauricular L nodes

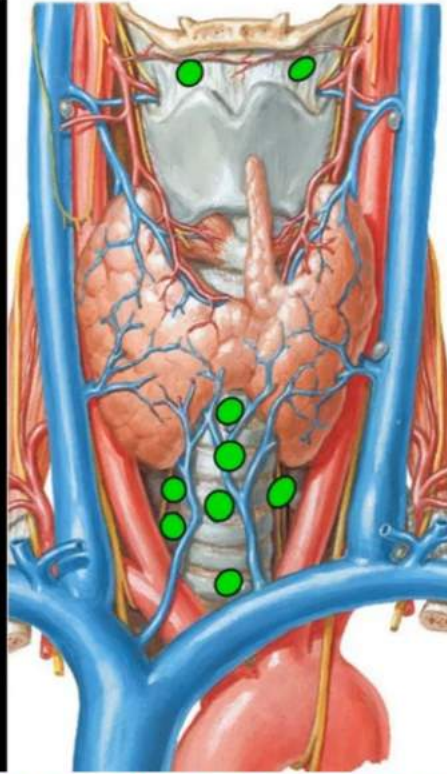Posterior part: to the
mastoid & occipital
lymph nodes



DEEP CERVICAL LYMPH NODES

1. IN THE MIDLINE

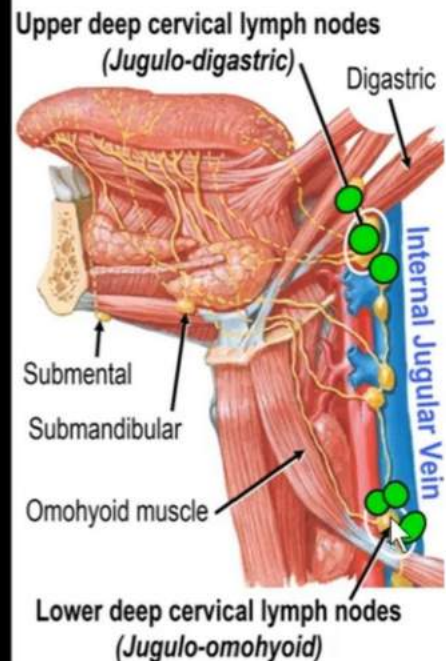
- 1. Pretracheal:** on front of the trachea. Drain thyroid g & trachea
- 2. Paratracheal:** on each side of the trachea & esophagus. Drain the thyroid gland and trachea.
- 3. Laryngeal (infrahyoid):** below the hyoid bone. Drain the larynx.
- 4. Retropharyngeal:** behind the upper part of the pharynx. Drain the pharynx.



DEEP CERVICAL LYMPH NODES

2. ON EACH SIDE OF THE NECK

- Are arranged along the carotid sheath & the internal jugular vein
- Are divided into 2 groups:
 - 1. Upper deep cervical:** where the post belly of the digastric crosses the IJV “jugulo-digastric LN”. Drain palatine tonsil & post 1/3 of tongue
 - 2. Lower deep cervical:** where the tendon of the omohyoid crosses the IJV “jugulo-omohyoid nodes”

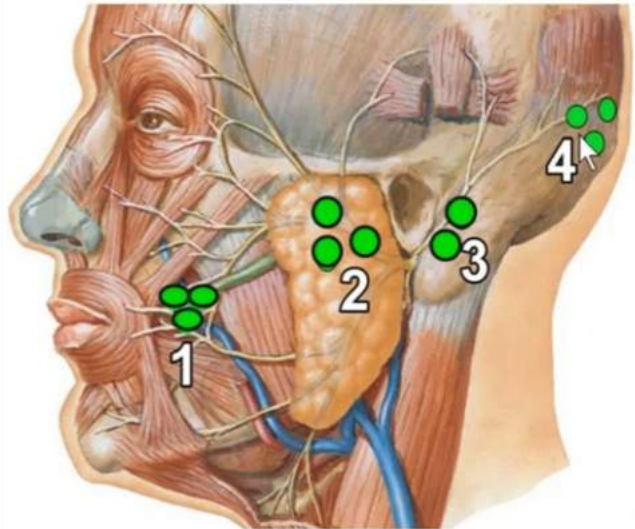


SUPERFICIAL LYMPH NODES

1. IN THE HEAD:

- 1. Buccal:** on the buccinator
- 2. Parotid:** "preauricular" on the surface and inside the parotid gland. Drain the scalp, face and ear.
- 3. Mastoid:** "retroauricular" on the mastoid process behind the auricle. Drain the scalp and ear
- 4. Occipital:** on the occipital bone. Drain the scalp.

In Head & in Neck



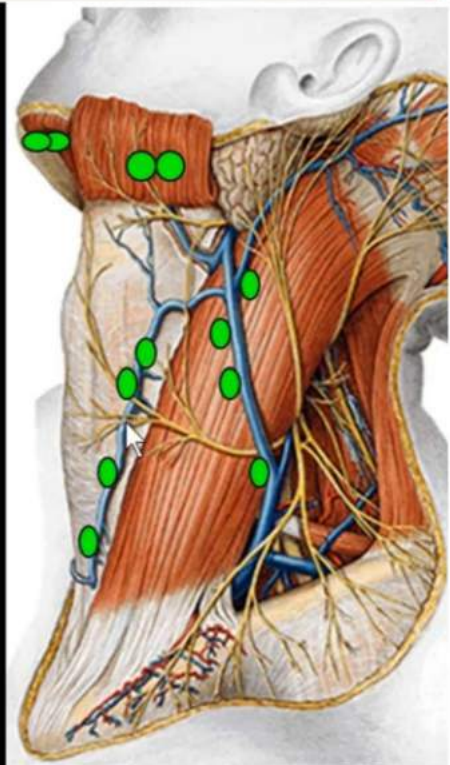
1: Buccal
2: Parotid

3: Mastoid
4: Occipital

SUPERFICIAL LYMPH NODES

2. IN THE NECK:

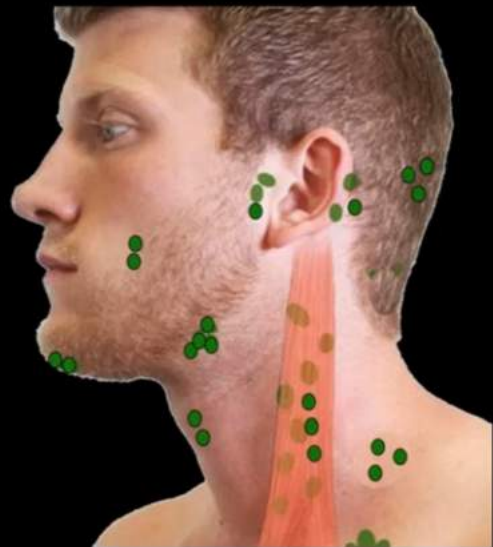
- 1. Submental:** below the chin. Drain the chin, tip of tongue, central part of lower lip & lower incisors.
- 2. Submandibular:** on the surface of the submandibular salivary gland. Drain the forehead, face, ant 2/3 of the tongue and upper and lower teeth.
- 3. Superficial cervical:** along the external jugular vein.
- 4. Anterior cervical:** along the anterior jugular vein. Drain the skin of the front of the neck



LYMPH DRAINAGE

**Superficial
Lymph Nodes**

**Deep Lymph
Nodes**



ORGANIZATION OF THE LYMPH NODES

1. Superficial Lymph Nodes:

- 📌 **They are present** in the superficial fascia.
- 📌 **Drain** the skin & superficial fascia
- 📌 **They drain into** the deep cervical nodes.

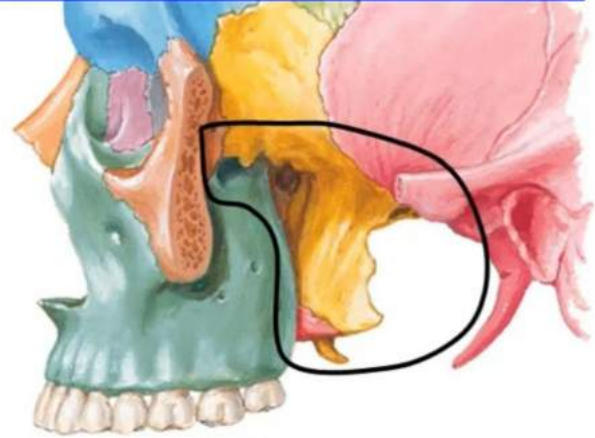
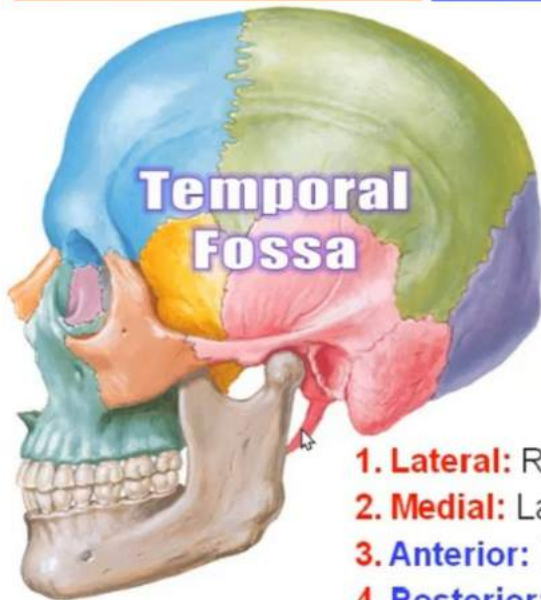2. Deep Cervical Lymph Nodes:

- 📌 **They are present** deep to the deep fascia.
- 📌 **Drain** the deep tissues
- 📌 **Their efferent vessels** form the **jugular lymph trunk** which ends in the:
 1. **Right side:** in the **right lymphatic duct.**
 2. **Left side:** in the **thoracic duct.**

INFRATEMPORAL FOSSA

BOUNDARIES

The space deep to the ramus of mandible

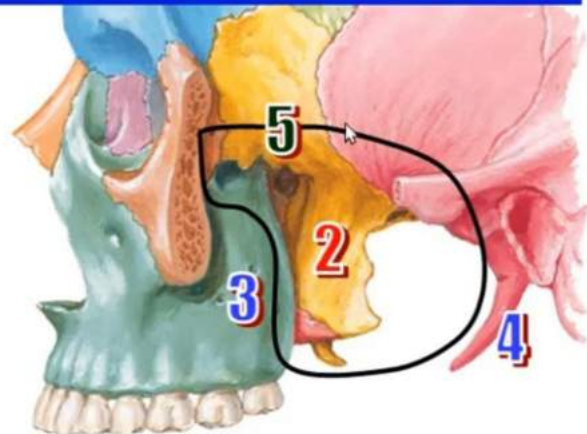
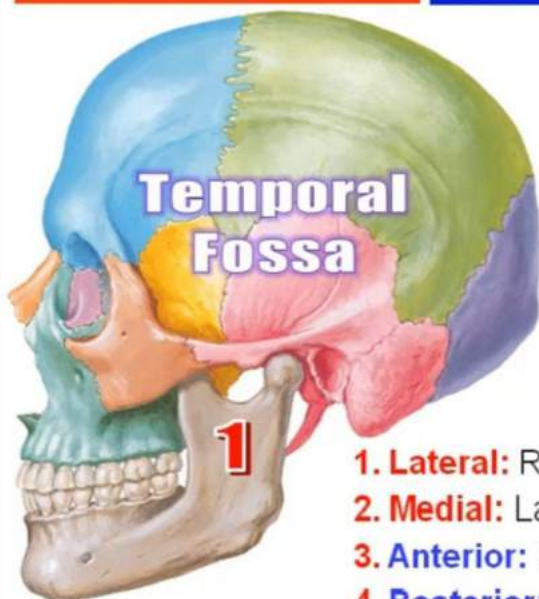


1. **Lateral:** Ramus of mandible & Zygomatic arch
2. **Medial:** Lateral pterygoid plate & pterygomax fissure
3. **Anterior:** Maxilla
4. **Posterior:** Styloid and mastoid processes
5. **Roof:** Greater wing of sphenoid + FO + FS

INFRATEMPORAL FOSSA

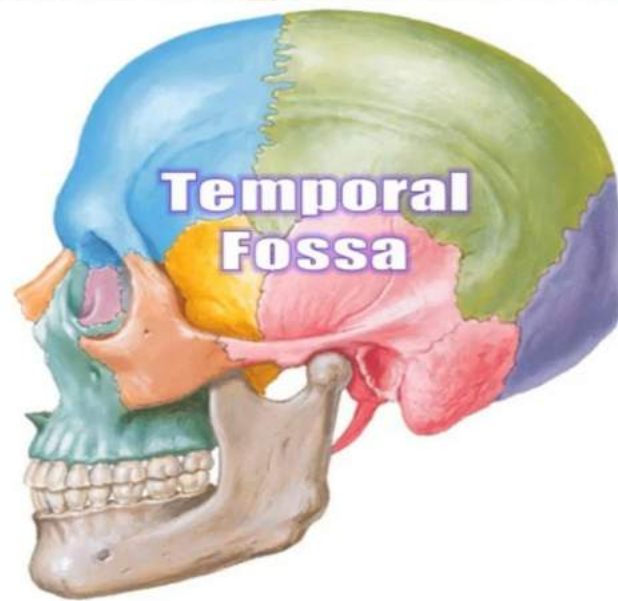BOUNDARIES

The space deep to the ramus of mandible



1. **Lateral:** Ramus of mandible & Zygomatic arch
2. **Medial:** Lateral pterygoid plate & pterygomax fissure
3. **Anterior:** Maxilla
4. **Posterior:** Styloid and mastoid processes
5. **Roof:** Greater wing of sphenoid + FO + FS

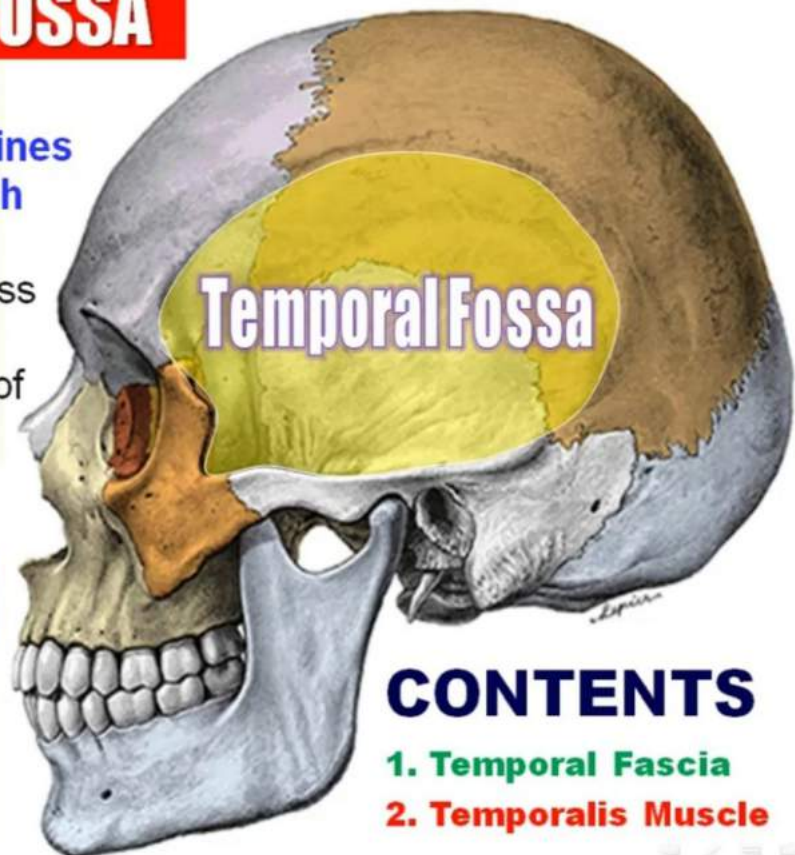
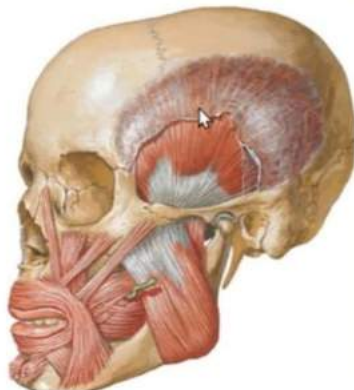Temporal & Infratemporal Fossa



TEMPORAL FOSSA

Boundaries:

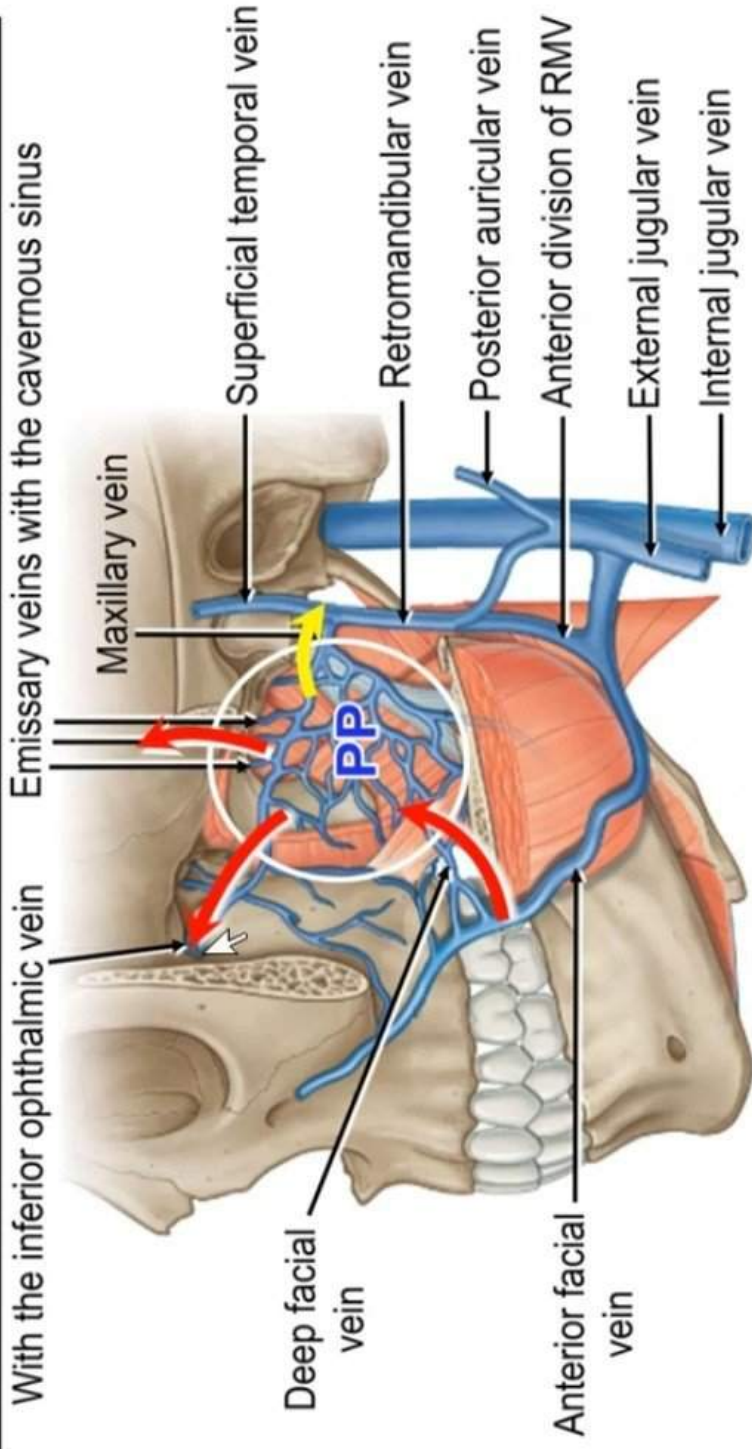
1. Sup: 2 temporal lines
2. Inf: zygomatic arch
3. Anterior:
 - a. Zygomatic process of frontal bone
 - b. Frontal process of zygomatic bone



CONTENTS

1. Temporal Fascia
2. Temporalis Muscle

Communication of the Pterygoid Plexus



1. With the Cavernous Sinus by emissary vein thru foramen ovale
2. With the Anterior Facial Vein: by the deep facial vein
3. With the Inf Ophthalmic Vein: thru the inferior orbital fissure
4. With the Pharyngeal Plexus

DISTRIBUTION

Dental Distribution

- Inferior alveolar artery
- Superior alveolar arteries

Nasal Distribution

- Sphenopalatine artery
- Greater palatine artery

Palatine Distribution

- Greater palatine artery → HP
- Sphenopalatine artery → HP
- Lesser palatine artery → SP

Pharyngeal Distribution

- Pharyngeal artery

Dr Adel Bondok®

Pterygoid Venous Plexus

Site: on the pterygoid muscles

Termination:

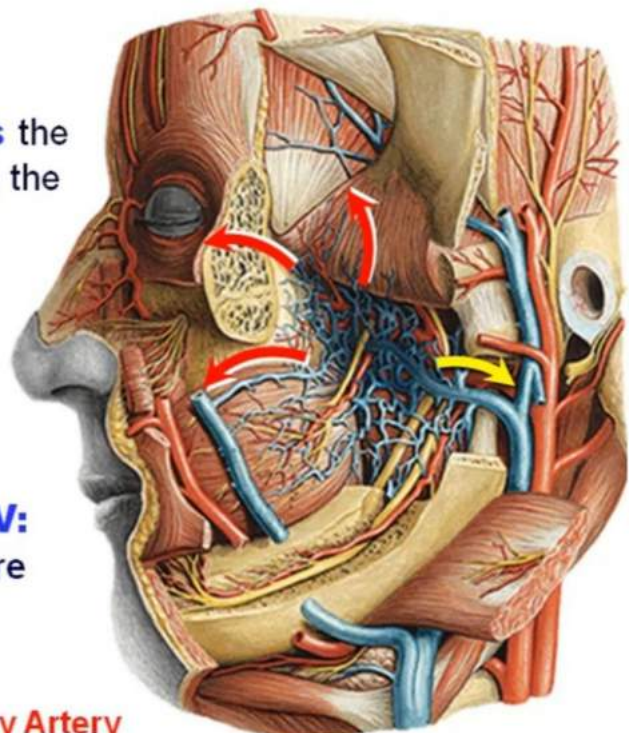
Into the **maxillary vein** which joins the **superficial temporal vein** to form the **posterior facial vein**

Communication:

1. **With Cavernous sinus:**
by emissary vein thru FO
2. **With Ant Facial Vein:**
by the deep facial vein
3. **With Inferior ophthalmic V:**
thru the inferior orbital fissure
4. **With Pharyngeal Plexus**

Tributaries:

Veins with branches of the **Maxillary Artery**

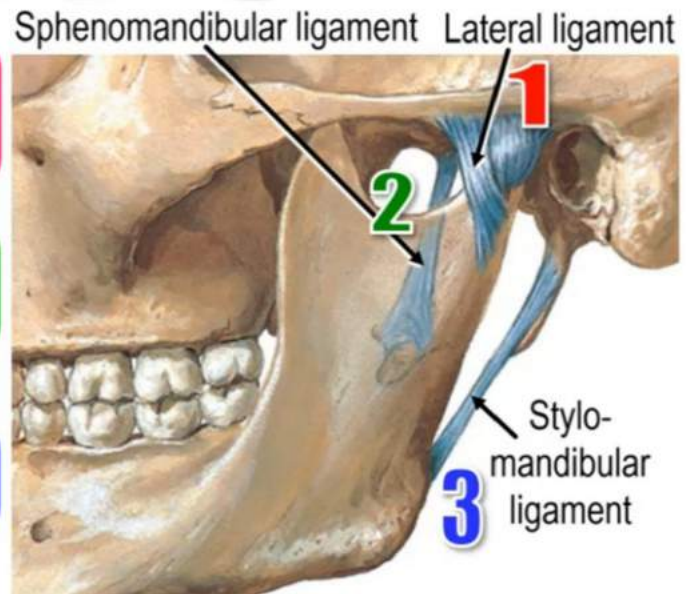


3 Accessory Ligaments

1. Lat temporomandibular ligament

2. Sphenomandibular ligament

3. Stylomandibular ligament



Arterial Supply: Maxillary & Superficial temporal artery

Nerve Supply: auriculotemporal n & nerve to masseter

Movements of the TMJ

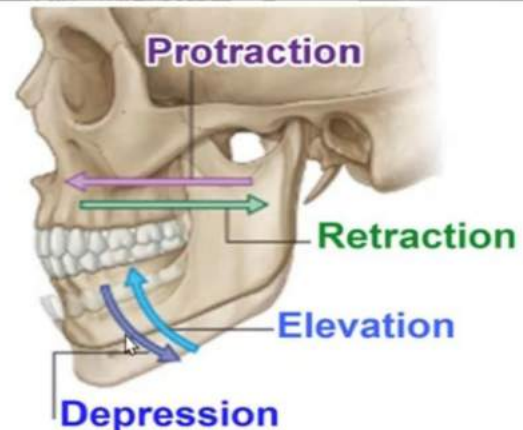
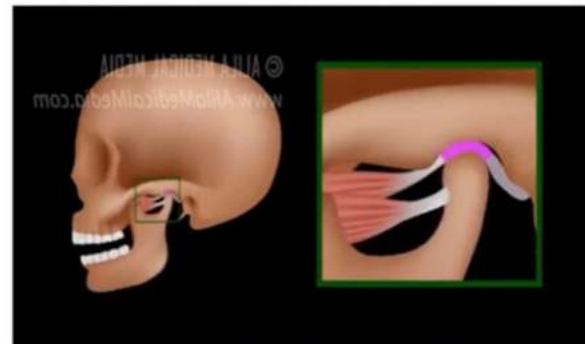Protraction

Retraction

Elevation

Depression

Side to Side



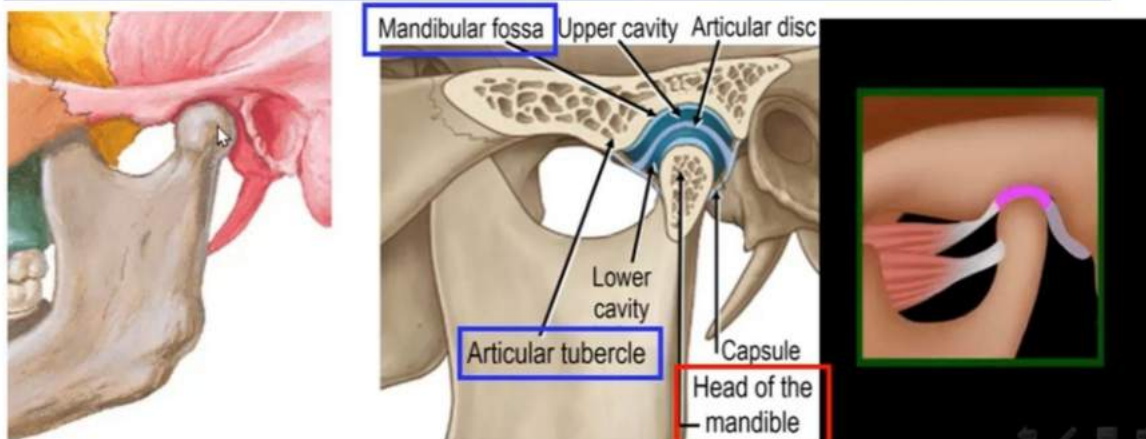
Temporomandibular Joint

TYPE: Condylar synovial joint

ARTICULAR SURFACES:

Above: mandibular fossa & articular tubercle

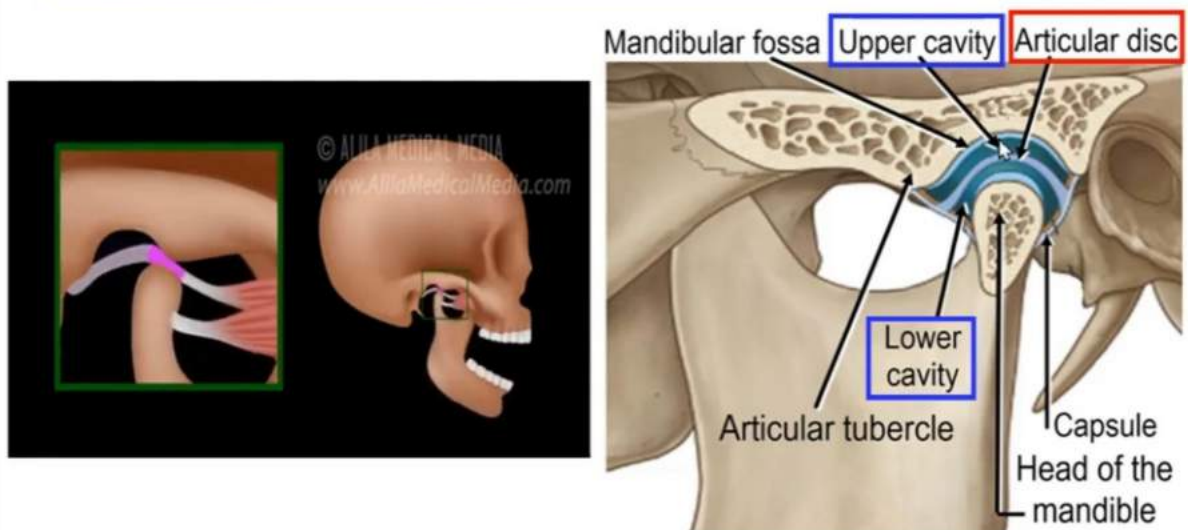
Below: head of the mandible



Articular Disc

Divides the cavity into 2 cavities:

1. Upper cavity: for protrusion & retraction
2. Lower cavity: for upward & downward rotation



Lateral Pterygoid Muscle

UPPER BORDER:

1. Deep temporal nerves
2. Nerve to masseter

LOWER BORDER:

1. Lingual nerve
2. Inferior alveolar nerve
3. 1st part of maxillary artery

BETWEEN 2 HEADS:

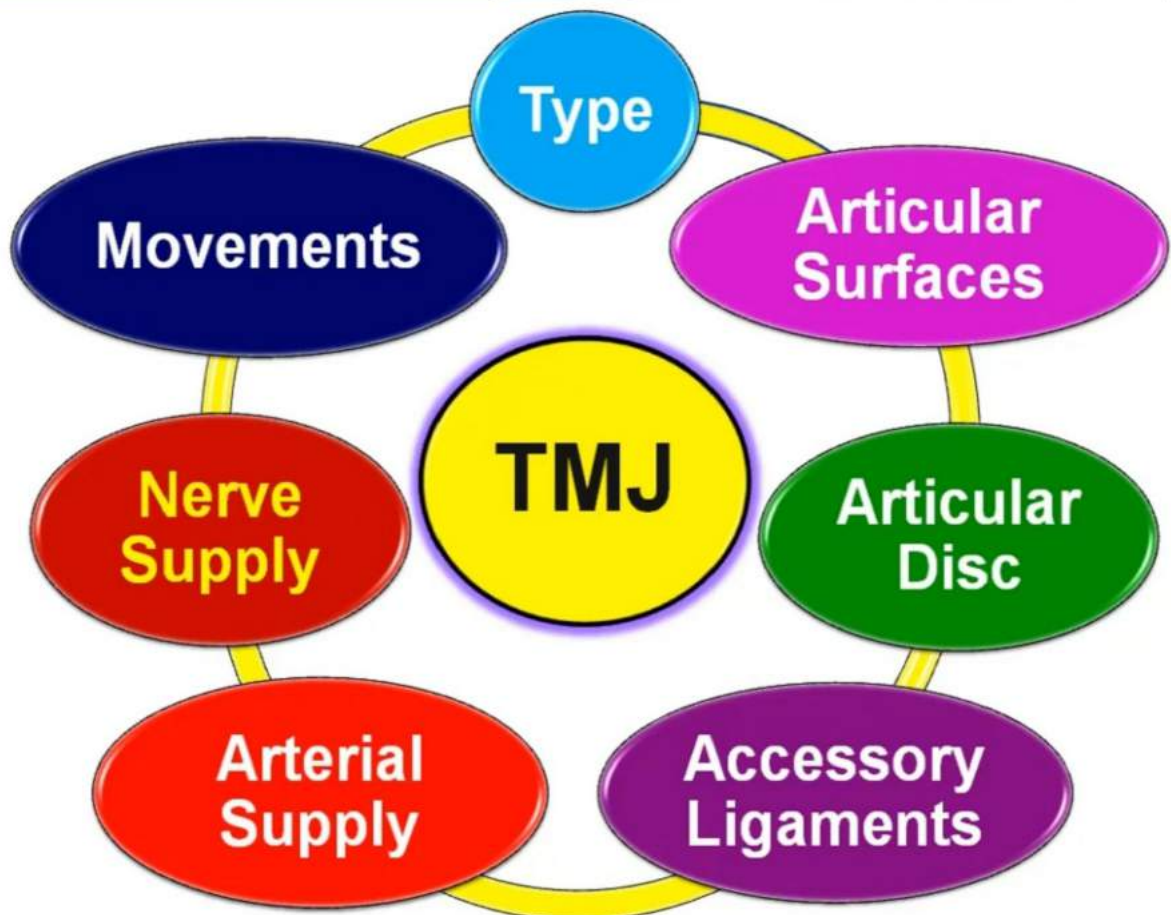
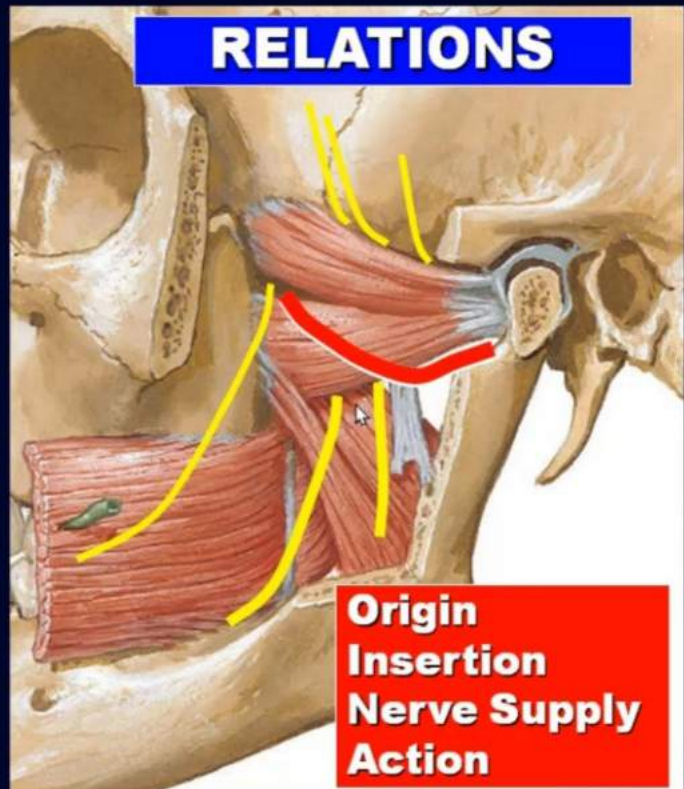
1. Buccal nerve
2. Maxillary artery to become 3rd

SUPERFICIAL:

1. Masseter, temporalis, mandible
2. 2nd part of maxillary artery
3. Superficial head of med pterygo

DEEP:

1. Mandibular nerve trunk
2. Otic ganglion
3. Chorda tympani
4. Deep head of medial pterygoid



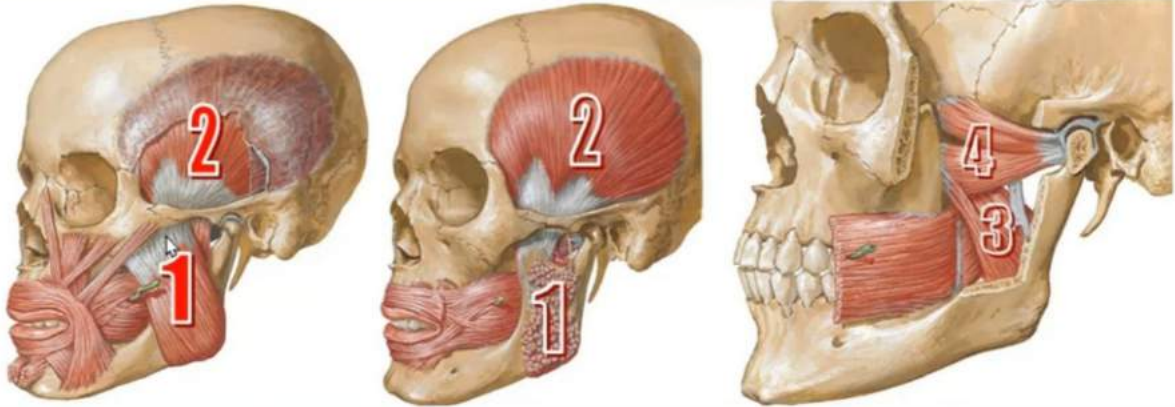
4 MUSCLES OF MASTICATION

1. Masseter

2. Temporalis

3. Medial pterygoid

4. Lateral pterygoid



Nerve Supply: mandibular nerve

why ???

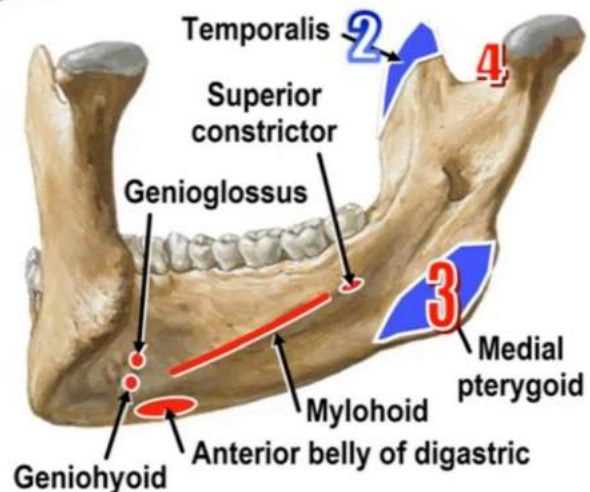
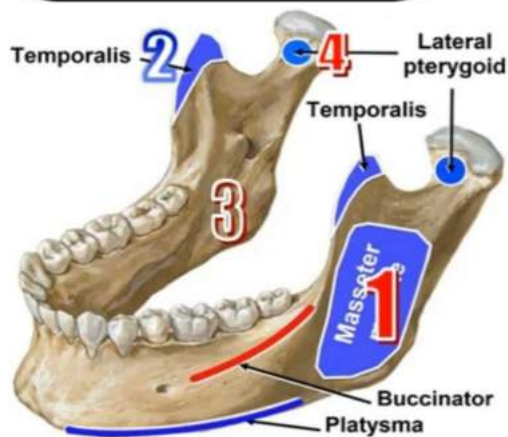
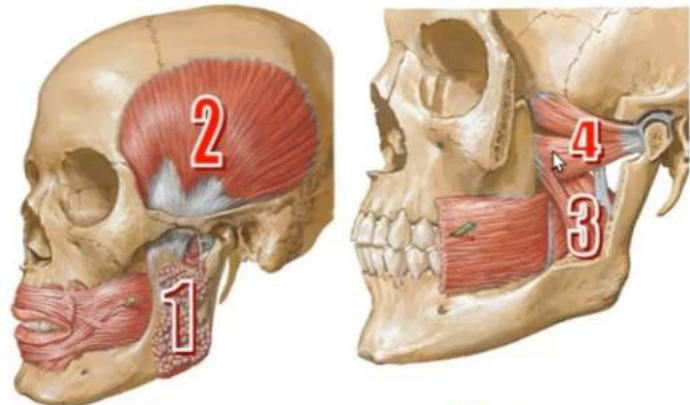
ACTION:

1. All elevate the mandible except lateral pterygoid "depress"
2. All protrude the mandible except temporalis "retract"

Origin: from the skull

Insertion: mandible

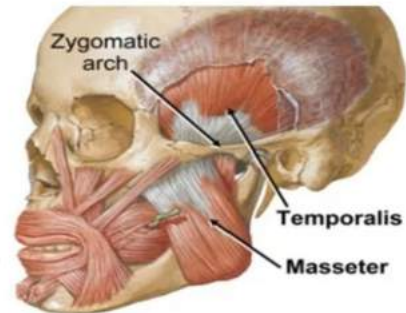
1. Masseter
2. Temporalis
3. Medial pterygoid
4. Lateral pterygoid



Contents

3 Muscles of Mastication:

Medial pterygoid + lateral pterygoid + insertion of Temporalis

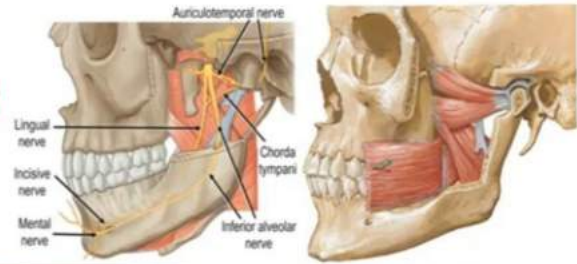


Ligament:

Sphenomandibular ligament

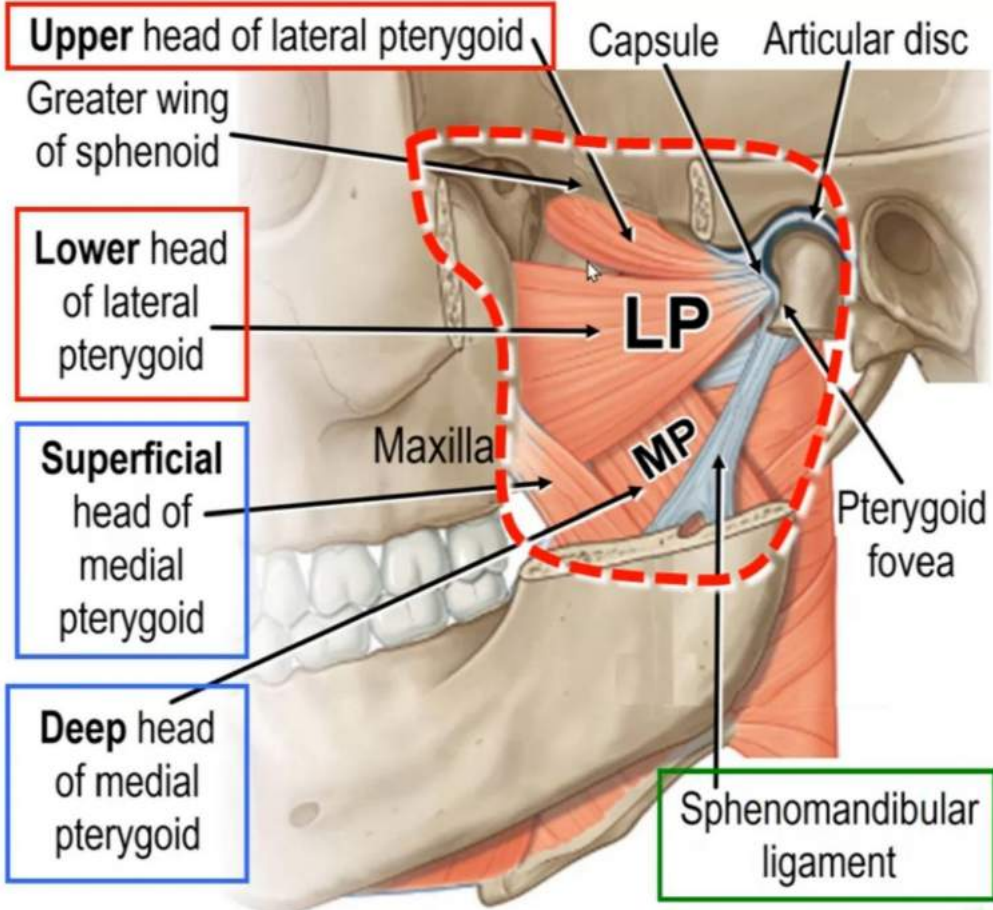
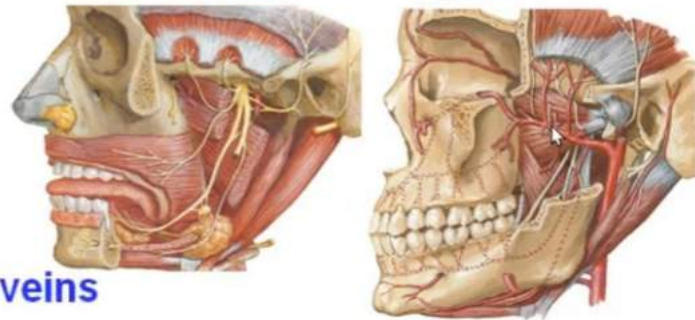
Nerves:

1. Mandibular nerve
2. Chorda tympani
3. Otic ganglion
4. Maxillary nerve

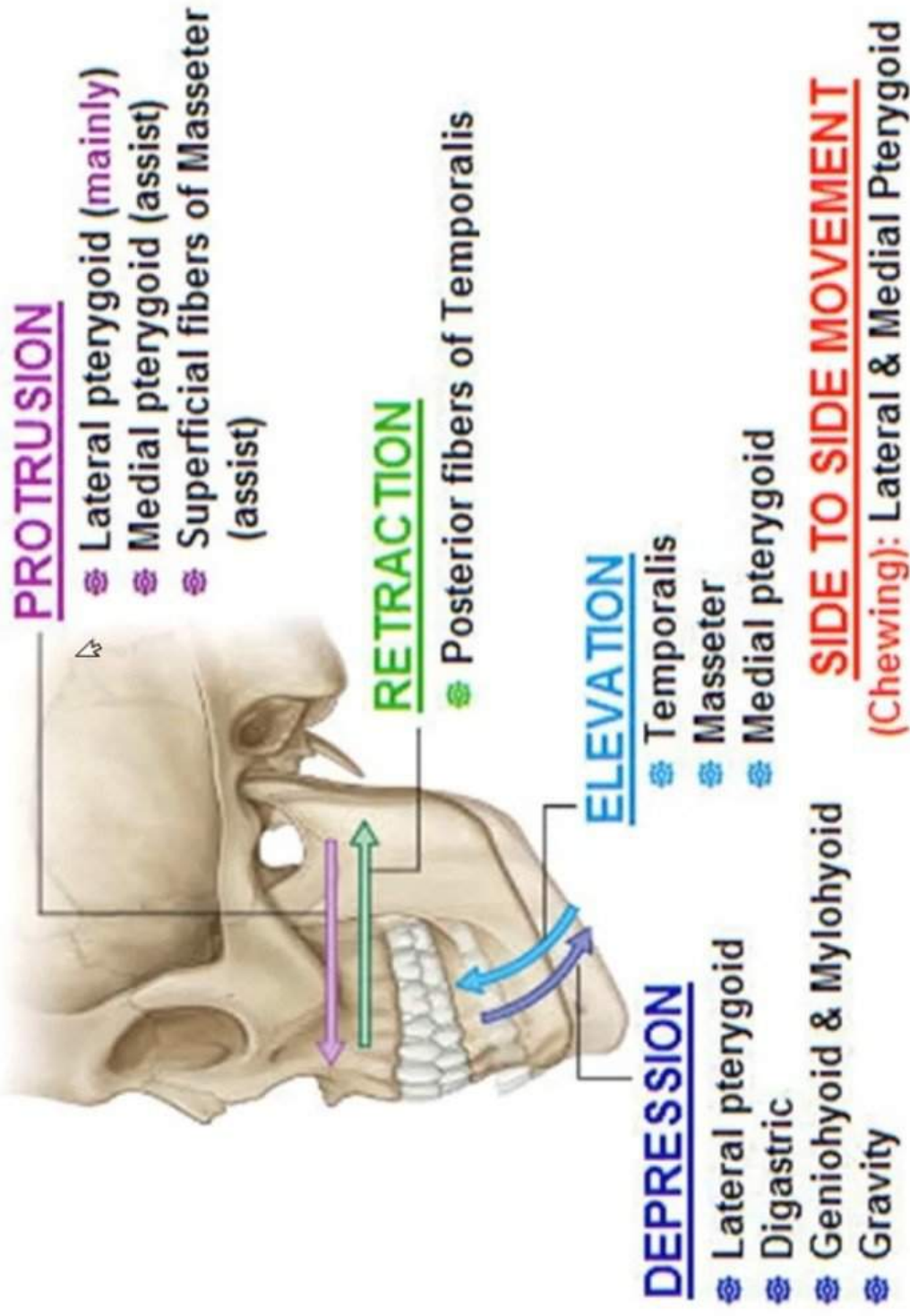


Vessels:

1. Maxillary artery
2. Pterygoid plexus of veins



MOVEMENTS OF THE TMJ

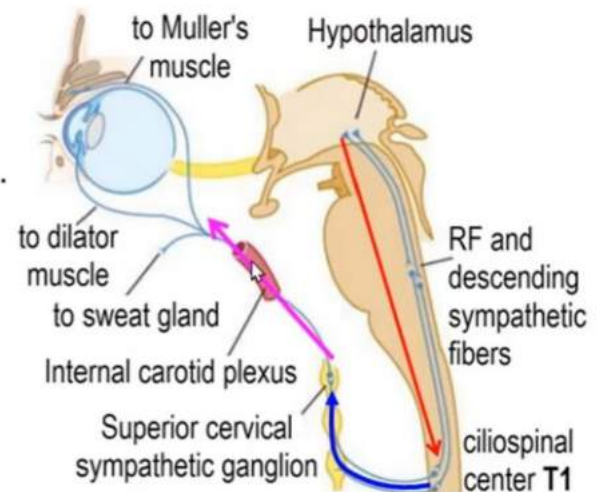


Causes of Horner's Syndrome

It is due to loss of the sympathetic innervation of the eye & face.

The lesion may be:

- 1. Central:** between the hypothalamus and the ciliospinal center in T1 segment of the spinal cord in the descending autonomic fibers.
- 2. Preganglionic:** between the ciliospinal center & the SCSG.
- 3. Postganglionic:** in the branches of the SCSG.



Dr Adel Bondok ®

5 Signs of Horner's Syndrome

- 1. Incomplete ptosis:** drooping of the upper eyelid - due to paralysis of 1st Muller's muscle
- 2. Miosis:** constriction of the pupil
- 3. Anhidrosis:** decreased sweating
- 4. Enophthalmos:** sunken eyeball
- 5. Flushing of the face:** VD of BV
Vasodilation of blood vessels

Dr Adel Bondok ®

CERVICAL SYMPATHETIC CHAIN

SITE:

Behind the carotid sheath

FORMATION:

3 ganglia: sup, middle & inferior

BRANCHES: 3 routes

1. Along nerves:

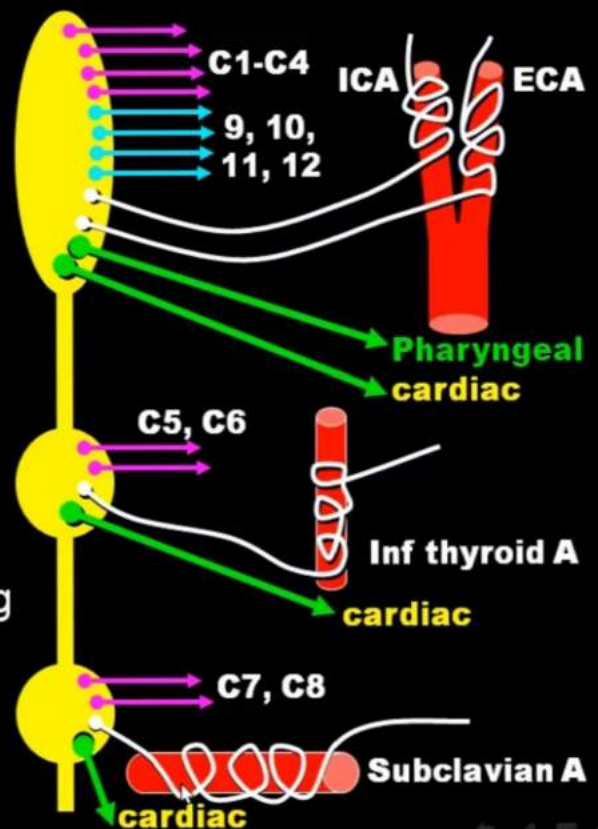
2. Along arteries (vascular):

3. Direct:

Note:

Ansa subclavia: loop connecting the middle with inferior ganglia

Stellate ganglion: fused inferior cervical & 1st thoracic ganglia



Lesion of the Cervical Sympathetic Chain

HORNER'S SYNDROME

1. **Ptosis: incomplete**

2. **Miosis** - Constriction of pupil due to paralysis of dilator pupillae muscle

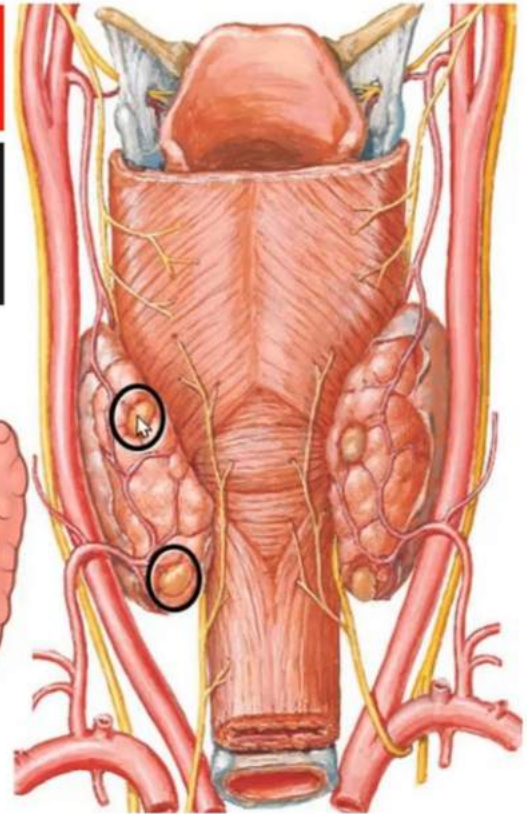
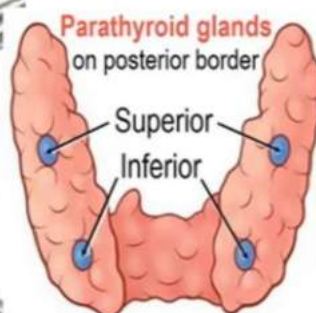
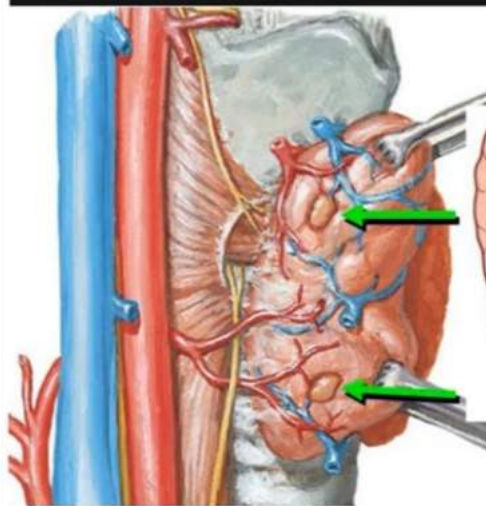
3. **Anhidrosis** Due to paralysis of sweat glands of face

4. **Enophthalmos** Sunken eye due to paralysis of 3rd molar muscle Which closes the inferior orbital fissure

POSTERIOR BORDER

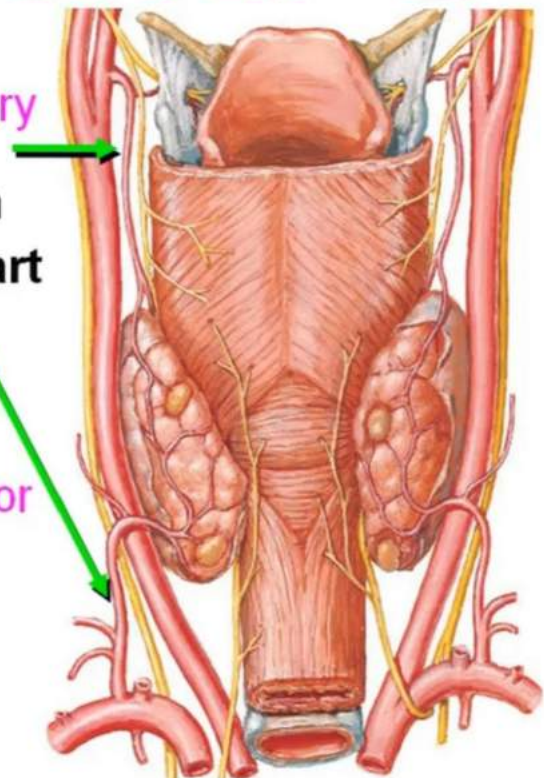
**Superior Parathyroid Gland:
in the middle**

**Inferior Parathyroid Gland:
at lower end**



ARTERIAL SUPPLY 3

- 1. Superior thyroid artery:**
from the **external carotid artery**
- 2. Inferior thyroid artery:** from
the **thyrocervical trunk (1st part
of subclavian artery)**
- 3. Thyroid ima artery:** in 10%.
It arises **from the aortic arch or
the brachiocephalic artery**. It
supplies the isthmus. **Ima =
the lowest**



MEDIAL SURFACE

2 Tubes Above

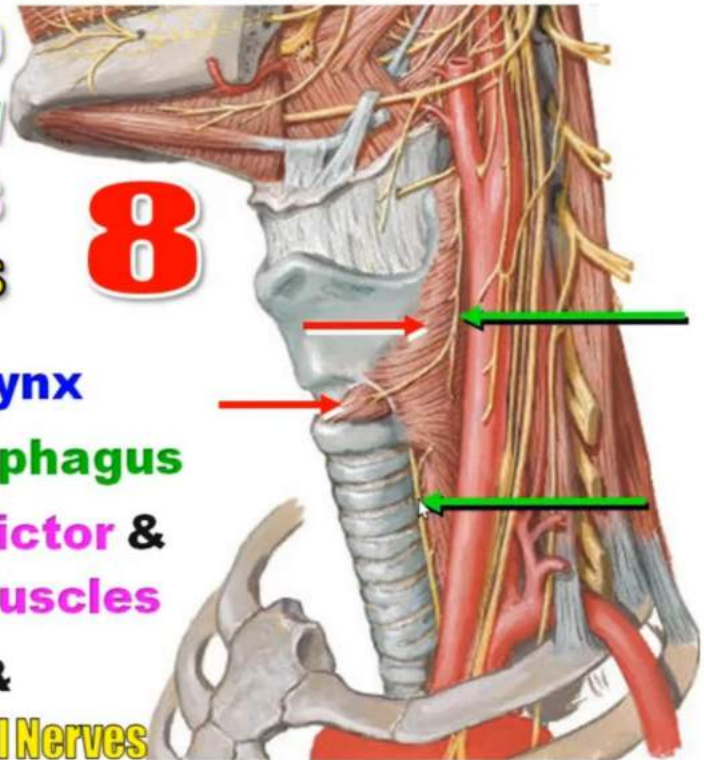
2 Tubes Below

2 Muscles

2 Nerves

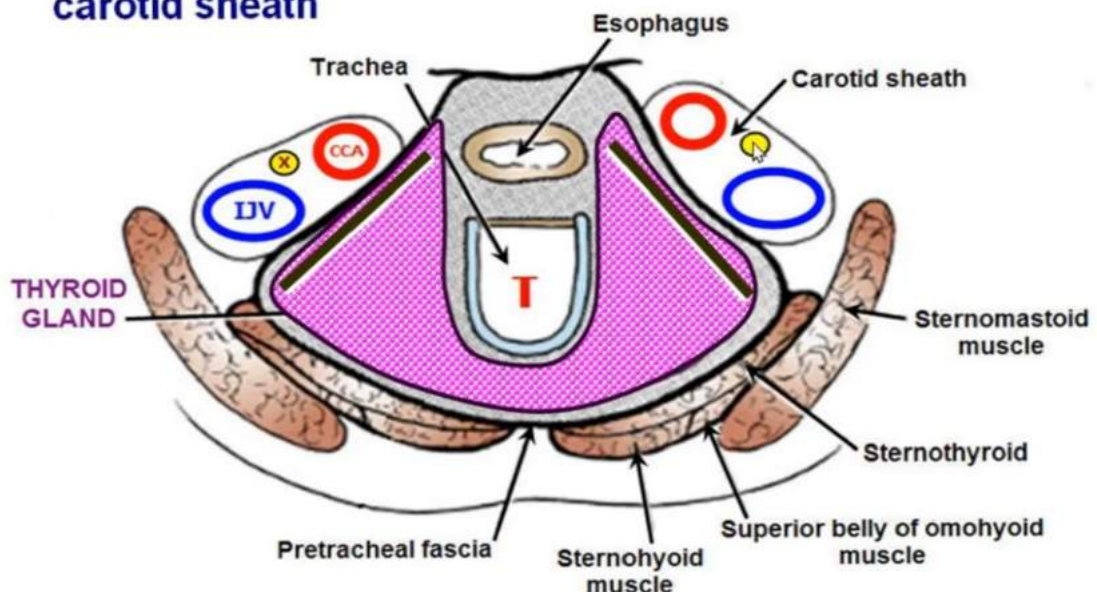
8

-  **Larynx & Pharynx**
-  **Trachea & Esophagus**
-  **Inferior Constrictor & Cricothyroid Muscles**
-  **External Laryngeal & Recurrent laryngeal Nerves**



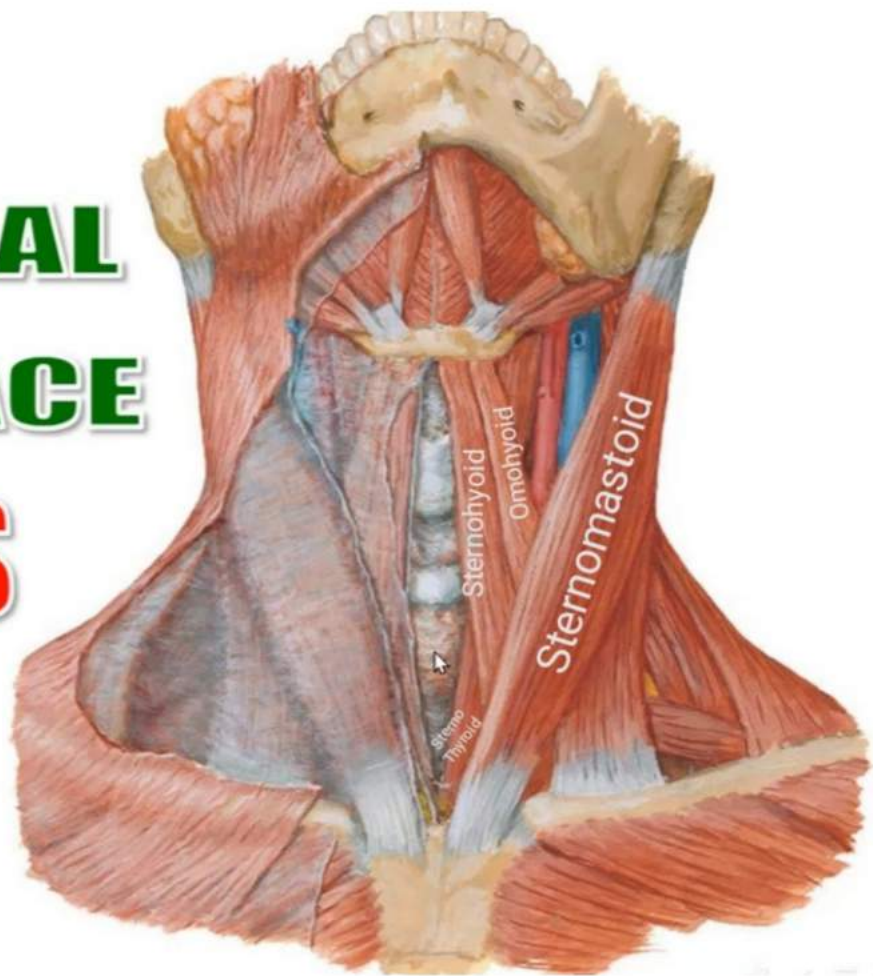
POSTERIOR SURFACE

- Carotid Sheath:** containing common carotid artery, internal jugular vein & the vagus nerve
- Sympathetic chain & prevertebral muscles** behind carotid sheath



LATERAL SURFACE

5 S



MEDIAL SURFACE

2 Tubes Above

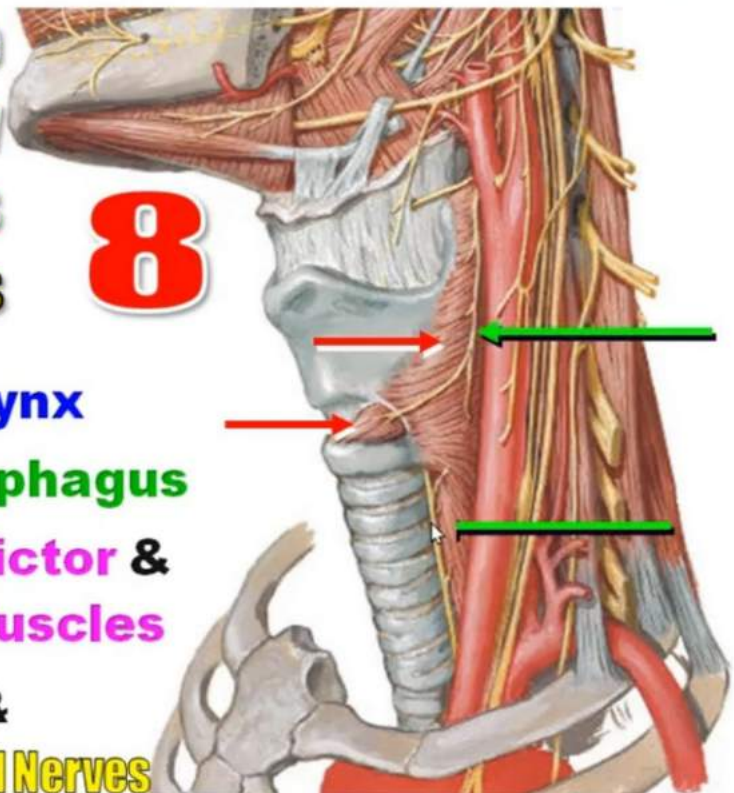
2 Tubes Below

2 Muscles

2 Nerves

8

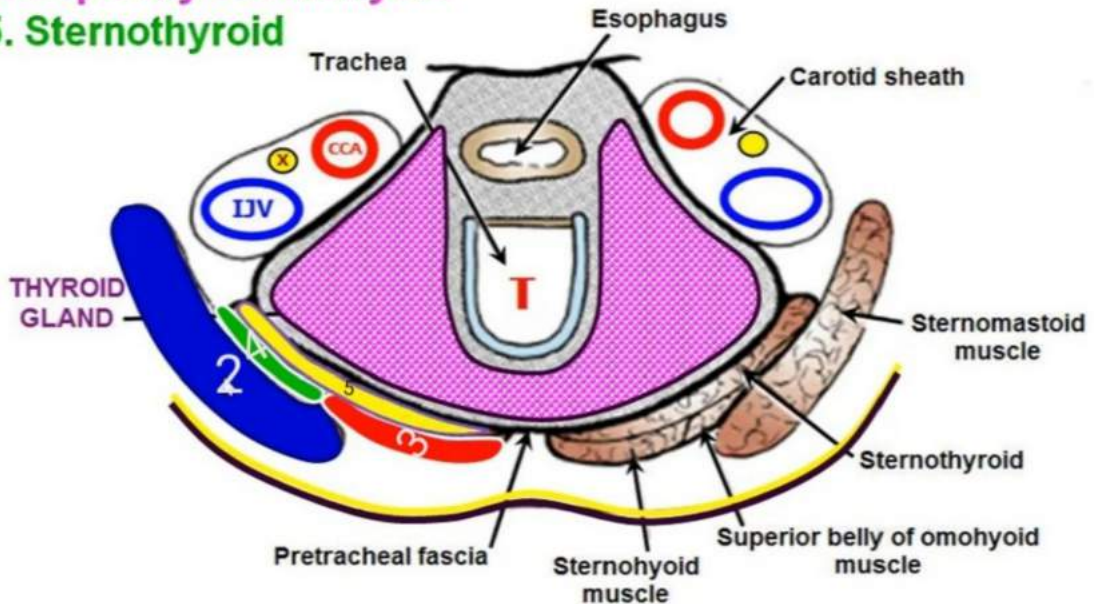
-  Larynx & Pharynx
-  Trachea & Esophagus
-  Inferior Constrictor & Cricothyroid Muscles
-  External Laryngeal & Recurrent laryngeal Nerves



LATERAL SURFACE

1. Skin and Fascia
2. Sternomastoid
3. Sternohyoid
4. Sup belly of omohyoid
5. Sternothyroid

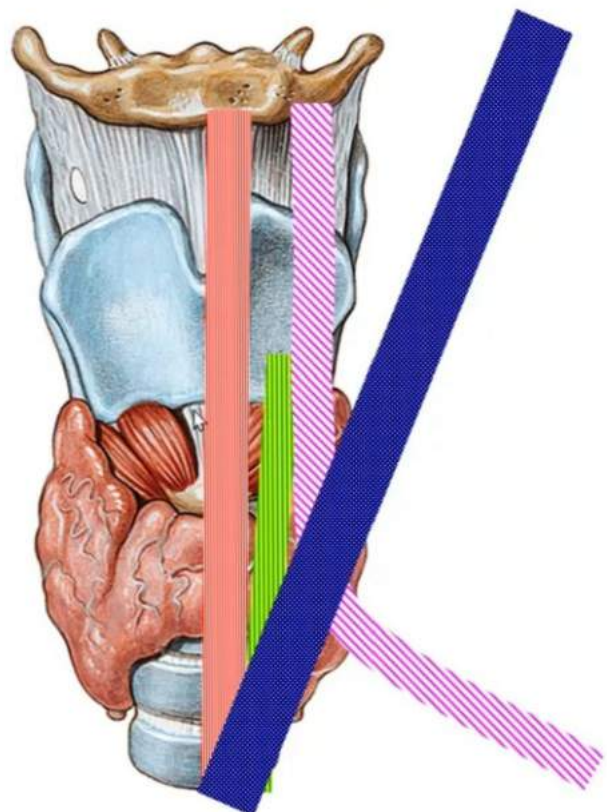
5 S



LATERAL SURFACE

5 S

1. Skin and Fascia
2. Sternomastoid
3. Sternohyoid
4. Sup belly of omohyoid
5. Sternothyroid



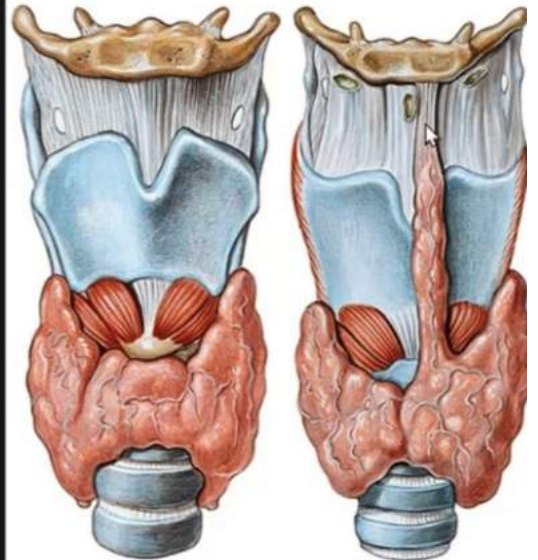
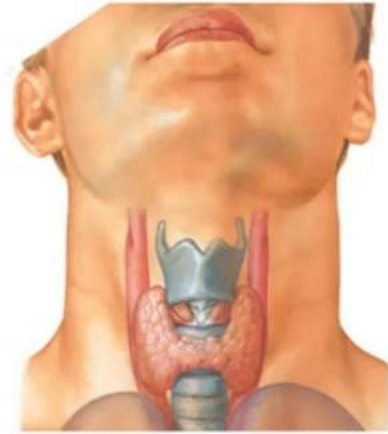
SHAPE:

It is made up of 2 lobes & isthmus

- a. The **isthmus** overlies the 2nd, 3rd & 4th tracheal rings
- b. **Each lobe** extends from the oblique line of thyroid cartilage to the 5th or 6th tracheal ring.

A **small pyramidal lobe** may project upward from the upper border of the isthmus

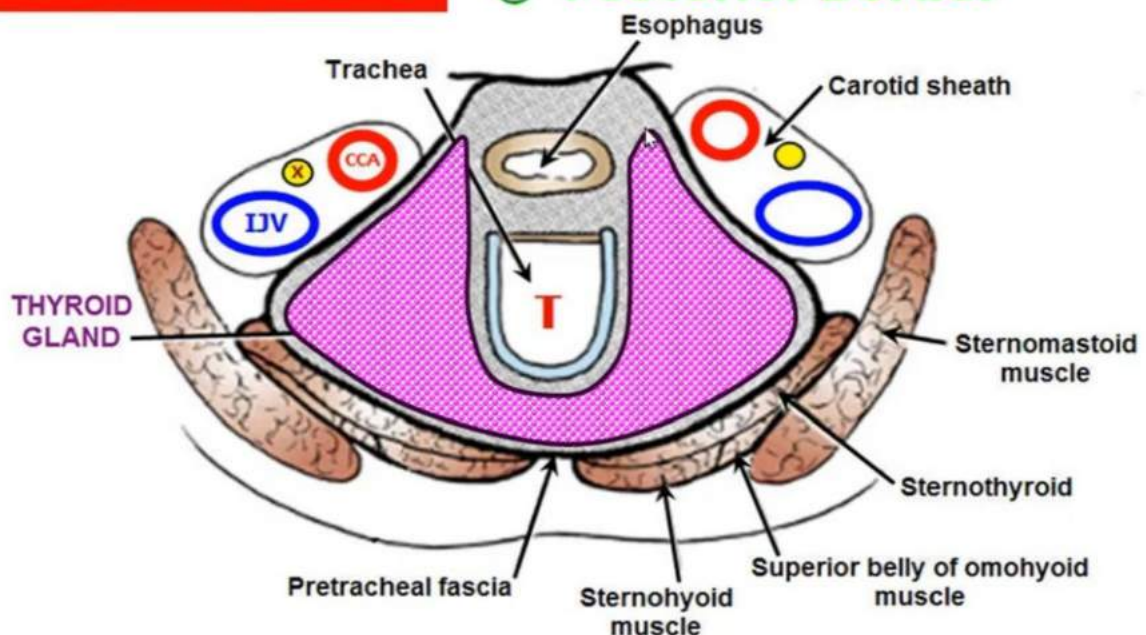
It is **connected to the hyoid bone** by fibrous band called **levator glandulae thyroidae**. It is remnant of thyroglossal duct



RELATIONS OF THE THYROID GLAND

3
SURFACES

1. Lateral or Superficial
2. Medial
3. Posterior
@ **Posterior Border**



Thyroid Gland

Position

Shape

Surfaces

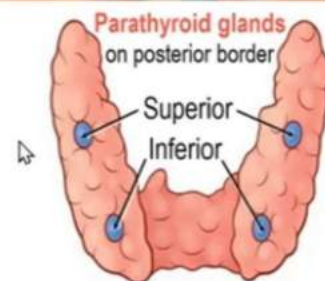
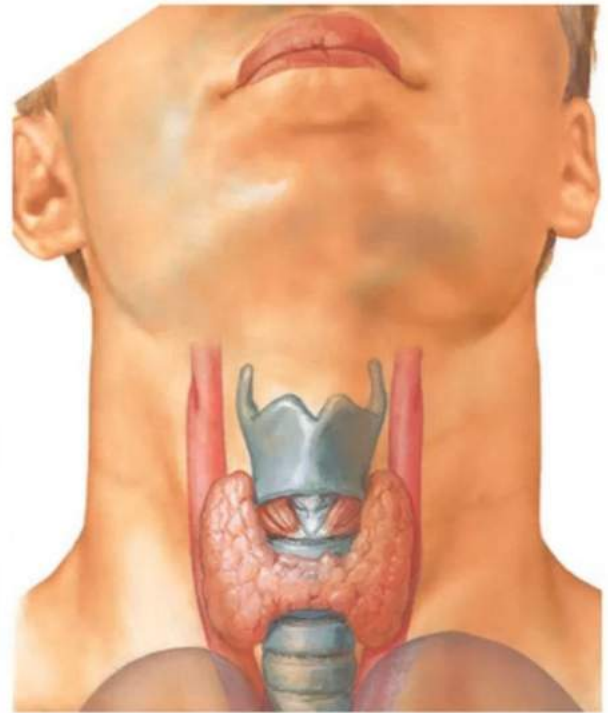
Relations

Arterial Supply

Venous Drainage

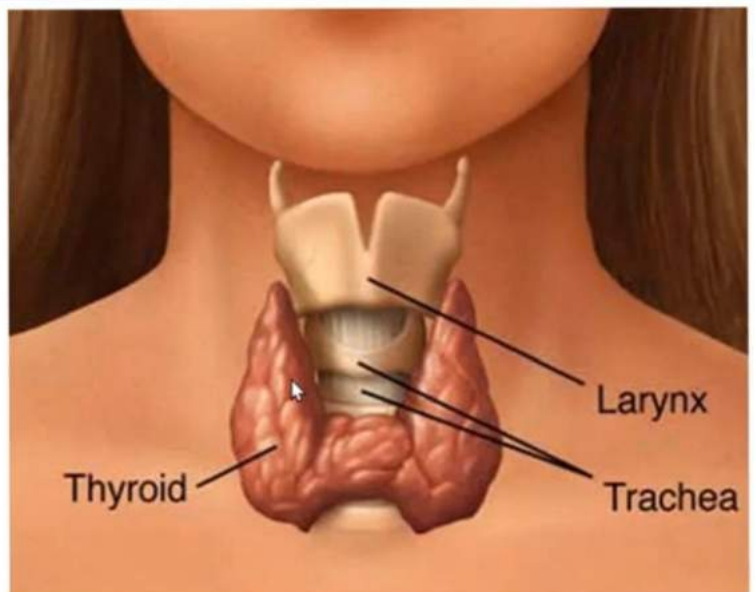
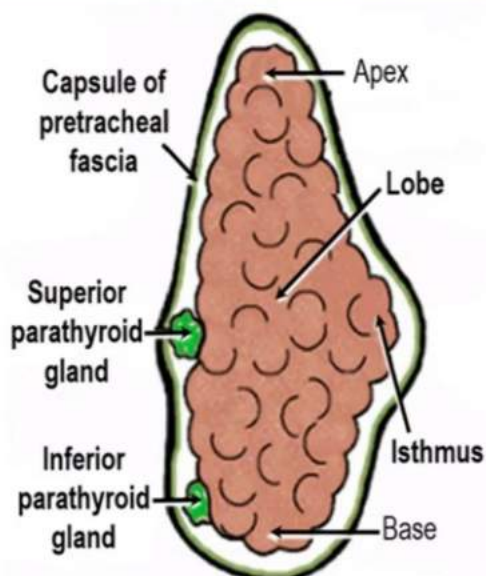
Lymph Drainage

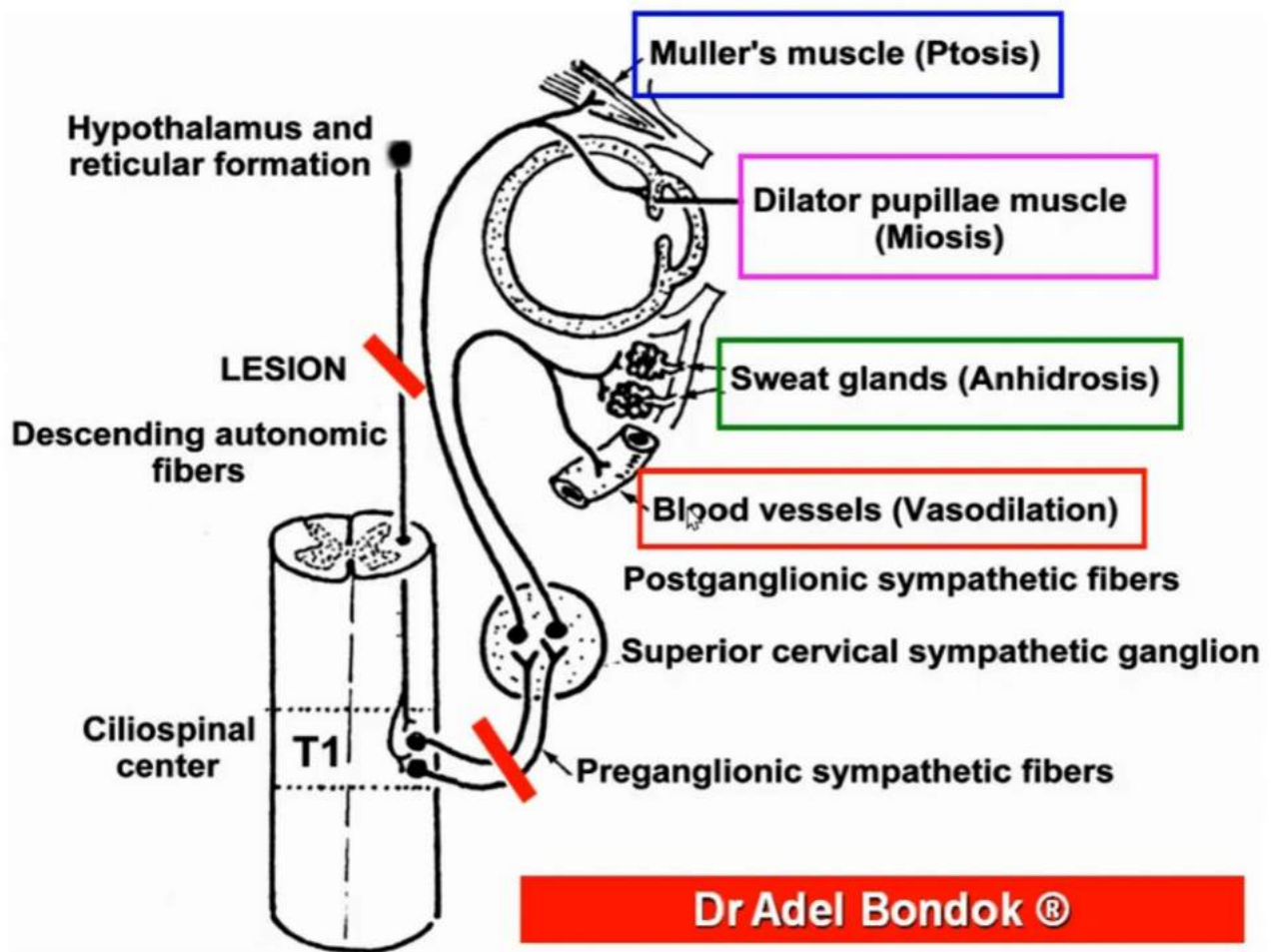
Parathyroid Gland



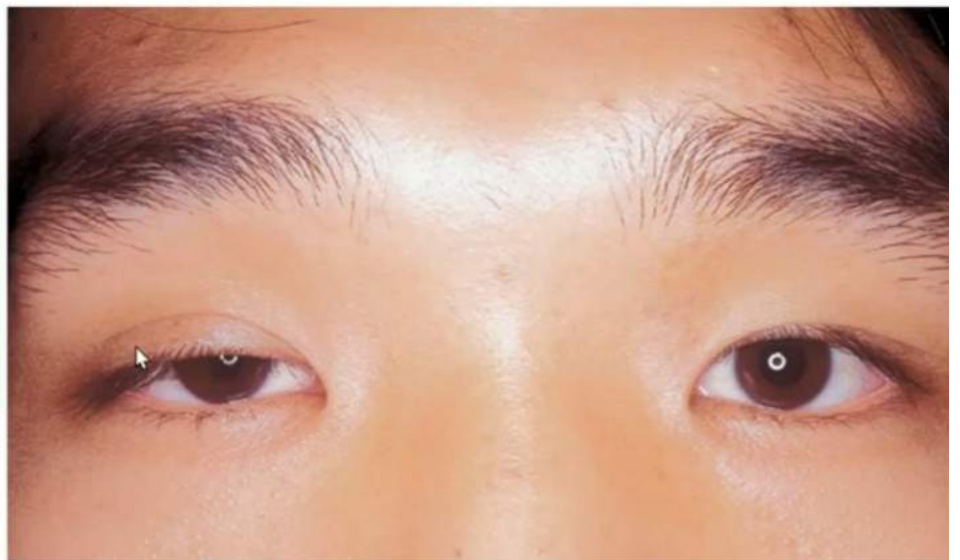POSITION:

- In front of** the lower part of the neck
- Surrounds** the front & sides of upper part of the trachea
- It is covered by** the **pretracheal fascia** which fixes the gland to the trachea so the gland moves with swallowing

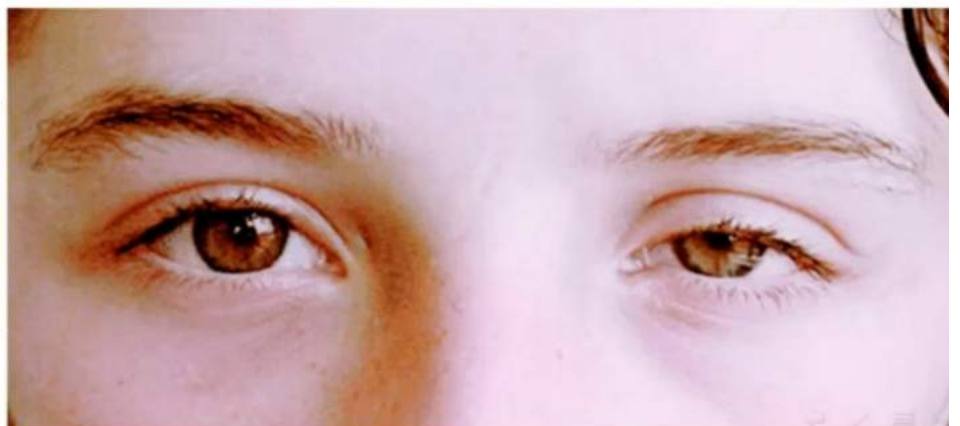



Rt Horner's Syndrome



Lt Horner's Syndrome



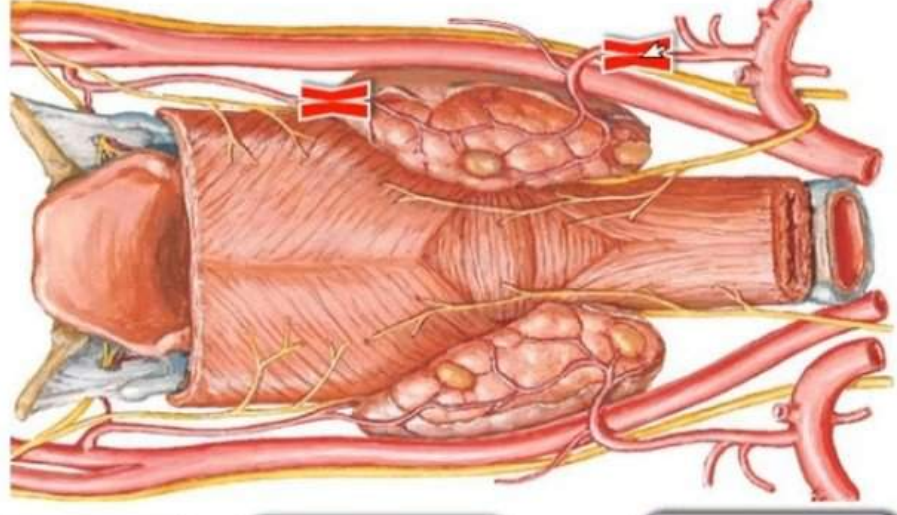
CLINICAL NOTE

Ligation of the thyroid arteries during **thyroidectomy**

The **superior thyroid artery** is ligated close to the upper pole of the thyroid gland to avoid injury of the **external laryngeal nerve**

Dr Adel Bondok®

The **inferior thyroid artery** is ligated away from the gland close to its origin to avoid injury of the **recurrent laryngeal nerve**



LYMPH DRAINAGE

1. Isthmus:

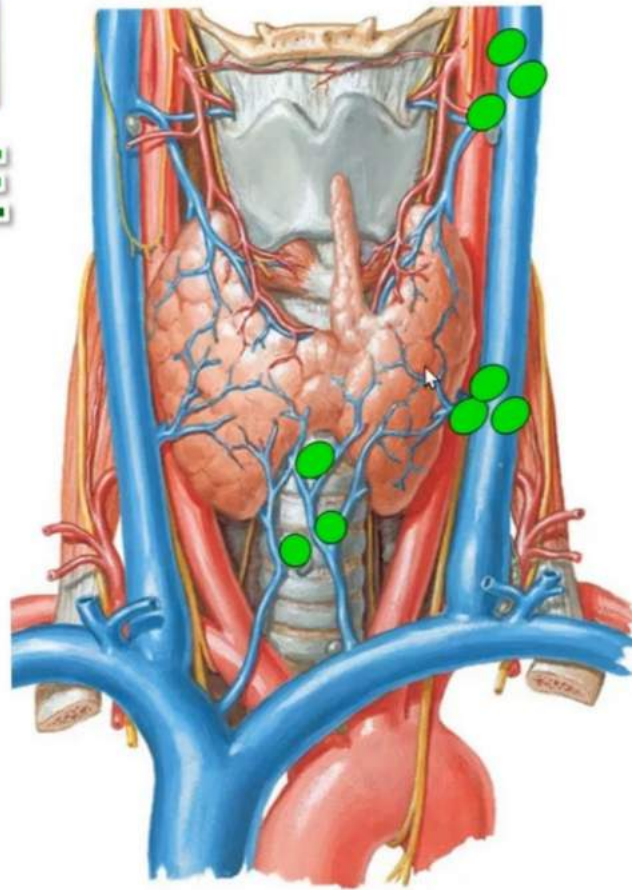
to the pretracheal lymph nodes

2. Upper Part:

to the upper deep cervical lymph nodes

3. Lower Part:

to the lower deep cervical lymph nodes



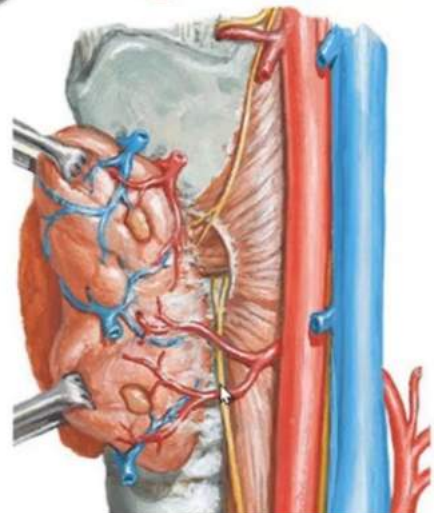
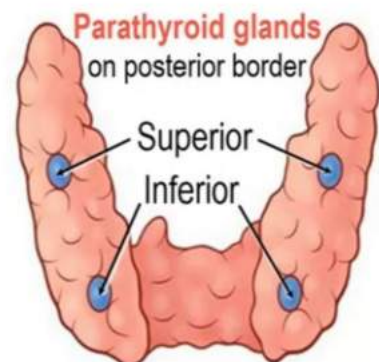
Clinical Note

2 structures may be injured during **thyroidectomy**

Parathyroid Glands

Dr Adel Bondok®

External & recurrent laryngeal nerves



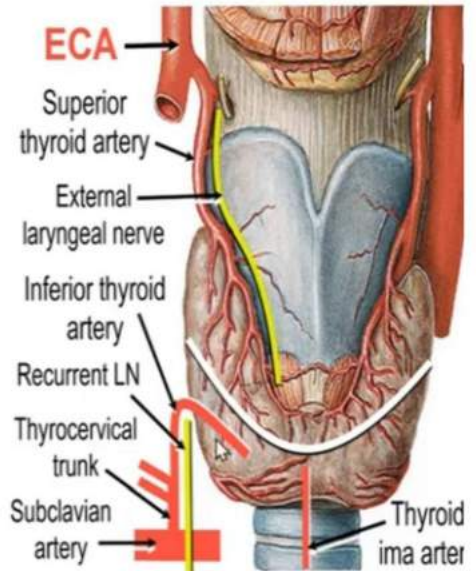
ARTERIAL SUPPLY

1. Superior thyroid artery:

- ❑ Accompanied by the external laryngeal nerve
- ❑ Supplies **upper 1/3** of the lobe & **upper 1/2** of the isthmus

2. Inferior thyroid artery:

- ❑ Accompanied by the recurrent laryngeal nerve
- ❑ Supplies **lower 2/3** of the lobe & **lower 1/2** of the isthmus and the parathyroid glands



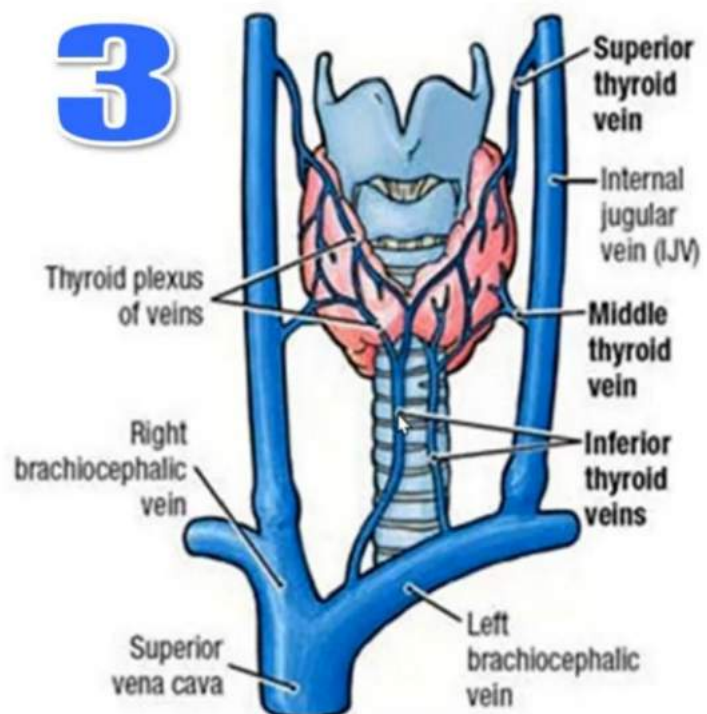
3. Thyroid ima artery: to the isthmus

VENOUS DRAINAGE

1. Superior thyroid vein:
ends in the internal jugular vein

2. Middle thyroid vein:
ends in the internal jugular vein. It is the widest and shortest

3. Inferior thyroid veins:
ends in the left brachiocephalic vein



THE TONGUE

Structure:

1. Mucous membrane
2. Muscles

Divisions: 2 parts

1. Oral part: **body**
anterior 2/3
2. Pharyngeal part: **root**
posterior 1/3

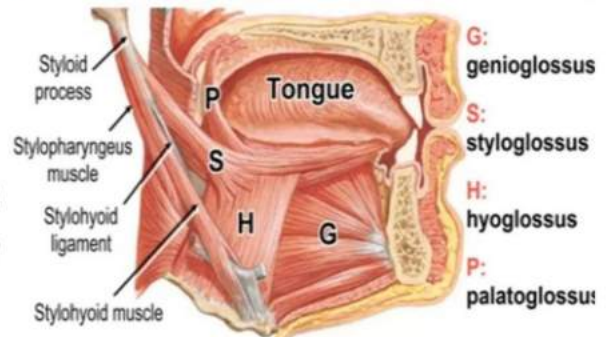
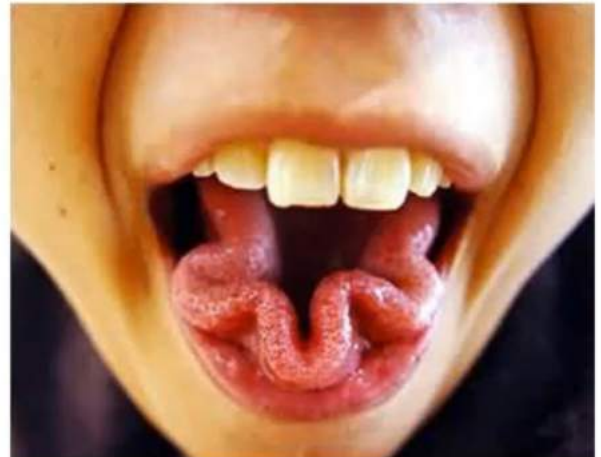Muscles: 8 muscles

1. Extrinsic muscles: 4
2. Intrinsic muscles: 4

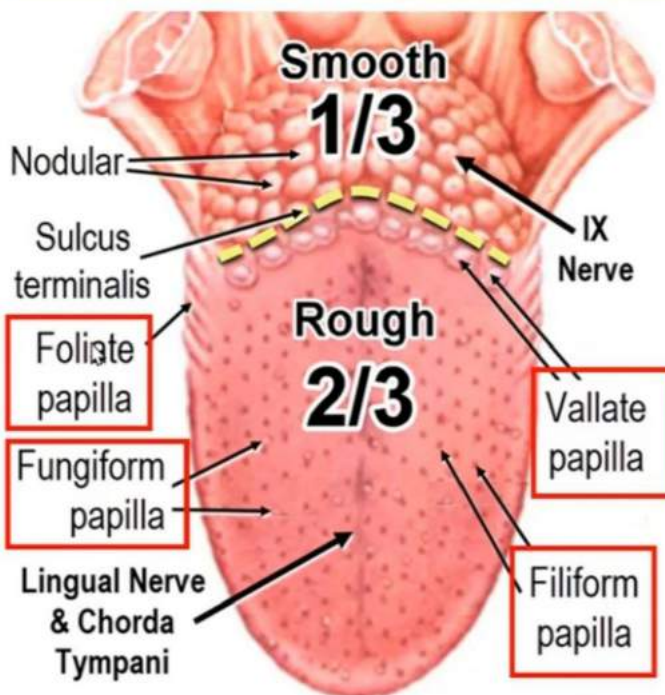
Blood Supply: lingual art & vein

Nerve Supply: motor & sensory

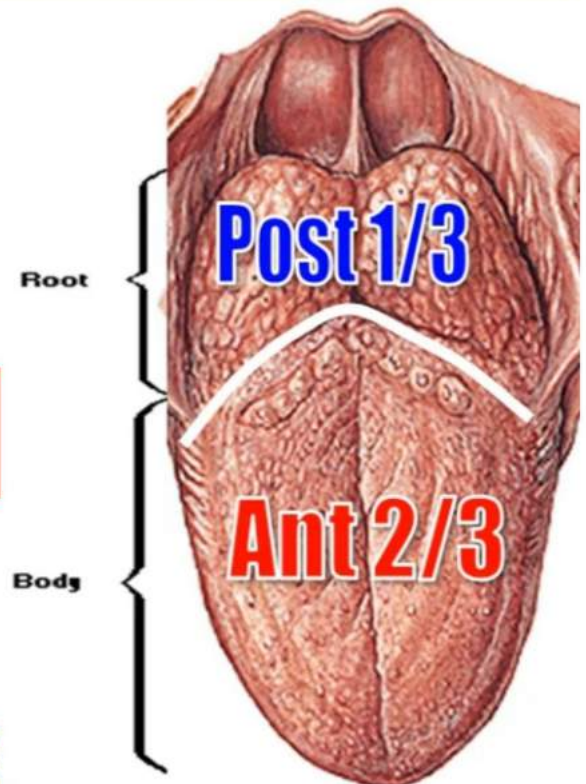
Lymphatic Drainage:



MUCOUS MEMBRANE



DORSAL SURFACE



Nerve Supply of the Gingiva

Maxillary Gingiva:

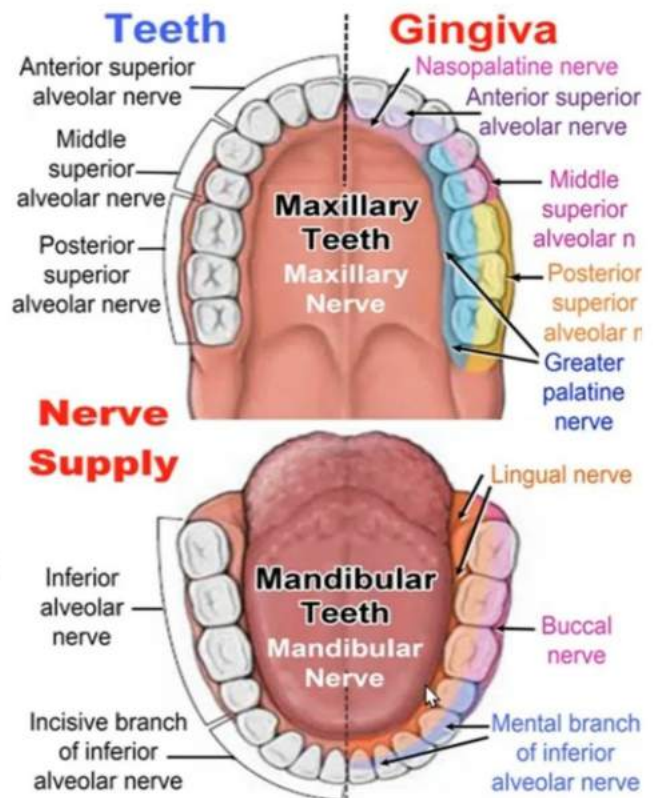
By the maxillary nerve

- Buccal Surface:** by the anterior, middle & posterior alveolar nerves
- Lingual Surface:** by the nasopalatine and greater palatine nerves

Mandibular Gingiva:

By the mandibular nerve

- Buccal Surface:** by the buccal and mental nerves
- Lingual Surface:** by the lingual nerve



ARTERIAL SUPPLY OF THE ORAL CAVITY

Hard Palate: maxillary artery

- Greater palatine artery
- Sphenopalatine artery

Soft Palate:

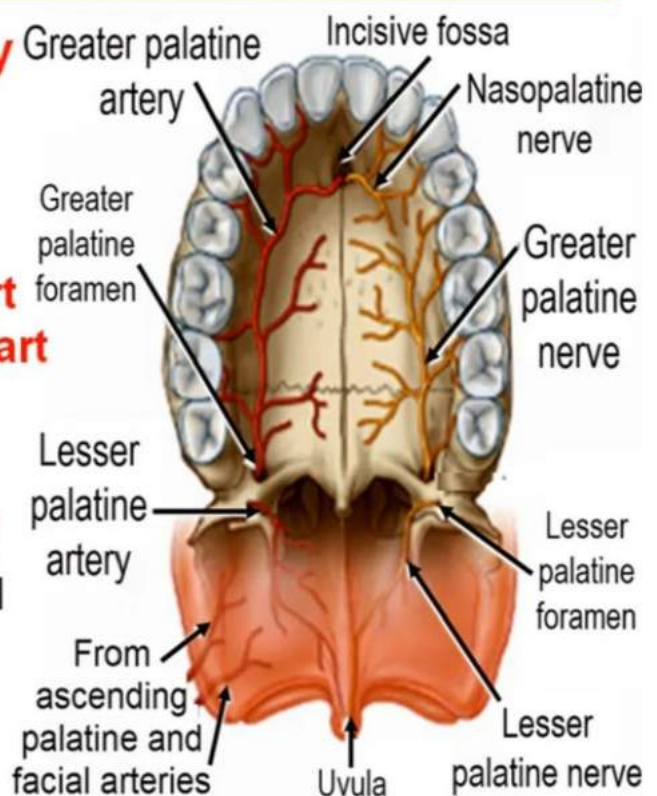
- Lesser palatine art: **max art**
- Ascending palatine: **facial art**
- Palatine branches of the ascending pharyngeal art

Lips and Cheek: facial artery

Superior labial & inferior labial

Floor: lingual artery

- Dorsal lingual arteries
- Sublingual artery



Nerve Supply of the Oral Cavity

1. Roof: Palate

sphenopalatine ganglion of the **maxillary nerve**

A. Greater palatine nerve

B. Lesser palatine nerve

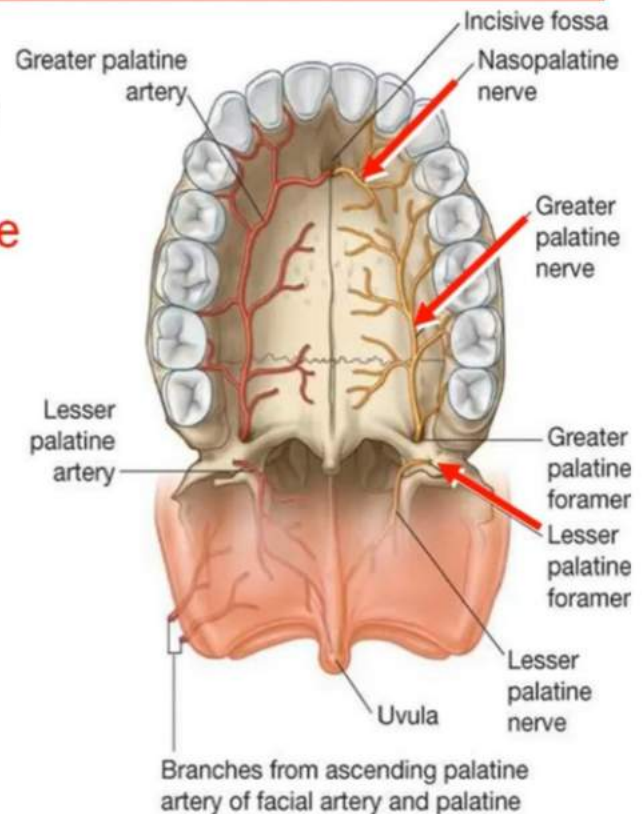
C. Nasopalatine nerve

2. Floor:

Lingual nerve from the mandibular nerve

3. Cheek:

Buccal nerve from the mandibular nerve



Nerve Supply of the Teeth

Maxillary Teeth:

By the maxillary nerve

1. Ant sup alveolar nerve:

the incisors and canine

2. Middle sup alveolar nerve:

the premolar teeth

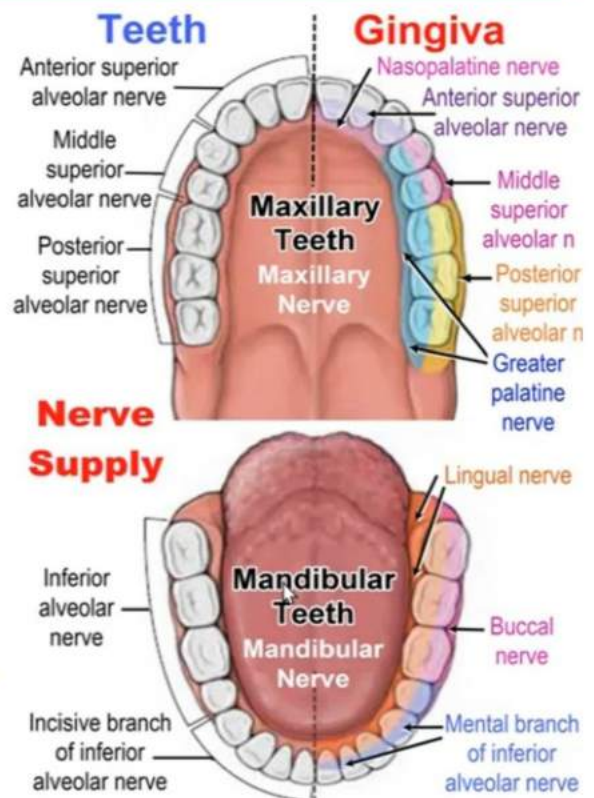
3. Post sup alveolar nerve:

the molar teeth

Mandibular Teeth:

By the mandibular nerve

Inferior alveolar nerve and its incisive branch



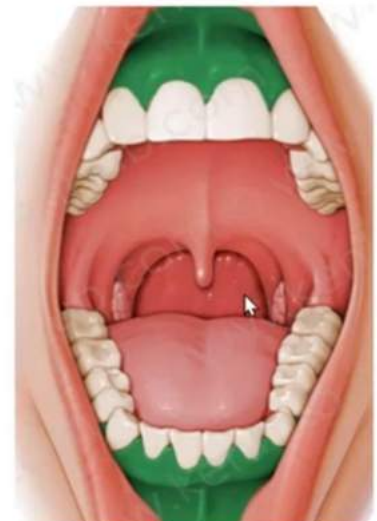
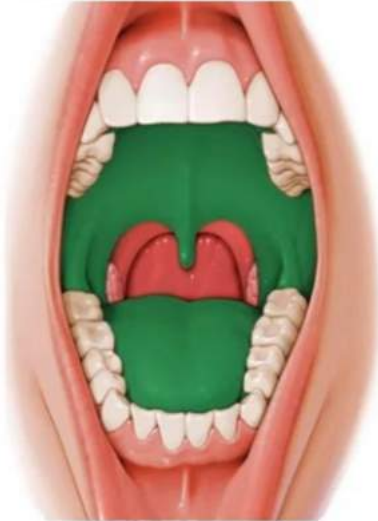Divisions of the Oral Cavity

Mouth Cavity Proper

Lies inside the alveolar arches (teeth and gums)

Vestibule

Lies outside the alveolar arches (teeth and gums)



Ducts Opening Into the Oral Cavity

1. Parotid duct:

in the vestibule opposite the upper 2nd molar tooth

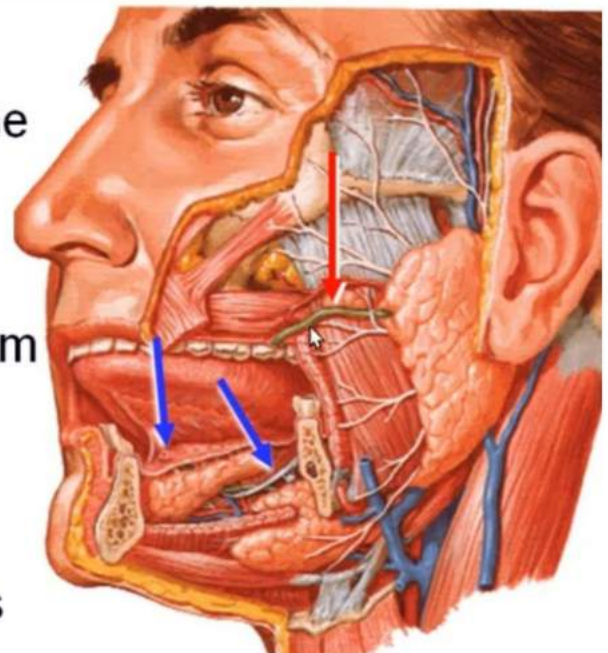
2. Submandibular duct:

on each side of the frenulum

3. Sublingual ducts: 10 - 12

on the sublingual fold

4. Mucous glands: numerous



ORAL CAVITY

Boundaries:

Roof – Floor – Sides – Ant & Post

Divisions:

1. Cavity proper
2. Vestibule

Contents

1. Tongue
2. Teeth

Ducts of Glands:

Nerve Supply:

Arterial Supply:

Lymph Drainage:



Boundaries

Roof: palate

1. Hard palate: anterior 2/3
2. Soft palate: posterior 1/3

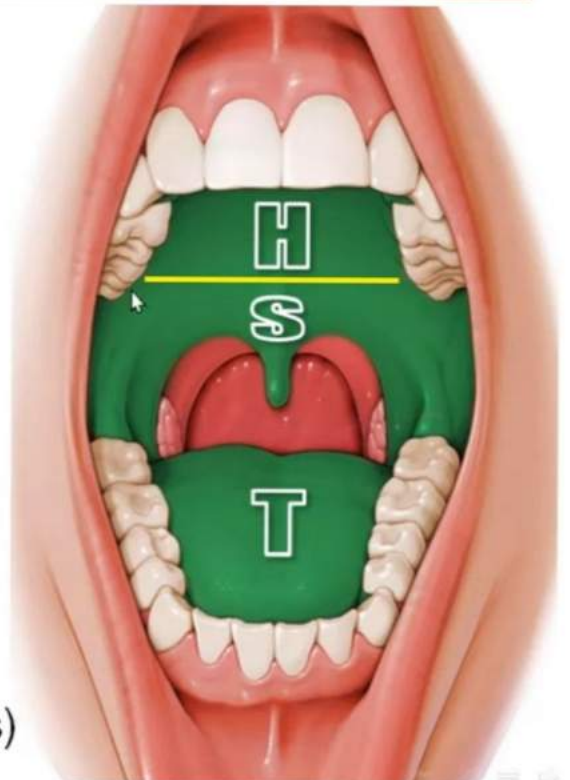
Floor:

1. anterior 2/3 of the tongue
2. Floor of the mouth

Front and Sides:

1. Cheeks
2. Lips

Posterior: Oropharynx (isthmus)



NERVE SUPPLY

1. MOTOR:

all the muscles are supplied by the **XII nerve** except palatoglossus muscle which is supplied by the **vagus nerve** (pharyngeal plexus)

2. SENSORY:

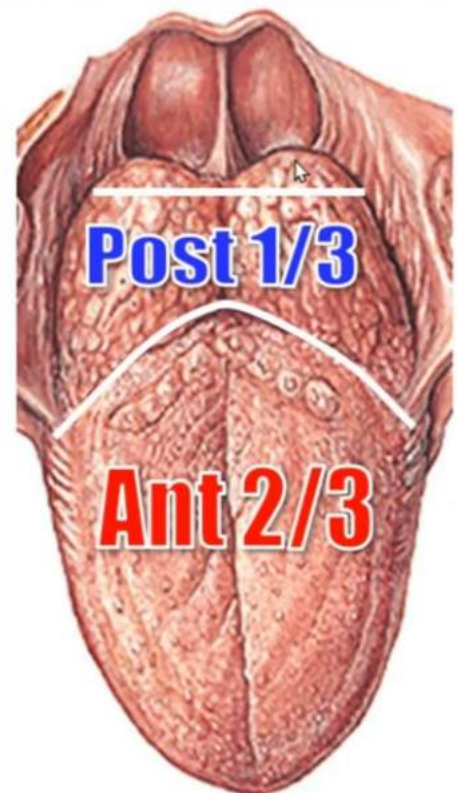
a. Anterior 2/3:

1. **Lingual nerve**: general sensation

2. **Chorda tympani**: taste sensation

b. **Posterior 1/3**: Glossopharyngeal nerve (general & taste sensation)

c. **Most posterior part**: vagus nerve



LYMPH DRAINAGE OF THE TONGUE

TIP:

to submental Lymph nodes

ANTERIOR 2/3:

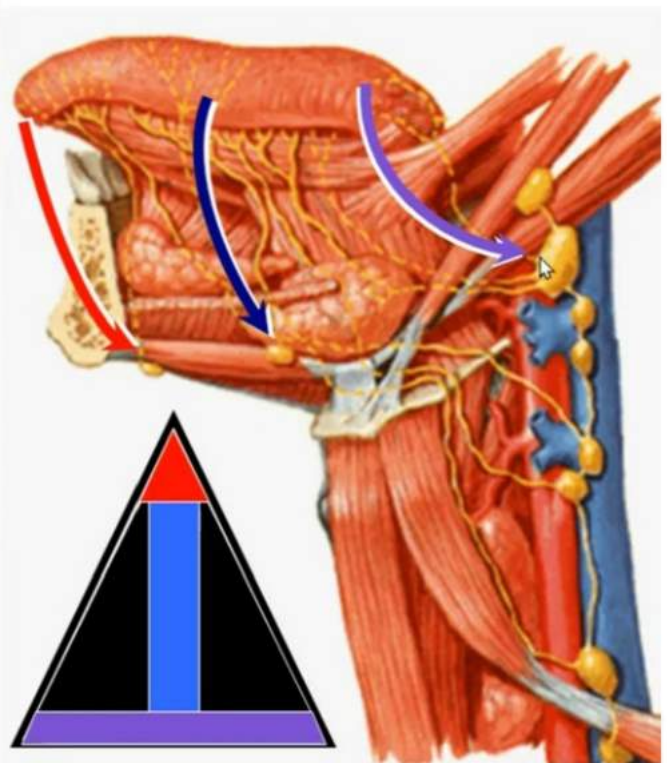
Submandibular lymph nodes

Central part: bilateral

Peripheral part: unilateral

POSTERIOR 1/3:

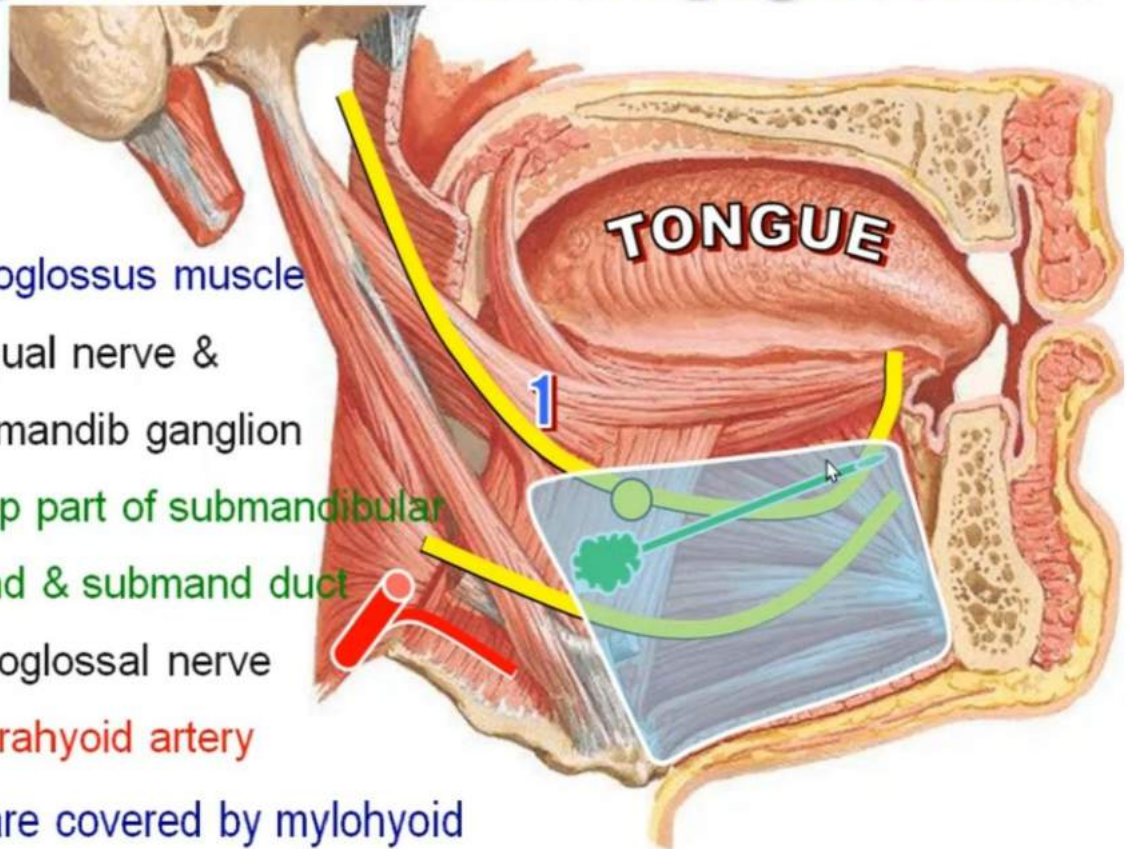
upper deep cervical lymph nodes



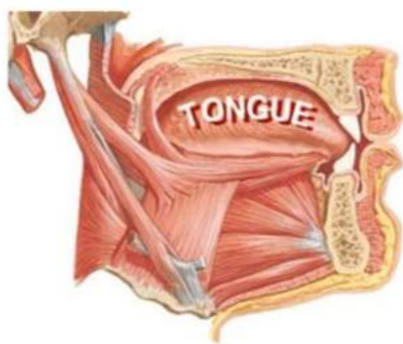
Superficial Relation of Hyoglossus: 5

1. Styloglossus muscle
2. Lingual nerve & submandib ganglion
3. Deep part of submandibular gland & submand duct
4. Hypoglossal nerve
5. Suprahyoid artery

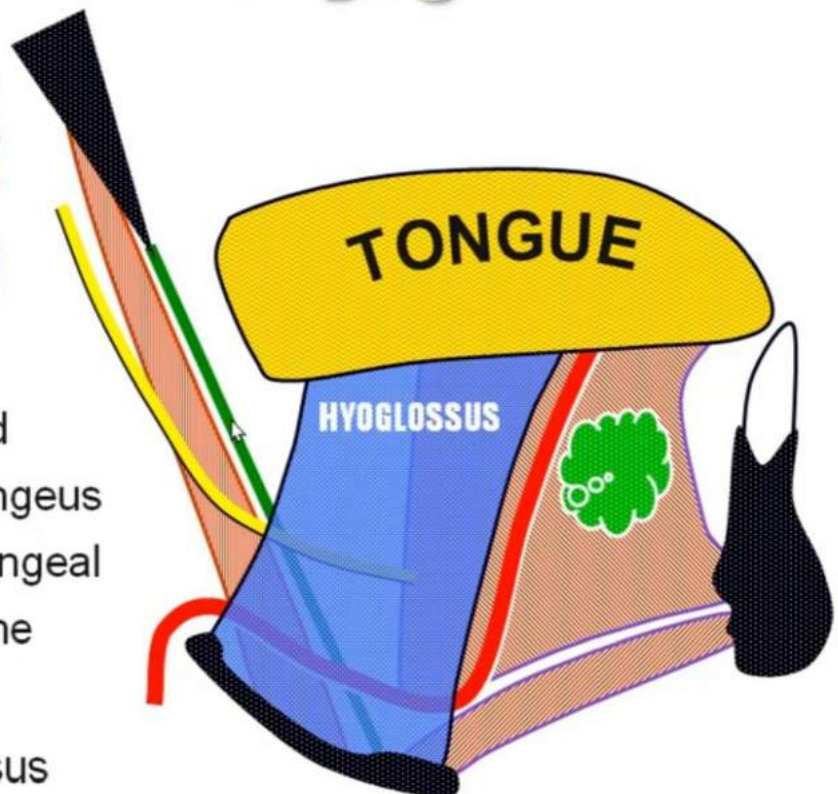
They are covered by mylohyoid



Deep Relation of Hyoglossus: 5



1. **Ligament:** stylohyoid
2. **Muscle:** stylopharyngeus
3. **Nerve:** glossopharyngeal
4. **Artery:** 2nd part of the lingual artery
5. **Muscle :** genioglossus



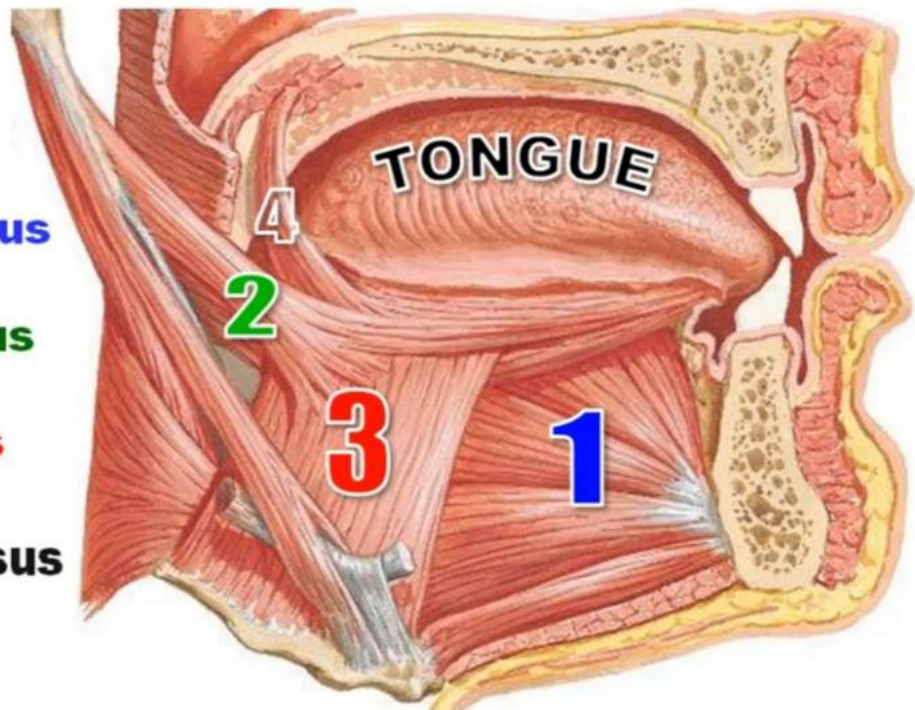
Extrinsic Muscles

1. Genioglossus

2. Styloglossus

3. Hyoglossus

4. Palatoglossus



All the muscles are supplied by the XII nerve except palatoglossus which is supplied by the vagus

Superficial Relation of Hyoglossus: 5

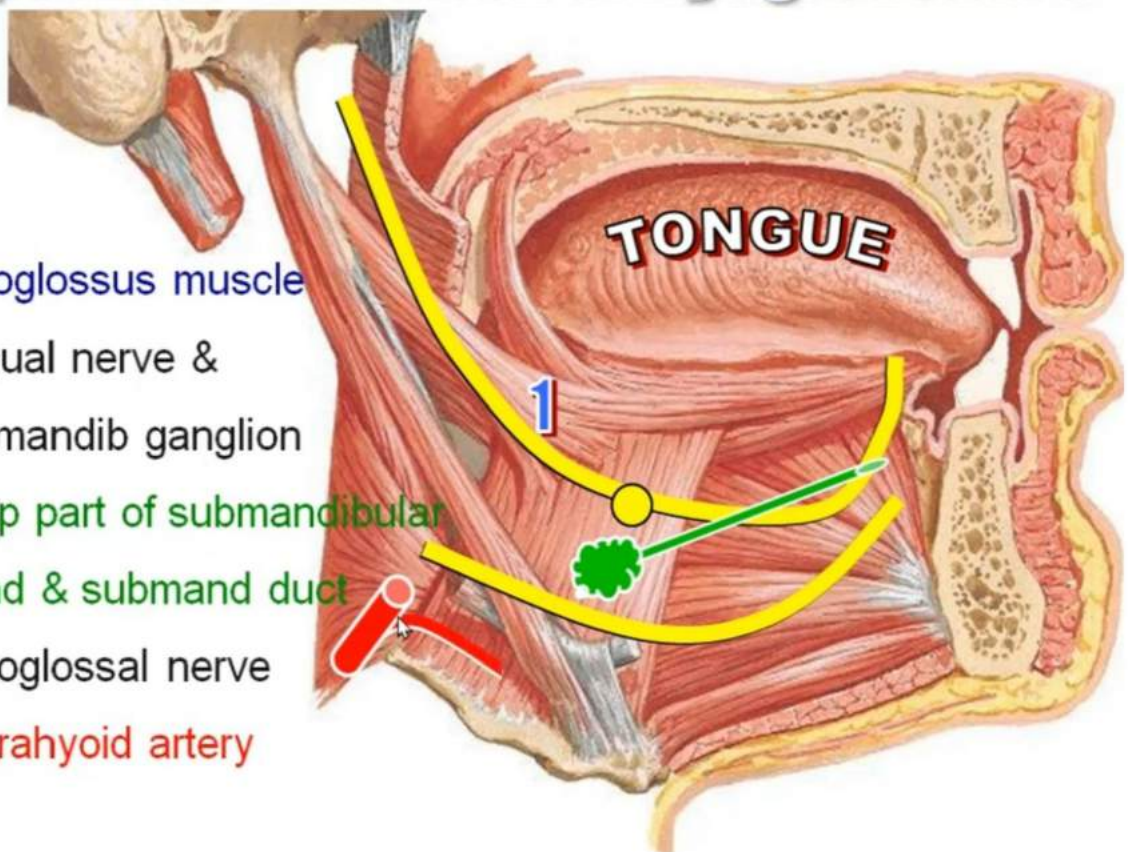
1. Styloglossus muscle

2. Lingual nerve & submandib ganglion

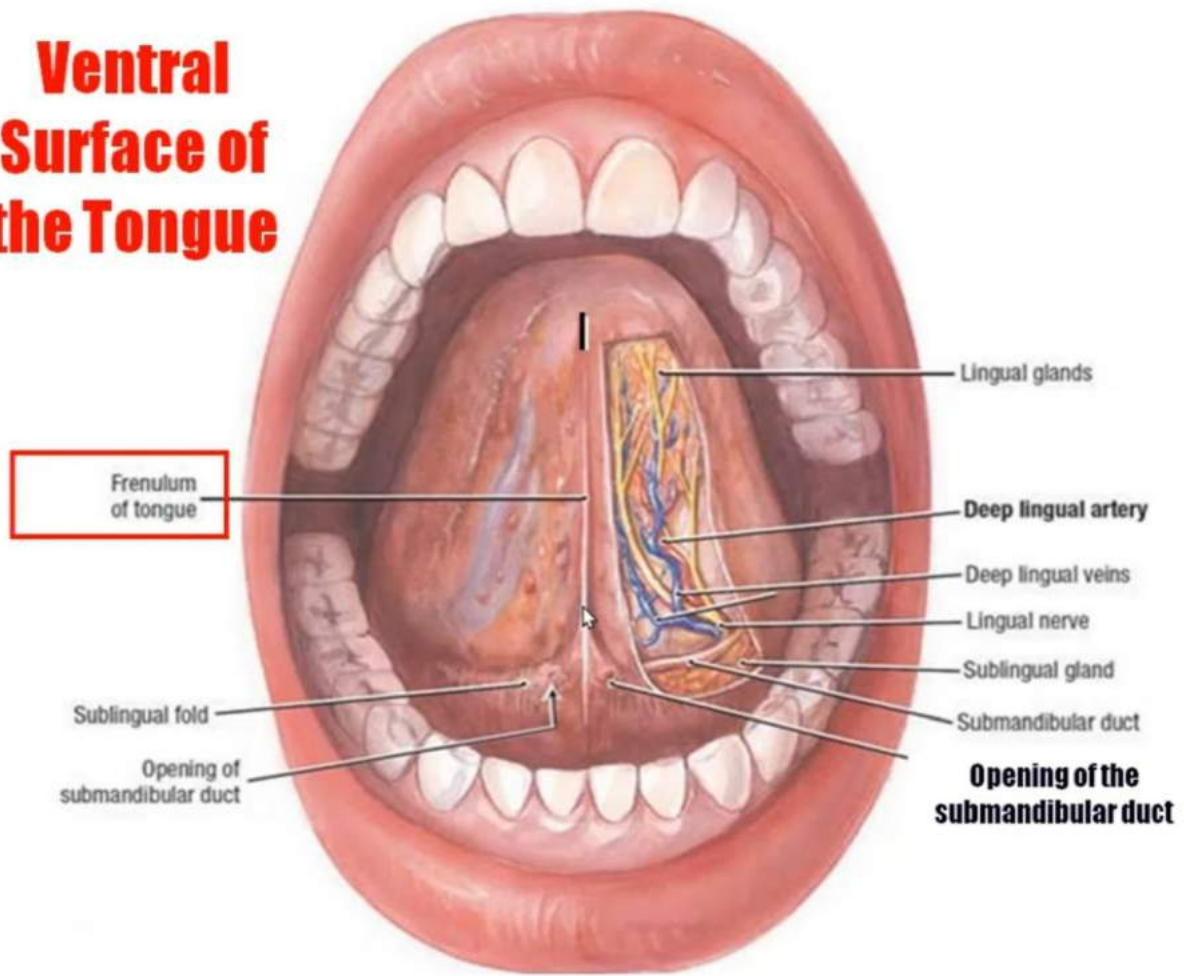
3. Deep part of submandibular gland & submand duct

4. Hypoglossal nerve

5. Suprahyoid artery



Ventral Surface of the Tongue



8 MUSCLES

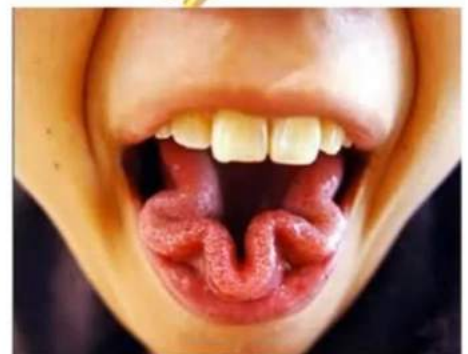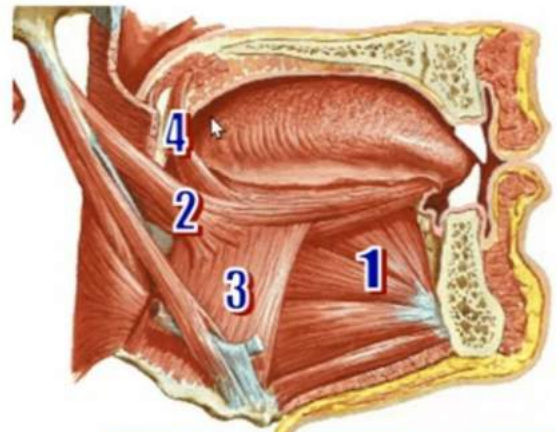
4 Extrinsic & 4 Intrinsic

Extrinsic Muscles

1. Genioglossus: protrusion
2. Styloglossus: retraction
3. Hyoglossus: depression
4. Palatoglossus: elevation

Intrinsic Muscles

1. Longitudinal: superior & inferior
2. Vertical
3. Transverse
4. Oblique



Compare Between Oral & Pharyngeal Part

	ORAL	PHARYNGEAL
SIZE	Anterior 2/3	Posterior 1/3
POSITION	In the oral cavity	In the pharynx
Mucous Membrane	Rough due to presence of papillae	Smooth due to absence of papillae
Lymphoid Follicles	Absent	Present & the surface is nodular. Called lingual tonsil
Nerve Supply	Lingual & chorda tympani	Glossopharyngeal nerve
Development	1st arch	3rd arch
Arterial Supply	Deep lingual artery	Dorsal lingual arteries

Ventral Surface of the Tongue

In the Midline:

Frenulum of the tongue

On Each Side:

1. **Deep Lingual Vein**, with the **deep lingual artery** & **lingual nerve**
2. **Fimbriated fold**
3. **Sublingual fold** and the openings of the **sublingual ducts**
4. **Opening of the submandibular duct**

