



CONTENTS

ENT

Ear (Fundamentals of Ear)	2
Anatomy of External Ear	8
Diseases of External Ear	12
Anatomy of Middle Ear	20
Eustachian Tube	26
Anatomy of Inner Ear	30
Neural Pathway of Sound	39
Physiology of Hearing	41
Tests of Hearing	46
Facial Nerve and it's disorders	53
Otitis Media	63
Complications of Otitis Media	76
Otosclerosis	83
Glomus Tumor	88
Diseases of Inner Ear	91
Vestibular Schwannoma / Acoustic Neuroma	97
Anatomy and Disease of CP Angle	99
Hearing Devices	101
Introduction to Paranasal sinuses	106
X- rays of Paranasal sinuses	108
Embryology of nose & Face	110
Congenital lesions of Nose	112
Anatomy of Disorder of External Nose	115
Anatomy of Nasal cavity	118

Paranasal Sinuses Anatomy	121
Blood supply of Nasal septum & Epistaxis	127
Physiology of Nose	132
Nasal septum Disorders	135
Rhinosinusitis	138
Nasal Polyps	142
Nasal Disorders of Atrophy	145
Fungal Rhinosinusitis	147
Complication of sinusitis	149
Tumor of nose & Paranasal sinusitis	153
Miscellaneous	156
CSF Rhinorrhea	160
Introduction to Pharynx	164
Nasopharynx	166
Oropharynx	176
Hypopharynx / Laryngopharynx	184
Layers of Cervical Fascia	190
Deep Neck Spaces	192
Embryology of Larynx	199
Structural Anatomy of Larynx	200
Congenital Disease of Larynx	207
Acute & Chronic Inflammation of Larynx	209
Benign Lesions of Larynx	213
Vocal Fold Palsy	216
Carcinoma Larynx	221



LIST OF IMPORTANT TOPICS

👉 EAR

1. Embryology of Ear
2. Anatomy of Middle Ear (especially posterior wall)
3. Pure tone Audiometry Interpretation
4. BERA/ OAE interpretation and uses
5. Malignant Otitis Externa
6. Complications of CSOM
7. Otosclerosis
8. Meniere's Disease
9. Vestibular Schwannoma
10. Hearing devices/ Implants such as Cochlear Implant, Auditory Brainstem Implant, BAHA
11. Noise Induced Hearing Loss
12. Ototoxicity

👉 NOSE

1. Blood supply of Nasal Septum
2. Allergic fungal Rhinosinusitis
3. Ca Maxilla
4. CSF Rhinorrhoea
5. Nasal Polyps
6. CT Scan of Nose and PNS

👉 PHARYNX

1. Juvenile Nasopharyngeal Angiofibroma
2. Nasopharyngeal Carcinoma
3. Membranous Tonsillitis
4. Tonsillectomy

👉 LARYNX

1. Muscles of Larynx
2. Spaces in Larynx: Pre-epiglottic space, paraglottic space, Reinke's space
3. Vocal Folds Palsy
4. Juvenile onset recurrent respiratory papillomatosis
5. Carcinoma Larynx
6. Tracheostomy and Cricothyrotomy



LEARNING OBJECTIVES

EAR

- Anatomy and Disease of External Ear, Middle Ear, Inner Ear
- Facial Nerve and Its Disorders
- Otitis Media and Complications
- Tests of Hearing and HA



1 FUNDAMENTALS OF EAR (OSTEOLOGY AND EMBRYOLOGY)

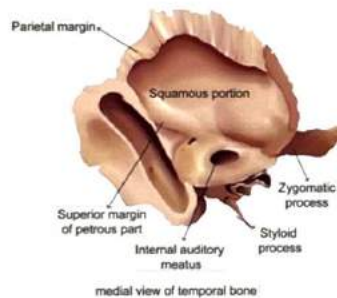
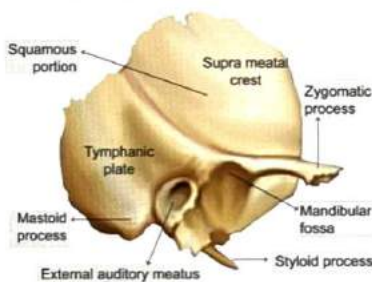
EAR FUNDAMENTALS

00:02:16

- Temporal bone is most complex bone in the body with 20 ossification centers

Parts of Temporal Bone

- Squamous
- Petromastoid
 - After birth it differentiates into
 - Petrous
 - Mastoid
- Tympanic
- Styloid process



Squamous part

- Covers temporal lobe of brain
- Forms zygomatic process of temporal bone
- Supra meatal crest: Part of inferior temporal line

MASTOID PART OF TEMPORAL BONE

00:06:51

- Starts developing 6 months after birth (Due to pull of Sternocleidomastoid muscle)
- Mastoid tip appears by 2 years of Age
- Reaches adult size by 18-19 years of age
 - Cancellous bone: consist of air cells
 - Largest air cell - mastoid antrum



Important Information

- Antrum is of adult size at the time of birth

PETROUS PART

- On medial side of Temporal bone inner ear is present
- Most complex part of Temporal bone (14 ossification centers)

- Densest/hardest bone in body
- Internal Auditory Canal/ Internal Auditory Meatus opens into posterior wall of petrous part

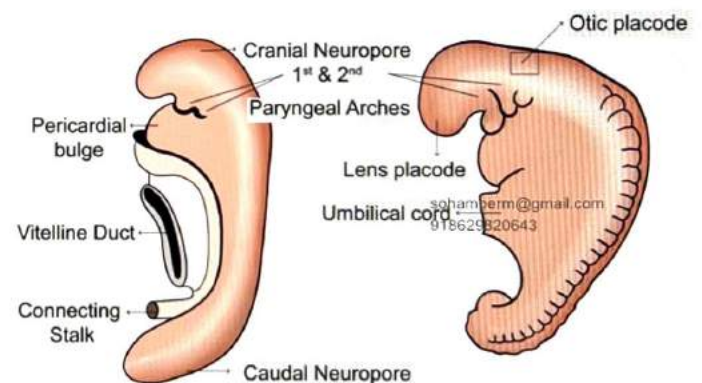
Contents of Internal Auditory Canal:

00:12:06

- Vestibulocochlear nerve (CN VIII)
 - cochlearnerve
 - Vestibular nerve
- Labyrinthine artery (Branch of AICA)
- Facial nerve(CN VII)
- Vestibular ganglion (Superior and inferior vestibular nerves)
- Nerve of Wrisberg (Nervus Intermedius)- carries sensory and secretomotor fibers for facial nerve and after this FN becomes mixed CN

EMBRYOLOGY OF INNER EAR FORMATION

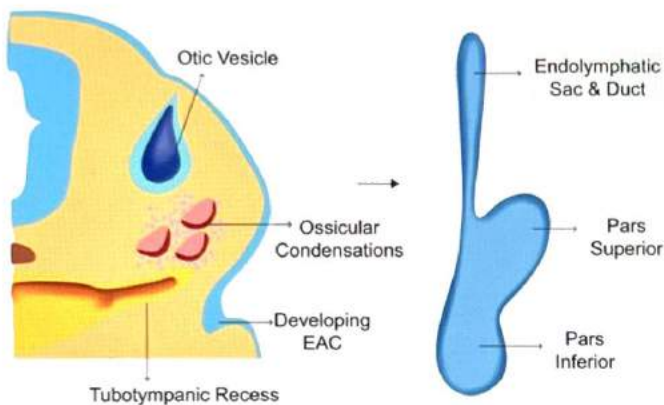
00:14:14



- In rhombencephalon stage, near 1st and 2nd Pharyngeal arches there is formation of Otic placode
- Otic placode formed from surface ectoderm
- Otic placode converts to Otic pit and leads to formation of Otic vesicle / Auditory vesicle / Otocyst
- Otic vesicle forms → Membranous labyrinth (Sensory part of Inner ear)
- Otic capsule is the embryological cartilaginous structure developed from 2° mesoderm
 - It is cartilaginous framework for inner ear
- Otic capsule ossifies(14 ossification centers)and forms Inner ear [Bony Labyrinth] → Enchondral Bone
 - Bony inner ear in the petrous part of temporal bone
 - This is called Enchondral ossification or calcification

OTIC VESICLE/PASS SUPERIOR/ PASS INFERIOR

00:21:46



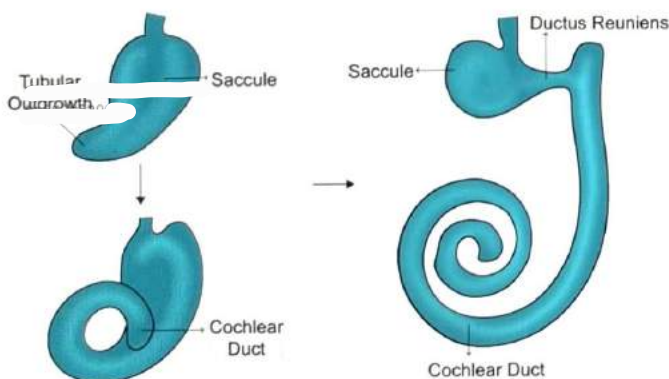
OTIC-VESICLE:types

Endolymphatic sac and duct

Pars superior

Pars inferior

- Utricle
- Semicircular canal
- Saccule
- Cochlea



Previous Year's Questions

Q. Saccule of Ear develops from? (NEET PG Jan 2020)

- Pars superior
- Pars inferior
- Sacculus anterior
- Sacculus posterior

Stylomastoid foramen

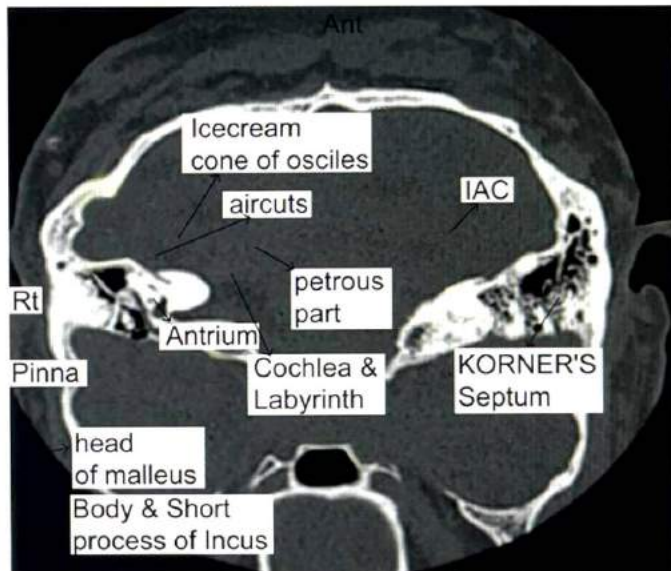
- Present b/w styloid process and mastoid process
- Facial nerve [VII CN] comes out
- Stylomastoid artery goes in

- Post aural incision is not given to a child < 2yrs of age
- Between squamous & petrous part, Petro squamous suture present in embryo, disappears after birth

KOERNER'S SEPTUM

00:25:05

- Persistent petro squamous suture
- Koerner's septum is lateral to mastoid antrum(its difficult to find the antrum if koerner septum is found while surgery)



PHARYNGEAL / BRANCHIAL ARCHES

00:33:20

- 5 branchial arches on each side [1, 2, 3, 4, 6]
- Development of the otic placode near the 1st and 2nd arch
- All 3 germs layers are present



Important Information

Own blood & nerve supply and forms its own Musculo-cartilaginous structure

Refer Picture 1.1

Structures formed from clefts and pouches

Refer Table 1.1



How to remember

- 1ST ARCH - "M"

Refer Table 1.2



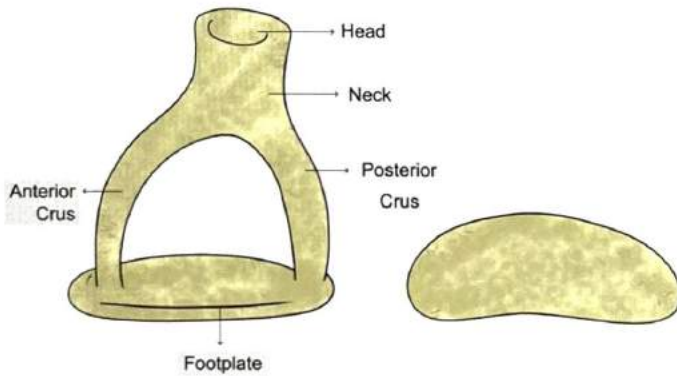
How to remember

- 2ND ARCH- "S"

STAPES

00:45:05

- Stapes is formed by the Reicherts cartilage except the medial surface of stapes foot plate
- Medial surface of stapes foot plate is formed by otic capsule



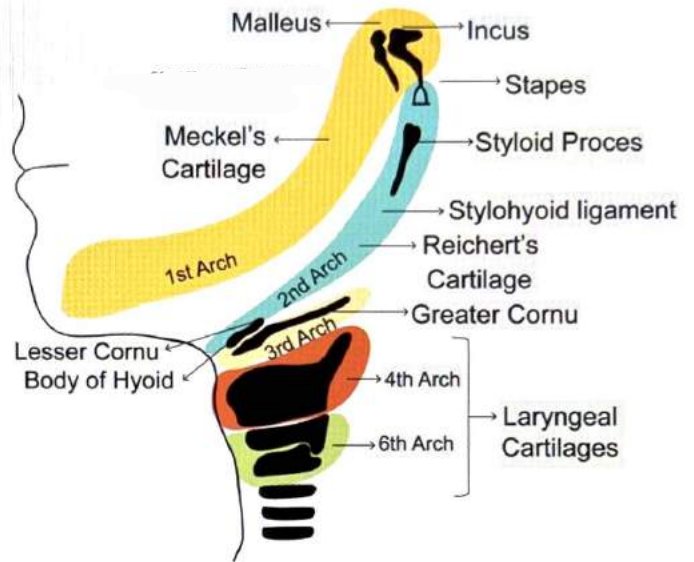
HYOID BONE

00:46:12

- Smaller cornu & superior part of body is formed by second arch
- Greater cornu & lower part of body is formed by third arch

Refer Picture 1.2

Arch	Artery	Muscles	Skeleton
III	Common Carotid & 1 st part of Internal Carotid Artery	Glossopharyngeal CN IX	Greater Horn and Lower part of the body of Hyoid bone



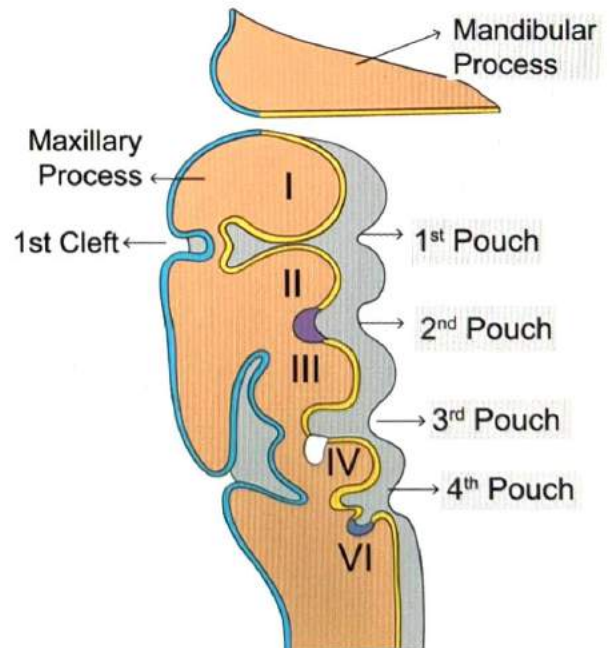
Previous Year's Questions

Which muscle originates from 1st pharyngeal arch?
(NEET PG Jan 2019)

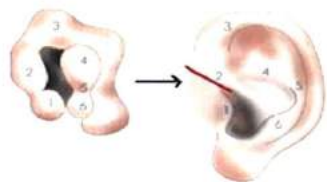
- A. Buccinator
- B. Posterior belly of digastric
- C. Masseter
- D. stylopharyngeus

CLEFT

00:54:37



Clefts	Pouches
1st arch – EAC	1 st pouch -Tubotympanic recess-eustachian tube, middle ear
2nd to 4th clefts are obliterated	2 nd pouch – Tonsillar fossa, Palatine fossa
	3 rd pouch – Inferior Parathyroid gland, thymus
	4 th pouch – Superior Parathyroid gland



5th pouch – Ultimobranchial body (Parafollicular 'C' cells) secrete calcitonin hormone

- Inner Ear
 - Bony Labyrinth: Otic capsule (Secondary Mesoderm)
 - Membranous Labyrinth: Otic Vesicle (Surface Ectoderm)



Previous Year's Questions

Q. Eustachian tube develops from: (FMGE June 2018)

- A. 2nd and 3rd pharyngeal pouch
- B. 1st pharyngeal pouch
- C. 2nd pharyngeal pouch
- D. 3rd pharyngeal pouch

Development of Pinna

🕒 00:59:00

- Around the EAC, the 1st & 2nd arch form 6 swellings called HILLOCKS OF HIS
 - Pinna is formed from 6 hillocks of his
 - 1st HILLOCK (TRAGUS) forms from 1st arch
 - Remaining Hillocks forms from 2nd

SUMMARY OF EAR EMBRYOLOGY

- External Ear
 - Pinna: Hillocks of HIS (1st & 2nd Arch)
 - EAC: 1st Arch
- Middle Ear
 - Tympanic Membrane: All 3 Germ layers
 - Middle Ear cavity + Eustachian tube: 1st Pouch
 - Ossicles: Malleus & Incus: 1st Arch, Stapes: 2nd Arch

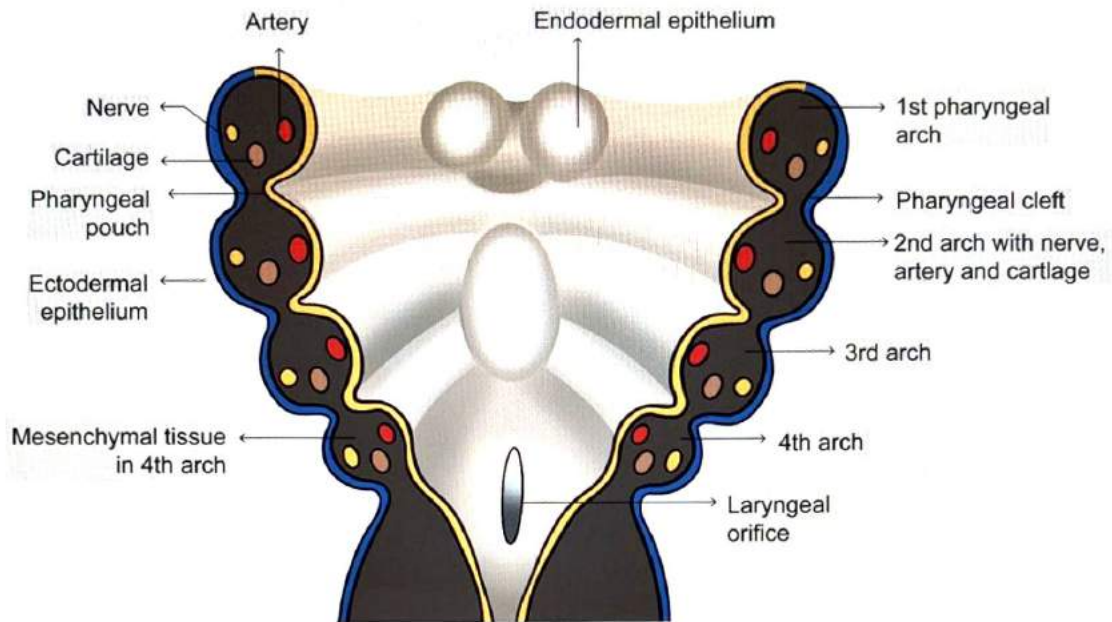
Table 1.1

Arch	Artery	Nerves	Muscles	Skeleton
Mandibular Arch ("M" Arch) (Maxillary & Mandibular Process)	<ul style="list-style-type: none"> Maxillary Artery 	<ul style="list-style-type: none"> Post- Trematic Mandibular N Pre - Trematic Chorda typani 	<ul style="list-style-type: none"> Muscles of Mastication (Masseter, Medial and lateral pterygoids, Temporalis) Mylohyoid Anterior belly of digastric Tensor tympani Tensor veli palatini 	<ul style="list-style-type: none"> Quadrante cartilage (Maxillary process) Maxilla Premaxilla Zygomatic bone Squamous part of temporal bone Meckel's Cartilage (Mandibular process) Mandible Malleus & Incus Anterior ligament of malleus Sphenomandibular ligment

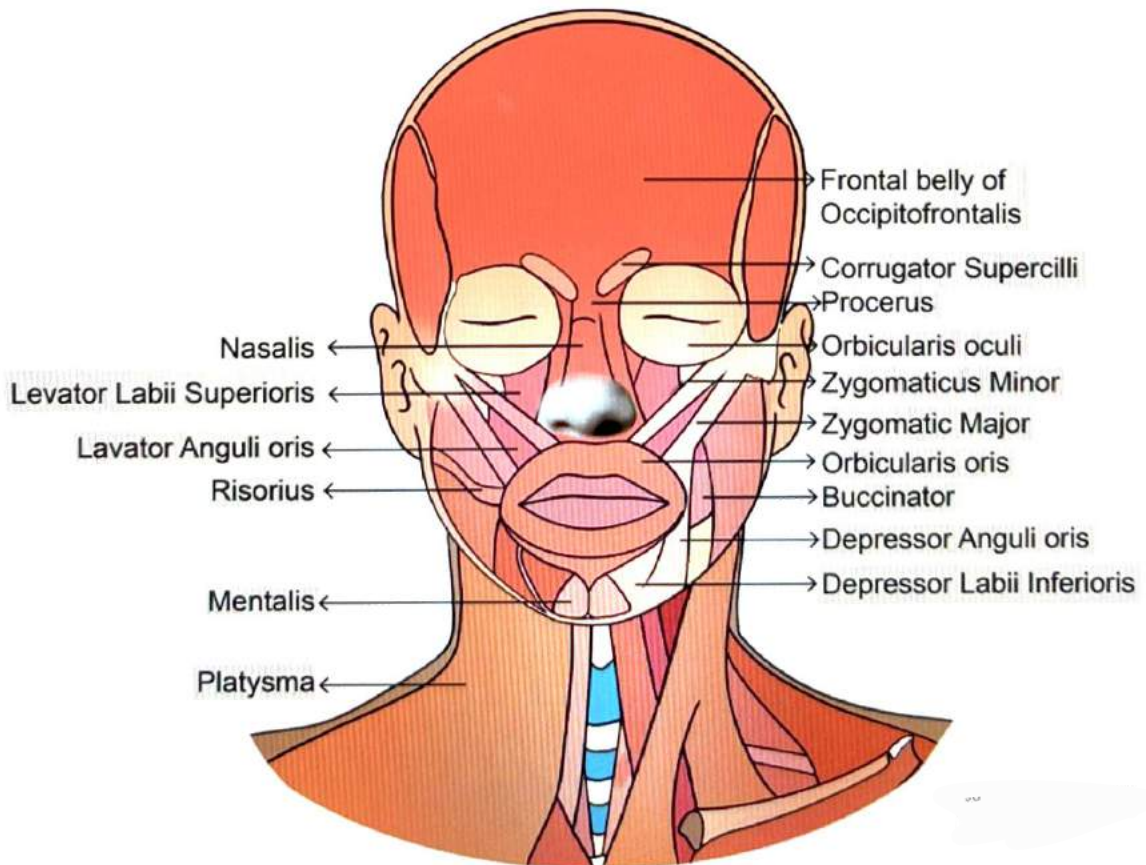
Table 1.2

Arch	Artery	Nerves	Muscles	Skeleton
Hyoid Arch "S" Arch	<ul style="list-style-type: none"> Stapedial Artery 	<ul style="list-style-type: none"> Post - Trematic Seventh CN (Facial Nerve) Pre-Trematic Jacobson's Nerve 	<ul style="list-style-type: none"> Muscles of facial expression Buccinator Auricularis, Frontalis, Platysma, Orbicularis oris, Orbicularis oculi) Posterior belly of Digastric Stapedius Stylohyoid 	<ul style="list-style-type: none"> Reichert's cartilage (except medial surface of Footplate: Derived from Otic capsule) Styloid process Stylohyoid ligment , Hyoid body {Lesser (smaller) horn & upper (superior) part of Body}

Picture 1.1



Picture 1.2





2

ANATOMY OF EXTERNAL EAR

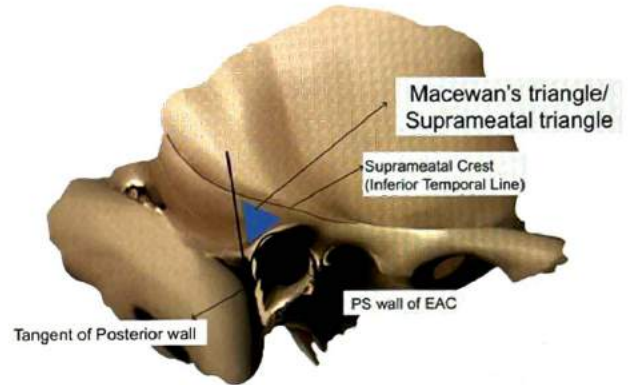
PINNA

00:00:50

- Formed from single piece of yellow elastic cartilage except lobule
- Lobules have only fat
 - Never ossifies
 - Also seen in tip of nose and epiglottis

Parts

- Includes lobule, Tragus, Helix, Antihelix, Antitragus
- Part above the helix: Cymba conchae
- Part below the helix: Cavum conchae



- Mastoid antrum is present 1.25-1.5 cm deep to MacEwen's triangle
- Boundaries
 - Suprameatal crest/ Inferior Temporal line
 - Postero-superior wall of EAC
 - Tangent between above (2)



Important Information

- Cymba concha is the anatomical (surface) landmark of mastoid antrum.

Surgical approach to ear

00:04:40

- Incisura Terminalis
 - Line of fusion of 1st and 2nd arch.
 - Incision on Incisura terminalis is done by Endaural approach. That incision is named as **LEMPERT'S INCISION**
- Post aural approach by **William Wilde's** approach behind pinna-preferred incision. No scar seen so it is cosmetically most preferred.
- Trans canal approach / Permeatal approach / Endomeatal approach by **Rosen's Incision**. Incision is given inside the EAC.
- Wilde's incision is contraindicated before 2 year of age
 - Because Mastoid tip develops after 2 yrs of age. In between the tip and styloid process stylomastoid foramen is present and the facial nerve comes out of these foramen.
 - Before 2 yr, if wilde's incision made it has chances of facial nerve injury.



Important Information

- Surgical landmark of Mastoid Antrum- suprameatal triangle

'MACEWEN'S TRIANGLE / SUPRAMEATAL TRIANGLE

00:13:26

EXTERNAL AUDITORY CANAL

00:18:41

- Length = 24mm
 - Lateral 1/3rd = 8mm → Cartilaginous
 - Medial/Inner 2/3rd = 16mm → Bony
- Isthmus – Narrowest point, 6mm lateral to Tympanic membrane
- TM is attached at an angle of 55° with Anteroinferior [floor] wall of EAC.
 - At birth TM is almost horizontal
 - At 4 yrs of age it attains 55° angle with Anteroinferior [Floor] wall of EAC
 - Anteroinferior wall is longest wall of EAC
 - Posterosuperior is shortest wall.
- Cartilaginous part has sweat glands, Sebaceous, Ceruminous glands & hairs

CERUMINOUS GLANDS

00:21:34

- Modified sweat gland- secretes cerumen.

Sweat Glands

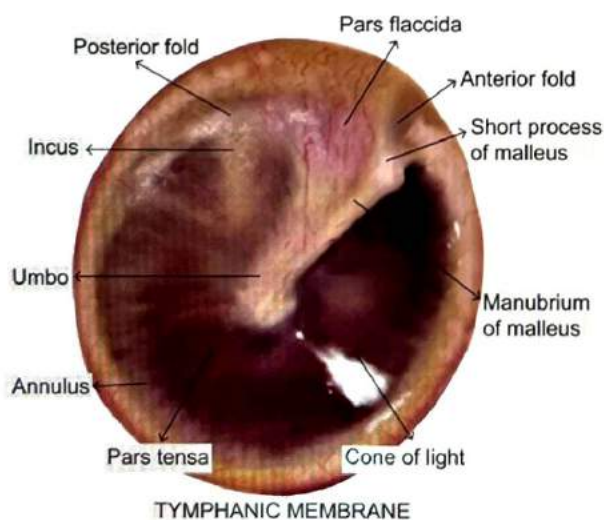
Eccrine / Typical

Apocrine / Atypical (AAA)

- | | |
|--|--|
| <ul style="list-style-type: none"> Present all over the body Opens on skin surface Supplied by cholinergic nerve fibers | <ul style="list-style-type: none"> Only at axilla, nipple / areola, pubic area, perianal Open inside hair follicles Supplied by adrenergic nerve fibers Modifications <ul style="list-style-type: none"> Ceruminous- EAC Ciliary (Moll's) glands – Eye lids Mammary glands |
|--|--|
-
- All secretory glands in the body are supplied by parasympathetic system except SWEAT glands (By Sympathetic system)
 - Ceruminous glands secrete cerumen
 - Wax is formed by mixture of all secretions + dead epithelial cells & hairs.
 - Wax has pH of 4

TYMPANIC MEMBRANE

00:30:22



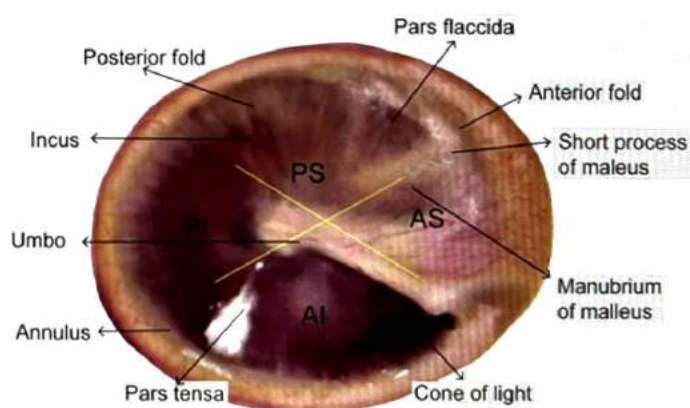
- Trimeric structure formed from all three germ layers
 - Outer Epithelial layer from ectoderm
 - Middle Fibrous layer from mesoderm
 - Inner Mucosal layer from endoderm
- Pearly grey / Translucent grey in color
- Thickness of TM- 0.1mm
- TM is divided into two parts:
 - Pars Flaccida (Sharpnel's membrane)

- Pars Tensa
- Fibrous layer is scanty and unorganized in Pars flaccida and pars tensa is organised.
- Fibrous layer forms Annulus tympanicum.
 - It attaches the TM to bony EAC. [Bony annulus]
 - Is fibrocartilaginous in nature
 - Notch of RIVINUS → Deficiency in bony annulus superiorly covered by P. Flaccida
- Tip of handle of malleus is called Umbo which is most visible and anatomical landmark of TM
- Cone of light is present in Anteroinferior quadrant because of the reflection of light. Handle of malleus brings TM to 90° due to this cone of light is present in AI quadrant.



Important Information

- Lateral process of malleus is the most reliable landmark of TM



FOREIGN BODY IN EC REMOVAL

00:49:13

Different ways

- Probing (jobson horne probe with ring curette)
- Micro forceps
- Syringing (simpson's aural syringe 50ml)
- Posterosuperior direction
 - Water at 37°C (if cold/hot water is used it will stimulate the inner ear and causes vertigo) this stimulation is called Caloric stimulation.

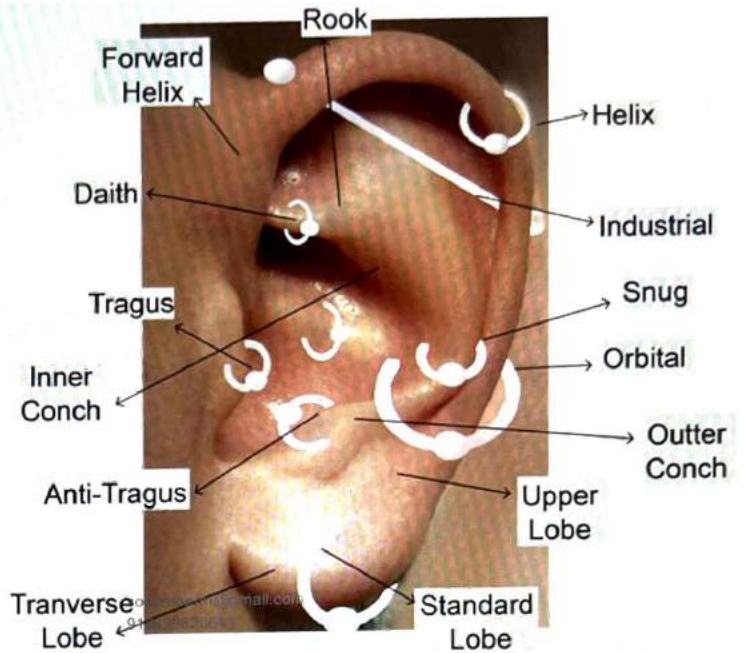


How to remember

- COWS

- Contra Indication for syringing
 - FB beyond isthmus
 - Acute infection of external and middle ear
 - Big impacted foreign body
 - Vegetative Foreign body

- Micro suction
 - Best way of remove impacted foreign body
 - Creates negative pressure, minimum damage.
 - Removal of live insects: With Lukewarm oil



Previous Year's Questions

Q. Cold water is not used for ear cleaning because?
(FMGE June 2018)

- A. It will make the wax hard
- B. Damage to tympanic membrane
- C. Caloric stimulation caused by cold water
- D. It will cause infection

GREATER AURICULAR NERVE IS MOSTLY INVOLVED IN LEPROSY

🕒 01:07:49

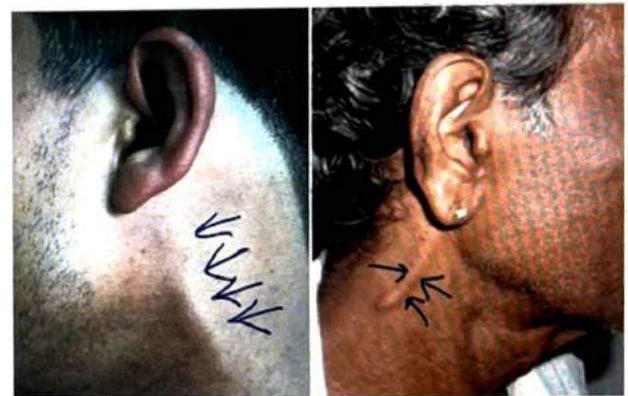Removal of live insect from EAC:

- Live insect cant be removed by microsuction, probing, syringing, micro forceps.
- By putting few drops of lukewarm oil like coconut oil, mustard oil which is non-irritant. The live insects come out of own

NERVE SUPPLY TO PINNA

🕒 01:00:17

- Split lobule due to Ear piercing
 - Rx by Lobuloplasty
 - Greater Auricular Nerve block is used (C2 & C3)
- Lateral surface
 - Anterior part of pinna is form by 1st arch.
 - Supplied by auriculotemporal nerve (V3)
 - Concha: CN 7th & 10th
 - Majority: Greater auricular Nerve

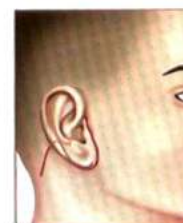

Gets thickened behind Ear Pinna

RHYTIDECTOMY

🕒 01:08:55

- Surgical Removal of rhytids (Facial wrinkles)
- To get rid rhytids Botex injection is used
- Incisions done behind pinna and mastoid
- Also called as Face lift surgery.
- M/C nerve involved – Greater Auricular nerve (sensory)
- M/C motor nerve involved – Zygomatic branch of facial nerve
- Sometimes, it may damage Auriculotemporal nerve it is called face syndrome.



Rhytidectomy Incision
(Facelift Incision)



How to remember

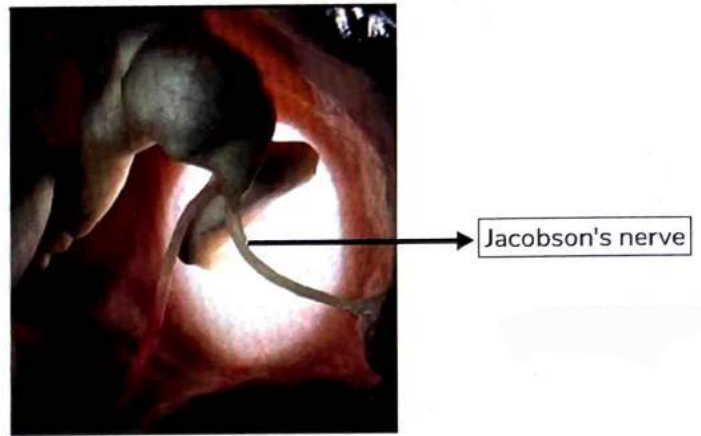
- LATERAL - V3

Medial surface

- Majority part: Greater auricular Nerve
- Smaller part: Lesser occipital Nerve

? Previous Year's Questions

- Q. Following parotidectomy numbness on face while shaving is due to injury of? (AIIMS May 2019)
- A. Greater auricular nerve
 - B. Mandibular nerve
 - C. Facial nerve
 - D. Auriculo-temporal nerve



Nerve Supply to EAC

🕒 01:15:38

- Antero-superior → Auriculotemporal nerve
 - Floor/Antero-inferior → ARNOLD'S branch of Vagus
 - Posterior-superior → Facial nerve

★ Important Information

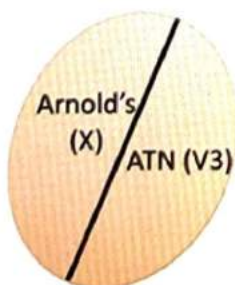
- Cough reflex during ear syringing is due to Arnold nerve
- Normal cough reflex is due to internal laryngeal nerve in larynx.

- Loss of sensory sensation in this part → HITZELBERGER sign seen in vestibular schwannoma

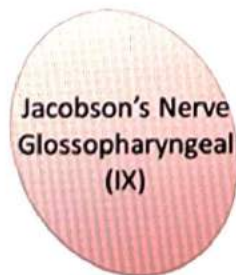Nerve Supply to Tympanic Membrane

🕒 01:18:32

- **Lateral Aspect**
 - Anterior half: Auriculotemporal Nerve
 - Posterior half: Arnold's Nerve
- **Medial Aspect**
 - Jacobson's nerve (Branch of CN) [Sensory supply to middle ear also]



Lateral Aspect



Medial Aspect

? Previous Year's Questions

- Q. Cough reflex on scratching the floor of external auditory meatus is due to which nerve? (NEET PG Jan 2020)
- A. Auricular branch of vagus
 - B. Auriculo-temporal
 - C. Greater auricular nerve
 - D. Facial nerve



3

DISEASES OF EXTERNAL EAR

BRANCHIAL SINUS

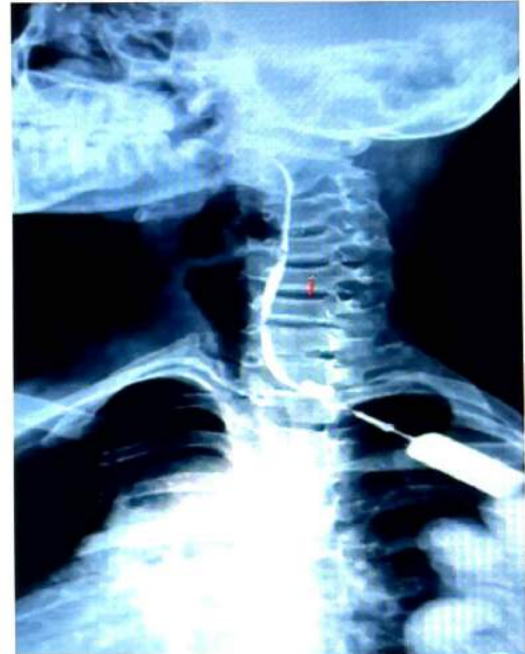00:01:33

- Sinus is epithelium lined blind ending tract
- The most common branchial sinus forms from 2nd cleft
- Opening of the branchial sinus is from the anterior border of SCM upper 2/3rd and lower 1/3rd of junction.

BRANCHIAL FISTULA

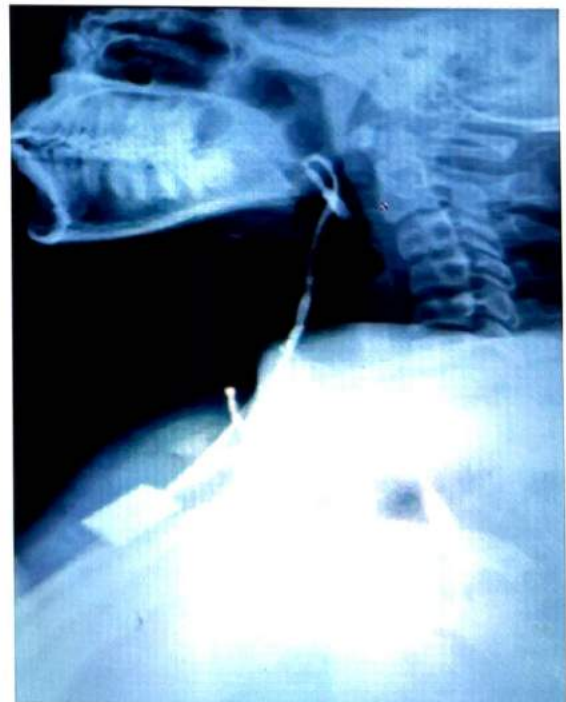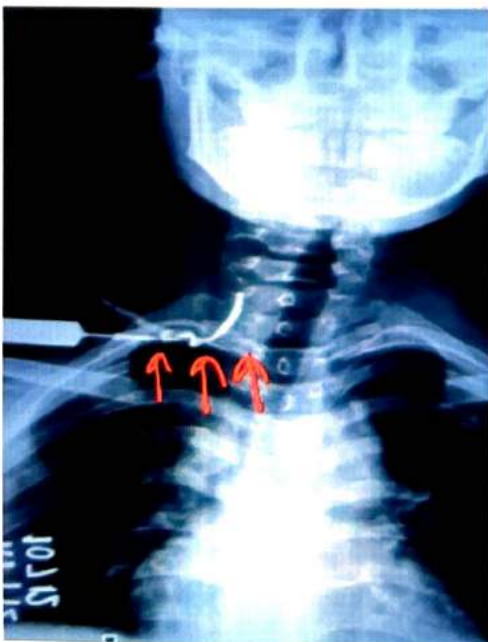
00:03:45

- The most common external opening is from the 2nd branchial cleft.
- It has two openings: external and internal
- Fistula- epithelium lined tract with two opening - it connects one cavity to another or connects cavity to outside.
- The most common is the 2nd branchial fistula
- The internal opening is in the tonsillar fossa(posterior tonsillar pillar)
- The treatment for the branchial sinus and fistula is the SURGICAL EXCISION(step ladder incision)
- The 3rd branchial fistula is seen in pyriform sinus



Important Information

- Investigation of choice: SINOGRAM or FISTULOGRAM



PREAURICULAR SINUS

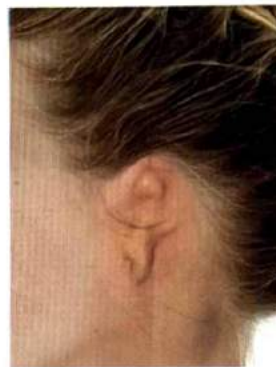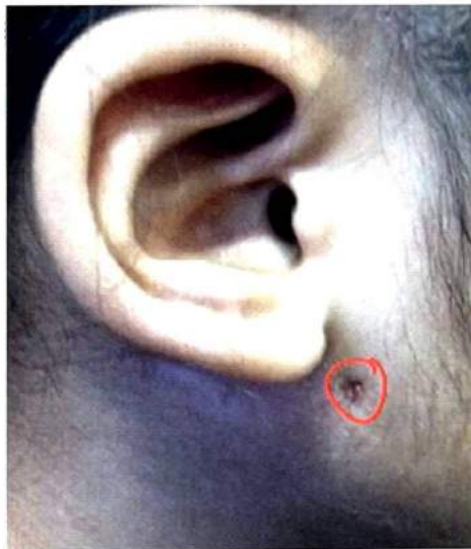🕒 00:10:39

- Anterior opening to the pinna (above the tragus)
- Defect of fusion of HILLOCKS OF HIS (1st & 2nd arches)
- It may be adherent to the cartilage
- **Treatment: surgical excision.**

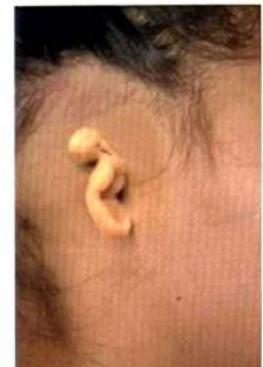COLLAURAL FISTULA

🕒 00:12:27

- Fistula between the angle of mandible and the anterior border of SCM
- Defect of 1st cleft
- Internal opening: floor of EAC
- Treatment: surgical excision (facial nerve may get damaged)
- Excision must be done immediately before infection but in preauricular sinus excision can be done at any age.



Anotia



Microtia

EAC ATRESIA

🕒 00:19:02

- Defect in 1st Arch FN course is also Aberrant in such cases
- RX; Canaloplasty
- U - Unilateral EAC Atresia + Anotia
 - Rx: PC - Pinnaplasty first then Canaloplasty



How to remember

- UPC

- Bilateral EAC Atresia + Anotia
 - Rx: BAHA

BAT EAR

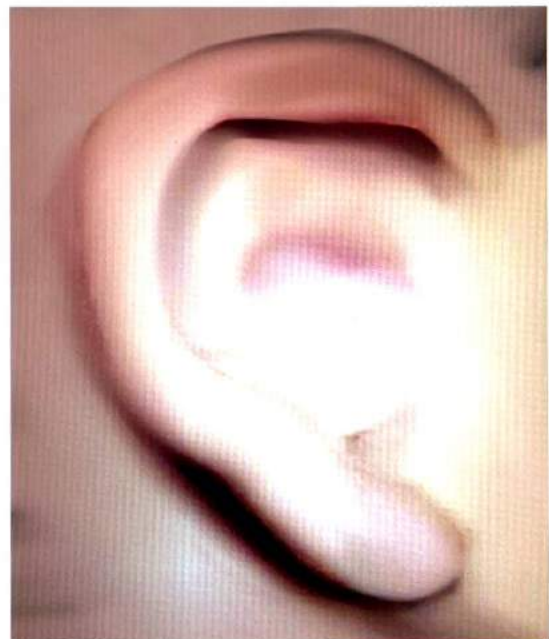🕒 00:16:21

- MC congenital anomaly of the pinna.
- It is due to absence of anti-helix and concha increases
- Also known as OTOPLASTY

ANOTIA/MICROTIA

🕒 00:17:28

- Anotia → Absent pinna → Rx → Pinnaplasty
- Microtia → Small pinna → Rx → Pinnaplasty
- Pinnaplasty
 - Done by rib / costal cartilage
 - Rib cartilage develops by 4-5 years of age
 - Pinnaplasty done at 5-7 years age.



EAC ATRESIA



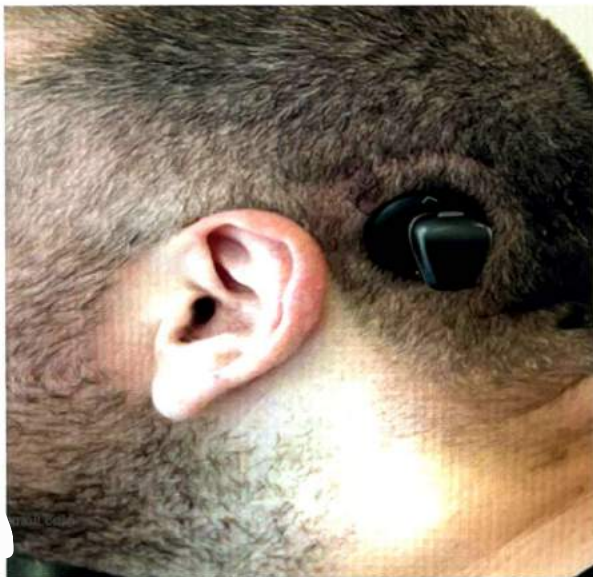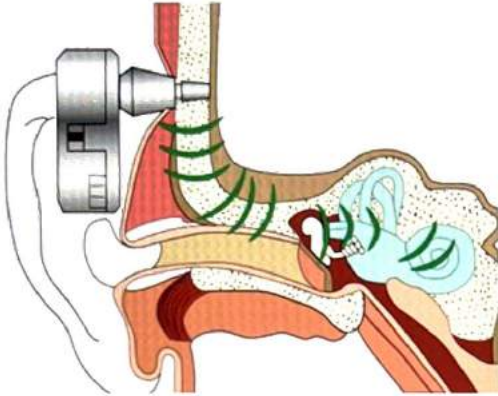
How to remember

- 'A'NOTIA - 'A'BSENT

BONE ANCHORED HEARING AID (BAHA)

00:22:17

- Titanium screw has Osseointegration property
 - Requires 2.5 – 3 mm bone thickness achieved around 5 yrs of age US- FDA norms → Can't implant < 5yrs , UK-NHS norms Allow after 3 years after doing CT scan [2.5 mm]
- Before prescribed age, we can Rx with SOFT BAND HEARING AID

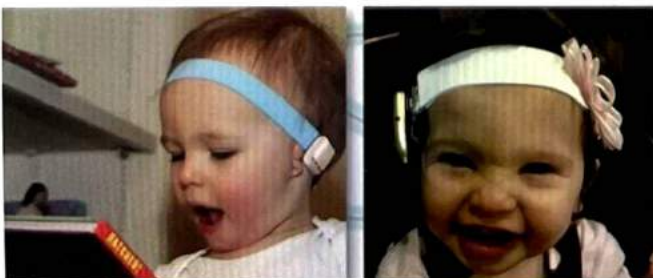

BAHA

SOFT HAND HEARING AID

00:27:11

- The children before achieving 3mm or 3-5 years , BAHA cannot be implanted. In this case, soft hand HA is used.



MEATOPLASTY

00:28:36

- Widening the meatus and done usually in cartilagenous part
- Canaloplasty- making a new canal
- Meatoplasty is done along with MODIFIED RADICAL MASTOIDECTOMY



Previous Year's Questions

Q. Surgery to widen the cartilaginous part of EAC?

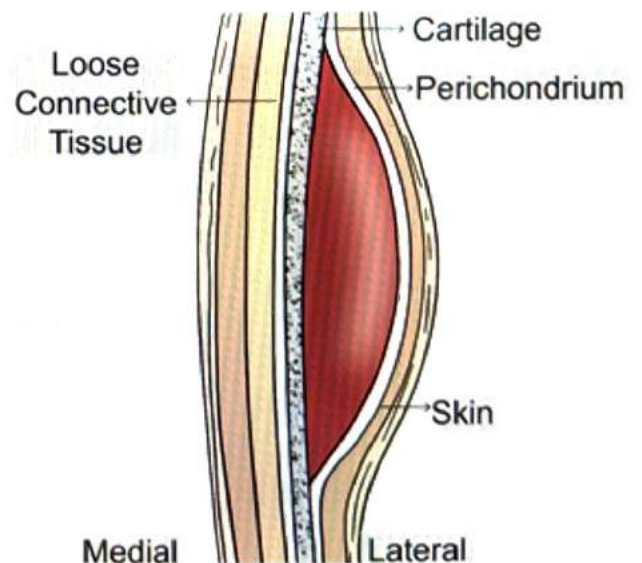
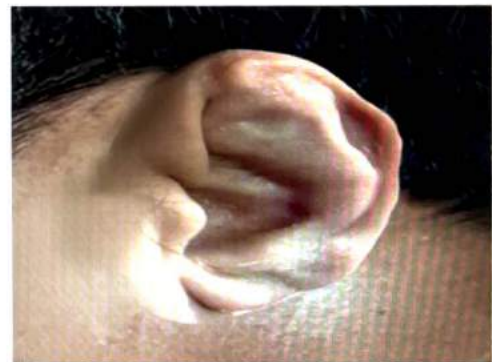(NEET PG JAN 2020)

- A. Myringoplasty
- B. Meatoplasty
- C. Otoplasty
- D. Tympanoplasty

PINNA HEMATOMA (CAULIFLOWER EAR/BOXER'S EAR)

00:30:33

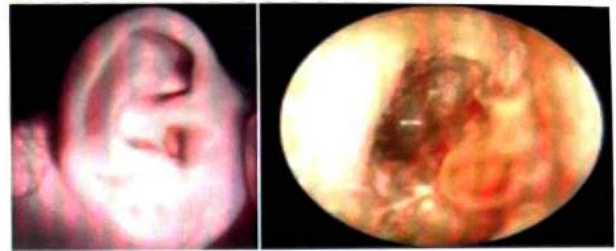
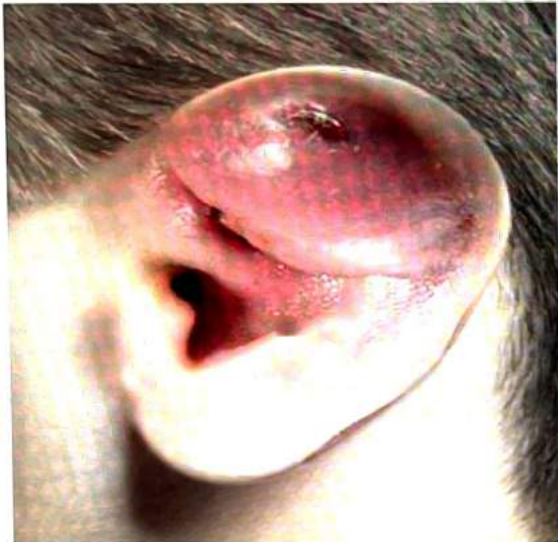- It is Due to blunt trauma to pinna
- Collection of blood between cartilage and Perichondrium
- Rx - needle aspiration followed by pressure dressing



PERICHONDritis OF PINNA

00:33:36

- M/c causative organism: Pseudomonas
- Treatment:
 - Ciprofloxacin (Antibiotic of choice)
 - Analgesics (NSAIDS)
 - Incision and Drainage



Furunculosis

Diffuse

- Presentation of AOE: Severe pain / excruciating pain
Obliteration of post aural groove
- O/E: Tragal Sign → POSITIVE in both localized and diffuse types
- Patient moves always when pressure is applied on tragus present in both localized & Diffuse Otitis externa
- Rx
 - Antibiotics
 - Analgesics
 - 10% Ichthymol glycerin packing
→ Ichthymol; Local antiseptic
→ Glycerin: Hygroscopic

CERUMEN/WAX

00:35:03

- Cerumen is the secretion of ceruminous gland and wax is collection of all secretions.
- pH of wax- 4
- Wax grows completely and blocks is known as Keratosis Obturans
- Wax is removed by microsuction after giving wax dissolvants

Keratosis Obturans

- Deposition of wax along with dead epithelial cells in EAC
- Can erode the bone & can even cause facial palsy

ACUTE OTITIS EXTERNA

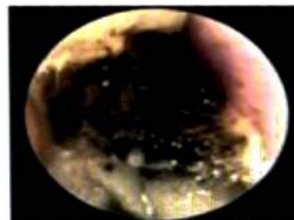
00:37:09

- Acute infection of EAC
- More common in hot and humid climate so it known as TROPICAL OR SWIMMER'S EAR
- Types
 - Localized / Furunculosis
 - Diffuse
- **Localized / Furunculosis**
 - Staph. aureus infection of hair follicles → furuncle
 - Localized to outer 1/3rd
 - Obliteration of posterior aural groove [Furuncle on posterior wall]
- **Diffuse**
 - Mc causative organism → Pseudomonas

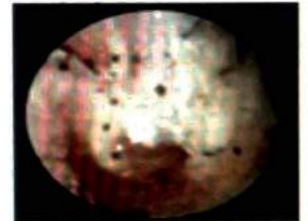
OTOMYCOSIS (SINGAPORE EAR)

00:42:10

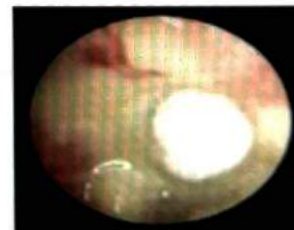
- Fungal infection of EAC
- Causative organism
 - Aspergillus Niger (M/C): Forms black colonies
 - Aspergillus Fumigatus: Forms green colonies
 - Candida albicans: Forms white cottony colonies



Aspergillus Niger



Aspergillus Fumigatus



Candida albicans

- Patient presents with Severe itching present, ↓ Hearing, discharge, mild pain.
- O/E: Wet blotting paper appearance of TM
- Rx: Aural toilet by micro suction
 - Topical antifungal ear drops × 4 weeks

- Keratolytic agents: Salicylic/ Acetic Acid
- Gentian Violet: Prevent biofilm formation (**SODIUM BICARBONATE DROPS NOT USED**)

MALIGNANT OTITIS EXTERNA / ACUTE NECROTISING OTITIS EXTERNA

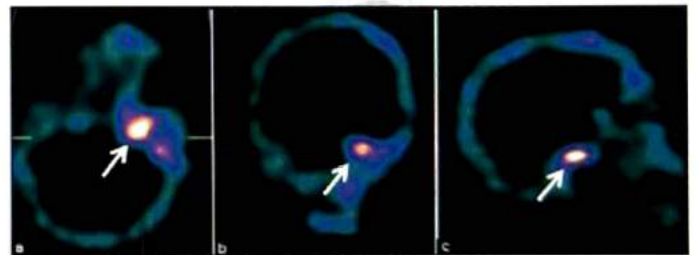
00:52:43

- Term Malignant → Misnomer (Mitotic figures are not high)
- Caused by "Pseudomonas Aeruginosa"
- Rapidly spreading infection (Predisposing factor)
 - Immunocompromised patients (HIV)
 - Elderly uncontrolled **diabetes**
 - Chemotherapy
- C/F – Pain, greenish black discharge
- O/E: Granulations in EAC
- It spreads to Skull Base: Lateral skull base osteomyelitis
 - Multiple Cranial nerve palsies (M/C CN involved is facial nerve)
 - Spread to skull bone through
 - 2-4 Fissures of Santorini in anterior cartilaginous wall of EAC
 - In bony EAC via Foramen of Huschka which Closes by 4yrs of age (In floor → cause parotitis in < 4 yrs of age)

Diagnosis

00:58:53

- CT scan in MOE but all the bones are destroyed in late stages
- In early stage, scanning in MOE/ Diagnostic investigation of choice- Tc 99m scan(even the bone is inflamed, the technetium is absorbed by osteoclasts)
- Tc 99m scan t1/2- 9 months
- SPECT Scan- 3 dimensional study is also used for further investigation



Treatment

01:01:05

- DOC is Ciprofloxacin
 - Anti-pseudomonal antibiotics IV
 - Ceftazidime
 - Cefoperazone + Sulbactam
 - Piperacillin + Tazobactam
 - Carbapenem → Imipenem, Meropenem
- REGIME → 2 IV antibiotics + IV Ciprofloxacin for 6 weeks
- Mortality rate without antibiotics = 65%
- Even with IV antibiotics if cranial nerves are involved mortality rate = 25% therefore, aggressive approach has to be taken

Previous Year's Questions

Q. Otomycosis is most commonly caused by?
(FMGE June 2018/DNB June 2018)

- A. Actinomyces
- B. Aspergillus niger
- C. Mucor
- D. Candida albicans

EXOSTOSIS (SURFER'S EAR)

00:47:35

- Benign growth of bony EAC
- Found mainly in surfers
- Broad based, multiple growths
- Way of body defense mechanism

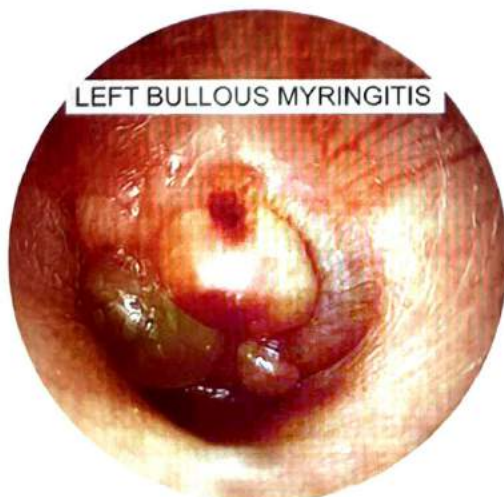
MYRINGITIS BULLOSA HAEMORRHAGICA

00:49:00

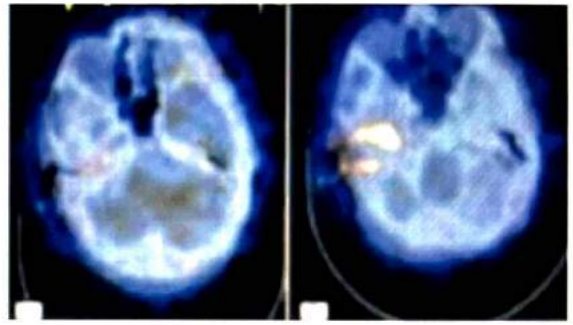
- It is also known as BULLOUS MYRINGITIS
- Formation of bleeding blebs on TM
- Bullas are the fluid filled lesion
- Blood mixed discharge present, painful & hearing loss
- Earlier it also known as otitis externa haemorrhagica
- Caused by pneumococcus (Streptococcus pneumoniae) {Earlier believed d/t Virus/ Mycoplasma}
- Treatment: Topical antibiotics+ topical steroids ear drops

Important Information

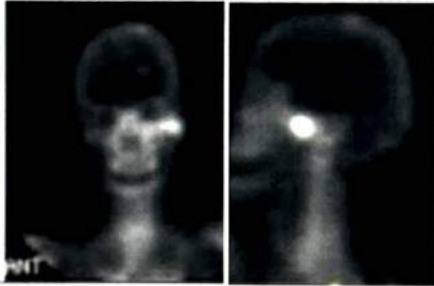- "Sago-grain appearance of TM" in healing phase.



- After 6 weeks, check ESR → (N) → Discharge with Tab. Ciprofloxacin [Double dose]
- Gallium scan
 - It is absorbed by the leucocytes which increases the inflammation
 - $t_{1/2} = 3-4$ days and used for testing every one week
- [Ga-67] [Prognostic Investigation of Choice] – Non specific



Gallium scan

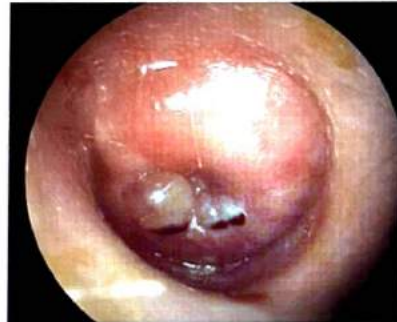

Bone scan



CLINICAL QUESTIONS

Q. A 17 yrs old boy presented with sudden onset of severe throbbing pain in his right ear following an upper respiratory tract infection. He also gives a history of bloodstained discharge couple of hours later along with hearing impairment in the affected ear. Following is the otoscopy findings of the patient. Most likely diagnosis is:



- A. Herpes zoster Oticus
- B. Bullous Myringitis
- C. Granular Myringitis
- D. Tympanic Membrane Haematoma

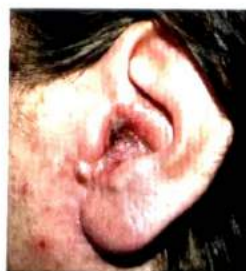Answer: B

Solution

Bullous myringitis (BM) is an acute inflammatory condition affecting the tympanic membrane (TM) characterized by the presence of bullae or vesicles on the surface of the TM. The bullae may be single or multiple, may affect segment or the whole of the TM and may even spread onto the adjacent ear canal. Diagnosis of this condition is clinical. Typically, patients present with sudden-onset severe otalgia, usually unilateral and often in association with an upper respiratory tract infection.

Otoscopy reveals bullae on the TM. Rupture of the bulla may be associated with scanty serosanguinous otorrhoea, which is usually short-lived due to the absence of a TM perforation.

Q. A 38yrs old female Pushpa presents with ear discharge, itch and severe pain since last 4 days. She gives history of using Cotton buds to clean ear wax 4 days back. Following image shows an oedematous narrow ear canal obscuring the Tympanic membrane. Most likely diagnosis is:



- A. Otomycosis
- B. Acute Otitis Externa
- C. Acute Suppurative Otitis Media
- D. Malignant Otitis Externa

Answer: B

Solution

This is a classic case of Otitis externa post self-trauma to ear.

Diffuse Otitis Externa

- It is also known as swimmer's ear, tropical ear, telephonist ear.
- Commonly seen after minor trauma to EAC skin like buds/ itching the ear.
- Most common organisms are Pseudomonas, E. coli, Staphylococcus aureus.
- Occurs in immunocompetent individuals.
- Burning sensation, ear pain, purulent discharge, itching, conductive deafness
- Treatment: Aural toilet, Ichthammol Glycerine wick and analgesics.



4 ANATOMY OF MIDDLE EAR

MIDDLE EAR CLEFT

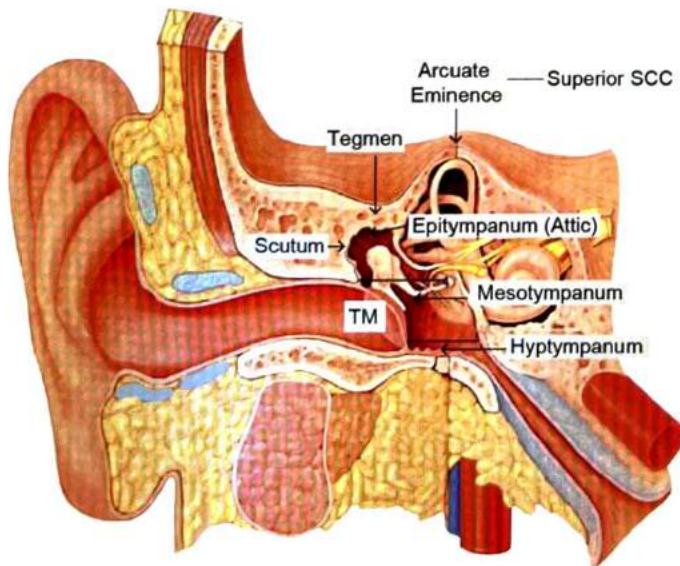
00:00:48

- Middle ear cleft = middle ear + mastoid + ET
- Middle ear volume is 1 ml.
- Mastoid volume is 5 ml.
- ET is closed at rest, so we don't consider the volume.
- Total Middle ear cleft volume is 6 ml
- Middle ear is connected to mastoid by a opening K/as aditus.
- Mastoid antrum is the largest air cell in mastoid. Antrum is of adult size at birth

LATERAL WALL OF MIDDLE EAR

00:02:31

- It is formed by Tympanic Membrane
- TM divides middle ear into
 - Part above TM is epitympanum/ Attic
 - Part Infront TM is mesotympanum
 - Part below TM is Hypotympanum
- Bony lateral wall of Attic(epitympanum) → Scutum
 - Erosion of scutum is characteristic CT scan finding of cholesteatoma (primary acquired)
 - bird beak appearance

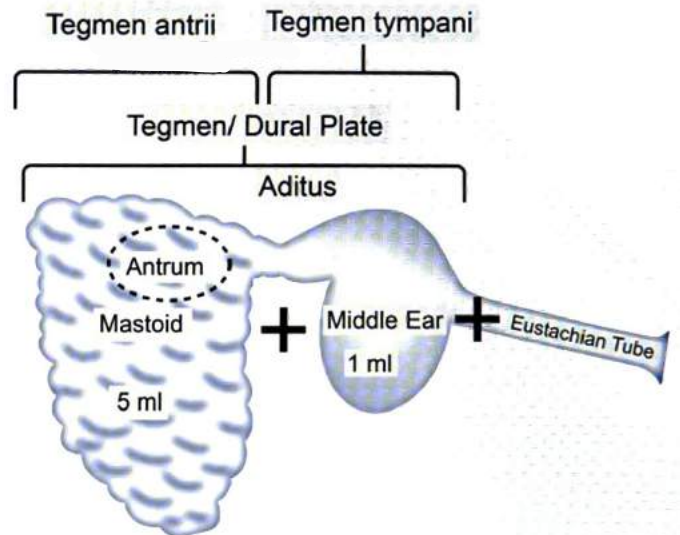


ROOF OF THE MIDDLE EAR

00:04:54

- Roof separates ME from Middle cranial fossa.
- Bony plate above the Middle ear & Mastoid: Tegmen / Dural Plate.
 - Part above the ME: Tegmen Tympani.
 - Part above the antrum: T. Antrii

- Aditus connects ME/Attic to antrum.
 - It is called as Attic Ad Antrum



- Tegmen has a bulge which can be seen from cranial side. It is K/as arcuate eminence, it is due to push by superior semi-circular canal.
- It is the important surgical landmark for facial nerve surgery in the middle cranial fossa approach.

BOX MODEL OF THE MIDDLE EAR

00:10:15

- Anterior wall contains 2 openings
 - Upper small opening for canal of tensor tympani.
 - Lower big opening for Eustachian tube/auditory tube / pharyngo tympani tube (ET connects middle ear to nasopharynx)

OPEN BOX MODEL OF THE MIDDLE EAR

00:12:29

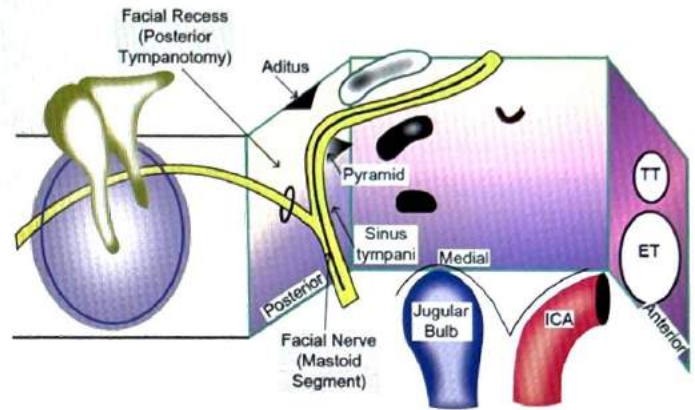
Refer Picture 4.1

- Medial wall contains 2 windows
 - Oval window/ fenestra vestibuli: It is covered by stapes foot plate.
 - Round window/Fenestra cochleae: It is covered by secondary TM.
 - There is a hook like structure Known as processus cochleariformis, this forms a hook for

tensor tympani muscle.

→ **Function:** Tensor tympani starts in the anterior wall from the canal and goes to medial where it turns at processus cochleariformis and comes out laterally and attaches to handle of malleus

- Horizontal segment/tympanic segment of facial nerve. (Facial nerve is in the bony canal known as fallopian canal it is the longest bony canal for the CN) → Length of fallopian canal is 27 mm
- Posterosuperior to facial nerve there is a dome of lateral semi-circular canal on medial of ME. This is the M/C site for labyrinthine fistula.



MEDIAL WALL OF THE MIDDLE EAR

🕒 00:20:33

- There is an outward bulge in the medial wall known as promontory.
- It is due to the first turn/basal turn of the cochlea.

DEPTH OF THE MIDDLE EAR

🕒 00:21:42

- Mesotympanum: Narrowest part of ME (2 mm)/Surgical position of ME
- Epitympanum: 6 mm
- Hypotympanum: 4 mm

BOUNDARIES OF SINUS TYMPANI

🕒 00:33:13

- Lies medial to Facial Nerve, hidden place in Middle ear
- M/C site for recurrent/residual cholesteatoma

★ Important Information

Boundaries

- Lateral: Facial nerve
- Posterior: Posterior wall
- Medial: Medial wall
 - Ponticulus: Superior bony ridge
 - Subiculum: Inferior bony ridge

★ Important Information

- Height = depth
- If surgical/anatomical position of ME is not mentioned, shallowest part of ME in surgical position - Mesotympanum

BOUNDARIES OF FACIAL RECESS

🕒 00:35:01

- Lateral to Facial Nerve
- This is the M/C site for posterior tympanotomy

★ Important Information

Boundaries

- Superior - Short process of Incus (Fossa Incudis)
- Lateral - Annulus of TM
- Medial - Facial Nerve
- Inferior - Chorda Facial angle

POSTERIOR WALL OF THE MIDDLE EAR

🕒 00:25:39

- Opening known as Aditus connects ME to mastoid
- Vertical segment / Mastoid segment of facial nerve present.
- Chorda Tympani Nerve - Branch from Mastoid segment, hangs like a cord in the ME, and exits from anterior wall through Canal of Huguier
 - 3rd opening in anterior wall is Canal of Huguier.
- Pyramid → From pyramid, arises stapedius (Smallest named muscle in body), goes and attaches neck of stapes.
- Area medial to facial nerves is sinus tympani (ME site for recurrence residual cholesteatoma)
- Area lateral to facial nerve and above chorda facial angle is known as facial recess

INFERIOR WALL OF THE MIDDLE EAR

🕒 00:40:17

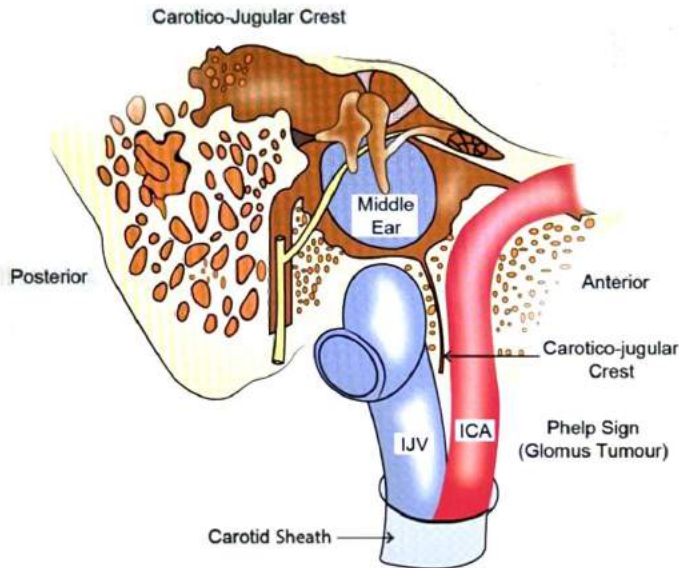
Floor

- Separates ME from jugular bulb and ICA.
- Jugular bulb and internal carotid artery are present below the floor in between them there is a bony crest known as carotico jugular crest.

Carotico Jugular Crest

00:41:31

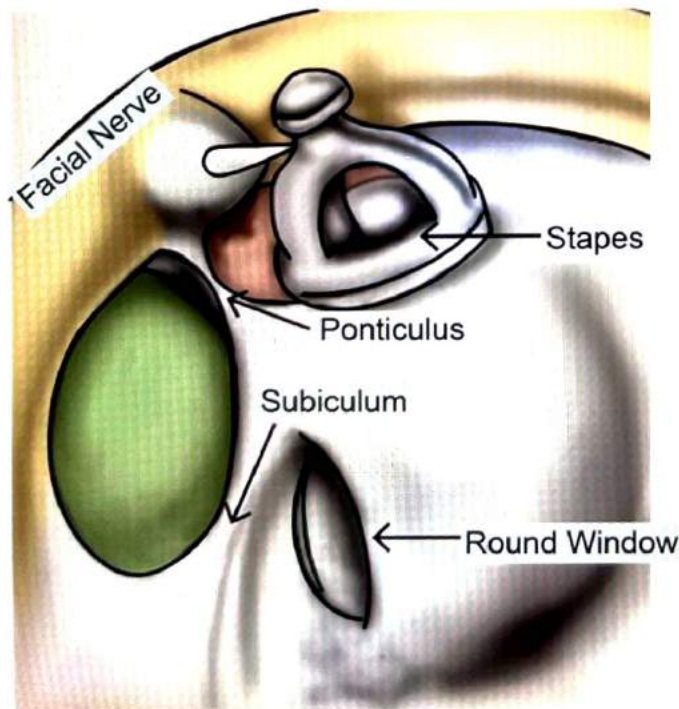
- ICA present anterior to the crest
- Jugular bulb present posterior to it.
- Helps in distinguishing b/w ICA & Jugular bulb
- Phelp Sign: Inability to distinguish between ICA & Jugular bulb due to erosion of Carotico jugular crest
→ Seen in CECT scan of Glomus tumor



SINUS TYMPANI

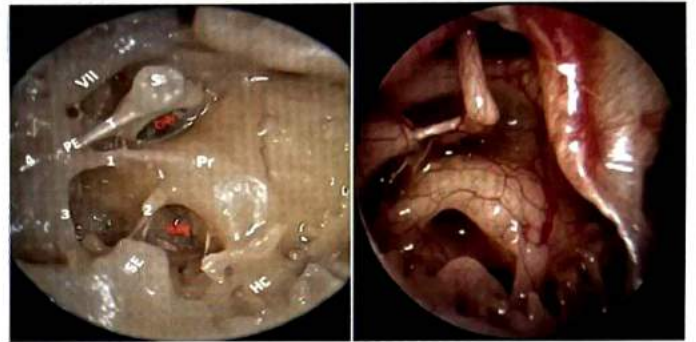
00:45:12

- It is a 3 dimensional space



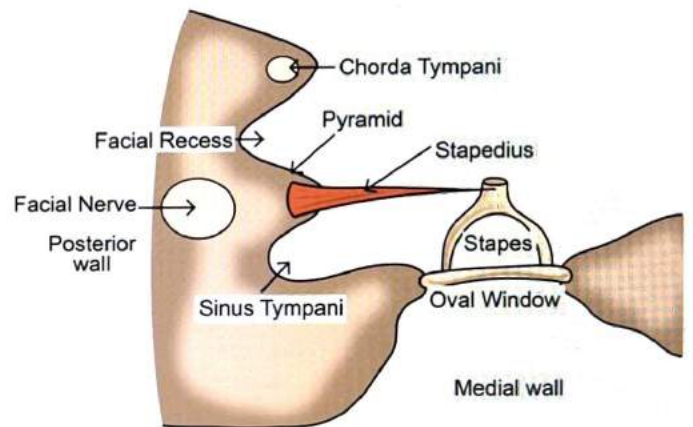
PONTICULUS AND SUBICULUM

00:47:54



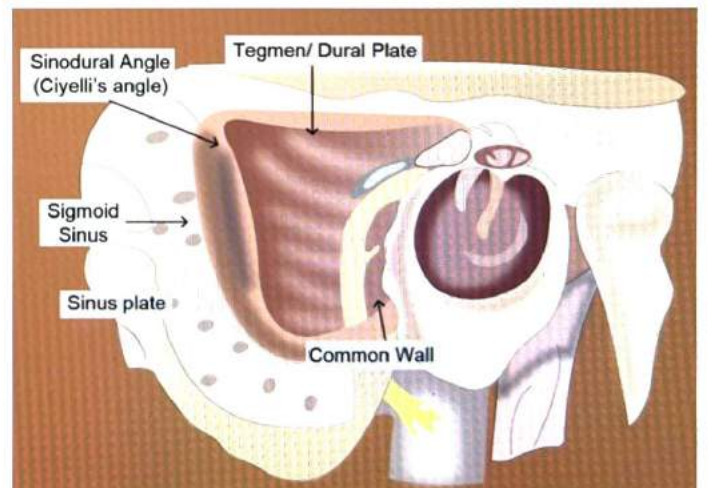
Identify the structures in the diagram

00:50:56



ANATOMY OF MASTOID PROCESS

00:54:15



- Superior wall** is Known as tegmen/Dural Plate.
- Anterior wall:** Posterior wall of Middle ear having FN & CTN
- In facial recess area we do posterior tympanotomy
- Common wall:** We can see the facial nerve vertical segment and the branch coming from it is chorda tympani.
- Behind the posterior wall of mastoid, we have the sigmoid sinus. Therefore, the posterior wall of mastoid

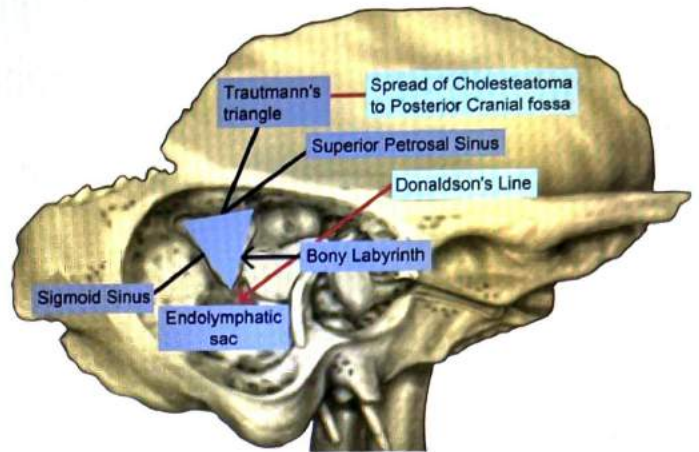
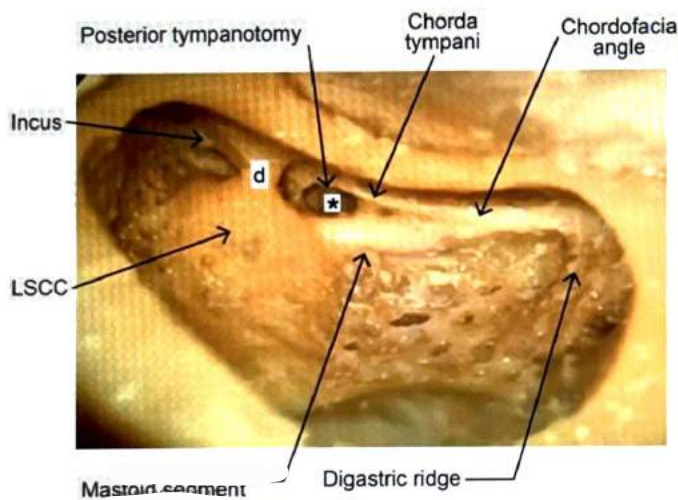
covers the sigmoid sinus K/as sinus plate.

- Angle between sinus plate and Dural plate is Known as sinodural angle Also called as citellis angle

POSTERIOR TYMPANOTOMY

00:59:39

- Entering into the middle ear from mastoid process
- Done for
 - Cochlear implant
 - Middle ear implantable hearing aids
- Through posterior tympanotomy we can view round window
- Anterior to round window promontory is present



- Trautman's triangle is seen

- **Boundaries**

- Posterior boundary: Sigmoid sinus
- Anterior boundary: Bony Labyrinth
- Superior boundary: Superior petrosal sinus.

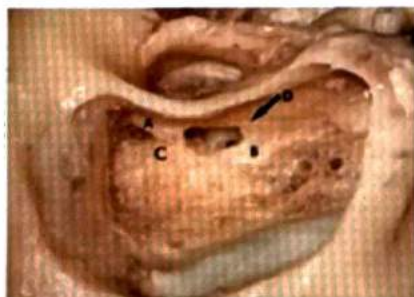- **Significance**

- The place where the cholesteatoma erodes the bone and goes into the posterior cranial fossa
- Anteriorly the bony labyrinth is difficult to erode because of inner ear is formed by enchondral ossification the hardest/densest bone in the body.
- Donaldson's line: along the lateral semicircular canal bisecting posterior semicircular canal where it hits the sigmoid sinus just below the place, we have the endolymphatic sac.
- Therefore, Donaldson's live is the surgical landmark for endolymphatic sac



Previous Year's Questions

Q. Which of the following represents lateral semicircular canal during cortical mastoidectomy?
(AIIMS NOV 2017)



- A. A
- B. B
- C. C
- D. D

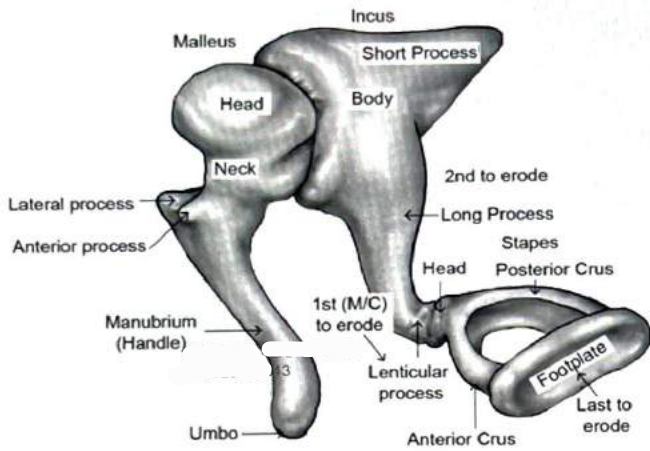
Dural Venous Sinuses

01:11:12

- The dura from the 2 sides fuses to form Falx cerebri
- Dura at the level of cerebellum forms Falx cerebelli
- Tentorium cerebelli is between the cerebrum and cerebellum
- 3 sinuses
 - Superior sagittal sinus
 - Inferior sagittal sinus
 - Occipital sinus

Contents of Middle ear

01:30:48



• 2 Muscles

	Tensor Tympani	Stapedius
Origin	• At canal for Tensor Tympani	• Pyramid
Insertion	• Handle of Malleus	• Neck of stapes
Nerve supply	• Mandibular nerve	• Facial nerve

• 3 Ossicles

- Malleus and Incus formed by (I) Mandibular arch → Meckel's cartilage
- Stapes by (II) Hyoid arch, except the medial surface of stapes foot plate (develops from otic capsule)
- Ossicles reach adult size at: 15 weeks of IUL
- Adult configuration at: 20 weeks of IUL
- Organ of Corti starts hearing at: 20 weeks of IUL
- Organ of Corti adult configuration: 25 weeks of IUL

- Mastoid process/ Maxillary Antrum/ Orbital Cavity: Not of Adult Size
- Types of Joints of Ossicles: Synovial joint
 - B/w Malleus & Incus: Saddle type
 - B/w Incus & Stapes: Ball & socket type
- **Parts of malleus**
 - Head
 - Neck
 - Lateral process: This is most reliable landmark of TM. It separates TM to pars flaccida and pars Tensa
 - Anterior process
 - Manubrium /handle: The tip is K/as umbo; it is most visible anatomical landmark of TM. Umbo divides the pars tensa into 4 quadrants.
- **Parts of incus**
 - Body
 - Short process: it is in fossa includes: It forms the superior boundary for Post tympanotomy
 - Long process
 - Lenticular process
- **Parts of stapes**
 - Head
 - Short neck
 - 2 crura's: anterior and posterior crus
 - Foot plate
 - Stapes develops from second arch and Reichert's cartilage except the medial surface of foot plate.
 - First Most Common part to undergo erosion: lenticular process of Incus.
 - 2nd Most common part to undergo erosion: long process of Incus
 - Last to undergo erosion is foot plate of stapes. Because it develops from otic capsule.



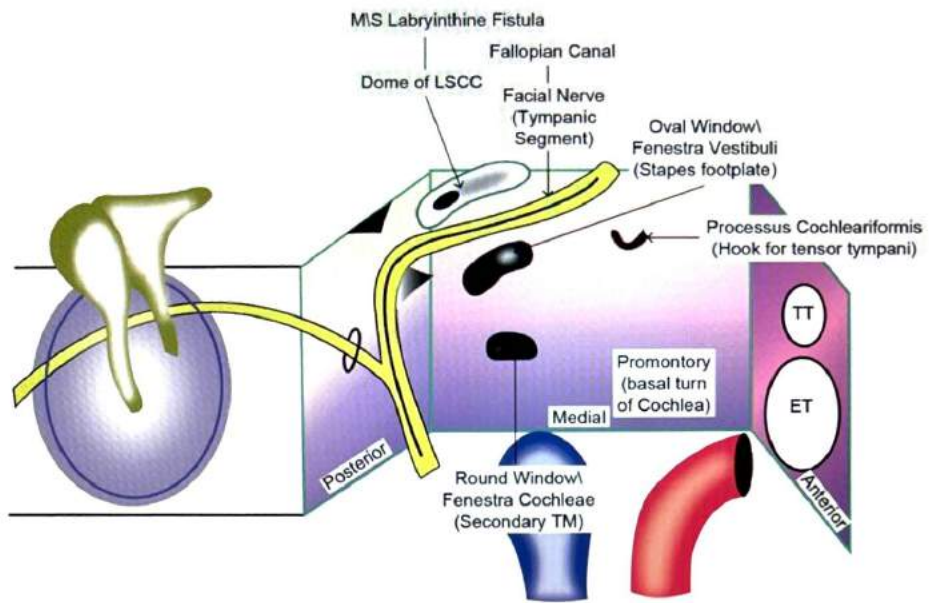
How to remember

- Abimanyu- Adult (25 Weeks)

Structure attaining adult size at the time of birth

- Ossicles
- ME/Tympanic cavity
- Cochlea/labyrinth
- Mastoid Antrum

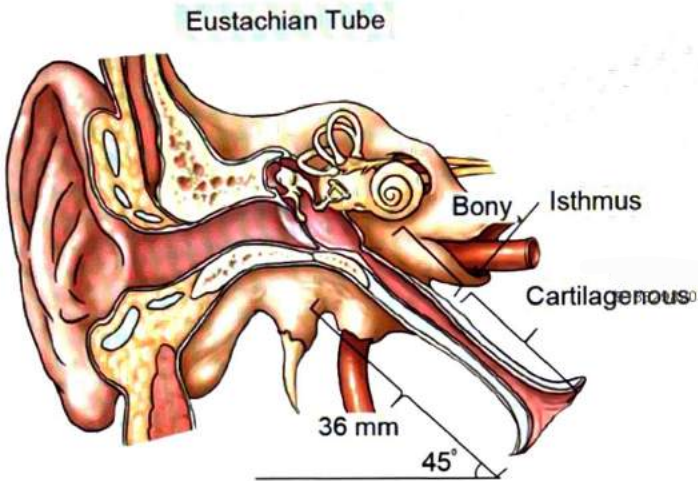
Picture 4.1





5 EUSTACHIAN TUBE

ANATOMY OF EUSTACHIAN TUBE 00:00:19

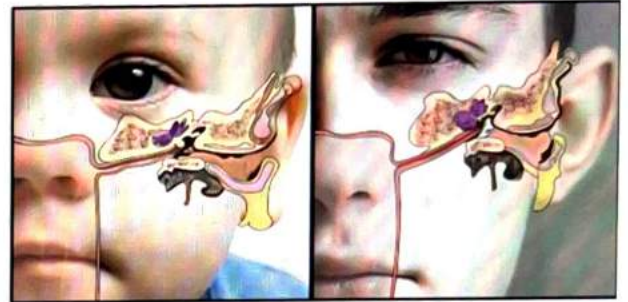


- Its is also called as Auditory tube / Pharyngo tympanic tube
- Connects anterior wall of middle ear to lateral wall of nasopharynx.
- The ET tube is 36 mm length
 - Lateral 1/3rd is bony: 12 mm
 - Medial 2/3rd is cartilaginous: 24 mm
 - Isthmus: (3 mm) Narrowest part of eustachian tube. It lies at bony cartilaginous junction
- Cartilagenous end of the ET is TORUS TUBARIUS which protrudes into the nasopharynx
- In adult ET makes an angle of 45° to the horizontal line
- ET is 16-18mm in length at birth and almost horizontal. Therefore, the infection in middle ear is more common in children as it can travel from nasopharynx to middle ear

Infant Vs Adult Eustachian Tube 00:04:41

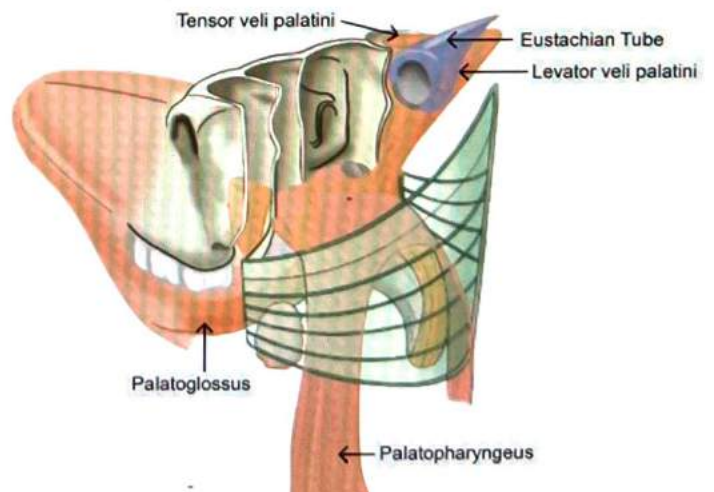
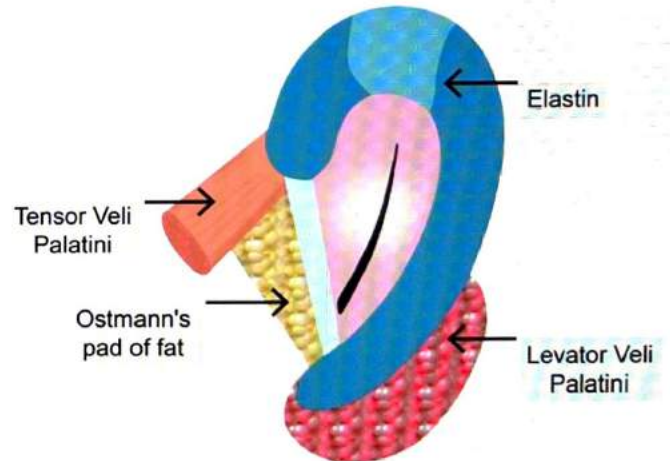
- Infant eustachian tube in shorter and horizontal so the chances of infection is more in children.

Infant ET	Adult ET
• 16-18mm in length	• 36mm in length
• Almost horizontal and shorter	• At an angle of 45° with the horizontal



Ostmann's pad of fat

- It keeps the ET closed at rest
- Medial fibres of Tensor veli palatini is the main opener/dilation of ET
 - It is also known as dilator tubae
- When the tensor veli palatini contracts, it pulls the cartilage of ET anteriorly, that leads to the opening of ET.
- Levator veli palatini secondarily supports to the opening.





Important Information

- Tensor veli palatini, levator veli palatini, palatoglossus, palatopharyngeus forms the **soft palate**.
- in cleft palate patients, these muscles not able to meet in the centre, so ET dysfunction causes and it leads to Middle Ear Disorder

FUNCTIONS OF EUSTACHIAN TUBE ⌚ 00:08:30

- Maintains the Middle ear air pressure equals to outside Atmospheric air pressure
- Drains the secretions of Middle Ear
- Prevents infections/food particles from going to Middle ear
- Normally ET is closed in position because of Ostmann's pad of fat at rest; it opens when we yawn or swallow with the help of tensor veli palatini muscle.
- Middle ear is lined by mucosa. This mucosa absorbs O_2 from atmospheric air
 - In ME, more CO_2 and less O_2 compare to atmospheric air
 - Advantage: low O_2 will not allow to grow aerobic bacteria inside middle ear. So, it maintains the sterile environment
 - In perforated tympanic membrane, chances of infection is more

EUSTACHIAN TUBE FUNCTION TESTS ⌚ 00:12:24

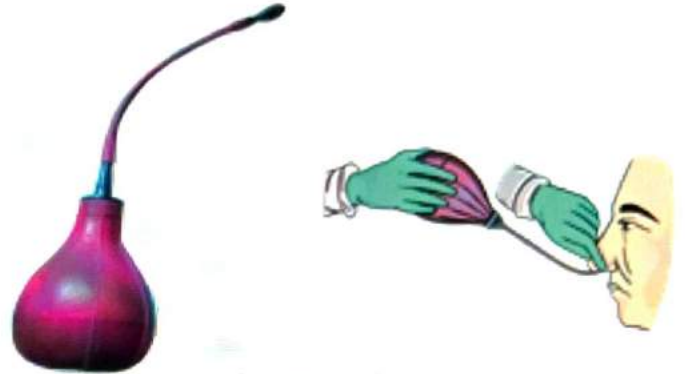
Passive test or non-physiological tests (not opened by muscles)

- Valsalva test/maneuver
 - Principle: Positive pressure in the nasopharynx causes air to enter the eustachian tube and reach middle ear which causes pop up sound due to bulging of TM.
 - TM Movement can also be seen by examiner with otoscope



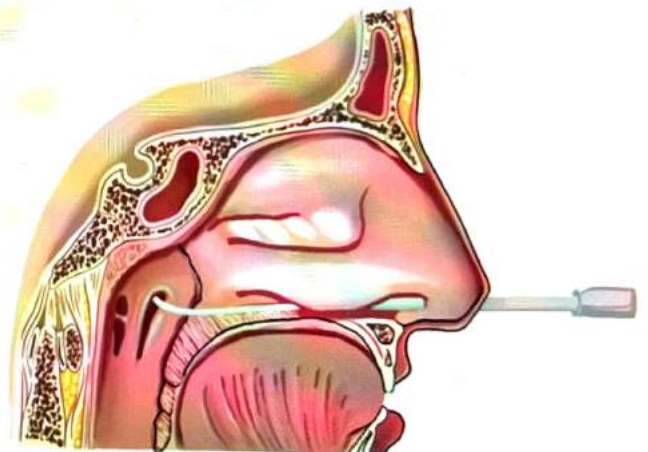• Politzer test

- Designed for those who can't perform Valsalva test eg. Children
 - Politzer bag is connected to rubber tube
 - Tube is placed in one nostril and other is closed
 - Air is blown with pressure by pressing the bulb
 - Air enters nasopharynx → opens eustachian tube & enters middle ear → pops out TM



• E.T. Catheterization

- Done using ET Catheter- curved tube/catheter with ring attached which tells about the direction of curve



ET catheter is inserted into nose and nasopharynx

↓
rotated by 90° to medial side and pulled back

↓
catheter engages behind nasal septum

↓
now catheter rotated at 180°

↓
enters eustachian tube

↓
air blown using syringe or Politzer bag

↓
air will enter middle ear and pops out TM

↓
Can be seen using otoscope or patient informs pop up

sound in ear

Active test or Physiological test

00:18:35

• **Toynbee test**

Ask the patient to close the nose and swallow small amount of liquid

Negative pressure is created in nasopharynx

Eustachian tube opens up d/t action of Tensor veli palatini

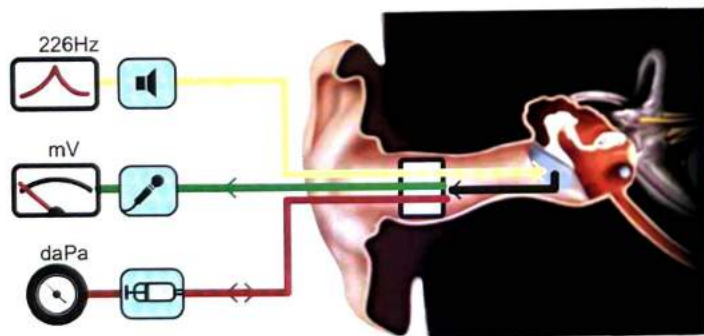
Air is sucked out of middle ear

TM gets retracted

Movement can be seen with otoscope by examiner



• **Tympanometry**



- Also known as Inflation Deflation test
- It has sound source, microphone, pressure meter
- Tympanometry device can measure the pressure changes in EAC
- This test is also done in perforated tympanic membrane
- It has 2 parts: Non physiological and physiological

→ Device is placed in EAC and pt. is asked to perform Valsalva

Air enters middle ear and TM bulges out

Pressure in EAC rises and is noted

→ Deflation part of test is done using Toynbee test

Patient is asked to swallow against closed nose

Negative pressure is created in nasopharynx

Air moves out of middle ear

TM gets retracted and pressure can be measured

TEST FOR PERFORATED TYMPANIC MEMBRANE

- **Radiological test:** Instill radio-opaque dye into middle ear against perforated TM

Take x-ray

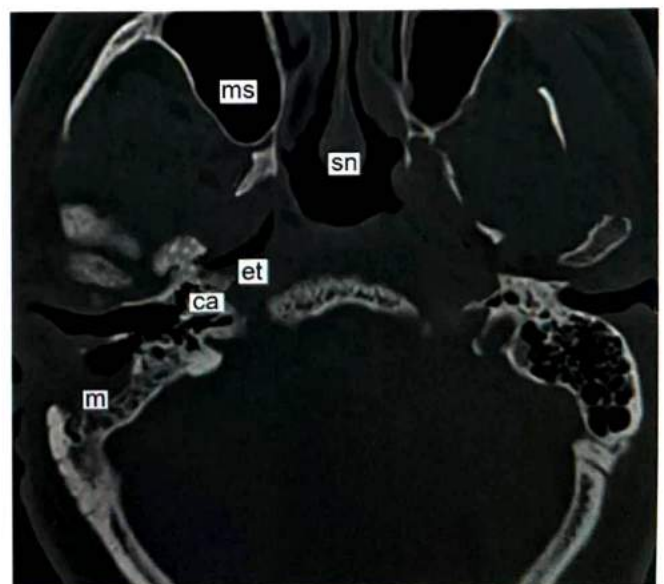
Dye goes through whole eustachian tube to reach nasopharynx

Eustachian tube anatomy can be seen

- **Saccharine or Methylene blue test**
Instill methylene blue dye against perforated TM into middle ear

Dye comes into nasopharynx and oropharynx through eustachian tube & can be seen coming out Saccharine is a sweet agent so, sweet taste sensed

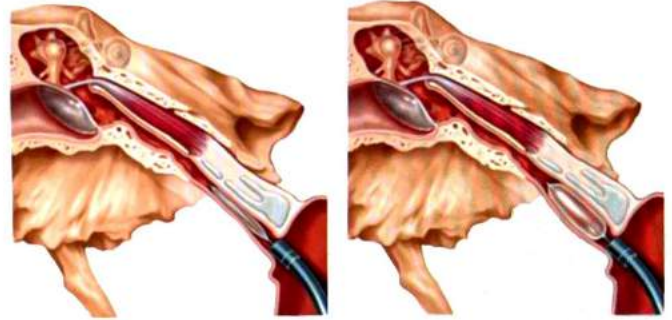
- **Other test:** CT scan



- Patulous ET: When eustachian tube has air in it
- Predisposing factors
 - Thyroid disorder
 - Pregnancy
 - Rapid weight loss
- Patient can have Autophony (i.e hears own voice). This condition is seen in Patulous ET. Also seen in superior semicircular dehiscence
- Rx: inject silicon paste (teflon injection is not used due to ICA near the ET)
- Sono-tubometry
 - Sound signal is given in nose and nasopharynx, through eustachian tube it reaches middle ear and a microphone is placed in EAC to detect it
 - So, we can detect the functioning of Eustachian tube

Eustachian tube balloon dilatation

- To open the eustachian tube in case of chronic obstruction
- A balloon catheter is inserted through nose till nasopharynx against endoscopic vision and is rotated so that balloon can be inserted into ET and is then blown up. This produces micro fractures in eustachian tube and open up eustachian tube which remain open afterwards.



Previous Year's Questions

- Q. Politzer bag maneuver is used to test:
(JIPMER - Nov - 2017)
- A. Eustachian tube
 - B. Larynx
 - C. Esophagus
 - D. Nasal cavity

Causes of eustachian tube obstruction & its treatment 🕒 00:29:10

- Obstruction is due to mass, polyp, tumor
- Frequent infection in ET causes scarring. ET may undergoes Astenosis internally in those chronic ET disorders we undergo ET balloon dilatation

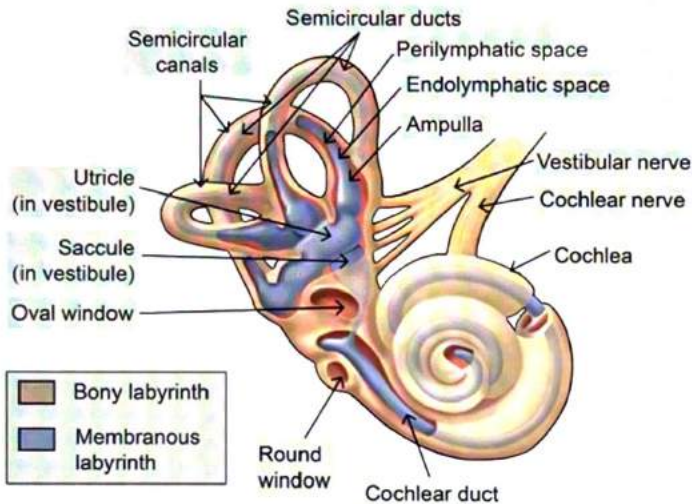


6

ANATOMY OF INNER EAR

Anatomy of Inner ear

00:00:13



- Embryologically inner ear has 2 parts
 - Bony labyrinth
 - Membranous labyrinth
- Between Bony labyrinth and Membranous labyrinth there is space filled with Perilymph: Known as Perilymphatic space.
- Inside Membranous labyrinth: Endolymph fluid is present known as Endolymphatic space

Based on function inner ear has 2 parts

- Auditory part
 - Cochlea
 - Spiral structure
 - 2.75 turns around central bony axis MODIOLUS
- Vestibular part
 - Vestibule (2 sacs) and 3 Semicircular canals
 - Utricle
 - Saccule/Sacculus
 - semicircular canals
 - Posterior/Vertical
 - Lateral/Horizontal
 - Superior/Anterior

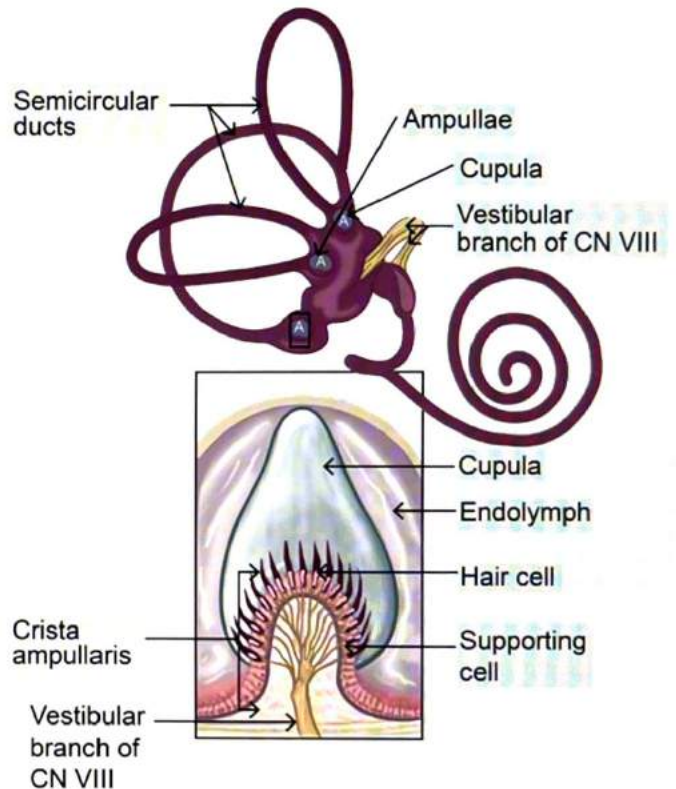
SEMICIRCULAR CANALS

00:04:30

- Superior, Posterior and lateral
- Each canal has 2 openings, 3 big openings known as ampulla and small openings called non ampullated end.
- Totally there are 5 openings because the non-

ampullated end of posterior and superior joined together to form crus commune

- Inside Ampulla there are hair known as cristae ampullaris
- Cristae ampullaris are inside a structure known as cupula ampullaris and their function is to detect Angular acceleration or Rotational motion.



- **Angles of Semicircular Canal**
 - The Lateral SCC may be known as Horizontal canal but it is not horizontal
 - It is at an angle of 30° to the horizontal line
 - Posterior canal is also known as vertical canal
 - Superior canal is also known as anterior canal

NYSTAGMUS

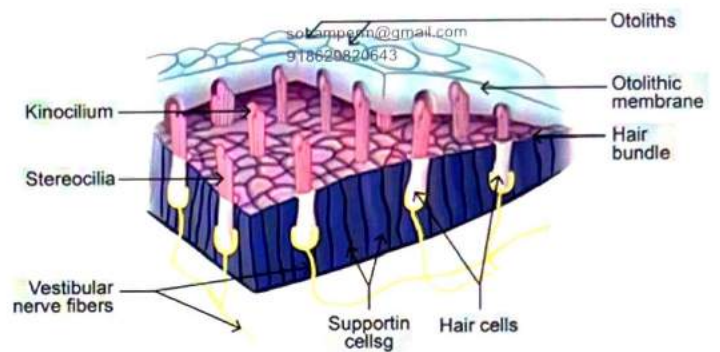
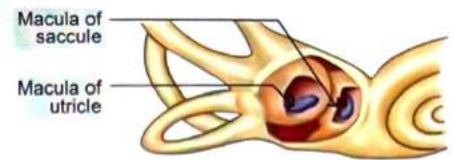
00:10:31

- Involuntary, Rapid, To & Fro, movement of eyeballs
- If lateral SCC is stimulated there is a vestibulo-ocular reflex
- Irritation to SCC produce – Nystagmus
 - Lateral SCC: Horizontal nystagmus
 - Posterior SCC: Vertical nystagmus
 - Superior SCC: Torsional nystagmus
- 2 types

- Peripheral: Problems in the peripheral sense organ (vestibular organ/labyrinth)
- central nystagmus (cerebellum)

Peripheral nystagmus characteristics – 5D's

- D - Delay- after few seconds of stimulus
- D - Duration
- D - Decay (On repeated stimulus)
- D - Decreases on gaze fixation (Frenzel glasses +20 D lenses)
- D - Direction
 - Fast & Slow Components
 - Fast component gives the direction
 - Vertical nystagmus can be Geotropic or Ageotropic nystagmus
 - Torsional nystagmus can be clockwise Or anticlockwise



How to remember

- PERIPHERAL - 5D's
- CENTRAL - 'C'erebellum

VESTIBULE

00:19:19

Function of utricle and saccule

- Inside utricle and saccule, there is macula
- Macula consist of hairs, on the surface of these hairs there is a gelatinous matrix which is covered by a layer of calcium carbonate crystals k/as Otoconia
- With the help of this Otoconia, macula help in detecting the linear acceleration
- Utricle helps in detecting horizontal linear acceleration.
- Saccule helps in detection vertical linear acceleration.
- By gravity, posterior SCC is the most dependent so otoconia displaced will always get deposited in Posterior SCC

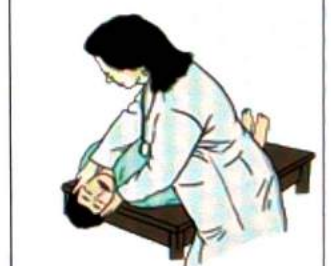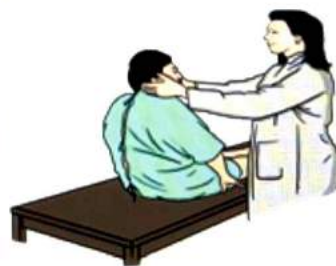BENIGN PAROXYSMAL POSITIONAL VERTIGO (BPPV)

00:24:45

Aka Otolithiasis/Canalolithiasis/Cupulolithiasis

- Most common cause of Vertigo
- Displacement of Otoconia to Posterior semicircular canal (M/C) where they are k/as otolith
- Vertigo
 - Change in head position (vertical plane)
 - Paroxysm: Sudden burst
 - Duration: seconds to minutes
- Diagnosis confirmed by → DIX: HALLPIKE'S MANOEUVRE

Dix-Hallpike's Maneuver



How to remember

- U tricle - horizontal
- S accule - vertical

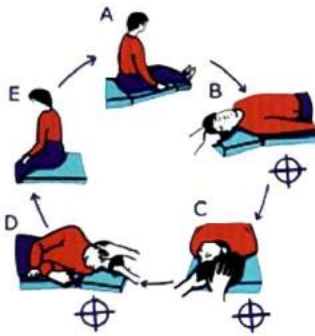
- Turn head by 45° towards side which you want to test & make the patient Supine especially the posterior SCC of right side to vertical → Patient experiences Nystagmus
- This nystagmus is Peripheral nystagmus.
 - Delays
 - Duration: lasts upto a minutes
 - Decay
 - Decrease in intensity
 - Direction-upbeating
- 5D's of Peripheral Nystagmus are observed during Dix-

Hallpike maneuver, Direction of Nystagmus is mainly vertical (Geotropic / ageotropic with torsional component present)

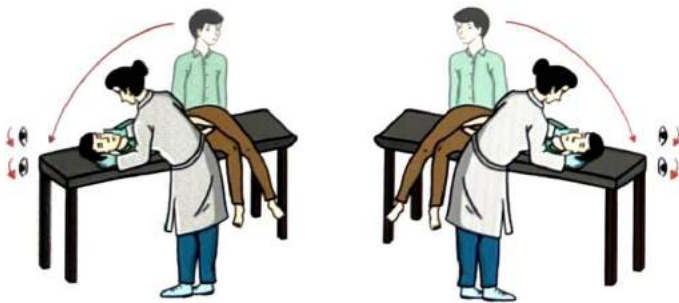
- Pure vertical nystagmus is only seen in central nystagmus.
- Rx: Epley's Manoeuvre (posterior canal)

(1st sitting treats: 80-90%)

- 1st Step: Same as Dix-Hallpike's to confirm the side
- 2nd Step: Turn the head to opposite side by 90°
- 3rd Step: Roll the whole body by 90°
- 4th Step: Bring patient back to sitting position



- Other Maneuvers for RX
 - SEMONT'S/LIBERATORY MANEUVER

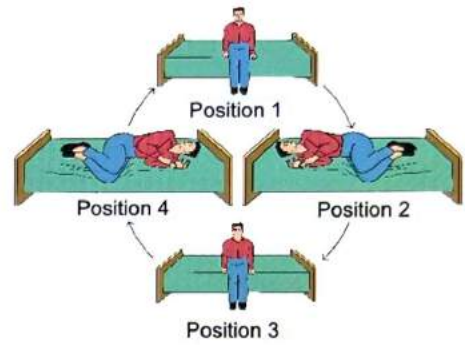


- After any of these 2 maneuver ask the patient to lay down in FOWLER'S position for 24hrs

Flower's Position



- Repeated BPPV attacks recommend the patient for some home exercises i.e BRANDT-DAROFF (Each step for 30 seconds & repeat 3 times a day)



- Wait for 30 seconds to 1 minute during each step

Lateral canal BPPV patients we do 2 maneuvers for Rx

- Lemperts Maneuver: Complete rotation
- Log Roll (Barbecue)

Refer Image 6.1

? Previous Year's Questions

Q. Hallpike maneuver is done for: (FMGE JUNE 2018)

- A. Vestibular function
- B. Audiometry
- C. Cochlear function
- D. Corneal test

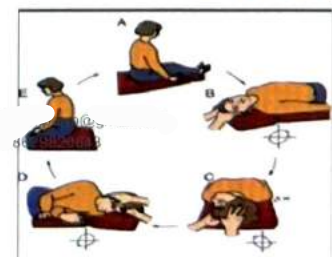
? Previous Year's Questions

Q. A person presented to ENT OPD with complaints of vertigo and nausea in the morning on change in position of the head. What is your diagnosis? (AIIMS Nov 2019)

- A. Labyrinthitis
- B. BPPV
- C. Vestibular neuronitis
- D. Meniere's disease

? Previous Year's Questions

Q. Name the maneuver shown in the image? (NEET PG Jan 2019)



- A. Lempert
- B. Semont
- C. Brandt daroff
- D. Epley

TESTS OF VESTIBULAR LABYRINTH

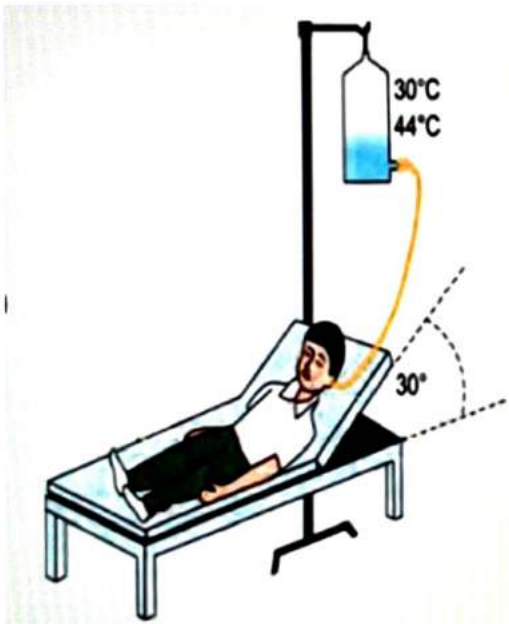
? Previous Year's Questions

- Q. A clinical case of vertigo lasting for a few seconds associated with movement of Head posture. The condition was treated with EPLEY's Maneuvre. What is the diagnostic test? (AIIMS June 2020)
- Brandt daroff exercise
 - Epleys maneuver
 - Dix hallpike
 - Heimlich maneuver

CALORIC TESTING

🕒 00:49:16

- Fitzgerald Hallpike's Test:



- Syringing is done with hot (44 C) and cold (30 C) water, (37 ± 7 C)
- It produces nystagmus by stimulating lateral semi-circular canal (horizontal nystagmus)
- Syringing done with
 - Cold water: Opposite side Nystagmus
 - Hot water: Same side Nystagmus

💡 How to remember

- COWS

- Modified Kobrak Test



- Instead of Hot and cold water at 0 c is used because cold stimulus is strongest stimulus than warm Temperature.
- Dundas Grant Test



- Cold air is used when Syringing is C/I in perforated Tympanic membrane

? Previous Year's Questions

- Q. Caloric test was done on right side with cold water. Eyes moved to the opposite side. Which of the following corresponds to correct interpretation of nystagmus in this test? (AIIMS May 2018)
- Fast component to left side
 - Slow component to left side
 - Fast component to right side
 - Slow component to right side

VEMP (VESTIBULAR EVOKED MYOGENIC POTENTIAL)

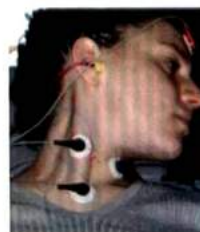🕒 00:57:40

- Give stimulus in vestibular system and check the response in muscles

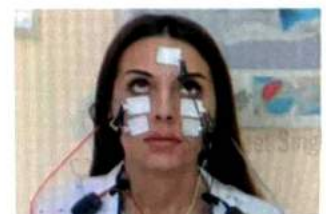2 types

Cervical Vemp ↓ Evaluates saccule and inferior vestibular nerve	Ocular Vemp ↓ Evaluates utricle and superior vestibular nerve
---	---

Cervical VEMP



Ocular VEMP



Galvanic Vestibular Stimulation


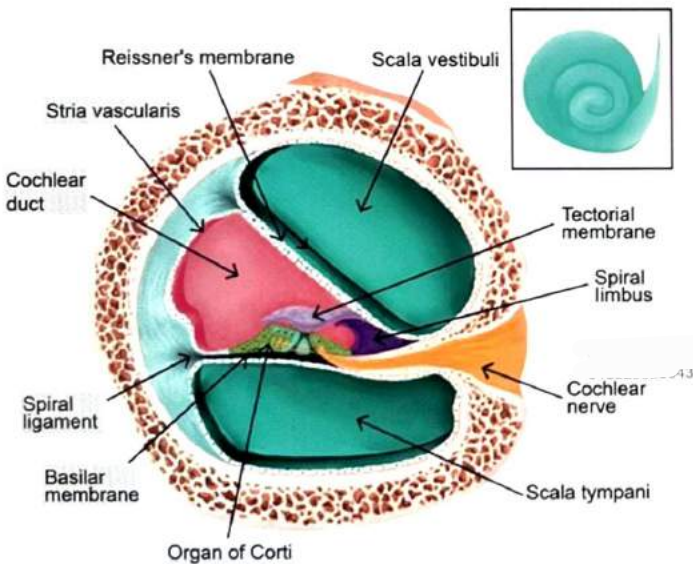
01:00:22

- Test of vestibular nerve with small voltage of current



Cochlea (Auditory Labyrinth)

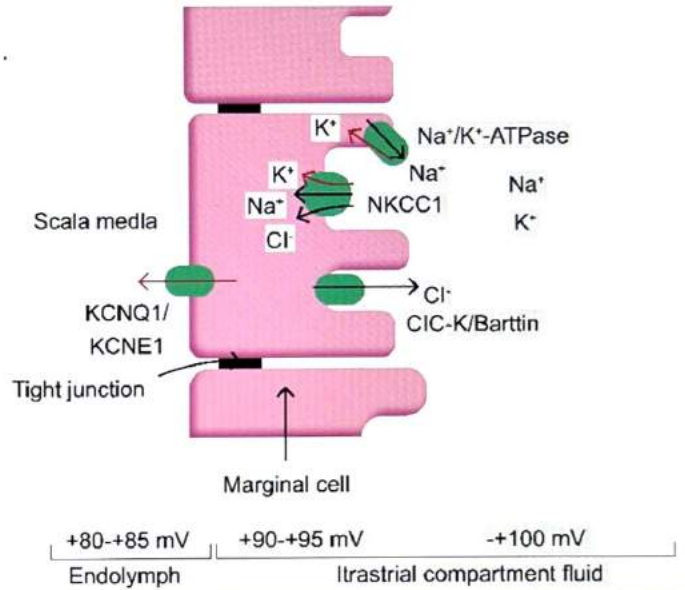
01:00:58



- Scala vestibule and scala tympani are filled with Perilymph
- Scala Media it is filled with Endolymph
- Endolymph is high in potassium and low in sodium (like ICF)
- Endolymph is secreted by stria vascularis with the help of Na⁺ - K⁺ ATPase pump
- Due to high K⁺ ions, Endolymph as positive potential inside it k/as endocochlear potential(+80-85 mv)
- Endolymph is also secreted by Dark cells of macula
- Endolymphatic sac → Present along the DONALDSON'S LINE

Endo Cochlear Potential

- Normal physiological potential
- +80 to +85 mV
- Not dependent on sound
- DC potential
- Generated by Na / K ATPase pump

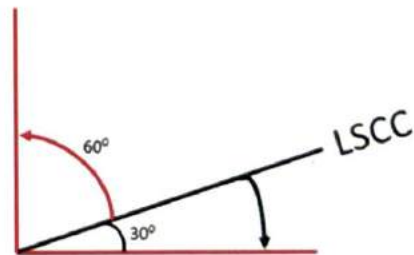


Previous Year's Questions

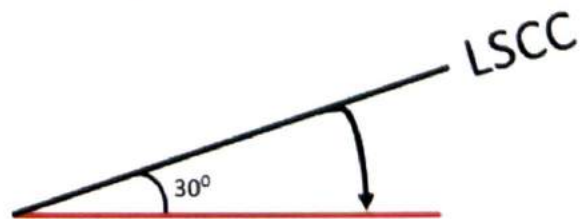
Q. Endolymph is secreted by: (FMGE Dec 2017)

- Basilar membrane
- Reissner's membrane
- Stria vascularis
- Tectorial membrane

Q. How to make Lateral SCC to vertical?
 Ans: Ask the patient to turn his head backwards by 60°



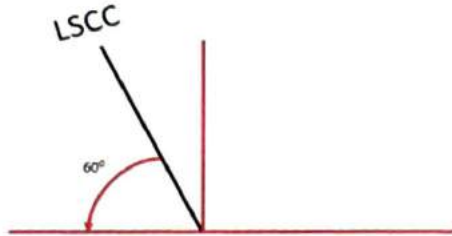
Q. How to make Lateral SCC to Horizontal?
 Ans: Ask the patient to bend his head forwards by 30°



- If the patient is in supine position, that means Lateral SCC has turned backwards by another 90°

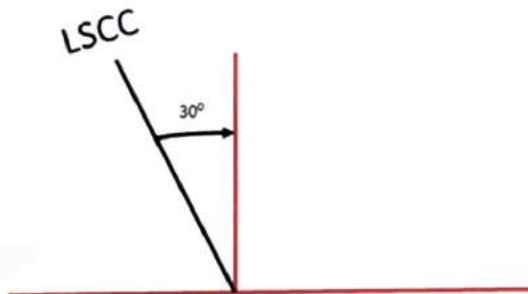
Q. How to make Lateral SCC in horizontal position if patient is supine?

Ans. Ask the patient to turn his head backwards by 60°

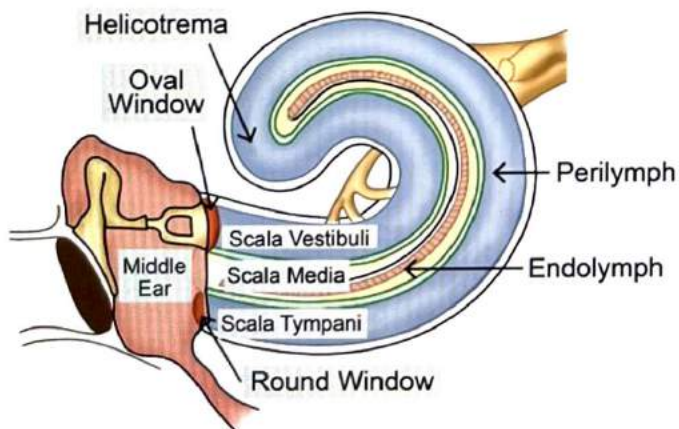


Q. How to make Lateral SCC in vertical position if patient is supine?

Ans: Ask the patient to bend his head forwards by 30°

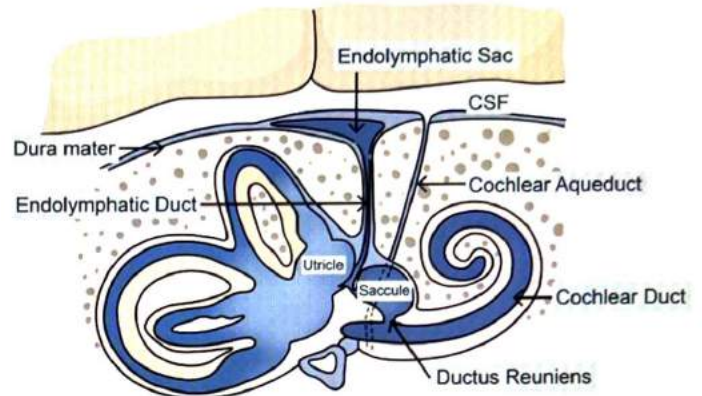


Unspiralled Cochlea



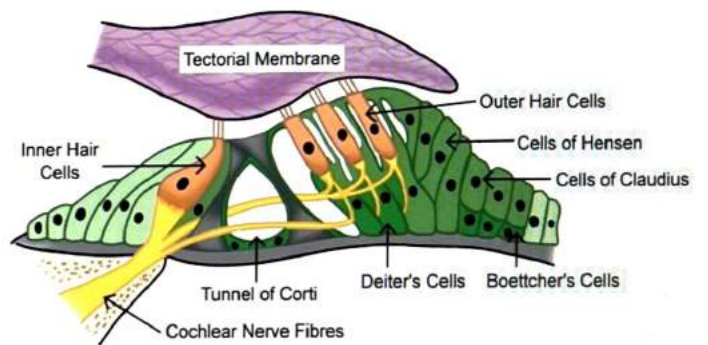
- Scala vestibule and scala tympani communicates with each other at the apex and this communication is k/as Helicotrema.
- Scale tympani also communicate with the sub-arachnoid space through cochlear aqueduct. So, Perilymph is same as CSF → M/c route of spread of infection from brain to inner ear during meningitis.
- Cochlear Aqueduct: Connects Scala Tympani to Subarachnoid space, Perilymph is same as CSF

- During meningitis, M/C route of infection from brain to inner ear is Cochlear aqueduct causing Labyrinthitis



SENSORY ORGAN OF COCHLEA: ORGAN OF CORTI

00:23:43



- Inside the cochlea there is sensory organ resting on basilar membrane known as organ of Corti.
- There are 2 hair cells k/as outer hair cells & Inner hair cells (95% of stimulus)

Outer Hair cells	Inner Hair cells
• More in number (13-14 k)	• Less in Number (3500)
• More in Rows (3-5)	• Less in rows (single)
• Late development (more time)	• Early to develop
• More sensitive to <ul style="list-style-type: none"> ○ Ototoxic Drugs ○ Acoustic trauma (NIHL) (1st structure to be damaged is stereocilia of outer hair cells) 	• Less sensitive
• Amplify sound	• Mechanoelectrical transduction
• It produces OAE (Otto Acoustic emission)	

? Previous Year's Questions

- Q. A steel worker presented with noise induced hearing loss. which part of inner ear is most likely affected? (AIIMS Nov 2017)
- Inner hair cell
 - Outer hair cell
 - Macula
 - Cupula

? Previous Year's Questions

- Q. Which of the following is a cochleotoxic drug: (FMGE Dec 2017)
- Streptomycin
 - Gentamycin
 - Kanamycin
 - Minocycline

Ototoxicity

🕒 01:28:42

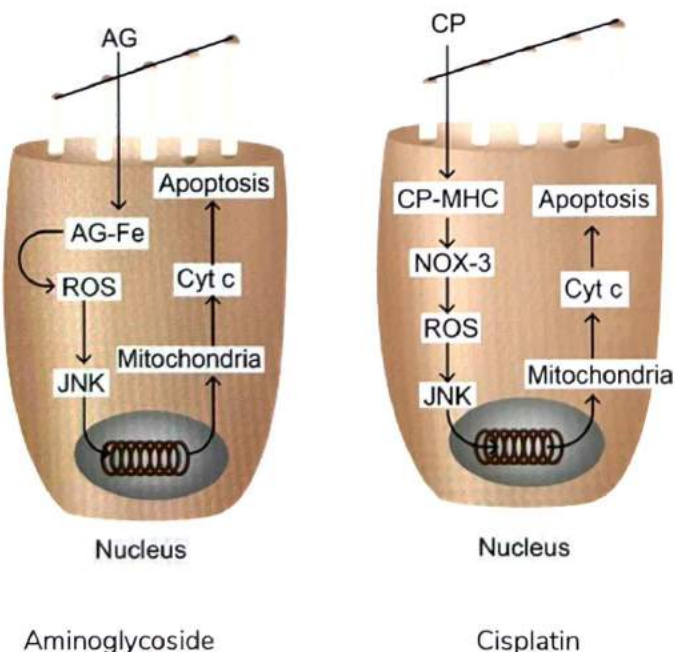
- Aminoglycosides: Irreversible ototoxicity
 - Streptomycin, Gentamycin: vestibulo toxic drugs
 - Kanamycin, Amikacin, Neomycin, Tobramycin: cochleotoxic
- Platinum based Chemotherapy drugs → Cisplatin/ Carboplatin [Reversible → Irreversible]
- Loop Diuretics: Furosemide, Ethacrynic Acid → Dose dependent ototoxicity
- Macrolides: Erythromycin
- Antimalaria: Quinine/ Chloroquine/ hydroxychloroquine
- NSAIDs: Ibuprofen, Naproxen
- Chemicals: Alcohol, Tobacco, Marijuana, Carbon monoxide poisoning
- Miscellaneous: Ampicillin, Propranolol, Propylthiouracil

OTO-ACOUSTIC EMISSIONS (OAE)

🕒 01:33:45

Outer hair cells produce – Oto-Acoustic emissions – objective test

- Low intensity sounds in response to a sound stimulus
- Spontaneous OAE: No clinical Significance
- Evoked OAE
 - Transient Evoked OAE (TE – OAE) single frequency sound
 - Distortion Product OAE (DP – OAE) double frequency sound
- Ototoxicity first affects high frequency sounds, so earlier High Frequency Audiometry was done for Ototoxicity.
- Now OAE is the most sensitive test to Detect Ototoxicity
- Transient Evokes OAE is most sensitive test of outer Hair cells.
- OAE Directly coming from outer Hair cells so most sensitive test for detecting Noise Induced Hearing loss as well as Ototoxicity
- OAE are used as screening test for Neonatal Deafness.



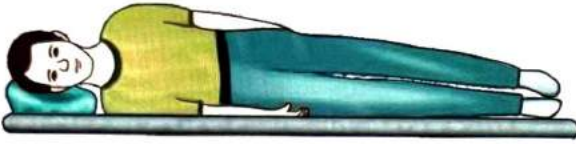
Screening test for neonatal deafness

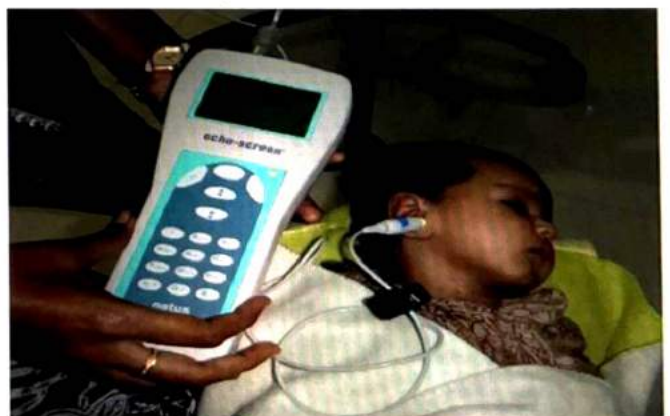

Image 6.1

Log Roll (barbecue)

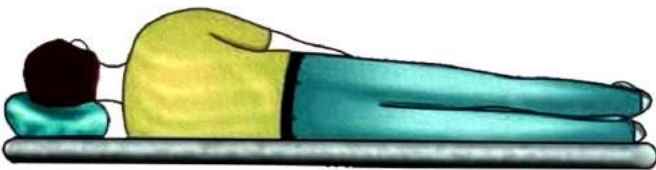
Position 1 (bad ear down)



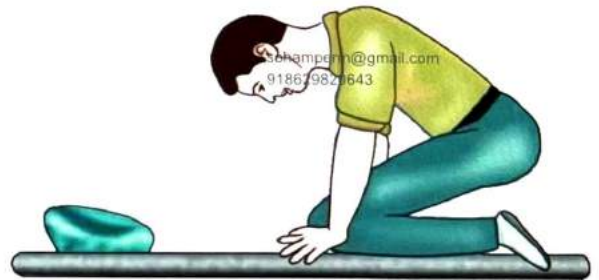
Position 2 (supine)



Position 3 (bad ear up)



Position 4 (on hands/knees)





CLINICAL QUESTIONS



Q. 65 years old male came to your clinic with complaints of Sensorineural hearing loss associated with vertigo and tinnitus. To rule out labyrinthitis, you are thinking of doing Fitzgerald hall pike test. Which of the following is stimulated by this test?

- A. Cochlea
- B. Lateral semicircular canal
- C. Posterior semicircular canal
- D. Superior semicircular canal

Answer: B

Solution

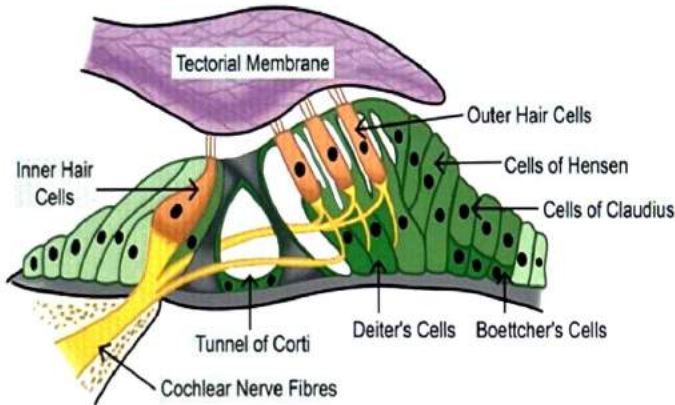
- CALORIC TESTS
 - The principle of the caloric test is that changes in temperature in the external auditory canal influence the level of activity of the vestibular labyrinth.
- How to perform:
 - In order to obtain a satisfactory nystagmic response, the subject has to lie down with the head raised 30 degrees above horizontal. This places the lateral semicircular canal in an approximately vertical position; the more lateral position of this canal leaves it more accessible to external temperature changes.
- The caloric test stimulates the lateral semicircular canal, the bulge of which is present on the medial wall of the middle ear.
- Water irrigation at 30°C and 44°C ($37 \pm 7^\circ\text{C}$) is the standard technique.
- Each irrigation should last for 40 sec
- RESULTS:
 - Cold irrigation induces horizontal nystagmus beating in the opposite direction of irrigation, and ipsilaterally during warm irrigation (cold-opposite-warm-same (COWS)).



7 NEURAL PATHWAY OF SOUND

ORGAN OF CORTI

00:00:31



- Inside the cochlea there is sensory organ resting on basilar membrane known as **organ of Corti**.
- From the organ of Corti, cochlear nerve starts. It is the part of 8th cranial nerve.
- The nerve fibres take stimulus from inner hair cells (95%) and outer hair cells (5%).
- These fibres start from the outer hair cells.

NEURONAL PATHWAY OF SOUND

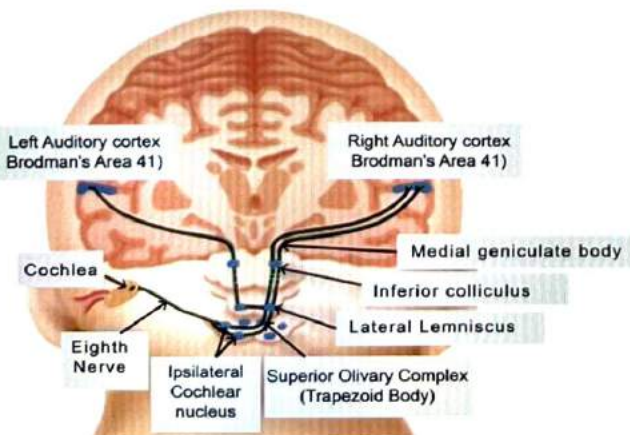
00:01:50

- Cochlear nucleus is in brain stem



Important Information

- E- 8th nerve COLI → Brainstem MA → Cerebrum



How to remember

- ECOLI-MA

- **E:** Eight Nerve
- **C:** Cochlear nucleus a/k/a Spiral Ganglion (located on the lateral recess of 4th ventricle)
- **O:** Superior olivary complex (lies in the Trapezoid body)
- **L:** Lateral lemniscus (Largest)
- **I:** Inferior colliculus
- **M:** Medial Geniculate body
- **A:** Auditory cortex (Brodman's area 4)



Important Information

- Cross over of sound takes place at superior olivary nucleus (Through TRAPEZOID BODY)



Previous Year's Questions

- Q. Arrange the sequence of auditory pathway from peripheral to central? (AIIMS - May - 2019)
- Inferior colliculus
 - Cochlear nucleus
 - Auditory cortex
 - Medial geniculate body
- ANS: B - A - D - C



How to remember

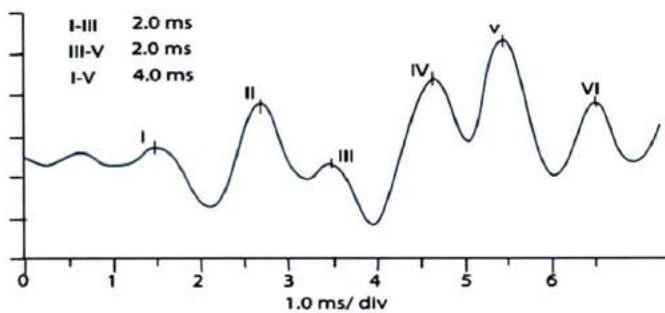
- EE-COLI

BRAINSTEM EVOKED RESPONSE AUDIOMETRY (BERA/ABR)

00:07:27

- ABR- Auditory Brainstem Response
- Study of electric waves produced along the neural pathway of sound.

- E-Wave I → Produced by distal part of Eighth nerve (1.5ms)
- E-Wave II → Produced by proximal part of Eighth nerve
 - Distal → away from the brain
 - Proximal → near the brain
- C-Wave III → Produced from cochlear nucleus (3.5ms)
- O-Wave IV → Produced from superior olivary complex
- L-Wave V → Produced from Lateral lemniscus (5.5 ms)
- I-Wave VI → Produced from Inferior colliculus
- Wave I, III, V → stable wave
- Wave V → Largest / Tallest / Most stable / Most significant wave
- Wave I-V = Interpeak Latency (4.0 ms)



- BERA is used as **confirmatory (specific) test** for neonatal deafness.
- Best test for neonatal deafness → BERA/ABR
 - Best test for screening -OAE
- Also used to detect Malingering
- BERA is an objective test

? Previous Year's Questions

- Q. Findings of BERA in vestibular schwannoma: (JIPMER - May - 2018)
- Increased latency in waves I-V
 - Decreased latency in waves I-V
 - Increased latency in waves VI-VII
 - Decreased latency in waves VI-VII

? Previous Year's Questions

- Q. True about BERA? (FMGE Dec 2020)
- Invasive testy
 - Subjective test
 - Done only for those who are above 18 yrs
 - Done for Sensorineural hearing loss

? Previous Year's Questions

- Q. False regarding assessment in children? (JIPMER Nov 2017)
- Done for all normal babies to assess hearing
 - Using BERA
 - Using OAE
 - Using pure tone audiometry

? Previous Year's Questions

CASE DISCUSSION FOR QUESTIONS ON BERA:

- If no waves / not identifiable waves / wave I absent / all waves absent . patient has **cochlear deafness or sensory hearing loss**
- If wave I is present and wave V is absent → **Retro-cochlear hearing loss**
- If wave I is present and wave V is delayed (Wave I-V interpeak Latency ≥ 4.4 ms) → **Retro-cochlear hearing loss.**

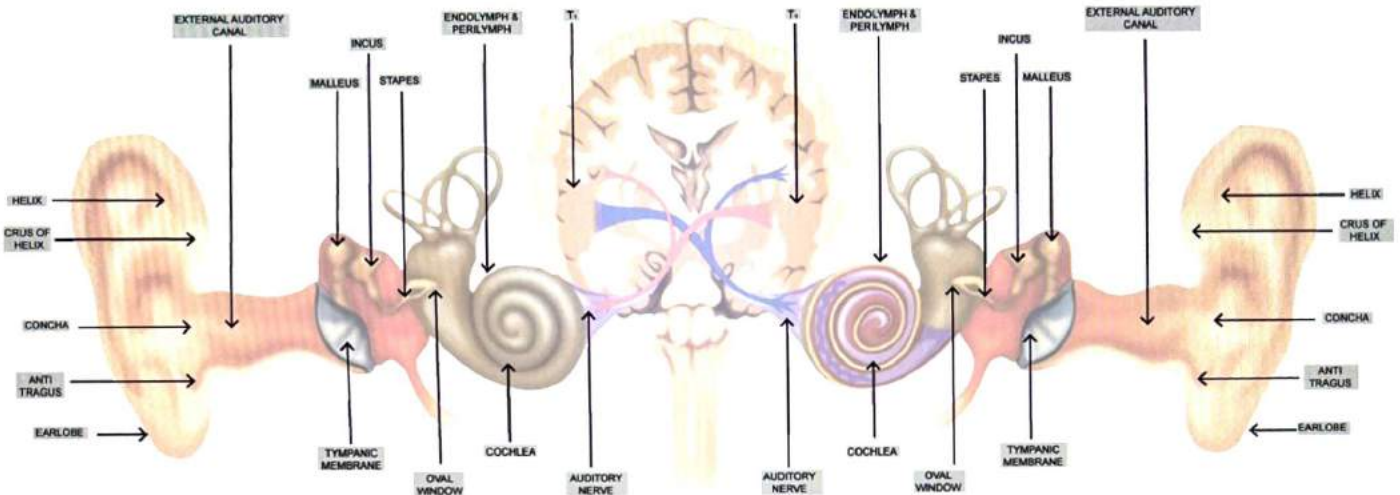
DIAGNOSTIC IMPORTANCE OF BERA:

🕒 00:20:08



8 PHYSIOLOGY OF HEARING

BINAURAL VS MONOAUURAL HEARING



- Binaural Hearing by 2 ears
- Monoaural Hearing by 1 ear
- Advantages of Binaural → help in sound localization → d/t head shadow effect

PINNA & VERTICAL SOUND LOCALIZATION:

🕒 00:06:48

- Vertical sound localization occurs because of shape of Pinna

COCKTAIL PARTY EFFECT

🕒 00:07:22

- Better hearing in noisy environment i.e. listening to one person voice clearly in the presence of background noise

MIDDLE EAR MECHANICS

🕒 00:08:53

- Total surface area of Tympanic membrane = 90 mm^2
- Effective vibratory area of TM = 55 mm^2
- Surface area of stapes foot plate = 3.2 mm^2
- Areal ratio = 17: 1
- Lever ratio = 1.3:1
 - Between length of Handle of Malleus & long process of Incus
 - TORQUE = Force X length

Refer Image 8.1

- Middle ear transformer ratio (Ossicular Coupling) = 22:1
- **Most mobile part of Tympanic Membrane is periphery of Pars Tensa.**

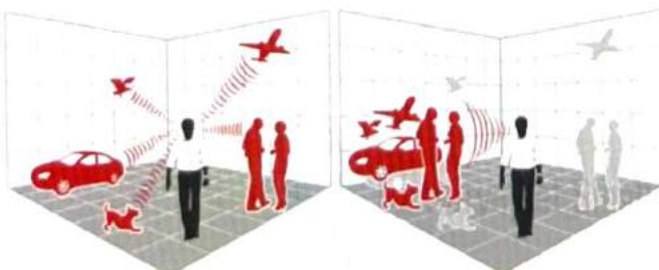


Important Information

- Neural pathway of sound also does the sound localization by speech/sound processing

Binaural Hearing

Monoaural Hearing





Important Information

- Umbo is the mobile part of Malleus

CURVED MEMBRANE EFFECT

00:17:13

- Because of vibrating periphery of Pars Tensa Curved membrane effect is created.
- It increases the sound force almost 2 times
- It is also known as Catenary Lever.
- Sound travels faster in solids than air due to which the 2 windows are in phase difference



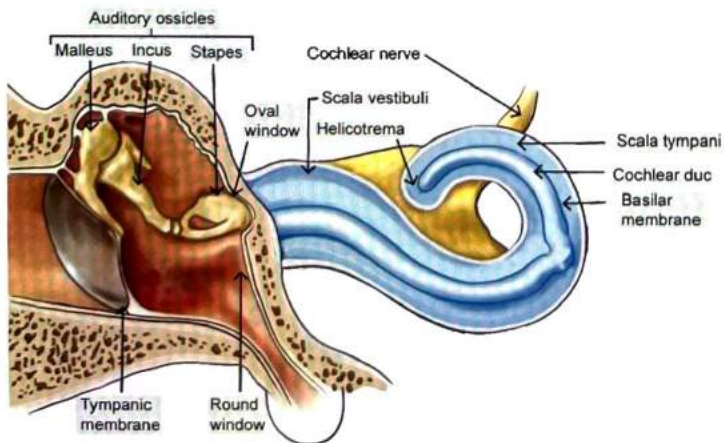
Important Information

- Air- 343 m/s
- Liquid- 1400m/s
- Solid -4000-5000m/s

ACOUSTIC COUPLING

00:19:04

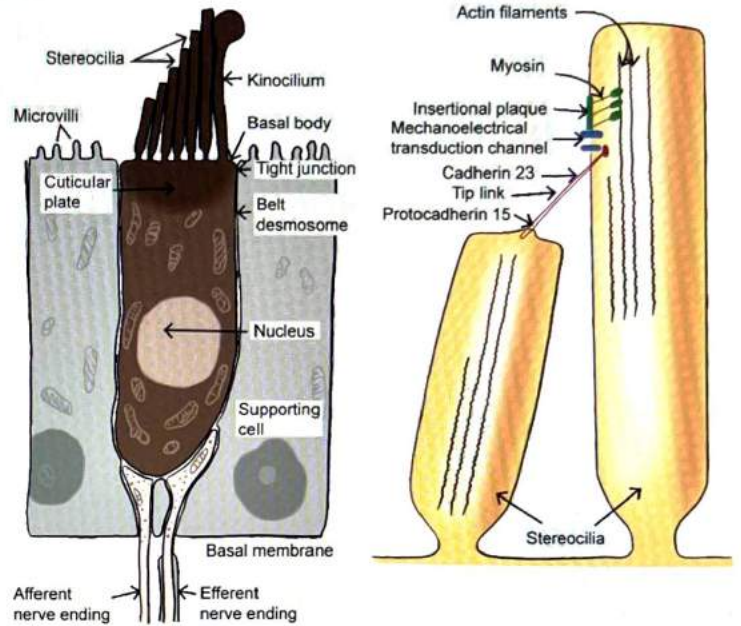
- Phase Difference- two windows move different.
- Middle ear - Also Amplifies sound by creating phase difference between Oval & Round Window.
- This is known as Acoustic coupling.
- Middle ear Mechanics involves in Impedance Matching with the Ossicular Coupling + Acoustic Coupling
- In inner ear - Sound waves move perilymph in Scala vestibuli → This movement reaches Scala tympani
- Above Scala tympani there is basilar membrane which has Organ of Corti



ORGAN OF CORTI:

00:23:50

- The stereocilia on Hair cells in Organ of Corti have "tip link" which join one stereocilia to next bigger stereocilia



- Sound waves move the Basilar membrane which in turn move the stereocilia of the hair cells
- ↓
- This leads to stretching of tip link and opening of cation (Positive ion) Channels
- ↓
- Movement of K^+ and Ca^{2+} from Scala media into Stereocilia (Hair cells)
- ↓
- This movement of ions create a potential inside the inner ear called as Cochlear microphonics. Ca^{2+} ions stimulate Myosin protein inside the stereocilia and close the cation channel by moving it down and relaxing tip link.

USHER SYNDROME

00:26:40

- SNHL + Vision loss (Retinitis pigmentosa)
- Mutation of gene encoding: Cadherin 23 or Protocadherin 15
- Autosomal recessive inheritance
- Finnish population and Ashkenazi Jewish Heritage

DEPOLARIZATION AND HYPERPOLARIZATION:

00:27:26

- Cochlear Microphonics
 - Electrical potential in the inner ear
 - Produced d/t influx of K^+ due to opening of Ion channels in response to a sound stimulus.
 - This is an AC potential.

Summating Potential

- o Potential produced inside the outer hair cells in response to movement of K^+ ions
- o Have higher latency period than cochlear microphonics
- o **DC potential**

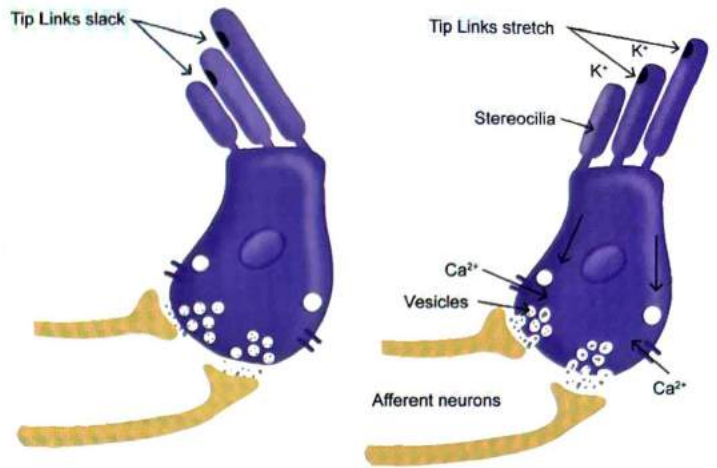
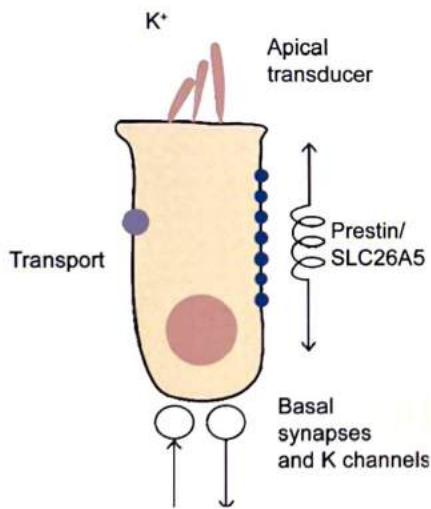
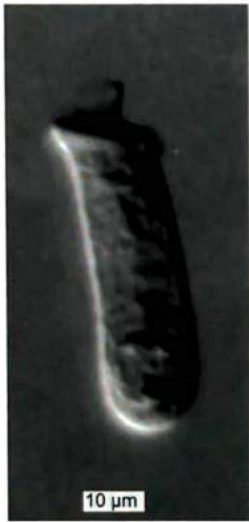Eighth Nerve Action Potential

- o All or None Phenomenon: Produced Only when Sound stimulus is above hearing threshold

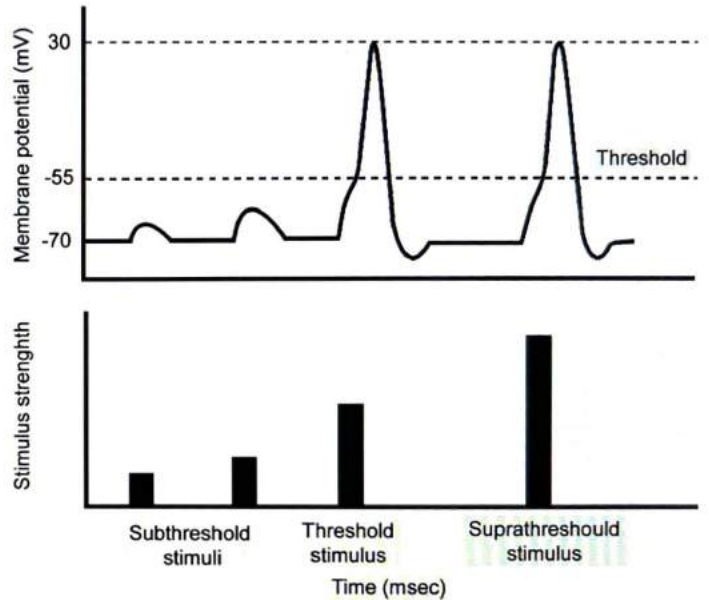
OHC'S & AMPLIFICATION:

🕒 00:33:40

- o Outer hair cells have a protein called prestin (in wall of OHC)
 - o Prestin is a contractile protein
 - o Also have voltage sensing ability
 - o When cation goes in OHC contracts which amplifies the movement of basement membrane. This is called as somatic electromotility. This further is transmitted to inner hair cells.



8th Nerve Action Potential



INNER HAIR CELLS & MECHANOELECTRICAL TRANSDUCTION

🕒 00:35:36

- o These are flask shaped cells.
- o When tip links are stimulated K^+ goes inside & causing calcium influx

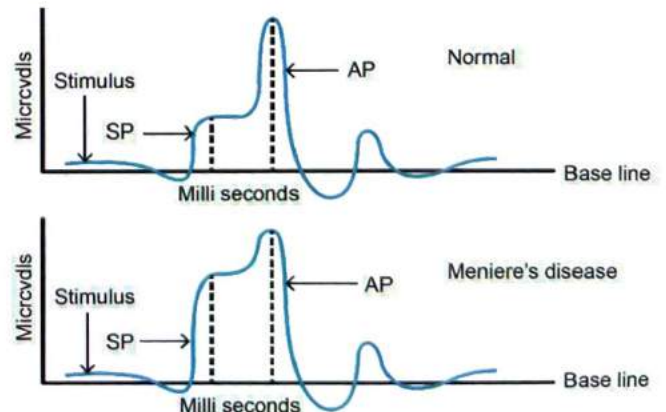
↓
 Ca^{2+} binds to glutamate vesicles which further uses with the cell membrane causing release of Neurotransmitter
 ↓
 Leads to generation of 8th Nerve action potential (having all or none phenomenon)

ELECTRO COCHLEOGRAPHY

🕒 00:38:27

Summating Potential vs Action Potential

- o In normal ear → SP < 30% AP
- o In Meniere's disease → SP > 70% AP is confirmatory → SP > 45% AP is Indicative

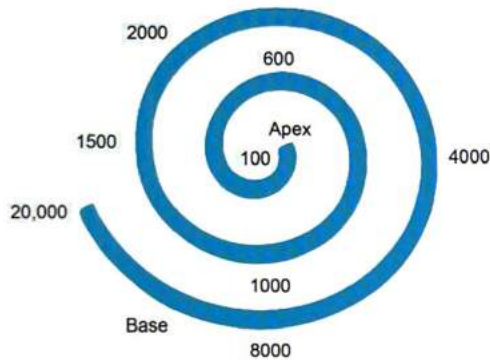


- Electrocochleography is the confirmatory test for Meniere's disease
- Invasive investigation: have to make a hole in Tympanic Membrane to place electrode on Round Window

FREQUENCY LOCALIZATION IN COCHLEA

00:40:00

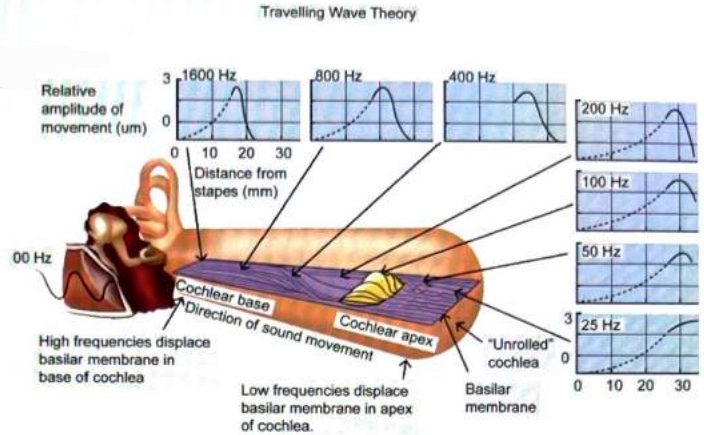
- Normal hearing range → 20-20000 HZ
- 20Hz is heard at apex of Cochlea 20,000Hz is heard at Base of Cochlea
- From every part of cochlea, a neuron comes which carries a different frequency



TRAVELLING WAVE THEORY

00:42:46

- Peak – at which sound heard maximum
- As frequency increases, the peak shift towards base
- As frequency decreases, the peak shift towards apex
- This theory given by Von Bekesy who got noble prize in physiology or medicine [1961]
- Neural Pathway is Frequency coded.



SPEECH INTENSITY

00:47:33

- It is measured in dB
- Sound of whisper – 30 dB
- Normal conversation – 45-60 dB
- Noisy market – 60 dB
- > 80 dB sound is dangerous
- As per WHO guidelines, sound intensity > 140 dB can lead to deafness even if for few μsec

Refer Image 8.2



Important Information

- Maximum audible tolerance of sound according to WHO guidelines and "Factory act 1948" (G.O.I) guidelines is 85 dB for 8 hrs
- After this WHO follows 3 dB exchange rate i.e if you ↑ the sound intensity by 3 dB you ↓ the time duration by half
 - Eg. 88 dB - 4hrs 91 dB - 2hrs
- For G.O.I there is 5 dB exchange rate Eg. 90 dB - 4 hrs



Previous Year's Questions

Q. Maximum audible tolerance is?

- 90 dB for 6hr
- 90 dB for 8hr
- 85 dB for 6hr
- 85 dB for 8hr



Important Information

- Frequency Localization in Cochlea.

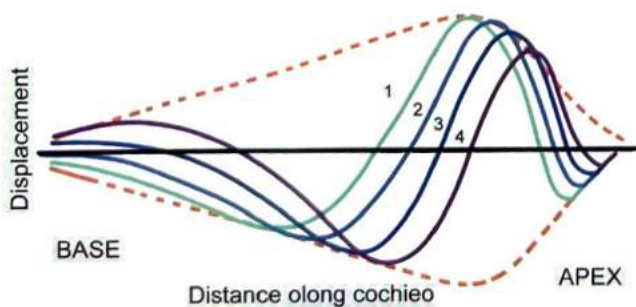


Image 8.1

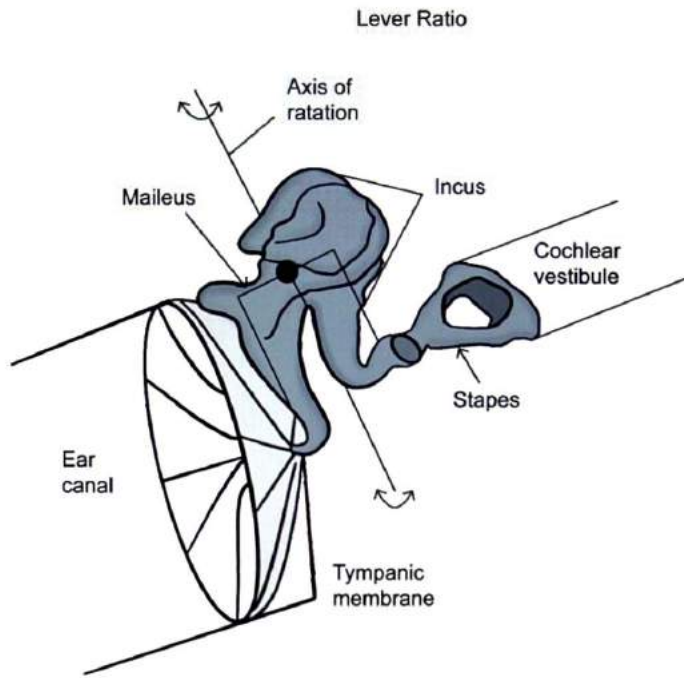
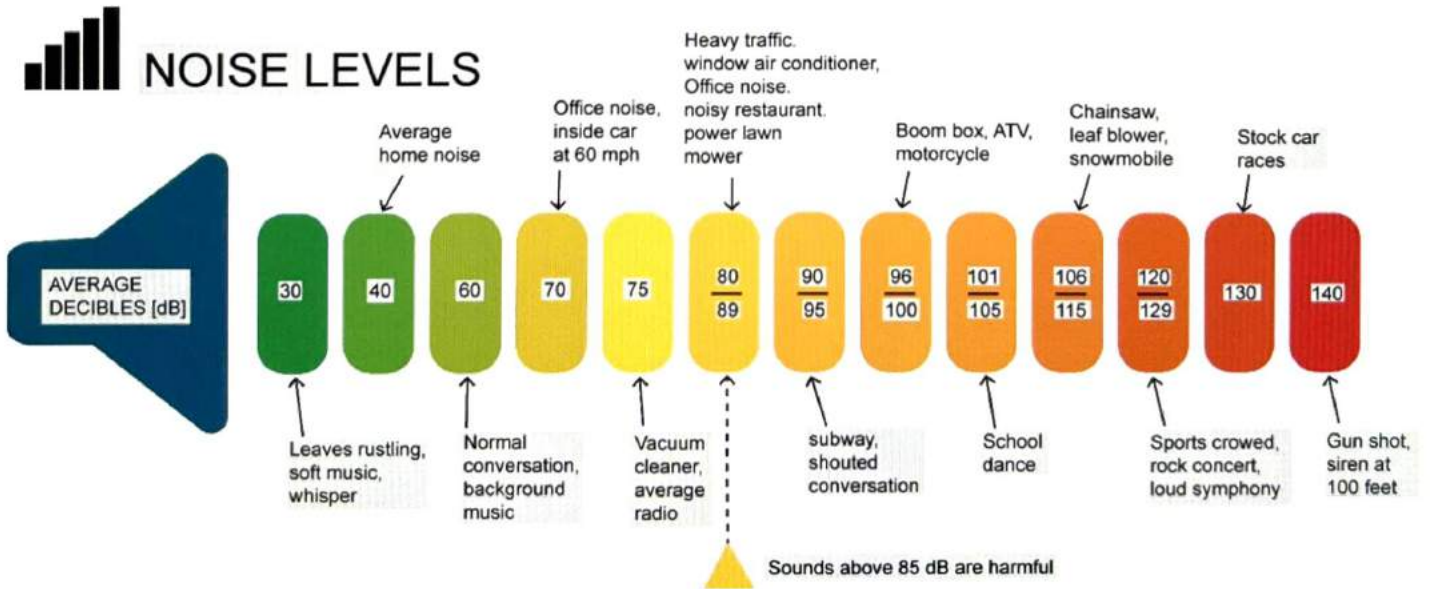


Image 8.2





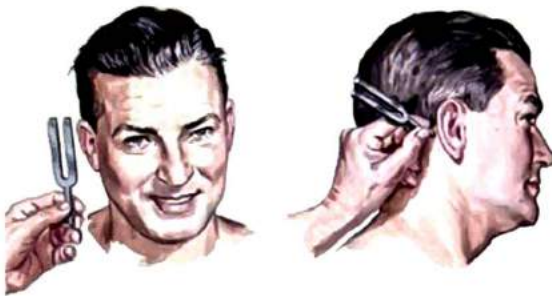9 TESTS OF HEARING

TUNING FORK TESTS

00:00:10

- Mcused-512 Hz
- Not used-128 Hz [Used in neurological hearing]

RINNE'S TEST



Air Conduction

Bone Conduction

- AC > BC: Rinne's positive → Normal, SNHL
- BC > AC: Rinne's negative → CHL
 - Diseases of External ear
 - Disease of Middle ear
- AC > BC: SNHL (U/L)
- BC > AC: Severe SNHL (Dead ear)/ False negative Rinne's (Bone conduction by other ear)

256 Hz	512 Hz	1024 Hz	CHL
-	+	+	20-30 dB
-	-	+	30-45 dB
-	-	-	> 45 dB

- Most sensitive tuning fork: 256 Hz
- Minimum CHL required to make at least one tuning fork -ve: 20 Hz (First one to become -ve is 256Hz)

WEBER'S TEST

- Tuning fork placed in the midline of vertex.
- Sound heard in the better ear SNHL
- Sound heard in the bad ear CHL
- Normal weber's is heard in the center.
- More sensitive than Rinne's test. (5 db)
- Simple funda: Always check the weber's first in tuning fork test questions



Important Information

- Weber goes away from SNHL
- Weber goes towards CHL
- 4 step method of Tuning fork test
 - Step 1: Check weber's
 - Step 2: Check patient's complaints
 - Step 3: Check Rinne's negative side
 - Step 4: Rinne's positive both sides (Then it is SNHL)

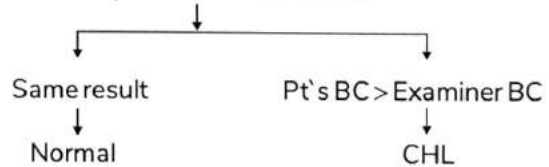
ABSOLUTE BONE CONDUCTION TEST (ABC)

- Comparison test between patient & examiner
- Examiner is assumed to be normal
- Press Tragus to close the air conduction
- Patient BC < Examiner's BC → SNHL
- Patient BC = Examiner's BC Normal

Schwabach Test

- Comparison test between pt. & examiner
- Examiner is assumed to be normal
- No pressing of Tragus
- Patient BC < Examiner BC → SNHL
- Patient BC = Examiner BC

Repeat test reverse order



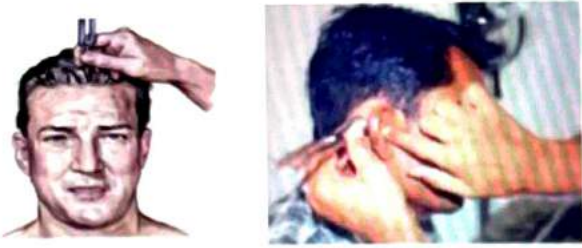SIEGEL'S SPECULUM

- Used for
 - M - Magnification
 - M - Mobility
 - M - Medication of Tympanic membrane
 - G - Gelle's Test
 - F - Fistula Test
- Cannot remove F.B.



How to remember

- M3GF



Bing Test

- Modification of Weber's test
 - Vibrate TF & keep at Mastoid
- ↓
- As soon as patient stops hearing
- ↓
- Close EAC
- ↓
- If he hears again
- ↓
- BING'S POSITIVE**
- ↓
- Seen in Normal hearing & SNHL
- Vibrate TF & keep at Mastoid
- ↓
- As soon as patient stops hearing
- ↓
- Close EAC
- ↓
- If he hears nothing
- ↓
- BING'S NEGATIVE**
- ↓
- Seen in CHL

Gelle's Test (earlier done to detect otosclerosis)

- Vibrate TF & keep at mastoid
- ↓
- Raise the pressure with Siegel's speculum
- ↓
- ↓ Loudness of sound
- ↓
- Seen in Normal hearing & SNHL
- Vibrate TF & keep at mastoid
- ↓
- Raise the pressure with Siegel's speculum
- ↓
- No change in loudness
- ↓
- Seen in otosclerosis

For Malingering

- Chimani- Moos test
- Stenger's test
- Lombard test [B/L Malingering]

PURE TONE AUDIOMETRY (PTA)

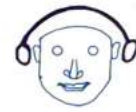00-36-36

- Can determine
 - Degree/Amount of hearing loss
 - Type of hearing loss
 - Calculates the hearing threshold
- Minimum intensity at a particular frequency at which a person starts hearing → Hearing/ Auditory Threshold
- Uses single frequency sounds
- O' (Zero) values doesn't mean 'O' in true sense, it is hearing threshold of a normal person. It is different for different frequencies
- AC & BC = 0 for Normal person

Right side

Red
 ○○○○
 <-<-<-<-
 [[[[

AC
 BC
 BC with masking
 (Sound in non test ear)



Left side

Blue
 XXXX
 ->->->->
]]]]

? Previous Year's Questions

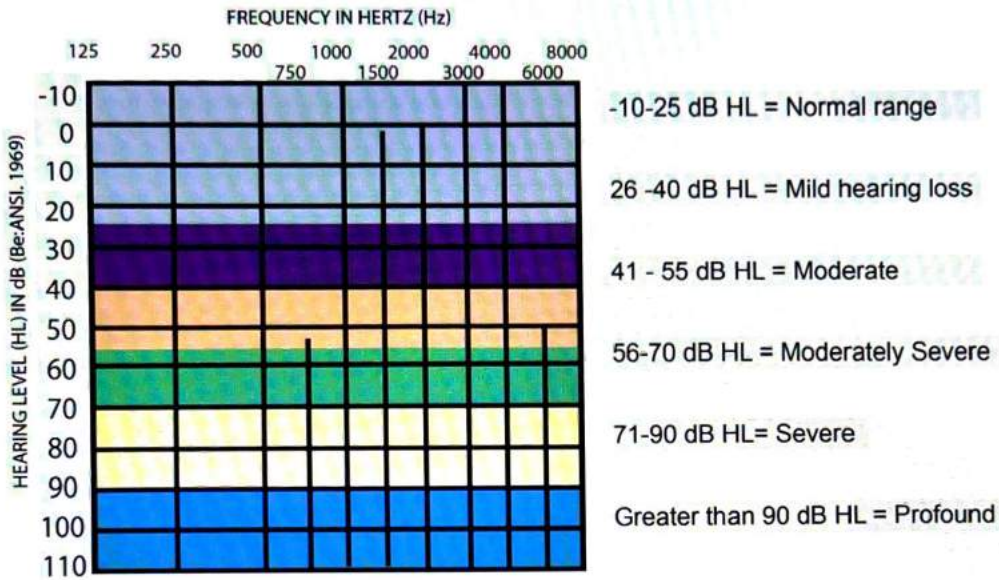
- Q. Patient presents with severe hearing loss. For the amount of decibel loss he has, which of the following sound can he heard by him? (JIPMER Nov 2017)
- A. Rustling of leaves
 - B. Start of car engine at 10 feet
 - C. Sound of Niagara falls
 - D. Noisy environment Night street

? Previous Year's Questions

- Q. Which of the following conditions will show decrease in Bone Conduction in Pure Tone Audiometry? (FMGE Dec 2020)
- A. Fixation of footplate of Stapes
 - B. Tympanic Membrane Perforation
 - C. EAC Pathology
 - D. Cochlear Pathology

Range of SNHL: Clarke's (1981)

- -10 - + 25 dB - Normal
- 26 - 40 dB - Mild
- 41 - 55 dB - Moderate
- 56 - 70 dB - Moderate severe
- 71 - 90 dB - Severe
- ≥91 dB - Profound



WHO classification

Refer Image 9.1

Hearing graphs

Refer Image 9.2

Types of Hearing Loss

- Conductive Hearing Loss: AB gap (Air Bone gap) is seen

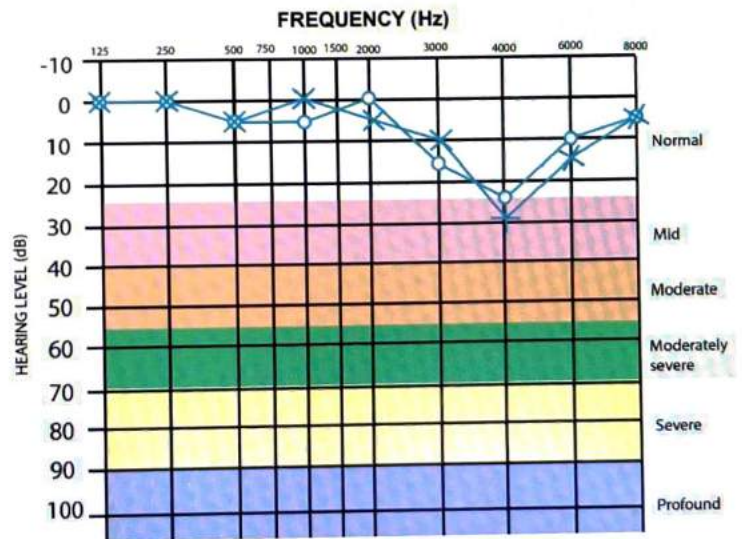
SNHL

- Dip @ 4000 Hz in BC → Boiler's Notch
- Noise induced hearing loss is a type of SNHL
- Maximum loss is seen between 3000-6000Hz with a max dip at 4000Hz
- The first structure to be damaged in noise induced hearing loss is the Steriocilia of outer hair cells
- Test to find out NIHL even before on audiometry → OAE
 - NO AB gap
- Notch is seen only in BC curves (AC curve Notch are insignificant)

MIXED HEARING LOSS

- AB gap present
- Both SNHL & CHL

Q. Identify the cause of hearing loss??



Ans: B/L Noise Induced Hearing Loss



Important Information

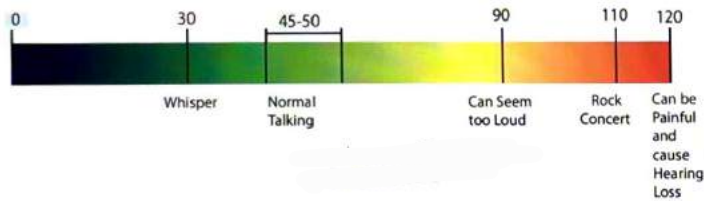
- Boiler's notch is seen in Noise induced hearing loss

Stereocilia of outer hair cells



Speech intensity

- Intensity of sounds (measured in Decibels-dB)



Audible tolerance limits

01:04:06

Previous Year's Questions

Q. Maximum audible tolerance is? (JIPMER Nov 2018)

- A. 85dB for 8hr
- B. 90 dB for 8hr
- C. 85 dB for 6 hr
- D. 90dB for 6hr

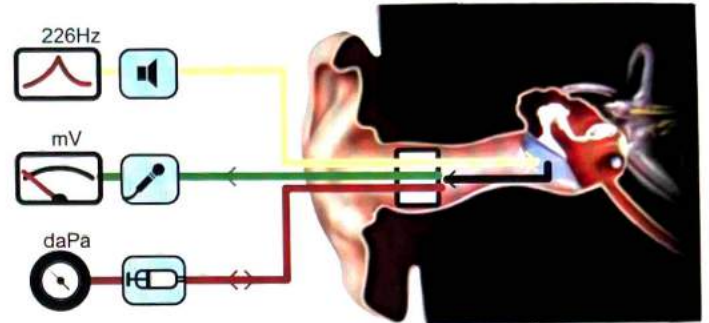
Table of Equivalent Noise Exposures

Steady sound level (dBA)	Duration
82	16 hours
85	8 hours
88	4 hours
91	2 hours
94	1 hours
97	30 minutes
100	15 minutes
103	7.5 minutes
106	3.75 minutes
109	1.88 minutes

IMPEDENCE AUDIOMETRY

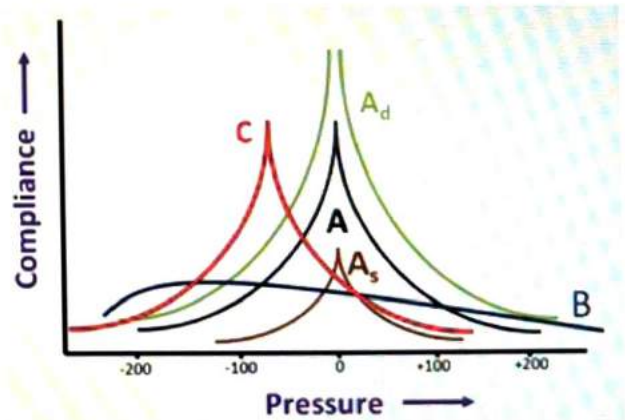
01:07:23

- Consist of
 - Tympanometry
 - Stapedial reflex/ Acoustic reflex



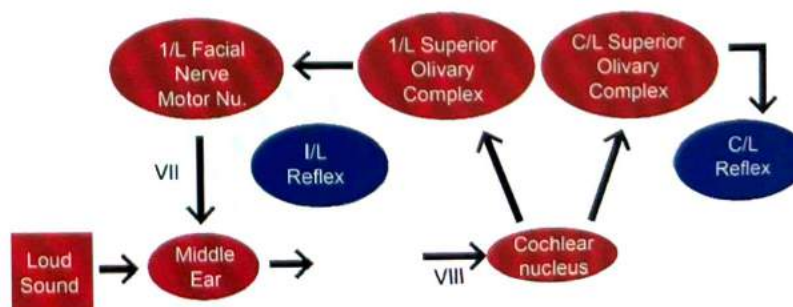
Types of Curves seen in Tympanometry:

- Type A: Seen in Normal Individual
- Type A_s: Seen in Stiffness/ Small/ Sclerosis
 - Otosclerosis [Stapes becomes stiff]
 - Tympanosclerosis
 - TM become chalky white
- Type A₀: Seen in Ossicular Discontinuity/ Decrease in stiffness/ Dimeric
- Type B: Seen Fluid in the ME
 - Glue ear (Serous otitis)
- Type C: Seen in Retracted Tympanic membrane [We will apply same negative pressure first as TM is retracted]



STAPEDIAL REFLEX

- Also known as Middle ear muscles(MEM) reflex, attenuation reflex or auditory reflex.
- Protects inner ear from noise trauma
- Stapedius muscle contracts on hearing loud sound

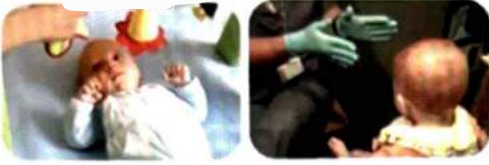

SPECIAL AUDIOMETRY TESTS

01:27:57

Behavioural Observation Audiometry (BOA)

- If we claps, Baby moves head in towards the sound



Very young babies (under 6 months)

Visual Reinforcement Orientation Audiometry (VROA)

- Signal can be reinforced to child with visual clues



Infants: 7 months -3 years

Play Audiometry (3-9YEARS)

- On hearing sound child has to pick a toy and put it in a bucket



SPEECH AUDIOMETRY

01:31:21

Speech Reception Threshold (SRT)

- Minimum intensity at which 50% of spondee (Disyllable with equal stress) words are correctly identified
- Spondaic words
 - Pancake
 - Hardware
 - Playground
 - Bat ball

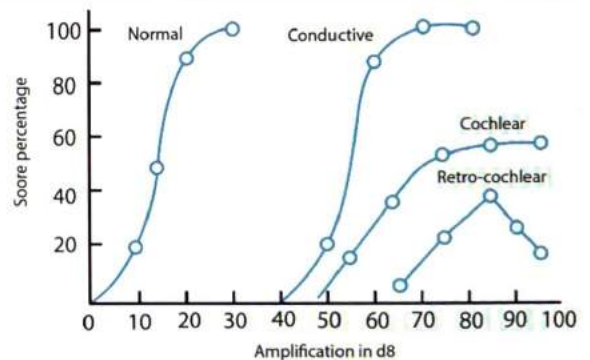
Speech Discrimination Score (SDS)

- Percentage of phonetically balanced (Single syllable) words correctly identified at 40dB above SRT
- Phonetically balanced words – Hit, Pin, Tin, Bin
- PB max score normally reaches 100% 40dB above SRT
- IDENTIFIES RETROCOCHLEAR HEARING LOSS by ROLLOVER Phenomenon



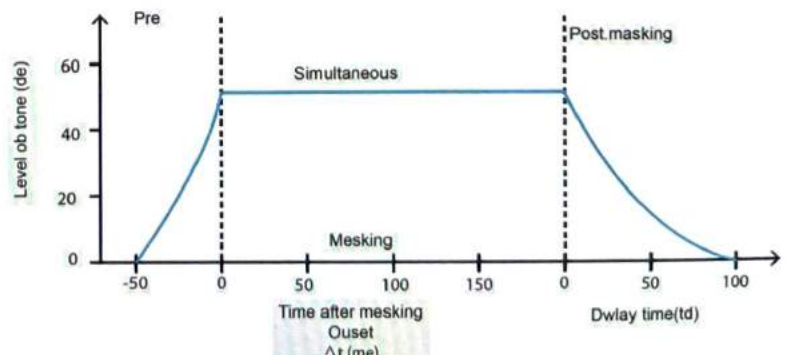
How to remember

- 40MSDS



Tone Decay Test

- If a normal individual is given a sound tone within his hearing threshold or 5 dB within hearing threshold, he should be able to hear the sound for 60 sec
- Identifies retro cochlear hearing loss > 25 dB increase in sound intensity so that patient can hear tone for 60 seconds.



Hearing Assessment

Subjective

Objective

BIRTH TODDLER SCHOOL-AGED*

Request responses

Condition responses

Observe responses

• Tympanometry

• Acoustic reflex

• ECochG

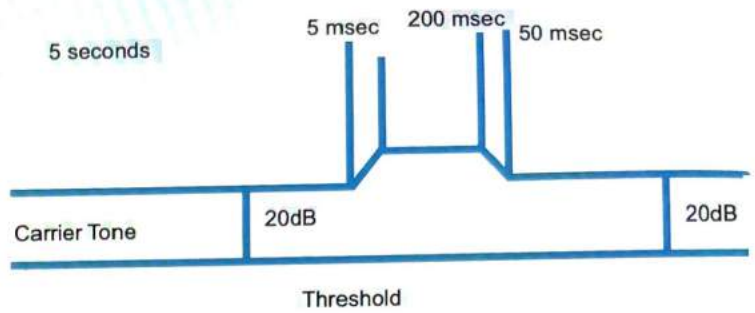
• OAE

• BERA/ABR

Need to consider individual's functional age

Tone Decay Test

Tone	Decay	Pathology
dB	Type	
0 – 5	Absent	Normal
10 – 15	Mild	Cochlear
20 -25	Moderate	Cochlear
< 25	Severe	Retrocochlear



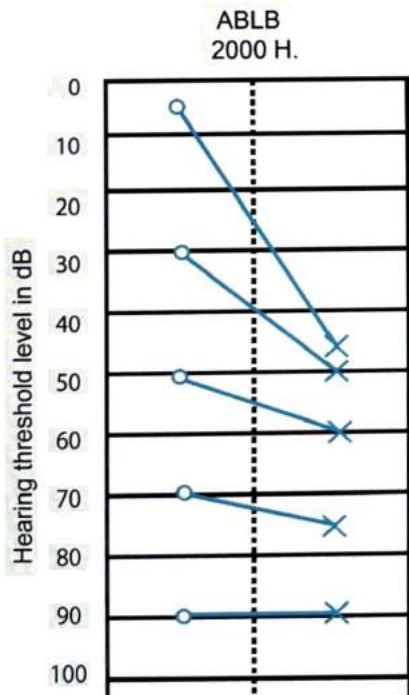
COCHLEAR VS RETRO-COCHLEAR 01:43:52

Test	Cochlear	Retro-cochlear
Speech audiometry	SDS = 60 – 80%	< 40%, Roll over phenomenon
Tone decay	Negative (< 25 dB)	Positive (> 25 dB)
S.I.S.I	Positive (> 70%)	Negative
A.B.L.B Laddergram	Converging	Diverging
B.E.R.A (Wave V latency)	< / = 4.2 msec	> 4.2 msec

Recruitment

- Present in cochlear hearing loss
- The sound that is given appears louder than actual

ABLB LADDERGRAM (ALTERNATE BINAURAL LOUDNESS BALANCE TEST)



- Laddergram is converging in Meniere's Disease (Cochlear deafness) due to recruitment

SISI (SHORT INCREMENT SENSITIVITY INDEX)

- Pt. is given 1 dB increasing clicks above the 20 dB of his hearing threshold, and observed how many clicks he can be able identify
- Test for cochlear hearing loss (Recruitment phenomenon) >70% correct identification

Image 6.1

Hearing loss grades

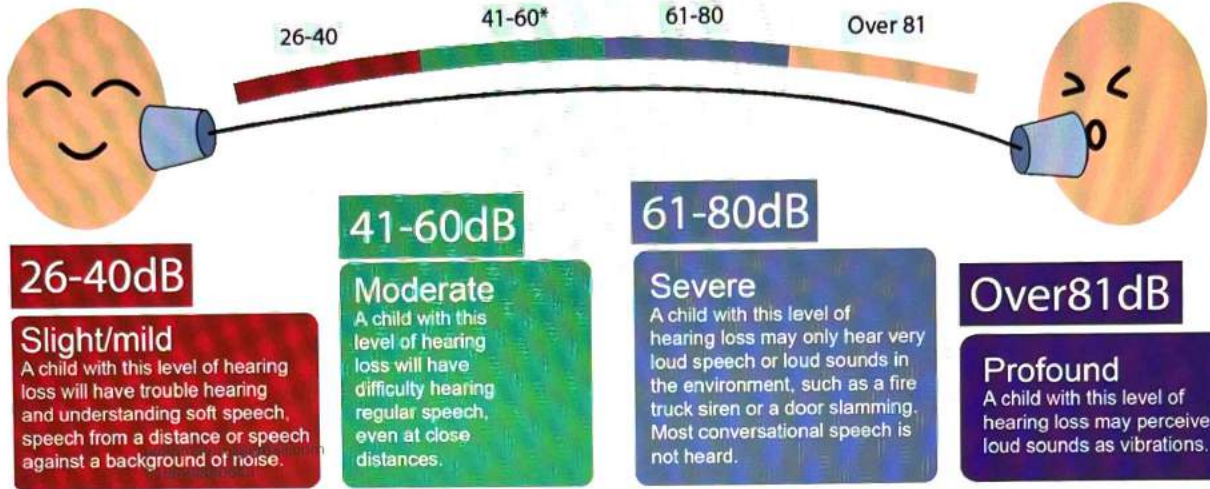
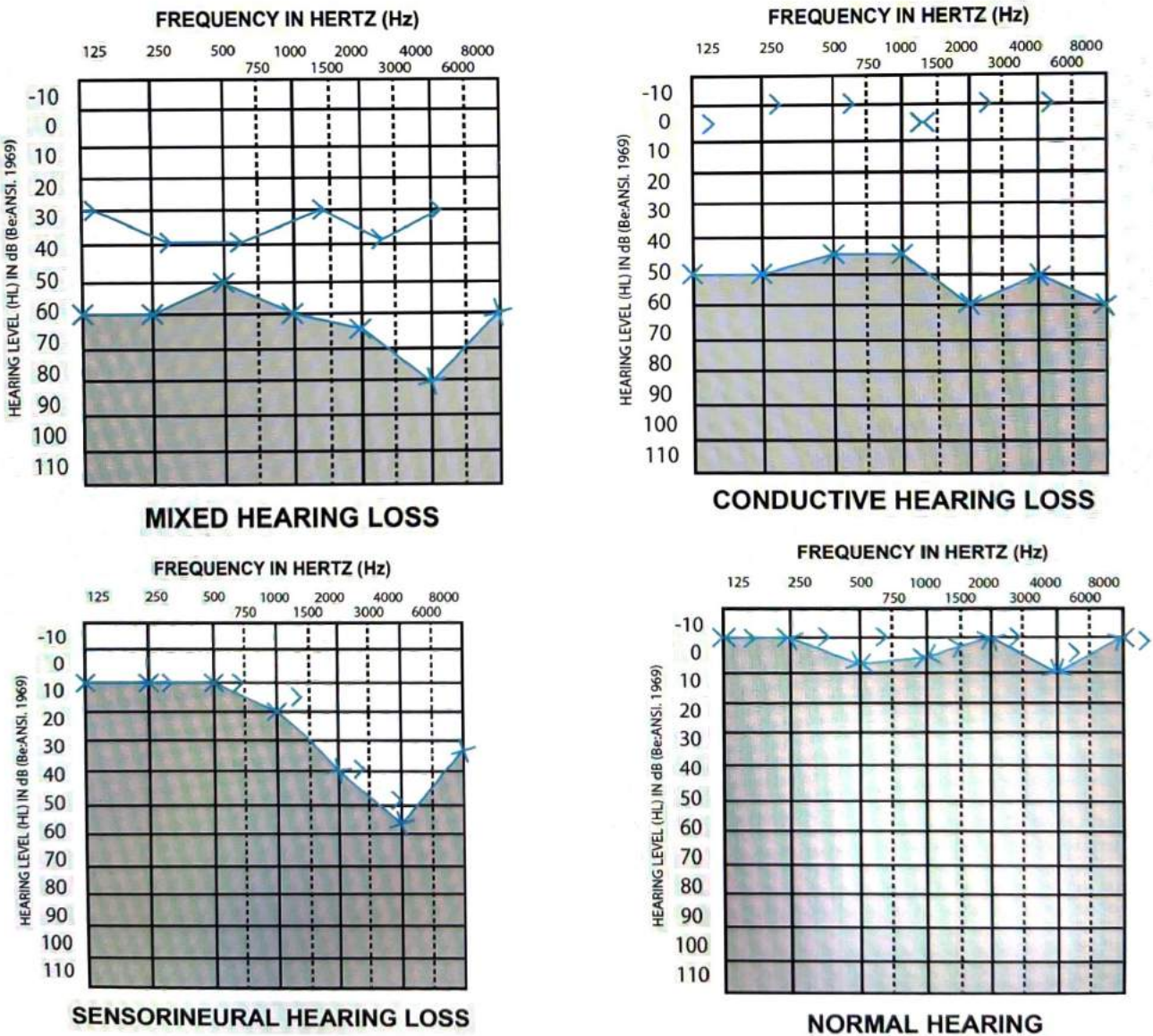


Image 6.2





10 FACIAL NERVE AND ITS DISORDER

ANATOMY OF FACIAL NERVE

00:00:39

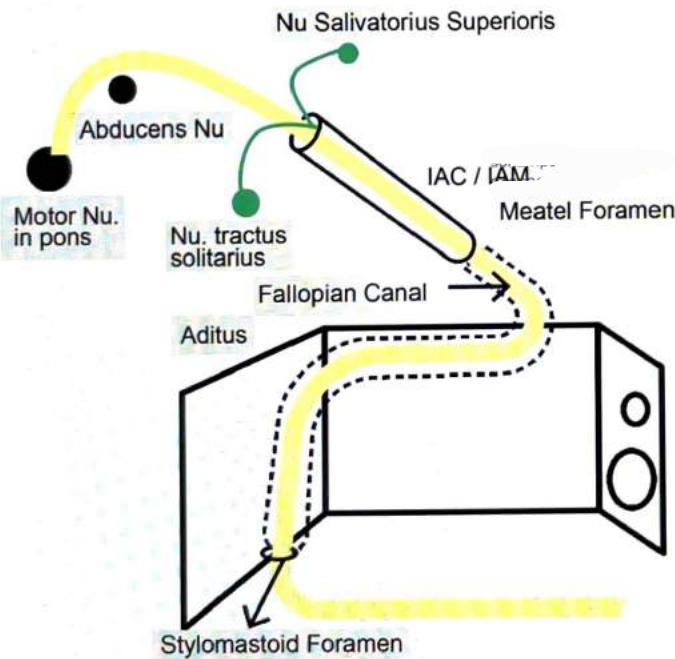
- 7th Mixed CRANIAL NERVE: Motor, sensory, secretomotor
- 3 Nuclei
 - Motor Nucleus: Pons
 - Nucleus Tractus Solitarius: Touch (sensory)
 - Nucleus Salivatorius Superior is: Secretomotor nerve fibers from Nucleus Tracts Solitaries and Salivatorius Superiors forms Nerve of Wrisberg (Nerves Intermedius)



Important Information

Millard Gubler Syndrome: Lesion around 6th Nerve nucleus along 7th Nerve nucleus and facial nerve

- Sensory part → Nerve of Wrisberg



4 Segments

- Intracranial segment (15–20 mm)
- Intra meatal segment (8–10 mm)
- Intra temporal segment / Fallopian canal
 - Labyrinthine segment [Shortest (3mm) / Narrowest (0.68mm)] 1st genu (3–5 mm)
 - Tympanic / Horizontal segment 2nd genu (8–12mm)

- Mastoid / vertical segment stylomastoid foramen
- Extra temporal segment (15–20 mm)
 - Fallopian canal – 27 mm
 - Longest bony canal of any Cranial Nerve.
 - Facial N. is accompanied by 8th nerve in Intra Auditory Meatus.
 - 1st & 2nd genu present in intra temporal segment.
 - 1st genu has Genuiculate ganglion



How to remember

DANCE = 3-4-3

BRANCHES OF FACIAL NERVE

00:19:59

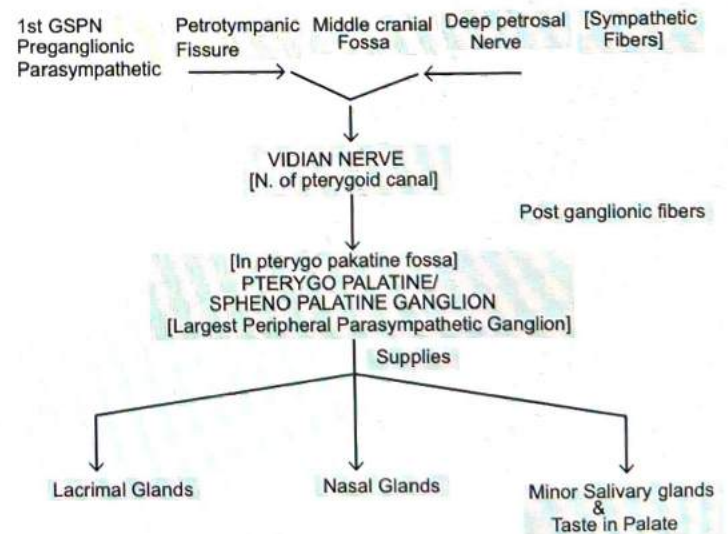
- No branches from segment I, II & IIIa
- From 1st genu – 3 branches
 - Greater Superficial Petrosal Nerve → carries preganglionic parasympathetic fibers.
 - Lesser Petrosal Nerve
 - External Petrosal Nerve



Important Information

GSPN is the 1st branch of facial nerve

Greater Superficial Petrosal Nerve





Important Information

GSPN combine with Deep Petrosal Nerve (Sympathetic fibers)

Lesser petrosal nerve

- Major fibres from Glossopharyngeal nerve
- Less fibres from 7th CN
- Goes to infratemporal fossa → otic ganglion → Auriculo temporal nerve (5th CN)
- This Auriculo temporal nerve takes away all fibres from Lesser petrosal nerve
- Supplies to sweat gland & parotid gland

No Branches for III b

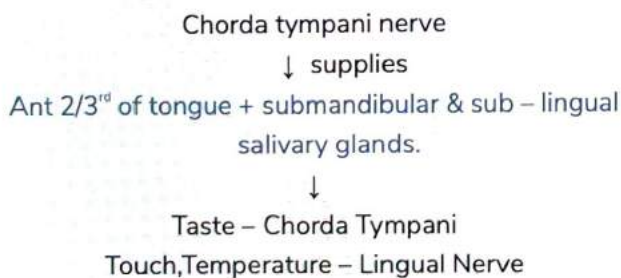
- Just after 2nd genu, Facial Nerve gives a branch → Nerve to Stapedius
 - 1st motor branch of Facial Nerve
- Before Facial N. goes into stylomastoid foramen it gives a branch → Chorda Tympani nerve (First embryological branch)
- Comes in from the posterior wall and comes out from anterior wall through Canal of Huguier



How to remember

HUG

Chorda Tympani Nerve



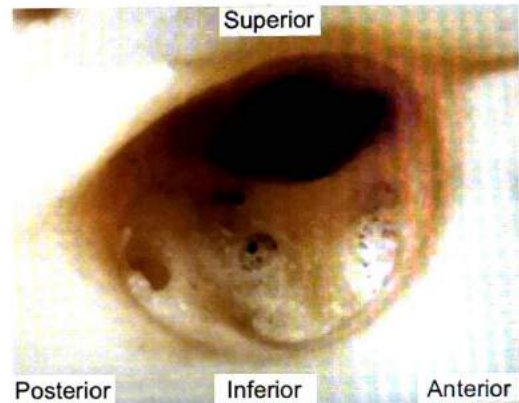
Important Information

- sub mandibular & Sub lingual salivary glands supplied by → Chorda tympani [VII]
- Parotid gland supplied by → Glossopharyngeal N. [IX]

- After coming out of stylomastoid foramen, Facial nerve goes into the Parotid gland and divides Parotid gland into 2 lobes
 - Superficial lobe
 - Deep lobe.
- In parotid gland facial Nerve divides into 5 terminal branches
 - TEMPORAL
 - ZYGOMATIC
 - BUCCAL
 - MARGINAL MANDIBULAR
 - CERVICAL
 → GOOSE FEET ARRANGEMENT OR PES ANSERINUS

MEATAL FORAMEN

Metal foramen



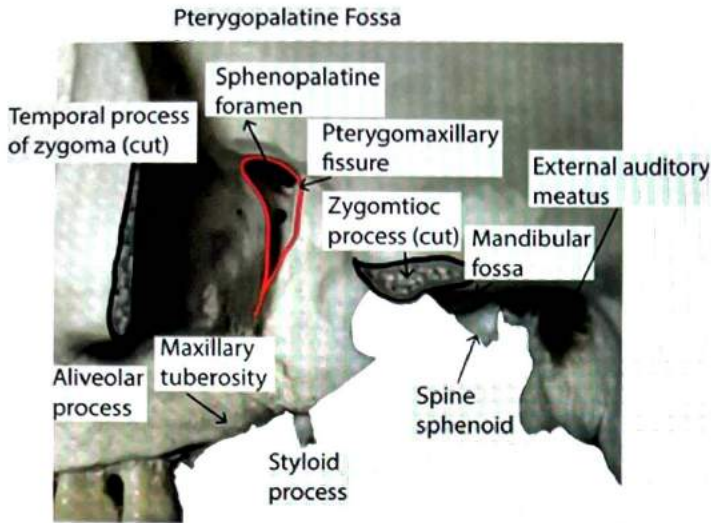
- Meatal Foramen divided into 2 parts Transverse Crest
- Upper Crest is further divided into 2 Parts (anterior & Posterior) by a vertical ridge of Bone K/a Bill's Bar.
- Anterior to Bill's Bar: Facial Nerve
- Posterior to Bill's Bar: Superior Vestibular Nerve
- In Inferior part: inferior Vestibular Nerve
- In Anterior side: Cochlear nerve
 - Named after Dr. William House.
 - Important surgical landmark for Facial N. (Tympano-mastoid suture)



How to remember

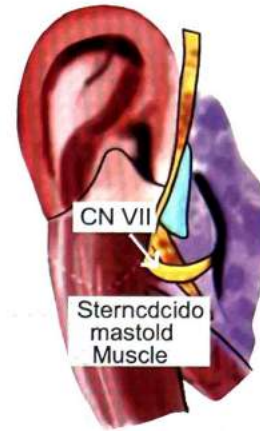
TUP

PTERYGO PALATINE FOSSA

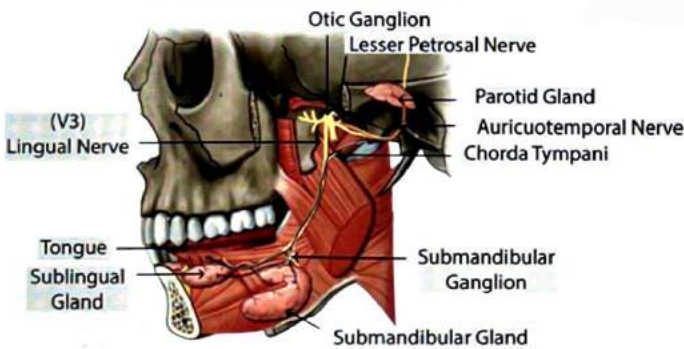


- Facial nerve is superficial and anterior to the styloid process

Landmark of facial N. in parotid Sx

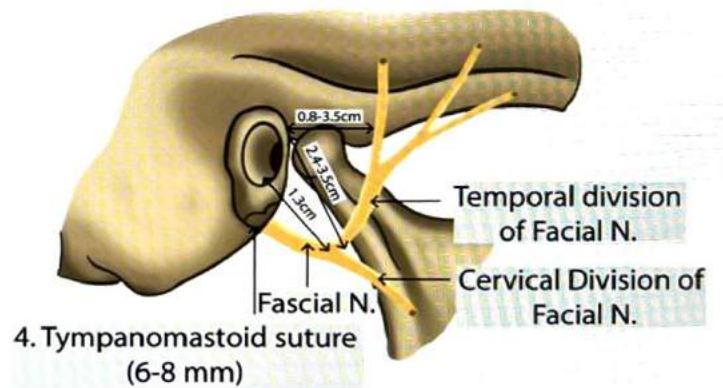


Chorda Tympani and Lingual Nerve



- Tympanomastoid suture: Facial nerve is 6 to 8 mm ahead of Tympanomastoid suture
 - Reverse dissection of peripheral branches of Facial nerve

Tympanomastoid suture



Refer Diagram 10.1

Previous Year's Questions

Q. Patient underwent removal of submandibular gland and lingual nerve was damaged during surgery. Which of the following is NOT correct?

(FMGE AUG 2020)

- A. Rate of sublingual secretions is reduced
- B. Ant. 2/3rd tongue taste sensation is lost
- C. Sensation in floor of mouth lost
- D. Tongue deviated to side

SX LANDMARKS OF FACIAL NERVE FOR PAROTID SURGERY

- Facial nerve lies 1.5cm deep and internal to the cartilaginous tragal pointer
- Facial nerve is anterior and superior to the digastric muscle

Previous Year's Questions

Q. Not a landmark of facial nerve identification in parotid surgery?

(NEET JAN 2020)

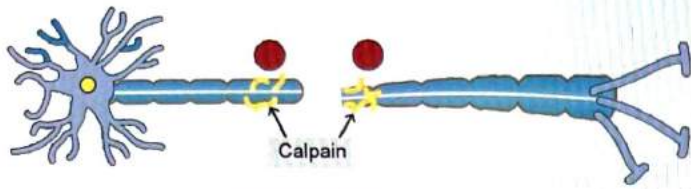
- A. Inferior belly of omohyoid
- B. Peripheral branches
- C. Post belly of Digastric
- D. Tragal pointer

TESTS OF FACIAL NERVE

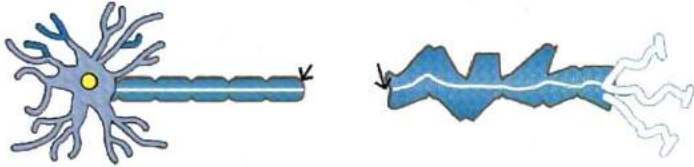
01:10:37

Topodiagnostic Tests of Facial Nerve

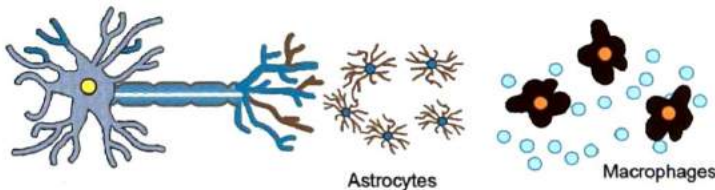
- These tests help us to identify the site of injury to facial nerve



After 5-60 mins

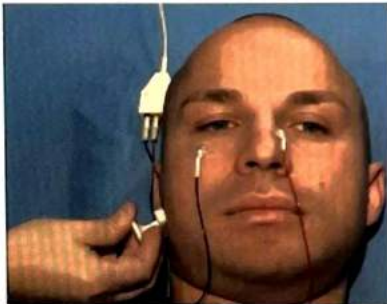

After 24-48 hrs



After > 72 hrs

Electrophysiological Testing of facial Nerve



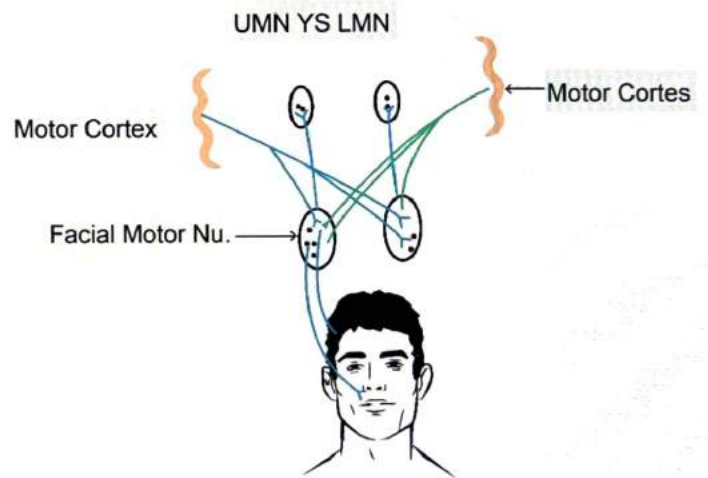
- Based on Wallerian Degeneration.
- Wait for 72 hours before doing Electrophysiological test (Prognostic test)
- **Nerve Excitability testing (NET)**
 - Electrical stimulus is varied from 2.4 - 16.2 mA
 - Significant if difference >3.5 m amp
- **Maximal stimulation test (MST)**
 - Stimulus producing maximum twitch is recorded
- **Electroneurography (ENoG)**
 - Muscle's compound action potential is recorded

- AKA Evoked Electromyography
- Most useful test 3rd to 14th day of the onset of palsy
- Best guideline for Facial N decompression
- **Electromyography (E.M.G)**
 - Spontaneous activity of facial muscle
 - Takes 14-21 days for fibrillation potential to develop
 - After 21 days: Most reliable test to follow course of denervation
 - Alerts the physician to sub clinical evidence of early regeneration.

DISORDERS OF FACIAL NERVE

UMN v/s LMN Lesions of Facial Nerve

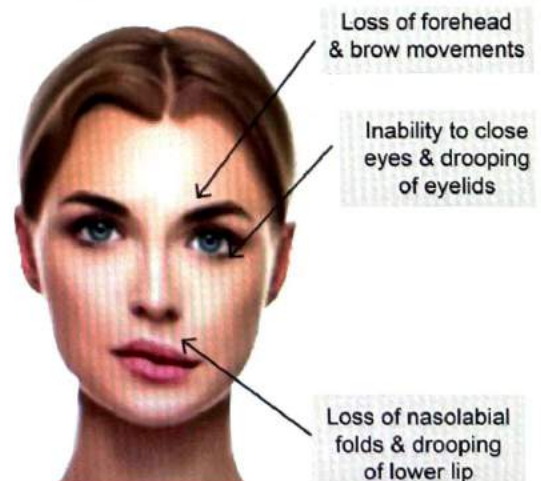
01:38:15



LMN	UMN
<ul style="list-style-type: none"> • Ipsilateral • Forehead not spared 	<ul style="list-style-type: none"> • Contralateral • Lower half of face involved (Forehead spared)

BELL'S PALSY

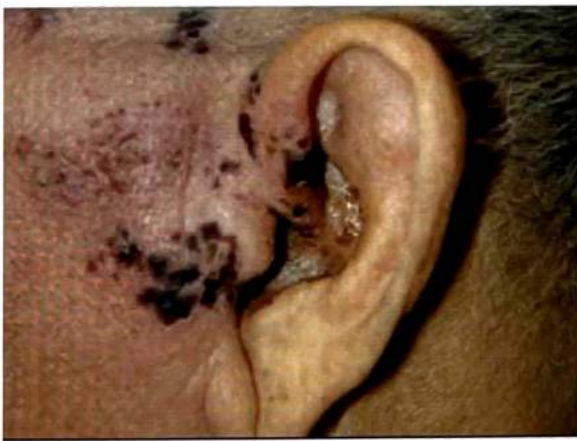01:43:18



- Idiopathic I/L LMN palsy
- **Viral infection** theory: Compression of labyrinthine segment
- Treatment: Steroids, Antiviral (72 hrs), Eye Protection, Physiotherapy
- **Theories**
 - Viral infection (Herpes)
 - Autoimmune theory
 - Hypersensitivity/ Allergy theory
→ Edema of facial nerve
- But fallopian canal doesn't expand → compresses FN → Bell's Palsy

RAMSAY HUNT SYNDROME / HERPES ZOSTER OTICUS 🕒 01:47:00

- LMN Facial palsy + Vesicular rash in external ear + otalgia
- Poor Prognosis as compared to Bell's palsy.



- 70 % of Bell's palsy – Complete recovery
- 15 % of Bell's palsy – Incomplete recovery
 - 85% recovery without treatment
- 50% of HZ Oticus → 50% partial Recovery [Poor prognosis]
- Involves other nerves also.

Treatment of Bell's palsy

- Needed to increase recovery rate and decrease recovery time
- Steroids -1
 - Prednisolone – for 7 days (dose 1mg/kg/day)
 - ↓ No improvement
7 days more
 - ↓ No improvement

- Taper the dose & stop
- Electrophysiological Nerve testing
- Surgical compression of the nerve
- Antiviral-2
 - Acyclovir 800mg, 5 times/day, 5 days (within in 72 hours)
- Eye protective-3
 - Artificial Tear drops
 - Wear goggles, avoid sunny areas, avoid windy areas
 - Pad the eye in night times & tape it
- Facial physiotherapy-4
- 1 2 3 4 X 7 Days → NO improvement
- Steroids
- Eye protection
- Physiotherapy
 - To be continued for 7 days more
 - Antivirals → stopped
- After 2 wks → No improvement
- Steroids → Taper the dose & stop
 - Electrophysiological Nerve testing
 - If good prognosis → Electro physiotherapy
 - If Bad Prognosis → Sx [Labyrinthine decompression of Facial Nerve] - Middle Cranial Fossa Approach



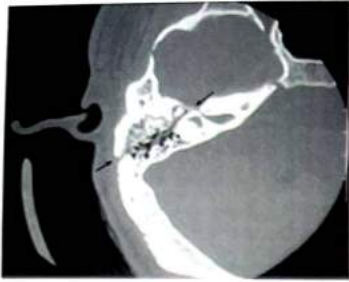Previous Year's Questions

- Q. Most common cause of facial nerve palsy:
(FMGE Dec 2017, Jun 2018, DNB Jun 2018)
- Idiopathic Bell's palsy
 - Herpes zoster oticus
 - Mastoid surgery
 - Chronic suppurative otitis media

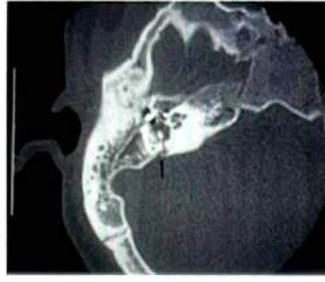
TEMPORAL BONE FRACTURE 🕒 02:00:38

- **Longitudinal fracture**
 - Along the axis of temporal bone
 - Cause → parietal or temporal blow
 - They are approximately 80%
 - Due to blow from side
 - Only 10% of Longitudinal fracture have facial nerve palsy
- **Transverse fracture**
 - Perpendicular to the axis of temp. Bone
 - Occipital blow cause transverse fracture (20%)
 - In Transverse fracture – 50% have facial nerve palsy
- **Mixed fracture (54%)**
 - Most Common type of temporal bone fracture

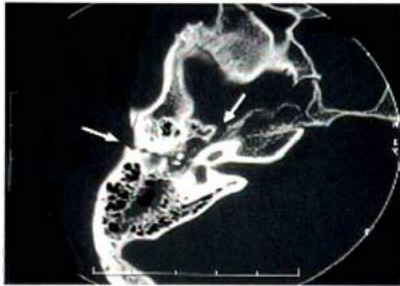
Longitudinal fracture



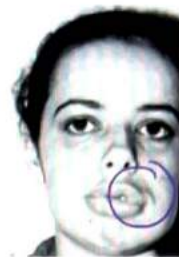Transverse fracture



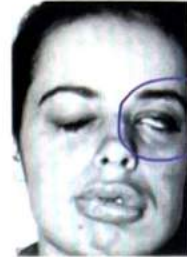Mixed fracture



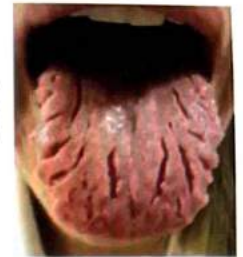MELKERSSON ROSENTHAL SYNDROME



Non tender Persistent Lip Swelling



LMN Facial Palsy



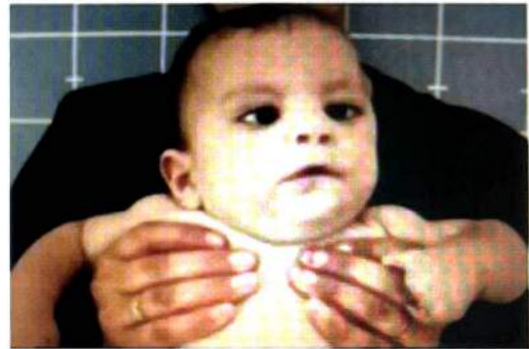Lingua Plicata (Fissured Tongue)

MOEBIUS SYNDROME

02:12:21

- Congenital 7th and 6th nerve palsy[B/L]

MOEBIUS SYNDROME



Congenital VII & VI Nerve Palsy

CLASSIFICATION OF FRACTURES

02:03:52

- Now a days, Temporal bone # are known as
 - Otic capsule sparing → less complications
 - Otic capsule involving → more complications

Case scenario:

- RTA, sudden & complete palsy - Facial N decompressing
- Delayed & complete palsy - Medical management (Steroids)
- Sudden & incomplete palsy - wait for 3 days- Medical management (Steroids) & electrophysiology testing
 - Poor prognosis - Surgery
 - Good prognosis- wait

Iatrogenic Facial Palsy

- M/C cause: Mastoidectomy
- Injury is generally in the Vertical segment just after 2nd Genu

MELKERSSON ROSENTHAL SYNDROME

02:11:34

- AKA Orofacial Granulomatosis
- Non tender persistent lip swelling
- LMN Facial palsy
- Lingua Plicata (Fissured Tongue)



Previous Year's Questions

Q. Which cranial nerves are affected in Moebius syndrome?

(DNB Jun 2018)

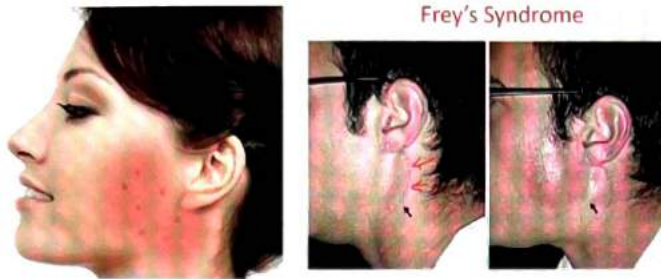- 5.6 CN
- 5.7 CN
- 6.7 CN
- 6.9 CN

FREY'S SYNDROME

02:13:20

- Baillarger's Syndrome, Dupuy's Syndrome, auriculotemporal syndrome, Frey-Baillarger's syndrome
- It is a syndrome d/t damage of Auriculotemporal nerve
- Auriculotemporal nerve is a branch of the Mandibular nerve, However this also carries fibers of the CN 9

(Glossopharyngeal nerve) brought by the Lesser Petrosal Nerve and if these fibers are damaged there is a mixing of 5th and 9th nerves fibers when patient eats there will be flushing and sweating near parotid area



Frey's Syndrome

- Fascia lata: Between skin and underlying fat
- Tympanic Neurectomy: Section of Tympanic branch of CN 9 will interrupt these fibers and give relief



Previous Year's Questions

- Q. All of the following statements are true about Frey's Syndrome except? (NEET JAN 2019)
- Gustatory sweating
 - Aberrant misdirection of parasympathetic fibres of auriculotemporal nerve
 - Botulinum toxin is one of the treatment suggested
 - less chances with enucleation than parotidectomy



Previous Year's Questions

- Q. Which of the following nerve is damaged in Frey's Syndrome? (DNB Jun 2018)
- Facial nerve
 - Mandibular nerve
 - Auriculotemporal nerve
 - Trigeminal nerve



Previous Year's Questions

- Q. Frey's syndrome occurs due to aberrant misdirection of fibres from salivary glands to sweat glands. These fibres come from which of the following? (NEET Jan 2019)
- Facial
 - Trigeminal
 - Vagus
 - Glossopharyngeal



Important Information

- Tongue :
 - Ant 2/3rd supplied by chorda tympani of 7th CN
 - Post 1/3rd - 9th CN
- Salivary gland:
 - Ant-Submandibular and Sublingual supplied by chorda tympani of 7th CN
 - Post- is supplied by 9th CN

- Treatment of Frey Syndrome (02:19:12)
 - Antiperspirant: Aluminum chloride
 - Botulinum toxin: injected into affected skin

CROCODILE TEARS SYNDROME/BOGORAD'S SYNDROME (02:22:20)

- Injury to Facial nerve before 1st genu of Facial nerve
- C/F : lacrimation while eating.

Condition that cause Recurrent facial palsy (02:24:07)

- Bells palsy
- Ramsay hunt syndrome
- Sickle cell disease
- Tumor
- Behcets disease
- Melkersson-Rosenthal syndrome

Condition that cause Bilateral Facial Nerve Palsy (02:24:40)

- Bells palsy
- Gullian Barre syndrome
- Lyme disease (infective cause)
- Sarcoidosis
- Meningitis
- Brain stem encephalitis
- Benign intracranial hypertension
- leukemia
- Melkersson-Rosenthal syndrome
- Diabetes mellitus
- HIV
- Syphilis
- Infectious mononucleosis
- Moebius syndrome

HOUSE BRACKMANN GRADING OF FACIAL NERVE PALSY

02:25:47

Grade	Description	Characteristics
I	Normal	Normal facial function in all areas
II	Mild dysfunction	Slight weakness noticeable on close inspection may have very slight synkinesis
III	Moderate dysfunction	Obvious, but not disfiguring, difference between 2 sides; noticeable, but not severe, synkinesis contracture, or hemifacial spasm; complete eye closure with effort
IV	Moderately severe dysfunction	Obvious weakness or disfiguring asymmetry; normal symmetry and tone at rest, incomplete eye closure
V	Severe dysfunction	Only barely perceptible motion; asymmetry at rest
VI	Total paralysis	No movement

Right sided Lower Motor Neurone Lesion

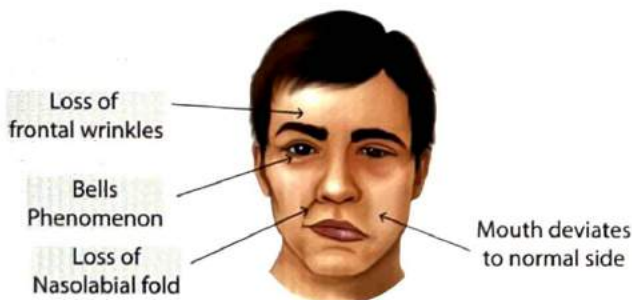
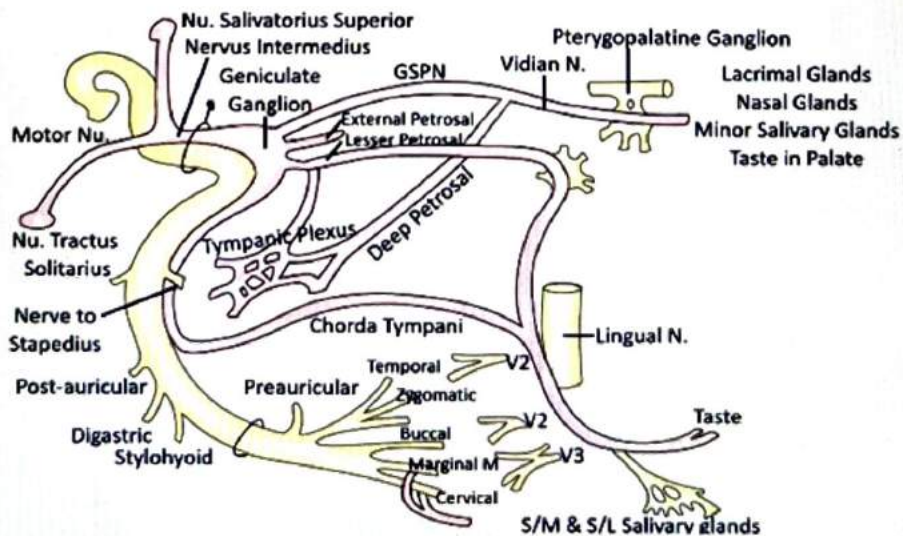


Image 10.1





CLINICAL QUESTIONS



Q. 62-year-old judge became aware of subtle weakness of his left lower face that he first noted while shaving. Two months later, he noted that he could no longer close his left eye lid fully and he was having increasing weakness of the remainder of his left face. Which of the following is a narrowest segment of the nerve in the ear involved here?

- A. Labyrinthine segment
- B. Tympanic segment
- C. Mastoid segment
- D. Meatal segment

Answer: A

Solution

Labyrinthine segment (3.0 mm)

- From fundus of meatus to geniculate ganglion where nerve takes a turn posteriorly forming a "genu."
- Nerve in labyrinthine segment has the narrowest diameter (0.61–0.68 mm) and bony canal in this segment is also the narrowest.
- Thus oedema or inflammation can easily compress nerve and cause paralysis.
- This is also the shortest segment of the nerve.



11 OTITIS MEDIA

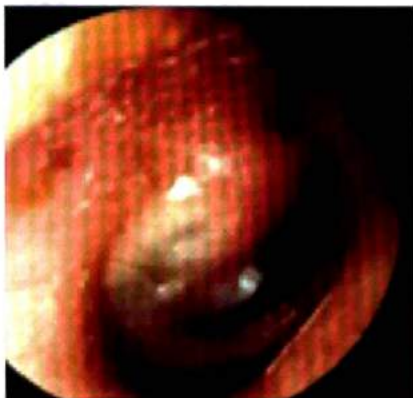
AOM / ASOM (ACUTE SUPPURATIVE OTITIS MEDIA / ACUTE OTITIS MEDIA) 00:01:18

- Otitis media - Inflammation of Middle ear
- M/C causative organism – Streptococcus pneumonia
- other
 - Moraxella Catarrhalis
 - H. Influenza
- These bacteria come from nose & pharynx through the Eustachian tube
- M/C seen in children
- Functions of Eustachian tube:
 - Maintains the middle ear pressure equals to the outside atmospheric pressure
 - It drains the secretions of middle ear

ASOM:STAGES 00:03:51

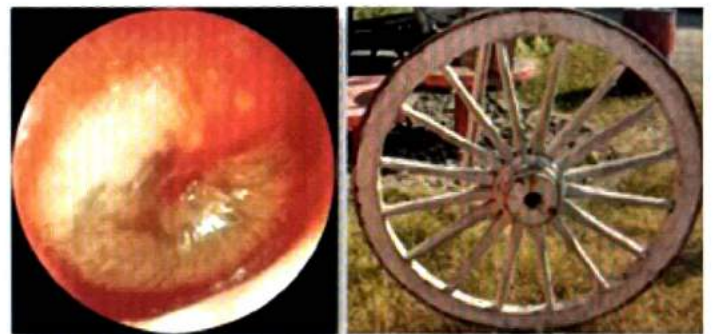
- **Stage I – Stage of tubal occlusion**
 - Infection in nose & nasopharynx
 - Eustachian tube is blocked in the nasopharyngeal end or cartilaginous end
 - Middle ear air pressure Decreases
 - Tympanic membrane is retracted (cone of light is distorted or absent)
 - O/E
 - Dull & luster less, non shiny
 - Cone of light absent or distorted
 - Complains of Pain, hearing loss (conductive)

Stage 1 : Stage of Tubal occlusion



- **Stage II: Stage of pre-suppurative**
 - Serous, mucoid secretion accumulate in ME + bacteria is present in ME
 - TM bulges out, Blood vessels becomes prominent → Cart wheel Appearance.

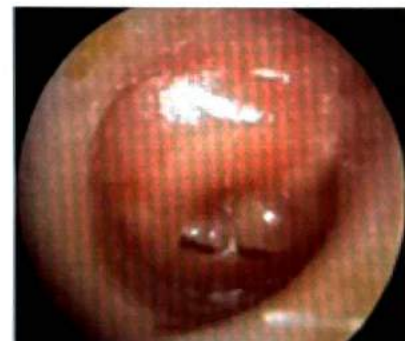
STAGE II : STAGE OF PRE- SUPPURATION



Cartwheel Appearance

- **Stage III: Stage of suppuration**
 - Fluid PUS (bacteria macrophages)
 - Severe pain present
 - Tragus sign negative
 - Hearing decreases
 - O/E: Red congested bulging TM ready to burst

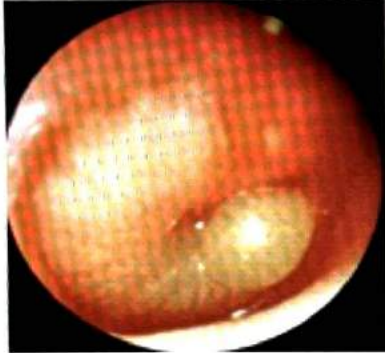
STAGE III : STAGE OF SUPPURATION



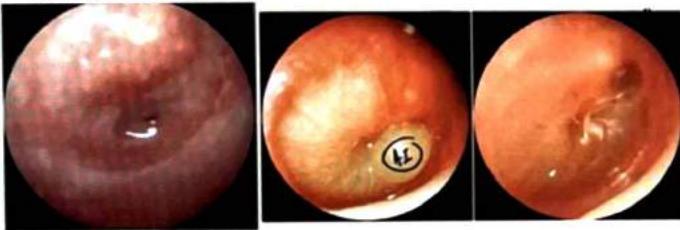- **Stage IV: Stage of resolution**
 - MC site of TM perforation → Antero inferior quadrant of tympanic membrane (its most dependent quadrant)

- After few weeks, perforation heals & hearing becomes Normal
- A healed TM → Dimeric (No fibrous layer)
- Signs
 - Light house sign (Pus is coming out constantly)
 - Reservoir sign

STAGE IV : STAGE OF RESOLUTION

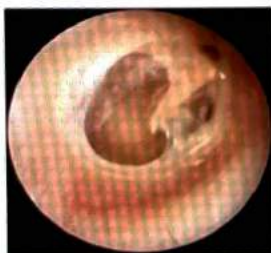

Light house sign



- **Reservoir sign** : Fluid is keep on coming even after removing fluid from EAC (seen in Mastoiditis)
- After few weeks, perforation heals within 3-6 weeks & healing becomes normal
- A healed TM → Dimeric (No fibrous layer)

Healed TM: Dimeric

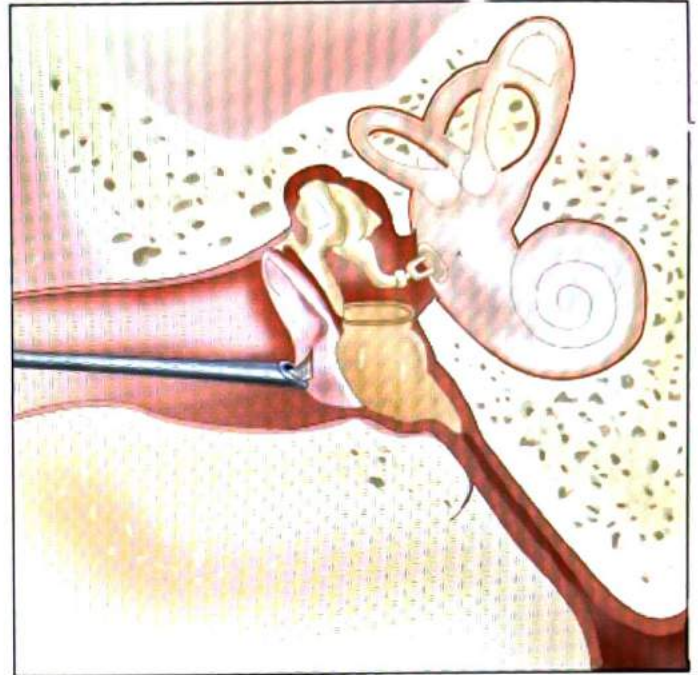


AOM:TREATMENT

00:19:09

- Stage I & II: Antibiotics, analgesics, Nasal decongestant drops (Xylometazoline, oxymetazoline)
- Stage III: Myringotomy (Performed in Posteroinferior quadrant)
 - Rate of growth: PS > PI > AI > AS
- Stage IV: wait & watch for the perforations to heal on its own (90%)

MYRINGOTOMY IN PI QUADRANT



AOM COMPLICATION

00:24:17

- Most common complication → perforation
- In 10% - 12% can have permanent perforation
 - This causes hearing loss and perforation may leads to CHRONIC OTITIS MEDIA



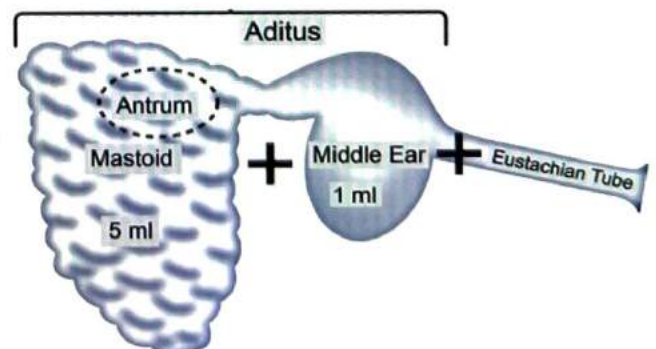
Important Information

- M/C complication: Perforation < Mastoiditis

ACUTE MASTOIDITIS

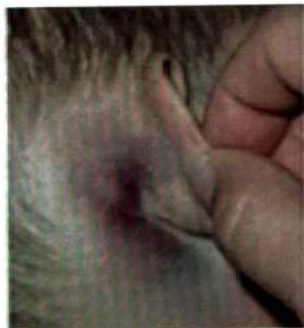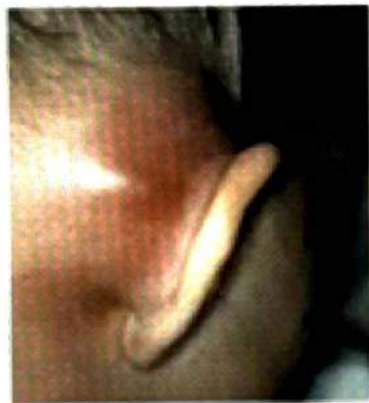00:25:15

- In 6-7% cases seen (infection travels from ME to mastoid)
- Seen in child with fever
- Sign → more pain & tenderness on the cymba concha
 - Cymba concha is the anatomical landmark for mastoid antrum
- Mastoid red, hot, ironed out

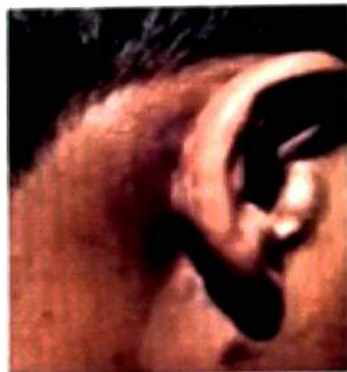

- Sign over Mastoid
 - Ironed out mastoid
 - Battle sign → Hematoma over mastoid d/t fracture of middle cranial fossa
 - Griesinger Sign → Pitting edema over mastoid due to sigmoid sinus thrombosis (thrombosis of emissary vein)

Ironed Out Mastoid



Battle sign
#MCF



Griesinger's sign

- Treatment:
 - IV Antibiotics
 - Analgesics
 - Myringotomy



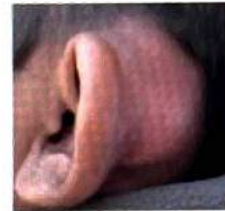Important Information

- RESERVOIR SIGN POSITIVE - ACUTE MASTOIDITIS



Previous Year's Questions

- Q. A young man with history of ear infection presents with a smooth erythematous swelling on mastoid process. What is the most likely diagnosis?
(AIIMS Nov 2019)



- A. Furunculosis
- B. Acute Mastoiditis
- C. Fibrous Dysplasia
- D. Facial palsy



Previous Year's Questions

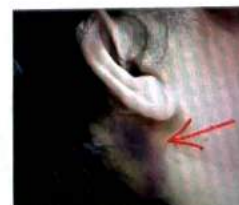- Q. A boy with history of ear discharge presented with pain in the ear and hearing loss. On examination redness was present behind the ear. Reservoir Sign was positive. What is the most likely diagnosis?
(FMGE Aug 2020)

- A. CSF Otorrhea
- B. Acute Mastoiditis
- C. ASOM
- D. Otitis Externa



Previous Year's Questions

- Q. A boy with history of ear discharge presented with pain in the ear and hearing loss. On examination redness was present behind the ear. Reservoir Sign was positive. What is the most likely diagnosis?
(FMGE Aug 2020)



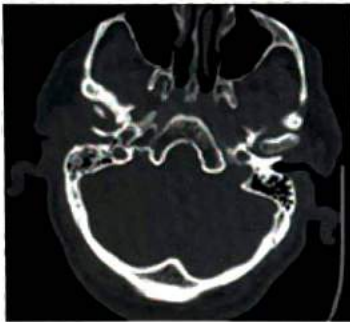
- A. CSF Otorrhea
- B. Acute Mastoiditis
- C. ASOM
- D. Otitis Externa

COALESCENT MASTOIDITIS

00:33:07

- It is a chronic complication
- ME inflammation resolved
- Long term / persistent pain over mastoid even after resolution of middle ear infection
- Confirm diagnosis → CT scan
- But mastoid remain inflamed, there is clouding of mastoid air cells (filled with fluid)

Coalescent Mastoiditis



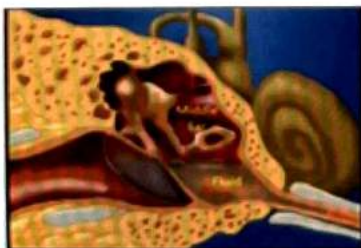- Treatment:
 - 3 weeks of IV Antibiotics → IOC
 - If Not resolved by antibiotics then MASTOIDECTOMY (simple/cortical/Schwartz)
- Coalescent mastoiditis earlier known as surgical mastoiditis (before Rx was surgery)

SEROUS OTITIS MEDIA (SOM)

00:38:07

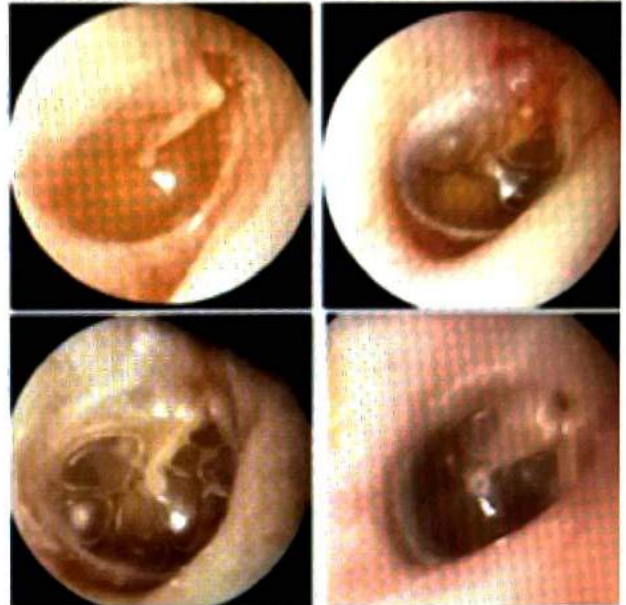- Also known as Muroid OM / Secretory OM / Non-Suppurative OM/ Glue Ear
- Long standing collection of serous or mucoid fluid collection in the middle ear
- It is a disease of Eustachian tube dysfunction
- Reasons
 - Tumor in Nose / Nasopharynx (JNA)
 - Malignancy (Nasopharyngeal Ca)
 - Polyp (Antrochoanal polyp)
 - Adenoid (seen in 5-7 yr children)
 - Chronic infection
- Complaints : Patient have hearing loss (Conductive)
- No pain due to chronic long standing disease

Serous OM/ Muroid OM/ Secretory OM
Non - suppurative OM/ Glue ear



- On examination:
 - TM → Bulging / thin with fluid in middle ear
 - Air bubbles in fluid
 - Air fluid level

Serous OM/ Glue Ear



- Blue TM (sometimes) due to venous stasis. Also seen in certain conditions:
 - Serous Otitis media
 - Haemotympanum (Laufer's sign : blood in middle ear seen in MCF fracture)
 - Cholesterol Granuloma



Important Information

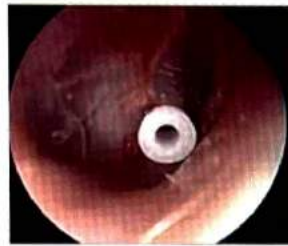
- Glomus → Have Reddish Blue tympanic membrane

- To Confirm diagnosis:
 - Pure tone Audiometry: AB gap Conductive hearing loss 25-30 dB
 - Impedance Audiometry → B type curve (Flat cure → Fluid)
- Treatment:
 - Treat the cause
 - Remove fluid from ME by myringotomy in Anterior inferior quadrant and grommet insertion done

Myringotomy and Grommet Insertion



Grommet in AI Quadrant

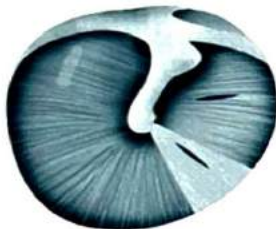


"BEER CAN" PRINCIPLE

🕒 00:50:21

- 2 incisions, 1 in Antero superior quadrant for air entry other incision in Antero inferior quadrant for pus drainage

Beer - Can principle

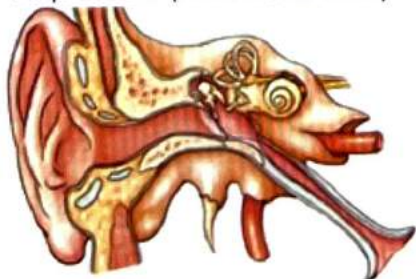


AIRPLANE EAR (OTITIC BAROTRAUMA)

🕒 00:51:31

- Travel in airplane → Air pressure ↓↓, Eustachian tube balances it
- But when there is a rapid descent from height the Eustachian tube unable to maintain the pressure in the middle ear, causing injury
- If pressure difference is > 90 mmHg due to rapid descent, all the soft tissues around the eustachian tube are sutured in leading to locking of eustachian tube. The fluid gets accumulated in M.E bulging the T.M.
- Patients present with:
 - Pain in ear
 - Fullness/Hearing loss
 - TM → Red/congested
 - Traumatic TM

Airplane Ear (otic Barotrauma)



Important Information

- Otitic Barotrauma is also seen in deep sea divers when rapid ascent

- Treatment
 - Nasal decongestion
 - Steam Inhalation
 - Chewing/Swallowing exercises
 - Myringotomy
- Rapid Ascend (More serious)
 - > 90 mmHg
 - Positive pressure in M.E
 - May burst T.M, round window
 - If round window is burst, it will leak perilymph – causing vertigo



Previous Year's Questions

- Q. A 7 years old Child is complaining of hearing loss and sense of fullness in the ear. The tympanometry shows Type B Curve. What is the most likely diagnosis? (FMGE June 2021)
- Otosclerosis
 - Serous Otitis Media
 - Ossicular Discontinuity
 - Tympanosclerosis



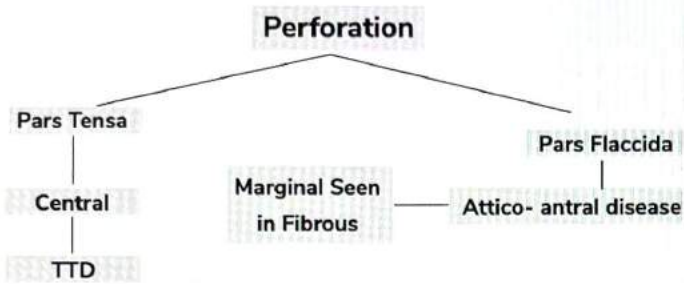
Previous Year's Questions

- Q. Barotraumatic otitis media is a result of? (JIPMER Nov 2018)
- Rapid descent while in an aircraft
 - Rapid ascent while in an aircraft
 - Sudden acceleration while in a bus
 - Sudden deceleration while in a bus

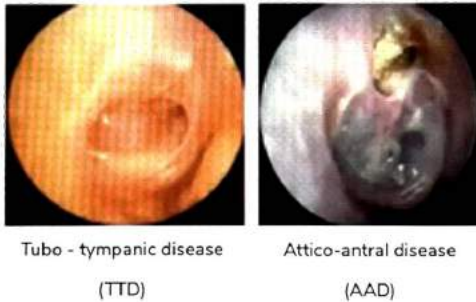CSOM (CHRONIC SUPPURATIVE OTITIS MEDIA)/ CHRONIC OTITIS MEDIA

🕒 00:58:29

- They can be divided into 2 types
 - Tubo Tympanic Disease (TTD) / safe CSOM
 - Attico-antral disease (AAD) / unsafe CSOM



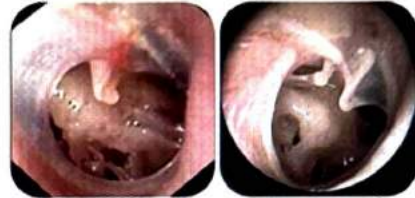
Chronic suppurative Otitis Media (CSOM/COM)



★ Important Information

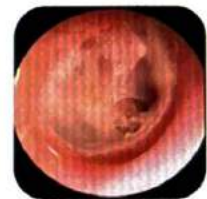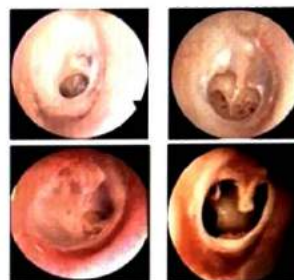- Sub total + fibrous annulus = total perforation and it is a marginal perforation.

Subtotal Perforation : 4 Quadrants



Central Perforation

Small Perforation: 1 Quadrant

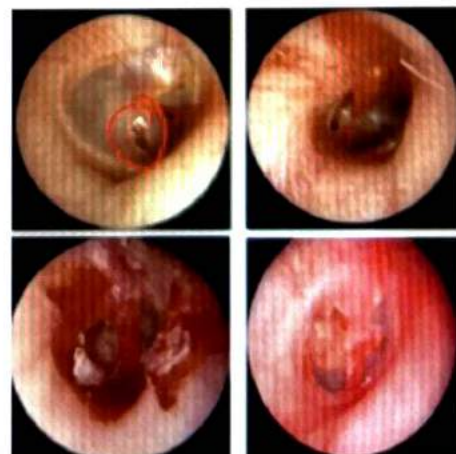

TUBOTYMPANIC DISEASES

🕒 01:02:44

- Central perforation not involving fibrous annulus.
 - Conductive Hearing Loss (AB gap → 10-40 dB) (depends on site & size of perforation)
 - If perforation and ossicular chain erosion both occurs, AB gap will be 45dB
 - Ear Discharge
 - Long standing history
 - Continuous or intermittent
 - Mucoïd (or) Mucopurulent
 - Non foul smelling
 - Copious in Quantity
 - It is also called as Mucosal disease
 - Active (Discharge coming and it may cause complications)
 - Inactive discharge (Not coming)
 - Tubotympanic disease is earlier known as SAFE CSOM
 - Central perforation is also present
 - It is circular and kidney shaped
 - Well healed margins
 - Types:
 - Small perforations → 1 quadrant involved
 - Medium perforations → 2 quadrants involved
 - Large perforations → 3 quadrants involved
 - subtotal (if all quadrants involved) → 4 quadrants involved

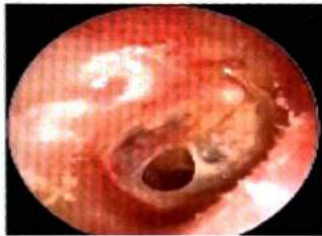- Traumatic perforation
 - Irregular, rough/ragged margins
 - Blood clots around perforation
 - M/C is slap injury
 - Rx- 90-95% heal on their own with 3-6 weeks so it is a simple injury
 - This injury comes under an act 320 IPC
 - It comes under PERMANENT PRIVATION OF EITHER EAR OR HEARING CLAUSE.
 - In this case, examination done after 6 weeks, if hearing is affected and not healed, it will come under grievous injury



Previous Year's Questions

Q. A patient after being slapped 3 days ago presents with decrease in hearing and no pain. Following is the examination findings of tympanic membrane. What is the next line of treatment?

(FMGE Aug 2020)

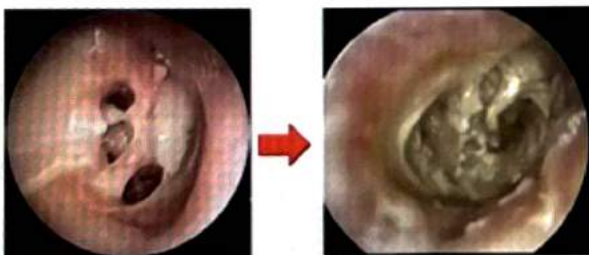

- A. Tympanoplasty.
- B. Myringoplasty
- C. Wait and watch
- D. Antibiotics and follow up

TUBERCULOSIS OF MIDDLE EAR ⌚ 01:17:40

- Chronic, painless, foul smelling, otorrhea
- Multiple perforations (sieve like TM)
- Pale granulations in middle ear
- Severe hearing loss
 - CHL (out of proportion to signs and symptoms)
 - SNHL (involvement of labyrinth)
- Facial nerve palsy

Tuberculaosis of Middle ear



Multiple perforations
(sieve like TM)

Large central perforation with
pale granulations

Previous Year's Questions

Q. Tuberculous Otitis Media of the middle ear has all of the following except? (NEET PG JAN 2020)

- A. Multiple perforations are seen
- B. Pale granulomas are seen
- C. ATT should be started
- D. Painful otorrhea is seen

TREATMENT OF TUBOTYMPANIC DISEASE ⌚ 01:20:46

- Also known as Mucosal disease
 - Active – Antibiotics (For discharge)
 - In active – Tympanoplasty [Myringoplasty + repair of ossicles]
 - RxOC for TTD – Tympanoplasty
 - Myringoplasty [repair of TM]

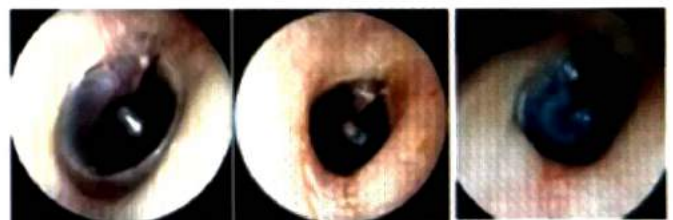TYMPNOPLASTY

Type I-Myringoplasty

- Epithelial & Mucosal layer forms but fibrous layer do not regenerate.
- Sometime in large perforation margins heal leaving a permanent gap in b/w
- Rx:
 - Freshen up margins
 - Put a graft (fibrous Tissue)
 - Epithelium grows back
- Graft used
 - Temporalis fascia is most commonly used because
 - Can be obtained by same incision
 - Consistency same as of TM
 - Perichondrium
 - Fascia lata
 - Cartilage can also be used in cases of recurrence

Type II- TM perforation + ossicular chain erosion

Blue TM



Serosus Otitis
Media

Haemotympanum
(Laugier's sign: MCF #)

Cholesterol
Granuloma

- Areal and Lever ratio is re-established
 - M/C site is lenticular process / Long process of incus
 - K-helix is implanted
- #### Type III- Myringostapediopexy
- Done when both malleus & incus are eroded
 - Graft on stapes

- Columella effect
- Areal Ratio maintained
- Lever ratio Not maintained
 - IIIa – Graft is directly on stapes head
 - IIIb-PORP (Partial, Ossicular Reconstruction Prosthesis)
 - IIIc -TORP (Total Ossicular Reconstruction Prosthesis)

Type IV

- Even stapes foot plate is gone, Sound directly vibrates the both membranes cancel → No sound
- Put a graft on round window
- No amplification of sound occurs
- Only phase difference present (Baffle effect)

Type VI

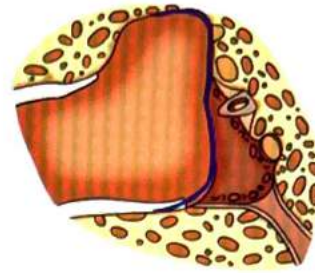
- Graft on oval window → Sono Inversion



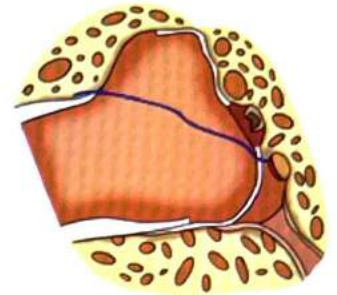
How to remember

- IV → VI (reverse)

Type V



Type VI



Previous Year's Questions

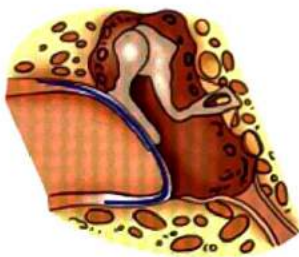
Q. Columella effect is seen in which type of tympanoplasty? (JIPMER MAY 2018)

- Type I
- Type II
- Type III
- Type IV

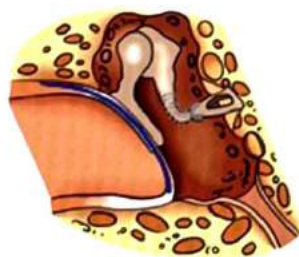
Type V - Fenestration operation

- Fistula is made in lateral semi circular canals
- Now obsolete (earlier done for otosclerosis)

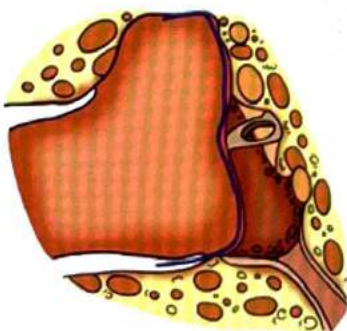
Type I



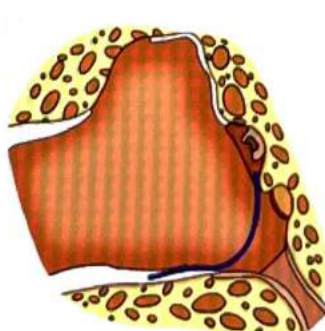
Type II



Type III



Type IV

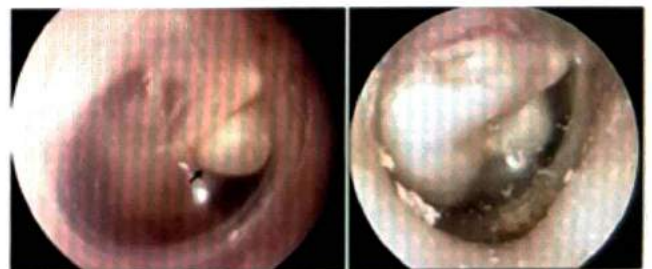


ATTICOANTRAL DISEASE: CHOLESTEATOMA

01:42:38

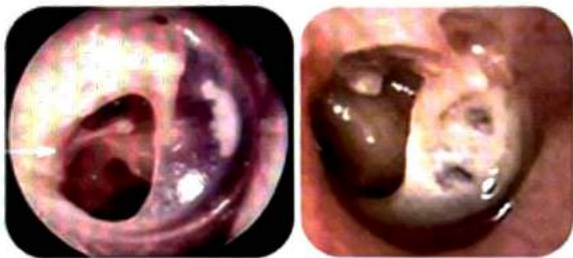Cholesteatoma [Keratoma]

- Normal keratinizing Stratified squamous epithelium [Ectoderm]
- In wrong place [Middle ear cleft → (endoderm)]
- Types
 - CONGENITAL (Mckenzie)
 - ACQUIRED
 - PRIMARY ACQUIRED
 - SECONDARY ACQUIRED
- Congenital Cholesteatoma
 - Epithelium is trapped inside, during or before the formation of Middle ear cleft
 - White pearly mass behind T.M
 - No history of TM perforation / Surgery



- Acquired Cholesteatoma
 - Epithelium goes into the middle ear cleft after birth
- Secondary Acquired cholesteatoma
 - secondary to perforation
 - Migration of squamous epithelium
 - Squamous epithelium From EAC migrates / invades into ME along the marginal perforation
 - Squamous metaplasia
 - Due to chronic infection / inflammation, mucous epithelium in ME transforms into squamous epithelium

Inwards Migration of Epithelium



Types of Invasion

- LATERAL → Pars Flaccida & Scutum
- Other theories
 - Squamous metaplasia
 - Basal cell hyperplasia
- M/C site → with acquired cholesteatoma

Primary acquired cholesteatoma



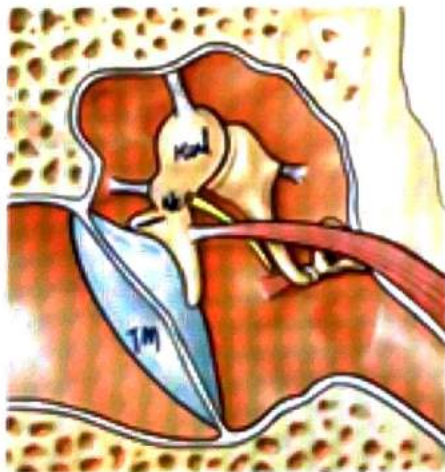
In Acute Otitis Media

- Stage I
 - Negative pressure in ME +nt → TM pulled in
 - Forms RETRACTION POCKET

1° ACQUIRED CHOLESTEATOMA

🕒 01:16:55

WITTMACK 'S (theory of Invagination) / Retraction Pocket Theory



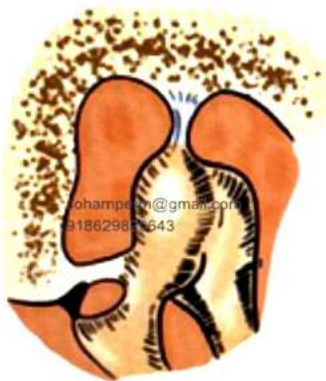- PRUSSACK'S SPACE – BOUNDARIES
 - SUPERIOR → Lateral malleal ligament
 - MEDIAL → Neck Of malleus
 - INFERIOR → Lateral process of malleus

- Has epithelial & mucus layers
- Epithelium shed off subsequently & get infected
 - Pus formation occurs
- Exerts pressure & pocket grows in size & more epithelium dies a cycle continues
- After a point, it starts eroding surrounding bones
- Erosion of bones is d/t release of enzymes from lysosomes of dead cells, which activates osteoclasts
- Erosion of scutum is characteristic feature of primary acquired cholesteotoma
- Subsequently erodes antrum → ATTICO ANTRAL DISEASE
- CT Scan → Cholesteotoma (primary acquired)

- Retraction pocket theory
- Basal cell hyperplasia theory
- Basement membrane cells grows & for cholesteatoma
- Primary squamous theory
- Mucosa under goes metaplasia & forms cholesteatoma
- Most accepted theory
- MC site of lo acquired cholesteatoma Formation
→ Prussack's Space
- Prussack's space located in Epitympanum

Basal Cell Hyperplasia (Ruedi's) Theory

Basal Cell Hyperplasia



Squamous Metaplasia (Sade's) Theory

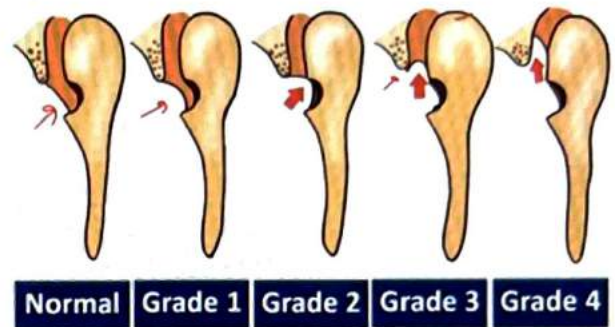
Squamous Metaplasia



PARS FLACCIDA

01:59:14

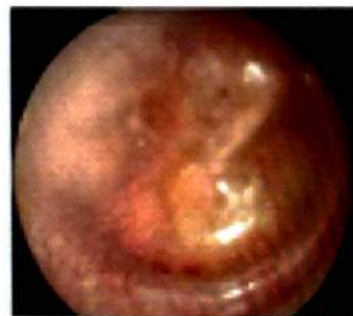
PARS FLACCIDA/ ATTIC RETRACTION GRADE



PARS TENSA RETRACTION : GRADE 02:01:37

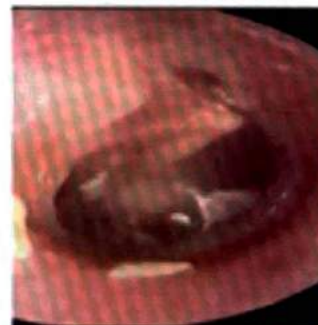
- Grading was done by Sade.
- **Grade 1 retraction**
 - Dull, Lusterless
 - Non shining
 - Cone of light → absent, distorted
 - Handle of malleus is foreshortened
 - Anterior & posterior maleolar folds are more prominent

Grade 1 retraction



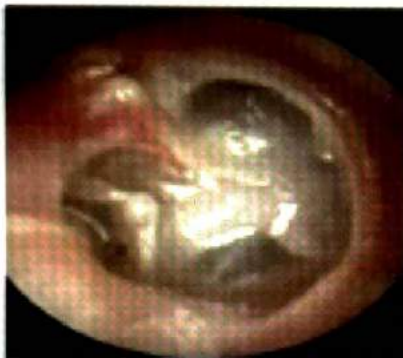- **Grade 2 retraction**
 - It adherent to Incus & stapes joint
 - Long process of Incus / stapes head

Grade 2 retraction



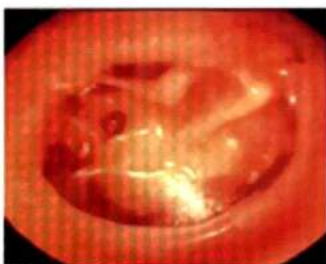- **Grade 3 retraction**
 - TM has retracted to the promontory
 - Seigel spectrum TM move out

Grade 3 retraction

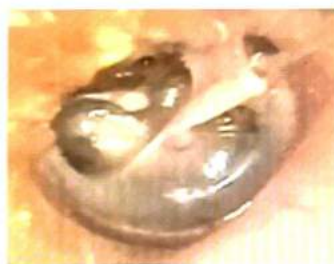

- **Grade 4 retraction**
 - Adhered to promontory
 - On seigelisation TM don't move
 - Postero superior retraction pocket
- Pars Tensa → PS quadrant can form a retraction pocket, which moves eroding the stapes & incus also forms choleostoma
- Also known to form primary acquired cholesteatoma

Grade 4 retraction



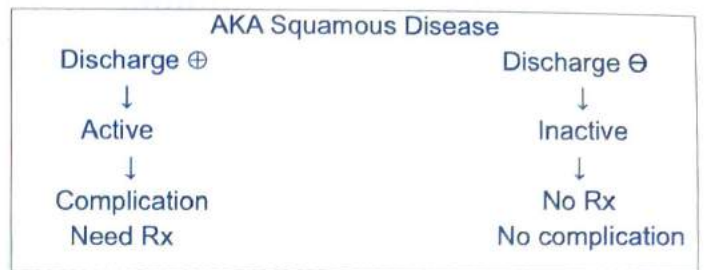
PS Retraction Pocket



ATTICO-ANTRAL DISEASE SYMPTOMS

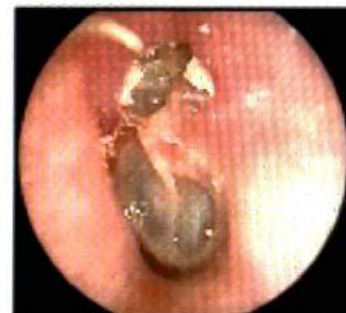🕒 02:06:41

- Conductive hearing loss + (SNHL → toxins)
- AB gap – 45 dB
- Ear Discharge
 - Long standing
 - Intermittent/ continuous
 - Scanty in quantity
 - Purulent
 - Foul smelling
 - Blood stained



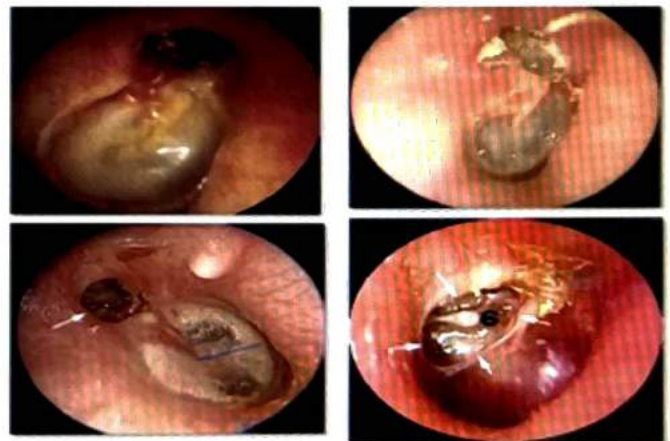
? Previous Year's Questions

Q. Identify the disease in the picture shown below?
(NEET PG Jan 2019)



- Keratosis obturans
- Acquired cholesteatoma
- Congenital cholesteatoma
- Osteoma

Primary Acquired Cholesteatoma

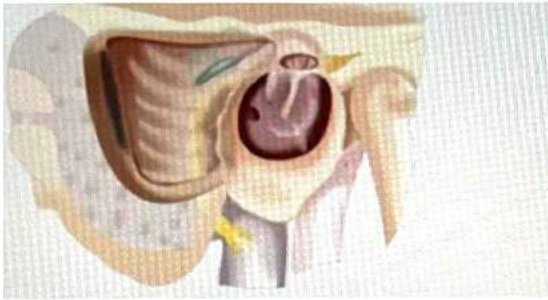


AAD : TREATMENT

🕒 02:17:15

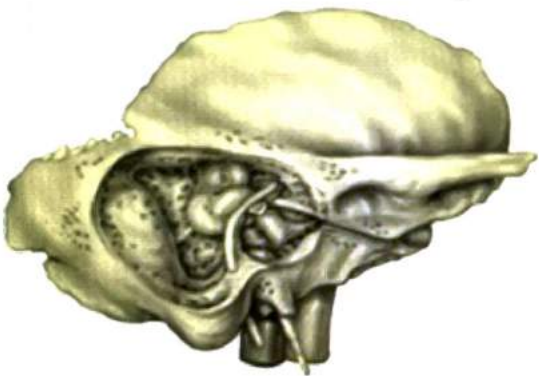
- Treatment of choice → Modified Radical Mastoidectomy
- Mastoidectomy – Types

Simple/Cortical/Schwartz Mastoidectomy



- We don't touch middle ear
- Just drill in the mastoid
- Indicated for
 - Coalescent mastoiditis
 - Cochlear implant
 - After cortical mastoidectomy, posterior tympanotomy done

Radical Mastoidectomy



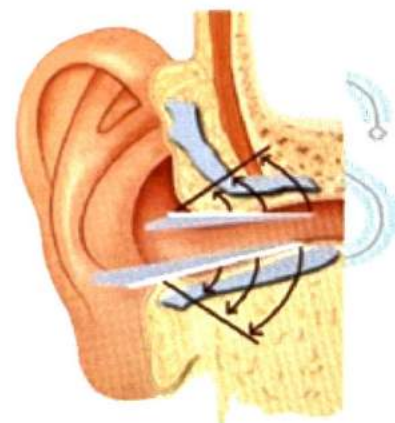
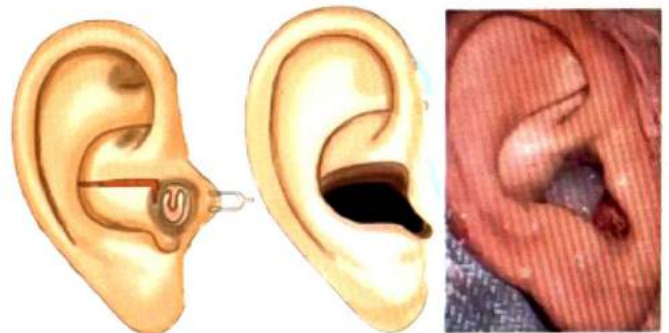- Common cavity of mastoid & middle ear is created by removing common wall (post. wall of ME) between the two.
- Remove the conductive apparatus (Tm and Ossicles), don't remove the stapes.
- Facial nerve have to be intact
- The MC Iatrogenic cause of facial palsy is MASTOIDECTOMY
- Aim: complete eradication of disease
- Modified Radical Mastoidectomy
- Same as radical mastoidectomy, however conductive

hearing apparatus is also preserved, if conductive apparatus has been damaged, it is repaired

- Indications of Radical Mastoidectomy:
 - CA middle ear
 - Glomus tumor
 - As an approach to petrous apex
 - Cholesteatoma in warding
 - ET
 - Round window tube
 - Perilabyrinthine or hypotympanic cells
 - Repeated Recurrence of cholesteatoma

MEATOPLASTY

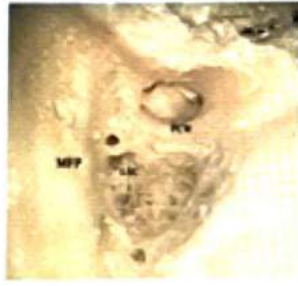
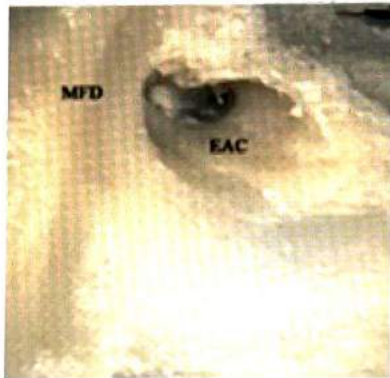
- Increase the size of meatus



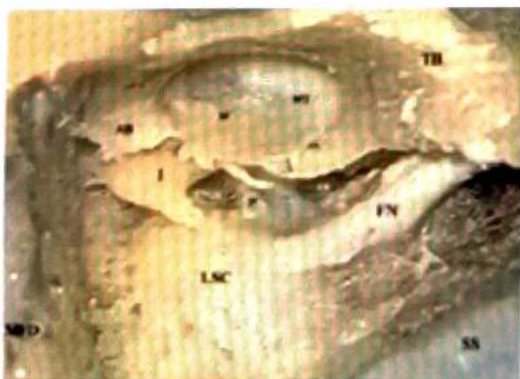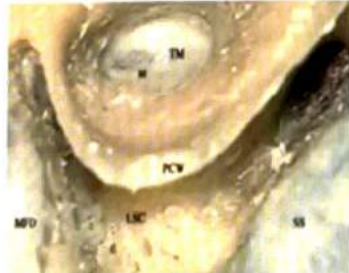Modified Radical Mastoidectomy

- Same as Radical Mastoidectomy but conductive apparatus also preserved, if conductive apparatus has been damaged, it will be repaired
- Primary Aim → Complete eradication of disease

- Secondary Aim → Preservation of Conductive hearing never at the cost of primary aim
- Steps of mastoidectomy: Surgery
 - open the mastoid and middle ear and common wall b/w the two is removed → Create common cavity
 - Preserve Facial nerve



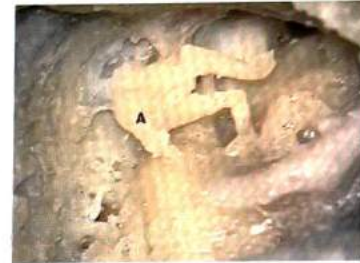- We will remove conductive apparatus except stapes



Previous Year's Questions

Q. Identify the structure marked as A?

(AIIMS May 2018)



- A. Malleus
- B. Incus
- C. Stapes
- D. Lateral semicircular canal

CANAL WALL DOWN MASTOIDECTOMY

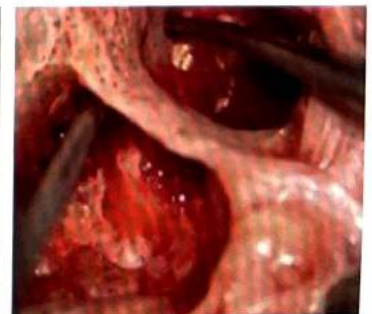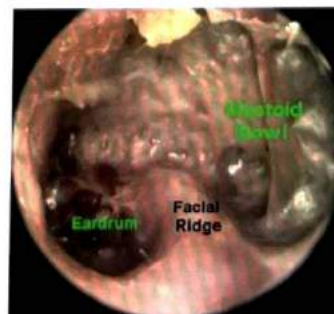
02:36:04

- Other name for MRM
- Canal wall is removed

Canal Wall Up Mastoidectomy

- Common wall (Posterior wall of ME) b/w mastoid and ME is preserved
- Advantages
 - Hearing results are better d/t normal positioning of TM during Tympanoplasty
 - Can go for swimming
 - No cavity problems → Debris / infected → Discharge
 - Regular visits
- Disadvantages
 - Rate of recurrence is higher
 - Advised to follow up by relook 2nd stage Surgery after 6 months

Canal Wall Down vs Canal Wall Up





CLINICAL QUESTIONS



Q. 35 years old male came to your hospital with complaints of symptoms relevant to acute otitis media. On further examination, you diagnosed that case as apical petrositis. which of the following features are seen in apical petrositis?

1. Post auricular pain
 2. Retro orbital pain
 3. Vertigo
 4. Facial nerve palsy
 5. 6th nerve palsy
-
- A. Only 1, 2, 3 is correct
 - B. Only 2, 4, 5 is correct
 - C. Only 2, 3, 4, 5 is correct
 - D. All are correct

Answer: C

Solution

Post auricular pain is the feature of mastoiditis

Apical petrositis:

- Complication of AOM
- The infection spreads within temporal bone into petrous apex

→ Gradenigo triad or syndrome:

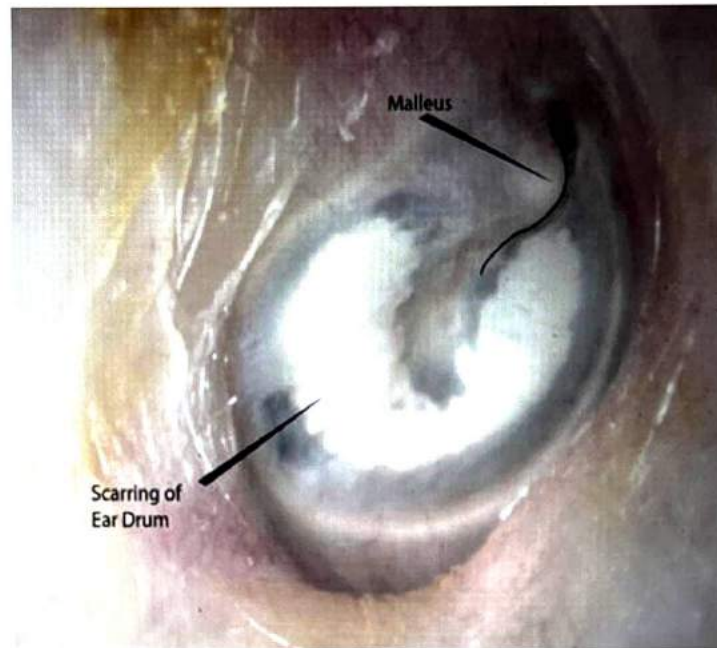
- 6th nerve palsy
- Retro orbital pain

Persistent ear discharge

→ Facial nerve palsy & recurrent vertigo can be seen

→ Dx- CT/MRI

Q. A patient presented to ENT OPD with following picture on Otoscopy. He gives history of ear discharge 4 years back which resolved with medication. What could be the possible diagnosis?



- A. Otosclerosis
- B. Adhesive otitis media
- C. Tympanosclerosis
- D. Cholesteatoma

Answer: C

Solution

Picture shows chalky white patch over a thin membrane- indicates Tympanosclerosis

TYMPANOSCLEROSIS:

- Defined as Hyalinization & subsequent calcification of subepithelial connective tissue.
- Seen in remnants of tympanic membrane or under mucosa of middle ear.
- Seen as white chalky deposit on the promontory, ossicles, joints, tendons and oval and round windows.

Tympanosclerotic masses may interfere with the mobility of these structures and cause conductive deafness



12 COMPLICATIONS OF OTITIS MEDIA

★ Important Information

- M/C complication of Otitis Media: AOM
- M/C complication of CSOM: Ossicular Chain Erosion-CHL

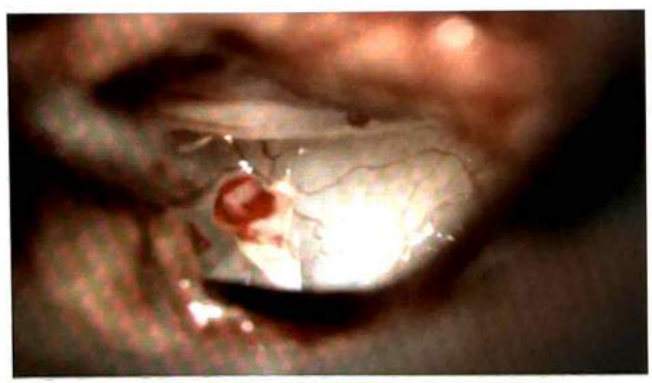
COMPLICATIONS OF CHRONIC OTITIS MEDIA

🕒 00:04:22

- INTRA CRANIAL
- EXTRA CRANIAL
 - INTRA TEMPORAL
 - EXTRA TEMPORAL

Intra Temporal Extracranial Complications

- **OSSICULAR CHAIN EROSION** 🕒 00:05:01
 - It is the most common complication of COM
 - TM perforation: 10-40 dB
 - TM perforation + ossicular discontinuity: 45 dB
 - TM intact + ossicular discontinuity: 54 dB



Conductive Hearing Loss

LABYRINTHITIS

🕒 00:09:04

- Infection in the middle ear goes to the inner ear
- Patients presents with
 - SNHL
 - Vertigo
 - Tinnitus (constant ringing sensation in the ear)
- Types:

- Serous labyrinthitis
 - Toxins in Inner Ear
 - SNHL reversible
- Suppurative labyrinthitis
 - Bacteria in Inner Ear
 - SNHL Irreversible
 - In later, Fibrosis inside the inner ear inside the cochlea
 - This fibrosis leads to calcification. (basal turn of cochlea to apex)
 - Treatment: IV Antibiotics
 - Cochlear implant is done for current SNHL and also to prevent further calcifications.
 - This cochlear impalnt is done as Semi-emergency process
 - If Labyrinthine ossificans is completely ossified then cochlear implant is C/I

★ Important Information

- Progressive SNHL even after the treatment of Labyrinthitis. This is known as Labyrinthitis Ossificans

LABYRINTHINE FISTULA

🕒 00:15:43

- Mc site - Dome of lateral Semicircular canal
- FISTULA SIGN /TEST - Pressing on tragus with finger vertigo or nystagmus occurs
 - True +ve fistula Test- Fictula present Fistula sign +ve
- SEIGELIZATION - Tragus pressure with seigel speculum

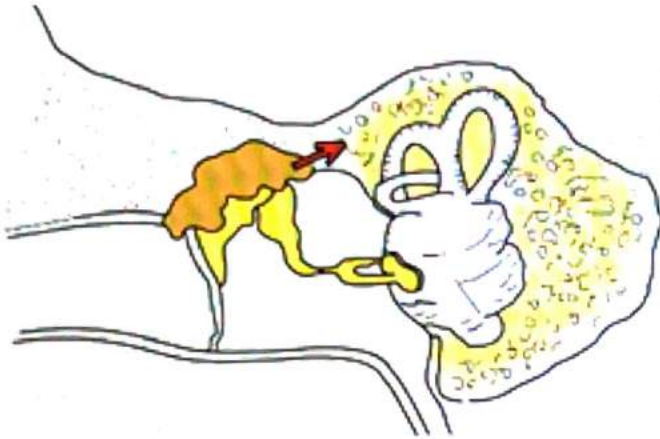
💡 How to remember

- M3GF
 - False - ve fistula Test - Fictula present Fistula sign - ve
 - Seen in Dead ear and Cholesteatoma sac covering fistula
 - False +ve fistula test- fistula -nt,Fistula sign + ve

- Congenital syphilis & Meniere's Disease
- Also known as HENNEBERT'S SIGN
- Also seen in Hypermobile stapes and after stapedectomy

PETROSITIS

00:20:58



- Infection of the petrous part
- Gradenigo syndrome: Grade D syndrome
 - D → Long standing Discharge
 - D → Deep seated retro orbital pain
 - D → Diplopia or Lateral gaze
 - D/t Lateral Rectus palsy
 - D/t Abducent nerve palsy [6th CN]
 - [D/t inflamed DORELLO's CANAL [6th n. canal]
 - D → Dorello's canal

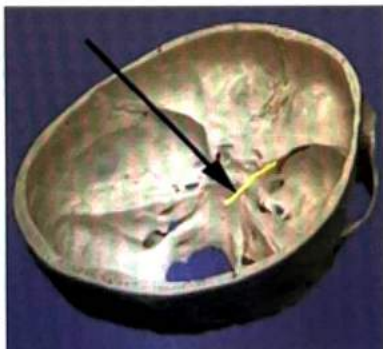
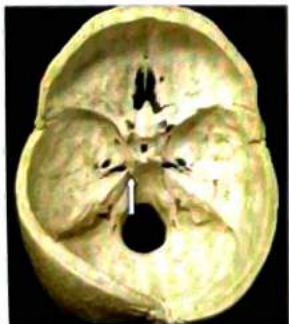

How to remember

- 4D's

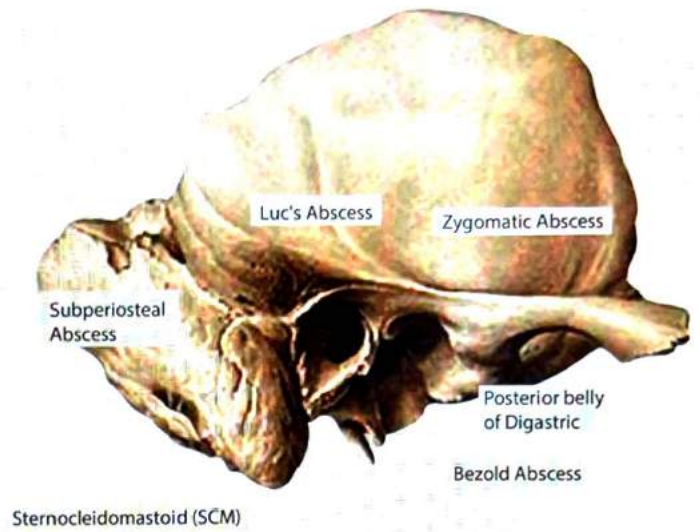
Dorello's Canal

Abducens Nerve Course



EXTRA TEMPORAL EXTRACRANIAL COMPLICATIONS

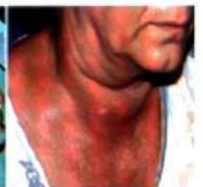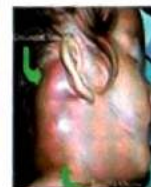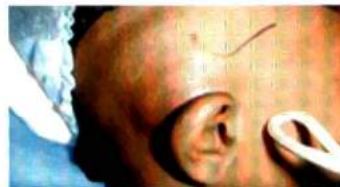
00:25:08



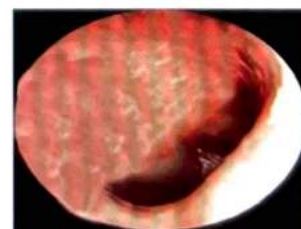
- **Post Aural / Sub Periosteal Abscess**
 - Just behind the pinna
 - Most common extra temporal extra cranial complications.
- **Bezold Abscess**
 - Present with torticollis [Spasm OF Sternocleidomastoid muscle]
- **LUC's Abscess**
 - Abscess in the posterior superior wall of EAC but the skin is intact
- **Zygomatic Abscess**
 - Cholestoma erode and goes to the root of the zygomatic process
 - Abscess in anterior and superior to the tragus
- **Citelli's Abscess :**
 - Anterior to mastoid along the posterior belly of digastric
 - Posterior to mastoid

Post Aural / Sub Periosteal Abscess

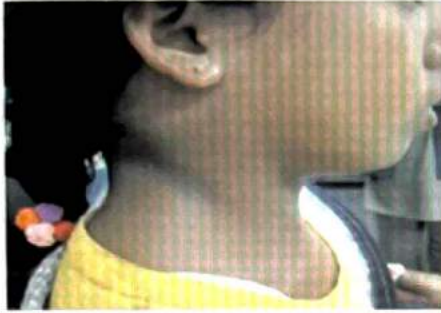Bezold Abscess



Luc's Abscess



Citelli's Abscess



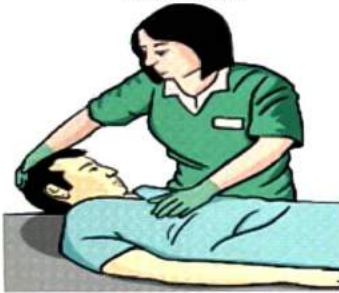Zygomatic Abscess



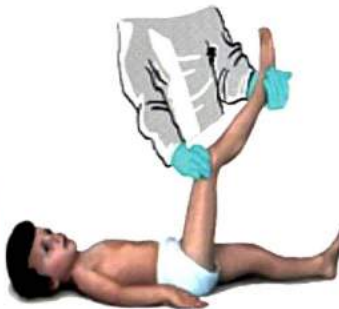IntraCranial Complications

00:33:41

Nuchal Rigidity



Kernig's Sign



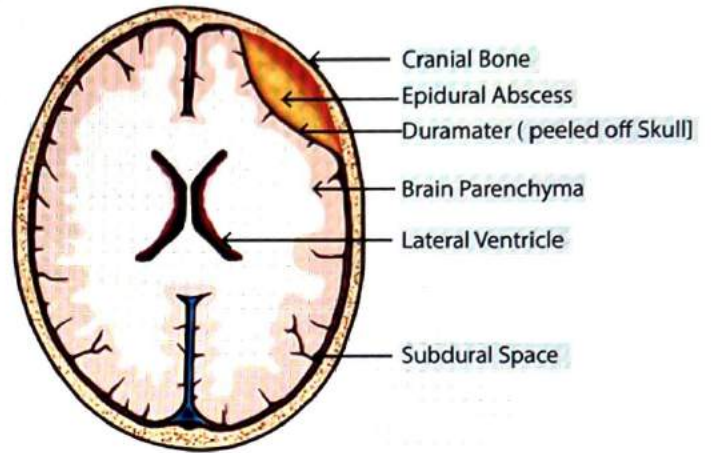
Brudzinski Neck Sign



- Meningitis (M/C)
 - Kernig and Brudzinski signs have low sensitivity but high specificity

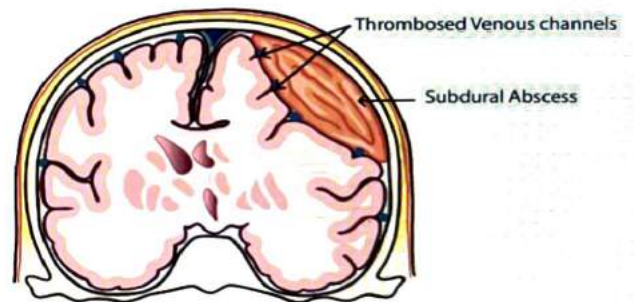
- Extra dural abscess/Epidural abscess

Extradural/ Epidural Abscess



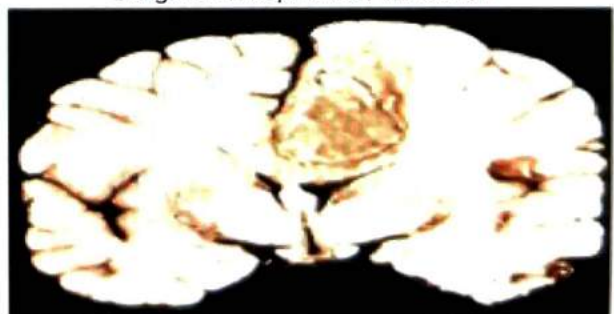
- Sub dural abscess

Subdural Abscess

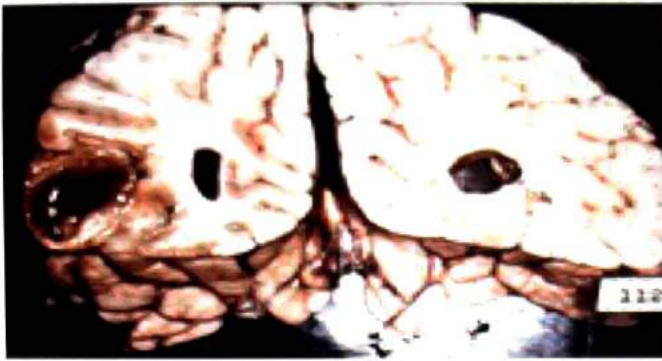


- Brain abscess
 - Stage 1: Encephalitis / cerebritis - 1 to 3 days
 - Stage 2: Latency / Localization (capsule formation) = 4th - 7th day
 - Stage 3: Expansion & Rupture = 8-14 days
 - IOC: MRI
 - 2 types
 - Temporal lobe Abscess (MC)
 - Cerebellar Abscess - through Traucular Triangle

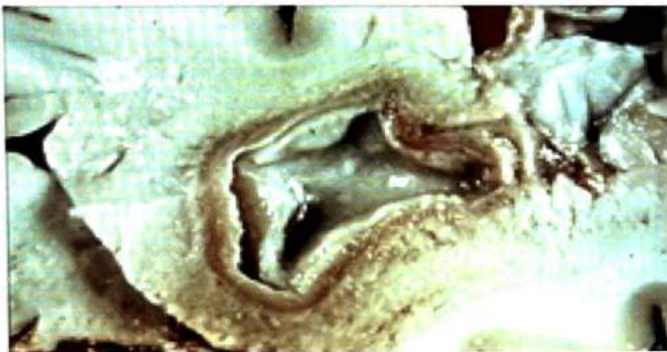Stage 1: Encephalitis / cerebritis



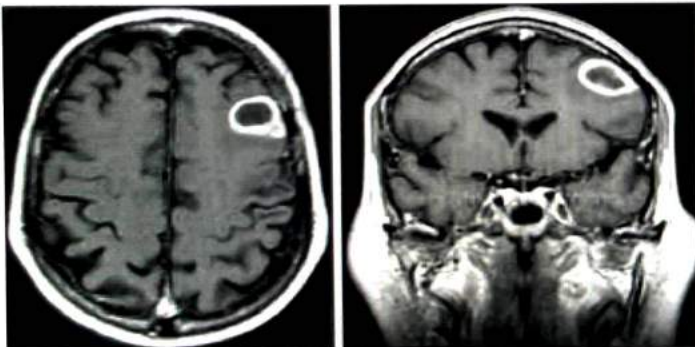
Stage 2: Latency / Localization



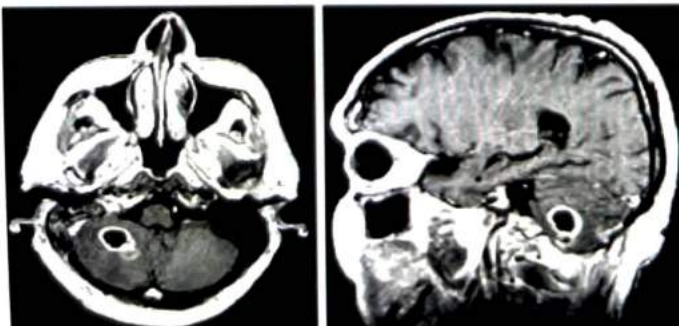
Stage 3: Expansion & Rupture



Temporal Lobe Abscess



Cerebellar Abscess




SIGMOID / LATERAL SINUS THROMBOSIS

00:42:57

- C/F:
 - Pallor
 - Headache
 - Picket Fence Fever
 - Temperature does not come to normal base line
 - Remittent fever
 - [Intermittent fever seen in malaria]
 - Edema over the mastoid surface - GRIESINGER'S SIGN

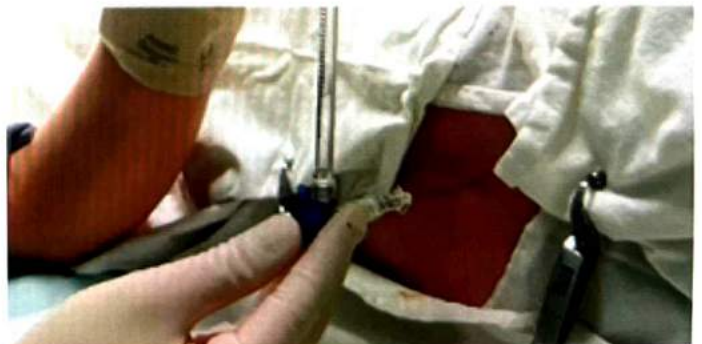Picket Fence Fever: Remittent Fever



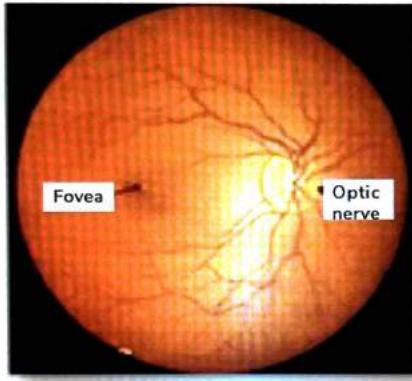
Management

- Tobey Ayer / Queckenstedt test.
 - Compression over IJV on normal side , increases CSF pressure in lateral sinus thrombosis by lumbar puncture
 - Invasive test
- Crow beck test
 - Compression over IJV on same side leads to engorgement of Retinal veins.

Tobey Ayer/ Queckenstedt Test

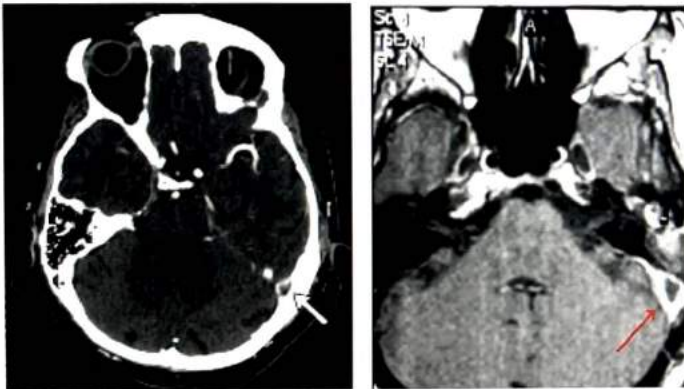


Crow Beck Test



- CECT/MRI
 - Empty Delta sign
 - Confirmatory test (IOC)

Empty Delta sign



- Treatment:
 - Surgery + IV Antibiotics



Previous Year's Questions

Q. CSOM with Picket fence fever is seen in: (FMGE JUN 2018)

- A. Meningitis
- B. Sigmoid sinus thrombosis
- C. Brain abscess
- D. Extradural abscess



Previous Year's Questions

Q. Tobey-Ayer test is done for: (FMGE JUN 2018)

- A. Acantholysis
- B. Hemoglobinuria
- C. Ketosis
- D. Lateral sinus thrombosis



13 OTOSCLEROSIS

PATHOPHYSIOLOGY OF OTOSCLEROSIS

00:00:32

- Enchondral Bone changes to Spongy bone.
 - M.C site of formation of spongy bone is at Fissula Ante Fenestrum
 - It is just anterior to the oval window
 - Most common site for otosclerosis
- This spongy bone grows and completely fix the stapes foot plates & results in decreased hearing.



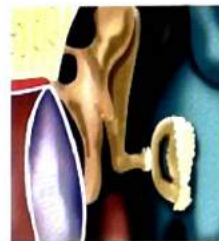Blue sclera

- Patient presents with bilateral hearing loss

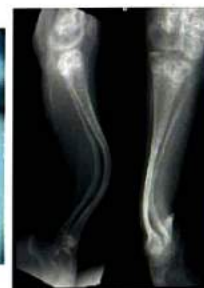

How to remember

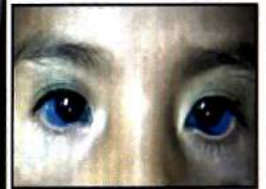- VANDER - O₂B



Otosclerosis



Osteogenesis Imperfecta



Blue Sclera

EXAMINATION

00:07:22

- Tympanic membrane usually NORMAL
- Sometimes, show flamingo pink colour → Schwartz Sign
 - It is Seen when enchondral bone changes to spongy bone (Active/Early phase of disease) → Otospongiosis
 - During this change, increase blood flow to stapes foot plate.



Important Information

- M.C site for fixation of stapes is Anterior 1/3 or anterior crura.

CLINICAL PRESENTATION:

00:03:30

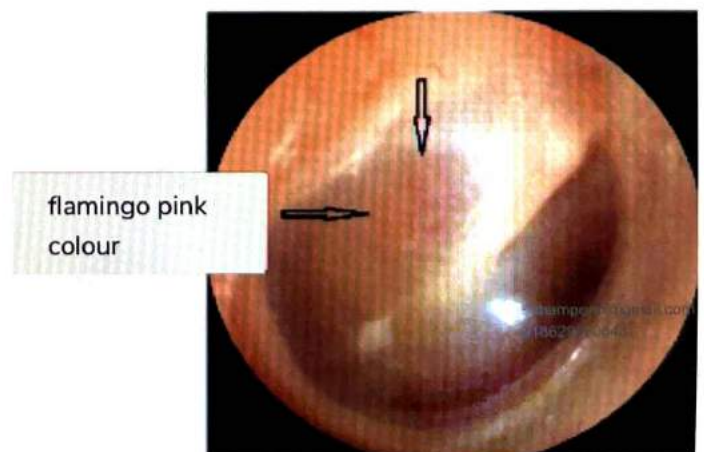
- Female : male = 2:1
- Predominant in Females (20-30 yrs).
- Increased Incidence in pregnancy.
- AD (50% patient have positive family history)
- Bilateral disease
- Hearing loss (conductive)
- Paracusis Willisii
 - Hear better in Noisy environment

VANDER HOEVE SYNDROME

00:06:48

- It consists of Otosclerosis + osteogenesis imperfecta +

Schwartz Sign



flamingo pink colour

INVESTIGATIONS

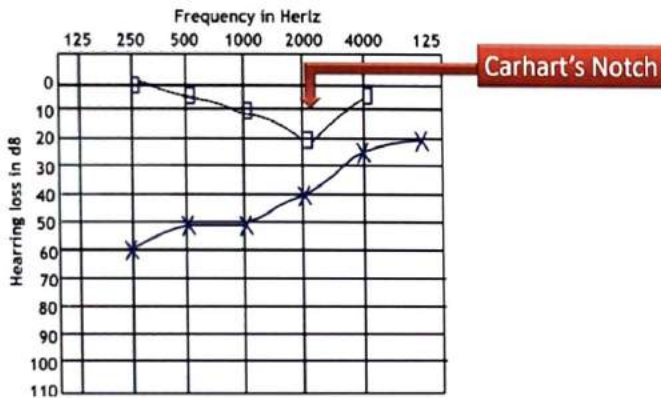
00:09:29

Pure Tone Audiometry

Disease	AB GAP
SOM	25-30dB
TM perforation	10-40dB
TM perforation + Ossicular chain erosion	45dB
TM intact + Ossicular discontinuity	54dB
Otosclerosis	Upto 60 dB (it is the max. CHL)

CARHART'S NOTCH

00:13:37



- CARHART'S NOTCH → Dip present at 2000 Hz
 - In bone conduction seen
 - It is conductive hearing loss

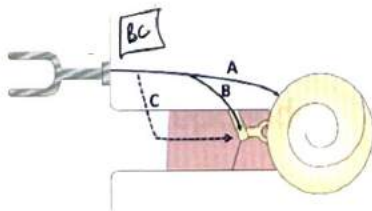


Important Information

- In NIHL dip at 4000Hz (SNHL)
- Hz in bone conduction seen

Reason for Carhart's Notch:

- bone conduction reaches the cochlea by 3 ways:
 - Directly
 - Through ME ossicles
 - Through EAC



CARHART'S EFFECT

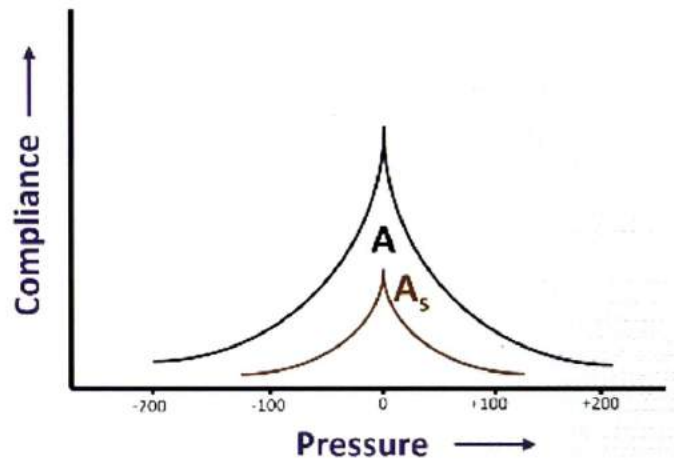
00:17:04

- Air through ME ossicles and via EAC will not happen
- Carharts notch at 2000 Hz will be affected
- Carharts notch will also seen in other CHL

IMPEDANCE AUDIOMETRY (INVESTIGATION)

00:18:52

- As curve seen
- Tympanometry along with stapedial reflex testing
 - Stapedial reflex is absent because the stapes footplate is fixed
 - Testing: Negative

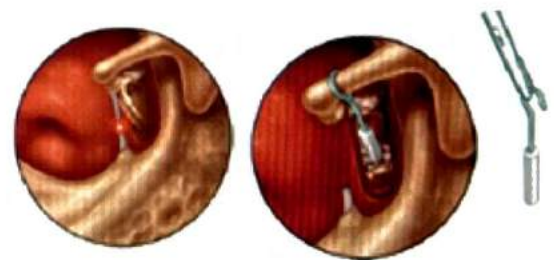


TREATMENT

00:20:10

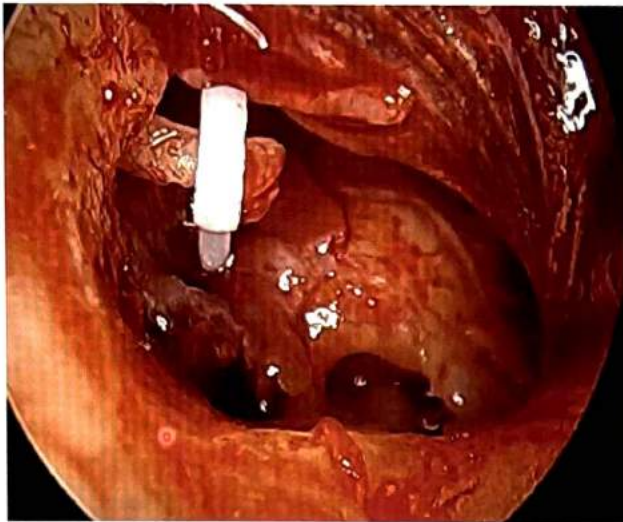
- RxOC - Laser Stapedotomy
 - Hole made in stapes footplate and anchored with piston

Laser Stapedotomy



- Stapedectomy:
 - Remove stapes foot plate & graft is placed at the oval window & piston is placed.
 - But is has the Risk of SNHL
- Even before stapedectomy, Fenestration operation or Type V tympanoplasty is done.
- Teflon piston is the MC stapes piston used in India

Stapes Piston



? Previous Year's Questions

- Q. Schwartz sign is seen in? (JIPMER Dec 2019)
- Meniere's disease
 - Acoustic neuroma
 - Otosclerosis
 - Otitis media with effusion

? Previous Year's Questions

- Q. Which among the following is not true about otosclerosis? (JIPMER May 2019)
- Hearing better in louder conditions
 - Eustachian tube is always abnormal
 - Tympanic membrane is normal
 - Bilateral progressive conductive deafness

? Previous Year's Questions

- Q. Gelle test is done in? (AIIMS May 2018)
- Otosclerosis
 - Serous Otitis media
 - Traumatic hearing loss
 - Age related hearing loss

? Previous Year's Questions

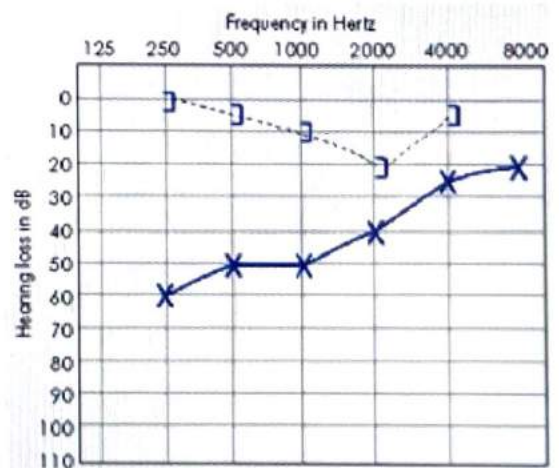
- Q. Carhart's notch in audiometry is seen in? (DNB JUN 2018)
- Ossicular discontinuity
 - Hemotympanum
 - Otomycosis
 - Otosclerosis

? Previous Year's Questions

- Q. A patient hears better in noise. The diagnosis is? (FMGE JUN 2018)
- Hyperacusis
 - Hypoacusis
 - Presbycusis
 - Paracusis

? Previous Year's Questions

- Q. A 35 yrs old female patient presents with hearing loss with improvement in hearing in noisy environment. On examination Rinne's negative and weber's is centralized. Following is the audiometry report. What is the most likely diagnosis: (AIIMS MAY 2019)

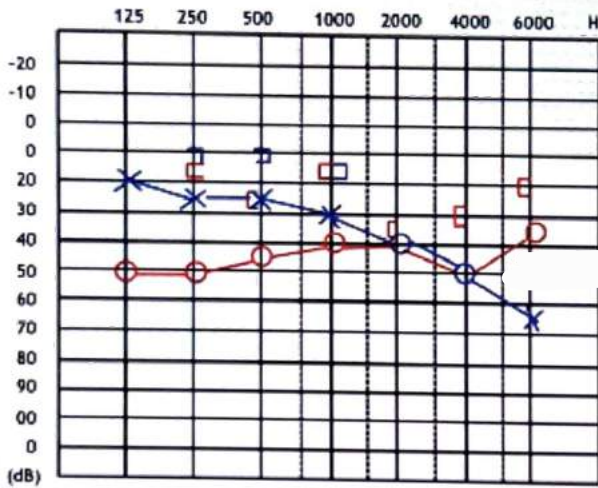


- Meniere's disease
- Perilymph fistula
- Stapedial otosclerosis
- Vestibular schwannoma



Previous Year's Questions

Q. Identify the cause of hearing loss in a 30 yrs old pregnant female who pure tone audiogram image given below:



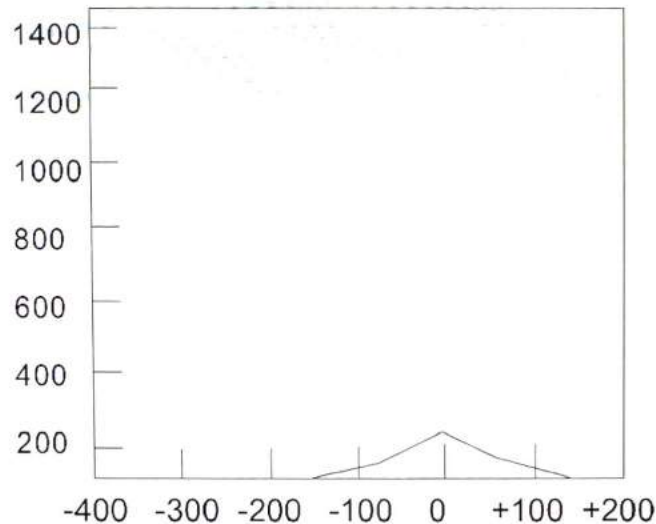
- A. Ototoxicity
- B. Otosclerosis
- C. Noise induced hearing loss
- D. Meniere's disease



CLINICAL QUESTIONS



Q. A 40 yr old pregnant woman came to ENT OPD with hearing loss. Tuning fork tests revealed Conductive hearing loss. Otoscopic examination showed normal tympanic membrane. Consultant advised patient to undergo tympanometry & following finding is found. What could be possible diagnosis?



- A. Serous Otitis media
- B. Meniere's disease
- C. Otosclerosis
- D. CSOM Mucosal disease

Answer: C

Solution

Picture shows reduced compliance at ambient air pressure- As type of tympanogram

- Compliance is lower at or near ambient air pressure.
- Seen in fixation of ossicles, e.g. otosclerosis or malleus fixation.

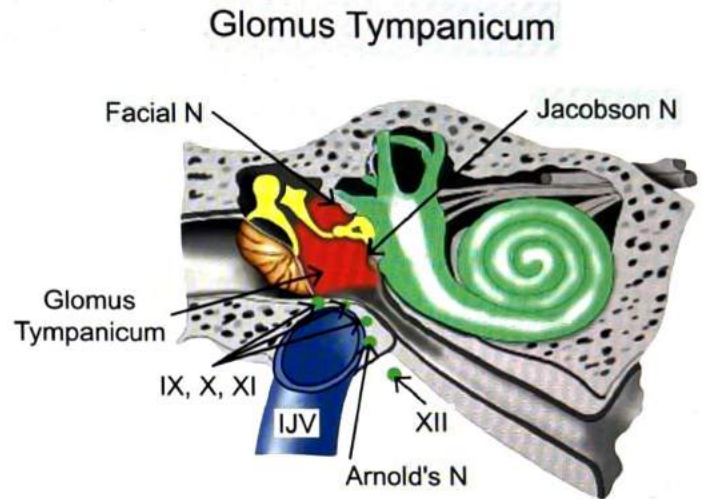
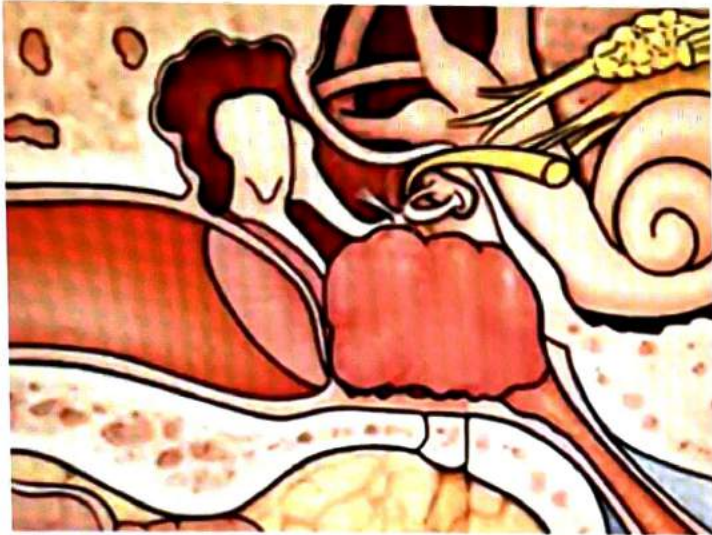TYMPANOMETRY FINDINGS IN OTOSCLEROSIS:

- Tympanometry may be normal in early cases but later shows a curve of ossicular stiffness- Foot plate gets fixed in later stages with gradual replacement of enchondral bone by irregularly laden spongy bone with increased vascularity.
- This reduces compliance of middle ear- Since thickened foot plate resists conduction of sound.
- Stapedial reflex becomes absent when stapes is fixed



14

GLOMUS TUMOR



ORIGIN OF GLOMUS TUMOR

00:00:41

- MC benign tumor of middle ear.
- Arises from jugulotympanic paraganglions (In association with Jacobson's and Arnold's nerves)

Glomus Jugulare

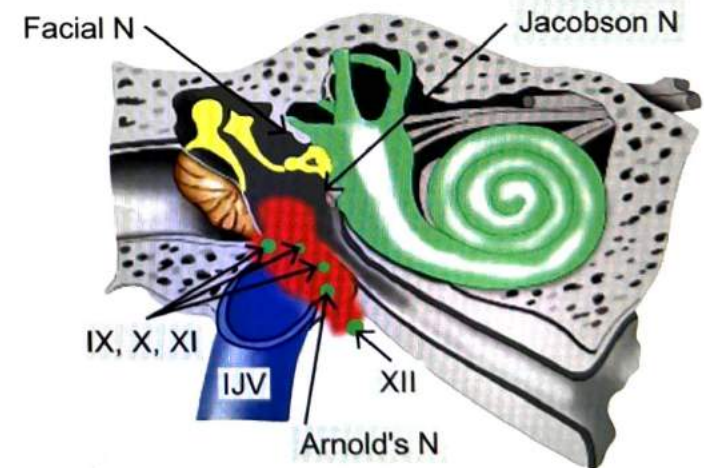
- Arises from the dome of jugular bulb
- Leads to palsy of IX, X, XI, XII cranial nerves



Important Information

- JACOBSON'S NERVE- IX Nerve
- ARNOLD'S NERVE-X Nerve

Glomus Jugulare



TYPES OF GLOMUS TUMOR

00:02:31

- Based on Paraganglionic cells- two types:
 - Glomus Tympanicum
 - Glomus Jugulare
- **Glomus Tympanicum**
 - Arises from the promontory along the course of Jacobson's nerve
 - It involves the 7th cranial nerve (Facial nerve)
 - Leads to facial nerve palsy most commonly

BLEEDING AURAL POLYP

00:04:19

- If there is a bleeding polyp in EAC then, biopsy is absolutely contra indicated
- First, CT scan to diagnose the tumor
- Glomus tumor is locally invasive & highly vascular



Important Information

- MC blood supply of glomus tumor - Inferior tympanic branch of the Ascending pharyngeal artery

CLINICAL PRESENTATION

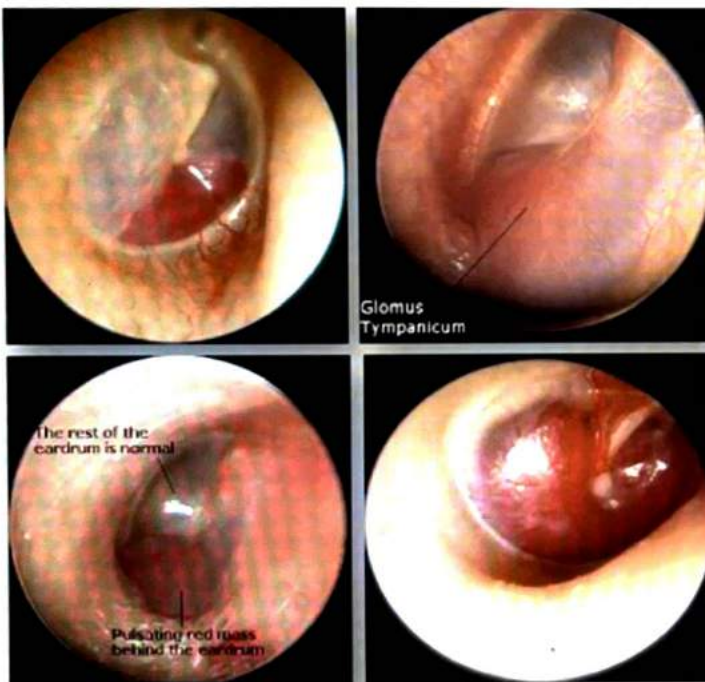🕒 00:05:58

- Age: 40-50yrs
- Female: Male ratio - 5:1
- Mass in middle ear
- Symptoms
 - CHL
 - Pulsatile tinnitus present (most significant)
 - Profusely bleeding polyp in EAC

ON EXAMINATION

🕒 00:07:37

- RISING SUN/AQUINO/BROWN SIGN



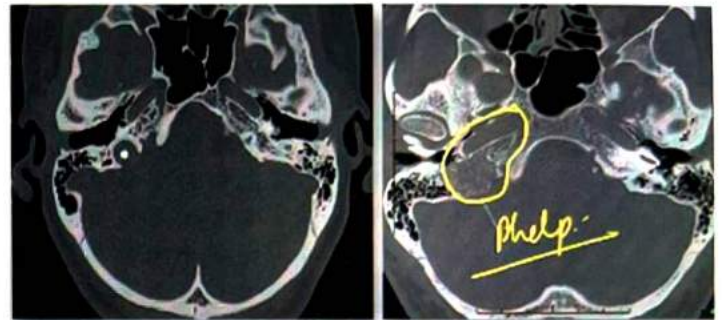
- Rising sun sign: Reddish blue rising from hypotympanum
- Aquino sign: Jugular pressure finger leads to improving of Tinnitus.
- Brown sign: On seigelization, tumor blanches & becomes white
 - Brown sign also known as Pulsation sign
 - Sometimes Blue Tympanic membrane is seen.

INVESTIGATION

🕒 00:10:15

- Investigation of choice: CECT
 - Confirmatory Test.

- Phlep sign seen on CT (Inability to distinguish between internal carotid Artery & jugular bulb d/t erosion of caroticojugular crest.)



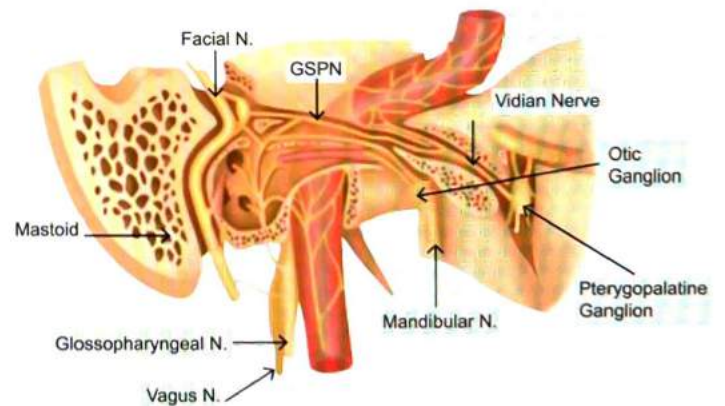
STAGING OF GLOMUS TUMOR

🕒 00:12:48

Fisch Classification (Glomus Tympanicum)

- TYPE A - Middle ear cleft
- TYPE B - Tympano mastoid area
- TYPE C - Infra labyrinthine compartment / petrous apex
 - C₁: Limited involvement of vertical portion of carotid canal
 - C₂: Invasion of vertical portion of carotid canal
 - C₃: Invasion of horizontal portion of carotid canal
- TYPE D - Intra cranial involvement
 - D₁: I/C extension (< 2cm in diameter)
 - D₂: I/C extension (> 2cm in diameter)

Fisch Classification (glomus tympanicum)



TREATMENT

🕒 00:17:32

- Surgical excision is the treatment of choice

RULE OF 10S

🕒 00:20:21

- 10% Familial
- 10% Multicentric
- 10% Functional (Secretes catecholamines)



How to remember

• 10



Previous Year's Questions

- Q. Tuberculous Otitis Media of the middle ear has all of the following except? (NEET JAN 2020)
- A. Multiple perforations are seen
 - B. Pale granulomas are seen
 - C. ATT should be started
 - D. Painful otorrhea is seen

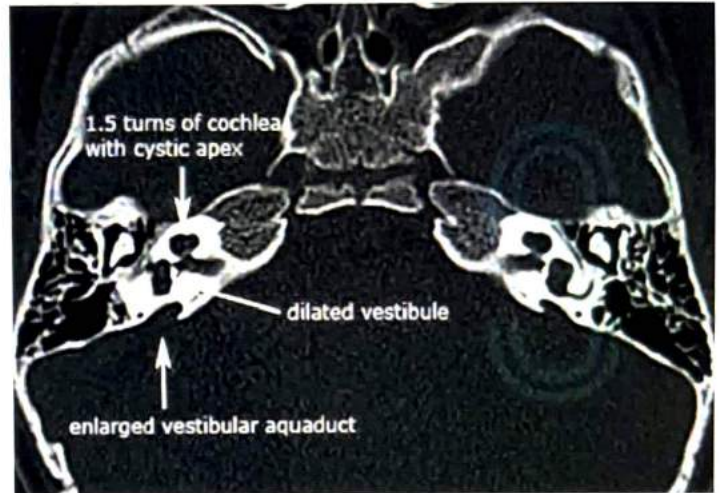
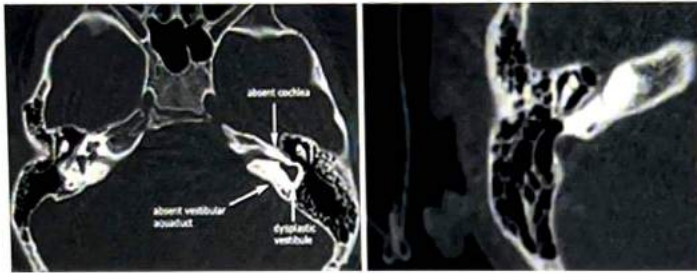


15 DISEASES OF INNER EAR

MICHEL'S APLASIA

00:00:25

- Complete Absence of cochlea
- Absolute C/I of cochlear implant



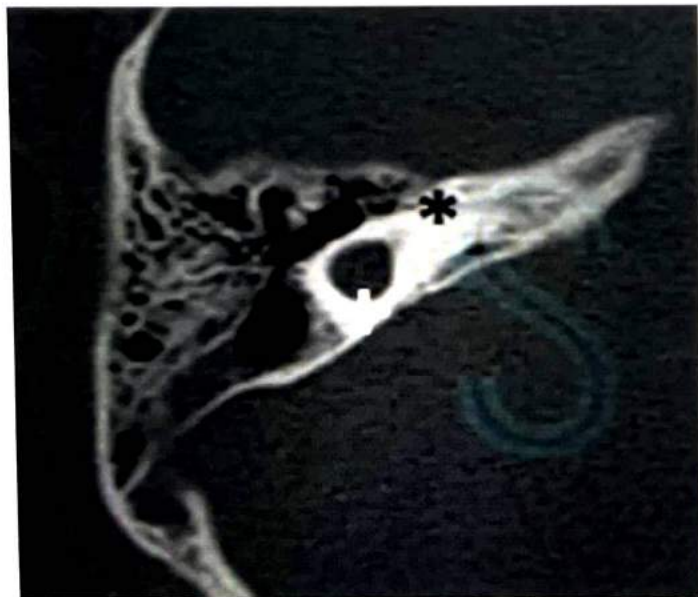How to remember

- MICHEL'S NEVER LISTEN

SCHEIBES DYSPLASIA

00:02:42

- M/C congenital anomaly of inner ear
- Absolute C/I of cochlear implant
- Is also known as Cochleosaccular Dysplasia



- M/C congenital anomaly of cochlea
- Cochlea have only 1.5 turns
 - 2nd & 3rd turn of cochlea fuses together
- Relative contraindication for cochlear implantation

ALEXENDER'S DYSPLASIA

00:06:11

- Basal turn of cochlea is absent
- Absolute C/I for cochlear implant

Considerations before cochlear implant

- Extent of surface epithelium
- Status of opposite ear
- How much response present

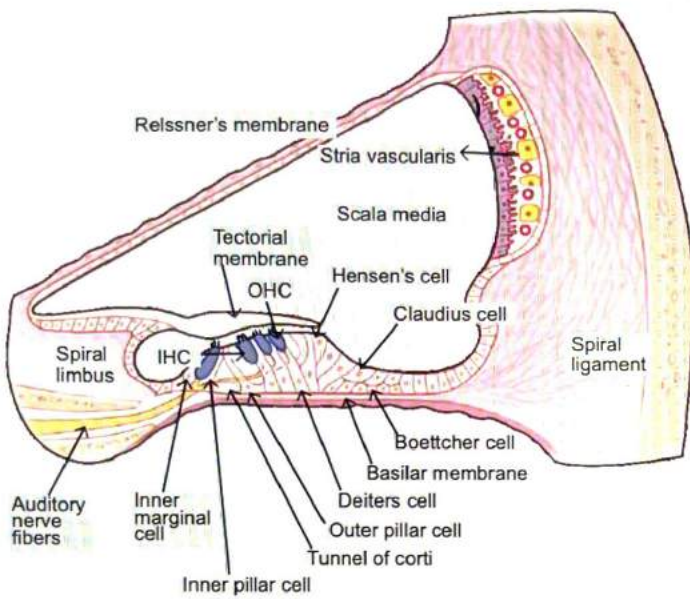
MENIERE'S DISEASE / ENDOLYMPHATIC HYDROPS

00:07:27

- Endolymph - Normal Physiology
- Secreted by stria vascularis has Na⁺/K⁺ pump
- Transported to endolymphatic sac by endo lymphatic duct
- Endolymph absorbed by endolymphatic sac
- Ductus reuniens takes the endolymph from scala media to the utricle and saccule and from there arises the endolymphatic duct which takes the endolymph to the sac. It is also known as Longitudinal flow of endolymph.

MONDINI'S DYSPLASIA

00:03:42




- Endo Lymphatic Hydrops: Collection of endolymph in inner ear due to:
 - Excessive production
 - Blockage of duct
 - Defective absorption

PATHO PHYSIOLOGY OF MENIERE' S DISEASE

🕒 00:13:12

- Due to increasing pressure, at some point Reissner's membrane breaks and all the endolymph enters into the perilymph
 - VERTIGO [d/t K⁺ entry into perilymph and causes irritation]
 - SNHL [d/t ion gradient imbalance]
 - Tinnitus / Aural fullness
- After some time, Reissner's membrane heals, ion gradient returns → Hearing comes back to normal
 - K⁺ restores in endolymph → Vertigo subsides



- And again the above cycle continues, leading to triad
- Clinical features:
 - U/L disease, Common in 35 - 40 yr, Male: female = 1:1



How to remember

TRAI D:

- Episodic vertigo
- Fluctuating SNHL
- Tinnitus and Aural fullness

TULLIO'S PHENOMENON

🕒 00:16:08

- Loud Nose Precipitates Vertigo
- Buldge of reissner's membrane causes adhesion of RM with medial aspect of stapes foot plate



TUMARKIN' S CRISIS

🕒 00:16:59

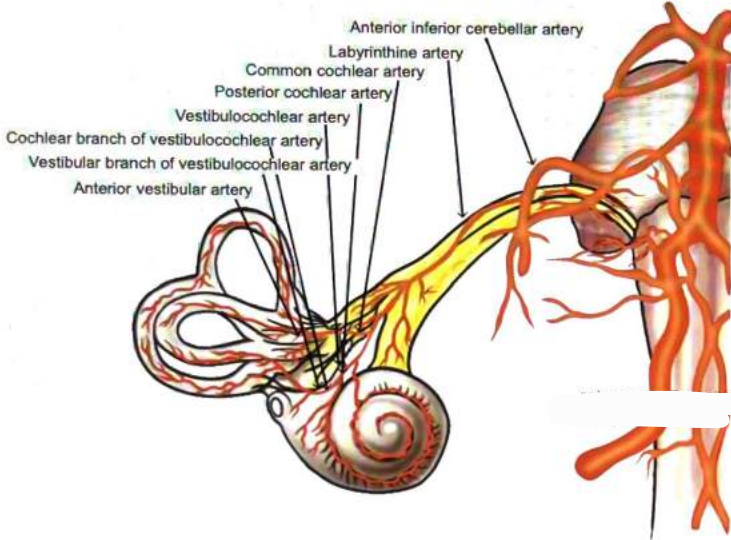
- Sudden Fall Attack
- Buldging utricle stimulates otolith causing dis-balance



LERMOYEZ SYNDROME

00:17:55

- Vertigo Relieves SNHL
- SNHL comes before vertigo
- Hearing loss occurs due to sudden spasm of labyrinthine artery



INVESTIGATION

00:19:55

- Pure Tone Audiometry (to confirm SNHL)
- ↓
- IV glycerol [1.5 ml/kg] [Glycerol test]
- ↓
- Repeat Pure tone audiometry after 30 min
- ↓
- Hearing improved ≥ 10 dB
- ↓
- MENIERE'S disease



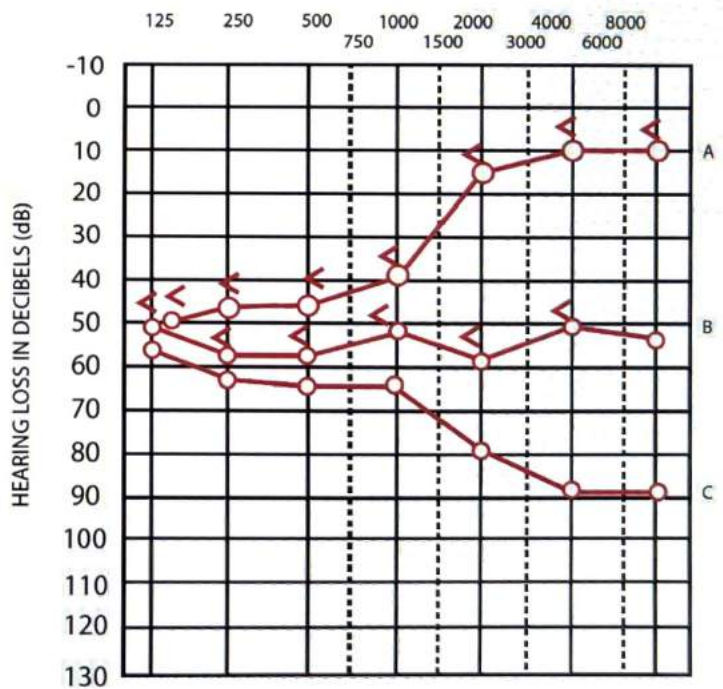
Important Information

Glycerol test

- 10 dB in SNHL in PTA
- 10% in SDS IN Speech Audiometry

AUDIOGRAM IN MENIER'S DISEASE

FREQUENCY IN HERTZ



- **Early Meniere's disease** → **Rising curve**
 - More hearing loss at low frequencies
 - High hearing loss at less frequencies
- **Late Meniere's disease** → **Sloping curve**
 - More hearing loss at high frequencies
 - U/L sloping curve



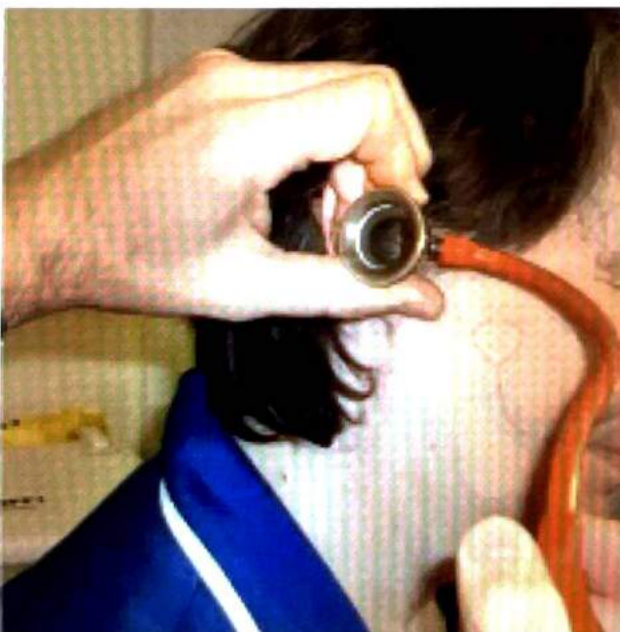How to remember

- LERMOYEZ - LABYRINTHINE

HENNEBERT'S SIGN

00:19:17

- False +ve Fistula Test
- Present in Meniere's & congenital syphilis

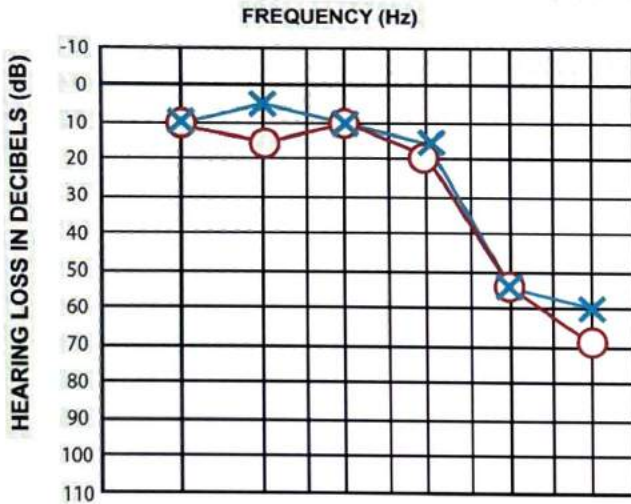




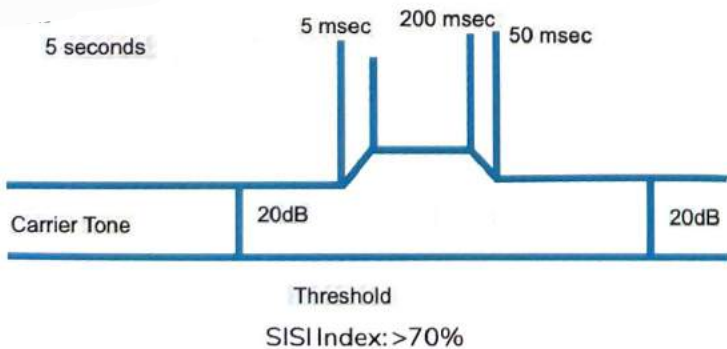
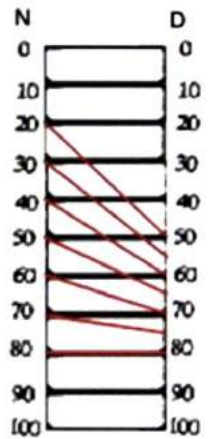
Important Information

- [B/L Sloping curve → Presbycusis / ototoxicity]

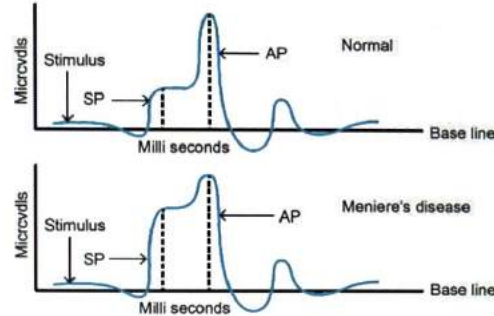
PRESBYACUSIS: age related hearing loss



- Cochlear deafness: Recruitment positive



- Electro Cochleography
 - Confirmatory test
 - In Normal ear, summing potential (SP) < 30% AP
 - In Meniere's disease,
 - SP > 45% AP = Suggestive of Meniere's disease
 - SP > 70% AP = confirmatory of Meniere's disease
 - Invasive procedure



Normal Person
SP < 30% AP
SP/AP Ratio < 0.3

Meniere's
SP > 45% AP
SP/AP Ratio > 0.45

TREATMENT OF MENIERE'S DISEASE:

00:26:43

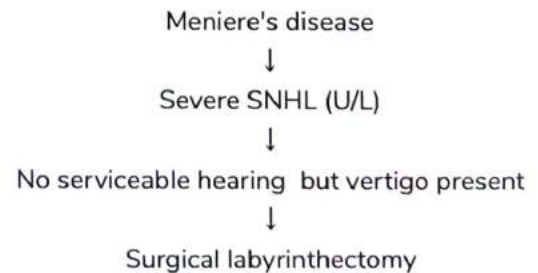
- Acute phase: Labyrinthine sedatives
- Maintenance phase is done between 2 episodes
 - **Medical**
 - K⁺ sparing diuretics → Decreases Endolymph production
 - β Blockers → Increases absorptions
 - Antihistamines-cystaminics → Improves blood circulation
 - **Surgical**
 - Conservative: Endolymphatic sac decompression, vestibular neurectomy
 - Radical: Surgical labyrinthectomy

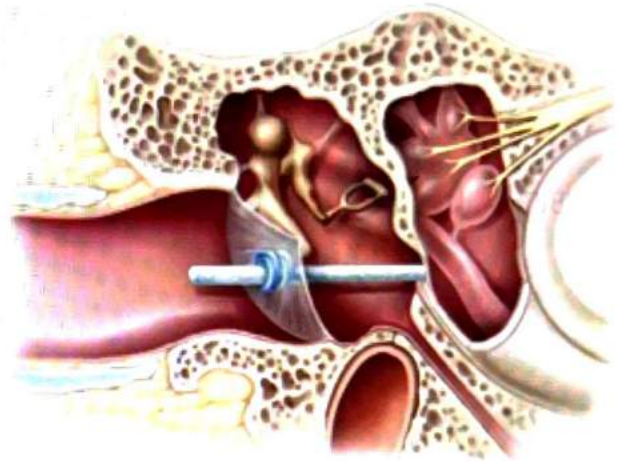
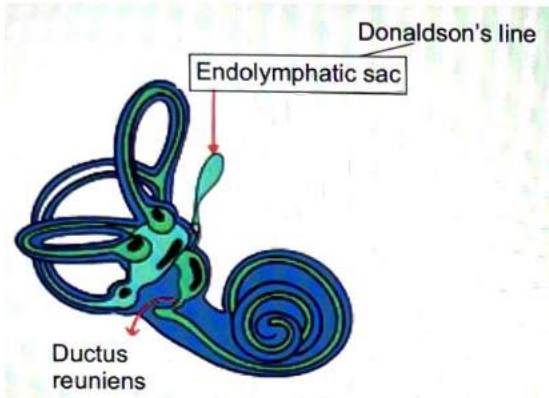
Surgical landmark's Donaldson's line



How to remember

- NO INNER EAR - NO VERTIGO





- Surgical labyrinthectomy is done in a patient with chronic Menier's disease with severe SNHL because of which U/L ear is not serviceable for hearing and patient has vertigo

★ Important Information

Q. Gold standard treatment for intractable vertigo in a patient of Menier's disease?

Ans: Surgical labyrinthectomy

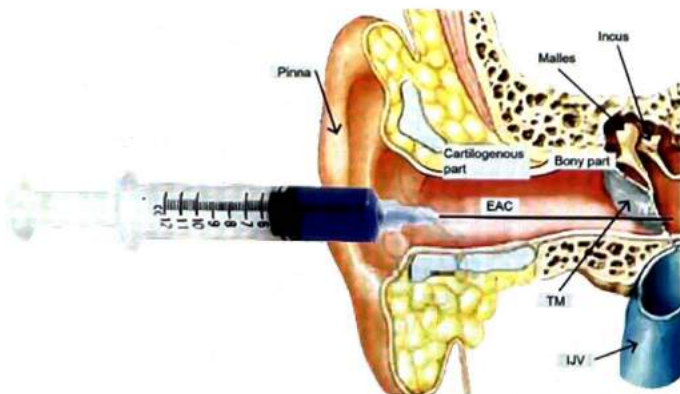
(AIIMS)

INTRATYMPANIC GENTAMYCIN THERAPY

00:34:01

- Gentamycin is selective vestibulotoxic
- AKA Chemical Labyrinthectomy

Intratympanic Gentamicin Therapy



SILVERSTEIN MICROWICK MICROCATHERETER

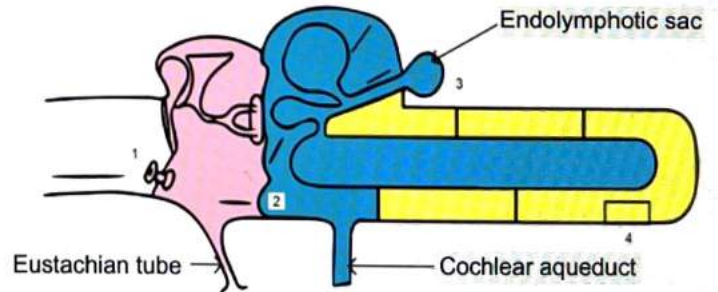
00:34:45

- Micro catheter is inserted from EAC to RW
- Drug delivery system to the inner ear

MENIETT' S DEVICE

00:36:08

- Intermittent low-pressure pulse therapy device
- US FDA approved
- Grommet is inserted in tympanic membrane to deliver low intermittent pulse pressure to the round window
- Intermittent low pulse pressure applied to EAR from where it reaches to middle ear cavity & from there to round window exerting pressure on Endolymph in EL duct leading to opening of the obstructions, further, fluid reaches EL Sac & gets observed



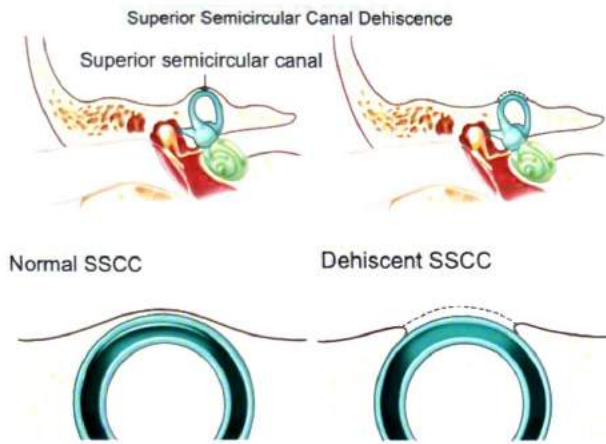
★ Important Information

- Disease of external ear → Ds of middle ear cause CHL
- Disease of inner ear → 8th nerve cause SNHL (Cochlear / Retro cochlear)

SUPERIOR SEMI-CIRCULAR CANAL DEHISCENCE / 3RD WINDOW SYNDROME

00:40:04

- Disease of inner ear leading to CHL
- Superior SCC dehiscence creates a 3rd window
 - When oval window goes in some part of energy is lost via 3rd window Phenomenon.
 - leads to CHL



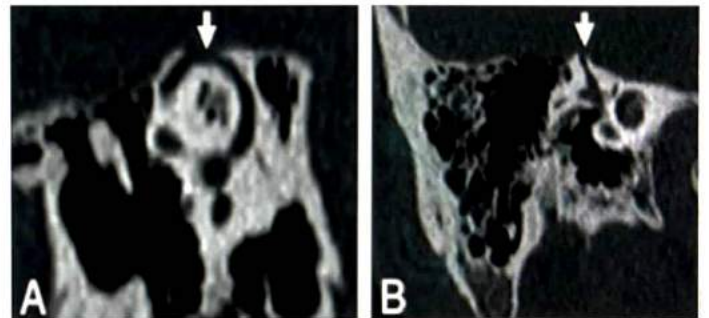
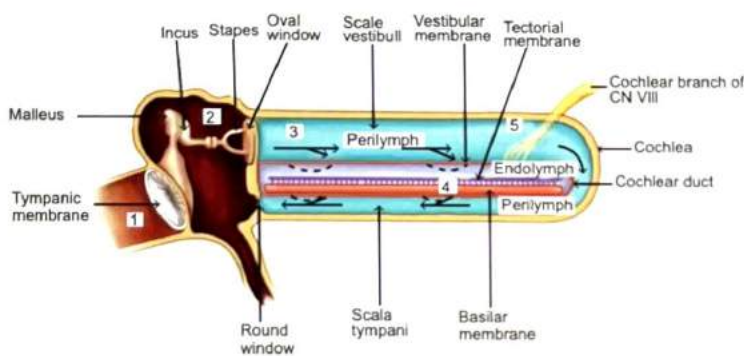
Clinical features

- Vertigo
- Oscillopsia
- Autophony
- Tullio's phenomenon
- Fullness / pressure in the ears

Diagnosis

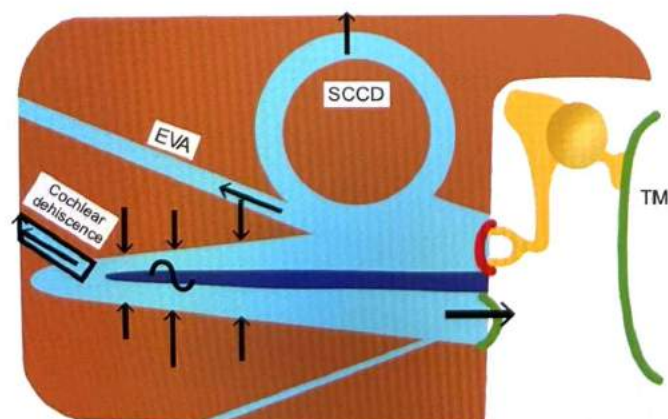
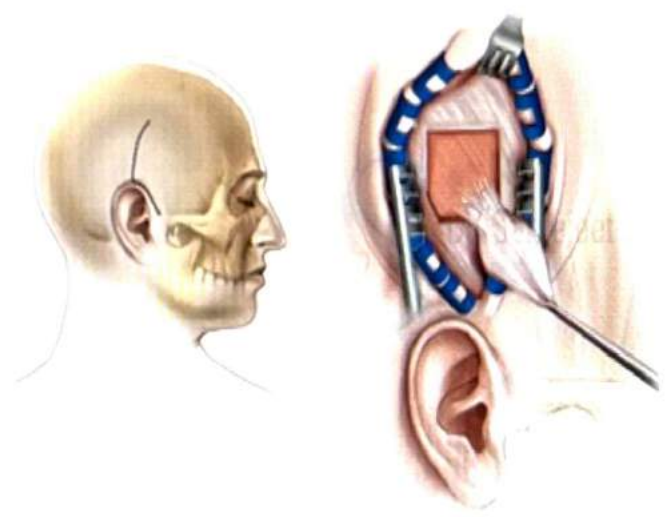
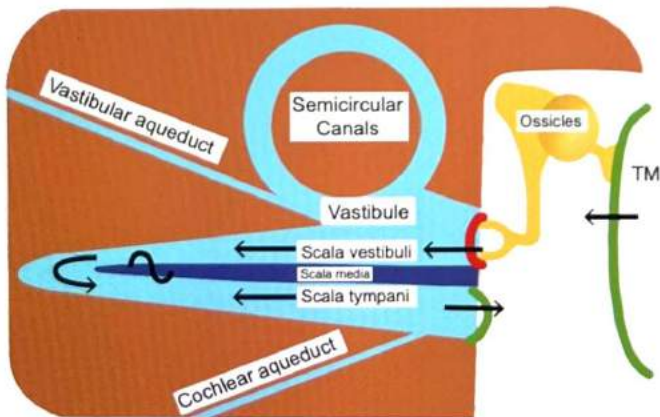
- HRCT temporal bone
- Patients bone conduction is super normal
- On pure tone audiometry → AB GAP present → suggestive of conductive hearing loss

The Third Window Phenomenon



Rx

- Repair the SCC dehiscence through middle cranial fossa approach

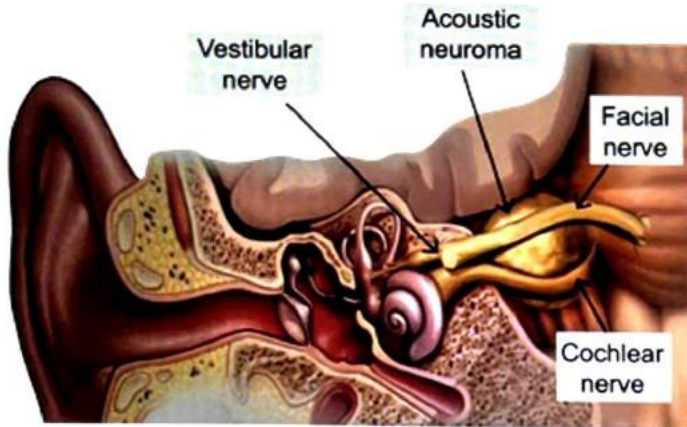




16 VESTIBULAR SCHWANNOMA

INTRODUCTION

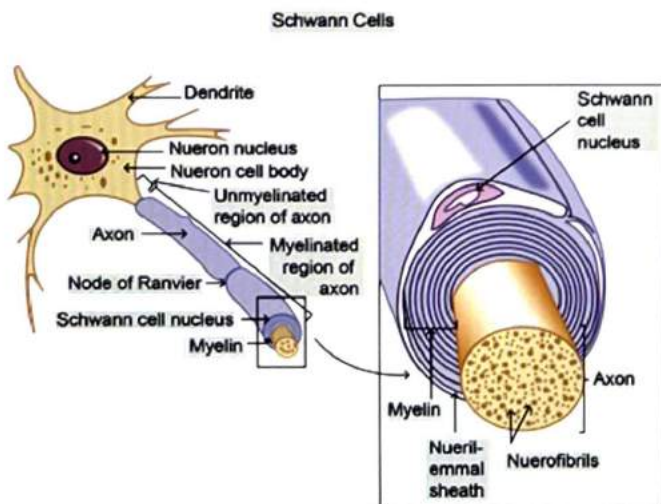
00:00:10



- Earlier K/as Acoustic Neuroma (it's a misnomer)
- M/C Benign tumor of CP angle (Cerebellopontine angle)
- M.C site of origin - Schwann cells of inferior vestibular Nerve inside the Internal auditory canal.

NEURON

00:04:25

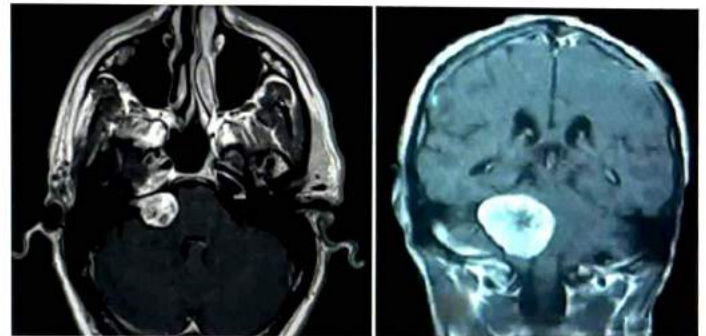


CLINICAL PRESENTATION

00:05:42

- Elderly male patient 50-70years
- Symptoms
 - U/L slow progressive SNHL (M/C)
 - Tinnitus

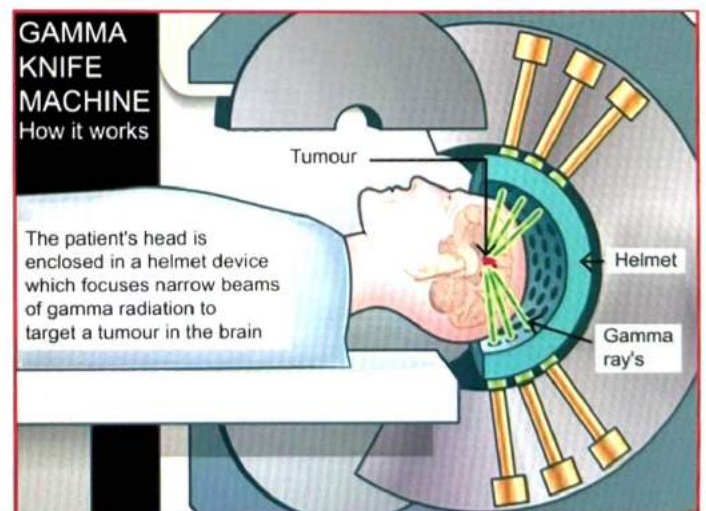
- Signs
 - Loss of corneal reflex (5th nerve involvement): earliest sign
 - Hitzelberger Sign: sensory supply to Posterosuperior wall of EAC is lost d/t involvement 7th Nerve.
- IOC: Contrast enhanced MRI (Gadolinium contrast)

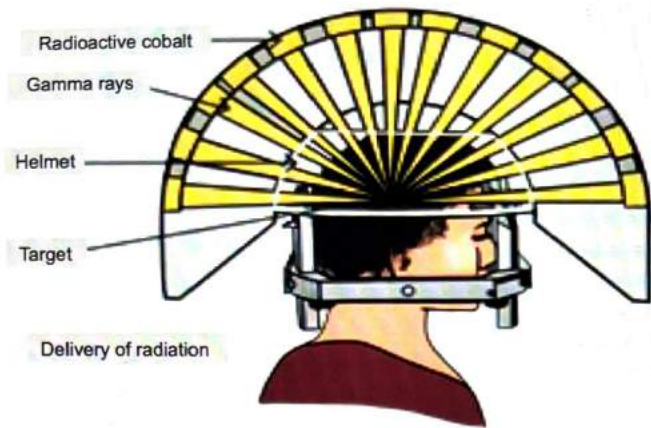


TREATMENT

00:08:17

- Treatment of Large Tumor
 - Surgical excision
- Treatment of small tumor
 - Old patient, slow growing tumor
 - Rx: is Wait and watch
 - MRI is done every 6th month and observation
 - Young Patient, Fast Growing Tumor
 - Rx: Gamma Knife Excision/ Cyber knife excision
 - This is targeted radiotherapy technique a/k/a stereotactic radiotherapy



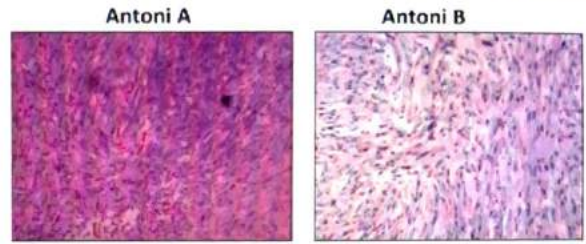


DIFFERENT OPTIONS FOR SURGICAL EXCISION

- When there is no hearing present
 - TRANSLABYRINTHINE approach
- If hearing present
 - Middle cranial fossa approach (Limited access)
 - Retro sigmoid /sub occipital approach

MICROSCOPIC PATHOLOGY

00:12:20



- After Sx excision, tumor is sent for histopathology
 - ANTONY A CELLS
 - More common
 - Densely packed cells with small spindle shaped nuclei
 - ANTONY B CELLS
 - Loosely arranged, vacuolated pleomorphic cells

Cyber Knife Excision



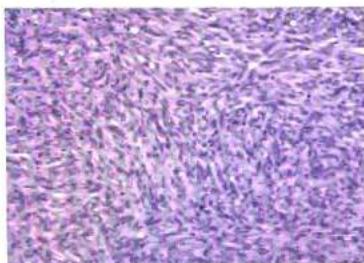
? Previous Year's Questions

Q. Antoni A and Antoni B area are seen in?
(NEET PG Jan 2020)

- A. Schwannoma
- B. Astrocytoma
- C. Meningioma
- D. Oligodendroglioma

? Previous Year's Questions

Q. A 50yr old male presented with tinnitus, ear fullness and hearing loss in his right ear. Seven years later, he began to experience vertigo, headache. Audiometry showed moderate SNHL in the right ear. The histopathology of the condition is given below. What is the most likely diagnosis? (INI CET July 2021)

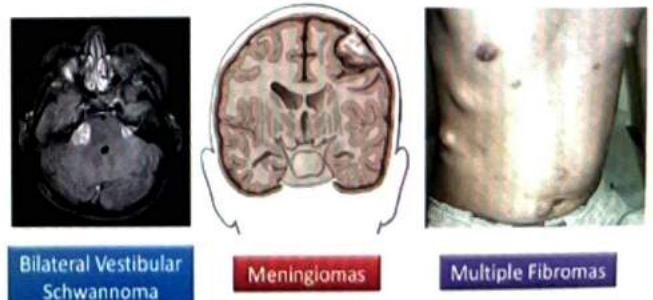


- a) Vestibular Schwannoma
- b) Rhabdomyosarcoma
- c) Neuroblastoma
- d) leiomyoma

NEUROFIBROMATOSIS TYPE 2

- Mutation in gene NF2
- Patient presents with:
 - Bilateral Vestibular Schwannoma
 - Meningiomas
 - Multiple fibromas
- Young patients
- Aggressive
- Rx:
 - B/L large tumor - B/L vestibular schwannoma excision
 - Rehabilitation of hearing by ABI is implanted in the Cochlear Nucleus

Neurofibromatosis -2



Bilateral Vestibular Schwannoma

Meningiomas

Multiple Fibromas



17

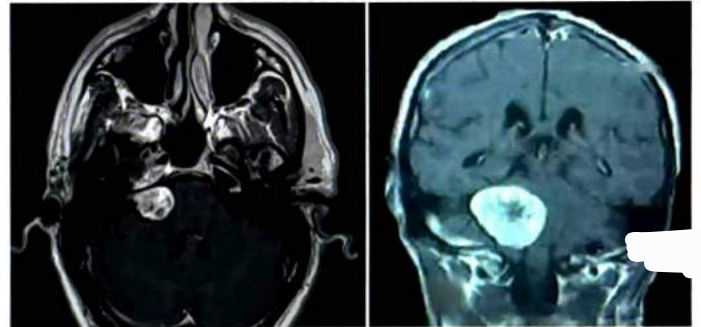
ANATOMY AND DISEASE OF CP ANGLE

INTRODUCTION

🕒 00:00:14

- Earlier known as – Acoustic neuroma
- MC Benign tumor of cerebellopontine angle. (CP angle)
- Usually U/L But B/L in Neurofibromatosis II.
- Arises most commonly from Inferior vestibular Nerve in IAC (60-92%cases)
- Sometimes superior vestibular Nerve
- Rarely from cochlear Nerve

- **Diagnosis:** Gadolinium Enhanced MRI → (IOC)



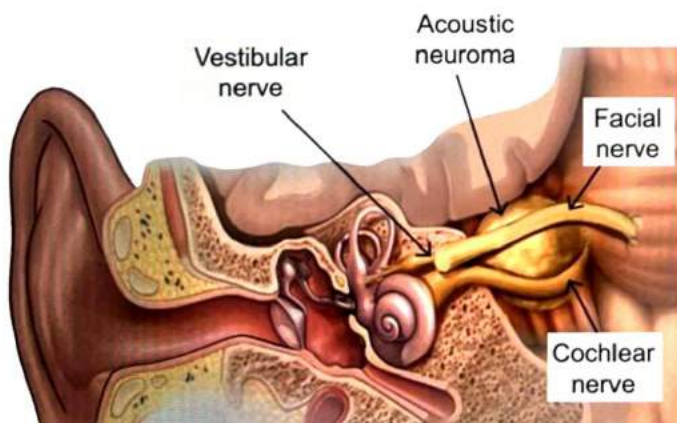
Important Information

- Arises from Schwann cells in the myelin sheath. **not from the nerve** → SCHWANNOMA

TREATMENT

🕒 00:07:33

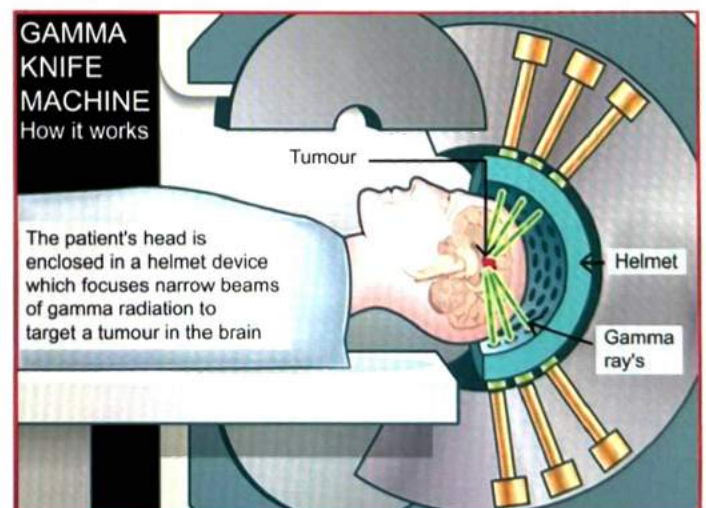
- Earlier it was surgical excision, now differentiated.
- Large Tumor – Surgical excision
- Small Tumor
 - Old patient, slow growing tumor - Serial MRI every 6month
 - Young patient, fast growing tumor - Gamma knife excision

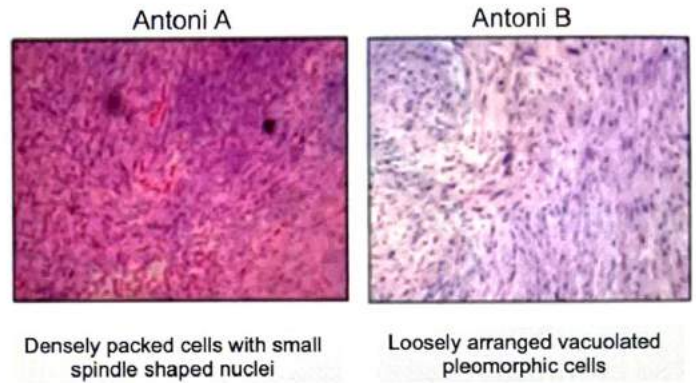
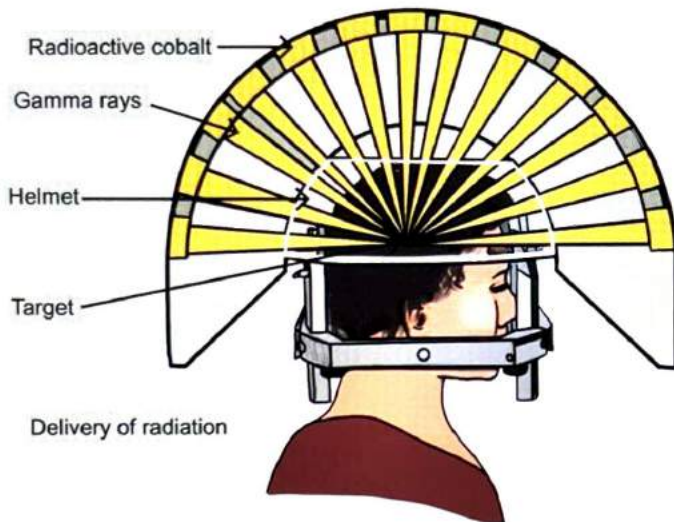


CLINICAL PRESENTATION:

🕒 00:04:50

- SNHL
 - Slow & progressive
 - Most common presentation
- Tinnitus
- Vertigo / Dizziness (Not prominent)
- **Signs**
 - Earliest: Loss of corneal reflex (Due to 5th nerve Involvement)
 - Hitzelberger sign: Loss of sensory supply by the facial Nerve in the postero-superior Wall of EAC





DIFFERENT OPTIONS FOR SURGICAL EXCISION

00:10:00

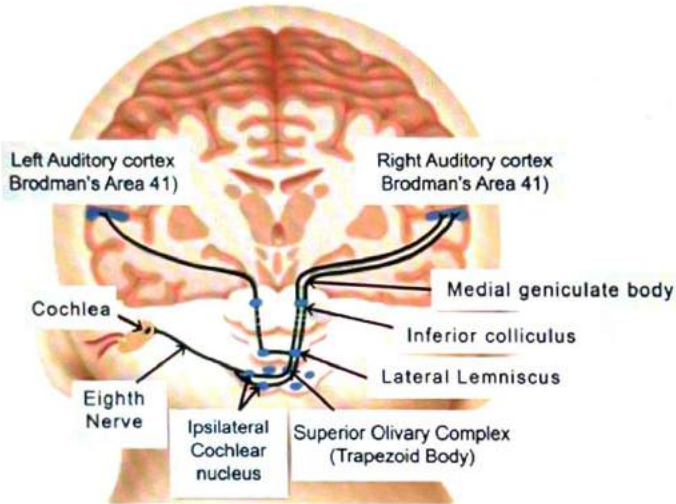
- When there is no hearing present
 - TRANSLABYRINTHINE approach
- If hearing present
 - Middle cranial fossa approach (Limited access)
 - Retro sigmoid /sub occipital approach
- After Sx excision, tumor is sent for histopathology
 - **ANTONY A CELLS**
 - More common
 - Densely packed cells with small spindle shaped nuclei
 - **ANTONY B CELLS**
 - Loosely arranged, vacuolated pleomorphic cells



18 HEARING DEVICES

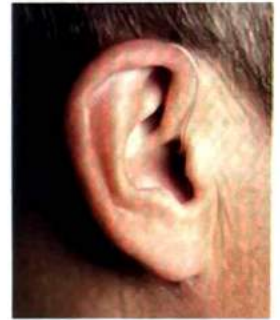NEURAL PATHWAY

00:01:08



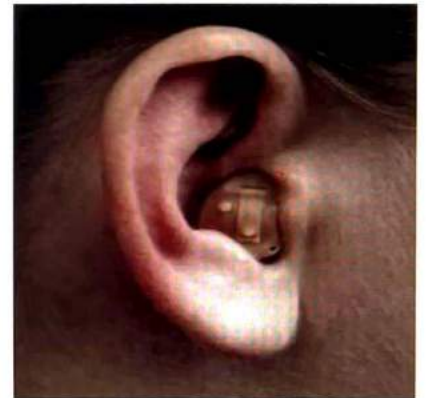RIC: Receiver In Canal HA

00:14:16



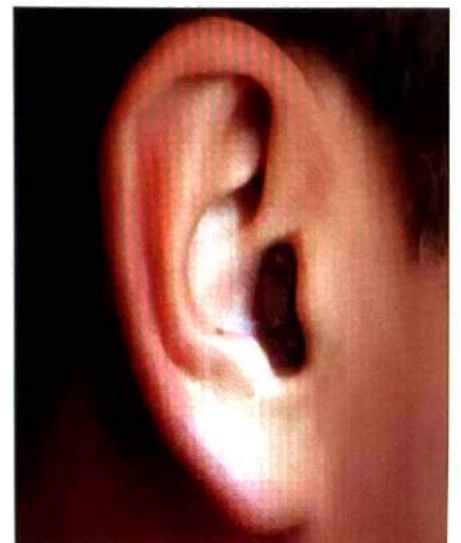ITC: In the Canal HA

00:15:39



CIC: Completely in Canal HA

00:16:24



How to remember

- ECOLI MA

HEARING AIDS

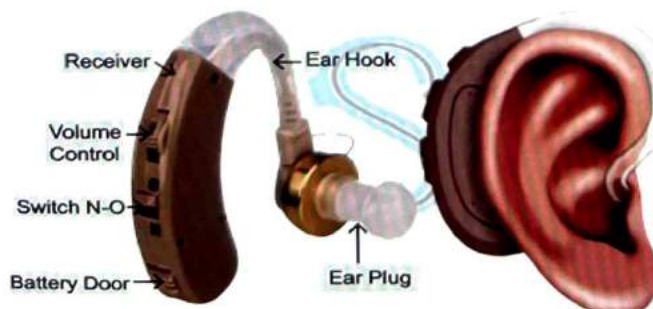00:02:09

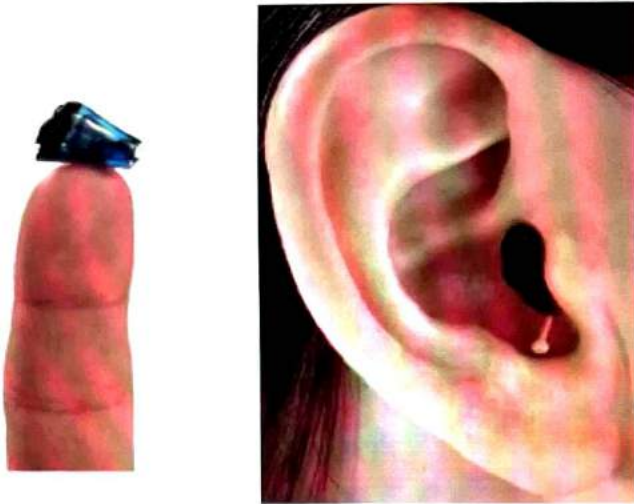
2 types

- Analog: Simple amplifier- not used nowadays
- Digital: It breakdown sound into different frequencies
 - Channels- digital HA dividing the sound into different parts
 - Have upto 128 different channels
 - Using more than 1 (2 or 3)microphones
 - Bluetooth mic

BTE: Behind The ear HA

00:09:22

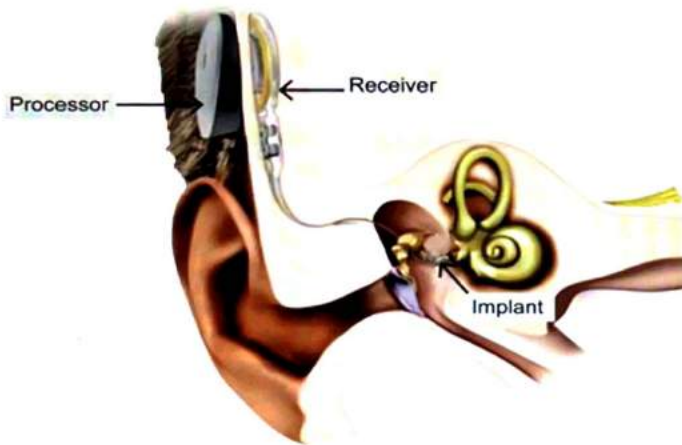




Middle ear Implantable Hearing Aids

🕒 00:17:57

- Implant directly in the middle ear
- Directly gives amplification to the stapes which transfer to the inner ear



Fully implantable Hearing Aid:

🕒 00:20:25



★ Important Information

- To implant internal HA, the prior condition is to use external HA for 6 months to test the benefits
- Pt should have stable hearing loss not progressive

BONE ANCHORED HEARING AID (BAHA)

🕒 00:22:15

- Titanium screw has osseointegration property
- The BAHA bypass directly the external ear and the middle ear

Indications of BAHA

🕒 00:25:44

- Bilateral conductive hearing loss
 - EAC Atresia
 - Chronic otorrhea
 - Chronic otitis media/externa
 - Uncontrollable feedback (meatoplasty / radical mastoidectomy)
- Patient using a conventional BC hearing aid
- Only hearing ear
 - Otosclerosis
 - Tympanosclerosis
 - Canal atresia
- Single-side deafness with better ear BC loss <45 dB HL and SDS >60%
 - Unilateral deaf ear- cross hearing aid (hear the sound from other side-sound localization)

Contraindications of BAHA

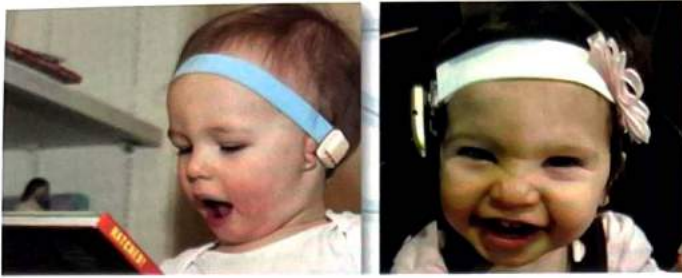🕒 00:34:03

- BC >45 dB, SDS <60% in target ear
- Emotional instability
- Development delay
- Drug abuse
- Age <5 years
 - Requires 2.5- 3 mm bone thickness achieved around 5 yrs of age US- FDA norms → Can't implant < 5 yrs, UK- NHS norms Allow after 3 years after doing CT scan [2.5 mm]
- Cannot use BAHA in bilateral SNHL

Soft hand HA

🕒 00:37:46

- The children before achieving 3mm or 3-5 years, BAHA cannot be implanted. In this case, soft hand HA is used.



COCHLEAR IMPLANT (BIONIC SENSE DEVICE)

00:40:12

- Implant an electrode in Scala tympani [Nearest to VIIIth nerve]
- We enter Scala tympani through cochleostomy near round window or through round window
- Parts
 - External body worn part
 - Microphone: Receives sound
 - Speech processor: Converts sound to electromagnetic waves
 - Transmitter: Transfers EMW across the layer of skin
 - Internal/ Implantable part
 - Receiver stimulator - Stimulates electrode array
 - Electrode array: Implanted inside Cochlea (Scala Tympani) and stimulate Eighth Nerve

Indications of cochlear implant

00:44:03

- B/L severe profound SNHL
 - ≥ 70 dB in Adults & ≥ 90 dB in Children
- Poor speech perception: SDS < 20-30%
- No improvement with Hearing Aids
- Age 1 year or older



Important Information

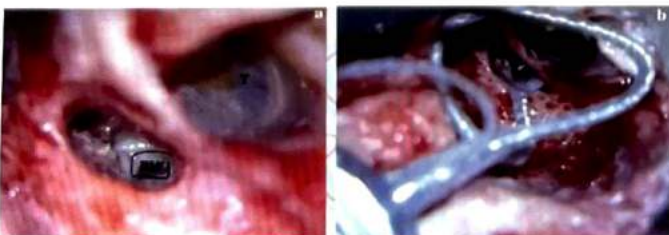
Patient should have tried hearing aid for at least 6 months

Priority for cochlear implant

00:46:25

- Post-Lingual Deaf Child is given maximum preference
- Prelingual deaf adult >7years, don't implant
- For implantation: cortical mastoidectomy is done priorly

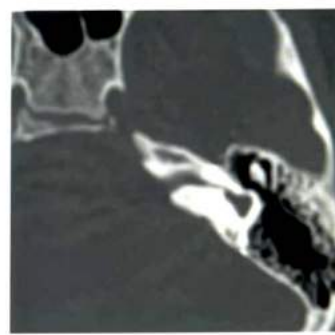
cochlear implant



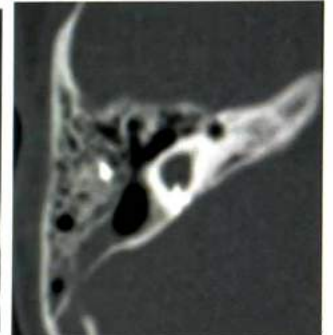
Contraindications of cochlear implant

00:55:26

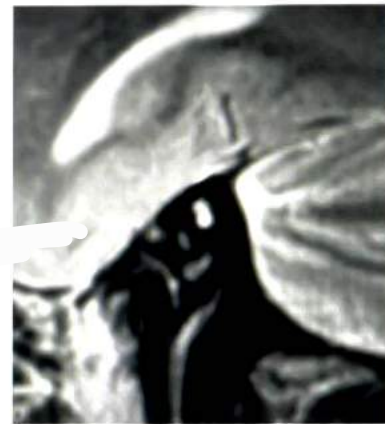
- Absolute C/I for cochlear implant:
 - Michel's aplasia- Absence of cochlea
 - 8th nerve aplasia
 - 8th nerve tumor
 - Neurofibromatosis Type II with Bilateral vestibular schwannoma
 - Scheibe dysplasia (Cochleosaccular / pars inferior dysplasia)
 - M/C congenital anomaly of inner ear
- Relative C/I
 - Mondini's dysplasia Cochlea has only 1.5 turns
 - Can do cochlear implantation
 - M/C congenital anomaly of Cochlea



Michel Aplasia



Scheibe dysplasia



8th Nerve aplasia



Previous Year's Questions

Q. Which of the following is Not a contraindication for cochlear implant? (JIPMER May 2019)

- Mondini dysplasia
- Michel aplasia
- Scheibe dysplasia
- Alexander dysplasia

AUDITORY BRAINSTEM IMPLANT (ABI)

🕒 01:04:20

- Implantation on brain stem
- Cochlear nucleus is in 4th ventricle in lateral recess
- It stimulates the spiral ganglion
- Indication of ABI is the absolute C/I of BAHA



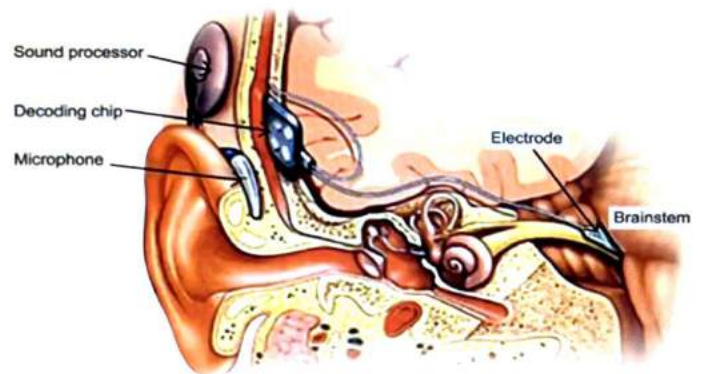
Important Information

- 4th ventricle for implanting ABI is entered through Foramen of Lushka



Previous Year's Questions

- Q. Site for placing an electrode in auditory brain stem implant is? (NEET Jan 2018)
- A. Sinus tympani
 - B. Round window
 - C. Lateral ventricle
 - D. Recess of fourth ventricle





LEARNING OBJECTIVES

Nose

- Paranasal Sinus Anatomy and Embryology of Nose
- Nasal Septum Blood Supply
- Rhinosinusitis and Tumors of Nose



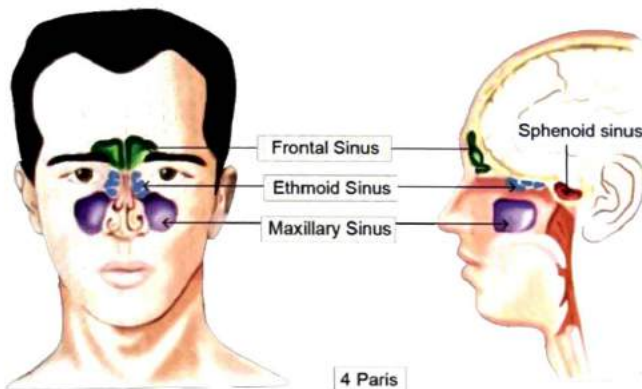
19 INTRODUCTION TO PARANASAL SINUSES

Paranasal sinus

00:00:27

- Paranasal Sinuses → Air filled space around the nasal cavity

Paranasal Sinuses



- Paranasal Sinuses
 - Anterior: Frontal, Maxillary, Ant. ethmoidal sinus
 - Posterior: Sphenoid, post ethmoidal sinus



Important Information

- Lined by → Ciliated pseudostratified columnar epithelium

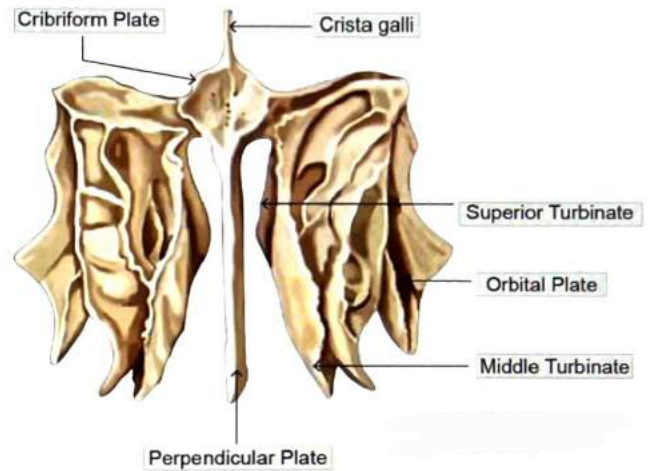
MAXILLARY SINUS

00:02:17

- 1st to develop at 12 weeks (3M) of Intrauterine life
- Present at birth
- Reaches adult size 15 – 18 years
- Largest Paranasal sinus – adult volume 15ml
- Aka Antrum of Highmore / Maxillary Antrum
- Visible on
 - Plain X – Ray: 4 – 5 Month after birth
 - CT Scan: at Birth

ETHMOID BONE & ETHMOID SINUSES

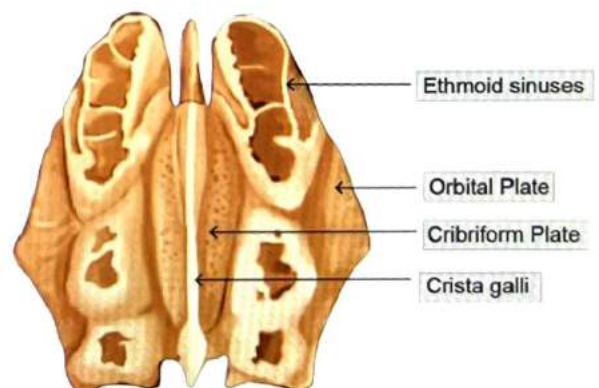
00:05:34



- Unpaired bone
- Perpendicular plate – divides nasal cavity into 2 parts
- Cribriform plate forms roof of nasal cavity (thinnest bone in the body)
- Orbital plate (lateral wall of ethmoid bone) forms medial wall of orbit – k/a Lamina papyracea because it is papery thin
- Lamina papyracea is the thinnest wall of the orbit.

Cranial view of Ethmoid bone

Ethmoid Bone : Cranial View



- Ethmoid sinuses starts developing in IU life
- Present at birth
- Visible on : X-ray – 1 year
: CT scan – at birth

- Reach adult size by 12 years of age
- Has 2 groups
 - Anterior Ethmoid sinus
 - Posterior Ethmoid sinus

SPHENOID SINUS

🕒 00:11:34

- Location: Sphenoid Bone – Unpaired
- Body undergoes pneumatization to form sphenoid sinus
- Inter sinus septum
 - Left sphenoid sinus
 - Right sphenoid sinus
- Present at Birth as a small cavity, can be seen in CT scan
- Pneumatization: 2 years
- Adult size: 15 years
- Visible on X-ray: 6-7 yrs of age

FRONTAL SINUS

🕒 00:15:37

- Location: Frontal bone – Unpaired
- Frontal bone undergoes Pneumatization causing Frontal Sinus.
- Inter Sinus Septum:
 - Right frontal sinus
 - Left frontal sinus
- Last to develop – (Early Adulthood), Last to reach adult size (~18yrs)
- Frontal sinus Present as a small cavity at Birth, but indistinguishable from Anterior Ethmoid, can't be seen on CT scan before 1 year of age
- Pneumatization: After 2 years
- Crosses brow line: 4yrs of age
- Seen on plain X-ray: 4-5yrs of age

Development of Paranasal Sinus

🕒 00:22:24

Sinuses	Present (at Birth)	First X-Ray Appr.	Adult size
M - Maxillary	Yes	4 – 5 M after birth	15 – 18 years
E - Ethmoid	Yes	1 year	12 years
S - Sphenoid	Yes	6 -7 years	15 years
F - Frontal	Yes (NOT in CT Scan)	4 – 5 years	18 years



How to remember

- MESF



Previous Year's Questions

Q. X-ray appearances of Paranasal sinuses according to years is: (FMGE Jun 2018)

1. Ethmoid 1 years
 2. Frontal 4 years
 3. Maxillary 4-6 months
 4. Sphenoid 7 years
- A. 1,2,3
B. 3,4
C. 1,2
D. All are correct



Previous Year's Questions

Q. Which of the following sinus grows till early adulthood? (AIIMS Nov 2017)

- A. Maxillary
- B. Ethmoidal
- C. Frontal
- D. Sphenoid



20

X-RAY OF PARANASAL SINUS

WATER'S VIEW

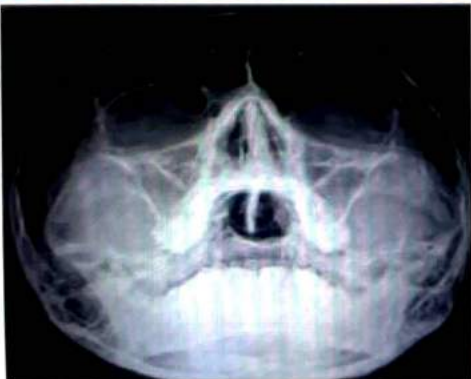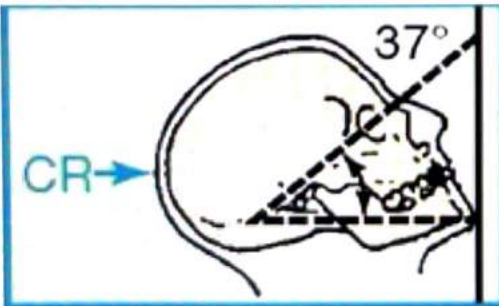
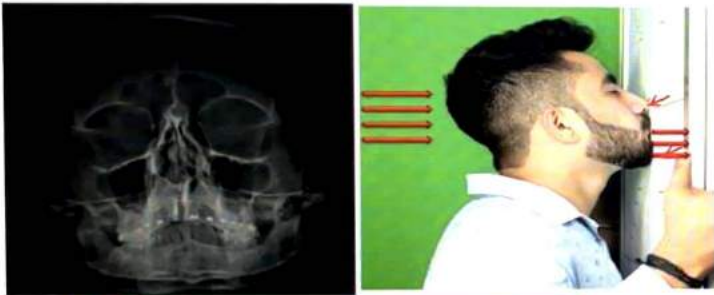
00:00:59

- Most common view done for Paranasal Sinuses.
- Aka occipitomental view aka Nose Chin Position
- In water's view, Frontal sinus, Maxillary sinus, Nasal septum, Anterior Ethmoid sinus is seen
- In water's view with open mouth, along with frontal, maxillary, Ant. ethmoid sinus, Sphenoid Sinus is also seen. This view is known as Pierre's view
- Best for Maxillary sinus and anterior ethmoids
- Mainly used for diagnostic purposes of maxillary sinus



Important Information

- Posterior Ethmoid Sinus is not seen



Previous Year's Questions

Q. Water's view is used to obtain diagnostic information of? (NEET Jan 2018)

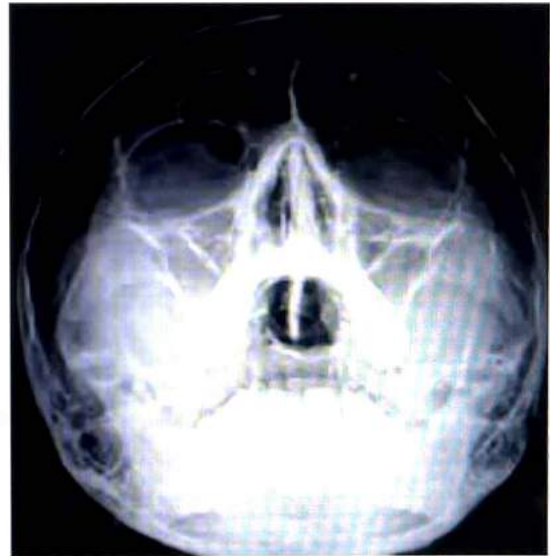- Maxillary sinus
- Ethmoidal sinuses
- Frontal sinus
- Sphenoid sinus



Previous Year's Questions

Q. Occipito-mental view with open mouth seen as shown in the given figure is also known as?

(NEET PG Jan 2020)

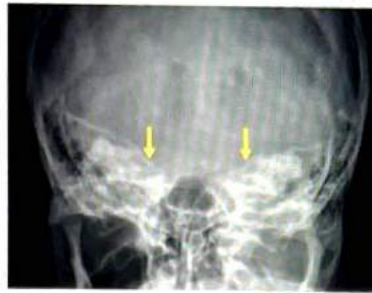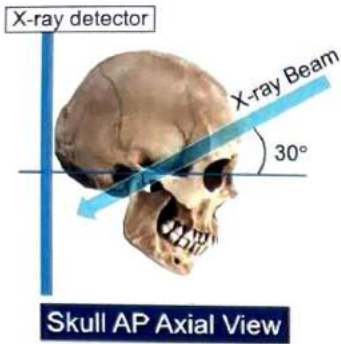


- Water's view
- Caldwell's view
- Towne's view
- Pierre's view

TOWNE'S VIEW

00:08:52

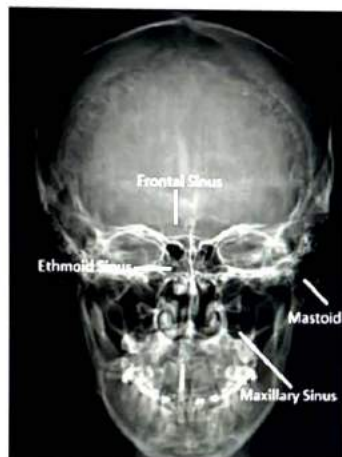
- This view is used to examine the Internal Auditory canal



00:09:53

CALDWELL'S VIEW

- Aka occipito frontal (Nose forehead position).
- Best view for frontal & Ethmoidal Sinus



Important Information

- Ethmoidal Sinus is seen in Caldwell's > Water's view
- Because, in water's view, only Anterior Ethmoidal Sinus is seen



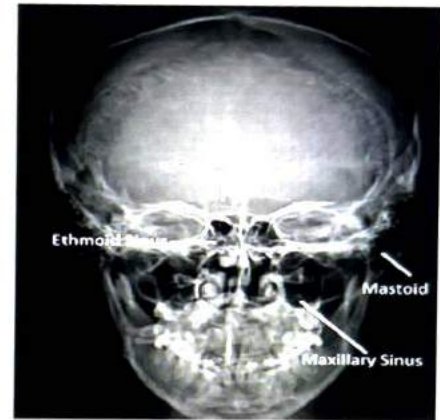
Previous Year's Questions

- Q. Caldwell's view is used for? (NEET Jan 2018)
- Maxillary sinus
 - Frontal sinus
 - Ethmoidal sinus
 - All of the above



Previous Year's Questions

- Q. Which of the following views is best for Frontal Sinus? (INI-CET NOV 2020)

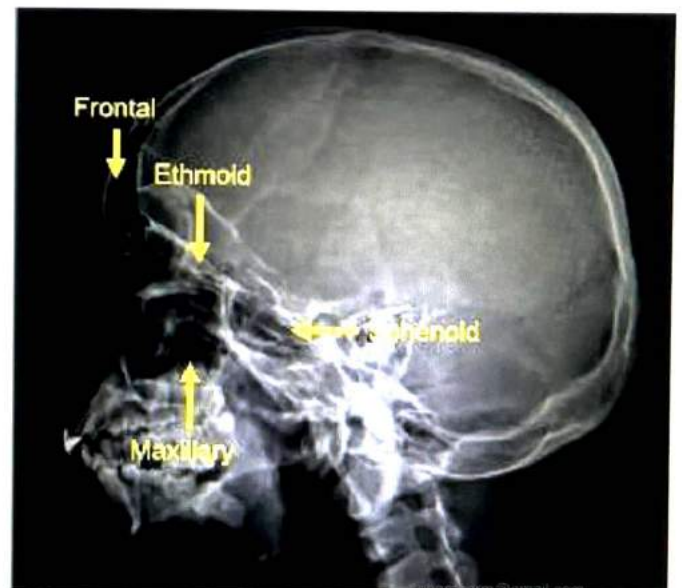


- Caldwell luc's view
- Water's view
- Pierre's view
- Towne's view

00:13:47

LATERAL VIEW

- All Sinus are visible



918629820643



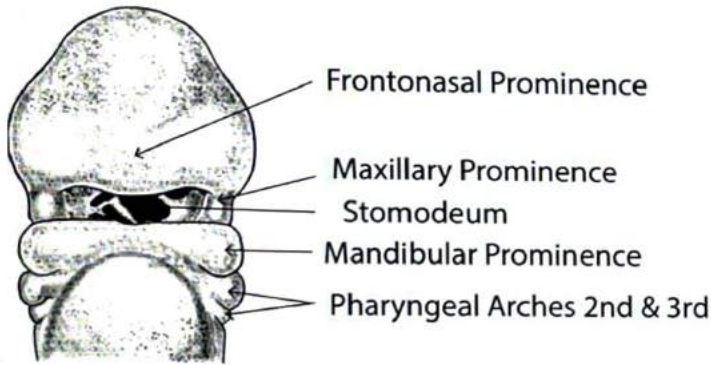
21

EMBRYOLOGY OF NOSE & FACE

FACIAL DEVELOPMENT:

00:00:35

- Develops from 4-8 weeks of IUL
- Develops from 5 prominences / processes, with develops around primitive mouth k/a – stomodeum
- **5 Prominences / Processes:**
 - Maxillary prominence (paired – one on each side)
 - Mandibular prominence (paired – are on each side)
 - Frontonasal prominence – (comes from above)
- On frontonasal prominence, two ectodermal thickenings are present are each side k/a nasal placode



5 WEEK EMBRYO

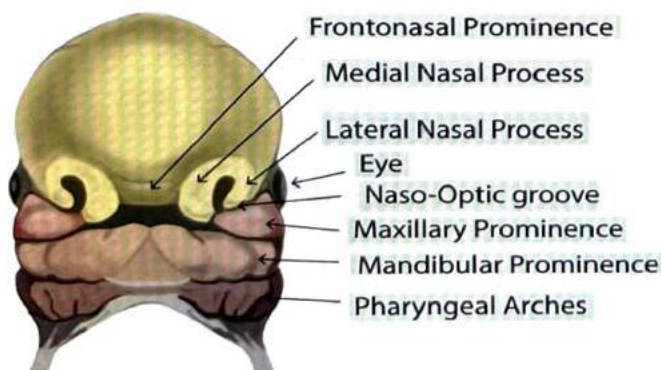
00:02:42

- Nasal Placode which turns into nasal pit

6 WEEK EMBRYO

00:03:47

- Around the Nasal Pit, Frontonasal prominence forms which forms the horse-shoe thickening known as Medial & Lateral Nasal Processes are formed.
- Naso-optic groove is formed which leads to formation of nasolacrimal duct



7 Week Embryo

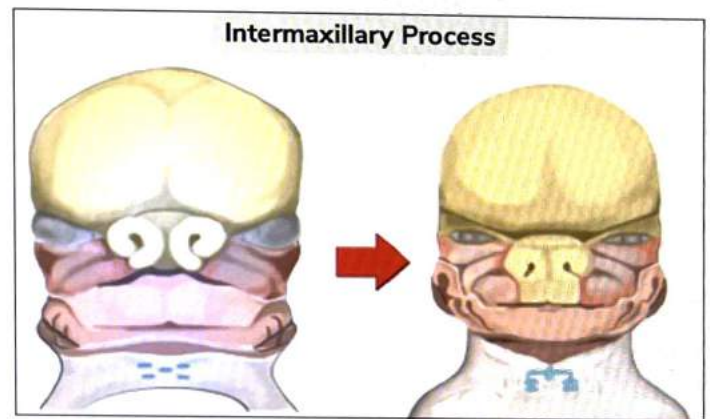
00:05:38

- Medial migration of maxillary prominence – push medial nasal processes

INTRA MAXILLARY PROCESS

00:06:31

- 2 medial nasal process fuse to form intramaxillary process.



STRUCTURES CONTRIBUTING TO DEVELOPMENT OF FACE

00:10:56

Process	Structures formed
1. Frontonasal	Forehead, Bridge of Nose, septum medial & lateral Nasal process
2. Maxillary	Cheeks, lateral part of Upper lip
3. Medial Nasal	Philtrum, Crest & Tip of Nose
4. Lateral Nasal	Alae of nose, Lateral nasal wall
5. Mandibular	Lower lip and Jaw

ORONASAL MEMBRANE

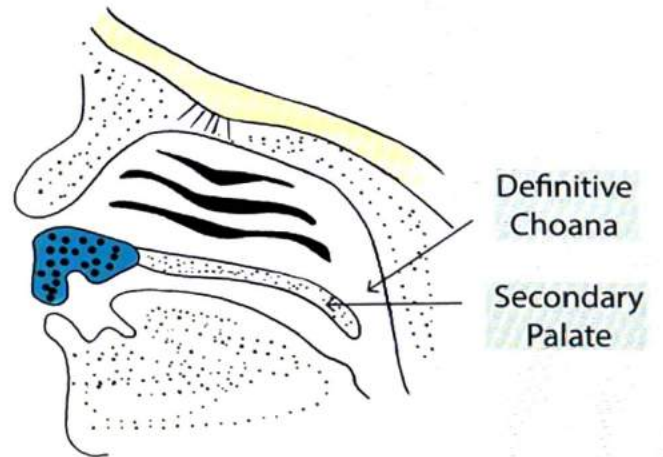
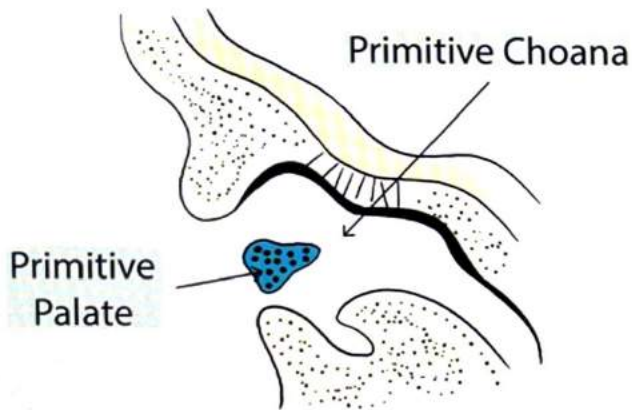
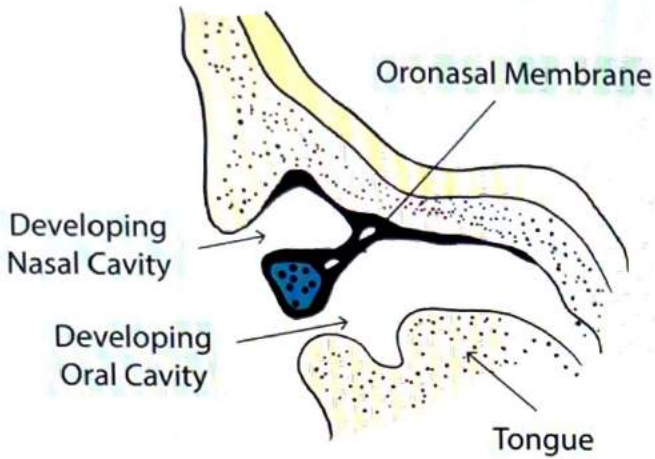
00:12:00

- Separates developing nasal cavity and oral cavity
- Breaks down at 7 weeks of intrauterine life and formation of primitive palate and primitive choana occur.

9 WEEKS: SECONDARY PALATE & DEFINITIVE CHOANA

00:12:55

- Secondary palate forms due to fusion of maxillary processes in the center
- Definitive choana is also formed
- If oronasal membrane does not break down, leads to condition k/a choanal atresia
- If palatine process of maxillary process does not fuse leads to a condition k/a cleft palate
- If the intermaxillary process doesn't fuse with the maxillary process, leads to a condition k/a cleft lip





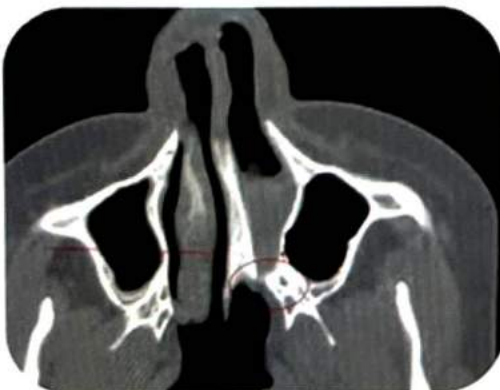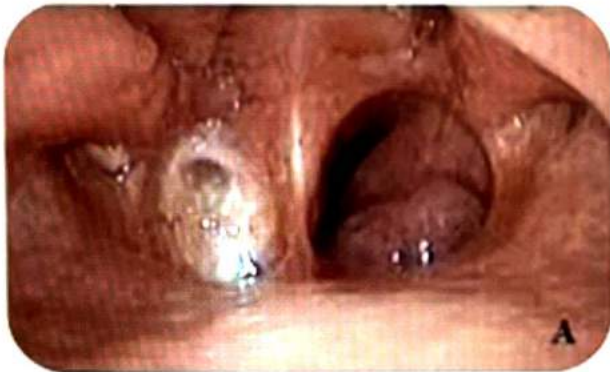22 CONGENITAL LESIONS OF NOSE

CHOANAL ATRESIA

00:00:22

- Persistence of Oronasal membrane
- 1:8000 live births
- Seen in hyperthyroid mothers with H/O methimazole /carbimazole intake
- U/L: B/L = 2:1
- Earlier, Bony (90%)/ membranous (10%)
- Recent , Pure bony (29%) / bony – membranous mixed (71%)
- Pure membranous – rare
- **U/L Choanal Atresia**
 - No symptoms at birth
 - U/L Nasal obstruction /infection /discharge in later age

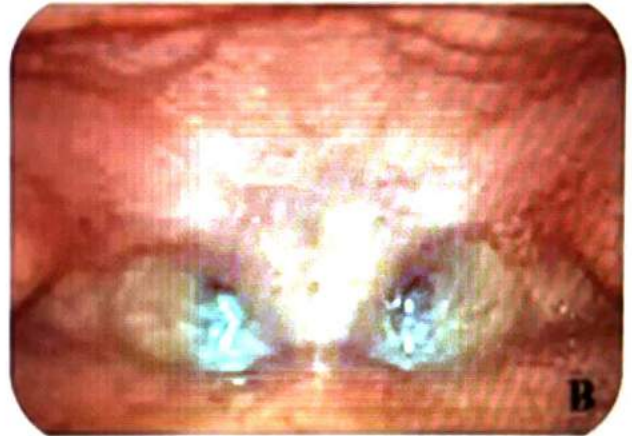
U/L Choanal Atresia



- **B/L Choanal Atresia**
 - At birth, humans are obligate nasal breathers
 - After 1 month, we learn mouth breathing

- Therefore in B/L choanal atresia, at birth, child suffers from respiratory distress, presents with cyanosis.

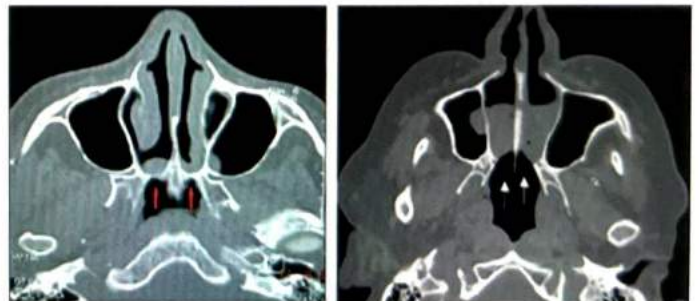
Bilateral Choanal Atresia



Previous Year's Questions

- Q. Child pink while crying, blue when silent diagnosis?
- B/L Choanal atresia
 - Put suction cannula first in mouth, then in nose in case of choanal atresia. the cannula rotates and comes back: this confirms diagnosis within few minutes.

- Confirmation – CT scan



- Immediate management – Guedel's Oropharyngeal airway

GUEDEL'S OROPHARYNGEAL AIRWAY:

- This will keep the mouth open and prevent Tongue fall

Guedel's Oropharyngeal Airway

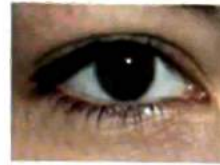

00:08:52

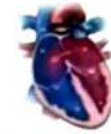

How to remember

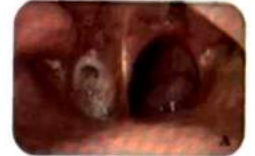- CHARGE



Coloboma



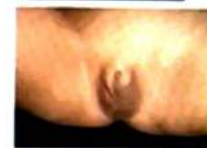Heart Defects



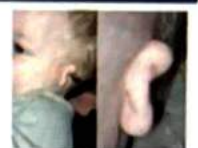Atresia of Choana



Retardation of Growth



Genitourinary Hypoplasia



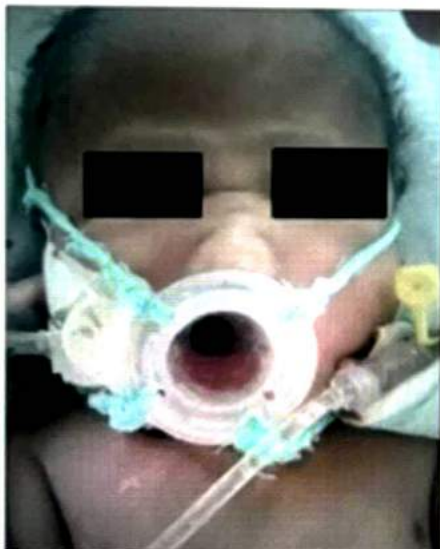Ear Anomalies

00:09:35

MCGOVERN TECHNIQUE

- If Guedel's oropharyngeal airway not available, put a nipple with wide hole (k/a McGovern Technique)

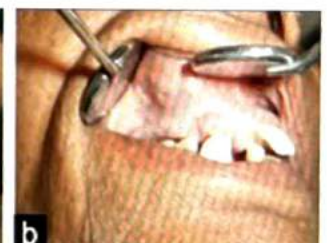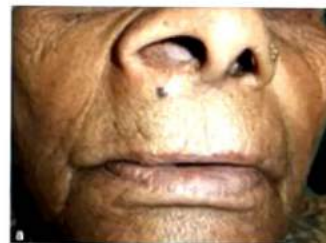Mc Govern Technique



00:12:18

NASOALVEOLAR /NASOLABIAL /KLESTADT'S CYST

- Non – odontogenic
- Painless, cystic swellings in the area of nasolabial fold
- Treatment – surgical excision by sub-labial approach

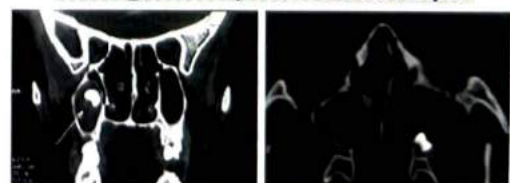


00:13:59

DENTIGEROUS CYSTS / FOLLICULAR CYST

- Develop from unerrupted /partially erupted tooth
- Most common = 3rd mandibular molar / maxillary canine
- Collection of dead epithelium
- Grows rapidly, hence, some becomes weak and this can lead to fractures
- Surgical T/t
 - Excision with extraction of tooth
 - If not complete – Marsupialization of cyst

Dentigerous Cysts/ Follicular Cyst



TREATMENT OF CHOANAL ATRESIA:

- Endoscopic excision of Atresia

00:10:29

CHARGE SYNDROME:

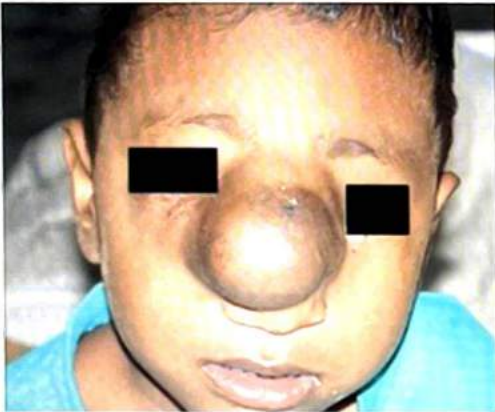- Coloboma
- Heart defects
- Atresia of choana
- Retardation of growth
- Genitourinary hypoplasia
- Ear anomalies

00:11:08

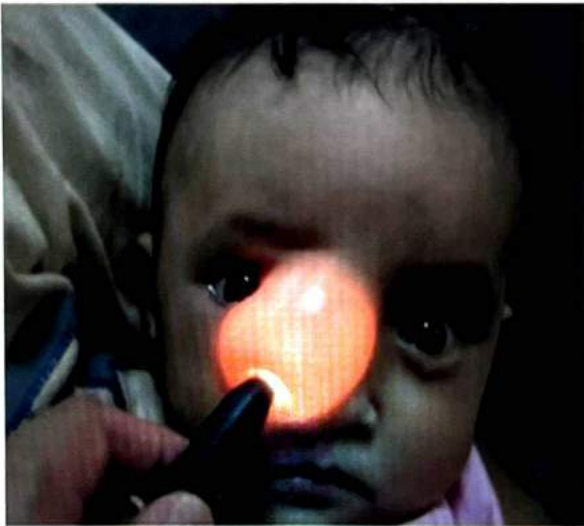00:16:15

ENCEPHALOCELE & MENINGOCELE

- Meningocele - Meninges alone
- Meningoencephalocele - Meninges + Brain
- Hydroencephalomeningocele - Meningoencephalocele + Ventricle
- Present at birth
- M/C location: occipital >> frontal
- Hydrocephalus, eyeball, tear duct defects & other neurological defects present
- Intranasal mass leads to Nasal obstruction
- **On examination:**
 - Bluish, soft, pulsatile and compressible swelling
 - Trans illumination test – positive

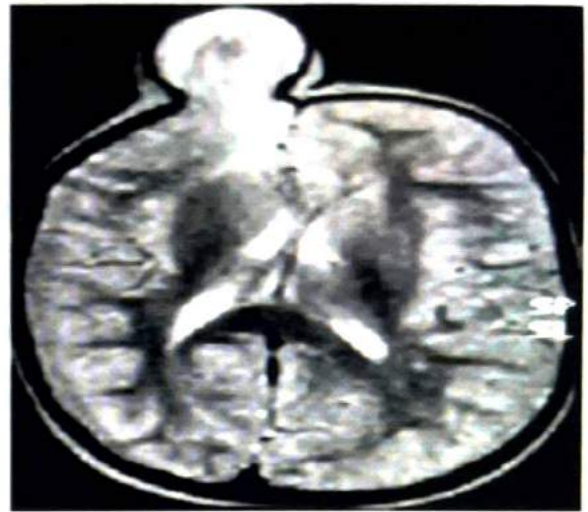

Transillumination Test : Positive



- **Imaging: CT+MRI**
 - Furstenberg test : Positive in Encephalocoeles

Imaging: CT + MRI

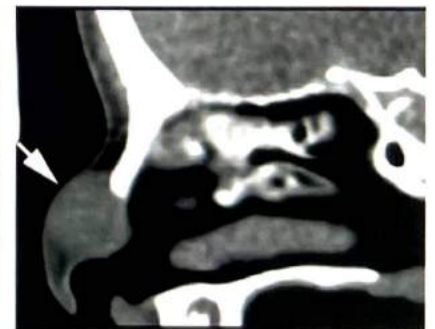
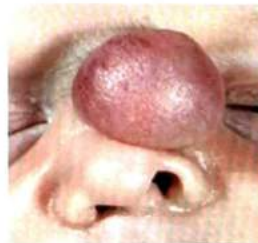
- Mass increase in size of coughing, sneezing, pressing jugular vein, because mass is in direct communication with cranial cavity.

NASAL GLIOMA (NASAL GLIAL HETEROTROPIA, GLIAL HAMARTOMA)

00:21:02

- Non- compressable swellings
- Furstenberg test : Negative
- Trans illumination test : Negative
- **Classification:**
 - Extranasal (60%) – subcutaneous bridge of nose
 - Intranasal (30%) – superior nasal cavity
 - Mixed (10%) – subcutaneous tissues and nasal cavity (large lesions)
- CT+MRI
- T/t – Excision + repair



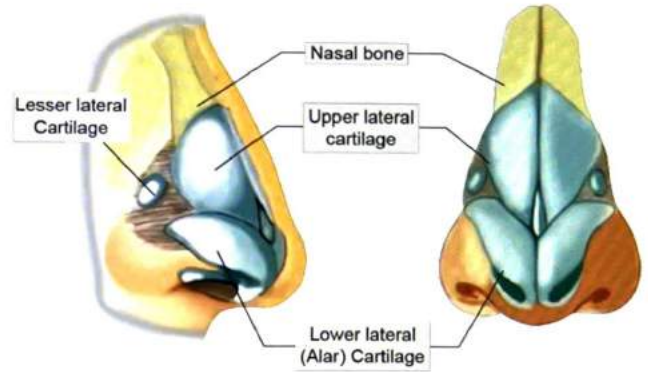
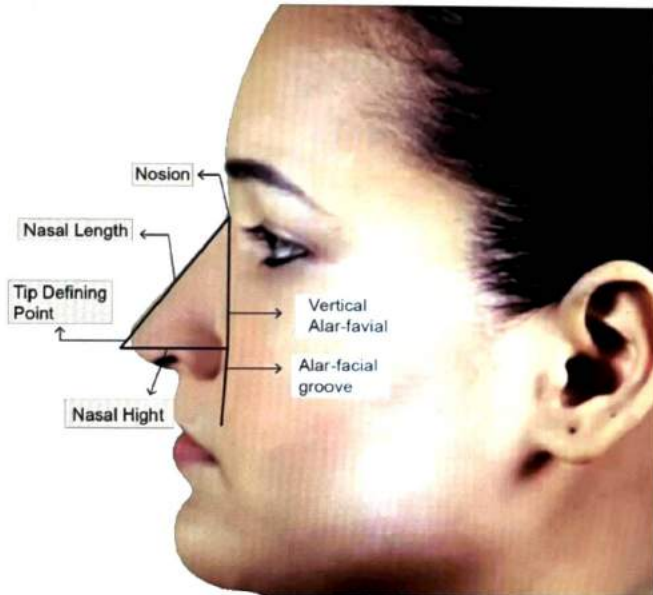


23

ANATOMY & DISORDERS OF EXTERNAL NOSE

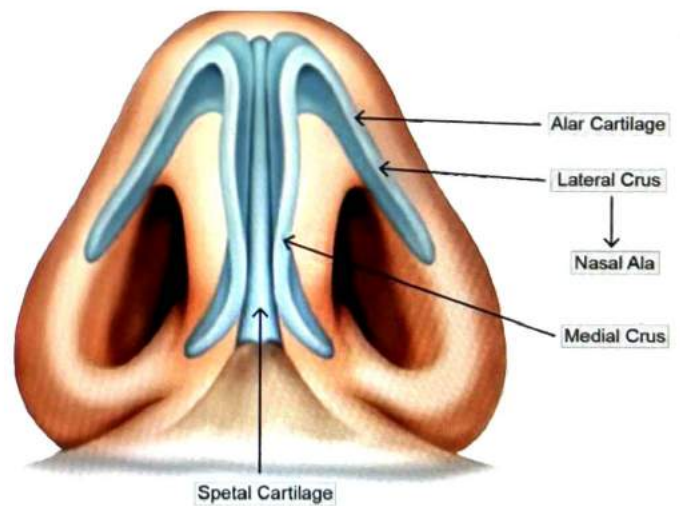
HOW TO DETERMINE DIMENSIONS OF NOSE 🕒 00:01:25

- **Front profile**
 - Nose Occupies
 - Length: Middle 1/3rd of face
 - Width: Middle 1/5th of face
- **Lateral profile**
 - Goode Ratio = $\frac{\text{Nasal height}}{\text{Nasal Length}}$
 - Ideal: 0.55 – 0.6



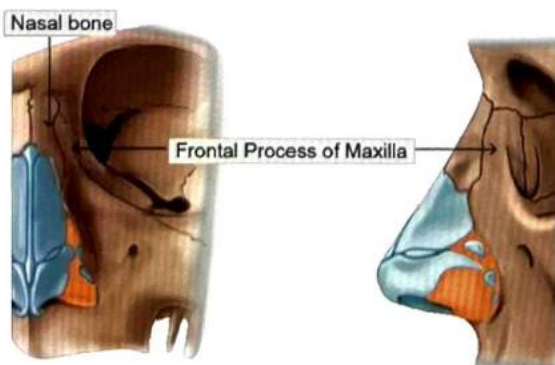
NASAL CARTILAGES 🕒 00:04:40

- Paired cartilages
 - Upper Lateral cartilage
 - Lower Lateral / lesser Alar cartilage
 - Lesser Lateral / lesser Alar cartilage
 - Unpaired cartilages
 - Septal/Quadrilateral/ Quadrangular cartilage
- Alar cartilage**



EXTERNAL NOSE 🕒 00:03:54

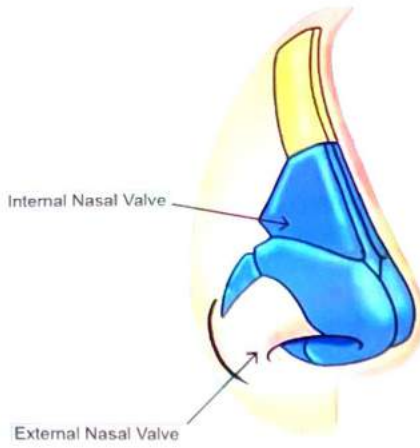
- Upper 1/3rd
 - Bony, formed by nasal bone supported by frontal process of maxilla



- Lower 2/3rd – Cartilaginous (3 paired & 1 unpaired)

- Alar cartilage has 2 parts:
 - Lateral crus (forms Ala of nose)
 - Medial Crus of Alar Cartilage forms Columellar Septum
- Main Component of Ala of Nose is Fibrofatty Tissue therefore, Nose piercing is preferred at ala of nose

INTERNAL NOSE VALVE 🕒 00:08:05



- Nose has 2 valves
 - External Nasal valve – formed by ala & nasal septum
 - Internal nasal valve – Formed by lower end of upper lateral cartilage and nasal septum
- Responsible for 50% of nasal airway resistance
- Angle b/w lower and upper lateral cartilage and nasal septum should be $>10-15^\circ$
- $<10-15^\circ$ → Nasal obstruction



Important Information

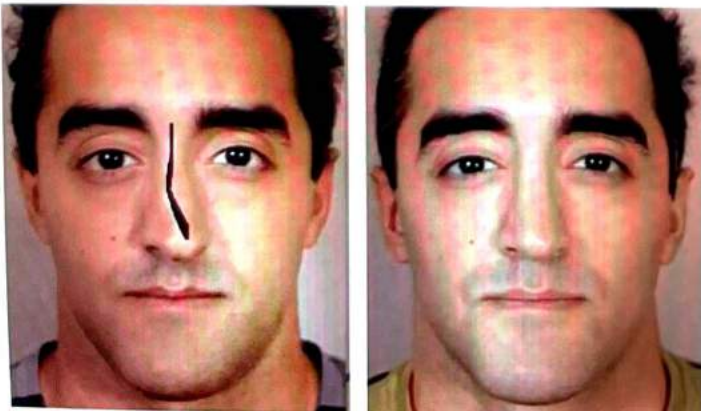- 50% of Nasal Airway Resistance is due to Internal Nasal Valve
- To check if nasal obstruction is d/t internal nasal valve collapse, Cottle's test is used
- Procedure**
 - Keep fingers in cheek of patient & pull them laterally. If the obstruction is d/t internal nasal valve collapse, airway will open up

DISORDERS OF EXTERNAL NOSE

- Deviated Nose 🕒 00:13:33
 - External deformity, not deviated nasal septum
 - Rx – Rhinoplasty

Deviated Nose

Rhinoplasty



- Crooked Nose / C – shape deformity
 - Nasal bridge is deviated but tip is in the center
 - Rx – Rhinoplasty

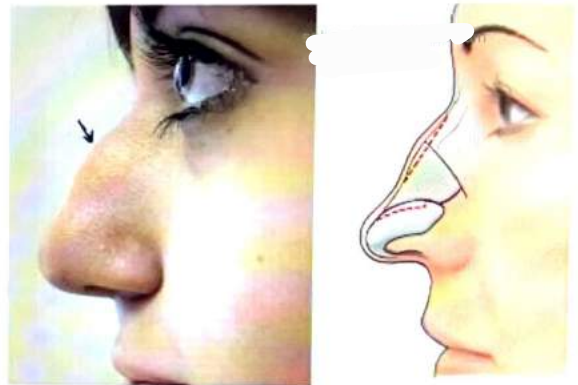
Crooked Nose



- Nasal Hump
 - Bony and cartilaginous
 - Rx: Reduction Rhinoplasty

Nasal Hump

Reduction Rhinoplasty



- Saddle Nose
 - Dorsum has collapsed inside
 - Rx – Augmentation Rhinoplasty

Saddle Nose

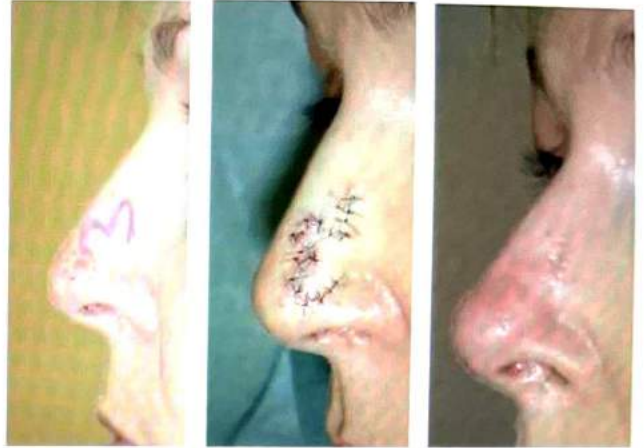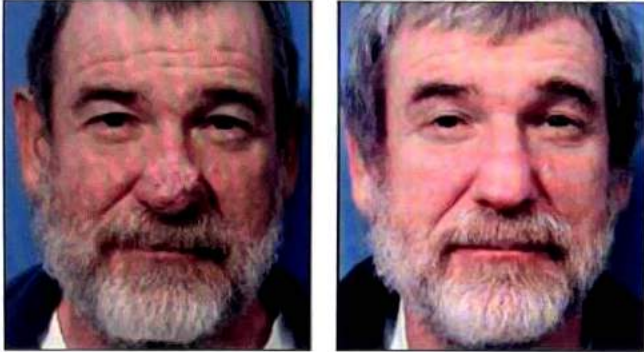
Augmentation Rhinoplasty



- Rhinophyma / potato tumors
 - MC seen in males, 35 – 40 years.
 - Associated with long standing Acne Rosacea (Pilosebaceous duct is blocked)

- Benign hypertrophy of sebaceous glands → Presence of lobulated mass
- Not a tumor (No hyperplasia), cosmetic problem
- Rx: TOC- CO₂ laser Dermabrasion

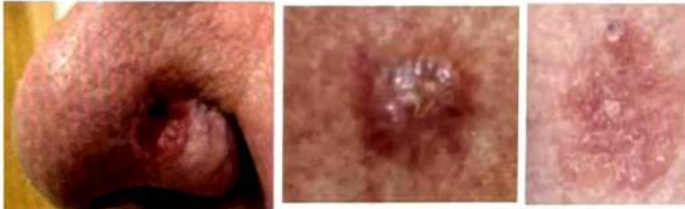
Rhinophyma (Potato Tumor)



RODENT ULCER (BASAL CELL CARCINOMA)

🕒 00:23:08

- MC malignancy of the skin
- Sun exposed Areas (UV-B rays)
- More common in fair people
- Face, Dorsum of hands (MC location)
 - Locally invasive malignancy, Distant metastasis is rare
 - Age: 40-60yrs (M=F)
 - Can present as a "cyst/papulo-pearly nodule/ulcer with rolled edges"



- Rx: Wide local excision



Previous Year's Questions

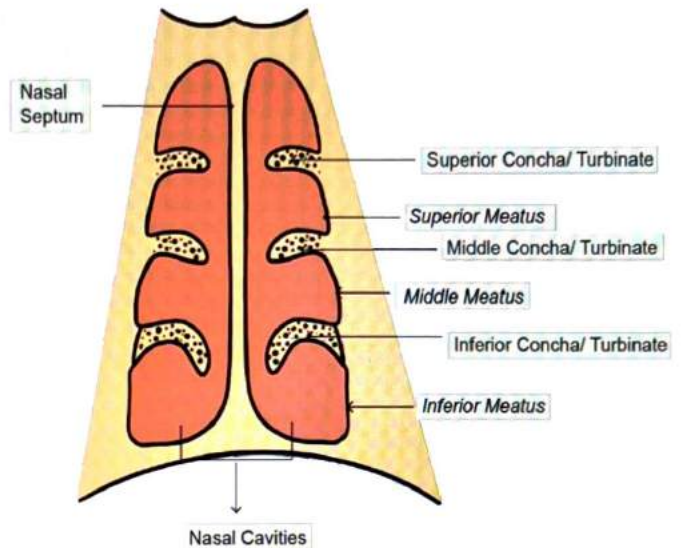
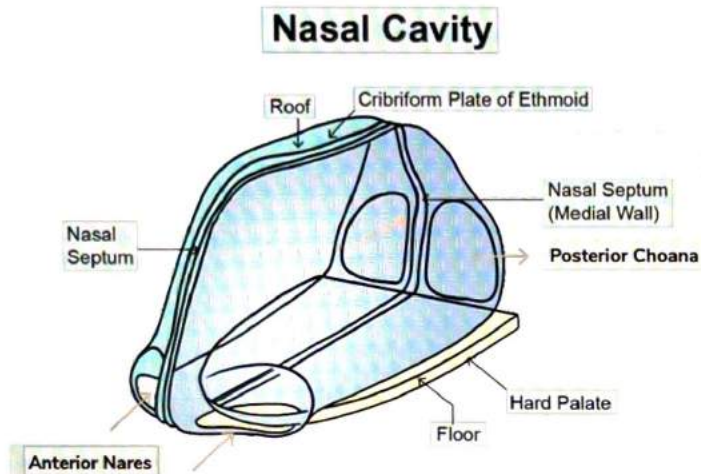
- Q. Which does not drain into middle meatus? (JIPMER Dec 2019)
- A. Frontal Sinus
 - B. Maxillary Sinus
 - C. Posterior ethmoid
 - D. Anterior Ethmoid



23 ANATOMY OF NASAL CAVITY

Introduction

00:00:20



Boundaries of Nasal Cavity

- Roof: Cribriform plate of Ethmoid (thinnest bone)
- Floor: Hard Palate
 - Anteriorly: Maxilla
 - Posteriorly: Palatine bone
- Medial wall: Nasal Septum

- Sometimes 4th turbinate is present k/a supreme turbinate therefore, space below it (sphenoidal recess) now k/a Supreme meatus

Lateral Wall of the Nose

00:03:43

- Presence of hair on anterior most part k/a – Vibrissae
- Act as filter

LATERAL WALL OF NASAL CAVITY

00:01:57

- Has 3 flap like structures
 - Superior choana/turbinate
 - Middle choana/turbinate
 - Inferior choana/turbinate

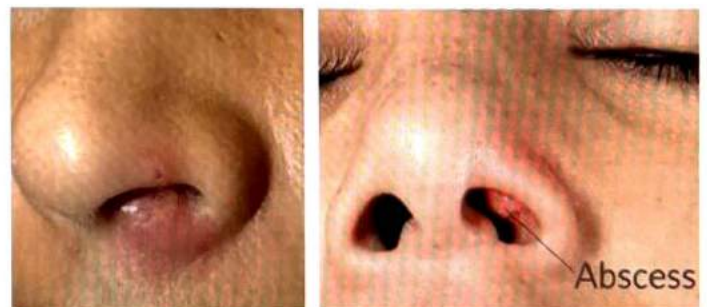
NASAL VESTIBULITIS

Nasal Vestibulitis

Coronal cross section of Nasal Cavity

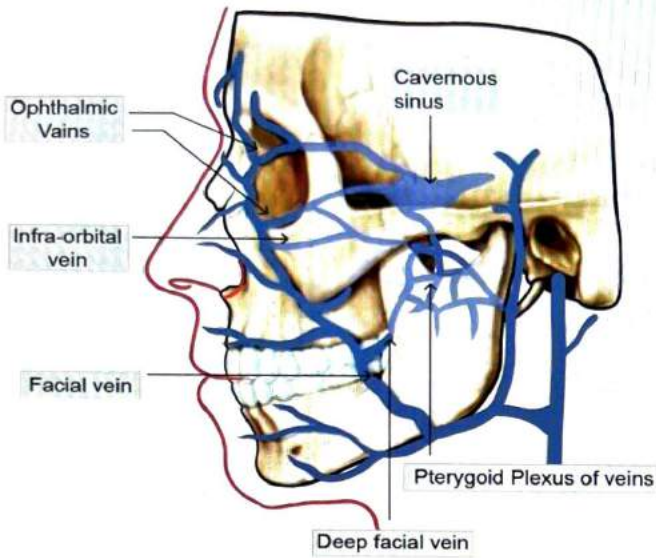
00:02:43

- In the centre of nasal cavity, Nasal Septum present.
- 3 flap like structures seen is known as Turbinate/Concha
- Parts below each turbinate k/a meatus
 - Inferior meatus (Largest)
 - Middle meatus
 - Superior meatus



- Any Furuncle in nasal vestibule
- Presents with Pain & swelling (Red & Hard), Abscess
- MC causative organism Staph aureus.
- **Rx:** systemic Antibiotics (Oral/IV) & Analgesics.
- Systemic antibiotics are given to prevent risk of Cavernous Sinus thrombosis

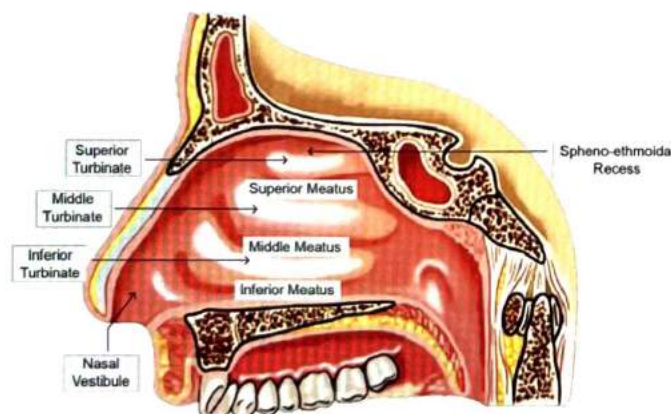
DANGEROUS AREA OF FACE



- Area between upper lip & lower part of nose.
- Veins drain into cavernous sinus through pterygoid plexus.
- Infection of this area causes cavernous sinus thrombosis.
 - Direct communication
 - Blood supply of face is high- Chances of infection travelling is high
 - Direction of flow is towards Cavernous sinus

★ Important Information

- Veins do have Valves



NASOLACRIMAL DUCT (NLD)

🕒 00:13:18

- Opens into inferior meatus through valve of Hasner
- Direction of NLD
 - N - Inwards

- L - Laterally
- D - Downwards

- Dacryocystorhinostomy is done for chronic dacryocystitis, NLD obstruction.
- Patient comes with complaints of excessive Epiphora.
- In DCR, New NLD opening is made in middle meatus.
- DCR 2 ways: Open DCR, Endoscopic DCR.
- Endoscopic DCR preferred therefore gives no scar on face
- NLD syringing is also done for NLD obstruction



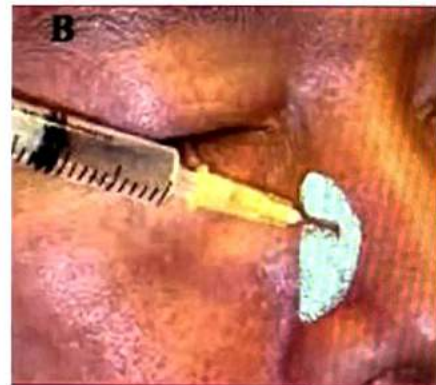How to remember

- NLD- I(N)LD

Anterior Ethmoidal Nerve Block

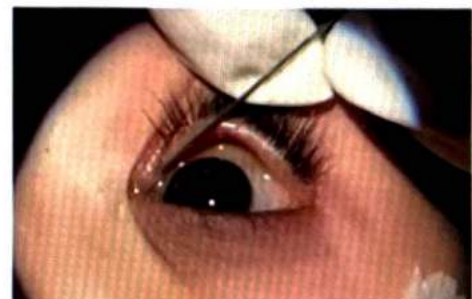🕒 00:20:14

- Given while doing Rhinoplasty, Nasal bone fracture reduction, external nasal procedure to decrease the pain.



Previous Year's Questions

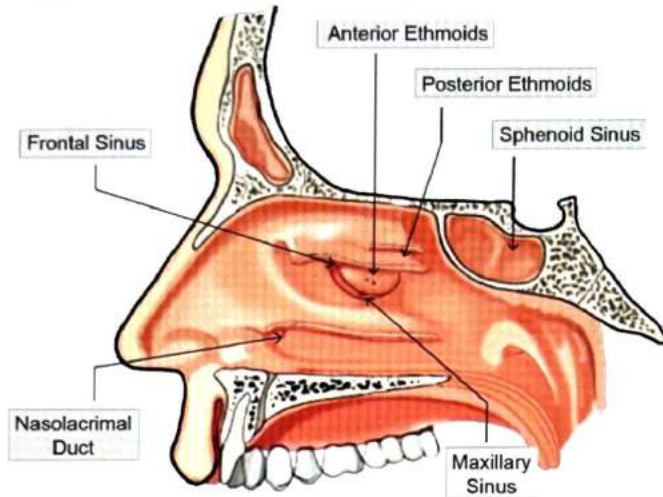
Q. Choose procedure done in following given image?
(AIIMS June 2020)



- Vidian nerve block
- Frontal sinus trephination
- Anterior ethmoidal block
- NLD Syringing

OSTEO MEATAL COMPLEX (OMC)

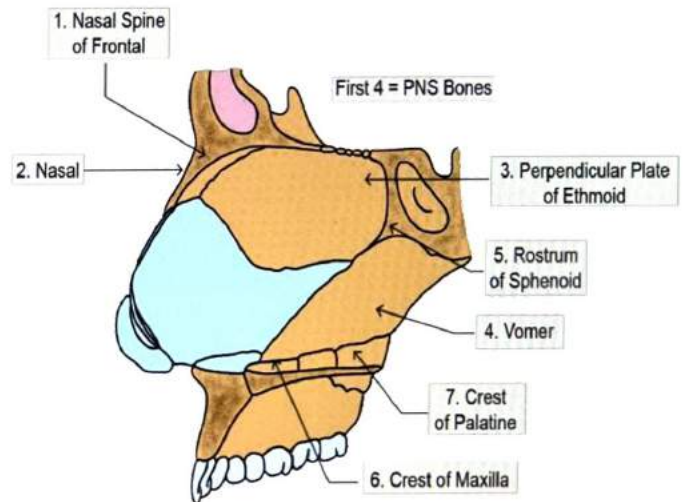
00:27:38



- Present in middle meatus
- 3 sinuses open
 1. Frontal
 2. Anterior ethmoidal
 3. Maxillary sinus
- Infection / Mass will block all 3 sinuses

MEDIAL WALL / NASAL SEPTUM

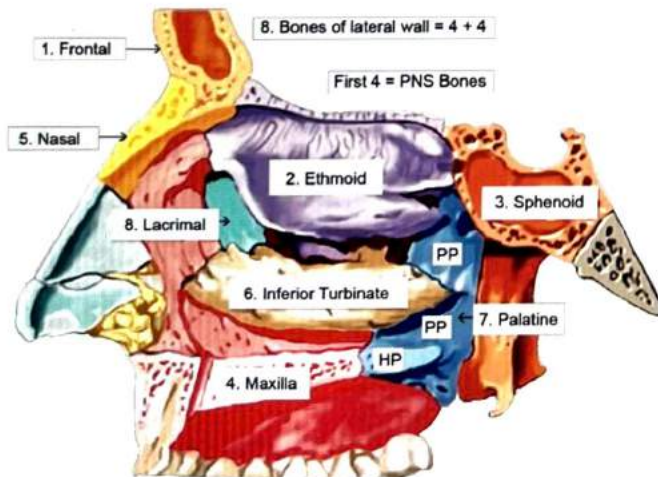
- Has 3 parts
 - Columellar septum is formed by Medial crus of alar cartilage
 - Membranous septum
 - Septal piercing
 - No bone & cartilage
 - Septum proper 7 bones (4+3)



BONY ANATOMY OF LATERAL WALL

00:23:48

- Contains total 8 Bones (4+4)



- Frontal bone
- Ethmoid bone
- Sphenoid bone
- Maxilla
- Nasal bone
- Inferior Turbinate: Individual bone
- Palatine bone: L shaped
- Lacrimal bone

Bony anatomy of Nasal Septum

00:33:08

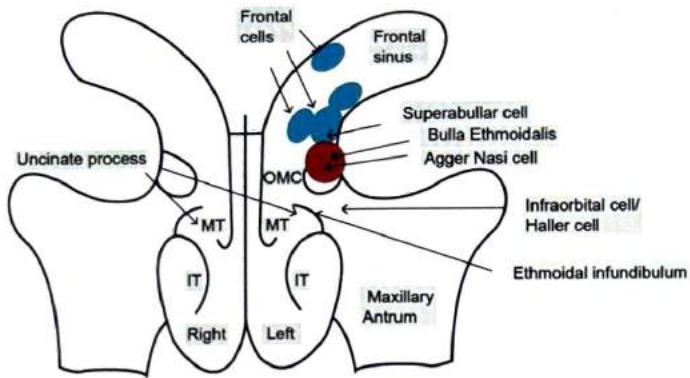
- First 4 PNS Bones:
 - Nasal spine of frontal bone
 - Perpendicular plate of Ethmoid
 - Rostrum of sphenoid
 - Crest of maxilla
- 3 bones
 - Nasal bone
 - Crest of palatine bone
 - Vomer
 - Vomer- exclusive to nasal septum
 - Lacrimal & inferior turbinate – exclusive to lateral wall



25 PARANASAL SINUSES ANATOMY

CORONAL CROSS SECTION OF THE NOSE AND PARANASAL SINUSES

00:00:52



- Bulla Ethmoidalis is most consistent cell of ethmoids
 - It belong to Anterior Ethmoidal air cells
 - Drains into Middle meatus.

Ethmoidalis

- Suprabullar cells – superior to bulla ethmoidalis
- Infraorbital cells / Haller cells – determine the severity of sinusitis as their presence makes ethmoidal infundibulum narrower which results in blockage
- Agger nasi cells
 - Anterior most cells of ethmoids
 - Present anterior to Bulla Ethmoidalis
 - Present in close approximation to lacrimal bone & lacrimal sac
 - Endoscopic DCR is done by identifying agger nasi cells
- Cell above the Agger Nasi, that blocks the drainage of frontal sinus is called Frontal Cells.
 - There can be one or more Frontal cells.

ONODI CELL

00:22:54

- It is one of the Posterior Ethmoidal Air cells
- Also the Posterior most ethmoidal air cell
- Lies in close proximity to sphenoid sinus
- Lies lateral to sphenoid sinus i.e. 1.5 cm behind the anterior wall of sphenoid sinus
- Has optic nerve in it, patient can land up into blindness during sphenoid surgery therefore, identification of Onodi cell is must be done by CT Scan before performing Sinus surgery.



Important Information

- Middle meatus : Maxillary Antrum, Frontal Sinus, Bulla ethmoidalis
- This together known as Osteomeatal Complex.



How to remember

OMC



How to remember

- ONODI - OPTIC - OO



Previous Year's Questions

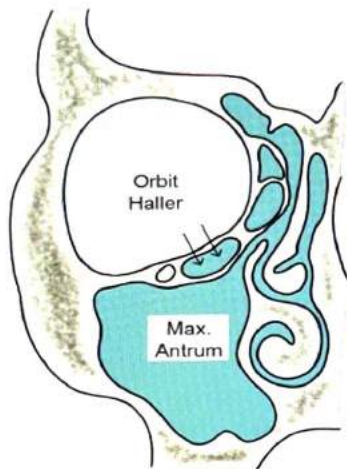
- Q. Optic nerve injury following sinus surgery is due to removal which ethmoidal cells?
- Haller cell
 - Agger nasi cell
 - Onodi cell
 - Bullae Ethmoidalis

- Uncinate process
 - Flap like process
 - Part of ethmoid bone
 - Makes drainage pathway of axillary sinus long & narrow k/a ethmoidal infundibulum
 - Maxillary Sinus Ostium is present at the lower end of ethmoidal infundibulum.
- Ethmoidal infundibulum ends at 2-D plane b/w Bulla Ethmoidalis & Uncinate process k/a Hiatus Semilunaris
- Others Anterior ethmoidal cells in relation to Bulla

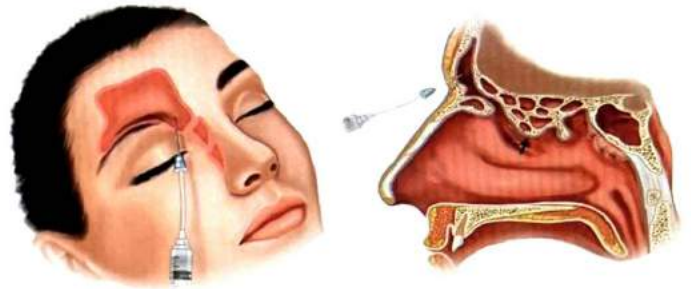- All the cells are not present always in an individuals.
- Bulla ethmoidalis is the most consistent cell of Ethmoids

Identification of the cells

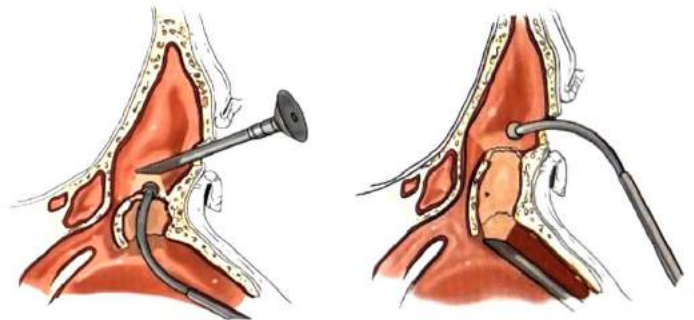
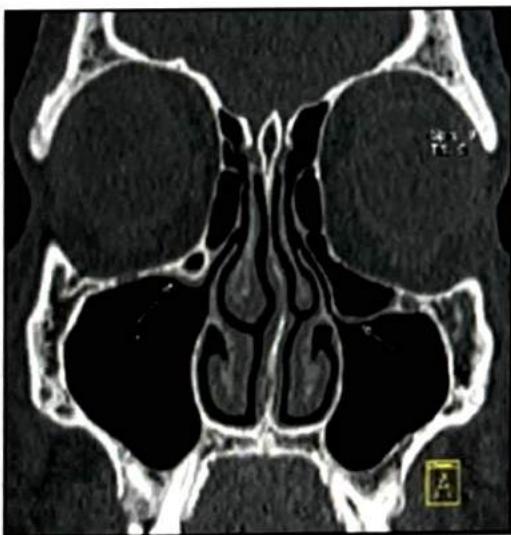00:25:35



- **Kuhn's classification**- 4 Different types of frontal cells
 - Type I frontal cell- Single cell above Agger Nasi In the frontal recess
 - Type II frontal cell- Multiple cells above Agger Nasi In the frontal recess
 - Type III frontal cell / Supraorbital cell - Into the frontal sinus, above the orbit, secretions can block the frontal sinus
 - Type IV loner cell / satellite cell- Single isolated cell in the frontal sinus

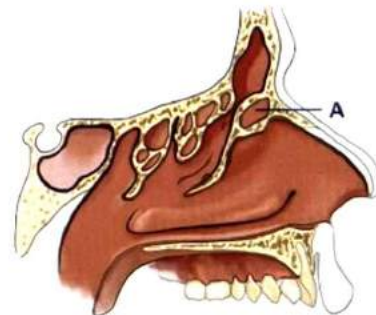


NCCT Scan of PNS

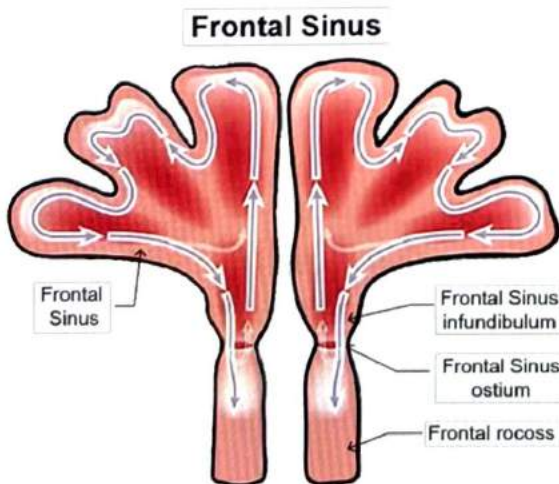


Previous Year's Questions

Q. Identify the structure marked as "A" in below picture? (AIIMS Jun 2020)



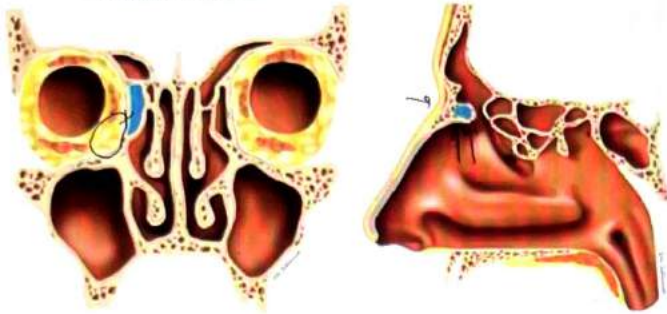
- A. Bulla Ethmoidalis
- B. Agger nasi
- C. Concha Bullosa
- D. Fossa ethmoidalis



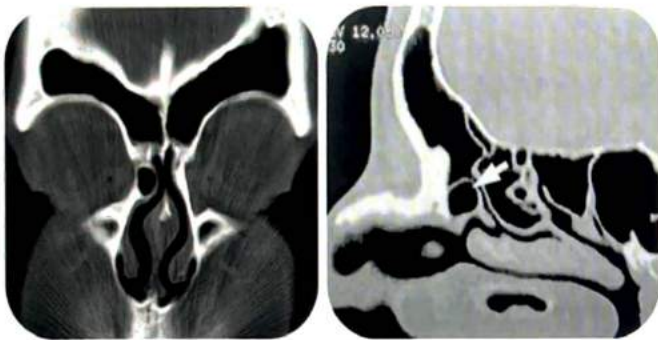
AGGER NASI

00:40:55

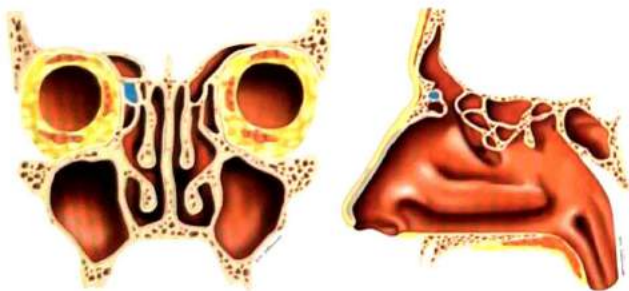Agger Nasi



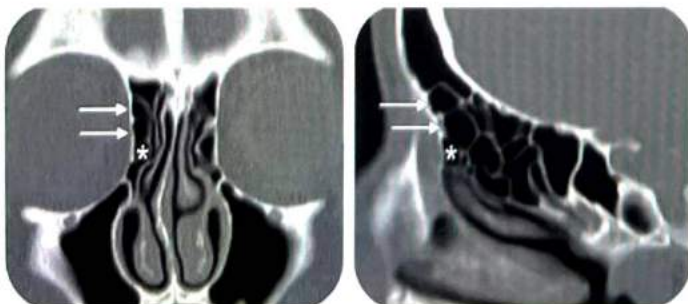
CT Scan of Agger Nasi



- Supra agger cells
 - Cells above Agger nasi cells
 - Can be single or multiple
 - All in the Anterior wall of Drainage pathway.

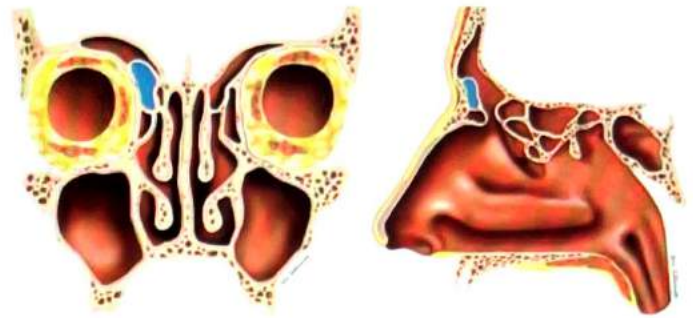

Supra Agger Cell

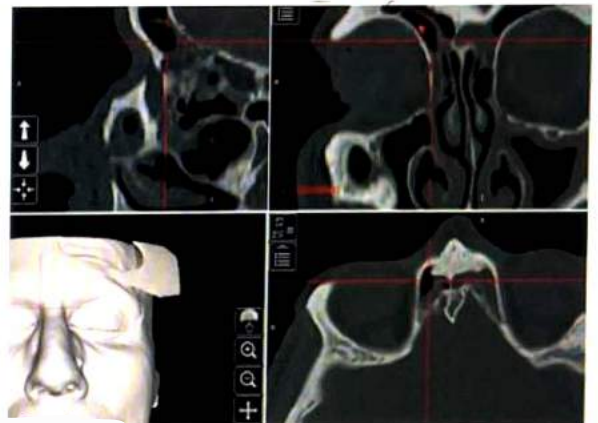


Supra Agger frontal cell

- If supra agger cells goes in the frontal sinus

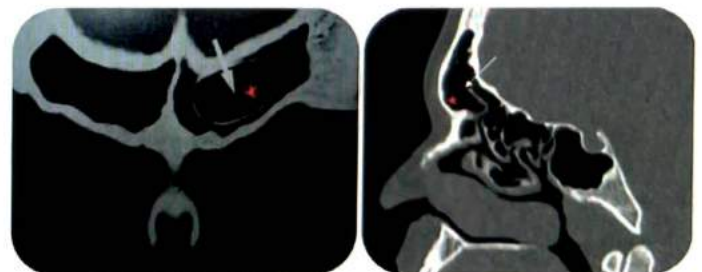
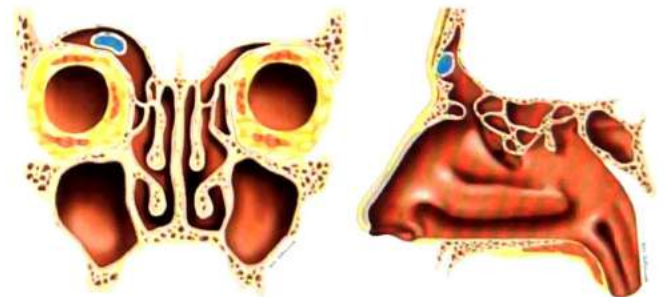
Supra Agger Frontal Cell



Type 4 frontal cells

00:45:18

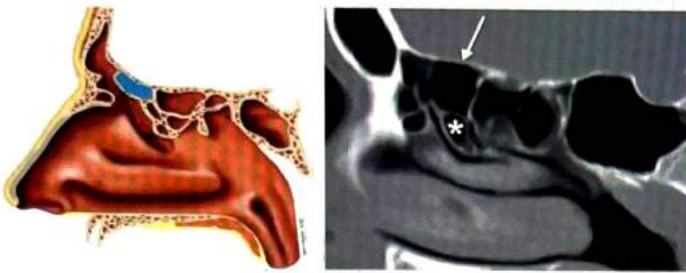


Bulla Ethmoidalis

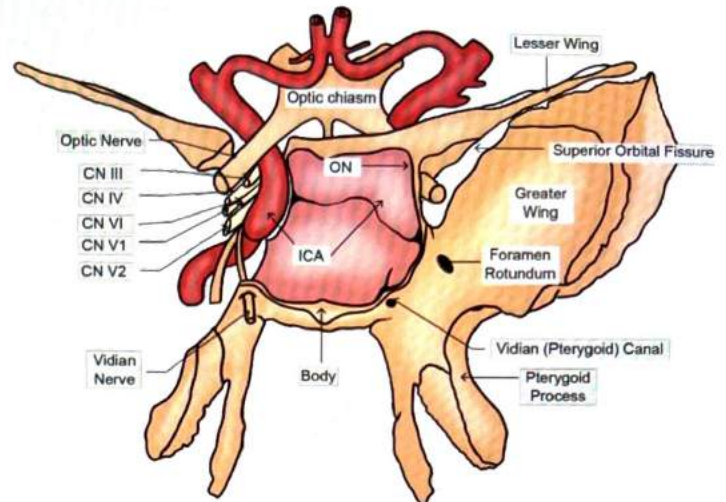
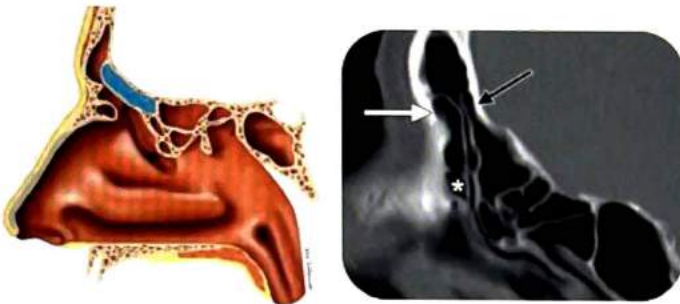
00:46:05

- Suprabullar cell
 - Lies above bulla ethmoidalis
 - Lies in posterior wall of drainage pathway

Suprabullar Cell



Supra Bulla Frontal Cell



- Structures passing through Foramen Ovale
 - M - Mandibular Nerve (V₃)
 - A - Accessory Meningeal Artery
 - L - Lesser Petrosal nerve
 - E - Emissary Vein

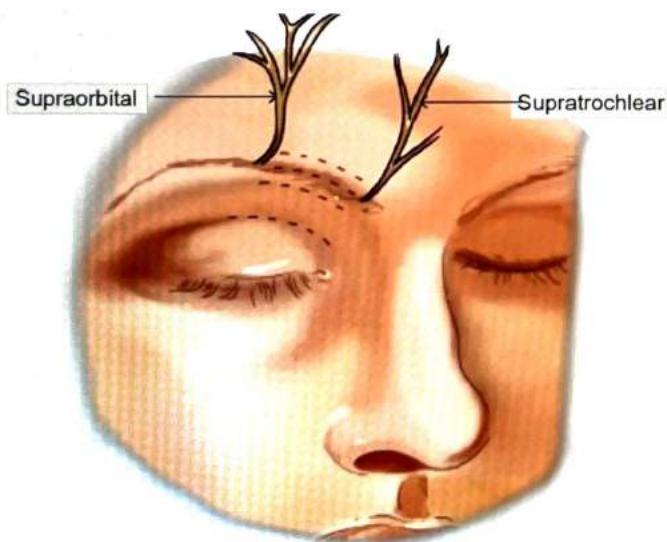

How to remember

- MALE

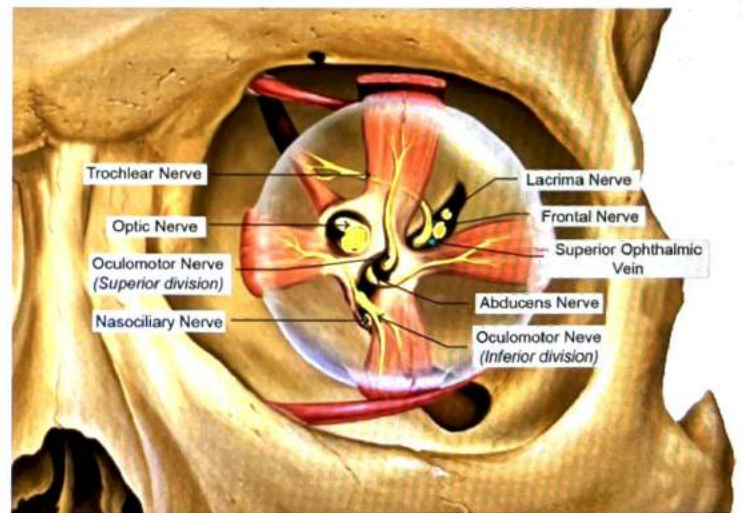
- Structure passing through superior orbital fissure

FRONTAL SINUS TREPHINATION 00:49:55



- Making opening in frontal sinus
- Supraorbital and Supratrochlear nerve must be intact
- Assists in
 - Locating the frontal sinus pathway
 - Endoscope insertion to assist opening frontal sinus by drilling from below and vice versa

SPHENOIDAL BONE 00:53:31



- Lacrimal Nerve
- Frontal Nerve
- Trochlear Nerve (CN IV)
- Superior Ophthalmic Vein
- Superior division of oculomotor Nerve
- Abducens Nerve (CN VI)
- Inferior division of Oculomotor Nerve
- Nasociliary nerve



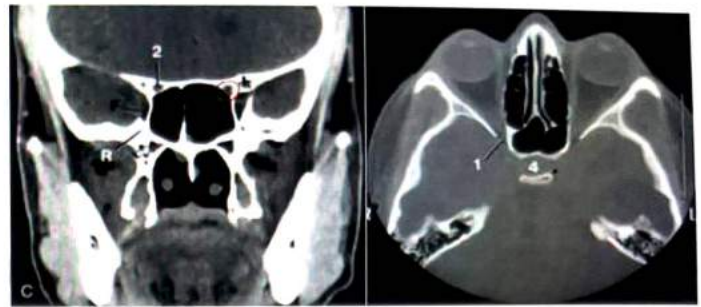
How to remember

- OPTIC - O₂C



Important Information

- OPTIC CANAL - 3 nerve
 - Optic nerve
 - Ophthalmic nerve
 - Central vein of Retina
- Optic Canal is in the Lesser Wing.



Coronal View

Axial View

Onodi cell

- Optic nerve present in the onodi cell
- It lies lateral to sphenoid sinus
- While surgery, have to be careful that optic nerve must not to be damaged.

SUPERIOR ORBITAL FISSURE SYNDROME

🕒 01:04:48

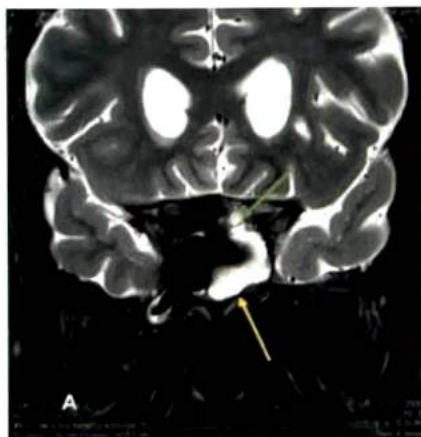- Is also known as Rochon-Dubigneaud Syndrome
 - M/C cause is trauma
 - Ophthalmoplegia
 - Ptosis
 - Proptosis
 - Fixed dilated pupil
 - Lacrimal hyosecretion
 - Eyelid or forehead anesthesia
 - Loss of corneal reflex

d/t involvement of (CN III, IV, VI, V₁)

ORBITAL APEX SYNDROME: JACOD SYNDROME

🕒 01:06:22

- Causes
 - Inflammatory, infectious causes, tumors etc
 - Involvement of optic nerve- main differentiator



🕒 01:07:46

Sphenoid Sinus

- Optic nerve lies in the lateral wall of sphenoid sinus



Previous Year's Questions

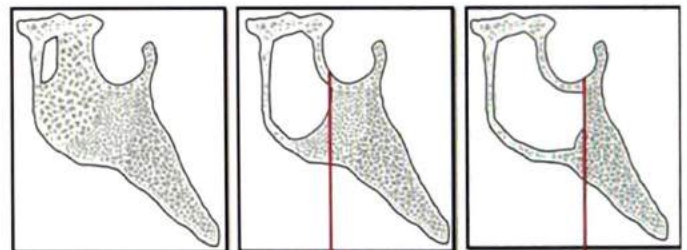
Q. Optic nerve injury following sinus surgery is due to removal of which ethmoidal cells?

(JIPMER May 2018)

- Haller cell
- Agger nasi cell
- Onodi cell
- Bullae ethmoidalis

SPHENOID PNEUMATIZATION

🕒 01:16:01



Conchal
(Least Common)

Presellar

Sellar
(Most Common)

Types

- Conchal pneumatization [Least common, 1-4%]
- Pre sellar pneumatization
- Sellar pneumatization [M/c, 54%]
- Mixed pneumatization [2nd M/c] [27%]

Clinical significance

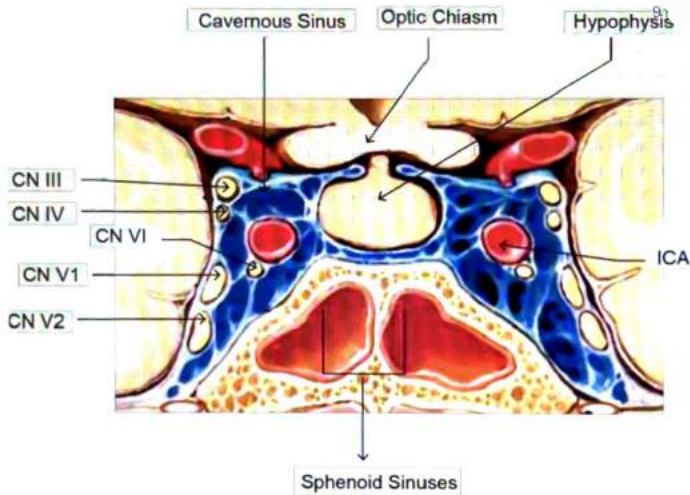
- Pituitary gland surgery can be done through endoscopic approach by breaking sphenoid bone
- Quicker, safer and has less complications
- In case of conchal pneumitization → Special drill is needed

- Experienced surgeon is required
- Take care of not to damage optic nerve and ICA
- More time is required
- More chances of complications

CAVERNOUS SINUS

01:21:21

Cavernous Sinus

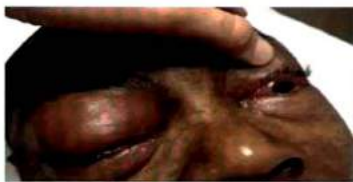

- Only sinus through which artery and nerve passes
- Has trabeculae
- Cavernous Sinus thrombosis can occur d/t spread of infections through cavernous sinus

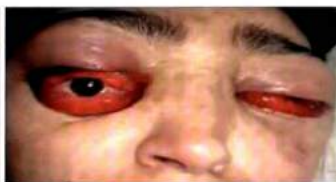Cavernous sinus thrombosis

01:24:18

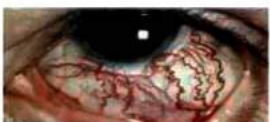
- Clinical features:
 - Headache
 - Fever
 - Swelling around eye



Periorbital Ddema



Chemosis



Caput Medusae



Lateral Rectus Palsy

- Ocular manifestations of CST

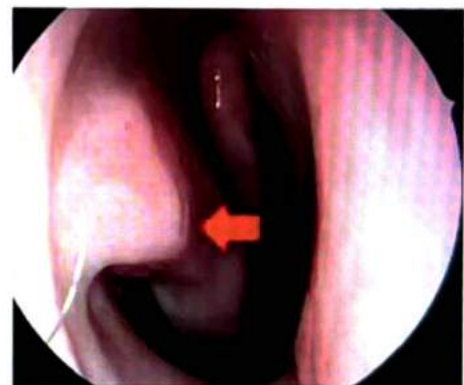Signs	Involved structures
Ptosis	CN III, Sympathetic Plexus, Edema of Upper Eyelid
Chemosis	Thrombosis of Superior & Inferior Ophthalmic Vein
Proptosis	Venous Engorgement
Sensory loss / periorbital pain	CN V
Lateral Rectus Palsy	CN VI
Ophthalmoplegia	CN III, IV, VI

- Horner syndrome is present, which differentiates it from superior orbital fissure syndrome and Jacod syndrome
- Rx of Carvenous sinus thrombosis: High dose of Antibiotics



Previous Year's Questions

Q. Identify the structure marked in the following Endoscopic image of nasal cavity? (INICET Nov 2020)



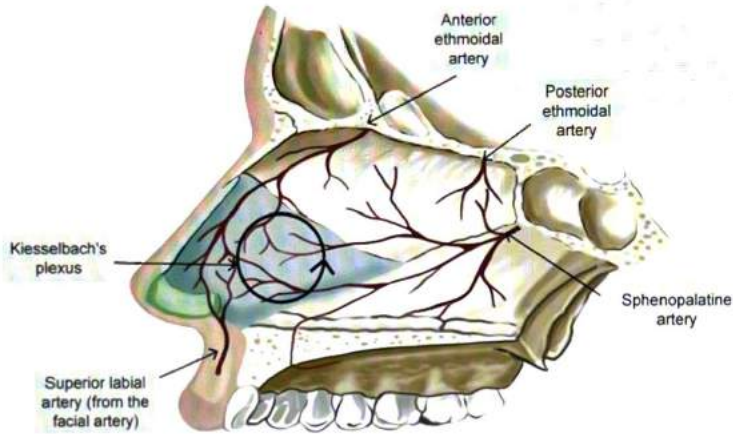
- Inferior Turbinate
- Middle Turbinate
- Superior Turbinate
- Septum



26 BLOOD SUPPLY OF NASAL SEPTUM & EPISTAXIS

Blood Supply Nasal septum

00:00:22



- Septum is supplied by 5 Arteries
 - Anterior Ethmoidal Artery: Branch of Ophthalmic Artery which is a branch of ICA
 - Posterior Ethmoidal Artery: Branch of Ophthalmic Artery which is a branch of ICA
 - Sphenopalatine Artery: Branch of internal maxillary artery
 - Greater Palatine artery: Branch of internal maxillary artery
 - Septal branch of superior labial artery: Branch of Facial Artery
- Both facial artery and internal maxillary artery is branch of ECA.
- Nose is being supplied by Both ICA and ECA systems.

Little's Area

- In the anterior inferior part of nasal septum there is an arterial plexus formed by 4 arteries k/a Kiesselbach's plexus in the area k/a Little's area
- Posterior Ethmoidal Artery does not contribute to Kiesselbach's plexus.
- Branch of ICA which contribute to the Kiesselbach's Plexus: Anterior Ethmoidal Artery



Important Information

Most common site for epistaxis is Kiesselbach's plexus



Previous Year's Questions

Q. Which of the following is not the branch of external carotid artery in Kiesselbach's plexus? (AIIMS Nov 2017)

- A. Anterior Ethmoidal Artery
- B. Sphenopalatine Artery
- C. C. Greater Palatine Artery
- D. D. Septal Branch of Superior Labial artery



Previous Year's Questions

Q. All are the branches of ECA that supply nasal septum except:

(AIIMS May 2019)

- A. Anterior ethmoidal artery
- B. Sphenopalatine artery
- C. Facial artery
- D. Superior labial artery

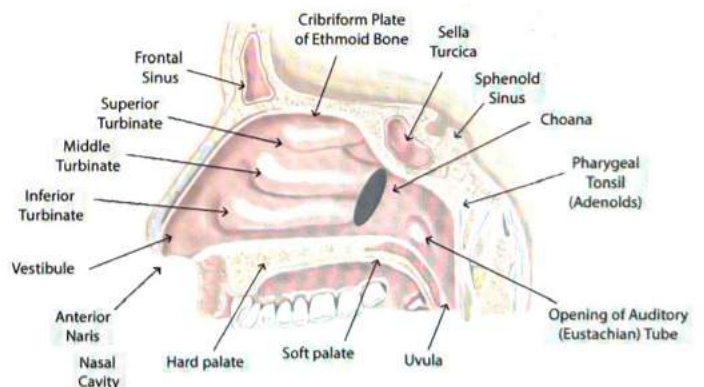
NOSE PICKING:

00:07:02

- Most common cause of Anterior epistaxis

POSTERIOR EPISTAXIS

00:07:49



- Most common site for posterior epistaxis is area behind the posterior end of middle and inferior turbinate on the lateral wall - k/a Woodruff's plexus

- Woodruff's plexus:
 - Venous plexus
 - Supplied by Sphenopalatine artery (K/a artery of epistaxis) and Ascending pharyngeal artery
- Most common cause Idiopathic
- HTN is no longer a cause of epistaxis
- 3 contributing factors:
 - Alcohol intake
 - NSAID
 - Season

BROWNE'S AREA

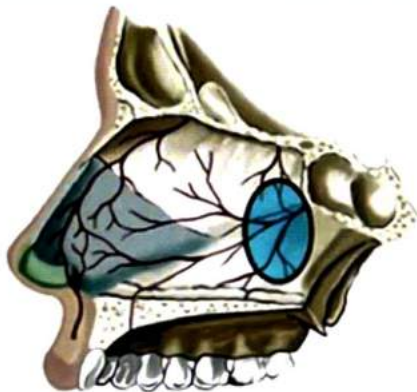
00:16:57

- Posterior inferior part of nasal septum Retrocolumellar vein: Cause for epistaxis sometimes



How to remember

BR(owne's)



TROTTER'S METHOD

00:18:47

- O/E :Nose pinching for 3 – 5 minutes by Trotter's method
- Bleeding time for normal person is 1-3 min.

Trotter's Method



Sit and Lean Forward



Pinch Nose and Breathe Through Mouth

CHEMICAL CAUTERY

00:20:30

- For Anterior Epistaxis
- By using Silver nitrate, TCA, Carbolic acid
- This Acid burn cause a Coagulative Necrosis. (superficial)



Important Information

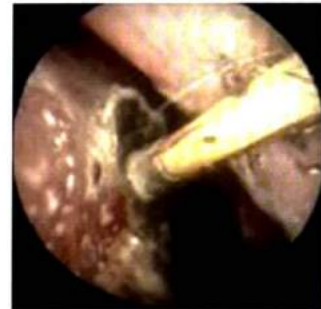
Alkali cause liquefactive necrosis and goes Deeper so more Dangerous.



How to remember

CC

Chemical Cautery



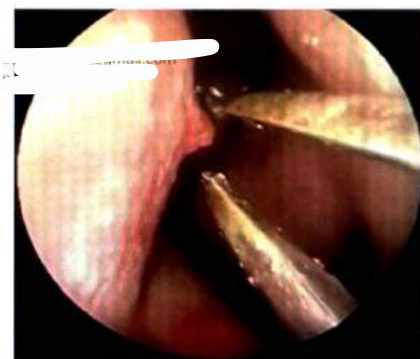- Foreign body like Button Battery accidentally goes in, it cause Liquefactive Necrosis because of its Alkali nature.
- This cause disruption so removal of FB ASAP

ENDOSCOPIC ELECTROCAUTERY

00:26:10

- If cannot identify the Bleeding Point, then its a case of Posterior Epistaxis.
- TOC: Endoscopic electrocautery/ligation (80%) for posterior epistaxis

Endoscopic Electrocautery

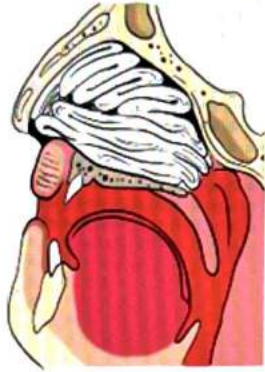

ANTERIOR NASAL PACKING:

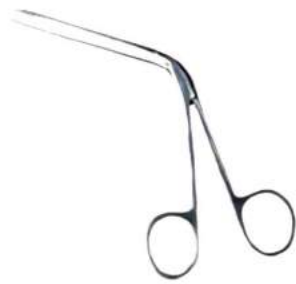00:27:07

- It is done by placing Ribbon Gauze in the anterior nasal cavity.
- B/L nasal packing is done
- Tilley's Nasal Packing Forceps is used

Anterior Nasal Packing



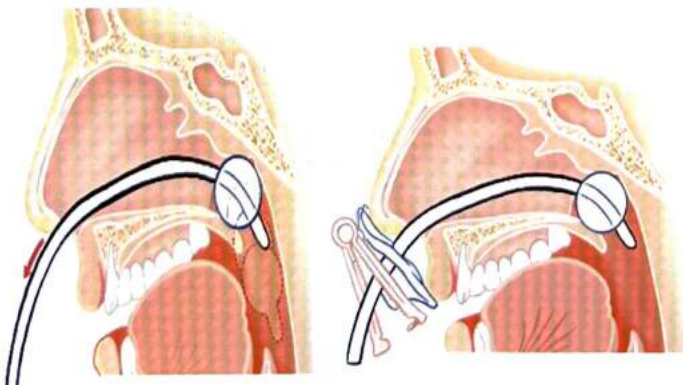
Tilley's Nasal Packing Forceps



POSTERIOR EPISTAXIS: FOLEY'S CATHETER

00:29:57

- Posterior Nasal Packing is done with the help of Foley's Catheter.
- When Catheter is visible behind the tongue/palate, inflated
- Advantage: simple/ under Local Anaesthesia

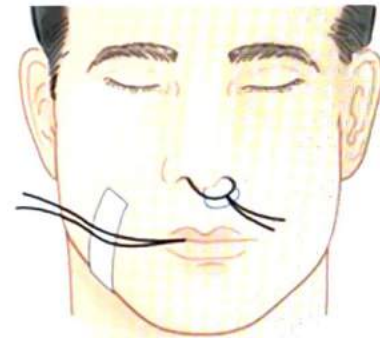
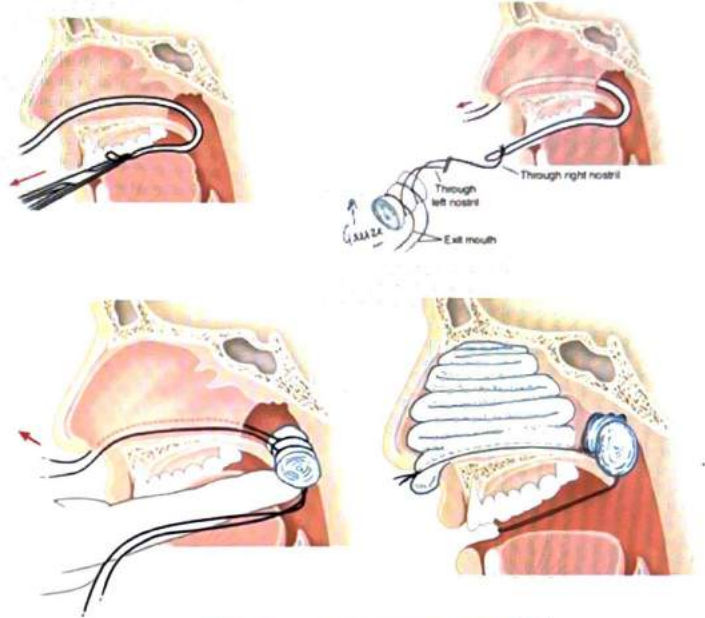


CLASSICAL POSTERIOR NASAL PACKING

00:31:47

- Done only under General Anaesthesia
- Bellocq's Pack AKA Nasopharyngeal Pack

Classical Posterior Nasal packing



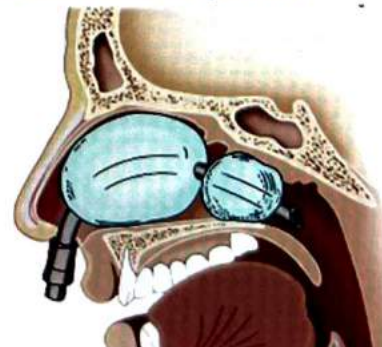
Bellocq's Pack

EPISTAXIS CATHETER:

00:35:10

- Balloon catheters used for Nasal packing

Anterior and Posterior Epistaxis

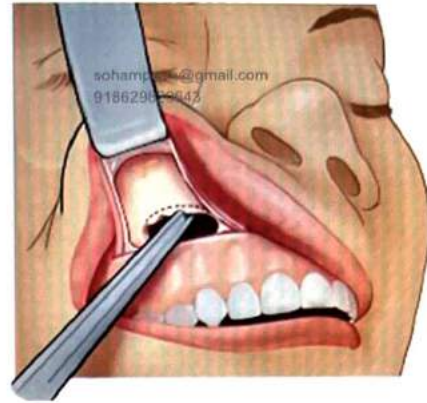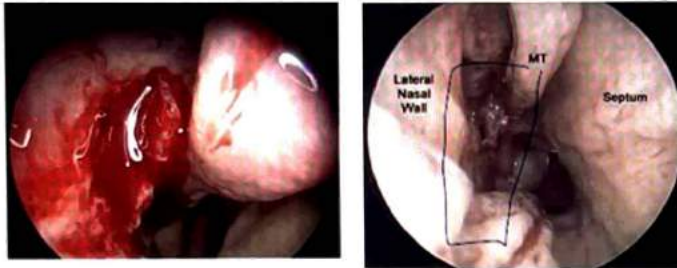


- Usually nasal packing are kept for 48-72hrs
- After 3 days still bleeding , Ligation is done to stop bleeding
- Artery of Epistaxis –Sphenopalatine Artery

ENDOSCOPIC SPA LIGATION: ⌚ 00:38:12

- First vessel to be ligated is Sphenopalatine Artery.
- SPA comes from Sphenopalatine foramen lies posterior end of MT on lateral wall.

Endoscopic SPA Ligation



EXTERIOR CAROTID ARTERY LIGATION:

⌚ 00:47:02

- Ligate the ECA in neck
- Even after ECA ligation, bleeding is not stopped then last option is to ligate the Anterior Ethmoidal Artery.



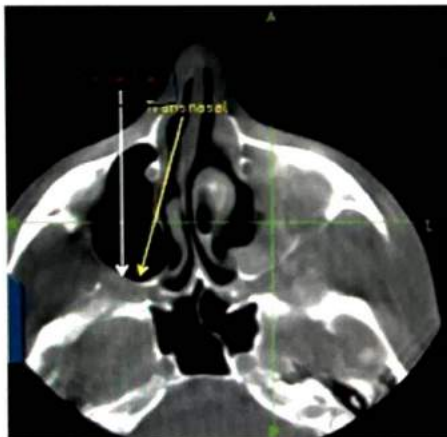
Important Information

- ICA is never ligated because it leads to stroke.

IMA LIGATION: ⌚ 00:39:58

- If tumor is present, SPA ligation cant be done
- Instead , internal maxillary artery is ligated
- IMA is ligated in the pterygopalatine fossa
- Trans nasal approach - endoscopic
- Trans antral approach done earlier.

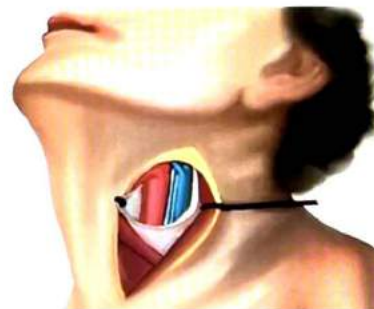
IMA Ligation



Caldwell luc operation

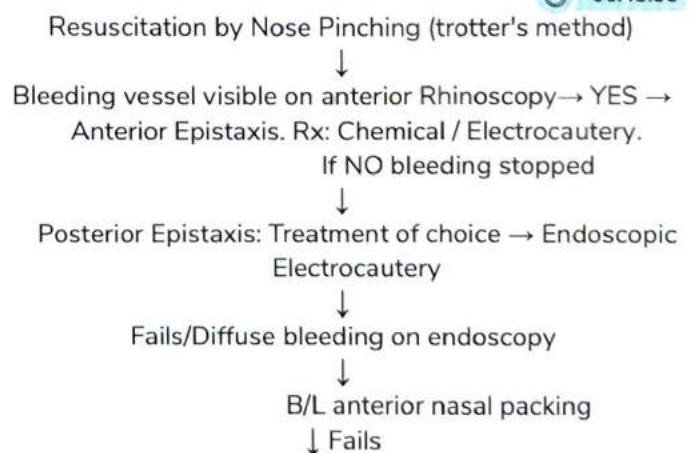
- M/c complication
 - Damage to infraorbital nerve, leading to paresthesia
 - Oro antral fistula
- Take out the fistula tract, close again
- Repeat Caldwell LUC operation

External Carotid Artery Ligation

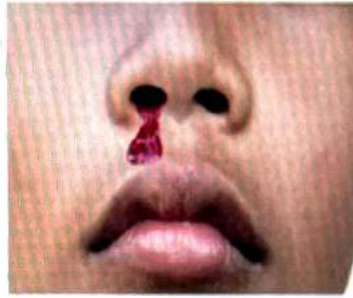

MANAGEMENT STRATEGY FOR EPISTAXIS

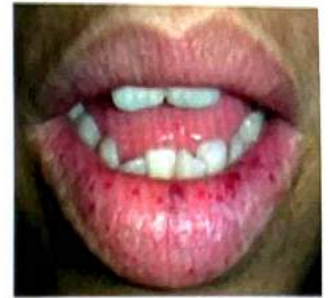⌚ 00:49:30



B/L Anterior packing + Posterior Nasal Packing (48-72 hrs)
↓
Vessel Ligation
Endoscopic Sphenopalatine artery ligation
↓ not respond
Internal maxillary / Artery ligation
↓ not respond
External carotid artery ligation



Spontaneous Recurrent Epistaxis



Telangiectasias at Lips/ Oral cavity Finger/nose

HEREDITARY HEMORRHAGIC TELANGIECTASIA (HHT) OSLER WEBER RENDU DISEASE

🕒 00:52:50

- Autosomal Dominant Disease. Diagnosis is done by "Curacao Criteria"
- CURACAO Criteria Consists of 4 Things (At least 3 criteria out of 4 criteria should be present to confirm it as a case of Osler Weber Rendu Disease)



Important Information

- Spontaneous recurrent epistaxis (H/O of bleeding without any cause, trauma)
- Multiple Telangiectasia at Lips / Oral Cavity / Fingers / Nose
- Arterio-venous malformation in liver, gut
- Family history in first degree relatives



Visceral lesion AVMS



Family History

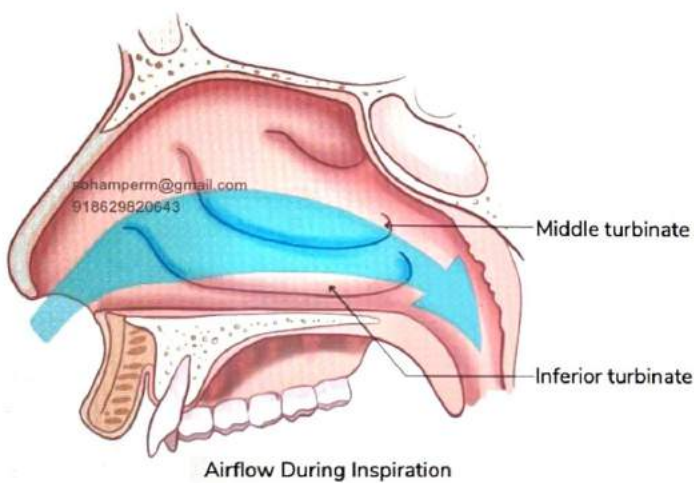


27 PHYSIOLOGY OF NOSE

INSPIRATION

00:00:19

- During normal tidal inspiration, the maximum air passes through middle meatus in parabolic curve, Air flows in Laminar flow
- Air comes out from paranasal sinuses
- Paranasal sinuses helps in air conditioning



EXPIRATION

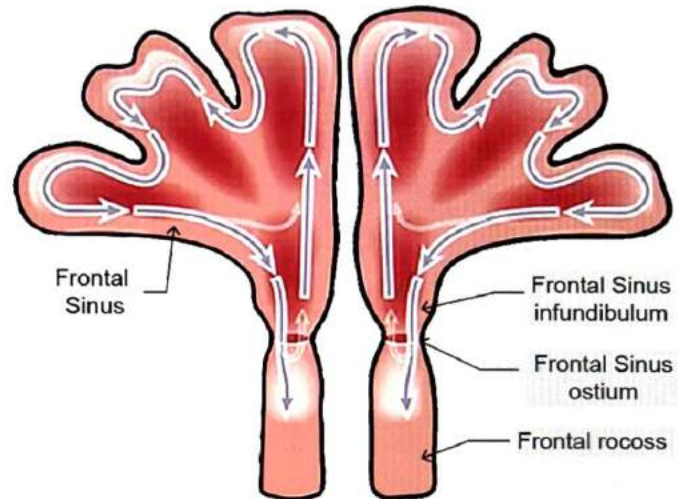
00:01:34

- During expiration, the paranasal sinuses are aerated & air comes out during inspiration
- During expiration, this air flow is re-rotated back and there is creation of Eddie current around the middle Turbinate → This help in Aeration of Para-nasal sinus as well as Retero nasal olfaction.
- BERNOULLI'S PHENOMENON: during inspiration it creates Negative pressure. (laminar flow of mass creates negative pressure)
- PNS role: Air conditioning during inspiration and helps preserving heat & moisture during expiration.
- Nasal mucosa
 - Pseudo stratified ciliated columnar epithelium
 - Has Goblet cells
 - Cilia Beat together in a rhythm and transfer the mucous baci into nasal cavity - Mucociliary Flow / Mucociliary Clearance
 - Goes upto 6-20mm/minute

FRONTAL SINUS DRAINAGE

00:11:21

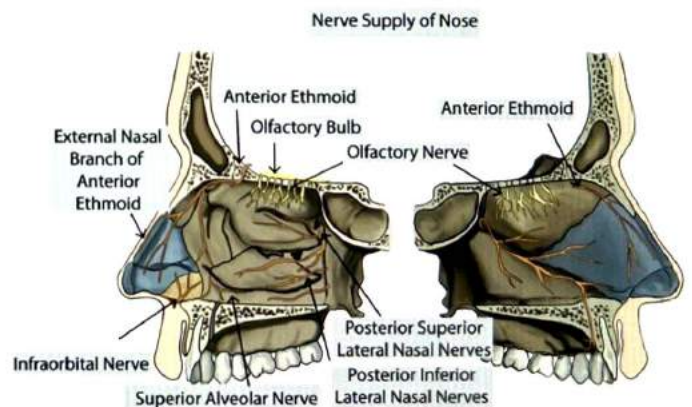
Frontal Sinus



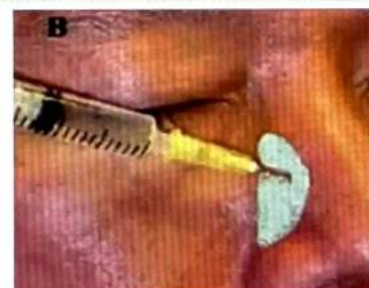
NERVE SUPPLY OF NOSE

00:12:21

- Most Important Nerve Supply-Olfactory Nerve(CN1)
 - Shortest CN
 - It arises from the Olfactory Bulb
- External Nasal branch of Anterior Ethmoid



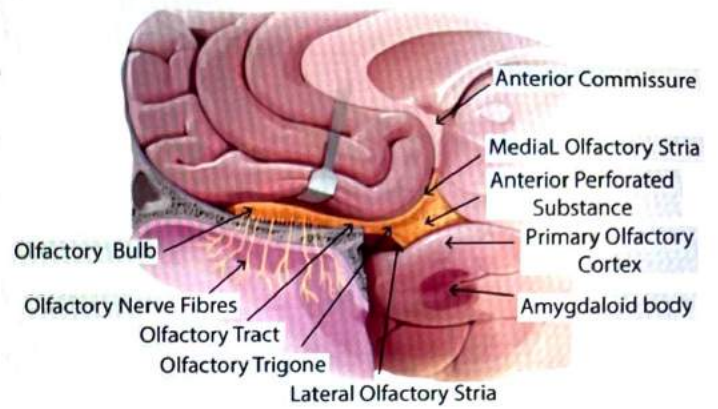
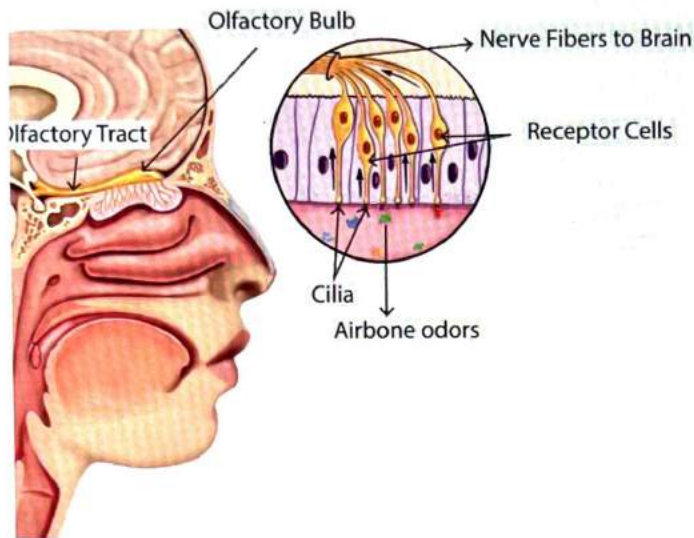
Anterior Ethmoidal Nerve Block:



OLFACTORY REGIONS:

00:14:32

- Olfactory nerve fibres are Bipolar Neurons
- This neuron has Two ends:
 - Cilia in the nasal cavity - picks the smell and gives to Receptor cell then to Nerve fibres of Brain-Olfactory nerve



OLFACTION

00:19:00

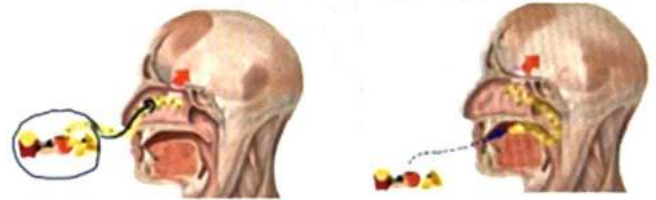Olfaction

Orthonasal

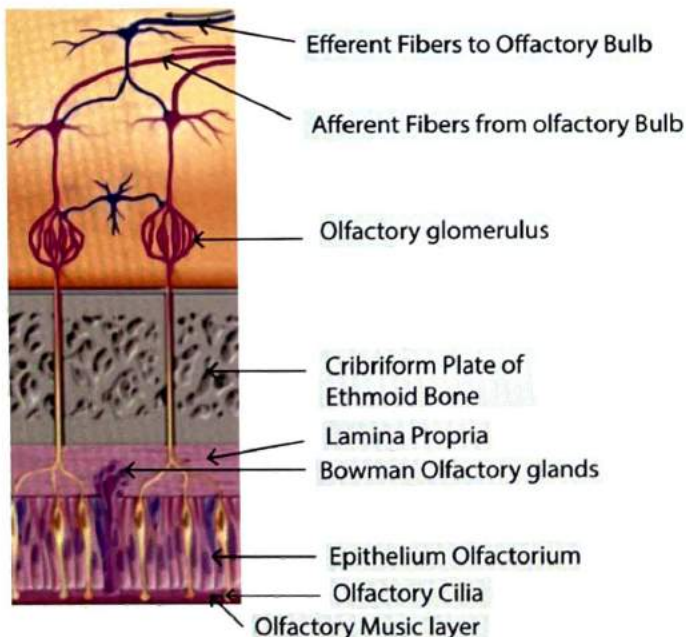
- Odour in inspired air

Retronasal

- Odour in expired air



OLFACTORY Pathway:



- Olfactory pathway consists only 2 neurons
- The only sensory pathway which does not rely in Thalamus and directly reach the cortex.

- Food in mouth - swallowing & deglutition
- Stimulates:
 - (7th CN) Chorda tympani – taste (anterior 2/3rd tongue)
 - (5th CN) Lingual nerve – Pain, Tactile & temperature from anterior tongue
 - GSPN – Taste from palate (9th & 10th CN taste from posterior tongue and throat)
 - Gives Feedback stimulation to the Olfactory Pathway and so it Adds smell to taste
- Retro nasal olfaction is also due to Cranial Nerve 5, 7, 9, 10.



Previous Year's Questions

Q. Cranial nerve that is not involved in olfaction

- Glossopharyngeal
- Vagus
- Hypoglossal
- Trigeminal



Important Information

- Hypoglossal nerve - Pure motor nerve



How to remember

- (A)coustic- (A)natomy

NASAL CYCLE:

🕒 00:23:00

- Physiological cycle
- 1.5-4 hrs nasal cavity undergoes:
 - One cavity - Congestion
 - Other cavity- Decongestion (more airflow)
 - And then it will reverse
- Patient presents with Nasal obstruction (alternating b/w 2 nasal cavities)
 - Only give counseling

COTTLE'S TEST:

🕒 00:25:58

To check for obstruction, we can do:

- Cottle's test: test for internal nasal valve collapse
- Cold spatula test: test for only expiration
- Cotton wool test: test for both inspiration and expiration (better physiology test)

Cottle's Test

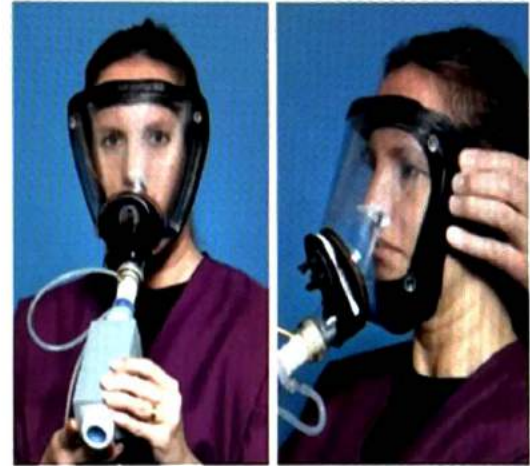

RHINOMANOMETRY:

🕒 00:28:06

- To check for nasal resistance, speed of nasal air flow
- Provides functional measure of the nasal airway resistance or conductance
- Acoustic rhinometry – provides anatomical measurement of cross-sectional area or nasal volume

Rhinomanometry



Acoustic Rhinometry





28

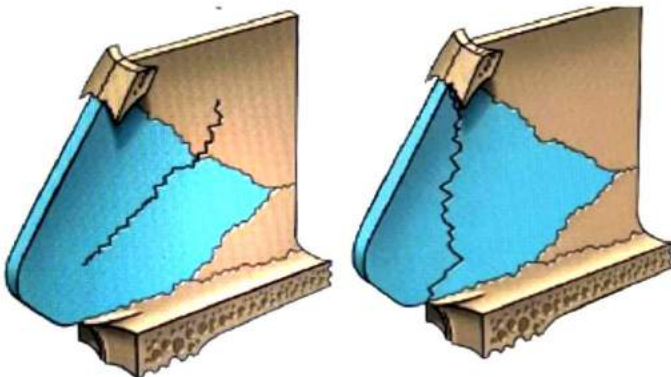
NASAL SEPTAL DISORDERS

SEPTAL FRACTURES

00:00:36

- **JARJAWAY FRACTURE:**
 - Injury of nasal septum such as blow from side
 - Line parallel to cartilage vomer junction
- **CHEVALLET FRACTURE:**
 - line starts from anterior most point to maxillary crest (Nasal spine of maxilla) to the nasal spine of frontal bone
 - Punch / impact from below

Septal Fractures



Jarjaway #

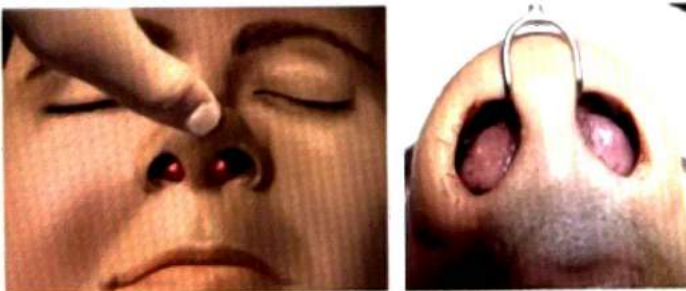
Chevallet #

SEPTAL HEMATOMA

00:05:35

- Collection of blood between septal cartilage & mucoperichondrium
- MCC = Trauma
- B/L nasal obstruction
- Rx:
 - Incision and Drainage
 - B/L anterior Nasal packing to stop the bleeding .

Septal Hematoma

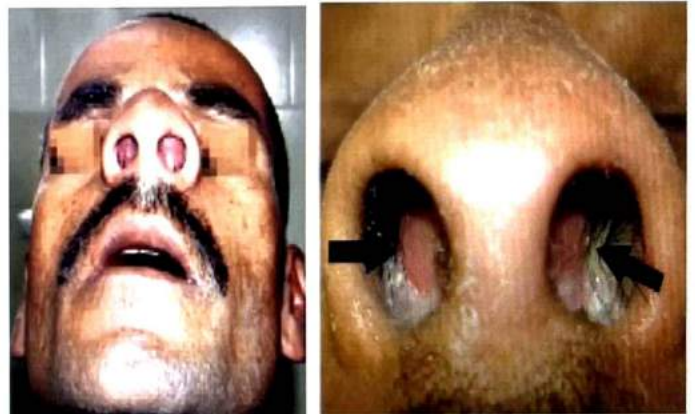

SEPTAL ABSCESS

00:10:54

- Collection of pus between cartilages & its mucoperichondrium
- Severe Pain, swelling, B/L Nasal obstruction, Red , Hot, Fever
- Rx:
 - I & D
 - B/L Anterior Nasal packing
 - 7-10 days I.V. Antibiotics initially, later oral
- M.C. complication:- septal perforation
- O/E : Septum is swollen on both sides

Septal Abscess



SEPTAL PERFORATION

00:15:06

- Hole in the septum
- Most common cause: Trauma
 - Nose pricking(MC)
 - Penetrating injury
 - Iatrogenic injury (septal Sx)
- Other causes
 - Septal abscess
 - Septal piercing (membranous septum)
 - Cocaine abuse
 - Granulomatous disorders
 - **Cartilaginous Septal perforation** (E.g. TB, Leprosy, Lupus Vulgaris)



CLINICAL QUESTIONS



Q. A 21 yr old lady had undergone Septal surgery. She was discharged after surgery & informed to meet consultant after 2 days for pack removal. She did not attend her appointment. After 15 days, she came back to ENT clinic with nausea, Vomiting, hypotension & rash along with purulent secretions from nose. What could be diagnosis?

- A. Septal abscess
- B. Furuncle
- C. Septal hematoma
- D. Toxic shock syndrome

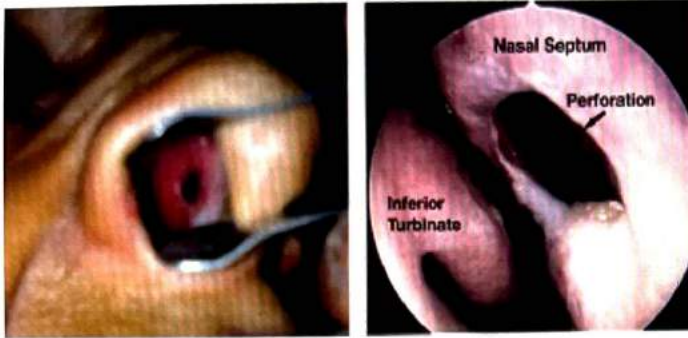
Answer: A

Solution

TOXIC SHOCK SYNDROME:

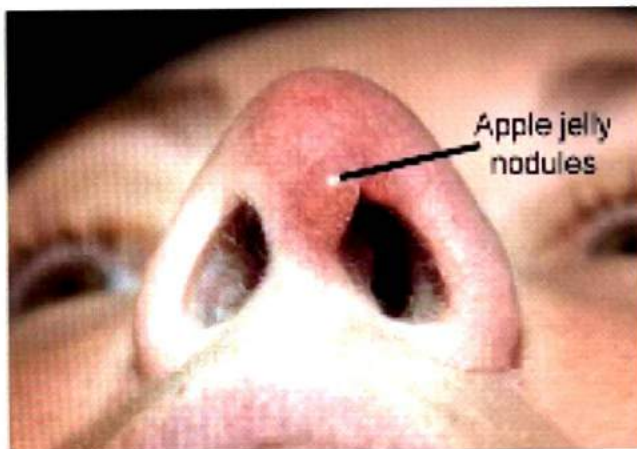
- Rare after septal surgery.
- Can follow staphylococcal (sometimes streptococcal) infection
- Characterized by nausea, vomiting, purulent secretions, hypotension and rash.
- Should be diagnosed early.
- Treated by removal of packing, hydration, maintaining BP and administering proper antibiotics.

Septal Perforation



APPLE JELLY NODULES: LUPUS VULGARIS

00:22:05



- Bony Septal perforation (E.g. Syphilis)
- Both (Cartilaginous and Bony)- E.g. Wegner's Granulomatosis



Important Information

- Wegner's Granulomatosis : C-ANCA (specific test)



Previous Year's Questions

- Q. Syphilis affects which part of the nose?
(FMGE Aug 2020)
- A. Bony septum
 - B. Lateral nose
 - C. Floor of nose
 - D. Vestibule

SEPTAL SURGERY

00:24:17

SMR (Sub mucus Resection)

Septoplasty

- | | |
|---|---|
| <ul style="list-style-type: none"> • Rise the Mucoperichondrium & Mucoperiosteal flaps on both sides & remove bone & cartilage leaving L shaped • More chances of perforation | <ul style="list-style-type: none"> • Rise both flaps on one side & remove only deviated septum • More conservative Sx • Low chances of perforation |
|---|---|

• COTTLE'S LINE

- Anterior to line –septoplasty
- Posterior to line- SMR

• COTTLE'S TEST

- Test of nasal valve / Limen nasi/Limen vestibuli

• Most septal Perforation is caused by Anterior Perforation

- Small perforations - most common
- Large perforations

• Rx : flap rotation Sx

INDICATIONS OF SEPTAL SX

00:37:05

- DNS causing nasal obstruction
- DNS causing recurrent epistaxis
- DNS causing chronic infection (Rhinitis)
 - DNS itself is not an indication
- As a part of other Sx
- To give access to other Sx

CONTACT POINT HEADACHE:

00:47:55

- Spur [sharp development of nasal septum, bony cartilaginous junction]Contact point headache
- Sluder's Neuralgia (Anterior ethmoidal N. Syndrome)



Important Information

- Chronic DNS
- Congenital DNS
- Prolonged DNS
 - Not an indication unless causing problem



29 RHINOSINUSITIS

INTRODUCTION

00:00:13

- Inflammation in the Nasal cavity - Rhinitis
- Inflammation in the Sinus cavity – Sinusitis

Rhinitis	Sinusitis
<ul style="list-style-type: none"> • Nose is lined by pseudo stratified ciliated columnar epithelium [respiratory epithelium] 	<ul style="list-style-type: none"> • PNS lined by pseudo stratified ciliated columnar epithelium

- Common term – Rhinosinusitis
- M.C sinus = Maxillary (Adults/ children)

ACUTE RHINOSINUSITIS / COMMON COLD

00:05:13

- Acute inflammation of Nose and sinuses
- Most common disease in the world
- MC causative agents – Rhino virus
 - Mucoïd discharge
- Clinical presentations:
 - Cough, sore throat
 - Running nose (nasal discharge)
 - Nasal congestion
 - Fever, headache, lethargy
- Rx- symptomatic

NOVEL CORONAVIRUS (SARS-COV 2)

- Acute Rhinosinusitis is also caused by corona virus
- RNA virus-single strand
- COVID-19 Clinical Presentation
 - Fever
 - Dry Cough
 - Tiredness/fatigue
 - Running Nose
 - Sore Throat
 - Shortness of Breath
 - Loss of Smell & Taste
- Case definition-Confirmed case: A person who
 - Tests positive to a Validated specific SARS-CoV-2 nucleic acid test.
 - Has the virus isolated in cell culture (with PCR confirmation)

- Presence of SARS-CoV2-IgG antibody level (or >4 times increase in titres)
- **Clinical criteria:**
 - Fever (>37.5°C) or history of fever (eg. Night, sweats, chills)
 - Acute respiratory infection (eg. Cough, shortness of breath, sore throat)
 - Loss of smell or taste.
- **Probable case:**
 - A person who has detection of SARS-CoV-2 neutralising or IgG antibody
 - Compatible clinical illness
 - Meets one or more of the epidemiological criteria outlined in the suspect case definition
- **Suspect case:** clinical and Public health judgement should be used to determine the need for testing in hospitalised patients and patients who do not meet the clinical or epidemiological criteria
- **Epidemiological criteria :** in the 14days prior to illness onset:
 - Close contact with a confirmed or probable case
 - International or interstate travel
 - Passengers or crew who have travelled on a cruise ship
 - Healthcare, aged or residential care workers and staff with direct patient contact
 - Lived in or travelled through a geographically localised area with elevated risk of community transmission.
- **COVID-19 Close Contact definition:**
 - Face-to-face contact >15minutes in one week, (confirmed or probable case)
 - Sharing of a closed space > 2hours



Previous Year's Questions

Q. A doctor posted in ICU came to ENT opd on April 2020 with loss of smell and taste for 3-4 days. There is no history of trauma. What is the next step in Management? (FMGE Aug 2020)

- Nasopharyngeal Web
- MRI Brain
- Chest Xray
- HRCT Chest

00:17:23

- **Mcc: strep. Pneumonia**
 - Moraxella catarrhal
 - H. influenza
- **Yellowish / mucopurulent discharge**
- **MC sinus involved – maxillary sinus**
- **Rx: - Antibiotics + symptomatic Rx**

Management

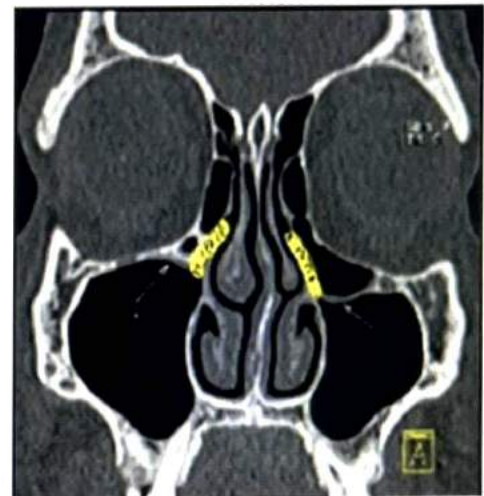
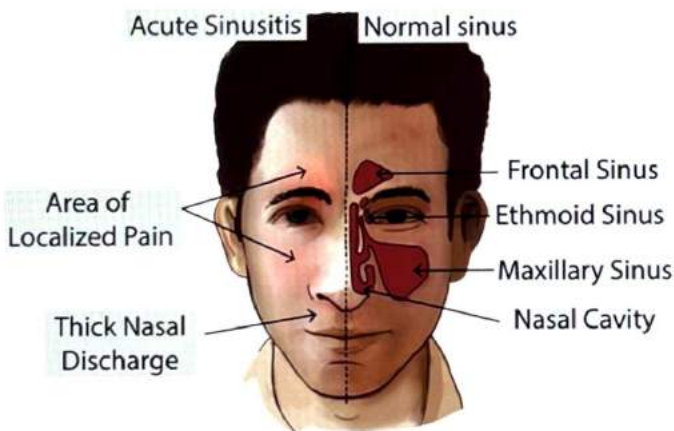
- **TOC → Medical management**
 - **Culture directed antibiotics + Nasal decongestant.**
 - ↓ Not improving
 - **Antral puncture & lavage - puncture made in Maxillary antrum from the Inf.meatus with help of Antral Trocar & Cannula/Antral wash (obsolete)**
 - ↓ Recurrence
 - **Nowadays, FESS (functional endoscopic sinus sx)**
 - Re-establishes mucociliary flow
- **Sphenoid sinusitis:** Occipital headache
 - **Gold Standard to diagnosis chronic rhinosinusitis = Antral puncture**



Important Information

Acute viral Rhinosinusitis : colorless, mucoid discharge

Acute Bacterial Rhinosinusitis



CHRONIC RHINOSINUSITIS

00:21:07

- Infection > 12 wks (3m)
- < 2 weeks – acute
- 2w - > 3m:- subacute
- **Mc causative : staph aureus**
- **Chronic infection + chronic hypertrophy & obstruction**
- Dull Aching Pain
- Nasal congestion / obstruction
- **Frontal sinusitis: office headache / frontal headache.** Keeps on increasing and reaching peak around 10-11 AM

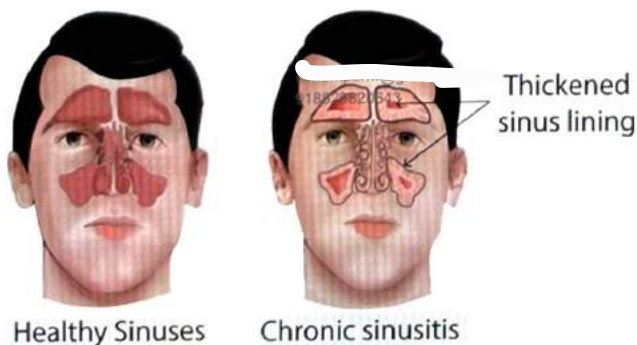


Previous Year's Questions

Q. Gold standard investigation before FESS function Endoscopic sinus surgery) is: (FMGE Aug 2020)

- A. CT scan
- B. MRI
- C. X Ray
- D. Antral Lavage

Chronic Rhinosinusitis



ALLERGIC RHINOSINUSITIS

00:38:07

- **Mc allergen – House dust mite / carpet dust mite (Dermatophagoides)**
- **Mc in urban areas & high socio-economic status & developed countries**
- **Mc in snow covered areas because dermatotophagoides are killed by sunlight**

Symptoms

Intermittent symptoms	Persistent symptoms
<ul style="list-style-type: none"> <4 days per week Or <4 weeks 	<ul style="list-style-type: none"> 4 days per week AND >4 weeks
Mild	Moderate – severe one or more items
<ul style="list-style-type: none"> Normal sleep Normal daily activities Normal work & school Normal troublesome symptoms 	<ul style="list-style-type: none"> Abnormal sleep Impairment of daily activities, sports etc. Problems at school or work Troublesome symptoms

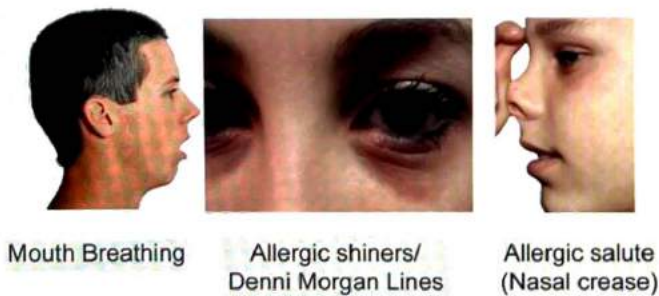
On examination

- Lethargic
- Allergic/atopic facies
- Allergic shiners/ Denni Morgan lines
- Allergic salute/Nasal crease

On Nasal Examination

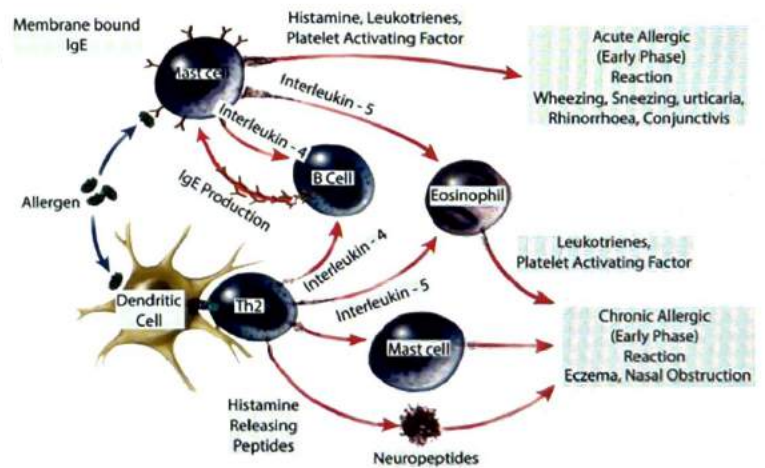
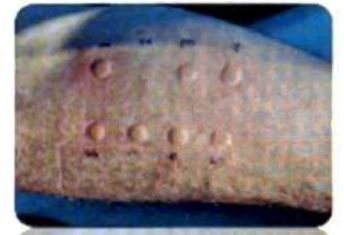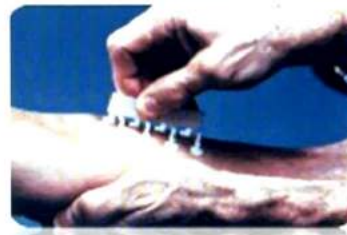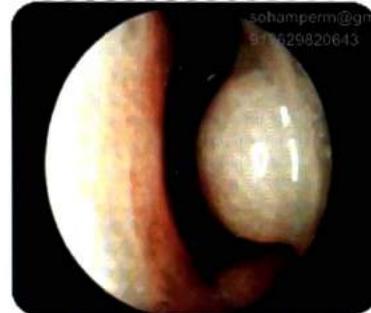- Rx
 - Mild – Intermittent: 2nd generation non sedative Antihistamine
 - Moderate to severe/ Persistent: Intranasal steroid spray is given and if not responds to pharmacotherapy, then immunotherapy is given

Face Examination



- Mucoid secretion in nasal cavity
- Mulberry appearance of Nasal mucosa
- Nasal mucosa is hypertrophied, pale bluish
- Confirmatory Test
- Skin prick test – IOC
 - 1st is histamine used (As positive control)
 - 2nd is normal saline (negative control)
- Nasal allergen challenge test/provocation test (gold std.)
 - Inhalational test
 - Not commonly done

Nasal Examination



Rx

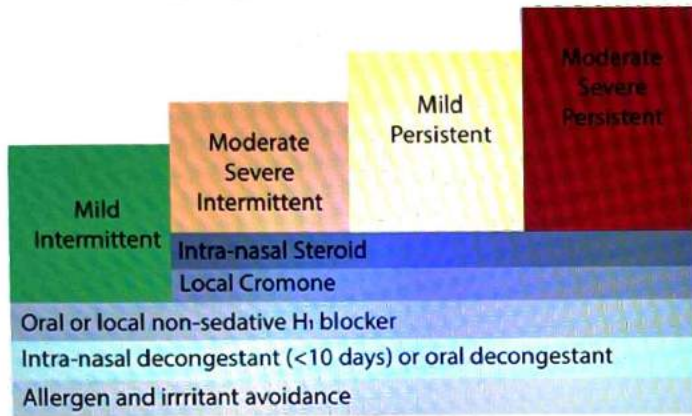
- Step Ladder Treatment Of AR : ARIA
- Steroids (intra nasal spray) – DOC
- Non respondent to pharmacotherapy, then immunotherapy is given
- Immunotherapy is given to decrease the hypersensitivity of the patient.
- Aka desensitization therapy



Important Information

- Immunotherapy is the only curative therapy for chronic allergic Rhinosinusitis

Step ladder treatment of AR: ARIA



- Course duration : 3-5 years. It is the only curative therapy for allergic rhinosinusitis.

VASOMOTOR RHINOSINUSITIS ⌚ 01:04:36

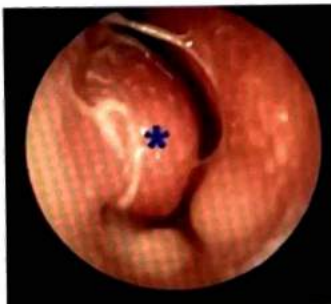- d/t increase in parasympathetic discharge (Vidian nerve)
- It will stimulate the nasal gland and secretions are more
- Mc in emotional females
- Non allergic non infective perennial Rhinosinusitis (NANIPER)



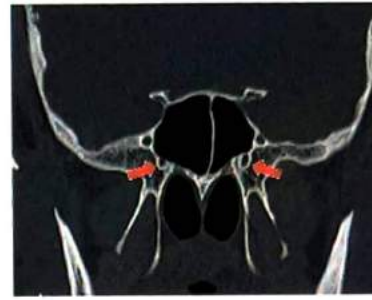How to remember

NANIPER

Vasomotor Rhinosinusitis



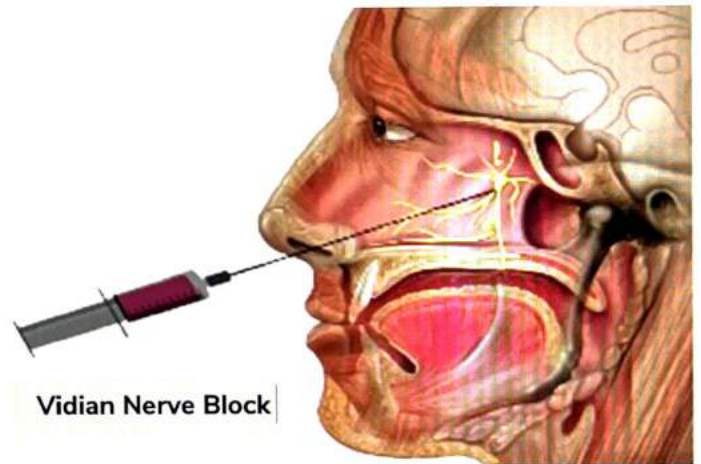
Vidian Nerve



Rx

- Anticholinergic (Intra nasal - Ipratropium Bromide)
- Conservative therapy - Vidian nerve block is given in the lesion of the sphenopalatine foramen. Vidian nerve cryotherapy
- Vidian Neurectomy – Gold std

Vidian Nerve



Vidian Nerve Block

RHINITIS MEDICAMENTOSA ⌚ 01:14:04

- Excess usage of Nasal decongestant drops Xylo/oxymetazolines
- REDOUND PHENOMENON - initial decongestion followed by rebound congestion
- Hypertrophy of mucosa
- Rx
 - Stop decongestants
 - DOC- intra nasal corticosteroid spray (topical)

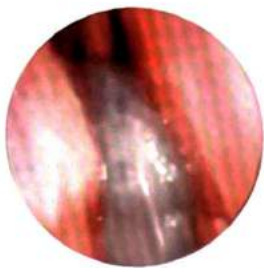


30 NASAL POLYPS

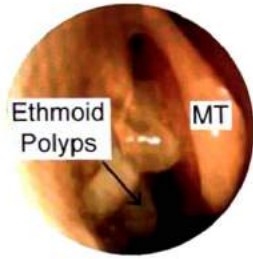
ANTROCHOANAL POLYP [AC POLYP] & ETHMOIDAL POLYP

00:00:46

Nasal Polyp



Antrochoanal Polyp (AC Polyp)

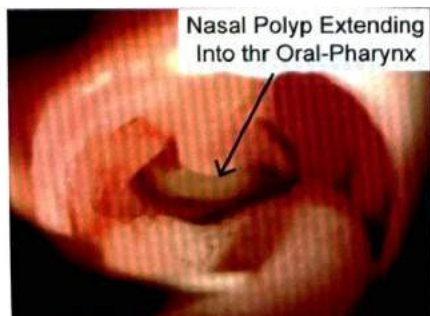


Ethmoidal Polyp

Antrochoanal Polyp [AC Polyp]	Ethmoidal Polyp
-------------------------------	-----------------

- | | |
|--|--|
| <ul style="list-style-type: none"> Starts from maxillary antrum Single, large, U/L Grows posteriorly towards choana Children an infection C/F: Both U/L & B/L obstruction | <ul style="list-style-type: none"> Starts from ethmoidal air cells Small, multiple, B/L Comes out anteriorly Adults allergy B/L Nasal obstruction |
|--|--|

Antrochoanal Polyp (AC Polyp)



Nasal Polyp Extending Into the Oral-Pharynx

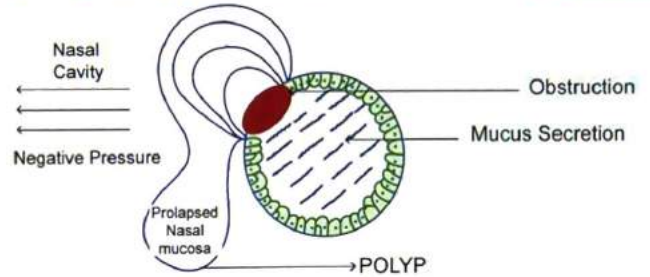
NASAL OBSTRUCTION

00:05:58

- Ac polyp - Unilateral obstruction
- Ethmoidal polyp - Bilateral Obstruction

PATHOPHYSIOLOGY OF A POLYP

00:07:25



- Chronic inflammation → Chronic hypertrophy
 - Allergy
 - Infection
- Prolapsed sinus mucosa due to negative pressure in Nasal cavity.
- No Nerve Supply, No Blood supply
 - No bleeding or pain on touch
 - Pale & Glistening polyps
 - IOC → NCCT of Nose & PNS

Treatment

00:12:52

- Polypectomy
- FESS (TOC)
- IOC : NCCT scan.

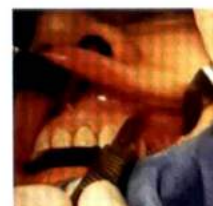

Previous Year's Questions

- Q. Most common site of obstruction by a Nasal Polyp of Maxillary sinus? (FMGE Aug 2020)
- Inferior Meatus
 - Middle meatus
 - Superior Meatus
 - Sphenoethmoidal Recess

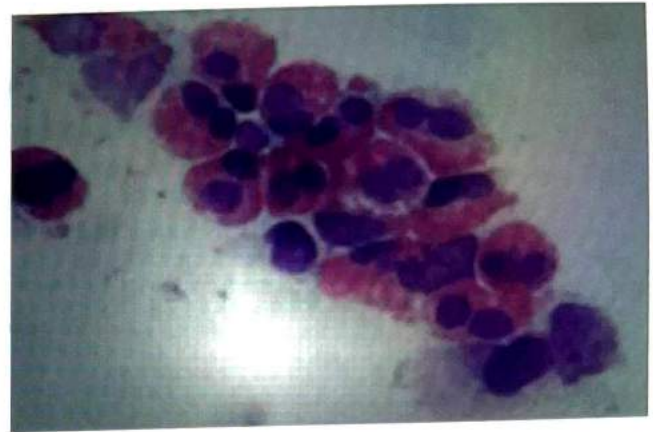
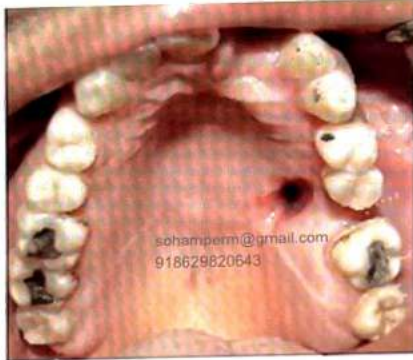CADWELL LUC'S OPERATION

00:17:11



- Sublabial incision- break the ant.wall of maxilla
- Done for AC polyp earlier (recurrent)
- With Killian's polypectomy forceps
- Complication
 - Oroantral fistula - fistula between oral cavity and maxillary antrum

Oroantral Fistula



Allergic fungal rhinosinusitis

- Multiple nasal polyps
- U/L

Chronic Nasal polyps Syndrome associated:

SAMTER'S TRIAD (ASA TRIAD)

🕒 00:21:45

- Aspirin (NSAID) sensitivity
- Sino nasal polyps
- Asthma

KARTAGENER SYNDROME

🕒 00:22:25

- Situs inversus with dextrocardia
- Bronchiectasis
- Chronic Rhinosinusitis

YOUNG SYNDROME

🕒 00:22:28

- Bronchiectasis
- Azoospermia
- Chronic Rhinosinusitis

CHURG STRAUSS SYNDROME / EGPA

🕒 00:23:22

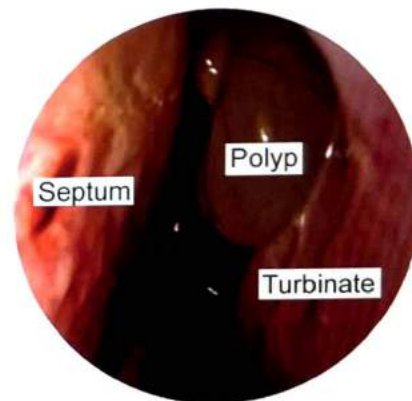
- Systemic vasculitis, peripheral eosinophilia
- Late onset asthma

Symptoms of EGPA

NARES

- Non-allergic patient
- Associates with Nasal Polyp

Allergic Fungal Rhinosinusitis

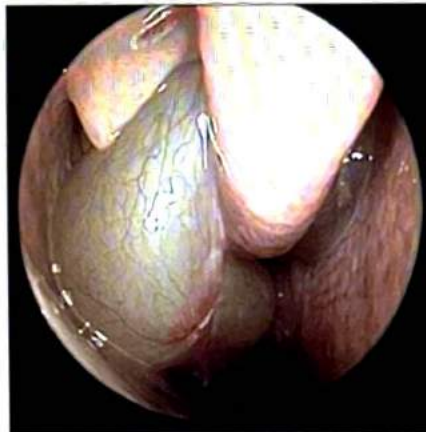



CLINICAL QUESTIONS



Q. A 40yr old patient with recurrent sneezing episodes and nasal discharge came to OPD. On Endoscopic examination, following finding is seen. All of the following may be associated with this condition except:



- A. Aspirin Intolerance
- B. Sarcoidosis
- C. Young's syndrome
- D. Nonallergic rhinitis with eosinophilia syndrome

Answer: B

Solution

- This is a case of multiple nasal polyps filling nasal cavity.
- **MOST PROBABLE DIAGNOSIS IS ETHMOIDAL POLYPOSIS**
- All of the following conditions may be associated with etiology of ETHMOIDAL POLYPOSIS:
 - Allergic rhinosinusitis
 - **Nonallergic rhinitis with eosinophilia syndrome (NARES)** is a form of chronic rhinitis associated with polyps.
 - **Samter's triad** consists of nasal polyps, asthma and aspirin intolerance.
 - **Cystic fibrosis**: Twenty per cent of patients with cystic fibrosis form polyps. It is due to abnormal mucus.
 - **Allergic fungal sinusitis**: Almost all cases of fungal sinusitis form nasal polyps.
 - **Kartagener syndrome**: Consists of bronchiectasis, sinusitis, situs inversus and ciliary dyskinesia.
 - **Young syndrome**: It consists of sinopulmonary disease and azoospermia.
 - **Churg–Strauss syndrome**: Consists of asthma, fever, eosinophilia, vasculitis and granuloma.
 - **Nasal mastocytosis**: It is a form of chronic rhinitis in which nasal mucosa is infiltrated with mast cells but few eosinophils. Skin tests for allergy and IgE levels are normal.
- Sarcoidosis is not related to Nasal Polyposis



31

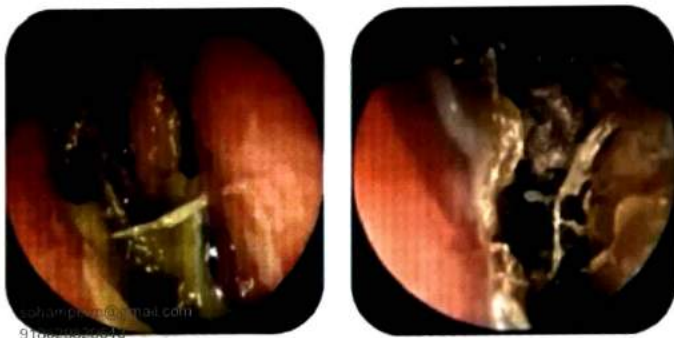
NASAL DISORDERS OF ATROPHY

ATROPHIC RHINOSINUSITIS (OZAENA)

00:00:24

- Causative organism: klebsiella ozaena/Perez bacillus
- Young females (20-30yrs of age)
- low socioeconomic status.
 - Iron deficiency
 - Multivitamin def mainly vit D deficiency.
 - Poor hygiene
 - Hormonal/Hereditary causes
- Pseudostratified ciliated columnar epithelium (thick) is replaced by stratified squamous epithelium(thin)
 - So, Air flow increases.
 - Decrease mucous production
→ Leads to dryness which forms Crust
- M.C complaint – B/L Nasal obstruction (crust formed)
 - Foul smell
 - **Anosmia (merciful Anosmia)**
- O/E
 - Larger roomy cavity foul smelling crusts.

Atrophic Rhinosinusitis/ Ozaena



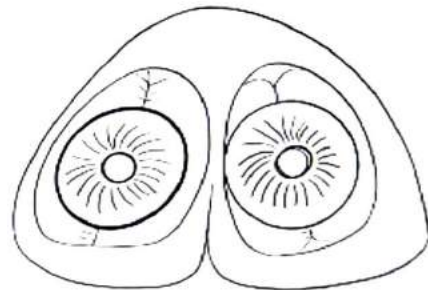
- The only way is to stop the AIRFLOW by Young's Operation.

YOUNG'S OPERATION

00:13:37

- Alternative closure of each nasal cavity for 6 months
- **Modified Young's operation** - close the both nasal cavity by leaving small part. (2-3mm)-partial closure

Modified Young Operation



Previous Year's Questions

Q. Young's operation is done in:

(JIPMER- Nov- 2017)
(FMGE- DEC- 2017)
(FMGE- JUNE- 2018)

- A. Rhinophyma
- B. Atrophic rhinitis
- C. Rhinitis sicca
- D. Hypertrophic rhinitis

TREATMENT OF ATROPIC RHINITIS:

00:07:09

- Alkaline nasal douching (NaCl+NaHCO₃+ Na baborate)
- 25% glucose (nourishment) in glycerin (hygroscopic)
- Antibiotics
- Iron & vitamin D supplements
- Estrogen spray
- After giving all the medical Rx, yet patient is not responding. Because the patient already undergone Vicious cycle.



Previous Year's Questions

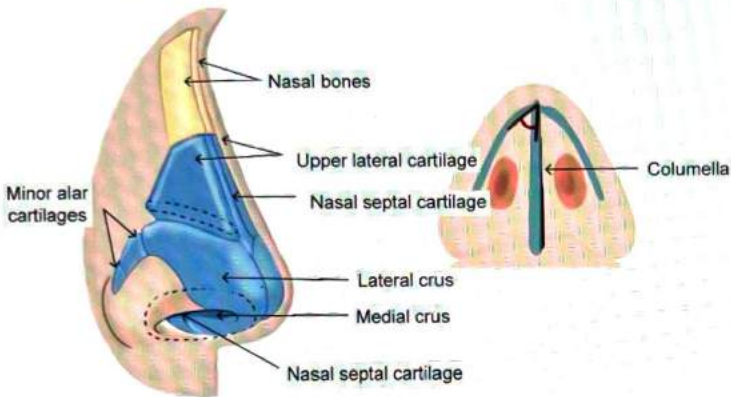
Q. Partial Closure of nose is done in which condition:
(NEET PG- Jan- 2020)

- A. Allergic rhinitis
- B. Atropic rhinitis
- C. Vasomotor rhinitis
- D. Occupational rhinitis

TEFLON INJECTION

00:16:03

In internal nasal valve- 50% of Nasal Airway Resistance



RHINOSCLEROMA/ RESPIRATORY SCLEROMA

00:17:57

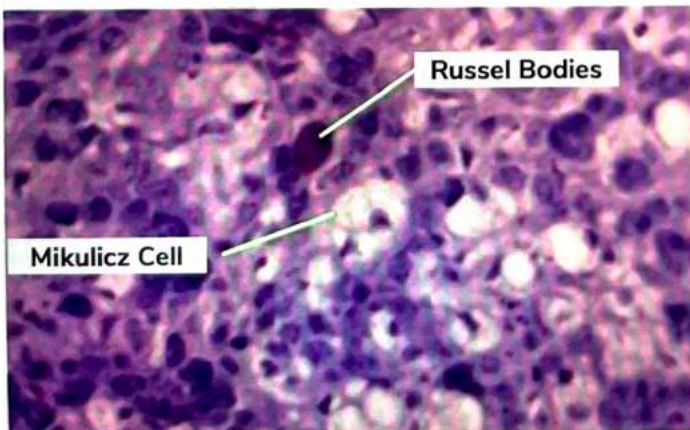
- Caused by klebsiella Rhinoscleromatic / Frisch Bacillus
 - Stage of atrophy
 - Stage of granuloma formation (Patient have Nasal obstruction)
 - Biopsy + HPE for confirmation (IOC)
 - Mikulicz cells & Russell bodies are seen
 - Stage of sclerosis / fibrosis/ cicatrization
 - AKA woody nose/Hebra nose/ Tapir nose
 - Seen in stage 3



Important Information

- Woody induration initially seen in Stage 2.

Mikulicz Cell and Russel Bodies



Previous Year's Questions

- Q. Mikulicz cells and Russell bodies are seen in:
(FMGE Jun 2018)
- Rhinoscleroma
 - Rhinosporidiosis
 - Rhinophyma
 - Rhinitis

TREATMENT

00:23:34

- DOC → Rifampicin
- Rx OC → Laser excision + Base electrocautery



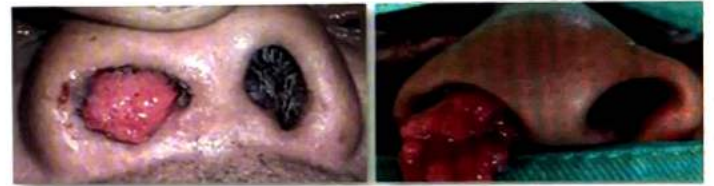Important Information

- Rhinoscleroma → Disease of Respiratory epithelium
New Name → Respiratory Scleroma

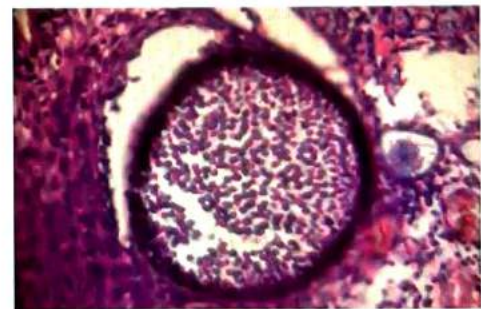
RHINOSPORIDIOSIS/STRAWBERRY GRANULOMA

00:25:43

Rhinosporidiosis



- Caused by Rhinosporidium seeberi
 - Aquatic protozoa
 - Affects only mucosal surfaces
- Seen in southern-Eastern coast of India, Sri-Lanka, Bangladesh.
- Rural population, pond bathing-cause infection from animals
 - Humans accidental host
- Red leafy fragile granuloma- AKA strawberry granuloma
- Nasal obstruction present
- Confirmatory tests - Bx + HPE
 - Multiple thick-walled sporangia



TREATMENT:

00:32:05

- DOC → Dapsone Amphotericin-B
- TOC → Laser excision Base electrocautery

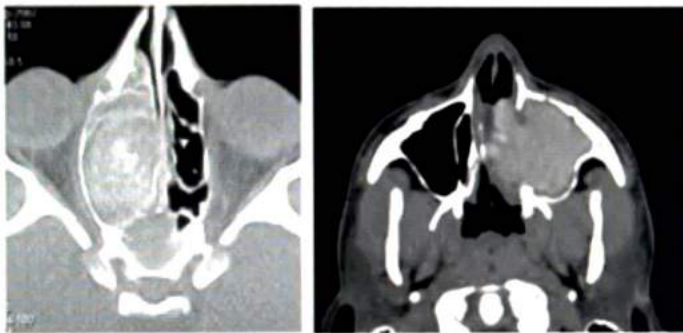


32 FUNGAL RHINOSINUSITIS

FUNGAL BALL / MYCETOMA

00:00:24

- M/C : Aspergillus fumigatus
- Also known as Aspergilloma
- Immuno competent patients; No mucosal sensitivity
- No invasion by fungus, No reaction from nasal mucosa, keeps on growing
- Rx
 - Evacuation by FESS
 - No role of Antifungal

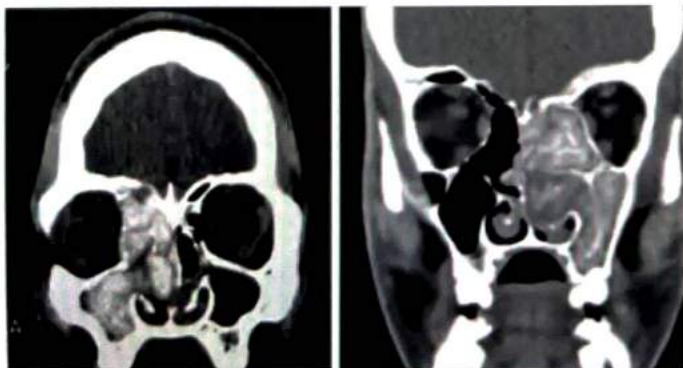


Aspergilloma

ALLERGIC FUNGAL RHINOSINUSITIS (AFRS)

00:05:28

- Type 1 hypersensitivity
- M/C causative organism: Bipolaris
 - Others: Curvilaria , Aspergillus Fumigatus
- Criteria: Bent & Kuhn Diagnostic criteria



BENT AND KUHN DIAGNOSTIC CRITERIA

00:08:45

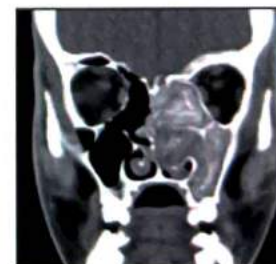Major	Minor
<ul style="list-style-type: none"> • Type I hypersensitivity • Nasal polyposis • Characteristic CT findings • Eosinophilic mucin without invasion • Positive fungal stain 	<ul style="list-style-type: none"> • Asthma • Unilateral disease • Bone erosion • Fungal cultures • Charcot-leyden crystal • Serum eosinophilia

- CT findings: U/L generally, but can be B/L
 - Bone erosion w/o invasion
 - Hyper densities [due to Ca²⁺ deposition in dense fungal hyphae.]
- Type 1 Hyper Sensitivity: Allergic mucin release
- Patient is immunocompetent
- Multiple nasal polyps, No invasion
- Positive fungal stain
- Characteristic of CT scan – Double dense appearance
- Rx
 - FESS & removal of fungus
 - Steroids oral → short course & prolonged nasal steroids
 - Immunotherapy



Previous Year's Questions

Q. A patient come to ENT OPD with following CT findings. He is on treatment for Allergic rhinitis. On examination of nose, multiple polyps are visible in nasal cavity. What would you name the appearance?
(NEET PG Jan 2019)



- Double dense
- Onion peel
- Ground glass
- Honey comb



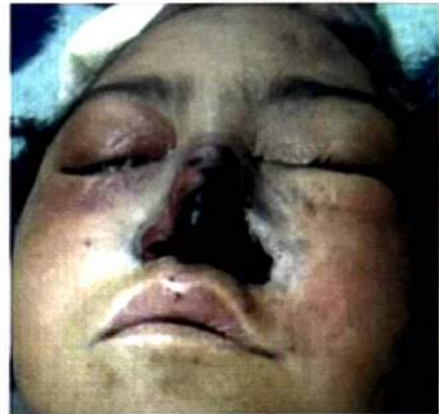Previous Year's Questions

Q. All of the following are major criteria for the diagnosis of allergic fungal sinusitis except?

(INI-CET July 2021)

- a. Nasal polyposis
- b. Characteristic CT finding
- c. Positive fungal culture
- d. Allergic mucin discharge

Rhinocerebral Mucormycosis



RHINO CEREBRAL MUCORMYCOSIS

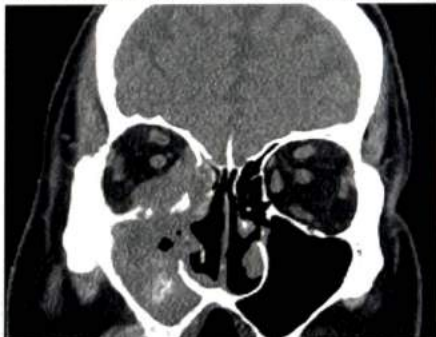
🕒 00:19:59

- Mucor/Rhizopus (Saprophytic fungus)
- Acute invasion fulminant fungal disease
- Immunocompromised patients – (Diabetic patients with uncontrolled sugar)
- Necrotizing vasculitis due to invasion of arteries.
 - Ophthalmic involvement → Sudden blindness
 - ICA involvement → Stroke

INVASIVE FUNGAL RHINOSINUSITIS (IFRS)

🕒 00:26:50

Invasive Fungal Rhinosinusitis (IFRS)



- DOC/TOC
 - Amphotericin – B
 - Surgical debridement
 - Diabetes control



Previous Year's Questions

Q. A 40yrs old uncontrolled diabetic Patient tested Covid-19 Positive few weeks back and presented with nasal congestion, black crusts in the nose and blackish discolouration of nasal bridge and cheek are. What could be the most likely cause?

(FMGE June 2021)

- A. Nasal Polyp
- B. Mucormycosis
- C. Allergic Sinusitis
- D. Atrophic Rhinitis



Previous Year's Questions

Q. A post Covid infection patient presented with Headache and black nasal discharge. What is the condition patient could be suffering from?

(FMGE June 2021)

- a) Aspergillosis
- b) Mucormycosis
- c) Coccidiosis
- d) Rhinosporidiosis



33

COMPLICATIONS OF SINUSITIS

INTRODUCTION:

🕒 00:00:20

3 types

- Local
- Orbital
- Intracranial complication

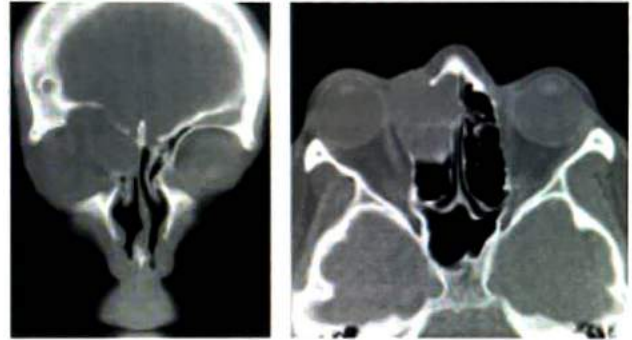
Local complication

🕒 00:00:58

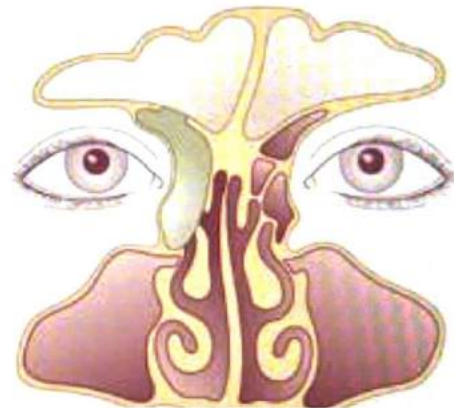1. Mucocele / Pyocele

- Painless swelling / extension of sinus in which bone becomes papery thin
- M/C sinus affected: frontal
- Pushes the eye ball downward, lateral.
- **Diagnosis:** Earlier, Xray PNS: loss of scalloping in frontal sinus

NCCT Scan: PNS

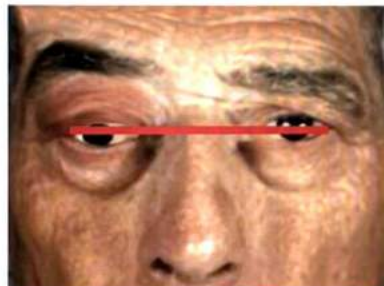
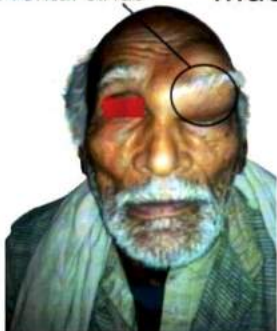
Treatment: Endoscopic Drainage



Frontal sinus

Mucocele/ Pyocele



RxOC: Endoscopic drainage

- k/a draft procedure in case frontal

3 types of Draft procedures:

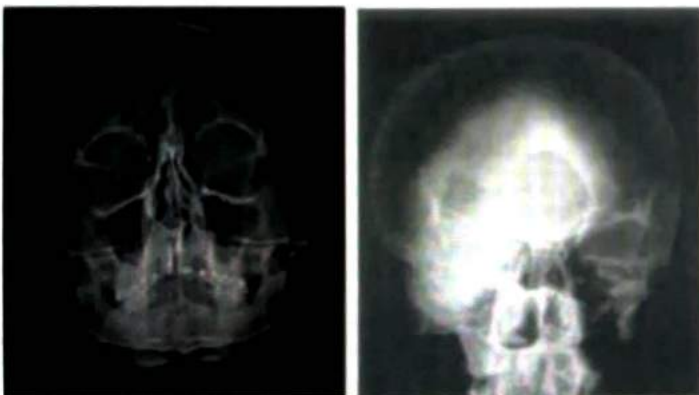
- Draft 1: Opening made in floor of frontal sinus
- Draft 2: Opening by drilling of medial to lateral wall
- Draft 3: Modified Lothrop's procedure: Draft 2 on both sides + removal of inter sinus septum modified lothrop's procedure

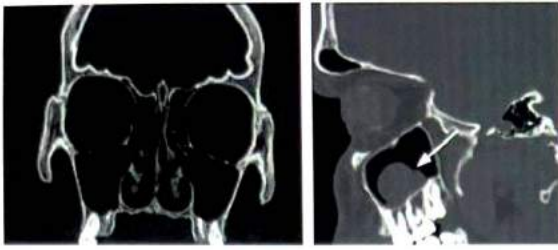
2. Mucous retention cyst

- Incidental finding
- Aries from floor of maxillary sinus
- Asymptomatic patient: do not require Rx

🕒 00:06:51

Xray PNS: loss of scalloping





Rx:

- Drainage of abscess along removal of sequestrum of bone + high dose of antibiotics



Important Information

D/D

- Mucous retention cyst convex surface whereas maxillary sinusitis has concave surfaces



Previous Year's Questions

Q. Potts puffy tumor is: (NEET PG Jan 2019)

- Osteomyelitis of ethmoid bone
- Osteomyelitis of frontal bone
- Allergic fungal sinusitis
- Sinusitis of dental origin

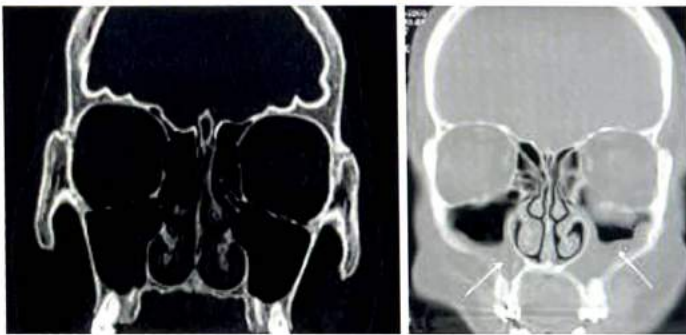


Previous Year's Questions

Q. Potts puffy tumor is: (DNB Jun 2018)

- Frontal mucocele
- Subperiosteal Abscess of Frontal Sinus
- Frontal Sinus Osteomyelitis
- Extradural Abscess between Frontal Sinus and Dura

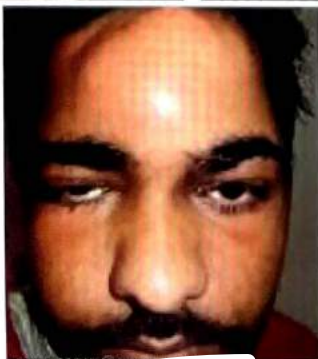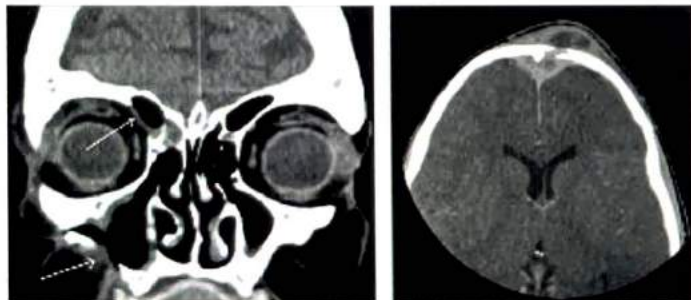
Mucous Retention Cyst Vs Sinusitis



3. Osteomyelitis

00:08:27

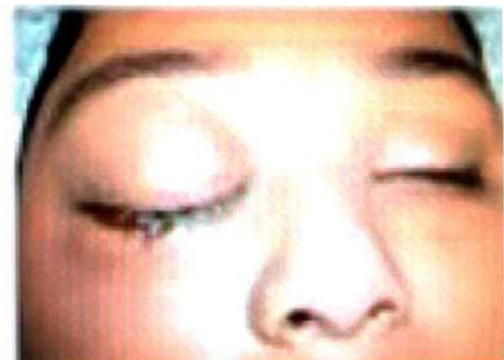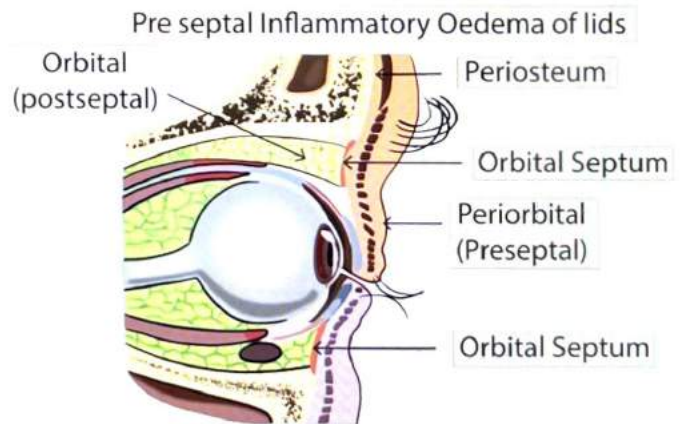
- Bone infection
- M/C bone involved
 - Frontal bone in adults
 - Maxillary sinusitis in children
- Pott's puffy tumour: subperiosteal abscess



ORBITAL COMPLICATIONS

00:12:13

Pre-septal inflammatory oedema of lids



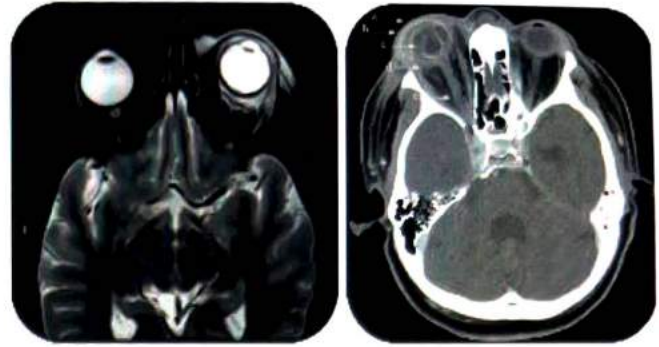
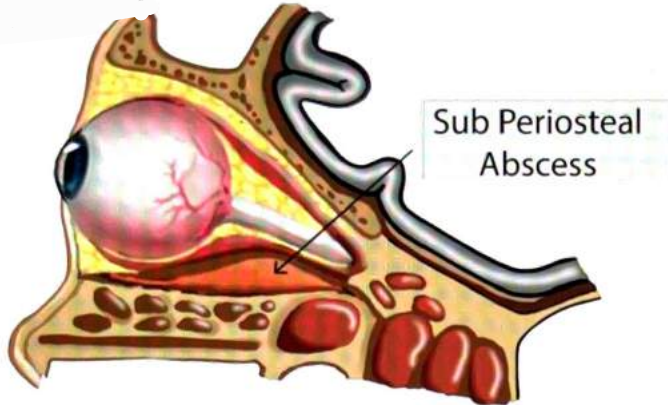
- Reactionary oedema of eyelids

SUBPERIOSTEAL ABSCESS

00:13:17

- Sometimes infection proceeds to subperiosteal abscess
- M/c involved sinus is ethmoid sinus as it is separated from orbital by very thin bone k/a lamina papyracea

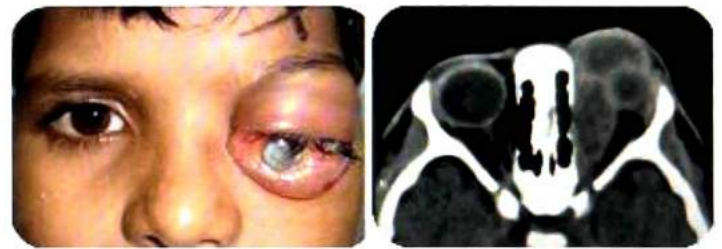Subperiosteal Abscess



Retro-orbital abscess :

- It has mass effect is orbit
- Proptosis is very severe
- Need immediate drainage of abscess to save the eye

Orbital Abscess

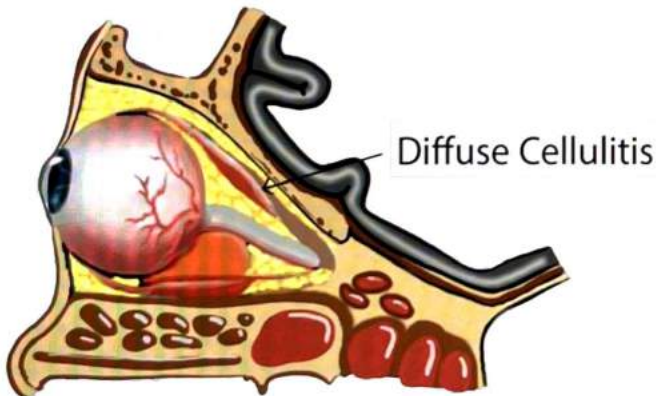

ORBITAL CELLULITIS

00:14:46

- Inflammation involved intra-orbital tissues

Orbital Cellulitis

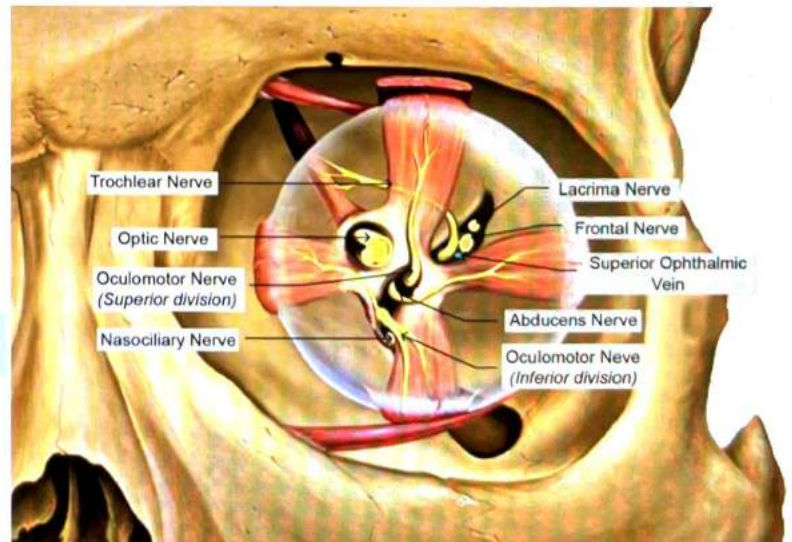


IMPORTANT SYNDROMES

00:18:52

Superior orbital fissure syndrome/ Rochon-duvigneaud syndrome

- Involvement of 3rd, 4th, 6th, V1 nerve give rise to Superior orbital fissure syndrome



Orbital apex syndrome/ Jacod syndrome

- Optic nerve involvement is main differentiator of Jacod syndrome and superior orbital fissure syndrome

Intracranial complication

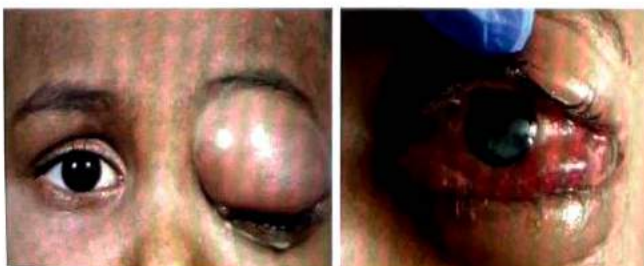1. 1st complication- Meningitis

Subperiosteal abscess

- Less proptosis
- Movement is not restricted

Orbital cellulitis

- More proptosis
- Movement of eye will be more restricted



2. Extradural Abscess

3. Subdural abscess

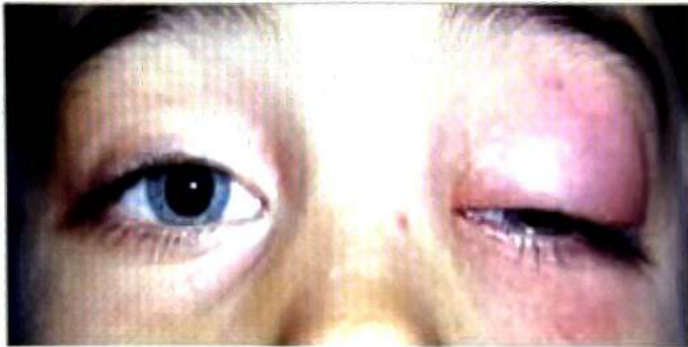4. Brain abscess

- Abscess formed inside the brain tissue

5. Cavernous sinus thrombosis

- Peri-orbital odema
- Caput medusae
- Lateral rectus palsy

Cavernous Sinus Thrombosis



Ocular Manifestations of CST

Signs	Involved structures
Ptosis	CN III, sympathetic plexus, Edema of Upper Eyelid
Chemosis	Thrombosis of superior and inferior ophthalmic vein
Proptosis	Venous Engorgement
Sensory loss/ periorbital pain	CN V
Lateral Rectus palsy	CN VI (1 st CN to get involved)
Ophthalmoplegia	CN III, IV, VI



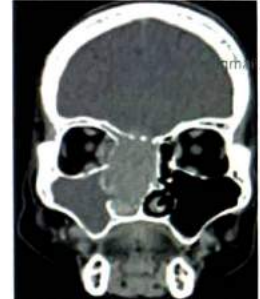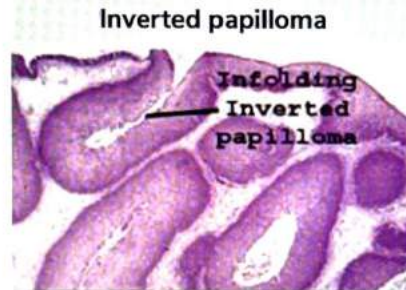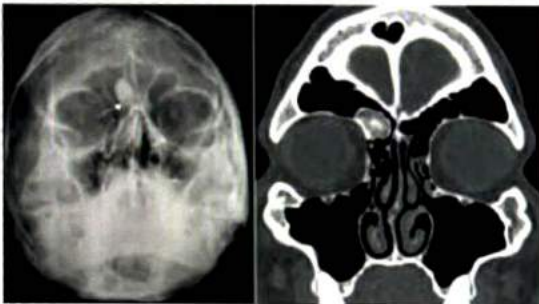
34 TUMORS OF NOSE AND PARANASALSINUS

Osteoma

00:00:46

- Mc benign tumour of PNS
- Mc site is frontal sinus > Ethmoidal sinus
- Patients present with Office headache
- Rx: is endoscopic excision

Osteoma

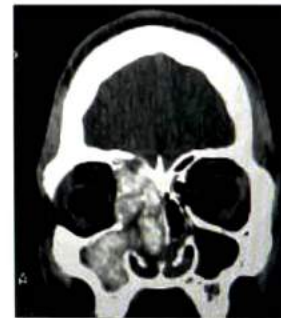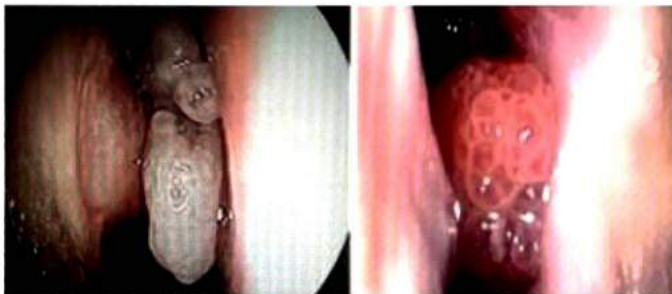


Allergic fungal Rhinosinusitis (AFRS) 00:13:57

- MC malignancy of PNS& Nasal Cavity : Squamous Cell Carcinoma
- MC location : Maxillary Sinus
- Squamous cell CA on the Nose Septum is known as Nose Picker's Tumor

Inverted Papilloma/ Ringertz Tumor 00:03:02

- Mc Benign tumour of Nasal Cavity
- Seen in Males with 50-60years age group
- Presents with U/L Nasal Obstruction with mild epistaxis.
- Arises from Schneiderian Membrane on lateral wall of nose in middle meatus / maxillary sinus area.
 - It consists of Transitional cell epithelium



Important Information

- Wood industry - Adenocarcinoma
- Nickel industry - Squamous cell carcinoma

- Diagnosis: Biopsy
- CECT scan is done to find the extent of the papilloma
 - Hyperdense/ homogenous
- Rx: Transnasal endoscopic excision
- It has a high rate of recurrence
 - Recurrence rate is depend on type of surgery
 - If Sx done in the Nasal Cavity, recurrence is 60%
 - If Total Maxillectomy is done, 2-3% of recurrence
- Papilloma may also undergo into Squamous cell CA.
- More the recurrence more the chances the of Sq.cell carcinoma

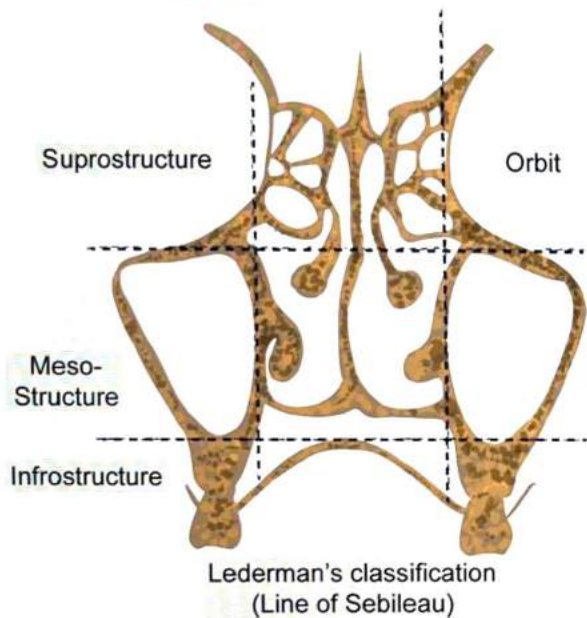
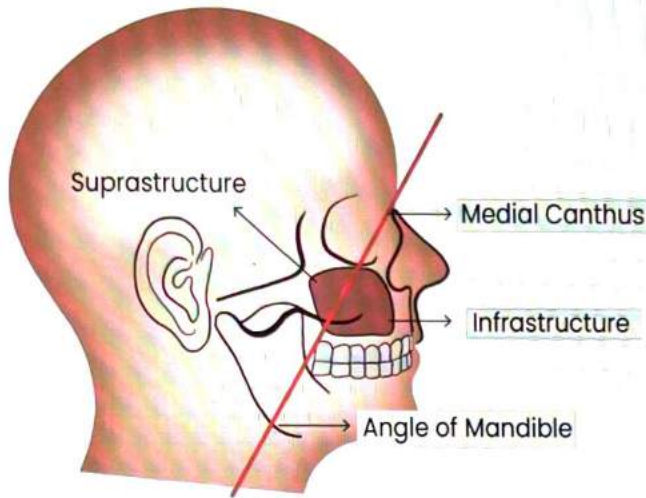
Ohngren's Line: 00:16:15

- From medial canthus to angle of mandible dividing it into supra and infrastructure
 - Supra structure malignancy: poor prognosis
 - Infrastructure malignancy: Good prognosis

Lederman's classification: 00:17:47

- Uses two lines called lines of Sibileau
 - 1st line passes through the roof of Maxillary sinus
 - 2nd line passes through the Floor
- which divides it into 3 parts
 - Supra structure: Poor Prognosis

- o Meso Structure
- o Infra-structure: Good Prognosis

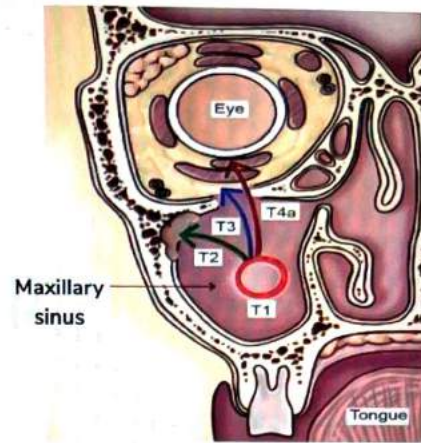


• **TNM Classification**

- o **T₁**: Involvement of Maxillary Sinus mucosa
- o **T₂**: Involvement of Bone except superior wall of maxillary Sinus
- o **T₃**: Involves the posteriosuperior wall or ethmoidal air cells or into subcutaneous tissue
- o **T_{4a}**: Involves the eye ball, orbit, skin
- o **T_{4b}**: Enter cranial cavity

• **Rx**

- o Surgery + Radiotherapy stage
- o T1 - surgery only
- o T2 - Partial Maxillectomy
- o T3 - Total Maxillectomy + Radiotherapy
- o T4 a - Extended Maxillectomy + radiotherapy.
- o T4 b - Palliative therapy



TNM



Previous Year's Questions

Q. MC malignancy of Maxillary Antrum?

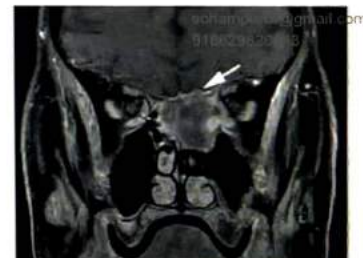(FMGE JUN 2018)

- Muco-epidermoid Carcinoma
- Adeno-cystic Carcinoma
- Adenocarcinoma
- Squamous cell Carcinoma

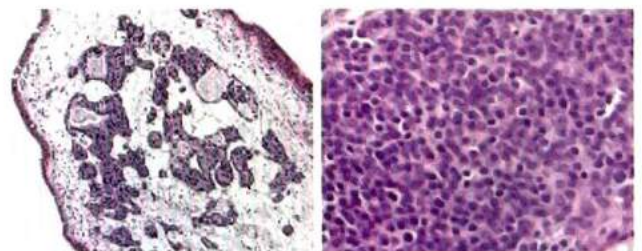
Esthesio-Neuroblastoma:

00:27:04

Esthesio-Neuroblastoma



- AKA Olfactory Neuroblastoma
- It arises from the olfactory neuro-epithelium in the roof of nasal cavity.
- Patients presents with U/L nasal obstruction
- O/E: mass from the Anterior cranial fossa
- Diagnosis: MRI and the HPE
- Rx: Endonasal Endoscopic Sinus Surgery.

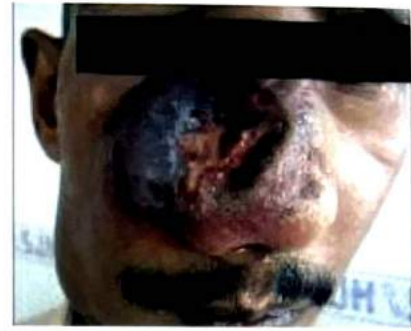

Neurofibrillary stroma and neurosecretory granules

Midline Lethal Granuloma

🕒 00:31:18

- AKA Stewart's Granuloma
- It is rapidly progressing Midline destructive lesion
- It is T cell or NK cell Lymphoma
- Diagnosis by HPE/IHC
- Rx - chemotherapy





35 MISCELLANEOUS

NASAL MYIASIS

00:00:24

- Maggots in Nose
- Causative: Chrysomya fly larvae
- Tx: 10 % chloroform → (To anaesthetize maggots)

↓
Removal

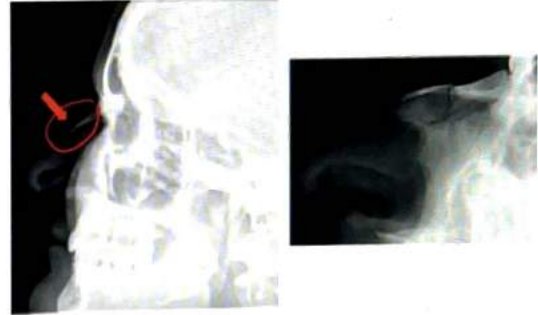
FOREIGN BODY NOSE

00:01:36

- MC seen in children
- U/L mucopurulent discharge or blood-stained discharge in child
- Investigation
 - Endoscopy (For confirmation)
 - X-Ray
- Rhinolith formation due to calcification [stone in nose]
- Rx: Removal a probe / eustachian tube catheter

- C/F
 - Cosmetic deformity(External)
 - Nasal obstruction(Functional)

Nasal Bone #



Rx

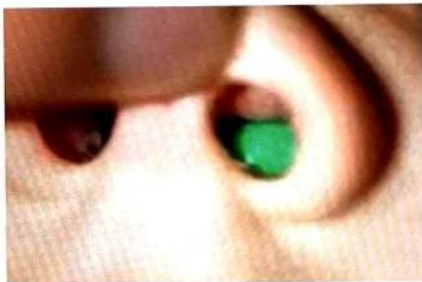- If only cosmetic deformity - always give option to the patient for further management.
- Best treatment-Closed reduction with external fixation
 - Time in 24 hours (Before onset of edema)
 - By using Asch and Walsham forceps
 - Is followed by External Nasal Splint
 - Closed Reduction is done immediately (<24hrs) before the development of edema
 - After 5-7 days (After reduction of edema)
 - Not done between 2 weeks – 3 weeks (Callus is formed)
 - If patient present after 3 weeks then Complete rhinoplasty after 3Months (Complete bone is formed)



Important Information

Posterior fb: Endoscopic removal under general anesthesia

Foreign Body Nose



Button Battery

00:03:39

- These batteries are Alkaline in nature which cause liquefactive necrosis.
- Removing As soon as possible.

NASAL BONE FRACTURE

00:05:57

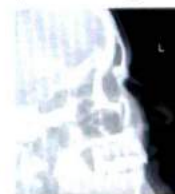
- MC facial bone to undergo fracture: Nasal Bone
- 2 types:
 - Open book deformity
 - Closed book deformity
- Give rise to angulated Nose or Depressed



Previous Year's Questions

Q. A boy fell down while playing and presents with deviated nose. The septum however was found to be normal. Following is the X-ray findings of the patient. What is the next step in management?

(FMGE Aug 2020)

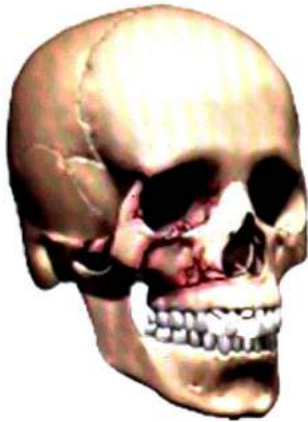

- Septo-rhinoplasty
- Open reduction
- Closed reduction after edema subsides in 7 days
- Closed reduction and swelling will decrease automatically

ZYGOMATIC BONE FRACTURE / TRIPOD FRACTURE

00:17:32

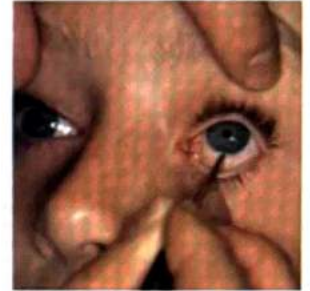
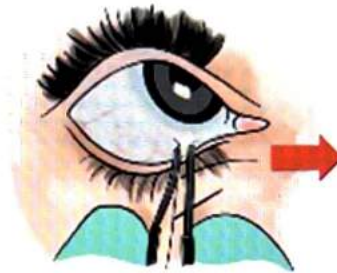
Zygomatic Bone



- 2nd MC facial bone fracture
- Now known as Quadripod fracture
- Malar prominence is lost
- Step deformity on palpation
- Rx: Open Reduction & Internal Fixation



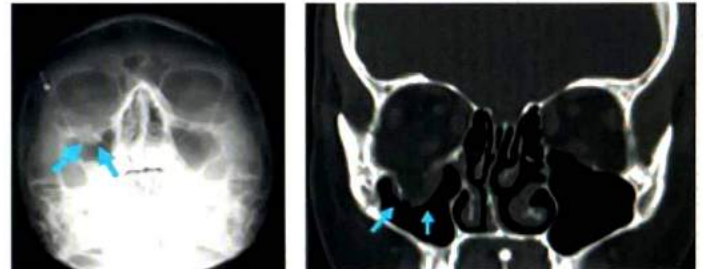
Forced Duction Test



Important Information

- Orbit hangs in the maxillary antrum
 - Tear drop sign

Blow out Fracture



BLOWOUT FRACTURE OF THE ORBIT

00:21:14

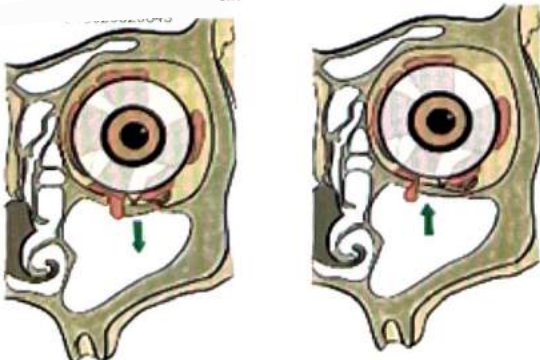
- Blunt injury to the eyeball
- Weakest wall of orbit: Floor
- Thinnest: Medial wall / Lamina papyracea

Inferior Rectus Muscle entrapment

00:23:07

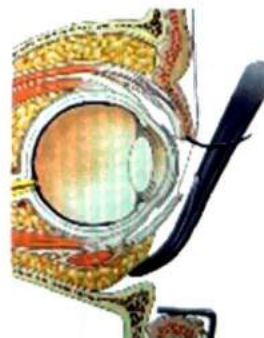- Diplopia due to Inferior Rectus intrapment
- There is entrapment of Inferior rectus muscle so Patient not able to look up confirmed it by forced duction test.

Inferior Rectus Muscle Entrapment

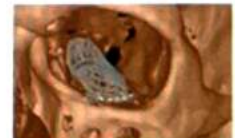

- Rx: Mesh application & reduction

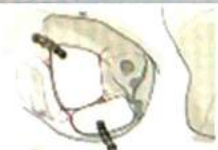
Treatment : Repair of Orbital Floor



Subperiosteal Dissection



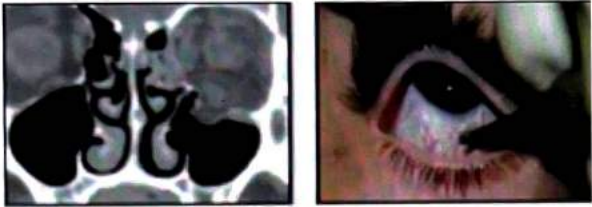
Pre Formed Orbital Implant



Bone Graft

? Previous Year's Questions

Q. A patient presented after RTA with left sided epistaxis & diplopia. On performing CT scan following finding is noted. What would be the cause for Diplopia? (NEET PG JAN 2019)



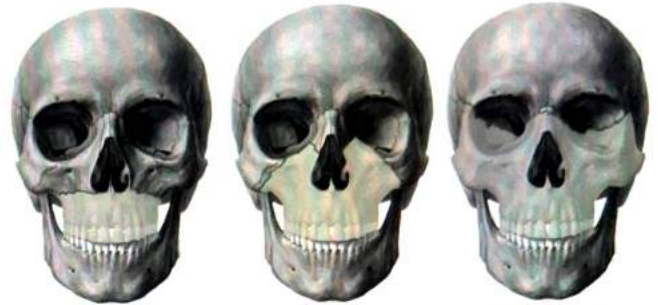- a) Fracture zygoma
- b) Blow out fracture
- c) Lefort fracture
- d) Fracture ethmoid bone

FRACTURE OF MAXILLARY (LE FORT #)

🕒 00:27:27

- **Le fort 1 # / Transverse #**
 - Line parallel to hard palate
 - Floating palate
- **Le fort 2 # / Pyramidal #**
 - Floating maxilla
- **Le fort 3 # / cranio facial dysfunction**
 - Most dangerous associated with maximum morbidity
 - Lower part forms Pigs snout Deformity

- Treatment of Lefort Fracture is open reduction internal fixation
- Both Le fort 2 and 3 can have CSF Rhinorrhoea



Le Fort I

Le Fort II

Le Fort III

? Previous Year's Questions

Q. A 40yrs old uncontrolled diabetic Patient tested Covid-19 Positive few weeks back and presented with nasal congestion, black crusts in the nose and blackish discolouration of nasal bridge and cheek are. What could be the most likely cause? (FMGE June 2021)

- A. Nasal Polyp
- B. Mucormycosis
- C. Allergic Sinusitis
- D. Atrophic Rhinitis



CLINICAL QUESTIONS



Q. 28 years old male came to the emergency department with an alleged history of a road traffic accident and sustained injury over the face. CT- scan revealed maxilla bone fracture. Which of the following is the most common nerve to be injured?

- A. Infraorbital nerve
- B. Trochlear nerve
- C. Mandibular nerve
- D. Supraorbital nerve

Answer: A

Solution

- **Clinical Features of maxillary fractures:**

- Ecchymosis of lid, conjunctiva and sclera
- Enophthalmos with inferior displacement of the eyeball or entrapment of inferior rectus and inferior oblique muscles.
- Hypoaesthesia or anesthesia of cheek and upper lip, if infraorbital nerve is involved

- **PRINCIPLES OF MANAGEMENT**

- **EMERGENCY TREATMENT:**

- Midfacial fracture can severely compromise the airway with torrential epistaxis and posterior impaction of the maxilla.
- The bleeding can be arrested by using epistats or anterior and posterior nasal packs.

- **REDUCTION:** The maxilla is mobilized by a combination of digital pressure and traction on arch bars or interdental wires.

- **FIXATION:** Internal fixation with the mini plates.



36 CSF RHINORRHEA

CSF FLOW

00:00:34

Produced by Choroid plexus in lateral ventricle

↓ Foramen of Monro

Third ventricle

↓ Aqueduct of Sylvius

Fourth Ventricle

↓ Foramen of Luschka & Magendie

Subarachnoid space over the brain and spinal cord

↓

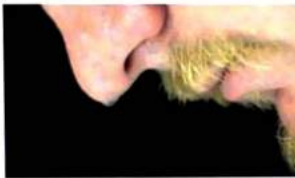Reabsorbed into venous sinus blood via arachnoid granulations

CSF RHINORRHEA

00:01:41

- M/C/C head injury (Trauma)
- M/c site fracture cribriform plate of ethmoid
- Clear, watery discharge from nose

CSF Rhinorrhea



- **Tea pot sign/Reservoir sign** : Increasing On coughing, sneezing, straining, bending forward

Character of discharge

Thin, clear, watery

Mucoid

Flow of discharge

Coughing, sneezing, straining, bending forward

Continuous

Sniff test

Negative

Positive

Glucose test

Positive (40-60 mg/dL)

Negative (<10mg/dL)

β2 transferrin (gold std)

Positive

Negative



Previous Year's Questions

Q. A male trauma patient admitted to hospital with watery discharge from nose. On investigation it showed damage in cribriform plate. What is the possible diagnosis?

(FMGE DEC2017)

- CSF Rhinorrhoea
- B. Vasomotor rhinitis
- Allergic rhinitis
- D. Atrophic rhinitis



Previous Year's Questions

Q. CSF Otorrhea is due to involvement/trauma of:

(FMGE Jun 2018)

- Cribriform plate of ethmoid bone
- Petrous temporal bone
- Parietal bone
- Tympanic membrane



Important Information

Reservoir sign:

- Nose - CSF Rhinorrhea
- Ear - Mastoiditis

DIFFERENCE BETWEEN CSF AND NASAL SECRETIONS:

00:04:48

FEATURES	CSF	Nasal Secretion
History	Surgery, Head injury, Intracranial tumor	Sneezing, nasal stuffiness, itching in the nose, Lacrimation



Important Information

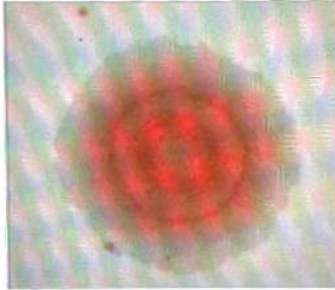
- **Paradoxical CSF Rhinorrhoea**
 - Fracture in temporal bone (Petrous part)
 - Can cause CSF Otorrhea also

HALO SIGN

00:12:21

- Mixed with blood, to differentiate between the CSF and Nasal secretions
- The secretion drop is put in the paper.
- CSF fluid will form a circular ring around the blood
- It is a onspot clinical test

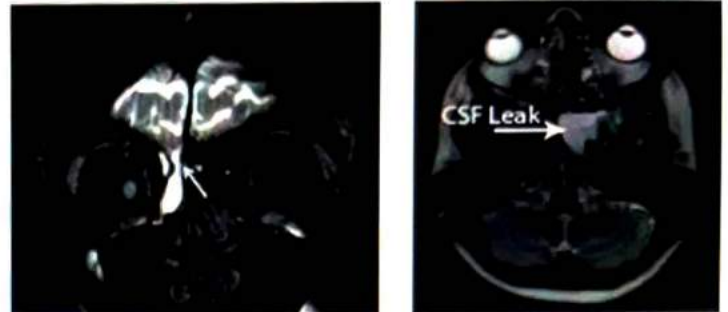
Halo Sign



MRI T2 WEIGHTED IMAGES (MR-CISTERNOGRAM)

00:20:51

MRI-T2 Weighted images (MR- Cisternography)

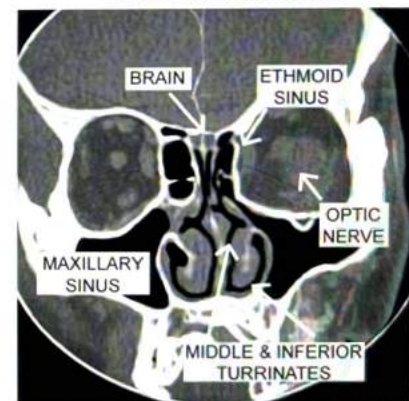


CT CISTERNOGRAM

00:22:46

- Most specific investigation: CT cisternography (can see both fracture and the CSF)
- Invasive procedure
- Pre-operative gold standard investigation.

CT Cisternogram



FLUORECEIN DYE INJECTION:

00:25:24

- Injected in the intra-Operative stage

Previous Year's Questions

Q. Target sign is seen in? (AIIMS Nov 2017)

- Spontaneous CSF Rhinorrhoea
- Traumatic CSF Rhinorrhoea
- Both
- None

Previous Year's Questions

Q. Gold standard investigation in CSF rhinorrhea?

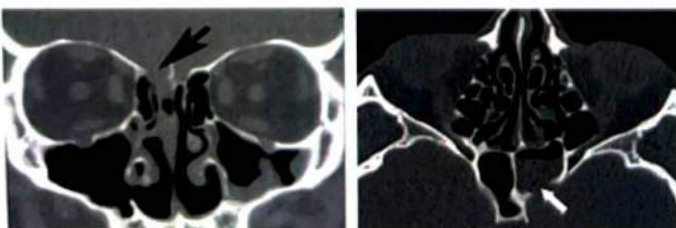
- $\beta 2$ transferrin levels (Not done because diagnose already done)
- HRCT of nose and PNS (To find site of leak) 1st inv. IOC
- MRI: T2 weighted images (Can't see both # the CSF at once)
- CT cisternography (Can see both #and the CSF)

HRCT NOSE AND PNS

00:18:27

- 1st investigation/IOC: HRCT of Nose & PNS (to find sites of leak)

HRCT Nose & PNS



Previous Year's Questions

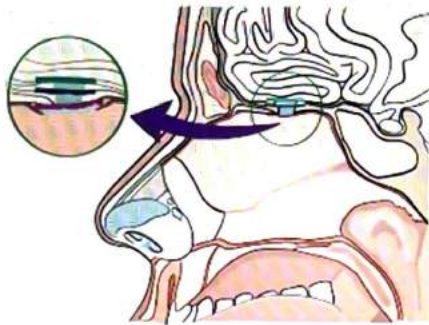
Q. 38 yrs old pt presented after RTA few hrs back with CSF Rhinorrhea. Next line of Mx:

- Conservative Mx [No active Surgical mid \rightarrow heal on itself]
- B/L Ant. nasal packing to stop CSF leak \rightarrow Nasal packing C/I
- Immediate endoscopic repair of Skull base
- Open neurosurgical Repair of skull base

TREATMENT OF CSF RHINORRHEA 00:27:41

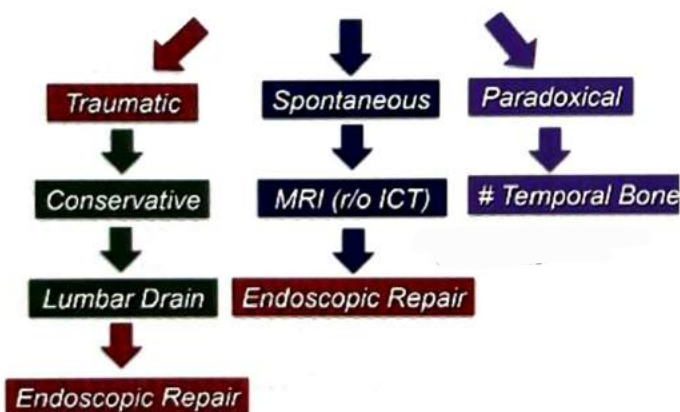
- Traumatic
 - Conservative Management - 7 days
 - No surgical intervention
 - Prophylactic Antibiotics / Acetazolamide
 - Stool softeners & bed rest
 - B/L anterior Nasal packing C/I (Causes meningitis)
 - No relief: Lumbar drain for 2 wks
 - No relief: Endoscopic repair

Endoscopic Repair



- Spontaneous CSF Rhinorrhea 00:34:16
 - No injury
 - Causes
 - Brain tumor – Do MRI for R/O cause of ICT
 - Repair (Endoscopic)
- Paradoxical CSF Rhinorrhoea
 - Fracture in temporal bone (Petrous part)
 - Can cause CSF Otorrhea also

Treatment of CSF Rhinorrhoea



ADVANCED APPLICATION OF ENDOSCOPIC SINUS SURGERY: 00:35:34

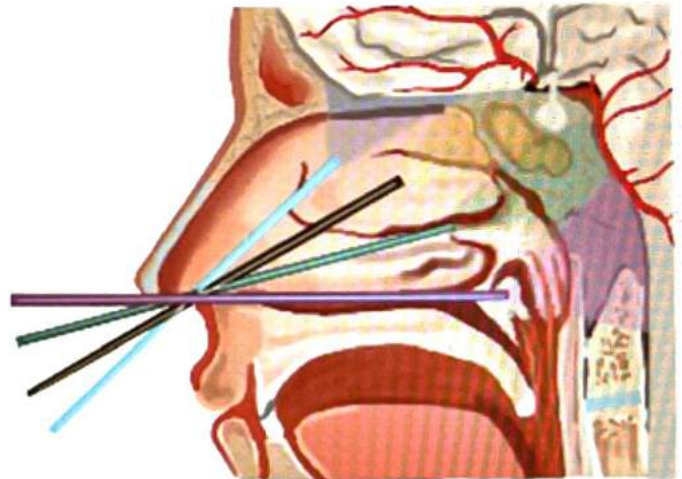
- Lacrimal sac and duct disorder: endoscopic DCR
- Orbital hematoma/ abscess
- Retro orbital tumors
- Optic nerve decompression surgeries
- C₁ and C₂ vertebral fracture
- Can operate in anterior cranial fossa, middle cranial fossa
- Pituitary gland tumor surgery



Important Information

- Posterior cranial fossa (cerebellum) cannot be approached with endoscope.

Advanced Applications of ESS





LEARNING OBJECTIVES

Pharynx

- ➔ Nasopharynx
- ➔ Oropharynx
- ➔ Hypopharynx

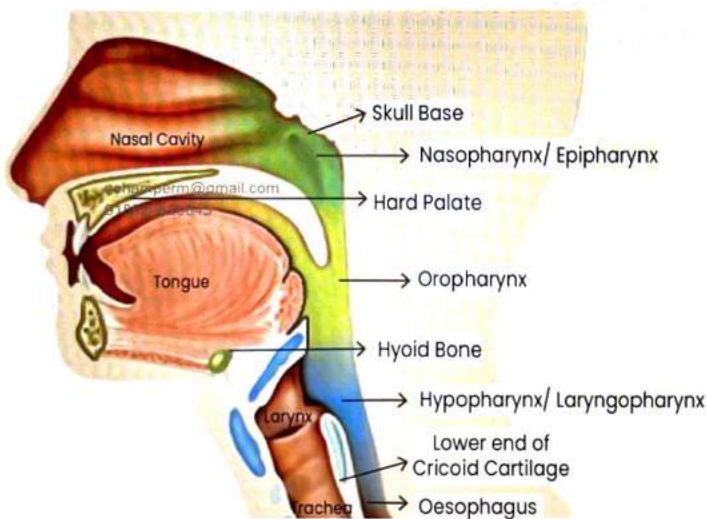


37 INTRODUCTION TO PHARYNX

Introduction:

🕒 00:00:13

- Pharynx is a cavity which starts behind the nose and goes up till the esophagus.
- It's a common passage for airways and food.
- The pharynx is located behind and around the larynx.



Boundaries of pharynx:

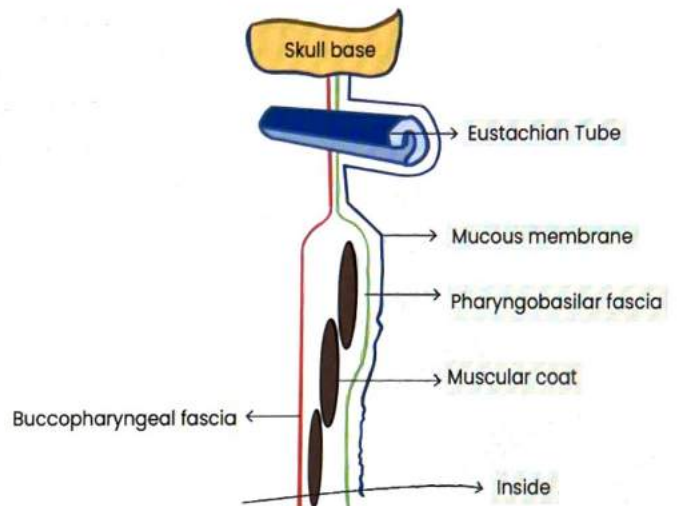
- Extends from skull base to lower end of cricoids cartilage
- Divide into 3 parts
 - Nasopharynx / epipharynx- From skull base to hard palate
 - Oropharynx - From hard palate to hyoid bone.
 - Hypopharynx/laryngopharynx – from hyoid bone to lower end of cricoid cartilage.

Layer's of pharyngeal wall

🕒 00:02:45

- Made up of 4 layers
 - Mucous membrane (Pseudo stratified ciliated columnar epithelium)
 - Pharyngo basilar fascia
 - Muscular coat
 - Buccopharyngeal fascia

LAYERS OF PHARYNGEAL WALL



Muscular coat

🕒 00:05:40

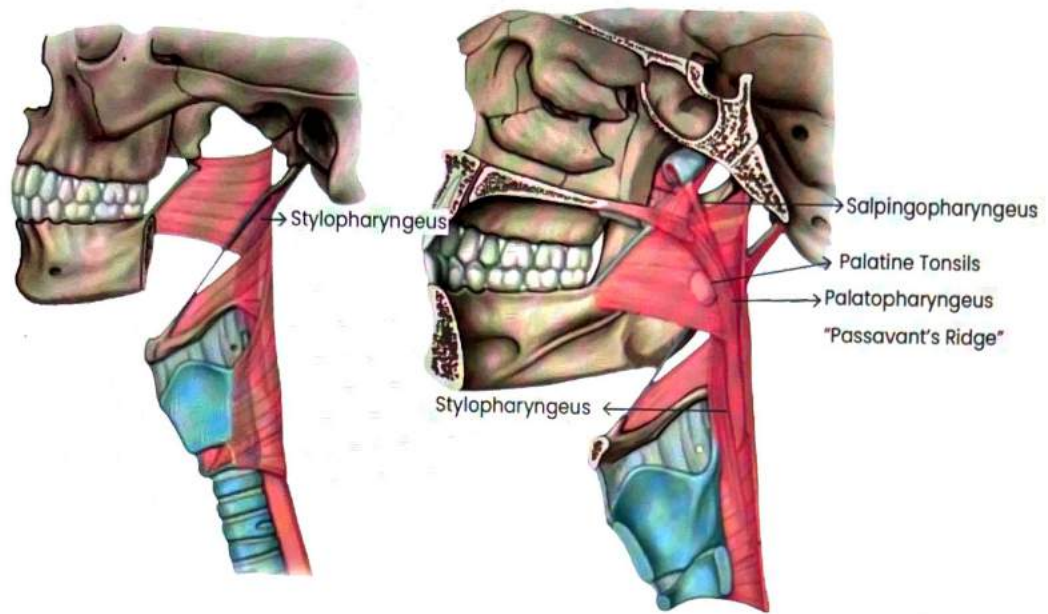
- The wall of pharynx is made up of muscles (constrictors)
 - Superior constrictor
 - Middle constrictor
 - Inferior constrictor

Outer layer
- All three muscles go around the pharynx and fuse with each other in the posterior midline at pharyngeal raphe
 - Stylopharyngeus muscle pierces the superior and middle constrictors to enter pharynx from deep layer with salpingopharynx and palatopharyngeus.
 - Palatopharyngeus forms a ridge- Passavant's ridge which prevents regurgitation, by closing nasopharynx
 - Superior constrictor muscles form the bed of palatine tonsils.
- Gap between the upper border of superior constrictor and skull base is k/a Sinus of Morgagni
- **Structures passing through sinus of Morgagni are**
 - Palatine Artery (Ascending)
 - Levator veli palatini
 - Eustachian tube
 - Ascending pharyngeal artery



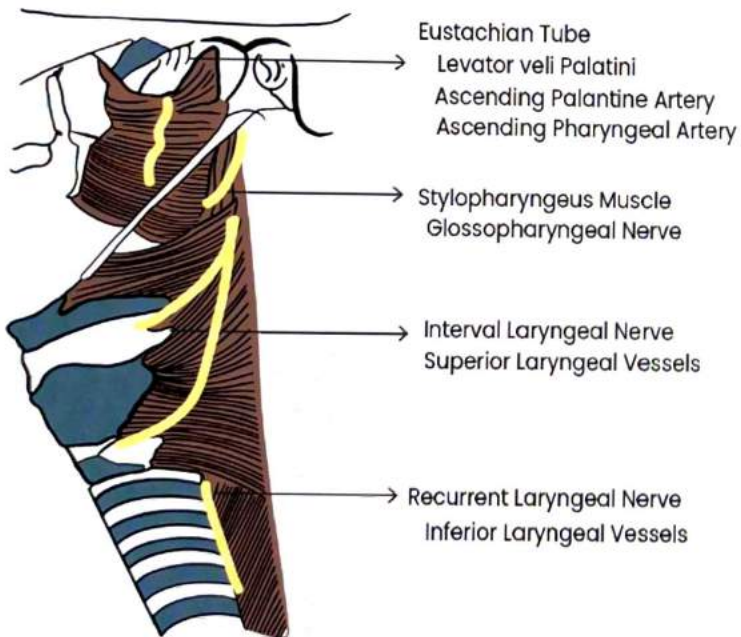
How to remember

PALATE



Structure passing through the Wall of Pharynx:

🕒 00:13:47



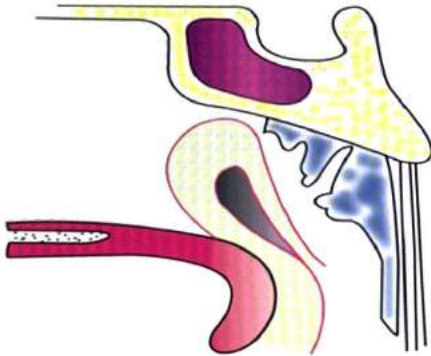


38 NASOPHARYNX

Introduction:

00:00:13

- Nasopharynx is also known as Epipharynx
- It lies behind the Nasal Cavity from the Skull Base to the Hard palate



Eustachian Tube Aka Pharyngo-Tympanic Tube

- Opens on lateral wall
- Connects Anterior wall of Middle ear to Nasopharynx
- Torus Tubarius: Cartilaginous Protrusions of Eustachian tube

Adenoids

- Lymphoid mass in the posterior-superior wall of Nasopharynx is k/a Adenoids
- Midline recess in the adenoid is k/a Nasopharyngeal bursa → denotes the place of attachment of notochord in the embryonic life
- Pharyngeal chordoma → M/c location is Nasopharyngeal bursa
- Blockage of Nasopharyngeal bursa leads to cystic mass disease known as Thornwaldt's disease
 - Patients present with B/L nasal blockage
 - Rx: Incision & Drainage.



Important Information

Incision- cruciate (least chances of closure)

Rathke's Pouch

- Pouch above the Nasopharyngeal bursa is k/a Rathke's pouch
- Rathke's Pouch: place from where pharyngeal mucosa invaginates, goes up in the embryonic life to form the

pituitary gland

- M/c location of formation of craniopharyngioma is Rathke's pouch

Tubal Tonsil of Gerlach

- Small lymphoid tissue around the Eustachian tube opening is k/a Tubal tonsils of Gerlach

Fossa of Rosen Muller

- Postero-superior to Eustachian tube opening
- It is a blind recess



Important Information

- M/c site for origin of Nasopharyngeal Carcinoma

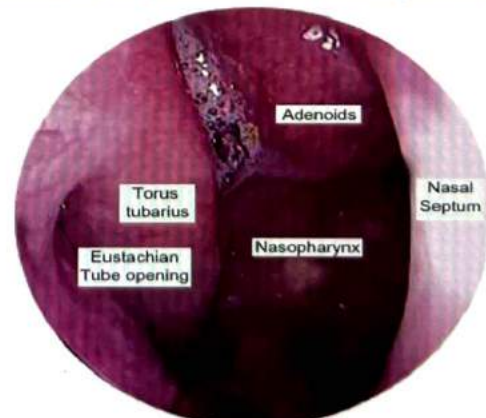


How to remember

NPC

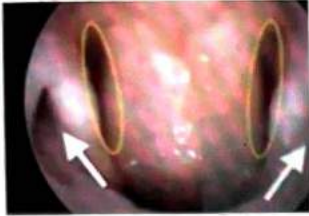
Chronic Adenoiditis / Chronic Adenoid Hypertrophy

- At the time of birth adenoids are small
- Start increasing in size by 3 -5 years
- 5-7 years they are of maximum size
- After 7 years they decrease in size
- Normally, Adenoids will not grow in Adults.
- Some time they grow more than the physiological growth it is k/a Chronic Adenoid Hypertrophy / Chronic Adenoiditis
 - Adenoid will grow and block the whole Nasopharynx
 - This photograph has been taken by putting a
 - endoscope at the posterior end of the right nasal cavity



? Previous Year's Questions

Q. Following is the Endoscopic Image of Nasopharynx. Identify the encircled site: (FMGE AUG 2020)



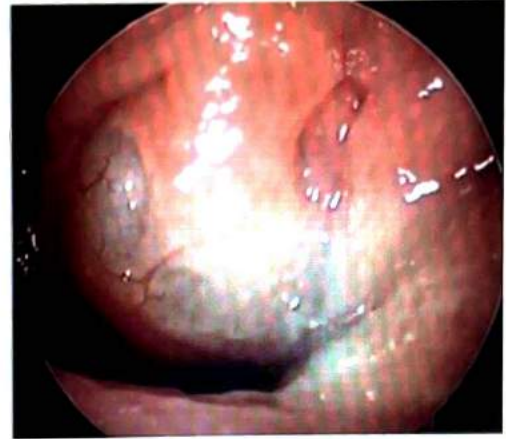- A. Eustachian tube Valve
- B. Adenoids
- C. Fossa of Rosenmuller
- D. Nasopharyngeal Bursa

Thornwaldt's disease:

🕒 00:19:11

- Blockage of Nasopharyngeal bursa leads to cystic mass disease known as Thornwaldt's disease
 - Patients present with B/L nasal blockage
 - Rx: Incision & Drainage. (cruciate)

Thornwaldt's Disease



? Previous Year's Questions

Q. Which of the following is true about Torus tubarius? (NEET Jan 2018)

- A. Nasopharyngeal bursitis
- B. Most common site of carcinoma Nasopharynx
- C. Tubal elevation in lateral wall of Nasopharynx
- D. Gives rise to Rathke's pouch

? Previous Year's Questions

Q. Pharyngeal bursa infections lead to? (DNB JUN 2018)

- a) Craniopharyngioma
- b) Chordoma
- c) Thornwaldt's cyst
- d) lymphoma

? Previous Year's Questions

Q. Nasopharyngeal chordoma arises from? (NEET Jan 2018)

- A Pharyngeal bursa
- B. Notochord
- C. Rathke's pouch
- D. Luschka's bursa

? Previous Year's Questions

Q. A Child presented with Nasal Discharge, Nasal obstruction and Recurrent URTI. On Examination Child has mouth breathing, high arched palate & associated failure to thrive. The most probable diagnosis is? (FMGE Dec 2020)

- A. Tonsils Hypertrophy
- B. Adenoids Hypertrophy
- C. Lingual Tonsils Hypertrophy
- D. Bezold Abscess

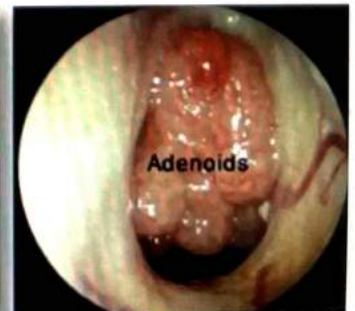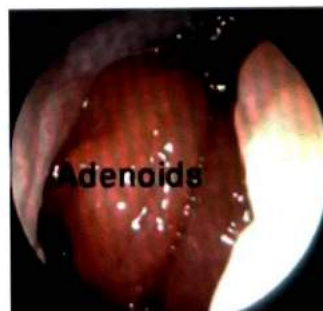? Previous Year's Questions

Q. Most common tumor from Rathke's pouch is: (FMGE DEC 2017)

- a. Meningioma
- b. Craniopharyngioma
- c. Ependyoma
- d. Low grade glioma

Chronic Adenoid Hypertrophy

🕒 00:20:52

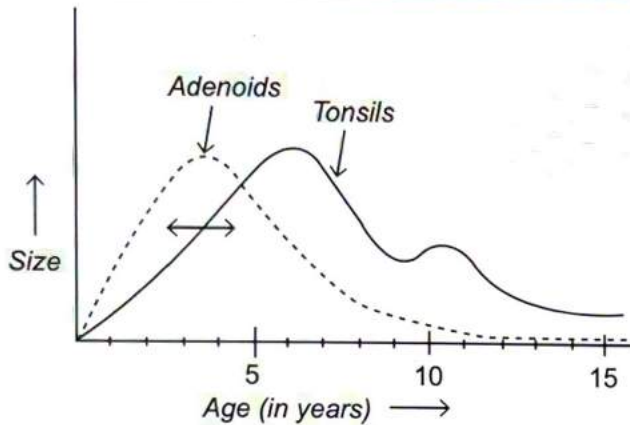


- Adenoid grows in Maximum size at 5-7 years
- After 7 years, starts decreasing.



Important Information

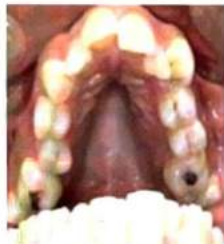- Tonsils : Reach Adult size at age 8-12years (at the time of Puberty)



- Patients presents with Bilateral Nasal Obstruction that leads to Mouth Breathing.
- Nasal Discharge leads to Chronic Rhinosinusitis
- **On examination:**
 - High Arched palate & Overcrowding of Anterior teeth

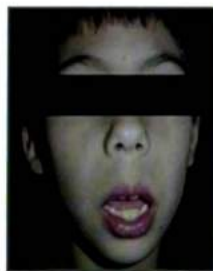Adenoid Facies:

- Overcrowding of Ant. teeth
- Nasal discharge
- Elongated face
- Pinched nose



High Arched Palate

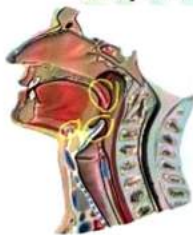Overcrowding of anterior teeth



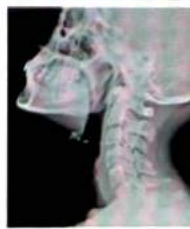Elongated face with open Mouth
pinched nose

- To confirm the chronic adenoidectomy- Xray STN Lateral view taken.

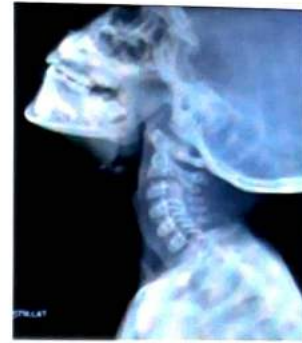Xray STN Lateral View



Sagittal Cross-Section

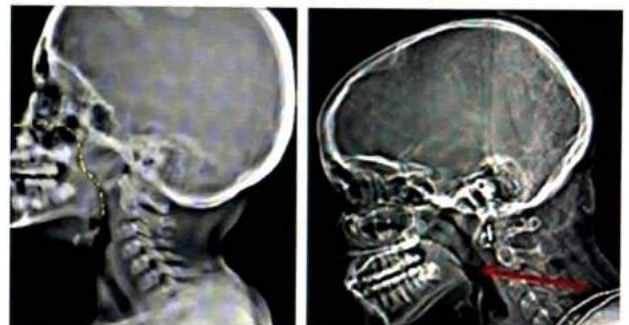


Normal Airway



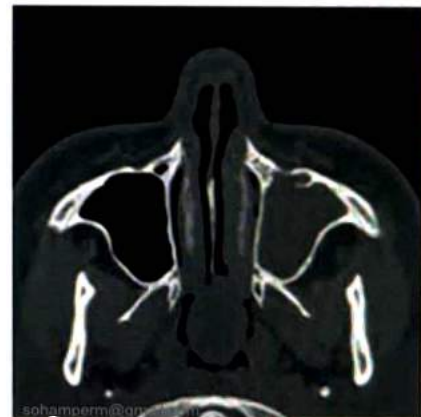
Adenoid Hypertrophy

Adenoid Vs AC Polyp



- X-ray show as mass hanging down and a space posterior-superior to the mass k/a Crescent Sign / Dodd's sign seen in antro-choanal polyp

Dodd Sign in CT Scan of AC Polyp



- Treatment: **Adenoidectomy**
- **Indications of Adenoidectomy**
 - Obstruction: Mouth Breathing, Rhinorrhea, OSA
→ Rhinorrhea clausa-Absence of Nasal Resonance in voice.
 - Adenoid facies
 - B/L serous otitis media
→ B/L ET block
→ B/L CHL
 - Recurrent attack of acute otitis media
 - CSOM Associated with chronic adenoiditis

- Recurrent & Rhino Sinusitis



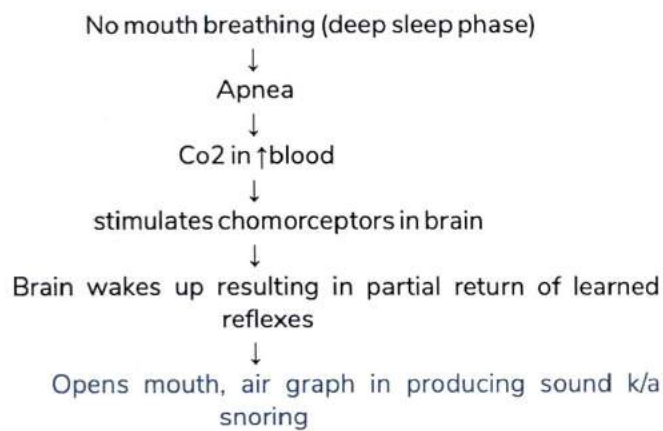
Important Information

- Rhinolalia Aperta- excess of resonance in voice
- This condition seen in Cleft Palate

OBSTRUCTIVE SLEEP APNOEA

00:42:46

- Complete cessation of breathing for atleast 10 sec.
- In deep sleep phase, all learned reflexes go away therefore, obstruction to airway



Apnoea

- Absence of breathing for at least 10 sec
- ≥ 90% drop in flow for 10 sec or longer along with ≥ 3% oxygen Desaturation
- There will be an Arousal

Hypnoea

- Reduction in breathing for at least 10 sec
- ≥ 30% drop in flow of air for 10 sec or longer along with ≥ 3% oxygen desaturation
- Patient will not wake up but can be measured by EEG / nasal flow limitation pattern (Respiratory-related arousal RERA)

Apnoea Hypopnoea Index (AHI)

- It is the hourly rate of Apnoea + hypopnoea
 - AHI < 5: Normal
 - AHI 5-15: Mild OSAH
 - AHI 16-30: Moderate
 - >30: severe OSAH

Obstructive Sleep Apnea/Hypopnea Syndrome

- >5 obstructed breaths/ hours and excessive day time sleepiness, not better explained by other factor or 2 or more of the following things
 - Choking or gasping in sleep
 - Recurrent awakenings
 - Unrefreshed sleep
 - Daytime fatigue
 - Impaired Concentration



Previous Year's Questions

- Q. Muller's maneuver is done for? (JIPMER Dec 2019)
- Eustachian tube
 - Vocal cord
 - Dysphagia
 - OSA

Cardiopulmonary Complications of OSAH

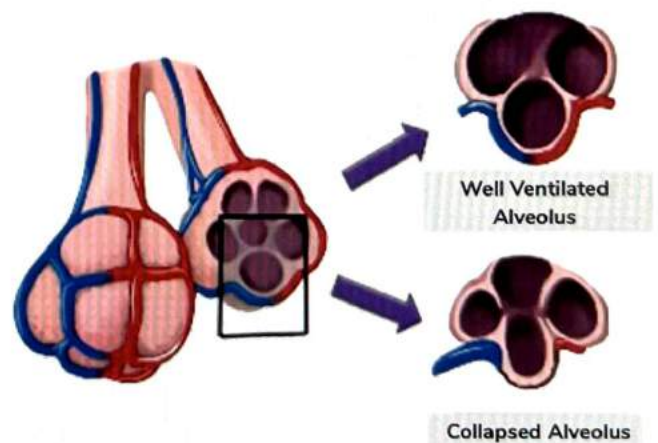
- Pulmonary Arterial Hypertension → lead to right ventricular hypertrophy → leading to right ventricular failure (cor-pulmonale).
- DM/HTN/stroke may cause.



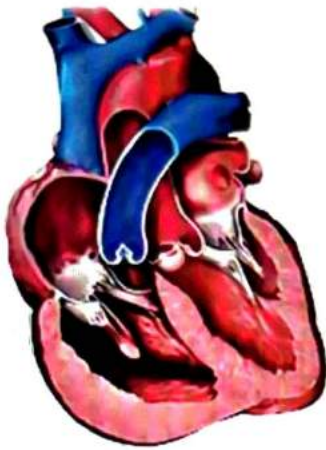Important Information

OSA patient leads to COR PULMONALE

Pulmonary Arterial Hypertension

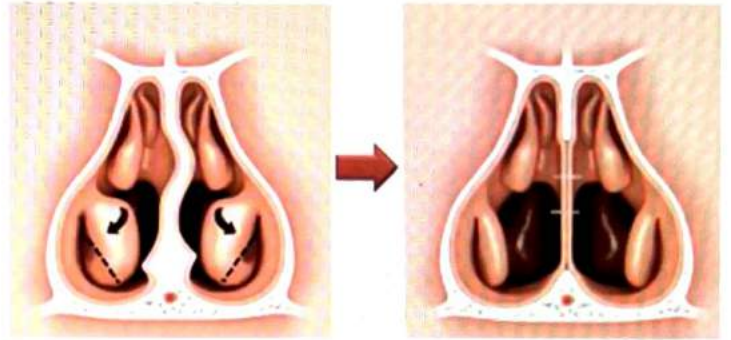


Cor Pulmonale



- Surgery: Depends on level of obstruction:
 - Nasal surgery
 - Uvulopalatopharyngoplasty (UPPP)
 - Genioglossus advancement surgery
 - Robotic tongue base surgery

Nasal Surgery



? Previous Year's Questions

Q. Long term complication in a child with upper respiratory blockage due to enlarged tonsils & Adenoids is: (FMGE Dec 2017)

- Atrial fibrillation
- Left ventricular hypertrophy
- Cor pulmonale
- Complete heart block

- T/t of OSA:
 - CPAP
- Disadvantage: poor compliance [some Patient may feel claustrophobic]

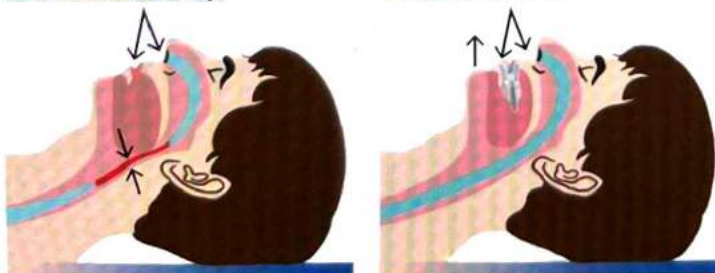


Alternative for CPAP : Mandibular advancement splint

Mandibular Advancement Splint

Restricted Airway

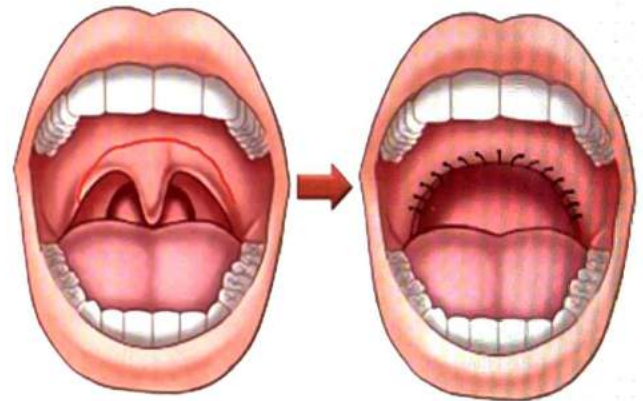
Airway Opens



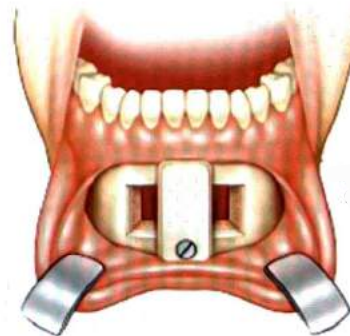
Without MAD

With MAD

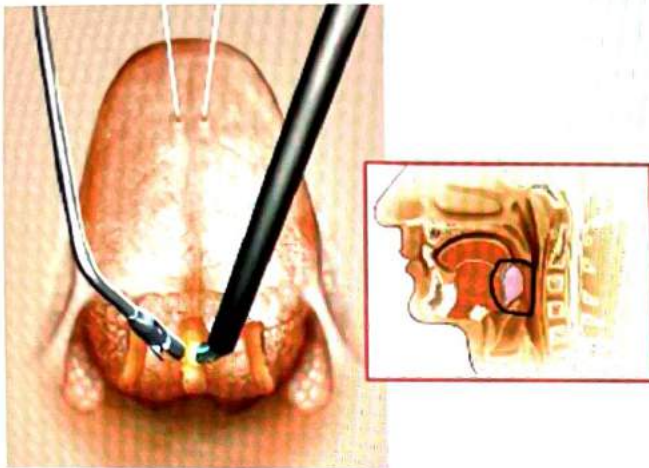
Uvulopalatopharyngoplasty (UPPP)



Genioglossus Advancement Surgery



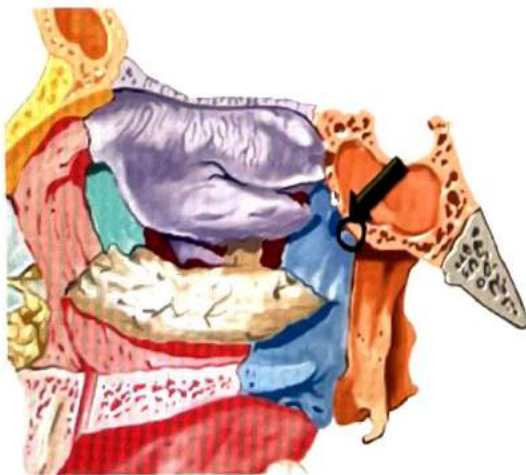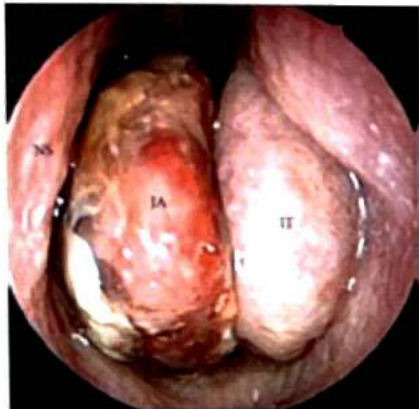
Robotic Tongue base Surgery



- No true capsule
- Multiple blood supply
- Vascular Tumor
 - Mc blood supply of JAF: Sphenopalatine Artery (br. of internal max. A)
- No tunica media
- Clinical presentation:
 - M/C presentation profuse recurrent epistaxis: Anemia
 - Nasal obstruction
 - Swelling in Cheek
 - Tunnel through which JNA comes from the nasal cavity to the cheek is k/a Pterygo-Maxillary Tunnel

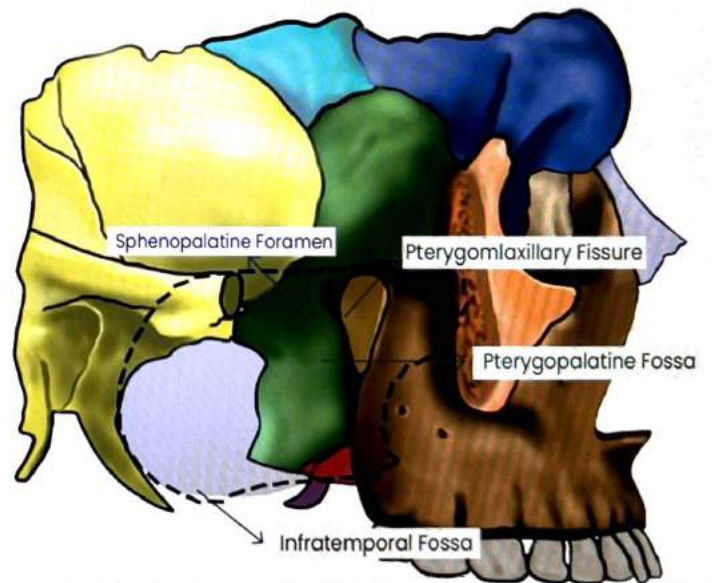
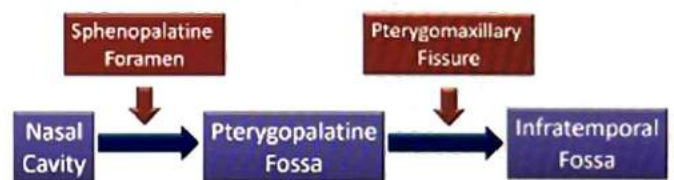
JUVENILE NASOPHARYNGEAL ANGIOFIBROMA/JNA

🕒 01:01:38



- Mc benign tumor of Nasopharynx
- Site of origin: Lateral nasal wall near sphenopalatine foramen & pterygoid base
- Characteristics of JNA
 - Testosterone Dependent Tumor (Exclusively seen in adolescent males)
 - 8-22 years

Pterygomaxillary Tunnel



- O/E
 - Reddish polypoid mass → Bleed on touch
 - Proptosis
 - Telecanthus
- If JNA goes into orbital cavity p/t has Proptosis +Telecanthus which is k/a Frog Face Deformity.

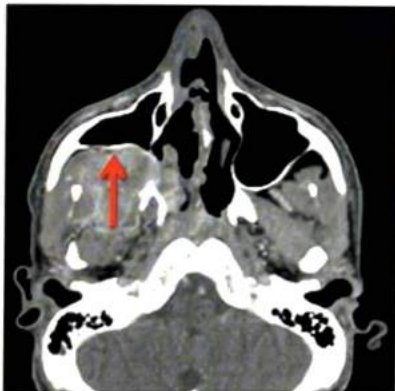
? Previous Year's Questions

Q. Angiofibroma bleeds profusely because:
(FMGE JUNE 2018)

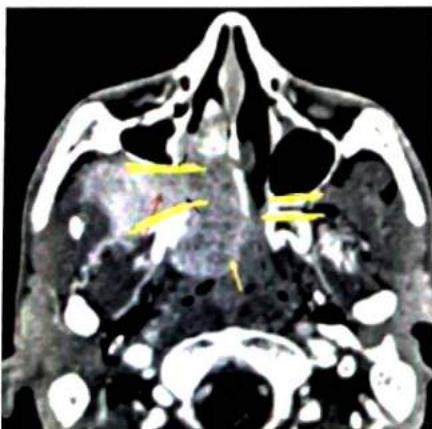
- A. It has multiple blood supply
- B. Its lacks capsule
- C. Vessels in it lack a contractile component
- D. All the above

- Dx
 - IOC: CECT
→ Hyperdense, spindle shape tumor – DUMBELL SHAPED TUMOR
 - CECT shows: ANTRAL/HOLMAN MILLER SIGN
 - Anterior bowing of posterior maxillary wall: ANTRA/HOLMANN MILLER SIGN
 - Widening of pterygo-maxillary tunnel: HONDUSA SIGN

Antral/Holman Miller Sign



Hondusa Sign



★ Important Information

Biopsy is contraindicated

- Rx – RxOC - Endoscopic excision

? Previous Year's Questions

Q. Most appropriate investigation for Juvenile Nasopharyngeal Angiofibromas? (FMGE Dec 2020)

- A. MRI
- B. CECT
- C. Angiography
- D. X-ray

? Previous Year's Questions

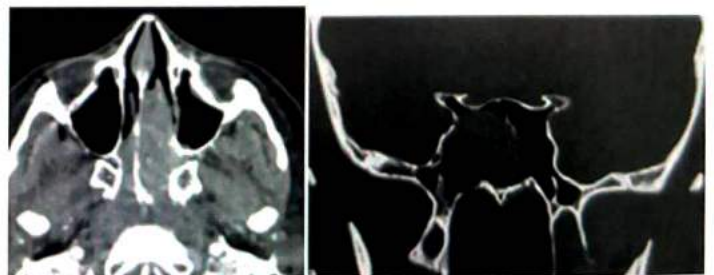
Q. A 15-year-old male patient presenting with nasal mass reaching upto cheek and causing unilateral nasal obstruction with intermittent epistaxis. Most likely diagnosis? (FMGE June 2019)

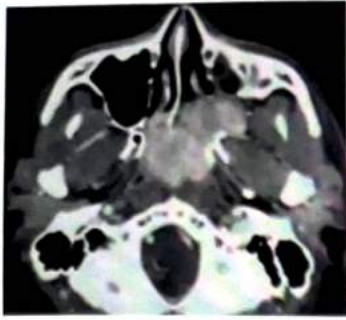
- A. Angiofibroma
- B. Nasal Polyp
- C. Nasopharyngeal carcinoma
- D. Inverted papilloma

Session Staging of JNA

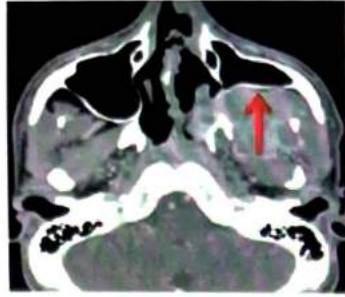
- Stage 1: Limited to Nasal Cavity/Nasopharynx
- Stage 1b: Extension into one or more Para nasal Sinuses.
- Stage 2a: Lateral extension goes in Pterygopalatine fossa.
- Stage 2b: Antral sign or extension into orbit
- Stage 2c: Goes in Infra temporal fossa
- Stage 3: Goes intra cranially

Stage 1:

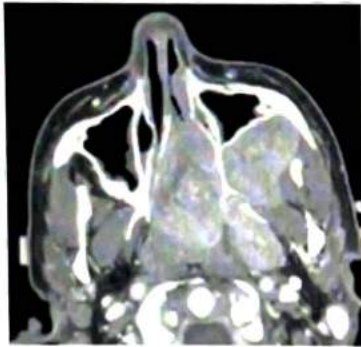




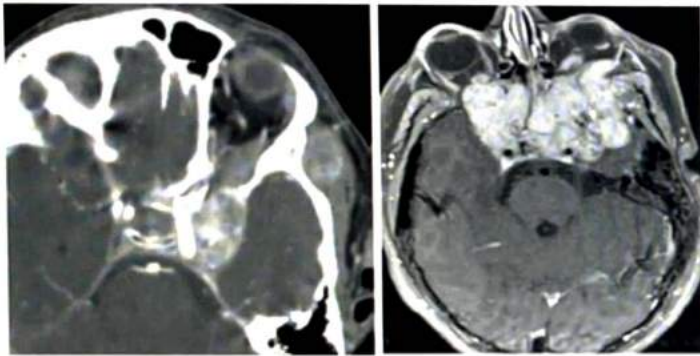
Ila: Pterygopalatine Fossa



IIb: Antral Sign or extension into Orbit



IIC: Infratemporal Fossa



Stage III: Intracranial Extension

- Stage II: Stage IIa, Stage IIb
 - Stage IIc: Infratemporal fossa extension without cheek or pterygoid plate involvement
- Stage III
 - Stage IIIa: Erosion of skull base (middle cranial fossa or pterygoids with minimal intracranial spread)
 - Stage IIIb: Erosion of skull base with intracranial extension with or without cavernous sinus involvement



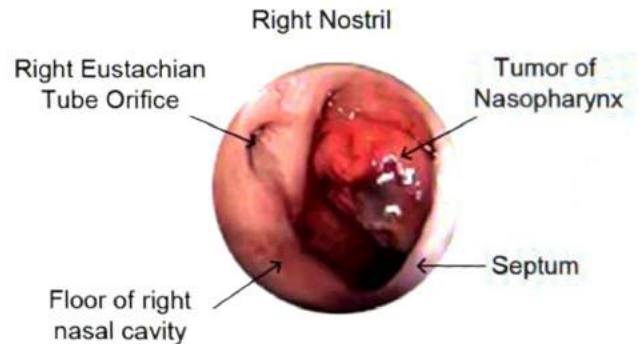
Previous Year's Questions

Q. A 14-year-old male presents with recurrent spontaneous bleeding from left nose. On examination a pink mass covered with mucosa is found in the Nasopharynx. Which of the following is not to be done? (AIIMS May 2018)

- A. Biopsy to confirm diagnosis
- B. CECT
- C. Endoscopic surgery
- D. Pre surgical embolization of artery

NASOPHARYNGEAL CARCINOMA (NPC)

🕒 01:31:14



- Mc site of origin → fossa of Rosen muller
- Mc type sq → cell CA (>85%)
- Etiology
 - Male
 - Bimodal age distribution (10 - 20 years & 60 - 70 years)
 - Common in Chinese
 - EBV Association
 - Chinese population



Previous Year's Questions

Q. A 16-year-old male complains of nasal obstruction and recurrent epistaxis for several months. On CT scan of Nose and Paranasal Sinuses, an enhancing mass is seen in the nasopharynx with minimal Extension into sphenoid sinus and no lateral extension. What is the stage of this lesion? (AIIMS Nov 2018)

- A. IA
- B. IB
- C. IIA
- D. IIB

Radowski Staging :

- Stage I: Stage Ia & Stage Ib



Important Information

- EBV Associated:
 - NPC
 - Hodgkin's Lymphoma
 - Non-Hodgkins Lymphoma(Burkitt's)
 - Gastric Adenocarcinoma

- M/C presentation: Cervical Lymph Node Metastasis (associated with good prognosis)



Important Information

- **Metastasis with Good Prognosis:**
 - NPC
 - Thyroid CA
- Trotter's Triad or Sinus of Morgagni Syndrome (NPC)
 - I/L Cranial nerve V involvement: I/L trigeminal neuralgia (N)
 - I/L cranial nerve X involvement: I/L palatal palsy (P)
 - U/L Serous otitis media: U/L Conductive hearing loss (C)



How to remember

NPC

- NPC can involve all cranial nerves except CN-1
- M/C cranial nerve involved is CN-6 to involve CN-6 it has to cross the FORAMEN LACERUM. in skull base.

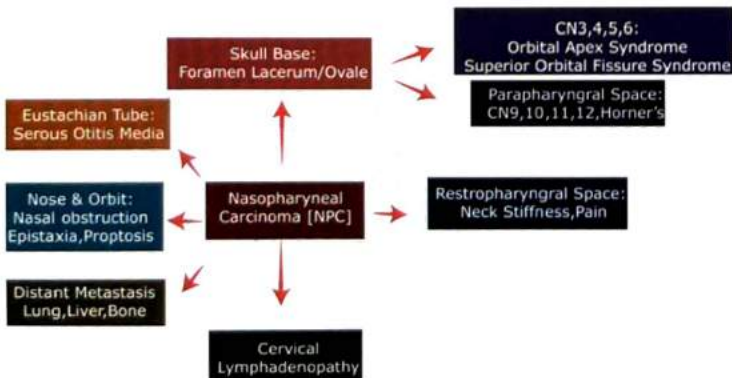


Previous Year's Questions

Q. Most common manifestation of NPC? (FMGE June 2018)

- Epistaxis
- Headache
- Nasal obstruction
- Cervical lymphadenopathy

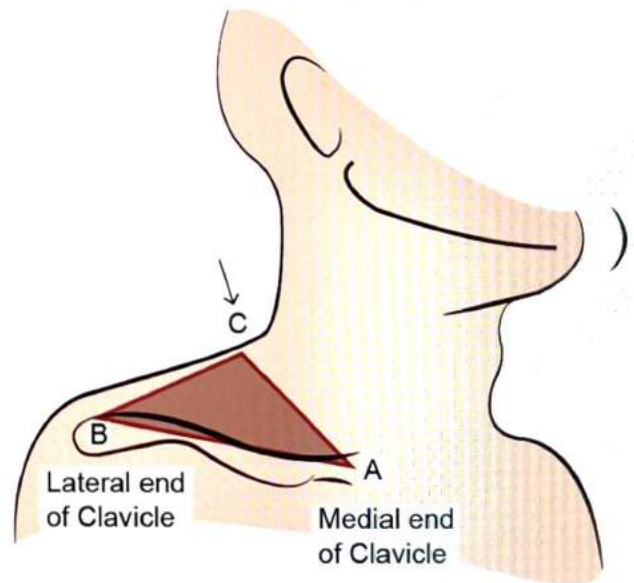
Spread OF CA Nasopharynx



TNM Staging:

- T
 - T₁ → Limited to Soft tissues of NP
 - T₂ → To nasal cavity or oropharynx
 - T-3 → To bone / PNS
 - T-4 → To cranial cavity or hypo pharynx or cranial nerves
- M
 - M₀ → No Distant metastasis
 - M₁ → Distant metastasis
- N → For all Head & Neck malignancies except CA NASOPHARYNX
 - N₁ → < 3cm Ipsilateral, Single
 - N₂ → 3 - 6 cm
 - N_{2a} → Ipsilateral / single
 - N_{2b} → Ipsilateral / multiple
 - N_{2c} → B/L Or contra lateral
 - N₃ → >6cm
- N
 - N= → < 6cm, Any one Side N2 → < 6cm, B/L
 - N3a → >6cm
 - N3b → HO 'S Triangle or Supraclavicular fossa

Supraclavicular Fossa / Ho's Triangle



Previous Year's Questions

Q. Patient presented with Bilateral Neck Swellings. Temporo-parietal Neuralgia and Unilateral Hearing loss. What is the most likely diagnosis? (FMGE Dec 2020)

- Juvenile Nasopharyngeal Angiofibroma
- Nasopharyngeal Carcinoma
- Hypopharyngeal Carcinoma
- Laryngeal Carcinoma



Previous Year's Questions

Q. Nasopharyngeal Carcinoma is associated with which of the following virus? (FMGE Dec 2020)

- A. EBV
- B. CMV
- C. HZV
- D. Parainfluenza Virus



Previous Year's Questions

Q. Treatment of Nasopharyngeal carcinoma? (FMGE Dec 2017)

- A. Surgery
- B. Chemotherapy
- C. Radiation
- D. chemoradiation

Treatment of NPC

- Radio sensitive Tumor: Radio therapy is mainstay T/t in all stages.
- Stage 1 & Early Stage 2: Radiotherapy (TOC)
- Stage 2 late, stage 3 & 4 Chemo radiation (TOC)
- Treatment of choice: chemo radiation
- **Prognostic Markers:** IgA/VCA & IgA/EA (VCA: Viral Capsid Antigen, EA: Early Antigen of EBV)
- IgA/VCA: Serological screening of NPC (More sensitive)



39 OROPHARYNX

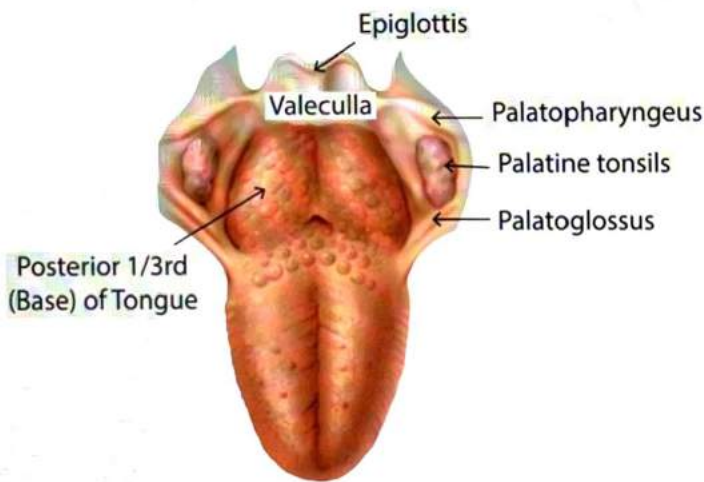
Introduction:

00:00:20

- Oropharynx is the middle part of pharynx and lies behind the oral cavity
- It extends from hard palate to hyoid bone

What is present in Oropharynx:

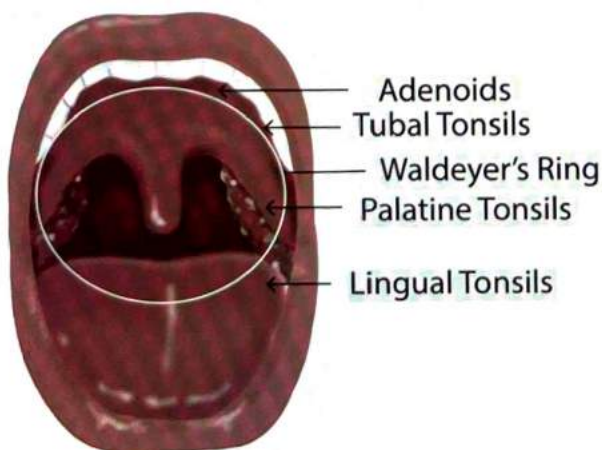
00:00:35



- Anterior wall - Palatoglossus
- Posterior wall - Palatopharyngeus
- Glossoepiglottic fold - mucosal layer which divides the Valeculla into 2 parts
- Vallecula- space between the Epiglottis and Base of tongue

WALDEYER's Ring

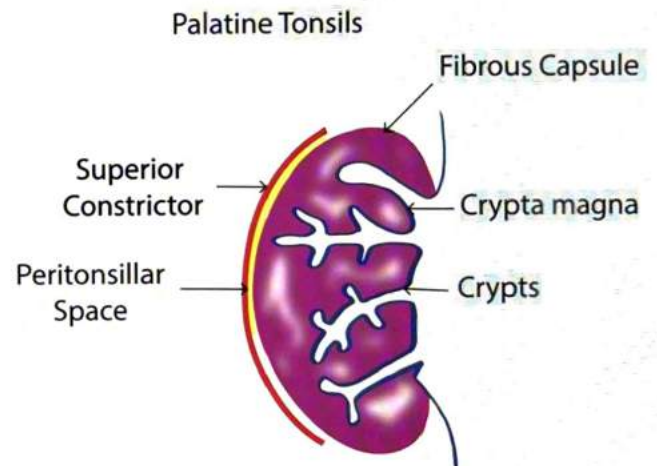
Waldeyer's Ring



- Adenoids are located In the Midline in nasopharynx in posterior superior wall
- Tubal tonsils are located on the lateral sides of Adenoids
- Palatine tonsils are located in the oropharynx
- Lingual tonsils are located on the base of tongue
 - Together all these lymphoid tissue forms a ring called Waldeyer's ring
 - 1st line of defense against ingested or inhaled microorganisms

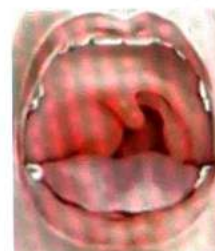Palatine Tonsils:

00:04:40



- B/L, covered by fibrous capsule and forms crypts (Primary, Secondary, tertiary)
- Crypta magna (largest crypt in palatine tonsil)
- Denotes presence of 2nd Pharyngeal pouch in embryonic life
- Tonsillar bed formed by superior constrictor muscle
- Peritonsillar Space → Between fibrous capsule and superior Constrictor muscle.
 - Infection of this space is known as – Quinsy / peritonsillar Abscess

QUINSY / PERITONSILLAR ABSCESS:



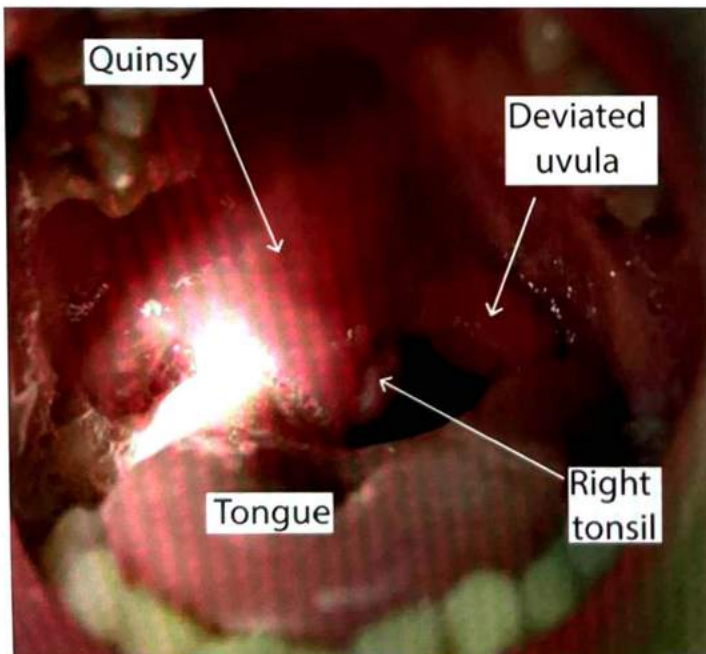
- Present with
 - Pain in throat
 - Fever
 - Dysphagia, Odynophagia
- O/E
 - Red enlarged congested enlarged tonsil
 - Pushing soft palate to opposite side
 - Uvula pointing towards normal side
 - Hot potato voice / Muffled voice
- Treatment
 - Intra oral Incision & Drainage
 - Antibiotic iv (10-14 days)
 - Interval Tonsillectomy done 6 weeks after episode of quinsy
 - Hot tonsillectomy (Tonsillectomy at the time of quinsy) is not advisable -- d/t bleeding



Important Information

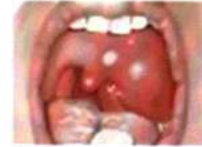Hot potato voice also seen in:

- Acute parapharyngeal abscess
- Acute epiglottitis



Previous Year's Questions

Q. A 6 years old boy presented with fever with pain in the throat and difficulty in deglutition. On examination following findings are seen. What is the most likely diagnosis? (NEET PG Jan 2020)

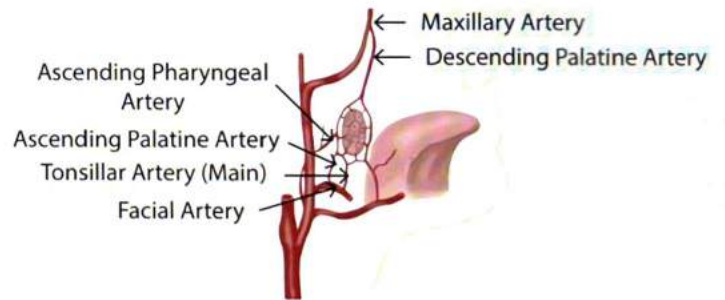


- Peritonsillar abscess
- Parapharyngeal abscess
- Ludwig's angina
- Retropharyngeal abscess

Blood supply of Tonsils:

00:17:35

Blood Supply of Tonsils: 5 Arteries (TADAD)



Tonsils are supplied by 5 Arteries.

- Tonsillar Artery (Main): Branch of Facial Artery
- Ascending Palatine Artery: Branch of Facial Artery
- Descending Palatine Artery: Branch of maxillary artery
- Ascending Pharyngeal Artery: Branch of ECA
- Dorsal Lingual Artery: Branch of lingual artery



How to remember

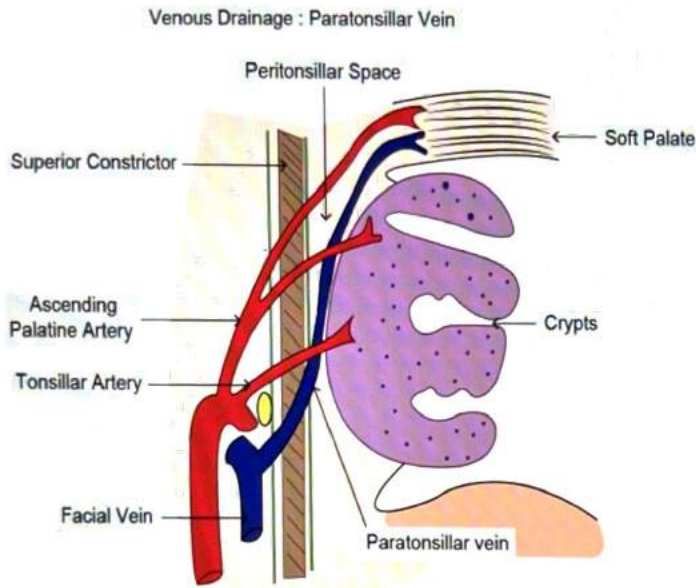
TADAD

- All these branches are branches of External carotid artery.
- Internal carotid artery does not supply tonsils

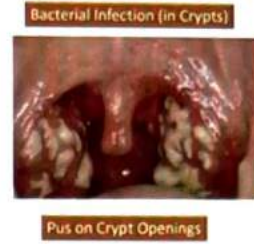Venous Drainage: Para Tonsillar Vein 00:21:38

- Venous drainage of Para-Tonsillar vein

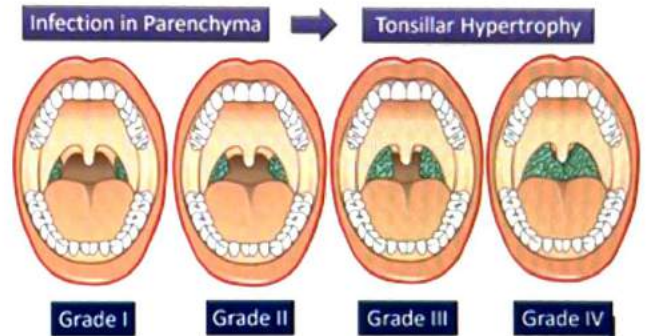
- Jacobson's Nerve [Branch of glossopharyngeal nerve] is responsible for referred pain in ear d/t acute tonsillitis/Quinsy



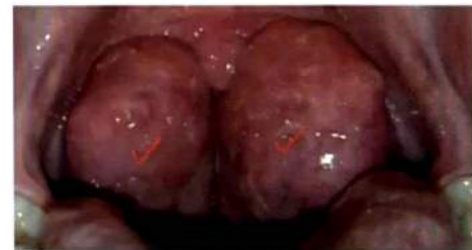Acute Follicular Tonsillitis



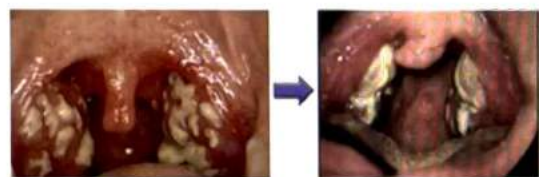Acute Parenchymal Tonsillitis



Grade 4 Hypertrophy: Kissing Tonsils



Acute Membranous Tonsillitis

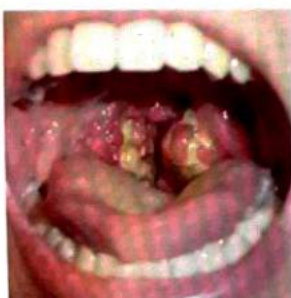

Acute Tonsillitis & Types:

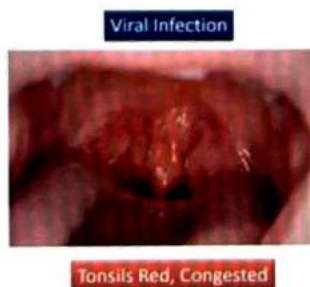
00:26:21

- Most common: Hemolytic Streptococci
- Common in children
- Classification:**
 - Acute Catarrhal Tonsillitis (MC): when there is viral infection, tonsils are red, congested but they are inside Tonsillar fossa
 - Acute follicular Tonsillitis: Due to Bacteria goes in crypts and there is presence of Pus in crypts openings
 - Acute Parenchymal Tonsillitis: Infection in Parenchyma which result in Tonsillar Hypertrophy → Grade 4 Tonsillar Hypertrophy is called Kissing Tonsils
 - Acute Membranous Tonsillitis: When Pus in Crypt forms a Membrane over tonsils.
 - This can be seen in case of
 - Pyogenic tonsillitis
 - Faucial Diphtheria: corynebacterium diphtheriae

Acute Tonsillitis



Acute Catarrhal Tonsillitis

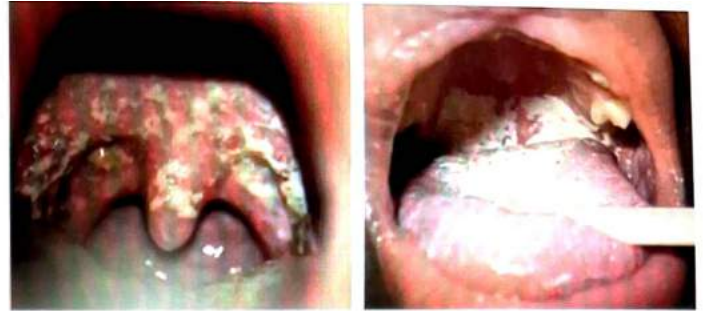
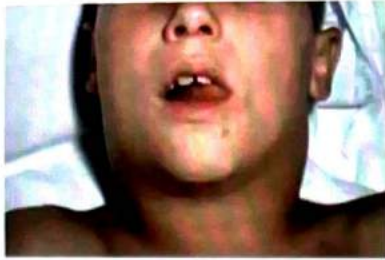
Faucial Diphtheria:

00:32:38

- Corynebacterium diphtheria
- Age: 2-3yrs
- Non immunized child
 - Fever (mild to moderate) (approximate 38°C)
 - Toxic appearance
- On examination
 - B/L cervical Lymphadenopathy k/a Bull neck
 - Dirty grey coloured membrane (Pseudomembrane) it peels with bleeding
 - Albert staining – metachromatic granules (Chinese letter appearance)

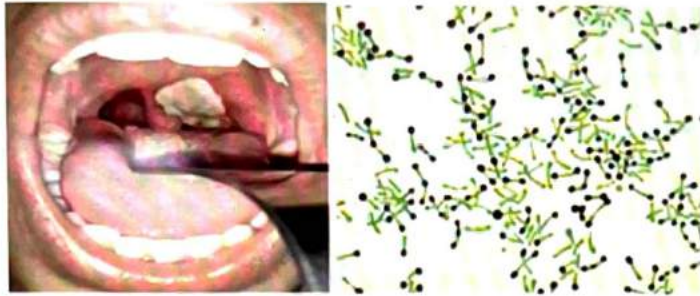
B/L Cervical Lymphadenopathy:



Vincent's Angina / Trench Mouth

🕒 00:42:55

- Acute necrotizing Gingivitis
- Caused by *Borrelia vincentii* + *Fusobacterium nucleatum*
- It is associated with membrane over the tonsil known as Ludwig's Angina
 - Ludwig's Angina = Infection of submandibular space



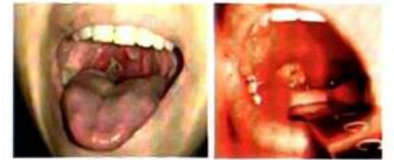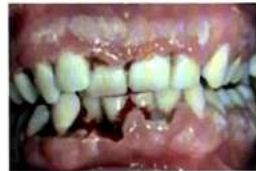Pseudomembrane

Albert Stain

- Rx: Give diphtheria antitoxin
- Differential Diagnosis:
 - IM
 - Candidiasis
 - Vincent's Angina

Vincent's Angina (Trench Mouth)

Vincent's Angina (Trench Mouth)



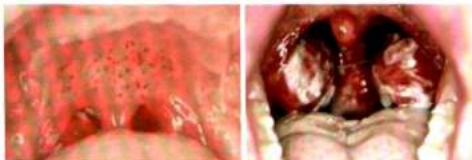Borrelia vincentii + *Fusobacterium Nucleatum*

Infectious Mononucleosis:

🕒 00:38:19

- Caused by EBV
- Fever, B/L cervical LAP, B/L tonsillar hypertrophy
 - Age: 20-30yrs
 - Palatal petechiae
- Blood test:
 - Paul bunnell test
 - Monospot test
 - CBC → ↑Leucocytosis, Lymphocytosis
 - On P.S. 10% = atypical cells

Infectious Mononucleosis



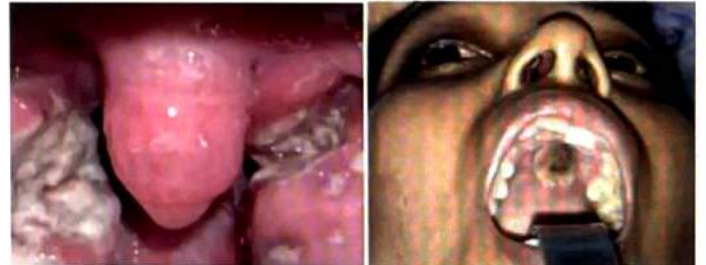Palatal Petechiae

Agranulocytosis:

🕒 00:44:55

- Leucocyte count <2000

Agranulocytosis

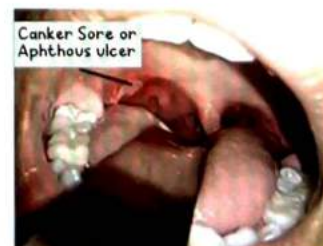

Aphthous ulcer / canker sore

🕒 00:45:42

- Very painful
- Odynophagia : severe
- Red margin around ulcer

Aphthous Ulcer



Candidiasis / Oral thrush

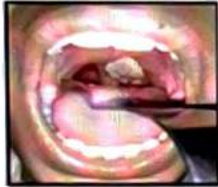🕒 00:41:18

- Caused by candida albicans
- Seen in immunocompromised Pt. [DM / Ashtma COPD on Inhalational Steroids]

? Previous Year's Questions

Q. An unimmunized 2 years old girl present with high grade fever and sore throat. On examination she is toxic in appearance & having bilateral Cervical lymphadenopathy. Throat examination showed below finding. What is the most likely diagnosis?

(NEET PG JAN 2019)

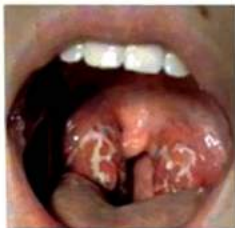

- a. Diphtheria
- b. Candidiasis
- c. Acute membranous tonsillitis
- d. Vincent's angina

Chronic Tonsillitis:

🕒 00:48:52

Chronic Tonsillitis



- Bacteria grow and resides in crypts
- Recurrent sore throat
- Types:
 - Chronic follicular tonsillitis
 - Chronic parenchymatous tonsillitis
 - Chronic Atrophic/fibrotic tonsillitis
- Irwin Moore Sign
 - Press the anterior Tonsillar Pillar, Pus come out of crypts shows there is chronic Bacterial infections inside the tonsils
 - Anterior tonsillar pillar are more congested
 - Cervical LAP
- Management
 - I/V antibiotics
 - If not responding to antibiotics → Tonsillectomy

Tonsillectomy:

🕒 00:53:23

- Recurrent sore throat
 - ≥ 7 episodes/ 1 year
 - ≥ 5 episodes year for 2 years
 - ≥ 3 episodes/year for last 3 consecutive years

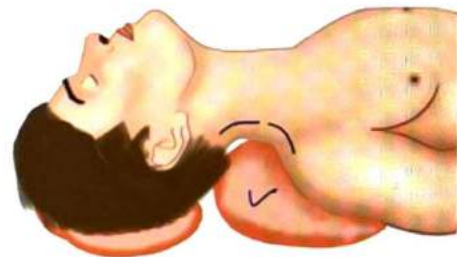
- Child misses school for ≥ 14 days absence in 1 year
 - PARADISE CRITERIA OF SORE THROAT
- Quinsy
 - Single episode in child
 - 2 episodes in Adult
- Absolute indication

- Obstruction
- Febrile seizures
- Biopsy for Malignancy

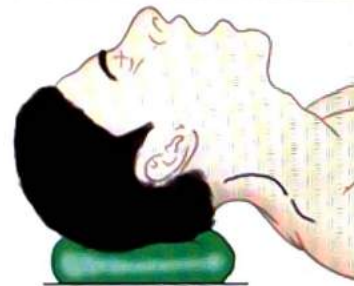Position:

- Rose's position [For adenoidectomy too]
 - Cervical joint & Thoraco-cervical joints are extended.
 - Advantage
 - Prevents the entry of blood in airways
- Boyce position / Morning sniff / BARKING DOG
 - Cervical joint - Extended
 - Thoracic joint - Flexed
 - Used for laryngoscopy, esophagoscopy, Bronchoscopy

Rose Position



Boyce / Morning Sniff / Barking



Important Information

Important information

Rose position:

- Tonsillectomy
- Adenoidectomy
- Tracheostomy

Complication of tonsillectomy

- Haemorrhage (m/c)
- Types:

Primary	Reactionary	Secondary
<ul style="list-style-type: none"> • Intra operative • Venous bleeding • Mc source → para tonsillar vein • Rx → ligation 	<ul style="list-style-type: none"> • Within 24 hrs • Slippage of ligature • Most dangerous • Rx → Repeat ligation 	<ul style="list-style-type: none"> • 5-7 days • d/t secondary infection • Warning bleeding present • IV Antibiotics

- Referred pain to ear (D/t glossopharyngeal Nerve injury)

Classical Method:

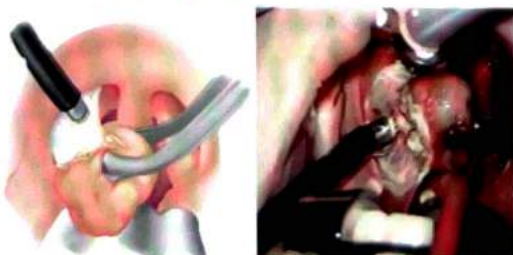
- **DISSECTION & SNARE METHOD / COLD STEEL INSTRUMENTS**
 - Crushed & cut with EVE's Tonsillar snare
 - Pain minimal (No heat used)
 - Bleeding is maximum
- **Electro Cautery**
 - No bleeding
 - Post op pain is maximum
- **CO- Ablation Tonsillectomy:**
 - Uses radiofrequency to break NaCl to Na⁺ & cl⁻ ions
 - Na⁺ ions used to dissect the tissue → no bleeding
 - Minimal post op. pain – no heat used
 - High cost & healing is slow

Coblation Tonsillectomy



Coblation Tonsillectomy
Ionized Na: Bloodless, Painless

Coblation Tonsillectomy



Previous Year's Questions

Q. In Peritonsillar abscess pain is referred to ear by: (JIPMER May 2018)

- a. V Nerve
- b. IX Nerve
- c. X Nerve
- d. VII Nerve

Previous Year's Questions

Q. During acute tonsillitis pain in the ear is due to effects of which nerve: (NEET Jan 2018)

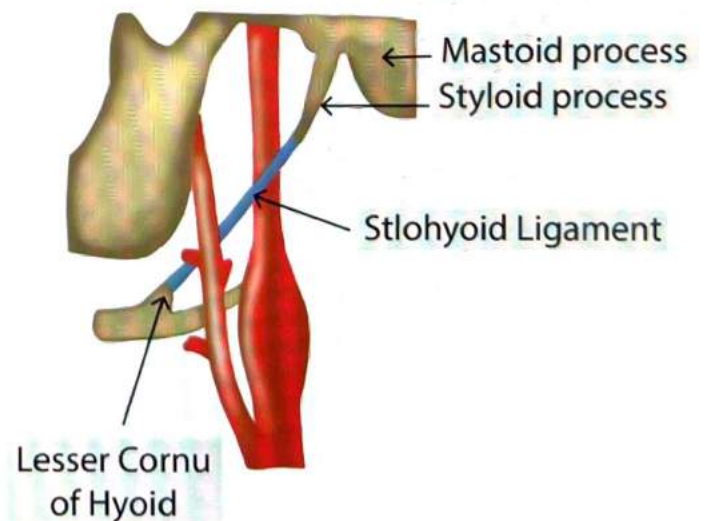
- a. Glossopharyngeal nerve
- b. Facial nerve
- c. Trigeminal nerve
- d. Vagus nerve

Styagia/ Eagle's Syndrome

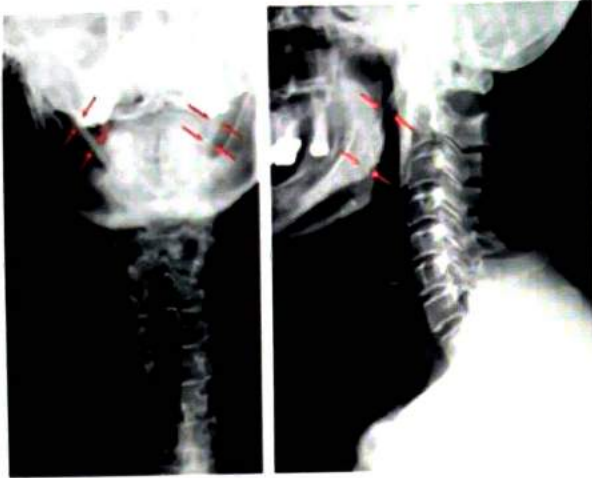
01:20:03

- Calcification of stylohyoid ligament
- Pain in throat
- Rx: Styloidectomy Or Tonsillectomy → styloid process removal
- Caution:
 - Behind styloid process, ICA is present, hence care should be taken while removal
 - ICA Aneurysm: Pulsatile mass in tonsillar fossa

Styagia/Eagle's Syndrome



Stylogia/ Eagle's Syndrome



Previous Year's Questions

Q. Stylogia may present with ear pain. Which nerve may refer the pain?
(FMGE June 2018)

- a. Auriculotemporal nerve
- b. Posterior auricular nerve
- c. Occipital nerve
- d. Glossopharyngeal nerve



CLINICAL QUESTIONS

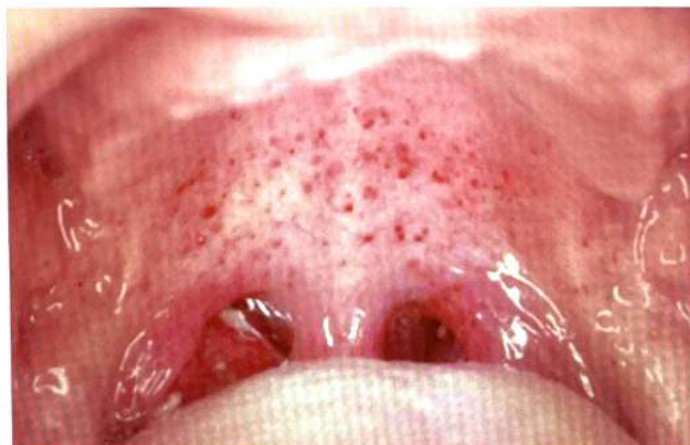Q. A 20 yrs old girl presented with sore throat. On examination there is enlarged lymph nodes with tonsillar enlargement & membrane over tonsil. Condition persists despite a course of antibiotic therapy. What should be the specific test for this condition?

- A. Throat swab & culture
- B. Tonsillar Biopsy
- C. Paul Bunnell test
- D. Blood smear

Answer: C

Solution

- **The history and examination findings are suggestive of INFECTIOUS MONONUCLEOSIS:**
 - This often affects young adults.
 - EBV is an etiological agent
 - Both tonsils are very much enlarged, congested and covered with membrane. Local discomfort is marked.
 - Lymph nodes are enlarged in the posterior triangle of neck along with splenomegaly.
 - Attention to disease is attracted because of failure of the antibiotic treatment.
 - Blood smear may show more than 50% lymphocytes, of which about 10% are atypical.
 - White cell count may be normal in the first week but rises in the second week.
 - Paul–Bunnell test (Monospot test) will show high titre of heterophil antibody



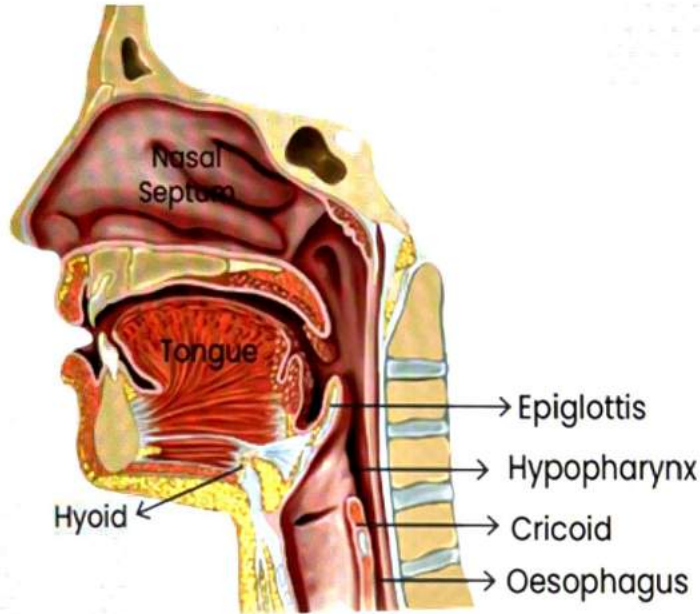


40 HYPOPHARYNX / LARYNGOPHARYNX

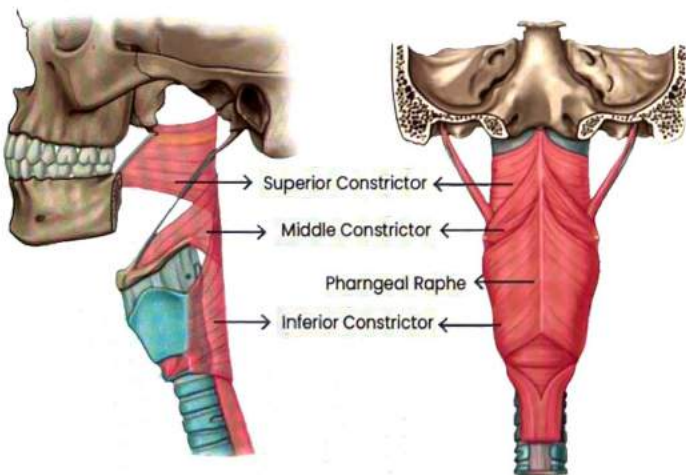
Hypopharynx: Anatomy

00:00:16

- Lower most part of pharynx
- It is located around & behind the larynx
- It extends from Hyoid bone superiorly to lower end of cricoid cartilage



Pharyngeal wall is made up of 3 constrictor muscles



- Superior constrictor
- Middle constrictor
- Inferior constrictor
 - Fuse at Midline Pharyngeal Raphe
 - All these muscles are supplied by CN X (vagus) – superior laryngeal nerve



Important Information

- **Vagus-Accessory Anastomosis** - Vagus nerve which is supplying muscle carrying the Fibres of Accessory Nerve.

- Inferior constrictor arises from two cartilage Thyroid & cricoid cartilage k/a Thyropharyngeus & Cricopharyngeas respectively
- Except cricopharyngeas everything else is supplied by SLN cricopharyngeas supplied by RLN



Important Information

- Thyropharyngeus Supplied by SLN
- Cricopharyngeus by RLN
 - Supplied by X nerve

Anatomical anomalies:

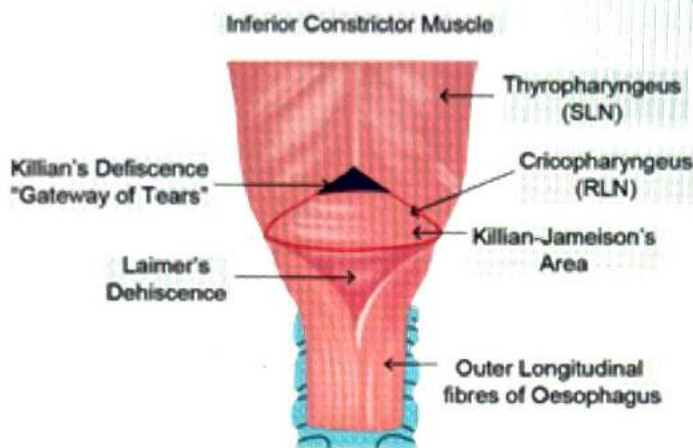
- Thyropharyngeas is oblique cricopharyneas is Transquare because of this arrangement there is triangle of Gap is created k/a Killian Dehiscence/ Gateway of Tears.



Important Information

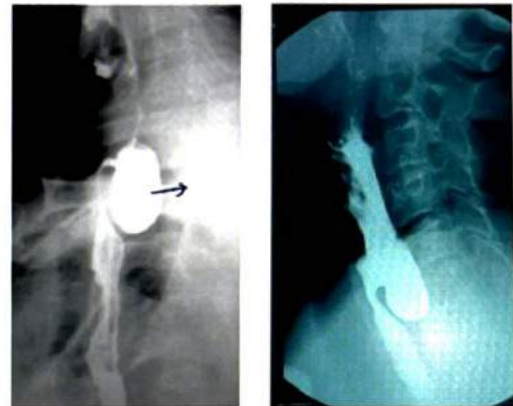
- Killian Dehiscence is the Most common site for esophageal perforation
- MC cause: Iatrogenic (oesophagoscopy)

- There another anatomical gap b/w oblique & transverse fibres of cricopharyngeas Killian Jameison's Area.
- Between circular fibres of esophagus & the cricopharyngeas transverse fiber – Laimer's Dehiscence
- Also develop from laimer's dehiscence and Killian – Jameison diverticulum



- Dx
 - Barium swallow arial Pharyngoesophageal Pouch
 - 10% arial develop Sq. cell ca
 - In case of malignancy
- Irregular margins present
- Filling defect present
 - It is also present in case of food particles
 - Do repeat barium swallow after some time, constant filling defect

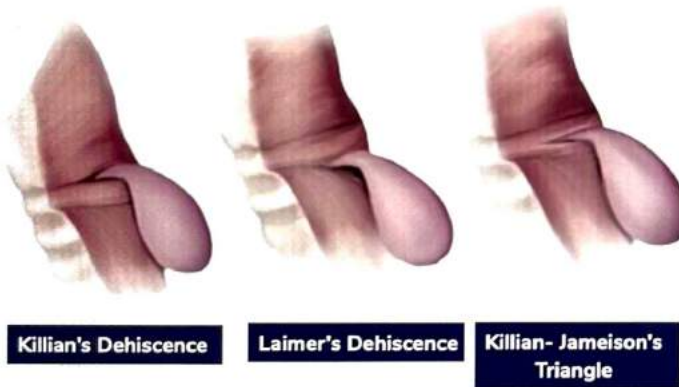
Barium Swallow



ZENKER'S / Pulsion Diverticulum

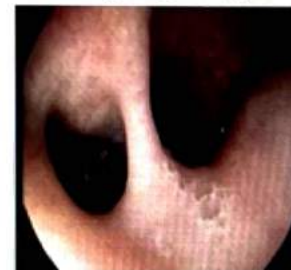
🕒 00:09:31

- M/C Site: Killian's Dehiscence
- Other site
 - Laimer's Dehiscence
 - Killian-Jamieson's Area
- MCC – Incoordination of muscles



- Video fluoroscopy
 - Can check filling defects instead of doing repeat barium swallow
- Oesophagoscopy or Endoscopy are c/I [Risk of perforation]
- To take Biopsy, it is indicated [Not for Dx].
 - IOC for Malignancy in zenkers diverticulum

Oesophagoscopy



- Rx
 - Excision arial for large pouch
 - Conservative- Cricopharyngeal Myotomy
 - DOHLMAN 'S Operation / Endoscopic Diathermy → TOC
 - Endoscopic stapling of septum
 - Common wall btw diverticulum & esophagus removed
 - Remove the intervening wall

? Previous Year's Questions

Q. Pharyngeal pouch is located between ?
FMGE Aug 2020

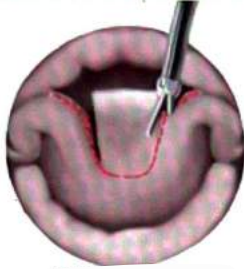
- Superior and middle constrictors
- Middle and Inferior constrictors
- Inferior Constrictor and Oesophagus
- Thyroid and Cricoid

- C/F
 - Male – 60-70 yrs
 - Dysphagia (M/c)
 - Halitosis
 - Regurgitation of old eaten food at night times

→ Nowadays, Endoscopic stapling is used

Used instead of Dohlman's surgery

Endoscopic Diathermy/
Dohlman's operation

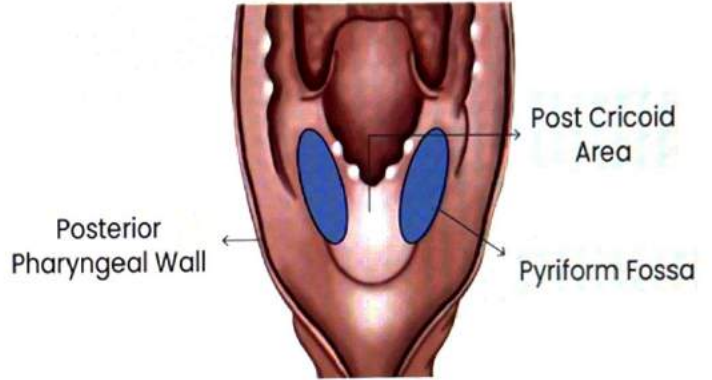


- ZD develops above the upper esophageal sphincter
- epiphrenic diverticulum develops above the lower esophageal sphincter
- ZD is a pseudo diverticulum
- TRACTION DIVERTICULUM is a true diverticulum because all layers of esophagus are present.

Hypopharynx: 3 compartment

00:29:30

- Post pharyngeal wall
- Post cricoid area
- Pyriform fossa



- Arise from the post cricoid area
 - Post cricoid webs
 - Iron deficiency anaemia
 - More common in Females, low socio economic status & developing countries
 - Koilonychias
 - Post cricoids webs → Pre malignant condition
 - More common in females → post cricoid cancer.

Previous Year's Questions

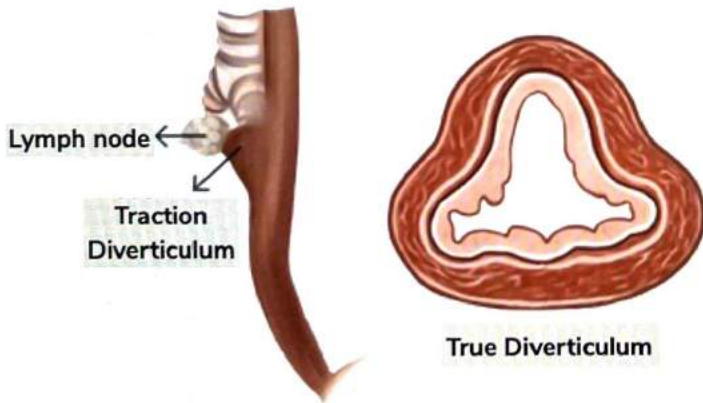
Q. Dohlman surgery in Zenker's diverticulum is?
NEET PG JAN 2019

- Endoscopic stapling of septum
- Endoscopic suturing of pouch
- Resection of pouch
- Laser division of pouch

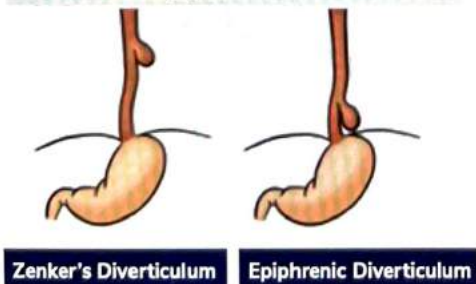
Epiphrenic & Traction Diverticulum:

00:27:18

Traction Diverticulum



Zenker's & Epiphrenic Diverticulum



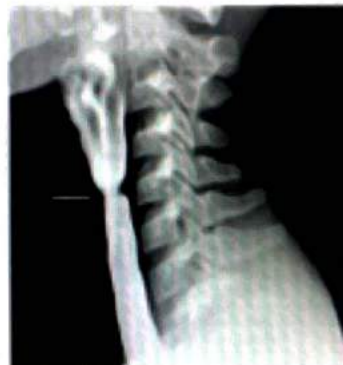Plummer Vinson Syndrome / Patterson Brown

00:36:13

Kelly SYNDROME

- Barrium swallow is done to check the filling defects in post.cricoid web
- At the level of C5-C6 vertebra

Plummer Vinson Syndrome

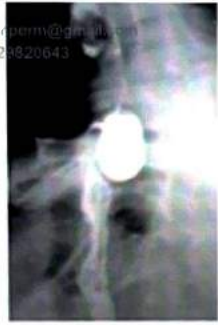

- Post Cricoid webs
- Iron def Anaemia
- Koilonychia

Previous Year's Questions

Q. A 70yrs old patient presented with history of fever, repeated aspiration and coughing in the night. On examination there is a swelling on left side of Neck which produces gurgling sound on compression. Following is the barium swallow study of patient. What is the most likely Diagnosis?

NEET PG JAN 2020



- A. Zenkers diverticulum
- B. Laryngocele
- C. Plummer vinson syndrome
- D. Dysphagia lusoria

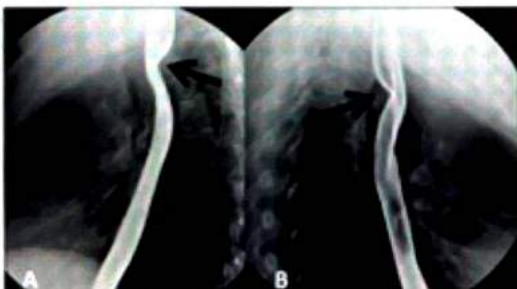- Boyce sign – Gurgling sound produced by the escape of food & liquid materials on compression (only when the touch is big enough)

Dysphagia Lusoria

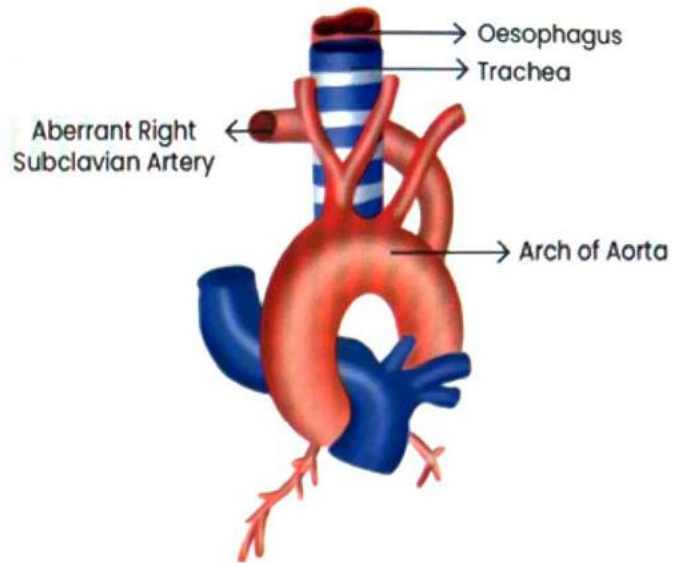
00:39:20

- It's a congenital anomaly
- During the development of Aortic arches when proximal part of 4th arch disappears instead of the distal part Right subclavian Artery, it will arise from Arch of Aorta.
- This artery takes a turn and goes behind the esophagus to the right side and compress the esophagus causing dysphagia lusoria

Dysphagia Lusoria



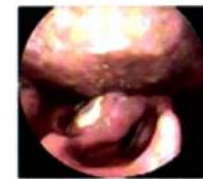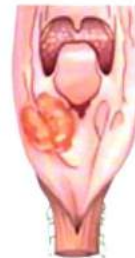Dysphagia Lusoria



Ca. hypopharynx

- Arises from Pyriform fossa (mainly), sometimes from post cricoid area
- Dysphagia / pain in throat / FB, lump feeling in throat (Globus pharyngeus)

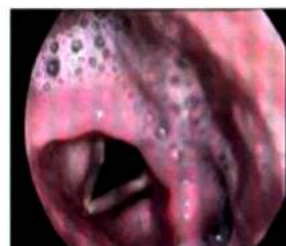Ca Hypopharynx



On examination

- Moure Sign / Bocca's Sign:
 - Post cricoid crepitus (Muir's Crackle)
 - Absent in case of post cricoid malignancy
- CHEVALIER JACKSON'S SIGN - Collection of secretion in pyriform fossa

Chevalier Jackson's sign



Pooling of Saliva in PFS

Moure sign / Bocca's Sign

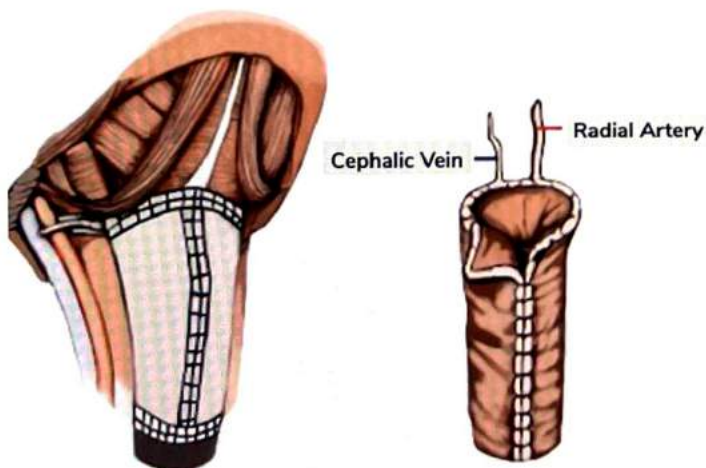
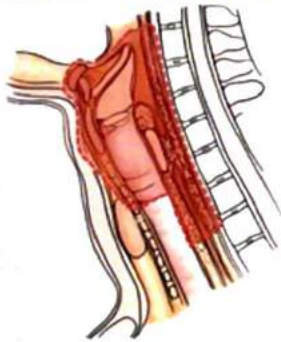


Ca Hypopharynx T staging & Treatment:

00:45:57

- T staging
 - T₁ : Involves only 1 component of hypopharynx, size <2cm
 - T₂ : (2-4cm), involves more than 1 component without affecting vocal fold mobility
 - T₃ : Involves more than 1 component, vocal fold mobility affected or Size >4cm OR involves oesophagus
 - T₄ : Into the neck
 - T4a: Anywhere other than T4b
 - T4b-Prevertebral space , Sup. Mediastinum , Encases carotid artery
- Rx:
 - Early/small tumor – Radiotherapy
 - CCRT-Rx OC
 - Surgery generally not done
- Sx: Total Laryngectomy with partial Pharyngectomy

Total Laryngectomy with partial Pharyngectomy



Previous Year's Questions

- Q. A patient presents with Carcinoma in pyriform fossa. On laryngoscopy Right vocal folds are not mobile. There is No lymph Node involvement and No distant metastasis. What is the TNM staging for the malignancy? (FMGE Aug 2020)
- T2N0M0
 - T3N0M0
 - T4aN0M0
 - T4bN0M0



Previous Year's Questions

- Q. Patient with lump in throat with no difficulty in swallowing? (DNB JUN 2018)
- Globus pharyngeus
 - Ca hypopharynx
 - Ca esophagus
 - Pharyngeal pouch



CLINICAL QUESTIONS



Q. A 25 years old female from low socio-economic status came to the hospital with complaints of difficulty in swallowing. On further examination, the patient present with spoon-shaped nails. Laboratory investigations revealed microcytic hypochromic anemia. Which of the following is the most common site of carcinoma in this case?

- A. Posterior pharyngeal wall
- B. Post cricoid region
- C. Medial wall of Pyriform sinus

Lateral wall of Pyriform sinus

Answer: B

Solution

- Plummer-Vinson Syndrome/ Patterson-Kelly-Brown Syndrome:
- Triad consisting of:
 - Post cricoid webs- dysphagia
 - Iron Deficiency Anemia (Glossitis / Angular cheilitis)
 - Koilonychia (Spoon shaped nails)
- The post cricoid webs are premalignant and lead to the formation of Squamous cell carcinoma at post cricoid area in females suffering from Plummer-Vinson syndrome

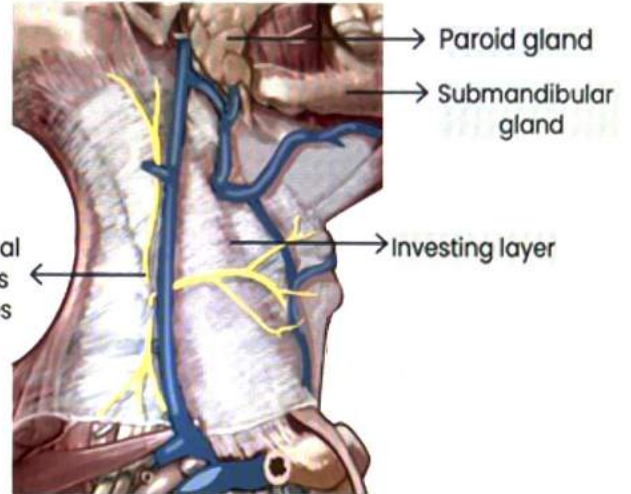


41 LAYERS OF CERVICAL FASCIA

Cervical fascia

00:00:37

- Consists of 2 layers:
 - Superficial
 - Deep
 - Superficial layer
 - Middle layer
 - Deep layer

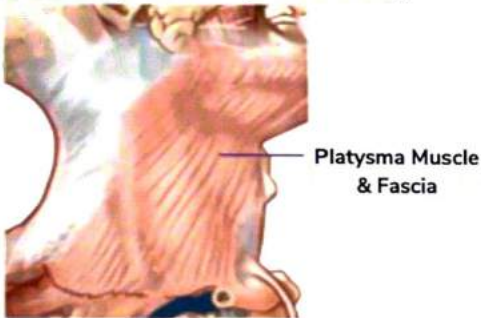


Superficial layer of Cervical fascia

00:01:04

- Also known as Cervicocephalic fascia

SUPERFICIAL LAYER OF VERVICAL FASCIA (Cervicocephalic Fascia)

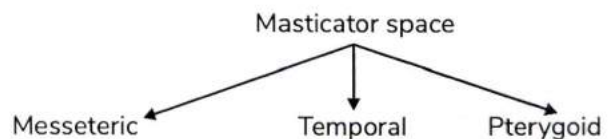


Superficial layer of Deep Cervical fascia

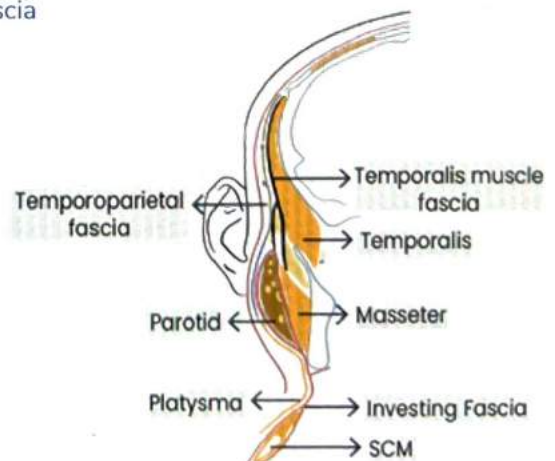
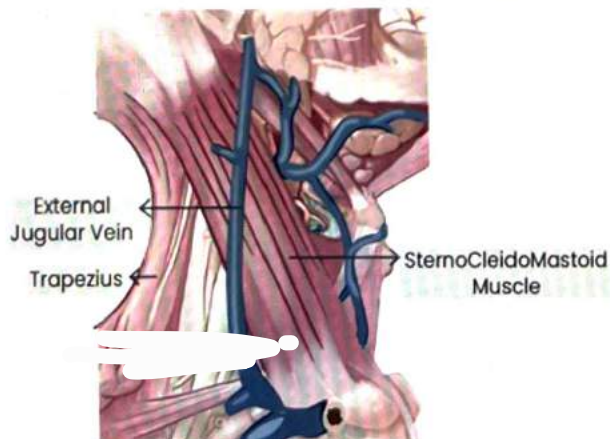
00:01:55

- Covers neck all around therefore also k/a anterior / enveloping / external / investing layer
- It envelops the SCM and Trapezius muscle.
- It is in the sub-platysmal plane
- Roof of the posterior triangle of neck is formed by superficial layer of Deep cervical fascia.
- It encloses the parotid and sub mandibular gland

- Rule of 2:
 - 2 muscles
 - Trapezius
 - sternocleidomastoid
 - 2 glands
 - Submandibular
 - parotid
 - 2 spaces
 - Space of posterior triangle
 - Suprasternal space of burns

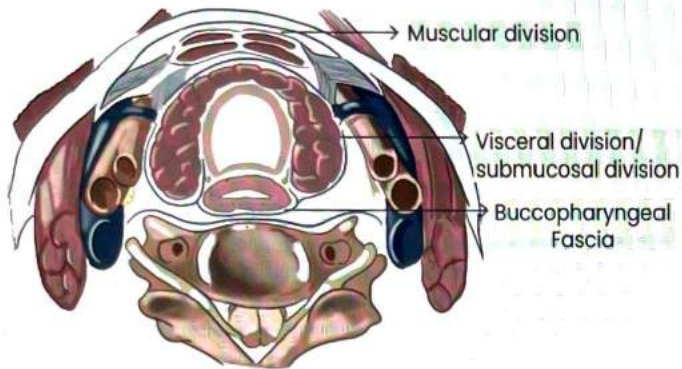


- M/C graft used for Tympanoplasty = Temporalis muscle fascia

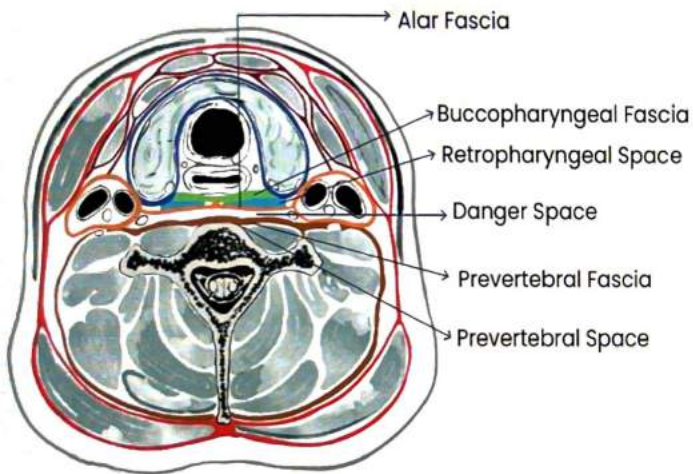


Middle layer of deep cervical fascia ⌚ 00:12:23

- Also called Prethyroid fascia / Pretracheal fascia
- This layer forms the Buccopharyngeal Fascia



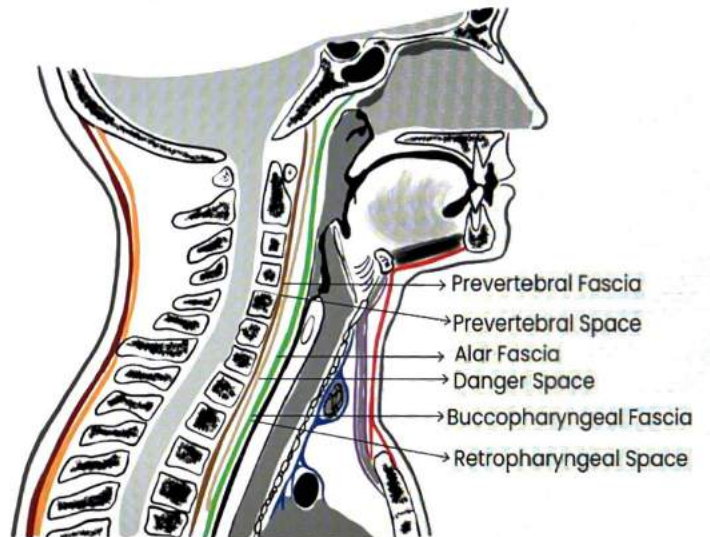
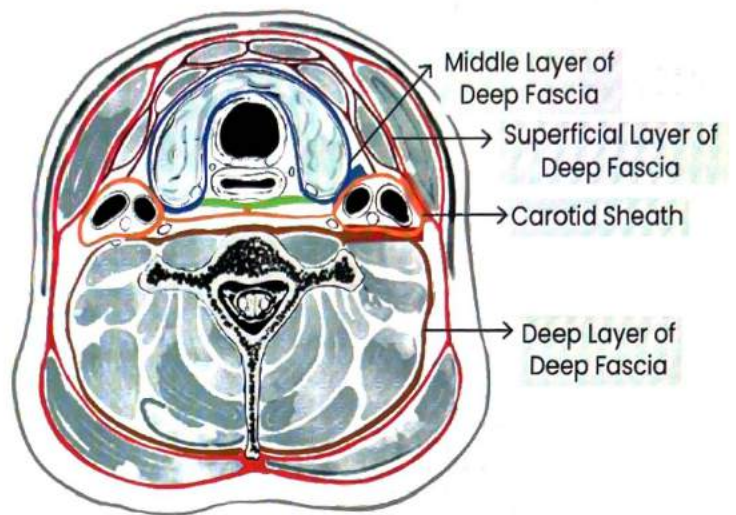
Deep layer of deep cervical fascia ⌚ 00:15:29



- It is divided into Alar Fascia and Prevertebral Fascia.
- Prevertebral space btw the prevertebral fascia and vertebra
- Danger space btw the alar fascia and prevertebral fascia
 - It extends from the skull base to diaphragm
 - It transfers all the infection from mediastinum to diaphragm
- Retropharyngeal space- it extends from skull base to level of T1 & T2 vertebra.
- Potential spaces – appear only when there is an infection/disease/tumor, not present actually

Sagittal cross section: ⌚ 00:19:52

Carotid sheath ⌚ 00:20:46



- **Anterolateral aspect** – Superior layer of deep cervical fascia
sohamperm@gmail.com
918629820643
- **Antero medial aspect**- Middle layer of deep cervical fascia
- **Posterior aspect** – deep layer of cervical fascia
- All these layers combined and form carotid sheath
- Carotid sheath spaces - ICA, IJV, CNX (Vagus)

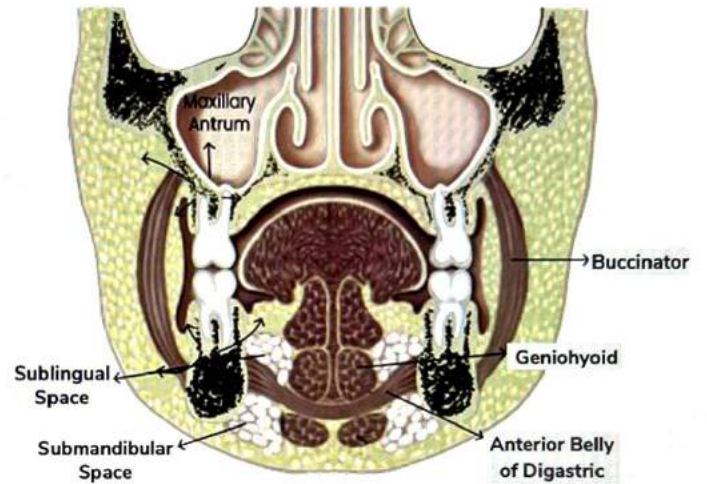
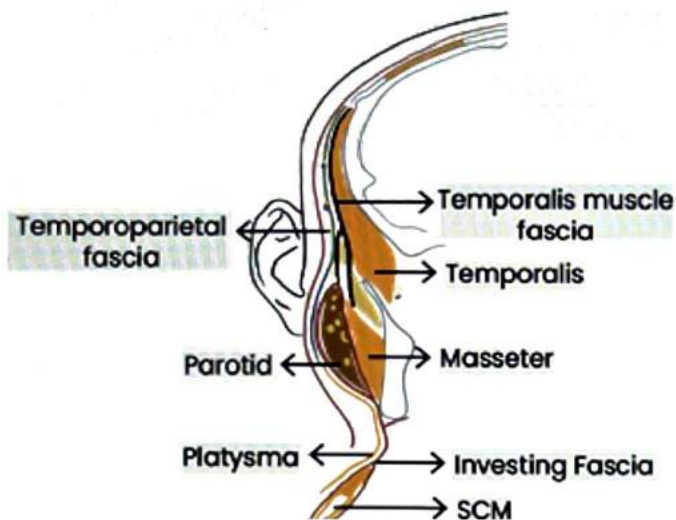


42 DEEP NECK SPACES

Superficial space

00:00:33

- Entire length of neck

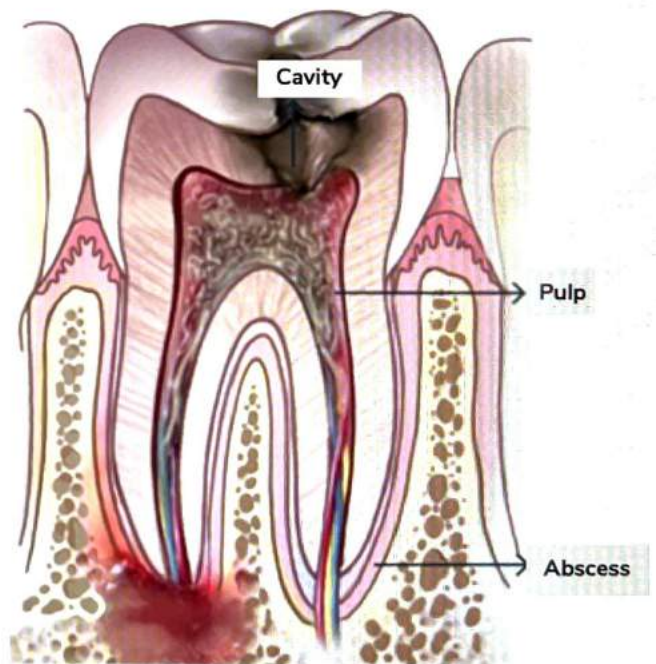


Deep Neck Spaces:

00:02:06

Divided into 4 categories

- In the face
 - Buccal space
 - Canine space
 - Masticator space
 - Parotid space
- In suprahyoid neck:
 - Peritonsillar space
 - Submandibular space
 - Lateral pharyngeal space
- In Infrahyoid neck:
 - Anterior visceral space
- Extending the length of Neck:
 - Retropharyngeal space
 - Danger space
 - Prevertebral space
 - Carotid sheath space



Dental infection

00:03:33

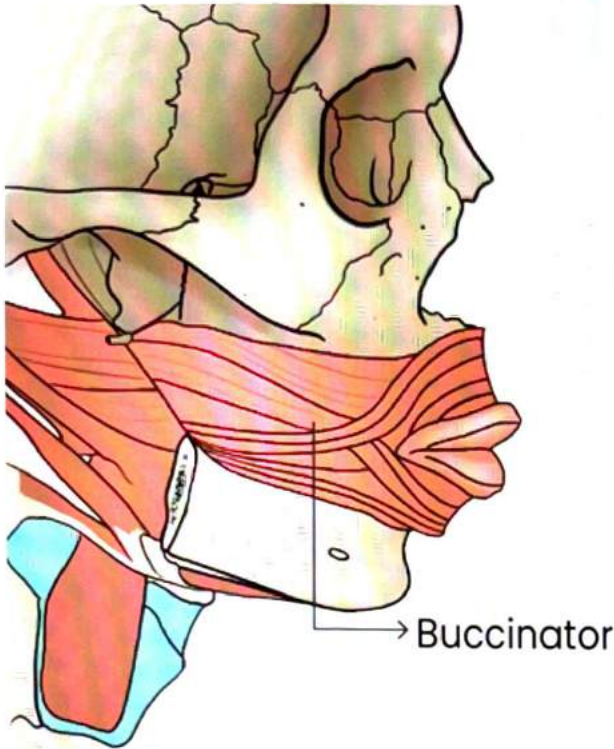
- MC source of infection Dental Infection.
- Infection goes to pulp and then apex and there forms abscess known as Periapical abscess.

Buccal space

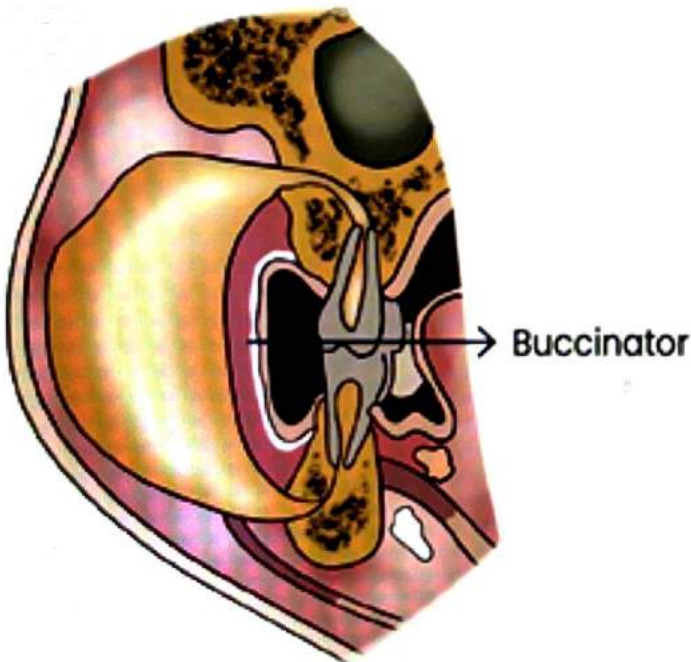
00:04:26

- Buccinator
 - Primary function – Facial expression
 - Accessory muscle of mastication (acts by pushing the food into oral cavity)
 - Buccal space formed between buccinator muscles and superficial layer of deep cervical fascia
 - Infection from the tooth goes lateral to the buccinator

- Between the superficial layer of deep cervical fascia and buccinators an abscess is formed



Buccal Space

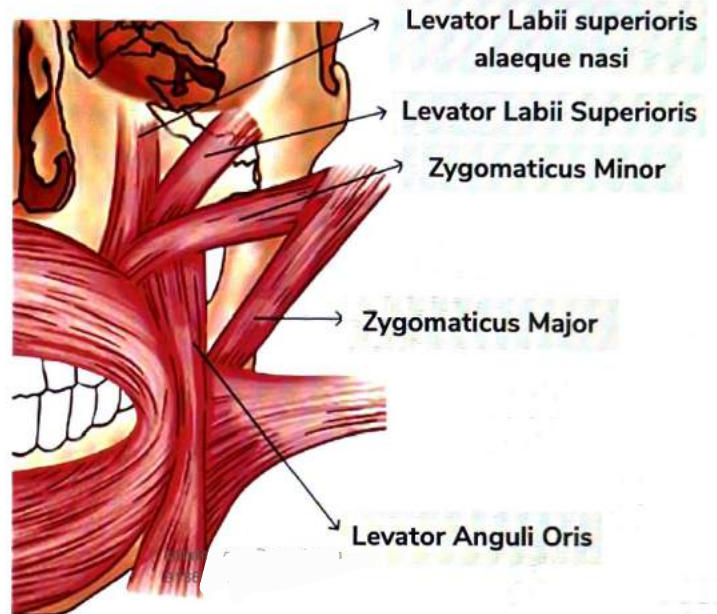


Canine Space

00:06:58

- Formed in the canine fossa in antero-lateral wall of maxilla which is covered by different muscles namely
 - Zygomaticus major (forms lateral boundary of canine fossa)

- Levator anguli oris
- Zygomaticus minor
- Levator labii superioris
- Levator labii superioris alaeque nasi
- In between these muscles the canine space is present which posteriorly communicates with buccal space.
- Infection in canine tooth will lead to formation of abscess in the canine space (canine space abscess)

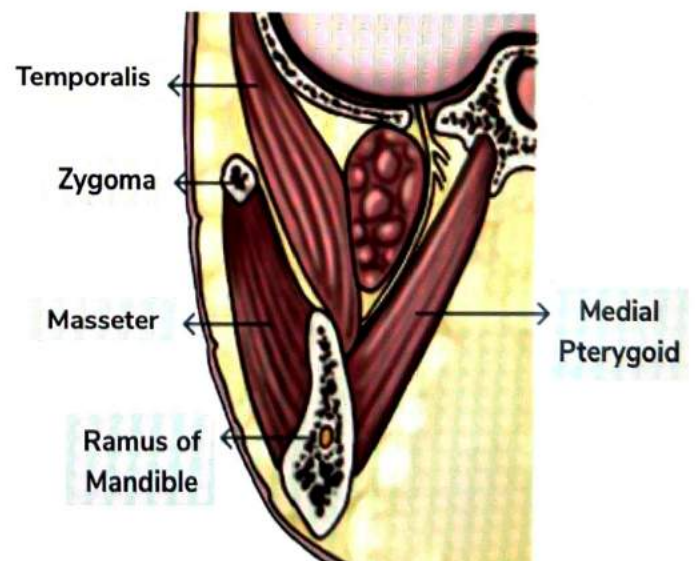


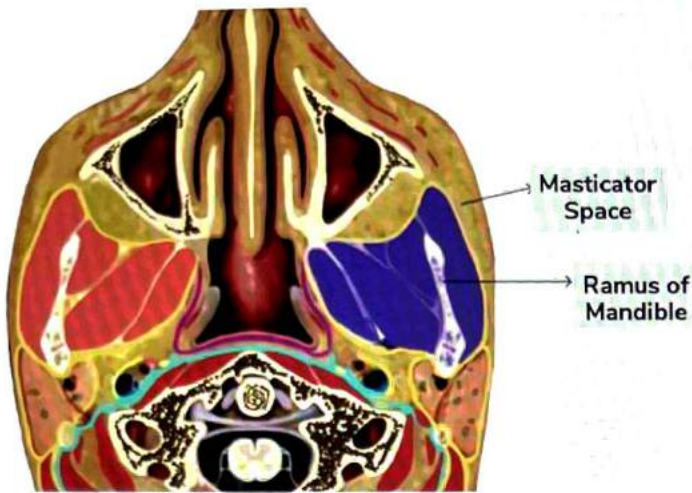
Masticator space

00:08:27

Divided into 3 spaces

- Masseteric space
- Pterygoid space
- Temporal space

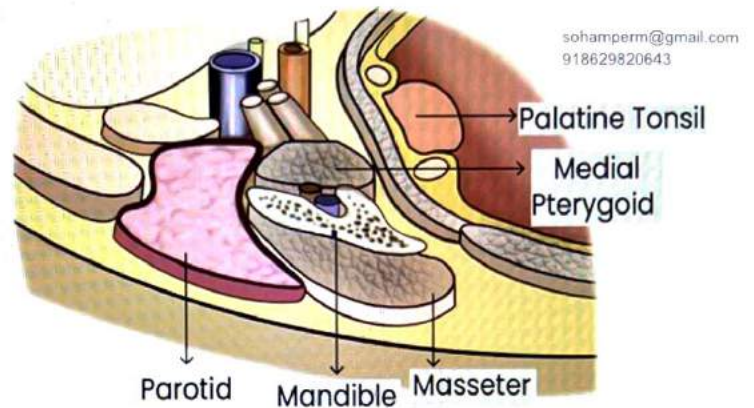




- Masticatory space is covered by superficial layer of deep cervical fascia between the fascia and muscle tissue

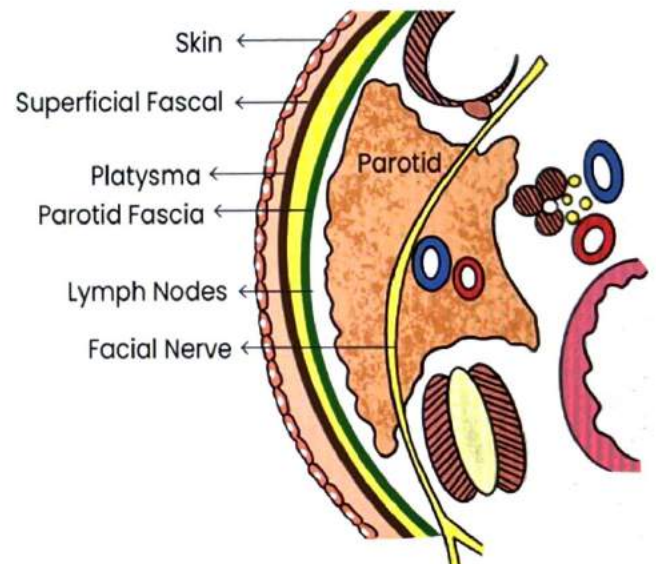
Parotid space

00:13:59



The masticators Muscles are:

- Ramus of mandible
- Masseter
- Zygoma
- Temporalis
- Medial pterygoid
- Lateral pterygoid
 - Lateral pterygoid is a depressor muscle (open the jaw)



How to remember

LD

- All the masticatory muscles are derivatives of 1st pharyngeal arch (Mandibular), Hence they are supplied by Mandibular nerve (V_3)
- Buccinator muscle is a derivative of 2nd pharyngeal arch. Hence supplied by facial nerve (primarily facial expression muscle, accessory masticatory muscle)
- **Masticatory space abscess:**
 - Facial swelling
 - Trismus is a characteristic feature of masticator space abscess (Differentiate between Buccal space)
- **Structures passing through foramen ovale:**
 - M-Mandibular nerve (V_3)
 - A-Accessory Meningeal artery
 - L-Lesser petrosal nerve
 - E-Emissary vein

- This is the last space in the face
- It is also covered by superficial layer of deep cervical fascia, it condenses and forms the parotid gland
- Parotid gland is surrounded by
 - Ramus of Mandible
 - Masseter
 - Medial pterygoid
 - Posterior belly of digastric
 - Sternocleidomastoid
 - Deep to deep lobe parapharyngeal space (or) Lateral pharyngeal space
- Surgical anatomy of parotid layers:
 - Skin
 - Superficial fascia
 - Platysma



How to remember

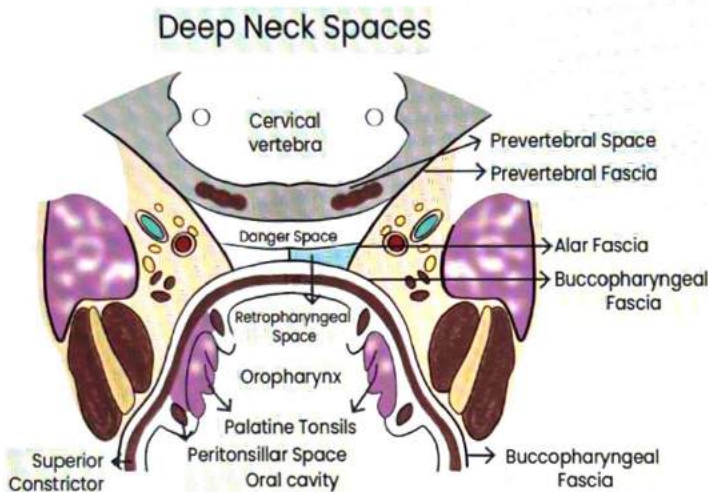
MALE

- Parotid fascia
- Lymph node
- Facial nerve divides parotid into superficial and deep lobe.

Other Deep neck spaces:

00:18:40

Peritonsillar space:



- Located between palatine tonsil and superior constrictor muscle
- Infection of this space is called peritonsillar abscess AKA quinsy
- In quinsy the tonsils may get red, enlarged and congested it may even reach the midline

Prevertebral space:

- Located between prevertebral fascia and cervical vertebral
- If there's an abscess it will be present in the posterior pharyngeal wall
- It will be in the midline always

Danger space

- Extend from skull base to diaphragm
- Located between prevertebral fascia and alar fascia
- Any infection in this space will be taken to mediastinum.

Retropharyngeal space

Located between Alar fascia and Buccopharyngeal fascia

- The retropharyngeal abscess will also be located in the posterior pharyngeal wall but will be restricted to either right or left side

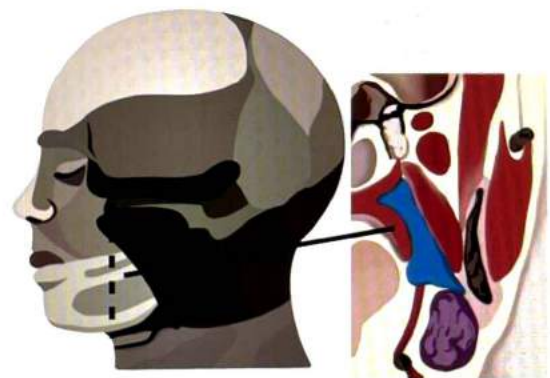
Parapharyngeal space

- Lateral:
 - Deep lobe of parotid gland
 - Ramus of mandible
 - Medial pterygoid muscle
- Medial:
 - Buccopharyngeal fascia
 - Superior constrictor muscle
 - Palatine tonsil
 - Soft palate
- Posterior: Paravertebral fascia

Parapharyngeal Space

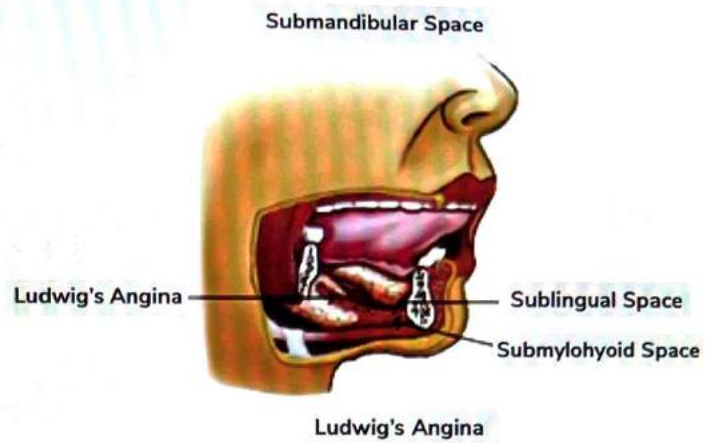
00:28:47

Parapharyngeal Space



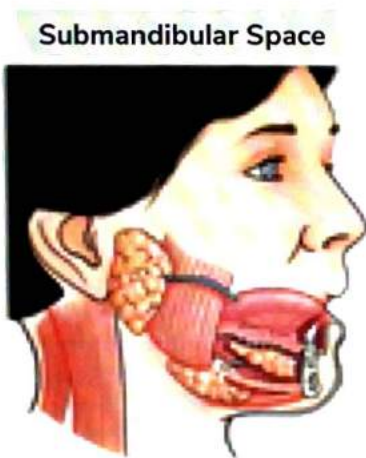- It is an inverted pyramid shaped in which the base lies at skull base and the tip at hyoid bone.
- The styloid apparatus divides the parapharyngeal space into
 - Pre-styloid (Anterior)
 - Fat
 - Lymph nodes
 - Post-styloid (Posterior)
 - IIV
 - ICA
 - CN 9,10,11,12
 - Sympathetic chains
- The abscess for parapharyngeal space is located on the lateral pharyngeal wall it will also push the tonsils to midline
- Isolated abscess of pre-styloid components will affect the medial pterygoid muscle which will eventually lead to trismus.

- Trismus is a characteristic of Anterior component it won't be seen in post-styloid
- Medial pterygoid muscle is the most common muscle to be affected and cause trismus.
- Deep lobe tumor of parotid will appear in the lateral pharyngeal wall
- Superficial lobe tumor of parotid will push the ear lobe laterally and up.
- Deep neck spaces are interconnected
- Sometimes anterior parapharyngeal space abscess may spread to submandibular space.



Submandibular space:

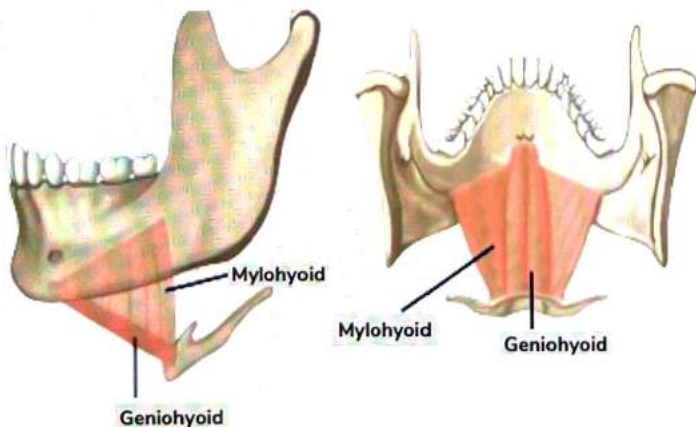
00:41:44



sohampem@gmail.com
918629820643

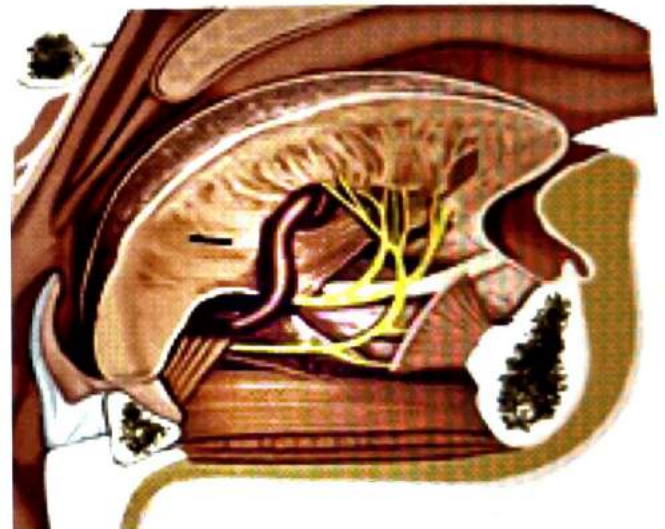
- Sublingual space consists of:
 - Sublingual gland
 - Wharton's duct
 - Tail of submandibular gland
 - Lingual artery
 - Lingual nerve
 - Hypoglossal nerve

- Located between superficial layer of deep cervical fascia and floor of mouth
- Consists of
 - Mylohyoid
 - Geniohyoid



- Mylohyoid divided Sm space into
 - Sublingual space (above)
 - Sub mylohyoid space (below)

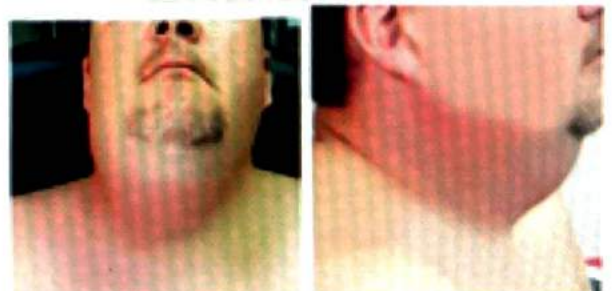Submandibular Space



Ludwig's Angina:

00:45:34

Ludwig's Angina



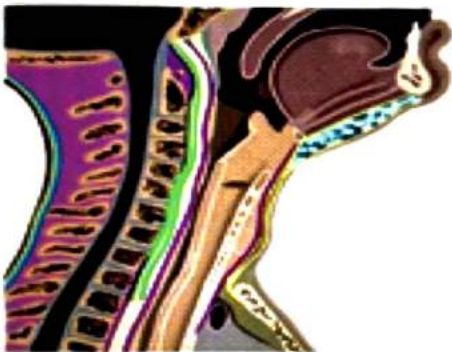- Infection of submandibular space is known as Ludwig's Angina
- Rapidly spreading cellulitis of sub mandibular spaces
- It can cause obstructed airway
- Hence it has to be treated with urgency
 - Rx:-Incisions and Drainage (Mainly to relieve the pressure)
 - IV Antibiotics
 - Tracheostomy

Anterior visceral space

🕒 00:48:43

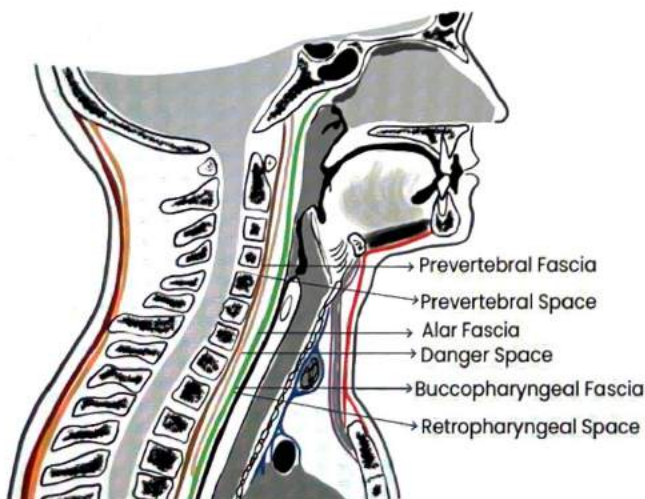
- It lies below hyoid
- Middle cervical fascia has two parts
 - Muscular division
 - Visceral division
- The visceral division continues into the mediastinum and forms the AVS

ANTERIOR VISCERAL SPACE



Spaces along the length of the Neck

🕒 00:49:28

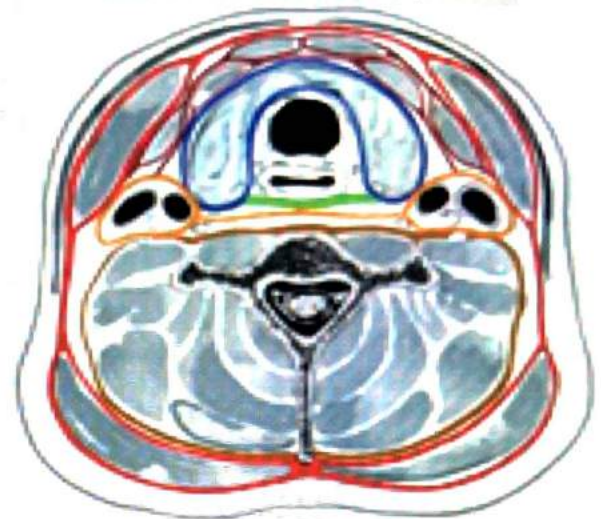


Carotid sheath space:

🕒 00:51:06

- This space is formed by all three layers
- Consists ICA, IJV, CNX
- It can also lead to mediastinitis
- This space is also known as Lincoln's highway

Carotid Sheath Space



? Previous Year's Questions

- Q. Ludwig's Angina occurs due to infection of:
(DNB June 2018)
- Submandibular space
 - Retropharyngeal space
 - Pharyngomaxillary space
 - Peritonsillar space

? Previous Year's Questions

- Q. A 15yrs old boy presented with history of fever since last 2 days. He is unable to swallow food and having muffled voice. On examination it is noted that right tonsil is shifted to midline. What is the diagnosis:
(FMGE DEC 2017, JUNE 2018, DEC 2018, JUN 2019, DEC 2019)
- Quinsy
 - Acute tonsillitis
 - Parapharyngeal abscess
 - Acute retropharyngeal abscess

? Previous Year's Questions

- Q. A 7yrs old child presented with Quinsy & severe Trismus. What will be the next line of Management?
- Intraoral incision & drainage
 - IV antibiotics for 48 hrs
 - External drainage
 - Tracheostomy



LEARNING OBJECTIVES



Larynx

- Anatomy of larynx
- Congenital Disease & Benign Lesions of Larynx



43

EMBRYOLOGY OF LARYNX

Branchial Arches

00:00:46

- Larynx is formed by 2 arches:
 - 4th Branchial arch
 - 6th Branchial Arch

4th Branchial arch

- Blood supply
 - Right-Rt. Subclavian Artery
 - Left-Arch of Aorta
- Nerve supply: Superior laryngeal Nerve branch of vagus nerve.
 - Supplies to cricothyroid and all constrictor muscle except cricopharyngeus

6th Branchial Arch

- Blood supply
 - Right - Rt. Pulmonary Artery
 - Left - Ductus Arteriosus
- Nerve supply: Recurrent laryngeal nerve branch of vagus nerve
 - It supplies to Cricopharyngeus muscle and all intrinsic muscle except cricothyroid muscle.

Cartilages of larynx

00:04:08

4th Branchial arch

- 4th Branchial arch + 3rd Branchial arch they together they

form a Hypobranchial eminence.

- Hypobranchial eminence form posterior 1/3rd of tongue and epiglottis
- 4th Branchial arch also forms thyroid, corniculate, cuneiform cartilage

6th Branchial Arch

- 6th Branchial arch forms the Cricoid and arytenoid cartilage

3 unpaired cartilages

- Thyroid (forms Adam's apple)
- Epiglottis (never ossify)
- Cricoid (only complete ring of cartilage)

3 paired cartilages

- Arytenoid
- Corniculate
- Cuneiform



Previous Year's Questions

Q. Which of the following structure of larynx has least chances of getting calcified?

(FMGE June 2021)

- A. Thyroid cartilage
- B. Epiglottis cartilage
- C. Cricoid cartilage
- D. Arytenoid cartilage



44

STRUCTURAL ANATOMY OF LARYNX

ANATOMY OF LARYNX

00:01:00

- Adults - C3 to C6 Vertebra
 - Can't eat and breathe at same time
- Neonate - C2 to C4
 - Eat and breathe at a same time

Arytenoid Cartilage:

- Pyramid in shape
- Muscular process gives attach to intrinsic muscle
- Posterior 1/3rd of vocal folds are formed by vocal process of arytenoid cartilage

CARTILAGES OF LARYNX

00:03:36

3 unpaired cartilages

- Thyroid (forms Adam's apple)
- Epiglottis (never ossify)
- Cricoid (only complete ring of cartilage)

3 paired cartilages

- Arytenoid
- Corniculate
- Cuneiform

Epiglottis:

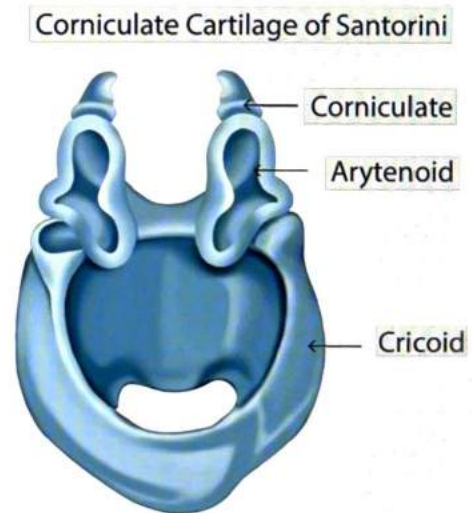
- Thin leaf like elastic cartilage
- Never ossifies

Thyroid cartilage:

- Made up of Hyaline Cartilage
- Two laminae meet and form an Thyroid angle.
- Male - 90°; Female - 120°
- Laryngeal prominence of thyroid cartilage - Adam's Apple

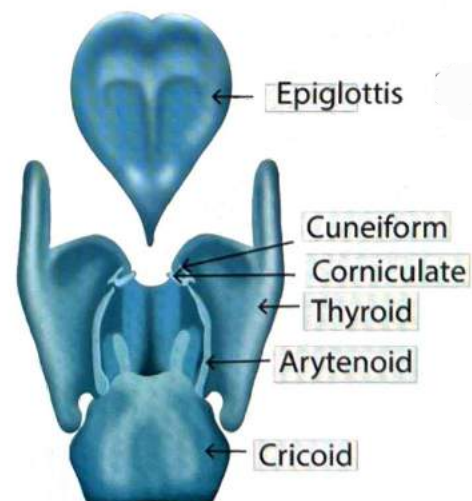
Corniculate Cartilage:

- Above the arytenoid, a pair of Corniculate cartilage is found
- Made of small fibroelastic cartilage



Cuneiform cartilage:

- Fibroelastic cartilage
- Found inside AE Fold (Aryepiglottic)
- Mucosal fold - AE fold



Previous Year's Questions

Q. Adam's apple seen in boys is because of: (FMGE Jun 2018)

- Hyoid bone
- Tracheal rings
- Thyroid cartilage
- Cricoid cartilage

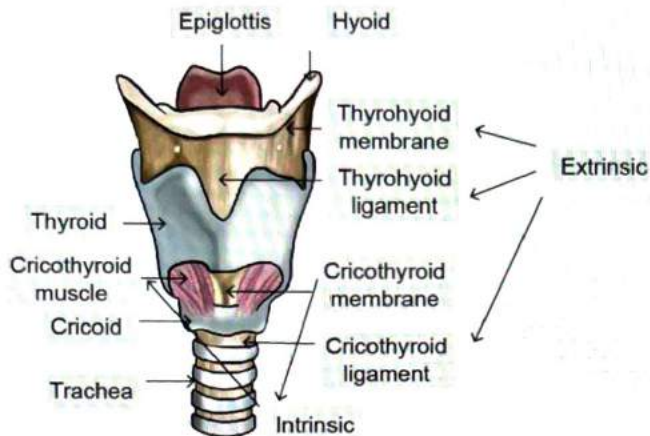
Cricoid cartilage:

- Only complete Ring
- Also made up of Hyoid bone
- Ossifies with age
- Cricoarytenoid and cricothyroid joint are Synovial Joint.

STRUCTURES OF LARYNX

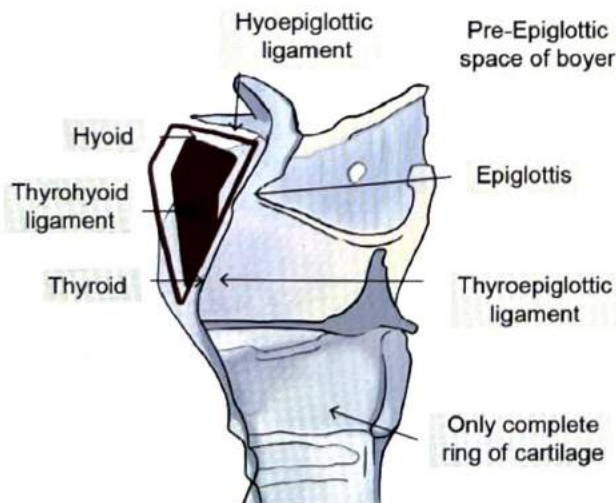
00:15:02

Front view of Larynx



- Any muscle / Membrane/ Ligament that is present in b/w 2 cartilage: Intrinsic
- Any muscle/ membrane/ligament that connects cartilage to external surface: Extrinsic
- Extrinsic structure
 - Thyroid membrane
 - Thyrohyoid ligament
 - Cricotracheal ligament
 - Hypoepiglottic ligament
- Intrinsic Structure
 - Cricothyroid membrane
 - (ELN) Cricothyroid muscle
 - Cricothyroid ligament
 - Thyroepiglottic ligament

CROSS SECTION OF LARYNX



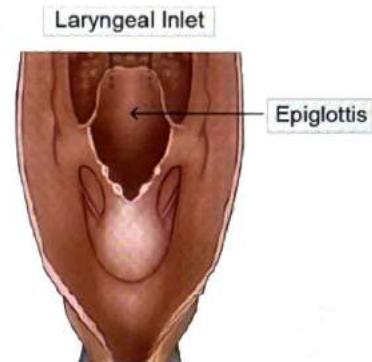
- Cricoid cartilage - only complete ring of cartilage in whole human airway
- Anterior to epiglottis there is space ka Pre Epiglottic Space of Boyer

Pre Epiglottic-Space of Boyer

- Boundaries
 - Superior: Hyoepiglottic ligament
 - Posterior: Epiglottis and thyroepiglottic ligament
 - Anteriorly: Body of Hyoid, Thyrohyoid ligament and small part of thyroid cartilage
 - Space is open on 2 sides and communicate with paraglottic space of tucker

LARYNGEAL INLET

00:24:29



- Consist of epiglottis, Arytenoid in the posterior end , between the Arytenoid and epiglottis there is Aryepiglottic fold

PARTS OF LARYNX

00:26:32

- Glottis: part that contain vocal folds
- Supraglottis: part above the glottis
- Sub Glottis is formed by a complete ring of Cricoid cartilage

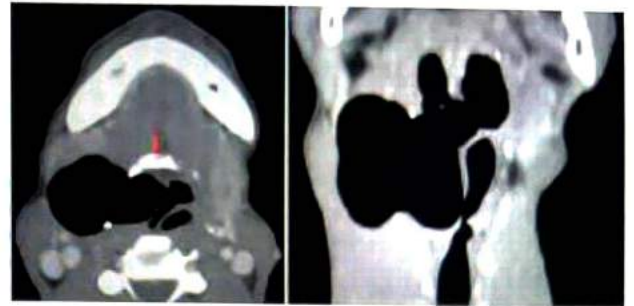
SUPRAGLOTTIS

00:27:28

- In Supraglottis there is a false vocal cord.
- Between the Arytenoid and epiglottis there is Aryepiglottic fold
- Laryngeal vestibule, Imaginary space in the airway which starts from the laryngeal inlet and ends in the false vocal cord
- Nowadays False vocal cord is known as Vestibular/ventricular folds
- Inside Vestibular folds there is membrane of k/a Quadrangular membrane
- They are called ventricular folds because they enclose a space k/a ventricle.
- Ventricle is only true space of larynx Rest all are potential spaces.
- Inside the supraglottis
 - Epiglottis
 - AE folds
 - Arytenoids
 - Vestibular folds
- Hyoid bone divides the epiglottis into 2 parts:

- Suprahyoid
- Infrahyoid
- Malignancy subsites for Supraglottis
 - Suprahyoid
 - Infrahyoid
 - AE folds
 - Pair of Arytenoids
 - A pair of ventricular folds
- Pressure produced by glottis closure
- Ventricles starts increasing in size
- Ventricle will cross the level of thyroid cartilage and comes out to neck forms a cystic swelling known as LARYNGOCELE

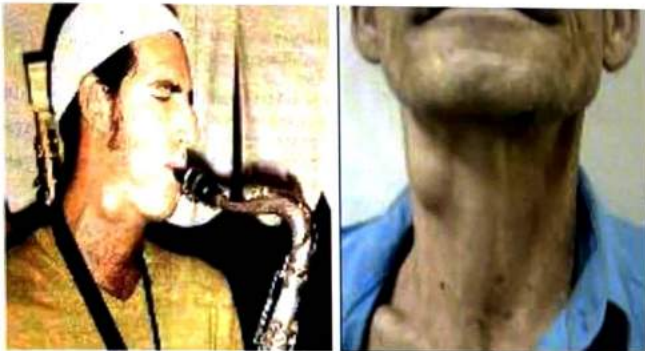- Investigation of choice for laryngocele:
 - CT scan in Valsalva Procedure



LARYNGOCELE

🕒 00:42:07

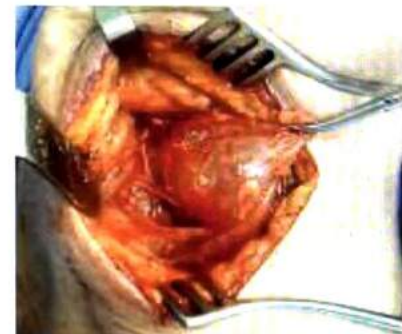
- Air filled cystic swelling in the Neck
- Arises from Anterior most part of ventricle-SACCULE



TREATMENT OF LARYNGOCELE

🕒 00:47:16

- External - Surgical excision
- Internal - Micro laryngeal Surgery
- Combined - Surgical excision

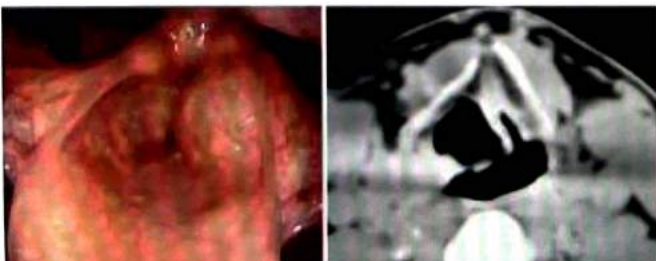


- Types:
 - External - BRYCE sign : on pressing, the swelling decreases with a gurgling sound of air escape
 - BOYCE SIGN- seen in Zenker's diverticulum(Sound of fluid escape)

INTERNAL LARYNGOCELE:

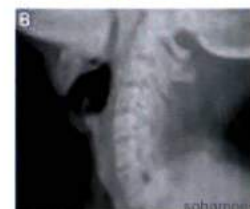🕒 00:44:49

- Foreign body sensation in throat, cough, noisy breath.
- Voice change, difficulty in breathing
- O/E - smooth swelling of vestibular fold & Ant epiglottic fold.



Previous Year's Questions

Q. A professional trumpet blower presents with left sided neck swelling which is reducible. Following is the Xray findings of the patient. What is the most likely diagnosis?(FMGE Aug 2020)



- Laryngocele
- Thyroglossal cyst
- Pharyngeal pouch
- Branchial cyst

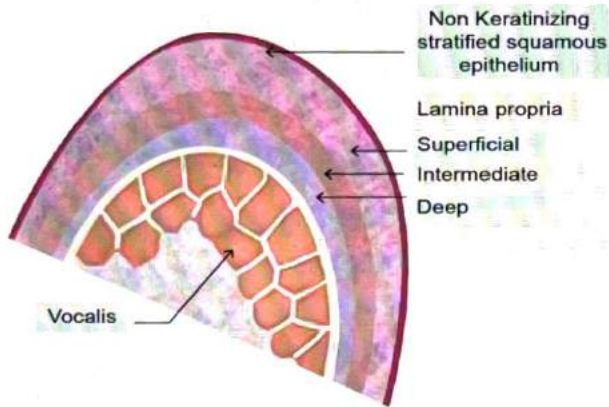
GLOTTIS

- Pair of vocal folds - true vocal cord

00:49:43

LAYERS OF VOCAL FOLD

00:50:39



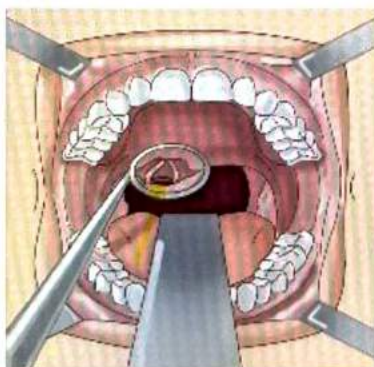
5 layers:

- Vocal fold consists of
 - Non keratinizing stratified Squamous epithelium
 - Lamina propria
- Superficial layer of lamina propria consists of loose areolar tissue known as Reinke's space
 - Reinke's edema is seen in smokers
- Intermediate and deep layer combines to form the vocal ligament.

INDIRECT LARYNGOSCOPY

00:54:38

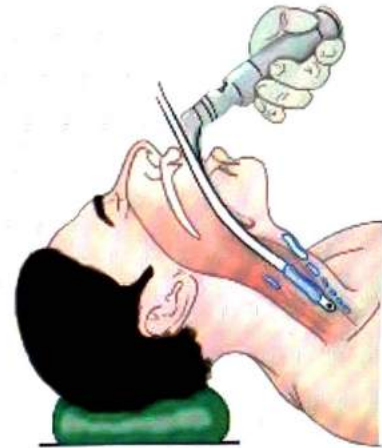- Structures seen:
 - Epiglottis
 - Anterior commissure
 - Vestibular folds
 - Vocal folds
 - Pyriform fossa
 - Posterior commissure
 - Rima glottidis – area b/w free margins of two vocal folds
 - Glottis – narrowest part of airway is adults
 - Subglottis is narrowest part of airway is neonates



DIRECT LARYNGOSCOPY

00:59:33

- Used while endotracheal intubation



INDIRECT LARYNGOSCOPY VS DIRECT LARYNGOSCOPY:

01:00:25

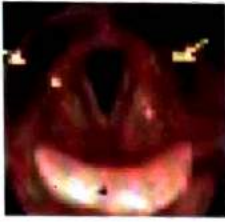Indirect Laryngoscopy	Direct Laryngoscopy
Image: Virtual, Smaller, Inverted	Actual larynx
Ease of Procedure Can be done in OPD	Requires OT
Phonation Possible (vocal fold movement can be seen)	Not possible (movement cannot be seen)
Patient Cooperation Required (cannot be done in Children)	Not required (can be done)
Additional Procedures (Biopsy) Cannot be done	Can be done
Hidden areas Not seen	Seen

Hidden areas of Larynx

- Ventricle
- Subglottis
- Anterior commissure
- Laryngeal surface of epiglottis
- Post cricoids area

Previous Year's Questions

Q. Identify the structure being marked as "B"?



- a. Pyriform fossa
- b. Epiglottis
- c. Laryngeal Inlet
- d. Aryepiglottic Fold

SUBGLOTTIS

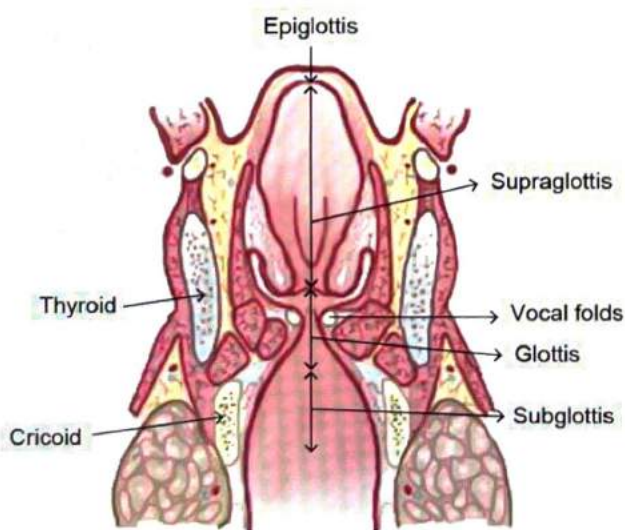
01:06:18

- Subglottis always proceeds with stridor
- Consists of ring of cricoid cartilage

BOUNDARIES OF PARAGLOTTIC SPACE OF TUCKER

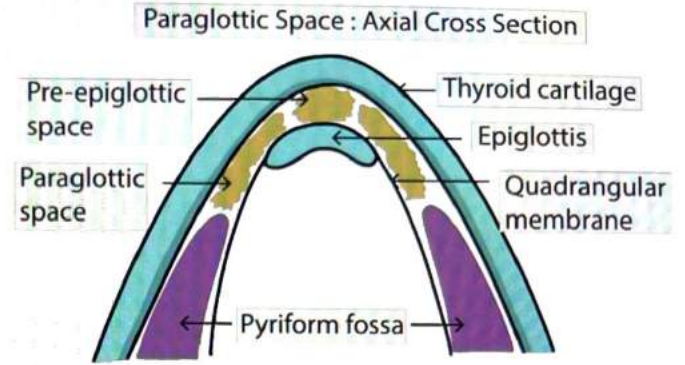
01:07:11

- Anterior lateral: Thyroid cartilage
- Superomedial: vestibular folds along with the Quadrangular membrane
- Inferio medial boundary: conus elasticus
 - Conus Elasticus: At the inferior surface of the vocal folds there is a membrane which Connects the vocal ligament to the Cricoid cartilage
- Any Malignancy that reaches Paraglottic space of Tucker is K/a Trans-glottic Malignancy and is considered as T3 stage



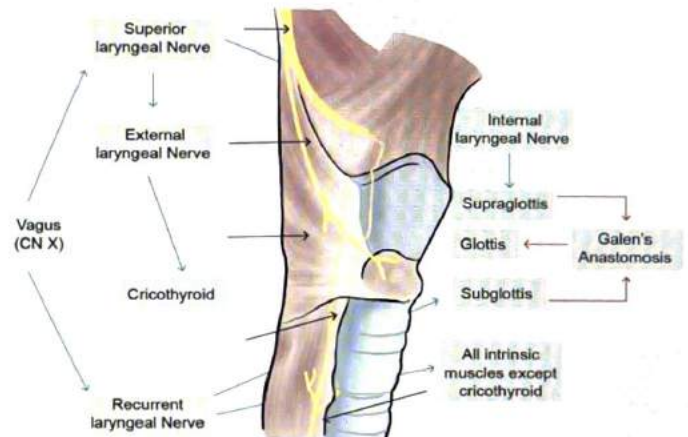
AXIAL CROSS SECTION OF PARAGLOTTIC FACE

01:14:48



NERVE SUPPLY OF LARYNX

01:17:28



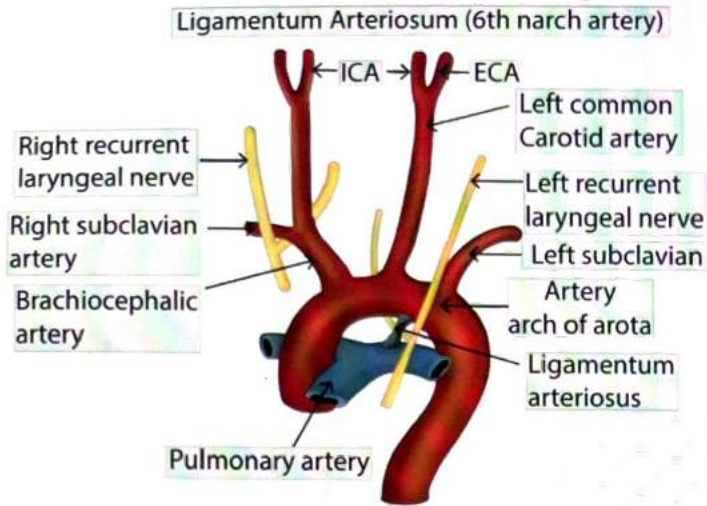
- Larynx is supplied by vagus verve (X.C.N)

2 Terminal branches

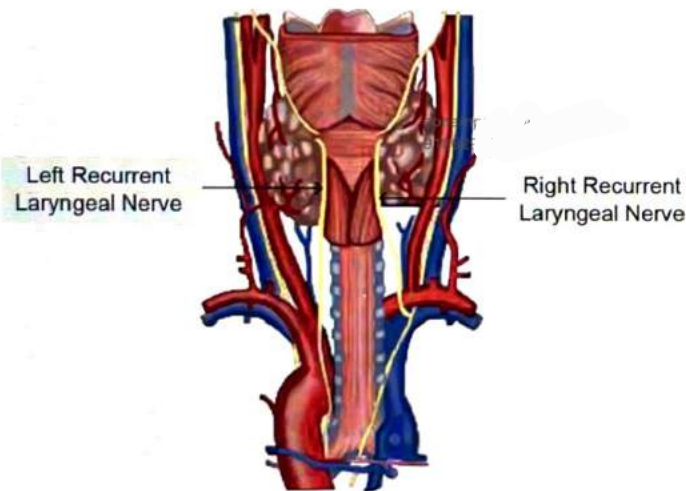
1. Superior laryngeal nerve (SLN)
 2. Recurrent laryngeal nerve (RLN)
- Superior laryngeal nerve, near the hyoid bone further divides into 2 Branches
 - External laryngeal nerve
 - External laryngeal nerve supplies cricothyroid muscle (Only intrinsic muscle, supplied by External laryngeal Nerve)
 - Internal laryngeal nerve
 - Internal laryngeal nerve gives sensory supply to Supraglottis
 - Recurrent laryngeal nerve supplies all intrinsic muscles except cricothyroid.
 - Also give sensory supply to subglottis
 - At level of glottis internal laryngeal nerve from Supraglottis & recurrent laryngeal nerve from subglottis both comes & from Galen's anastomosis
 - Galen's Anastomosis supply glottis

DEVELOPMENT OF AORTIC ARCH

01:21:01



- Left RLN has a longer course because it takes a turn around the 6th arch artery (Ligamentum arteriosum)
- M/c injured in thyroid surgery: external laryngeal nerve
- Left recurrent laryngeal nerve has a longer course so it is more commonly injured in cardiothoracic surgery
- Right recurrent laryngeal nerve is superficial therefore its more commonly injured in neck surgery



Previous Year's Questions

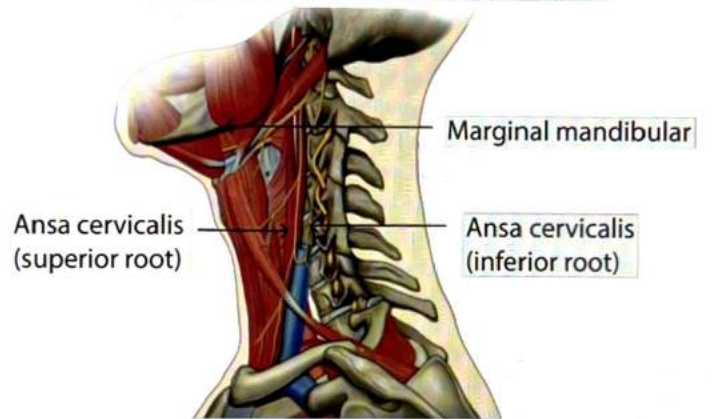
Q. Which of the structures has changes of least injury during Thyroid Surgery?

- Recurrent Laryngeal Nerve
- Superior Laryngeal Nerve
- Ansa Cervicalls
- Marginal Mandibular Nerve

ANSA CERVICALIS & MARGINAL MANDIBULAR

01:27:43

Marginal Mandibular & Ansa Cervicalis



MUSCLES OF THE LARYNX

01:29:37

- Muscles include
 - Thyroarytenoid muscle
 - Lateral cricoarytenoid
 - Posterior cricoarytenoid: posterior most muscle of larynx
 - Interarytenoid: only unpaired intrinsic muscle of larynx and its having bilateral innervations
 - Cricothyroid: only intrinsic muscle present on the external surface
- Primary function of larynx is to protect the Airway
- Voice production - secondary function
- All the muscles are adductors except posterior cricoarytenoid (only abductor of Larynx)
- Safety muscle of Larynx: Posterior cricoarytenoid

Lateral cricoarytenoid muscle:

- If muscle contracts, it rotates the arytenoid, brings vocal fold together causes Adduction.

Transverse Arytenoid :

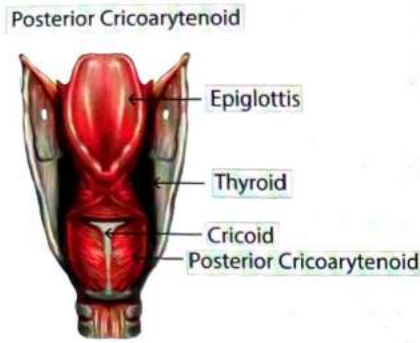
- It is the interarytenoid
- It is the only unpaired intrinsic muscle
- Supplied by RLN for both Right & Left.

Previous Year's Questions

Q. Left Recurrent laryngeal Nerve has a longer course because of which arch artery? (NEET PG Jan 2020)

- 1 Arch
- 2nd Arch
- 4th Arch
- 6th Arch

Posterior Cricoarytenoid:



- Posterior most muscle of Larynx
- This muscle contracts, opens airway
- Only abductor muscle of larynx
- Safety muscle of larynx

Cricothyroid muscle:

- Tensor of vocal folds: Cricothyroid
- Vocal fold - longer, sharp margin.



Previous Year's Questions

Q. What is the tensor of vocal cords? (NEET Jan 2018)

- Cricothyroid
- Lateral cricoarytenoid
- Lateral part of thyroarytenoids
- Posterior cricoarytenoids

PHONASTHENIA

01:45:23



Previous Year's Questions

Q. Which of the following Laryngeal Muscles is the Abductor of Vocal Folds? (JIPMER Nov 2017)

- Cricothyroid
- Cricoarytenoid
- Posterior Cricoarytenoid
- Lateral Cricoarytenoid

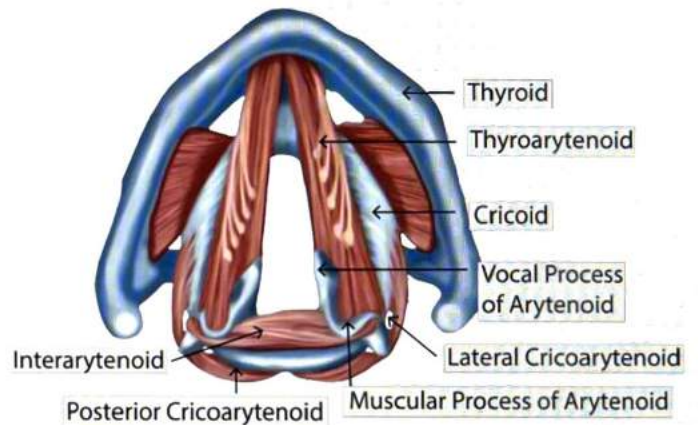


Previous Year's Questions

Q. Life saving muscle of vocal cord is (FMGE June 2018)

- Posterior Cricoarytenoid
- Cricothyroid
- Thyroarytenoid
- Lateral Cricoarytenoid

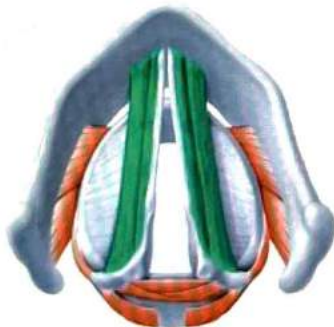
Phonasthenia



- Vocal fatigue
- Thyroarytenoid phonasthenia- spindle shaped defect
- Interarytenoid phonasthenia - posterior Triangular gap
- Combined phonasthenia - key hole appearance of glottis
- Rx: Voice rest followed by speech therapy

Thyroarytenoid and Vocalis:

- Relaxer of vocal fold: vocalis (medial fibers of Thyroarytenoid)
- Short, thick



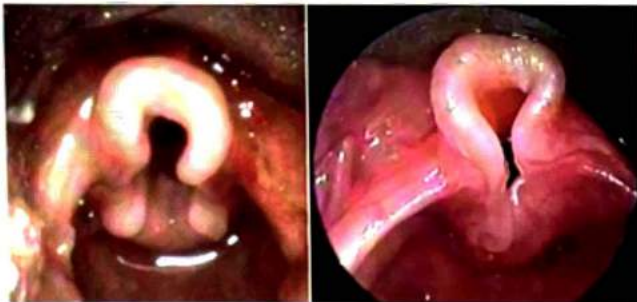

45 CONGENITAL LESIONS OF LARYNX

LARYNGOMALACIA

00:00:27

- M/C Congenital Anomaly of larynx
- Child is born with soft cartilages.
- Inspiratory stridor at Birth
- Cry is Normal as expiration is normal
- Crying increases Stridor
- Stridor decreases in prone position.



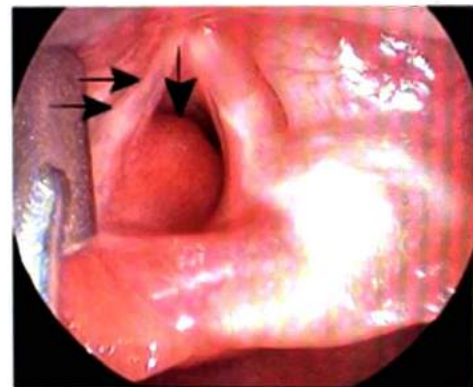
- Laryngoscopy is done to confirm Diagnosis.
- O/E: Omega shaped epiglottis, Floppy AE Folds, Prominent Arytenoids.
- RX: Conservative Treatment
- Disappears on its own by 2 yrs of age
- Surgery: SUPRAGLOTTOPLASTY

SUB GLOTTIC HEMANGIOMA

00:08:03

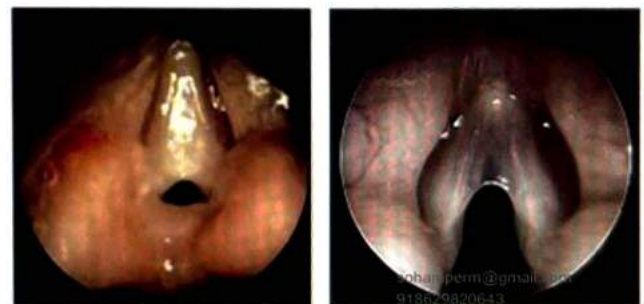
- Vascular Malformation in the Subglottis.
- C/F: Inspiratory stridor at child of 4-5 months of age
- Starts increasing in size at 3-5 months
- 50% of patients have Cutaneous hemangioma
- Diagnosis: Laryngoscopy - Reddish Blue Mass seen
- Rx:
 - Tracheostomy (secure airway)
 - CO₂ laser excision
 - Sclerotherapy
 - Injection of steroids
- Starts decreasing after 7-9 years of age

SUB GLOTTIC HEMANGIOMA



LARYNGEAL WEB

00:13:43



- Membrane formed due to incomplete canalization of airway
- M/C Site = Anterior Glottis (1/3rd)
- C/F: Biphasic stridor from birth
- Two types:



Important Information

- Laryngomalacia Stridor - mild to moderate which improves in Prone Position
- Subglottic Hemangioma stridor - Severe

SUPRAGLOTTOPLASTY

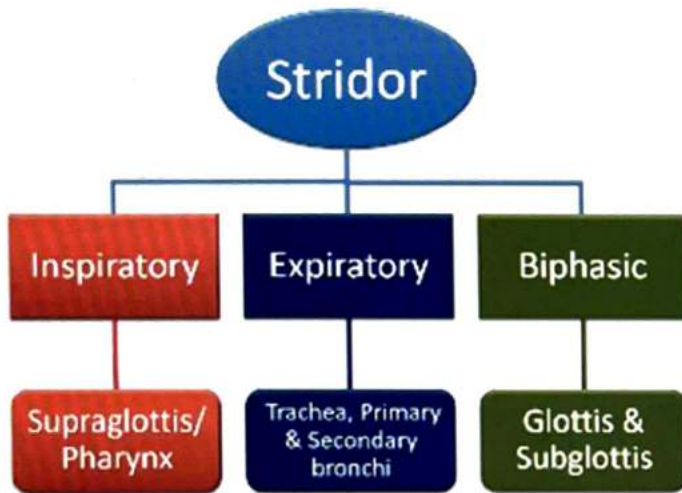


- Congenital
 - Incomplete canalization of airway
 - Cartilagenous
- Acquired
 - Due to trauma of vocal folds
 - Membranous
 - To prevent adhesions of vocal cord, both vocal cords surgery is not done at a same time.
- RX:CO₂ laser Excision + silicon keel

STRIDOR AND PHYSIOLOGY

00:18:17

- Supra glottis & Pharynx: Inspiratory Stridor
- Glottis & subglottis: Biphasic Stridor
- Trachea & bronchi: Expiratory Stridor



Previous Year's Questions

Q. Most common site for Laryngeal web is?

(FMGE DEC 2017/ FMGE JUN 2018)

- A. Supraglottis
- B. Subglottis
- C. Anterior glottis
- D. Posterior glottis

STRIDOR IN SUBGLOTTIC HEMANGIOMA

00:23:07

- Inspiratory stridor
- Airway negative pressure, exerts the pressure on hemangioma and pulled in
- Due to this, more blood goes to Hemangioma, size increases during Inspiration and shrinks during expiration
- So, during inspiration its blocks the airway causing Inspiratory stridor in Subglottic Hemangioma



Previous Year's Questions

Q. Inspiratory stridor is due to lesions of?

(NEET Jan 2019)

- A. Supraglottis
- B. Subglottis
- C. Trachea
- D. Bronchi



46 ACUTE & CHRONIC INFLAMMATION OF LARYNX

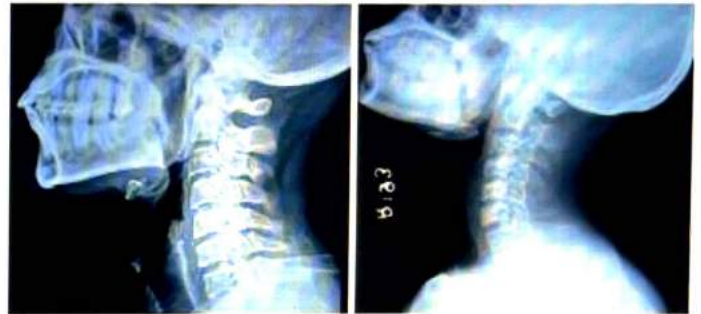ACUTE EPIGLOTTITIS / SUPRA - GLOTTITIS

00:00:13

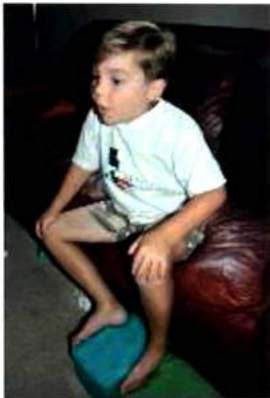- MCC : hemophilus influenza type B (HIB)
- In developed countries – streptococcus pneumonia
- Children = 2-7 years
- C/F:
 - Fever, Sore throat
 - Dysphagia
 - Drooling of saliva
 - Dyspnea
 - Tachypnea
 - Tachycardia
 - Tripod sign
 - Rising sun sign → red inflamed epiglottis

- Dx: X-ray STN- IOC
 - Thumb sign - swollen Thumb
 - Thickening of epiglottis

X - ray STN Lateral View

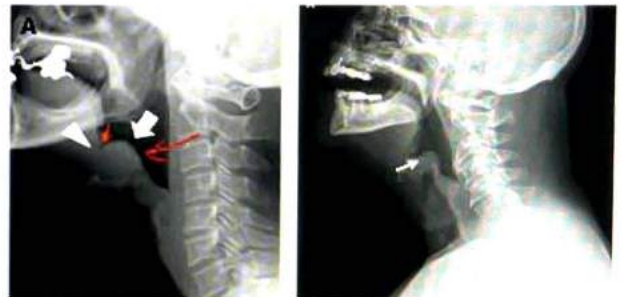

Tripod sign

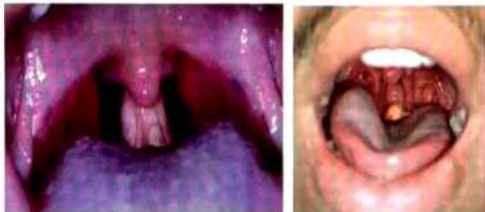


- Rx:
 - DOC → IV ceftriaxone
 - Steroids nebulization
 - Tracheostomy (if stridor is present)

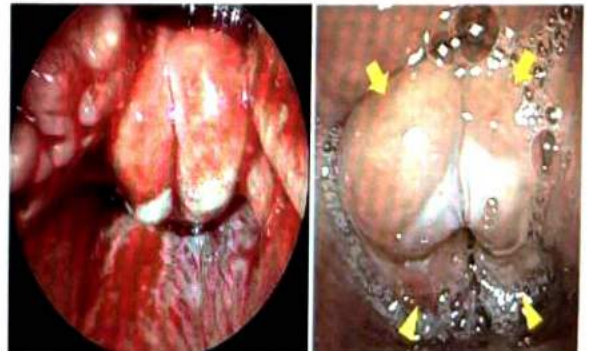
Vallecula Sign



Rising Sun Sign



Laryngoscopy: C/I



Important Information

Tongue depressor Laryngoscopy . Instrumentations is C/I

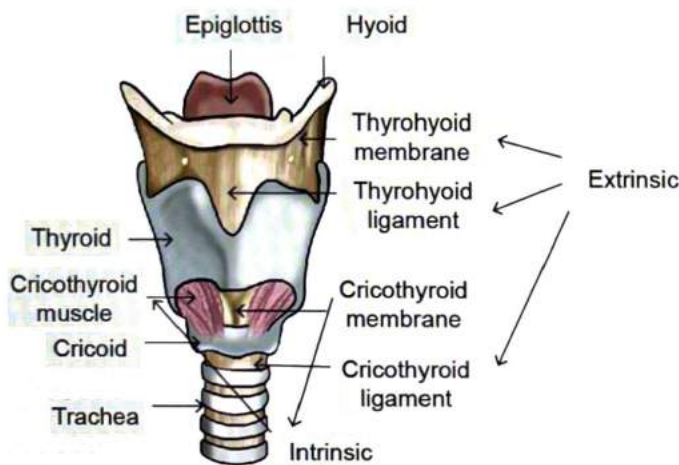
Previous Year's Questions

Q. A child presents with High Fever. Inspiratory Stridor and Develops Swallowing Difficulty with Drooling of Saliva Since last 4-6 Hours. Which of the following treatment is recommended Apart from General Airway Management? (AIIMS June 2020)

- A. Nebulized Racemic Epinephrine
- B. Anti Diphtheria Toxin
- C. Corticosteroids
- D. IV Ceftriaxone

SURGICAL ANATOMY OF NECK

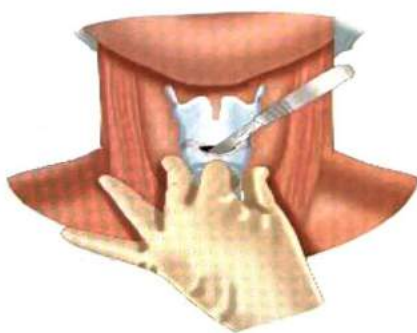
00:15:03



CRICOTHYROTOMY:

00:15:45

- Used to open up the airway in emergency situation (Done outside the hospital)
- Incision is given in cricothyroid membrane



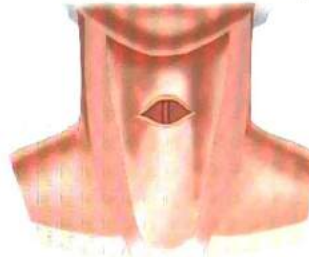
TRACHEOSTOMY

00:18:59

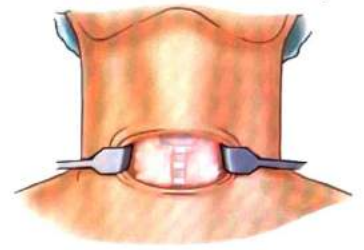
- Done in emergency/Planned
- In the hospital
- Steps of Tracheostomy:
 - Transverse incision through platysma
 - Midline of strap muscles

- Cricoid cartilage, 1st, 2nd, 3rd tracheal rings, thyroid gland visible
- Incise b/w 2nd & 3rd tracheal rings

Steps of Tracheostomy



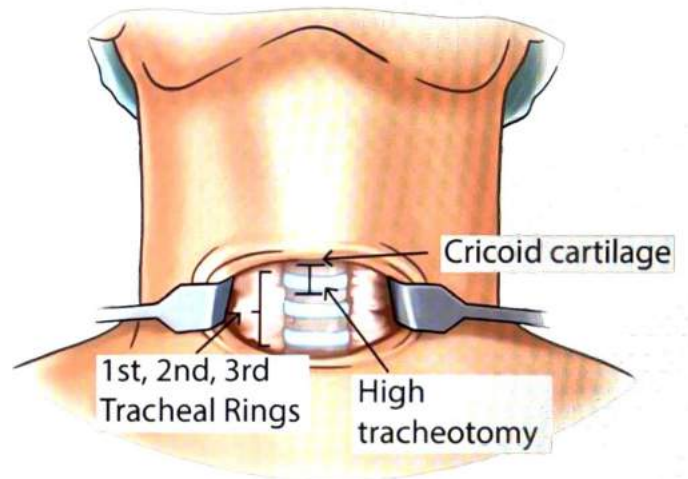
Steps of Tracheostomy



High Tracheostomy:

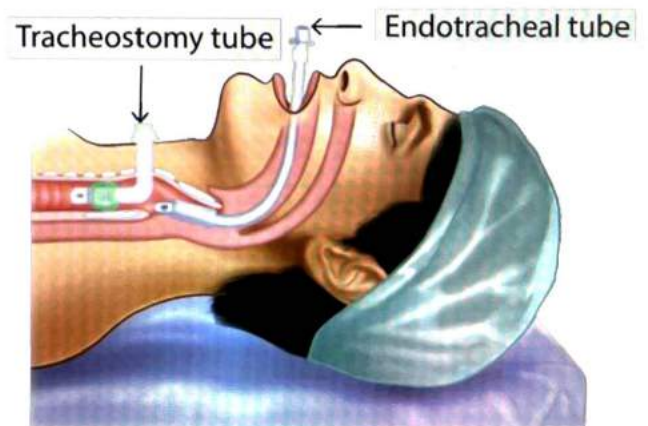
- Done in case of Carcinoma larynx, incision given b/w 1st & 2nd tracheal ring

High Tracheostomy



Tracheostomy tube Vs Endotracheal tube:

Tracheostomy vs Endotracheal Tube



Indication of Tracheostomy: 5R's

- Respiratory obstruction → High tracheostomy b/w 1/2nd rings
- Respiratory collapse

- Respiratory secretions
- Respiratory insufficiency → To decrease the Dead space .
Low tracheostomy - b/w 3/4th rings
- To secure the Respiratory pathway

- O/E:
 - Sub coastal, inter coastal retraction
 - B/L conducted sound on Auscultation
- C-X-Ray : Steeple sign
- Rx → Symptomatic Treatment.



How to remember

5R's

Complications of tracheostomy

- M/c (intraoperative) – Hemorrhage
- M/c (postoperative) - Subcutaneous Emphysema



Previous Year's Questions

Q. High tracheostomy is done in?(NEET Jan 2018)

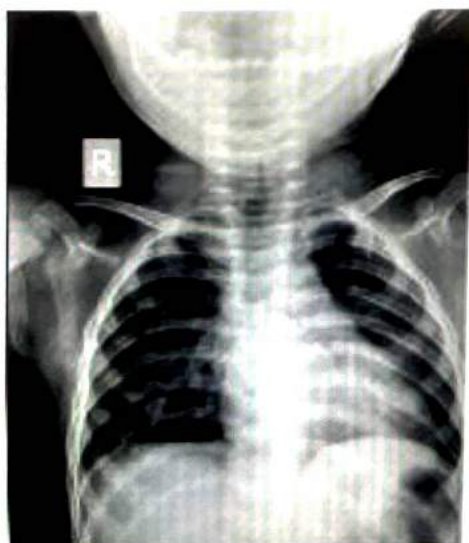- Vocal cord palsy
- Laryngeal carcinoma
- Subglottic Stenosis
- Laryngomalacia

ACUTE LARYNGO – TRACHEO BRONCHITIS (CROUP)

🕒 00:33:27

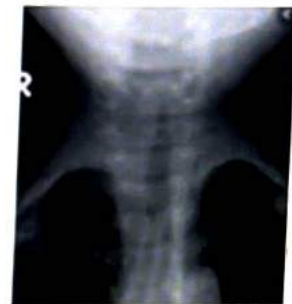- MCC- Para Influenza virus type 1,2
- Children = 3 months – 3 years
- C/F – Fever, cough (barking cough) , sore throat, Expiratory stridor
- Stridor: Initially it is Inspiratory later on become biphasic, some have expiratory stridor.

Steeple Sign



Previous Year's Questions

Q. A 2yrs old child presented with following X-ray finding. What is the most likely diagnosis ? (NEET PG Jan 2020)



- Actual Laryngotracheobronchitis
- Acute epiglottitis
- Acute Pharyngitis
- Parapharyngeal abscess



Previous Year's Questions

Q. A 2yrs old child presents with complaints of fever, barking cough and stridor for 2 days. What is the most likely diagnosis ? (FMGE June 2018)

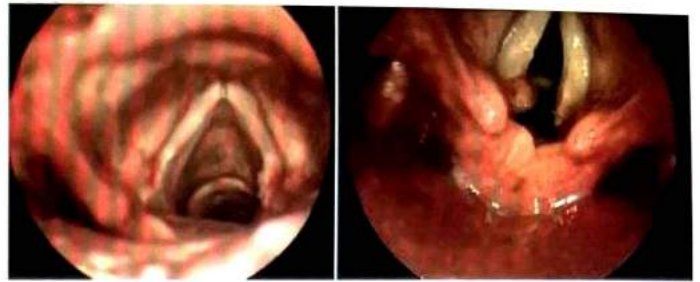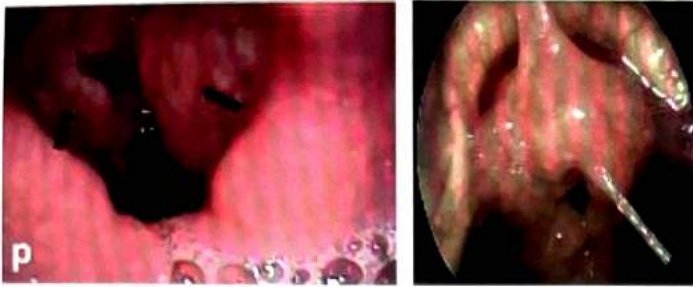
- Acute Tonsillitis
- Acute Tonsillitis
- Croup
- Adenoiditis

LARYNGEAL TB

🕒 00:39:42

- Always associated with pulmonary TB
- Submucosal nodules
 - M/C site : Posterior larynx
 - 1st sign : Hyperemia of vocal fold with Incomplete adduction
 - Mamillated appearance of nodules
 - Mouse nibbled appearance of vocal folds
 - Turban epiglottis
- Rx:
 - Pulmonary TB

LARYNGEAL TB

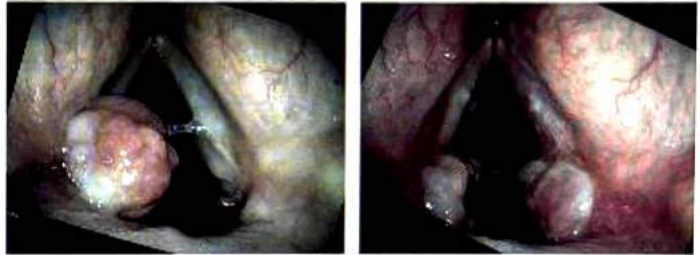


CONTACT ULCER / GRANULOMA

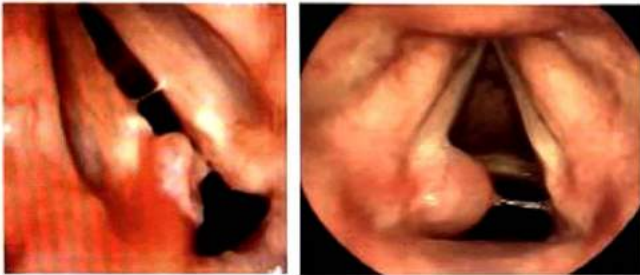
00:44:10

- M/c site: Posterior 1/3 of vocal folds
- MCC: LPR (Laryngo-pharyngeal reflux)
 - Other Vocal abuse
- C/F → Hoarseness of voice
- In long term intubation - intubation granuloma
- Rx
 - PPIs with speech therapy (For LPR)
 - Intubation granuloma - Rx → Antibiotics and steroids

Intubation granuloma



CONTACT ULCER / GRANULOMA





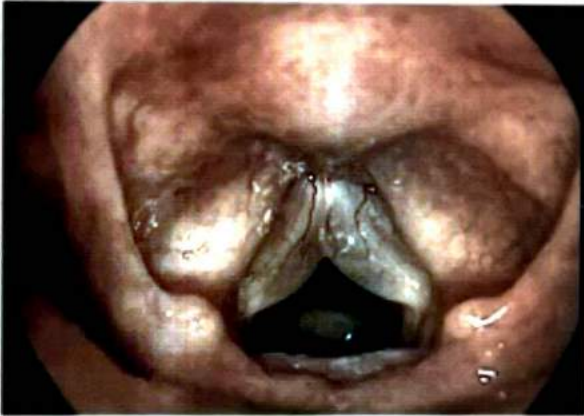47 BENIGN LESIONS OF LARYNX

REINKE'S EDEMA

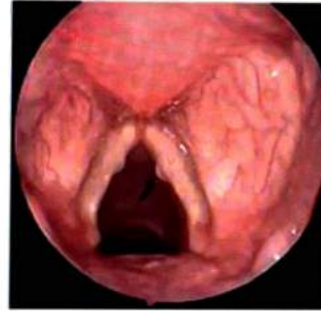00:00:18

- Edema of Reinke's space
- Mcc – Smoking
 - Other- Faulty speech
- Boggy spindle shaped vocal folds → SMOKER'S POLYPS
- Females
- Rx:
 - Cessation of smoking
 - Strippling of epithelium from vocal folds

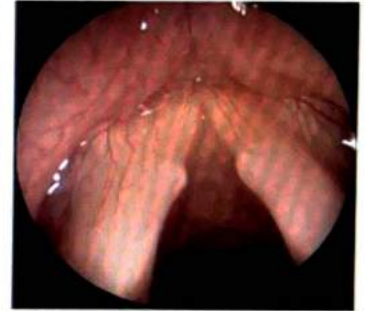Reinke's Oedema



Vocal Nodule/ Singer's Nodule



Early (Soft) Nodule



Late (Hard) Nodule

VOCAL NODULE / SINGER'S NODULE / SCREAMER'S NODULE

00:03:50

- It is due to chronic misuse of voice
- C/C: Hoarseness of voice
- O/E: B/L symmetrical, Vocal nodule is sessile on free margin
- It is present at Junction of Anterior 1/3rd and posterior 2/3rd (area of maximum vibration)
- Rx:
 - Speech therapy (TOC)
 - PPI (LPR's is a major contributor).
 - **Early/ soft nodules**
 - With speech therapy & PPI
 - **Late/ hard nodules**
 - RxOC – speech therapy & PPI
 - Surgery



Previous Year's Questions

- Q. Which of the following is true regarding Singer's nodule? (NEET Jan 2018)
- Lasert therapy is treatment of choice
 - It occurs at junction of anterior 1/3rd and posterior 2/3rd
 - Requires excision as its potentially malignant
 - Most common symptom is pain

VOCAL POLYP

00:10:45

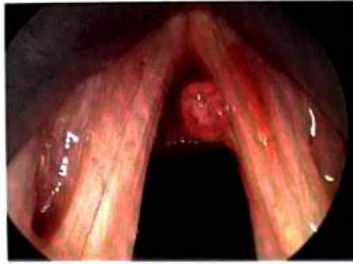- Single, U/L, pedunculated, moves Respiration
- M/C site → Anterior 1/3rd and posterior 2/3rd
- Cause - Sudden vocal abuse
- C/F - Hoarseness, diplophonia
- Rx → Micro laryngeal Surgery



How to remember

MLS

Vocal Polyp

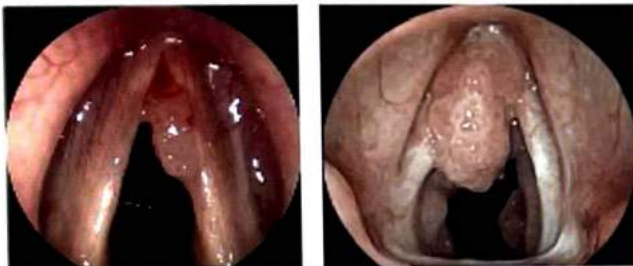

LARYNGEAL PAPILOMA

00:14:10

- Caused by HPV6, 11
- Benign lesion
- Adult papilloma
 - Single, U/L, large
 - Hoarseness of voice
 - Rx: MLS
 - Low recurrence

Laryngeal Papilloma

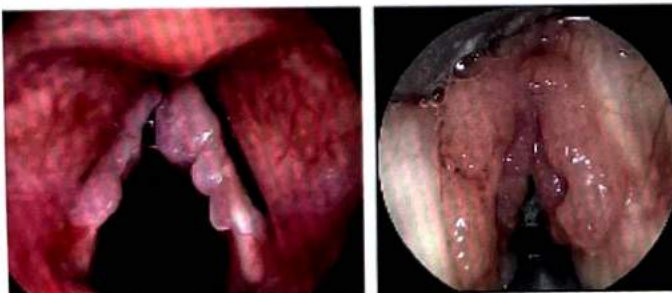


JUVENILE ONSET RECURRENT RESPIRATORY PAPILOMA (JORRP)

00:15:42

- Children (3-4 yrs age)
- Acquires during birth from mother (i.e. during NVD)
- M.c. in Primigravida
- Present with hoarseness/stridor
- Multiple/Bilateral/Small/ Arising at the junction
- Very high rate of recurrence

Juvenile Onset Recurrent Respiratory Papilloma (JORRP)



Treatment:

- Tracheostomy: Relative C/I
- If required, do low tracheostomy
- Do surgical excision
 - Earlier-Cold steel
 - Bleeding - scarring - high recurrence
 - Nowadays, CO₂ laser excision
 - Smoke fumes (Contagious) therefore perform microdebrider excision (T.O.C)
- Medical Rx (Adjunctive)
 - Interferon
 - Antiviral
 - Antiproliferative
 - Immunomodulatory
 - Bevacizumab – prevents angiogenesis
 - Cidofovir – Antiviral drug, Intralesional
 - Ribavirin-Antiviral drug, Aerosol spray/ Acyclovir, Cimetidine
- Photodynamic Therapy
 - Dihematoporphyrin Ether (DHE) Accumulates in papilloma
 - ↓
 - Give 50J of 630nm, of Argon laser light (TOC)
- Another therapy – Zinc therapy (to prevent the recurrence of JORRP)



Previous Year's Questions

- Q. Juvenile recurrent laryngeal papillomatosis is caused by: FMGE Dec 2017)
- A. EBV
 - B. HSV
 - C. HPV
 - D. VZV



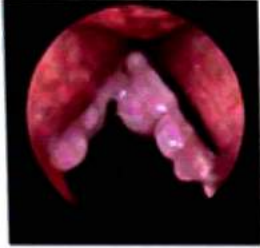
Previous Year's Questions

- Q. All are done for recurrent laryngeal papillomatosis except? (JIPMER Nov 2018)
- A. Zinc therapy
 - B. Intralesional cidofovir
 - C. Interferon alpha
 - D. Steroids



Previous Year's Questions

Q. A 2 month child who was borne by normal delivery to a primigravida lady presented with hoarseness and below finding on Laryngoscopy. What could be possible diagnosis?



- A. Laryngomalacia
- B. Recurrent laryngeal Papillomatosis
- C. Rienke's edema
- D. Malignancy

VOCAL CYST

00:33:36

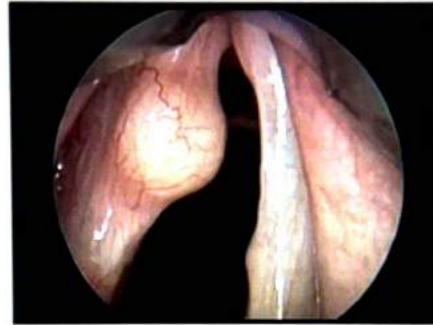- Collection of fluid in vocal fold
- Patient present with hoarseness of voice
- Rx: Micro laryngeal Sx (MLS)



Important Information

- D/D: Lipoma (Diagnosis made during Sx)

Vocal Cyst





48 VOCAL FOLD PALSY

ANATOMY OF LARYNX

00:00:39

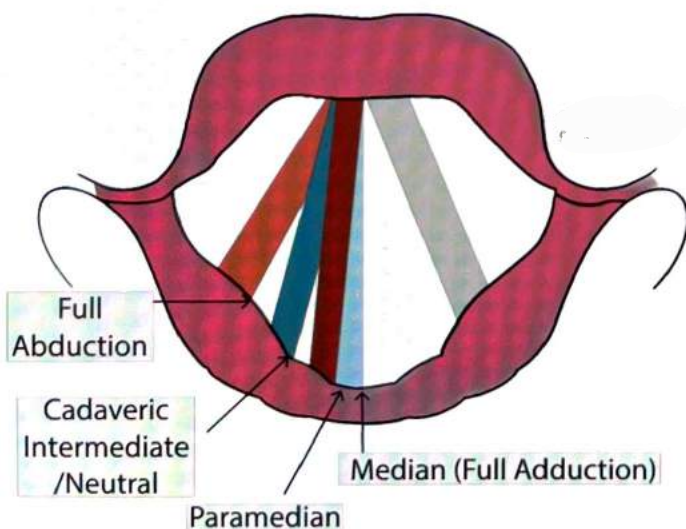
Nerves Supply of larynx

- Larynx is supplied by vagus nerve (X C.N)
 - Superior laryngeal nerve (SLN)
 - Recurrent laryngeal nerve (RLN)
- Superior laryngeal nerve, near the hyoid bone further divides into 2 Branches
 - External laryngeal nerve
 - External laryngeal nerve supplies cricothyroid muscle (Only intrinsic muscle, supplied by External laryngeal Nerve)
 - Internal laryngeal nerve
 - Internal laryngeal nerve gives sensory supply to Supraglottis
- Recurrent laryngeal nerve supplies all intrinsic muscles except cricothyroid.
- All the muscles are adductors except posterior cricoarytenoid (only abductor of Larynx)
- Tensor of vocal folds: Cricothyroid
- Relaxer of vocal fold: vocalis (medial fibers of Thyroarytenoid)

POSITION OF VOCAL FOLD

00:02:43

- Median
- Para-median
- Cadaveric/intermediate/neutral position
- Full Abduction



? Previous Year's Questions

- Q. Neutral position of Vocal cord is? (JIPMER May 2018)
- Paramedian
 - Median
 - Intermediate
 - Abduction

Semon's Law

00:05:49

- In case of any progressive neurological disorders, the Abductor fibres of RLN are 1st to be affected [Phylogenetically new] →Vocal folds lie in adduction

Wagner & Grossman Hypothesis

- All muscle are causing adduction in larynx, In RLN palsy all undergo palsy except cricothyroid [Supplied by external laryngeal Nerve] which is the reason for unopposed adduction

VOCALFOLD PALSY

U/L external laryngeal nerve palsy

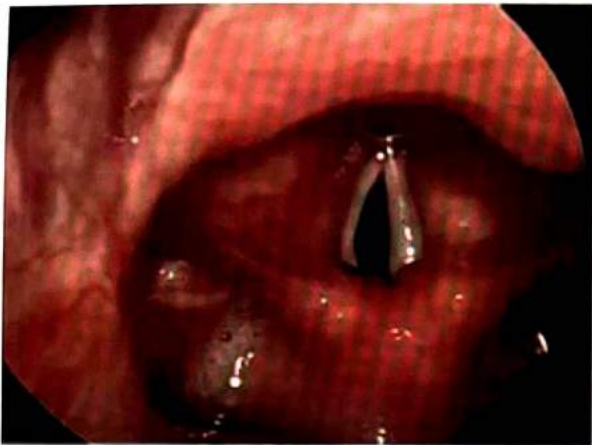
- M.C Cause: Thyroid surgery
- M.C Nerve injured in thyroid surgery is external laryngeal nerve
- ELN > right RLN > left RLN
- Go unnoticed
- There is loss of pitch
- If patient has U/L superior laryngeal Nerve palsy (External laryngeal nerve + internal laryngeal nerve palsy): P/t has aspiration
- Rx: Conservative

U/L Recurrent laryngeal nerve palsy

00:17:38

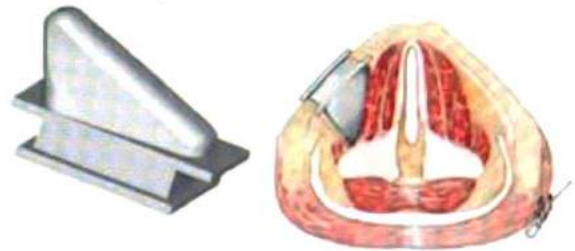- AKA Abductor Palsy
- Right is M.C Injured during thyroid surgery
- Left is M.C injured during cardiothoracic surgery as it has longer course in thorax
- Patient present with transient Hoarseness
- Vocal ford lies in Para median position due to unopposed Adduction.
- Compensatory hypertrophy of other vocal fold in few weeks-months →voice will improve
- Rx: conservative

Unilateral RLN (abductor) Palsy



- Rx: Thyroplasty Type-I
 - Type I - ISSHIKI THYROPLASTY
 - Thyroplasty 1 Aka medialization thyroplasty , Approximation laryngoplasty
 - Benefits :
 - Improves the voice
 - In X nerve palsy, it prevents aspiration

Thyroplasty Type-I

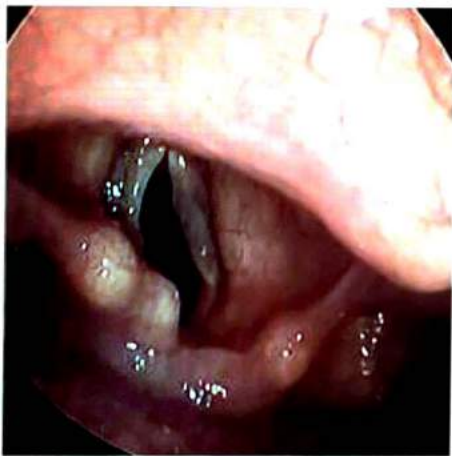

U/L 10TH CRANIAL NERVE PALSY

00:22:30

- (ELN + ILN + RLN) palsy
- M/C cause: Surgery
- C/C: Hoarseness, Aspiration
- Vocal folds lie in cadaveric position
- U/L vagus Nerve injury [ILN also included]
 - Problem of aspiration also present

Unilateral X Nerve (SLN+RLN)



? Previous Year's Questions

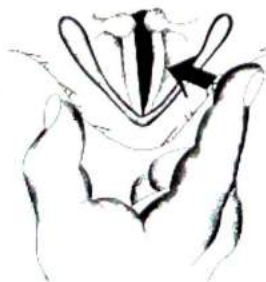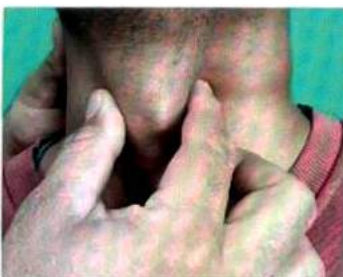- Q. What is the symptom of a person with unilateral abductor paralysis? (JIPMER Nov 2018)
- Dyspnoea on exertion
 - Transient hoarseness
 - Husky voice
 - Inspiratory stridor

? Previous Year's Questions

- Q. All of the following is seen in Superior Laryngeal Nerve palsy except: (FMGE Dec 2017, FMGE Jun 2018)
- Aspiration
 - Stridor
 - Bowel vocal cord
 - Loss of pitch

- Manual Compression test is done

RLN + SLN Palsy



Manual Compression Test

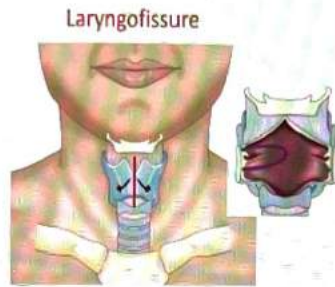

B/L RECURRENT LN PALSY

00:32:16

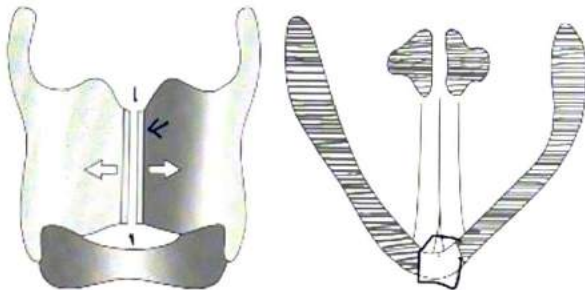
- M.C cause: Thyroid surgery
- Only 2-3 mm airway to breath
- C/C: Biphasic Stridor but voice Quality is good
- Both vocal folds lie in Para median position
 - ↓
 - So, airway is inadequate
- A/k/as B/L Abductor cord Palsy
- Rx:
 - Tracheostomy: to save airway
 - Type 2 Thyroplasty / Lateralization Thyroplasty
 - Laryngo fissure- Opening larynx from front in the

- midline
 → Kashima's operation (Endoscopic laser Cordectomy)
 → Kashima's operation: remove a part of posterior 1/3 rd of the vocal folds

**Kashima's Operation
 (Endoscopic Laser Cordectomy)**



Type 2 Thyroplasty: B/L RLN Palsy



★ Important Information

Severe Aspiration:

- Endotracheal intubation and Tracheostomy
- Thyroplasty type I-U/L

? Previous Year's Questions

Q. A patient underwent Lateral Skull base surgery few months back and has presented with complaints of recurrent aspirations. There is no change in voice of patient. Which of the following nerve is most likely injured during surgery? (AIIMS Nov 2019)

- A. Vagus
- B. Glossopharyngeal
- C. SLN
- D. RLN

PUBERPHONIA

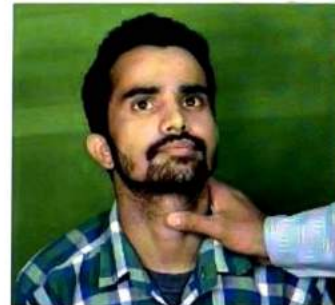00:54:25

- Female like voice in males
- GUTZMANN PRESSURE TEST – done to confirm whether the patient will improve with type 3 thyroplasty
- TYPE 3 THYROPLASTY (shortening/relaxation) is done

? Previous Year's Questions

Q. Kashima 's operation done for all conditions except? (JIPMER Nov 2018)

- A. Vocal cord dysplasia
- B. Calarynx
- C. Nasopharyngeal Ca
- D. Bilateral abductor palsy

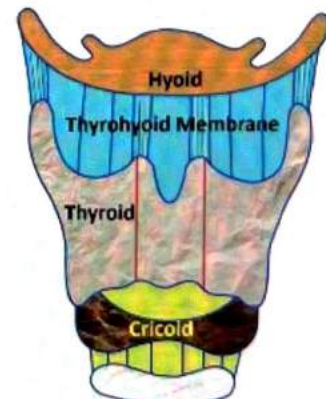


GUTZMANN PRESSURE TEST

B/L SUPERIOR LARYNGEAL NERVE PALSRY 00:43:02

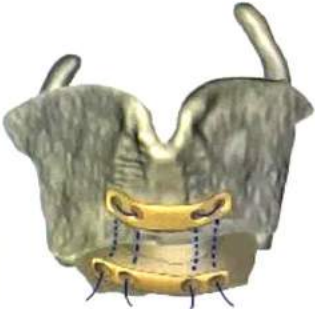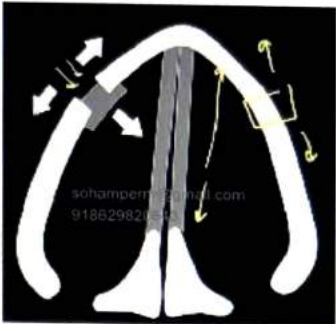- MC cause Thyroid surgery
- Cough reflex on both sides gone →Aspiration
- Gold standard Rx for Intractable aspiration → Tracheal separation & Permanent Tracheostomy - under LA
- Total laryngectomy + permanent tracheostomy also done under GA

TYPE 3 THYROPLASTY



Type 4 Thyroplasty

- Done for Androphonia [Male like voice in a female]
- lengthening/ Tension Thyroplasty





CLINICAL QUESTIONS



Q. A 21 years old female came to your clinic with complaints of a rough, low-pitched, unpleasant voice. The reason for the voice is found to be: phonation with the ventricular bands. Which of the following is responsible for the patient's condition(phonation)?

- A. False vocal cords
- B. True vocal cords
- C. Ventricle of larynx
- D. Epiglottis

Answer: A

Solution

DYSPHONIA PLICA VENTRICULARIS/VENTRICULAR DYSPHONIA:

- Voice is produced by ventricular folds (false vocal cords).
- Voice is rough, low-pitched, and unpleasant.



49

CARCINOMA LARYNX

INTRODUCTION

00:00:40

- Males (50-60yrs)
- M/C type – Squamous cell carcinoma (>95%)
- M/C site – glottis

RISK FACTORS OF CARCINOMA - GLOTTIS

00:02:06

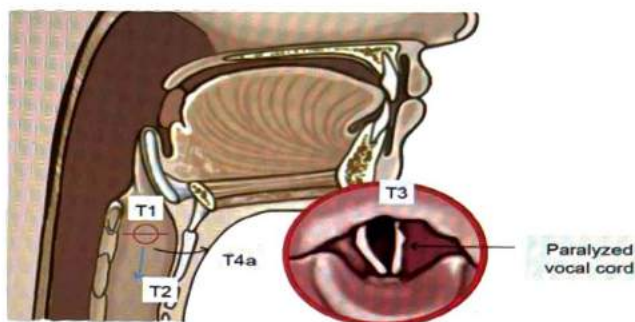
- Smoking –RR-3.4
- Alcohol –RR-6
- Combined RR-15

RISK FACTORS FOR HEAD AND NECK CANCERS

00:03:21

- Tobacco
- Alcohol
- Prolonged sun exposure
- Viruses – HPV, EBV
- Gender – M > F
- Age >40 yrs
- Oral/ dental hygiene – betel nut consumption
- Environmental/ occupational
- Poor nutrition – Vit A & B deficiency, IDA

- IOC - Direct laryngoscopic biopsy
- CT scan of neck- Extent of neck(T)
- X - Ray chest- Distant metastasis (M)



- T₁ → Free vocal fold mobility
 - T_{1a} one Vocal cord mobile
 - T_{1b} two Vocal folds mobile
- T₂ → Impaired vocal fold mobility
- T₃ → Fixed vocal fold (Palsy)



Important Information

3P

- Pre epiglottic
- Para glottic
- Post cricoid area

- T₄ → Outside larynx
 - T_{4a}
 - T_{4b}
 - Superior mediastinum
 - Prevertebral space
 - Encases carotid artery

Previous Year's Questions

Q. Which of the following is not a cause of Squamous cell carcinoma for head & neck: (AIIMS May 2019)

- EBV
- HPV
- Betel Nut
- Vitamin A

MOST COMMON PRESENTATION

00:07:28

- MC presentation for CA glottis
 - Hoarseness
 - Best prognosis - early presentation, late spread
- MC presentation for CA supraglottis
 - Foreign body sensation in throat
- MC presentation for CA subglottis
 - Stridor
 - Poor prognosis presents late

TNM STAGING FOR CA GLOTTIS

00:10:19

- Dx

TREATMENT FOR CA GLOTTIS

00:18:02

- T₁/T₂ Stage of CA Glottis
 - TOC- Radiotherapy (Follow up of 6 Wks required)
- T_{1a} -Laser Cordectomy
 - Poor voice results
 - Single sitting is enough
- T₃ Lesions
 - New TOC- Concurrent Chemo Radiotherapy (CCRT)
 - Exception
 - High volume tumor >20ml
 - Perichondritis, cartilage erosion / invasion is Absolute C/I For CCRT

- T_{4a} Stage :combined (surgery + Radiotherapy ± chemotherapy)
- T_{4b} Stage:
 - Incurable
 - Palliative therapy

TREATMENT FOR CARCINOMA SUPRAGLOTTIS

- T₁ -Radiotherapy
- T₂ - Partial laryngectomy + neck dissection
 - CCRT can be used if no LN involvement
- T₃ - Total laryngectomy + neck dissection
- T_{4a}
 - Combined modality
 - Total laryngectomy + RT ± CT
- T_{4b}
 - Incurable
 - Palliative therapy

00:36:46



Important Information

If anterior commissure is involved stage is T₁ but treated as T_{4a} lesion.

TNM STAGING FOR CA SUPRAGLOTTIS

00:29:51

- 5 sub sites
 - Supra hyoid epiglottis
 - Infra hyoid epiglottis
 - Arytenoids
 - Vestibular Folds
 - Aryepiglottic Vold



How to remember

VAASI

- T₁: any 1 subsite
- T₂: >1 subsite
 - Mucosa of base of tongue of glottis spread (No vocal fold palsy)
- T₃ →Vocal fold fixed
- T₄ →outside larynx
 - T_{4a}
 - T_{4b}:
 - Superior mediastinum
 - Prevertebral space
 - Encases carotid artery

TNM STAGING FOR CA SUBGLOTTIS:

00:34:22

- T₁
- T₂
 - Not seen as patient presents late
- T₃ →Fixed vocal Voids [Palsy]
- T₄ →Outside larynx
 - T_{4a}
 - T_{4b}
 - Superior mediastinum
 - Prevertebral space
 - Encases carotid artery



Previous Year's Questions

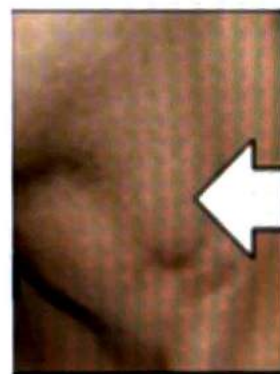
Q. A patient presents with hoarseness of Voice. On examination an ulcero-proliferative Mass is seen on Right Vocal Cord. Cord was however mobile. There is no lymph node involvement and no metastasis. Which of the following is the best treatment modality for this patient? (FMGE Aug 2020)

- Total laryngectomy
- Conservative laryngectomy
- Radiotherapy
- Chemotherapy



Previous Year's Questions

Q. A 60 years old patient presented with Hoarseness of voice. On examination following Finding is shown below. What could be diagnosis? (NEET PG JAN 2019)

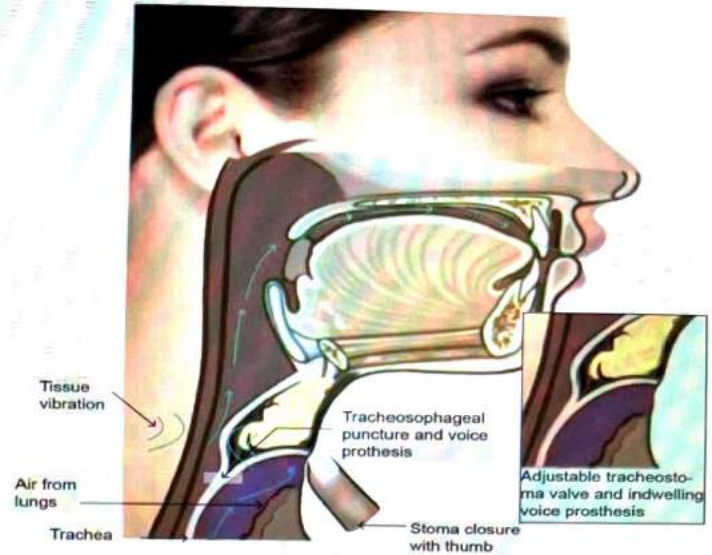
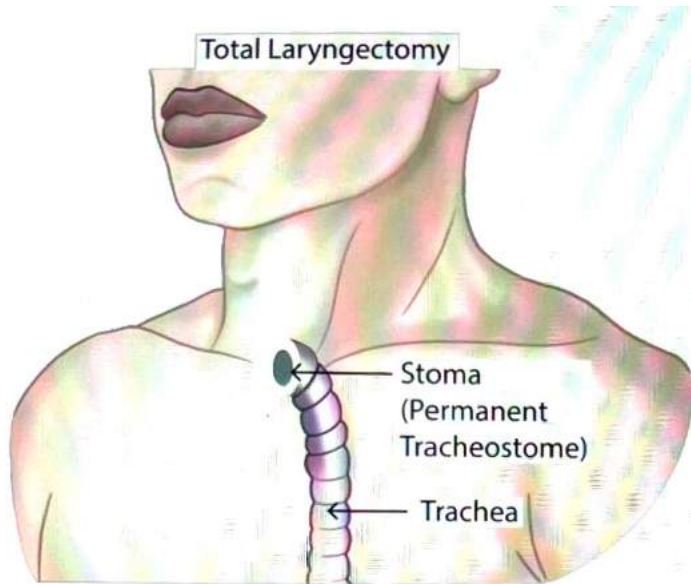


- Multinodular goiter
- Secondaries neck
- TB lymphadenitis
- Sternomastoid tumor

TOTAL LARYNGECTOMY

00:42:21

- High tracheostomy done in total Laryngectomy



REHABILITATION OF VOICE (ELECTRO LARYNX)

🕒 00:44:09

Refer Table 49.1

OESOPHAGEAL SPEECH

🕒 00:45:39

Refer Table 49.2

TRACHEO-OESOPHAGEAL SPEECH

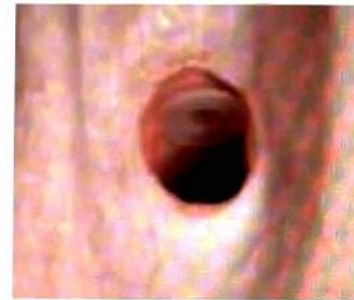🕒 00:48:10

- Consist a one way valve →TEP (Tracheoesophageal voice prosthesis).
- Placed between trachea and Esophagus
- Doesn't allow Food particles to go into trachea but air is moved to move from trachea into oesophagus
- Can speak complete sentences
- Best way of voice rehabilitation .
- Advantage
 - Voice quality is good
- Disadvantage
 - Has to be replaced once From 6 months - 2 years depending on the hygiene
 - Costly cannot be done in low socio-economic status people those who cannot follow up



Previous Year's Questions

Q. Identify the mechanism of given prosthesis used For voice production in a post laryngectomy Patient? (AIIMS Jun 2020)



- A. Chicago Prosthesis
- B. Tracheo-oesophageal speech
- C. Oesophageal speech device
- D. Electrolarynx

Table 49.1

Electro Larynx

- Small hand held device
 - Puts at Floor of mouth
 - Gives vibrations → converted into speech
- Disadvantage - Produces monotonous robotic voice

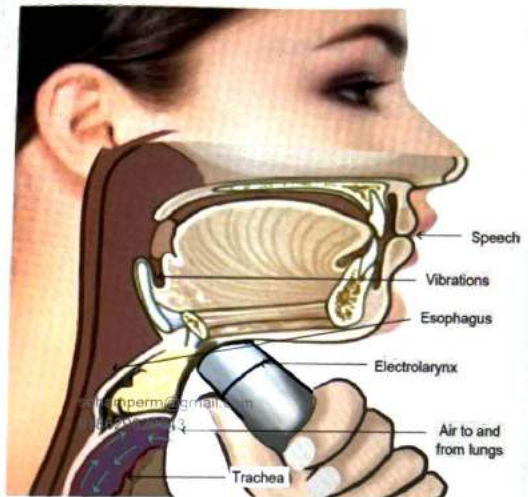
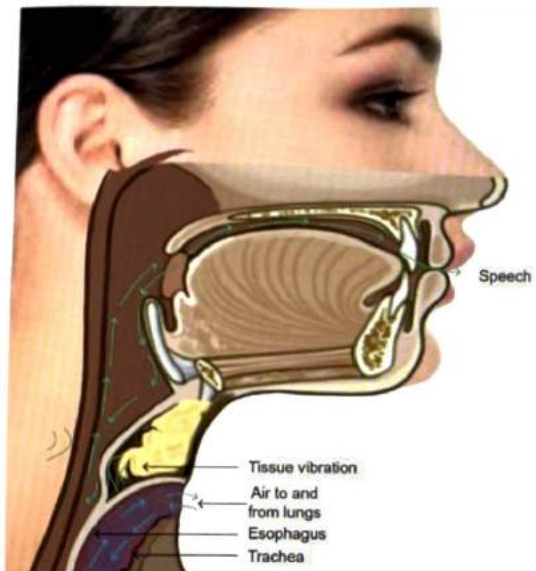


Table 49.2

- Airway is separated from digestive pathway
- Advantage
 - Voice quality is good
- Disadvantage
 - Only speaks Few words at a time, cannot speak complete sentence
 - Patient needs a lot of motivation and practice speech





CLINICAL QUESTIONS



Q. A 45 years old chronic smoker came with the history of hoarseness , foreign body sensation for the last 6 months. 2 weeks back, patient developed pain during swallowing. your ENT professor diagnosed it as laryngeal carcinoma and total laryngectomy done. Post operative esophageal speech rehabilitation given. Dynamic component of phonation in esophageal speech in laryngectomy lies at

- A. Trachea
- B. Mouth
- C. Pharyngoesophageal segment
- D. Gastroesophageal segment

Answer: C

Solution

Solution:

Comparison of speech production before and after laryngectomy

Physical requirements	Normal laryngeal voice production	Oesophageal speech production	Surgical voice production
Initiator	Moving column of air from the lungs	Moving column of air from the oesophagus	Moving column of air from the lungs
Vibrator	Vocal cords	Vibratory /pharyngo-oesophageal (PE) segment	Vibratory / pharyngo-oesophageal (PE) segment
Resonators	Resonating cavities: nose, mouth, pharynx	Resonating cavities; nose, mouth, pharynx	Resonating cavities; nose, mouth pharynx

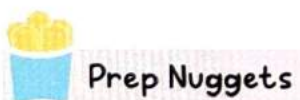
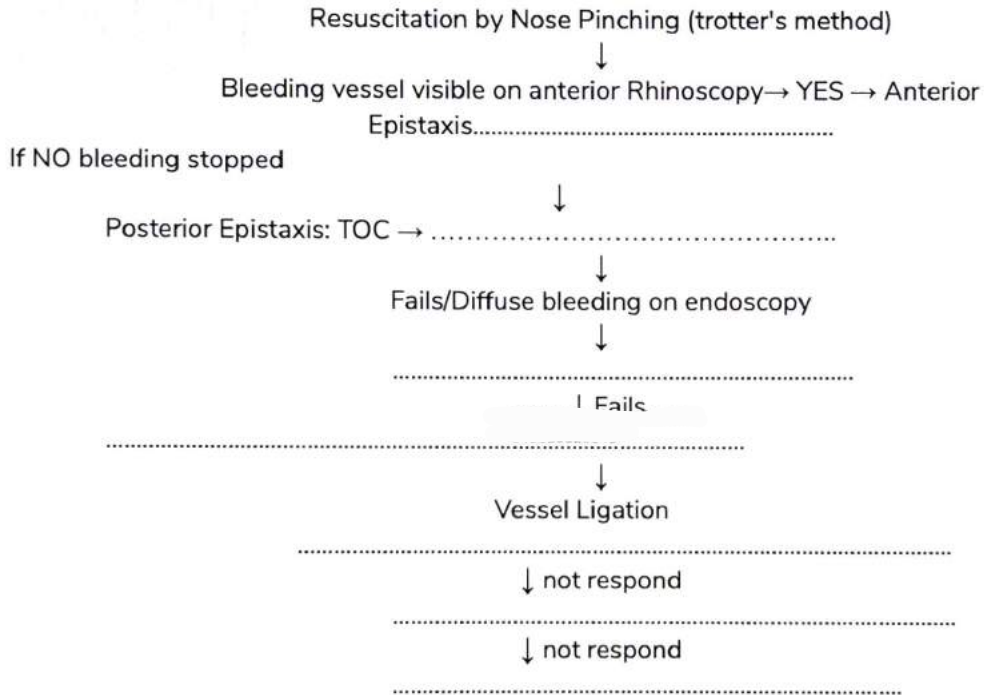
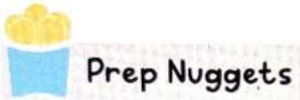
Q. A 65 years old chronic smoker came to the hospital with complaints of hoarseness and foreign body sensation in the larynx. Biopsy revealed laryngeal carcinoma. You and your senior doctor planned for a total laryngectomy. Which of the following is best for the maintenance of the airway during laryngectomy ?

- A. Tracheostomy
- B. Laryngeal mask airway
- C. Laryngeal tube
- D. Combi tube

Answer: A



PREP NUGGETS



256 HZ	512 HZ	1024 HZ	CHL
.....		20-30 dB
.....		30-45 dB
.....		> 45 dB



Prep Nuggets

Test	Cochlear	Retro-Cochlear
• S.I.S.I	Negative
• A.B.L.B Laddergram	Converging
• Tone Decay (< 25 dB) (> 25 dB)
• Speech Audiometry	SDS = 60-80%
• B.E.R.A (Wave V Latency)	> 4.2 ms



Prep Nuggets

Session Staging of JNA

Stage 1
Stage 1b
Stage 2a
Stage 2b
Stage 2c
Stage 3



Prep Nuggets

Cartilages of larynx

3 unpaired cartilages

3 paired cartilages

.....

.....

.....

.....

.....

.....



Prep Nuggets

Topodiagnostic Tests of Facial Nerve

Test	Normal	Abnormal
Schirmer's test	NEGATIVE:.....	POSITIVE:.....
Stapedial Reflex test	POSITIVE:.....	NEGATIVE:.....
Taste Test- chorda tympani nerve	POSITIVE:.....	NEGATIVE:.....
Submandibular Salivary flow Rate	NEGATIVE:.....	POSITIVE:.....