

## 1

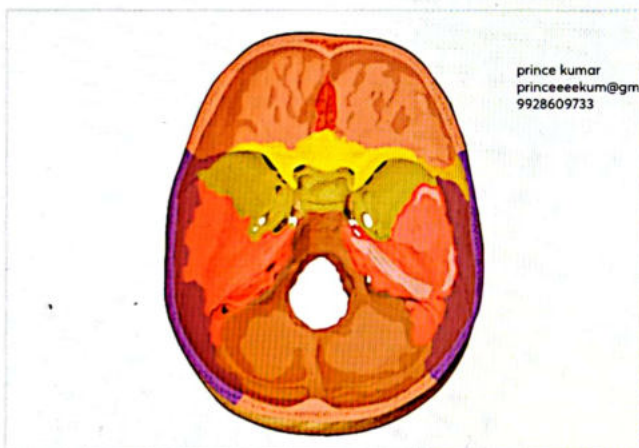
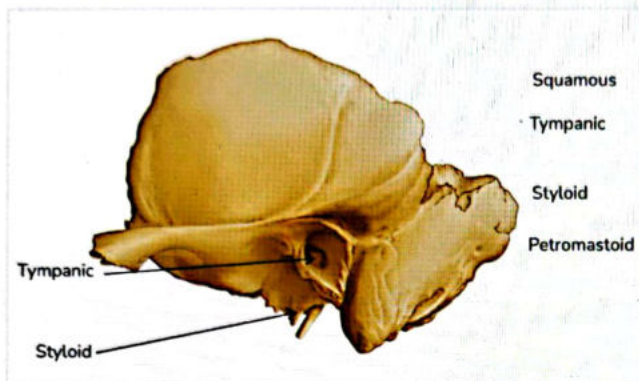
## ANATOMY OF EXTERNAL EAR AND MIDDLE EAR



- When talking about the anatomy of the ear, the first important concept is that of the temporal bone.

### Temporal Bone Anatomy

00:01:15



prince kumar  
princeeeekum@gmail.com  
9928609733

- This petrous bone continues as the mastoid temporal bone posteriorly, thus forming the **petromastoid complex**.
- On the posterior slant, there is a canal present known as the **internal auditory canal** or internal auditory meatus.
- The petrous apex lies in very close relation to the brain stem, which continues downwards as the spinal cord. From the brain stem, there exist the 5th, 6th, 7th, and 8th nerves coming from the Pons. The **5th and the 6th cranial nerve** go anteriorly toward the **petrous apex**, which is present medially towards the brain stem. **7th and the 8th cranial nerves** go into the **internal auditory canal**.

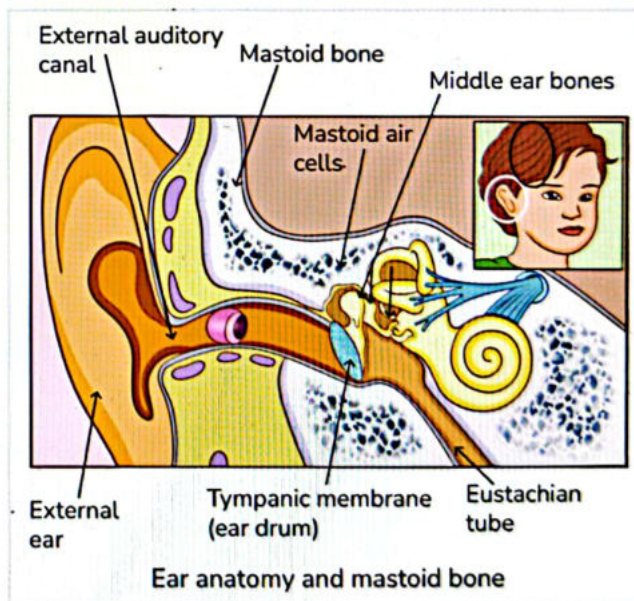
### Anatomy of the Ear

00:06:53

The ear is divided into three parts. Going from **lateral to medial**, they are -

- External ear
- Middle ear
- Inner ear

### External Ear



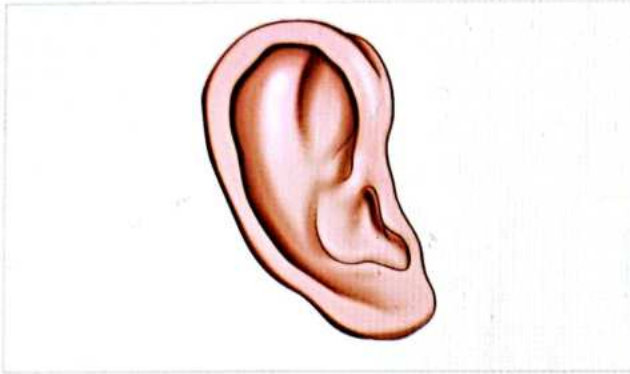
- The temporal bone is made up of five parts. They are -
  - Part 1: Squamous:** It is one of the **biggest parts** and lies at the upper end of the temporal bone.
  - Part 2: Tympanic:** It is present between the styloid and the zygomatic Part. It contains the middle ear.
  - Part 3: Styloid:** It is the **elongated projection** at the base of the temporal bone.
  - Part 4: Petromastoid:** On the lateral surface, the mastoid part is present, and on the medial surface is the petrous Part.
  - Part 5: Zygomatic:** It **projects anteriorly** from the squamous Part.
- The petrous part has two slants - **anterior and posterior** slants.
- The anterior slant articulates with the squamous temporal bone, and the posterior slant articulates with the **occipital bone**.

The external ear is divided into three parts:

- Pinna
- External auditory canal
- Tympanic membrane

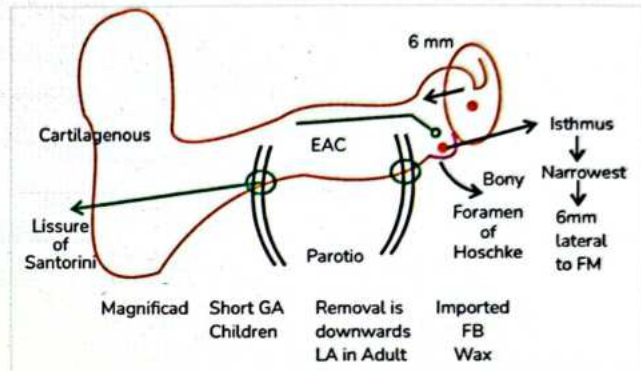
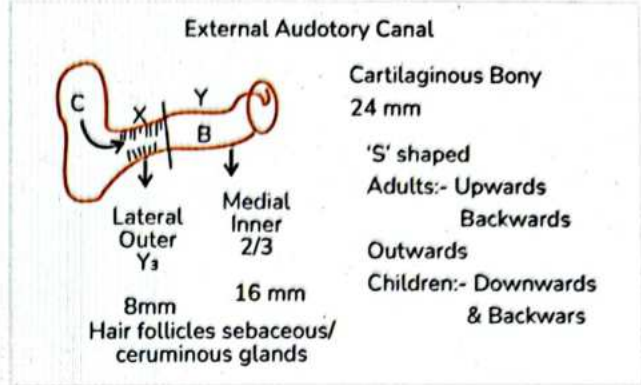


**Pinna**



- It is also called the **auricle**.
- The pinna is made up of **elastic cartilage**.
- There are various elevations and depressions present over the pinna.
- The first and most prominent elevation is known as the **helix**. It is present on the **outermost part** of the pinna.
- Along the helix, in the **reverse direction**, another smaller projection is present, which is known as the **anti-helix**.
- A triangular projection is present medial to the anti-helix known as the **tragus**.
- In the reverse direction of the tragus, there is another projection present which is called the **anti-tragus**.
- A **depression** is present, which is surrounded by the anti-tragus, tragus, and anti-helix. This depression is known as **cavum concha**. This is the biggest depression on the pinna.
- Above the concha, there is a triangular depression known as the **triangular fossa**.
- The **elastic cartilage** is present all over the pinna except for two sites -
  - The area between the tragus and the beginning of the helix does not have cartilage. This area is called **incisura terminalis**.
  - The **lobule** of the ear is also devoid of cartilage.
- The importance of area devoid of cartilage is the **incisura terminalis**
- The **incisura terminalis** is the site of **incision** in an **endaural surgery** (like taking a surgical approach from the external auditory canal).
- **Incisura terminalis** is chosen because, in case of post-operative infection, the **lack of cartilage** prevents the chances of underlying **cartilage necrosis** which further causes deformity of the pinna.
- This incision is known as **Lempert endaural incision**.
- The lobule of the pinna has **high-fat content**; due to which it becomes the site of **fat graft harvest**.

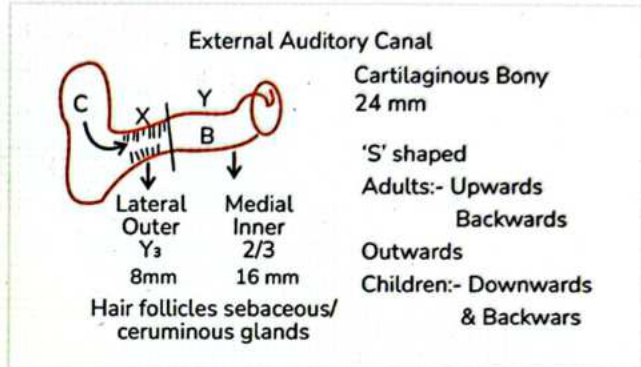
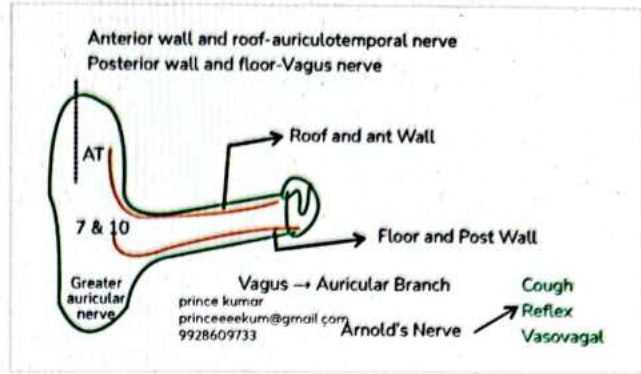
**External Auditory Canal**



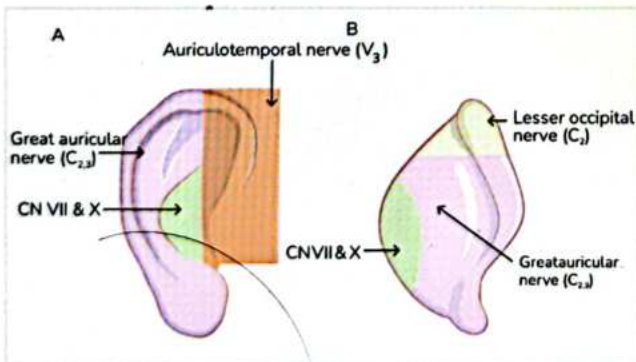
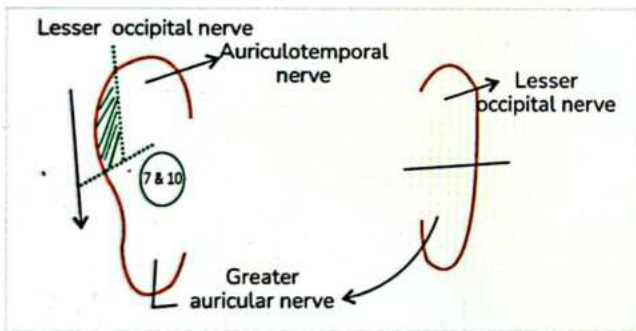
- It is the continuation of the pinna.
- The length of the external auditory canal is **24mm**.
- It is divided into two parts - The **cartilaginous part** and the **bony part**.
- The **lateral section** is the cartilaginous or the outer Part. It accounts for **1/3rd** of the external auditory canal, i.e., **8mm**.
- The **medial section** is the bony or the inner Part. It accounts for the rest of the **2/3rd portion** of the external auditory canal, i.e., **16mm**.
- The canal is not straight. In fact, the **canal is S-shaped**. This shape makes visualizing the tympanic membrane from the outside difficult.
- So, it is necessary to straighten the canal before visualizing. To do so, the pinna is stretched **upwards, backward, and outwards** in adult patients.
- In children, the pinna is stretched **downwards and backward** because the bony portion of the external auditory canal has not been fully developed.
- There are some **hair follicles, sebaceous glands, and ceruminous glands** present on the cartilaginous part of the external auditory canal thus **otitis externa or folliculitis** (staphylococcus infection) only happens in the outer 1/3rd part of the canal.
- **Communications:** There are two communications presents between the external auditory canal and the parotid gland, which can cause to and fro infections. They are -



- o **Fissure of Santorini:** It is present between the underlying parotid gland and the cartilaginous part of the canal.
- o **Foramen of Huschke:** It is present between the parotid gland and the bony part of the canal.
- These two communications usually disappear by the **age of 5-7 years**.
- The **narrowest portion** of the external auditory canal is called the **isthmus** and is present **6mm lateral** to the tympanic membrane.
- As the isthmus is the narrowest part, there are chances of foreign bodies or wax impaction in this area.
- While extracting wax or a foreign body from the isthmus using a probe, there are chances of **tympanic membrane perforation** as the distance between the two is very small, and the visualization is poor, and due to discomfort, the patient may move suddenly.
- This is why it is preferred to give **local anaesthesia in adults and sedation/short general anaesthesia in children** before extraction to prevent any movements.
- Also, an **endoscope or microscope** is used to magnify the space between the foreign body and the tympanic membrane which helps in preventing any trauma to the tympanic membrane.



## Nerve Supply of Pinna And External Auditory Canal



The mnemonic is **LAG 7 & 10**. The nerve supply is:

1. Lesser occipital nerve
2. Auriculotemporal nerve
3. Greater auricular nerve
4. 7th and 10th cranial nerves (Facial and vagus nerve)

- The major portion of the pinna is supplied by the **greater auricular nerve** (mainly, the lower portion).
- The auriculotemporal nerve supplies the anterior portion in the upper half of the pinna.
- The lower occipital nerve supplies the **medial portion** of the upper half pinna (near the mastoid).
- The concha is supplied by the **7th and 10th cranial nerves**.
- The auriculotemporal nerve will extend into the canal and supply the roof and the anterior wall of the external auditory canal.
- **Arnold's nerve** is the auricular branch of the **vagus nerve** and supplies the posterior wall and the floor of the external auditory canal.
- Stimulation of **Arnold's nerve** during any procedure will cause a **cough reflex**. This is because Arnold's nerve is part of the vagus nerve, which innervates the larynx as well and thus causes the cough on stimulation.
- Also, Arnold's nerve can precipitate a **vasovagal attack or syncope on stimulation**.
- Both the auriculotemporal nerve and Arnold's nerve supply the lateral surface of the tympanic membrane.

## IMPORTANT QUESTION

**Q.** A 50-year-old male presented with the complaint of decreased hearing. On examination, there was wax accumulated in the external auditory canal. While removing the wax, the patient coughed. This reflex is mediated by which nerve?

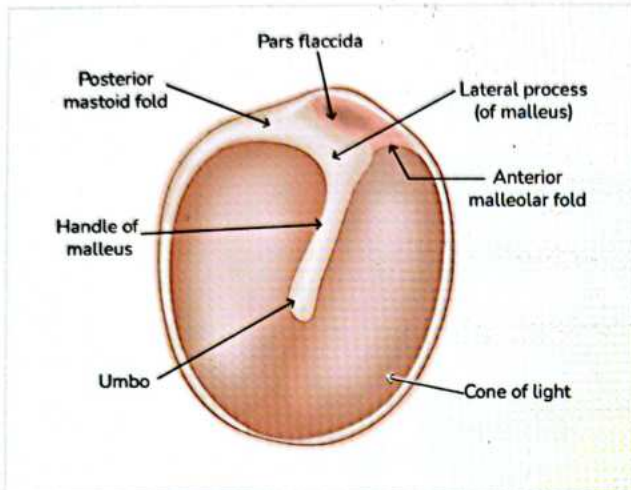
**Ans:** Arnold's nerve.



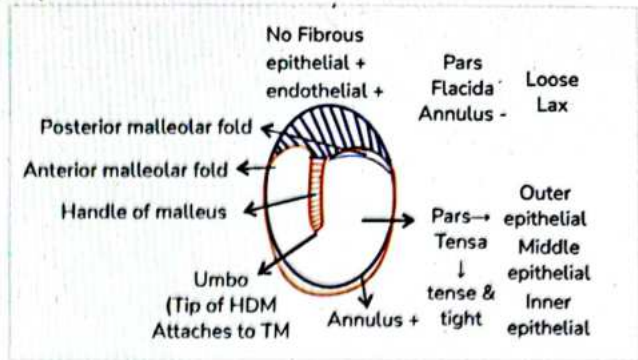
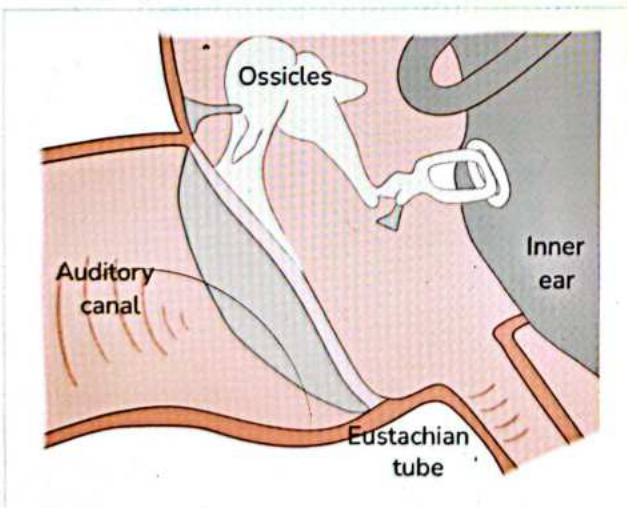
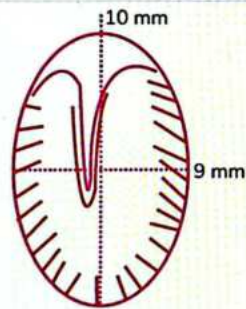
## Tympanic Membrane Parts of Tympanic Membrane

00:41:20

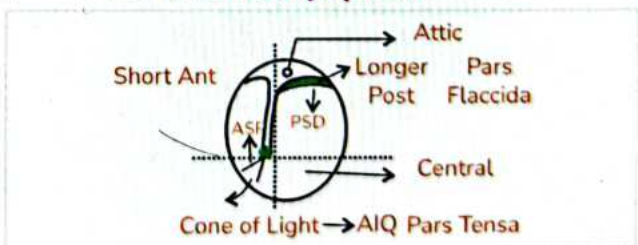
	Pars Tensa	Pars Flaccida
Annulus	Present	Absent
No. of layers	3	2
Umbo and cone of light	Umbo in center and cone of light in antero-inferior part	



**Tympanic Membrane**  
Partition between external ear and middle ear  
It is obliquely placed  
9-10 mm tall  
8 mm wide  
0.1 mm thick  
1 Sa-  $10 \times 9 = 90 \text{ mm}^2$   
Vibrating = Peripheric  
Effective vibrating area  
 $= \frac{1}{2} \text{ TSA} = \frac{1}{2} \times 90 \text{ mm}^2 = 45 \text{ mm}^2$



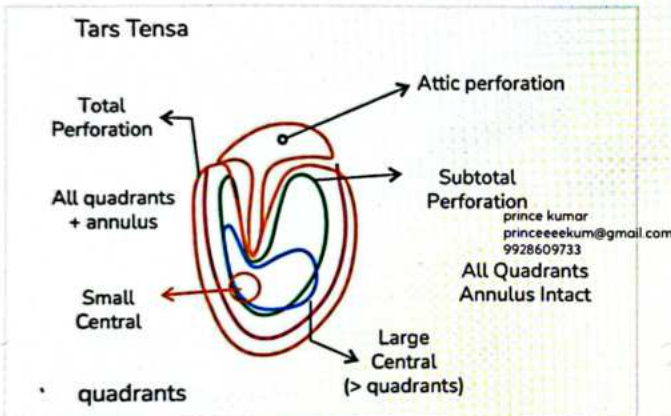
- It is a **partition** between the external ear and the middle ear.
- It is obliquely placed to the canal at an angle of **45 degrees** to the floor of the canal.
- It is an **oval-shaped structure**, so it has a longer vertical axis and a shorter horizontal axis which are **10mm long and 9mm wide**, respectively. It is **0.1 mm** in thickness.
- The total surface area of the tympanic membrane is **90mm<sup>2</sup>**
- The **vibrating area of the tympanic membrane is the peripheral portion**. This is because, in the center, the handle of the malleus bone rests medially on the membrane, which prevents vibrations.
- So, the **effective vibrating area is half of the total surface area, i.e., 45mm<sup>2</sup>**
- Parts of the tympanic membrane: The tympanic membrane has two parts –
  - Pars Tensa: It is tense and tight in nature.
    - It makes up the **lower portion** of the tympanic membrane.
    - There is a **fibrous cartilaginous ring** around the membrane known as the annulus. The cartilage stretches the membrane making it taut.
    - It has **three parts**: The outer epithelial layer, the middle fibrous layer, and the inner endothelial layer.
    - The fibrous layer provides **tensile strength** to the membrane.
  - Pars Flaccida: It is loose and lax in nature.
    - It makes up the **upper portion** of the tympanic membrane.
    - The annulus is **absent** in this portion.
    - It has **two parts**: The outer epithelial layer and the inner endothelial layer.
    - There is **no fibrous layer present**.



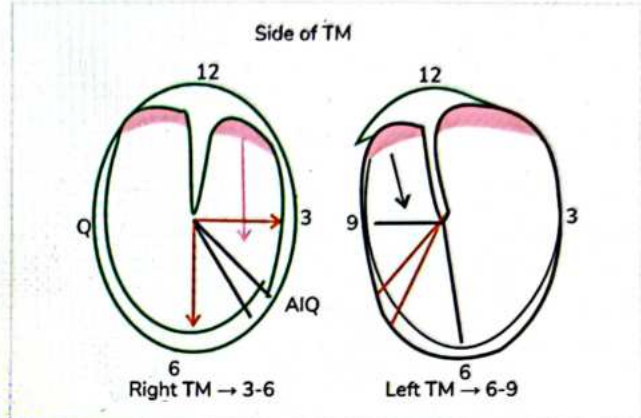
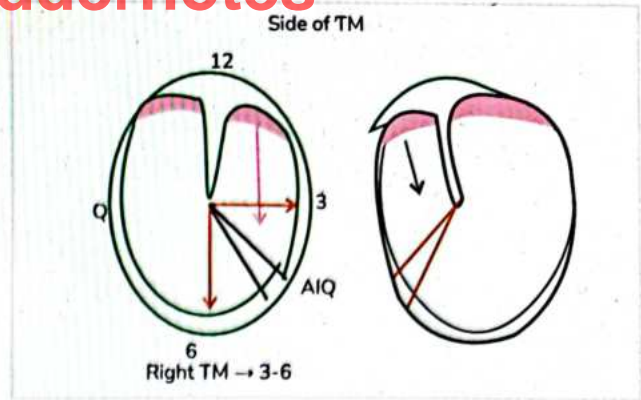


- **Projections on the tympanic membrane:** These are –
  - **The handle of the malleus:** It is seen centrally on the tympanic membrane.
  - **Umbo:** The handle of the malleus lies medially to the tympanic membrane. The point at which the tip of the malleus attaches to the membrane is known as the umbo.
  - **Malleolar folds:** There are two folds that come out of the malleus, known as the anterior and posterior malleolar folds. The shorter fold is the anterior malleolar fold, and the posterior malleolar fold is the longer one.
  - **Quadrants of the pars tensa:** The pars tensa is divided into four sections with the help of two imaginary lines. These lines pass through the umbo horizontally, and the other passes through the handle of the malleus vertically.
- This divides the pars tensa into-anterosuperior quadrant, anteroinferior quadrant, posterosuperior quadrant, and posteroinferior quadrant.
  - **Cone of light:** It is present in the anteroinferior quadrant of the pars tensa.

### Important Points



- Any perforation in the pars tensa is known as a **central perforation**.
- Any perforation in the pars flaccida is known as an **attic perforation**.
- A perforation involving only one quadrant is called a **small central perforation**.
- If a perforation involves more than one quadrant, then it is called a **large central perforation**.
- If a perforation involves all the quadrants of the pars tensa, but the annulus is intact, then it is called a **subtotal perforation**.
- If a perforation involves all the quadrants and the annulus, then it is called **total perforation**.
- **Side of the tympanic membrane:** This is the way to identify the side of the tympanic membrane.



- **Cone of light:** If the cone of light is present in the 3 o'clock to 6 o'clock position, then it is the **right tympanic membrane**. If it is present in the 6 o'clock to 9 o'clock position, then it is the **left tympanic membrane**.

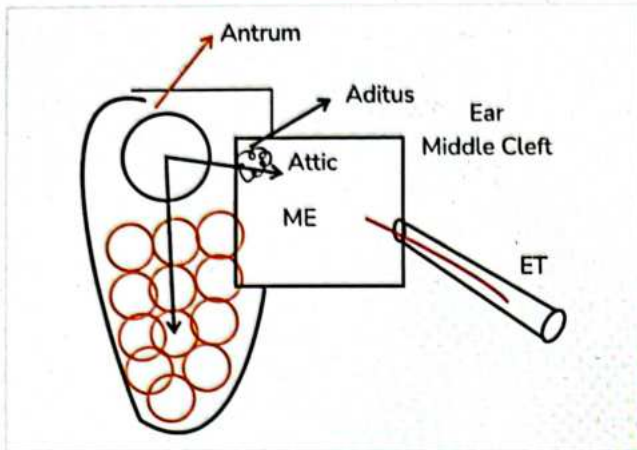
### Middle Ear Cleft

01:04:33

- Middle ear
- Eustachian tube
- Aditus
- Antrum
- Mastoid air cells
- As the name suggests, the middle ear is a cleft, i.e., a composition of many structures which are vital for the ventilation of the middle ear. The middle ear is composed of the following structures:
  - **Middle ear proper:** It is divided into four parts - epitympanum, mesotympanum, hypotympanum, and protympanum.
  - **Epitympanum:** It is that part of the middle ear that is lying against the pars flaccida. It is also called the attic.
  - **Mesotympanum:** It is that part of the middle ear that lies against the pars tensa
  - **Hypotympanum:** It is that part of the middle ear that lies below the level of the annulus.
  - **Protympanum:** It is that part of the middle ear anteriorly which has the opening of the eustachian tube.



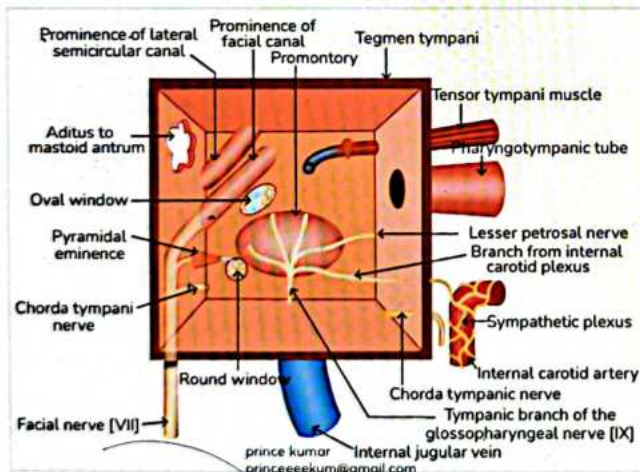
- o Opening of the eustachian tube is present anteriorly. The eustachian tube connects the middle ear to the nasopharynx.
- o Mastoid air cells are present posteriorly. Air is kept as a reservoir in the mastoid bone.



- **Ventilatory pathway of the middle air (anterior to posterior):**  
On inhalation, the air reaches the nose → nasopharynx → eustachian tube → middle ear proper (middle ear gets its ventilation) → attic tympanum → aditus (communication between the attic tympanum and the largest mastoid air cell) → antrum (largest mastoid air cell) → rest of the mastoid air cells.
- This pathway is called the **middle ear cleft**.

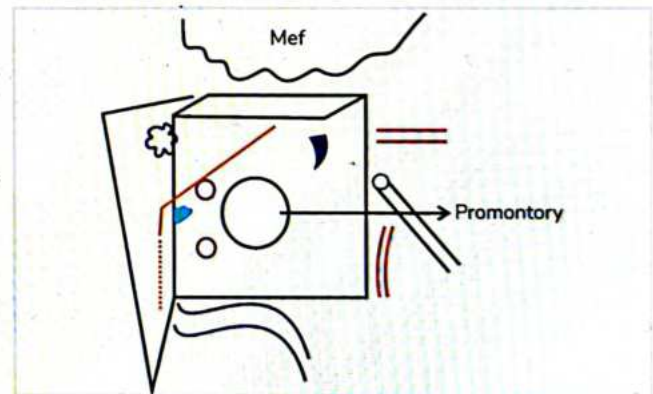
**Anatomy of the Middle Ear Proper**

01:12:11



- It is an **hourglass-shaped structure**.
- At the level of the **attic**, the anteroposterior dimension is **4mm**.
- At the level of **mesotympanum**, the anteroposterior dimension is **2mm**.
- At the level of **hypotympanum**, the anteroposterior dimension is **6mm**.

- It has **six walls** - The lateral wall, medial wall, anterior wall, posterior wall, roof, and floor.
- Structures of the middle ear:
  - Lateral wall:** The lateral wall of the middle ear is formed by the **tympanic membrane** and the **scutum** (it is the outer attic wall).
  - Roof:** The roof of the middle ear is formed by a thin plate of bone called the **tegmen tympani**. It separates the middle ear from the middle cranial fossa.
  - Floor:** The floor of the middle ear is formed by a thin plate of bone that separates the middle ear from the **internal jugular vein** (which is the continuation of the sigmoid sinus present in the mastoid).
  - Anterior wall:**
    - o The anterior wall contains the opening of the eustachian tube.
    - o Above this opening, there is a canal for the **tensor tympani muscle**.
    - o Below the eustachian tube opening, the anterior wall contains the **internal carotid artery**.
  - Posterior wall:**
    - o The posterior wall separates the middle ear from the mastoid air cells. The posterior wall has the communication between the **middle ear and the mastoid antrum**, known as the **aditus ad antrum**.
    - o The posterior wall also contains a projection called the **pyramid**.

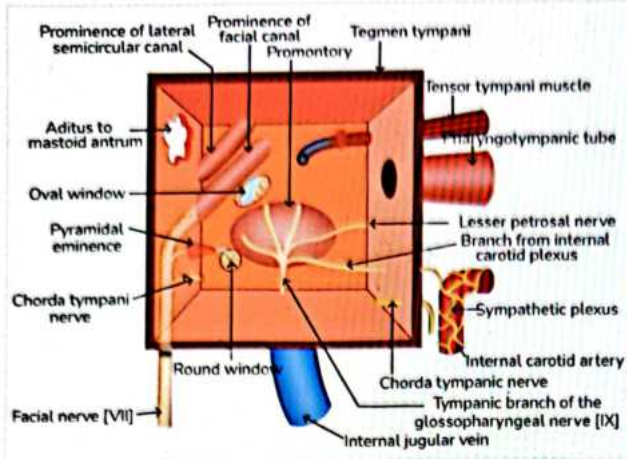


- Medial wall:**
  - o The medial wall separates the middle ear from the inner ear.
  - o It has 2 impressions, two windows, one nerve, and one projection.
  - o Impressions on the medial wall are formed by the **basal turn of the cochlea**, known as the **promontory**, and the lateral semicircular canal which are present in the inner ear.
  - o It has an **oval window** above and a **round window** below.
  - o The **facial nerve** is present on the medial wall.
  - o The **cochleariform process** is the projection present on the medial wall.

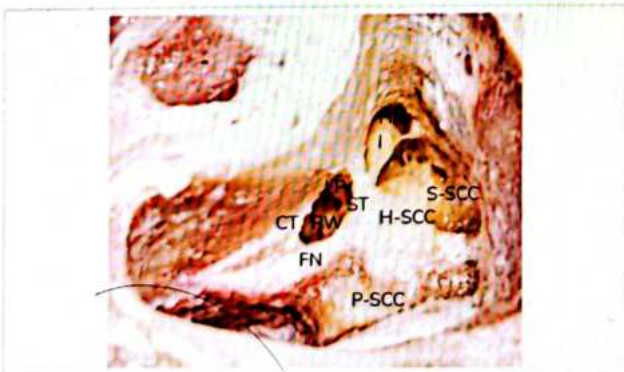


**Facial Nerve Landmarks in The Middle Ear**

01:28:31

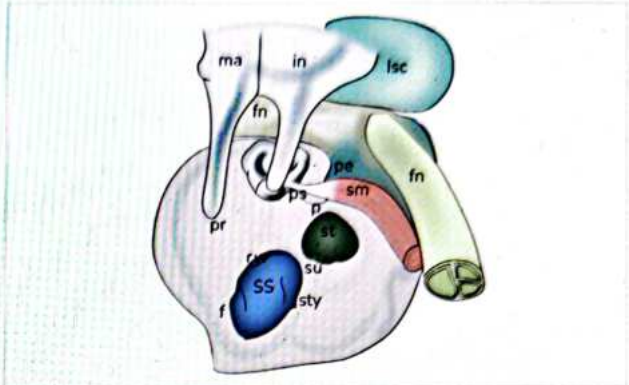


- The facial comes from the inner ear and enters the middle ear through the medial wall of the middle ear.
- It takes the first turn which is known as the **1st geniculate ganglion (genu)** of the middle ear.
- The landmark for the 1st geniculate ganglion is the **cochleariform process**.
- Next, the nerve runs horizontally in a bony canal known as the **fallopian canal** and it is congenitally dehiscent in 50% of the patients. This is called the horizontal segment of the facial nerve.
- The landmark for the horizontal segment is the **oval window below it and the lateral semicircular canal above it**.
- Further, the facial nerve goes towards the posterior wall and here it forms a second bend called the **2nd geniculate**.
- The landmark for the 2nd genu is the **pyramid on the posterior wall**.
- **Applied aspects of the middle ear anatomy:** This includes the recesses related to/around the pyramid. They are
  - **Facial recess:** It is the **supra pyramidal recess**.



- **Boundary:** The facial nerve runs vertically on the posterior wall. This vertical segment of the facial nerve gives a branch called the **chorda tympani**. So, the facial recess is bordered by the vertical segment of the facial nerve, chorda tympani, and the **fossa incus** (space below the incus).

- The facial recess is used as an approach to reach the middle ear. In this, the middle ear is reached from the mastoid root through the facial recess and this procedure is known as **posterior tympanotomy**.
- This approach is used for **cochlear implant surgery**.
  - **Sinus tympani:** It is the **infra pyramidal recess**.



- It is a hidden space which is difficult to visualize.
- It is the **most common site for residual cholesteatoma**.
- **Boundary:** It is bounded by the **ponticulus** from above and the **subiculum** from below.
- **Ponticulus:** It is an extension from the promontory going to the pyramid.
- **Subiculum:** It is the extension from the promontory to the round window.

**Important Information**

- While doing posterior tympanostomy or cochlear implant surgery, the vertical segment of the facial nerve and chorda tympani are at risk.

**Contents of the Middle Ear**

01:41:16

- The middle ear contains three small bones/ossicles -
  - a. **Malleus:** It attaches to the tympanic membrane. It has a **handle (manubrium)**, **head**, **neck**, **lateral process** (short process), and **anterior process**.
  - b. **Incus:** The body of the incus articulates with the malleus and the long process of the incus articulates with the stapes.
  - c. **Stapes:** It has a **head**, **neck**, **anterior crus**, **posterior crus**, and **footplate**. It is the **smallest bone** in the body.
- The head of the malleus and the body of the incus lies in the **epitympanum/attic**.
- The rest of the middle ear ossicles are present in the **mesotympanum**.
- **Intratympanic muscles:** There are two muscles present. These are the **tensor tympani** and **stapedius**.
- **Tensor tympani** is the muscle coming from the first embryological arch and thus is supplied by the **mandibular**



branch of the trigeminal nerve. It is attached to the neck of the malleus.

- **Stapedius** is formed from the second embryological arch and is supplied by the **facial nerve**. It is attached to the stapes.
- On exposure to a loud sound, these two muscles will contract and fix the entire ossicular chain. This means the bones will not be able to vibrate.
- This reduces the amplitude of the sound conducted to the inner ear and thus **protects the inner ear from noise trauma**.
- **Tympanic plexus**: Over the promontory, a neural plexus is present which is called the tympanic plexus.
- **The tympanic plexus is formed by two nerves** - The tympanic branch of the glossopharyngeal nerve called the Jacobson's nerve and the sympathetic plexus which is present on the internal carotid artery forming the tympanic plexus.

## Mastoid Antrum

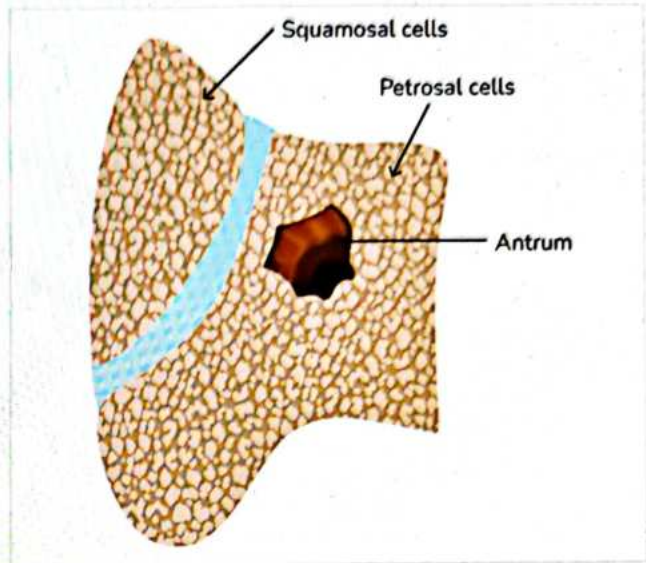
- The largest air cell of the mastoid bone is called the **antrum**.
- The antrum receives its ventilation from a communication called the **aditus**.
- If the mastoid bone has the antrum and the rest of the part is bony, then it is known as the **sclerotic mastoid**.
- If the mastoid bone has the antrum and numerous air-filled cells within it, then it is known as the **pneumatic mastoid**.
- If the mastoid has the antrum and has a mixture of bony structures and is air-filled, then it is known as the **diploic mastoid**.
- **MacEwen triangle**: It is an important landmark for identifying the mastoid antrum.
- It is marked by the following structures:
  - The **supra mastoid crest**. It is a true line/ridge present on the mastoid bone.
  - An **imaginary line from the posterior wall of the external auditory canal**.
  - The third line is a **tangential line** connecting the first and the second line.
- The space between these three lines is MacEwen triangle through which a **hole is drilled to reach the mastoid antrum**.
- To perform mastoidectomy, a post-aural incision is given behind the pinna.
- The skin and the subcutaneous tissues are elevated to identify the mastoid bone.
- The supra mastoid crest is identified and then the **two imaginary lines are drawn**.
- Through this space, a hole is drilled to reach the mastoid antrum **without causing any harm to any vital structures**.
- The vital structure that is present is the **tegmen antri**. Supra mastoid crest is the superior landmark to identify the tegmen antri. The middle cranial fossa lies above it so it acts as a warning/identifying structure to prevent any injury to the cranial fossa.
- The imaginary line drawn across the posterior canal wall indicates that the hole should be drilled **behind the line** as

beyond this line lies the facial nerve.

- The tangential line represents the sigmoid sinus present at the posterior border of the mastoid. So, the hole is drilled in front of the **tangential line** as behind it is the sigmoid sinus.

## Korner's Septum

01:54:12



- The mastoid bone has **superficial and deep cells**.
- The superficial cells of the mastoid develop from the **squamous temporal bone** and the deep cells of the mastoid develop from the **petrous temporal bone**.
- When the squamous cells and the petrous cells fuse, they form a **petrosquamous suture** which usually disappears.
- If the suture **persists**, then it is called the **Korner's septum**.
- Korner's septum will cause **difficulty in identifying the antrum** while going from superficial to deep mastoid cells and thus it will result in **incomplete removal of the disease** by mastoidectomy.






# CROSS WORD PUZZLES



Crossword Puzzle 1




**Across**

- \_\_\_\_\_ part of the temporal bone contains the middle ear.
- The internal auditory canal is present on the \_\_\_\_\_ slant of the petromastoid temporal bone.

**Down**

- Pinna is also called the \_\_\_\_\_.
- The biggest depression on the pinna is \_\_\_\_\_.

Crossword Puzzle 2



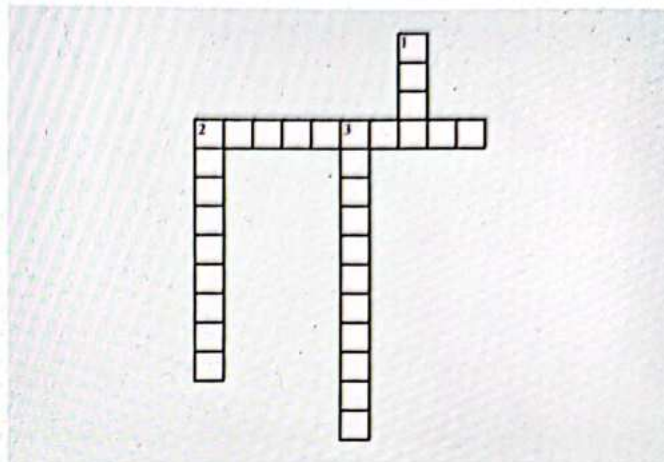
**Across**

- Otitis externa or folliculitis only happens in the \_\_\_\_\_ part of the external auditory canal.
- The major portion of the pinna is supplied by the \_\_\_\_\_ nerve.
- The length of the external auditory canal is \_\_\_\_\_.

**Down**

- \_\_\_\_\_ and lobule of the pinna are devoid of the elastic cartilage.

Crossword Puzzle 3



**Across**

- The basal turn of the cochlea in the middle ear is known as the \_\_\_\_\_.

**Down**

- The point at which the tip of the malleus attaches to the membrane is known as the \_\_\_\_\_.
- Annulus is present around the \_\_\_\_\_.
- The eustachian tube connects the middle ear to the \_\_\_\_\_.

prince kumar  
princeekum@gmail.com  
9928609733





## 2

# ANATOMY OF INNER EAR

- Also called as labyrinth
- Made of:
  - Bony labyrinth: outer covering
  - Membranous labyrinth: content within bony labyrinth

### Parts of Inner Ear

00:00:30

#### Vestibule:

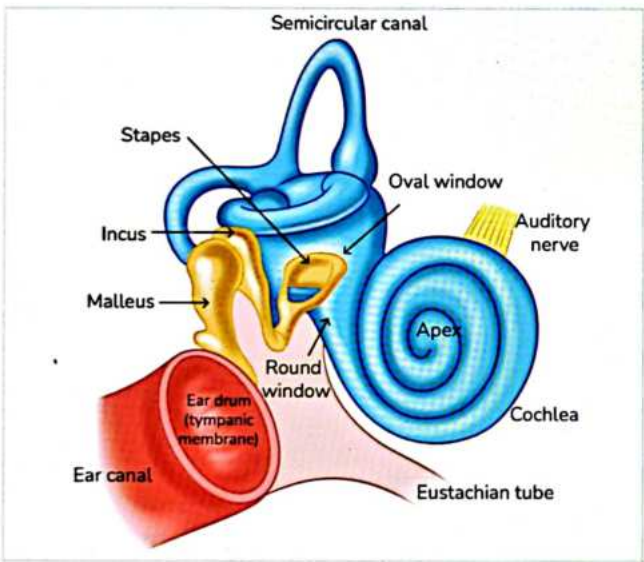
- Utricle
- Saccule

#### Cochlea:

- Cochlear duct


#### Semi-circular canal:

- Semi-circular canal duct



#### Vestibule

- It is the central chamber



#### 2 bony recesses/bony depressions

##### (i) Elliptical recess:

- contains utricle - posteriorly connected to the opening of SSC duct
- Bony covering over the SSC ducts is the bony SSC

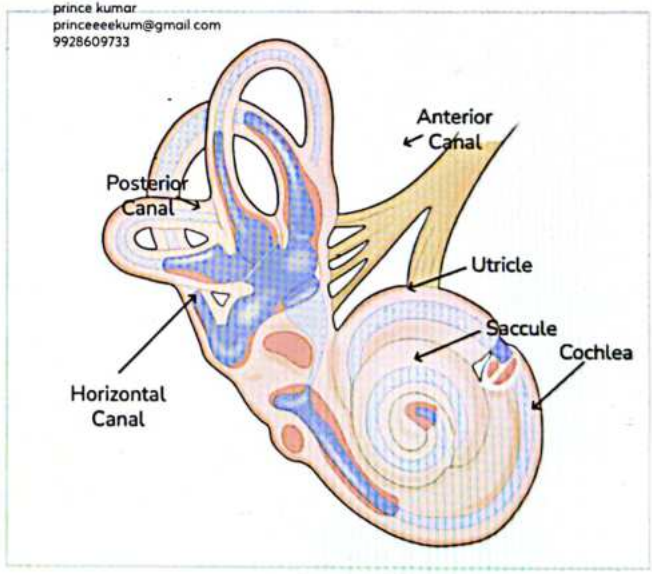
##### (ii) Spherical recess:

- contains saccule: anteriorly it is connected to cochlear duct via ductus/canalis reuniens
- The cochlear duct is covered with a bony cochlea

#### Functions:

- Cochlea: hearing
- Semi circular canals: balance
- Vestibule: hearing + balance
- Maculae
- Neurosensory epithelium present in saccule & utricle are responsible for hearing & balance

#### Semi-circular canals (SSC)

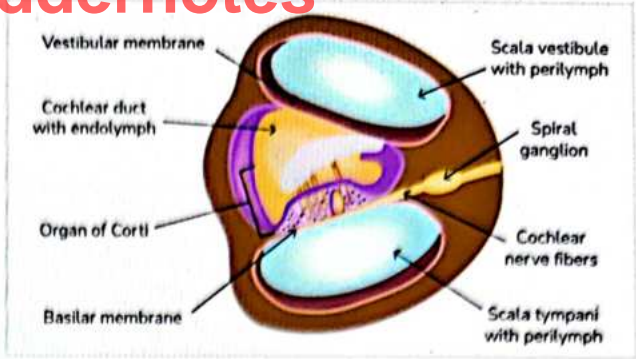


#### Three in number:

- Superior SSC/Anterior canal
- Lateral SSC
- Posterior SSC
- All these SSC's are angulated at 90° to each other
- Responsible for maintaining the balance in all the 3 axis (vertical, horizontal & oblique axis)
- Each canal will have a dilated end & a non dilated end
- Each canal has 2 openings thus utricle should receive 6 openings of SSC,




- However, utricle receives only 5 openings because:
- The non ampulated end of superior canal fuses with non ampulated end of posterior canal and forms a common opening known as crus commune.
- 3 ampulated ends & 2 non dilated ends
- Crista ampularis:
  - o Neurosensory epithelium in the ampulated end of SSC
  - o Function: responsible only for angular or rotatory motion



**Cochlear duct**

00:35:29



- A spiral shaped structure that resembles a snail
- It rotates around the central axis known as: modiolus
- Number of turns taken by cochlea around it is  $2^{1/2}$  &  $2^{3/4}$
- Cochlear chamber is cochlear duct/scala media
- Over it is the bony covering
- Compartment above the cochlear duct is scala vestibuli
- Compartment below the cochlear duct is scala tympani

**At the basal part:**

- scala vestibuli on one end is covered with oval window, which is further covered by footplate of stapes
- Scala tympani is covered by round window

**At the apex:**

- Scala vestibuli is communicating with the scala tympani is known as helicotrema
- Scala media is a blind duct as it doesn't communicate with any structure
- Contains a vascular structure known as striae vascularis, responsible for production & reabsorption of endolymph
- Vestibular/reissners membrane: separates scala vestibuli & scala media
- Basilar membrane: separates scala media from scala tympani
- Organ of corti:
  - o Neurosensory epithelium responsible for hearing
  - o Present on the basilar membrane in scala media

prince kumar  
princeeekum@igma  
9928609783

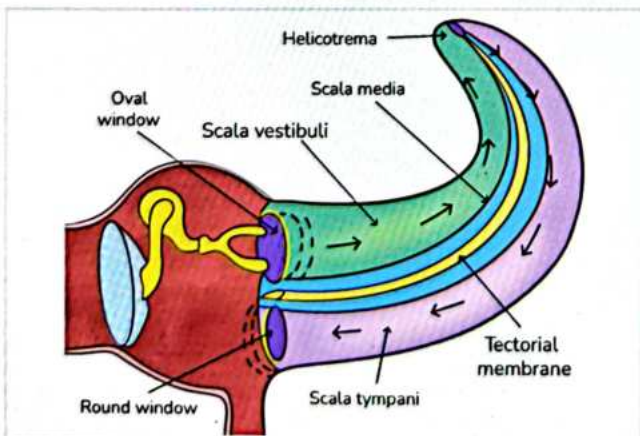
**Aqueduct of cochlea:**

- Communication between scala tympani & sub arachnoid space.

**Perilymph:**

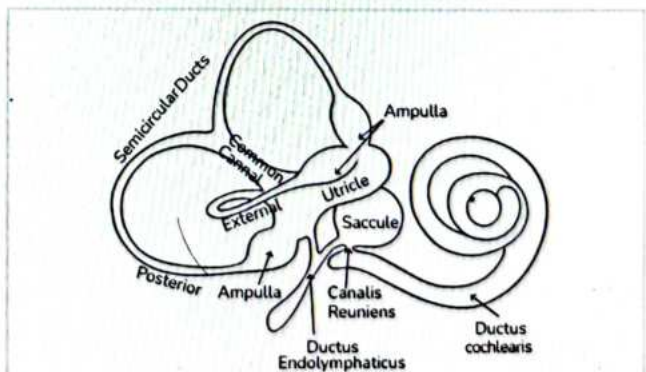
- Ultra filtertrate of CSF reaches S. tympani & S. vestibuli
- Fluid in S. media is endolymph, produced & gets reabsorbed by striae vascularis
- It flows between the bony & membranous labyrinth

**Cross-section of cochlea:**



**Membranous Labyrinth**

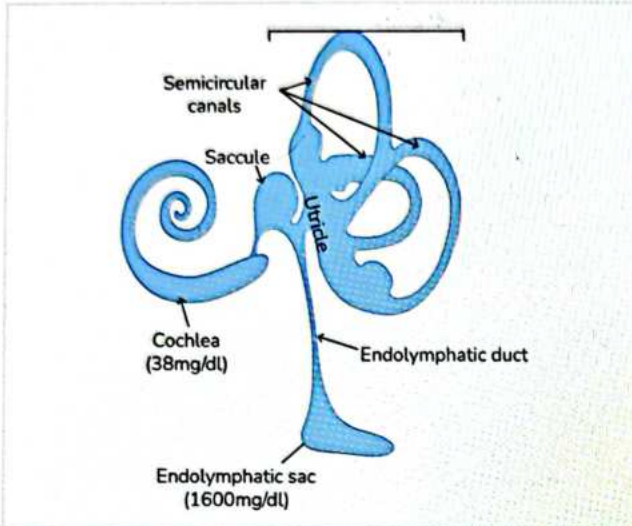
00:29:29






- Semicircular canal
- Sacculle
- Utricle
- Endolymphatic duct
- Endolymphatic sac
- Cochlear duct

### Endolymph



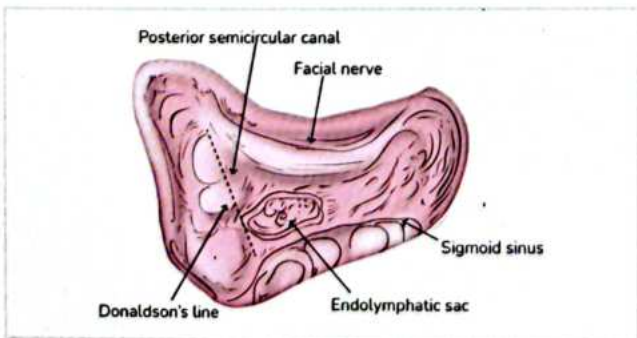
- Fluid inside the membranous labyrinth
- Flow of endolymph:



- Bony covering over the endolymphatic duct is vestibular aqueduct

### Landmark for endolymphatic duct

00:37:29



- Donaldson's line : it is imaginary line passing from lateral semicircular canal and bisecting posterior semicircular canal

### Perilymph:

00:39:49

- It is present between bony and membranous labyrinth
- It communicates with CSF through aqueduct of cochlea
- Two theories regarding its formation:
- It is a filtrate of blood serum and is formed by capillaries of the spiral ligament and
- It is a direct continuation of CSF and reaches the labyrinth via aqueduct of cochlea

prince kum  
princeek  
992860973

### Endolymph:

- It fills the membranous labyrinth
- Produced and reabsorbed by the stria vascularis
- It is rich in potassium

### Organ of Corti

00:40:39

- It is sense organ of hearing located on basilar membrane in scala media.
- It has hair cells which are receptors for hearing and transduce sound energy into electrical energy.
- Inner hair cells are in single row and transmit auditory impulses
- Outer hair cells are in 3-4 rows and modulate function of inner hair cells.
- Deiter and hensen cells are supporting cells responsible for providing nutrition to hair cells.
- Tectorial membrane overlies organ of corti.

### Hair cells

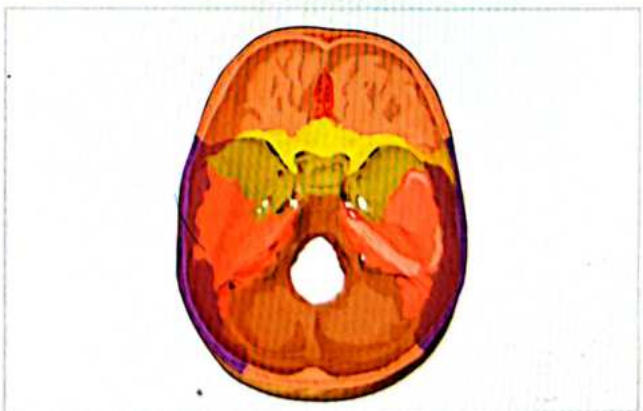00:41:39

Two types

Type 1	Type 2
Single	Multiple
Affrant Secretes excitatory neurotransmitter	Efferent secretes inhibitory neurotransmitter
Inner hair cells	Outer hair cells

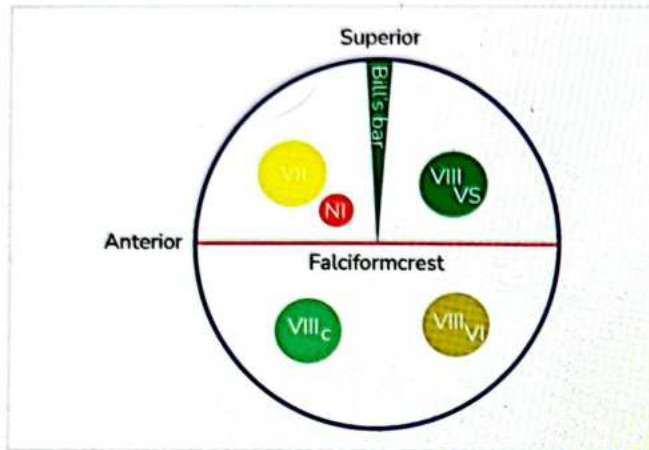
### Internal auditory canal

00:45:09





- Present in petrous part of temporal bone
- Anteriorly → Petrous part communicating with squamous part
- Posteriorly → petrous part communicating with the occipital bone
- 2 nerves: 7<sup>th</sup> & 8<sup>th</sup> nerve travel within it
- Cross-sections: vertical crest of bone known as bills bars
- Horizontal crest of bone known as falciform crest



- In antero-superior quadrant → facial nerve
- Antero-inferior quadrant → cochlear nerve
- Postero-superior quadrant → superior vestibular nerve
- Postero-inferior quadrant → inferior vestibular nerve

## Embryology

00:48:59

- 5 pharyngeal arches, or outside is ectoderm/cleft & endoderm pouch on inside.
- Cleft of 1<sup>st</sup> arch → external auditory canal
- Remaining arches fuse together to form cervical sinus
- Cervical sinus normally disappears with age, if it persists it forms collaral fistula (between EAC and cervical sinus)

## Mesoderm of 5 arches:

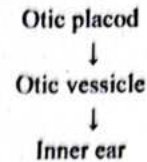
- 1<sup>st</sup> and 2<sup>nd</sup> arch forms 6 tubercles known as hillocks of his
- 1<sup>st</sup> hillock gives rise to tragus
- Other hillocks fuse together to form pinna

## Development of Middle Ear and tympanic membrane

- Pouch of 1<sup>st</sup> and 2<sup>nd</sup> arch fuse to form tubotympanic recess, which is responsible for formation of eustachian tube and middle ear.
- Tympanic membrane is formed from all three layers (ectoderm, endoderm and mesoderm)
- Petrous and squamous cells together form mastoid
- Incomplete fusion of hillocks of his will result in preauricular sinus/collaral fistula

prince kumar  
princeekum@gmail.com

## Inner Ear development



## Ossicles development

- Malleus and incus from mesoderm of 1<sup>st</sup> arch
- Stapes from mesoderm of 2<sup>nd</sup> arch
- Footplate of stapes from otic capsules

Ear part	Embryonic layer	Arch
Pinna	Mesoderm	1 and 2 arch
External auditory canal	Ectoderm	1 <sup>st</sup> cleft
Tympanic membrane	All three layers	1 <sup>st</sup> cleft and 2 <sup>nd</sup> pouch along with mesoderm
Middle ear cleft	Endoderm	1 <sup>st</sup> and 2 <sup>nd</sup> forms tubotympanic recess
Malleus and incus	Mesoderm	1 <sup>st</sup> arch
Superstructure of stapes	Mesoderm	2 <sup>nd</sup> arch
Foot plate of stapes	Mesoderm	Otic capsule
Mastoid	Mesoderm	Squamous and petrous parts of temporal bone

## Questions

00:59:46

Q. Duct of cochlea connecting with subarachnoid space?

Ans. Aqueduct of cochlea

Q. Endolymphatic duct is formed by?

Ans. Utricle and saccule

Q. Cochlear duct is?

Ans. Scala media

Q. Cochlear duct is connected to saccule by?

Ans. Ductus reuniens

Q. Scala media is separated from scala tympani by?

Ans. Basilar membrane

Q. Scala media is separated from Scala vestibular by?

Ans. Reissners membrane



**Q.** Call aural fistula is anomaly of which arch?

**Ans.** 1<sup>st</sup> arch

**Q.** Correction of deformities of EAC is done at what age?

**Ans.** 5 to 7 years

**Q.** Vertical crest at the internal auditory canal is

**Ans.** Bills bar

**Q.** Stapes develops from?

**Ans.** Mesoderm

**Q.** Inner ear is present in which bone

**Ans.** Petrous part

**Q.** Number of turns made by the cochlea?

**Ans.** 2 ½ - 2 ¾

**Q.** Intrauterine hearing starts at what period of gestation?

**Ans.** 20 weeks

**Q.** Angular movements are sensed by?

**Ans.** Cristae

**Q.** Fluid having highest potassium and low sodium content is?

**Ans.** Endolymph

**Q.** Fluid having higher sodium and low potassium content is?

**Ans.** Perilymph

**Q.** Communications causing to and for infections from the parotid gland?

**Ans.** Fissure of Santorini, foramen of huscheke

**Q.** other name for pars flaccida?

**Ans.** Sharpneil's membrane

**Q.** Most mobile portion tympanic membrane?

**Ans.** Peripheral part

**Q.** Total surface area and effective vibratory area of TM?

**Ans.**  $10 \times 9 = 90 \text{ mm}^2$

$\frac{1}{2} = 45 \text{ mm}^2$

**Q.** Arnolds nerve is?

**Ans.** Auricular branch of X nerve

**Q.** Jacobsons nerve is?

**Ans.** Tympanic branch of IX nerve.

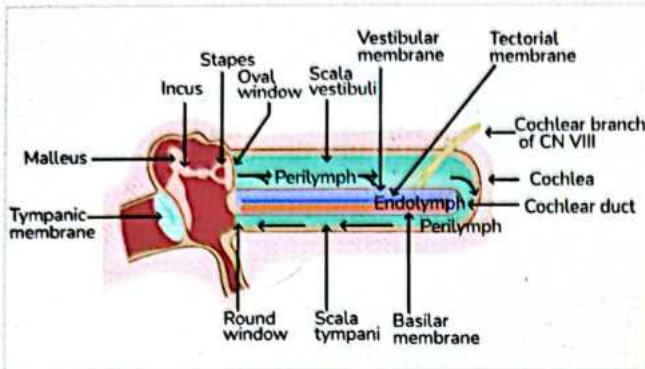
prince kumar  
princeekum@gmail.com  
9928609733





**Physiology of Hearing**

There are 3 basic steps involved in the physiology of hearing.



- Sound wave reaches the auditory canal through the external environment and hits the tympanic membrane.
- When a sound wave hits the tympanic membrane, it goes to the ossicles (malleus, incus, stapes) and then footplate.
- The foot plate covers the oval window, which covers the the scala vestibuli of the cochlea.
- Then impulses travel to the scala tympani and then hit the round window.
- After hitting the oval window, impulses are carried out from the cochlea via the 8th nerve to the brain.

**Mechanical Conduction**

- The external ear and the Middle ear constitute the conductive apparatus (both are air-containing mediums).
- Sounds travel from the external ear to the middle ear, and there is no change of energy from the outer ear to the middle ear but the amplitude of the sound is increasing. (Conductive pathway of mechanical energy).

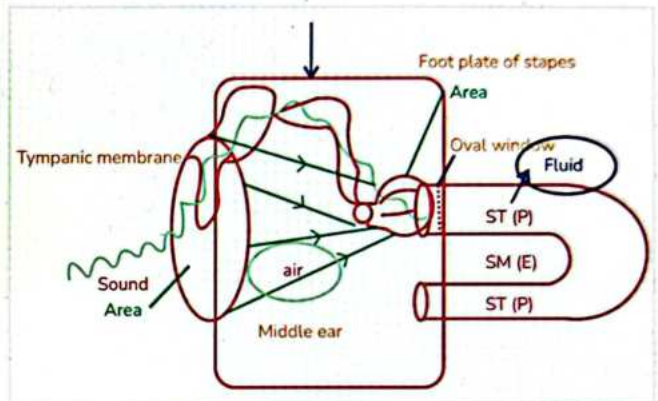
**Transduction**

- When the sound reaches the inner ear (mechanical energy is converted into electrical energy) by a sensory system of the cochlea. This process is called **Transduction**.
- The inner ear is a fluid-containing medium, and this fluid offers resistance, resistance will be overcome by the middle ear. This process is called the **Impedance matching mechanism**.
- The middle ear makes the sound more powerful so that it can be able to penetrate the fluids of the inner ear, which offers resistance.

**Conduction of electrical impulses to the brain**

- The 8th cranial nerve (Vestibular and Cochlear nerves) carries electrical energy from the auditory pathway to the brain.

**Impedance Matching Mechanism**

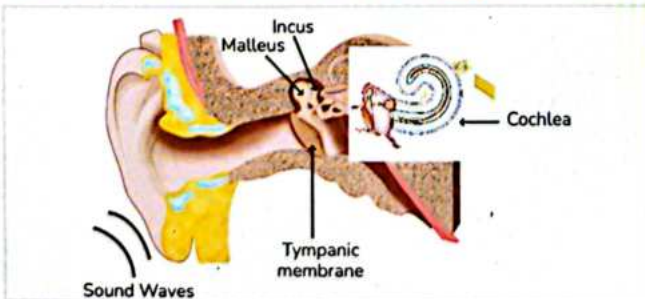


- When sound travels from the air middle ear to the fluid inner ear, its amplitude decreases by fluid impedance (resistance).
- Only 0.1% of sound energy goes to the inner ear.
- The middle ear amplifies sound intensity to compensate for this loss. It converts the sound of low pressure, high amplitude to high pressure, low amplitude vibration (increases the power of sound to penetrate inside the inner ear). This is called as impedance matching system.
- When the sound hits the tympanic membrane, then the sound travels via the malleus, incus, and stapes (middle ear).
- From the stapes, the sound hits the oval window to the scala vestibuli then goes to the scala tympani.
- Sound travels from air-containing medium in the middle ear to the fluid (perilymph in scala tympani and scala vestibuli and endolymph in scala media) containing medium in the inner ear.
- Fluids offer resistance. To overcome this resistance, the middle ear makes the sound more powerful to penetrate the inner ear.

**Basic Steps involved in Sound Transmission**

prince kumar  
princekum@gmail.com

00:05:12

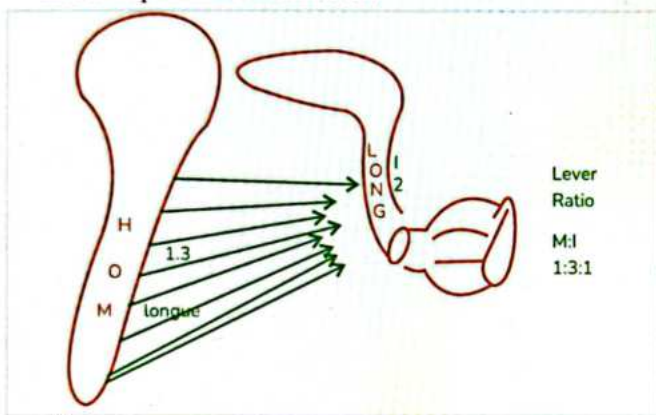




It has 2 mechanisms by which sound becomes more powerful

00:08:10

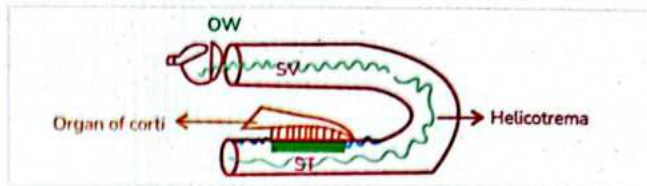
- **Mechanism I** - Sound travels from the tympanic membrane through the ossicles to the footplate of stapes.
- Sound is transmitted from the larger surface area to the smaller surface area. So, there is a condensation of energy of these sound waves and it becomes more powerful to get into the fluid of the inner ear (perilymph).
- The ratio of the tympanic membrane (only the effective vibrating area =  $45-55\text{mm}^2$ ) to the area of the foot plate of stapes ( $3.2\text{mm}^2$ ) tells how much time the sound is stronger.
- Effective vibrating area / Area of the footplate of stapes =  $4.5/3.2 \approx 14:1$
- It is also called the **Areal ratio**.
- So, when the sound travels from the tympanic membrane to the foot plate of stapes, it becomes 14 times stronger. Then, the sound penetrates the inner ear.



- **Mechanism II**- The malleus is about 1.3 times longer than the incus (sound energy goes from the bigger ossicle to the smaller ossicle).
- Due to this, there will be aggregation, a submissive effect. As a result, sound becomes stronger when it goes from malleus to incus.
- The ratio between malleus to incus (M:I) is called as **Lever ratio**.
- **M:I = 1.3:1**
- Total transformation time or ratio when it travels from the middle ear to the inner ear.
- Total transformation ratio = Areal ratio  $\times$  Lever ratio =  $14 \times 1.3 = 18$ .
- So, the sound becomes 18 times more powerful when it travels from the middle ear to the inner ear.

Effective vibratory area	$45\text{mm}^2 / 55\text{mm}^2$
Foot plate area	$3.2\text{mm}^2$
Areal ratio	$14.1/17.1$
Lever ratio	$1.3:1$
Total transformer ratio	$14 \times 1.3 = 18.1$ $17 \times 1.3 = 22.1$

## What Happens To The Inner Ear?



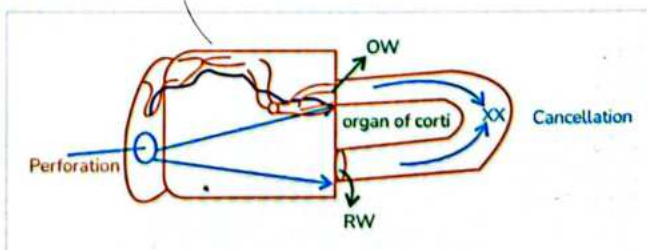
- The sound first goes to scala vestibuli of cochlea.
- The footplate of the stapes covers the oval window, and this oval window covers cochlea's the scala vestibuli (SV) of the cochlea.
- SV connects via **helicotrema** and via the helicotrema, SV is connected to scala tympani (ST).
- Once the sound waves hit the footplate of stapes into the SV, it travels to the fluids.
- It produces motion of fluids that causes vibration of a fluid. So sound waves hit the round window. As a result, it causes the movement of fluid in the inner ear.
- It also causes movement of the basilar membrane (**shearing force** because of the fluid vibration).
- On the basilar membrane, there is the organ of Corti that contains hair cells (receptors of hearing), when the basilar membrane vibrates, hair cells also vibrate against the tectorial membrane (the mechanical energy is converted into electrical energy). Because of the hair cells and the tectorial membrane, there is friction that converts mechanical energy into electrical energy.
- There's an activity of type 1 hair cells which are afferent hair cells that secrete excitatory neurotransmitters called **glutamate**. This glutamate stimulates the 8th nerve (via auditory pathway it reaches the brain).
- This conversion of mechanical energy to electrical energy is called **Transduction**.

## Phase Difference

00:12:12

- Sound travels from the SV to the ST. Then the sound hits the oval window first, then the round window. So, it creates a difference in time. This difference is called **Phase difference**.
- Because of the phase difference, it creates movement of the basilar membrane. If the phase difference is lost. There will be no effective vibration of the basilar membrane.

## Golden Point





- If the person got perforation in the tympanic membrane. So, when the sounds travel to the perforation. Can it hit the oval window and round window simultaneously?
- The answer is yes. Some of the amount of sound goes through the ossicles, but through the perforation, sound can also be conducted.
- If the sound wave goes and hit the round and oval window simultaneously. Will there be a cancellation of these sound waves?
- No, there will be no shearing force to push the basilar membrane and cause movement. As a result, the patient can have **hearing loss**.
- So, the **phase difference** is important to cause an effective vibration of the basilar membrane.

prince kumar  
princeekumar@gmail.com  
9928609733

and area 42 is associated auditory cortex where it recognizes a final perception of sound.

## Functions of Auditory Pathway

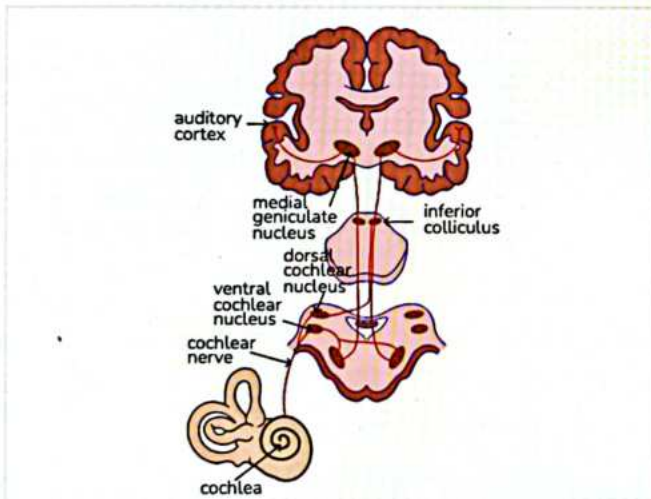
00:31:12

### Golden Point

- **Tonotopic organization of cochlea**- The basal turn of the cochlea is responsible for recognizing high-frequency sound (20000, 18000, 16000 Hz). While the apical turn is responsible for recognizing low-frequency sound (125, 250, 500 Hz). So this difference in recognizing high and low-frequency sounds is called the **Tonotopic organization of the cochlea**.
- The receptor of the cochlea is responsible for recognizing the **pitch of the sound**.

## Auditory Pathway

- Sound reaches the cochlea, and from the cochlea, it goes the 8th nerve to the brain. This entire pathway is called the **Auditory pathway**.



### Golden Point

#### Order of the auditory pathway

#### Mnemonic ECOLIMA

- **E**- Eight nerve (8<sup>th</sup>)
- **C**- Cochlear Nucleus
- **O**- Superior olivary complex
- **L**- Lateral lemniscus
- **I**- Inferior colliculus
- **M**- Medial geniculate body
- **A**- Auditory cortex
- When sound travels from the cochlear nucleus to the superior olivary complex, it travels by a body called a **Trapezoid body**.

#### How The Sound Travels From The Pinna To The Brain?

- Sound travels from the 8th nerve to the superior temporal gyrus present in **area number 41** (primary auditory complex)

Part of pathway	Function
Pitch of Frequency	Cochlea
Amplitude or intensity	Cochlear nerve
Feature detection	Higher auditory centers
Localization of sound	Higher auditory centres

### Important Questions

**Q. How much sound energy goes to the inner ear.**

**Ans.** Only 0.1% of sound energy goes to the inner ear.

**Q. Receptor of the cochlea is responsible for?**

**Ans.** Recognizing the pitch of a sound. mechanism.

**Q. Effective vibrating area / Area of the foot plate of stapes?**

**Ans.**  $4.5/3.2 = \sim 14:1$

**Q. The basal turn of the cochlea is responsible for recognizing high-frequency sounds (20000, 18000, 16000 Hz). While the apical turn is responsible for recognizing low-frequency sound (125, 250, 500 Hz). So this difference of recognizing high and low-frequency sounds is called?**

**Ans.** Tonotopic organization of the cochlea.

**Q. On the basilar membrane, there is an organ of Corti that contains hair cells (receptor of hearing), when the basilar membrane vibrates, hair cells also vibrate against the tectorial membrane (the mechanical energy is converted into electrical energy). It converts?**

**Ans.** Mechanical energy into electrical energy.

**Q. When the sound travels from the cochlear nucleus to the superior olivary complex, it travels by a body called-**

**Ans.** Trapezoid body






# CROSS WORD PUZZLES



## Crossword Puzzle 1



### Across


- 3. \_\_\_\_\_ is the ratio between malleus to incus (M:I).
- 4. The \_\_\_\_\_ cranial nerve carries electrical energy from the auditory pathway to the brain.

### Down

- 1. \_\_\_\_\_ is the effective vibratory area of the tympanic membrane.
- 2. \_\_\_\_\_ is the process when the sound reaches to the inner ear by sensory system of cochlea.

princeeeekum@gmail.com  
9928609733

## Crossword Puzzle 2



### Across


- 3. \_\_\_\_\_ is secreted by type I hair cells that stimulate the 8<sup>th</sup> nerve.
- 4. \_\_\_\_\_ makes the sound more powerful so that it can penetrate to the inner ear.

### Down

- 2. \_\_\_\_\_ is the total transformation ratio.

- 3. \_\_\_\_\_ decreases by fluid impedance, when sound travels from air middle ear to fluid inner ear.

## Crossword Puzzle 3



### Across

- 2. As sound travels from the tympanic membrane to the footplate of the stapes, it becomes \_\_\_\_\_ times stronger.
- 3. \_\_\_\_\_ is responsible for recognizing the pitch of sound.

### Down

- 1. \_\_\_\_\_ is important to cause the good vibration of the basilar membrane.
- 4. \_\_\_\_\_ organization of cochlea is the difference of recognizing high and low frequency sound.



## 4

## ASSESSMENT OF HEARING



### Format for the order of examination

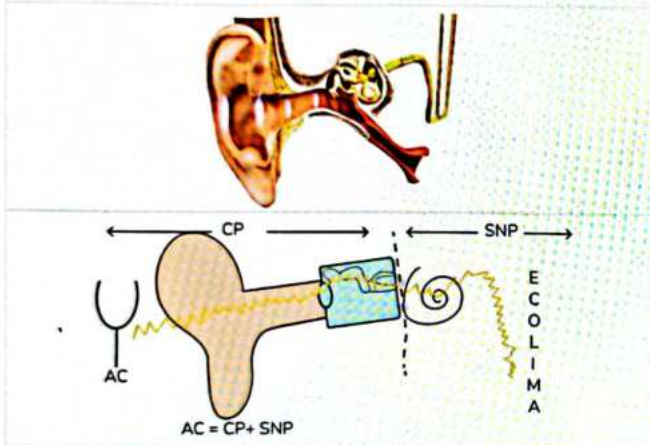
00:01:13

#### Tuning Fork Tests

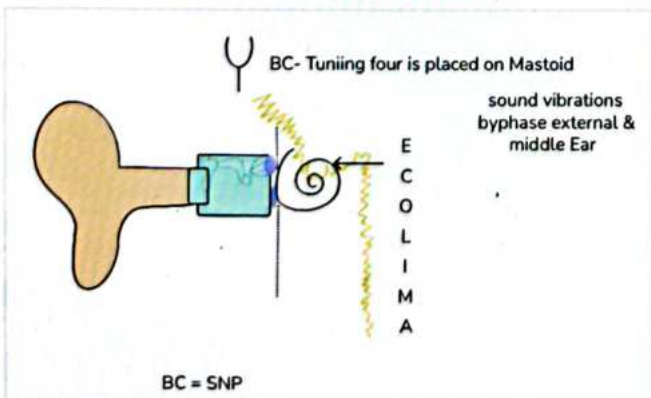
- Rinne
- Weber
- Absolute bone conduction test
- Pure tone audiometry
- Impedance audiometry
- Speech Audiometry
- Special tests like OAE, BERA, Ecog.

**Tuning Fork Test:** It is the first test that is done for every patient with a hearing loss problem. It is the preliminary test to understand the hearing pathway or if there is any problem with it.

#### Understanding air conduction and bone conduction



- When a tuning fork is kept in the air, the sounds are being conducted from the air to the pinna this is called **air conduction**. In the process of air conduction, the sound travels from the external auditory canal and hits the tympanic membrane. Goes to the malleus, incus and stapes to oval window and from there to the cochlea. Where it goes via the auditory pathways to the brain. This entire pathway from the outer ear to the brain is called **air conduction**.



- When a vibrating tuning fork is placed on the **mastoid bone** the pathway will be called **bone conduction**. In this process, the sound passes the external ear, middle ear and goes directly to the internal ear and finally to the brain. Conductive pathway is a pathway from pinna to footplate of stapes
- The **sensory neural pathway** is the cochlear and the retro cochlear pathway together. So therefore air conduction is equal to the conduction pathway plus the sensory neuron pathway. Bone conduction does not follow the conductive pathway of the ear. But it is following the sensory neural pathway

#### Rinne Test

00:07:12

- $AC (>) BC \rightarrow$  RINNE (+ve)
  - Longer
  - Louder
- The Rinne test differentiates sound transmission via air conduction from sound transmission via bone conduction. It can serve as a quick screen for conductive hearing loss. The tuning fork is placed on the mastoid bone and the patient asks to inform when he/she stops hearing. When sound is stopped the tuning fork is moved from the mastoid and will be positioned near pinna to test for air conduction pathway.
- The patient will once again start hearing sounds and the air conduction will go on longer than bone conduction. When tuning fork is louder and goes for longer period of time in the air conduction pathway it is called  $AC > BC$ . Rinne positive means the patient does not have hearing loss.
- When the air conduction is lesser than the bone conduction it is called **Rinne negative** which is caused by conducting hearing loss. Air conduction is affected by this because it comprises of both the conduction pathway and sensory neural pathway. **In conductive hearing loss  $AC < BC$ .**

#### Sensory neural hearing loss

- In sensory neural hearing loss, the sensory neuron is damaged, which is a part of both air conduction and bone conduction. But bone conduction is going to be affected more than air conduction. In sensory neural hearing loss **when  $AC > BC$ , it is called Rinne positive**. Rinne Positive can be seen in two conditions when the person is having sensory neural hearing loss or if the person has normal hearing.

#### False negative Rinne

- In some conditions, there can be false negative Rinne. Typically in negative Rinne, air conduction is lesser than



bone conduction.

- This is mostly found in unilateral severe to profound sensory neural hearing loss. When the tuning fork is placed in the air conduction pathway the sound will travel from the external ear to the middle ear on the affected side as well. Since the inner ear is severely damaged, the impulses won't be transmitted to the brain. So therefore in a false negative Rinne, the air conduction is not heard.
- The bone conduction sound on the affected side is not heard. But through the bones of the skull, the sound can be transmitted from the affected side to the normal side with the help of the interconnecting bones. Which means sound can travel through the cranial vault to the opposite cochlea. Hence, bone conduction will be presumed to be more than air conduction on the affected side.
- When  $AC < BC$  it is Rinne Negative. It is not a true negative, it is a false negative Rinne.

### Weber Test

- In a weber test, the tuning fork is vibrated and is placed on the top of the patient's head in the midline and asked the patient where they hear the sound.
- Normally, the sound is felt in the centre of the head and will be heard equally in both ears.
- **Conductive hearing loss:** In conductive hearing loss there is some pathology between the external ear and the middle ear such as wax, perforation, middle ear effusion etc.. On the side with conductive hearing loss, the cochlea has to overact or become hyperactive because it has to compensate for the loss.
- So the patient will have hyperactive cochlea on one side and normal cochlea on another side. When the vibrating tuning fork is placed in the middle at the top of the head of the patient the sound will get pulled towards the affected side as it has a hyperactive cochlea.

### Sensory neural hearing loss:

- Sound is lateralized towards the (N) side
- If there is a hypo functional cochlea on one side and a normal functioning cochlea on another side the sound will travel towards the normal side as it has more power. **If it is right side Weber positive it means it either has right conductive hearing loss or left sensory hearing loss.**
- Correlation with Weber and Rinne test.
- Weber positive in right side and Rinne is positive in both right and left it means the patient has Left side sensory neural hearing loss.

### Absolute bone conduction test

00:25:37

1. Examiner's hearing (N)

### 2. AC route should be occluded

Pt = Examiner = (N)

Pt → Shorter → (SNHL)

When absolutely the bone conducting the test is taken, it is called the absolute bone conducting a test.

- Prerequisite of the test:
  - The examiner has to have normal hearing.
  - The air conduction pathway should be occluded.
- Test process:
  - The vibrating tuning fork will be placed on the mastoid of the patient. And the patient will be instructed that their air conduction pathway will be occluded and to hand raise when he/she stops hearing the sound.
  - When the patients stop hearing the sound the examiner will check whether they hear the sound or not for the same duration. If they do means the person has normal bone conduction.
  - Therefore if the bone conduction of the patient is shorter than the examiner they might have issues at the level of the sensory neural pathway.
- Conductive pathway problems cannot be assessed by this test. The same test can be done without occluding the external air canal which is called the **Schwabach test**.

### Bings Test

00:31:30

- Bings test uses bone conduction route to assess the Sound transmission. The vibrating tuning is placed on the mastoid and alternately open and close the tragus to check whether the patient can hear the sound or not.
- When the tragus is closed the patient should be able to hear the sound louder and when the tragus is open the patient should be able to hear the sound softer. The patient should be able to understand and comprehend the increase and decrease of the sound this is called **Bings positive**.
- **Bings negative** is seen in conductive hearing loss.

### Gelles Test

00:33:08

- A Siegle's pneumatic speculum is used in this test to increase or decrease the air pressure in the external canal while placing a vibrating tuning fork on the mastoid process.
- Patients with conductive hearing loss especially ossicular fixation will not be able to appreciate the increase and decrease of pressure, which is referred to as **Gelle's negative**.
- Increase and decrease pressure in the external auditory canal will be appreciated in both healthy people and those with **sensorineural hearing loss** that means they are **Gelles test positive**

### Pure Tone Audiometry

00:37:10

- Air conduction is tested from 125hz to 8000hz



- Bone conduction is tested from 250 to 4000hz
- The charted graph is called an audiogram
- This confirms the type of hearing loss (Conductive / Sensorineural / Mixed)
- Degree of hearing loss can also be measured accurately.
- Pure tone audiometry is a procedure to asses both air conduction and bone conduction. Headphones for air conduction and vibrators placed on mastoid are connected to the audiometer required for this exam.
- When the patient detects a sound, they are instructed to indicate it. Each tone's minimum loudness requirement is graphed.
- One ear at a time receives pure tones at a particular frequency and amplitude. **Pure-tone audiometry is the gold standard for establishing the kind, degree, and configuration of a patient's hearing loss, including the proportion of conductive to sensorineural hearing loss.**

prince kumar  
princeeeekum@gmail.com  
992860733

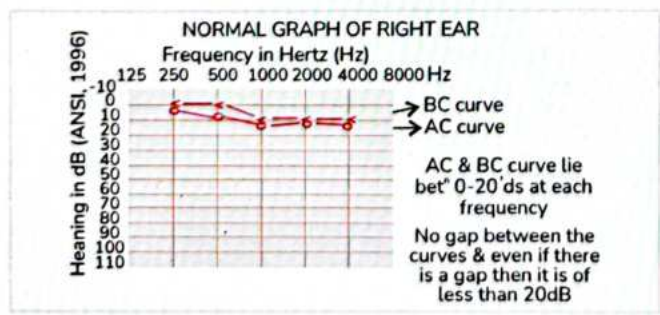


The patient is made to sit in a sound proof room.

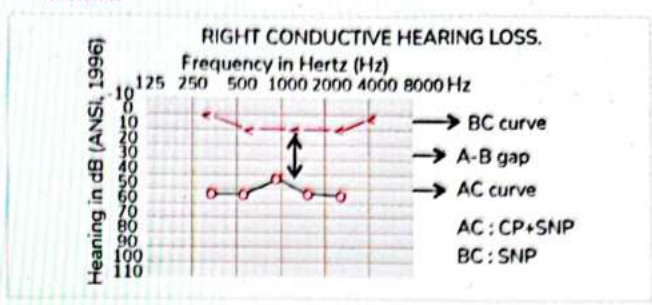
**Symbols used in Audiograms**

	Right Ear	Left Ear
AC unmasked	0	X
AC masked	Δ	[]
BC unmasked	<	>
BC masked	[	]
No responses	↙○	○↘

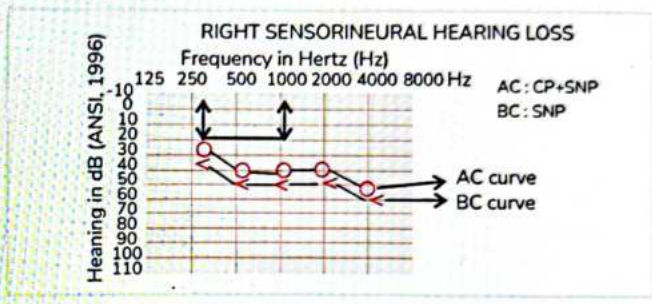
Right ear is depicted in red color and left ear in the blue color.



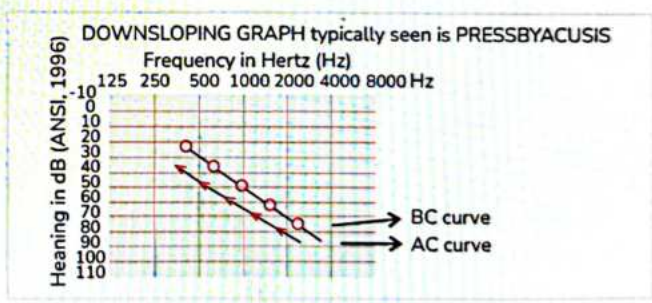
- The 0 in the graph indicates air conduction. If the lowest point of hearing for all frequencies of air conduction and bone conduction lies between 0 to 25 decibels it is considered normal.



- BC curve is in the normal range and the AC curve is in the abnormal range with a significant air gap which indicates Conductive hearing loss.
- When the A - B gap is more than 20 decibels it is very significant.

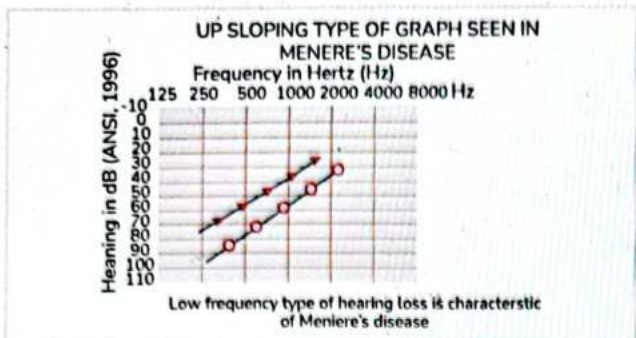


- The air condition is abnormal and the bone conduction is also abnormal it indicating sensory neural Pathology.
- There is no significant air gap present.

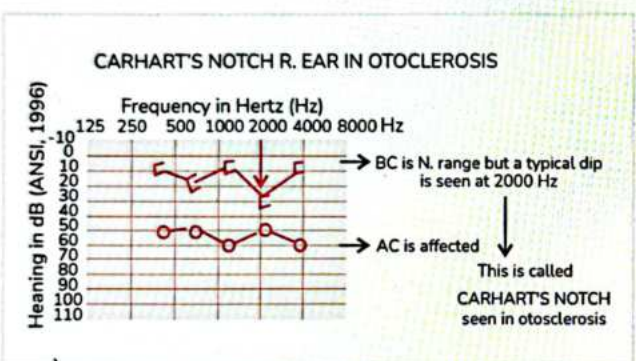


- Presbycusis is a sensory hearing loss which happens with ageing.
- X depict the air condition curve of the left ear.
- BC is abnormal so is the AC, with no A-B gap. This is a typical scene in sensorineural hearing loss. **A down-sloping graph is very specific in presbycusis.**



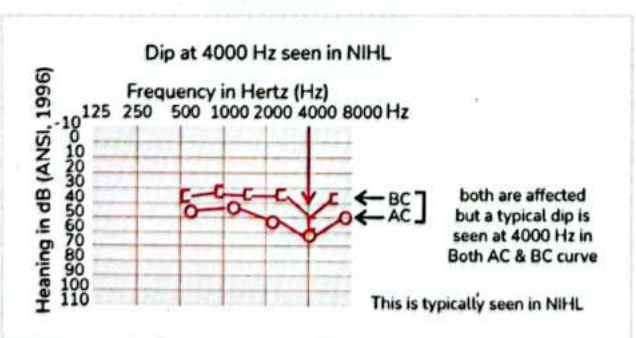


- Menieres disease affects the inner ear where there is an increase in **endolymphatic pressure**. This is a lesion that affects the cochlea, and any cochlear type of pathology will be related to sensory neuronal hearing loss.
- AC and BC are both abnormal, with no A- B indicating SN hearing loss.
- A higher amount of hearing loss can be seen at low-frequency.
- **Up sloping graph is specific for menieres disease.**



- At 2000hz the BC is abnormal but everywhere else it is normal, indicating Charhart's Notch.
- Otosclerosis is a condition that impairs hearing by causing the stapes, a small bone inside the ear, to fuse (connect) with other ear structures. Charhart's notch is specific for otosclerosis.

### Noise Induced Hearing Loss

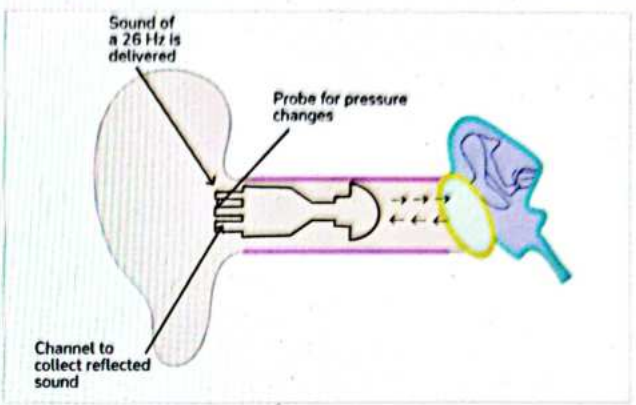


- The BC and AC curve of the right ear is in the abnormal range, which means there is sensory neural hearing loss.

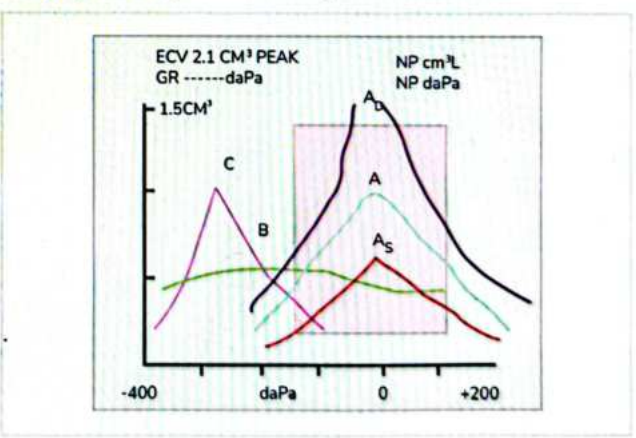
- At 4000 Hz there is a dip in both AC and BC, this is called the **boiler's notch** which is specific in noise-induced hearing loss.

### Impedance Audiometry

00:59:15



- Impedance means the resistance which is offered by the **tympanic membrane**.
- When the sound goes and hits the tympanic membrane, how stiff or placid the tympanic membrane is will determine the compliance of tympanic membrane and middle ear pressure.
- It is the **objective test** where a machine is responsible for the response.
- There is a probe inserted in the external auditory canal which has three channels. One channel delivers sound which is 226 Hz and the second channel is responsible for receiving the sound and delivering the reflected sound to a machine where the reports are recorded. The third channel will record the pressure changes.
- Impedance audiometry comprises of **acoustic reflex** and tympanometry.



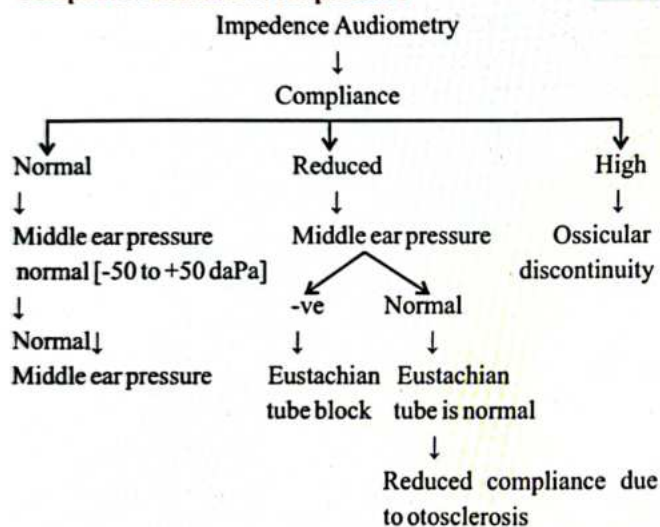
- When the peak is almost at 0 and occupies almost half of the Y-Axis. This is called **A** type of graph.
- When the peak of the curve is at 0 but covering the lesser than half of the Y- axis, it is called **As** a type of graph.
- When the peak is more than half of the length of the Y-Axis. This is called an **Ab** type of graph.



- A single straight line is called the B type of graph.
- When an A type of graph is formed on the negative side on X axis is called a C type of graph.
- **A-type:** This type of graph is seen in the Normal condition.
- **A<sub>o</sub> type:** This type of graph is seen in an **Ossicular discontinuity**.
- **A<sub>s</sub> type:** This type of graph is seen in **Otosclerosis** and **Tympanosclerosis**.
- **B type:** This type of graph is seen in the Fluid in the middle ear.
- **C type:** This type of graph is seen in the negative middle ear pressure which is seen in **Eustachian tube dysfunction**.

**Compliance and middle ear pressure**

01:09:50



**Compliance is the vibrating capacity of the tympanic membrane.**

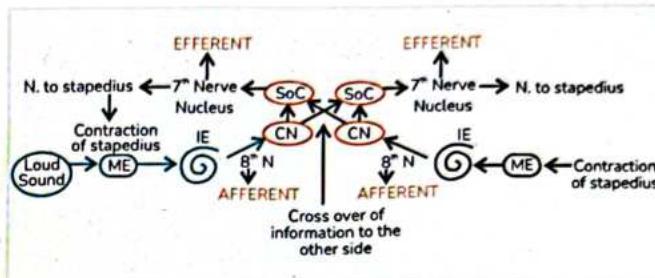
- If the compliance and the middle ear pressure are normal then it indicates the patient is normal.
- If compliance is high and the middle ear pressure is normal, this happens when there is an **Ossicular discontinuity**.
- If the compliance is low and the middle ear pressure is normal there is an **ossicular fixation**.
- If the compliance is low and the middle ear pressure is also negative then there is **Eustachian tube dysfunction**.

**Stapedial Reflex**

01:14:32

- Whenever a person hear some loud sound this will cause contraction of the middle ear muscles. There are two middle ear muscles (MEMs): **the stapedius and the tensor tympani**.
- The contraction of the muscle will reduce the amount of sound travelling from the external ear to the tympanic membrane, protecting the ear from noised trauma.
- This is not a subjective test in which a machine will inform whether the person is having stapedial reflex or not.
- For instance, loud sound is given to the patient's ear, the sound travels from the external ear via the ossicles to the inner ear.

- From there the sound is carried forward by the 8th nerve, and from there the impulses will go to the **cochlear nucleus**. From there it will go to the **superior olivary complex**. Now there is lateral decussation of fibres to the facial nerve nucleus.
- From the 7th nerve nucleus of the ipsilateral side and the contralateral side, the impulse will go to the 7th nerve. Now it will move to the stapedius, which will cause the contraction of the stapedius muscles.



- Whenever there is 8th nerve pathology or cochlear pathology there is the bilateral loss of stapedial reflex. **7<sup>th</sup> nerve pathology causes Unilateral loss of stapedial reflex.**

**Stapedial Reflex – Uses**

1. Test for assessment of hearing in infants and children
2. To identify Malingers
3. To identify if there is a cochlear pathology
4. To identify 8<sup>th</sup> nerve pathology
5. To identify 7<sup>th</sup> nerve pathology

**Speech Audiometry**

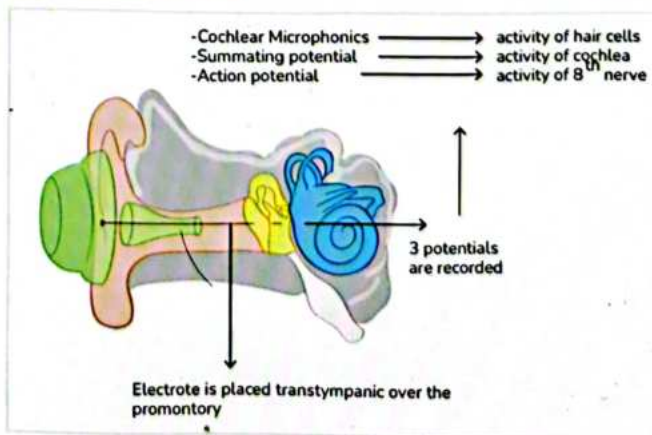
01:22:28

For speech audiometry there are two tests:

- **Speech reception threshold:** It is a threshold at which 50% of the words spoken are repeated correctly. It is a Subjective test.
- **Speech Discrimination Score:** It is the ability of a patient to correctly identify phonetically balanced words like box, and fox. <50% score means the patient has some retro cochlear hearing loss, SDS is affected. It is a Subjective test.

**Electrocochleography**

01:25:31





- It measures the electric potential of the cochlea which is charted in a graph. Through the tympanic membrane, one electrode is placed at the basal turn of the cochlea. This electrode will produce some sound which will create stimulation the cochlea response observed at the first 5 milliseconds is recorded by the electrode. Testing the electrical activity produced by the eighth nerve and cochlea is known as electrocochleography and it is investigation of choice to diagnose meniere disease. **SP/AP < 30% is suggestive of meniere disease.** It can be used for intraoperative cochlear and eighth nerve monitoring.

**Brainstem evoked response audiometry**

- It is a test to assess the auditory pathway from the 8<sup>th</sup> nerve to brainstem
- Its non-invasive test
- Clicks and tone bursts are used to elicit a response
- In a normal person 5-7 electrical waves are generated
- Each wave represents a particular area on the auditory pathway.
- The sound will travel from the external ear to the middle ear to the inner ear. And via the 8th nerve, the impulses will go to the brainstem. The aim of the test is to recognise the response coming from the brainstem. The first sound that will be recorded on the electrode is from the distal part of the 8th nerve.

**Pneumonic**

These seven waves produced in first 10ms represents

• Wave I - Distal part of CN VIII	E
• Wave II - Proximal part of CN VIII near the brainstem	E
• Wave III - Cochlear nucleus	C
• Wave IV - Superior olivary complex	O
• Wave V - Lateral lemniscus	L
• Wave VI and VII - Inferior Colliculus	I

**Uses of BERA:**

- Confirming hearing loss in infants.
- Non-organic hearing loss.
- Differentiating cochlea from retro cochlea hearing loss.
- **Best audiometric test for acoustic neuroma (delay in wave 5 is suggestive of acoustic neuroma).**
- Objective test for hearing.

**Otoacoustic Emission**

01:36:57

- **Otoacoustic emissions** are the emissions generated by the outer hair cells of the cochlea. In the cochlea, there are two types of hair cells:
  - Outer hair cells, which are generally efferent.
  - Inner hair cells, which are generally afferent.

- Some of the impulses go towards the external auditory canal where an ultra-high sensitive probe connected to a handheld machine is placed. If the probe is able to record these emissions without any sound stimulation these are called spontaneous emissions. If these emissions are recorded with or without sound stimulation then it can be said the patient is said to have passed the test.
- It is a screening test.
- When the stimulations are absent then patient is referred but hearing loss is not confirmed.

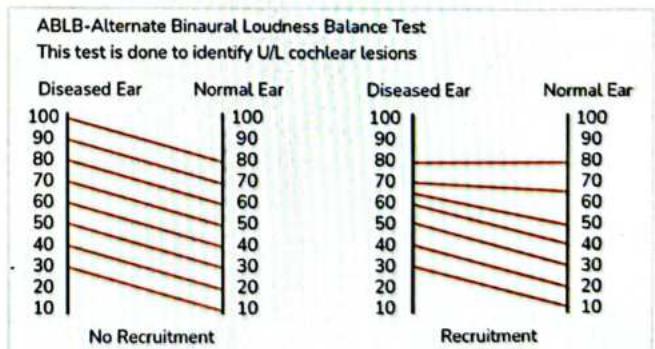
**Uses:**

1. Best audiometric test for **SCREENING** hearing loss in neonates, infants and children
2. Can differentiate cochlear from retro cochlear hearing loss
3. Useful for early detection of noise induced hearing loss.

**Recruitment: (Test for cochlear Pathology)**

01:43:39

1. It's a phenomenon where there is abnormal growth in the loudness of the sound
  2. Sounds of low intensity are heard as loud sounds
  3. It seen in lesions affecting cochlea like Meniere's presbycusis
  4. This helps to differentiate from retro cochlear pathology
- A patient who suffers from sensorineural hearing loss experiences a rapid increase in the loudness at high-intensity noises, despite the fact that they are unable to detect low-intensity sounds. This happens when partial hair cells of the cochlear become ineffective.
  - A low-frequency sound won't be able to cross the initial inactive hair cells. In case of loud noise, more area of the cochlear is getting activated which will result in normal cells in the middle also getting activated. Which are hyperactive as they have to compensate for the loss.



- For individuals with unilateral hearing loss, the alternate binaural loudness balance (ABL) test assesses the **perceived loudness disparities between the ears.** It can be used as a recruitment test. By analysing the loudness disparities at high-intensity levels, the test is interpreted.



# Telegram - @nextprepladdernotes

## SISI (Short Increment Sensitivity Index)

1. Patients with cochlear pathology are able to appreciate small changes in the intensity of sound as compared to those of retro cochlear lesion or normal person
2. This test also differentiates cochlear from retro cochlear pathology
  - The purpose of the SISI test is to determine whether or not the patient can detect very minute variations in sound strength. Knowing this is crucial because if the cochlea is affected, the patient will be able to perceive changes that are smaller than what the typical ear can pick up.

## Threshold Tone Decay Test

1. It's a test for retrocochlear pathology
2. Normal person hears a tone continuously for 60 sec while in patients with retro cochlear pathology they stop hearing earlier due to fatigue of the auditory nerve.
  - If the patient has 8th nerve pathology or retro cochlear pathology then the nerve will undergo fatigue and the tone won't be heard for 60 seconds.

## Results of various tests to differentiate a cochlear from a retrocochlear lesion

	Normal	Cochlear lesion	Retrocochlear lesion
Pure tone audiogram	Normal	Sensorineural hearing loss	Sensorineural hearing loss
Speech discrimination score	90-100%	Below 90%	Very poor
Recruitment	Absent	Present	Absent
SISI score	0-15%	Over 70%	0-20%
Threshold tone decay test	0-15 dB	Less than 25 dB	Above 25 dB
Stapedial reflex	Present	Present	Absent
Stapedial reflex decay	Normal	Normal	Abnormal
BERA	Normal interval between wave I & V	Normal interval between wave I & V	Wave delayed or absent

prince kumar  
princeekum@gmail.com  
9928609733






## CROSS WORD PUZZLES



### Crossword Puzzle 1




**Across**

- 2. C type: This type of graph is seen in the negative middle ear pressure which is seen in \_\_\_\_\_.
- 3. AD type: This type of graph is seen in an \_\_\_\_\_.

**Down**

- 1. AS type: This type of graph is seen in Otosclerosis and \_\_\_\_\_.

### Crossword Puzzle 2




**Across**

- 3. At 2000hz the BC is abnormal but everywhere else it is normal, indicating \_\_\_\_\_.

**Down**

- 1. \_\_\_\_\_ is a sensory hearing loss which happens with ageing.
- 2. \_\_\_\_\_ means the resistance which is offered by the tympanic membrane.

### Crossword Puzzle 3



**Across**

- 3. \_\_\_\_\_ affects the inner ear where there is an increase in endolymphatic pressure.
- 4. When the air conduction is lesser than the bone conduction it is called \_\_\_\_\_.

**Down**

- 1. Otoacoustic emissions are the emissions generated by the \_\_\_\_\_ of the cochlear.
- 2. A down-sloping graph is very specific in \_\_\_\_\_.

prince kumar  
princeeeekum@gm  
9928609733



## 5

# PHYSIOLOGY OF VESTIBULAR SYSTEM



- The vestibular organ in the inner ear is responsible for balance in our body.

### Basic Concept

00:00:32

- The central part of the Vestibular chamber - hearing and balance. Whereas semicircular canals - only balance.
- Vestibule consists of Utricle and Saccule as part of membranous labyrinth.
- A Neuro sensory epithelium called a Macule covers Saccule and Utricle.
- Utricle opens into Semi-circular canal ducts which are Superior, lateral, and posterior Semi-circular canals.

### Nerve Supply

00:01:31

- Superior Vestibular Nerve- Utricle, Superior and lateral Semicircular canals.
- Inferior Vestibular Nerve- Saccule and posterior Semi circular canal.



### Important Information

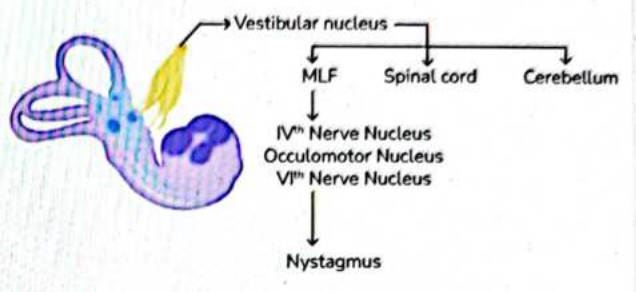
- Inferior and Superior Vestibular Nerves are branches of the Vestibular nerve which is part of eight cranial nerves known as the Vestibulocochlear Nerve.

- Sensory Impulses from the Inferior and Superior Vestibular Nerves connect, forming Vestibular Nerve. It carries impulses to First Order Neuron in Scarpas Ganglion.
- Then, impulses are travelled to Second Order Neuron Called Vestibular Neuron.
- From Vestibular Neuron, the sensory impulses are travelled as efferent pathways to the Median Longitudinal fascicle supplying the oculomotor nerves 3,4 and 6, which in turn supply muscles of the eye.
- Stimulation of the Median longitudinal fascicle results in a reflex called Vestibular Ocular Reflex (Nystagmus).
- Additionally, it travels to the Spinal Cord supplying Spinal muscles (Sternocleidomastoid mainly) and results in Vestibulo Spinal Reflex stimulation.
- Finally, impulses circulate to the Cerebellar region and pass on as Vestibulo Cerebellar Pathways.

00:03:02

Q. Where is First Order Neurons present?  
 Ans. Scarpa's Ganglion

### VESTIBULAR PATHWAY



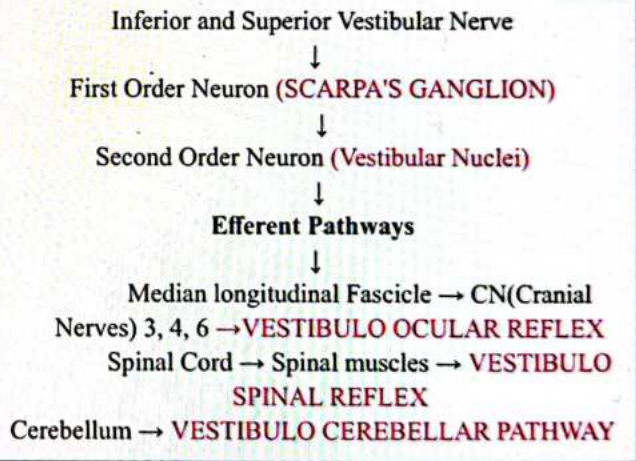### Important Information

- SCARPA'S GANGLION is situated very close to the Lateral end of the Internal Auditory Meatus.



### Important Information

00:05:32



### Functioning

#### Vestibular system

- Peripheral receptors in membranous labyrinth
  - Utricle and saccule - also called otolith organs. They act as stretch receptors and gravity acts a stimulus
    - Linear acceleration
    - Gravity
  - Semi-circular canals
    - Change of head position
- Contains cristae are the ampullated end which is responsible for angular acceleration and deacceleration
- And it has otolith membrane



- It is gelatinous mass embedded with otolith/ otoconia
  - These are crystals of calcium carbonate
2. **Vestibular nerve:** Fibres end in the vestibular nuclei while some end in cerebellum

00:08:02

Movement	Responsive part of the inner ear
1. Angular/ rotational	CRISTAE → cochlear duct
2. Linear <ul style="list-style-type: none"> <li>• Horizontal</li> <li>• Vertical</li> </ul>	MACULAE → Utricle and saccule
3. Sense of gravity or position of head	

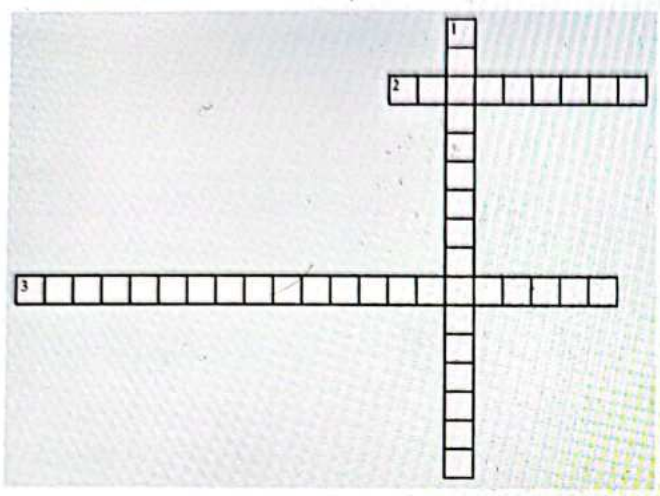




## CROSS WORD PUZZLES



### Crossword Puzzle 1



**Across**

- 2. Stimulation of the Median longitudinal fascicle results in
- 3. Stimulation of sternocleidomastoid causes

**Down**

- 1. Second order Neuron

**Answers**


**Across**

- 2. Vestibulo Ocular Reflex
- 3. Vestibulo Spinal Reflex

**Down**

- 1. Vestibular Nuclei

### Crossword Puzzle 2



**Across**

- 2. Semi-circular ducts are opened from?
- 3. Superior and Inferior vestibular nerves join to form?

**Down**

- 1. What is the First Order Neuron that carries impulses from the vestibular nerve?

**Answers**

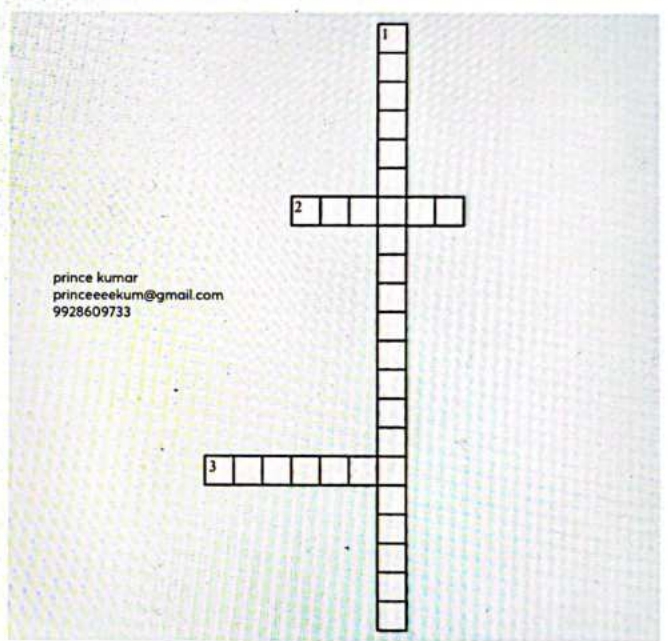
**Across**

- 2. Utricle
- 3. Vestibular Nerve

**Down**

- 1. Scarpas ganglion

### Crossword Puzzle 3



**Across**

- 2. Lining covering Utricle and Saccule is?
- 3. Semicircular Canals are responsible for which movements?

**Down**

- 1. Stimulation of ocular muscles in Median Longitudinal fascicle results in which reflex?

**Answers**

**Across**

- 2. Macule
- 3. Angular

**Down**

- 1. Vestibulo Ocular Reflex

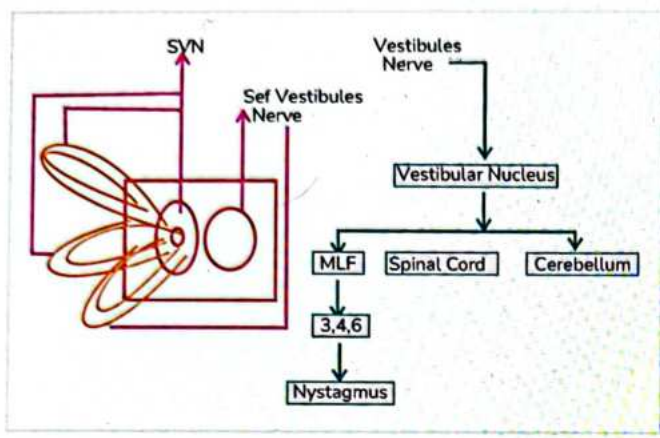


## 6

# ASSESSMENT OF VESTIBULAR SYSTEM



- A central chamber called the **vestibule** is present that contains the elliptical recess and the spherical recess.



- The spherical recess contains within it the **sacculus**, and the elliptical recess contains the **utricle**.
- The utricle receives within it the opening of the semi-circular canal ducts. The impulses from the utricle from the superior semi-circular canal and the lateral semi-circular canal are carried by the superior vestibular nerve.
- The impulses from the saccule and the posterior semi-circular canal are carried by the inferior vestibular nerve. The impulses from both will go through the vestibular nerve into the **vestibular nucleus**.
- **Three efferents** are present in the vestibular nucleus.
  - a. The first efferent goes into the medial longitudinal fasciculus, where the 3rd, 4th, and 6th nerve nucleus lies. When these are stimulated, a movement of the eye, known as **Nystagmus**, is produced.
  - b. The second efferent lies in the **spinal cord** and the spinal muscles.
  - c. The third efferent lies towards the **cerebellum**.
- Whenever there is stimulation of the utricle, saccule, and semicircular canal, the medial longitudinal fasciculus is also stimulated via the vestibular nerve pathway, which causes **Nystagmus**. This reflex is called the **vestibulo-ocular reflex**.
- Certain clinical tests and laboratory tests are conducted to check if the inner ear is functioning properly.
  - a. The to and fro movement of the eye is assessed through the nystagmus test.
  - b. The communication between the middle ear and inner ear is tested through the fistula test.
  - c. The position effect on vertigo is checked by the Dix Hallpike Manoeuvre.
  - d. The normalcy of the vestibular system is checked by conducting **laboratory tests**.

CLINICAL TEST	LABORATORY TEST
Spontaneous Nystagmus	Caloric tests
Fistula Test	Electronystagmography
Dix Hallpike Manoeuvre	Optokinetic Nystagmus
Gait Past Pointing	Rotation test Galvanic test

### Nystagmus 00:04:00

- When the labyrinth is stimulated, that oscillatory movement of the eyeball is called **nystagmus**. It can be of a few types.

1. **Spontaneous nystagmus** – When nystagmus occurs without any stimulation of the labyrinth, the movement is called spontaneous nystagmus. Spontaneous nystagmus is usually organic and indicates central pathology. It can also happen in peripheral disorders.
2. **Gaze-evoked nystagmus** – The object is held 30 cm away from the patient's eye. The object is moved 30 degrees to the right, left, up, and down in the direction of gaze. The patient is asked to look at the object. If the patient is asked to look toward the left and there is a movement of the eye toward that side, it means that gaze-evoked nystagmus is present.
  - When one moves the object in the direction of the gaze and the patient gets nystagmus, that is known as **gaze-evoked nystagmus**. When the object is moved, there is a movement of the eye, fluctuation of the eyeball, rhythmic movement of the eyeball, and oscillation of the eyeball. It evoked nystagmus in that direction. If the object is moved to the opposite side, evoked nystagmus is also observed in the opposite direction. The presence of a gaze-evoked nystagmus indicates that a peripheral lesion is present.

### Central And Peripheral Described

- If the lesion originates from the brain stem (vestibular nucleus) and onwards, it is a **central lesion**. If there is a lesion present in the labyrinth or the vestibular nerve, it is called a **peripheral lesion**. Therefore, a lesion from the brain stem is called central. A lesion in the labyrinth/vestibular nerve is called peripheral. Every nystagmus contains a fast and a slow component. It is important to note that the direction of the **fast component** will tell the direction of Nystagmus.

### Rules of Nystagmus 00:09:37

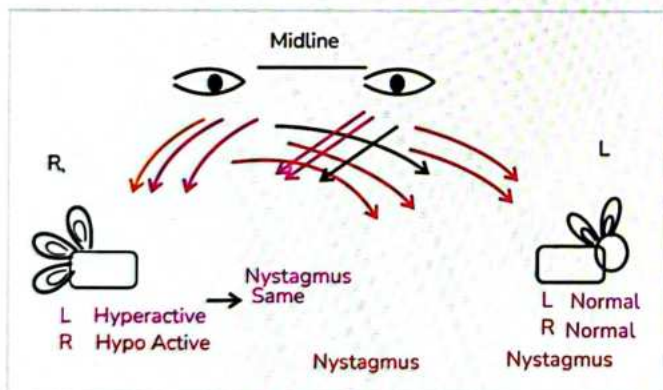
- The rules state what happens when there is a peripheral labyrinth lesion and what the direction of the nystagmus is accordingly.



**Actual Concept**

- The right labyrinth has the tendency to push the eye toward the opposite (left) side. The left labyrinth pushes the eye toward the right side. Since both of these are equally competing against one another, the brain does not interfere, and it causes the equal and opposite forces to cause the eyes to remain in their respective places in the midline position.
- If there is a right-sided **hypoactive** labyrinth, it will not be able to push the eye to the left side effectively. If the left one is normal, it can push the eye towards the right side. By this rule, the eye should drift toward the hypoactive side, but it does not happen because the brain interferes and compensates. The brain compensates by pushing the eyeball to the opposite side in a very fast way drifting the eye toward the opposite side. Hypoactive lesions will cause nystagmus towards the opposite side.
- **Hyperactive lesions:** If the right side is hyperactive and the left side is the normal side, the right side will push the eyeball with extra intensity toward the left side. The left side is normal and can push the eye towards the opposite side. The right side is stronger, and the brain will try to compensate by pushing or drifting the eye toward the same side. This will cause the eye to get drifted to the right side.

**Shorter Version of Concept**



- This is a shorter version of the concept and is not the actual or the whole concept.
- The right labyrinth is trying to pull the eye towards the right side, and the left labyrinth is trying to draw the eye toward the left side. The equal and opposite forces cause the eyes to stay in the midline position.
- When the right side is hyperactive, and the left side is normal, the deflection of the eye will happen toward the more powerful side, that is, the right side. In hyperactive lesions, the nystagmus will be on the same side.
- When the right side is hypoactive and the left side is normal, the left side has more power. This will cause the eye to get deflected toward the opposite side. Nystagmus is also seen toward the opposite side.

**Summary:**

- Right labyrinth causes pushing of the eye toward the left.
- Left labyrinth causes pushing of the eye toward the right.
- Hypoactive lesion will cause nystagmus toward the opposite side.

CASE	EFFECT
Right side when hyperactive	Pushes the eyeball to the left side with extra intensity. The eye drifts toward the right side because of compensation from the brain.
Left side when normal	Causes pushing of the eye toward right side

Eye	Position Of Eyeball In Hyper/hypoactive State
Normal eye	Midline.
Hyperactive	Deflected toward the same side.
Hypoactive	Deflected toward the opposite side.

**Peripheral Nystagmus and Central Nystagmus**

00:21:15

	Peripheral	Central
Latency	2-20 sec	No latency
Duration	Less than a minute	More than 1 minute
Direction of nystagmus	Fixed, towards the under most ear	Direction keeps changing
Fatiguability intensity of Vertigo	Fatigable severe	Non-Fatigable Mild
Incidence	Common	Rare

- When there is a peripheral lesion, there is a latency. From the time of stimulation of the labyrinth to the period of nystagmus, there lies a lag time of 10-20 sec.
- First, the labyrinth is stimulated, and the impulses are carried by the vestibular nerve, then to the vestibular nucleus, to the longitudinal fasciculus, to the 3rd, 4th, and 6th nerve nucleus, and then comes the nystagmus.
- This causes the **latency period**. The following table describes the common differences between peripheral and central nystagmus. However, if there is a central cause, there will be immediate firing from the brain stem. It does not require as much time. The latency is usually **absent** in the case of central lesions.



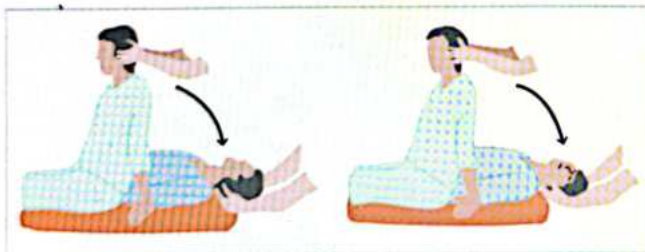- Due to peripheral and labyrinthine causes, the nerves, receptors, labyrinth, macula, and all of the vestibular apparatus undergo fatigue. The brain stem, the spinal cord, and the medial longitudinal fasciculus, however, do not undergo fatigue. The nystagmus duration is limited to less than a minute in peripheral causes and is more than a minute in central causes.
- Nystagmus is **fatigable** in peripheral causes but is non-fatigable or mild in central causes.
- The **rule of nystagmus** applies to peripheral causes only. For a central cause, it can be jerky nystagmus, pendular nystagmus, or vertical nystagmus, with the direction always changing. Fixed direction towards the innermost ear indicates that it is a peripheral cause.
- Commonly if a patient presents with severe vertigo, peripheral pathology should be given precedence and not central pathology.

Properties	Peripheral	Central
Latency	2-20 sec	No latency
Duration	Less than a minute	More than 1-minute
Direction of nystagmus	Fixed, towards the undermost ear	Direction keeps changing
Fatigue	Common	Rare

## Induced Nystagmus

00:24:35

1. Position-Dix Hallpike test
2. Nystagmus by putting head in a particular position-Dix-Hallpike test.



- The rest of the tests conducted can be classified under 3 major subheadings. These assess vertigo of labyrinthine origin.
  - **Position**

- **Pressure**
- **Temperature**

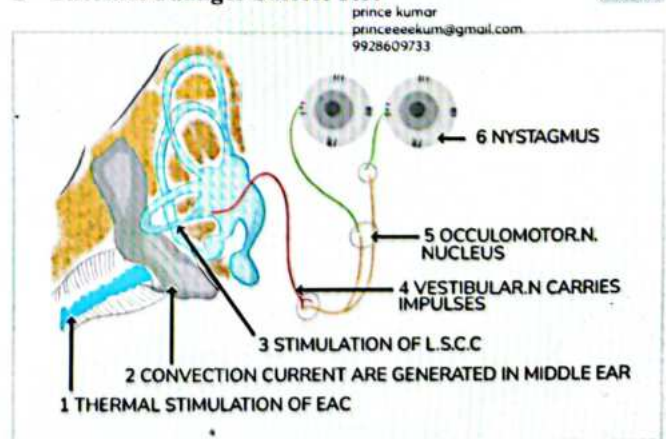
- Nystagmus is induced by causing a change of position, pressure, and temperature.

## I. Position: Dix Hallpike Test

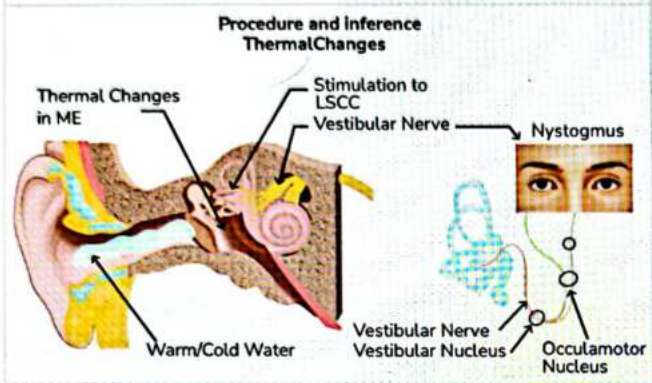
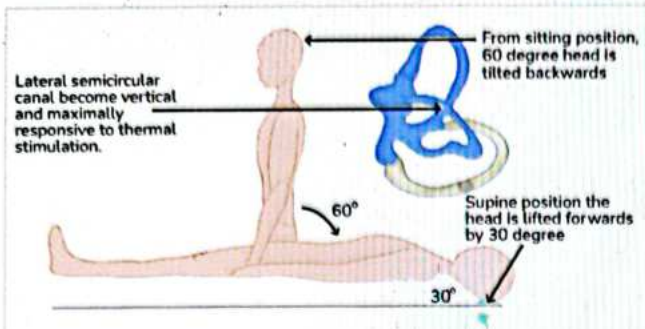
- It is a diagnostic test that is carried out for a condition called benign paroxysmal positional vertigo (BPPV). It consists of the displacement of otolith (small crystals of calcium carbonate). These crystals get displaced from the ampulated end of the semicircular canals and enter into the semicircular canal duct and stimulate the semicircular canals to cause vertigo and nystagmus.
- To carry on this test:
  - a. The patient is first made to sit at a table.
  - b. The patient's head is rotated by 45 degrees either to the right or to the left.
  - c. Then the patient is taken down in that position with the head hanging from the edge of the table (the head should hang at an angle of 30 degrees).
  - d. In this position, if there is a displacement of **the otolith**, it is possible that the displaced otolith might move into the semicircular canal duct while causing stimulation of the labyrinth. The responses will go from the semicircular canal to the vestibular nucleus, into the medial longitudinal fasciculus and will ultimately show as a movement of the eyeball is called nystagmus.
  - e. As because the posterior semicircular canal is more in a gravity-dependent situation, the otolith will get displaced most commonly in this canal. The direction of the nystagmus is toward the undermost ear with a **torsional component** being present. Once the nystagmus and vertigo have subsided, the patient is to be back in the neutral position. The position change is thus causing nystagmus. If the Dix Hallpike Test is positive the diagnosis is BPPV. If it is negative it means that the patient is normal, with no displacement of the otolith.

## 2 Thermal Changes Caloric Test

00:33:04







- Temperature is being used as a **stimulant** for the labyrinth in this test. This test is called the caloric test. When there are temperature changes in the external auditory canal by putting warm water or cold water, convection currents will be generated in the middle ear. These currents stimulate the lateral semicircular canal, and then there are vestibular carrier impulses into the oculomotor nucleus, and finally, this causes nystagmus.
- The position at which the patient is kept is in a supine position with the head being tilted forwards by 30 degrees. The patient may be kept in a sitting position with a 60-degree head tilt backwards. In the supine position, the canal is more horizontal, and hence more responsive to the stimulation provided. A video is played to demonstrate this concept (Timestamp: 00:36:02).
- **Thermal changes** induce nystagmus in everyone, and it indicates that we entire vestibular pathway is functional. To conduct this test,
  - a. The canal is irrigated with 5 ml of cold water or warm water, constantly for 60 seconds. If nystagmus happens, it is normal. If no nystagmus happens, the quantity of water is increased from 5 ml to 10 ml, 15 ml, 20 ml, 25 ml, 30 ml, and so on.
  - b. On increasing the volume, if nystagmus is produced, it indicates that the labyrinth is hypofunctional and hence required a larger stimulation to produce nystagmus. However, even at 40 ml, if no nystagmus is produced, it would mean that the labyrinth is not functional, and is a dead labyrinth or vestibular pathway.

- a. The mnemonic for this concept is **COWS**, Cold water will induce nystagmus toward the Opposite side and Warm water will induce nystagmus towards the Same side.
- d. When only cold water is used for stimulation in the test, then the name given to such test is **modified Kobrak's test**.
- e. When cold water plus warm water is used for the test, the test is called **Fitzgerald-Hallpike test**.
- f. When water has a temperature of 7 degrees below our body temperature (37°C), ie 30°C, it is defined as **cold water**.
- g. When water has a temperature of 7 degrees above our body temperature (37°C), ie 44°C, it is defined as **warm water**.

**Exceptions**

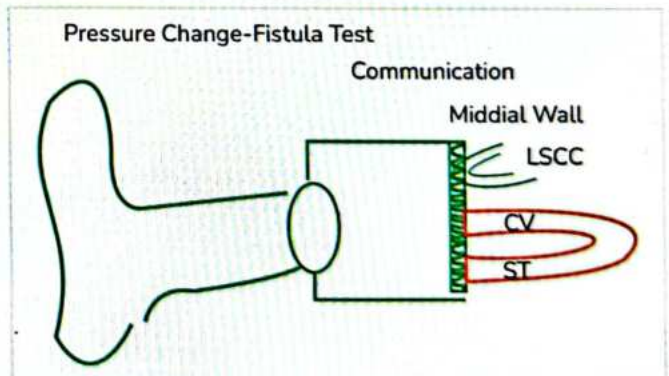
00:43:00

If a patient has a perforation of the tympanic membrane then the assessment of the vestibular system cannot be done by irrigation of the canal with warm or cold water with 60 seconds is not possible. The caloric test is done to see if the vestibular pathway is working. In case of a tympanic membrane perforation to assess the Labyrinthine function, air instead of water can be used. This test is called the **Dunda's Grant tube test**.

- If there is a patient who has a **congenital absence of the pinna**, in such a case, the patient is made to sit on a rotating chair. When the rotatory movements are done on the chair, the crista gets stimulated (It is responsible for recognising angular motion). The vestibular pathway is activated, and nystagmus takes place. The patient is made to wear **VR glasses** which are connected to a monitor and will assess the nystagmus. This test is known as Barany's rotational chair test.

**3. Pressure Change Fistula Test**

00:46:30

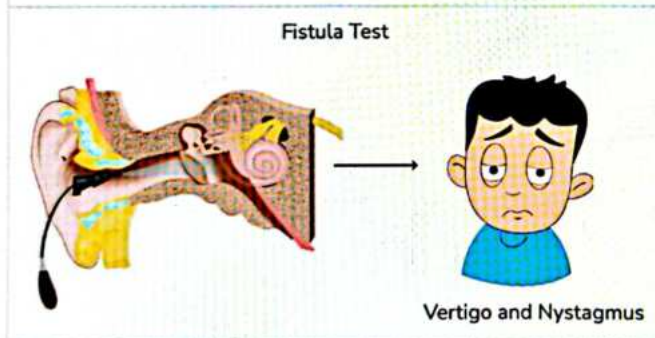
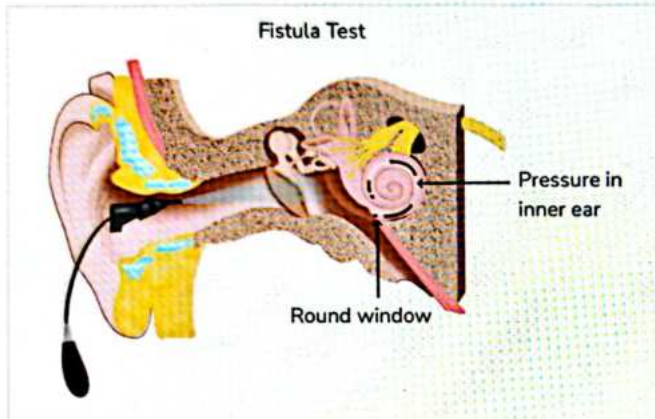


- **Fistula** means communication, and here it is the communication between the middle ear and inner ear. Normally the pinna is present going into the external auditory canal, tympanic membrane, and then into the middle ear. The medial wall of the inner ear separates the middle ear from the inner ear.
- Certain bulges are present in this medial wall, namely the impression of the lateral semi-circular canal, two windows



(the oval window covering the Scala vestibuli of the cochlear and the round window covering the Scala tympani of the cochlear). These windows are covered with membranes. Ideally, there is no communication between the middle ear and the inner ear.

- If the pressure is **increased** in the external auditory canal, pressure will go into the middle ear because the tympanic membrane will be pushed inwards. However, normally the pressure from the middle ear will not get transported into the inner ear because the **medial wall** is mostly bony and has small well protected membranes, which do not allow any pressure changes to go into the inner ear.
- If the inner ear is not stimulated by pressure change, there will be no vertigo or nystagmus.



- If there is a situation where there is communication between the inner ear and the middle ear because of a hole in the semi-circular canal, this can cause the pressure changes to go from the middle ear to the inner ear. This **communication** being formed is called the fistula and can stimulate the inner ear to cause vertigo and nystagmus. The Fistula test will show positively in such a condition.
- This condition is depicted through a video

### Inference

- A **positive** Fistula test indicates that there is some form of communication between the middle ear and the inner ear. The most common sites for this communication include, the lateral semicircular canal, the oval window, and the round window.

- A **negative** Fistula test indicates that conditions are normal with no communication between the middle ear and the inner ear.
- A **false positive** Fistula test may be seen in cases of congenital syphilis. In such a condition there will be no communication, but the result will be positive.
- The foot plate of the stapes is hypermobile and covers the oval window. It pushes the pressure of the middle ear into the inner ear very easily. In congenital syphilis, the false positive Fistula test is also called **Hennebert's sign**.
- A **false negative** Fistula test may be seen when there is a fistula but the test shows negative. A patient is suffering from cholesteatoma, which has eroded the lateral semicircular canal and has destroyed the labyrinth as well. The cholesteatoma, has thus, gone from the middle ear into the inner ear and destroyed the labyrinth. Due to the communication, the test should be positive however the test comes out negative and is actually a false negative. This will happen because the labyrinth is destroyed and is non responsive.

### Refer Table 6.1



### Important Information

- If only cold water is used in the Caloric test then it is known as Modified Kobrak's Test.
- Cold means that the temperature of the water is 7 degrees below 37 degrees (body temperature).
- Warm water means that the temperature of the water is 7 degrees above 37 degrees.
- When cold water plus warm water is used for the test, the test is called the Fitzgerald-Hallpike test.



### Important Information

- Positive fistula test means communication between the middle and inner ear is present.
- Negative fistula test means no communication between the middle ear and internal ear.
- False positive fistula test in case of congenital syphilis patient it is Hennebert's Sign.
- False negative fistula test seen in patients with a dead labyrinth.

### QUESTIONS

Q. Suppose a patient has perforation of the tympanic membrane. How is the assessment of the vestibular system carried out?

Ans: In this case, the air is used instead of water, and the name given to this test is Dundas Grant test.

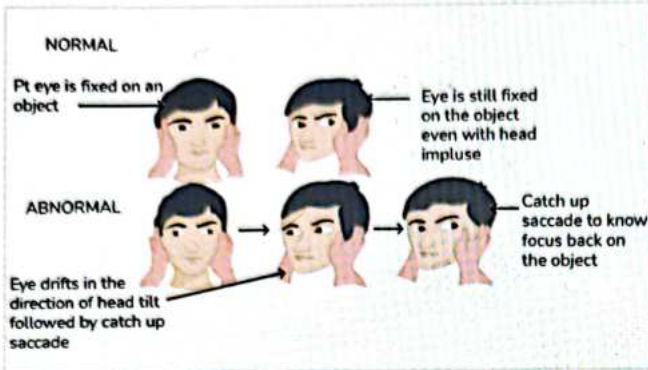


Q. Suppose a patient has a congenital absence of pinna. How is the assessment carried out?

Ans: Barany's Rotational Chair test.

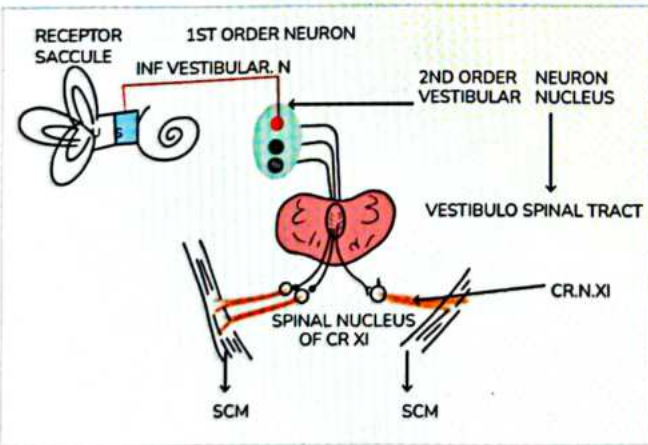
**Head Impulse Test**

00:58:30



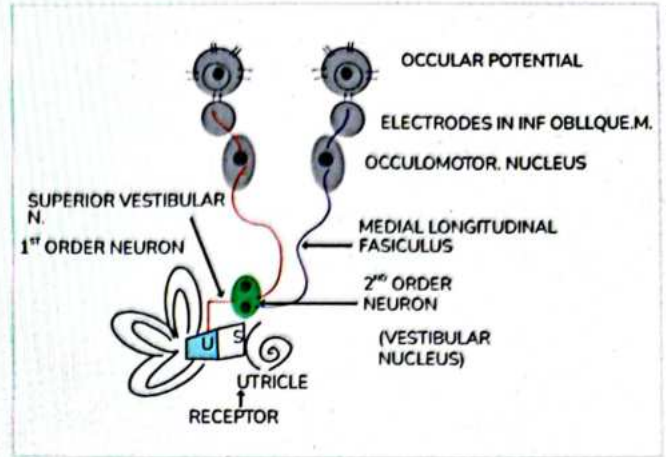
- In this test the patient sits in front of the examiner and is asked to look at a particular object on the face of the examiner. If the patient is asked to look at the tip of the examiners nose. The examiner drifts their head by 30 degrees to the left or to the right suddenly. The patient should ideally/normally continue to watch the tip of the nose. Normally the eyes of the patient are fixed on the object.
- But if the patients eye drifts in the direction of the head tilt and is followed by them looking at the point of the nose again, it would be considered abnormal. This catch-up saccade is considered to be abnormal.

**C-Vemp**



- Once the impulses go to the spinal cord, vestibulo-spinal tract is activated. This track will give impulses to the sternocleidomastoid muscle (SCM). Vestibular stimulation should lead to the contraction of the SCM.
- Myogenic potential will be able to be recorded from the stimulated muscle (VEMP). VEMP from the cervical reason is known as cervical VEMP and is initiated by the inferior vestibular nerve.

**O-VEMP**



- **Ocular Vestibular Evoked Myogenic Potential**
- In this case, the utricle is stimulated. The impulses from the utricle is carried through the superior vestibular nerve, medial longitudinal fasciculus, 3rd, 4th, and 6th nerve nucleus, and then, the contractional myogenic potential is generated in the extraocular region (superior inferior oblique, rectus). It is recorded through electrodes in the inferior oblique muscle. This stimulus is known as ocular VEMP.

C-VEMP	O-VEMP
• Inferior vestibular nerve is stimulated.	• The impulses are carried through the superior vestibular nerve.
• The impulses are carried via the saccules.	• Utricle is getting stimulated.
• There is a contraction of the SCM.	• There is a contraction of the ocular muscles.

**Other Tests**

01:05:08

- **Romberg sign**- Here, the patient is made to stand at a point and close his eyes. It is then checked if the patient is swaying from side to side.
- **Gait Test**- the patient is asked to walk in a straight line with the heel of one foot touching the toe of the other foot.
- **Unterberger Test**- The patient is asked to stretch his hands and march.

These tests are conducted to check if the cerebellum pathway coordination is present.



Table 6.1

Cause Of Nystagmus	Test	About	Position	Procedure
Position	Dix Hallpike test. Positive- abnormal. Negative- normal.	N y s t a g m u s by putting the head in a particular position.	45 degrees rotation of the head either to the left or right in a sitting position.	The patient is made to sit with the head rotated at 45 degrees the lean back (the head should be hanging from the table at 30 degrees).
Temperature	Caloric test.  Positive- normal. Negative- abnormal.	Temperature changes in the external auditory canal. Convection currents are generated.	60 degrees down in a sitting position or 30 degrees head-up position in a supine position. Cold water induces nystagmus to the opposite side whereas warm water to the same side.	5 ml of water is used to irrigate the canal (warm/cold) for 60 sec - Nystagmus when seen indicates a normal labyrinth. If no nystagmus is seen, then put 10 to 40 ml of water if nystagmus is seen then the labyrinth is hypoactive. If nystagmus is not seen then the labyrinth is dead.
Pressure	Fistula test.  Positive - abnormal. Negative - normal.	Pressure changes in the middle ear when leading to nystagmus, it means the fistula test is positive.	Siegel's speculum is kept in the external auditory canal in a sitting position.	Siegel's speculum is kept in the external auditory canal and pressure in the canal increases pressure in the middle ear. Normally no connection between the middle and internal ear so no nystagmus, but if nystagmus is seen, it means a positive fistula test.

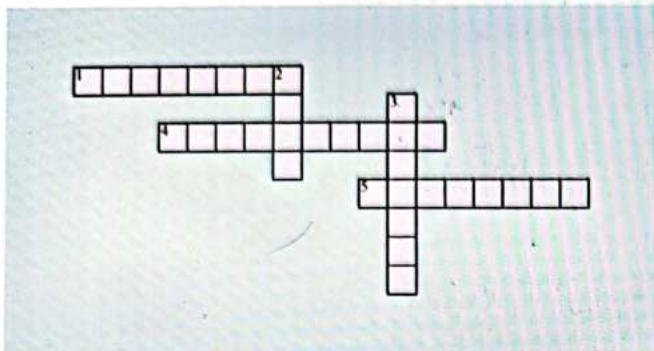




# CROSS WORD PUZZLES



## Crossword puzzle 1



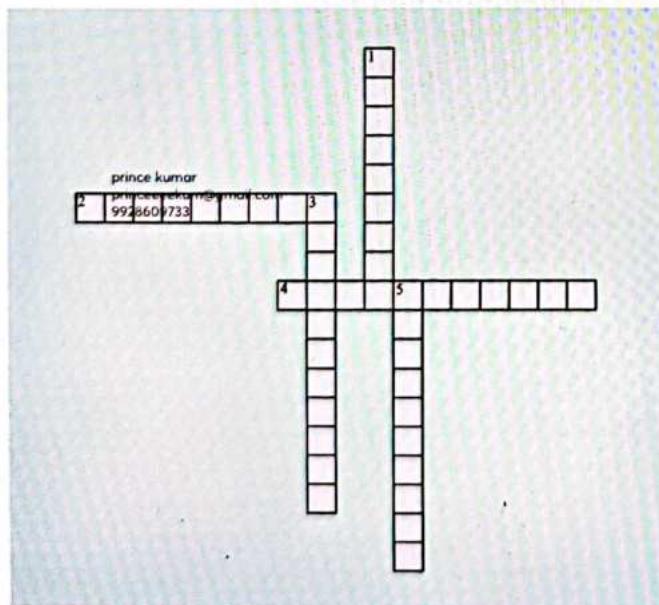
### Across

1. In -----'s Test, the patient is made to stand at a point and close his eyes. It is then checked if the patient is swaying from side to side.
4. Suppose a patient has perforation of the tympanic membrane, assessment of the ----- system is carried out through the Dundas Grant test.
5. If only cold water is used in the Caloric test then it is known as ----- Kobrak's Test.

### Down

2. In the ----- test, the patient is asked to walk in a straight line with the heel of one foot touching the toe of the other foot.
3. When cold water plus warm water is used for the ----- test, the test is called the Fitzgerald-Hallpike test.

## Crossword puzzle 2




### Across

2. When the labyrinth is stimulated, that oscillatory movement of the eyeball is called ----- . It can be of a few types.
4. In the ----- Test, the patient is asked to stretch his hands and march.

### Down

1. A central chamber called the ----- is present that contains the elliptical recess and the spherical recess.
3. ----- nystagmus is when nystagmus occurs without any stimulation of the labyrinth.
5. Suppose a patient has congenital absence of pinna, the assessment is carried out by the Barany's ----- Chair test.

## Crossword puzzle 3



### Across

3. Positive ----- test means communication between the middle and inner ear is present.
5. In the caloric test, temperature changes in the external ----- canal by putting warm water or cold water takes place.

### Down

1. ----- currents will be generated in the middle ear with temperature change, and these currents stimulate the lateral semicircular canal.
2. False ----- fistula test is commonly seen in the case of congenital syphilis patients and is called Hennebert's Sign.
4. Dix ----- test is a diagnostic test that is carried out for a condition called benign paroxysmal positional vertigo or BPPV.





- Vestibular disease is linked to balance disorder, which leads to problems such as vertigo and dizziness.

**Vertigo**

00:00:33

- A sensation of **whirling** and loss of balance caused by the disease affecting the inner ear or **vestibular nerve** is called vertigo.
- The patient feels like the room around them is spinning. So, that room-spinning sensation is called vertigo.
- If the patient cannot walk properly or falls while walking, it is called an imbalance.
- So, vertigo and imbalance are not synonymous with each other.
- Vertigo is a whirling sensation, whereas an imbalance is an inability to have a coordinated movement.

**Vestibular Disease**

00:00:44

- Peripheral vestibule means that the inner ear is responsible for causing these symptoms.
- Central vestibular disease means that the brain is responsible for causing these symptoms.
- The type of vestibular diseases are mentioned below in the table, categorized under Peripheral and Central vestibular diseases:

Peripheral vestibular disorders	Central vestibular disorders
Meniere's Disease	Vertebrobasilar insufficiency
Benign Paroxysmal Positional Vertigo (BPPV)	PICA syndrome
Vestibular neuronitis	Basilar migraine
Labyrinthitis	Cerebellar disease
Vestibulo toxic drugs	Multiple sclerosis
Perilymph fistula	Tumors of brainstem
Acoustic neuroma	Epilepsy

- **Central vestibular disorder** - It is characterized by sensory hallucinations due to a malfunction of the vestibular structure in the brain (CNS).

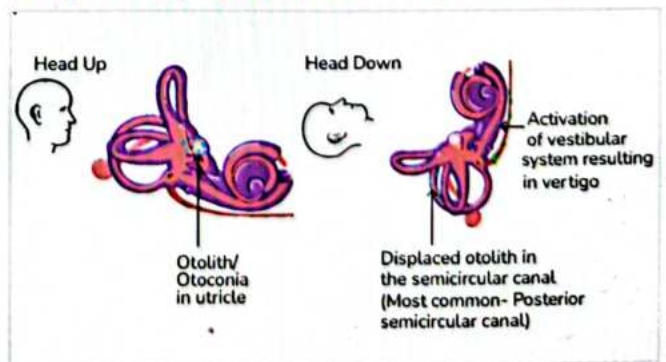
Here's a quick brief about central vestibular disease types.

Central vestibular disorders	Definition
Vertebrobasilar insufficiency PICA syndrome	Results in poor blood flow to the brain's posterior (back) region.
Basilar migraine	In this rare form of migraine with aura, symptoms such as dysarthria, vertigo, or ataxia occurs without motor dysfunction.
Cerebellar disease	It is a Brain disorder affecting nerves at the back.
Multiple sclerosis	Causes you to lose control of your body and become less mobile slowly.
Tumors of the brainstem	A brainstem tumor occurs when healthy cells change and grow out of control.

**Meniere's Disease**

- It is characterized by triad disease.
- Triad of **Meniere's disease**, which includes **vertigo**, **sensorineural hearing loss (SNHL)**, and **Tinnitus**.
- It is due to either excessive endolymph production or decreased absorption.
- Due to this, there is **endolymphatic hypertension**.
- Because of organ of corti involvement there is SNHL and tinnitus.
- Because of macula and cristae involvement there is vertigo.
- Vertigo in patients with Meniere's disease is sudden in onset.
- It lasts for **minutes to hours** with accompanied nausea, vomiting and vagal symptoms.

**Benign Paroxysmal Positional Vertigo (BPPV)**



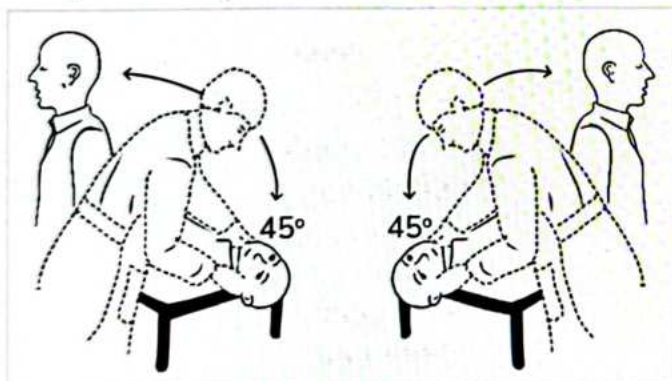


- The otoliths/ otoconia are small calcium carbonate crystals present in the dilated end/ ampullated end of the semicircular canal and where they open into the utricle.
- When a patient is in a certain position, the otolith should be available in the ampullated end of the semicircular canal.
- If a patient has BPPV and goes in head down position, the axis of the labyrinth changes.
- The posterior semicircular canal becomes more gravity dependent. And if there is a displacement of otoliths, if it gets displaced, it will go into the semicircular canal duct.
- And once it goes into the semicircular canal ducts, it will stimulate the canal, causing vertigo.
- Therefore, in the head-down position, there will be displacement of the otolith. When the otolith is displaced, it will enter the semicircular canal, and the patient will experience vertigo.
- **Most common semicircular canal involved is posterior semicircular canal.** Because it is the gravity dependent canal.
- **Vertigo without hearing loss: BPPV**

## Diagnosis of BPPV

### 1. Dix Hallpike test

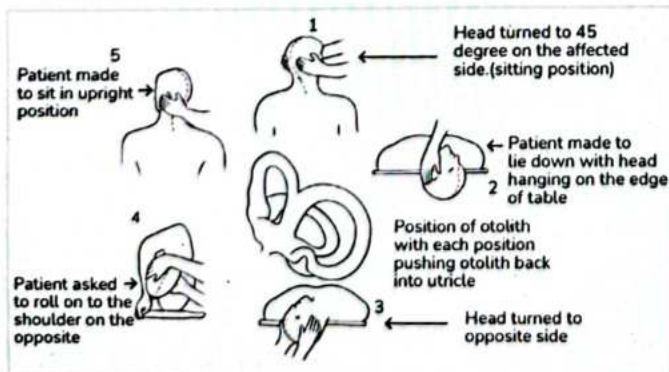
- Patient sits on the table and turns his head to 45 degrees.
- Then, take the head of the patient down, hanging from the table at 30 degrees from the edge of the table.
- In this position, if the otolith gets displaced, the patient experiences vertigo.



## Treatment

00:16:07

### • EPLEY'S MANEUVER



- A maneuver is required to diagnose BPPV, known as Dix Hallpike Test. If the Dix Hallpike test is positive, the person is treated with Epley's Maneuver.
- So, Epley's Maneuver is done with the patient having BPPV.
- The patient made to go down with the head hanging from the edge of the table in the direction where the Dix Hallpike test was positive. Done for at least one to two minutes.
- Then, the patient's head is turned towards the opposite side and kept in this position for one to two minutes.
- Next, the patient is said to roll over the left or opposite shoulder and be in that position for a minute or two.
- Lastly, the patient is said to look down with the back upright.

## Vestibular Neuronitis

18:47:00

- It is characterized by sudden onset of vertigo, nausea, and vomiting without deafness and tinnitus.
- There is no hearing loss.
- It is an inflammatory process in the vestibular nerve.
- It lasts from a few days to weeks.
- Occurs due to labyrinthine stimulation by factors like- Viral infection and Idiopathic.

## Clinical Features

21:49:00

- Sense of dizziness or spinning motion in the surroundings, also known as Vertigo.
- In vertigo, a person undergoes nausea and vomiting.
- There is no hearing loss in vestibular neuronitis.

## Diagnosis

- **Caloric test shows canal paresis and directional preponderance.**

## Treatment

- The person is advised for bed rest /labyrinthine sedatives.
- Doses of drugs like Prochlorperazine and Promethazine are advised.
- Another drug recommended is Cinnarizine.

## Labyrinthitis

22:12:00

- A post-viral condition characterizes it.
- In this disease, the entire labyrinth gets affected.
- It leads to inflammation of the entire labyrinth.
- The problem is observed to exist for several days to a few months.
- In this, a person has hearing loss.

## Perilymph Fistula

24:28:00

- Perilymph leaks through the oval window and round window
- **Causes:** Defect in any 3 locations oval window, round window, and optic capsule.



**Defect in Oval window:**

- Occurs due to the eye part's injury due to barometric or water pressure changes. It is also called high-pressure Barotrauma.
- A complication of stapedectomy. It is a surgery to treat hearing loss caused by otosclerosis.

**Defect in Round window:**

- In this, injury is caused by Barotrauma. Injuries caused by elevated water or air pressure are referred to as barotrauma.

**Defect in Otic capsule:**

- It is a superior canal dehiscence syndrome.
- Fenestration surgery is recommended for this.
- There is an erosion of the horizontal semicircular canal.
- A sudden pressure change in the middle ear, like barotrauma or weight lifting.

	Meiners	BPPV	Vestibular neuritis	Labyrinthitis	PF
Vertigo	Min to Hours	Sec to min	Days - weeks	Days - Weeks	Intermittent Vertigo
	Vagal	Positional	Post viral	Post viral	Surgery, Trauma, CSOM
Hearing loss	Present	Absent	Absent	SNHL	+/-
Tinnitus	Roaring	Absent	Absent	Present	+/-

prince kumar  
 princeeeekum@gmail.com  
 9928609733

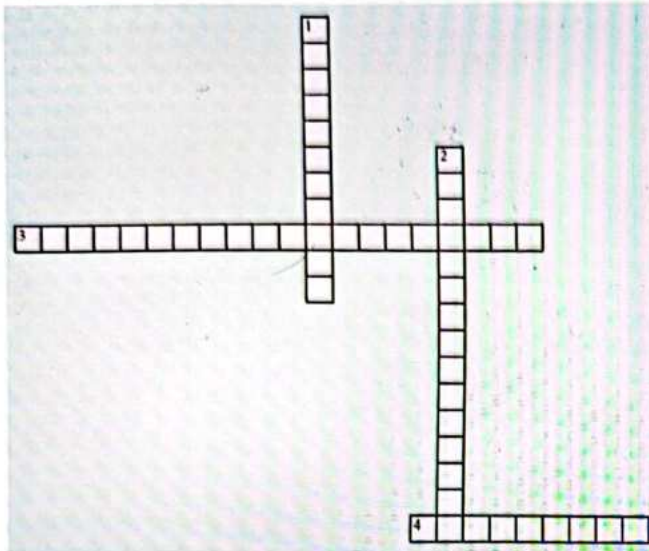




# CROSS WORD PUZZLES



Crossword Puzzle 1



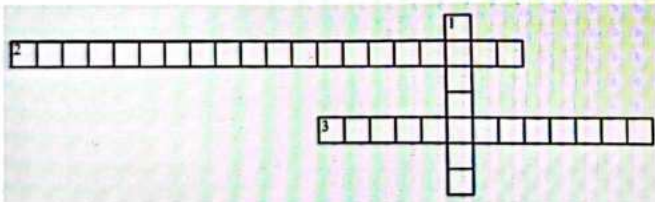
**Across**

- 3. \_\_\_\_\_ Leaks through the oval window and round window.
- 4. \_\_\_\_\_ is characterized by sudden onset of vertigo.

**Down**

- 1. \_\_\_\_\_ test shows canal paresis and directional preponderance.
- 2. \_\_\_\_\_ is characterized by triad disease.

Crossword Puzzle 2



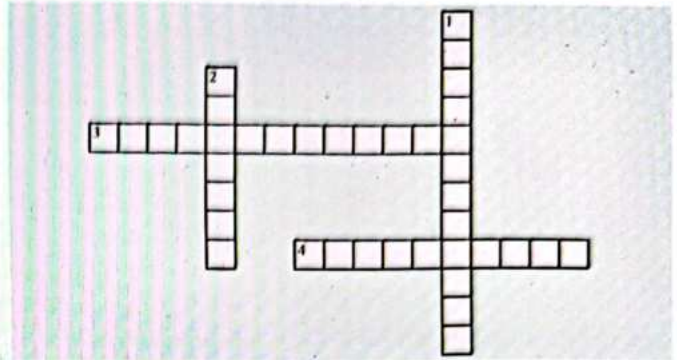
**Across**

- 3. \_\_\_\_\_ is inflammation of the labyrinth.
- 4. \_\_\_\_\_ has no hearing loss.

**Down**

- 1. \_\_\_\_\_ is a superior canal dehiscence syndrome.
- 2. \_\_\_\_\_ are small calcium carbonate crystals present at the end of the semicircular canal.

Crossword Puzzle 3



**Across**

- 3. \_\_\_\_\_ is a symptom of Multiple Sclerosis.
- 4. \_\_\_\_\_ occurs Due to the part's injury due to changes in barometric or water pressure, also called high-pressure.

**Down**

- 1. \_\_\_\_\_ occurs due to Vertebrobasilar insufficiency.
- 2. \_\_\_\_\_ comes under the Dix Hallipke test.

prince  
princee  
9928609

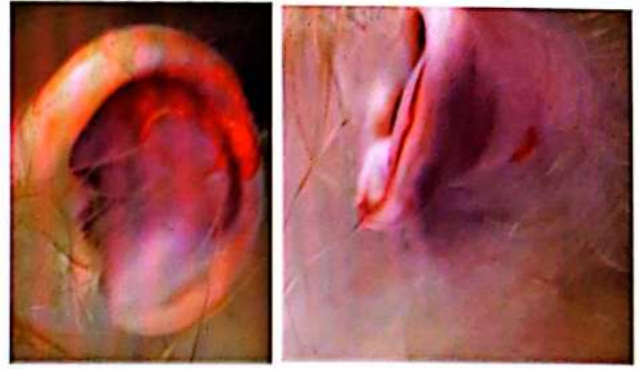
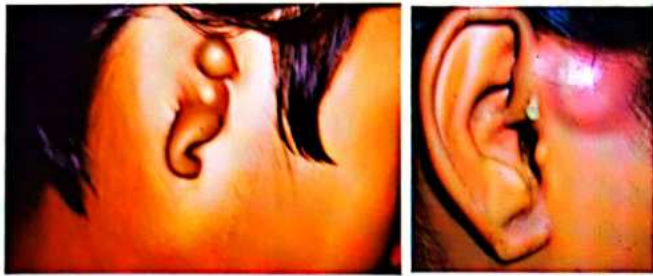
**Congenital abnormalities of the Pinna**

00:00:40

**Abnormalities of the middle ear and inner ear:**

- **Macrotia**- The size of the pinna is larger or not proportional to the skull.
- **Microtia**- Small pinna
- **Anotia** - Complete absence of the pinna
- **Bat ear**- Protruding ear



**Important Information**

- There should be compressed packing in hematoma surgery to avoid reaccumulation.
- Sometimes there may be quilting suture or mattress suture.

**Peri auricular sinus / appendages**

- It is a congenital malformation that is caused by incomplete fusion of first hillock and other five hillocks. As pinna develops from six hillocks, the first hillock gives rise to tragus and other five form the rest of pinna.
- Outside it can present as a pit but inside it has a large tract and a sac.
- Recurrent infection, with cheesy discharge and can progress to become an abscess.
- Not all peri auricular sinus requires treatment but if recurrent infection is there, surgery can be done. In surgery entire sac is removed. Methylene blue is used to demarcate the borders of sac.
- Peri auricular appendages are small skin tags which are present from tragus to the angle of mandible.

**Perichondritis –**

- Inflammation in the perichondrium is perichondritis.
- The causes are trauma and surgical trauma. And from the extra auditory canal, there can be a source of infection. Organisms responsible for its causes are mostly *pseudomonas*, *staphylococcus*, *streptococcus*.

**Clinical Features:**

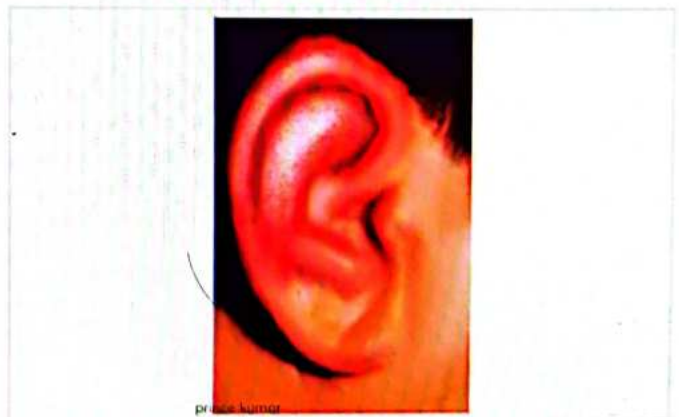- Severe pain
- Red swollen ear pinna
- **Sparing of the lobule is a very important feature of the perichondrium.**
- Anti-pseudomonal antibiotics and topical antibiotics are given as a line of treatment.
- **Relapse polychondritis** is an autoimmune condition which involves multiple cartilages in body.

**Acquired Abnormalities**

00:07:11

**Hematoma Auris –**

- Accumulation of blood between the cartilage and overlying perichondrium.
- If there is a history of direct trauma or hit that causes hematoma, mainly it occurs in boxers that's why it is called **BOXERS EAR**.
- It can also be acquired iatrogenic. Here depressions and elevations are not seen so this is also called **cauliflower ear**.
- For small hematomas just aspirate and for larger hematomas, incision, and drainage are required along with antibiotics.

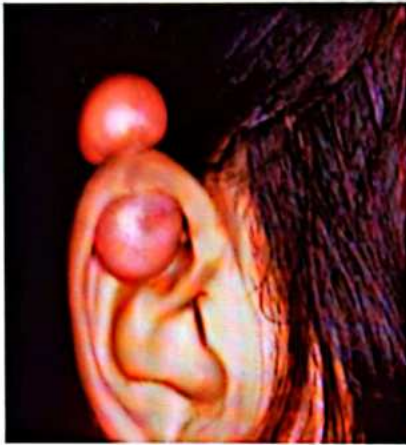

prince kumar  
princeeeekum@gmail.com  
9928609733



## Keloid

- Common causes are trauma and ear piercing.
- Trauma will result in excessive collagen production during healing and will lead to irregular scarring which is a keloid.
- Disfigure appearance. It is not a malignancy.
- Treatment- Steroids, Excision, Radiotherapy, Radiofrequency currents
- There are high chances of recurrence.

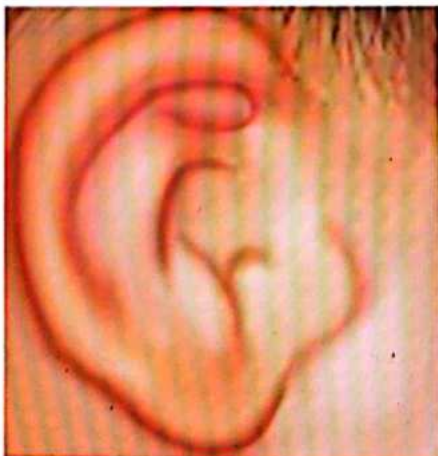

## Congenital abnormalities of the external auditory canal

00:21:32

### Atresia

- Complete non-development of the external auditory canal.
- There is no opening, the tympanic membrane is present in some cases and in some cases, it is not there.
- Some patients can have oral atresia associated with normal tympanic membrane in the middle ear.
- Some of them can have abnormal tympanic membranes at the middle ear.
- Patient's hearing can be rehabilitated by using BAHA (Bone anchored hearing aid).



## Acquired abnormalities of the external auditory canal

00:24:09

### Wax/Cerumen

- Waxes are the secretions coming from the sebaceous gland, ceruminous gland, squamous epithelium, and keratin debris.
- Colour of the wax may vary according to race.
- They are acidic in pH, bacteriostatic and fungistatic.
- Protective structure in the auditory canal.
- Wax retention can occur when there is a small external auditory canal or epithelial migration defect.
- Conductive hearing loss may be there.
- Ringing sensation in the ear.
- Pain and giddiness.
- **Jobson horne probe** can be used for the removal of wax.

### Localised Otitis Externa

- Also called furunculosis.
- Causes of the otitis externa is a staphylococcal infection of the hair follicle.
- Extreme or severe pain with certain amount of hearing loss.
- Pain during chewing and jaw actions.
- Tragal sign is positive.
- Purulent discharge because the external auditory canal has squamous epithelium, there is no mucoid cell. Whenever there is mucoid discharge, it is from the middle ear not from the canal.
- There is an obliteration of the retro auricular groove.
- If the patient is immunocompromised or diabetic there is recurrent furunculosis.

### Diffuse Otitis Externa

- It is also called swimmer's ear, tropical ear, and telephonist ear.
- It is a pseudomonas infection.
- Because of the constant humidity and swimming pH of the wax changes from acidic to alkaline. Alkaline pH favours the group of bacteria.
- It is seen in immunocompetent individuals.
- Pain, discharge, swelling, and obliteration of the retro auricular groove. These symptoms increase with the movement of the jaw.
- Systemic Antibiotics, topical ear packs, antibiotic ear drops, and glycerine packs are used for treatment.

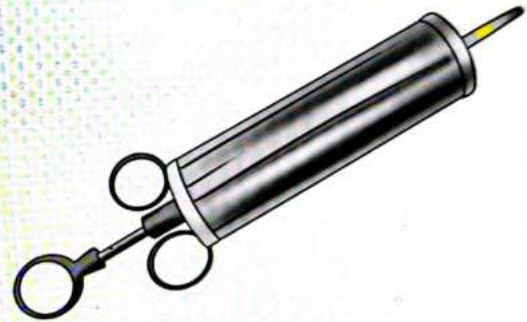
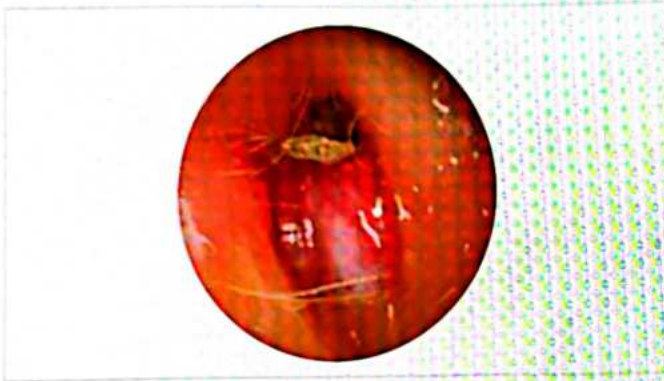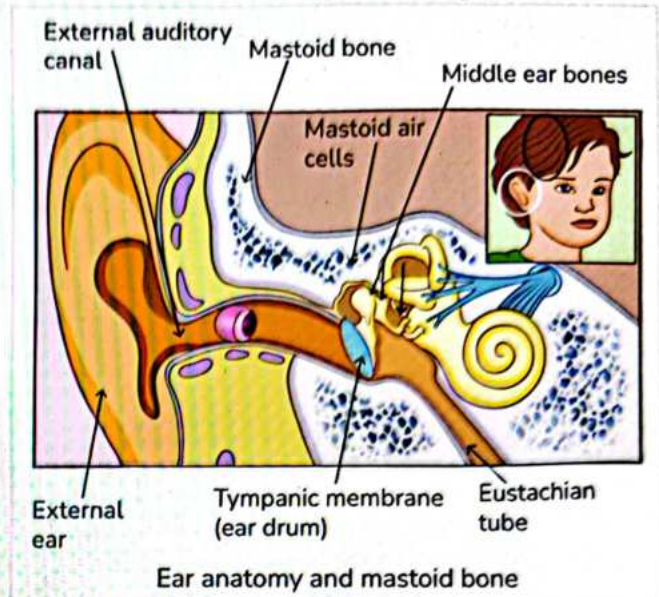
### Malignant Otitis Externa

- Caused by pseudomonas and the patient is immunosuppressed.
- Severe excruciating ear pain will occur. Anteriorly this infection can go to TMJ causing pain and limitation of movement in TMJ.
- It can spread exclusively because the patient's immunity is



low.

- Cranial nerves may get involved, first, the cranial nerve involved is the 7<sup>th</sup> cranial nerve causing facial nerve palsy, then the lower cranial nerves and the jugular foramen get involved.
- Red granulation tissues are diagnosed at the bony cartilaginous of the external auditory canal.
- Biopsy and culture can be done to diagnose.
- TC99 can be used for early diagnosis of the disease.
- For checking whether the infection is resolved or not gallium 67 is used.
- For assessing intracranial spread MRI is used and a CT scan is used to assess erosion of bone.
- Antipseudomonal antibiotics are used for treatment.



### Otomycosis

- It is caused by *Aspergillus* species.
- It can occur in both immunocompetent and immunosuppressed persons.
- But it is most often seen in immunocompromised people.
- Whitish discharge is there and black spores on this white discharge are seen. **Wet newspaper appearance** is there.
- There is itching in the extra auditory canal.
- Local toileting is done along with anti-fungal ear drops and oral antifungals can also be given.

### Foreign Body

- Unilateral Foul-smelling discharge is there. Most common in toddlers.
- Foreign bodies can be removed by syringing, crocodile forceps, lidocaine solution, or any form of an ear drop.
- Syringing is contraindicated for an organic foreign body removal.

### Commonly extracted Foreign Bodies

- Inorganic (beads/pellets)
- Grasable non-living
- Living insects
- Organic and button batteries

prince kumar  
princekumar@gmail.com  
9928609733

**Simpsons aural syringe** is directed toward posterior superior canal wall to avoid any direct trauma. The temperature of water should be like body temperature to avoid any stimulation of labyrinthine which can cause vertigo or nystagmus.

### Complications

- Tympanic perforation
- Labyrinthine stimulation
- Stimulation of Arnold's nerve or vagus nerve causing syncopal attacks.

### Keratinosis Obturans

- If a patient has ciliary motility defect, movement of squamous epithelium will not occur. It will get retained on the extra auditory canal can several layers of squamous epithelium will form like an onion skin, that pattern is called **onion skin laminar arrangement**.
- Cause widening of the adjacent extra auditory canal will occur.
- It can be associated with other ciliary motility disorders such as sinusitis, bronchiectasis.



- Facial nerve can be involved.
- Removal is done under general anaesthesia and sedation.

### Ramsay Hunt Syndrome/Herpes Zoster Otiticus

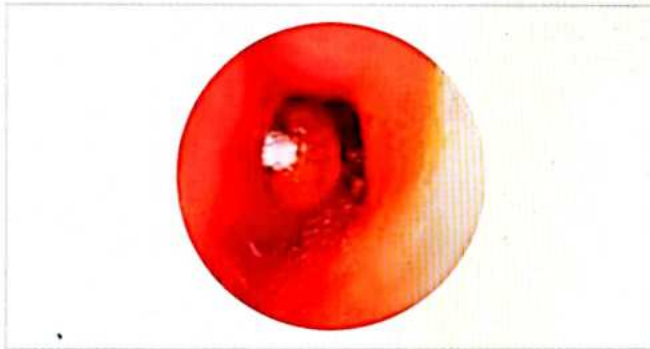- Herpes zoster virus becomes latent in the geniculate ganglion.
- Whenever there is the reactivation of this virus there is a pain and vesicles distribution along with facial nerves, and facial nerve palsy occurs along with sensory neural hearing loss.
- Antiviral acyclovir is given along with steroids.

### Diseases of the tympanic membrane

01:11:18

#### Myringitis Bullosa Haemorrhagica

- Haemorrhagic bullae on the tympanic membrane is called myringitis bullosa Haemorrhagica.
- It occurs due to streptococcus pneumonia, mycoplasma, and influenza virus.
- Severe pain in canal.
- Systemic antibiotics should be given.



### Traumatic perforation of tympanic membrane

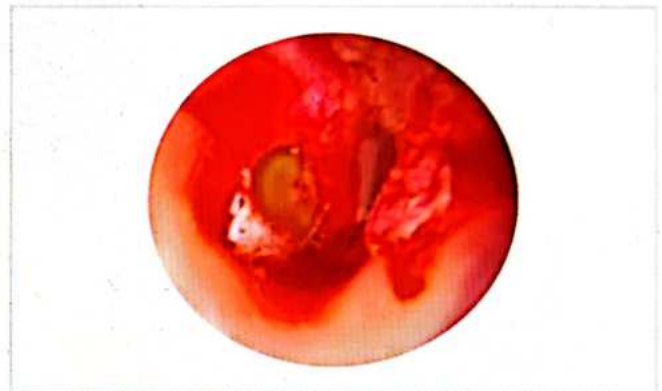High pressure trauma causing perforation in tympanic membrane

- Hearing loss
- Some bleeding
- Fresh edges

prince kumar  
princekumarn@gmail.com  
9928609733

Treatment is wait and watch for 4 to 6 weeks as it will heal spontaneously.

If it fails to heal myringoplasty is done. Ear canal should be kept dry.








## CROSS WORD PUZZLES



### Crossword Puzzle 1




#### Across

4. \_\_\_\_\_ is also called onion skin laminar arrangement.

#### Down

- 1. \_\_\_\_\_ is caused by trauma and ear piercing.
- 2. Haemorrhagic bullae on the tympanic membrane are called \_\_\_\_\_.
- 3. Jqbson horne probe can be used for the removal of \_\_\_\_\_.

### Crossword Puzzle 2




#### Across

- 2. Local toileting is done \_\_\_\_\_.
- 4. \_\_\_\_\_ can be used for early diagnosis of malignant otitis externa.

#### Down

- 1. Foul-smelling discharge occurs when it is \_\_\_\_\_.
- 3. \_\_\_\_\_ is caused by Aspergillus species.

### Crossword Puzzle 3



prince kumar  
princeeeekum@gmail.com  
9928609733

#### Across

3. Herpes zoster virus becomes latent in the \_\_\_\_\_.

#### Down

- 1. Syringing should never be used if the foreign body is \_\_\_\_\_.
- 2. \_\_\_\_\_ pH favors the group of bacteria.





# 9 EUSTACHIAN TUBE

00:00:10

- Eustachian tube is that link that connects the nasopharynx to that of the ear.
- The important connection between the nasopharynx and the middle ear is the eustachian tube.
- Air reaches the middle ear via the eustachian tube. This eustachian tube opens in the anterior wall of the middle ear.

### Dimensions of the Eustachian tube

	External auditory canal	Eustachian tube
Total length	24 mm	36 mm
Bony part	2/3 (16mm) (Medial)	1/3 (12 mm) (lateral)
Cartilaginous part	1/3 (8 mm) (Lateral)	2/3 (24 mm) (Medial)

### Difference between Adult and Children

	External auditory canal	Eustachian tube
Length	13-18mm	36mm
Orientation	Horizontal, short, wide and straight.	Angulated
Cartilaginous part	Flaccid allowing easy reflux	Rigid and hence remains closed most often
Ostmann's pad of fat	Less in volume	More in volume
Ventilatory function	Poorly developed	Well developed

- In children eustachian tube is horizontal and more flaccid towards cartilaginous end which makes it easier for the nasopharynx contents to enter eustachian tube causing infections.
- Primarily the Eustachian tube in adults is closed, angulated and tighter. Two muscles help to open, Tensor Veli Palatini and Levator Veli Palatini.
- Ostmann's Pad of fat is present in the nasopharyngeal end of the eustachian tube.

00:12:40

### Functions of the eustachian tube

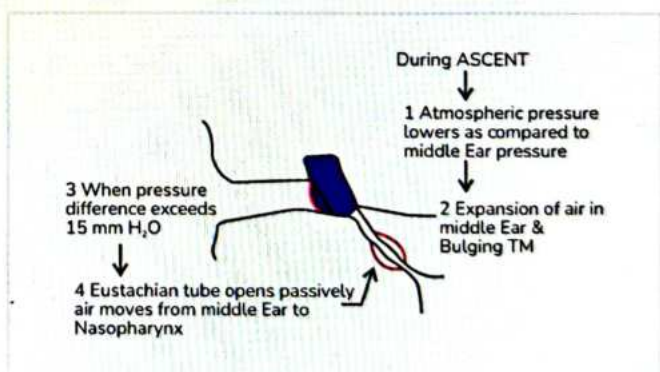
- The part of the pharynx that lies behind the nose is called the nasopharynx. The main function of the eustachian tube is to allow the air coming from the nose to go to the nasopharynx from there to the middle ear. It is mainly for maintaining pressure in the middle ear.
- Clearance of secretion in the middle ear.
- Protection of the middle ear from nasopharyngeal secretions.

### Disorders of Eustachian tubes

#### Patulous Eustachian Tube

- The word patulous means something loose, relaxed and flaccid. The Ostmann's pad of fat can disappear when a person ages or loses a lot of weight, the eustachian tube will no longer have the same effect. This will lead to excessive air entering from the nasopharynx to the middle air will result in increased air volume in the middle air and the patient will have autophony.
- This often does not require any treatment; they are managed conservatively.
- Symptoms do not resolve spontaneously with conservative therapy:
- Inserting a grommet in the tympanic membrane to release the access air is recommended.
- Insert Teflon paste in the cartilaginous portion of the eustachian tube.

### Barotrauma -Ascent

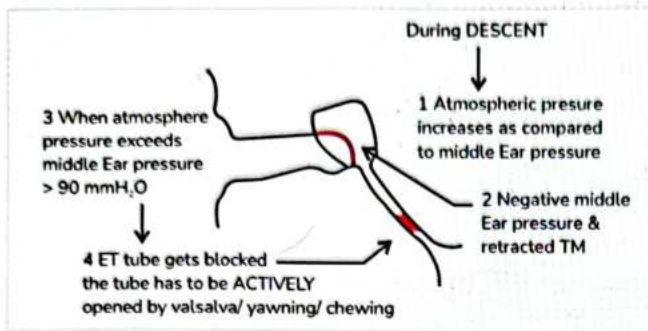


- Barotrauma stands for pressure-induced trauma.
- Ascent: When a person travels on a tour of an elevated area the atmospheric pressure is lower as compared to the middle ear pressure.
  - As a result, the middle ear gas will start expanding resulting in a bulging tympanic membrane.
  - When the difference between the atmospheric pressure



and the middle ear pressure exceeds 15mm H<sub>2</sub>O will open the eustachian tube allowing the air from the middle ear to escape into the Nasopharynx.

## Descent



- Descent: When a patient is going from the land level to a lower pressure area the atmospheric pressure will increase as compared to the middle ear pressure like scuba divers.
  - There is negative pressure in the middle ear. This will cause **shrinkage of the eustachian tube**.
  - When the difference between the atmospheric pressure and the middle ear pressure exceeds 90mm H<sub>2</sub>O the eustachian tube gets blocked. The patient will have some block sensation in the ear, difficulty in hearing and pain. The ET tube has to be actively opened by **Valsalva, yawning or chewing** something that will activate the Tensor Veli Palatini and Levator Veli Palatini to open the ET tube.

## Treatment of Barotrauma is

- **Conservative management** with antihistaminic, nasal decongestants and Valsalva exercise.
- Politzerization and catheterization is done to actively insufflate **air into the middle ear**
- If there is effusion or severe pain not managed with conservative therapies then a myringotomy may be done.

## Tests for Eustachian tube dysfunction



### Important Information

- **Tympanometry** is the most reliable test for Eustachian tube dysfunction.
- Tympanometry
- Pneumatic otoscopy
- Nasopharyngoscopy
- Eustachian tube catheterization
- Valsalva and politzerization
- Toynbee manoeuvre
- Frenzel manoeuvre
- Sonotubometry






# CROSS WORD PUZZLES



## Crossword Puzzle 1



prince kumar  
princekum@gmail.com  
9928609733

**Across**  
2. \_\_\_\_\_ is the most reliable test for Eustachian tube dysfunction.

3. Inserting a grommet in the \_\_\_\_\_ to release the access air.

**Down**  
1. Negative pressure in the middle ear will cause \_\_\_\_\_ of the eustachian tube.

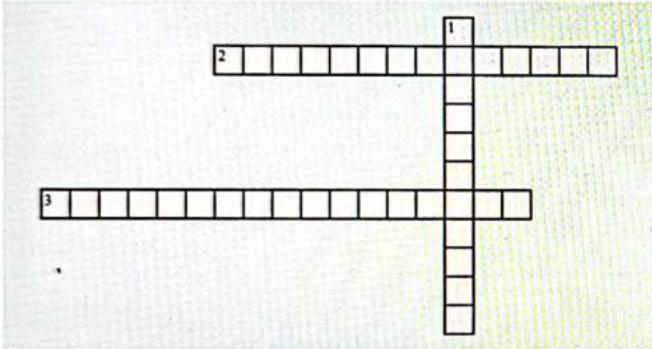
**Across**

- 2. Means something which is loose, relaxed and flaccid.
- 3. Ostmann's Pad of fat is less volume in \_\_\_\_\_.

**Down**

- 1. \_\_\_\_\_ Which is the symptom in which the patient complains of the loudness of their own voice.

## Crossword Puzzle 2




**Across**

- 2. \_\_\_\_\_ is that link that connects the nasopharynx to that of the ear.
- 3. The \_\_\_\_\_ is the medial part of the Eustachian tube.

**Down**

- 1. The part of the pharynx that lies behind the nose is called the \_\_\_\_\_.

## Crossword Puzzle 3





10

MIDDLE EAR DISEASES : ASOM /SOM



Pathophysiology of Middle Ear Disorder 00:01:25

- The main cause of the majority of middle ear disorders is Eustachian tube dysfunction.

The pathophysiology is as follows:

- The Eustachian tube goes to the middle ear.
- Anteriorly, there's an opening of Eustachian tube which communicates to the middle ear. Posteriorly, from here, there are mastoid air cells.
- In any middle ear disease, the Eustachian tube gets occluded (Eustachian tubal obstruction), which can occur due to any nasal or nasopharyngeal cause since the Eustachian tube primarily opens into the nasopharynx.
- Whenever there's a nasopharyngeal obstruction or Eustachian tubal occlusion (ETO) due to any adenoid or a mass in the nasopharynx or if the ventilation to the nasopharynx or the Eustachian tube is getting affected due to any pathology in the nose, the air reaching the Eustachian tube or the ventilation to the middle ear gets reduced. This results in negative pressure in the middle ear.
- If this negative pressure is present for some time, it acts on the mucosal cells of the middle ear. Slowly there's exudate formation in the middle ear. If this exudate is infective, it is called suppurative otitis media (SOM). Otitis media is the infection of the middle ear. If the exudate is not infective, then it is called non-suppurative otitis media (NSOM).
- If the duration of infection is of less than four weeks' duration, then it is called acute suppurative otitis media (ASOM) and if it is of more than 12 weeks, then it is called as chronic suppurative otitis media (CSOM).
- Whenever there's a palatal abnormality, these muscles won't be able to open the Eustachian tube affecting the air ventilation. Thus, in some cases, the middle ear disorder is due to palatal cause.



Important Information

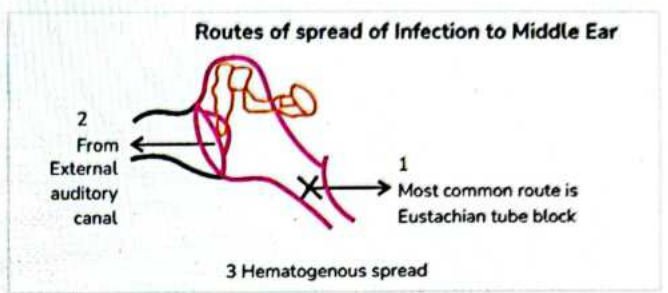
- The main cause of the majority of middle ear disorders is Eustachian tube dysfunction. Which occurs secondary to nasal or nasopharyngeal pathology.

Acute Suppurative Otitis Media 00:07:30

- It is defined as an inflammation of the middle ear cleft by pyogenic organisms.
- The disease is acute (less than four weeks duration).
- Suppurative means that it is an infective disease.

- Otitis media means it's in the middle ear.
- Acute onset of infection in the middle ear is called acute suppurative otitis media (ASOM).

Routes of infection 00:08:02



- Eustachian tube: This is the most common route.
- External auditory canal: Any infection from the external auditory canal can reach the middle ear via a pre-existing perforation or it can go through the tympanic membrane into the middle ear.
- Blood: There can be a hematogenic spread of infection via blood in rare cases.

Q. Why is ASOM more common in children and infants?

Answer: It is more common in children and infants because the Eustachian tube is shorter, straighter, and more horizontal. In adults, there's an angulation between the middle ear and the Eustachian tube that reduces the reflux of the contents from the nasopharynx to the middle ear. In the case of horizontal and straighter tubes, there's easy reflux of content, which results in easy infection in children and infants.

Predisposing Factors 00:10:18

- Recurrent attacks of common cold and upper respiratory tract infection (URTI).
- Exanthematous fever like diphtheria, measles, and whooping cough.
- Chronic sinusitis and rhinitis.
- Nasal allergy.
- Nasal packing for epistaxis.
- Nasopharyngeal tumors.
- Above given predisposing factors lead to a decrease in middle ear ventilation.
- Cleft palate.



## Bacteriology

00:12:08

- ASOM is an infectious disease.
- Most common infective agents causing ASOM in infants and children are **Streptococcus pneumoniae** and **H. influenzae**.
- Other infective agents include Moraxella, Staphylococcus aureus, and E. coli.

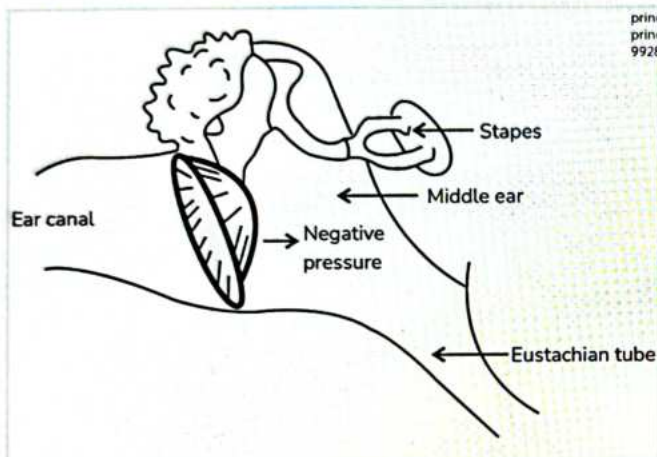


### Important Information

- The most common infective agents causing ASOM in infants and children are **Streptococcus pneumoniae** and **H. influenzae**.

## Stages of ASOM

00:13:00

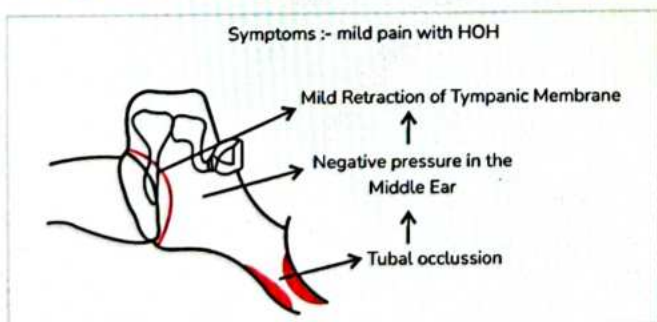


prince kumar  
princeeeekum@gmail.com  
9928609733

- Tubal occlusion:** The ventilation to the Eustachian tube is occluded.
- Pre-suppurative**
- Suppurative**
- Resolution**

### (1) Stage of Tubal occlusion

00:13:30



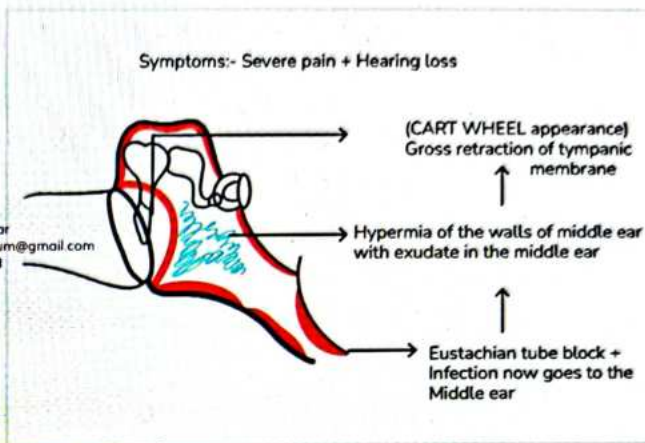
- Due to nasal pathology (e.g., DNS, polyp, tumor) or nasopharyngeal causes (enlarged adenoid), tubal occlusion occurs which leads to reduced air entry in the Eustachian tube.
- This leads to negative pressure that acts on the tympanic

membrane and causes its mild retraction towards the middle ear. This is the initial stage of the disease. Thus, there's mild pain or mild hearing loss at this stage.

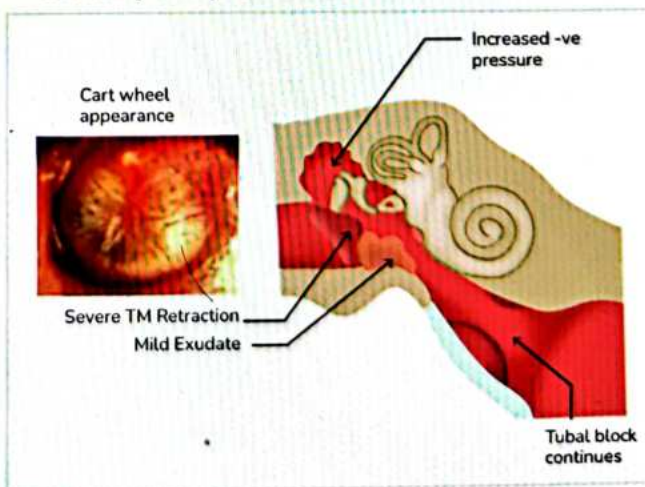
- If therapy isn't sought, it can progress to the next stage i.e., the stage of pre-suppurative.

### (2) Stage of pre-suppurative

00:17:43



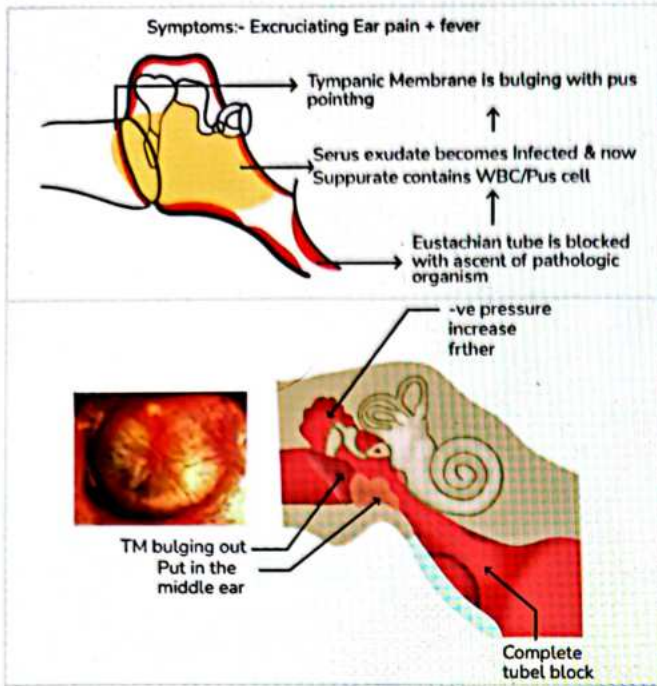
- In this stage, there's a **continuous Eustachian tube blockade** since the patient hasn't taken any treatment.
- The bacteria ascend to the middle ear leading to inflammatory and infective exudate.
- This leads to a gross increase in the negative pressure in the middle ear.
- The tympanic membrane has gross retraction leading to blood vessel stretch.
- When the blood vessels are stretched, they appear as radiating from the periphery to the center. This appearance is called the **CART WHEEL appearance**.
- There's severe pain and severe hearing loss.
- There may or may not be a fever.





(3) Stage of suppuration

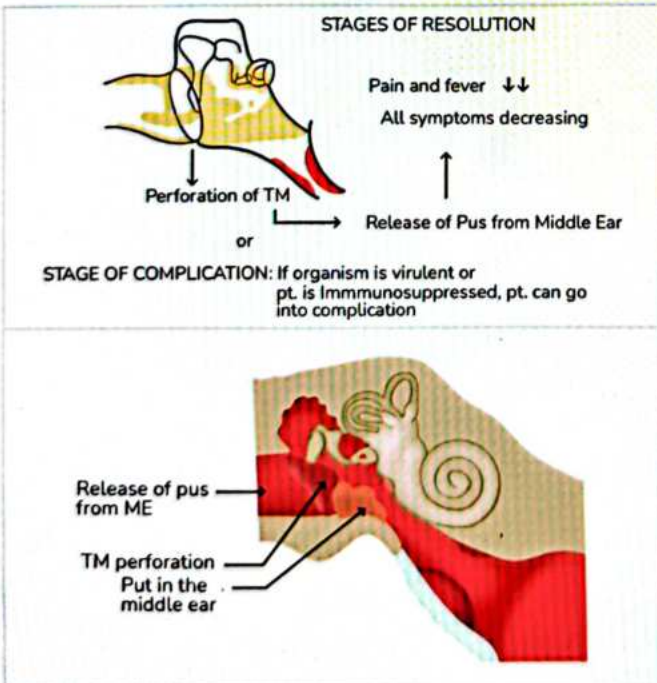
00:20:51



- In this stage, the Eustachian tube blockade continues, and the pathological organism ascends.
- The exudate gets infected, and the entire middle ear gets filled with pus.
- The Tympanic membrane bulges forward due to being pushed by pus.
- The symptoms included excruciating ear pain, high fever, and severe hearing loss.

(4) Stage of resolution

00:23:28

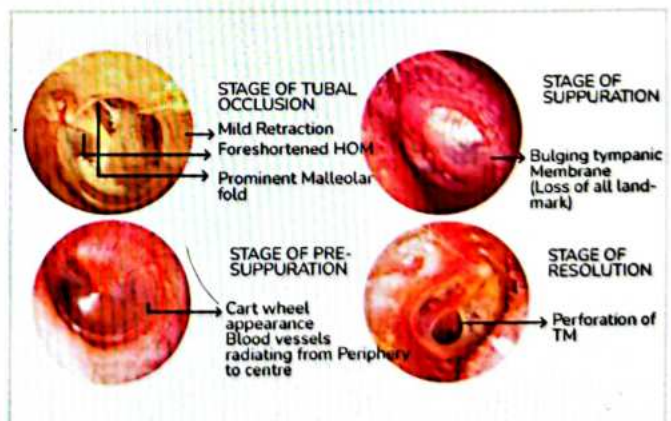


- The body has the capacity to heal.
- The tympanic membrane ruptures (perforation of the tympanic membrane) and the pus is released from the middle ear to the external auditory canal.
- All the symptoms like pain and fever decrease.
- Due to the pressure, the pus comes out in a pulsatile form. This is called **Pulsatile otorrhea**.
- This pus reflects light in alternate visualizations. This is called a **lighthouse sign**.
- If the patient has low immunity and the organism is virulent, then there can be complications.

Summary of the stages of ASOM

00:27:44

Stage	Pathology	Symptoms	Signs
1. Tubal occlusion	Oedema of ET leading to negative pressure and retraction of TM	Mild deafness and ear ache	Retracted TM
2. Pre-suppurat	Invasion of organism and mild inflammatory exudate	Fever Severe Deafness	Cart wheel TM (congested TM)
3. Suppurat	Frank Pus	High grade fever, excruciating ear ache deafness	Bulging tympanic membrane
4. Resolution	TM ruptures with release of pus	Everything decreases	Small perforation in anterior-inferior pars tensa with hypermia of TM
5. Complications			



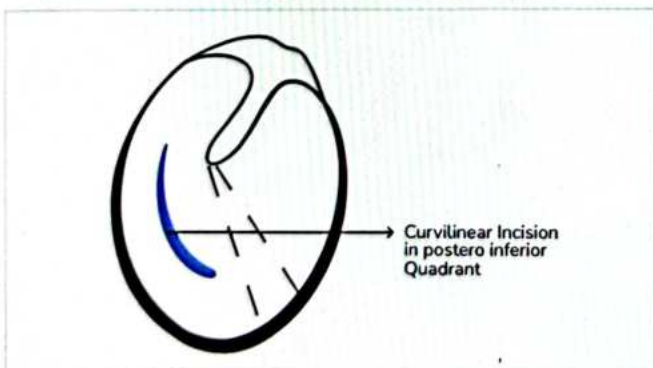


- Initially the symptoms are mild. Then they become severe in the stage of saturation. The symptoms decrease in the resolutions stage.
- If the sign is in the tubal occlusion, then we can see mild retraction, the foreshortened handle of the malleus, and a prominent malleolar fold.
- In the stage of pre-suppurative, there's gross retraction and **Cart Wheel appearance**.
- In the stage of suppurative, there's a **bulge of the tympanic membrane**.
- In the stage of resolution, there's **perforation in the anteroinferior quadrant of the pars-tensa**.

### Treatment of ASOM

00:28:57

- Antibacterial therapy:** Antibiotics are given till the fever is reduced, tympanic membranes appear normal, and hearing is normal. The minimum duration of treatment is 10 days.
- Ampicillin or amoxicillin is the most common and used for 8-10 days**
- Inadequate therapy can lead to serous otitis media.
- We can also give supportive therapy like nasal decongestants to relieve Eustachian tube edema, oral decongestants, analgesics and antipyretics, ear toilet, and dry local heat.
- Myringotomy (opening in the tympanic membrane) can be performed in case of severe pain with a bulging drum, persistent effusion for more than 12 weeks, incomplete resolution despite antibiotics, and ASOM with facial palsy.**
- Myringotomy is performed in the **Posteroinferior Quadrant** because it is a dependent quadrant where a lot of pus gets accumulated. Thus, an incision can help in draining a lot of pus. Also, the **epithelial turnover rate** is slightly less taking longer to heal. This allows the pus to drain naturally from the middle ear. Another reason is that in the posteroinferior quadrant, there's no major or vital structure.



- A curvilinear incision in the posteroinferior quadrant is made as it heals slower and allows the pus to drain out from the middle ear.

### Necrotizing Otitis Media

- It is the same as ASOM but it is caused by **Group A beta-hemolytic streptococcus**
  - It is More Aggressive

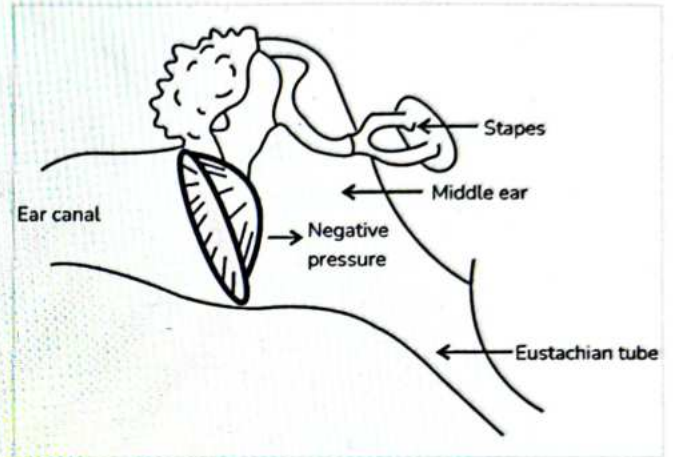
### Non-Suppurative Otitis Media [Secretory Om, Serous Om, Glue Ear, Ome]

00:37:07

- It is defined as the accumulation of non-inflammatory exudate in the middle ear cavity.
- It is common in children aged 2-6 years.

### Pathogenesis

00:39:58



- In this type, there's no active infection in the Eustachian tube.
- The source is non-infective. Negative pressure on the Eustachian tube acts on the mucosal cells causing non-infective exudate.
- As the exudate is non-infective, it is also called serous otitis media, NSOM, glue-ear, and secretory otitis media. There is **sterile fluid accumulated** in the middle ear.

### Etiology

00:40:53

- The tubal occlusion is due to the following reasons:**
  - Nasopharyngeal cause: Adenoids, benign and malignant tumors in the nasopharynx.
  - Nasal cause: sinusitis, tonsillitis, and chronic rhinitis.
  - Palatal causes.
- The most common cause of unilateral serous otitis media in a juvenile age group is **Juvenile Nasopharyngeal Angiofibroma (JNA)**, and in adults is **nasopharyngeal carcinoma (NPC)**.
- The most common cause of bilateral serous otitis media in children is **adenoid hypertrophy**.

#### Important Information

- Macular area (occipital pole) on the occipital visual cortex has dual blood supply from the
  - **Posterior cerebral artery (PCA)**



- o Middle cerebral artery (MCA)
- If there is a block in the posterior cerebral artery (PCA), there is contralateral homonymous hemianopia with macular sparing, because the macular area on the occipital lobe has a dual blood supply.

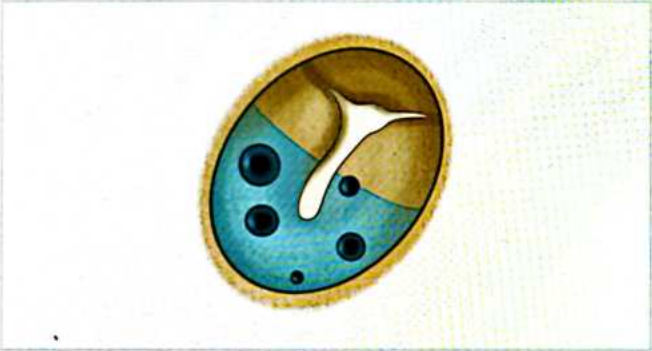Symptoms of NSOM

00:43:05

- There is no pain or fever as there is no infection.
- It results in conducting hearing loss (CHL) but the child can't appreciate it but the teacher in class complains of the child not paying attention.
- Block sensation of the ear.
- Poor school performance: Inattentiveness is an indirect indicator.
- Delayed speech.
- Autophony.
- Nasal discharge and obstruction.

Signs of NSOM

00:44:52



- Dull lusterless tympanic membrane with absent light reflex.
- Fluid present.
- Retracted tympanic membrane.
- Air bubbles.
- Decreased mobility of the tympanic membrane.
- Crescent sign (air-fluid level) is the diagnostic hallmark of NSOM. The color can vary.

**Important Information**

- The crescent sign (air-fluid level) is the diagnostic hallmark of NSOM.

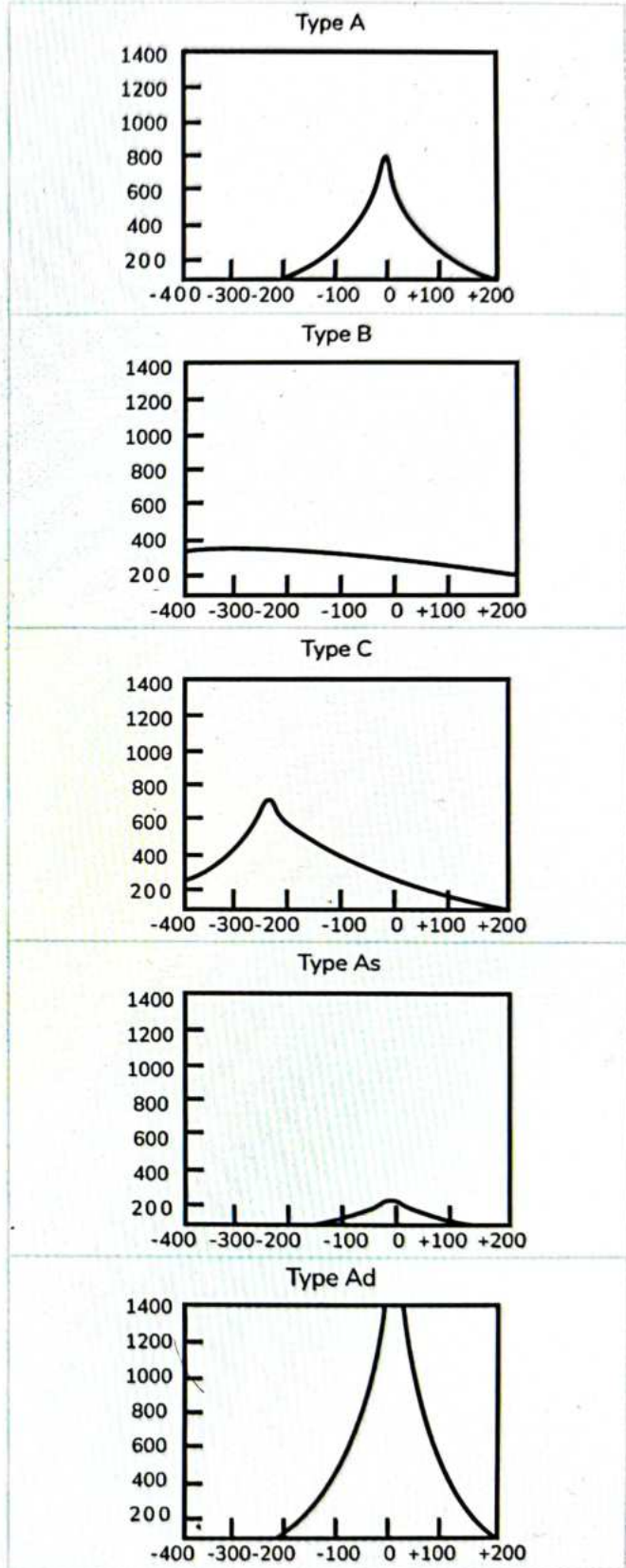
Conductive hearing loss

00:47:05

- Tuning fork test shows an inference of conductive hearing loss.
- The Rinne test is negative.
- The Weber test: The child will hear the fork towards the affected ear.
- There's no role of absolute bone conduction test as this isn't a sensory-neural pathology.

prince kumar  
princeeeekum@gmail.com  
9928609733

- The conductive hearing loss can be confirmed by audiometry. In this, the bone conduction will be in the normal range and air conduction will be affected.





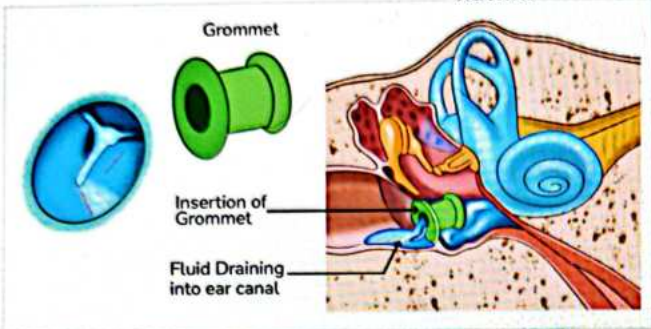
- Tympanometry is the diagnostic test of serous otitis media. Type B or a flat hologram is specific in serous otitis media.

**Important Information**

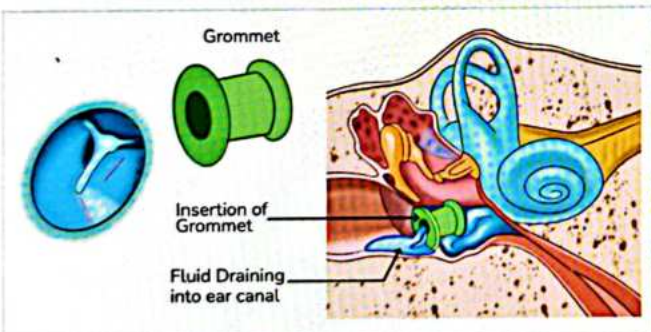
- Tympanometry is the diagnostic test of serous otitis media. Type B or a flat hologram is specific in serous otitis media.

### Treatment of NSOM

prince kumar  
princeekum@gmail.com  
9928609733



- Watchful waiting for 3 months is recommended as it is known to resolve spontaneously.
- Prevention of secretory otitis media is done by anti-allergy treatment and decongestants (Their role is debatable).
- Middle ear aeration: This is done by repeated Valsalva or politzerization.
- In case the above fails after three months, then Myringotomy with Grommet (ventilating tube) insertion and treatment of the underlying cause (adenoidectomy) is done.



- Myringotomy site is the anteroinferior quadrant. A radial incision is given to insert a ventilating tube as it will be held better. Myringotomy is contraindicated in the posterosuperior quadrant since there are vital structures like the incudostapedial joint. Also, it can cause trauma to the cauda tympani nerve, oval window, or facial nerve.
- Grommet is a ventilating tube that will initially help in draining the content of the middle ear. Later, it will keep the ear dry. It is done to bridge the time gap between myringotomy and restoration of the Eustachian tube ventilation. This is done to prevent the recurrence of NSOM. The grommet expels in 6 months.

**Important Information**

- Treatment of the underlying cause is the most important in NSOM.
- Myringotomy is contraindicated in the postero-superior quadrant since there are vital structures like the incudostapedial joint. Also, it can cause trauma to the cauda tympani nerve, oval window, or facial nerve.

### Summary Of Difference Between ASOM And SOM 00:57:38

	ASOM	SOM
<b>Cause</b>	Usually infective: Streptococcus pneumonia	Non-infective cause. (nasal or nasopharyngeal cause)
<b>Symptoms</b>	Primary symptoms are pain, hearing loss, and fever.	Hearing loss, poor school performance, inattention.
<b>Signs</b>	Mild retraction progressing to Cartwheel appearance, bulging tympanic membrane, perforation, pulsatile otorrhea, and lighthouse sign	Presence of air bubbles and air-fluid level (hallmark for SOM).
<b>Investigation</b>	None.	Tuning fork test, audiometry, and tympanometry (B type of ausiogram) (diagnostic test).
<b>Treatment</b>	Medical therapy: antibiotics, nasal decongestants, analgesics, and anti-inflammatory drugs. Surgery includes myringotomy at the posteroinferior quadrant and curvilinear incision	Initially wait and watch, and provide medical therapy for 3 months. Beyond three months, myringotomy with grommet and treatment of the underlying cause. The site of myringotomy is the anteroinferior quadrant. It is a radial incision.



## Summary

01:02:36

**Q. Acute infections of the middle ear commonly occur at which age?**

**Answer:** Younger age group (children and infants) since the Eustachian tube is shorter, straighter, and more horizontal.

**Q. Organism responsible for ASOM?**

**Answer:** Streptococcus pneumonia

**Q. Cartwheel sign seen in?**

**Answer:** Pre-suppurative stage.

**Q. Bulging Tympanic membrane is seen in?**

**Answer:** Suppurative stage.

**Q. Lighthouse sign is seen in?**

**Answer:** Resolution stage.

**Q. Indication for Myringotomy in ASOM?**

**Answer:** In case of severe pain with a bulging drum, persistent effusion for more than 12 weeks, incomplete resolution despite antibiotics, and ASOM with facial palsy.

**Q. Appearance of tympanic membrane is SOM?**

**Answer:** Crescent signs and air bubbles.

**Q. Unilateral SOM is suggestive of?**

**Answer:** The most common cause of unilateral serous otitis media in a juvenile age group is Juvenile Nasopharyngeal Angiofibroma (JNA), and in adults is nasopharyngeal carcinoma (NPC). The most common cause of bilateral serous otitis media in children is adenoid hypertrophy.

**Q. The diagnostic test for SOM?**

**Answer:** Tympanometry.

**Q. Indication of Myringotomy in SOM?**

**Answer:** If it fails to resolve after three months of watching, then myringotomy is indicated with grommet and treatment of underlying cause.

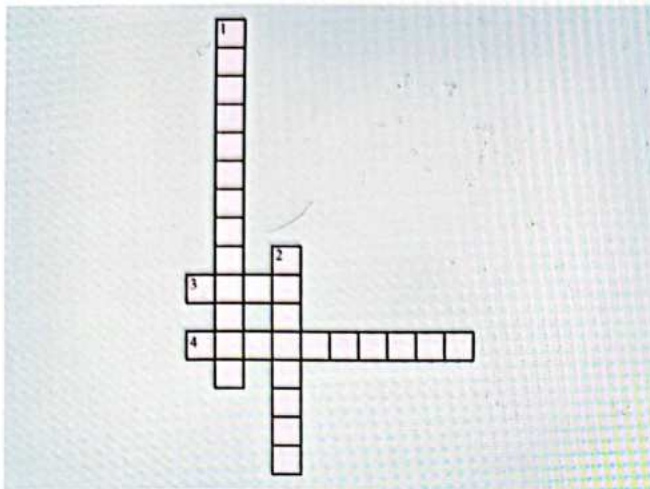




# CROSS WORD PUZZLES



## Crossword Puzzle 1




**Across**

- 3. \_\_\_\_\_ onset of infection in the middle ear is called acute suppurative otitis media.
- 4. \_\_\_\_\_ tube dysfunction is the main cause of the majority of middle ear disorders.

**Down**

- 1. \_\_\_\_\_ pneumonia and *H. influenza* are the most common infective agents causing ASOM in infants and children.
- 2. \_\_\_\_\_ pressure acts on the tympanic membrane and causes its mild refraction towards the middle ear.

## Crossword Puzzle 2



**Across**

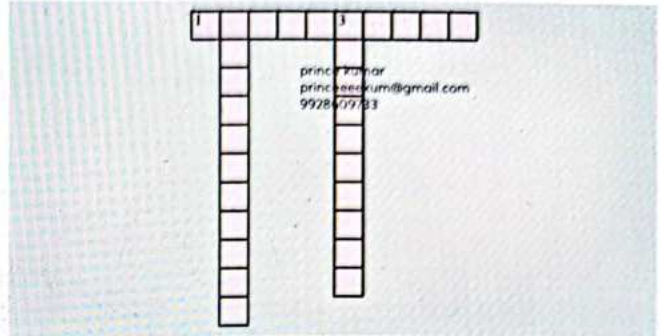
- 3. \_\_\_\_\_ stage of ASOM involves perforation in the anteroinferior quadrant of the pars-tensa
- 4. \_\_\_\_\_ gets infected, and the entire middle ear gets filled with pus in the suppuration stage of ASOM.

**Down**

- 1. \_\_\_\_\_ sign means the pus reflects light in alternate visualizations.

- 2. \_\_\_\_\_ increase in the negative pressure in the middle ear is seen in pre-suppurative stage of ASOM.

## Crossword Puzzle 3



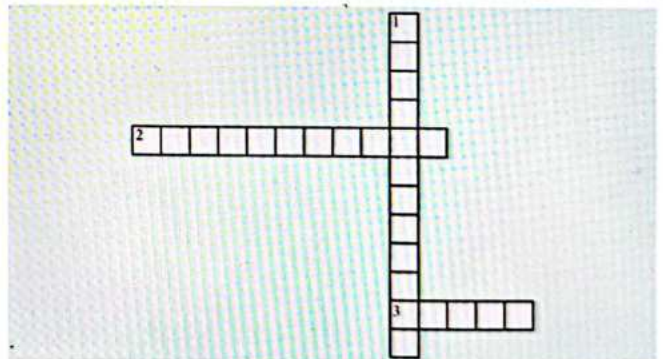
**Across**

- 1. \_\_\_\_\_ or amoxicillin are most commonly used to treat ASOM.

**Down**

- 2. \_\_\_\_\_ can be performed in case of severe pain with a bulging drum, persistent effusion for more than 12 weeks, incomplete resolution despite antibiotics, and ASOM with facial palsy.
- 3. \_\_\_\_\_ therapy can lead to serious otitis media.

## Crossword Puzzle 4



**Across**

- 2. \_\_\_\_\_ incision in the posteroinferior quadrant is made in the Myringotomy for ASOM as it heals slower and allows the pus to drain out from the middle ear.
- 3. \_\_\_\_\_ test is negative in conductive hearing loss.

**Down**

- 1. \_\_\_\_\_ is the diagnostic test of serous otitis media.





- One of the most common ENT diseases.
- Oma generally means tumor.
- The external auditory canal is lined by stratified squamous epithelium, and the middle ear is lined by cuboidal epithelium.
- The presence of stratified squamous epithelium in the middle ear is cholesteatoma.
- It has a gross pearly-white(due to the presence of keratin) appearance.

00:00:58

another form of epithelium.

- So, the cuboidal epithelium transforms into the stratified squamous epithelium.

5. **Basal Cell Hyperplasia Theory**

princeeeekum@gmail.com

00:10:50

- In some people, hyperplasia of the cuboidal epithelium can occur.
- This more or less resembles stratified squamous epithelium.

Theories for formation of Cholesteatoma

1. **Congenital Theory**

00:03:06

- The external auditory canal develops from the cleft (ectoderm) of the 1st arch, whereas the middle ear is from the pouch of 1st and 2nd arch (endoderm).
- Entrapment of the ectodermal cells in the endodermal cells is called cholesteatoma. Since this happens before birth, it is called congenital cholesteatoma.

2. **Epithelial Invasion Theory**

00:05:56

- This occurs mainly due to childhood diseases like ASOM(Acute Suppurative Otitis Media) which lead to the perforation of the tympanic membrane.
- This perforation can cause epithelial cells to proliferate and migrate into the middle ear.
- This is called epithelial invasion theory.

3. **Retraction Pocket Theory**

00:06:42

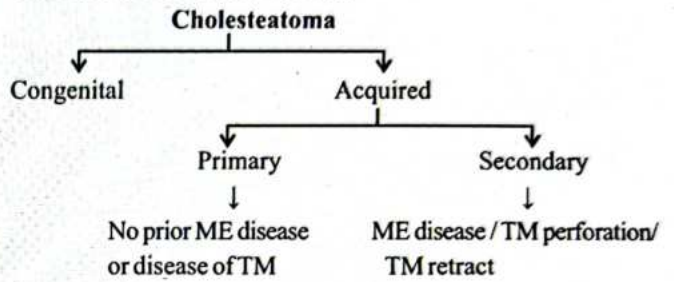
- Due to abnormality in the eustachian tube, there is negative pressure in the middle ear.
- The pars flaccida part of the tympanic membrane is loose (as it lacks the fibrous layer) and tends to get retracted.
- As the pars flaccida goes into the retraction pocket, some cells from the external auditory canal can also go into this pocket.
- This part can now get disconnected to form a middle ear cholesteatoma.

4. **Metaplastic Theory**

00:08:44

- Chronic diseases like ASOM(Acute Suppurative Otitis Media) and SOM( Suppurative Otitis Media) can cause eustachian tube abnormality, and this can lead to negative pressure development.
- If this negative pressure is persistent, metaplasia can occur.
- **Metaplasia is the conversion of one form of the epithelium to**

Classification of Cholesteatoma



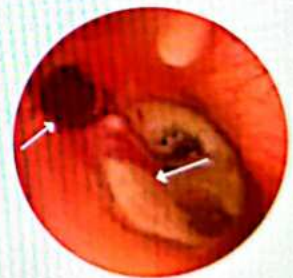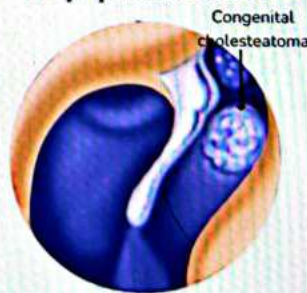
Types of Cholesteatoma

00:15:58

- **Congenital:** Seen in the middle ear, petrous apex, and Cerebellopontine angle.
- **Acquired, primary:** Cholesteatoma in an ear which was previously normal
- **Acquired, secondary:** Cholesteatoma in previously pathological ear (old perforation)

Congenital Cholesteatoma	Acquired Cholesteatoma
--------------------------	------------------------

- |   |   |
|---|---|
| <ul style="list-style-type: none"> <li>• Commonly seen at three sites: Middle ear, petrous apex, Cp angle</li> <li>• Intact tympanic membrane. The cholesteatoma is seen as white pearly mass through the tympanic membrane.</li> </ul> | <ul style="list-style-type: none"> <li>• Can occur any site</li> <li>• Tympanic membrane perforation is seen</li> </ul> |
|---|---|





## Levenson's criteria for congenital Cholesteatoma 00:18:40

- Whitish mass.
- Normal tympanic membrane.
- No history of otorrhoea or perforation.
- No prior otological surgeries.

## Properties of Cholesteatoma 00:20:32

- It is locally aggressive disease as it has **bone-destroying properties** because of enzymes like collagenase and acid phosphatase.
- It spreads due to enzyme degradation and not pressure.
- It spreads along the **path of least resistance, and the dome of the lateral semicircular canal is the most common site.**
- It can also go superiorly to the tegmen, inferiorly to the jugular vein, posteriorly to the mastoid, or anteriorly to the external auditory canal.

## Cholesteatoma Hearer 00:23:46

- Cholesteatoma has eroded the incudo-malleolar joint, so there is a discontinuity leads to conductive hearing loss.
- If the cholesteatoma bridges the gap between the joint, there is lesser hearing loss pre-operatively (40-50 dB lesser).
- These patients are called cholesteatoma hearers.
- Post-operation there is a greater hearing loss(60-80dB) as there is a discontinuity in the joint.
- The first aim in patients with the cholesteatoma is the ear to be safe and avoid complication that is caused by cholesteatoma spread.
- The hearing can be restored in the next stage.

## Clinical Question

A 50-year-old male presented to you with cholesteatoma pre-operatively had a hearing loss of 30 dB, and post-operatively it was 60 dB hearing loss. This could be due to which of the following:

- Surgeon's error
- He was a cholesteatoma hearer
- Psychological issue experienced by the patient
- Inorganic for the patient

**Answer:** (B) He was a cholesteatoma hearer.

## Round window shielding effect 00:28:06

- When we have a perforation or cholesteatoma, there will be some amount of ear discharge.
- A person can hear better when there is discharge than when the ear is dry.
- For a person with a perforation, when the sound waves come and hit the tympanic membrane, it simultaneously hits the oval window and round window.
- Now, the fluid moving the scala vestibule and scala tympani

move at the same speed canceling the effect of each other.

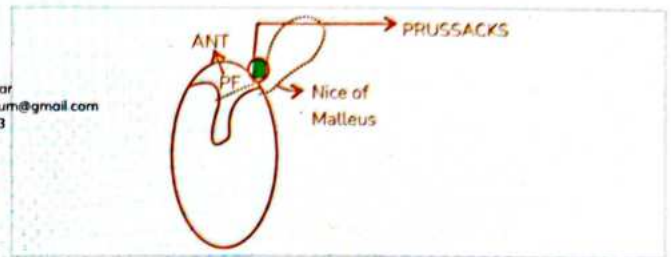
- So the electrical impulses that should be generated in the basilar membrane do not occur, and this leads to hearing loss.
- So when ear discharge is near the round window, it creates the phase difference between the two fluids, and the patient will have better hearing.

## Most common sites occurrence

### Origin of cholesteatoma 00:31:08

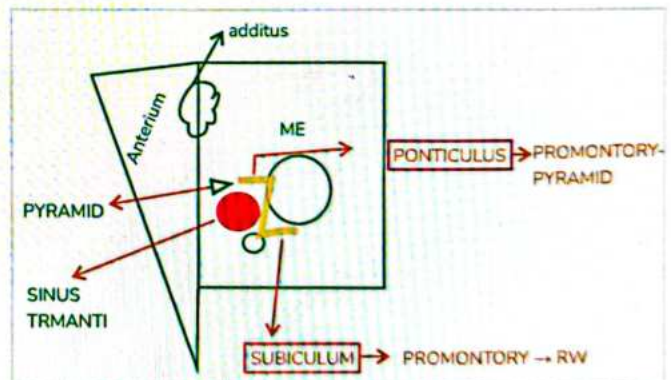
#### Prussak's space

- It is the space between the pars flaccida (anterior) and the neck of the malleus (posterior).



## Recurrence 00:32:42

- **Sinus tympani.**
- It is an infra-pyramidal space.
- It is between the Ponticulus and Subiculum.
- There are extensions from the promontory. The one from the promontory to the pyramid on posterior wall is the Ponticulus. Subiculum is an extension from promontory to the round window.



## Ossicle to be eroded 00:35:51

- Long process or lenticular process of Incus

## Erosion

- Lateral semicircular canals

## Symptoms 00:38:10

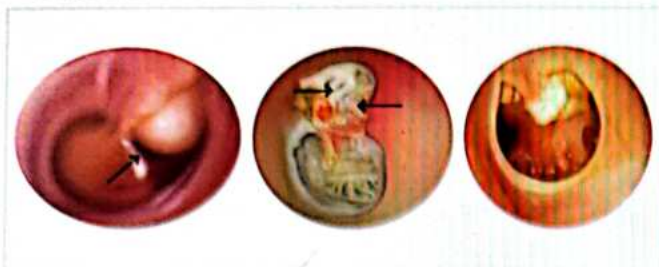- Scanty foul smelling, painless discharge
- **Keratin flakes - hallmark**
- Blood while using earbuds
- Hearing loss



## Examination

00:40:03

- Whitish mass behind tympanic membrane- Congenital cholesteatoma.
- Presence of **retraction pocket** with whitish flakes of Keratin- Acquired cholesteatoma.



## Diagnosis

00:42:00

- Otoscopy- a whitish mass of keratin.
- Observe under a microscope.
- CT scan of the temporal bone- As the disease is erosive, the spread of the disease is checked by this method.
- Audiological test- Conductive hearing loss.

Q. What is your investigation of choice for cholesteatoma?

Answer: CT scan of the temporal bone.

- It is an unsafe disease, and it can erode the bones of the cranial cavity, labyrinth, or mastoid so we need to assess the spread.

## Treatment

00:43:50

- Surgery
- Modified Radical Mastoidectomy

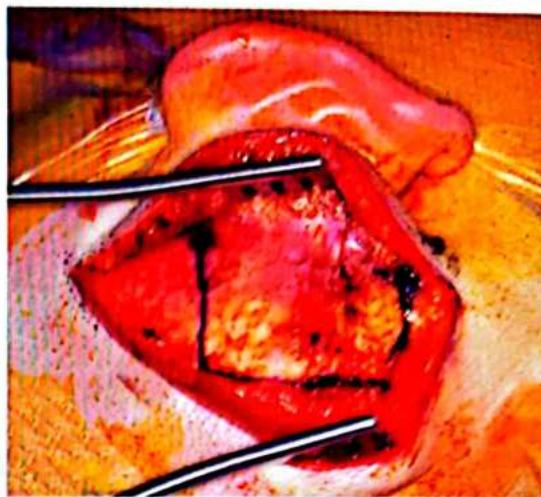
## Mastoidectomy

00:45:00

- A post-oral incision( incision behind the pinna) is taken. It's taken 1cm behind the retro-auricular sulcus. This is **William Wilde's incision**.



- The first landmark is the supra mastoid crest, the second is the imaginary line across the posterior wall of the external auditory canal and the third line is the tangent joining the two. The triangle formed is **MacEwen's triangle**. It is the surface landmark to identify the mastoid antrum.



- Drill and remove all the air cells of the mastoid till the tegmen superiorly, sigmoid bulge posteriorly, and the tip of the mastoid inferiorly are visible. This is the **cortical mastoidectomy also called schwartze operation**.
- The posterior wall of the external auditory canal is intact so this is also called intact canal wall down surgery.
- In canal wall-down surgery or **modified radical mastoidectomy**, the posterior wall is removed. Now the external auditory canal, middle ear, and mastoid as one single ear cavity.

## Comparison between the two surgeries

00:56:42

	Canal wall up	Canal wall down
Meatus	Normal meatus	Widely open meatus communicating with mastoid
Dependence	No cleaning required	Cleaning mastoid cavity once or twice a year
Recurrence	High rate	Low rate
Second Look Surgery	Second look after six months to rule out cholesteatoma	Not required
Patients Limitations	No limitations	Swimming as this can lead to mastoid cavity infection
Auditory Rehabilitation	Easy to wear a hearing aid if necessary	Problems in fitting hearing aid






# CROSS WORD PUZZLES



Crossword Puzzle 1



**Across:**

- 1) Extension between the promontory and pyramid
- 3) Epithelium in middle ear


**Down:**

- 2) Most common site of recurrence of cholesteatoma

**ANSWER KEY:**

- 1) Ponticulus
- 2) Sinus tympani
- 3) Cuboidal

Crossword Puzzle 2



**Across:**

- 2) Cholesteatoma hearers have \_\_\_\_\_ hearing loss post-operation
- 3) Extension between the promontory and round window


**Down:**

- 1) Pearly- white colour of cholesteatoma is due to presence of

**ANSWER KEY:**

- 1) Keratin
- 2) Greater
- 3) Subiculum

Crossword Puzzle 3



**Across:**

- 2) Cortical mastoidectomy is also called \_\_\_\_\_ operation

**Down:**

- 1) Oma means
- 3) Investigative choice of cholesteatoma is the CT scan of \_\_\_\_\_ bone

**ANSWER KEY:**

- 1) Tumor
- 2) Schwartz
- 3) Temporal





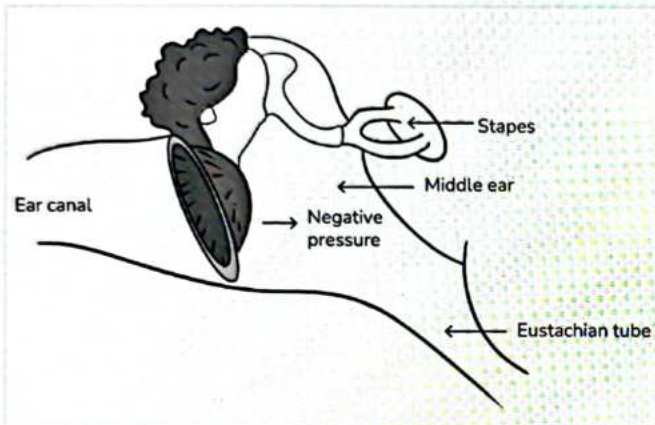
**12**

**MIDDLE EAR DISEASES: CSOM**

00:00:10

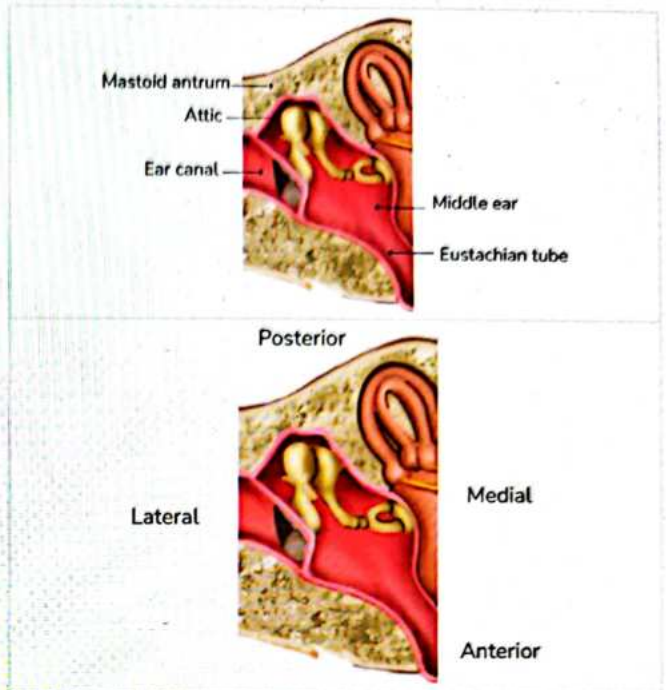
- CSOM stands for **Chronic Suppurative Otitis Media**. Any disease that lasts for more than 12 weeks is chronic. The word suppurative indicates pus. If the pus is in the **middle ear**, it is called **otitis media**.
- CSOM is a long-standing infection of a part or whole of the middle ear cleft characterised by ear discharge and a **permanent perforation**. Permanent perforation occurs when the edge of the perforation is covered by squamous epithelium and does not heal spontaneously.

**Types of CSOM**

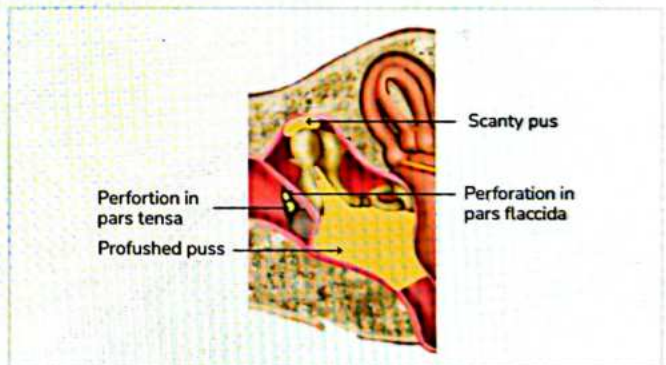


**There are two types of CSOM:**

- **Tubotympanic Perforation:** The disease begins at the eustachian tube and goes to the middle ear cavity.
  - o Usually seen in younger age groups.
  - o Whenever nasal pathology or nasopharyngeal pathology eustachian tube will not get adequately ventilated, and there is inappropriate ventilation in the middle ear. It will create negative pressure in the middle ear. When this pressure stays long, it will lead to puss in the middle ear.
  - o Antero inferior part of the middle ear is affected in the eustachian pathology.
- **Atticoantral Perforation:** The disease begins in the atticoantral and goes posteriorly into the mastoid air cells.
  - o A disease associated with cholesteatoma is often seen in older people.
  - o The posterosuperior part of the middle ear is affected.



- In a Tubo-tympanic type of disease, the cause is in the eustachian tube affecting the middle ear. A large area of the middle ear is involved, which gets filled with profused puss.



- Compared to an Atticoantral type of disease, the disease begins in the attic. It goes posteriorly into the mastoid air cells. It affects the superior part of the middle ear and the posterior part of the mastoid. It involves a small part of the middle ear, resulting in a scanty puss.

Tubo-Tympanic	Atticoantral
Causes profused puss.	Causes scanty pus.
Non-foul smell.	Foul-smelling pus as it involves bone.
Non-blood stained.	Bloodstained pus.

prince kumar  
princeeeeek  
9928609733



It involves the Antero inferior part of the middle ear.	Involves the posterosuperior part of the middle ear is affected.
Hearing loss occurs.	The hearing loss is higher.
Complications are rare.	It can cause complications such as <ul style="list-style-type: none"> <li>• Tegmen erosion,</li> <li>• Ossicular erosion,</li> <li>• Osteitis and granulation and</li> <li>• Facial nerve erosion.</li> </ul>

Hearing loss	Mild-Moderate	Moderate to severe
Tegmen tympani erosion	Rare	Common
Intracranial complications	Rare	Common
Polyp	Pale	Red, fleshy
Safe/Unsafe	Safe	Unsafe
Tympanosclerosis	Common	Rare
Cholesterol granuloma	Rare	Common

Treatment of primary pathology is the main stay.	Treatment is 'Ear Surgery' depending on the extent of disease
+	+
Reconstructive surgery (Myringoplasty / Tympanoplasty)	Reconstructive surgery (Myringoplasty / Tympanoplasty / reconstruction of ossicular chain)

**Examination of CSOM**

00:17:45

- The ear is examined under a microscope: In CSOM, the indication is perforation which can be observed under a microscope.
- **Evaluate Pathology:** In the nose or the nasopharynx, nasal endoscopy, CT scan of the nose or paranasal sinuses.
- **High-resolution CT scan of the temporal bone:** To evaluate the extent of erosion inside.
- **Audiological Evaluation:** Confirm how much hearing loss is preoperative.

	Tubo-tympanic	Attico-antral
Cause	Tubal cause, ASOM, allergy. (in children measles)	Cholesteatoma
Age	Children	Adults
Perforation	Central	Attic
Area involved	Antero-inferior	Postero-superior
Discharge quantity	Profuse	Scanty
Osteitis and granulation tissue	Rare	Common
Bone destruction	Rare	Common of annulus, tympanic bone, ossicles, tegmen tympani
Discharge smell	Odourless and mucoid	Foul and purulent
Osteitis and granulation tissue	Rare	Common
Ossicular necrosis	Rare	Common (Most commonly long process of incus)

**Treatment**

- It must be done with a microscope examination.
- An audiogram should be performed to assess the degree of hearing loss.
- A culture should be performed to know the sensitivity of the ear discharge.
- Mastoid x-rays must be taken to know the extent of bone destruction.

**Medical treatment:**

- Aural toilet: Debris and aural polyp should be removed before treatment.
- Ear drop: Neomycin+ Polymyxin + Chloromycetin or gentamicin is used.
- Systemic Antibiotics: Limited use only in acute exacerbation.
- Medication is given to keep the ear dry.
- There are two types of treatment:

Tubo-tympanic	Attico-Antral
• Treatment of primary pathology	• It can be treated with ear surgery depending on the extent of the disease.



- It can be treated with reconstructive surgery like myringoplasty or tympanoplasty.
- Modified radical mastoidectomy is commonly done.

- Reconstructive surgery like myringoplasty, tympanoplasty and reconstruction of the ossicular chain can be performed.

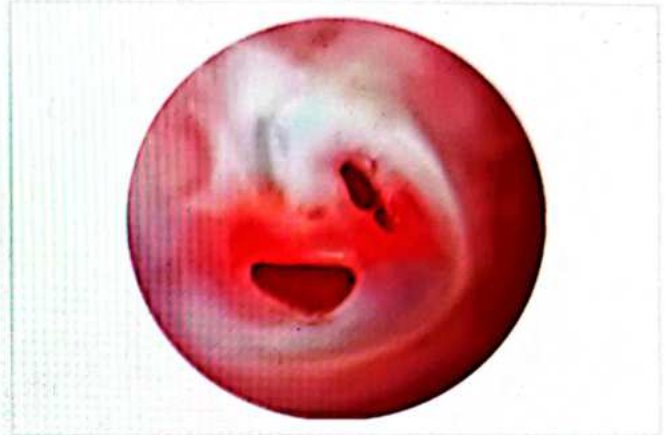- If the primary cause is not treated first, the disease will recur.

### CSOM is classified into two categories:

- Mucosal: In mucosal, there is:
  - Active: There is active discharge and perforation in the middle ear.
  - Inactive: There is dry perforation with no active discharge. It is an inactive type of mucosal disease.
- Squamousal: In squamousal, there is:
  - Active: In an active squamous cholesteatoma with active discharge.
  - Inactive: There will be scanty, foul-smelling discharge. Quiescent disease.

### Tubercular Otitis Media

- Painless foul smelling ear discharge.
- Multiple ear perforations
- Facial paralysis
- Severe hearing loss out of proportion to symptoms



- The perforations caused by tubercular otitis media are permanent. Multiple ear perforation is an indication of tubercular otitis media. It can also cause a painless foul-smelling ear discharge. In severe cases, it can lead to facial paralysis and severe hearing loss.

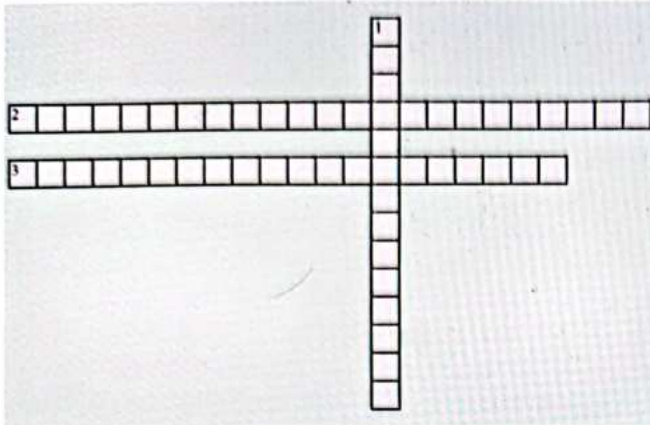




## CROSS WORD PUZZLES



Crossword Puzzle 1




**Across**

2. \_\_\_\_\_ begins at the eustachian tube from there it goes to the middle ear cavity.
3. \_\_\_\_\_ is when the edge of the perforation is covered by squamous epithelium and does not heal spontaneously.

**Down**

1. \_\_\_\_\_ part of the middle ear is affected in the eustachian pathology.

Crossword Puzzle 2



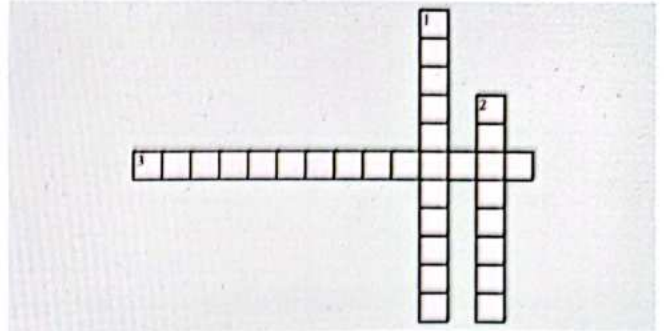
**Across**

1. \_\_\_\_\_ begins in the attic from there it goes posteriorly into the mastoid air cells.
3. When there is \_\_\_\_\_ in the middle ear it will create negative pressure in the middle ear.

**Down**

2. If the primary cause is not treated first there will be a \_\_\_\_\_ of the disease.

Crossword Puzzle 3



**Across**

3. Multiple \_\_\_\_\_ is the indication of tubercular otitis media.

**Down**

1. Debris and aural polyp should be removed before local treatment is called \_\_\_\_\_.
2. In treatment of CSOM Ear drop: \_\_\_\_\_ + polymyxin + chlormycetin or gentamycetin is used.

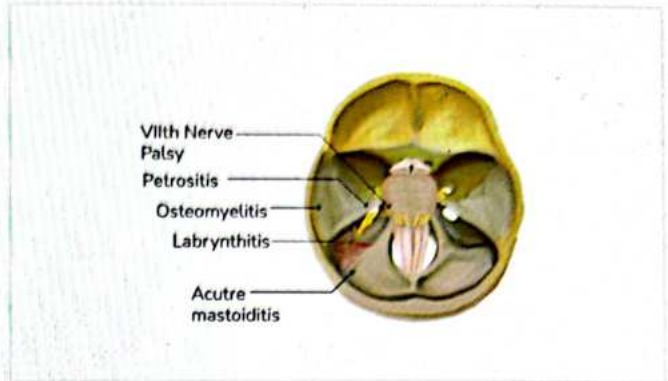




**Routes of spread** 00:00:35

- Natural communication: Possibility of infection through the oval/round window, infection can go to the inner ear and to the adjacent structures
- Bone erosion as a result of disease process/iatrogenic: Cholesteatoma
- Venous thrombophlebitis

Extracranial complications	Intracranial complications
Mastoiditis	Meningitis
Labyrinthitis	Extradural abscess
Facial nerve palsy	Subdural abscess
Petrositis	Brain abscess
Osteomyelitis	Lateral sinus thrombophlebitis
Septicemia	Otitic hydrocephalus

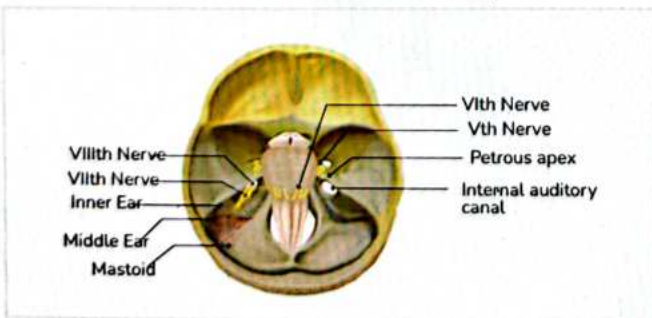
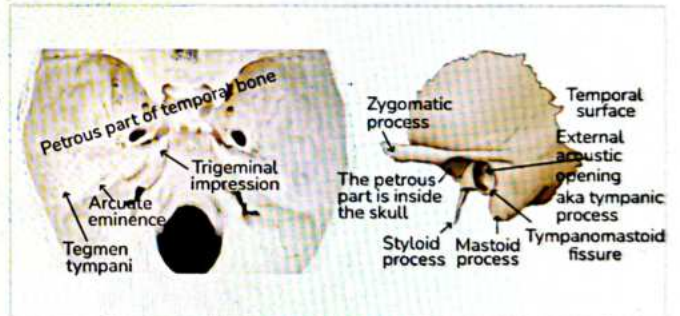


	Acute otitis media	Chronic otitis media
Most common intracranial complication	Meningitis	Intracerebral abscess
Most common extracranial complication	Mastoiditis	Postauricular abscess

**Extracranial Complications**

- Diseases in the middle ear, most common route where infection can spread is mastoid via the aditus. Through the aditus, the infection goes posteriorly to the mastoid bone. This condition is known as Acute mastoiditis.
- If the disease goes from middle ear to inner ear known as Labyrinthitis. This is due to inflammation of labyrinthine
- If the disease goes towards internal auditory meatus or anywhere along the course of facial nerve, this complication is known as Facial nerve palsy
- Infection towards the apex of the petrous bone is known as Petrositis
- Osteomyelitis: Involvement of squamous temporal bone
- Blood spread will result in septicemia.

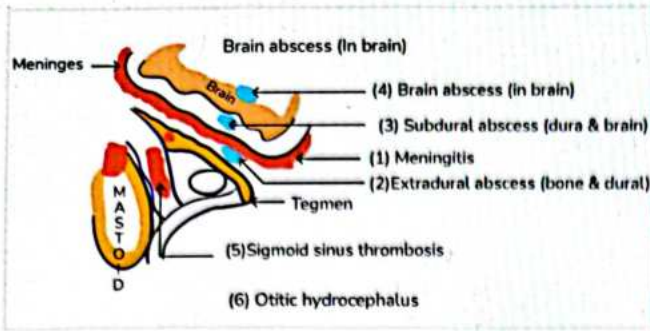
**Intracranial Complications** 00:08:58



• **Two routes for intracranial complications**

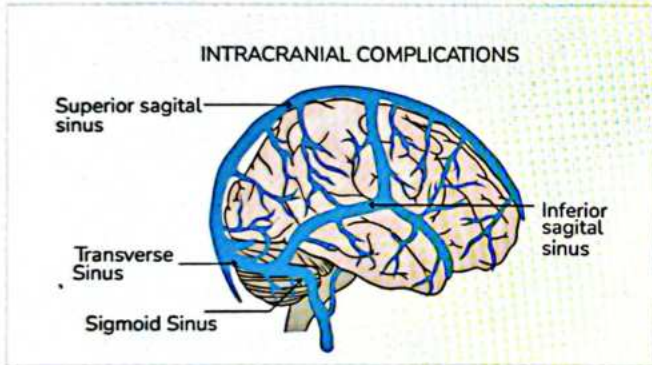
- Middle ear to middle cranial fossa involving temporal lobe
  - Disease can break the tegmen (tegmen-roof of middle ear- which separates the middle ear from middle cranial fossa)
  - From middle ear, it comes to the middle cranial fossa to cause temporal lobe abscesses and meningitis.
- Involves the petrous apex: cerebellar abscess



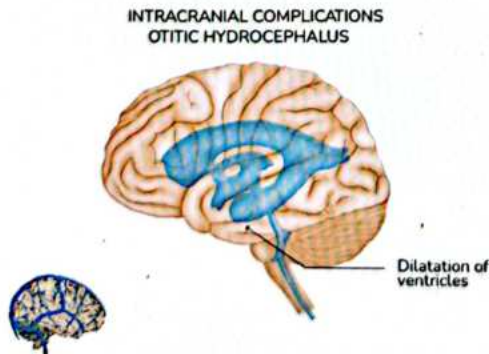


- Inflammation of meninges known as **Meningitis**
- Localization of pus between bone and dura is known as **Extradural abscess**
- Localization of pus between dura and brain is known as **Subdural abscess** and it goes inside the brain parenchyma known as **Brain abscess**.
- Posterior border of mastoid is in relation to the sigmoid sinus **cause thrombosis** called as **Sigmoid sinus thrombosis**.
- Dilatation of ventricles in the brain called as **Otitic hydrocephalus**.

prince kumar  
princeekum@  
9928609733



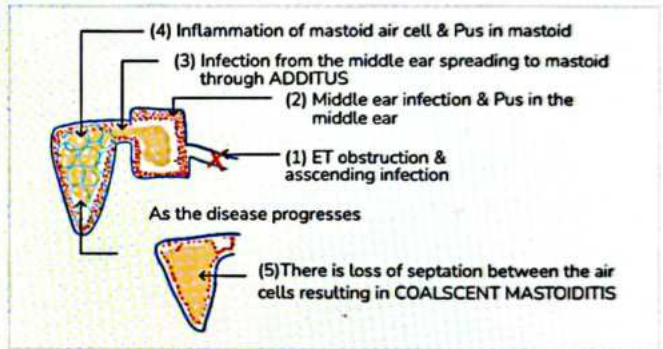
- If there is sigmoid sinus thrombosis, superior and inferior sagittal sinus cannot drain, transverse sinus which is draining into sigmoid sinus also blocks causes obstruction to the drainage of the cranial circulation. This obstruction causes **dilatation of the ventricles of brain** known as **Otitic hydrocephalus**.



**Acute Mastoiditis**

00:13:03

- Inflammation of mastoid air cells
- It's most common extracranial complication of acute otitis media
- Symptoms: Most often there is a prior episode of ASOM following mastoiditis occurs. The symptoms are similar to ASOM but exaggerated. additional symptoms
  - o Fever
  - o Pain behind the ear
  - o Ear discharge: Profuse and persistent discharge may be pulsatile.
    - Pulsatile otorrhea and Light house sign are seen in ASOM and Acute mastoiditis.
    - Pulsatile otorrhea: Discharge coming out from perforation in a pulsatile form
- **Organism: S.pneumonia (most common), f/b beta hemolytic streptococcus**
- Staphylococcus aureus
- H. Influenza
- Pseudomonas

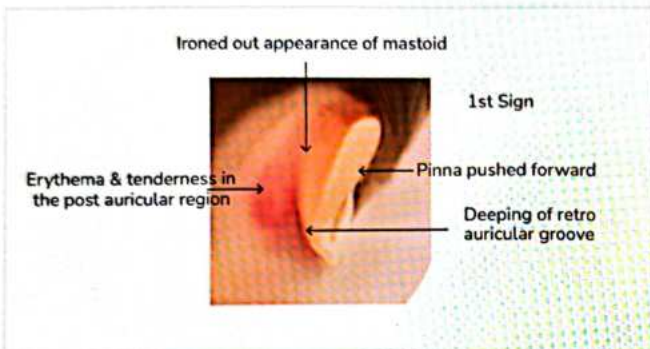
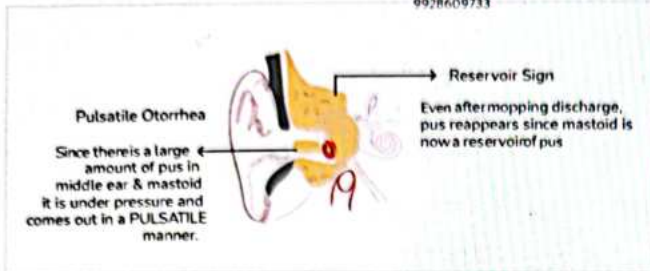


- Initially causes ET obstruction and ascending infection
- This will affect ventilation in middle ear leads to middle ear infection and pus in ME
- Infection from the middle ear spreading to mastoid through Aditus
- Inflammation of the mastoid air cell and pus in mastoid
- As the disease progresses, there is loss of septation between the air cells resulting in Coalescent mastoiditis (all air cells filled with pus)
- Signs:
  - o Ironed out appearance of the mastoid- First sign of acute mastoiditis which occurs due to inflammation of mastoid periosteum.
  - o Positive reservoir sign: Discharge rapidly fills up after mopping the canal which is specific for mastoiditis.
    - Immediate appearance of pus after mopping : Acute mastoiditis
    - Delayed reappearance of pus after mopping: ASOM

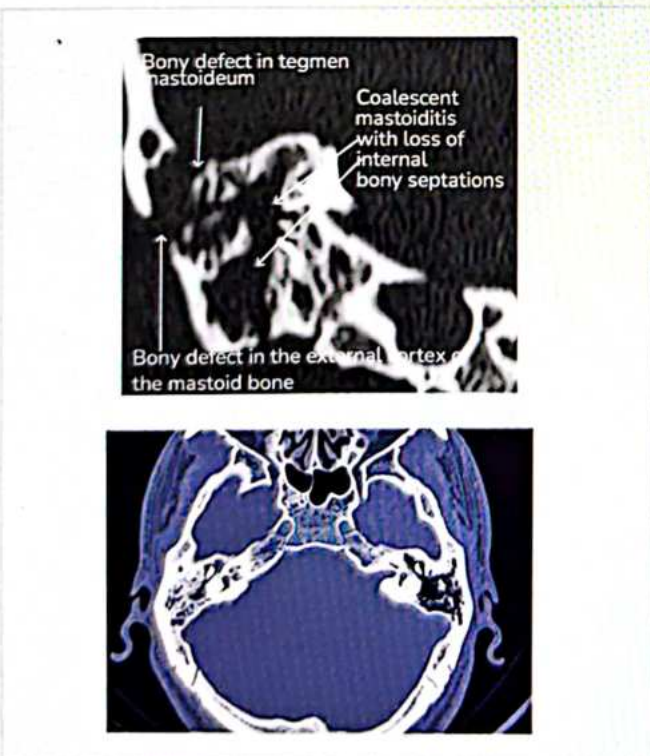


- Tenderness in the mastoid region on the area of MacEwen's triangle
- Sagging of the posteriosuperior meatal wall
- Perforation of the pars tensa
- Swelling over the mastoid pushes the pinna forward and downwards, with deepening of retro auricular sulcus.

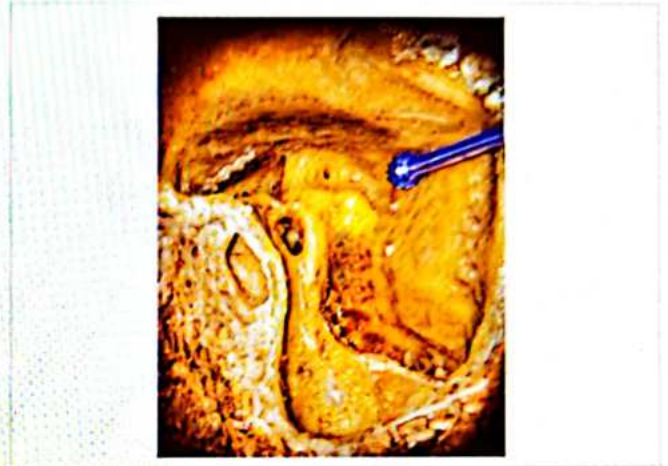
prince kumar  
princeeeekum@gmail.com  
9928609733



- Diagnosis
  - X-ray and CT scan



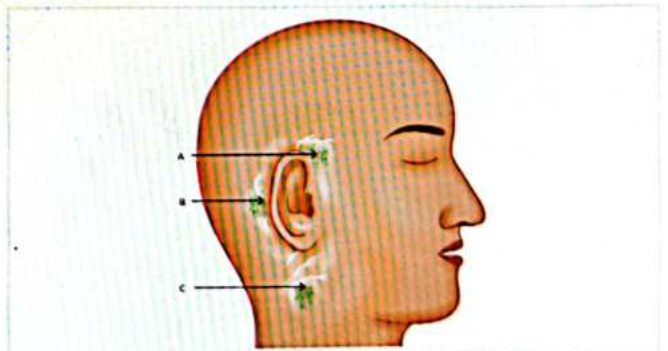
- Treatment of choice: Cortical mastoidectomy (Schwartz operation)
  - Also called as Intact canal wall mastoidectomy
  - Procedure: Remove all mastoid air cells and making it into one single cavity
  - Landmarks: Tegmen, sigmoid sinus, tip of the mastoid, bulge of lateral semicircular canal. All of these landmarks should be visible if patient undergone cortical mastoidectomy
  - Posterior wall of external auditory canal is left intact



### Abscess in relation to mastoid

00:24:57

- Post auricular abscess/Sub periosteal abscess - Most common
- Bezold's abscess- pus passes through mastoid tip and presents as a upper neck swelling. (MC location: deep to SCM)
- Zygomatic abscess
- Luc's abscess- Meatal abscess
- Citelli's abscess- Digastric triangle
- Parapharyngeal and retropharyngeal abscess



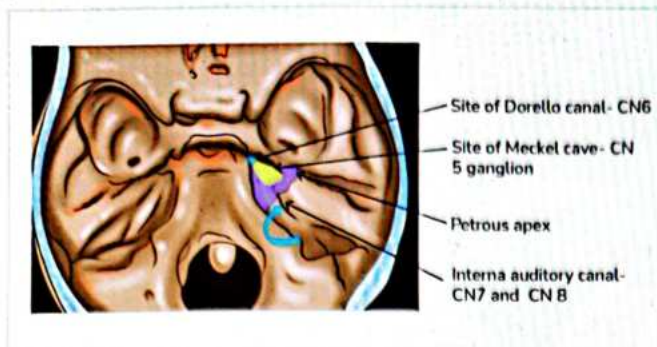
### Petrositis

00:28:00

- Inflammation of the petrous apex
- Gradenigo triad
  - 5<sup>th</sup> nerve involvement causes deep seated retro-orbital pain



- o 6<sup>th</sup> nerve involvement: Lateral rectal palsy
- o Persistent ear discharge due to CSOM



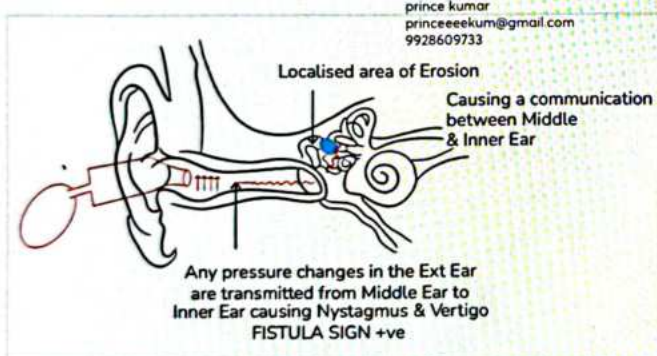
## Labyrinthitis

00:30:43

- Inflammation of the labyrinth is called Labyrinthitis. It is of three types

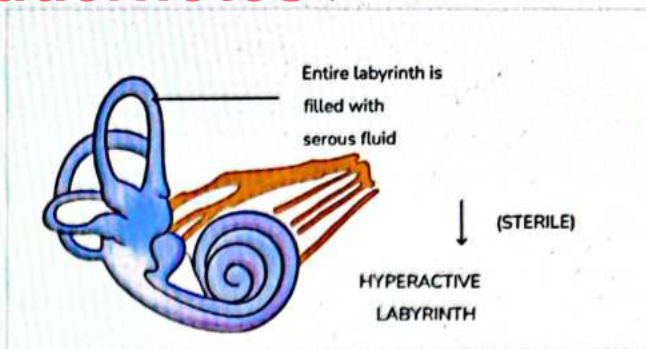
### Circumscribed labyrinthitis

- Localized area of labyrinth got eroded
- Most common canal to be eroded is Lateral semicircular canal
- As a result, pressure changes in external ear transmitted to middle ear to inner ear causing **Nystagmus and Vertigo: Fistula positive sign**
- It is a reversible condition.



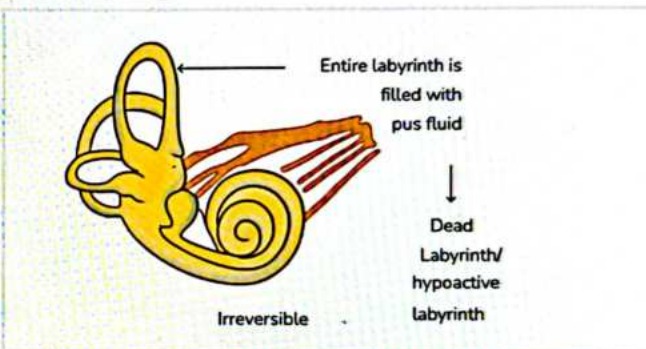
### Diffuse serous labyrinthitis

- Entire labyrinth is filled with serous sterile fluid which occurs due to inflammatory response from bacterial toxins.
- There is no bacterial invasion or pus in the labyrinth as a result the labyrinth is irritative and hyperactive.
- **Symptoms include vertigo (single long episode) with SNHL. Since the labyrinth is hyperactive nystagmus is towards the affected side. Appropriate management can reverse the disease**



### Diffuse suppurative labyrinthitis

- This follows serous labyrinthitis and there is active infection in the labyrinth resulting in PUS in the entire labyrinth.
- This is a dead or hypoactive labyrinth
- Clinical feature: There is a severe vertigo with SNHL and high grade fever, **Nystagmus is towards the opposite**. The vertigo and nystagmus disappear after 3 to 4 weeks due to central compensation.
- This can not reversible
- Management: Antibiotics with labyrinthine sedatives and mastoid exploration is need to clear the PUS.



Refer Table 13.1

### Intracranial Complications

00:39:35

- Pus goes to tegmen and erode the tegmen, causes inflammation of meninges called as Meningitis
- Pus between bone and dura: Extradural abscess
- Pus between dura and brain parenchyma: Subdural abscess
- Abscess goes inside the brain parenchyma called Brain abscess
- Diseases goes from middle ear to mastoid, sigmoid sinus can be involved so the pus goes from ME to mastoid cause initial inflammation of wall called periphlebitis and then endophlebitis and the cause aggregation of platelets casing Sigmoid sinus thrombosis
- Otitic hydrocephalus



## Meningitis

00:42:14

- The most common intracranial complication of a unsafe disease is meningitis
- Symptoms: High grade fever, projectile vomiting, headache, altered sensorium, drowsiness and irritability
- Signs
  - Brudzinski's sign: Flexion of neck results in flexion of hip and knee
  - Kernig's sign: With the thighs flexed on the abdomen there is pain while lying to extend it
- Diagnosis is made on the basis of Lumbar puncture
- Treatment: High dose antibiotics with mastoid exploration

## Extradural abscess

00:43:14

- This is an abscess which lies between the bone and the dura hence it is called as an extradural abscess
- Most often they do not present with any symptoms hence it is called as a SILENT abscess
- Management:
  - Modified radical mastoidectomy is done for clearance of the disease and the abscess os drained with IV antibiotics

## Subdural abscess

00:43:34

- Here the abscess lies between the dura and the brain parenchyma
- It is the RAREST intracranial complication
- The symptoms are similar to abrain abscess like fever, headache, vomiting's with localizing neurological signs
- Diagnosis is made by MRI which shows the presence of an abscess
- Treatment: The patient has to be stabilized with antibiotics and drugs that lower the intracranial pressure followed by mastoid exploration

## Brain abscess

00:44:00

- It is the most common intracranial complication of CSOM
- Organism: Both aerobic and anaerobic bacteria are associated with the brain abscess
- Types
  - Cerebral abscess (MC) site: Temporal lobe of brain
  - Cerebellar abscess (involves cerebellum)
- Clinical feature:
  - Due to raised intracranial tension
    - Headache, vomiting, lethargy, drowsiness, confusion, stupor
    - Papilledema and bradycardia
  - Localizing feature (depending on the lobe of brain that is involved)
    - Temporal lobe abscess: Nominal aphasia, homonymous hemianopia, contralateral motor

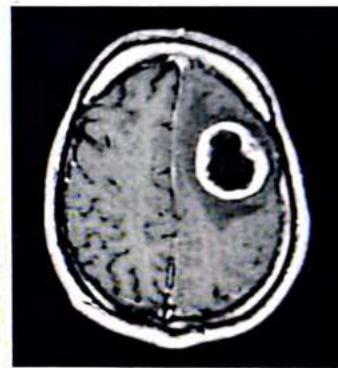
paralysis, epilepsy

→ Cerebellar abscess: Ataxia, dysmetria and dysdiadochokinesia

- Diagnosis is made on a MRI where a RING sign is typically seen
- Treatment of Brain abscess:
  - Medical: IV antibiotics, dexamethasone and mannitol to stabilize the patient
  - Surgical:
    - Neurosurgical: Drainage of brain abscess
    - Otologic: Modified radical mastectomy for CSOM/Cholesteatoma

## One Liner

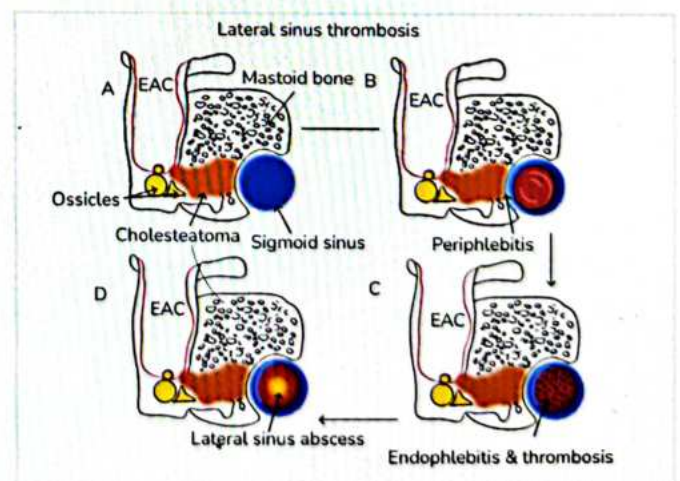
1. Which is the most common type of brain abscess? Temporal lobe abscess
2. Which lobe is most generally involved? Temporal lobe
3. Ring sign on MRI scan is seen in? Temporal lobe abscess (middle cranial fossa)
4. Ring sign seen in posterior cranial fossa? Cerebellar abscess



## Lateral sinus thrombophlebitis/Sigmoid sinus thrombophlebitis

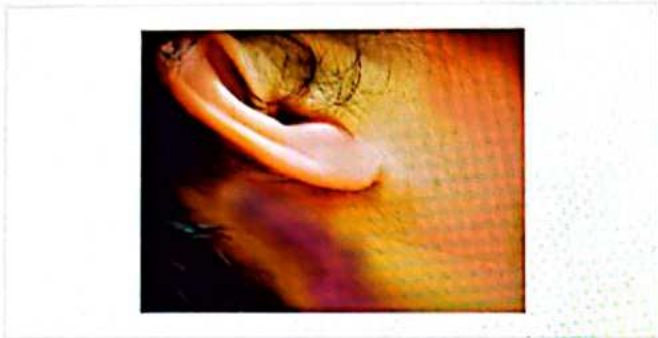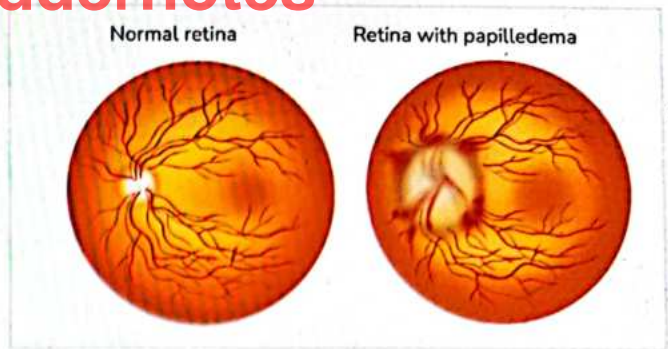
00:46:05

- It is a complication of Acute coalescent mastoiditis or CSOM or Cholesteatoma

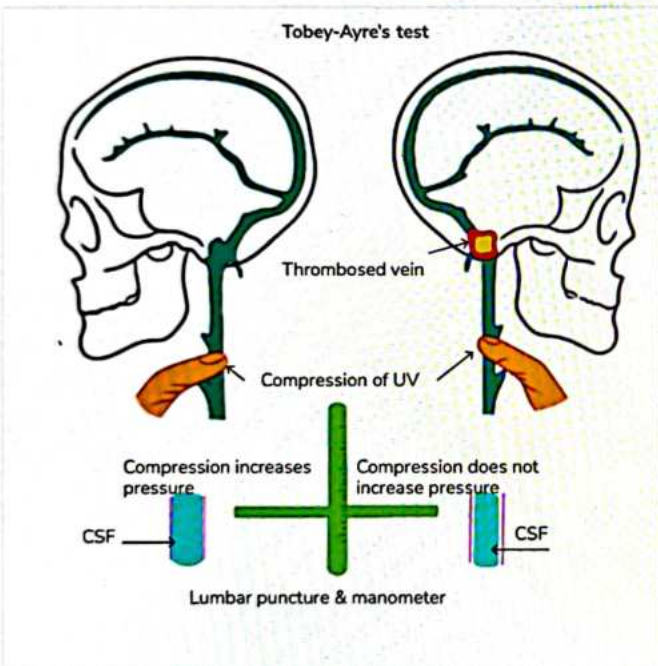
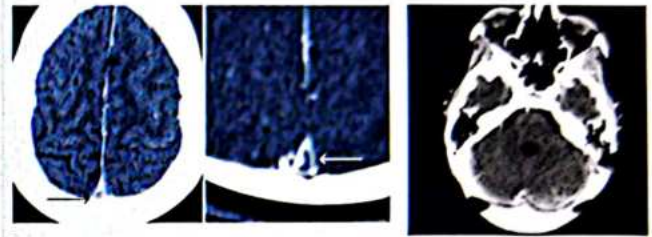




- Hectic picket fence type of fever with rigor
- **Griesingers sign:** Edema over the posterior part of mastoid due to thrombosis of mastoid emissary vein
  - Bluish discoloration of mastoid
- Papilledema- dilatation of the optic disc
- **Tobey-Ayer's test:** Compression of IJV on the healthy side produce rise in CSF pressure
- **Crowe-Beck test:** Pressure of the IJV on the healthy side produces engorgement of the retinal veins
- Tenderness over jugular vein



- Contrast enhanced CT/MRI shows Delta sign or Empty-delta sign



## Otitic Hydrocephalus

00:52:06

- Impairment in the venous outflow due to obstruction of the sigmoid sinus results in raised intracranial pressure leading to hydrocephalus
- Clinical features: **Raised ICT like headache, vomiting, papilledema**
- Diagnosis: CT scan which shows dilatation of ventricles
- Treatment:
  - Medical treatment to reduce intracranial pressure
  - Surgery like Ventriculoperitoneal shunt to redirect the CSF



	Circumscribed	Diffuse serous	Diffuse suppurative
<b>Pathology</b>	Thinning or erosion of bony capsule of labyrinth	Diffuse inflammation of labyrinth without pus	Pus or infection of labyrinth
	Labyrinth is exposed to external stimuli	Labyrinth is inflamed and irritable	Lost vestibular and cochlear functions
<b>Reversibility</b>		Reversible	Irreversible
<b>Fistula test</b>	Positive	Negative	Negative
<b>Nystagmus</b>	Positive pressure: nystagmus to same side. Negative pressure nystagmus to opposite side	Nystagmus to same side	Nystagmus to opposite side
	Transient vertigo on applying pressure to tragus	Vestibular and cochlear symptoms	Toxic + severe symptoms of serous labyrinthitis



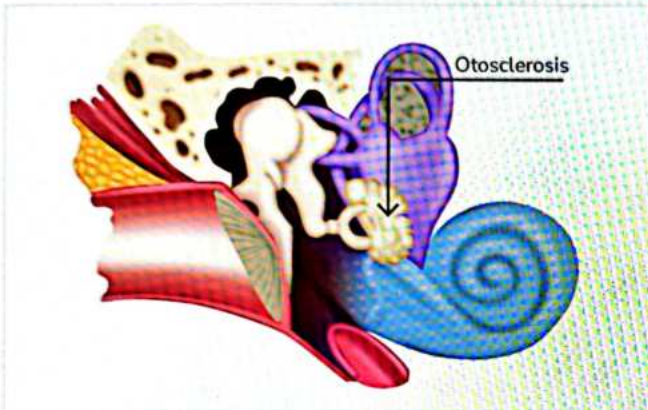
## 14

## OTOSCLEROSIS

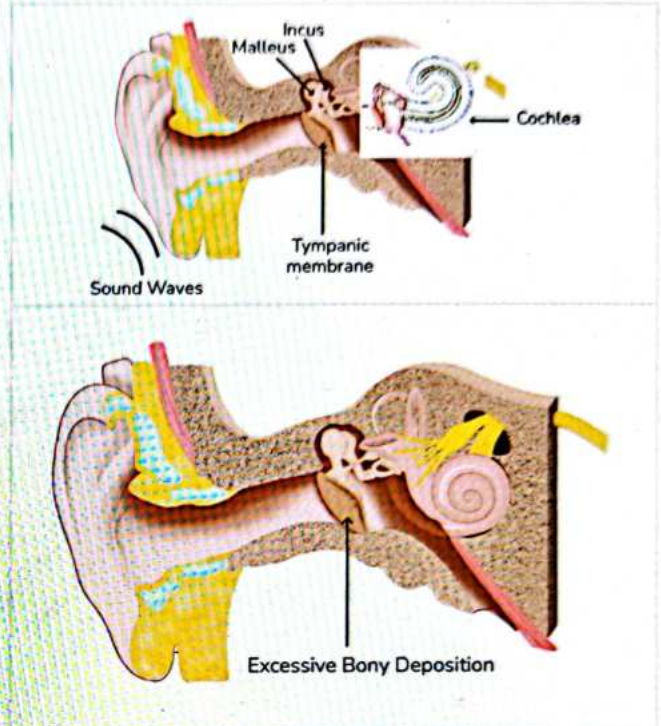
Oto means ear and sclerosis means excessive bone deposition. This disease affects the middle ear (ossicles of the middle ear or stapes footplate).

### Labyrinth

- The labyrinth or the inner ear has two parts: the outer bony part and the inner membranous part.
- The vestibule is the central chamber of the labyrinth. The cochlea is present anteriorly and the semi-circular canals posteriorly.



- The footplate is present on the oval window and stapes cover the oval window.

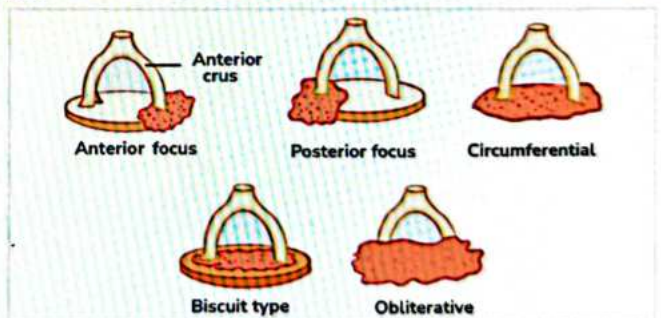


- What is it?
- 'A': It is a disease of the bony labyrinth.
- What happens in it? Normal Endochondral bone of Otic capsule is replaced by irregularly placed spongy bone.
- The sound waves enter the external auditory canal and reach the tympanic membrane. After the tympanic membrane, it goes via the ear ossicle.
- The first ear ossicle is the malleus, the second is the incus and the third one is the stapes.
- The stapes cover the footplate, and from the footplate, the sound waves reach the oval window, scala vestibuli, via helicotrema to the scala tympani.
- From the scala tympani, the sound waves come and hit the round window.
- The basilar membrane carries the impulses from the cochlea via the auditory pathway to the brain.
- In otosclerosis, there is excessive deposition of bone around the footplate of the stapes. So, the sound waves cannot be conducted from the external or middle ear to the inner ear, resulting in hearing loss.
- Any pathology that falls from the pinna to the footplate of the middle ear (conductive pathway) results in conductive hearing loss.

- Stapedial otosclerosis is the most common type of otosclerosis.

### Site of Stapedial Otosclerosis

00:05:48



- The most common site for stapedial otosclerosis is the fissa ante fenestram, which means anterior to the footplate.
- To understand anterior and posterior regions, look for pyramidal eminence and stapedial tendon. The pyramidal eminence is on the posterior wall of the middle ear, from here there is a stapedial tendon attached to the neck of the stapes.



**Types of Otosclerosis**

1. Stapedial: Most common.
  - fissula ante fenestram common site
  - Conductive hearing loss
2. Cochlear.
  - Round window common
  - SN hearing loss and tinnitus
3. Histological type

**Aetiology**

00:09:31

- Hereditary – Autosomal dominant with incomplete penetrance
- Sex: F>M but in India male predominant
- Age of onset: 20-40 years
- Hormonal – Increases in pregnancy and during menopause

**Trigger factors for otosclerosis**

- Progesterone excess
- Oral contraceptive pills (OCP)
- Measles infection
- Autoimmune disorders

**Syndrome associated with otosclerosis**

**Vander Hoeve syndrome**

- Osetogenesis Imperfecta: Collagen disease leading to weak bones with conductive hearing loss.
- Otosclerosis
- Blue sclera



- Associated with conductive hearing loss most commonly.

**Pathology(otosclerosis lesion)**

- **Grossly:** Excessive bony disposition appears as whitish plaque on the footplate of the stapes.
- **Microscopically:**
- Normally, the footplate of stapes has three layers, outer periosteal, middle endochondral layer, and an endosteal layer inside.
- The triggers for otosclerosis stimulate the endochonrdal cell rests. These cells proliferate osteoclasts, which cause bone resorption. Due to resorption there is increased vascular activity due to release of proteolytic enzymes, resulting in bone destruction. Remodeling, carried out by osteoblasts, happens whenever there is osteoclastic activity.

- The newly formed bone is spongy with increased vascularity and marrow spaces.
- The spongy bone slowly replaces the healthy bone, and the food plate becomes inactive (sclerotic bone) and cannot move.
- On H & E stain, it will appear blue due to increased vascularity, osteoclastic and osteoblastic activity, referred to as BLUE MANTLE OF MANASSE.
- Active lesions: Occurs when the trigger has occurred seen in the initial part of the disease when disease proliferates
- It shows numerous spongy or irregular bones, along with increased vascularity and blood vessels
- There is also an increased number of osteoclasts and blasts
- Inactive lesion: it is the end stage of disease we see solid sclerotic bone.
- Once the disease has reached the end stage, the progression cannot be prevented.

**Symptoms**

00:20:33

- Most common presenting feature:
  - Conductive hearing loss (bilateral)
- Mixed hearing loss when lesion extend to scala vestibuli
- Tinnitus when lesion extended to cochlea
- Paracusis willisii: Person hear better in noisy environment. It is a feature of stapedial otosclerosis
- Sometimes the deposition of bone can reach the scala vestibuli of cochlea and results in conductive as well as sensory neural components of hearing loss, referred to as mixed hearing loss.
- CHL and paracusis willisii (hearing better in the noisy environment rather than a silent environment) are commonly seen in the stapedial type of otosclerosis.
- No ear pain and ear discharge.
- Typically seen in middle-aged individuals.

**Symptoms of Cochlear Otosclerosis**

1. Sensorineural Hearing loss
2. Tinnitus

**Symptoms**

- Paracusis Willisii: Hears better in noisy than in quiet environment

	Stapedial	Cochlear
Incidence	Common	Less common
Hearing loss	Conductive	Sensorineural
Tinnitus, Vertigo	Rare	Common
Paracusis willisii	Common	No



**Signs**

00:23:58

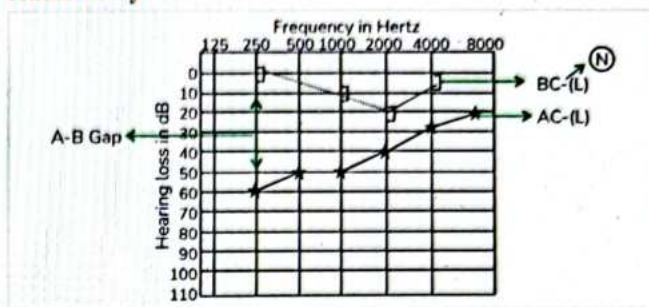
- Tympanic membrane is normal [90%]
- Tympanic membrane is mobile
- Schwartz Sign [10%]
- Active lesions have a flamingo-pink hue on the promontory and can be seen through an intact tympanic membrane.
- Stapes is fixed, and the tympanic membrane is fixed, although the mobility can be restricted.
- **Schwartz sign:** In active otosclerotic lesion, because of increased vascularity, the mucoperiosteum covering the inner ear, the bony labyrinth becomes red. Through the tympanic membrane, it appears flamingo pink.

**Stapedial Otosclerosis: Tests**

Test	Inference
Rinne	Negative
Weber	Lateralised to abnormal ear
Absolute bone conduction	Normal
Gelles test	Negative
Tympanometry	As-Type graph
Stapedial reflex	Absent
Pure tone audiometry	Carharts notch

- **Rinne Test:** The bone conduction(BC) is better than the air conduction(AC). When the tuning fork is placed on the mastoid, the patient will hear better as compared to air conduction.
- **Weber Test:** when the tuning fork is kept on the midline, the patient feels that the sound is getting lateralised to a diseased ear or abnormal ear.
- **Absolute bone conduction test** is done for sensory neural pathway problems and here there is only conductive hearing loss hence it is normal.
- **Gelle's Test:** When the pressure is increased or decreased on the external auditory canal and sound stimulation is given, the patient should be able to appreciate the increase and decrease in the intensity of sound. When the patient is unable to do this, the test is negative. And the patient is having otosclerosis.
- In tympanometry As-type of graph is seen, where 's' stands for sclerosis. It is most specific for otosclerosis.
- Stapedial reflex is absent because the stapes is not able to move because of its fixation.

**Audiometry**



- AC – Lower frequencies are affected.
- BC – Maximum dip is seen at 2000Hz which is called carhart's notch.
- Reverses after Stapedectomy
- In audiogram X indicates air conduction of left ear, and J indicates bone conduction.
- AC is in the abnormal range and BC is in the normal range with a gap known as AB (air-bone) gap. The AB gap is diagnostic of conducting hearing loss.
- Carhart's notch is a dip seen at 2000Hz in bone conduction in otosclerosis but it disappears after Stapedectomy.

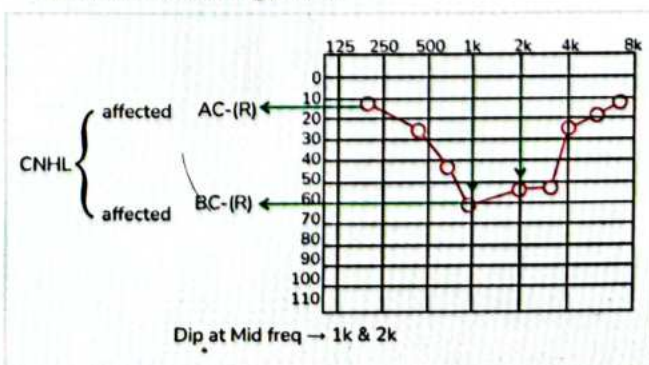
**Cochlear Otosclerosis: Tests**

Rinne	Positive
Weber	Lateralized to normal ear
Absolute bone conduction	Shortened
Pure tone audiometry	Carhart's notch

- Here AC > BC
- In cochlear otosclerosis there is sensory neural hearing loss

**Cochlear Otosclerosis**

- **COOKIE BITE CURVE** – A dip in the midfrequency range of both AC and BC is called cookie bite curve.
- 0 here indicates Air conduction of the right ear.
- < here indicates Bone conduction of right ear.
- In the middle frequency (1000 and 2000) there is a dip in both AC and BC Indicating SNHL.





## Treatment

- Medical:

1. Hearing aid: It is offered to all patients.
2. Sodium fluoride
  - It is given to arrest active focus and prevent further sensorineural loss due to cochlear otosclerosis

## Sodium Fluoride

- Mechanism of action
- Indication – Only in Active focus
- Contraindication –
  - Pregnancy and lactation
  - Renal disease
  - Rheumatoid arthritis
  - Skeletal fluorosis
- Sodium fluoride is only given in an active lesion to stop the further progression of an existing hearing loss.
- It inhibits the osteoclast and release of proteolytic enzymes.
- This further inhibits bone destruction.
- So, there is no further bone remodeling and no new bone deposition.
- Surgical:
  - Stapedectomy with the placement of a prosthesis is the treatment of choice
  - Stapedotomy and placement of prosthesis
  - Stapes mobilization
  - Lemperts Fenestration operation: reserved only for cases where footplate cannot be mobilised during stapedectomy

Indications for surgery	Contraindications for surgery
1. Hearing threshold is 30db or A-B gap is 25db or more	1. Only hearing ear
2. If there is Bilateral otosclerosis then worst ear is operated first.	2. Pregnancy/Children less than preadolescent age or age above 70 years
3. Speech discrimination should be above 60 percent	3. Occupational- Pilots and Divers.

- Speech discrimination indicates that the sensory neural pathway should be normal.
- Surgery carries the chances of complications so it should be avoided if the ear is only hearing ear.
- In occupations like pilots and drivers, due to barotrauma the piston can get replaced so surgery should be avoided, or they can be asked to change professions after surgery.

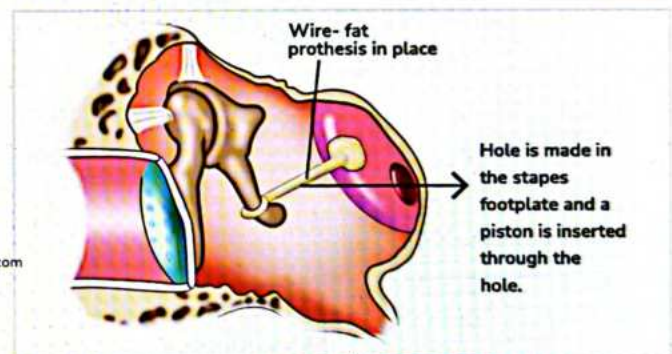
## Local Anesthesia or General Anesthesia?

00:46:54

- Local Anesthesia is preferred over general anesthesia:
  - To assess the improvement in hearing: The stapes are removed and replaced with a piston, ideally the piston should enter the incus and touch the oval window snugly. It varies from person to person. It is measured intraoperatively
  - To assess complication: the facial nerve runs just above the oval window. So, the signs can be easily assessed under local anesthesia.
  - To assess perilymph fistula: The stapes footplate covers the oval window, which covers the scala vestibule of the cochlea containing perilymph. When the footplate or oval window is operated, there is a possibility of leakage of perilymph from the oval window.
- When the fine area is operated there can be oval window tears and the perilymph may leak and come into middle ear. This can result in vertigo and nausea.

## Stapedotomy

00:51:30



- An endoral or endomeatal approach from the external auditory canal is used in the procedure.
- The tympanomeatal flap is elevated and firstly the mobility of ear ossicles is tested.
- The stapes is fixed.
- The incus is dislocated from the stapes suprastructure.
- Crurectomy: Anterior crura and posterior crura are dislocated and the suprastructure is taken out.
- A hole is made in the footplate.
- A piston is anchored from the incus to the stapes.
- The sound is now conducted from malleus incus and through the piston to the oval window.
- If the footplate is removed, it is known as stapedectomy.
- Stapedectomy has higher chances of perilymph leak, because, during the removal of the footplate, the perilymph may leak out due to tear. There is less chance of recurrence of the disease as footplate is removed.
- Stapedectomy is the preferred surgical procedure.
- In stapedotomy, only a hole is made in foot plate and it is intact, so there are less chances of perilymph leak. The



chances of recurrence of disease are higher as the footplate is intact.

#### Complications

00:56:08

1. Perilymph Fistula due to tear of oval window.
2. Recurrence due to displacement of prosthesis or due to new bone deposition in stapedotomy.
3. Necrosis of Incus when piston is fixed tightly leading to compromised blood supply.
4. Facial palsy because facial nerve lies close to the foot plate area.

#### When do you abandon surgery

1. Low lying facial nerve or nerve covering foot plate area.
2. Persistent stapedial artery as it is a branch of middle meningeal artery.
3. Floating footplate because it might lead to perilymph leak.

#### Summary

1. Tympanic membrane in otosclerosis is fixed or mobile?  
It is mobile
2. Unilateral or Bilateral? Bilateral
3. Mode of inheritance? Autosomal dominant
4. Type? Vander hoeve syndrome
5. Most common type? Stapedial
6. Type of hearing loss? Conductive
7. Paracusis willisii and Schwartz sign?
8. Tuning fork test finding?
9. Audiogram in stapedial and Cochlear type?
10. Tympanometry
11. Medical therapy and surgical therapy

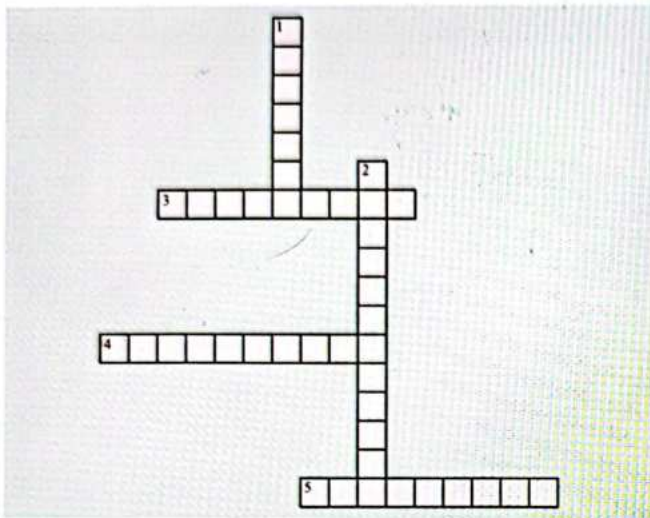




# CROSS WORD PUZZLES



## Crossword Puzzle 1




**Across**

- 3. has got the outer bony part and the inner membranous part
- 4. hearing loss is the pathology that falls from the pinna to the footplate of the middle ear.
- 5. is the central chamber of the labyrinth.

**Down**

- 1. membrane carries the impulses from the cochlea to the brain.
- 2. is characterized by excessive deposition of bone around the footplate of the stapes.

## Crossword Puzzle 2



**Across**


- 3. is the most common type of otosclerosis.

- 5. disposition appears as whitish plaque on the footplate of the stapes

**Down**

- 1. willisii is when the hearing better in Noisy environment rather than silene environment
- 2. sdera is seen in Vander Hoeve Syndrome.
- 4. cell rests stimulate the triggers for otosclerosis.

## Crossword Puzzle 3



**Across**

- 2. is delicated from the stapes suprastructure
- 4. is anchored from the incurs to the stapes
- 5. has higher chances of perilymph leak

**Down**

- 1. approach from the external auditory canal is used in the procedure.
- 3. disgrimation indicates that the sensory neural pathway should be normal.



**15**

**FACIAL NERVE AND ACOUSTIC NEUROMA**



**Facial Nerve**

00:00:55

- Facial nerve is one among the 12 cranial nerves. It is a **mixed** nerve, which means it has a sensory, motor and secretomotor root.
- The sensory root of the facial nerve is responsible for the supply of skin in the region of the concha. This nerve is called as the **Nerve of Wrisberg**.
- The motor root of the facial nerve is responsible for supplying the muscles of the facial expression, which usually come from the second Pharyngeal Arch. It gives secretomotor fibres to the **submandibular** and the **sublingual** salivary glands as well. Hence, it is not a single sensory root or its sensory nerve or a motor nerve, but it is a mixed nerve.
- The nucleus of the facial nerve is present in the anterior part of the **pons**. They possess a dorsal part and a ventral part.
- The **dorsal** part of the nucleus innervates the **upper** part of the face on the same side.
- The **ventral** part of the nucleus innervates the **lower** part of the face on the same side.
- The innervations coming from the cerebral cortex (supranuclear part) give supply to the dorsal part on the **ipsilateral (same)** and **contralateral (opposite)** sides.
- The innervations coming from the cerebral cortex (supranuclear part) give supply to the ventral part only on the **contralateral (opposite)** side.

In unilateral supra-nuclear palsy,

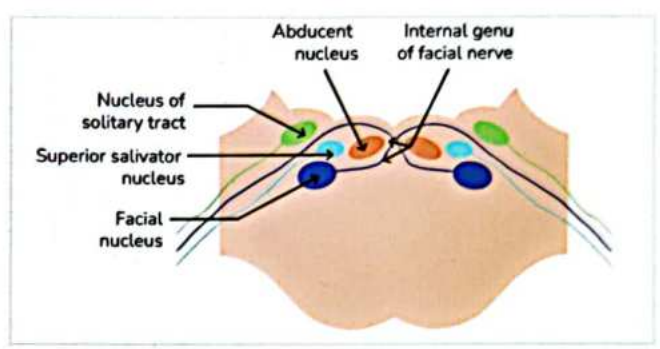
- ↓
- A lesion is present above the nucleus of the facial nerve.
- ↓
- Ventral and dorsal nuclei of the contralateral are affected along with the dorsal nucleus of the same side.
- ↓
- Paralysis of the lower part of the face occurs, but the **forehead is spared** as the dorsal nucleus receives innervations from the ipsilateral nucleus of the cerebral cortex.
- ↓
- This happens in **UMN** or upper motor neuron palsy.
- If **bilateral** supranuclear palsy occurs, the **forehead is not spared**.
  - In the case of the lower motor neuron (**LMN**) lesion or infra nuclear palsy, the **entire half of the ipsilateral side** is affected.

**Anatomy:**

- Facial nerve nucleus is present in the brainstem. It gives rise to the facial nerve and winds around the nucleus of the abducens nerve and exits through the pontomedullary junction.

**Facial Nerve in Brainstem**

00:10:20



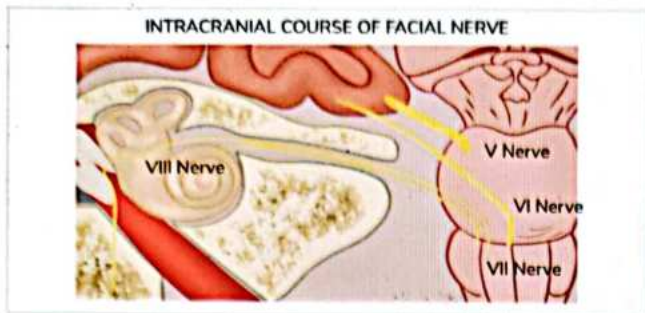
- If a patient has a **pontine stroke or lesion**, it can result in **facial nerve palsy** due to its involvement, **abducent nerve palsy** and **contralateral hemiplegia**. When these 3 features come together, it is called **Millard Gubler Syndrome**.
- The facial nerve has mainly three parts.
  1. Intracranial
  2. Infratemporal
  3. Extracranial

**Intracranial Course of Facial Nerve:**

- Emerges from the pons along with the trigeminal nerve and abducent nerve.
- ↓
- It winds around the nucleus of the sixth nerve.
- ↓
- Then exits from the pontomedullary junction.
- ↓
- Enter the internal auditory meatus (present in the petrous part of the temporal bone).
- The portion of the facial nerve from the pontomedullary junction up to the entrance of the internal auditory canal is called as **Intracranial part** of the facial nerve.

prince kumar  
princeekum@gmail.com  
9928609733

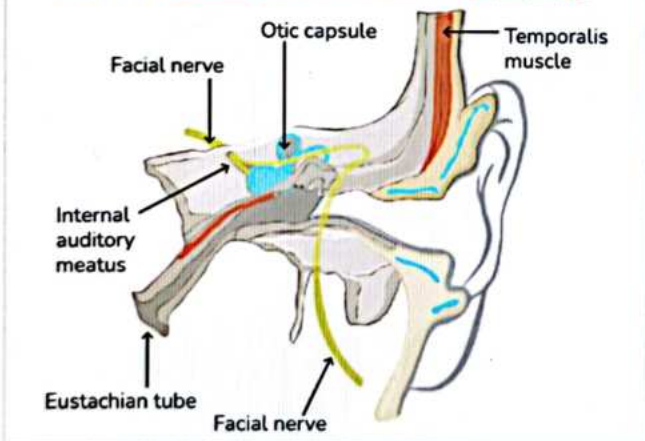
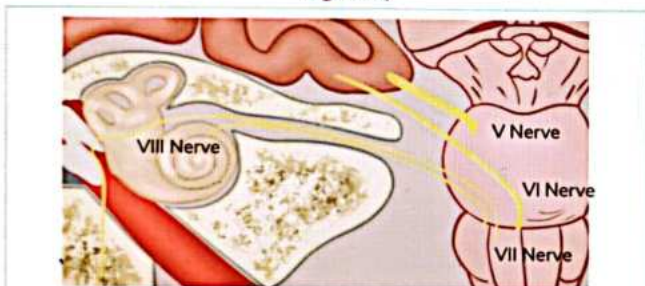




**Intratemporal Course of Facial Nerve:**

- Intratemporal segment of the facial nerve has 4 parts based on its course.

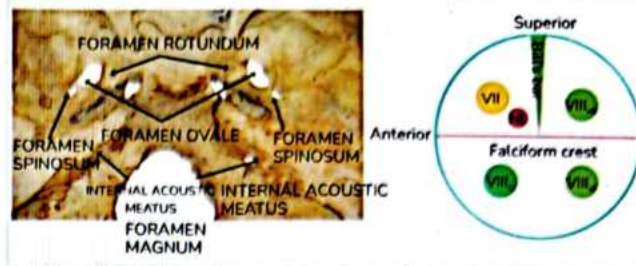
It passes through the internal auditory meatus. (Meatal segment)  
 ↓  
 It enters inside the inner ear. (Labyrinthine segment)  
 ↓  
 It passes through the middle ear. (Tympanic segment)  
 ↓  
 Then it passes through the mastoid segment. (Mastoid segment)



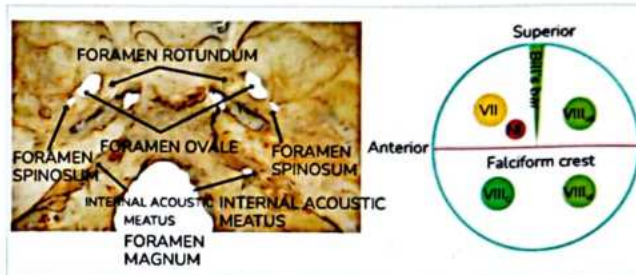
- The intratemporal segment is the longest portion.
- It is the only cranial nerve that passes through a bony canal through its course. This canal is called as Fallopian canal, fifty percentage of which is dehiscent.

**Meatal Segment**

00:18:55



- Bill's bar is a vertical projection in the internal acoustic meatus.
- The falciform crust is the horizontal projection in the acoustic meatus.
- In the anterosuperior quadrant, the 7th nerve is present, while in the anteroinferior 8th nerve, in the posterior superior, superior vestibular nerve and in the posteroinferior, there is the Inferior vestibular nerve.



**Labyrinthine Segment**

**Landmark of facial nerve in labyrinthine segment**

- Anteriorly there is cochlea, in middle there is vestibule and posteriorly there is semi-circular canals.
- The facial nerve runs above the vestibule, so anteriorly there is cochlea and posteriorly there is semi-circular canals.

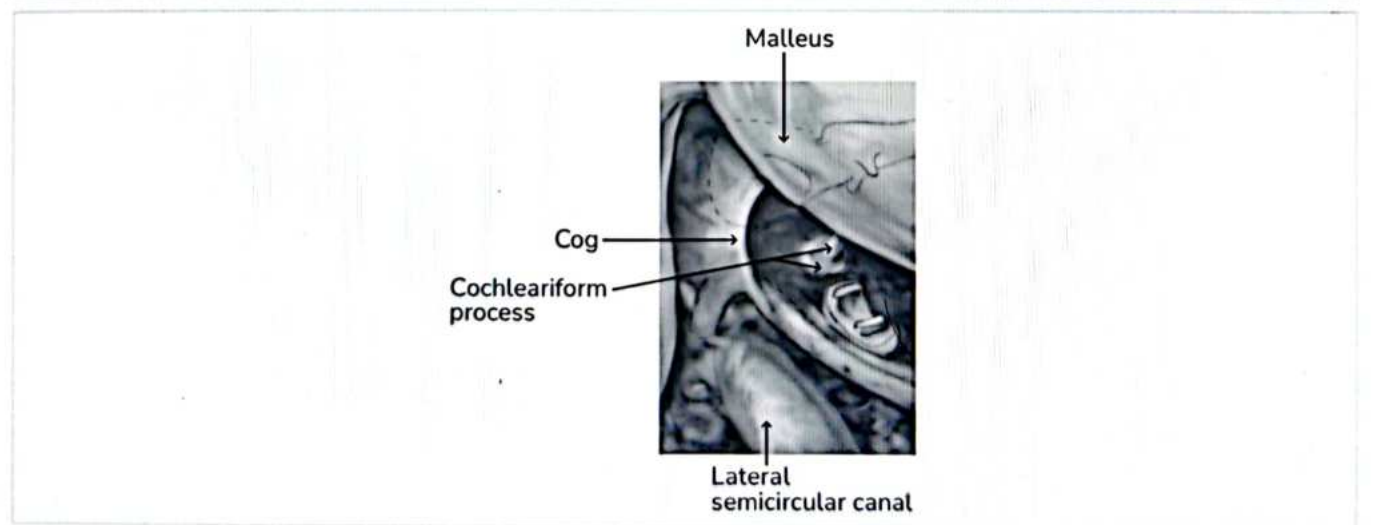
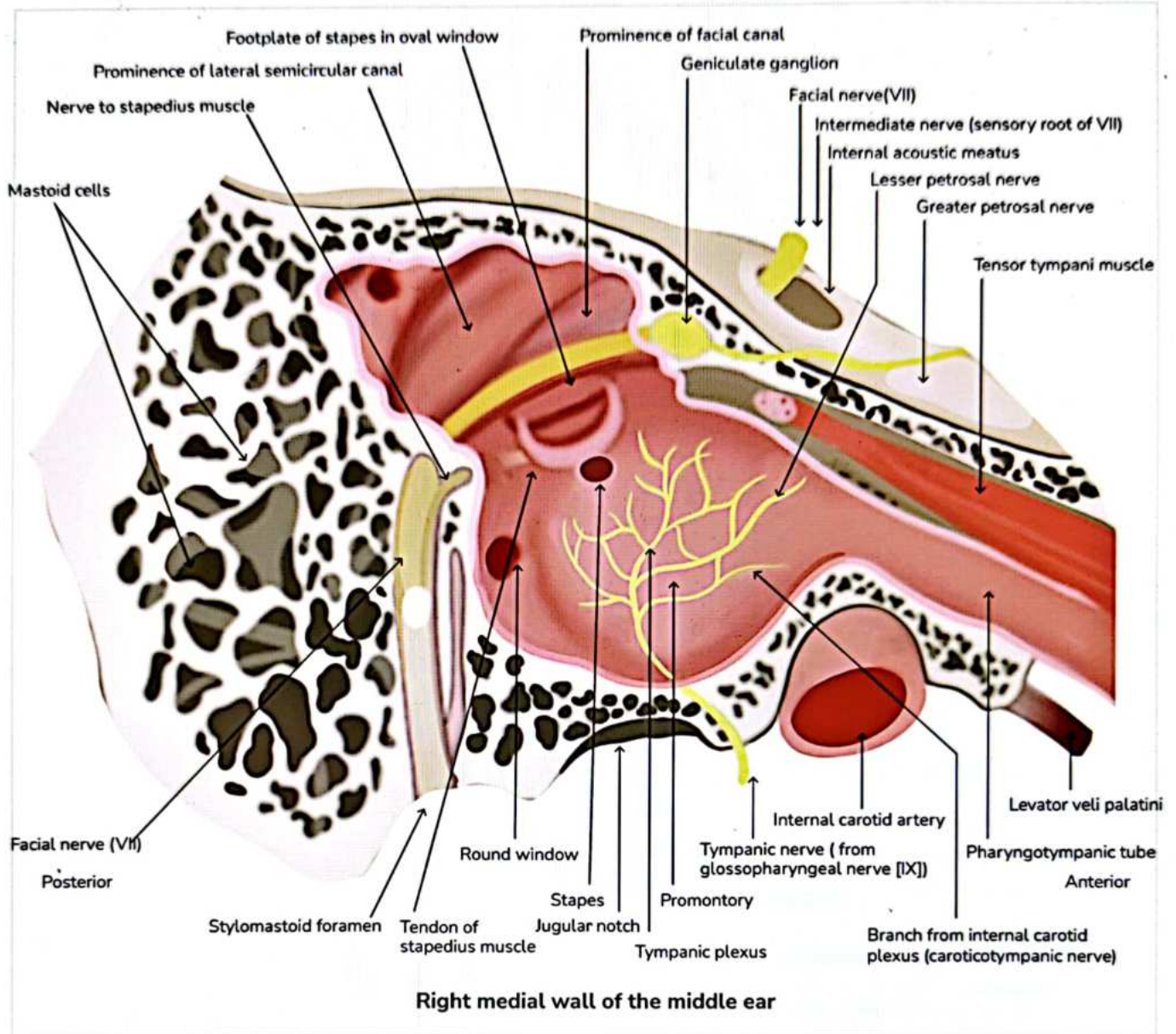
**Labyrinthine Segment (3-4 Length and 0.7mm Diameter, Shortest and Narrowest segment)**

- This part is the segment of facial nerve in the inner ear
- Since it's the narrowest portion its prone for ischemia and edema (bells palsy)

**Tympanic Segment**

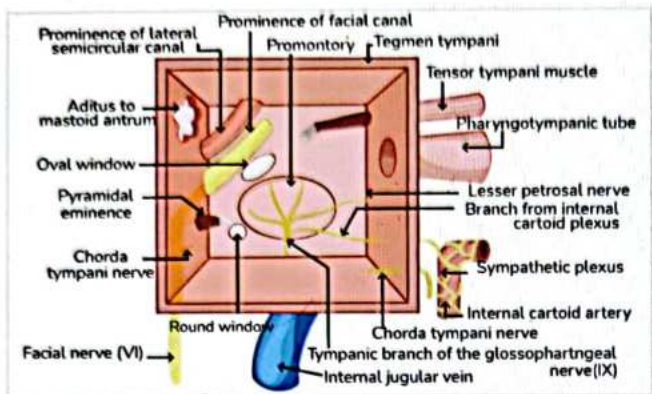
- First genu or geniculate ganglion is the first turn that the tympanic segment of the nerve takes on passing from the inner ear to the middle ear.
- The tympanic segment in the middle ear lies on the medial portion.
- This segment is also called the horizontal segment of the facial nerve.
- The cochleariform process is the landmark for the first genu of the facial nerve.







- It runs above the oval window.
- The horizontal segment when entering the mastoid takes the second turn, called the second genu.



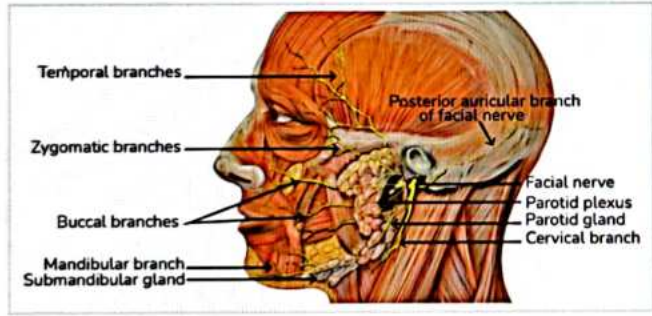
prince kumar  
princeeeekum@gmail.com  
9928609733 00:30:30

### Extracranial Segment:

- The facial nerve takes its exit outside through the stylomastoid foramen and enters the parotid gland. There the nerve is sandwiched between the superficial lobe and deep lobe and then exits out from the parotid.

Thereafter it gives rise to five terminal branches which are:

- Temporal
- Zygomatic
- Buccal
- Marginal mandibular
- Cervical

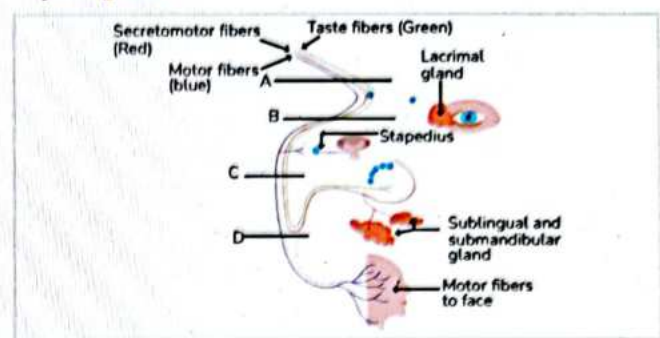


### Other Branches of The Facial Nerve

00:35:05

- Greater superficial petrosal nerve- It is responsible for lacrimation.
- Nerve to stapedius
- Chorda tympani nerve- Supply taste to the anterior two-thirds of the tongue.
- Secretomotor fibres to submandibular and sublingual gland.

### Topodiagnosis:



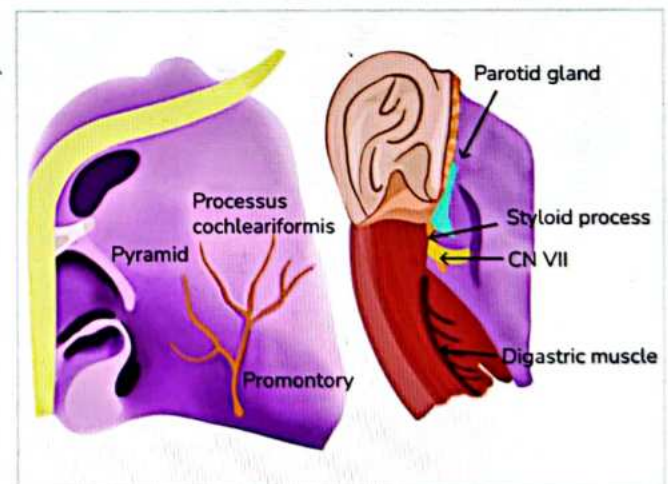
These tests are done to understand the extent of the nerve lesions.

- Schirmer's test - done to assess lacrimation and GSPN. It is done by placing a filter paper in the inner canthus of the eye and checking the level of wetting (at least 1 cm and equal on both sides).
- Acoustic reflex- done to assess nerve to stapedius.
- Tasting test- done on chorda tympani to assess taste sensation.
- In infra geniculate lesion all tests except the Schirmers and acoustic tests are negative.

### Surgical Landmarks of Facial Nerve

00:47:00

1. Processus cochleariformis: Geniculate ganglion lies in front of it.
2. Oval window and Horizontal canal: Facial nerve lies between.
3. Pyramid and fossa incudis
4. Digastric ridge



	Supra Geniculate	Infra Geniculate	Infra Stapedial	Infra Chronic
Schirmer's test	-	+	+	+



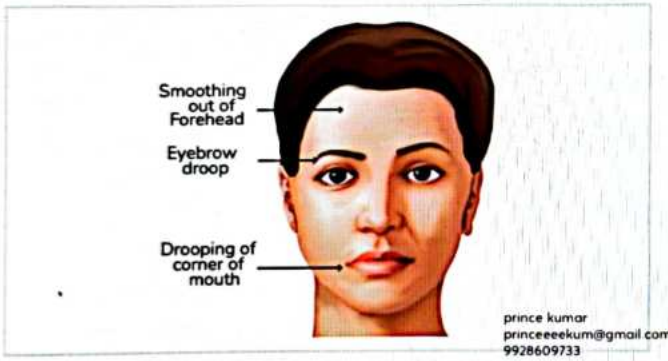
Stapedial reflex	-	-	+	+
Taste	-	-	-	+
Sub mandibular	-	-	-	-
LMN Palsy	-	-	-	-

**Bell's Palsy:** 00:52:26

- It is an idiopathic facial nerve palsy, where peripheral nerve lesions are most common than central nerve palsy.

**Clinical Features**

- Sudden onset symptoms, usually hours w/ maximal weakness w/in 48 hrs
- Unilateral
- Eyebrow sagging
- Inability to close eye
- Loss of nasolabial fold
- Decreased tearing
- **Hyperacusis**

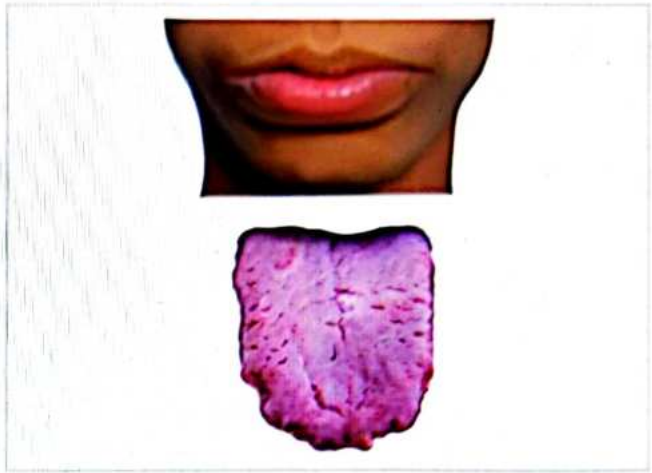


- The risk for this condition is high in the third trimester of pregnancy. Other risks include HSV and EBW with a high risk of diabetes.
- Hyperacusis- Increased sensitivity to sounds. It is seen in Bell's palsy because the stapedial reflex is lost.
- Usually associated with Upper respiratory tract infection.
- Diagnosis: Is by Exclusion
- Supportive treatment: Care of eye and physiotherapy
- Medical Management:
  - o Prednisolone (1mg/kg/day)
  - o 10 days if recovering
  - o 20 days if recovery incomplete
- Surgical management: Vertical, tympanic +/- labyrinthine segments are decompressed
- Prognosis: 90% recover. Good recovery in incomplete Bells palsy

**Melkersson - Rosenthal syndrome**

Triad:

1. Recurrent facial nerve palsy
2. Swelling of lips
3. Fissured tongue



Q What are the major causes of recurrent facial nerve palsy?

Ans Melkersson - Rosenthal syndrome, Diabetes, Sarcoidosis and tumours.

**Ramsay-Hunt Syndrome:** 00:59:00

- This condition is also called Herpes Zoster Oticus. The herpes zoster had entered the body during a previous infection.

↓  
Localizes in and remains in the first genu or geniculate ganglion.

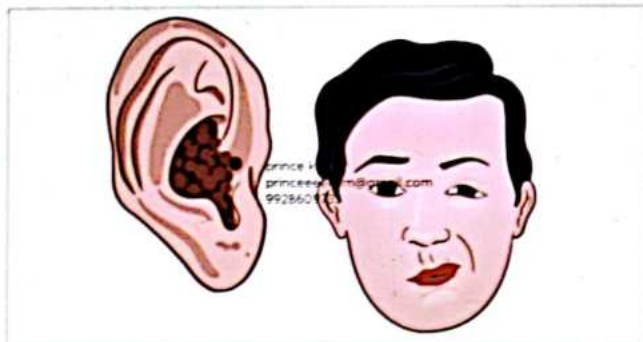↓  
Once the reactivation of the virus happens.

↓  
There would be the emergence of vesicles at the area of distribution of a facial nerve, especially in the concha.

↓  
These vesicles are extremely painful, water-filled blebs and cause extreme pain in area of distribution of a facial nerve, along with which the patient also gets **LMN lesion-type facial palsy.**

- There is often involvement of eight nerves, which results in sensory neural hearing loss (SNHL).
- Antiviral drugs along with steroids are used in treatment, although the prognosis is poor.





### Fractures of Temporal Bone:

- If a fracture runs **parallel** to the long axis of the petrous bone, then it is called a **longitudinal fracture** (a more common type).
- If a fracture runs **perpendicular** to the long axis of the petrous bone, then it is called a **transverse fracture** (less common type).
- In longitudinal fractures, there can be tympanic membrane perforation, involvement of the roof of the auditory canal, the roof of the middle ear and ossicular dislocation. The inner ear is often spared. The possible type of hearing loss is conductive hearing loss. The risk of SNHL and facial palsy is usually not there. Only at level 2 of this fracture, there is a direct involvement of the facial nerve.
- In transverse fracture, the risk of facial nerve palsy is high as there is the direct involvement of the facial nerve. Also this can result in SNHL. There is no tympanic membrane perforation. Instead, CSF rhinorrhoea is presented. This is because the perilymph leaked during the injury is an ultrafiltrate of CSF and it travels through the eustachian tube to the outside.

### FRACTURES OF TEMPORAL BONE

Q. Which is common?

Ans. Longitudinal Fracture – Tympanic membrane perforation

Q. TM perforation occurs commonly in?

Ans. Longitudinal Fracture

Q. Facial nerve palsy higher in?

Ans. Transverse Fracture

Q. CHL in?

Ans. Longitudinal Fracture

Q. SNHL in?

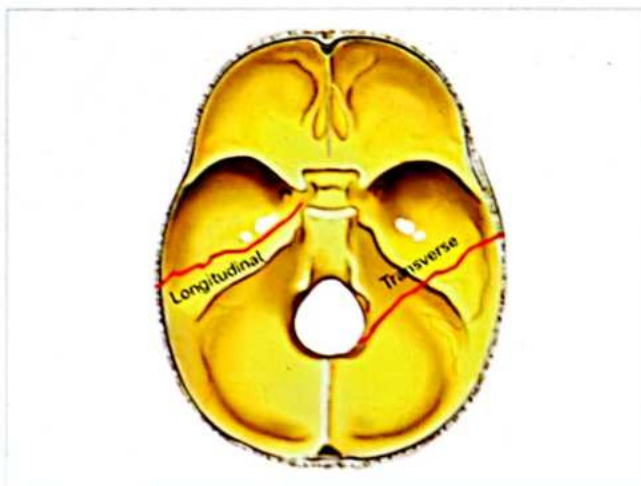
Ans. Transverse Fracture

Q. CSF otorrhea?

Ans. Longitudinal Fracture

Q. CSF rhinorrhea?

Ans. Transverse Fracture



### Electrophysiological Tests In Facial Palsy: 01:10:00

- **Electroneuronography**- Here we measure the conduction capacity of the nerve.
- **Electromyography**- Here the potentials of a single muscle (paralyzed) are measured at rest and voluntary function.
- Whenever there is a bad prognosis for facial nerve damage and the palsy that follows, nerve decompression or anastomosis can be done to help in the conduction of the nerve function.

### Electrophysiological Tests

Electroneuronography	Electromyography
<ul style="list-style-type: none"> <li>• Procedure</li> <li>• If &gt; 90 decrease in CMAP within 14 days of paralysis then chances of spontaneous recovery is negligible- consider surgical decompression</li> </ul>	<ul style="list-style-type: none"> <li>• Procedure Interpretation – if motor unit potentials are present then it means nerve is regenerating</li> <li>• If fibrillation potential are present then chances of spontaneous recovery is negligible.</li> <li>• No electric output then facial reanimation may be considered.</li> </ul>

### IMPORTANT QUESTIONS:

Q. Branch of facial nerve \_\_\_\_.

Ans. Greater superficial petrosal nerve



Q. Nerve involved in hyperacusis \_\_\_\_.

Ans. Nerve to stapedius.

Q. Lacrimation is affected when the facial nerve is injured at \_\_\_\_ level.

Ans. Supra genicular.

Q. Taste is affected when the facial nerve is injured at \_\_\_\_ level.

Ans. Infrastapedial

Q. Most common reason for facial nerve palsy

Ans. Trauma

Q. Iatrogenic facial palsy occurs is \_\_\_\_ surgery.

Ans. Parotid

Q. Facial nerve segment affected in ischemia and oedema.

Ans. Labyrinthine.

Q. Which segment of facial nerve is affected first in ischemia and edema

Ans. Labyrinthine segment

Q. Which segment of facial nerve is affected first in iatrogenic trauma

Ans. Second Genu

Q. Which fracture of petrous bone is responsible for facial nerve injury

Ans. Transverse Fracture

Q. Crocodile tears occur due to faulty reinnervation with

Ans. Auriculotemporal Nerve

**Frey's Syndrome:**

- This occurs because of faulty innervation of the auriculotemporal nerve.
- It is diagnosed with the help of an iodine starch test.
- It is treated by botox injection or tympanic neurectomy.

**Heerfordt Syndrome:**

- It refers to uveo-parotid fever.
- Symptoms involve parotitis, uveitis and facial nerve palsy.

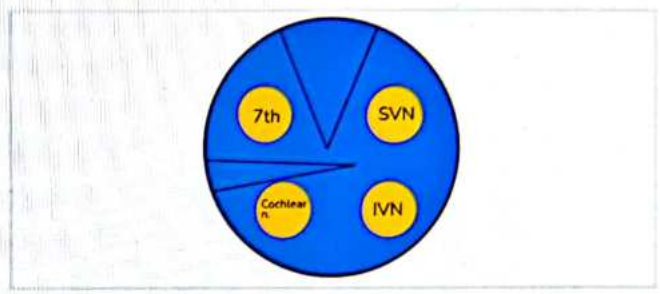
**Important Information**

- If the LMN type of facial palsy occurs on the right side, then the deviation is towards the left side as the muscles are paralysed on the right side. The inability to close the eye happens on the same side i.e., here right side itself.

**Acoustic Neuroma:**

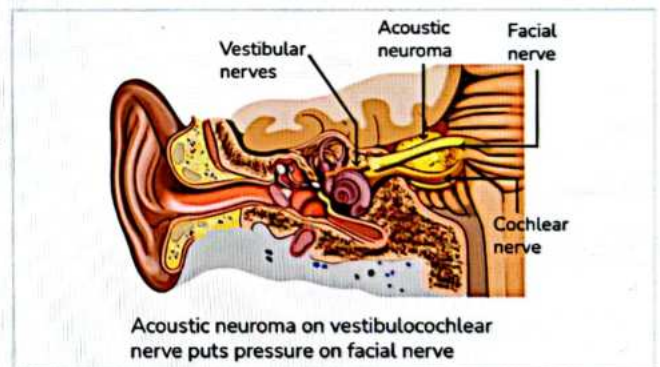
01.26.16

- This term is a misnomer used for the tumour involving Schwann cells of the vestibular nerve. Hence is called a vestibular schwannoma.
- Most commonly it emerges from the inferior vestibular nerve and rarely from the cochlear or superior vestibular nerve.
- 80% of cerebellopontine angle tumours are acoustic neuromas.
- Tumour coming from the inferior vestibular nerve compresses the superior vestibular nerve, cochlear nerve and facial nerve.

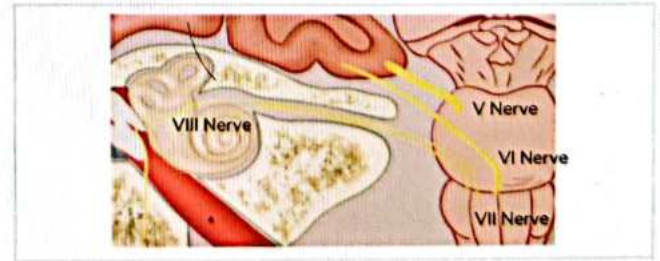


**Origin**

- Its benign encapsulated extremely slow growing tumour of the 8<sup>th</sup> nerve
- Originates from schwann cells of the vestibular nerve but sometimes even from the cochlear nerve
- As it expands it causes widening of the canal and appears in the CP angle



- When the tumour spreads superiorly and anteriorly it involves the 5th nerve and the 6th nerve. When tumour spreads inferiorly, it involves lower cranial nerves. Whereas when it spreads medially, it compresses the cerebellum and brainstem.



prince kumar  
princeeeekum@gn  
9928609733

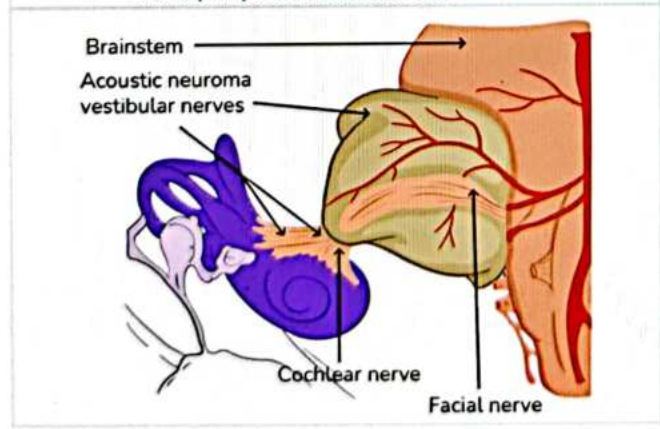
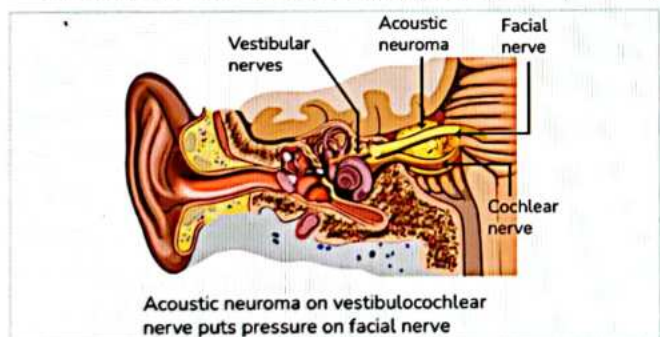


**Symptomatology:**

LOCALIZED IN INTERNAL AUDITORY MEATUS	ON SPREADING
<ul style="list-style-type: none"> <li>As the vestibular nerve is involved, <b>imbalance</b> occurs initially which is soon compensated by the opposite side.</li> <li>Cochlear nerve is affected, which results in retro cochlear type of <b>sensorineural hearing loss</b>.</li> <li>Facial nerves are involved.</li> <li>The sensory fibres are affected first, which results in <b>loss of sensation</b> in the concha. - <b>HITZELBERGER</b> sign.</li> <li>Later motor nerves are involved and cause motor paralysis of the face.</li> </ul>	<ul style="list-style-type: none"> <li>5th nerve involvement results in <b>loss of corneal reflex</b>.</li> <li>In 6th nerve it is <b>abducent palsy</b></li> <li>Involvement of 9th, 10th, 11th nerves cause swallowing and speech problems.</li> <li>Brainstem and cerebellar compression results in corresponding symptoms.</li> </ul>

**Growth**

- Spread - Picture
- Anterosuperiorly - 5<sup>th</sup> nerve
- Inferiorly - 9<sup>th</sup> 10<sup>th</sup> 11<sup>th</sup> nerve
- Later displacement of the brainstem, pressure on the cerebellum and raised intra cranial tension



**Classification**

- Intracanalicular
  - o Small : upto 1.5 cm
  - o Medium : 1.5 to 4 cm
  - o Large : more than 4 cm
- Any tumour of below 3cm can be resolved by radiosurgery, while that above requires surgical excision.

**Clinical Features**

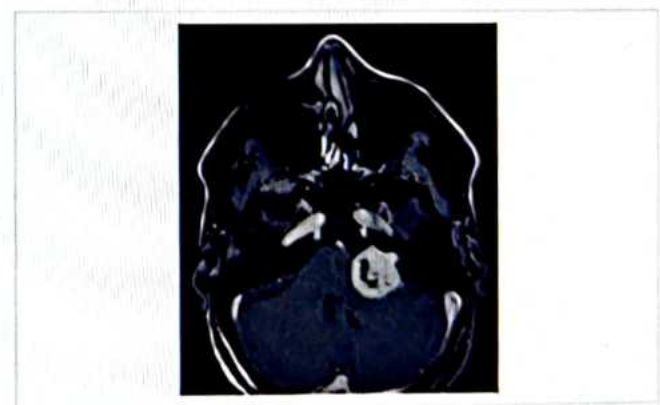
- This tumor is often seen in the age group of 40-60 years and is unilateral.
- Bilateral tumors are part of neurofibromatosis type 2
- Mainly progressive unilateral sensorineural hearing loss with tinnitus
- Difficulty in understanding speech out of proportion to the pure tone audiometry
- **Cranial nerve involvement**
- 5<sup>th</sup> nerve is the earliest affected and if its affected indicates tumour is more than 2.5 cm and in cp angle [reduced corneal sensation]

**Audiological IOC**

- Rinne test - Positive
- Weber - Lateralized to normal side
- ABC - Shortened
- Speech discrimination is POOR
- Acoustic reflex delay is POSITIVE
- Tone decay > 30db
- BERA - Delay in the appearance of wave 5
- Vestibular tests
- Caloric test - is reduced on the side of lesion
- VEMP is also reduced

**Investigations**

- MRI with contrast is the investigation of choice can detect even intra canalicular tumours



- **Ice cream cone** appearance in MRI is a characteristic feature.



## Treatment

- Surgical excision is treatment of choice.
- Radiosurgery for small tumors less than 30 cc in size.
- Biopsy shows typical ANTONI TYPE A and TYPE B cells.
- Radiosurgery refers to supplementing radiation in large dose in a single time so as to remove the tumor and it would appear, surgically






## CROSS WORD PUZZLES



Crossword Puzzle 1




**Across**

- 3. Paralysis accompanied by involuntary tremors
- 4. Another name for the Facial nerve

**Down**

- 1. Seventh cranial nerve
- 2. Occurs on the same side of the body.

Crossword Puzzle 2




**Across**

- 1. Caused by shingles outbreak near the ears

**Down**

- 1. Non-invasive test to study facial nerve
- 2. Blink reflex is also known as.
- 3. Is a benign tumour of nerve tissue

Crossword Puzzle 3



**Across**

- 2. Characteristic feature in MRI of acoustic neuroma
- 4. Millard-gubler syndrome.
- 5. Nerve responsible for loss of corneal reflex in acoustic neuroma

**Down**

- 1. Longest segment of facial nerve.
- 3. Facial nerve segment affected in ischemia and oedema

prince ku  
princeee  
99286097



16

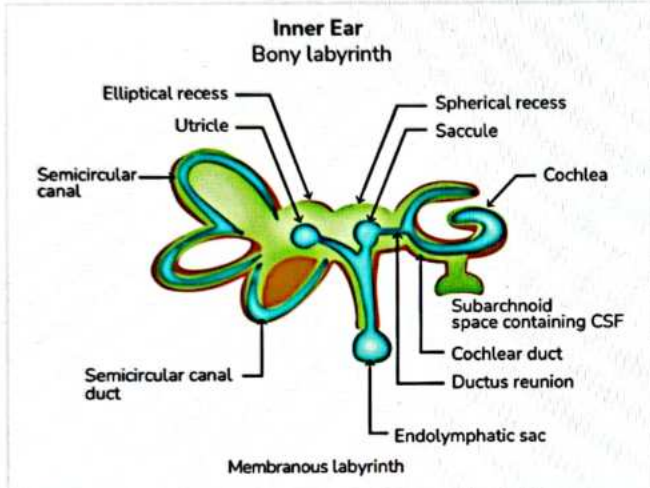
MENIERE'S DISEASE



- It is a triad characterized by VST- Vertigo, Sensorineural Hearing Loss, Tinnitus
  - Spontaneous attacks of vertigo.
  - Fluctuating sensorineural hearing loss
  - Tinnitus and Aural fullness
- It is a disease of the inner ear.

Anatomy of the Inner Ear

00.00:55

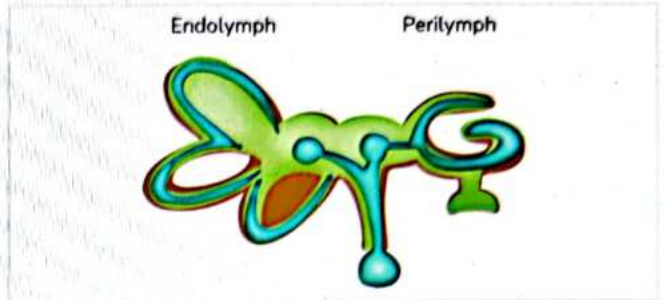


- The inner ear constitutes a bony labyrinth(covering) and a membranous labyrinth(content). The membranous labyrinth exists inside the bony labyrinth.
- The bony labyrinth has a central chamber called the vestibule. The vestibule contains a spherical recess and an elliptical recess.
- Anterior to vestibule, there exists the cochlea, and posterior to it, there exist the semi-circular canals. The semi-circular canal duct exists within the semi-circular canal.
- The saccule is present inside the spherical recess whereas the Utricle is present inside the elliptical recess. The cochlear duct is present inside the bony cochlea.
- The Ductus reunions connect the saccule and the cochlear duct.
- Utricular duct and circular duct join to form the endolymphatic duct, which goes to the sac.
- Semi-circular canal duct within the semicircular canal

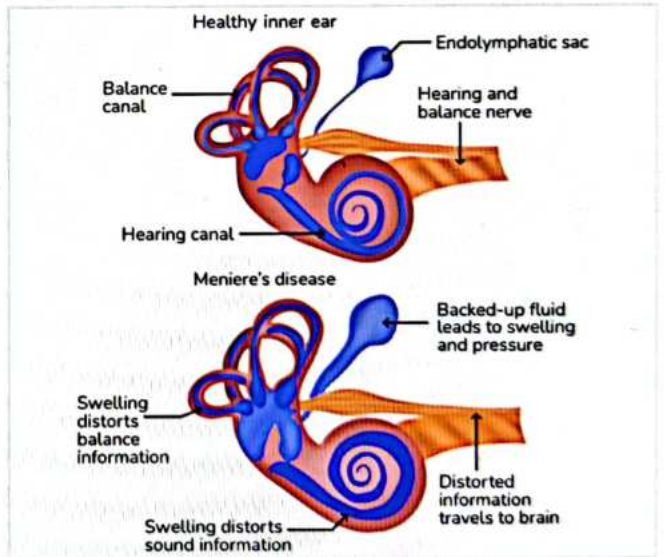
Fluids inside the Ear

00.02:04

- Endolymph is the fluid that is present inside the membranous labyrinth.
- It is produced from the cochlear duct and circulates to the entire membranous labyrinth. And reabsorbed in the cochlear duct (scala media)



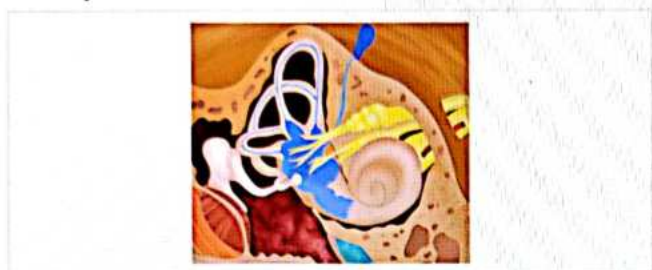- Perilymph is produced from the Cochlear aqueduct.
- Perilymph is an ultrafiltrate of CSF which fills the entire space present between the bony labyrinth and the membranous labyrinth.
- Endolymph is rich in potassium and perilymph is rich in sodium.
- This is necessary for generating a good amount of action potential at the cochlea receptors level, at the macula, which is the receptor in the Utricle and saccule, and at the semi-circular canal.
- Thus, to generate a depolarization so that the impulses are conducted to the respective nerves, these electrolytes i.e., sodium and potassium are necessary.



- Stria vascularis is a structure that produces and reabsorbs the endolymph.
- Consider a condition where there is excessive production of the endolymph and decreased reabsorption due to allergy/autoimmune cause/ genetic causes/ stress/ excessive salt and water consumption, etc.
- Stria vascularis is a structure that produces and reabsorbs the endolymph.

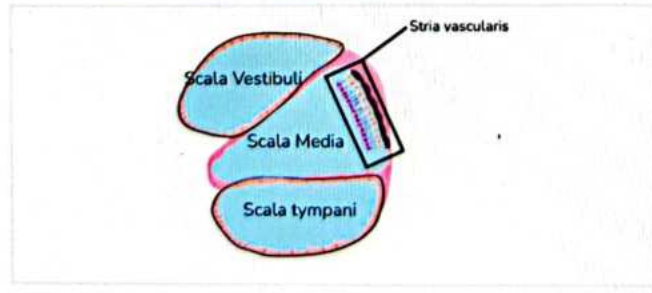


- As a result, the entire membranous labyrinth will swell up.
- The image below shows a comparison between a normal, healthy ear and Meniere's disease (swollen and distorted). There is a gross enlargement of the membranous labyrinth.
- But this membranous labyrinth cannot expand infinitely as it is enclosed within the bony labyrinth. Thus, bone is restricting the movement or the excessive swelling of the membranous labyrinth.
- Inside the membranous labyrinth, there is the presence of receptors.

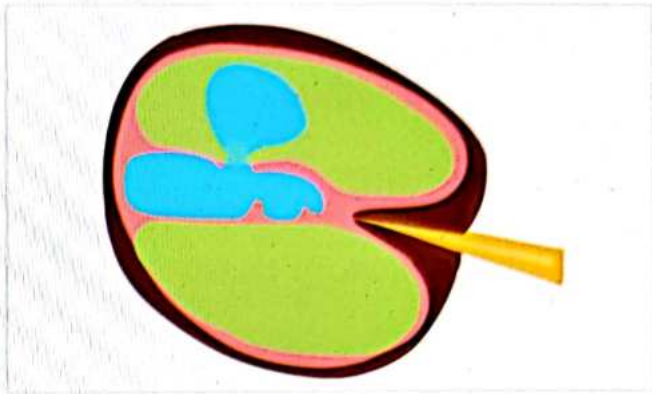


- Organ of Corti exists inside the cochlea
- Organ of Corti is responsible for hearing.
- Thus, if this organ of Corti doesn't get appropriate impulses because the entire Scala media is swollen up and there is excessive endolymph, there will be distortion in the conduction of impulses.
- This results in hearing loss (Sensorineural) in the patient.
- Both spherical recess and elliptical recess contain receptors called the macula and it is responsible for hearing and balance.
- In the case of distorted information passing the macula, both of them will get affected and there will be hearing loss and imbalance.
- The semi-circular canal ducts contain neurosensory epithelium/receptors with their amputated ends called Crista. It is responsible only for balance.
- If distorted information passes the Crista, there will be an imbalance.
- Thus, the patient will have Vertigo because of improper conduction of impulses from the Crista and the macula.
- The patient will have tinnitus whenever the firing within the cochlea or the nerve gets affected.
- Overall there is gross enlargement of membranous labyrinth

**Other reasons of these symptoms**



**Consider the structure of the cochlea:**



- The Scala vestibuli is on the top, Scala media in the middle, and Scala tympani at the bottom.
- The scala media is separated from scala vestibuli by Reissner's membrane and from the Scala tympani by the Basilar membrane.
- Stria vascularis is responsible for the production of endolymph and reabsorption of the endolymph.
- Suppose there is increased production and decreased reabsorption of the endolymph in the cochlear duct by stria vascularis. The entire Scala media would swell up.
- Reissner's membrane would stretch to produce micro tears. The fluid present in this scala vestibuli (perilymph) would mix with the fluid present in this scala media (endolymph).
- Perilymph is rich in sodium and endolymph is rich in potassium. Thus, sodium-potassium imbalance is not just happening at the level of the cochlear since the fluids are connected all over the labyrinth.
- It would happen at the macula and the Crista, resulting in possible Vertigo, hearing loss, and tinnitus.
- The tears will automatically heal after some time. The sodium-potassium balance will again get restored after a certain time and the patient's symptoms will improve.
- There won't be constant vertigo/hearing loss/tinnitus but rather fluctuating symptoms. Whenever there is a pressure increment, they will have symptoms. Whenever there is healing/medications, the symptoms will decrease.

**Types of Meniere's Disease**

00:13:40

- Primary Meniere's disease - idiopathic (no cause identified)
- Secondary Meniere's disease - it can occur due to infection, trauma, allergy, autoimmune diseases, or even stapedectomy.
- There is also a genetic predisposition as Chromosome 6 has been attributed to causing it although there is no direct causation.

**Predisposing Factors**

00:14:51

- Allergy



- Sodium and water retention
- Hypoadrenalism and Hypopituitarism
- Hypothyroidism
- These endocrinological abnormalities cause retention of the majority of the fluids, not just endolymph.

## Cardinal Features of Meniere's

00:15:20

**Vertigo** Severe sudden vertigo accompanied by nystagmus, nausea, vomiting and vagal disturbances like diarrhea, cold sweat, pallor, bradycardia

**Hearing loss**

- a. Sensorineural hearing loss
- b. Low frequency hearing loss.
- c. Distortion of sound (Diplacusis)
- d. Intolerance to loud sounds due to recruitment.
- e. Typically fluctuating

**Tinnitus** Low pitched roaring type

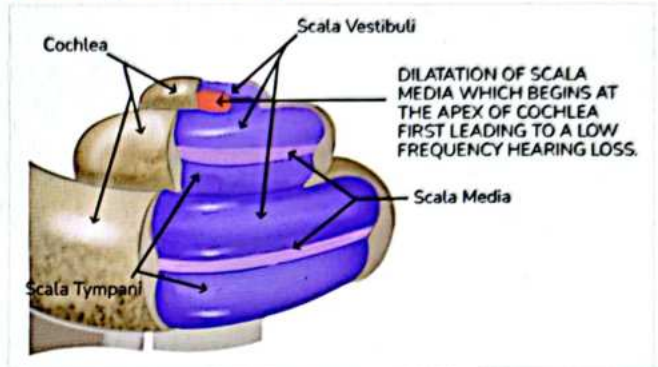
**Sense of fullness of ear**

- Vertigo
  - The Vertigo of Meniere's disease has a sudden onset. There may be an aura or tinnitus, after which the symptoms may appear.
  - It will last for a few minutes to a few hours. And resolves on its own.
  - It is accompanied by nausea, vomiting, and specifically vagal symptoms (Doesn't happen in any other disease) such as sweating, pallor, bradycardia, abdominal cramping, etc.
- Hearing Loss
  - Since this is an inner ear disease, there is a sensorineural hearing loss because external and middle ear diseases would cause conductive hearing loss whereas any lesion in the cochlea and the retro cochlear pathway would result in sensorineural hearing loss.
  - It is typically fluctuating and not constantly present.
  - Only during an attack, the patient will have hearing loss. The hearing loss will subside once the attack has aborted/once the symptom has disappeared.
  - They typically have involvement of low frequencies i.e., the 250-hertz or 500-hertz frequencies are affected.
  - The condition where one can hear double is called Diplacusis (specific to Meniere's)
- Tinnitus
  - Tinnitus present in Meniere's disease is a roaring type (as though a lion is roaring).

- Tullio's phenomenon
  - It occurs when they have an intolerance to loud sounds.
  - Whenever a patient with Meniere's disease listens to a loud sound, they get vertigo.

## Low-Frequency Hearing Loss

00:20:37



- The Scala media at the apex of the cochlea is involved first, and then the base of the cochlea.
- Apex is responsible for recognizing low frequency sounds i.e. 125 hertz, 250 hertz, etc. and the base of the cochlea is responsible for recognizing high frequency sounds.
- There is Tonotopic organisation of cochlea due to which the base of the cochlea is responsible for recognizing high frequency i.e., 20,000 hertz, 18,000 hertz, 16,000 hertz etc., whereas at the apex recognizes low-frequency sounds (125, 250 Hz)
- The disease begins at the apex of the cochlea. Thus, the low frequencies are affected first. Although, as the disease progresses, all the frequencies will get affected.
- The apex of the cochlea is narrow when compared to the base. Thus, when the pressure increases, the apex will be the first one to be affected, resulting in low-frequency hearing loss.



## Important Information

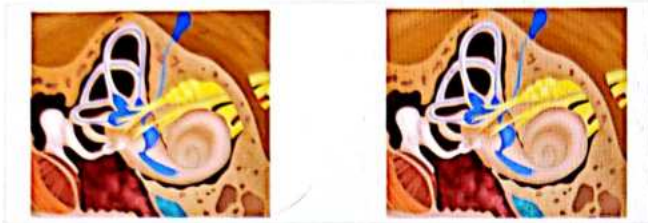- Excessive production or decreased reabsorption will result in endolymphatic hypertension.
- Spherical recess and elliptical recess contain receptors called the macula and it is responsible for hearing and balance.
- The patient will have Vertigo because of improper conduction of impulses from the Crista and the macula.
- The patient will have tinnitus whenever the firing within the cochlea or the nerve gets affected.
- Perilymph is rich in sodium and endolymph is rich in potassium.
- Tinnitus present in Meniere's disease is a roaring type.



**Tullio's Phenomenon**

00:22:58

- It is a condition where loud noise causes vertigo in a patient with Meniere's disease.
- This is because in a patient with Meniere's disease, the oval window lies in very close proximity to the saccule because it is dilated.



- The footplate covering the oval window lies a bit far away from the saccule in a normal patient. However, in Meniere's case, it lies in close proximity to the Saccule.
- Thus, when a sound enters through the malleus incus and hits the stapes and the oval window. These vibrations can be transmitted very quickly to the saccule.
- The saccule contains macula which is responsible for both hearing and balance, resulting in imbalance i.e. Vertigo.
- This can be provoked by loud sounds because the distended saccule lies against the oval window since the saccule is now dilated (Meniere's case). This phenomenon is called Tullio's phenomenon.
- This condition is also positive whenever the patient has a Perilymph Fistula or Congenital Syphilis or Superior Semi-circular Canal (SSC) Dehiscence.

**Examination**

00:26:28

These tests are not 100% specific for Meniere's disease.

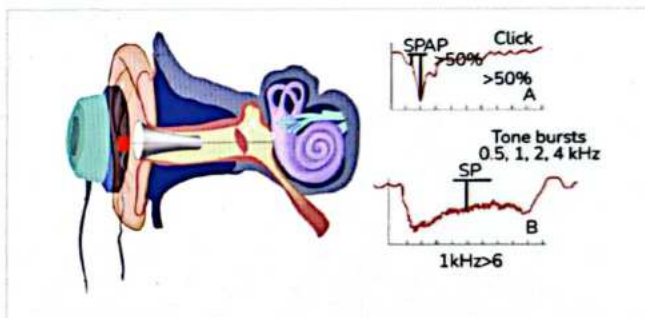
- Otoscopy: Normal
- Nystagmus: Since it's a disease of the inner ear, typically the external auditory canal will be normal.
  - But when encountering a patient with vertigo, the first thing to look for is misdiagnosis.
  - If a patient is encountered during the phase of vertigo, after checking for misdiagnosis, It will be observed that the fast component of the Nystagmus is towards the healthy ear.
- Tuning Fork Test (TFT): It will show the presence of sensorineural type of hearing loss because it's a cochlear pathology.
- Rinne and Weber: Thus, Rinne will be positive whereas Weber will be towards the opposite ear.
  - Absolute Bone Conduction (ABC) test will show decreased hearing sensitivity when compared to the examiner.
- Pure Tone Audiometry: There is a low-frequency hearing

loss observed.

- But if glycerol, a dehydrating agent is given, it will reabsorb the endolymph to a certain extent i.e., partially.
- As a result, endolymphatic pressure and pressure in the cochlea decrease. Thus, an improvement in the audiological scores is observed. This is called a glycerol test.
- Recruitment: It is a test done to identify a Cochlear pathology.
  - Since the Meniere's is a Cochlear disease, this test will be positive.
- Calorie test: Since the receptors are not able to send the impulses appropriately to the brain, there will be a Canal Paresis.
  - This means that if the ear is irrigated with warm/ cold water, there would be no response/ decreased response, this is called Canal Paresis.

**Electrocochleography**

00:29:28

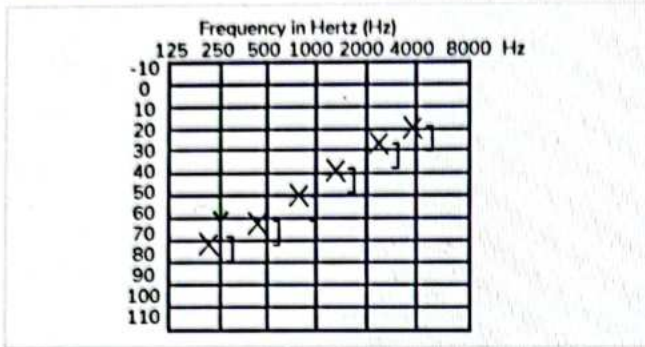


- It is the diagnostic test for Meniere's disease.
- Whenever the inner ear/Organ of Corti/Macula/Crista is being stimulated, there is a certain depolarization and action potential being generated at the receptor that will fire the impulses to the corresponding nerves.
- In a patient with Meniere's disease, The summing potential to action potential ratio i.e., SP/AP < 30% or 0.3 in normal individuals. But in Meniere's disease, SP/AP > 30% or 0.3.
- The test is done by passing an electrode through the tympanic membrane and placing it on the promontory, which is the basal turn of the cochlea.
- When sound impulses are given from an external sound source, it activates the receptors in the cochlea and generates an action potential.
- The SP/AP ratio is also recorded by this probe and can conclude whether the patient is having Meniere's disease.

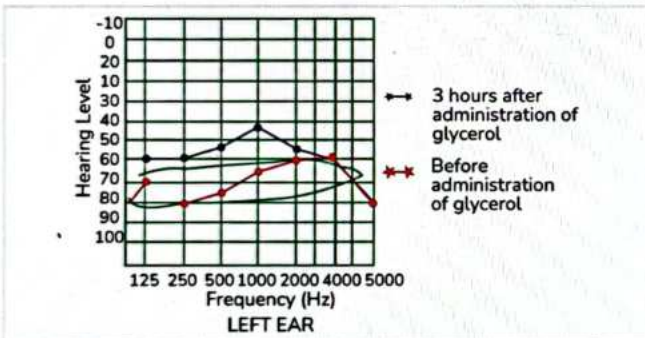


**Audiogram**

00:31:40



- The other test performed in patients with Meniere's disease is an audiogram where it is typically observed that the hearing loss is more at lower frequencies.
- Thus, at 250 hertz, the hearing threshold is at 70.
- X is for air conduction of your left ear and close bracket - ']' is for bone conduction of your left ear.
- Both air conduction and bone conduction are affected because it's a sensorineural pathology.
- At lower frequencies, the hearing loss is higher whereas at higher frequencies, the hearing is better. The graph is of an up-sloping type of audiogram.



- When an audiogram is done, it is observed that there is a certain amount of hearing loss. However, after three hours of administration of glycerol, there is an improvement at every frequency i.e., improvement in the audiological score.

**Role of MRI with Gadolinium Contrast**

00:33:31

- Gadolinium is a contrast agent, which when injected, stains the CSF (Cerebrospinal fluid)
- The ultrafiltrate of CSF i.e., perilymph fills scala vestibuli (SV) and scala tympani (ST) compartments of the cochlea.
- In a normal patient, if the contrast is given and performed MRI on, the dye must only be seen in SV and ST but not in SM.
- However, in a patient with Meniere's disease; the dye is seen in all three compartments because of the tear in the round window membrane or vestibular membrane.

**Variants of Meniere's Disease**

00:35:35

- It is not necessary that every patient with manias will manifest to you with all the three symptoms. Symptoms can be variable
- Cochlear Meniere's: Presence only of cochlear symptoms (only hearing loss) and no vestibular symptoms i.e., no vertigo.
- Vestibular Meniere's: Only vertigo and no cochlear symptoms and no tinnitus.
- Lermoyez Syndrome: The reverse of Meniere's triad that is tinnitus, followed by sensorineural hearing loss and vertigo. Reverse of Meniere's is Lermoyez Syndrome.
- Tumarkin's Otolithic Crisis: Sudden drop attacks without loss of consciousness. This occurs whenever there is a disruption of the autolytic membrane in the macula. The otolith is responsible for balance. Thus, the patient will fall suddenly but there is no loss of consciousness.

**Secondary Meniere's**

00:38:02

These can occur secondary to:

- Congenital and acquired Syphilis (infections)
- Trauma
- Paget's disease
- Post Stapedectomy

**Treatment: General Measures**

00:38:30

- Low salt diet (<1.5-2g/day)
- Stop smoking as nicotine cause vasospasm
- Avoid excessive intake of water and caffeine.
- Correct hormonal imbalances like hypothyroidism, hypopituitarism
- Elimination of allergen (in 50% allergens are found)
- The treatment of the cause itself is going to be the treatment of the disease.

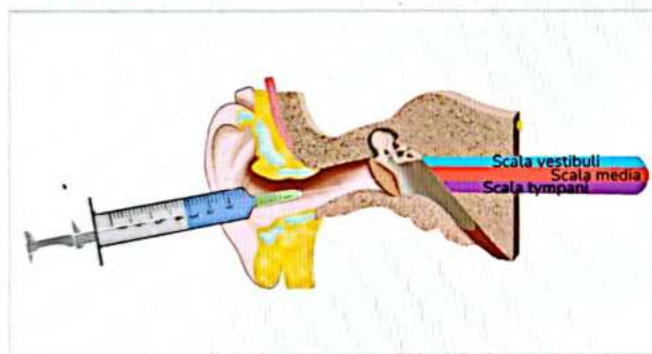
**Pharmacological Treatment**

00:39:27

	Acute attack	Chronic phase
Vestibular sedatives	<ul style="list-style-type: none"> <li>• Dimenhydrinate, promethazine, prochlorperazine</li> <li>• Diazepam suppresses activity of medial vestibular nucleus</li> </ul>	<ul style="list-style-type: none"> <li>• Prochlorperazine</li> </ul>
Vasodilators	<ul style="list-style-type: none"> <li>• Carbogen (5% CO<sub>2</sub> with 95% O<sub>2</sub>)</li> <li>• Histamine drip</li> </ul>	<ul style="list-style-type: none"> <li>• Nicotinic acid</li> <li>• Betahistine (Vertin)</li> </ul>
Other drugs	<ul style="list-style-type: none"> <li>• Atropine</li> </ul>	<ul style="list-style-type: none"> <li>• Diuretics</li> </ul>



- In an acute phase, the treatment is to give vestibular sedatives i.e., suppress the labyrinth.
- Labyrinthine symptoms must not appear.
- in an acute attack, Diphenhydramine, dimenhydrinate, Promethazine, Prochlorperazine. However, in a continuation to a chronic state, Prochlorperazine can be given.
- Vasodilators like Carbogen and histamine drip can be given in patients with acute phase.
- In continuation into the chronic phase, nicotinic acid and beta histidine are used.
- Other drugs like diuretics can be helpful but aren't usually given on a regular treatment basis.
- These drugs are going to only abort the attack but do not treat the disease itself.
- So, for treatment of the disease, certain sorts of steroids must be given. Systemic steroid can cause glaucoma, osteoporosis, liver dysfunction, renal dysfunction, etc.
- Thus a local acting steroid is preferred over system steroid is preferred. However, the local steroid is preferred more as there are less system adverse effects.
- The concentration of the drug that reaches the inner ear would be higher i.e., bio availability of the drug would be higher.
- Bioavailability will be higher in a local steroid as compared to systemic steroid.




- Intratympanic steroid/ medication is administered through the tympanic membrane into the middle ear.
  - The scala vestibuli is covered by the oval window and scala tympani by the round window.
  - When administered, the drug goes into scala tympani through the round window membrane.
  - The drug reaches the scala media through the basilar membrane.
  - We only give 0.3-0.4 ml of the drug as the middle ear can hold only that volume.
  - If this was to be given as an injection, the patient will have to take at least 4-6 doses of steroids.
  - Intratympanic injections can be painful where repeated injections must be avoided.

- A micro catheter/wick can be placed from the external auditory canal and put on the round window under local anaesthesia.
- Microwick and microcatheter are drug delivery devices that can be used for patients with meniere's disease.
- After intratympanic steroids, if the patient is not having improvement in symptoms, one can switch to gentamicin
  - Gentamicin, is an ototoxic medication i.e., it is going to destroy the labyrinth.
  - Even though the vertigo will definitely disappear since it is getting destroyed and becomes a dead labyrinth.
  - However, the patient will end up having a permanent SNHL.
- Another form of therapy is a Meniett device i.e., an intermittent pulse pressure device.
  - It is kept in the external auditory canal. This generates intermittent low pressure and the pressure helps in resorption of the endolymph in the inner ear.

**Surgical Management**

00:46:40

- Surgeries come into play when these pharmacological methods don't work i.e., intractable vertigo despite being treated with intratympanic steroids or gentamicin.



- Endolymphatic sac decompression
  - In the inner ear, the endolymphatic duct opens into the endolymphatic sac.
  - The vestibule and the semi-circular canal are supplied via the vestibular nerve, whereas the cochlea is supplied by the cochlear nerve.
  - The vestibular nerve, in turn divides into superior and inferior vestibular nerves.
- There are attempts to open up the Endolymphatic sac so that the endolymph is drained. If continuous drainage is desired, a draining tube can be kept into it. That is called an endolymphatic shunt.
- If this is also not helpful for the patient, vestibular nerve sectioning is chosen where the worst vestibular nerve is cut or sectioned. This is done so that no afferent impulses will go from the inner ear to the brain.



- When there are no afferent impulses travelling, the patient will not have symptoms.
- Other surgical options:

Conservative procedures (preserve hearing)	Destructive procedure (Destroy hearing)
<ul style="list-style-type: none"> <li>• Vestibular nerve sectioning</li> <li>• Decompression of endolymphatic sac</li> <li>• Endolymphatic shunt</li> <li>• Sacculotomy (Ficks procedure)</li> <li>• Cody tack procedure</li> <li>• Cochleosacculostomy (cochlear duct is punctured)</li> </ul>	<ul style="list-style-type: none"> <li>• Labyrinthectomy</li> </ul>

- Other forms of surgeries are also available i.e., making an opening into the cochlear duct/sacculae/both. Usually, these are not required.

## Update

00:48:52

Definition	Symptoms
Certain Meniere's disease	Definite Meniere's disease plus histopathologic confirmation
Definite Meniere's disease	<ul style="list-style-type: none"> <li>• 2 definitive spontaneous episodes of vertigo 20 min or longer. Audiometrically documented hearing loss on at least 1 occasion. Tinnitus or aural fullness in the treated ear.</li> <li>• Other causes excluded</li> </ul>
Probable Meniere's disease	<ul style="list-style-type: none"> <li>• One definitive episode of vertigo</li> <li>• Audiometrically documented hearing loss on at least 1 occasion</li> <li>• Tinnitus or aural fullness in the treated ear</li> <li>• Other causes excluded</li> </ul>
Possible Meniere's disease	<ul style="list-style-type: none"> <li>• Episodic vertigo without documented hearing loss, or Sensorineural hearing loss fluctuating or fixed, with disequilibrium but nonepisodic</li> <li>• Other causes excluded</li> </ul>

- **Certain meniere's disease:** certain only if there is a histopathological confirmation of meniere's.
- **Definite meniere's disease:** 2 or more episodes of vertigo lasting for 20 minutes or more.
  - 1 audiometrical evidence of sensorineural hearing loss at the time of Vertigo.
  - Tinnitus and aural fullness must be present.
- **Probable meniere's disease:** At least one episode of vertigo lasting for 20 minutes or longer, associated with one audiometric evidence of hearing loss, tinnitus and aural fullness.
- **Possible meniere's disease:** Episodic attacks of vertigo (May or may not have), without documented hearing loss, tinnitus or aural fullness.



## Important Information

- Vertigo is accompanied by nausea, vomiting, and specifically vagal symptoms
- The condition where one can hear double is called Diplacusis.
- A loud sound-provoking Vertigo is called Tullio's phenomenon.
- The fluid present in the scala vestibuli is perilymph.
- The fluid present in the scala media is endolymph.
- In a glycerol test, glycerol is given before audiometry test so that the audiometric scores are improved.
- Electrocochleography is the diagnostic test for meniere's disease.
- Upsloping audiogram is seen in meniere's disease.
- Reverse of Meniere's is Lermoyez Syndrome.






## CROSS WORD PUZZLES



### Crossword Puzzle 1




#### Across

- 1. The patient will have \_\_\_\_\_ because of improper conduction of impulses from the Crista and the macula.
- 3. Spherical recess and elliptical recess contain receptors called the \_\_\_\_\_.
- 5. The patient will have \_\_\_\_\_ whenever the firing within the cochlea or the nerve gets affected.

#### Down

- 2. Excessive production or decreased reabsorption will result in \_\_\_\_\_ hypertension.
- 4. Perilymph is rich in \_\_\_\_\_.

### Crossword Puzzle 2



#### Across

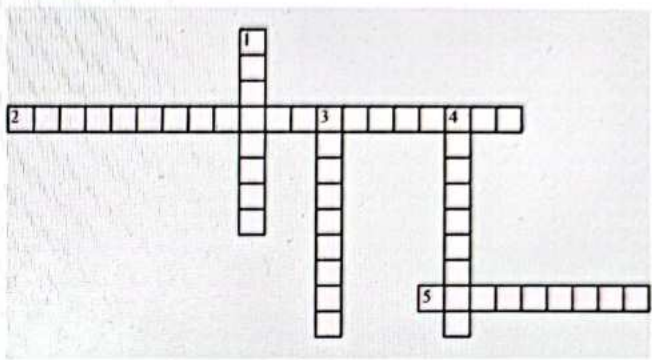
- 3. Endolymph is rich in \_\_\_\_\_.
- 5. Tinnitus present in Meniere's disease is a \_\_\_\_\_ type.

#### Down

- 1. The \_\_\_\_\_ of Meniere's disease has a sudden onset.
- 2. The condition where one can hear double is called \_\_\_\_\_.

- 4. A loud-sound-provoking Vertigo is called \_\_\_\_\_'s phenomenon.

### Crossword Puzzle 3



#### Across

- 2. \_\_\_\_\_ is the diagnostic test for Meniere's disease.
- 5. \_\_\_\_\_ audiogram is seen in meniere's disease.

#### Down

- 1. \_\_\_\_\_ is given before the audiometry test so that the audiometric scores are improved.
- 3. The fluid present in the scala media is \_\_\_\_\_.
- 4. The fluid present in the scala vestibuli is \_\_\_\_\_.



17

GLOMUS TUMOR



- Glomus tumor is a tumor originating from the paraganglionic cells.
- Para ganglionic cells are the cells of the sympathetic nervous system and are responsible for auto-regulation. The paraganglionic cells are also known as glomus bodies.
- One very important feature of the para ganglionic cells are the glomus bodies is that they secrete catecholamines, namely epinephrine, nor-epinephrine, and dopamine.
- Glomus is a benign tumor but is a locally invasive tumor.
- These glomus bodies or the para ganglionic cells are seen in the major blood vessels, near the aortic arch, near the common carotid, internal and external carotid, and the internal jugular vein, because these blood vessels carry major blood supply to our body and chemoreceptor are needed in such areas to sense if there is an elevation, decrease in the pressure, decreased oxygenation, increased carbon dioxide, and to maintain internal homeostasis.
- The chemoreceptor in this case will be the glomus bodies. These glomus bodies are found around major blood vessels. If something inappropriate is happening these will immediately compensate for it.
- The Glomus tumor is most common benign tumor of the middle ear. The glomus bodies are the para -ganglionic cells of the sympathetic nervous system.
- They are present around major blood vessels like the aortic arch, and jugular vein, and are responsible for auto regulation. Glomus tumors originating from the para ganglionic cells are called paragangliomas.
- Glomus is one such paraganglioma which will secrete catecholamines. Because the glomus tumors secrete catecholamines there will be a sympathetic excess.

- Microscopically, glomus tumors have loose blood sinusoids. The blood vessels in this tumor typically lack the tunica media layer or the smooth muscle layer.
- This will cause the blood vessels to not be able to contract. Therefore, from these areas, one can present with profuse bleeding. When there is a glomus tumor in the scenario, one must think of profuse bleeding as a clinical manifestation.
  - a. So, there is a lack of tunica media.
  - b. These tumors have no capsules causing the tumor to be able to spread locally to the adjacent sides.
  - c. The arrangement of cells present in the tumor, microscopically when seen, resembles a pattern. This pattern is called the Zell Ballen pattern.

Important Pointers

00:07:43

- Can be associated with Von Recklinghausen neurofibromatosis, Sturge weber syndrome, tuberous sclerosis and Von Hippel Lindau
- Rule of 10
  - o 10% familial
  - o 10% secrete catecholamines
  - o 10% MULTICENTRIC

These are some important pointers about the glomus tumor considering its origin from the paraganglionic cells.

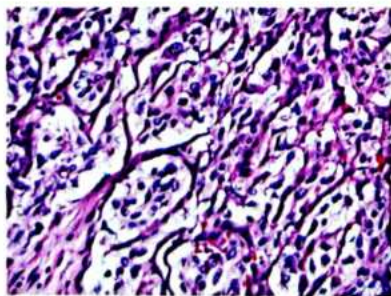
- RULE OF 10
  - o 10% of them are familial.
- This means that there is a genetic history and through the family, the tumor can be happening 10%.
  - o 10% of them secrete catecholamines.
  - o 10% are multicentric. It means it can happen in multiple site.
- This means that it is not a rule that every glomus tumor will secrete catecholamines. Only 10% of such tumors secrete catecholamines. Multicentric means that it can happen on multiple sites. Glomus tumors can be associated with Von Recklinggausen neurofibromatosis, Sturge Weber syndrome, tuberous sclerosis, and Von Hippel Lindau disease. (clinical MCQs)

Microscopically

00:04:52

- Benign and slow growing
- Thin walled blood sinusoids with no contractile muscle – hence excessive bleeding; extremely vascular
- No capsule and hence locally invasive

prince kumar  
princeekum@gmail.com  
9978411331

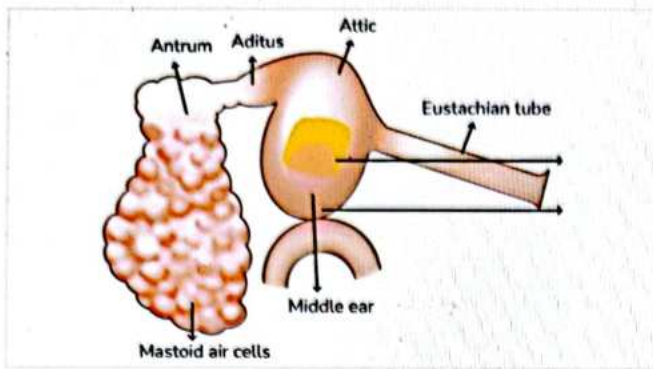


Types of Glomus

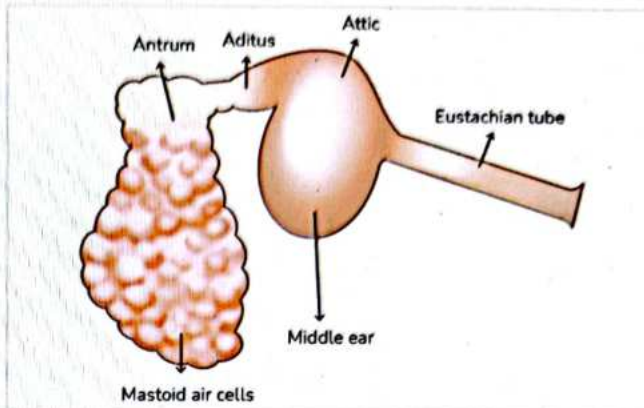
00:09:40

- Glomus tympanicum – arises from promontory
- Glomus jugulare – arises from the dome of the jugular bulb

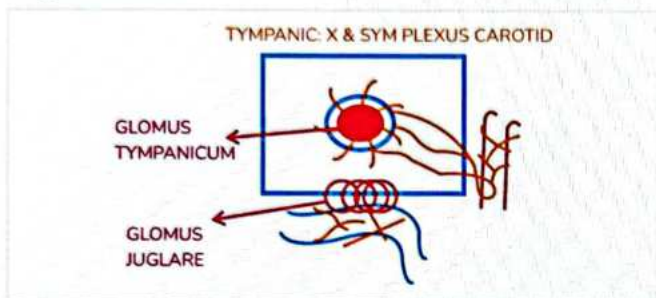




- Posteriorly mastoid
- Superiorly into brain

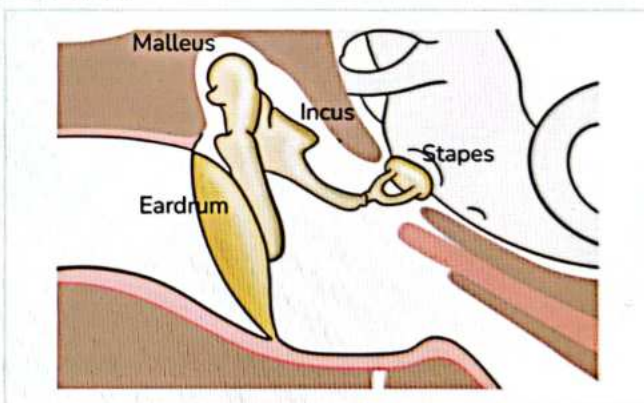


- Glomus is a tumor originating from the cells of the sympathetic nervous system, which are glomus cells or glomus bodies.



- Glomus is a locally invasive lesion due to the lack of capsules. The roof of the middle ear is formed by the tegmen tympanum which separates the middle ear from the middle cranial fossa. If the tumor goes superiorly it can enter the middle cranial fossa.
- If the tumor goes inferiorly, it will go towards the jugular foramen and be the internal jugular vein. The anterior wall of the middle ear contains the opening to the eustachian tube, and if the tumor goes anteriorly it will go towards the eustachian tube. Posteriorly, the tumor can go toward the mastoid air cells. The spread of the tumor depends on its location.

- The promontory can be seen. On the promontory, there lies a plexus of nerves called the Tympanic plexus. The Tympanic plexus is formed by the glossopharyngeal nerve and the sympathetic plexus around the carotid.
- The carotid is present near the anterior wall of the middle ear and is covered in some sympathetic plexus. These sympathetic plexus present contribute to the tympanic plexus present in the middle ear. Now, it can be seen that there is the presence of a sympathetic plexus over a major blood vessel contributing to the tympanic plexus on the promontory. From this area, there can be tumor growth.
- If such a tumor grows from the promontory, it will be called glomus tympanicum (because it is coming from the tympanic plexus covering the promontory). The floor of the middle ear has a vein called the internal jugular vein which is also covered with sympathetic plexus.
- If there is a tumor growth from the sympathetic plexus covering the internal jugular vein, such a tumor will be called the glomus jugulare.



- Laterally, the tumor can spread to the tympanic membrane and present as a bleeding polyp of the external auditory canal.
- Medially, the tumor will go into the petrous pyramid. When a tumor spreads, it can have associated clinical features. If it goes into the temporal lobe of the brain, there can be localizing features of a temporal lobe lesion like aphasia, hemiplegia, and hemianopia, these features present are indication of cranial spread.
- When there is a jugular involvement, the 9th, 10th, and 11th cranial nerves could also be involved. If the tumor spreads to

**The two types of glomus tumors are:**

- Glomus tympanicum
- Glomus jugulare

**Spread**

00:13:15

- Inferiorly – jugular foramen
- Anteriorly – ET to nasopharynx



the inner ear the patient can have vertigo. To understand the clinical scenario it is important to know that a tumor in the middle ear can spread to the surroundings.

## Clinical Features

00:16:12

### Intratympanic tumor

- Gradually progressive hearing loss
- Tinnitus: What is the character ?????
- Otoscopy: Red reflex through intact tympanic membrane
- Rising sun appearance: When tumor arises from floor of middle ear
- Pulsation sign / Brown sign: When pressure in the ear canal increases the tumor pulsates vigorously.

### I. Bleeding

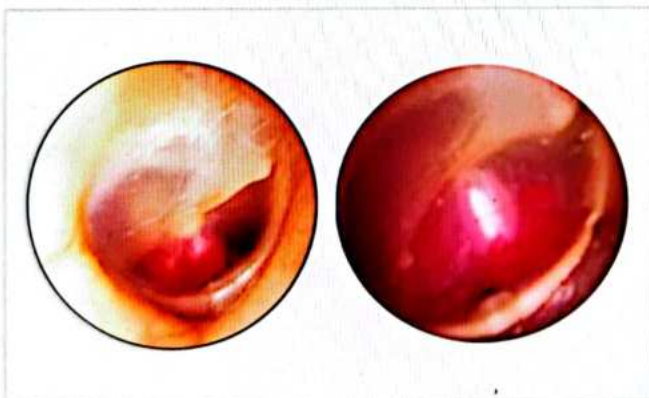- Because it is an extremely vascular tumor and the blood vessels like the smooth muscle layer, when it starts to bleed, it will bleed profusely.

### II. Gradually progressive conductive hearing loss

- Loss of conduction of sound from the external ear into the middle ear happens gradually over time along with the growth of the tumor.

### III. Pulsatile Tinnitus

- Typically the tumor comes from the sympathetic plexus that surrounds the blood vessels. When blood flows from these major blood vessels, transmitted pulsations go to the tumor which can be heard by the patient. The patient will complain of hearing sounds in the ear that resembles the heartbeat, in such a case. There is pulsatile tinnitus.
- When one is complaining of pulsatile tinnitus, the glomus tumor must be ruled out. Pulsatile tinnitus is always suggestive of a glomus tumor.



### IV. Rising Sun Appearance

- If there is a mass in the middle ear, it can either be a glomus tympanicum or it can be a glomus jugulare. But when one sees from the external auditory canal, red bulging can be seen

in the tympanic membrane in the case of glomus tympanicum. In patients with glomus jugulare, a red reflex is present on the floor of the middle ear that represents a **Rising Sun**. This appearance is a very important sign in patients with glomus tumors.

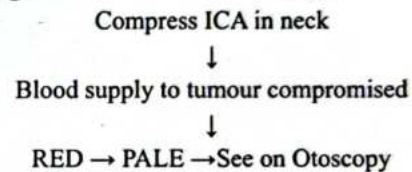
- The slide to the left shows a red reflex on the floor of the middle ear suggestive of glomus jugulare. When there is a tumor originating from the promontory, it looks like the slide on the right where the tympanic membrane is red and bulging.

### V. The Brown Sign

- There is a glomus jugular tumor in the middle ear. If a **Seigel's Pneumatic Speculum** is put in the external auditory canal, and the cuff is inflated, the pressure in the middle ear will increase. This will cause the tumor to vibrate vigorously and become pale, turning to a pink-brown. However, it will again become red. This **pink-brown color** is known as the brown sign.

prince kumar  
princeekum@gmail.com  
9928609733

### Aquino's sign



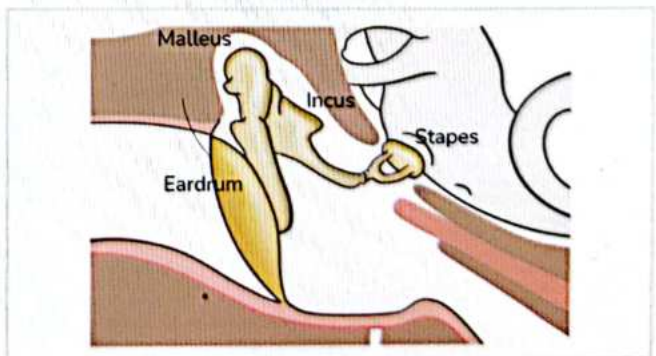
### VI. Aquino's sign

- These tumors typically get their blood supply from branches of the ICA (ascending pharyngeal artery). Near the hyoid bone, the common carotid bifurcates into internal and external. If the ICA is compressed by applying pressure on the neck and then wait for some time, the blood supply to the ascending pharyngeal artery is reduced, and therefore to the blood supply to tumor will get cut off. The red tumor will start becoming pale as can be seen through an **otoscopic examination**.

### Clinical features based on the spread

00:25:57

- Laterally – Red fleshy bleeding polyp
- Medially – Dizziness, facial palsy





## Clinical Features

- Intracranial spread causes cranial nerve palsy: Late feature
- 9<sup>th</sup> to 12<sup>th</sup> nerves are involved
- Eustachian tube block
- When a tumor is going laterally into the external auditory canal it will present as a bleeding polyp of the external auditory canal.
- When a tumor grows medially it will cause dizziness and facial palsy.
- If the tumor grows superiorly can spread intracranial, it will cause cranial nerve palsy.
- If the tumor grows inferiorly, it can involve the 9th, 10th, and 11th nerves. If it goes anteriorly, the Eustachian tube gets blocked. Intracranial spread is a late feature and the jugular foramen is involved whenever there is the involvement of the floor.

## Symptoms due to excess Catecholamines

- Glomus tumor is a paraganglioma and secretes catecholamines (adrenaline, noradrenaline, and dopamine) in 10% of the patients (rule of 10) causing sympathetic excess. Such a patient can present with:
  - Headache
  - Sweating
  - Palpitation
  - Hypertension
  - Anxiety

## Diagnosis

00:30:26

- CT scan with contrast is the IOC
- MRI
- Angiography
- Serum levels of catecholamines and their byproducts like Vanillylmandelic acid and metanephrines

## CECT

- When there is a patient who is presenting with all of the above-discussed symptoms showing that there is a probability of it being a glomus tumor, the investigation of choice would be a **CT scan**. The middle ear is surrounded by bones, except for the thin tympanic membrane. Since this is locally invasive, the erosion of the bones will be understood on a CT scan.

## MRI

- It is an extremely vascular condition, the vascularity of the tumor hence needs to be understood. A contrast CT Scan (CECT) is carried out to understand the intravenous vascularity of the tumor. One can also assess the erosion of the bones.
- In some individuals, there might be a cranial spread. If the

tegmen is eroded or the jugular is involved, one can opt for an MRI to assess the intracranial spread of the disease.

## Angiography

- Angiography is done to identify the feeding vessel and embolize it. The feeder is ascending pharyngeal artery
- Serum levels of catecholamines and their byproducts like vanillylmandelic acid and metanephrines

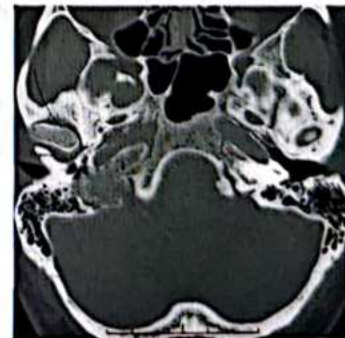
## Treatment of choice:

- Embolization followed by Surgical excision
- Radiation for inoperable tumors
- The feeding vessel to the tumor needs to be identified which is possible through angiography. The most common blood supply to the tumor is through the Ascending pharyngeal artery. (MCQ) The tumor has a major blood vessel that is giving its branches and this blood vessel is identified through angiography.
- Embolization is also carried out through angiography. Embolization is when the feeding blood vessel to the tumor is identified and blocked. This will cause that tumor to become avascular and one can now operate on the tumor through surgical excision.
- Once the blood vessel is blocked after embolization, the tumor will stop getting its nutrition and become avascular. About 24 to 48 hours later, an operation is done to remove the tumor.
- If there is a patient at home then surgery cannot be done because there is an extensive cranial spread or neck spread or if the tumor is not receiving the supply from one artery but from multiple arteries, or when it is getting direct supply from the carotid, radiation is done for such in operable tumors.
- Serum levels of catecholamines and their byproducts like vanillylmandelic acid and metanephrines are also checked because during surgery sympathetic excess is unwanted. It can lead to fatal complications such as uncontrolled hypertension.

## Radiological Signs

00:36:00

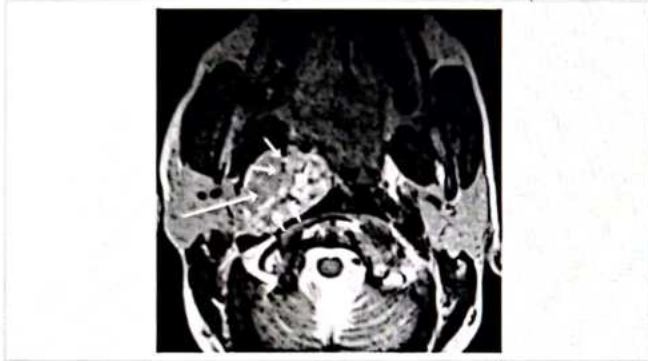### Phelps Sign





- In the CECT, a very typical sign seen is Phelps sign. It is a radiological sign. As can be seen in the slide there is the ICA bulge on both sides.
- The sigmoid sinus then identified which lies in the posterior border of the mastoid; it continues towards the internal jugular vein. A dense bone is present between the jugular and the mastoid called the carotico-jugular spine.
- On the disease's side, this bone is absent. Some soft tissue is present there, which is the glomus tumor that eroded the bone. The erosion of the **carotico-jugular spine bone** is called the Phelps sign.

### MRI showing Salt and Pepper appearance



- The MRI of a patient suffering from a glomus tumor will have areas that are white and areas that are grey (due to the microhemorrhages that happen within the tumor). White and grey dots can be seen in the slide above. This appearance is called Salt and Pepper appearance.

### Fisch Classification

00:43:00

- The classification and the type give an idea of the spread of the tumor and the according approach to surgery will be decided.

Type	Description
A	Tumors restricted to middle ear (glomus tympanicum tumor)
B	Tumors restricted to tympanomastoid site
C	Tumors involving the infra-labyrinth portion towards the petrous apex
D1	Tumor with intracranial invasion (<2cm)
D2	Tumor with intracranial invasion (>2cm)

- When the tumor is localized only to the middle ear, it is called a **Fisch type A tumor**.
- When the tumor is localized from the middle ear to the mastoid, it is called a **Fisch type B tumor**.
- If the tumor is going from the middle ear to the mastoid, to the apex of the petrous bone, it is a **type C**.
- When there is a cranial spread, it is a **type D**.






# CROSS WORD PUZZLES



## Crossword Puzzle 1




### Across

- 2. When the tumor is localized only to the middle ear, it is called ----- type A tumor.
- 4. Glomus is a benign tumor but is a locally ----- tumor.
- 5. These glomus bodies or the paraganglionic cells are seen in the major ----- vessels.

### Down

- 1. Glomus tumor is a tumor originating in the ----- cells.
- 3. When the tumor is localized from the middle ear to the -----, it is called a Fisch type B tumor.

## Crossword Puzzle 2



### Across

- 3. The blood vessels in this tumor typically lack the tunica media layer or the ----- muscle layer.
- 4. One very important feature of the para ganglionic cells or the


glomus bodies is that they secrete -----.

- 5. This lack of the tunica media layer will cause the blood vessels to not be able to contract and from these areas, one can present with profuse -----.

### Down

- 1. In the case of the brown sign, the red tumor will start becoming pale as can be seen through an ----- examination.
- 2. Paraganglionic cells are the cells of the sympathetic nervous system and are responsible for -----.

## Crossword Puzzle 3



### Across

- 3. Because the glomus tumors secrete catecholamines, there will be a ----- excess.
- 5. Roof of the middle ear is formed by the tegmen tympanum which separates the middle ear from the middle cranial -----

### Down

- 1. If there is a tumor growth from the sympathetic plexus covering the internal jugular vein, such a tumor will be called the glomus -----.
- 2. The carotid is present near the ----- wall of the middle ear and is covered in some sympathetic plexus.
- 4. On the promontory, there lies a plexus of nerves called the ----- plexus.





00:05:02

- Hearing Rehabilitation is the process of offering different therapies to improve hearing for those who are hearing impaired.

### Cochlear Implant (CI)

- A cochlear implant is one of the recent technology in the field of ENT, invented by Dr. William House (Father of Neurotology).
- The cochlear implant is a rehabilitated device that stimulates the 8th nerve with an artificial device. With the help of a cochlear implant, firing directly goes to the auditory nerve.
- In other words, the cochlear implant is a surgery where an electrode is inserted through the round window membrane into the scala tympani of the cochlea. Because scala tympani is very close to the basilar membrane which has the organ of corti.
- Through the organ of corti, the 8th nerve is passed that carries the signal to the brain.
- If the patient has cochlear pathology, then the impulse does not carry out from the cochlea to the 8th nerve. But if this cochlea is replaced with a cochlea implant, then the impulses will be carried out via the 8th nerve.

### Indications/Contraindications of hearing implant

#### Indications

**Bilateral severe to profound hearing loss >70-90% of hearing loss)**

- Hearing is completely absent or negligible in both ears.

#### Prelingual or postlingual

- **Prelingual hearing** loss occurs before a child develops speech and are deaf by birth. This child who is born deaf has not yet developed speech.
- **Postlingual hearing** loss occurs after a child/ adult develops speech.
- When a boy or a girl is born, an OAE screening test is done as neonatal hearing screening program for the identification of hearing of sound called **otoacoustic emissions (OAE)**.
- If the OAE is absent, then the Brainstem Evoked Response Audiometry (**BERA**) will be used.
- Rehabilitation of hearing at an early stage is very important in this condition. So, that child will be able to develop speech.
- Speech development starts from the time of birth and the speech cortex will be able to achieve maximum stimulation by **3 years of age**. So, the approach is- the child should be able to speak by at least by 3 years of age.

- If during this period of time, the child did not receive auditory stimulation between 0-3 years then the speech will not develop.
- Between 0-7 years, there is a possibility of developing speech with an implant. Even if the child hears, he may not be able to develop a speech.
- Beyond 7 years, there is very less chance of developing speech in a child with a cochlear implant.
- In prelingual deaf children, the earlier the doctor diagnoses, the earlier the better treatment, and the earlier the rehabilitation of speech.
- In post lingual deaf children, post-meningitis and post-trauma during adulthood or the later stages of childhood life, hearing loss can be seen.
- Earlier rehabilitation will be provided to the patient for better results.
- The implant is always placed into the **scala tympani and the electrode is inserted through the round window**.

### Contraindications

00:11:10

- **Congenitally, if only the cochlea is absent the implant will be helpful?**
- No. Because there will be no structure present.
- Cochlear aplasia is the contraindication of the cochlear implant. Because there will be no structure of the cochlea so cochlea implant can't be implanted.
- If there is an 8th nerve abnormality (like aplasia, or retro-cochlear pathology, conduction via the auditory nerve is dysfunctional). In these situations, a cochlear implant can't be used.

### Essential criteria prior to doing an implant

00:13:18

#### Age

- A cochlear implant can be used as early as possible, between **3-6 months for neonates**.
- Beyond the 7 years of age, there will be no improvement in speech in congenital deaf child. Because the speech cortex failed to develop auditory stimulus by that time.

### Failed trial of hearing aid

- An implant is inserted in scala tympani which contains perilymph (nitrate of CSF). So, there are many complications to be considered.
- First hearing aid is preferred for 3 months if it is failed or no improvement in hearing, or speech then the cochlear implant is preferred.

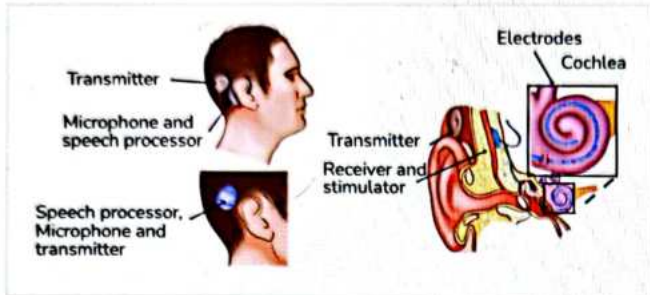




## Important Information

- Structurally cochlea must be present, and the 8th nerve must be structurally and functionally active, then the implant can be used. There should be no evidence of retro cochlear pathology.

## Parts of Cochlear Implant



- There are two important components (External and Internal components).

### External component

- It contains a microphone, speech processor, and transmitter.
- The microphone receives the sound from the external environment and transfers it to the speech processor (converts sound energy into electrical energy) then transmits it to

### Internal component:

- Internal component includes the receiver and stimulator with the electrode array.
- Receiver and stimulator receive the electrical impulses, the electrode array into the cochlea, and transfers electrical signals to the 8th nerve.

## Preoperative Evaluation

00:21:02

### Audiometry

- Audiometry is done in children 5 years old or above.
- Audiometry shows bilateral severe to profound sensory hearing loss.

### Ototoxic Emissions (OAE)

- OAE is the screening test in infants to diagnose whether the cochlea is working or not.
- If this test is failed, then the patient will refer to BERA.

### Brainstem Evoked Response Audiometry (BERA) or Auditory Brain Stem Response

- BERA shows if there is any cochlear pathology or retro cochlear pathology.
- It assesses the amount of hearing loss in both the cochlea. If there is cochlear pathology and the retro cochlear pathway is normal, then a cochlear implant can be done.

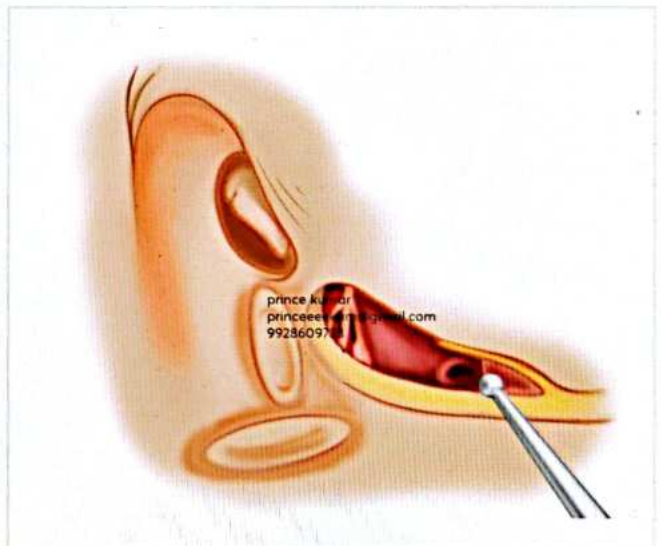
## High-Resolution Computed Tomography (HRCT) and Magnetic Resonance Imaging (MRI)

- To understand the anatomy of the middle ear, HRCT is done.
- MRI is done to see whether the cochlea (8th nerve) is present structurally or if there is any abnormality in the cochlea.

## Approach

### Posterior tympanotomy or Facial recess approach

- It is called Posterior tympanotomy (opening made to the middle ear through the posterior route or mastoid route).
- Present between the facial. In the mastoid, a vertical segment of the facial nerve is present that gives chorda-tympani nerve.
- Facial recess is present between the facial nerve, chorda-tympani nerve, and the fossa-incudis (space near the body of incus). This is called facial recess.
- Through the round window, an electrode is inserted into the scala tympani of the cochlea then it goes to all overturn of the cochlea.
- Once it is tested, the soft seal (fat or connective tissue) is put around the electrode because there is a possibility of leakage of perilymph.



## Complications

- Injury to the facial nerve, injury to chorda-tympani, and injury to the incus.
- In cochlear implant, there is always a risk of meningitis. An implant is always placed to the scala tympani of the cochlea and the scala tympani is communicated to the sub-arachnoid space by cochlear aqueduct.
- When an electrode is inserted or surgery is done, the approach is to use sterile but there is always a possibility of infection by 1%.





### Important Information

- In this situation, an infection can occur via the scala tympani into the subarachnoid space, via the cochlear aqueduct cause meningitis.
- Meningitis risk increases after the cochlear implant.

#### How to prevent complications?

- By the use of pre-operative pneumococcal and meningococcal vaccination prior to the cochlear implant, meningitis risk can be decreased and even if it occurs, the gross complication will not be there.

#### Post-Operative Assessment

##### Xray

- A routine X-ray is done to understand whether the implant is in position or not, whether it is placed inside the cochlea properly, and whether the turns bound the cochlea properly or not.

##### HRCT

- HRCT is rarely used to find any complications.

##### MRI

- MRI after the cochlear implant is usually not contraindicated. Because most implants are compatible with MRI.

#### Bone-Anchored Hearing Aid (BAHA)

- Bone conduction follows only the sensory neural pathway. Whenever sound stimulus is given to the bone, it bypasses the external ear and middle ear, and it directly passes to the cochlea or inner ear.
- It is used in the management of abnormality in the external ear and the middle ear. In BAHA, when an implant is placed into the bone, it bypasses the external and middle ear and directly passes to the inner ear.
- If the patient has microtia, anotia, or external auditory canal atresia and MRM cavity cholesteatoma. So, air conduction cannot be done by this route for sound because it already has pathologies.
- Another route is used for the conduction of sound (Bone conduction). The hearing aid is anchored to the bone by a small titanium screw.
- The titanium screw is integrated into the temporal bone. When it is fixed to the surrounding bone, over that abutment is placed and processor after six months.
- Six months later because to get the titanium screw incorporated with surrounding bones.
- Because of external ear pathologies, sound cannot travel via air conduction route. So, the sound is carried through the

processor that transfers directly to the inner ear (sound directly goes from the cochlea to the brain because of bone conduction).


#### Indication

- When there is a conduction pathology of the external ear or middle ear (microtia, anotia, or external auditory canal atresia and MRM cavity cholesteatoma).

#### Unilateral severe to profound sensorineural hearing loss

- In this condition, one cochlea is not functional, so BAHA will be aid to the dead ear or non-functional ear.
- Now the sound can transmit to the diseased ear but cannot be conducted to the brain because the cochlea is severe to profound impaired. But via the bones of the skull, the sound goes to the opposite cochlea.
- From the opposite cochlea, it is carried to the brain.
- It cannot be used in bilateral severe to profound hearing loss because both cochlea are damaged or not functioning, it will not be able to conduct the impulses to the brain. The cochlear implant is used in this condition.

#### Parts of BAHA



- The screw that is inserted into the squamous temporal bone, takes six months to integrate with surrounding bones. Then abutment and the sound processor are placed.
- It receives the sound and transmits it to the cochlea. BAHA has minor or no complications.

#### Auditory Brainstem Implant

- When there is 8th nerve pathology (trauma, tumor arising from the 8th nerve) then the approach is to implant an electrode into the brainstem.

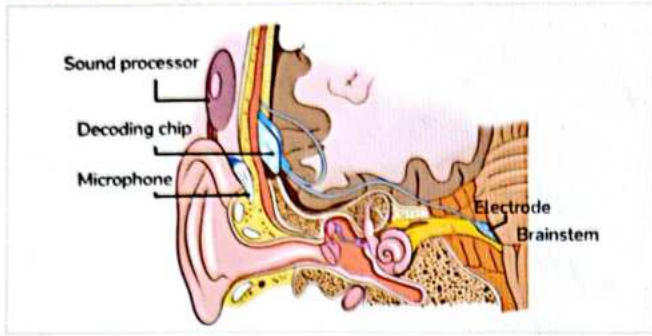


### Important Information

- Position of the implant- Lateral recess of the 4th ventricle.
- Electrode bypasses the cochlea and 8th nerve; it directly passes to the brainstem
- This implant directly stimulates the cochlear nucleus directly, then impulses are carried to the auditory cortex.



### Parts of Auditory Brainstem Implant



- **Brainstem surgery** is very risky because the brainstem has vital centres like breathing, and cardiac. But it can be used for patients who are very young and can benefit from this surgery.

### Indications

- **Bilateral acoustic neuromas**
- **CP angle tumour/surgery**
- It originates from the vestibule nerve. When surgery is done then the cochlear nerve (8th nerve) can damage, and impulses may not be conducted. In this condition, Brainstem surgery should be done.
- **Cochlear aplasia or 8th nerve aplasia**



### Important Information

- Hearing aid only amplifies the sound to the inner ear from where it is conducted.
- It is useful for moderate to severe conductive or sensory neuron hearing loss.
- If the cochlea is hypofunctional, the hearing aid is used to amplify the sound.

### Important Questions

00:29:05

**Q.1 CI is contraindicated in which of the following**

- A. Scheibe dysplasia
- B. Mandini's dysplasia
- C. Alexanders dysplasia
- D. Michel aplasia

**Ans- Michael aplasia**

### Scheibe Dysplasia

- Dysplasia of the cochlea and saccule

### Montidi's Dysplasia

- Cochlea takes 2 1/2 turns normally. But if it takes less turn than 2 1/2.

### Alexanders Dysplasia

- Basal turn is dysplastic

### Michael aplasia

- It's a complete cochlea non-development.

**Q.2 In a case of bilateral profound hearing loss, the best method to rehabilitate is**

**Ans- Cochlear implant**

**Q.3 A 3 year old child has been diagnosed as bilateral moderate sensorineural hearing loss. The best way for rehabilitation is**

**Ans- Hearing aid**

**Q.4 What is the ideal time for treatment of hearing loss in infants is**

**Ans- As Early As Possible**

**Q.5 BAHA is used in which clinical scenario -**

**Ans:** External/middle ear abnormality, unilateral severe to profound sensory-neuro hearing loss.

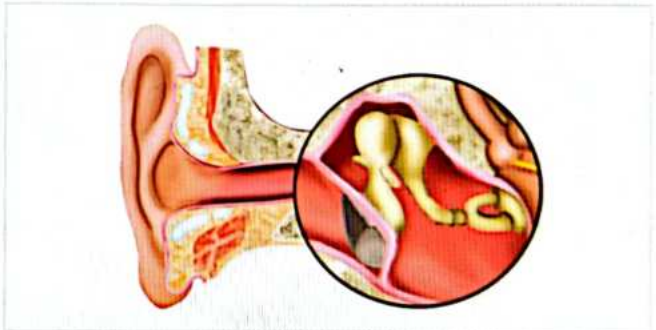
**Q.6 Electrode of cochlear implant stimulates**

**Ans:** Auditory Nerve

**Q.7 In cochlear implant electrodes are placed through**

**Ans:** Round window to scala tympani

**Q.8 Identify?**



**Ans: Middle ear implant**

### Middle Ear Implant

- Middle ear implants are suitable for those with a mild – moderate mixed or conductive hearing loss or a sensorineural hearing loss
- A middle ear implant is a more recent hearing implant, offering an alternative to conventional hearing aids.
- It maybe considered for those who suffer with ear mold allergies, skin problems in their ears, outer ear infections, narrow, collapsed or closed ear canals, or malformed ears.

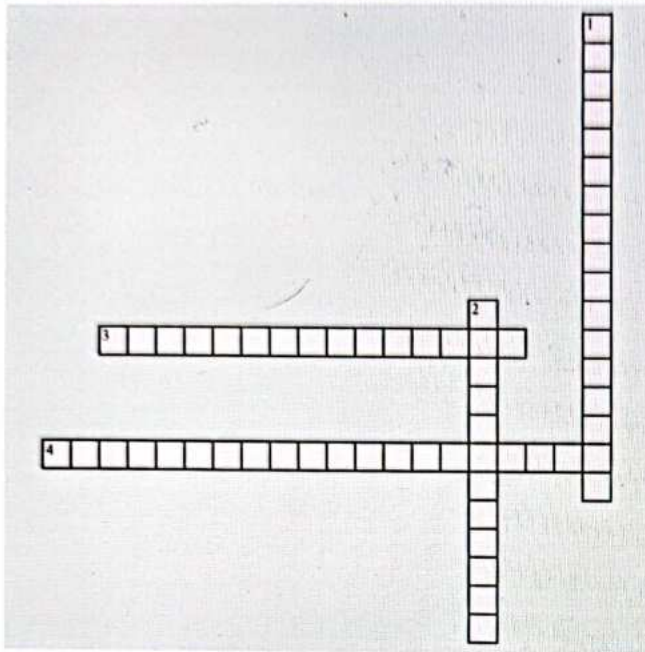




# CROSS WORD PUZZLES



Crossword Puzzle 1



**Across**

- 3. \_\_\_ is the complication of Posterior tympanotomy
- 4. \_\_\_ shows bilateral severe to profound sensory hearing loss.

**Down**

- 1. \_\_\_ must be present and the 8th nerve must be structurally and functionally active then the implant can be used.
- 2. \_\_\_ shows if there is any cochlea pathology or retrocochlear pathology.


**Across**

- 3. \_\_\_ is the contraindication of the cochlear implant.
- 4. \_\_\_ is the process of offering different therapies to improve hearing for those who are hearing impaired.

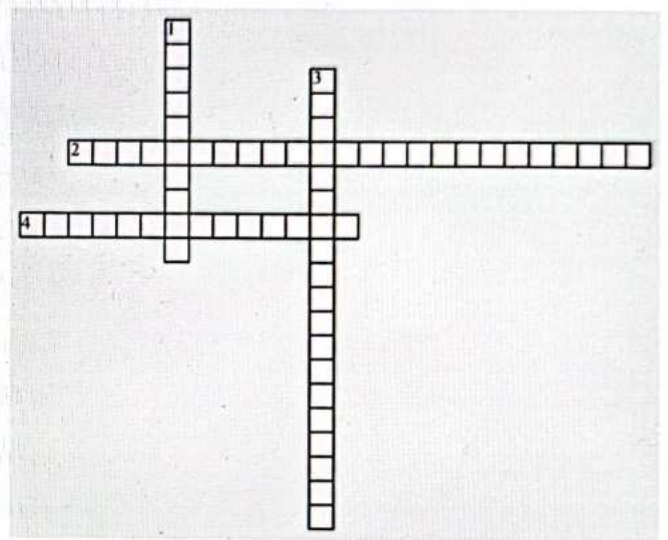
**Down**

- 1. \_\_\_ occurs before a child develops speech or loses his/her hearing in early childhood.
- 2. \_\_\_ is the father of neurotology.

Crossword Puzzle 2



Crossword Puzzle 3



**Across**

- 3. By using \_\_\_ prior to the cochlear implant, meningitis risk can be decreased.
- 4. \_\_\_ increases after the cochlear implant.

**Down**

- 1. \_\_\_ can only amplify the sound that is conducted to the inner ear.
- 2. \_\_\_ is a screening test used in infants to determine whether or not the cochlea is working.





Otalgia means pain in the ear.

00:00:44

### Classified Based on the Cause

#### Primary Otalgia

- The cause of pain is in the ear, e.g., wax in the external auditory canal (EAC), acute suppurative otitis media (ASOM), otitis externa (OE), foreign body (FB), etc.

#### Referred Otalgia

- The cause of pain is elsewhere. The pain is referred to the ear by the nerve that supply the ear, e.g., LAG (Lesser occipital, auriculotemporal (AT), and greater auricular nerves), seventh nerve, and the tenth nerve supply the pinna.
- The lesser occipital nerve and the greater auricular nerve come from C2 and C3. The auriculotemporal is a branch of the trigeminal nerve (fifth nerve).
- The EAC is supplied by the AT, which is a branch of the fifth nerve, and the auricular branch of the vagus nerve, called ARNOLD'S nerve, which is a branch of the tenth nerve.
- The middle ear is supplied by the tympanic branch of the glossopharyngeal nerve, called JACOBSON'S nerve.

- one-third of the tongue, or on the posterior pharyngeal wall at the level of the oropharynx, which are radiated by the ninth nerve, then this can cause ear pain since the ninth nerve supplies the tympanic branch of the middle ear. If a patient post-tonsillectomy presents with pain in the ear, then the cause of the pain is the glossopharyngeal nerve.
- The larynx and the hypopharynx get their supply from the vagus nerve. This causes referred pain. If a patient presents with laryngeal carcinoma and complains of pain inside the ear, then the nerve responsible for causing this pain is the vagus nerve.
- Cervical spondylosis at the level of C2 and C3 via the lesser occipital and greater auricular nerves can cause referred otalgia.
- The cervical esophagus is supplied by the vagus nerve, from where it can cause otalgia.

prince kumar  
princeekum@gmail.com  
9928609733

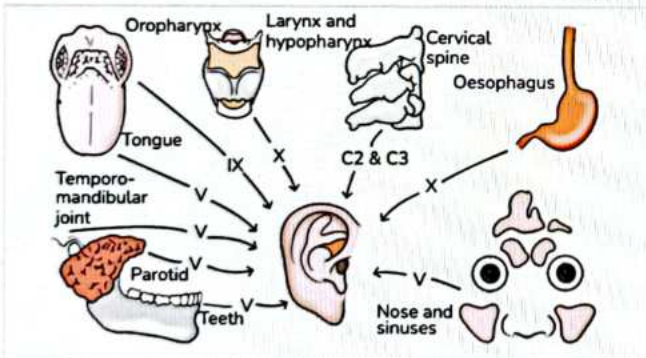
### Summary of causes of otalgia

00:08:00

Local causes	Referred causes
External ear.	Via the fifth cranial nerve.
	Via the ninth cranial nerve.
Middle ear.	Via the tenth cranial nerve.
	Via C2 and C3.

### Mechanism of Referred Otalgia

00:04:31



- If there's any lesion in area of distribution of the trigeminal nerve, like dental pain, or pain at the anterior part of the oral cavity, etc., then it is referred by this nerve to the pinna and EAC. This is how it causes referred otalgia.
- Similarly, the temporomandibular (TMJ) joint, the parotid, and the oral cavity will cause referred otalgia by the trigeminal nerve. If a patient with dental pain or TMJ pain complains of pain in the ear, then the cause of the pain is the trigeminal nerve.
- The oropharynx is supplied by the glossopharyngeal (ninth) nerve. If there's a lesion on the tonsil, posterior

### Tinnitus

00:09:08

- Tinnitus is a ringing sensation in the ear.
- There are two types of tinnitus:
  - Subjective tinnitus: Here the patient himself experiences the tinnitus, which cannot be detected by the examiner.
  - Objective tinnitus: In this type, both the patient and the examiner are able to understand the organic cause of tinnitus.

### Causes of Tinnitus

00:09:49

Subjective causes	Objective causes
<ul style="list-style-type: none"> <li>Otologic causes include, e.g., tympanic membrane perforation due to ear wax, fluid in the middle ear, etc.</li> <li>Metabolic causes, e.g., hyperthyroidism, hyperdynamic circulation, etc.</li> </ul>	<ul style="list-style-type: none"> <li>Vascular causes, e.g., high riding jugular, dehiscence of the bone covering the jugular, dehiscence of the carotid.</li> <li>The patulous Eustachian tube causes, e.g., synchronous sound with respiration.</li> </ul>



- Neurologic causes, e.g., brain stroke, brain infarction, trauma to the head, fractures, etc.
- Cardiovascular causes, e.g., anemia, hyper-dynamic circulation, etc.
- Pharmacologic causes, e.g., ototoxic drugs
- Psychogenic causes, e.g., The patient feels there's ringing in the ear, but all other tests are normal.

prince kumar  
princeekum@gmail.com  
9928609733

### Treatment of Tinnitus

00:12:51

- Tinnitus has no standardized treatment.
- Treatment involves ruling out all the general, otologic, and systemic causes.
- When there's no known cause, the treatment is tinnitus-retaining therapy.
- The patient is counselled that tinnitus will persist and is advised to distract themselves from the sound whenever it is heard in case of subjective tinnitus. In cases of objective tinnitus, the underlying cause is treated.






# CROSS WORD PUZZLES



## Crossword Puzzle 1




### Across

- 2. \_\_\_\_\_ means pain in the ear.
- 3. \_\_\_\_\_ otalgia means cause of pain is elsewhere.

### Down

- 1. \_\_\_\_\_ otalgia means the cause of pain is in the ear.

## Crossword Puzzle 2




### Across

- 2. \_\_\_\_\_ is supplied by the glossopharyngeal (ninth) nerve.
- 3. \_\_\_\_\_ and the hypopharynx get their supply from the vagus nerve.

### Down

- 1. \_\_\_\_\_ spondylosis at the level of C2 and C3 via the lesser occipital and greater auricular nerves can cause referred otalgia.

## Crossword Puzzle 3




### Across

- 2. \_\_\_\_\_ is a ringing sensation in the ear.

### Down

- 1. \_\_\_\_\_ causes of tinnitus include tympanic membrane perforation due to ear wax, fluid in the middle ear, etc.
- 3. \_\_\_\_\_ tinnitus means that the patient himself experiences the tinnitus, which cannot be detected by the examiner.

## Crossword Puzzle 4



### Across

- 3. \_\_\_\_\_ causes of tinnitus include hyperthyroidism, hyperdynamic circulation, etc.

### Down

- 1. \_\_\_\_\_ causes of tinnitus include anemia, hyperdynamic circulation, etc.
- 2. \_\_\_\_\_ causes of tinnitus include high riding jugular, dehiscence of the bone covering the jugular, dehiscence of the carotid.

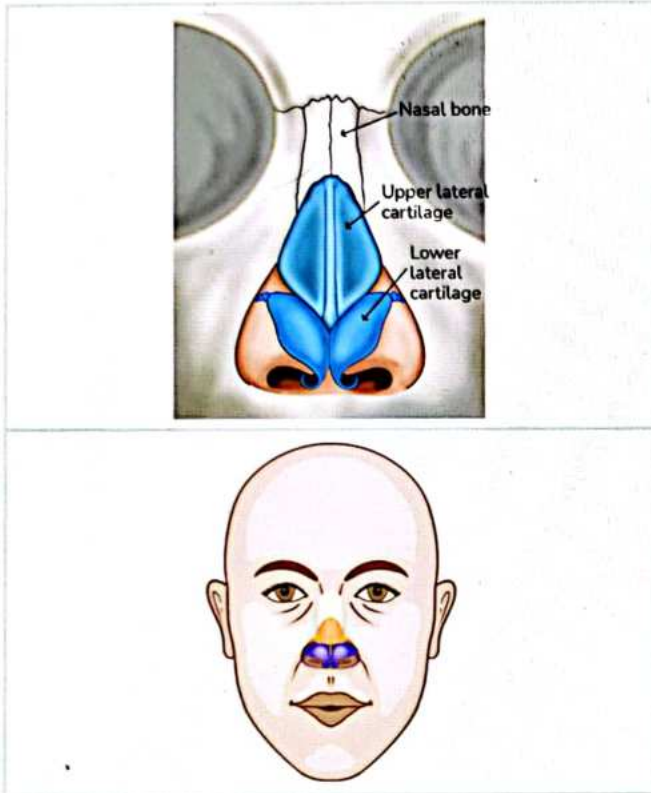




Anatomy of Nose

00:00:27

External Nose Anatomy



- The external bone is made up of 2 components
  - **The Bony part** – accounts for 1/3 of the nose.
  - **Cartilaginous part** – accounts for 2/3 of the nose.
- These parts are made of certain paired bones and unpaired bones.
- The bony pyramid of the nose consists of
  - **Paired bones**
    - Nasal bones articulate in the midline (left and right nasal bones).
    - The Ascending process of Maxilla – it comes from the maxilla and goes towards the nose. It is ascending upwards. It forms the upper third of the nose.
  - **Unpaired bone**
    - The frontal bone is the only unpaired bone.
- The cartilaginous pyramid of the nose also has some paired and unpaired cartilages.
  - **Paired cartilages**
    - Upper lateral cartilage
    - Lower lateral cartilage

→ Sesamoid cartilage

○ **Unpaired cartilage**

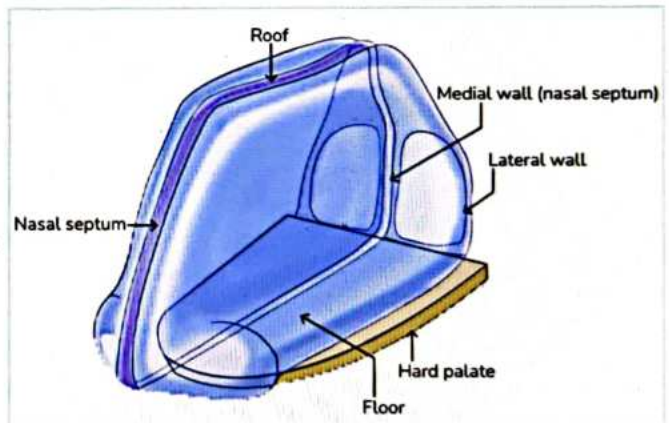
→ Septum is the unpaired cartilage that comes from below and supports the Dorsum.

**Landmarks**

- **Nasion** – it is the point on the Dorsum of the nose where the frontal bone articulates with the nasal bone in the midline.
- **Rhinion** - it is the point on the Dorsum of the nose where the nasal bone articulates with the upper lateral cartilage.
- **Limen Nasi** – it is the lower border of the upper lateral cartilage.
  - Limen Nasi is the site of incision for internal Rhinoplasty.
  - The Limen Nasi also forms the boundary of the Internal Nasal Valve, which is the narrowest portion of the nasal cavity.

**Internal Nose Anatomy/Nasal Cavity Proper**

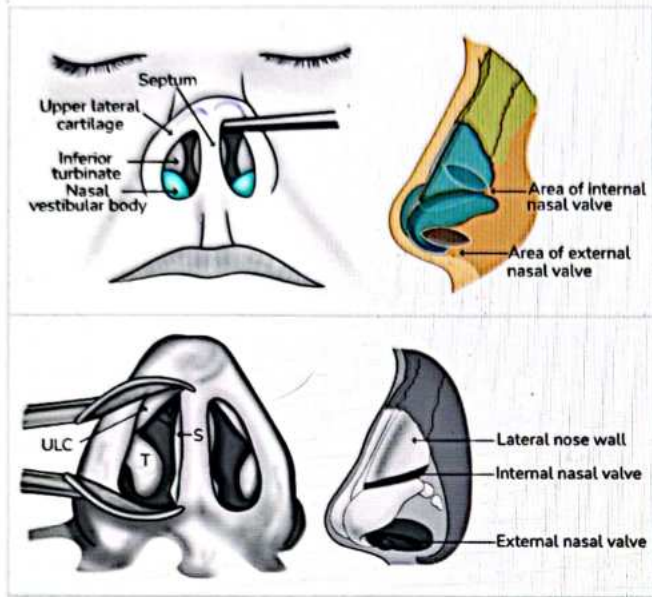
00:11:54



- The vestibule of the nose is the portion where the nose begins anteriorly.
- Posteriorly, communication between the nose and the nasopharynx is known as **Choanae**.
- The roof of the nose separates the nasal cavity from the cranial fossa.
- The floor of the nose separates the nasal cavity from the oral cavity.
- The septum forms the medial valve. It separates the right side of the nose from the left side, which divides the nasal cavity into two halves.
- The lateral valve of the nose.



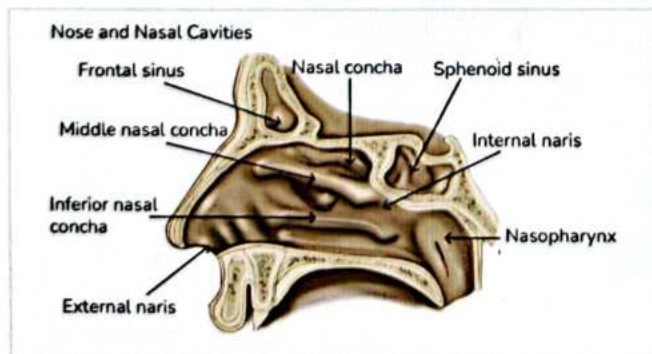
**Vestibule**



- A vestibule is the inlet of the nose.
- A vestibule is lined by stratified squamous epithelium, which has hair follicles.
- These hair follicles are present only in the vestibule. It is not present in the rest of the nasal cavity.
- The vestibule of the nose also has 2 valves – one on the outside and one on the inside.
- The valve which is present on the outside is known as **External Nasal Valve (ENV)**.
- **Internal Nasal Valve (INV)** is a bit inside the Vestibule.
- INV is the narrowest portion of the nasal cavity (10 to 15 degrees)
- The **external Nasal Cavity** is bounded by Columella medially, the Ala of the nose laterally, and the skin of the floor inferiorly.
- The **internal nasal valve** is bounded by the septum medially, the lower border of the upper lateral cartilage superiorly, and the head of the inferior turbinate inferiorly.

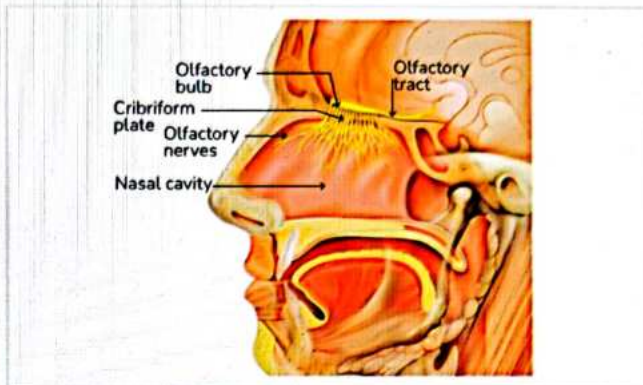
**Choanae**

00:19:00



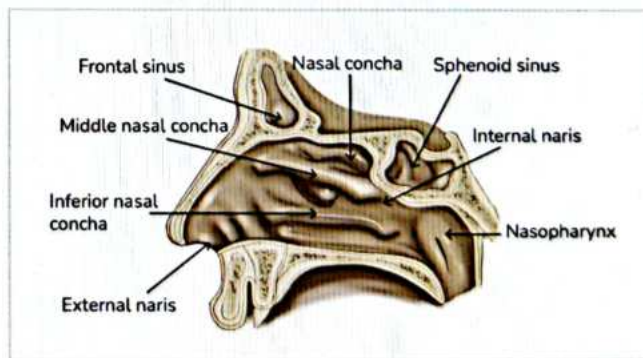
- The choanae is the outlet of the nose.
- The choanae is the posterior end of the nose where the nose communicates with the nasopharynx.

**Roof of the Nose**



- The roof of the nose is part of the nose that separates the nasal cavity from the anterior cranial fossa.
- The roof of the nose is made up of 3 parts of bone:
  - In the anterior 1/3 part, the roof is formed by the frontal bone and the nasal bone.
  - The middle 1/3 part is formed by the cribriform plate of the Ethmoid bone. The Cribriform plate has numerous holes or sieve-like structures. The olfactory fibres pass through the cribriform plate to the frontal lobe of the brain.
  - The posterior 1/3 part is formed by the sphenoid bone.

**Floor of the Nose**



- The floor of the nose is formed by the palate – the hard palate anteriorly and part of the soft palate posteriorly.
- The **hard palate** is formed by the crest of the maxilla anteriorly and the crest of the palatine bone posteriorly.

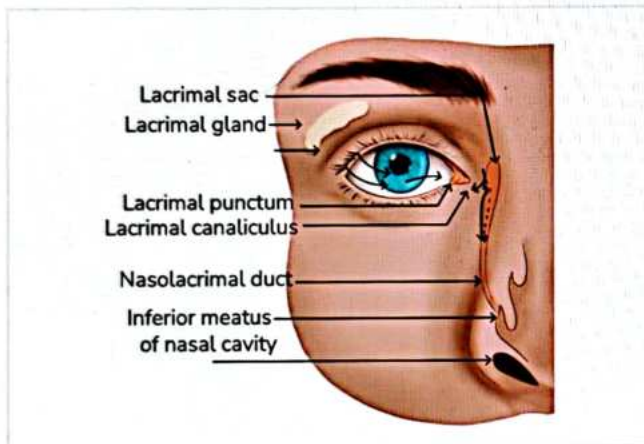






- There is inferior turbinate, middle turbinate, and superior turbinate.
- Sometimes, there may be a fourth turbinate prince kumar known as the supreme turbinate. It is not present in everyone but can be present in some.
- There are spaces below the turbinate. These spaces are known as Meatus which are inferior, middle, and superior.
- Each of these meatus receives the opening of certain structures.

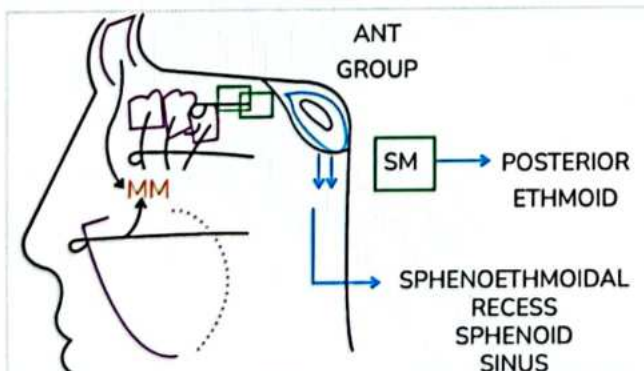
### Inferior Meatus of the Nose



- The inferior meatus of the nose receives the opening of the nasolacrimal duct.
- In the eye, the upper and lower canaliculus both joins to form the common canaliculus which opens in the Lacrimal sac. From the lacrimal sac, there is a nasolacrimal duct which opens in the inferior meatus of the nose. This opening is guarded by a valve known as the **valve of Hasner**.

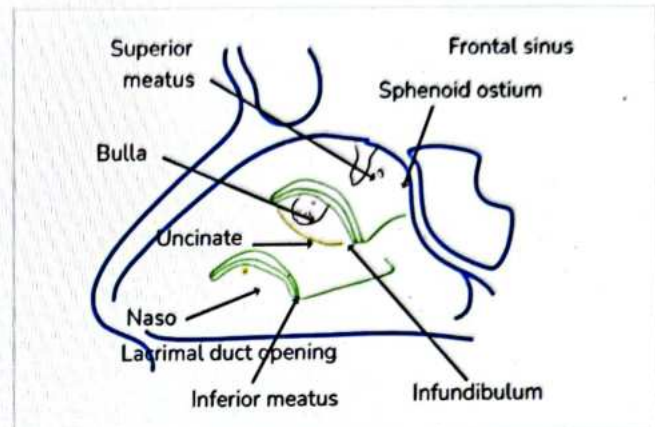
### Drainage of Sinuses

00:41:00

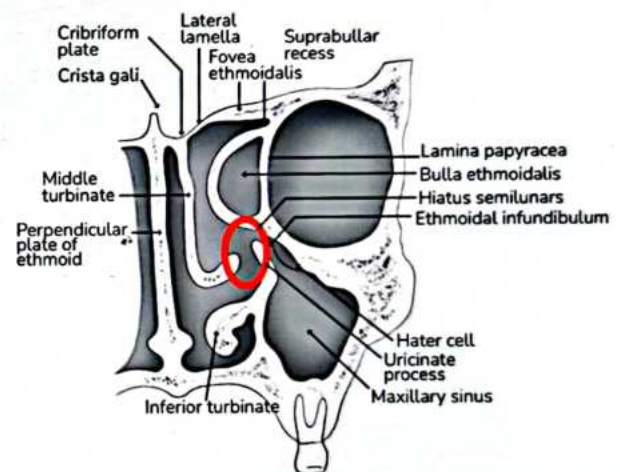


- The middle meatus receives the drainage of an anterior group of sinuses – **Frontal sinus**, **Maxillary sinus**, and **Anterior Ethmoidal sinus**.
- The superior meatus receives the drainage of posterior Ethmoids.
- The sphenoid sinus drains into the **Sphenoethmoidal Recess**.

### Anatomy of Middle Meatus of The Nose



### Osteomeatal complex [Picadli's circle]



- In the middle meatus of the nose, there is a **boomerang-shaped bone** known as the **Uncinate process** present anteriorly.
- Behind the uncinat process, there is a big **Ethmoidal air cell** known as **Bulla ethmoidalis**.
- The space between the uncinat process and the Bulla ethmoidalis is known as **Hiatus semilunaris**. This inferiorly leads to another space known as **Infundibulum**.
- The maxillary sinus opens at the level of the Infundibulum.
- The Osteomeatal complex or Picadli's circle is the common point of drainage of an anterior group of sinuses.



### Important Information

- The external nose has 2 paired bones, 1 unpaired bone, 3 paired cartilages, and 1 unpaired cartilage.
- The other name for pseudostratified columnar epithelium is the **Schneiderian membrane**.
- Intra Nasal Valve (INV) is the narrowest portion of the nasal cavity.
- INV is bounded by the septum medially, the lower border of the upper lateral cartilage superiorly, and the head of the inferior turbinate inferiorly.



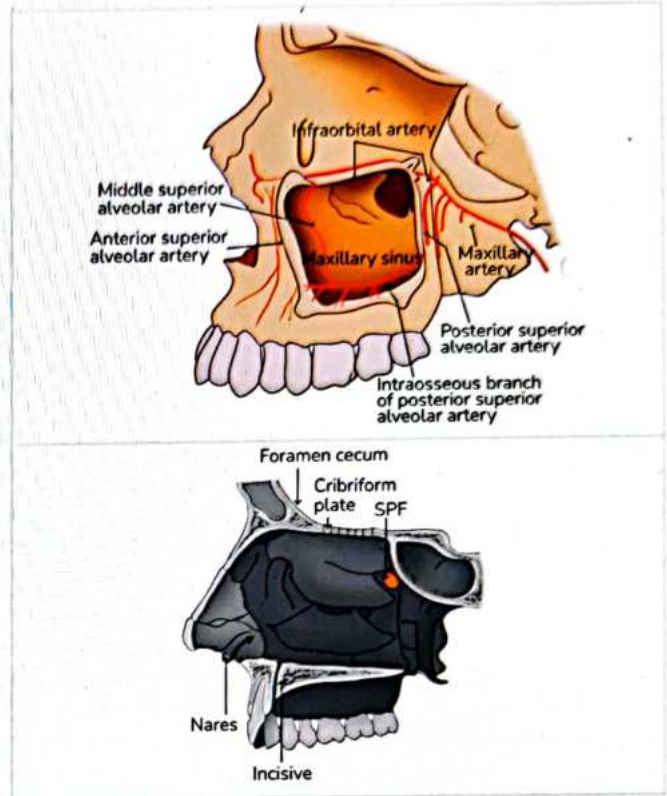
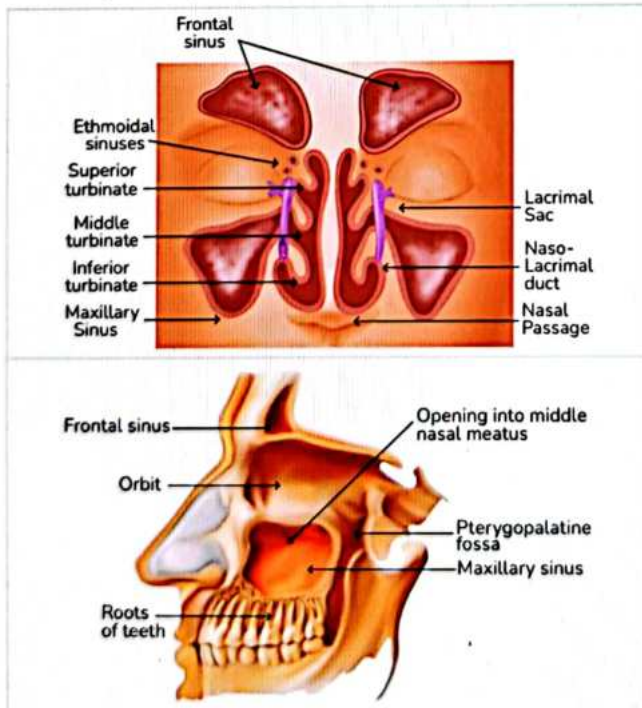
- The INV angle is about 10-25 degrees.
- The vestibule is the inlet of the nose and Chonae is the outlet of the nose.
- Nasion is where the frontal bone meets the nasal bone.
- Rhinion is where the nasal bone meets the upper lateral cartilage and Limen Nasi is the lower border of the upper lateral cartilage.
- An inferior turbinate is not a part of the Ethmoid bone.
- The medial wall is the wall of the septum.
- Palatine arteries supply the blood to the inferior portion of the septum.
- Ethmoidal arteries supply the blood to the superior portion of the septum.
- All the arteries anastomose at the anteroinferior portion of the septum which is known as Little's area or Kiesselbach's plexus.
- All the arteries anastomose together except the posterior ethmoidal artery.
- The direction of the nasolacrimal duct is downwards, backwards, and lateral.

### Anatomy of Paranasal Sinuses

00:47:00

- There are 4 groups of sinuses:
  1. Maxillary sinus
  2. Frontal sinus
  3. Ethmoid sinus
  4. Sphenoid sinus.

### Maxillary Sinus (Antrum of Highmore)



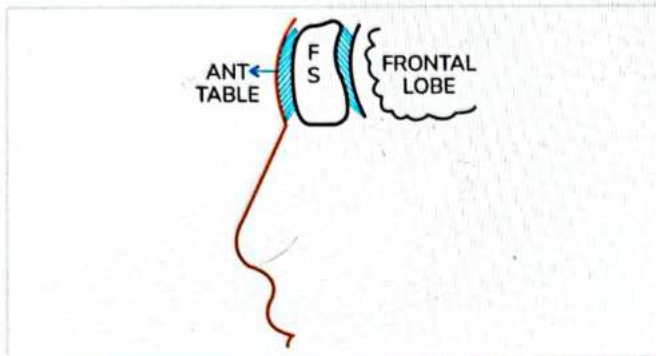
- The maxillary sinus is also known as the **Antrum of Highmore**.
- The maxillary sinus is the 1<sup>st</sup> sinus to develop and the first sinus to be visible radiologically.
- The maxillary sinus is the **largest of all the sinuses**.
- The maxillary sinus has certain walls.
  - Base – it separates the maxillary sinus from the lateral wall of the nose.
  - Apex – is at the level of zygoma.
  - Roof – is formed by the floor of the orbit.
  - Floor – floor of the maxillary sinus is with 2 teeth (second premolar and first molar).
- There is skin and subcutaneous tissue in the anterior wall of the maxillary sinus.
- Behind the posterior wall, there is a fossa known as the **Pterygopalatine fossa**.
- The Pterygopalatine fossa consists of an artery known as **Internal Maxillary Artery**.
- The Internal Maxillary Artery (IMA) gives rise to 2 branches:
  - Sphenopalatine artery – enters the nose through the sphenopalatine foramen which is near the posterior wall of the maxillary sinus about 8-10mm behind the middle turbinate.
  - Greater palatine artery – this artery descends inferiorly to the palate and goes to supply the nasal cavity.

### Frontal Sinus

- Last sinus to develop/Absent at birth



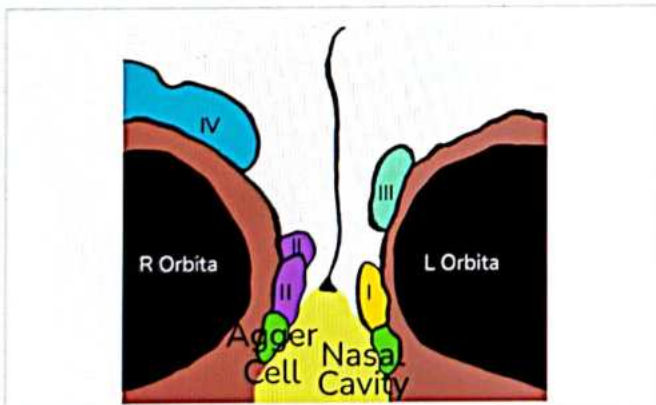
- Pyramidal in shape
- Anterior wall formed by outer table of frontal bone
- Posterior wall separates it from cranial cavity
- Floor separates orbit
- Medially separated from other frontal sinus by septum



**TABLE I**

**Frontal Cell Types I-IV**

Type I	Single frontal recess cell above agger nasi cell
Type II	Tier of cells in frontal recess above agger nasi cell
Type III	Singles massive cell pneumatizing cephalad into frontal sinus
Type IV	Single isolated cell within the frontal sinus



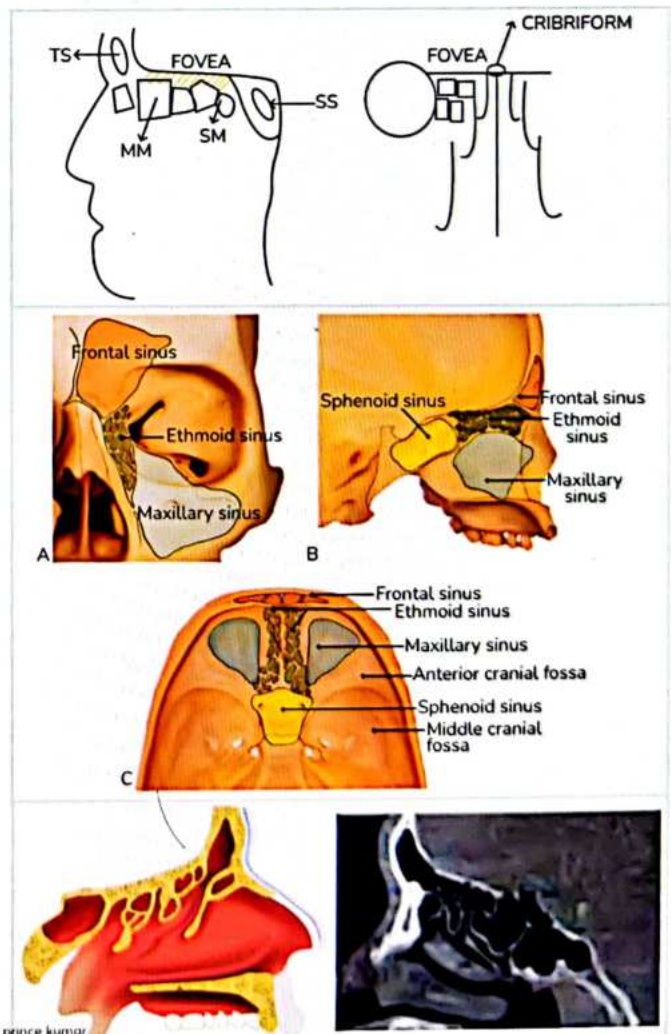
- The frontal sinus is an air-filled pneumatization.
- The frontal sinus is absent at birth and the last sinus to develop.
- The frontal sinus is pyramidal in shape and has walls the same as that of the maxillary sinus.
- The anterior wall of the frontal sinus is formed by the anterior table of the frontal bone.
- The posterior wall of the frontal sinus is formed by the posterior table of the frontal bone.
- The posterior wall of the frontal sinus separates the frontal sinus from the frontal lobe of the brain.
- The medial wall of the frontal sinus is formed by a septum which separates the right frontal from the left frontal sinus.

- The floor of the frontal sinus is formed by the roof of the orbit.
- This frontal sinus drains inferiorly into the middle meatus of the nose.
- The frontal Recess is the area of the drainage pathway of the frontal sinus.
- In the frontal sinus, the anterior-most cell is Agger nasi and there is Bulla and the other ethmoidal air cells behind that.

**Kuhn Cells (Kuhn's Classification)**

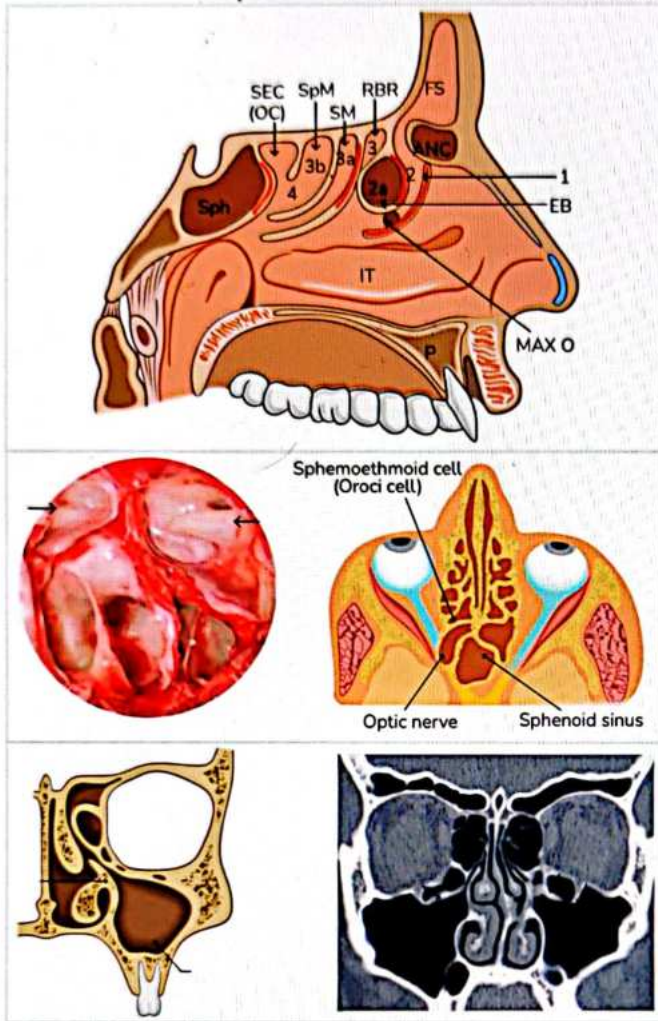
- TYPE I - If there is a single cell above the Agger nasi (frontal recess).
- TYPE II - if there are rows of cells above the Agger nasi.
- TYPE III - if there is a single cell pneumatization into the frontal sinus but is occupying less than 50% of the frontal sinus.
- TYPE IV - if there is a single isolated cell in the frontal sinus.
- These Kuhn cells can narrow down the frontal recess and obstruct the drainage of the frontal sinus resulting in the retention of secretions.

**Ethmoidal Sinus**



prince kumar  
princeekumar@gmail.com  
9928609733



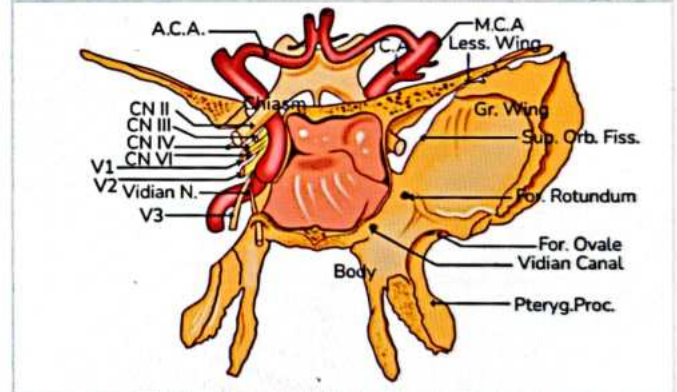
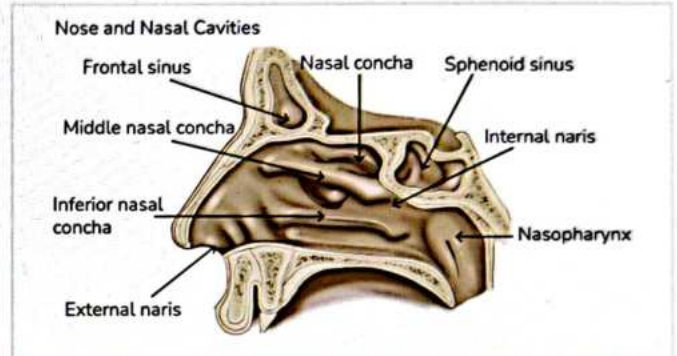


→ Sometimes, it may also contain Internal Carotid Artery.

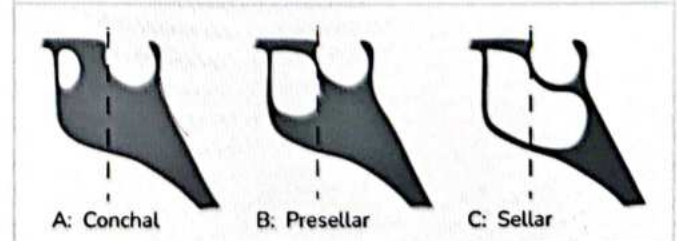
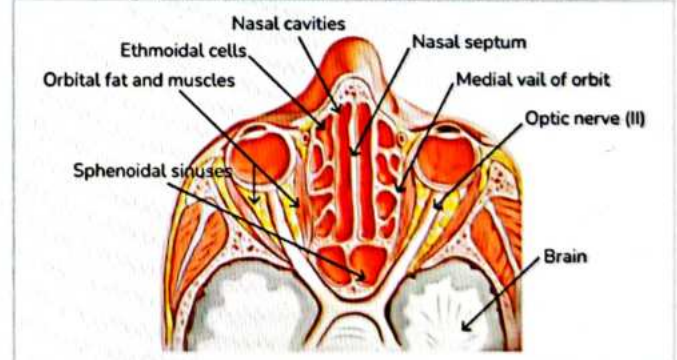
o **Haller cell**

- If there is an air cell present on the floor of the orbit, then the cell is known as the Haller cell.
- A Haller cell can be anterior or posterior.
- If there is an ethmoidal air cell which is inferomedial to the orbit, it is the Haller cell.

**Sphenoid Sinus**



- These cells are sandwiched between the frontal sinus anteriorly and the sphenoid sinus posteriorly.
- The roof of the ethmoidal air cells is known as **Fovea Ethmoidalis**.
- Fovea ethmoidalis separates the ethmoidal sinuses from the frontal lobe of the brain.
- The medial limit of the ethmoidal air cells extends medially from the middle turbinate.
- They extend laterally from the medial wall of the orbit.
- Few named air cells are
  - o **Agger Nasi**
    - The Agger Nasi is the anterior most or the 1st ethmoidal air cell.
  - o **Bulla ethmoidalis**
    - Bulla Ethmoidalis is behind the Agger Nasi.
    - It is the largest ethmoidal air cell
  - o **Onodi cell**
    - The Onodi cell is the posterior ethmoidal air cell that extends into the sphenoid sinus in the posterior and lateral directions.
    - Sometimes, these cells may have an optic nerve within them.





- The Sphenoid sinus is the posterior-most sinuses – present very posteriorly in the nasal cavity.
- There is a depression in the roof of the sphenoid sinus which is known as **Sella Turcica** which lodges the pituitary gland.
- The lateral wall of the sphenoid sinus is related to the optic nerve.
- In addition to the optic nerve, it is related to an artery superiorly and laterally known as Internal Carotid Artery.
- The Sphenoid sinus is also associated with the Cavernous sinus and its contents.
- In the Cavernous sinus, there are 3rd nerve, 4th nerve, the ophthalmic and the maxillary division of the Trigeminal nerve, and the 6th nerve.
- On the floor of the sphenoid sinus, there are **Foramina – Vidian Canal below and Foramen Rotundum above.**

### Pneumatization Pattern of The Sphenoid

The types of pneumatisation are

- 1) **Conchal** – if the air-filled pneumatisation of the sphenoid sinus is not present at all and there is a very small Pneumatized cavity and the rest of the entire sphenoid is bony.
- 2) **Presellar** – if the air-filled cavity in the sphenoid sinus extends up to the anterior wall of the Sella Turcica.
- 3) **Sellar** – if the pneumatisation extends up to the posterior wall of the Sella Turcica.
- 4) **Post Sellar** – if the pneumatisation extends beyond the posterior wall of the Sella Turcica.



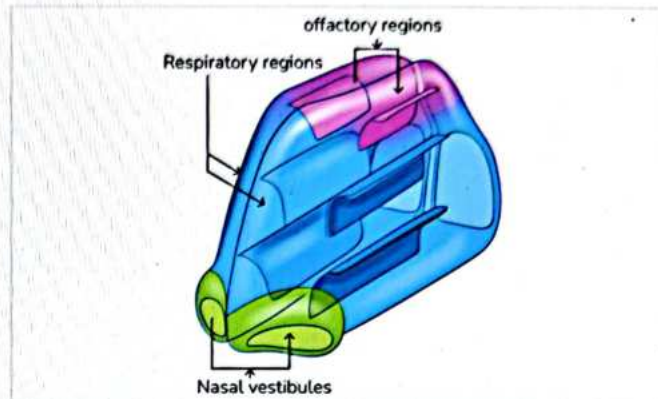
### Important Information

- The sinus draining into the Hiatus Semilunaris present in the middle meatus is the frontal sinus and anterior ethmoidal sinus.
- The sinus draining into the infundibulum is the maxillary sinus.
- The sinus draining into the superior meatus is the posterior ethmoids.
- The Sphenoid sinus drains into the Sphenoethmoidal Recess.
- The maxillary sinus is the largest.
- The frontal sinus is the last sinus to develop.
- The frontal sinus is absent at birth and the last one to develop.
- The development of the maxillary sinus coincides with the development of the secondary dentition.
- The maxillary sinus is the earliest sinus to develop and to be visible radiologically.
- The most common sinusitis in children is ethmoids.
- The most common sinusitis in adults is the maxillary sinus.

prince kumar  
princeekum@gmail.com  
9928609733

### Lining Membrane of the Nose

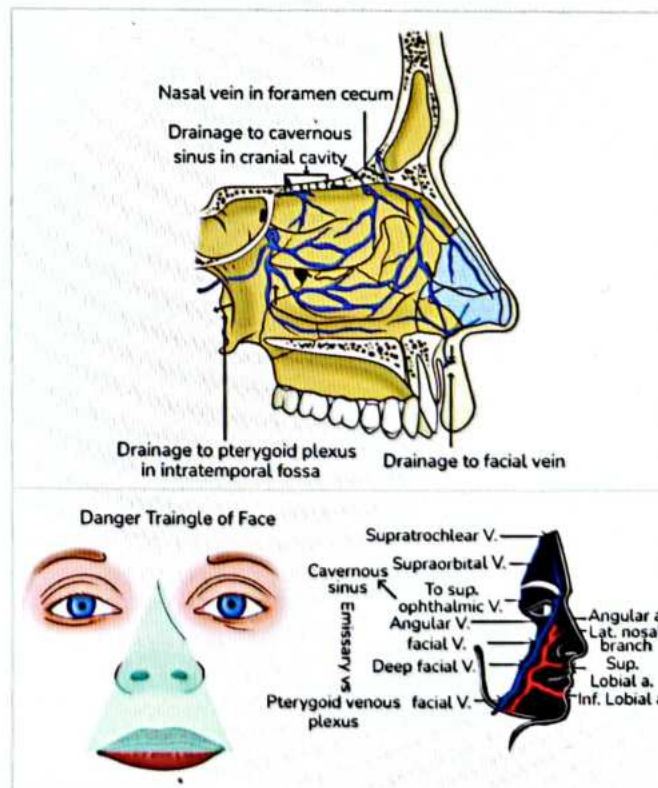
01:17:49



- The vestibule or the inlet of the nose is lined by stratified squamous epithelium and hair follicles.
- The rest of the nose is lined by the respiratory epithelium. Respiratory epithelium is also known as the **Schneiderian membrane**. It is the pseudostratified ciliated columnar epithelium.
- The roof of the nose has the olfactory epithelium present in the olfactory cleft.
- An olfactory cleft is bounded medially by the upper portion of the septum, laterally by the superior turbinate, and superiorly by the cribriform plate of the ethmoid.

### Venous Drainage of the Nose

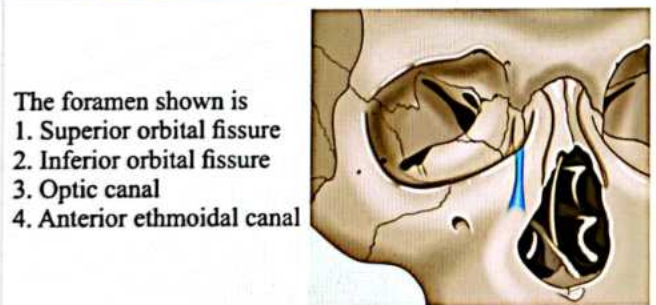
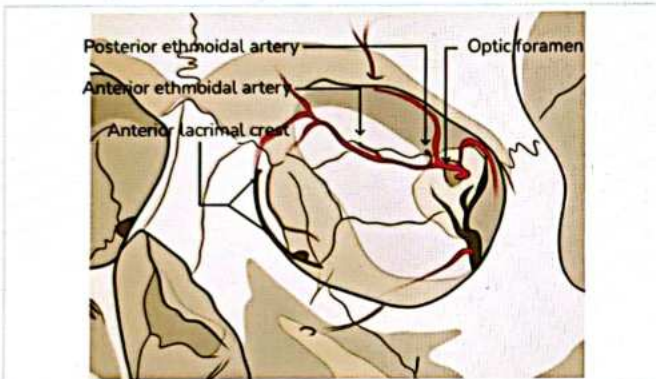
01:21:42



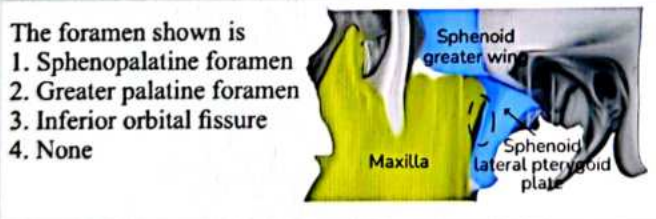

- The venous part of the nose drains into the ophthalmic veins and goes to the Cavernous sinus.
- The posterior part of the nose drains into the facial veins and then to the Pterygoid flexus of the vein.
- From the Pterygoid flexus, it drains into the Cavernous sinus.
- The valves that are present here are valve less. Therefore, any infection in the nose or the dangerous area of the face (triangle which is bounded by nasion and the angle of lips.). Any infection in this space can go to the Cavernous sinus through the venous pathway because the veins are valve less.

### Extra Edge



- The foramen shown is
1. Superior orbital fissure
  2. Inferior orbital fissure
  3. Optic canal
  4. Anterior ethmoidal canal



- The foramen shown is
1. Sphenopalatine foramen
  2. Greater palatine foramen
  3. Inferior orbital fissure
  4. None

- The foramens present on the medial wall of the orbit are

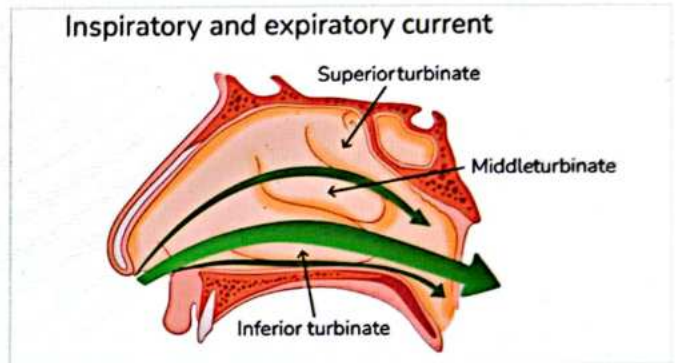
  1. Anterior Ethmoidal Foramen
  2. Posterior Ethmoidal Foramen
  3. Optic canal

  - The distance from the anterior lacrimal crest to the anterior ethmoidal foramen is 24mm.
  - The distance from the anterior ethmoidal foramen to the posterior ethmoidal foramen is 12mm.
  - The distance from the posterior ethmoidal foramen to the optic canal is 6mm.
  - The sphenopalatine foramen is present near the posterior wall of the maxillary sinus.

### Functions of the Nasal Cavity

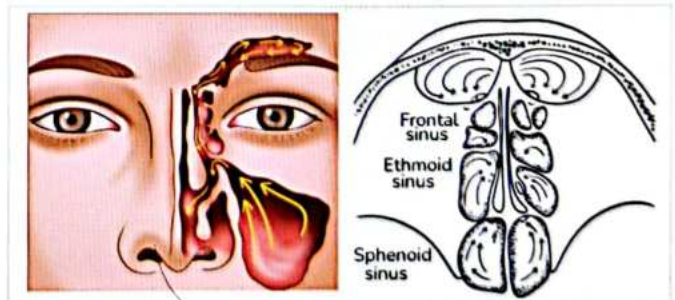
1. Nasal purification.
2. Purification of the air.
3. Humidification of air.
4. Gives resonance to the voice.
5. Responsible for smell or olfaction.
6. Acts as an outlet for lacrimal secretions

### Inspiratory And Expiratory Currents



- **Inspiratory current** – the maximum air goes into the middle meatus of the nose.
- **Expiratory current** – when the air current comes from a wider area to a narrower area, the circulation currents are established. These currents are known as **Eddie's currents** which help in pushing the air into the sinuses.
- Thus, the ventilation of sinus happens during expiration.
- During expiration, the other gases with little oxygen also come out apart from carbon dioxide. When there are Eddie's currents, this carbon dioxide breaks into carbon monoxide, nitrogen oxide, and free oxygen radicals. These free radicals help in killing the bacteria.
- Hence, sinus ventilation happens during expiration and not during inspiration.

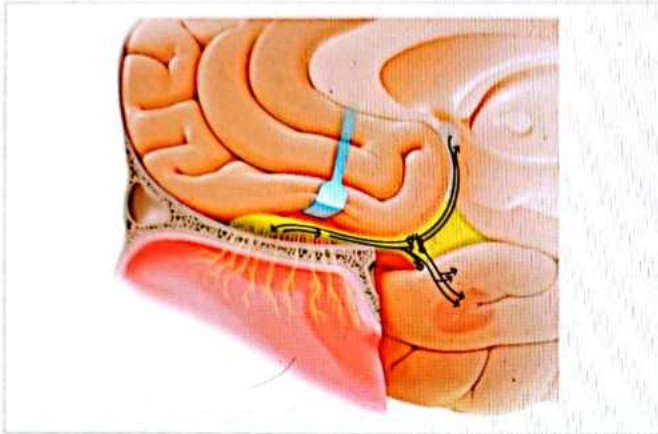
### Mucocilliary Clearance



- The cilia beat in a way the mucus from the nose and the paranasal sinus cavity gets drained out. They move in a centripetal direction from medial to lateral in the frontal sinus and in a centrifugal direction from outwards to inwards in the maxillary sinus to clear the secretion from the sinuses.



**Olfactory Tract**



- The olfactory epithelium is present in the roof of the nose.
- The olfactory receptors present in the cribriform plate carry the olfaction of the impulses of the smell from the nose to the olfactory bulb present below the base of the frontal lobe.
- From the olfactory bulb, the olfactory nerves carry the impulses to the amygdala present in the frontal lobe of the brain.



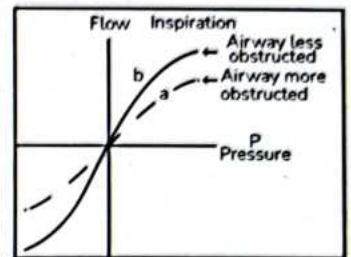
**Important Information**

- Hyposmia is the decrease in the perception of a smell.
- Anosmia is when there is no perception of a smell.
- Presbyosmia is an age-related decrease in the perception of a smell.
- Paraosmia is the alteration in the perception of odour.
- Cacosmia is the condition when the normal smell is felt as foul smelling.
- Dysosmia is a condition in which the normal smell is not foul smelling but smells differently.
- Phantosmia is the smell perception in the absence of an odorous stimulus.

**Upsit Test (University of Pennsylvania Smell Identification Test)**

- This test helps to understand if the patient's ability to perceive the smell is good or bad.
- The patient is given some scratch cards of odorous stimulus and asked to write down the smell.
- Electrical conduction studies are also done to understand the functioning of the olfactory nerves.

**Rhinomanometry**



- Rhinomanometry is an objective function to assess the nasal airflow.
- If there is an obstruction, it can be corrected by doing surgery and checked for improvement after the surgery.

**CLINICAL QUESTIONS**

Q. Which is the narrowest portion of the nasal cavity?

Ans: Internal Nasal Valve.

Q. What is the dangerous area of the face?

Ans: Triangle bounded by the Nasion and the angle of lips.

Q. What opens into the inferior meatus of the nose?

Ans: Nasolacrimal duct.

Q. Which valve guards the opening of the inferior meatus of the nose?

Ans: Valve of Hasner.

Q. What is the anterior group of sinuses?

Ans: Frontal, Maxillary, and anterior Ethmoidal sinuses.

Q. What opens at the level of the Infundibulum?

Ans: Maxillary sinus.

Q. Which is the largest sinus?

Ans: Maxillary sinus.

Q. Which artery is present in the pterygopalatine fossa?

Ans: Internal maxillary artery.

Q. Where is sphenopalatine foramen present?

Ans: it is present in the posterior wall of the maxillary sinus about 8-10mm behind the middle turbinate.

Q. Which sinus is absent at birth?

Ans: Frontal sinus.

Q. Which is the largest Ethmoid air cell?

Ans: Bulla Ethmoidalis.



# Telegram - @nextprepladdernotes

**Q.** Which is the last sinus?

**Ans:** Sphenoid sinus.

**Q.** Which is the most common type of pneumatization pattern in the sphenoid sinus?

**Ans:** Presellar

**Q.** Which is the most common sinus to be affected in adults?

**Ans:** Maxillary sinus.

**Q.** Which is the most common sinus to be affected in infants and young children?

**Ans:** Ethmoid sinus.

**Q.** In which sinus the development coincides with the development of 2<sup>nd</sup> dentition?

**Ans:** Maxillary sinus

**Q.** What is Little's area also known as?

**Ans:** Kiesselbach's plexus.

**Q.** What is the direction of the nasolacrimal duct?

**Ans:** Downwards, backwards, and laterally.






## CROSS WORD PUZZLES



### Crossword Puzzle 1




#### Across

2. \_\_\_\_\_ is the condition where the normal smell is felt as foul smelling.  
4. \_\_\_\_\_ is the alterations in the perception of odour.

#### Down

1. \_\_\_\_\_ is the decrease in the perception of a smell.  
3. \_\_\_\_\_ is no perception of the smell.

### Crossword Puzzle 2




#### Across

4. \_\_\_\_\_ is a condition where the normal smell is not foul smelling but smells differently.

#### Down

1. \_\_\_\_\_ is smell perception in the absence of an odorous stimulus.  
2. \_\_\_\_\_ is an age-related decrease in the perception of a smell.  
3. \_\_\_\_\_ is the point on the dorsum of the nose where the frontal bone articulates with the nasal bone in the midline.

### Crossword Puzzle 3



#### Across

3. \_\_\_\_\_ is used to assess the nasal flow.  
4. \_\_\_\_\_ is the portion where the nose begins anteriorly.

#### Down

1. \_\_\_\_\_ is the outlet of the nose.  
2. \_\_\_\_\_ is the point on the dorsum of the nose where the frontal bone articulates with the upper lateral cartilage.



21

DISEASES OF THE EXTERNAL NOSE

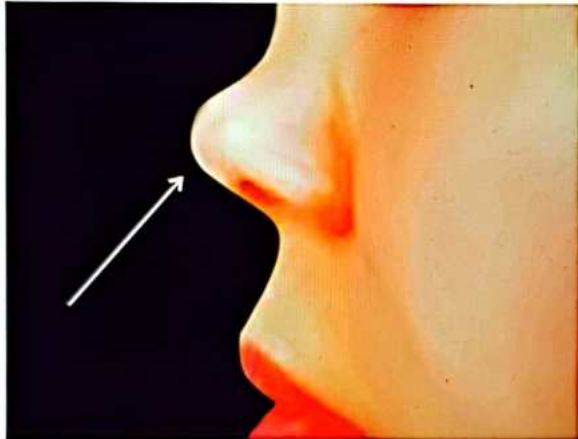


- The diseases of the external nose include those seen on the outside of the nose and can be seen with the naked eye.

00:00:10

Saddle Nose Deformity

00:00:45



- When there is a depression of the dorsum of the nose, it is called saddle nose deformity.
- Septal surgeries like sub-mucosal resectable surgeries can lead to this condition.
- The causes of saddle nose deformity are as follows:
  - It can be caused due to either traumatic or non-traumatic reasons.
  - The traumatic causes include sudden falls or septal surgeries like submucosal resection surgery (iatrogenic).
  - The non-traumatic causes include granulomatous diseases, septal abscesses, or septal hematoma.
  - Granulomatous nose diseases like tuberculosis, leprosy, and syphilis will affect the cartilage of the nose.
  - The septal abscess can cause the infection of the underlying cartilage, and if this cartilage is not removed, it will lead to chondritis, leading to necrosis of entire quadrangular cartilage of septum.
- Symptoms:
  - The primary concerns include cosmetic concerns.
  - Most of the patient's insecurities stem from their nasal features, which can result in low self-esteem and depression.
- Treatment:
  - Augmentation rhinoplasty is performed to fix the deformity.
  - Depression is filled with fat, bone (bone graft used is iliac crest), or cartilage.

Hump-Nose Deformity

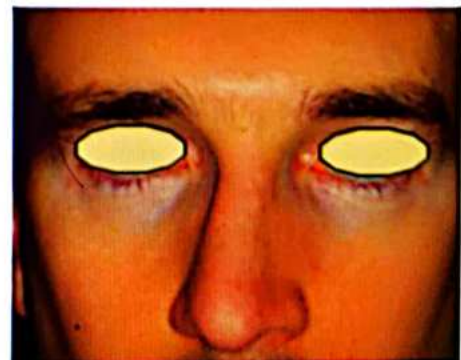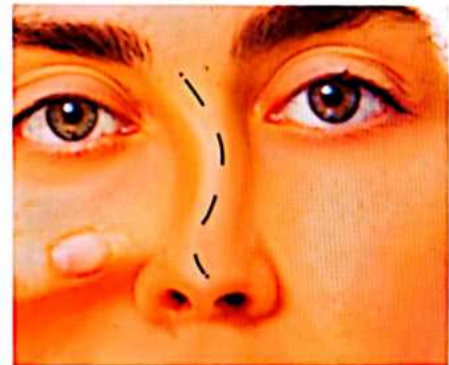
00:06:22



- The nose has been projected out excessively.
- Symptoms:
  - The primary concerns include cosmetic concerns.
- Treatment:
  - Reduction Rhinoplasty is made to remove the excess bone ledge.

Crooked Nose and Deviated Nose

00:07:24






# Telegram - @nextprepladdernotes

- The difference between a crooked and deviated nose is that in a crooked nose, both the nasion and tip lie on the mid-line, whereas in a deviated nose, only the nasion is in the mid-line.
- **Symptoms:**
  - Cosmetic concerns are the significant issues faced by the patient.
- **Treatment:**
  - Septo-Rhinoplasty is done to correct this deformity.

## Rhinophyma

00:10:13

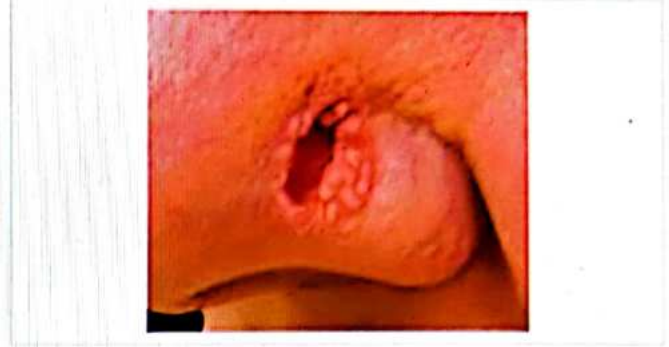
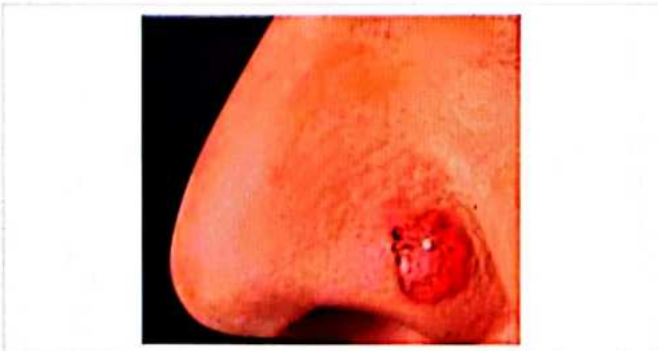
- It is also called **potato nose**.
- It is not pre-malignant, or it does not cause cancer.
- **Causes:**
  - It is the **hypertrophy of the sebaceous glands** of patients with acne rosacea or diabetes mellitus or in elderly patients.
- **Symptoms:**
  - Cosmetic concerns are the significant issues faced by the patient.
- **Treatment:**
  - Removal of the tissue by **carbon dioxide laser debridement of the hypertrophic tissue with skin graft**.

## Malignancy - Basal Cell Carcinoma

00:13:16

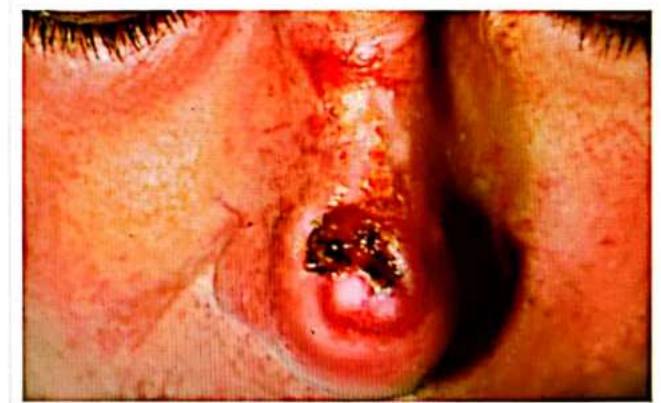- Mc malignant tumour of the skin of external nose
- **Presentation:** Cyst / Papulo pearly nodule or ulcer with rolled in edges
- **Treatment:**



- Basal cell carcinoma is also called **rodent ulcer**.
- It is the most common tumour of the skin of external nose.
- **Causes:**
  - It is caused by exposure to UV radiation.
- **Symptoms:**
  - Cyst/ papulo pearly nodules or ulcer with rolled-in edges are seen in this disease.
  - Moh's micrographic technique is used to detect it.
  - If it continues to occur, then radiation therapy is done.

## Squamous Cell Carcinoma

00:16:15



- It is the second most common lesion after basal cell carcinoma.
- **Causes:**
  - It is caused by exposure to UV radiation.
- **Symptoms:**
  - Nodules or ulcers with rolled-out edges are seen in this disease.
- **Treatment:**
  - Excision is the primary form of treatment for treating cancer.
  - If it persists, then radiation therapy is done.






# CROSS WORD PUZZLES



**Crossword Puzzle 1**



**Across**


3) \_\_\_\_\_ rhinoplasty is done for saddle nose deformity.

**Down**

1) \_\_\_\_\_ rhinoplasty is done for humped nose deformity.

2) \_\_\_\_\_ disease is also called potato nose disease.

**Crossword Puzzle 2**



**Across**


2. \_\_\_\_\_ radiations cause basal cell carcinoma.

3. \_\_\_\_\_ cell carcinoma is the second most common lesion.

**Down**

1. \_\_\_\_\_ carcinoma is also called rodent ulcer.

**Crossword Puzzle 3**



**Across**

3. \_\_\_\_\_ laser debridement of the hypertrophic tissue in rhinophyma.

**Down**

1. The nose has been projected out excessively in \_\_\_\_\_ nose deformity.

2. \_\_\_\_\_ nose is the depression of the dorsum of the nose.

prince kumar  
princeeeekum@gmail.com  
9928609733





## 22

# ACUTE AND CHRONIC RHINITIS

00:06:04

- Rhinitis is defined as the inflammation and swelling of the mucous membrane of nose characterized by a stuffy nose and runny nose and is typically brought on by the common cold or a seasonal allergy.

### I. Allergic Rhinitis

- Allergic rhinitis is a reaction of your body when the body or your nose gets irritated by allergens, such as pollen, food, and other molecules causing allergic reactions.
- Allergy can be described as a multi-system disease because it can affect the nasal, skin, and eyes.
- Nasal allergy symptoms usually affect the upper and lower airway and co-exist with asthma called **United airway disease (UAD)**.
- Allergy is the hypersensitivity reaction (**type I IgE mediated reaction**).

- Finally, IgE binds to the mast cell receptors which causes degranulation and release of inflammatory mediators (histamine, serotonin, leukotriene, prostaglandin)
- These inflammatory mediators are responsible for symptoms.

### Etiology

- Inhalant allergen
- Ingestant allergen
- Genetic predisposition

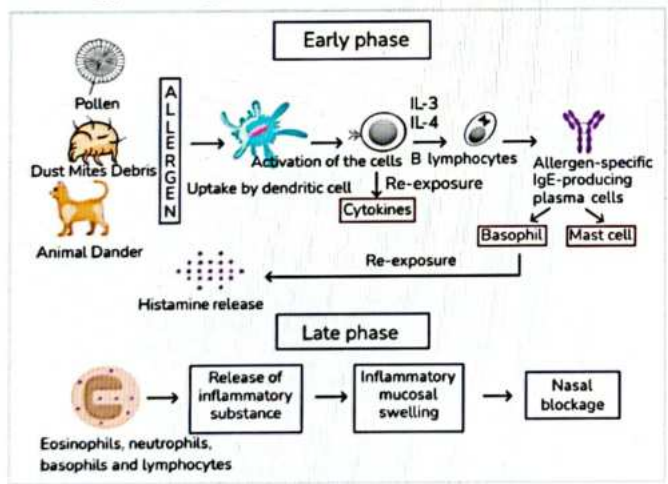
### Types of Allergy

00:10:07

#### I. Seasonal Allergy

- Only during a particular season is when pollen of plants released.
- Most occur in monsoon to winter when there is of allergen in the air during this transition period called seasonal allergic rhinitis.
- If the patient has symptoms throughout the year.
- For example, an allergy to dust mites throughout the year is called a **perennial allergy**.

### Pathology of allergy



There are two phases of allergy: Early phase and Late phase response.

#### Early phase response

- When the body is exposed to any allergen and allergen can be anything like an inhalant or ingested allergen
- Allergen is taken up by dendritic cells, these dendritic cells present antigens to the T-cells
- T-cells further proliferate into **Th1 and Th2 cells**
- Th2 cells stimulate B-cell lymphocytes and B-cells produce **immunoglobulin E or IgE**

### Clinical Features

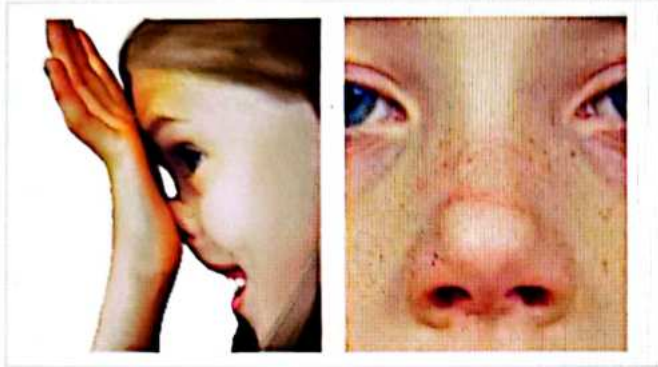- Cardinal Symptoms of seasonal allergy includes:
  - Nasal symptoms- nasal obstruction, difficulty in breathing, excessive sneezing, itching in the nose, watery nasal discharge.
  - Ocular symptoms- itching in the eyes.
  - Skin symptoms- dryness in the skin, itching of the skin.
  - Pulmonary symptoms- asthma, bronchospasm.

### Ocular Signs

- Oedema of lids
- Congestion and cobble stone appearance of the conjunctiva
- Dark circles under the eyes



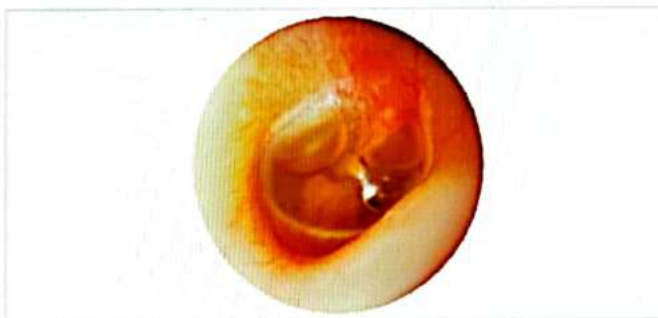

**Nasal Signs**

- Darier sign- Due to constant rubbing of the nose, the black line forms on the dorsum of nose is called the darier's line.
- Salute sign - patient will keep on pushing and rubbing the nose upwards, it looks like a salute.

**Otological Signs**

- When there is an allergy, it causes nasal obstruction which results in the effect of ventilation to the eustachian tube, which can result in middle ear disease.
- Most common middle ear diseases- Retracted tympanic membrane or serous otitis media, secretory otitis media, and blue ear as a result of eustachian tube blockage.
- Air bubbles and air-fluid levels are the diagnostic criteria of serous otitis media.

**Clinical investigations****Serum level of IgE**

- Serum level of igE typically increased in patients with allergic rhinitis.

**Total and differential counts**

- The level of eosinophil is increased in patients with allergic rhinitis.
- Nasal smear shows a large number of eosinophils in allergic rhinitis.

**Skin tests**

- Skin tests help to identify the specific allergen by doing a skin prick test.

- In the skin prick test, multiple antigen injections (only common antigen injections) are given to the patient's forearm.
- When a wheel and flare reaction is seen, it indicates that the patient is allergic to a particular antigen.
- Disadvantages: It requires multiple pricks and risk of angioedema is there so it can be done in a hospital settings.

**Radioallergosorbent test (RAST) or Invitro test**

- It measures the specific IgE antibody concentration in the patient's serum.
- This technique uses blood for investigation.
- At least 5-10 ml of blood is taken from the patient. This blood is put in various tubes which contain radio-labeled antigen substances like antigens against pollen, dust, and animal dander.
- Once the drop of blood is put into each of the test tubes and if the patient has allergic reactions and he/she would have IgE antibody against that antigen.
- If the patient is allergic to animal dander, the patient will have antibodies against the animal dander
- So, when blood is put into the test tube for animal dander antigen, the antibody against animal dander will come and bind with animal dander antigen. As a result, the Ag-Ab reaction will occur.
- Because of the radio-labeled antigens, it shows immunofluorescence which explains that the patient has an allergy to animal dander.
- If the patient does not have an antibody, the antigen will not react with the antibody and no immunofluorescence will occur.
- Advantages: no pain, no injections, no chance of angioedema.
- Disadvantages: very costly, because radio- labeled antigens are very costly.

**Treatment**

- Avoidance of allergens (ingestant allergens can be avoided but not inhalant allergens like pollens).
- Treatment with drugs: Nasal decongestants, Corticosteroids, Antihistamines, Anti-leukotrienes, Sympathomimetics, Mast cell stabilizers.
- Immunotherapy (Hyposensitisation):
- Immunotherapy is the exposure of the patient to a known allergen from low dose to high dose.
- Immunotherapy suppresses the formation of IgE. So, the Ag-Ab complex is not formed and it is used when the allergic symptoms are very high.
- Suppose a patient is allergic to pollen but the patient can not avoid pollen every time. In this condition, an extract of pollen is given in a very small dose and then gradually increase the dose.



- As a result, immunity will be able to tolerate the pollen dose.
- This immunotherapy requires a prolonged period of time at least 1-3 years to develop tolerance to that particular allergen.
- It also raises the titer of specific Ig antibody.
- Types: Subcutaneous immunotherapy (SCIT) and Sublingual immunotherapy (SLIT)
- Subcutaneous immunotherapy (SCIT): An antigenic extract is given to the patient by subcutaneous route daily by increasing the dose gradually.
- Sublingual immunotherapy (SLIT): An antigen is given via a sublingual route in the form of drops that increases gradually. It is preferred method.

## Complications

00:29:11

- Recurrent sinusitis
- Nasal polyps are usually ethmoid polyps
- Serous otitis media
- Orthodontic problems and other ill-effects of prolonged mouth breathing especially in children.
- Bronchial asthma

## II. Vasomotor rhinitis or Non-allergic rhinitis

- When the symptoms are similar to allergy but serum IgE is normal, eosinophil count is normal called Vasomotor rhinitis.
- In other words, it is defined as allergic rhinitis but clinically stimulates nasal allergy with symptoms of nasal obstruction, rhinorrhea, and sneezing but the serum IgE level is normal.

## Pathogenesis

- Vasomotor rhinitis occurs due to an imbalance of the sympathetic and non-sympathetic nervous system.
- The sympathetic nervous system is responsible for vasoconstriction.
- It shrinks the mucosa and paranasal sinuses size of the nose because of vasoconstriction and decreases the blood supply. As a result, the patient will have a wide airway.
- If vasoconstriction occurs in the mucosal glands, it will produce less mucus.
- The parasympathetic nervous system is responsible for vasodilation.
- Mucosa will become boggy because of vasodilation. As a result, the patient will have narrow space for breathing.
- If vasodilation occurs in the mucosal gland, it will increase the production of mucus.
- As a result, it will cause itching, running nose.

## Clinical Features

- Paroxysmal sneezing

- Excessive rhinorrhoea
- Nasal obstruction
- Post nasal drip

## Treatment

### Medical

- Antihistamines and oral nasal decongestants
- Topical steroids
- Systemic steroids can be given for a short period of time in very severe cases

### Surgical

- **Reduction of turbinates:** Turbinates are responsible for the humidification and purification of the air.
- When turbinates of the nose become boggy, it causes difficulty in breathing and increases the discharge of mucus.
- In this condition, surgically reduce the size of turbinates. As a result, it will create a good space for the airway to breathe.
- **Vidian neurectomy:** Vidian nerve is formed by the greater superficial petrosal nerve and deep petrosal nerve.
- This vidian nerve is responsible for the autonomic innervation of the nasal cavity.
- If the autonomic innervation is cut off, the symptoms will disappear but it can cause dryness in the nose.
- Vidian neurectomy is done only in very advanced conditions when the symptoms are not controlled with medical therapy.

## III. Rhinitis Medicamentosa versus Drug-Induced Rhinitis

00:39:42

- **Rhinitis Medicamentosa:** If the patient abuses decongestant drugs like xylometazoline and oxymetazoline ( $\alpha$ -adrenergic agonists).
- When the patient uses these drugs for a long period of time, it causes tolerance and rebound.

## Rhinitis Medicamentosa Versus Drug Induced Rhinitis

Rhinitis Medicamentosa	Drug induced Rhinitis
<ul style="list-style-type: none"> <li>• Due to excessive use of topical decongestants which cause rebound on withdrawal</li> <li>• Treatment                             <ol style="list-style-type: none"> <li>1. Stop topical decongestants</li> <li>2. Short course of systemic steroids</li> </ol> </li> </ul>	<ul style="list-style-type: none"> <li>• Sympathetic blockers: Reserpine, Guanethidine, propranolol</li> <li>• Cholinergic drugs like neostigmine (anti-cholinesterase)</li> </ul>



- Drugs like Xylometazoline and Oxymetazoline ( $\alpha$ -Adrenergic Agonist) are responsible for vasoconstriction which may result in **rebound nasal congestion**.
- For the upregulation of receptor, the use of oxymetazoline, and xylometazoline should be ceased. So, short course of systemic steroids is given for the upregulation of receptors. As due to tolerance it causes down regulation of receptors.
- Down regulation of receptors will decrease adrenergic activity which causes increase in parasympathetic activity in nose and thus nasal congestion.
- If the drug as a side effect is causing rhinitis, then it is called **drug-induced rhinitis**.
- **Guanethidine and Propranolol** are known to cause rhinitis as a side effect, causing **drug induced rhinitis**.

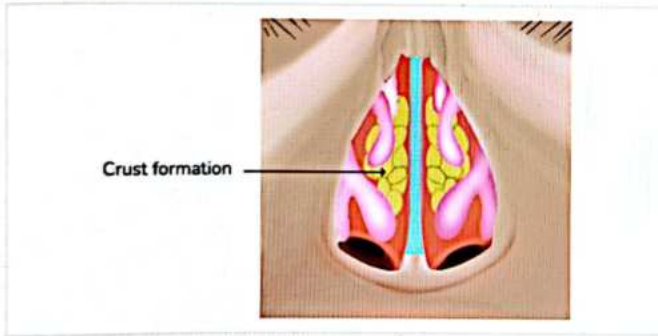


### Important Information

- For up regulation of receptors after the abuse of alpha adrenergic agonists a short course of systemic steroids is prescribed

## IV. Atrophic Rhinitis

00:45:34



- Atrophic rhinitis is a clinical term that causes progressive atrophy of the entire nose including mucosa, turbinates, septum, olfactory fibers, and paranasal sinuses. As a result, it causes a wide nasal cavity.
- Nasal cavities are roomy and full of foul-smelling crusts.
- When air current goes through a wide nose, it causes crust inside the nose and the current will not go to the olfactory lobe.
- Because of the atrophy of **olfactory fibres**, the patient will not be able to smell.
- The patient will have **Merciful Anosmia** that causes a wide nasal chamber and crusting inside the nose.
- Atrophic rhinitis is classified into two types: **Primary atrophic rhinitis** and **Secondary atrophic rhinitis**.
- Various theories have been put for Primary atrophic rhinitis but exact cause is not known.
- Secondary atrophic rhinitis is secondary to infections like syphilis, lupus, leprosy, rhinoscleroma, radiotherapy to nose

or excessive surgical removal of turbinates or severe deviated septum.

### Primary atrophic rhinitis theories

- **Various theories have been put forward**
  1. Hereditary: More than one member in the family are affected
  2. Endocrine: The disease starts at puberty, involves females more than males disease tends to subside after menopause
  3. Racial: American > Asian
  4. Nutritional deficiency: Vit A, Vit D or Iron
  5. Infective: Klebsiella Ozaenae (Perez bacillus)
  6. Autoimmune

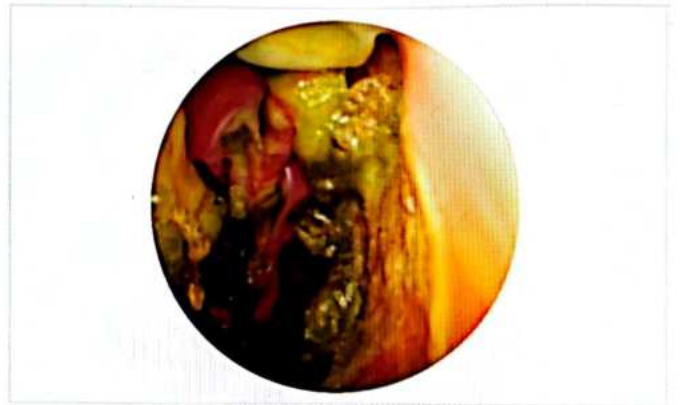

### Important Information

- The infection responsible for primary atrophic rhinitis is **Klebsiella Ozaenae (Perez bacillus)**.

### Clinical Features

- **Merciful anosmia**: Patient himself is unaware of the smell due to marked anosmia.
- Patient may complain of **nasal obstruction** in spite of unduly wide nasal chambers.



### Examination findings

- Nose
  - Filled with crusts.
  - Roomy cavities
  - Atrophic pale mucosa
  - Small turbinates
- Paranasal sinuses: Small with thick walls
- Atrophic pharyngitis
- Atrophic laryngitis

### Medical Management

- Alkaline nasal douching solution
- Nasal irrigation with an alkaline solution made by dissolving powder with sodium bicarbonate 1 part, sodium baborate 1 part, sodium chloride 2 parts in 280 ml of water.

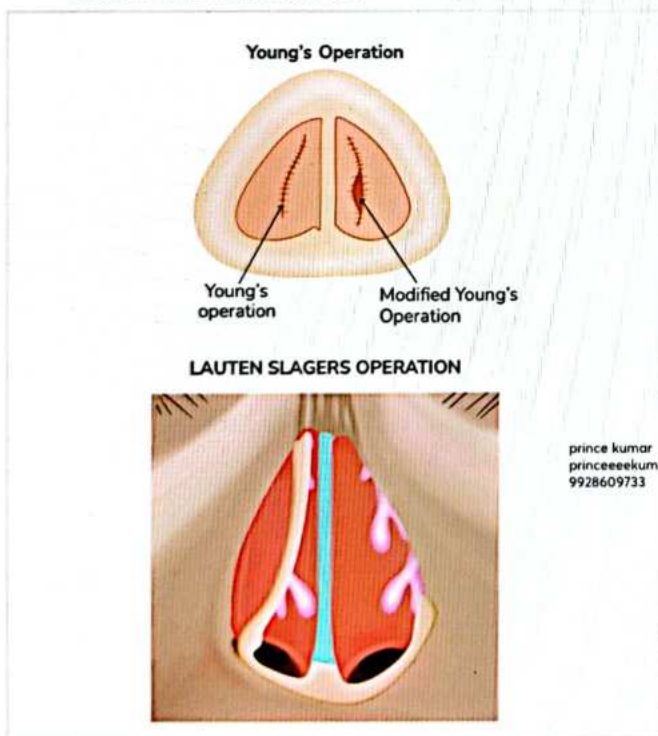


# Telegram - @nextprepladdernotes

- 25% glucose in glycerine
- Local antibiotics: **Kemicetine antlozaena solution** (chlormycetin, estradiol, vitamin D2)
- Oestradiol spray: increase vascularity
- Placental extract submucosal injection
- Systemic streptomycin
- Potassium iodine
- To avoid dryness and crusting in the nose, irrigation of the nose with certain solutions is suggested to keep the nose clean and moist.
- **Alkaline nasal douching solution:** This solution is used to irrigate the nose with the help of a nasal wash bottle.

## Surgical Management

- Youngs operation: Mucosal flaps are elevated to close nasal cavity
- Narrowing of nasal cavity:
  1. Submucosal injection of Teflon
  2. Lautenslagers operation- Section and medial displacement of lateral wall of nose.
  3. Insertion of fat, cartilage, bone under mucoperiosteum of floor and lateral wall of nose.



- **Young's operation:** This procedure involves elevating the mucosa across the vestibule or the inlet of the nose (completely close the nose) from medially, laterally, and suture altogether.
- **Modified Young's operation:** It made an opening of 10mm close to the rest of the nasal cavity.
- **Narrowing of the nasal cavity:** To reduce large amount of air

current to the nose, and to reduce crust.

1. **Subcutaneous injection of Teflon** to the lateral walls of the nose so that the nose becomes narrow.
2. **Lautenslagers operation:** Fracture the lateral wall and push it towards the midline.

## V. Rhinitis Sicca

- Rhinitis sicca occurs in those people who expose to hot-dry climates, typically seen in people who work in bakeries.



## Important Information

- When the hot air current from the oven goes to the **anterior**  $\frac{1}{3}$  of the nose that makes the nose dry.

## VI. Rhinitis Caseosa (Nasal Cholesteoma)

- It occurs due to the obstruction of sinuses to sinusitis. So, sinuses will not be able to drain the secretions. As a result, there will be a retention of secretion in the sinuses.
- Once it causes chronic retention of a secretion at the sinuses, it will form a waxy, sebaceous, sticky mass inside the nose called rhinitis caseosa.
- Usually seen in males
- Unilateral
- Treatment is debriding the tissue and treating the cause.

## Important Questions

00:31:02

**Q.** Which infection is responsible for primary atrophic rhinitis?  
**Ans:** Klebsiella Ozaenae (Perez bacillus)

**Q.** Rhinitis caseosa occurs due to the  
**Ans:** Obstruction of the sinuses to sinusitis

**Q.** Vidian nerve is formed by the  
**Ans:** Greater superficial petrosal nerve and deep petrosal nerve

**Q.** Nasal allergy symptoms usually affect the upper and lower airway and co-exist with asthma called as  
**Ans:** United airway disease (UAD)

**Q.** Allergy is the hypersensitivity reaction mediated by  
**Ans:** Type I IgE-mediated reaction

**Q.** IgE binds to the mast cell receptors which causes degranulation and release of inflammatory mediators  
**Ans:** Histamine, serotonin, leukotriene, prostaglandin

**Q.** Rhinitis sicca occurs in those people who are exposed to  
**Ans:** Hot-dry climates, typically seen in people who work in bakeries



# Telegram - @nextprepladdernotes

**Q.** Young's operation is the surgical treatment of

**Ans:** Atrophic rhinitis

**Q.** Allergic shiner is a feature of

**Ans:** Seasonal rhinitis

**Q.** Drugs like Xylometazoline and Oxymetazoline are responsible for

**Ans:** Vasoconstriction may result in rebound nasal congestion

**Q.** Merciful Anosmia is the clinical feature of

**Ans:** Atrophic rhinitis

**Q.** Guanethidine and Propranolol are known to cause

**Ans:** Rhinitis as a side effect

**Q.** Alkaline nasal douching solution is used to irrigate the

**Ans:** Nose with the help of nasal wash bottle

prince kumar  
princeeeekum@gmail.com  
9928609733






# CROSS WORD PUZZLES



Crossword Puzzle 1




**Across**

- 3. \_\_\_ immunoglobulins produced by B-cells.
- 4. \_\_\_ is defined as allergic rhinitis but clinically stimulates nasal allergy with symptoms of nasal obstruction, rhinorrhea, and sneezing, but the serum IgE level is normal.

**Down**

- 1. \_\_\_ is the treatment of seasonal allergy.
- 2. \_\_\_ appearance is the ocular sign of seasonal rhinitis.

Crossword Puzzle 2



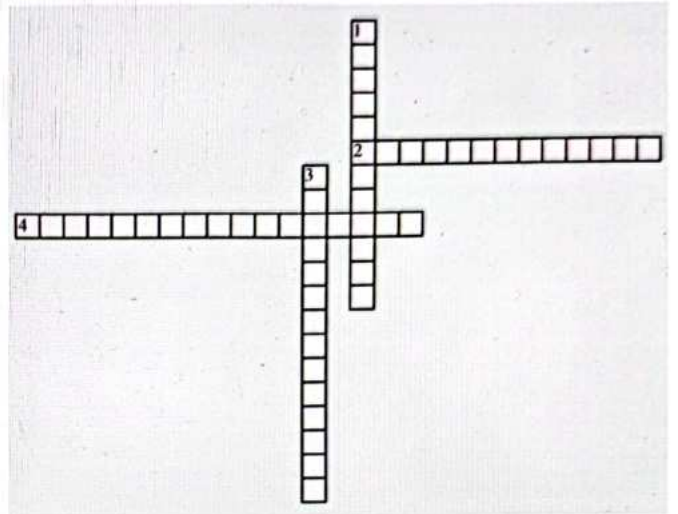
**Across**

- 3. \_\_\_ is responsible for primary atrophic rhinitis.
- 4. \_\_\_ level is increased in patients with allergic rhinitis.

**Down**

- 1. \_\_\_ causes tolerance and rebound when used for a long period of time.
- 2. \_\_\_ is known to cause rhinitis as a side effect.

Crossword Puzzle 3



**Across**

- 2. \_\_\_ suppresses the formation of IgE.
- 4. \_\_\_ is caused by an imbalance between the sympathetic and parasympathetic nervous systems.

**Down**

- 1. \_\_\_ causes a narrow space for breathing.
- 3. \_\_\_ presents antigens to the T-cells.





## 23

# CSF RHINORRHEA

### What is CSF Rhinorrhea?

00:00:01

- CSF rhinorrhea involves a leak of CSF into the nasal cavity and the presence of nasal discharge.
- The roof of the nose separates the nasal cavity from the anterior cranial fossa.
- The frontal lobe is present in the anterior cranial fossa, which is surrounded by the CSF. Whenever there's a breach in the bone, the CSF can leak from the cranial cavity and present in the nasal cavity as a nasal discharge. It can also happen if there's a defect in the paranasal sinuses.
- **The most common cause of CSF rhinorrhea is trauma.** It can be a direct trauma, like a motor vehicle accident, or it can be due to surgery.
- **The most common site is the cribriform plate of the ethmoid,** since it is the weakest bone.

### Cause of CSF Rhinorrhea

00:03:32

- **Traumatic causes** account for 95% of the cases of CSF rhinorrhea.
- **Non-traumatic causes (spontaneous) of CSF rhinorrhea:**
  - **High-pressure leak:** The pressure inside the cranial cavity is high enough to erode the bone at the base of the site, causing CSF rhinorrhea. For example, a brain tumor can increase the intracranial pressure, resulting in the progressive thinning of the bone. In benign intracranial hypertension (BIH), the intracranial pressure is high enough to erode the bone.
  - **Normal pressure leak:** CSF rhinorrhea can occur with normal pressure in cases of congenital defects in the skull base, erosion of the bone from below in cases of tumor, osteomyelitis, etc.

### Clinical Presentation of CSF Rhinorrhea

00:06:53

- **Clinically, the patient will present with a watery nasal discharge.**
- **Usually, it is a unilateral discharge.**
- **It is difficult to distinguish only on the basis of history,** when there's no history of trauma, whether the fluid leaking out of the nose is nasal fluid or CSF. Thus, unilateral discharge can be CSF rhinorrhea.

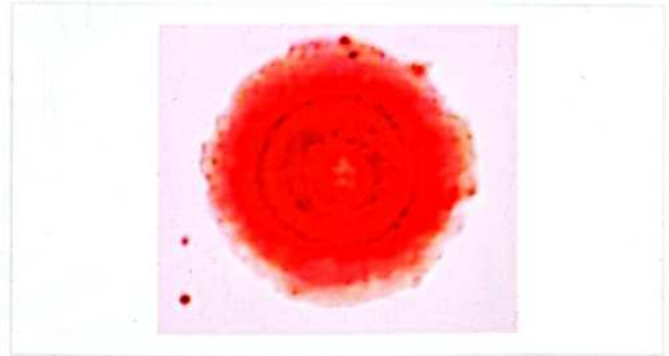
### Differentiation of CSF Rhinorrhea From Simple Rhinorrhea

00:08:14

- **The Sniff Test:** If there is a cold, it is possible to sniff back the nasal fluid, while CSF cannot be sniffed back.

### Halo Sign, Target Sign, or Double Ring Sign

00:09:14



- **Halo sign, target sign, or double ring sign:** In the case of trauma, if there's blood in the nasal cavity, then the secretion is taken on a Whatman's filter paper. If there's a central red spot indicating blood and a peripheral halo is surrounding it indicating CSF, then it's suggestive of traumatic CSF rhinorrhea.

### Reservoir Sign

00:10:14

- The patient is asked to rest supine. There's a collection of CSF in the nasal cavity and paranasal sinuses (PNS).
- Then, the patient is propped up and asked to bend forward. The flow of CSF will be noticed. This is called a reservoir sign, also called a teapot sign.
- CSF rhinorrhea shows a positive reservoir sign.

### Handkerchief Test

00:12:04

- In cases of the common cold, upon blowing into the handkerchief, there's stiffening of handkerchief. However, in patients with CSF rhinorrhea, there's no stiffening of the handkerchief.

### Glucose Estimation Test

00:12:40

- The sniff test, reservoir test, handkerchief test, and target sign do not conclusively tell whether the fluid is CSF or not. Thus, biochemical analysis is required to confirm the presence of CSF.
- The glucose estimation of the nasal fluid is done. The glucose content of the fluid should be 2/3rd of the blood glucose of the patient.
- Still, this test is not the confirmatory test of the presence of CSF.

### BETA-2 Transferrin Test

00:14:10

- **If beta-2 transferrin is positive, then it's 100% CSF.**



Exception: Perilymph and aqueous humor are ultrafilters of CSF, which can present beta-2 transferrin positivity. However, their possibility to leak through the nose is extremely low. This is most likely CSF if beta-2 transferrin is positive.



## Important Information

- The beta-2 transferrin test is the hallmark test for CSF since beta-2 transferrin is a protein present only in the CSF.

### Beta-Trace Protein

00:15:12

- Beta-trace protein is even more specific protein than beta-2 transferrin.
- Beta-trace protein is a protein derived from beta-2 transferrin.

### Radiological Examination of CSF Rhinorrhea

- **HRCT test** 00:17:00
- High-resolution CT (HRCT) of the temporal bone is the investigation of choice for determining the site of the leak.

### CT Cisternography

00:17:50

- CT cisternography is useful to determine whether it's an active or inactive leak; e.g., if the patient has fracture at three sites, the CT cisternography can help in identifying the active leak site.
- A lumbar puncture is performed to get the CSF. This CSF is mixed with 5% fluorescein dye. This is reinjected into the intrathecal space. This dye will stain the entire CSF around the brain and the spinal cord. It will also leak from the active site of CSF leakage. This helps in identifying the exact site of the leak.

### MRI

00:20:41

- MRI can be done to assess if there's any intracranial abnormality. It can also indirectly reveal if there's a CSF leak. However, it isn't very specific in detecting the CSF.

### Treatment of CSF Rhinorrhea

00:21:16

- The treatment of traumatic CSF rhinorrhea involves conservative measures to reduce the CSF leak. If it is persistent, then reparation is done.
- Endoscopic endonasal approaches are preferred. Rarely external approaches are done.
- A transcranial approach is taken if the defect is big, the site is inaccessible, or if there's a recurrence.
- The defect can be sealed with a graft, usually a patch plug overlaid with fascia lata. We can use conchal cartilage and septal cartilage.

- Depending upon the size, site, and type of leak, the treatment approach would vary.
- A transnasal endoscopic repair approach is preferred to repair the CSF.

### Management of CSF Rhinorrhea

00:23:00

- The conservative approach includes bed rest, diuretics, avoidance of straining, and prophylactic antibiotics.
- Surgical management includes repair of the defect via an external or endoscopic approach.

### One-Line Questions

00:23:24

Q. What is the most common cause of CSF rhinorrhea?

Ans. Traumatic.

Q. Facial fractures with CSF rhinorrhea?

Ans. Class 3 nasal fracture, or report 3 fracture.

Q. What is the most common site for a CSF leak?

Ans. The cribriform plate of the ethmoid.

Q. Diagnostic investigation of choice for CSF leak?

Ans. Beta-2 transferrin.

Q. Investigation of choice for localizing the defect?

Ans. HRCT of the nose and paranasal sinuses.

Q. Investigation of choice to localize an active CSF leak?

Ans. CT cisternography.

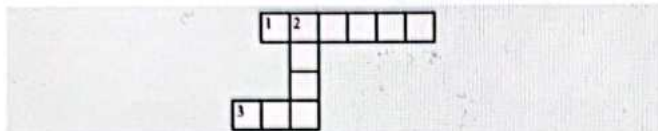




# CROSS WORD PUZZLES



## Crossword Puzzle 1




### Across

- \_\_\_\_\_ is the most common cause of CSF rhinorrhea.
- \_\_\_\_\_ rhinorrhea involves a leak of CSF into the nasal cavity and the presence of nasal discharge.

### Down

- \_\_\_\_\_ of the nose separates the nasal cavity from the anterior cranial fossa.

## Crossword Puzzle 2




### Across

- \_\_\_\_\_ reservoir sign is seen in CSF rhinorrhea.
- \_\_\_\_\_ plate of the ethmoid is the most common site of CSF rhinorrhea.

### Down

- \_\_\_\_\_ of the handkerchief does not occur upon blowing in case of CSF rhinorrhea.

## Crossword Puzzle 3




### Across

- \_\_\_\_\_ transferrin test is the hallmark test for CSF since beta-2 transferrin is a protein present only in the CSF.
- \_\_\_\_\_ content of the fluid should be 2/3rd of the blood glucose of the patient.

### Down

- \_\_\_\_\_ endoscopic repair approach is preferred to repair the CSF.
- \_\_\_\_\_ test, reservoir test, handkerchief test, and target sign does not conclusively tell whether the fluid is CSF or not.

## Crossword Puzzle 4



### Across

- \_\_\_\_\_ of the temporal bone is the investigation of choice for determining the site of the leak.

### Down

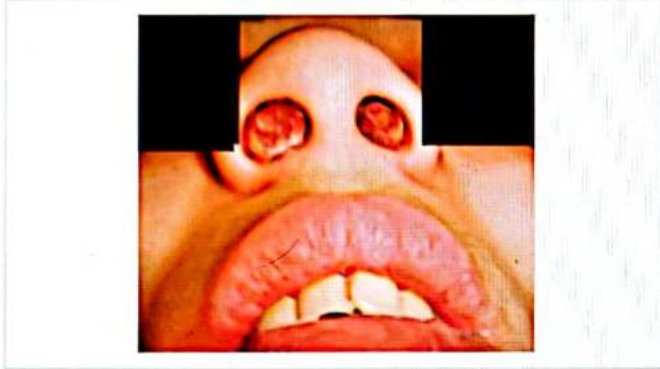
- \_\_\_\_\_ puncture is performed to get the CSF.
- \_\_\_\_\_ cisternography is useful to determine whether it's an active or inactive leak.





Rhinoscleroma

00:00:52



- Rhinoscleroma is a bacterial infection. It is a granulomatous disease that is caused by bacteria.

Etiology

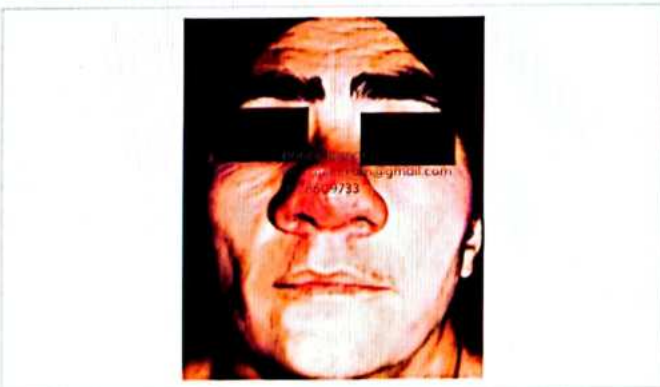
- Gram-negative bacillus bacteria are responsible for causing rhinoscleroma, which is called *Klebsiella rhinoscleromatis* (or) Frisch bacillus.
- Rhinoscleroma is endemic in northern parts of India when compared to southern parts.

Mode of acquiring infection

00:02:26

- The mode of acquiring infection is through air droplet infection. Air droplet infection means while the infected person sneezes the nose, blows the nose, coughs, or in their droplets, the bacteria will present that cause infection.

Clinical Features



Atrophic stage

00:04:15

- Once the bacteria reach the nose of a patient.
- The bacteria will multiply under a favorable environment for its growth.
- If immunoglobulins are present in the nose, they destroy the bacteria.

- So, bacteria will destroy mucin-producing cells where immunoglobulins are present thus there will be **no mucus**.
- It leads to **dryness of the nose** which results in **foul-smelling purulent nasal discharge and crust**.
- This stage is called the **First stage of Rhinoscleroma** (or) also called an **atrophic stage**.

Granulomatous stage

00:05:15

- Body's immune system fights against the bacteria by sending neutrophils, macrophages, epithelioid cells, and giant cells.
- It is the **II stage**, where all inflammatory cells surround the bacteria and destroy them, resulting in a central core of dead tissue with all the bacteria, and all the dead debris surrounded by the inflammatory cells.
- The inflammatory cells together with the central area of necrosis are known as granuloma, **II stage of Rhinoscleroma** (or) granuloma stage. This stage leads to
  - Nodules in the nose giving a **WOODY** feel.
    - Such a woody hard nodule will also result in deformity of the nose, known as a **Hebra nose**.
  - Nodules are seen in the **lower part of the external nose and lip**.
  - Nodules are **painless and non-ulcerative**.
    - Generally nodules are painful whenever the infection is present, but these nodules are painless.

Cicatrizing stage

00:08:52

- In this stage of healing, all the dead areas/ destroyed areas need to heal. Healing tends to fibrosis, leading to narrowing of the nose (or) stenosis. It results in **cicatrizing stage/ III stage of Rhinoscleroma/stage of healing**.
- This stage results in stenosis of the nose, and nasopharynx. The deformity that occurs was named **Tapir nose**.

Rhinoscleroma: Spread

00:11:25

- Starts in the nose and spreads to the pharynx, larynx, trachea, and bronchus.
- If the airway is involved, then the **subglottic larynx** is most affected.
- In the laryngeal scleroma the most commonly affected site is the **subglottic larynx**.

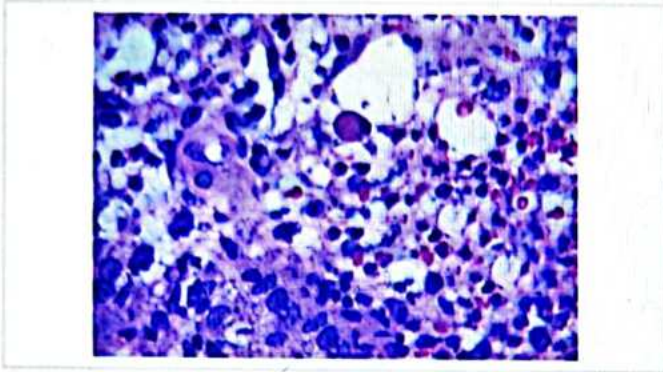
Diagnosis

00:12:56

- The most important thing or vital for diagnosis is to take a **tissue biopsy** send for culture and histopathological examination.



- Although clinically woody hard nodules are sufficient, hebra nose, and tapir nose also present. Confirmatory diagnosis can be established only by biopsy.



- On biopsy and histopathological examination there are two types of cells present. they are
  - Mikulicz cells are vacuolated histiocytes
  - Russell bodies are eosinophilic inclusions in plasma cells.

### Culture

- Rhinoscleroma can be cultured using macconkey's agar medium. Thus, culture establishes the diagnosis.

### Treatment

00:16:11

- Treatment for rhinoscleroma is mainly medical therapy followed by complementary surgical therapy.

### Medical therapy

- Streptomycin, tetracycline, and rifampicin are the drugs of choice for rhinoscleroma.

### Streptomycin and tetracycline for a minimum period of 4-6 weeks.

- After 4-6 weeks of treatment, culture samples need to be examined.
  - If the culture is positive, then continue the treatment.
  - If the culture is negative, take another repeat culture after one week.
  - If after one week the culture is negative, then stop the treatment.
- The treatment is stopped only when two subsequent cultures are negative.

### Steroids are given to decrease fibrosis.

- To reduce the fibrosis and stenosis in the cicatrization stage, steroids are given.
- 2% Acriflavine is given to treat skin inflammation and is also used for topical therapy for nodules.

### Surgery


- Surgery is preferred to debride the dead tissue.

- When the disease was not responding to medical therapy or complementary surgery. In very rare cases, irradiation can be used in the treatment of rhinoscleroma.

### Rhinosporidiosis

00:20:12

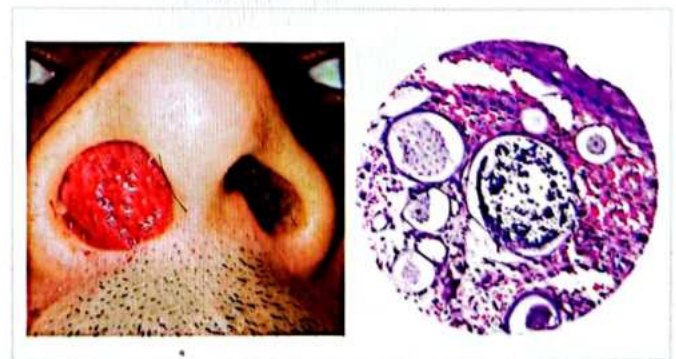
- Rhinosporidiosis is not a bacterial/viral/fungal infection. For a few years, rhinosporidiosis is classified as a fungal infection. Presently it was classified as an infection caused by aquatic protozoa.
- The causative organism of rhinosporidiosis is *Rhinosporidium seeberi*. As the name indicates, it is a waterborne infection. So, the infection is transmitted via water.
- When a patient with rhinosporidiosis takes bath in ponds, swimming pools, etc, if somebody else gets in contact with the same infected water, there is a possibility of acquiring it.
- More Prevalent in south India, Pakistan, and Sri Lanka than in North India.



- Whenever there is an infection with contaminated water. In the layers of the epidermis the protozoa go inside, multiply, and result in red polypoidal mass. The appearance of redness is due to extreme vascular mass.
- As the infection is caused by protozoa there will be spores of the protozoa, these spores appear as whitish dots.
- So, typically on the skin or inside the nose, or external nose there is a red polypoidal mass with whitish dots on the surface.
- It is like a red strawberry mass that resembles strawberry fruit.
- Hence strawberry-like mass appears in the nasal cavity due to Rhinosporidiosis.

### Clinical HPE Finding

00:24:54





**Symptoms**

- Bleeding is the primary manifestation as it is a vascular mass.
- Nasal obstruction, bleeding from the nose and difficulty in breathing are the common manifestations.
- In the case of external polypoidy, cosmetic deformities can be presented by the patient.

**Characteristic appearance on examination would be**

- Leafy, pink, purple, polypoidal mass.
- It is studded with white dots representing the sporangia of protozoa, not fungus.
- Typically in histopathology studies, there is sporangia with spores that reflects rhinosporidiosis.
- Diagnosis cannot be established on culture in rhinosporidiosis.
- Diagnosis can be mainly established by history, clinical examination, and histopathological findings showing sporangia with spores.

**Rhinosporidiosis-Treatment**

00:27:55

Surgery followed by medicines is the treatment for rhinosporidiosis.

- Complete excision of the mass with a diathermy knife and cauterization of its base.
- Recurrence is very common in rhinosporidiosis.
- Medical treatment with dapsons is partially effective and can be given to reduce recurrence.

prince kumar  
princeekum@gmail.com

**Comparison between Rhinoscleroma and Rhinosporidiosis**

00:29:10

	Rhinoscleroma	Rhinosporidiosis
<b>Cause</b>	Bacterial infection (Gram-negative)	Aquatic protozoa
<b>Mode of Infection</b>	Air droplets	water
<b>Stages</b>	3 stages	Multiples of epidermis
<b>Clinical appearance</b>	Hebra nose, tapir, and woody nose	Strawberry like mass
<b>Diagnosis</b>	HPE and culture Mikulicz cells and Russell bodies are present	HPE Presence of sporangia with spores
<b>Treatment</b>	Medical therapy with adjuvant surgery	Mainly surgery and medical treatment are given to prevent a recurrence.

**Tuberculosis**

00:33:32

- Tuberculosis is an infection caused by Mycobacterium tuberculosis.

**Symptomatology in the Nose is - nodules followed by an ulcer and then perforation.**

- Mycobacterium tuberculosis does not affect bony portions of the septum; it will affect the cartilaginous portion of the septum.
- In the cartilaginous portion of the septum initially there is a nodule that will progress to ulcer and later it will progress to perforation.

**Diagnosis of Tuberculosis**

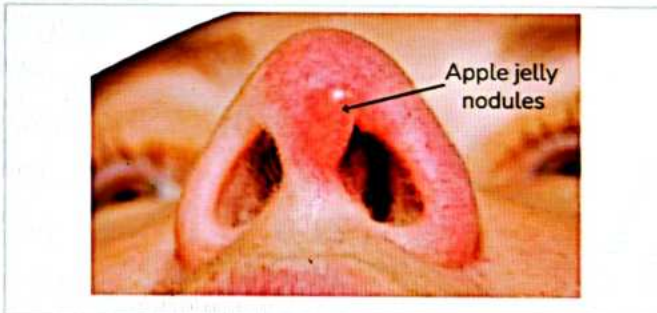
- Histopathological examination
- Montoux test
- Acid fast staining
- Culture and GeneXpert test

Based on all these microbiological and pathological, and histopathological findings, the diagnosis of tuberculosis can be established.

**Lupus Vulgaris**

Lupus vulgaris is a low-grade tubercular infection.

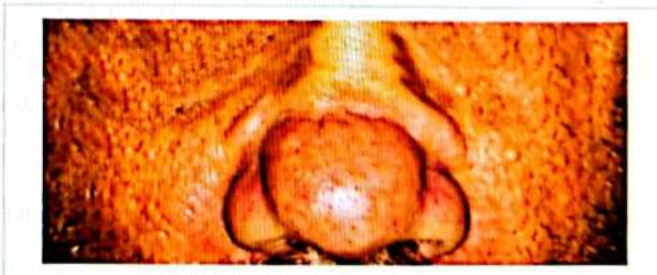- Characteristic nodules are seen on nose called Apple jelly nodules. These nodules are pale reddish seen on dorsum or tip of nose. When pressure is applied they get blanched.



**Leprosy**

00:36:15

- Leprosy is caused by Mycobacterium leprae.



- Mycobacterium leprae, typically in the nose, will involve a cartilaginous portion of the septum causing septal destruction, which results in a deformity known as Lepra nose.
- Typically, in Lepra nose, saddle nose deformity can be observed which was depicted in the above image.



- Because there is a destruction of the cartilage, as a result, there is supratip depression. This supratip depression is called Saddle nose deformity.
- Saddle nose deformity was typically seen in the Leprae nose along with the retrusion of the alar.

prince kumar  
princeekum@gmail.com  
811609233

Based on the cell mediated immunity, there are three variants

- **Tuberculoid Leprosy**
  - Occurs in those who have got good cell-mediated immunity.
  - Granulomatous reaction is present.
- **Lepromatous Leprosy**
  - People with lepromatous leprosy do not have good cell mediated immunity but have poor cell mediated immunity.
  - Granulomatous reaction is absent.
- **Intermediate Variant**
  - In between tuberculoid leprosy and granulomatous leprosy, there is an intermediate variant.

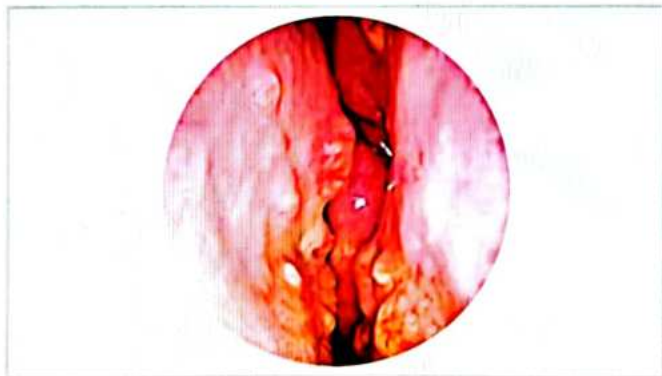
#### Treatment

- Dapsone, Clofazimine, and Rifampicin are used for the treatment of leprosy.

#### Sarcoidosis

00:41:50

- Sarcoidosis is a multisystem disease.



- It doesn't affect only the nose; it is an autoimmune and also non-caseating granulomatous disease that will affect almost all the systems.
- Typically in sarcoidosis, non-caseating granulomas are present, which can affect any of the systems like the eye, nose, joints, skin, CNS, and cardiovascular system, etc.,
- Strawberry-like appearance of the nasal mucosa is the nasal manifestation in sarcoidosis.

#### Identification of Sarcoidosis

- Kveim test
- Identifying the sarcoid antigen.
- Typically, tissue diagnosis is always preferred.
  - Take the nasal tissue sample and send it for histopathological examination. Presence of non-caseating granuloma is specific for sarcoidosis.
- Lupus pernio is very specific for sarcoidosis.
  - If reddish blue lesions are seen in the eye, skin, and on the nose. It is due to Lupus pernio

#### Treatment

- Major manifestation and the treatment of sarcoidosis are mainly given by corticosteroids and immunomodulators accordingly.

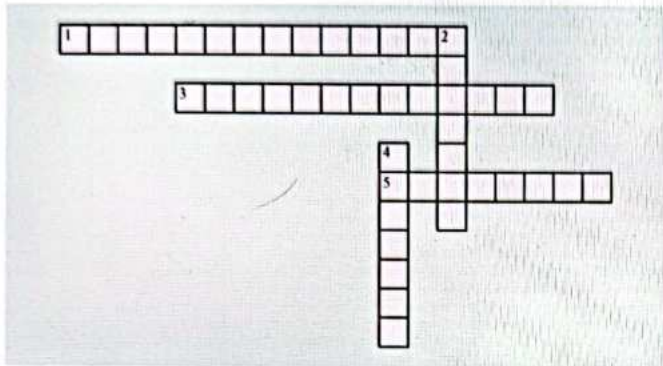




## CROSS WORD PUZZLES



### Crossword Puzzle 1




#### Down

- 1 .....also called Klebsiella rhinoscleromatis.
- 3 .....is a bacterial infection.
- 4 .....stage is the first stage of rhinoscleroma.

#### Across

- 2 .....is the main treatment for rhinosporidiosis.
- 4 .....given to reduce recurrence.

### Crossword Puzzle 2



#### Down


- 1 .....nose is seen in a granulomatous stage.
- 2 .....test was done to identify sarcoidosis.
- 4 .....are characteristic features of Lupus vulgaris.

#### Across

- 3 .....stage is the healing stage in rhinoscleroma.

- 5 .....is also known as low grade tubercular infection.

### Crossword Puzzle 3



prince kumar  
princeekumar@  
9928609733

#### Down

- 1 .....with spores are typical on histopathology examination for rhinosporidiosis.
- 3 ..... specific for Sarcoidosis.

#### Across

- 2 .....cells and russel bodies are seen in diagnosis of rhinoscleroma.
- 4 .....depression is called saddle nose deformity.





25

CONGENITAL ANOMALIES OF THE NOSE

Choanal Atresia

- **Choana** is a communication between the nose (anteriorly) and the nasopharynx (posteriorly). Atresia means non-development. **Choanal atresia** means when there is a non-communication between the nose and the nasopharynx.

**Classification:** It can either be bony- 90% (most commonly seen) or membranous 10%.

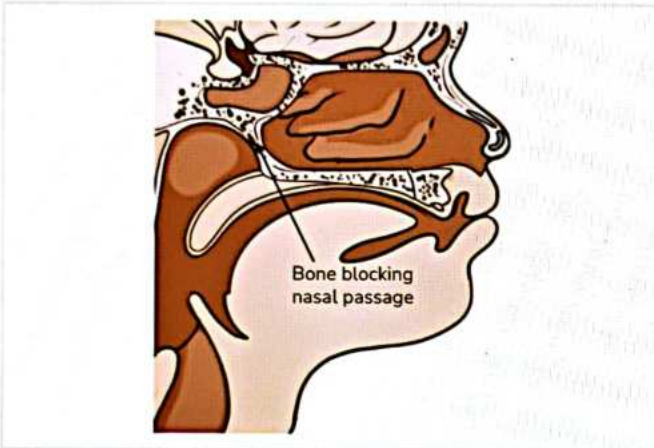
Types of choanal atresia

**Bilateral atresia.**

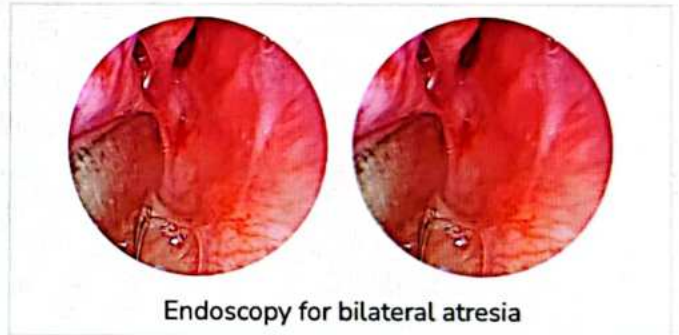
- The choana is seen to be not communicating with the nasopharynx; this is bilateral choanal atresia. This is an emergency because in such a condition the child cannot breathe through the nose at all. Infants, up to 3 months of age, are obligatory nasal/natural breathers and do not know how to breathe through the mouth at all. This is presented at birth and the newborn shows signs of respiratory distress. An endoscopic image of a child with choanal atresia is given below.

Etiology

00:02:13



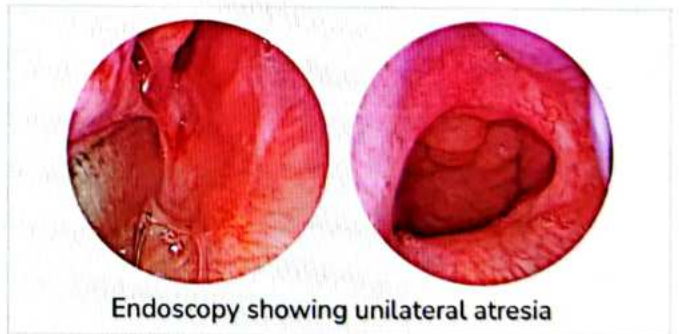
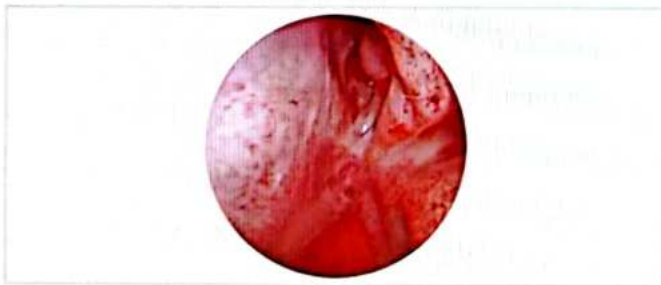
- Choanal atresia occurs due to the persistence of the **bucconasal membrane** (during development there is a membrane that separates the nasal cavity from the oral cavity).
- The bucconasal membrane should normally disappear, but if it persists, it will result in a condition known as Choanal atresia.



Endoscopy for bilateral atresia

**Unilateral atresia**

- The choana is seen to be communicating with the nasopharynx, this is unilateral choanal atresia. Since only one choana is blocked, leaving the other open to breathe in and out, this is not an emergency.



Endoscopy showing unilateral atresia

- An endoscopic image of a child with choanal atresia is shown.
- iii. Choana is the posterior end of the nasal cavity. The septum is present medially, and the lateral wall is present laterally. If there is the thickening of the vomer which is present in the posterior-inferior portion of the septum, and there is **excessive bowing** of the lateral wall of the nose, and in case of **fusion** between these two regions, this causes the development of choanal atresia.

**Charge Syndrome**

Choanal atresia is associated with charge syndrome

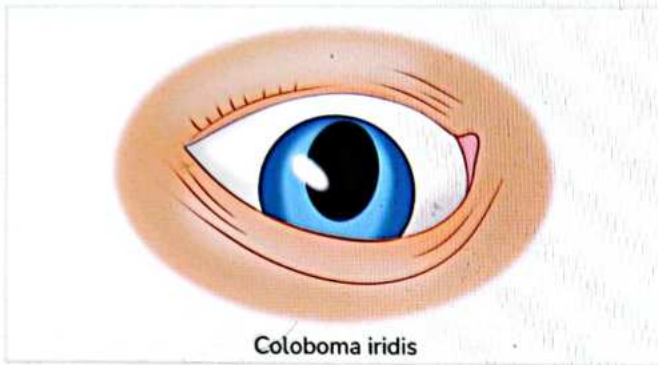
- C:** Coloboma Iridis
- H:** Heart effects
- A:** Atresia
- R:** Retardation.
- G:** Genital.

00:09:50



## E: Ear abnormalities.

**Coloboma iridis** - The condition where the pupil communicates with the Iris is known as coloboma iridis.

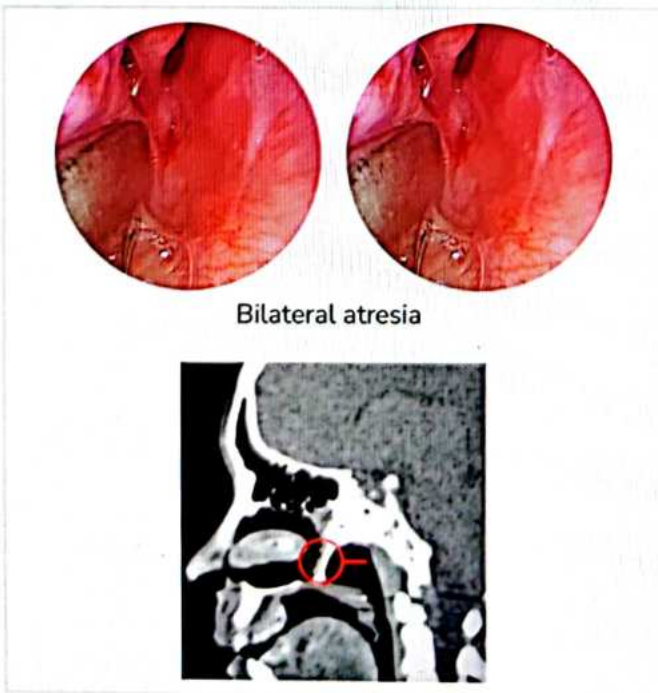


## Choanal Atresia

00:10:40

- When the choana is seen to be not communicating with the nasopharynx; this is bilateral choanal atresia.
- This is an emergency because in such a condition the child cannot breathe through the nose at all. Infants are nasal/natural breathers and do not know how to breathe through the mouth at all. This is presented at birth and the newborn shows signs of respiratory distress.
- Typically, when a child is born, the first thing that a pediatrician will do is make the child cry. For children with bilateral choanal atresia, the mouth is closed the child cannot breathe from the nose because the choana is blocked, at rest the child will have respiratory distress.
- Now, when the child opens the mouth and cries, the air will get sucked in through the oral cavity into the larynx and the trachea and the respiratory distress will disappear on crying. This condition is called cyclical cyanosis.

prince kumar  
princeeekum@gmail.com  
9928609733



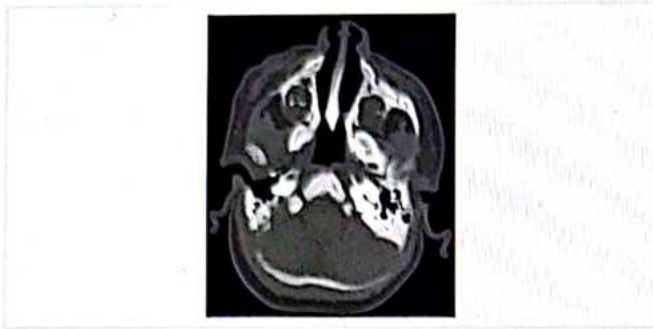- When the child stops crying such respiratory distress will happen again. In such a case the pediatrician establishes an oral airway called the **McGovern's nipple** that contains a feeding tube, this enables the child to feed and breathe simultaneously.
- A tracheostomy has to be done, where one has to bypass the nose and the upper airway. Intubation is also an option but not for a long time. A **tracheostomy tube** can be inserted and the child can be discharged.
- The atresia can be treated by opening the atretic segment, but that is not possible in a newborn because their noses are very small. The child will also not be fit for anesthesia due to less weight.
- A tracheostomy can thus be performed, till the child becomes 1 and a half years of age, when the nose will become wider and bigger, allowing easy instrumentation, allowing it to be easy to take care of the bleeding, making the child sit for anesthesia, and correcting the atresia.
- When the atresia is treated, the choana is opened up. Some stents are left behind after that for 6 to 8 weeks until epithelialization occurs. Once the epithelialization occurs, the stents are pulled out.
- In the case of unilateral choanal atresia, only one choana is blocked. The other choana is open for breathing. It is not an emergency and will also not present at birth but it can present at a later stage in life when there is an upper respiratory tract infection, or when there is mucus in the nose blocking the choana because of the infection.

## Diagnosis

00:19:03

- Typically normal secretions from the nose are drained into the nasopharynx, from there to the oropharynx, and then they get absorbed into the aerodigestive tract. In the case of choanal atresia, secretions cannot get drained into the nasopharynx. This will cause anterior rhinorrhoea (**anterior nasal discharge**);
- Anterior nasal discharge indicates that nose is not communicating with the column of air in the nasopharynx. There will be no air bubbles in the nasal secretions. The absence of air bubbles in the nasal discharge will be suggestive of a possibility of choanal atresia.
- An infant **feeding tube** is put through the nose, and then, it is checked if it goes into the nasopharynx. If it does not, and any resistance is seen in the process, and there is a failure to pass this tube, it is suggestive of a possibility of choanal atresia.
- When a radio-opaque dye is put into the nose, this should normally go into the nasopharynx. This will not be possible in the case of choanal atresia. This can be checked with the help of an x-ray. Further, **radiological tests** like X-rays or CT scans can be carried out to check if there is choanal atresia.





- The above slide shows a CT scan having bilateral choanal atresia. There is no communication between the nose and the nasopharynx. Excessive thickening of the vomer and excessive bowing of the lateral wall of the nose. There is a fusion of the elements in the region of the choana. It is an emergency being presented at birth.

**Treatment**

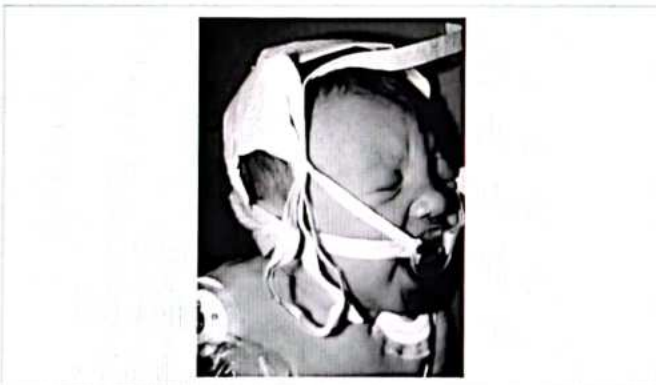1. Emergency airway has to be created.

**McGovern's technique:** A feeding nipple with a large hole provides a good oral airway.

prince kumar  
princeeeekum@gmail.com  
9928609733

**Definitive treatment**

- Correction of atresia at 1.5 years of age.



**Meningocele / Meningoencephalocele**

00:27:30

**Etiology**

- Midline defect in the base of skull leading to the herniation of brain tissue.

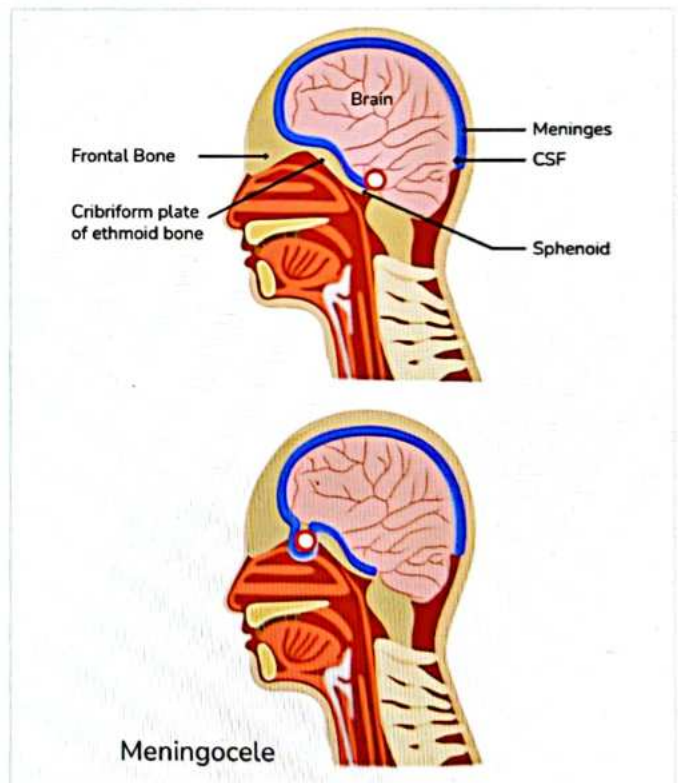
**Meningocele :** Herniation of only meninges.

**Meningoencephalocele :** Herniation of meninges and the brain tissue.

- The anterior cranial fossa is separated from the nasal cavity by the roof of the nose. The roof of the nose is divided into 3 segments.
- In the anterior one, there lies the **frontal bone** and the nasal bone. In the middle one-third, a plate of bone is present,

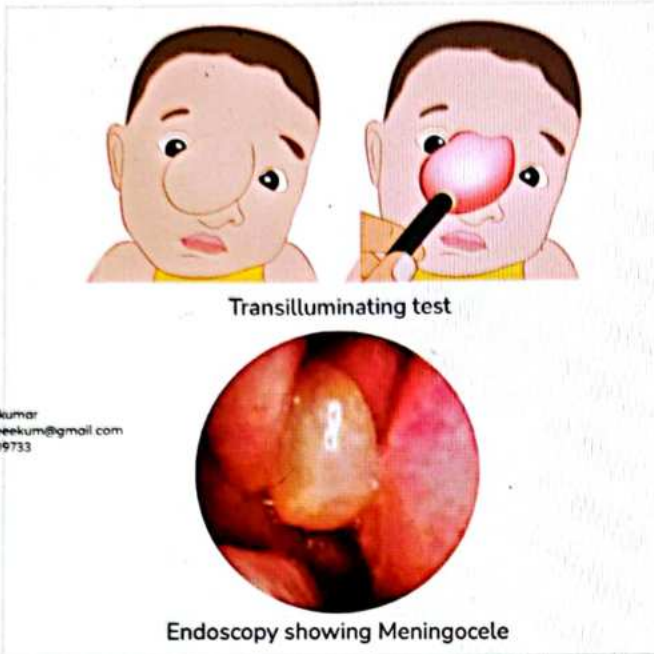
called the **cribriform plate** of the ethmoid bone.

- Posterior to it lies the body of the **sphenoid bone**. The anterior cranial fossa has the frontal lobe of the brain which is covered with meninges. During development, the nasal bone and the frontal bone will develop separately.
- The cribriform and the ethmoidal bone will develop separately. The sphenoid will also develop separately.
- Later all of these will come together and fuse. During the process of fusion when the cribriform will fuse with the sphenoid, but if the frontal bone did not fuse with the cribriform plate of the ethmoid, there will be a **defect in the roof of the nose**.
- Through this defect, the content in the meninges and the brain tissue can herniate into the nasal cavity. When there is **herniation of meninges only**, it is **meningocele**. When there is the **herniation of meninges and brain tissue**, it is **meningoencephalocele**.



- This swelling is in communication with the cranial cavity. The meninges herniate through a small defect in the wide nasal cavity and will balloon out. These will be of **soft cystic consistency**.
- The **compressibility test** will be positive for such swelling.
- The **reducibility test** will be positive. When the swelling is pushed upwards into the cranial cavity, it will become smaller in size.





prince kumar  
princeekum@gmail.com  
9928609733

- Since it is a cystic swelling, the **transillumination test** conducted by shining torch light on the swelling will be positive.
- A **cough impulse test** is also conducted by making an adult or a child cry, the pressure in the cranial cavity will increase. This pressure will get transmitted to the swelling causing it to expand and increase in size. A cough impulse test will be **positive in such a case**.
- **Furstenberg test**: The jugular vein is compressed to see the raise in intracranial pressure. All tests conducted are, thus, positive.
- Meningocele can appear as a swelling in the nose resembling a nasal polyp. In children when there is a polypoidal swelling in the nose, it has to be checked for Meningocele. It can present as an external deformity or an external swelling of the nose. The **transillumination test** will also be positive in such cases.

### Treatment of Meningocele

00:39:15

- The tissue that has herniated from above has to be excised as the herniated amount of brain tissue will no longer be functional.
- There still would lie a possibility of CSF rhinorrhoea; to avoid or treat this condition, one has to reconstruct and close the defect in the roof of the nose or the base of the skull.

### Glioma

00:41:03

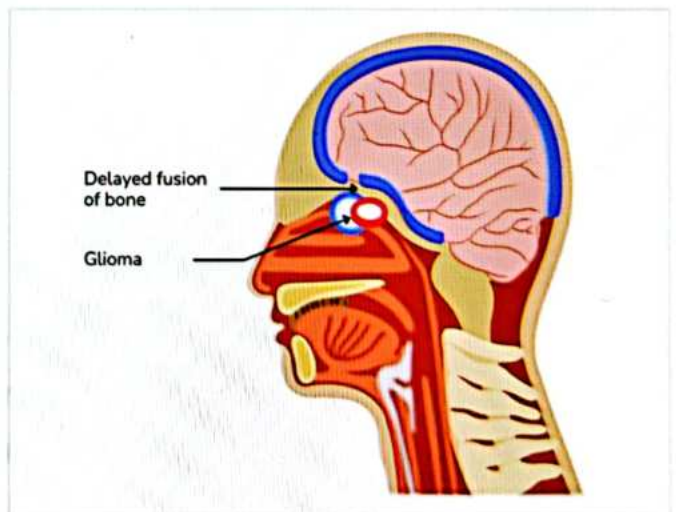
- It is the presence of glial cells outside the central nervous system. Glial cells are cells of the central nervous system.

### How do these come out of the CNS?

- The roof of the nose is made out of three bones, the frontal bone, the cribriform plate of the ethmoid bone, and the sphenoid bone.
- If there is incomplete fusion of these bones during the development, there is herniation of brain tissue and meninges.
- In some children, there is an **initial non-fusion** but there is a **delayed fusion**. In case of delayed fusion, the cells of the CNS are getting disconnected and enter the nasal cavity.
- This way there are CNS cells outside the CNS. The local nasal immune cells will recognize them as foreign cells and try to destroy them.
- There will then be an **antigen-antibody reaction** which will lead to **Fibrosis**. This swelling will become firm in consistency.
- This will be a non-cystic swelling. It will no longer be communicating with the intracranial cavity and CNS. Any intracranial pressure will not get transmitted to the swelling.

### Clinical Features

- If the swelling is firm in consistency, the **compressibility test** will be negative.
- It is not communicating with the intracranial cavity; the swelling will therefore not reduce in size when pushed. The **reducibility test** will be negative.
- The **transillumination test** will also come negative.
- The **cough impulse test** will also come negative because this no longer any communication with the swelling.

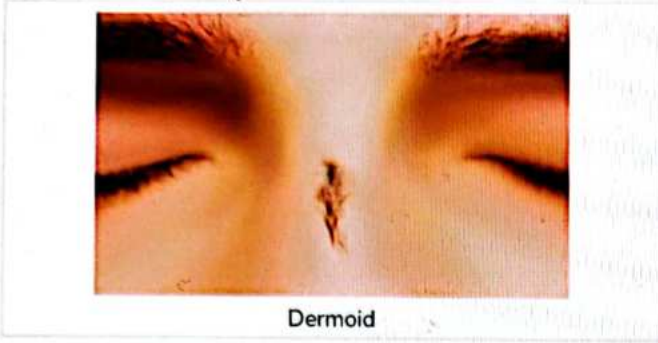


- Initially, there is a non-fusion and then there is a herniation forming a meningoencephalocele or meningocele. Then there is delayed fusion at the base of the skull, causing migration of disconnected CNS cells in the nasal cavity, This is **glioma**.



Dermoid

00:48:08



Dermoid

- Dermoids are Hamartomas, tissues consisting of all 3 embryological layers, namely ectoderm, endoderm, and mesoderm.

**Etiology**

- Dermoid occur in the **line of fusion of the bones**. Anywhere there is a fusion between the frontal bone and the nasal bone, frontal bone, and cribriform plate of the ethmoid bone, between the cribriform plate of the ethmoid bone and the sphenoid bone, dermoid can be present.
- On the outside, these may appear as a small pit or a sinus but

internally, they can have a very big size.

- Dermoid can be in communication with the intracranial cavity and sometimes can be non-communicating.

**Clinical Features**

- Dermoids contain **cheesy sebaceous material**. They are soft swellings and are non-cystic in consistency.
- The **compressibility test** will be positive. The **reducibility test** will be negative because most of the time they are not communicating with the cranial cavity.
- **Trans-illumination test** will be negative.
- The **cough impulse test** will be negative.

**Treatment**

- The treatment of a dermoid will be **complete excision**. For all kinds of congenital anomalies of the nose, **radiological studies** are done to identify the origin and the extent.
- A **CT scan of the nose** and the para nasal sinuses is to understand if there is a defect in the base of the skull. **MRIs** are done additionally in case of herniation.

**Comparative Chart**

00:54:00

	Meningocele / meningo – encephalocele	Glioma	Dermoid
Content	Meninges with or without brain tissues	Encephalocele with obliterated intracranial connection	Sebaceous material, presence of pit, hair may protrude from mass
Pathology	Midline skull base defect	Nipped off portion of encephalocele during embryonic development	Entrapment of ectodermal elements long the lines of embryonic closure
Compressibility test	Compressible	Non compressible	Compressible
Transillumination test	Positive	Negative	Negative
Furstenberg	Positive	Negative	Negative






# CROSS WORD PUZZLES



## Crossword Puzzle 1




### Across

- Choanal atresia means that there is a non-communication between the nose and the -----.
- is a communication between the nose (anteriorly) and the nasopharynx (posteriorly).
- occur in the line of fusion of the bones.

### Down

- When there is the herniation of meninges and brain tissue, it is -----.
- When there is only herniation of meninges, it is -----.

## Crossword Puzzle 2



### Across


- Choanal atresia occurs due to the persistence of the ----- membrane.
- If there is incomplete fusion of the bones during the development, there is ----- of brain tissue and meninges.

- choanal atresia is an emergency because in such a condition the child cannot breathe through the nose at all.

### Down

- The roof of the nose is made out of three bones, the frontal bone, the ----- plate of the ethmoid bone, and the sphenoid bone.
- means nondevelopment.

## Crossword Puzzle 3



### Across

- In the case of Glioma, a delayed fusion of the bones will lead to an antigen-antibody reaction which will lead to -----.
- On herniation, if the swelling is firm in consistency, the compressibility test will be -----.
- Meningocele can appear as a swelling in the nose resembling a nasal -----.

### Down

- In the ----- test, the jugular vein is compressed to see the raise in intracranial pressure.
- contain cheesy sebaceous material. They are soft swellings and are non-cystic in consistency.

prince kumar  
princeekum@gmail.com  
9928609733



**26**

**NASAL POLYPS**

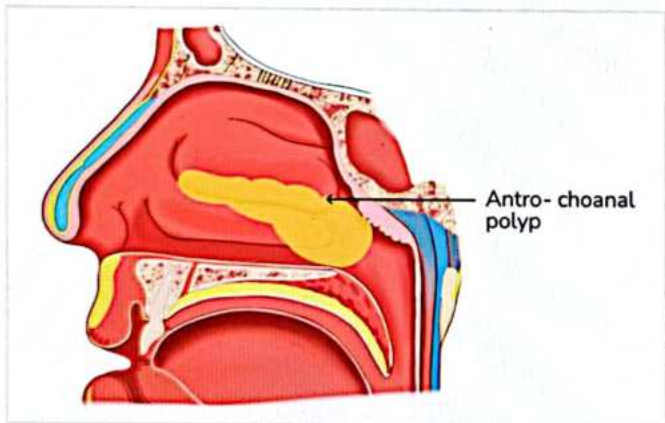


**Definition:** A polyp is chronically inflamed oedematous tissues. Whenever the tissues are chronically inflamed and become oedematous, the tissue prolapses into a hollow cavity, which is the nasal cavity, which is a **nasal polyp**. The polyp will be named according to the site where there is inflammation, making the tissue become oedematous and prolapse into a hollow cavity.

- **Benign:** Polyps are benign lesions of the nasal cavity and are not malignant.
- **Types:** In the paranasal sinuses, the two types of polyps are seen:
  1. **Antrochoanal Polyp-** The disease is starting from the maxillary area and goes into the choana posteriorly.
  2. **Ethmoidal Polyp-** These are coming from the ethmoidal air cells.

**Antrochoanal Polyp**

00:03:07



**Origin:**

- The "antro", comes from antra; and the "choanal" from choana. These polyps originate in the maxillary antrum, go into the nasal cavity, and are directed posteriorly toward the choana.

**Extent:**

- The extent of this polyp is posteriorly towards the choana and not anteriorly towards the nasal vestibule.

**The three parts of the polyp are:**

- **The Antral part:** This is in the maxillary antrum from where it originates.
- **The Nasal part:** It goes into the nasal cavity.
- **The Choanal part:** From the nose, it goes into the choana (communication between the nose and the nasopharynx) posteriorly.
- **Single/Unilateral:** Antrochoanal polyps are single polyps.

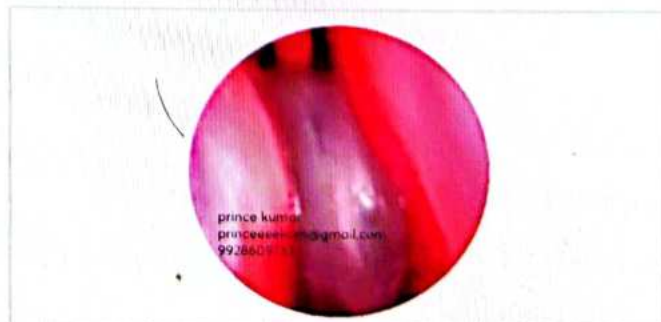This is a one-unit polyp present in one side of the nasal cavity or sinuses. It is not bilateral.

- **Age:** It is often seen in younger individuals.
- **Male Predominance**
- **Cause/Etiology:** The cause for these kinds of polyps are due to infection and not an allergy. The organism responsible for causing this polyp is **streptococcus pneumonia**.

**Clinical Features/Symptoms:**

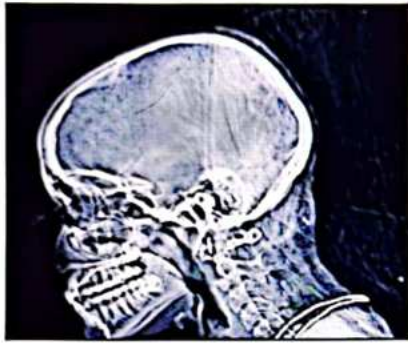
- When there is a unilateral mass in the nasal cavity, the symptoms experienced by the patient are:
  - **Nasal obstruction:** There will be a nasal obstruction and difficulty in breathing because there is a mass that is occluding the nasal cavity.
  - **Nasal discharge:** There is edema and inflammation which has resulted in the polyp. The normal major secretions are not able to drain posteriorly because the mass is occluding it.
  - **Hyposmia/Anosmia:** The air that is reaching the cribriform plate will get reduced because there is some mass that is occluding the nasal cavity.
  - **Rhinolalia Clausa:** The nose acts as a resonator that ensures a good quality of voice. When the nasal block will be causing hypotonic voice(Nasal Twang). **Rhinolalia Clausa** will happen because the nasopharynx is closed, and there will be nasal intonation in the voice.
  - **Hampered Ventilation:** When the air is going into the choana or posteriorly into the nasopharynx, ventilation that reaches the nasopharynx will be hampered. Ventilation via the Eustachian tubes to the middle ear will also be hampered and will result in middle ear diseases like nonsuppurative otitis media. This is not an infective condition but is rather noninfective. The disease will be unilateral because the polyp is unilateral.

**On Examination**





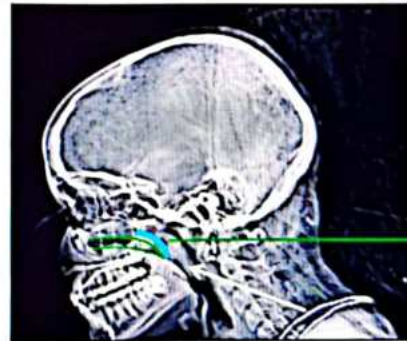
- **On anterior rhinoscopy:** A greyish-white mass can be seen in the nasal cavity. Typically, this cannot be seen going into the choana but can be seen with the help of posterior rhinoscopy (A mirror has to be used behind the uvula. In the mirror one has to look at the reflection of the polyps that are present in the choana or nasopharynx, that can be seen in the mirror.) **The posterior rhinoscopy is done to assess the spread posteriorly.**



- Whenever there is a unilateral nasal mass, a differential diagnosis may be carried out. As per the age, the differential diagnosis may vary.
- If the diagnosis is of a **child or a young individual**, one must think of congenital lesions, typically **meningocele or meningoencephalocele** (Their appearance resembles that of a polyp). Others may consist of a glioma or a dermoid.
- If the symptoms are seen in a **juvenile/adolescent age group**, one must rule out a **juvenile nasopharyngeal angiofibroma**. This can also present as a unilateral mass in the nasal cavity, with nasal obstruction, difficulty in breathing, hypotonic voice, hyposmia, and unilateral middle ear disease. On examination, it is not greyish white but a **red and vascular mass**. The difference between JNA and an AC polyp is AC polyp never presents with bleeding from the nose (spontaneous, recurrent, unprovoked, provoked, profuse epistaxis- these are not features of AC polyp that are definite features of JNA.)
- If the same thing is seen in **older individuals**, any other type of **malignancy or benign tumors** such as **inverted papilloma**.
- **Imaging:** Initially, an x-ray can be done but it cannot provide specificity to understand the extent of the disease. It only has a good sensitivity to pick up the disease. A **Non-Contrast CT Scan of the nose and para nasal sinuses** is thus the best option initially for a patient with nasal polyp. This scan can help understand the extent and origin of the polyp, if there are any bony erosions around it, and if there is a disease extending beyond the choana or nasopharynx. After the scan further investigation can be carried out to rule out other differential diagnosis.

## Treatment

- **No role of medical therapy:** There is no role in medical therapy for patients with AC polyps. Antibiotics can be given to clear the infection, but the inflamed edema that has prolapsed into the nasal cavity, going to the choana will not disappear with antibiotics.
- Surgery has to be performed: **The surgery of choice is Functional Endoscopic Sinus Surgery.** It is called functional because only diseased tissues are removed and not the normal tissue. Removal is done with the help of an endoscope. The medical procedure takes place by going into the sinus. As much normal mucosa as possible is preserved.
- Whenever such a surgery is performed, before proceeding, the unilateral nasal mass has to be palpated to check if it is bleeding on touch.
- One has to take a syringe and aspirate and see if they are getting any fluid. If there is bleeding on touch, there is the probability of a tumor like an inverted papilloma. **If the patient is in an adolescent age group, one must think of angiofibroma.** This will lead to a change of surgical plans and approach to the patient.
- If there is fluid on aspiration, it is either a meningocele or meningoencephalocele. One has to be extra careful while performing surgery otherwise it can lead to intracranial complications.



CRESCENT SIGN  
DOOD'S SIGN

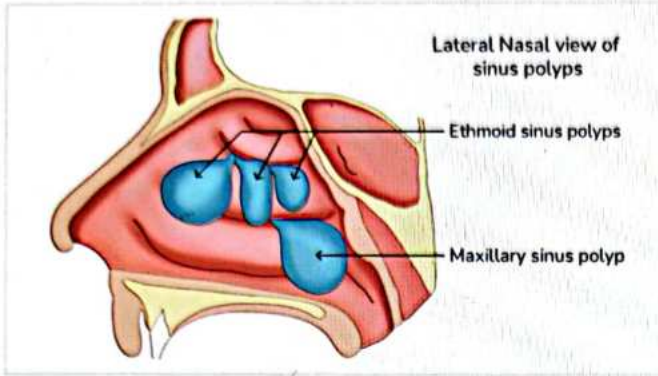
## Crescent Sign

- A **crescent sign** is seen in a patient with an **AC polyp**. There is a mass coming from the maxillary sinus that is going into the nasal cavity and nasopharynx. There is a column of air present between the mass and the posterior pharyngeal wall called the **crescent sign or Dodd's sign**. A lateral view is supposed to be studied to find out if this sign is present. **In malignancy or tumors, or JNA, this sign is absent.**



## Ethmoidal Polyps

00:21:58



### Origin:

- As the name suggests these are originating from the Ethmoidal air cells. The anatomy of these air cells shows that they are sandwiched in between the frontal sinus anteriorly, and those sphenoid sinuses posteriorly. From the Ethmoidal air cells, there are inflamed tissues which are the Ethmoidal polyps. These polyps grow anteriorly.

### Extent:

- The extent of the spread of the disease is anterior and not posterior
- **Age:** This disease is typically seen in adults and middle-aged groups.

### Etiology:

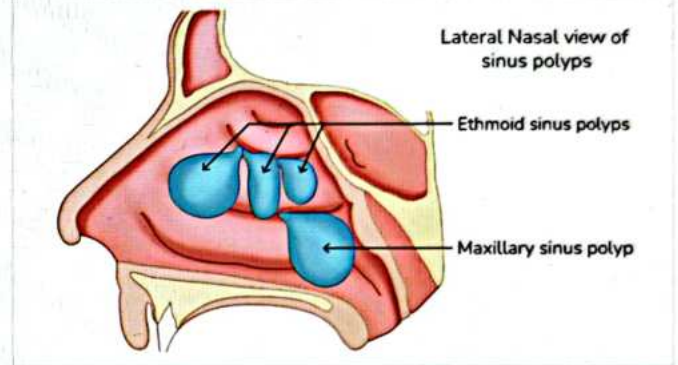
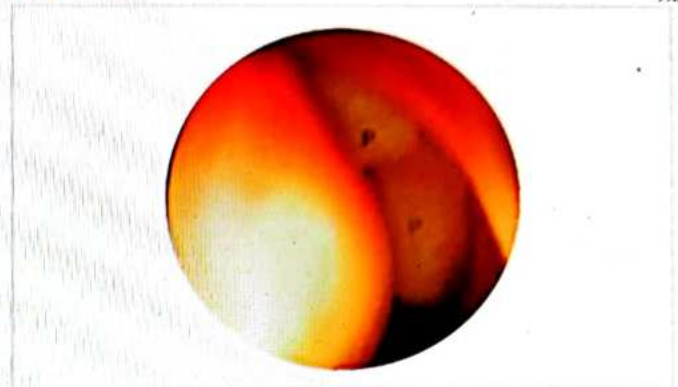
- These polyps are caused by allergic origin or diseases of ciliary motility. In ciliary disorders, the mucociliary clearance (not just of the nose and paranasal sinuses, but up to the trachea, alveoli, bronchus, and into the lungs, causes bronchiectasis, sinusitis, etc.)
- There are certain syndromes associated with ciliary motility defects. These polyps are associated with certain syndromes:
  - Chronic rhinosinusitis
  - Asthma
  - Cystic fibrosis
  - **Kartagener's syndrome:** Bronchiectasis, sinusitis, situs inversus.
  - **Young syndrome:** Sinopulmonary syndrome and azoospermia.
  - **Churg Strauss syndrome:** Asthma, fever, eosinophilia, vasculitis, granuloma.

### Sampter's Triad:

- Asthma
- Aspirin sensitivity (to be avoided in patients with nasal polyposis as it can cause a reaction that can be fatal to the patient).
- Nasal polyposis

## Diagnosis:

prince kumar  
princeekum  
9928609733



- The symptoms will be the same as that of an AC polyp. It is the local manifestation of systemic disease. Since allergy is present in both nasal cavities, ciliary motility disorder will happen in both, so ethmoidal polyps are **bilateral**.
  - There will be a bilateral nasal obstruction and difficulty in breathing.
  - Bilateral nasal intonation in the voice
  - Bilateral hyposmia
  - Eustachian tube blocked (bilateral)
  - Excessive sneezing
  - Anosmia
  - Snoring
  - Headache
  - Bilateral middle ear disease

### Examination

- In this case, an anterior rhinoscopy is sufficient since these polyps are growing anteriorly, it is not mandatory to do a posterior rhinoscopy.
- Typically, pale oedematous tissue with multiple pedunculated masses insensitive to touch and bleeding, which are resembling a bunch of grapes, is a hallmark of the ethmoidal polyp.

### Treatment

- Before treatment diagnosis is very important. X-ray and non-contrast CT scan or the diagnosis of choice. **CT Scan is more**



sensitive and specific and is the investigation of choice.

- These polyps are recurrent because they are allergic in origin and associated with ciliary motility disorder.
- Investigation for allergy with **elevated serum IgE levels**, **elevated eosinophil count**, and absolute eosinophil count is to be looked for.
- For the diagnosis of a **ciliary motility disorder**, there are multiple tests. Typically, a **Saccharin test** is performed where a drop of saccharin is placed in the nose. If the patient is unable to have that sweet taste in the mouth after a certain time, there is a ciliary motility defect because of which it is not going into the nasopharynx. This test is done in an OPD just to assess if there is proper ciliary motility function.
- The other test carried out is **Nasal Nitric Oxide measurement**. Nitric oxide is usually produced by para-nasal sinuses. This nitric oxide will be elevated in patients suffering from ciliary motility disorder.
- For cystic fibrosis, a **Raised Sweat chloride test** is performed.
- Along with this **Raised Trans-Nasal Electrical Epithelial potential difference** in an **electron microscopy test** will tell if there is a probability of cystic fibrosis.
- **Gene and DNA analysis** will again confirm the presence and absence of any genetic abnormality that is associated.
- For Treatment, a patient suffering from ethmoidal polyps is given medical therapy. There is chronic inflammation, and allergic in etiology most often.
- Treatment is **started with a short course of systemic steroids**, **topical intranasal steroids** along with **anti-histamines**, and **nasal decongestants**.
- After medical therapy, there is reevaluation because there is a possibility of the polyps shrinking in size or disappearing altogether.

- If they are still present there has to be an operation and surgery. The type of surgery performed here is **Functional Endoscopic Sinus Surgery**. Only the polyps are removed and the normal nasal tissue is preserved. Purification of air and humidification of air, which are the normal functions of these tissues, are going to be preserved. Only the diseased mucosa is removed.
- Earlier for AC polyps, a **Caldwell-Luc approach** was taken where the doctors went through the sub-labial incision, elevate the mucoperiosteum over the maxilla, and enter the maxillary sinus. A front-ethmoidectomy external was also performed to reach the sinuses. Today these are obsolete. **Most of the patients are managed with FESS.**

### Comparison of Antrochoanal Polyp and Ethmoidal Polyp 00:37:01

	Antrochoanal polyp	Ethmoidal polyp
Age	Young	Middle and adult
Etiology	Infection	Allergy
Number	Single	Multiple
Laterality	Unilateral	Bilateral
Origin	Maxillary sinus	Ethmoid sinus
Growth	Posteriorly	Anteriorly
Medical Treatment	No role	In initial phase
Surgery	FESS	FESS
Recurrence	Less	High

prince kumar  
princeeeekum@gmail.com  
9928609733






# CROSS WORD PUZZLES



Crossword 1




**Across**

- 2. AC polyps have a low ----- rate.
- 5. Ethmoidal polyps have a high recurrence rate because it can be triggered by -----.

**Down**

- 1. AC polyps has no treatments involving ----- therapy.
- 3. ----- polyps involve medical therapy.
- 4. AC polyps are caused by -----.

Crossword 2



**Across**


- 3. AC polyps are single polyps and are -----.
- 5. Ethmoidal polyps all multiple and -----.

**Down**

- 1. AC polyps are seen in ----- age groups.
- 2. Ethmoidal polyps are seen in ----- age group and adults.

- 4. For ----- polyps, treatment is started with the short course of systemic steroids, topical intranasal steroids along with anti-histamines and nasal decongestants.

Crossword 3



**Across**

- 2. Antrochoanal polyps originate in the ----- antrum, go into the nasal cavity and is directed posteriorly towards the choana.
- 4. Since allergy is present in both the nasal cavities, ciliary ----- disorder will happen in both, so ethmoidal polyps are bilateral.
- 5. In functional endoscopic sinus surgery, deceased tissues are with the help of an -----.

**Down**

- 1. A ----- sign is seen in a patient with AC polyp also called Dodd's sign.
- 3. ----- polyps are single polyps.



**27**

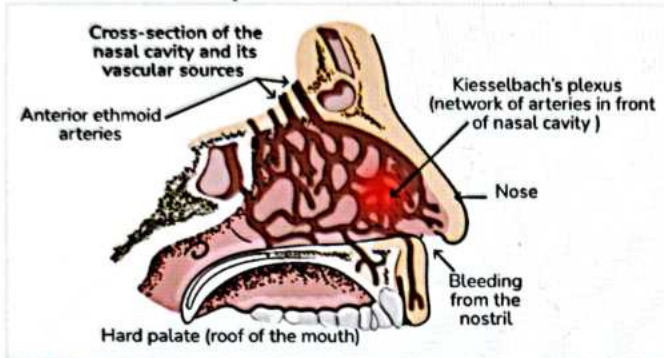
**EPISTAXIS**



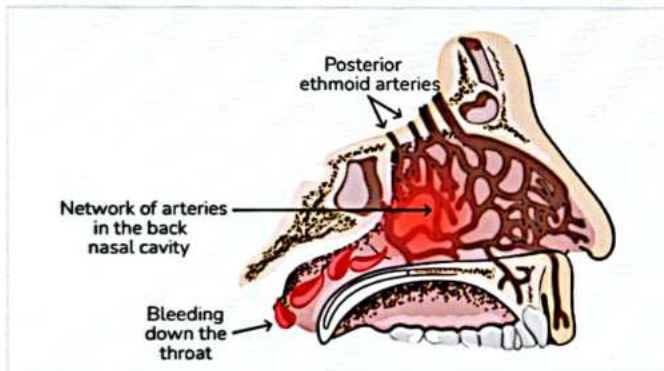
**Epistaxis**

00:00:58

- The epistaxis means bleeding from the nose. Epistaxis can be classified into two parts:



- **Anterior Epistaxis:** Any bleeding that occurs anterior to the pyriform aperture is called anterior epistaxis.



- Any bleeding that occurs posterior to the pyriform aperture is called posterior epistaxis.

**Epistaxis is also divided into primary and secondary.**

- **Primary:** When there is no attributable cause or when it is idiopathic it is called primary epistaxis.
- **Secondary:** Any bleeding causing secondary to a specific cause like infection, trauma, or Neoplasm drug-related issue, liver pathology, etc.
- Epistaxis is also divided into childhood epistaxis and adult epistaxis. Bleeding occurs for anyone less than the age of 16 years is called childhood epistaxis.

	<b>Anterior Epistaxis</b>	<b>Posterior epistaxis</b>
Incidence	More common	Less common
Site	Little's area	Woodruff's plexus
Age	Children	After 40 years of age
Cause	Trauma	HTN
Bleeding	Mild can be controlled by local pressure or anterior pack	Bleeding is severe, require hospitalization and postnasal pack

The septum is divided into two imaginary halves.

- The upper half of the septum receives its blood from the internal carotid artery.
  - It is giving rise to the ophthalmic artery which is further divided into an anterior ethmoidal artery and a posterior ethmoidal artery.
- The lower half of the septum receives its blood from the external carotid artery. This is further divided into two parts:
  - **Facial artery:** This gives rise to a superior labial artery. The superior labial artery supplies the septum inferiorly via the septal branch.
  - **Internal maxillary artery:** It is further divided into the sphenopalatine artery and the greater palatine artery.

<b>Kiesselbach's</b>	<b>Woodruff's plexus</b>
• Arterial	• Venous
• Anteriorly	• Posteriorly
• Children	• Adults
• Mild	• Severe

- All these arteries supply to the septum and they will form a plexus in the anteroinferior portion of the septum except the Posterior Ethmoidal artery. This is called the little's area also called **Kiesselbach's plexus**. It is an arterial plexus.
- Corresponding to the arteries some veins drain the Posterior inferior part of the Septum. That venous plexus is called a **Woodruff's plexus**.

**Causes of Epistaxis**

00:12:20

- Causes of epistaxis can be divided into:

<b>1. Local causes</b>	<b>2. General cause</b>	<b>3. Idiopathic</b>
• Trauma	• Hypertension	
• Infection	• Disorders of Blood vessels	
• Foreign body	• Coagulopathy	
• Neoplasm of nose and paranasal sinus	• Liver disease	
• Deviated nasal septum	• Renal disease	
	• Drugs	
	• Vicarious Menstruation	

- Local causes
- General causes or systemic factors.
- **Idiopathic causes:** When there is no attributable cause for the nosebleed it is called an idiopathic cause.

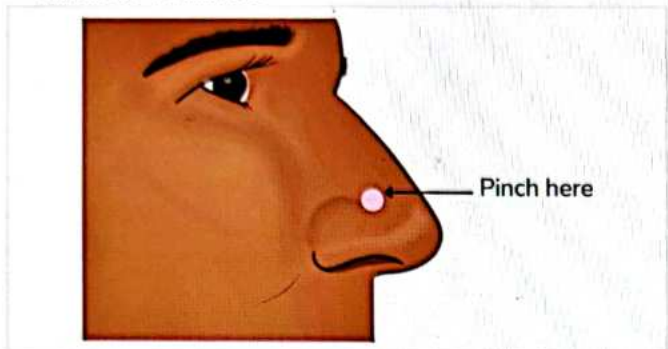


## Management of Epistaxis

00:15:07

### Trotters method digital pressure

- Application of digital pressure over Kesselbach's plexus for at least 15-20 minutes



- In this method, the patient is asked to pinch their nose and bend their head forward, and stay in this position for 15 to 20 minutes. By pinching the nose, the patient is applying pressure in the little area which is the most common site of bleeding. Only pinching the nose is called Hippocrates method.

### Initial medical review and resuscitation

- In this process, the patient is asked about the history of the bleeding. An order to access any trauma, infection, or any other problem that has caused this bleeding.
- The query will also determine whether the cause is local, general, or idiopathic. The blood samples are sent or CBC, coagulation profile to rule out any coagulopathies.
- With this, the patient is also given IV fluid, Crystalloids or colloids to replace the intravascular volume or whatever amount of blood loss has occurred. This entire process is called initial medical review and resuscitation.

### Prepare for Nasal Endoscopy

- This will give a clear picture of whether any internal bleeding is still taking place or not in the patient. Since the patient will already be in panic due to bleeding, it is recommended to give a pledge of cotton soaked in 4% Xylocaine + Adrenaline.

1. Initial medical review
2. Direct therapy
3. Indirect therapy
4. Surgeries
5. Embolization

- In endoscopy if there is a single bleeding point then it needs to be cauterised:
  - Chemical cautery: silver nitrate solution can be used.
  - Electrical cautery: Thermal cautery.

### Anterior nasal packing

↓Fails

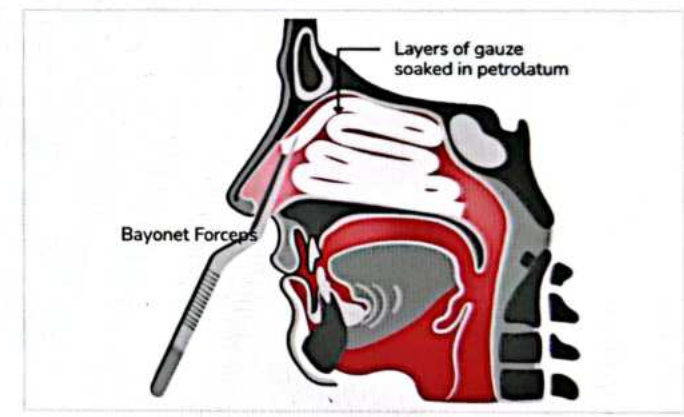
### Posterior nasal packing

↓Fails

- Surgeries (Ligation of artery)
  1. Sphenopalatine Artery
  2. Internal Maxillary Artery
  3. Ethmoidal Artery
  4. ECA
- In case no endoscopy is available or multiple bleeding points are spotted during the endoscopy, the next step to be followed is packing.
  - In this case, the surgeon can do the packing; it is an indirect therapy. First anterior nasal packing is done if that fails after that posterior nasal packing is done. And when posterior nasal packing also fails, surgery is the only option. Ligation of arteries: firstly, the sphenopalatine artery is ligated as it is called the artery of epistaxis. Embolization should be done if surgery fails.

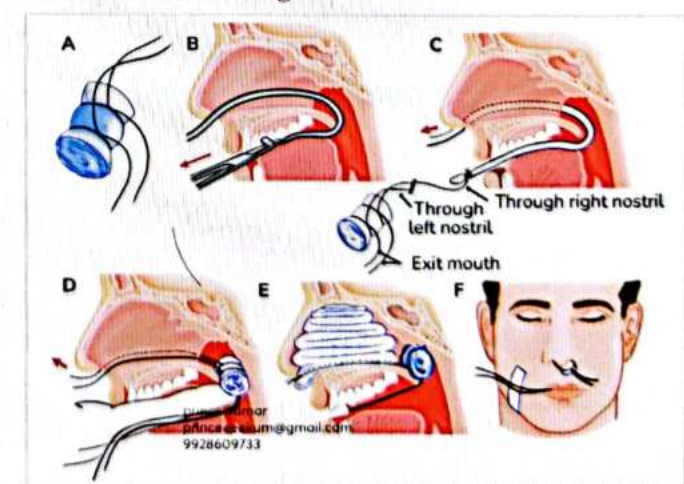
### Anterior Nasal Packing

00:27:07



- Anterior nasal packing means packing the nasal cavity from the vestibule anteriorly to the choana posteriorly. A Ribbon gauze is inserted which is dipped into bismuth iodoform paraffin paste.

### Posterior Nasal Packing



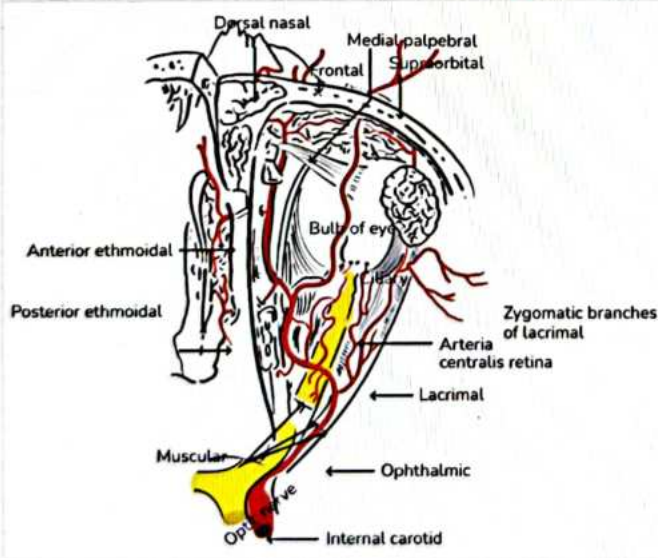
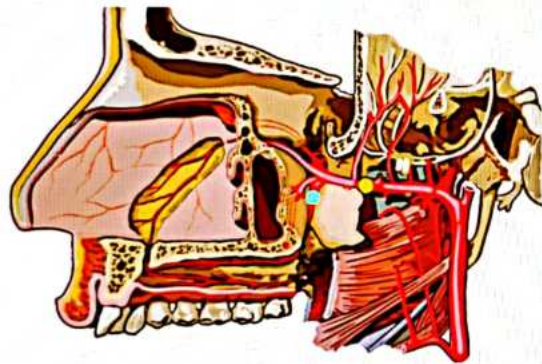


- Posterior nasal packing is performed to achieve haemostasis in cases of epistaxis from a suspected source located posteriorly in the nasal cavity, nasopharynx is also occluded in posterior nasal packing.
- Modern-day packing is generally performed in the emergency department, commonly using balloon catheters.

### Ligation of Arteries

1. Sphenopalatine artery → Artery of Epistaxis
2. Internal maxillary artery → Pterygopalatine fossa
3. Ethmoidal artery
4. External carotid artery

- HYOID → CCA { ICA  
ECA Branches



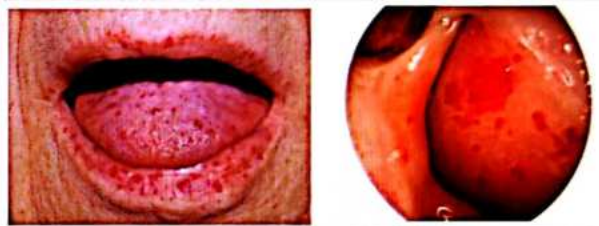
- Ligation of the artery begins with ligation of the Sphenopalatine artery is present in the sphenopalatine foramen, which is present near the posterior wall of the maxillary sinus.
- Internal maxillary artery: it is ligated in the **Pterygopalatine fossa**.
- Anterior and posterior ethmoidal arteries are found on the

medial wall of the orbit. On the medial wall of the orbit, about 24 mm behind the Anterior ethmoidal foramen is presently transmitting the anterior ethmoidal artery. About 12 mm posterior to it posterior ethmoidal foramen is present transmitting the posterior ethmoidal artery. 6 mm behind that is the optic canal transmitting the optic nerve.

- External carotid artery: It must be ligated at the level of the neck. At the level of the hyoid bone, the common carotid artery is divided into internal carotid and external carotid arteries (it has branches).

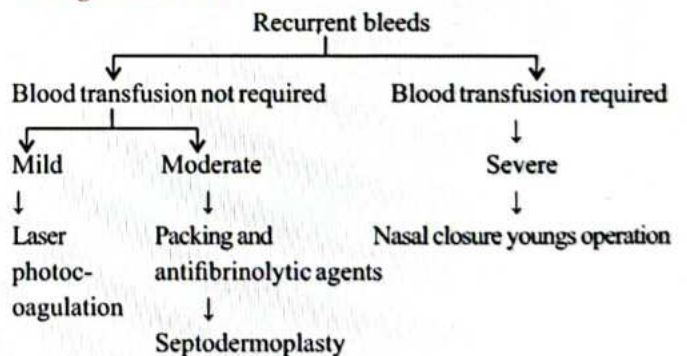
### Hereditary Haemorrhagic Telangiectasia (HHT) 00:37:20

- Autosomal dominant condition
- Affects the blood vessels



- Hereditary haemorrhagic telangiectasia (HHT) is an autosomal dominant condition that affects the blood vessels. The most common locations affected are the nose, lungs, brain, and liver. Management is different as compared to the normal epistaxis patient.

### Management of HHT



- The first thing in the management of HHT is to check whether the bleeding is mild or severe. If a blood transfusion is not required, it is mild bleeding. If a blood transfusion is needed, then it is severe bleeding. In Septodermoplasty the mucosa is elevated over the septum and the entire mucosa is removed.
- Along with the mucosa, the telangiectasia spots will also get removed. The cartilage and the bone of the septum are covered with facias or skin drafts. Complete closure of the nasal cavity is called a **young's operation**.

pnfriceeekum@gmail.com  
9928609733

### One Liners

- Most common cause of epistaxis is **trauma**



- Most common cause of epistaxis in children is **trauma**
- Most common cause of epistaxis with foul smelling nasal discharge which is unilateral in children is **FB**
- Most common cause of recurrent unprovoked profuse epistaxis in adolescent male is **JNA**
- Most common cause of epistaxis in elderly is **HTN**
- Most common site of epistaxis is from **Little's area**
- Anterior epistaxis if venous occurs from **Retrocolcemella-V**
- Artery of epistaxis is **SPA**
- Posterior epistaxis occurs from **WOODRUFF'S**
- **TESPAL** stands for **Transnasal endoscopic sphenopalatine artery ligation**

### Fill in the blanks

- If a nosebleed comes from the **posterior** portion of the nose from the **SP** artery, then you need to call an ENT because the bleed is life-threatening.

### Question/Answer

**Q.** If you have a patient that is leaning forward and spitting up blood; what type of nosebleed would you assume?

**Ans.** It is due to posterior epistaxis.

**Q.** If someone comes into clinic with a nosebleed, upon per abdominal examination, you notice they also have a distended abdomen, what should you first thought be?

**Ans.** Portal hypertension or cirrhosis which is causing a distended abdomen. Also, whenever there is a liver disease nasal bleeding can occur.

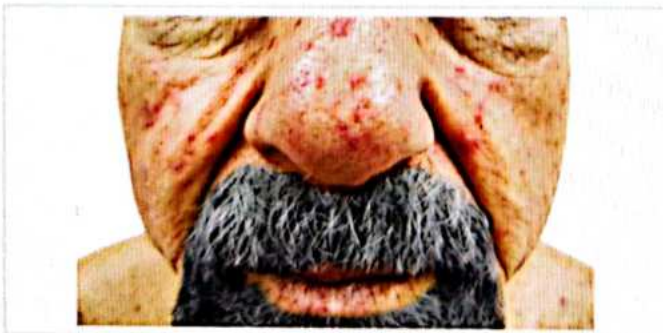**Q.** Why is silver nitrate contraindicated for a bilateral nose bleed?

**Ans.** Silver nitrate is contraindicated for a bilateral nosebleed. Because if it is applied to the corresponding area. It can result in septal perforation.

**Q.** If you are working in an urgent care and have a patient who complains of biweekly nosebleeds from unknown origins, what would be your initial work up?

**Ans.** Most often there could be systemic causes there can be local causes but since the cause mentioned here is unknown it can be a system cause.

- Epistaxis with a clinical picture like shown in the image, the probable diagnosis would be?



HHT management procedure should be followed.

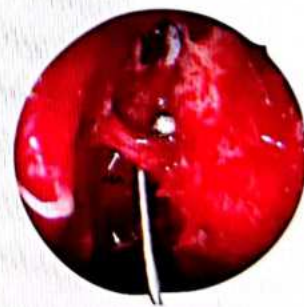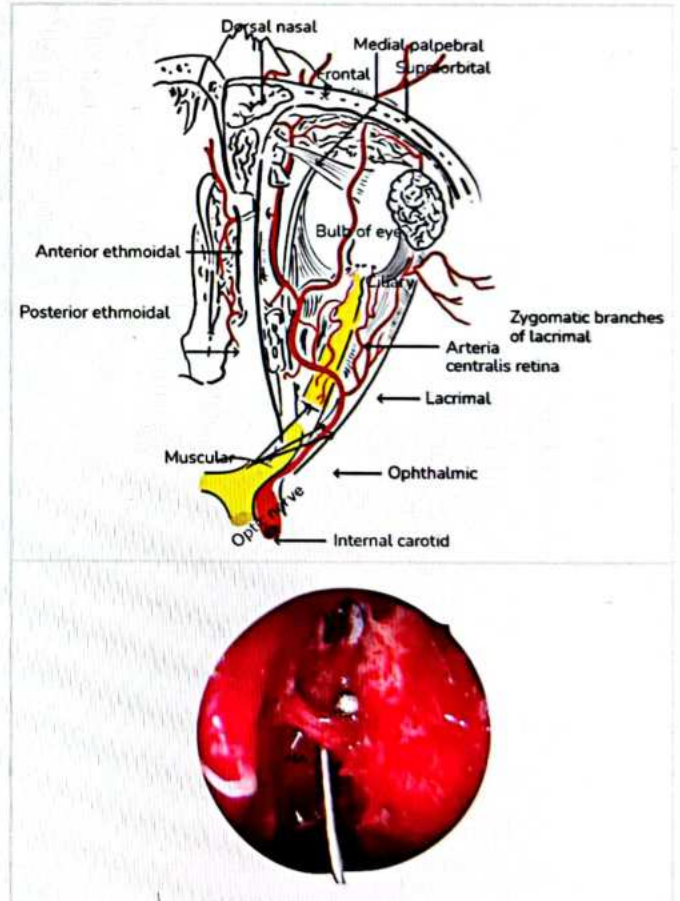
**Q.** Why patients with COPD and advanced cardiac conditions are preferable avoided with nasal packing?

**Ans.** The patient will not be able to breathe properly and especially when the sleeping, the tongue is more likely to fall backwards, resulting in sleep apnoea.

### MCQ

**Q.** After endoscopic sinus surgery a patient developed periorbital ecchymosis and blurring of vision. The cause of this is

- Sphenopalatine bleeding
- Anterior ethmoidal artery bleed**
- IMA bleed
- Facial artery bleed



- Blurring of vision is mostly caused by the traumatized ethmoidal artery. As they are travelling from the medial wall of the orbit to the ethmoidal sinuses.






# CROSS WORD PUZZLES



**Crossword Puzzle 1**




**Across**

3. Most common site of epistaxis is \_\_\_\_\_.

**Down**

- 1. Most common cause of epistaxis in the elderly is \_\_\_\_\_.
- 2. Most common cause of epistaxis in children is \_\_\_\_\_.

**Crossword Puzzle 2**




**Across**

3. Anterior epistaxis if venous occurs from \_\_\_\_\_.

**Down**

- 1. Artery of epistaxis is \_\_\_\_\_.
- 2. Posterior epistaxis occurs from \_\_\_\_\_.

**Crossword Puzzle 3**



**Across**

3. Any bleeding that occurs anterior to the \_\_\_\_\_ is called anterior epistaxis.

**Down**

- 1. The upper half of the septum receives its blood from the \_\_\_\_\_ artery.
- 2. Silver nitrate is \_\_\_\_\_ for a bilateral nosebleed.

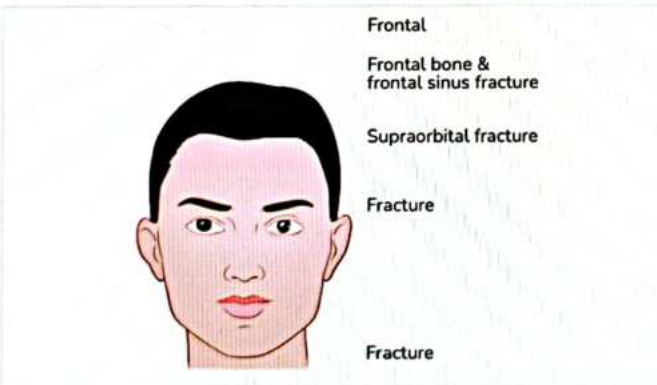


Facial Trauma

00:01:00

Fractures of the face

Upper third	Middle third	Lower third
Frontal sinuses	Nasal bones and septum	Alveolar process
Supraorbital Ridge	Naso- orbital area	Symphysis
Frontal bone	<ul style="list-style-type: none"> <li>Zygoma</li> <li>Zygomatic arch</li> <li>Orbital floor</li> <li>Maxilla                             <ul style="list-style-type: none"> <li>Le fort I (transverse)</li> <li>Le Fort II (pyramidal)</li> <li>Le Fort III (craniofacial dysfunction)</li> </ul> </li> </ul>	<ul style="list-style-type: none"> <li>Body</li> <li>Angle</li> <li>Ascending ramus</li> <li>Condyle</li> <li>Temporomandibular joint</li> </ul>



- An injury or fracture to the face known as facial trauma may involve the upper jaw, lower jaw, cheek, nose, eye socket, or forehead.
- The face is divided into 3 parts- upper, middle, and lower face.
  - The upper third of the face has a frontal bone with the frontal sinus and supraorbital bridge.
  - The middle third part of the face has nose. Nasal bone fracture is the most common type of fracture on the face because of the most common projection on the face.
- Other sites of fracture are the maxilla, orbital floor, and zygomatic bone.

- The lower third of the face has mandible which is a common fracture in the lower third part of face.

Fractures of Nasal septum

	Jarjavay fracture (class 2)	Chevallet fracture (class1)
Direction of blow	From front	From below
Direction of fracture	horizontal	vertical

- Fracture of the nose is classified into three types
  - Class 1- Chevallet fracture**
    - The fracture line is vertical, and the direction of injury is below the nose
  - Jarjavay fracture**
    - The fracture line is horizontal, and the direction of fraction is from the side of the nose or from the front of the nose.
  - Naso-orbito-ethmoid fracture**

**Important Information**

**Pig nose deformity is seen in which class?**


- When the fracture occurs in the Naso-orbito-ethmoid fracture (deformity in the perpendicular plate of ethmoid bone, ethmoid sinus, orbit in the septum), compressed together pushing the rest of the nose dorsum in an upward direction which resembles the pig's nose known as pig nose deformity.
- Hence, pig nose deformity is seen in class 3 (Naso-orbito-ethmoid fracture).

- Which class is associated with CSF leak?**
- When a fracture occurs on the perpendicular plate of ethmoid bone, ethmoid sinus, orbit in the septum. There is a high chance of leakage of CSF.
  - Hence, CSF leak is associated with Class 3, Naso-orbito-ethmoid fracture.



## Treatment of fractures

00:10:24



## Timing of prediction

- If the patient has come to a doctor early (less than 3 hours before the fracture), there is no edema this time.
- This will be easy for doctors to assess the deformity of the nose, and the correction will be more appropriate.
- If the patient comes after 3 hours, edema is trapped in the tissue of nose. Assessment and correction would be more difficult and inappropriate.
- 5-7 days is the ideal time for the reduction of edema. Because edema will settle down and correction will be more appropriate.
- Beyond the 7 days, the callus is formed, and bone integration is started.

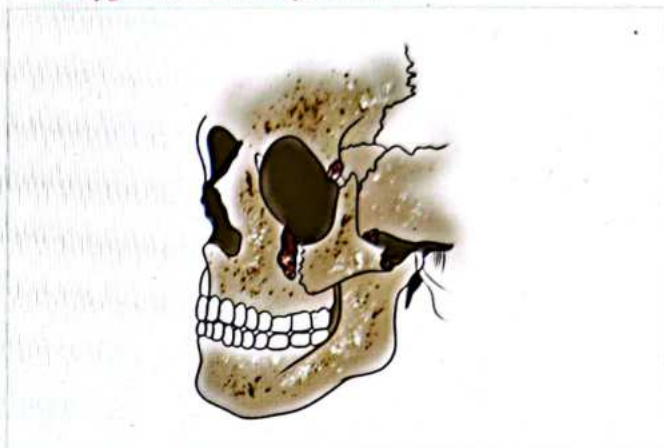## Local anesthesia or General anesthesia (LA or GA)

- Local anesthesia is preferred because a reduction of the nasal bone occurs very quickly.
- General anesthesia is preferred normally because it is a painful procedure but sometimes not used because of age, comorbidity, etc.
- Once the fracture is reduced, Plaster of Paris is used to prevent the movement of reduction.
- To correct the nasal bone, Walsham forceps is used, and for the correction of the septum, Asch forceps is used.
- Asch forceps is angulated in shape and Walsham's forceps is straight in shape.
- Walsham's forceps has a rubber guard on one of the end (nasal bone) to prevent any orbital trauma, as one end goes inside the nose.

## Zygomatic Fracture

- A zygoma fracture (zygomatic fracture) is a facial fracture caused by the zygomatic bone (cheekbone).
- Zygomatic fracture is also called tripod fracture because three fracture lines are aligned like a tripod.
- 3 fracture lines are between the frontal bone and zygoma

(zygomaticofrontal fracture), zygomaticotemporal fracture, and zygomaticomaxillary fracture.



## Clinical features

Clinical features depend on the extent of the injury

- Flattening of malar eminence (the portion of zygomaticomaxillary complex).
- Periorbital Ecchymosis is involved in the floor and lateral walls of the orbital.
- Deformity of the face.

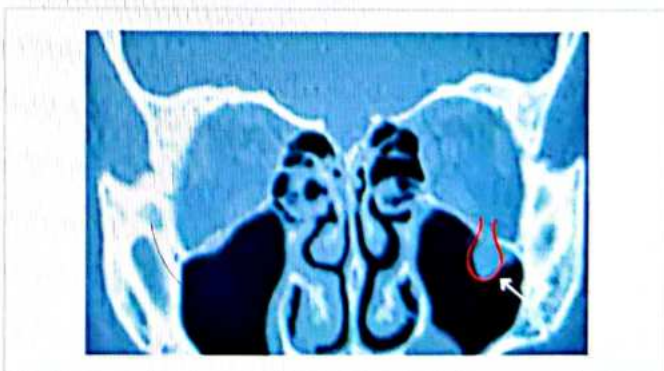
## Which nerve is affected?

- This nerve emerges from the floor of the orbit called infraorbital nerve because zygomatic fracture is very close to the orbit.
- When there is the involvement of the infraorbital nerve, it can cause anesthesia over the cheeks that decrease the sensation.

## Which deformity is seen?

- Step deformity, because it causes elevation, depression which considers a step.
- Zygoma is the second most common fracture after the nasal bone.

## Fracture floor of Orbit



- The fracture floor of orbit is also called Blow out fracture. Because it is the most susceptible wall that can be injured.



- The roof and lateral wall are formed by thick rigid bones but the medial and floor wall are very thin.
- Among the medial wall and the floor, the floor is very liable to injury. Because it has a hollow cavity below the floor of maxillary sinus.
- Whenever there is trauma to the floor and it has no resistance because of the hollow air-filled cavity. So, the chances of injury are more on the floor.
- When there is trauma to the medial wall, the chances of injury are less.

### Clinical Features

- When the fracture occurs on the orbit floor, the contents of the orbit push into the maxillary sinus. As a result, causes sunken eye is called **enophthalmos**.
- Impingement of the inferior rectus muscle within the fracture can cause restriction in the movement of the eyeball.
- Because of the floor of orbit fracture, it can cause periorbital ecchymosis, periorbital edema, and periorbital emphysema.
- Infraorbital nerve is involved.

### Radiology sign?

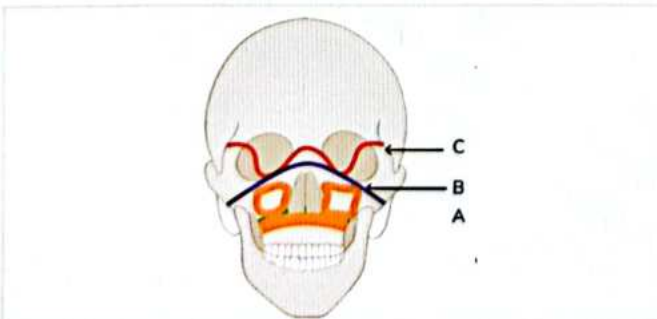
- The orbital is herniating into the maxillary sinus like a teardrop. This sign is a hallmark radiology sign of the floor of orbit fracture called a **teardrop sign**.

### What is the traction test? Forced duction test

- When the inferior rectus impinged in the fracture segment and as a result, the patient has restricted mobility of the eyeball.
- To know whether there is impingement of the inferior rectus in the fracture segment, the forced duction test is used.
- A small forceps is used to release the inferior rectus from the fracture site and check if there is any improvement in the movement of the eyeball.
- If there is an improvement in the movement of the eyeball, it indicates the probability of inferior rectus impingement.

### Fracture of maxilla or Le Fort fracture

00:28.09

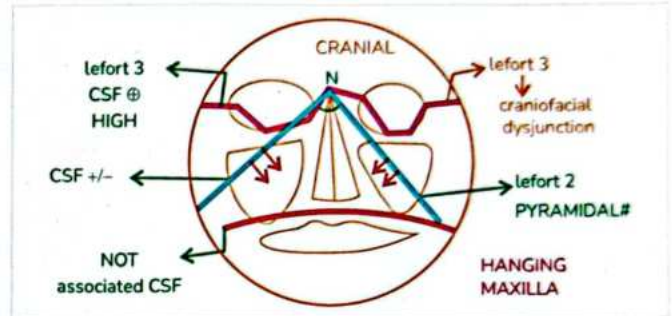


It is classified into 3 types

### Le fort 1 fracture or Guerin sign or Transverse fracture

- If the fracture line runs from the floor of the nose and floor of maxillary sinus
- It disconnects the palate from the nose. So, it looks like a **hanging palate and hanging teeth** which are the hallmark of Le fort 1 fracture.
- A greater palatine artery goes toward the palate and when there is a fracture, it can also rupture. As a result, the palatine artery cause palate bluish discoloration called a **Guerin sign**.
- Le fort 1 fracture is not associated with **CSF rhinorrhea**.
- The fracture line is **horizontal**.

### Le fort 2 fracture or Pyramidal fracture



- When the fracture line goes from nasion via the lacrimal bone, the floor of the orbit then to the maxilla called Le fort 2 fracture.
- This fracture disconnects the maxilla from the facial skeleton resulting in a **hanging maxilla**.
- CSF rhinorrhea may or may not be happened.

### Le fort 3 fracture

- When the fracture goes from the nasion, medial wall of the orbit, lateral wall of the orbit, floor of the orbit, and zygoma is called Le fort 3 fracture
- It is also called **craniofacial dysjunction** because it separates the cranial cavity from the facial skeleton.
- High risk of **CSF rhinorrhea**.

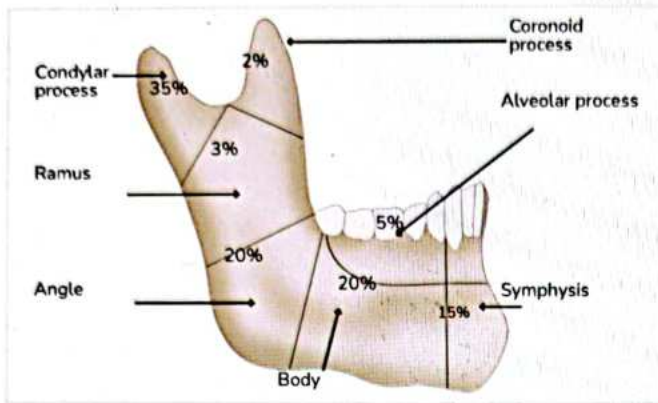
### CT/XRAY

- Floating palate or floating teeth is seen in **Le fort 1**
- Hanging maxilla is seen **Le fort 2**
- CSF rhinorrhea is not a feature of which lefort fracture **Le fort 1**

### Fractures of mandible

- The common site of fracture is the mandible on the lower 1/3 of the face.
- The mandible common site of fracture is the **sub-condylar process or sub-condylar region**.
- The condylar site is involved in this fracture because it is the weakest part of the mandible and is more liable for injury when there is trauma.



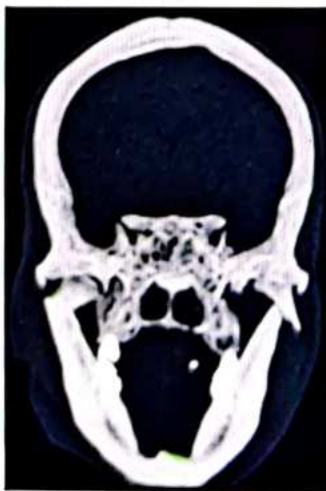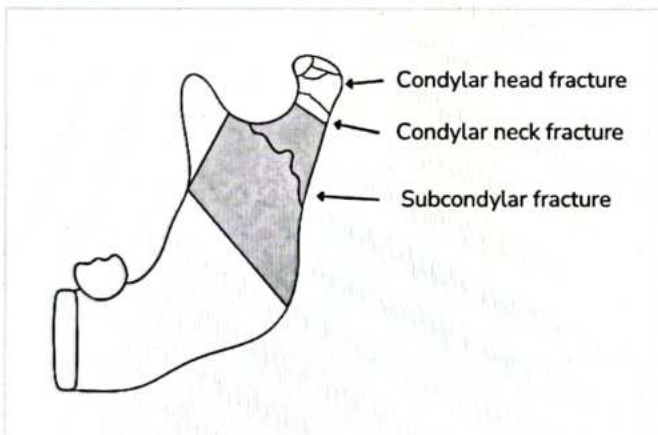


- When there is trauma on the right side because of the contrecoup injury, the energy transfers to the opposite side. Hence, the fracture can be seen on the opposite side of the sub condylar region of the mandible.

#### Clinical Features

- Lockjaw
- Difficulty in chewing
- Difficulty in speaking and talking

#### What is guardsman fracture or parade ground fracture?



- If the fracture occurs in **symphysis menti and bilateral sub condylar region** is called guardsman fracture or parade ground fracture.
- The patient is advised not to be immobile for more than 3 weeks in mandible fracture because it can result in **TMJ ankylosis**.
- TMJ ankylosis results in permanent difficulty in opening the mouth.
- When movement needs very quickly, open reduction with wiring is done (titanium wires) is kept and immobilized for 2-3 days (maximum 1 week) then slowly loosens that allows the movement of joints to prevent **TMJ ankylosis**.

#### Important Questions

00:42:11

##### One Liners

- Most common site of mandibular fractures is at **Subcondylar**
- Subcondylar fractures occur due to trauma to body of mandible from ....(same side / **opposite side**)
- When a closed reduction is done, mandible should not be immobilized for **>3 weeks**
- Other name for guardsman fracture? **Parade Ground fracture**

Q. Le fort 3 fracture is also called

Ans: Craniofacial dysjunction because it separates the cranial cavity from the facial skeleton.

Q. High risk of CSF rhinorrhea is seen in

Ans: Le fort 3 fracture

Q. If the fracture occurs in symphysis menti and bilateral sub condylar region, it is called as

Ans: Guardsman fracture or parade ground fracture

Q. Hanging palate and hanging teeth are the hallmarks of

Ans: Le fort 1 fracture

Q. Guerin's fracture is the other name of

Ans: Le fort 1 fracture

Q. The upper third of the face has a frontal bone with

Ans: Frontal sinus and supraorbital bridge

Q. Class 1- Chevallet fracture, the direction of injury is

Ans: The direction of injury is below the nose

Q. Class 2- jarjavy fracture, the direction of injury is

Ans: The direction of fracture is from the side of the nose or from the front of the nose

Q. Why Forced duction test is performed



# Telegram - @nextprepladdernotes

**Ans:** To know whether there is impingement of the inferior rectus in the fracture segment

**Q.** Pig nose deformity.

**Ans:** Pig nose deformity is seen in Class 3 (Naso-orbito-ethmoid fracture).

**Q.** Which class is associated with CSF leak?

**Ans:** CSF leak is associated with Class 3, Naso-orbito-ethmoid fracture.






# CROSS WORD PUZZLES



Crossword Puzzle 1



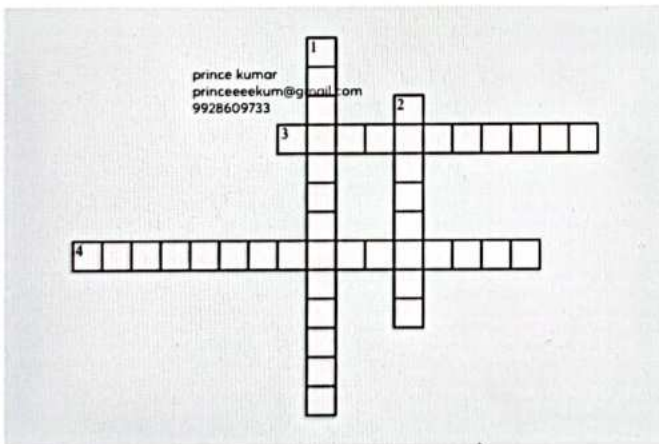
**Across**

- 3. \_\_\_ is the sign of Le fort 2 fracture.
- 4. \_\_\_ is a hallmark radiology sign of the floor of orbit fracture.

**Down**

- 1. \_\_\_ is associated with Le fort 3 fracture.
- 2. \_\_\_ is not associated with Le fort 1 fracture.

Crossword Puzzle 2



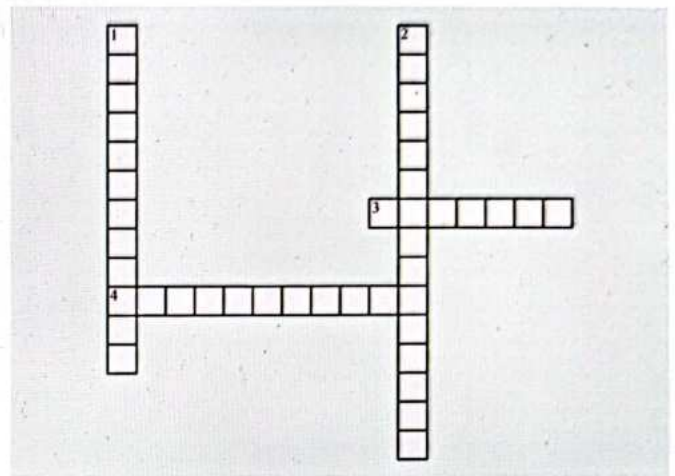
**Across**

- 3. \_\_\_ is used for the correction of the septum.
- 4. \_\_\_ is the second-class fracture of nose.

**Down**

- 1. \_\_\_ is used to correct the nasal bone.
- 2. \_\_\_ fracture line is seen in class chevallet fracture.

Crossword Puzzle 3



**Across**

- 3. \_\_\_ is the clinical feature of mandible fracture.
- 4. \_\_\_ region is the most the mandible common site of fracture in mandible fracture.

**Down**

- 1. \_\_\_ results in permanent difficulty in opening the mouth.
- 2. \_\_\_ nerve is associated with fracture floor of the orbit.



29

SINUSITIS AND ITS COMPLICATIONS



Sinusitis

00:01:37 prince kumar princeeeekum@gmail.com 992816973

- Definition: Inflammation of the paranasal sinuses
  - Acute: <3 weeks
  - Subacute: 3 weeks to 3 months
  - Chronic: >3months
  - Recurrent: 4 or more episodes per year lasting more than 7 to 10 days

One liners

- Which is the most common sinus affected in adult? **Maxillary sinus (Largest)**
- Which is the most common sinus affected in children? **Ethmoidal sinus**
- Which is the least common sinus affected? **Sphenoid sinus**

Etiology of acute sinusitis

- Exciting factors
  - **Nasal infection: Most acute sinusitis start as viral infections followed by bacterial invasion**
  - Swimming and diving
  - Trauma
  - Dental infection
    - Predisposing factors for maxillary sinus can be due to dental infection. Maxillary sinus is related to 2<sup>nd</sup> premolar and 1<sup>st</sup> molar.

Q. How sinusitis occur?

- All the sinus have their own drainage pathway or drainage ostia. If there is obstruction to the ventilation of the sinuses due to edema, mucus, polyps, URTI hence there will be inflammation of all the mucosal lining of sinuses. These inflammation of mucosal cell produce exudate which can be sterile or infected.
- **If sinus is infected known as Suppurative sinusitis. If non-infected known as Sterile sinusitis.**
  - Majority of cases, bacterial infection occurs.
  - Most common bacteria for causing acute sinusitis: **S.pneumoniae**
  - Sinusitis of dental origin, the bacteria affected is Mixed infection (aerobic and anaerobic infection)

Predisposing factors

- Obstruction to sinus ventilation and drainage
- Stasis of secretion in nasal cavity (cystic fibrosis)
  - Ciliary motility defect predispose to mostly chronic sinus infection

Allergy

- Mucosal edema will obstruct the ventilation of sinuses causing retention of secretion and infection resulting in sinusitis

Systemic factors

- Attack of exanthematous fever (measles, chicken pox, whooping cough)
- Nutritional deficiencies
- Immune deficiencies

Bacteriology

00:07:52

- Bacteria: **Streptococcus pneumoniae, H.influenza, Moraxella, Streptococcus pyogenes, Staphylococcus aureus**
- Anaerobic organisms and mixed infections are seen in sinusitis of dental origin

Sinusitis secondary to dental infection

- Secondary to infections of roots of molar and 2<sup>nd</sup> premolar teeth
- Causes maxillary sinusitis
- Oroantral fistula following tooth extraction is a cause
  - Oroantral fistula is communication between maxillary sinus and oral cavity
- Anaerobic organisms and mixed infections are seen in sinusitis of dental origin
- Dental infections are very fulminating and result in suppurative sinusitis

Clinical features of Acute sinusitis

00:08:54

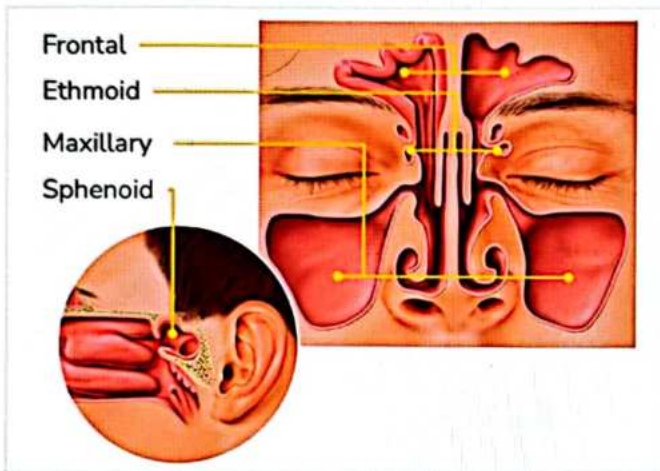
Major criteria	Minor criteria
Nasal obstruction	Headache
Facial pain or pressure	
Purulent nasal discharge	Cough
Fever	Halitosis
Nasal congestion	Ear pain and pressure
Hyposmia or anosmia	Dental pain
Facial congestion or fullness	NA



- For diagnosis 2 major or 1 major and 2 minor symptoms are required

## Refer table 29.1

- Pus in sphenothmoidal recess leads to sphenoid sinusitis
- Pus in superior meatus leads to posterior ethmoidal sinusitis
- Pus in middle meatus leads to Frontal or Maxillary or Anterior ethmoidal sinusitis



## Maxillary sinusitis

00:19:20

- Postural test is done to differentiate maxillary sinus from frontal and ethmoidal sinusitis
- Postural test:
  - Clean the pus in middle meatus and then put the patient in head lying (tilt) opposite side.
  - If there is reappearance of pus, then it is identified as maxillary sinusitis.
  - If no reappearance of pus, ask the patient to sit upright head hanging down position, gravity depended reappearance of sinus indicates Frontal sinusitis.
    - If no reappearance on both position, then it is called as Ethmoidal sinusitis.

## Frontal sinusitis

00:22:37

- Pain has characteristic periodicity or Office headache
  - Office headache: While sleeping, anti-gravity position will cause retention of secretion in frontal sinus, the sinus with full of pus while wake-up causes severe headache in morning. In sitting position throughout the day, there will be gravity depended drainage by evening sinus become little less accumulation with no headache.
- Tenderness on the floor of frontal sinus just above medial canthus
- Edema of upper eyelid.

## Ethmoidal sinusitis

00:24:39

- Pain is located on the bridge of nose, deep to the eye, aggravated by movements of eyeball
- Orbital cellulitis

## Sphenoidal sinusitis

00:24:49

- Characteristic feature: Vertex headache or occipital headache
- Post nasal discharge

## Diagnosis of Acute sinusitis

- Clinical examination
- Diagnostic nasal endoscopy
- X-ray is the FIRST investigation to be done
- CT scan in acute sinusitis is done only when a high risk complication is anticipated
- Sinus puncture and bacterial culture- GOLD STANDARD FOR DIAGNOSING BACTERIAL SINUS INFECTION
- Accurate method of diagnosis is sinuscopy and biopsy


## Treatment of Acute sinusitis

- Medical: Antibiotic TOC + decongestants + analgesics + hot fomentation
- Surgical:
  - If no response to medical therapy
  - If it's progressing to complication
  - FESS (most preferred) / Ethmoidectomy/Trephination of frontal sinus

## Chronic Sinusitis

00:28:13

- > 12 weeks
- Cause: Failure of resolution of acute infection
- Maxillary sinus is most commonly involved
- Symptoms: Purulent nasal discharge is the most common symptom with nasal obstruction
- Syndromic causes and ciliary motility disorders suggestive of chronic sinusitis
- Investigation of choice: Plain CT scan of nose and paranasal sinus
- Treatment:
  - Medical therapy: Antibiotics with antral irrigation is tried
  - Surgery:
    - Required for ventilating the sinuses
    - Endoscopic sinus surgery
    - Rarely open procedures like intranasal antrostomy or caldwell luc operation



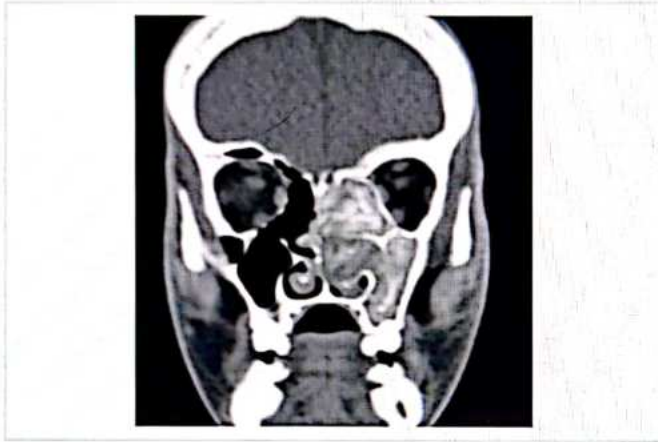

## AFRS (Allergic Fungal Rhino Sinusitis)

00:31:35

- It is a non-invasive form
- Bent and Kuhn criteria for AFRS
  - Serum IgE level elevated
  - KOH stain Positive
  - Allergic mucin
  - Nasal polyposis
  - Double density

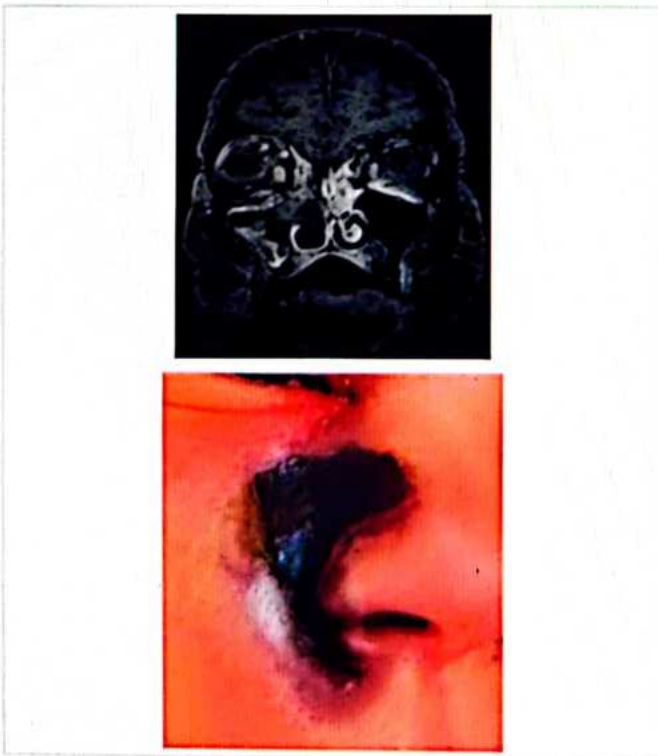
- Causative organism? Angioinvasive fungus
- Mode of spread? Rapidly progressive condition
- **Black turbinate sign? Seen on MRI (hallmark sign)**
  - Radiological IOC: MRI with contrast
  - Diagnosis is done by histopathology and culture
- Treatment? Liposomal Amphotericin B + Radical debridement



- Caused by Aspergillus
- AFRS and Fungal ball does not cause erosion of bone

### IDENTIFY?

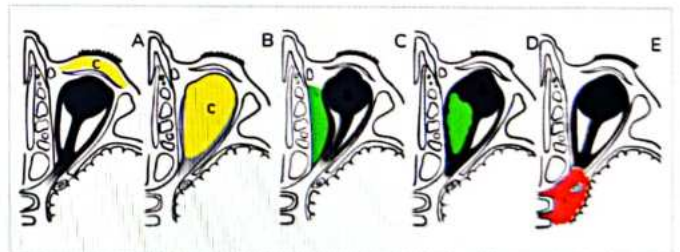
- Diagnosis? MUCORMYCOSIS
  - This fungus enter into blood vessel and obstruct many blood vessels, no bloody supply causing tissue ischemia which leads to necrosis turning into Black eschar



## Complications of Sinusitis

00:41:09

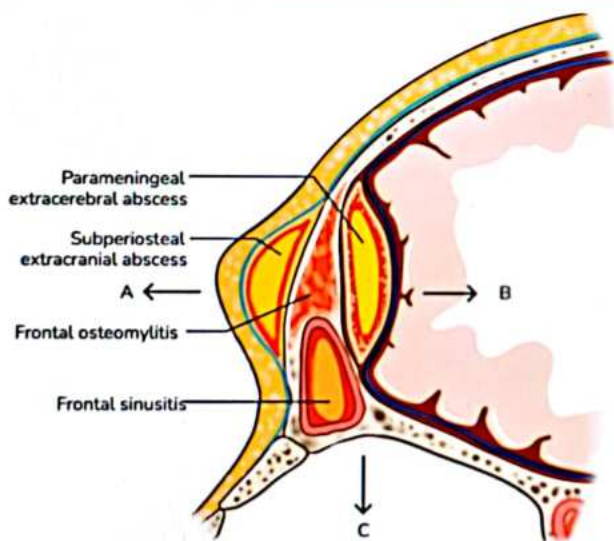
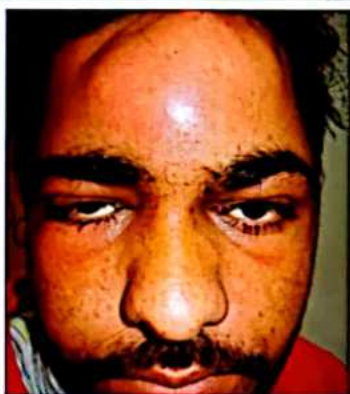- Types:
  - **Local: Limited to the sinuses**
    - Maxillary sinus: cystic transformation of mucosa known as Retention cyst. If there is obstruction to the sinus ostium, there will be accumulation of mucus in the sinus with epithelial lined sac around it known as Mucocoele.
    - Mucocoele will gradually expands and cause thinning and destruction of the overlying bone.
    - If mucocoele infected and forms Pyocoele.
    - Infection of overlying bone known as Osteomyelitis
  - **Orbital**
    - Preseptal cellulitis
    - Cellulitis of skin and subcutaneous tissue: Orbital cellulitis
    - Subperiosteal abscess
    - Orbital abscess
    - Cavernous sinus thrombosis



- **Intracranial**
  - Meningitis
  - Extradural abscess
  - Subdural abscess
  - Brain abscess
- **Descending infection**
  - Adenoiditis
  - Tonsillitis
  - Pharyngitis
  - Laryngitis



What is this complication called?



Local	Mucocoele, pyocoele, retention cyst, osteomyelitis
Orbital	Chandlers classification
Intracranial	Meningitis, abscess
Descending infection	Tonsillitis, Pharyngitis, Laryngitis, Tracheobronchitis

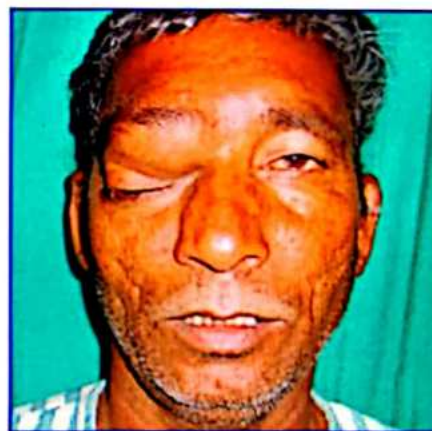- Osteomyelitis of the frontal bone causing subperiosteal abscess known as Pott's puffy tumor
- Orbital cellulitis is particularly common in ethmoid sinusitis

**Mucocoele**

00:50:18

- Most commonly involves frontal sinus
- Least commonly involves sphenoid sinus
- Frontal sinus mucocoele:
  - Site: superomedial quadrant of orbit
  - Symptoms: eye is displaced forward, downward, laterally

- Swelling: Cystic, non-tender, egg shell cracking
- X-ray: Loss of scalloped margins
- Treatment: Frontoethmoidectomy to promote drainage of frontal sinus



**Cavernous Sinus Thrombosis**

00:51:39

- Etiology: Infection of ethmoids or sphenoid sinuses is most common cause
- But infection can spread from nose, ear, throat, and orbit
- **Orbital cellulitis can secondarily lead to cavernous sinus thrombosis**

**Cavernous Sinus Thrombosis V/S Orbital Cellulitis**

	Cavernous sinus thrombosis	Orbital cellulitis
Source	Nose, sinuses, orbit, ear or pharynx	Ethmoid sinuses
Onset	Abrupt with chills and rigors	Slow
Toxemia	Present	Late
Laterality	Bilateral	Unilateral
Edema of eyelids	Bilateral edema of eyelids, chemosis and proptosis	Unilateral edema of eyelids, near the inner canthus leading to chemosis and proptosis
Cranial nerve involvement	Involves individually and sequentially	Involved concurrently with complete ophthalmoplegia

prince kumar  
princeekumar@gmail.com  
9928609733



## Syndromes

00:53:20

Condition	Cranial nerves involved	Cranial nerves not involved
Orbital apex syndrome	II, III, IV±V2	
Superior orbital fissure syndrome	III, IV, VI±V2	II
Cavernous sinus syndrome	III, IV, VI	II, V2

Table 29.1

	Maxillary	Frontal	Ethmoid	Sphenoid
<b>Headache or pain</b>	Usually seen over cheek and forehead and can be confused with frontal sinusitis	Localised to frontal sinuses above medial canthus	Localised over bridge of nose, medial and deep to the eye	Occiput or vertex <small>princeeekum@gmail.com 9928609733</small>
<b>Tenderness</b>	Cheek (pressing over canine fossa)	Over frontal sinus (pressing on the floor of frontal sinus)	Bridge of nose	NIL
<b>Redness and edema</b>	Cheek, lower eyelid swelling	Upper eyelid puffiness	Both eyelids become puffy	NIL
<b>Site of nasal discharge</b>	Middle meatus	Vertical streak of mucopus high up in anterior portion of middle meatus	Seen in middle or superior meatus depending on involvement of anterior or posterior group	Seen in posterior rhinoscopy on the roof and posterior wall of nasopharynx
<b>Early Complications</b>	Orbital cellulitis, Osteomyelitis, Frontal sinusitis	Orbital cellulitis, Osteomyelitis, intracranial abscess	Orbital cellulitis; vision loss, cavernous sinus thrombosis, intracranial abscess	





**30**

**TUMORS OF THE NOSE AND SINUSES**

- The classification of benign and malignant tumors includes the following:

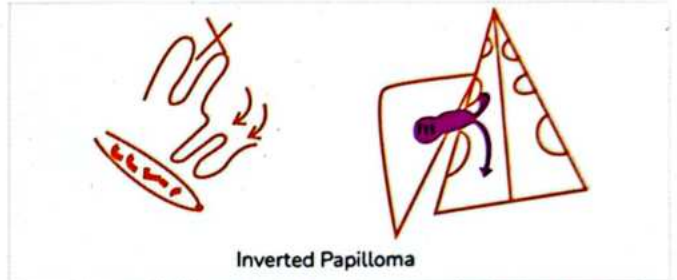
Benign	Malignant
Squamous Papilloma	Squamous cell Carcinoma
Inverted papilloma	Adenocarcinoma
Pleomorphic adenoma	Malignant melanoma
Schwannoma	Esthesioneuroblastoma
Meningioma	Haemangiopericytoma
Haemangioma	Lymphoma
Chondroma	Solitary plasmacytoma
Angiofibroma	Various types of sarcomas
Encephalocele	
Glioma	
Dermoid	

prince kumar  
princeeeekum@gmail.com  
9928609733

- This tumor originates from the lateral wall of the nose. So, it can spread from the nose to the maxilla and go posterior to the concha and anterior.
- There is a 10-15% chance that this tumor can turn malignant if left untreated.

**Why is it called an inverted papilloma?**

00:04:36



Inverted Papilloma

- This tumor has finger-like projections. They don't grow towards the surface.
- However, they grow towards the stroma in the reverse direction.
- This is the reason these tumors are called inverted papilloma.

**Diagnosis**

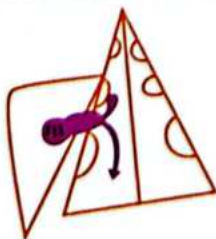00:05:33

- In a typically inverted papilloma, the following are the clinical observations.
- Finger-like projections observed don't grow towards the surface but towards the stroma.
- Such observations confirm it is due to inverted papilloma.
- It can be confirmed by histopathological examination.
- On examination, tiny finger-like projections are seen coming from the lateral wall of the nose.
- In inverted papilloma,
  - Blood stains from the nasal discharge are present.
  - Blood stains in nasal discharge will rule out polyp's condition.
  - It can be seen in malignant tumors.

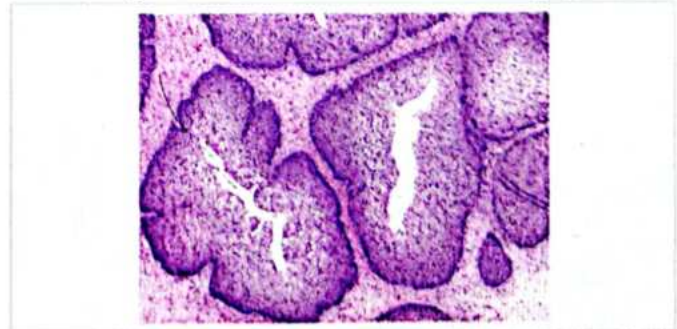
**Inverted Papilloma**

00:00:16

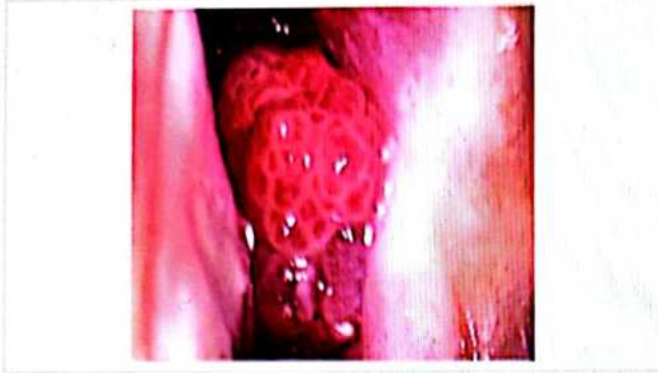- Inverted papilloma is a type of tumor.
- The other names for inverted papilloma are:
  - Transitional cell papilloma
  - Ringertz tumor
  - Schneiderian papilloma
- Basically, Schneiderian membrane means the nasal mucosa.
- If the tumor originates from the nasal mucosa, it is called a Schneiderian tumor.
- It is the most common benign tumor of the nasal cavity.
- Although it is a benign tumor, it is locally invasive.
- It is also a pre-malignant condition.
- It is usually seen in males when compared with females.
- It is associated with HPV infection.
- HPV 6 and 11 are usually associated.
- This tumor has a high recurrence rate.



**How to diagnose whether a tumor is an inverted papilloma?**







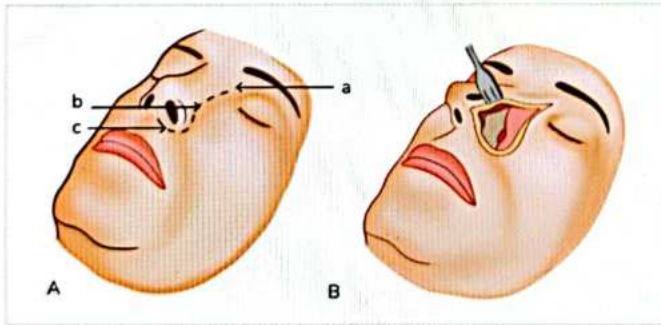
- **History**
- **Clinical observations**
- When a person comes with a history of blood stains in the nasal discharge/ nasal obstruction in the nose, there is a red vascular mass inside the nose that was observed with finger-like projections.
- Biopsy of the lesion should be done. Biopsy is the confirmatory test.
- On histopathological examination, if the finger-like projections are going towards the stroma, it confirms an inverted papilloma.

## Treatment

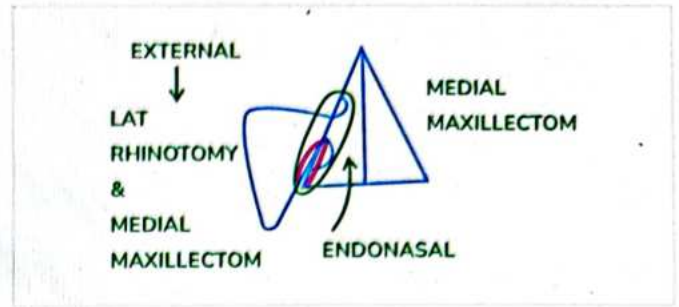
00:07:50

### Medial Maxillectomy

- This test is done for inverted papilloma.
- It can be done either via an external approach or endoscopy.
- The external approach is a midfacial degloving incision/ lateral rhinotomy incision.
- Lateral rhinotomy /midfacial degloving approach
- Endoscopic medial maxillectomy



- Near the lateral wall of the nose and ala, an incision is made, as shown in the image.
- Once the mucosa is elevated over the lateral wall and the ala, reflect the mucosa at the subcutaneous tissue. The nose's lateral wall and the maxillary sinus's medial wall can be seen.
- Resect the lateral wall of the nose and medial wall of the maxillary sinus along with the tumor. It is known as lateral rhinotomy or midfacial degloving approach.

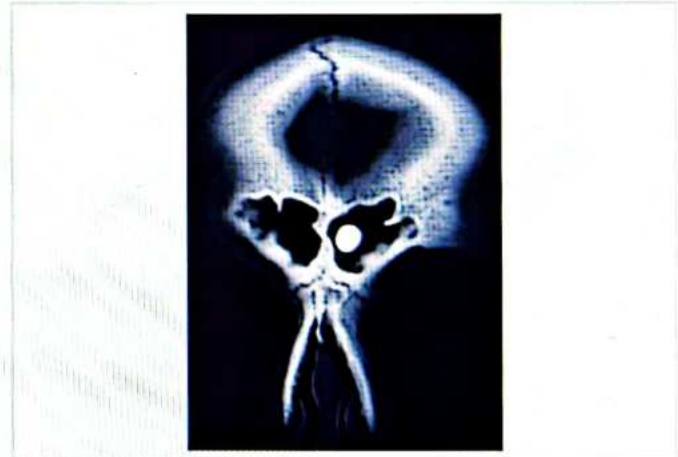

- By considering the above image as the nose,
  - The middle meatus receives the opening of the maxillary sinus.
  - The lateral wall of the nose is very close to the medial wall of the maxilla.
  - Once an incision is made, the entire lateral wall of the nose and the medial wall of the maxilla can be removed. This surgery is called a medial maxillectomy.
- Maxillectomy can be done by either an endonasal /endoscopic or external approach.
- External approach: It is seen in lateral rhinotomy or medial maxillectomy.

## Osteoma

00:12:00

- The word osteoma suggests it is a bone tumor inside the paranasal sinuses.
- It is the most common benign tumor of paranasal sinuses.
- The most common site for osteoma is the frontal sinus.



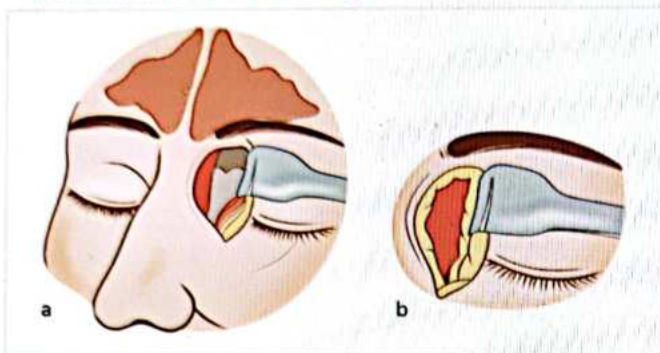
- Since they are very bony, a whitish mass is seen radiologically inside the frontal sinus.
- Because these osteomas are known to be expansile, they can cause headaches and diplopia and can cause deformity.
- When they expand, they can cause orbit displacement, which causes diplopia.
- Ivory osteoma, there is a lack of a haversian canal system.
- Normally, bone has a haversian canal. In this condition, the haversian canal was replaced by a completely bone-filled trachea.



**Treatment**

00:14:06

- It is difficult to remove bony tumor endonasal.
- Any osteoma is often easier to treat by an external approach.
- The external approach can be done by Lynch Howarth External fronto ethmoidectomy.



- Depending on the site of the osteoma, the external approach would be decided.
  - This incision begins from the medial end of the eyebrow and goes downwards in between the imaginary line drawn between the medial canthus to the dorsum of the nose.
  - It ends at the nasofacial sulcus.
  - This incision is called a Lynch Howarth incision.
  - Through external frontal openings/ ethmoidal/ both frontal and ethmoidal openings can be made.
  - From here, there will be access to the frontal sinus, as well as to the ethmoidal sinus.
- Frontal Trephination
  - Frontal trephination is done in cases where they do not require external incision downwards.
  - Instead, an incision is made at the medial end of the eyebrow. Incisions can also be made in the floor of the frontal sinus.

**MCQS**

Q. What does Gardner syndrome include?

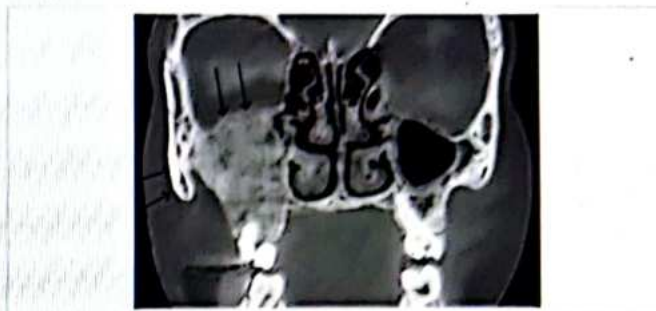- Osteomas
- Soft tissue tumors
- Intestinal polyposis
- All of the above

Ans: All of the above because Gardner syndrome consists of osteomas, soft tissue tumors and intestinal polyposis.

**Fibrous Dysplasia**

00:17:20

- The word **dysplasia** means there is a change in bone.
- Fibrous dysplasia means the medullary bone is replaced by fibro-osseous bone.
- The most common sinus affected by fibrous dysplasia is the maxillary sinus.

**Diagnosis**

- The diagnostic hallmark of fibrous dysplasia is the ground glass appearance on the CT scan.

**Treatment**

- Typically, fibrous dysplasia causes bone remodeling. It should be removed, leaving the rest of the bone.
- It can be done by surgically sculpting the diseased bone and re-sculpting the area.

**Basal Cell Carcinoma**

00:19:46

- Basal cell carcinoma is a common skin carcinoma of the external nose.
- It is also known as a rodent ulcer.
- It happens because of prolonged exposure to UV rays.
- Especially in continents like Australia, where there is more UV exposure, and people are more sensitive to UV rays.
- It can involve the nose and other areas of the face.
- It has a site of predilection-line joining angle of mouth to ear lobule.
- It is locally aggressive.

**Treatment****• MOHS MICROGRAPHIC SURGERY**

- Suppose a patient presents with malignancy. The margin of malignancy is resected and sent for a frozen section biopsy.
- If the frozen section biopsy is negative, then surgical resection is not required.
- If the frozen biopsy is positive, a 2-3 mm tissue rim is removed and resent for frozen biopsy.
- If the frozen test is negative. The surgical resection would be stopped.
- If the frozen section is positive, remove a 2-3 mm tissue rim and resend for frozen.
- This process must be continued until a negative margin is obtained. This is called Mohs micrographic surgery.


**Olfactory Neuroblastoma**

00:22:40

- The name comes from the olfactory cleft/olfactory neuroepithelium.



- It is also known as **esthesioneuroblastoma**.
- It is known to arise from the **olfactory cleft**.



- Olfactory cleft is the space between the septum and a cribriform plate of ethmoid superiorly and superior turbinate laterally.
- If the tumor coming from this olfactory cleft is called olfactory neuroblastoma.
- It has bimodal age occurrence.

## Diagnosis

- When a tumor originates from olfactory epithelium, the tumor is known to cause **blood-stained nasal discharge and obstruction**.
- It is a **neuroendocrine tumor** that can secrete hormones and catecholamines.

## Treatment

- **Surgical resection** followed by **Radiotherapy**.
- **KADISH** classification is used for **grading and staging** olfactory neuroblastoma.






# CROSS WORD PUZZLES



Crossword Puzzle 1



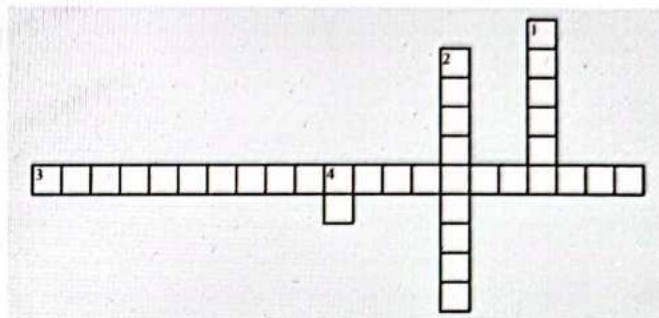
**Down**

- 1 .....is the common benign paranasal sinus tumor.
- 2 ..... maxillectomy is done for inverted papilloma.

**Across**

- 3 .....is also called basal cell carcinoma.
- 4 .....classification is used for grading and staging olfactory neuroblastoma.

Crossword Puzzle 3




**Across**

- 3. Olfactory neuroblastoma is also known as

**Down**

- 1. Basal carcinoma, also known as \_\_\_\_ ulcer
- 2. A sinus affected by fibrous dysplasia
- 4. Which rays are the cause of basal cell carcinoma

Crossword Puzzle 2



**Down**

- 1 ..... is the common tumor of the nasal cavity.

**Across**

- 2 ..... on CT scan is the diagnostic hallmark of fibrous dysplasia.
- 3 ..... are secreted in olfactory neuroblastoma.
- 3 ..... is the most common site for osteoma.





### Etiology

prince kumar  
princeekumar@gmail.com

00:00:18

- The aetiology of the **paranasal sinuses** is very much like other carcinomas. Most carcinomas are caused due to **smoking, alcohol, and tobacco** due to exposure to certain irritants, so there needs to be an **exposure** to a specific **carcinogen** which is when there will be a process of **carcinogenesis**.
- There is the **same** case with malignancies of paranasal sinuses.
- Malignancy is often seen in males.
- Age of **40 to 70 yrs**.
- It is associated with **smoking, wood dust, nickel dust and snuff**.
- Any irritant can **predispose** an individual to develop carcinomas.
- Common carcinogens are responsible for causing malignancy.
- If talking about the malignancy of the paranasal sinus, **carcinoma of the maxillary sinus** happens to be the most common cancer, followed by other cancers of the **ethmoid sinus, sphenoid sinus, and frontal sinus**.

### Morphological Classification

00:01:22

- Morphologically, the most common is squamous cell carcinoma, like all other ENT malignancies.
- **Rarely: adenocarcinoma, basal cell carcinoma, and sarcoma** are seen inside the sinuses.
- If the skin of the **external nose**, there can be **basal cell carcinoma**, but in the case of a paranasal sinus, a basal cell carcinoma or sarcoma is rare.
- The maxillary sinus is **most involved** in the **causation of cancer**.
- Other sinuses are **less involved** as compared to the maxillary sinuses.
- It is said that adenocarcinoma is **not** that common, but squamous cell carcinoma is very **common** if exposed to **hardwood dust**; they are **predisposed** to adenocarcinoma of the ethmoid sinus.
- **Soft wood dust predisposes** to Squamous cell carcinoma.
- It is the exception that **hardwood dust exposure** would lead to the **causation of adenocarcinoma and not the squamous cell carcinoma**.



### Important Information

- Maxillary sinus is most involved in cancer causation.
- Most common malignancy of hardwood exposure resulting in carcinoma would be adenocarcinoma.
- But for all the other carcinogens, it will be squamous cell carcinoma.

### Clinical Features

00:03:07

- In malignancy, there is a very **common complaint** of **blood stains**, whether nasal, laryngeal, tracheal, or pulmonary carcinoma.
- When there is a blood stain, there is a possibility of something **abnormal**, and there is a possibility of the **process of carcinogenesis** as a common **differential diagnosis**.
- Although, it could also occur in certain **benign** conditions like **JNA and nasopharyngeal carcinoma**.
- If blood is associated with the discharge, the cancer process can be ruled out.
- The patient will complain of **blood stain nasal discharge**. They will also have symptoms of adjoining areas where carcinoma has spread in conditions like maxillary sinus cancer, ethmoid cancer, or **frontal sinus cancer**.
- For example, if there is a carcinoma of the **maxillary sinus**, they can complain of **orbital pain** because of **close association** with the orbit, complain of **loosening of teeth, dental pain, swelling of the cheek, nasal obstruction, and eye involvement** because the floor of the maxillary sinus is in relation to the **second molar and premolar**. Depending on the adjacent areas, there will be symptoms.
- Dull pain over the sinus.
- **Watering** from the eye because there can be an obstruction to the drainage of the nasolacrimal duct.
- When there is drainage to this duct, there can be watering from the eyes. This is known as **ipsilateral epiphora**.
- Bloodstain nasal discharge, nasal obstruction, and toothache as the carcinoma also involved the teeth.
- All the structures which are **close** to the sinuses will be involved.

### Diagnosis

00:05:20

- **Tissue diagnosis** to be present to **confirm** the malignancy.
- **Histopathological examination** is necessary to **confirm** whether its malignancy or not.
- The investigation of choice will be a **biopsy**.
- A **Biopsy** after **radiological evaluation** because after taking a biopsy, there will be **surrounding inflammation**. And if the radiological evaluation is done after that, it might show **excessive lesions** making the disease a **stage higher**. This may **exaggerate** the disease process.
- Pre-Biopsy Radiological studies should always be done first.
- Radiological studies cannot just be **limited** by **CT scans** of the **nose and paranasal sinuses**. CT scan along with that MRI should be done.

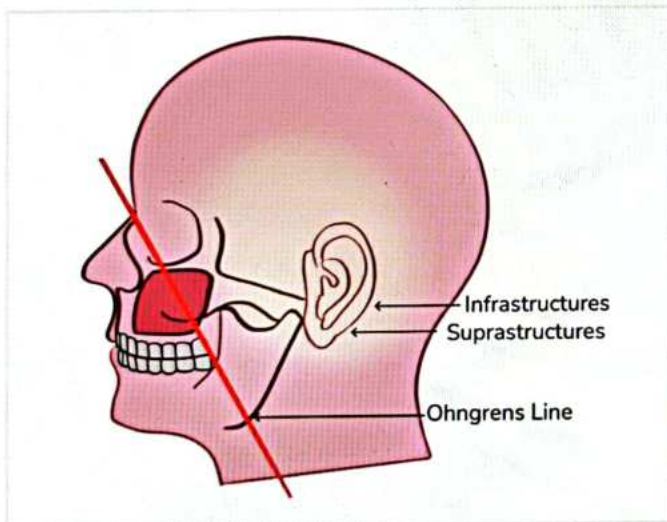


- To understand the involvement of soft tissues, orbit, the base of the skull, and the cranium, an MRI is done.
- It is advisable to do both CT and MRI with contrast as it helps to delineate the tumour and stage more correctly.
- So, this is the initial radiological evaluation where a CT scan is done, and MRI is to know whether it is a carcinoma or not on the radiological finding.
- Then biopsy is done. Based on the biopsy report, whether it is squamous cell carcinoma, adenocarcinoma, or any other carcinoma.
- Sometimes, immunohistochemistry is required to diagnose the patient further.
- PET-CT scan may be required to see whether there is a systemic involvement. PET-CT is required in some situations if there is metastasis or involvement of distant sites.

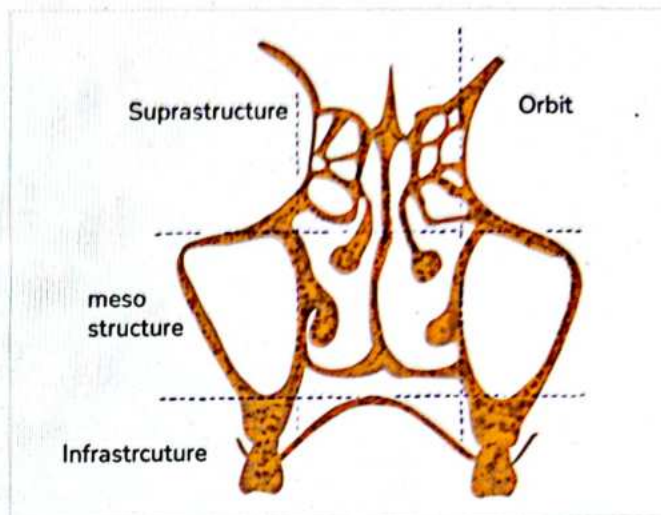
### Prognostic Classification

00:09:58

There are two classifications for maxillary sinus carcinoma.



- **Ohngrens Line:** It is the line drawn from the medial canthus to the angle of the mandible.
- **Significance:**
  - Any malignancy above this line will have a poor prognosis because it's near the orbit to the brain.
  - Any malignancy above this line has a poor prognosis compared to the prognosis below this line.
  - Any malignancy below will have a good prognosis.
  - Ohngrens line is used for prognostication or to know which carcinoma will have a good and bad prognosis.
  - It has nothing to do with the treatment.
  - To understand the prognosis, the Ohngrens line is used.
- **Ledermans Classification-** Used for prognosis.
  - Two imaginary lines are drawn passing from the medial wall of the orbit, one from the medial wall of the left orbit and one from the medial wall of the right orbit.



- Then, two horizontal lines, the first from the floor of the orbit and the second from the floor of the nose and the floor of the maxillary sinus.
- The face is classified into three structures, one above the level of the maxillary sinus, one below the level of the maxillary sinus, and one at the level of the maxillary sinus.
- They are called supra structure, meso structure, and infrastructure malignancy.
- Higher malignancy will be a poor prognosis.
- Lower malignancy will be a better prognosis.

### Treatment of Maxillary Sinus Carcinoma

00:14:44

- Total Maxillectomy.
- The maxillary sinus is the most common site for cancer.
- Remove maxillary sinuses, ipsilateral palate, lateral wall of the nose, ethmoid sinus and even the ipsilateral eyeball.
- After a total maxillectomy, the patient is sent for chemotherapy and radiotherapy if necessary.
- Treatment is mainly surgical.

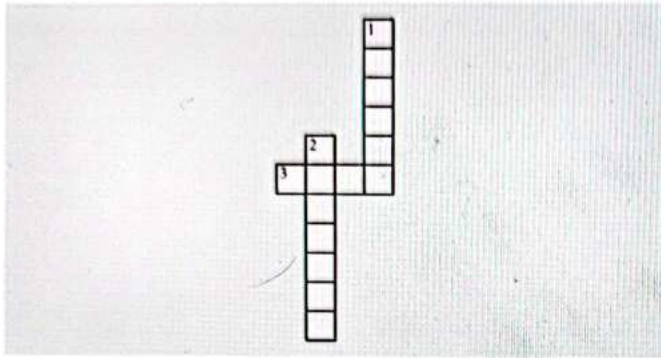




# CROSS WORD PUZZLES



## Crossword Puzzle 1



**Across**


3. The higher the malignancy \_\_\_\_\_ will be the prognosis.

**Down**

1. Lower the malignancy \_\_\_\_\_ will be the prognosis.

2. Tissue diagnosis is to be present to \_\_\_\_\_ the malignancy.

## Crossword Puzzle 2



**Across**


3. PET-CT scan may be required to see whether there is a \_\_\_\_\_ involvement.

**Down**

1. Radiological studies should always be done \_\_\_\_\_.

2. Maxillary sinus is the most \_\_\_\_\_ site for cancer.

## Crossword Puzzle 3



**Across**

2. \_\_\_\_\_ carcinoma is prevalent.

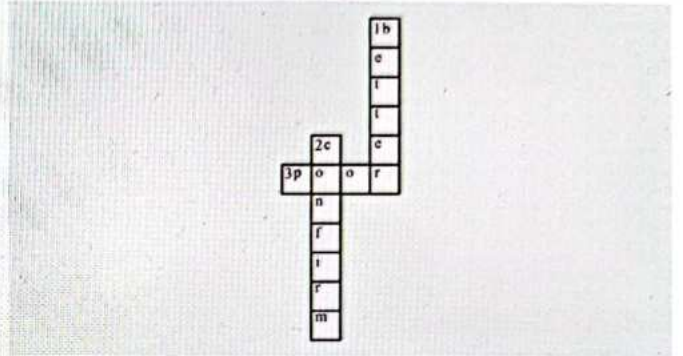
**Down**

1. The maxillary sinus is most commonly involved in the \_\_\_\_\_ of cancer

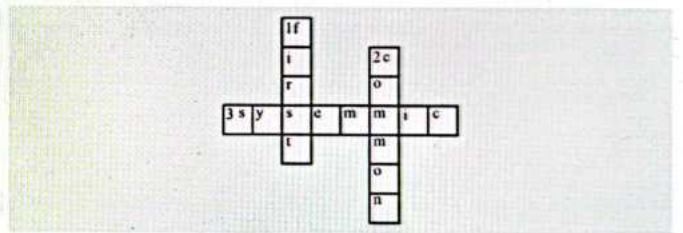
3. Malignancy is often seen in \_\_\_\_\_.

**ANSWERS**

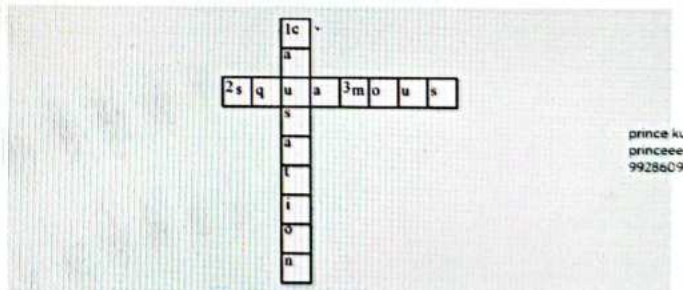
1.



2.



3.



prince kumar  
princeeeekum@gm  
9928609733





**Deviated Nasal Septum**

00.02.23

- Deviated nasal septum is the septum that is not in the midline position and is deviated to one side. It could be right, left or both sides having a sharp bony projection.

**Etiology**

- **Trauma**
  - It is the most common cause which can be by birth or can occur at later stages of life.
  - During normal vaginal delivery, there can be compressive forces or during the development stage when the child is growing.
  - It can occur if a child falls during walking or crawling.
  - These trivial falls affect the face and the most projected area which is the nose.
  - Whenever there is a trauma, there will be some micro fractures which result in the deviation of the fracture line. As a result, there will be a deviation of the septum.
- **Developmental deformities of the palate**
  - The septum is sandwiched between the palate inferiorly and the skull base superiorly.
  - If there is any abnormality of the palate, for eg. High arching of the palate which happens in children with adenoids (hypertrophy).
  - If there is high arching of the palate, the septum will bend.
  - Any palatal abnormality can be associated with Septal diseases such as high arching of the palate, sub-mucosal cleft, cleft palate, or any palatal deficiencies.

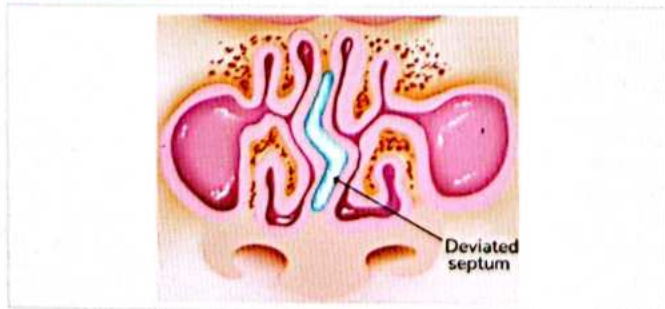
prince kumar  
princekumar@gmail.com  
9928609733

- If the patient is symptomatic, it is important to know the indication for surgery.
- Only if the patient with DNS has symptoms, surgery is advised.
- DNS can occur in most people but they might not be symptomatic and they do not require surgery.
- Nasal obstruction
- The symptoms can occur due to the difficulty in airflow through the nose because of the deviation which results in nasal obstruction.
  - **Headache** – The ventilation to the sinus gets affected when the air does not go through the nose adequately. The negative pressure gets build up in the sinus and causes sinus headaches.
  - **Sinusitis** – The ventilation to the sinuses will get affected and also causes sinus pains, facial pains, and sinusitis (inflammation of the mucosal lining of the nose and paranasal sinuses).
  - **Epistaxis** – When there is a sharp bony projection from the septum, the mucosa overlying this projection may get thinned out and because of the small trivial traumas like picking the nose, sneezing, or blowing the nose will cause mucosal tears and lead to bleeding. This condition is known as Epistaxis.
  - **Anosmia** – The air current that reaches the olfactory fibres (present in the roof of the nose) is reduced. The patients can have symptoms of a decrease in the perception of smell known as **Hyposmia** or there can be a complete loss of smell known as **Anosmia**.
  - **External deformity** – There will be external deformity of the nose wherever the septum deviates.
  - **Middle ear infection** – The air goes from the nose to the nasopharynx and via the nasopharynx reaches the middle ear. If the ventilation to the Eustachian tube is decreased, it can result in middle ear infection.

**Types of deviated nasal septum**

- Anterior dislocation – There can be anterior dislocation if the septum does not attach to the anterior nasal spine and has got deviated onto the floor of the nose.
- C-shaped
- S-shaped
- Sharp bony projection
- Spur – Diffused thickening of the septum

**Symptomology**



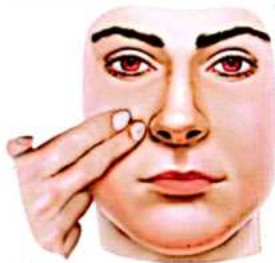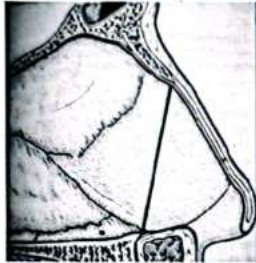
**Types of surgery for DNS**

- **Septoplasty**
  - It is a conservative surgery.
  - In Septoplasty, an incision is made only on one side. The mucosal flap over the cartilage and bone is elevated only on one side.
  - Only minimal resection of the septum is done and the flap is repositioned.
- **SMR**
  - It is a radical surgery (submucosal resection of the septum).



- An incision is made on both sides of the septum. The mucosal flaps covering the septum are elevated both over the cartilage and bone on the right side as well as the left side. Almost complete cartilage and bone are resected.
- The entire septum is removed except for a small strut anteriorly and superiorly.
- The flap is then closed and the septum is sutured.

## Cottles Line



- It is a line drawn from the frontal spine (spine coming from a frontal bone) to the anterior nasal spine.
- Any deviations which are frontal or anterior to it must be treated only with Septoplasty.
- The deviations which are posterior to this line are treated either by Septoplasty or by SMR.
- The word Cottle is associated with another important clinical test known as the Cottle's test. It helps in understanding the patency of the internal nasal valve (the narrowest portion of the nasal cavity).
- The boundaries of the INV (Internal Nasal Valve) are:
  - Upper lateral cartilage superiorly.
  - Inferior turbinate inferiorly or laterally.
  - Septum medially.
- A Cottle's test is done to understand if the INV has got compromised or not by placing two fingers on the side patient complains of having obstruction. Pull the side. If there is improvement in breathing it means the patient has an obstruction.



### Important Information

prince kumar  
princeekumar@gmail.com

- Only if the patient with DNS has symptoms, surgery is advised.
- Surgery is required only if the person is symptomatic, not resolving with medical therapy, and compromising the general work habits.

- Hyposmia is the decrease in the perception of a smell.
- Anosmia is the complete loss of smell.
- Spur is the one that is typically present in Epistaxis.
- Cottle's line is the line drawn from the frontal spine to the anterior nasal spine.
- Cottle's test helps us understand the patency of the internal nasal valve.

## Differences between septoplasty and SMR

00:25:50

### Septoplasty

- Conservative surgery (minimal resection).
- Avoided in children – It is done less often in children as compared to adults because the growth of the septum continues until puberty. Even if surgery is done, there might be a recurrence. If there is a need it can be done in children also.
- Elevation of flaps – It is elevated only on a single side.
- Removal of cartilage - Only the deviated portion is removed and the rest of the cartilage from the bone is spared (very minimal).
- Caudal dislocation – Any deviation anterior to the Cottle's line is treated with Septoplasty.
- Septal perforation – Rarely seen.
- Supratip deformity and columellar retraction – Rarely seen
- Revision surgery – High chance of Revision surgery.

### SMR

- Radical surgery (submucosal section of the septum).
- Elevation of flaps – On both sides.
- Removal of cartilage – Gross in the submucosal section of the septum.
- Caudal dislocation – The septum deformity is anterior to the Cottle's line. Not treated with SMR.
- Septal perforation – Seen more often.
- Supratip deformity and Columellar retraction – Seen more often
- Revision surgery – Less chance of Revision surgery.



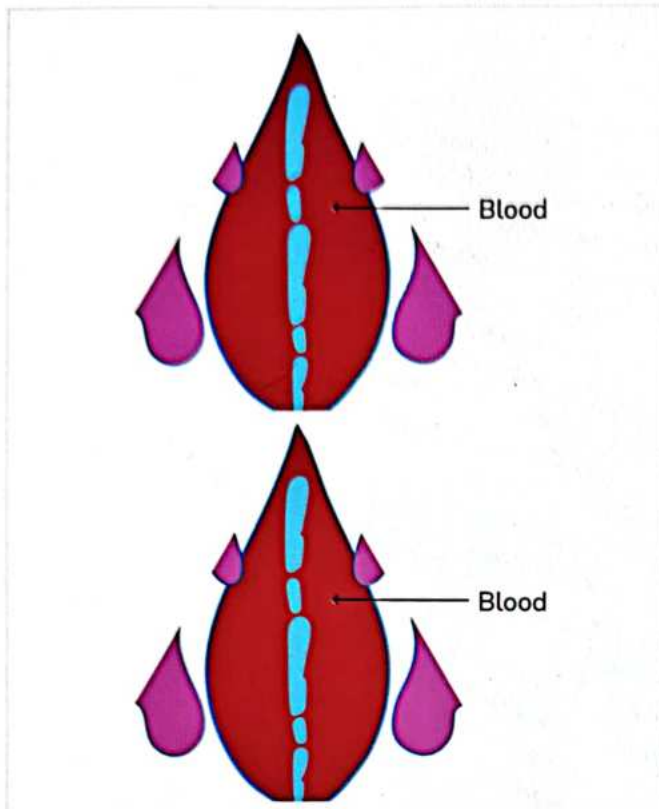
### Important Information

- Septoplasty is avoided in children up to 17-18 years of age.
- In Septoplasty, conservative surgery is chosen over SMR.
- Caudal dislocation is the anterior dislocation where the septum deformity is anterior to the Cottle's line.
- Medical therapy is not discussed for patients with DNS.



## Septal Hematoma

00:32:30



- Septal hematoma is an accumulation of blood between the septum and the overlying mucosa.
- Whenever there is blood accumulation, there will be a history of trauma.
- Hematoma can also occur after the surgery.

### Etiology

- Trauma
  - It is the most common cause of septal hematoma.
  - Trauma can be direct, surgical, or iatrogenic.

### Symptoms

- **Nasal obstruction**- A pinkish-blue swelling on either side of the septum is seen and the patient will not be able to breathe well. The swelling will obstruct the airways.
- **Pain** - When the mucosa is stretched and bulged, the pain fibers get activated. The pain will be at the level of the bridge of the nose.

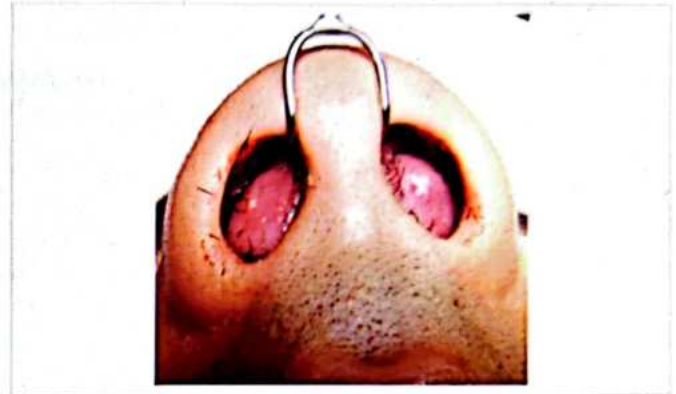### Treatment

- For small Hematomas - Aspiration is done with a wide-bore needle.
- For large Hematomas - An incision is given on the septum and the Hematoma is drained.
- To prevent reaccumulation, pressure is applied on either side

of the septum. Compressed nasal packing is mandatory to be done in a patient with Septal Hematoma. If not done, the patient will end up having reaccumulation and come back with Septal Hematoma.

## Septal Abscess

00:37:09



- Swelling on either side of the septum which is bilateral and symmetrical swellings.

### Etiology

- Abscess can occur following a Septal Hematoma.
- If a Septal Hematoma is not treated it can progress to a Septal Abscess.
- It can also occur because of an infection in the nose, or finger picking.
- It can happen secondary to **Furunculosis**.

### Clinical Features

- The symptoms are the same as that of Hematoma.
- In addition to nasal obstruction and pain, the other features are Fever, Headache, and Lymphadenopathy (enlarged submental or sub mandibular lymph node).

### Treatment

- Either aspiration or immediate intervention with incision and drainage of the Abscess. The removal of an infected piece of cartilage is very important. If not removed, it can result in cartilage necrosis and lead to deformity in the nose. This deformity is known as the Saddle nose or Deformity.
- Systemic antibiotics are given to treat the infection.
- Compressed nasal packing is not done.
- The Septal Abscess is in the dangerous triangle (from nasion to the angle of lips). Any infection in this space due to Furunculosis, Meningitis, or an Abscess has to be treated diligently.
- If not treated, it can cause **Cavernous Sinus Thrombosis** because the veins are connected to the Cavernous sinus and the veins present are valveless.



- Immediate treatment has to be done for a patient with Septal Abscess.



## Important Information

- There is no fever, headache, and lymphadenopathy in Septal Hematoma.
- If the patient has only pain and obstruction, it is Hematoma.
- If the patient has pain, obstruction, fever, headache, and lymphadenopathy, it is an Abscess.
- Compressed nasal packing is mandatory for a patient with Septal Hematoma.

### Perforation of Septum

00:45:00

- Perforation is the hole in the septum.
- Septal perforation occurs mostly due to trauma. It can be a direct trauma due to a fall, an accident, nasal piercing or iatrogenic trauma, or surgical trauma.
- It can happen following sub-mucosal resection of the septum
- It can happen following any surgery of the nose.
- It can occur secondary to any surgery that leads to access for other surgeries like Trans nasal approach to the pituitary gland.
- Septal perforation can occur because of other causes like exposure to industrial fumes, and working in a chemical industry where there are arsenic and mustard gases. These fumes are chronically inhaled and the drug gets deposited into the septum which can result in Septal perforation over a chronic duration of time.
- A common drug Cocaine causes Vasoconstriction and results in Ischemic necrosis which can lead to Septal Perforation.
- Apart from these, autoimmune causes and infective causes can also result in Septal Perforation.
- Almost all the infections that affect the septum to cause Septal Perforation will affect only the cartilaginous portion. Bony perforation is caused by syphilis
- Total Septal Perforation involving the cartilage and bony portion of the septum occurs in Wegener's granulomatosis.

### Symptoms

- Small Perforations – Only cause whistling sounds.
- Large Perforations – When the large air current is flowing through the perforation it produces symptoms like dryness and crusting. These crusts cause bleeding from the nose when they fall.

### Treatment

- Conservative therapy is given for most of the patients either in the form of Silastic buttons princeekum@gmail.com 09733
- Nasal saline sprays are given to keep the nose moist.

- Surgery is done if there is any risk of severe symptoms for closure. This is rarely done.



## Important Information

- Almost all the infections that affect the septum to cause Septal Perforation will affect only the cartilaginous portion.
- Total Septal Perforation involving the cartilage and bony portion of the septum occurs in Wegener's granulomatosis.

### Clinical Questions

Q. What are the types of surgeries for a patient with DNS?

Ans: Septoplasty and SMR are the two types of surgery for a patient with DNS.

Q. Why is a Cottle's test done?

Ans: Cottle's test helps us understand the patency of the internal nasal valve.

Q. Will the patient suffering from DNS have nasal obstruction?

Ans: Yes.

Q. If the patient has only nasal obstruction and pain. What is the name of this condition?

Ans: Septal Hematoma

Q. What is the perforation of the septum?

Ans: If there is any hole in the septum, it is called Septal Perforation.






# CROSS WORD PUZZLES



Crossword Puzzle 1




**Across**

- 3. \_\_\_\_\_ is the most common cause of Deviated Nasal Septum.
- 4. \_\_\_\_\_ is the complete loss of smell.

**Down**

- 1. \_\_\_\_\_ is a sharp bony projection seen on the septum.
- 2. \_\_\_\_\_ is a conservative surgery.

Crossword Puzzle 2




**Across**

- 2. \_\_\_\_\_ is the decrease in the perception of the smell.

**Down**

- 1. \_\_\_\_\_ is radical surgery.
- 3. \_\_\_\_\_ is done with a wide bore needle for small Hematoma.

Crossword Puzzle 3



**Across**

- 2. \_\_\_\_\_ is an enlarged submental or submandibular lymph node.
- 3. \_\_\_\_\_ bony septal perforation.

**Down**

- 1. \_\_\_\_\_ is caused due to large air currents.

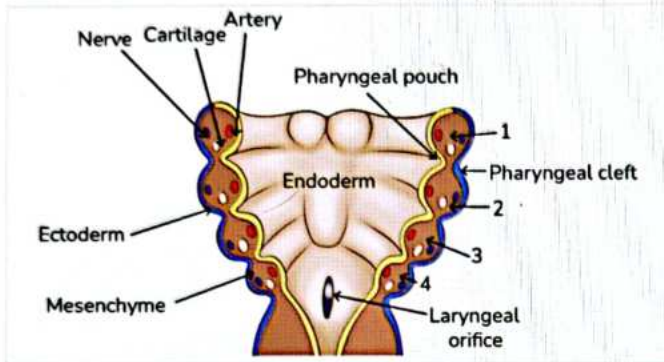
prince kumar  
princeeeek@gmail.com  
9928609731





Derivatives Of The Pharynx From Embryological Arches

00:00:49



- On the outside of the embryological arch, clefts are present; on the inside, the structures present are called the pouch.
- The clefts make up the ectodermal components and the pouch makes up the endodermal components.
- In between the cleft and pouch is the mesoderm.
- There are 1, 2, 3, 4, and 6 embryological arches. The 5th arch disappears during the development.
- These are the relevant derivatives from each of the embryological arches:
  - Arch I/Mandibular arch: The muscles of mastication, tensor veli palatini (opens the eustachian tube), tensor tympani, mylohyoid, and anterior belly of digastric muscle are derived from this arch.
    - The bones malleus and incus are derived from the 1st arch.
    - This arch is supplied by the cranial nerve V i.e., the trigeminal nerve (mandibular branch).
    - The cleft of the arch I gives rise to the external auditory canal.
    - The pouch of the arch I fuses with the pouch of the arch II and gives rise to the tubo-tympanic recess which further forms the eustachian tube and the middle ear proper.
  - Arch II/Hyoid arch: The muscles of facial expressions, stapedius, stylohyoid, and posterior belly of the digastric muscles is derived from this arch.
    - The ear bone stapes, the lesser horn of the hyoid and part of the hyoid body are derived from this arch.
    - It is supplied by the VII cranial nerve i.e., the facial nerve.
    - The cleft of arch II fuses with the cleft of arch III, IV, and VI to give rise to the cervical sinus which normally disappears during development.

→ However, if the sinus persists, it forms a communication between the external auditory canal and the middle ear which is called the collaural fistula.

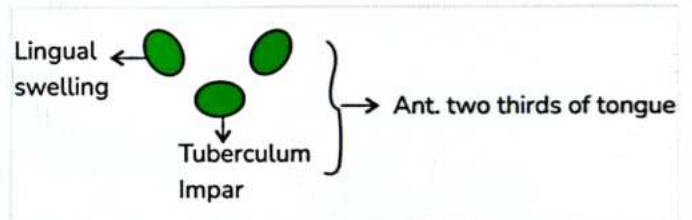
- Arch III/Glossopharyngeal arch: The stylopharyngeus muscles are derived from this arch.
  - It gives rise to the greater horn of the hyoid bone and part of the hyoid body.
  - It is supplied by the IX cranial nerve i.e., the glossopharyngeal nerve.
- Arch IV and VI (Vagal arch): It gives rise to the pharyngeal and laryngeal musculature and cartilage.
  - It is supplied by the X cranial nerve i.e., the Vagus nerve.

princeeekum@gmail.com  
9928609733

Development of Tongue

00:08:06

- From 1<sup>st</sup> arch mesoderm there are three thickenings



- From the mesoderm of 3<sup>rd</sup> and 4<sup>th</sup> pharyngeal arches there is another midline swelling called as HYPOBRANCHIAL EMINENCE
- Cranial → Posterior 1/3 tongue
- Cardial → Posterior most part posterior to posterior 1/3 tongue
- Hypobranchial eminence
- Anterior 1/3
- 1<sup>st</sup> arch
- 3<sup>rd</sup> arch and 4<sup>th</sup> arch
- All muscles are derived from occipital somites supplied by HYPOGLOSSAL NERVE except PALATOGLOSSUS supplied by pharyngeal plexus
- The tongue is divided into two parts - anterior 2/3 and posterior 1/3 by the sulcus terminalis. The circumvallate papillae are present in this area.
- The mesoderm of the arch I give rise to 3 thickenings - 2 lingual swelling and 1 tuberculum impar.
- These three thickenings fuse and form the anterior 2/3 of the tongue which is innervated by the lingual nerve (branch of the mandibular nerve) for sensory impulses.
- The mesoderm of arch III and IV gives rise to a midline swelling called the hypobranchial eminence.



- The hypobranchial eminence is divided into cranial (arch III) and caudal (arch IV) parts.
- The cranial part gives rise to the posterior 1/3 of the tongue and the caudal part forms the posterior-most part of the tongue.
- The sensory functions of this area are supplied by the glossopharyngeal nerve and the vagus nerve.
- All of the tongue muscles develop from the occipital somites, so the motor supply of the tongue is by the hypoglossal nerve except for the palatoglossus muscle.
- The palatoglossus muscle receives its motor supply from the vagus nerve.
- The taste from the anterior 2/3 of the tongue is carried by the chorda tympani nerve (branch of the facial nerve) and from the posterior 1/3 it's carried by the glossopharyngeal nerve.

→ Glossopharyngeal nerve

→ Stylopharyngeal muscle

- The space between middle and inferior constrictor muscles: The contents of this space is derived from arch IV. They are

→ Internal laryngeal nerve

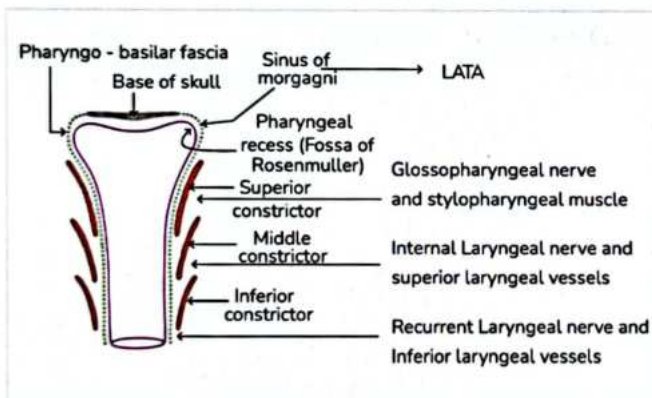
→ Superior laryngeal vessels

- The space below the inferior constrictor muscle: The contents of this area is derived from arch VI. They are

→ Recurrent laryngeal nerve

→ Inferior laryngeal vessels

## Structures Between The Base of The Skull And The Pharynx

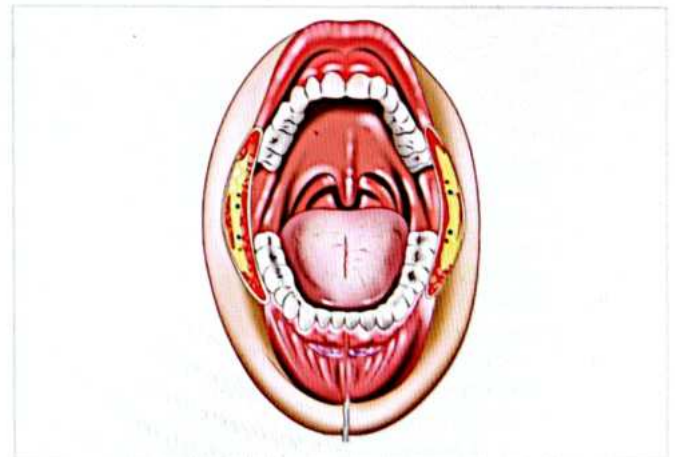


## Nose, Oral Cavity, Larynx, And Pharynx

00:21:30

- The pharynx is like a continuous tube which is approximately 10 cm long.
- It begins superiorly at the base of the skull and inferiorly it extends up to the 6th cervical vertebrae.
- At the level of the C6 vertebrae, the anteriorly cricoid cartilage is present. This means the lower border of the cricoid cartilage corresponds with the C6 vertebrae.
- Pharynx lies behind the nasal cavity, oral cavity, and larynx.
- The part of the pharynx that lies behind the nose is called the nasopharynx, behind the oral cavity is called the oropharynx and behind the larynx is called the laryngopharynx/hypopharynx.

## Oral Cavity

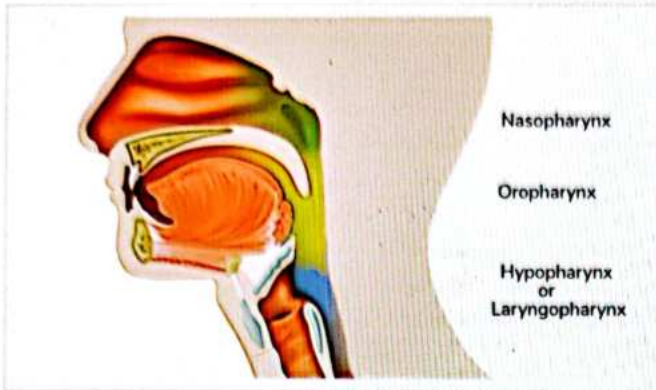


- The wall of the pharynx is made up of different layers (inside to outside) - the mucosal layer, pharyngo-basilar fascia, the 3 constrictor muscles (superior, middle and inferior), and the outermost layer is bucco-pharyngeal fascia.
- There are some deficiencies between the base of the skull and the superior constrictor, superior and middle constrictor and middle and inferior constrictor muscles.
  - Sinus of Morgagni: It is the space between the base of the skull and the superior constrictor.
- The structures passing through this area are (LATA) -
  - Levator veli palatini
  - Auditory tube/eustachian tube: It opens with the help of tensor veli palatini and levator veli palatini muscles.
  - Tensor veli palatini
  - Ascending palatine artery
- This space is derived from arch I and II as their derivatives pass through this space.
  - The space between the superior and the middle constrictor muscles: The contents of this space are derived from arch III. These are

- The boundaries of the oral cavity are:
  - Anterior and lateral - The lips, gum and teeth.
  - Posterior - The oropharyngeal isthmus: It is formed by the uvula with anterior pillar (anterior pillar formed by the palatoglossus muscle).
  - Superior/Roof: It is formed by the palate.
  - Inferior/Floor: It is formed by the tongue, muscles and mucous membrane.



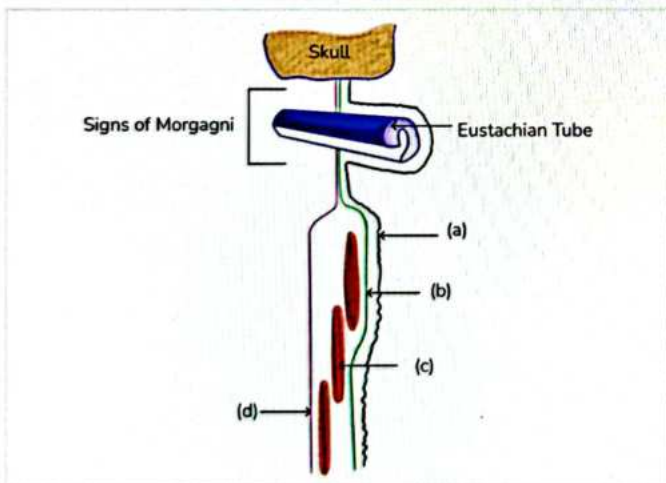
**Division of Pharynx**



These are the 3 divisions of the pharynx:

- Nasopharynx/Epipharynx:** Superiorly it is bound by the base of the skull and inferiorly its border is made up by an imaginary line passing through the palate.
- Oropharynx:** It extends superiorly to the imaginary line through the palate and inferiorly by an imaginary line passing through the tip of the epiglottis (hard palate to hyoid bone).
- Laryngopharynx/Hypopharynx:** It extends superiorly from the imaginary line passing through the tip of the epiglottis to inferiorly to the lower border of the cricoid cartilage which corresponds to the C6 vertebrae.

**Structure of Pharyngeal Wall**

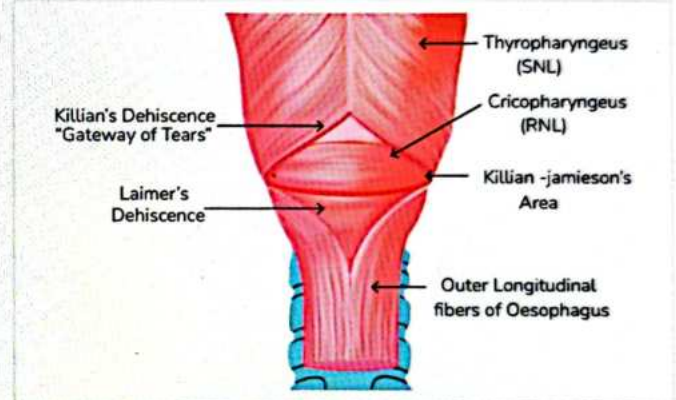
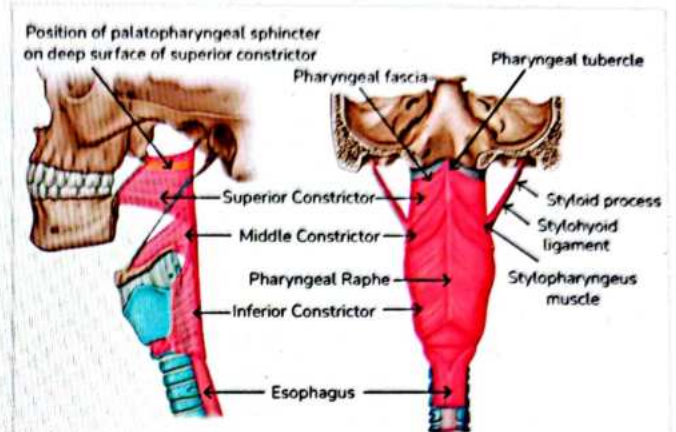


These are the different layers of the pharyngeal wall:

- Mucosal layer
- Pharyngo-basilar fascia
- Muscular layer: It is divided into two parts:
  - External layer:** It is formed by the superior, middle, and inferior constrictor muscles.
  - Internal layer:** It is formed by the stylopharyngeus, salpingopharyngeus and palatopharyngeus muscles.

**d. Bucco-pharyngeal fascia**

**Constrictor Muscle of The Pharynx**

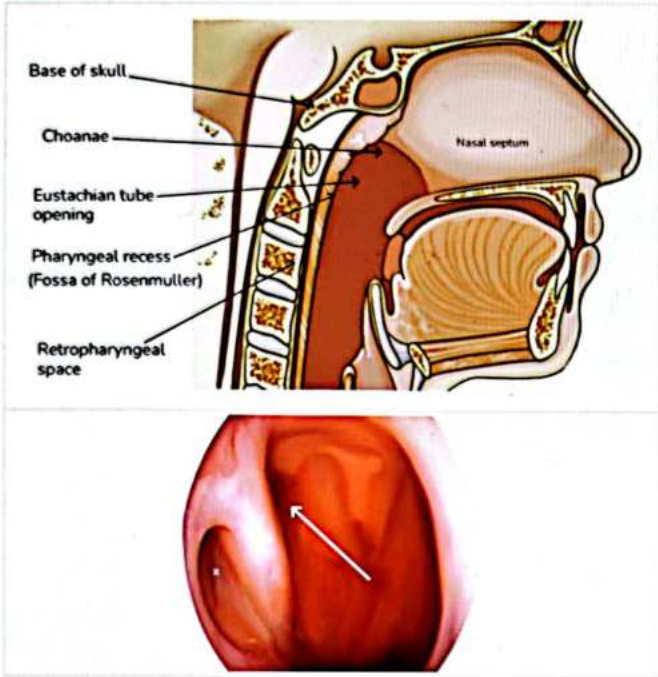


- Inferior constrictor:** It is made up of the oblique fibres of the thyropharyngeus and the horizontal fibres of the cricopharyngeus.
- As a result, between these two types of fibres, there is a triangular area of dehiscence in the midline which is known as **Killian's dehiscence** or gateway of tears.
- Any outpouching of mucosa from this dehiscence is called a **pharyngeal pouch** or **Zenker's diverticulum**.
- Killian-Jamieson's area:** It is dehiscence which is present laterally and below the inferior constrictor muscle. It is formed by the inferior constrictor and the upper fibres of the oesophagus.
- Laimer's dehiscence:** It is also a midline dehiscence which is present below Killian's dehiscence.



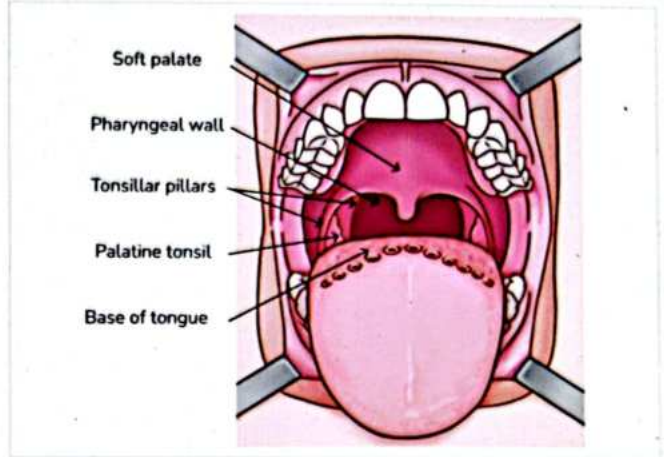
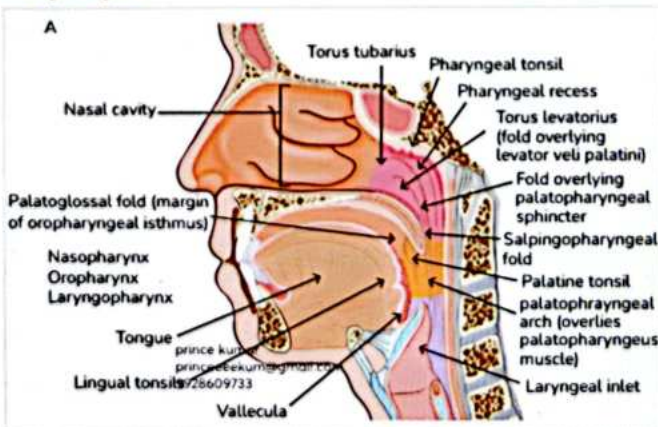
Nasopharynx

00:34:48



- It is the part of the pharynx that lies behind the nasal cavity.
- The boundaries of the nasopharynx are as follows
  - Superior: It is formed by the base of the skull.
  - Inferior: It is formed by the imaginary line passing through the palate.
  - Anterior: The nasopharynx connects with the nasal cavity through the choanae.
  - Posterior: It is related to the C1 vertebrae.
- The roof and the posterior wall forms one continuous wall.
- On the lateral wall of the nasopharynx, there is an opening of the eustachian tube. This eustachian tube is covered by a cushion-like structure known as the **torus tubarius**.
- Behind the torus tubarius is a recess known as the **Fossa of Rosenmuller**.
- The nasopharynx is separated from the oropharynx below while swallowing by the palatopharyngeus muscle also called the **Passavant's ridge**.

Oropharynx

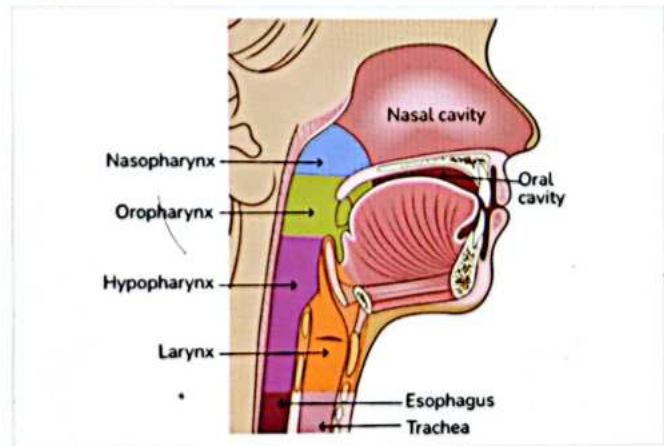


- It is the part of the pharynx which lies behind the oral cavity.
- The boundaries of the oropharynx are as follows:
  - Superior: It is formed by the imaginary line passing through the palate.
  - Inferior: It is formed by the imaginary line passing through the tip of the epiglottis.
  - Anterior: It communicates to the oral cavity.
  - Posterior: It is related to the C7 vertebrae.
  - Lateral: It is formed by anterior (palatoglossus muscle) and posterior pillars (palatopharyngeus muscle). The lymphoid tissue present between the two pillars is the **palatine tonsils**.
  - The uvula with anterior pillar is known as oropharyngeal isthmus. It separates the oral cavity from oropharynx
- The base of the tongue (posterior 1/3rd portion) is also present in the oropharynx.
- On the base of the tongue, there can be a presence of lymphoid tissues called the **lingual tonsils**.

Functions of Oropharynx

- It is a **conduit for food and air**.
- It helps in **speech**.
- It helps in the **perception of taste**.
- It provides **immunity and local defence** due to the palatine and lingual tonsils.

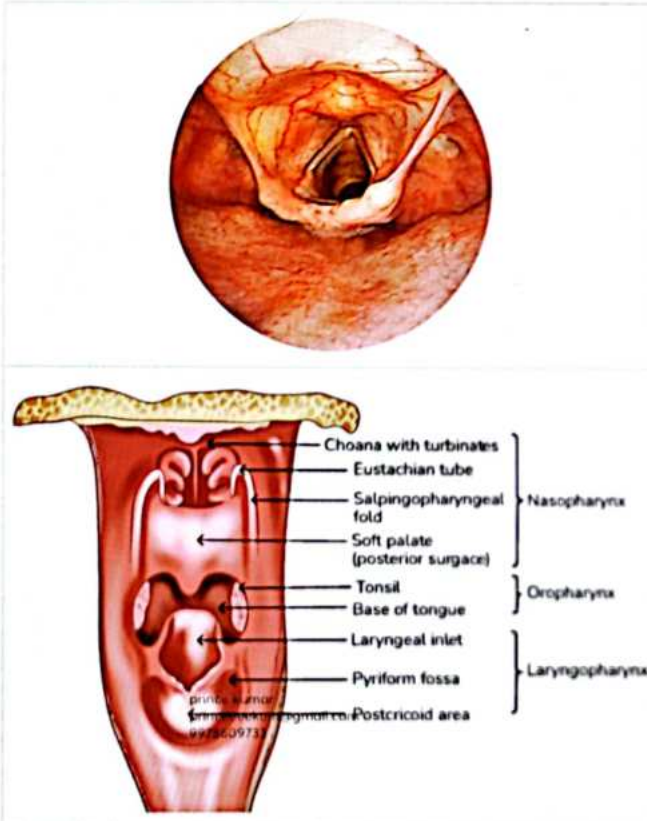
Hypopharynx





- It is the part of the pharynx that lies behind the larynx.
- The boundaries of the hypopharynx are as follows:
  - **Superior:** It is formed by the imaginary line passing through the tip of the epiglottis.
  - **Inferior:** It is formed by an imaginary line through the lower border of the cricoid cartilage anteriorly and the C6 vertebrae posteriorly.
  - Hypopharynx lies opposite the 3rd, 4th, 5th and 6th cervical vertebrae.
  - **Anterior:** It communicates with the larynx.

## Subdivisions



- There are three subdivisions of the hypopharynx. They are (3Ps)
  - **Pyramidal fossa:** These are two depressions on the lateral sides of the aryepiglottic folds. They are also known as the **smuggler's pouch**.
  - **Post cricoid region:** It is a depression in the midline below the arytenoids.
  - **Posterior pharyngeal wall:** It is a continuous wall of the hypopharynx.
- Hypopharynx continues down to the oesophagus.

## Applied Anatomy

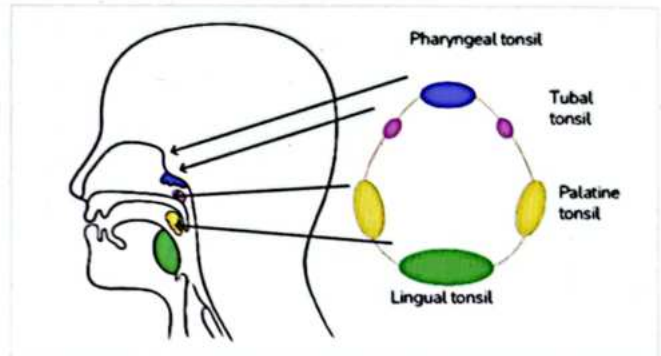
- The **internal laryngeal nerve** (branch of the superior laryngeal nerve) runs submucosally in the lateral wall of the

- pyriform sinus. Hence, any lesion in this area can cause **pain in the ear via the vagus nerve (Arnold's nerve)** and this is known as **referred otalgia**.
- The post-cricoid region is a common site for carcinoma in females suffering from **Plummer Vinson syndrome**.

## Functions

- It is a **common pathway for air and food**.
- It provides **resonance for speech**.
- It helps in **deglutition**.

## Waldeyer's Ring



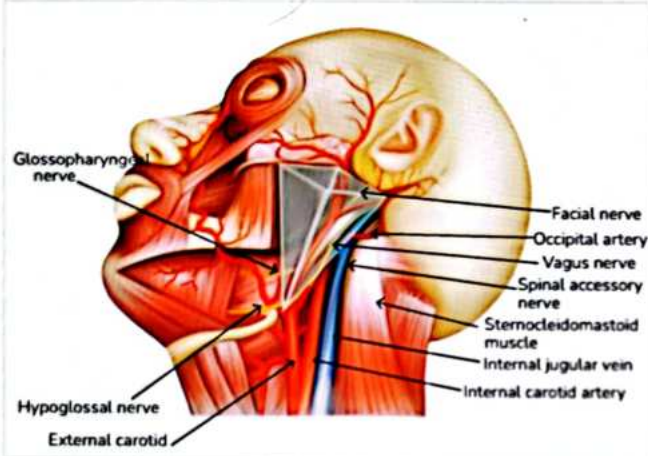
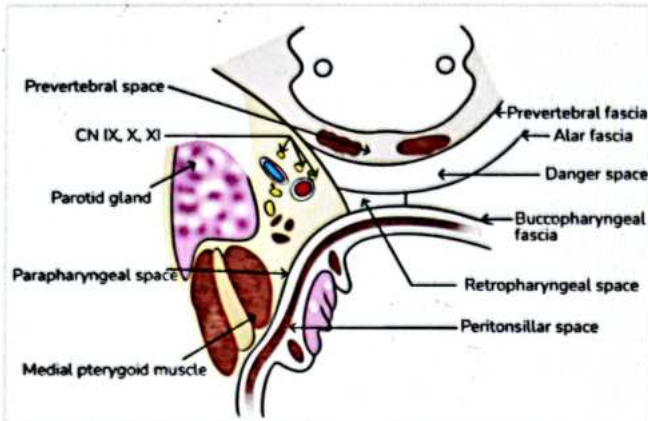
- It is formed by the lymphoid tissues present in the upper aerodigestive tract. These lymph nodes protect the body from harmful organisms that enter the body via breathing/eating.
- The lymphoid tissues in the Waldeyer's ring are -
  1. **Pharyngeal tonsil:** It is present in the nasopharynx in the midline. These are also called **adenoids** or **Luschka's tonsil**.
  2. **Tubal tonsil:** These are present around the eustachian tube that opens in the nasopharynx. They are a paired structure. They are also called **Gerlach's tonsil**.
  3. **Palatine tonsils:** These are paired structures present laterally in the oropharynx.
  4. **Lingual tonsil:** It is present in the oropharynx in the midline over the base of the tongue.

## Anatomy Of The Pharyngeal Spaces

00:55:20

- The applied anatomy of these spaces is that abscesses can form in these spaces and it's important to know the anatomy for the treatment procedure.
- There are four pharyngeal spaces:
  1. **Peritonsillar space:** The bed of the tonsil is formed by the superior constrictor muscle.
  - So, it is the space **between the capsule of the tonsil and the superior constrictor muscle**.
  - It is a **paired structure**.

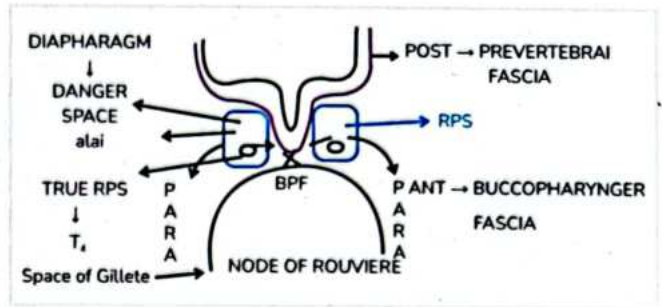




2. Parapharyngeal space: It is also called pterygomaxillary space.

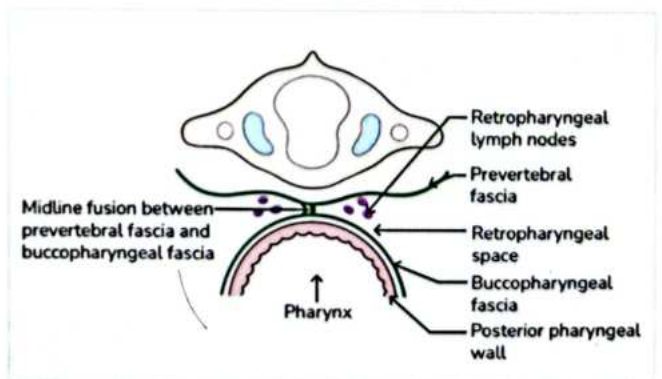
- It is a paired space which looks like an **inverted pyramid**. The boundaries of this space are -
  - **Superior:** It is formed by the base of the skull.
  - **Inferior:** The space ends at the level of the hyoid bone.
  - **Lateral:** It is formed by the mandible to which the medial and the lateral pterygoid muscles are attached and the parotid gland.
  - **Anteromedial:** It is formed by the bucco-pharyngeal fascia.
  - **Posterior:** It is formed by the internal carotid artery, internal jugular vein and lower cranial nerves.
  - **Posteromedial:** It communicates with the retropharyngeal space.
- The space is divided by the styloid process into **prestyloid and poststyloid compartments**.
- The source of infection in this space is from the tonsil.
- Pus formation in the **prestyloid compartment** can cause the **bulge or push of the tonsil**.
- If the pus formation is in the **poststyloid compartment** then, the **bulge is seen in the pharyngeal wall posterior to the tonsil**.

prince kumar  
princeekum@gmail.com  
9938609733

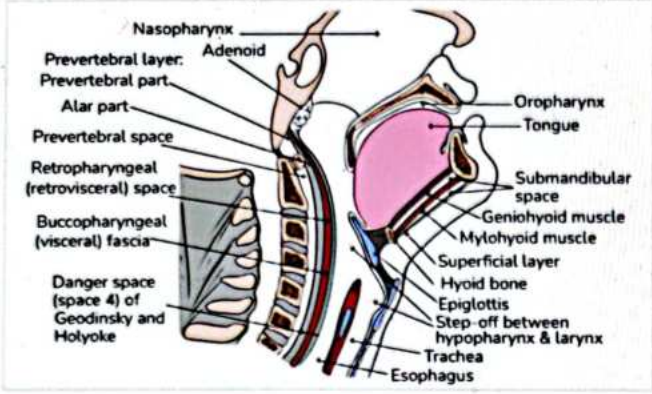


3. Retropharyngeal space: It is the space that lies behind the pharynx.

- It is a **paired space** which is present on either side of the midline. The boundaries of this space are
  - **Anterior:** It is formed by the buccopharyngeal fascia.
  - **Posterior:** It is formed by the prevertebral fascia.
  - **Lateral:** They communicate with the parapharyngeal space.
  - **Medial:** The right and the left retropharyngeal space don't communicate with each other due to the **septum** formed by the bucco-pharyngeal and prevertebral fascia.
  - **Superior:** It is formed by the base of the skull.
  - **Inferior:** It extends upto the level of 4th thoracic vertebrae.
- The retropharyngeal space is divided into **two compartments** by the **Alar fascia**. These compartments are the **anterior compartment** or the **true retropharyngeal space** and the **posterior compartment** or the **danger space**.
- The **danger space** inferiorly extends into the mediastinum upto the level of the diaphragm.
- The **true retropharyngeal space** inferiorly extends upto the T4 and is also called the **space of Gillette**. This also contains some lymph nodes called the **node of Rouviere**.
- Infection of the true space happens due to the **suppuration of the lymph nodes secondary to tonsillitis/adenoiditis**.
- This condition is more common in children.
- The abscess will form a bulge on either side of the midline.
- The infection of the danger space happens due to **cox spine**.







<b>Usual source of infection</b>	Infection of lymph nodes. As lymph nodes disappear with age, this infection is common in children.	Caries of spine which is usually tubercular
----------------------------------	--	---

4. **Prevertebral space:** It is the space between the vertebrae and the prevertebral fascia.
- It is a **single space present on the midline.**
  - These are the boundaries of this space
    - **Anterior:** It is formed by the prevertebral fascia.
    - **Posterior:** It is formed by the body of vertebrae.
    - **Superior:** It is formed by the base of the skull.
    - **Inferior:** It extends upto the level of coccyx where the vertebrae ends.
  - Infection in this space happens due to the **cox or tuberculosis of the spine.**
  - This abscess will form a **midline bulge.**

- The peritonsillar space is between the capsule of the tonsil and the superior constrictor muscle.
- All the pharyngeal spaces extend superiorly from the base of the skull.
- The parapharyngeal space extends inferiorly upto the hyoid.
- The true retropharyngeal space extends inferiorly upto T4 and the danger space extends inferiorly upto the diaphragm.
- The prevertebral space extends inferiorly upto the coccyx.
- The smallest space is the retropharyngeal space.
- The commonest cause for the parapharyngeal abscess is tonsillar infections.

One Liners

prince kumar  
princekumar@gmail.com  
9928609713

	Retropharyngeal space	Prevertebral space
<b>Location</b>	Between buccopharyngeal fascia covering constrictors of pharynx and prevertebral fascia	Between vertebral fascia and vertebra
<b>Vertical extension</b>	From base of skull to bifurcation of trachea(T4) in mediastinum	From base of skull to coccyx
<b>Horizontal</b>	Divided in to two spaces (spaces of gillite) which do not communicate across midline	Single cavity across midline
<b>Contents</b>	Retropharyngeal nodes which disappear by 4-5 years	NIL

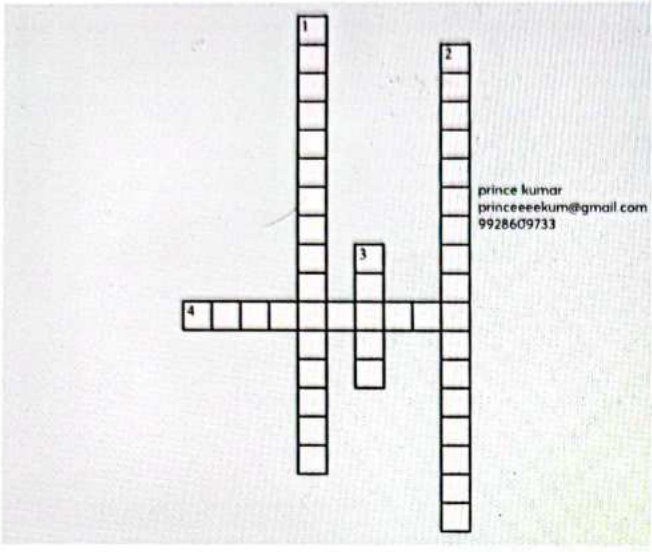




## CROSS WORD PUZZLES



### Crossword Puzzle 1



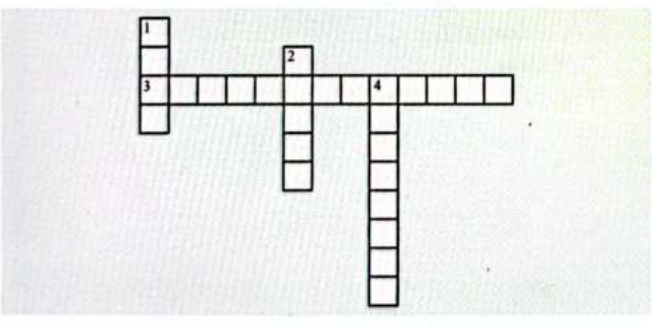
**Across**

4. The arch I is supplied by the \_\_\_\_\_ branch of the trigeminal nerve.

**Down**

- 1. The communication between the external auditory canal and the middle ear is called the \_\_\_\_\_.
- 2. The tongue is divided into two parts by the \_\_\_\_\_.
- 3. The \_\_\_\_\_ makes up the endodermal components from the embryological arch.

### Crossword Puzzle 2



**Across**


3. The taste from the anterior 2/3 of the tongue is carried by the \_\_\_\_\_ nerve.

**Down**

- 1. The pharynx is a continuous tube which is \_\_\_\_\_ long.
- 2. The palatoglossus muscle receives its motor supply from the \_\_\_\_\_ nerve.

4. Sinus of \_\_\_\_\_ is the space between the base of the skull and the superior constrictor.

### Crossword Puzzle 3



**Across**

- 3. \_\_\_\_\_ space lies between the capsule of the tonsil and the superior constrictor muscle.
- 4. The true retropharyngeal space contains some lymph nodes called the node of \_\_\_\_\_.

**Down**

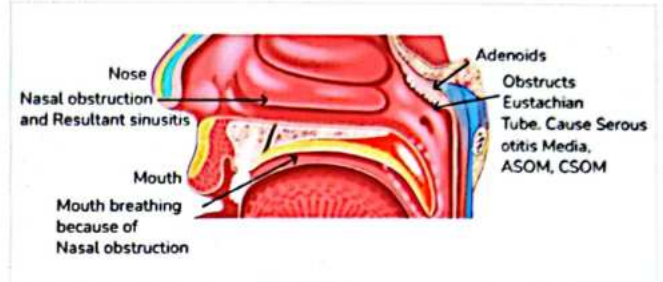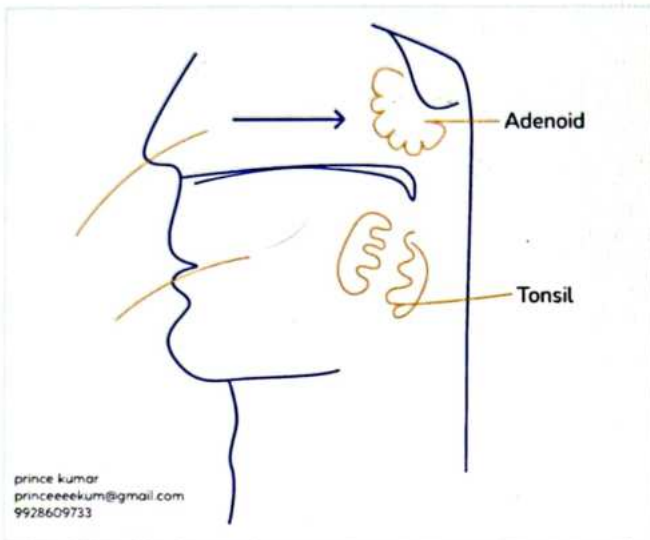
- 1. The smallest space is the \_\_\_\_\_ space.
- 2. Gateway of tears is also known as \_\_\_\_\_ dehiscence.





00:01:00

Adenoid Hypertrophy



- Adenoids are the lymphoid tissues of the nasopharynx.
- Tonsils are the lymphoid tissues of the oropharynx.
- These adenoids and tonsils provide protection till the age of 3-4yr because until then the rest of the lymphoreticular organs are not fully developed.

Anatomy

Adenoids

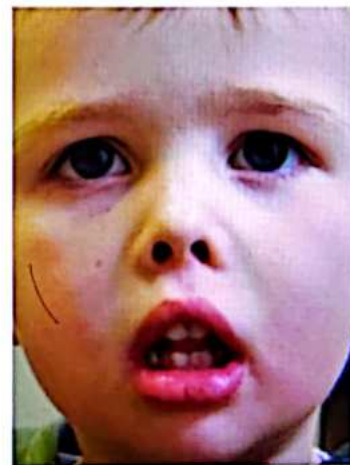- It is a midline structure present at the junction of the roof and the posterior wall of the nasopharynx.
- It is also called the nasopharyngeal tonsils.
- It is a single structure.
- It is lined by the ciliated columnar epithelium.
- No capsules or crypts are present.
- **Growth:** It is present at birth and grows until the age of 6.
- Then it goes into atrophy at puberty and completely disappears by the age of 20.

Tonsils

- These are present in the oropharynx.
- They are a paired structure.
- They are lined by stratified squamous epithelium.
- A capsule is present on the lateral surface (hemi-encapsulated).
- Crypts are present on the medial surface.
- These are present throughout life.

Symptoms

- It is also called adenoiditis when the adenoids are inflamed and infected.
- This results in the obstruction of the airway and the child starts breathing from the mouth.
- This continuous mouth-breathing will result in the mal-development of the mouth and facial structures.
- It can result in a high-arch palate which leads to deviated nasal septum.
- This results in the development of a dull elongated face with dental malocclusion known as the adenoid facies.
- Also, there is a stasis of secretions in the nasal cavity as they can't drain into the nasopharynx.
- This stasis results in infection which can spread to paranasal sinuses resulting in sinusitis.
- A nasopharyngeal mass like enlarged adenoids can also obstruct the eustachian tube which leads to the infection of the middle ear.
- So, it can cause serous otitis media, acute suppurative otitis media, and chronic suppurative otitis media.



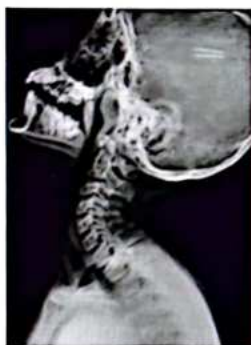

## Adenoid Facies

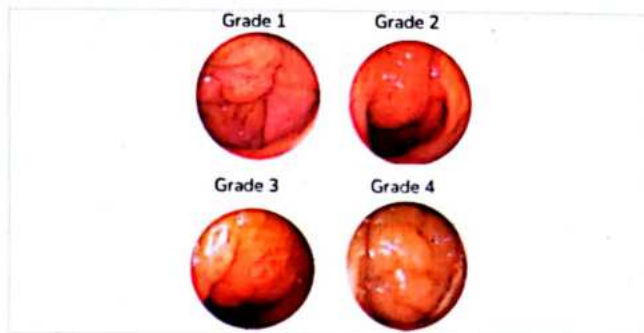
The following are the features of adenoid facies:

1. Elongated dull long expressionless face.
2. Pinched-in nose due to disuse atrophy of the alae nasi muscles and the alar cartilage.
3. An open mouth and dropping lower jaw give the face an elongated appearance.
4. Hitched up upper lip.
5. Crowded upper teeth.
6. High-arched palate as the moulding effect of the tongue on the palate is lost.

## Diagnosis



- **X-Ray:** It is diagnosed by an X-ray of the nasopharynx in the lateral view with the soft tissue window.
- **Grading of the hypertrophy:** Trace an imaginary line on the base of the skull and another imaginary line parallel to it passing through the palate.
- The space between the two lines represents the airway space.
- Now divide this space into four parts horizontally where each part constitutes 25% of the space.
- **Grade I:** If the adenoid occupies 0-25% of the airway space.
- **Grade II:** If the adenoid occupies 25-50% of the airway space.
- **Grade III:** If the adenoid occupies 50-75% of the airway space.
- **Grade IV:** If the adenoid occupies 75-100% of the airway space.
- **Endoscopy:** The adenoid hypertrophy is graded according to the degree of choanal space occupied. Adenoids look like a bag of worms.
- **Grade I:** If the adenoid occupies 0-25% of the choanal space.
- **Grade II:** If the adenoid occupies 25-50% of the choanal space.
- **Grade III:** If the adenoid occupies 50-75% of the choanal space.
- **Grade IV:** If the adenoid occupies >75% of the choanal space.
- **Endoscopy grading is always superior to X-ray grading.**
- But, endoscopy is not easier to do on children due to a lack of cooperation.



## Treatment

In the case of grade I and grade II adenoids, the symptoms will be mild to moderate. These can be treated conservatively by:

- Instructing breathing exercises.
- Decongestants.
- Anti-histamines.
- **Intranasal steroids:** They don't affect the growth of the child as their systemic bioavailability is very less.
- **For moderate to severe cases:** It usually requires surgery that is an adenoidectomy.
- It is done to free up the airway space so that the child doesn't go through mal-development.
- Earlier adenoidectomy was done using cold instruments like curettes.
- Now, we use hot instruments/methods like coblation, radiofrequency, and the use of microdebrider under visualisation through endoscopy.

## Indications Of Adenoidectomy

The symptoms should include:

1. **Recurrent sinusitis:** Due to the stasis of secretions which causes infection in the paranasal sinuses which in turn infects the adenoids.
2. **Sleep apnoea :** Cessation of breathing for 10 secs or more during sleep. The prolonged condition can cause cardiac and pulmonary abnormalities.
3. **Dental malocclusion:** After the adenoidectomy, the dental malocclusions are treated using braces and other malocclusion-correcting appliances.

## Contraindications

Adenoidectomy is contraindicated in the following conditions:

1. **Velopharyngeal insufficiency:** Normally the nasopharynx and the oropharynx are separated by the velopharyngeal sphincter which is formed by the palatopharyngeus muscle.
  - In cases where this sphincter is incompetent, it results in the regurgitation of food into the nasopharynx which is known as velopharyngeal insufficiency.
2. Acute adenoiditis.
3. Bleeding disorders.
4. **Cleft palate:** It predisposes to velopharyngeal insufficiency.



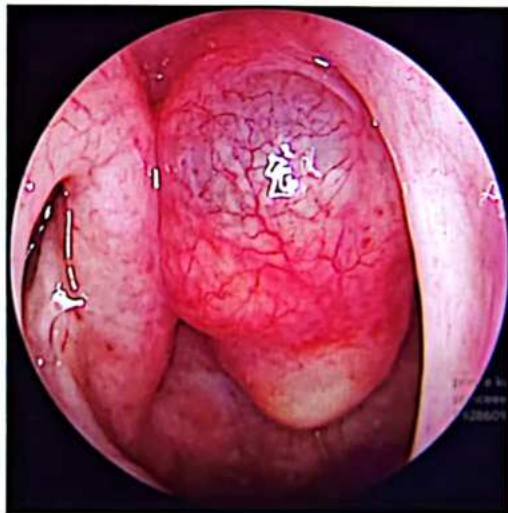
## Complications

They are:

1. Hemorrhage
2. **Hypernasality**: It is the increased resonance in the voice due to a higher open airway space. It is also called **rhinolalia aperta**.
3. Eustachian tube injury.
4. **Grisel's syndrome**: It is a **non-traumatic atlantoaxial subluxation/dislocation**. This is due to inflammation of the ligaments around this joint which increases the laxity and thus causes subluxation.

## Thornwaldt's disease Bursa

00:33:11



- It is an **inconsistent blind sac** present in the midline.
- It represents the persistence of embryonic communication between the roof of the primitive pharynx (**Pharyngeal endoderm**) and the **notochord**.
- Bursa might get closed due to an infection due to a cyst or abscess formation.
- It is a **smooth cystic swelling**.
- This can lead to nasal obstruction or eustachian tube infection. So, irrespective of the size, it needs to be **surgically removed**.
- **Indication of the surgery**: The cyst needs to be removed surgically if it is causing symptoms.
- **Marsupialization and excision** of the cyst is the treatment.

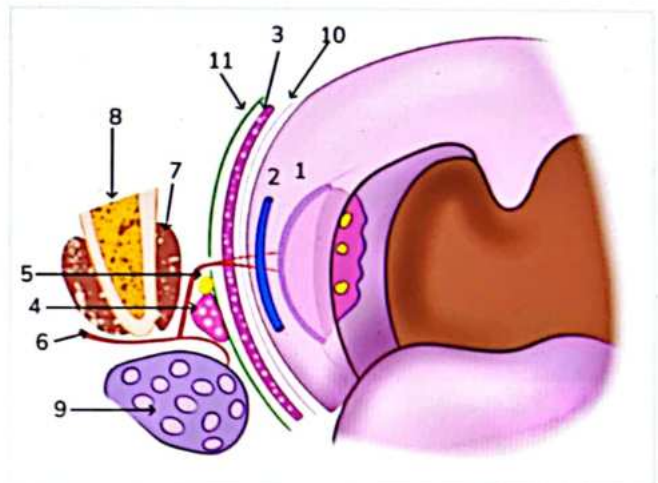
## Tonsils

- **Location of the tonsils**: These are the lymphoid tissues of the oropharynx present between the **anterior and the posterior pillars**.
- **Anatomy**
  - The **anterior pillar** is formed by the **palatoglossus muscle**.

- The **posterior pillar** is formed by the **palatopharyngeus muscle**.
- **Bed of the tonsil**: It is formed by the superior constrictor and styloglossus muscles.

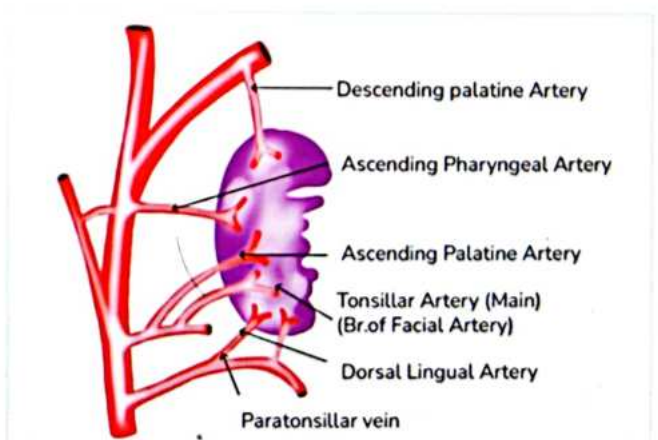
## Bed of the tonsil

Identify the following structures:



1. It is the capsule of the tonsils which doesn't surround the tonsils completely, so the tonsils are **hemicapsulated**.
2. **Peritonsillar vein**: It is the most common bleeder following tonsillectomy.
3. Superior constrictor muscle.
4. Styloglossus.
5. Glossopharyngeal nerve.
6. **Tonsillar artery**: It is a branch of the facial artery.
7. Medial and lateral pterygoid muscles.
8. Mandible.
9. Submandibular salivary gland.
10. **Pharyngobasilar fascia**: It lies on the inner side of the superior constrictor muscle.
11. **Buccopharyngeal fascia**: It lies outside the superior constrictor muscle.

## Blood Supply





- The tonsillar branch of the facial artery is its main artery. (pneumonic **T-DAAD**.)
- Other structures that provide blood supply are:
- **Ascending pharyngeal.**
- **Ascending palatine.**
- **Dorsal lingual branches of the lingual artery.**
- **Descending palatine branch of the maxillary artery.**

### Lymphatic Supply

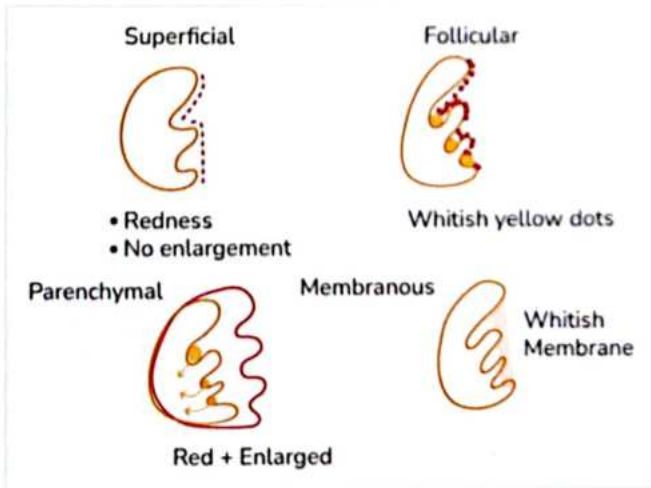
- The lymphatic drainage is done by **upper deep cervical nodes**, particularly the **jugulodigastric node** situated below the angle of the mandible.

### Tonsillitis

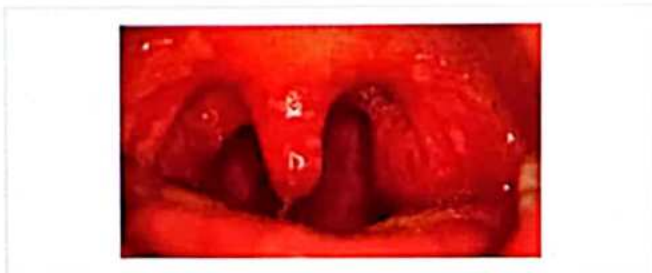00:43:48

- Tonsillitis can be divided into two types:
- **Acute:** If the disease is present for <4 weeks.
- **Chronic:** If the disease is present for >12 weeks.
- **Etiology:** **Group A  $\beta$  Hemolytic streptococcus** is the most common infecting organism.
- This hemolytic streptococcus has a **cross-reactive antigen** for the myocardium, glomerulus, and joints.
- So, it can cause a cross-reactivity to cause **myocarditis, glomerulonephritis, polyarthritis, and rheumatic fever.**
- **Age:** It most commonly affects school-going children but it can happen in adults too.
- It is rare in infants and in adults >50 years of age.

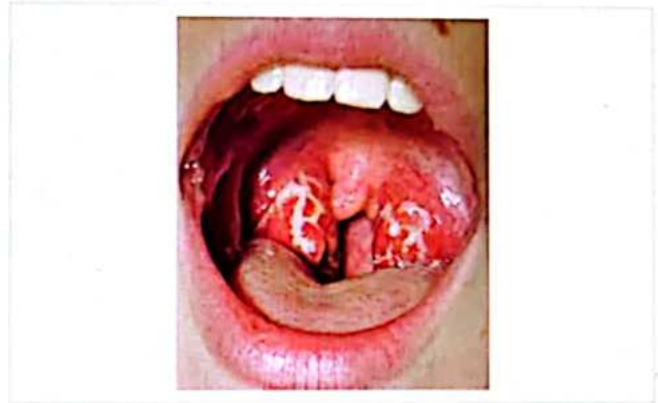### Acute Tonsillitis



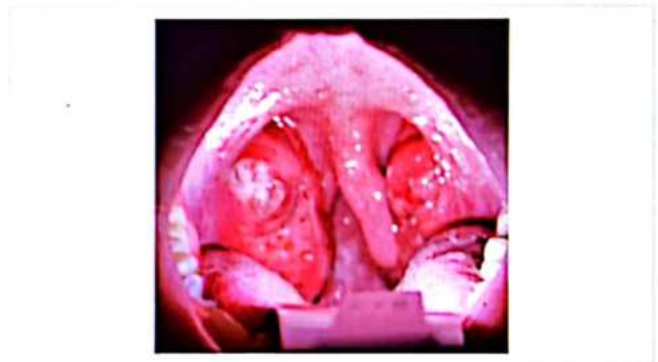- There are 4 types:



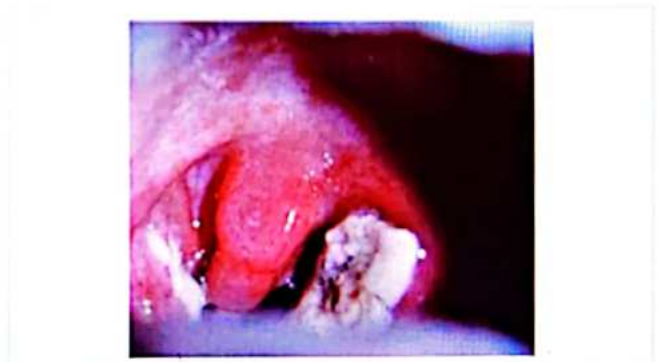1. **Acute superficial tonsillitis:** The infection is limited to the superficial mucosa of the tonsil. Only redness is seen, and no enlargement of the tonsils.



2. **Acute follicular tonsillitis:** The infection reaches the crypts of the tonsils and pus is present in those crypts. Whitish yellow dots are seen on the surface of the tonsils.



3. **Acute parenchymal tonsillitis:** The infection reaches the parenchyma of the tonsils. The tonsils become red and enlarged.



4. **Acute membranous tonsillitis:** A pearly white membrane forms on the tonsil which is the result of all the dead tissues and debris from the tonsils and the bacteria. It is a **true membrane**.
  - It is only present on the tonsils and **doesn't spread to the surrounding structures.**

prince kumar  
princeekum@gmail.com  
9928609733



- If you try to peel the membrane, the underneath structure will not bleed.

**Symptoms**

They are:

1. **Fever:** A very high-grade fever will occur.
2. Sore throat.
3. Difficulty in swallowing their own saliva, so drooling of saliva will occur.
4. Malaise
5. Lymphadenopathy
6. **Earache:** It is a referred otalgia following tonsillitis due to the stimulation of the glossopharyngeal nerve. This glossopharyngeal nerve is a part of the tonsillar bed as well as it gives a plexus, i.e., tympanic plexus into the middle ear.

**Signs**

- There will be throat redness with hyperemia of pillars, soft palate, and uvula.
- Jugulodigastric lymph nodes are enlarged.

**Treatment**

- **Antibiotics:** The drug of choice is penicillin. If the patient is allergic then erythromycin is given.
- **Duration:** The drugs are given for a minimum of 8-10 days to ensure that no subclinical infection persists. This subclinical infection can lead to chronic tonsillitis.
- Bed rest
- Plenty of fluids
- Analgesics

**Complications**

The complications can occur either due to streptococcus or due to the disease itself. They can be:

- Chronic tonsillitis
- Peritonsillar abscess
- Parapharyngeal abscess
- Cervical abscess due to the suppuration of the jugulodigastric lymph nodes.
- Acute otitis media
- Rheumatic fever
- Acute glomerulonephritis
- Subacute bacterial endocarditis

**Differential Diagnosis of Membranes on the Tonsils**

They are -

- Membranous tonsillitis
- Diphtheria
- Vincent's angina
- Infectious mononucleosis
- Agranulocytosis
- Leukemia

- Aphthous ulcers
- Malignancy tonsil
- Traumatic ulcer
- Candidal infection

**Differences between membranous tonsillitis and diphtheria:**

Membranous tonsillitis	Diphtheria
True membrane: Made up of dead tonsillar tissues.	Pseudomembrane: It is made up of exotoxin.
Pearly white in colour.	Dirty white/greyish in colour.
The membrane is limited to the tonsil.	The membrane spreads to the adjacent sites.
On peeling it will not bleed.	On peeling it will bleed.
	Toxic features and bull neck are hallmark criteria of diphtheria.

**Chronic Tonsillitis**

01.08.50

- **Etiology:** A chronic infection in the teeth or sinus can be a predisposing factor.
- Subclinical infection of the tonsil.
- **Clinical features:** They are -
- Recurrent attacks of sore throat.
- Cough with throat irritation.
- A bad taste in the mouth.
- Thick speech with swallowing difficulty.

prince kumar  
princeekum@gmail.com  
733

**Types of Chronic Tonsillitis**

It is of 3 types:

1. **Chronic follicular tonsillitis:** Infection is present in the crypts of the tonsil. It has enlarged tonsils with yellow pus.
2. **Chronic parenchymatous tonsillitis:** Infection is present in the parenchyma of the tonsil. The tonsils are enlarged.
3. **Chronic fibroid tonsillitis:** Due to the antigen-antibody reaction, it leads to fibrosis. So, the tonsil decreases in size and become firm.



**Important Information**

- **Irwin Moore test:** As the tonsil is small in chronic fibroid tonsillitis, it is necessary to differentiate it from a normal tonsil. In this test, pressure is applied to the tonsillar crypts with a probe. The pus will ooze out of the tonsils and this is called Irwin Moore sign.



## Tonsillectomy Indications

The indications can be of two types:

1. **Absolute indications:** In this, tonsillectomy is the only treatment option. These are -
  - a. **Obstructive sleep apnoea:** Huge tonsils cause an oropharyngeal obstruction which is combined with enlarged adenoids, and they together block the airway space.
    - o When the child goes to sleep, he can't breathe through the nose or mouth and the tongue falls back as the muscles lose their tone during sleep.
    - o This condition will predispose the child to **chronic hypoxia** leading to **pulmonary hypertension** which will further cause **right ventricular hypertrophy (RVH)**.
    - o This condition is known as **cor pulmonale: RVH** secondary to pulmonary hypertension.
  - b. **Malignancy of the tonsil is present.**
2. **Relative indications:** In this, alternative treatment options can also be given. These are -
  - o Recurrent tonsillitis
  - o **2nd attack of quinsy:** It is the **peritonsillar abscess - I and D** for the first attack.
  - o Chronic tonsillitis
  - o Tonsillitis causing febrile seizures, cardiac disease, IGA nephropathy: Antibiotic injections can be given.
3. **Non-tonsillar indications:** Excision of the styloid process and UPPP (uvulopalatopharyngoplasty). The tonsil is removed as a part of another surgery.
4. **Styloidectomy:** During the transoral approach to do styloidectomy, tonsils are removed.
5. **Uvulo palato pharyngoplasty (UPPP):** Many adults have sleep apnoea due to laxity of the palate and pharyngeal wall because of obesity.
6. Due to this uvula and the pharyngeal muscles will sag and the oropharyngeal space gets compromised.
7. To enlarge this space, we need to reshape the uvula, pharyngeal wall, and palate. The tonsil is removed to increase the size of the airway space.

## Contraindications of Tonsillectomy

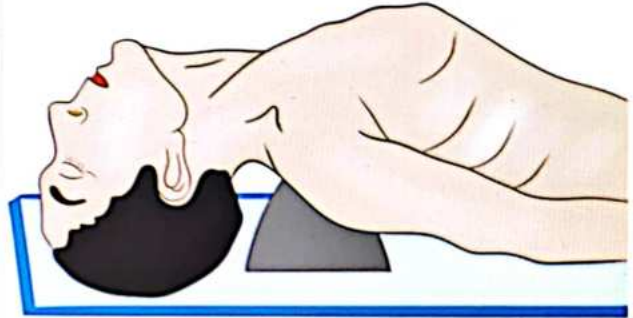
These are of two types:

1. **Absolute:** They are -
  - a. **Polio epidemic:** The child is at a **higher risk of attaining community-related infections** after tonsil removal. Now the child can get **AFP (acute flaccid paralysis)** of the limb.
  - b. **Submucous cleft palate:** To avoid velopharyngeal insufficiency.
2. **Relative:** They are -
  - a. Acute tonsillar infection.
  - b. The age of the child is <3 years.
  - c. Any recent acute respiratory tract infection.

## Tonsillectomy Position



Draffin's bipod stand  
Boyle tongue (depressor) blade  
Davis mouth gag



- **Rose position:** There is an extension at the neck and the atlanto occipital joint. A pillow is kept below the shoulder of the patient and the neck is extended.
- This is done to bring the **oropharynx to a lower level than the larynx** and if there is any bleeding during the surgery, this position will prevent aspiration.
- **Instruments used:** To open the mouth - **Boyle-Davis mouth gag**. This has two parts: The upper part is the **Davis mouth gag** retracting the upper jaw and teeth. The lower **Boyle tongue (depressor) blade** retracts the tongue.
- **Draffin's bipod stand:** It stabilizes the mouth gag.

## Techniques of Tonsillectomy

There are two types of methods:

1. **Cold methods:** It uses the dissection and snare method.
  - o Microdebrider
  - o Harmonic scalpel
  - o Cryosurgery
2. **Hot methods:** They are -
  - o Cautery
  - o LASER
  - o Radiofrequency
  - o Coblation

## Complications of Tonsillectomy

1. **Immediate:** These can be -





- **Hemorrhage - Primary** (occurs during the surgery due to peritonsillar vein or tonsillar artery) and **reactionary** (happens after the surgery up to 24 hours due to slipping of ligature and requires immediate re-exploration).
  - Injuries to tonsillar pillars, uvula, and soft palate.
  - Injury to teeth and TMJ.
  - Aspiration of blood.
  - Facial oedema.
  - Surgical emphysema.
- 2. Delayed:** These can be -
- **Secondary hemorrhage** - It occurs 24 hours after the surgery and up to 14 days. It can happen secondary to infection so initially, antibiotics are given, if bleeding persists then re-exploration is done.
  - Infection.
  - **Lung complications due to aspiration.**
  - Scarring of tonsillar pillars and soft palate.
  - Tonsillar remnants.
  - Lingual tonsil hypertrophy.

prince kumar  
princeeeekum@gmail.com  
9928609333






# CROSS WORD PUZZLES



## Crossword Puzzle 1




**Across**

- 2. \_\_\_\_\_ are hemicapsulated.
- 4. Tonsils are lined by \_\_\_\_\_ epithelium

**Down**

- 1. The high-arch palate, long face, and deviated nasal septum are the features of \_\_\_\_\_.
- 3. Adenoids are the lymphoid tissues of the \_\_\_\_\_.

## Crossword Puzzle 2



**Across**


- 3. \_\_\_\_\_ grading is always superior to X-ray grading for diagnosing adenoid hypertrophy.

- 4. The pharyngeal bursa is the communication between the pharyngeal endoderm and the \_\_\_\_\_.

**Down**

- 1. The anterior pillar is formed by the \_\_\_\_\_ muscle.
- 2. \_\_\_\_\_ looks like a bag of worms.

## Crossword Puzzle 3



**Across**

- 2. In acute membranous tonsillitis, there is a formation of a \_\_\_\_\_ membrane.
- 4. The referred otalgia in tonsillitis is due to the stimulation of \_\_\_\_\_ nerve.

**Down**

- 1. The hemolytic streptococcus has a cross-reactive antigen for the \_\_\_\_\_, glomerulus, and joints.
- 3. \_\_\_\_\_ is given if the child is allergic to penicillin to treat tonsillitis.



35

# JUVENILE NASOPHARYNGEAL ANGIOFIBROMA

- This condition is exclusively seen in juvenile age group.
- Location - Nasopharynx
- Angiofibroma is a tumor filled with lots of blood vessels and fibrous tissue.
- It is a benign tumor.
- It is a rare tumor but most common tumor of the Nasopharynx.
- Exclusively seen in males because it depends upon testosterone.

- Benign and non-encapsulated tumor
- Locally invasive lesion

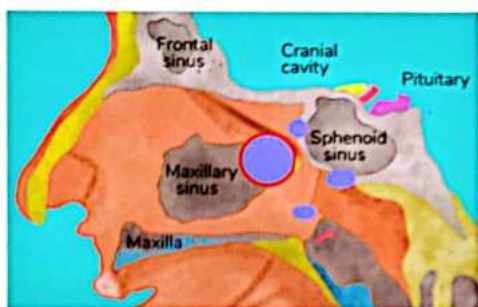### Clinical Feature

00:07:42

- Bleeding: Recurrent unprovoked profuse epistaxis.
- Nasal obstruction and Eustachian tube obstruction
  - Unilateral serous otitis media and conductive hearing loss (Eustachian tube obstruction)
  - Frog face deformity
  - Hyponasal speech
- Cranial spread: Cranial involvement (2<sup>nd</sup>, 3<sup>rd</sup>, 4<sup>th</sup>, 5<sup>th</sup>, 6<sup>th</sup> CN palsy)
  - Extension into sphenoid and cavernous sinus causing nerve palsies

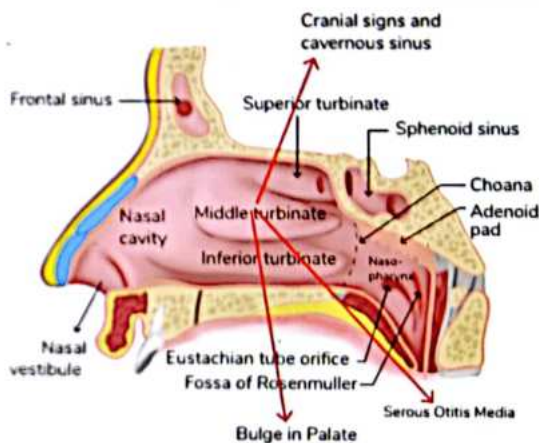
### Site of Origin

00:03:09



- Most common site of origin is from sphenopalatine foramen (near posterior wall of maxillary sinus).
- Sphenopalatine foramen is located 8-10 mm behind the posterior end of middle turbinate.
- Other side of origin:
  - Anterior wall of sphenoid sinus
  - Roof of nasopharynx
  - Lateral wall of nasopharynx

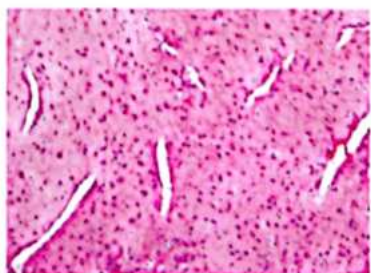
### Extension and Clinical Symptoms



### Pathology

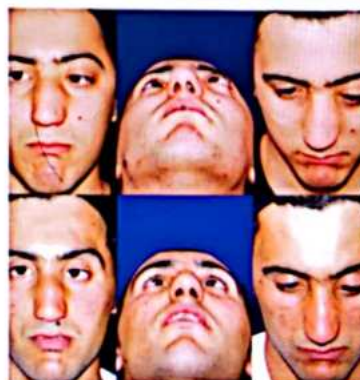00:05:59

- Endothelium lined blood vessel without muscular layer.



1. Nasal obstruction
2. Widening of nasal bridge
3. Swelling of cheek
4. Proptosis
5. Frog face deformity

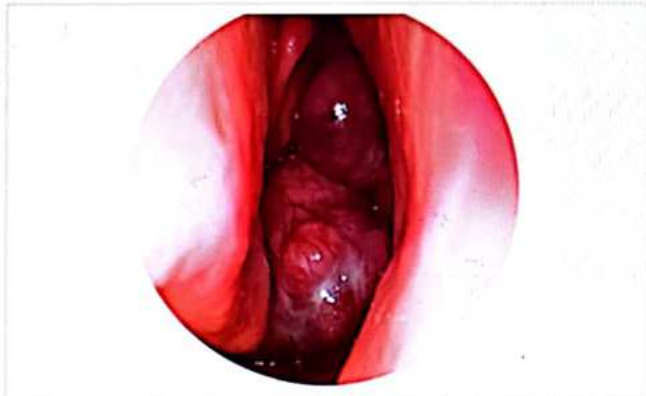
1. No vasoconstriction
2. No effect of adrenaline
3. Recurrent unprovoked profuse epistaxis
4. No biopsy (never do FNAC, probe test or digital palpation)





**Clinical Examination**

00:13:27

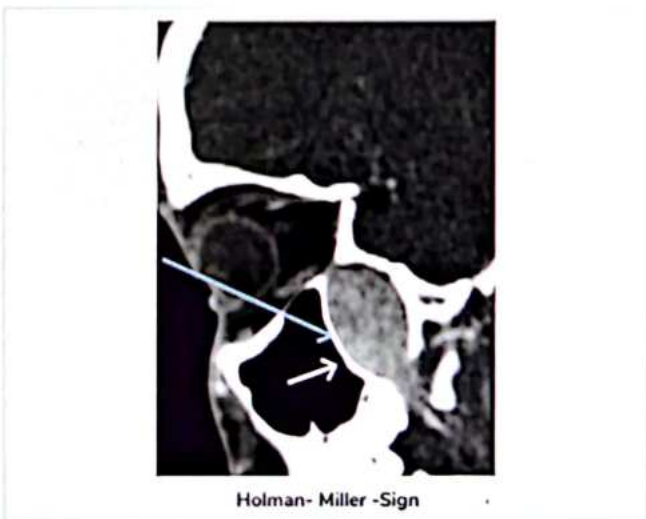

- Anterior rhinoscopy: Globular pink mass in the posterior part of nasal cavity, septum being pushed to the opposite side.
- Posterior nasal examination: Pink to purple globular mass with dilated blood vessels.
- Probe test: Contraindicated
- Digital palpation of tumor is contraindicated.

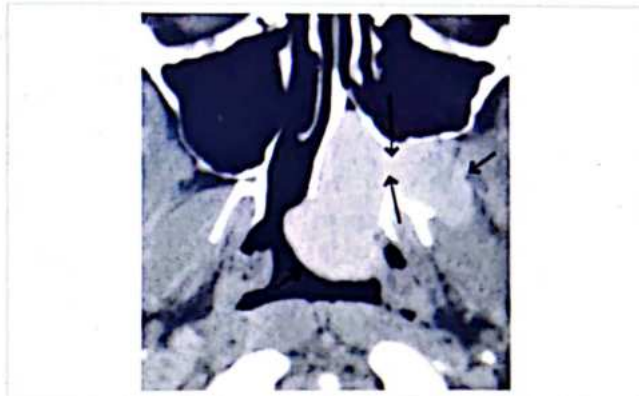
**Evaluation**

00:14:48

- History: Mainstay
- Examination:
  - X-ray neck lateral view
  - X-ray PNS
  - CECT scan – IOC
  - MRI
  - Angiography
  - No biopsy
- Plain X-ray/CT scan: Anterior bowing of posterior wall of maxillary sinus – **Holman Miller sign**



- Hondusa's sign: in distance between maxillary sinus and mandible on CT scan.
- Opacification of sphenoid sinus.

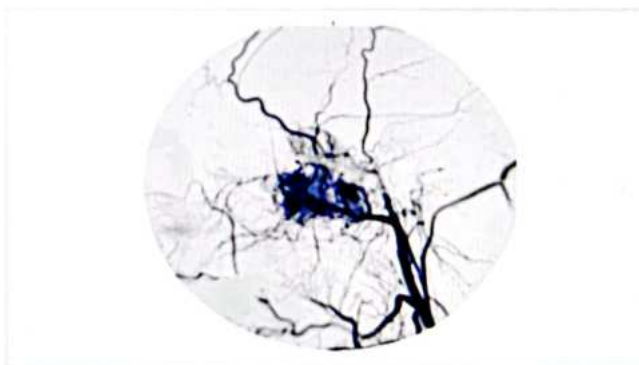
**Role of CT scan**

CT diagnosis is based on two constant features

- Mass in the nose and pterygopalatine fossa.
  - Erosion of bone behind the sphenopalatine foramen at the root of the pterygoid plate.
- When the wedge of pterygoid is eroded so the medial and lateral pterygoid plate look like a separate plate, that is called **Chopstick sign**.

**Role of MRI**

- MRI accesses the relation of the tumor to the critical structures such as the internal carotid artery, cavernous sinus and pituitary gland.
- Recurrent and residual tumors are the best appreciated on the MRI.

**Role of Angiography**

- Angiography provides information on the specific blood supply of the tumor.
- The most common blood vessel supplying the tumor is internal maxillary artery.
- It is also used as treatment with embolization.

**Blood supply**

00:24:13

- The internal maxillary artery is the most common vascular source from which juvenile nasopharyngeal angiofibroma arises.



- Other known vessels include ascending pharyngeal artery

## When is biopsy done

00:25:12

- No biopsy for juvenile nasopharyngeal angiofibroma
- Exception: Only when radiotherapy is contemplated due to inoperability of tumor.

## Staging

00:26:00

Stage	Description
IA	Limited to nose and nasopharyngeal area
IB	Extension into 1 or more sinuses
IIA	Minimal extension into pterygopalatine fossa
IIB	Occupation of the pterygopalatine fossa with or without orbital erosion
IIC	Infratemporal fossa extension with or without cheek or pterygoid plate involvement
IIIA	Erosion of the skull base (middle cranial fossa or pterygoids)
IIIB	Erosion of skull base with intracranial extension with or without cavernous sinus involvement

## Treatment

00:29:10

- Treatment of choice for juvenile nasopharyngeal angiofibroma is surgery with preoperative embolization.
- To decrease vascularity:
  - Embolization 24-48 hours before surgery
  - A course of estrogen therapy (stilbesterol 2.5 mg thrice daily for three weeks)
  - Cryotherapy

## Role of Radiotherapy

00:30:04

- **Indication:**
  - Intracranial involvement
  - Direct blood supply from internal carotid artery
  - Unresectable tumor
  - Multiple recurrences may be good candidate for radiation therapy
- Recurrence rate of 20-30% can expected with radiation therapy alone.
- Newer technique in radio therapy treatment such as intense modulated conformal radiotherapy (IMRT) and gamma knife have shown good results.

## Hormonal Therapy & Chemotherapy

- Diethylstilbestrol with flutamide because it is testosterone dependence
- Chemo for residual/recurrent disease: doxorubicin, vincristine and dacarbazine

## Summary

00:31:29

- Most common benign tumor of nasopharynx
- Locally aggressive
- Extremely vascular
- Origin: sphenopalatine foramen
- Pubertal male
- Recurrent unprovoked profuse epistaxis
- Nasal obstruction and hypo nasal speech
- Conductive hearing loss with serous otitis media
- Proptosis, broad nasal bridge, swelling of cheek, frog face deformity
- Involvement of 2,3,4,5,6 cranial nerve
- CT scan/X-ray: Holman miller sign, antral sign
- Carotid angiography to know the vascularity of tumor.
- Biopsy is contraindicated
- Pre - op embolization and hormone therapy
- Treatment of choice - surgery

## Nasopharyngeal Cancer

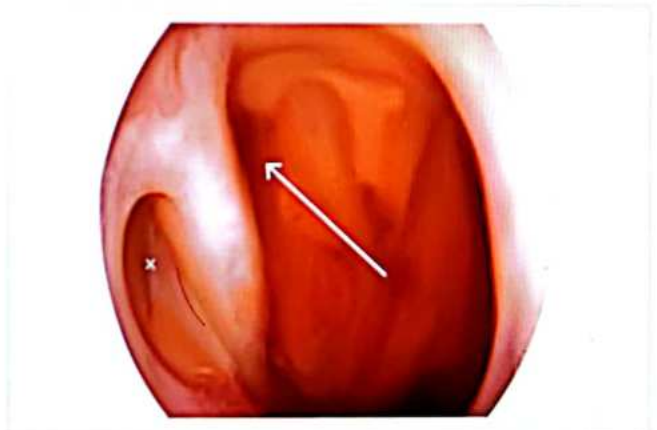
00:35:02

### Etiology

- Chinese have higher genetic susceptibility. In India it is common in northeast regions where people are predominantly of mongoloid origin.
- Epstein Barr virus
- Environment
  - Smoking of tobacco, opium
  - Nitrosamines from dry salted fish
  - Smoke from burning of incense sticks

### Most Common Site of Origin

00:36:16



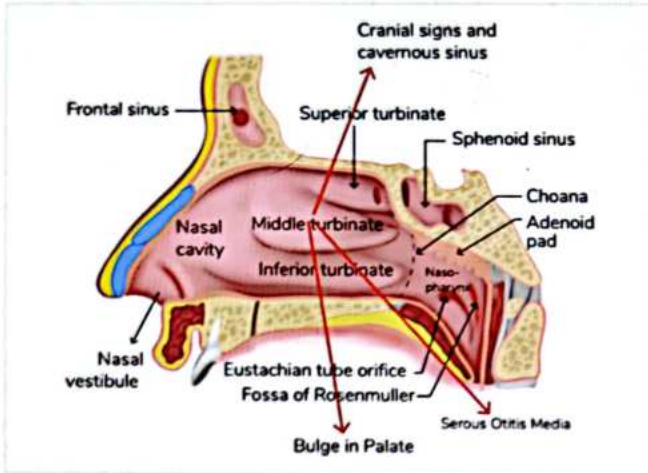
- Fossa of rossenmuller



## Most common histopathological type:

- Squamous cell carcinoma
- Commonest presentation: Cervical lymphadenopathy because of rich lymphatics
- Males are three times more commonly affected

## Extension And Clinical Symptoms



1. Nasal obstruction
2. Otolological
3. Cranial nerve

- Small tumor → lymphatic spread → cervical lymphadenopathy → earliest and commonest manifestation
- Nasal obstruction and eustachian tube obstruction
- Cranial nerve involvement (2,3,4,5,6,9,10,11)
- Horner's syndrome → cervical sympathetic chain
- Unilateral serous otitis media
  - Presence of unilateral serous otitis media in an adult should raise suspicion of nasopharyngeal cancer.
  - Presence of unilateral serous otitis media in a teenage boy should raise suspicion of nasopharyngeal angiofibroma.
- Cranial nerve involvement
  - Nearly all the cranial nerves can be involved
  - Horner's syndrome can also occur due to involvement of sympathetic chain
  - Jugular foramen syndrome due to involvement of 9<sup>th</sup>, 10<sup>th</sup>, 11<sup>th</sup> CN in jugular foramen

## Trotter's Triad

00:47:49

- Conductive deafness due to block of eustachian tube
- Ipsilateral temporo-parietal neuralgia due to 5<sup>th</sup> nerve involvement
- Palatal paralysis (10<sup>th</sup> nerve involvement)

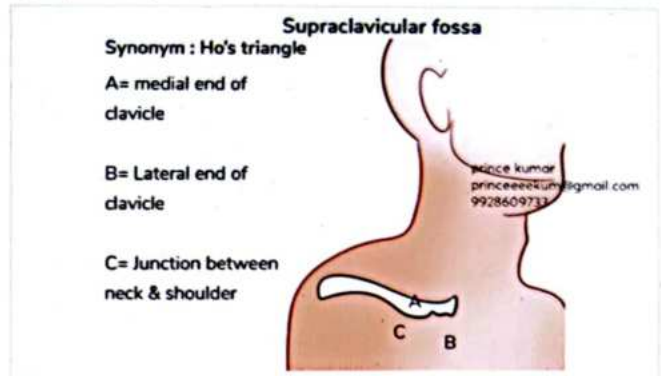
It is diagnostic of nasopharyngeal carcinoma

## Trotter's triad:

- Unilateral conductive hearing loss
- Ipsilateral earache and facial pains
- Ipsilateral immobilization of soft palate

## Lymphatic Spread

00:48:41



Most common lymph node involved: LN between angle of jaw and mastoid and LN along spinal accessory and in posterior triangle of neck in HO's triangle.

## Diagnosis

- Biopsy (IOC)
- Endoscopic evaluation
- Imaging: MRI (Radiological IOC)
- Audiological test
- Screening
  - Viral capsid antigen and early antigen (Ig A antibody elevated). This cannot monitor treatment and cannot be used to screen recurrence
  - EBV DNA can be used for screening and monitoring treatment and to identify recurrence.

## Staging

T-staging	
T <sub>1</sub>	Nose/nasopharynx or oropharynx
T <sub>2</sub>	Parapharyngeal space
T <sub>3</sub>	Skull bone
T <sub>4</sub>	Intra-cranial
N-staging	
N <sub>0</sub>	No lymphatic spread
N <sub>1</sub>	< 6 cm : unilateral supraclavicular fossa
N <sub>2</sub>	< 6 cm : bilateral supraclavicular fossa
N <sub>3</sub>	> 6 cm



Metastasis	
M <sub>0</sub>	No distant metastasis
M <sub>1</sub>	Distant metastasis

**Treatment**

- Stage 1 and 2: Radiotherapy is curative
- Stage 3 and 4: Chemo-radiotherapy
- IMRI (Intensity modulated radiotherapy)

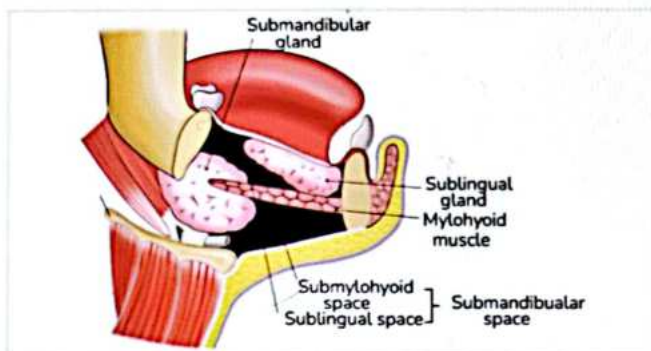
	Juvenile Nasopharyngeal Angiofibroma	Nasopharyngeal Cancer
Nature	Benign	Malignancy
Age	Jvenile	Older
Sex	Males (exclusive)	M & F (M>F)
Origin	Sphenopalatine – foramen	fossa of rosenmuller
Bleeding	Recurrent (unprovoked) profuse	Blood stained
Cranial nerve palsy	2,3,4,5,6	All CN
Lymphoid	-	Yes
Diagnosis	CECT	Biopsy
Treatment	Embolization followed by surgery	RT (IMRT) chemo RT





## Ludwig's Angina

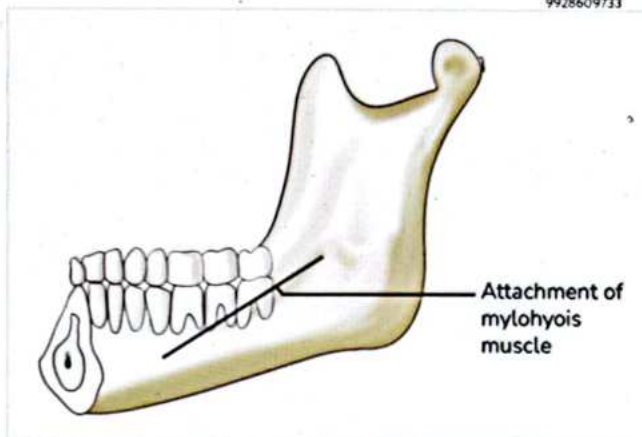
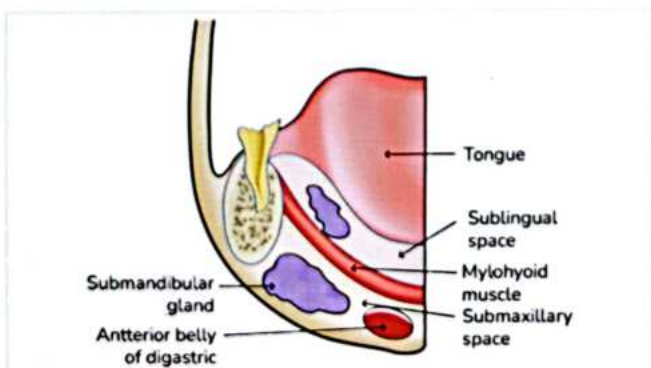
00:00:33



- It is the **cellulitis of the submandibular space**.
- It is **not an abscess**.
- The name Ludwig is given with respect to the German scientist who discovered this condition. Angina is given because the pain is so severe that it resembles the pain of angina pectoris.
- The mylohyoid muscle is also known as the **diaphragm of the floor of the mouth**.
- This mylohyoid muscle divides the submandibular space into two compartments. The upper compartment is called the **sublingual space**, and the lower compartment is called the **sub-mylohyoid space**.
- Sub mylohyoid space and sublingual space together make up the **submandibular space**.

## Etiology

- It is a **mixed /polymicrobial infection** involving both anaerobes and aerobes.
- Alpha-hemolytic Streptococci, Staphylococci, and Bacteroides are the most common infective organisms among these.
- The source of infection is usually from the surrounding structures like:
  - Dental infections.
  - Submandibular sialadenitis.
  - Injuries or infection of the oral mucosa.
  - Fractures of the mandible.



## Symptoms of Ludwig's Angina

- The **swelling in the mouth's floor (below the mandible's angle)** will always be **bilateral**.
- Due to the submandibular space infection, the tongue will be pushed upwards and backward, and there will be airway obstruction.
- Pain or tenderness in the floor of the mouth underneath the tongue.
- The area will be **woody hard on palpation**.
- High-grade fever.
- Difficulty in swallowing.
- Drooling of saliva.
- Problems in speech.
- Neck pain.
- Swelling of the neck.
- Redness on the neck.
- Airway obstruction as the **tongue is pushed upwards and inwards** due to the swelling. (Important feature)

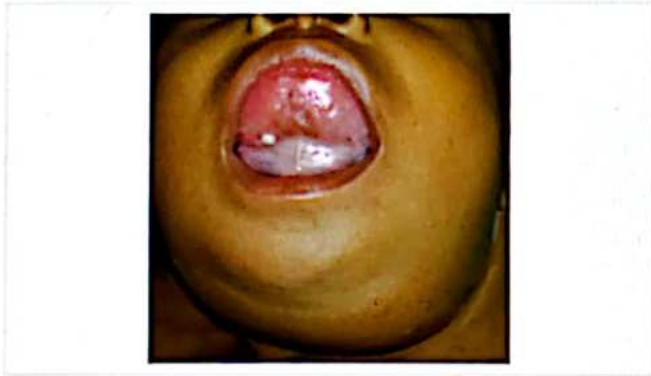## Criteria for Diagnosis

- It is **cellulitis and not an abscess**.
- The spread of the infection is via **connected tissue spaces** and not through lymphatics.
- It is always **bilateral**.
- Sparing of submandibular and sublingual salivary glands. These glands are not involved in the infection.
- There is the presence of **serosanguinous discharge**, and there is **no pus**.

## On Examination

- Swelling in the floor of the mouth i.e., in Submandibular space.
- Tongue is pushed upwards and backwards.



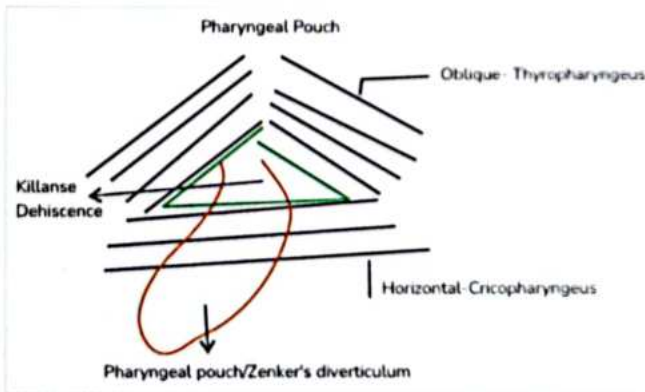


**Management**

- If the patient presents with Ludwig's angina and the diagnosis has been confirmed, **immediate intubation** needs to be done even if the airway is not obstructed.
- In such cases, oral intubation can be difficult, so **nasal fiberoptic intubation** is preferred.
- However, if the patient presents with airway obstruction, a **tracheostomy** is done.
- Systemic antibiotics are given.
- Incision and drainage are done to relieve the swelling. It can be done in two ways -
  - **Intraoral:** If the infection is localized to the sublingual space.
  - **External:** If the infection involves submaxillary space.

**Pharyngeal Pouch**

00:16:48



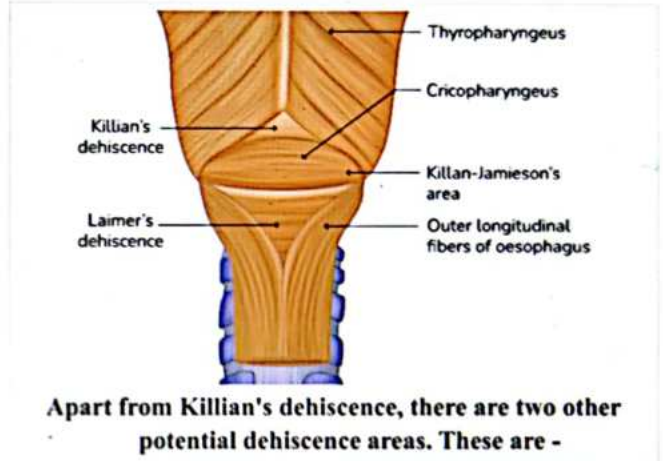
- It is also known as **Zenker's diverticulum**.

**Pathophysiology:** It is as follows -

- The pharynx is covered by three layers - superior, middle, and inferior constrictor.
- The **inferior constrictor muscle** has oblique fibers of the **thyropharyngeus** and horizontal fibers of the **cricopharyngeus**.
- **Between these two types of fibers is an area of dehiscence known as Killian's dehiscence.**

prince kumar  
princeeeekum@gmail.com  
9928609733

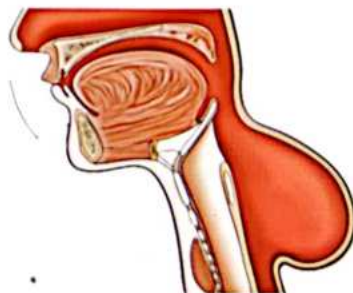
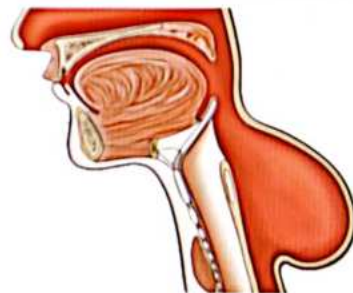
- **Killian's dehiscence** is present posteriorly in the midline.
- If there is an outpouching of mucosa through this dehiscence, it is called the **pharyngeal pouch or Zenker's diverticulum**.
- It is a **pseudo-diverticulum** as only the mucosal layer is herniating.
- It is also known as **pulsion or false diverticulum**.
- Herniation of pouch starts in the midline. It is at first behind the esophagus and then comes to lie on its left.
- **Mouth of the sac is wider than the opening of esophagus and food preferentially enters the sac.**



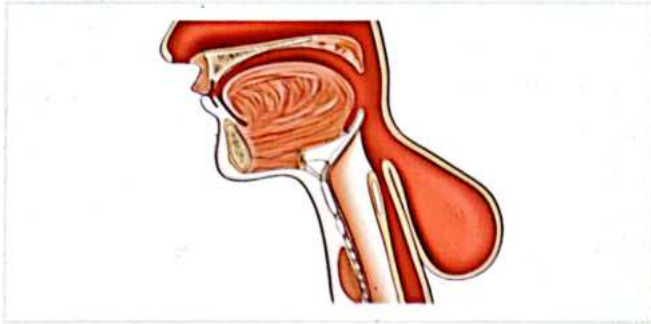Apart from Killian's dehiscence, there are two other potential dehiscence areas. These are -

- **Killian-Jamieson area** is present below Killian's dehiscence, and its position is superolateral to the outer longitudinal fibers of Esophagus.
- **Laimer's dehiscence:** It is also present below Killian's dehiscence, but its position is in the midline below the cricopharyngeus.

**Clinical Features**

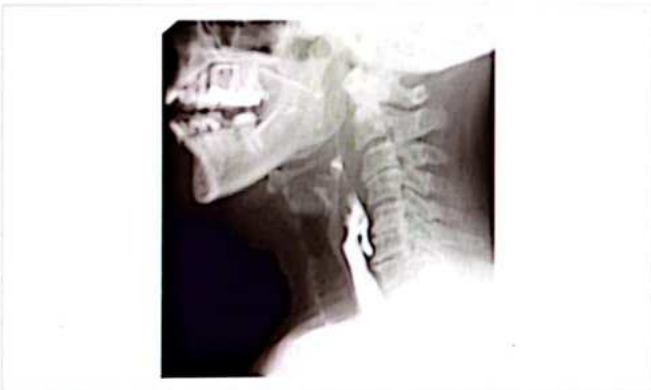





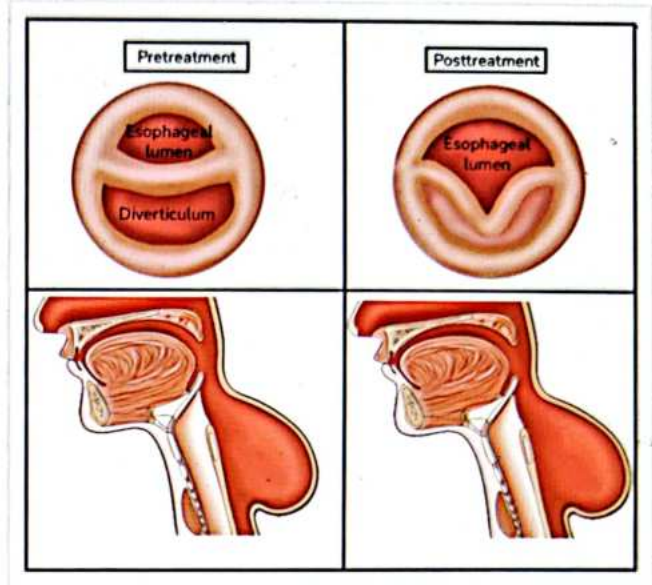
- The mouth of the sac/diverticulum becomes **wider than the esophagus**. Due to this, the food will now enter the diverticulum.
- So, **initially**, there will be **no dysphagia**. However, the food will not be able to reach the stomach. There will be no feeling of fullness/satiety.
- After a few swallows, the pouch will get filled. Any further swallows will produce a **gurgling sound** known as **Boyce's sign**.
- After a few more swallows, the pouch will start compressing on the esophagus, which will cause dysphagia. Thus, **dysphagia is a late symptom**.
- **Sleep cough**: This happens when the patient goes to sleep, and the contents of the sac regurgitate into the larynx causing the patient to cough.

### Diagnosis



- The diagnosis of this condition is made using a **barium swallow**.
  - A meal mixed with barium is given to the patient, which enters the pouch, and then an X-ray is taken.

### Treatment



There can be two types of treatment for this condition:

- **Excision of pouch and cricopharyngeal myotomy** can be done through a cervical approach.
- **Dohlman's procedure**: The partition wall between the esophagus and the pouch is divided by diathermy through an endoscope. This is done in poor-risk debilitated patients.

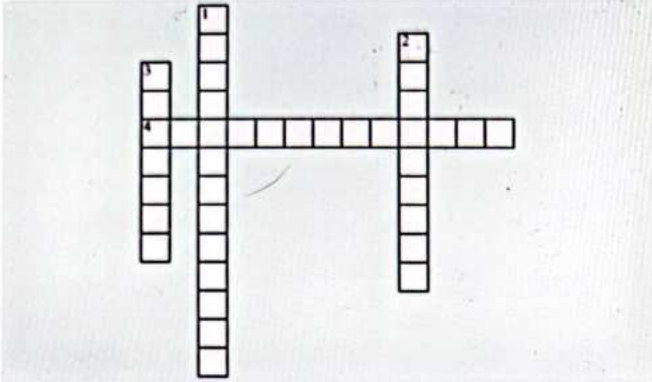




## CROSS WORD PUZZLES

prince.kumar  
princeeeekum@gmail.com  
9928609733

### Crossword Puzzle 1




#### Across

4. Alpha-hemolytic Streptococci, \_\_\_\_\_, and Bacteroides most commonly cause Ludwig's angina.

#### Down

- 1. Sub mylohyoid space and sublingual space together make up the \_\_\_\_\_ space.
- 2. \_\_\_\_\_ muscle is known as the diaphragm of the floor of the mouth.
- 3. Ludwig's angina is not an \_\_\_\_\_.

### Crossword Puzzle 2




#### Across

4. \_\_\_\_\_ discharge is collected in Ludwig's angina.

#### Down

- 1. \_\_\_\_\_ is done in patients presenting with airway obstruction.
- 2. The swelling in the floor of the mouth in Ludwig's angina is always \_\_\_\_\_.
- 3. Pharyngeal pouch is also known as \_\_\_\_\_ diverticulum.

### Crossword Puzzle 3



#### Across

- 2. Pharyngeal pouch is diagnosed with \_\_\_\_\_ swallow.
- 3. The mouth of the diverticulum becomes wider than the \_\_\_\_\_.

#### Down

- 1. Killian's dehiscence is present posteriorly in the \_\_\_\_\_.
- 2. The gurgling sound produced during swallowing is called the \_\_\_\_\_ sign.



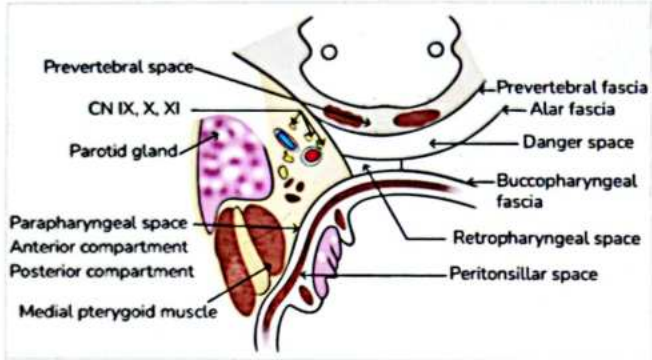
## 37

# ABSCESS IN RELATION TO THE PHARYNX



### Pharyngeal Spaces

00:00:30



- Pharyngeal spaces refer to the four air-filled spaces in the neck and throat region.
- The retropharyngeal, para pharyngeal, peritonsillar, and prevertebral spaces.
- These spaces are critical in respiration, swallowing, and vocalization.

### Spaces to the Pharynx

00:02:30

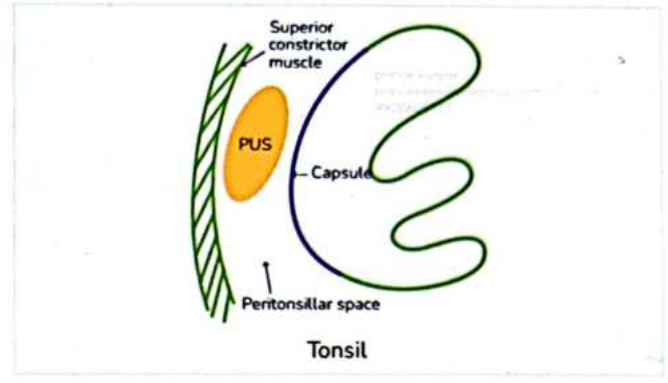
- **Peritonsillar Space:** The space between the tonsil capsule and the superior constrictor muscle is called the peritonsillar space. It is a small area on each side of the throat adjacent to the tonsils. It contains several important structures, including nerves, blood vessels, and lymph nodes. Peritonsillar abscesses can form in this region.
- **Parapharyngeal Space:** On the sides of the pharynx exists the parapharyngeal space. It is a small area in the deep neck adjacent to the pharynx. Parapharyngeal abscess form here.
- **Retro-Pharyngeal Space:** The space behind the pharynx is called the Retro-Pharyngeal space. Retro-Pharyngeal abscess form here.
- **Prevertebral Space:** The space in front of the vertebrae, that is, between the vertebrae and prevertebral fascia, is called the prevertebral space. Prevertebral abscess form here

### Peritonsillar Abscess (Quinsy)

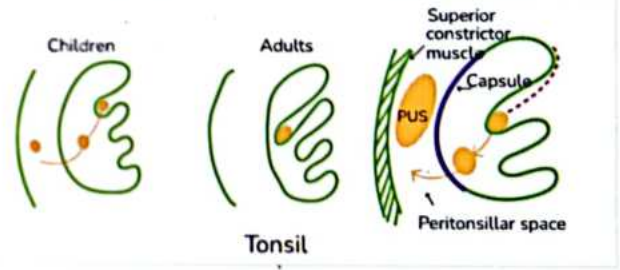
00:05:00

- Collection of pus in the peritonsillar space which lies between the capsule of tonsil and the superior constrictor muscle.
- Causative organism – Streptococcus pyogenes, S.aureus or anaerobic organisms. More often the growth is mixed.

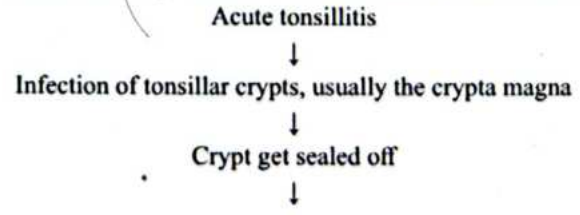
Dr. Prince Kumar  
prince\_kumar@9928609753



- Peritonsillar abscesses is also known as quinsy.
- This abscess occurs in the tissues surrounding the tonsils.
- The space between the tonsil capsule and the superior constrictor muscle is called the peritonsillar space.
- The superior constrictor muscle forms the bed of the tonsil.
- Accumulation of pus in the peritonsillar space is called quinsy. It is a common complication of tonsillitis.

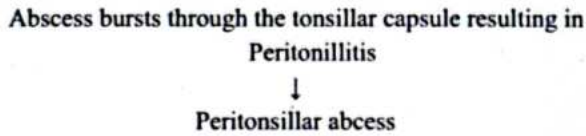


- **Streptococcus pyogenes** is the organism responsible for causing this condition. Initially, there is an infection of the mucosa, and from there, it goes to the crypt of the tonsil, forming an intra-tonsillar abscess. There is then a possibility of the infection going into the parenchyma of the tonsil.
- In the case of a peritonsillar abscess, the crypts are not very deep in children but superficial. The infection of the mucosa going into the crypt of the tonsil and into the parenchyma of the tonsil will not be seen very commonly in children.
- In adults, these crypts are deep. Thus there lies a very high possibility that if the crypt gets infected, the infection will then move into the peritonsillar space. Tonsillitis is common in children, but peritonsillar abscess is common in adults.





**Inratonsillar abscess**



- First, the infection leads to acute tonsillitis. The infection goes into the biggest crypt, which happens to be the **crypta magna**. This causes the crypt to get sealed off. The infection can then possibly go into the tonsillar parenchyma and form an intra-tonsillar abscess. The abscess will burst open into the peritonsillar space and form a peritonsillar abscess. A peritonsillar abscess is most commonly secondary to tonsillar infection.



**Important Information**

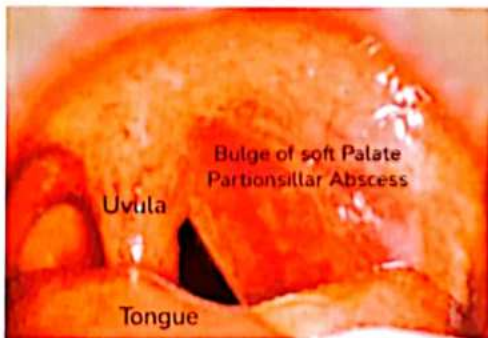**Causative Organism**

- **Streptococcus pyogenes**, **S. Aureus**, or anaerobic organisms are the most common causative organisms in Peritonsillar abscesses.

**Clinical Features**

00:05:47

1. Throat pain usually unilateral
2. Odynophagia
3. Hot potato voice
4. Referred otalgia
5. Trismus



In case of a peritonsillar abscess, the following symptoms will be observed.

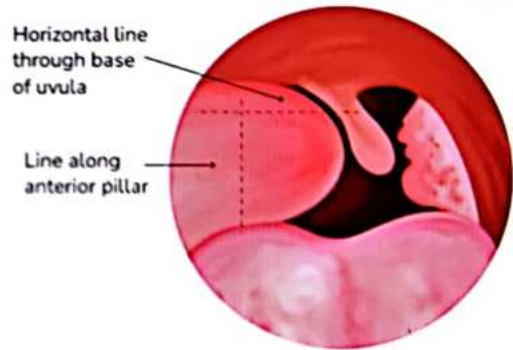
- There is **severe pain in the throat** while swallowing in a peritonsillar abscess.
- High-grade fever will be observed during peritonsillar abscess..
- There is drooling of saliva because the patient cannot swallow his own saliva. **Difficulty in swallowing** is prominent in patients while dealing with quinsy.
- Thick muffled voice, also known as hot potato voice (similar to that of a person trying to talk with a hot potato in his mouth). This is an important MCQ. The question may be

asked that a 15-year-old boy presents with throat pain, fever, muffled voice, hot potato voice, and a unilateral bulge of the tonsil. Peritonsillar abscess is the most common diagnosis in such a case.

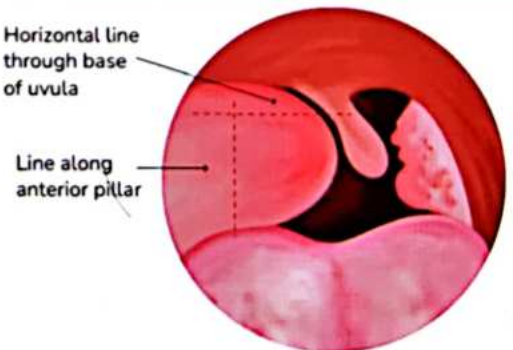
- The patient may also complain of ear pain. Referred otalgia occurs due to the involvement of the glossopharyngeal nerve.
- **Cellulitis can occur. It can involve the pterygoid muscles and cause trismus or difficulty in opening the mouth.**
- The tonsil is also pushed toward the midline.

**Treatment**

- Medical
  - IV antibiotics
  - Analgesics
  - Hydration
  - Oral Hygiene
- Surgical
  - Incision and drainage
  - Tonsillectomy – interval/hot



- IV Antibiotics are given initially for treatment.
- Analgesics also can be given during the treatment of a peritonsillar abscess.
- Hydration is important to reduce pain in quinsy.
- Oral Hygiene is a must to treat Peritonsillar abscesses.
- **Incision and drainage** could be performed in severe cases.
- Four to six weeks of time is given, after which a tonsillectomy is performed. This procedure is called **interval tonsillectomy**. **Incision and drainage**, when carried out with tonsillectomy, are called **hot tonsillectomy**.



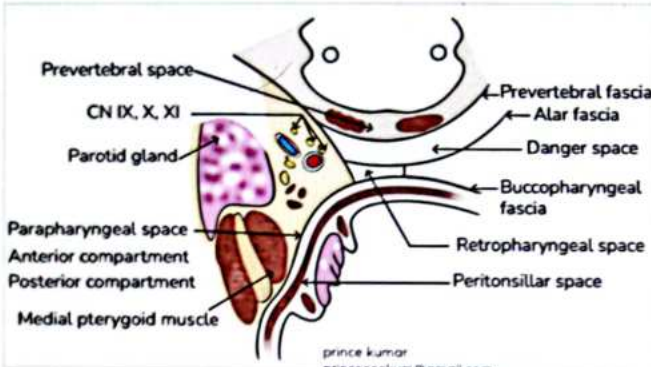


- When performing a tonsillectomy, it is important to know the point from which the abscess is to be drained. An imaginary line is drawn through the base of the uvula, and another imaginary line is drawn going through the anterior pillar. The incision and drainage are to be carried on at this point of intersection of the two lines. Incisions carried out beyond this point cause a risk of carotid injury.


## Parapharyngeal Abscess

00:10:10

- Most common infected space



- The para-pharyngeal space is like an inverted pyramid. Superiorly it begins from the base of the skull and inferiorly extends up to the hyoid bone. Medially the buccopharyngeal fascia is present. Laterally the mandible is present. The medial and lateral pterygoids are attached to the mandible and to the parotid gland. Posteriorly the carotid sheath with its contents is present. Posteriorly the para-pharyngeal space communicates with the retropharyngeal space. This para-pharyngeal space is divided into two compartments, pre-styloid and post-styloid para-pharyngeal space.
- The source of infection in a parapharyngeal abscess is usually the tonsil. The infection can also occur secondary to foreign bodies, such as a fishbone injury. These are the most commonly infected spaces.
- When the infection goes from the tonsil or the pharyngeal wall, it can be either localized to the pre-styloid compartment or to the post-styloid compartment. There can also be an abscess involving both compartments.
- An abscess only in the pre-styloid compartment will push the tonsil to the midline and cause a bulge of the tonsil. But if there is a post-styloid abscess, it will cause a bulge behind the posterior pillar of the tonsil.



## Etiology

- There is a tonsillar infection and dental infection, and the spread of infection is from the retropharyngeal, prevertebral and submandibular space.

## Clinical Features

- In such a case, the tonsils are pushed medially.
- Trismus is present.
- There is a bulge in the neck at the angle of the jaw (an abscess in the space can cause a bulge below the mandible at the angle of the jaw) and torticollis.
- When an MCQ is given with an image-based question on a unilateral bulge of the tonsil, two very important differential diagnoses should be considered. The first diagnosis is that it can either be Quinsy. There will be no neck swelling present in this condition. The second diagnosis can be a pre-styloid para pharyngeal abscess. Neck swelling is present in such a condition.

## Retropharyngeal Abscess

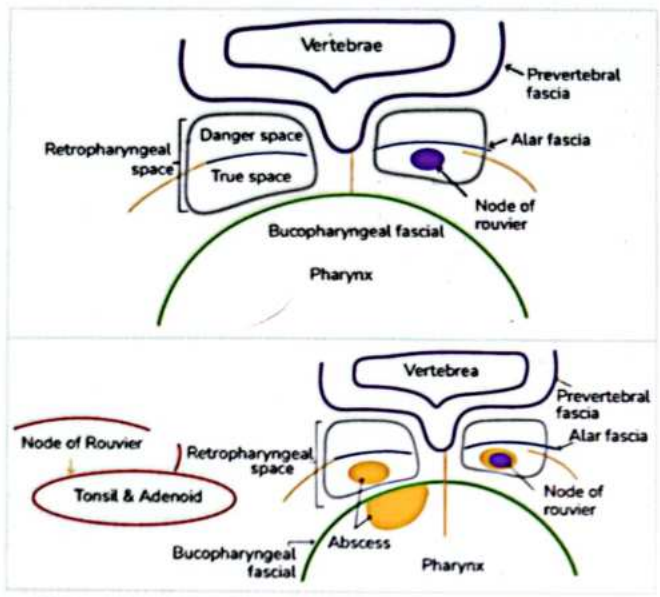
00:15:34

### Acute Retropharyngeal Abscess

- Acute Suppurative lymphadenitis of lymph nodes of rouvier (retropharyngeal lymph nodes)
- More common in children due to tonsillitis and adenoiditis
- In adults in secondary to posterior pharyngeal wall injury (e.g. fish bone)
- Retropharyngeal space is the space present between the outermost layer of the pharynx, which happens to be the buccopharyngeal fascia. In front of the vertebra, there is the pre-vertebral fascia. The space in between is the retropharyngeal space. The two spaces on either side of the midline do not communicate.
- This space comes from the base of the skull, and inferiorly it extends to the level of T4. The retropharyngeal space is divided into two compartments by the alar fascia. The anterior compartment is the true retropharyngeal space. The true retropharyngeal space consists of a lymph node called the nodes of Rouviere. The posterior compartment is the danger space. This abscess occurs in the tissues behind the pharynx, in the cervical spine area.
- Acute suppurative lymphadenitis of lymph nodes of rouviere (retropharyngeal lymph nodes)
- More common in children duet o tonsillitis and adenoiditis
- In adults its secondary to posterior pharyngeal wall injury (e.g. fish bone)



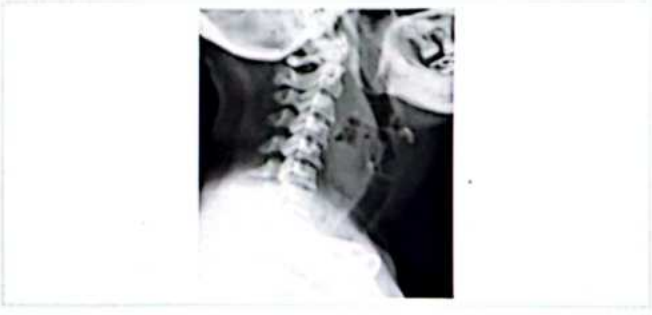prince kumar  
princeekum@gmail.com  
9928609733



- This node drains the nasopharynx and the oropharynx. In children, when there is an infection in the tonsil and adenoiditis, it can go into these nodes, causing the nodes to suppurate. This will lead to an abscess. Therefore acute suppurative lymphadenitis of the nodes of Rouviere occurs due to the **suppuration of the lymph nodes**.
- It is usually an acute condition. It is seen more commonly in children due to tonsillitis and adenoiditis.
- When there is an abscess in the true retropharyngeal space, it will present as a swelling or a bulge of the midline.

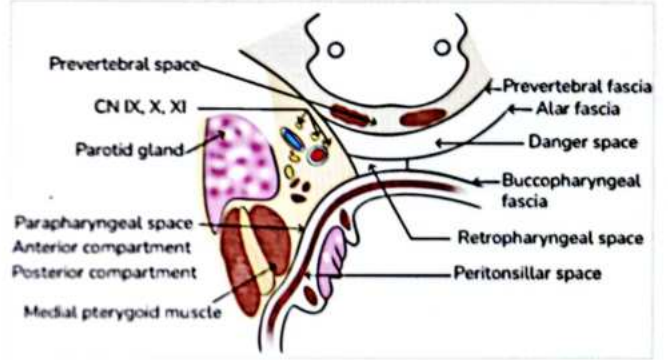
**Clinical Features**

- On infection of tonsillitis and adenoiditis, the nodes of Rouviere will suppurate leading to a true compartment abscess. This leads to pharyngeal wall bulge and causes the following symptoms:
  - Fever
  - Dysphagia
  - Stridor
  - Torticollis



- An incision and drainage can be carried out, but an X-ray is also done to see if there is actually an abscess. A typical finding in such a case is the pre-vertebral soft tissue shadow.

- Normally this shadow should not be more than the size of the vertebra. If it is more than two times the size of the vertebra, there is a retropharyngeal abscess.
- The second thing that can be noticed is the **straightening of the cervical spine**. Normally the cervical spine has a curvature.
  - The presence of **air bubbles** will also be noticed.
  - On X-Ray, it is usually difficult to differentiate it from a pre-vertebral abscess. Therefore an additional CT and MRI are done to confirm the findings. When there is a clinical scenario of a child following tonsillitis and adenoiditis, with a bulge on one side of the midline, an acute retropharyngeal abscess should be considered.



- Abscess can also occur in the **danger space**. It is the space between the alar fascia and the pre-vertebral fascia. The source of infection in such a case will be from the spine. TB is a chronic disease. Danger space abscess will usually be a chronic retropharyngeal abscess. An acute retropharyngeal abscess will be seen in the true retropharyngeal space.
- An acute retropharyngeal abscess happens due to suppurative lymph nodes. A dangerous space abscess is a chronic abscess that happens due to tuberculosis of the spine.

**On Examination**

- It is present as a unilateral paramedian bulge on the posterior pharyngeal wall as opposed to a midline diffuse bulge on the prevertebral abscess.

**Treatment**

- Incision and drainage are important forms of treatment.
- Systemic antibiotics can also be considered.
- A tracheostomy will be performed if needed.
- A chronic retropharyngeal abscess is more common in adults.
- The most common cause for this condition is Tuberculosis secondary to Pot's spine/Caries spine. Treatment consists of ATT f/b Incision and drainage



## Prevertebral Abscess

00:22:48

- Prevertebral space is the space between the vertebral body and the pre-vertebral fascia. This is a single space and a midline space. There is a midline bulge of the pharynx in case of the prevertebral abscess. A pre-vertebral abscess is more common in adults.
- The most common cause for this condition includes tuberculosis infection secondary to Pott's spine/Caries' spine.
- Since it is secondary to tuberculosis, ATT can be given as a mainstay of treatment.
- Incision and drainage can also be carried out if required.



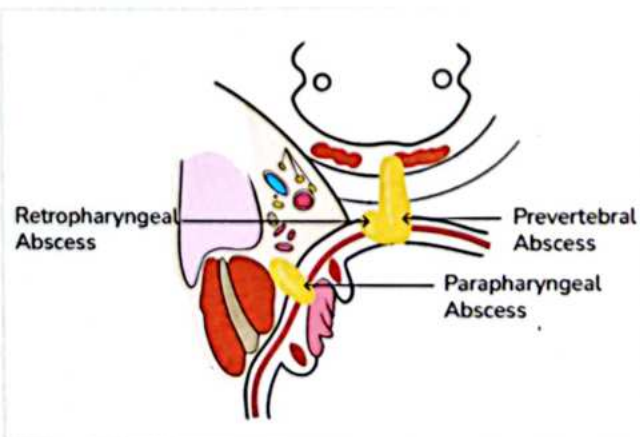
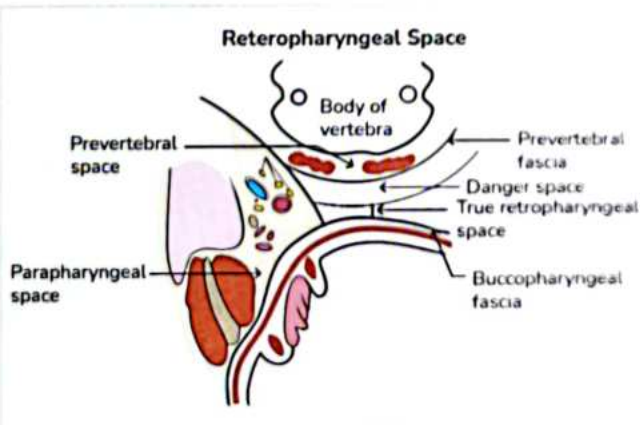
### Important Information

Common symptoms of abscesses are

- One of the most common symptoms is fever; the temperature can be too high, or complete body aches can be a major symptom.
- **Dysphagia** - Difficulty swallowing while eating or engulfing the saliva in a para pharyngeal abscess.
- **Stridor** - An abnormal, high-pitched, musical breathing sound made by the voice box in this abscess.

## Difference Between Retropharyngeal Abscess and Prevertebral Abscess

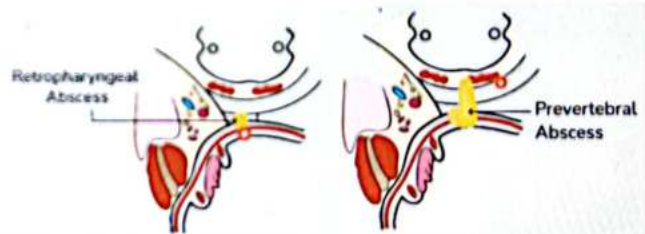
00:25:08



## Retropharyngeal Abscess

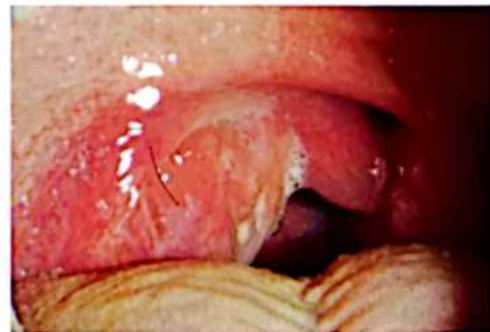## Prevertebral Abscess

- |   |   |
|---|---|
| <ul style="list-style-type: none"> <li>• Retropharyngeal space is a paired space. These abscesses can occur in the side of the midline due to that reason.</li> <li>• A retropharyngeal abscess (RPA) can begin superiorly from the base of the skull. Inferiorly, if it is a true compartment abscess, it will end at the level of T4. If it is a danger space abscess, it will end at the level of the diaphragm.</li> <li>• Retropharyngeal abscess appears due to the the suppuration of lymph nodes. Usually, it is an acute disease. Danger space abscess occurs due to the tuberculosis of the spine and is usually a chronic disease.</li> <li>• Retropharyngeal abscess presents as a bulge on the side of the midline.</li> </ul> | <ul style="list-style-type: none"> <li>• Prevertebral abscess will always be a single space.</li> <li>• Prevertebral abscess also begins at the base of the skull. Inferiorly it extends to the coccyx.</li> <li>• Prevertebral abscess is usually due to tuberculosis.</li> <li>• Prevertebral abscess presents as a midline bulge.</li> </ul> |
|---|---|



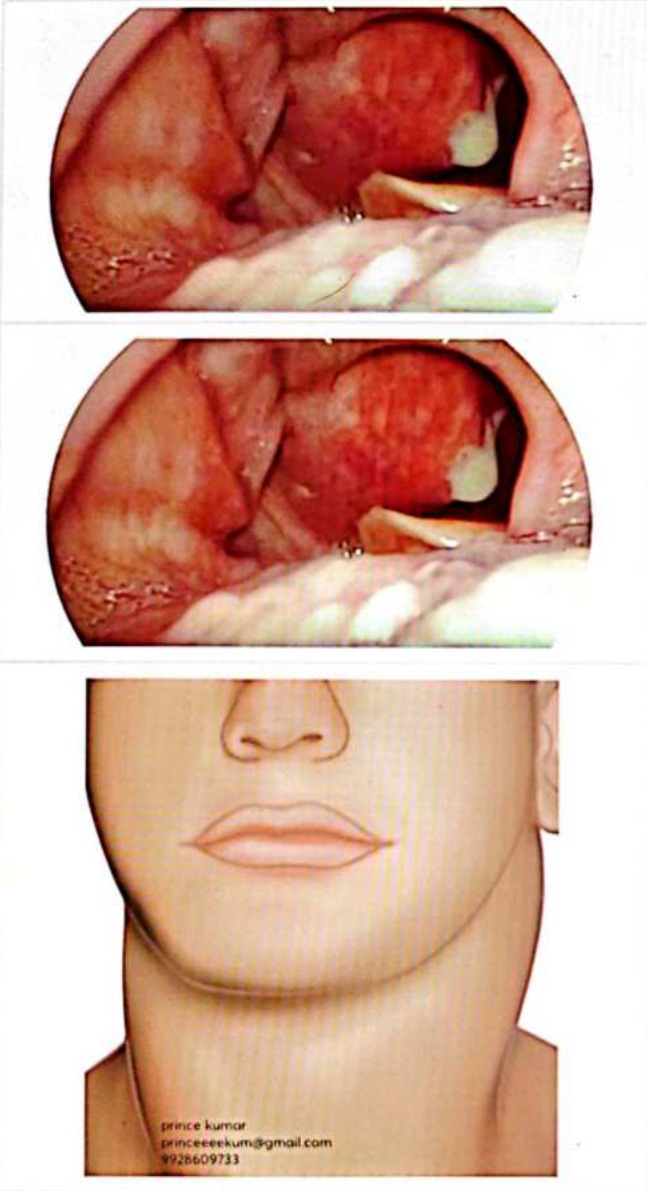
## Spot the Diagnosis

00:27:00

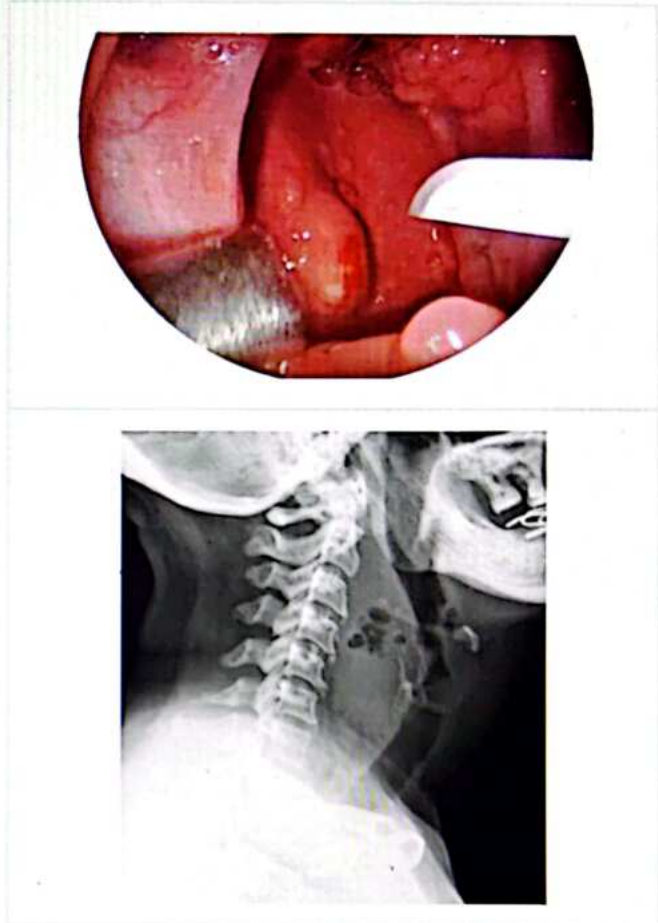




- In the slide above, a unilateral bulged of the tonsil can be seen. The uvula is shifted to the opposite side. This can either be Quinsy or pre-styloid PPA. In Quinsy, there will be no neck swelling. But in pre-styloid PPA, there is next swelling.



- In the slide above, a pus point can be seen. The anterior pillar of the tonsil can also be seen. The posterior pillar, uvula, and tonsil can be seen. There is a bulge behind the posterior pillar, which is the post-styloid parapharyngeal abscess. Neck swelling is also a feature of PPA, whether a pre-styloid or post-styloid.



- The posterior pharyngeal wall can be seen in the slide above. There is swelling on one side of the midline, and there is a retropharyngeal abscess, with the opposite side being normal. The X-ray confirms that it is a retropharyngeal abscess.

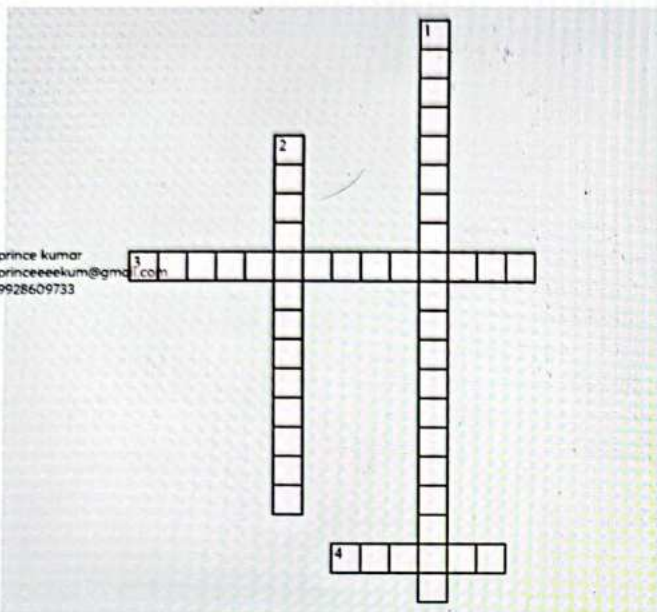




# CROSS WORD PUZZLES



## Crossword Puzzle 1



prince kumar  
princeeeekum@gmail.com  
9928609733


### Across

- 3. Clinical Features of Peritonsillar Abscess is \_\_\_\_\_.
- 1. Causative Organisms in Peritonsillar Abscess is \_\_\_\_\_.

### Down

- 4. The name of the Peritonsillar Abscess is \_\_\_\_\_.
- 2. Treatment for Peritonsillar Abscess is \_\_\_\_\_.

## Crossword Puzzle 2



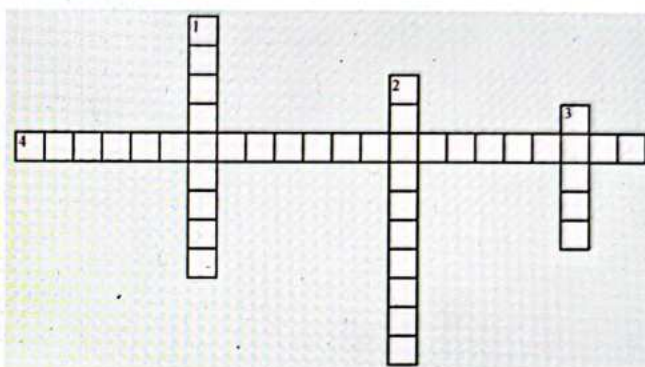
### Across

- 3. The space located behind the pharynx is \_\_\_\_\_.
- 4. Small space located on each side of the pharynx is \_\_\_\_\_.

### Down

- 1. Space is a small area located deep inside the neck is \_\_\_\_\_.
- 2. Space in front of vertebrae is \_\_\_\_\_.

## Crossword Puzzle 3



### Across

- 4. Occurs in tissues behind the pharynx is \_\_\_\_\_.

### Down

- 1. The clinical feature of parapharyngeal abscess is \_\_\_\_\_.
- 2. Treatment for a peritonsillar abscess is \_\_\_\_\_.
- 3. A common symptom of retropharyngeal abscess is \_\_\_\_\_.





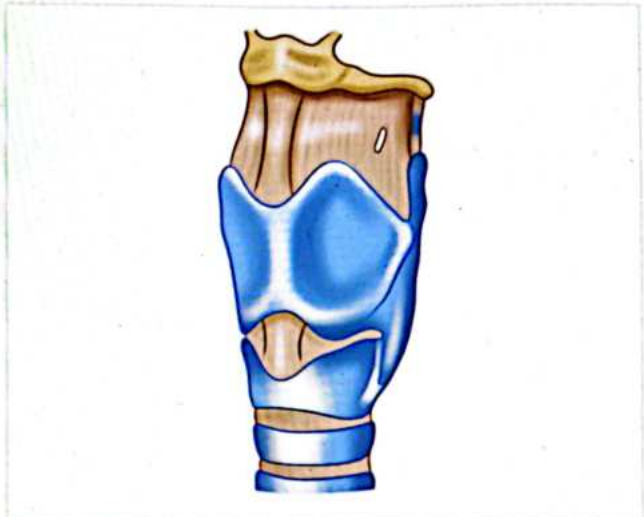**38**

**ANATOMY OF LARYNX**

**Cartilage**

00:01:00

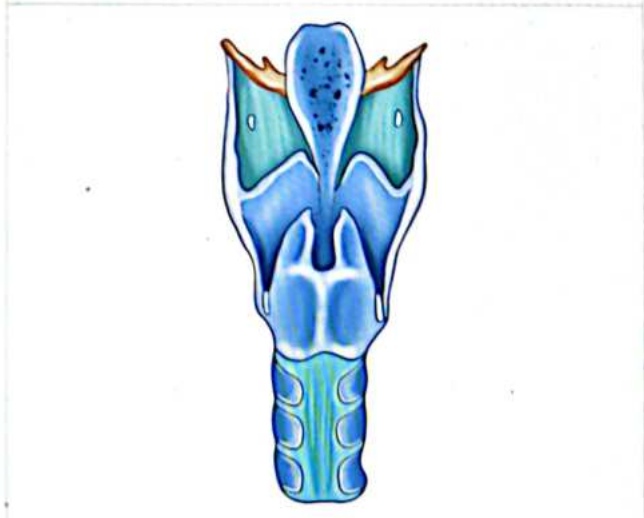- Paired
  - Cuneiform
  - Corniculate
  - Arytenoid
- Unpaired
  - Thyroid
  - Cricoid
  - Epiglottis
- Hyaline: Calcify with age
  - Thyroid
  - Cricoid
  - Arytenoid
- Elastic
  - Epiglottis
  - Corniculate
  - Cuneiform



**Location**

00:06:01

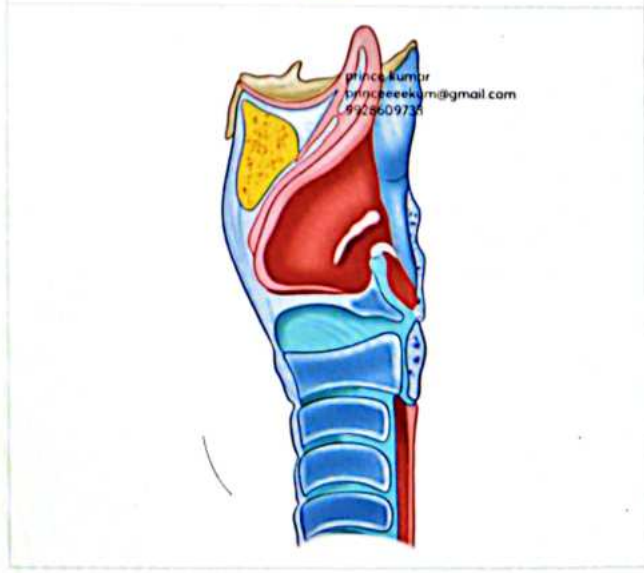
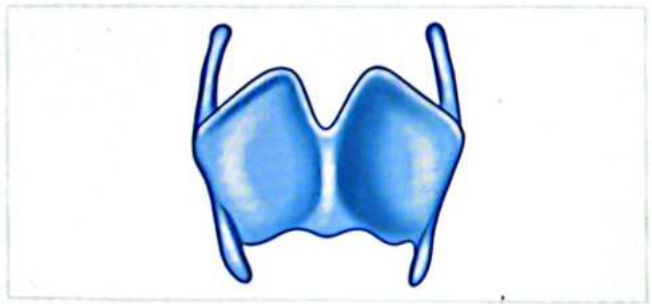- Lies opposite 3<sup>rd</sup> to 6<sup>th</sup> cervical vertebra.
- Posterior: Hypopharynx/ laryngopharynx
- Anteriorly in the neck
- Continues inferiorly as trachea



**Thyroid cartilage**

00:07:50

- Unpaired/ Hyaline
- Ala (2 ALA of single cartilage)
  - 90 in males
  - 120 in females
- Oblique line of thyroid cartilage gives attachment to
  - Sternum to thyroid: Sternothyroid muscle
  - Thyroid to hyoid: Thyrohyoid
  - Thyroid to pharynx: Thyropharyngus
- Thyroid cartilage gives attachment to
  - Epiglottis: Above
  - Vocal cords: Below



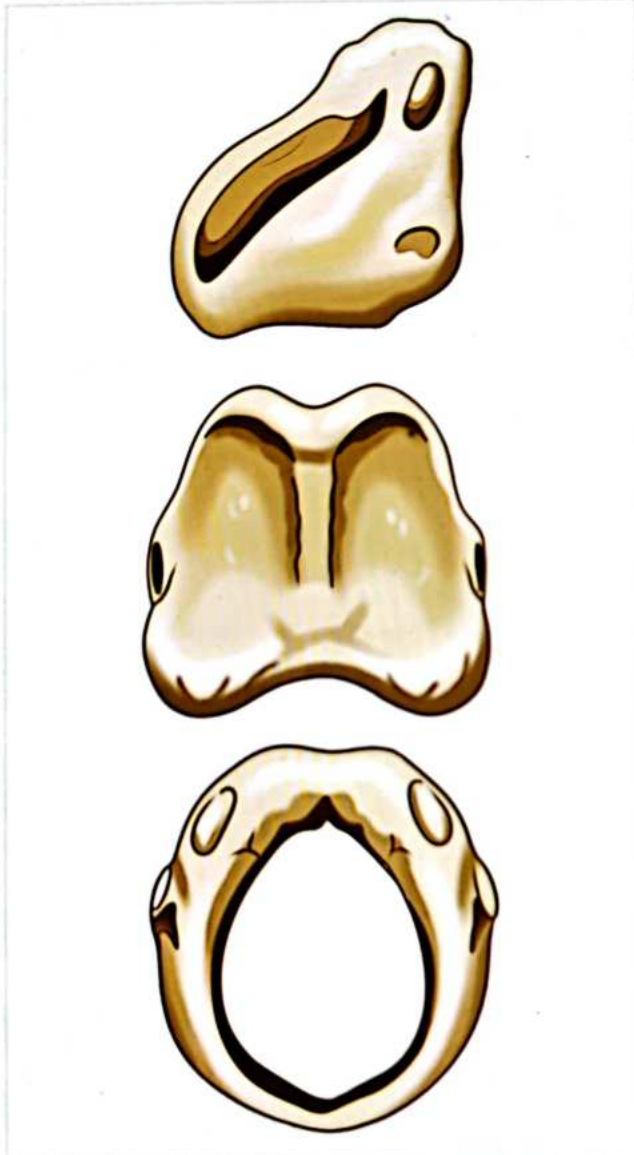




## Cricoid Cartilage

00:13:22

- The only complete cartilaginous ring in the entire air
- Anteriorly: Arch is narrow
- Posteriorly: Lamina is wide
- Facets
  - Superior: Arytenoid
  - Inferior: Inferior horn of thyroid cartilage

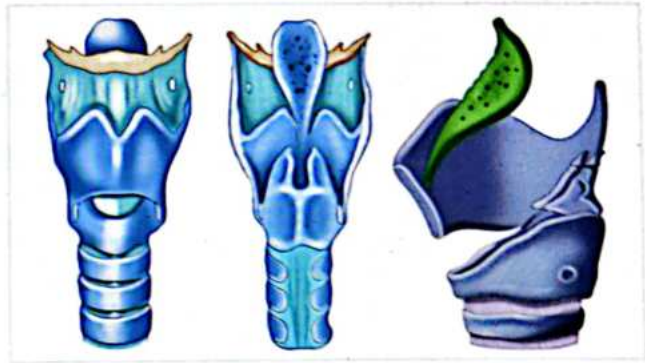

## Epiglottis

00:16:44

- Attachment
  - Base: Inner surface of thyroid cartilage
- Parts: Based on the imaginary line passing through the hyoid bone
  - Suprahyoid epiglottis
  - Infrahyoid epiglottis
- Surface

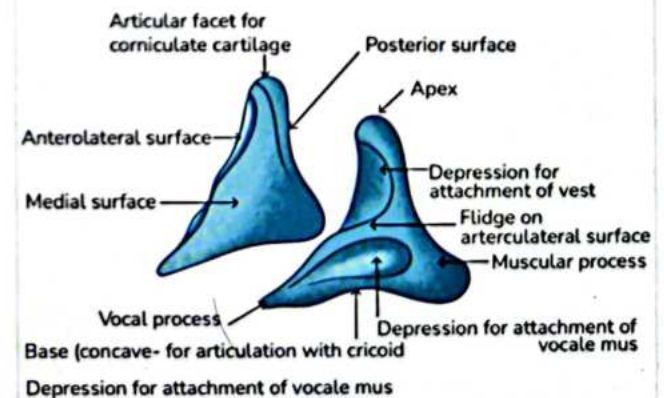
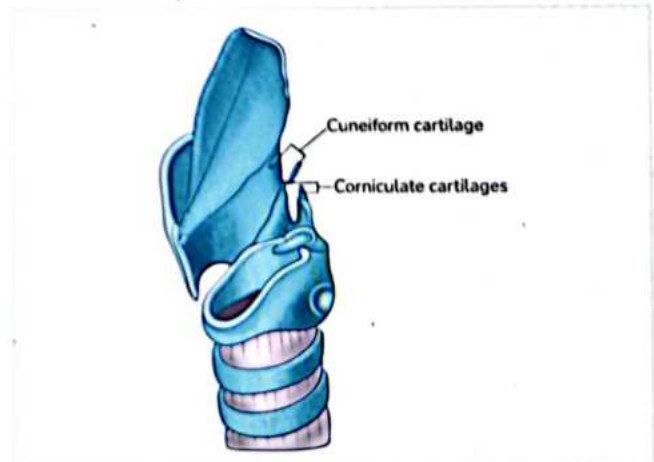
- Lingual: Faces base of tongue
- Laryngeal: Faces the larynx



## Arytenoid cartilage

00:19:23

- Paired/ Hyaline
- Pyramid cartilage
- Parts and attachments
  - Apex: Corniculate, cuneiform
  - Base: Rests on the superior facet of cricoid.
  - Vocal process: vocal cords
  - Muscular process

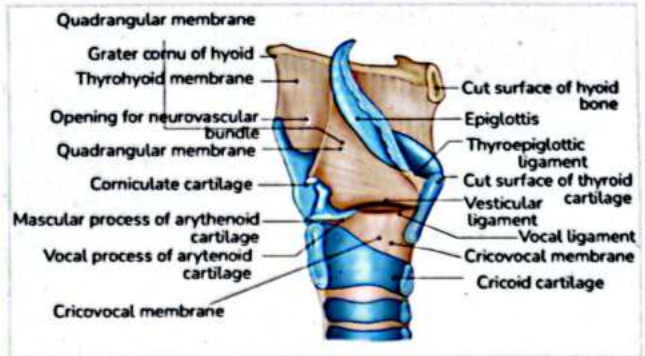
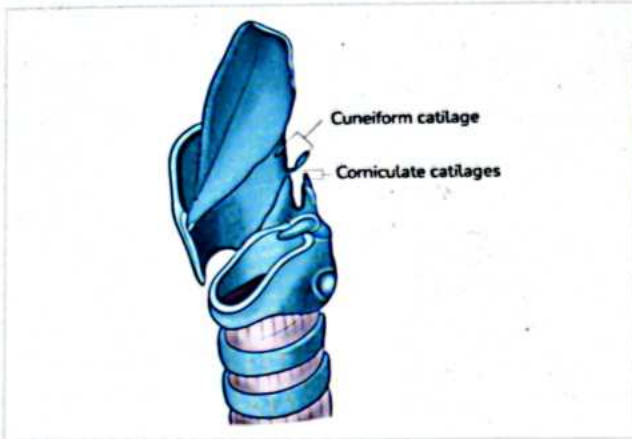




## Corniculate and Cuneiform cartilage

00:22:05

- Corniculate: Cartilage of Santorini
- Cuneiform: Cartilage of wrisberg



## Important Information

- Lower fibres of Quadrangular membrane condense to form the false cords or vestibular ligament
- Upper fibres of Cricovocal membrane forms true cords or vocal ligament.

## Subdivision of larynx

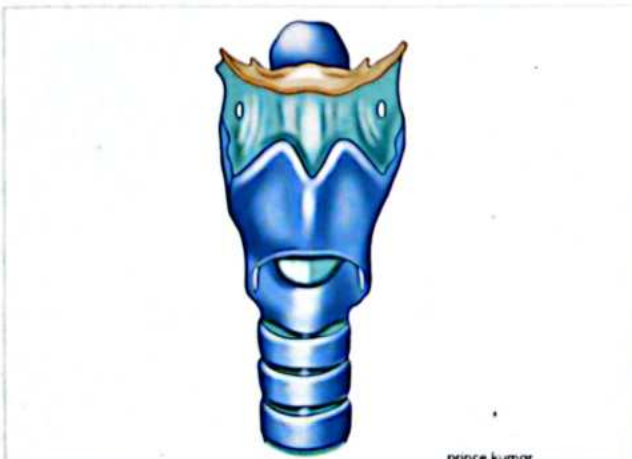00:24:12

- Supraglottis: Above vocal cord
  - Epiglottis
  - Aryepiglottic fold
  - False cord
- Glottis: Lies at the level of vocal cord and 1 cm below
- Subglottis: 1 cm below vocal cord to lower border of the cricoid.

## Membranes

00:28:52

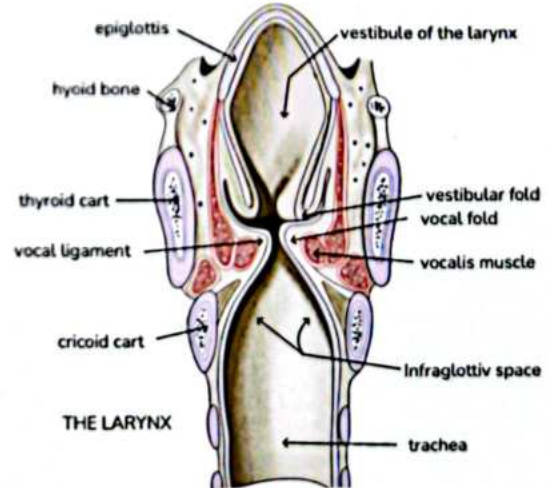
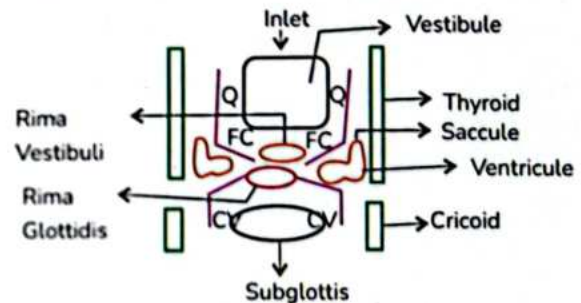
- Extrinsic: Connecting laryngeal cartilage to extra laryngeal cartilage.
  - Thyrohyoid
  - Cricotracheal
- Intrinsic: Connecting laryngeal cartilage to another laryngeal cartilage
  - Cricothyroid membrane
  - Quadrangular membrane
  - Cricovocal/ Conus elasticus membrane



prince kumar  
princeekum@gmail.com  
9928609733

## Laryngeal Cavity

00:36:28



- Rima Vestibuli: Space between 2 false cords
- Rima glottitis: Space between between 2 true cords
- Ventricle: Space between false cords above and true cords below
  - Elongation from ventricle: Sacculle





- Narrowest Portion
  - Glottis: Adults
  - Subglottis: Children

**Development**

00:41:46

- Supraglottis: 4<sup>th</sup> arch
- Glottis and subglottis: 6<sup>th</sup> arch

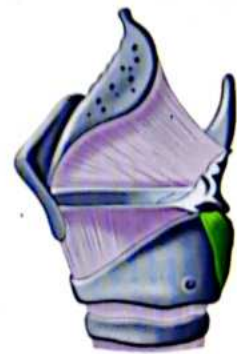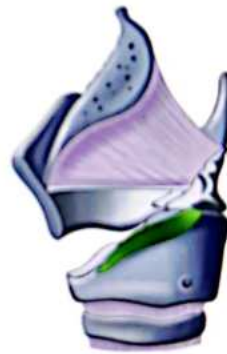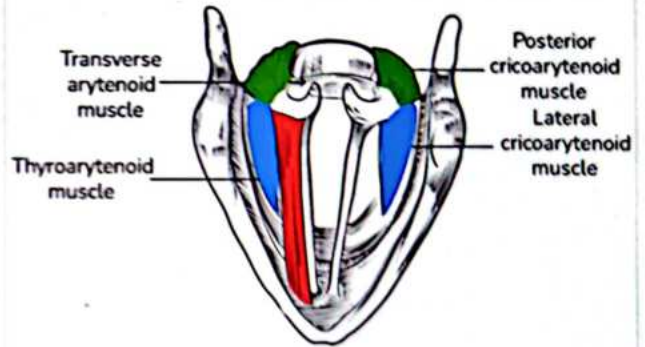
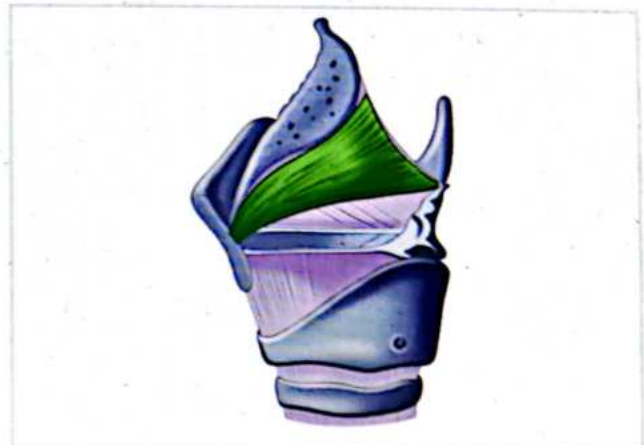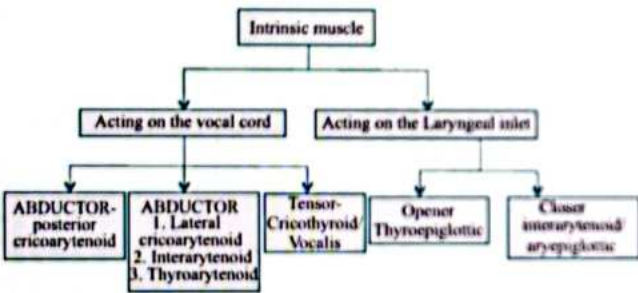
**Epithelium**

- Lined by pseudostratified ciliated columnar epithelium
- Except 3 sites: Stratified squamous epithelium
  - Lingual surface of epiglottis
  - Aryepiglottic fold
  - Superior surface of vocal cords

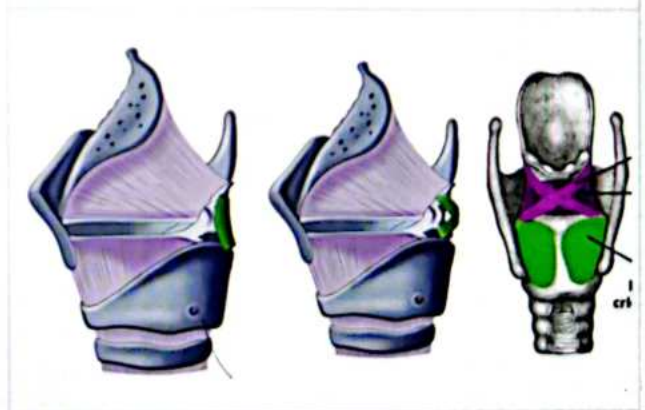
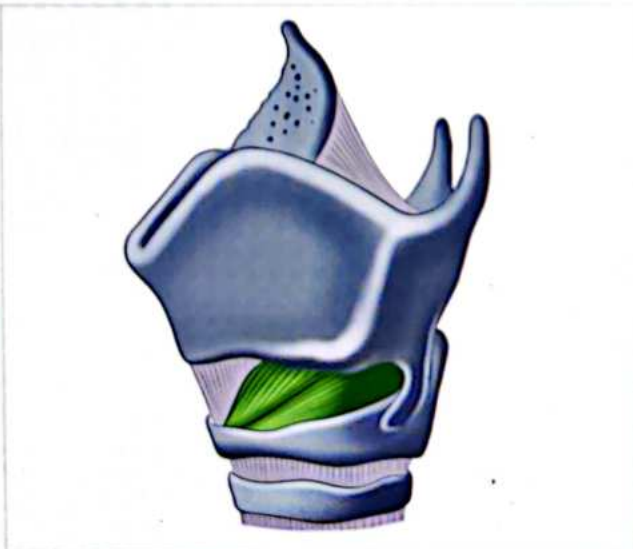**Lymphatics**

- Supraglottis: Drains into upper deep cervical lymph nodes
- Subglottis: Prelaryngeal and pretracheal lymph nodes into lower deep cervical lymph nodes or mediastinal nodes.
- Glottis: No lymphatics

**Muscle of Larynx**



**Identify**



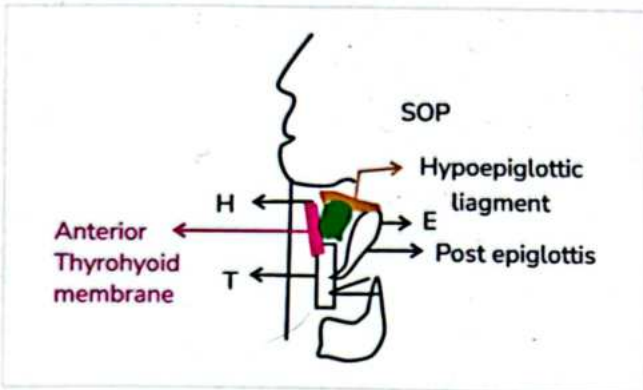
**Spaces of Larynx**

- Preepiglottic space of Boyer

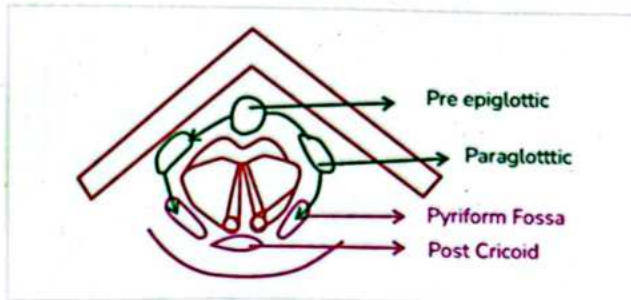




- Paraglottic space
- Reinkes spaces



- Above: Quadrangular membrane
- Below: Cricovocal membrane



**Preepiglottic space of Boyer**

- Anteriorly: Thyrohyoid membrane
- Superiorly: Hyoepiglottic ligament
- Posteriorly: Epiglottis
- Laterally: Paraglottic space

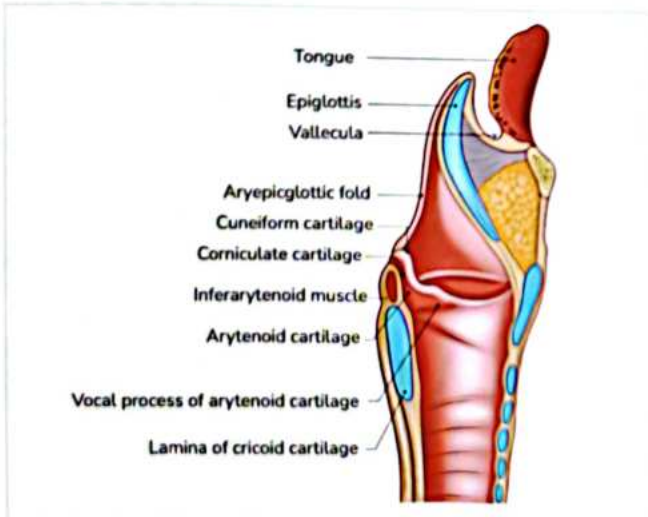
01:00:08

**Reinkes Spaces**  
**Vocal cord layer**

- Mucosa
- Superficial lamina propia
- Vocal ligament
- Vocalis membrane
- Space between mucosa and superficial lamina. Propia: Reinke's spaces

**Functions of larynx**

- Protection of lower airways
- Phonation
- Respiration
- Fixation of the chest



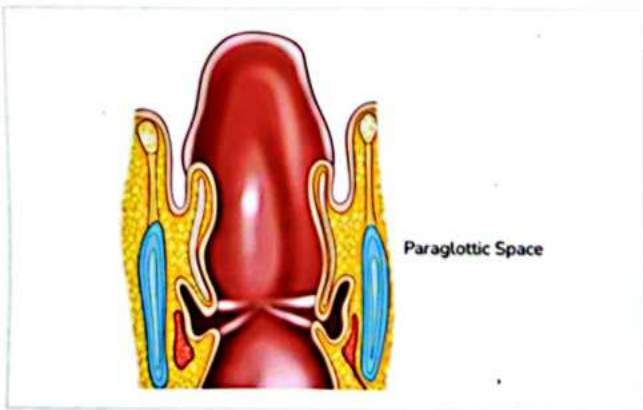
**Difference between Adult and Infant Larynx**

01:00:56

	Infants	Adults
Position	C2 – C3	C – 3 4 5 6
Epiglottis	Curled	Leaf shaped
Thyroid cartilage	Flat	Angulated
Narrowest part	Subglottis	Glottis
Submucosal tissue	More	Less
Cartilage	Soft	Ossified

**Paraglottic space**

00:56:41



- Laterally: Thyroid cartilage
- Medially

**One Liners**

- Larynx develops from 4 & 6 arch
- Supraglottis develops from 4.
- Glottis and subglottis develops from 6.
- Larynx lies against C<sub>3</sub>, C<sub>4</sub>, C<sub>5</sub>, C<sub>6</sub> vertebrae.
- Laryngeal crepitus ( → (N) occurs due to movement of Cricoid against Vertebrae.
- Laryngeal crepitus is absent in Post cricoid CA/ Retro Pharyngeal abscess & Prevertebral abscess.



- Hyaline cartilages in larynx are Thyroid, Cricoid, Arytenoid.
- Elastic cartilages in larynx are Epiglottic, Corniculate, Cuneiform.
- Largest cartilage in Larynx Thyroid.
- Signet ring cartilage is Cricoid.
- Angle at which thyroid ala meets in male 90 and female 120.
- Oblique line of the thyroid cartilage gives attachment to Thyrohyoid, Sternothyroid, Thyropharyngeus
- Two surfaces of epiglottis are Laryngeal and Lingual.
- Part of epiglottis: Suprahyoid & Infrahyoid.
- Only complete cartilaginous ring in the entire airway: Cricoid
- Narrowest portion of the adult larynx is Glottic and paediatric larynx is Subglottic.
- Cartilage of Santorini is Corniculate.
- Cartilage of wisber is Cuneiform.
- Average length of vocal cords in males is 24 mm and females is 36 mm.
- Membranous portion is 2/3 and cartilaginous portion is 1/3.
- Sinus of Morgagni of larynx is Ventricle.
- Rima vestibuli is False cord.
- Rima glottitis is True cord.
- Space of Tucker is Paraglottic.
- Space of boyer is Pre-Epiglottic.
- Only unpaired laryngeal muscle is Interarytenoid.
- Only muscle which receive dual innervation Interarytenoid.
- Only abductor of vocal cord: Post CA
- Tensor is Cricothyroid.

prince kumar  
princeekum@gmail.com  
9928609733





**39**

**INFLAMMATORY CONDITIONS OF THE LARYNX**

00:00:01

**1. Acute Epiglottitis**

**2. Croup**

- Both are pediatric emergencies.
- These diseases involve the airway. Any compromise in the airway results in breathing issues for the child and is presented as an emergency.
- Acute epiglottitis is inflammation of epiglottitis.
- Acute larynx-trachea-bronchitis inflammation of the larynx-trachea and bronchus.

**Acute Epiglottitis**

**Larynx-Trachea-Bronchitis**

Inflammation of epiglottis. Inflammation of the larynx, Only supraglottic structures, trachea and bronchus. Epiglottis, epiglottic fold and arytenoids are involved.

Initially, it was H influenza, but It is a viral infection usually since vaccines, are given. The para influenza 1 & 2. inflammation is secondary to Secondary it can be also bacteria such as streptococcus invaded by bacteria. pneumonia.

Age group 3-6 years.

Age group 3 months to 3 years.

**Symptoms:**

- **Respiratory:** Inspiratory strider
- **Digestive:** Dysphagia, Odynophagia and drooling of saliva.
- **Phonatory:** No change in voice and no cough.
- **Respiratory:** Biphasic strider.
- **Digestive:** Not present or mild.
- **Phonatory:** Change in voice and cough (barking seal-like cough).

This inflammation spreads to the adjacent areas such as the base of the tongue and oropharynx as well. Whenever there is swelling in the structure of the airway first and foremost will be there is breathing difficulty.

**The examination should be avoided in both cases.**

**Diagnosis: Lateral View X-ray** of the neck. A thumb sign is seen. (important for MCQ)

**Diagnosis: Anteroposterior** view of the neck. A steeple sign is seen. (important for MCQ)

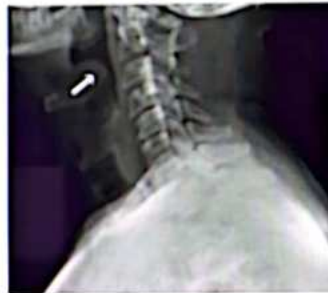**Treatment:**

- Antibiotic with Steroids is given to reduce airway edema.
- Racemic adrenaline nebulization is a Vaso constrictor it will reduce airway edema.
- Intubation of tracheostomy if there is an airway emergency.

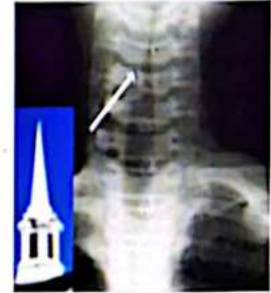**Treatment:**

- Antibiotic with Steroids is given to reduce airway edema.
- Voice rest will be helpful.
- Cough suppressant.
- A bronchodilator is required.
- Racemic adrenaline nebulization.
- Intubation of tracheostomy.

Thumb sign (Epiglottitis)



Steeple sign (Croup)



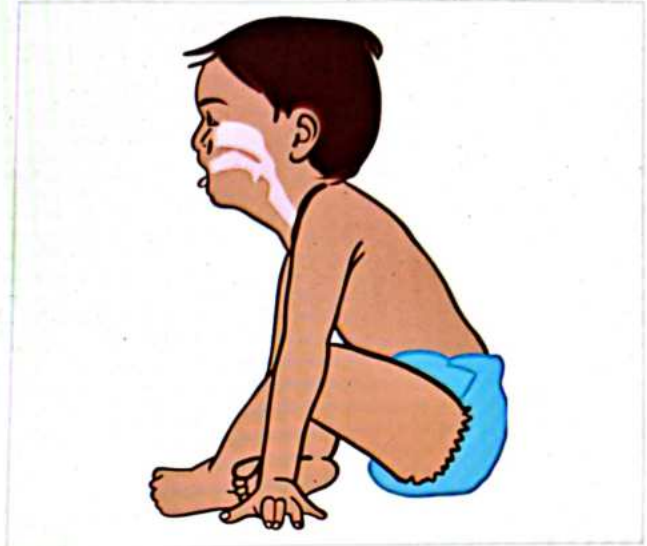	Acute Epiglottitis	Acute Laryngo-tracheo-Bronchitis
Onset	Sudden	Slow
Progression	Rapid progression in children	Can progress to obstruction but slowly
Malaise, Fever	Present in children it can go up to 40 degrees Celsius and child looks toxic	Present but low grade or no fever and child is not toxic



Sore throat	Present. Severe odynophagia with drooling of saliva leading to dehydration	Present
Cough	Usually absent	Present (Barking seal like)
Hoarseness of voice	Absent	Present
Dyspnoea and Stridor	Very common in children due to obstruction in supra glottic area	Common in children due to obstruction in sub-glottic area

- Epiglottitis is caused by S. Pneumoniae
- Croup is caused by Para Influenza
- Thumb sign is seen in – Epiglottitis
- Steeple sign is seen in – Croup
- Cry is normal in → Epiglottitis
- Cry is affected in Croup
- Rapidly progressive condition is Epiglottitis
- Barking cough is seen Croup

Q. Name this position and in which condition is this seen?



Ans: Epiglottitis






## CROSS WORD PUZZLES



### Crossword Puzzle 1




#### Across

- 2. Racemic adrenaline nebulization is a Vaso constrictor it will reduce \_\_\_\_\_.
- 3. Acute epiglottitis is inflammation of \_\_\_\_\_.

#### Down

- 1. \_\_\_\_\_ view of the neck for croup diagnosis.

### Crossword Puzzle 2




#### Across

- 2. Influenza Croup is caused by \_\_\_\_\_.
- 3. Epiglottitis is \_\_\_\_\_ progressive condition.

#### Down

- 1. \_\_\_\_\_ cough is seen in Croup.

### Crossword Puzzle 3



#### Across

- 3. Epiglottitis is caused by \_\_\_\_\_.

#### Down

- 1. \_\_\_\_\_ position in which the epiglottitis patient sits.
- 2. \_\_\_\_\_ sign seen in Epiglottitis x-ray.

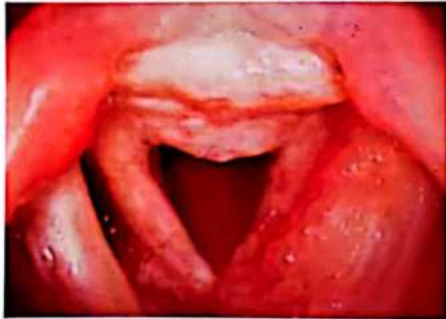

40

## BENIGN INFLAMMATORY LESIONS OF THE LARYNX

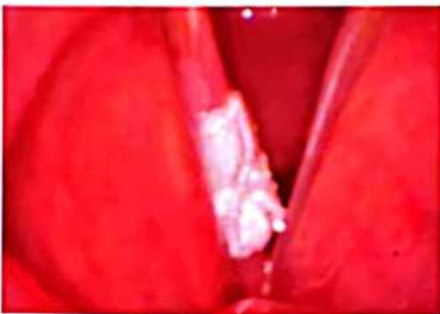

### Contact Ulcer / Pachydermia Laryngitis / Kiss Ulcer



- Happens due to **excessive voice abuse or reflux**, during which the rubbing of arytenoid with another there will hypertrophy on one side more. This hypertrophy will compress on the other side to create a depression, resulting in an ulcer on the other side.
- This typically involves the posterior portion of the larynx. Whenever there is a similar lesion there will be a change in voice, crosses of voice.
- **Cause:**
  - Extreme Voice abuse.
  - Reflux
- The image is of a Pseudo ulcer as one arytenoid hypertrophic is present and an ulcer on another one.
- **Differentiation diagnosis:** Tuberculosis and carcinoma. Histopathology will give the diagnosis. For Pachydermia laryngitis, there will be Hyperkeratosis and Acanthosis.
- It is not a premalignant conduction.
- Treatment of pachydermia laryngitis is voice rest, antireflux therapy, and if it sustains for a long period of time laser excision of the lesion.

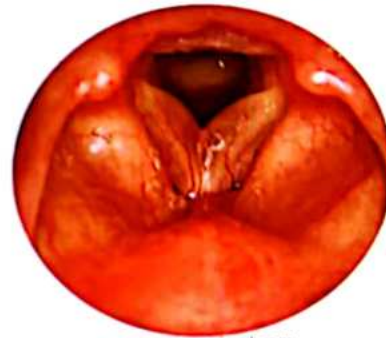
### Keratosi Larynx/Leukoplakia



- Leukoplakia happens due to chronic irritation, caused by excessive voice abuse, smoking, chewing tobacco etc.

- Whenever there is chronic irritation there is the transformation of the epithelium, initially there will be leukoplakia then carcinoma and then into invasive carcinoma.
- Smoking is one of the most common causes.
- **Differentiation diagnosis:** Candidiasis, Carcinoma and this can be confirmed with the help of Histopathology examination.
- This is a premalignant condition, if it is not treated it can become premalignant.
- **Treatment:** Excisional biopsy. Instead of two procedures the entire lesion is removed and sent for biopsy. Commonly called *Stripping of the vocal cord*.

### Reinke's Edema

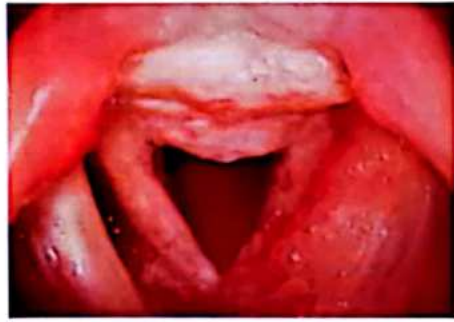


- In the vocal cord there are **four** layers: Thyroarytenoid muscle, deep lamina propria, intermediate lamina propria, superficial lamina propria, and the squamous epithelium. The space between the epithelium and the superficial lamina propria is called **Reinke's space**.
- So, whenever there is an accumulation of the edematous tissue or the myxomatous tissue in Reinke's space it is called Reinke's oedema.
- It involves the anterior  $\frac{3}{4}$  rd which is the membranous portion of the vocal cord.
- **Causes:** Chronic irritation, caused excessive voice abuse, reflux, smoking, chewing tobacco, etc and it can also cause due to hormonal abnormalities.
- Patients suffering from Reinke's edema have complained about diplophonia or a change in voice. And the larynx is examined with the help of a 70-degree rigid endoscope or with help of an indirect laryngoscopic mirror, there will be a bag with a water-like appearance.
- There are bilateral symmetrical swellings on the vocal cord.
- **Treatment:** Stripping of the vocal cord.

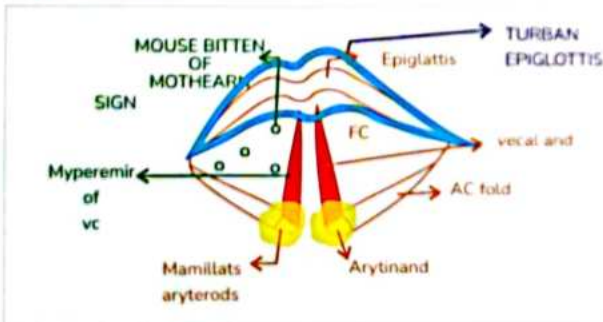


**Tuberculosis of Larynx**

00:15:26



- In this case there is pulmonary tuberculosis along with tuberculosis of the larynx.
- Tuberculosis is caused by Mycobacterium tuberculosis and the mode spreading in by air droplet.
- Clinical features: Commonly the posterior part of the larynx is involved less often anterior part.
- Laryngeal tuberculosis is a painful condition that causes odynophagia (painful swallowing) and a change in voice.
- First presenting symptom is a weak voice.
- Daigonis is culture or histopathology.
- When it is confirmed that it is tuberculosis treatment is ATT (anti-tuberculosis therapy). There is no role of surgery unless the patient involved is a professional or there is any sulcus or granuloma.



- **Earliest signs:**
  - Redness of the vocal cord which is also called **Hyperemia of the vocal cord**.
  - Swollen arytenoids called **Mammillated arytenoids**.
  - **Discountinous multiple Ulcerations** on the vocal cords are called **mouse-bitten or moth-eaten appearance**.
  - **Swelling of the epiglottis** is the last sign (**Turban epiglottis**)

**Lupus of Larynx**

00:25:00

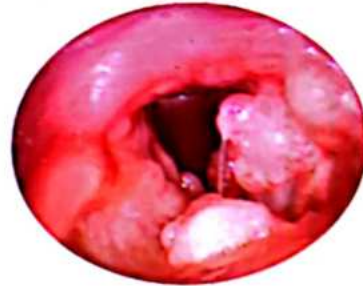- **Lupus of the larynx and tuberculosis larynx** more or less are similar conditions. It is **not active tuberculosis** or not connected to pulmonary tuberculosis. **Indolent tubercular infection** associated with lupus of the nose and pharynx.

Affects the anterior part of the Larynx, and the epiglottis is first involved.

	TB larynx	Lupus Larynx
1. Pulmonary TB	Yes	No
2. Activity of TB	Active	No
3. Parts affected	Posterior	Anterior
4. Symptomatic	Yes	No

**Laryngeal Papillomas**

00:26:53



- Papilloma means finger-like projections.
- This is caused by a virus called human papillomavirus HPV 6 /HPV 11 are responsible. HPV 11 is more aggressive.
- There are two types of papillomas:

Juvenile-onset laryngeal papillomatosis	Adult-onset laryngeal papillomatosis
---	--------------------------------------

It is a more aggressive type that causes symptoms before age 12.

Adult-onset laryngeal papillomatosis causes symptoms during adulthood.

It is transferred from the mother to the child during vaginal birth. (Juvenile onset recurrent respiratory papillomatosis)

The mode of transmission is sexual.

No specific location every area is prone to it.

Usually are seen only at the vocal cord at the anterior 2/3 rd of the vocal cord.

Multiple papillomas. **Recurrence chances are high.** Treatment is surgery microdebrider.

They are single papillomas. Less recurrence and less aggressive.

Presentation in both is the same, initially, there will be **voice change** but later on, there can be **obstruction of the airway**.

prince kumar  
princeekum@gmail.c  
9928609733



- Both of these should be diagnosed by histopathology
- Mainstay treatment is Surgery - Microdebrider
- Laser treatments are not used in the surgery as they produce fumes that mix up with papilloma which make plumes, which can go to distal airways and can lead to the formation of papillomas grow in the trachea and other areas.
- Antivirals in the form of Cidofovir, alpha-interferon, and even monochrome antibodies such as bevacizumab.

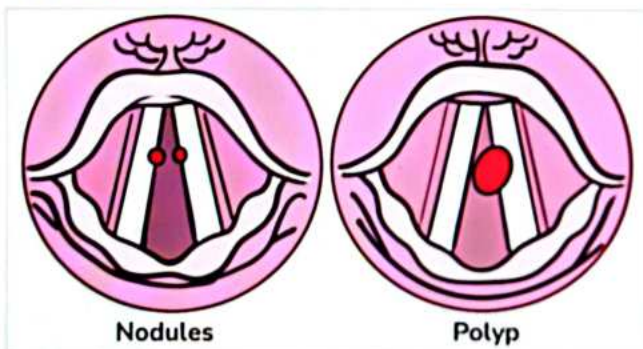
### One Liner revision:

- Pachydermia laryngitis involves..... part of vocal cord {Anterior/Posterior}
- Painful laryngeal condition is
- Premalignant condition is
- Not a true ulcer is
- Stripping of vocal cords is done in

### One-liner Revision

- Vocal nodules and polyps occur at the junction of ....
- Sessile is..... and pedunculated is .....
- Diplophonia is seen in .....
- Micro laryngeal surgery is the treatment of choice in .....
- Voice rest is the treatment of choice in .....
- Bilateral and symmetrical lesions are .....
- Ulcer on one side and heaped-up epithelium on the other side is seen in.....
- Micro laryngeal surgery involves using a microscope to excise the lesion with a focal length of.....

### Vocal Nodule And Polyp



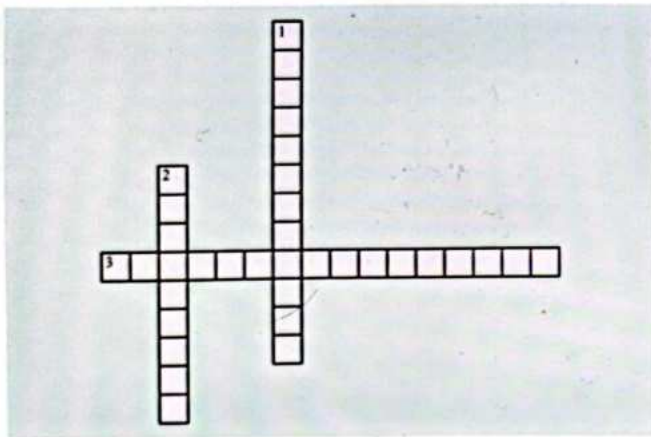
Nodules (Teacher, singers nodule)	Polyp
Nodule is Caused by chronic voice abuse.	Sudden voice abuse. (sudden shouting)
Occurs at the junction of the anterior 1/3 <sup>rd</sup> and posterior 2/3 <sup>rd</sup> of the vocal cord.	Occurs at the junction of the anterior 3 <sup>rd</sup> of the vocal cord.
Vocal nodules are <b>bilateral</b> lesions.	Polyps are <b>unilateral</b> lesions.
Nodules are usually <b>sessile</b> masses.	Polyps are usually <b>pedunculated</b> masses.
<b>Initially Voice rest. If it fails microscopic excision without injuring vocal cords</b>	<b>No voice rest, surgery needs to be conducted.</b>

prince kumar  
princeeeekum@gmail.com  
9928609733





CROSSWORD 1




Across

3. \_\_\_\_\_ in which instead of two procedures the entire lesion is removed and sent for biopsy.

Down

1. Differentiation diagnosis of pachydermia laryngitis \_\_\_\_\_ 2. and \_\_\_\_\_.

CROSSWORD 2



Across


2. Tuberculosis is caused by \_\_\_\_\_.  
 3. In the vocal cord there are \_\_\_\_\_ layers.

Down

1. The space between the epithelium and the superficial lamina propria is called \_\_\_\_\_.

princeeeekum@gmail.com  
 9928609733

CROSSWORD 3



Across

2. Whenever there is an accumulation of the \_\_\_\_\_ tissue or the \_\_\_\_\_ tissue in Reinke's space is called Reinke's oedema.  
 3. \_\_\_\_\_

Down

1. \_\_\_\_\_ is a painful condition not only that also causes odynophagia (painful swallowing).





41

VOICE PATHOLOGIES



Voice Pathology

00:00:31

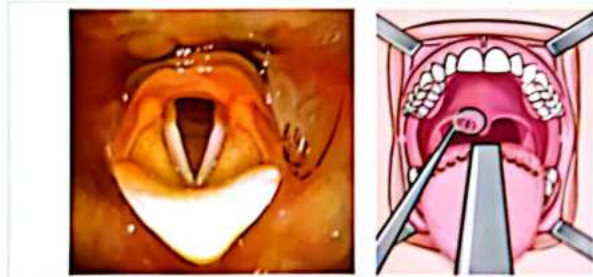
- A voice disorder is a change in how the voice sounds.
- The voice box, also called the larynx, is made of a smooth covering, muscle and soft, moist areas. The vocal cords vibrate to create sound.
- If vocal cords become swollen, or inflamed, develop growths or can't move as they should, they can't work properly. Any of these might cause a voice disorder.
- There are certain conditions which are mentioned below:

Refer Table 41.1

00:23:01

Laryngeal Examination:

00:23:31



- Also called laryngoscopy.
- Laryngoscopy is a medical procedure to access the larynx, specifically the vocal cords and the glottis.

It can be done in different ways -

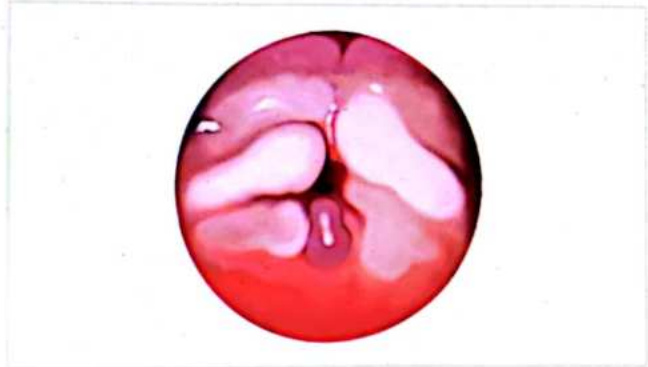1. Direct laryngoscopy:

- Direct laryngoscopy is the use of the laryngoscope to visualise the vocal cords (larynx) under direct vision, usually to facilitate endotracheal intubation.
- It done by pushing down the tongue and lifting up the epiglottis.

prince kumar  
princeeeeeekum@gmail.com  
9928609733

2. Indirect laryngoscopy:

- An indirect laryngoscopy examination can be done by passing a mirror behind the uvula. And in the mirror, the larynx will be easily visualised by the reflection of the larynx.
- The patient is asked to put the tongue out so that the mirror can be easily inserted behind the uvula.
- While examining the larynx, alternate flashes of dark and bright light are given. So this will give a sense of apparent motion or vibratory pattern of the vocal cord and understanding the movement of vocal cords. This process is known as stroboscopy but without that if we just see the larynx we call it laryngoscopy.



Thyroplasty

00:28:07

- Thyroplasty is a surgical procedure done to change the position of vocal cords to improve voice and ability to cough.
- Types of thyroplasty -

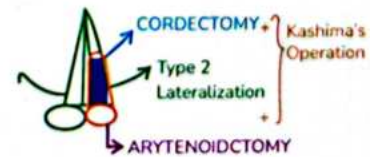
Type 1 thyroplasty (medialization of vocal cords)

- In Typxe 1 thyroplasty, a rectangular portion of the thyroid cartilage is mobilised and pushed towards the medial side using a piece of silastic block of proper shape under local anaesthesia.



Type 2 thyroplasty (lateralization thyroplasty)

- It is a surgical procedure for lateralization of vocal
- Lateralization of vocal cord is done either by resecting the arytenoid known as arytenoidectomy or via corpectomy (removal of posterior 2/3<sup>rd</sup> of vocal cords)
- Kashima's operation ( corpectomy + arytenoidectomy)



Type 3 thyroplasty (shortening of vocal cords)

- This procedure is generally done to lower the vocal pitch by shortening the thyroid.
- Generally done in cases of puberphonia.





**Type 4 thyroplasty**  
(lengthening of vocal cords)

- This procedure is done to elevate the vocal pitch.
- Generally done in cases of androphonia and in sex change operation.
- This consists of lengthening the thyroid cartilage which includes cricothyroid approximation.

Table 41.1

Conditions	Characteristic feature	Causes	Diagnosis	Treatment
<b>Dysphonia Plica ventricularis</b>	<ul style="list-style-type: none"> <li>• Ventricular dysphonia is characterized by typical rough, low-pitched voice quality.</li> <li>• Occurs due to pathological interference of the false vocal cords during phonation.</li> <li>• False cords come towards the midline instead of true cords and vibrate to produce sound.</li> <li>• This condition further leads to <b>hypertrophy of false cords</b>.</li> </ul>	<ul style="list-style-type: none"> <li>• If there is any lesion fixation of the vocal cords, that's not letting the vocal cords to vibrate.</li> <li>• Also, due functional problem such as psychological feeling that the vocal cords are not moving and patient is not able to produce the sound, then the false cords will adapt to produce the voice.</li> <li>• Can also be occur due to mimicry of voices.</li> </ul>	<ul style="list-style-type: none"> <li>• Low pitched voice production and low quality of voice.</li> <li>• Laryngeal examination</li> </ul>	<ul style="list-style-type: none"> <li>• Counsel the patient.</li> <li>• Speech therapy.</li> <li>• If the patient still have the symptoms even after speech therapy then they can opt for reduction of false cords.</li> </ul>
<b>Spasmodic dysphonia</b>	<ul style="list-style-type: none"> <li>• There is a spasm of a muscle and because of that the patient is having a change in voice called spasmodic dysphonia.</li> <li>• It is usually associated with certain neurological conditions not with local laryngeal conditions, so patients with parkinsonism and</li> </ul>	<ul style="list-style-type: none"> <li>• Adductor spasmodic dysphonia causes a strangulated scratchy (croaky) voice.</li> <li>• Abductor spasmodic dysphonia causes a breathy voice.</li> </ul>	<ul style="list-style-type: none"> <li>• Strangulated or scratchy (croaky) voice.</li> <li>• Breathly voice.</li> <li>• Laryngeal examination</li> </ul>	<ul style="list-style-type: none"> <li>• Botox are the neurotoxins that are given to relax the muscle. So the spasm, which is there, gets relaxed because of Botox.</li> <li>• It can be either injected into thyroarytenoid muscle to treat adductor spasmodic dysphonia and in to</li> </ul>

prince kumar  
princeeeekum@gmail.com  
9928609733



patients with Alzheimer's disease can have spasmodic dysphonia.

- Associated with Oromandibular dystonia and blepharospasm

There are three types of dysphonia -

1. Adductor spasmodic dysphonia: In this thyroarytenoid or the vocalist muscle is in spasm. So it will vibrate freely and there will be spastic movements.
2. Abductor spasmodic dysphonia: The posterior cricoarytenoid is going into spasm leading to airway space in between.
3. Mixed spasmodic dysphonia: It is a combination of both spasmodic dysphonia.

posterior cricoarytenoid muscle to treat abductor spasmodic dysphonia.

**Puberphonia**

- Puberphonia is an inappropriate persistence of adolescent, and often female-like voice even after puberty and is commonly seen in males more than females.
- If the vocal cord and the thyroid cartilage do not grow at the same rate while, the vocal cord will stretch itself and subsequently there will be increased tension and lengthening of the vocal cord due to this they will have a female type of voice.
- Gutzmann pressure test: Patient can be typically diagnosed by compressing the adam's apple which is nothing but the thyroid cartilage resulting in to the changed in voice.
- Treatment can be done by shortening of vocal cords also called Type 3 thyroplasty method.

**Phonasthenia**

- Weakness of voice due to weakness in the thyroarytenoid muscle and the inter arytenoid muscle which will lead to the bowing of vocal cords.
- Laryngoscopy.
- Keyhole appearance will be the diagnostic characteristic for phonasthenia.

prince kumar  
princeekum@gmail.com  
99% Thyroplasty.





**42**

# CONGENITAL LESIONS OF LARYNX AND STRIDOR

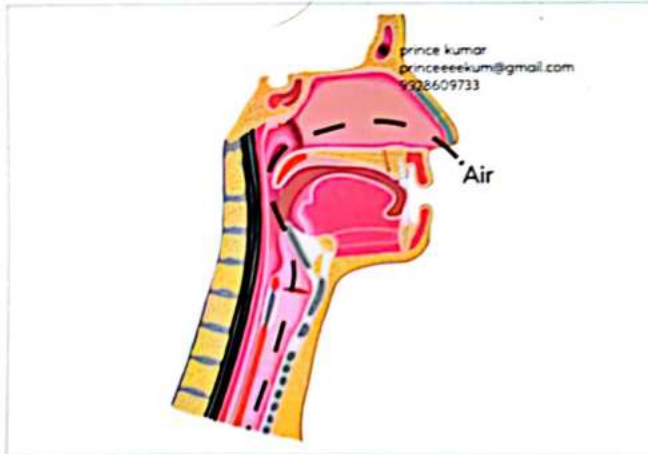Congenital anomalies of the larynx are relatively rare. Congenital laryngeal disorders include:

- Laryngomalacia.
- Congenital subglottic stenosis.
- Congenital laryngeal web.
- Subglottic hemangioma.

- In the Prone position, the child will not have stridor as the epiglottis is away from the larynx.

## Laryngomalacia

00:00:42



- Most common congenital anomaly
- Malacia = Weakness of tissue
- Excessive flaccidity of epiglottis or the supraglottis occurs

### Clinical Features

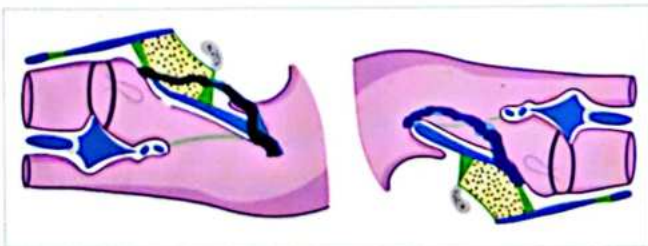
- Presence of Inspiratory stridor



### Important Information

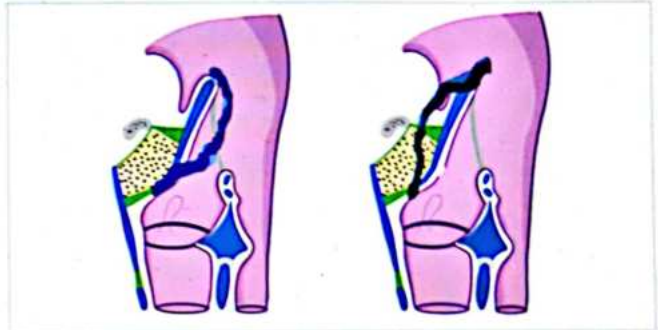
- In laryngomalacia, there will be no expiratory stridor. Only inspiratory stridor is present.

### Supine and Prone position



- In the Supine position, the child will have a stridor as the epiglottis covers the laryngeal inlet.

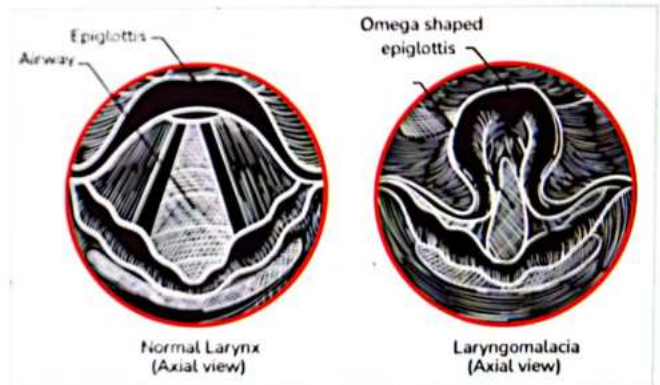
### Crying



- During crying, a negative intrathoracic pressure builds up in the lung and the epiglottis will be sucked inside, covering the laryngeal inlet, and as a result, the stridor will increase.

Q. Omega shaped epiglottis is a feature seen in?

Ans. Laryngomalacia



### Treatment

- Epiglottopexy is the surgery done for laryngomalacia.

### Subglottic Stenosis

00:11:03

- Subglottis is children's narrowest portion of the pharynx but in adults it is glottis.
- Subglottis diameter <4mm in neonates and <3mm in a premature neonate is considered abnormal.
- 3rd leading congenital anomaly of the larynx.
- When subglottic narrowing occurs due to excessive thickening of the cricoid cartilage, Subglottic stenosis occurs.
- Not present at birth.



**Classification of Subglottic stenosis**

- This classification system is called **Cotton Myer Classification**

**Refer Table 1**


**Diagnosis**

- Laryngoscopic Examination

**Treatment**

- Balloon dilatation
- Resection of stenotic section

Montgomery T-tube are used after resection of stenotic segment to keep the airway patent.



**Role of mitomycin**

- It is an **anti-proliferative agent**, so, it will inhibit the epithelial proliferation. As a result, restenosis will not occur.

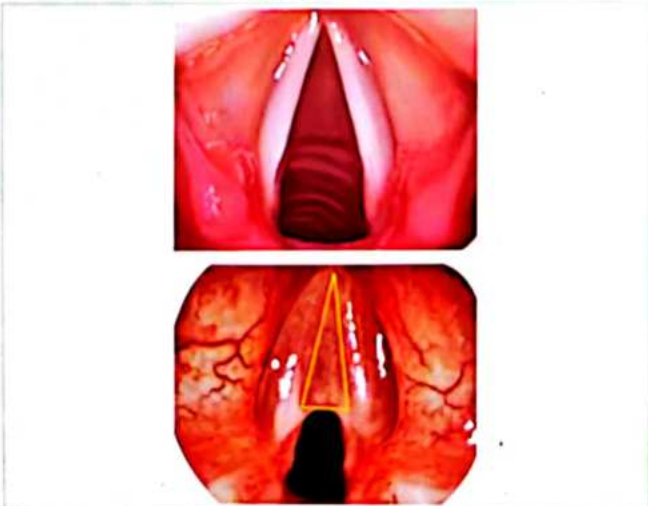

**Important Information**

- Anti-proliferative agent are substances used to prevent or retard the spread of cells

**Laryngeal Web**

- It can be a partial obstruction called partial web or complete obstruction called complete web.



- Supra glottis develops from 4<sup>th</sup> arch and glottis and sub glottis develops from 6<sup>th</sup> arch .and the two arches fuse to make a complete canal.
- It occurs due to **incomplete canalisation of the supraglottis** with that of the glottis and subglottis.
- Most common site - Anterior 2/3rd of the vocal cord.
- **Present at birth.**
- Present with **biphasic stridor.**

**Treatment**

- Urgent Tracheostomy- This is a surgical opening done into the trachea.

**Subglottic Hemangioma**

00:25:15

- Small malformation of the arteriovenous system in subglottis is called a subglottic hemangioma.
- They may present at birth depending upon the size of the hemangioma.
- There will be no inspiratory and expiratory stridor. If present, **biphasic stridor** is present.
- **Crying will increase stridor.**

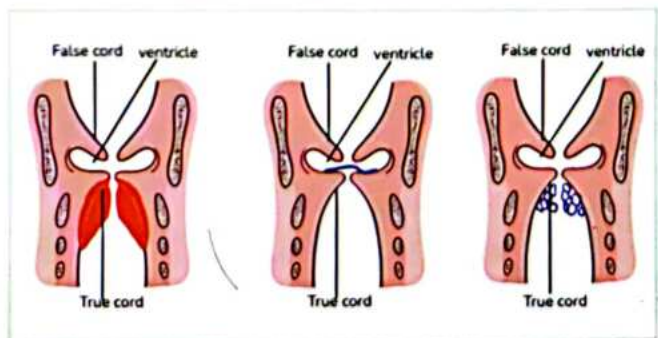
**Treatment**

- Intralesional steroids.
- If subglottic hemangioma persists, **laser vaporization** is done.

**Comparison**

00:30:03

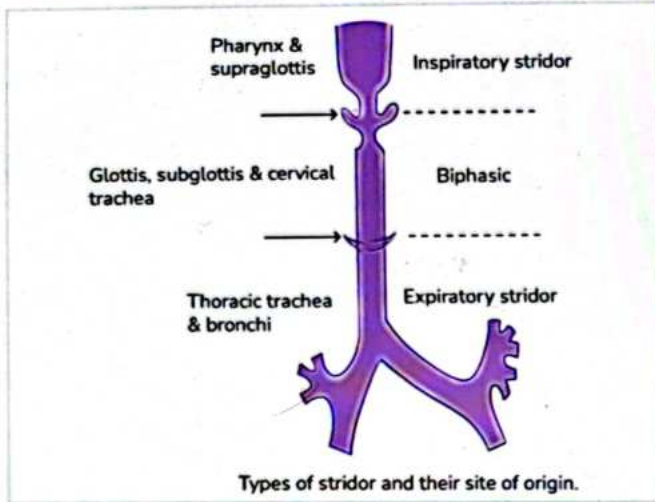
Subglottic Stenosis	Laryngeal Web	Subglottic hemangioma
<ul style="list-style-type: none"> <li>• Diameter- &lt;4 mm</li> <li>• Do not present at birth</li> <li>• No effect on inspiration and expiration.</li> <li>• No effect of crying</li> </ul>	<ul style="list-style-type: none"> <li>• Present at birth</li> <li>• Biphasic stridor present</li> <li>• Emergency condition</li> <li>• Crying increases stridor</li> </ul>	<ul style="list-style-type: none"> <li>• May or may not present at birth</li> <li>• Biphasic stridor present</li> <li>• No effect on inspiration and expiration</li> <li>• Crying increases stridor</li> </ul>





**Stridor**

00:36:30



- Stridor is noisy respiration produced by turbulent airflow through the narrowed air passages.

**Types**

- **Inspiratory Stridor**
  - Any pathology above the vocal cord will lead to inspiratory stridor.
- **Expiratory Stridor**
  - Any pathology below the cervical trachea will lead to expiratory stridor.
- **Biphasic Stridor**
  - Any pathology between the vocal cord and cervical trachea will lead to biphasic stridor.

**Causes of Stridor**

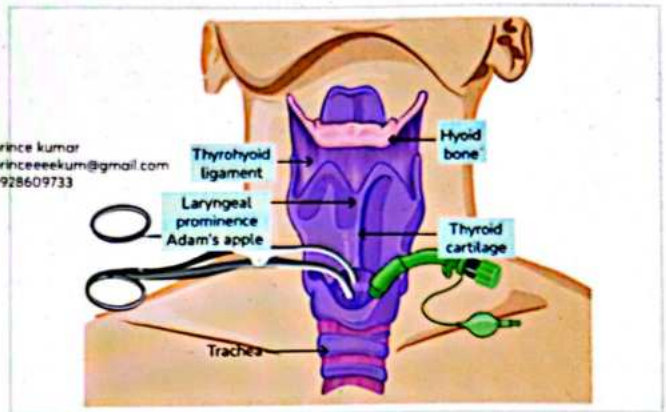
00:39:32

	Nasopharyngeal	Laryngeal	Tracheal
<b>Neonates</b>	Neonatal rhinitis Choanal atresia or Stenosis craniofacial abnormalities Micrognathia	Laryngomalacia Intubation trauma Reflux laryngitis Laryngotracheal stenosis Vocal cord palsy	Tracheobronchomalacia Tracheal Stenosis Vascular Compression
<b>Children</b>	Allergic Rhinitis Adenoiditis Adenotonsillar Hypertrophy Foreign bodies	Croup Hemangioma Papillomatosis Intubation trauma	Foreign bodies Tracheal Stenosis

**Cricothyrotomy**

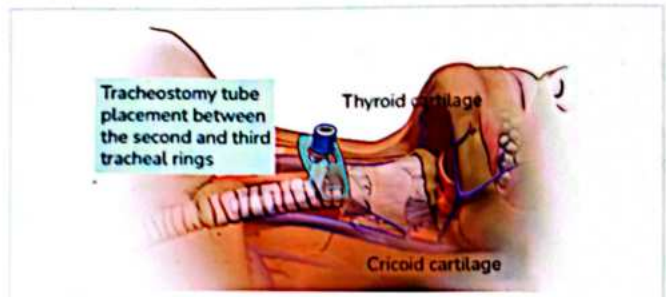
00:40:52

- During Emergency, access to the airway is achieved by piercing cricothyroid membrane. This procedure is called a cricothyrotomy.



**Tracheostomy**

00:45:03

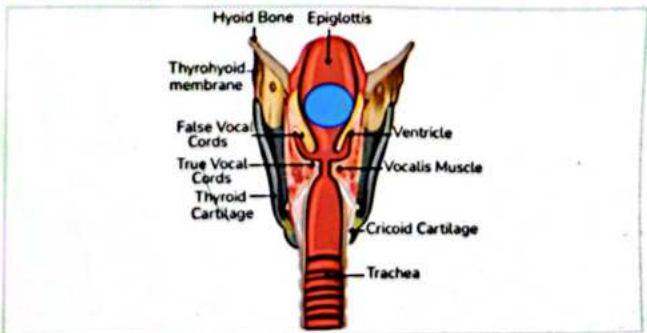


- Surgical opening in the trachea is called a tracheostomy.
- Normally, tracheostomy is done at the level of the 2nd and 3rd tracheal rings. This is called **Mid tracheostomy** (Most Commonly Performed).
- If a tracheostomy is done at the level of 1st tracheal ring. This is called a **High tracheostomy**. Mainly done in patients with **total laryngectomy**.
- If a tracheostomy is done below the 4th tracheal ring. This is called **Low tracheostomy**.
- Low tracheostomy is done in patients with **Recurrent Respiratory Papillomatosis**.

**Foreign bodies of air passages**

00:48:15

**Size of Foreign Body and Location**





- A small foreign body will lodge in supraglottis or glottis or subglottis.

**Q.** Bronchial Foreign body most likely to lodge in the right or left trachea?

**Ans.** Right Trachea because it is shorter, straighter and more horizontal than the left trachea.

**Q** Which foreign bodies are more dangerous?

1. Metallic
2. Vegetable foreign bodies

**Ans.** Metallic foreign bodies are dangerous especially button batteries as they cause alkaline tissue necrosis. However vegetable foreign bodies are hygroscopic as they swell up and can cause oedema of trachea leading to vegetable bronchitis and complete obstruction.

**Clinical Features**

- Initial period of choking, gagging and coughing.
- Symptom less period where the mucosa adapts to a foreign body.
- Late symptoms: can cause cough, stridor, and hoarseness of voice.
- Stage of complications: Depends on the extent of obstruction.
- **Tracheal foreign body** - a smooth FB will move up and down in the trachea with inspiration and expiration producing "audible slap" and "palpatory thud".
- Asthmatooid wheeze may also be present

**Bronchial Foreign Body**

- **Causing Partial Obstruction**
  - o Allows air in and out.
  - o Only wheeze.
- **Causing Complete Obstruction**
  - o Air doesn't enter into the lungs.
  - o Lung collapses, causing atelectasis.
- **Causing One-Way Obstruction Like A Valve**
  - o Do not allow air to go inside the lung.
  - o Air goes out but doesn't enter into lungs.
  - o Lung collapses, causing atelectasis.
- **Do not allow air to go outside the lung-**
  - o In this case, the Foreign body is acting like a valve allowing air into the lung but not out.
  - o Causes swelling of the lung with air or emphysema.
  - o Emphysematous bullae may rupture, causing spontaneous pneumothorax.

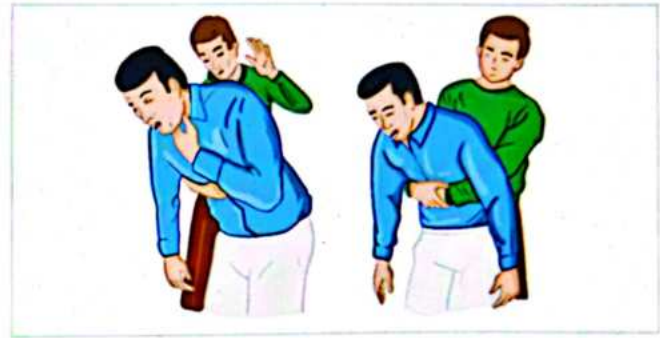**Investigations**

- X-ray of neck, thorax, and abdomen in **AP view and lateral view.**

**X-ray is indicated for radiolucent foreign body**

- Radiolucent FB can sometimes be seen as a radiolucent shadow.
- Indirect signs like atelectasis and emphysema.
- If the X-ray is negative, it does not rule out a foreign body.
- Bronchogram, video laryngoscopy and clinical examination may show a radiolucent foreign body.

**Management of laryngeal foreign body**



**Partial or no Obstruction**

- **Heimlich Manoeuvre** is done.





**Complete Obstruction**

- The above manoeuvre is **contraindicated**. It can further increase obstruction.
- Emergency tracheostomy followed by removal of Foreign body by laryngoscopy.

**Management of bronchial foreign body**

- Not an emergency.
- Emergency removal is indicated only in case of complete obstruction or in the presence of a bronchial Foreign body.
- **Methods:**
  1. Rigid or flexible bronchoscopy
  2. Dormia baskets
  3. Thoracotomy or bronchotomy



Classification	From	To	Symptom	Endoscopic appearance
Grade I	No Obstruction	50% Obstruction	Asymptomatic	
Grade II	51% Obstruction	70% Obstruction	Asymptomatic	
Grade III	71% Obstruction	99%Obstruction	Noisy Respiration	
Grade IV	No Detectable Lumen		Cyanosis Respiratory distress	


prince kumar  
princeeeekumar@gmail.com  
9928609733





# CROSS WORD PUZZLES

**Crossword Puzzle 1**




**Across**

- 3. Occurs due to incomplete canalization of epiglottis
- 4. Surgical opening of trachea

**Down**

- 1. Most common congenital anomaly
- 2. Procedure in which access to the airway is achieved by piercing cricothyroid membrane.

**Crossword Puzzle 2**



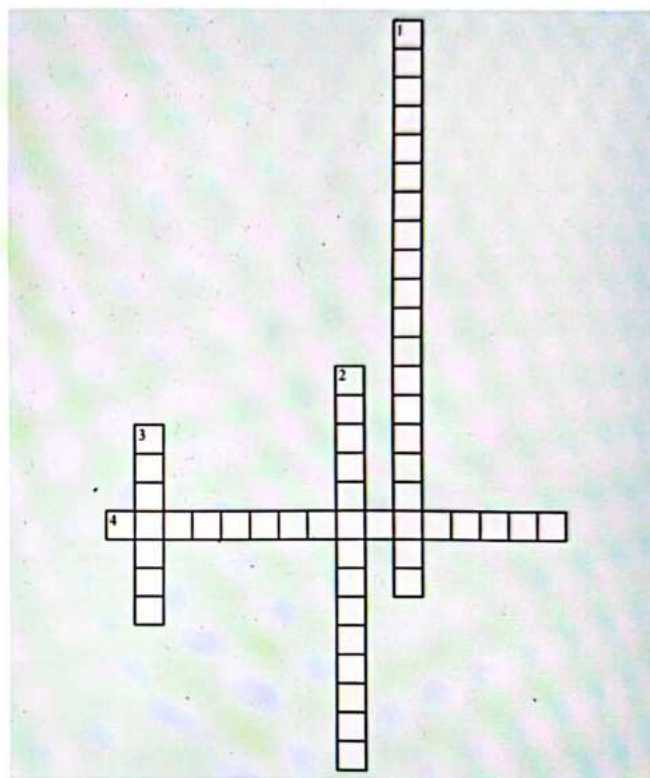
**Across**

- 3. Narrowest portion of the pharynx in children
- 4. Surgery done for laryngomalacia

**Down**

- 1. Omega shaped epiglottis seen in
- 2. Small malformation of AV system in subglottis

**Crossword Puzzle 3**



**Across**

- 4. Tracheostomy done at the level of 1st tracheal ring

**Down**

- 1. Intralesional steroids given in
- 2. Stridor having neonatal rhinitis
- 3. Noisy respiration produced by turbulent airflow

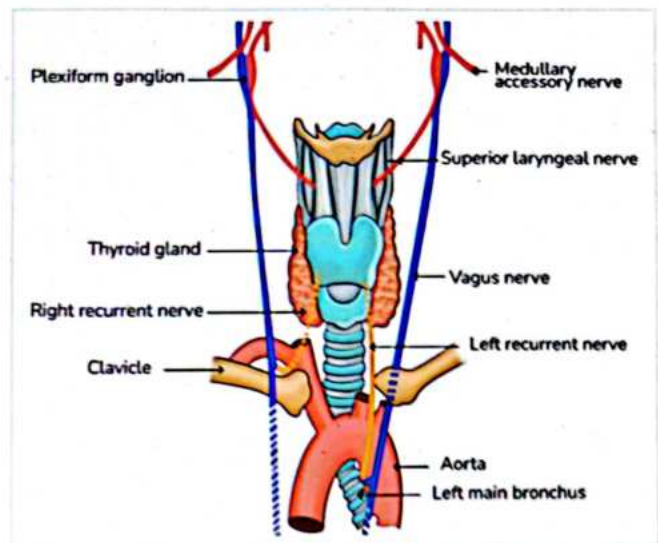
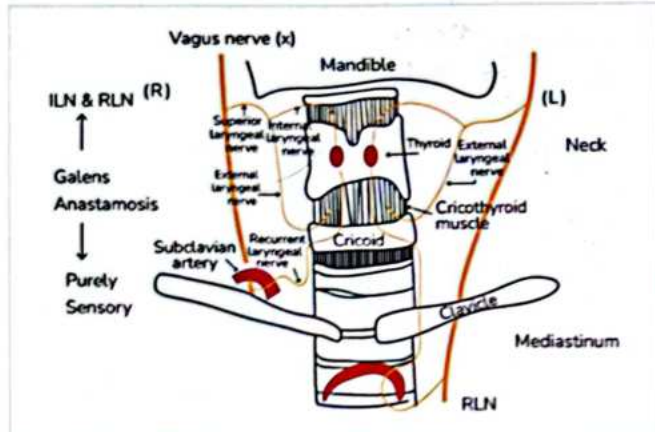


Vocal Cord Paralysis

Anatomy of Larynx

00:01:30

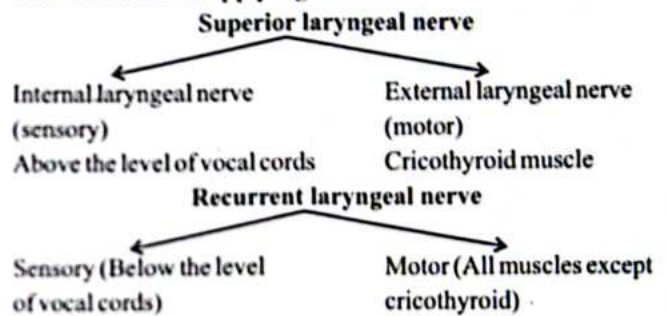
- Two nerves are involved in vocal cord paralysis: The Superior laryngeal nerve and the recurrent laryngeal nerve.



The Vagus nerve is present on both the right and left sides.

Right side	Left side
<p>At the level of the hyoid gives a branch, the superior laryngeal nerve again divides into</p> <ol style="list-style-type: none"> <li>Internal laryngeal nerve (piercing thyrohyoid membrane and sensory nerve supply to larynx above vocal cords)</li> <li>External laryngeal nerve (motor to cricothyroid muscle)</li> </ol> <p>At the level of the right subclavian artery, it gives recurrent laryngeal nerve and gives sensory nerve supply to the larynx below the vocal cords and supplies all muscles of the larynx except the cricothyroid muscle).</p>	<p>At the level of the hyoid gives a branch, the superior laryngeal nerve again divides into</p> <ol style="list-style-type: none"> <li>Internal laryngeal nerve (piercing thyrohyoid membrane and sensory nerve supply to larynx above vocal cords)</li> <li>External laryngeal nerve (motor to cricothyroid muscle)</li> </ol> <p>The vagus nerve continues down, enters the mediastinum and at the level of the aortic arch it gives recurrent laryngeal nerve enters the tracheoesophageal groove and gives sensory nerve supply to the larynx below the vocal cords and supplies all larynx muscles except cricothyroid muscle.</p>

Individual nerve supply is given below:



Nerve Supply of larynx

00:14:49

	Recurrent laryngeal nerve	Superior laryngeal nerve
<b>Sensory supply</b>	The Inferior part of the larynx	The Superior part of the larynx
<b>Motor supply</b>	All muscles of the larynx except cricothyroid (Posterior cricoarytenoid - abductor)	Cricothyroid only tensor additionally secondary adduction function
<b>Paralysis</b>	Impaired abduction mainly	Impaired tensor function

Causes of vocal cord paralysis

00:19:01

- Surgical trauma → In thyroid surgery right recurrent laryngeal nerve has more possibility to get injured than left recurrent laryngeal nerve.
- Idiopathic
- Malignancy

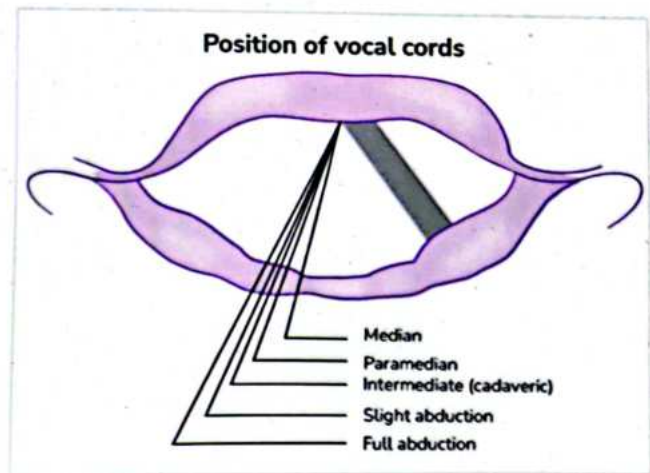


- Infections- viral, bacterial
- Non-surgical trauma →Ortner's Syndrome or cardio vocal syndrome (Left atrial hypertrophy → compression of RLN)

Q. Which nerve is at greater risk of palsy, left or right RLN?  
 Ans. Left recurrent laryngeal nerve as it has longer course

Q. Which nerve is at risk during thyroid surgery, left or right RLN?  
 Ans. Right recurrent laryngeal nerve.

Q. Which nerve is at risk in bronchogenic carcinoma, left or right RLN?  
 Ans. Left laryngeal nerve

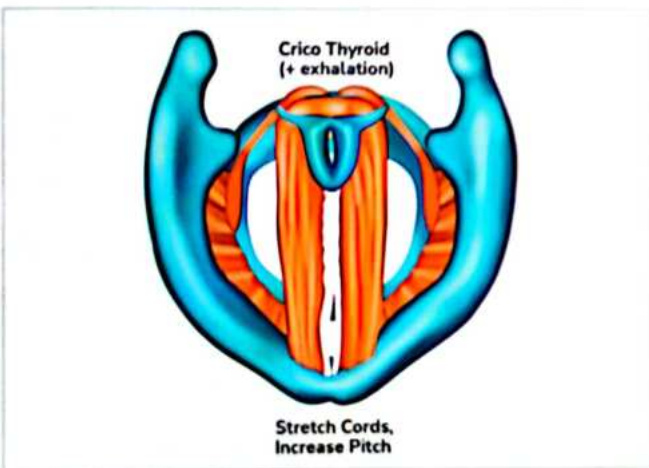


**Functions**

**Phonation**

- Cricothyroid muscle acts as both tensor(primary) and adductor(secondary) which is required for phonation.
- In paralysis of cricothyroid or palsy of the external branch of SLN, vocal cords will be floppy, and voice is affected.

princeeekum@gmail.com  
 9928609733



**Position of vocal cord in health & disease**

Position	Location of cord from midline	Situation in	
		Health	Disease
Median	Midline	Phonation	RLN paralysis
Intermediate (cadaveric)	3.5 mm (This is neutral position of cricoarytenoid joint. Abduction takes place from this position)	-	Combined paralysis (both RLN & SLN)
Gentle abduction	7 mm	Quiet respiration	Paralysis of adductors
Full abduction	9.5 mm	Deep inspiration	-

**Respiration**

- Posterior Cricoarytenoid acts as an abductor and helps in deep inhalation letting in air.
- RLN palsy abduction is impaired, and respiration is affected.

**Position of Vocal Cords**

00:30:06

- Normal position: Intermediate position/ Cadaveric position of the vocal cords =3.5mm away from the midline (due to opposing action of cricothyroid and Posterior Cricoarytenoid)
- Vocal cords will come to midline position during phonation.
- Abducted position

**One Liners**

- Sensory innervation below the vocal cord is RLN
- Sensory innervation above the vocal cord is SLN
- All muscles receive motor innervation from RLN except Cricothyroid
- Most common cause of RLN palsy is Traumatic
- Most common cause of RLN on left side is Bronchogenic CA

**Nerve Palsy**

00:37:41

**Unilateral RLN Palsy**

00:37:42

1. Sensory loss: Below the vocal cords on the same side.
2. Motor loss: All muscles are paralyzed on the same side except CRICOTHYROID.
3. Position of the vocal cord: Paralyzed side lies in the midline



position. The normal side lies in an intermediate position.

4. Phonation: Not affected.
5. Respiration: Dyspnoea on exertion.

**Treatment:** No requirement for immediate intervention.

### Bilateral RLN Palsy

00:45:48

1. Sensory loss: Below the vocal cords on the BOTH side.
2. Motor loss: All muscles are paralyzed on the BOTH side except CRICOTHYROID.
3. Position of the vocal cord: Both vocal cords lie midline.
4. Phonation: Not affected much.
5. Respiration: STRIDOR

### Treatment

- TRACHEOSTOMY
- Type 2 Thyroplasty

### Unilateral SLN Palsy

00:49:25

1. Sensory loss: Above the vocal cords on the same side.
2. Motor loss: Only CRICOTHYROID is paralyzed on the same side.
3. Position of the vocal cord: Paralyzed vocal cord lies abducted. The normal side lies in an intermediate position.
4. Phonation: Pitch and tone are affected.
5. Respiration: Not affected.
6. Increased risk for aspiration.

**Treatment:** Type 1 Thyroplasty.

### Bilateral SLN Palsy

00:56:23

1. Sensory loss: Above the vocal cords on the BOTH side.
2. Motor loss: Only Bilateral CRICOTHYROID palsy.
3. Position of the vocal cord: Both vocal cords lie abducted.
4. Phonation: Aponia.
5. Respiration: Not affected.
6. Aspiration present (highest risk).

### Treatment: Directed for

- Voice
- Prevention of aspiration

### Unilateral Combined Palsy

01:00:33

1. Sensory loss: Present on one half of the larynx
2. Motor loss: All the muscles are paralyzed on the affected side.
3. Position of the vocal cord: Both lie in an intermediate position, but paralyzed vocal cord is floppy and loose.
4. Phonation: Affected (mild-moderate)
5. Respiration: Not affected much
6. Mild Risk for aspiration.

**Treatment:** Nil

### Bilateral Combined Palsy

01:04:33

1. Sensory loss: Entire larynx
2. Motor loss: All the muscles are paralyzed.
3. Position of the vocal cord: Both lie in an intermediate position and are floppy.
4. Phonation: Aponia
5. Respiration: Not affected.
6. Moderate Risk for aspiration.

**Treatment:** Varies

Refer table 43.1

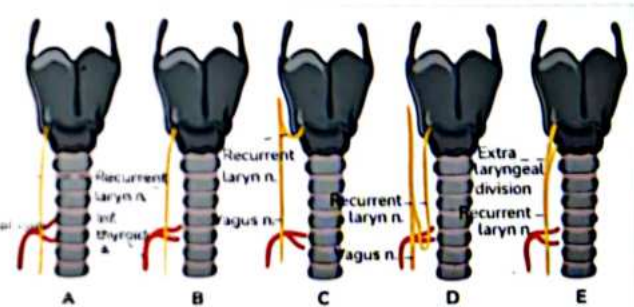
### RLN Identification

01:11:04

### Relation to inferior thyroid artery

01:11:30

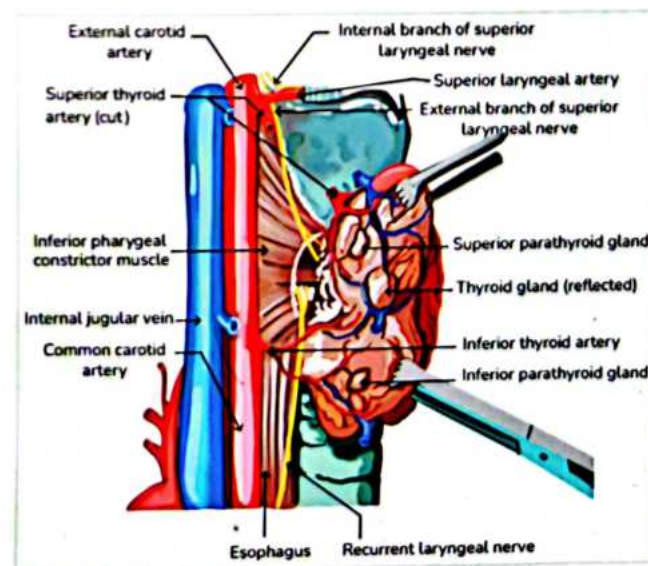
- The recurrent laryngeal nerve has got very close proximity to the inferior thyroid artery, and it varies.



### Triangles identify recurrent laryngeal nerves.

#### 1. BEAHR's triangle

- Boundaries are Medial= Recurrent laryngeal nerve
- Lateral= Common carotid artery
- Superior= Inferior thyroid artery





## 2. LORE's triangle

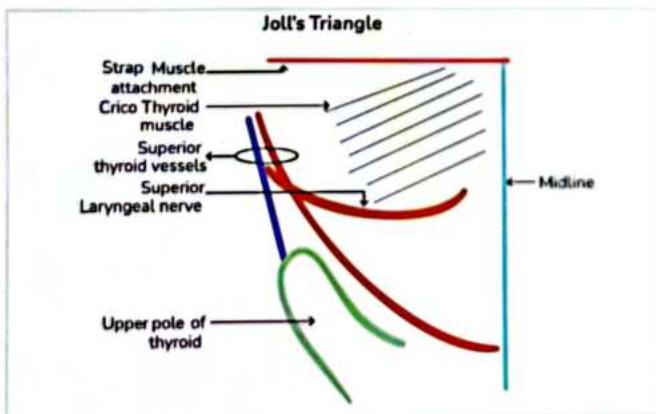
- Boundaries are Medial= Recurrent laryngeal nerve, trachea and oesophagus
- Lateral= Common carotid artery
- Superior= Lower pole of the thyroid

## 3. SIMON's triangle

- Boundaries are Medial= Recurrent laryngeal nerve
- Lateral= Common carotid artery
- Superior = Cricothyroid muscle

## 4. JOLL's triangle

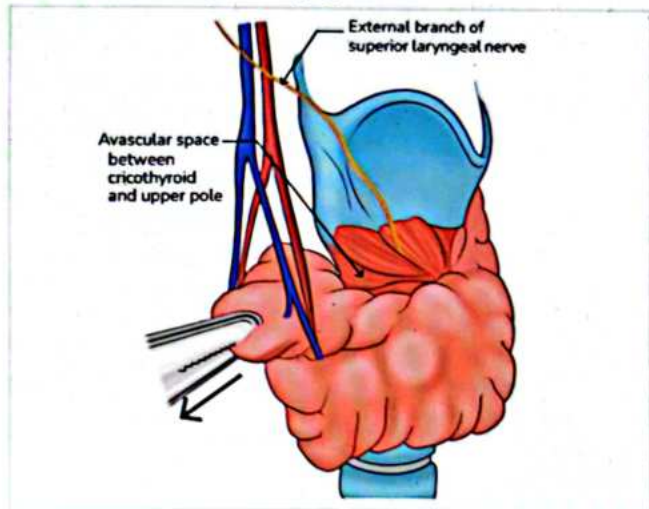
- Aim: Used for identifying the external branch of the superior laryngeal nerve.
- Boundaries are Medial= Midline
- Lateral = Upper pole of the thyroid gland and superior thyroid vessels
- Superior = Insertion of strap muscles
- Near the upper pole= Superior laryngeal nerve and the superior thyroid vessel
- Floor = Cricothyroid muscle



## Cricothyroid space of Reeves

- Avascular zone between the upper pole of the thyroid and cricothyroid muscle.

Use: Identify the superior laryngeal nerve



Q. Name purely sensory anastomosis between internal laryngeal and recurrent laryngeal nerve.

Ans: Galen's anastomosis

Q. Name the avascular zone between the upper pole of the thyroid and the cricothyroid muscle.

Ans: Cricothyroid space of reeves

Q. Two conditions where aphonia is present.

Ans: Bilateral combined palsy and bilateral sln palsy

Q. Name the nerve entering the mediastinum.

Ans: Left RLN



Table 43.1

	RLN- Unilateral palsy	RLN- Bilateral palsy	SLN- Unilateral palsy	SLN - Bilateral palsy	Combined unilateral palsy	Combined bilateral palsy
<b>Sensory loss</b>	Ipsilateral anaesthesia of larynx below vocal cords	Bilateral anaesthesia of larynx below vocal cords	In SLN palsy ipsilateral anaesthesia above vocal cords.	In SLN palsy bilateral anaesthesia above vocal cords.	Complete ipsilateral anaesthesia of larynx	Complete bilateral anaesthesia of larynx
<b>Motor loss</b>	Ipsilateral paralysis of all intrinsic muscles except cricothyroid  <small>prince kumar princeeeekum@gmail.com 9928609733</small>	Bilateral paralysis of all intrinsic muscles except cricothyroid	Ipsilateral paralysis of cricothyroid	Bilateral paralysis of cricothyroid	Ipsilateral paralysis of all intrinsic muscles except interarytenoid which receive bilateral innervation	All laryngeal muscles are paralyzed






# CROSS WORD PUZZLES



**Crossword Puzzle 1**



**Across**


- 4. Used for identifying external branch of superior laryngeal nerve
- 5. Position in which paralyzed cord is in abducted position with some tilting

**Down**

- 1. Which is the most common cause for left-sided recurrent laryngeal nerve palsy?
- 2. Palsy in which highest risk of Aspiration present
- 3. Muscle helps in phonation

**Crossword Puzzle 2**

prince kumar  
princeeeekumar@gmail.com  
9928609733




**Across**

- 1. Respiratory problem seen in bilateral rln palsy
- 3. Supply cricothyroid muscle

**Down**

- 2. Palsy causing impaired abduction

**Crossword Puzzle 3**



**Across**

- 2. Nerve that is sensory to the larynx below the vocal cord
- 3. Nerve that divides at the level of hyoid

**Down**

- 1. Most common cause of surgical trauma to nerve supplying vocal cords



00:01:45

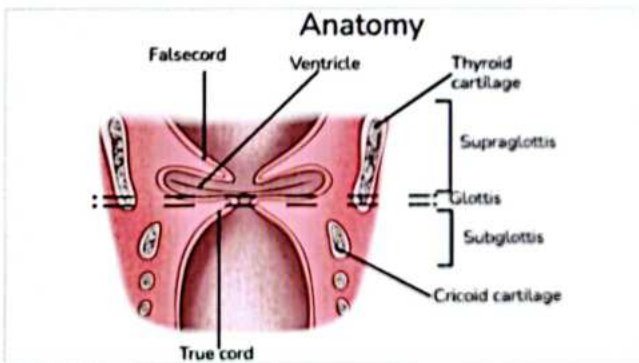
- It is a squamous cell carcinoma.
- It mostly affects males.

**Etiology**

These are the causes of laryngeal carcinoma:

- HPV 6 and 11: They cause respiratory papillomatosis leading to a predisposition to carcinoma.
- Benzopyrene in cigarette smoke.
- Alcohol consumption.
- Any previous history of radiation.
- Occupational exposure to asbestos, mustard gas, and petroleum.

**Types of Laryngeal Carcinoma**



The pharynx is divided into three parts:

- **Supraglottis:** The part of the larynx that lies above the vocal cords.
- **Glottis:** The part of the larynx that lies at the level of vocal cords and 1 cm below.
- **Subglottis:** The part of the larynx that lies 1 cm below the level of vocal cords to the level of the cricoid cartilage.
- According to the site of malignancy, carcinomas can be divided into supraglottic, glottic, and subglottic carcinomas.
- The most common carcinoma is glottic carcinoma.
- It is followed by supraglottic carcinoma.
- The least common carcinoma is subglottic carcinoma.

**Pearls**

	Supraglottis	Glottis	Subglottic
Incidence	Intermediate	Most common	Least common
Site	Most common in epiglottis	Most commonly at free edge and superior	Most common in midline in anterior half.

Appearance	Suprahyoid-exophyte Sub hyoid-ulcerative	surface of anterior and middle 1/3 <sup>rd</sup> of vocal cord Nodule or ulcer or thickening of vocal cord	Submucosal Nodule
Vocal cord	Vocal cord involvement is very late. So hoarseness of voice is late.	Vocal cord involvement of voice is early. But vocal cord fixation indicates infiltration of thyroarytenoid muscle and is a very bad prognostic sign	Late

	Supraglottis	Glottis	Subglottic
Metastases	Very early due to rich lymphatic supply Bilateral lymph nodes are involved in case of epiglottis carcinoma as it is midline Upper and middle deep cervical lymph nodes are involved	Never because of scant lymphatics in vocal cords	Early Bilateral  Lower deep cervical, pretracheal and para tracheal
Appearance	Silent until late. Dysphagia, throat pain, pain in ear, respiratory distress are late features	Hoarseness of voice	Silent Respiratory distress are late features
Nature	Anaplastic and highly malignant	Well differentiated and less malignant	



	Supraglottis	Glottis	Subglottic
Prognosis	Bad because symptoms are late as it is silent most of the time Early lymphatic metastases because of rich metastases Anaplastic and highly malignant	Good because Presents early with HOV. No lymphatic metastases Well differentiated	Worst

**Important Point**

- If a patient presents with a hoarse voice and a non-healing ulcer on their vocal cords for more than 4 weeks, it should be considered for cancer.
- Glottic cancer has the best prognosis.
- Subglottic cancer has the worst prognosis and is followed by supraglottic cancer.

**Investigations**

- The diagnosis of cancer is done by histopathological examination.
- So, the investigation of choice is a biopsy.
- The initial investigation will be a contrast-enhanced CT scan (CECT).
- The most accurate test to assess cartilage involvement or space involvement is an MRI scan.
- MRI is not the first choice as MRI takes more time, has more artifacts (due to the movement of the patient), the patient has to hold the breath for longer, and is expensive.

**Staging**

00:26:48

The TNM classification according to different stages is as follows:

- Stage 1: T1 N0 M0
- Stage 2: T2 N0 M0
- Stage 3: T1,2,3 N1 M0
- Stage 4a: T1,2,3,4a N2 M0
- Stage 4b: T1,2,3,4a,4b N3 M0
- Stage 4c: Any T Any N M1

**TNM Classification**

- T1: Only 1 sub site is involved and the vocal cords are mobile.
- T2: More than 1 sub site is involved and the vocal cord can be normal/mobile or can have restricted mobility.
- T3: More than 1 sub site is involved, vocal cords are fixed, invasion of cartilage (inner perichondrium) of the larynx, and involvement of spaces around the larynx.
- T4a: It is the local spread.

- T4b: It is a distant spread.
- N0: No neck nodes are involved.
- N1: The size of the lymph node is <3 cm and it is ipsilateral.
- N2a: Single ipsilateral node between 3-6 cm.
- N2b: Multiple ipsilateral nodes between 3-6 cm.
- N2c: Single or multiple contralateral nodes between 3-6 cm.
- N3a: The size of the lymph node is >6 cm and there is no extranodal spread.
- N3b: The size of the lymph node is >6 cm and there is extranodal spread.
- M0: No metastasis involved.
- M1: Metastasis is present.

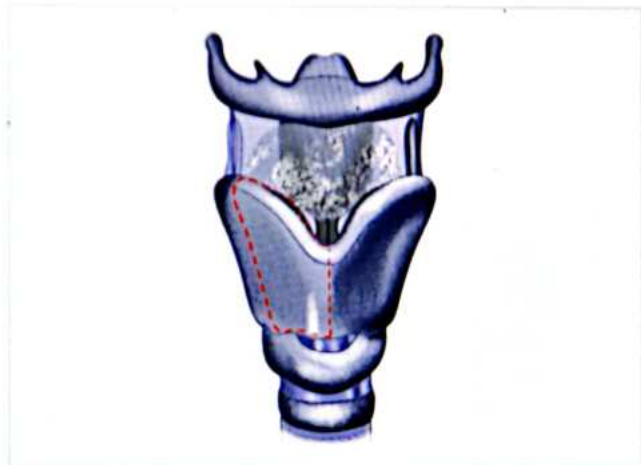**Treatment of Laryngeal Cancer**

**Stages 1 and 2**

- This is M0 and T2 N0 M0.
- There is no fixation of the vocal cords.
- The treatment of choice is radiotherapy as the aim of the treatment is organ preservation.
- Exception: Micro laryngeal surgery (MLS) is done when the carcinoma is in the middle 1/3 of the vocal cord.
- Conservative surgeries are done in patients with recurrence of the carcinoma as radiation therapy failed to treat their primary carcinoma.

**Conservative surgeries are of two types:**

**1. Vertical hemilaryngectomy:**

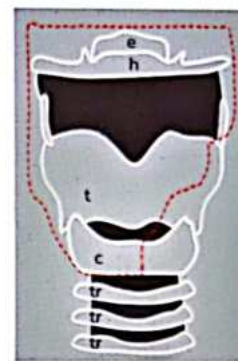


- One-half of the larynx is removed vertically in this surgery.
- Indications: Involvement of cancer in the vertical one-half of the larynx with a subglottic extension not more than 1 cm. It is done when there is recurrence.



2. Subglottic Laryngectomy

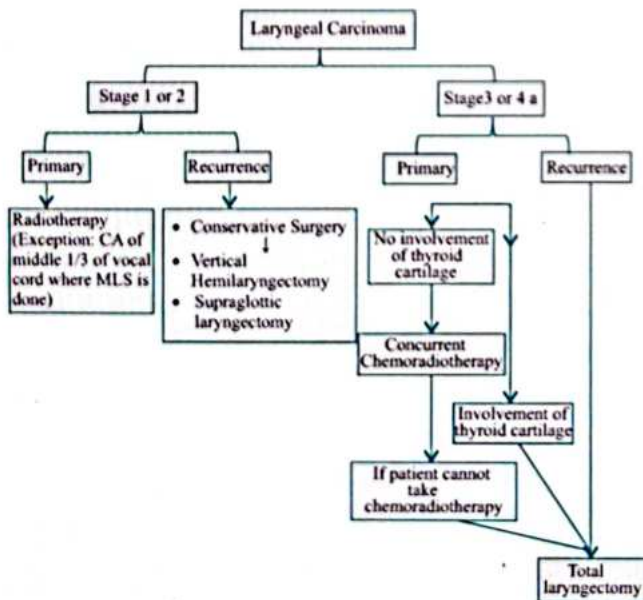
princeeeekum@gmail.com  
9928609733



- In this surgery, the complete larynx is excised above the level of vocal cords.
- **Indication:** If the cancer is a supraglottic carcinoma not involving the vocal cords.
- **Exception:** This is the treatment of choice for recurrent T3 carcinoma only when pre-epiglottic space is involved.

Stages 3 and 4A

- The first line of treatment is concurrent chemo RT for stage 3 and early stage 4 (Cisplatin/ carboplatin/cetuximab).
- This means the treatment is suitable for all carcinomas in which the thyroid or the cricoid cartilage is not involved.



- **Near Total Laryngectomy:** This is for stage 3 or stage 4a with one arytenoid spared.
- **Indications:** If there is the involvement of the thyroid cartilage, then the treatment of choice becomes near-total laryngectomy.
- For patients with recurrent cancer.
- If the patient is not fit for chemo RT.
- If there is a bilateral arytenoid involvement then the surgery becomes a total laryngectomy.

Important Points

- Any patient in the cancer age group is having persistent or gradually increasing hoarseness of voice (HOV) for 3 weeks must have a laryngeal examination to exclude cancer.
- The impairment of vocal cord mobility indicates deeper infiltration into the thyroarytenoid muscle, crico-arytenoid joint or invasion of the recurrent laryngeal nerve.
- Toluidine blue helps in differentiating carcinoma in situ from leukoplakia. This is done with the help of contact endoscopy.
- Radiotherapy is curative in early vocal cord lesions with normal mobility in 90% of the patients.
- The disadvantage of laryngectomy is that the patient will have a permanent tracheostome and loss of voice.

Vocal Rehabilitation

01:19:29

- During normal speech, there is an air column during expiration that comes out of the trachea.
- This air column vibrates the vocal cords and turns into speech when it comes out of the mouth.
- So, the source of normal phonation is the column of air in the trachea.
- The vocal cord is the vibrator.
- The articulator is the oral cavity/oropharynx and nasopharynx.

In the patient with a permanent tracheostome and no larynx, here are the vocal rehabilitation options:

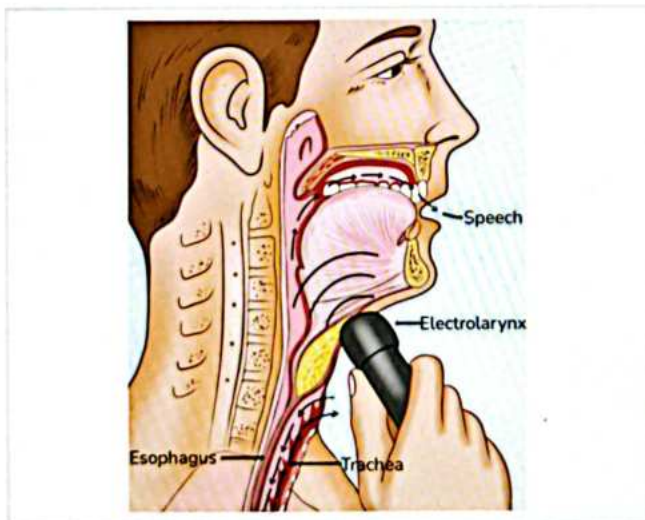
**Esophageal Speech:** In this, the patient is asked to swallow a gulp of air before speaking.



- Here the source of phonation is the column of air in the oesophagus.
- The vibrator here is the cricopharyngeal sphincter that will generate sound waves.
- The speech articulators are the same as normal speech, i.e., the oral cavity/oropharynx and nasopharynx.
- However, this doesn't resonate with natural speech. The patient will be able to speak 6-10 words before re-swallowing.

**TRACHEO-OESOPHAGEAL SPEECH:** In this, the patient is asked to close the tracheostome with the help of a finger.

- There is a prosthesis (for example - bloom singer valve) placed between the trachea and the oesophagus.
- Now the air column in the trachea will get redirected into the oesophagus which will hit the upper oesophageal sphincter and generate acoustic waves turning into speech.
- The source is the column of the air in the trachea.
- The vibrator is the upper pharyngeal sphincter/oesophageal sphincter/cricopharyngeal sphincter.
- The speech articulators are the same as normal speech, i.e., the oral cavity/oropharynx and nasopharynx.
- It resembles normal speech more than oesophageal speech. The patient can speak a few sentences.



prince kumar  
princeekum@gmail.com  
9928609733

**Electrolarynx:** In this, a hand-held external device is placed below the chin which will produce the acoustic vibrations for the articulators to produce speech.

### One Liner

- Lymph node metastasis in the neck is almost never seen with glottic carcinoma.
- The highest lymph node involvement is seen in subglottic and supraglottic carcinoma.
- In the case of laryngeal cartilage involvement, the

investigation of choice is MRI.

- Malignancy presenting with early hoarseness of voice is in glottic malignancy.
- The lymphatic drainage of the supraglottis is via upper deep cervical lymph nodes.
- The lymphatic drainage of the subglottis is seen in pretracheal and prelaryngeal lymph nodes.
- The highest lymph node involvement is seen in subglottic malignancy.
- In laryngeal cancer involving T1N0M0/T2N0M0, the treatment of choice is radiotherapy.
- The exception to the above is the carcinoma of the middle 1/3 of the vocal cord.
- In laryngeal cancer with recurrence T1N0M0/T2N0M0, the treatment of choice is conservative surgery.
- In T3N0M0, the treatment of choice is concurrent chemo RT.
- In recurrent T3N0M0, the treatment is total laryngectomy.
- The indication of total laryngectomy is recurrent T3 or T4, the patient can't tolerate chemo RT in stage T3 or T4a, T3 or T4a with an invasion of the thyroid cartilage, and bilateral involvement of arytenoid cartilage.
- The prosthesis used in tracheo-oesophageal speech is bloom singer, provox, Dr Rao's prosthesis, Panje's prosthesis, etc.






## CROSS WORD PUZZLES



Crossword Puzzle 1



prince kumar  
princeeeekum@gmail.com  
9928609733


**Across**

- 2. The least common carcinoma is \_\_\_\_\_ carcinoma.
- 4. Laryngeal carcinoma is a \_\_\_\_\_ carcinoma.

**Down**

- 1. The most common carcinoma is \_\_\_\_\_ carcinoma.
- 3. Etiology of laryngeal carcinoma is the presence of \_\_\_\_\_ in cigarette smoke.

Crossword Puzzle 2



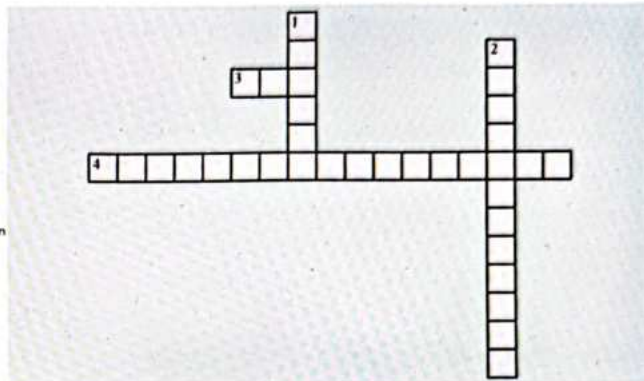
**Across**

- 2. There will be no/rare lymphatic metastasis in \_\_\_\_\_ carcinoma.
- 3. The most accurate test to assess cartilage involvement or space involvement is an \_\_\_\_\_ scan.
- 4. The initial investigation will be a \_\_\_\_\_.

**Down**

- 1. \_\_\_\_\_ lesions are exophytic in appearance.

Crossword Puzzle 3



**Across**

- 3. Multiple ipsilateral nodes between 3-6 cm are present in \_\_\_\_\_.
- 4. The first line of treatment is \_\_\_\_\_ for stage 3 and early stage 4.

**Down**

- 1. In T1 the vocal cords are \_\_\_\_\_.
- 2. For stages 1 and 2 the treatment of choice is \_\_\_\_\_.