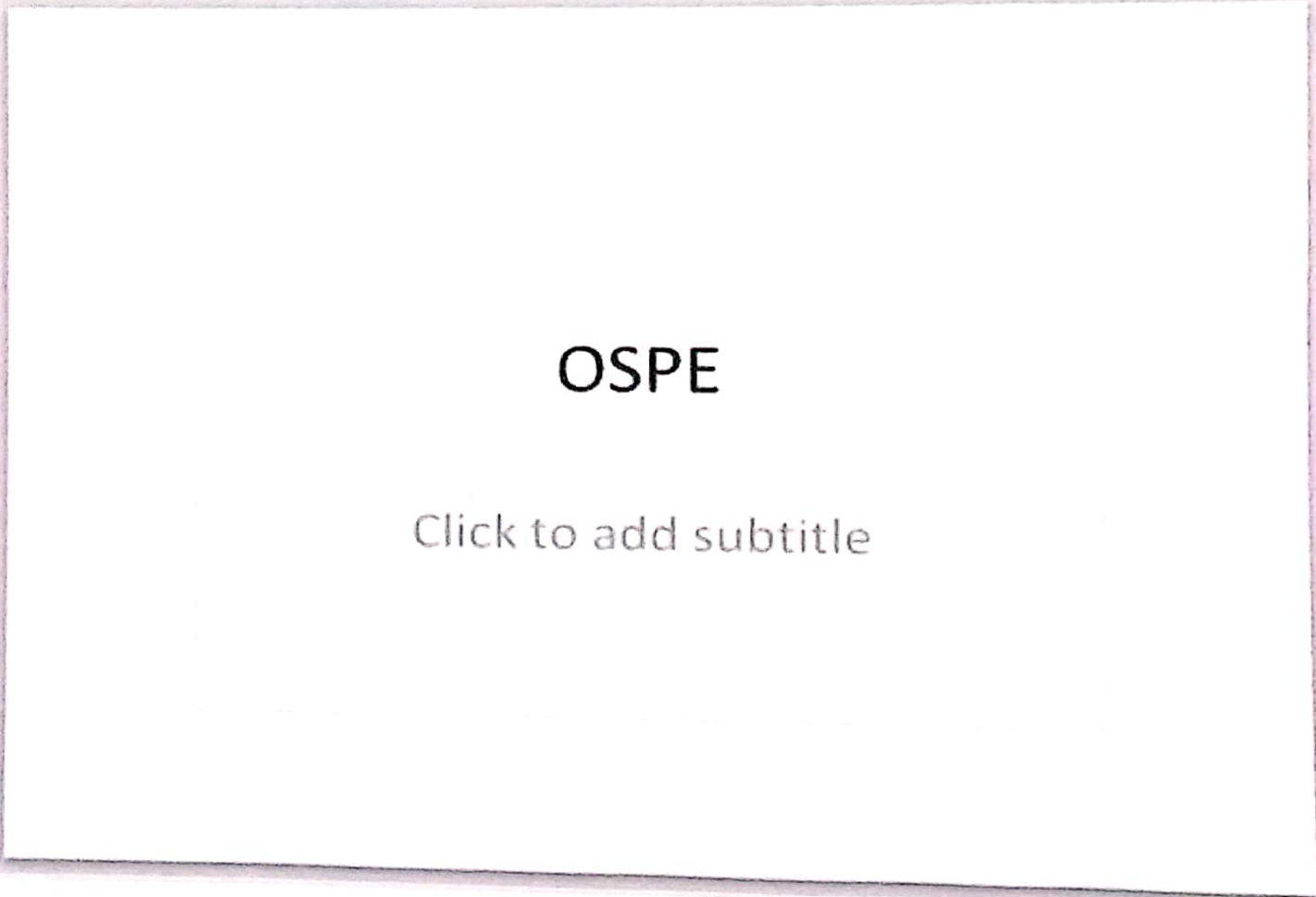
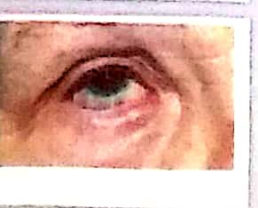
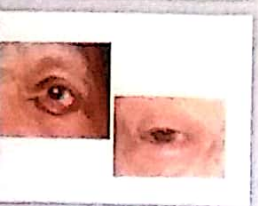

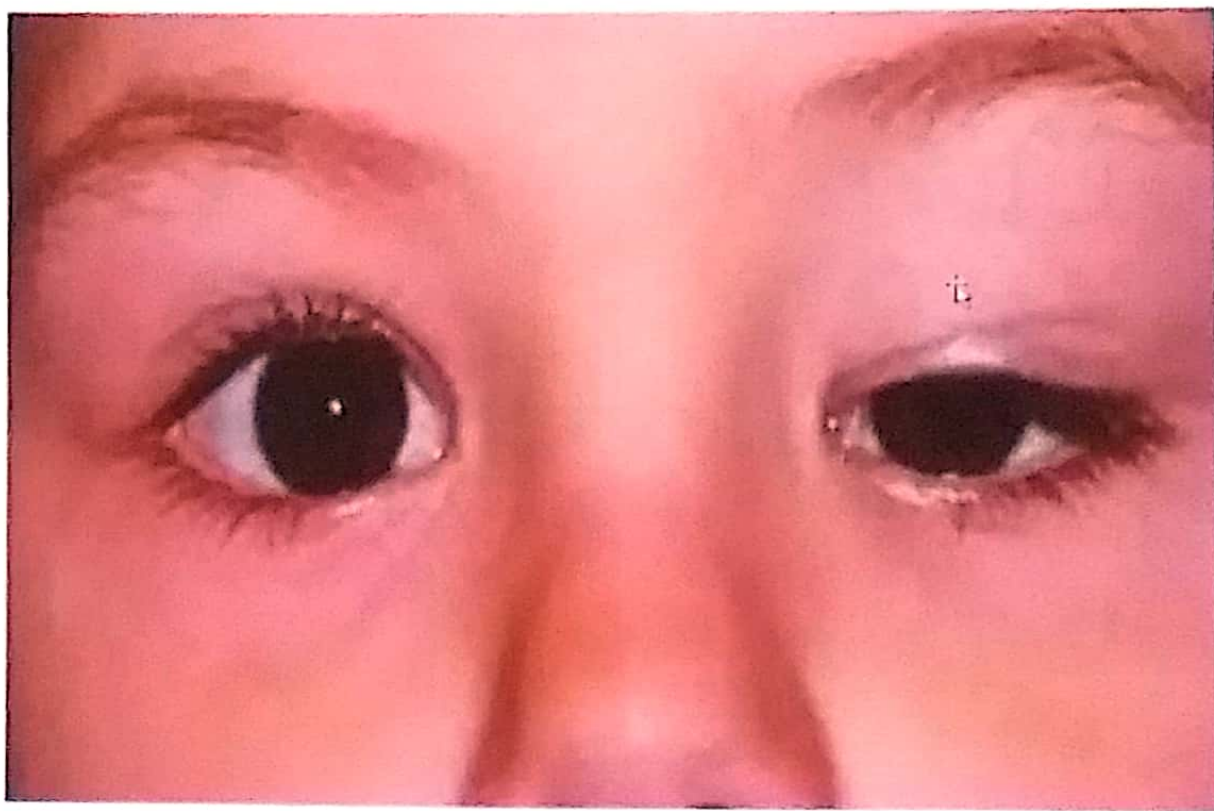
OSPE

Click to add subtitle

Click to add notes

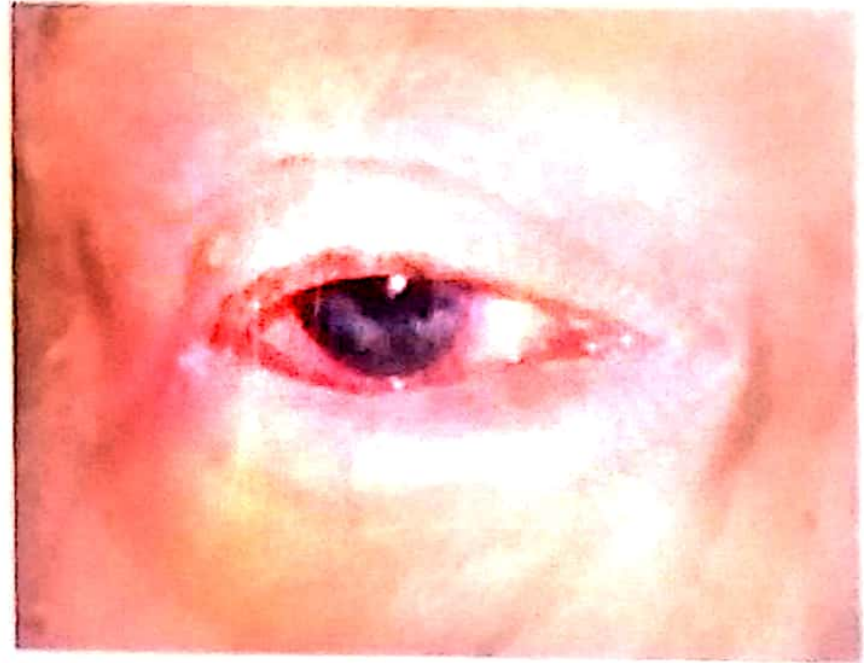
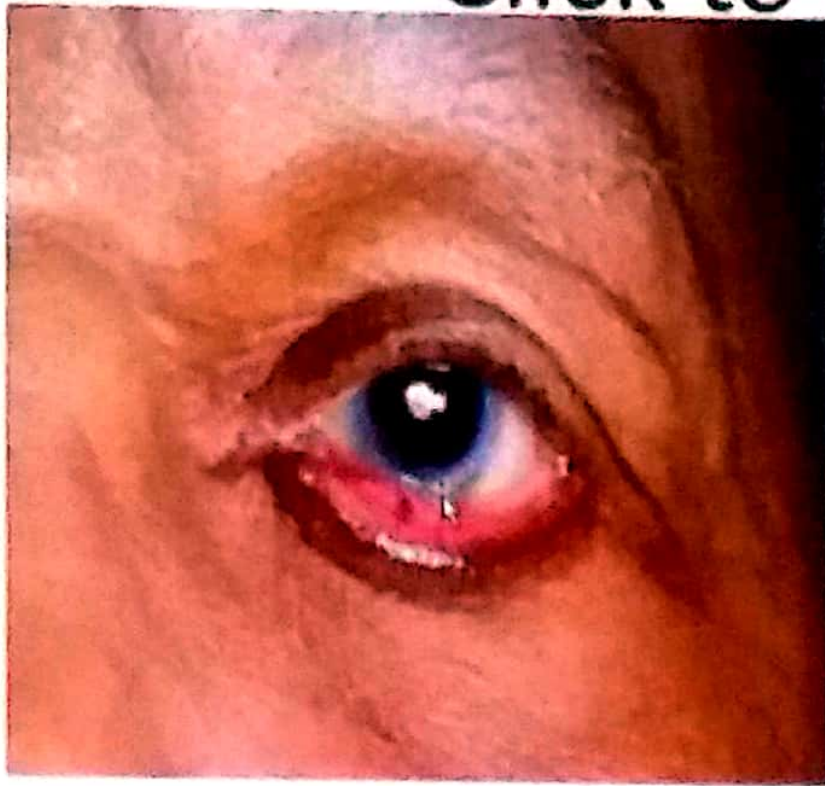
Outline

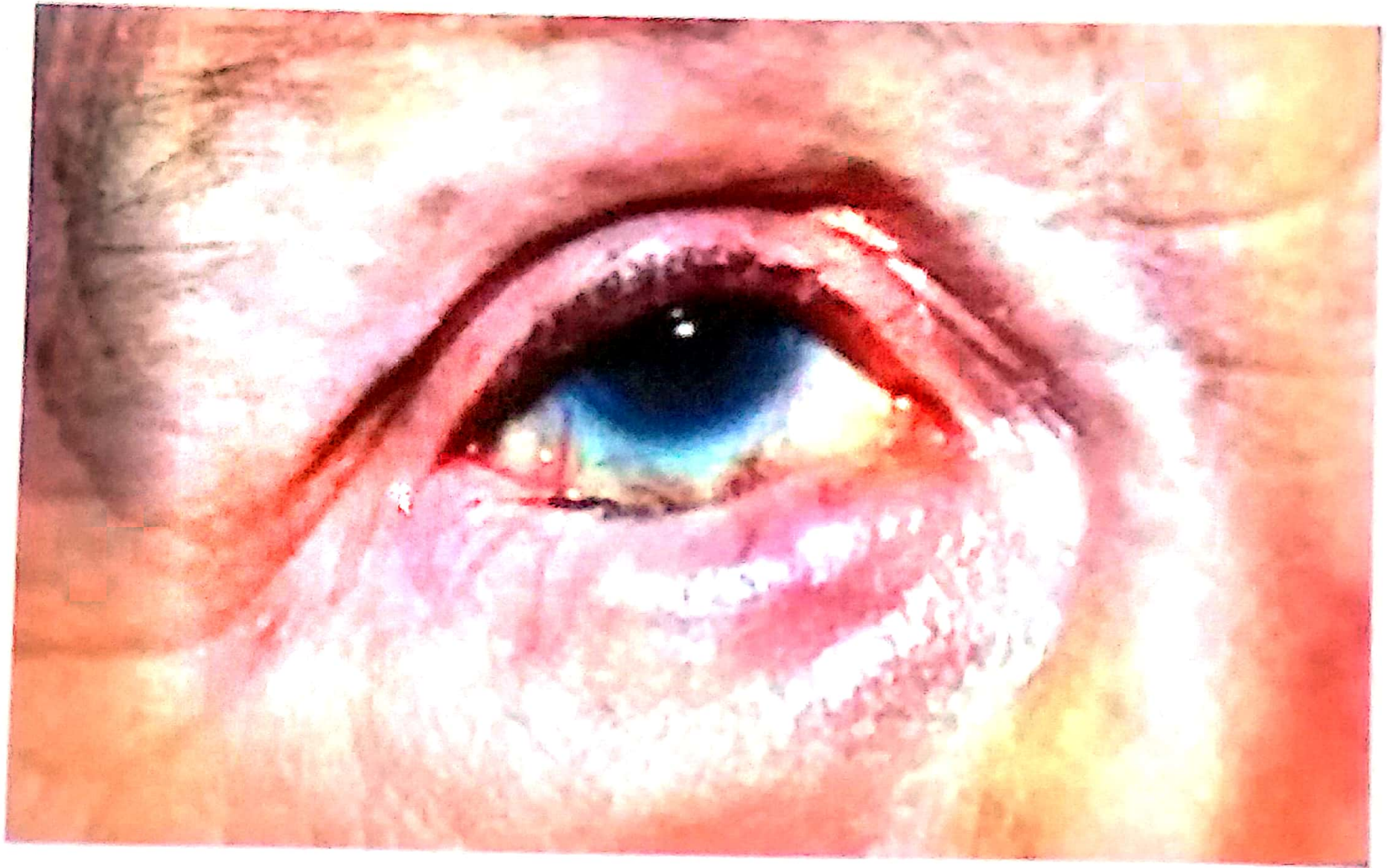OSPE

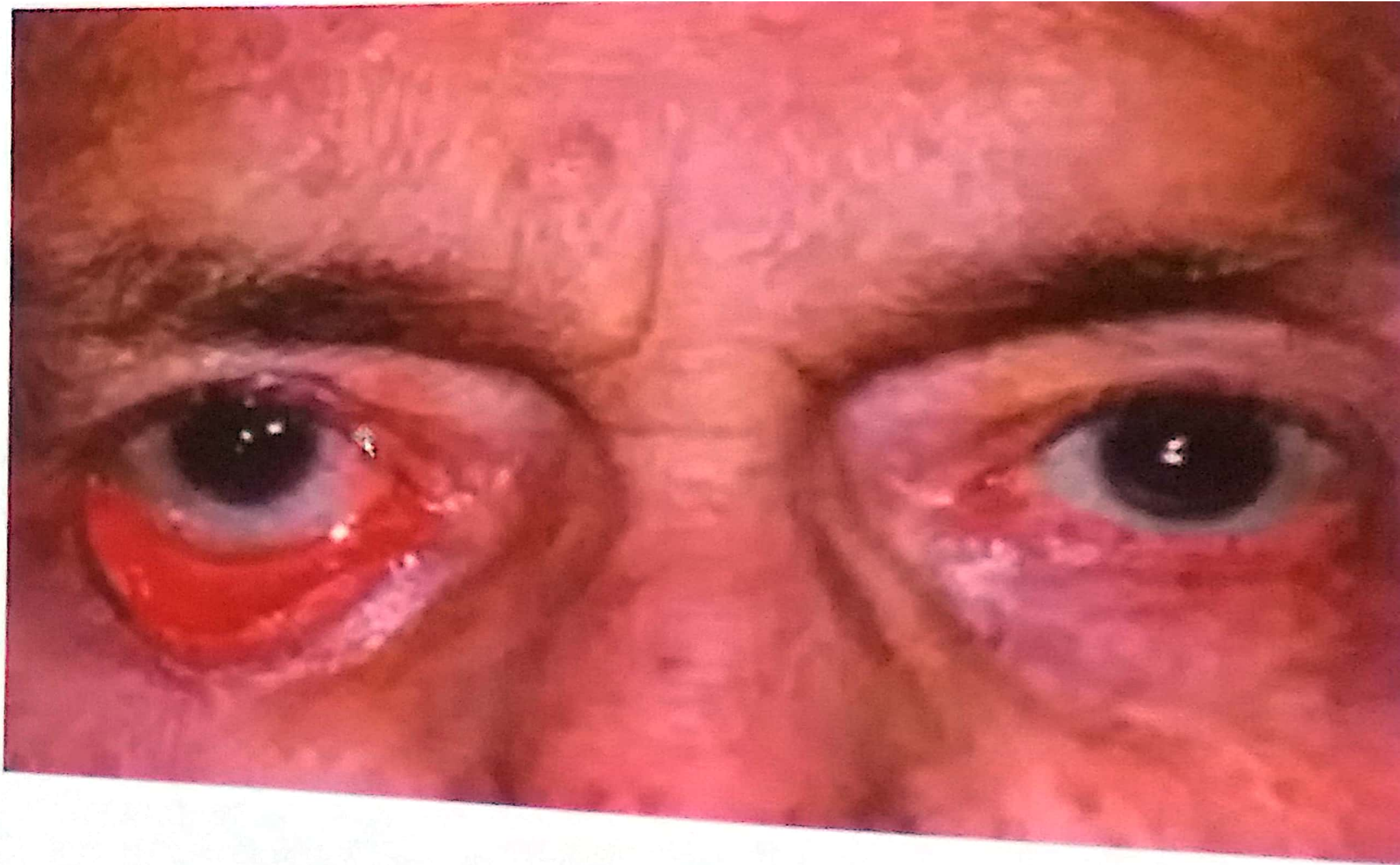

Click to add notes

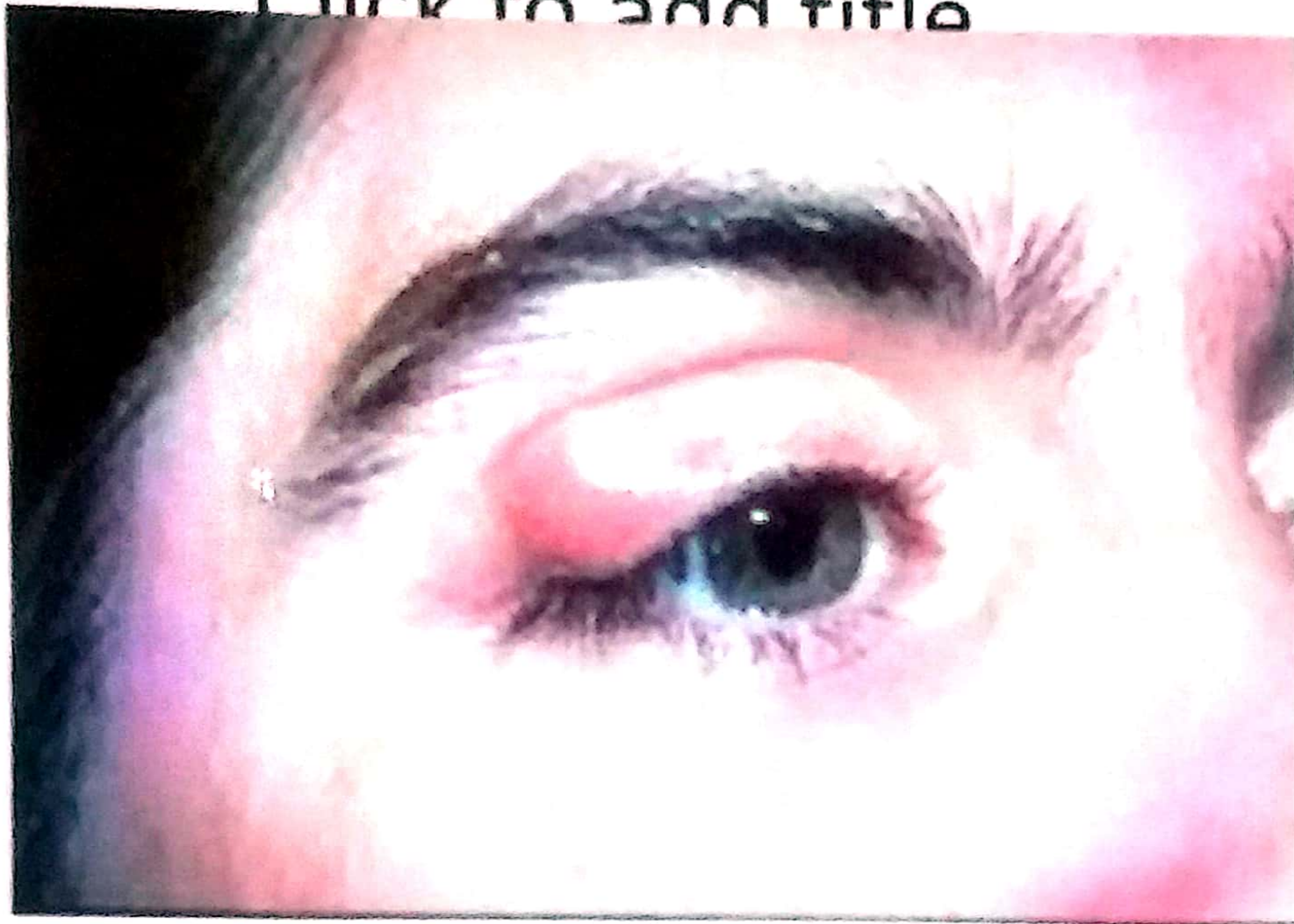Click to add title

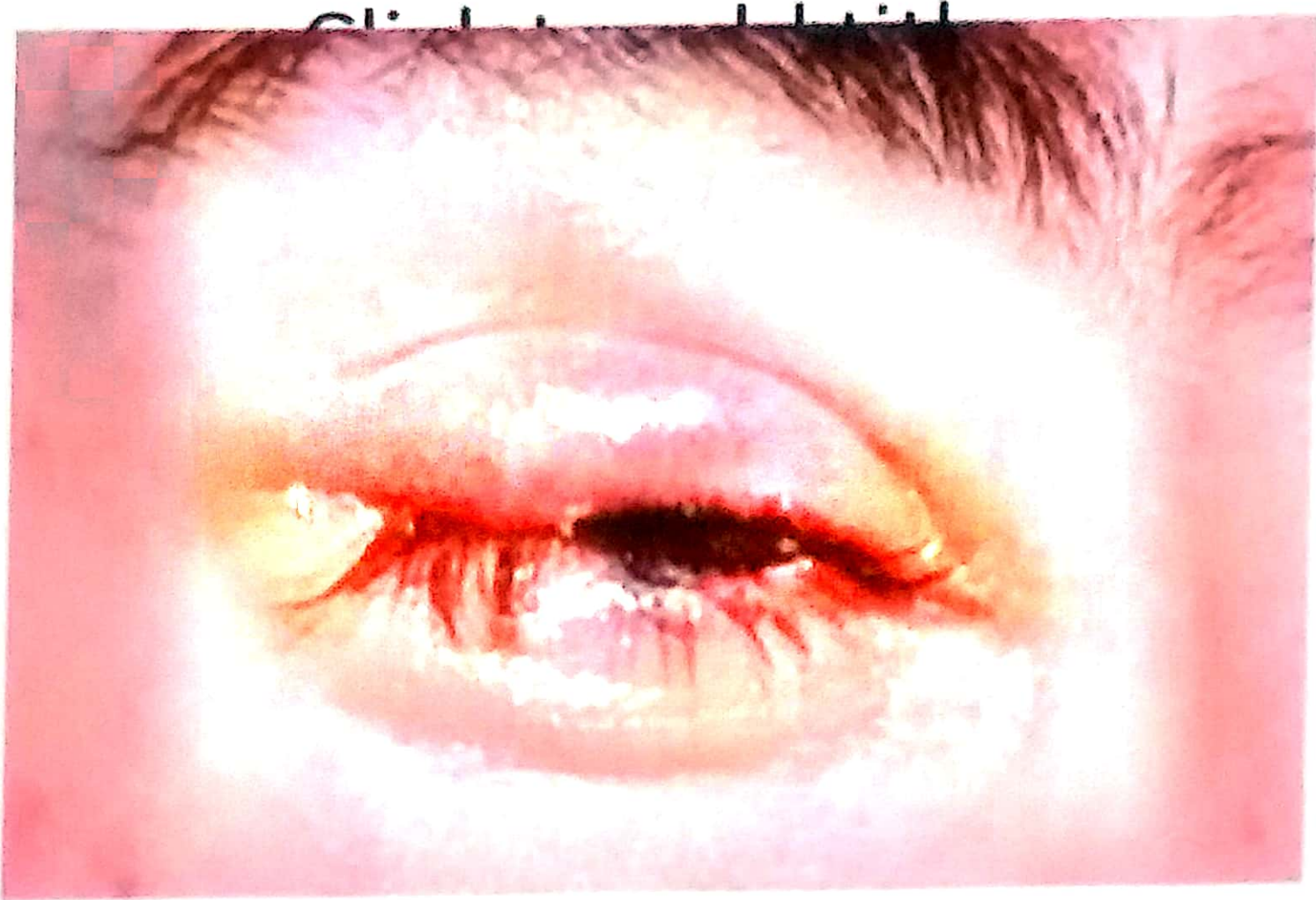

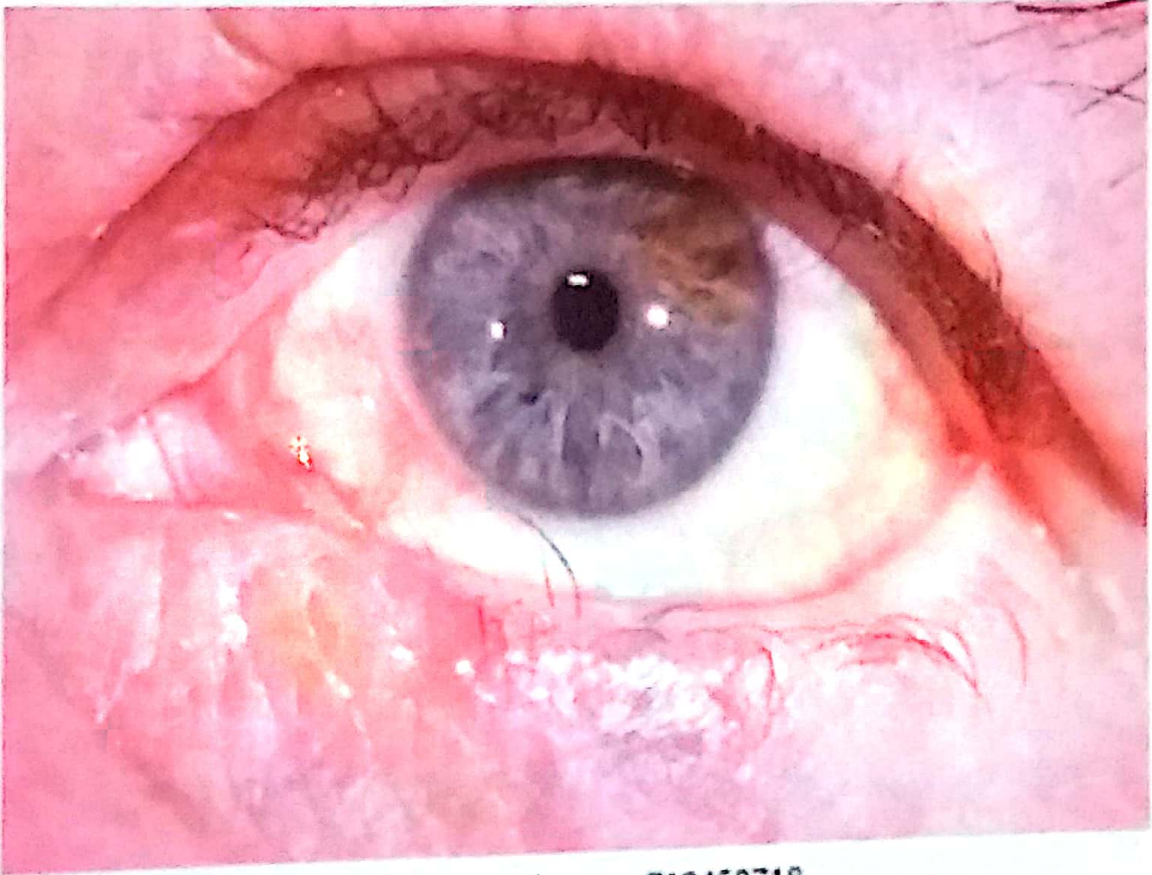




Click to add title





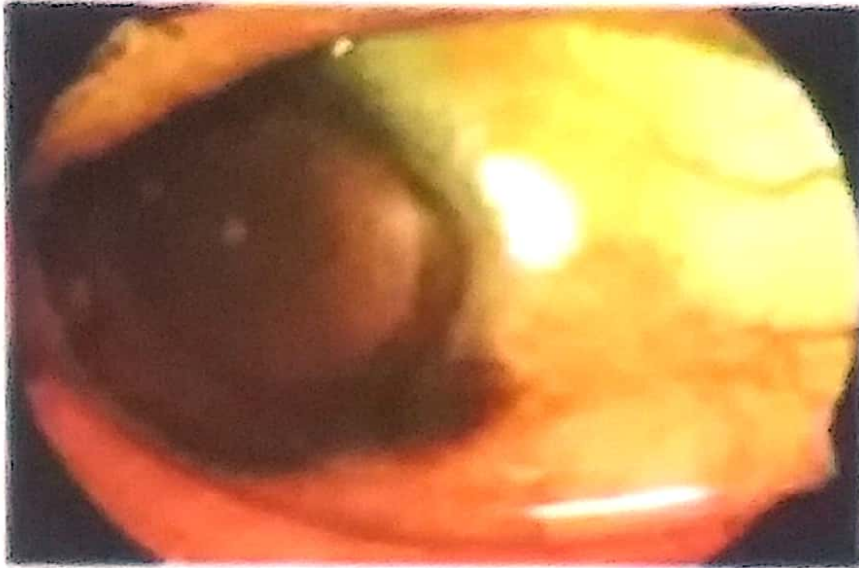


shutterstock.com · 718452718

©2010 The University of Iowa

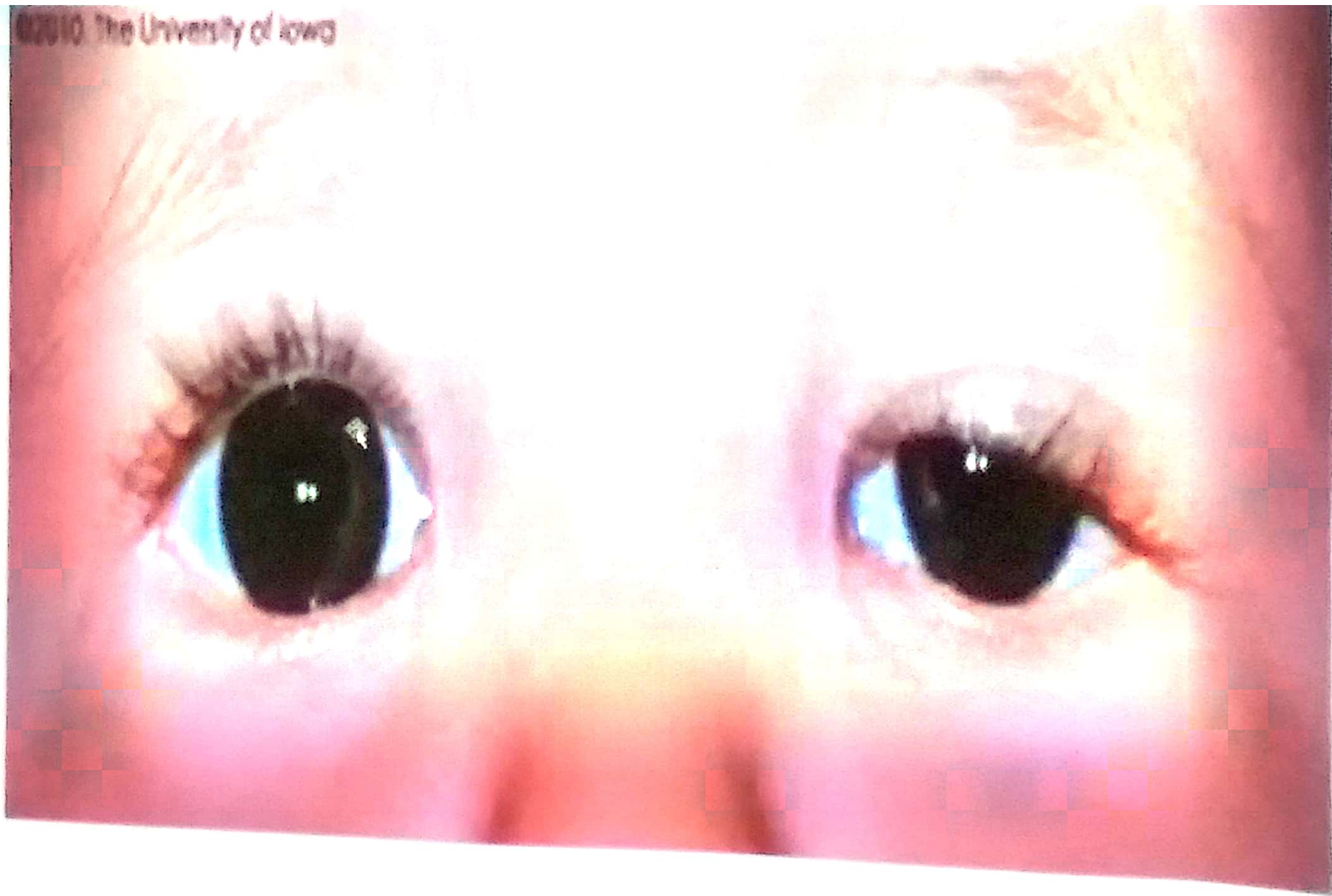

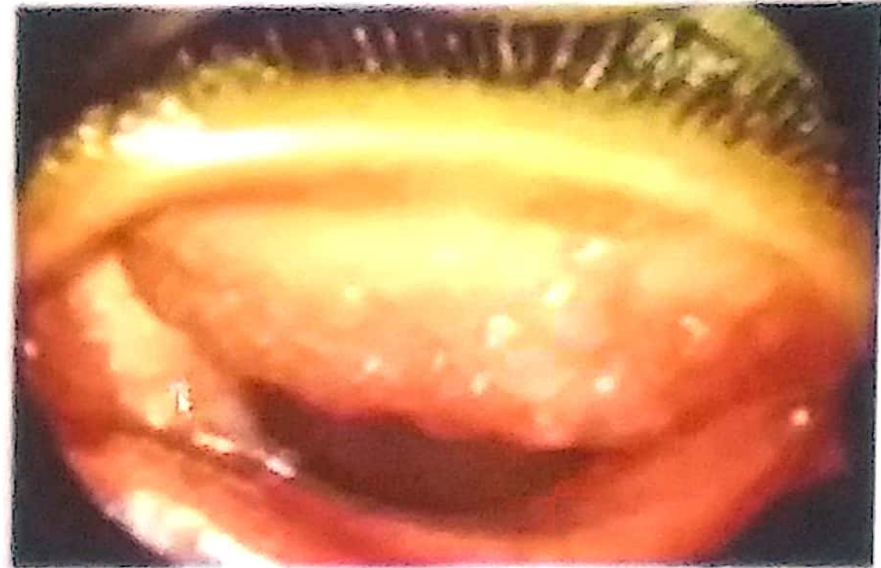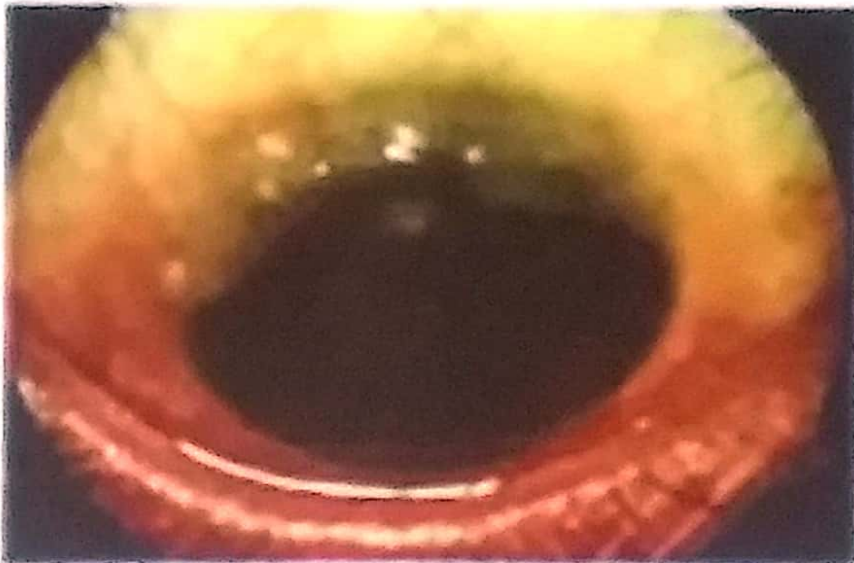
Figure 1 Clinical forms of VKC Limbal or bulbar, palpebral and mixed



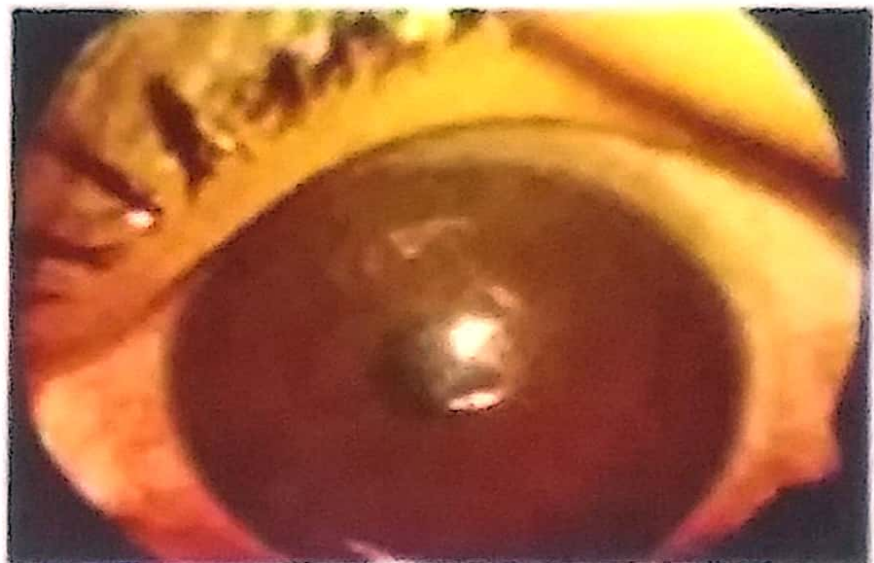Limbal form of VKC Gelatinous translucent appearance



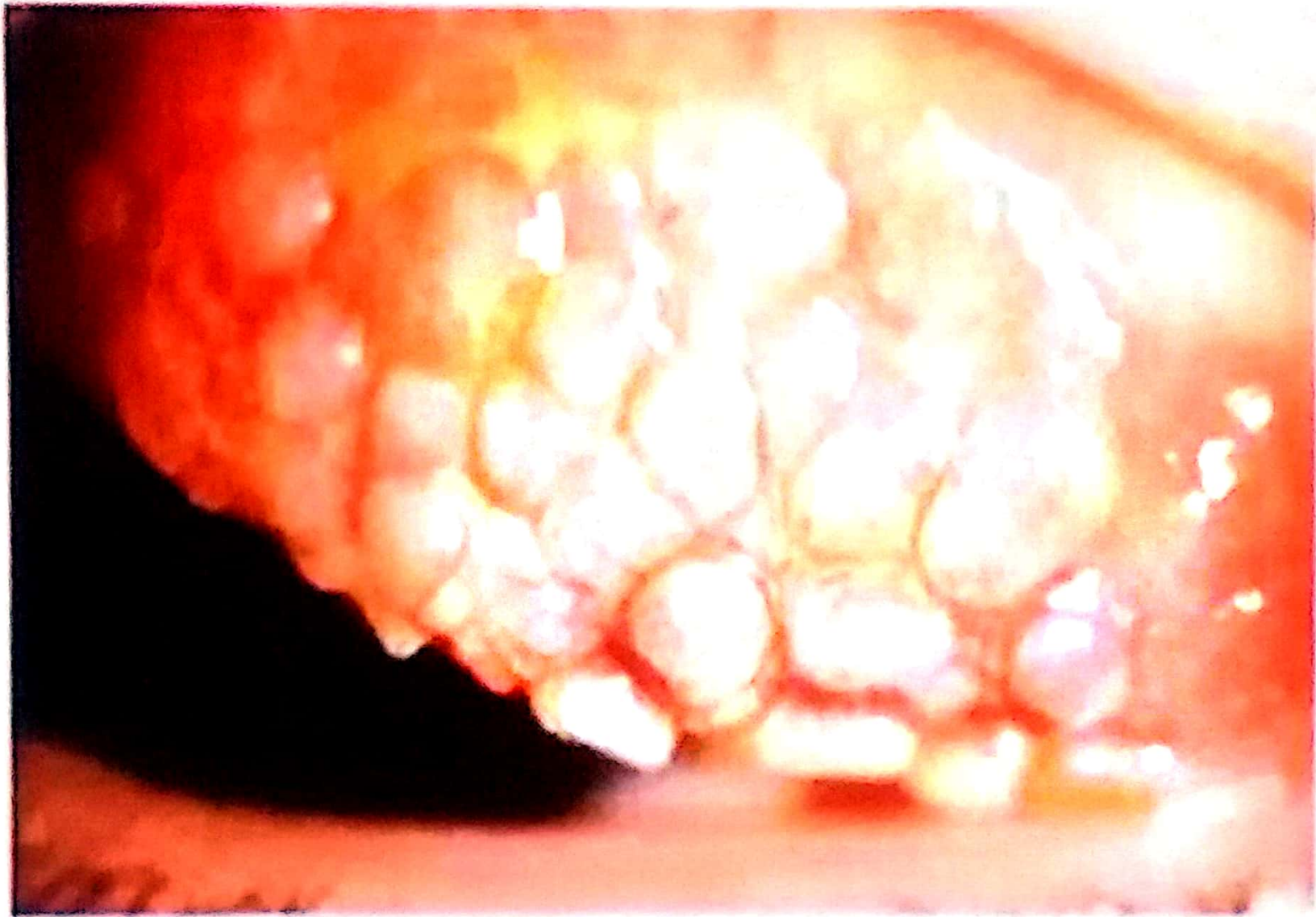
Palpebral form of VKC Lobble stone papillae seen after flipping of upper lid



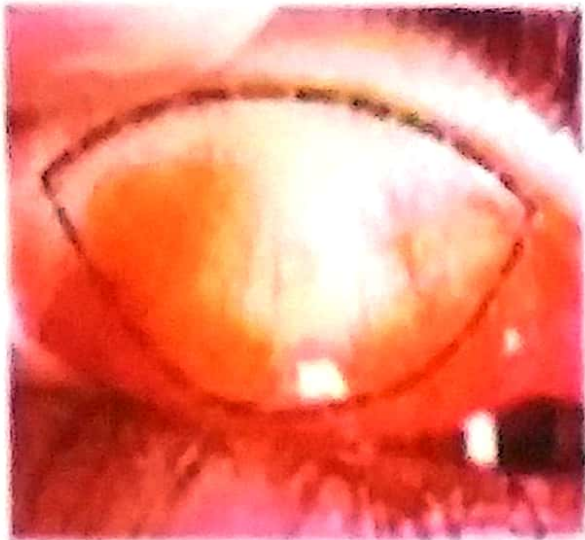
Yellow Horner-Trantas dots more



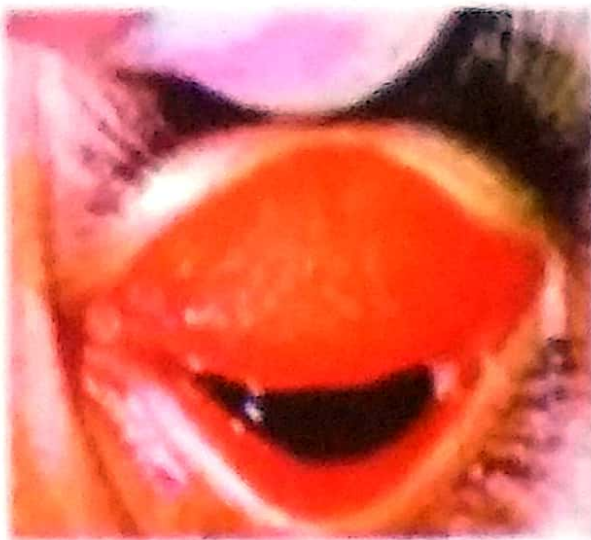Roughness of epithelium as



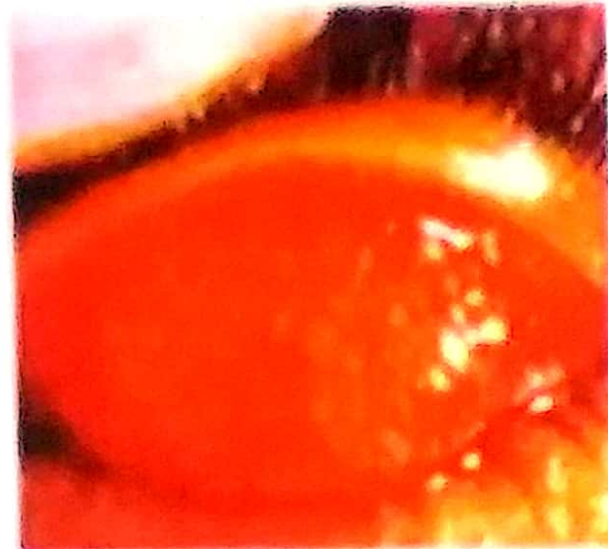a



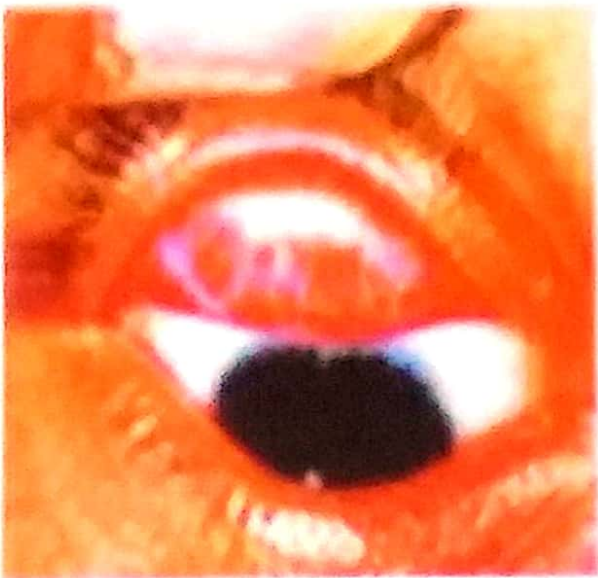b



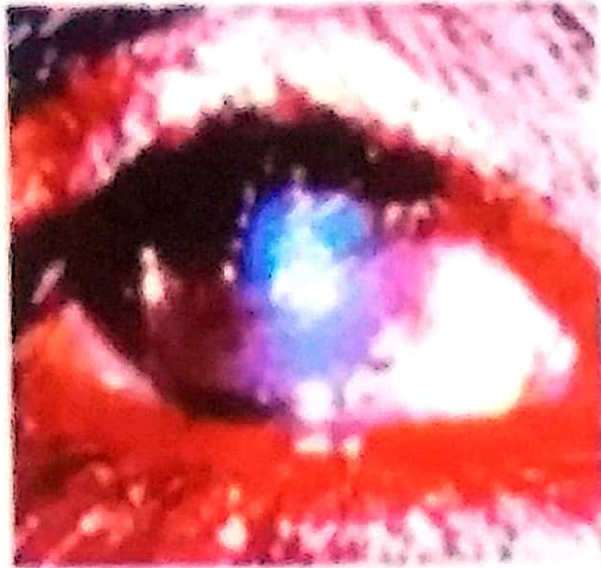c



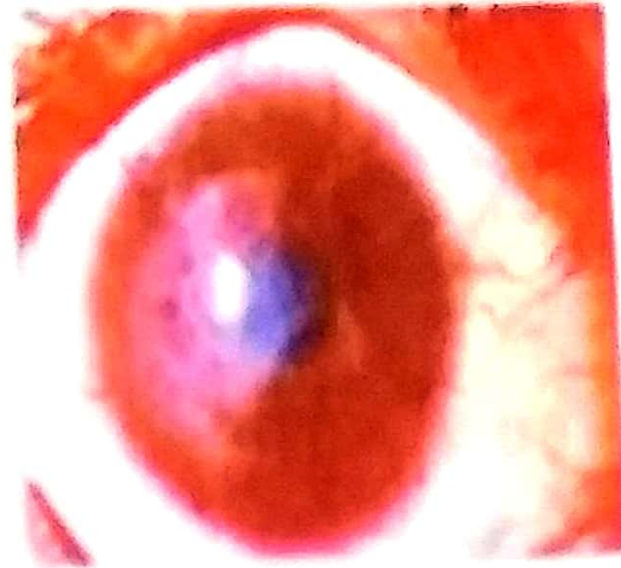
d

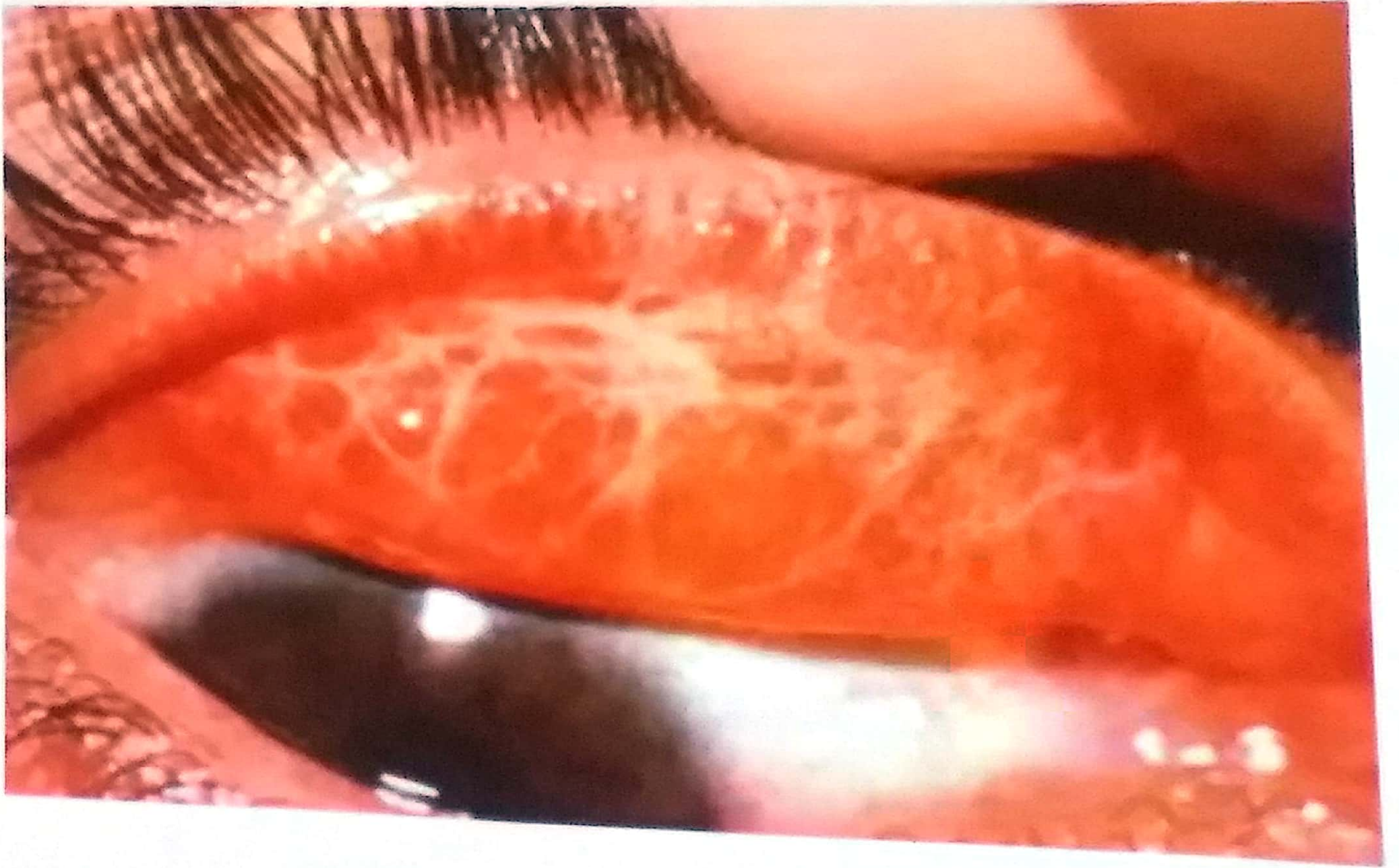

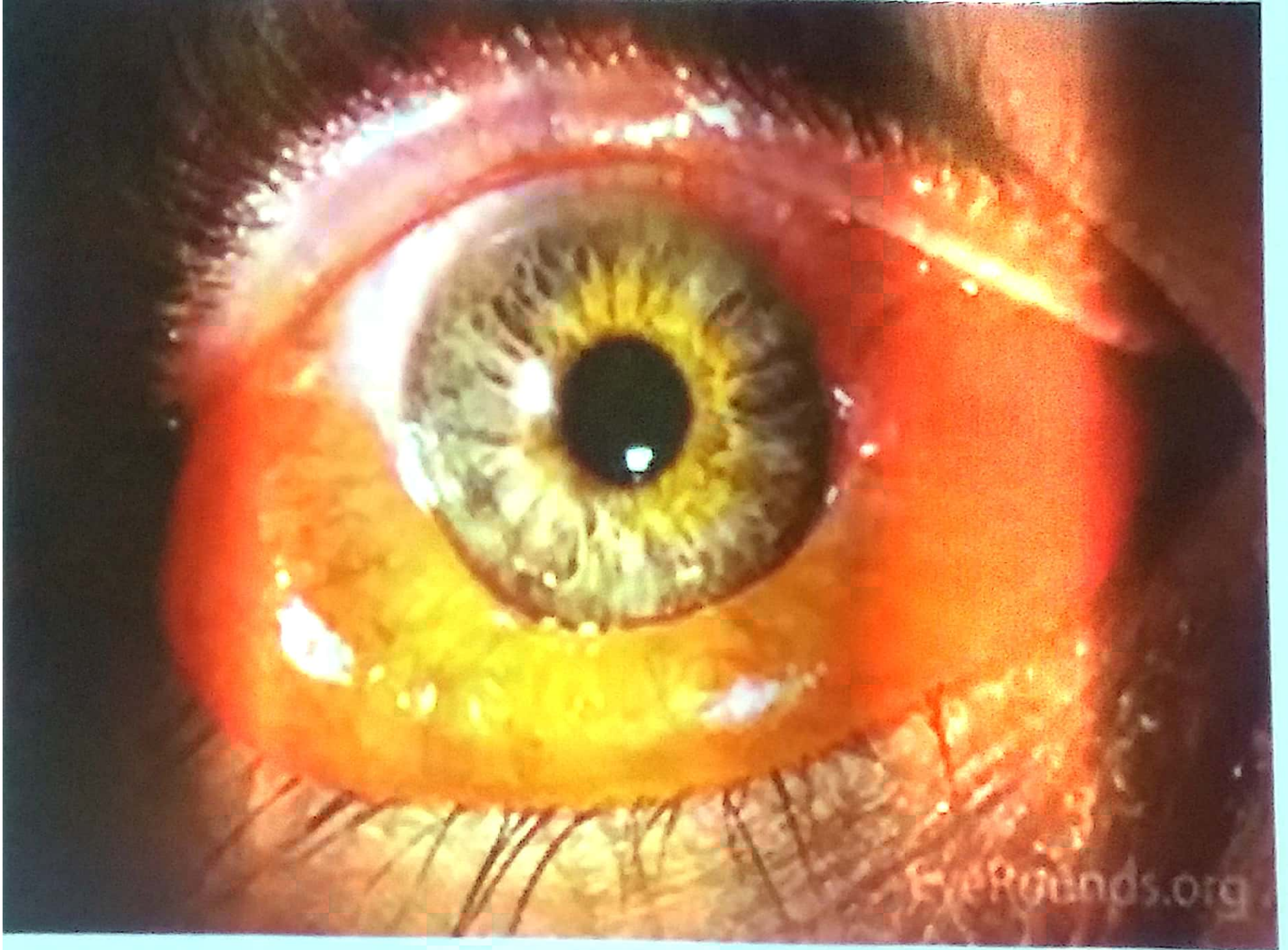
e



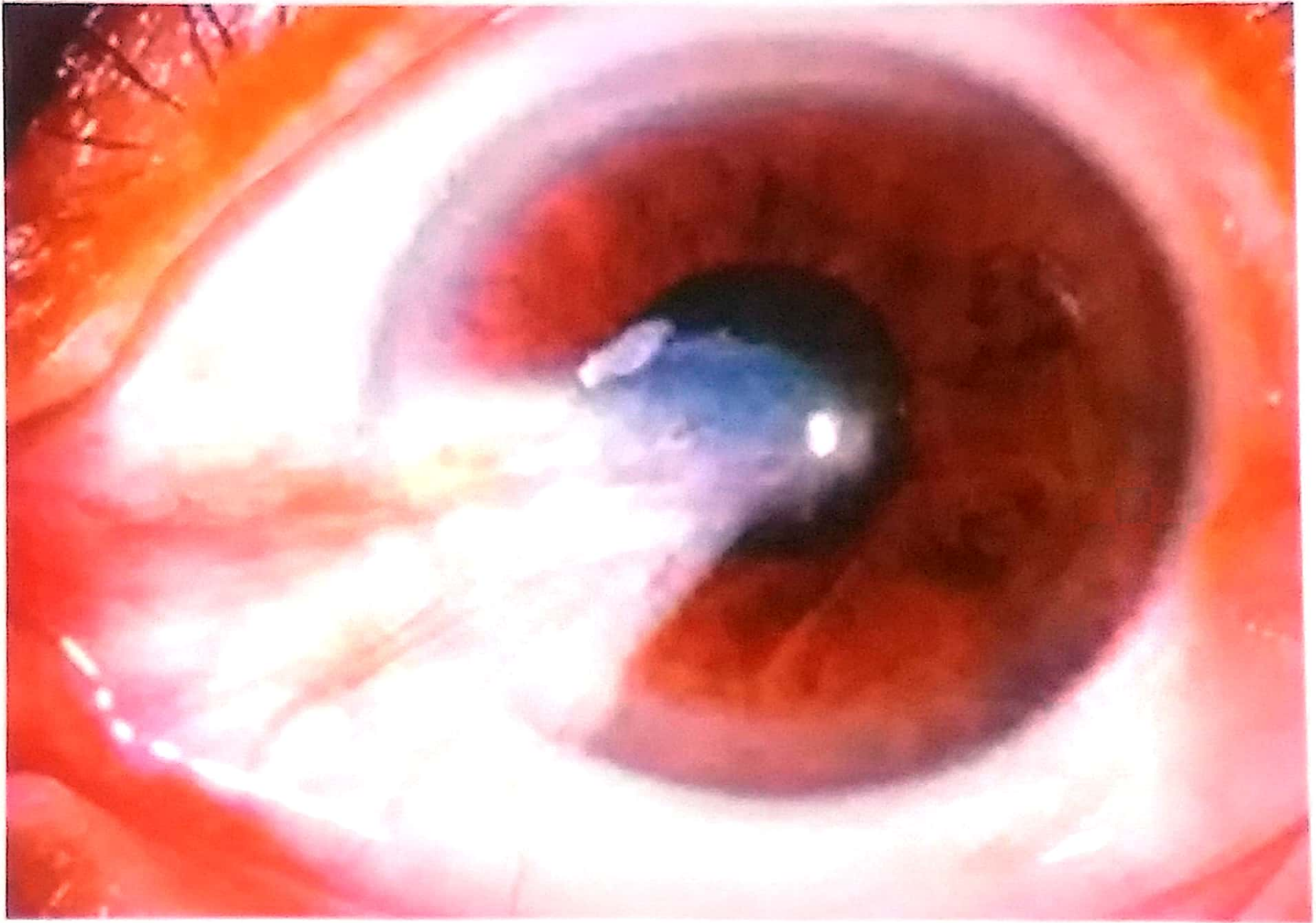
f

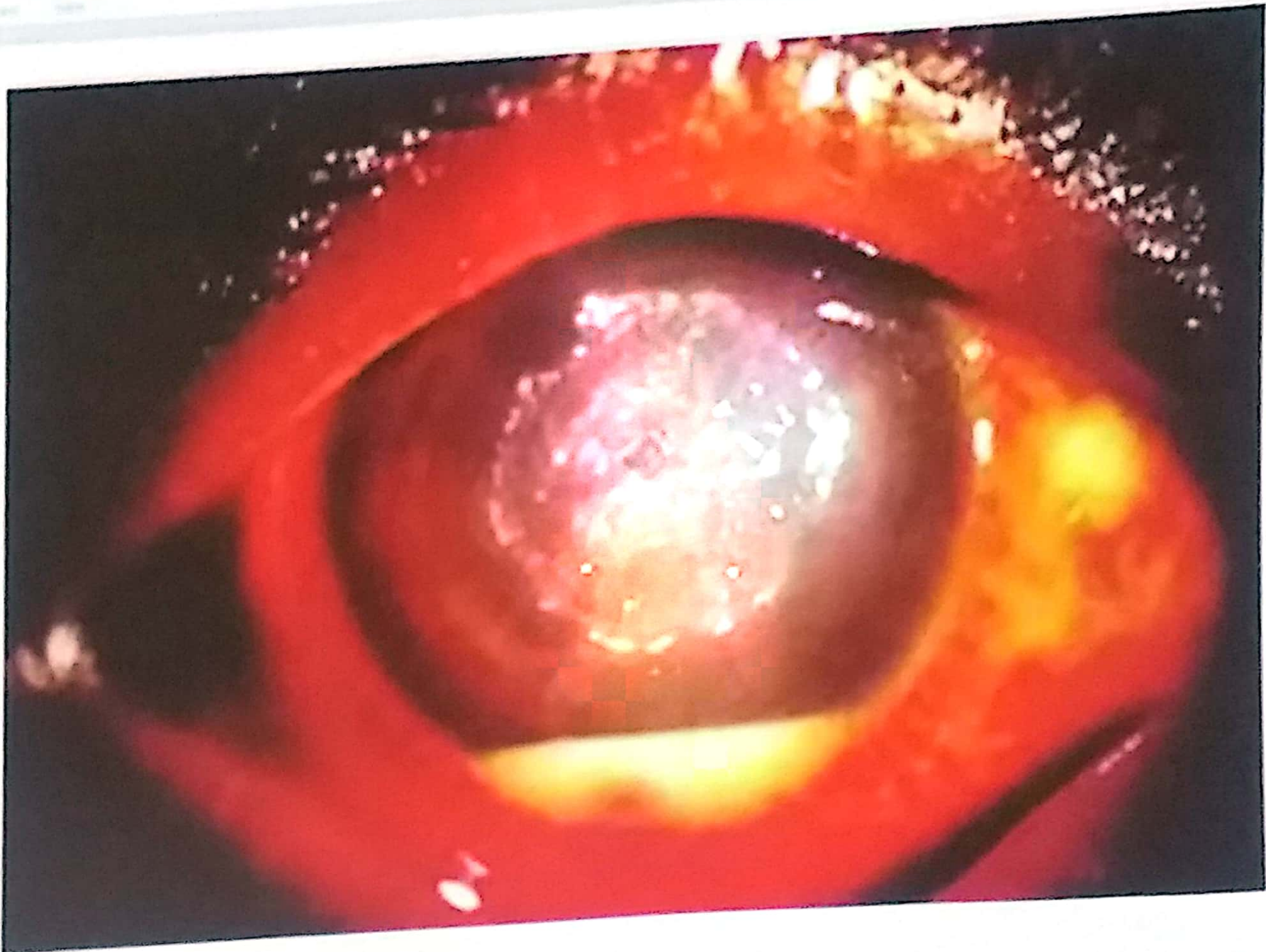


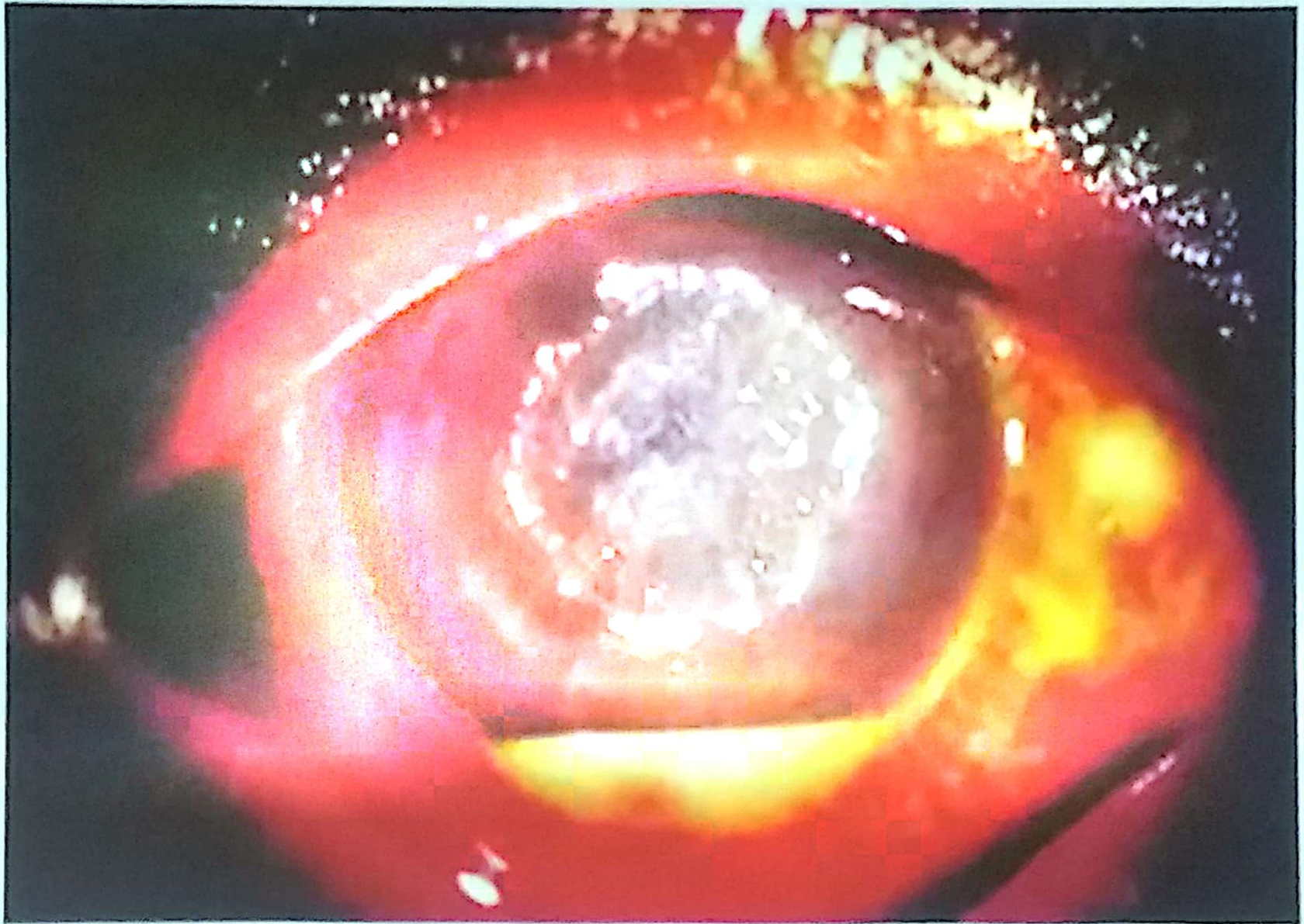




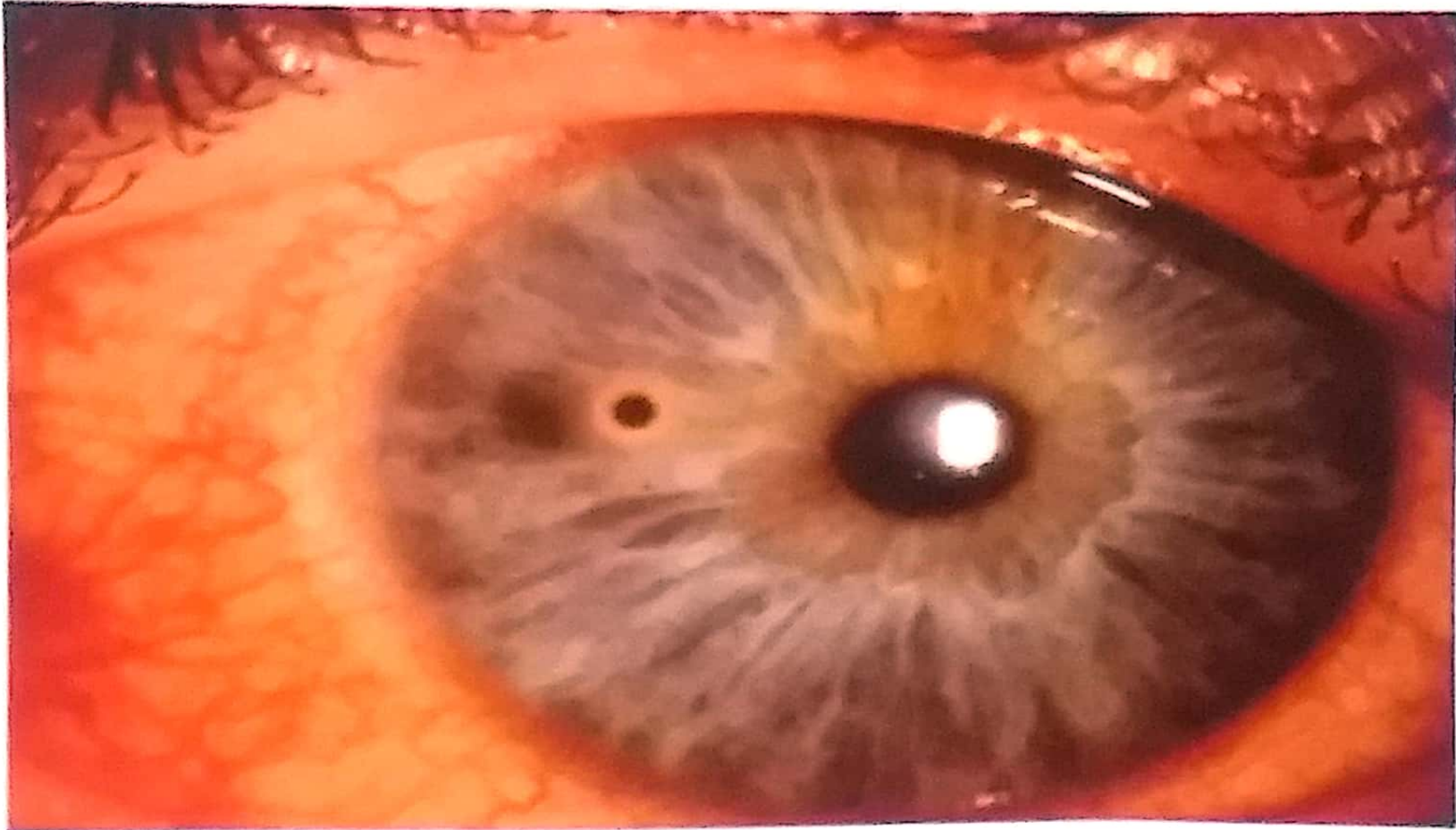EyeFounds.org



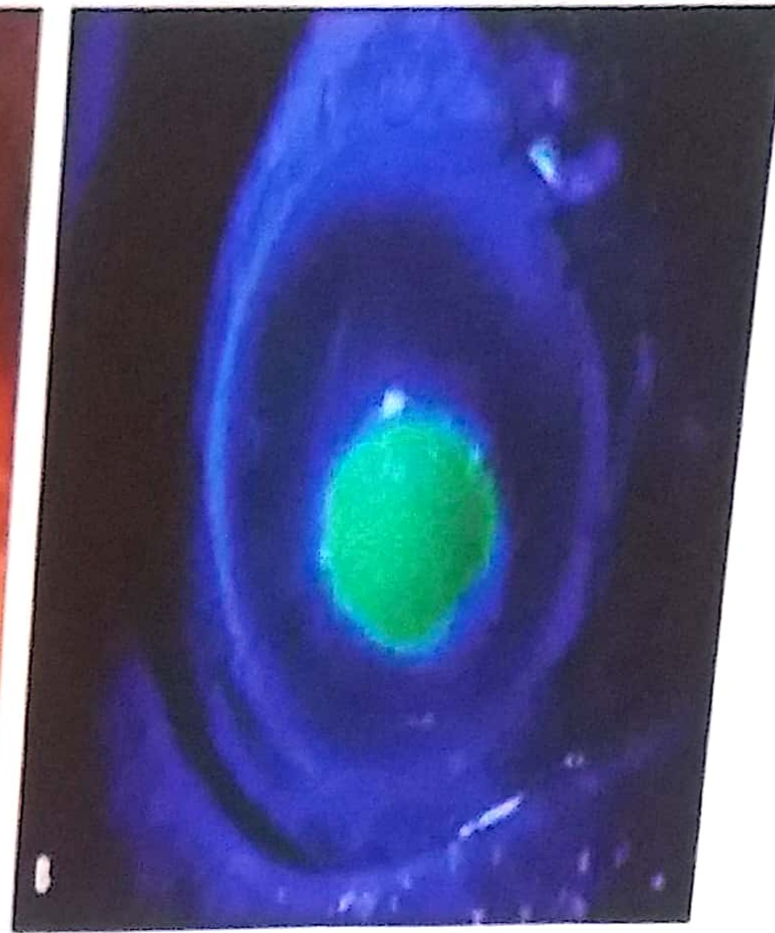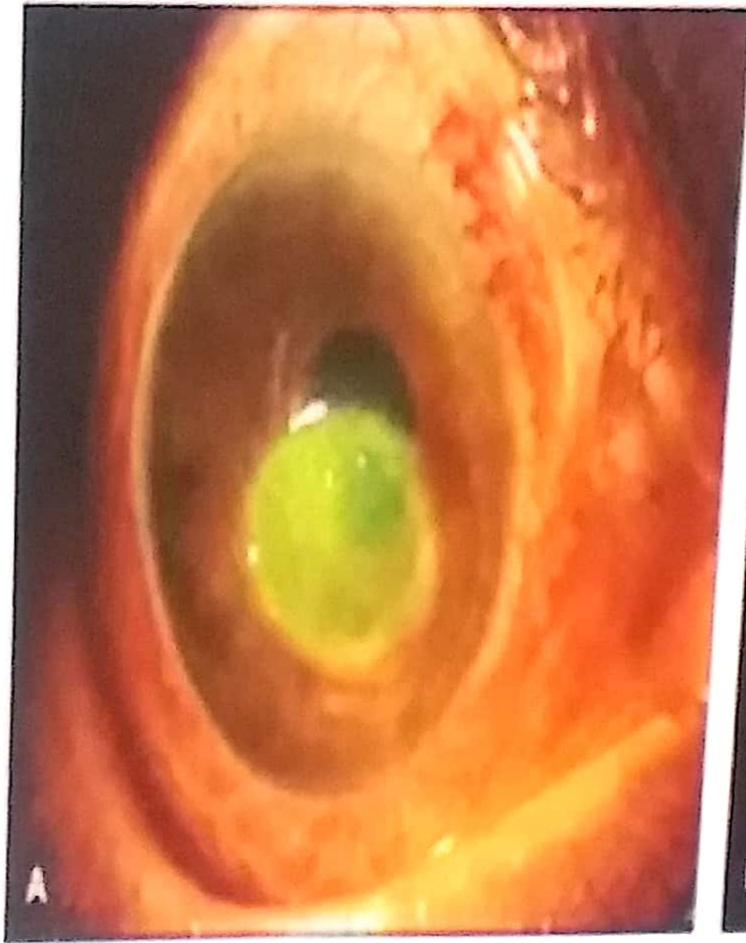


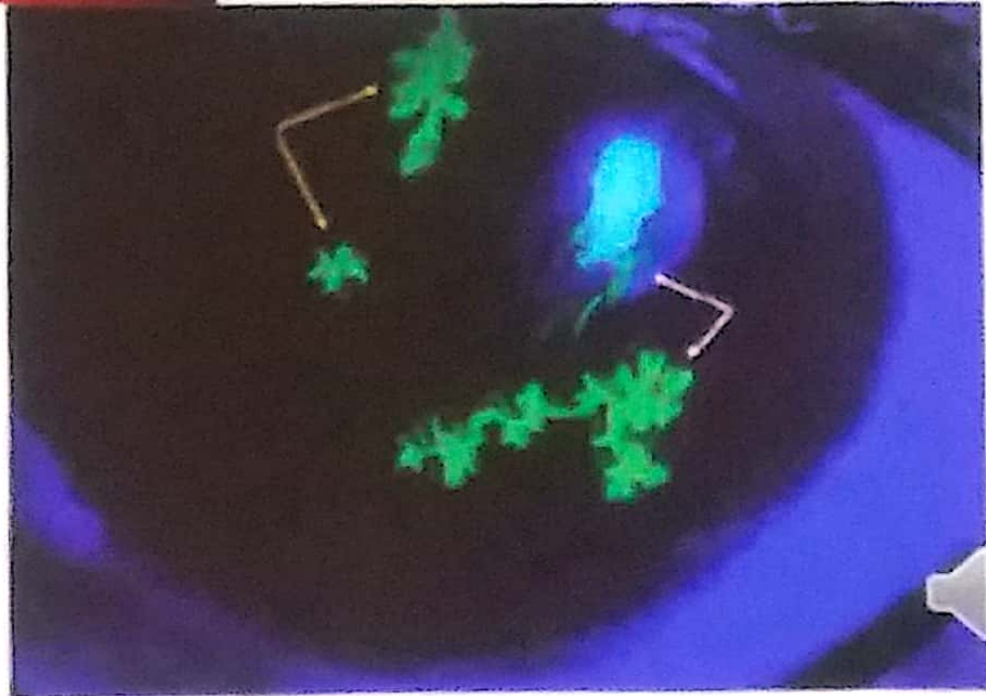

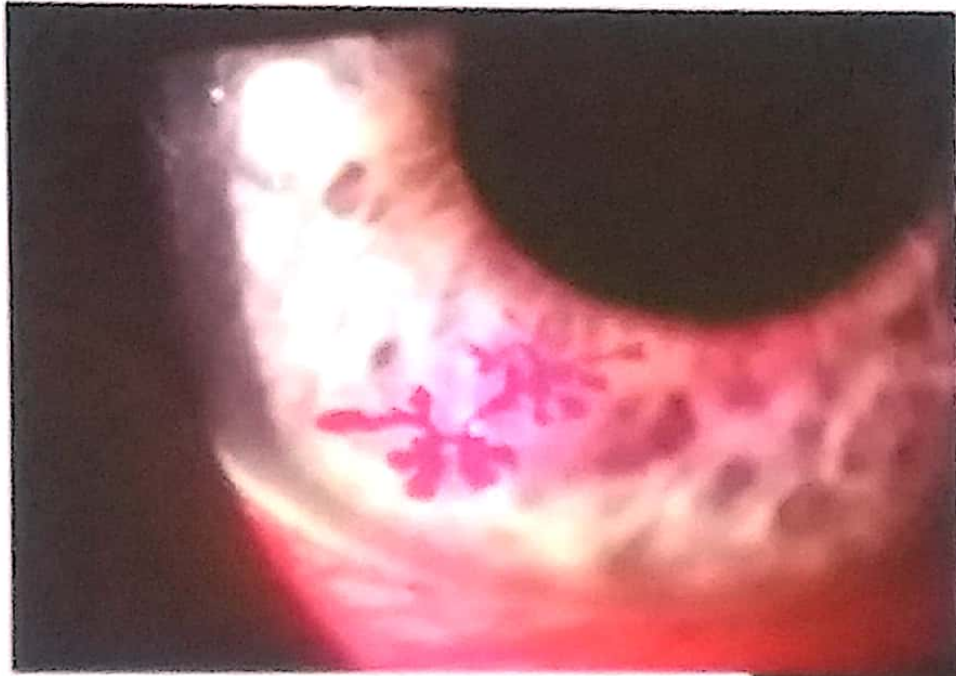
Corneal Foreign Body

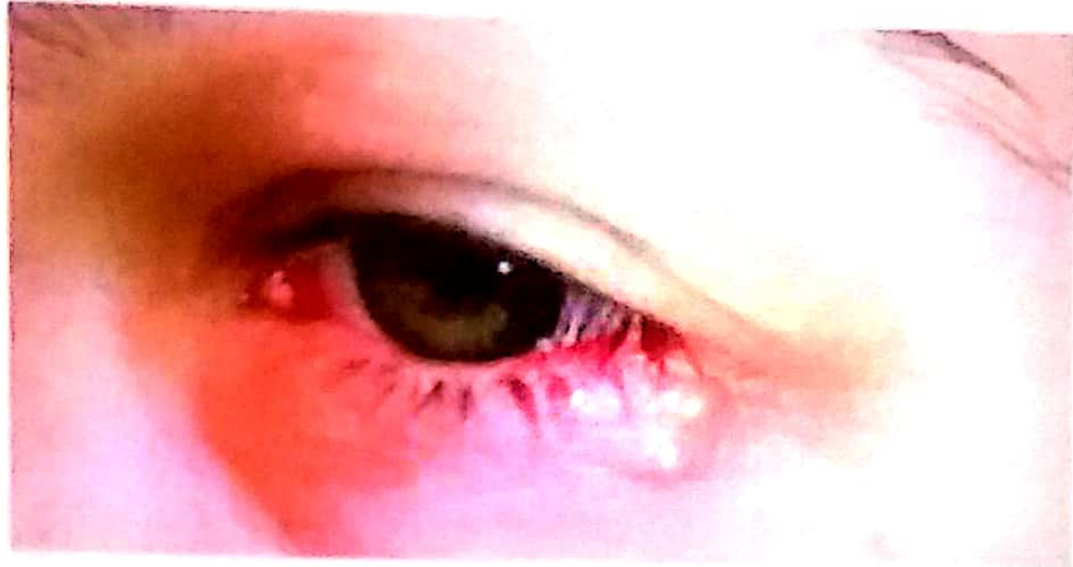

Corneal Abrasion stained with Fluorescein



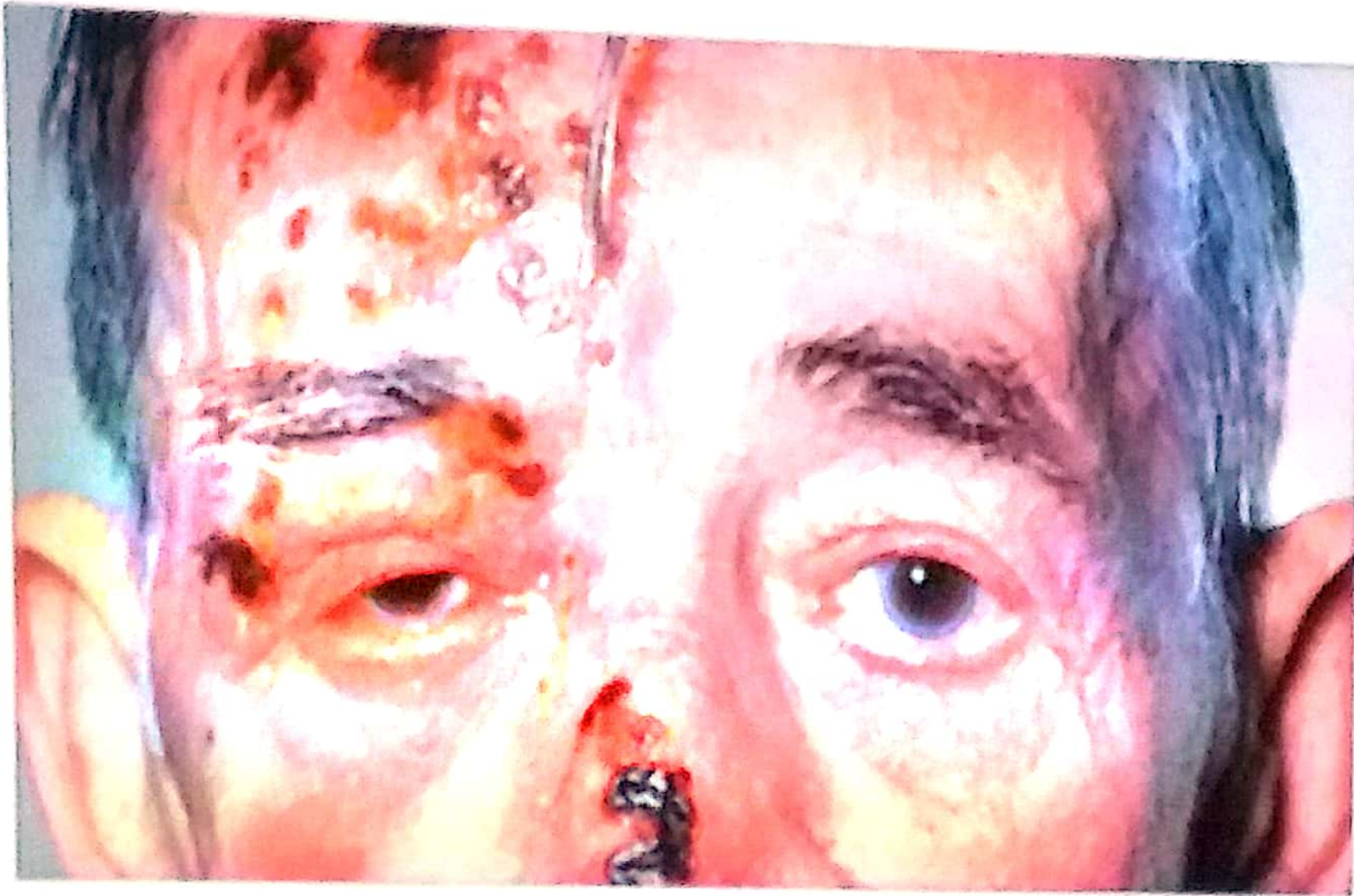

HERPES SIMPLEX PRIMARY INFECTION



Subclinical with mild symptoms

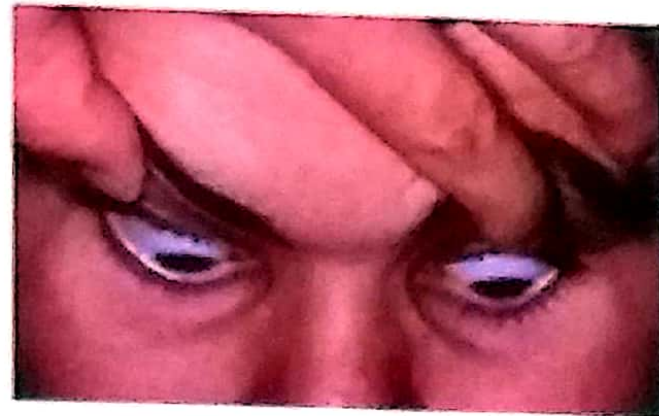
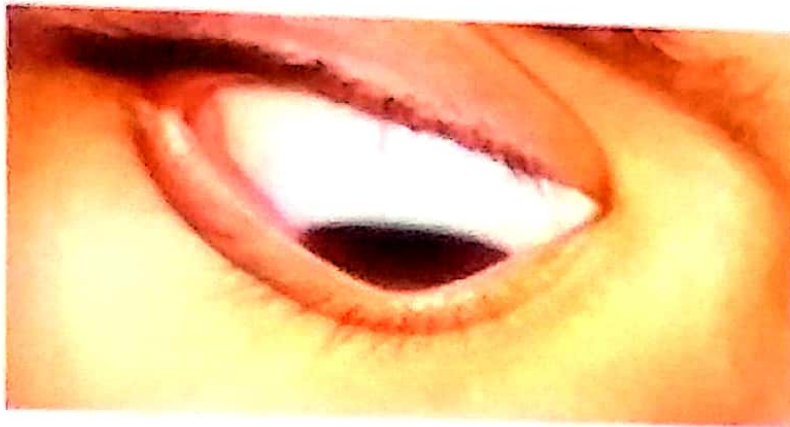- Lid vesicles, blephritis and follicular conjunctivitis



© 2005 Elsevier Ltd. Spalton et al: Atlas of Clinical Ophthalmology 3e

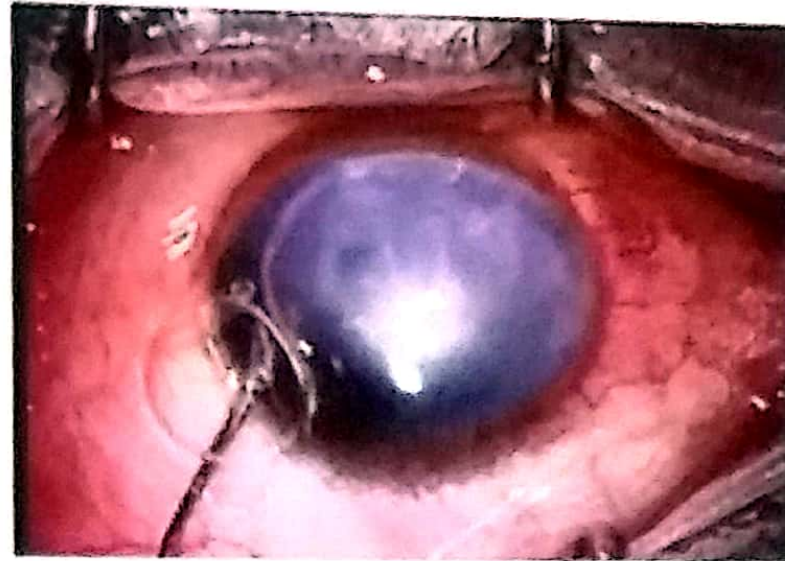
Keratoconus Presentation

- **Munson sign**; bulging of lower eyelid in downgaze.



Keartoconus

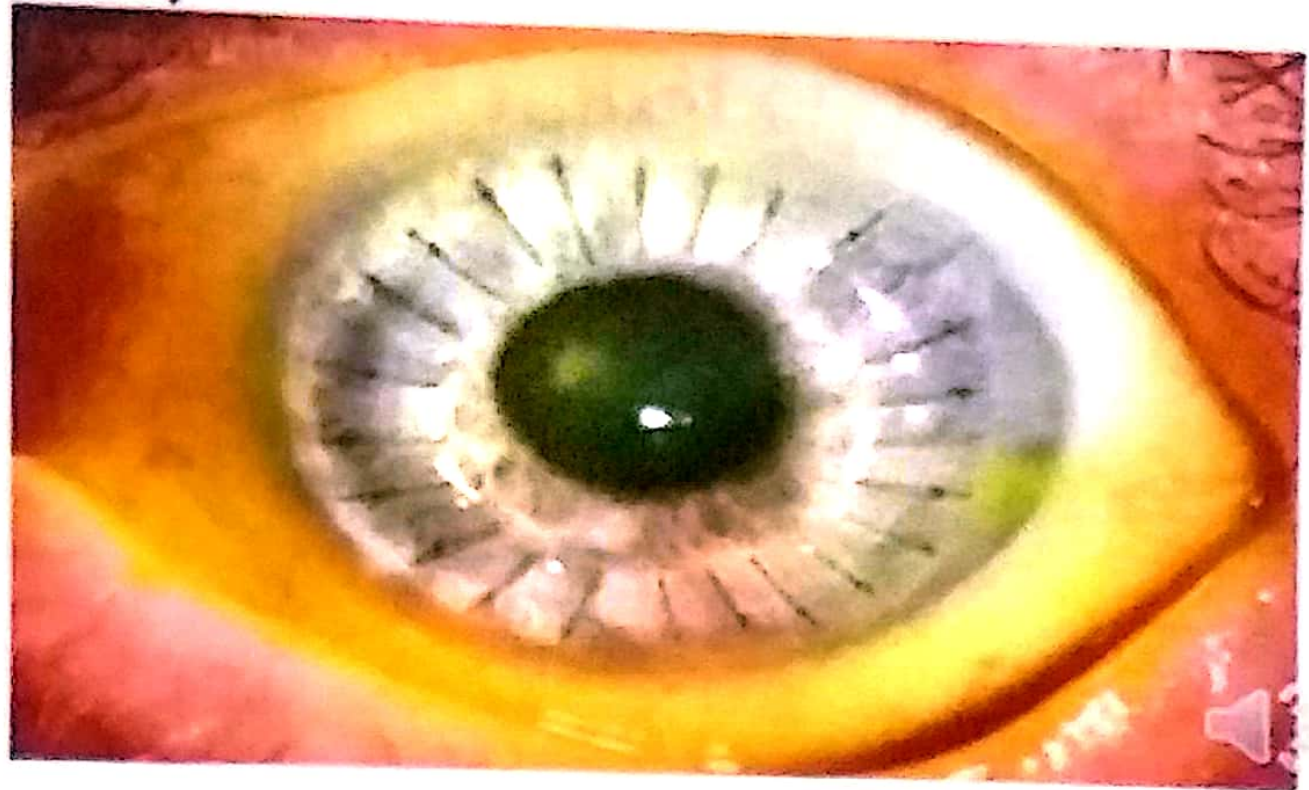Acute Hydrops Treatment



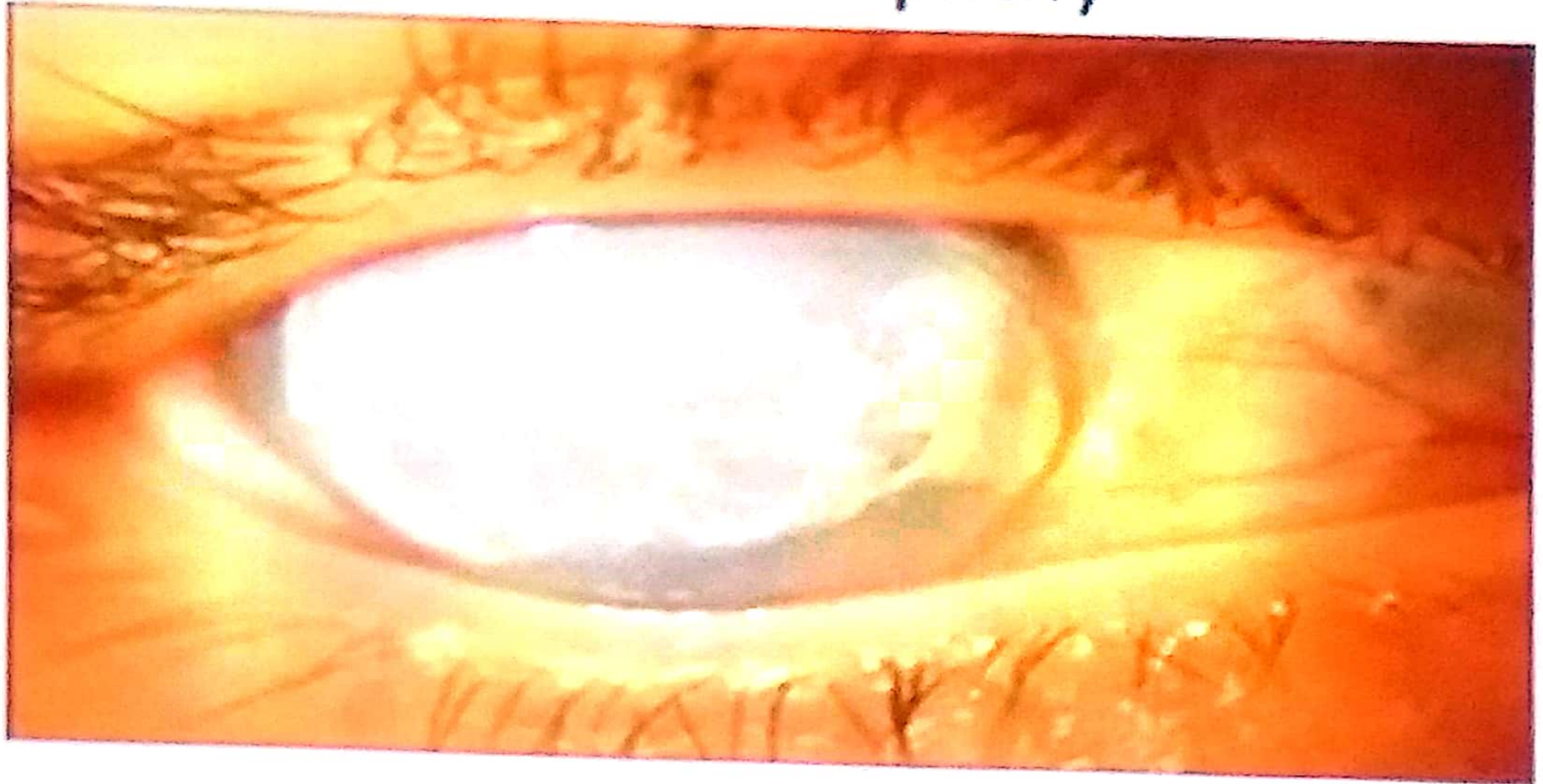
- Ophthalmic Emergency
- Cycloplegic Drops
- 5% Hypertonic Saline Eye Drops
- Eye Patching
- Soft bandage contact lens

Keartoconus Treatmnt

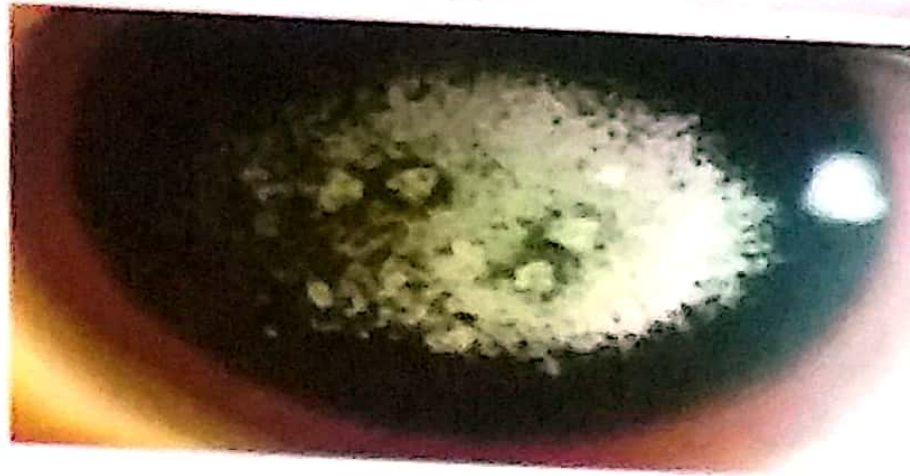
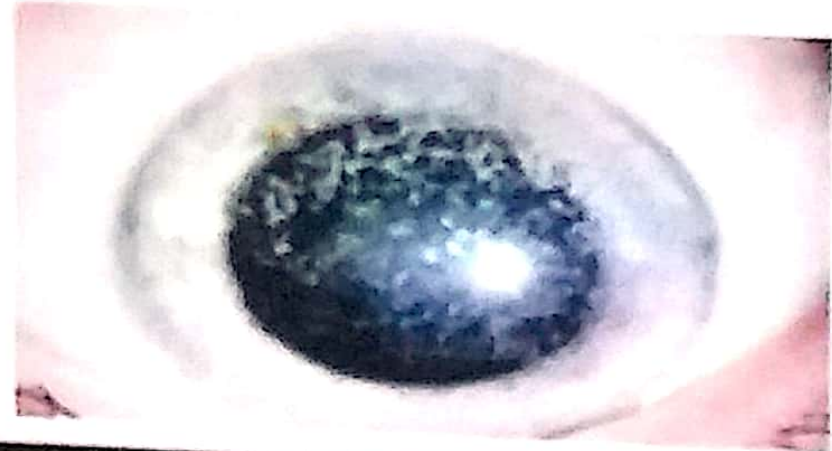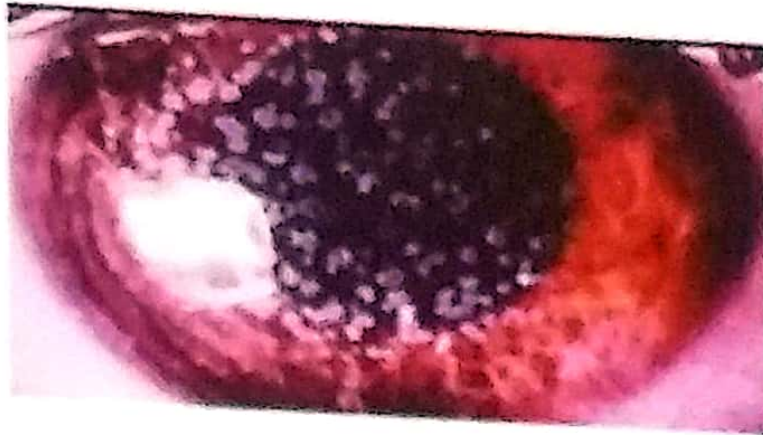
- keratoplasty



Corneal Degeneration Band Keratopathy

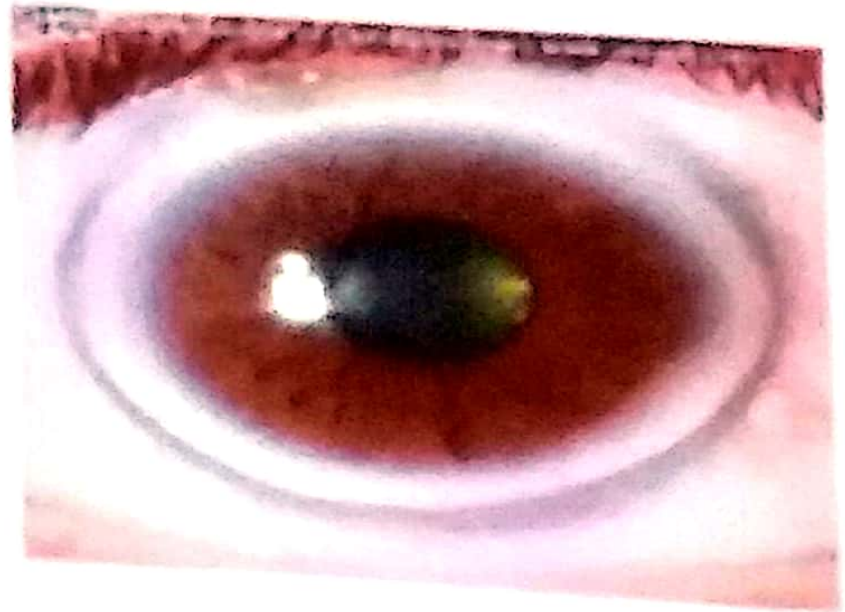
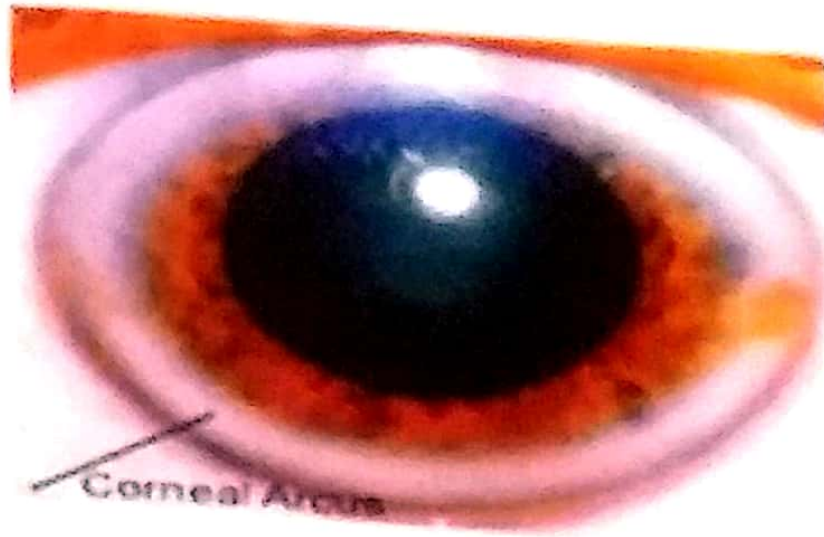
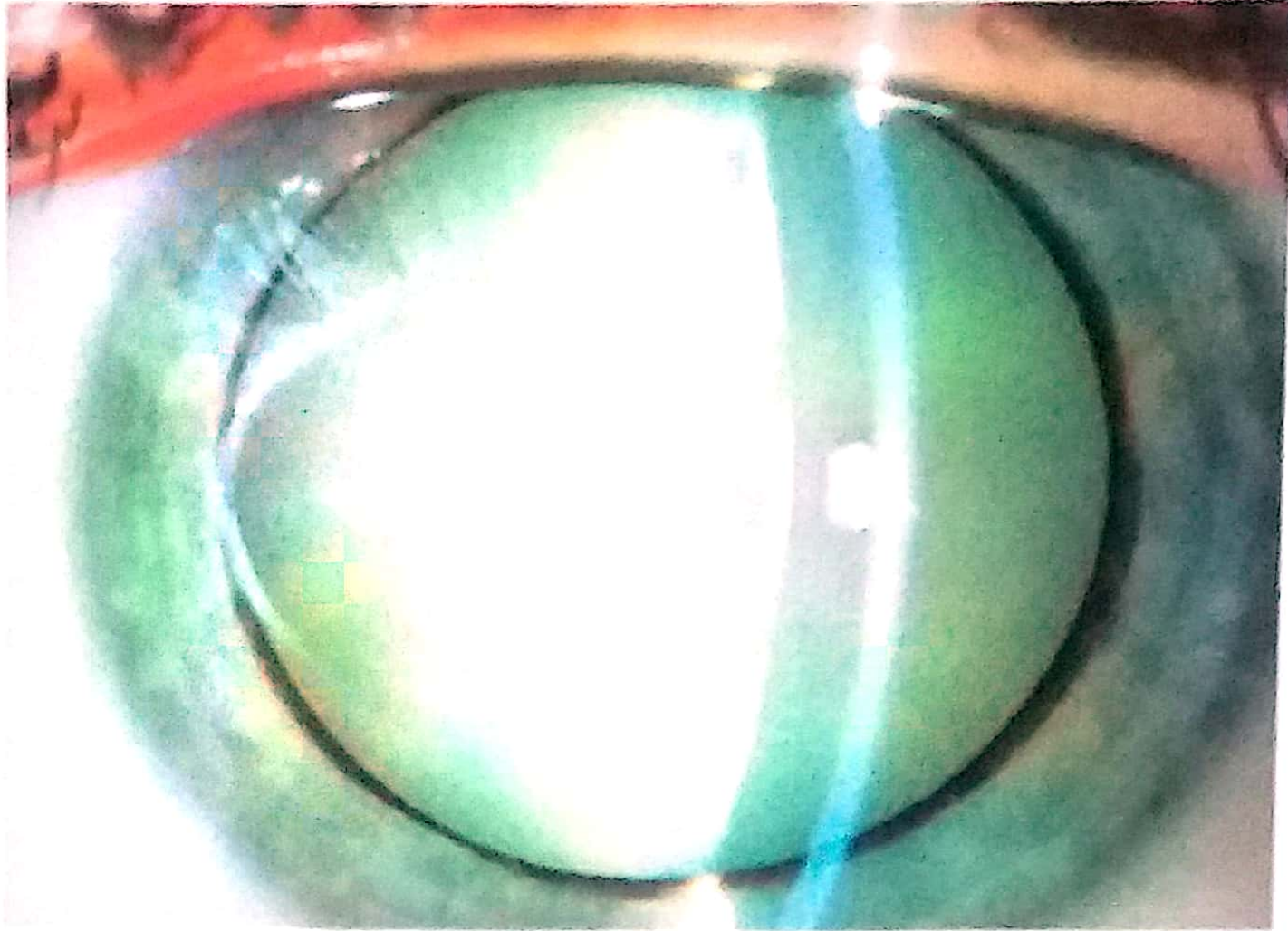
Corneal Dystrophies



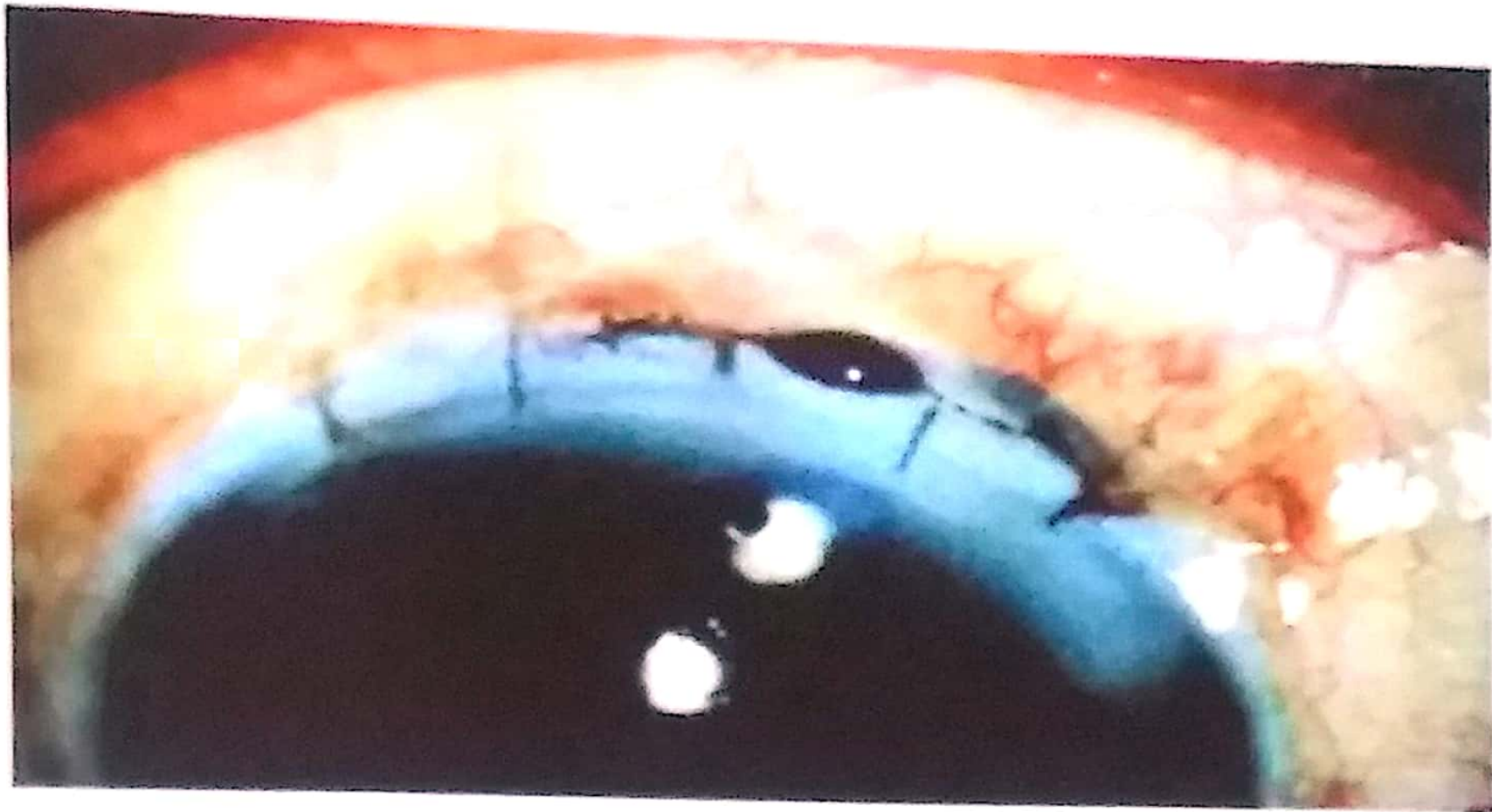Corneal Degeneration

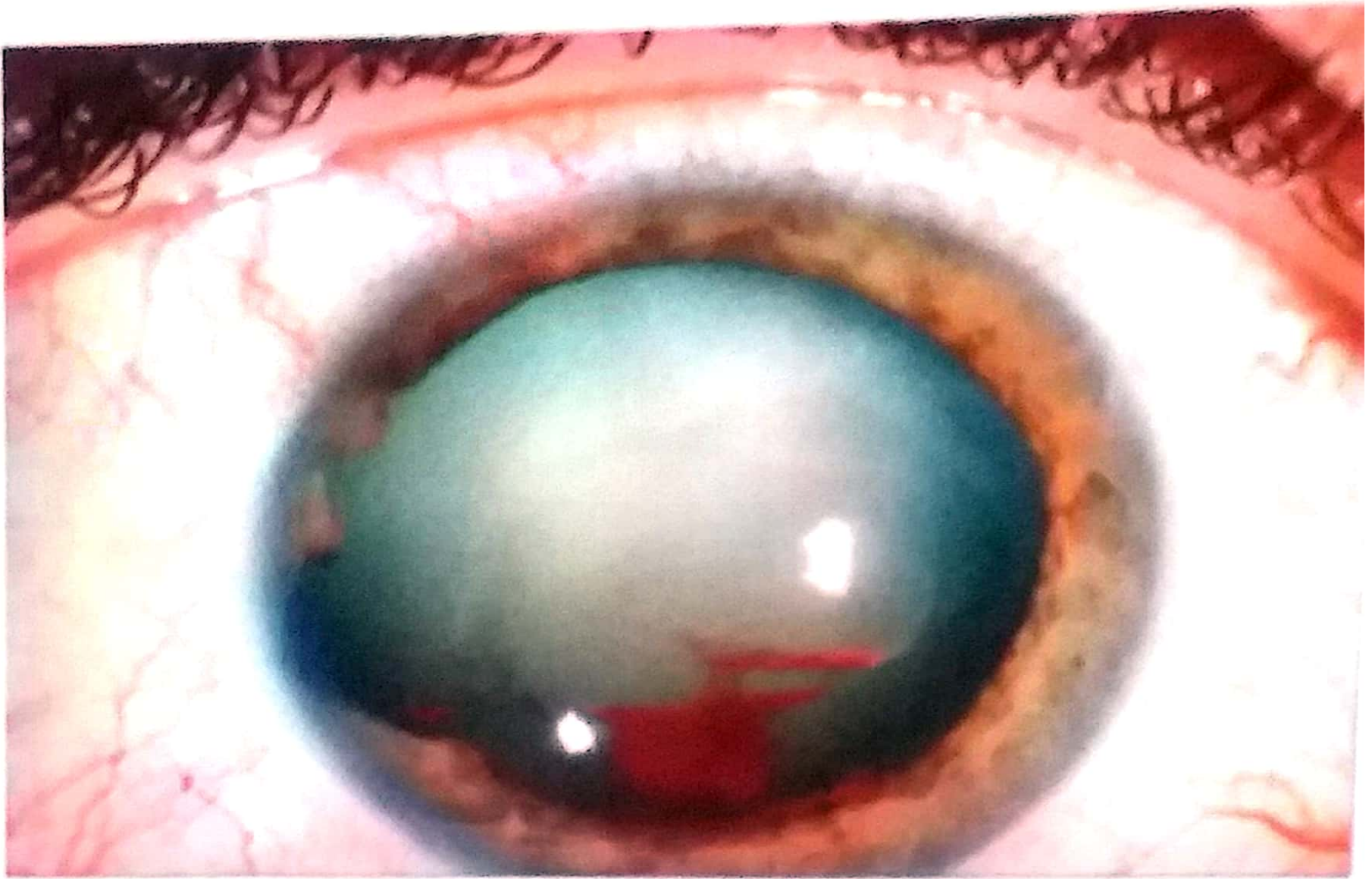- Arcus Senilis





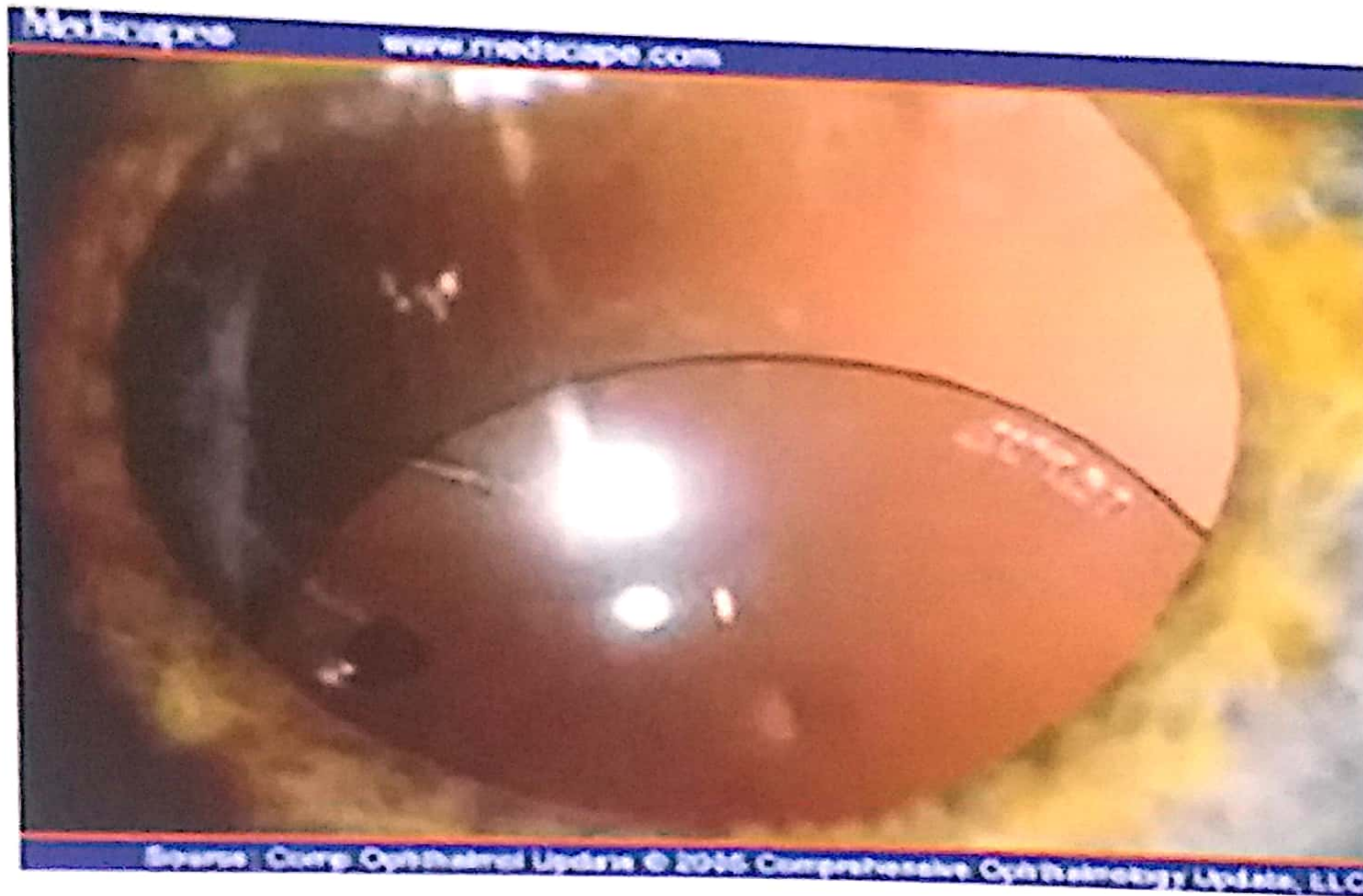
Iris Prolapse

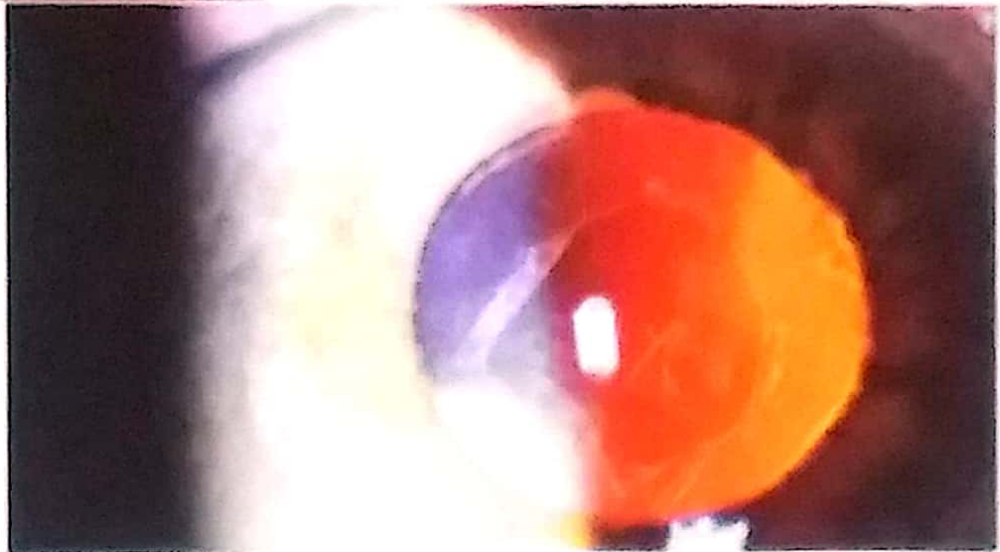
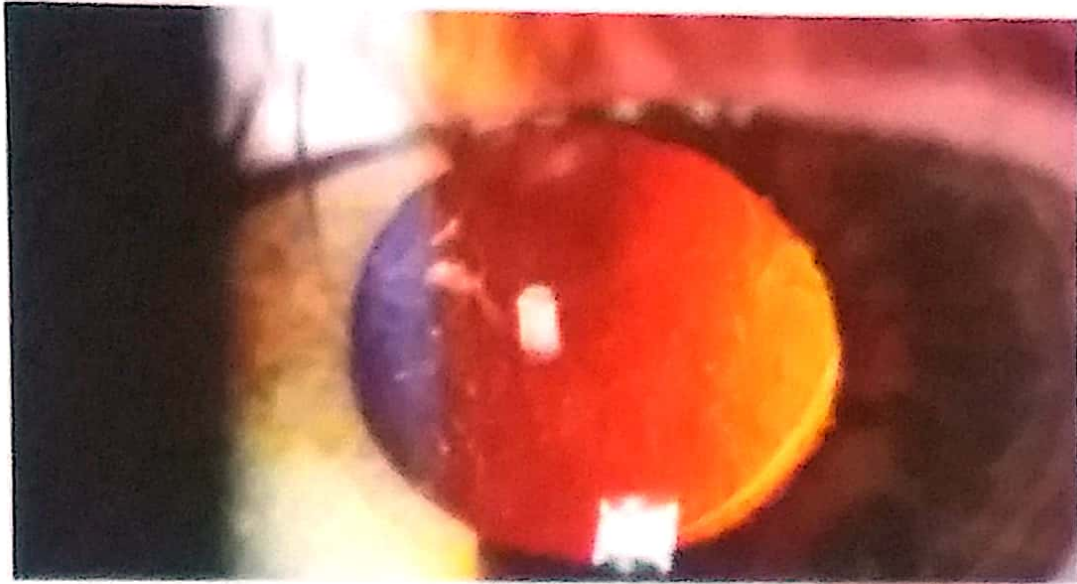




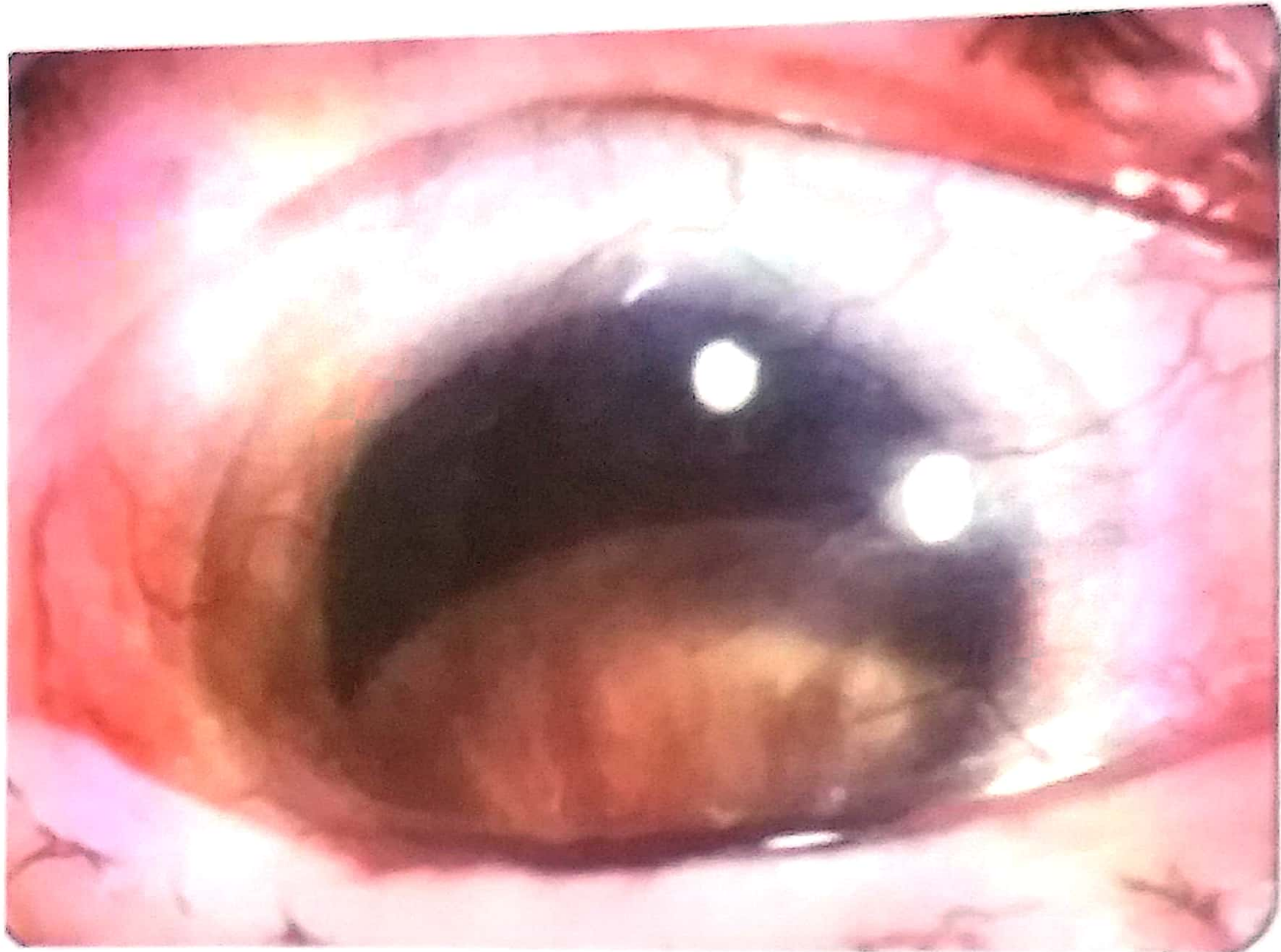

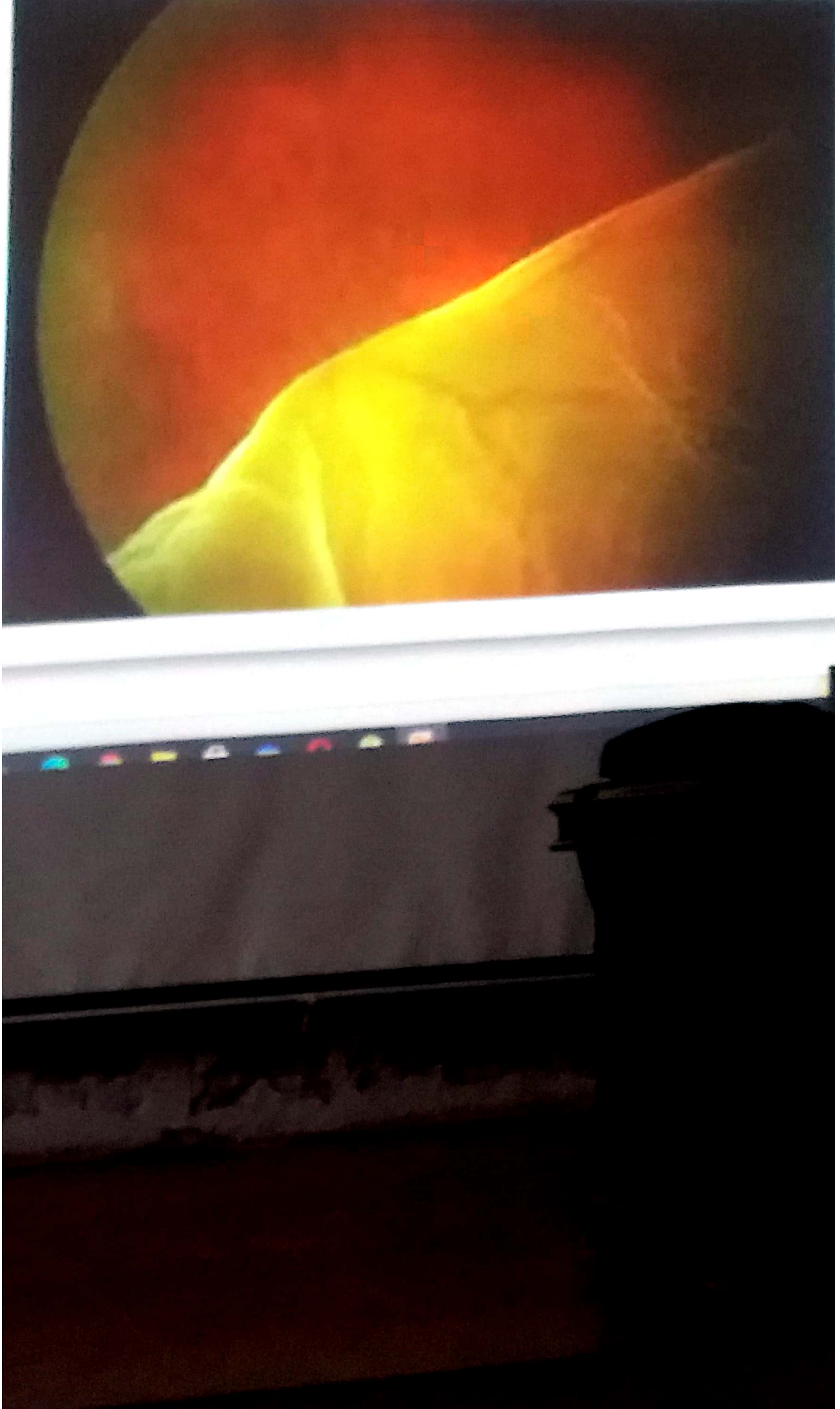
IOL decentration





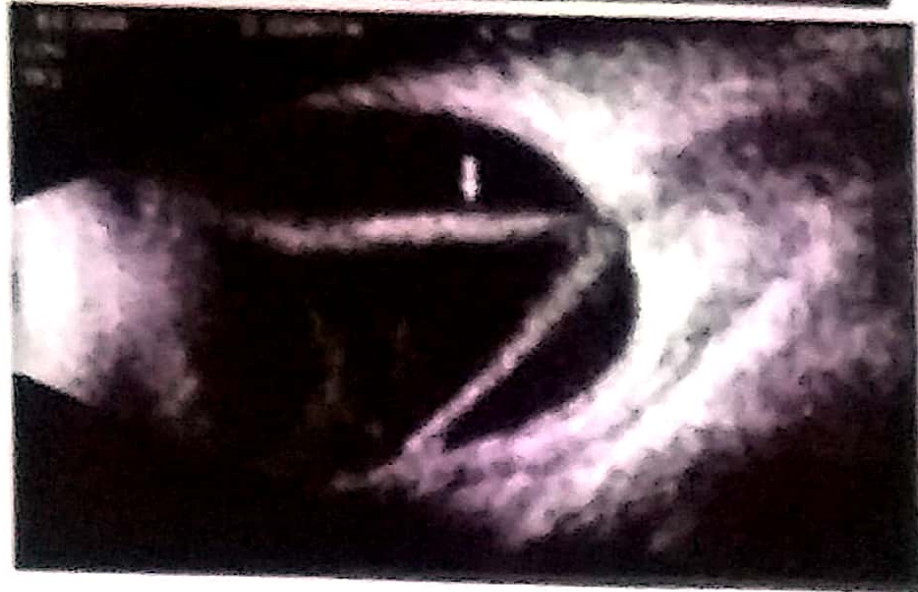
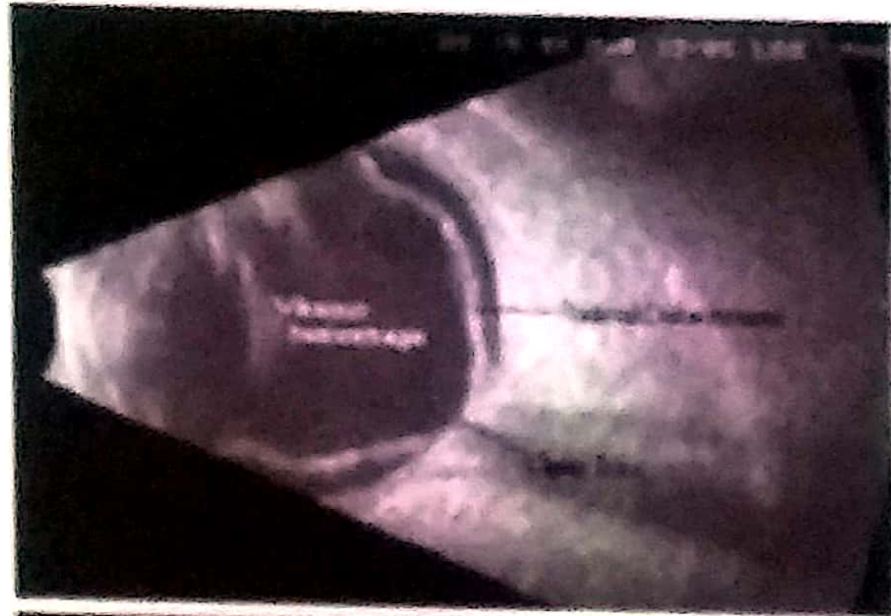


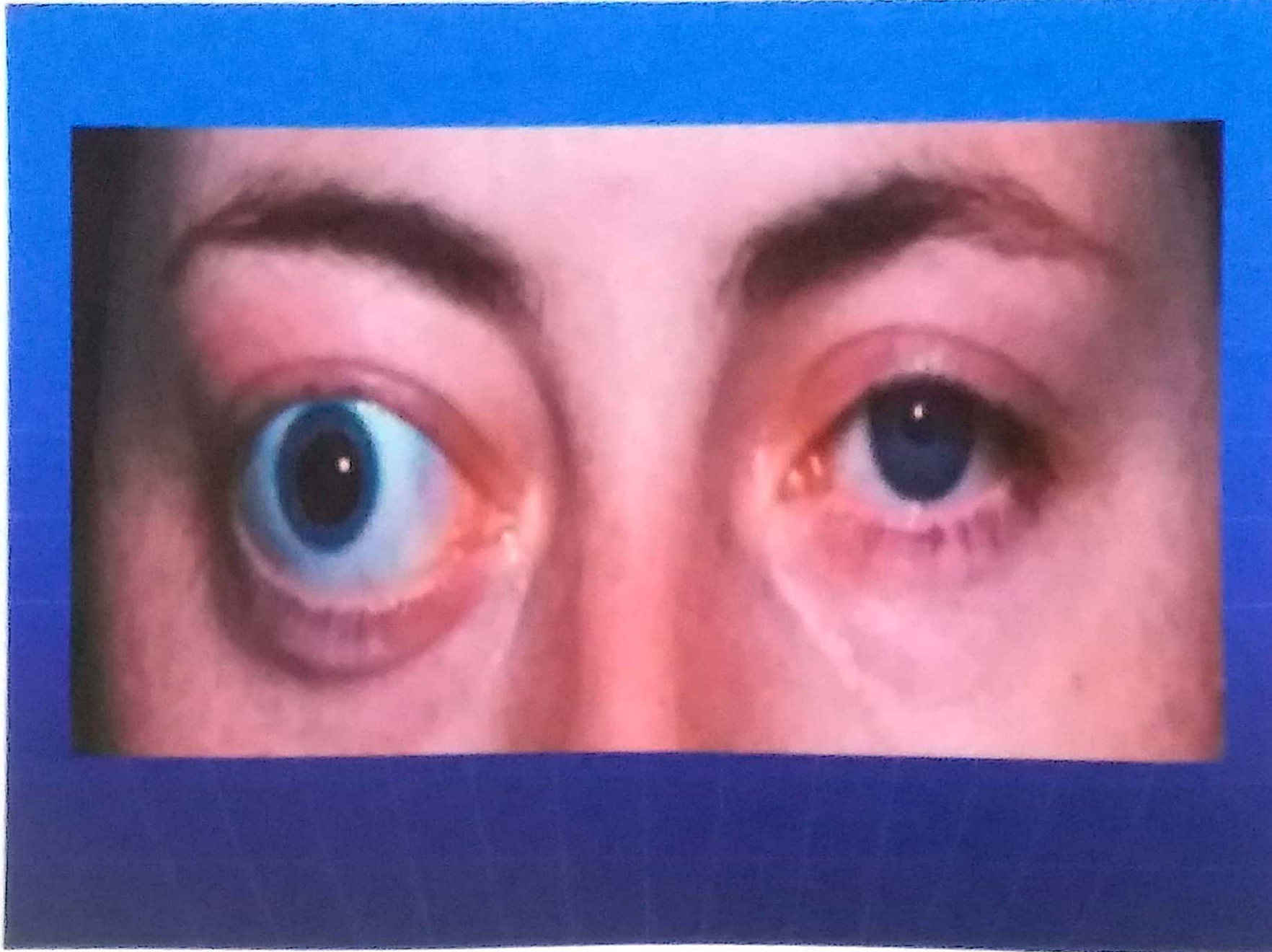




Investigations

- B Scan



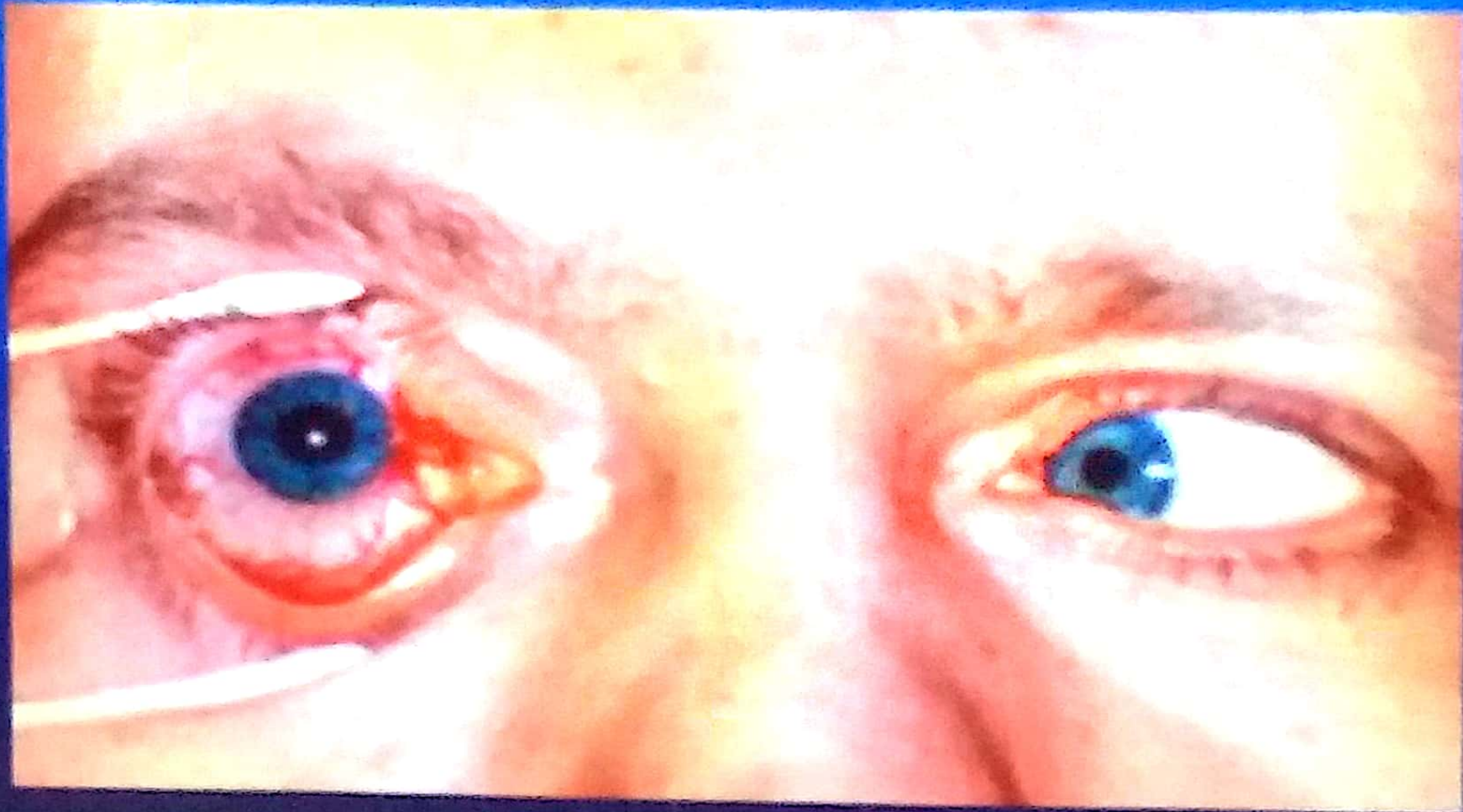


ENOPHTHALMOS

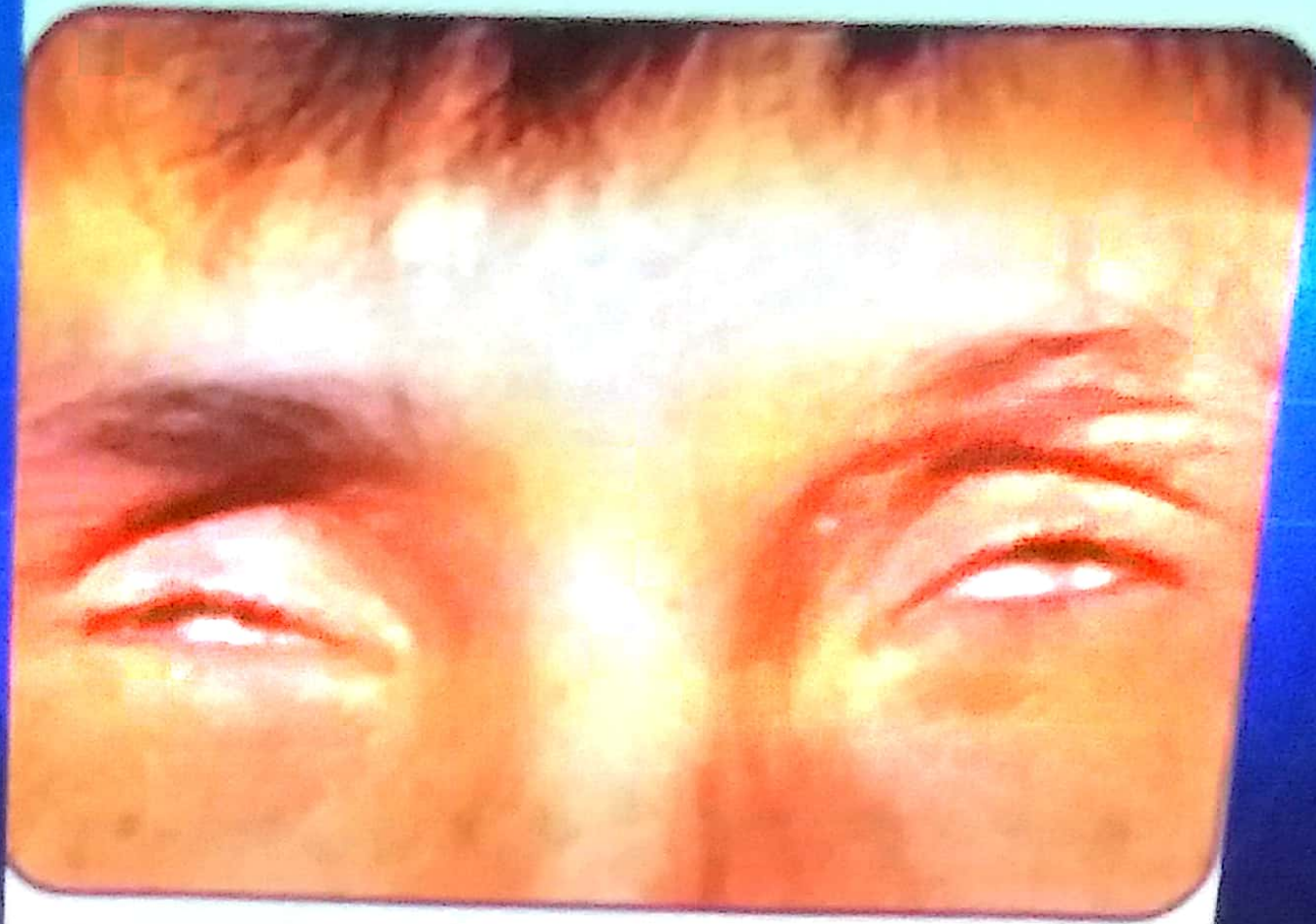


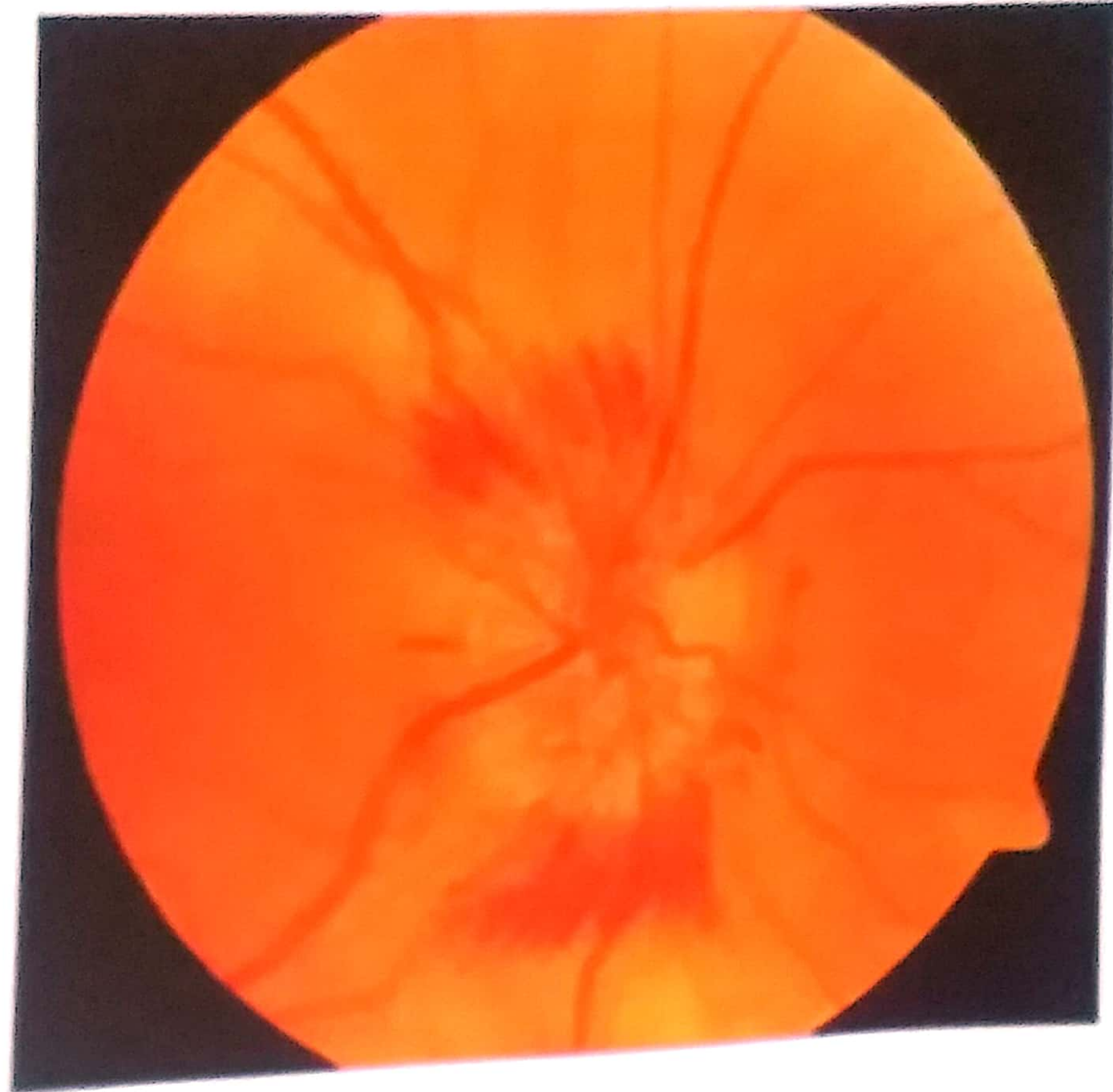Fig. 3.4

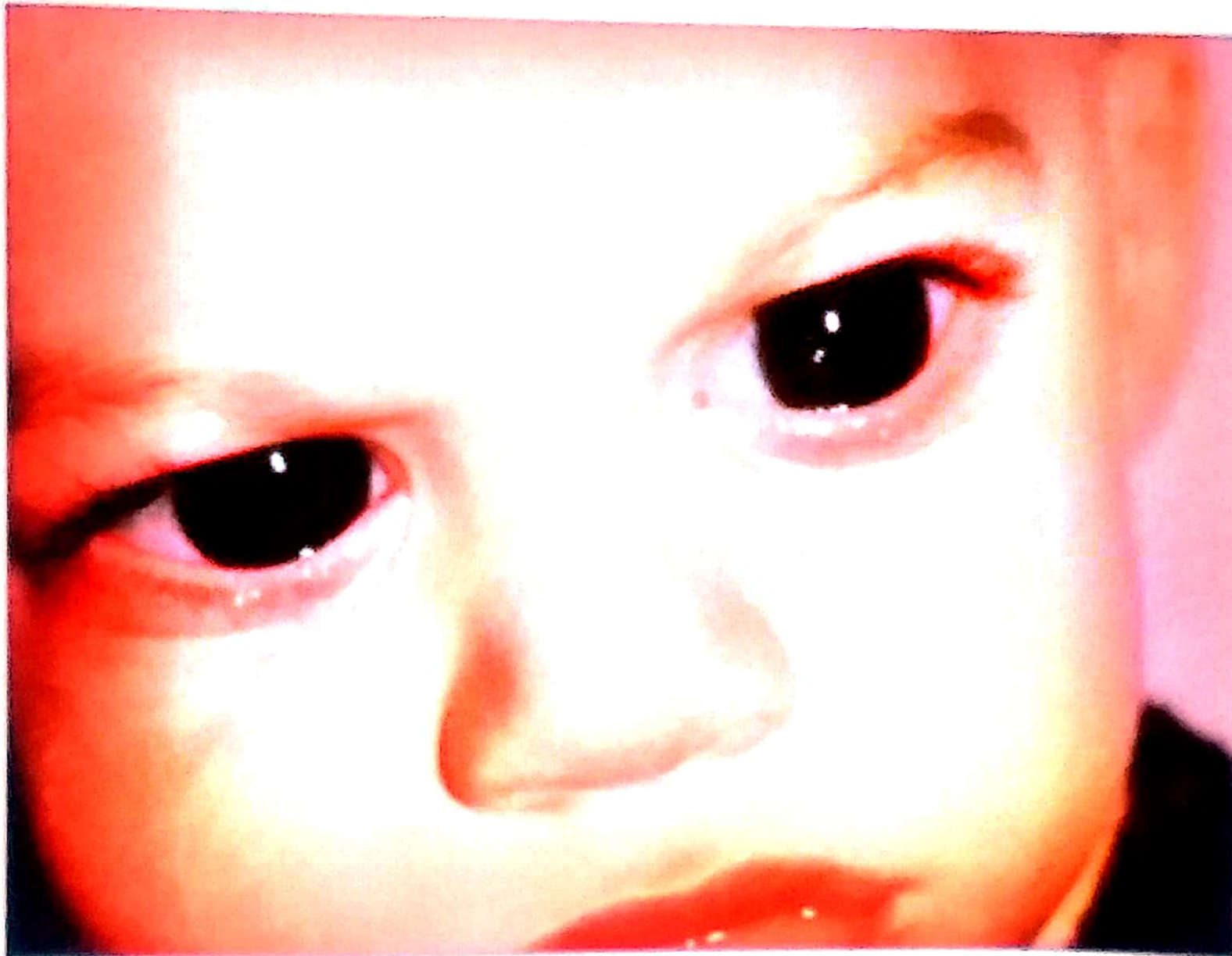RESTRICTED MYOPATHY



Treatment patching / penalization









© 2005 Elsevier Ltd. Spalton et al: Atlas of Clinical Ophthalmology 3e

HERTEL EXOOPHTHALMOMETER

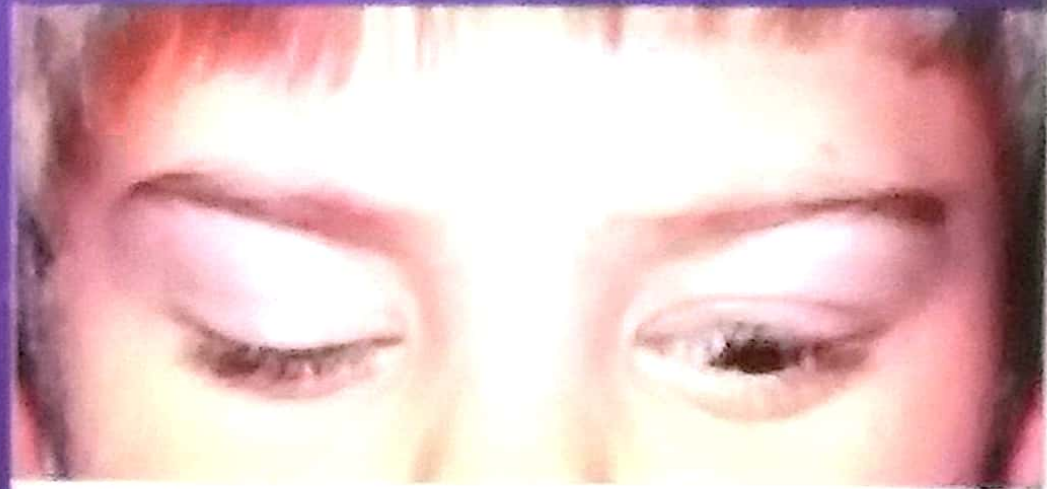

© 2004 Elsevier Ltd. Sutton et al. *Atlas of Clinical Optometry*, 4e

Click to add title

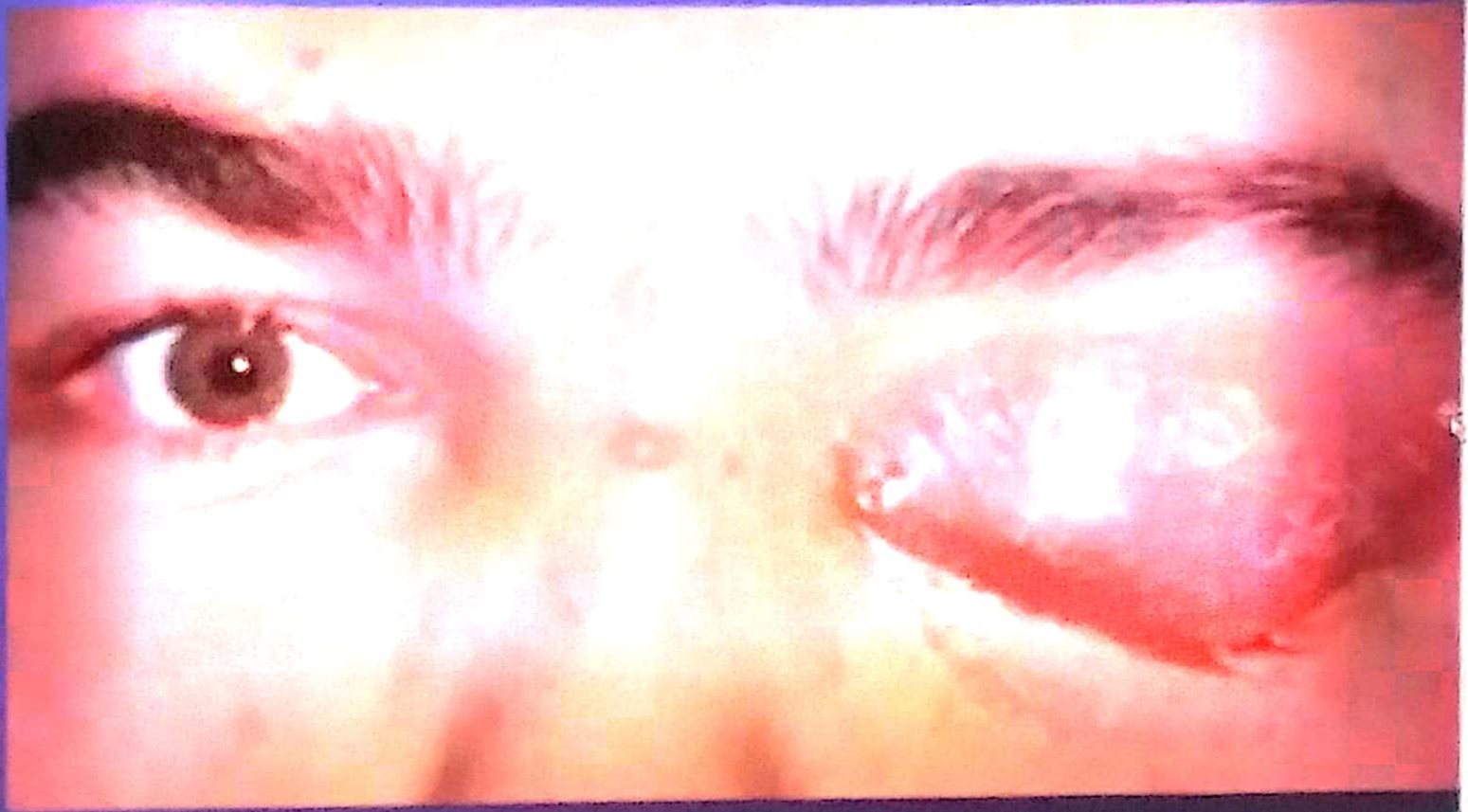VON GRAFE SIGN

- Retarded descent of upper lid in down gaze

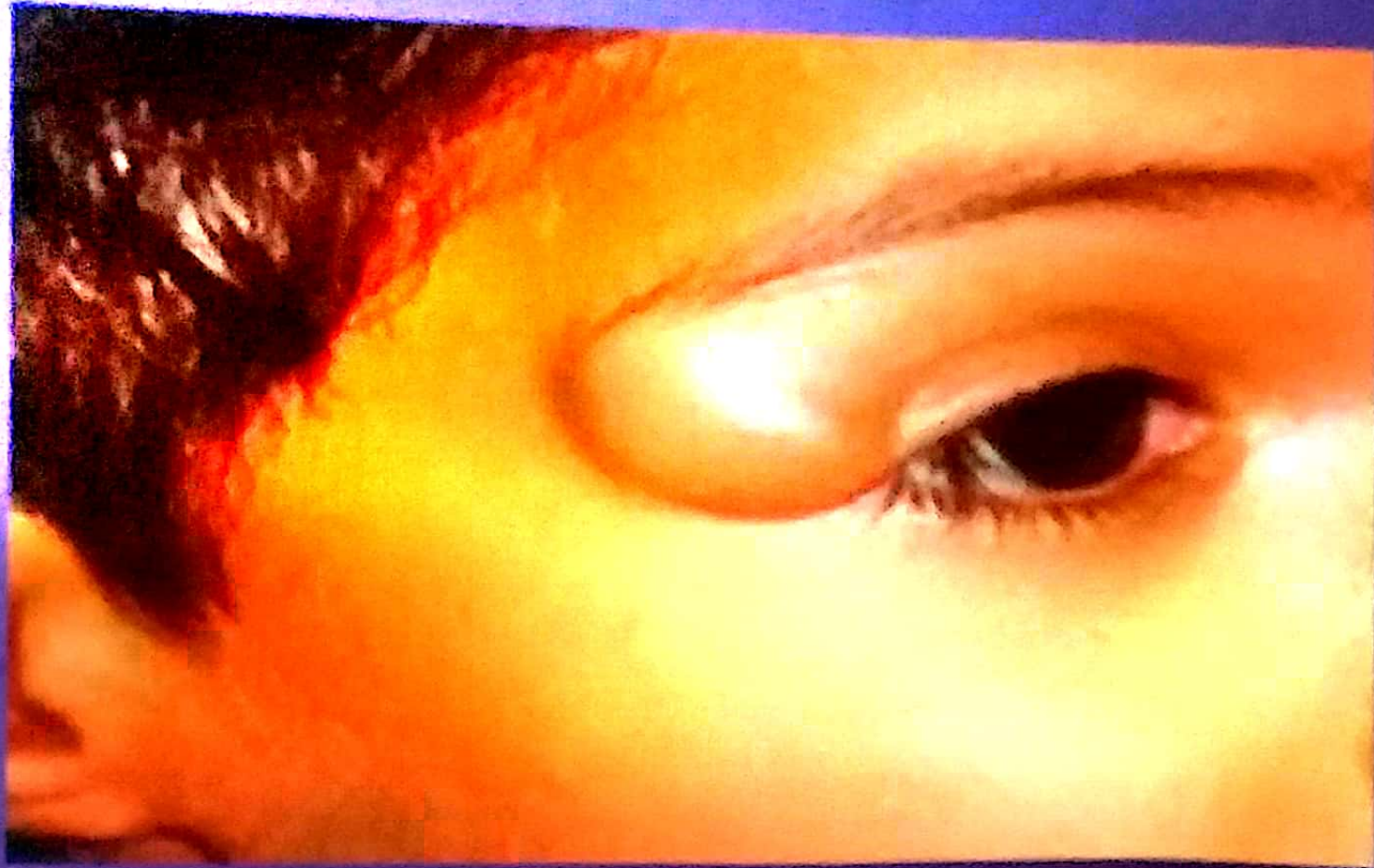

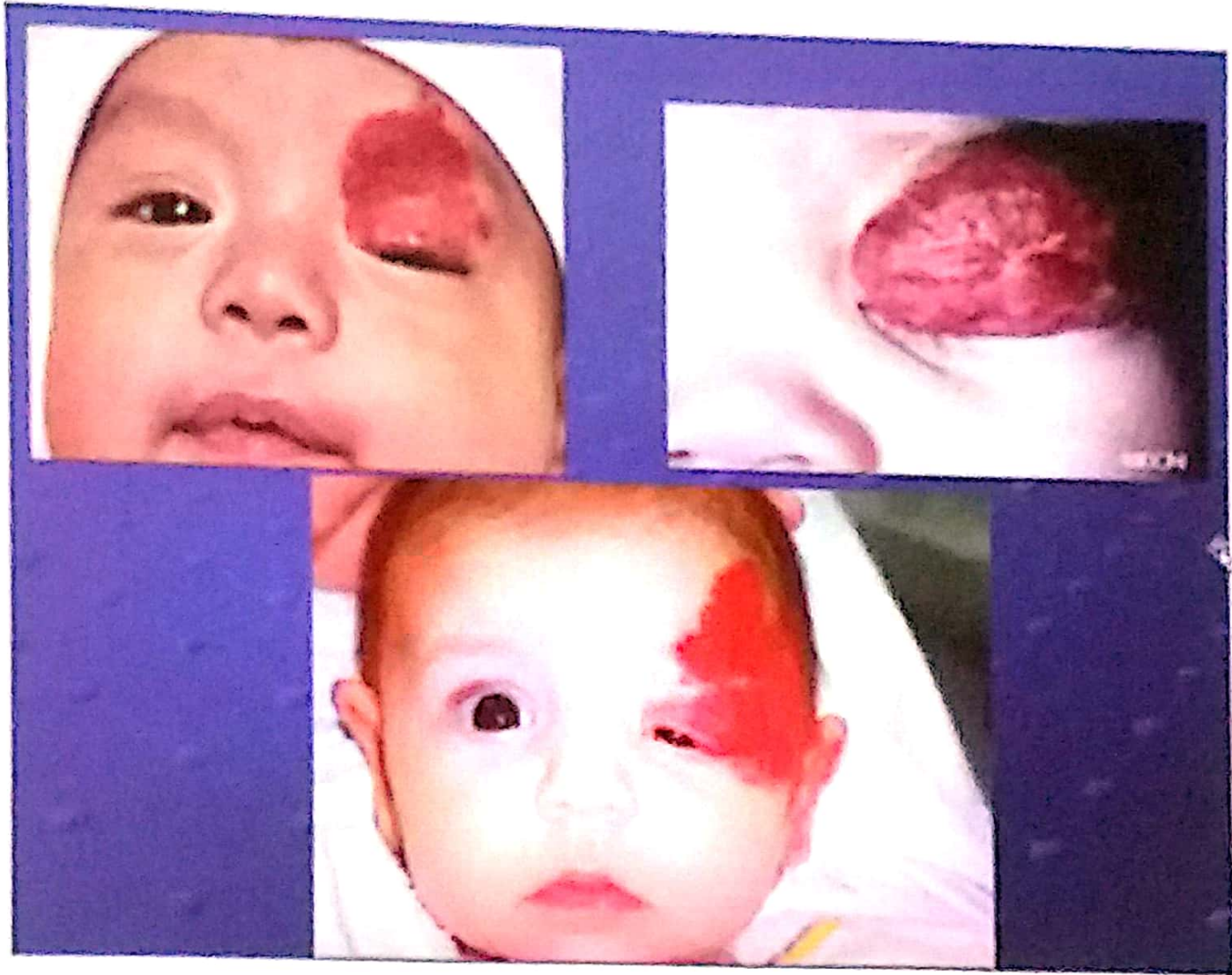
© 2005 Elsevier Ltd. Spalton et al. Atlas of Clinical Ophthalmology, 3e

Orbital Cellulitis

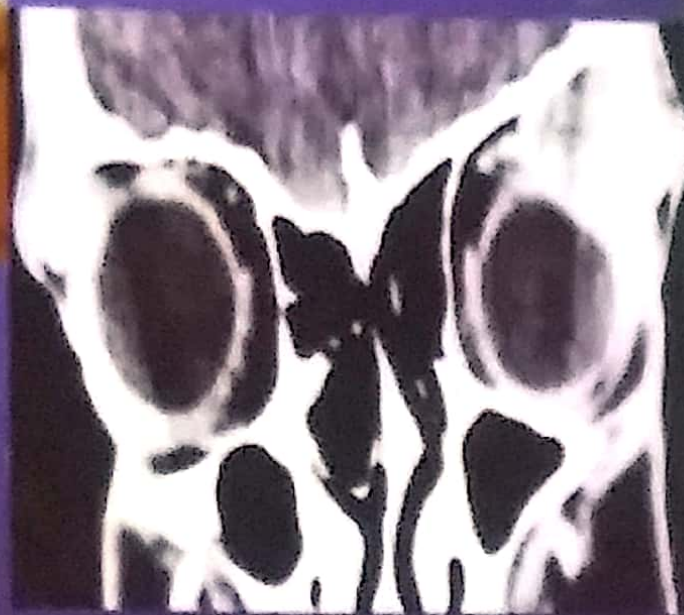
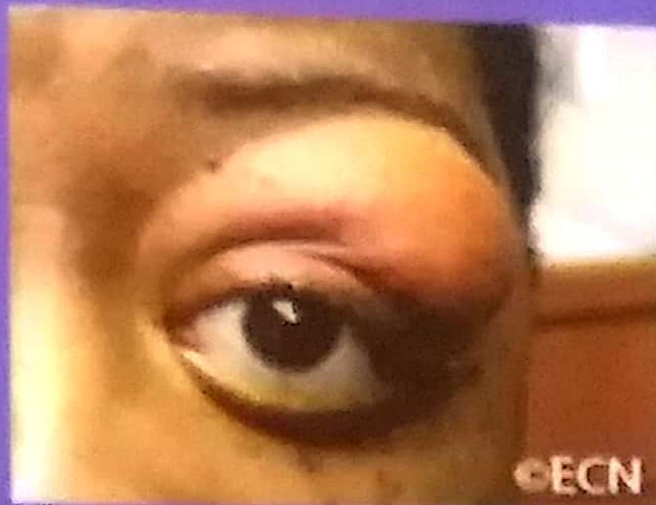

Dermoid Cyst



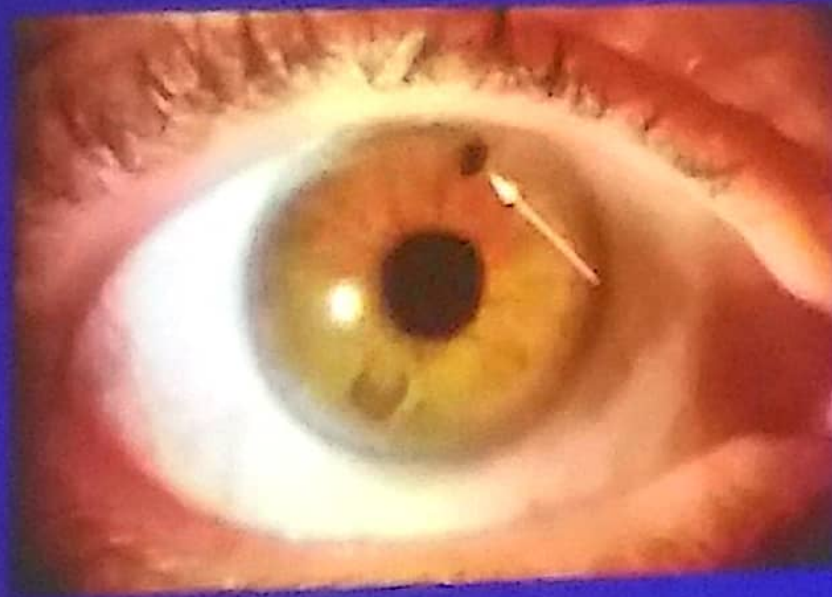

Lacrimal Gland Tumor

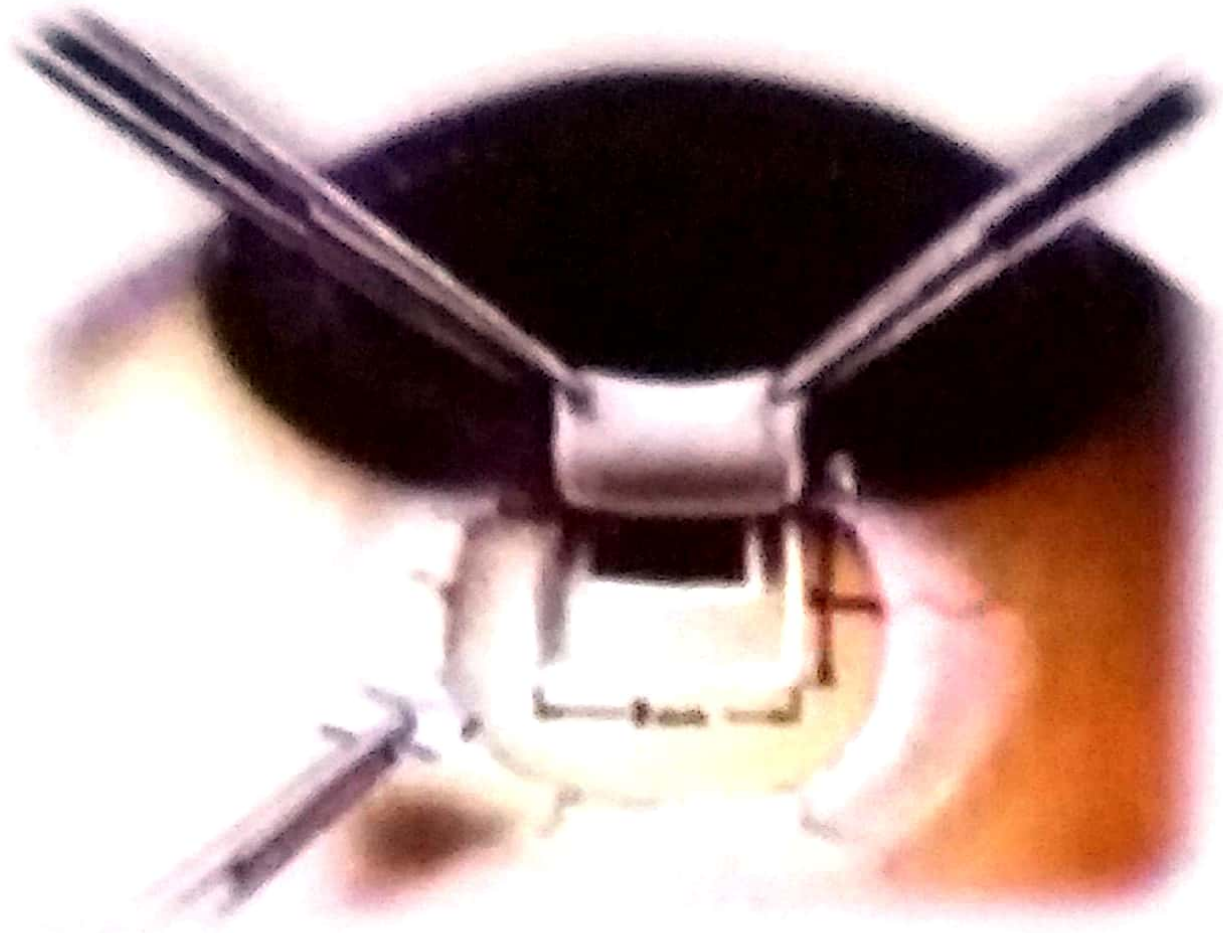


Laser peripheral iridotomy

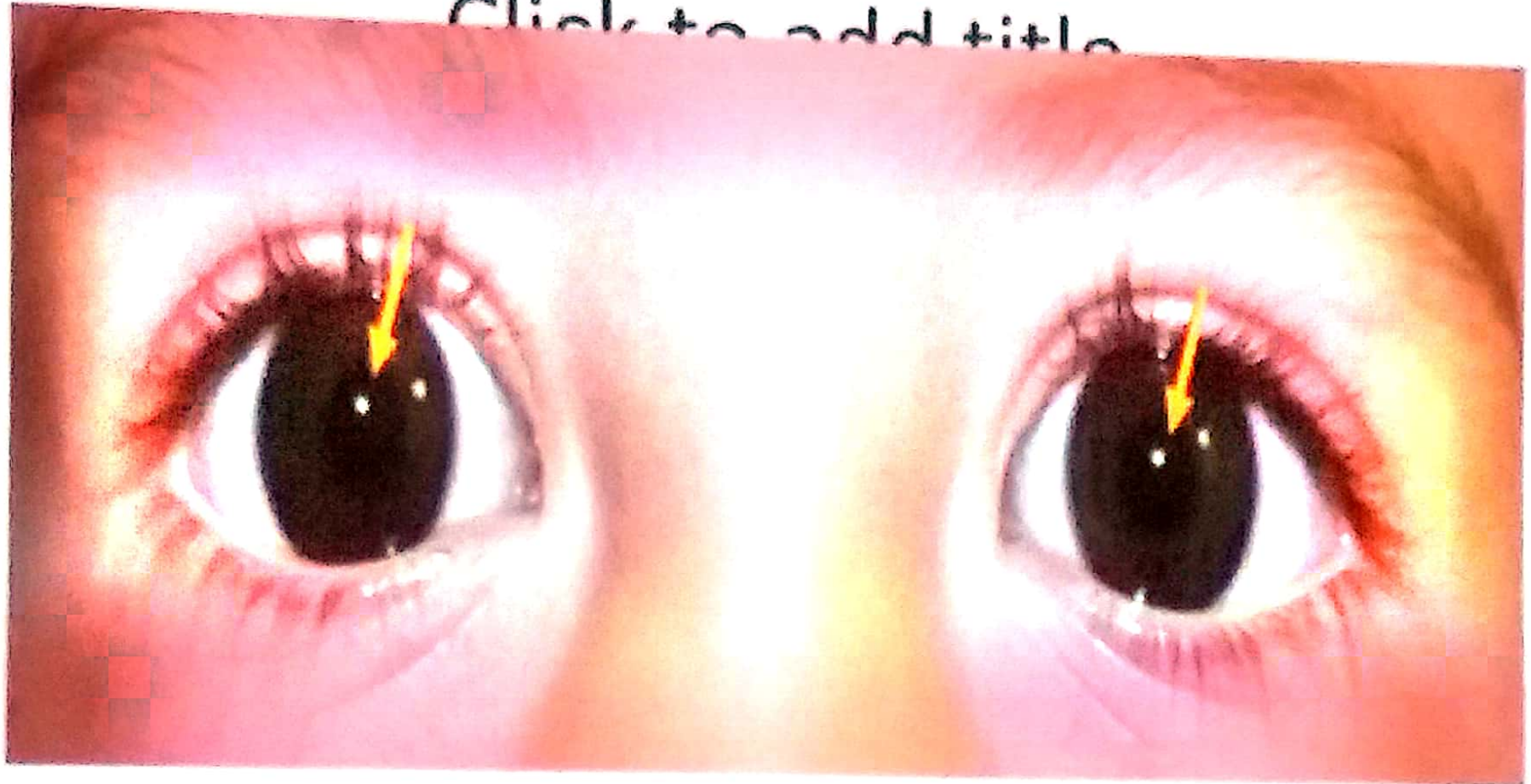- To create a hole in iris to relieve pupil block



Click to add title

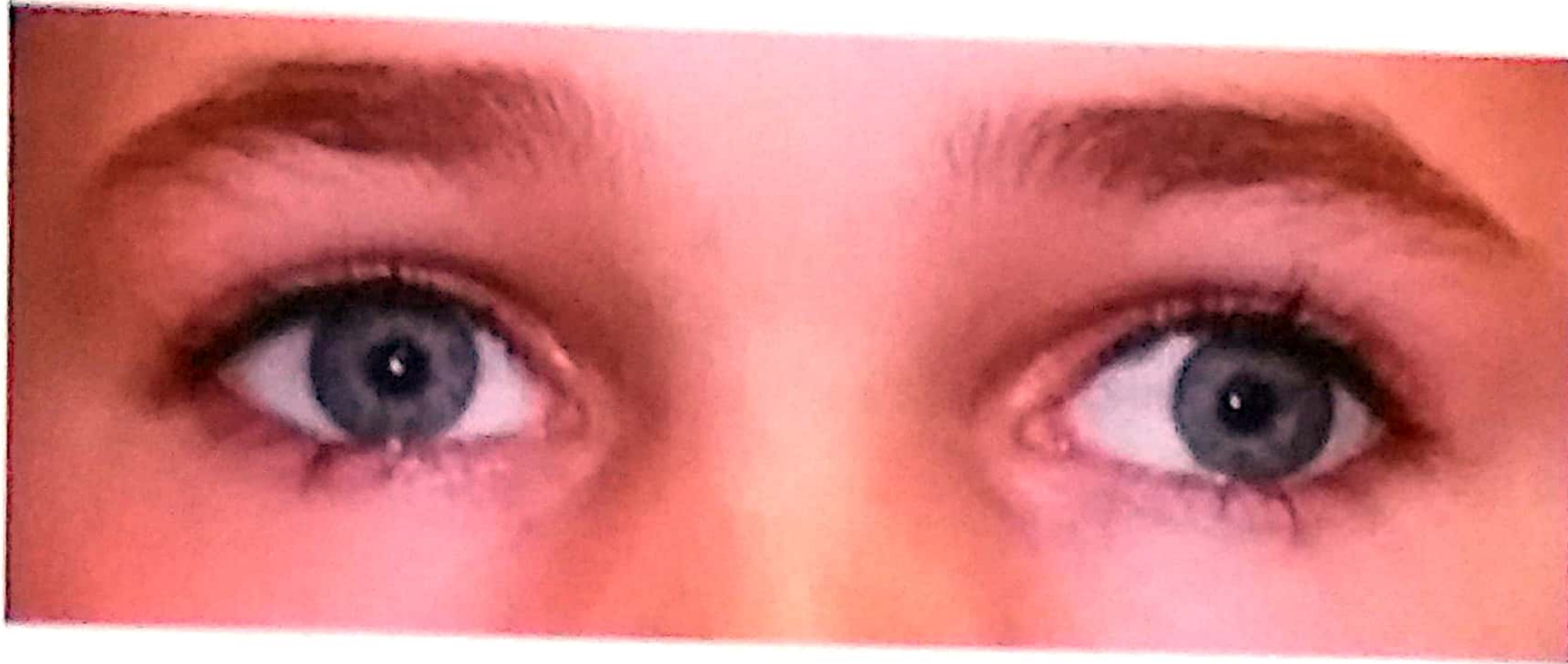

Click to add title

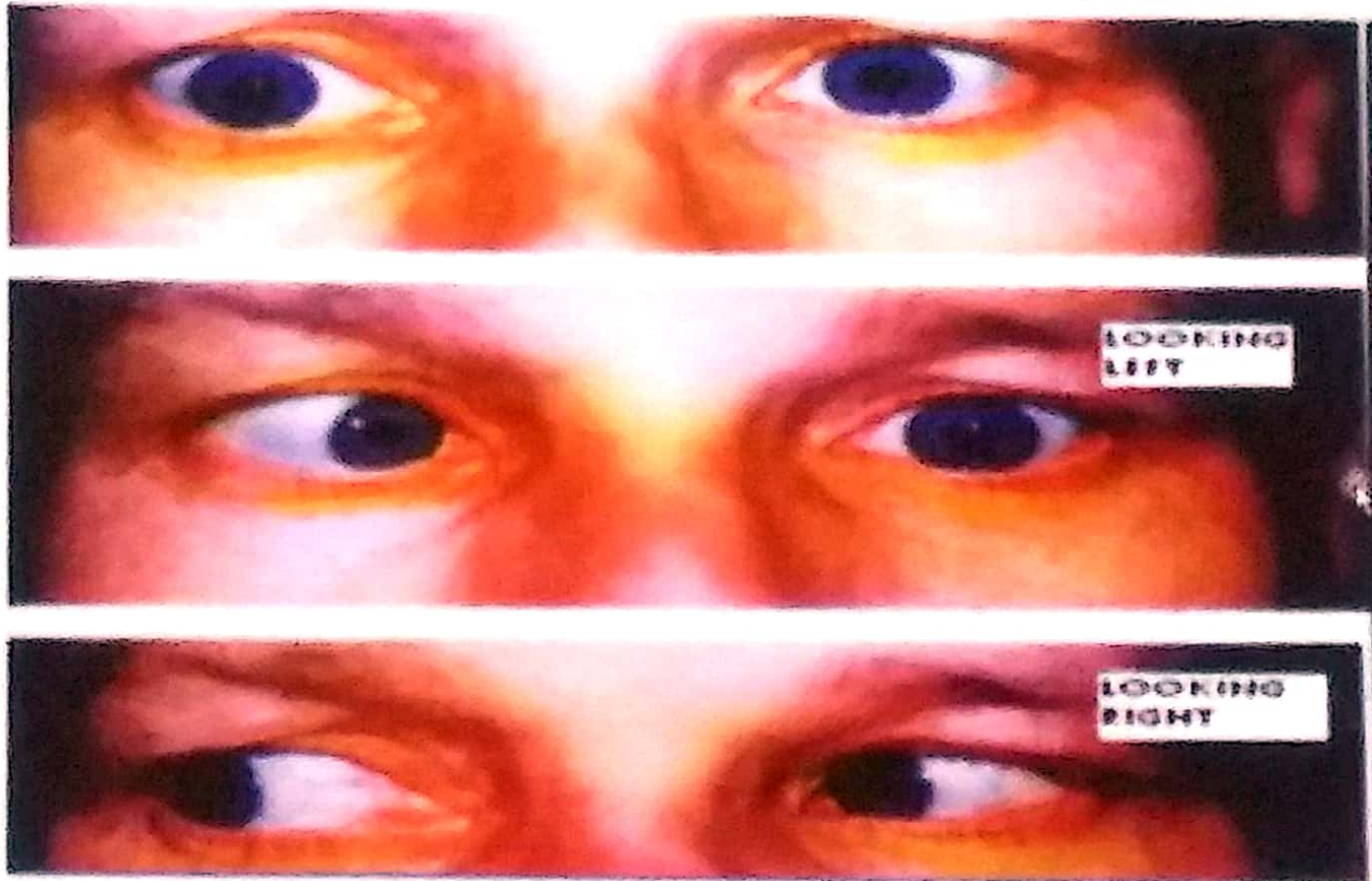


4

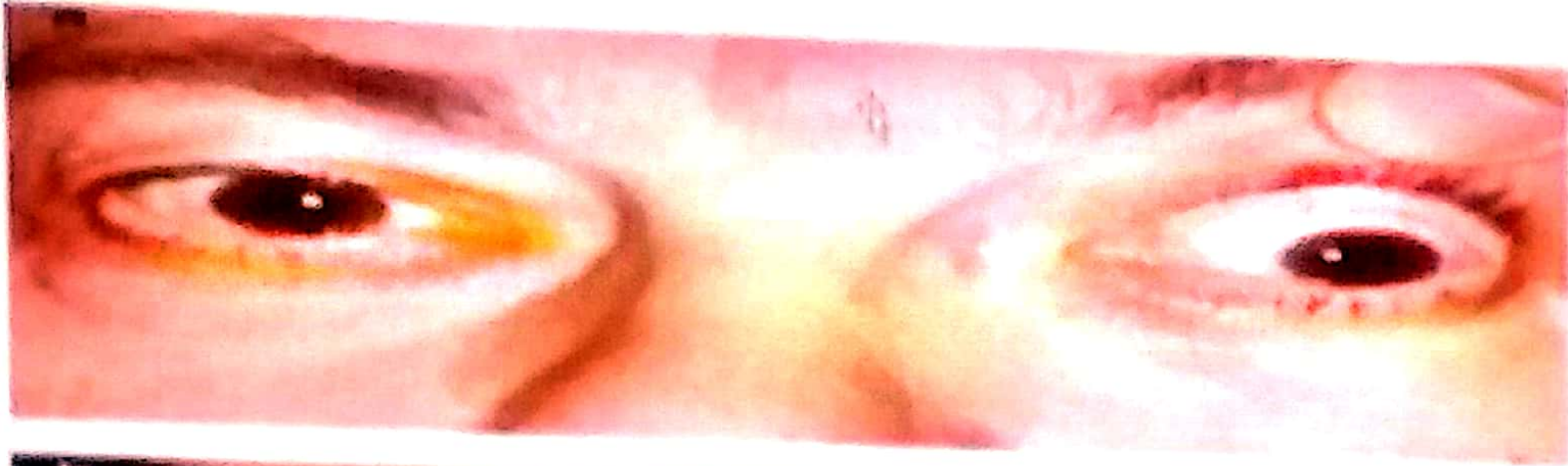Click to add title



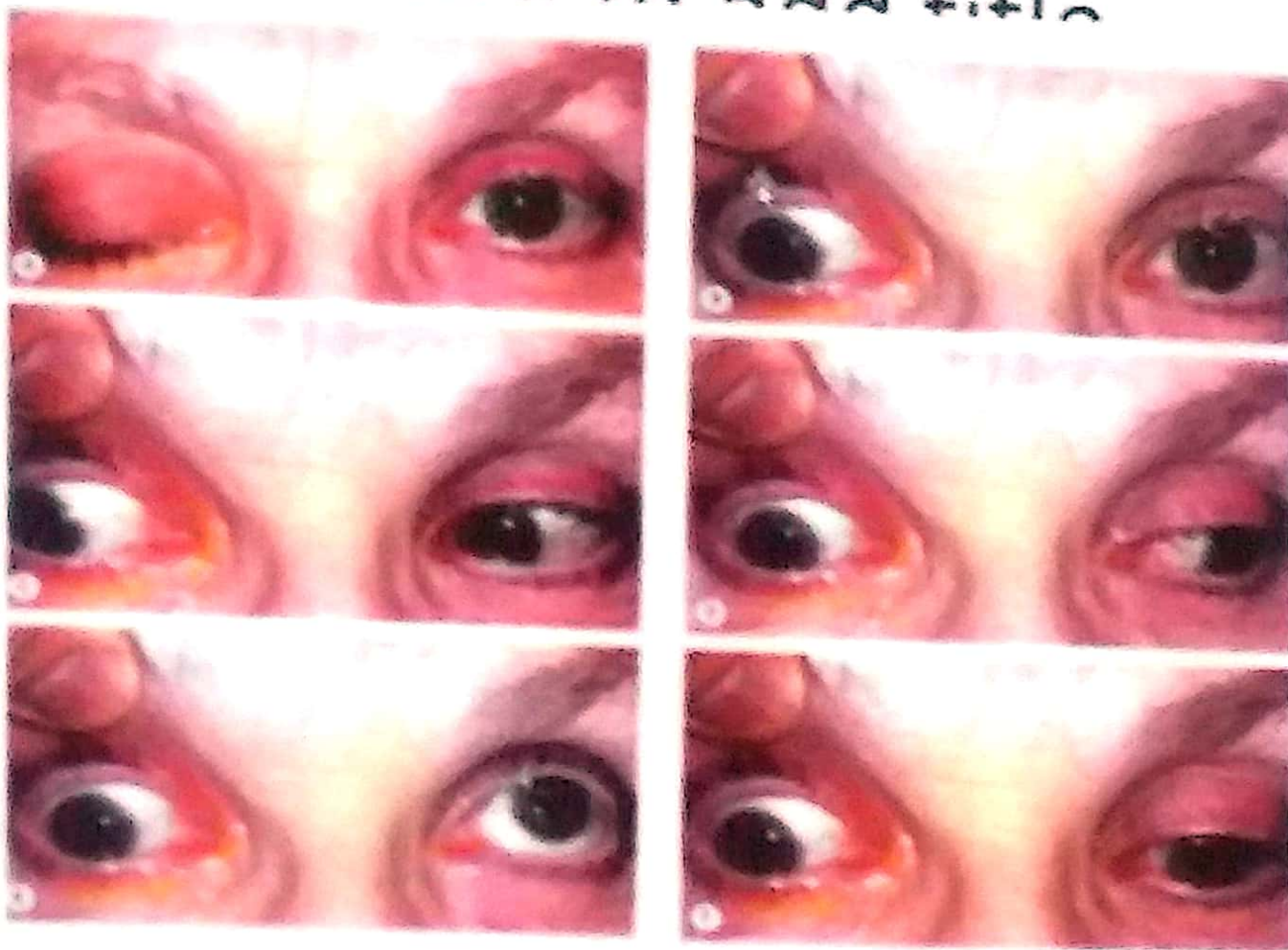Click to add title



Click to add title

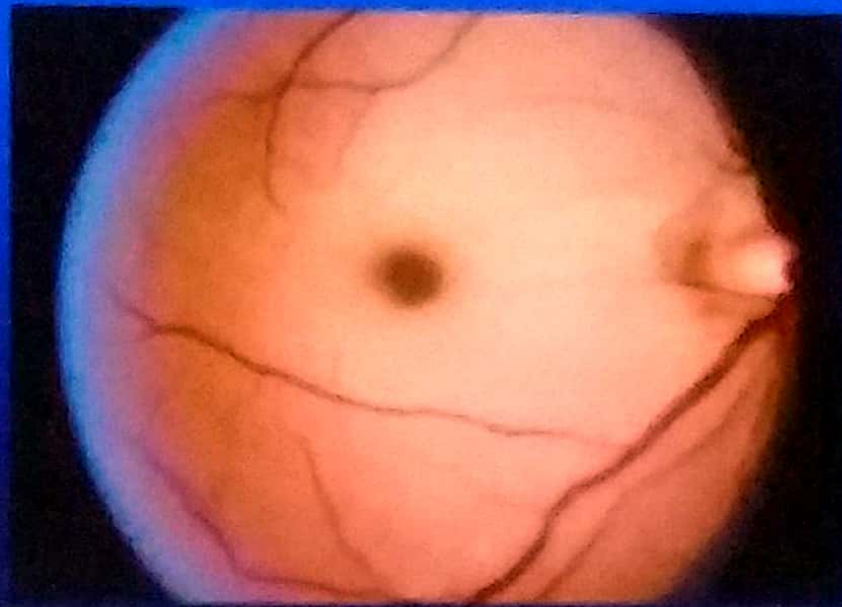


Click to add title

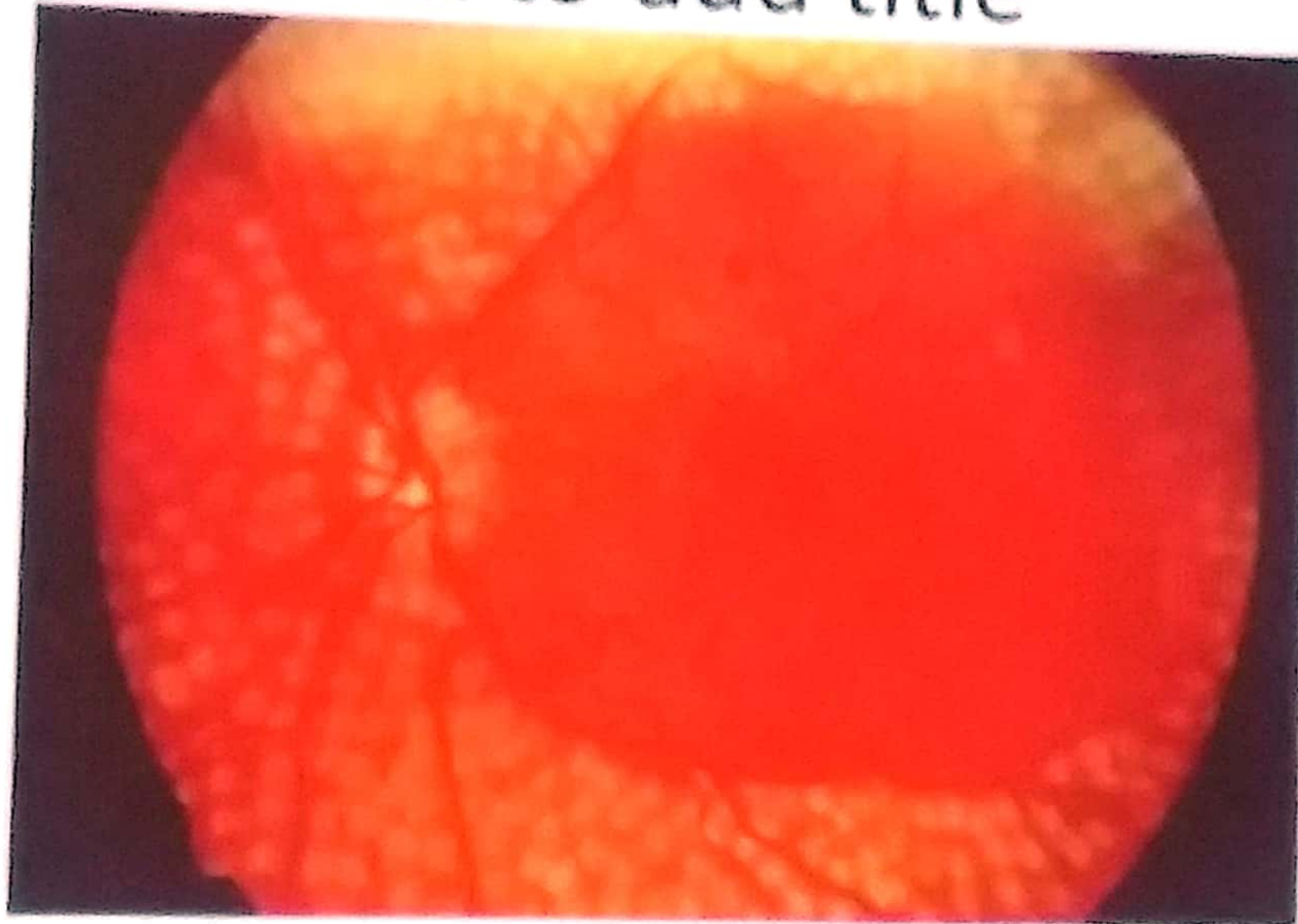

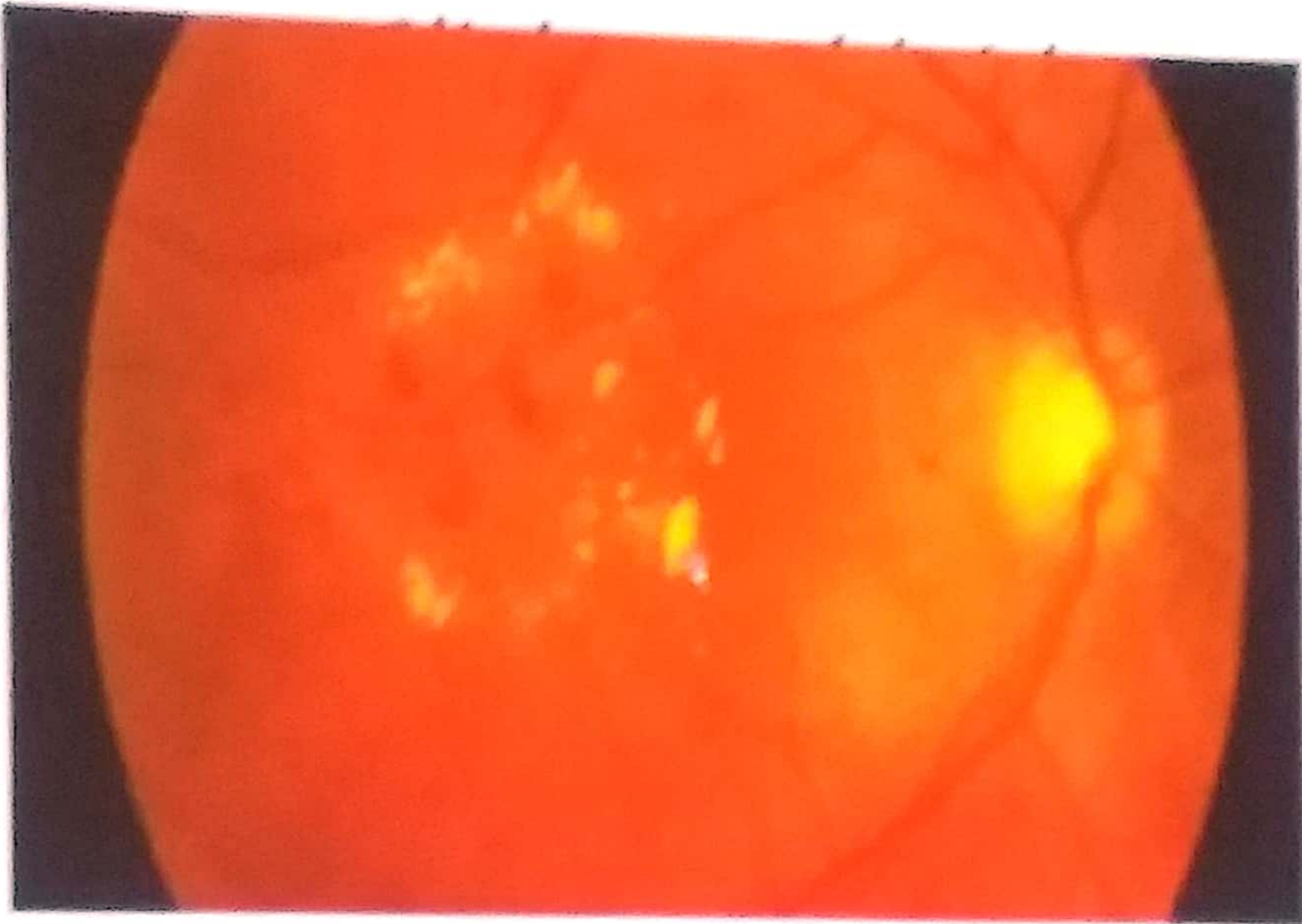Click to add title

CRAO

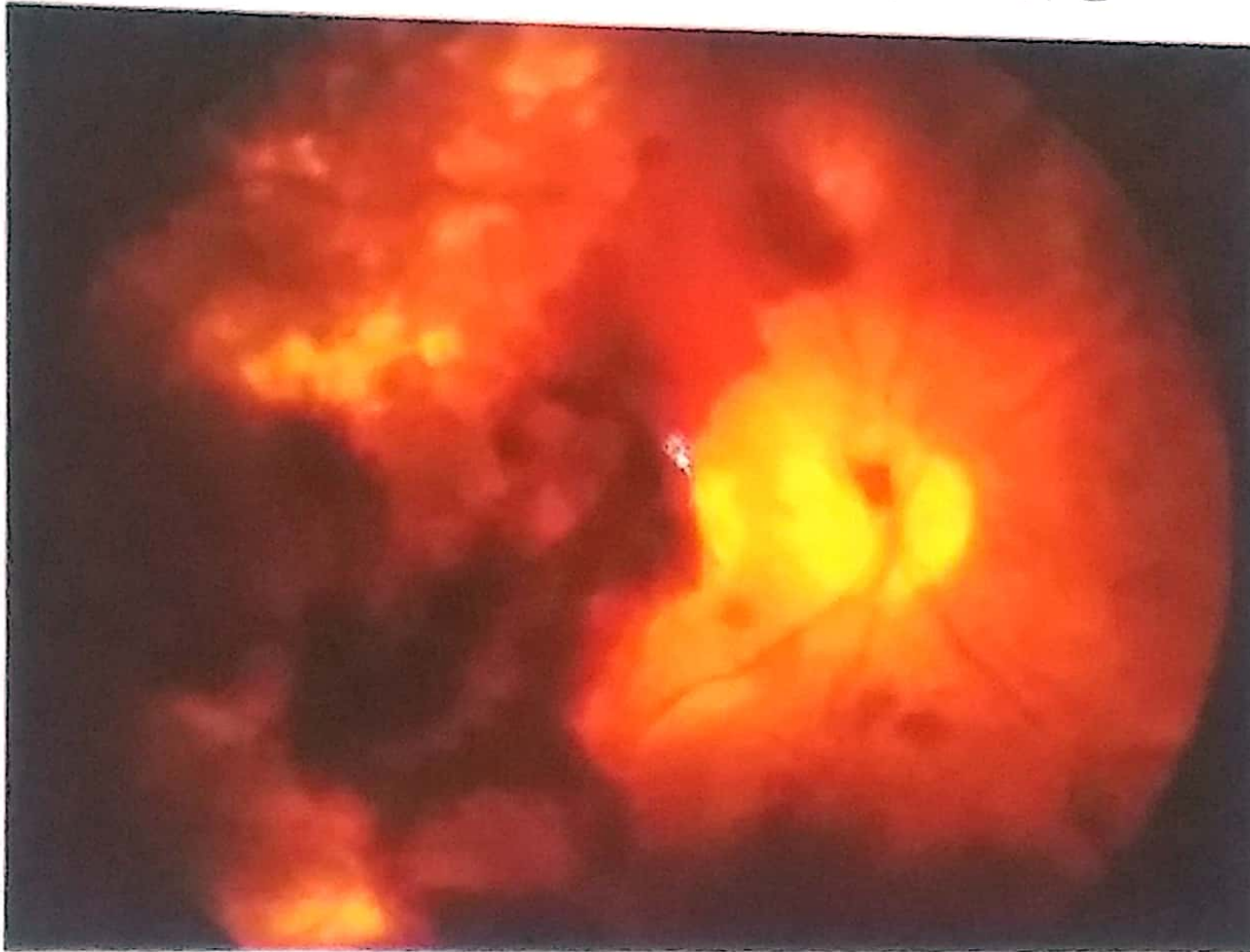


Click to add title

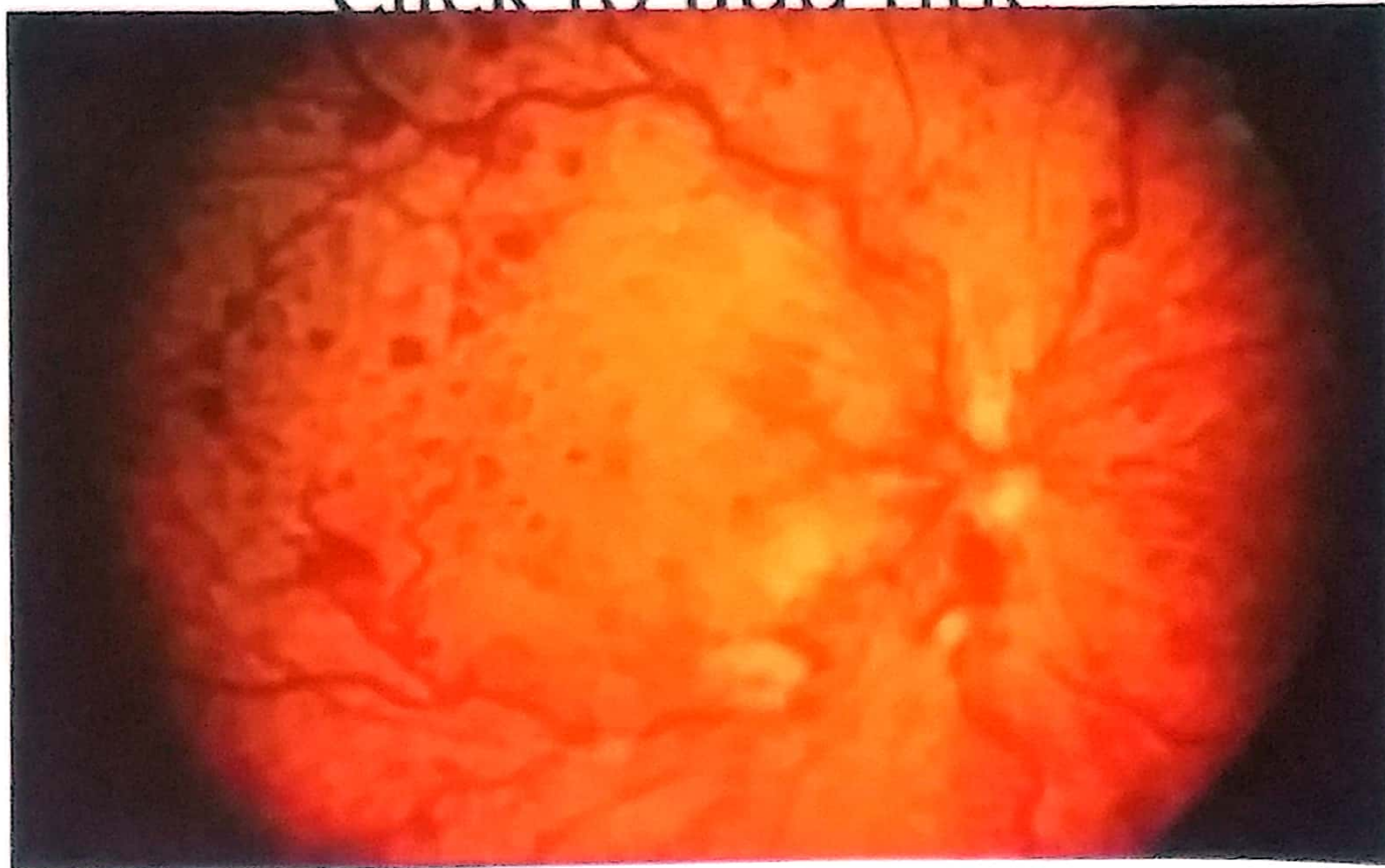




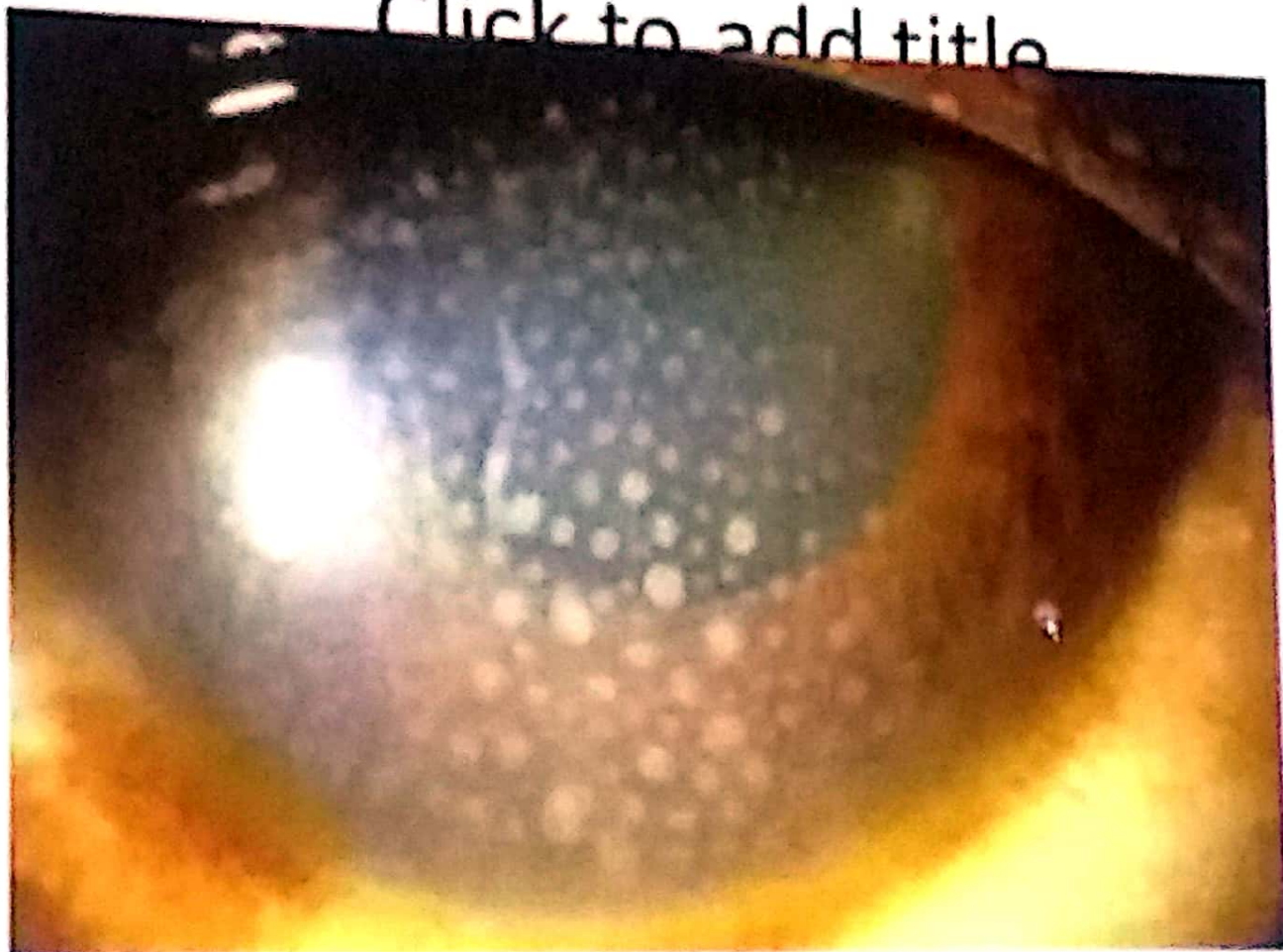Click to add title

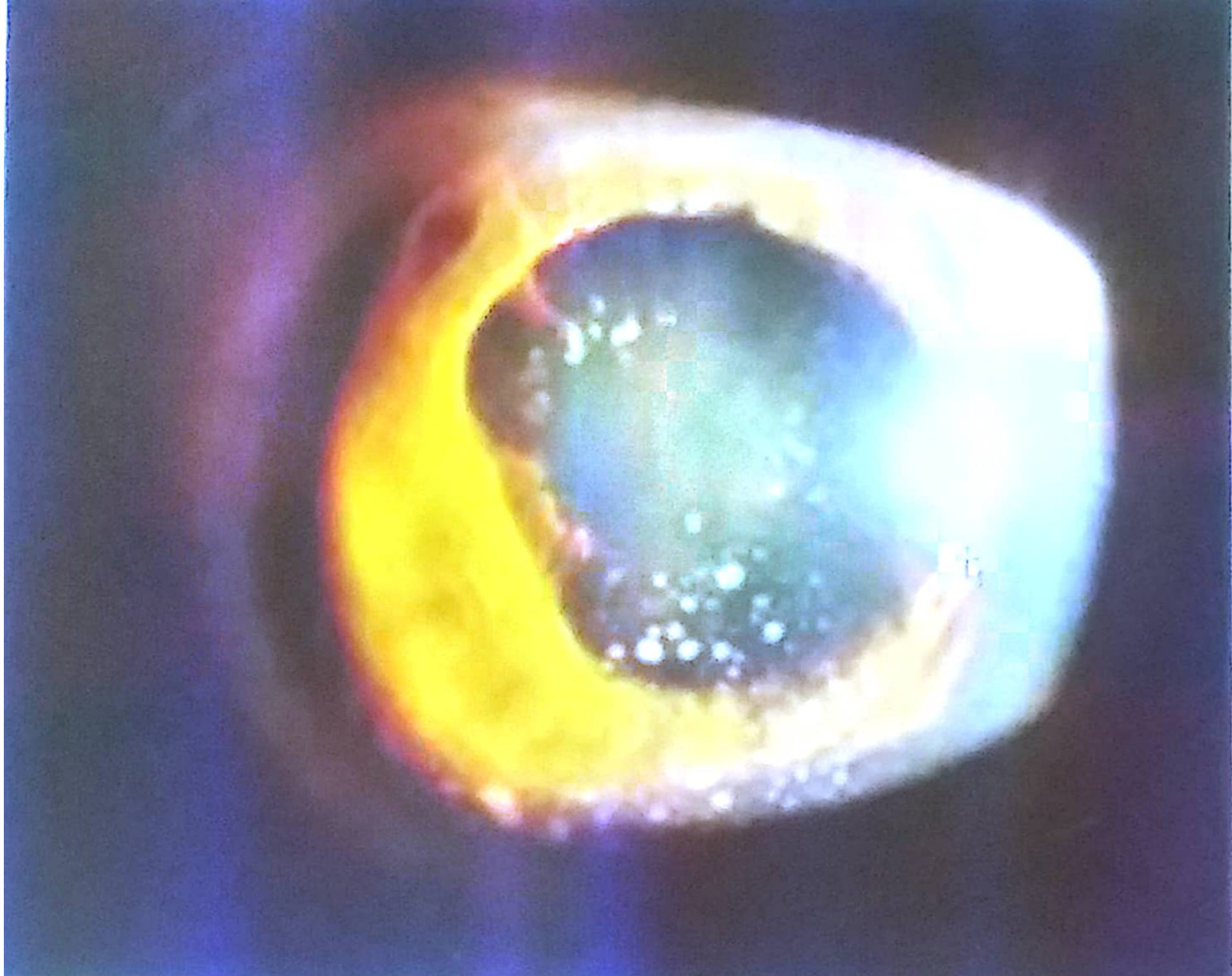


Click to add title



Click to add title





Click to add title

