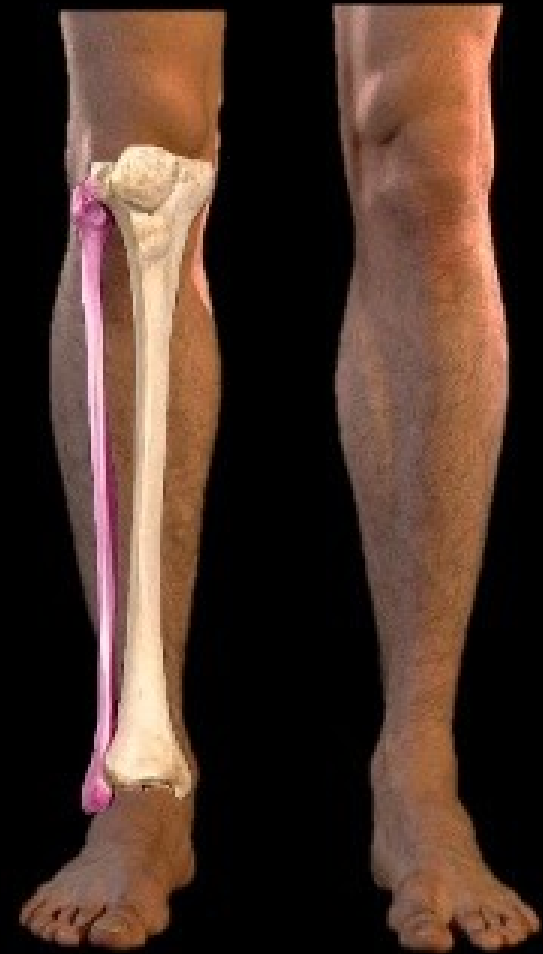

# FIBULA BONE

DR NAJMA ATTAULLAH  
LECTURER ANATOMY KGMC

There are two bones in the leg

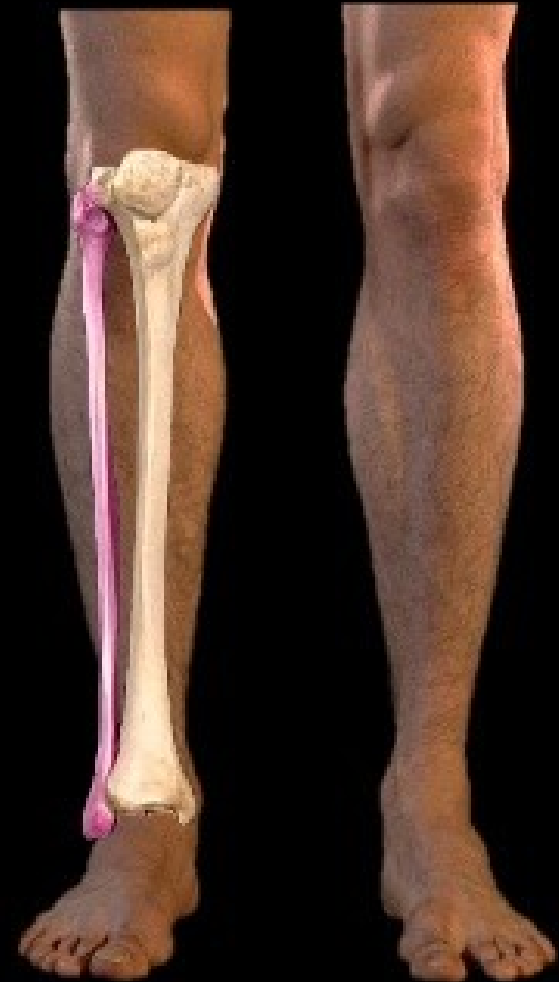Fibula



There are two bones in the leg

## The Fibula

- Lies Laterally
- Is shorter
- Is not a weight-bearing bone



# The Fibula

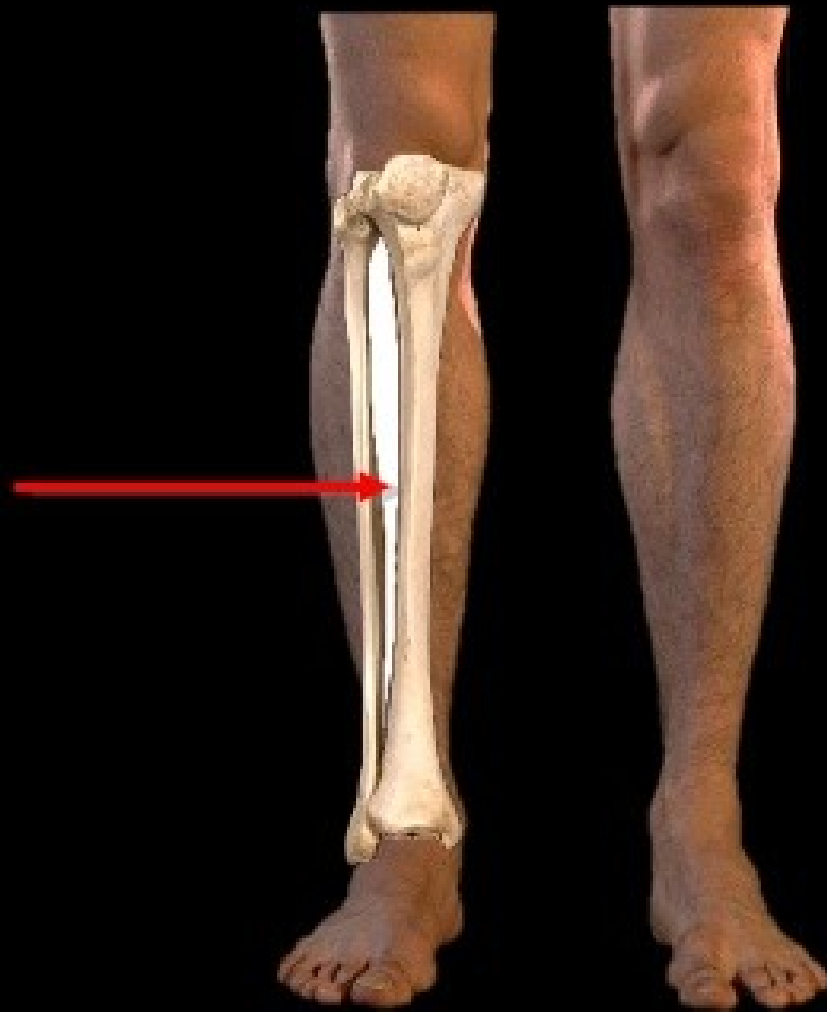**The Fibula** is the lateral bone of the leg and is homologous with the ulna of the forearm.

- In Latin, the term fibula means “pin”; therefore the lateral bone of leg is rightly referred to as fibula because it's a long pin-like bone.


It's a long thin postaxial bone of the leg and will take part in the transmission of the body weight.

Its main function is to act as an attachment for muscles, and not as a weight-bearer.

The Fibula and Tibia are  
joined together by the  
Interosseous Membrane



The Fibula is a long bone and is divided into thirds



# Articulations of the fibula

It has three main articulations:

**Proximal tibiofibular joint** – articulates with the lateral condyle of the tibia.

**Distal tibiofibular joint** – articulates with the fibular notch of the tibia.

**Ankle joint** – articulates with the talus bone of the foot.

## **SIDE DECISION AND ANATOMICAL POSITION**

- The side of fibula can be set by holding it vertically in such a way that:
  - Its round end termed head is directed upward.
  - Its comparatively flattened end is pointed downward.
  - A triangular articular facet on its lower end faces medially.
  - A depression at the lower end (malleolar fossa) is located behind and below the triangular articular facet at this end.



# The Proximal Fibula (Head of the Fibula)

## The Proximal Fibula



The Head of the Fibula is quadrilateral in shape

## The Proximal Fibula

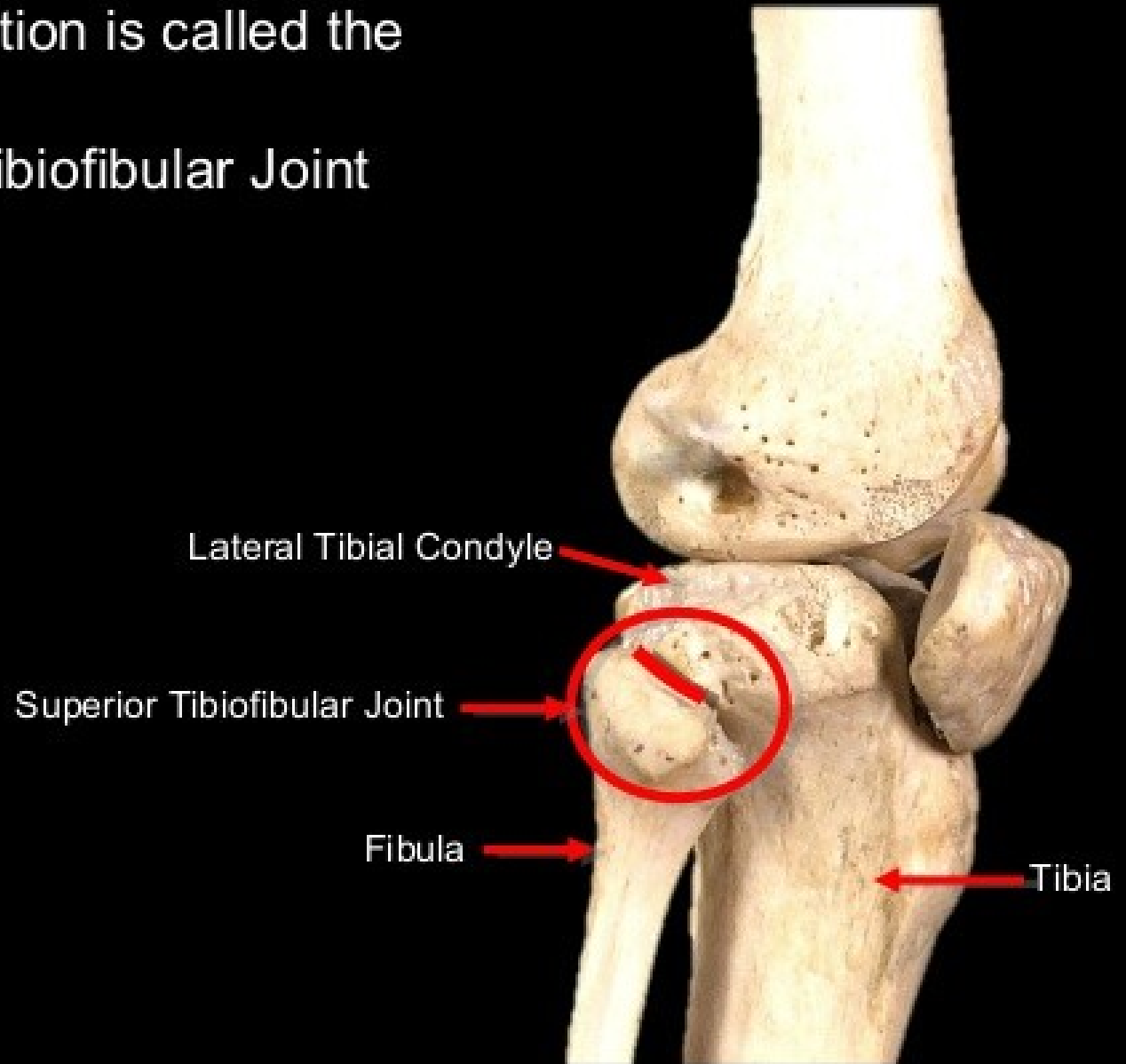


On the upper surface  
is a smooth oval facet  
covered in articular  
hyaline cartilage


This region articulates  
with the  
Lateral Tibial Condyle

This articulation is called the  
Superior Tibiofibular Joint

Lateral view knee joint



## The Proximal Fibula



The Styloid Process or  
Apex of the Head of the Fibula  
lies postero-lateral to the  
articular facet

# The Proximal Fibula



Arcuate Popliteal Ligament  
and  
Fibular Collateral Ligament  
attach to the Styloid  
Process

# The Proximal Fibula



The Neck of the Fibula is  
immediately distal to the  
Head of the Fibula

# The Proximal Fibula



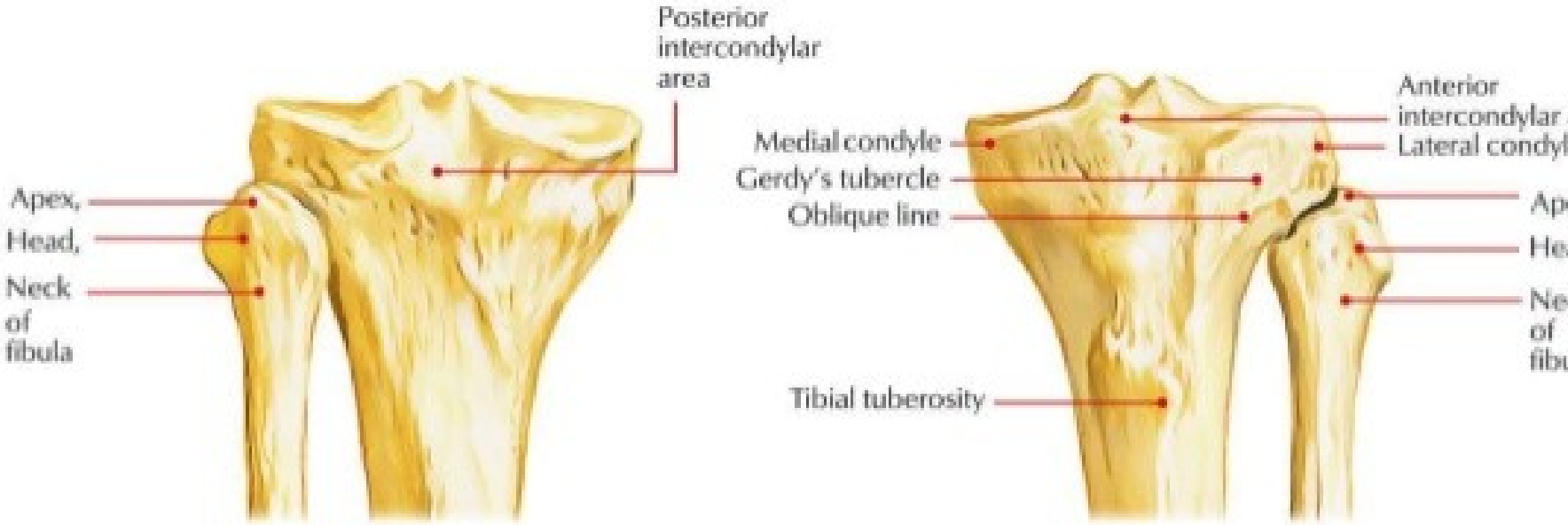
The Common Peroneal Nerve wraps around the Neck of the Fibula before dividing into its two terminal branches

- Superficial Peroneal Nerve
- Deep Peroneal Nerve





# Head of the fibula



# Neck of the fibula

- **Neck** It's a constriction below the head linking it with the shaft.
- The common peroneal nerve is associated with the posterolateral aspect of neck and anterior tibial artery on its medial aspect.

# SHAFT OF FIBULA

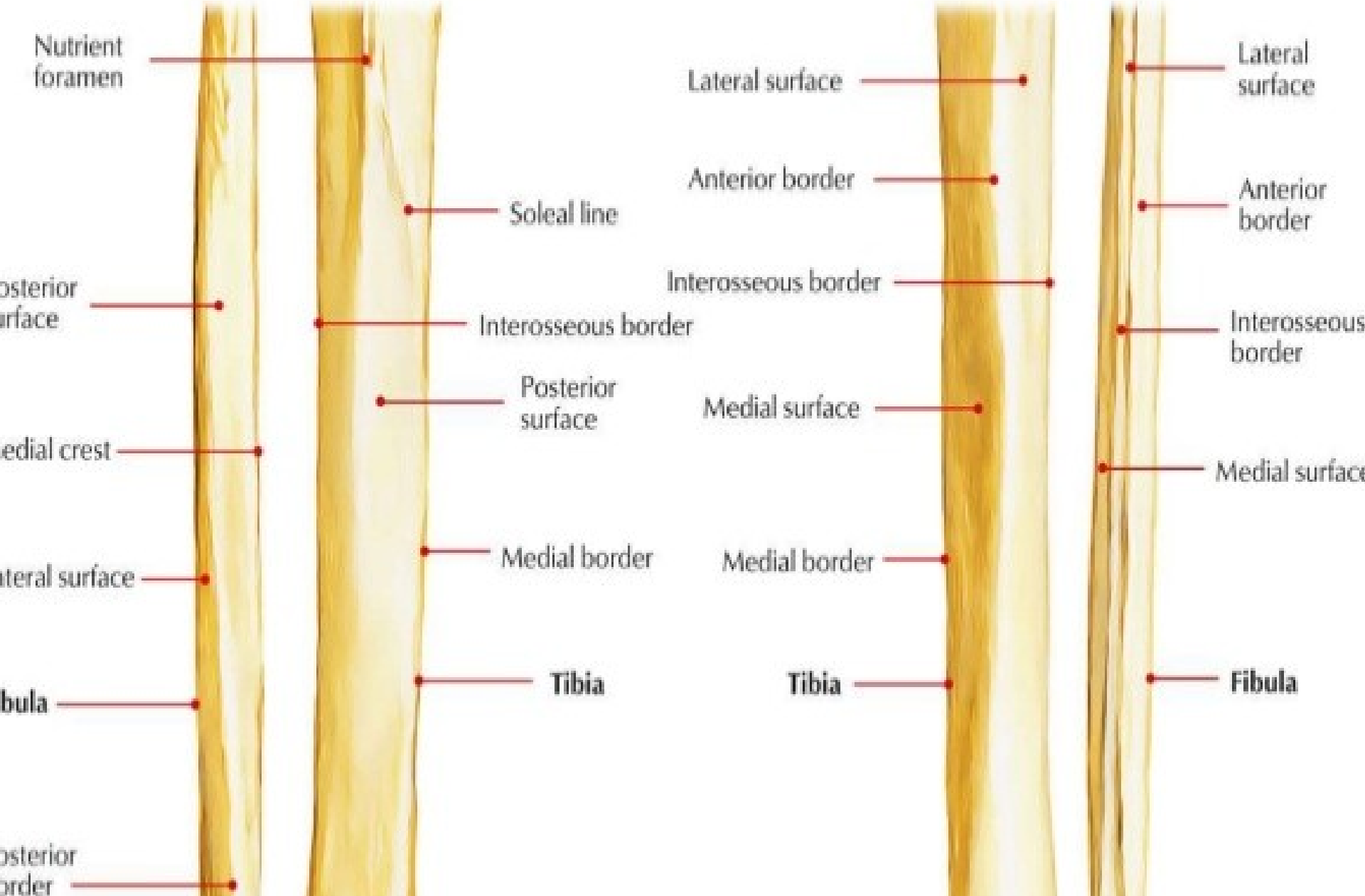
- **3 BORDERS**

- ANTERIOR BORDER
- POSTERIOR BORDER
- MEDIAL (INTEROSSEOUS BORDER)

- **3 SURFACES**

- **MEDIAL SURFACE (INTEROSSEOUS SURFACE)**
- LATERAL SURFACE
- POSTERIOR SURFACE

# SHAFT of the fibula



## **Anterior border**

- The anterior border begins just below the anterior aspect of the head.
- At its lower end it divides to enclose an elongated triangular area which is continuous with the lateral surface of the lateral malleolus.
  - It gives connection to the anterior intermuscular septum of the leg in its upper three-fourth.

# Posterior Border

The posterior border is rounded.

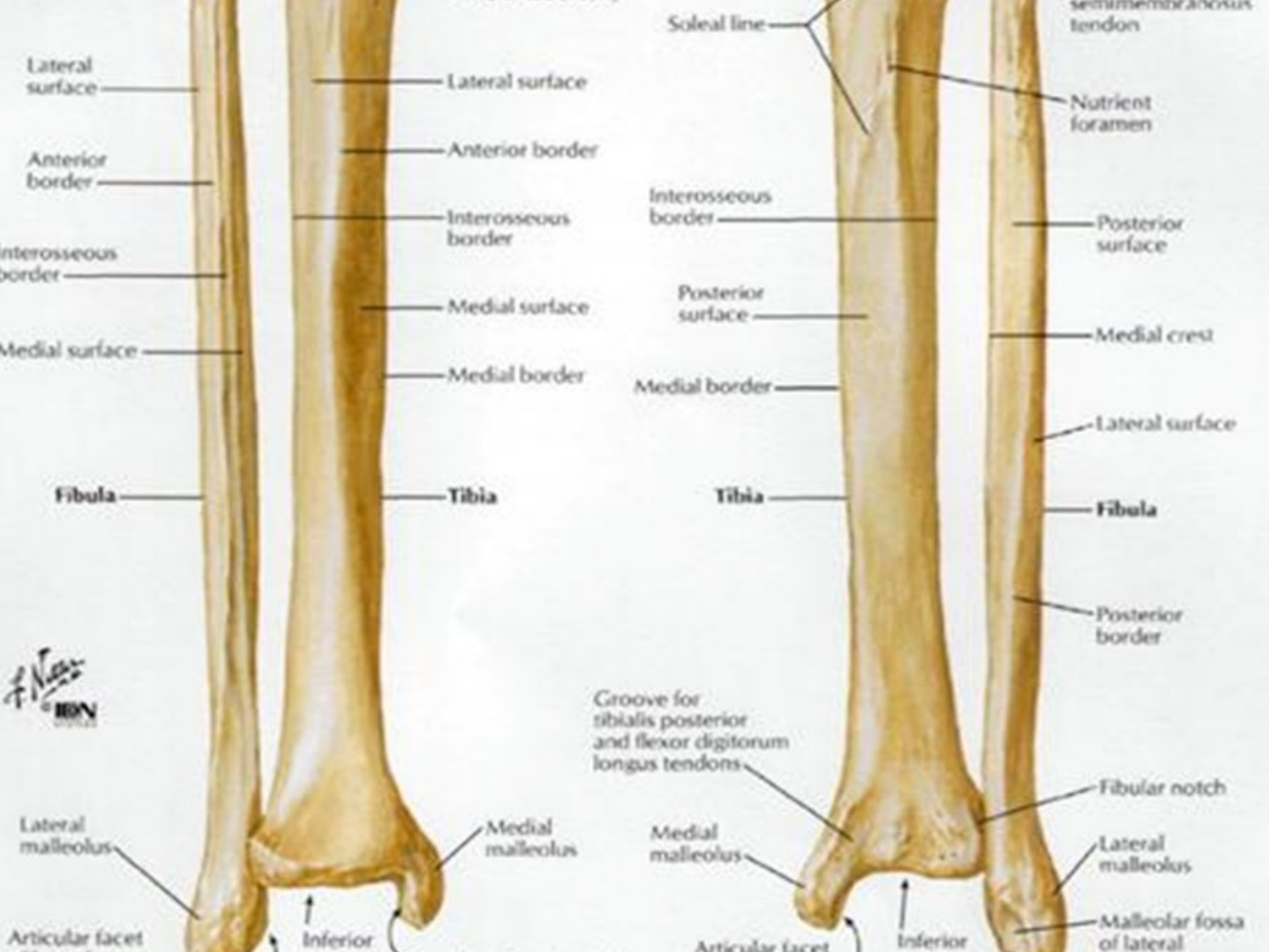
Its upper end lies in line with the styloid process. Below, the border is continuous with the medial margin of the groove on the back of the lateral malleolus.

It goes from the posterior aspect of head to the lateral margin of groove on the posterior surface of the lateral malleolus.

Posterior intermuscular septum of the leg is connected to its upper three fourth.

# Interosseous or medial Border

- The interosseous or medial border lies just medial to the anterior border, but on a more posterior plane.
- It terminates below at the upper end of a roughened area above the talar facet of the lateral malleolus.
- In its upper two-thirds, the interosseous border lies very close to the anterior border and may be indistinguishable from it.
- Interosseous membrane is connected along its entire length with the exception of at the upper end to make a gap for the passage of anterior tibial vessels.





anterior border

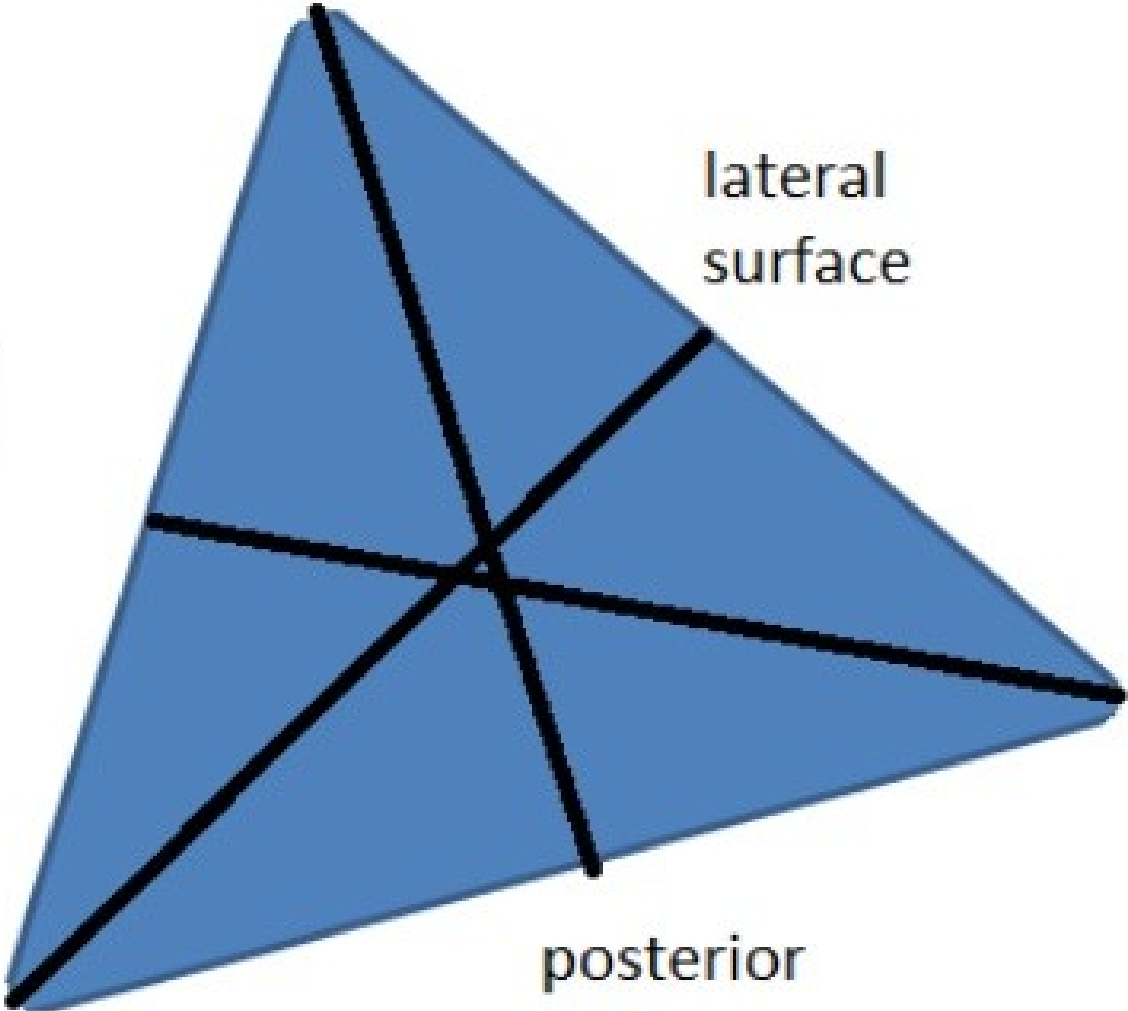
lateral surface

anterior surface

posterior border

posterior surface

medial border



# Medial (Extensor) Surface

It's narrow and is located between the anterior and interosseous edges.

It gives origin to extensor digitorum longus in upper three-fourth (entire width of its upper fourth and anterior half of its middle 2-fourth).

Extensor hallucis longus originates from the posterior half of the middle two-fourth medial to the extensor digitorum longus.

Its lower quarter gives origin to the peroneus tertius.

## Lateral (Peroneal) Surface

- It is located between the anterior and posterior border.
- Peroneus longus originates from the upper two-third (whole width of upper one-third and the posterior half of the middle one-third).
- Peroneus brevis originates from the anterior half of its middle one-third and entire width of its lower one-third.

# Posterior (Flexor) Surface

It's wide-ranging and is located between the interosseous and posterior edges.

Its upper two-third is split into medial concave and flattened lateral parts by a sharp vertical ridge medial crest.

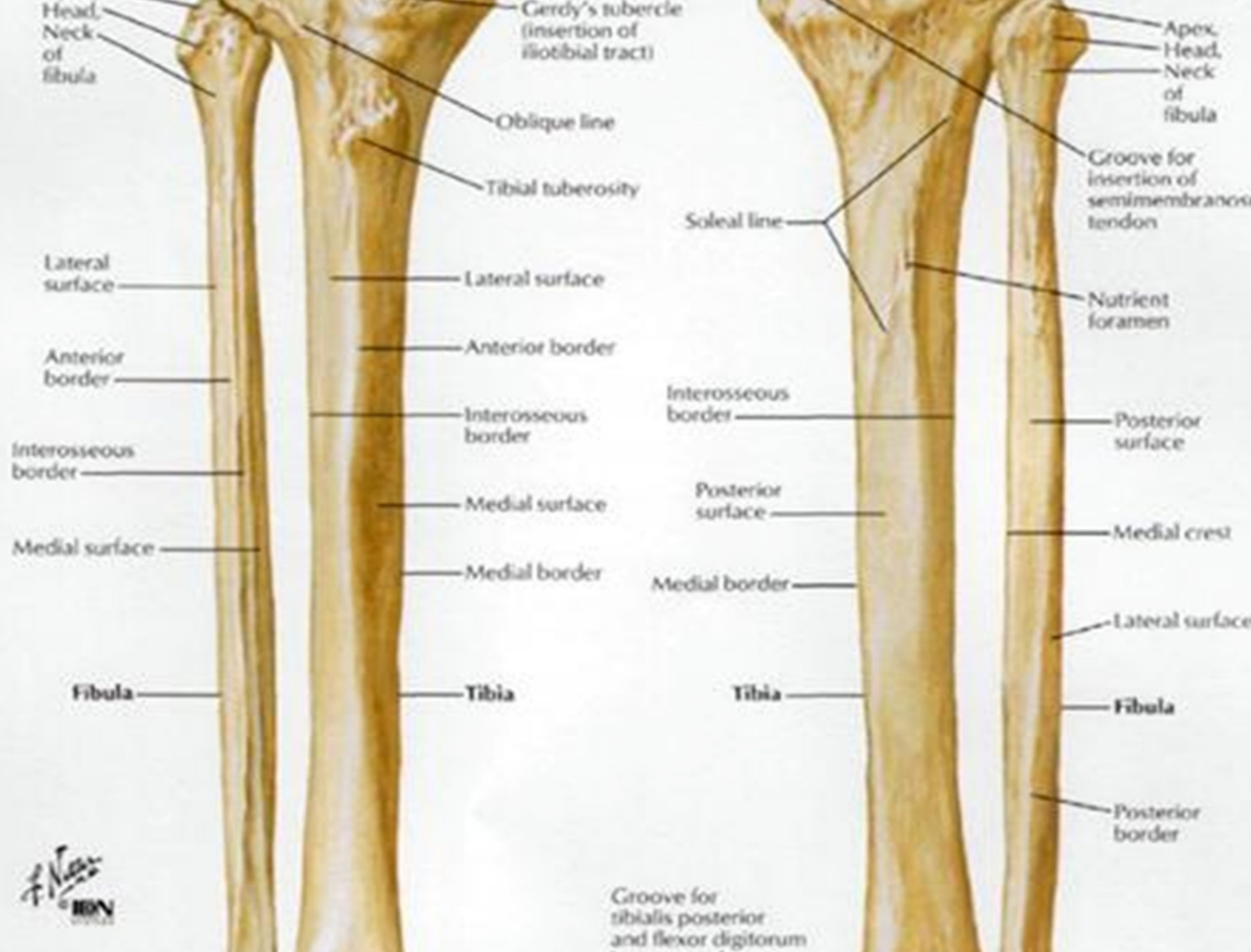
**Fascia** covering the **tibialis posterior** is connected to the medial crest.

Medial concave part gives origin to tibialis posterior.

Lateral flattened part gives origin to the soleus in upper quarter and to the **flexor hallucis longus** in lower three-fourth.

**Peroneal artery** descends along medial crest.

Nutrient artery, a branch of the **peroneal artery**, enters the nutrient foramen present just above the middle of the posterior surface.



# The Distal Fibula

# The Distal Fibula



The distal end of  
the Fibula is  
conical or  
triangular in shape

# The Distal Fibula

It is easily palpable  
in the ankle



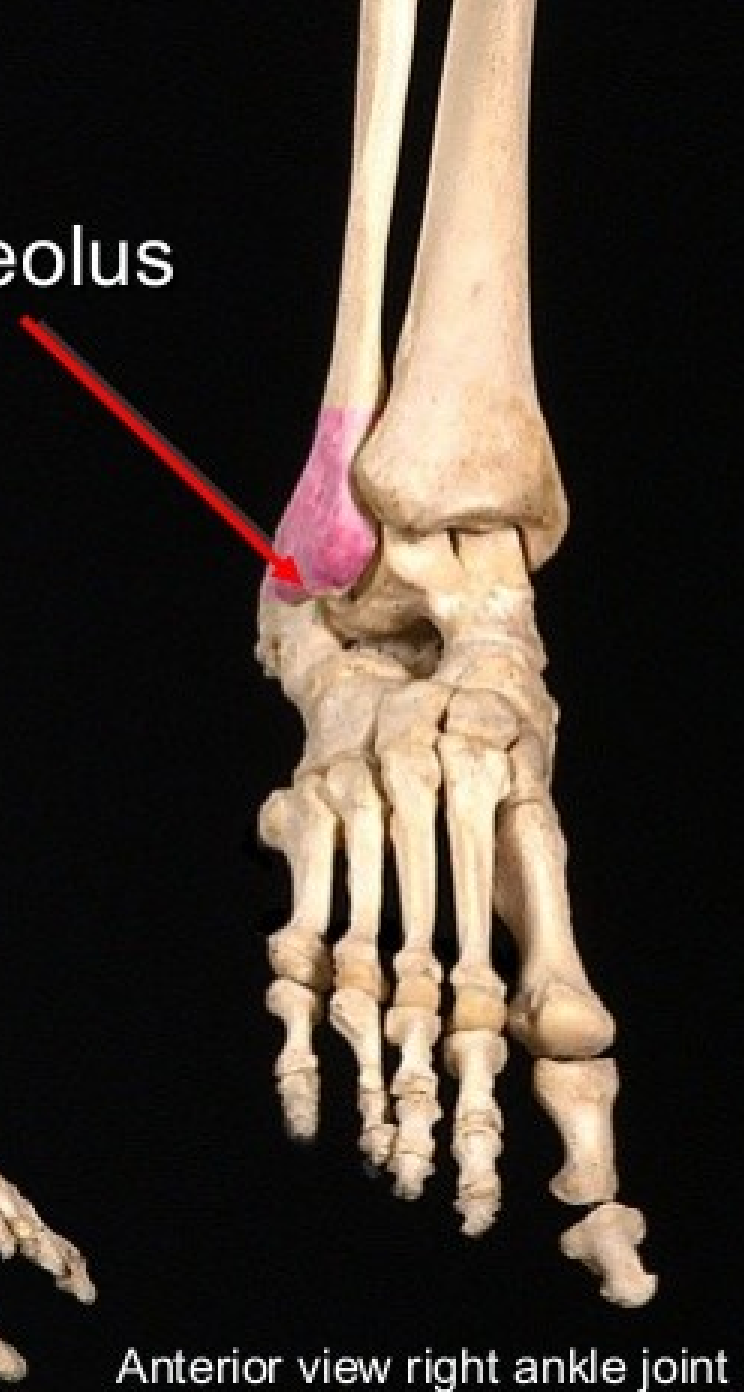
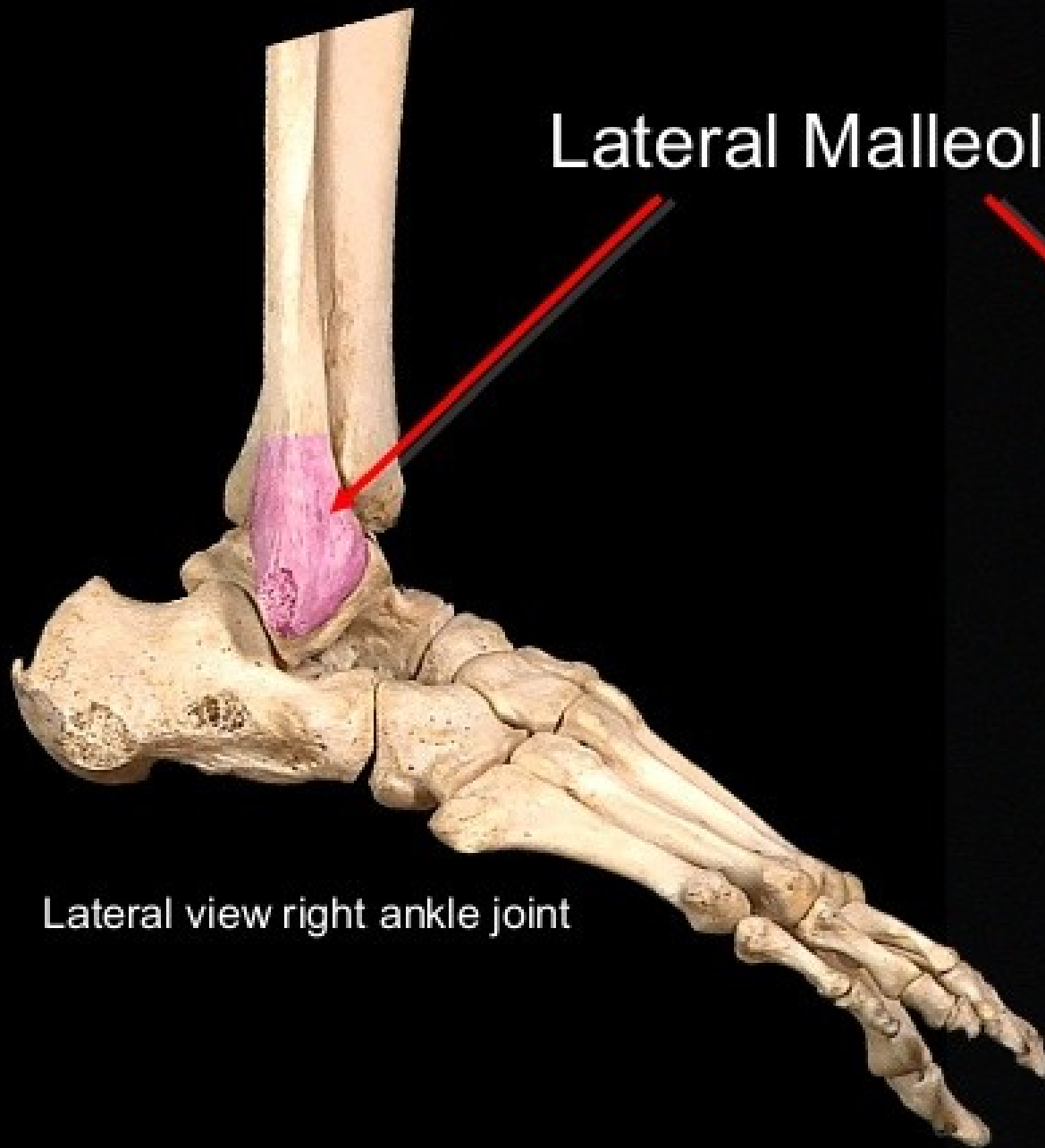
This conical  
projection of bone is  
called the  
Lateral Malleolus

Lateral Malleolus



# The Distal Fibula

## Lateral Malleolus



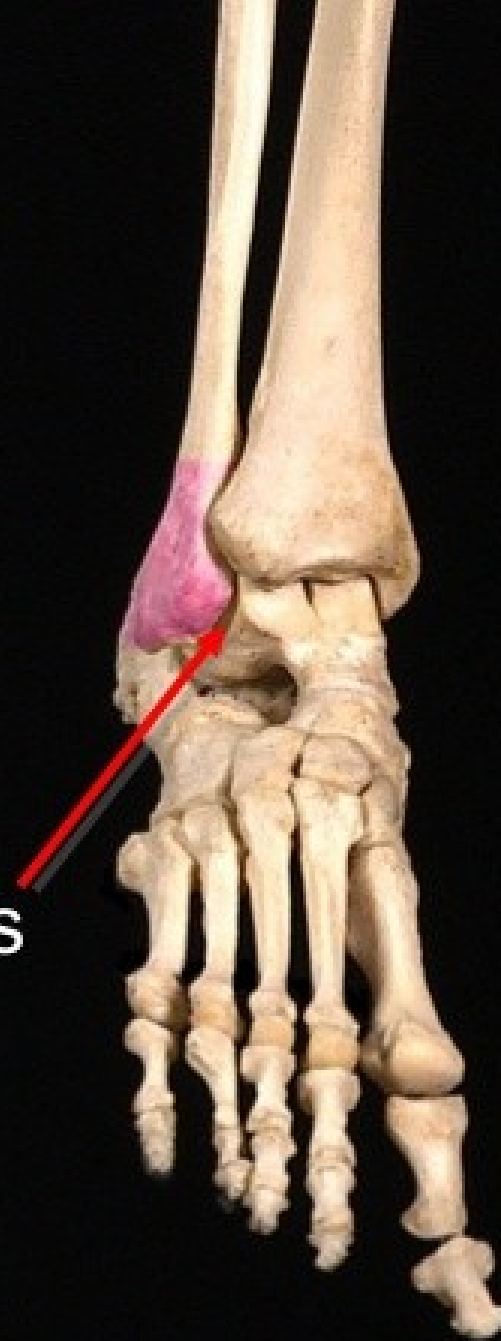# The Distal Fibula

On the Medial side of the Lateral Malleolus is a triangular facet

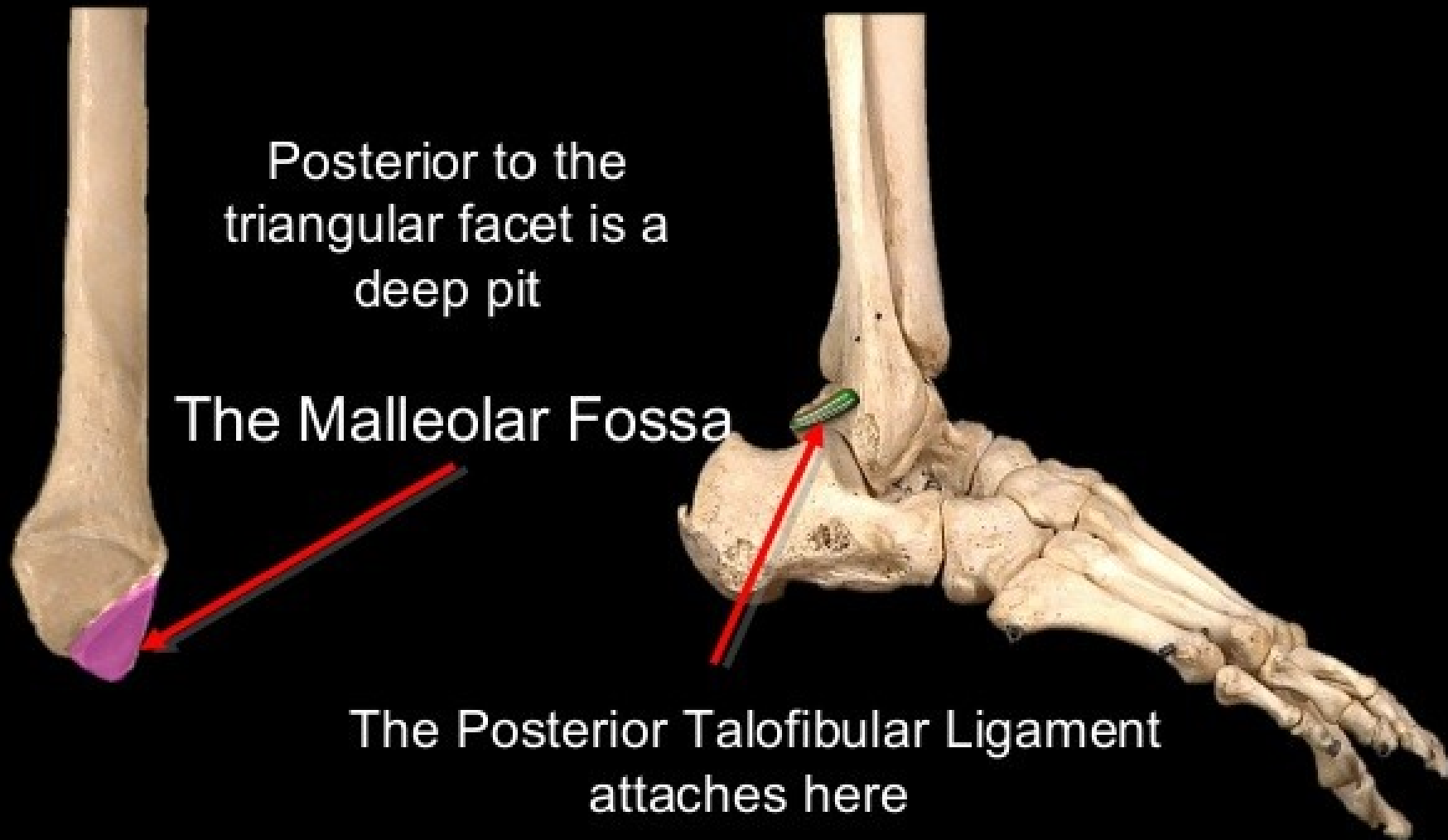


This facet articulates with with the lateral surface of the body of the Talus

Talus



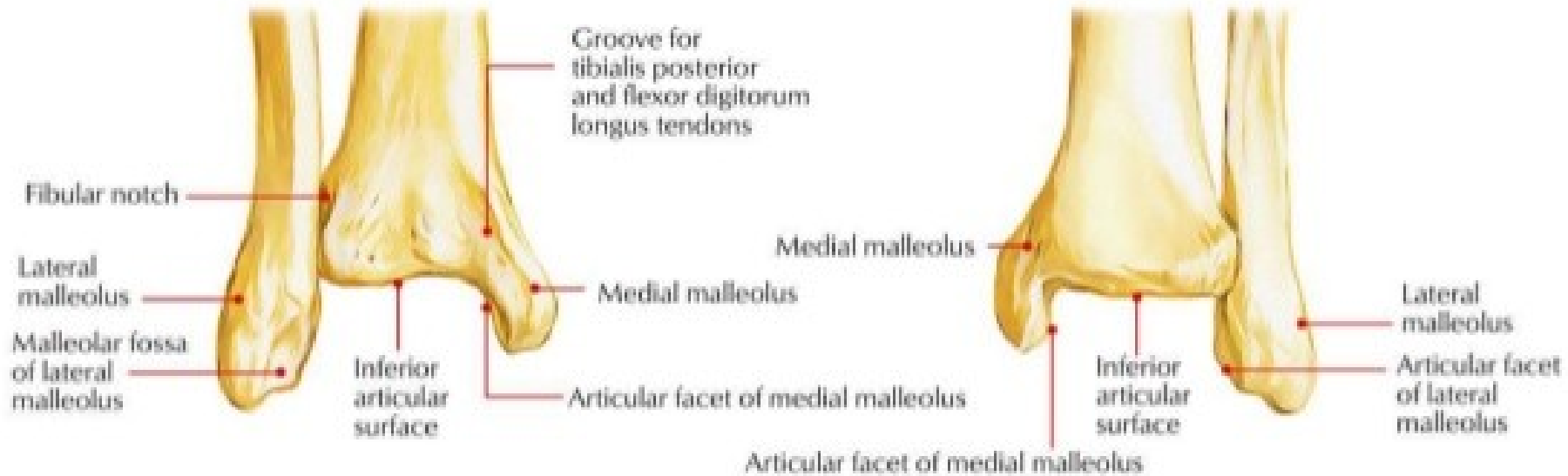
# The Distal Fibula



## Malleolar fossa

- The upper part of malleolar fossa gives connection to
  - The posterior tibiofibular ligament.
  - Its lower part to the posterior talofibular ligament.

# LOWER END



lateral surface



triangular subcutaneous area

fibular groove

lateral malleolus

lateral surface



triangular subcutaneous area

fibular groove

lateral malleolus



- One muscle the biceps femoris is inserted in the head of fibula
- All the other muscles take origin from the fibula.

### **Anterior muscles arise from anterior part of the medial Surface of Fibula**

**Extensor digitorum longus**- from the the upper 3/4th of the medial surface.

**Peroneus tertius**-from the From the lower 1/4th of medial surface.

**Extensor hallucis longus** – From the middle 2/4(1/2) of the medial surface

### **Anterior muscles arise from the lateral surface of fibula**

**The peroneus longus**: from its upper 2/3<sup>rd</sup> of lateral surface.

**The peroneus brevis**: from the lower 1/3<sup>rd</sup> of lateral surface.

### **Posterior muscles arise from the posterior surface of Fibula**

**Tibialis Posterior** – from the medial side of the posterior surface.

**Soleus** – from the back of the head & Upper one third of the posterior surface.

**Flexor hallucis longus** – from the lateral side of the posterior surface.

# Remember the following facts about the fibula

Three structures are related to its upper end: a muscle, a nerve, & a ligament.

- The biceps is inserted in the head of fibula
- The lateral popliteal nerve, can be palpated against posterolateral aspect of the head.
- The lateral ligament of the knee, attached to a flattened impression on the lateral aspect of the head.

The lower part of the fibula has two triangular areas:

- One immediately above the medial surface of the lateral malleolus.
- One immediately above the lateral surface of the lateral malleolus (which is subcutaneous)

The subcutaneous part of the fibula are:

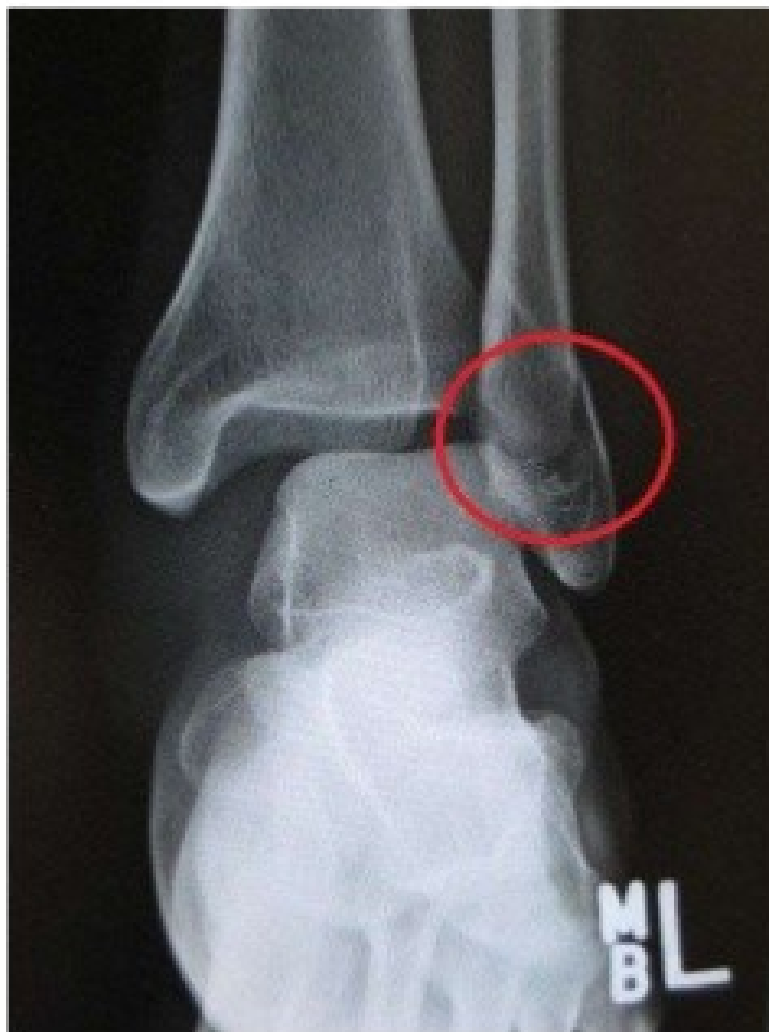- The head at about the level of the tuberosity of the tibia.
- The lateral malleolus.
- The triangular area at the lower 1/3<sup>rd</sup> of the lateral surface of the shaft.



# FRACTURE OF FIBULA

- At the ankle, the lateral malleolus of the fibula is prone to fracture. There are two main ways in which this occurs.
- The first way is by forced external rotation of the ankle. This force of the talus against the bone causes a spiral fracture of the lateral malleolus.
- The other, less common way, by the foot being twisted outwards (called eversion). Again, the talus presses against the lateral malleolus, and this time causes a transverse fracture.

# Fracture of the Fibula



# CLINICAL SIGNIFICANCE

- **BONE GRAFTS**

- Since the fibula doesn't take part in the transmission of body weight, it's a common source of bone for grafting.
- The upper and lower ends of the fibula are subcutaneous and palpable.
- The common peroneal nerve can be rolled against the neck of the fibula. This nerve is commonly injured here.
- In the first stage of Pott's fracture, the lower end of the fibula is fractured spirally.
- Though it does not bear any weight, the lateral malleolus and the ligaments attached to it are very important in maintaining stability at the ankle joint.