

FIRST AID FOR THE[®]

USMLE[®] 1
STEP 1

2022

A STUDENT-TO-STUDENT GUIDE

Fully updated study advice for the new Step 1 pass/fail exam

Expanded communication skills section reflects the current Step 1 blueprint

Over 1,300 must-know concepts with many new high-yield facts

Enhanced tables and mnemonics for rapid learning and high retention

Beautiful illustrations and images help you visualize key concepts

**Mc
Graw
Hill**

TAO LE ■ VIKAS BHUSHAN ■ MATTHEW SOCHAT
CAROLINE COLEMAN ■ CONNIE QIU

Contents

Contributing Authors	vii	General Acknowledgments	xiii
Associate Authors	viii	How to Contribute	xv
Faculty Advisors	ix	How to Use This Book	xvii
Preface	xi	Selected USMLE Laboratory Values	xviii
Special Acknowledgments	xii	First Aid Checklist for the USMLE Step 1	xx

▶ SECTION I GUIDE TO EFFICIENT EXAM PREPARATION 1

Introduction	2	Test-Taking Strategies	19
USMLE Step 1—The Basics	2	Clinical Vignette Strategies	21
Learning Strategies	11	If You Think You Failed	22
Timeline for Study	14	Testing Agencies	22
Study Materials	18	References	23

▶ SECTION I SUPPLEMENT SPECIAL SITUATIONS 25

▶ SECTION II HIGH-YIELD GENERAL PRINCIPLES 27

How to Use the Database	28	Pathology	203
Biochemistry	31	Pharmacology	229
Immunology	93	Public Health Sciences	257
Microbiology	121		

▶ SECTION III		HIGH-YIELD ORGAN SYSTEMS		281
Approaching the Organ Systems	282	Neurology and Special Senses		503
Cardiovascular	285	Psychiatry		575
Endocrine	331	Renal		601
Gastrointestinal	365	Reproductive		635
Hematology and Oncology	411	Respiratory		683
Musculoskeletal, Skin, and Connective Tissue	453	Rapid Review		713

▶ SECTION IV		TOP-RATED REVIEW RESOURCES		737
How to Use the Database	738	Biochemistry		742
Question Banks	740	Cell Biology and Histology		742
Web and Mobile Apps	740	Microbiology and Immunology		742
Comprehensive	741	Pathology		743
Anatomy, Embryology, and Neuroscience	741	Pharmacology		743
Behavioral Science	742	Physiology		744
Abbreviations and Symbols	745	Index		771
Image Acknowledgments	753	About the Editors		828

Biochemistry

“The nitrogen in our DNA, the calcium in our teeth, the iron in our blood, the carbon in our apple pies were made in the interiors of collapsing stars. We are made of starstuff.”

—Carl Sagan

“Biochemistry is the study of carbon compounds that crawl.”

—Mike Adams

“We think we have found the basic mechanism by which life comes from life.”

—Francis H. C. Crick

DNA was the first three-dimensional Xerox machine.

—Kenneth Ewart Boulding

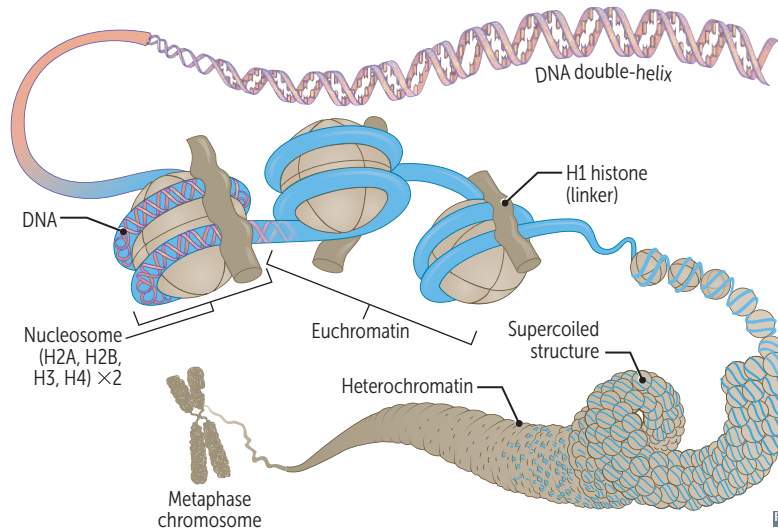
This high-yield material includes molecular biology, genetics, cell biology, and principles of metabolism (especially vitamins, cofactors, minerals, and single-enzyme-deficiency diseases). When studying metabolic pathways, emphasize important regulatory steps and enzyme deficiencies that result in disease, as well as reactions targeted by pharmacologic interventions. For example, understanding the defect in Lesch-Nyhan syndrome and its clinical consequences is higher yield than memorizing every intermediate in the purine salvage pathway.

Do not spend time learning details of organic chemistry, mechanisms, or physical chemistry. Detailed chemical structures are infrequently tested; however, many structures have been included here to help students learn reactions and the important enzymes involved. Familiarity with the biochemical techniques that have medical relevance—such as ELISA, immunoelectrophoresis, Southern blotting, and PCR—is useful. Review the related biochemistry when studying pharmacology or genetic diseases as a way to reinforce and integrate the material.

▶ Molecular	32
▶ Cellular	44
▶ Laboratory Techniques	50
▶ Genetics	54
▶ Nutrition	63
▶ Metabolism	71

► BIOCHEMISTRY—MOLECULAR

Chromatin structure



DNA exists in the condensed, chromatin form to fit into the nucleus. DNA loops twice around a histone octamer to form a nucleosome (“beads on a string”). H1 binds to the nucleosome and to “linker DNA,” thereby stabilizing the chromatin fiber.

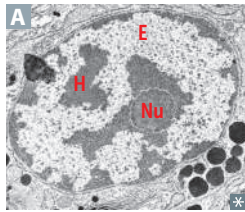
DNA has \ominus charge from phosphate groups.

Histones are **large** and have \oplus charge from **lysine** and **arginine**.

In mitosis, DNA condenses to form chromosomes. DNA and histone synthesis occurs during S phase.

Mitochondria have their own DNA, which is circular and does not utilize histones.

Heterochromatin



Condensed, appears darker on EM (labeled H in **A**; Nu, nucleolus). Sterically inaccessible, thus transcriptionally inactive. \uparrow methylation, \downarrow acetylation.

Heterochromatin = highly condensed.

Barr bodies (inactive X chromosomes) may be visible on the periphery of nucleus.

Euchromatin

Less condensed, appears lighter on EM (labeled E in **A**). Transcriptionally active, sterically accessible.

Eu = true, “truly transcribed.”

Euchromatin is expressed.

DNA methylation

Changes the expression of a DNA segment without changing the sequence. Involved with aging, carcinogenesis, genomic imprinting, transposable element repression, and X chromosome inactivation (lyonization).

DNA is methylated in imprinting.

Methylation within gene promoter (CpG islands) typically represses (silences) gene transcription. CpG **methylation** makes DNA **mute**.

Dysregulated DNA methylation is implicated in Fragile X syndrome.

Histone methylation

Usually causes reversible transcriptional suppression, but can also cause activation depending on location of methyl groups.

Histone **methylation** mostly makes DNA **mute**.

Lysine and arginine residues of histones can be methylated.

Histone acetylation

Removal of histone's \oplus charge \rightarrow relaxed DNA coiling \rightarrow \uparrow transcription.

Thyroid hormone receptors alter thyroid hormone synthesis by acetylation.

Histone **acetylation** makes DNA **active**.

Histone deacetylation

Removal of acetyl groups \rightarrow tightened DNA coiling \rightarrow \downarrow transcription.

Histone deacetylation may be responsible for the altered gene expression in Huntington disease.

Nucleotides

Nucleoside = base + (deoxy)ribose (sugar).

Nucleotide = base + (deoxy)ribose + phosphate;
linked by 3'-5' phosphodiester bond.

Purines (A,G)—2 rings.

Pyrimidines (C,U,T)—1 ring.

Deamination reactions:

Cytosine → uracil

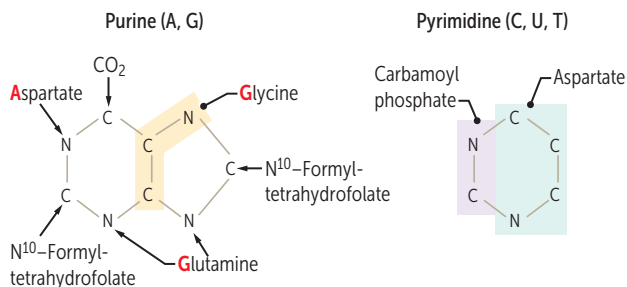
Adenine → hypoxanthine

Guanine → xanthine

5-methylcytosine → thymine

Uracil found in RNA; thymine in DNA.

Methylation of uracil makes thymine.



5' end of incoming nucleotide bears the triphosphate (energy source for the bond).
α-Phosphate is target of 3' hydroxyl attack.

Pure As Gold.

CUT the pyramid.

Thymine has a methyl.

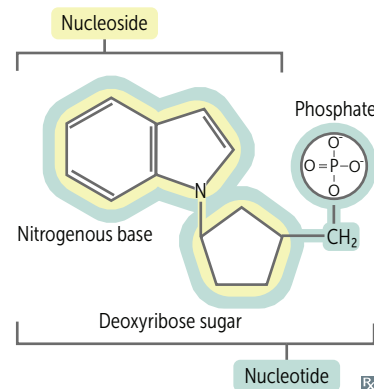
C-G bond (3 H bonds) stronger than A-T bond (2 H bonds). ↑ C-G content → ↑ melting temperature of DNA. “**C-G** bonds are like **Crazy Glue**.”

Amino acids necessary for **purine** synthesis (cats **pur** until they **GAG**):

Glycine

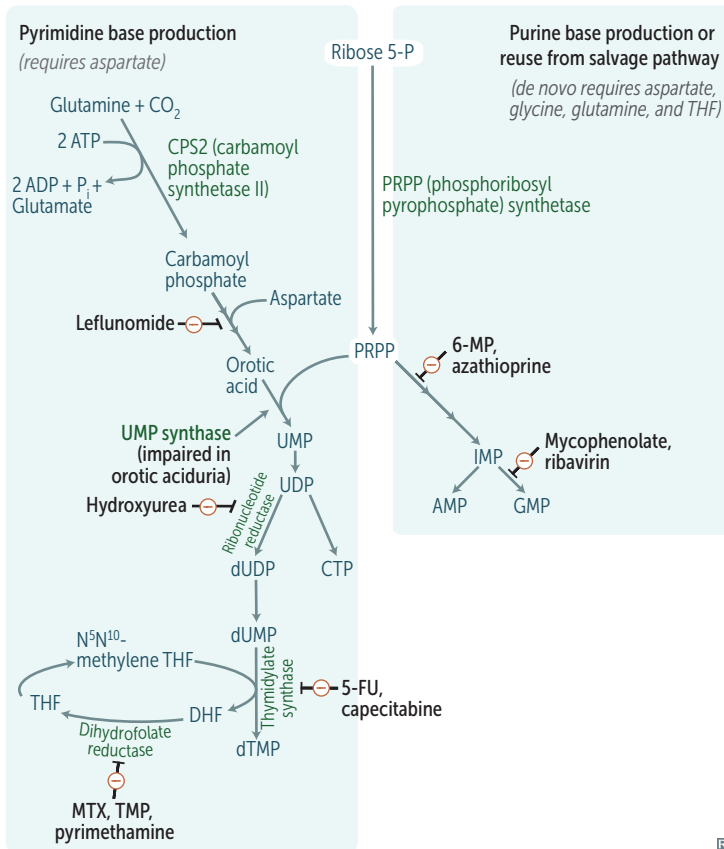
Aspartate

Glutamine



De novo pyrimidine and purine synthesis

Various immunosuppressive, antineoplastic, and antibiotic drugs function by interfering with nucleotide synthesis:



Pyrimidine synthesis:

- **Leflunomide:** inhibits dihydroorotate dehydrogenase
- **5-fluorouracil (5-FU)** and its prodrug **capecitabine:** form 5-F-dUMP, which inhibits thymidylate synthase (↓ dTMP)

Purine synthesis:

- **6-mercaptopurine (6-MP)** and its prodrug **azathioprine:** inhibit de novo purine synthesis; azathioprine is metabolized via purine degradation pathway and can lead to immunosuppression when administered with xanthine oxidase inhibitor
- **Mycophenolate** and **ribavirin:** inhibit inosine monophosphate dehydrogenase

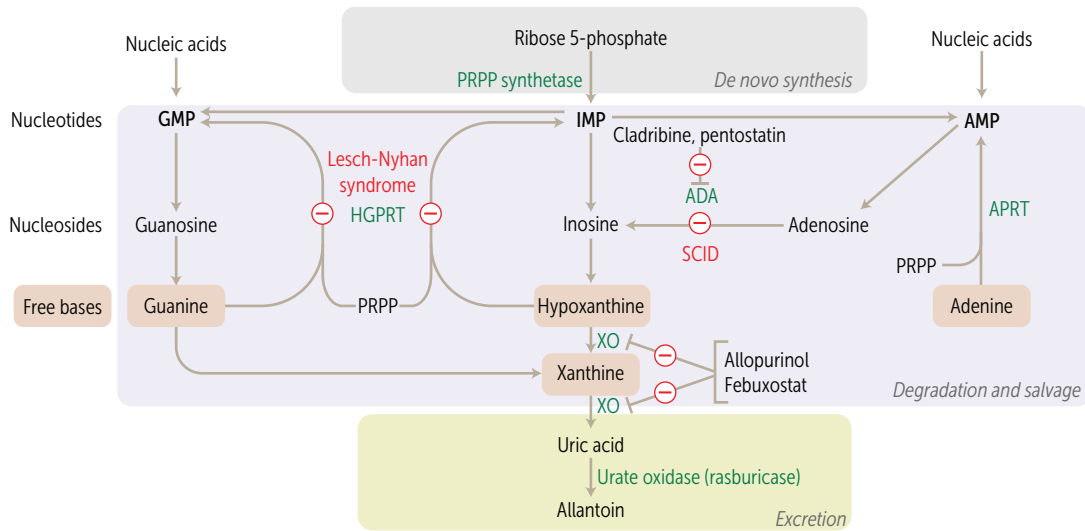
Purine and pyrimidine synthesis:

- **Hydroxyurea:** inhibits ribonucleotide reductase
- **Methotrexate (MTX), trimethoprim (TMP),** and **pyrimethamine:** inhibit dihydrofolate reductase (↓ deoxythymidine monophosphate [dTMP]) in **humans** (methotrexate), **bacteria** (trimethoprim), and **protozoa** (pyrimethamine)

CPS1 = mItochondria, urea cycle, found in liver and kidney cells

CPS2 = cytwosol, pyrimidine synthesis, found in most cells

Purine salvage deficiencies



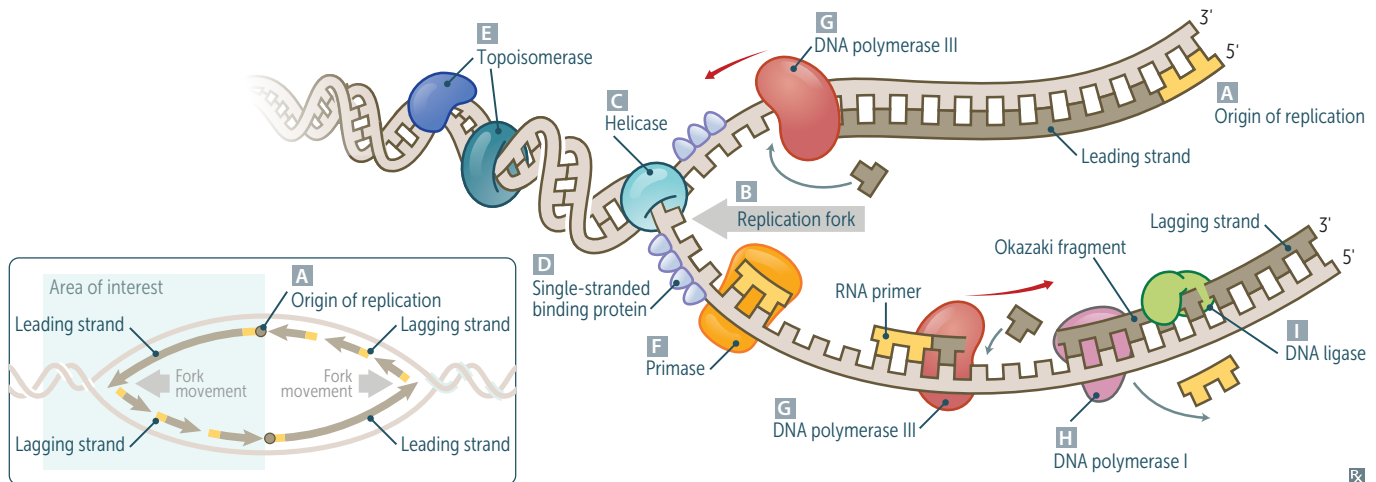
ADA, adenosine deaminase; APRT, adenosine phosphoribosyltransferase; HGPRT, hypoxanthine guanine phosphoribosyltransferase; XO, xanthine oxidase; SCID, severe combined immune deficiency (autosomal recessive inheritance)

Adenosine deaminase deficiency	<p>ADA is required for degradation of adenosine and deoxyadenosine. ↓ ADA → ↑ dATP → ↓ ribonucleotide reductase activity → ↓ DNA precursors in cells → ↓ lymphocytes.</p>	<p>One of the major causes of autosomal recessive SCID.</p>
Lesch-Nyhan syndrome	<p>Defective purine salvage due to absent HGPRT, which converts hypoxanthine to IMP and guanine to GMP. Compensatory ↑ in purine synthesis (↑ PRPP amidotransferase activity) → excess uric acid production. X-linked recessive.</p> <p>Findings: intellectual disability, self-mutilation, aggression, hyperuricemia (red/orange “sand” [sodium urate crystals] in diaper), gout, dystonia, macrocytosis.</p>	<p>HGPRT: Hyperuricemia Gout Pissed off (aggression, self-mutilation) Red/orange crystals in urine Tense muscles (dystonia) Treatment: allopurinol, febuxostat.</p>

Genetic code features

Unambiguous	<p>Each codon specifies only 1 amino acid.</p>	
Degenerate/redundant	<p>Most amino acids are coded by multiple codons. Wobble—codons that differ in 3rd (“wobble”) position may code for the same tRNA/amino acid. Specific base pairing is usually required only in the first 2 nucleotide positions of mRNA codon.</p>	<p>Exceptions: methionine (AUG) and tryptophan (UGG) encoded by only 1 codon.</p>
Commaless, nonoverlapping	<p>Read from a fixed starting point as a continuous sequence of bases.</p>	
Universal	<p>Genetic code is conserved throughout evolution.</p>	
		<p>Exceptions: some viruses.</p>
		<p>Exception in humans: mitochondria.</p>

DNA replication	Occurs in 5' → 3' direction (“5ynth3sis”) in continuous and discontinuous (Okazaki fragment) fashion. Semiconservative. More complex in eukaryotes than in prokaryotes, but shares analogous enzymes.	
Origin of replication A	Particular consensus sequence in genome where DNA replication begins. May be single (prokaryotes) or multiple (eukaryotes).	AT-rich sequences (such as TATA box regions) are found in promoters and origins of replication.
Replication fork B	Y-shaped region along DNA template where leading and lagging strands are synthesized.	
Helicase C	Unwinds DNA template at replication fork.	Helicase halves DNA. Deficient in Bloom syndrome (<i>BLM</i> gene mutation).
Single-stranded binding proteins D	Prevent strands from reannealing or degradation by nucleases.	
DNA topoisomerases E	Creates a single- (topoisomerase I) or double- (topoisomerase II) stranded break in the helix to add or remove supercoils (as needed due to underwinding or overwinding of DNA).	In eukaryotes: irinotecan/topotecan inhibit topoisomerase (TOP) I, etoposide/teniposide inhibit TOP II. In prokaryotes: fluoroquinolones inhibit TOP II (DNA gyrase) and TOP IV.
Primase F	Makes an RNA primer on which DNA polymerase III can initiate replication.	
DNA polymerase III G	Prokaryotes only. Elongates leading strand by adding deoxynucleotides to the 3' end. Elongates lagging strand until it reaches primer of preceding fragment.	DNA polymerase III has 5' → 3' synthesis and proofreads with 3' → 5' exonuclease. Drugs blocking DNA replication often have a modified 3' OH, thereby preventing addition of the next nucleotide (“chain termination”).
DNA polymerase I H	Prokaryotes only. Degrades RNA primer; replaces it with DNA.	Same functions as DNA polymerase III, also excises RNA primer with 5' → 3' exonuclease.
DNA ligase I	Catalyzes the formation of a phosphodiester bond within a strand of double-stranded DNA.	Joins Okazaki fragments. Ligase links DNA.
Telomerase	Eukaryotes only. A reverse transcriptase (RNA-dependent DNA polymerase) that adds DNA (TTAGGG) to 3' ends of chromosomes to avoid loss of genetic material with every duplication.	Upregulated in progenitor cells and also often in cancer; downregulated in aging and progeria. Telomerase TAGs for Greatness and Glory.

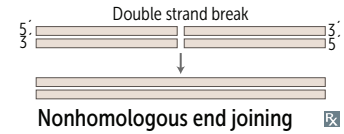


DNA repair

Double strand

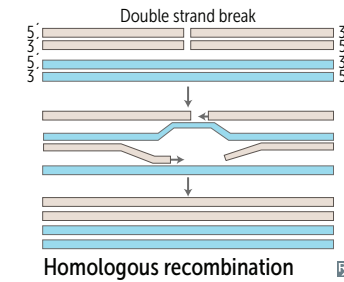
Nonhomologous end joining

Brings together 2 ends of DNA fragments to repair double-stranded breaks. Homology not required. Part of the DNA may be lost or translocated.



Homologous recombination

Requires 2 homologous DNA duplexes. A strand from damaged dsDNA is repaired using a complementary strand from intact homologous dsDNA as a template. Defective in breast/ovarian cancers with *BRCA1* or *BRCA2* mutations and in Fanconi anemia. Restores duplexes accurately without loss of nucleotides.



Single strand

Nucleotide excision repair

Specific endonucleases remove the oligonucleotides containing damaged bases; DNA polymerase and ligase fill and reseal the gap, respectively. Repairs bulky helix-distorting lesions (eg, pyrimidine dimers).

Occurs in G₁ phase of cell cycle. Defective in **xeroderma pigmentosum** (inability to repair DNA pyrimidine dimers caused by UV exposure). Presents with dry skin, photosensitivity, skin cancer.

Base excision repair

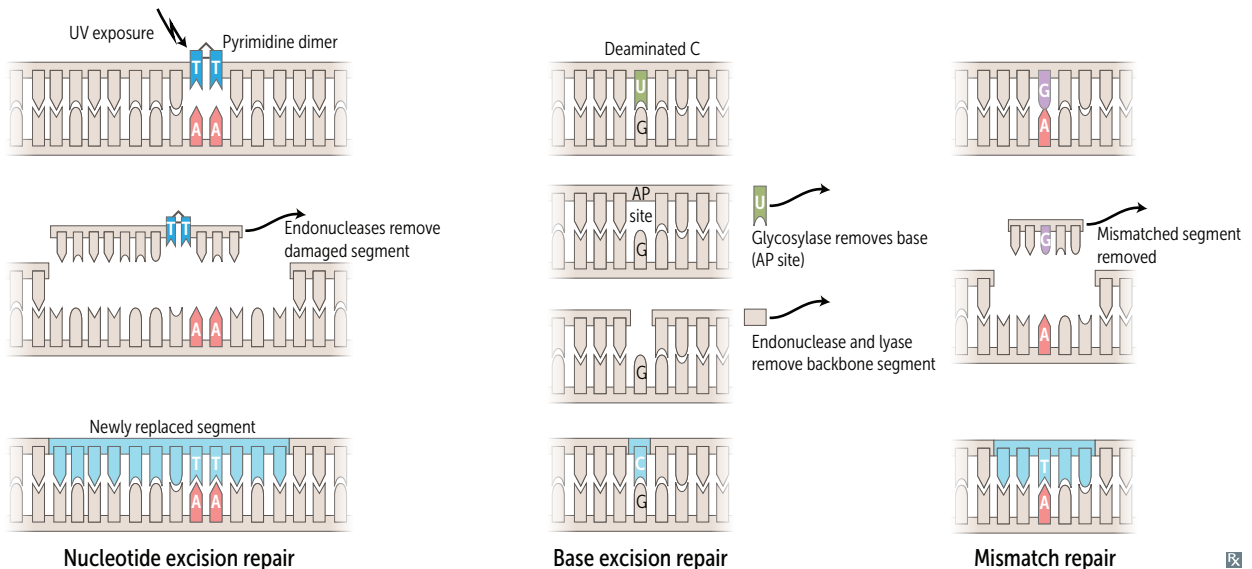
Base-specific **G**lycosylase removes altered base and creates AP site (apurinic/aprimidinic). One or more nucleotides are removed by AP-**E**ndonuclease, which cleaves 5' end. AP-**L**yase cleaves 3' end. DNA **P**olymerase-β fills the gap and DNA **L**igase seals it.

Occurs throughout cell cycle. Important in repair of spontaneous/toxic deamination. **“GEL Please.”**

Mismatch repair

Mismatched nucleotides in newly synthesized strand are removed and gap is filled and resealed.

Occurs predominantly in S phase of cell cycle. Defective in Lynch syndrome (hereditary nonpolyposis colorectal cancer [HNPCC]).



Mutations in DNA

Degree of change: silent \ll missense $<$ nonsense $<$ frameshift. Single nucleotide substitutions are repaired by DNA polymerase and DNA ligase. Types of single nucleotide (point) mutations:

- **Transition**—purine to purine (eg, A to G) or pyrimidine to pyrimidine (eg, C to T).
- **Transversion**—purine to pyrimidine (eg, A to T) or pyrimidine to purine (eg, C to G).

Single nucleotide substitutions**Silent mutation**

Codes for **same** (synonymous) amino acid; often involves 3rd position of codon (tRNA wobble).

Missense mutation

Results in changed amino acid (called conservative if new amino acid has similar chemical structure). Examples: sickle cell disease (substitution of glutamic acid with valine).

Nonsense mutation

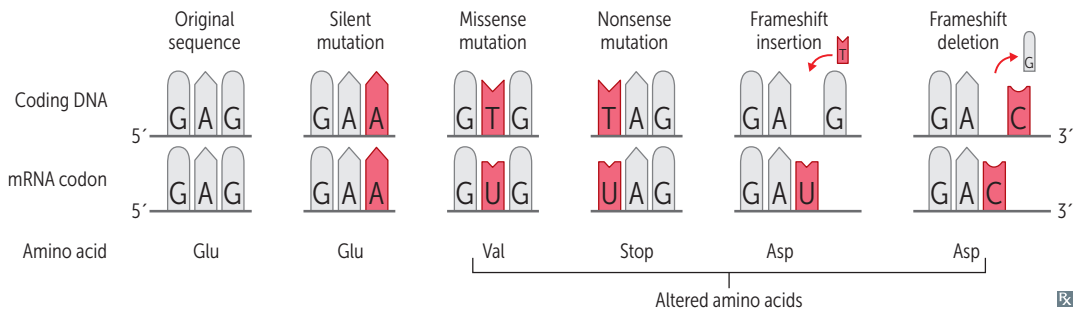
Results in early **stop** codon (UGA, UAA, UAG). Usually generates nonfunctional protein. **Stop the nonsense!**

Other mutations**Frameshift mutation**

Deletion or insertion of any number of nucleotides not divisible by 3 \rightarrow misreading of all nucleotides downstream. Protein may be shorter or longer, and its function may be disrupted or altered. Examples: Duchenne muscular dystrophy, Tay-Sachs disease.

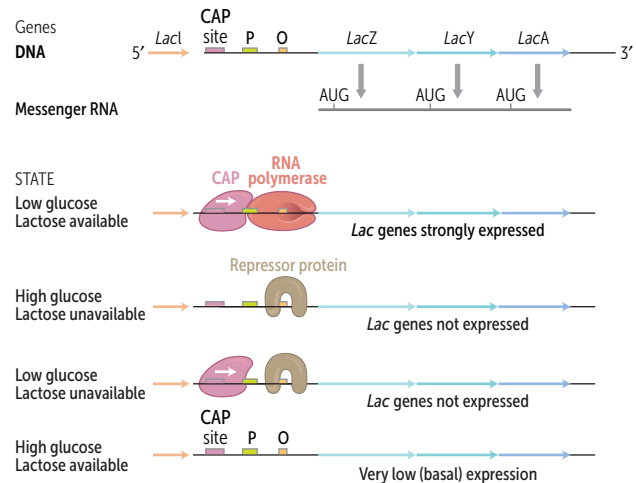
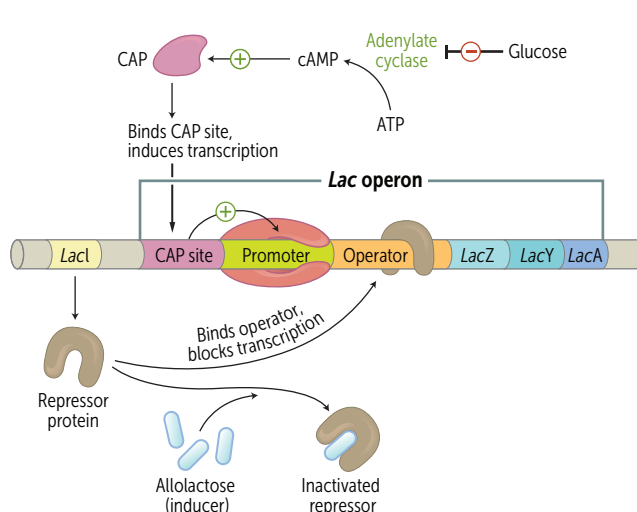
Splice site mutation

Retained intron in mRNA \rightarrow protein with impaired or altered function. Examples: rare causes of cancers, dementia, epilepsy, some types of β -thalassemia, Gaucher disease, Marfan syndrome.

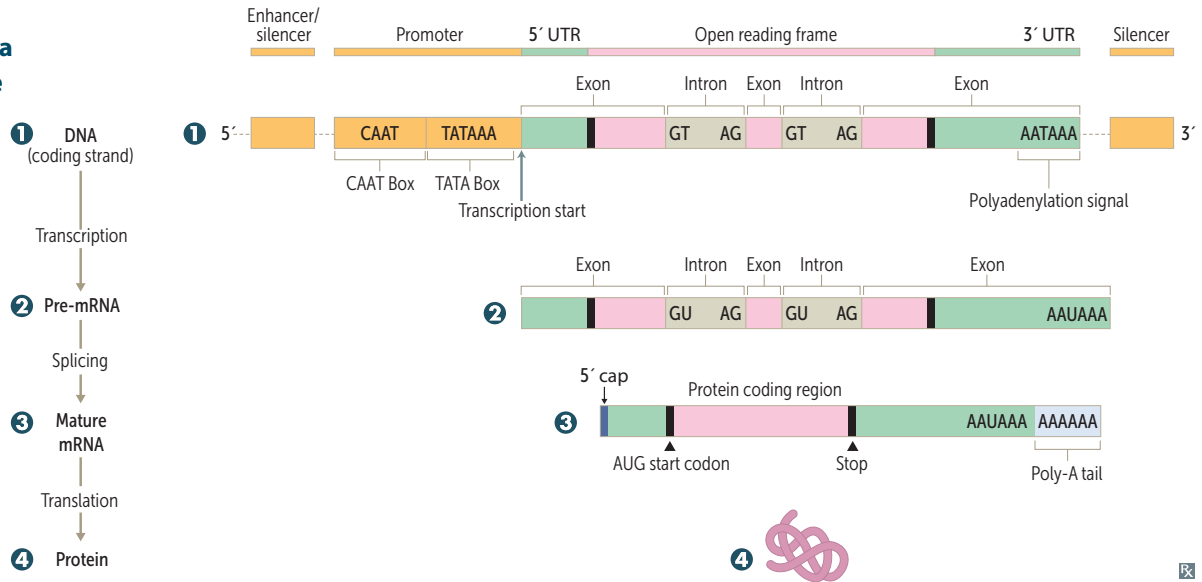
**Lac operon**

Classic example of a genetic response to an environmental change. Glucose is the preferred metabolic substrate in *E. coli*, but when glucose is absent and lactose is available, the *lac* operon is activated to switch to lactose metabolism. Mechanism of shift:

- Low glucose \rightarrow \uparrow adenylate cyclase activity \rightarrow \uparrow generation of cAMP from ATP \rightarrow activation of catabolite activator protein (CAP) \rightarrow \uparrow transcription.
- High lactose \rightarrow unbinds repressor protein from repressor/operator site \rightarrow \uparrow transcription.



Functional organization of a eukaryotic gene



Regulation of gene expression

Promoter

Site where RNA polymerase II and multiple other transcription factors bind to DNA upstream from gene locus (AT-rich upstream sequence with TATA and CAAT boxes, which differ between eukaryotes and prokaryotes).

Promoter mutation commonly results in dramatic ↓ in level of gene transcription.

Enhancer

DNA locus where regulatory proteins (“**activators**”) bind, **increasing** expression of a gene on the same chromosome.

Enhancers and silencers may be located close to, far from, or even within (in an intron) the gene whose expression they regulate.

Silencer

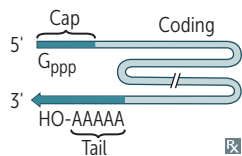
DNA locus where regulatory proteins (“**repressors**”) bind, **decreasing** expression of a gene on the same chromosome.

Epigenetics

Changes made to gene expression (heritable mitotically/meiotically) without a change in underlying DNA sequence.

Primary mechanisms of epigenetic change include DNA methylation, histone modification, and noncoding RNA.

RNA processing (eukaryotes)



Initial transcript is called heterogeneous nuclear RNA (hnRNA). hnRNA is then modified and becomes mRNA.

The following processes occur in the nucleus:

- Capping of 5' end (addition of 7-methylguanosine cap; cotranscriptional)
- Polyadenylation of 3' end (~200 A's → poly-A tail; posttranscriptional)
- Splicing out of introns (posttranscriptional)

Capped, tailed, and spliced transcript is called mRNA.

mRNA is transported out of nucleus to be translated in cytosol.

mRNA quality control occurs at cytoplasmic processing bodies (P-bodies), which contain exonucleases, decapping enzymes, and microRNAs; mRNAs may be degraded or stored in P-bodies for future translation. Poly-A polymerase does not require a template. AAUAAA = polyadenylation signal. Mutation in polyadenylation signal → early degradation prior to translation.

RNA polymerases

Eukaryotes

RNA polymerase I makes **r**rRNA, the most common (**r**ampant) type; present only in nucleolus.

RNA polymerase II makes **m**mRNA (**m**assive), **mi**croRNA (**mi**RNA), and **s**mall **n**uclear RNA (**sn**RNA).

RNA polymerase III makes 5S rRNA, **t**tRNA (**t**iny).

No proofreading function, but can initiate chains. RNA polymerase II opens DNA at promoter site.

I, II, and III are numbered in the same order that their products are used in protein synthesis: rRNA, mRNA, then tRNA.

α -amanitin, found in *Amanita phalloides* (death cap mushrooms), inhibits RNA polymerase II. Causes dysentery and severe hepatotoxicity if ingested.

Dactinomycin inhibits RNA polymerase in both prokaryotes and eukaryotes.

Prokaryotes

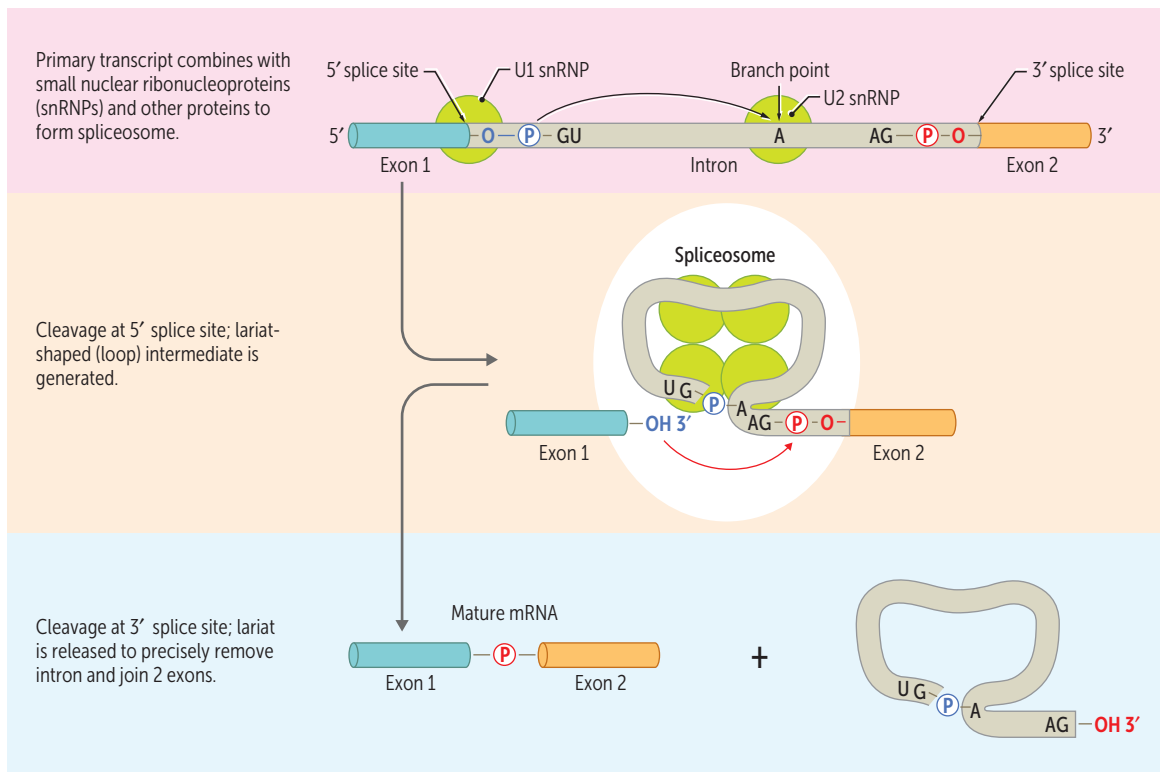
1 RNA polymerase (multisubunit complex) makes all 3 kinds of RNA.

Rifamycins (rifampin, rifabutin) inhibit DNA-dependent RNA polymerase in prokaryotes.

Splicing of pre-mRNA

Part of process by which precursor mRNA (pre-mRNA) is transformed into mature mRNA. Introns typically begin with GU and end with AG. Alterations in snRNP assembly can cause clinical disease; eg, in spinal muscular atrophy, snRNP assembly is affected due to \downarrow SMN protein \rightarrow congenital degeneration of anterior horns of spinal cord \rightarrow symmetric weakness (hypotonia, or “floppy baby syndrome”).

snRNPs are snRNA bound to proteins (eg, Smith [Sm]) to form a spliceosome that cleaves pre-mRNA. Anti-U1 snRNP antibodies are associated with SLE, mixed connective tissue disease, other rheumatic diseases.



Introns vs exons

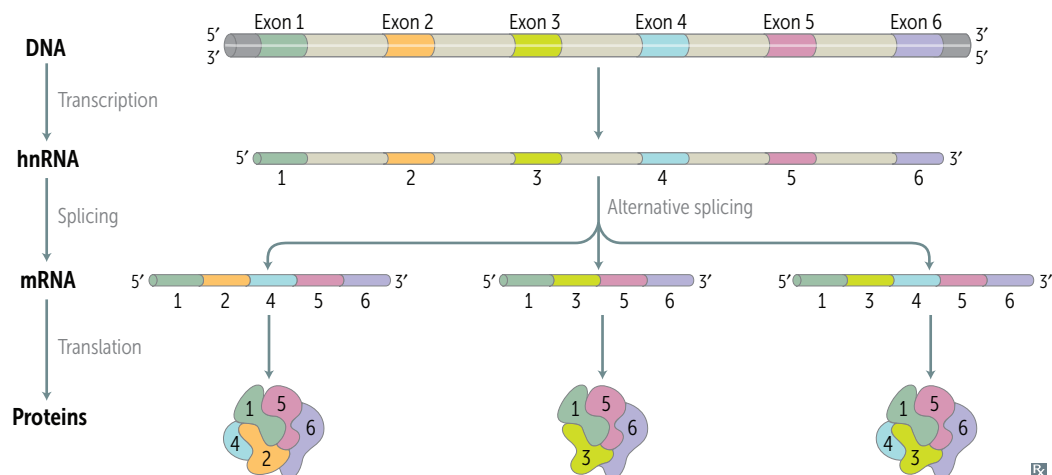
Exons contain the actual genetic information coding for protein or functional RNA.

Introns do not code for protein, but are important in regulation of gene expression.

Different exons are frequently combined by alternative splicing to produce a larger number of unique proteins.

Introns are **intervening** sequences and stay **in** the nucleus, whereas **exons exit** and are **expressed**.

Alternative splicing—can produce a variety of protein products from a single hnRNA (heterogenous nuclear RNA) sequence (eg, transmembrane vs secreted Ig, tropomyosin variants in muscle, dopamine receptors in the brain, host defense evasion by tumor cells).



tRNA

Structure

75–90 nucleotides, 2° structure, cloverleaf form, anticodon end is opposite 3' aminoacyl end. All tRNAs, both eukaryotic and prokaryotic, have CCA at 3' end along with a high percentage of chemically modified bases. The amino acid is covalently bound to the 3' end of the tRNA. **CCA Can Carry Amino acids.**

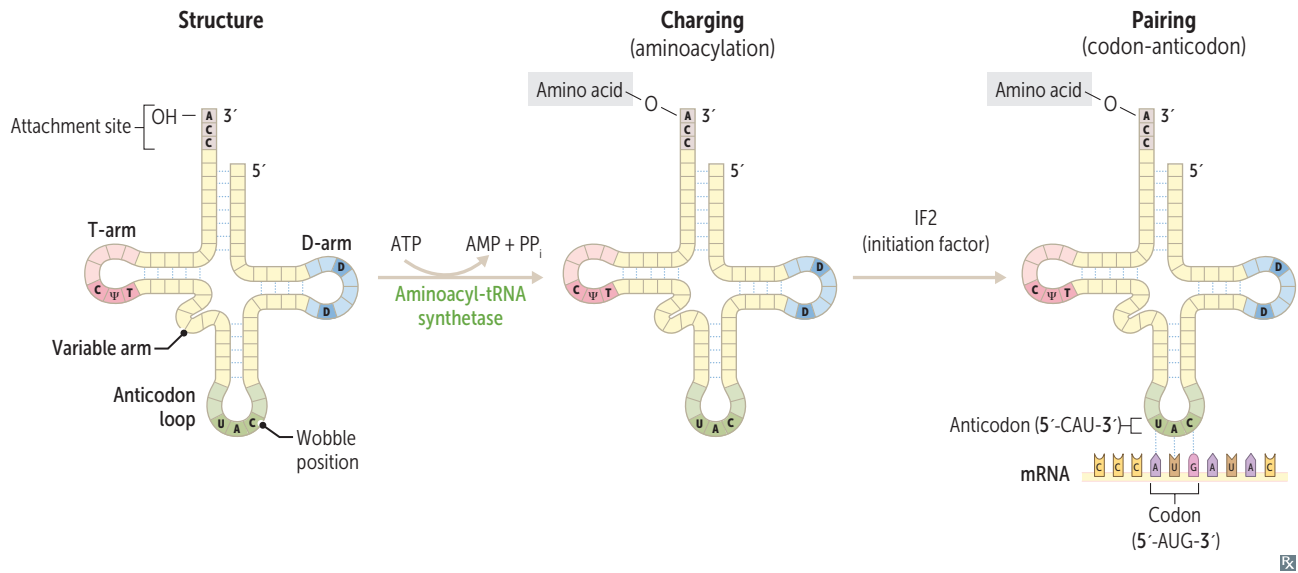
T-arm: contains the TΨC (ribothymidine, pseudouridine, cytidine) sequence necessary for tRNA-ribosome binding. **T-arm Tethers** tRNA molecule to ribosome.

D-arm: contains **D**ihydrouridine residues necessary for tRNA recognition by the correct aminoacyl-tRNA synthetase. **D-arm allows Detection** of the tRNA by aminoacyl-tRNA synthetase.

Attachment site: 3'-**ACC**-5' is the amino acid **ACC**eptor site.

Charging

Aminoacyl-tRNA synthetase (uses ATP; 1 unique enzyme per respective amino acid) and binding of charged tRNA to the codon are responsible for the accuracy of amino acid selection. Aminoacyl-tRNA synthetase matches an amino acid to the tRNA by scrutinizing the amino acid before and after it binds to tRNA. If an incorrect amino acid is attached, the bond is hydrolyzed. A mischarged tRNA reads the usual codon but inserts the wrong amino acid.



Start and stop codons

mRNA start codon	AUG.	AUG in AUG urates protein synthesis.
Eukaryotes	Codes for methionine, which may be removed before translation is completed.	
Prokaryotes	Codes for <i>N</i> -formylmethionine (fMet).	fMet stimulates neutrophil chemotaxis.
mRNA stop codons	UGA, UAA, UAG. Recognized by release factors.	UGA = U G o A way. UAA = U A re A way. UAG = U A re G one.

Protein synthesis

Initiation

1. Eukaryotic initiation factors (eIFs) identify the 5' cap.
2. eIFs help assemble the 40S ribosomal subunit with the initiator tRNA.
3. eIFs released when the mRNA and the ribosomal 60S subunit assemble with the complex. Requires GTP.

Eukaryotes: 40S + 60S → 80S (even).
 Prokaryotes: 30S + 50S → 70S (prime).
 Synthesis occurs from N-terminus to C-terminus.

ATP—tRNA **A**ctivation (charging).
 GTP—tRNA **G**ripping and **G**oing places (translocation).

Elongation

- 1 Aminoacyl-tRNA binds to A site (except for initiator methionine, which binds the P site), requires an elongation factor and GTP.
- 2 rRNA (“ribozyme”) catalyzes peptide bond formation, transfers growing polypeptide to amino acid in A site.
- 3 Ribosome advances 3 nucleotides toward 3' end of mRNA, moving peptidyl tRNA to P site (translocation).

Think of “going **APE**”:

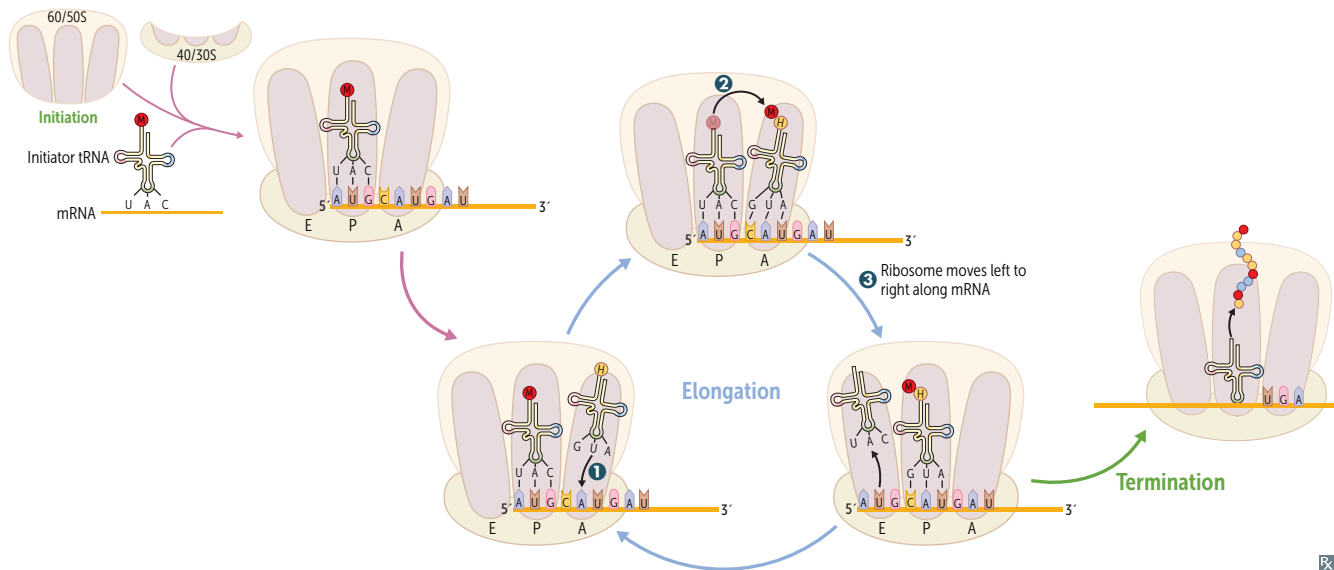
A site = incoming **A**minoacyl-tRNA.
P site = accommodates growing **P**eptide.
E site = holds **E**mpy tRNA as it **E**xits.

Elongation factors are targets of bacterial toxins (eg, *Diphtheria*, *Pseudomonas*).

Shine-Dalgarno sequence—ribosomal binding site in prokaryotic mRNA. Recognized by 16S RNA in ribosomal subunit. Enables protein synthesis initiation by aligning ribosome with start codon so that code is read correctly.

Termination

Eukaryotic release factors (eRFs) recognize the stop codon and halt translation → completed polypeptide is released from ribosome. Requires GTP.



Posttranslational modifications

Trimming

Removal of N- or C-terminal propeptides from zymogen to generate mature protein (eg, trypsinogen to trypsin).

Covalent alterations

Phosphorylation, glycosylation, hydroxylation, methylation, acetylation, and ubiquitination.

Chaperone protein

Intracellular protein involved in facilitating and maintaining protein folding. In yeast, heat shock proteins (eg, HSP60) are constitutively expressed, but expression may increase with high temperatures, acidic pH, and hypoxia to prevent protein denaturing/misfolding.

► BIOCHEMISTRY—CELLULAR

Cell cycle phases

Checkpoints control transitions between phases of cell cycle. This process is regulated by cyclins, cyclin-dependent kinases (CDKs), and tumor suppressors. M phase (shortest phase of cell cycle) includes mitosis (prophase, prometaphase, metaphase, anaphase, telophase) and cytokinesis (cytoplasm splits in two). G_1 is of variable duration.

REGULATION OF CELL CYCLE

Cyclin-dependent kinases

Constitutively expressed but inactive when not bound to cyclin.

Cyclin-CDK complexes

Cyclins are phase-specific regulatory proteins that activate CDKs when stimulated by growth factors. The cyclin-CDK complex can then phosphorylate other proteins (eg, Rb) to coordinate cell cycle progression. This complex must be activated/inactivated at appropriate times for cell cycle to progress.

Tumor suppressors

$p53 \rightarrow p21$ induction \rightarrow CDK inhibition \rightarrow Rb hypophosphorylation (activation) \rightarrow G_1 -S progression inhibition. Mutations in tumor suppressor genes can result in unrestrained cell division (eg, Li-Fraumeni syndrome).

Growth factors (eg, insulin, PDGF, EPO, EGF) bind tyrosine kinase receptors to transition the cell from G_1 to S phase.

CELL TYPES

Permanent

Remain in G_0 , regenerate from stem cells.

Neurons, skeletal and cardiac muscle, RBCs.

Stable (quiescent)

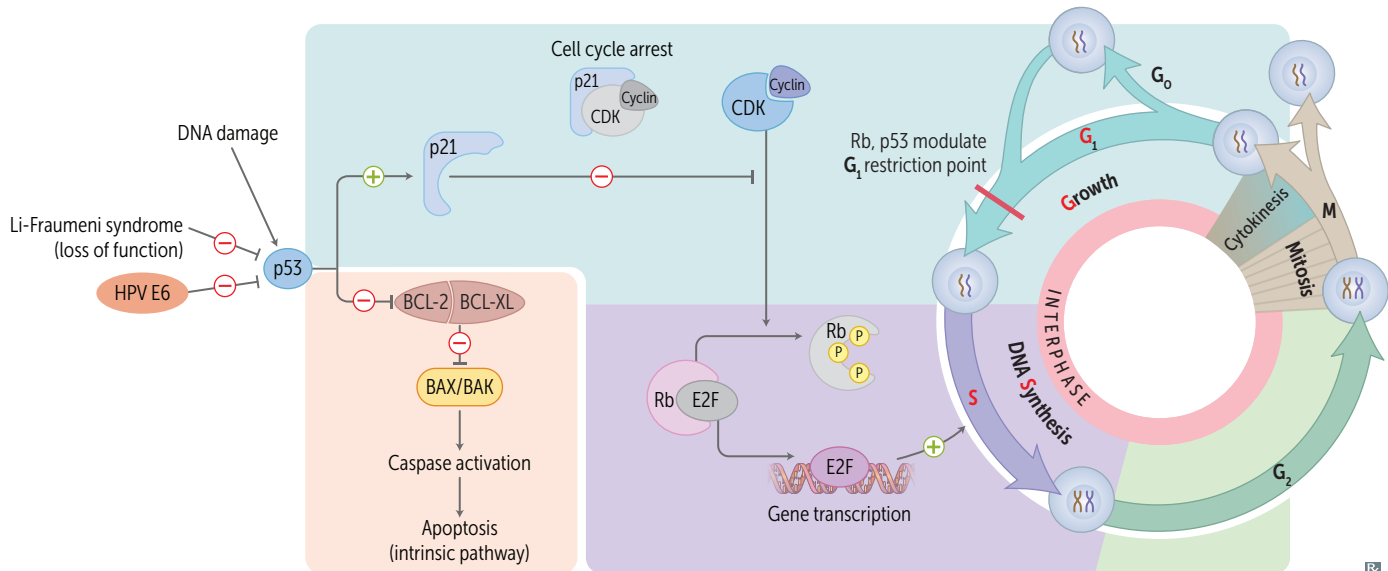
Enter G_1 from G_0 when stimulated.

Hepatocytes, lymphocytes, PCT, periosteal cells.

Labile

Never go to G_0 , divide rapidly with a short G_1 .
Most affected by chemotherapy.

Bone marrow, gut epithelium, skin, hair follicles, germ cells.



Rough endoplasmic reticulum

Site of synthesis of secretory (exported) proteins and of N-linked oligosaccharide addition to lysosomal and other proteins.
 Nissl bodies (RER in neurons)—synthesize peptide neurotransmitters for secretion.
 Free ribosomes—unattached to any membrane; site of synthesis of cytosolic, peroxisomal, and mitochondrial proteins.

N-linked glycosylation occurs in the endoplasmic reticulum.
 Mucus-secreting goblet cells of small intestine and antibody-secreting plasma cells are rich in RER.
 Proteins within organelles (eg, ER, Golgi bodies, lysosomes) are formed in RER.

Smooth endoplasmic reticulum

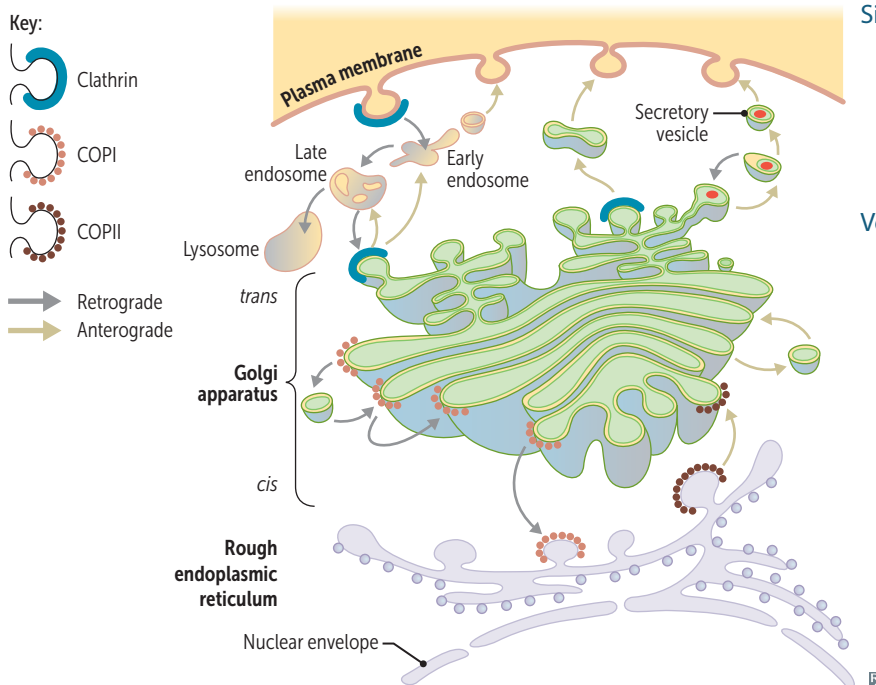
Site of steroid synthesis and detoxification of drugs and poisons. Lacks surface ribosomes.
 Location of glucose-6-phosphatase (last step in both glycogenolysis and gluconeogenesis).

Hepatocytes and steroid hormone-producing cells of the adrenal cortex and gonads are rich in SER.

Cell trafficking

Golgi is distribution center for proteins and lipids from ER to vesicles and plasma membrane.
 Posttranslational events in Golgi include modifying N-oligosaccharides on asparagine, adding O-oligosaccharides on serine and threonine, and adding mannose-6-phosphate to proteins for lysosomal and other proteins.
 Endosomes are sorting centers for material from outside the cell or from the Golgi, sending it to lysosomes for destruction or back to the membrane/Golgi for further use.

I-cell disease (inclusion cell disease/mucopolidosis type II)—inherited lysosomal storage disorder (autosomal recessive); defect in N-acetylglucosaminyl-1-phosphotransferase → failure of the Golgi to phosphorylate mannose residues (↓ mannose-6-phosphate) on glycoproteins → enzymes secreted extracellularly rather than delivered to lysosomes → lysosomes deficient in digestive enzymes → buildup of cellular debris in lysosomes (inclusion bodies). Results in coarse facial features, gingival hyperplasia, corneal clouding, restricted joint movements, claw hand deformities, kyphoscoliosis, and ↑ plasma levels of lysosomal enzymes. Symptoms similar to but more severe than Hurler syndrome. Often fatal in childhood.



Signal recognition particle (SRP)—abundant, cytosolic ribonucleoprotein that traffics polypeptide-ribosome complex from the cytosol to the RER. Absent or dysfunctional SRP → accumulation of protein in cytosol.

Vesicular trafficking proteins

- COPI: Golgi → Golgi (retrograde); cis-Golgi → ER.
- COPII: ER → cis-Golgi (anterograde). “Two (COPII) steps forward (anterograde); one (COPI) step back (retrograde).”
- Clathrin: trans-Golgi → lysosomes; plasma membrane → endosomes (receptor-mediated endocytosis [eg, LDL receptor activity]).

Peroxisome

Membrane-enclosed organelle involved in:

- β -oxidation of very-long-chain fatty acids (VLCFA) (strictly peroxisomal process)
- α -oxidation of branched-chain fatty acids (strictly peroxisomal process)
- Catabolism of amino acids and ethanol
- Synthesis of bile acids and plasmalogens (important membrane phospholipid, especially in white matter of brain)

Zellweger syndrome—autosomal recessive disorder of peroxisome biogenesis due to mutated *PEX* genes. Hypotonia, seizures, jaundice, craniofacial dysmorphism, hepatomegaly, early death.

Refsum disease—autosomal recessive disorder of α -oxidation → buildup of phytanic acid due to inability to degrade it. Scaly skin, ataxia, cataracts/night blindness, shortening of 4th toe, epiphyseal dysplasia. Treatment: diet, plasmapheresis.

Adrenoleukodystrophy—X-linked recessive disorder of β -oxidation due to mutation in *ABCD1* gene → VLCFA buildup in **adrenal** glands, white (**leuko**) matter of brain, testes. Progressive disease that can lead to adrenal gland crisis, progressive loss of neurologic function, death.

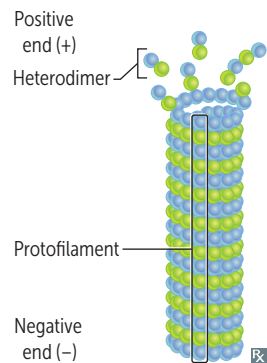
Proteasome

Barrel-shaped protein complex that degrades ubiquitin-tagged proteins. Defects in the ubiquitin-proteasome system have been implicated in some cases of Parkinson disease.

Cytoskeletal elements

A network of protein fibers within the cytoplasm that supports cell structure, cell and organelle movement, and cell division.

TYPE OF FILAMENT	PREDOMINANT FUNCTION	EXAMPLES
Microfilaments	Muscle contraction, cytokinesis	Actin, microvilli.
Intermediate filaments	Maintain cell structure	Vimentin, desmin, cytokeratin, lamins, glial fibrillary acidic protein (GFAP), neurofilaments.
Microtubules	Movement, cell division	Cilia, flagella, mitotic spindle, axonal trafficking, centrioles.

Microtubule

Cylindrical outer structure composed of a helical array of polymerized heterodimers of α - and β -tubulin. Each dimer has 2 GTP bound. Incorporated into flagella, cilia, mitotic spindles. Also involved in slow axoplasmic transport in neurons.

Molecular motor proteins—transport cellular cargo toward opposite ends of microtubule.

- Retrograde to microtubule (+ → -)—**dynein**.
- Anterograde to microtubule (- → +)—**kinesin**.

Clostridium tetani toxin, herpes simplex virus, poliovirus, and rabies virus use dynein for retrograde transport to the neuronal cell body.

Drugs that act on microtubules (**m**icrotubules **g**et **c**onstructed **v**ery **t**erribly):

- **M**ebendazole (antihelminthic)
- **G**riseofulvin (antifungal)
- **C**olchicine (antigout)
- **V**inca alkaloids (anticancer)
- **T**axanes (anticancer)

Negative end **n**ear **n**ucleus.

Positive end **p**oints to **p**eriphery.

Ready? Attack!

Cilia structure

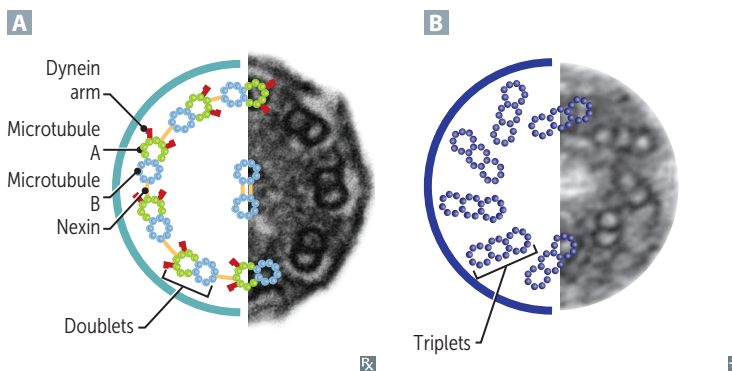
Motile cilia consist of 9 doublet + 2 singlet arrangement of microtubules (axoneme) **A**.

Basal body (base of cilium below cell membrane) consists of 9 microtubule triplets **B** with no central microtubules.

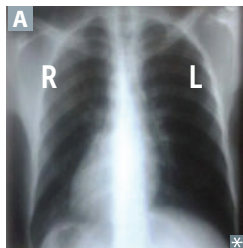
Nonmotile (primary) cilia work as chemical signal sensors and have a role in signal transduction and cell growth control. Dysgenesis may lead to polycystic kidney disease, mitral valve prolapse, or retinal degeneration.

Axonemal dynein—ATPase that links peripheral 9 doublets and causes bending of cilium by differential sliding of doublets.

Gap junctions enable coordinated ciliary movement.



Primary ciliary dyskinesia



Also called Kartagener syndrome. Autosomal recessive. Dynein arm defect → immotile cilia → dysfunctional ciliated epithelia.

Developmental abnormalities due to impaired migration and orientation (eg, situs inversus **A**, hearing loss due to dysfunctional eustachian tube cilia); recurrent infections (eg, sinusitis, ear infections, bronchiectasis due to impaired ciliary clearance of debris/pathogens); infertility (↑ risk of ectopic pregnancy due to dysfunctional fallopian tube cilia, immotile spermatozoa).

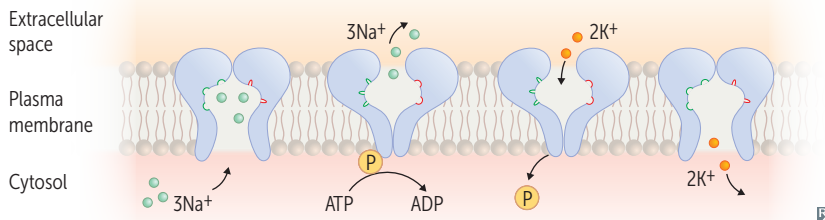
Lab findings: ↓ nasal nitric oxide (used as screening test).

Sodium-potassium pump

Na^+/K^+ -ATPase is located in the plasma membrane with ATP site on cytosolic side. For each ATP consumed, **2 K^+** go **in** to the cell (pump dephosphorylated) and **3 Na^+** go **out** of the cell (pump phosphorylated).

2 strikes? K , you're still in. 3 strikes? Nah, you're out!

Cardiac glycosides (digoxin and digitoxin) directly inhibit Na^+/K^+ -ATPase → indirect inhibition of $\text{Na}^+/\text{Ca}^{2+}$ exchange → ↑ $[\text{Ca}^{2+}]_i$ → ↑ cardiac contractility.

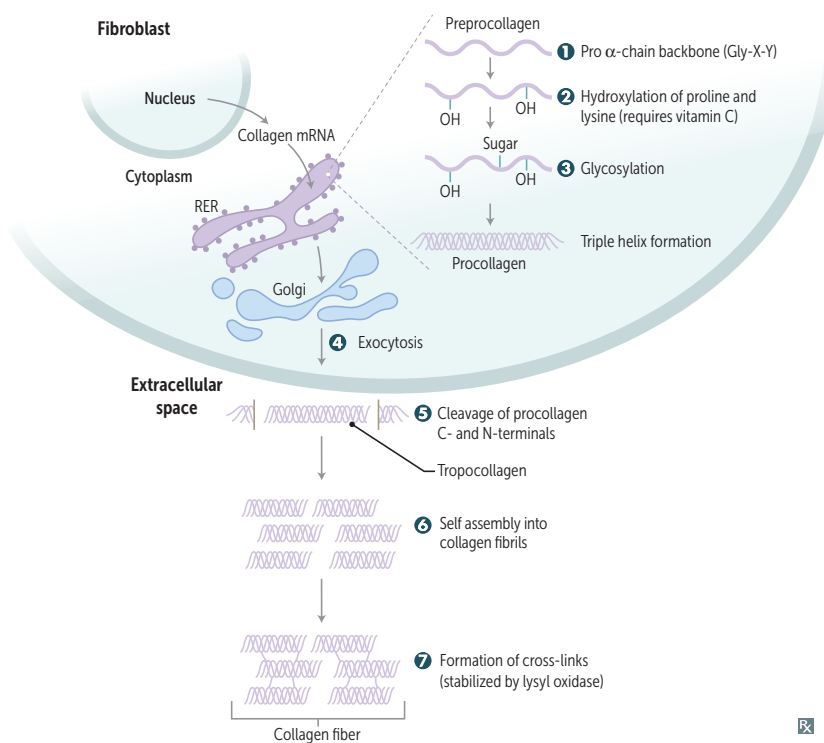


Collagen

Most abundant protein in the human body. Extensively modified by posttranslational modification. Organizes and strengthens extracellular matrix. Types I to IV are the most common types in humans.

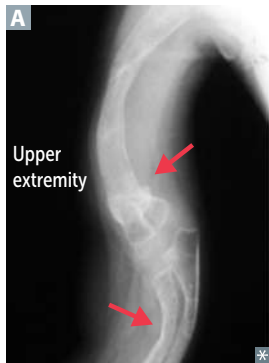Type I - **S**keleton
 Type II - **C**artilag**e**
 Type III - **A**rteries
 Type IV - **B**asement membrane
SCAB

Type I	Most common (90%)—Bone (made by osteoblasts), Skin, Tendon, dentin, fascia, cornea, late wound repair.	Type I : bone , tendon . ↓ production in osteogenesis imperfecta type I.
Type II	Cartilage (including hyaline), vitreous body, nucleus pulposus.	Type II : cartilage .
Type III	Reticulin—skin, blood vessels , uterus, fetal tissue, early wound repair.	Type III : deficient in vascular type of Ehlers-Danlos syndrome (three D) .
Type IV	Basement membrane/basal lamina (glomerulus, cochlea), lens.	Type IV : under the floor (basement membrane). Defective in Alport syndrome; targeted by autoantibodies in Goodpasture syndrome. Myofibroblasts are responsible for secretion (proliferative stage) and wound contraction.

Collagen synthesis and structure

- Synthesis**—translation of collagen α chains (preprocollagen)—usually Gly-X-Y (X is often proline or lysine and Y is often hydroxyproline or hydroxylysine). Collagen is 1/3 glycine; glycine content of collagen is less variable than that of lysine and proline.
- Hydroxylation**—hydroxylation (“hydroxycylation”) of specific proline and lysine residues. Requires vitamin C; deficiency \rightarrow scurvy.
- Glycosylation**—glycosylation of pro- α -chain hydroxylysine residues and formation of procollagen via hydrogen and disulfide bonds (triple helix of 3 collagen α chains). Problems forming triple helix \rightarrow osteogenesis imperfecta.
- Exocytosis**—exocytosis of procollagen into extracellular space.
- Proteolytic processing**—cleavage of disulfide-rich terminal regions of procollagen \rightarrow insoluble tropocollagen.
- Assembly and alignment**—collagen assembles in fibrils and aligns for cross-linking.
- Cross-linking**—reinforcement of staggered tropocollagen molecules by covalent lysine-hydroxylysine cross-linkage (by copper-containing lysyl oxidase) to make collagen fibrils. Cross-linking of collagen \uparrow with age. Problems with cross-linking \rightarrow Menkes disease.

Osteogenesis imperfecta



Genetic bone disorder (brittle bone disease) caused by a variety of gene defects (most commonly *COL1A1* and *COL1A2*). Most common form is autosomal dominant with ↓ production of otherwise normal type I collagen (altered triple helix formation). Manifestations include:

- Multiple fractures and bone deformities (arrows in **A**) after minimal trauma (eg, during birth)
- Blue sclerae **B** due to the translucent connective tissue over choroidal veins
- Some forms have tooth abnormalities, including opalescent teeth that wear easily due to lack of dentin (dentinogenesis imperfecta)
- Conductive hearing loss (abnormal ossicles)

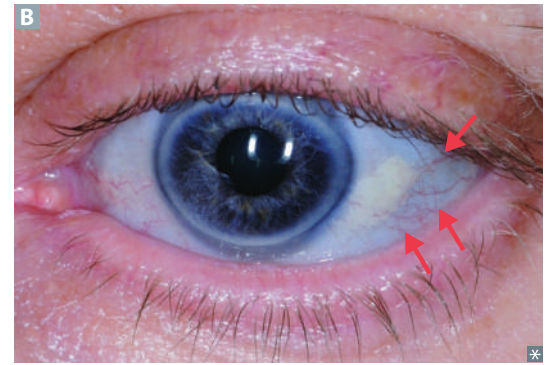
May be confused with child abuse.
Treat with bisphosphonates to ↓ fracture risk.
Patients can't **BITE**:

Bones = multiple fractures

I (eye) = blue sclerae

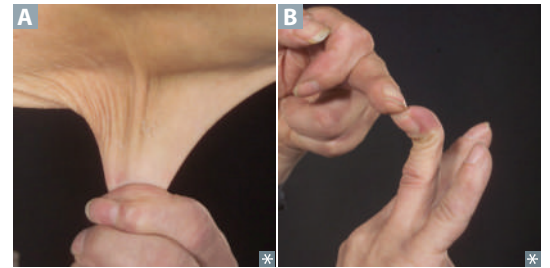
Teeth = dental imperfections

Ear = hearing loss



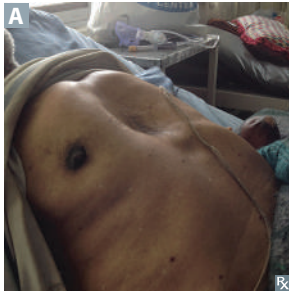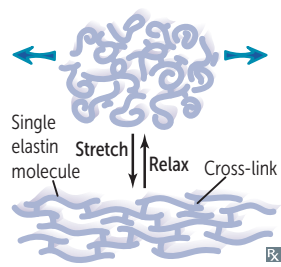
Ehlers-Danlos syndrome

Faulty collagen synthesis causing hyperextensible skin **A**, hypermobile joints **B**, and tendency to bleed (easy bruising). Multiple types. Inheritance and severity vary. Can be autosomal dominant or recessive. May be associated with joint dislocation, berry and aortic aneurysms, organ rupture. Hypermobility type (joint instability): most common type. Classical type (joint and skin symptoms): caused by a mutation in type V collagen (eg, *COL5A1*, *COL5A2*). Vascular type (fragile tissues including vessels [eg, aorta], muscles, and organs that are prone to rupture [eg, gravid uterus]): mutations in type III procollagen (eg, *COL3A1*).



Menkes disease

X-linked recessive connective tissue disease caused by impaired copper absorption and transport due to defective Menkes protein *ATP7A* (Absent copper), vs *ATP7B* in Wilson disease (copper Buildup). Leads to ↓ activity of lysyl oxidase (copper is a necessary cofactor) → defective collagen cross-linking. Results in brittle, “kinky” hair, growth and developmental delay, hypotonia, ↑ risk of cerebral aneurysms.

Elastin

Stretchy protein within skin, lungs, large arteries, elastic ligaments, vocal cords, epiglottis, ligamenta flava (connect vertebrae → relaxed and stretched conformations).

Rich in nonhydroxylated proline, glycine, and lysine residues, vs the hydroxylated residues of collagen.

Tropoelastin with fibrillin scaffolding.

Cross-linking occurs extracellularly via lysyl oxidase and gives elastin its elastic properties.

Broken down by elastase, which is normally inhibited by α_1 -antitrypsin.

α_1 -Antitrypsin deficiency results in unopposed elastase activity, which can cause COPD.

Marfan syndrome—autosomal dominant (with variable expression) connective tissue disorder affecting skeleton, heart, and eyes. *FBNI* gene mutation on chromosome 15 (fifteen) results in defective fibrillin-1, a glycoprotein that forms a sheath around elastin and sequesters TGF- β . Findings: tall with long extremities; chest wall deformity (pectus carinatum [pigeon chest] or pectus excavatum **A**); hypermobile joints; long, tapering fingers and toes (arachnodactyly); cystic medial necrosis of aorta; aortic root aneurysm rupture or dissection (most common cause of death); mitral valve prolapse; ↑ risk of spontaneous pneumothorax.

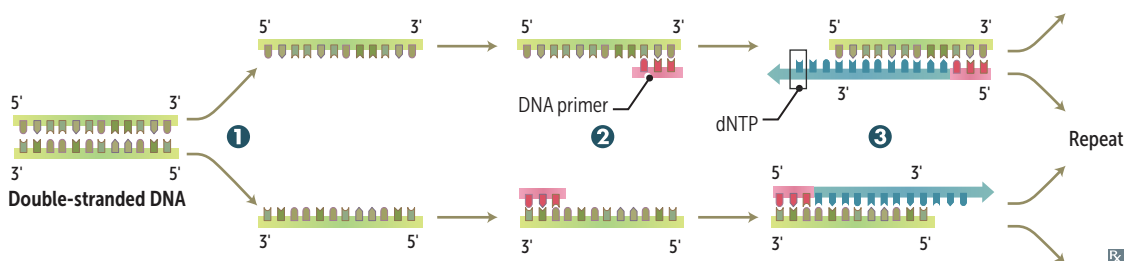
Homocystinuria—most commonly due to cystathionine synthase deficiency leading to homocysteine buildup. Presentation similar to Marfan syndrome with pectus deformity, tall stature, ↑ arm:height ratio, ↓ upper:lower body segment ratio, arachnodactyly, joint hyperlaxity, skin hyperelasticity, scoliosis.

	Marfan syndrome	Homocystinuria
INHERITANCE	Autosomal dominant	Autosomal recessive
INTELLECT	Normal	Decreased
VASCULAR COMPLICATIONS	Aortic root dilatation	Thrombosis
LENS DISLOCATION	Upward/temporal (Marfan fans out)	Downward/nasal

► BIOCHEMISTRY—LABORATORY TECHNIQUES

Polymerase chain reaction

Molecular biology lab procedure used to amplify a desired fragment of DNA. Useful as a diagnostic tool (eg, neonatal HIV, herpes encephalitis).

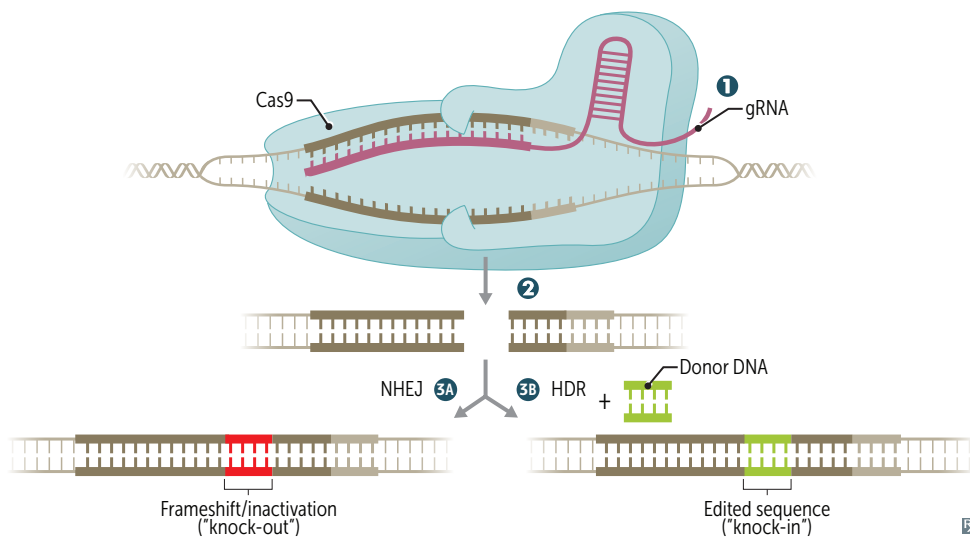


- 1 Denaturation**—DNA template, DNA primers, a heat-stable DNA polymerase, and deoxynucleotide triphosphates (dNTPs) are heated to $\sim 95^\circ\text{C}$ to separate the DNA strands.
- 2 Annealing**—sample is cooled to $\sim 55^\circ\text{C}$. DNA primers anneal to the specific sequence to be amplified on the DNA template.
- 3 Elongation**—temperature is increased to $\sim 72^\circ\text{C}$. DNA polymerase adds dNTPs to the strand to replicate the sequence after each primer.

Heating and cooling cycles continue until the amount of DNA is sufficient.

CRISPR/Cas9

A genome editing tool derived from bacteria. Consists of a guide RNA (gRNA) ①, which is complementary to a target DNA sequence, and an endonuclease (Cas9), which makes a single- or double-strand break at the target site ②. Imperfectly cut segments are repaired by nonhomologous end joining (NHEJ) → accidental frameshift mutations (“knock-out”) ③A, or a donor DNA sequence can be added to fill in the gap using homology-directed repair (HDR) ③B. Potential applications include removing virulence factors from pathogens, replacing disease-causing alleles of genes with healthy variants (in clinical trials for sickle cell disease), and specifically targeting tumor cells.



Blotting procedures

Southern blot

1. DNA sample is enzymatically cleaved into smaller pieces, which are separated on a gel by electrophoresis, and then transferred to a membrane.
2. Membrane is exposed to labeled DNA probe that anneals to its complementary strand.
3. Resulting double-stranded, labeled piece of DNA is visualized when membrane is exposed to film or digital imager.

Northern blot

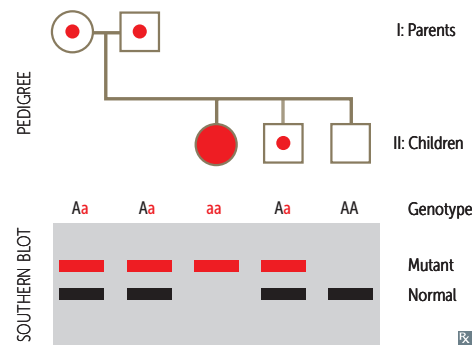
Similar to Southern blot, except that an RNA sample is electrophoresed. Useful for studying mRNA levels, which are reflective of gene expression.

Western blot

Sample protein is separated via gel electrophoresis and transferred to a membrane. Labeled antibody is used to bind to relevant protein.

Southwestern blot

Identifies DNA-binding proteins (eg, c-Jun, c-Fos [leucine zipper motif]) using labeled double-stranded DNA probes.



SNoW DRoP:

- Southern = DNA
- Northern = RNA
- Western = Protein

Northern blots detect splicing errors.

Southern (DNA) + Western (protein) = Southwestern (DNA-binding protein).

Flow cytometry

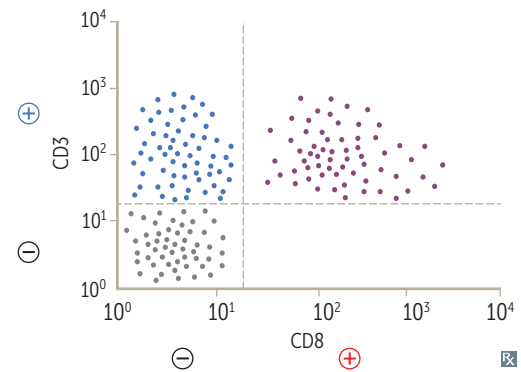
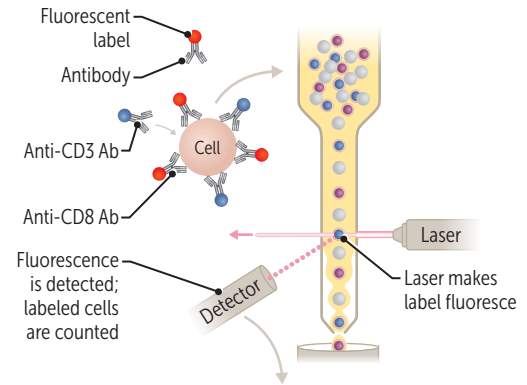
Laboratory technique to assess size, granularity, and protein expression (immunophenotype) of individual cells in a sample.

Cells are tagged with antibodies specific to surface or intracellular proteins. Antibodies are then tagged with a unique fluorescent dye. Sample is analyzed one cell at a time by focusing a laser on the cell and measuring light scatter and intensity of fluorescence.

Data are plotted either as histogram (one measure) or scatter plot (any two measures, as shown). In illustration:

- Cells in left lower quadrant \ominus for both CD8 and CD3.
- Cells in right lower quadrant \oplus for CD8 and \ominus for CD3. In this example, right lower quadrant is empty because all CD8-expressing cells also express CD3.
- Cells in left upper quadrant \oplus for CD3 and \ominus for CD8.
- Cells in right upper quadrant \oplus for both CD8 and CD3.

Commonly used in workup of hematologic abnormalities (eg, leukemia, paroxysmal nocturnal hemoglobinuria, fetal RBCs in pregnant person's blood) and immunodeficiencies (eg, CD4⁺ cell count in HIV).

**Microarrays**

Array consisting of thousands of DNA oligonucleotides arranged in a grid on a glass or silicon chip. The DNA or RNA samples being compared are attached to different fluorophores and hybridized to the array. The ratio of fluorescence signal at a particular oligonucleotide reflects the relative amount of the hybridizing nucleic acid in the two samples.

Used to compare the relative transcription of genes in two RNA samples. Can detect single nucleotide polymorphisms (SNPs) and copy number variants (CNVs) for genotyping, clinical genetic testing, forensic analysis, and cancer mutation and genetic linkage analysis when DNA is used.

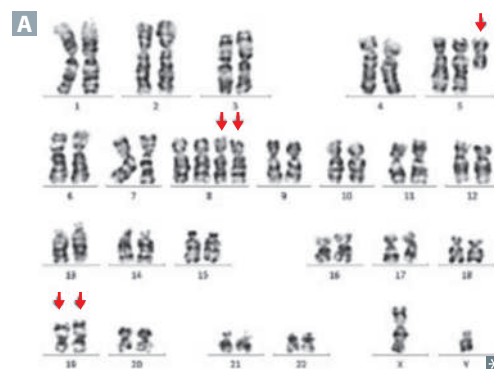Enzyme-linked immunosorbent assay

Immunologic test used to detect the presence of either a specific antigen or antibody in a patient's blood sample. Detection involves the use of an antibody linked to an enzyme. Added substrate reacts with the enzyme, producing a detectable signal. Can have high sensitivity and specificity, but is less specific than Western blot. Often used to screen for HIV infection.

Karyotyping

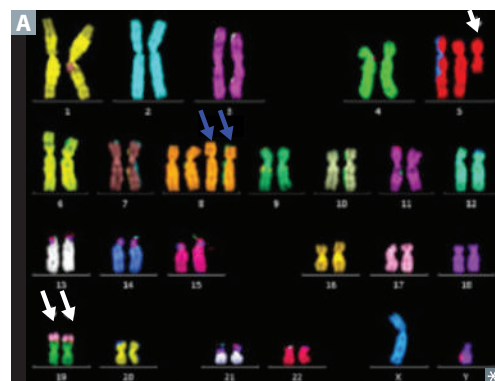Colchicine is added to cultured cells to halt chromosomes in metaphase. Chromosomes are stained, ordered, and numbered according to morphology, size, arm-length ratio, and banding pattern (arrows in **A** point to extensive abnormalities in a cancer cell).

Can be performed on a sample of blood, bone marrow, amniotic fluid, or placental tissue. Used to diagnose chromosomal imbalances (eg, autosomal trisomies, sex chromosome disorders).

**Fluorescence in situ hybridization**

Fluorescent DNA or RNA probe binds to specific gene or other site of interest on chromosomes (arrows in **A** point to abnormalities in a cancer cell; each fluorescent color represents a chromosome-specific probe). Used for specific localization of genes and direct visualization of chromosomal anomalies.

- Microdeletion—no fluorescence on a chromosome compared to fluorescence at the same locus on the second copy of that chromosome.
- Translocation—fluorescence signal that corresponds to one chromosome is found in a different chromosome (two white arrows in **A** show fragments of chromosome 17 that have translocated to chromosome 19).
- Duplication—a second copy of a chromosome, resulting in a trisomy or tetrasomy (two blue arrows in **A** duplicated chromosomes 8, resulting in a tetrasomy).

**Molecular cloning**

Production of a recombinant DNA molecule in a bacterial host. Useful for production of human proteins in bacteria (eg, human growth hormone, insulin).

Steps:

1. Isolate eukaryotic mRNA (post-RNA processing) of interest.
2. Add reverse transcriptase (an RNA-dependent DNA polymerase) to produce complementary DNA (cDNA, lacks introns).
3. Insert cDNA fragments into bacterial plasmids containing antibiotic resistance genes.
4. Transform (insert) recombinant plasmid into bacteria.
5. Surviving bacteria on antibiotic medium produce cloned DNA (copies of cDNA).

Gene expression modifications

Transgenic strategies in mice involve:

- Random insertion of gene into mouse genome
- Targeted insertion or deletion of gene through homologous recombination with mouse gene

Knock-**out** = removing a gene, taking it **out**.
Knock-**in** = **in**serting a gene.

Random insertion—constitutive expression.
Targeted insertion—conditional expression.

RNA interference

Process whereby small non-coding RNA molecules target mRNAs to inhibit gene expression.

MicroRNA

Naturally produced by cell as hairpin structures. Loose nucleotide pairing allows broad targeting of related mRNAs. When miRNA binds to mRNA, it blocks translation of mRNA and sometimes facilitates its degradation.

Abnormal expression of miRNAs contributes to certain malignancies (eg, by silencing an mRNA from a tumor suppressor gene).

Small interfering RNA

Usually derived from exogenous dsRNA source (eg, virus). Once inside a cell, siRNA requires complete nucleotide pairing, leading to highly specific mRNA targeting. Results in mRNA cleavage prior to translation.

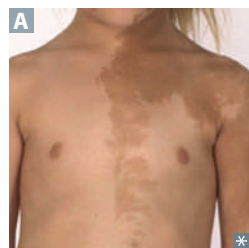Can be produced by transcription or chemically synthesized for gene “knockdown” experiments.

► BIOCHEMISTRY—GENETICS**Genetic terms**

TERM	DEFINITION	EXAMPLE
Codominance	Both alleles contribute to the phenotype of the heterozygote.	Blood groups A, B, AB; α_1 -antitrypsin deficiency; HLA groups.
Variable expressivity	Patients with the same genotype have varying phenotypes.	Two patients with neurofibromatosis type 1 (NF1) may have varying disease severity.
Incomplete penetrance	Not all individuals with a disease show the disease. % penetrance \times probability of inheriting genotype = risk of expressing phenotype.	<i>BRCA1</i> gene mutations do not always result in breast or ovarian cancer.
Pleiotropy	One gene contributes to multiple phenotypic effects.	Untreated phenylketonuria (PKU) manifests with light skin, intellectual disability, musty body odor.
Anticipation	Increased severity or earlier onset of disease in succeeding generations.	Trinucleotide repeat diseases (eg, Huntington disease).
Loss of heterozygosity	If a patient inherits or develops a mutation in a tumor suppressor gene, the wild type allele must be deleted/mutated/eliminated before cancer develops. This is not true of oncogenes.	Retinoblastoma and the “two-hit hypothesis,” Lynch syndrome (HNPCC), Li-Fraumeni syndrome.
Epistasis	The allele of one gene affects the phenotypic expression of alleles in another gene.	Albinism, alopecia.
Aneuploidy	An abnormal number of chromosomes; due to chromosomal nondisjunction during mitosis or meiosis.	Down syndrome, Turner syndrome, oncogenesis.

Genetic terms (continued)

TERM	DEFINITION	EXAMPLE
Dominant negative mutation	Exerts a dominant effect. A heterozygote produces a nonfunctional altered protein that also prevents the normal gene product from functioning.	A single mutated <i>p53</i> tumor suppressor gene results in a protein that is able to bind DNA and block the wild type <i>p53</i> from binding to the promoter.
Linkage disequilibrium	Tendency for certain alleles to occur in close proximity on the same chromosome more or less often than expected by chance. Measured in a population, not in a family, and often varies in different populations.	
Mosaicism	Presence of genetically distinct cell lines in the same individual. Somatic mosaicism—mutation arises from mitotic errors after fertilization and propagates through multiple tissues or organs. Germline (gonadal) mosaicism—mutation only in egg or sperm cells. If parents and relatives do not have the disease, suspect gonadal (or germline) mosaicism.	McCune-Albright syndrome —due to G_s -protein activating mutation. Presents with unilateral café-au-lait spots A with ragged edges, polyostotic fibrous dysplasia (bone is replaced by collagen and fibroblasts), and at least one endocrinopathy (eg, precocious puberty). Lethal if mutation occurs before fertilization (affecting all cells), but survivable in patients with mosaicism.
Locus heterogeneity	Mutations at different loci result in the same disease.	Albinism, retinitis pigmentosa, familial hypercholesteremia.
Allelic heterogeneity	Different mutations in the same locus result in the same disease.	β -thalassemia.
Heteroplasmy	Presence of both normal and mutated mtDNA, resulting in variable expression in mitochondrially inherited disease.	mtDNA passed from mother to all children.
Uniparental disomy	Offspring receives 2 copies of a chromosome from 1 parent and no copies from the other parent. Heterodisomy (heterozygous) indicates a meiosis I error. Isodisomy (homozygous) indicates a meiosis II error or postzygotic chromosomal duplication of one of a pair of chromosomes, and loss of the other of the original pair.	Uniparental is euploid (correct number of chromosomes). Most occurrences of uniparental disomy (UPD) → normal phenotype. Consider isodisomy in an individual manifesting a recessive disorder when only one parent is a carrier. Examples: Prader-Willi and Angelman syndromes.



Hardy-Weinberg population genetics

	A (p)	a (q)
A (p)	AA (p ²)	Aa (pq)
a (q)	Aa (pq)	aa (q ²)

If **p** and **q** represent the frequencies of alleles A and a, respectively, in a population, then **p + q = 1**:

- **p²** = frequency of homozygosity for allele A
- **q²** = frequency of homozygosity for allele a
- **2pq** = frequency of heterozygosity (carrier frequency, if an autosomal recessive disease)

Therefore, the sum of the frequencies of these genotypes is **p² + 2pq + q² = 1**.
The frequency of an X-linked recessive disease in males = q and in females = q².

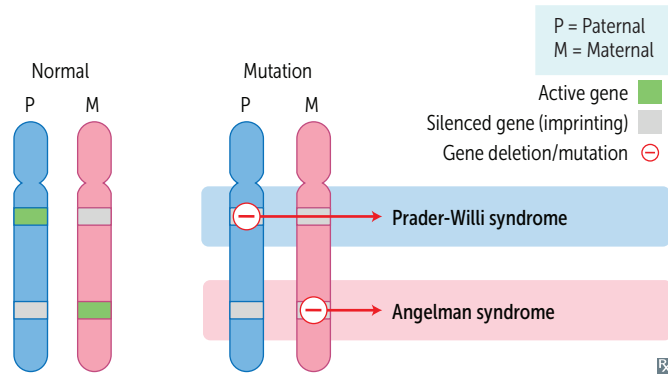
Hardy-Weinberg law assumptions include:

- No mutation occurring at the locus
- Natural selection is not occurring
- Completely random mating
- No net migration
- Large population

If a population is in Hardy-Weinberg equilibrium, then the values of p and q remain constant from generation to generation.

Disorders of imprinting **Imprinting**—one gene copy is silenced by methylation, and only the other copy is expressed → parent-of-origin effects. The expressed copy may be mutated, may not be expressed, or may be deleted altogether.

	Prader-Willi syndrome	Angelman syndrome
WHICH GENE IS SILENT?	Maternally derived genes are silenced Disease occurs when the p aternal allele is deleted or mutated	Paternally derived <i>UBE3A</i> is silenced Disease occurs when the m aternal allele is deleted or mutated
SIGNS AND SYMPTOMS	Hyperphagia, obesity, intellectual disability, hypogonadism, hypotonia	S eizures, A taxia, severe I ntellectual disability, inappropriate L aughter Set SAIL for Angel Island
CHROMOSOMES INVOLVED	Chromosome 15 of paternal origin	<i>UBE3A</i> on maternal copy of chromosome 15
NOTES	25% of cases are due to maternal uniparental disomy	5% of cases are due to paternal uniparental disomy
	POP : P rader-Willi, O besity/overeating, P aternal allele deleted	MAMAS : M aternal allele deleted, A ngelman syndrome, M ood, A taxia, S eizures

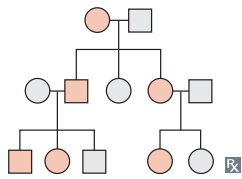


Modes of inheritance

Autosomal dominant

Often due to defects in structural genes. Many generations, both males and females are affected.

Often pleiotropic (multiple apparently unrelated effects) and variably expressive (different between individuals). Family history crucial to diagnosis. With one affected (heterozygous) parent, each child has a 50% chance of being affected.

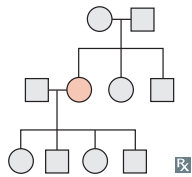


	A	a
a	Aa	aa
a	Aa	aa

Autosomal recessive

With 2 carrier (heterozygous) parents, on average: each child has a 25% chance of being affected, 50% chance of being a carrier, and 25% chance of not being affected nor a carrier.

Often due to enzyme deficiencies. Usually seen in only 1 generation. Commonly more severe than dominant disorders; patients often present in childhood.



	A	a
A	AA	Aa
a	Aa	aa

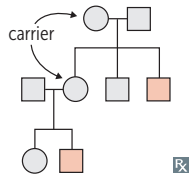
↑ risk in consanguineous families.

Unaffected individual with affected sibling has 2/3 probability of being a carrier.

X-linked recessive

Sons of heterozygous mothers have a 50% chance of being affected. No male-to-male transmission. Skips generations.

Commonly more severe in males. Females usually must be homozygous to be affected.

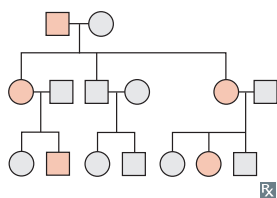


	X	X	X	X
X	XX	XX	X	XX
Y	XY	XY	Y	XY

X-linked dominant

Transmitted through both parents. Children of affected mothers each have a 50% chance of being affected. 100% of daughters and 0% of sons of affected fathers will be affected.

Examples: fragile X syndrome, Alport syndrome, hypophosphatemic rickets (also called X-linked hypophosphatemia)—phosphate wasting at proximal tubule → ricketslike presentation.



	X	X	X	X
X	XX	XX	X	XX
Y	XY	XY	Y	XY

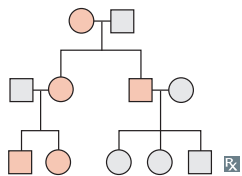
Mitochondrial inheritance

Transmitted only through the mother. All offspring of affected females may show signs of disease.

Caused by mutations in mtDNA.

Examples: mitochondrial myopathies, Leber hereditary optic neuropathy.

Variable expression in a population or even within a family due to heteroplasmy.



□ = unaffected male; ■ = affected male; ○ = unaffected female; ● = affected female.

Autosomal dominant diseases

Achondroplasia, autosomal dominant polycystic kidney disease, familial adenomatous polyposis, familial hypercholesterolemia, hereditary hemorrhagic telangiectasia (Osler-Weber-Rendu syndrome), hereditary spherocytosis, Huntington disease, Li-Fraumeni syndrome, Marfan syndrome, multiple endocrine neoplasias, myotonic muscular dystrophy, neurofibromatosis type 1 (von Recklinghausen disease), neurofibromatosis type 2, tuberous sclerosis, von Hippel-Lindau disease.

Autosomal recessive diseases

Mostly consist of enzyme defects. **O**culocutaneous albinism, **p**henylketonuria, **c**ystic fibrosis, **s**ickle cell disease, **W**ilson disease, **s**phingolipidoses (except Fabry disease), **h**emochromatosis, **g**lycogen storage diseases, **t**halassemia, **m**ucopolysaccharidoses (except Hunter syndrome), **F**riedreich ataxia, **K**artagener syndrome, **ARPKD**. Oh, please! Can students who score high grades tell me features of the kidney disorder **Autosomal Recessive Polycystic Kidney Disease**?

Cystic fibrosis**GENETICS**

Autosomal recessive; defect in *CFTR* gene on chromosome 7; commonly a deletion of gene on chromosome 7 ($\Delta F508$). Most common lethal genetic disease in patients with European ancestry.

PATHOPHYSIOLOGY

CFTR encodes an ATP-gated Cl^- channel that secretes Cl^- in lungs and GI tract, and reabsorbs Cl^- in sweat glands. Phe508 deletion \rightarrow misfolded protein \rightarrow improper protein trafficking and protein retention in RER \rightarrow protein absent from cell membrane \rightarrow \downarrow Cl^- (and H_2O) secretion; \uparrow intracellular Cl^- results in compensatory \uparrow Na^+ reabsorption via epithelial Na^+ channels (ENaC) \rightarrow \uparrow H_2O reabsorption \rightarrow abnormally thick mucus secreted into lungs and GI tract. \uparrow Na^+ reabsorption also causes more negative transepithelial potential difference.

DIAGNOSIS

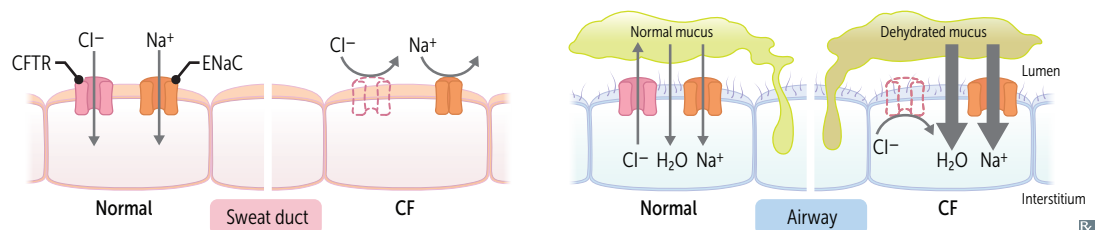
\uparrow Cl^- concentration in pilocarpine-induced sweat test is diagnostic. Can present with contraction alkalosis and hypokalemia (ECF effects analogous to a patient taking a loop diuretic) because of ECF $\text{H}_2\text{O}/\text{Na}^+$ losses via sweating and concomitant renal K^+/H^+ wasting. \uparrow immunoreactive trypsinogen (newborn screening) due to clogging of pancreatic duct.

COMPLICATIONS

Recurrent pulmonary infections (eg, *S aureus* [infancy and early childhood], *P aeruginosa* [adulthood], allergic bronchopulmonary aspergillosis [ABPA]), chronic bronchitis and bronchiectasis \rightarrow reticulonodular pattern on CXR, opacification of sinuses. Nasal polyps, nail clubbing. Pancreatic insufficiency, malabsorption with steatorrhea, and fat-soluble vitamin deficiencies (A, D, E, K) progressing to endocrine dysfunction (CF-related diabetes), biliary cirrhosis, liver disease. Meconium ileus in newborns. Infertility in males (absence of vas deferens, spermatogenesis may be unaffected) and subfertility in females (amenorrhea, abnormally thick cervical mucus).

TREATMENT

Multifactorial: chest physiotherapy, albuterol, aerosolized dornase alfa (DNase), and inhaled hypertonic saline facilitate mucus clearance. Azithromycin used as anti-inflammatory agent. Ibuprofen slows disease progression. Pancreatic enzyme replacement therapy (pancrelipase) for pancreatic insufficiency. Combination of lumacaftor or tezacaftor (each corrects misfolded proteins and improves their transport to cell surface) with ivacaftor. (opens Cl^- channels \rightarrow improved chloride transport).

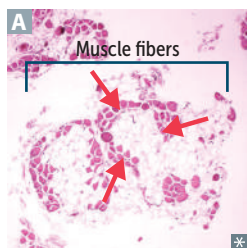


X-linked recessive diseases

Bruton agammaglobulinemia, Duchenne and Becker muscular dystrophies, Fabry disease, G6PD deficiency, hemophilia A and B, Hunter syndrome, Lesch-Nyhan syndrome, ocular albinism, ornithine transcarbamylase deficiency, Wiskott-Aldrich syndrome.

Females with Turner syndrome (45,XO) are more likely to have an X-linked recessive disorder.

X-inactivation (lyonization)—during development, one of the X chromosomes in each XX cell is randomly deactivated and condensed into a Barr body (methylated heterochromatin). If skewed inactivation occurs, XX individuals may express X-linked recessive diseases (eg, G6PD); penetrance and severity of X-linked dominant diseases in XX individuals may also be impacted.

Muscular dystrophies**Duchenne**

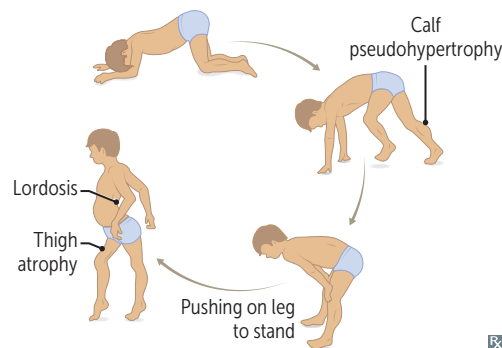
X-linked recessive disorder typically due to **frameshift** deletions or nonsense mutations → truncated or absent dystrophin protein → progressive myofiber damage. Weakness begins in pelvic girdle muscles and progresses superiorly. Pseudohypertrophy of calf muscles due to fibrofatty replacement of muscle **A**. Waddling gait.

Onset before 5 years of age. **Dilated** cardiomyopathy is common cause of **death**.

Gowers sign—patient uses upper extremities to help stand up. Classically seen in Duchenne muscular dystrophy, but also seen in other muscular dystrophies and inflammatory myopathies (eg, polymyositis).

Duchenne = deleted dystrophin.

Dystrophin gene (*DMD*) is the largest protein-coding human gene → ↑ chance of spontaneous mutation. Dystrophin helps to anchor muscle fibers to the extracellular matrix, primarily in skeletal and cardiac muscles. Loss of dystrophin → myonecrosis. ↑ CK and aldolase; genetic testing confirms diagnosis.

**Becker**

X-linked recessive disorder typically due to **non-frameshift** deletions in dystrophin gene (partially functional instead of truncated). Less severe than Duchenne (**Becker is better**). Onset in adolescence or early adulthood.

Deletions can cause both Duchenne and Becker muscular dystrophies. 2/3 of cases have large deletions spanning one or more exons.

Myotonic dystrophy

Autosomal dominant. Onset 20–30 years. **CTG** trinucleotide repeat expansion in the *DMPK* gene → abnormal expression of myotonin protein kinase → myotonia (eg, difficulty releasing hand from handshake), muscle wasting, cataracts, testicular atrophy, frontal balding, arrhythmia.

Cataracts, Toupee (early balding in males), **Gonadal atrophy**.

Mitochondrial diseases Rare disorders arising 2° to failure in oxidative phosphorylation. Tissues with ↑ energy requirements are preferentially affected (eg, CNS, skeletal muscle).

Mitochondrial myopathies—include **MELAS** (mitochondrial encephalomyopathy with lactic acidosis and strokelike episodes) and **MERRF** (myoclonic epilepsy with ragged red fibers). Light microscopy with stain: ragged red fibers due to compensatory proliferation of mitochondria. Electron microscopy: mitochondrial crystalline inclusions.

Leber hereditary optic neuropathy—mutations in complex I of ETC → neuronal death in retina and optic nerve → subacute bilateral vision loss in teens/young adults (males > females). Usually permanent. May be accompanied by neurologic dysfunction (eg, tremors, multiple sclerosis–like illness).

Rett syndrome Sporadic disorder seen almost exclusively in females (affected males die in utero or shortly after birth). Most cases are caused by de novo mutation of *MECP2* on X chromosome. Symptoms of **Rett** syndrome usually appear between ages 1–4 and are characterized by regression (“**re**ttur”) in motor, verbal, and cognitive abilities; ataxia; seizures; growth deceleration; and stereotyped hand-wringing.

Fragile X syndrome X-linked dominant inheritance. Trinucleotide repeats in *FMR1* → hypermethylation of cytosine residues → ↓ expression. Most common inherited cause of intellectual disability (Down syndrome is most common genetic cause, but most cases occur sporadically).

Trinucleotide repeat expansion [(CGG)_n] occurs during oogenesis. Premutation (50-200 repeats) → tremor, ataxia, 1° ovarian insufficiency. Full mutation (>200 repeats) → postpubertal macroorchidism (enlarged testes), long face with large jaw, large everted ears, autism, mitral valve prolapse, hypermobile joints. Self-mutilation is common and can be confused with Lesch-Nyhan syndrome.

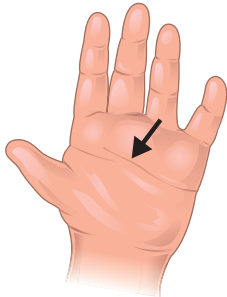
Trinucleotide repeat expansion diseases May show genetic anticipation (disease severity ↑ and age of onset ↓ in successive generations).

DISEASE	TRINUCLEOTIDE REPEAT	MODE OF INHERITANCE	MNEMONIC
Huntington disease	(CAG) _n	AD	Caudate has ↓ ACh and GABA
Myotonic dystrophy	(CTG) _n	AD	Cataracts, Toupee (early balding in males), Gonadal atrophy in males, reduced fertility in females
Fragile X syndrome	(CGG) _n	XD	Chin (protruding), Giant Gonads
Friedreich ataxia	(GAA) _n	AR	Ataxic GAAit

Autosomal trisomies

Autosomal monosomies are incompatible with life due to a high chance of expression of recessive traits for that chromosome. Incidence of trisomies: Down > Edwards > Patau.

Down syndrome (trisomy 21)



Single palmar crease

Findings: intellectual disability, flat facies, prominent epicanthal folds, single palmar crease, incurved 5th finger, gap between 1st 2 toes, duodenal atresia, Hirschsprung disease, congenital heart disease (eg, ASD), Brushfield spots (whitish spots at the periphery of the iris). Associated with early-onset Alzheimer disease (chromosome 21 codes for amyloid precursor protein), ↑ risk of AML/ALL.

95% of cases due to meiotic nondisjunction, most commonly during meiosis I (↑ with advanced maternal age: from 1:1500 in females < 20 to 1:25 in females > 45).

4% of cases due to unbalanced Robertsonian translocation, most typically between chromosomes 14 and 21. Only 1% of cases are due to postfertilization mitotic error.

Drinking age (21).

Most common viable chromosomal disorder and most common cause of genetic intellectual disability.

First-trimester ultrasound commonly shows

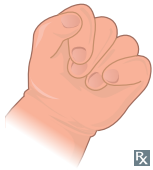↑ nuchal translucency and hypoplastic nasal bone. Markers for Down syndrome are **hi** up: ↑ **hCG**, ↑ **inhibin**.

↑ risk of umbilical hernia (incomplete closure of umbilical ring).

The **5 A's** of Down syndrome:

- **A**dvanced maternal age
- **A**tresia (duodenal)
- **A**trioventricular septal defect
- **A**lzheimer disease (early onset)
- **A**ML (<5 years of age)/ALL (>5 years of age)

Edwards syndrome (trisomy 18)

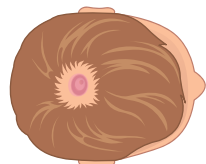

Findings: **PRINCE** Edward—**P**rominent occiput, **R**ocker-bottom feet, **I**ntellectual disability, **N**ondisjunction, **C**lenched fists with overlapping fingers, low-set **E**ars, micrognathia (small jaw), congenital heart disease (eg, VSD), omphalocele, myelomeningocele. Death usually occurs by age 1.

Election age (18).

2nd most common autosomal trisomy resulting in live birth (most common is Down syndrome). In **Edwards syndrome**, every prenatal screening marker **d**ecreases.

Patau syndrome (trisomy 13)

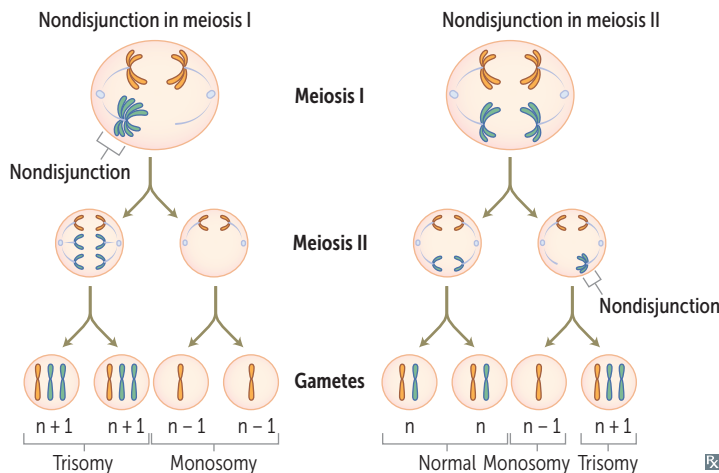


Cutis aplasia

Findings: severe intellectual disability, rocker-bottom feet, microphthalmia, microcephaly, cleft lip/palate, holoprosencephaly, polydactyly, cutis aplasia, congenital heart (pump) disease, polycystic kidney disease, omphalocele. Death usually occurs by age 1.

Puberty at age 13.

Defect in fusion of prechordal mesoderm → midline defects.



1st trimester screening		
Trisomy	β-hCG	PAPP-A
21	↑	↓
18	↓	↓
13	↓	↓

2nd trimester (quadruple) screening				
Trisomy	β-hCG	Inhibin A	Estriol	AFP
21	↑	↑	↓	↓
18	↓	— or ↓	↓	↓
13	—	—	—	—

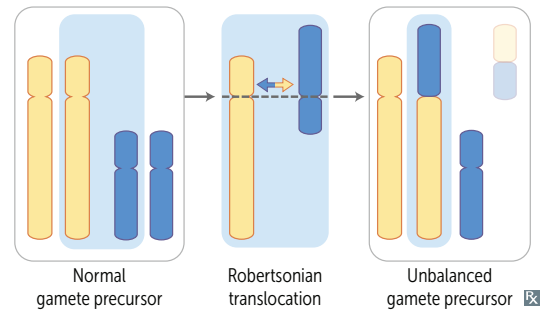
Noninvasive prenatal testing is recommended over first- and second-trimester screening.

Genetic disorders by chromosome

CHROMOSOME	SELECTED EXAMPLES
3	von Hippel-Lindau disease, renal cell carcinoma
4	ADPKD (<i>PKD2</i>), achondroplasia, Huntington disease
5	Cri-du-chat syndrome, familial adenomatous polyposis
6	Hemochromatosis (<i>HFE</i>)
7	Williams syndrome, cystic fibrosis
9	Friedreich ataxia, tuberous sclerosis (<i>TSC1</i>)
11	Wilms tumor, β -globin gene defects (eg, sickle cell disease, β -thalassemia), MEN1
13	Patau syndrome, Wilson disease, retinoblastoma (<i>RBI</i>), <i>BRCA2</i>
15	Prader-Willi syndrome, Angelman syndrome, Marfan syndrome
16	ADPKD (<i>PKD1</i>), α -globin gene defects (eg, α -thalassemia), tuberous sclerosis (<i>TSC2</i>)
17	Neurofibromatosis type 1, <i>BRCA1</i> , <i>TP53</i> (Li-Fraumeni syndrome)
18	Edwards syndrome
21	Down syndrome
22	Neurofibromatosis type 2, DiGeorge syndrome (22q11)
X	Fragile X syndrome, X-linked agammaglobulinemia, Klinefelter syndrome (XXY)

Robertsonian translocation

Chromosomal translocation that commonly involves chromosome pairs 21, 22, 13, 14, and 15. One of the most common types of translocation. Occurs when the long arms of 2 acrocentric chromosomes (chromosomes with centromeres near their ends) fuse at the centromere and the 2 short arms are lost. Balanced translocations (no gain or loss of significant genetic material) normally do not cause abnormal phenotype. Unbalanced translocations (missing or extra genes) can result in miscarriage, stillbirth, and chromosomal imbalance (eg, Down syndrome, Patau syndrome).

**Cri-du-chat syndrome**

Cri du chat = cry of the cat. Congenital deletion on short arm of chromosome 5 (46,XX or XY, 5p-).

Findings: microcephaly, moderate to severe intellectual disability, high-pitched **crying**, epicanthal folds, cardiac abnormalities (**VSD**). I **cry** when I am **Very SaD**.

Williams syndrome

Congenital microdeletion of long arm of chromosome 7 (deleted region includes elastin gene). Findings: distinctive “elfin” facies, intellectual disability, hypercalcemia, well-developed verbal skills, extreme friendliness with strangers, cardiovascular problems (eg, supravalvular aortic stenosis, renal artery stenosis).

▶ BIOCHEMISTRY—NUTRITION

Essential fatty acids	<p>Polyunsaturated fatty acids that cannot be synthesized in the body and must be provided in the diet (eg, nuts/seeds, plant oils, seafood). Linoleic acid (omega-6) is metabolized to arachidonic acid, which serves as the precursor to leukotrienes and prostaglandins. Linolenic acid (omega-3) and its metabolites have cardioprotective and antihyperlipidemic effects.</p>	<p>In contrast, consumption of <i>trans</i>-unsaturated fatty acids (found in fast food) promotes cardiovascular disease by ↑ LDL and ↓ HDL.</p>
Vitamins: fat soluble	<p>A, D, E, K. Absorption dependent on bile emulsification, pancreatic secretions, and intact ileum. Toxicity more common than for water-soluble vitamins because fat-soluble vitamins accumulate in fat.</p>	<p>Malabsorption syndromes with steatorrhea (eg, cystic fibrosis and celiac disease) or mineral oil intake can cause fat-soluble vitamin deficiencies.</p>
Vitamins: water soluble	<p>B₁ (thiamine: TPP) B₂ (riboflavin: FAD, FMN) B₃ (niacin: NAD⁺) B₅ (pantothenic acid: CoA) B₆ (pyridoxine: PLP) B₇ (biotin) B₉ (folate) B₁₂ (cobalamin) C (ascorbic acid)</p>	<p>Wash out easily from body except B₁₂ and B₉. B₁₂ stored in liver for ~ 3–4 years. B₉ stored in liver for ~ 3–4 months. B-complex deficiencies often result in dermatitis, glossitis, and diarrhea. Can be coenzymes (eg, ascorbic acid) or precursors to coenzymes (eg, FAD, NAD⁺).</p>

Vitamin A

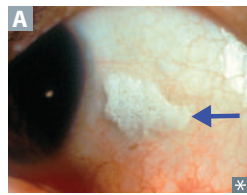
Includes retinal, retinol, retinoic acid.

FUNCTION

Antioxidant; constituent of visual pigments (**retinal**); essential for normal differentiation of epithelial cells into specialized tissue (pancreatic cells, mucus-secreting cells); prevents squamous metaplasia.

Retinol is vitamin **A**, so think **retin-A** (used topically for wrinkles and **A**cne).
 Found in liver and leafy vegetables.
 Supplementation in vitamin A-deficient measles patients may improve outcomes.
 Use oral isotretinoin to treat severe cystic acne.
 Use *all-trans* retinoic acid to treat acute promyelocytic leukemia.

DEFICIENCY



Night blindness (nyctalopia); dry, scaly skin (xerosis cutis); dry eyes (xerophthalmia); conjunctival squamous metaplasia → Bitot spots (keratin debris; foamy appearance on conjunctiva **A**); corneal degeneration (keratomalacia); immunosuppression.

EXCESS

Acute toxicity—nausea, vomiting, ↑ ICP (eg, vertigo, blurred vision).
 Chronic toxicity—alopecia, dry skin (eg, scaliness), hepatic toxicity and enlargement, arthralgias, and idiopathic intracranial hypertension.

Teratogenic (cleft palate, cardiac abnormalities), therefore a ⊖ pregnancy test and two forms of contraception are required before isotretinoin (vitamin A derivative) is prescribed.
Isotretinoin is teratogenic.

Vitamin B₁

Also called thiamine.

FUNCTION

In thiamine pyrophosphate (TPP), a cofactor for several dehydrogenase enzyme reactions (**Be APT**):

- **B**ranching-chain ketoacid dehydrogenase
- **α**-Ketoglutarate dehydrogenase (TCA cycle)
- **P**yruvate dehydrogenase (links glycolysis to TCA cycle)
- **T**ransketolase (HMP shunt)

DEFICIENCY


Impaired glucose breakdown → ATP depletion worsened by glucose infusion; highly aerobic tissues (eg, brain, heart) are affected first. In patients with chronic alcohol overuse or malnutrition, give thiamine before dextrose to ↓ risk of precipitating Wernicke encephalopathy.
 Diagnosis made by ↑ in RBC transketolase activity following vitamin B₁ administration.

DISORDER

CHARACTERISTICS

Wernicke encephalopathy	Acute, reversible, life-threatening neurologic condition. Symptoms: C onfusion, O phthalmoplegia/ N ystagmus, A taxia (C or O NA beer).
Korsakoff syndrome	Amnesic disorder due to chronic alcohol overuse; presents with confabulation, personality changes, memory loss (permanent).
Wernicke-Korsakoff syndrome	Damage to medial dorsal nucleus of thalamus, mammillary bodies. Presentation is combination of Wernicke encephalopathy and Korsakoff syndrome.
Dry beriberi	Polyneuropathy, symmetric muscle wasting.
Wet beriberi	High-output cardiac failure (due to systemic vasodilation).

Spell beriberi as **Ber1Ber1** to remember vitamin **B₁**.

Vitamin B₂	Also called riboflavin.	
FUNCTION	Component of flavins FAD and FMN, used as cofactors in redox reactions, eg, the succinate dehydrogenase reaction in the TCA cycle.	FAD and FMN are derived from ribo F lavin (B ₂ ≈ 2 ATP).
DEFICIENCY	Cheilosis (inflammation of lips, scaling and fissures at the corners of the mouth), “magenta” tongue, corneal vascularization.	The 2 C ’s of B ₂ .
Vitamin B₃	Also called niacin, nicotinic acid.	
FUNCTION	Constituent of NAD ⁺ , NADP ⁺ (used in redox reactions and as cofactor by dehydrogenases). Derived from tryptophan. Synthesis requires vitamins B ₂ and B ₆ . Used to treat dyslipidemia (↓ VLDL, ↑ HDL).	NAD derived from N iacin (B ₃ ≈ 3 ATP).
DEFICIENCY	Glossitis. Severe deficiency of B ₃ leads to pellagra, which can also be caused by Hartnup disease, malignant carcinoid syndrome (↑ tryptophan metabolism → ↑ serotonin synthesis), and isoniazid (↓ vitamin B ₆). Symptoms of B ₃ deficiency (pellagra) (the 3 D ’s): d iarrhea, d ementia (also hallucinations), d ermatitis (C3/C4 dermatome circumferential “broad collar” rash [Casal necklace], hyperpigmentation of sun-exposed limbs A).	Hartnup disease —autosomal recessive. Deficiency of neutral amino acid (eg, tryptophan) transporters in proximal renal tubular cells and on enterocytes → neutral aminoaciduria and ↓ absorption from the gut → ↓ tryptophan for conversion to niacin → pellagra-like symptoms. Treat with high-protein diet and nicotinic acid. Pellagra = vitamin B ₃ levels fell .
		
EXCESS	Facial flushing (induced by prostaglandin, not histamine; can avoid by taking aspirin with niacin), hyperglycemia, hyperuricemia.	Podagra = vitamin B ₃ OD (overdose).
Vitamin B₅	Also called pantothenic acid. B ₅ is “ pento ”thenic acid.	
FUNCTION	Component of coenzyme A (CoA, a cofactor for acyl transfers) and fatty acid synthase.	
DEFICIENCY	Dermatitis, enteritis, alopecia, adrenal insufficiency may lead to burning sensation of feet (“burning feet syndrome”; distal paresthesias, dysesthesia).	
Vitamin B₆	Also called pyridoxine.	
FUNCTION	Converted to pyridoxal phosphate (PLP), a cofactor used in transamination (eg, ALT and AST), decarboxylation reactions, glycogen phosphorylase. Synthesis of glutathione, cystathionine, heme, niacin, histamine, and neurotransmitters including serotonin, epinephrine, norepinephrine (NE), dopamine, and GABA.	
DEFICIENCY	Convulsions, hyperirritability, peripheral neuropathy (deficiency inducible by isoniazid and oral contraceptives), sideroblastic anemia (due to impaired hemoglobin synthesis and iron excess).	

Vitamin B₇

Also called biotin.

FUNCTION

Cofactor for carboxylation enzymes (which add a 1-carbon group):

- Pyruvate carboxylase (gluconeogenesis): pyruvate (3C) → oxaloacetate (4C)
- Acetyl-CoA carboxylase (fatty acid synthesis): acetyl-CoA (2C) → malonyl-CoA (3C)
- Propionyl-CoA carboxylase (fatty acid oxidation and branched-chain amino acid breakdown): propionyl-CoA (3C) → methylmalonyl-CoA (4C)

DEFICIENCY

Relatively rare. Dermatitis, enteritis, alopecia. Caused by long-term antibiotic use or excessive ingestion of raw egg whites.

“**Avidin** in egg whites **avidly** binds biotin.”**Vitamin B₉**

Also called folate.

FUNCTION

Converted to tetrahydrofolic acid (THF), a coenzyme for 1-carbon transfer/methylation reactions.

Important for the synthesis of nitrogenous bases in DNA and RNA.

Found in leafy green vegetables. Also produced by gut microbiota. **Folate** absorbed in **jejunum** (think **foli**age in the “**jejun**”gle).

Small reserve pool stored primarily in the liver.

DEFICIENCY

Macrocytic, megaloblastic anemia; hypersegmented polymorphonuclear cells (PMNs); glossitis; no neurologic symptoms (as opposed to vitamin B₁₂ deficiency).

Labs: ↑ homocysteine, normal methylmalonic acid levels. Seen in chronic alcohol overuse and in pregnancy.

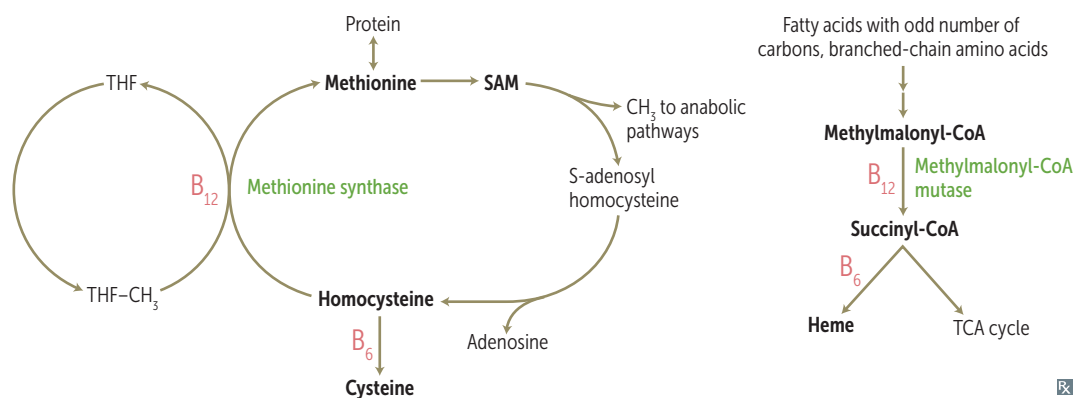
Deficiency can be caused by several drugs (eg, phenytoin, trimethoprim, methotrexate).

Supplemental folic acid at least 1 month prior to conception and during pregnancy to ↓ risk of neural tube defects. Give vitamin B₉ for the **9** months of pregnancy, and 1 month prior to conception.

Vitamin B₁₂

Also called cobalamin.

FUNCTION	Cofactor for methionine synthase (transfers CH ₃ groups as methylcobalamin) and methylmalonyl-CoA mutase. Important for DNA synthesis.	Found in animal products. Synthesized only by intestinal microbiota. Site of synthesis in humans is distal to site of absorption; thus B ₁₂ must be consumed via animal products.
DEFICIENCY	Macrocytic, megaloblastic anemia; hypersegmented PMNs; paresthesias and subacute combined degeneration (degeneration of dorsal columns, lateral corticospinal tracts, and spinocerebellar tracts) due to abnormal myelin. Associated with ↑ serum homocysteine and methylmalonic acid levels, along with 2° folate deficiency. Prolonged deficiency → irreversible nerve damage.	Very large reserve pool (several years) stored primarily in the liver. Deficiency caused by malabsorption (eg, sprue, enteritis, <i>Diphyllobothrium latum</i> , achlorhydria, bacterial overgrowth, alcohol overuse), lack of intrinsic factor (eg, pernicious anemia, gastric bypass surgery), absence of terminal ileum (surgical resection, eg, for Crohn disease), certain drugs (eg, metformin), or insufficient intake (eg, veganism). B ₉ (folate) supplementation can mask the hematologic symptoms of B ₁₂ deficiency, but not the neurologic symptoms.



Vitamin C

Also called ascorbic acid.

FUNCTION	Antioxidant; also facilitates iron absorption by reducing it to Fe ²⁺ state. Necessary for hydroxylation of proline and lysine in collagen synthesis. Necessary for dopamine β-hydroxylase (converts dopamine to NE).	Found in fruits and vegetables. Pronounce “ absorbic ” acid. Ancillary treatment for methemoglobinemia by reducing Fe ³⁺ to Fe ²⁺ .
DEFICIENCY	Scurvy —swollen gums, easy bruising, petechiae, hemarthrosis, anemia, poor wound healing, perifollicular and subperiosteal hemorrhages, “corkscrew” hair. Weakened immune response.	Deficiency may be precipitated by tea and toast diet. Vitamin C deficiency causes sCurvy due to a C ollagen hydro C ylation defect.
EXCESS	Nausea, vomiting, diarrhea, fatigue, calcium oxalate nephrolithiasis (excess oxalate from vitamin C metabolism). Can ↑ iron toxicity in predisposed individuals by increasing dietary iron absorption (ie, can worsen hemochromatosis or transfusion-related iron overload).	

Vitamin D

D₃ (cholecalciferol) from exposure of skin (stratum basale) to sun, ingestion of fish, milk, plants.

D₂ (ergocalciferol) from ingestion of plants, fungi, yeasts.

Both converted to 25-OH D₃ (storage form) in liver and to the active form 1,25-(OH)₂ D₃ (calcitriol) in kidney.

FUNCTION

↑ intestinal absorption of Ca²⁺ and PO₄³⁻.

↑ bone mineralization at low levels.

↑ bone resorption at higher levels.

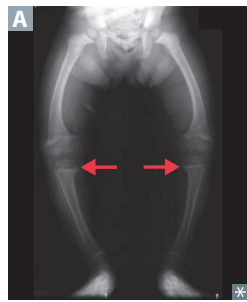
REGULATION

↑ PTH, ↓ Ca²⁺, ↓ PO₄³⁻

→ ↑ 1,25-(OH)₂D₃ production.

1,25-(OH)₂D₃ feedback inhibits its own production.

↑ PTH → ↑ Ca²⁺ reabsorption and ↓ PO₄³⁻ reabsorption in the kidney.

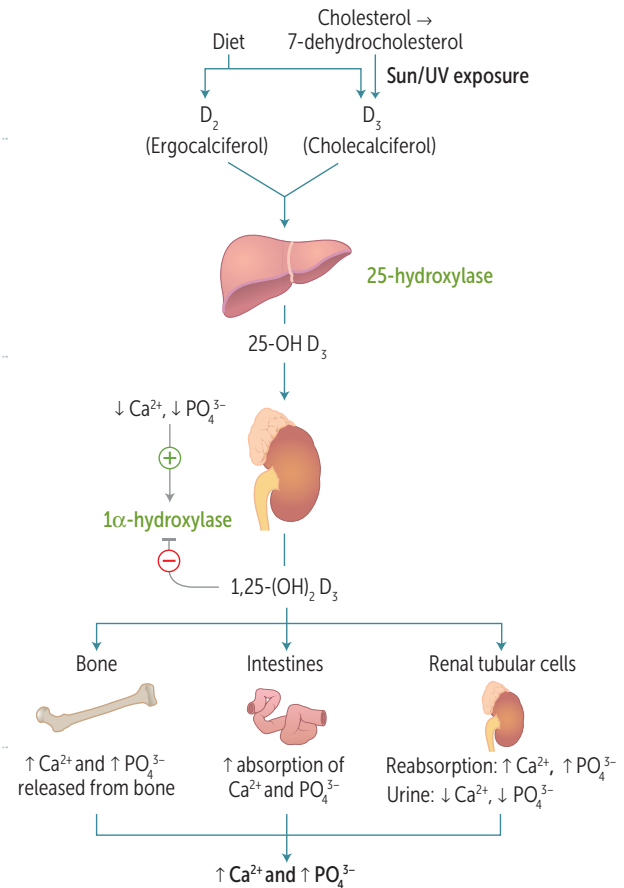
DEFICIENCY

Rickets in children (deformity, such as genu varum “bowlegs” **A**), osteomalacia in adults (bone pain and muscle weakness), hypocalcemic tetany.

Caused by malabsorption, ↓ sun exposure, poor diet, chronic kidney disease (CKD), advanced liver disease. Give oral vitamin D to breastfed infants. Darker skin and prematurity predispose to deficiency.

EXCESS

Hypercalcemia, hypercalciuria, loss of appetite, stupor. Seen in granulomatous diseases (↑ activation of vitamin D by epithelioid macrophages).



R

Vitamin E

Includes tocopherol, tocotrienol.

FUNCTION

Antioxidant (protects RBCs and neuronal membranes from free radical damage).

DEFICIENCY

Hemolytic anemia, acanthocytosis, muscle weakness, demyelination of posterior columns (↓ proprioception and vibration sensation) and spinocerebellar tract (ataxia).

Neurologic presentation may appear similar to vitamin B₁₂ deficiency, but without megaloblastic anemia, hypersegmented neutrophils, or ↑ serum methylmalonic acid levels.

EXCESS

Risk of enterocolitis in **e**nphants (infants) with **e**xcess of vitamin **E**.

High-dose supplementation may alter metabolism of vitamin K → enhanced anticoagulant effects of warfarin.

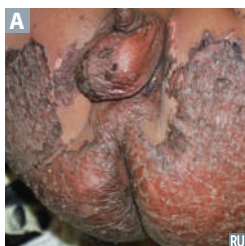Vitamin K

Includes phytymenadione, phylloquinone, phytonadione, menaquinone.

FUNCTION	Activated by epoxide reductase to the reduced form, which is a cofactor for the γ -carboxylation of glutamic acid residues on various proteins required for blood clotting. Synthesized by intestinal microbiota.	K is for K oagulation. Necessary for the maturation of clotting factors II, VII, IX, X, and proteins C and S. Warfarin inhibits vitamin K–dependent synthesis of these factors and proteins.
DEFICIENCY	Neonatal hemorrhage with \uparrow PT and \uparrow aPTT but normal bleeding time (neonates have sterile intestines and are unable to synthesize vitamin K). Can also occur after prolonged use of broad-spectrum antibiotics.	Not in breast milk; “breast-fed infants D on’t K now about vitamins D and K ”. Neonates are given vitamin K injection at birth to prevent hemorrhagic disease of the newborn.

Zinc

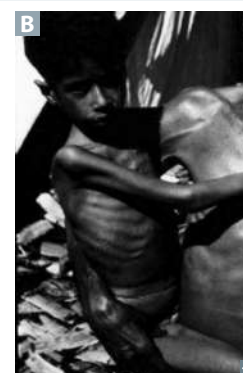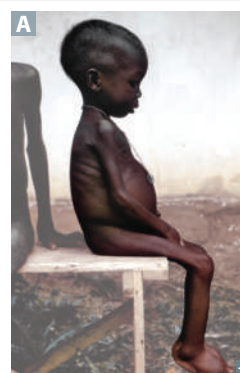FUNCTION	Mineral essential for the activity of 100+ enzymes. Important in the formation of zinc fingers (transcription factor motif).
DEFICIENCY	Delayed wound healing, suppressed immunity, male hypogonadism, \downarrow adult hair (axillary, facial, pubic), dysgeusia, anosmia. Associated with acrodermatitis enteropathica (A , defect in intestinal zinc absorption). May predispose to alcoholic cirrhosis.

**Protein-energy malnutrition****Kwashiorkor**

Protein malnutrition resulting in skin lesions, edema due to \downarrow plasma oncotic pressure (due to low serum albumin), liver malfunction (fatty change due to \downarrow apolipoprotein synthesis and deposition). Clinical picture is small child with swollen abdomen **A**.

Kwashiorkor results from protein-deficient **MEALS**:

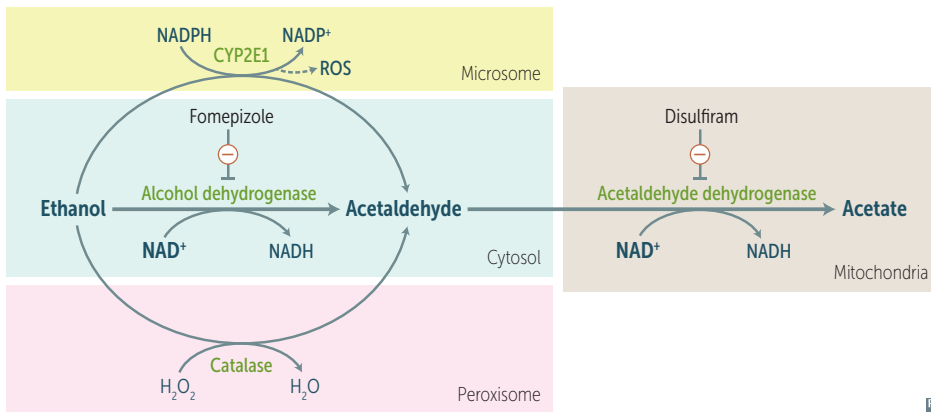
- M**alnutrition
- E**dema
- A**nemia
- L**iver (fatty)
- S**kin lesions (eg, hyperkeratosis, dyspigmentation)

**Marasmus**

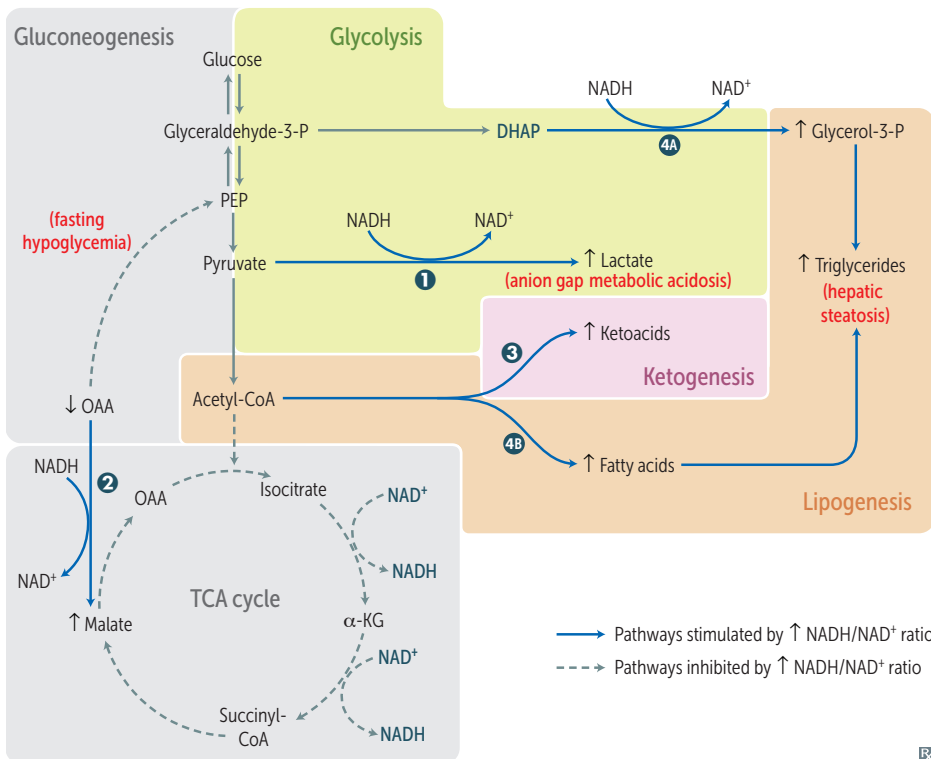
Malnutrition not causing edema. Diet is deficient in calories but no nutrients are entirely absent.

Marasmus results in **m**uscle wasting **B**.

Ethanol metabolism



✕



✕

↑ NADH/NAD⁺ ratio inhibits TCA cycle → ↑ acetyl-CoA used in ketogenesis (→ ketoacidosis), lipogenesis (→ hepatosteatosis). Females are more susceptible than males to effects of alcohol due to ↓ activity of gastric alcohol dehydrogenase, ↓ body size, ↓ percentage of water in body weight.

NAD⁺ is the limiting reagent. Alcohol dehydrogenase operates via zero-order kinetics.

Ethanol metabolism ↑ NADH/NAD⁺ ratio in liver, causing:

- 1 Lactic acidosis—↑ pyruvate conversion to lactate
- 2 Fasting hypoglycemia—↓ gluconeogenesis due to ↑ conversion of OAA to malate
- 3 Ketoacidosis—diversion of acetyl-CoA into ketogenesis rather than TCA cycle
- 4 Hepatosteatosis—↑ conversion of DHAP to glycerol-3-P
 - 4A; acetyl-CoA diverges into fatty acid synthesis 4B, which combines with glycerol-3-P to synthesize triglycerides

Fomepizole—competitive inhibitor of alcohol dehydrogenase; preferred antidote for overdoses of methanol or ethylene glycol. Alcohol dehydrogenase has higher affinity for ethanol than for methanol or ethylene glycol → ethanol can be used as competitive inhibitor of alcohol dehydrogenase to treat methanol or ethylene glycol poisoning.

Disulfiram—blocks acetaldehyde dehydrogenase → ↑ acetaldehyde → ↑ hangover symptoms → discouraging drinking.

▶ BIOCHEMISTRY—METABOLISM

Enzyme terminology	An enzyme's name often describes its function. For example, glucokinase is an enzyme that catalyzes the phosphorylation of glucose using a molecule of ATP. The following are commonly used enzyme descriptors.
Kinase	Catalyzes transfer of a phosphate group from a high-energy molecule (usually ATP) to a substrate (eg, phosphofructokinase).
Phosphorylase	Adds inorganic phosphate onto substrate without using ATP (eg, glycogen phosphorylase).
Phosphatase	Removes phosphate group from substrate (eg, fructose-1,6-bisphosphatase 1).
Dehydrogenase	Catalyzes oxidation-reduction reactions (eg, pyruvate dehydrogenase).
Hydroxylase	Adds hydroxyl group (–OH) onto substrate (eg, tyrosine hydroxylase).
Carboxylase	Transfers CO ₂ groups with the help of biotin (eg, pyruvate carboxylase).
Mutase	Relocates a functional group within a molecule (eg, vitamin B ₁₂ -dependent methylmalonyl-CoA mutase).
Synthase/synthetase	Joins two molecules together using a source of energy (eg, ATP, acetyl-CoA, nucleotide sugar).

Rate-determining enzymes of metabolic processes

PROCESS	ENZYME	REGULATORS
Glycolysis	Phosphofructokinase-1 (PFK-1)	AMP ⊕, fructose-2,6-bisphosphate ⊕ ATP ⊖, citrate ⊖
Gluconeogenesis	Fructose-1,6-bisphosphatase 1	AMP ⊖, fructose-2,6-bisphosphate ⊖
TCA cycle	Isocitrate dehydrogenase	ADP ⊕ ATP ⊖, NADH ⊖
Glycogenesis	Glycogen synthase	Glucose-6-phosphate ⊕, insulin ⊕, cortisol ⊕ Epinephrine ⊖, glucagon ⊖
Glycogenolysis	Glycogen phosphorylase	Epinephrine ⊕, glucagon ⊕, AMP ⊕ Glucose-6-phosphate ⊖, insulin ⊖, ATP ⊖
HMP shunt	Glucose-6-phosphate dehydrogenase (G6PD)	NADP ⁺ ⊕ NADPH ⊖
De novo pyrimidine synthesis	Carbamoyl phosphate synthetase II	ATP ⊕, PRPP ⊕ UTP ⊖
De novo purine synthesis	Glutamine-phosphoribosylpyrophosphate (PRPP) amidotransferase	AMP ⊖, inosine monophosphate (IMP) ⊖, GMP ⊖
Urea cycle	Carbamoyl phosphate synthetase I	N-acetylglutamate ⊕
Fatty acid synthesis	Acetyl-CoA carboxylase (ACC)	Insulin ⊕, citrate ⊕ Glucagon ⊖, palmitoyl-CoA ⊖
Fatty acid oxidation	Carnitine acyltransferase I	Malonyl-CoA ⊖
Ketogenesis	HMG-CoA synthase	
Cholesterol synthesis	HMG-CoA reductase	Insulin ⊕, thyroxine ⊕, estrogen ⊕ Glucagon ⊖, cholesterol ⊖

Metabolism sites

Mitochondria

Fatty acid oxidation (β -oxidation), acetyl-CoA production, TCA cycle, oxidative phosphorylation, ketogenesis.

Cytoplasm

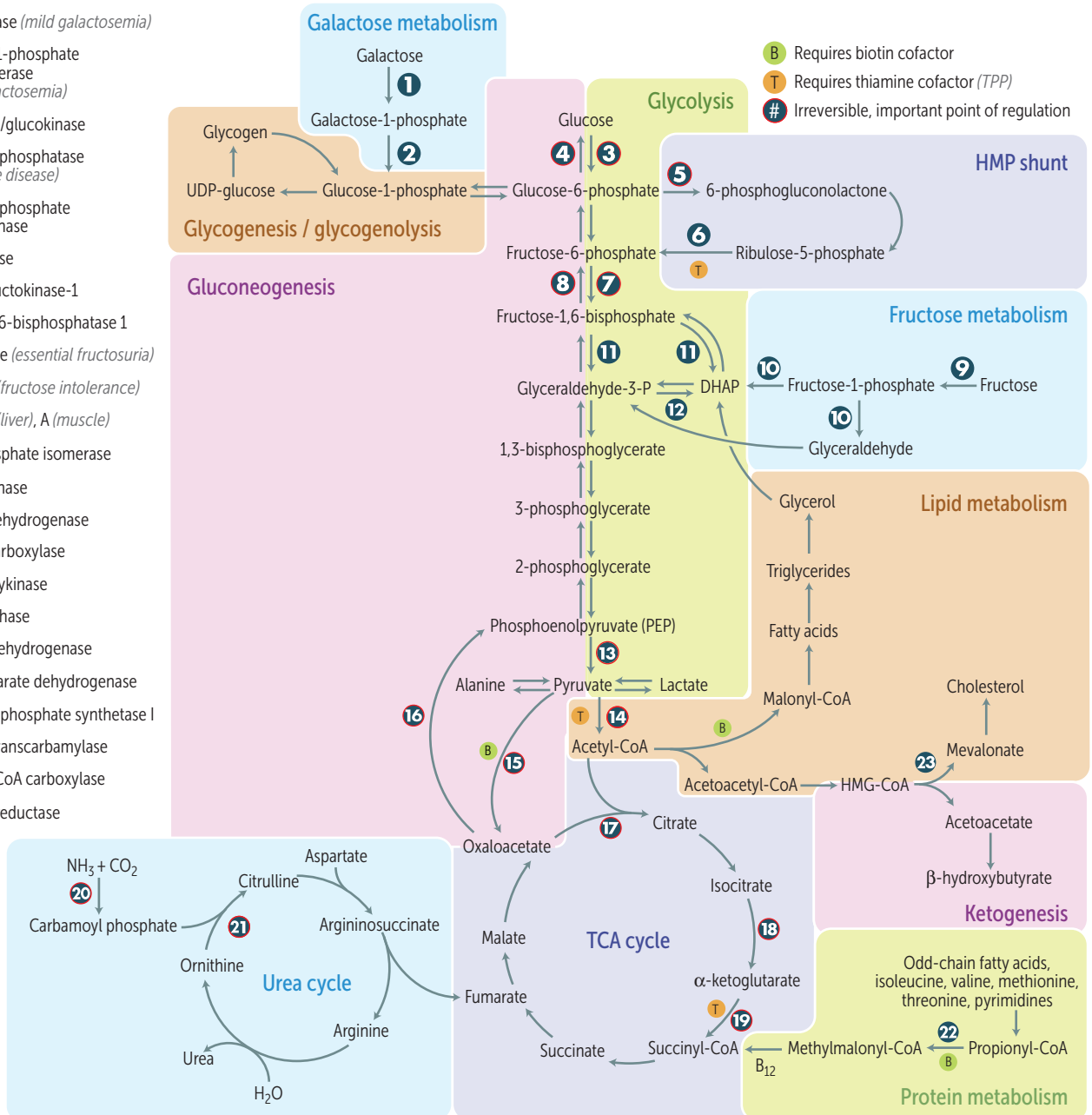
Glycolysis, HMP shunt, and synthesis of cholesterol (SER), proteins (ribosomes, RER), fatty acids, and nucleotides.

Both

Heme synthesis, urea cycle, gluconeogenesis. **Hugs** take **two** (both).

Summary of pathways

- 1 Galactokinase (*mild galactosemia*)
- 2 Galactose-1-phosphate uridylyltransferase (*severe galactosemia*)
- 3 Hexokinase/glucokinase
- 4 Glucose-6-phosphatase (*von Gierke disease*)
- 5 Glucose-6-phosphate dehydrogenase
- 6 Transketolase
- 7 Phosphofruktokinase-1
- 8 Fructose-1,6-bisphosphatase 1
- 9 Fructokinase (*essential fructosuria*)
- 10 Aldolase B (*fructose intolerance*)
- 11 Aldolase B (*liver*), A (*muscle*)
- 12 Triose phosphate isomerase
- 13 Pyruvate kinase
- 14 Pyruvate dehydrogenase
- 15 Pyruvate carboxylase
- 16 PEP carboxykinase
- 17 Citrate synthase
- 18 Isocitrate dehydrogenase
- 19 α -ketoglutarate dehydrogenase
- 20 Carbamoyl phosphate synthetase I
- 21 Ornithine transcarbamylase
- 22 Propionyl-CoA carboxylase
- 23 HMG-CoA reductase



ATP production

Aerobic metabolism of one glucose molecule produces 32 net ATP via malate-aspartate shuttle (heart and liver), 30 net ATP via glycerol-3-phosphate shuttle (muscle). Anaerobic glycolysis produces only 2 net ATP per glucose molecule. ATP hydrolysis can be coupled to energetically unfavorable reactions.

Arsenic causes glycolysis to produce zero net ATP.

Activated carriers

CARRIER MOLECULE	CARRIED IN ACTIVATED FORM
ATP	Phosphoryl groups
NADH, NADPH, FADH ₂	Electrons
CoA, lipoamide	Acyl groups
Biotin	CO ₂
Tetrahydrofolates	1-carbon units
S-adenosylmethionine (SAM)	CH ₃ groups
TPP	Aldehydes

Universal electron acceptors

Nicotinamides (NAD⁺, NADP⁺ from vitamin B₃) and flavin nucleotides (FAD from vitamin B₂). NAD⁺ is generally used in **catabolic** processes to carry reducing equivalents away as NADH. NADPH is used in **anabolic** processes (eg, steroid and fatty acid synthesis) as a supply of reducing equivalents.

NADPH is a product of the HMP shunt. NADPH is used in:

- Anabolic processes
- Respiratory burst
- Cytochrome P-450 system
- Glutathione reductase

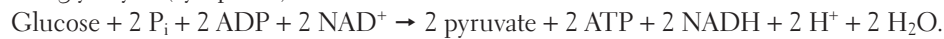Hexokinase vs glucokinase

Phosphorylation of glucose to yield glucose-6-phosphate is catalyzed by glucokinase in the liver and hexokinase in other tissues. Hexokinase sequesters glucose in tissues, where it is used even when glucose concentrations are low. At high glucose concentrations, glucokinase helps to store glucose in liver. Glucokinase deficiency is a cause of maturity onset diabetes of the young (MODY) and gestational diabetes.

	Hexokinase	Glucokinase
Location	Most tissues, except liver and pancreatic β cells	Liver, β cells of pancreas
K _m	Lower (↑ affinity)	Higher (↓ affinity)
V _{max}	Lower (↓ capacity)	Higher (↑ capacity)
Induced by insulin	No	Yes
Feedback inhibition by	Glucose-6-phosphate	Fructose-6-phosphate

Glycolysis regulation, key enzymes

Net glycolysis (cytoplasm):

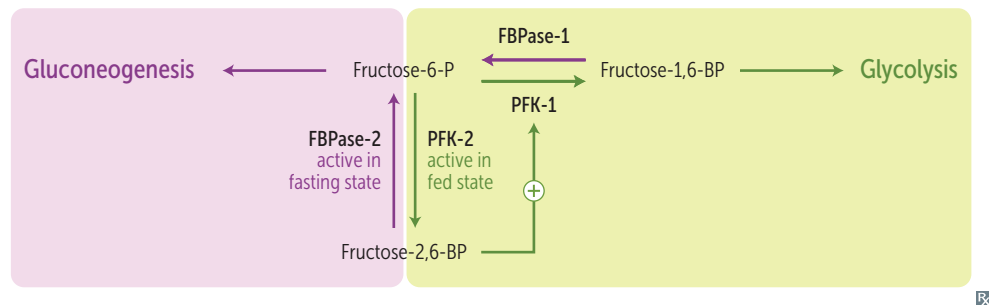


Equation not balanced chemically, and exact balanced equation depends on ionization state of reactants and products.

REQUIRE ATP	Glucose $\xrightarrow{\text{Hexokinase/glucokinase}}$ Glucose-6-P	Glucose-6-P \ominus hexokinase. Fructose-6-P \ominus glucokinase.
	Fructose-6-P $\xrightarrow{\text{Phosphofructokinase-1 (rate-limiting step)}}$ Fructose-1,6-BP	AMP \oplus , fructose-2,6-bisphosphate \oplus . ATP \ominus , citrate \ominus .
PRODUCE ATP	1,3-BPG $\xleftrightarrow{\text{Phosphoglycerate kinase}}$ 3-PG	
	Phosphoenolpyruvate $\xrightarrow{\text{Pyruvate kinase}}$ Pyruvate	Fructose-1,6-bisphosphate \oplus . ATP \ominus , alanine \ominus , glucagon \ominus .

Regulation by fructose-2,6-bisphosphate

Fructose biphosphatase-2 (FBPase-2) and phosphofructokinase-2 (PFK-2) are the same bifunctional enzyme whose function is reversed by phosphorylation by protein kinase A.



Fasting state: \uparrow glucagon \rightarrow \uparrow cAMP \rightarrow \uparrow protein kinase A \rightarrow \uparrow FBPase-2, \downarrow PFK-2, less glycolysis, more gluconeogenesis.

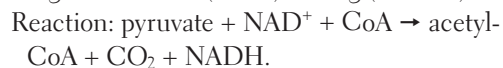
FaBian the **P**easant (**FBP**) has to work hard when starving.

Fed state: \uparrow insulin \rightarrow \downarrow cAMP \rightarrow \downarrow protein kinase A \rightarrow \downarrow FBPase-2, \uparrow PFK-2, more glycolysis, less gluconeogenesis.

Prince FredericK (PFK) works only when fed.

Pyruvate dehydrogenase complex

Mitochondrial enzyme complex linking glycolysis and TCA cycle. Differentially regulated in fed (active)/fasting (inactive) states.



Contains 3 enzymes requiring 5 cofactors:

1. **T**hiamine pyrophosphate (B_1)
2. **L**ipoic acid
3. **C**oA (B_5 , pantothenic acid)
4. **F**AD (B_2 , riboflavin)
5. **N**AD $^+$ (B_3 , niacin)

Activated by: \uparrow NAD $^+$ /NADH ratio, \uparrow ADP
 \uparrow Ca $^{2+}$.

The complex is similar to the α -ketoglutarate dehydrogenase complex (same cofactors, similar substrate and action), which converts α -ketoglutarate \rightarrow succinyl-CoA (TCA cycle).

The lovely coenzymes for nerds.

Arsenic inhibits lipoic acid. Arsenic poisoning clinical findings: imagine a vampire (pigmentary skin changes, skin cancer), vomiting and having diarrhea, running away from a cutie (**QT** prolongation) with garlic breath.

Pyruvate dehydrogenase complex deficiency

Causes a buildup of pyruvate that gets shunted to lactate (via LDH) and alanine (via ALT).
X-linked.

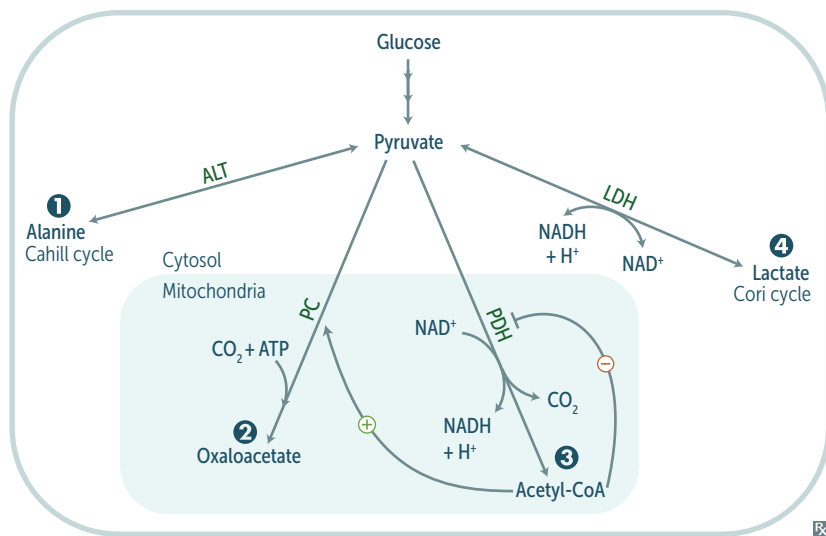
FINDINGS

Neurologic defects, lactic acidosis, ↑ serum alanine starting in infancy.

TREATMENT

↑ intake of ketogenic nutrients (eg, high fat content or ↑ lysine and leucine).

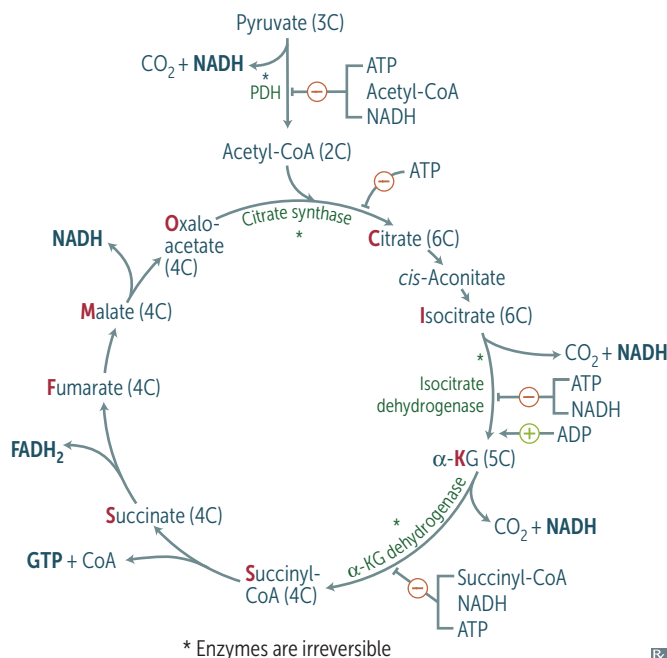
Pyruvate metabolism



Functions of different pyruvate metabolic pathways (and their associated cofactors):

- 1 Alanine aminotransferase (B₆): alanine carries amino groups to the liver from muscle
- 2 Pyruvate carboxylase (B₇): oxaloacetate can replenish TCA cycle or be used in gluconeogenesis
- 3 Pyruvate dehydrogenase (B₁, B₂, B₃, B₅, lipoic acid): transition from glycolysis to the TCA cycle
- 4 Lactic acid dehydrogenase (B₃): end of anaerobic glycolysis (major pathway in RBCs, WBCs, kidney medulla, lens, testes, and cornea)

TCA cycle



Also called Krebs cycle. Pyruvate → acetyl-CoA produces 1 NADH, 1 CO₂.

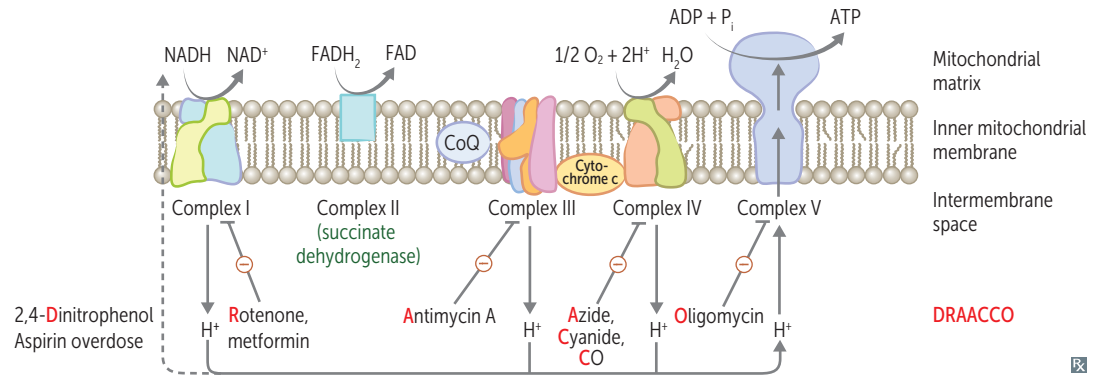
The TCA cycle produces 3 NADH, 1 FADH₂, 2 CO₂, 1 GTP per acetyl-CoA = 10 ATP/ acetyl-CoA (2× everything per glucose). TCA cycle reactions occur in the mitochondria.

α-ketoglutarate dehydrogenase complex requires the same cofactors as the pyruvate dehydrogenase complex (vitamins B₁, B₂, B₃, B₅, lipoic acid).

Citrate is Krebs' starting substrate for making oxaloacetate.

Electron transport chain and oxidative phosphorylation

NADH electrons from glycolysis enter mitochondria via the malate-aspartate or glycerol-3-phosphate shuttle. FADH₂ electrons are transferred to complex II (at a lower energy level than NADH). The passage of electrons results in the formation of a proton gradient that, coupled to oxidative phosphorylation, drives the production of ATP.



ATP PRODUCED VIA ATP SYNTHASE

1 NADH → 2.5 ATP; 1 FADH₂ → 1.5 ATP.

OXIDATIVE PHOSPHORYLATION POISONS

Electron transport inhibitors	Directly inhibit electron transport, causing a ↓ proton gradient and block of ATP synthesis.	Rotenone : complex one inhibitor. “An- 3 -mycin” (antimycin) A : complex 3 inhibitor. Cyanide , carbon monoxide, azide (the -ides , 4 letters) inhibit complex IV .
ATP synthase inhibitors	Directly inhibit mitochondrial ATP synthase, causing an ↑ proton gradient. No ATP is produced because electron transport stops.	Oligomycin.
Uncoupling agents	↑ permeability of membrane, causing a ↓ proton gradient and ↑ O ₂ consumption. ATP synthesis stops, but electron transport continues. Produces heat.	2,4-Dinitrophenol (used illicitly for weight loss), aspirin (fevers often occur after overdose), thermogenin in brown fat (has more mitochondria than white fat).

Gluconeogenesis, irreversible enzymes

All enzymes may be subject to activation by glucagon in fasting state.

Pathway produces fresh glucose.

Pyruvate carboxylase

In mitochondria. Pyruvate → oxaloacetate.

Requires biotin, ATP. Activated by acetyl-CoA.

Phosphoenolpyruvate carboxykinase

In cytosol. Oxaloacetate → phosphoenolpyruvate (PEP).

Requires GTP.

Fructose-1,6-bisphosphatase 1

In cytosol. Fructose-1,6-bisphosphate → fructose-6-phosphate.

Citrate ⊕, AMP ⊖, fructose 2,6-bisphosphate ⊖.

Glucose-6-phosphatase

In ER. Glucose-6-phosphate → glucose.

Occurs primarily in liver; serves to maintain euglycemia during fasting. Enzymes also found in kidney, intestinal epithelium. Deficiency of the key gluconeogenic enzymes causes hypoglycemia. (Muscle cannot participate in gluconeogenesis because it lacks glucose-6-phosphatase).

Odd-chain fatty acids yield 1 propionyl-CoA during metabolism, which can enter the TCA cycle (as succinyl-CoA), undergo gluconeogenesis, and serve as a **glucose** source (It's **odd** for **fatty acids** to make **glucose**). Even-chain fatty acids cannot produce new glucose, since they yield only acetyl-CoA equivalents.

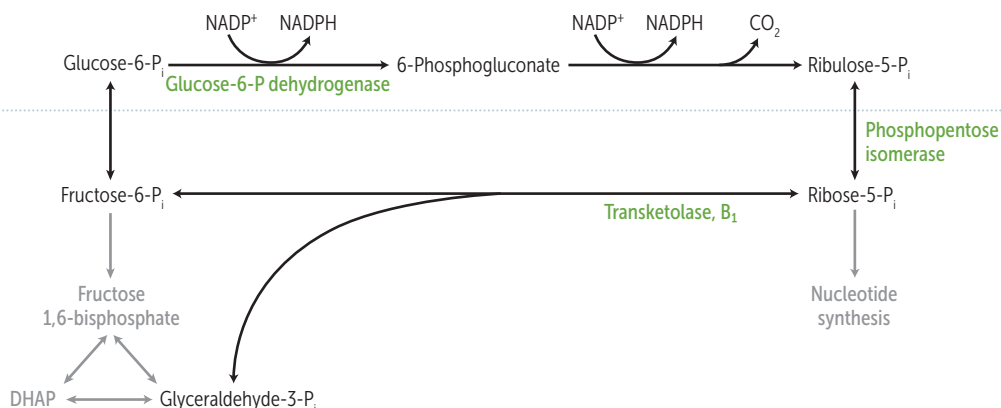
Pentose phosphate pathway

Also called HMP shunt. Provides a source of NADPH from abundantly available glucose-6-P (NADPH is required for reductive reactions, eg, glutathione reduction inside RBCs, fatty acid and cholesterol biosynthesis). Additionally, this pathway yields ribose for nucleotide synthesis. Two distinct phases (oxidative and nonoxidative), both of which occur in the cytoplasm. No ATP is used or produced.
 Sites: lactating mammary glands, liver, adrenal cortex (sites of fatty acid or steroid synthesis), RBCs.

REACTIONS

Oxidative (irreversible)

Nonoxidative (reversible)



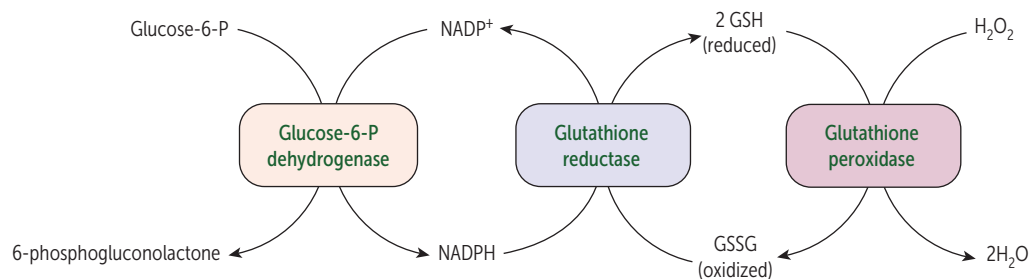
Glucose-6-phosphate dehydrogenase deficiency

NADPH is necessary to keep glutathione reduced, which in turn detoxifies free radicals and peroxides. ↓ NADPH in RBCs leads to hemolytic anemia due to poor RBC defense against oxidizing agents (eg, fava beans, sulfonamides, nitrofurantoin, primaquine/chloroquine, antituberculosis drugs). Infection (most common cause) can also precipitate hemolysis; inflammatory response produces free radicals that diffuse into RBCs, causing oxidative damage.

X-linked recessive disorder; most common human enzyme deficiency; more prevalent among descendants of populations in malaria-endemic regions (eg, sub-Saharan Africa, Southeast Asia).

Heinz bodies—denatured globin chains precipitate within RBCs due to oxidative stress.

Bite cells—result from the phagocytic removal of Heinz bodies by splenic macrophages. Think, “**Bite** into some **Heinz** ketchup.”



Disorders of fructose metabolism

Essential fructosuria

Involves a defect in **fructokinase**. Autosomal recessive. A benign, asymptomatic condition (fructo**kin**ase deficiency is **kin**der), since fructose is not trapped in cells. Hexokinase becomes 1° pathway for converting fructose to fructose-6-phosphate.

Symptoms: fructose appears in blood and urine.

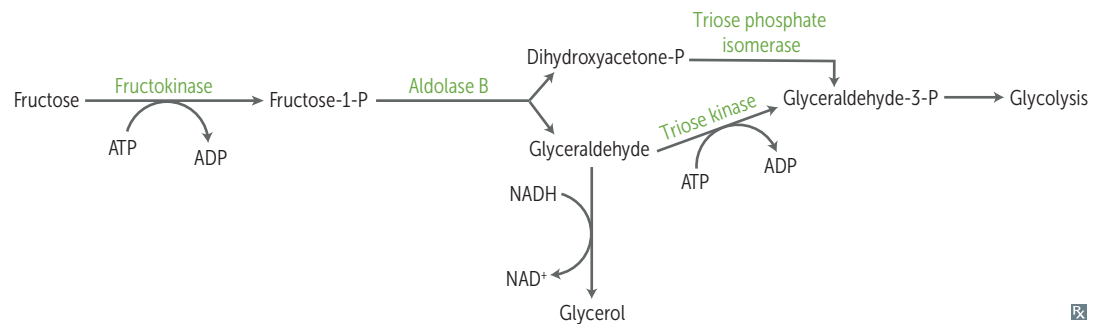
Disorders of fructose metabolism cause milder symptoms than analogous disorders of galactose metabolism.

Hereditary fructose intolerance

Hereditary deficiency of **aldolase B**. Autosomal recessive. Fructose-1-phosphate accumulates, causing a ↓ in available phosphate, which results in inhibition of glycogenolysis and gluconeogenesis. Symptoms present following consumption of fruit, juice, or honey. Urine dipstick will be ⊖ (tests for glucose only); reducing sugar can be detected in the urine (nonspecific test for inborn errors of carbohydrate metabolism).

Symptoms: hypoglycemia, jaundice, cirrhosis, vomiting.

Treatment: ↓ intake of fructose, sucrose (glucose + fructose), and sorbitol (metabolized to fructose).



Disorders of galactose metabolism

Galactokinase deficiency

Hereditary deficiency of **galactokinase**. Galactitol accumulates if galactose is present in diet.

Relatively mild condition. Autosomal recessive.

Symptoms: galactose appears in blood (galactosemia) and urine (galactosuria); infantile cataracts.

May present as failure to track objects or to develop a social smile. Galacto**kin**ase deficiency is **kin**der (benign condition).

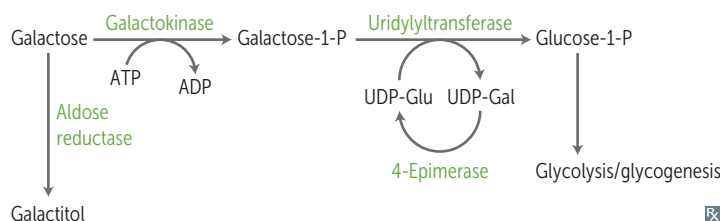
Classic galactosemia

Absence of **galactose-1-phosphate uridylyltransferase**. Autosomal recessive. Damage is caused by accumulation of toxic substances (including galactitol, which accumulates in the lens of the eye).

Symptoms develop when infant begins feeding (lactose present in breast milk and routine formula) and include failure to thrive, jaundice, hepatomegaly, infantile cataracts, intellectual disability.

Can predispose to *E coli* sepsis in neonates.

Treatment: exclude galactose and lactose (galactose + glucose) from diet.



Fructose is to **Aldolase B** as Galactose is to **UridylTransferase (FAB GUT)**.

The more serious defects lead to PO_4^{3-} depletion.

Sorbitol

An alternative method of trapping glucose in the cell is to convert it to its alcohol counterpart, sorbitol, via aldose reductase. Some tissues then convert sorbitol to fructose using sorbitol dehydrogenase; tissues with an insufficient amount/activity of this enzyme are at risk of intracellular sorbitol accumulation, causing osmotic damage (eg, cataracts, retinopathy, and peripheral neuropathy seen with chronic hyperglycemia in diabetes). High blood levels of galactose also result in conversion to the osmotically active galactitol via aldose reductase.

Liver, ovaries, and seminal vesicles have both enzymes (they **lose** sorbitol).



Lens has primarily Aldose reductase. Retina, Kidneys, and Schwann cells have only aldose reductase (**LARKS**).

Lactase deficiency

Insufficient lactase enzyme → dietary lactose intolerance. Lactase functions on the intestinal brush border to digest lactose (in milk and milk products) into glucose and galactose.

Primary: age-dependent decline after childhood (absence of lactase-persistent allele), common in people of Asian, African, or Native American descent.

Secondary: loss of intestinal brush border due to gastroenteritis (eg, rotavirus), autoimmune disease.

Congenital lactase deficiency: rare, due to defective gene.

Stool demonstrates ↓ pH and breath shows ↑ hydrogen content with lactose hydrogen breath test (H⁺ is produced when colonic bacteria ferment undigested lactose). Intestinal biopsy reveals normal mucosa in patients with hereditary lactose intolerance.

FINDINGS	Bloating, cramps, flatulence (all due to fermentation of lactose by colonic bacteria → gas), and osmotic diarrhea (undigested lactose).
TREATMENT	Avoid dairy products or add lactase pills to diet; lactose-free milk.

Amino acids

Only L-amino acids are found in proteins.

Essential

PVT TIM HaLL: Phenylalanine, Valine, Tryptophan, Threonine, Isoleucine, Methionine, Histidine, Leucine, Lysine.

Glucogenic: Methionine, histidine, valine. We **met his valentine**, who is so **sweet** (glucogenic).

Glucogenic/ketogenic: Isoleucine, phenylalanine, threonine, tryptophan.

Ketogenic: leucine, lysine. The **only** purely ketogenic amino acids.

Acidic

Aspartic **acid**, glutamic **acid**.

Negatively charged at body pH.

Basic

Arginine, histidine, lysine.

Arginine is most **basic**. Histidine has no charge at body pH.

Arginine and histidine are required during periods of growth.

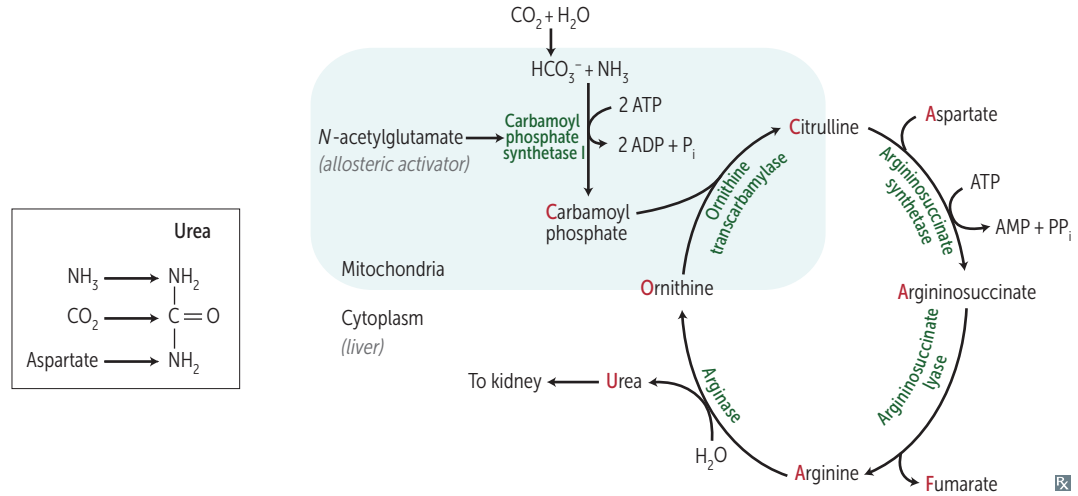
Arginine and lysine are ↑ in histones which bind negatively charged DNA.

His lys (lies) **are basic**.

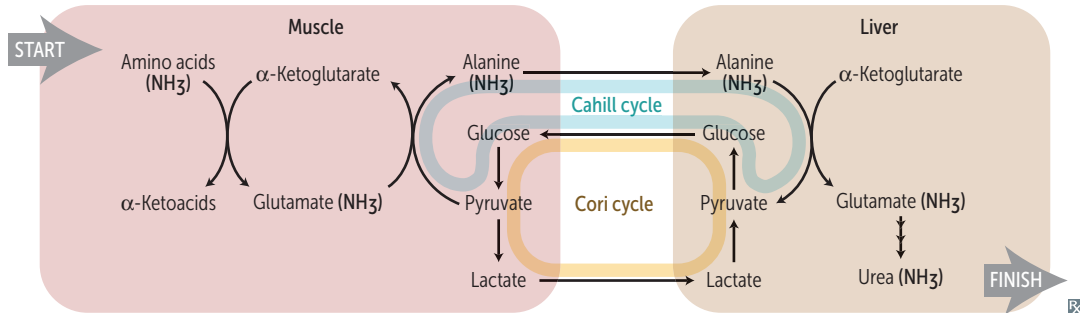
Urea cycle

Amino acid catabolism generates common metabolites (eg, pyruvate, acetyl-CoA), which serve as metabolic fuels. Excess nitrogen is converted to urea and excreted by the kidneys.

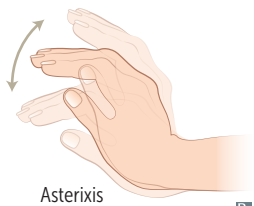
Ordinarily, Careless Crappers Are Also Frivolous About Urination.



Transport of ammonia by alanine



Hyperammonemia

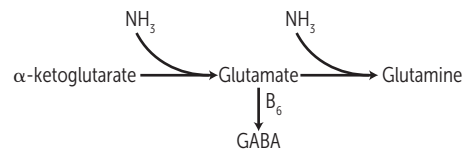


Can be acquired (eg, liver disease) or hereditary (eg, urea cycle enzyme deficiencies). Presents with flapping tremor (asterixis), slurring of speech, somnolence, vomiting, cerebral edema, blurring of vision. $\uparrow \text{NH}_3$ changes relative amounts of α -ketoglutarate, glutamate, GABA, and glutamine to favor \uparrow glutamine. CNS toxicity may involve \downarrow GABA, \downarrow α -ketoglutarate, TCA cycle inhibition, and cerebral edema due to glutamine-induced osmotic shifts.

Treatment: limit protein in diet.

May be given to \downarrow ammonia levels:

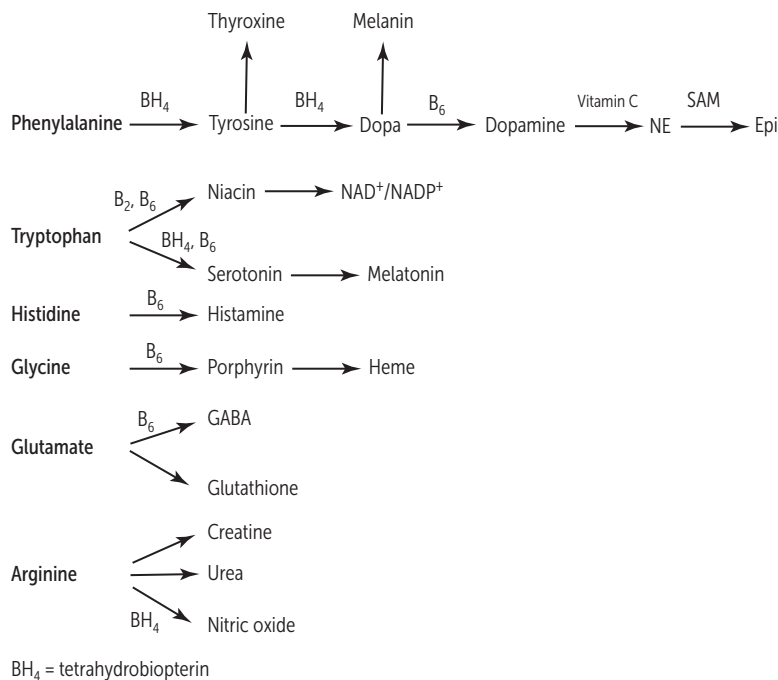
- Lactulose to acidify GI tract and trap NH_4^+ for excretion.
- Antibiotics (eg, rifaximin) to \downarrow ammoniogenic bacteria.
- Benzoate, phenylacetate, or phenylbutyrate react with glycine or glutamine, forming products that are excreted renally.



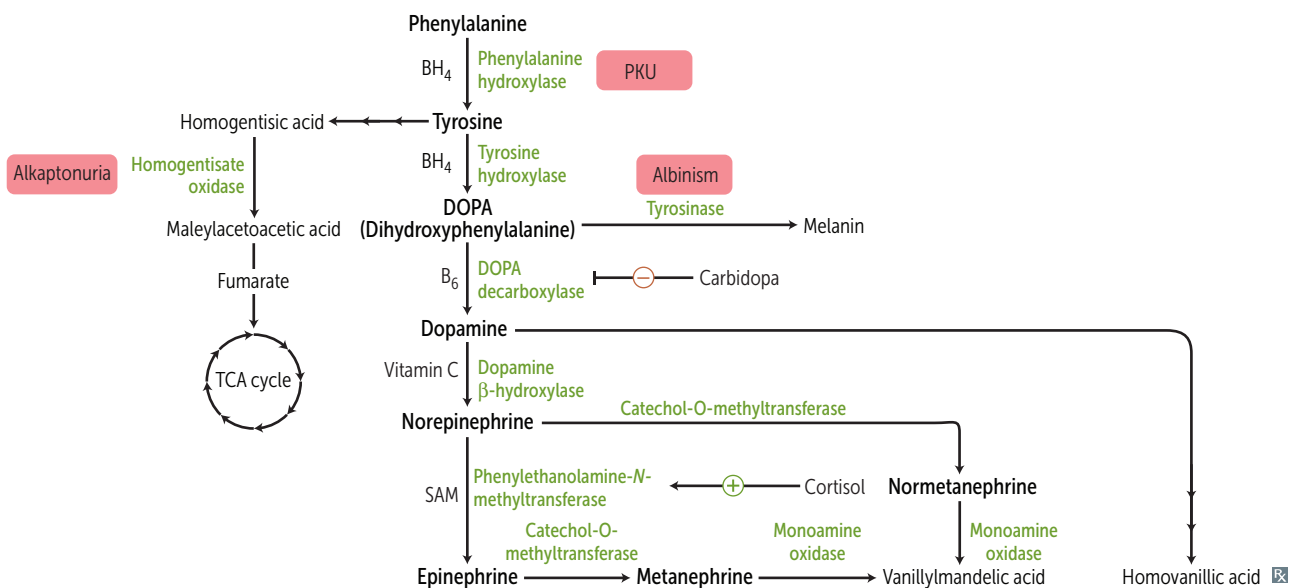
Ornithine transcarbamylase deficiency

Most common urea cycle disorder. X-linked recessive (vs other urea cycle enzyme deficiencies, which are autosomal recessive). Interferes with the body's ability to eliminate ammonia. Often evident in the first few days of life, but may present later. Excess carbamoyl phosphate is converted to orotic acid (part of the pyrimidine synthesis pathway). Findings: ↑ orotic acid in blood and urine, ↓ BUN, symptoms of hyperammonemia. No megaloblastic anemia (vs orotic aciduria).

Amino acid derivatives



Catecholamine synthesis/tyrosine catabolism



Phenylketonuria

Caused by ↓ phenylalanine hydroxylase (PAH).

Tyrosine becomes essential. ↑ phenylalanine → ↑ phenyl ketones in urine.

Tetrahydrobiopterin (BH₄) deficiency—BH₄ essential cofactor for PAH. BH₄ deficiency → ↑ phenylalanine. Varying degrees of clinical severity. Untreated patients typically die in infancy.

Phenylalanine embryopathy—↑ phenylalanine levels in pregnant patients with untreated PKU can cause fetal growth restriction, microcephaly, intellectual disability, congenital heart defects. Can be prevented with dietary measures.

Autosomal recessive.

Screening occurs 2–3 days after birth (normal at birth because of maternal enzyme during fetal life).

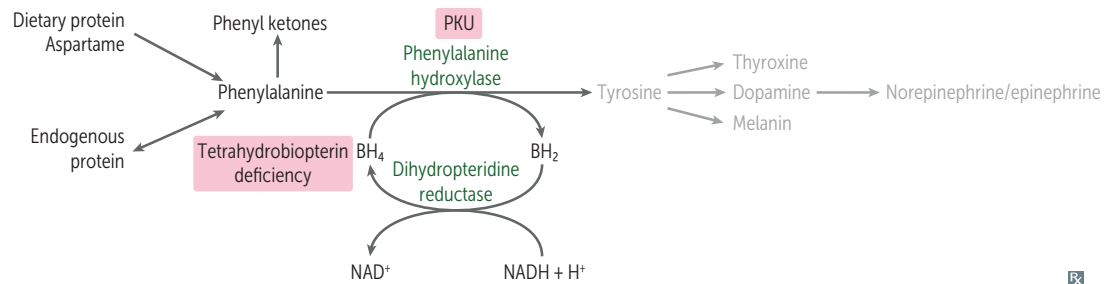
Findings: intellectual disability, microcephaly, seizures, hypopigmented skin, eczema, musty body odor.

Treatment: ↓ phenylalanine and ↑ tyrosine in diet (eg, soy products, chicken, fish, milk), tetrahydrobiopterin supplementation.

Phenyl ketones—phenylacetate, phenyllactate, and phenylpyruvate.

Disorder of **aromatic** amino acid metabolism → musty body **odor**.

Patients with PKU must avoid the artificial sweetener aspartame, which contains phenylalanine.

**Maple syrup urine disease**

Blocked degradation of **branched** amino acids (**I**soleucine, **l**eucine, **v**aline) due to ↓ branched-chain α-ketoacid dehydrogenase (B₁). Causes ↑ α-ketoacids in the blood, especially those of leucine.

Treatment: restriction of isoleucine, leucine, valine in diet, and thiamine supplementation.

Autosomal recessive.

Presentation: vomiting, poor feeding, urine smells like maple syrup/burnt sugar. Causes progressive neurological decline.

I love **V**ermont **m**aple **s**yrup from maple trees (with **B**₁**r**anches).

Alkaptonuria

Congenital deficiency of homogentisate oxidase in the degradative pathway of tyrosine to fumarate → pigment-forming homogentisic acid builds up in tissue **A**. Autosomal recessive. Usually benign.

Findings: bluish-black connective tissue, ear cartilage, and sclerae (ochronosis); urine turns black on prolonged exposure to air. May have debilitating arthralgias (homogentisic acid toxic to cartilage).

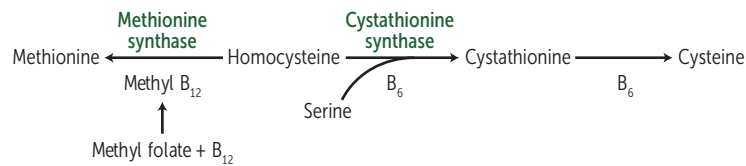
Homocystinuria

Causes (all autosomal recessive):


- Cystathionine synthase deficiency (treatment: ↓ methionine, ↑ cysteine, ↑ B₆, B₁₂, and folate in diet)
- ↓ affinity of cystathionine synthase for pyridoxal phosphate (treatment: ↑↑ B₆ and ↑ cysteine in diet)
- Methionine synthase (homocysteine methyltransferase) deficiency (treatment: ↑ methionine in diet)
- Methylene tetrahydrofolate reductase (MTHFR) deficiency (treatment: ↑ folate in diet)

All forms result in excess homocysteine.

HOMOCYstinuria: ↑↑ Homocysteine in urine, **O**steoporosis, **M**arfanoid habitus, **O**cular changes (downward and inward lens subluxation), **C**ardiovascular effects (thrombosis and atherosclerosis → stroke and MI), **kY**phosis, intellectual disability, hypopigmented skin. In homocystinuria, lens subluxes “down and in” (vs Marfan, “up and fans out”).



Cystinuria



Hereditary defect of renal PCT and intestinal amino acid transporter that prevents reabsorption of **C**ystine, **O**rnithine, **L**ysine, and **A**rginine (**COLA**).

Cystine is made of 2 cysteines connected by a disulfide bond.

Excess cystine in the urine can lead to recurrent precipitation of hexagonal cystine stones **A**.

Treatment: urinary alkalinization (eg, potassium citrate, acetazolamide) and chelating agents (eg, penicillamine) ↑ solubility of cystine stones; good hydration; diet low in methionine.

Autosomal recessive. Common (1:7000).

Cystinuria detected with urinary sodium-cyanide nitroprusside test and proton nuclear magnetic resonance spectroscopy of urine.

Organic acidemias

Most commonly present in infancy with poor feeding, vomiting, hypotonia, high anion gap metabolic acidosis, hepatomegaly, seizures. Organic acid accumulation:

- Inhibits gluconeogenesis → ↓ fasting blood glucose levels, ↑ ketoacidosis → high anion gap metabolic acidosis
- Inhibits urea cycle → hyperammonemia

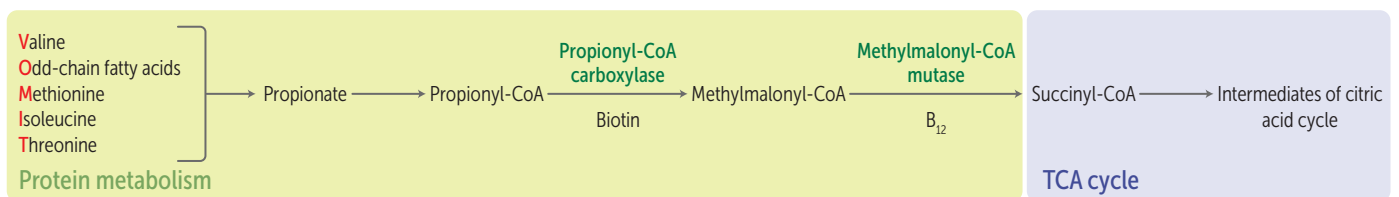
Propionic acidemia

Deficiency of propionyl-CoA carboxylase → ↑ propionyl-CoA, ↓ methylmalonic acid.

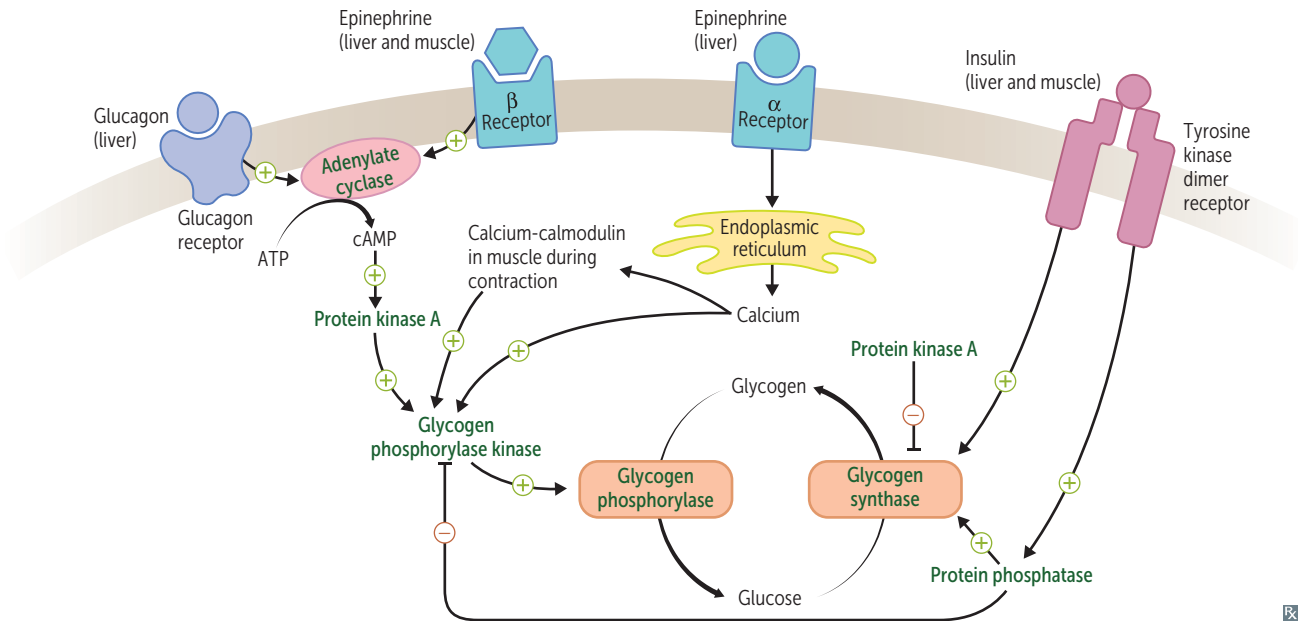
Treatment: low-protein diet limited in substances that metabolize into propionyl-CoA: **V**aline, **O**dd-chain fatty acids, **M**ethionine, **I**soleucine, **T**hreonine (**VOMIT**).

Methylmalonic acidemia

Deficiency of methylmalonyl-CoA mutase or vitamin B₁₂.



Glycogen regulation by insulin and glucagon/epinephrine



Glycogen

Branches have α -(1,6) bonds; linear linkages have α -(1,4) bonds.

Skeletal muscle

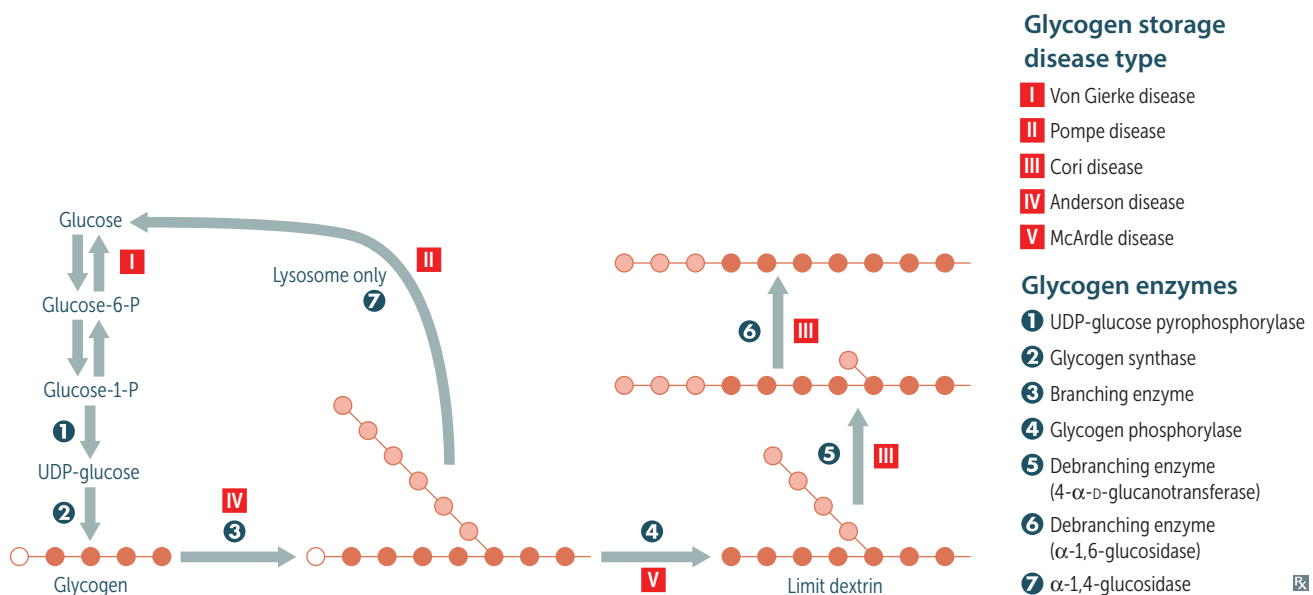
Glycogen undergoes glycogenolysis \rightarrow glucose-1-phosphate \rightarrow glucose-6-phosphate, which is rapidly metabolized during exercise.

Hepatocytes

Glycogen is stored and undergoes glycogenolysis to maintain blood sugar at appropriate levels.

Glycogen phosphorylase **4** liberates glucose-1-phosphate residues off branched glycogen until 4 glucose units remain on a branch. Then 4- α -D-glucanotransferase (debranching enzyme **5**) moves 3 of the 4 glucose units from the branch to the linear linkage. Then α -1,6-glucosidase (debranching enzyme **6**) cleaves off the last residue, liberating a free glucose.

Limit dextrin—2–4 residues remaining on a branch after glycogen phosphorylase has shortened it.



Glycogen storage disease type

- I** Von Gierke disease
- II** Pompe disease
- III** Cori disease
- IV** Anderson disease
- V** McArdle disease

Glycogen enzymes

- 1** UDP-glucose pyrophosphorylase
- 2** Glycogen synthase
- 3** Branching enzyme
- 4** Glycogen phosphorylase
- 5** Debranching enzyme (4- α -D-glucanotransferase)
- 6** Debranching enzyme (α -1,6-glucosidase)
- 7** α -1,4-glucosidase

Note: A small amount of glycogen is degraded in lysosomes by **7** α -1,4-glucosidase (acid maltase).

Glycogen storage diseases

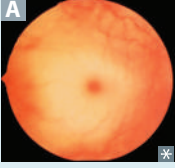
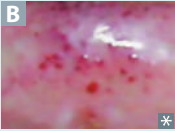
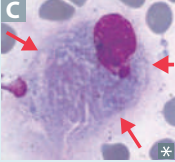

At least 15 types have been identified, all resulting in abnormal glycogen metabolism and an accumulation of glycogen within cells. Periodic acid–Schiff stain identifies glycogen and is useful in identifying these diseases.

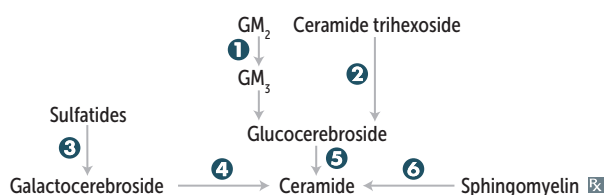
Vice **p**resident can't accept **m**oney.
Types I-V are autosomal recessive.
Andersen: **B**ranching.
Cori: **D**ebranching. (**ABCD**)

DISEASE	FINDINGS	DEFICIENT ENZYME	COMMENTS
Von Gierke disease (type I)	Severe fasting hypoglycemia, ↑↑ Glycogen in liver and kidneys, ↑ blood lactate , ↑ triglycerides , ↑ uric acid (Gout) , and hepatomegaly, renomegaly. Liver does not regulate blood glucose.	G lucose-6-phosphatase.	Treatment: frequent oral glucose/cornstarch; avoidance of fructose and galactose. Impaired gluconeogenesis and glycogenolysis.
Pompe disease (type II)	Cardiomyopathy, hypotonia, exercise intolerance, enlarged tongue, and systemic findings lead to early death.	Lysosomal acid α-1,4- glucosidase (acid maltase) with α-1,6- glucosidase activity.	Pompe trashes the pump (1st and 4th letter; heart, liver, and muscle).
Cori disease (type III)	Similar to von Gierke disease, but milder symptoms and normal blood lactate levels. Can lead to cardiomyopathy. Limit dextrin–like structures accumulate in cytosol.	D ebranching enzymes (α-1,6- glucosidase and 4-α-D- glucanotransferase).	Gluconeogenesis is intact.
Andersen disease (type IV)	Most commonly presents with hepatosplenomegaly and failure to thrive in early infancy. Other findings include infantile cirrhosis, muscular weakness, hypotonia, cardiomyopathy early childhood death.	B ranching enzyme. Neuromuscular form can present at any age.	Hypoglycemia occurs late in the disease.
McArdle disease (type V)	↑ glycogen in muscle, but muscle cannot break it down → painful m uscle cramps, myoglobinuria (red urine) with strenuous exercise, and arrhythmia from electrolyte abnormalities. Second-wind phenomenon noted during exercise due to ↑ muscular blood flow .	Skeletal muscle glycogen phosphorylase (m yophosphorylase). Characterized by a flat venous lactate curve with normal rise in ammonia levels during exercise.	Blood glucose levels typically unaffected. McArdle = m uscle.

Lysosomal storage diseases

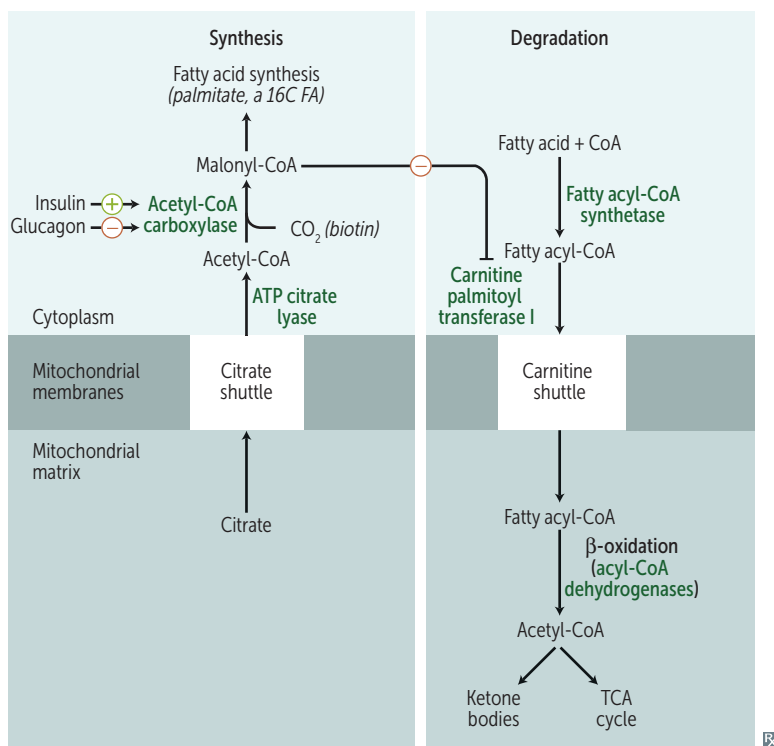
Lysosomal enzyme deficiency → accumulation of abnormal metabolic products. ↑ incidence of Tay-Sachs, Niemann-Pick, and some forms of Gaucher disease in Ashkenazi Jews.

DISEASE	FINDINGS	DEFICIENT ENZYME	ACCUMULATED SUBSTRATE	INHERITANCE
Sphingolipidoses				
Tay-Sachs disease 	Progressive neurodegeneration, developmental delay, hyperreflexia, hyperacusis, “cherry-red” spot on macula A (lipid accumulation in ganglion cell layer), lysosomes with onion skin, no hepatosplenomegaly (vs Niemann-Pick).	1 Hexosaminidase A (“T A y-Sax”).	GM ₂ ganglioside.	AR
Fabry disease 	Early: triad of episodic peripheral neuropathy, angiokeratomas B , hypohidrosis. Late: progressive renal failure, cardiovascular disease.	2 α-galactosidase A.	Ceramide trihexoside (globotriaosylceramide).	XR
Metachromatic leukodystrophy	Central and peripheral demyelination with ataxia, dementia.	3 Arylsulfatase A.	Cerebroside sulfate.	AR
Krabbe disease	Peripheral neuropathy, destruction of oligodendrocytes, developmental delay, optic atrophy, globoid cells.	4 Galactocerebrosidase (galactosylceramidase).	Galactocerebroside, AR psychosine.	AR
Gaucher disease 	Most common. Hepatosplenomegaly, pancytopenia, osteoporosis, avascular necrosis of femur, bone crises, Gaucher cells C (lipid-laden macrophages resembling crumpled tissue paper).	5 Glucocerebrosidase (β-glucosidase); treat with recombinant glucocerebrosidase.	Glucocerebroside.	AR
Niemann-Pick disease 	Progressive neurodegeneration, hepatosplenomegaly, foam cells (lipid-laden macrophages) D , “cherry-red” spot on macula A .	6 Sphingomyelinase.	Sphingomyelin.	AR
Mucopolysaccharidoses				
Hurler syndrome	Developmental delay, skeletal abnormalities, airway obstruction, corneal clouding, hepatosplenomegaly.	α-L-iduronidase.	Heparan sulfate, dermatan sulfate.	AR
Hunter syndrome	Mild Hurler + aggressive behavior, no corneal clouding.	Iduronate-2 (two)-sulfatase.	Heparan sulfate, dermatan sulfate.	XR



Hunters see clearly (no corneal clouding) and aggressively aim for the **X** (X-linked recessive).

Fatty acid metabolism



Fatty acid synthesis requires transport of citrate from mitochondria to cytosol. Predominantly occurs in liver, lactating mammary glands, and adipose tissue.

Long-chain fatty acid (LCFA) degradation requires carnitine-dependent transport into the mitochondrial matrix.

“Sytrate” = synthesis.

Carnitine = carnage of fatty acids.

Systemic 1° carnitine deficiency—no cellular uptake of carnitine → no transport of LCFAs into mitochondria → toxic accumulation of LCFAs in the cytosol. Causes weakness, hypotonia, hypoketotic hypoglycemia, dilated cardiomyopathy.

Medium-chain acyl-CoA dehydrogenase deficiency—↓ ability to break down fatty acids into acetyl-CoA → accumulation of fatty acyl carnitines in the blood with hypoketotic hypoglycemia. Causes vomiting, lethargy, seizures, coma, liver dysfunction, hyperammonemia. Can lead to sudden death in infants or children. Treat by avoiding fasting.

Ketone bodies

In the liver, fatty acids and amino acids are metabolized to acetoacetate and β -hydroxybutyrate (to be used in muscle and brain).

In prolonged starvation and diabetic ketoacidosis, oxaloacetate is depleted for gluconeogenesis. With chronic alcohol overuse, high NADH state leads to accumulation of oxaloacetate (downregulated TCA cycle), shunting it to malate.

Ketone bodies: acetone, acetoacetate, β -hydroxybutyrate.

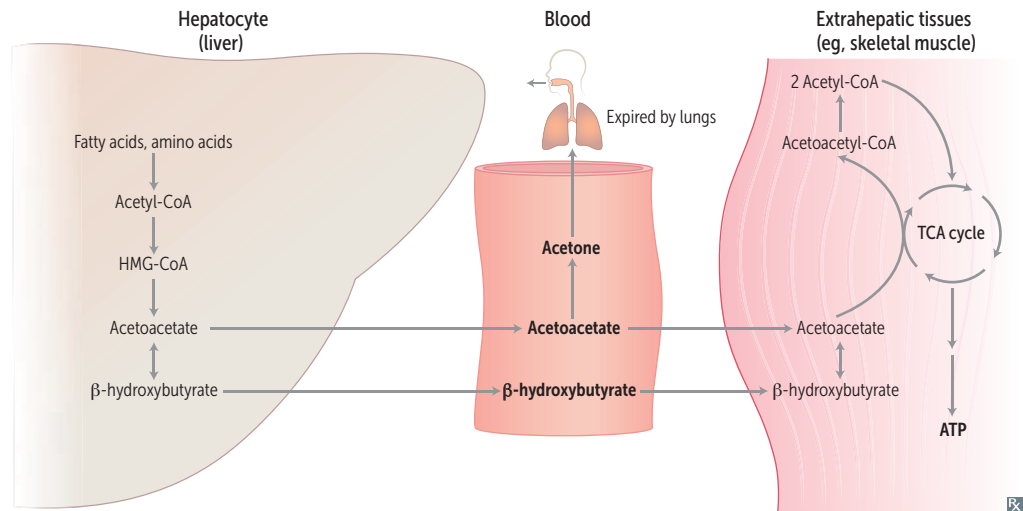
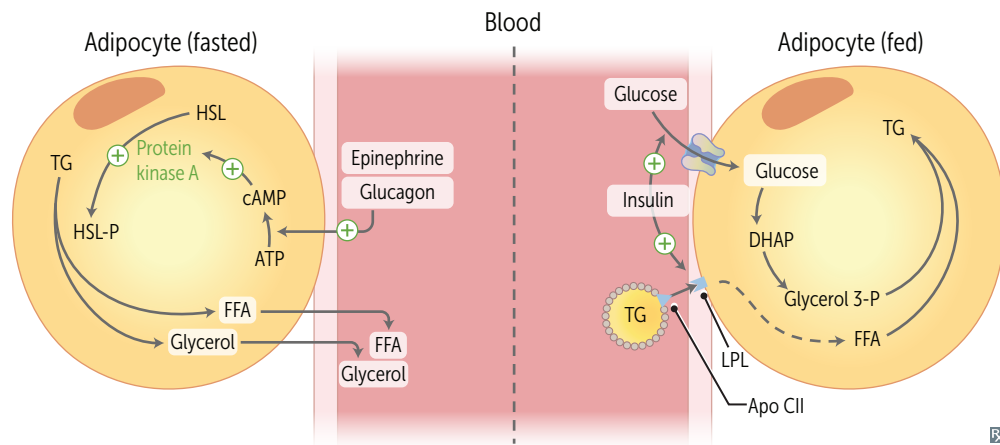
Breath smells like acetone (fruity odor).

Urine test for ketones can detect acetoacetate, but not β -hydroxybutyrate.

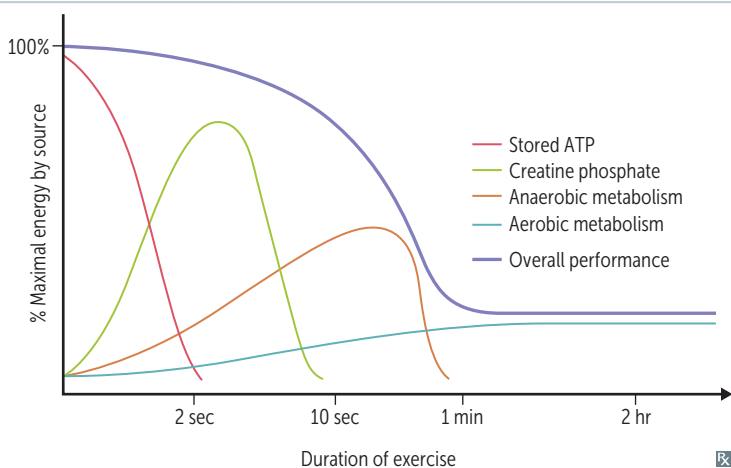
RBCs cannot utilize ketone bodies; they strictly use glucose.

HMG-CoA lyase for ketone body production.

HMG-CoA reductase for cholesterol synthesis.

**Fasted vs fed state**

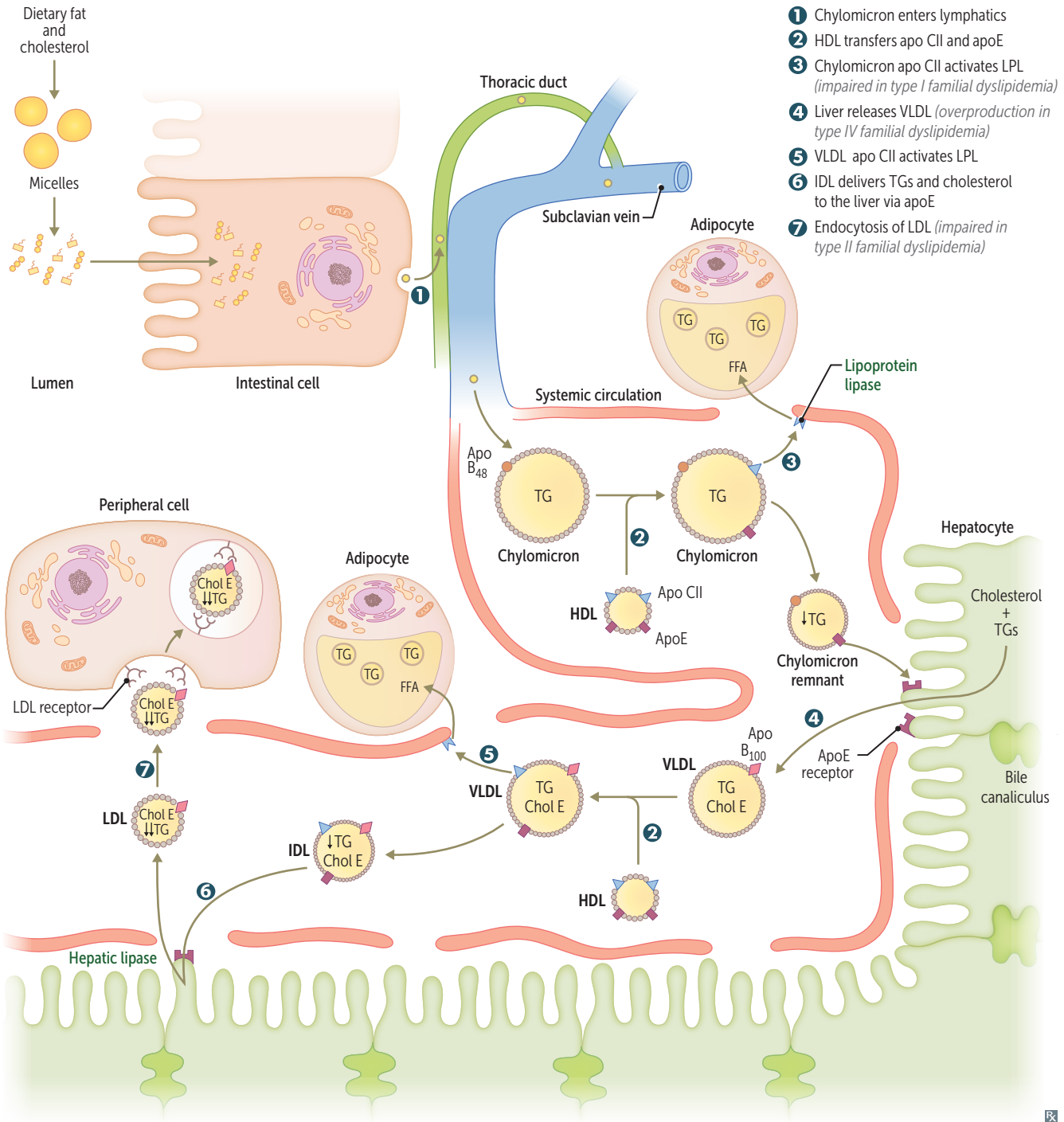
Metabolic fuel use



1g **carb**/protein = 4 kcal
 1g **alcohol** = 7 kcal
 1g **fatty acid** = 9 kcal
 (# letters = # kcal)

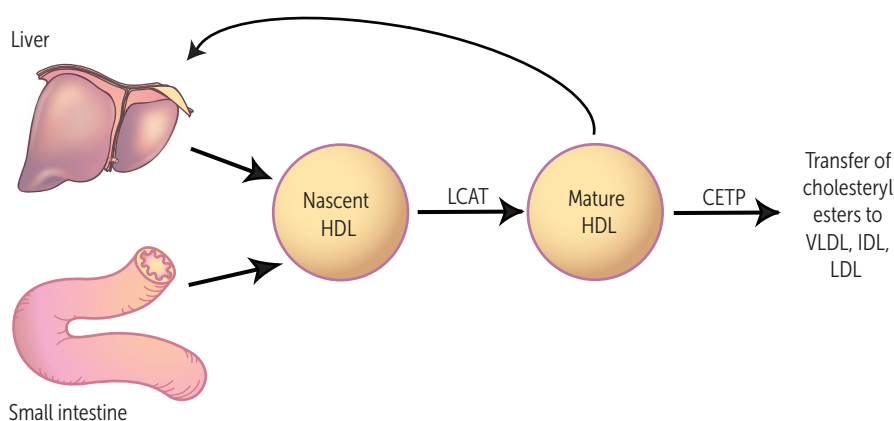
Fasting and starvation	Priorities are to supply sufficient glucose to the brain and RBCs and to preserve protein.	
Fed state (after a meal)	Glycolysis and aerobic respiration.	Insulin stimulates storage of lipids, proteins, and glycogen.
Fasting (between meals)	Hepatic glycogenolysis (major); hepatic gluconeogenesis, adipose release of FFA (minor).	Glucagon and epinephrine stimulate use of fuel reserves.
Starvation days 1–3	Blood glucose levels maintained by: <ul style="list-style-type: none"> ▪ Hepatic glycogenolysis ▪ Adipose release of FFA ▪ Muscle and liver, which shift fuel use from glucose to FFA ▪ Hepatic gluconeogenesis from peripheral tissue lactate and alanine, and from adipose tissue glycerol and propionyl-CoA (from odd-chain FFA—the only triacylglycerol component that contributes to gluconeogenesis) 	Glycogen reserves depleted after day 1. RBCs lack mitochondria and therefore cannot use ketone bodies.
Starvation after day 3	Adipose stores (ketone bodies become the main source of energy for the brain). After these are depleted, vital protein degradation accelerates, leading to organ failure and death. Amount of excess stores determines survival time.	

Lipid transport



Key enzymes in lipid transport

Cholesteryl ester transfer protein	Mediates transfer of cholesteryl esters to other lipoprotein particles.
Hepatic lipase	Degrades TGs remaining in IDL and chylomicron remnants.
Hormone-sensitive lipase	Degrades TGs stored in adipocytes. Promotes gluconeogenesis by releasing glycerol.
Lecithin-cholesterol acyltransferase	Catalyzes esterification of 2/3 of plasma cholesterol (ie, required for HDL maturation).
Lipoprotein lipase	Degrades TGs in circulating chylomicrons and VLDL.
Pancreatic lipase	Degrades dietary TGs in small intestine.
PCSK9	Degrades LDL receptor → ↑ serum LDL. Inhibition → ↑ LDL receptor recycling → ↓ serum LDL.



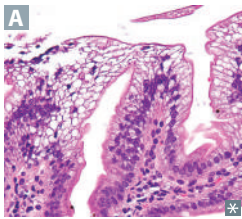
Major apolipoproteins

APOLIPOPROTEIN	FUNCTION	CHYLOMICRON						
		CHYLOMICRON	REMNANT	VLDL	IDL	LDL	HDL	
E	Mediates remnant uptake (everything except LDL)	✓	✓	✓	✓		✓	
A1	Found only on alpha-lipoproteins (HDL), activates LCAT						✓	
CII	Lipoprotein lipase cofactor that catalyzes cleavage	✓		✓	✓		✓	
B₄₈	Mediates chylomicron secretion into lymphatics Only on particles originating from the intestines	✓	✓					
B₁₀₀	Binds LDL receptor Only on particles originating from the liver (I hope I live to Be 100)			✓	✓	✓		

Lipoprotein functions

Lipoproteins are composed of varying proportions of proteins, cholesterol, TGs, and phospholipids. LDL and HDL carry the most cholesterol. Cholesterol is needed to maintain cell membrane integrity and synthesize bile acids, steroids, and vitamin D.

Chylomicron	Delivers dietary TGs to peripheral tissues. Delivers cholesterol to liver in the form of chylomicron remnants, which are mostly depleted of their TGs. Secreted by intestinal epithelial cells.
VLDL	Delivers hepatic TGs to peripheral tissue. Secreted by liver.
IDL	Delivers TGs and cholesterol to liver. Formed from degradation of VLDL.
LDL	Delivers hepatic cholesterol to peripheral tissues. Formed by hepatic lipase modification of IDL in the liver and peripheral tissue. Taken up by target cells via receptor-mediated endocytosis. LDL is Lethal.
HDL	Mediates reverse cholesterol transport from peripheral tissues to liver. Acts as a repository for apoC and apoE (which are needed for chylomicron and VLDL metabolism). Secreted from both liver and intestine. Alcohol ↑ synthesis. HDL is Healthy.

Abetalipoproteinemia

Autosomal recessive. Mutation in gene that encodes microsomal transfer protein (*MTP*). Chylomicrons, VLDL, LDL absent. Deficiency in apo B₄₈- and apo B₁₀₀-containing lipoproteins. Affected infants present with severe fat malabsorption, steatorrhea, failure to thrive. Later manifestations include retinitis pigmentosa, spinocerebellar degeneration due to vitamin E deficiency, progressive ataxia, acanthocytosis. Intestinal biopsy shows lipid-laden enterocytes **A**. Treatment: restriction of long-chain fatty acids, large doses of oral vitamin E.

Familial dyslipidemias

TYPE	INHERITANCE	PATHOGENESIS	↑ BLOOD LEVEL	CLINICAL
I—Hyperchylomicronemia	AR	Lipoprotein lipase or apo CII deficiency	Chylomicrons, TG, cholesterol	Pancreatitis, hepatosplenomegaly, and eruptive/pruritic xanthomas (no ↑ risk for atherosclerosis). Creamy layer in supernatant.
II—Hypercholesterolemia	AD	Absent or defective LDL receptors, or defective apo B ₁₀₀	IIa: LDL, cholesterol IIb: LDL, cholesterol, VLDL	Heterozygotes (1:500) have cholesterol ≈ 300 mg/dL; homozygotes (very rare) have cholesterol ≥ 700 mg/dL. Accelerated atherosclerosis (may have MI before age 20), tendon (Achilles) xanthomas, and corneal arcus.
III—Dysbetalipoproteinemia	AR	ApoE (defective in type III)	Chylomicrons, VLDL	Premature atherosclerosis, tuberoeruptive and palmar xanthomas.
IV—Hypertriglyceridemia	AD	Hepatic overproduction of VLDL	VLDL, TG	Hypertriglyceridemia (> 1000 mg/dL) can cause acute pancreatitis. Related to insulin resistance.

Immunology

“I hate to disappoint you, but my rubber lips are immune to your charms.”

—Batman & Robin

“Imagine the action of a vaccine not just in terms of how it affects a single body, but also in terms of how it affects the collective body of a community.”

—Eula Biss

“Some people are immune to good advice.”

—Saul Goodman, *Breaking Bad*

“Now is the time, if ever there was one, for us to care selflessly about one another.”

—Anthony Fauci

Learning the components of the immune system and their roles in host defense at the cellular level is essential for both the understanding of disease pathophysiology and clinical practice. Know the immune mechanisms of responses to vaccines. Both congenital and acquired immunodeficiencies are very testable. Cell surface markers are high yield for understanding immune cell interactions and for laboratory diagnosis. Know the roles and functions of major cytokines and chemokines.

▶ Lymphoid Structures 94

▶ Cellular Components 97

▶ Immune Responses 102

▶ Immunosuppressants 118

▶ IMMUNOLOGY—LYMPHOID STRUCTURES

Immune system organs

1° organs:

- Bone marrow—immune cell production, B cell maturation
- Thymus—T cell maturation

2° organs:

- Spleen, lymph nodes, tonsils, Peyer patches
- Allow immune cells to interact with antigen

Lymph node

A 2° lymphoid organ that has many afferents, 1 or more efferents. Encapsulated, with trabeculae

A B. Functions are nonspecific filtration by macrophages, circulation of B and T cells, and immune response activation.

Follicle

Located in outer cortex; site of B-cell localization and proliferation. 1° follicles are dense and quiescent. 2° follicles have pale central germinal centers and are active.

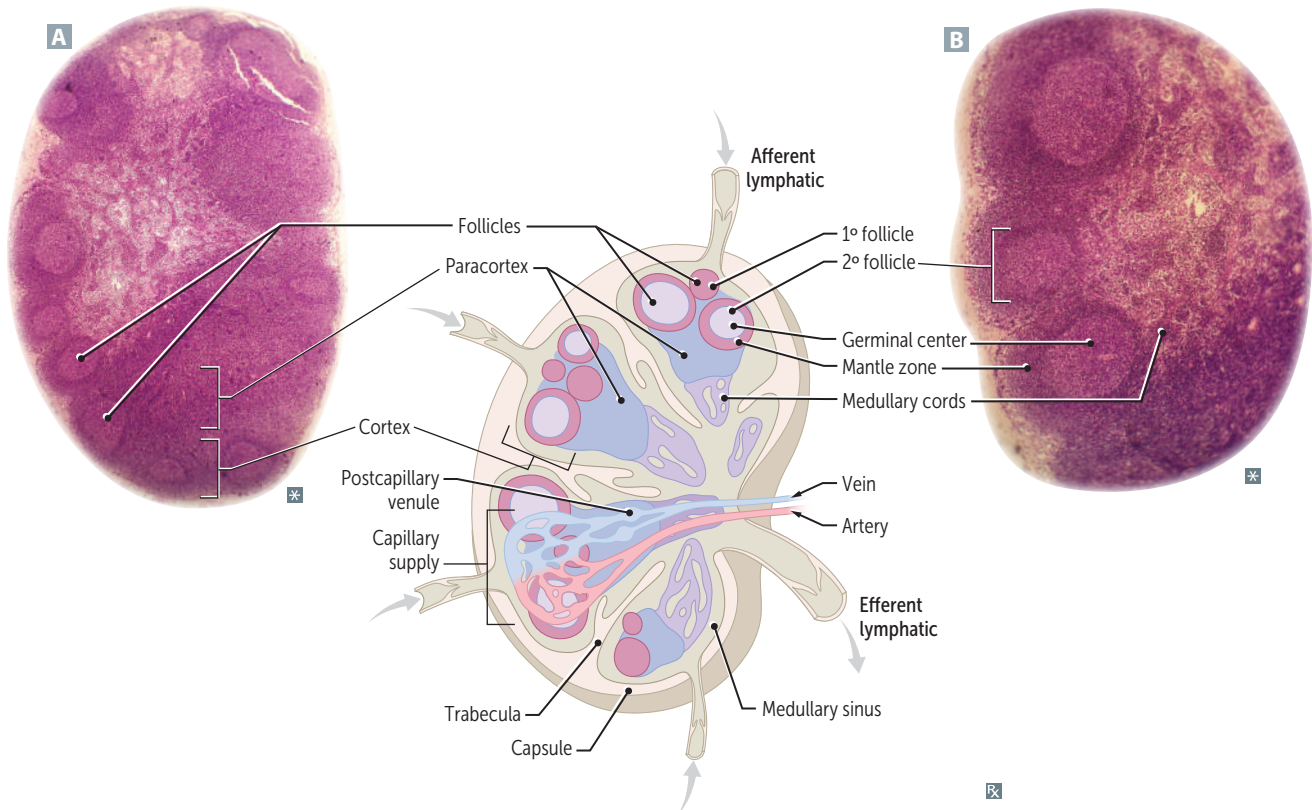
Medulla

Consists of medullary cords (closely packed lymphocytes and plasma cells) and medullary sinuses (contain reticular cells and macrophages). Medullary sinuses communicate with efferent lymphatics.

Paracortex

Contains T cells. Region of cortex between follicles and medulla. Contains high endothelial venules through which T and B cells enter from blood. Underdeveloped in patients with DiGeorge syndrome.

Paracortex enlarges in an extreme cellular immune response (eg, EBV and other viral infections → paracortical hyperplasia → lymphadenopathy).



Lymphatic drainage associations

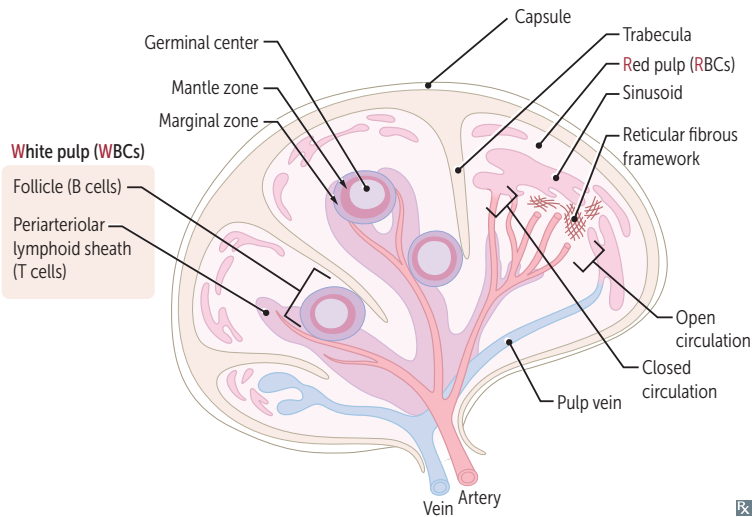
Lymph node cluster	Area of body drained	Associated pathology
Submandibular, submental	Oral cavity, anterior tongue, lower lip	Malignancy of and metastasis to the oral cavity
Deep cervical	Head, neck, oropharynx	Upper respiratory tract infection Infectious mononucleosis Kawasaki disease Malignancy of head, neck, oropharynx
Supraclavicular	Right: right hemithorax Left (Virchow node): left hemithorax, abdomen, pelvis	Malignancies of thorax, abdomen, pelvis
Mediastinal	Trachea, esophagus	Pulmonary TB (unilateral hilar) Sarcoidosis (bilateral hilar)
Hilar	Lungs	Lung cancer Granulomatous disease
Axillary	Upper limb, breast, skin above umbilicus	Mastitis Metastasis (especially breast cancer)
Epitrochlear	Hand, forearm	Secondary syphilis
Celiac	Liver, stomach, spleen, pancreas, upper duodenum	
Superior mesenteric	Lower duodenum, jejunum, ileum, colon to splenic flexure	Mesenteric lymphadenitis Inflammatory bowel disease Celiac disease
Inferior mesenteric	Colon from splenic flexure to upper rectum	
Periumbilical (Sister Mary Joseph node)	Abdomen, pelvis	Gastric cancer
Para-aortic	Pair of testes, ovaries, kidneys, fallopian tubes (uterus)	Metastasis
External iliac	Cervix, vagina (upper third), superior bladder, body of uterus	
Internal iliac	Lower rectum to anal canal (above pectinate line), bladder, vagina (middle third), cervix, prostate	Sexually transmitted infections Medial foot/leg cellulitis (superficial inguinal)
Superficial inguinal	Anal canal (below pectinate line), skin below umbilicus (except popliteal area), scrotum, vulva, vagina (lower third)	
Popliteal ("pop-lateral")	Dorsolateral foot, posterior calf	Lateral foot/leg cellulitis

● Palpable lymph node
○ Nonpalpable lymph node

■ Right lymphatic duct drains right side of body above diaphragm into junction of the right subclavian and internal jugular vein



Spleen



Located in LUQ of abdomen, anterolateral to left kidney, protected by 9th-11th ribs. Splenic dysfunction (eg, postsplenectomy, sickle cell disease autosplenectomy) → ↓ IgM → ↓ complement activation → ↓ C3b opsonization → ↑ susceptibility to encapsulated organisms.

Postsplenectomy findings:

- Howell-Jolly bodies (nuclear remnants)
- Target cells
- Thrombocytosis (loss of sequestration and removal)
- Lymphocytosis (loss of sequestration)

Vaccinate patients undergoing splenectomy or with splenic dysfunction against encapsulated organisms (pneumococci, Hib, meningococci).

Periarteriolar lymphatic sheath

Contains T cells. Located within white pulp.

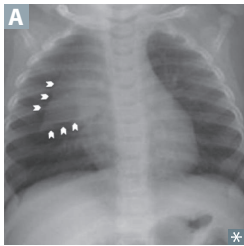
Follicle

Contains B cells. Located within white pulp.

Marginal zone

Contains macrophages and specialized B cells. Site where antigen-presenting cells (APCs) capture blood-borne antigens for recognition by lymphocytes. Located between red pulp and white pulp.

Thymus



Located in the anterosuperior mediastinum. Site of T-cell differentiation and maturation. Encapsulated. **T**hymus epithelium is derived from **t**hird pharyngeal pouch (endoderm), whereas thymic lymphocytes are of mesodermal origin. Cortex is dense with immature T cells; **m**edulla is pale with **m**ature T cells and Hassall corpuscles containing epithelial reticular cells.

Normal neonatal thymus “sail-shaped” on CXR (asterisks in **A**), involutes by age 3 years.

T cells = **T**hymus

B cells = **B**one marrow

Absent thymic shadow or hypoplastic thymus seen in some immunodeficiencies (eg, SCID, DiGeorge syndrome).

Thymoma—neoplasm of thymus. Associated with myasthenia gravis, superior vena cava syndrome, pure red cell aplasia, Good syndrome.

▶ IMMUNOLOGY—CELLULAR COMPONENTS

Innate vs adaptive immunity

	Innate immunity	Adaptive immunity
COMPONENTS	Neutrophils, macrophages, monocytes, dendritic cells, natural killer (NK) cells (lymphoid origin), complement, physical epithelial barriers, secreted enzymes	T cells, B cells, circulating antibodies
MECHANISM	Germline encoded	Variation through V(D)J recombination during lymphocyte development
RESPONSE TO PATHOGENS	Nonspecific Occurs rapidly (minutes to hours) No memory response	Highly specific, refined over time Develops over long periods; memory response is faster and more robust
SECRETED PROTEINS	Lysozyme, complement, C-reactive protein (CRP), defensins, cytokines	Immunoglobulins, cytokines
KEY FEATURES IN PATHOGEN RECOGNITION	Toll-like receptors (TLRs): pattern recognition receptors that recognize pathogen-associated molecular patterns (PAMPs) and lead to activation of NF-κB. Examples of PAMPs: LPS (gram ⊖ bacteria), flagellin (bacteria), nucleic acids (viruses)	Memory cells: activated B and T cells; subsequent exposure to a previously encountered antigen → stronger, quicker immune response

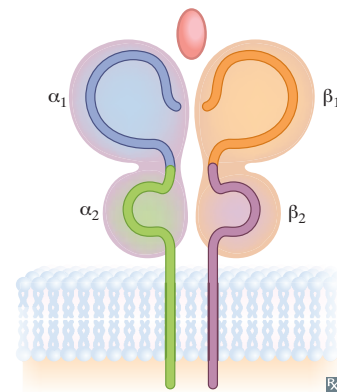
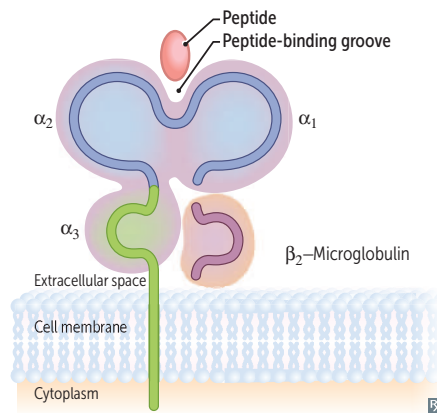
Immune privilege

Organs (eg, eye, brain, placenta, testes) and tissues where suppressive mechanisms limit immune responses to foreign antigens to avoid damage that would occur from inflammatory sequelae. Allograft rejection at these sites is less likely.

Major histocompatibility complex I and II

MHC encoded by HLA genes. Present antigen fragments to T cells and bind T-cell receptors (TCRs).

	MHC I	MHC II
LOCI	HLA-A, HLA-B, HLA-C MHC I loci have 1 letter	HLA-DP, HLA-DQ, HLA-DR MHC II loci have 2 letters
BINDING	TCR and CD8	TCR and CD4
STRUCTURE	1 long chain, 1 short chain	2 equal-length chains (2 α , 2 β)
EXPRESSION	All nucleated cells, APCs, platelets (except RBCs)	APCs
FUNCTION	Present endogenous antigens (eg, viral or cytosolic proteins) to CD8+ cytotoxic T cells	Present exogenous antigens (eg, bacterial proteins) to CD4+ helper T cells
ANTIGEN LOADING	Antigen peptides loaded onto MHC I in RER after delivery via TAP (transporter associated with antigen processing)	Antigen loaded following release of invariant chain in an acidified endosome
ASSOCIATED PROTEINS	β_2 -microglobulin	Invariant chain
STRUCTURE		

**HLA subtypes associated with diseases**

HLA SUBTYPE	DISEASE	MNEMONIC
B27	P soriatic arthritis, A nkylosing spondylitis, I BD-associated arthritis, R eactive arthritis	PAIR
B57	Abacavir hypersensitivity	
DQ2/DQ8	Celiac disease	I ate (8) too (2) much gluten at Dairy Queen
DR3	DM type 1, SLE, Graves disease, Hashimoto thyroiditis, Addison disease	DM type 1: HLA-3 and -4 (1 + 3 = 4) SL3 (SLE)
DR4	R heumatoid arthritis, DM type 1, Addison disease	There are 4 walls in 1 "rheum" (room)

Functions of natural killer cells

Lymphocyte member of innate immune system.
Use perforin and granzymes to induce apoptosis of virally infected cells and tumor cells.
Activity enhanced by IL-2, IL-12, IFN- α , and IFN- β .
Induced to kill when exposed to a nonspecific activation signal on target cell and/or to an absence of an inhibitory signal such as MHC I on target cell surface.
Also kills via antibody-dependent cell-mediated cytotoxicity (CD16 binds Fc region of bound IgG, activating the NK cell).

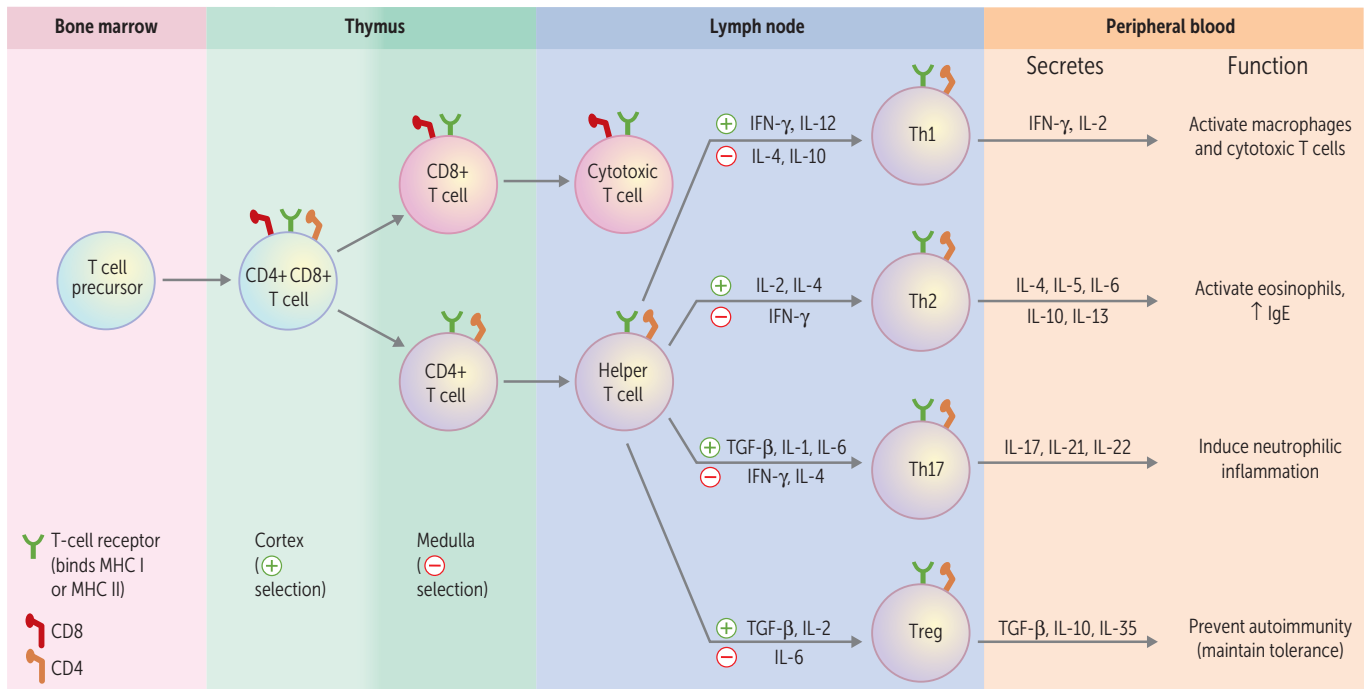
Major functions of B and T cells**B cells**

Humoral immunity.
Recognize and present antigen—undergo somatic hypermutation to optimize antigen specificity.
Produce antibody—differentiate into plasma cells to secrete specific immunoglobulins.
Maintain immunologic memory—memory B cells persist and accelerate future response to antigen.

T cells

Cell-mediated immunity.
CD4⁺ T cells help B cells make antibodies and produce cytokines to recruit phagocytes and activate other leukocytes.
CD8⁺ T cells directly kill virus-infected and tumor cells via perforin and granzymes (similar to NK cells).
Delayed cell-mediated hypersensitivity (type IV).
Acute and chronic cellular organ rejection.
Rule of 8: MHC II \times CD4 = 8; MHC I \times CD8 = 8.

Differentiation of T cells

**Positive selection**

Thymic cortex. Double-positive (CD4+/CD8+) T cells expressing TCRs capable of binding self-MHC on cortical epithelial cells survive.

Negative selection

Thymic medulla. T cells expressing TCRs with high affinity for self antigens undergo apoptosis or become regulatory T cells. Tissue-restricted self-antigens are expressed in the thymus due to the action of autoimmune regulator (**AIRE**); deficiency leads to autoimmune polyendocrine syndrome-1 (**C**hronic mucocutaneous candidiasis, **H**ypoparathyroidism, **A**drenal insufficiency, **R**ecurrent *Candida* infections). “Without **AIRE**, your body will **CHAR**”.

Macrophage-lymphocyte interaction

Th1 cells secrete IFN- γ , which enhances the ability of monocytes and macrophages to kill microbes they ingest. This function is also enhanced by interaction of T cell CD40L with CD40 on macrophages. Macrophages also activate lymphocytes via antigen presentation.

Cytotoxic T cells

Kill virus-infected, neoplastic, and donor graft cells by inducing apoptosis. Release cytotoxic granules containing preformed proteins (eg, perforin, granzyme B). Cytotoxic T cells have CD8, which binds to MHC I on virus-infected cells.

Regulatory T cells

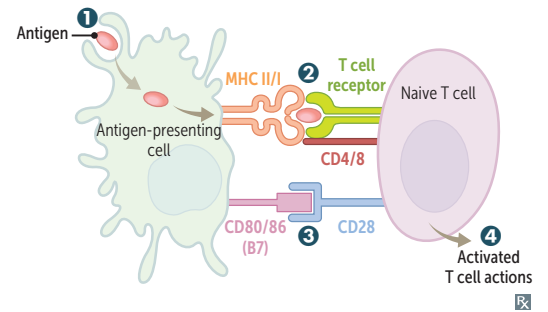
Help maintain specific immune tolerance by suppressing CD4+ and CD8+ T-cell effector functions. Identified by expression of CD3, CD4, CD25, and FOXP3. Activated regulatory T cells (Tregs) produce anti-inflammatory cytokines (eg, IL-10, TGF- β).

IPEX (Immune dysregulation, Polyendocrinopathy, Enteropathy, X-linked) syndrome—genetic deficiency of FOXP3 \rightarrow autoimmunity. Characterized by enteropathy, endocrinopathy, nail dystrophy, dermatitis, and/or other autoimmune dermatologic conditions. Associated with diabetes in male infants.

T- and B-cell activation APCs: B cells, dendritic cells, Langerhans cells, macrophages.
Two signals are required for T-cell activation, B-cell activation, and class switching.

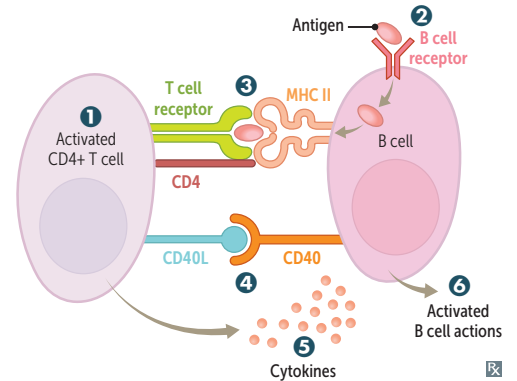
T-cell activation

- 1 APC ingests and processes antigen, then migrates to the draining lymph node.
- 2 T-cell activation (signal 1): exogenous antigen is presented on MHC II and recognized by TCR on Th (CD4+) cell. Endogenous or cross-presented antigen is presented on MHC I to Tc (CD8+) cell.
- 3 Proliferation and survival (signal 2): costimulatory signal via interaction of B7 protein (CD80/86) on dendritic cell and CD28 on naïve T cell.
- 4 Activated Th cell produces cytokines. Tc cell able to recognize and kill virus-infected cell.



B-cell activation and class switching

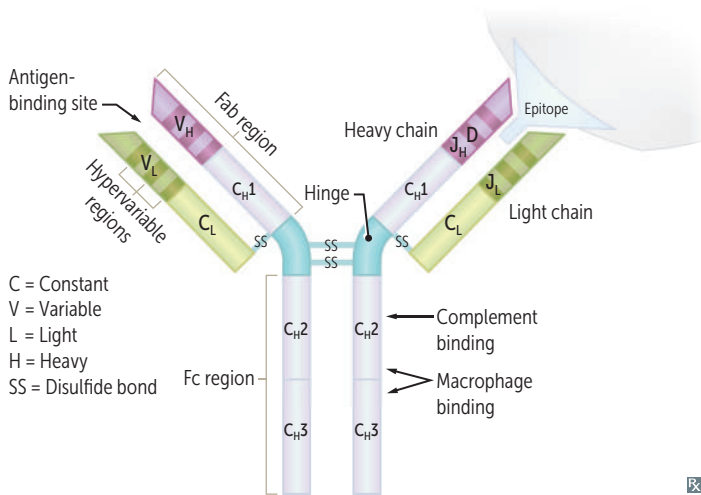
- 1 Th-cell activation as above.
- 2 B-cell receptor-mediated endocytosis.
- 3 Exogenous antigen is presented on MHC II and recognized by TCR on Th cell.
- 4 CD40 receptor on B cell binds CD40 ligand (CD40L) on Th cell.
- 5 Th cells secrete cytokines that determine Ig class switching of B cells.
- 6 B cells are activated and produce IgM. They undergo class switching and affinity maturation.



► IMMUNOLOGY—IMMUNE RESPONSES

Antibody structure and function

Fab fragment consisting of light (L) and heavy (H) chains recognizes antigens. Fc region of IgM and IgG fixes complement. Heavy chain contributes to Fc and Fab regions. Light chain contributes only to Fab region.

**Fab:**

- **F**ragment, **a**ntigen **b**inding
- Determines idiotype: unique antigen-binding pocket; only 1 antigenic specificity expressed per B cell

Fc (5 C's):

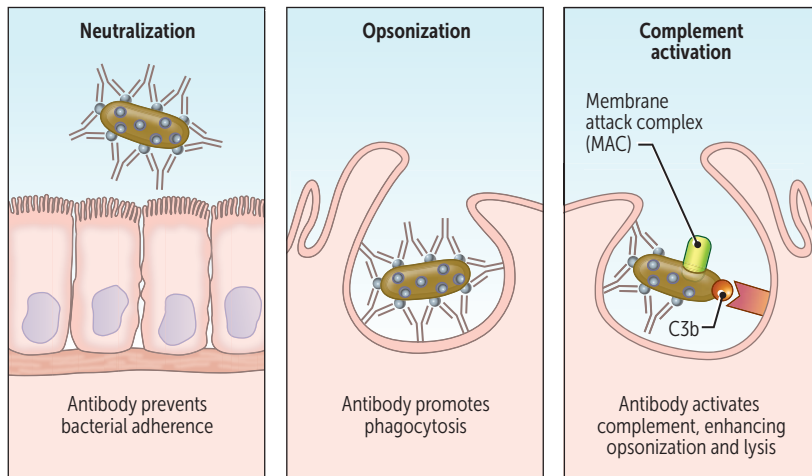
- **C**onstant
- **C**arboxy terminal
- **C**omplement binding
- **C**arbohydrate side chains
- **C**onfers (determines) isotype (IgM, IgD, etc)

Generation of antibody diversity (antigen independent)

1. Random recombination of VJ (light-chain) or V(D)J (heavy-chain) genes by RAG1 and RAG2
2. Random addition of nucleotides to DNA during recombination by terminal deoxynucleotidyl transferase (TdT)
3. Random combination of heavy chains with light chains

Generation of antibody specificity (antigen dependent)

4. Somatic hypermutation and affinity maturation (variable region)
5. Isotype switching (constant region)



Immunoglobulin isotypes

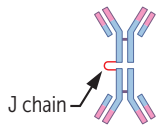
All isotypes can exist as monomers. Mature, naïve B cells prior to activation express IgM and IgD on their surfaces. They may differentiate in germinal centers of lymph nodes by isotype switching (gene rearrangement; induced by cytokines and CD40L) into plasma cells that secrete IgA, IgG, or IgE. “For B cells, IgM om and IgD ad mature to plasma cells as they AGE.” Affinity refers to the individual antibody-antigen interaction, while avidity describes the cumulative binding strength of all antibody-antigen interactions in a multivalent molecule.

IgG



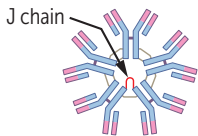
Main antibody in 2° response to an antigen. Most abundant isotype in serum. Fixes complement, opsonizes bacteria, neutralizes bacterial toxins and viruses. Only isotype that crosses the placenta (provides infants with passive immunity that starts to wane after birth). “IgG G greets the G rowing fetus.” Associated with warm autoimmune hemolytic anemia (“warm weather is Great!”).

IgA



Prevents attachment of bacteria and viruses to mucous membranes; does not fix complement. Monomer (in circulation) or dimer (with J chain when secreted). Crosses epithelial cells by transcytosis. Produced in GI tract (eg, by Peyer patches) and protects against gut infections (eg, *Giardia*). Most produced antibody overall, but has lower serum concentrations. Released into secretions (tears, saliva, mucus) and breast milk. Picks up secretory component from epithelial cells, which protects the Fc portion from luminal proteases.

IgM



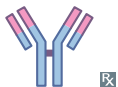Produced in the 1° (IMmediate) response to an antigen. Fixes complement. Antigen receptor on the surface of B cells. Monomer on B cell, pentamer with J chain when secreted. Pentamer enables avid binding to antigen while humoral response evolves. Associated with cold autoimmune hemolytic anemia.

IgD



Unclear function. Found on surface of many B cells and in serum.

IgE



Binds mast cells and basophils; cross-links when exposed to allergen, mediating immediate (type I) hypersensitivity through release of inflammatory mediators such as histamine. Contributes to immunity to parasites by activating Eosinophils.

Antigen type and memory

Thymus-independent antigens

Antigens lacking a peptide component (eg, lipopolysaccharides from gram \ominus bacteria); cannot be presented by MHC to T cells. Weakly immunogenic; vaccines often require boosters and adjuvants (eg, capsular polysaccharide subunit of *Streptococcus pneumoniae* PPSV23 vaccine).

Thymus-dependent antigens

Antigens containing a protein component (eg, diphtheria toxoid). Class switching and immunologic memory occur as a result of direct contact of B cells with Th cells.

Complement

System of hepatically synthesized plasma proteins that play a role in innate immunity and inflammation. Membrane attack complex (MAC) defends against gram \ominus bacteria. The CH₅₀ test is used to screen for activation of the classical complement pathway.

ACTIVATION PATHWAYS

Classic—IgG or IgM mediated.

General Motors makes **classic** cars.

Alternative—microbe surface molecules.

Lectin—mannose or other sugars on microbe surface.

FUNCTIONS

C3b—opsonization.

C3b binds to lipopolysaccharides on bacteria.

C3a, C4a, C5a—**anaphylaxis**.

MAC complex is important for neutralizing

C5a—neutrophil chemotaxis.

Neisseria species. Deficiency results in recurrent infection.

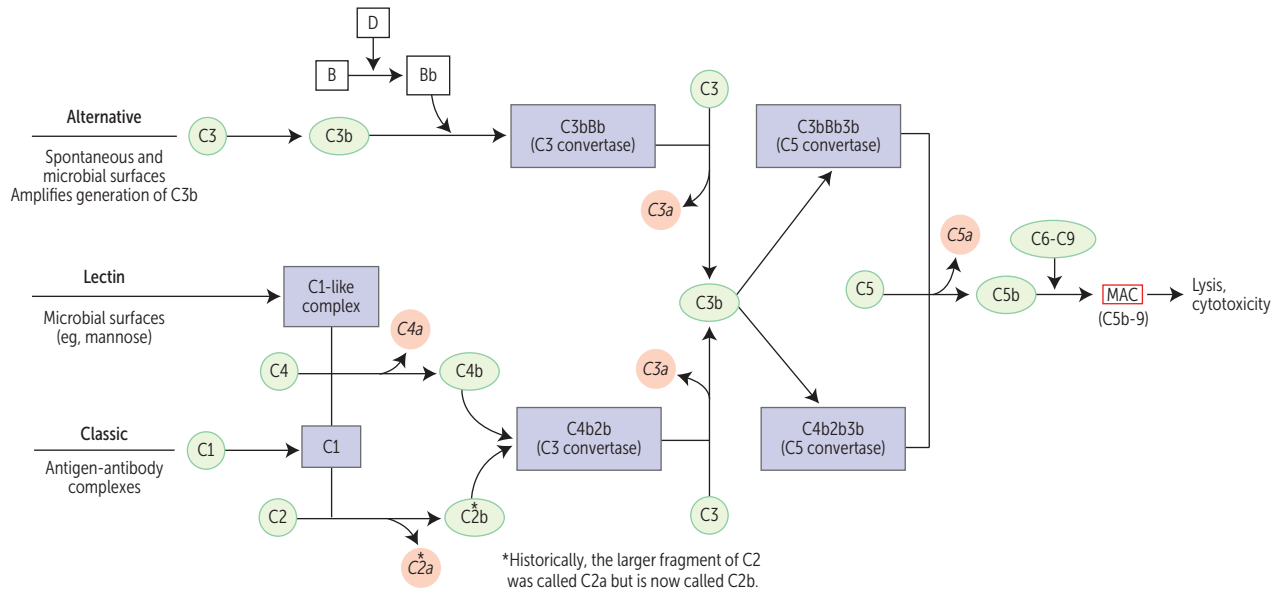
C5b-9 (MAC)—**cytolysis**.

Get “**Neis**” (nice) Big **MACs** from 5-9 pm.

Opsonins—C3b and IgG are the two 1^o opsonins in bacterial defense; enhance phagocytosis. C3b also helps clear immune complexes.

Opsonin (Greek) = to prepare for eating.

Inhibitors—decay-accelerating factor (DAF, also called CD55) and C1 esterase inhibitor help prevent complement activation on self cells (eg, RBCs).



Complement disorders**Complement protein deficiencies**

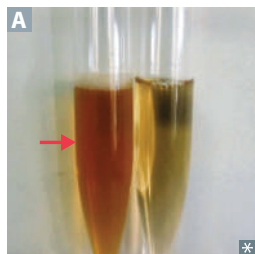
Early complement deficiencies (C1–C4) ↑ risk of severe, recurrent pyogenic sinus and respiratory tract infections. C3b used in clearance of antigen-antibody complexes → ↑ risk of **SLE** (think **SLEarly**).

Terminal complement deficiencies (C5–C9) ↑ susceptibility to recurrent *Neisseria* bacteremia.

Complement regulatory protein deficiencies

C1 esterase inhibitor deficiency Causes hereditary angioedema due to unregulated activation of kallikrein → ↑ bradykinin. Characterized by ↓ C4 levels. ACE inhibitors are contraindicated (also ↑ bradykinin).

Paroxysmal nocturnal hemoglobinuria A defect in the *PIGA* gene prevents the formation of glycosylphosphatidylinositol (GPI) anchors for complement inhibitors, such as decay-accelerating factor (DAF/CD55) and membrane inhibitor of reactive lysis (MIRL/CD59). Causes complement-mediated intravascular hemolysis → ↓ haptoglobin, dark urine **A**.



Can cause atypical venous thrombosis (eg, Budd-Chiari syndrome; portal vein, cerebral, or dermal thrombosis).

Important cytokines Acute (IL-1, IL-6, TNF- α), then recruit (IL-8, IL-12).

Secreted by macrophages

Interleukin-1	Causes fever, acute inflammation. Activates endothelium to express adhesion molecules. Induces chemokine secretion to recruit WBCs. Also called osteoclast-activating factor.	“ Hot T-bone stEAK ”: IL-1: fever (hot). IL-2: stimulates T cells. IL-3: stimulates bone marrow. IL-4: stimulates Ig E production. IL-5: stimulates Ig A production. IL-6: stimulates a K ute-phase protein production.
Interleukin-6	Causes fever and stimulates production of acute-phase proteins.	
Tumor necrosis factor-α	Activates endothelium. Causes WBC recruitment, vascular leak.	Causes cachexia in malignancy. Maintains granulomas in TB. IL-1, IL-6, TNF- α can mediate fever and sepsis.
Interleukin-8	Major chemotactic factor for neutrophils.	“ Clean up on aisle 8. ” Neutrophils are recruited by IL-8 to clear infections.
Interleukin-12	Induces differentiation of T cells into Th1 cells. Activates NK cells.	Facilitates granuloma formation in TB.

Secreted by T cells

Interleukin-2	Stimulates growth of helper, cytotoxic, and regulatory T cells, and NK cells.	
Interleukin-3	Supports growth and differentiation of bone marrow stem cells. Functions like GM-CSF.	

From Th1 cells

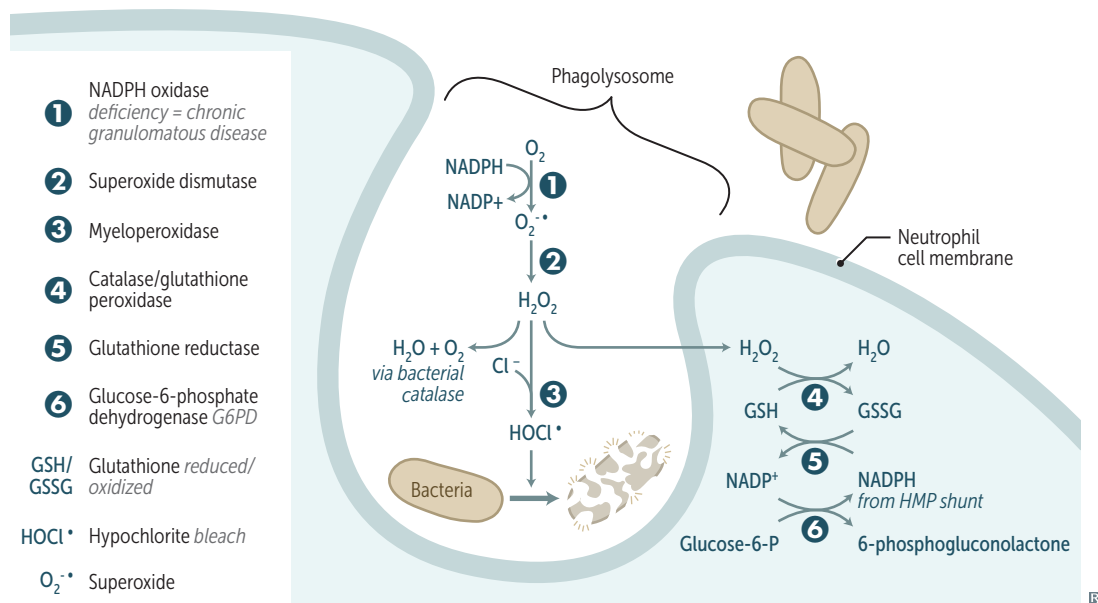
Interferon-γ	Secreted by NK cells and T cells in response to antigen or IL-12 from macrophages; stimulates macrophages to kill phagocytosed pathogens. Inhibits differentiation of Th2 cells. Induces IgG isotype switching in B cells.	Increases MHC expression and antigen presentation by all cells. Activates macrophages to induce granuloma formation.
---------------------------------------	--	--

From Th2 cells

Interleukin-4	Induces differentiation of T cells into Th (helper) 2 cells. Promotes growth of B cells. Enhances class switching to Ig E and Ig G .	Ain't too proud 2 BEG 4 help .
Interleukin-5	Promotes growth and differentiation of B cells. Enhances class switching to Ig A . Stimulates growth and differentiation of E osinophils.	I have 5 BAEs .
Interleukin-10	Attenuates inflammatory response. Decreases expression of MHC class II and Th1 cytokines. Inhibits activated macrophages and dendritic cells. Also secreted by regulatory T cells.	TGF- β and IL- 10 both attenuate the immune response.
Interleukin-13	Promotes IgE production by B cells. Induces alternative macrophage activation.	Interleukin thirt EE n promotes Ig E .

Respiratory burst

Also called oxidative burst. Involves the activation of the phagocyte NADPH oxidase complex (eg, in neutrophils, monocytes), which utilizes O₂ as a substrate. Plays an important role in the immune response → rapid release of reactive oxygen species (ROS). NADPH plays a role in both the creation and neutralization of ROS. Myeloperoxidase contains a blue-green, heme-containing pigment that gives sputum its color.



Phagocytes of patients with CGD can utilize H₂O₂ generated by invading organisms and convert it to ROS. Patients are at ↑ risk for infection by catalase ⊕ species (eg, *S aureus*, *Aspergillus*) capable of neutralizing their own H₂O₂, leaving phagocytes without ROS for fighting infections. Pyocyanin of *P aeruginosa* generates ROS to kill competing pathogens. Oxidative burst leads to release of lysosomal enzymes. Lactoferrin is a protein found in secretory fluids and neutrophils that inhibits microbial growth via iron chelation.

Interferons

IFN-α, IFN-β, IFN-γ.

MECHANISM

A part of innate host defense, **interferons interfere** with both RNA and DNA viruses. Cells infected with a virus synthesize these glycoproteins, which act on local cells, priming them for viral defense by downregulating protein synthesis to resist potential viral replication and by upregulating MHC expression to facilitate recognition of infected cells. Also play a major role in activating antitumor immunity.

CLINICAL USE

Chronic HBV, Kaposi sarcoma, hairy cell leukemia, condyloma acuminatum, renal cell carcinoma, malignant melanoma, multiple sclerosis, chronic granulomatous disease.

ADVERSE EFFECTS

Flulike symptoms, depression, neutropenia, myopathy, interferon-induced autoimmunity.

Cell surface proteins

T cells	TCR (binds antigen-MHC complex), CD3 (associated with TCR for signal transduction), CD28 (binds B7 on APC)	
Helper T cells	CD4, CD40L, CXCR4/CCR5 (coreceptors for HIV)	
Cytotoxic T cells	CD8	
Regulatory T cells	CD4, CD25	
B cells	Ig (binds antigen), CD19, CD20, CD21 (receptor for Epstein-Barr virus), CD40, MHC II, B7 (CD80/86)	Must be 21 to drink at a Barr
NK cells	CD16 (binds Fc of IgG), CD56 (suggestive marker for NK cells)	
Macrophages	CD14 (receptor for PAMPs [eg, LPS]), CD40, CCR5, MHC II, B7, Fc and C3b receptors (enhanced phagocytosis)	
Hematopoietic stem cells	CD34	

Anergy

State during which a cell cannot become activated by exposure to its antigen. T and B cells become anergic when exposed to their antigen without costimulatory signal (signal 2). Another mechanism of self-tolerance.

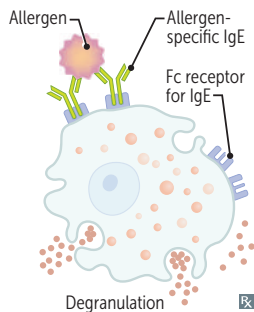
Passive vs active immunity

	Passive	Active
MEANS OF ACQUISITION	Receiving preformed antibodies	Exposure to exogenous antigens
ONSET	Rapid	Slow
DURATION	Short span of antibodies (half-life = 3 weeks)	Long-lasting protection (memory)
EXAMPLES	IgA in breast milk, maternal IgG crossing placenta, antitoxin, humanized monoclonal antibody	Natural infection, vaccines, toxoid
NOTES	After exposure to tetanus toxin, HBV, varicella, rabies virus, botulinum toxin, or diphtheria toxin, unvaccinated patients are given preformed antibodies (passive)—“to H eal v ery r apidly b efore d ying”	Combined passive and active immunizations can be given for hepatitis B or rabies exposure

Vaccination		Induces an active immune response (humoral and/or cellular) to specific pathogens.	
VACCINE TYPE	DESCRIPTION	PROS/CONS	EXAMPLES
Live attenuated vaccine	Microorganism rendered nonpathogenic but retains capacity for transient growth within inoculated host. MMR and varicella vaccines can be given to people living with HIV without evidence of immunity if CD4+ cell count ≥ 200 cells/mm ³ .	Pros: induces cellular and humoral responses. Induces strong, often lifelong immunity. Cons: may revert to virulent form. Contraindicated in pregnancy and patients with immunodeficiency.	A denovirus (nonattenuated, given to military recruits), t yphoid (Ty21a, oral), p olio (Sabin), v aricella (chickenpox), s mallpox, B CG, y ellow fever, i nfluenza (intranasal), M MR, r otavirus. “Attention teachers! Please vaccinate s mall, B eautiful young i nfants with M MR regularly!”
Killed or inactivated vaccine	Pathogen is inactivated by heat or chemicals. Maintaining epitope structure on surface antigens is important for immune response. Mainly induces a humoral response.	Pros: safer than live vaccines. Cons: weaker cell-mediated immune response; booster shots usually needed.	Hepatitis A , T yphoid (Vi polysaccharide, intramuscular), R abies, I nfluenza (intramuscular), P olio (Sal K). A T RIP could K ill you.
Subunit, recombinant, polysaccharide, and conjugate	All use specific antigens that best stimulate the immune system.	Pros: targets specific epitopes of antigen; lower chance of adverse reactions. Cons: expensive; weaker immune response.	HBV (antigen = HBsAg), HPV, acellular pertussis (aP), <i>Neisseria meningitidis</i> (various strains), <i>Streptococcus pneumoniae</i> (PPSV23 polysaccharide primarily T-cell-independent response; PCV13 conjugated polysaccharide produces T-cell-dependent response), <i>Haemophilus influenzae</i> type b, herpes zoster.
Toxoid	Denatured bacterial toxin with an intact receptor binding site. Stimulates immune system to make antibodies without potential for causing disease.	Pros: protects against the bacterial toxins. Cons: antitoxin levels decrease with time, thus booster shots may be needed.	<i>Clostridium tetani</i> , <i>Corynebacterium diphtheriae</i> .
mRNA	A lipid nanoparticle delivers mRNA, causing cells to synthesize foreign protein (eg, spike protein of SARS-CoV-2). Induces cellular and humoral immunity.	Pros: high efficacy, safe in pregnancy. Cons: local and transient systemic (fatigue, headache, myalgia) reactions are common. Rare myocarditis, pericarditis particularly in young males.	SARS-CoV-2

Hypersensitivity types Four types (**ABCD**): **A**naphylactic and **A**tophic (type I), **A**nti**B**ody-mediated (type II), **I**mmune **C**omplex (type III), **D**elayed (cell-mediated, type IV). Types I, II, and III are all antibody-mediated.

Type I hypersensitivity



- Anaphylactic and atopic—two phases:
- Immediate (minutes): antigen crosslinks preformed IgE on presensitized mast cells → immediate degranulation → release of histamine (a vasoactive amine), tryptase (marker of mast cell activation), and leukotrienes.
 - Late (hours): chemokines (attract inflammatory cells, eg, eosinophils) and other mediators from mast cells → inflammation and tissue damage.

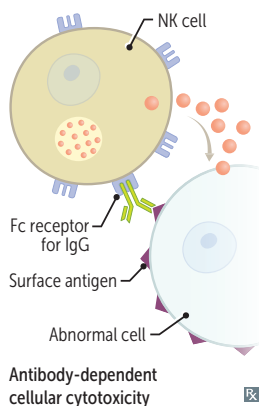
First (type) and **F**ast (anaphylaxis).

Test: skin test or blood test (ELISA) for allergen-specific IgE.

Example:

- Anaphylaxis (eg, food, drug, or bee sting allergies)
- Allergic asthma

Type II hypersensitivity



Antibodies bind to cell-surface antigens or extracellular matrix → cellular destruction, inflammation, and cellular dysfunction.

- Cellular destruction—cell is opsonized (coated) by antibodies, leading to either:
- Phagocytosis and/or activation of complement system.
 - NK cell killing (antibody-dependent cellular cytotoxicity).

Inflammation—binding of antibodies to cell surfaces → activation of complement system and Fc receptor-mediated inflammation.

Cellular dysfunction—antibodies bind to cell-surface receptors → abnormal blockade or activation of downstream process.

Direct Coombs test—detects antibodies attached **directly** to the RBC surface.

Indirect Coombs test—detects presence of unbound antibodies in the serum.

Examples:

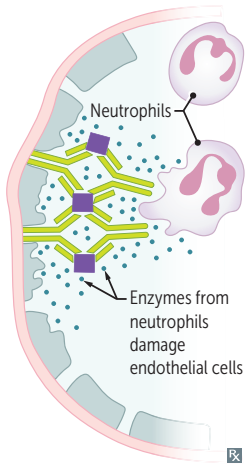
- Autoimmune hemolytic anemia (including drug-induced form)
- Immune thrombocytopenia
- Transfusion reactions
- Hemolytic disease of the newborn

Examples:

- Goodpasture syndrome
- Rheumatic fever
- Hyperacute transplant rejection

Examples:

- Myasthenia gravis
- Graves disease
- Pemphigus vulgaris

Hypersensitivity types (continued)**Type III hypersensitivity**

Immune complex—antigen-antibody (mostly IgG) complexes activate complement, which attracts neutrophils; neutrophils release lysosomal enzymes.

Can be associated with vasculitis and systemic manifestations.

Serum sickness—the prototypic immune complex disease. Antibodies to foreign proteins are produced and 1–2 weeks later, antibody-antigen complexes form and deposit in tissues → complement activation → inflammation and tissue damage (↓ serum C3, C4).

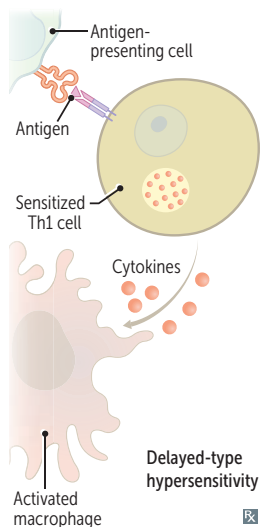
Arthus reaction—a local subacute immune complex-mediated hypersensitivity reaction. Intradermal injection of antigen into a presensitized (has circulating IgG) individual leads to immune complex formation in the skin (eg, enhanced local reaction to a booster vaccination). Characterized by edema, fibrinoid necrosis, activation of complement.

In type **III** reaction, imagine an immune complex as **3** things stuck together: antigen-antibody-complement.

Examples:

- SLE
- Rheumatoid arthritis
- Reactive arthritis
- Polyarteritis nodosa
- Poststreptococcal glomerulonephritis
- IgA vasculitis

Fever, urticaria, arthralgia, proteinuria, lymphadenopathy occur 1–2 weeks after antigen exposure. Serum sickness–like reactions are associated with some drugs (may act as haptens, eg, penicillin, monoclonal antibodies) and infections (eg, hepatitis B).

Type IV hypersensitivity

Two mechanisms, each involving T cells:

1. Direct cell cytotoxicity: CD8+ cytotoxic T cells kill targeted cells.
2. Inflammatory reaction: effector CD4+ T cells recognize antigen and release inflammation-inducing cytokines (shown in illustration).

Response does not involve antibodies (vs types I, II, and III).

Examples:

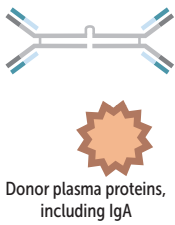
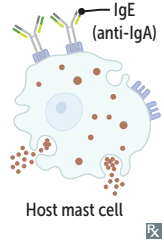

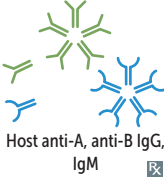


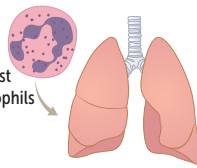
- Contact dermatitis (eg, poison ivy, nickel allergy)
- Graft-versus-host disease

Tests: PPD for TB infection; patch test for contact dermatitis; *Candida* skin test for T cell immune function.

4T's: **T** cells, **T**ransplant rejections, **T**B skin tests, **T**ouching (contact dermatitis).

Fourth (type) and **last** (delayed).

Immunologic blood transfusion reactions

TYPE	PATHOGENESIS	TIMING	CLINICAL PRESENTATION	DONOR BLOOD	HOST BLOOD
Allergic/ anaphylactic reaction	Type I hypersensitivity reaction against plasma proteins in transfused blood IgA-deficient individuals should receive blood products without IgA	Within minutes to 2–3 hr (due to release of preformed inflammatory mediators in degranulating mast cells)	Allergies: urticaria, pruritus Anaphylaxis: wheezing, hypotension, respiratory arrest, shock	 Donor plasma proteins, including IgA	 Host mast cell IgE (anti-IgA)
Acute hemolytic transfusion reaction	Type II hypersensitivity reaction Typically causes intravascular hemolysis (ABO blood group incompatibility)	During transfusion or within 24 hr (due to preformed antibodies)	Fever, hypotension, tachypnea, tachycardia, flank pain, hemoglobinuria (intravascular), jaundice (extravascular)	 Donor RBC with A and/or B group antigens	 Host anti-A, anti-B IgG, IgM
Febrile nonhemolytic transfusion reaction	Cytokines created by donor WBCs accumulate during storage of blood products Reactions prevented by leukoreduction of blood products	Within 1–6 hr (due to preformed cytokines)	Fever, headaches, chills, flushing More common in children	 Donor WBC releases preformed cytokines	
Transfusion- related acute lung injury	Two-hit mechanism: <ul style="list-style-type: none"> Neutrophils are sequestered and primed in pulmonary vasculature due to recipient risk factors Neutrophils are activated by a product (eg, antileukocyte antibodies) in the transfused blood and release inflammatory mediators → ↑ capillary permeability → pulmonary edema 	Within minutes to 6 hr	Respiratory distress, noncardiogenic pulmonary edema	 Donor antileukocyte antibody	 Host neutrophils
Delayed hemolytic transfusion reaction	Anamnestic response to a foreign antigen on donor RBCs (Rh [D] or other minor blood group antigens) previously encountered by recipient Typically causes extravascular hemolysis	Onset over 24 hr Usually presents within 1–2 wk (due to slow destruction by reticuloendothelial system)	Generally self limited and clinically silent Mild fever, hyperbilirubinemia		

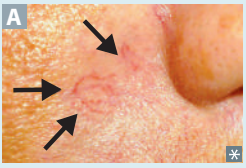
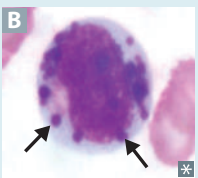
Autoantibodies

AUTOANTIBODY	ASSOCIATED DISORDER
Anti-postsynaptic ACh receptor	Myasthenia gravis
Anti-presynaptic voltage-gated calcium channel	Lambert-Eaton myasthenic syndrome
Anti- β_2 glycoprotein I	Antiphospholipid syndrome
Antinuclear (ANA)	Nonspecific screening antibody, often associated with SLE
Anticardiolipin, lupus anticoagulant	SLE, antiphospholipid syndrome
Anti-dsDNA, anti-Smith	SLE
Antihistone	Drug-induced lupus
Anti-U1 RNP (ribonucleoprotein)	Mixed connective tissue disease
Rheumatoid factor (IgM antibody against IgG Fc region), anti-cyclic citrullinated peptide (anti-CCP, more specific)	Rheumatoid arthritis
Anti-Ro/SSA, anti-La/SSB	Sjögren syndrome
Anti-Scl-70 (anti-DNA topoisomerase I)	Scleroderma (diffuse)
Anticentromere	Limited scleroderma (CREST syndrome)
Antisynthetase (eg, anti-Jo-1), anti-SRP, anti-helicase (anti-Mi-2)	Polymyositis, dermatomyositis
Antimitochondrial	1° biliary cholangitis
Anti-smooth muscle, anti-liver/kidney microsomal-1	Autoimmune hepatitis
Myeloperoxidase-antineutrophil cytoplasmic antibody (MPO-ANCA)/perinuclear ANCA (p-ANCA)	Microscopic polyangiitis, eosinophilic granulomatosis with polyangiitis, ulcerative colitis, 1° sclerosing cholangitis
PR3-ANCA/cytoplasmic ANCA (c-ANCA)	Granulomatosis with polyangiitis
Anti-phospholipase A ₂ receptor	1° membranous nephropathy
Anti-hemidesmosome	Bullous pemphigoid
Anti-desmoglein (anti-desmosome)	Pemphigus vulgaris
Antithyroglobulin, antithyroid peroxidase (antimicrosomal)	Hashimoto thyroiditis
Anti-TSH receptor	Graves disease
IgA anti-endomysial, IgA anti-tissue transglutaminase, IgA and IgG deamidated gliadin peptide	Celiac disease
Anti-glutamic acid decarboxylase, islet cell cytoplasmic antibodies	Type 1 diabetes mellitus
Antiparietal cell, anti-intrinsic factor	Pernicious anemia
Anti-glomerular basement membrane	Goodpasture syndrome

Immunodeficiencies

DISEASE	DEFECT	PRESENTATION	FINDINGS
B-cell disorders			
X-linked (Bruton) agammaglobulinemia	Defect in BTK , a tyrosine kinase gene → no B -cell maturation; X-linked recessive (↑ in B oys)	Recurrent bacterial and enteroviral infections after 6 months (↓ maternal IgG)	Absent B cells in peripheral blood, ↓ Ig of all classes. Absent/scanty lymph nodes and tonsils (1° follicles and germinal centers absent) → live vaccines contraindicated
Selective IgA deficiency	Cause unknown Most common 1° immunodeficiency	Majority A symptomatic Can see A irway and GI infections, A utoimmune disease, A topy, A naphylaxis to IgA in blood products	↓ IgA with normal IgG, IgM levels ↑ susceptibility to giardiasis Can cause false-negative celiac disease test
Common variable immunodeficiency	Defect in B-cell differentiation. Cause unknown in most cases	May present in childhood but usually diagnosed after puberty ↑ risk of autoimmune disease, bronchiectasis, lymphoma, sinopulmonary infections	↓ plasma cells, ↓ immunoglobulins
T-cell disorders			
Thymic aplasia	22q11 microdeletion; failure to develop 3rd and 4th pharyngeal pouches → absent thymus and parathyroids DiGeorge syndrome —thymic, parathyroid, cardiac defects Velocardiofacial syndrome —palate, facial, cardiac defects	CATCH-22 : Cardiac defects (conotruncal abnormalities [eg, tetralogy of Fallot, truncus arteriosus]), A bnormal facies, T hymic hypoplasia → T-cell deficiency (recurrent viral/fungal infections), C left palate, H ypocalcemia 2° to parathyroid aplasia → tetany	↓ T cells, ↓ PTH, ↓ Ca ²⁺ Thymic shadow absent on CXR
IL-12 receptor deficiency	↓ Th1 response; autosomal recessive	Disseminated mycobacterial and fungal infections; may present after administration of BCG vaccine	↓ IFN-γ Most common cause of Mendelian susceptibility to mycobacterial diseases (MSMD)
Autosomal dominant hyper-IgE syndrome (Job syndrome)	Deficiency of Th17 cells due to STAT3 mutation → impaired recruitment of neutrophils to sites of infection	Cold (noninflamed) staphylococcal A bscesses, retained B aby teeth, C oarse facies, D ermatologic problems (eczema), ↑ IgE , bone F ractures from minor trauma	↑ IgE ↑ eosinophils Learn the ABCDEF 's to get a Job!
Chronic mucocutaneous candidiasis	T-cell dysfunction Impaired cell-mediated immunity against <i>Candida</i> sp Classic form caused by defects in AIRE	Persistent noninvasive <i>Candida albicans</i> infections of skin and mucous membranes	Absent in vitro T-cell proliferation in response to <i>Candida</i> antigens Absent cutaneous reaction to <i>Candida</i> antigens

Immunodeficiencies (continued)

DISEASE	DEFECT	PRESENTATION	FINDINGS
B- and T-cell disorders			
Severe combined immunodeficiency	Several types including defective IL-2R gamma chain (most common, X-linked recessive); adenosine deaminase deficiency (autosomal recessive); RAG mutation → VDJ recombination defect	Failure to thrive, chronic diarrhea, thrush Recurrent viral, bacterial, fungal, and protozoal infections	↓ T-cell receptor excision circles (TRECs) Part of newborn screening for SCID Absence of thymic shadow (CXR), germinal centers (lymph node biopsy), and T cells (flow cytometry)
Ataxia-telangiectasia 	Defects in ATM gene → failure to detect DNA damage → failure to halt progression of cell cycle → mutations accumulate; autosomal recessive	Triad: cerebellar defects (A taxia), spider A ngiomas (telangiectasia A), IgA deficiency ↑↑ sensitivity to radiation (limit x-ray exposure)	↑ A FP ↓ IgA, IgG, and IgE Lymphopenia, cerebellar atrophy ↑ risk of lymphoma and leukemia
Hyper-IgM syndrome	Most commonly due to defective CD40L on Th cells → class switching defect; X-linked recessive	Severe pyogenic infections early in life; opportunistic infection with <i>Pneumocystis</i> , <i>Cryptosporidium</i> , CMV	Normal or ↑ IgM ↓↓ IgG, IgA, IgE Failure to make germinal centers
Wiskott-Aldrich syndrome	Mutation in WAS gene; leukocytes and platelets unable to reorganize actin cytoskeleton → defective antigen presentation; X-linked recessive	WATER: W iskott-Aldrich: T hrombocytopenia, E czema, R ecurrent (pyogenic) infections ↑ risk of autoimmune disease and malignancy	↓ to normal IgG, IgM ↑ IgE, IgA Fewer and smaller platelets
Phagocyte dysfunction			
Leukocyte adhesion deficiency (type 1)	Defect in LFA-1 integrin (CD18) protein on phagocytes; impaired migration and chemotaxis; autosomal recessive	L ate separation (>30 days) of umbilical cord, a bsent pus, d ysfunctional neutrophils → recurrent skin and mucosal bacterial infections	↑ neutrophils in blood Absence of neutrophils at infection sites → impaired wound healing
Chédiak-Higashi syndrome 	Defect in lysosomal trafficking regulator gene (<i>LYST</i>) Microtubule dysfunction in phagosome-lysosome fusion; autosomal recessive	PLAIN: P rogressive neurodegeneration, L ymphohistiocytosis, A lbinism (partial), recurrent pyogenic I nfections, peripheral N europathy	Giant granules (B , arrows) in granulocytes and platelets Pancytopenia Mild coagulation defects
Chronic granulomatous disease	Defect of NADPH oxidase → ↓ reactive oxygen species (eg, superoxide) and ↓ respiratory burst in neutrophils; X-linked form most common	↑ susceptibility to catalase ⊕ organisms Recurrent infections and granulomas	Abnormal dihydrorhodamine (flow cytometry) test (↓ green fluorescence) Nitroblue tetrazolium dye reduction test (obsolete) fails to turn blue

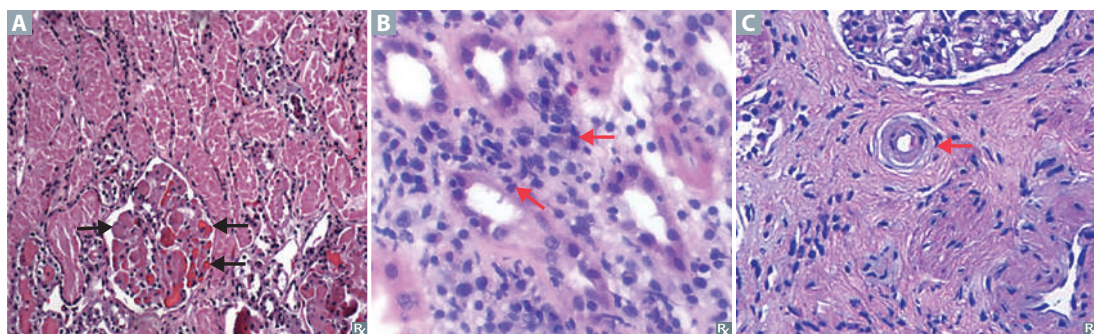
Infections in immunodeficiency

PATHOGEN	↓ T CELLS	↓ B CELLS	↓ GRANULOCYTES	↓ COMPLEMENT
Bacteria	Sepsis	Encapsulated (Please SHINE my SKiS): <i>Pseudomonas aeruginosa</i> , <i>Streptococcus pneumoniae</i> , <i>Haemophilus Influenzae</i> type b, <i>Neisseria meningitidis</i> , <i>Escherichia coli</i> , <i>Salmonella</i> , <i>Klebsiella pneumoniae</i> , group B <i>Streptococcus</i>	Some B acteria Produce No Serious granules: <i>Staphylococcus</i> , <i>Burkholderia cepacia</i> , <i>Pseudomonas aeruginosa</i> , <i>Nocardia</i> , <i>Serratia</i>	Encapsulated species with early complement deficiencies <i>Neisseria</i> with late complement (C5–C9) deficiencies
Viruses	CMV, EBV, JC virus, VZV, chronic infection with respiratory/GI viruses	Enteroviral encephalitis, poliovirus (live vaccine contraindicated)	N/A	N/A
Fungi/parasites	<i>Candida</i> (local), PCP, <i>Cryptococcus</i>	GI giardiasis (no IgA)	<i>Candida</i> (systemic), <i>Aspergillus</i> , <i>Mucor</i>	N/A

Note: **B**-cell deficiencies tend to produce recurrent **b**acterial infections, whereas T-cell deficiencies produce more fungal and viral infections.

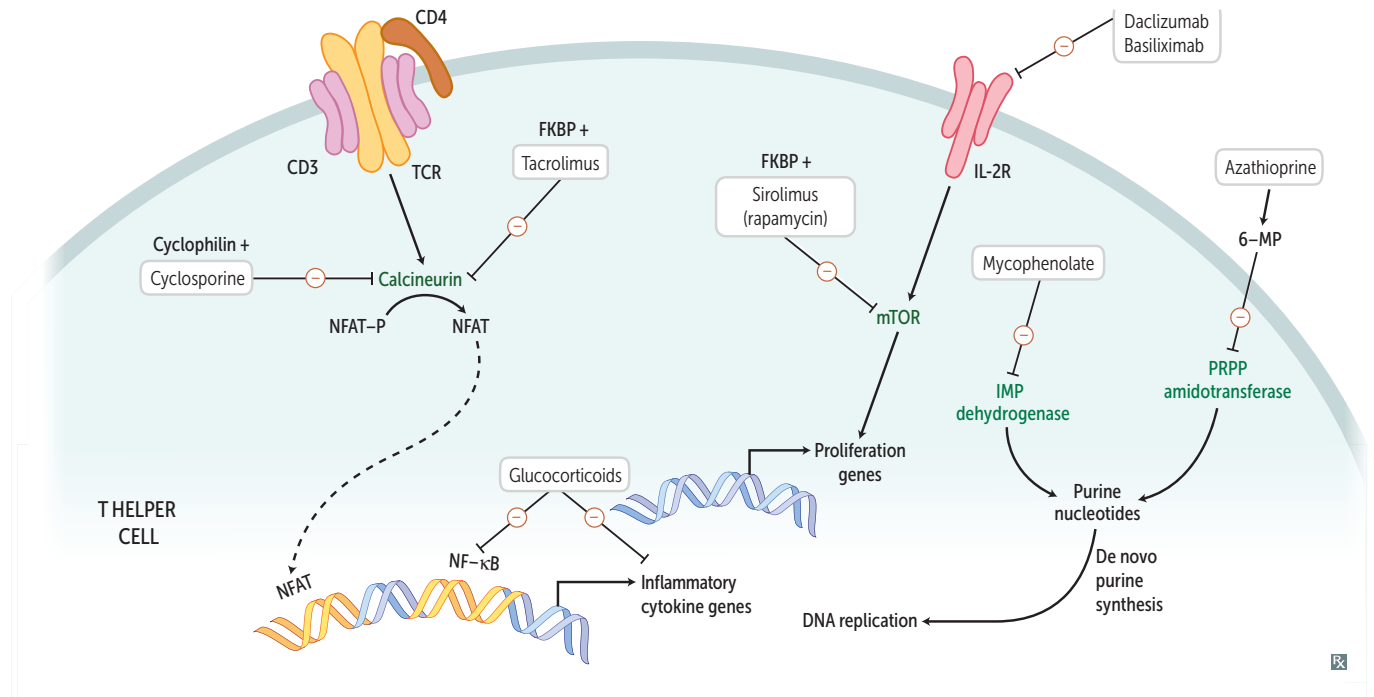
Transplant rejection

TYPE OF REJECTION	ONSET	PATHOGENESIS	FEATURES
Hyperacute	Within minutes	Pre-existing recipient antibodies react to donor antigen (type II hypersensitivity reaction), activate complement	Widespread thrombosis of graft vessels (arrows within glomerulus A) → ischemia and fibrinoid necrosis Graft must be removed
Acute	Weeks to months	Cellular: CD8+ T cells and/or CD4+ T cells activated against donor MHCs (type IV hypersensitivity reaction) Humoral: similar to hyperacute, except antibodies develop after transplant (associated with C4d deposition)	Vasculitis of graft vessels with dense interstitial lymphocytic infiltrate B Prevent/reverse with immunosuppressants
Chronic	Months to years	CD4+ T cells respond to recipient APCs presenting donor peptides, including allogeneic MHC Both cellular and humoral components (type II and IV hypersensitivity reactions)	Recipient T cells react and secrete cytokines → proliferation of vascular smooth muscle, parenchymal atrophy, interstitial fibrosis Dominated by arteriosclerosis C Organ-specific examples: ▪ Chronic allograft nephropathy ▪ Bronchiolitis obliterans ▪ Accelerated atherosclerosis (heart) ▪ Vanishing bile duct syndrome
Graft-versus-host disease	Varies	Grafted immunocompetent T cells proliferate in the immunocompromised host and reject host cells with “foreign” proteins → severe organ dysfunction HLA mismatches (most importantly HLA-A, -B, and -DR antigens) ↑ the risk for GVHD Type IV hypersensitivity reaction	Maculopapular rash, jaundice, diarrhea, hepatosplenomegaly Usually in bone marrow and liver transplants (rich in lymphocytes) Potentially beneficial in bone marrow transplant for leukemia (graft-versus-tumor effect) For patients who are immunocompromised, irradiate blood products prior to transfusion to prevent GVHD



▶ IMMUNOLOGY—IMMUNOSUPPRESSANTS

Immunosuppressants Agents that block lymphocyte activation and proliferation. Reduce acute transplant rejection by suppressing cellular immunity (used as prophylaxis). Frequently combined to achieve greater efficacy with ↓ toxicity. Chronic suppression ↑ risk of infection and malignancy.



DRUG	MECHANISM	INDICATIONS	TOXICITY	NOTES
Cyclosporine	Calcineurin inhibitor; binds cyclophilin Blocks T-cell activation by preventing IL-2 transcription	Psoriasis, rheumatoid arthritis	Nephrotoxicity , hypertension, hyperlipidemia, neurotoxicity, gingival hyperplasia, hirsutism	Both calcineurin inhibitors are highly nephrotoxic, especially in higher doses or in patients with ↓ renal function
Tacrolimus (FK506)	Calcineurin inhibitor; binds FK506 binding protein (FKBP) Blocks T-cell activation by preventing IL-2 transcription	Immunosuppression after solid organ transplant	Similar to cyclosporine, ↑ risk of diabetes and neurotoxicity; no gingival hyperplasia or hirsutism	
Sirolimus (Rapamycin)	mTOR inhibitor; binds FKBP Blocks T-cell activation and B-cell differentiation by preventing response to IL-2	Kidney transplant rejection prophylaxis specifically Sir Basil's kidney transplant	“Pans ir topenia” (pancytopenia), insulin resistance, hyperlipidemia; not nephrotoxic	Kidney “ sir -vives.” Synergistic with cyclosporine Also used in drug-eluting stents
Basiliximab	Monoclonal antibody; blocks IL-2R		Edema, hypertension, tremor	

Immunosuppressants (continued)

DRUG	MECHANISM	INDICATIONS	TOXICITY	NOTES
Azathioprine	Antimetabolite precursor of 6-mercaptopurine Inhibits lymphocyte proliferation by blocking nucleotide synthesis	Rheumatoid arthritis, Crohn disease, glomerulonephritis, other autoimmune conditions	Pancytopenia	6-MP degraded by xanthine oxidase; toxicity ↑ by allopurinol Pronounce “azathio- purine ”
Mycophenolate Mofetil	Reversibly inhibits IMP dehydrogenase, preventing purine synthesis of B and T cells	Glucocorticoid-sparing agent in rheumatic disease	GI upset, pancytopenia, hypertension Less nephrotoxic and neurotoxic	Associated with invasive CMV infection
Glucocorticoids	Inhibit NF-κB Suppress both B- and T-cell function by ↓ transcription of many cytokines Induce T cell apoptosis	Many autoimmune and inflammatory disorders, adrenal insufficiency, asthma, CLL, non-Hodgkin lymphoma	Cushing syndrome, osteoporosis, hyperglycemia, diabetes, amenorrhea, adrenocortical atrophy, peptic ulcers, psychosis, cataracts, avascular necrosis (femoral head)	Demargination of WBCs causes artificial leukocytosis Adrenal insufficiency may develop if drug is stopped abruptly after chronic use

Recombinant cytokines and clinical uses

CYTOKINE	AGENT	CLINICAL USES
Bone marrow stimulation		
Erythropoietin	Epoetin alfa (EPO analog)	Anemias (especially in renal failure) Associated with ↑ risk of hypertension, thromboembolic events
Colony stimulating factors	Filgrastim (G -CSF), Sargramostim (GM -CSF)	Leukopenia; recovery of g ranulocyte and m onocyte counts
Thrombopoietin	Romiplostim (TPO analog), eltrombopag (think “el th rombopag.” TPO receptor agonist)	Autoimmune thrombocytopenia P latelet s timulator
Immunotherapy		
Interleukin-2	Aldesleukin	Renal cell carcinoma, metastatic melanoma
Interferons	IFN-α	Chronic hepatitis C (not preferred) and B, renal cell carcinoma
	IFN-β	Multiple sclerosis
	IFN-γ	Chronic g ranulomatous disease

Therapeutic antibodies

AGENT	TARGET	CLINICAL USE	NOTES
Autoimmune disease therapy			
Adalimumab, infliximab	Soluble TNF- α	IBD, rheumatoid arthritis, ankylosing spondylitis, psoriasis	Pretreatment screening (CMV, EBV, HBV, HCV, TB, VZV) due to risk of reactivation Etanercept is a decoy TNF- α receptor and not a monoclonal antibody
Eculizumab	Complement protein C5	Paroxysmal nocturnal hemoglobinuria	Associated with \uparrow risk of meningococcal infection
Guselkumab	IL-23	Psoriasis	
Ixekizumab, secukinumab	IL-17A	Psoriasis, psoriatic arthritis	
Natalizumab	α 4-integrin	Multiple sclerosis, Crohn disease	α 4-integrin: WBC adhesion Risk of PML in patients with JC virus
Ustekinumab	IL-12/IL-23	Psoriasis, psoriatic arthritis	
Vedolizumab	α 4-integrin	IBD	Gut-specific anti-integrin, preventing migration of leukocytes to the gastrointestinal tract
Other applications			
Denosumab	RANKL	Osteoporosis; inhibits osteoclast maturation (mimics osteoprotegerin)	D enosumab helps make d ense bones
Emicizumab	Factor IXa and X	Hemophilia A	Bispecific; mimics factor VIII
Omalizumab	IgE	Refractory allergic asthma; prevents IgE binding to Fc ϵ RI	
Palivizumab	RSV F protein	RSV prophylaxis for high-risk infants	Palivizumab— v irus

Microbiology

“Support bacteria. They’re the only culture some people have.”
—Steven Wright

“What lies behind us and what lies ahead of us are tiny matters compared to what lies within us.”
—Henry S. Haskins

“Wise and humane management of the patient is the best safeguard against infection.”
—Florence Nightingale

“I sing and play the guitar, and I’m a walking, talking bacterial infection.”
—Kurt Cobain

▶ Basic Bacteriology	122
▶ Clinical Bacteriology	132
▶ Mycology	149
▶ Parasitology	152
▶ Virology	159
▶ Systems	175
▶ Antimicrobials	184

Microbiology questions on the Step 1 exam often require two (or more) steps: Given a certain clinical presentation, you will first need to identify the most likely causative organism, and you will then need to provide an answer regarding some features of that organism or relevant antimicrobial agents. For example, a description of a child with fever and a petechial rash will be followed by a question that reads, “From what site does the responsible organism usually enter the blood?”

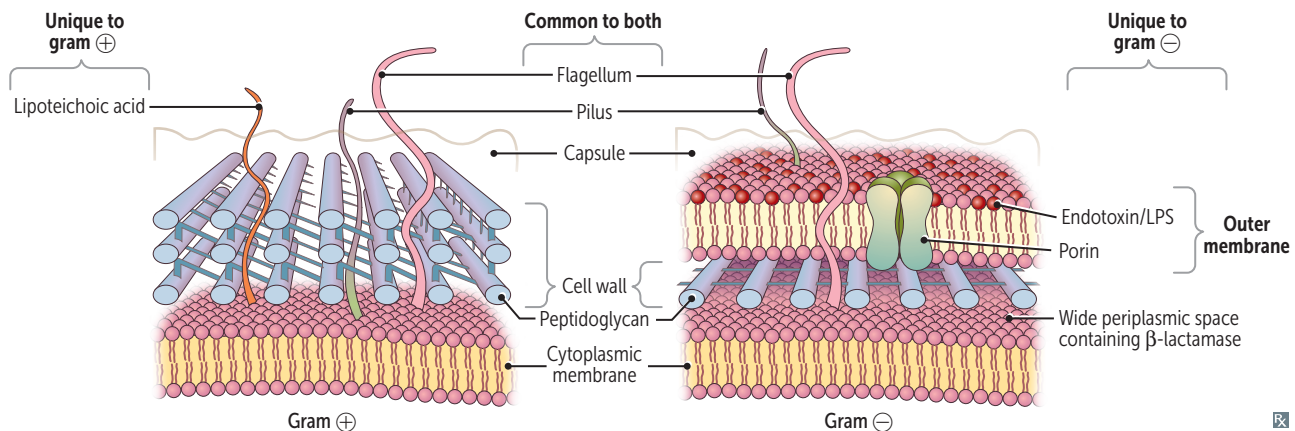
This section therefore presents organisms in two major ways: in individual microbial “profiles” and in the context of the systems they infect and the clinical presentations they produce. You should become familiar with both formats. When reviewing the systems approach, remind yourself of the features of each microbe by returning to the individual profiles. Also be sure to memorize the laboratory characteristics that allow you to identify microbes.

► MICROBIOLOGY—BASIC BACTERIOLOGY

Bacterial structures

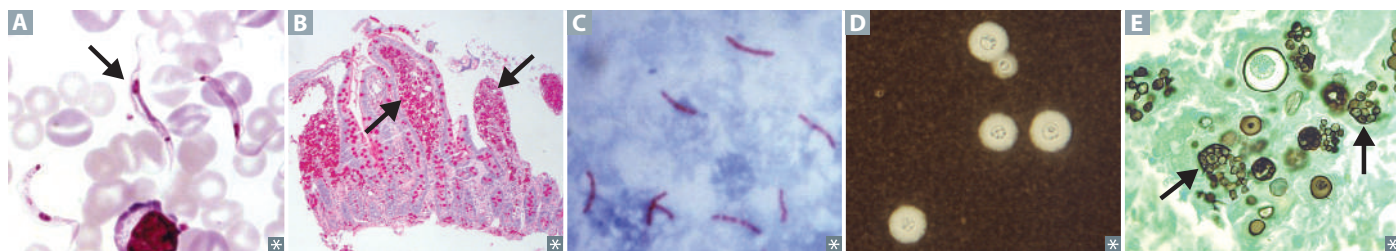
STRUCTURE	CHEMICAL COMPOSITION	FUNCTION
Appendages		
Flagellum	Proteins	Motility
Pilus/fimbria	Glycoprotein	Mediate adherence of bacteria to cell surface; sex pilus forms during conjugation
Specialized structures		
Spore	Keratinlike coat; dipicolinic acid; peptidoglycan, DNA	Gram \oplus only Survival: resist dehydration, heat, chemicals
Cell envelope		
Capsule	Discrete layer usually made of polysaccharides (and rarely proteins)	Protects against phagocytosis
Slime (S) layer	Loose network of polysaccharides	Mediates adherence to surfaces, plays a role in biofilm formation (eg, indwelling catheters)
Outer membrane	Outer leaflet: contains endotoxin (LPS/LOS) Embedded proteins: porins and other outer membrane proteins (OMPs) Inner leaflet: phospholipids	Gram \ominus only Endotoxin: lipid A induces TNF and IL-1; antigenic O polysaccharide component Most OMPs are antigenic Porins: transport across outer membrane
Periplasm	Space between cytoplasmic membrane and outer membrane in gram \ominus bacteria (peptidoglycan in middle)	Accumulates components exiting gram \ominus cells, including hydrolytic enzymes (eg, β -lactamases)
Cell wall	Peptidoglycan is a sugar backbone with peptide side chains cross-linked by transpeptidase	Netlike structure gives rigid support, protects against osmotic pressure damage
Cytoplasmic membrane	Phospholipid bilayer sac with embedded proteins (eg, penicillin-binding proteins [PBPs]) and other enzymes Lipoteichoic acids (gram p ositive) only extend from membrane to exterior	Site of oxidative and transport enzymes; PBPs involved in cell wall synthesis Lipoteichoic acids induce TNF- α and IL-1

Cell envelope



Stains

Gram stain	First-line lab test in bacterial identification. Bacteria with thick peptidoglycan layer retain crystal violet dye (gram ⊕); bacteria with thin peptidoglycan layer turn red or pink (gram ⊖) with counterstain. These bugs do not Gram stain well (These Little Microbes May Unfortunately Lack Real Color But Are Everywhere):	
	<i>Treponema</i> , <i>Leptospira</i>	Too thin to be visualized
	Mycobacteria	Cell wall has high lipid content
	<i>Mycoplasma</i> , <i>Ureaplasma</i>	No cell wall
	<i>Legionella</i> , <i>Rickettsia</i> , <i>Chlamydia</i> , <i>Bartonella</i> , <i>Anaplasma</i> , <i>Ehrlichia</i>	Primarily intracellular; also, <i>Chlamydia</i> lack classic peptidoglycan because of ↓ muramic acid
Giemsa stain	<i>Chlamydia</i> , <i>Rickettsia</i> , Trypanosomes A , <i>Borrelia</i> , <i>Helicobacter pylori</i> , <i>Plasmodium</i>	Clumsy Rick Tripped on a Borrowed Helicopter Plastered in Gems
Periodic acid–Schiff stain	Stains glycogen , mucopolysaccharides; used to diagnose Whipple disease (<i>Tropheryma whipplei</i> B)	PaSs the sugar
Ziehl-Neelsen stain (carbol fuchsin)	Acid-fast bacteria (eg, <i>Mycobacteria</i> C , <i>Nocardia</i> ; stains mycolic acid in cell wall); protozoa (eg, <i>Cryptosporidium</i> oocysts)	Auramine-rhodamine stain is more often used for screening (inexpensive, more sensitive)
India ink stain	<i>Cryptococcus neoformans</i> D ; mucicarmine can also be used to stain thick polysaccharide capsule red	
Silver stain	<i>Helicobacter pylori</i> , <i>Legionella</i> , <i>Bartonella henselae</i> , and fungi (eg, <i>Coccidioides</i> E , <i>Pneumocystis jirovecii</i> , <i>Aspergillus fumigatus</i>)	HeLiCoPters Are silver
Fluorescent antibody stain	Used to identify many bacteria, viruses, <i>Pneumocystis jirovecii</i> , <i>Giardia</i> , and <i>Cryptosporidium</i>	Example is FTA-ABS for syphilis



Special culture requirements

BUG	MEDIA USED FOR ISOLATION	MEDIA CONTENTS/OTHER
<i>H influenzae</i>	Chocolate agar	Factors V (NAD ⁺) and X (hematin)
<i>N gonorrhoeae</i> , <i>N meningitidis</i>	Thayer-Martin agar	Selectively favors growth of <i>Neisseria</i> by inhibiting growth of gram ⊕ organisms with vancomycin, gram ⊖ organisms except <i>Neisseria</i> with trimethoprim and colistin, and fungi with nystatin Very typically cultures <i>Neisseria</i>
<i>B pertussis</i>	Bordet-Gengou agar (Bordet for <i>Bordetella</i>) Regan-Lowe medium	Potato extract Charcoal, blood, and antibiotic
<i>C diphtheriae</i>	Tellurite agar, Löffler medium	
<i>M tuberculosis</i>	Löwenstein-Jensen medium, Middlebrook medium, rapid automated broth cultures	
<i>M pneumoniae</i>	Eaton agar	Requires cholesterol
Lactose-fermenting enterics	MacConkey agar	Fermentation produces acid, causing colonies to turn pink
<i>E coli</i>	Eosin–methylene blue (EMB) agar	Colonies with green metallic sheen
<i>Brucella</i> , <i>Francisella</i> , <i>Legionella</i> , <i>Pasteurella</i>	Charcoal yeast extract agar buffered with cysteine and iron	The Ella siblings, Bruce , Francis , a legionnaire , and a pasteur (pastor), built the Sistine (cysteine) chapel out of charcoal and iron
Fungi	Sabouraud agar	“ Sab ’s a fun guy!”

Anaerobes

Examples include *Clostridium*, *Bacteroides*, *Fusobacterium*, and *Actinomyces israelii*. They lack catalase and/or superoxide dismutase and are thus susceptible to oxidative damage. Generally foul smelling (short-chain fatty acids), are difficult to culture, and produce gas in tissue (CO₂ and H₂).

Anaerobes **Can't Breathe Fresh Air**.

Anaerobes are normal microbiota in GI tract, typically pathogenic elsewhere.

AminO₂glycosides are ineffective against anaerobes because these antibiotics require O₂ to enter into bacterial cell.

Facultative anaerobes

May use O₂ as a terminal electron acceptor to generate ATP, but can also use fermentation and other O₂-independent pathways.

Streptococci, staphylococci, and enteric gram ⊖ bacteria.

Intracellular bacteria

Obligate intracellular

Rickettsia, *Chlamydia*, *Coxiella*
Rely on host ATP

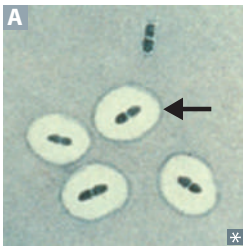
Stay inside (cells) when it is **Really Chilly and Cold**

Facultative intracellular

Salmonella, *Neisseria*, *Brucella*, *Mycobacterium*, *Listeria*, *Francisella*, *Legionella*, *Yersinia pestis*

Some **Nasty Bugs May Live FacultativeLY**

Encapsulated bacteria



Examples are *Pseudomonas aeruginosa*, *Streptococcus pneumoniae* **A**, *Haemophilus influenzae* type b, *Neisseria meningitidis*, *Escherichia coli*, *Salmonella*, *Klebsiella pneumoniae*, and group B **Strep**. Their capsules serve as an antiphagocytic virulence factor.

Capsular polysaccharide + protein conjugate serves as an antigen in vaccines.

Please **SHiNE** my **SKiS**.

Are opsonized, and then cleared by spleen. Asplenic (**No Spleen Here**) have ↓ opsonizing ability and thus ↑ risk for severe infections; need vaccines to protect against:

- **N meningitidis**
- **S pneumoniae**
- **H influenzae**

Encapsulated bacteria vaccines

Some vaccines containing polysaccharide capsule antigens are conjugated to a carrier protein, enhancing immunogenicity by promoting T-cell activation and subsequent class switching. A polysaccharide antigen alone cannot be presented to T cells.

Pneumococcal vaccines: PCV13 (pneumococcal conjugate vaccine), PPSV23 (pneumococcal polysaccharide vaccine with no conjugated protein).

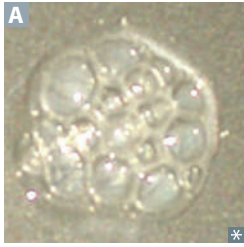
H influenzae type b (conjugate vaccine).

Meningococcal vaccine (conjugate vaccine).

Urease-positive organisms

Proteus, *Cryptococcus*, *H pylori*, *Ureaplasma*, *Nocardia*, *Klebsiella*, *S epidermidis*, *S saprophyticus*. Urease hydrolyzes urea to release ammonia and CO₂ → ↑ pH. Predisposes to struvite (magnesium ammonium phosphate) stones, particularly *Proteus*.

Pee **CHUNKSS**.

Catalase-positive organisms

Catalase degrades H_2O_2 into H_2O and bubbles of O_2 **A** before it can be converted to microbicidal products by the enzyme myeloperoxidase. People with chronic granulomatous disease (NADPH oxidase deficiency) have recurrent infections with certain catalase \oplus organisms.

Big Catalase \oplus organisms include *Bordetella pertussis*, *Helicobacter pylori*, *Burkholderia cepacia*, *Nocardia*, *Pseudomonas*, *Listeria*, *Aspergillus*, *Candida*, *E coli*, *Serratia*, *Staphylococci*. Cats Have BeeN to PLACCESS.

Pigment-producing bacteria

Actinomyces israelii—**yellow** “sulfur” granules, **Israel** has **yellow sand** which are composed of filaments of bacteria

S aureus—**golden** yellow pigment **Aureus** (Latin) = **gold**

P aeruginosa—blue-**green** pigment (pyocyanin and pyoverdin) **Aerugula** is **green**

Serratia marcescens—**red** pigment Think **red Sriracha** hot sauce

In vivo biofilm-producing bacteria

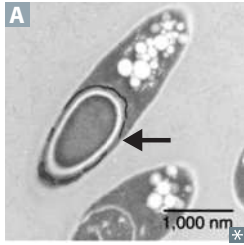
S epidermidis Catheter and prosthetic device infections

Viridans streptococci (*S mutans*, *S sanguinis*) Dental plaques, infective endocarditis

P aeruginosa Respiratory tree colonization in patients with cystic fibrosis, ventilator-associated pneumonia
Contact lens-associated keratitis

Nontypeable (unencapsulated) *H influenzae* Otitis media

Spore-forming bacteria



Some gram \oplus bacteria can form spores **A** when nutrients are limited. Spores lack metabolic activity and are highly resistant to heat and chemicals. Core contains dipicolinic acid (responsible for heat resistance). Must autoclave to kill spores (as is done to surgical equipment) by steaming at 121°C for 15 minutes. Hydrogen peroxide and iodine-based agents are also sporicidal.

Examples: *B anthracis* (anthrax), *B cereus* (food poisoning), *C botulinum* (botulism), *C difficile* (pseudomembranous colitis), *C perfringens* (gas gangrene), *C tetani* (tetanus).

Bacterial virulence factors

These promote evasion of host immune response.

Capsular polysaccharide

Highly charged, hydrophilic structure. Acts as barrier to phagocytosis and complement-mediated lysis. Major determinant of virulence.

Protein A

Binds Fc region of IgG. Prevents opsonization and phagocytosis. Expressed by *S aureus*.

IgA protease

Enzyme that cleaves IgA, allowing bacteria to adhere to and colonize mucous membranes. Secreted by *S pneumoniae*, *H influenzae* type b, and *Neisseria* (**SHiN**).

M protein

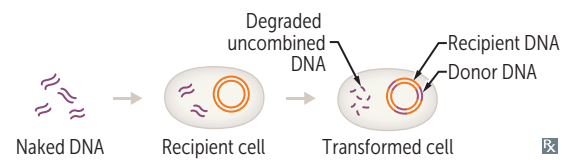
Helps prevent phagocytosis. Expressed by group A streptococci. Sequence homology with human cardiac myosin (**m**olecular **m**imicry); possibly underlies the autoimmune response seen in acute rheumatic fever.

Bacterial genetics

Transformation

Competent bacteria can bind and import short pieces of environmental naked bacterial chromosomal DNA (from bacterial cell lysis). The transfer and expression of newly transferred genes is called transformation. A feature of many bacteria, especially *S pneumoniae*, *H influenzae* type b, and *Neisseria* (**SHiN**).

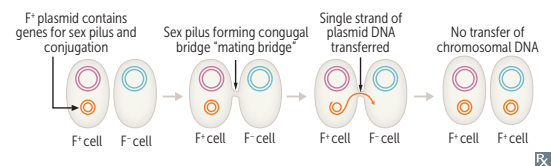
Adding deoxyribonuclease degrades naked DNA, preventing transformation.



Conjugation

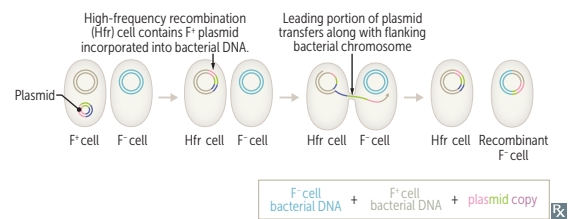
$F^+ \times F^-$

F^+ plasmid contains genes required for sex pilus and conjugation. Bacteria without this plasmid are termed F^- . Sex pilus on F^+ bacterium contacts F^- bacterium. A single strand of plasmid DNA is transferred across the conjugal bridge ("mating bridge"). No transfer of chromosomal DNA.



$Hfr \times F^-$

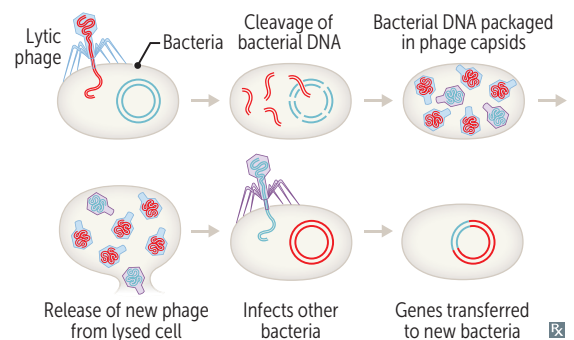
F^+ plasmid can become incorporated into bacterial chromosomal DNA, termed high-frequency recombination (Hfr) cell. Transfer of leading part of plasmid and a few flanking chromosomal genes. High-frequency recombination may integrate some of those bacterial genes. Recipient cell remains F^- but now may have new bacterial genes.



Transduction

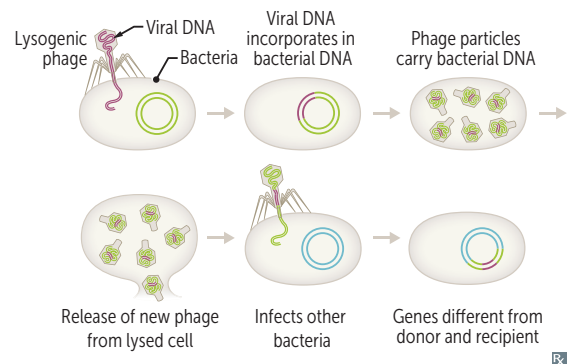
Generalized

A "packaging" error. Lytic phage infects bacterium, leading to cleavage of bacterial DNA. Parts of bacterial chromosomal DNA may become packaged in phage capsid. Phage infects another bacterium, transferring these genes.



Specialized

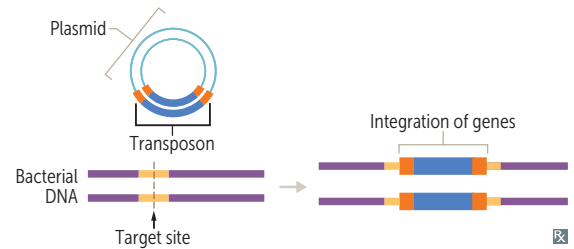
An "excision" event. Lysogenic phage infects bacterium; viral DNA incorporates into bacterial chromosome. When phage DNA is excised, flanking bacterial genes may be excised with it. DNA is packaged into phage capsid and can infect another bacterium. Genes for the following 5 bacterial toxins are encoded in a lysogenic phage (**ABCD'S**): Group **A** strep erythrogenic toxin, **B**otulinum toxin, **C**holera toxin, **D**iphtheria toxin, **S**higa toxin.



Bacterial genetics (continued)

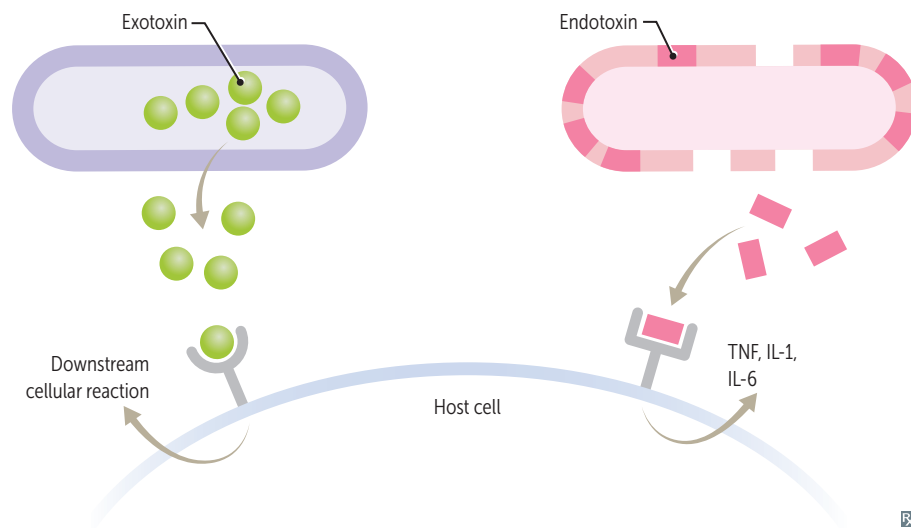
Transposition

A “jumping” process involving a transposon (specialized segment of DNA), which can copy and excise itself and then insert into the same DNA molecule or an unrelated DNA (eg, plasmid or chromosome). Critical in creating plasmids with multiple drug resistance and transfer across species lines (eg, Tn1546 with *vanA* from *Enterococcus* to *S aureus*).



Main features of exotoxins and endotoxins

	Exotoxins	Endotoxins
SOURCE	Certain species of gram ⊕ and gram ⊖ bacteria	Outer cell membrane of most gram ⊖ bacteria
SECRETED FROM CELL	Yes	No
CHEMISTRY	Polypeptide	Lipid A component of LPS (structural part of bacteria; released when lysed)
LOCATION OF GENES	Plasmid or bacteriophage	Bacterial chromosome
TOXICITY	High (fatal dose on the order of 1 μg)	Low (fatal dose on the order of hundreds of micrograms)
CLINICAL EFFECTS	Various effects (see following pages)	Fever, shock (hypotension), DIC
MODE OF ACTION	Various modes (see following pages)	Induces TNF, IL-1, and IL-6
ANTIGENICITY	Induces high-titer antibodies called antitoxins	Poorly antigenic
VACCINES	Toxoids used as vaccines	No toxoids formed and no vaccine available
HEAT STABILITY	Destroyed rapidly at 60°C (except staphylococcal enterotoxin and <i>E coli</i> heat-stable toxin)	Stable at 100°C for 1 hr
TYPICAL DISEASES	Tetanus, botulism, diphtheria, cholera	Meningococcemia; sepsis by gram ⊖ rods



Bacteria with exotoxins

BACTERIA	TOXIN	MECHANISM	MANIFESTATION
Inhibit protein synthesis			
<i>Corynebacterium diphtheriae</i>	Diphtheria toxin ^a	Inactivate elongation factor (EF-2)	Pharyngitis with pseudomembranes in throat and severe lymphadenopathy (bull neck), myocarditis
<i>Pseudomonas aeruginosa</i>	Exotoxin A ^a		Host cell death
<i>Shigella spp</i>	Shiga toxin ^a	Inactivate 60S ribosome by removing adenine from rRNA	Damages GI mucosa → dysentery
Enterohemorrhagic <i>E coli</i>			Enhances cytokine release → hemolytic-uremic syndrome (HUS; prototypically in EHEC serotype O157:H7) Unlike <i>Shigella</i> , EHEC does not invade host cells
Increase fluid secretion			
Enterotoxigenic <i>E coli</i>	Heat- labile toxin (LT) ^a	Overactivates adenylate cyclase (↑ cAMP) → ↑ Cl ⁻ secretion in gut and H ₂ O efflux	Watery diarrhea: “ labile in the A ir (A denylate cyclase), stable on the G round (G uanylate cyclase)” Bacteria that ↑ cAMP include C holera, A nthraxis, P ertussis, E coli ; “ I ncrease cAMP with C APE”
	Heat- stable toxin (ST)	Overactivates guanylate cyclase (↑ cGMP) → ↓ resorption of NaCl and H ₂ O in gut	
<i>Bacillus anthracis</i>	Anthrax toxin ^a	Mimics adenylate cyclase (↑ cAMP)	Likely responsible for characteristic edematous borders of black eschar in cutaneous anthrax
<i>Vibrio cholerae</i>	Cholera toxin ^a	Overactivates adenylate cyclase (↑ cAMP) by permanently activating G _s	Voluminous “rice-water” diarrhea
Inhibit phagocytic ability			
<i>Bordetella pertussis</i>	Pertussis toxin ^a	Activates adenylate cyclase (↑ cAMP) by inactivating inhibitory subunit (G _i).	Whooping cough —child coughs on expiration and “whoops” on inspiration; can cause “100-day cough” in adults; associated with posttussive emesis
Inhibit release of neurotransmitter			
<i>Clostridium tetani</i>	Tetanospasmin ^a	Both are proteases that cleave SNARE (soluble NSF attachment protein receptor), a set of proteins required for neurotransmitter release via vesicular fusion	Toxin prevents release of inhibitory (GABA and glycine) neurotransmitters from Renshaw cells in spinal cord → spastic paralysis, risus sardonicus, trismus (lockjaw), opisthotonos
<i>Clostridium botulinum</i>	Botulinum toxin ^a		Infant botulism—caused by ingestion of spores (eg, from soil, raw honey). Toxin produced in vivo Foodborne botulism—caused by ingestion of preformed toxin (eg, from canned foods)

^aAn AB toxin (also called two-component toxin [or three for anthrax]) with **B** enabling **B**inding and triggering uptake (endocytosis) of the **A**ctive **A** component. The A components are usually ADP ribosyltransferases; others have enzymatic activities as listed in chart.

Bacteria with exotoxins (continued)

BACTERIA	TOXIN	MECHANISM	MANIFESTATION
Lyse cell membranes			
<i>Clostridium perfringens</i>	Alpha toxin	Phospholipase (lecithinase) that degrades tissue and cell membranes	Degradation of phospholipids → myonecrosis (“gas gangrene”) and hemolysis (“double zone” of hemolysis on blood agar)
<i>Streptococcus pyogenes</i>	Streptolysin O	Protein that degrades cell membrane	Lyses RBCs; contributes to β-hemolysis; host antibodies against toxin (ASO) used to diagnose rheumatic fever (do not confuse with immune complexes of poststreptococcal glomerulonephritis)
Superantigens causing shock			
<i>Staphylococcus aureus</i>	Toxic shock syndrome toxin (TSST-1)	Cross-links β region of TCR to MHC class II on APCs outside of the antigen binding site → overwhelming release of IL-1, IL-2, IFN-γ, and TNF-α → shock	Toxic shock syndrome: fever, rash, shock; other toxins cause scalded skin syndrome (exfoliative toxin) and food poisoning (heat-stable enterotoxin)
<i>Streptococcus pyogenes</i>	Erythrogenic exotoxin A		Toxic shock–like syndrome: fever, rash, shock; scarlet fever

Endotoxin

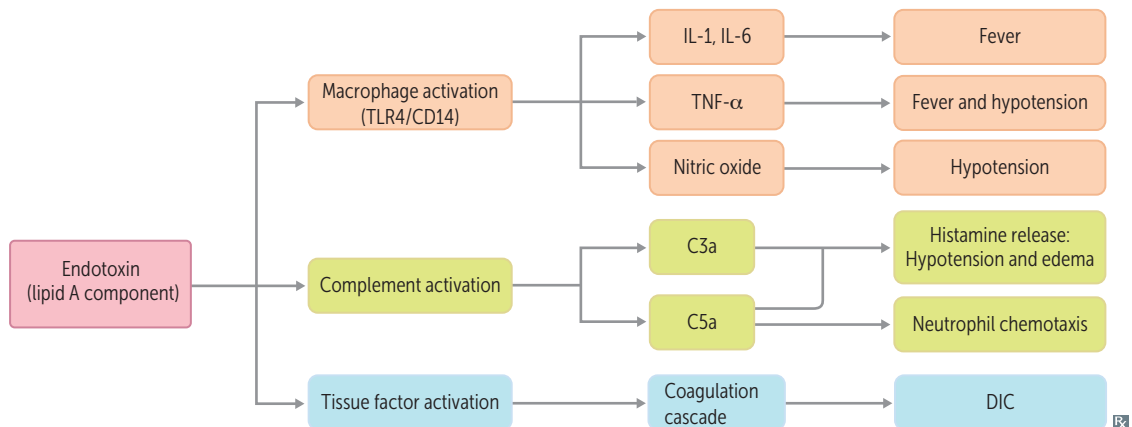
LPS found in outer membrane of gram ⊖ bacteria (both cocci and rods). Composed of O-antigen + core polysaccharide + lipid A (the toxic component). *Neisseria* have lipooligosaccharide.

Released upon cell lysis or by living cells by blebs detaching from outer surface membrane (vs exotoxin, which is actively secreted).

Three main effects: macrophage activation (TLR4/CD14), complement activation, and tissue factor activation.

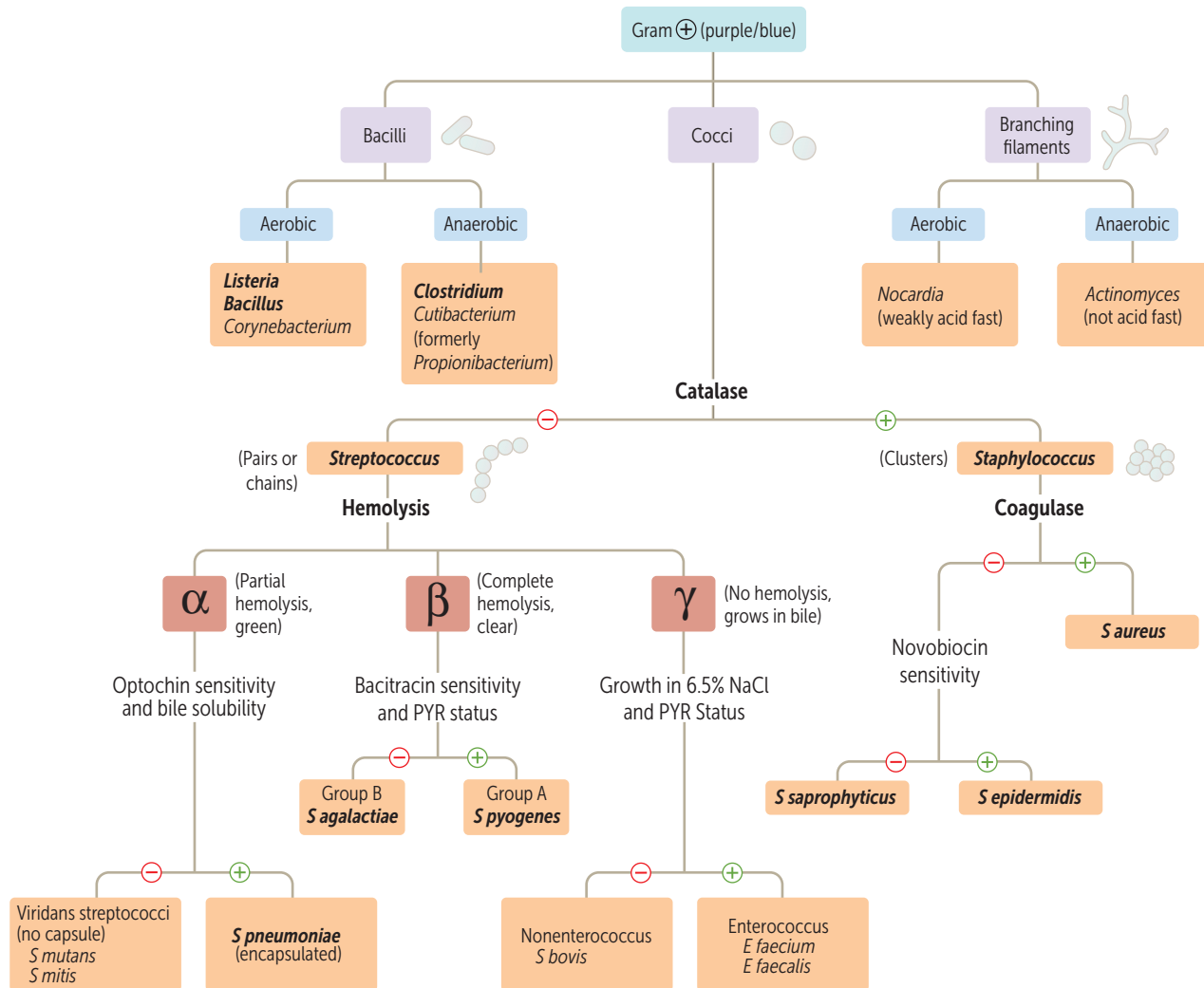
ENDOTOXINS:

- Edema
- Nitric oxide
- DIC/Death
- Outer membrane
- TNF-α
- O-antigen + core polysaccharide + lipid A
- eXtremely heat stable
- IL-1 and IL-6
- Neutrophil chemotaxis
- Shock



▶ MICROBIOLOGY—CLINICAL BACTERIOLOGY

Gram-positive lab algorithm



Important **tests** are in **bold**. Important **pathogens** are in **bold italics**.
 Note: Enterococcus is either α - or γ -hemolytic.



Gram-positive cocci antibiotic tests

Staphylococci

Novobiocin—*Saprophyticus* is resistant;
epidermidis is sensitive

Sapro is a no-go on **Novo**

Streptococci

Optochin—*Viridans* is **Resistant**; *Pneumoniae* is
Sensitive

OVRPS (overpass)

Bacitracin—group **B** strep are **Resistant**; group
A strep are **Sensitive**

B-BRAS

Hemolytic bacteria **α -hemolytic bacteria**

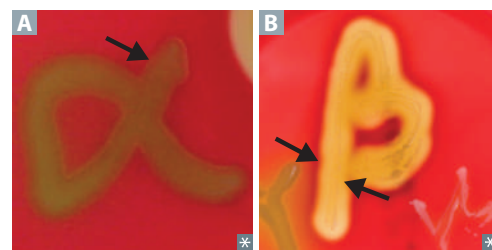
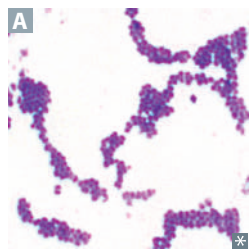
Partial oxidation of hemoglobin → greenish or brownish color without clearing around growth on blood agar **A**.

Include *Streptococcus pneumoniae* and viridans streptococci.

 β -hemolytic bacteria

Complete lysis of RBCs → pale/clear area surrounding colony on blood agar **B**.

Include *Staphylococcus aureus*, *Streptococcus pyogenes* (group A strep), *Streptococcus agalactiae* (group B strep), *Listeria monocytogenes*.)

***Staphylococcus aureus***

Gram \oplus , β -hemolytic, catalase \oplus , coagulase \oplus cocci in clusters **A**. Protein A (virulence factor) binds Fc-IgG, inhibiting complement activation and phagocytosis. Commonly colonizes the nares, ears, axilla, and groin.

Causes:

- Inflammatory disease—skin infections, organ abscesses, pneumonia (often after influenza virus infection), infective endocarditis, septic arthritis, and osteomyelitis.
- Toxin-mediated disease—toxic shock syndrome (TSST-1), scalded skin syndrome (exfoliative toxin), rapid-onset food poisoning (enterotoxins).

MRSA (methicillin-resistant *S aureus*)—important cause of serious healthcare-associated and community-acquired infections. Resistance due to altered penicillin-binding proteins (conferred by *mecA* gene). Some strains release Panton-Valentine leukocidin (PVL), which kills leukocytes and causes tissue necrosis.

TSST-1 is a superantigen that binds to MHC II and T-cell receptor, resulting in polyclonal T-cell activation and cytokine release.

Staphylococcal toxic shock syndrome (TSS)—fever, vomiting, diarrhea, rash, desquamation, shock, end-organ failure. TSS results in \uparrow AST, \uparrow ALT, \uparrow bilirubin. Associated with prolonged use of vaginal tampons or nasal packing.

Compare with *Streptococcus pyogenes* TSS (a toxic shock–like syndrome associated with painful skin infection).

S aureus food poisoning due to ingestion of preformed toxin → short incubation period (2–6 hr) followed by nonbloody diarrhea and emesis. Enterotoxin is heat stable → not destroyed by cooking.

S aureus makes coagulase and toxins. Forms fibrin clot around itself → abscess.

Staphylococcus epidermidis

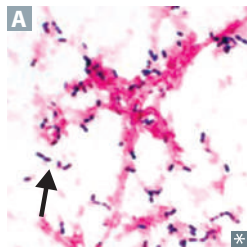
Gram \oplus , catalase \oplus , coagulase \ominus , urease \oplus cocci in clusters. Novobiocin sensitive. Does not ferment mannitol (vs *S aureus*).

Normal microbiota of skin; contaminates blood cultures.

Infects prosthetic devices (eg, hip implant, heart valve) and IV catheters by producing adherent biofilms.

Staphylococcus saprophyticus

Gram \oplus , catalase \oplus , coagulase \ominus , urease \oplus cocci in clusters. Novobiocin resistant.
Normal microbiota of female genital tract and perineum.
Second most common cause of uncomplicated UTI in young females (most common is *E coli*).

Streptococcus pneumoniae

Gram \oplus , α -hemolytic, lancet-shaped diplococci **A**.
Encapsulated. IgA protease. Optochin sensitive and bile soluble.

Most commonly causes **MOPS**:

- Meningitis
- Otitis media (in children)
- Pneumonia
- Sinusitis

Pneumococcus is associated with “rusty” sputum, patients with hyposplenism or asplenia.
No virulence without capsule.

Viridans group streptococci

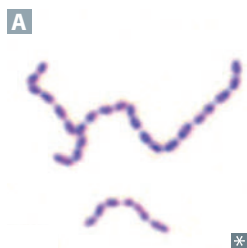
Gram \oplus , α -hemolytic cocci. Optochin resistant and bile insoluble. Normal microbiota of the oropharynx.

Streptococcus mutans and *S mitis* cause dental caries.

S sanguinis makes dextrans that bind to fibrin-platelet aggregates on damaged **heart** valves, causing infective endocarditis.

Viridans group strep live in the mouth, because they are not afraid **of-the-chin** (**op-to-chin** resistant).

Sanguinis = **blood**. Think, “there is lots of **blood** in the **heart**” (infective endocarditis).

***Streptococcus pyogenes* (group A streptococci)**

Gram \oplus cocci in chains **A**. Group A strep cause:

- Pyogenic—pharyngitis, cellulitis, impetigo (“honey-crusted” lesions), erysipelas
- Toxigenic—scarlet fever, toxic shock–like syndrome, necrotizing fasciitis
- Immunologic—rheumatic fever, glomerulonephritis

Bacitracin sensitive, β -hemolytic, pyrrolidonyl arylamidase (PYR) \oplus . Hyaluronic acid capsule and M protein inhibit phagocytosis. Antibodies to M protein enhance host defenses against *S pyogenes* but can give rise to rheumatic fever.

Diagnose strep pharyngitis via throat swab, which can be tested with an antigen detection assay (rapid, in-office results) or cultured on blood agar (results in 48 hours).

“**Ph**”yogenes **pharyngitis** can result in rheumatic “**p**hever” and glomerulone**ph**ritis.

Strains causing impetigo can induce glomerulonephritis.

Key virulence factors include DNase, erythrogenic exotoxin, streptokinase, streptolysin O. ASO titer or anti-DNase B antibodies indicate recent *S pyogenes* infection.

Scarlet fever—blanching, sandpaperlike body rash, strawberry tongue, and circumoral pallor in the setting of group A streptococcal pharyngitis (erythrogenic toxin \oplus).

***Streptococcus agalactiae* (group B streptococci)**

Gram \oplus cocci, bacitracin resistant, β -hemolytic, Group **B** for **B**abies!
 colonizes vagina; causes pneumonia, meningitis, and sepsis, mainly in **babies**.
 Polysaccharide capsule confers virulence.
 Produces CAMP factor, which enlarges the area of hemolysis formed by *S aureus*. (Note: CAMP stands for the authors of the test, not cyclic AMP.) Hippurate test \oplus . PYR \ominus .
 Screen pregnant patients at 35–37 weeks' gestation with rectal and vaginal swabs.
 Patients with \oplus culture receive intrapartum penicillin/ampicillin prophylaxis.

Streptococcus bovis

Gram \oplus cocci, colonizes the gut. *S gallolyticus* (*S bovis* biotype 1) can cause bacteremia and infective endocarditis. Patients with *S bovis* endocarditis have \uparrow incidence of colon cancer. **B**ovis in the **b**lood = **c**ancer in the **c**olon.

Enterococci

Gram \oplus cocci. Enterococci (*E faecalis* and *E faecium*) are normal colonic microbiota that are penicillin G resistant and cause UTI, biliary tract infections, and infective endocarditis (following GI/GU procedures). Catalase \ominus , PYR \oplus , typically nonhemolytic. VRE (vancomycin-resistant enterococci) are an important cause of healthcare-associated infection.

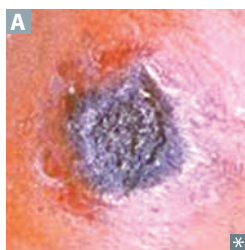Enterococci are more resilient than streptococci, can grow in 6.5% NaCl and bile (lab test).
Entero = intestine, *faecalis* = feces, *strepto* = twisted (chains), *coccus* = berry.

Bacillus anthracis

Gram \oplus , spore-forming rod that produces anthrax toxin (an exotoxin consisting of protective antigen, lethal factor, and edema factor). Has a polypeptide capsule (poly D-glutamate). Colonies show a halo of projections, sometimes called “medusa head” appearance. Both cutaneous and pulmonary anthrax may be complicated by hemorrhagic meningitis.

Cutaneous anthrax

Painless papule surrounded by vesicles \rightarrow ulcer with black eschar **A** (painless, necrotic)
 \rightarrow uncommonly progresses to bacteremia and death.

**Pulmonary anthrax**

Inhalation of spores, most commonly from contaminated animals or animal products, although also a potential bioweapon \rightarrow flulike symptoms that rapidly progress to fever, pulmonary hemorrhage, mediastinitis (CXR may show widened mediastinum), and shock. Also called woolsorter's disease. Prophylaxis with ciprofloxacin or doxycycline when exposed.

Bacillus cereus

Gram ⊕ rod. Causes food poisoning. Spores survive cooking rice (reheated rice syndrome).

Keeping rice warm results in germination of spores and enterotoxin formation.

Emetic type causes nausea and vomiting within 1–5 hours. Caused by cereulide, a preformed toxin.

Diarrheal type causes watery, nonbloody diarrhea and GI pain within 8–18 hours.

Management: supportive care (antibiotics are ineffective against toxins).

Clostridia

Gram ⊕, spore-forming, obligate anaerobic rods. Tetanus toxin and botulinum toxin are proteases that cleave SNARE proteins involved in neurotransmission.

Clostridium tetani

Pathogen is noninvasive and remains localized to wound site. Produces tetanospasmin, an exotoxin causing tetanus. Tetanospasmin spreads by retrograde axonal transport to CNS and blocks release of GABA and glycine from Renshaw cells in spinal cord.

Causes **spastic** paralysis, trismus (lockjaw), risus sardonicus (raised eyebrows and open grin), opisthotonos (spasms of spinal extensors).

Tetanus is **tetanic** paralysis.

Prevent with tetanus vaccine. Treat with antitoxin +/- vaccine booster, antibiotics, diazepam (for muscle spasms), and wound debridement.

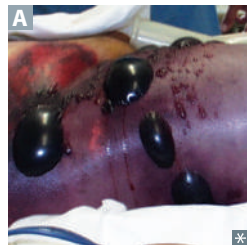
Clostridium botulinum

Produces a heat-labile toxin that inhibits ACh release at the neuromuscular junction, causing botulism. In babies, ingestion of spores (eg, in honey) leads to disease (**floppy** baby syndrome). In adults, disease is caused by ingestion of preformed toxin (eg, in canned food).

Symptoms of botulism (the **5 D's**): **d**iplopia, **d**ysarthria, **d**ysphagia, **d**yspnea, **d**escending **f**laccid paralysis. Does not present with sensory deficits.

Botulinum is from bad **b**ottles of food, juice, and honey.

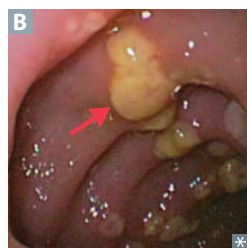
Treatment: human botulinum immunoglobulin. Local botulinum toxin A (Botox) injections used to treat focal dystonia, hyperhidrosis, muscle spasms, and cosmetic reduction of facial wrinkles.

Clostridium perfringens

Produces α-toxin (lecithinase, a phospholipase) that can cause myonecrosis (gas gangrene **A**); presents as soft tissue crepitus) and hemolysis. If heavily spore-contaminated food is cooked but left standing too long at < 60°C, spores germinate → vegetative bacteria → heat-labile enterotoxin → late-onset (10–12 hours) food poisoning symptoms, resolution in 24 hours.

Perfringens perforates a gangrenous leg.

Spontaneous gas gangrene (via hematogenous seeding; associated with colonic malignancy) is most commonly caused by *Clostridium septicum*.

Clostridioides difficile

Produces toxins A and B, which damage enterocytes. Both toxins lead to watery diarrhea → pseudomembranous colitis **B**. Often 2° to antibiotic use, especially clindamycin, ampicillin, cephalosporins, fluoroquinolones; associated with PPIs.

Fulminant infection: toxic megacolon, ileus, shock.

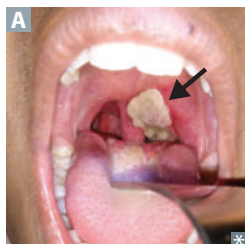
Difficile causes **d**iarrhea.

Diagnosed by PCR or antigen detection of one or both toxins in stool.

Treatment: oral vancomycin or fidaxomicin.

For recurrent cases, consider repeating prior regimen or fecal microbiota transplant.

Corynebacterium diphtheriae



Gram ⊕ rods occurring in angular arrangements; transmitted via respiratory droplets. Causes diphtheria via exotoxin encoded by β-prophage. Potent exotoxin inhibits protein synthesis via ADP-ribosylation of EF-2, leading to possible necrosis in pharynx, cardiac, and CNS tissue.

Symptoms include pseudomembranous pharyngitis (grayish-white membrane **A**) with lymphadenopathy (“bull’s neck” appearance). Toxin dissemination may cause myocarditis, arrhythmias, neuropathies.

Lab diagnosis based on gram ⊕ rods with metachromatic (blue and red) granules and ⊕ Elek test for toxin.

Toxoid vaccine prevents diphtheria.

Coryne = club shaped (metachromatic granules on Löffler media).

Black colonies on cystine-tellurite agar.

ABCDEFGF:

ADP-ribosylation

β-prophage

C*orynebacterium*

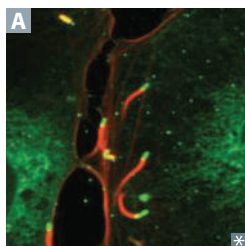
D*iphtheriae*

Elongation **F**actor 2

Granules

Treatment: diphtheria antitoxin +/- erythromycin or penicillin.

Listeria monocytogenes



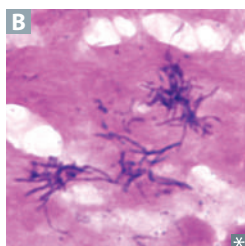
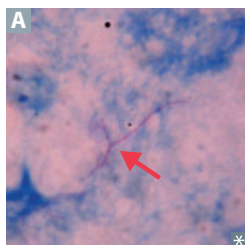
Gram ⊕, facultative intracellular rod; acquired by ingestion of unpasteurized dairy products and cold deli meats, transplacental transmission, by vaginal transmission during birth. Grows well at refrigeration temperatures (“cold enrichment”).

Forms “rocket tails” (red in **A**) via actin polymerization that allow intracellular movement and cell-to-cell spread across cell membranes, thereby avoiding antibody. Listeriolysin generates pores in phagosomes, allowing its escape into cytoplasm. Characteristic tumbling motility in broth.

Can cause amnionitis, septicemia, and spontaneous abortion in pregnant patients; granulomatosis infantiseptica; meningitis in immunocompromised patients, neonates, and older adults; mild, self-limited gastroenteritis in healthy individuals.

Treatment: ampicillin.

Nocardia vs Actinomyces



Both are gram ⊕ and form long, branching filaments resembling fungi.

Nocardia

Aerobe

Acid fast (weak) **A**

Found in soil

Causes pulmonary infections in immunocompromised (can mimic TB but with ⊖ PPD); cutaneous infections after trauma in immunocompetent; can spread to CNS → cerebral abscess

Treat with sulfonamides (TMP-SMX)

Treatment is a **SNAP**: Sulfonamides—*Nocardia*; *Actinomyces*—Penicillin

Actinomyces

Anaerobe

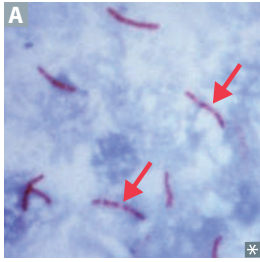
Not acid fast **B**

Normal oral, reproductive, and GI microbiota

Causes oral/facial abscesses that drain through sinus tracts; often associated with dental caries/extraction and other maxillofacial trauma; forms yellow “sulfur granules”; can also cause PID with IUDs

Treat with penicillin

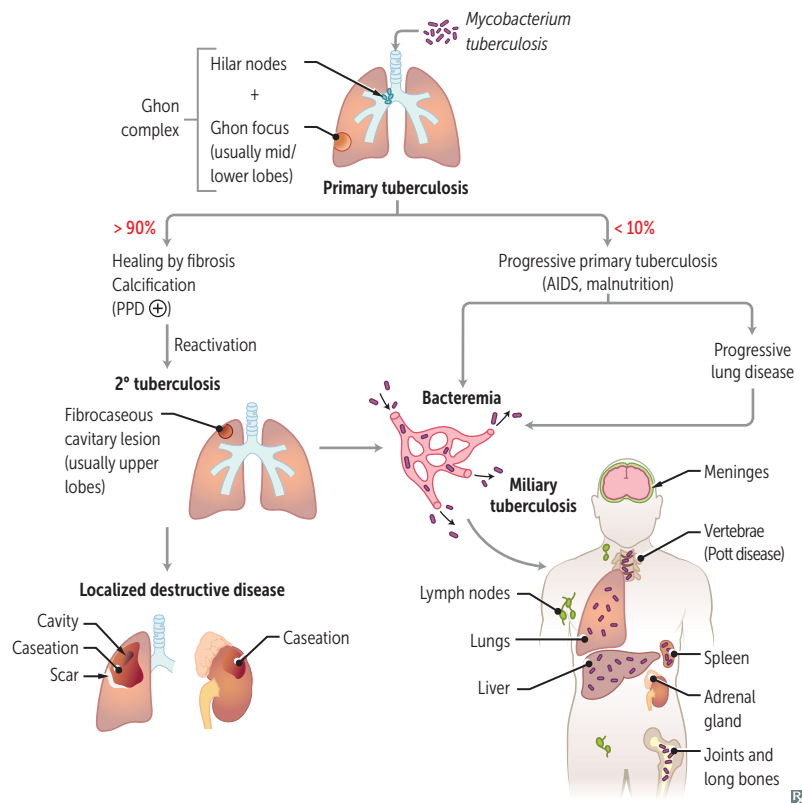
Mycobacteria



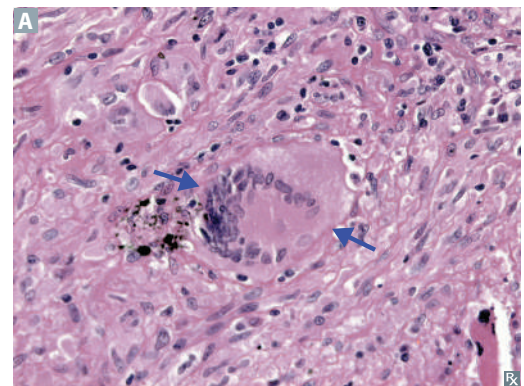
Acid-fast rods (pink rods, arrows in **A**).
Mycobacterium tuberculosis (TB, often resistant to multiple drugs).
M. avium-intracellulare (causes disseminated, non-TB disease in AIDS; often resistant to multiple drugs).
M. scrofulaceum (cervical lymphadenitis in children).
M. marinum (hand infection in aquarium handlers).

TB symptoms include fever, night sweats, weight loss, cough (nonproductive or productive), hemoptysis.
 Cord factor creates a “serpentine cord” appearance in virulent *M. tuberculosis* strains; activates macrophages (promoting granuloma formation) and induces release of TNF- α . Sulfatides (surface glycolipids) inhibit phagolysosomal fusion.

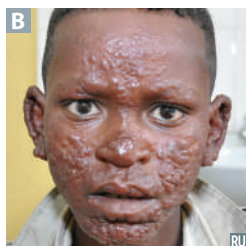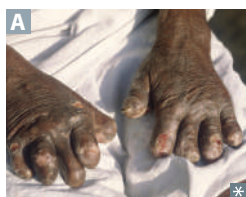Tuberculosis



PPD \oplus if current infection or past exposure.
 PPD \ominus if no infection and in immunocompromised patients (especially with low CD4+ cell count).
 Interferon- γ release assay (IGRA) has fewer false positives from BCG vaccination.
 Caseating granulomas with central necrosis and Langhans giant cell (single example in **A**) are characteristic of 2° tuberculosis. Do not confuse Langhans giant cell (fused macrophages) with Langerhans cell (dermal APC).
 TB reactivation risk highest in immunocompromised individuals (eg, HIV, organ transplant recipients, TNF- α inhibitor use). Reactivation has a predilection for the apices of the lung (due to the bacteria being highly aerobic).



Leprosy



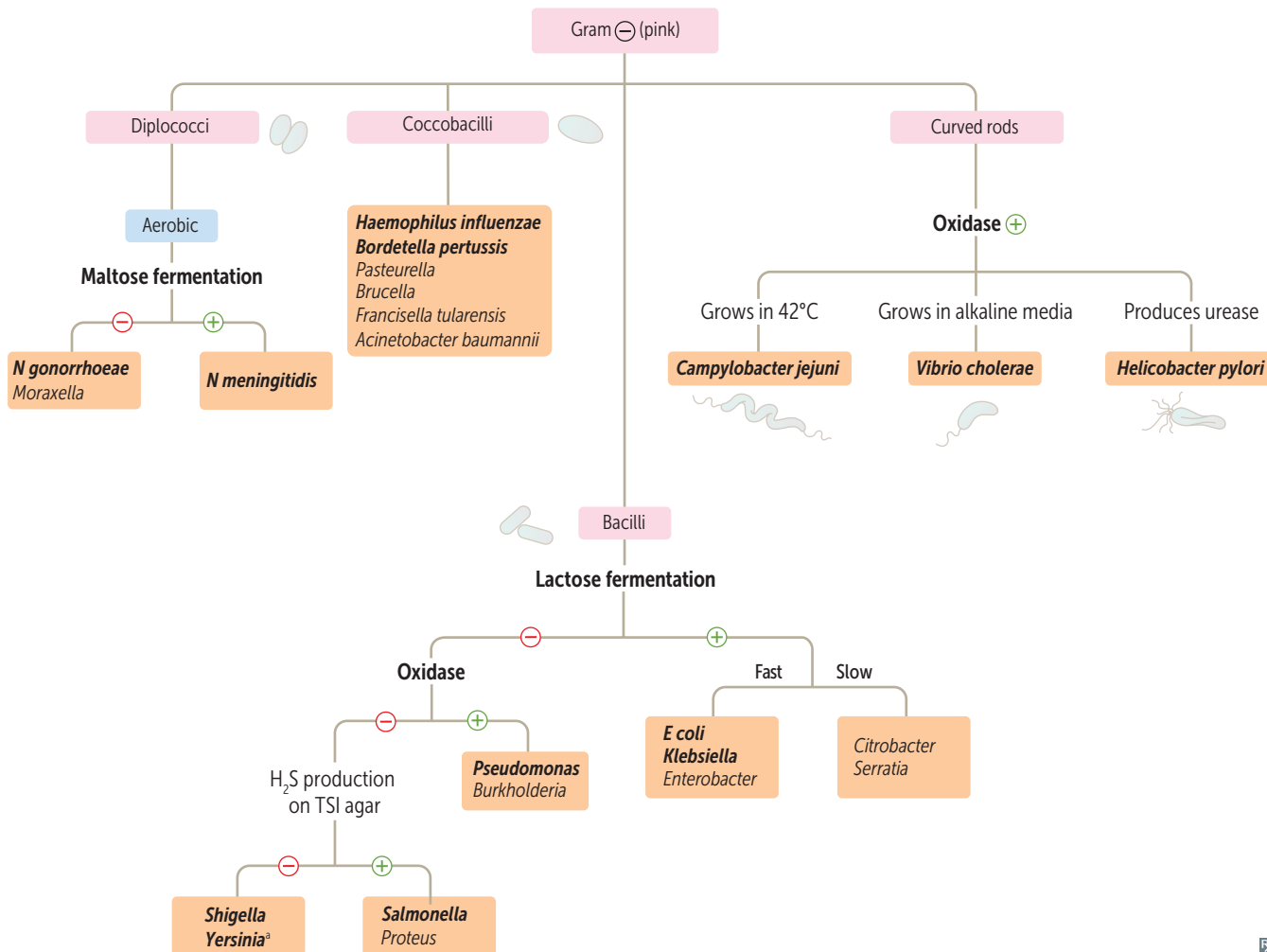
Also called Hansen disease. Caused by *Mycobacterium leprae*, an acid-fast bacillus that likes cool temperatures (infects skin and superficial nerves—“glove and stocking” loss of sensation **A**) and cannot be grown in vitro. Diagnosed via skin biopsy or tissue PCR. Reservoir in United States: armadillos.

Leprosy has 2 forms (many cases fall temporarily between two extremes):

- **Lepromatous**—presents diffusely over the skin, with **leonine** (**l**ionlike) facies **B**, and is communicable (high bacterial load); characterized by low cell-mediated immunity with a largely Th2 response. **L**epromatous form can be **l**ethal.
- **Tuberculoid**—limited to a few hypoesthetic, hairless skin plaques; characterized by high cell-mediated immunity with a largely Th1-type response and low bacterial load.

Treatment: dapsone and rifampin for tuberculoid form; clofazimine is added for lepromatous form.

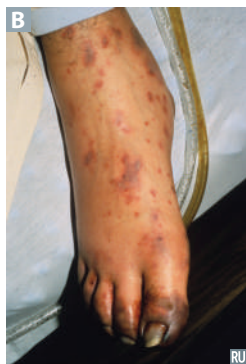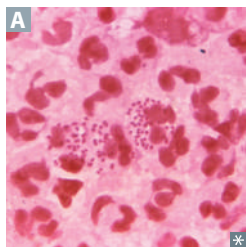
Gram-negative lab algorithm



Important **tests** are in **bold**. Important **pathogens** are in **bold italics**.

^aPleomorphic rod/coccobacillus



Neisseria

Gram \ominus diplococci. Metabolize glucose and produce IgA proteases. Contain lipooligosaccharides (LOS) with strong endotoxin activity.

N gonorrhoeae is often intracellular (within neutrophils) **A**.

Acid production: meningococci—maltose and glucose; gonococci—glucose.

Gonococci

No polysaccharide capsule

No maltose acid detection

No vaccine due to antigenic variation of pilus proteins

Sexually or perinatally transmitted

Causes gonorrhea, septic arthritis, neonatal conjunctivitis (2–5 days after birth), pelvic inflammatory disease (PID), and Fitz-Hugh–Curtis syndrome

Diagnosed with NAAT

Condoms ↓ sexual transmission, erythromycin eye ointment prevents neonatal blindness

Treatment: single dose IM ceftriaxone; if chlamydial coinfection not excluded by molecular testing, add doxycycline

Meningococci

Polysaccharide capsule

Maltose acid detection

Vaccine (type B vaccine available for at-risk individuals)

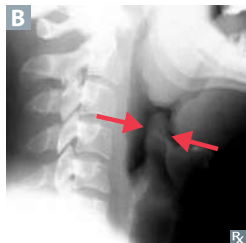
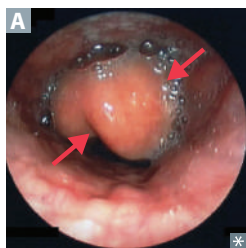
Transmitted via respiratory and oral secretions. More common among individuals in close quarters (eg, army barracks, college dorms)

Causes meningococemia with petechial hemorrhages and gangrene of toes **B**, meningitis, Waterhouse-Friderichsen syndrome (acute hemorrhagic adrenal insufficiency)

Diagnosed via culture-based tests or PCR

Rifampin, ciprofloxacin, or ceftriaxone prophylaxis in close contacts

Treatment: ceftriaxone or penicillin G

Haemophilus influenzae

Small gram \ominus (coccobacillary) rod. Aerosol transmission. Nontypeable (unencapsulated) strains are the most common cause of mucosal infections (otitis media, conjunctivitis, bronchitis) as well as invasive infections since the vaccine for capsular type b was introduced. Produces IgA protease.

Culture on chocolate agar, which contains factors V (NAD⁺) and X (hematin) for growth; can also be grown with *S aureus*, which provides factor V via RBC hemolysis.

Haemophilus causes epiglottitis (endoscopic appearance in **A**, can be “cherry red” in children; “thumb sign” on lateral neck x-ray **B**), meningitis, otitis media, and pneumonia.

Vaccine contains type b capsular polysaccharide (polyribosylribitol phosphate) conjugated to diphtheria toxoid or other protein. Given between 2 and 18 months of age.

Does not cause the flu (influenza virus does).

Treatment: amoxicillin +/- clavulanate for mucosal infections; ceftriaxone for meningitis; rifampin prophylaxis for close contacts.

Burkholderia cepacia complex

Aerobic, catalase \oplus , gram \ominus rod. Causes pneumonia in and can be transmitted between patients with cystic fibrosis. Often multidrug resistant. Infection is a relative contraindication to undergoing lung transplant due to its association with poor outcomes.

Bordetella pertussis

Gram \ominus , aerobic coccobacillus. Virulence factors include pertussis toxin (disables G_i), adenylate cyclase toxin (\uparrow cAMP), and tracheal cytotoxin. Three clinical stages:

- **Catarrhal**—low-grade fevers, coryza.
- **Paroxysmal**—paroxysms of intense cough followed by inspiratory “whoop” (“whooping cough”), posttussive vomiting.
- **Convalescent**—gradual recovery of chronic cough.

Prevented by Tdap, DTaP vaccines.

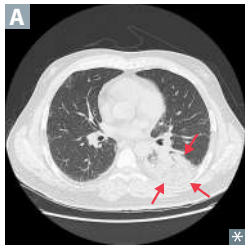
Produces lymphocytosis (unlike most acute bacterial infections).

Treatment: macrolides; if allergic use TMP-SMX.

Brucella

Gram \ominus , aerobic coccobacillus. Transmitted via ingestion of contaminated animal products (eg, unpasteurized milk). Survives in macrophages in the reticuloendothelial system. Can form non-caseating granulomas. Typically presents with undulant fever, night sweats, and arthralgia.

Treatment: doxycycline + rifampin or streptomycin.

Legionella pneumophila

Gram \ominus rod. Gram stains poorly—use silver stain. Grow on charcoal yeast extract medium with iron and cysteine. Detected by presence of antigen in urine. Labs may show hyponatremia.

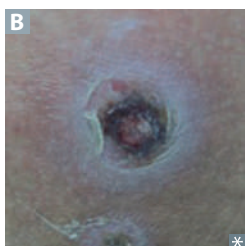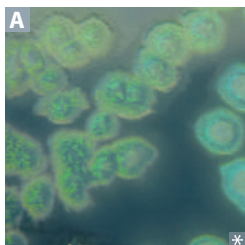
Aerosol transmission from environmental water source habitat (eg, air conditioning systems, hot water tanks). Outbreaks associated with cruise ships, nursing homes. No person-to-person transmission.

Treatment: macrolide or quinolone.

Think of a French **legionnaire** (soldier) with his **silver** helmet, sitting around a campfire (**charcoal**) with his **iron** dagger—he is missing his **sister** (cysteine).

Legionnaires' disease—severe pneumonia (often unilateral and lobar **A**), fever, GI and CNS symptoms. Risk factors include older age, tobacco smoking, chronic lung disease.

Pontiac fever—mild flulike symptoms.

Pseudomonas aeruginosa

Aeruginosa—aerobic; motile, catalase \oplus , gram \ominus rod. Non-lactose fermenting. Oxidase \oplus . Frequently found in water. Has a grapelike odor.

PSEUDOMONAS is associated with:

Pneumonia, **S**epsis, **E**cthyma gangrenosum, **U**TI, **D**iabetes, **O**steomyelitis, **M**ucoid polysaccharide capsule, **O**titis externa (swimmer's ear), **N**osocomial (healthcare-associated) infections (eg, catheters, equipment), **A**ddiction (injection drug use), **S**kin infections (eg, hot tub folliculitis, wound infection in burn victims).

Mucoid polysaccharide capsule may contribute to chronic pneumonia in patients with cystic fibrosis due to biofilm formation.

Produces **PEEP**: **P**hospholipase C (degrades cell membranes); **E**ndotoxin (fever, shock); **E**xotoxin A (inactivates EF-2); **P**igments: pyoverdine and pyocyanin (blue-green pigment **A**); also generates ROS).

Corneal ulcers/keratitis in contact lens wearers/minor eye trauma.

Ecthyma gangrenosum—rapidly progressive, necrotic cutaneous lesion **B** caused by *Pseudomonas* bacteremia. Typically seen in immunocompromised patients.

Treatments:

- Antipseudomonal penicillins in combination with β -lactamase inhibitor (eg, piperacillin-tazobactam)
- 3rd- and 4th-generation cephalosporins (eg, ceftazidime, cefepime)
- Monobactams
- Fluoroquinolones
- Carbapenems

Salmonella vs Shigella Both *Salmonella* and *Shigella* are gram \ominus rods, non-lactose fermenters, oxidase \ominus , and can invade the GI tract via M cells of Peyer patches.

	<i>Salmonella typhi</i> (ty-Vi)	<i>Salmonella</i> spp. except <i>S typhi</i>	<i>Shigella</i>
RESERVOIRS	Humans only	Humans and animals	Humans only
SPREAD	Hematogenous spread	Hematogenous spread	Cell to cell; no hematogenous spread
H ₂ S PRODUCTION	Yes	Yes	No
FLAGELLA	Yes (salmon swim)	Yes (salmon swim)	No
VIRULENCE FACTORS	Endotoxin; Vi capsule (pronounce “ty Vi ”)	Endotoxin	Endotoxin; Shiga toxin (enterotoxin)
INFECTIOUS DOSE (ID ₅₀)	High—large inoculum required; acid-labile (inactivated by gastric acids)	High	Low—very small inoculum required; acid stable (resistant to gastric acids)
EFFECT OF ANTIBIOTICS ON FECAL EXCRETION	Prolongs duration	Prolongs duration	Shortens duration (shortens Shigella)
IMMUNE RESPONSE	Primarily monocytes	PMNs in disseminated disease	Primarily PMN infiltration
GI MANIFESTATIONS	Constipation, followed by diarrhea	Diarrhea (possibly bloody)	Crampy abdominal pain → tenesmus, bloody mucoid stools (bacillary dysentery)
VACCINE	Oral vaccine contains live attenuated <i>S typhi</i> IM vaccine contains Vi capsular polysaccharide	No vaccine	No vaccine
UNIQUE PROPERTIES	<ul style="list-style-type: none"> Causes typhoid fever (rose spots on abdomen, constipation, abdominal pain, fever [pulse-temperature dissociation]; later GI ulceration and hemorrhage); treat with ceftriaxone or fluoroquinolone Carrier state with gallbladder colonization 	<ul style="list-style-type: none"> Poultry, eggs, pets, and turtles are common sources Antibiotics not indicated Gastroenteritis is usually caused by non-typhoidal <i>Salmonella</i> 	<ul style="list-style-type: none"> 4 F’s: fingers, flies, food, feces In order of decreasing severity (less toxin produced): <i>S dysenteriae</i>, <i>S flexneri</i>, <i>S boydii</i>, <i>S sonnei</i> Invasion of M cells is key to pathogenicity: organisms that produce little toxin can cause disease

Yersinia enterocolitica Gram \ominus pleomorphic rod/coccobacillus with bipolar staining. Usually transmitted from pet feces (eg, cats, dogs), contaminated milk, or pork. Can cause acute bloody diarrhea, pseudoappendicitis (right lower abdominal pain due to mesenteric adenitis and/or terminal ileitis), reactive arthritis in adults.

Lactose-fermenting enteric bacteria

Fermentation of **lactose** → pink colonies on Mac**Con**key agar. Examples include *Citrobacter*, *E coli*, *Enterobacter*, *Klebsiella*, *Serratia*.

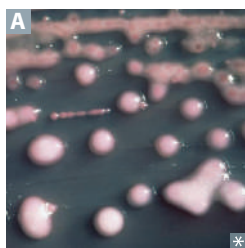
Mc**Cow**key **CEEKS** milk.
EMB agar—lactose fermenters grow as purple/black colonies. *E coli* grows colonies with a green sheen.

Escherichia coli

Gram \ominus , indole \oplus rod. *E coli* virulence factors: fimbriae—cystitis and pyelonephritis (P pili); K capsule—pneumonia, neonatal meningitis; LPS endotoxin—septic shock.

STRAIN	TOXIN AND MECHANISM	PRESENTATION
Enteroinvasive <i>E coli</i>	Microbe invades intestinal mucosa and causes necrosis and inflammation.	EIEC is I nvasive; dysentery. Clinical manifestations similar to <i>Shigella</i> .
Enterotoxigenic <i>E coli</i>	Produces heat-labile and heat-stable entero T oxins. No inflammation or invasion.	E T EC; T raveler’s diarrhea (watery).
Enteropathogenic <i>E coli</i>	No toxin produced. Adheres to apical surface, flattens villi, prevents absorption.	Diarrhea, usually in children (think E P EC and P ediatrics).
Enterohemorrhagic <i>E coli</i>	O157:H7 is most common serotype in US. Often transmitted via undercooked meat, raw leafy vegetables. Shiga toxin causes hemolytic-uremic syndrome —triad of anemia, thrombocytopenia, and acute kidney injury due to microthrombi forming on damaged endothelium → mechanical hemolysis (with schistocytes on peripheral blood smear), platelet consumption, and ↓ renal blood flow.	Dysentery (toxin alone causes necrosis and inflammation). Does not ferment sorbitol (vs other <i>E coli</i>). E H EC associated with h emorrhage, h amburgers, h emolytic-uremic syndrome.

Klebsiella

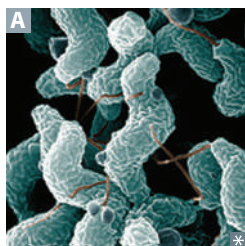


Gram \ominus rod; intestinal microbiota that causes lobar pneumonia; more common in patients with heavy alcohol use or with impaired host defenses. Very mucoid colonies **A** caused by abundant polysaccharide capsules. Dark red “currant jelly” sputum (blood/mucus).
Also cause of healthcare-associated UTIs.
Associated with evolution of multidrug resistance (MDR).

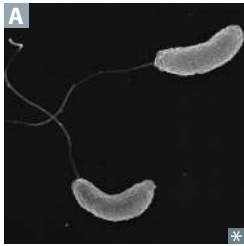
ABCDE’s of Klebsiella:

- A**spiration pneumonia
- aB**sscess in lungs and liver
- “**C**urrant jelly” sputum
- D**iabetes mellitus
- E**tOH overuse

Campylobacter jejuni

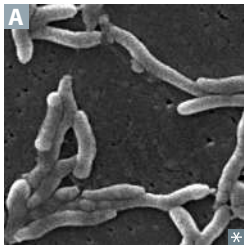

Gram \ominus , comma or S shaped (with polar flagella) **A**, oxidase \oplus , grows at **42°C** (“*Campylobacter* likes the **hot campfire**”).
Major cause of bloody diarrhea, especially in children. Fecal-oral transmission through person-to-person contact or via ingestion of undercooked contaminated poultry or meat, unpasteurized milk. Contact with infected animals (dogs, cats, pigs) is also a risk factor.
Common antecedent to Guillain-Barré syndrome and reactive arthritis.

Vibrio cholerae

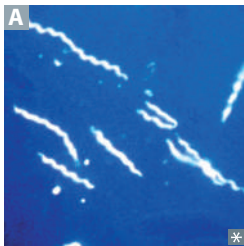
Gram \ominus , flagellated, comma shaped **A**, oxidase \oplus , grows in alkaline media. Endemic to developing countries. Produces profuse rice-water diarrhea via enterotoxin that permanently activates G_s , \uparrow cAMP. Sensitive to stomach acid (acid labile); requires large inoculum (high ID_{50}) unless host has \downarrow gastric acidity. Transmitted via ingestion of contaminated water or uncooked food (eg, raw shellfish). Treat promptly with oral rehydration solution.

Vibrio vulnificus—gram \ominus bacillus, usually found in marine environments. Causes severe wound infections or septicemia due to exposure to contaminated sea water. Presents as cellulitis that can progress to necrotizing fasciitis in high-risk patients, especially those with liver disease (eg, cirrhosis, hemochromatosis). Serious wound infection requires surgical debridement.

Helicobacter pylori

Curved, flagellated (motile), gram \ominus rod **A** that is **triple** \oplus : catalase \oplus , oxidase \oplus , and urease \oplus (can use urea breath test or fecal antigen test for diagnosis). Urease produces ammonia, creating an alkaline environment, which helps *H pylori* survive in acidic mucosa. Colonizes mainly antrum of stomach; causes gastritis and peptic ulcers (especially duodenal). Risk factor for peptic ulcer disease, gastric adenocarcinoma, and MALT lymphoma.

Most common initial treatment is **triple** therapy: amoxicillin (metronidazole if penicillin allergy) + clarithromycin + proton pump inhibitor; antibiotics cure *Pylori*. Bismuth-based quadruple therapy if concerned about macrolide resistance.

Spirochetes

Spiral-shaped bacteria **A** with axial filaments. Includes *Leptospira*, *Treponema*, and *Borrelia*. Only *Borrelia* can be visualized using aniline dyes (Wright or Giemsa stain) in light microscopy due to size. *Treponema* is visualized by dark-field microscopy or direct fluorescent antibody (DFA) microscopy.

Little Twirling Bacteria**Lyme disease**

Caused by *Borrelia burgdorferi*, which is transmitted by the *Ixodes* deer tick **A** (also vector for *Anaplasma* spp. and protozoa *Babesia*). Natural reservoir is the mouse; deer are essential to tick life cycle but do not harbor *Borrelia*.

Common in northeastern United States. Stage 1—early localized: erythema migrans (typical “bull’s-eye” configuration **B** is pathognomonic but not always present), flulike symptoms.

Stage 2—early disseminated: secondary lesions, carditis, AV block, facial nerve (Bell) palsy, migratory myalgias/transient arthritis.

Stage 3—late disseminated: encephalopathy, chronic arthritis, peripheral neuropathy.

A Key Lyme pie to the FACE:

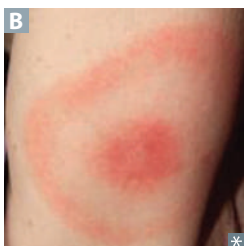Facial nerve palsy (typically bilateral)

Arthritis

Cardiac block

Erythema migrans

Treatment: doxycycline (1st line); amoxicillin (pregnant patients, children < 8 years old); ceftriaxone if IV therapy required



Leptospira interrogans Spirochete with hook-shaped ends found in water contaminated with animal urine.

Leptospirosis—flulike symptoms, myalgias (classically of calves), jaundice, photophobia with conjunctival suffusion (erythema without exudate). Prevalent among surfers and in tropics (eg, Hawaii).

Weil disease (icterohemorrhagic leptospirosis)—severe form with jaundice and azotemia from liver and kidney dysfunction, fever, hemorrhage, and anemia.

Syphilis

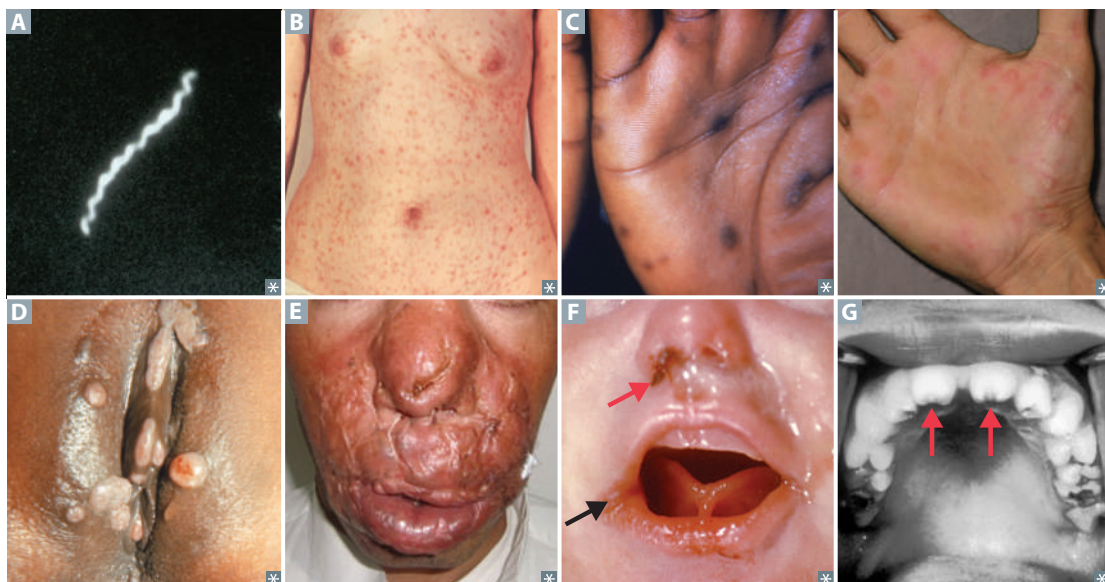Caused by spirochete *Treponema pallidum*. Treatment: penicillin G.

Primary syphilis Localized disease presenting with **painless** chancre. Use fluorescent or dark-field microscopy to visualize treponemes in fluid from chancre **A**. VDRL ⊕ in ~ 80%.

Secondary syphilis Disseminated disease with constitutional symptoms, maculopapular rash **B** (including palms **C** and soles), condylomata lata **D** (smooth, painless, wartlike white lesions on genitals), lymphadenopathy, patchy hair loss; also confirmable with dark-field microscopy. Serologic testing: VDRL/RPR (nonspecific), confirm diagnosis with specific test (eg, FTA-ABS). **Secondary syphilis = systemic**. Latent syphilis (⊕ serology without symptoms) may follow.

Tertiary syphilis Gummas **E** (chronic granulomas), aortitis (vasa vasorum destruction), neurosyphilis (tabes dorsalis, “general paresis”), Argyll Robertson pupil (constricts with accommodation but is not reactive to light). Signs: broad-based ataxia, ⊕ Romberg, Charcot joint, stroke without hypertension. For neurosyphilis: test spinal fluid with VDRL, FTA-ABS, and PCR.

Congenital syphilis Presents with facial abnormalities such as rhagades (linear scars at angle of mouth, black arrow in **F**), snuffles (nasal discharge, red arrow in **F**), saddle nose, notched (Hutchinson) teeth **G**, mulberry molars, and short maxilla; saber shins; CN VIII deafness. To prevent, treat patient early in pregnancy, as placental transmission typically occurs after first trimester.

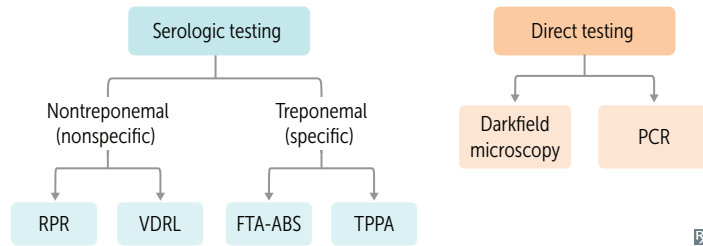


Diagnosing syphilis

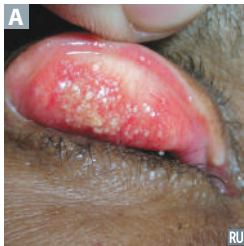
VDRL and RPR detects nonspecific antibody that reacts with beef cardiolipin. Quantitative, inexpensive, and widely available test for syphilis (sensitive but not specific). Nontreponemal tests (VDRL, RPR) revert to negative after treatment. Direct treponemal test results will remain positive.

False-Positive results on **VDRL** with:

- P**regnancy
- V**iral infection (eg, EBV, hepatitis)
- D**rugs (eg, chlorpromazine, procainamide)
- R**heumatic fever (rare)
- L**upus (anticardiolipin antibody) and **L**eprosy

**Jarisch-Herxheimer reaction**

Flulike symptoms (fever, chills, headache, myalgia) after antibiotics are started due to host response to sudden release of bacterial antigens. Usually occurs during treatment of spirochetal infections (eg, syphilis, Lyme disease).

Chlamydiae

Chlamydiae cannot make their own ATP. They are obligate intracellular organisms that cause mucosal infections. 2 forms:

- **E**lementary body (small, dense) is “infectious” and enters cell via endocytosis; transforms into reticulate body.
- **R**eticulate body replicates in cell by fission; reorganizes into elementary bodies.

Chlamydia trachomatis causes neonatal and follicular adult conjunctivitis **A**, nongonococcal urethritis, PID, and reactive arthritis.

Chlamydophila pneumoniae and *Chlamydophila psittaci* cause atypical pneumonia; transmitted by aerosol.

Chlamydial cell wall lacks classic peptidoglycan (due to reduced muramic acid), rendering β -lactam antibiotics ineffective.

Chlamys = cloak (intracellular).

C psittaci—has an avian reservoir (**p**arrots), causes atypical **p**neumonia.

Lab diagnosis: PCR, NAAT. Cytoplasmic inclusions (reticulate bodies) seen on Giemsa or fluorescent antibody–stained smear.

Treatment: azithromycin (favored because one-time treatment) or doxycycline. Add ceftriaxone for possible concomitant gonorrhea.

Chlamydia trachomatis* serotypes*Types A, B, and C**

Chronic infection, cause blindness due to follicular conjunctivitis in resource-limited areas.

ABC = **A**frica, **B**lindness, **C**hronic infection.

Types D–K

Urethritis/PID, ectopic pregnancy, neonatal pneumonia (staccato cough) with eosinophilia, neonatal conjunctivitis (1–2 weeks after birth).

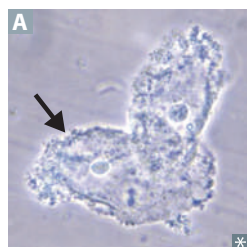
D–K = everything else.

Neonatal disease can be acquired during vaginal birth if pregnant patient is infected.

Types L1, L2, and L3

Lymphogranuloma venereum—small, painless ulcers on genitals → swollen, painful inguinal lymph nodes that ulcerate (buboes). Treat with doxycycline.

Gardnerella vaginalis



A pleomorphic, gram-variable rod involved in bacterial vaginosis. Presents as a gray vaginal discharge with a fishy smell; nonpainful (vs vaginitis). Associated with sexual activity, but not sexually transmitted. Bacterial vaginosis is also characterized by overgrowth of certain anaerobic bacteria in vagina (due to ↓ lactobacilli). Clue cells (vaginal epithelial cells covered with *Gardnerella*) have stippled appearance along outer margin (arrow in **A**).

Amine whiff test—mixing discharge with 10% KOH enhances fishy odor.
Vaginal pH >4.5 during infection.
Treatment: metronidazole or clindamycin.

Zoonotic bacteria

Zoonosis—infectious disease transmitted between animals and humans.

SPECIES	DISEASE	TRANSMISSION AND SOURCE
<i>Anaplasma</i> spp	Anaplasmosis	<i>Ixodes</i> ticks (live on deer and mice)
<i>Bartonella</i> spp	Cat scratch disease, bacillary angiomatosis	Cat scratch
<i>Borrelia burgdorferi</i>	Lyme disease	<i>Ixodes</i> ticks (live on deer and mice)
<i>Borrelia recurrentis</i>	Relapsing fever	Louse (recurrent due to variable surface antigens)
<i>Brucella</i> spp	Brucellosis/ undulant fever	Un pasteurized dairy
<i>Campylobacter</i>	Bloody diarrhea	Feces from infected pets/animals; contaminated meats/foods/hands
<i>Chlamydophila psittaci</i>	Psittacosis	Parrots, other birds
<i>Coxiella burnetii</i>	Q fever	Aerosols of cattle/sheep amniotic fluid
<i>Ehrlichia chaffeensis</i>	Ehrlichiosis	<i>Amblyomma</i> (Lone Star tick)
<i>Francisella tularensis</i>	Tularemia	Ticks, rabbits, deer flies
<i>Leptospira</i> spp	Leptospirosis	Animal urine in water; recreational water use
<i>Mycobacterium leprae</i>	Leprosy	Humans with lepromatous leprosy; armadillo (rare)
<i>Pasteurella multocida</i>	Cellulitis, osteomyelitis	Animal bite, cats, dogs
<i>Rickettsia prowazekii</i>	Epidemic typhus	Human to human via human body louse
<i>Rickettsia rickettsii</i>	Rocky Mountain spotted fever	<i>Dermacentor</i> (dog tick)
<i>Rickettsia typhi</i>	Endemic typhus	Fleas
<i>Salmonella</i> spp (except <i>S typhi</i>)	Diarrhea (which may be bloody), vomiting, fever, abdominal cramps	Reptiles and poultry
<i>Yersinia pestis</i>	Plague	Fleas (rats and prairie dogs are reservoirs)

Rickettsial diseases and vector-borne illnesses

Treatment: doxycycline.

RASH COMMON

Rocky Mountain spotted fever

Rickettsia rickettsii, vector is tick. Despite its name, disease occurs primarily in the South Atlantic states, especially North Carolina. Rash typically starts at wrists **A** and ankles and then spreads to trunk, palms, and soles.

Classic triad—headache, fever, rash (vasculitis). **Palms** and **soles** rash is seen in **Coxsackievirus A** infection (hand, foot, and mouth disease), **Rocky Mountain spotted fever**, and **2° Syphilis** (you drive **CARS** using your **palms** and **soles**).

Typhus

Endemic (fleas)—*R typhi*.
Epidemic (human body louse)—*R prowazekii*.
Rash starts centrally and spreads out, sparing palms and soles.

Rickettsii on the wrists, typhus on the trunk.

RASH RARE

Ehrlichiosis

Ehrlichia, vector is tick. **Monocytes** with morulae **B** (mulberrylike inclusions) in cytoplasm.

MEGA:

Monocytes = Ehrlichiosis
Granulocytes = Anaplasmosis

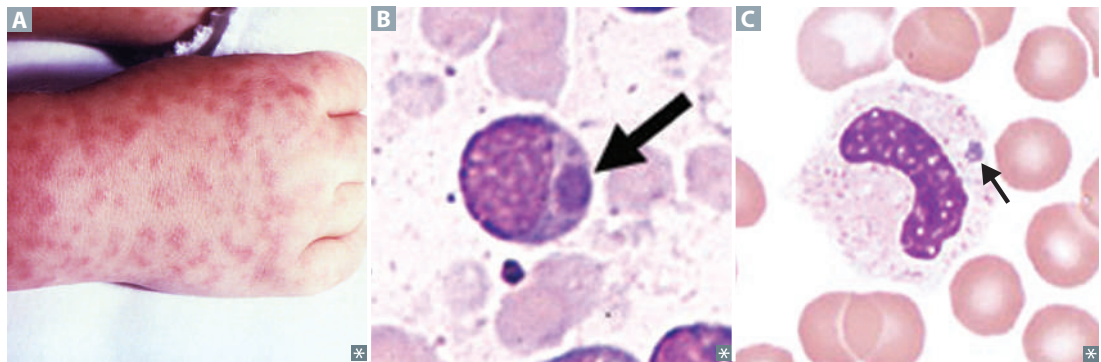
Anaplasmosis

Anaplasma, vector is tick. **Granulocytes** with morulae **C** in cytoplasm.

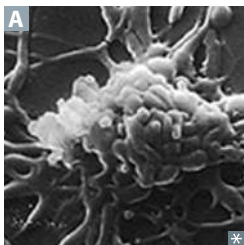
Q fever

Coxiella burnetii, no arthropod vector. Bacterium inhaled as aerosols from cattle/sheep amniotic fluid. Presents with headache, cough, flulike symptoms, pneumonia, possibly in combination with hepatitis. Common cause of culture \ominus endocarditis.

Q fever is caused by a **Quite Complicated** bug because it has no rash or vector and its causative organism can survive outside in its endospore form. Not in the *Rickettsia* genus, but closely related.



Mycoplasma pneumoniae



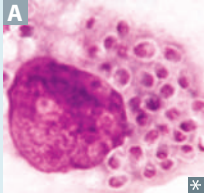


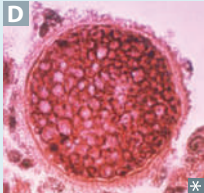

Classic cause of atypical “walking pneumonia” (insidious onset, headache, nonproductive cough, patchy or diffuse interstitial infiltrate, macular rash).
Occurs frequently in those <30 years old; outbreaks in military recruits, prisons, colleges.
Treatment: macrolides, doxycycline, or fluoroquinolone (penicillin ineffective since *Mycoplasma* has no cell wall).

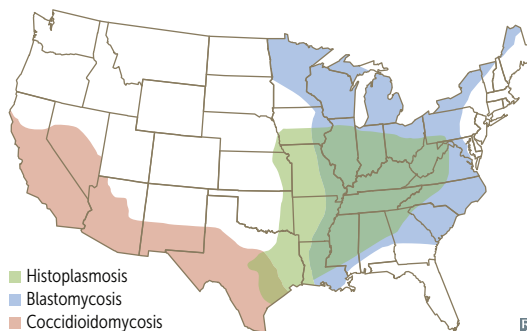
Not seen on Gram stain. Pleomorphic **A**.
Bacterial membrane contains sterols for stability. Grown on Eaton agar.
CXR appears more severe than patient presentation. High titer of **cold** agglutinins (IgM), which can agglutinate RBCs. *Mycoplasma* gets **cold** without a **coat** (no cell wall).
Can cause atypical variant of Stevens-Johnson syndrome, typically in children and adolescents.

▶ MICROBIOLOGY—MYCOLOGY

Systemic mycoses

All of the following can cause pneumonia and can disseminate. All are caused by dimorphic fungi: **cold** (20°C) = **mold**; **heat** (37°C) = **yeast**. Only exception is *Coccidioides*, which is a spherule (not yeast) in tissue. Systemic mycoses can form granulomas (like TB); cannot be transmitted person-to-person (unlike TB). Treatment: fluconazole or itraconazole for **local** infection; amphotericin B for **systemic** infection.

DISEASE	ENDEMIC LOCATION	PATHOLOGIC FEATURES	UNIQUE SIGNS/SYMPTOMS	NOTES
<p>Histoplasmosis</p> 	Mississippi and Ohio River Valleys	Macrophage filled with <i>Histoplasma</i> (smaller than RBC) A	Palatal/tongue ulcers, splenomegaly, pancytopenia, erythema nodosum	Histo hides (within macrophages) Associated with bird or bat droppings (eg, caves) Diagnosis via urine/serum antigen
<p>Blastomycosis</p> 	Eastern and Central US, Great Lakes	Broad -based budding of <i>Blastomyces</i> (same size as RBC) B	Inflammatory lung disease Disseminates to bone/skin (verrucous lesions C , may mimic SCC).	Blasto buds broadly 
<p>Coccidioidomycosis</p> 	Southwestern US, California	Spherule (much larger than RBC) filled with endospores of <i>Coccidioides</i> D	Disseminates to bone/skin Erythema nodosum (desert bumps) or multiforme Arthralgias (desert rheumatism) Can cause meningitis	Associated with dust exposure in endemic areas (eg, archeological excavations, earthquakes)
<p>Para-coccidioidomycosis</p> 	Latin America	Budding yeast of <i>Paracoccidioides</i> with “ captain’s wheel ” formation (much larger than RBC) E	Similar to blastomycosis, males > females	Paracoccidio parasails with the captain’s wheel all the way to Latin America



Opportunistic fungal infections

Candida albicans

alba = white. Dimorphic; forms pseudohyphae and budding yeasts at 20°C **A**, germ tubes at 37°C **B**.

Systemic or superficial fungal infection. Causes oral **C** and esophageal thrush in immunocompromised (neonates, steroids, diabetes, AIDS), vulvovaginitis (diabetes, use of antibiotics), diaper rash, infective endocarditis (people who inject drugs), disseminated candidiasis (especially in neutropenic patients), chronic mucocutaneous candidiasis.

Treatment: oral fluconazole/topical azoles for vaginal; nystatin, azoles, or, rarely, echinocandins for oral; fluconazole, echinocandins, or amphotericin B for esophageal or systemic disease.

Aspergillus fumigatus

Septate hyphae that branch at 45° **Acute Angle D**.

Causes invasive aspergillosis in immunocompromised patients, especially those with neutrophil dysfunction (eg, chronic granulomatous disease) because *Aspergillus* is catalase ⊕.

Can cause aspergillomas **E** in pre-existing lung cavities, especially after TB infection.

Some species of *Aspergillus* produce **A**flatoxins (associated with hepatocellular carcinoma).

Treatment: voriconazole or echinocandins (2nd-line).

Allergic bronchopulmonary aspergillosis (ABPA)—hypersensitivity response to *Aspergillus* growing in lung mucus. Associated with asthma and cystic fibrosis; may cause bronchiectasis and eosinophilia.

Cryptococcus neoformans

5–10 μm with narrow budding. Heavily encapsulated yeast. Not dimorphic. ⊕ PAS staining.

Found in soil, pigeon droppings. Acquired through inhalation with hematogenous dissemination to meninges. Highlighted with India ink (clear halo **F**) and mucicarmine (red inner capsule **G**).

Latex agglutination test detects polysaccharide capsular antigen and is more sensitive and specific. Causes cryptococcosis, which can manifest with meningitis, pneumonia, and/or encephalitis (“soap bubble” lesions in brain), primarily in immunocompromised.

Treatment: amphotericin B + flucytosine followed by fluconazole for cryptococcal meningitis.

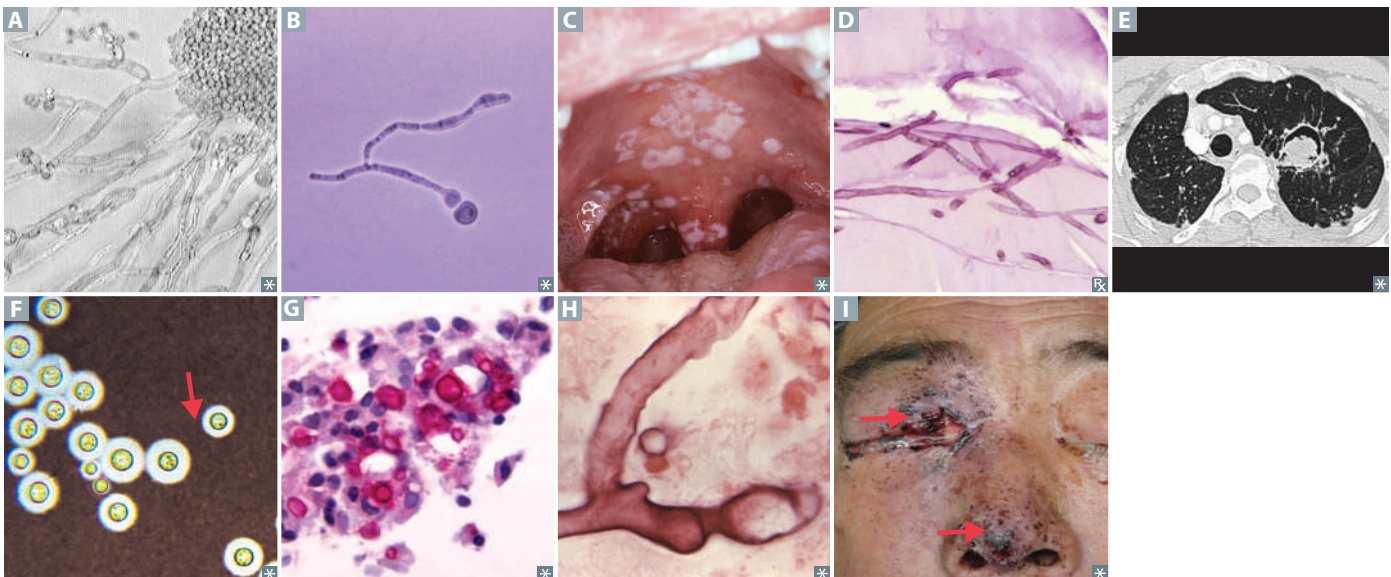
Mucor and Rhizopus spp

Irregular, broad, nonseptate hyphae branching at wide angles **H**.

Causes mucormycosis, mostly in patients with DKA and/or neutropenia (eg, leukemia). Inhalation of spores → fungi proliferate in blood vessel walls, penetrate cribriform plate, and enter brain.

Rhinocerebral, frontal lobe abscess; cavernous sinus thrombosis. Headache, facial pain, black necrotic eschar on face **I**; may have cranial nerve involvement.

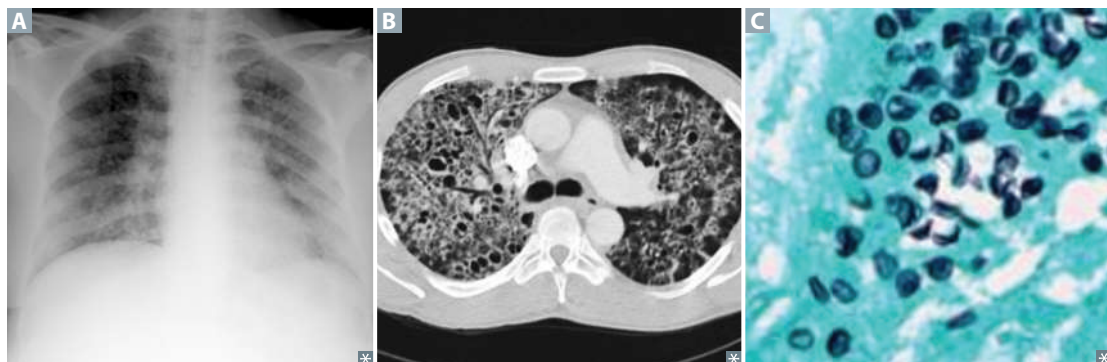
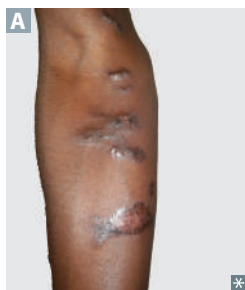Treatment: surgical debridement, amphotericin B or isavuconazole.



Pneumocystis jirovecii

Causes *Pneumocystis* pneumonia (PCP), a diffuse interstitial pneumonia **A**. Yeastlike fungus (originally classified as protozoan). Most infections are asymptomatic. Immunosuppression (eg, AIDS) predisposes to disease. Diffuse, bilateral ground-glass opacities on chest imaging, with pneumatoceles **B**. Diagnosed by bronchoalveolar lavage or lung biopsy. Disc-shaped yeast seen on methenamine silver stain of lung tissue **C** or with fluorescent antibody.

Treatment/prophylaxis: TMP-SMX, pentamidine, dapsone (prophylaxis as single agent, or treatment in combination with TMP), atovaquone. Start prophylaxis when CD4+ cell count drops to < 200 cells/mm³ in people living with HIV.

***Sporothrix schenckii***

Causes sporotrichosis. Dimorphic fungus. Exists as a **cigar**-shaped yeast at 37 °C in the human body and as hyphae with spores in soil (conidia). Lives on vegetation. When spores are traumatically introduced into the skin, typically by a thorn (“**rose gardener’s** disease”), causes local pustule or ulcer with nodules along draining lymphatics (ascending lymphangitis **A**).

Disseminated disease possible in immunocompromised host.

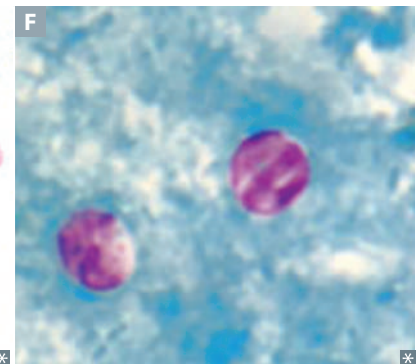
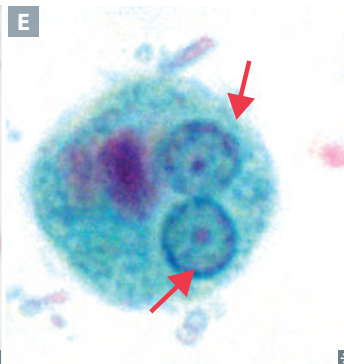
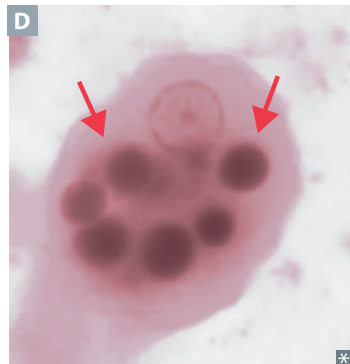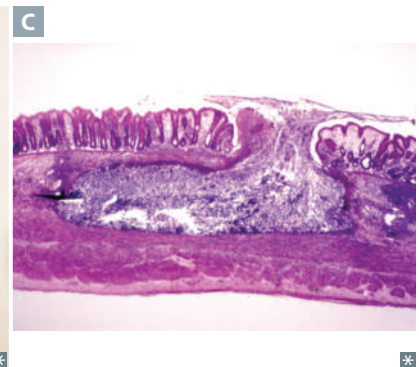
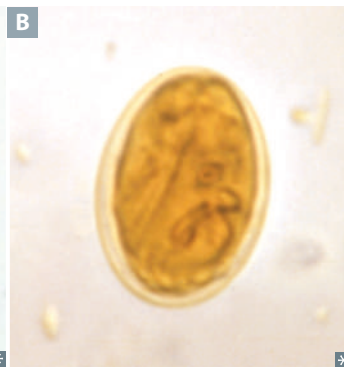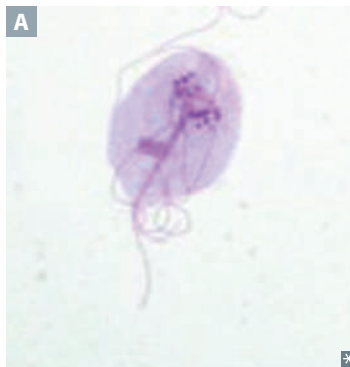Treatment: itraconazole or **pot**assium iodide (only for cutaneous/lymphocutaneous).

Think of a **rose gardener** who smokes a **cigar** and **pot**.

▶ MICROBIOLOGY—PARASITOLOGY

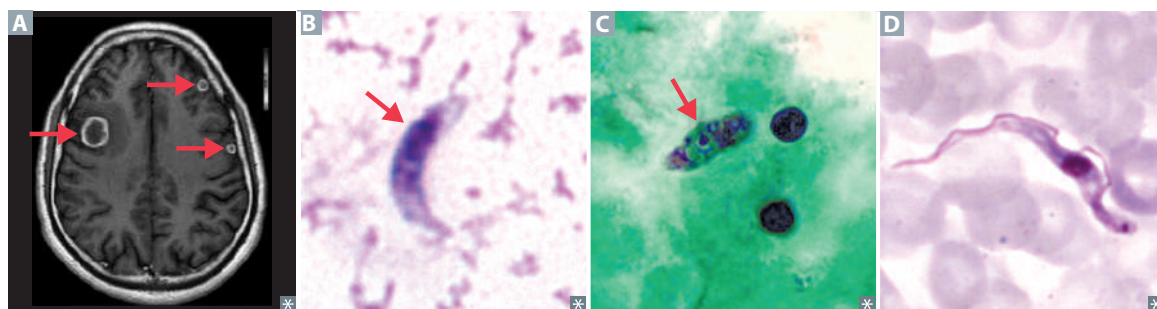
Protozoa—gastrointestinal infections

ORGANISM	DISEASE	TRANSMISSION	DIAGNOSIS	TREATMENT
<i>Giardia lamblia</i>	Giardiasis —bloating, flatulence, foul-smelling, nonbloody, fatty diarrhea (often seen in campers/hikers)—think fat-rich Ghirardelli chocolates for fatty stools of Giardia	Cysts in water	Multinucleated trophozoites A or cysts B in stool, antigen detection, PCR	Metronidazole
<i>Entamoeba histolytica</i>	Amebiasis —bloody diarrhea (dysentery), liver abscess (“anchovy paste” exudate), RUQ pain; histology of colon biopsy shows flask-shaped ulcers C	Cysts in water	Serology, antigen testing, PCR, and/or trophozoites (with engulfed RBCs D in the cytoplasm) or cysts with up to 4 nuclei in stool E ; Entamoeba Eats Erythrocytes	Metronidazole; paromomycin or iodoquinol for asymptomatic cyst passers
<i>Cryptosporidium</i>	Severe diarrhea in AIDS Mild disease (watery diarrhea) in immunocompetent hosts	Oocysts in water	Oocysts on acid-fast stain F , antigen detection, PCR	Prevention (by filtering city water supplies); nitazoxanide in immunocompetent hosts



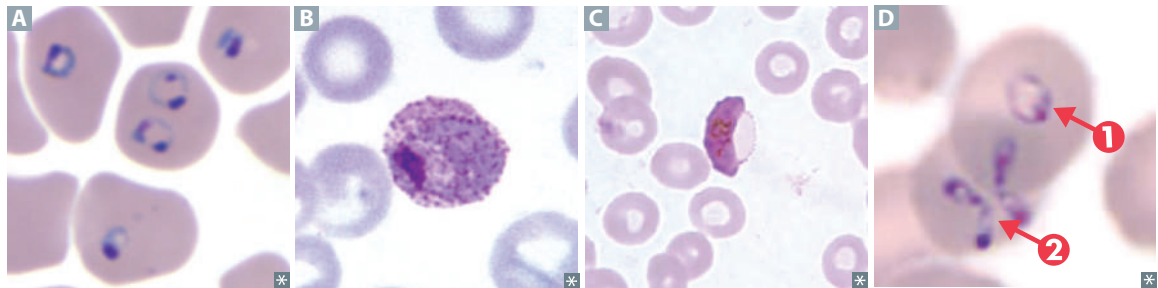
Protozoa—CNS infections

ORGANISM	DISEASE	TRANSMISSION	DIAGNOSIS	TREATMENT
<i>Toxoplasma gondii</i>	Immunocompetent: mononucleosis-like symptoms, ⊖ heterophile antibody test Reactivation in AIDS → brain abscesses usually seen as multiple ring-enhancing lesions on MRI A Congenital toxoplasmosis: classic triad of chorioretinitis, hydrocephalus, and intracranial calcifications	Cysts in meat (most common); oocysts in cat feces; crosses placenta (pregnant patients should avoid cats)	Serology, biopsy (tachyzoite) B ; PCR of amniotic fluid for possible intrauterine disease	Sulfadiazine + pyrimethamine Prophylaxis with TMP-SMX when CD4+ cell count < 100 cells/mm ³
<i>Naegleria fowleri</i>	Rapidly fatal meningoencephalitis	Swimming in warm freshwater; enters via cribriform plate	Amoebas in CSF C	Amphotericin B has been effective for a few survivors
<i>Trypanosoma brucei</i>	African sleeping sickness —enlarged lymph nodes, recurring fever (due to antigenic variation), somnolence, coma	Tsetse fly, a painful bite	Trypomastigote in blood smear D	Suramin for blood-borne disease or melarsoprol for CNS penetration (“I sure am mellow when I’m sleeping ”)



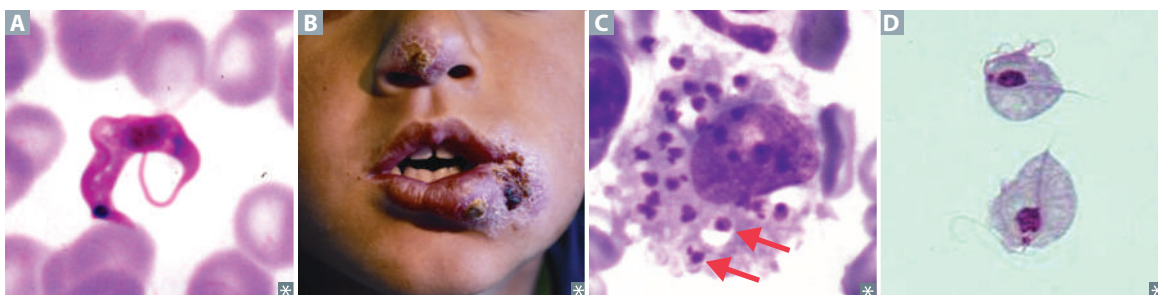
Protozoa—hematologic infections

ORGANISM	DISEASE	TRANSMISSION	DIAGNOSIS	TREATMENT
<i>Plasmodium</i>	Malaria —cyclic fevers, headache, anemia, splenomegaly; hypoglycemia in severe disease	<i>Anopheles</i> mosquito		If sensitive, chloroquine; if resistant, mefloquine, doxycycline or atovaquone/proguanil If life threatening, use intravenous quinine or artesunate (test for G6PD deficiency)
<i>P malariae</i>	72-hr fever cycle (quartan)		Blood smear with trophozoite ring (headphone shaped) within RBC A	
<i>P vivax/ovale</i>	48-hr fever cycle (tertian); dormant form (hypnozoite) in liver		Blood smear with trophozoites and Schüffner stippling (small red granules) within RBC cytoplasm B	Add primaquine to target hypnozoites
<i>P falciparum</i>	Severe, irregular fever pattern; parasitized RBCs may occlude capillaries in brain (cerebral malaria), kidneys, lungs		Blood smear with trophozoite ring within RBC; crescent-shaped gametocytes C	
<i>Babesia</i>	Babesiosis —fever and hemolytic anemia; predominantly in northeastern and north central United States; asplenia ↑ risk of severe disease due to inability to clear infected RBCs	<i>Ixodes</i> tick (also vector for <i>Borrelia burgdorferi</i> and <i>Anaplasma</i> spp)	Blood smear: ring form D1 , “Maltese cross” D2 ; PCR	Atovaquone + azithromycin



Protozoa—others

ORGANISM	DISEASE	TRANSMISSION	DIAGNOSIS	TREATMENT
Visceral infections				
<i>Trypanosoma cruzi</i>	Chagas disease—dilated cardiomyopathy with apical atrophy, mega colon, mega esophagus; (<i>T cruzi</i> causes big problems); predominantly in South America Unilateral periorbital swelling (Romaña sign) characteristic of acute stage	Triatomine insect (kissing bug) bites and defecates around the mouth or eyes → fecal transmission into bite site or mucosa	Trypomastigote in blood smear A	Benznidazole or nifurtimox
<i>Leishmania</i> spp	Visceral leishmaniasis (kala-azar) —spiking fevers, hepatosplenomegaly, pancytopenia Cutaneous leishmaniasis —skin ulcers B	Sandfly	Macrophages containing amastigotes C	Amphotericin B, sodium stibogluconate
Sexually transmitted infections				
<i>Trichomonas vaginalis</i>	Vaginitis —foul-smelling, greenish discharge; itching and burning; do not confuse with <i>Gardnerella vaginalis</i> , a gram-variable bacterium associated with bacterial vaginosis	Sexual (cannot exist outside human because it cannot form cysts)	Trophozoites (motile) D on wet mount; punctate cervical hemorrhages (“strawberry cervix”)	Metronidazole for patient and partner(s) (prophylaxis; check for STI)



Nematode routes of infection

Ingested—*Enterobius*, *Ascaris*, *Toxocara*, *Trichinella*, *Trichuris*
 Cutaneous—*Strongyloides*, *Ancylostoma*, *Necator*
 Bites—*Loa loa*, *Onchocerca volvulus*, *Wuchereria bancrofti*

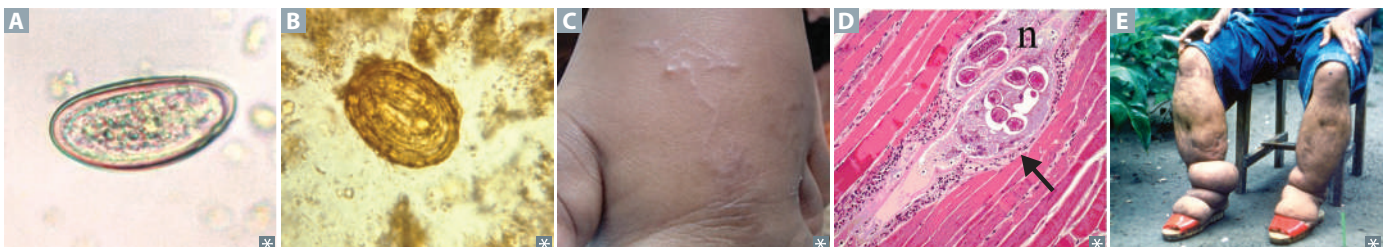You'll get sick if you **EATTT** these!

These get into your feet from the **SANd**

Lay **LOW** to avoid getting bitten

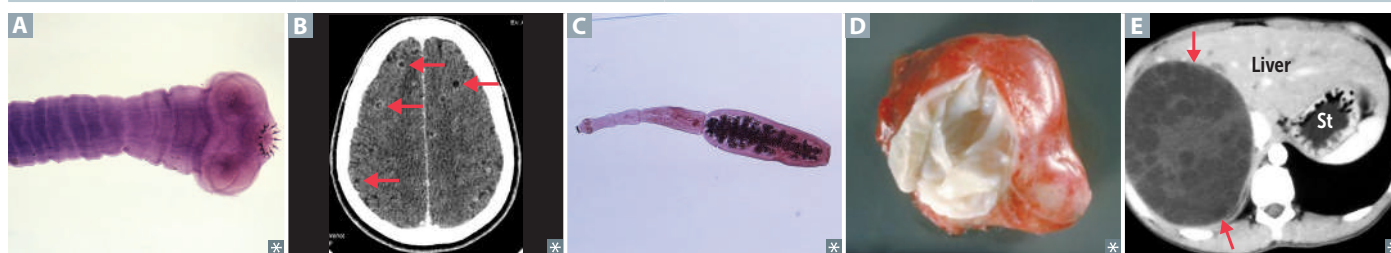Nematodes (roundworms)

ORGANISM	DISEASE	TRANSMISSION	TREATMENT
Intestinal			
<i>Enterobius vermicularis</i> (pinworm)	Causes anal pruritus (diagnosed by seeing egg A via the tape test).	Fecal-oral.	Bendazoles, pyrantel pamoate.
<i>Ascaris lumbricoides</i> (giant roundworm)	May cause obstruction at ileocecal valve, biliary obstruction, intestinal perforation, migrates from nose/mouth. Migration of larvae to alveoli → Löeffler syndrome (pulmonary eosinophilia).	Fecal-oral; knobby-coated, oval eggs seen in feces under microscope B .	Bendazoles.
<i>Strongyloides stercoralis</i> (threadworm)	GI (eg, duodenitis), pulmonary (eg, dry cough, hemoptysis), and cutaneous (eg, pruritus) symptoms. Hyperinfection caused by autoinfection (larvae in blood stream) in the immunocompromised.	Larvae in soil penetrate skin; rhabditiform larvae seen in feces under microscope.	Ivermectin or bendazoles.
<i>Ancylostoma</i> spp, <i>Necator americanus</i> (hookworms)	Cause microcytic anemia by sucking blood from intestinal wall. Cutaneous larva migrans—pruritic, serpiginous rash C .	Larvae penetrate skin from walking barefoot on contaminated beach/soil.	Bendazoles or pyrantel pamoate.
<i>Trichinella spiralis</i>	Larvae enter bloodstream, encyst in striated muscle D → myositis. Trichinosis—fever, vomiting, nausea, periorbital edema, myalgia.	Undercooked meat (especially pork); fecal-oral (less likely).	Bendazoles.
<i>Trichuris trichiura</i> (whipworm)	Often asymptomatic; loose stools, anemia, rectal prolapse in children.	Fecal-oral.	Bendazoles.
Tissue			
<i>Toxocara canis</i>	Visceral larva migrans—migration into blood → inflammation of liver, eyes (visual impairment, blindness), CNS (seizures, coma), heart (myocarditis). Patients often asymptomatic.	Fecal-oral.	Bendazoles.
<i>Onchocerca volvulus</i>	Skin changes, loss of elastic fibers, river blindness (black skin nodules, “black sight”); allergic reaction possible.	Female black fly.	Ivermectin (ivermectin for river blindness).
<i>Loa loa</i>	Swelling in skin, worm in conjunctiva.	Deer fly, horse fly, mango fly.	Diethylcarbamazine.
<i>Wuchereria bancrofti</i> , <i>Brugia malayi</i>	Lymphatic filariasis (elephantiasis)—worms invade lymph nodes. → inflammation → lymphedema E ; symptom onset after 9 mo–1 yr.	Female mosquito.	Diethylcarbamazine.

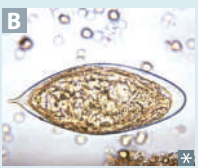


Cestodes (tapeworms)

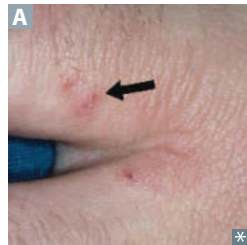
ORGANISM	DISEASE	TRANSMISSION	TREATMENT
<i>Taenia solium</i> A	Intestinal tapeworm	Ingestion of larvae encysted in undercooked pork	Praziquantel
	Cysticercosis, neurocysticercosis (cystic CNS lesions, seizures) B	Ingestion of eggs in food contaminated with human feces	Praziquantel; albendazole for neurocysticercosis
<i>Diphyllobothrium latum</i>	Vitamin B ₁₂ deficiency (tapeworm competes for B ₁₂ in intestine) → megaloblastic anemia	Ingestion of larvae in raw freshwater fish	Praziquantel, niclosamide
<i>Echinococcus granulosus</i> C	Hydatid cysts D (“eggshell calcification”) in liver E ; cyst rupture can cause anaphylaxis	Ingestion of eggs in food contaminated with dog feces Sheep are an intermediate host	Albendazole; surgery for complicated cysts



Trematodes (flukes)

ORGANISM	DISEASE	TRANSMISSION	TREATMENT
<i>Schistosoma</i>	Liver and spleen enlargement (A shows <i>S mansoni</i> egg with lateral spine), fibrosis, inflammation, portal hypertension; <i>S mansoni</i> and <i>S japonicum</i> can both also cause intestinal schistosomiasis, presenting with diarrhea, abdominal pain, iron deficiency anemia Chronic infection with <i>S haematobium</i> (egg with terminal spine B) can lead to squamous cell carcinoma of the bladder (painless hematuria) and pulmonary hypertension	Snails are intermediate host; cercariae penetrate skin of humans in contact with contaminated fresh water (eg, swimming or bathing)	Praziquantel
 B			
<i>Clonorchis sinensis</i>	Biliary tract inflammation → pigmented gallstones Associated with cholangiocarcinoma	Undercooked fish	Praziquantel


Ectoparasites

Sarcoptes scabiei

Mites burrow into stratum corneum and cause **scabies**—pruritus (worse at night) and serpiginous burrows (lines) often between fingers and toes **A**.

Common in children, crowded populations (jails, nursing homes); transmission through skin-to-skin contact (most common) or via fomites.

Treatment: permethrin cream, oral ivermectin, washing/drying all clothing/bedding, treat close contacts.

Pediculus humanus and *Phthirus pubis*

Blood-sucking lice that cause intense pruritus with associated excoriations, commonly on scalp and neck (head lice), waistband and axilla (body lice), or pubic and perianal regions (pubic lice).

Body lice can transmit *Rickettsia prowazekii* (epidemic typhus), *Borrelia recurrentis* (relapsing fever), *Bartonella quintana* (trench fever).

Treatment: pyrethroids, malathion, or ivermectin lotion, and nit **B** combing. Children with head lice can be treated at home without interrupting school attendance.

Cimex lectularius and *Cimex hemipterus*

Bed bugs. Blood-feeding insects that infest dwellings. Painless bites result in a range of skin reactions, typically pruritic, erythematous papules with central hemorrhagic punctum. A clustered or linear pattern of bites seen upon awakening is suggestive. Diagnosis is confirmed by direct identification of bed bugs in patient's dwelling.

Bed bugs can spread among rooms; cohabitants may exhibit similar symptoms. Infestations can also spread via travelers from infested hotels and the use of unwashed, used bedding.

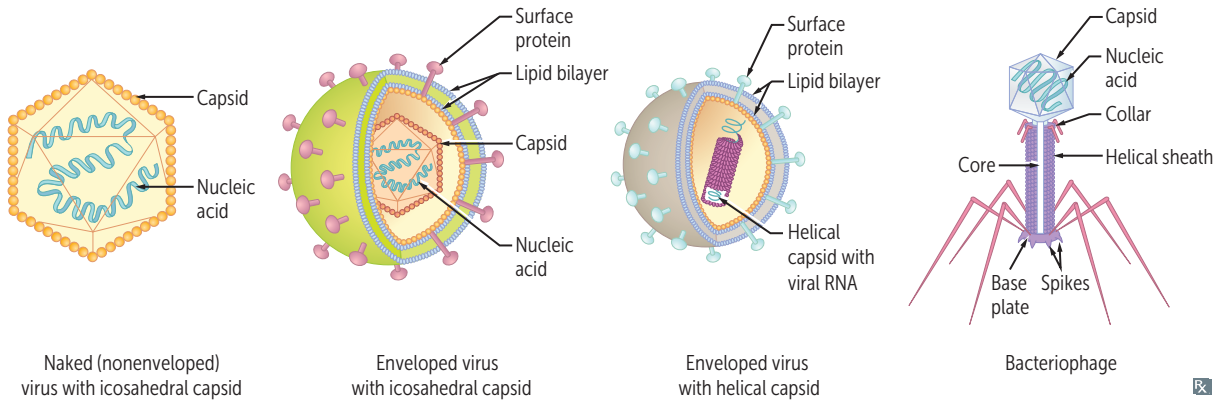
Treatment: bites self resolve within 1 week. Eradication of the infestation is critical.

Parasite hints

ASSOCIATIONS	ORGANISM
Biliary tract disease, cholangiocarcinoma	<i>Clonorchis sinensis</i>
Brain cysts, seizures	<i>Taenia solium</i> (neurocysticercosis)
Hematuria, squamous cell bladder cancer	<i>Schistosoma haematobium</i>
Liver (hydatid) cysts, exposure to infected dogs	<i>Echinococcus granulosus</i>
Iron deficiency anemia	<i>Ancylostoma</i> , <i>Necator</i>
Myalgias, periorbital edema	<i>Trichinella spiralis</i>
Nocturnal perianal pruritus	<i>Enterobius</i>
Portal hypertension	<i>Schistosoma mansoni</i> , <i>Schistosoma japonicum</i>
Vitamin B ₁₂ deficiency	<i>Diphyllobothrium latum</i>

▶ MICROBIOLOGY—VIROLOGY

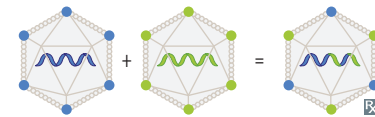
Viral structure—general features



Viral genetics

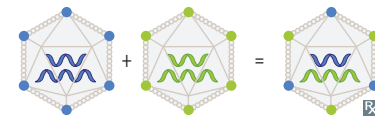
Recombination

Exchange of genes between 2 chromosomes by crossing over within regions of significant base sequence homology.



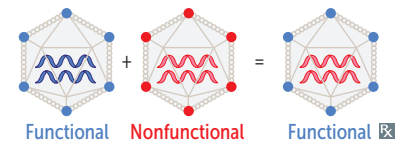
Reassortment

When viruses with segmented genomes (eg, influenza virus) exchange genetic material. For example, the 2009 novel H1N1 influenza A pandemic emerged via complex viral reassortment of genes from human, swine, and avian viruses. Has potential to cause antigenic shift.



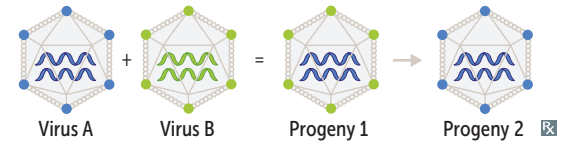
Complementation

When 1 of 2 viruses that infect the cell has a mutation that results in a nonfunctional protein, the nonmutated virus “complements” the mutated one by making a functional protein that serves both viruses. For example, hepatitis D virus requires the presence of replicating hepatitis B virus to supply HBsAg, the envelope protein for HDV.



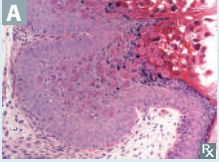
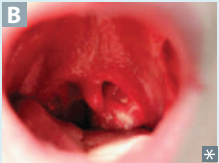
Phenotypic mixing

Occurs with simultaneous infection of a cell with 2 viruses. For progeny 1, genome of virus A can be partially or completely coated (forming pseudovirion) with the surface proteins of virus B. Type B protein coat determines the tropism (infectivity) of the hybrid virus. Progeny from subsequent infection of a cell by progeny 1 will have a type A coat that is encoded by its type A genetic material.



DNA viral genomes	All DNA viruses have dsDNA genomes except Parvoviridae (ssDNA). All are linear except papilloma-, polyoma-, and hepadnaviruses (circular).	All are dsDNA (like our cells), except “ part-of-a-virus ” (parvovirus) is ssDNA. <i>Parvus</i> = small.												
RNA viral genomes	All RNA viruses have ssRNA genomes except Reoviridae (dsRNA). ⊕ stranded RNA viruses: I went to a retro (retrovirus) toga (togavirus) party, where I drank flavored (flavivirus) Corona (coronavirus) and ate hippie (hepevirus) California (calicivirus) pickles (picornavirus).	All are ssRNA, except “ repeato-virus ” (reovirus) is dsRNA.												
Naked viral genome infectivity	Purified nucleic acids of most dsDNA viruses (except poxviruses and HBV) and ⊕ strand ssRNA (≈ mRNA) viruses are infectious. Naked nucleic acids of ⊖ strand ssRNA and dsRNA viruses are not infectious. They require polymerases contained in the complete virion.													
Viral envelopes	Generally, enveloped viruses acquire their envelopes from plasma membrane when they exit from cell. Exceptions include herpesviruses, which acquire envelopes from nuclear membrane. Naked (nonenveloped) viruses include papillomavirus, adenovirus, parvovirus, polyomavirus, calicivirus, picornavirus, reovirus, and hepevirus.	Enveloped DNA viruses (herpesvirus , hepadnavirus , poxvirus) have helpful protection .												
DNA virus characteristics	Some general rules—all DNA viruses: <table border="1"> <thead> <tr> <th data-bbox="391 1325 496 1346">GENERAL RULE</th> <th data-bbox="940 1325 1024 1346">COMMENTS</th> </tr> </thead> <tbody> <tr> <td data-bbox="391 1360 659 1388">Are HHAPPPPy viruses</td> <td data-bbox="940 1360 1354 1423">Hepadna, Herpes, Adeno, Pox, Parvo, Papilloma, Polyoma.</td> </tr> <tr> <td data-bbox="391 1438 610 1465">Are double stranded</td> <td data-bbox="940 1438 1273 1465">Except parvo (single stranded).</td> </tr> <tr> <td data-bbox="391 1480 618 1507">Have linear genomes</td> <td data-bbox="940 1480 1382 1585">Except papilloma and polyoma (circular, supercoiled) and hepadna (circular, incomplete).</td> </tr> <tr> <td data-bbox="391 1600 561 1627">Are icosahedral</td> <td data-bbox="940 1600 1179 1627">Except pox (complex).</td> </tr> <tr> <td data-bbox="391 1642 656 1669">Replicate in the nucleus</td> <td data-bbox="940 1642 1451 1705">Except pox (carries own DNA-dependent RNA polymerase).</td> </tr> </tbody> </table>		GENERAL RULE	COMMENTS	Are HHAPPPP y viruses	H epadna, H erpes, A deno, P ox, P arvo, P apilloma, P olyoma.	Are double stranded	Except parvo (single stranded).	Have linear genomes	Except papilloma and polyoma (circular, supercoiled) and hepadna (circular, incomplete).	Are icosahedral	Except pox (complex).	Replicate in the nucleus	Except pox (carries own DNA-dependent RNA polymerase).
GENERAL RULE	COMMENTS													
Are HHAPPPP y viruses	H epadna, H erpes, A deno, P ox, P arvo, P apilloma, P olyoma.													
Are double stranded	Except parvo (single stranded).													
Have linear genomes	Except papilloma and polyoma (circular, supercoiled) and hepadna (circular, incomplete).													
Are icosahedral	Except pox (complex).													
Replicate in the nucleus	Except pox (carries own DNA-dependent RNA polymerase).													

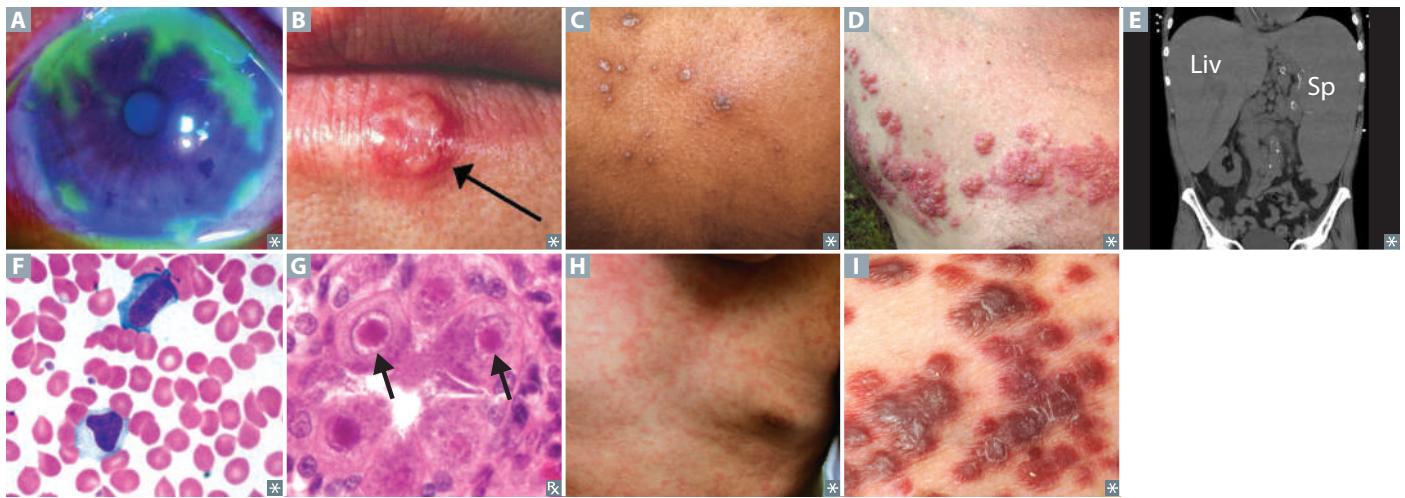
DNA virusesAll replicate in the nucleus (except poxvirus). “**P**ox is out of the **box** (nucleus).”

VIRAL FAMILY	ENVELOPE	DNA STRUCTURE	MEDICAL IMPORTANCE
Herpesviruses	Yes	DS and linear	See Herpesviruses entry
Poxvirus 	Yes	DS and linear (largest DNA virus)	Smallpox eradicated world wide by use of the live-attenuated vaccine Cowpox (“milkmaid blisters”) Molluscum contagiosum —flesh-colored papule with central umbilication; keratinocytes contain molluscum bodies A
Hepadnavirus	Yes	Partially DS and circular	HBV: <ul style="list-style-type: none"> ▪ Acute or chronic hepatitis ▪ Not a retrovirus but has reverse transcriptase
Adenovirus 	No	DS and linear	Febrile pharyngitis B —sore throat Acute hemorrhagic cystitis Pneumonia Conjunctivitis—“pink eye” Gastroenteritis Myocarditis
Papillomavirus	No	DS and circular	HPV—warts, cancer (cervical, anal, penile, or oropharyngeal); serotypes 1, 2, 6, 11 associated with warts; serotypes 16, 18 associated with cancer
Polyomavirus	No	DS and circular	JC virus—progressive multifocal leukoencephalopathy (PML) in immunocompromised patients (eg, HIV) BK virus—transplant patients, commonly targets kidney JC: Junky Cerebrum; BK: Bad Kidney
Parvovirus	No	SS and linear (smallest DNA virus)	B19 virus—aplastic crises in sickle cell disease, “slapped cheek” rash in children (erythema infectiosum, or fifth disease); infects RBC precursors and endothelial cells → RBC destruction → hydrops fetalis and death in fetus, pure RBC aplasia and rheumatoid arthritis–like symptoms in adults

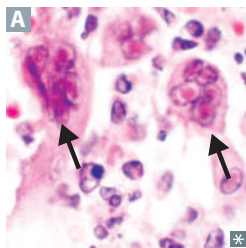
Herpesviruses Enveloped, DS, and linear viruses. Recent data suggest both HSV-1 and HSV-2 can affect both genital and extragenital areas.

VIRUS	ROUTE OF TRANSMISSION	CLINICAL SIGNIFICANCE	NOTES
Herpes simplex virus-1	Respiratory secretions, saliva	Gingivostomatitis, keratoconjunctivitis A , herpes labialis (cold sores) B , herpetic whitlow on finger, temporal lobe encephalitis, esophagitis, erythema multiforme	Most commonly latent in trigeminal ganglia Most common cause of sporadic encephalitis, can present as altered mental status, seizures, and/or aphasia
Herpes simplex virus-2	Sexual contact, perinatal	Herpes genitalis, neonatal herpes	Most commonly latent in sacral ganglia Viral meningitis more common with HSV-2 than with HSV-1
Varicella-zoster virus (HHV-3)	Respiratory secretions, contact with fluid from vesicles	Varicella-zoster (chickenpox C , shingles D), encephalitis, pneumonia Most common complication of shingles is post-herpetic neuralgia	Latent in dorsal root or trigeminal ganglia; CN V ₁ branch involvement can cause herpes zoster ophthalmicus
Epstein-Barr virus (HHV-4)	Respiratory secretions, saliva; also called “kissing disease,” (common in teens, young adults)	Mononucleosis —fever, hepatosplenomegaly E , pharyngitis, and lymphadenopathy (especially posterior cervical nodes); avoid contact sports until resolution due to risk of splenic rupture Associated with lymphomas (eg, endemic Burkitt lymphoma), nasopharyngeal carcinoma (especially Asian adults), lymphoproliferative disease in transplant patients	Infects B cells through CD 21 , “Must be 21 to drink B eer in a B arr” Atypical lymphocytes on peripheral blood smear F —not infected B cells but reactive cytotoxic T cells ⊕ Monospot test—heterophile antibodies detected by agglutination of sheep or horse RBCs Use of amoxicillin (eg, for presumed strep pharyngitis) can cause maculopapular rash
Cytomegalovirus (HHV-5)	Congenital, transfusion, sexual contact, saliva, urine, transplant	Mononucleosis (⊖ Monospot) in immunocompetent patients; infection in immunocompromised, especially pneumonia in transplant patients; esophagitis; AIDS retinitis (“ sight omegalovirus”): hemorrhage, cotton-wool exudates, vision loss Congenital CMV	Infected cells have characteristic “owl eye” intranuclear inclusions G Latent in mononuclear cells
Human herpesviruses 6 and 7	Saliva	Roseola infantum (exanthem subitum): high fevers for several days that can cause seizures, followed by diffuse macular rash (starts on trunk then spreads to extremities) H ; usually seen in children < 2 years old	Roseola : fever first, Rosy (rash) later Self-limited illness HHV-7—less common cause of roseola
Human herpesvirus 8	Sexual contact	Kaposi sarcoma (neoplasm of endothelial cells). Seen in HIV/AIDS and transplant patients. Dark/violaceous plaques or nodules I representing vascular proliferations	Can also affect GI tract and lungs

Herpesviruses (continued)



HSV identification



PCR of skin lesions is test of choice.

CSF PCR for herpes encephalitis.

Tzanck test (outdated)—a smear of an opened skin vesicle to detect multinucleated giant cells **A** commonly seen in HSV-1, HSV-2, and VZV infection.

Intranuclear eosinophilic Cowdry A inclusions also seen with HSV-1, HSV-2, VZV.

Receptors used by viruses

VIRUS	RECEPTOR(S)
CMV	Integrins (heparan sulfate)
EBV	CD21
HIV	CD4, CXCR4, CCR5
Parvovirus B19	P antigen on RBCs
Rabies	Nicotinic AChR
Rhinovirus	ICAM-1 (I CAMe to see the rhino)
SARS-CoV-2	ACE2

RNA viruses		All replicate in the cytoplasm (except retrovirus and influenza virus). “ Retro flu is outta cyt (sight).”		
VIRAL FAMILY	ENVELOPE	RNA STRUCTURE	CAPSID SYMMETRY	MEDICAL IMPORTANCE
Reoviruses	No	DS linear Multisegmented	Icosahedral (double)	Rotavirus—important cause of diarrhea in young children; may be fatal.
Picornaviruses	No	SS ⊕ linear	Icosahedral	P oliovirus—polio-Salk/Sabin vaccines—IPV/OPV E chovirus—aseptic meningitis R hinovirus—“common cold” C oxsackievirus—aseptic meningitis; herpangina (mouth blisters, fever); hand, foot, and mouth disease; myocarditis; pericarditis HAV —acute viral hepatitis PERCH
Hepevirus	No	SS ⊕ linear	Icosahedral	HEV
Caliciviruses	No	SS ⊕ linear	Icosahedral	Norovirus—viral gastroenteritis
Flaviviruses	Yes	SS ⊕ linear	Icosahedral	HCV Yellow fever ^a Dengue ^a West Nile virus ^a —meningoencephalitis, flaccid paralysis Zika virus ^a
Togaviruses	Yes	SS ⊕ linear	Icosahedral	Toga CREW — C hikungunya virus ^a (co-infection with dengue virus can occur), R ubella (formerly a togavirus), E astern and W estern equine encephalitis
Matonavirus	Yes	SS ⊕ linear	Icosahedral	Rubella
Retroviruses	Yes	SS ⊕ linear 2 copies	Icosahedral (HTLV), conical (HIV)	Have reverse transcriptase HTLV—T-cell leukemia HIV—AIDS
Coronaviruses	Yes	SS ⊕ linear	Helical	“Common cold,” SARS, COVID-19, MERS
Orthomyxoviruses	Yes	SS ⊖ linear 8 segments	Helical	Influenza virus
Paramyxoviruses	Yes	SS ⊖ linear Nonsegmented	Helical	PaRaMyxovirus : P arainfluenza—croup RSV —bronchiolitis in babies M easles, M umps
Rhabdoviruses	Yes	SS ⊖ linear	Helical	Rabies
Filoviruses	Yes	SS ⊖ linear	Helical	Ebola/Marburg hemorrhagic fever—often fatal.
Arenaviruses	Yes	SS ⊕ and ⊖ circular 2 segments	Helical	LCMV—lymphocytic choriomeningitis virus Lassa fever encephalitis—spread by rodents
Bunyaviruses	Yes	SS ⊖ circular 3 segments	Helical	California encephalitis ^a Sandfly/Rift Valley fevers ^a Crimean-Congo hemorrhagic fever ^a Hantavirus—hemorrhagic fever, pneumonia
Delta virus	Yes	SS ⊖ circular	Uncertain	HDV is “ D efective”; requires presence of HBV to replicate

SS, single-stranded; DS, double-stranded; ⊕, positive sense; ⊖, negative sense; ^a= **arbovirus**, **arthropod borne** (mosquitoes, ticks).

Negative-stranded viruses

Must transcribe \ominus strand to \oplus . Virion brings its own RNA-dependent RNA polymerase. They include **arenaviruses**, **bunyaviruses**, **paramyxoviruses**, **orthomyxoviruses**, **filoviruses**, and **rhabdoviruses**.

Always **bring polymerase** or **fail replication**.

Segmented viruses

All are RNA viruses. They include **Bunyaviruses** (3 segments), **Orthomyxoviruses** (influenza viruses) (8 segments), **Arenaviruses** (2 segments), and **Reoviruses** (10–12 segments).

BOARDing flight 382 in 10–12 minutes.

Picornavirus

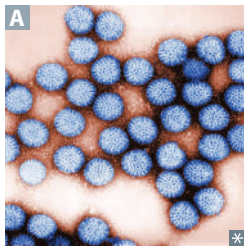
Includes **Poliovirus**, **Echovirus**, **Rhinovirus**, **Coxsackievirus**, and **HAV**. RNA is translated into 1 large polypeptide that is cleaved by virus-encoded proteases into functional viral proteins. Poliovirus, echovirus, and coxsackievirus are enteroviruses and can cause aseptic (viral) meningitis.

PicoRNAvirus = small **RNA** virus. **PERCH** on a “**peak**” (**pico**).

Rhinovirus

A picornavirus. Nonenveloped RNA virus. Cause of common cold; > 100 serologic types. Acid labile—destroyed by stomach acid; therefore, does not infect the GI tract (unlike the other picornaviruses).

Rhino has a runny **nose**.

Rotavirus

Segmented dsRNA virus (a reovirus) **A**. Most important global cause of infantile gastroenteritis. Major cause of acute diarrhea in the United States during winter, especially in day care centers, kindergartens. Villous destruction with atrophy leads to ↓ absorption of Na^+ and loss of K^+ .

Rotavirus = **right out the anus**. CDC recommends routine vaccination of all infants except those with a history of intussusception (rare adverse effect of rotavirus vaccination) or SCID.

Influenza viruses

Orthomyxoviruses. Enveloped, \ominus ssRNA viruses with segmented genome. Contain hemagglutinin (binds sialic acid and promotes viral entry) and neuraminidase (promotes progeny virion release) antigens. Patients at risk for fatal bacterial superinfection, most commonly *S aureus*, *S pneumoniae*, and *H influenzae*. Treatment: supportive +/- neuraminidase inhibitor (eg, oseltamivir, zanamivir).

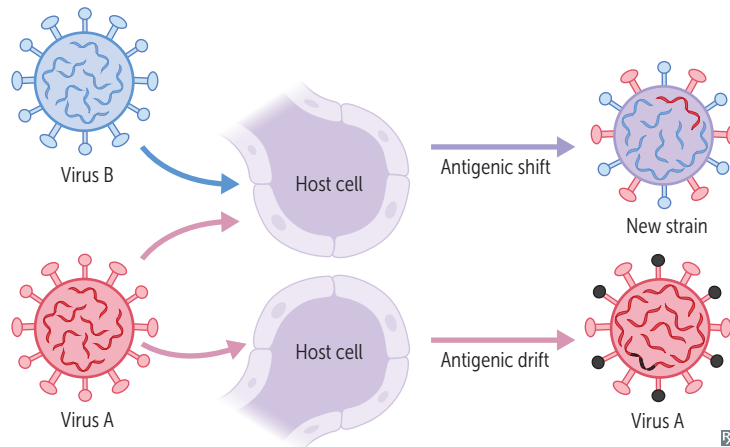
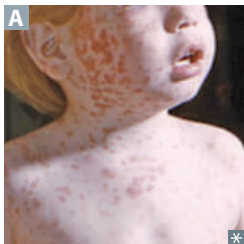Hemagglutin**in**: lets the virus **in**
 Neuraminid**aw**ays: sends the virus **away**
 Reformulated vaccine (“the flu shot”) contains viral strains most likely to appear during the flu season, due to the virus’ rapid genetic change. Killed viral vaccine is most frequently used. Live attenuated vaccine contains temperature-sensitive mutant that replicates in the nose but not in the lung; administered intranasally. Sudden **shift** is more deadly than **gradual drift**.

Genetic/antigenic shift

Infection of 1 cell by 2 different segmented viruses (eg, swine influenza and human influenza viruses) → RNA segment reassortment → dramatically different virus (genetic shift) → major global outbreaks (pandemics).

Genetic/antigenic drift

Random mutation in hemagglutinin (HA) or neuraminidase (NA) genes → minor changes in HA or NA protein (drift) occur frequently → local seasonal outbreaks (epidemics).

**Rubella virus**

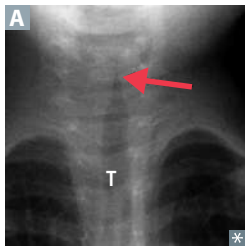
A matonavirus. Causes rubella, formerly called German (3-day) measles. Fever, postauricular and other lymphadenopathy, arthralgias, and fine, maculopapular rash that starts on face and spreads centrifugally to involve trunk and extremities **A**.

Causes mild disease in children but serious congenital disease (a TORCH infection). Congenital rubella findings include classic triad of sensorineural deafness, cataracts, and patent ductus arteriosus. “Blueberry muffin” appearance may be seen due to dermal extramedullary hematopoiesis.

Paramyxoviruses

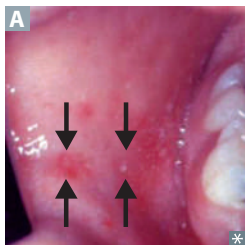
Paramyxoviruses cause disease in children. They include those that cause parainfluenza (croup), mumps, measles, RSV, and human metapneumovirus. All subtypes can cause respiratory tract infection (bronchiolitis, pneumonia) in infants. All contain surface F (fusion) protein, which causes respiratory epithelial cells to fuse and form multinucleated cells. Palivizumab (monoclonal antibody against F protein) prevents pneumonia caused by RSV infection in premature infants. Palivizumab for **p**aramyxovirus (RSV) **p**rophylaxis in **p**reemies.

Acute laryngotracheobronchitis



Also called croup. Caused by parainfluenza viruses. Virus membrane contains hemagglutinin (binds sialic acid and promotes viral entry) and neuraminidase (promotes progeny virion release) antigens. Results in a “seal-like” barking cough and inspiratory stridor. Narrowing of upper trachea and subglottis leads to characteristic steeple sign on x-ray **A**.

Measles (rubeola) virus



Usual presentation involves prodromal fever with cough, coryza, and conjunctivitis, then eventually Koplik spots (bright red spots with blue-white center on buccal mucosa **A**), followed 1–2 days later by a maculopapular rash that starts at the head/neck and spreads downward.

Lymphadenitis with Warthin-Finkeldey giant cells (fused lymphocytes) in a background of paracortical hyperplasia. Possible sequelae:

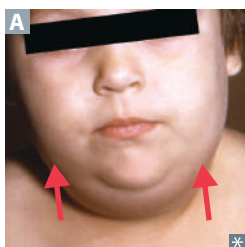- Subacute sclerosing panencephalitis (SSPE): personality changes, dementia, autonomic dysfunction, death (occurs years later)
- Encephalitis (1:1000): symptoms appear within few days of rash
- Giant cell pneumonia (rare except in immunosuppressed)

4 **C**'s of measles:

- C**ough
- C**oryza
- C**onjunctivitis
- “**C**”oplik spots

Vitamin A supplementation can reduce morbidity and mortality from measles, particularly in malnourished children. Pneumonia is the most common cause of measles-associated death in children.

Mumps virus



Uncommon due to effectiveness of MMR vaccine.

Symptoms: **P**arotitis **A**, **O**rchitis (inflammation of testes), aseptic **M**eningitis, and **P**ancreatitis. Can cause sterility (especially after puberty).

Mumps makes your parotid glands and testes as big as **POM-Poms**.

Arboviruses transmitted by *Aedes* mosquitoes

Chikungunya virus

An alphavirus member of togavirus family, transmitted by *Aedes* mosquito. Systemic infection that produces inflammatory polyarthritis that can become chronic. Other symptoms include high fever, maculopapular rash, headache, lymphadenopathy. Hemorrhagic manifestations are uncommon (vs dengue fever). Diagnosed with RT-PCR or serology. No antiviral therapy and no vaccine.

Dengue virus

A flavivirus, transmitted by *Aedes* mosquito; most common mosquito-borne viral disease in the world. Can present as dengue fever (fever, rash, headache, myalgias, arthralgias, neutropenia), dengue hemorrhagic fever (dengue fever + bleeding and plasma leakage due to thrombocytopenia and extremely high or low hematocrit), or dengue shock syndrome (plasma leakage leading to circulatory collapse). Diagnosed by PCR or serology.

Dengue hemorrhagic fever is most common in patients infected with a different serotype after their initial infection due to antibody-dependent enhancement of disease.

Presents similarly to Chikungunya virus and is transmitted by the same mosquito vector; coinfections can occur. Dengue virus is more likely to cause neutropenia, thrombocytopenia, hemorrhage, shock, and death.

Live, recombinant vaccine uses yellow fever virus as a backbone into which the genes for the envelope and premembrane proteins of dengue virus have been inserted.

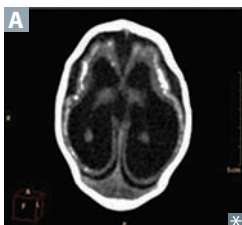
Yellow fever virus

A flavivirus (also an arbovirus) transmitted by *Aedes* mosquitoes. Virus has monkey or human reservoir. *Flavi* = yellow, jaundice.

Symptoms: high fever, black vomitus, jaundice, hemorrhage, backache. May see Councilman bodies (eosinophilic apoptotic globules) on liver biopsy.

Live, attenuated vaccine recommended for travelers to endemic countries.

Zika virus



A flavivirus most commonly transmitted by *Aedes* mosquito bites.

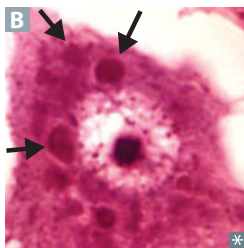
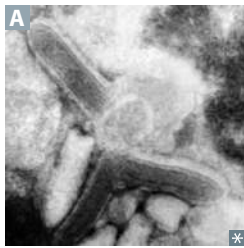
Causes conjunctivitis, low-grade pyrexia, and itchy rash in 20% of cases. Outbreaks more common in tropical and subtropical climates. Supportive care, no definitive treatment.

Diagnose with RT-PCR or serology.

Sexual and vertical transmission occurs.

In pregnancy, can lead to miscarriage or congenital Zika syndrome: brain imaging **A** shows ventriculomegaly, subcortical calcifications. Clinical features in the affected newborn include

- Microcephaly
- Ocular anomalies
- Motor abnormalities (spasticity, seizures)

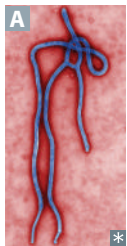
Rabies virus

Bullet-shaped virus **A**. Negri bodies (cytoplasmic inclusions **B**) commonly found in Purkinje cells of cerebellum and in hippocampal neurons. Rabies has long incubation period (weeks to months) before symptom onset. Postexposure prophylaxis is wound cleaning plus immunization with killed vaccine and rabies immunoglobulin. Example of passive-active immunity.

Travels to the CNS by migrating in a retrograde fashion (via dynein motors) up nerve axons after binding to ACh receptors.

Progression of disease: fever, malaise
→ agitation, photophobia, hydrophobia, hypersalivation → paralysis, coma → death.

Infection more commonly from bat, raccoon, and skunk bites than from dog bites in the United States; aerosol transmission (eg, bat caves) also possible.

Ebola virus

A filovirus **A**. Following an incubation period of up to 21 days, presents with abrupt onset of flulike symptoms, diarrhea/vomiting, high fever, myalgia. Can progress to DIC, diffuse hemorrhage, shock.

Diagnosed with RT-PCR within 48 hr of symptom onset. High mortality rate.

Transmission requires direct contact with bodily fluids, fomites (including dead bodies), infected bats or primates (apes/monkeys); high incidence of healthcare-associated infection.

Supportive care, no definitive treatment.

Vaccination of contacts, strict isolation of infected individuals, and barrier practices for healthcare workers are key to preventing transmission.

Severe acute respiratory syndrome coronavirus 2

SARS-CoV-2 is a novel ⊕ ssRNA coronavirus and the cause of the COVID-19 pandemic. Clinical course varies; often asymptomatic. Symptoms include

- Common: fever, dry cough, shortness of breath, fatigue.
- More specific: anosmia (loss of smell), dysgeusia (altered taste).

Complications include acute respiratory distress syndrome, hypercoagulability (→ thrombotic complications including cryptogenic and/or ischemic stroke), shock, organ failure, death.

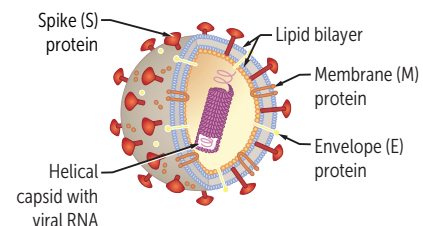
Risk factors for severe illness or death include increasing age (strongest risk factor), obesity, diabetes, hypertension, chronic kidney disease, severe cardiopulmonary illness.

Diagnosed by NAAT (most commonly RT-PCR). Tests detecting viral antigen are typically less sensitive than NAATs, but can be performed rapidly and may be more accessible.

Spreads through respiratory droplets and aerosols. Host cell entry occurs by attachment of viral spike protein to ACE2 receptor on cell membranes. Anti-spike protein antibodies confer immunity.

Vaccination induces humoral and cellular immunity, which decreases risk of contracting or transmitting the virus and prevents more serious disease, hospitalization, and death.

Supplemental oxygen and supportive care remain the mainstay of therapy for hospitalized patients. Dexamethasone, remdesivir, and IL-6 pathway inhibitors may benefit some severely ill patients.



Hepatitis viruses

Signs and symptoms of all hepatitis viruses: episodes of fever, jaundice, ↑ ALT and AST. Naked viruses (HAV and HEV) lack an envelope and are not destroyed by the gut: the **vowels** hit your **bowels**.

HBV DNA polymerase has DNA- and RNA-dependent activities. Upon entry into nucleus, the polymerase completes the partial dsDNA. Host RNA polymerase transcribes mRNA from viral DNA to make viral proteins. The DNA polymerase then reverse transcribes viral RNA to DNA, which is the genome of the progeny virus.

HCV lacks 3'-5' exonuclease activity → no proofreading ability → antigenic variation of HCV envelope proteins. Host antibody production lags behind production of new mutant strains of HCV.

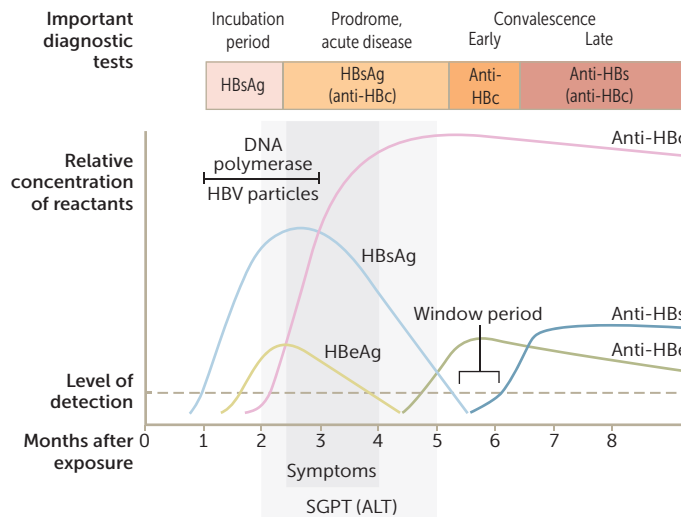
Virus	HAV	HBV	HCV	HDV	HEV
FAMILY	RNA picornavirus	DNA hepadnavirus	RNA flavivirus	RNA deltavirus	RNA hepevirus
TRANSMISSION	Fecal-oral (shellfish, travelers, day care)	Parenteral (B lood), sexual (B edroom), perinatal (B irthing)	Primarily blood (injection drug use, posttransfusion)	Parenteral, sexual, perinatal	Fecal-oral, especially waterborne
INCUBATION	Short (weeks)	Long (months)	Long	Superinfection (HDV after HBV) = short Coinfection (HDV with HBV) = long	Short
CLINICAL COURSE	A cute and self limiting (adults), A symptomatic (children)	Initially like serum sickness (fever, arthralgias, rash); may progress to carcinoma	May progress to C irrhosis or C arcinoma	Similar to HBV	Fulminant hepatitis in E xpectant (pregnant) patients
PROGNOSIS	Good	Adults → mostly full resolution; neonates → worse prognosis	Majority develop stable, C hronic hepatitis C	Superinfection → worse prognosis	High mortality in pregnant patients
HCC RISK	No	Yes	Yes	Yes	No
LIVER BIOPSY	Hepatocyte swelling, monocyte infiltration, Councilman bodies A bsent (no) carrier state	Granular eosinophilic "ground glass" appearance due to accumulation of surface antigen within infected hepatocytes; cytotoxic T cells mediate damage	Lymphoid aggregates with focal areas of macrovesicular steatosis	Similar to HBV	Patchy necrosis
NOTES	No carrier state	Carrier state common	C arrier state very common	D efective virus, D epends on HBV HBsAg coat for entry into hepatocytes	E nteric, E pidemic (eg, in parts of Asia, Africa, Middle East), no carrier state

Extrahepatic manifestations of hepatitis B and C

	Hepatitis B	Hepatitis C
HEMATOLOGIC	Aplastic anemia	Essential mixed cryoglobulinemia, ↑ risk B-cell NHL, ITP, autoimmune hemolytic anemia
RENAL	Membranous GN > membranoproliferative GN	Membranoproliferative GN > membranous GN
VASCULAR	Polyarteritis nodosa	Leukocytoclastic vasculitis
DERMATOLOGIC		Sporadic porphyria cutanea tarda, lichen planus
ENDOCRINE		↑ risk of diabetes mellitus, autoimmune hypothyroidism

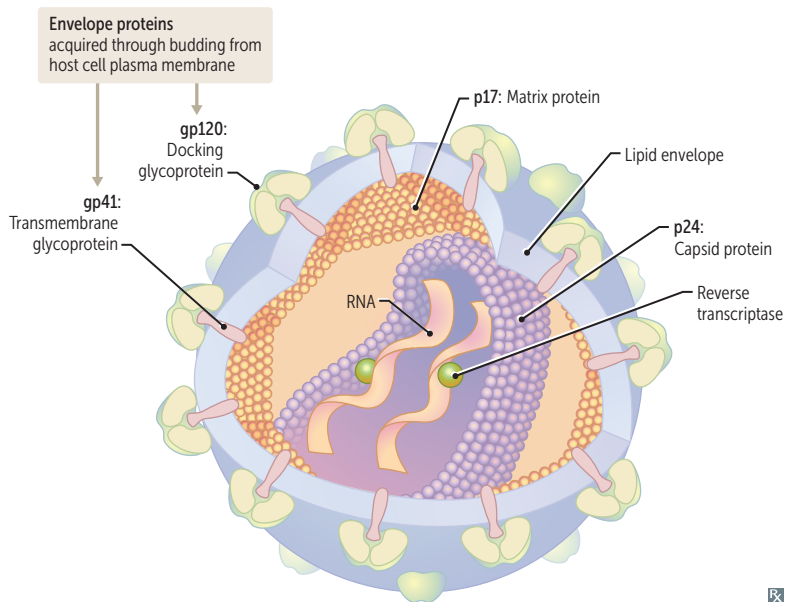
Hepatitis serologic markers

Anti-HAV (IgM)	IgM antibody to HAV; best test to detect acute hepatitis A.
Anti-HAV (IgG)	IgG antibody indicates prior HAV infection and/or prior vaccination; protects against reinfection.
HBsAg	Antigen found on surface of HBV; indicates hepatitis B infection.
Anti-HBs	Antibody to HBsAg; indicates immunity to hepatitis B due to vaccination or recovery from infection.
HBeAg	Antigen associated with core of HBV.
Anti-HBe	Antibody to HBeAg; IgM = acute/recent infection; IgG = prior exposure or chronic infection. IgM anti-HBe may be the sole ⊕ marker of infection during window period.
HBeAg	Secreted by infected hepatocyte into circulation. Not part of mature HBV virion. Indicates active viral replication and therefore high transmissibility and poorer prognosis.
Anti-HBe	Antibody to HBeAg; indicates low transmissibility.



	HBsAg	Anti-HBs	HBeAg	Anti-HBe	Anti-HBc
Acute HBV	✓		✓		IgM
Window				✓	IgM
Chronic HBV (high infectivity)	✓		✓		IgG
Chronic HBV (low infectivity)	✓			✓	IgG
Recovery		✓		✓	IgG
Immunized		✓			

HIV



Diploid genome (2 molecules of RNA).

The 3 structural genes (protein coded for):

- *env* (gp120 and gp41):
 - Formed from cleavage of gp160 to form envelope glycoproteins.
 - gp120—attachment to host CD4+ T cell.
 - gp41 (forty-one)—fusion and entry.
- *gag* (p24 and p17)—capsid and matrix proteins, respectively.
- *pol*—Reverse transcriptase, Integrase, Protease; RIP “Pol” (Paul)

Reverse transcriptase synthesizes dsDNA from genomic RNA; dsDNA integrates into host genome.

Virus binds CD4 as well as a coreceptor, either CCR5 on macrophages (early infection) or CXCR4 on T cells (late infection).

Homozygous CCR5 mutation = immunity.

Heterozygous CCR5 mutation = slower course.

ⓧ

HIV diagnosis

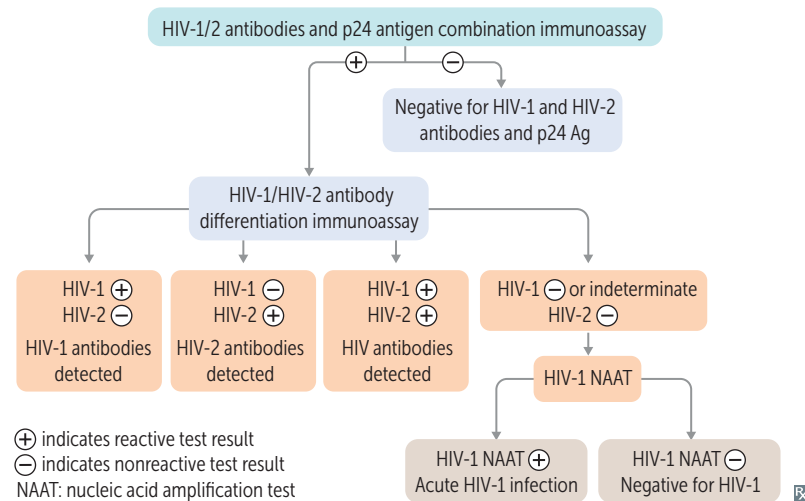
Diagnosis made with HIV-1/2 Ag/Ab immunoassays. These immunoassays detect viral p24 Ag capsid protein and IgG Abs to HIV-1/2. Very high sensitivity/specificity, but may miss early HIV disease if tested within first 2 weeks of infection.

Viral load tests determine the amount of viral RNA in the plasma. Use viral load (determined by NAAT) to monitor effect of drug therapy. Use HIV genotyping to determine appropriate therapy.

Western blot tests are no longer recommended by the CDC for confirmatory testing.

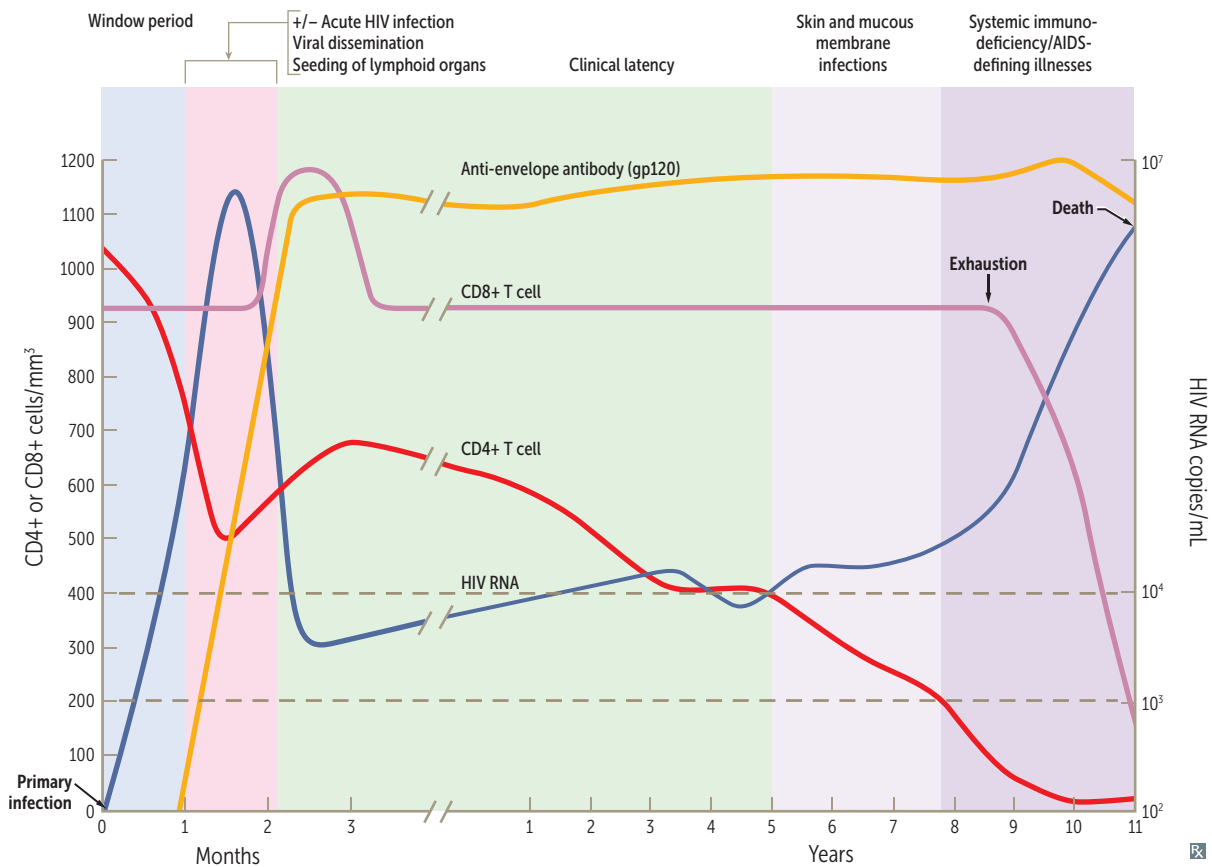
HIV-1/2 Ag/Ab testing is not recommended in babies with suspected HIV due to maternally transferred antibody. Use HIV viral load instead.

AIDS diagnosis: ≤ 200 CD4+ cells/mm³ (normal: 500–1500 cells/mm³) or HIV ⊕ with AIDS-defining condition (eg, *Pneumocystis pneumonia*).



ⓧ

Time course of untreated HIV infection



Dashed lines on CD4+ cell count axis indicate moderate immunocompromise (< 400 CD4+ cells/mm³) and when AIDS-defining illnesses emerge (< 200 CD4+ cells/mm³).

Most patients who do not receive treatment eventually die of complications of HIV infection.

Four stages of untreated infection:

1. **F**lulike (acute)
2. **F**eeling fine (latent)
3. **F**alling count
4. **F**inal crisis

During clinical latency phase, virus replicates in lymph nodes

Common diseases of HIV-positive adults

↓ CD4+ cell count → reactivation of past infections (eg, TB, HSV, shingles), dissemination of bacterial infections and fungal infections (eg, coccidioidomycosis), and non-Hodgkin lymphomas.

PATHOGEN	PRESENTATION	FINDINGS
CD4+ cell count < 500/mm³		
<i>Candida albicans</i>	Oral thrush	Scrapable white plaque, pseudohyphae on microscopy
EBV	Oral hairy leukoplakia	Unscrapable white plaque on lateral tongue
HHV-8	Kaposi sarcoma	Perivascular spindle cells invading and forming vascular tumors on histology
HPV	Squamous cell carcinoma at site(s) of sexual contact (most commonly anus, cervix, oropharynx)	
<i>Mycobacterium tuberculosis</i>	Increased risk of reactivation of latent TB infection	
CD4+ cell count < 200/mm³		
<i>Histoplasma capsulatum</i>	Fever, weight loss, fatigue, cough, dyspnea, nausea, vomiting, diarrhea	Oval yeast cells within macrophages
HIV	Dementia, HIV-associated nephropathy	Cerebral atrophy on neuroimaging
JC virus (reactivation)	Progressive multifocal leukoencephalopathy	Nonenhancing areas of demyelination on MRI
<i>Pneumocystis jirovecii</i>	<i>Pneumocystis</i> pneumonia	“Ground-glass” opacities on chest imaging
CD4+ cell count < 100/mm³		
<i>Bartonella</i> spp	Bacillary angiomatosis	Multiple red to purple papules or nodules Biopsy with neutrophilic inflammation
<i>Candida albicans</i>	Esophagitis	White plaques on endoscopy; yeast and pseudohyphae on biopsy
CMV	Colitis, Retinitis, Esophagitis, Encephalitis, Pneumonitis (CREEP)	Linear ulcers on endoscopy, cotton-wool spots on fundoscopy Biopsy reveals cells with intranuclear (owl eye) inclusion bodies
<i>Cryptococcus neoformans</i>	Meningitis	Encapsulated yeast on India ink stain or capsular antigen ⊕
<i>Cryptosporidium</i> spp	Chronic, watery diarrhea	Acid-fast oocysts in stool
EBV	B-cell lymphoma (eg, non-Hodgkin lymphoma, CNS lymphoma)	CNS lymphoma—ring enhancing, may be solitary (vs <i>Toxoplasma</i>)
<i>Mycobacterium avium–intracellulare</i> , <i>Mycobacterium avium</i> complex	Nonspecific systemic symptoms (fever, night sweats, weight loss) or focal lymphadenitis	Most common if CD4+ cell count < 50/mm ³
<i>Toxoplasma gondii</i>	Brain abscesses	Multiple ring-enhancing lesions on MRI

Prions

Prion diseases are caused by the conversion of a normal (predominantly α -helical) protein termed prion protein (PrP^c) to a β -pleated form (PrP^{sc}), which is transmissible via CNS-related tissue (iatrogenic CJD) or food contaminated by BSE-infected animal products (variant CJD). PrP^{sc} resists protease degradation and facilitates the conversion of still more PrP^c to PrP^{sc}. Resistant to standard sterilizing procedures, including standard autoclaving. Accumulation of PrP^{sc} results in spongiform encephalopathy and dementia, ataxia, startle myoclonus, and death.

Creutzfeldt-Jakob disease—rapidly progressive dementia, typically sporadic (some familial forms).

Bovine spongiform encephalopathy—also called “mad cow disease.”

Kuru—acquired prion disease noted in tribal populations practicing human cannibalism.

▶ MICROBIOLOGY—SYSTEMS**Normal microbiota:
dominant**

Neonates delivered by C-section have microbiota enriched in skin commensals.

LOCATION	MICROORGANISM
Skin	<i>S epidermidis</i>
Nose	<i>S epidermidis</i> ; colonized by <i>S aureus</i>
Oropharynx	Viridans group streptococci
Dental plaque	<i>S mutans</i>
Colon	<i>B fragilis</i> > <i>E coli</i>
Vagina	<i>Lactobacillus</i> ; colonized by <i>E coli</i> and group B strep

**Bugs causing food-
borne illness**

S aureus and *B cereus* food poisoning starts quickly and ends quickly.

MICROORGANISM	SOURCE OF INFECTION
<i>B cereus</i>	Reheated rice. “Food poisoning from reheated rice? Be serious! ” (<i>B cereus</i>)
<i>C botulinum</i>	Improperly canned foods (toxins), raw honey (spores)
<i>C perfringens</i>	Reheated meat
<i>E coli</i> O157:H7	Undercooked meat
<i>L monocytogenes</i>	Deli meats, soft cheeses
<i>Salmonella</i>	Poultry, meat, and eggs
<i>S aureus</i>	Meats, mayonnaise, custard; preformed toxin
<i>V paraahaemolyticus</i> and <i>V vulnificus</i> ^a	Raw/undercooked seafood

^a*V vulnificus* predominantly causes wound infections from contact with contaminated water or shellfish.

Bugs causing diarrhea

Bloody diarrhea	
<i>Campylobacter</i>	Comma- or S-shaped organisms; growth at 42°C
<i>E histolytica</i>	Protozoan; amebic dysentery; liver abscess
Enterohemorrhagic <i>E coli</i>	O157:H7; can cause HUS; makes Shiga toxin
Enteroinvasive <i>E coli</i>	Invades colonic mucosa
<i>Salmonella</i> (non-typhoidal)	Lactose ⊖; flagellar motility; has animal reservoir, especially poultry and eggs
<i>Shigella</i>	Lactose ⊖; very low ID ₅₀ ; produces Shiga toxin; human reservoir only; bacillary dysentery
<i>Y enterocolitica</i>	Day care outbreaks; pseudoappendicitis
Watery diarrhea	
<i>C difficile</i>	Pseudomembranous colitis; associated with antibiotics and PPIs; occasionally bloody diarrhea
<i>C perfringens</i>	Also causes gas gangrene
Enterotoxigenic <i>E coli</i>	Travelers' diarrhea; produces heat-labile (LT) and heat-stable (ST) toxins
Protozoa	<i>Giardia</i> , <i>Cryptosporidium</i>
<i>V cholerae</i>	Comma-shaped organisms; rice-water diarrhea; often from infected seafood
Viruses	Norovirus (most common cause in developed countries), rotavirus (↓ incidence in developed countries due to vaccination), enteric adenovirus

Common causes of pneumonia

NEONATES (< 4 WK)	CHILDREN (4 WK–18 YR)	ADULTS (18–40 YR)	ADULTS (40–65 YR)	ADULTS (65 YR +)
Group B streptococci	Viruses (RSV)	<i>Mycoplasma</i>	<i>S pneumoniae</i>	<i>S pneumoniae</i>
<i>E coli</i>	Mycoplasma	<i>C pneumoniae</i>	<i>H influenzae</i>	Influenza virus
	C trachomatis	<i>S pneumoniae</i>	Anaerobes	Anaerobes
	(infants–3 yr)	Viruses (eg, influenza)	Viruses	<i>H influenzae</i>
	C pneumoniae (school-aged children)		<i>Mycoplasma</i>	Gram ⊖ rods
	S pneumoniae			
	Runts May Cough			
	Chunky Sputum			

Special groups

Alcohol overuse	<i>Klebsiella</i> , anaerobes usually due to aspiration (eg, <i>Peptostreptococcus</i> , <i>Fusobacterium</i> , <i>Prevotella</i> , <i>Bacteroides</i>)
Injection drug use	<i>S pneumoniae</i> , <i>S aureus</i>
Aspiration	Anaerobes
Atypical	<i>Mycoplasma</i> , <i>Chlamydothyla</i> , <i>Legionella</i> , viruses (RSV, CMV, influenza, adenovirus)
Cystic fibrosis	<i>Pseudomonas</i> , <i>S aureus</i> , <i>S pneumoniae</i> , <i>Burkholderia cepacia</i>
Immunocompromised	<i>S aureus</i> , enteric gram ⊖ rods, fungi, viruses, <i>P jirovecii</i> (with HIV)
Healthcare-associated	<i>S aureus</i> , <i>Pseudomonas</i> , other enteric gram ⊖ rods
Postviral	<i>S pneumoniae</i> , <i>S aureus</i> , <i>H influenzae</i>
COPD	<i>S pneumoniae</i> , <i>H influenzae</i> , <i>M catarrhalis</i> , <i>Pseudomonas</i>

Common causes of meningitis

NEWBORN (0–6 MO)	CHILDREN (6 MO–6 YR)	6–60 YR	60 YR +
Group B <i>Streptococcus</i>	<i>S pneumoniae</i>	<i>S pneumoniae</i>	<i>S pneumoniae</i>
<i>E coli</i>	<i>N meningitidis</i>	<i>N meningitidis</i>	<i>N meningitidis</i>
<i>Listeria</i>	<i>H influenzae</i> type b	Enteroviruses	<i>H influenzae</i> type b
	Group B <i>Streptococcus</i>	HSV	Group B <i>Streptococcus</i>
	Enteroviruses		<i>Listeria</i>

Give ceftriaxone and vancomycin empirically (add ampicillin if *Listeria* is suspected).

Viral causes of meningitis: enteroviruses (especially coxsackievirus), HSV-2 (HSV-1 = encephalitis), HIV, West Nile virus (also causes encephalitis), VZV.

In HIV: *Cryptococcus* spp.

Note: Incidence of Group B streptococcal meningitis in neonates has ↓ greatly due to screening and antibiotic prophylaxis in pregnancy. Incidence of *H influenzae* meningitis has ↓ greatly due to conjugate *H influenzae* vaccinations. Today, cases are usually seen in unimmunized children.

Cerebrospinal fluid findings in meningitis

	OPENING PRESSURE	CELL TYPE	PROTEIN	GLUCOSE
Bacterial	↑	↑ PMNs	↑	↓
Fungal/TB	↑	↑ lymphocytes	↑	↓
Viral	Normal/↑	↑ lymphocytes	Normal/↑	Normal

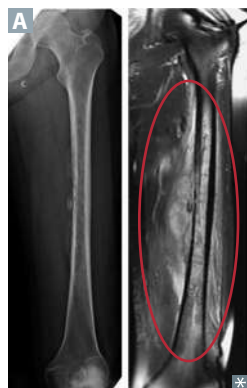Infections causing brain abscess

Most commonly viridans streptococci and *Staphylococcus aureus*. If dental infection or extraction precedes abscess, oral anaerobes commonly involved.

Multiple abscesses are usually from bacteremia; single lesions from contiguous sites: otitis media and mastoiditis → temporal lobe and cerebellum; sinusitis or dental infection → frontal lobe.

Toxoplasma reactivation in AIDS.

Osteomyelitis



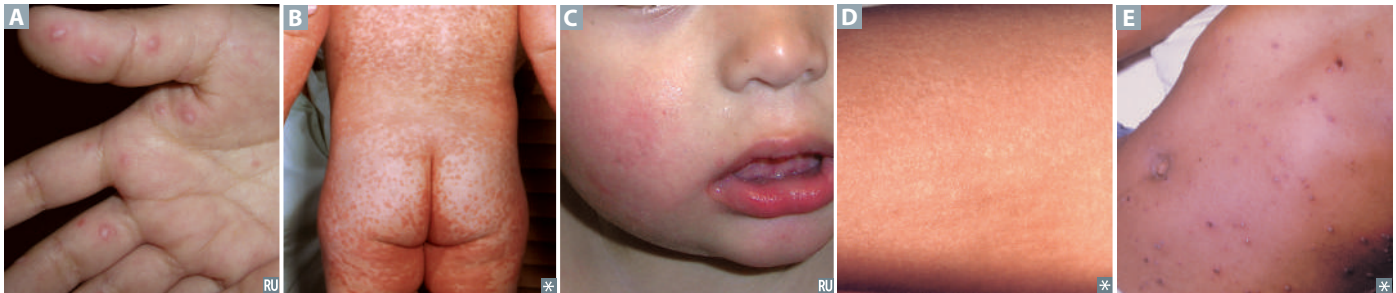RISK FACTOR	ASSOCIATED INFECTION
Assume if no other information is available	<i>S aureus</i> (most common overall)
Sexually active	<i>Neisseria gonorrhoeae</i> (rare), septic arthritis more common
Sickle cell disease	<i>Salmonella</i> and <i>S aureus</i>
Prosthetic joint replacement	<i>S aureus</i> and <i>S epidermidis</i>
Vertebral involvement	<i>S aureus</i> , <i>M tuberculosis</i> (Pott disease)
Cat and dog bites	<i>Pasteurella multocida</i>
Injection drug use	<i>S aureus</i> ; also <i>Pseudomonas</i> , <i>Candida</i>

Elevated ESR and CRP sensitive but not specific.

Radiographs are insensitive early but can be useful in chronic osteomyelitis (A, left). MRI is best for detecting acute infection and detailing anatomic involvement (A, right). Biopsy or aspiration with culture necessary to identify organism.

Red rashes of childhood

AGENT	ASSOCIATED SYNDROME/DISEASE	CLINICAL PRESENTATION
Coxsackievirus type A	Hand-foot-mouth disease	Oval-shaped vesicles on palms and soles A ; vesicles and ulcers in oral mucosa (herpangina)
Human herpesvirus 6	Roseola (exanthem subitum)	Asymptomatic rose-colored macules appear on body after several days of high fever; can present with febrile seizures; usually affects infants
Measles virus	Measles (rubeola)	Confluent rash beginning at head and moving down B ; preceded by cough, coryza, conjunctivitis, and blue-white (Koplik) spots on buccal mucosa
Parvovirus B19	Erythema infectiosum (fifth disease)	“Slapped cheek” rash on face C
Rubella virus	Rubella	Pink macules and papules begin at head and move down, remain discrete → fine desquamating truncal rash; postauricular lymphadenopathy
Streptococcus pyogenes	Scarlet fever	Sore throat, Circumoral pallor, group A strep, Rash (sandpaperlike D , from neck to trunk and extremities), Lymphadenopathy, Erythrogenic toxin, strawberry Tongue (SCARLET)
Varicella-zoster virus	Chickenpox	Vesicular rash begins on trunk E , spreads to face and extremities with lesions of different stages



Urinary tract infections

Cystitis presents with dysuria, frequency, urgency, suprapubic pain, and WBCs (but not WBC casts) in urine. Primarily caused by ascension of microbes from urethra to bladder. Ascension to kidney results in pyelonephritis, which presents with fever, chills, flank pain, costovertebral angle tenderness, hematuria, and WBC casts.

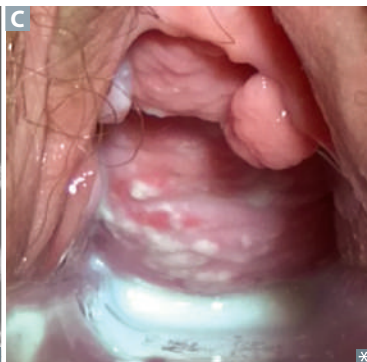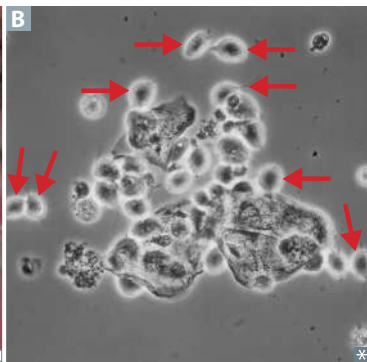
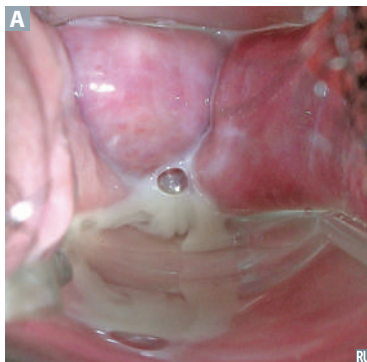
Ten times more common in females (shorter urethras colonized by fecal microbiota).

Risk factors: obstruction (eg, kidney stones, enlarged prostate), kidney surgery, catheterization, congenital GU malformation (eg, vesicoureteral reflux), diabetes, pregnancy.

SPECIES	FEATURES	COMMENTS
<i>Escherichia coli</i>	Leading cause of UTI. Colonies show strong pink lactose-fermentation on MacConkey agar.	Diagnostic markers: ⊕ Leukocyte esterase = evidence of WBC activity.
<i>Staphylococcus saprophyticus</i>	2nd leading cause of UTI, particularly in young, sexually active females.	⊕ Nitrite test = reduction of urinary nitrates by gram ⊖ bacterial species (eg, <i>E. coli</i>).
<i>Klebsiella pneumoniae</i>	3rd leading cause of UTI. Large mucoid capsule and viscous colonies.	
<i>Serratia marcescens</i>	Some strains produce a red pigment; often healthcare-associated and drug resistant.	
<i>Enterococcus</i>	Often healthcare-associated and drug resistant.	
<i>Proteus mirabilis</i>	Motility causes “swarming” on agar; associated with struvite stones. Produces urease.	
<i>Pseudomonas aeruginosa</i>	Blue-green pigment and fruity odor; usually healthcare-associated and drug resistant.	

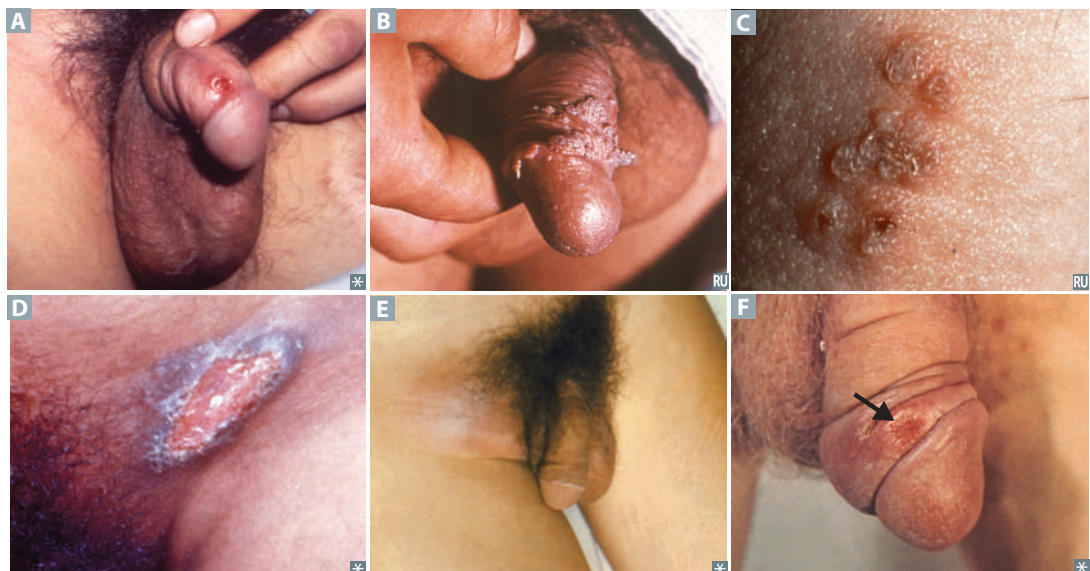Common vaginal infections

	Bacterial vaginosis	<i>Trichomonas vaginitis</i>	<i>Candida vulvovaginitis</i>
SIGNS AND SYMPTOMS	No inflammation Thin, white discharge A with fishy odor	Inflammation (“strawberry cervix”) Frothy, yellow-green, foul-smelling discharge	Inflammation Thick, white, “cottage cheese” discharge C
LAB FINDINGS	Clue cells pH > 4.5 ⊕ KOH whiff test	Motile pear-shaped trichomonads B pH > 4.5	Pseudohyphae pH normal (4.0–4.5)
TREATMENT	Metronidazole or clindamycin	Metronidazole Treat sexual partner(s)	Azoles



Sexually transmitted infections

DISEASE	CLINICAL FEATURES	PATHOGEN
AIDS	Opportunistic infections, Kaposi sarcoma, lymphoma	HIV
Chancroid	Painful genital ulcer with exudate, inguinal adenopathy A	<i>Haemophilus ducreyi</i> (it's so painful, you “do cry”)
Chlamydia	Urethritis, cervicitis, epididymitis, conjunctivitis, reactive arthritis, PID	<i>Chlamydia trachomatis</i> (D–K)
Condylomata acuminata	Genital warts B , koilocytes	HPV-6 and -11
Herpes genitalis	Painful penile, vulvar, or cervical vesicles and ulcers C ; can cause systemic symptoms such as fever, headache, myalgia	HSV-2, less commonly HSV-1
Gonorrhea	Urethritis, cervicitis, PID, prostatitis, epididymitis, arthritis, creamy purulent discharge	<i>Neisseria gonorrhoeae</i>
Granuloma inguinale (Donovanosis)	Painless, beefy red ulcer that bleeds readily on contact D Uncommon in US	<i>Klebsiella (Calymmatobacterium) granulomatis</i> ; cytoplasmic Donovan bodies (bipolar staining) seen on microscopy
Hepatitis B	Jaundice	HBV
Lymphogranuloma venereum	Infection of lymphatics; painless genital ulcers, painful lymphadenopathy (ie, buboes E)	<i>C trachomatis</i> (L1–L3)
Primary syphilis	Painless chancre F	<i>Treponema pallidum</i>
Secondary syphilis	Fever, lymphadenopathy, skin rashes, condylomata lata	
Tertiary syphilis	Gummas, tabes dorsalis, general paresis, aortitis, Argyll Robertson pupil	
Trichomoniasis	Vaginitis, strawberry cervix, motile in wet prep	<i>Trichomonas vaginalis</i>

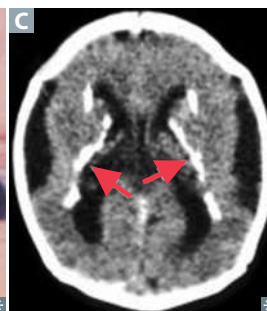
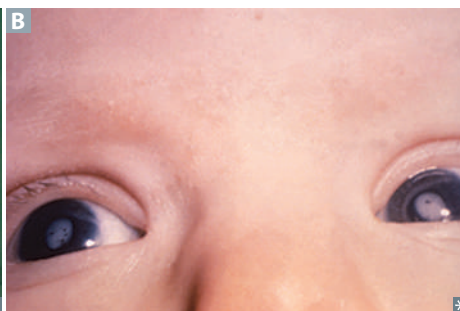
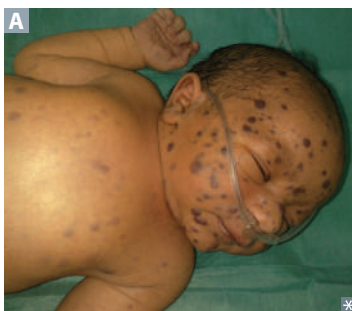TORCH infections

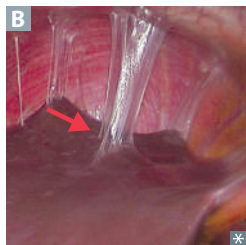
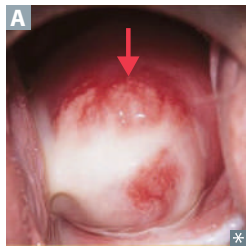
Microbes that may pass from mother to fetus. Transmission is transplacental in most cases, or via vaginal delivery (especially HSV-2). Nonspecific signs common to many **ToRCHHeS** infections include hepatosplenomegaly, jaundice, thrombocytopenia, and growth restriction.

Other important infectious agents include *Streptococcus agalactiae* (group B streptococci), *E coli*, and *Listeria monocytogenes*—all causes of meningitis in neonates. Parvovirus B19 causes hydrops fetalis.

AGENT	MATERNAL ACQUISITION	MATERNAL MANIFESTATIONS	NEONATAL MANIFESTATIONS
<i>Toxoplasma gondii</i>	Cat feces or ingestion of undercooked meat	Usually asymptomatic; lymphadenopathy (rarely)	Classic triad: chorioretinitis, hydrocephalus, and intracranial calcifications, +/- “blueberry muffin” rash A
Rubella	Respiratory droplets	Rash, lymphadenopathy, polyarthrititis, polyarthralgia	Classic triad: abnormalities of eye (cataracts B) and ear (deafness) and congenital heart disease (PDA); +/- “blueberry muffin” rash. “ I (eye) ♥ ruby (rubella) earrings ”
Cytomegalovirus	Sexual contact, organ transplants	Usually asymptomatic; mononucleosis-like illness	Hearing loss, seizures, petechial rash, “blueberry muffin” rash, chorioretinitis, periventricular calcifications C
HIV	Sexual contact, needlestick	Variable presentation depending on CD4+ cell count	Recurrent infections, chronic diarrhea
Herpes simplex virus-2	Skin or mucous membrane contact	Usually asymptomatic; herpetic (vesicular) lesions	Meningoencephalitis, herpetic (vesicular) lesions
Syphilis	Sexual contact	Chancre (1°) and disseminated rash (2°) are the two stages likely to result in fetal infection	Often results in stillbirth, hydrops fetalis; if child survives, presents with facial abnormalities (eg, notched teeth, saddle nose, short maxilla), saber shins, CN VIII deafness



Pelvic inflammatory disease



Top bugs—*Chlamydia trachomatis* (subacute, often undiagnosed), *Neisseria gonorrhoeae* (acute).

C trachomatis—most common bacterial STI in the United States.

Signs include cervical motion tenderness, adnexal tenderness, purulent cervical discharge **A**.

PID may include salpingitis, endometritis, hydrosalpinx, and tubo-ovarian abscess.

Salpingitis is a risk factor for ectopic pregnancy, infertility, chronic pelvic pain, and adhesions. Can lead to perihepatitis (**Fitz-Hugh-Curtis syndrome**)—infection and inflammation of liver capsule and “violin string” adhesions of peritoneum to liver **B**.

Healthcare-associated infections

E coli (UTI) and *S aureus* (wound infection) are the two most common causes.

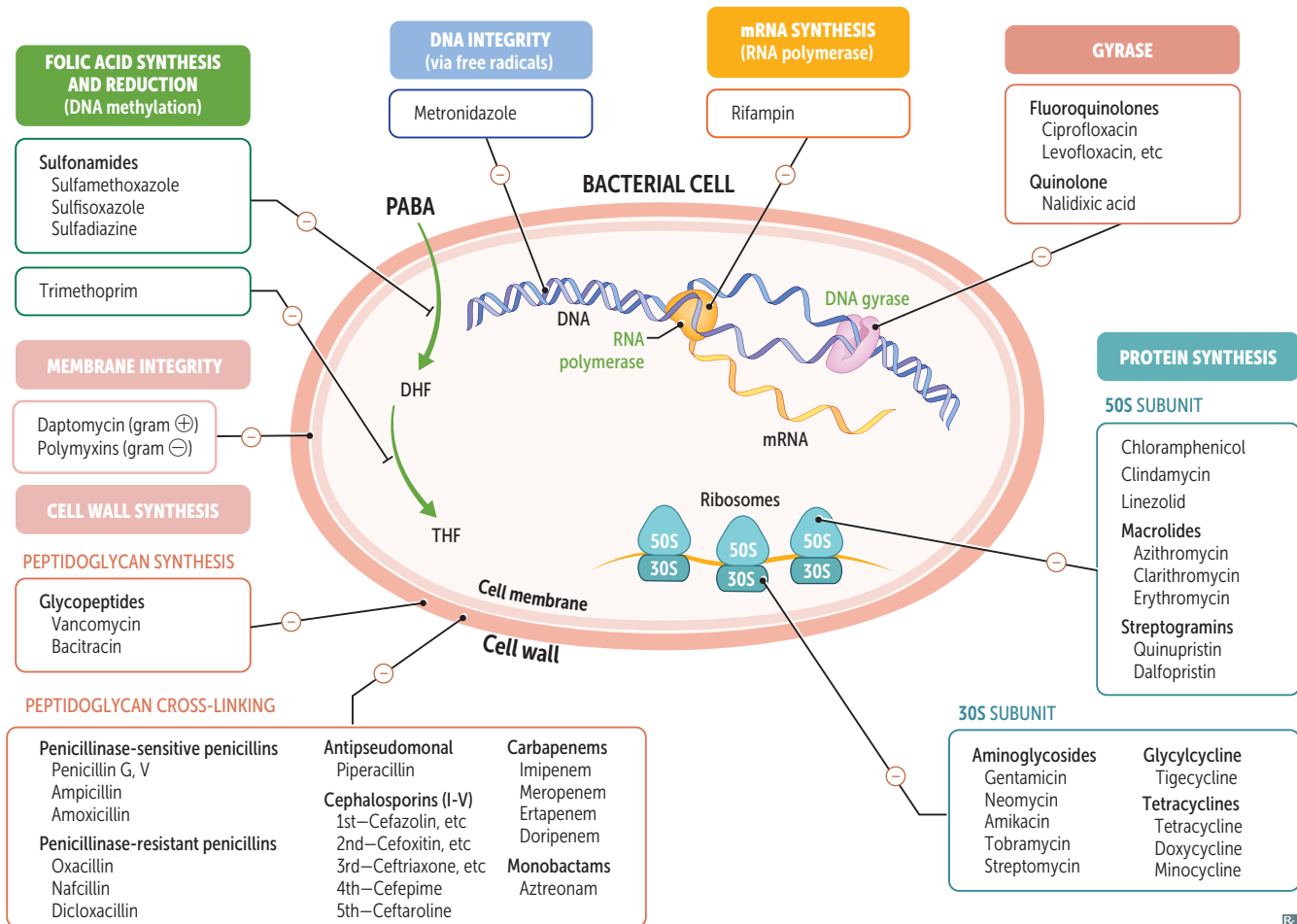
RISK FACTOR	PATHOGEN	UNIQUE SIGNS/SYMPTOMS
Antibiotic use	<i>Clostridium difficile</i>	Watery diarrhea, leukocytosis
Aspiration (2° to altered mental status, old age)	Polymicrobial, gram \ominus bacteria, often anaerobes	Right lower lobe infiltrate or right upper/middle lobe (patient recumbent); purulent malodorous sputum
Decubitus ulcers, surgical wounds, drains	<i>S aureus</i> (including MRSA), gram \ominus anaerobes (<i>Bacteroides</i> , <i>Prevotella</i> , <i>Fusobacterium</i>)	Erythema, tenderness, induration, drainage from surgical wound sites
Intravascular catheters	<i>S aureus</i> (including MRSA), <i>S epidermidis</i> (long term)	Erythema, induration, tenderness, drainage from access sites
Mechanical ventilation, endotracheal intubation	Late onset: <i>P aeruginosa</i> , <i>Klebsiella</i> , <i>Acinetobacter</i> , <i>S aureus</i>	New infiltrate on CXR, \uparrow sputum production; sweet odor (<i>Pseudomonas</i>)
Renal dialysis unit, needlestick	HBV, HCV	
Urinary catheterization	<i>Proteus</i> spp, <i>E coli</i> , <i>Klebsiella</i> (PEcK)	Dysuria, leukocytosis, flank pain or costovertebral angle tenderness
Water aerosols	<i>Legionella</i>	Signs of pneumonia, GI symptoms (diarrhea, nausea, vomiting), neurologic abnormalities

Bugs affecting unvaccinated children

CLINICAL PRESENTATION	FINDINGS/LABS	PATHOGEN
Dermatologic		
Rash	Beginning at head and moving down with postauricular lymphadenopathy	Rubella virus
	Beginning at head and moving down; preceded by cough, coryza, conjunctivitis, and Koplik spots	Measles virus
Neurologic		
Meningitis	Microbe colonizes nasopharynx	<i>H influenzae</i> type b
	Can also lead to myalgia and paralysis	Poliovirus
Tetanus	Muscle spasms and spastic paralysis (eg, lockjaw, opisthotonus)	<i>Clostridium tetani</i>
Respiratory		
Epiglottitis	Fever with dysphagia, drooling, and difficulty breathing due to edema	<i>H influenzae</i> type b (also capable of causing epiglottitis in fully immunized children)
Pertussis	Low-grade fevers, coryza → whooping cough, posttussive vomiting → gradual recovery	<i>Bordetella pertussis</i>
Pharyngitis	Grayish pseudomembranes (may obstruct airways)	<i>Corynebacterium diphtheriae</i>

▶ MICROBIOLOGY—ANTIMICROBIALS

Antimicrobial therapy

**Penicillin G, V**

Penicillin G (IV and IM form), penicillin V (oral). Prototype β -lactam antibiotics.

MECHANISM

D-Ala-D-Ala structural analog. Bind penicillin-binding proteins (transpeptidases). Block transpeptidase cross-linking of peptidoglycan in cell wall. Activate autolytic enzymes.

CLINICAL USE

Mostly used for gram \oplus organisms (*S pneumoniae*, *S pyogenes*, *Actinomyces*). Also used for gram \ominus cocci (mainly *N meningitidis*) and spirochetes (mainly *T pallidum*). Bactericidal for gram \oplus cocci, gram \oplus rods, gram \ominus cocci, and spirochetes. β -lactamase sensitive.

ADVERSE EFFECTS

Hypersensitivity reactions, direct Coombs \oplus hemolytic anemia, drug-induced interstitial nephritis.

RESISTANCE

β -lactamase cleaves the β -lactam ring. Mutations in PBPs.

Penicillinase-sensitive penicillins	Amoxicillin, ampicillin; aminopenicillins.	
MECHANISM	Same as penicillin. Wider spectrum; penicillinase sensitive. Also combine with clavulanic acid to protect against destruction by β -lactamase.	Aminopenicillins are amped-up penicillin. Amoxicillin has greater oral bioavailability than ampicillin.
CLINICAL USE	Extended-spectrum penicillin— <i>H influenzae</i> , <i>H pylori</i> , <i>E coli</i> , Enterococci, <i>Listeria monocytogenes</i> , <i>Proteus mirabilis</i> , <i>Salmonella</i> , <i>Shigella</i> .	Coverage: ampicillin/amoxicillin HHEELPSS kill enterococci.
ADVERSE EFFECTS	Hypersensitivity reactions, rash, pseudomembranous colitis.	
MECHANISM OF RESISTANCE	Penicillinase (a type of β -lactamase) cleaves β -lactam ring.	
Penicillinase-resistant penicillins	Dicloxacillin, nafcillin, oxacillin.	
MECHANISM	Same as penicillin. Narrow spectrum; penicillinase resistant because bulky R group blocks access of β -lactamase to β -lactam ring.	
CLINICAL USE	<i>S aureus</i> (except MRSA).	“Use naf (nafcillin) for staph .”
ADVERSE EFFECTS	Hypersensitivity reactions, interstitial nephritis.	
MECHANISM OF RESISTANCE	MRSA has altered penicillin-binding protein target site.	
Piperacillin	Antipseudomonal penicillin.	
MECHANISM	Same as penicillin. Extended spectrum. Penicillinase sensitive; use with β -lactamase inhibitors.	
CLINICAL USE	<i>Pseudomonas</i> spp. and gram \ominus rods.	
ADVERSE EFFECTS	Hypersensitivity reactions.	

Cephalosporins

MECHANISM	<p>β-lactam drugs that inhibit cell wall synthesis but are less susceptible to penicillinases. Bactericidal.</p>	<p>Organisms typically not covered by 1st–4th generation cephalosporins are LAME: <i>Listeria</i>, Atypicals (<i>Chlamydia</i>, <i>Mycoplasma</i>), MRSA, and Enterococci.</p>
CLINICAL USE	<p>1st generation (cefazolin, cephalexin)—gram \oplus cocci, <i>Proteus mirabilis</i>, <i>E coli</i>, <i>Klebsiella pneumoniae</i>. Cefazolin used prior to surgery to prevent <i>S aureus</i> wound infections.</p> <p>2nd generation (cefaclor, cefoxitin, cefuroxime, cefotetan)—gram \oplus cocci, <i>H influenzae</i>, <i>Enterobacter aerogenes</i>, <i>Neisseria</i> spp., <i>Serratia marcescens</i>, <i>Proteus mirabilis</i>, <i>E coli</i>, <i>Klebsiella pneumoniae</i>.</p> <p>3rd generation (ceftriaxone, cefotaxime, cefpodoxime, ceftazidime, cefixime)—serious gram \ominus infections resistant to other β-lactams.</p> <p>4th generation (cefepime)—gram \ominus organisms, with \uparrow activity against <i>Pseudomonas</i> and gram \oplus organisms.</p> <p>5th generation (ceftaroline)—broad gram \oplus and gram \ominus organism coverage; unlike 1st–4th generation cephalosporins, ceftaroline covers MRSA, and <i>Enterococcus faecalis</i>—does not cover <i>Pseudomonas</i>.</p>	<p>1st generation—\oplus PEcK.</p> <p>2nd graders wear fake fox fur to tea parties. 2nd generation—\oplus HENS PEcK.</p> <p>Can cross blood-brain barrier. Ceftriaxone—meningitis, gonorrhea, disseminated Lyme disease. Ceftazidime—<i>Pseudomonas</i>.</p>
ADVERSE EFFECTS	<p>Hypersensitivity reactions, autoimmune hemolytic anemia, disulfiram-like reaction, vitamin K deficiency. Low rate of cross-reactivity even in penicillin-allergic patients. \uparrow nephrotoxicity of aminoglycosides.</p>	
MECHANISM OF RESISTANCE	<p>Inactivated by cephalosporinases (a type of β-lactamase). Structural change in penicillin-binding proteins (transpeptidases).</p>	
β-lactamase inhibitors	<p>Include Clavulanic acid, Avibactam, Sulbactam, Tazobactam. Often added to penicillin antibiotics to protect the antibiotic from destruction by β-lactamase.</p>	<p>CAST (eg, amoxicillin-clavulanate, ceftazidime-avibactam, ampicillin-sulbactam, piperacillin-tazobactam).</p>

Carbapenems

Doripenem, imipenem, meropenem, ertapenem.

“Pens” (carbapenems) cost a dime.”

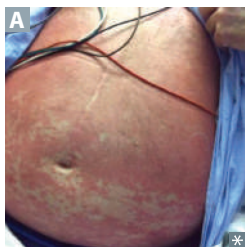
MECHANISM	Imipenem is a broad-spectrum, β -lactamase-resistant carbapenem. Binds penicillin-binding proteins \rightarrow inhibition of cell wall synthesis \rightarrow cell death. Always administered with cilastatin (inhibitor of renal dehydropeptidase I) to \downarrow inactivation of drug in renal tubules.	With imipenem, “the kill is lastin ’ with cilastatin .” Newer carbapenems include ertapenem (limited <i>Pseudomonas</i> coverage) and doripenem.
CLINICAL USE	Gram \oplus cocci, gram \ominus rods, and anaerobes. Wide spectrum and significant adverse effects limit use to life-threatening infections or after other drugs have failed. Meropenem has a \downarrow risk of seizures and is stable to dehydropeptidase I.	
ADVERSE EFFECTS	GI distress, rash, and CNS toxicity (seizures) at high plasma levels.	
MECHANISM OF RESISTANCE	Inactivated by carbapenemases produced by, eg, <i>K pneumoniae</i> , <i>E coli</i> , <i>E aerogenes</i> .	

Aztreonam

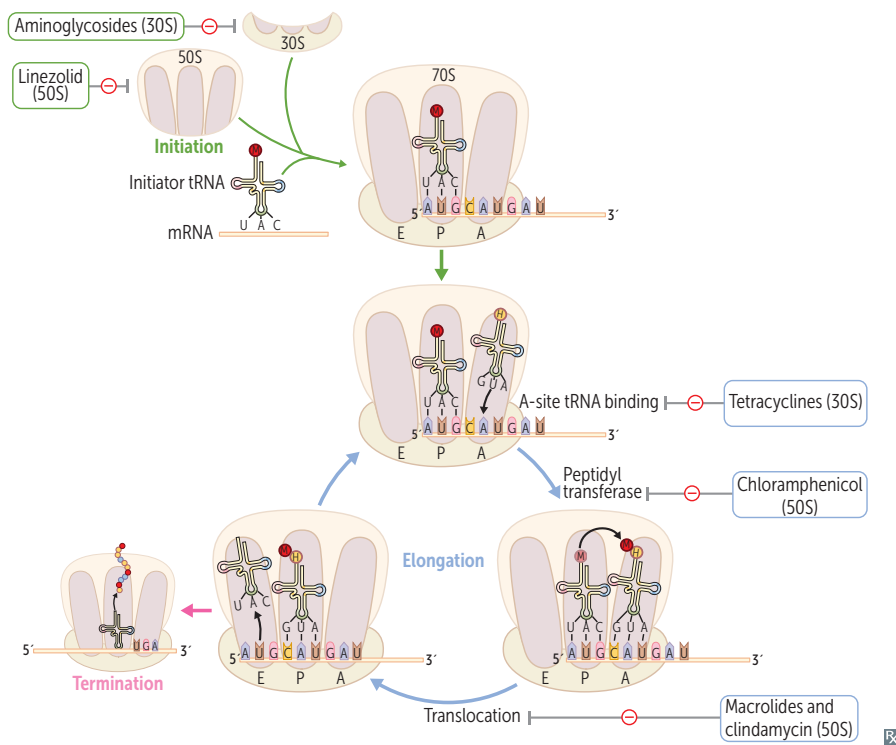
MECHANISM	Less susceptible to β -lactamases. Prevents peptidoglycan cross-linking by binding to penicillin-binding protein 3. Synergistic with aminoglycosides. No cross-allergenicity with penicillins.
CLINICAL USE	Gram \ominus rods only—no activity against gram \oplus rods or anaerobes. For penicillin-allergic patients and those with renal insufficiency who cannot tolerate aminoglycosides.
ADVERSE EFFECTS	Usually nontoxic; occasional GI upset.

Vancomycin

MECHANISM	Inhibits cell wall peptidoglycan formation by binding D-Ala-D-Ala portion of cell wall precursors. Bactericidal against most bacteria (bacteriostatic against <i>C difficile</i>). Not susceptible to β -lactamases.
CLINICAL USE	Gram \oplus bugs only—for serious, multidrug-resistant organisms, including MRSA, <i>S epidermidis</i> , sensitive <i>Enterococcus</i> species, and <i>Clostridium difficile</i> (oral route).
ADVERSE EFFECTS	Well tolerated in general but not trouble free: nephrotoxicity, ototoxicity, thrombophlebitis, diffuse flushing (vancomycin infusion reaction A)—idiopathic reaction largely preventable by pretreatment with antihistamines), DRESS syndrome.
MECHANISM OF RESISTANCE	Occurs in bacteria (eg, <i>Enterococcus</i>) via amino acid modification of D-Ala-D-Ala to D-Ala-D-Lac . “If you Lack a D-Ala (dollar), you can’t ride the van (vancomycin).”



Protein synthesis inhibitors



Specifically target smaller bacterial ribosome (70S, made of 30S and 50S subunits), leaving human ribosome (80S) unaffected.

All are bacteriostatic, except aminoglycosides (bactericidal) and linezolid (variable).

30S inhibitors

Aminoglycosides

Tetracyclines

50S inhibitors

Chloramphenicol, clindamycin

Erythromycin (macrolides)

Linezolid

“Buy at 30, ccel (sell) at 50.”

Aminoglycosides

Gentamicin, Neomycin, Amikacin, Tobramycin, Streptomycin.

“Mean” (aminoglycoside) GNATS cannot kill anaerobes.

MECHANISM

Bactericidal; irreversible inhibition of initiation complex through binding of the 30S subunit. Can cause misreading of mRNA. Also block translocation. Require O₂ for uptake; therefore ineffective against anaerobes.

CLINICAL USE

Severe gram \ominus rod infections. Synergistic with β -lactam antibiotics. Neomycin for bowel surgery.

ADVERSE EFFECTS

Nephrotoxicity, neuromuscular blockade (absolute contraindication with myasthenia gravis), ototoxicity (especially with loop diuretics), teratogenicity.

MECHANISM OF RESISTANCE

Bacterial transferase enzymes inactivate the drug by acetylation, phosphorylation, or adenylation.

Tetracyclines	
	Tetracycline, doxycycline, minocycline.
MECHANISM	Bacteriostatic; bind to 30S and prevent attachment of aminoacyl-tRNA. Limited CNS penetration. Doxycycline is fecally eliminated and can be used in patients with renal failure. Do not take tetracyclines with milk (Ca^{2+}), antacids (eg, Ca^{2+} or Mg^{2+}), or iron-containing preparations because divalent cations inhibit drugs' absorption in the gut.
CLINICAL USE	<i>Borrelia burgdorferi</i> , <i>M pneumoniae</i> . Drugs' ability to accumulate intracellularly makes them very effective against <i>Rickettsia</i> and <i>Chlamydia</i> . Also used to treat acne. Doxycycline effective against community-acquired MRSA.
ADVERSE EFFECTS	GI distress, discoloration of teeth and inhibition of bone growth in children, photosensitivity. "Teratocyclines" are teratogenic; generally avoided in pregnancy and in children (except doxycycline).
MECHANISM OF RESISTANCE	↓ uptake or ↑ efflux out of bacterial cells by plasmid-encoded transport pumps.

Tigecycline

MECHANISM	Tetracycline derivative. Binds to 30S, inhibiting protein synthesis. Generally bacteriostatic.
CLINICAL USE	Broad-spectrum anaerobic, gram \ominus , and gram \oplus coverage. Multidrug-resistant organisms (eg, MRSA, VRE).
ADVERSE EFFECTS	Nausea, vomiting.

Chloramphenicol

MECHANISM	Blocks peptidyltransferase at 50S ribosomal subunit. Bacteriostatic.
CLINICAL USE	Meningitis (<i>Haemophilus influenzae</i> , <i>Neisseria meningitidis</i> , <i>Streptococcus pneumoniae</i>) and rickettsial diseases (eg, Rocky Mountain spotted fever [<i>Rickettsia rickettsii</i>]). Limited use due to toxicity but often still used in developing countries because of low cost.
ADVERSE EFFECTS	Anemia (dose dependent), aplastic anemia (dose independent), gray baby syndrome (in premature infants because they lack liver UDP-glucuronosyltransferase).
MECHANISM OF RESISTANCE	Plasmid-encoded acetyltransferase inactivates the drug.

Clindamycin

MECHANISM	Blocks peptide transfer (translocation) at 50S ribosomal subunit. Bacteriostatic.
CLINICAL USE	Anaerobic infections (eg, <i>Bacteroides</i> spp., <i>Clostridium perfringens</i>) in aspiration pneumonia, lung abscesses, and oral infections. Also effective against invasive group A streptococcal infection. Treats anaerobic infections above the diaphragm vs metronidazole (anaerobic infections below diaphragm).
ADVERSE EFFECTS	Pseudomembranous colitis (<i>C difficile</i> overgrowth), fever, diarrhea.

Linezolid

MECHANISM	Inhibits protein synthesis by binding to 50S subunit and preventing formation of the initiation complex.
CLINICAL USE	Gram \oplus species including MRSA and VRE.
ADVERSE EFFECTS	Myelosuppression (especially thrombocytopenia), peripheral neuropathy, serotonin syndrome (due to partial MAO inhibition).
MECHANISM OF RESISTANCE	Point mutation of ribosomal RNA.

Macrolides

Azithromycin, clarithromycin, erythromycin.

MECHANISM	Inhibit protein synthesis by blocking translocation (“ macroslides ”); bind to the 23S rRNA of the 50S ribosomal subunit. Bacteriostatic.
CLINICAL USE	Atypical pneumonias (<i>Mycoplasma</i> , <i>Chlamydia</i> , <i>Legionella</i>), STIs (<i>Chlamydia</i>), gram \oplus cocci (streptococcal infections in patients allergic to penicillin), and <i>B pertussis</i> .
ADVERSE EFFECTS	MACRO : Gastrointestinal Motility issues, Arrhythmia caused by prolonged QT interval, acute Cholestatic hepatitis , Rash , eOsinophilia . Increases serum concentration of theophylline, oral anticoagulants. Clarithromycin and erythromycin inhibit cytochrome P-450.
MECHANISM OF RESISTANCE	Methylation of 23S rRNA-binding site prevents binding of drug.

Polymyxins

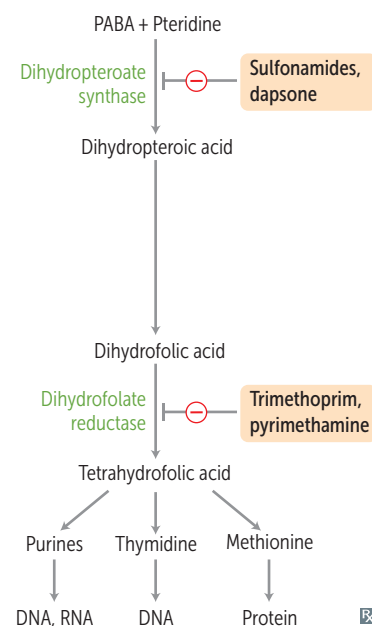
Colistin (polymyxin E), polymyxin B.

MECHANISM	Cation polypeptides that bind to phospholipids on cell membrane of gram \ominus bacteria. Disrupt cell membrane integrity \rightarrow leakage of cellular components \rightarrow cell death.
CLINICAL USE	Salvage therapy for multidrug-resistant gram \ominus bacteria (eg, <i>P aeruginosa</i> , <i>E coli</i> , <i>K pneumoniae</i>). Polymyxin B is a component of a triple antibiotic ointment used for superficial skin infections.
ADVERSE EFFECTS	Nephrotoxicity, neurotoxicity (eg, slurred speech, weakness, paresthesias), respiratory failure.

Sulfonamides	Sulfamethoxazole (SMX), sulfisoxazole, sulfadiazine.
MECHANISM	Inhibit dihydropteroate synthase, thus inhibiting folate synthesis. Bacteriostatic (bactericidal when combined with trimethoprim).
CLINICAL USE	Gram ⊕, gram ⊖, <i>Nocardia</i> . TMP-SMX for simple UTI.
ADVERSE EFFECTS	Hypersensitivity reactions, hemolysis if G6PD deficient, nephrotoxicity (tubulointerstitial nephritis), photosensitivity, Stevens-Johnson syndrome, kernicterus in infants, displace other drugs from albumin (eg, warfarin).
MECHANISM OF RESISTANCE	Altered enzyme (bacterial dihydropteroate synthase), ↓ uptake, or ↑ PABA synthesis.

Dapsone	
MECHANISM	Similar to sulfonamides, but structurally distinct agent.
CLINICAL USE	Leprosy (lepromatous and tuberculoid), <i>Pneumocystis jirovecii</i> prophylaxis, or treatment when used in combination with TMP.
ADVERSE EFFECTS	Hemolysis if G6PD deficient, methemoglobinemia, agranulocytosis.

Trimethoprim	
MECHANISM	Inhibits bacterial dihydrofolate reductase. Bacteriostatic.
CLINICAL USE	Used in combination with sulfonamides (trimethoprim-sulfamethoxazole [TMP-SMX]), causing sequential block of folate synthesis. Combination used for UTIs, <i>Shigella</i> , <i>Salmonella</i> , <i>Pneumocystis jirovecii</i> pneumonia treatment and prophylaxis, toxoplasmosis prophylaxis.
ADVERSE EFFECTS	Hyperkalemia (high doses), megaloblastic anemia, leukopenia, granulocytopenia, which may be avoided with coadministration of leucovorin (folinic acid). TMP Treats Marrow Poorly.



Fluoroquinolones

Ciprofloxacin, enoxacin, norfloxacin, ofloxacin; respiratory fluoroquinolones: gemifloxacin, levofloxacin, moxifloxacin.

MECHANISM	Inhibit prokaryotic enzymes topoisomerase II (DNA gyrase) and topoisomerase IV. Bactericidal. Must not be taken with antacids.	
CLINICAL USE	Gram \ominus rods of urinary and GI tracts (including <i>Pseudomonas</i>), some gram \oplus organisms, otitis externa.	
ADVERSE EFFECTS	GI upset, superinfections, skin rashes, headache, dizziness. Less commonly, can cause leg cramps and myalgias. Contraindicated during pregnancy or breastfeeding and in children < 18 years old due to possible damage to cartilage. Some may prolong QT interval.	May cause tendonitis or tendon rupture in people > 60 years old and in patients taking prednisone. Ciprofloxacin inhibits cytochrome P-450. Fluoroquinolones hurt attachments to your bones.
MECHANISM OF RESISTANCE	Chromosome-encoded mutation in DNA gyrase, plasmid-mediated resistance, efflux pumps.	

Daptomycin

MECHANISM	Lipopeptide that disrupts cell membranes of gram \oplus cocci by creating transmembrane channels.	
CLINICAL USE	<i>S aureus</i> skin infections (especially MRSA), bacteremia, infective endocarditis, VRE.	Not used for pneumonia (avidly binds to and is inactivated by surfactant). “Dapto- myo-skin ” is used for skin infections but can cause myopathy .
ADVERSE EFFECTS	Myopathy, rhabdomyolysis.	

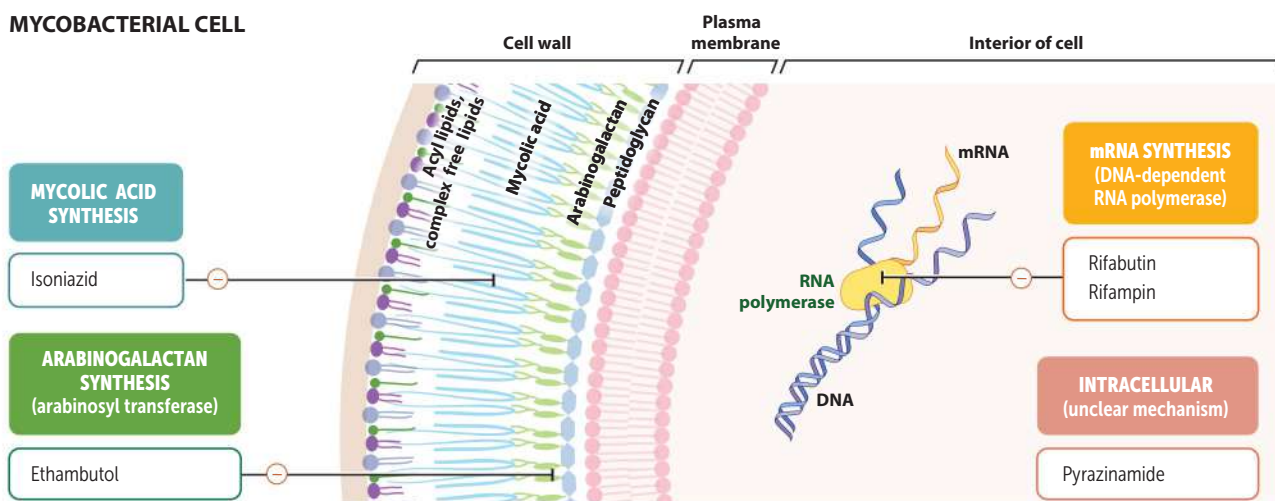
Metronidazole

MECHANISM	Forms toxic free radical metabolites in the bacterial cell that damage DNA. Bactericidal, antiprotozoal.	
CLINICAL USE	Treats <i>Giardia</i> , <i>Entamoeba</i> , <i>Trichomonas</i> , <i>Gardnerella vaginalis</i> , Anaerobes (<i>Bacteroides</i> , <i>C difficile</i>). Can be used in place of amoxicillin in <i>H pylori</i> “triple therapy” in case of penicillin allergy.	GET GAP on the Metro with metronidazole! Treats anaerobic infection below the diaphragm vs clindamycin (anaerobic infections above diaphragm).
ADVERSE EFFECTS	Disulfiram-like reaction (severe flushing, tachycardia, hypotension) with alcohol; headache, metallic taste.	

Antimycobacterial therapy

BACTERIUM	PROPHYLAXIS	TREATMENT
<i>M tuberculosis</i>	Rifamycin-based regimen for 3–4 months	Rifampin, Isoniazid, Pyrazinamide, Ethambutol (RIPE for treatment)
<i>M avium–intracellulare</i>	Azithromycin, rifabutin	Azithromycin or clarithromycin + ethambutol Can add rifabutin or ciprofloxacin
<i>M leprae</i>	N/A	Long-term treatment with dapsone and rifampin for tuberculoid form Add clofazimine for lepromatous form

MYCOBACTERIAL CELL



Rifamycins

Rifampin, rifabutin, rifapentine.

MECHANISM	Inhibit DNA-dependent RNA polymerase.	Rifampin's 4 R's: RNA polymerase inhibitor Ramps up microsomal cytochrome P-450 Red/orange body fluids Rapid resistance if used alone
CLINICAL USE	<i>Mycobacterium tuberculosis</i> ; delay resistance to dapsone when used for leprosy. Used for meningococcal prophylaxis and chemoprophylaxis in contacts of children with <i>H influenzae</i> type b.	Rifampin ramps up cytochrome P-450, but rifabutin does not.
ADVERSE EFFECTS	Minor hepatotoxicity and drug interactions (↑ cytochrome P-450); orange body fluids (nonhazardous side effect). Rifabutin favored over rifampin in patients with HIV infection due to less cytochrome P-450 stimulation.	
MECHANISM OF RESISTANCE	Mutations reduce drug binding to RNA polymerase. Monotherapy rapidly leads to resistance.	

Isoniazid

MECHANISM	↓ synthesis of mycolic acids. Bacterial catalase-peroxidase (encoded by KatG) needed to convert INH to active metabolite.	
CLINICAL USE	<i>Mycobacterium tuberculosis</i> . Also used as monotherapy for latent TB.	Different INH half-lives in fast vs slow acetylators.
ADVERSE EFFECTS	Hepatotoxicity, cytochrome P-450 inhibition, drug-induced SLE, anion gap metabolic acidosis, vitamin B ₆ deficiency (peripheral neuropathy, sideroblastic anemia), seizures (in high doses, refractory to benzodiazepines). Administer with pyridoxine (B ₆).	INH Injures Neurons and Hepatocytes.
MECHANISM OF RESISTANCE	Mutations leading to underexpression of KatG.	

Pyrazinamide

MECHANISM	Mechanism uncertain. Works best at acidic pH (eg, in host phagolysosomes).	
CLINICAL USE	<i>Mycobacterium tuberculosis</i> .	
ADVERSE EFFECTS	Hyperuricemia, hepatotoxicity.	

Ethambutol

MECHANISM	↓ carbohydrate polymerization of mycobacterium cell wall by blocking arabinosyltransferase.	
CLINICAL USE	<i>Mycobacterium tuberculosis</i> .	
ADVERSE EFFECTS	Optic neuropathy (red-green color blindness, usually reversible). Pronounce “ ey ethambutol.”	

Streptomycin

MECHANISM	Interferes with 30S component of ribosome.	
CLINICAL USE	<i>Mycobacterium tuberculosis</i> (2nd line).	
ADVERSE EFFECTS	Tinnitus, vertigo, ataxia, nephrotoxicity.	

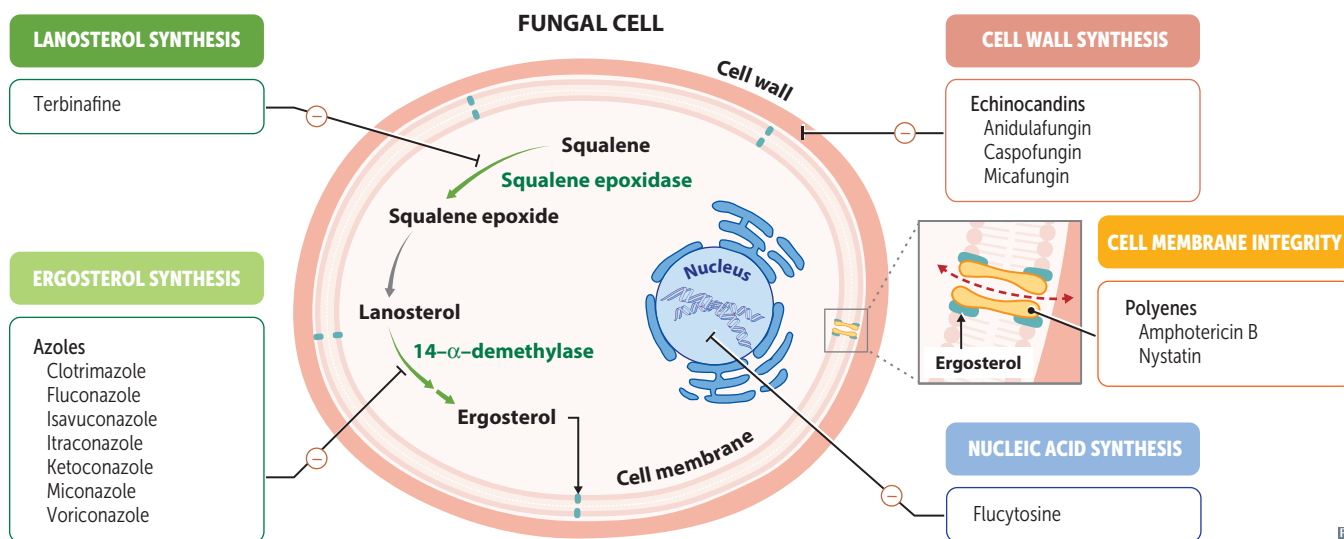
Antimicrobial prophylaxis

CLINICAL SCENARIO	MEDICATION
Exposure to meningococcal infection	Ceftriaxone, ciprofloxacin, or rifampin
High risk for infective endocarditis and undergoing surgical or dental procedures	Amoxicillin
History of recurrent UTIs	TMP-SMX
Malaria prophylaxis for travelers	Atovaquone-proguanil, mefloquine, doxycycline, primaquine, or chloroquine (for areas with sensitive species)
Pregnant patients carrying group B strep	Intrapartum penicillin G or ampicillin
Prevention of gonococcal conjunctivitis in newborn	Erythromycin ointment on eyes
Prevention of postsurgical infection due to <i>S aureus</i>	Cefazolin; vancomycin if ⊕ for MRSA
Prophylaxis of strep pharyngitis in child with prior rheumatic fever	Benzathine penicillin G or oral penicillin V

Prophylaxis in HIV infection/AIDS

CELL COUNT	PROPHYLAXIS	INFECTION
CD4+ < 200 cells/mm ³	TMP-SMX	<i>Pneumocystis pneumonia</i>
CD4+ < 100 cells/mm ³	TMP-SMX	<i>Pneumocystis pneumonia</i> and toxoplasmosis

Antifungal therapy



Amphotericin B

MECHANISM	Binds ergosterol (unique to fungi); forms membrane pores that allow leakage of electrolytes.	Amphotericin “tears” holes in the fungal membrane by forming pores.
CLINICAL USE	Serious, systemic mycoses. <i>Cryptococcus</i> (amphotericin B +/- flucytosine for cryptococcal meningitis), <i>Blastomyces</i> , <i>Coccidioides</i> , <i>Histoplasma</i> , <i>Candida</i> , <i>Mucor</i> . Intrathecally for coccidioidal meningitis.	Supplement K ⁺ and Mg ²⁺ because of altered renal tubule permeability.
ADVERSE EFFECTS	Fever/chills (“shake and bake”), hypotension, nephrotoxicity, arrhythmias, anemia, IV phlebitis (“ amphoterrible ”).	Hydration ↓ nephrotoxicity. Liposomal amphotericin ↓ toxicity.

Nystatin

MECHANISM	Same as amphotericin B. Topical use only as too toxic for systemic use.	
CLINICAL USE	“Swish and swallow” for oral candidiasis (thrush); topical for diaper rash or vaginal candidiasis.	

Flucytosine

MECHANISM	Inhibits DNA and RNA biosynthesis by conversion to 5-fluorouracil by cytosine deaminase.	
CLINICAL USE	Systemic fungal infections (especially meningitis caused by <i>Cryptococcus</i>) in combination with amphotericin B.	
ADVERSE EFFECTS	Myelosuppression.	

Azoles

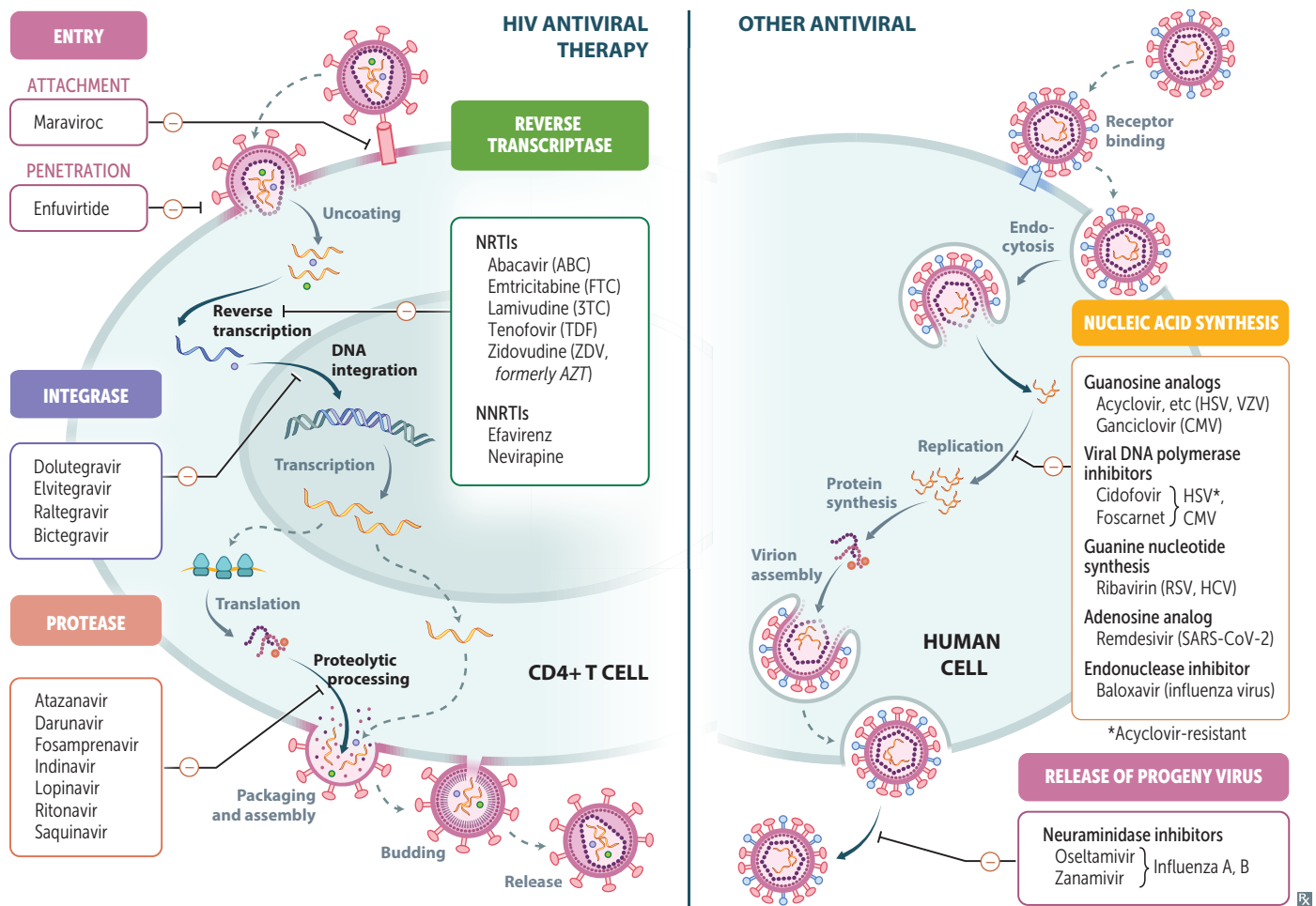
MECHANISM	Clotrimazole, fluconazole, isavuconazole, itraconazole, ketoconazole, miconazole, voriconazole. Inhibit fungal sterol (ergosterol) synthesis by inhibiting the cytochrome P-450 enzyme that converts lanosterol to ergosterol.	
CLINICAL USE	Local and less serious systemic mycoses. Fluconazole for chronic suppression of cryptococcal meningitis in people living with HIV and candidal infections of all types. Itraconazole may be used for <i>Blastomyces</i> , <i>Coccidioides</i> , <i>Histoplasma</i> , <i>Sporothrix schenckii</i> . Clotrimazole and miconazole for topical fungal infections. Voriconazole for <i>Aspergillus</i> and some <i>Candida</i> . Isavuconazole for serious <i>Aspergillus</i> and <i>Mucor</i> infections.	
ADVERSE EFFECTS	Testosterone synthesis inhibition (gynecomastia, especially with ketoconazole), liver dysfunction (inhibits cytochrome P-450), QT interval prolongation.	

Terbinafine

MECHANISM	Inhibits the fungal enzyme squalene epoxidase.	
CLINICAL USE	Dermatophytoses (especially onychomycosis—fungal infection of finger or toe nails).	
ADVERSE EFFECTS	GI upset, headaches, hepatotoxicity, taste disturbance.	

Echinocandins	Anidulafungin, caspofungin, micafungin.
MECHANISM	Inhibit cell wall synthesis by inhibiting synthesis of β -glucan.
CLINICAL USE	Invasive aspergillosis, <i>Candida</i> .
ADVERSE EFFECTS	GI upset, flushing (by histamine release).
Griseofulvin	
MECHANISM	Interferes with microtubule function; disrupts mitosis. Deposits in keratin-containing tissues (eg, nails).
CLINICAL USE	Oral treatment of superficial infections; inhibits growth of dermatophytes (tinea, ringworm).
ADVERSE EFFECTS	Teratogenic, carcinogenic, confusion, headaches, disulfiram-like reaction, \uparrow cytochrome P-450 and warfarin metabolism.
Antiprotozoal therapy	Pyrimethamine (toxoplasmosis), suramin and melarsoprol (<i>Trypanosoma brucei</i>), nifurtimox (<i>T cruzi</i>), sodium stibogluconate (leishmaniasis).
Anti-mite/louse therapy	Permethrin, malathion (acetylcholinesterase inhibitor), topical or oral ivermectin. Used to treat scabies (<i>Sarcoptes scabiei</i>) and lice (<i>Pediculus</i> and <i>Pthirus</i>).
Chloroquine	
MECHANISM	Blocks detoxification of heme into hemozoin. Heme accumulates and is toxic to plasmodia.
CLINICAL USE	Treatment of plasmodial species other than <i>P falciparum</i> (frequency of resistance in <i>P falciparum</i> is too high). Resistance due to membrane pump that \downarrow intracellular concentration of drug. Treat <i>P falciparum</i> with artemether/lumefantrine or atovaquone/proguanil. For life-threatening malaria, use quinidine in US (quinine elsewhere) or artesunate.
ADVERSE EFFECTS	Retinopathy (dependent on cumulative dose); pruritus (especially in dark-skinned individuals).
Anthelmintic therapy	Pyrantel pamoate, ivermectin, mebendazole (microtubule inhibitor to treat “bendy worms”), praziquantel (\uparrow Ca^{2+} permeability, \uparrow vacuolization), diethylcarbamazine.

Antiviral therapy



Oseltamivir, zanamivir

MECHANISM	Inhibit influenza neuraminidase → ↓ release of progeny virus.
CLINICAL USE	Treatment and prevention of influenza A and B. Beginning therapy within 48 hours of symptom onset may shorten duration of illness.

Baloxavir

MECHANISM	Inhibits the “cap snatching” (transfer of the 5' cap from cell mRNA onto viral mRNA) endonuclease activity of the influenza virus RNA polymerase → ↓ viral replication.
CLINICAL USE	Treatment within 48 hours of symptom onset shortens duration of illness.

Remdesivir

MECHANISM	Prodrug of an ATP analog. The active metabolite inhibits viral RNA-dependent RNA polymerase and evades proofreading by viral exoribonuclease (ExoN) → ↓ viral RNA production.
CLINICAL USE	Recently approved for treatment of COVID-19 requiring hospitalization.

Acyclovir, famciclovir, valacyclovir

MECHANISM	Guanosine analogs. Monophosphorylated by HSV/VZV thymidine kinase and not phosphorylated in uninfected cells → few adverse effects. Triphosphate formed by cellular enzymes. Preferentially inhibit viral DNA polymerase by chain termination.
CLINICAL USE	No activity against CMV because CMV lacks the thymidine kinase necessary to activate guanosine analogs. Used for HSV-induced mucocutaneous and genital lesions as well as for encephalitis. Prophylaxis in patients who are immunocompromised. Also used as prophylaxis for immunocompetent patients with severe or recurrent infection. No effect on latent forms of HSV and VZV. Valacyclovir, a prodrug of acyclovir, has better oral bioavailability. For herpes zoster, use famciclovir.
ADVERSE EFFECTS	Obstructive crystalline nephropathy and acute kidney injury if not adequately hydrated.
MECHANISM OF RESISTANCE	Mutated viral thymidine kinase.

Ganciclovir

MECHANISM	Guanosine analog. 5'-monophosphate formed by a CMV viral kinase. Triphosphate formed by cellular kinases. Preferentially inhibits viral DNA polymerase.
CLINICAL USE	CMV, especially in patients who are immunocompromised. Valganciclovir, a prodrug of ganciclovir, has better oral bioavailability.
ADVERSE EFFECTS	Myelosuppression (leukopenia, neutropenia, thrombocytopenia), renal toxicity. More toxic to host enzymes than acyclovir.
MECHANISM OF RESISTANCE	Mutated viral kinase.

Foscarnet

MECHANISM	Viral DNA/RNA polymerase inhibitor and HIV reverse transcriptase inhibitor. Binds to pyrophosphate-binding site of enzyme. Does not require any kinase activation.	Foscarnet = pyro fos phate analog.
CLINICAL USE	CMV retinitis in immunocompromised patients when ganciclovir fails; acyclovir-resistant HSV.	
ADVERSE EFFECTS	Nephrotoxicity, multiple electrolyte abnormalities can lead to seizures.	
MECHANISM OF RESISTANCE	Mutated DNA polymerase.	

Cidofovir

MECHANISM	Preferentially inhibits viral DNA polymerase. Does not require phosphorylation by viral kinase.
CLINICAL USE	CMV retinitis in immunocompromised patients; acyclovir-resistant HSV. Long half-life.
ADVERSE EFFECTS	Nephrotoxicity (coadminister cidofovir with probenecid and IV saline to ↓ toxicity).

HIV therapy

Antiretroviral therapy (ART): often initiated at the time of HIV diagnosis.

Strongest indication for use with patients presenting with AIDS-defining illness, low CD4+ cell counts (< 500 cells/mm³), or high viral load. Regimen consists of 3 drugs to prevent resistance: 2 NRTIs and preferably an integrase inhibitor.

Most ARTs are active against both HIV-1 and HIV-2 (exceptions: NNRTIs and enfuvirtide not effective against HIV-2).

DRUG	MECHANISM	TOXICITY
NRTIs		
Abacavir (ABC) Emtricitabine (FTC) Lamivudine (3TC) Tenofovir (TDF) Zidovudine (ZDV, formerly AZT)	Competitively inhibit nucleotide binding to reverse transcriptase and terminate the DNA chain (lack a 3' OH group). T enofovir is a nucleo T ide; the others are nucleosides. All need to be phosphorylated to be active. ZDV can be used for general prophylaxis and during pregnancy to ↓ risk of fetal transmission. Have you dined (vudine) with my nuclear (nucleosides) family?	Myelosuppression (can be reversed with granulocyte colony-stimulating factor [G-CSF] and erythropoietin), nephrotoxicity. Abacavir contraindicated if patient has HLA-B*5701 mutation due to ↑ risk of hypersensitivity.
NNRTIs		
Efavirenz Nevirapine	Bind to reverse transcriptase at site different from NRTIs. Do not require phosphorylation to be active or compete with nucleotides.	Rash and hepatotoxicity are common to all NNRTIs. Vivid dreams and CNS symptoms are common with efavirenz.
Integrase inhibitors		
Bictegravir Dolutegravir Elvitegravir Raltegravir	Inhibits HIV genome integration into host cell chromosome by reversibly inhibiting HIV integrase.	↑ creatine kinase, weight gain.
Protease inhibitors		
Atazanavir Darunavir Lopinavir Ritonavir	Assembly of virions depends on HIV-1 protease (<i>pol</i> gene), which cleaves the polypeptide products of HIV mRNA into their functional parts. Thus, protease inhibitors prevent maturation of new viruses. Navir (never) tease a protease .	Hyperglycemia, GI intolerance (nausea, diarrhea). Rifampin (potent CYP/UGT inducer) ↓ protease inhibitor concentrations; use rifabutin instead. Ritonavir (cytochrome P-450 inhibitor), ↑ other drug concentrations.
Entry inhibitors		
Enfuvirtide	Binds gp41, inhibiting viral entry.	Skin reaction at injection sites. Enfuvirtide inhibits fusion .
Maraviroc	Binds CCR-5 on surface of T cells/monocytes, inhibiting interaction with gp120.	Maraviroc inhibits docking .
Pre-exposure prophylaxis	Administered to patients with a negative HIV test, normal renal function, and any of the following indications: <ul style="list-style-type: none"> Men who have sex with men without protection Sexual activity with an HIV ⊕ partner or multiple partners of unknown HIV status Injection drug use with high-risk needle behavior Treatment: tenofovir + emtricitabine. Counsel on adherence and risk reduction with follow-up HIV testing every 3 months.	

Hepatitis C therapy Chronic HCV infection treated with multidrug therapy that targets specific steps within HCV replication cycle (HCV-encoded proteins). Examples of drugs are provided.

DRUG	MECHANISM	TOXICITY
NS5A inhibitors		
Ledipasvir Ombitasvir Velpatasvir	Inhibits NS5A, a viral phosphoprotein that plays a key role in RNA replication Exact mechanism unknown	Headache, diarrhea
NS5B inhibitors		
Sofosbuvir Dasabuvir	Inhibits NS5B, an RNA-dependent RNA polymerase acting as a chain terminator Prevents viral RNA replication	Fatigue, headache
NS3/4A inhibitors		
Grazoprevir Simeprevir	Inhibits NS3/4A, a viral protease, preventing viral replication	Grazoprevir: headache, fatigue Simeprevir: photosensitivity reactions, rash
Alternative drugs		
Ribavirin	Inhibits synthesis of guanine nucleotides by competitively inhibiting IMP dehydrogenase Used as adjunct in cases refractory to newer medications	Hemolytic anemia, severe teratogen

Disinfection and sterilization Goals include the reduction of pathogenic organism counts to safe levels (disinfection) and the inactivation of all microbes including spores (sterilization).

Chlorine and **heat** are sporicidal.

Autoclave	Pressurized steam at > 120°C. Sporicidal. May not reliably inactivate prions.
Alcohols	Denature proteins and disrupt cell membranes. Not sporicidal.
Chlorhexidine	Disrupts cell membranes and coagulates intracellular components.
Chlorine	Oxidizes and denatures proteins. Sporicidal.
Ethylene oxide	Alkylating agent. Sporicidal.
Hydrogen peroxide	Free radical oxidation. Sporicidal.
Iodine and iodophors	Halogenation of DNA, RNA, and proteins. May be sporicidal.
Quaternary amines	Impair permeability of cell membranes. Not sporicidal.

Antimicrobials to avoid in pregnancy

ANTIMICROBIAL	ADVERSE EFFECT
Sulfonamides	Kernicterus
Aminoglycosides	Ototoxicity
Fluoroquinolones	Cartilage damage
Clarithromycin	Embryotoxic
Tetracyclines	Discolored teeth, inhibition of bone growth
Ribavirin	Teratogenic
Griseofulvin	Teratogenic
Chloramphenicol	Gray baby syndrome

Safe children take really good care.

Pathology

“Digressions, objections, delight in mockery, carefree mistrust are signs of health; everything unconditional belongs in pathology.”

—Friedrich Nietzsche

“You cannot separate passion from pathology any more than you can separate a person’s spirit from his body.”

—Richard Selzer

“My business is not prognosis, but diagnosis. I am not engaged in therapeutics, but in pathology.”

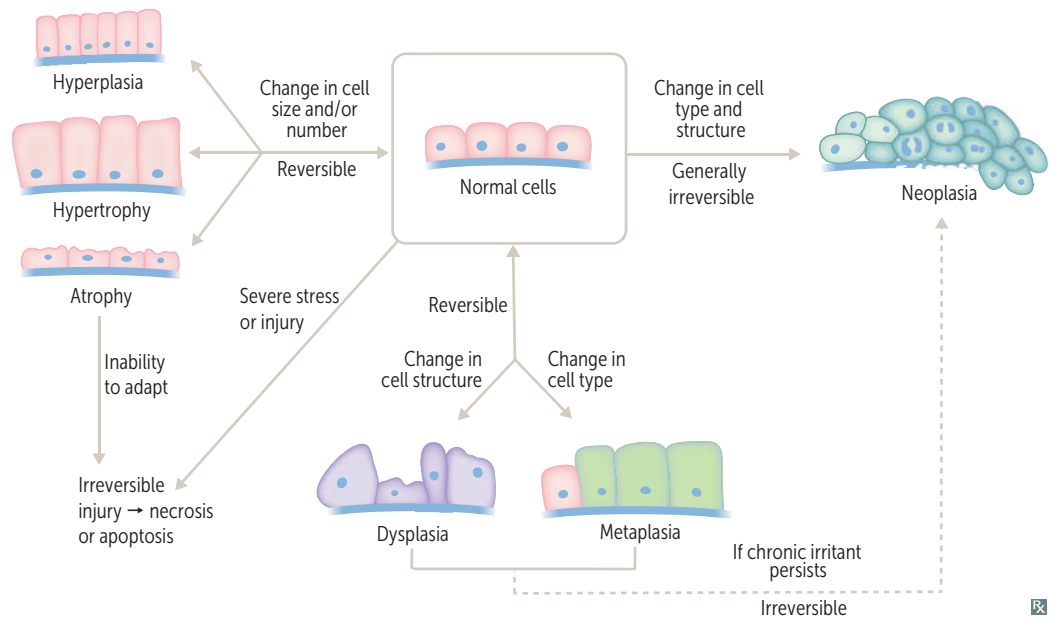
—H.L. Mencken

The fundamental principles of pathology are key to understanding diseases in all organ systems. Major topics such as inflammation and neoplasia appear frequently in questions across different organ systems, and such topics are definitely high yield. For example, the concepts of cell injury and inflammation are key to understanding the inflammatory response that follows myocardial infarction, a very common subject of board questions. Similarly, a familiarity with the early cellular changes that culminate in the development of neoplasias—for example, esophageal or colon cancer—is critical. Finally, make sure you recognize the major tumor-associated genes and are comfortable with key cancer concepts such as tumor staging and metastasis.

▶ Cellular Injury	204
▶ Inflammation	211
▶ Neoplasia	217
▶ Aging	227

▶ PATHOLOGY—CELLULAR INJURY

Cellular adaptations	Reversible changes that can be physiologic (eg, uterine enlargement during pregnancy) or pathologic (eg, myocardial hypertrophy 2° to systemic HTN). If stress is excessive or persistent, adaptations can progress to cell injury (eg, significant LV hypertrophy → myocardial injury → HF).
Hypertrophy	↑ structural proteins and organelles → ↑ in size of cells. Example: cardiac hypertrophy.
Hyperplasia	Controlled proliferation of stem cells and differentiated cells → ↑ in number of cells (eg, benign prostatic hyperplasia). Excessive stimulation → pathologic hyperplasia (eg, endometrial hyperplasia), which may progress to dysplasia and cancer.
Atrophy	↓ in tissue mass due to ↓ in size (↑ cytoskeleton degradation via ubiquitin-proteasome pathway and autophagy; ↓ protein synthesis) and/or number of cells (apoptosis). Causes include disuse, denervation, loss of blood supply, loss of hormonal stimulation, poor nutrition.
Metaplasia	Reprogramming of stem cells → replacement of one cell type by another that can adapt to a new stress. Usually due to exposure to an irritant, such as gastric acid (→ Barrett esophagus) or tobacco smoke (→ respiratory ciliated columnar epithelium replaced by stratified squamous epithelium). May progress to dysplasia → malignant transformation with persistent insult (eg, Barrett esophagus → esophageal adenocarcinoma). Metaplasia of connective tissue can also occur (eg, myositis ossificans, the formation of bone within muscle after trauma).
Dysplasia	Disordered, precancerous epithelial cell growth; not considered a true adaptive response. Characterized by loss of uniformity of cell size and shape (pleomorphism); loss of tissue orientation; nuclear changes (eg, ↑ nuclear:cytoplasmic ratio and clumped chromatin). Mild and moderate dysplasias (ie, do not involve entire thickness of epithelium) may regress with alleviation of inciting cause. Severe dysplasia often becomes irreversible and progresses to carcinoma in situ. Usually preceded by persistent metaplasia or pathologic hyperplasia.

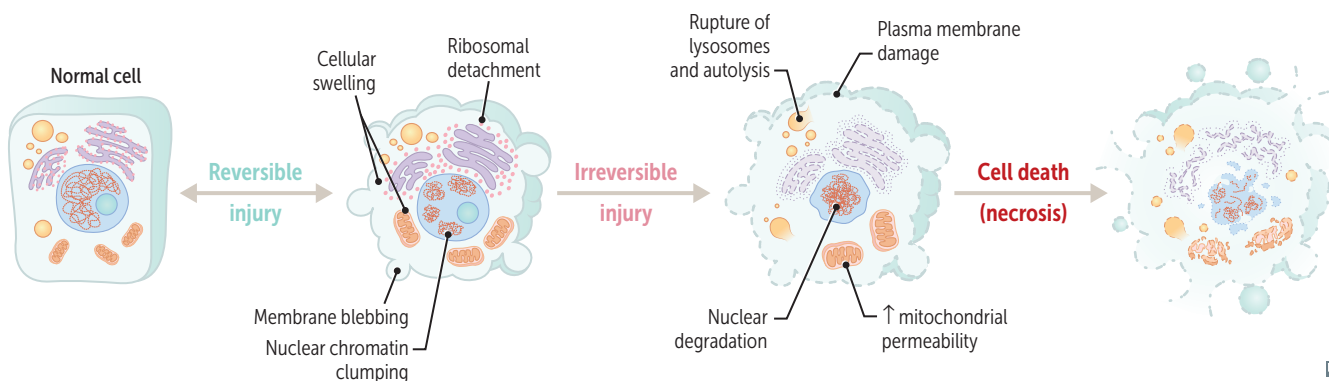


Cell injury**Reversible cell injury**

- \downarrow ATP \rightarrow \downarrow activity of Ca^{2+} and Na^+/K^+ pumps \rightarrow cellular swelling (cytosol, mitochondria, endoplasmic reticulum/Golgi), which is the earliest morphologic manifestation
- Ribosomal/polysomal detachment \rightarrow \downarrow protein synthesis
- Plasma membrane changes (eg, blebbing)
- Nuclear changes (eg, chromatin clumping)
- Rapid loss of function (eg, myocardial cells are noncontractile after 1-2 minutes of ischemia)
- Myelin figures (aggregation of peroxidized lipids)

Irreversible cell injury

- Breakdown of plasma membrane \rightarrow cytosolic enzymes (eg, troponin) leak outside of cell, influx of Ca^{2+} \rightarrow activation of degradative enzymes
- Mitochondrial damage/dysfunction \rightarrow loss of electron transport chain \rightarrow \downarrow ATP
- Rupture of lysosomes \rightarrow autolysis
- Nuclear degradation: pyknosis (nuclear condensation) \rightarrow karyorrhexis (nuclear fragmentation caused by endonuclease-mediated cleavage) \rightarrow karyolysis (nuclear dissolution)
- Amorphous densities/inclusions in mitochondria



Apoptosis

ATP-dependent programmed cell death.

Intrinsic and extrinsic pathways; both pathways activate caspases (cytosolic proteases) → cellular breakdown including cell shrinkage, chromatin condensation, membrane blebbing, and formation of apoptotic bodies, which are then phagocytosed.

Characterized by deeply eosinophilic cytoplasm and basophilic nucleus, pyknosis, and karyorrhexis. Cell membrane typically remains intact without significant inflammation (unlike necrosis).

DNA laddering (fragments in multiples of 180 bp) is a sensitive indicator of apoptosis.

Intrinsic (mitochondrial) pathway

Involved in tissue remodeling in embryogenesis. Occurs when a regulating factor is withdrawn from a proliferating cell population (eg, ↓ IL-2 after a completed immunologic reaction → apoptosis of proliferating effector cells). Also occurs after exposure to injurious stimuli (eg, radiation, toxins, hypoxia).

Regulated by Bcl-2 family of proteins. **BAX** and **BAK** are proapoptotic (**BA**d for survival), while **Bcl-2** and **Bcl-xL** are antiapoptotic (**Be** clever, **live**).

BAX and BAK form pores in the mitochondrial membrane → release of cytochrome C from inner mitochondrial membrane into the cytoplasm → activation of caspases.

Bcl-2 keeps the mitochondrial membrane impermeable, thereby preventing cytochrome C release.

Bcl-2 overexpression (eg, follicular lymphoma t[14;18]) → ↓ caspase activation → tumorigenesis.

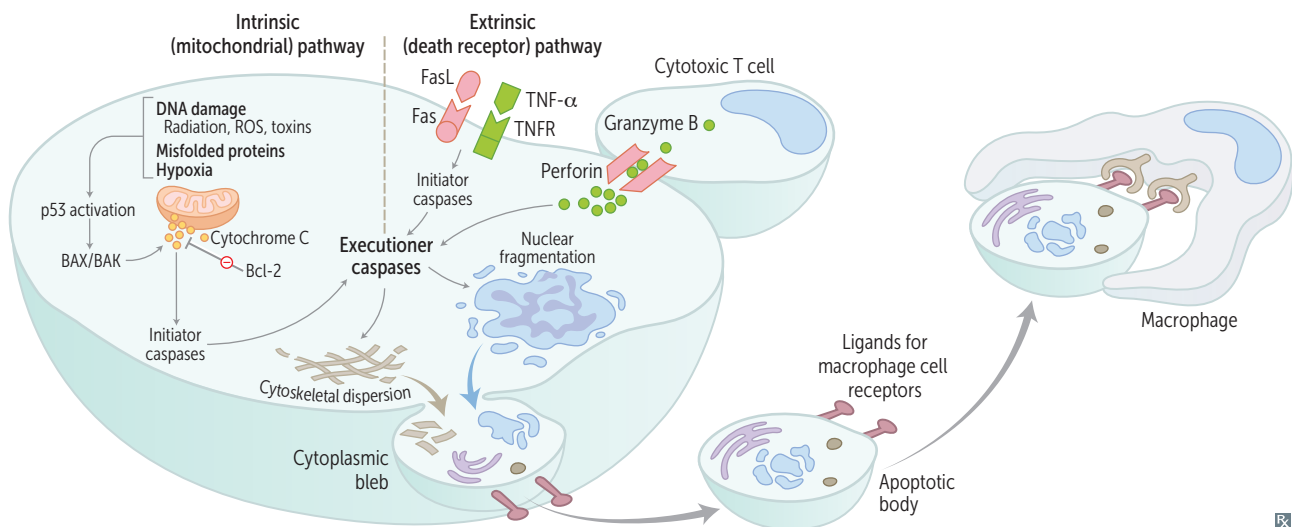
Extrinsic (death receptor) pathway

2 pathways:

- Ligand receptor interactions (FasL binding to Fas [CD95] or TNF- α binding to its receptor)
- Immune cell (cytotoxic T-cell release of perforin and granzyme B)

Fas-FasL interaction is necessary in thymic medullary negative selection.

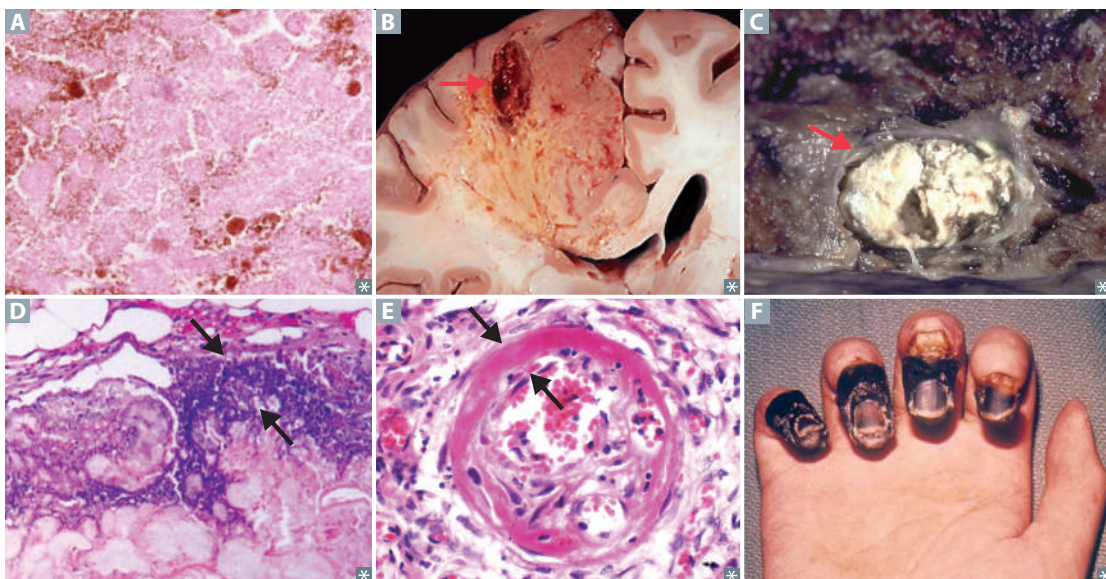
Autoimmune lymphoproliferative syndrome—caused by defective Fas-FasL interaction → failure of clonal deletion → ↑ numbers of self-reacting lymphocytes. Presents with lymphadenopathy, hepatosplenomegaly, autoimmune cytopenias.

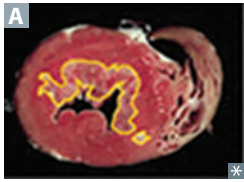


Necrosis

Exogenous injury → plasma membrane damage → cell undergoes enzymatic degradation and protein denaturation, intracellular components leak → local inflammatory reaction (unlike apoptosis).

TYPE	SEEN IN	DUE TO	HISTOLOGY
Coagulative	Ischemia/infarcts in most tissues (except brain)	Ischemia or infarction; injury denatures enzymes → proteolysis blocked	Preserved cellular architecture (cell outlines seen), but nuclei disappear; ↑ cytoplasmic binding of eosin stain (→ ↑ eosinophilia; red/pink color) A
Liquefactive	Bacterial abscesses, CNS infarcts	Neutrophils release lysosomal enzymes that digest the tissue B	Early: cellular debris and macrophages Late: cystic spaces and cavitation (CNS) Neutrophils and cell debris seen with bacterial infection
Caseous	TB, systemic fungi (eg, <i>Histoplasma capsulatum</i>), <i>Nocardia</i>	Macrophages wall off the infecting microorganism → granular debris	Fragmented cells and debris surrounded by lymphocytes and macrophages (granuloma) Cheeselike gross appearance C
Fat	Enzymatic: acute pancreatitis (saponification of peripancreatic fat) Nonenzymatic: traumatic (eg, injury to breast tissue)	Damaged pancreatic cells release lipase, which breaks down triglycerides; liberated fatty acids bind calcium → saponification (chalky-white appearance)	Outlines of dead fat cells without peripheral nuclei; saponification of fat (combined with Ca ²⁺) appears dark blue on H&E stain D
Fibrinoid	Immune vascular reactions (eg, PAN) Nonimmune vascular reactions (eg, hypertensive emergency, preeclampsia)	Immune complex deposition (type III hypersensitivity reaction) and/or plasma protein (eg, fibrin) leakage from damaged vessel	Vessel walls contain eosinophilic layer of proteinaceous material E
Gangrenous	Distal extremity and GI tract, after chronic ischemia	Dry: ischemia F Wet: superinfection	Coagulative Liquefactive superimposed on coagulative



Ischemia

Inadequate blood supply to meet demand. Mechanisms include ↓ arterial perfusion (eg, atherosclerosis), ↓ venous drainage (eg, testicular torsion, Budd-Chiari syndrome), shock. Regions most vulnerable to hypoxia/ischemia and subsequent infarction:

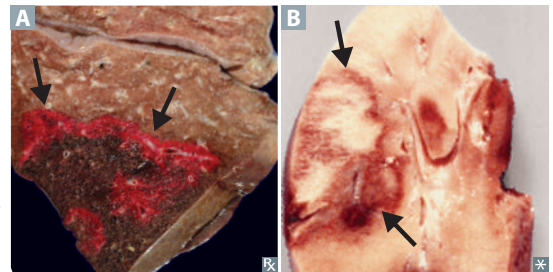
ORGAN	REGION
Brain	ACA/MCA/PCA boundary areas ^{a,b}
Heart	Subendocardium of LV (yellow lines in A outline a subendocardial infarction)
Kidney	Straight segment of proximal tubule (medulla) Thick ascending limb (medulla)
Liver	Area around central vein (zone III)
Colon	Splenic flexure (Griffith point), ^a rectosigmoid junction (Sudeck point) ^a

^aWatershed areas (border zones) receive blood supply from most distal branches of 2 arteries with limited collateral vascularity. These areas are susceptible to ischemia from hypoperfusion.

^bNeurons most vulnerable to hypoxic-ischemic insults include Purkinje cells of the cerebellum and pyramidal cells of the hippocampus and neocortex (zones 3, 5, 6).

Types of infarcts**Red infarct**

Occurs in venous occlusion and tissues with multiple blood supplies (eg, liver, lung **A**, intestine, testes), and with reperfusion (eg, after angioplasty). **R**eperfusion injury is due to damage by free radicals.

**Pale infarct**

Occurs in solid organs with a single (end-arterial) blood supply (eg, heart, kidney **B**).

Free radical injury

Free radicals damage cells via membrane lipid peroxidation, protein modification, DNA breakage. Initiated via radiation exposure (eg, cancer therapy), metabolism of drugs (phase I), redox reactions, nitric oxide (eg, inflammation), transition metals (eg, iron, copper; form free radicals via Fenton reaction), WBC (eg, neutrophils, macrophages) oxidative burst. Free radicals can be eliminated by scavenging enzymes (eg, catalase, superoxide dismutase, glutathione peroxidase), spontaneous decay, antioxidants (eg, vitamins A, C, E), and certain metal carrier proteins (eg, transferrin, ceruloplasmin).

Examples:

- Oxygen toxicity: retinopathy of prematurity (abnormal vascularization), bronchopulmonary dysplasia, reperfusion injury after thrombolytic therapy
- Drug/chemical toxicity: acetaminophen overdose (hepatotoxicity), carbon tetrachloride (converted by cytochrome P-450 into CCl₃ free radical → fatty liver [cell injury → ↓ apolipoprotein synthesis → fatty change], centrilobular necrosis)
- Metal storage diseases: hemochromatosis (iron) and Wilson disease (copper)

Ionizing radiation toxicity

Ionizing radiation causes DNA (eg, double strand breaks) and cellular damage both directly and indirectly through the production of free radicals. Complications usually arise when patient is exposed to significant doses (eg, radiotherapy, nuclear reactor accidents):

- Localized inflammation and fibrosis
- Neoplasia (eg, leukemia, thyroid cancer)

Acute radiation syndrome—develops after sudden whole-body exposure to high doses of ionizing radiation → nausea, vomiting, diarrhea, hair loss, erythema, cytopenias, headache, altered mental status.

Stem cells of rapidly regenerating tissues (eg, skin, bone marrow, GI tract, gonads) are the most susceptible to radiation injury.

Radiotherapy damages cancer cells more than healthy cells because cancer cells have dysfunctional DNA repair mechanisms in addition to high replicative rates.

Types of calcification

Calcium deposits appear deeply basophilic (arrow in **A**) on H&E stain.

Dystrophic calcification

Metastatic calcification

Ca²⁺ DEPOSITION

In abnormal (diseased) tissues

In normal tissues

EXTENT

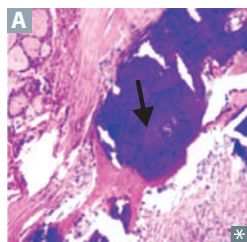
Tends to be localized (eg, calcific aortic stenosis)

Widespread (ie, diffuse, metastatic)

ASSOCIATED CONDITIONS

TB (lung and pericardium) and other granulomatous infections, liquefactive necrosis of chronic abscesses, fat necrosis, infarcts, thrombi, schistosomiasis, congenital CMV, toxoplasmosis, rubella, psammoma bodies, CREST syndrome, atherosclerotic plaques can become calcified

Predominantly in interstitial tissues of kidney, lung, and gastric mucosa (these tissues lose acid quickly; ↑ pH favors Ca²⁺ deposition)
Nephrocalcinosis of collecting ducts may lead to nephrogenic diabetes insipidus and renal failure



ETIOLOGY

2° to injury or necrosis

2° to hypercalcemia (eg, 1° hyperparathyroidism, sarcoidosis, hypervitaminosis D) or hyperphosphatemia (eg, chronic kidney disease)

SERUM Ca²⁺ LEVELS

Normal

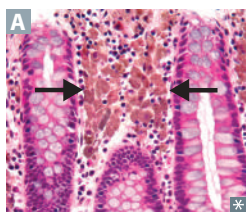
Usually abnormal

Lipofuscin

A yellow-brown “wear and tear” pigment **A** associated with normal aging.

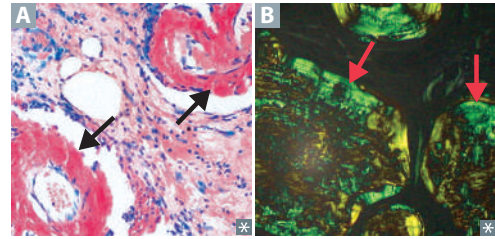
Composed of polymers of lipids and phospholipids complexed with protein. May be derived through lipid peroxidation of polyunsaturated lipids of subcellular membranes.

Autopsy of older adult will reveal deposits in heart, colon, liver, kidney, eye, and other organs.



Amyloidosis

Abnormal aggregation of proteins (or their fragments) into β -pleated linear sheets → insoluble fibrils → cellular damage and apoptosis. Amyloid deposits visualized by Congo red stain (red/orange on nonpolarized light [arrows in **A**], apple-green birefringence on polarized light [arrows in **B**]), and H&E stain.



COMMON TYPES	FIBRIL PROTEIN	DESCRIPTION	NOTES
Systemic			
Primary amyloidosis	AL (from Ig Light chains)	Seen in plasma cell disorders (eg, multiple myeloma)	Manifestations include: <ul style="list-style-type: none"> ▪ Cardiac (eg, restrictive cardiomyopathy) ▪ GI (eg, macroglossia, hepatomegaly) ▪ Renal (eg, nephrotic syndrome) ▪ Hematologic (eg, easy bruising, splenomegaly) ▪ Neurologic (eg, neuropathy) ▪ Musculoskeletal (eg, carpal tunnel syndrome)
Secondary amyloidosis	Serum Amyloid A (AA)	Seen in chronic inflammatory conditions, (eg, rheumatoid arthritis, IBD, familial Mediterranean fever, protracted infection)	
Dialysis-related amyloidosis	β_2 -microglobulin	Seen in patients with ESRD and/or on long-term dialysis	
Localized			
Alzheimer disease	β -amyloid protein	Cleaved from amyloid precursor protein (APP)	
Type 2 diabetes mellitus	Islet amyloid polypeptide (IAPP)	Caused by deposition of amylin in pancreatic islets	
Medullary thyroid cancer	Calcitonin		
Isolated atrial amyloidosis	ANP	Common in normal aging ↑ risk of atrial fibrillation	
Systemic senile (age-related) amyloidosis	Normal (wild-type) transthyretin (TTR)	Seen predominantly in cardiac ventricles	Cardiac dysfunction more insidious than in AL amyloidosis
Hereditary			
Familial amyloid cardiomyopathy	Mutated transthyretin (ATTR)	Ventricular endomyocardium deposition → restrictive cardiomyopathy, arrhythmias	
Familial amyloid polyneuropathies	Mutated transthyretin (ATTR)	Due to transthyretin gene mutation	

▶ **PATHOLOGY—INFLAMMATION**

Inflammation Response to eliminate initial cause of cell injury, to remove necrotic cells resulting from the original insult, and to initiate tissue repair. Divided into acute and chronic. The inflammatory response itself can be harmful to the host if the reaction is excessive (eg, septic shock), prolonged (eg, persistent infections such as TB), or inappropriate (eg, autoimmune diseases such as SLE).

SIGN	MECHANISM
Cardinal signs	
Rubor and calor	Redness and warmth. Vasodilation (relaxation of arteriolar smooth muscle) → ↑ blood flow. Mediated by histamine, prostaglandins, bradykinin, NO.
Tumor	Swelling. Endothelial contraction/disruption (eg, from tissue damage) → ↑ vascular permeability → leakage of protein-rich fluid from postcapillary venules into interstitial space (exudate) → ↑ interstitial oncotic pressure. Endothelial contraction is mediated by leukotrienes (C ₄ , D ₄ , E ₄), histamine, serotonin.
Dolor	Pain. Sensitization of sensory nerve endings. Mediated by bradykinin, PGE ₂ , histamine.
Functio laesa	Loss of function. Inflammation impairs function (eg, inability to make fist due to hand cellulitis).
Systemic manifestations (acute-phase reaction)	
Fever	Pyrogens (eg, LPS) induce macrophages to release IL-1 and TNF → ↑ COX activity in perivascular cells of anterior hypothalamus → ↑ PGE ₂ → ↑ temperature set point.
Leukocytosis	↑ WBC count; type of predominant cell depends on inciting agent or injury (eg, bacteria → ↑ neutrophils).
↑ plasma acute-phase reactants	Serum concentrations significantly change in response to acute and chronic inflammation. Produced by liver. Notably induced by IL-6.

Acute phase reactants

POSITIVE (UPREGULATED)	
C-reactive protein	Opsonin; fixes complement and facilitates phagocytosis. Measured clinically as a nonspecific sign of ongoing inflammation.
Ferritin	Binds and sequesters iron to inhibit microbial iron scavenging.
Fibrinogen	Coagulation factor; promotes endothelial repair; correlates with ESR.
Haptoglobin	Binds extracellular hemoglobin, protects against oxidative stress.
Hepcidin	↓ iron absorption (by degrading ferroportin) and ↓ iron release (from macrophages) → anemia of chronic disease.
Procalcitonin	Increases in bacterial infections; normal in viral infections.
Serum amyloid A	Prolonged elevation can lead to amyloidosis.
NEGATIVE (DOWNREGULATED)	
Albumin	Reduction conserves amino acids for positive reactants.
Transferrin	Internalized by macrophages to sequester iron.
Transthyretin	Also called prealbumin. Reduction conserves amino acids for positive reactants.

Erythrocyte sedimentation rate

RBCs normally remain separated via \ominus charges. Products of inflammation (eg, fibrinogen) coat RBCs \rightarrow \downarrow \ominus charge \rightarrow \uparrow RBC aggregation. Denser RBC aggregates fall at a faster rate within a pipette tube \rightarrow \uparrow ESR. Often co-tested with CRP (more specific marker of inflammation).

\uparrow ESR

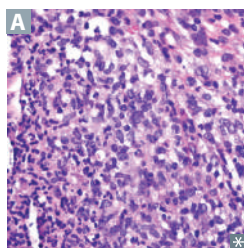
Most anemias
Infections
Inflammation (eg, giant cell [temporal] arteritis, polymyalgia rheumatica)
Cancer (eg, metastases, multiple myeloma)
Renal disease (end-stage or nephrotic syndrome)
Pregnancy

\downarrow ESR^a

Sickle cell anemia (altered shape)
Polycythemia (\uparrow RBCs “dilute” aggregation factors)
HF
Microcytosis
Hypofibrinogenemia

^aLower than expected.

Acute inflammation



Transient and early response to injury or infection. Characterized by neutrophils in tissue **A**, often with associated edema. Rapid onset (seconds to minutes) and short duration (minutes to days). Represents a reaction of the innate immune system (ie, less specific response than chronic inflammation).

STIMULI

Infections, trauma, necrosis, foreign bodies.

MEDIATORS

Toll-like receptors, arachidonic acid metabolites, neutrophils, eosinophils, antibodies (pre-existing), mast cells, basophils, complement, Hageman factor (factor XII).

Inflammasome—Cytoplasmic protein complex that recognizes products of dead cells, microbial products, and crystals (eg, uric acid crystals) \rightarrow activation of IL-1 and inflammatory response.

COMPONENTS

- Vascular: vasodilation (\rightarrow \uparrow blood flow and stasis) and \uparrow endothelial permeability (contraction of endothelial cells opens interendothelial junctions)
- Cellular: extravasation of leukocytes (mainly neutrophils) from postcapillary venules \rightarrow accumulation of leukocytes in focus of injury \rightarrow leukocyte activation

To bring cells and proteins to site of injury or infection.

Leukocyte extravasation has 4 steps: margination and rolling, adhesion, transmigration, and migration (chemoattraction).

OUTCOMES

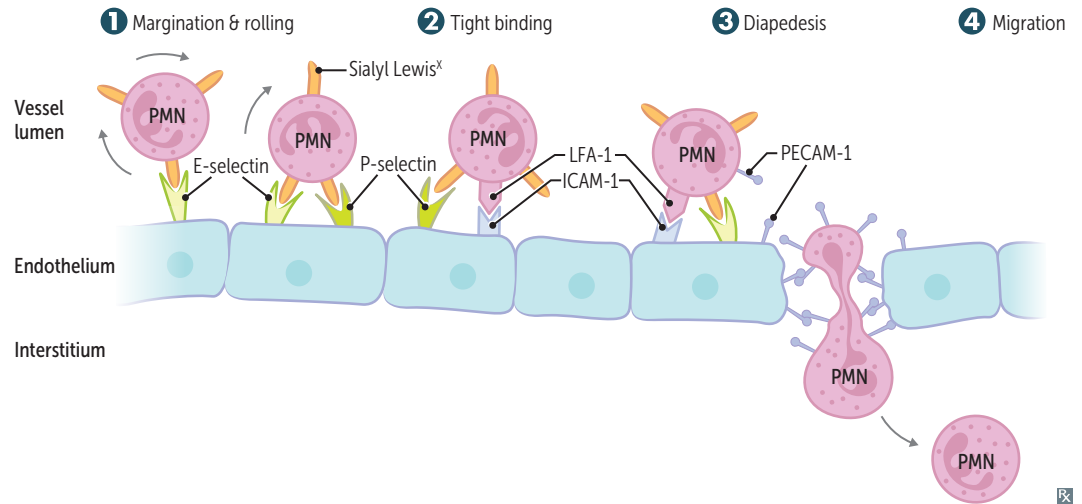
- Resolution and healing (IL-10, TGF- β)
- Persistent acute inflammation (IL-8)
- Abscess (acute inflammation walled off by fibrosis)
- Chronic inflammation (antigen presentation by macrophages and other APCs \rightarrow activation of CD4⁺ Th cells)
- Scarring

Macrophages predominate in the late stages of acute inflammation (peak 2–3 days after onset) and influence outcome by secreting cytokines.

Leukocyte extravasation

Extravasation predominantly occurs at postcapillary venules.

STEP	VASCULATURE/STROMA	LEUKOCYTE
1 Margination and rolling— defective in leukocyte adhesion deficiency type 2 (↓ Sialyl Lewis ^X)	E-selectin (upregulated by TNF and IL-1) P-selectin (released from Weibel- palade bodies) GlyCAM-1, CD34	Sialyl Lewis ^X Sialyl Lewis ^X L-selectin
2 Tight binding (adhesion)— defective in leukocyte adhesion deficiency type 1 (↓ CD18 integrin subunit)	ICAM-1 (CD54) VCAM-1 (CD106)	CD11/18 integrins (LFA-1, Mac-1) VLA-4 integrin
3 Dia PE desis (transmigration)— WBC travels between endothelial cells and exits blood vessel	PECAM-1 (CD31)	PECAM-1 (CD31)
4 Migration—WBC travels through interstitium to site of injury or infection guided by chemotactic signals	Chemotactic factors: C5a, IL-8, LTB ₄ , 5-HETE, kallikrein, platelet-activating factor, N-formylmethionyl peptides	Various



Chronic inflammation Prolonged inflammation characterized by mononuclear infiltration (macrophages, lymphocytes, plasma cells), which leads to simultaneous tissue destruction and repair (including angiogenesis and fibrosis). May be preceded by acute inflammation.

STIMULI	Persistent infections (eg, TB, <i>T pallidum</i> , certain fungi and viruses) → type IV hypersensitivity, autoimmune diseases, prolonged exposure to toxic agents (eg, silica) and foreign material.
MEDIATORS	Macrophages are the dominant cells. Interaction of macrophages and T cells → chronic inflammation. <ul style="list-style-type: none"> ▪ Th1 cells secrete IFN-γ → macrophage classical activation (proinflammatory) ▪ Th2 cells secrete IL-4 and IL-13 → macrophage alternative activation (repair and anti-inflammatory)
OUTCOMES	Scarring, amyloidosis, and neoplastic transformation (eg, chronic HCV infection → chronic inflammation → hepatocellular carcinoma; <i>Helicobacter pylori</i> infection → chronic gastritis → gastric adenocarcinoma).

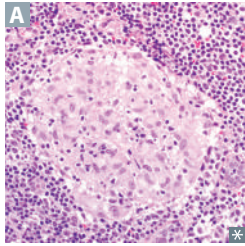
Wound healing

Tissue mediators	MEDIATOR	ROLE
	FGF	Stimulates angiogenesis
	TGF- β	Angiogenesis, fibrosis
	VEGF	Stimulates angiogenesis
	PDGF	Secreted by activated platelets and macrophages Induces vascular remodeling and smooth muscle cell migration Stimulates fibroblast growth for collagen synthesis
	Metalloproteinases	Tissue remodeling
	EGF	Stimulates cell growth via tyrosine kinases (eg, EGFR/ <i>ErbB1</i>)
PHASE OF WOUND HEALING	EFFECTOR CELLS	CHARACTERISTICS
Inflammatory (up to 3 days after wound)	Platelets, neutrophils, macrophages	Clot formation, ↑ vessel permeability and neutrophil migration into tissue; macrophages clear debris 2 days later
Proliferative (day 3–weeks after wound)	Fibroblasts, myofibroblasts, endothelial cells, keratinocytes, macrophages	Deposition of granulation tissue and type III collagen, angiogenesis, epithelial cell proliferation, dissolution of clot, and wound contraction (mediated by myofibroblasts) Delayed second phase of wound healing in vitamin C and copper deficiency
Remodeling (1 week–6+ months after wound)	Fibroblasts	Type III collagen replaced by type I collagen, ↑ tensile strength of tissue Collagenases (require zinc to function) break down type III collagen Zinc deficiency → delayed wound healing

Granulomatous inflammation

A pattern of chronic inflammation. Can be induced by persistent T-cell response to certain infections (eg, TB), immune-mediated diseases, and foreign bodies. Granulomas “wall off” a resistant stimulus without completely eradicating or degrading it → persistent inflammation → fibrosis, organ damage.

HISTOLOGY



Focus of epithelioid cells (activated macrophages with abundant pink cytoplasm) surrounded by lymphocytes and multinucleated giant cells (formed by fusion of several activated macrophages).

Two types:

Caseating: associated with **c**entral necrosis. Seen with infectious etiologies (eg, TB, fungal).

Noncaseating **A**: no central necrosis. Seen with autoimmune diseases (eg, sarcoidosis, Crohn disease).

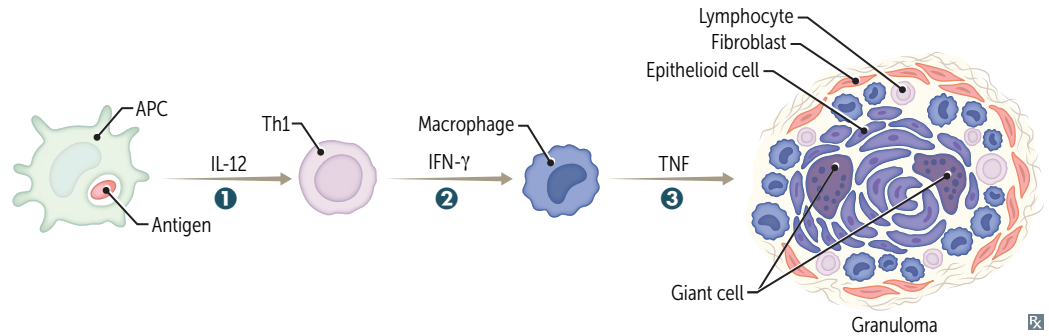
MECHANISM

- 1 APCs present antigens to CD4+ Th cells and secrete IL-12 → CD4+ Th cells differentiate into Th1 cells
- 2 Th1 secretes IFN-γ → macrophage activation
- 3 Macrophages ↑ cytokine secretion (eg, TNF) → formation of epithelioid macrophages and giant cells

Anti-TNF therapy can cause sequestering granulomas to break down → disseminated disease.

Always test for latent TB before starting anti-TNF therapy.

Associated with hypercalcemia due to ↑ 1α-hydroxylase activity in activated macrophages, resulting in ↑ vitamin D activity.



ETIOLOGIES

Infectious

Bacterial: *Mycobacteria* (tuberculosis, leprosy), *Bartonella henselae* (cat scratch disease; stellate necrotizing granulomas), *Listeria monocytogenes* (granulomatosis infantiseptica), *Treponema pallidum* (3° syphilis)
 Fungal: endemic mycoses (eg, histoplasmosis)
 Parasitic: schistosomiasis
 Catalase ⊕ organisms in chronic granulomatous disease

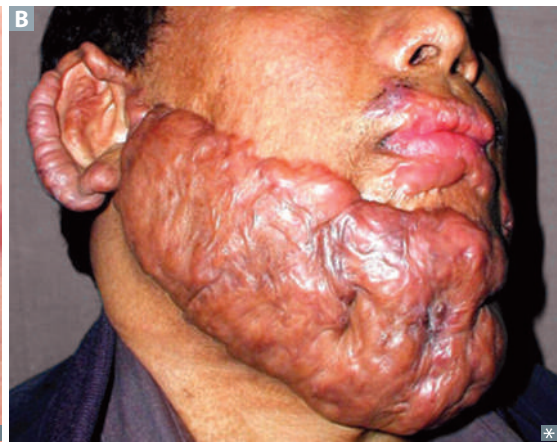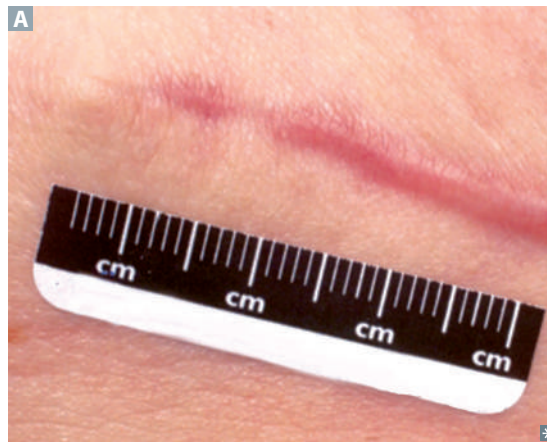Noninfectious

Immune-mediated: sarcoidosis, Crohn disease, 1° biliary cholangitis, subacute (de Quervain/granulomatous) thyroiditis
 Vasculitis: granulomatosis with polyangiitis, eosinophilic granulomatosis with polyangiitis, giant cell (temporal) arteritis, Takayasu arteritis
 Foreign bodies: berylliosis, talcosis, hypersensitivity pneumonitis

Scar formation

Occurs when repair cannot be accomplished by cell regeneration alone. Nonregenerated cells (2° to severe acute or chronic injury) are replaced by connective tissue. 70–80% of tensile strength regained at 3 months; little tensile strength regained thereafter. Excess TGF- β is associated with aberrant scarring, such as hypertrophic and keloid scars.

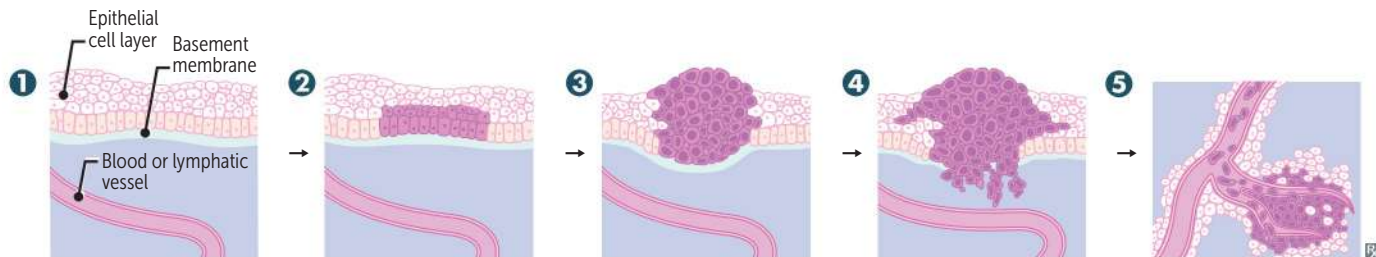
	Hypertrophic scar A	Keloid scar B
COLLAGEN SYNTHESIS	↑ (type III collagen)	↑↑↑ (types I and III collagen)
COLLAGEN ORGANIZATION	Parallel	Disorganized
EXTENT OF SCAR	Confined to borders of original wound	Extends beyond borders of original wound with “clawlike” projections typically on earlobes, face, upper extremities
RECURRENCE	Infrequent	Frequent
PREDISPOSITION	None	↑ incidence in people with darker skin



▶ PATHOLOGY—NEOPLASIA

Neoplasia and neoplastic progression

Uncontrolled, monoclonal proliferation of cells. Can be benign or malignant. Any neoplastic growth has two components: parenchyma (neoplastic cells) and supporting stroma (non-neoplastic; eg, blood vessels, connective tissue).



Normal cells

1 Normal cells with basal → apical polarity. See cervical example **A**, which shows normal cells and spectrum of dysplasia, as discussed below.

Dysplasia

2 Loss of uniformity in cell size and shape (pleomorphism); loss of tissue orientation; nuclear changes (eg, ↑ nuclear:cytoplasmic ratio) **A**; often reversible.

Carcinoma in situ/ preinvasive

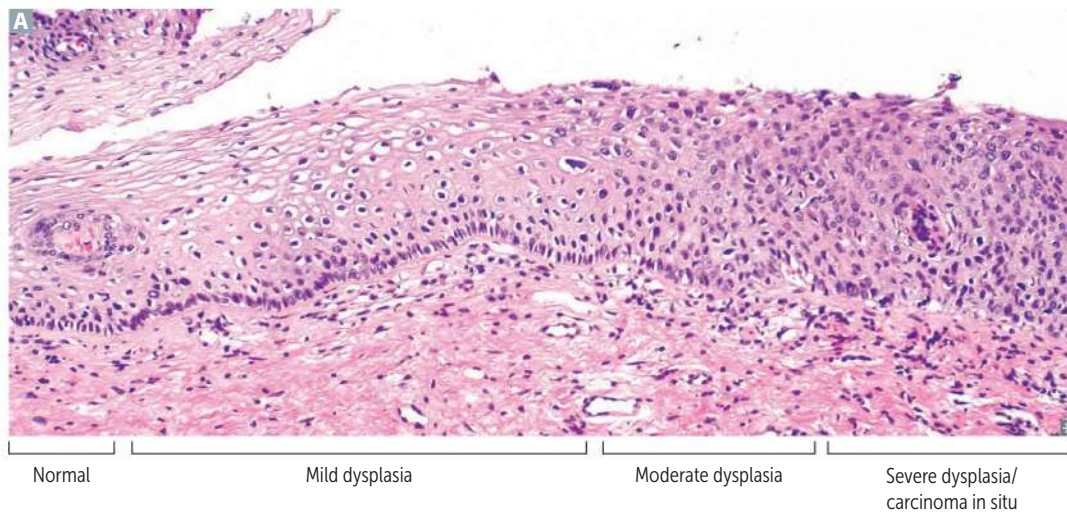
3 Irreversible severe dysplasia that involves the entire thickness of epithelium but does not penetrate the intact basement membrane **A**.

Invasive carcinoma

4 Cells have invaded basement membrane using collagenases and hydrolases (metalloproteinases). Cell-cell contacts lost by inactivation of E-cadherin.

Metastasis

5 Spread to distant organ(s) via lymphatics or blood.



Normal

Mild dysplasia

Moderate dysplasia

Severe dysplasia/
carcinoma in situ

Tumor nomenclature

Carcinoma implies epithelial origin, whereas **sarcoma** denotes mesenchymal origin. Both terms generally imply malignancy.

Benign tumors are usually well-differentiated and well-demarcated, with low mitotic activity, no metastases, and no necrosis.

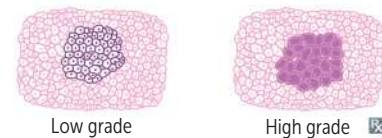
Malignant tumors (cancers) may show poor differentiation, erratic growth, local invasion, metastasis, and ↓ apoptosis.

Terms for non-neoplastic malformations include hamartoma (disorganized overgrowth of tissues in their native location, eg, Peutz-Jeghers polyps) and choristoma (normal tissue in a foreign location, eg, gastric tissue located in distal ileum in Meckel diverticulum).

CELL TYPE	BENIGN	MALIGNANT
Epithelium	Adenoma, papilloma	Adenocarcinoma, papillary carcinoma
Mesenchyme		
Blood cells		Leukemia, lymphoma
Blood vessels	Hemangioma	Angiosarcoma
Smooth muscle	Leiomyoma	Leiomyosarcoma
Striated muscle	Rhabdomyoma	Rhabdomyosarcoma
Connective tissue	Fibroma	Fibrosarcoma
Bone	Osteoma	Osteosarcoma
Fat	Lipoma	Liposarcoma
Melanocyte	Nevus/mole	Melanoma

Tumor grade vs stage**Grade**

Degree of cell differentiation (tissue of origin resemblance) and mitotic activity on histology. Ranges from low-grade (well differentiated) to high-grade (poorly differentiated or undifferentiated [anaplastic]). Higher grade often correlates with higher aggressiveness.



Low grade

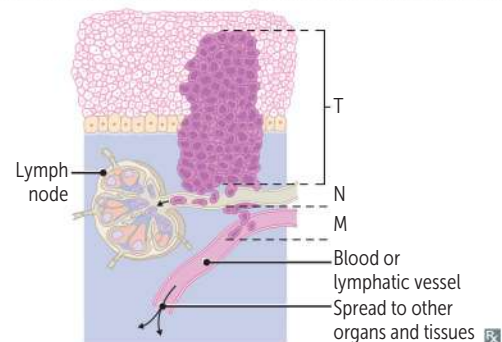
High grade

Stage

Degree of invasion and spread from initial site. Based on clinical (c) or pathologic (p) findings. **TNM** staging system (importance: M > N > T):

- Primary **t**umor size/invasion.
- Regional lymph **n**ode metastasis.
- Distant **m**etastasis.

Stage generally has more prognostic value than grade (eg, a high-stage yet low-grade tumor is usually worse than a low-stage yet high-grade tumor). **S**tage (**s**pread) determines **s**urvival.



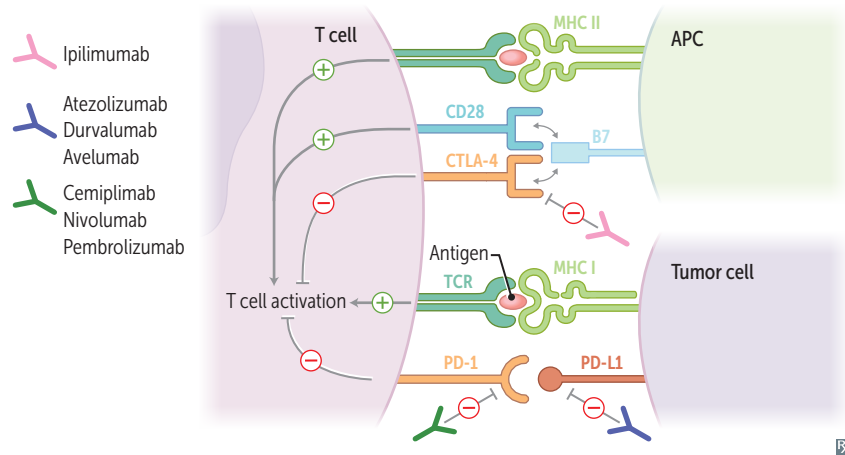
Hallmarks of cancer	Cancer is caused by (mostly acquired) DNA mutations that affect fundamental cellular processes (eg, growth, DNA repair, survival).
HALLMARK	MECHANISM
Growth signal self-sufficiency	Mutations in genes encoding: <ul style="list-style-type: none"> ▪ Proto-oncogenes → ↑ growth factors → autocrine loop (eg, ↑ PDGF in brain tumors) ▪ Growth factor receptors → constitutive signaling (eg, <i>HER2</i> in breast cancer) ▪ Signaling molecules (eg, <i>RAS</i>) ▪ Transcription factors (eg, <i>MYC</i>) ▪ Cell cycle regulators (eg, cyclins, CDKs)
Anti-growth signal insensitivity	<ul style="list-style-type: none"> ▪ Mutations in tumor suppressor genes (eg, <i>Rb</i>) ▪ Loss of E-cadherin function → loss of contact inhibition (eg, <i>NF2</i> mutations)
Evasion of apoptosis	Mutations in genes that regulate apoptosis (eg, <i>TP53</i> , <i>BCL2</i> → follicular B cell lymphoma).
Limitless replicative potential	Reactivation of telomerase → maintenance and lengthening of telomeres → prevention of chromosome shortening and cell aging.
Sustained angiogenesis	↑ pro-angiogenic factors (eg, VEGF) or ↓ inhibitory factors. Factors may be produced by tumor or stromal cells. Vessels can sprout from existing capillaries (neoangiogenesis) or endothelial cells are recruited from bone marrow (vasculogenesis). Vessels may be leaky and/or dilated.
Warburg effect	Shift of glucose metabolism away from mitochondrial oxidative phosphorylation toward glycolysis. Glycolysis provides rapidly dividing cancer cells with the carbon needed for synthesis of cellular structures.
Immune evasion in cancer	Normally, immune cells can recognize and attack tumor cells. For successful tumorigenesis, tumor cells must evade the immune system. Multiple escape mechanisms exist: <ul style="list-style-type: none"> ▪ ↓ MHC class I expression by tumor cells → cytotoxic T cells are unable to recognize tumor cells. ▪ Tumor cells secrete immunosuppressive factors (eg, TGF-β) and recruit regulatory T cells to down regulate immune response. ▪ Tumor cells up regulate immune checkpoint molecules, which inhibit immune response.
Tissue invasion	Loss of E-cadherin function → loosening of intercellular junctions → metalloproteinases degrade basement membrane and ECM → cells attach to ECM proteins (eg, laminin, fibronectin) → cells migrate through degraded ECM (“locomotion”) → vascular dissemination.
Metastasis	Tumor cells or emboli spread via lymphatics or blood → adhesion to endothelium → extravasation and homing. Site of metastasis can be predicted by site of 1° tumor, as the target organ is often the first-encountered capillary bed. Some cancers show organ tropism (eg, lung cancers commonly metastasize to adrenals).

Immune checkpoint interactions

Signals that modulate T-cell activation and function → ↓ immune response against tumor cells.

Targeted by several cancer immunotherapies. Examples:

- Interaction between PD-1 (on T cells) and PD-L1/2 (on tumor cells or immune cells in tumor microenvironment) → T-cell dysfunction (exhaustion). Inhibited by antibodies against PD-1 (eg, cemiplimab, nivolumab, pembrolizumab) or PD-L1 (eg, atezolizumab, durvalumab, avelumab).
- CTLA-4 on T cells outcompetes CD28 for B7 on APCs → loss of T-cell costimulatory signal. Inhibited by antibodies against CTLA-4 (eg, ipilimumab).



Cancer epidemiology

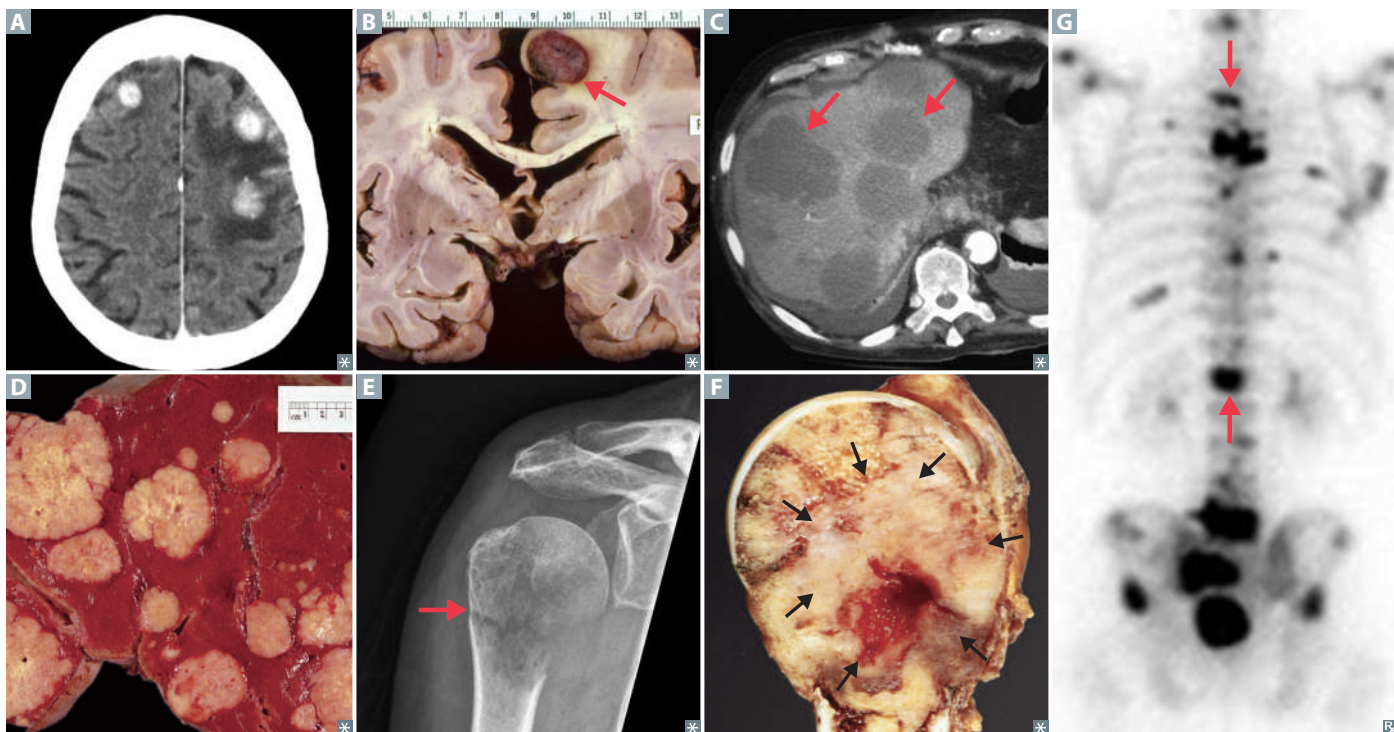
Skin cancer (basal > squamous >> melanoma) is the most common cancer (not included below).

	MALES	FEMALES	CHILDREN (AGE 0-14)	NOTES
Cancer incidence	1. Prostate 2. Lung 3. Colon/rectum	1. Breast 2. Lung 3. Colon/rectum	1. Leukemia 2. CNS 3. Neuroblastoma	Lung cancer incidence has ↓ in males, but has not changed significantly in females.
Cancer mortality	1. Lung 2. Prostate 3. Colon/rectum	1. Lung 2. Breast 3. Colon/rectum	1. Leukemia 2. CNS 3. Neuroblastoma	Cancer is the 2nd leading cause of death in the United States (heart disease is 1st).

Common metastases

Most **C**arcinomas spread via **L**ymphatics; most **S**arcomas spread **H**ematogenously (**CLaSH**).
 However, **four** carcinomas **route** hematogenously: **f**ollicular thyroid carcinoma, **c**horiocarcinoma, **r**enal cell carcinoma, and **h**epatocellular carcinoma.

SITE OF METASTASIS	1° TUMOR	NOTES
Brain	L ung > b reast > m elanoma, c olon, k idney (lots of brain metastases can kill)	50% of brain tumors are from metastases Commonly seen as multiple well-circumscribed tumors at gray/white matter junction A B
Liver	C olon >> s tomach > p ancreas (cancer sometimes p enetrates liver)	Liver C D and lung are the most common sites of metastasis after the regional lymph nodes
Bone	P rostate, b reast > k idney, t h thyroid, l ung (painful b ones kill the l ungs)	Bone metastasis E F >> 1° bone tumors (eg, multiple myeloma) Predilection for axial skeleton G Bone metastasis can be: <ul style="list-style-type: none"> ▪ Lytic (eg, thyroid, kidney, non-small cell lung cancer) ▪ Blastic (eg, prostate, small cell lung cancer) ▪ Mixed (eg, breast cancer)



Oncogenes

Gain of function mutation converts proto-oncogene (normal gene) to oncogene → ↑ cancer risk.
Requires damage to only **one** allele of a proto-**on**cogene.

GENE	GENE PRODUCT	ASSOCIATED NEOPLASM
<i>ALK</i>	Receptor tyrosine kinase	Lung adenocarcinoma
<i>EGFR (ERBB1)</i>	Receptor tyrosine kinase	Lung adenocarcinoma
<i>HER2 (ERBB2)</i>	Receptor tyrosine kinase	Breast and gastric carcinomas
<i>RET</i>	RE ceptor T yrosine kinase	MEN2A and 2B, medullary and papillary thyroid carcinoma, pheochromocytoma
<i>BCR-ABL</i>	Non-receptor tyrosine kinase	CML, ALL
<i>JAK2</i>	Non-receptor tyrosine kinase	Myeloproliferative neoplasms
<i>BRAF</i>	Serine/threonine kinase	Melanoma, non-Hodgkin lymphoma, colorectal carcinoma, papillary thyroid carcinoma, hairy cell leukemia
<i>c-KIT</i>	Cy to KI ne receptor (CD117)	Gastrointestinal stromal tumor (GIST), mastocytosis
<i>MYCC (c-myc)</i>	Transcription factor	Burkitt lymphoma
<i>MYCN (N-myc)</i>	Transcription factor	N euroblastoma
<i>KRAS</i>	RAS GTPase	Colorectal, lung, pancreatic cancers
<i>BCL-2</i>	Antiapoptotic molecule (inhibits apoptosis)	Follicular and diffuse large B-Cell L ymphomas

Tumor suppressor genes

Loss of function → ↑ cancer risk; both (**two**) alleles of a **tumor** suppressor gene must be lost for expression of disease (the Knudson 2-hit hypothesis).

GENE	GENE PRODUCT	ASSOCIATED CONDITION
<i>APC</i>	Negative regulator of β-catenin/WNT pathway	Colorectal cancer (associated with FAP)
<i>BRCA1/BRCA2</i>	BRCA1/BRCA2 proteins	BR east, ovarian, prostate, pancreatic CA ncers
<i>CDKN2A</i>	p16, blocks G ₁ → S phase	Many cancers (eg, melanoma, lung, pancreatic)
<i>DCC</i>	DCC — D eleted in C olorectal C ancer	Colorectal cancer
<i>SMAD4 (DPC4)</i>	DPC — D eleted in P ancreatic C ancer	Pancreatic cancer, colorectal cancer
<i>MEN1</i>	MEN in	M ultiple E ndocrine N eoplasia type 1
<i>NF1</i>	Neurofibromin (Ras GTPase activating protein)	N euro F ibromatosis type 1
<i>NF2</i>	Merlin (schwannomin) protein	N euro F ibromatosis type 2
<i>PTEN</i>	Negative regulator of PI3k/AKT pathway	P rostate, breasT , and EN dometrial cancers
<i>RB1</i>	Inhibits E2F; blocks G ₁ → S phase	R etinoblastoma, osteosarcoma (B one cancer)
<i>TP53</i>	p53, activates p21, blocks G ₁ → S phase	Most cancers, Li-Fraumeni (SBLA) syndrome (multiple malignancies at early age; S arcoma, B reast/ B rain, L ung/ L eukemia, A drenal gland)
<i>TSC1</i>	Hamartin protein	T uberous s clerosis
<i>TSC2</i>	Tu berin (“ 2 berin”)	Tuberous sclerosis
<i>VHL</i>	Inhibits hypoxia-inducible factor 1α	v on H ippel- L indau disease
<i>WT1</i>	Urogenital development transcription factor	W ilms T umor (nephroblastoma)

Carcinogens

TOXIN	EXPOSURE	ORGAN	IMPACT
Aflatoxins (<i>Aspergillus</i>)	Stored grains and nuts	Liver	Hepatocellular carcinoma
Alkylating agents	Oncologic chemotherapy	Blood	Leukemia/lymphoma
Aromatic amines (eg, benzidine, 2-naphthylamine)	Textile industry (dyes), tobacco smoke (2-naphthylamine)	Bladder	Transitional cell carcinoma
Arsenic	Herbicides (vineyard workers), metal smelting, wood preservation	Liver Lung Skin	Hepatic angiosarcoma Lung cancer Squamous cell carcinoma
Asbestos	Old roofing material, shipyard workers	Lung	Bronchogenic carcinoma > mesothelioma
Tobacco smoke		Bladder Cervix Esophagus Kidney Larynx Lung Oropharynx Pancreas	Transitional cell carcinoma Squamous cell carcinoma Squamous cell carcinoma/adenocarcinoma Renal cell carcinoma Squamous cell carcinoma Squamous cell and small cell carcinoma Squamous cell carcinoma Pancreatic adenocarcinoma
Ethanol		Esophagus Liver Breast	Squamous cell carcinoma Hepatocellular carcinoma Breast cancer
Ionizing radiation		Blood Thyroid	Leukemia Papillary thyroid carcinoma
Nickel, chromium, beryllium, silica	Occupational exposure	Lung	Lung cancer
Nitrosamines	Smoked foods	Stomach	Gastric cancer (intestinal type)
Radon	Byproduct of uranium decay, accumulates in basements	Lung	Lung cancer (2nd leading cause after tobacco smoke)
Vinyl chloride	Used to make PVC pipes	Liver	Hepatic angiosarcoma

Oncogenic microbes

MICROBE	ASSOCIATED CANCER
EBV	Burkitt lymphoma, Hodgkin lymphoma, nasopharyngeal carcinoma, 1° CNS lymphoma (in immunocompromised patients)
HBV, HCV	Hepatocellular carcinoma
HHV-8	Kaposi sarcoma
HPV (usually types 16, 18)	Cervical and penile/anal carcinoma, head and neck cancer
<i>H pylori</i>	Gastric adenocarcinoma and MALT lymphoma
HTLV-1	Adult T-cell Leukemia/Lymphoma
Liver fluke (<i>Clonorchis sinensis</i>)	Cholangiocarcinoma
<i>Schistosoma haematobium</i>	Squamous cell bladder cancer

Serum tumor markers Tumor markers should not be used as the 1° tool for cancer diagnosis or screening. They may be used to monitor tumor recurrence and response to therapy, but definitive diagnosis is made via biopsy. Some can be associated with non-neoplastic conditions.

MARKER	IMPORTANT ASSOCIATIONS	NOTES
Alkaline phosphatase	Metastases to bone or liver, Paget disease of bone, seminoma (PLAP).	Exclude hepatic origin by checking LFTs and GGT levels.
α-fetoprotein	Hepatocellular carcinoma, endodermal sinus (yolk sac) tumor, mixed germ cell tumor, ataxia-telangiectasia, neural tube defects.	Normally made by fetus. Transiently elevated in pregnancy. High levels associated with neural tube and abdominal wall defects, low levels associated with Down syndrome.
hCG	Hydatidiform moles and Choriocarcinomas (Gestational trophoblastic disease), testicular cancer, mixed germ cell tumor.	Produced by syncytiotrophoblasts of the placenta.
CA 15-3/CA 27-29	Breast cancer.	
CA 19-9	Pancreatic adenocarcinoma.	
CA 125	Epithelial ovarian cancer.	
Calcitonin	Medullary thyroid carcinoma (alone and in MEN2A, MEN2B).	Calcitonin.
CEA	Colorectal and pancreatic cancers. Minor associations: gastric, breast, and medullary thyroid carcinomas.	CarcinoEmbryonic Antigen. Very nonspecific.
Chromogranin	Neuroendocrine tumors.	
LDH	Testicular germ cell tumors, ovarian dysgerminoma, other cancers.	Can be used as an indicator of tumor burden.
Neuron-specific enolase	Neuroendocrine tumors (eg, small cell lung cancer, carcinoid tumor, neuroblastoma).	
PSA	Prostate cancer.	Prostate-Specific Antigen. Also elevated in BPH and prostatitis. Questionable risk/benefit for screening. Marker for recurrence after treatment.

Important immunohistochemical stains

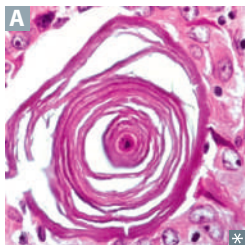
Determine primary site of origin for metastatic tumors and characterize tumors that are difficult to classify. Can have prognostic and predictive value.

STAIN	TARGET	TUMORS IDENTIFIED
Chromogranin and synaptophysin	Neuroendocrine cells	Small cell carcinoma of the lung, carcinoid tumor, neuroblastoma
Cytokeratin	Epithelial cells	Epithelial tumors (eg, squamous cell carcinoma)
Desmin	Muscle	Muscle tumors (eg, rhabdomyosarcoma)
GFAP	NeuroGlia (eg, astrocytes, Schwann cells, oligodendrocytes)	Astrocytoma, Glioblastoma
Neurofilament	Neurons	Neuronal tumors (eg, neuroblastoma)
PSA	Prostatic epithelium	Prostate cancer
S-100	Neural crest cells	Melanoma, schwannoma, Langerhans cell histiocytosis
TRAP	Tartrate-resistant acid phosphatase	Hairy cell leukemia
Vimentin	Mesenchymal tissue (eg, fibroblasts, endothelial cells, macrophages)	Mesenchymal tumors (eg, sarcoma), but also many other tumors (eg, endometrial carcinoma, renal cell carcinoma, meningioma)

P-glycoprotein

ATP-dependent efflux pump also called multidrug resistance protein 1 (MDR1). Classically seen in adrenocortical carcinoma but also expressed by other cancer cells (eg, colon, liver). Used to pump out toxins, including chemotherapeutic agents (one mechanism of ↓ responsiveness or resistance to chemotherapy over time).

Psammoma bodies



Laminated, concentric spherules with dystrophic calcification **A**, **PSAMMOMaS** bodies are seen in

- Papillary carcinoma of thyroid
- Somatostatinoma
- Adrenals (calcifying fibrous pseudotumor)
- Meningioma
- Malignant Mesothelioma
- Ovarian serous carcinoma
- Prolactinoma (Milk)
- Serous endometrial carcinoma

Cachexia

Weight loss, muscle atrophy, and fatigue that occur in chronic disease (eg, cancer, AIDS, heart failure, COPD). Mediated by TNF-α, IFN-γ, IL-1, and IL-6.

Paraneoplastic syndromes

MANIFESTATION	DESCRIPTION/MECHANISM	MOST COMMONLY ASSOCIATED TUMOR(S)
Musculoskeletal and cutaneous		
Dermatomyositis	Progressive proximal muscle weakness, Gottron papules, heliotrope rash	Adenocarcinomas, especially ovarian
Acanthosis nigricans	Hyperpigmented velvety plaques in axilla and neck	Gastric adenocarcinoma and other visceral malignancies
Sign of Leser-Trélat	Sudden onset of multiple seborrheic keratoses	GI adenocarcinomas and other visceral malignancies
Hypertrophic osteoarthropathy	Abnormal proliferation of skin and bone at distal extremities → clubbing, arthralgia, joint effusions, periostosis of tubular bones	Adenocarcinoma of the lung
Endocrine		
Hypercalcemia	PTHrP ↑ 1,25-(OH) ₂ vitamin D ₃ (calcitriol)	SCa ²⁺ mous cell carcinomas of lung, head, and neck; renal, bladder, breast, and ovarian carcinomas Lymphoma
Cushing syndrome	↑ ACTH	Small cell lung cancer
Hyponatremia (SIADH)	↑ ADH	
Hematologic		
Polycythemia	↑ Erythropoietin Paraneoplastic rise to High hematocrit levels	Pheochromocytoma, renal cell carcinoma, HCC, hemangioblastoma, leiomyoma
Pure red cell aplasia	Anemia with low reticulocytes	Thymoma
Good syndrome	Hypogammaglobulinemia	
Trousseau syndrome	Migratory superficial thrombophlebitis	Adenocarcinomas, especially pancreatic
Nonbacterial thrombotic endocarditis	Deposition of sterile platelet thrombi on heart valves	
Neuromuscular		
Anti-NMDA receptor encephalitis	Psychiatric disturbance, memory deficits, seizures, dyskinesias, autonomic instability, language dysfunction	Ovarian teratoma
Opsoclonus-myoclonus ataxia syndrome	“Dancing eyes, dancing feet”	Neuroblastoma (children), small cell lung cancer (adults)
Paraneoplastic cerebellar degeneration	Antibodies against antigens in Purkinje cells	Small cell lung cancer (anti-Hu), gynecologic and breast cancers (anti-Yo), and Hodgkin lymphoma (anti-Tr)
Paraneoplastic encephalomyelitis	Antibodies against Hu antigens in neurons	Small cell lung cancer
Lambert-Eaton myasthenic syndrome	Antibodies against presynaptic (P/Q-type) Ca ²⁺ channels at NMJ	
Myasthenia gravis	Antibodies against postsynaptic ACh receptors at NMJ	Thymoma

▶ PATHOLOGY—AGING

Normal aging	Time-dependent progressive decline in organ function resulting in ↑ susceptibility to disease. Associated with genetic (eg, telomere shortening), epigenetic (eg, DNA methylation), and metabolic (eg, mitochondrial dysfunction) alterations.
Cardiovascular	↓ arterial compliance (↑ stiffness), ↑ aortic diameter, ↓ left ventricular cavity size and sigmoid-shaped interventricular septum (due to myocardial hypertrophy), ↑ left atrial cavity size, aortic and mitral valve calcification, ↓ maximum heart rate.
Gastrointestinal	↓ LES tone, ↓ gastric mucosal protection, ↓ colonic motility.
Hematopoietic	↓ bone marrow mass, ↑ bone marrow fat; less vigorous response to stressors (eg, blood loss).
Immune	Predominant effect on adaptive immunity: ↓ naive B cells and T cells, preserved memory B cells and T cells. Immunosenescence impairs response to new antigens (eg, pathogens, vaccines).
Musculoskeletal	↓ skeletal muscle mass (sarcopenia), ↓ bone mass (osteopenia), joint cartilage thinning.
Nervous	↓ brain volume (neuronal loss), ↓ cerebral blood flow; function is preserved despite mild cognitive decline.
Special senses	Impaired accommodation (presbyopia), ↓ hearing (presbycusis), ↓ smell and taste.
Skin	Atrophy with flattening of dermal-epidermal junction; ↓ dermal collagen and ↓ elastin (wrinkles, senile purpura), ↓ sweat glands (heat stroke), ↓ sebaceous glands (xerosis cutis). <ul style="list-style-type: none"> ▪ Intrinsic aging (chronological aging)—↓ biosynthetic capacity of dermal fibroblasts. ▪ Extrinsic aging (photoaging)—degradation of dermal collagen and elastin from sun exposure (UVA); degradation products accumulate in dermis (solar elastosis).
Renal	↓ GFR (↓ nephrons), ↓ RBF, ↓ hormonal function. Voiding dysfunction (eg, urinary incontinence).
Reproductive	Males—testicular atrophy (↓ spermatogenesis), prostate enlargement, slower erection/ejaculation, longer refractory period. Less pronounced ↓ in libido as compared to females. Females—vulvovaginal atrophy; vaginal shortening, thinning, dryness, ↑ pH.
Respiratory	↑ lung compliance (↓ elastic recoil), ↓ chest wall compliance (↑ stiffness), ↓ respiratory muscle strength; ↓ FEV ₁ , ↓ FVC, ↑ RV (TLC is unchanged); ↑ A-a gradient, ↑ \dot{V}/\dot{Q} mismatch. Ventilatory response to hypoxia/hypercapnia is blunted. Less vigorous cough, slower mucociliary clearance.

Pharmacology

“Cure sometimes, treat often, and comfort always.”

—Hippocrates

“One pill makes you larger, and one pill makes you small.”

—Jefferson Airplane, *White Rabbit*

“For the chemistry that works on one patient may not work for the next, because even medicine has its own conditions.”

—Suzy Kassem

“I wondher why ye can always read a doctor’s bill an’ ye niver can read his purscription.”

—Finley Peter Dunne

“Love is the drug I’m thinking of.”

—The Bryan Ferry Orchestra

Preparation for pharmacology questions is not as straightforward as in years past. One major recent change is that the USMLE Step 1 has moved away from testing pharmacotherapeutics. That means you will generally not be required to identify medications indicated for a specific condition. You still need to know mechanisms and important adverse effects of key drugs and their major variants. Obscure derivatives are low-yield. Learn their classic and distinguishing toxicities as well as major drug-drug interactions.

Reviewing associated biochemistry, physiology, and microbiology concepts can be useful while studying pharmacology. The exam has a strong emphasis on ANS, CNS, antimicrobial, and cardiovascular agents as well as on NSAIDs, which are covered throughout the text. Specific drug dosages or trade names are generally not testable. The exam may use graphs to test various pharmacology content, so make sure you are comfortable interpreting them.

▶ Pharmacokinetics and Pharmacodynamics	230
▶ Autonomic Drugs	237
▶ Toxicities and Adverse Effects	248
▶ Miscellaneous	254

► PHARMACOLOGY—PHARMACOKINETICS AND PHARMACODYNAMICS

Enzyme kinetics

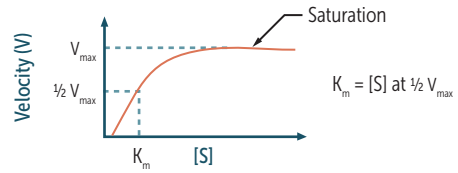
Michaelis-Menten kinetics

K_m is inversely related to the affinity of the enzyme for its substrate.

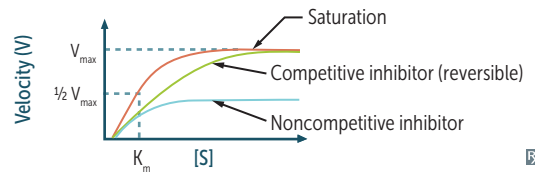
V_{max} is directly proportional to the enzyme concentration.

Most enzymatic reactions follow a hyperbolic curve (ie, Michaelis-Menten kinetics); however, enzymatic reactions that exhibit a sigmoid curve usually indicate cooperative kinetics (eg, hemoglobin).

$[S]$ = concentration of substrate; V = velocity.



Effects of enzyme inhibition



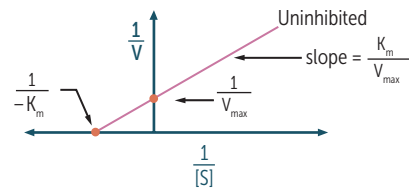
Lineweaver-Burk plot

The closer to 0 on the Y-axis, the higher the V_{max} .

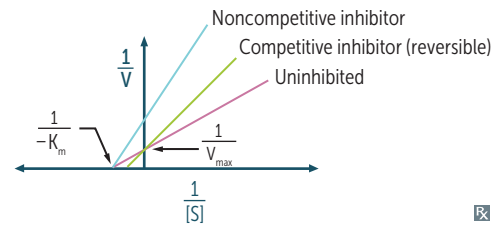
The closer to 0 on the X-axis, the higher the K_m .
The higher the K_m , the lower the affinity.

Competitive inhibitors cross each other, whereas noncompetitive inhibitors do not.

Competitive inhibitors increase K_m .



Effects of enzyme inhibition

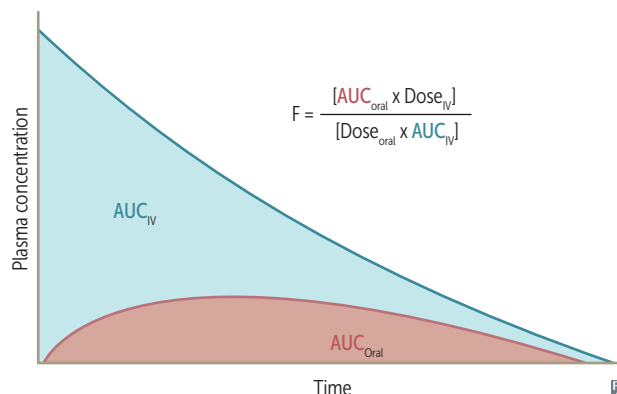


	Competitive inhibitors, reversible	Competitive inhibitors, irreversible	Noncompetitive inhibitors
Resemble substrate	Yes	Yes	No
Overcome by $\uparrow [S]$	Yes	No	No
Bind active site	Yes	Yes	No
Effect on V_{max}	Unchanged	\downarrow	\downarrow
Effect on K_m	\uparrow	Unchanged	Unchanged
Pharmacodynamics	\downarrow potency	\downarrow efficacy	\downarrow efficacy

Pharmacokinetics

Bioavailability (F)

Fraction of administered drug reaching systemic circulation unchanged. For an IV dose, F = 100%.
Orally: F typically < 100% due to incomplete absorption and first-pass metabolism. Can be calculated from the area under the curve in a plot of plasma concentration over time.



Volume of distribution (V_d)

Theoretical volume occupied by the total amount of drug in the body relative to its plasma concentration. Apparent V_d of plasma protein-bound drugs can be altered by liver and kidney disease (↓ protein binding, ↑ V_d). Drugs may distribute in more than one compartment. Hemodialysis is most effective for drugs with a low V_d.

$$V_d = \frac{\text{amount of drug in the body}}{\text{plasma drug concentration}}$$

V _d	COMPARTMENT	DRUG TYPES
Low	Intravascular	Large/charged molecules; plasma protein bound
Medium	ECF	Small hydrophilic molecules
High	All tissues including fat	Small lipophilic molecules, especially if bound to tissue protein

Clearance (CL)

The volume of plasma cleared of drug per unit time. Clearance may be impaired with defects in cardiac, hepatic, or renal function.

$$CL = \frac{\text{rate of elimination of drug}}{\text{plasma drug concentration}} = V_d \times K_e \text{ (elimination constant)}$$

Half-life (t_{1/2})

The time required to change the amount of drug in the body by ½ during elimination. Steady state is a dynamic equilibrium in which drug concentration stays constant (ie, rate of drug elimination = rate of drug administration).
In first-order kinetics, a drug infused at a constant rate takes 4–5 half-lives to reach steady state. It takes 3.3 half-lives to reach 90% of the steady-state level.

$$t_{1/2} = \frac{0.7 \times V_d}{CL} \text{ in first-order elimination}$$

# of half-lives	1	2	3	4
% remaining	50%	25%	12.5%	6.25%

Dosage calculations

$$\text{Loading dose} = \frac{C_p \times V_d}{F}$$

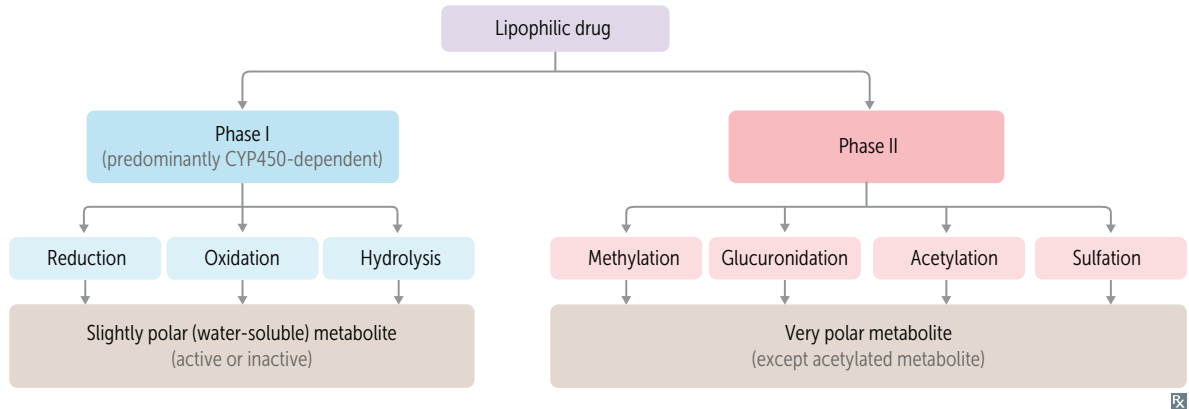
$$\text{Maintenance dose} = \frac{C_p \times CL \times \tau}{F}$$

C_p = target plasma concentration
τ = dosage interval (time between doses), if not administered continuously

In renal or liver disease, maintenance dose ↓ and loading dose is usually unchanged.
Time to steady state depends primarily on t_{1/2} and is independent of dose and dosing frequency.

Drug metabolism

Geriatric patients lose phase I first. Patients who are slow acetylators have ↑ adverse effects from certain drugs because of ↓ rate of metabolism (eg, isoniazid).



Elimination of drugs

Zero-order elimination

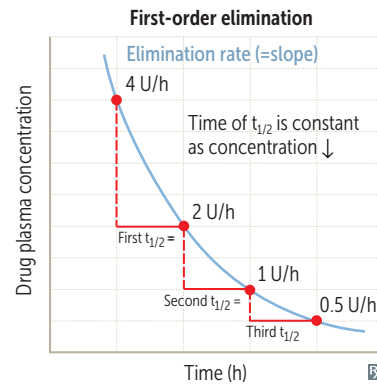
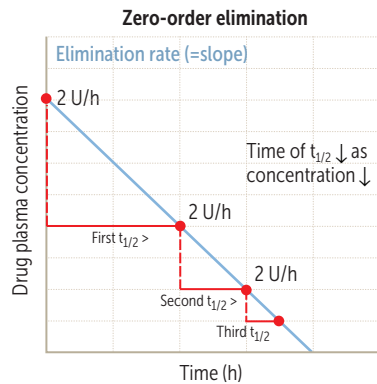
Rate of elimination is constant regardless of C_p (ie, constant **amount** of drug eliminated per unit time). C_p ↓ linearly with time. Examples of drugs—**P**henytoin, **E**thanol, and **A**spirin (at high or toxic concentrations).

Capacity-limited elimination. **PEA** (a pea is round, shaped like the “0” in **zero-order**).

First-order elimination

Rate of **first-order** elimination is directly proportional to the drug concentration (ie, constant **fraction** of drug eliminated per unit time). C_p ↓ exponentially with time. Applies to most drugs.

Flow-dependent elimination.

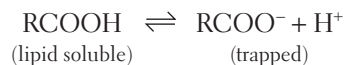


Urine pH and drug elimination

Ionized species are trapped in urine and cleared quickly. Neutral forms can be reabsorbed.

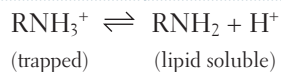
Weak acids

Examples: phenobarbital, methotrexate, aspirin (salicylates). Trapped in basic environments. Treat overdose with sodium bicarbonate to alkalize urine.



Weak bases

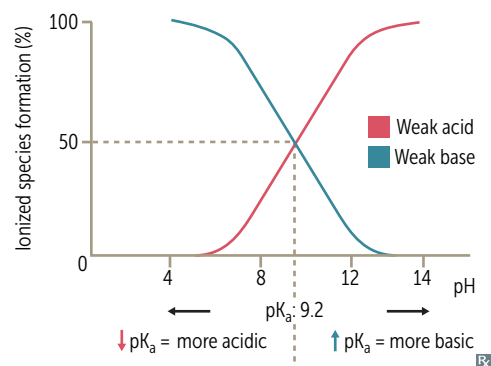
Examples: TCAs, amphetamines. Trapped in acidic environments.



TCA toxicity is initially treated with sodium bicarbonate to overcome the sodium channel-blocking activity of TCAs. This treats cardiac toxicity, but does not accelerate drug elimination.

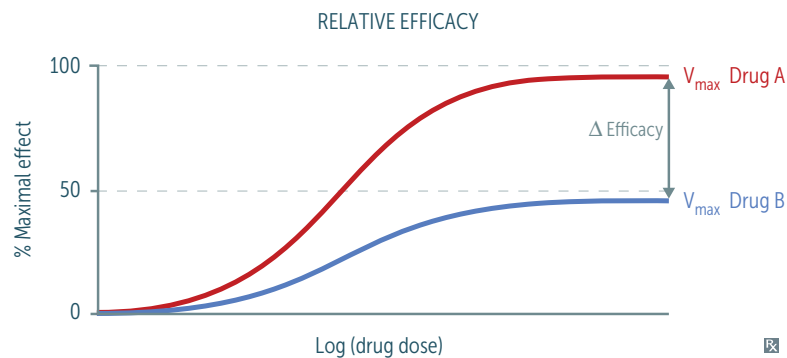
pKa

pH at which drugs (weak acid or base) are 50% ionized and 50% nonionized. The pKa represents the strength of the weak acid or base.

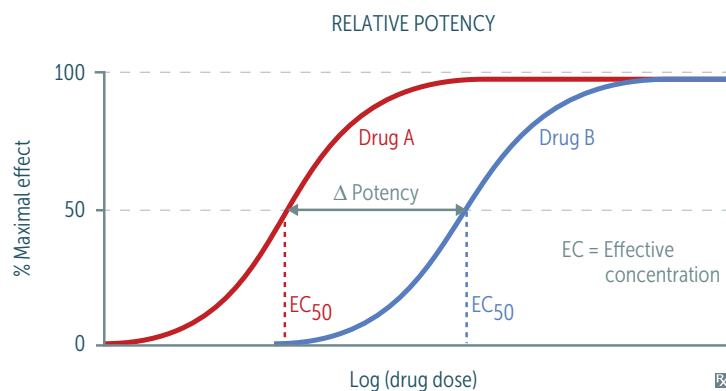


Efficacy vs potency**Efficacy**

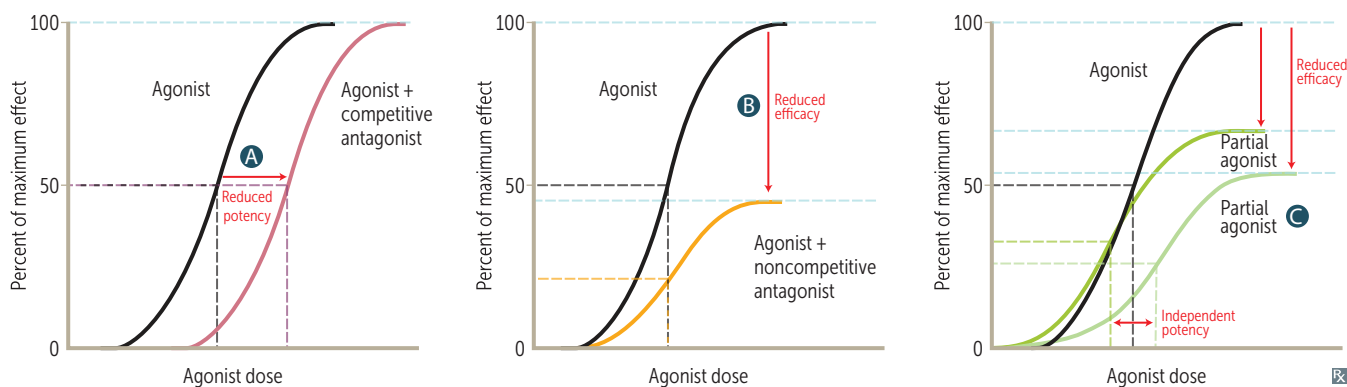
Maximal effect a drug can produce. Represented by the y-value (V_{max}). \uparrow y-value = $\uparrow V_{max}$ = \uparrow efficacy. Unrelated to potency (ie, efficacious drugs can have high or low potency). Partial agonists have less efficacy than full agonists.

**Potency**

Amount of drug needed for a given effect. Represented by the x-value (EC_{50}). Left shifting = $\downarrow EC_{50}$ = \uparrow potency = \downarrow drug needed. Unrelated to efficacy (ie, potent drugs can have high or low efficacy).



Receptor binding



AGONIST WITH	POTENCY	EFFICACY	REMARKS	EXAMPLE
A Competitive antagonist	↓	No change	Can be overcome by ↑ agonist concentration	Diazepam (agonist) + flumazenil (competitive antagonist) on GABA _A receptor.
B Noncompetitive antagonist	No change	↓	Cannot be overcome by ↑ agonist concentration	Norepinephrine (agonist) + phenoxybenzamine (noncompetitive antagonist) on α-receptors.
C Partial agonist (alone)	Independent	↓	Acts at same site as full agonist	Morphine (full agonist) vs buprenorphine (partial agonist) at opioid μ-receptors.

Therapeutic index

Measurement of drug safety.

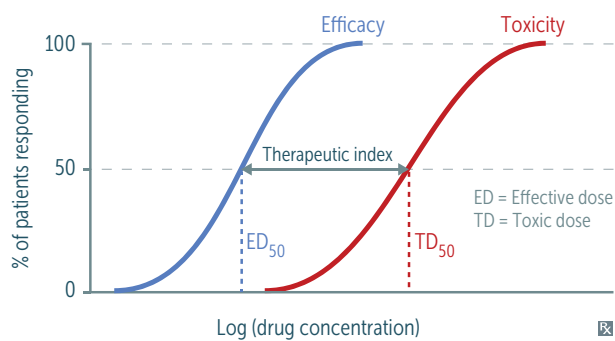
$$\frac{TD_{50}}{ED_{50}} = \frac{\text{median toxic dose}}{\text{median effective dose}}$$

Therapeutic window—range of drug concentrations that can safely and effectively treat disease.

TITE: Therapeutic Index = TD_{50} / ED_{50} .

Safer drugs have higher TI values. Drugs with lower TI values frequently require monitoring (eg, warfarin, theophylline, digoxin, antiepileptic drugs, lithium; **Warning! These drugs are lethal!**).

LD₅₀ (lethal median dose) often replaces TD₅₀ in animal studies.

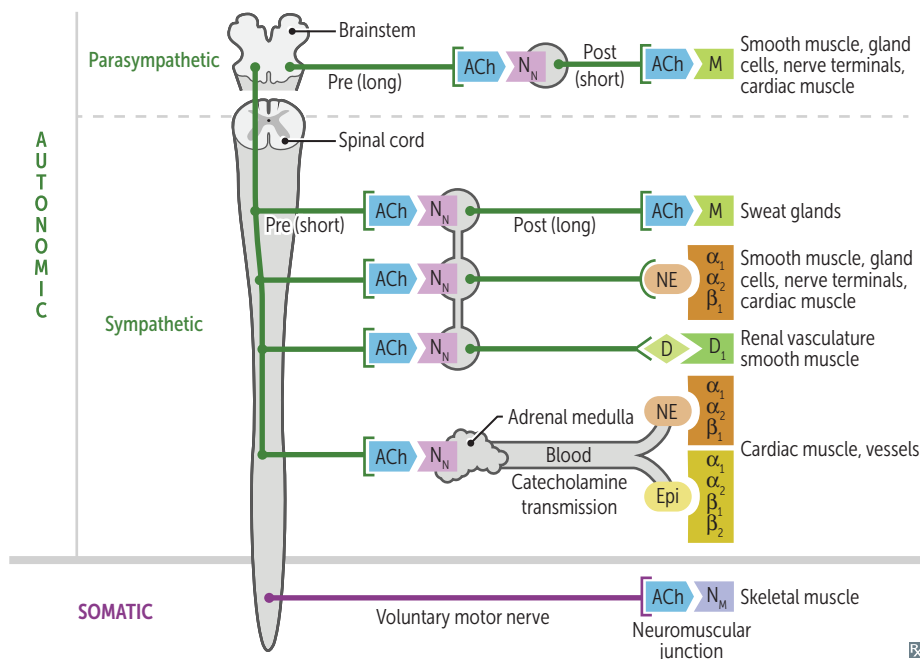


Drug effect modifications

TERM	DEFINITION	EXAMPLE
Additive	Effect of substances A and B together is equal to the sum of their individual effects	Aspirin and acetaminophen “ $2 + 2 = 4$ ”
Permissive	Presence of substance A is required for the full effects of substance B	Cortisol on catecholamine responsiveness
Synergistic	Effect of substances A and B together is greater than the sum of their individual effects	Clopidogrel with aspirin “ $2 + 2 > 4$ ”
Potentialiation	Similar to synergism, but drug B with no therapeutic action enhances the therapeutic action of drug A	Carbidopa only blocks enzyme to prevent peripheral conversion of levodopa “ $2 + 0 > 2$ ”
Antagonistic	Effect of substances A and B together is less than the sum of their individual effects	Ethanol antidote for methanol toxicity “ $2 + 2 < 4$ ”
Tachyphylactic	Acute decrease in response to a drug after initial/repeated administration	Repeat use of intranasal decongestant (eg, oxymetazoline) → ↓ therapeutic response (with rebound congestion)

▶ PHARMACOLOGY—AUTONOMIC DRUGS

Autonomic receptors



Pelvic splanchnic nerves and CNs III, VII, IX and X are part of the parasympathetic nervous system. Adrenal medulla is directly innervated by preganglionic sympathetic fibers.

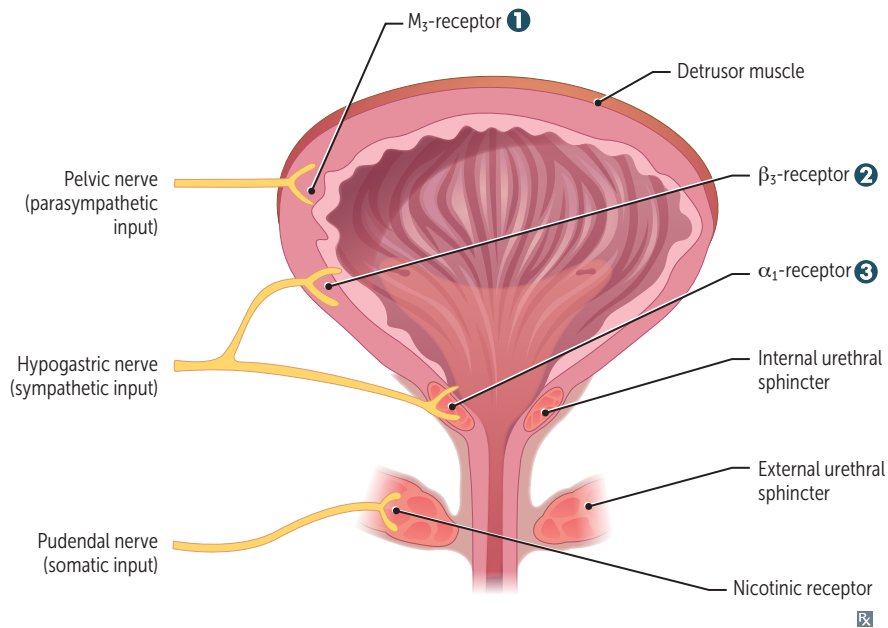
Sweat glands are part of the **sympathetic** pathway but are innervated by **cholinergic** fibers (**sympathetic** nervous system results in a “**chold**” **sweat**).

Acetylcholine receptors

Nicotinic ACh receptors are ligand-gated channels allowing efflux of K^+ and influx of Na^+ and in some cases Ca^{2+} . Two subtypes: N_N (found in autonomic ganglia, adrenal medulla) and N_M (found in neuromuscular junction of skeletal muscle).

Muscarinic ACh receptors are G-protein-coupled receptors that usually act through 2nd messengers. 5 subtypes: M_{1-5} found in heart, smooth muscle, brain, exocrine glands, and on sweat glands (cholinergic sympathetic).

Micturition control



Micturition center in pons regulates involuntary bladder function via coordination of sympathetic and parasympathetic nervous systems.

- ⊕ sympathetic → ↑ urinary retention.
- ⊕ parasympathetic → ↑ urine voiding.

Some autonomic drugs act on smooth muscle receptors to treat bladder dysfunction.

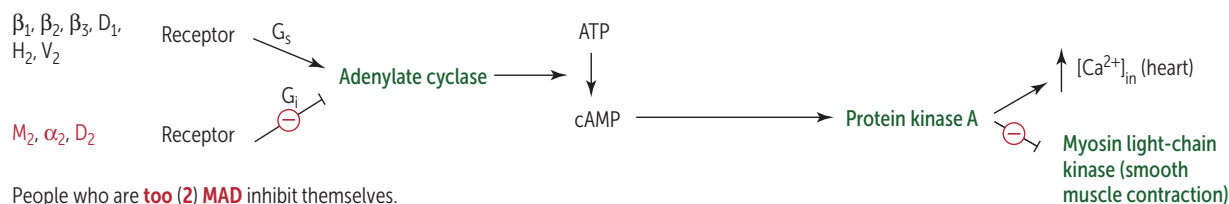
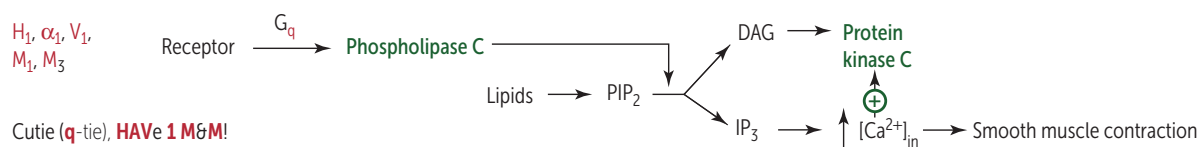
DRUGS	MECHANISM	APPLICATIONS
1 Muscarinic antagonists (eg, oxybutynin)	⊖ M ₃ receptor → relaxation of detrusor smooth muscle → ↓ detrusor overactivity	Urgency incontinence
1 Muscarinic agonists (eg, bethanechol)	⊕ M ₃ receptor → contraction of detrusor smooth muscle → ↑ bladder emptying	Urinary retention
2 Sympathomimetics (eg, mirabegron)	⊕ β ₃ receptor → relaxation of detrusor smooth muscle → ↑ bladder capacity	Urgency incontinence
3 α₁-blockers (eg, tamsulosin)	⊖ α ₁ -receptor → relaxation of smooth muscle (bladder neck, prostate) → ↓ urinary obstruction	BPH

Tissue distribution of adrenergic receptors

RECEPTOR	TISSUE	EFFECT(S)
α ₁	Vascular smooth muscle Visceral smooth muscle	Vasoconstriction Smooth muscle contraction
α ₂	Pancreas Presynaptic terminals Salivary glands	Inhibition of neurotransmitter release
β ₁	Heart Kidney	↑ heart rate ↑ renin secretion
β ₂	Bronchioles Cardiac muscle Liver Visceral smooth muscle	Bronchodilation ↑ heart rate, contractility Inhibition of insulin secretion Vasodilation
β ₃	Adipose	↑ lipolysis

G-protein-linked second messengers

RECEPTOR	G-PROTEIN CLASS	MAJOR FUNCTIONS
Adrenergic		
α_1	q	↑ vascular smooth muscle contraction, ↑ pupillary dilator muscle contraction (mydriasis), ↑ intestinal and bladder sphincter muscle contraction
α_2	i	↓ sympathetic (adrenergic) outflow, ↓ insulin release, ↓ lipolysis, ↑ platelet aggregation, ↓ aqueous humor production
β_1	s	↑ heart rate, ↑ contractility (one heart), ↑ renin release, ↑ lipolysis
β_2	s	Vasodilation, bronchodilation (two lungs), ↑ lipolysis, ↑ insulin release, ↑ glycogenolysis, ↓ uterine tone (tocolysis), ↑ aqueous humor production, ↑ cellular K^+ uptake
β_3	s	↑ lipolysis, ↑ thermogenesis in skeletal muscle, ↑ bladder relaxation
Cholinergic		
M_1	q	Mediates higher cognitive functions, stimulates enteric nervous system
M_2	i	↓ heart rate and contractility of atria
M_3	q	↑ exocrine gland secretions (eg, lacrimal, sweat, salivary, gastric acid), ↑ gut peristalsis, ↑ bladder contraction, bronchoconstriction, ↑ pupillary sphincter muscle contraction (miosis), ciliary muscle contraction (accommodation), ↑ insulin release, endothelium-mediated vasodilation
Dopamine		
D_1	s	Relaxes renal vascular smooth muscle, activates direct pathway of striatum
D_2	i	Modulates transmitter release, especially in brain, inhibits indirect pathway of striatum
Histamine		
H_1	q	↑ nasal and bronchial mucus production, ↑ vascular permeability and vasodilation, bronchoconstriction, pruritus, pain
H_2	s	↑ gastric acid secretion
Vasopressin		
V_1	q	↑ vascular smooth muscle contraction
V_2	s	↑ H_2O permeability and reabsorption via upregulating aquaporin-2 in collecting two tubules (tubules) of kidney, ↑ release of vWF

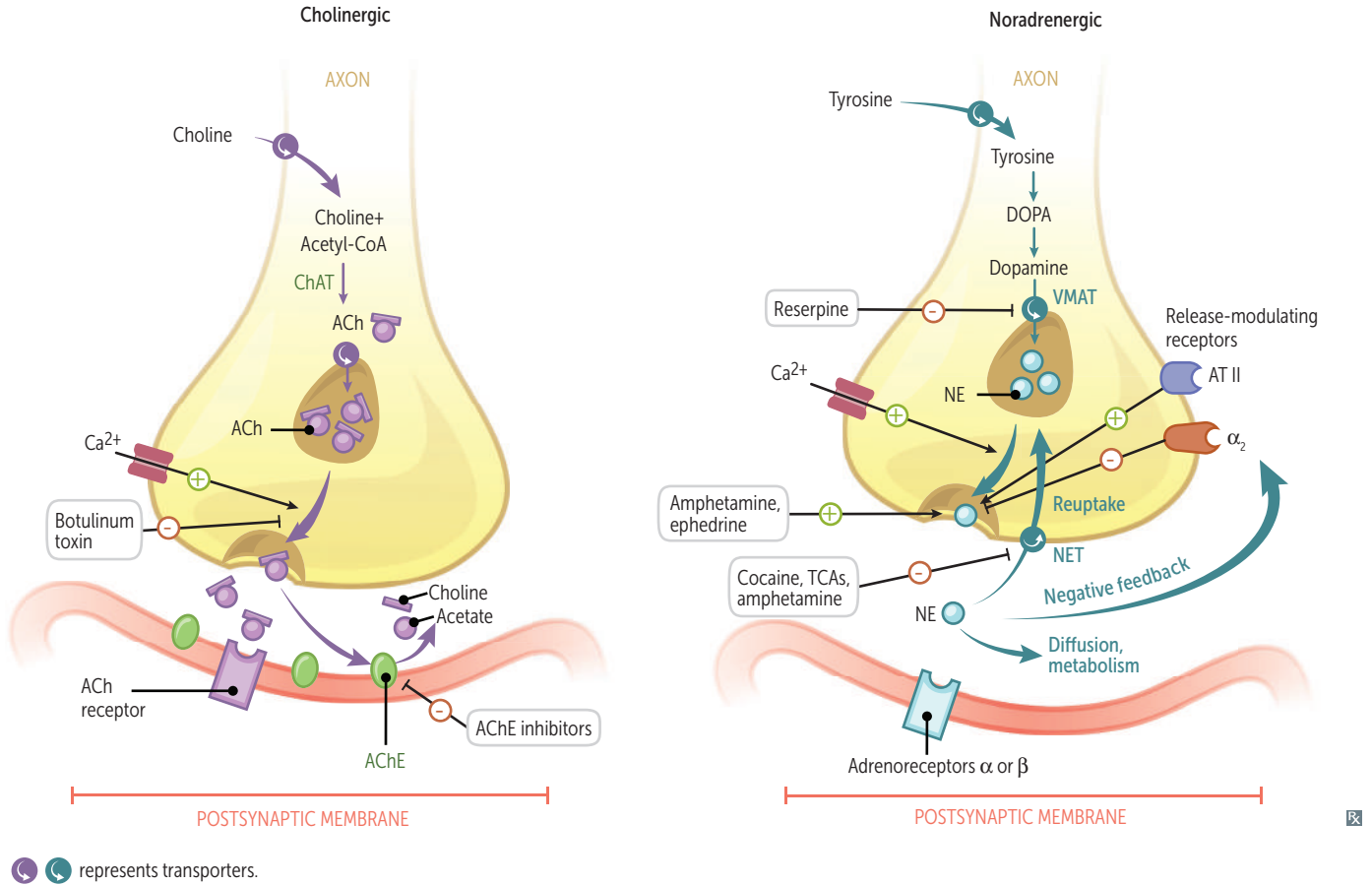


People who are **too (2) MAD** inhibit themselves.

Autonomic drugs

Release of norepinephrine from a sympathetic nerve ending is modulated by NE itself, acting on presynaptic α_2 -autoreceptors \rightarrow negative feedback.

Amphetamines use the NE transporter (NET) to enter the presynaptic terminal, where they utilize the vesicular monoamine transporter (VMAT) to enter neurosecretory vesicles. This displaces NE from the vesicles. Once NE reaches a concentration threshold within the presynaptic terminal, the action of NET is reversed, and NE is expelled into the synaptic cleft, contributing to the characteristics and effects of \uparrow NE observed in patients taking amphetamines.



Cholinomimetic agents

Watch for exacerbation of COPD, asthma, and peptic ulcers in susceptible patients.

DRUG	ACTION	APPLICATIONS
Direct agonists		
Bethanechol	Activates b ladder smooth muscle; resistant to AChE. Acts on muscarinic receptors; no nicotinic activity. “ Bethany, call me to activate your b ladder.”	Urinary retention.
Carbachol	Car bon copy of acetylcholine (but resistant to AChE).	Constricts pupil and relieves intraocular pressure in open-angle glaucoma.
Methacholine	Stimulates m uscarinic receptors in airway when inhaled.	Challenge test for diagnosis of asthma.
Pilocarpine	Contracts ciliary muscle of eye (open-angle glaucoma), pupillary sphincter (closed-angle glaucoma); resistant to AChE, can cross blood-brain barrier. “You cry, drool, and sweat on your ‘ p ilow.’”	Potent stimulator of sweat, tears, and saliva Open-angle and closed-angle glaucoma, xerostomia (Sjögren syndrome).
Indirect agonists (anticholinesterases)		
Donepezil, rivastigmine, galantamine	↑ ACh.	1st line for Alzheimer disease (Don Riva forgot the gala).
Edrophonium	↑ ACh.	Historically used to diagnose myasthenia gravis; replaced by anti-AChR Ab (anti-acetylcholine receptor antibody) test.
Neostigmine	↑ ACh. Neo CNS = no CNS penetration due to positive charge.	Postoperative and neurogenic ileus and urinary retention, myasthenia gravis, reversal of neuromuscular junction blockade (postoperative).
Pyridostigmine	↑ ACh; ↑ muscle strength. Does not penetrate CNS. Pyridostigmine gets rid of my asthenia gravis .	Myasthenia gravis (long acting). Used with glycopyrrolate, hyoscyamine, or propantheline to control pyridostigmine adverse effects.
Physostigmine	↑ ACh. Ph reely (freely) crosses blood-brain barrier as not charged → CNS.	Antidote for anticholinergic toxicity; physostigmine “ phyxes ” atropine overdose.
Anticholinesterase poisoning		
Muscarinic effects	D iarrhea, U rination, M iosis, B ronchospasm, B radycardia, E mesis, L acrimation, S weating, S alivation.	DUMBBELSS . Reversed by atropine, a competitive inhibitor. Atropine can cross BBB to relieve CNS symptoms.
Nicotinic effects	Neuromuscular blockade (mechanism similar to succinylcholine).	Reversed by pralidoxime, regenerates AChE via dephosphorylation if given early. Pralidoxime does not readily cross BBB.
CNS effects	Respiratory depression, lethargy, seizures, coma.	

Muscarinic antagonists

DRUGS	ORGAN SYSTEMS	APPLICATIONS
Atropine, homatropine, tropicamide	Eye	Produce mydriasis and cycloplegia
Benz tropine, trihexyphenidyl	CNS	P arkinson disease (“ park my Benz ”) Acute dystonia
Glycopyrrolate	GI, respiratory	Parenteral: preoperative use to reduce airway secretions Oral: reduces drooling, peptic ulcer
Hyoscyamine, dicyclomine	GI	Antispasmodics for irritable bowel syndrome
Ipratropium, tiotropium	Respiratory	COPD, asthma Duration: tiotropium > ipratropium
Solifenacin, Oxybutynin, Flavoxate, Tolterodine	Genitourinary	Reduce bladder spasms and urge urinary incontinence (overactive bladder) Make bladder SOFT
Scopolamine	CNS	Motion sickness

Atropine

Muscarinic antagonist. Used to treat bradycardia and for ophthalmic applications.

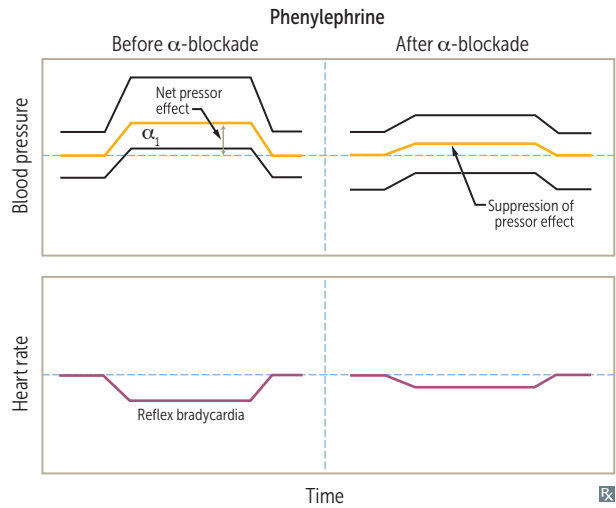
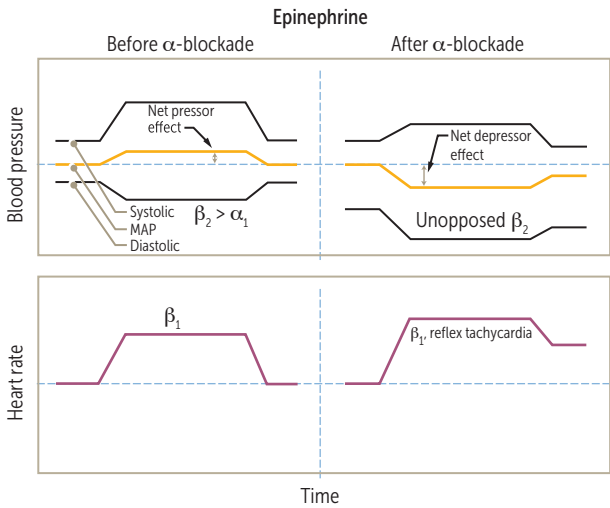
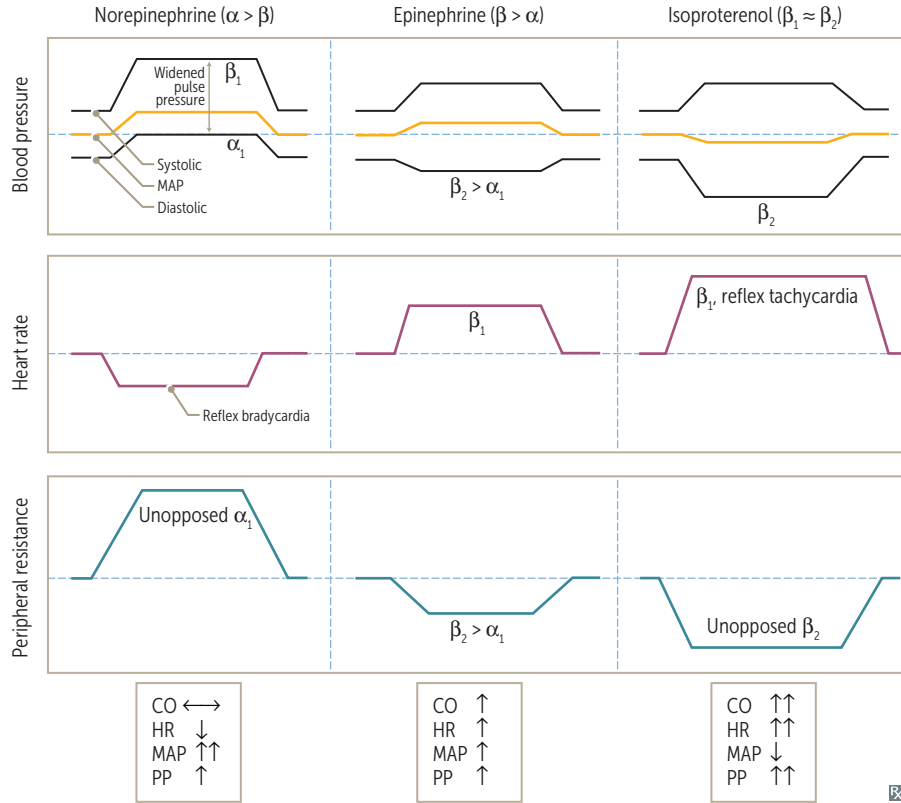
ORGAN SYSTEM	ACTION	NOTES
Eye	↑ pupil dilation, cycloplegia	Blocks muscarinic effects (DUMBBELSS) of anticholinesterases, but not the nicotinic effects
Airway	Bronchodilation, ↓ secretions	
Stomach	↓ acid secretion	
Gut	↓ motility	
Bladder	↓ urgency in cystitis	
ADVERSE EFFECTS	<p>↑ body temperature (due to ↓ sweating); ↑ HR; dry mouth; dry, flushed skin; cycloplegia; constipation; disorientation</p> <p>Can cause acute angle-closure glaucoma in older adults (due to mydriasis), urinary retention in men with prostatic hyperplasia, and hyperthermia in infants</p>	<p>Adverse effects:</p> <p>Hot as a hare Fast as a fiddle Dry as a bone Red as a beet Blind as a bat Mad as a hatter Full as a flask</p> <p>Jimson weed (<i>Datura</i>) → gardener’s pupil (mydriasis)</p>

Sympathomimetics

DRUG	SITE	HEMODYNAMIC CHANGES	APPLICATIONS
Direct sympathomimetics			
Albuterol, salmeterol, terbutaline	$\beta_2 > \beta_1$	↑ HR (little effect)	A lbuterol for acute asthma/COPD. S almeterol for serial (long-term) asthma/COPD. Terbutaline for acute bronchospasm in asthma and tocolysis.
Dobutamine	$\beta_1 > \beta_2, \alpha$	-/↓ BP, ↑ HR, ↑ CO	Cardiac stress testing, acute decompensated heart failure (HF) with cardiogenic shock (inotrope)
Dopamine	$D_1 = D_2 > \beta > \alpha$	↑ BP (high dose), ↑ HR, ↑ CO	Unstable bradycardia, shock; inotropic and chronotropic effects at lower doses via β effects; vasoconstriction at high doses via α effects.
Epinephrine	$\beta > \alpha$	↑ BP (high dose), ↑ HR, ↑ CO	Anaphylaxis, asthma, shock, open-angle glaucoma; α effects predominate at high doses. Stronger effect at β_2 -receptor than norepinephrine.
Fenoldopam	D_1	↓ BP (vasodilation), ↑ HR, ↑ CO	Postoperative hypertension, hypertensive crisis. Vasodilator (coronary, peripheral, renal, and splanchnic). Promotes natriuresis. Can cause hypotension, tachycardia, flushing, headache.
Isoproterenol	$\beta_1 = \beta_2$	↓ BP (vasodilation), ↑ HR, ↑ CO	Electrophysiologic evaluation of tachyarrhythmias. Can worsen ischemia. Has negligible α effect.
Midodrine	α_1	↑ BP (vasoconstriction), ↓ HR, -/↓ CO	Autonomic insufficiency and postural hypotension. May exacerbate supine hypertension.
Mirabegron	β_3		Urinary urgency or incontinence or overactive bladder. Think “mirab ³ gron.”
Norepinephrine	$\alpha_1 > \alpha_2 > \beta_1$	↑ BP, -/↓ HR (may have minor reflexive change in response to ↑ BP due to α_1 agonism outweighing direct β_1 chronotropic effect), -/↑ CO	Hypotension, septic shock.
Phenylephrine	$\alpha_1 > \alpha_2$	↑ BP (vasoconstriction), ↓ HR, -/↓ CO	Hypotension (vasoconstrictor), ocular procedures (mydriatic), rhinitis (decongestant), ischemic priapism.
Indirect sympathomimetics			
Amphetamine	Indirect general agonist, reuptake inhibitor, also releases stored catecholamines.		Narcolepsy, obesity, ADHD.
Cocaine	Indirect general agonist, reuptake inhibitor. Causes vasoconstriction and local anesthesia. Caution when giving β -blockers if cocaine intoxication is suspected (unopposed α_1 activation → ↑↑↑ BP, coronary vasospasm).		Causes mydriasis in eyes with intact sympathetic innervation → used to confirm Horner syndrome.
Ephedrine	Indirect general agonist, releases stored catecholamines.		Nasal decongestion (pseudoephedrine), urinary incontinence, hypotension.

Physiologic effects of sympathomimetics

NE ↑ systolic and diastolic pressures as a result of α_1 -mediated vasoconstriction → ↑ mean arterial pressure → reflex bradycardia. However, isoproterenol (rarely used) has little α effect but causes β_2 -mediated vasodilation, resulting in ↓ mean arterial pressure and ↑ heart rate through β_1 and reflex activity.



Epinephrine response exhibits reversal of mean arterial pressure from a net increase (the α response) to a net decrease (the β_2 response).

Phenylephrine response is suppressed but not reversed because it is a “pure” α -agonist (lacks β -agonist properties).

Sympatholytics (α_2 -agonists)

DRUG	APPLICATIONS	ADVERSE EFFECTS
Clonidine, guanfacine	Hypertensive urgency (limited situations), ADHD, Tourette syndrome, symptom control in opioid withdrawal	CNS depression, bradycardia, hypotension, respiratory depression, miosis, rebound hypertension with abrupt cessation
α-methyldopa	Hypertension in pregnancy	Direct Coombs \oplus hemolysis, drug-induced lupus, hyperprolactinemia
Tizanidine	Relief of spasticity	Hypotension, weakness, xerostomia

α -blockers

DRUG	APPLICATIONS	ADVERSE EFFECTS
Nonselective		
Phenoxybenzamine	Irreversible. Pheochromocytoma (used preoperatively) to prevent catecholamine (hypertensive) crisis.	Orthostatic hypotension, reflex tachycardia.
Phentolamine	Reversible. Given to patients on MAO inhibitors who eat tyramine-containing foods and for severe cocaine-induced hypertension (2nd line). Also used to treat norepinephrine extravasation.	
α_1 selective (-osin ending)		
Prazosin, terazosin, doxazosin, tamsulosin	Urinary symptoms of BPH; PTSD (prazosin); hypertension (except tamsulosin).	1st-dose orthostatic hypotension, dizziness, headache.
α_2 selective		
Mirtazapine	Depression.	Sedation, \uparrow serum cholesterol, \uparrow appetite.

β-blockers

Acebutolol, atenolol, betaxolol, bisoprolol, carvedilol, esmolol, labetalol, metoprolol, nadolol, nebivolol, pindolol, propranolol, timolol.

APPLICATION	ACTIONS	NOTES/EXAMPLES
Angina pectoris	↓ heart rate and contractility → ↓ O ₂ consumption	
Glaucoma	↓ production of aqueous humor	Timolol
Heart failure	Blockade of neurohormonal stress → prevention of deleterious cardiac remodeling → ↓ mortality	Bisoprolol, carvedilol, metoprolol (β-blockers curb mortality)
Hypertension	↓ cardiac output, ↓ renin secretion (due to β ₁ -receptor blockade on JG cells)	
Hyperthyroidism/ thyroid storm	Symptom control (↓ heart rate, ↓ tremor)	Propranolol
Hypertrophic cardiomyopathy	↓ heart rate → ↑ filling time, relieving obstruction	
Myocardial infarction	↓ O ₂ demand (short-term), ↓ mortality (long-term)	
Supraventricular tachycardia	↓ AV conduction velocity (class II antiarrhythmic)	Metoprolol, esmolol
Variceal bleeding	↓ hepatic venous pressure gradient and portal hypertension (prophylactic use)	Nadolol, propranolol, carvedilol
ADVERSE EFFECTS	Erectile dysfunction, cardiovascular (bradycardia, AV block, HF), CNS (seizures, sleep alterations), dyslipidemia (metoprolol), masked hypoglycemia, asthma/COPD exacerbations	Use of β-blockers for acute cocaine-associated chest pain remains controversial due to unsubstantiated concern for unopposed α-adrenergic stimulation
SELECTIVITY	β ₁ -selective antagonists (β ₁ > β ₂)—acebutolol (partial agonist), atenolol, betaxolol, bisoprolol, esmolol, metoprolol	Selective antagonists mostly go from A to M (β ₁ with 1st half of alphabet)
	Nonselective antagonists (β ₁ = β ₂)—nadolol, pindolol (partial agonist), propranolol, timolol	NonZelective antagonists mostly go from N to Z (β ₂ with 2nd half of alphabet)
	Nonselective α- and β-antagonists—carvedilol, labetalol	Nonselective α- and β-antagonists have modified suffixes (instead of “-olol”)
	Nebivolol combines cardiac-selective β ₁ -adrenergic blockade with stimulation of β ₃ -receptors (activate NO synthase in the vasculature and ↓ SVR)	NebivOlol increases NO

Phosphodiesterase inhibitors

Phosphodiesterase (PDE) inhibitors inhibit PDE, which catalyzes the hydrolysis of cAMP and/or cGMP, and thereby increase cAMP and/or cGMP. These inhibitors have varying specificity for PDE isoforms and thus have different clinical uses.

TYPE OF INHIBITOR	MECHANISM OF ACTION	CLINICAL USES	ADVERSE EFFECTS
Nonspecific PDE inhibitor Theophylline	↓ cAMP hydrolysis → ↑ cAMP → bronchial smooth muscle relaxation → bronchodilation	COPD/asthma (rarely used)	Cardiotoxicity (eg, tachycardia, arrhythmia), neurotoxicity (eg, seizures, headache), abdominal pain
PDE-5 inhibitors Sildenafil, vardenafil, tadalafil, avanafil	↓ hydrolysis of cGMP → ↑ cGMP → ↑ smooth muscle relaxation by enhancing NO activity → pulmonary vasodilation and ↑ blood flow in corpus cavernosum fills the penis	Erectile dysfunction Pulmonary hypertension Benign prostatic hyperplasia (tadalafil only)	Facial flushing, headache, dyspepsia, hypotension in patients taking nitrates; “hot and sweaty,” then headache, heartburn, hypotension Sildenafil only: cyanopia (blue-tinted vision) via inhibition of PDE-6 (six) in retina
PDE-4 inhibitor Roflumilast	↑ cAMP in neutrophils, granulocytes, and bronchial epithelium	Severe COPD	Abdominal pain, weight loss, depression, anxiety, insomnia
PDE-3 inhibitor Milrinone	In cardiomyocytes: ↑ cAMP → ↑ Ca ²⁺ influx → ↑ inotropy and chronotropy In vascular smooth muscle: ↑ cAMP → MLCK inhibition → vasodilation → ↓ preload and afterload	Acute decompensated HF with cardiogenic shock (inotrope)	Tachycardia, ventricular arrhythmias, hypotension
“Platelet inhibitors” Cilostazol ^a Dipyridamole ^b	In platelets: ↑ cAMP → inhibition of platelet aggregation	Intermittent claudication Stroke or TIA prevention (with aspirin) Cardiac stress testing (dipyridamole only, due to coronary vasodilation) Prevention of coronary stent restenosis	Nausea, headache, facial flushing, hypotension, abdominal pain

^aCilostazol is a PDE-3 inhibitor, but due to its indications is categorized as a platelet inhibitor together with dipyridamole.

^bDipyridamole is a nonspecific PDE inhibitor, leading to inhibition of platelet aggregation. It also prevents adenosine reuptake by platelets → ↑ extracellular adenosine → ↑ vasodilation.

▶ PHARMACOLOGY—TOXICITIES AND ADVERSE EFFECTS

Ingested seafood toxins Toxin actions include histamine release, total block of Na⁺ channels, or opening of Na⁺ channels to cause depolarization.

TOXIN	SOURCE	ACTION	SYMPTOMS	TREATMENT
Histamine (scombroid poisoning)	Spoiled dark-meat fish such as tuna, mahi-mahi, mackerel, and bonito	Bacterial histidine decarboxylase converts histidine to histamine Frequently misdiagnosed as fish allergy	Mimics anaphylaxis: oral burning sensation, facial flushing, erythema, urticaria, itching; may progress to bronchospasm, angioedema, hypotension	Antihistamines Albuterol +/- epinephrine
Tetrodotoxin	Pufferfish	Binds fast voltage-gated Na ⁺ channels in nerve tissue, preventing depolarization	Nausea, diarrhea, paresthesias, weakness, dizziness, loss of reflexes	Supportive
Ciguatoxin	Reef fish such as barracuda, snapper, and moray eel	Opens Na ⁺ channels, causing depolarization	Nausea, vomiting, diarrhea; perioral numbness; reversal of hot and cold sensations; bradycardia, heart block, hypotension	Supportive

Age-related changes in pharmacokinetics Aging alters the passage of drugs through the body and standard doses can result in ↑ plasma concentrations. Older patients often require reduced doses to prevent toxicity.

- Absorption—mostly unaffected.
- Distribution—↓ total body water (↓ V_d of hydrophilic drugs → ↑ concentration), ↑ total body fat (↑ V_d of lipophilic drugs → ↑ half-life).
- Metabolism—↓ hepatic mass and blood flow → ↓ first-pass metabolism, ↓ hepatic clearance. Phase I of drug metabolism is decreased; phase II is relatively preserved.
- Excretion—↓ renal mass and blood flow (↓ GFR) → ↓ renal clearance.

Beers criteria

Widely used criteria developed to reduce potentially inappropriate prescribing and harmful polypharmacy in the geriatric population. Includes > 50 medications that should be avoided in older patients due to ↓ efficacy and/or ↑ risk of adverse events. Examples:

- α-blockers (↑ risk of hypotension)
- Anticholinergics, antidepressants, antihistamines, opioids (↑ risk of delirium, sedation, falls, constipation, urinary retention)
- Benzodiazepines (↑ risk of delirium, sedation, falls)
- NSAIDs (↑ risk of GI bleeding, especially with concomitant anticoagulation)
- PPIs (↑ risk of *C difficile* infection)

Specific toxicity treatments

TOXIN	TREATMENT
Acetaminophen	N-acetylcysteine (replenishes glutathione)
AChE inhibitors, organophosphates	Atropine > pralidoxime
Antimuscarinic, anticholinergic agents	Physostigmine (crosses BBB), control hyperthermia
Arsenic	Dimercaprol, succimer
Benzodiazepines	Flumazenil
β-blockers	Atropine, glucagon, saline
Carbon monoxide	100% O ₂ , hyperbaric O ₂
Copper	“ Penny ”cillamine (penicillamine), trientine (3 copper pennies)
Cyanide	Hydroxocobalamin, nitrites + sodium thiosulfate
Dabigatran	Idarucizumab
Digoxin	Digoxin-specific antibody fragments
Direct factor Xa inhibitors (eg, apixaban)	Andexanet alfa
Heparin	Protamine sulfate
Iron (Fe)	De fer oxamine, de fer asirox, de fer iprone
Lead	Calcium disodium EDTA, dimercaprol, succimer, penicillamine
Mercury	Di mer caprol, succi mer
Methanol, ethylene glycol (antifreeze)	Fomepizole > ethanol, dialysis
Methemoglobin	Meth ylene blue, vitamin C (reducing agent)
Methotrexate	Leucovorin
Opioids	Nal ox one
Salicylates	NaHCO ₃ (alkalinize urine), dialysis
TCA _s	NaHCO ₃ (stabilizes cardiac cell membrane)
Warfarin	Vitamin K (delayed effect), PCC (prothrombin complex concentrate)/FFP (immediate effect)

Drug reactions—cardiovascular

DRUG REACTION	CAUSAL AGENTS
Coronary vasospasm	C ocaine, A mphetamines, S umatriptan, E rgot alkaloids (CASE)
Cutaneous flushing	V ancomycin, A denosine, N iacin, Ca ²⁺ channel blockers, E chinocandins, N itrates (flushed from VANCEN [dancing]) Vancomycin infusion reaction (formerly called red man syndrome)—rate-dependent infusion reaction to vancomycin causing widespread pruritic erythema due to histamine release. Manage with diphenhydramine, slower infusion rate.
Dilated cardiomyopathy	Alcohol, anthracycline (eg, d oxorubicin, d aunorubicin; prevent with d exrazoxane), trastuzumab
Torsades de pointes	Agents that prolong QT interval: anti A rrhythmics (class IA, III), anti B iotics (eg, macrolides, fluoroquinolones), anti“ C ”ychotics (eg, ziprasidone), anti D epressants (eg, TCAs), anti E metics (eg, ondansetron), anti F ungals (eg, fluconazole) (ABCDEF)

Drug reactions—endocrine/reproductive

DRUG REACTION	CAUSAL AGENTS	NOTES
Adrenocortical insufficiency	HPA suppression 2° to glucocorticoid withdrawal	
Diabetes insipidus	Lithium, demeclocycline	
Gynecomastia	Ketoconazole, cimetidine, spironolactone, GnRH analogs/antagonists, androgen receptor inhibitors, 5 α -reductase inhibitors	
Hot flashes	SERMs (eg, tamoxifen, clomiphene, raloxifene)	
Hyperglycemia	Tacrolimus, protease inhibitors, niacin, HCTZ, glucocorticoids	The people need High glucose
Hyperprolactinemia	Typical antipsychotics (eg, haloperidol), atypical antipsychotics (eg, risperidone), metoclopramide, methyl dopa, reserpine	Presents with hypogonadism (eg, infertility, amenorrhea, erectile dysfunction) and galactorrhea
Hyperthyroidism	Amiodarone, iodine, lithium	
Hypothyroidism	Amiodarone, lithium	I am lethargic
SIADH	Carbamazepine, Cyclophosphamide, SSRIs	Can't Concentrate Serum Sodium

Drug reactions—gastrointestinal

DRUG REACTION	CAUSAL AGENTS	NOTES
Acute cholestatic hepatitis, jaundice	Macrolides (eg, erythromycin)	
Diarrhea	Acamprosate, antidiabetic agents (acarbose, metformin, pramlintide), colchicine, cholinesterase inhibitors, lipid-lowering agents (eg, ezetimibe, orlistat), macrolides (eg, erythromycin), SSRIs, chemotherapy (eg, irinotecan)	
Focal to massive hepatic necrosis	Halothane, <i>Amanita phalloides</i> (death cap mushroom), valproate, acetaminophen	Liver “hAvac”
Hepatitis	Rifampin, isoniazid, pyrazinamide, statins, fibrates	
Pancreatitis	Didanosine, glucocorticoids, alcohol, valproate, azathioprine, diuretics (eg, furosemide, HCTZ)	Drugs generate a violent abdominal distress
Pill-induced esophagitis	Potassium chloride, NSAIDs, bisphosphonates, ferrous sulfate, tetracyclines Pills Not beneficial for food tube	Usually occurs at anatomic sites of esophageal narrowing (eg, near level of aortic arch); caustic effect minimized with upright posture and adequate water ingestion
Pseudomembranous colitis	Ampicillin, cephalosporins, clindamycin, fluoroquinolones, PPIs	Antibiotics predispose to superinfection by resistant <i>C difficile</i>

Drug reactions—hematologic

DRUG REACTION	CAUSAL AGENTS	NOTES
Agranulocytosis	Dapsone, clozapine, carbamazepine, propylthiouracil, methimazole, colchicine, ticlopidine, ganciclovir	Drugs can cause pretty major collapse to granulocytes
Aplastic anemia	Carbamazepine, methimazole, NSAIDs, benzene, chloramphenicol, propylthiouracil	Can't make New blood cells properly
Direct Coombs ⊕ hemolytic anemia	Penicillin, methylDopa, Cephalosporins	P Diddy Coombs
Drug Reaction with Eosinophilia and Systemic Symptoms	Phenytoin, carbamazepine, minocycline, sulfa drugs, allopurinol, vancomycin	DRESS is a delayed (type IV) hypersensitivity reaction DRESSes partially cover my skin and viscera
Gray baby syndrome	Chloramphenicol	
Hemolysis in G6PD deficiency	Isoniazid, sulfonamides, dapsone, primaquine, aspirin, ibuprofen, nitrofurantoin	Hemolysis is d pain
Megaloblastic anemia	Hydroxyurea, Phenytoin, Methotrexate, Sulfa drugs	You're having a mega blast with PMS
Thrombocytopenia	Indinavir, heparin, quinidine, ganciclovir, vancomycin, linezolid, abciximab	I have quickly gotten very low amounts
Thrombotic complications	Combined oral contraceptives, hormone replacement therapy, SERMs, epoetin alfa	Estrogen-mediated adverse effect

Drug reactions—musculoskeletal/skin/connective tissue

DRUG REACTION	CAUSAL AGENTS	NOTES
Drug-induced lupus	MethylDopa, minocycline, hydralazine, isoniazid, phenytoin, sulfa drugs, etanercept, procainamide	Lupus makes my hips extremely painful
Fat redistribution	Protease inhibitors, glucocorticoids	Fat protects glutes
Gingival hyperplasia	Cyclosporine, Ca ²⁺ channel blockers, phenytoin	Can Cause puffy gums
Hyperuricemia (gout)	Pyrazinamide, thiazides, furosemide, niacin, cyclosporine	Painful tophi and feet need care
Myopathy	Statins, fibrates, niacin, colchicine, daptomycin, hydroxychloroquine, interferon-α, penicillamine, glucocorticoids	
Osteoporosis	Glucocorticoids, depot medroxyprogesterone acetate, GnRH agonists, aromatase inhibitors, anticonvulsants, heparin, PPIs	
Photosensitivity	Sulfonamides, amiodarone, tetracyclines, 5-FU	Sat For photo
Rash (Stevens-Johnson syndrome)	Anti-epileptic drugs (especially lamotrigine), allopurinol, sulfa drugs, penicillin	Steven Johnson has epileptic allergy to sulfa drugs and penicillin
Teeth discoloration	Tetracyclines	Teethracyclines
Tendon/cartilage damage	Fluoroquinolones	

Drug reactions—neurologic

DRUG REACTION	CAUSAL AGENTS	NOTES
Cinchonism	Quinidine, quinine	Can present with tinnitus, hearing/vision loss, psychosis, and cognitive impairment
Parkinson-like syndrome	Antipsychotics, reserpine, metoclopramide	Cogwheel rigidity of arm
Peripheral neuropathy	Platinum agents (eg, cisplatin), isoniazid, vincristine, paclitaxel, phenytoin	Cis , it's very painful peripherally
Idiopathic intracranial hypertension	Vitamin A , growth hormones, tetracyclines	Always grow head tension
Seizures	Isoniazid, bupropion, imipenem/cilastatin, tramadol, enflurane	With seizures , I bite my tongue
Tardive dyskinesia	Antipsychotics, metoclopramide	
Visual disturbances	Topiramate (blurred vision/diplopia, haloes), hydroxychloroquine (↓ visual acuity, visual field defects), digoxin (yellow-tinged vision), isoniazid (optic neuritis), ivabradine (luminous phenomena), vigabatrin (visual field defects), PDE-5 inhibitors (blue-tinged vision), ethambutol (color vision changes)	These horrible drugs irritate very Precious eyes

Drug reactions—renal/genitourinary

DRUG REACTION	CAUSAL AGENTS	NOTES
Fanconi syndrome	Cisplatin, ifosfamide, expired tetracyclines, tenofovir	
Hemorrhagic cystitis	Cyclophosphamide, ifosfamide	Prevent by coadministering with mesna
Interstitial nephritis	Diuretics (Pee), NSAIDs (Pain-free), Penicillins and cephalosporins, PPIs , rifam P in, sulfa drugs	Remember the 5 P's

Drug reactions—respiratory

DRUG REACTION	CAUSAL AGENTS	NOTES
Dry cough	ACE inhibitors	
Pulmonary fibrosis	Methotrexate, nitrofurantoin, carmustine, bleomycin, busulfan, amiodarone	My nose cannot breathe bad air

Drug reactions—multiorgan

DRUG REACTION	CAUSAL AGENTS	NOTES
Antimuscarinic	Atropine, TCAs, H ₁ -blockers, antipsychotics	
Disulfiram-like reaction	1st-generation sulfonylureas, procarbazine, certain cephalosporins, griseofulvin, metronidazole	Sorry pals, can't go mingle
Nephrotoxicity/ ototoxicity	Loop diuretics, cisplatin, aminoglycosides, amphotericin, vancomycin	Listen cis , always adjust vancomycin in CKD. Cisplatin toxicity may respond to amifostine

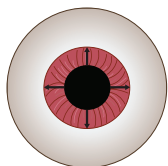
Drugs affecting pupil size

↑ pupil size (mydriasis)

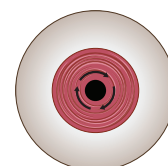
Anticholinergics (eg, atropine, TCAs, tropicamide, scopolamine, antihistamines)
 Indirect sympathomimetics (eg, amphetamines, cocaine, LSD), meperidine
 Direct sympathomimetics

↓ pupil size (miosis)

Sympatholytics (eg, α_2 -agonists)
 Opioids (except meperidine)
 Parasympathomimetics (eg, pilocarpine), organophosphates



Radial muscle contraction (α_1 receptor mediated)



Sphincter muscle contraction (M3 receptor mediated)

Cytochrome P-450 interactions (selected)

Inducers (+)

St. John's wort
Phenytoin
Phenobarbital
Modafinil
Nevirapine
Rifampin
Griseofulvin
Carbamazepine
Chronic alcohol overuse

Substrates

Theophylline
OCPs
Anti-epileptics
Warfarin

Inhibitors (-)

Sodium valproate
Isoniazid
Cimetidine
Ketoconazole
Fluconazole
Acute alcohol overuse
Chloramphenicol
Erythromycin/clarithromycin
Sulfonamides
Ciprofloxacin
Omeprazole
Amiodarone
Ritonavir
Grapefruit juice

St. John's funny funny (phen-phen) **mom never** refuses greasy **carbs** and **chronic alcohol**

The OCPs are **anti-war**

SICK FACES come when I **am** really drinking **grapefruit juice**

Sulfa drugs

Sulfonamide antibiotics, **Sulfasalazine**, **Probenecid**, **Furosemide**, **Acetazolamide**, **Celecoxib**, **Thiazides**, **Sulfonylureas**.
 Patients with sulfa allergies may develop fever, urinary tract infection, Stevens-Johnson syndrome, hemolytic anemia, thrombocytopenia, agranulocytosis, acute interstitial nephritis, and urticaria (hives), and photosensitivity.

Scary Sulfa Pharm FACTS

▶ PHARMACOLOGY—MISCELLANEOUS

Drug names

ENDING	CATEGORY	EXAMPLE
Antimicrobial		
-asvir	NS5A inhibitor	Ledipasvir
-bendazole	Antiparasitic/antihelminthic	Mebendazole
-buvir	NS5B inhibitor	Sofosbuvir
-cillin	Transpeptidase inhibitor	Ampicillin
-conazole	Ergosterol synthesis inhibitor	Ketoconazole
-cycline	Protein synthesis inhibitor	Tetracycline
-floxacin	Fluoroquinolone	Ciprofloxacin
-mivir	Neuraminidase inhibitor	Oseltamivir
-navir	Protease inhibitor	Ritonavir
-ovir	Viral DNA polymerase inhibitor	Acyclovir
-previr	NS3/4A inhibitor	Simeprevir
-tegravir	Integrase inhibitor	Elvitegravir
-thromycin	Macrolide	Azithromycin
Antineoplastic		
-case	Recombinant uricase	Rasburicase
-mustine	Nitrosourea	Carmustine
-platin	Platinum compound	Cisplatin
-poside	Topoisomerase II inhibitor	Etoposide
-rubicin	Anthracycline	Doxorubicin
-taxel	Taxane	Paclitaxel
-tecan	Topoisomerase I inhibitor	Irinotecan
CNS		
-ane	Inhaled anesthetic	Halothane
-apine, -idone	Atypical antipsychotic	Quetiapine, risperidone
-azine	Typical antipsychotic	Thioridazine
-barbital	Barbiturate	Phenobarbital
-benazine	VMAT inhibitor	Tetrabenazine
-caine	Local anesthetic	Lidocaine
-capone	COMT inhibitor	Entacapone
-curium, -curonium	Nondepolarizing neuromuscular blocker	Atracurium, pancuronium
-giline	MAO-B inhibitor	Selegiline
-ipramine, -triptyline	TCA	Imipramine, amitriptyline
-triptan	5-HT _{1B/1D} agonist	Sumatriptan
-zepam, -zolam	Benzodiazepine	Diazepam, alprazolam

Drug names (continued)

ENDING	CATEGORY	EXAMPLE
Autonomic		
-chol	Cholinergic agonist	Bethanechol
-olol	β -blocker	Propranolol
-stigmine	AChE inhibitor	Neostigmine
-terol	β_2 -agonist	Albuterol
-zosin	α_1 -blocker	Prazosin
Cardiovascular		
-afil	PDE-5 inhibitor	Sildenafil
-dipine	Dihydropyridine Ca^{2+} channel blocker	Amlodipine
-parin	Low-molecular-weight heparin	Enoxaparin
-plase	Thrombolytic	Alteplase
-pril	ACE inhibitor	Captopril
-sartan	Angiotensin-II receptor blocker	Losartan
-xaban	Direct factor Xa inhibitor	Apixaban
Metabolic		
-gliflozin	SGLT-2 inhibitor	Dapagliflozin
-glinide	Meglitinide	Repaglinide
-gliptin	DPP-4 inhibitor	Sitagliptin
-glitazone	PPAR- γ activator	Rosiglitazone
-glutide	GLP-1 analog	Liraglutide
-statin	HMG-CoA reductase inhibitor	Lovastatin
Other		
-caftor	CFTR modulator	Lumacaftor
-dronate	Bisphosphonate	Alendronate
-lukast	CysLT ₁ receptor blocker	Montelukast
-lutamide	Androgen receptor inhibitor	Flutamide
-pitant	NK ₁ blocker	Aprepitant
-prazole	Proton pump inhibitor	Omeprazole
-prost	Prostaglandin analog	Latanoprost
-sentan	Endothelin receptor antagonist	Bosentan
-setron	5-HT ₃ blocker	Ondansetron
-steride	5 α -reductase inhibitor	Finasteride
-tadine	H ₁ -antagonist	Loratadine
-tidine	H ₂ -antagonist	Cimetidine
-trozole	Aromatase inhibitor	Anastrozole
-vaptan	ADH antagonist	Tolvaptan

Biologic agents

ENDING	CATEGORY	EXAMPLE
Monoclonal antibodies (-mab)—target overexpressed cell surface receptors		
-ximab	Ch imeric human-mouse monoclonal antibody	Rituximab
-zumab	H umanized monoclonal antibody	Bevacizumab
-umab	H uman monoclonal antibody	Denosumab
Small molecule inhibitors (-ib)—target intracellular molecules		
-cyclib	C yclin-dependent kinase inhibitor	Palbociclib
-coxib	COX -2 inhibitor	Celecoxib
-parib	P oly(ADP-ri bose) polymerase inhibitor	Olaparib
-rafenib	BRAF inhibitor	Vemurafenib
-tinib	T yrosine kin ase inhibitor	Imatinib
-zomib	Proteasome inhibitor	Bortezomib
Interleukin receptor modulators (-kin)—agonists and antagonists of interleukin receptors		
-leukin	Inter leu kin-2 agonist/analog	Aldesleukin
-kinra	Interleukin r eceptor an tagonist	Anakinra

Public Health Sciences

“Medicine is a science of uncertainty and an art of probability.”

—Sir William Osler

“Whenever a doctor cannot do good, he must be kept from doing harm.”

—Hippocrates

“On a long enough timeline, the survival rate for everyone drops to zero.”

—Chuck Palahniuk, *Fight Club*

“Of all forms of discrimination and inequalities, injustice in health is the most shocking and inhuman.”

—Martin Luther King, Jr.

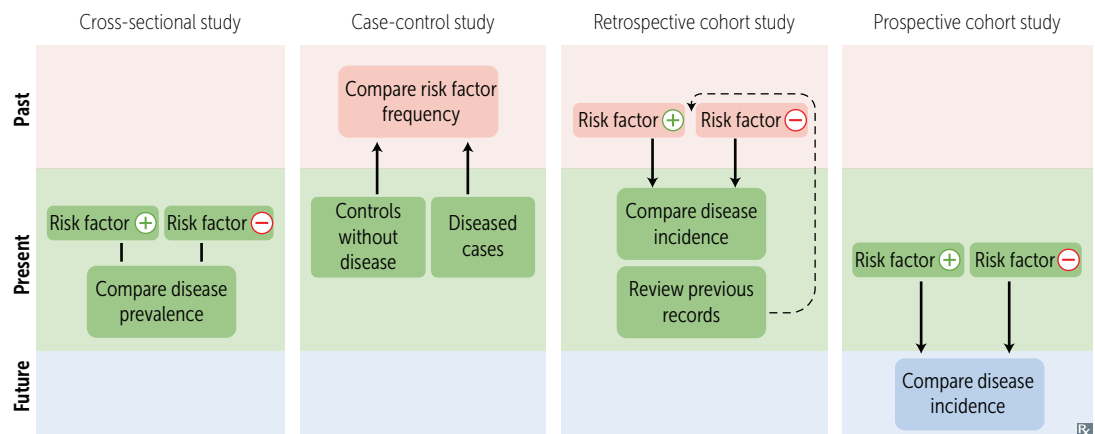
▶ Epidemiology and Biostatistics	258
▶ Ethics	268
▶ Communication Skills	271
▶ Healthcare Delivery	276
▶ Quality and Safety	278

A heterogeneous mix of epidemiology, biostatistics, ethics, law, healthcare delivery, patient safety, quality improvement, and more falls under the heading of public health sciences. Biostatistics and epidemiology are the foundations of evidence-based medicine and are very high yield. Make sure you can quickly apply biostatistical equations such as sensitivity, specificity, and predictive values in a problem-solving format. Also, know how to set up your own 2×2 tables, and beware questions that switch the columns. Quality improvement and patient safety topics were introduced a few years ago on the exam and represent trends in health system science. Medical ethics questions often require application of principles. Typically, you are presented with a patient scenario and then asked how you would respond. In this edition, we provide further details on communication skills and patient care given their growing emphasis on the exam. Effective communication is essential to the physician-patient partnership. Physicians must seek opportunities to connect with patients, understand their perspectives, express empathy, and form shared decisions and realistic goals.

PUBLIC HEALTH SCIENCES—EPIDEMIOLOGY AND BIostatISTICS

Observational studies

STUDY TYPE	DESIGN	MEASURES/EXAMPLE
Case series	Describes several individual patients with the same diagnosis, treatment, or outcome.	Description of clinical findings and symptoms. Has no comparison group, thus cannot show risk factor association with disease.
Cross-sectional study	Frequency of disease and frequency of risk-related factors are assessed in the present. Asks, “What is happening?”	Disease prevalence. Can show risk factor association with disease, but does not establish causality.
Case-control study	Retrospectively compares a group of people with disease to a group without disease. Looks to see if odds of prior exposure or risk factor differ by disease state. Asks, “What happened?”	Odds ratio (OR). Control the case in the OR . Patients with COPD had higher odds of a smoking history than those without COPD.
Cohort study	Compares a group with a given exposure or risk factor to a group without such exposure. Looks to see if exposure or risk factor is associated with later development of disease. Can be prospective or retrospective, but risk factor has to be present prior to disease development.	Disease incidence. Relative risk (RR). People who smoke had a higher risk of developing COPD than people who do not. Cohort = relative risk .
Twin concordance study	Compares the frequency with which both monozygotic twins vs both dizygotic twins develop the same disease.	Measures heritability and influence of environmental factors (“nature vs nurture”).
Adoption study	Compares siblings raised by biological vs adoptive parents.	Measures heritability and influence of environmental factors.
Ecological study	Compares frequency of disease and frequency of risk-related factors across populations. Measures population data not necessarily applicable to individuals (ecological fallacy).	Used to monitor population health. COPD prevalence was higher in more polluted cities.



Clinical trial

Experimental study involving humans. Compares therapeutic benefits of ≥ 2 interventions (eg, treatment vs placebo, treatment vs treatment). Study quality improves when clinical trial is randomized, controlled, and double-blinded (ie, neither subject nor researcher knows whether the subject is in the treatment or control group). Triple-blind refers to additional blinding of the researchers analyzing the data.

Crossover clinical trial—compares the effect of a series of ≥ 2 treatments on a subject. Order in which subjects receive treatments is randomized. Washout period occurs between treatments. Allows subjects to serve as their own controls.

Intention-to-treat analysis—all subjects are analyzed according to their original, randomly assigned treatment. No one is excluded. Attempts to avoid bias from attrition, crossover, and nonrandom noncompliance, but may dilute the true effects of intervention.

As-treated analysis—all subjects are analyzed according to the treatment they actually received. ↑ risk of bias.

Per-protocol analysis—subjects who fail to complete treatment as originally, randomly assigned are excluded. ↑ risk of bias.

Clinical trials occur after preclinical studies and consist of five phases (“Can **I SWIM?**”).

	STUDY POPULATION	MAIN PURPOSE
Phase 0	Very small number of either healthy volunteers or patients with disease of interest. Open-label.	Initial pharmacokinetic and pharmacodynamic assessment via microdosing. Often skipped.
Phase I	Small number of either healthy volunteers or patients with disease of interest. Open-label.	Safety assessment via dose escalation. Determines maximum tolerated dose.
Phase II	Moderate number of patients with disease of interest. Randomized, controlled, anonymized.	Efficacy assessment (does it Work?). Provides additional data on short-term adverse effects.
Phase III	Large number of patients with disease of interest. Randomized, controlled, anonymized.	Effectiveness assessment via comparison with current standard of care (any Improvement?).
Phase IV	Postmarketing surveillance of patients after treatment is approved. Open-label.	Provides data on long-term or rare adverse effects (can it stay on the Market?).

Off-label drug use

Use of a drug to treat a disease in a form, population group, or dosage that is not specifically approved by the FDA. Reasons for off-label use include treatment of an illness with no approved pharmacologic treatment or exploring alternative treatments after failure of approved options. Example: use of tricyclic antidepressants for treating neuropathic/chronic pain.

Bradford Hill criteria

A group of principles that provide limited support for establishing evidence of a causal relationship between presumed cause and effect.

Strength	Association does not necessarily imply causation, but the stronger the association, the more evidence for causation.
Consistency	Repeated observations of the findings in multiple distinct samples.
Specificity	The more specific the presumed cause is to the effect, the stronger the evidence for causation.
Temporality	The presumed cause precedes the effect by an expected amount of time.
Biological gradient	Greater effect observed with greater exposure to the presumed cause (dose-response relationship).
Plausibility	A conceivable mechanism exists by which the cause may lead to the effect.
Coherence	The presumed cause and effect do not conflict with existing scientific consensus.
Experiment	Empirical evidence supporting the presumed cause and effect (eg, animal studies, in vitro studies).
Analogy	The presumed cause and effect are comparable to a similar, established cause and effect.

Quantifying risk

Definitions and formulas are based on the classic 2×2 or contingency table.

		Disease or outcome	
		+	-
Exposure or intervention	+	a	b
	-	c	d

TERM	DEFINITION	EXAMPLE	FORMULA								
Odds ratio	Typically used in case-control studies. Represents the odds of exposure among cases (a/c) vs odds of exposure among controls (b/d). OR = 1 → odds of exposure are equal in cases and controls. OR > 1 → odds of exposure are greater in cases. OR < 1 → odds of exposure are greater in controls.	If in a case -control study, 20/30 patients with lung cancer and 5/25 healthy individuals report smoking, the OR is 8; so the patients with lung cancer are 8 times more likely to have a history of smoking. You take a case to the OR .	$OR = \frac{a/c}{b/d} = \frac{ad}{bc}$ <table border="1"> <tr> <td>a</td> <td>b</td> </tr> <tr> <td>20</td> <td>5</td> </tr> <tr> <td>c</td> <td>d</td> </tr> <tr> <td>10</td> <td>20</td> </tr> </table>	a	b	20	5	c	d	10	20
a	b										
20	5										
c	d										
10	20										
Relative risk	Typically used in cohort studies. Risk of developing disease in the exposed group divided by risk in the unexposed group. RR = 1 → no association between exposure and disease. RR > 1 → exposure associated with ↑ disease occurrence. RR < 1 → exposure associated with ↓ disease occurrence.	If 5/10 people exposed to radiation are diagnosed with cancer, and 1/10 people not exposed to radiation are diagnosed with cancer, the RR is 5; so people exposed to radiation have a 5 times greater risk of developing cancer. For rare diseases (low prevalence), OR approximates RR.	$RR = \frac{a/(a+b)}{c/(c+d)}$ <table border="1"> <tr> <td>a</td> <td>b</td> </tr> <tr> <td>5</td> <td>5</td> </tr> <tr> <td>c</td> <td>d</td> </tr> <tr> <td>1</td> <td>9</td> </tr> </table>	a	b	5	5	c	d	1	9
a	b										
5	5										
c	d										
1	9										
Relative risk reduction	The proportion of risk reduction attributable to the intervention as compared to a control.	If 2% of patients who receive a flu shot develop the flu, while 8% of unvaccinated patients develop the flu, then RR = 2/8 = 0.25, and RRR = 0.75.	$RRR = 1 - RR$								
Attributable risk	The difference in risk between exposed and unexposed groups.	If risk of lung cancer in people who smoke is 21% and risk in people who don't smoke is 1%, then the attributable risk is 20%.	$AR = \frac{a}{a+b} - \frac{c}{c+d}$ $AR\% = \frac{RR - 1}{RR} \times 100$								
Absolute risk reduction	The difference in risk (not the proportion) attributable to the intervention as compared to a control.	If 8% of people who receive a placebo vaccine develop the flu vs 2% of people who receive a flu vaccine, then ARR = 8% - 2% = 6% = 0.06.	$ARR = \frac{c}{c+d} - \frac{a}{a+b}$								
Number needed to treat	Number of patients who need to be treated for 1 patient to benefit. Lower number = better treatment.		$NNT = 1/ARR$								
Number needed to harm	Number of patients who need to be exposed to a risk factor for 1 patient to be har med. Higher number = safer exposure.		$NNH = 1/AR$								
Case fatality rate	Percentage of deaths occurring among those with disease.	If 4 patients die among 10 cases of meningitis, case fatality rate is 40%.	$CFR\% = \frac{\text{deaths}}{\text{cases}} \times 100$								

Evaluation of diagnostic tests

Sensitivity and specificity are fixed properties of a test. PPV and NPV vary depending on disease prevalence in population being tested.

	Disease			
	⊕	⊖		
Test	⊕	TP	FP	PPV = TP/(TP + FP)
	⊖	FN	TN	NPV = TN/(TN + FN)
	Sensitivity = TP/(TP + FN)	Specificity = TN/(TN + FP)	Prevalence = TP + FN (TP + FN + FP + TN)	

Sensitivity (true-positive rate)

Proportion of all people with disease who test positive, or the ability of a test to correctly identify those with the disease. Value approaching 100% is desirable for **ruling out** disease and indicates a **low false-negative rate**.

$= TP / (TP + FN)$
 $= 1 - FN \text{ rate}$
SN-N-OUT = highly **SeNsitive** test, when **Negative**, rules **OUT** disease
 High sensitivity test used for screening

Specificity (true-negative rate)

Proportion of all people without disease who test negative, or the ability of a test to correctly identify those without the disease. Value approaching 100% is desirable for **ruling in** disease and indicates a **low false-positive rate**.

$= TN / (TN + FP)$
 $= 1 - FP \text{ rate}$
SP-P-IN = highly **SPecific** test, when **Positive**, rules **IN** disease
 High specificity test used for confirmation after a positive screening test

Positive predictive value

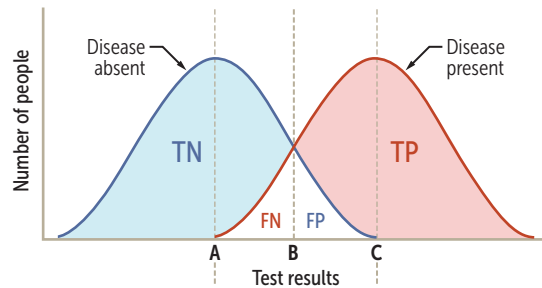
Probability that a person who has a positive test result actually has the disease.

$PPV = TP / (TP + FP)$
 PPV varies directly with pretest probability (baseline risk, such as prevalence of disease):
 high pretest probability → high PPV

Negative predictive value

Probability that a person with a negative test result actually does not have the disease.

$NPV = TN / (TN + FN)$
 NPV varies inversely with prevalence or pretest probability



Possible cutoff values for ⊕ vs ⊖ test result
A = 100% sensitivity cutoff value
B = practical compromise between specificity and sensitivity
C = 100% specificity cutoff value

Lowering the cutoff value: ↑ Sensitivity ↑ NPV
B → **A** (↑ FP ↓ FN) ↓ Specificity ↓ PPV

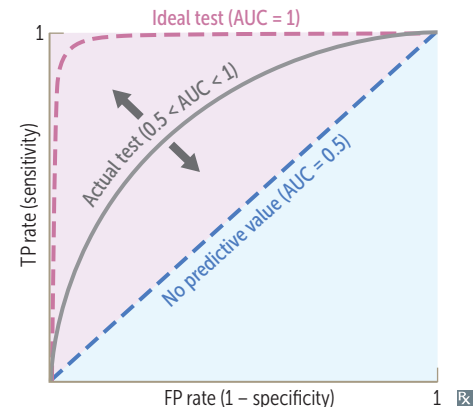
Raising the cutoff value: ↑ Specificity ↑ PPV
B → **C** (↑ FN ↓ FP) ↓ Sensitivity ↓ NPV

Receiver operating characteristic curve

ROC curve demonstrates how well a diagnostic test can distinguish between 2 groups (eg, disease vs healthy). Plots the true-positive rate (sensitivity) against the false-positive rate (1 – specificity).

The better performing test will have a higher area under the curve (AUC), with the curve closer to the upper left corner.

In diseases diagnosed based on low lab values (eg, anemia), the curve is flipped: lowering the cutoff further → ↓ FP, ↑ FN; raising the cutoff → ↓ FN, ↑ FP.



Precision vs accuracy

Precision (reliability)

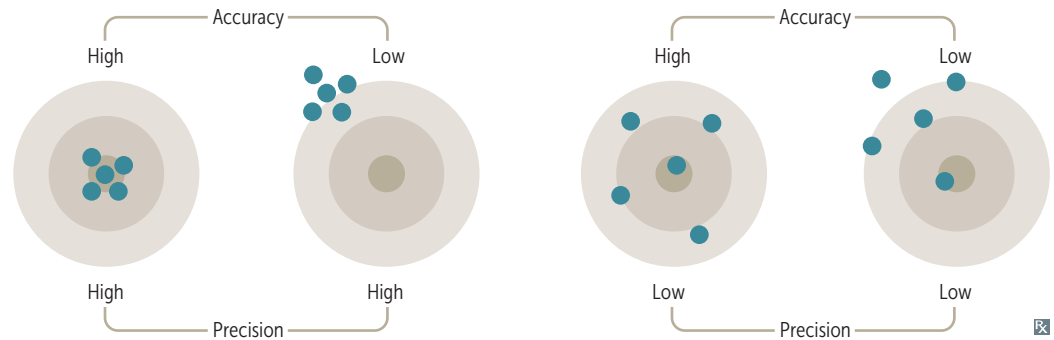
The consistency and reproducibility of a test.
The absence of random variation in a test.

Random error ↓ precision in a test.
↑ precision → ↓ standard deviation.
↑ precision → ↑ statistical power (1 - β).

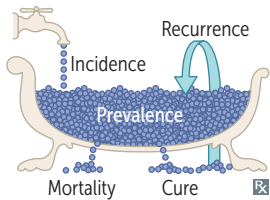
Accuracy (validity)

The closeness of test results to the true values.
The absence of systematic error or bias in a test.

Systematic error ↓ accuracy in a test.



Incidence vs prevalence



$$\text{Incidence} = \frac{\# \text{ of new cases}}{\# \text{ of people at risk}} \quad (\text{per unit of time})$$

Incidence looks at new cases (**incidents**).

$$\text{Prevalence} = \frac{\# \text{ of existing cases}}{\text{Total \# of people in a population}} \quad (\text{at a point in time})$$

Prevalence looks at **all** current cases.

$$\frac{\text{Prevalence}}{1 - \text{prevalence}} = \text{Incidence rate} \times \text{average duration of disease}$$

Prevalence ≈ incidence for short duration disease (eg, common cold).
Prevalence > incidence for chronic diseases, due to large # of existing cases (eg, diabetes).

Prevalence ~ pretest probability.
↑ prevalence → ↑ PPV and ↓ NPV.

SITUATION	INCIDENCE	PREVALENCE
↑ survival time	—	↑
↑ mortality	—	↓
Faster recovery time	—	↓
Extensive vaccine administration	↓	↓
↓ risk factors	↓	↓
↑ diagnostic sensitivity	↑	↑
New effective treatment started	—	↓
↓ contact between patients with and without noninfectious disease	—	—
↓ contact between infected and noninfected patients with airborne infectious disease	↓	↓

Bias and study errors

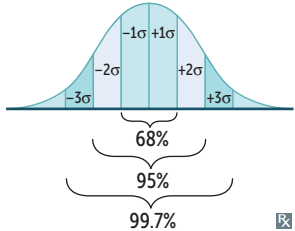
TYPE	DEFINITION	EXAMPLES	STRATEGIES TO REDUCE BIAS
Recruiting participants			
Selection bias	Nonrandom sampling or treatment allocation of subjects such that study population is not representative of target population Most commonly a sampling bias	Berkson bias —cases and/or controls selected from hospitals (bedside bias) are less healthy and have different exposures Attrition bias —participants lost to follow up have a different prognosis than those who complete the study	Randomization (creates groups with similar distributions of known and unknown variables) Ensure the choice of the right comparison/reference group
Performing study			
Recall bias	Awareness of disorder alters recall by subjects; common in retrospective studies	Patients with disease recall exposure after learning of similar cases	Decrease time from exposure to follow-up; use medical records as sources
Measurement bias	Information is gathered in a systemically distorted manner	Using a faulty automatic sphygmomanometer Hawthorne effect —participants change behavior upon awareness of being observed	Use objective, standardized, and previously tested methods of data collection that are planned ahead of time Use placebo group
Procedure bias	Subjects in different groups are not treated the same	Patients in treatment group spend more time in highly specialized hospital units	Blinding (masking) and use of placebo reduce influence of participants and researchers on procedures and interpretation of outcomes as neither are aware of group assignments
Observer-expectancy bias	Researcher's belief in the efficacy of a treatment changes the outcome of that treatment (also called Pygmalion effect)	An observer expecting treatment group to show signs of recovery is more likely to document positive outcomes	
Interpreting results			
Confounding bias	Factor related to both exposure and outcome (but not on causal path) distorts effect of exposure on outcome (vs effect modification, in which the exposure leads to different outcomes in subgroups stratified by the factor)	An uncontrolled study shows an association between drinking coffee and lung cancer; however, people who drink coffee may smoke more, which could account for the association	Multiple/repeated studies Crossover studies (subjects act as their own controls) Matching (patients with similar characteristics in both treatment and control groups) Effect modification —association is shown differently in individual subgroups due to stratification by given factor even when there is association between exposure and outcome
Lead-time bias	Early detection interpreted as ↑ survival, but the disease course has not changed	Breast cancer diagnosed early by mammography may appear to exaggerate survival time because patients are known to have the cancer for longer	Measure “back-end” survival (adjust survival according to the severity of disease at the time of diagnosis)

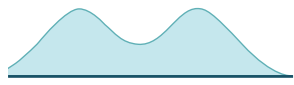
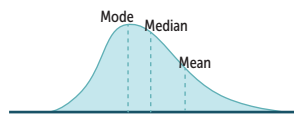
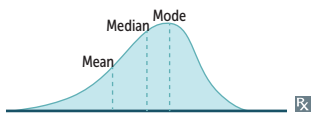
Bias and study errors (continued)

TYPE	DEFINITION	EXAMPLES	STRATEGY TO REDUCE BIAS
<i>Interpreting results (continued)</i>			
Length-time bias	Screening test detects diseases with long latency period, while those with shorter latency period become symptomatic earlier	A slowly progressive cancer is more likely detected by a screening test than a rapidly progressive cancer	A randomized controlled trial assigning subjects to the screening program or to no screening

Statistical distribution

Measures of central tendency	Mean = (sum of values)/(total number of values).	Most affected by outliers (extreme values).
	Median = middle value of a list of data sorted from least to greatest.	If there is an even number of values, the median will be the average of the middle two values.
	Mode = most common value.	Least affected by outliers.
Measures of dispersion	Standard deviation = how much variability exists in a set of values, around the mean of these values.	σ = SD; n = sample size. Variance = (SD) ² .
	Standard error = an estimate of how much variability exists in a (theoretical) set of sample means around the true population mean.	SE = σ/\sqrt{n} . SE ↓ as n ↑.

Normal distribution	<p>Gaussian, also called bell-shaped.</p> <p>Mean = median = mode.</p> <p>For normal distribution, mean is the best measure of central tendency.</p> <p>For skewed data, median is a better measure of central tendency than mean.</p>	
----------------------------	--	--

Nonnormal distributions		
Bimodal distribution	Suggests two different populations (eg, metabolic polymorphism such as fast vs slow acetylators; age at onset of Hodgkin lymphoma; suicide rate by age).	
Positive skew	Typically, mean > median > mode. Asymmetry with longer tail on right; mean falls closer to tail.	
Negative skew	Typically, mean < median < mode. Asymmetry with longer tail on left; mean falls closer to tail.	

Statistical hypothesis testing

Null hypothesis	Also called H_0 . Hypothesis of no difference or relationship (eg, there is no association between the disease and the risk factor in the population).
Alternative hypothesis	Also called H_1 . Hypothesis of some difference or relationship (eg, there is some association between the disease and the risk factor in the population).
P value	Probability of obtaining test results at least as extreme as those observed during the test, assuming that H_0 is correct. Commonly accepted as 0.05 (< 5% of results occur due to chance).

Outcomes of statistical hypothesis testing

Correct result	Stating that there is an effect or difference when one exists (H_0 rejected in favor of H_1). Stating that there is no effect or difference when none exists (H_0 not rejected).
-----------------------	--

		Reality	
		H_1	H_0
Study	rejects H_0	Power ($1 - \beta$)	α Type I error
	does not reject H_0	β Type II error	

Blue shading = correct result.

Testing errors

Type I error (α)	Stating that there is an effect or difference when none exists (H_0 incorrectly rejected in favor of H_1). α is the probability of making a type I error (usually 0.05 is chosen). If $P < \alpha$, then assuming H_0 is true, the probability of obtaining the test results would be less than the probability of making a type I error. H_0 is therefore rejected as false. Statistical significance \neq clinical significance.	Also called false-positive error. 1st time boy cries wolf, the town believes there is a wolf, but there is not (false positive). You can never “prove” H_1 , but you can reject the H_0 as being very unlikely. $\uparrow \alpha$ level (\uparrow statistical significance level).
Type II error (β)	Stating that there is not an effect or difference when one exists (H_0 is not rejected when it is in fact false). β is the probability of making a type II error. β is related to statistical power ($1 - \beta$), which is the probability of rejecting H_0 when it is false. \uparrow power and $\downarrow \beta$ by: <ul style="list-style-type: none"> ▪ \uparrow sample size ▪ \uparrow expected effect size ▪ \uparrow precision of measurement 	Also called false-negative error. 2nd time boy cries wolf, the town believes there is no wolf, but there is one. If you \uparrow sample size, you \uparrow power. There is power in numbers . Generally, when type I error increases, type II error decreases.

Statistical vs clinical significance

Statistical significance—defined by the likelihood of study results being due to chance. If there is a high statistical significance, then there is a low probability that the results are due to chance.

Clinical significance—measure of effect on treatment outcomes. An intervention with high clinical significance is likely to have a large impact on patient outcomes/measures.

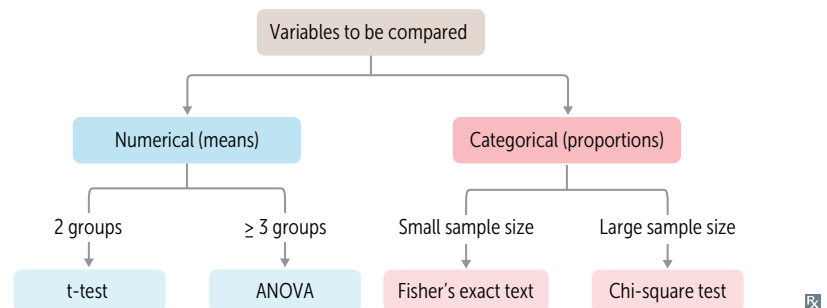
Some studies have a very high statistical significance, but the proposed intervention may not have any clinical impact/significance.

Confidence interval	<p>Range of values within which the true mean of the population is expected to fall, with a specified probability.</p> <p>CI = $1 - \alpha$. The 95% CI (corresponding to $\alpha = 0.05$) is often used. As sample size increases, CI narrows.</p> <p>CI for sample mean = $\bar{x} \pm Z(SE)$</p> <p>For the 95% CI, $Z = 1.96$.</p> <p>For the 99% CI, $Z = 2.58$.</p>	<p>H_0 is rejected (and results are significant) when:</p> <ul style="list-style-type: none"> ▪ 95% CI for mean difference excludes 0 ▪ 95% CI OR or RR excludes 1 ▪ CIs between two groups do not overlap <p>H_0 is not rejected (and results are not significant) when:</p> <ul style="list-style-type: none"> ▪ 95% CI for mean difference includes 0 ▪ 95% CI OR or RR includes 1 ▪ CIs between two groups do overlap
----------------------------	--	---

Meta-analysis	<p>A method of statistical analysis that pools summary data (eg, means, RRs) from multiple studies for a more precise estimate of the size of an effect. Also estimates heterogeneity of effect sizes between studies.</p> <p>Improves power, strength of evidence, and generalizability (external validity) of study findings. Limited by quality of individual studies and bias in study selection.</p>
----------------------	---

Common statistical tests

t-test	Checks differences between means of 2 groups.	Tea is meant for 2 . Example: comparing the mean blood pressure between men and women.
ANOVA	Checks differences between means of 3 or more groups.	3 words: AN alysis Of VA riance. Example: comparing the mean blood pressure between members of 3 different ethnic groups.
Fisher's exact test	Checks differences between 2 percentages or proportions of categorical, nominal outcomes. Use instead of chi-square test with small populations.	Example: comparing the percentage of 20 men and 20 women with hypertension.
Chi-square (χ^2)	Checks differences between 2 or more percentages or proportions of categorical outcomes (not mean values).	Pronounce chi-tegorical . Example: comparing the proportion of members of 3 age groups who have essential hypertension.



Pearson correlation coefficient

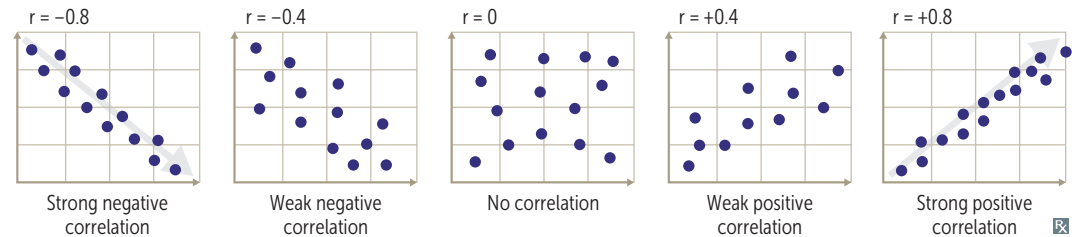
A measure of the linear correlation between two variables. r is always between -1 and $+1$. The closer the absolute value of r is to 1 , the stronger the linear correlation between the 2 variables.

Variance is how much the measured values differ from the average value in a data set.

Positive r value → positive correlation (as one variable ↑, the other variable ↑).

Negative r value → negative correlation (as one variable ↑, the other variable ↓).

Coefficient of determination = r^2 (amount of variance in one variable that can be explained by variance in another variable).



► PUBLIC HEALTH SCIENCES—ETHICS

Core ethical principles**Autonomy**

Obligation to respect patients as individuals (truth-telling, confidentiality), to create conditions necessary for autonomous choice (informed consent), and to honor their preference in accepting or not accepting medical care.

Beneficence

Physicians have a special ethical (fiduciary) duty to act in the patient's best interest. May conflict with autonomy (an informed patient has the right to decide) or what is best for society (eg, mandatory TB treatment). Traditionally, patient interest supersedes.

Nonmaleficence

"Do no harm." Must be balanced against beneficence; if the benefits outweigh the risks, a patient may make an informed decision to proceed (most surgeries and medications fall into this category).

Justice

To treat persons fairly and equitably. This does not always imply equally (eg, triage).

Decision-making capacity

Physician must determine whether the patient is psychologically and legally capable of making a particular healthcare decision.

Note that decisions made with capacity cannot be revoked simply if the patient later loses capacity.

Intellectual disabilities and mental illnesses are not exclusion criteria for informed decision-making unless the patient's condition presently impairs their ability to make healthcare decisions.

Capacity is determined by a physician for a specific healthcare-related decision (eg, to refuse medical care).

Competency is determined by a judge and usually refers to more global categories of decision-making (eg, legally unable to make any healthcare-related decision).

Four major components of decision-making:

- Understanding
- Appreciation
- Reasoning
- Expressing a choice

Informed consent	<p>A process (not just a document/signature) that requires:</p> <ul style="list-style-type: none"> ▪ Disclosure: discussion of pertinent information, including risks/benefits (using medical interpreter, if needed) ▪ Understanding: ability to comprehend ▪ Capacity: ability to reason and make one's own decisions (distinct from competence, a legal determination) ▪ Voluntariness: freedom from coercion and manipulation <p>Patients must have a comprehensive understanding of their diagnosis and the risks/benefits of proposed treatment and alternative options, including no treatment.</p> <p>Patients must be informed of their right to revoke written consent at any time, even orally.</p>	<p>Exceptions to informed consent (WIPE it away):</p> <ul style="list-style-type: none"> ▪ Waiver—patient explicitly relinquishes the right of informed consent ▪ Legally Incompetent—patient lacks decision-making capacity (obtain consent from legal surrogate) ▪ Therapeutic Privilege—withholding information when disclosure would severely harm the patient or undermine informed decision-making capacity ▪ Emergency situation—implied consent may apply
Consent for minors	<p>A minor is generally any person < 18 years old. Parental consent laws in relation to healthcare vary by state. In general, parental consent should be obtained, but exceptions exist for emergency treatment (eg, blood transfusions) or if minor is legally emancipated (eg, married, self-supporting, or in the military).</p>	<p>Situations in which parental consent is usually not required:</p> <ul style="list-style-type: none"> ▪ Sex (contraception, STIs, prenatal care—usually not abortion) ▪ Drugs (substance use disorder treatment) ▪ Rock and roll (emergency/trauma) <p>Physicians should always encourage healthy minor-guardian communication.</p> <p>Physician should seek a minor's assent (agreement of someone unable to legally consent) even if their consent is not required.</p>
Advance directives	<p>Instructions given by a patient in anticipation of the need for a medical decision. Details vary per state law.</p>	
Oral advance directive	<p>Incapacitated patient's prior oral statements commonly used as guide. Problems arise from variance in interpretation. If patient was informed, directive was specific, patient made a choice, and decision was repeated over time to multiple people, then the oral directive is more valid.</p>	
Written advance directive	<p>Delineates specific healthcare interventions that patient anticipates accepting or rejecting during treatment for a critical or life-threatening illness. A living will is an example.</p>	
Medical power of attorney	<p>Patient designates an agent to make medical decisions in the event that the patient loses decision-making capacity. Patient may also specify decisions in clinical situations. Can be revoked by patient if decision-making capacity is intact. More flexible than a living will.</p>	
Do not resuscitate order	<p>DNR order prohibits cardiopulmonary resuscitation (CPR). Patient may still consider other life-sustaining measures (eg, intubation, feeding tube, chemotherapy).</p>	

Ventilator-assisted life support

Ideally, discussions with patients occur before ventilator support is necessary. However, information about patient preferences may be absent at the time patients require this intervention to survive. Medical decision-making frequently relies on surrogate decision-makers (patient identified or legally appointed) when discussing the continuation or withdrawal of ventilatory support, focusing on both the prognosis of the condition and the believed wishes of the patient.

If surrogates indicate patient would not have wanted to receive life support with ventilation → withhold or withdraw life support regardless of what the surrogate prefers.

If the decision is made to withhold or withdraw life support, involve palliative care, chaplain services, and the primary care physician in medical discussions with the family and provide emotional support.

Surrogate decision-maker

If a patient loses decision-making capacity and has not prepared an advance directive, individuals (surrogates) who know the patient must determine what the patient would have done. Priority of surrogates: **spouse** → adult **children** → **parents** → adult **siblings** → other relatives (the **spouse chips** in).

Confidentiality

Confidentiality respects patient privacy and autonomy. If the patient is incapacitated or the situation is emergent, disclosing information to family and friends should be guided by professional judgment of patient's best interest. The patient may voluntarily waive the right to confidentiality (eg, insurance company request).

General principles for exceptions to confidentiality:

- Potential physical harm to self or others is serious and imminent
- Alternative means to warn or protect those at risk is not possible
- Steps can be taken to prevent harm

Examples of exceptions to patient confidentiality (many are state specific) include the following (“The physician’s good judgment **SAVED** the day”):

- Patients with **Suicidal/homicidal** ideation
- **Abuse** (children, older adults, and/or prisoners)
- Duty to protect—state-specific laws that sometimes allow physician to inform or somehow protect potential **Victim** from harm
- Patients with **Epilepsy** and other impaired automobile drivers
- Reportable **Diseases** (eg, STIs, hepatitis, food poisoning); physicians may have a duty to warn public officials, who will then notify people at risk. Dangerous communicable diseases, such as TB or Ebola, may require involuntary treatment.

Accepting gifts from patients

A complex subject without definitive regulations. Some argue that the patient-physician relationship is strengthened through accepting a gift from a patient, while others argue that negative consequences outweigh the benefits of accepting any gift.

In practice, patients often present items such as cards, baked goods, and inexpensive gifts to physicians. The physician's decision to accept or decline is based on an individual assessment of whether or not the risk of harm outweighs the potential benefit.

- Physicians should not accept gifts that are inappropriately large or valuable.
- Gifts should not be accepted if the physician identifies that the gift could detrimentally affect patient care.
- Gifts that may cause emotional or financial stress for the patient should not be accepted.

If a gift violates any of the guidelines above, the best practice is to thank the patient for offering a kind gift, but politely indicate that it must be declined. During this conversation it should be emphasized that the incident does not influence the physician-patient relationship in any way.

▶ PUBLIC HEALTH SCIENCES—COMMUNICATION SKILLS

Patient-centered interviewing techniques

Introduction	Introduce yourself and ask the patient their name and how they would like to be addressed. Address the patient by the name and pronouns given. Sit at eye level near the patient.
Agenda setting	Identify concerns and set goals by developing joint agenda between the physician and the patient.
Reflection	Actively listen and synthesize information offered by the patient, particularly with respect to primary concern(s).
Validation	Legitimize or affirm the patient's perspectives.
Recapitulation	Summarize what the patient has said so far to ensure correct interpretation.
Facilitation	Encourage the patient to speak freely without guiding responses or leading questions. Allow the patient to ask questions throughout the encounter.

Establishing rapport**PEARLS**

Partnership	Work together with patient to identify primary concerns and develop preferred solutions.
Empathy	Acknowledge the emotions displayed and demonstrate understanding of why the patient is feeling that way.
Apology	Take personal responsibility when appropriate.
Respect	Commend the patient for coming in to discuss a problem, pushing through challenging circumstances, keeping a positive attitude, or other constructive behaviors.
Legitimization	Assure patient that emotional responses are understandable or common.
Support	Reassure patient that you will work together through difficult times and offer appropriate resources.

Delivering bad news**SPIKES**

Setting	Offer in advance for the patient to bring support. Eliminate distractions, ensure privacy, and sit down with the patient to talk.
Perception	Determine the patient's understanding and expectations of the situation.
Invitation	Obtain the patient's permission to disclose the news and what level of detail is desired.
Knowledge	Share the information in small pieces without medical jargon, allowing time to process. Assess the patient's understanding.
Emotions	Acknowledge the patient's emotions, and provide opportunity to express them. Listen and offer empathetic responses.
Strategy	If the patient feels ready, discuss treatment options and goals of care. Offer an agenda for the next appointment.

Gender- and sexuality-inclusive history taking

Avoid making assumptions about sexual orientation, gender identity, gender expression, and behavior (eg, a patient who identifies as heterosexual may engage in same-sex sexual activity). Use gender-neutral terms (eg, refer to a patient's "partner" rather than assuming a spouse's gender). A patient's sex assigned at birth and gender identity may differ. Consider stating what pronouns you use when you introduce yourself (eg, "I'm Dr. Smith, and I use she/her pronouns") and asking patients how they would like to be addressed. Reassure them about the confidentiality of their appointments and be sensitive to the fact that patients may not be open about their sexual orientation or gender identity to others in their life. Do not bring up gender or sexuality if it is not relevant to the visit (eg, a gender-nonconforming patient seeking care for a hand laceration).

Culturally inclusive history taking

Identify the problem through the patient's perspective. Ask the patient to describe the problem in their own words, or how the patient would describe the problem to their family and friends. Identify cultural perceptions of factors leading to a problem. Ask the patient to explain why they think they are experiencing their problem. Identify how the patient's background influences their problem. Ask the patient about what makes their problem better or worse. Investigate roles of family, community, and spirituality. Identify how culture may impact current and future interventions. Ask the patient if they have any concerns about the current plan of treatment and if they have any suggestions. If they do not want to follow medical advice, investigate if there is a way to combine their plans with the standard medical regimen. Identify possible barriers to care based on culture. Ask the patient if there is anything that would prevent them from seeking care in a standard medical institution. Probe for explanations and what may increase the chance of maintaining a good patient-physician relationship.

Motivational interviewing

Counseling technique to facilitate behavior modification by helping patients resolve ambivalence about change. Useful for many conditions (eg, nicotine dependence, obesity). Helpful when patient has some desire to change, but it does not require that the patient be committed to making the change. May involve asking patients to examine how their behavior interferes with their life or why they might want to change it. Assess barriers (eg, food access, untreated trauma) that may make behavior change difficult. Assessing a patient's readiness for change is also important for guiding physician-suggested goals. These goals should be **S**pecific, **M**easurable, **A**chievable, **R**elevant, and **T**ime bound (**SMART**).

Trauma-informed care Patients with history of psychological trauma should receive thorough behavioral health screenings. Regularly assess mood, substance use, social supports, and suicide risk. Focus assessments on trauma-related symptoms that interfere with social and occupational function. Do not probe into details of the incident. Always be empathetic. Do not ask invasive questions requiring the patient to describe trauma in detail. Ask permission prior to discussion. Before the physical exam, reassure patients that they may signal to end it immediately if they experience too much physical or emotional discomfort. Offer the presence of additional staff for support. The **4 Rs** of trauma-informed care: **R**ealize, **R**ecognize, **R**espond, **R**esist retraumatization.

Communicating with patients with disabilities

Patients may identify with person-first (ie, “a person with a disability”) or identity-first (ie, “a disabled person”) language. Ask patients what terms they use. Under most circumstances, talk directly to the patient. Do not assume that nonverbal patients do not understand. Accompanying caregivers can add information to any discussion as needed. Ask if assistance is desired rather than assuming the patient cannot do something alone. Most people, including people with disabilities, value their independence. For patients with speech difficulties, provide extra time for the interview. If their speech is difficult to understand, consider asking them to write down a few words or ask them to rephrase their sentence. Repeat what they said to ensure you understood it correctly. For patients with a cognitive impairment, use concrete, specific language. Ask simple, direct questions. Eliminate background noise and distractions. Do not assume the patient can read. Adjust to how the patient understands best (eg, use hand gestures or ask them to demonstrate a task). Ask patients who are deaf or hard of hearing their preferred mode of communication. Use light touch or waving to get their attention. For patients who prefer to speak and lipread, eliminate background noise, face the patient, and do not change your mode of speaking. Consider using an interpreter when necessary. As with other parts of a medical history, do not bring up a disability if it is not relevant to a visit (eg, a patient in a wheelchair with an ear infection). Do not skip relevant parts of the physical exam even if the disability makes the exam challenging.

Use of interpreters

Visits with a patient who speaks little English should utilize a professionally trained medical interpreter unless the physician is conversationally fluent in the patient’s preferred language. If an interpreter is unavailable in person, interpretation services may be provided by telephone or video call. If the patient prefers to utilize a family member, this should be recorded in the chart. Do not assume that a patient is a poor English speaker because of name, skin tone, or accent. Ask the patient what language is preferred. The physician should make eye contact with the patient and speak to them directly, without use of third-person statements such as “tell him.” Allow extra time for the interview, and ask one question at a time. For in-person spoken language interpretation, the interpreter should ideally be next to or slightly behind the patient. For sign language interpretation, the interpreter should be next to or slightly behind the physician. In cases of emergency, facilitate communication by any tools available (eg, friends, family, sketches, interpreter apps) even though they do not comprise standard procedure otherwise.

Challenging patient and ethical scenarios

The most appropriate response is usually one that acknowledges the issues, validates emotions, and is open ended, empathetic, and patient centered. It often honors one or more of the principles of autonomy, beneficence, nonmaleficence, and justice. Appropriate responses are respectful of patients and other members of the healthcare team.

SITUATION	APPROPRIATE RESPONSE
Patient is not adherent.	Determine whether there are financial, logistical, or other obstacles preventing the patient's adherence. Do not coerce the patient into adhering or refer the patient to another physician. Schedule regular follow-up visits to track patient progress.
Patient desires an unnecessary procedure.	Attempt to understand why the patient wants the procedure and address underlying concerns. Do not refuse to see the patient or refer to another physician. Avoid performing unnecessary procedures.
Patient has difficulty taking medications.	Determine what factors are involved in the patient's difficulties. If comprehension or memory are issues, use techniques such as providing written instructions, using the teach-back method, or simplifying treatment regimens.
Family members ask for information about patient's prognosis.	Avoid discussing issues with relatives without the patient's permission.
A patient's family member asks you not to disclose the results of a test if the prognosis is poor because the patient will be "unable to handle it."	Explore why the family member believes this would be detrimental, including possible cultural factors. Explain that if the patient would like to know information concerning care, it will not be withheld. However, if you believe the patient might seriously harm self or others if informed, you may invoke therapeutic privilege and withhold the information.
A 17-year-old is pregnant and requests an abortion.	Many states require parental notification or consent for minors for an abortion. Unless there are specific medical risks associated with pregnancy, a physician should not sway the patient's decision for, or against, an elective abortion (regardless of patient's age or fetal condition). Discuss options for terminating the pregnancy and refer to abortion care, if needed.
A 15-year-old is pregnant and wants to raise the child. The patient's parents want you to tell the patient to give the child up for adoption.	The patient retains the right to make decisions regarding the child, even if the patient's parents disagree. Provide information to the teenager about the practical aspects of caring for a baby. Discuss options for terminating the pregnancy, if requested. Encourage discussion between the patient and parents to reach the best decision.
A terminally ill patient requests physician-assisted dying.	The overwhelming majority of states prohibit most forms of physician-assisted dying. Physicians may, however, prescribe medically appropriate analgesics even if they potentially shorten the patient's life.
Patient is suicidal.	Assess the seriousness of the threat. If patient is actively suicidal with a plan, suggest remaining in the hospital voluntarily; patient may be hospitalized involuntarily if needed.
Patient states that you are attractive and asks if you would go on a date.	Use a chaperone if necessary. Romantic relationships with patients are never appropriate. Set firm professional boundaries with direct communication. Transition care to another physician if necessary.
A woman who had a mastectomy says she now feels "ugly."	Find out why the patient feels this way. Do not offer falsely reassuring statements (eg, "You still look good").
Patient is angry about the long time spent in the waiting room.	Acknowledge the patient's anger, but do not take a patient's anger personally. Thank the patient for being patient and apologize for any inconvenience. Stay away from efforts to explain the delay.
Patient is upset with treatment received from another physician.	Suggest that the patient speak directly to that physician regarding the concern. If the problem is with a member of the office staff, reassure the patient you will speak to that person.

Challenging patient and ethical scenarios (continued)

SITUATION	APPROPRIATE RESPONSE
An invasive test is performed on the wrong patient.	Regardless of the outcome, a physician is ethically obligated to inform a patient that a mistake has been made.
A patient requires a treatment not covered by insurance.	Discuss all treatment options with patients, even if some are not covered by their insurance companies. Inform patient of financial assistance programs.
A 7-year-old boy loses a sister to cancer and now feels responsible.	At ages 5–7, children begin to understand that death is permanent, all life functions end completely at death, and everything that is alive eventually dies. Provide a direct, concrete description of his sister's death. Avoid clichés and euphemisms. Reassure the boy that he is not responsible. Identify and normalize fears and feelings. Encourage play and healthy coping behaviors (eg, remembering her in his own way).
Patient is victim of intimate partner violence.	Ask if patient is safe and help devise an emergency plan if there isn't one. Ask patient direct, open-ended questions about exam findings and summarize patient's answers back to them. Ask if patient has any questions. Do not necessarily pressure patient to leave a partner or disclose the incident to the authorities (unless required by state law).
Patient wants to try alternative or holistic medicine.	Explore any underlying reasons with the patient in a supportive, nonjudgmental manner. Advise the patient of known benefits and risks of treatment, including adverse effects, contraindications, and medication interactions. Consider referral to an appropriate complementary or alternative medicine provider.
Physician colleague presents to work impaired.	This presents a potential risk to patient safety. You have an ethical and usually a legal obligation to report impaired colleagues so they can cease patient care and receive appropriate assistance in a timely manner. Seek guidance in reporting as procedures and applicable law vary by institution and state.
Patient's family insists on maintaining life support after brain death has occurred, citing patient's movements when touched.	Gently explain to family that there is no chance of recovery, and that brain death is equivalent to death. Movement is due to spinal arc reflex and is not voluntary. Bring case to appropriate ethics board regarding futility of care and withdrawal of life support.
A pharmaceutical company offers you a sponsorship in exchange for advertising its new drug.	Reject this offer. Generally, decline gifts and sponsorships to avoid any conflict of interest. The AMA Code of Ethics does make exceptions for gifts directly benefitting patients; special funding for medical education of students, residents, fellows; grants whose recipients are chosen by independent institutional criteria; and funds that are distributed without attribution to sponsors.
Patient requests a nonemergent procedure that is against your personal or religious beliefs.	Provide accurate and unbiased information so patients can make an informed decision. In a neutral, nonjudgmental manner, explain to the patient that you do not perform the procedure but offer to refer to another physician.
Mother and 15-year-old daughter are unresponsive and bleeding heavily, but father refuses transfusion because they are Jehovah's Witnesses.	Transfuse daughter, but do not transfuse mother. Emergent care can be refused by the healthcare proxy for an adult, particularly when patient preferences are known or reasonably inferred, but not for a minor based solely on faith.
A dependent patient presents with injuries inconsistent with caretaker's story.	Document detailed history and physical. If possible and appropriate, interview the patient alone. Provide any necessary medical care. If suspicion remains, contact the appropriate agencies or authorities (eg, child or adult protective services) for an evaluation. Inform the caretaker of your obligation to report. Physicians are required by law to report any reasonable suspicion of abuse, neglect, or endangerment.
A pediatrician recommends standard vaccinations for a patient, but the child's parent refuses.	Address any concerns the parent has. Explain the risks and benefits of vaccinations and why they are recommended. Do not administer routine vaccinations without the parent's consent.

▶ PUBLIC HEALTH SCIENCES—HEALTHCARE DELIVERY

Disease prevention

PREVENTION LEVEL	DEFINITION	EXAMPLES
Primary	Prevent disease before it occurs	Healthy diet and exercise to prevent diabetes
Secondary	Screen for and manage presymptomatic disease	Glucose screening for type 2 diabetes mellitus
Tertiary	Treat to reduce complications from disease that is ongoing	Hemoglobin A _{1c} monitoring to guide treatment and prevent complications
Quaternary	Quit (avoid) unnecessary medical interventions to minimize incidental harm	Discontinuing sulfonylurea after multiple hypoglycemic events

Major medical insurance plans

PLAN	PROVIDERS	PAYMENTS	SPECIALIST CARE
Exclusive provider organization	Restricted to limited panel (except emergencies)		No referral required
Health maintenance organization	Restricted to limited panel (except emergencies)	Most affordable	Requires referral from primary care provider
Point of service	Patient can see providers outside network	Higher copays and deductibles for out-of-network services	Requires referral from primary care provider
Preferred provider organization	Patient can see providers outside network	Higher copays and deductibles for all services	No referral required
Accountable care organization	Providers voluntarily enroll	Medicare	Specialists voluntarily enroll

Healthcare payment models

Bundled payment	Healthcare organization receives a set amount per service, regardless of ultimate cost, to be divided among all providers and facilities involved.
Capitation	Physicians receive a set amount per patient assigned to them per period of time, regardless of how much the patient uses the healthcare system. Used by some HMOs.
Discounted fee-for-service	Insurer and/or patient pays for each individual service at a discounted rate predetermined by providers and payers (eg, PPOs).
Fee-for-service	Insurer and/or patient pays for each individual service.
Global payment	Insurer and/or patient pays for all expenses associated with a single incident of care with a single payment. Most commonly used during elective surgeries, as it covers the cost of surgery as well as the necessary pre- and postoperative visits.

Medicare and Medicaid

Medicare and Medicaid—federal social healthcare programs that originated from amendments to the Social Security Act.

Medicare is available to patients ≥ 65 years old, < 65 with certain disabilities, and those with end-stage renal disease.

Medicaid is joint federal and state health assistance for people with limited income and/or resources.

Medicar**E** is for **E**lderly.

Medicai**D** is for **D**isadvantaged.

The 4 parts of Medicare:

- Part **A**: hospital **A**dmissions, including hospice, skilled nursing
- Part **B**: **B**asic medical **b**ills (eg, physician fees, diagnostic testing)
- Part **C**: (parts A + B = **C**ombo) delivered by approved private **c**ompanies
- Part **D**: prescription **D**rugs

Palliative care

Medical care aiming to provide comfort, relieve suffering, and improve quality of life in patients with serious illness regardless of their diagnosis or prognosis. Often concurrent with curative or life-prolonging treatment.

Delivered by interdisciplinary team (physicians, nurses, social workers) in hospitals, outpatient clinics, or at home.

Hospice care (end-of-life care)—form of palliative care for patients with prognosis < 6 months when curative or life-prolonging treatment is no longer beneficial.

Common causes of death (US) by age

	< 1 YR	1–14 YR	15–34 YR	35–44 YR	45–64 YR	65+ YR ^a
#1	Congenital malformations	Unintentional injury	Unintentional injury	Unintentional injury	Cancer	Heart disease
#2	Preterm birth	Cancer	Suicide	Cancer	Heart disease	Cancer
#3	Sudden unexpected infant death	Congenital malformations	Homicide	Heart disease	Unintentional injury	Chronic lower respiratory disease

^aWith the ongoing pandemic, COVID-19 has been included as one of the most common causes of death among people 65+ years old.

PUBLIC HEALTH SCIENCES—QUALITY AND SAFETY

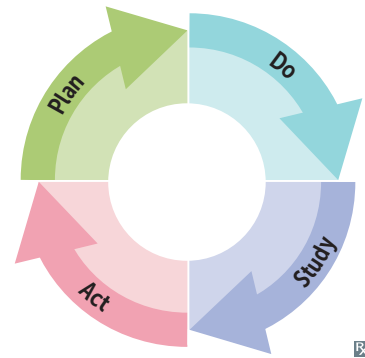
Safety culture Organizational environment in which everyone can freely bring up safety concerns without fear of penalty.

Human factors design Forcing functions (those that prevent undesirable actions [eg, connecting feeding syringe to IV tubing]) are the most effective. Standardization improves process reliability (eg, clinical pathways, guidelines, checklists). Simplification reduces wasteful activities (eg, consolidating electronic medical records).

Deficient designs hinder workflow and lead to staff workarounds that bypass safety features (eg, patient ID barcodes affixed to computers due to unreadable wristbands).

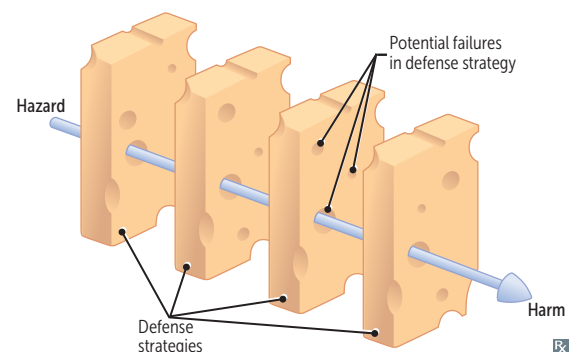
PDSA cycle Process improvement model to test changes in real clinical setting. Impact on patients:

- **P**lan—define problem and solution
- **D**o—test new process
- **S**tudy—measure and analyze data
- **A**ct—integrate new process into workflow

**Quality measurements**

	MEASURE	EXAMPLE
Structural	Physical equipment, resources, facilities	Number of diabetes educators
Process	Performance of system as planned	Percentage of patients with diabetes whose HbA _{1c} was measured in the past 6 months
Outcome	Impact on patients	Average HbA _{1c} of patients with diabetes
Balancing	Impact on other systems/outcomes	Incidence of hypoglycemia among patients who tried an intervention to lower HbA _{1c}

Swiss cheese model Focuses on systems and conditions rather than an individual's error. The risk of a threat becoming a reality is mitigated by differing layers and types of defenses. Patient harm can occur despite multiple safeguards when “the holes in the cheese line up.”



Types of medical errors		
Active error	Occurs at level of frontline operator (eg, wrong IV pump dose programmed).	Immediate impact.
Latent error	Occurs in processes indirect from operator but impacts patient care (eg, different types of IV pumps used within same hospital).	Accident waiting to happen.
Never event	Adverse event that is identifiable, serious, and usually preventable (eg, scalpel retained in a surgical patient's abdomen).	Major error that should never occur. Sentinel event —a never event that leads to death, permanent harm, or severe temporary harm.
Near miss	Unplanned event that does not result in harm but has the potential to do so (eg, pharmacist recognizes a medication interaction and cancels the order).	Narrow prevention of harm that exposes dangers.

Burnout vs fatigue

Burnout	Prolonged, excessive stress → medical errors due to reduced professional efficacy.
Fatigue	Sleep/rest deprivation → medical errors due to cognitive impairment.

Medical error analysis

	DESIGN	METHODS
Root cause analysis	R etrospective approach. Applied after failure event to prevent recurrence.	Uses records and participant interviews (eg, 5 whys approach, fishbone/cause-and-effect diagrams, process maps) to identify all the underlying problems (eg, process, people, environment, equipment, materials, management) that led to an error.
Failure mode and effects analysis	F orward-looking approach. Applied before process implementation to prevent failure occurrence.	Uses inductive reasoning to identify all the ways a process might fail and prioritizes them by their probability of occurrence and impact on patients.

Cardiovascular

“As for me, except for an occasional heart attack, I feel as young as I ever did.”

—Robert Benchley

“Hearts will never be practical until they are made unbreakable.”

—*The Wizard of Oz*

“As the arteries grow hard, the heart grows soft.”

—H. L. Mencken

“Nobody has ever measured, not even poets, how much the heart can hold.”

—Zelda Fitzgerald

“The art of medicine has its roots in the heart.”

—Paracelsus

“It is not the size of the man but the size of his heart that matters.”

—Evander Holyfield

▶ Embryology	286
▶ Anatomy	290
▶ Physiology	291
▶ Pathology	304
▶ Pharmacology	323

The cardiovascular system is one of the highest yield areas for the boards and, for some students, may be the most challenging. Focusing on understanding the mechanisms instead of memorizing the details can make a big difference. Pathophysiology of atherosclerosis and heart failure, MOA of drugs (particular physiology interactions) and their adverse effects, ECGs of heart blocks, the cardiac cycle, and the Starling curve are some of the more high-yield topics. Differentiating between systolic and diastolic dysfunction is also very important. Heart murmurs and maneuvers that affect these murmurs have also been high yield and may be asked in a multimedia format.

▶ CARDIOVASCULAR—EMBRYOLOGY

Heart morphogenesis First functional organ in vertebrate embryos; beats spontaneously by week 4 of development.

Cardiac looping Primary heart tube loops to establish left-right polarity; begins in week 4 of development.

Defect in left-right dynein (involved in left-right asymmetry) can lead to dextrocardia, as seen in Kartagener syndrome.

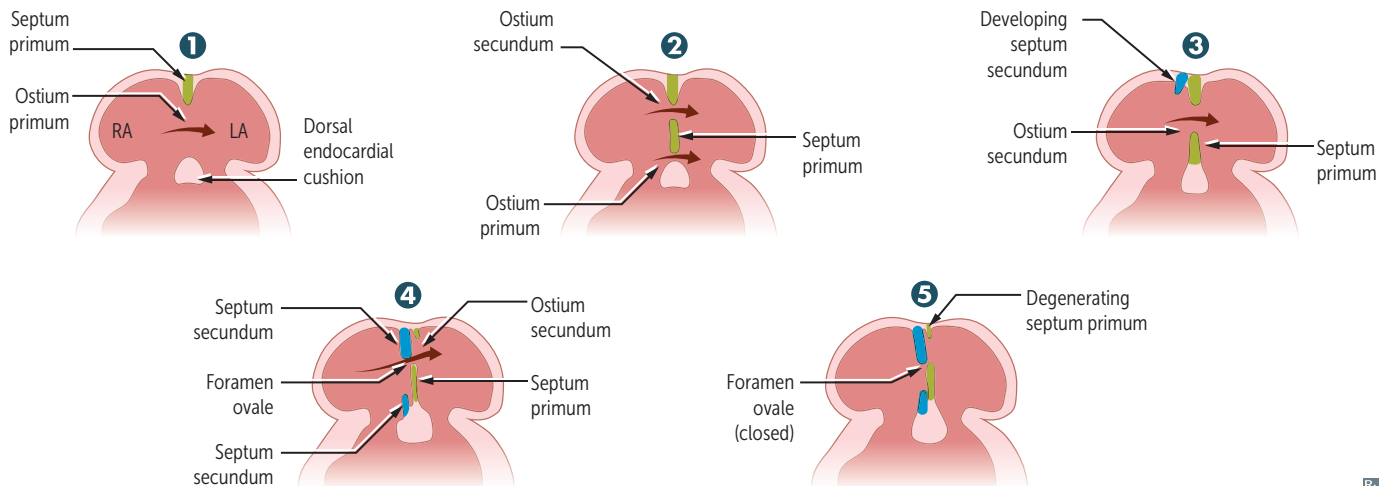
Septation of the chambers

Atria

- 1 Septum primum grows toward endocardial cushions, narrowing ostium primum.
- 2 Ostium secundum forms in septum primum due to cell death (ostium primum regresses).
- 3 Septum secundum develops on the right side of septum primum, as ostium secundum maintains right-to-left shunt.
- 4 Septum secundum expands and covers most of ostium secundum. The residual foramen is the foramen ovale.
- 5 Remaining portion of septum primum forms the one-way valve of the foramen ovale.

6. Septum primum closes against septum secundum, sealing the foramen ovale soon after birth because of \uparrow LA pressure and \downarrow RA pressure.
7. Septum secundum and septum primum fuse during infancy/early childhood, forming the atrial septum.

Patent foramen ovale—caused by failure of septum primum and septum secundum to fuse after birth; most are left untreated. Can lead to paradoxical emboli (venous thromboemboli entering the systemic arterial circulation through right-to-left shunt) as can occur in atrial septal defect (ASD).

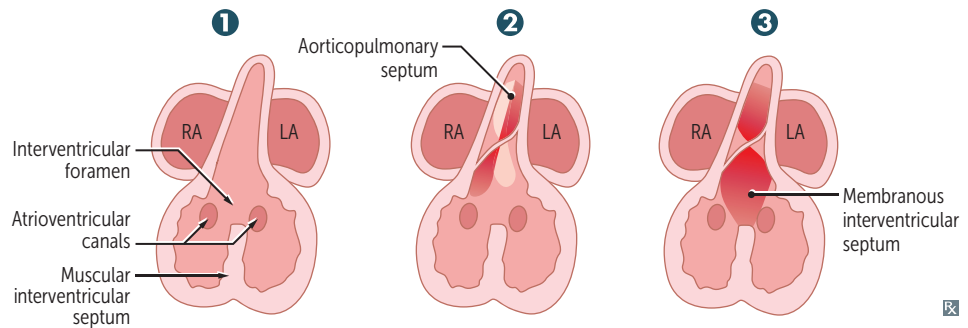


Heart morphogenesis (continued)

Ventricles

- 1 Muscular interventricular septum forms. Opening is called interventricular foramen.
- 2 Aorticopulmonary septum rotates and fuses with muscular ventricular septum to form membranous interventricular septum, closing interventricular foramen.
- 3 Growth of endocardial cushions separates atria from ventricles and contributes to both atrial septation and membranous portion of the interventricular septum.

Ventricular septal defect—most common congenital cardiac anomaly, usually occurs in membranous septum.



Outflow tract formation

Neural crest cell migrations → truncal and bulbar ridges that spiral and fuse to form aorticopulmonary septum → ascending aorta and pulmonary trunk.

Conotruncal abnormalities associated with failure of neural crest cells to migrate:

- Transposition of great arteries.
- Tetralogy of Fallot.
- Persistent truncus arteriosus.

Valve development

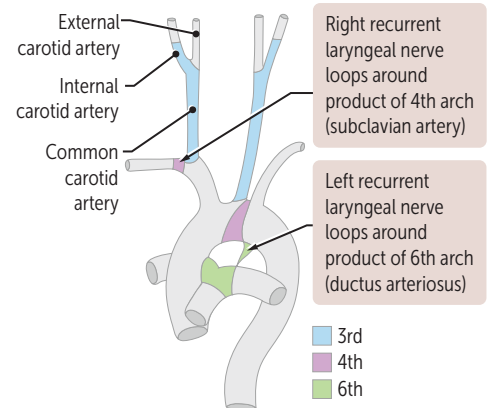
Aortic/pulmonary: derived from endocardial cushions of outflow tract.
Mitral/tricuspid: derived from fused endocardial cushions of the AV canal.

Valvular anomalies may be stenotic, regurgitant, atretic (eg, tricuspid atresia), or displaced (eg, Ebstein anomaly).

Aortic arch derivatives

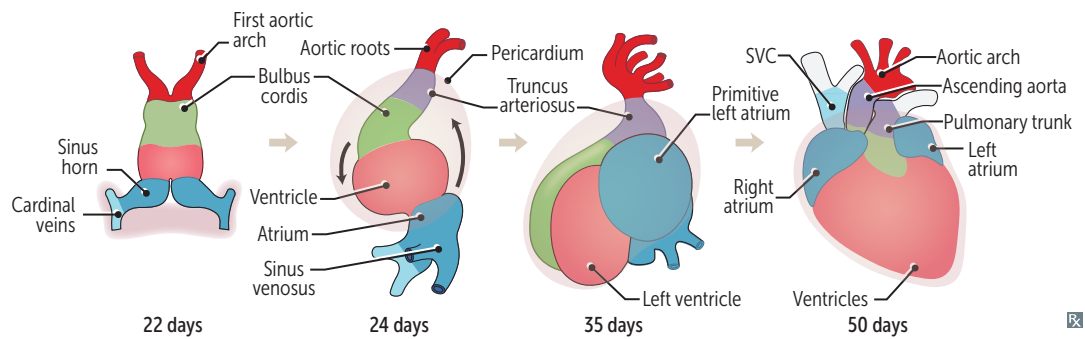
Develop into arterial system.

- 1st** Part of **max**illary artery (branch of external carotid). **1st** arch is **max**imal.
- 2nd** **S**tapedial artery and hyoid artery. **S**econd = **s**tapedial.
- 3rd** **C**ommon **c**arotid artery and proximal part of internal **c**arotid artery. **C** is **3rd** letter of alphabet.
- 4th** On left, aortic arch; on right, proximal part of right subclavian artery. **4th** arch (**4** limbs) = systemic.
- 6th** Proximal part of pulmonary arteries and (on left only) ductus arteriosus. **6th** arch = pulmonary and the pulmonary-to-systemic shunt (ductus arteriosus).

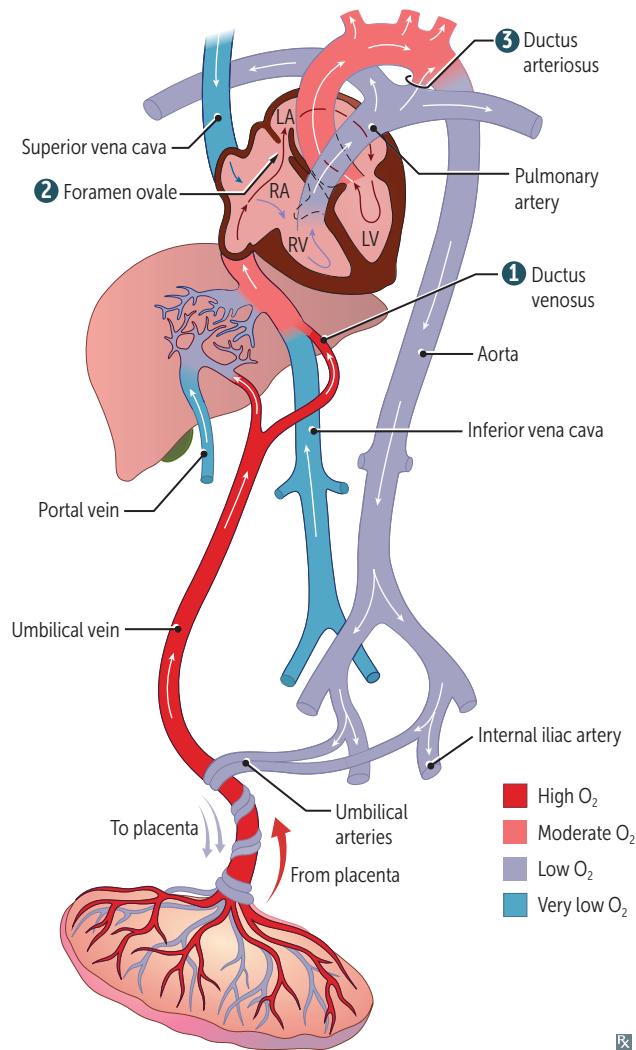


Heart embryology

EMBRYONIC STRUCTURE	GIVES RISE TO
Truncus arteriosus	Ascending aorta and pulmonary trunk
Bulbus cordis	Smooth parts (outflow tract) of left and right ventricles
Primitive ventricle	Trabeculated part of left and right ventricles
Primitive atrium	Trabeculated part of left and right atria
Left horn of sinus venosus	Coronary sinus
Right horn of sinus venosus	Smooth part of right atrium (sinus venarum)
Endocardial cushion	Atrial septum, membranous interventricular septum; AV and semilunar valves
Right common cardinal vein and right anterior cardinal vein	Superior vena cava (SVC)
Posterior cardinal, subcardinal, and supracardinal veins	Inferior vena cava (IVC)
Primitive pulmonary vein	Smooth part of left atrium



Fetal circulation



Blood in umbilical vein has a PO₂ of ≈ 30 mm Hg and is ≈ 80% saturated with O₂. Umbilical arteries have low O₂ saturation.

3 important shunts:

- 1 Blood entering fetus through the umbilical vein is conducted via the **ductus venosus** into the IVC, bypassing hepatic circulation.
- 2 Most of the highly oxygenated blood reaching the heart via the IVC is directed through the **foramen ovale** into the left atrium.
- 3 Deoxygenated blood from the SVC passes through the RA → RV → main pulmonary artery → **ductus arteriosus** → descending aorta; shunt is due to high fetal pulmonary artery resistance.

At birth, infant takes a breath → ↓ resistance in pulmonary vasculature → ↑ left atrial pressure vs right atrial pressure → foramen ovale closes (now called fossa ovalis); ↑ in O₂ (from respiration) and ↓ in prostaglandins (from placental separation) → closure of ductus arteriosus.

NSAIDs (eg, indomethacin, ibuprofen) or acetaminophen help close the patent ductus arteriosus → ligamentum arteriosum (remnant of ductus arteriosus). “**Endomethacin**” **ends** the PDA.

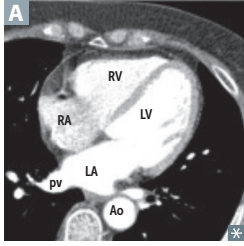
Prostaglandins **E₁** and **E₂** **kEEp** PDA open.

Fetal-postnatal derivatives

FETAL STRUCTURE	POSTNATAL DERIVATIVE	NOTES
Ductus arteriosus	Ligamentum arteriosum	Near the left recurrent laryngeal nerve
Ductus venosus	Ligamentum venosum	
Foramen ovale	F ossa o valis	
Allantois → urachus	Median umbilical ligament	Urachus is part of allantois between bladder and umbilicus
Umbilical arteries	Medial umbilical ligaments	
Umbilical vein	Ligamentum teres hepatis (round ligament)	Contained in falciform ligament

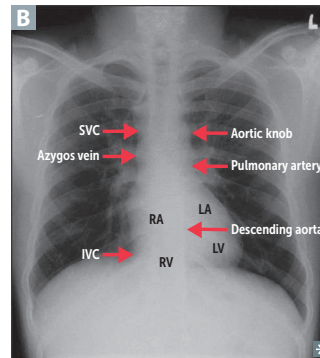
▶ CARDIOVASCULAR—ANATOMY

Heart anatomy



LA is the most posterior part of the heart **A**; enlargement of the LA (eg, in mitral stenosis) can lead to compression of the esophagus (dysphagia) and/or the left recurrent laryngeal nerve, a branch of the vagus nerve, causing hoarseness (**Ortner syndrome**).

RV is the most anterior part of the heart and most commonly injured in trauma. LV is about 2/3 and RV is about 1/3 of the inferior (diaphragmatic) cardiac surface **B**.



Pericardium

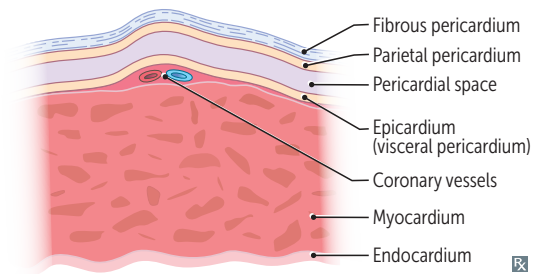
Consists of 3 layers (from outer to inner):

- Fibrous pericardium
- Parietal pericardium
- Epicardium (visceral pericardium)

Pericardial space lies between parietal pericardium and epicardium.

Pericardium innervated by phrenic nerve.

Pericarditis can cause referred pain to the neck, arms, or one or both shoulders (often left).



Coronary blood supply

LAD and its branches supply anterior 2/3 of interventricular septum, anterolateral papillary muscle, and anterior surface of LV. Most commonly occluded.

PDA supplies posterior 1/3 of interventricular septum, posterior 2/3 walls of ventricles, and posteromedial papillary muscle.

RCA supplies AV node and SA node. Infarct may cause nodal dysfunction (bradycardia or heart block). Right (acute) marginal artery supplies RV.

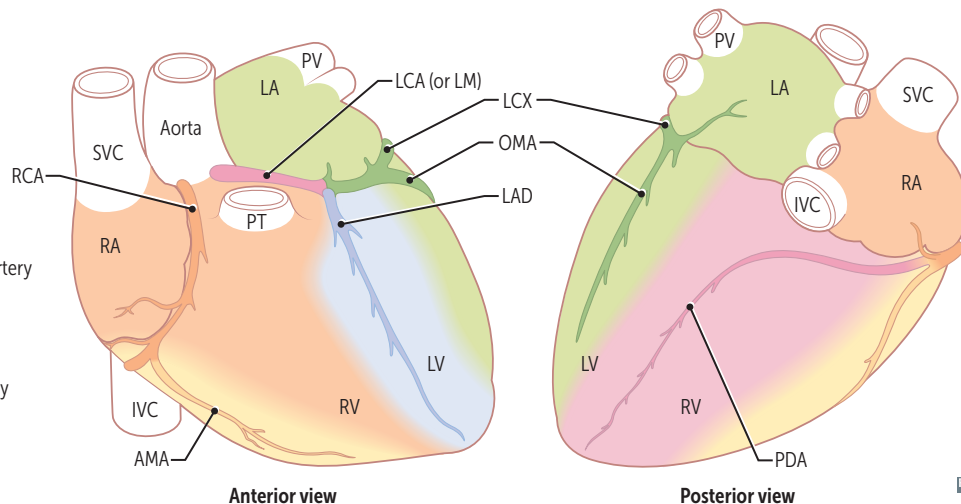
Dominance:

- Right-dominant circulation (most common) = PDA arises from RCA
- Left-dominant circulation = PDA arises from LCX
- Codominant circulation = PDA arises from both LCX and RCA

Coronary blood flow to LV and interventricular septum peaks in early diastole.

Coronary sinus runs in the left AV groove and drains into the RA.

- Key:
- AMA = Acute marginal artery
 - LAD = Left anterior descending artery
 - LCA (or LM) = Left (main) coronary artery
 - LCX = Left circumflex artery
 - OMA = Obtuse marginal artery
 - PDA = Posterior descending artery
 - PT = Pulmonary trunk
 - PV = Pulmonary vein
 - RCA = Right coronary artery



▶ CARDIOVASCULAR—PHYSIOLOGY

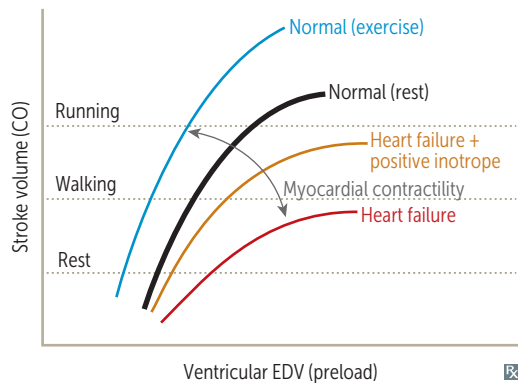
Cardiac output variables

<p>Stroke volume</p>	<p>Stroke Volume affected by Contractility, Afterload, and Preload. ↑ SV with:</p> <ul style="list-style-type: none"> ▪ ↑ Contractility (eg, anxiety, exercise) ▪ ↑ Preload (eg, early pregnancy) ▪ ↓ Afterload 	<p>SV CAP. A failing heart has ↓ SV (systolic and/or diastolic dysfunction).</p>
<p>Contractility</p>	<p>Contractility (and SV) ↑ with:</p> <ul style="list-style-type: none"> ▪ Catecholamine stimulation via β₁ receptor: <ul style="list-style-type: none"> ▪ Activated protein kinase A <ul style="list-style-type: none"> → phospholamban phosphorylation → active Ca²⁺ ATPase → ↑ Ca²⁺ storage in sarcoplasmic reticulum ▪ Activated protein kinase A → Ca²⁺ channel phosphorylation → ↑ Ca²⁺ entry → ↑ Ca²⁺-induced Ca²⁺ release ▪ ↑ intracellular Ca²⁺ ▪ ↓ extracellular Na⁺ (↓ activity of Na⁺/Ca²⁺ exchanger) ▪ Digoxin (blocks Na⁺/K⁺ pump → ↑ intracellular Na⁺ → ↓ Na⁺/Ca²⁺ exchanger activity → ↑ intracellular Ca²⁺) 	<p>Contractility (and SV) ↓ with:</p> <ul style="list-style-type: none"> ▪ β₁-blockade (↓ cAMP) ▪ Heart failure (HF) with systolic dysfunction ▪ Acidosis ▪ Hypoxia/hypercapnia (↓ PO₂/↑ PCO₂) ▪ Nondihydropyridine Ca²⁺ channel blockers
<p>Preload</p>	<p>Preload approximated by ventricular end-diastolic volume (EDV); depends on venous tone and circulating blood volume.</p>	<p>Vasodilators (eg, nitroglycerin) ↓ preload.</p>
<p>Afterload</p>	<p>Afterload approximated by MAP. ↑ wall tension per Laplace's law → ↑ pressure → ↑ afterload. LV compensates for ↑ afterload by thickening (hypertrophy) in order to ↓ wall stress.</p>	<p>Arterial vasodilators (eg, hydralazine) ↓ afterload. ACE inhibitors and ARBs ↓ both preload and afterload. Chronic hypertension (↑ MAP) → LV hypertrophy.</p>
<p>Cardiac oxygen demand</p>	<p>Myocardial O₂ demand is ↑ by:</p> <ul style="list-style-type: none"> ▪ ↑ contractility ▪ ↑ afterload (proportional to arterial pressure) ▪ ↑ heart rate ▪ ↑ diameter of ventricle (↑ wall tension) <p>Coronary sinus contains most deoxygenated blood in body.</p>	<p>Wall tension follows Laplace's law: Wall tension = pressure × radius Wall stress ∝ $\frac{\text{pressure} \times \text{radius}}{2 \times \text{wall thickness}}$</p>

Cardiac output equations

	EQUATION	NOTES
Stroke volume	$SV = EDV - ESV$	ESV = end-systolic volume.
Ejection fraction	$EF = \frac{SV}{EDV} = \frac{EDV - ESV}{EDV}$	EF is an index of ventricular contractility (↓ in systolic HF; usually normal in diastolic HF).
Cardiac output	$CO = \dot{Q} = SV \times HR$ Fick principle: $CO = \frac{\text{rate of O}_2 \text{ consumption}}{(\text{arterial O}_2 \text{ content} - \text{venous O}_2 \text{ content})}$	In early stages of exercise, CO maintained by ↑ HR and ↑ SV. In later stages, CO maintained by ↑ HR only (SV plateaus). Diastole is shortened with ↑↑ HR (eg, ventricular tachycardia) → ↓ diastolic filling time → ↓ SV → ↓ CO.
Pulse pressure	PP = systolic blood pressure (SBP) – diastolic blood pressure (DBP)	PP directly proportional to SV and inversely proportional to arterial compliance. ↑ PP in hyperthyroidism, aortic regurgitation, aortic stiffening (isolated systolic hypertension in older adults), obstructive sleep apnea (↑ sympathetic tone), anemia, exercise (transient). ↓ PP in aortic stenosis, cardiogenic shock, cardiac tamponade, advanced HF.
Mean arterial pressure	MAP = CO × total peripheral resistance (TPR)	MAP (at resting HR) = 2/3 DBP + 1/3 SBP = DBP + 1/3 PP.

Starling curves



Force of contraction is proportional to end-diastolic length of cardiac muscle fiber (preload).

↑ contractility with catecholamines, positive inotropes (eg, dobutamine, milrinone, digoxin).

↓ contractility with loss of functional myocardium (eg, MI), β-blockers (acutely), nondihydropyridine Ca²⁺ channel blockers, HF.

Resistance, pressure, flow

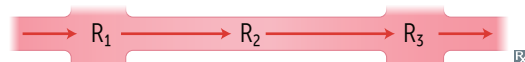
Volumetric flow rate (\dot{Q}) = flow velocity (v) × cross-sectional area (A)

Resistance

$$= \frac{\text{driving pressure } (\Delta P)}{\dot{Q}} = \frac{8\eta \text{ (viscosity)} \times \text{length}}{\pi r^4}$$


Total resistance of vessels in series:

$$R_T = R_1 + R_2 + R_3 \dots$$



Total resistance of vessels in parallel:

$$\frac{1}{R_T} = \frac{1}{R_1} + \frac{1}{R_2} + \frac{1}{R_3} \dots$$



$$Q \propto r^4$$

$$R \propto 1/r^4$$

Capillaries have highest total cross-sectional area and lowest flow velocity.

Pressure gradient drives flow from high pressure to low pressure.

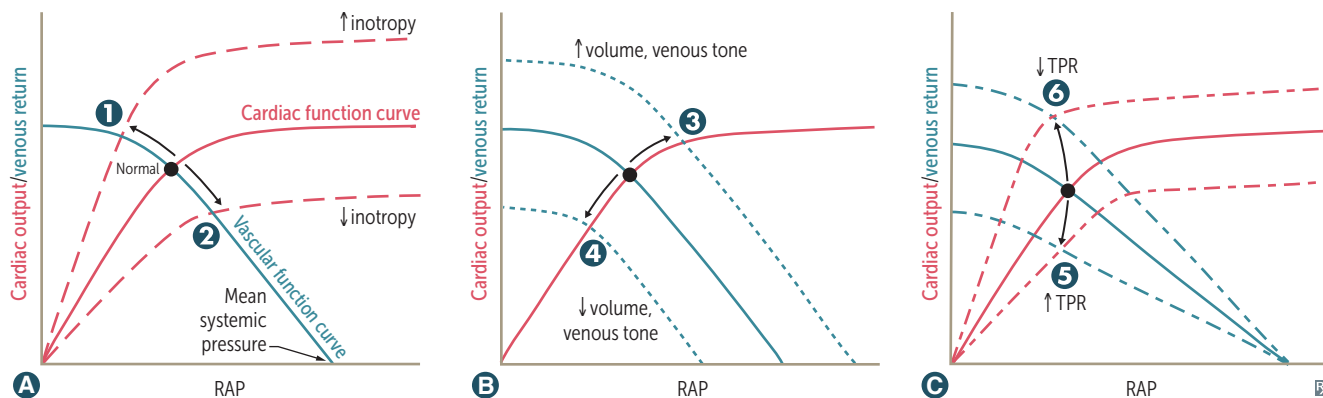
Arterioles account for most of TPR. Veins provide most of blood storage capacity.

Viscosity depends mostly on hematocrit.

Viscosity ↑ in hyperproteinemic states (eg, multiple myeloma), polycythemia.

Viscosity ↓ in anemia.

Cardiac and vascular function curves

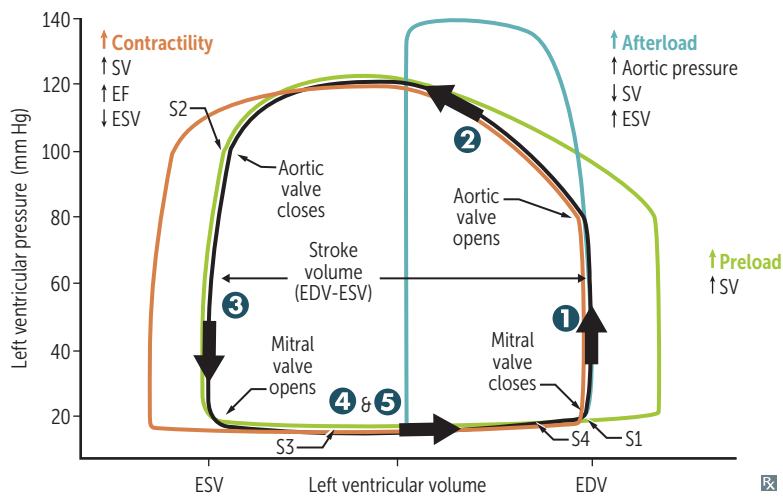


Intersection of curves = operating point of heart (ie, venous return and CO are equal, as circulatory system is a closed system).

GRAPH	EFFECT	EXAMPLES
A Inotropy	Changes in contractility → altered SV → altered CO/VR and RA pressure (RAP)	1 Catecholamines, dobutamine, milrinone, digoxin, exercise ⊕ 2 HF with reduced EF, narcotic overdose, sympathetic inhibition ⊖
B Venous return	Changes in circulating volume → altered RAP → altered SV → change in CO	3 Fluid infusion, sympathetic activity, arteriovenous shunt ⊕ 4 Acute hemorrhage, spinal anesthesia ⊖
C Total peripheral resistance	Changes in TPR → altered CO Change in RAP unpredictable	5 Vasopressors ⊕ 6 Exercise, arteriovenous shunt ⊖

Changes often occur in tandem, and may be reinforcing (eg, exercise ↑ inotropy and ↓ TPR to maximize CO) or compensatory (eg, HF ↓ inotropy → fluid retention to ↑ preload to maintain CO).

Pressure-volume loops and cardiac cycle



The black loop represents normal cardiac physiology.

Phases—left ventricle:

- 1 Isovolumetric contraction—period between mitral valve closing and aortic valve opening; period of highest O_2 consumption
- 2 Systolic ejection—period between aortic valve opening and closing
- 3 Isovolumetric relaxation—period between aortic valve closing and mitral valve opening
- 4 Rapid filling—period just after mitral valve opening
- 5 Reduced filling—period just before mitral valve closing

Heart sounds:

S1—mitral and tricuspid valve closure. Loudest at mitral area.

S2—aortic and pulmonary valve closure.

Loudest at left upper sternal border.

S3—in early diastole during rapid ventricular filling phase. Best heard at apex with patient in left lateral decubitus position. Associated with \uparrow filling pressures (eg, MR, AR, HF, thyrotoxicosis) and more common in dilated ventricles (but can be normal in children, young adults, athletes, and pregnancy). Turbulence caused by blood from LA mixing with \uparrow ESV.

S4—in late diastole (“atrial kick”). Turbulence caused by blood entering stiffened LV. Best heard at apex with patient in left lateral decubitus position. High atrial pressure. Associated with ventricular noncompliance (eg, hypertrophy). Can be normal in older adults. Considered abnormal if palpable.

Jugular venous pulse (JVP):

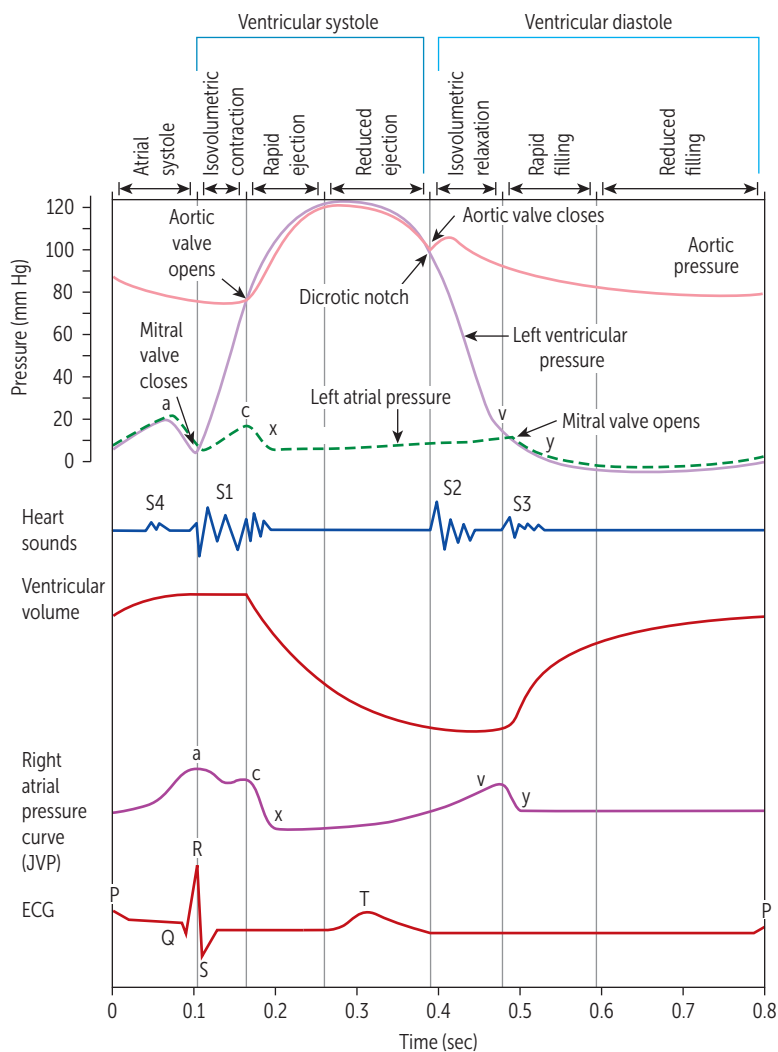
a wave—atrial contraction. Absent in atrial fibrillation.

c wave—RV contraction (closed tricuspid valve bulging into atrium).

x descent—atrial relaxation and downward displacement of closed tricuspid valve during rapid ventricular ejection phase. Reduced or absent in tricuspid regurgitation and right HF because pressure gradients are reduced.

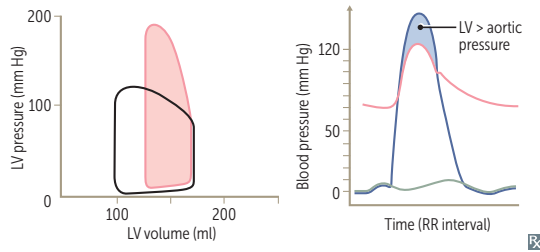
v wave— \uparrow RA pressure due to \uparrow volume against closed tricuspid valve.

y descent—RA emptying into RV. Prominent in constrictive pericarditis, absent in cardiac tamponade.



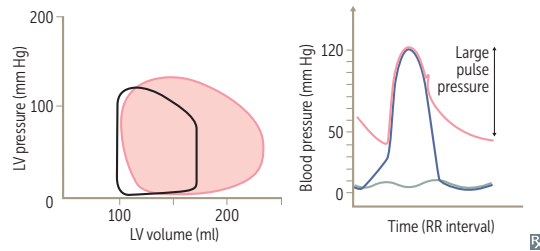
Pressure-volume loops and valvular disease

Aortic stenosis



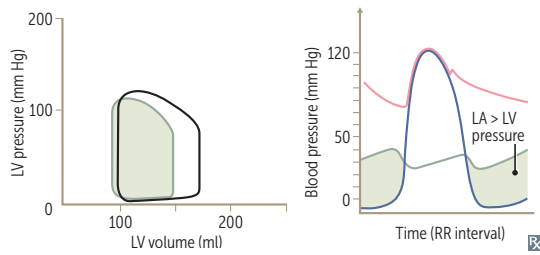
- ↑ LV pressure
- ↑ ESV
- No change in EDV (if mild)
- ↓ SV
- Ventricular hypertrophy → ↓ ventricular compliance → ↑ EDP for given EDV

Aortic regurgitation



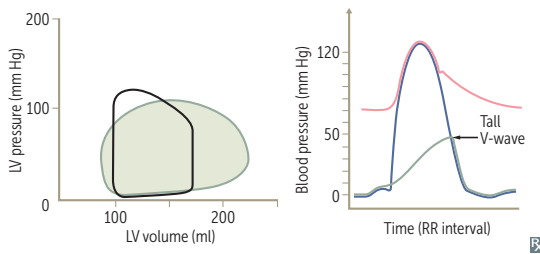
- No true isovolumetric phase
- ↑ EDV
- ↑ SV
- Loss of dicrotic notch

Mitral stenosis



- ↑ LA pressure
- ↓ EDV because of impaired ventricular filling
- ↓ ESV
- ↓ SV

Mitral regurgitation

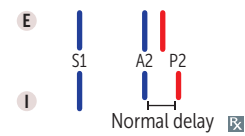


- No true isovolumetric phase
- ↓ ESV due to ↓ resistance and ↑ regurgitation into LA during systole
- ↑ EDV due to ↑ LA volume/pressure from regurgitation → ↑ ventricular filling
- ↑ SV (forward flow into systemic circulation plus backflow into LA)

Splitting of S2

Physiologic splitting

Inspiration → drop in intrathoracic pressure
 → ↑ venous return → ↑ RV filling → ↑ RV
 stroke volume → ↑ RV ejection time
 → delayed closure of pulmonic valve.
 ↓ pulmonary impedance (↑ capacity of the
 pulmonary circulation) also occurs during
 inspiration, which contributes to delayed
 closure of pulmonic valve.

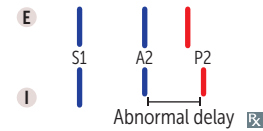


E = Expiration

I = Inspiration

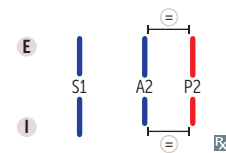
Wide splitting

Seen in conditions that delay RV emptying (eg,
 pulmonic stenosis, right bundle branch block).
 Causes delayed pulmonic sound (especially
 on inspiration). An exaggeration of normal
 splitting.



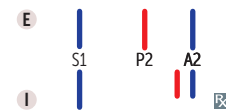
Fixed splitting

Heard in ASD. ASD → left-to-right shunt
 → ↑ RA and RV volumes → ↑ flow through
 pulmonic valve → delayed pulmonic valve
 closure (independent of respiration).



Paradoxical splitting

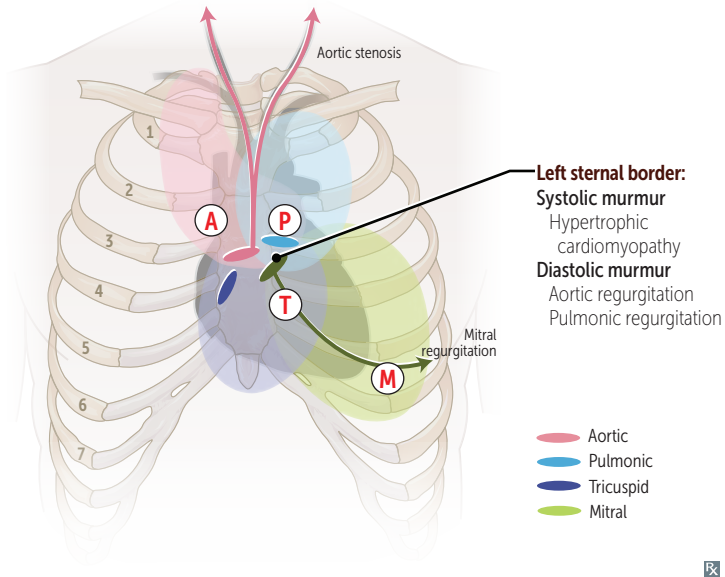
Heard in conditions that delay aortic valve
 closure (eg, aortic stenosis, left bundle branch
 block). Normal order of semilunar valve
 closure is reversed: in **paradoxical splitting** **P2**
 occurs before **A2**. On inspiration, P2 closes
 later and moves closer to A2, “paradoxically”
 eliminating the split. On expiration, the split
 can be heard (opposite to physiologic splitting).



Auscultation of the heart

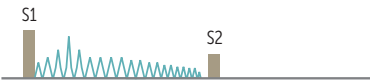
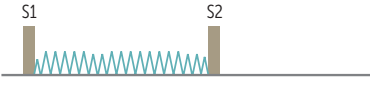
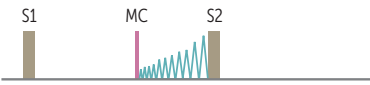
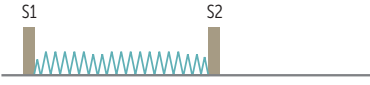
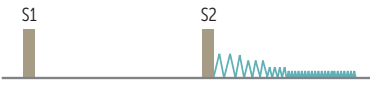
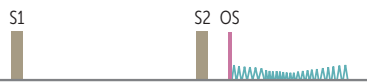
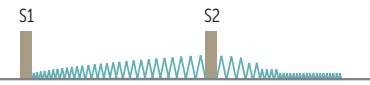
Where to listen: **APT M**

- A Aortic area:**
Systolic murmur
Aortic stenosis
Flow murmur
(eg, physiologic murmur)
Aortic valve sclerosis
- P Pulmonic area:**
Systolic ejection murmur
Pulmonic stenosis
Atrial septal defect
Flow murmur
- T Tricuspid area:**
Holosystolic murmur
Tricuspid regurgitation
Ventricular septal defect
Diastolic murmur
Tricuspid stenosis
- M Mitral area (apex):**
Systolic murmur
Mitral regurgitation
Mitral valve prolapse
Diastolic murmur
Mitral stenosis



MANEUVER	CARDIOVASCULAR CHANGES	MURMURS THAT INCREASE WITH MANEUVER	MURMURS THAT DECREASE WITH MANEUVER
Standing, Valsalva (strain phase)	↓ preload (↓ LV volume)	MVP (↓ LV volume) with earlier midsystolic click HCM (↓ LV volume)	Most murmurs (↓ flow through stenotic or regurgitant valve)
Passive leg raise	↑ preload (↑ LV volume)		MVP (↑ LV volume) with later midsystolic click HCM (↑ LV volume)
Squatting	↑ preload, ↑ afterload (↑ LV volume)	Most murmurs (↑ flow through stenotic or regurgitant valve)	
Hand grip	↑↑ afterload → ↑ reverse flow across aortic valve (↑ LV volume)	Most other left-sided murmurs (AR, MR, VSD)	AS (↓ transaortic valve pressure gradient) HCM (↑ LV volume)
Inspiration	↑ venous return to right heart, ↓ venous return to left heart	Most right-sided murmurs	Most left-sided murmurs

Heart murmurs

	AUSCULTATION	CLINICAL ASSOCIATIONS	NOTES
Systolic			
<p>Aortic stenosis</p> 	<p>Crescendo-decrescendo ejection murmur, loudest at heart base, radiates to carotids</p> <p>Soft S2 +/- ejection click</p> <p>“Pulsus parvus et tardus”—weak pulses with delayed peak</p>	<p>In older (>60 years old) patients, most commonly due to age-related calcification</p> <p>In younger patients, most commonly due to early-onset calcification of bicuspid aortic valve</p>	<p>Can lead to Syncope, Angina, Dyspnea on exertion (SAD)</p> <p>LV pressure > aortic pressure during systole</p>
<p>Mitral/tricuspid regurgitation</p> 	<p>Holosystolic, high-pitched “blowing” murmur</p> <p>MR: loudest at apex, radiates toward axilla</p> <p>TR: loudest at tricuspid area</p>	<p>MR: often due to ischemic heart disease (post-MI), MVP, LV dilatation, rheumatic fever</p> <p>TR: often due to RV dilatation</p> <p>Either MR or TR: infective endocarditis</p>	
<p>Mitral valve prolapse</p> 	<p>Late crescendo murmur with midsystolic click (MC) that occurs after carotid pulse</p> <p>Best heard over apex</p> <p>Loudest just before S2</p>	<p>Usually benign, but can predispose to infective endocarditis</p> <p>Can be caused by rheumatic fever, chordae rupture, or myxomatous degeneration (1° or 2° to connective tissue disease)</p>	<p>MC due to sudden tensing of chordae tendineae as mitral leaflets prolapse into LA (chordae cause crescendo with click)</p>
<p>Ventricular septal defect</p> 	<p>Holosystolic, harsh-sounding murmur</p> <p>Loudest at tricuspid area</p>	<p>Congenital</p>	<p>Larger VSDs have lower intensity murmur than smaller VSDs</p>
Diastolic			
<p>Aortic regurgitation</p> 	<p>Early diastolic, decrescendo, high-pitched “blowing” murmur best heard at base (aortic root dilation) or left sternal border (valvular disease)</p>	<p>Causes include BEAR:</p> <ul style="list-style-type: none"> ▪ Bicuspid aortic valve ▪ Endocarditis ▪ Aortic root dilation ▪ Rheumatic fever <p>Wide pulse pressure, pistol shot femoral pulse, pulsing nail bed (Quincke pulse)</p>	<p>Hyperdynamic pulse and head bobbing when severe and chronic</p> <p>Can progress to left HF</p>
<p>Mitral stenosis</p> 	<p>Follows opening snap (OS)</p> <p>Delayed rumbling mid-to-late murmur (↓ interval between S1 and OS correlates with ↑ severity)</p>	<p>Late and highly specific sequelae of rheumatic fever</p> <p>Chronic MS can result in LA dilation and pulmonary congestion, atrial fibrillation, Ortner syndrome, hemoptysis, right HF</p>	<p>OS due to abrupt halt in leaflet motion in diastole after rapid opening due to fusion at leaflet tips</p> <p>LA >> LV pressure during diastole</p>
Continuous			
<p>Patent ductus arteriosus</p> 	<p>Continuous machine-like murmur, best heard at left infraclavicular area</p> <p>☒ Loudest at S2</p>	<p>Often due to congenital rubella or prematurity</p>	<p>You need a patent for that machine.</p>

Myocardial action potential

Phase 0 = rapid upstroke and depolarization—voltage-gated Na^+ channels open.

Phase 1 = initial repolarization—inactivation of voltage-gated Na^+ channels. Voltage-gated K^+ channels begin to open.

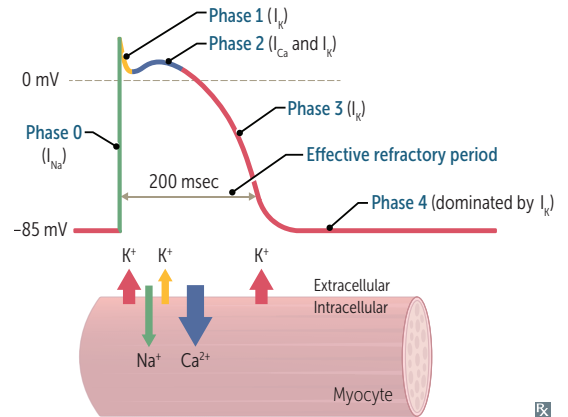
Phase 2 = plateau (“platwo”)— Ca^{2+} influx through voltage-gated Ca^{2+} channels balances K^+ efflux. Ca^{2+} influx triggers Ca^{2+} release from sarcoplasmic reticulum and myocyte contraction (excitation-contraction coupling).

Phase 3 = rapid repolarization—massive K^+ efflux due to opening of voltage-gated slow delayed-rectifier K^+ channels and closure of voltage-gated Ca^{2+} channels.

Phase 4 = resting potential—high K^+ permeability through K^+ channels.

In contrast to skeletal muscle:

- Cardiac muscle action potential has a plateau due to Ca^{2+} influx and K^+ efflux.
- Cardiac muscle contraction requires Ca^{2+} influx from ECF to induce Ca^{2+} release from sarcoplasmic reticulum (Ca^{2+} -induced Ca^{2+} release).
- Cardiac myocytes are electrically coupled to each other by gap junctions.



Occurs in all cardiac myocytes except for those in the SA and AV nodes.

Pacemaker action potential

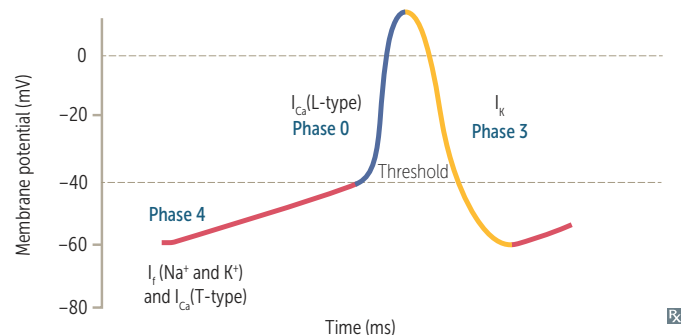
Occurs in the SA and AV nodes. Key differences from the ventricular action potential include:

Phase 0 = upstroke—opening of voltage-gated Ca^{2+} channels. Fast voltage-gated Na^+ channels are permanently inactivated because of the less negative resting potential of these cells. Results in a slow conduction velocity that is used by the AV node to prolong transmission from the atria to ventricles. Phases 1 and 2 are absent.

Phases 1 and 2 are absent.

Phase 3 = repolarization—inactivation of the Ca^{2+} channels and \uparrow activation of K^+ channels $\rightarrow \uparrow \text{K}^+$ efflux.

Phase 4 = slow spontaneous diastolic depolarization due to I_f (“funny current”). I_f channels responsible for a slow, mixed Na^+ inward/ K^+ outward current; different from I_{Na} in phase 0 of ventricular action potential. Accounts for automaticity of SA and AV nodes. The slope of phase 4 in the SA node determines HR. ACh/adenosine \downarrow the rate of diastolic depolarization and \downarrow HR, while catecholamines \uparrow depolarization and \uparrow HR. Sympathetic stimulation \uparrow the chance that I_f channels are open and thus \uparrow HR.



Electrocardiogram

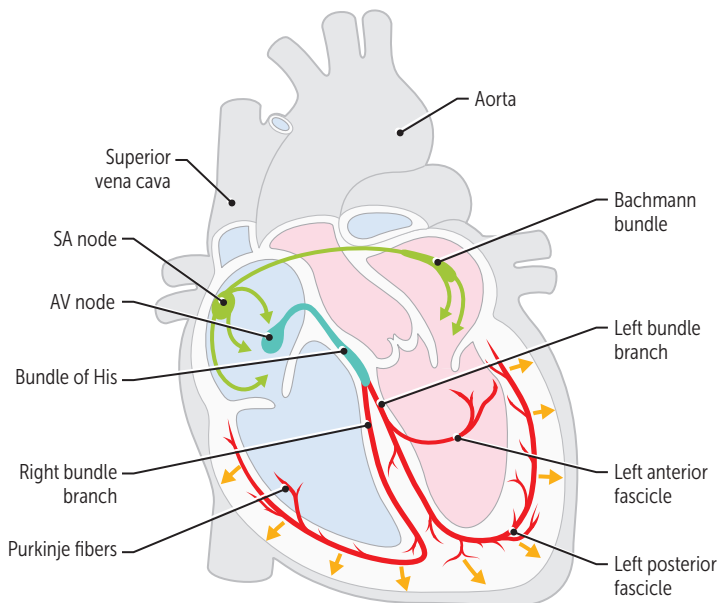
Conduction pathway: SA node → atria → AV node → bundle of His → right and left bundle branches → Purkinje fibers → ventricles; left bundle branch divides into left anterior and posterior fascicles.

SA node—located at junction of RA and SVC; “pacemaker” inherent dominance with slow phase of upstroke.

AV node—located in posteroinferior part of interatrial septum. Blood supply usually from RCA. 100-msec delay allows time for ventricular filling.

Pacemaker rates: SA > AV > bundle of His/Purkinje/ventricles.

Speed of conduction: **His-Purkinje** > **Atria** > **Ventricles** > **AV node**. **He Parks At Ventura AVenue**.



P wave—atrial depolarization.

PR interval—time from start of atrial depolarization to start of ventricular depolarization (normally 120-200 msec).

QRS complex—ventricular depolarization (normally < 100 msec).

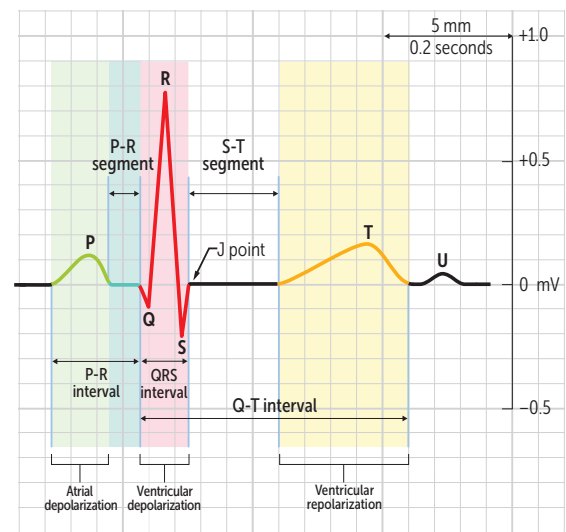
QT interval—ventricular depolarization, mechanical contraction of the ventricles, ventricular repolarization.

T wave—ventricular repolarization. T-wave inversion may indicate ischemia or recent MI.

J point—junction between end of QRS complex and start of ST segment.

ST segment—isolectric, ventricles depolarized.

U wave—prominent in hypokalemia (think hyp“U”kalemia), bradycardia.



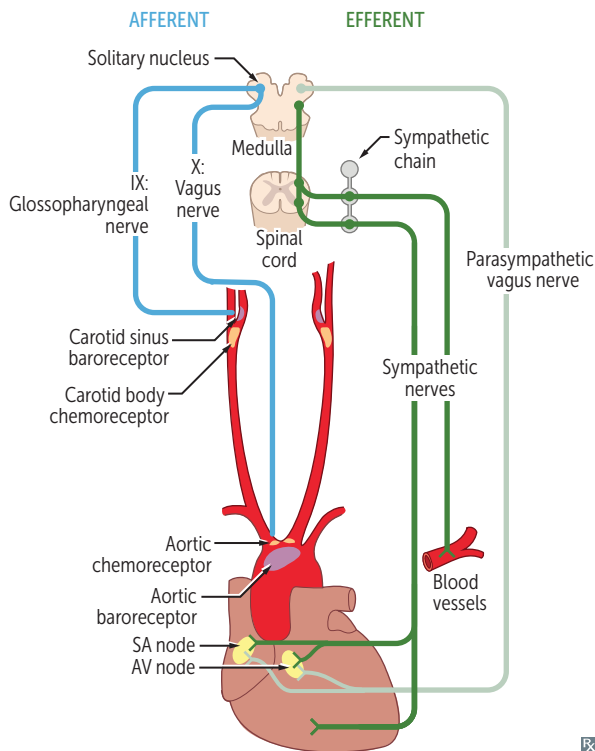
Atrial natriuretic peptide

Released from **atrial myocytes** in response to ↑ blood volume and atrial pressure. Acts via cGMP. Causes vasodilation and ↓ Na⁺ reabsorption at the renal collecting tubule. Dilates afferent renal arterioles and constricts efferent arterioles, promoting diuresis and contributing to “aldosterone escape” mechanism.

B-type (brain) natriuretic peptide

Released from **ventricular myocytes** in response to ↑ tension. Similar physiologic action to ANP, with longer half-life. BNP blood test used for diagnosing HF (very good negative predictive value).

Baroreceptors and chemoreceptors



Receptors:

- Aortic arch transmits via vagus nerve to solitary nucleus of medulla (responds to changes in BP).
- Carotid sinus (dilated region superior to bifurcation of carotid arteries) transmits via glossopharyngeal nerve to solitary nucleus of medulla (responds to changes in BP).

Chemoreceptors:

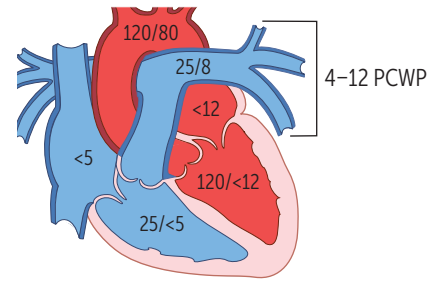
- Peripheral—carotid and aortic bodies are stimulated by ↑ PCO₂, ↓ pH of blood, and ↓ PO₂ (< 60 mm Hg).
- Central—are stimulated by changes in pH and PCO₂ of brain interstitial fluid, which in turn are influenced by arterial CO₂ as H⁺ cannot cross the blood-brain barrier. Do not directly respond to PO₂. Central chemoreceptors become less responsive with chronically ↑ PCO₂ (eg, COPD) → ↑ dependence on peripheral chemoreceptors to detect ↓ O₂ to drive respiration.

Baroreceptors:

- Hypotension—↓ arterial pressure → ↓ stretch → ↓ afferent baroreceptor firing → ↑ efferent sympathetic firing and ↓ efferent parasympathetic stimulation → vasoconstriction, ↑ HR, ↑ contractility, ↑ BP. Important in the response to hypovolemic shock.
- Carotid massage—↑ carotid sinus pressure → ↑ afferent baroreceptor firing → ↑ AV node refractory period → ↓ HR → ↓ CO. Also leads to peripheral vasodilation. Can cause presyncope/syncope. Exaggerated in underlying atherosclerosis, prior neck surgery, older age.
- Component of Cushing reflex (triad of hypertension, bradycardia, and respiratory depression)—↑ intracranial pressure constricts arterioles → cerebral ischemia → ↑ pCO₂ and ↓ pH → central reflex sympathetic ↑ in perfusion pressure (hypertension) → ↑ stretch → peripheral reflex baroreceptor-induced bradycardia.

Normal resting cardiac pressures

Pulmonary capillary wedge pressure (PCWP; in mm Hg) is a good approximation of left atrial pressure, except in mitral stenosis when PCWP > LV end diastolic pressure. PCWP is measured with pulmonary artery catheter (Swan-Ganz catheter).


Autoregulation

How blood flow to an organ remains constant over a wide range of perfusion pressures.

ORGAN	FACTORS DETERMINING AUTOREGULATION	
Lungs	Hypoxia causes vasoconstriction	The pulmonary vasculature is unique in that alveolar hypoxia causes vasoconstriction so that only well-ventilated areas are perfused. In other organs, hypoxia causes vasodilation
Heart	Local metabolites (vasodilatory): NO, CO ₂ , ↓ O ₂	
Brain	Local metabolites (vasodilatory): CO ₂ (pH)	
Kidneys	Myogenic (stretch reflex of afferent arteriole) and tubuloglomerular feedback	
Skeletal muscle	Local metabolites during exercise (vasodilatory): CO₂, H⁺, Adenosine, Lactate, K⁺ At rest: sympathetic tone in arteries	
Skin	Sympathetic vasoconstriction most important mechanism for temperature control	

Capillary fluid exchange

Starling forces determine fluid movement through capillary membranes:

- P_c = capillary hydrostatic pressure—pushes fluid out of capillary
- P_i = interstitial hydrostatic pressure—pushes fluid into capillary
- π_c = plasma oncotic pressure—pulls fluid into capillary
- π_i = interstitial fluid oncotic pressure—pulls fluid out of capillary

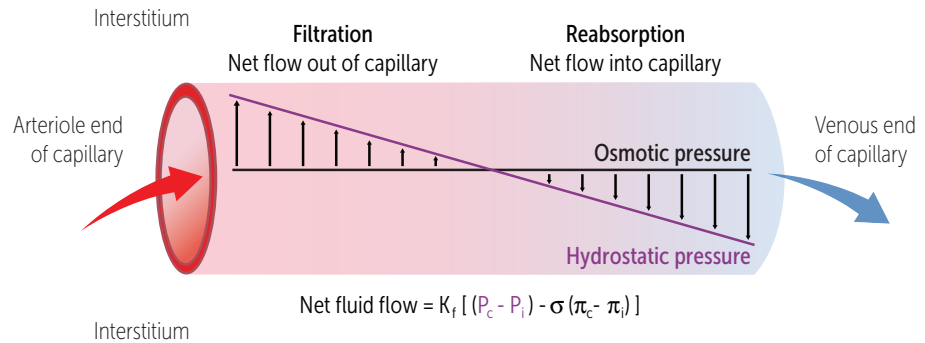
$$J_v = \text{net fluid flow} = K_f [(P_c - P_i) - \sigma(\pi_c - \pi_i)]$$

K_f = capillary permeability to fluid

σ = reflection coefficient (measure of capillary impermeability to protein)

Edema—excess fluid outflow into interstitium commonly caused by:

- \uparrow capillary pressure ($\uparrow P_c$; eg, HF)
- \uparrow capillary permeability ($\uparrow K_f$; eg, toxins, infections, burns)
- \uparrow interstitial fluid oncotic pressure ($\uparrow \pi_i$; eg, lymphatic blockage)
- \downarrow plasma proteins ($\downarrow \pi_c$; eg, nephrotic syndrome, liver failure, protein malnutrition)



▶ CARDIOVASCULAR—PATHOLOGY

Congenital heart diseases

RIGHT-TO-LEFT SHUNTS

Early cyanosis—“blue babies.” Often diagnosed prenatally or become evident immediately after birth. Usually require urgent surgical treatment and/or maintenance of a PDA.

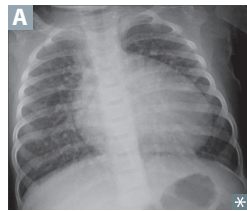
The **5 T**'s:

1. **T**runcus arteriosus (**1** vessel)
2. **T**ransposition (**2** switched vessels)
3. **T**ricuspid atresia (**3** = **Tri**)
4. **T**etralogy of Fallot (**4** = **Tetra**)
5. **TAPVR** (**5** letters in the name)

Persistent truncus arteriosus

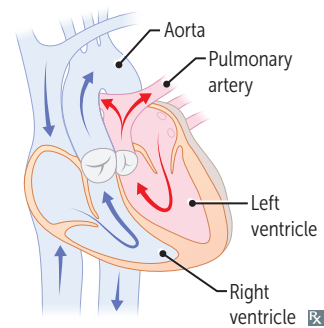
Truncus arteriosus fails to divide into pulmonary trunk and aorta due to failure of aorticopulmonary septum formation; most patients have accompanying VSD.

D-transposition of great arteries



Aorta leaves RV (anterior) and pulmonary trunk leaves LV (posterior) → separation of systemic and pulmonary circulations. Not compatible with life unless a shunt is present to allow mixing of blood (eg, VSD, PDA, or patent foramen ovale).

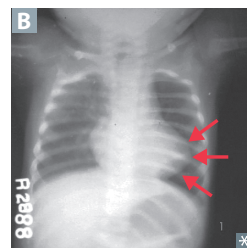
Due to failure of the aorticopulmonary septum to spiral (“egg on a string” appearance on CXR) **A**. Without surgical intervention, most infants die within the first few months of life.



Tricuspid atresia

Absence of tricuspid valve and hypoplastic RV; requires both ASD and VSD for viability.

Tetralogy of Fallot



Caused by anterosuperior displacement of the infundibular septum. Most common cause of early childhood cyanosis.

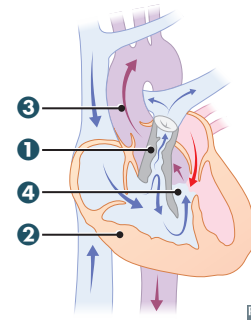
- 1 **P**ulmonary infundibular stenosis (most important determinant for prognosis)
- 2 **R**ight ventricular hypertrophy (RVH)—boot-shaped heart on CXR **B**
- 3 **O**verriding aorta
- 4 **V**SD

Pulmonary stenosis forces right-to-left flow across VSD → RVH, “tet spells” (often caused by crying, fever, and exercise due to exacerbation of RV outflow obstruction).

PROVe.

Squatting: ↑ SVR, ↓ right-to-left shunt, improves cyanosis.

Associated with 22q11 syndromes.



Total anomalous pulmonary venous return

Pulmonary veins drain into right heart circulation (SVC, coronary sinus, etc); associated with ASD and sometimes PDA to allow for right-to-left shunting to maintain CO.

Ebstein anomaly

Displacement of tricuspid valve leaflets downward into RV, artificially “atrializing” the ventricle. Associated with tricuspid regurgitation, accessory conduction pathways, right-sided HF.

Can be caused by lithium exposure in utero.

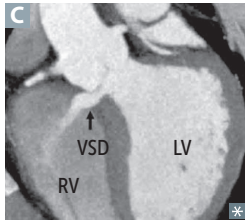
Congenital heart diseases (continued)

LEFT-TO-RIGHT SHUNTS

Acyanotic at presentation; cyanosis may occur years later. Frequency: VSD > ASD > PDA.

Right-to-left shunts: **early** cyanosis.
Left-to-right shunts: **“later”** cyanosis.

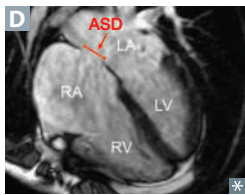
Ventricular septal defect



Asymptomatic at birth, may manifest weeks later or remain asymptomatic throughout life. Most self resolve; larger lesions **C** may lead to LV overload and HF.

O₂ saturation ↑ in RV and pulmonary artery.

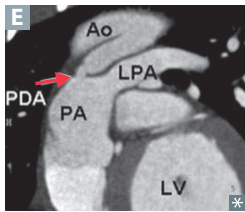
Atrial septal defect



Defect in interatrial septum **D**; wide, fixed split S2. Ostium secundum defects most common and usually an isolated finding; ostium primum defects rarer and usually occur with other cardiac anomalies. Symptoms range from none to HF. Distinct from patent foramen ovale, which is due to **failed fusion**.

O₂ saturation ↑ in RA, RV, and pulmonary artery. May lead to paradoxical emboli (systemic venous emboli use ASD to bypass lungs and become systemic arterial emboli). Associated with Down syndrome.

Patent ductus arteriosus

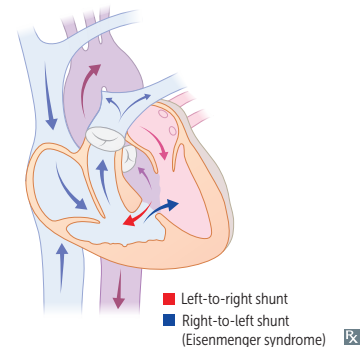


In fetal period, shunt is right to left (normal). In neonatal period, ↓ pulmonary vascular resistance → shunt becomes left to right → progressive RVH and/or LVH and HF. Associated with a continuous, “machinelike” murmur. Patency is maintained by PGE synthesis and low O₂ tension. Uncorrected PDA **E** can eventually result in late cyanosis in the lower extremities (differential cyanosis).

PDA is normal in utero and normally closes only after birth.

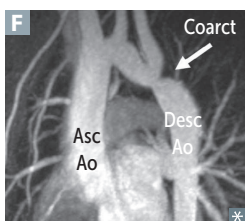
Eisenmenger syndrome

Uncorrected left-to-right shunt (VSD, ASD, PDA) → ↑ pulmonary blood flow → pathologic remodeling of vasculature → pulmonary arterial hypertension. RVH occurs to compensate → shunt becomes right to left when RV > LV pressure (see illustration). Causes late cyanosis, clubbing, and polycythemia. Age of onset varies depending on size and severity of initial left-to-right shunt.



OTHER ANOMALIES

Coarctation of the aorta



Aortic narrowing **F** near insertion of ductus arteriosus (“juxtaductal”). Associated with bicuspid aortic valve, other heart defects, and Turner syndrome. Hypertension in upper extremities. Lower extremities are cold with weak, delayed pulses (brachiofemoral delay). With age, intercostal arteries enlarge due to collateral circulation; arteries erode ribs → notched appearance on CXR. Complications include HF, ↑ risk of cerebral hemorrhage (berry aneurysms), aortic rupture, and possible infective endocarditis.

Congenital cardiac defect associations

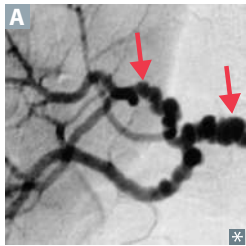
ASSOCIATION	DEFECT
Prenatal alcohol exposure (fetal alcohol syndrome)	VSD, PDA, ASD, tetralogy of Fallot
Congenital rubella	PDA, pulmonary artery stenosis, septal defects
Down syndrome	AV septal defect (endocardial cushion defect), VSD, ASD
Infant of patient with diabetes during pregnancy	Transposition of great vessels, truncus arteriosus, tricuspid atresia, VSD
Marfan syndrome	MVP, thoracic aortic aneurysm and dissection, aortic regurgitation
Prenatal lithium exposure	Ebstein anomaly
Turner syndrome	Bicuspid aortic valve, coarctation of aorta
Williams syndrome	Supravalvular aortic stenosis
22q11 syndromes	Truncus arteriosus, tetralogy of Fallot

Hypertension

Persistent systolic BP \geq 130 mm Hg and/or diastolic BP \geq 80 mm Hg.

RISK FACTORS

↑ age, obesity, diabetes, physical inactivity, high-sodium diet, excess alcohol intake, tobacco smoking, family history; incidence greatest in Black > White > Asian populations.

FEATURES

90% of hypertension is 1° (essential) and related to ↑ CO or ↑ TPR. Remaining 10% mostly 2° to renal/renovascular diseases such as fibromuscular dysplasia (characteristic “string of beads” appearance of renal artery **A**, usually seen in adult females) and atherosclerotic renal artery stenosis or to 1° hyperaldosteronism.

Hypertensive urgency—severe (\geq 180/ \geq 120 mm Hg) hypertension without acute end-organ damage.

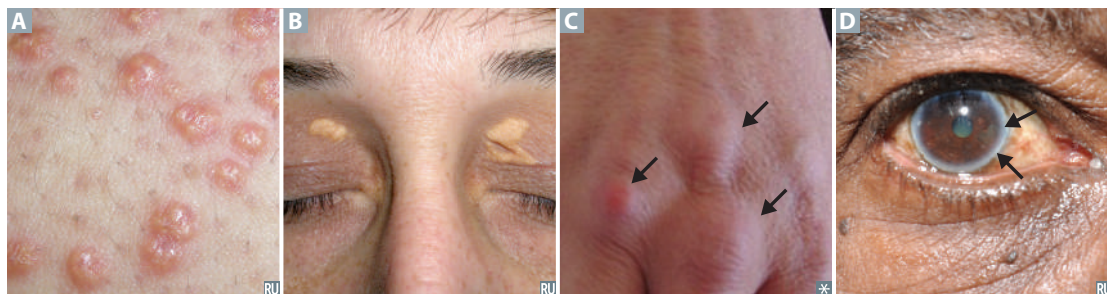
Hypertensive emergency—formerly called malignant hypertension. Severe hypertension with evidence of acute end-organ damage (eg, encephalopathy, stroke, retinal hemorrhages and exudates, papilledema, MI, HF, aortic dissection, kidney injury, microangiopathic hemolytic anemia, eclampsia). Arterioles may show fibrinoid necrosis.

PREDISPOSES TO

CAD, LVH, HF, atrial fibrillation; aortic dissection, aortic aneurysm; stroke; CKD (hypertensive nephropathy); retinopathy.

Hyperlipidemia signs

Xanthomas	Plaques or nodules composed of lipid-laden histiocytes in skin A , especially the eyelids (xanthelasma B).
Tendinous xanthoma	Lipid deposit in tendon C , especially Achilles tendon and finger extensors.
Corneal arcus	Lipid deposit in cornea. Common in older adults (arcus senilis D), but appears earlier in life with hypercholesterolemia.

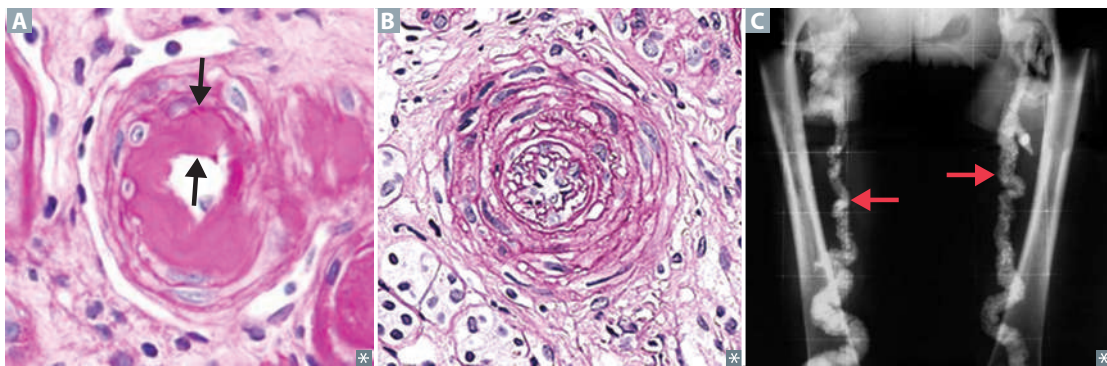


Arteriosclerosis

Hardening of arteries, with arterial wall thickening and loss of elasticity.

Arteriolosclerosis	Common. Affects small arteries and arterioles. Two types: <ul style="list-style-type: none"> ▪ Hyaline—thickening of vessel walls 2° to plasma protein leak into endothelium in essential hypertension or diabetes mellitus A. ▪ Hyperplastic—“onion skinning” B in severe hypertension with proliferation of smooth muscle cells.
---------------------------	--

Mönckeberg sclerosis	Also called m edial calcific sclerosis. Uncommon. Affects m edium-sized arteries. Calcification of internal elastic lamina and media of arteries → vascular stiffening without obstruction. “Pipestem” appearance on x-ray C . Does not obstruct blood flow; intima not involved.
-----------------------------	--



Cholesterol emboli syndrome

Microembolization of cholesterol displaced from atherosclerotic plaques in large arteries (usually the aorta). Results in end-organ damage due to small artery emboli and an inflammatory response (eg, livedo reticularis, digital ischemia [blue toe syndrome], acute renal failure, cerebrovascular accident, gut ischemia). Pulses remain palpable because larger arteries are unaffected. May follow invasive vascular procedures (angiography, angioplasty, endovascular grafting).

Atherosclerosis

Very common. Disease of elastic arteries and large- and medium-sized muscular arteries; a form of arteriosclerosis caused by buildup of cholesterol plaques in tunica intima.

LOCATION

Abdominal aorta > coronary artery > popliteal artery > carotid artery > circle of Willis.
A copy cat named Willis.

RISK FACTORS

Modifiable: hypertension, tobacco smoking, dyslipidemia (↑ LDL, ↓ HDL), diabetes.
Non-modifiable: age, male sex, postmenopausal status, family history.

SYMPTOMS

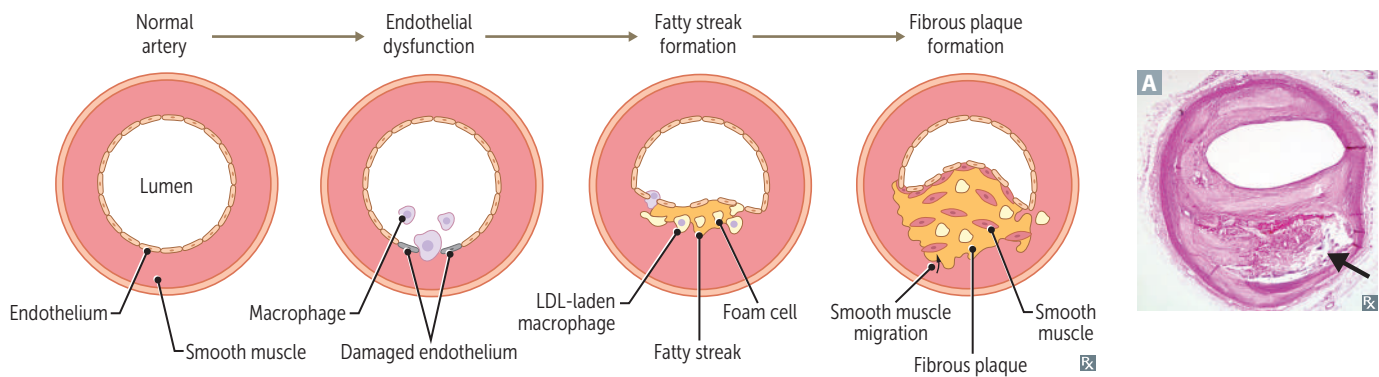
Angina, claudication, but can be asymptomatic.

PROGRESSION

Inflammation important in pathogenesis: endothelial cell dysfunction → macrophage and LDL accumulation → foam cell formation → fatty streaks → smooth muscle cell migration (involves PDGF and FGF), proliferation, and extracellular matrix deposition → fibrous plaque → complex atheromas **A** → calcification (calcium content correlates with risk of complications).

COMPLICATIONS

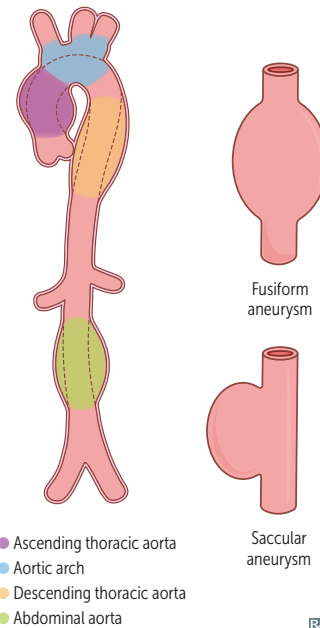
Aneurysms, ischemia, infarcts, peripheral vascular disease, thrombus, emboli.

**Aortic aneurysm**

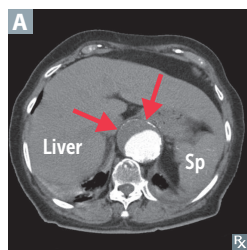
Localized pathologic dilation of the aorta. May cause abdominal and/or back pain, which is a sign of leaking, dissection, or imminent rupture.

Thoracic aortic aneurysm

Associated with cystic medial degeneration. Risk factors include hypertension, bicuspid aortic valve, connective tissue disease (eg, Marfan syndrome). Also associated with 3° syphilis (obliterative endarteritis of the vasa vasorum). Aortic root dilatation may lead to aortic valve regurgitation.

**Abdominal aortic aneurysm**

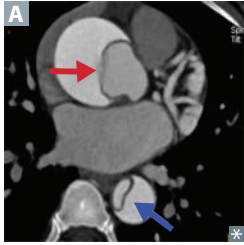
Associated with transmural (all 3 layers) inflammation and extracellular matrix degradation. Risk factors include tobacco use, ↑ age, male sex, family history. May present as palpable pulsatile abdominal mass (arrows in **A** point to outer dilated aortic wall). Rupture may present as triad of pulsatile abdominal mass, acute abdominal/back pain, and resistant hypotension. Most often infrarenal (distribution of vasa vasorum is reduced).



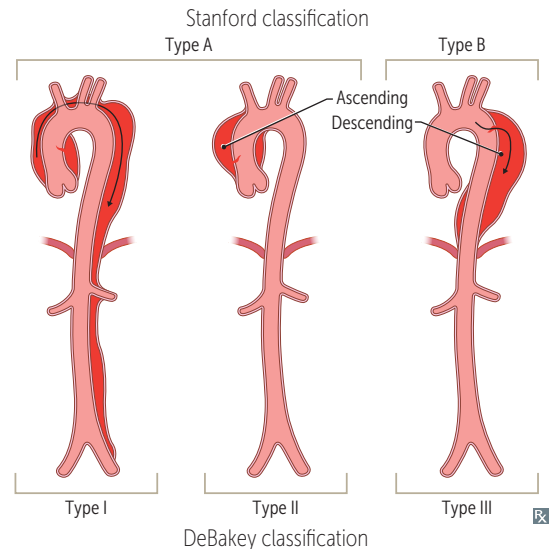
Traumatic aortic rupture

Due to trauma and/or deceleration injury, most commonly at aortic isthmus (proximal descending aorta just distal to origin of left subclavian artery). X-ray may reveal widened mediastinum.

Aortic dissection

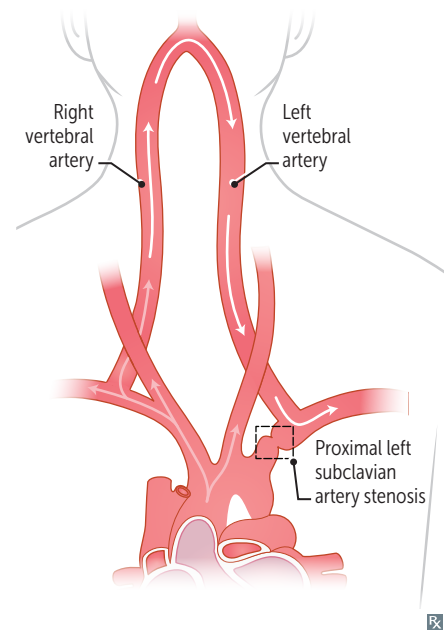


Longitudinal intimal tear forming a false lumen. Associated with hypertension, bicuspid aortic valve, inherited connective tissue disorders (eg, Marfan syndrome). Can present with tearing, sudden-onset chest pain radiating to the back +/- markedly unequal BP in arms. CXR can show mediastinal widening. Can result in organ ischemia, aortic rupture, death. Stanford type **A** (proximal): involves **A**scending aorta (red arrow in **A**). May extend to aortic arch or descending aorta (blue arrow in **A**). May result in acute aortic regurgitation or cardiac tamponade. Treatment: surgery. Stanford type **B** (distal): involves only descending aorta (**B**elow left subclavian artery). Treatment: β -blockers, then vasodilators.



Subclavian steal syndrome

Stenosis of subclavian artery proximal to origin of vertebral artery → hypoperfusion distal to stenosis → reversed blood flow in ipsilateral vertebral artery → reduced cerebral perfusion on exertion of affected arm. Causes arm ischemia, pain, paresthesia, vertebrobasilar insufficiency (dizziness, vertigo). >15 mm Hg difference in systolic BP between arms. Associated with arteriosclerosis, Takayasu arteritis, heart surgery.

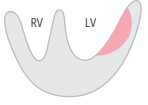

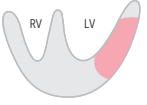



Ischemic heart disease manifestations

Angina

Chest pain due to ischemic myocardium 2° to coronary artery narrowing or spasm; no necrosis.

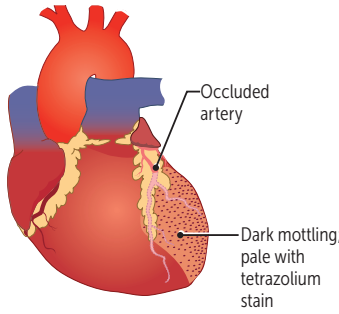
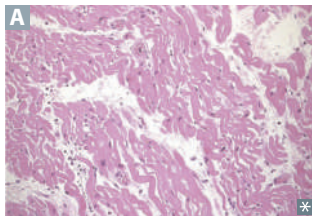
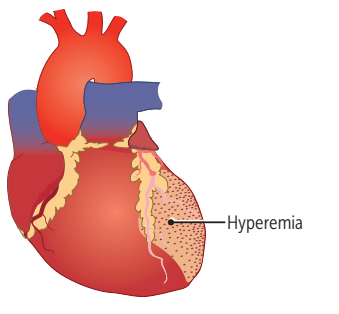
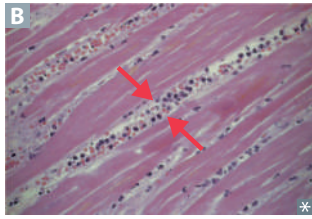
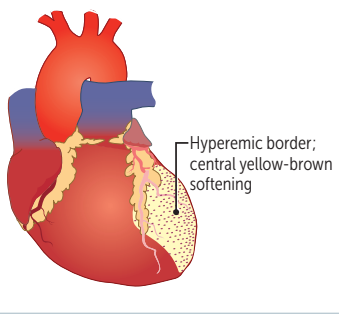
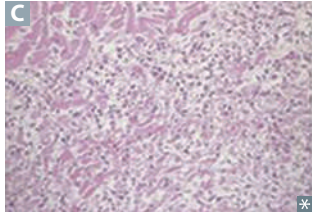
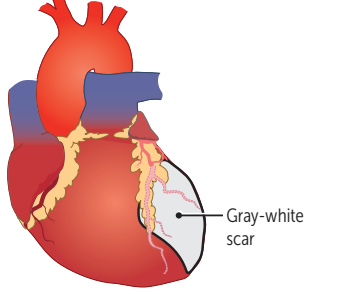
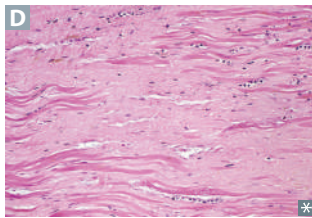
- **Stable**—usually 2° to atherosclerosis ($\geq 70\%$ occlusion); exertional chest pain in classic distribution (possibly with ST depression on ECG), resolving with rest or nitroglycerin.
- **Vasospastic** (formerly Prinzmetal or variant)—occurs at rest 2° to coronary artery spasm; transient ST elevation on ECG. Tobacco smoking is a risk factor; hypertension and hypercholesterolemia are not. Triggers include cocaine, alcohol, and triptans. Treat with Ca²⁺ channel blockers, nitrates, and smoking cessation (if applicable).
- **Unstable**—thrombosis with incomplete coronary artery occlusion; +/- ST depression and/or T-wave inversion on ECG but no cardiac biomarker elevation (unlike non-ST-segment elevation MI [STEMI]); ↑ in frequency or intensity of chest pain or any chest pain at rest.

	Stable Angina	Unstable Angina	NSTEMI	STEMI
PAIN	On exertion	Mild exertion or at rest	At rest	At rest
TROPONIN LEVEL	No elevation	No elevation	Elevated	Elevated
INFARCTION	None	None	 Subendocardial 	 Transmural 
ECG CHANGES	None	Possible ST depressions or T-wave inversions	ST depression	ST elevation
Coronary steal syndrome	Distal to coronary stenosis, vessels are maximally dilated at baseline. Administration of vasodilators (eg, dipyridamole, regadenoson) dilates normal vessels → blood is shunted toward well-perfused areas → ischemia in myocardium perfused by stenosed vessels. Principle behind pharmacologic stress tests with coronary vasodilators.			
Sudden cardiac death	Death occurs within 1 hour of symptoms, most commonly due to lethal arrhythmia (eg, ventricular fibrillation). Associated with CAD (up to 70% of cases), cardiomyopathy (hypertrophic, dilated), and hereditary ion channelopathies (eg, long QT syndrome, Brugada syndrome). Prevent with ICD.			
Chronic ischemic heart disease	Progressive onset of HF over many years due to chronic ischemic myocardial damage. Myocardial hibernation —potentially reversible LV systolic dysfunction in the setting of chronic ischemia. Contrast with myocardial stunning , a transient LV systolic dysfunction after a brief episode of acute ischemia.			
Myocardial infarction	Most often due to rupture of coronary artery atherosclerotic plaque → acute thrombosis. ↑ cardiac biomarkers (CK-MB, troponins) are diagnostic.			
	NSTEMI		STEMI	
INFARCT LOCATION	Subendocardial		Transmural	
LAYERS INVOLVED	Subendocardium (inner 1/3) especially vulnerable to ischemia		Full thickness of myocardial wall	
ECG CHANGES	ST-segment depression		ST-segment elevation, pathologic Q waves	

Evolution of myocardial infarction

Commonly occluded coronary arteries: LAD > RCA > circumflex.

Symptoms: diaphoresis, nausea, vomiting, severe retrosternal pain, pain in left arm and/or jaw, shortness of breath, fatigue.

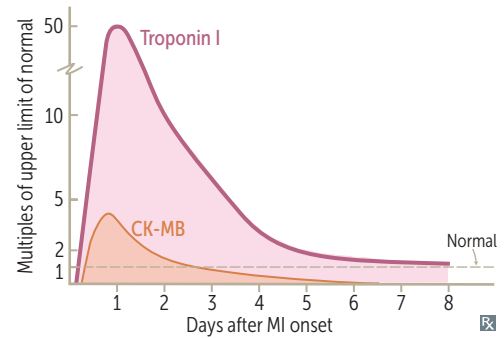
TIME	GROSS	LIGHT MICROSCOPE	COMPLICATIONS
0–24 hours	 <p>Occluded artery</p> <p>Dark mottling; pale with tetrazolium stain</p>	<p>Wavy fibers (0–4 hr), early coagulative necrosis (4–24 hr)</p> <p>A → cell content released into blood; edema, hemorrhage</p> <p>Reperfusion injury → free radicals and ↑ Ca²⁺ influx → hypercontraction of myofibrils (dark eosinophilic stripes)</p> 	Ventricular arrhythmia, HF, cardiogenic shock
1–3 days	 <p>Hyperemia</p>	<p>Extensive coagulative necrosis</p> <p>Tissue surrounding infarct shows acute inflammation with neutrophils B</p> 	Postinfarction fibrinous pericarditis
3–14 days	 <p>Hyperemic border; central yellow-brown softening</p>	<p>Macrophages, then granulation tissue at margins C</p> 	Free wall rupture → tamponade; papillary muscle rupture → mitral regurgitation; interventricular septal rupture due to macrophage-mediated structural degradation → left-to-right shunt LV pseudoaneurysm (risk of rupture)
2 weeks to several months	 <p>Gray-white scar</p>	<p>Contracted scar complete D</p> 	Dressler syndrome, HF, arrhythmias, true ventricular aneurysm (risk of mural thrombus)

Diagnosis of myocardial infarction

In the first 6 hours, ECG is the gold standard. Cardiac troponin I rises after 4 hours (peaks at 24 hr) and is ↑ for 7–10 days; more specific than other protein markers.

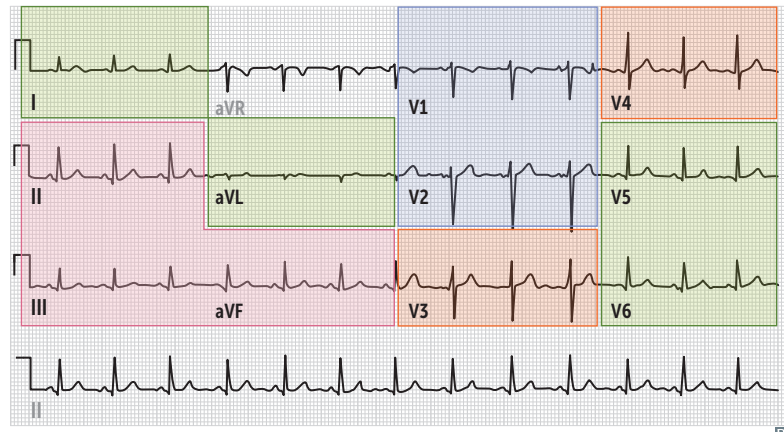
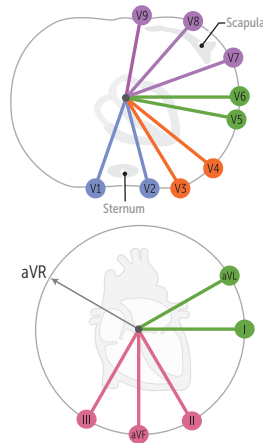
CK-MB increases after 6–12 hours (peaks at 16–24 hr) and is predominantly found in myocardium but can also be released from skeletal muscle. Useful in diagnosing reinfarction following acute MI because levels return to normal after 48 hours.

ECG changes can include ST elevation (STEMI, transmural infarct), ST depression (NSTEMI, subendocardial infarct), hyperacute (peaked) T waves, T-wave inversion, and pathologic Q waves or poor R wave progression (evolving or old transmural infarct).

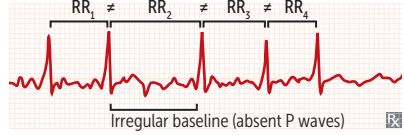
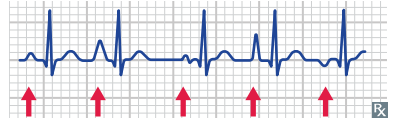
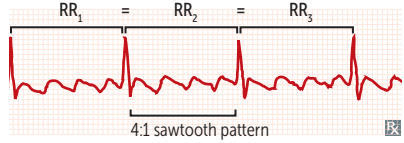
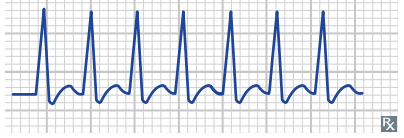
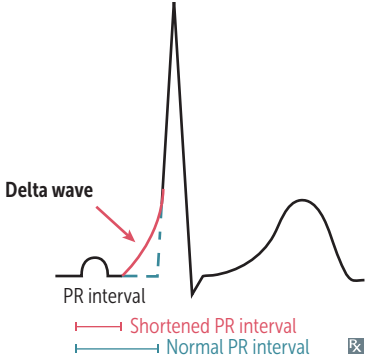


ECG localization of STEMI

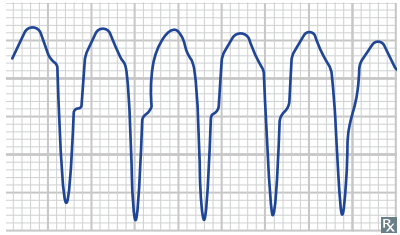
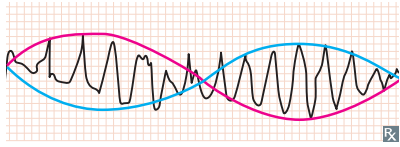


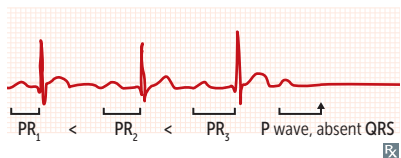
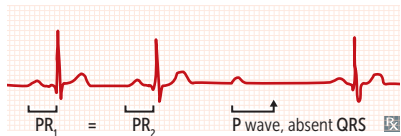
INFARCT LOCATION	LEADS WITH ST-SEGMENT ELEVATIONS OR Q WAVES
Anteroseptal (LAD)	V ₁ –V ₂
Anteroapical (distal LAD)	V ₃ –V ₄
Anterolateral (LAD or LCX)	V ₅ –V ₆
Lateral (LCX)	I, aVL
InFerior (RCA)	II, III, aVF
Posterior (PDA)	V ₇ –V ₉ , ST depression in V ₁ –V ₃ with tall R waves



Narrow complex tachycardias

ARRHYTHMIA	DESCRIPTION	ECG FINDINGS
Atrial fibrillation	Irregularly irregular rate and rhythm with no discrete P waves. Common risk factors include hypertension and CAD. May predispose to thromboembolic events, particularly stroke. Management: rate and rhythm control, cardioversion. Definitive treatment is ablation of pulmonary vein ostia or left atrial appendage. Consider anticoagulation based on stroke risk.	
Multifocal atrial tachycardia	Irregularly irregular rate and rhythm with at least 3 distinct P wave morphologies, due to multiple ectopic foci in atria. Associated with underlying conditions such as COPD, pneumonia, HF.	
Atrial flutter	Rapid succession of identical, consecutive atrial depolarization waves causing “sawtooth” appearance of P waves. Treat like atrial fibrillation +/- catheter ablation of region between tricuspid annulus and IVC.	
Paroxysmal supraventricular tachycardia	Most often due to a reentrant tract between atrium and ventricle, most commonly in AV node. Commonly presents with sudden-onset palpitations, lightheadedness, diaphoresis. Treatment: terminate reentry rhythm by slowing AV node conduction (eg, vagal maneuvers, IV adenosine), electrical cardioversion if hemodynamically unstable. Definitive treatment is catheter ablation of reentry tract.	
Wolff-Parkinson-White syndrome	Most common type of ventricular preexcitation syndrome. Abnormal fast accessory conduction pathway from atria to ventricle (bundle of Kent) bypasses rate-slowing AV node → ventricles partially depolarize earlier → characteristic delta wave with widened QRS complex and shortened PR interval. May result in reentry circuit → supraventricular tachycardia. Treatment: procainamide. Avoid AV nodal blocking drugs.	

Wide complex tachycardias

ARRHYTHMIA	DESCRIPTION	ECG FINDINGS
Ventricular tachycardia	Typically regular rhythm, rate > 100, QRS > 120 ms. Most commonly due to structural heart disease (eg cardiomyopathy, scarring after myocardial infarction). High risk of sudden cardiac death.	
Torsades de pointes	Polymorphic ventricular tachycardia. Shifting sinusoidal waveforms. May progress to ventricular fibrillation. Long QT interval predisposes to torsades de pointes. Caused by drugs, ↓ K ⁺ , ↓ Mg ²⁺ , ↓ Ca ²⁺ . Torsades de pointes = twisting of the points Treatment: magnesium sulfate. Drug-induced long QT (ABCDEF+NO): <ul style="list-style-type: none"> ▪ anti-Arrhythmics (Ia and III), Arsenic ▪ anti-Biotics (macrolides, fluoroquinolones) ▪ anti-Cychotics (haloperidol), Chloroquine ▪ anti-Depressants (TCAs), Diuretics (thiazides) ▪ anti-Emetics (ondansetron) ▪ anti-Fungals (Fluconazole) ▪ Navir (protease inhibitors) ▪ Opioids (methadone) 	
Ventricular fibrillation	Disorganized rhythm with no identifiable waves. Treatment: fatal without immediate CPR and defibrillation.	 No discernible rhythm
Conduction blocks		
ARRHYTHMIA	DESCRIPTION	ECG FINDINGS
First-degree AV block	Prolonged PR interval (>200 msec). Treatment: none required (benign and asymptomatic).	
Second-degree AV block		
Mobitz type I (Wenckebach)	Progressive lengthening of PR interval until a beat is “dropped” (P wave not followed by QRS complex). Variable RR interval with a pattern (regularly irregular). Treatment: none required (usually asymptomatic)	
Mobitz type II	Dropped beats that are not preceded by a change in PR interval. May progress to 3rd-degree block, as it usually indicates a structural abnormality such as ischemia, fibrosis, or sclerosis. Treatment: usually a pacemaker.	

Conduction blocks (continued)

ARRHYTHMIA	DESCRIPTION	ECG FINDINGS
Third-degree (complete) AV block	<p>P waves and QRS complexes rhythmically dissociated. Atria and ventricles beat independently of each other. Atrial rate > ventricular rate.</p> <p>May be caused by Lyme disease.</p> <p>Treatment: usually a pacemaker.</p>	
Bundle branch block	<p>Interruption of conduction of normal left or right bundle branches. Affected ventricle depolarizes via slower myocyte-to-myocyte conduction from the unaffected ventricle, which depolarizes via the faster His-Purkinje system.</p> <p>Commonly due to ischemic (eg, MI) or degenerative (eg, cardiomyopathy, infiltrative disease) changes.</p>	

Premature beats

ARRHYTHMIA	DESCRIPTION	ECG FINDINGS
Premature atrial contraction	<p>Extra beats arising from ectopic foci in atria instead of the SA node. Often 2° to ↑ adrenergic drive (eg, caffeine consumption). Benign, but may increase risk for atrial fibrillation and flutter.</p> <p>Narrow QRS complex with preceding P wave on ECG.</p>	
Premature ventricular contraction	<p>Ectopic beats arising from ventricle instead of the SA node. Shortened diastolic filling time → ↓ SV compared to a normal beat. Prognosis is largely influenced by underlying heart disease.</p> <p>Wide QRS complex with no preceding P wave on ECG.</p>	

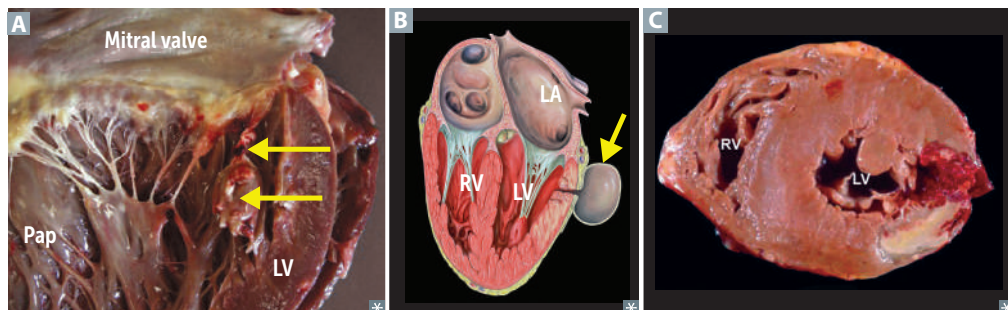
Hereditary channelopathies

ARRHYTHMIA	DESCRIPTION
Brugada syndrome	<p>Autosomal dominant. Most commonly due to loss of function mutation of Na⁺ channels. Pseudoright bundle branch block and ST-segment elevations in leads V1-V2 on ECG.</p> <p>Treatment: prevent sudden cardiac death with ICD.</p>
Congenital long QT syndrome	<p>Caused by mutations of <i>KCNQ1</i> → loss of function mutation of K⁺ channels (affects repolarization).</p> <p>Includes</p> <ul style="list-style-type: none"> ▪ Romano-Ward syndrome—autosomal dominant, pure cardiac phenotype (no deafness). ▪ Jervell and Lange-Nielsen syndrome—autosomal recessive, sensorineural deafness.

Sick sinus syndrome	<p>Age-related degeneration of SA node. ECG can show bradycardia, sinus pauses, sinus arrest, junctional escape beats.</p>	
----------------------------	--	--

Myocardial infarction complications

COMPLICATION	TIMEFRAME	FINDINGS	NOTES
Cardiac arrhythmia	First few days to several weeks	Can be supraventricular arrhythmias, ventricular arrhythmias, or conduction blocks.	Due to myocardial death and scarring. Important cause of death before reaching the hospital and within the first 48 hours post-MI.
Peri-infarction pericarditis	1–3 days	Pleuritic chest pain, pericardial friction rub, ECG changes, and/or small pericardial effusion.	Usually self-limited.
Papillary muscle rupture	2–7 days	Can result in acute mitral regurgitation → cardiogenic shock, severe pulmonary edema.	Posteromedial >> anterolateral papillary muscle rupture A , as the posteromedial has single artery blood supply (PDA) whereas anterolateral has dual (LAD, LCX).
Interventricular septal rupture	3–5 days	Symptoms can range from mild to severe with cardiogenic shock and pulmonary edema.	Macrophage-mediated degradation → VSD → ↑ O ₂ saturation and ↑ pressure in RV.
Ventricular pseudoaneurysm	3–14 days	May be asymptomatic. Symptoms may include chest pain, murmur, arrhythmia, syncope, HF, embolus from mural thrombus. Rupture → cardiac tamponade.	Free wall rupture contained by adherent pericardium or scar tissue B —does not contain endocardium or myocardium. More likely to rupture than true aneurysm.
Ventricular free wall rupture	5–14 days	Free wall rupture C → cardiac tamponade; acute form usually leads to sudden death.	LV hypertrophy and previous MI protect against free wall rupture.
True ventricular aneurysm	2 weeks to several months	Similar to pseudoaneurysm: symptoms may include chest pain, murmur, arrhythmia, syncope, HF, embolus from mural thrombus. Rupture → cardiac tamponade.	Outward bulge with contraction (“dyskinesia”). Associated with fibrosis.
Postcardiac injury syndrome	Weeks to several months	Fibrinous pericarditis due to autoimmune reaction.	Also called Dressler syndrome. Cardiac antigens released after injury → deposition of immune complexes in pericardium → inflammation.



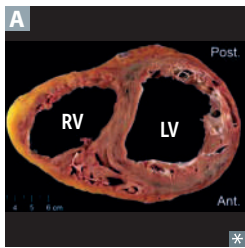
Acute coronary syndrome treatments

Unstable angina/NSTEMI—Anticoagulation (eg, heparin), antiplatelet therapy (eg, aspirin) + ADP receptor inhibitors (eg, clopidogrel), β -blockers, ACE inhibitors, statins. Symptom control with nitroglycerin +/- morphine.

STEMI—In addition to above, reperfusion therapy most important (percutaneous coronary intervention preferred over fibrinolysis). If RV affected (eg, RCA occlusion), support venous return/preload to maintain cardiac output (eg, IV fluids, avoiding nitroglycerin).

Cardiomyopathies

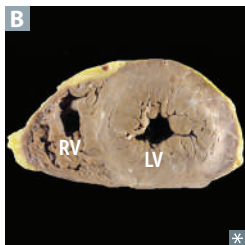
Dilated cardiomyopathy



Most common cardiomyopathy (90% of cases). Often idiopathic or familial (eg, due to mutation of *TTN* gene encoding the sarcomeric protein titin). Other etiologies include drugs (eg, alcohol, cocaine, doxorubicin), infection (eg, coxsackie B virus, Chagas disease), ischemia (eg, CAD), systemic conditions (eg, hemochromatosis, sarcoidosis, thyrotoxicosis, wet beriberi), peripartum cardiomyopathy. Findings: HF, S3, systolic regurgitant murmur, dilated heart on echocardiogram, balloon appearance of heart on CXR. Treatment: Na⁺ restriction, ACE inhibitors/ARBs, β -blockers, sacubitril, diuretics, mineralocorticoid receptor blockers (eg, spironolactone), digoxin, ICD, heart transplant.

Leads to systolic dysfunction. Displays eccentric hypertrophy **A** (sarcomeres added in series). Compare to athlete's heart, where LV and RV enlargement facilitates \uparrow SV and \uparrow CO. **Stress cardiomyopathy** (also called takotsubo cardiomyopathy, broken heart syndrome)—ventricular apical ballooning likely due to \uparrow sympathetic stimulation (eg, stressful situations).

Hypertrophic cardiomyopathy



60–70% of cases are familial, autosomal dominant (most commonly due to mutations in genes encoding sarcomeric proteins, such as myosin binding protein C and β -myosin heavy chain). Causes syncope during exercise and may lead to sudden death (eg, in young athletes) due to ventricular arrhythmia. Findings: S4, systolic murmur. May see mitral regurgitation due to impaired mitral valve closure. Treatment: cessation of high-intensity athletics, use of β -blocker or nondihydropyridine Ca²⁺ channel blockers (eg, verapamil). ICD if high risk. Avoid drugs that decrease preload (eg, diuretics, vasodilators).

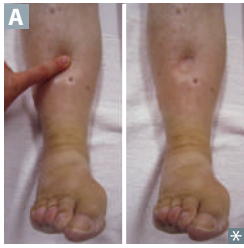Diastolic dysfunction ensues. Displays ventricular concentric hypertrophy (sarcomeres added in parallel) **B**, often septal predominance. Myofibrillar disarray and fibrosis. Classified as hypertrophic obstructive cardiomyopathy when LV outflow tract is obstructed. Asymmetric septal hypertrophy and systolic anterior motion of mitral valve \rightarrow outflow obstruction \rightarrow dyspnea, possible syncope. Other causes of concentric LV hypertrophy: chronic HTN, Friedreich ataxia.

Restrictive/infiltrative cardiomyopathy

Postradiation fibrosis, **L**öffler endocarditis, **E**ndocardial fibroelastosis (thick fibroelastic tissue in endocardium of young children), **A**myloidosis, **S**arcoidosis, **H**emochromatosis (**PLEASE Help!**).

Diastolic dysfunction ensues. Can have low-voltage ECG despite thick myocardium (especially in amyloidosis). **L**öffler endocarditis—associated with hypereosinophilic syndrome; histology shows eosinophilic infiltrates in myocardium.

Heart failure



Clinical syndrome of cardiac pump dysfunction → congestion and low perfusion. Symptoms include dyspnea, orthopnea, fatigue; signs include S3 heart sound, rales, jugular venous distention (JVD), pitting edema **A**.

Systolic dysfunction—heart failure with reduced ejection fraction (HFrEF), ↑ EDV; ↓ contractility often 2° to ischemia/MI or dilated cardiomyopathy.

Diastolic dysfunction—heart failure with preserved ejection fraction (HFpEF), normal EDV; ↓ compliance (↑ EDP) often 2° to myocardial hypertrophy.

Right HF most often results from left HF. Cor pulmonale refers to isolated right HF due to pulmonary cause.

ACE inhibitors, ARBs, angiotensin receptor–neprilysin inhibitors, β-blockers (except in acute decompensated HF), and aldosterone receptor antagonists ↓ mortality in HFrEF. Loop and thiazide diuretics are used mainly for symptomatic relief. Hydralazine with nitrate therapy improves both symptoms and mortality in select patients.

Left heart failure

Orthopnea

Shortness of breath when supine: ↑ venous return from redistribution of blood (immediate gravity effect) exacerbates pulmonary vascular congestion.

Paroxysmal nocturnal dyspnea

Breathless awakening from sleep: ↑ venous return from redistribution of blood, reabsorption of peripheral edema, etc.

Pulmonary edema

↑ pulmonary venous pressure → pulmonary venous distention and transudation of fluid. Presence of hemosiderin-laden macrophages (“HF” cells) in lungs.

Right heart failure

Congestive hepatomegaly

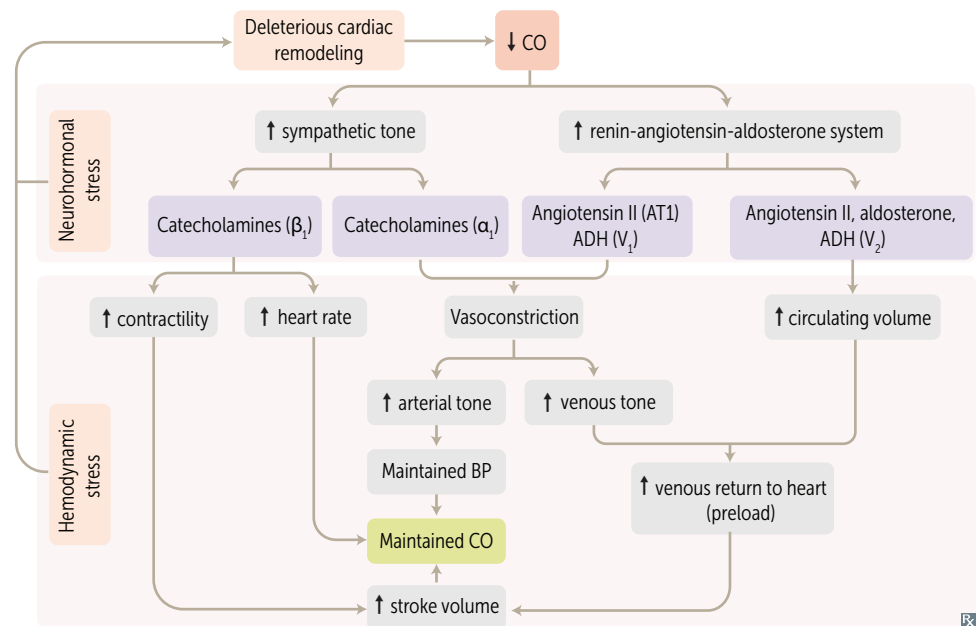
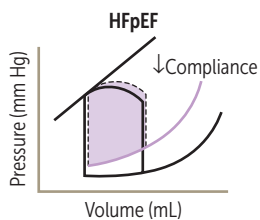
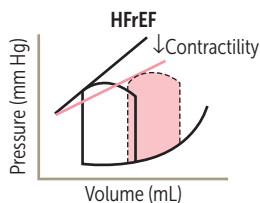
↑ central venous pressure → ↑ resistance to portal flow. Rarely, leads to “cardiac cirrhosis.” Associated with nutmeg liver (mottled appearance) on gross exam.

Jugular venous distention

↑ venous pressure.

Peripheral edema

↑ venous pressure → fluid transudation.



High-output heart failure

Uncommon form of HF characterized by ↑ CO. High-output state is due to ↓ SVR from either vasodilation or arteriovenous shunting. Causes include severe obesity, advanced cirrhosis, severe anemia, hyperthyroidism, wet beriberi, Paget disease of bone. Presents with symptoms and signs of pulmonary and/or systemic venous congestion.

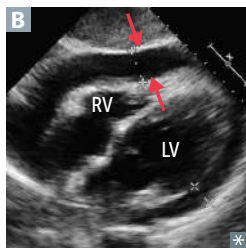
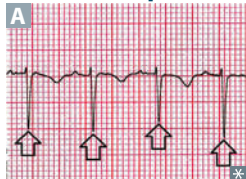
Shock

Inadequate organ perfusion and delivery of nutrients necessary for normal tissue and cellular function. Initially may be reversible but life threatening if not treated promptly.

TYPE	CAUSED BY	MECHANISM	SKIN	CVP (RIGHT HEART PRELOAD)	PCWP (LEFT HEART PRELOAD)	CO	SVR (AFTERLOAD)	SVO ₂ (MIXED VENOUS CONTENT)
Hypovolemic shock	Hemorrhage, dehydration, burns	Volume depletion		↓	↓↓	↓	↑	↓
Cardiogenic shock	MI, HF, vascular dysfunction, arrhythmia	Left heart dysfunction	Cold, clammy	↑	↑	↓↓	↑	↓
Obstructive shock	Cardiac tamponade, PE, tension pneumothorax	Right heart dysfunction		↑	↑ ^a	↓↓	↑	↓
Distributive shock	Sepsis (early), anaphylaxis	Systemic vasodilation	Warm, dry	↓	↓	↑	↓↓	↑
	CNS injury			↓	↓	↓	↓↓	normal/↑

Double arrow = primary physiologic disorder driving the shock.
^a↑ in cardiac tamponade.

Cardiac tamponade



Compression of the heart by fluid (eg, blood, effusions) → ↓ CO. Equilibration of diastolic pressures in all 4 chambers.

Findings: Beck triad (hypotension, distended neck veins, distant heart sounds), ↑ HR, pulsus paradoxus. ECG shows low-voltage QRS and electrical alternans **A** (due to “swinging” movement of heart in large effusion). Echocardiogram shows pericardial effusion (arrows in **B**), systolic RA collapse, diastolic RV collapse, and IVC plethora.

Treatment: pericardiocentesis or surgical drainage.

Pulsus paradoxus—↓ in amplitude of systolic BP by > 10 mm Hg during inspiration. ↑ venous return during inspiration → ↑ RV filling → interventricular septum bows toward LV (due to ↓ pericardial compliance) → ↓ LV ejection volume → ↓ systolic BP. Seen in constrictive pericarditis, obstructive pulmonary disease (eg, Croup, OSA, Asthma, COPD), cardiac Tamponade (pea COAT).

Infective endocarditis

Infection of the endocardial surface of the heart, typically involving ≥ 1 heart valves. Caused by bacteria \gg fungi. Forms:

- **Acute**—classically *S aureus* (high virulence). Large destructive vegetations **A** on previously normal valves. Rapid onset.
- **Subacute**—classically viridans streptococci (low virulence). Smaller vegetations on congenitally abnormal or diseased valves. Sequela of dental procedures. Gradual onset.

Presents with fever (most common), new murmur, vascular and immunologic phenomena.

Vascular phenomena—septic embolism, petechiae, splinter hemorrhages (linear hemorrhagic lesions on nail bed **B**), Janeway lesions (painless, flat, erythematous lesions on palms or soles **C**).

Immunologic phenomena—immune complex deposition, glomerulonephritis, **Osler nodes** (painful [“Ouchy”], raised, violaceous lesions on finger or toe pads **D**), **Roth spots** (**R**etinal hemorrhagic lesions with pale centers **E**).

Mitral valve (most common) $>$ aortic valve.

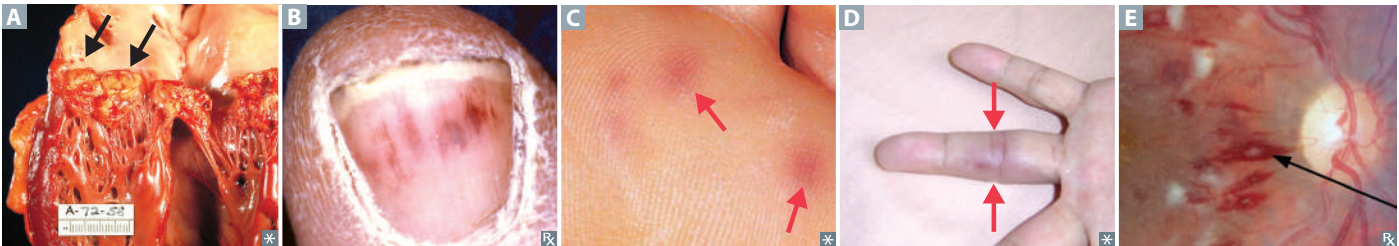Tricuspid valve involvement is associated with injection **d**rug use (don't “**tri**” **d**rugs).

Common associations:

- Prosthetic valves—*S epidermidis*
- GI/GU procedures—*Enterococcus*
- Colon cancer—*S gallolyticus* (formerly *S bovis*)
- Gram \ominus —**HACEK** organisms (*Haemophilus*, *Aggregatibacter* [formerly *Actinobacillus*], *Cardiobacterium*, *Eikenella*, *Kingella*)
- Culture \ominus —*Coxiella*, *Bartonella*
- Injection drug use—*S aureus*, *Pseudomonas*, *Candida*

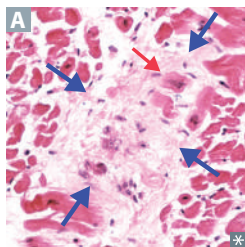
Endothelial injury \rightarrow formation of vegetations consisting of platelets, fibrin, and microbes on heart valves \rightarrow valve regurgitation, septic embolism (systemic circulation in left-sided endocarditis, pulmonary in right-sided).

Diagnosis requires multiple blood cultures and echocardiography.

**Nonbacterial thrombotic endocarditis**

Also called marantic endocarditis. Rare, noninfective. Vegetations typically arise on mitral or aortic valve and consist of sterile, platelet-rich thrombi that dislodge easily. Usually asymptomatic until embolism occurs.

Associated with the hypercoagulable state seen in advanced malignancy (especially pancreatic adenocarcinoma) or SLE (called **Libman-Sacks endocarditis** in this setting).

Rheumatic fever

A consequence of pharyngeal infection with group A β -hemolytic streptococci. Late sequelae include rheumatic heart disease, which affects heart valves—mitral > aortic >> tricuspid (high-pressure valves affected most). Early valvular regurgitation, late valvular stenosis.

Associated with Aschoff bodies (granuloma with giant cells [blue arrows in **A**]), Anitschkow cells (enlarged macrophages with ovoid, wavy, rodlike nucleus [red arrow in **A**]), \uparrow anti-streptolysin O (ASO) and \uparrow anti-DNase B titers.

Immune mediated (type II hypersensitivity); not a direct effect of bacteria. Antibodies to **M** protein cross-react with self antigens, often myosin (molecular mimicry).

Treatment/prophylaxis: penicillin.

JONES (major criteria):

Joint (migratory polyarthrititis)

♥ (carditis)

Nodules in skin (subcutaneous)

Erythema marginatum (evanescent rash with ring margin)

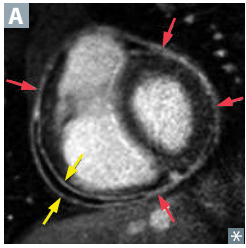
Sydenham chorea (involuntary irregular movements of limbs and face)

Syphilitic heart disease

3° syphilis disrupts the vasa vasorum of the aorta with consequent atrophy of vessel wall and dilation of aorta and valve ring.

May see calcification of aortic root, ascending aortic arch, and thoracic aorta. Leads to “tree bark” appearance of aorta.

Can result in aneurysm of ascending aorta or aortic arch, aortic insufficiency.

Acute pericarditis

Inflammation of the **pericardium** (red arrows in **A**). Commonly presents with sharp pain, aggravated by inspiration, and relieved by sitting up and leaning forward. Often complicated by pericardial effusion (between yellow arrows in **A**). Presents with friction rub. ECG changes include widespread/diffuse ST-segment elevation and/or PR depression.

Causes include **S**urgery (cardiac), **C**onnective tissue disorders, **C**ardiovascular events (eg, acute MI, Dressler syndrome), **A**utoimmune (eg, SLE, rheumatoid arthritis), **R**adiation, **R**enal failure (uremia), **I**diopathic (most common; presumed viral), **I**nfection (eg, coxsackievirus B), **N**eoplasm. **SCCARR IIN pericardium**.

Treatment: NSAIDs, colchicine, glucocorticoids, dialysis (uremia).

Myocarditis

Inflammation of myocardium → global enlargement of heart and dilation of all chambers. Major cause of SCD in adults < 40 years old.

Presentation highly variable, can include dyspnea, chest pain, fever, arrhythmias (persistent tachycardia out of proportion to fever is characteristic).

Multiple causes:

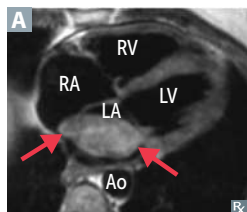
- Viral (eg, adenovirus, coxsackie B, parvovirus B19, HIV, HHV-6); lymphocytic infiltrate with focal necrosis highly indicative of viral myocarditis
- Parasitic (eg, *Trypanosoma cruzi*, *Toxoplasma gondii*)
- Bacterial (eg, *Borrelia burgdorferi*, *Mycoplasma pneumoniae*, *Corynebacterium diphtheriae*)
- Toxins (eg, carbon monoxide, black widow venom)
- Rheumatic fever
- Drugs (eg, doxorubicin, cocaine)
- Autoimmune (eg, Kawasaki disease, sarcoidosis, SLE, polymyositis/dermatomyositis)

Complications include sudden death, arrhythmias, heart block, dilated cardiomyopathy, HF, mural thrombus with systemic emboli.

Cardiac tumors

Most common cardiac tumor is a metastasis (eg, melanoma).

Myxomas



Most common 1° cardiac tumor in **adults** (arrows in **A**). 90% occur in the atria (mostly left atrium). Myxomas are usually described as a “ball valve” obstruction in the left atrium (associated with multiple syncopal episodes). IL-6 production by tumor → constitutional symptoms (eg, fever, weight loss). May auscultate early diastolic “tumor plop” sound (mimics mitral stenosis). Murmur and symptoms worsen in upright position, improve when lying down. Histology: gelatinous material, myxoma cells immersed in glycosaminoglycans.

Adults make **6 myxed** drinks.

Rhabdomyomas

Most frequent 1° cardiac tumor in children (associated with tuberous sclerosis). Histology: hamartomatous growths. More common in the ventricles.

Kussmaul sign

Paradoxical ↑ in JVP on inspiration (normally, inspiration → negative intrathoracic pressure → ↑ venous return → ↓ JVP).

Impaired RV filling → RV cannot accommodate ↑ venous return during inspiration → blood backs up into vena cava → Kussmaul sign. May be seen with constrictive pericarditis, restrictive cardiomyopathy, right HF, massive pulmonary embolism, right atrial or ventricular tumors.

Hereditary hemorrhagic telangiectasia

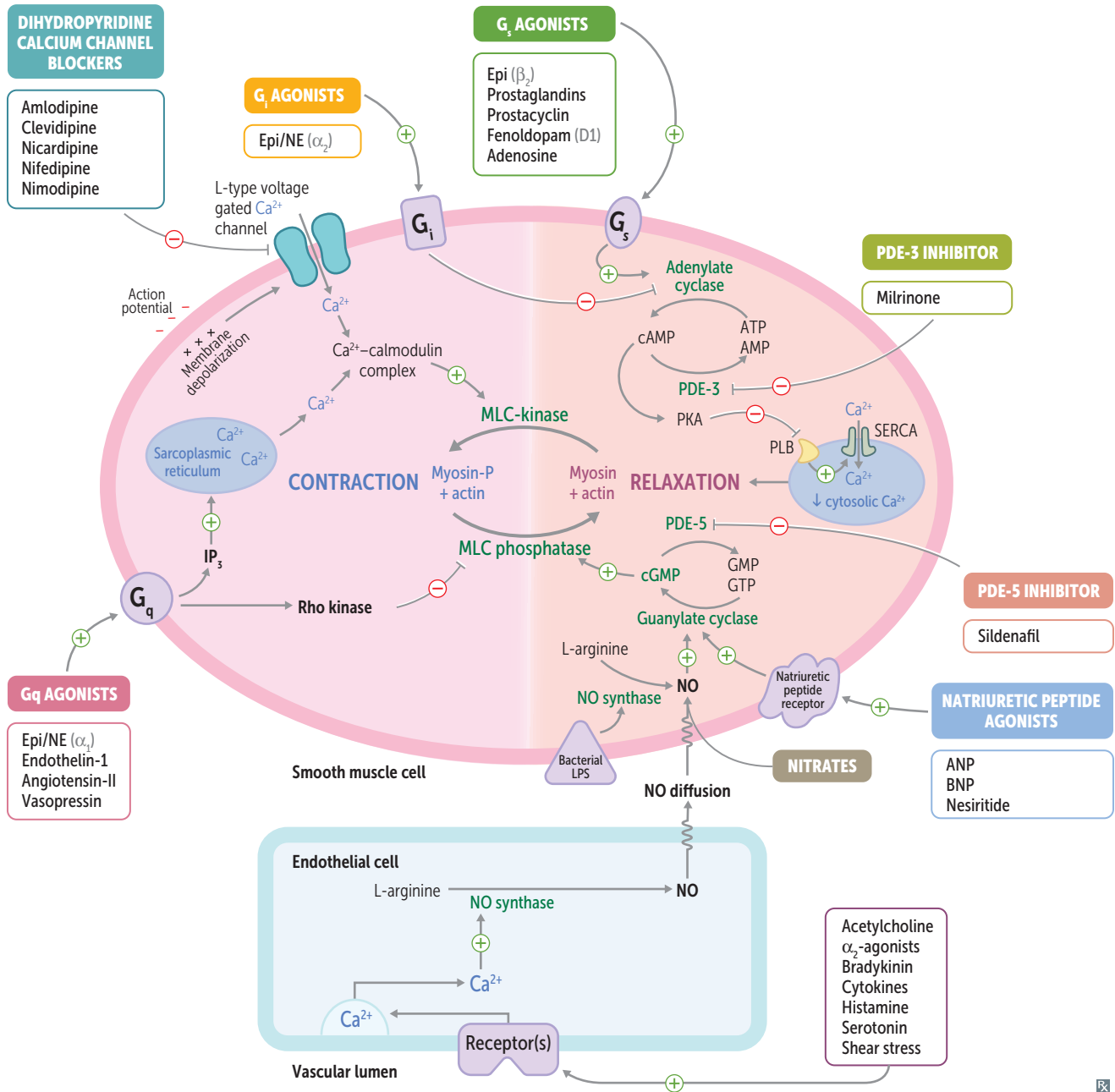
Also called Osler-Weber-Rendu syndrome. Autosomal dominant disorder of blood vessels. Findings: blanching lesions (telangiectasias) on skin and mucous membranes, recurrent epistaxis, AVMs (eg, brain, lung, liver), GI bleeding, hematuria.

► CARDIOVASCULAR—PHARMACOLOGY

Hypertension treatment

Primary (essential) hypertension	Thiazide diuretics, ACE inhibitors, angiotensin II receptor blockers (ARBs), dihydropyridine Ca ²⁺ channel blockers.	
Hypertension with heart failure	Diuretics, ACE inhibitors/ARBs, β-blockers (compensated HF), aldosterone antagonists.	β-blockers must be used cautiously in decompensated HF and are contraindicated in cardiogenic shock. In HF, ARBs may be combined with the neprilysin inhibitor sacubitril.
Hypertension with diabetes mellitus	ACE inhibitors/ARBs, Ca ²⁺ channel blockers, thiazide diuretics, β-blockers.	ACE inhibitors/ARBs are protective against diabetic nephropathy. β-blockers can mask hypoglycemia symptoms.
Hypertension in asthma	ARBs, Ca ²⁺ channel blockers, thiazide diuretics, cardioselective β-blockers.	Avoid nonselective β-blockers to prevent β ₂ -receptor-induced bronchoconstriction. Avoid ACE inhibitors to prevent confusion between drug or asthma-related cough.
Hypertension in pregnancy	Nifedipine, methyl dopa, labetalol, hydralazine.	New moms love hugs.

Cardiovascular agents and molecular targets



Calcium channel blockers	Amlodipine, clevidipine, nicardipine, nifedipine, nimodipine (dihydropyridines, act on vascular smooth muscle); diltiazem, verapamil (nondihydropyridines, act on heart).
MECHANISM	Block voltage-dependent L-type calcium channels of cardiac and smooth muscle → ↓ muscle contractility. Vascular smooth muscle—amlodipine = nifedipine > diltiazem > verapamil. Heart—verapamil > diltiazem > amlodipine = nifedipine.
CLINICAL USE	Dihydropyridines (except nimodipine): hypertension, angina (including vasospastic type), Raynaud phenomenon. D ihydropyridine mainly d ilates arteries. Nimodipine: subarachnoid hemorrhage (prevents cerebral vasospasm). Nicardipine, clevidipine: hypertensive urgency or emergency. Nondihydropyridines: hypertension, angina, atrial fibrillation/flutter.
ADVERSE EFFECTS	Gingival hyperplasia. Dihydropyridine: peripheral edema, flushing, dizziness. Nondihydropyridine: cardiac depression, AV block, hyperprolactinemia (verapamil), constipation.
Hydralazine	
MECHANISM	↑ cGMP → smooth muscle relaxation. H ydralazine vasodilates a rterioles > veins; a fterload reduction.
CLINICAL USE	Severe hypertension (particularly acute), HF (with organic nitrate). Safe to use during pregnancy. Frequently coadministered with a β-blocker to prevent reflex tachycardia.
ADVERSE EFFECTS	Compensatory tachycardia (contraindicated in angina/CAD), fluid retention, headache, angina, drug-induced lupus.
Hypertensive emergency	
	Treat with labetalol, clevidipine, fenoldopam, nicardipine, nitroprusside.
Nitroprusside	Short acting vasodilator (arteries = veins); ↑ cGMP via direct release of NO. Can cause cyanide toxicity (releases cyanide).
Fenoldopam	D opamine D ₁ receptor agonist—coronary, peripheral, renal, and splanchnic vasodilation. ↓ BP, ↑ natriuresis. Also used postoperatively as an antihypertensive. Can cause hypotension, tachycardia, flushing, headache, nausea.
Nitrates	
MECHANISM	Vasodilate by ↑ NO in vascular smooth muscle → ↑ in cGMP and smooth muscle relaxation. Dilate veins >> arteries. ↓ preload.
CLINICAL USE	Angina, acute coronary syndrome, pulmonary edema.
ADVERSE EFFECTS	Reflex tachycardia (treat with β-blockers), methemoglobinemia, hypotension, flushing, headache, “Monday disease” in industrial nitrate exposure: development of tolerance for the vasodilating action during the work week and loss of tolerance over the weekend → tachycardia, dizziness, headache upon reexposure. Contraindicated in right ventricular infarction, hypertrophic cardiomyopathy, and with concurrent PDE-5 inhibitor use.

Antianginal therapy

Goal is reduction of myocardial O₂ consumption (MVO₂) by ↓ 1 or more of the determinants of MVO₂: end-diastolic volume, BP, HR, contractility.

COMPONENT	NITRATES	β-BLOCKERS	NITRATES + β-BLOCKERS
End-diastolic volume	↓	No effect or ↑	No effect or ↓
Blood pressure	↓	↓	↓
Contractility	↑ (reflex response)	↓	Little/no effect
Heart rate	↑ (reflex response)	↓	No effect or ↓
Ejection time	↓	↑	Little/no effect
MVO ₂	↓	↓	↓↓

Verapamil is similar to β-blockers in effect.

Pindolol and acebutolol are partial β-agonists that should be used with caution in angina.

Ranolazine

MECHANISM	Inhibits the late phase of inward sodium current thereby reducing diastolic wall tension and oxygen consumption. Does not affect heart rate or blood pressure.
CLINICAL USE	Refractory angina.
ADVERSE EFFECTS	Constipation, dizziness, headache, nausea.

Sacubitril

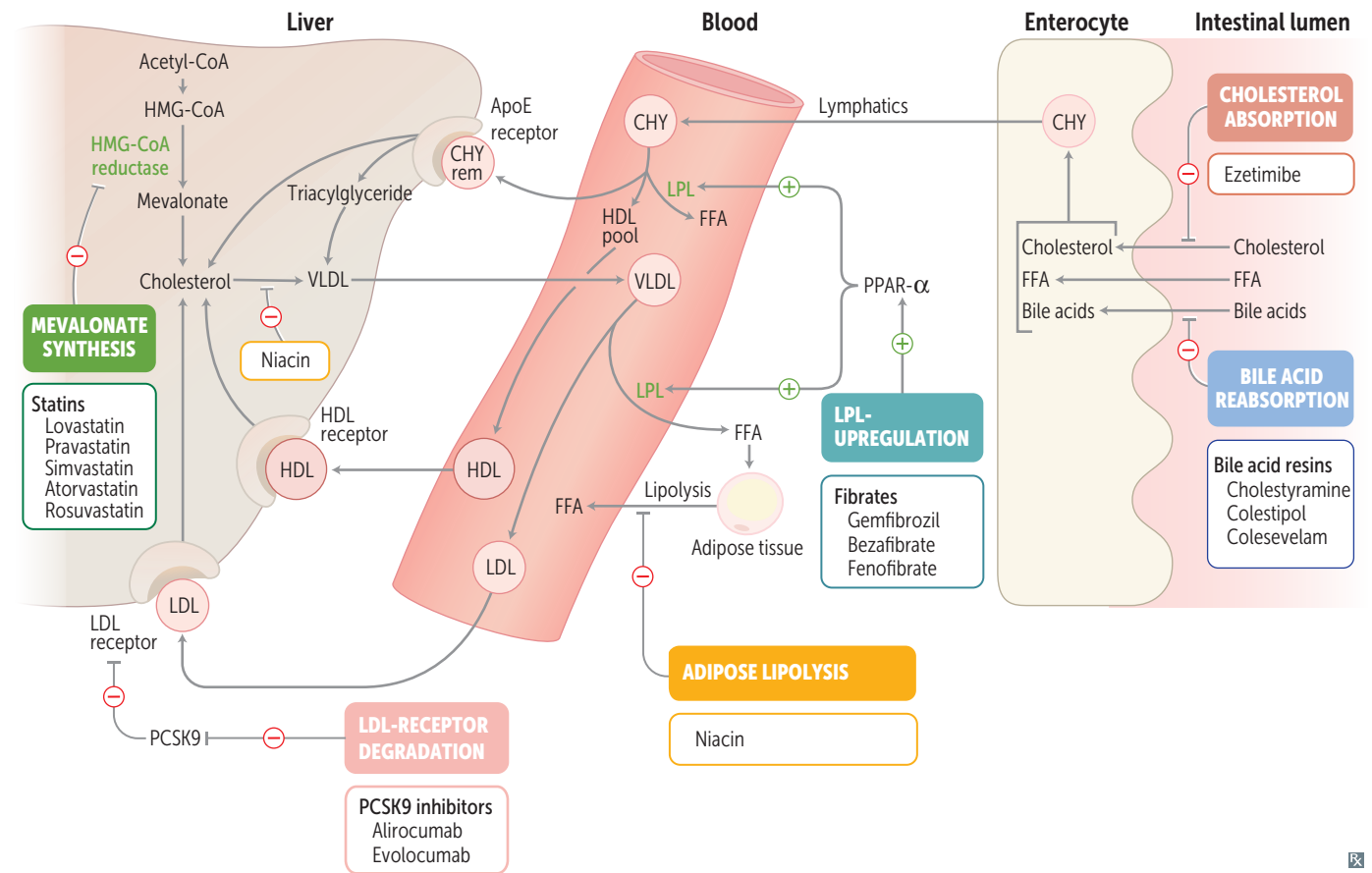
MECHANISM	A neprilysin inhibitor; prevents degradation of bradykinin, natriuretic peptides, angiotensin II, and substance P → ↑ vasodilation, ↓ ECF volume.
CLINICAL USE	Used in combination with valsartan (an ARB) to treat HFrEF.
ADVERSE EFFECTS	Hypotension, hyperkalemia, cough, dizziness; contraindicated with ACE inhibitors due to angioedema (both drugs ↑ bradykinin).

Lipid-lowering agents

DRUG	LDL	HDL	TRIGLYCERIDES	MECHANISM	ADVERSE EFFECTS/PROBLEMS
HMG-CoA reductase inhibitors Atorvastatin, simvastatin	↓↓↓	↑	↓	Inhibit conversion of HMG-CoA to mevalonate, a cholesterol precursor; → ↓ intrahepatic cholesterol → ↑ LDL receptor recycling → ↑ LDL catabolism ↓ in mortality in patients with CAD	Hepatotoxicity (↑ LFTs), myopathy (especially when used with fibrates or niacin)
Bile acid resins Cholestyramine, colestipol, colesevelam	↓↓	↑ slightly	↑ slightly	Prevent intestinal reabsorption of bile acids; liver must use cholesterol to make more	GI upset, ↓ absorption of other drugs and fat-soluble vitamins
Ezetimibe	↓↓	↑/—	↓/—	Prevents cholesterol absorption at small intestine brush border	Rare ↑ LFTs, diarrhea

Lipid-lowering agents (continued)

DRUG	LDL	HDL	TRIGLYCERIDES	MECHANISM	ADVERSE EFFECTS/PROBLEMS
Fibrates Gemfibrozil, bezafibrate, fenofibrate	↓	↑	↓↓↓	Activate PPAR-α → upregulate LPL → ↑ TG clearance Activate PPAR-α → induce HDL synthesis	Myopathy (↑ risk with statins), cholesterol gallstones (via inhibition of cholesterol 7α-hydroxylase)
Niacin	↓↓	↑↑	↓	Inhibits lipolysis (hormone- sensitive lipase) in adipose tissue; reduces hepatic VLDL synthesis	Flushed face (prostaglandin mediated; ↓ by NSAIDs or long- term use) Hyperglycemia Hyperuricemia
PCSK9 inhibitors Alirocumab, evolocumab	↓↓↓	↑	↓	Inactivation of LDL-receptor degradation → ↑ removal of LDL from bloodstream	Myalgias, delirium, dementia, other neurocognitive effects
Fish oil and marine omega-3 fatty acids	↑ slightly	↑ slightly	↓ at high doses	Believed to decrease FFA delivery to liver and decrease activity of TG-synthesizing enzymes	Nausea, fishlike taste

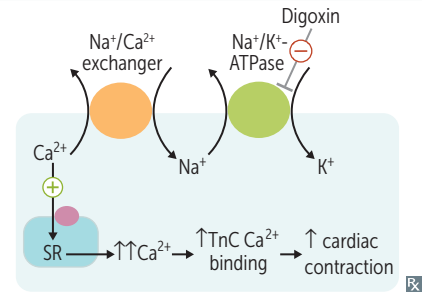


Cardiac glycosides

Digoxin.

MECHANISM

Direct inhibition of Na^+/K^+ -ATPase.
 → indirect inhibition of $\text{Na}^+/\text{Ca}^{2+}$ exchanger.
 $\uparrow [\text{Ca}^{2+}]_i \rightarrow$ positive inotropy. Stimulates vagus nerve $\rightarrow \downarrow$ HR.

**CLINICAL USE**

HF (\uparrow contractility); atrial fibrillation (\downarrow conduction at AV node and depression of SA node).

ADVERSE EFFECTS

Cholinergic effects (nausea, vomiting, diarrhea), blurry yellow vision (“van Glow”), arrhythmias, AV block.

Can lead to hyperkalemia, which indicates poor prognosis.

Factors predisposing to toxicity: renal failure (\downarrow excretion), hypokalemia (permissive for digoxin binding at K^+ -binding site on Na^+/K^+ -ATPase), drugs that displace digoxin from tissue-binding sites, and \downarrow clearance (eg, verapamil, amiodarone, quinidine).

ANTIDOTE

Slowly normalize K^+ , cardiac pacer, anti-digoxin Fab fragments, Mg^{2+} .

Antiarrhythmics—sodium channel blockers (class I)

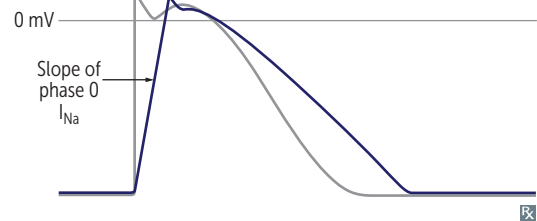
Slow or block conduction (especially in depolarized cells). \downarrow slope of phase 0 depolarization.
 \uparrow action at faster HR. State dependent \uparrow HR \rightarrow shorter diastole, Na^+ channels spend less time in resting state (drugs dissociate during this state) \rightarrow less time for drug to dissociate from receptor.
 Effect most pronounced in $\text{IC} > \text{IA} > \text{IB}$ due to relative binding strength. **Fast taxi CAB.**

Class IA

Quinidine, procainamide, disopyramide.
 “The queen proclaims Diso’s pyramid.”

MECHANISM

Moderate Na^+ channel blockade.
 \uparrow AP duration, \uparrow effective refractory period (ERP) in ventricular action potential, \uparrow QT interval, some K^+ channel blocking effects.

**CLINICAL USE**

Both atrial and ventricular arrhythmias, especially reentrant and ectopic SVT and VT.

ADVERSE EFFECTS

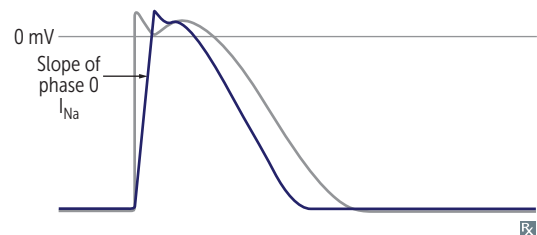
Cinchonism (headache, tinnitus with quinidine), reversible SLE-like syndrome (procainamide), HF (disopyramide), thrombocytopenia, torsades de pointes due to \uparrow QT interval.

Class IB

Lidocaine, phenytoin, mexiletine.
 “I’d Buy Liddy’s phine Mexican tacos.”

MECHANISM

Weak Na^+ channel blockade.
 \downarrow AP duration. Preferentially affect ischemic or depolarized Purkinje and ventricular tissue.

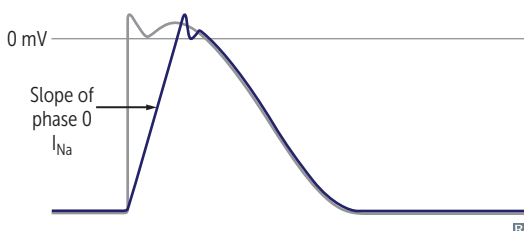
**CLINICAL USE**

Acute ventricular arrhythmias (especially post-MI), digitalis-induced arrhythmias.
IB is Best post-MI.

ADVERSE EFFECTS

CNS stimulation/depression, cardiovascular depression.

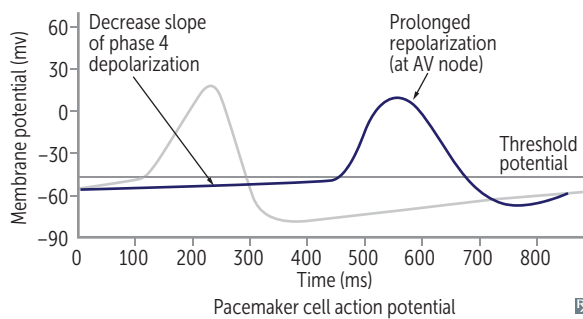
Antiarrhythmics—sodium channel blockers (class I) (continued)

Class IC	Flecainide, propafenone. “Can I have fries, please?”	
MECHANISM	Strong Na ⁺ channel blockade. Significantly prolongs ERP in AV node and accessory bypass tracts. No effect on ERP in Purkinje and ventricular tissue. Minimal effect on AP duration.	
CLINICAL USE	SVTs, including atrial fibrillation. Only as a last resort in refractory VT.	
ADVERSE EFFECTS	Proarrhythmic, especially post-MI (contraindicated). IC is Contraindicated in structural and ischemic heart disease.	

Antiarrhythmics—β-blockers (class II)

Metoprolol, propranolol, esmolol, atenolol, timolol, carvedilol.

MECHANISM	Decrease SA and AV nodal activity by ↓ cAMP, ↓ Ca ²⁺ currents. Suppress abnormal pacemakers by ↓ slope of phase 4.
	AV node particularly sensitive—↑ PR interval. Esmolol very short acting.
CLINICAL USE	SVT, ventricular rate control for atrial fibrillation and atrial flutter.
ADVERSE EFFECTS	Impotence, exacerbation of COPD and asthma, cardiovascular effects (bradycardia, AV block, HF), CNS effects (sedation, sleep alterations). May mask the signs of hypoglycemia. Metoprolol can cause dyslipidemia. Propranolol can exacerbate vasospasm in vasospastic angina. β-blockers (except the nonselective α- and β-antagonists carvedilol and labetalol) cause unopposed α ₁ -agonism if given alone for pheochromocytoma or for cocaine toxicity (unsubstantiated). Treat β-blocker overdose with saline, atropine, glucagon.



**Antiarrhythmics—
potassium channel
blockers (class III)**

Amiodarone, Ibutilide, Dofetilide, Sotalol.

AIDS.

MECHANISM

↑ AP duration, ↑ ERP, ↑ QT interval.

CLINICAL USE

Atrial fibrillation, atrial flutter; ventricular tachycardia (amiodarone, sotalol).

ADVERSE EFFECTS

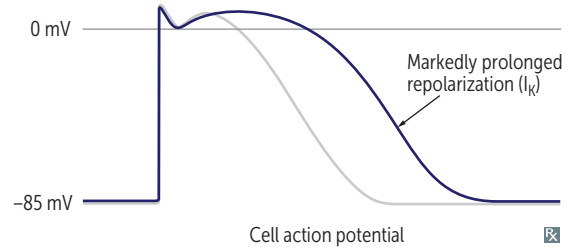
Sotalol—torsades de pointes, excessive β blockade.

Ibutilide—torsades de pointes.

Amiodarone—pulmonary fibrosis, hepatotoxicity, hypothyroidism or hyperthyroidism (amiodarone is 40% iodine by weight), acts as hapten (corneal deposits, blue/gray skin deposits resulting in photodermatitis), neurologic effects, constipation, cardiovascular effects (bradycardia, heart block, HF).

Remember to check PFTs, LFTs, and TFTs when using amiodarone.

Amiodarone is lipophilic and has class I, II, III, and IV effects.

**Antiarrhythmics—
calcium channel
blockers (class IV)**

Diltiazem, verapamil.

MECHANISM

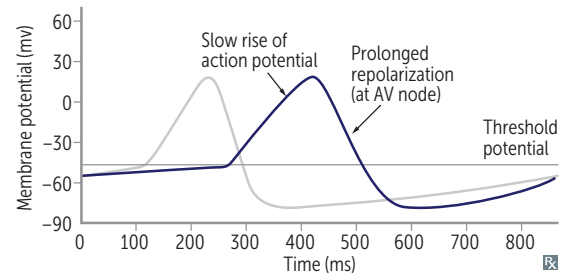
Decrease conduction velocity, ↑ ERP, ↑ PR interval.

CLINICAL USE

Prevention of nodal arrhythmias (eg, SVT), rate control in atrial fibrillation.

ADVERSE EFFECTS

Constipation, flushing, edema, cardiovascular effects (HF, AV block, sinus node depression).

**Other antiarrhythmics****Adenosine**

↑ K⁺ out of cells → hyperpolarizing the cell and ↓ I_{Ca}, decreasing AV node conduction. Drug of choice in diagnosing/terminating certain forms of SVT. Very short acting (~ 15 sec). Effects blunted by theophylline and caffeine (both are adenosine receptor antagonists). Adverse effects include flushing, hypotension, chest pain, sense of impending doom, bronchospasm.

Magnesium

Effective in torsades de pointes and digoxin toxicity.

Ivabradine

MECHANISM

Ivabradine prolongs slow depolarization (phase “IV”) by selectively inhibiting “funny” sodium channels (I_f).

CLINICAL USE

Chronic stable angina in patients who cannot take β -blockers. Chronic HFrEF.

ADVERSE EFFECTS

Luminous phenomena/visual brightness, hypertension, bradycardia.

Endocrine

“If you skew the endocrine system, you lose the pathways to self.”

—Hilary Mantel

“Sometimes you need a little crisis to get your adrenaline flowing and help you realize your potential.”

—Jeannette Walls, *The Glass Castle*

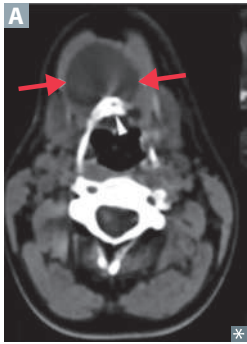“Chocolate causes certain endocrine glands to secrete hormones that affect your feelings and behavior by making you happy.”

—Elaine Sherman, *Book of Divine Indulgences*

The endocrine system comprises widely distributed organs that work in a highly integrated manner to orchestrate a state of hormonal equilibrium within the body. Generally speaking, endocrine diseases can be classified either as diseases of underproduction or overproduction, or as conditions involving the development of mass lesions—which themselves may be associated with underproduction or overproduction of hormones. Therefore, study the endocrine system first by learning the glands, their hormones, and their regulation, and then by integrating disease manifestations with diagnosis and management. Take time to learn the multisystem connections.

▶ Embryology	332
▶ Anatomy	333
▶ Physiology	334
▶ Pathology	344
▶ Pharmacology	360

▶ ENDOCRINE—EMBRYOLOGY

Thyroid development

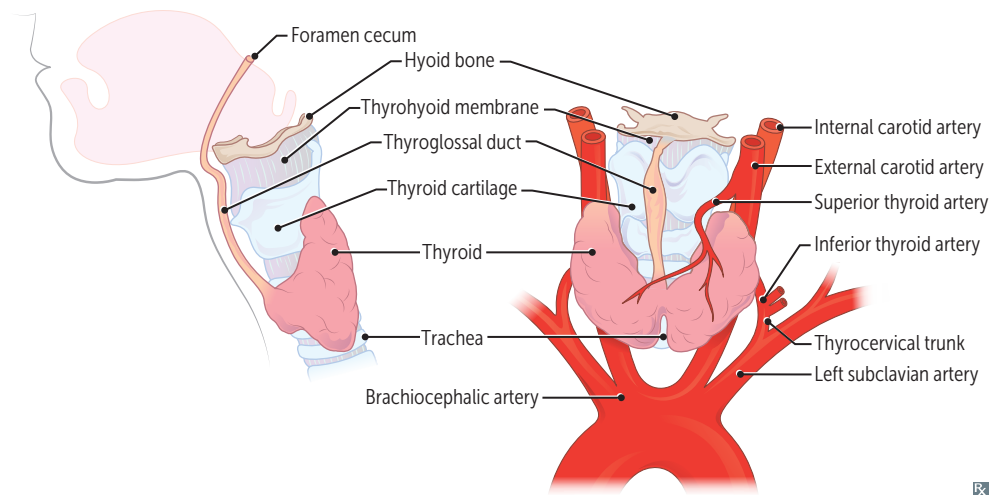
Thyroid diverticulum arises from floor of primitive pharynx and descends into neck. Connected to tongue by thyroglossal duct, which normally disappears but may persist as cysts or the pyramidal lobe of thyroid. Foramen cecum is normal remnant of thyroglossal duct.

Most common ectopic thyroid tissue site is the tongue (lingual thyroid). Removal may result in hypothyroidism if it is the only thyroid tissue present.

Thyroglossal duct cyst **A** presents as an anterior midline neck mass that moves with swallowing or protrusion of the tongue (vs persistent cervical sinus leading to pharyngeal cleft cyst in lateral neck).

Thyroid follicular cells derived from endoderm.

Parafollicular cells arise from 4th pharyngeal pouch.



► ENDOCRINE—ANATOMY

Pituitary gland

Anterior pituitary (adenohypophysis)

Secretes FSH, LH, ACTH, TSH, prolactin, GH, and β -endorphin. Melanotropin (MSH) secreted from intermediate lobe of pituitary. Derived from oral ectoderm (Rathke pouch).

- α subunit—hormone subunit common to TSH, LH, FSH, and hCG.
- β subunit—determines hormone specificity.

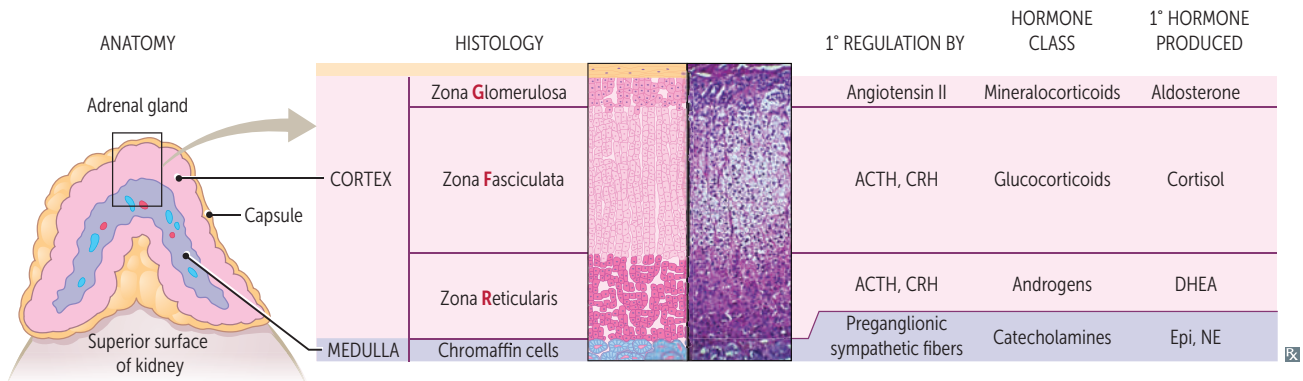
Proopiomelanocortin derivatives— β -endorphin, ACTH, and MSH. Go **pro** with a **BAM!**
FLAT PiG: FSH, LH, ACTH, TSH, PRL, GH.
B-FLAT: Basophils—FSH, LH, ACTH, TSH.
Acid PiG: Acidophils — PRL, GH.

Posterior pituitary (neurohypophysis)

Stores and releases vasopressin (antidiuretic hormone, or ADH) and oxytocin, both made in the hypothalamus (supraoptic and paraventricular nuclei) and transported to posterior pituitary via neurophysins (carrier proteins). Derived from **neuro**ectoderm.

Adrenal cortex and medulla

Adrenal cortex (derived from mesoderm) and medulla (derived from neural crest).

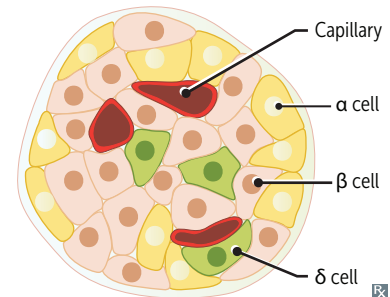


GFR corresponds with **salt** (mineralocorticoids), **sugar** (glucocorticoids), and **sex** (androgens).

Endocrine pancreas cell types

Islets of Langerhans are collections of α , β , and δ endocrine cells. Islets arise from pancreatic buds.

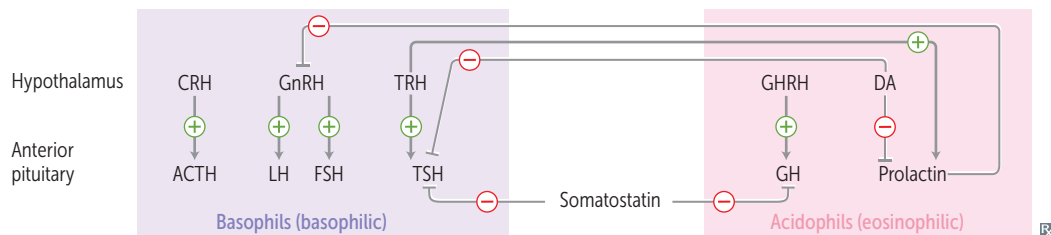
α = gluc **α** gon (peripheral)
 β = insulin (central)
 δ = somatostatin (interspersed)



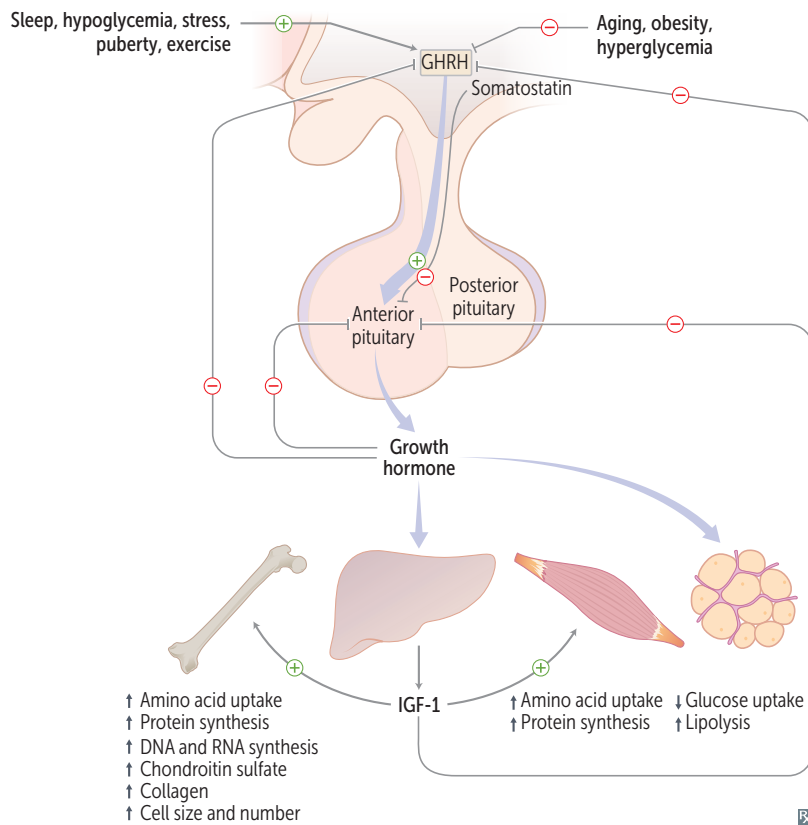
► ENDOCRINE—PHYSIOLOGY

Hypothalamic-pituitary hormones

HORMONE	FUNCTION	CLINICAL NOTES
ADH	↑ water permeability of distal convoluted tubule and collecting duct cells in kidney to ↑ water reabsorption	Stimulus for secretion is ↑ plasma osmolality, except in syndrome of inappropriate ADH secretion (SIADH), in which ADH is elevated despite ↓ plasma osmolality
CRH	↑ ACTH, MSH, β-endorphin	↓ in chronic glucocorticoid steroid use
Dopamine	↓ prolactin, TSH	Also called prolactin-inhibiting factor Dopamine antagonists (eg, antipsychotics) can cause galactorrhea due to hyperprolactinemia
GHRH	↑ GH	Analog (tesamorelin) used to treat HIV-associated lipodystrophy
GnRH	↑ FSH, LH	Suppressed by hyperprolactinemia Tonic GnRH analog (eg, leuprolide) suppresses hypothalamic–pituitary–gonadal axis. Pulsatile GnRH leads to puberty, fertility
MSH	↑ melanogenesis by melanocytes	Causes hyperpigmentation in Cushing disease, as MSH and ACTH share the same precursor molecule, proopiomelanocortin
Oxytocin	Causes uterine contractions during labor. Responsible for milk letdown reflex in response to suckling.	Modulates fear, anxiety, social bonding, mood, and depression
Prolactin	↓ GnRH Stimulates lactogenesis.	Pituitary prolactinoma → amenorrhea, osteoporosis, hypogonadism, galactorrhea Breastfeeding → ↑ prolactin → ↓ GnRH → delayed postpartum ovulation (natural contraception)
Somatostatin	↓ GH, TSH	Also called growth hormone inhibiting hormone (GHIH) Analogues used to treat acromegaly
TRH	↑ TSH, prolactin	↑ TRH (eg, in 1°/2° hypothyroidism) may increase prolactin secretion → galactorrhea



Growth hormone



Also called somatotropin. Secreted by anterior pituitary. Stimulates linear growth and muscle mass through IGF-1 (somatomedin C) secretion by liver. ↑ insulin resistance (diabetogenic). Released in pulses in response to growth hormone-releasing hormone (GHRH). Secretion ↑ during sleep, hypoglycemia, stress, puberty, exercise. Secretion ↓ with aging, obesity, hyperglycemia, somatostatin, somatomedin (regulatory molecule secreted by liver in response to GH acting on target tissues). Excess secretion of GH (eg, pituitary adenoma) may cause acromegaly (adults) or gigantism (children). Treatment: somatostatin analogs (eg, octreotide) or surgery.

Antidiuretic hormone

Also called vasopressin.

SOURCE

Synthesized in hypothalamus (supraoptic and paraventricular nuclei), stored and secreted by posterior pituitary.

FUNCTION

Regulates blood pressure (V_1 -receptors) and serum osmolality (V_2 -receptors). Primary function is serum osmolality regulation (ADH ↓ serum osmolality, ↑ urine osmolality) via regulation of aquaporin channel insertion in principal cells of renal collecting duct.

ADH level is ↓ in central diabetes insipidus (DI), normal or ↑ in nephrogenic DI.

Nephrogenic DI can be caused by mutation in V_2 -receptor.

Desmopressin (ADH analog) is a treatment for central DI and nocturnal enuresis.

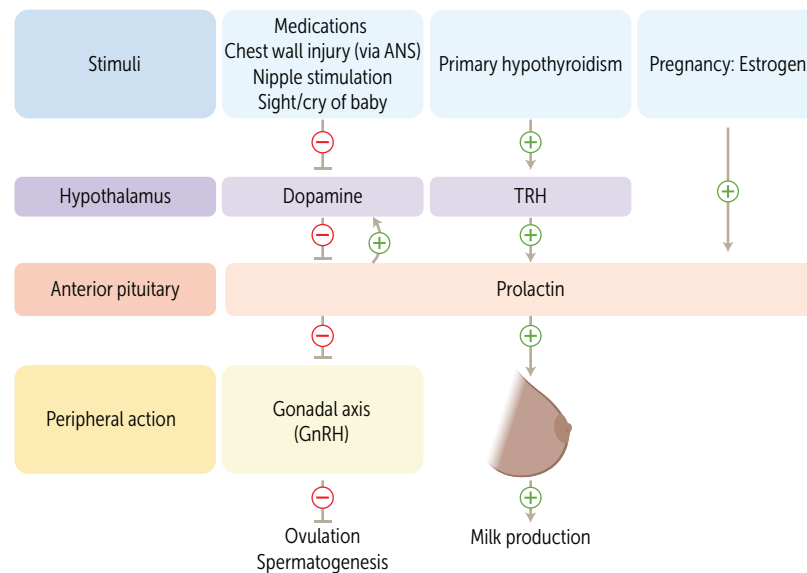
Vasopressin is also a potent vasopressor that can be used to increase organ perfusion in septic shock.

REGULATION

Plasma osmolality (1°); hypovolemia.

Prolactin

SOURCE	Secreted mainly by anterior pituitary.	Structurally homologous to growth hormone.
FUNCTION	Stimulates milk production in breast; inhibits ovulation in females and spermatogenesis in males by inhibiting GnRH synthesis and release.	Excessive amounts of prolactin associated with ↓ libido.
REGULATION	Prolactin secretion from anterior pituitary is tonically inhibited by dopamine from tuberoinfundibular pathway of hypothalamus. Prolactin in turn inhibits its own secretion by ↑ dopamine synthesis and secretion from hypothalamus. TRH ↑ prolactin secretion (eg, in 1° or 2° hypothyroidism). Dopamine has stronger effect on prolactin regulation than TRH does.	Dopamine agonists (eg, bromocriptine, cabergoline) inhibit prolactin secretion and can be used in treatment of prolactinoma. Dopamine antagonists (eg, most antipsychotics, metoclopramide) and estrogens (eg, OCPs, pregnancy) stimulate prolactin secretion.



Thyroid hormones

Thyroid produces triiodothyronine (T_3) and thyroxine (T_4), iodine-containing hormones that control the body's metabolic rate.

SOURCE

Follicles of thyroid. 5'-deiodinase converts T_4 (the major thyroid product) to T_3 in peripheral tissue (5, 4, 3). Peripheral conversion is inhibited by glucocorticoids, β -blockers, and propylthiouracil (PTU). Reverse T_3 (r T_3) is a metabolically inactive byproduct of the peripheral conversion of T_4 and its production is increased by growth hormone and glucocorticoids. Functions of thyroid peroxidase include oxidation, organification of iodine, and coupling of monoiodotyrosine (MIT) and diiodotyrosine (DIT). Inhibited by PTU and methimazole. $DIT + DIT = T_4$. $DIT + MIT = T_3$. Wolff-Chaikoff effect—protective autoregulation; sudden exposure to excess iodine temporarily turns off thyroid peroxidase \rightarrow $\downarrow T_3/T_4$ production.

FUNCTION

Only free hormone is active. T_3 binds nuclear receptor with greater affinity than T_4 . T_3 functions —7 B's:

- **B**rain maturation
- **B**one growth (synergism with GH)
- **β** -adrenergic effects. $\uparrow \beta_1$ receptors in heart \rightarrow \uparrow CO, HR, SV, contractility; β -blockers alleviate adrenergic symptoms in thyrotoxicosis
- **B**asal metabolic rate \uparrow (via $\uparrow Na^+/K^+$ -ATPase \rightarrow $\uparrow O_2$ consumption, RR, body temperature)
- **B**lood sugar (\uparrow glycogenolysis, gluconeogenesis)
- **B**reak down lipids (\uparrow lipolysis)
- Stimulates surfactant synthesis in **B**abies

REGULATION

TRH \rightarrow \oplus TSH release \rightarrow \oplus follicular cells. Thyroid-stimulating immunoglobulin (TSI) may \oplus follicular cells in Graves disease.

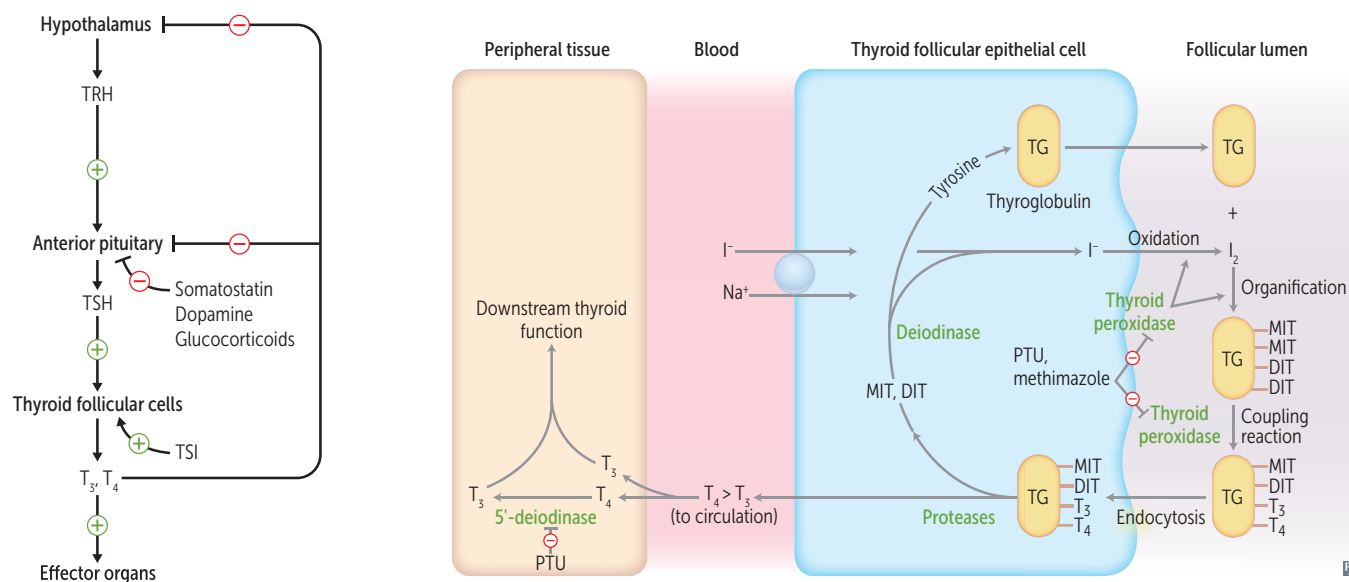
Negative feedback primarily by free T_3/T_4 :

- Anterior pituitary \rightarrow \downarrow sensitivity to TRH
- Hypothalamus \rightarrow \downarrow TRH secretion

Thyroxine-binding globulin (TBG) binds most T_3/T_4 in blood. Bound T_3/T_4 = inactive.

- \uparrow TBG in pregnancy, OCP use (estrogen \rightarrow \uparrow TBG) \rightarrow \uparrow total T_3/T_4
- \downarrow TBG in steroid use, nephrotic syndrome

T_3 and T_4 are the only lipophilic hormones with charged amino acids and require specific transporters to diffuse into the cell (facilitated diffusion).



Parathyroid hormone

SOURCE

Chief cells of parathyroid

FUNCTION

↑ free Ca^{2+} in the blood (1° function)
 ↑ Ca^{2+} and PO_4^{3-} absorption in GI system
 ↑ Ca^{2+} and PO_4^{3-} from bone resorption
 ↑ Ca^{2+} reabsorption from DCT
 ↓ PO_4^{3-} reabsorption in PCT
 ↑ 1,25-(OH) $_2$ D $_3$ (calcitriol) production by activating 1 α -hydroxylase in **PCT** (tri to make D $_3$ in the **PCT**)

PTH ↑ serum Ca^{2+} , ↓ serum PO_4^{3-} , ↑ urine PO_4^{3-} , ↑ urine cAMP

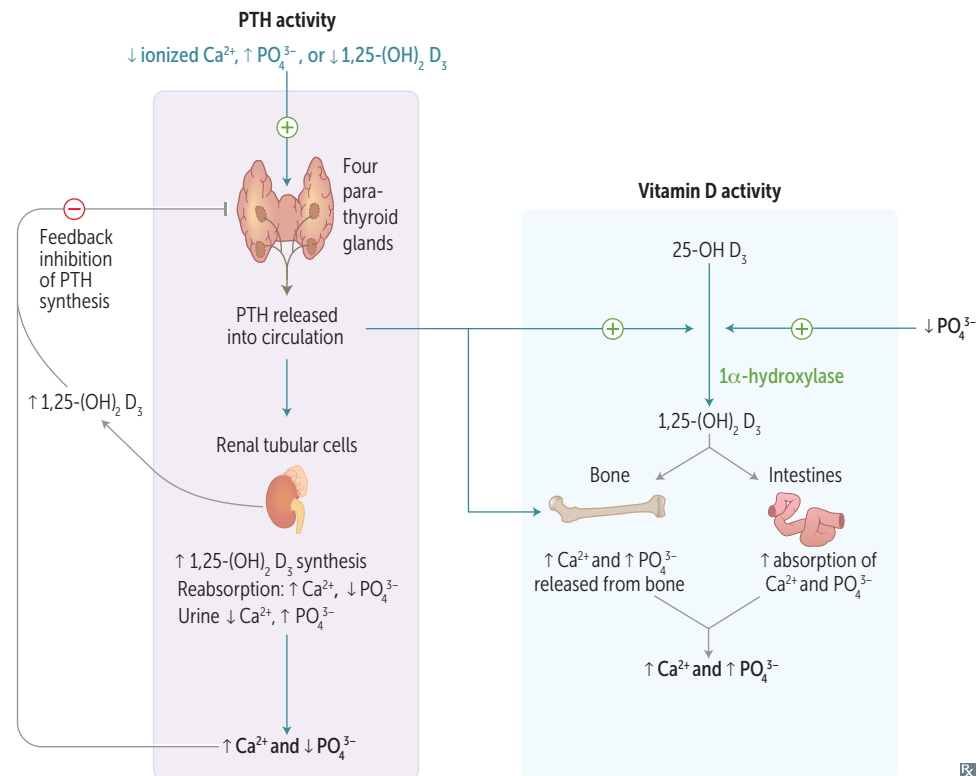
↑ RANK-L (receptor activator of NF- κ B ligand) secreted by osteoblasts and osteocytes; binds RANK (receptor) on osteoclasts and their precursors to stimulate osteoclasts and ↑ Ca^{2+} → bone resorption (intermittent PTH release can also stimulate bone formation)

PTH = Phosphate-Trashing Hormone

PTH-related peptide (PTHrP) functions like PTH and is commonly increased in malignancies (eg, squamous cell carcinoma of the lung, renal cell carcinoma)

REGULATION

↓ serum Ca^{2+} → ↑ PTH secretion
 ↑ serum PO_4^{3-} → ↑ PTH secretion
 ↓ serum Mg^{2+} → ↑ PTH secretion
 ↓↓ serum Mg^{2+} → ↓ PTH secretion
 Common causes of ↓ Mg^{2+} include diarrhea, aminoglycosides, diuretics, alcohol use disorder



Calcium homeostasis

Plasma Ca^{2+} exists in three forms:

- Ionized/free (~ 45%, active form)
- Bound to albumin (~ 40%)
- Bound to anions (~ 15%)

Ionized/free Ca^{2+} is 1° regulator of PTH; changes in pH alter PTH secretion, whereas changes in albumin concentration do not

Ca^{2+} competes with H^+ to bind to albumin

↑ pH (less H^+) → albumin binds more Ca^{2+} → ↓ ionized Ca^{2+} (eg, cramps, pain, paresthesias, carpopedal spasm) → ↑ PTH

↓ pH (more H^+) → albumin binds less Ca^{2+} → ↑ ionized Ca^{2+} → ↓ PTH

Calcitonin

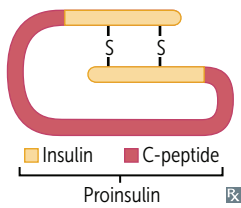
SOURCE	Parafollicular cells (C cells) of thyroid.	Calcitonin opposes actions of PTH. Not important in normal Ca^{2+} homeostasis Calcitonin tones down serum Ca^{2+} levels and keeps it in bones
FUNCTION	↓ bone resorption.	
REGULATION	↑ serum Ca^{2+} → ↑ calcitonin secretion.	

Glucagon

SOURCE	Made by α cells of pancreas.
FUNCTION	Promotes glycogenolysis, gluconeogenesis, lipolysis, ketogenesis. Elevates blood sugar levels to maintain homeostasis when bloodstream glucose levels fall too low (ie, fasting state).
REGULATION	Secreted in response to hypoglycemia. Inhibited by insulin, amylin, somatostatin, hyperglycemia.

Insulin

SYNTHESIS



Preproinsulin (synthesized in RER of pancreatic β cells) \rightarrow cleavage of “presignal” \rightarrow proinsulin (stored in secretory granules) \rightarrow cleavage of proinsulin \rightarrow exocytosis of insulin and C-peptide equally. Both insulin and C-peptide are \uparrow in endogenous insulin secretion (eg, type 2 DM, insulin secretagogues, insulinoma), whereas exogenous insulin lacks C-peptide.

FUNCTION

Binds **insulin** receptors (tyrosine kinase activity **1**), **inducing** glucose uptake (carrier-mediated transport) **into** insulin-dependent tissue **2** and gene transcription.

Anabolic effects of insulin:

- \uparrow glucose transport in skeletal muscle and adipose tissue
- \uparrow glycogen synthesis and storage
- \uparrow triglyceride synthesis
- \uparrow Na^+ retention (kidneys)
- \uparrow protein synthesis (muscles)
- \uparrow cellular uptake of K^+ and amino acids
- \downarrow glucagon release
- \downarrow lipolysis in adipose tissue

Unlike glucose, insulin does not cross placenta.

Insulin-dependent glucose transporters:

- GLUT4: adipose tissue, striated muscle (exercise can also \uparrow GLUT4 expression)

Insulin-independent transporters:

- GLUT1: RBCs, brain, cornea, placenta
- GLUT2 (**bi**directional): β islet cells, liver, kidney, GI tract (think **2**-way street)
- GLUT3: brain, placenta
- GLUT5 (fructose): spermatocytes, GI tract
- SGLT1/SGLT2 (Na^+ -glucose cotransporters): kidney, small intestine

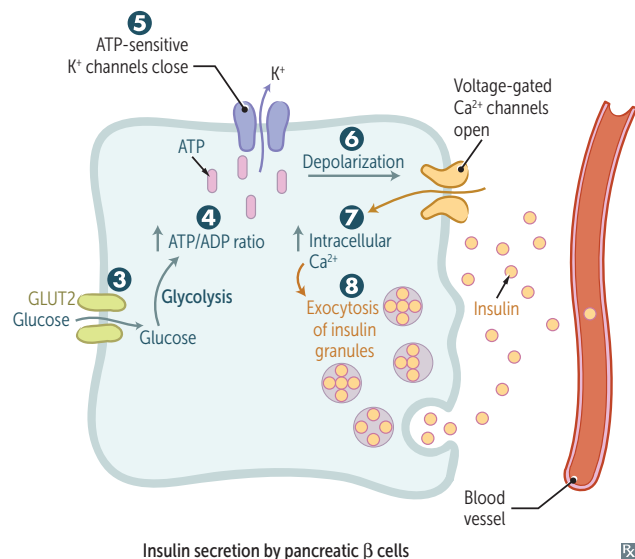
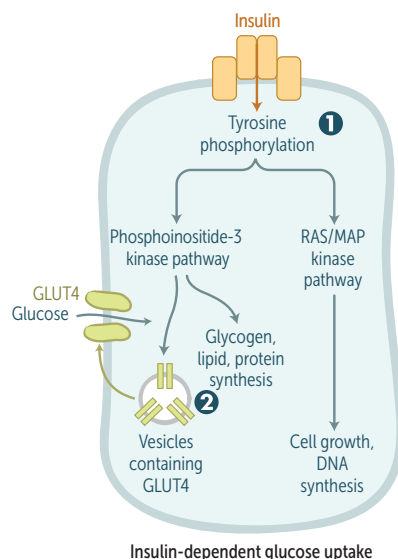
Brain prefers glucose, but may use ketone bodies during starvation. RBCs utilize only glucose, as they lack mitochondria for aerobic metabolism.

BRICK LIPS (insulin-independent glucose uptake): **B**rain, **R**BCs, **I**ntestine, **C**ornea, **K**idney, **L**iver, **I**slet (β) cells, **P**lacenta, **S**permatocytes.

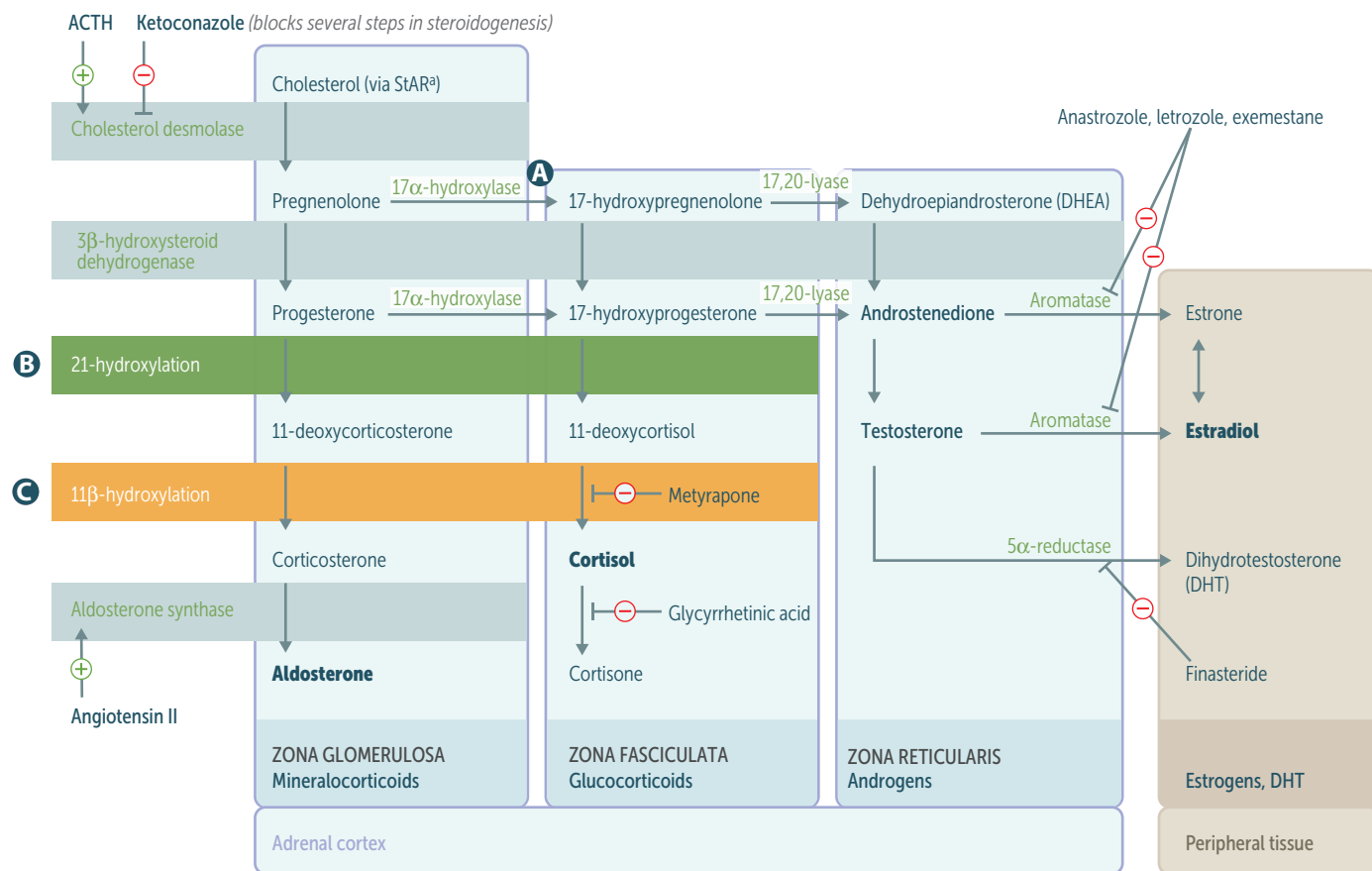
REGULATION

Glucose is the major regulator of insulin release. \uparrow insulin response with oral vs IV glucose due to incretins (eg, glucagonlike peptide 1 [GLP-1], glucose-dependent insulinotropic polypeptide [GIP]), which are released after meals and \uparrow β cell sensitivity to glucose. Release \downarrow by α_2 , \uparrow by β_2 stimulation (**2** = regulates **insulin**).

Glucose enters β cells **3** \rightarrow \uparrow ATP generated from glucose metabolism **4** closes K^+ channels (target of sulfonylureas) **5** and depolarizes β cell membrane **6**. Voltage-gated Ca^{2+} channels open \rightarrow Ca^{2+} influx **7** and stimulation of insulin exocytosis **8**.



Adrenal steroids and congenital adrenal hyperplasias



^aRate-limiting step.

ENZYME DEFICIENCY	MINERALOCORTICOIDS	[K ⁺]	BP	CORTISOL	SEX HORMONES	LABS	PRESENTATION
A 17α-hydroxylase ^a	↑	↓	↑	↓	↓	↓ androstenedione	XY: atypical genitalia, undescended testes XX: lacks 2° sexual development
B 21-hydroxylase ^a	↓	↑	↓	↓	↑	↑ renin activity ↑ 17-hydroxyprogesterone	Most common Presents in infancy (salt wasting) or childhood (precocious puberty) XX: virilization
C 11β-hydroxylase ^a	↓ aldosterone ↑ 11-deoxycorticosterone (results in ↑ BP)	↓	↑	↓	↑	↓ renin activity	Presents in infancy (severe hypertension) or childhood (precocious puberty) XX: virilization

^aAll congenital adrenal enzyme deficiencies are autosomal recessive disorders and most are characterized by skin hyperpigmentation (due to ↑ MSH production, which is coproduced and secreted with ACTH) and bilateral adrenal gland enlargement (due to ↑ ACTH stimulation).

If deficient enzyme starts with 1, it causes hypertension; if deficient enzyme ends with 1, it causes virilization in females.

Cortisol

SOURCE

Adrenal zona fasciculata.

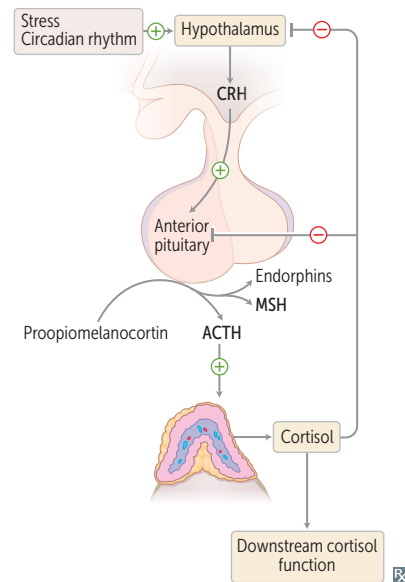
FUNCTION

- ↑ **A**ppetite
- ↑ **B**lood pressure:
 - Upregulates α_1 -receptors on arterioles → ↑ sensitivity to norepinephrine and epinephrine (permissive action)
 - At high concentrations, can bind to mineralocorticoid (aldosterone) receptors
- ↑ **I**nsulin resistance (diabetogenic)
- ↑ **G**luconeogenesis, lipolysis, and proteolysis (↓ glucose utilization)
- ↓ **F**ibroblast activity (poor wound healing, ↓ collagen synthesis, ↑ striae)
- ↓ **I**nflammatory and **I**mmune responses:
 - Inhibits production of leukotrienes and prostaglandins
 - Inhibits WBC adhesion → neutrophilia
 - Blocks histamine release from mast cells
 - Eosinopenia, lymphopenia
 - Blocks IL-2 production
- ↓ **B**one formation (↓ osteoblast activity)

Bound to corticosteroid-binding globulin.

Cortisol is **A BIG FIB**.

Exogenous glucocorticoids can cause reactivation of TB and candidiasis (blocks IL-2 production).



REGULATION

CRH (hypothalamus) stimulates ACTH release (pituitary) → cortisol production in adrenal zona fasciculata. Excess cortisol ↓ CRH, ACTH, and cortisol secretion.

Chronic stress may induce prolonged cortisol secretion, cortisol resistance, impaired immunocompetency, and dysregulation of HPA axis.

Appetite regulation**Ghrelin**

Stimulates hunger (orexigenic effect) and GH release (via GH secretagog receptor). Produced by stomach. Sleep deprivation, fasting, or Prader-Willi syndrome → ↑ ghrelin production.

Ghrelin makes you **gh**row **hungh**ry. Acts on lateral area of hypothalamus (hunger center) to ↑ appetite.

Leptin

Satiety hormone. Produced by adipose tissue. Mutation of leptin gene → severe obesity. Obese people have ↑ leptin due to ↑ adipose tissue but are tolerant or resistant to leptin's anorexigenic effect. Sleep deprivation or starvation → ↓ leptin production.

Leptin keeps you **thin**. Acts on ventromedial area of hypothalamus (satiety center) to ↓ appetite.

Endocannabinoids

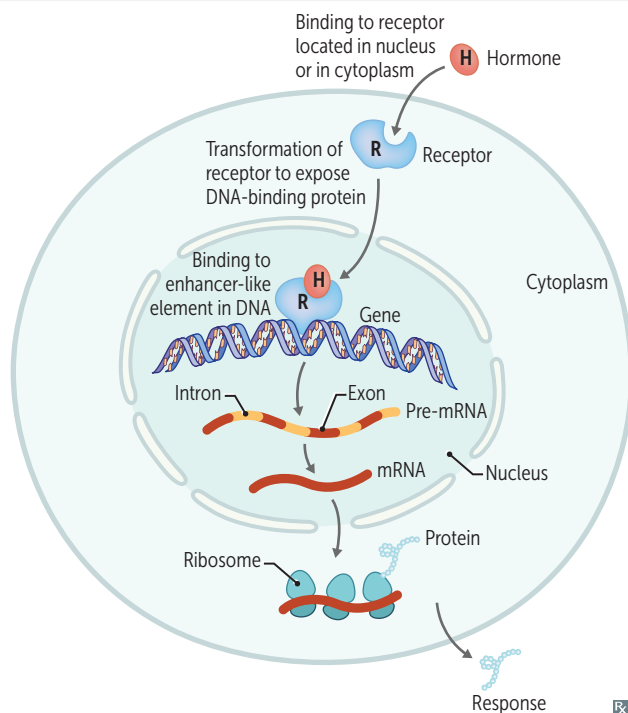
Act at cannabinoid receptors in hypothalamus and nucleus accumbens, two key brain areas for the homeostatic and hedonic control of food intake → ↑ appetite.

Exogenous cannabinoids cause “the munchies.”

Signaling pathways of endocrine hormones

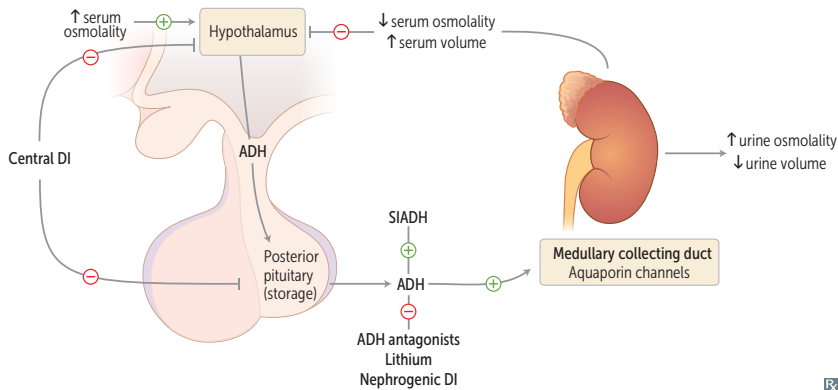
cAMP	FSH, LH, ACTH, TSH, CRH, hCG, ADH (V ₂ -receptor), MSH, PTH, Calcitonin, Histamine (H ₂ -receptor), Glucagon, GHRH	FLAT ChAMPs CH₁₁GG
cGMP	BNP, ANP, EDRF (NO)	BAD G_{ra}MP_a Think vasodilation and diuresis
IP₃	GnRH, Oxytocin, ADH (V ₁ -receptor), TRH, Histamine (H ₁ -receptor), Angiotensin II, Gastrin	GOAT HAG
Intracellular receptor	Progesterone, Estrogen, Testosterone, Cortisol, Aldosterone, T₃/T₄, Vitamin D	PET CAT in TV
Receptor tyrosine kinase	IGF-1, FGF, PDGF, EGF, Insulin	MAP kinase pathway Get Found In the MAP
Nonreceptor tyrosine kinase	G-CSF, Erythropoietin, Thrombopoietin, Prolactin, Immunomodulators (eg, cytokines IL-2, IL-6, IFN), GH	JAK/STAT pathway Think acidophils and cytokines GET a JAKed PIG

Signaling pathways of steroid hormones



Steroid hormones are lipophilic and therefore must circulate bound to specific binding globulins, which ↑ their solubility. In males, ↑ sex hormone-binding globulin (SHBG) lowers free testosterone → gynecomastia. In females, ↓ SHBG raises free testosterone → hirsutism. ↑ estrogen (eg, OCPs, pregnancy) → ↑ SHBG.

▶ ENDOCRINE—PATHOLOGY

Syndrome of inappropriate antidiuretic hormone secretion

Characterized by excessive free water retention, euvolemic hyponatremia with continued urinary Na^+ excretion, urine osmolality $>$ serum osmolality.

Body responds to water retention with \downarrow aldosterone and \uparrow ANP and BNP \rightarrow \uparrow urinary Na^+ secretion \rightarrow normalization of extracellular fluid volume \rightarrow euvolemic hyponatremia.

Treatment: fluid restriction (first line), salt tablets, IV hypertonic saline, diuretics, ADH antagonists (eg, conivaptan, tolvaptan, demeclocycline).

SIADH causes include (**HEELD**-up water):

- **H**ead trauma/CNS disorders
- **E**ctopic ADH (eg, small cell lung cancer)
- **E**xogenous hormones (eg, vasopressin, desmopressin, oxytocin)
- **L**ung disease
- **D**rugs (eg, SSRIs, carbamazepine, cyclophosphamide)

Primary polydipsia and diabetes insipidus

Characterized by the production of large amounts of dilute urine +/- thirst. Urine specific gravity $<$ 1.006. Urine osmolality usually $<$ 300 mOsm/kg. Central DI may be transient if damage is below hypothalamic median eminence or in the posterior pituitary (ADH in hypothalamus can still be secreted systemically via portal capillaries in median eminence).

	Primary polydipsia	Central DI	Nephrogenic DI
DEFINITION	Excessive water intake	\downarrow ADH release	ADH resistance
CAUSES	Psychiatric illnesses, hypothalamic lesions affecting thirst center	Idiopathic, brain injury (trauma, hypoxia, tumor, surgery, infiltrative diseases)	Hereditary (ADH receptor mutation), drugs (eg, lithium, demeclocycline), hypercalcemia, hypokalemia
SERUM OSMOLALITY	\downarrow	\uparrow	\uparrow
ADH LEVEL	\downarrow or normal	\downarrow	Normal or \uparrow
WATER RESTRICTION ^a	Significant \uparrow in urine osmolality ($>$ 700 mOsm/kg)	No change or slight \uparrow in urine osmolality	No change or slight \uparrow in urine osmolality
DESMOPRESSIN ADMINISTRATION ^b	—	Significant \uparrow in urine osmolality ($>$ 50%)	Minimal change in urine osmolality
TREATMENT	Water restriction	Desmopressin (DDAVP)	Manage the underlying cause; low-solute diet, HCTZ, amiloride, indomethacin

^aNo water intake for 2–3 hours followed by hourly measurements of urine volume and osmolality as well as plasma Na^+ concentration and osmolality.

^bDesmopressin (ADH analog) is administered if serum osmolality $>$ 295–300 mOsm/kg, plasma $\text{Na}^+ \geq 145$ mEq/L, or urine osmolality does not increase despite \uparrow plasma osmolality.

Hypopituitarism


Undersecretion of pituitary hormones due to

- Nonsecreting pituitary adenoma, craniopharyngioma
- **Sheehan syndrome**—ischemic infarct of pituitary following severe postpartum hemorrhage; pregnancy-induced pituitary growth → ↑ susceptibility to hypoperfusion. Usually presents with failure to lactate, absent menstruation, cold intolerance
- **Empty sella syndrome**—atrophy or compression of pituitary (which lies in the sella turcica), often idiopathic, common in obese females; associated with idiopathic intracranial hypertension
- **Pituitary apoplexy**—sudden hemorrhage of pituitary gland, often in the presence of an existing pituitary adenoma. Usually presents with sudden onset severe headache, visual impairment (eg, bitemporal hemianopia, diplopia due to CN III palsy), and features of hypopituitarism
- Brain injury
- Radiation

Treatment: hormone replacement therapy (glucocorticoids, thyroxine, sex steroids, human growth hormone)

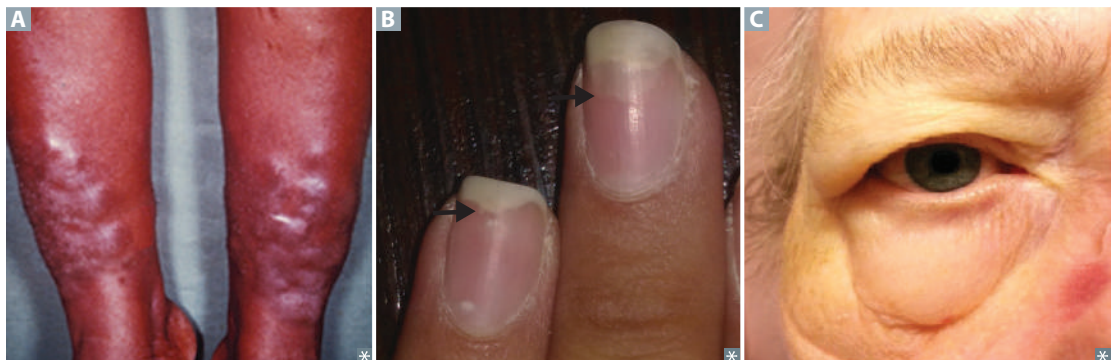
Acromegaly

Excess GH in adults. Typically caused by pituitary adenoma.

FINDINGS	Large tongue with deep furrows, frontal bossing, coarsening of facial features with aging A , deep voice, diaphoresis (excessive sweating), impaired glucose tolerance (insulin resistance), HTN, LVH, diastolic HF (most common cause of death).	<p>↑ GH in children → gigantism (↑ linear bone growth).</p> 
DIAGNOSIS	↑ serum IGF-1; failure to suppress serum GH following oral glucose tolerance test; pituitary mass seen on brain MRI.	
TREATMENT	Pituitary adenoma resection. If not cured, treat with octreotide (somatostatin analog), pegvisomant (GH receptor antagonist), or dopamine agonists (eg, cabergoline).	

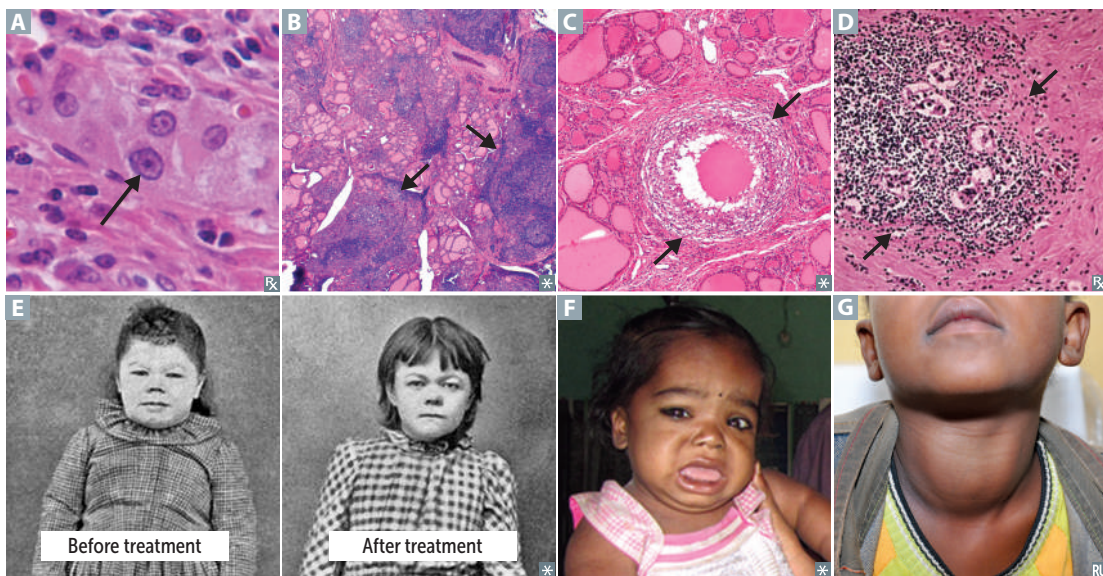
Hypothyroidism vs hyperthyroidism

	Hypothyroidism	Hyperthyroidism
METABOLIC	Cold intolerance, ↓ sweating, weight gain (↓ basal metabolic rate → ↓ calorogenesis), hyponatremia (↓ free water clearance)	Heat intolerance, ↑ sweating, weight loss (↑ synthesis of Na ⁺ /K ⁺ -ATPase → ↑ basal metabolic rate → ↑ calorogenesis)
SKIN/HAIR	Dry, cool skin (due to ↓ blood flow); coarse, brittle hair; diffuse alopecia; brittle nails; puffy facies and generalized nonpitting edema (myxedema A) due to ↑ GAGs in interstitial spaces → ↑ osmotic pressure → water retention	Warm, moist skin (due to vasodilation); fine hair; onycholysis (B); pretibial myxedema in Graves disease
OCULAR	Periorbital edema C	Ophthalmopathy in Graves disease (including periorbital edema, exophthalmos), lid lag/retraction (↑ sympathetic stimulation of levator palpebrae superioris and superior tarsal muscle)
GASTROINTESTINAL	Constipation (↓ GI motility), ↓ appetite	Hyperdefecation/diarrhea (↑ GI motility), ↑ appetite
MUSCULOSKELETAL	Hypothyroid myopathy (proximal weakness, ↑ CK), carpal tunnel syndrome, myoedema (small lump rising on the surface of a muscle when struck with a hammer)	Thyrotoxic myopathy (proximal weakness, normal CK), osteoporosis/↑ fracture rate (T ₃ directly stimulates bone resorption)
REPRODUCTIVE	Abnormal uterine bleeding, ↓ libido, infertility	Abnormal uterine bleeding, gynecomastia, ↓ libido, infertility
NEUROPSYCHIATRIC	Hypoactivity, lethargy, fatigue, weakness, depressed mood, ↓ reflexes (delayed/slow relaxing)	Hyperactivity, restlessness, anxiety, insomnia, fine tremors (due to ↑ β-adrenergic activity), ↑ reflexes (brisk)
CARDIOVASCULAR	Bradycardia, dyspnea on exertion (↓ cardiac output)	Tachycardia, palpitations, dyspnea, arrhythmias (eg, atrial fibrillation), chest pain and systolic HTN due to ↑ number and sensitivity of β-adrenergic receptors, ↑ expression of cardiac sarcolemmal ATPase and ↓ expression of phospholamban
LABS	↑ TSH (if 1°) ↓ free T ₃ and T ₄ Hypercholesterolemia (due to ↓ LDL receptor expression)	↓ TSH (if 1°) ↑ free T ₃ and T ₄ ↓ LDL, HDL, and total cholesterol



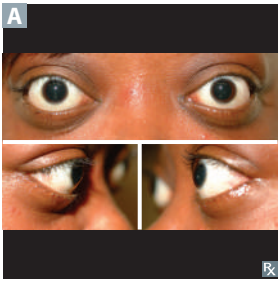
Hypothyroidism

Hashimoto thyroiditis	<p>Also called chronic autoimmune thyroiditis. Most common cause of hypothyroidism in iodine-sufficient regions. Associated with HLA-DR3 (differs by ethnicity), ↑ risk of primary thyroid lymphoma (typically diffuse large B-cell lymphoma). Findings: moderately enlarged, nontender thyroid. May be preceded by transient hyperthyroid state (“Hashitoxicosis”) due to follicular rupture and thyroid hormone release. Serology: ⊕ antithyroid peroxidase (antimicrosomal) and antithyroglobulin antibodies. Histology: Hürthle cells A, lymphoid aggregates with germinal centers B. Postpartum thyroiditis—mild, self-limited variant of Hashimoto thyroiditis arising < 1 year after delivery.</p>
Subacute granulomatous thyroiditis	<p>Also called de Quervain thyroiditis. Usually, a self-limited disease. Natural history: transient hyperthyroidism → euthyroid state → hypothyroidism → euthyroid state. Often preceded by viral infection. Findings: ↑ ESR, jaw pain, very tender thyroid (de Quervain is associated with pain). Histology: granulomatous inflammation C.</p>
Riedel thyroiditis	<p>Also called invasive fibrous thyroiditis. May be associated with IgG₄-related disease (eg, autoimmune pancreatitis, retroperitoneal fibrosis, noninfectious aortitis), a variant of autoimmune thyroiditis, or part of a systemic fibrosing disorder. Hypothyroidism occurs in 1/3 of patients. Fibrosis may extend to local structures (eg, trachea, esophagus), mimicking anaplastic carcinoma. Findings: slowly enlarging, hard (rocklike), fixed, nontender thyroid. Histology: thyroid replaced by fibrous tissue and inflammatory infiltrate D.</p>
Congenital hypothyroidism	<p>Formerly called cretinism. Most commonly caused by thyroid dysgenesis (abnormal thyroid gland development; eg, agenesis, hypoplasia, ectopy) or dyshormonogenesis (abnormal thyroid hormone synthesis; eg, mutations in thyroid peroxidase) in iodine-sufficient regions. Findings (6 P's): pot-bellied, pale, puffy-faced child E with protruding umbilicus, protuberant tongue F, and poor brain development.</p>
Other causes	<p>Iodine deficiency (most common cause worldwide; typically presents with goiter G), iodine excess (Wolff-Chaikoff effect), drugs (eg, amiodarone, lithium), nonthyroidal illness syndrome (also called euthyroid sick syndrome; ↓ T₃ with normal/↓ T₄ and TSH in critically ill patients).</p>



Hyperthyroidism

Graves disease



Most common cause of hyperthyroidism. Thyroid-stimulating immunoglobulin (IgG, can cause transient neonatal hyperthyroidism; type II hypersensitivity) stimulates TSH receptors on thyroid (hyperthyroidism, diffuse goiter), dermal fibroblasts (pretibial myxedema), and orbital fibroblasts (Graves orbitopathy). Activation of T-cells → lymphocytic infiltration of retroorbital space → ↑ cytokines (eg, TNF- α , IFN- γ) → ↑ fibroblast secretion of hydrophilic GAGs → ↑ osmotic muscle swelling, muscle inflammation, and adipocyte count → exophthalmos **A**. Often presents during stress (eg, pregnancy). Associated with HLA-DR3 and HLA-B8.
Histology: tall, crowded follicular epithelial cells; scalloped colloid.

Toxic multinodular goiter

Focal patches of hyperfunctioning follicular cells distended with colloid working independently of TSH (due to TSH receptor mutations in 60% of cases). ↑ release of T₃ and T₄. Hot nodules are rarely malignant.

Thyroid storm

Uncommon but serious complication that occurs when hyperthyroidism is incompletely treated/untreated and then significantly worsens in the setting of acute stress such as infection, trauma, surgery. Presents with agitation, delirium, fever, diarrhea, coma, and tachyarrhythmia (cause of death). May see ↑ LFTs. Treat with the **4 P's**: β -blockers (eg, propranolol), propylthiouracil, glucocorticoids (eg, prednisolone), potassium iodide (Lugol iodine). Iodide load → ↓ T₄ synthesis → Wolff-Chaikoff effect.

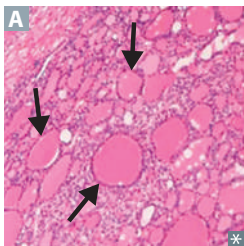
Jod-Basedow phenomenon

Iodine-induced hyperthyroidism. Occurs when a patient with iodine deficiency and partially autonomous thyroid tissue (eg, autonomous nodule) is made iodine replete. Can happen after iodine IV contrast or amiodarone use. Opposite to Wolff-Chaikoff effect.

Causes of goiter

Smooth/diffuse: Graves disease, Hashimoto thyroiditis, iodine deficiency, TSH-secreting pituitary adenoma.
Nodular: toxic multinodular goiter, thyroid adenoma, thyroid cancer, thyroid cyst.

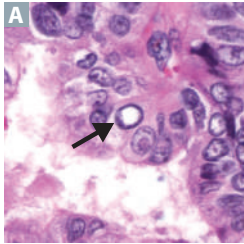
Thyroid adenoma



Benign solitary growth of the thyroid. Most are nonfunctional (“cold” on radioactive iodine scan), can rarely cause hyperthyroidism via autonomous thyroid hormone production (“hot” or “toxic”). Most common histology is follicular (arrows in **A**); absence of capsular or vascular invasion (unlike follicular carcinoma).

Thyroid cancer

Typically diagnosed with fine needle aspiration; treated with thyroidectomy. Complications of surgery include hypocalcemia (due to removal of parathyroid glands), transection of recurrent laryngeal nerve during ligation of inferior thyroid artery (leads to dysphagia and dysphonia [hoarseness]), and injury to the external branch of the superior laryngeal nerve during ligation of superior thyroid vascular pedicle (may lead to loss of tenor usually noticeable in professional voice users).

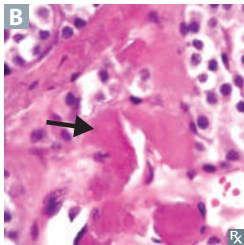
Papillary carcinoma

Most common. Empty-appearing nuclei with central clearing (“Orphan Annie” eyes) **A**, psammoma bodies, nuclear grooves (**Papi** and **Moma** adopted **Orphan Annie**). ↑ risk with *RET/PTC* rearrangements and *BRAF* mutations, childhood irradiation.

Papillary carcinoma: most prevalent, palpable lymph nodes. Good prognosis.

Follicular carcinoma

Good prognosis. Invades thyroid capsule and vasculature (unlike follicular adenoma), uniform follicles; hematogenous spread is common. Associated with *RAS* mutation and *PAX8-PPAR-γ* translocations. Fine needle aspiration cytology may not be able to distinguish between follicular adenoma and carcinoma.

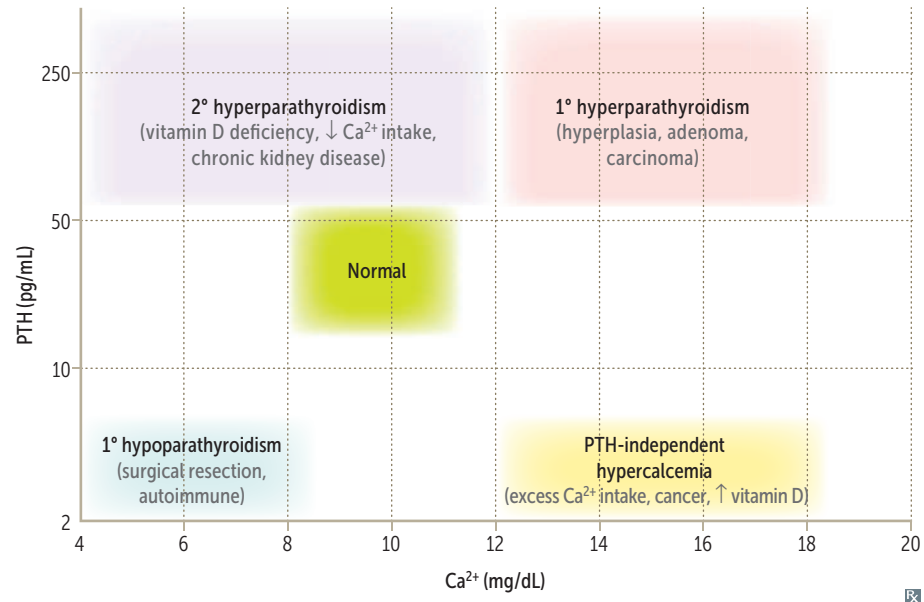
Medullary carcinoma

From parafollicular “C cells”; produces calcitonin, sheets of polygonal cells in an amyloid stroma **B** (stains with Congo red). Associated with MEN 2A and 2B (*RET* mutations).

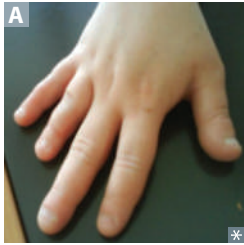
**Undifferentiated/
anaplastic carcinoma**

Older patients; presents with rapidly enlarging neck mass → compressive symptoms (eg, dyspnea, dysphagia, hoarseness); very poor prognosis. Associated with *TP53* mutation.

Diagnosing parathyroid disease



Hypoparathyroidism



Due to injury to parathyroid glands or their blood supply (usually during thyroid surgery), autoimmune destruction, or DiGeorge syndrome. Findings: tetany, hypocalcemia, hyperphosphatemia.

Chvostek sign—tapping of facial nerve (tap the **C**heek) → contraction of facial muscles.

Trousseau sign—occlusion of brachial artery with BP cuff (cuff the **T**riceps) → carpal spasm.

Pseudohypoparathyroidism type 1A—autosomal dominant, maternally transmitted mutations (imprinted *GNAS* gene). *GNAS1*-inactivating mutation (coupled to PTH receptor) that encodes the G_s protein α subunit → inactivation of adenylate cyclase when PTH binds to its receptor → end-organ resistance (kidney and bone) to PTH.

Physical findings: Albright hereditary osteodystrophy (shortened 4th/5th digits **A**, short stature, round face, subcutaneous calcifications, developmental delay).

Labs: ↑ PTH, ↓ Ca²⁺, ↑ PO₄³⁻.

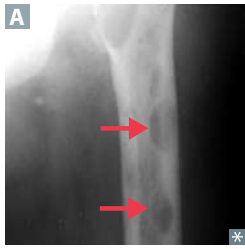
Pseudopseudohypoparathyroidism—autosomal dominant, paternally transmitted mutations (imprinted *GNAS* gene) but without end-organ resistance to PTH due to normal maternal allele maintaining renal responsiveness to PTH.

Physical findings: same as Albright hereditary osteodystrophy.

Labs: normal PTH, Ca²⁺, PO₄³⁻.

Lab values in hypocalcemic disorders

DISORDER	Ca ²⁺	PO ₄ ³⁻	PTH	ALP	VITAMIN D
Vitamin D deficiency	↓	↓	↑	↑	↓
Hypoparathyroidism	↓	↑	↓	—	↓
2° hyperparathyroidism (CKD)	↓	↑	↑	↑	—/↓
Pseudohypoparathyroidism	↓	↑	↑	↑	—
Hyperphosphatemia	↓	↑	↑	↑	↓

Hyperparathyroidism**Primary hyperparathyroidism**

Usually due to parathyroid adenoma or hyperplasia. **Hypercalcemia**, hypercalciuria (renal **stones**), polyuria (**thrones**), hypophosphatemia, ↑ PTH, ↑ ALP, ↑ urinary cAMP. Most often asymptomatic. May present with **bone** pain, weakness, constipation (“**groans**”), abdominal/flank pain (kidney stones, acute pancreatitis), neuropsychiatric disturbances (“**psychiatric overtones**”).

Osteitis fibrosa cystica—cystic **bone** spaces filled with brown fibrous tissue **A** (“brown tumor” consisting of osteoclasts and deposited hemosiderin from hemorrhages; causes bone pain). Due to ↑ PTH, classically associated with 1° (but also seen with 2°) hyperparathyroidism.

“**Stones, thrones, bones, groans, and psychiatric overtones.**”

Secondary hyperparathyroidism

2° hyperplasia due to ↓ Ca²⁺ absorption and/or ↑ PO₄³⁻, most often in chronic kidney disease (causes hypovitaminosis D and hyperphosphatemia → ↓ Ca²⁺). **Hypocalcemia**, hyperphosphatemia in chronic kidney disease (vs hypophosphatemia with most other causes), ↑ ALP, ↑ PTH.

Renal osteodystrophy—renal disease → 2° and 3° hyperparathyroidism → bone lesions.

Tertiary hyperparathyroidism

Refractory (autonomous) hyperparathyroidism resulting from chronic kidney disease. ↑↑ PTH, ↑ Ca²⁺.

Familial hypocalciuric hypercalcemia

Defective G-coupled Ca²⁺-sensing receptors in multiple tissues (eg, parathyroids, kidneys). Higher than normal Ca²⁺ levels required to suppress PTH. Excessive renal Ca²⁺ reabsorption → mild hypercalcemia and hypocalciuria with normal to ↑ PTH levels.

Diabetes mellitus

ACUTE MANIFESTATIONS

Polydipsia, polyuria, polyphagia, weight loss, DKA (type 1), hyperosmolar hyperglycemic state (type 2).

Rarely, can be caused by unopposed secretion of GH and epinephrine. Also seen in patients on glucocorticoid therapy (steroid diabetes).

CHRONIC COMPLICATIONS

Nonenzymatic glycation:

- Small vessel disease (diffuse thickening of basement membrane) → retinopathy (hemorrhage, exudates, microaneurysms, vessel proliferation), glaucoma, nephropathy. Nodular glomerulosclerosis → progressive proteinuria (initially microalbuminuria; ACE inhibitors and ARBs are renoprotective). Arteriolosclerosis (causing hypertension) → chronic kidney disease.
- Large vessel atherosclerosis, CAD, peripheral vascular occlusive disease, gangrene → limb loss, cerebrovascular disease. MI most common cause of death.

Osmotic damage (sorbitol accumulation in organs with aldose reductase and ↓ or absent sorbitol dehydrogenase):

- Neuropathy: motor, sensory (glove and stocking distribution), autonomic degeneration (eg, GERD, gastroparesis, diabetic diarrhea).
- Cataracts.

DIAGNOSIS

TEST

HbA_{1c}

DIAGNOSTIC CUTOFF

≥ 6.5%

NOTES

Reflects average blood glucose over prior 3 months (influenced by RBC turnover)

Fasting plasma glucose

≥ 126 mg/dL

Fasting for > 8 hours

2-hour oral glucose tolerance test

≥ 200 mg/dL

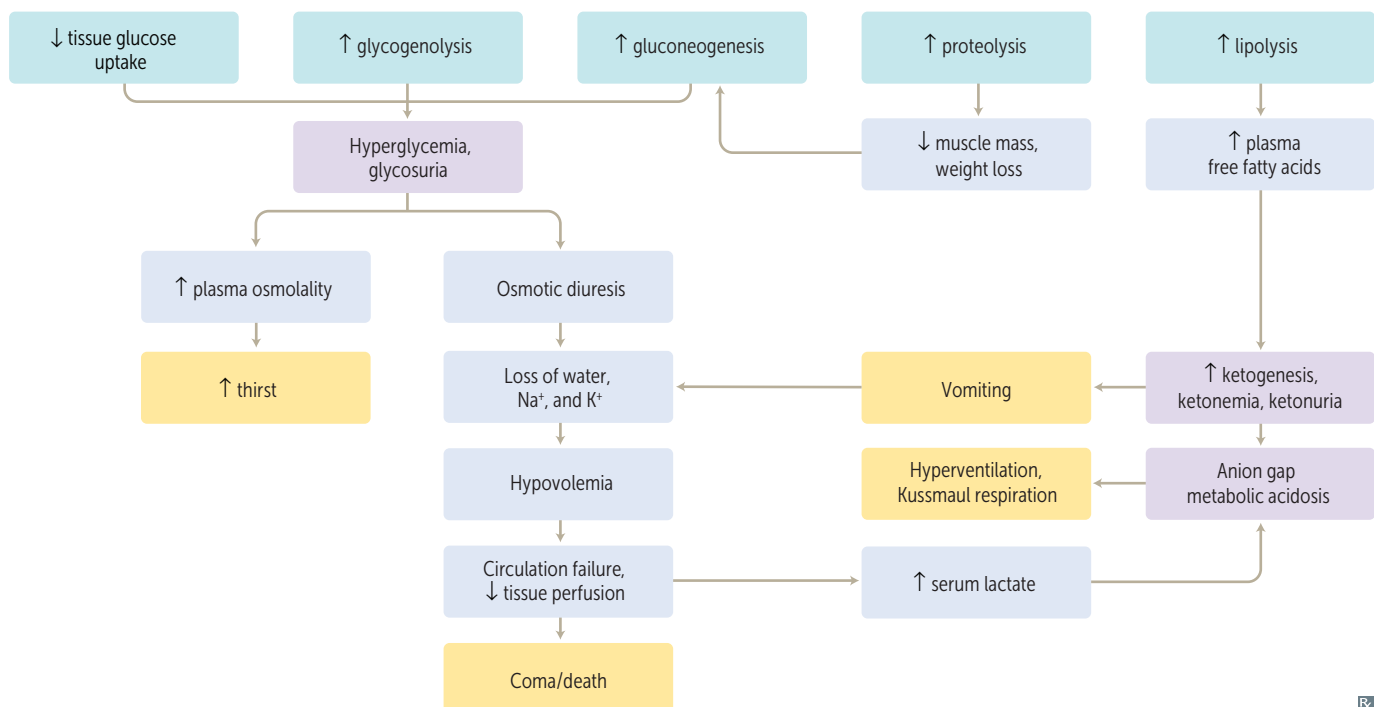
2 hours after consumption of 75 g of glucose in water

Random plasma glucose

≥ 200 mg/dL

Presence of hyperglycemic symptoms is required

Insulin deficiency or severe insulin insensitivity



Type 1 vs type 2 diabetes mellitus

	Type 1	Type 2
1° DEFECT	Autoimmune T-cell–mediated destruction of β cells (eg, due to presence of glutamic acid decarboxylase antibodies)	\uparrow resistance to insulin, progressive pancreatic β -cell failure
INSULIN NECESSARY IN TREATMENT	Always	Sometimes
AGE (EXCEPTIONS COMMON)	< 30 yr	> 40 yr
ASSOCIATION WITH OBESITY	No	Yes
GENETIC PREDISPOSITION	Relatively weak (50% concordance in identical twins), polygenic	Relatively strong (90% concordance in identical twins), polygenic
ASSOCIATION WITH HLA SYSTEM	Yes, HLA-DR4 and -DR3 (4 – 3 = type 1)	No
GLUCOSE INTOLERANCE	Severe	Mild to moderate
INSULIN SENSITIVITY	High	Low
KETOACIDOSIS	Common	Rare
β -CELL NUMBERS IN THE ISLETS	\downarrow	Variable (with amyloid deposits)
SERUM INSULIN LEVEL	\downarrow	\uparrow initially, but \downarrow in advanced disease
CLASSIC SYMPTOMS OF POLYURIA, POLYDIPSIA, POLYPHAGIA, WEIGHT LOSS	Common	Sometimes
HISTOLOGY	Islet leukocytic infiltrate	Islet amyloid polypeptide (IAPP) deposits

Hyperglycemic emergencies

	Diabetic ketoacidosis	Hyperosmolar hyperglycemic state
PATHOGENESIS	Insulin noncompliance or \uparrow requirements due to \uparrow stress (eg, infection) \rightarrow lipolysis and oxidation of free fatty acids \rightarrow \uparrow ketone bodies (β -hydroxybutyrate > acetoacetate). Insulin deficient, ketones present.	Profound hyperglycemia \rightarrow excessive osmotic diuresis \rightarrow dehydration and \uparrow serum osmolality \rightarrow HHS. Classically seen in older patients with type 2 DM and limited ability to drink. Insulin present, ketones deficient.
SIGNS/SYMPTOMS	DKA is D eadly: D elirium/psychosis, K ussmaul respirations (rapid, deep breathing), A bdominal pain/nausea/vomiting, D ehydration. Fruity breath odor due to exhaled acetone.	Thirst, polyuria, lethargy, focal neurologic deficits, seizures.
LABS	Hyperglycemia, \uparrow H^+ , \downarrow HCO_3^- (\uparrow anion gap metabolic acidosis), \uparrow urine and blood ketone levels, leukocytosis. Normal/ \uparrow serum K^+ , but depleted intracellular K^+ due to transcellular shift from \downarrow insulin and acidosis. Osmotic diuresis \rightarrow \uparrow K^+ loss in urine \rightarrow total body K^+ depletion.	Hyperglycemia (often > 600 mg/dL), \uparrow serum osmolality (> 320 mOsm/kg), normal pH (no acidosis), no ketones. Normal/ \uparrow serum K^+ , \downarrow intracellular K^+ .
COMPLICATIONS	Life-threatening mucormycosis, cerebral edema, cardiac arrhythmias.	Can progress to coma and death if untreated.
TREATMENT	IV fluids, IV insulin, and K^+ (to replete intracellular stores). Glucose may be required to prevent hypoglycemia from insulin therapy.	

Hypoglycemia in diabetes mellitus

Usually occurs in patients treated with insulin or insulin secretagogues (eg, sulfonylureas, meglitinides) in the setting of high-dose treatment, inadequate food intake, and/or exercise.

- Neurogenic (autonomic) symptoms: diaphoresis, tachycardia, tremor, anxiety, hunger. Allow perception of ↓ glucose (hypoglycemia awareness).
- Neuroglycopenic symptoms: altered mental status, seizures, death due to insufficient glucose in CNS. May occur in the absence of preceding neurogenic symptoms in patients with attenuated autonomic response (hypoglycemia unawareness).

Treatment: simple carbohydrates (eg, glucose tablets, fruit juice), IM glucagon, IV dextrose.

Cushing syndrome

ETIOLOGY

↑ cortisol due to a variety of causes:

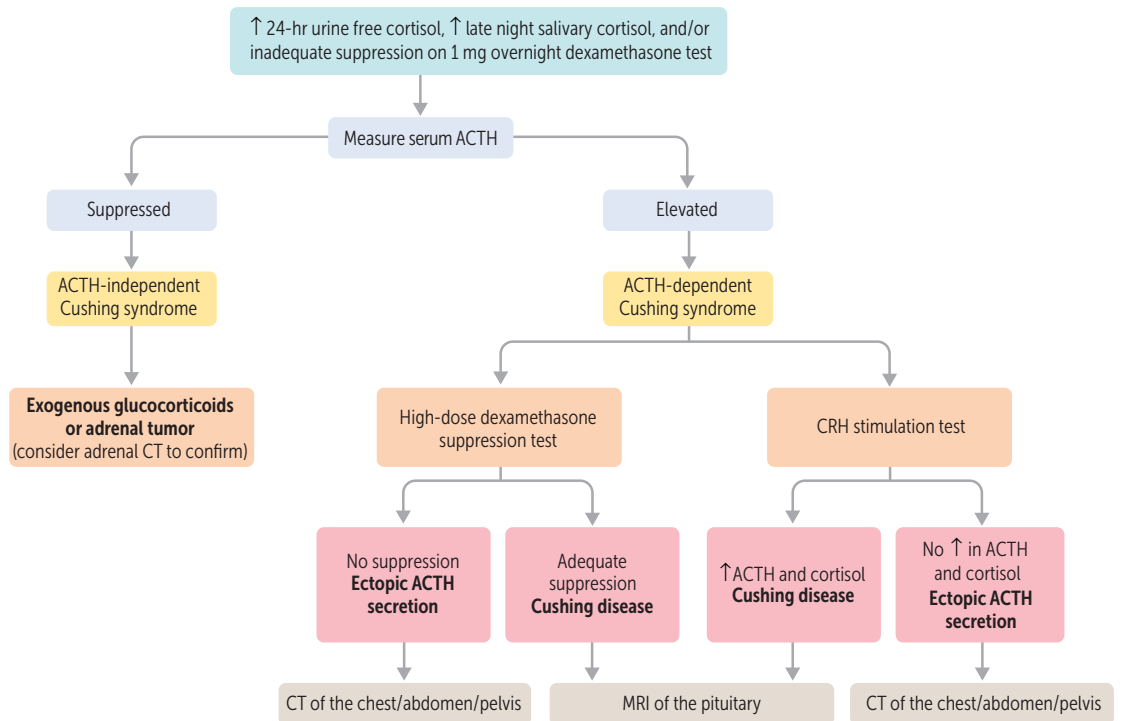
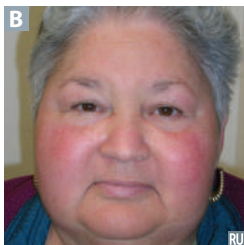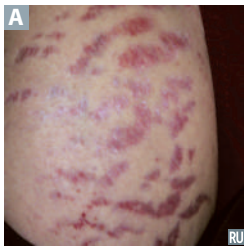
- Exogenous glucocorticoids → ↓ ACTH → bilateral adrenal atrophy. Most common cause.
- Primary adrenal adenoma, hyperplasia, or carcinoma → ↓ ACTH → atrophy of uninvolved adrenal gland.
- ACTH-secreting pituitary adenoma (Cushing disease); paraneoplastic ACTH secretion (eg, small cell lung cancer, bronchial carcinoids) → bilateral adrenal hyperplasia. Cushing disease is responsible for the majority of endogenous cases of Cushing syndrome.

FINDINGS

CUSHING Syndrome: ↑ Cholesterol, ↑ Urinary free cortisol, **S**kin changes (thinning, striae **A**, facial plethora, acanthosis nigricans), **H**ypertension, **I**mmunosuppression, **N**eoplasm (a cause, not a finding), **G**rowth restriction (in children), ↑ Sugar (hyperglycemia, insulin resistance). Also, amenorrhea, moon facies **B**, buffalo hump, osteoporosis, ↑ weight (truncal obesity), hirsutism.

DIAGNOSIS

Screening tests include: ↑ free cortisol on 24-hr urinalysis, ↑ late night salivary cortisol, and no suppression with overnight low-dose dexamethasone test.



Nelson syndrome

Enlargement of pre-existing ACTH-secreting pituitary adenoma after bilateral adrenalectomy for refractory Cushing disease → ↑ ACTH (hyperpigmentation), mass effect (headaches, bitemporal hemianopia).

Treatment: transsphenoidal resection, postoperative pituitary irradiation for residual tumor.

Adrenal insufficiency

Inability of adrenal glands to generate enough glucocorticoids +/- mineralocorticoids for the body's needs. Can be acute or chronic. Symptoms include weakness, fatigue, orthostatic hypotension, muscle aches, weight loss, GI disturbances, sugar and/or salt cravings.

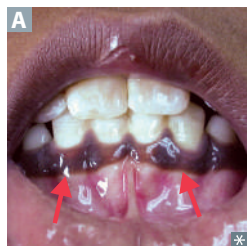
Treatment: glucocorticoid +/- mineralocorticoid replacement.

Primary adrenal insufficiency

↓ gland function → ↓ cortisol, ↓ aldosterone → hypotension (hyponatremic volume contraction), hyperkalemia, metabolic acidosis, skin/mucosal hyperpigmentation **A** (↑ melanin synthesis due to ↑ MSH, a byproduct of POMC cleavage). **Primary** pigments the skin/mucosa.

Addison disease—chronic 1° adrenal insufficiency; caused by adrenal atrophy or destruction.

Most commonly due to autoimmune adrenalitis (resource-rich countries) or TB (resource-limited countries).



Secondary and tertiary adrenal insufficiency

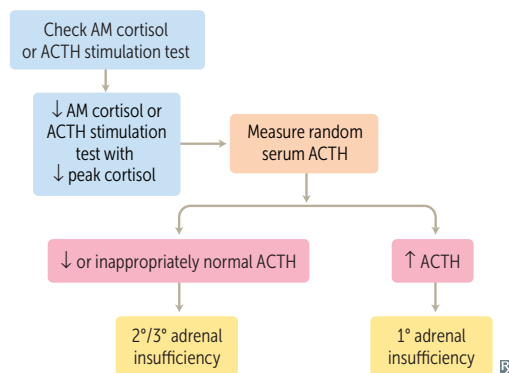
↓ pituitary ACTH secretion (secondary) or ↓ hypothalamic CRH secretion (tertiary). No hyperkalemia (aldosterone synthesis preserved due to functioning adrenal gland, intact RAAS), no hyperpigmentation.

2° adrenal insufficiency is due to pituitary pathologies, 3° adrenal insufficiency is most commonly due to abrupt cessation of chronic glucocorticoid therapy (HPA suppression). **Tertiary** from treatment.

Acute adrenal insufficiency

Also called adrenal (addisonian) crisis; often precipitated by acute stressors that ↑ glucocorticoid requirements (eg, infection) in patients with pre-existing adrenal insufficiency or on glucocorticoid therapy. May present with acute abdominal pain, nausea, vomiting, altered mental status, shock.

Waterhouse-Friderichsen syndrome—bilateral adrenal hemorrhage in the setting of sepsis (eg, meningococemia) → acute 1° adrenal insufficiency.

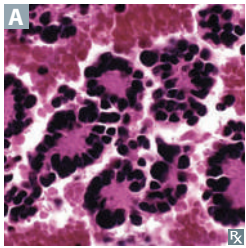


Hyperaldosteronism	Increased secretion of aldosterone from adrenal gland. Clinical features include hypertension, ↓ or normal K^+ , metabolic alkalosis. 1° hyperaldosteronism does not directly cause edema due to aldosterone escape mechanism. However, certain 2° causes of hyperaldosteronism (eg, heart failure) impair the aldosterone escape mechanism, leading to worsening of edema.
Primary hyperaldosteronism	Seen in patients with bilateral adrenal hyperplasia or adrenal adenoma (Conn syndrome). ↑ aldosterone, ↓ renin. Leads to treatment-resistant hypertension.
Secondary hyperaldosteronism	Seen in patients with renovascular hypertension, juxtaglomerular cell tumors (renin-producing), and edema (eg, cirrhosis, heart failure, nephrotic syndrome).

Neuroendocrine tumors

Heterogeneous group of neoplasms originating from neuroendocrine cells (which have traits similar to nerve cells and hormone-producing cells).
 Most neoplasms occur in the GI system (eg, carcinoid, gastrinoma), pancreas (eg, insulinoma, glucagonoma), and lungs (eg, small cell carcinoma). Also in thyroid (eg, medullary carcinoma) and adrenals (eg, pheochromocytoma).
 Neuroendocrine cells (eg, pancreatic β cells, enterochromaffin cells) share a common biologic function through amine precursor uptake decarboxylase (APUD) despite differences in embryologic origin, anatomic site, and secretory products (eg, chromogranin A, neuron-specific enolase [NSE], synaptophysin, serotonin, histamine, calcitonin). Treatment: surgical resection, somatostatin analogs.

Neuroblastoma



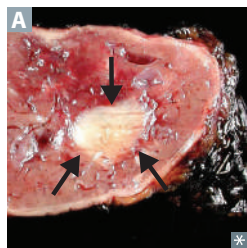
Most common tumor of the adrenal medulla in **children**, usually < 4 years old. Originates from **n**eural crest cells. Occurs anywhere along the sympathetic chain.

Most common presentation is abdominal distension and a firm, irregular mass that can cross the midline (vs Wilms tumor, which is smooth and unilateral). Less likely to develop hypertension than with pheochromocytoma (**n**euroblastoma is **n**ormotensive). Can also present with opsoclonus-myoclonus syndrome (“dancing eyes-dancing feet”).

↑ HVA and VMA (catecholamine metabolites) in urine. Homer-Wright rosettes (neuroblasts surrounding a central area of neuropil **A**) characteristic of neuroblastoma and medulloblastoma. Bombesin and **NSE** ⊕. Associated with amplification of **N**-myc oncogene.

Pheochromocytoma

ETIOLOGY



Most common tumor of the adrenal medulla in **adults** **A**. Derived from chromaffin cells (arise from neural crest).

May be associated with germline mutations (eg, *NF-1*, *VHL*, *RET* [MEN 2A, 2B]).

Rule of 10's:

- 10%** malignant
- 10%** bilateral
- 10%** extra-adrenal (eg, bladder wall, organ of Zuckerkandl)
- 10%** calcify
- 10%** kids

SYMPTOMS

Most tumors secrete epinephrine, norepinephrine, and dopamine, which can cause episodic hypertension. May also secrete EPO → polycythemia.

Symptoms occur in “spells”—relapse and remit.

Episodic hyperadrenergic symptoms (**5 P's**):

- P**ressure (↑ BP)
- P**ain (headache)
- P**erspiration
- P**alpitations (tachycardia)
- P**allor

FINDINGS

↑ catecholamines and metanephrines (eg, homovanillic acid, vanillylmandelic acid) in urine and plasma.

Chromogranin, synaptophysin and NSE ⊕.

TREATMENT

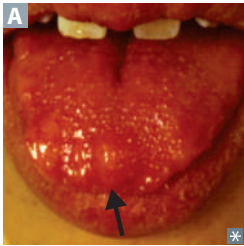
Irreversible α-antagonists (eg, phenoxybenzamine) followed by β-blockers prior to tumor resection. α-blockade must be achieved before giving β-blockers to avoid a hypertensive crisis. **A** before **B**.

Phenoxybenzamine for **pheochromocytoma**.

Multiple endocrine neoplasias

All **MEN** syndromes have autosomal **dominant** inheritance.
The X-**MEN** are **dominant** over villains.

SUBTYPE	CHARACTERISTICS	COMMENTS
MEN1	<p>Pituitary tumors (prolactin or GH)</p> <p>Pancreatic endocrine tumors—Zollinger-Ellison syndrome, insulinomas, VIPomas, glucagonomas (rare)</p> <p>Parathyroid adenomas</p> <p>Associated with mutation of <i>MEN1</i> (tumor suppressor, codes for menin, chromosome 11), angiofibromas, collagenomas, meningiomas</p>	
MEN2A	<p>Parathyroid hyperplasia</p> <p>Medullary thyroid carcinoma—neoplasm of parafollicular C cells; secretes calcitonin; prophylactic thyroidectomy required</p> <p>Pheochromocytoma (secretes catecholamines)</p> <p>Associated with mutation in <i>RET</i> (protooncogene, codes for receptor tyrosine kinase, chromosome 10)</p>	
MEN2B	<p>Medullary thyroid carcinoma</p> <p>Pheochromocytoma</p> <p>Mucosal neuromas A (oral/intestinal ganglioneuromatosis)</p> <p>Associated with marfanoid habitus; mutation in <i>RET</i> gene</p>	



MEN1 = 3 **P**'s: **p**ituitary, **p**arathyroid, and **p**ancreas

MEN2A = 2 **P**'s: **p**arathyroid and **p**heochromocytoma

MEN2B = 1 **P**: **p**heochromocytoma

Pancreatic islet cell tumors**Insulinoma**

Tumor of pancreatic β cells \rightarrow overproduction of insulin \rightarrow hypoglycemia.
 May see Whipple triad: low blood glucose, symptoms of hypoglycemia (eg, lethargy, syncope, diplopia), and resolution of symptoms after normalization of plasma glucose levels. Symptomatic patients have \downarrow blood glucose and \uparrow C-peptide levels (vs exogenous insulin use). \sim 10% of cases associated with MEN1 syndrome.

Treatment: surgical resection.

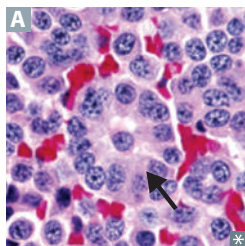
Glucagonoma

Tumor of pancreatic α cells \rightarrow overproduction of glucagon.
 Presents with **6 D's**: **d**ermatitis (necrolytic migratory erythema), **d**iabetes (hyperglycemia), **DVT**, **d**eclining weight, **d**epression, **d**iarrhea.

Treatment: octreotide, surgical resection.

Somatostatinoma

Tumor of pancreatic δ cells \rightarrow overproduction of somatostatin \rightarrow \downarrow secretion of secretin, cholecystokinin, glucagon, insulin, gastrin, gastric inhibitory peptide (GIP).
 May present with diabetes/glucose intolerance, steatorrhea, gallstones, achlorhydria.
 Treatment: surgical resection; somatostatin analogs (eg, octreotide) for symptom control.

Carcinoid tumors

Carcinoid tumors arise from neuroendocrine cells, most commonly in the intestine or lung.
 Neuroendocrine cells secrete 5-HT, which undergoes hepatic first-pass metabolism and enzymatic breakdown by MAO in the lung. If 5-HT reaches the systemic circulation (eg, after liver metastasis), carcinoid tumor may present with **carcinoid syndrome**—episodic flushing, diarrhea, wheezing, right-sided valvular heart disease (eg, tricuspid regurgitation, pulmonic stenosis), niacin deficiency (pellagra), \uparrow urinary 5-HIAA.

Histology: prominent rosettes (arrow in **A**), chromogranin A \oplus , synaptophysin \oplus .

Treatment: surgical resection, somatostatin analog (eg, octreotide) or tryptophan hydroxylase inhibitor (eg, telotristat) for symptom control.

Rule of thirds:

- 1/3** metastasize
- 1/3** present with 2nd malignancy
- 1/3** are multiple

Zollinger-Ellison syndrome

Gastrin-secreting tumor (gastrinoma) of duodenum or pancreas. Acid hypersecretion causes recurrent ulcers in duodenum and jejunum. Presents with abdominal pain (peptic ulcer disease, distal ulcers), diarrhea (malabsorption). Positive secretin stimulation test: \uparrow gastrin levels after administration of secretin, which normally inhibits gastrin release. May be associated with MEN1.

▶ ENDOCRINE—PHARMACOLOGY

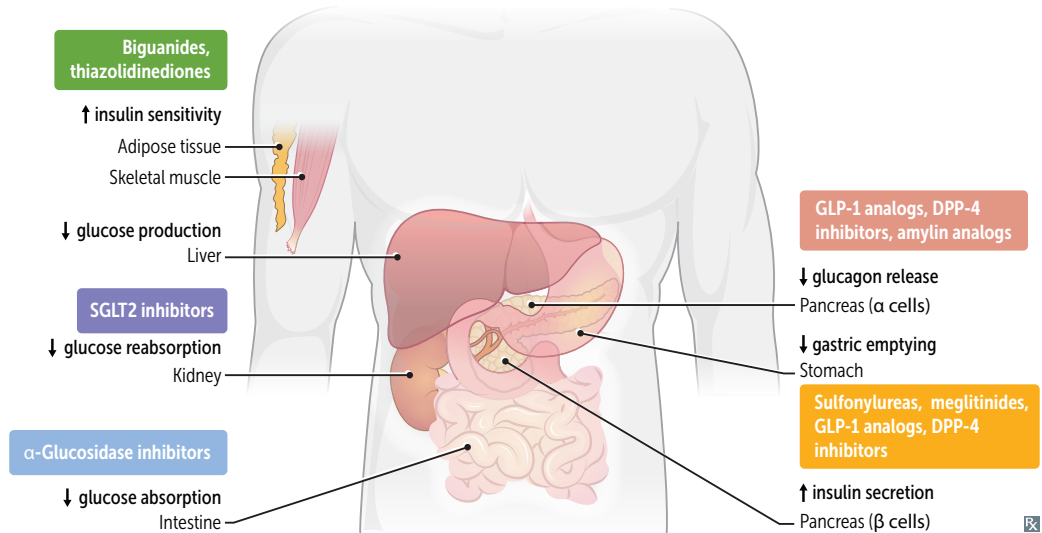
Diabetes mellitus therapy

All patients with diabetes mellitus should receive education on diet, exercise, blood glucose monitoring, and complication management. Treatment differs based on the type of diabetes and glycemic control:

- Type 1 DM—insulin replacement
- Type 2 DM—oral agents (metformin is first line), non-insulin injectables, insulin replacement; weight loss particularly helpful in lowering blood glucose
- Gestational DM—insulin replacement if nutrition therapy and exercise alone fail

Regular (short-acting) insulin is preferred for DKA (IV), hyperkalemia (+ glucose), stress hyperglycemia.

These drugs help **To** normalize pancreatic function (-glits, -glins, -glips, -glifs).



DRUG CLASS

MECHANISM

ADVERSE EFFECTS

Insulin preparations

Rapid acting (1-hr peak): **Lispro**, **Aspart**, **Glulisine** (no LAG)

Short acting (2–3 hr peak): regular

Intermediate acting (4–10 hr peak): NPH

Long acting (no real peak): detemir, glargine

Bind insulin receptor (tyrosine kinase activity)

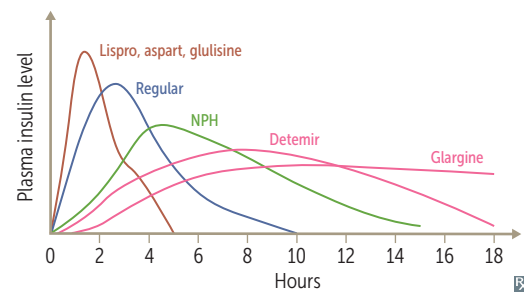
Liver: ↑ glucose storage as glycogen

Muscle: ↑ glycogen, protein synthesis

Fat: ↑ TG storage

Cell membrane: ↑ K⁺ uptake

Hypoglycemia, lipodystrophy, hypersensitivity reactions (rare), weight gain



Diabetes mellitus therapy (continued)

DRUG CLASS	MECHANISM	ADVERSE EFFECTS
Increase insulin sensitivity		
Biguanides Metformin	Inhibit mitochondrial glycerol-3-phosphate dehydrogenase (mGPD) → inhibition of hepatic gluconeogenesis and the action of glucagon. ↑ glycolysis, peripheral glucose uptake (↑ insulin sensitivity).	GI upset, lactic acidosis (use with caution in renal insufficiency), vitamin B ₁₂ deficiency. Weight loss (often desired).
Thiazolidinediones “-glits” Pioglitazone, rosiglitazone	Activate PPAR-γ (a nuclear receptor) → ↑ insulin sensitivity and levels of adiponectin → regulation of glucose metabolism and fatty acid storage.	Weight gain, edema, HF, ↑ risk of fractures. Delayed onset of action (several weeks). Rosiglitazone: ↑ risk of MI, cardiovascular death.
Increase insulin secretion		
Sulfonylureas (1st gen) Chlorpropamide, tolbutamide		Disulfiram-like reaction with first-generation sulfonylureas only (rarely used).
Sulfonylureas (2nd gen) Glipizide, glyburide	Close K ⁺ channels in pancreatic B cell membrane → cell depolarizes → insulin release via ↑ Ca ²⁺ influx.	Hypoglycemia (↑ risk in renal insufficiency), weight gain.
Meglitinides “-glins” Nateglinide, repaglinide		
Increase glucose-induced insulin secretion		
GLP-1 analogs Exenatide, liraglutide, semaglutide	↓ glucagon release, ↓ gastric emptying, ↑ glucose-dependent insulin release.	Nausea, vomiting, pancreatitis. Weight loss (often desired). ↑ satiety (often desired).
DPP-4 inhibitors “-glips” Linagliptin, saxagliptin, sitagliptin	Inhibit DPP-4 enzyme that deactivates GLP-1 → ↓ glucagon release, ↓ gastric emptying. ↑ glucose-dependent insulin release.	Respiratory and urinary infections, weight neutral. ↑ satiety (often desired).
Decrease glucose absorption		
Sodium-glucose co-transporter 2 inhibitors “-glifs” Canagliflozin, dapagliflozin, empagliflozin	Block reabsorption of glucose in proximal convoluted tubule.	Glucosuria (UTIs, vulvovaginal candidiasis), dehydration (orthostatic hypotension), weight loss. Use with caution in renal insufficiency (↓ efficacy with ↓ GFR).
α-glucosidase inhibitors Acarbose, miglitol	Inhibit intestinal brush-border α-glucosidases → delayed carbohydrate hydrolysis and glucose absorption → ↓ postprandial hyperglycemia.	GI upset, bloating. Not recommended in renal insufficiency.
Others		
Amylin analogs Pramlintide	↓ glucagon release, ↓ gastric emptying.	Hypoglycemia, nausea. ↑ satiety (often desired).

Thionamides

Propylthiouracil, methimazole.

MECHANISM	Block thyroid peroxidase, inhibiting the oxidation of iodide as well as the organification and coupling of iodine → inhibition of thyroid hormone synthesis. PTU also blocks 5'-deiodinase → ↓ P eripheral conversion of T ₄ to T ₃ .
CLINICAL USE	Hyperthyroidism. PTU used in P rimary (first) trimester of pregnancy (due to methimazole teratogenicity); methimazole used in second and third trimesters of pregnancy (due to risk of PTU-induced hepatotoxicity). Not used to treat Graves ophthalmopathy (treated with glucocorticoids).
ADVERSE EFFECTS	Skin rash, agranulocytosis (rare), aplastic anemia, hepatotoxicity. PTU use has been associated with ANCA-positive vasculitis. Methimazole is a possible teratogen (can cause aplasia cutis).

Levothyroxine, liothyronine

MECHANISM	Hormone replacement for T ₄ (levothyroxine) or T ₃ (liothyronine).
CLINICAL USE	Hypothyroidism, myxedema. May be misused for weight loss. Distinguish exogenous hyperthyroidism from endogenous hyperthyroidism by using a combination of TSH receptor antibodies, radioactive iodine uptake, and/or measurement of thyroid blood flow on ultrasound.
ADVERSE EFFECTS	Tachycardia, heat intolerance, tremors, arrhythmias.

Hypothalamic/pituitary drugs

DRUG	CLINICAL USE
Conivaptan, tolvaptan	ADH antagonists SIADH (block action of ADH at V ₂ -receptor)
Demeclocycline	ADH antagonist, a tetracycline SIADH (interferes with ADH signaling)
Desmopressin	ADH analog Central DI, von Willebrand disease, sleep enuresis, hemophilia A
GH	GH deficiency, Turner syndrome
Oxytocin	Induction of labor (stimulates uterine contractions), control uterine hemorrhage
Somatostatin (octreotide)	Acromegaly, carcinoid syndrome, gastrinoma, glucagonoma, esophageal varices

Fludrocortisone

MECHANISM	Synthetic analog of aldosterone with glucocorticoid effects. Fludrocortisone retains fluid .
CLINICAL USE	Mineralocorticoid replacement in 1° adrenal insufficiency.
ADVERSE EFFECTS	Similar to glucocorticoids; also edema, exacerbation of heart failure, hyperpigmentation.

Cinacalcet

MECHANISM	Sensitizes calcium -sensing receptor (CaSR) in parathyroid gland to circulating Ca^{2+} → ↓ PTH. Pronounce “ Senacalcet .”
CLINICAL USE	2° hyperparathyroidism in patients with CKD receiving hemodialysis, hypercalcemia in 1° hyperparathyroidism (if parathyroidectomy fails), or in parathyroid carcinoma.
ADVERSE EFFECTS	Hypocalcemia.

Sevelamer

MECHANISM	Nonabsorbable phosphate binder that prevents phosphate absorption from the GI tract.
CLINICAL USE	Hyperphosphatemia in CKD.
ADVERSE EFFECTS	Hypophosphatemia, GI upset.

Cation exchange resins Patiromer, sodium polystyrene sulfonate, zirconium cyclosilicate.

MECHANISM	Bind K^+ in colon in exchange for other cations (eg, Na^+ , Ca^{2+}) → K^+ excreted in feces.
CLINICAL USE	Hyperkalemia.
ADVERSE EFFECTS	Hypokalemia, GI upset.

Gastrointestinal

“A good set of bowels is worth more to a man than any quantity of brains.”
—Josh Billings

“Man should strive to have his intestines relaxed all the days of his life.”
—Moses Maimonides

“All right, let’s not panic. I’ll make the money by selling one of my livers. I can get by with one.”
—Homer Simpson, *The Simpsons*

“The truth does not change according to our ability to stomach it emotionally.”
—Flannery O’Connor

When studying the gastrointestinal system, be sure to understand the normal embryology, anatomy, and physiology and how the system is affected by various pathologies. Study not only disease pathophysiology, but also its specific findings, so that you can differentiate between two similar diseases. For example, what specifically makes ulcerative colitis different from Crohn disease? Also, be comfortable with basic interpretation of abdominal x-rays, CT scans, and endoscopic images.

▶ Embryology	366
▶ Anatomy	369
▶ Physiology	380
▶ Pathology	385
▶ Pharmacology	407

▶ GASTROINTESTINAL—EMBRYOLOGY

**Normal
gastrointestinal
embryology**

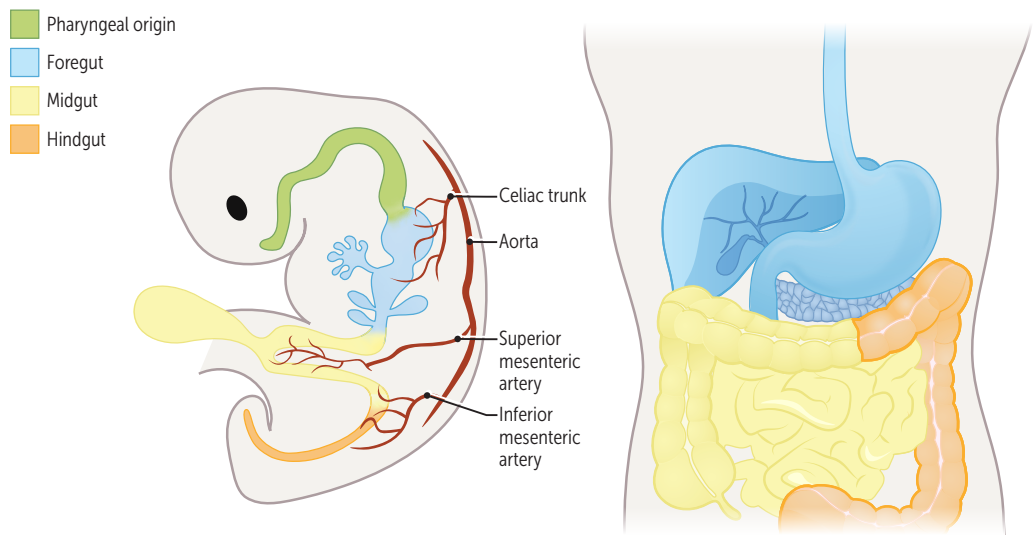
Foregut—esophagus to duodenum at level of pancreatic duct and common bile duct insertion (ampulla of Vater).

Midgut—lower duodenum to proximal 2/3 of transverse colon.

Hindgut—distal 1/3 of transverse colon to anal canal above pectinate line.

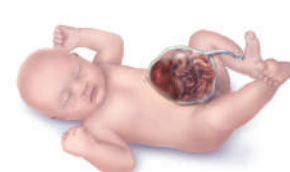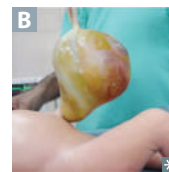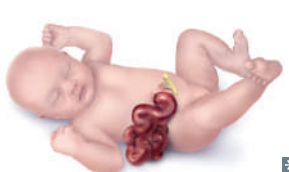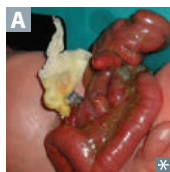Midgut:

- 6th week of development—physiologic herniation of midgut through umbilical ring
- 10th week of development—returns to abdominal cavity + rotates around superior mesenteric artery (SMA), total 270° counterclockwise



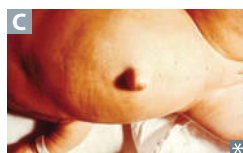Ventral wall defects Developmental defects due to failure of rostral fold closure (eg, sternal defects [ectopia cordis]), lateral fold closure (eg, omphalocele, gastroschisis), or caudal fold closure (eg, bladder exstrophy).

	Gastroschisis	Omphalocele
PRESENTATION	Extrusion of abdominal contents through abdominal wall defect	Herniation of abdominal contents through umbilicus
COVERAGE	Not covered by peritoneum or amnion A ; “the g uts come out of the g ap (sch ism) in the letter G ”	Covered by peritoneum and amnion B (light gray shiny sac); “abdominal contents are se aled in the letter O ”
ASSOCIATIONS	Not associated with chromosome abnormalities; g ood prognosis	Associated with congenital anomalies (eg, trisomies 13 and 18, Beckwith-Wiedemann syndrome) and other structural abnormalities (eg, cardiac, GU, neural tube)



Congenital umbilical hernia

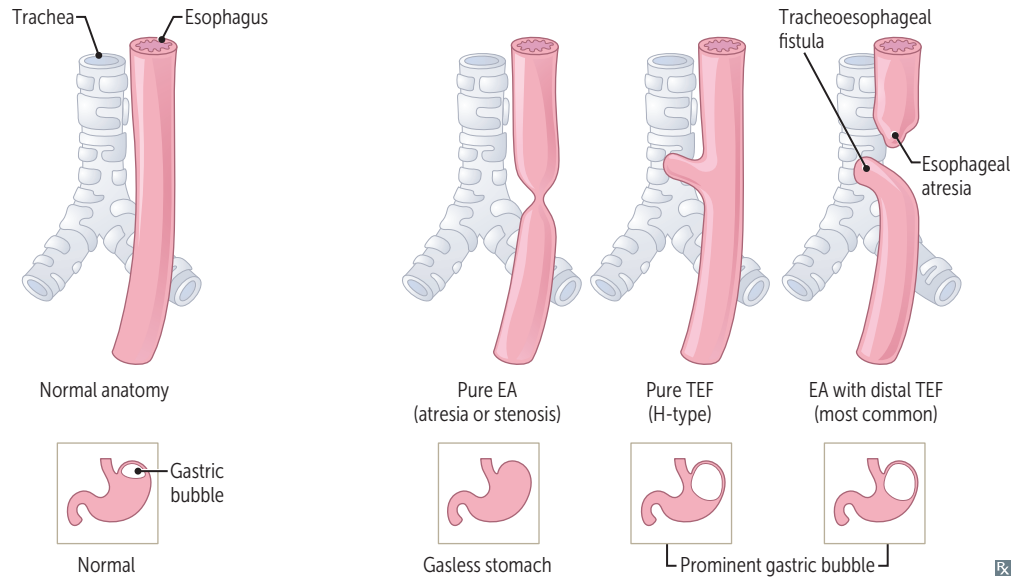
Failure of umbilical ring to close after physiologic herniation of midgut. Covered by skin **C**. Protrudes with ↑ intra-abdominal pressure (eg, crying). May be associated with congenital disorders (eg, Down syndrome, congenital hypothyroidism). Small defects usually close spontaneously.



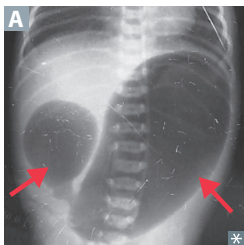
Tracheoesophageal anomalies

Esophageal atresia (EA) with distal tracheoesophageal fistula (TEF) is the most common (85%) and often presents as polyhydramnios in utero (due to inability of fetus to swallow amniotic fluid). Neonates drool, choke, and vomit with first feeding. TEFs allow air to enter stomach (visible on CXR). Cyanosis is 2° to laryngospasm (to avoid reflux-related aspiration). Clinical test: failure to pass nasogastric tube into stomach.

In **H**-type, the fistula resembles the letter **H**. In pure EA, CXR shows gasless abdomen.



Intestinal atresia

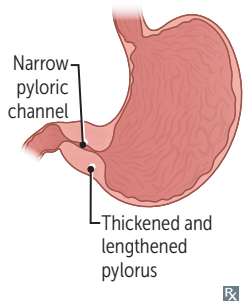


Presents with bilious vomiting and abdominal distension within first 1–2 days of life.

Duodenal atresia—failure to recanalize. X-ray **A** shows “double bubble” (dilated stomach, proximal duodenum). Associated with **D**own syndrome.

Jejunal and ileal atresia—disruption of mesenteric vessels (typically SMA) → ischemic necrosis of fetal intestine → segmental resorption: bowel becomes discontinuous. X-ray may show “triple bubble” (dilated stomach, duodenum, proximal jejunum) and gasless colon. Associated with cystic fibrosis. May be caused by maternal cigarette smoking or use of vasoconstrictive drugs (eg, cocaine) during pregnancy.

Hypertrophic pyloric stenosis



Most common cause of gastric outlet obstruction in infants. Palpable olive-shaped **m**ass in epigastric region, visible peristaltic waves, and nonbilious projectile vomiting at ~ 2–6 weeks old.

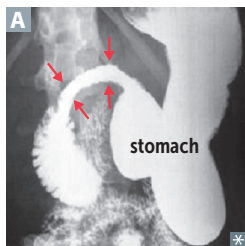
More common in firstborn **m**ales; associated with exposure to **m**acrolides.

Results in hypokalemic hypochloremic **m**etabolic alkalosis (2° to vomiting of gastric acid and subsequent volume contraction).

Ultrasound shows thickened and lengthened pylorus.

Treatment: surgical incision of pyloric muscles (pyloro**m**ytomy).

Pancreas and spleen embryology

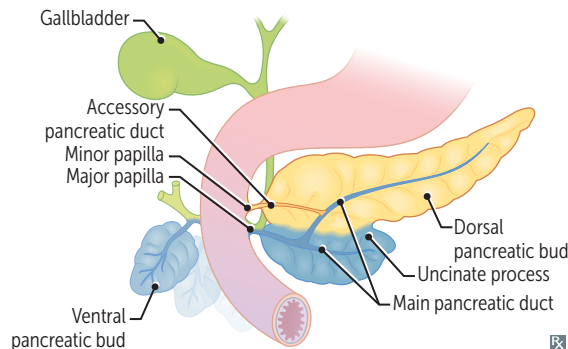


Pancreas—derived from foregut. Ventral pancreatic bud contributes to uncinete process. Both ventral and dorsal buds contribute to pancreatic head and main pancreatic duct.

Annular pancreas—abnormal rotation of ventral pancreatic bud forms a ring of pancreatic tissue → encircles 2nd part of duodenum; may cause duodenal narrowing (arrows in **A**) and vomiting. Associated with Down syndrome.

Pancreas divisum—ventral and dorsal parts fail to fuse at 7 weeks of development. Common anomaly; mostly asymptomatic, but may cause chronic abdominal pain and/or pancreatitis.

Spleen—arises in mesentery of stomach (hence is mesodermal) but has foregut supply (celiac trunk → splenic artery).



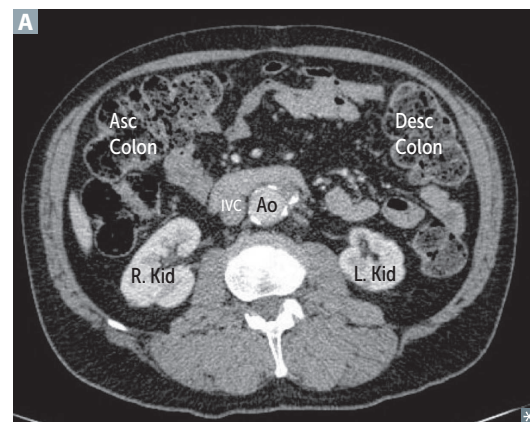
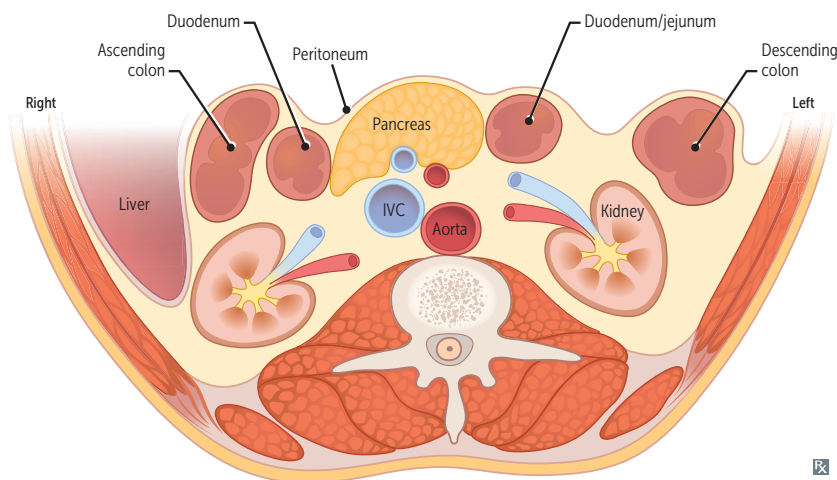
▶ GASTROINTESTINAL—ANATOMY

Retroperitoneal structures

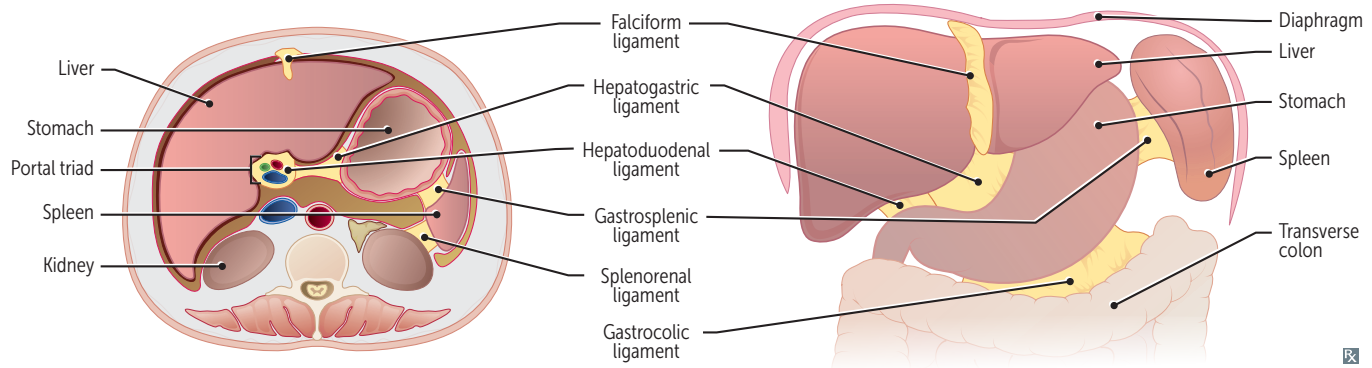
Retroperitoneal structures **A** are posterior to (and outside of) the peritoneal cavity. Injuries to retroperitoneal structures can cause blood or gas accumulation in retroperitoneal space.

SAD PUCKER:

- Suprarenal (adrenal) glands [not shown]
- A**orta and IVC
- D**uodenum (2nd through 4th parts)
- P**ancreas (except tail)
- U**reters [not shown]
- C**olon (descending and ascending)
- K**idneys
- E**sophagus (thoracic portion) [not shown]
- R**ectum (partially) [not shown]



Important gastrointestinal ligaments



LIGAMENT	CONNECTS	STRUCTURES CONTAINED	NOTES
Falciform ligament	Liver to anterior abdominal wall	Ligamentum teres hepatis (derivative of fetal umbilical vein), patent paraumbilical veins	Derivative of ventral mesentery
Hepatoduodenal ligament	Liver to duodenum	Portal triad: proper hepatic artery, portal vein, common bile duct	Derivative of ventral mesentery Pringle maneuver —ligament is compressed manually or with a vascular clamp in omental foramen to control bleeding from hepatic inflow source (portal vein, hepatic artery) vs outflow (hepatic veins, IVC) Borders the omental foramen, which connects the greater and lesser sacs Part of lesser omentum
Hepatogastric ligament	Liver to lesser curvature of stomach	Gastric vessels	Derivative of ventral mesentery Separates greater and lesser sacs on the right May be cut during surgery to access lesser sac Part of lesser omentum
Gastrocolic ligament	Greater curvature and transverse colon	Gastroepiploic arteries	Derivative of dorsal mesentery Part of greater omentum
Gastrosplenic ligament	Greater curvature and spleen	Short gastrics, left gastroepiploic vessels	Derivative of dorsal mesentery Separates greater and lesser sacs on the left Part of greater omentum
Splenorenal ligament	Spleen to left pararenal space	Splenic artery and vein, tail of pancreas	Derivative of dorsal mesentery

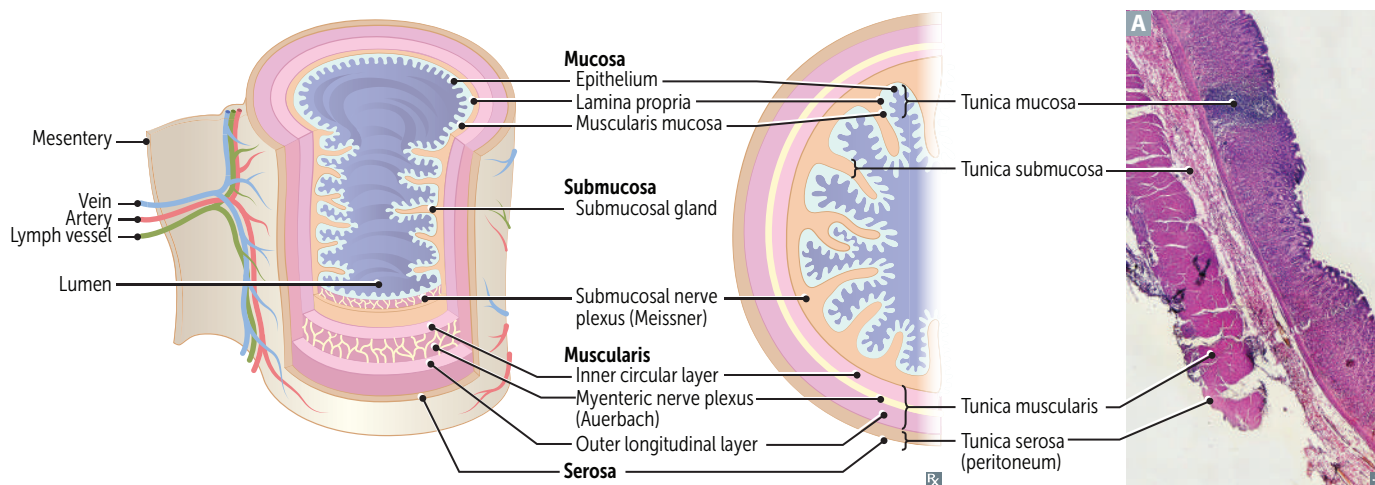
Digestive tract anatomy

Layers of gut wall **A** (inside to outside—**MSMS**):

- **M**ucosa—epithelium, lamina propria, muscularis mucosa
- **S**ubmucosa—includes submucosal nerve plexus (Meissner), secretes fluid
- **M**uscularis externa—includes myenteric nerve plexus (Auerbach), motility
- **S**erosa (when intraperitoneal), adventitia (when retroperitoneal)

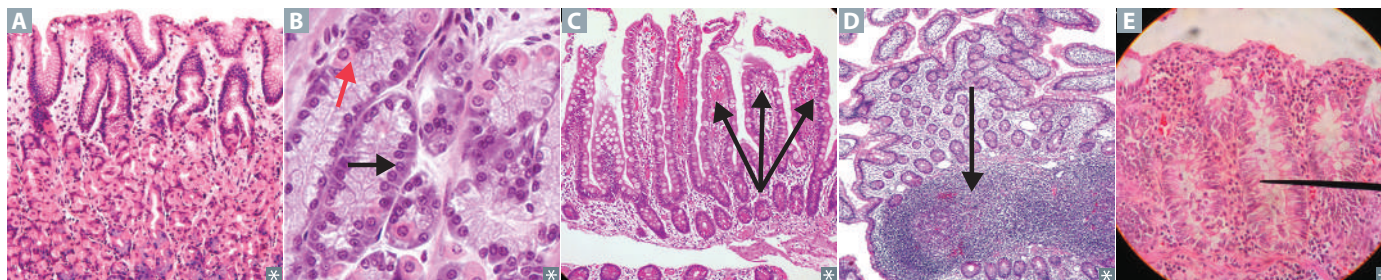
Ulcers can extend into submucosa, inner or outer muscular layer. Erosions are in mucosa only.

Frequency of basal electric rhythm (slow waves), which originate in the interstitial cells of Cajal: duodenum > ileum > stomach.

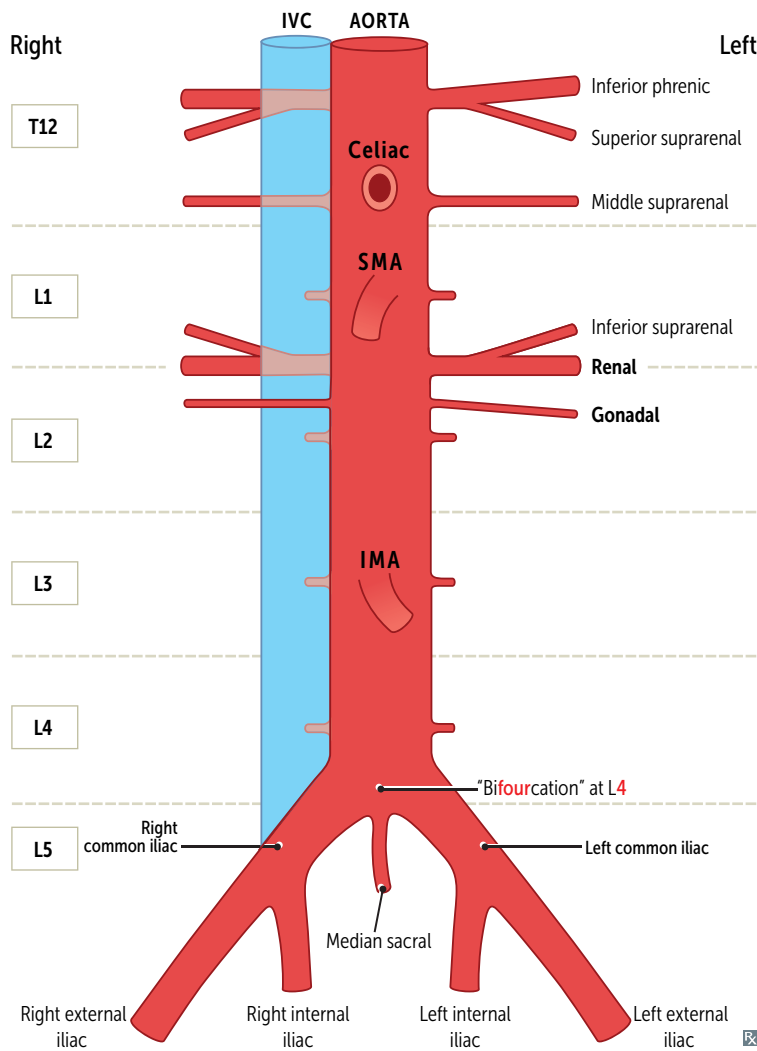


Digestive tract histology

Esophagus	Nonkeratinized stratified squamous epithelium. Upper 1/3, striated muscle; middle and lower 2/3 smooth muscle, with some overlap at the transition.
Stomach	Gastric glands A . Parietal cells are eosinophilic (pink, red arrow in B), chief cells are basophilic (black arrow in B).
Duodenum	Villi C and microvilli ↑ absorptive surface. Brunner glands (bicarbonate-secreting cells of submucosa), crypts of Lieberkühn (contain stem cells that replace enterocytes/goblet cells and Paneth cells that secrete defensins, lysozyme, and TNF), and plicae circulares (distal duodenum).
Jejunum	Villi, crypts of Lieberkühn, and plicae circulares (taller, more prominent, numerous [vs ileum]) → feathered appearance with oral contrast and ↑ surface area.
Ileum	Villi, Peyer patches (arrow in D ; lymphoid aggregates in lamina propria, submucosa), plicae circulares (proximal ileum), crypts of Lieberkühn. Largest number of goblet cells in small intestine.
Colon	Crypts of Lieberkühn with abundant goblet cells, but no villi E .



Abdominal aorta and branches



Arteries supplying GI structures are single and branch anteriorly.

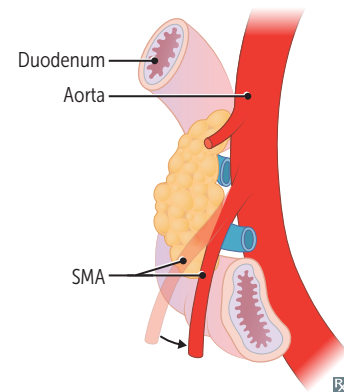
Arteries supplying non-GI structures are paired and branch laterally and posteriorly.

Two areas of the colon have dual blood supply from distal arterial branches ("watershed regions") → susceptible in colonic ischemia:

- Splenic flexure—SMA and IMA
- Rectosigmoid junction—the last sigmoid arterial branch from the IMA and superior rectal artery

Nutcracker syndrome—compression of left renal vein between superior mesenteric artery and aorta. May cause abdominal (flank) pain, gross hematuria (from rupture of thin-walled renal varicosities), left-sided varicocele.

Superior mesenteric artery syndrome—characterized by intermittent intestinal obstruction symptoms (primarily postprandial pain) when SMA and aorta compress transverse (third) portion of duodenum. Typically occurs in conditions associated with diminished mesenteric fat (eg, low body weight/malnutrition).



Gastrointestinal blood supply and innervation

EMBRYONIC GUT REGION	ARTERY	PARASYMPATHETIC INNERVATION	VERTEBRAL LEVEL	STRUCTURES SUPPLIED
Foregut	Celiac	Vagus	T12/L1	Pharynx (vagus nerve only) and lower esophagus (celiac artery only) to proximal duodenum; liver, gallbladder, pancreas, spleen (mesoderm)
Midgut	SMA	Vagus	L1	Distal duodenum to proximal 2/3 of transverse colon
Hindgut	IMA	Pelvic	L3	Distal 1/3 of transverse colon to upper portion of anal canal

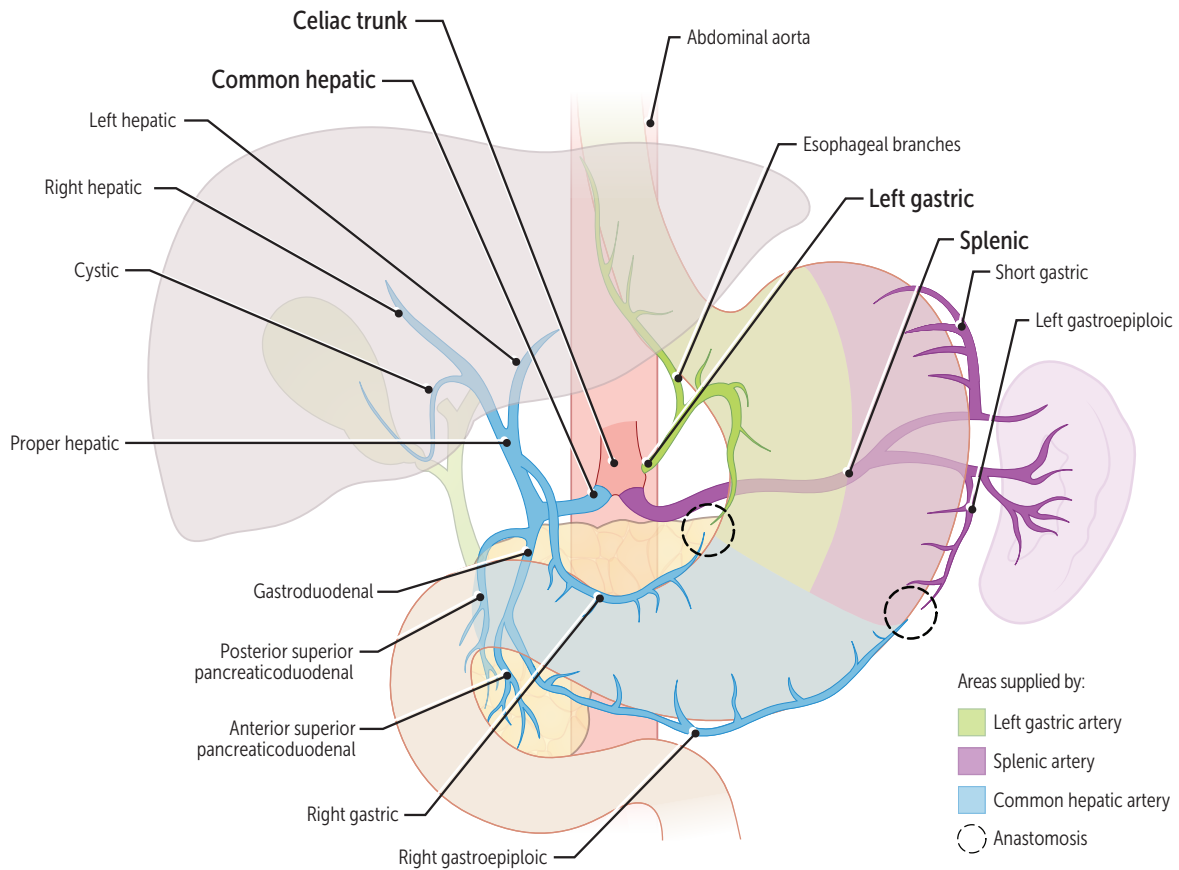
Sympathetic innervation arises from abdominal prevertebral ganglia: celiac, superior mesenteric, and inferior mesenteric.

Celiac trunk

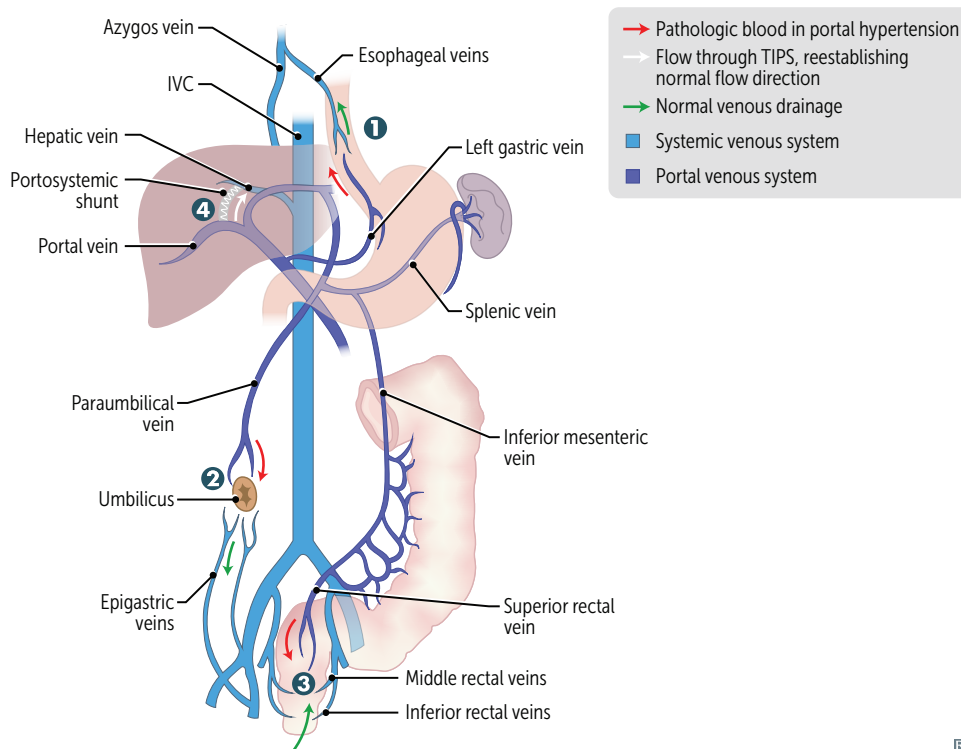
Branches of celiac trunk: common hepatic, splenic, and left gastric. These constitute the main blood supply of the foregut.

Strong anastomoses exist between:

- Left and right gastroepiploics
- Left and right gastrics



Portosystemic anastomoses



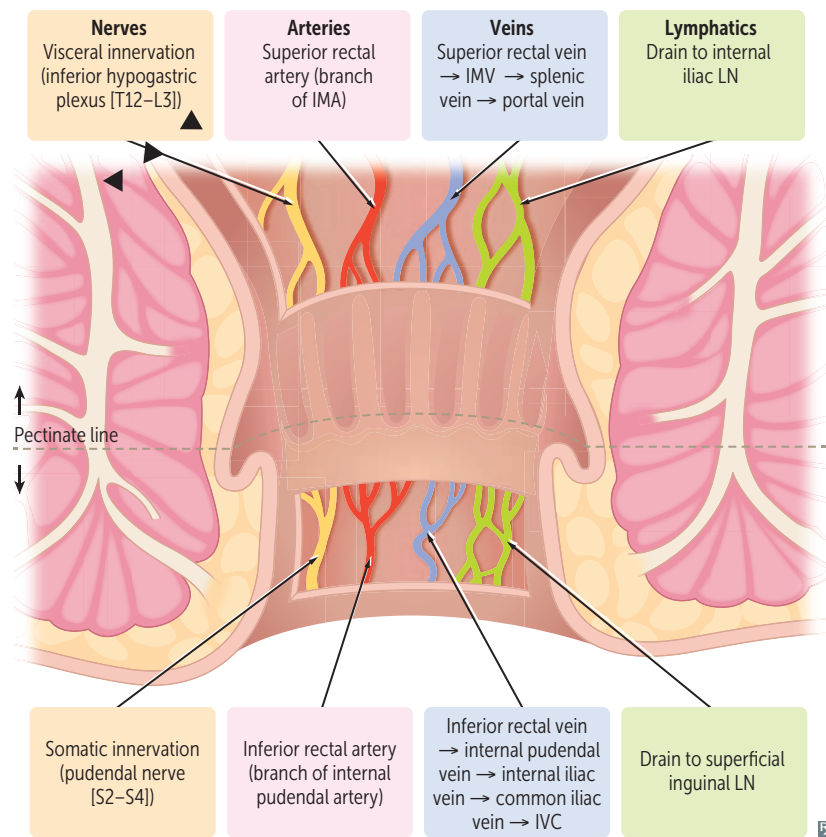
SITE OF ANASTOMOSIS	CLINICAL SIGN	PORTAL ↔ SYSTEMIC
① Esophagus	Esophageal varices	Left gastric ↔ esophageal (drains into azygos)
② Umbilicus	Caput medusae	Paraumbilical ↔ small epigastric veins (branches of inferior and superficial epigastric veins) of the anterior abdominal wall
③ Rectum	Anorectal varices	Superior rectal ↔ middle and inferior rectal

Varices of **gut**, **butt**, and **caput** (medusae) are commonly seen with portal hypertension.

- ④ Treatment with a **T**ransjugular **I**ntrahepatic **P**ortosystemic **S**hunt (**TIPS**) between the portal vein and hepatic vein relieves portal hypertension by shunting blood to the systemic circulation, bypassing the liver. TIPS can precipitate hepatic encephalopathy due to ↓ clearance of ammonia from shunting.

Pectinate line

Also called dentate line. Formed where endoderm (hindgut) meets ectoderm.



Above pectinate line: internal hemorrhoids, adenocarcinoma.

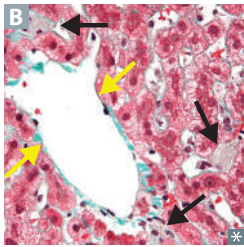
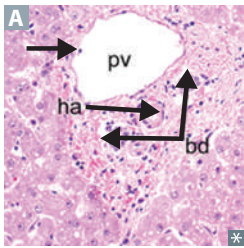
Internal hemorrhoids—abnormal distention of anal venous plexus. Risk factors include older age and chronic constipation. Receive visceral innervation and are therefore **not painful**.

Below pectinate line: external hemorrhoids, anal fissures, squamous cell carcinoma.

External hemorrhoids—receive somatic innervation (inferior rectal branch of pudendal nerve) and are therefore **painful** if thrombosed.

Anal fissure—tear in anoderm below pectinate line. **Pain** while **p**ooping; blood on toilet **p**aper. Located in the **p**osterior midline because this area is **p**oorly perfused. Associated with low-fiber diets and constipation.

Liver tissue architecture



The functional unit of the liver is made up of hexagonally arranged lobules surrounding the central vein with portal triads on the edges (consisting of a portal vein, hepatic artery, bile ducts, as well as lymphatics) **A**.

Apical surface of hepatocytes faces bile canaliculi. Basolateral surface faces sinusoids. Kupffer cells (specialized macrophages) located in sinusoids (black arrows in **B**; yellow arrows show central vein) clear bacteria and damaged or senescent RBCs.

Hepatic stellate (Ito) cells in space of Disse store vitamin A (when quiescent) and produce extracellular matrix (when activated). Responsible for hepatic fibrosis.

Zone I—periportal zone:

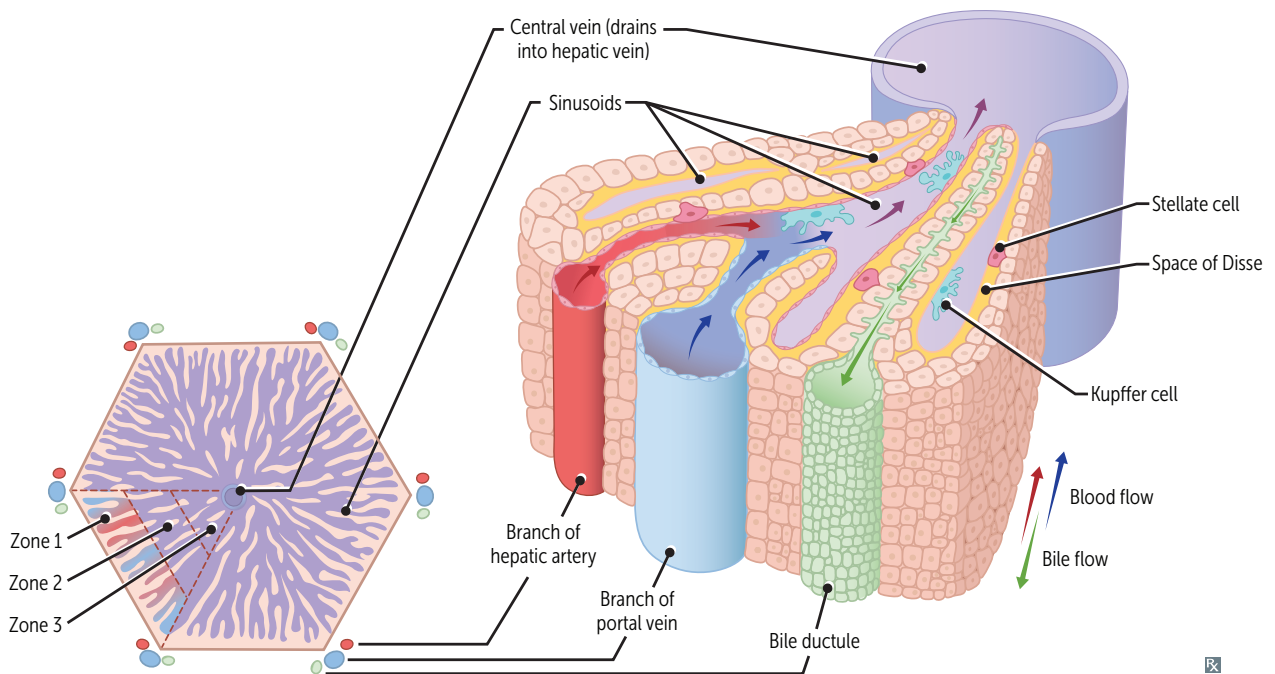
- Affected 1st by viral hepatitis
- Best oxygenated, most resistant to circulatory compromise
- Ingested toxins (eg, cocaine)

Zone II—intermediate zone:

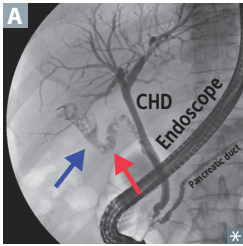
- Yellow fever

Zone III—pericentral (centrilobular) zone:

- Affected 1st by ischemia (least oxygenated)
- High concentration of cytochrome P-450
- Most sensitive to metabolic toxins (eg, ethanol, CCl₄, halothane, rifampin, acetaminophen)
- Site of alcoholic hepatitis



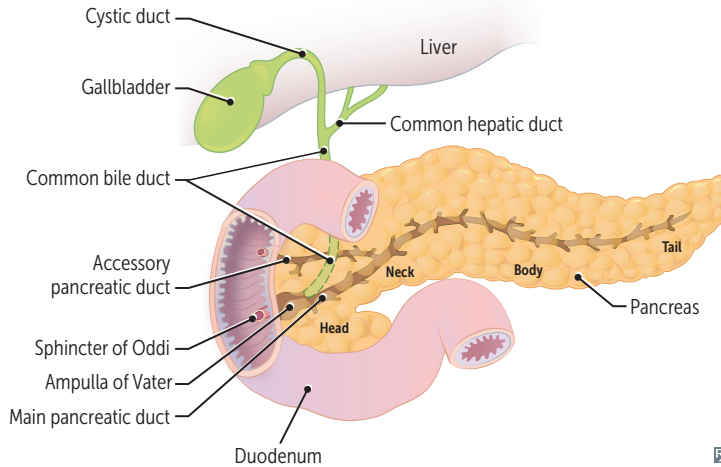
Biliary structures



Cholangiography shows filling defects in gallbladder (blue arrow in **A**) and cystic duct (red arrow in **A**).

Gallstones that reach the confluence of the common bile and pancreatic ducts at the ampulla of Vater can block both the common bile and pancreatic ducts (double duct sign), causing both cholangitis and pancreatitis, respectively.

Tumors that arise in head of pancreas (usually ductal adenocarcinoma) can cause obstruction of common bile duct → enlarged gallbladder with painless jaundice (Courvoisier sign).



Femoral region

ORGANIZATION

Lateral to medial: nerve-artery-vein-lymphatics. You go from **lateral to medial** to find your **navel**.

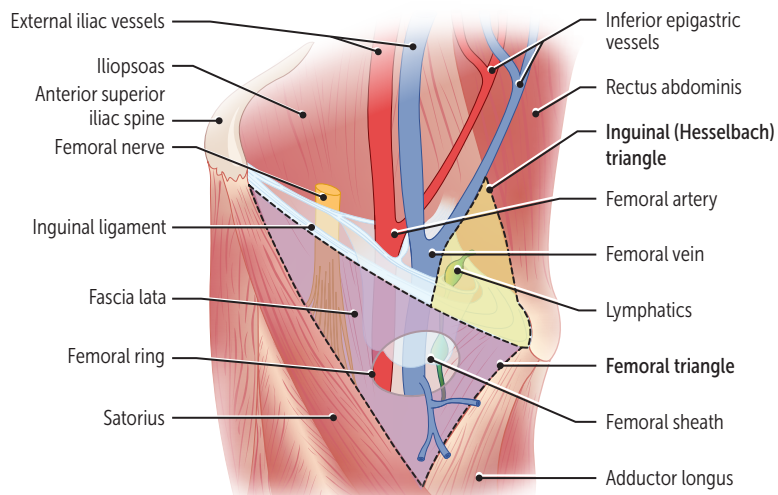
Femoral triangle

Contains femoral nerve, artery, vein.

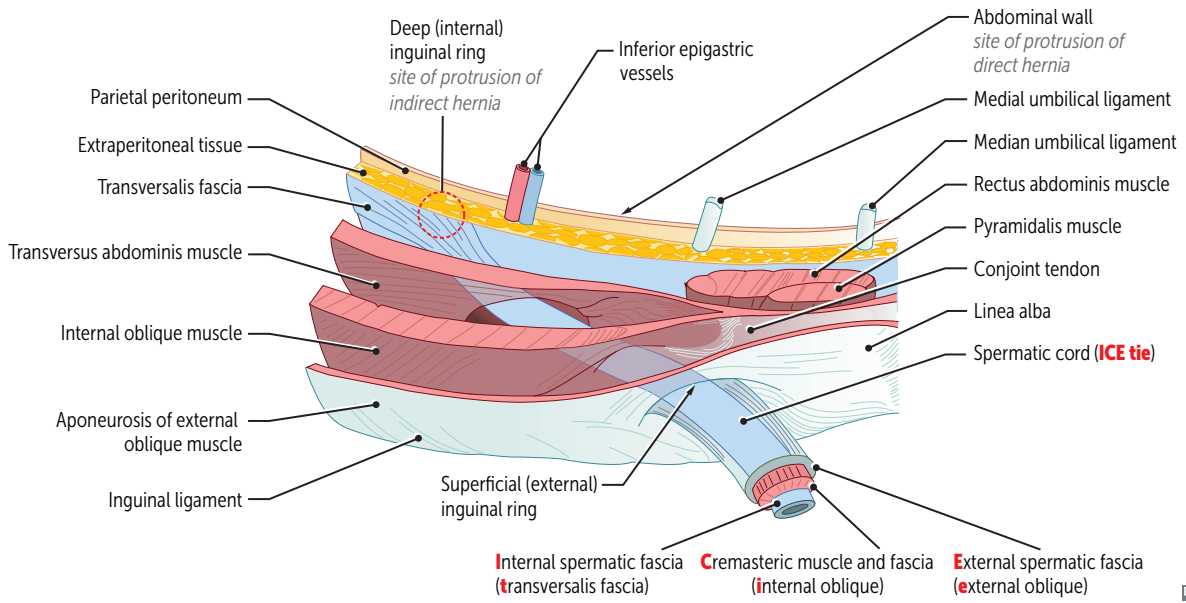
Venous near the **penis**.

Femoral sheath

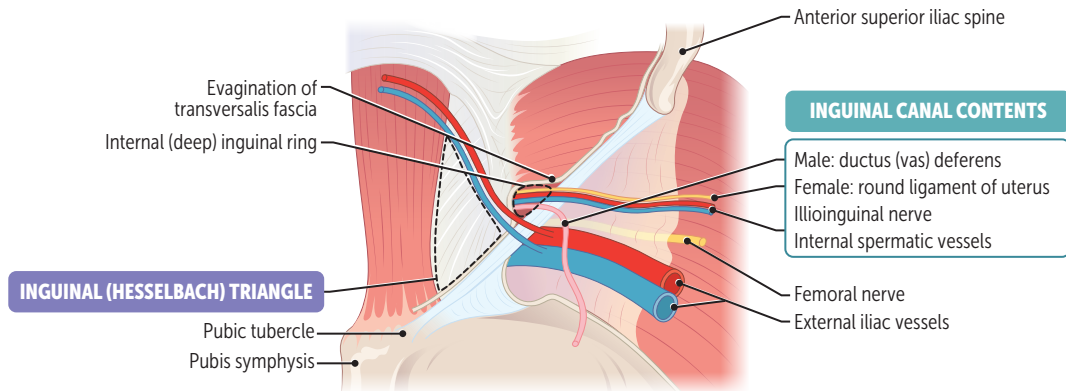
Fascial tube 3–4 cm below inguinal ligament. Contains femoral vein, artery, and canal (deep inguinal lymph nodes) but not femoral nerve.



Inguinal canal



Myopectineal orifice



Anterior abdominal wall
(viewed from inside)

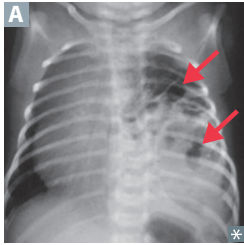
FX

FX

Hernias

Protrusion of peritoneum through an opening, usually at a site of weakness. Contents may be at risk for incarceration (not reducible back into abdomen/pelvis) and strangulation (ischemia and necrosis). Complicated hernias can present with tenderness, erythema, fever.

Diaphragmatic hernia

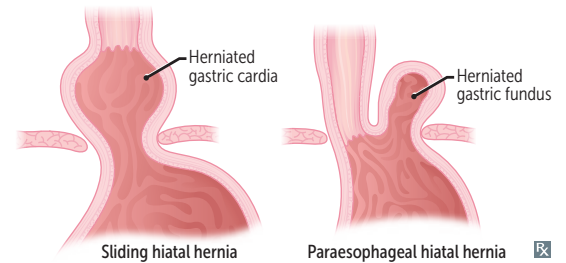


Abdominal structures enter the thorax. Most common causes:

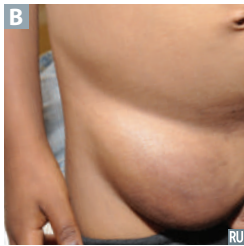- Infants—congenital defect of pleuroperitoneal membrane → left-sided herniation (right hemidiaphragm is relatively protected by liver) **A**.
- Adults—laxity/defect of phrenoesophageal membrane → **hiatal hernia** (herniation of stomach through esophageal hiatus).

Sliding hiatal hernia—gastroesophageal junction is displaced upward as gastric cardia slides into hiatus; “hourglass stomach.” Most common type. Associated with GERD.

Paraesophageal hiatal hernia—gastroesophageal junction is usually normal but gastric fundus protrudes into the thorax.

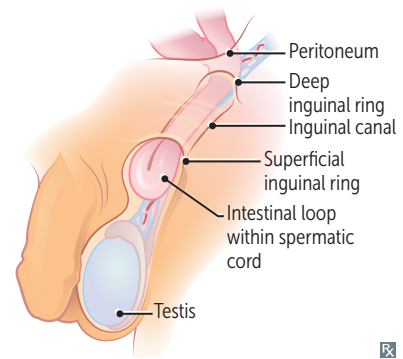


Indirect inguinal hernia



Goes through the internal (deep) inguinal ring, external (superficial) inguinal ring, and into the groin. Enters internal inguinal ring lateral to inferior epigastric vessels. Caused by failure of processus vaginalis to close (can form hydrocele). May be noticed in **infants** or discovered in adulthood. Much more common in males **B**.

Follows the pathway of testicular descent. Covered by all 3 layers of spermatic fascia.



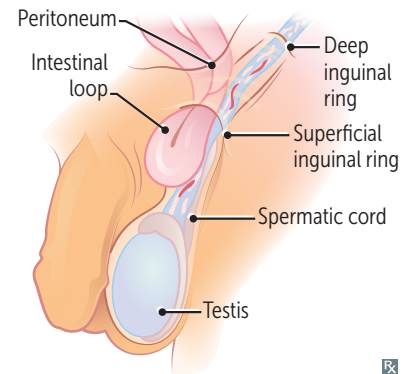
Direct inguinal hernia

Protrudes through inguinal (Hesselbach) triangle. Bulges directly through parietal peritoneum medial to the inferior epigastric vessels but lateral to the rectus abdominis. Goes through external (superficial) inguinal ring only. Covered by external spermatic fascia. Usually occurs in older males due to acquired weakness of transversalis fascia.

MDs don't lie:

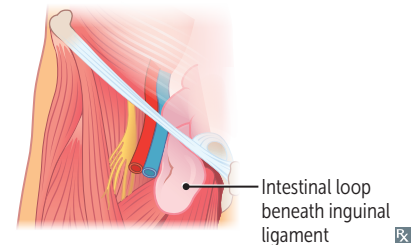
Medial to inferior epigastric vessels = **D**irect hernia.

Lateral to inferior epigastric vessels = **i**ndirect hernia.



Femoral hernia

Protrudes below inguinal ligament through femoral canal below and lateral to pubic tubercle. More common in **females**, but overall inguinal hernias are the most common. More likely to present with incarceration or strangulation (vs inguinal hernia).



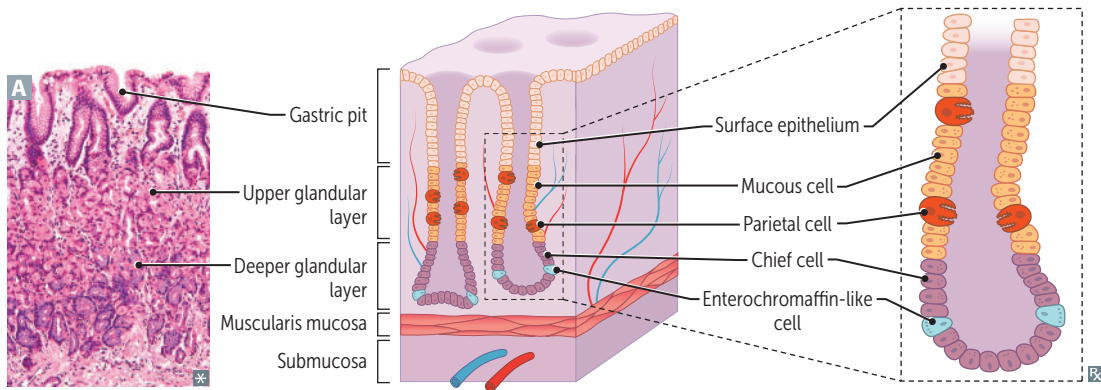
▶ GASTROINTESTINAL—PHYSIOLOGY

Gastrointestinal regulatory substances

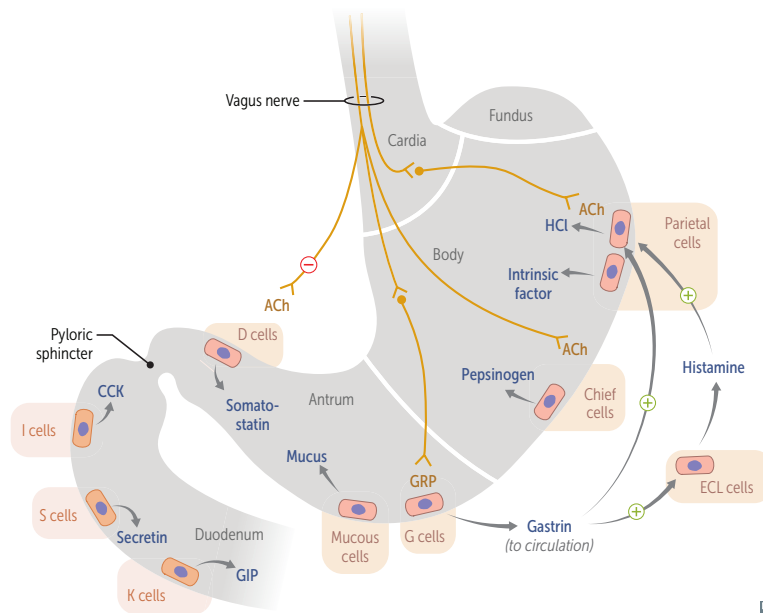
REGULATORY SUBSTANCE	SOURCE	ACTION	REGULATION	NOTES
Gastrin	G cells (antrum of stomach, duodenum)	<ul style="list-style-type: none"> ↑ gastric H⁺ secretion ↑ growth of gastric mucosa ↑ gastric motility 	<ul style="list-style-type: none"> ↑ by stomach distention/alkalinization, amino acids, peptides, vagal stimulation via gastrin-releasing peptide (GRP) ↓ by pH < 1.5 	<ul style="list-style-type: none"> ↑ by chronic PPI use ↑ in chronic atrophic gastritis (eg, <i>H pylori</i>) ↑↑ in Zollinger-Ellison syndrome (gastrinoma)
Somatostatin	D cells (pancreatic islets, GI mucosa)	<ul style="list-style-type: none"> ↓ gastric acid and pepsinogen secretion ↓ pancreatic and small intestine fluid secretion ↓ gallbladder contraction ↓ insulin and glucagon release 	<ul style="list-style-type: none"> ↑ by acid ↓ by vagal stimulation 	<ul style="list-style-type: none"> Inhibits secretion of various hormones (encourages somato-stasis) Ocreotide is an analog used to treat acromegaly, carcinoid syndrome, VIPoma, and variceal bleeding
Cholecystikinin	I cells (duodenum, jejunum)	<ul style="list-style-type: none"> ↑ pancreatic secretion ↑ gallbladder contraction ↓ gastric emptying ↑ sphincter of Oddi relaxation 	<ul style="list-style-type: none"> ↑ by fatty acids, amino acids 	<ul style="list-style-type: none"> Acts on neural muscarinic pathways to cause pancreatic secretion
Secretin	S cells (duodenum)	<ul style="list-style-type: none"> ↑ pancreatic HCO₃⁻ secretion ↓ gastric acid secretion ↑ bile secretion 	<ul style="list-style-type: none"> ↑ by acid, fatty acids in lumen of duodenum 	<ul style="list-style-type: none"> ↑ HCO₃⁻ neutralizes gastric acid in duodenum, allowing pancreatic enzymes to function
Glucose-dependent insulinotropic peptide	K cells (duodenum, jejunum)	<ul style="list-style-type: none"> Exocrine: ↓ gastric H⁺ secretion Endocrine: ↑ insulin release 	<ul style="list-style-type: none"> ↑ by fatty acids, amino acids, oral glucose 	<ul style="list-style-type: none"> Also called gastric inhibitory peptide (GIP) Oral glucose load ↑ insulin compared to IV equivalent due to GIP secretion
Motilin	Small intestine	Produces migrating motor complexes (MMCs)	<ul style="list-style-type: none"> ↑ in fasting state 	<ul style="list-style-type: none"> Motilin receptor agonists (eg, erythromycin) are used to stimulate intestinal peristalsis.
Vasoactive intestinal polypeptide	Parasympathetic ganglia in sphincters, gallbladder, small intestine	<ul style="list-style-type: none"> ↑ intestinal water and electrolyte secretion ↑ relaxation of intestinal smooth muscle and sphincters 	<ul style="list-style-type: none"> ↑ by distention and vagal stimulation ↓ by adrenergic input 	<ul style="list-style-type: none"> VIPoma—non-α, non-β islet cell pancreatic tumor that secretes VIP; associated with Watery Diarrhea, Hypokalemia, Achlorhydria (WDHA syndrome)
Nitric oxide		<ul style="list-style-type: none"> ↑ smooth muscle relaxation, including lower esophageal sphincter (LES) 		<ul style="list-style-type: none"> Loss of NO secretion is implicated in ↑ LES tone of achalasia
Ghrelin	Stomach	<ul style="list-style-type: none"> ↑ appetite (“ghrowlin’ stomach”) 	<ul style="list-style-type: none"> ↑ in fasting state ↓ by food 	<ul style="list-style-type: none"> ↑ in Prader-Willi syndrome ↓ after gastric bypass surgery

Gastrointestinal secretory products

PRODUCT	SOURCE	ACTION	REGULATION	NOTES
Gastric acid	Parietal cells (stomach A)	↓ stomach pH	↑ by histamine, vagal stimulation (ACh), gastrin	
Intrinsic factor	Parietal cells (stomach)	Vitamin B ₁₂ -binding protein (required for B ₁₂ uptake in terminal ileum)	↓ by somatostatin, GIP, prostaglandin, secretin	Autoimmune destruction of parietal cells → chronic gastritis and pernicious anemia
Pepsin	Chief cells (stomach)	Protein digestion	↑ by vagal stimulation (ACh), local acid	Pepsinogen (inactive) is converted to pepsin (active) in the presence of H ⁺
Bicarbonate	Mucosal cells (stomach, duodenum, salivary glands, pancreas) and Brunner glands (duodenum)	Neutralizes acid	↑ by pancreatic and biliary secretion with secretin	Trapped in mucus that covers the gastric epithelium



Locations of gastrointestinal secretory cells

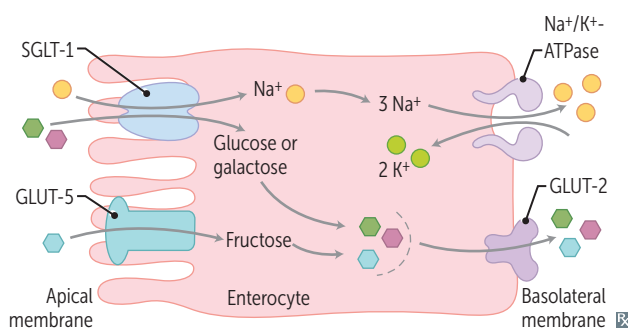


Gastrin ↑ acid secretion primarily through its effects on enterochromaffin-like (ECL) cells (leading to histamine release) rather than through its direct effect on parietal cells.

Pancreatic secretions Isotonic fluid; low flow → high Cl^- , high flow → high HCO_3^- .

ENZYME	ROLE	NOTES
α-amylase	Starch digestion	Secreted in active form
Lipases	Fat digestion	
Proteases	Protein digestion	Includes trypsin, chymotrypsin, elastase, carboxypeptidases Secreted as proenzymes also called zymogens
Trypsinogen	Converted to active enzyme trypsin → activation of other proenzymes and cleaving of additional trypsinogen molecules into active trypsin (positive feedback loop)	Converted to trypsin by enterokinase/ enteropeptidase, a brush-border enzyme on duodenal and jejunal mucosa Dipeptides and tripeptides degraded within intestinal mucosa

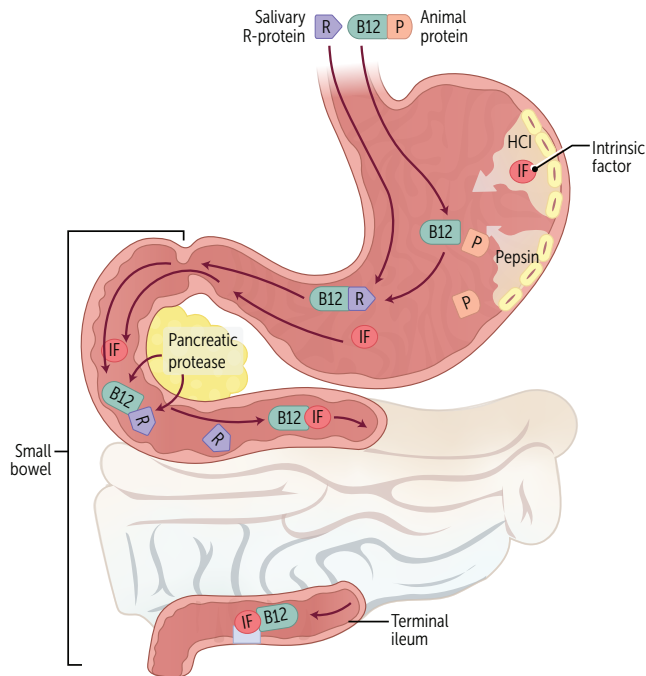
Carbohydrate absorption



Only monosaccharides (glucose, galactose, fructose) are absorbed by enterocytes. Glucose and galactose are taken up by SGLT1 (Na^+ dependent). Fructose is taken up via facilitated diffusion by GLUT5. All are transported to blood by GLUT2.

D-xylose test: simple sugar that is passively absorbed in proximal small intestine; blood and urine levels ↓ with mucosal damage, normal in pancreatic insufficiency.

Vitamin and mineral absorption



Bx

Iron fist, Bro

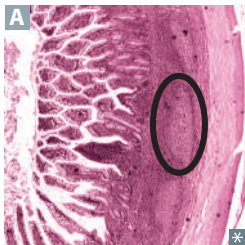
Vitamin and mineral deficiencies may develop in patients with small bowel disease, bowel resection, or bariatric surgery (eg, vitamin B₁₂ deficiency after terminal ileum resection).

Iron absorbed as Fe²⁺ in duodenum.

Folate absorbed in small bowel.

Vitamin B₁₂ absorbed in terminal ileum along with bile salts, requires intrinsic factor.

Peyer patches



Unencapsulated lymphoid tissue **A** found in lamina propria and submucosa of ileum. Contain specialized **M**icrofold (**M**) cells that sample and present antigens to **i**mmune cells. B cells stimulated in germinal centers of Peyer patches differentiate into IgA-secreting plasma cells, which ultimately reside in lamina propria. IgA receives protective secretory component and is then transported across the epithelium to the gut to deal with intraluminal antigen.

Think of **IgA**, the **I**ntra-gut **A**ntibody

Bile

Composed of bile salts (bile acids conjugated to glycine or taurine, making them water soluble), phospholipids, cholesterol, bilirubin, water, and ions. Cholesterol 7 α -hydroxylase catalyzes rate-limiting step of bile acid synthesis.

Functions:

- Digestion and absorption of lipids and fat-soluble vitamins
- Bilirubin and cholesterol excretion (body's 1^o means of elimination)
- Antimicrobial activity (via membrane disruption)

↓ absorption of enteric bile salts at distal ileum (as in short bowel syndrome, Crohn disease) prevents normal fat absorption and may cause bile acid diarrhea.

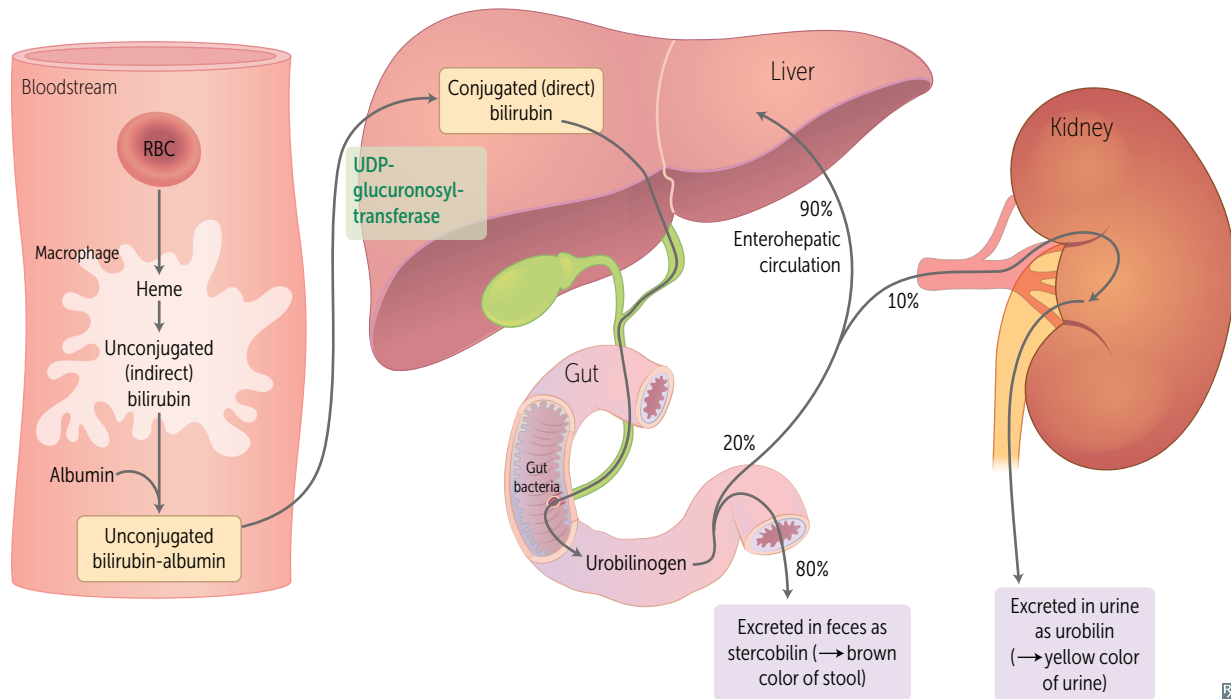
Calcium, which normally binds oxalate, binds fat instead, so free oxalate is absorbed by gut → ↑ frequency of calcium oxalate kidney stones.

Bilirubin

Heme is metabolized by heme oxygenase to biliverdin (green), which is subsequently reduced to bilirubin (brown). Unconjugated bilirubin is removed from blood by liver, conjugated with glucuronate, and excreted in bile.

Direct bilirubin: conjugated with glucuronic acid; water soluble (**d**issolves in water).

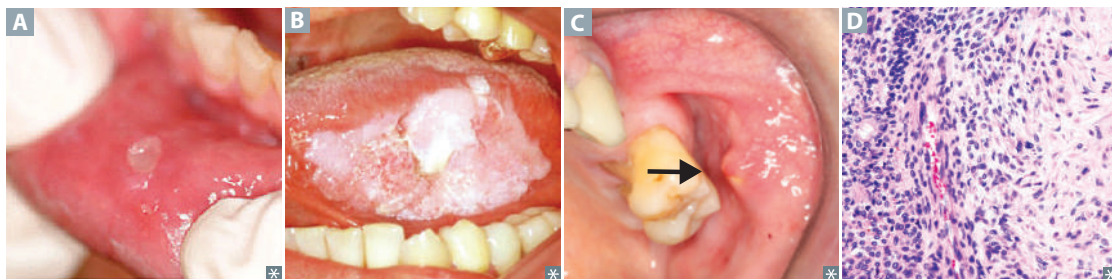
Indirect bilirubin: unconjugated; water **i**nsoluble.



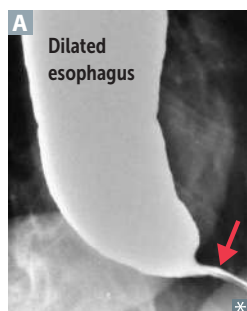
▶ GASTROINTESTINAL—PATHOLOGY

Oral pathologies

Aphthous ulcers	Also called canker sores. Common oral lesions that appear as painful, shallow, round to oval ulcers covered by yellowish exudate A . Recurrent aphthous stomatitis is associated with celiac disease, IBD, SLE, Behçet syndrome, HIV infection.
Squamous cell carcinoma	Most common malignancy of oral cavity. Usually affects the tongue. Associated with tobacco, alcohol, HPV-16. Presents as nonhealing ulcer with irregular margins and raised borders. Leukoplakia (white patch B) and erythroplakia (red patch) are precursor lesions.
Sialolithiasis	Stone formation in ducts of major salivary glands (parotid C , submandibular, or sublingual). Associated with salivary stasis (eg, dehydration) and trauma. Presents as recurrent pre-/periprandial pain and swelling in affected gland.
Sialadenitis	Inflammation of salivary gland due to obstruction, infection (eg, <i>S aureus</i> , mumps virus), or immune-mediated mechanisms (eg, Sjögren syndrome).
Salivary gland tumors	Usually benign and most commonly affect the parotid gland. Submandibular, sublingual, and minor salivary gland tumors are more likely to be malignant. Typically present as painless mass/swelling. Facial paralysis or pain suggests malignant involvement. <ul style="list-style-type: none"> ▪ Pleomorphic adenoma (benign mixed tumor)—most common salivary gland tumor D. Composed of chondromyxoid stroma and epithelium and recurs if incompletely excised or ruptured intraoperatively. May undergo malignant transformation. ▪ Warthin tumor (papillary cystadenoma lymphomatosum)—benign cystic tumor with germinal centers. May be bilateral or multifocal. Typically found in people who smoke. “Warriors from Germany love smoking.” ▪ Mucoepidermoid carcinoma—most common malignant tumor. Mucinous and squamous components.



Achalasia



Failure of LES to relax due to degeneration of inhibitory neurons (containing NO and VIP) in the myenteric (Auerbach) plexus of esophageal wall.

1° achalasia is idiopathic. 2° achalasia may arise from Chagas disease (*T cruzi* infection) or extraesophageal malignancies (mass effect or paraneoplastic). **Chagas disease can cause achalasia.**

Presents with progressive dysphagia to solids and liquids (vs obstruction—primarily solids).

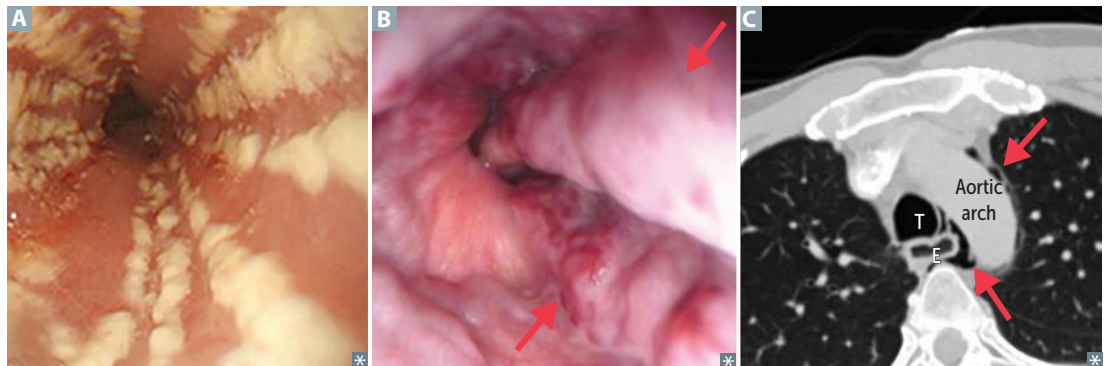
Associated with ↑ risk of esophageal cancer.

Manometry findings include uncoordinated or absent peristalsis with ↑ LES resting pressure. Barium swallow shows dilated esophagus with area of distal stenosis (“bird’s beak” **A**).

Treatment: surgery, endoscopic procedures (eg, botulinum toxin injection).

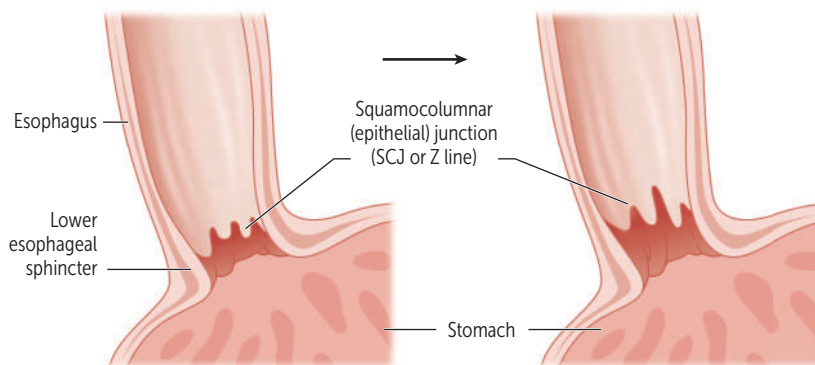
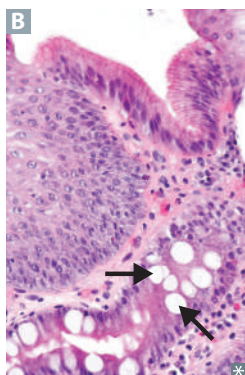
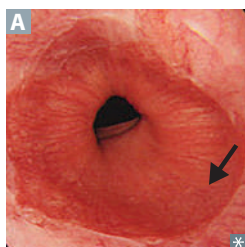
Other esophageal pathologies

Gastroesophageal reflux disease	Transient decreases in LES tone. Commonly presents as heartburn, regurgitation, dysphagia. May also present as chronic cough, hoarseness (laryngopharyngeal reflux). Associated with asthma. Complications include erosive esophagitis, strictures, and Barrett esophagus.
Esophagitis	Associated with reflux, infection in immunocompromised (<i>Candida</i> : white pseudomembrane A ; HSV-1: punched-out ulcers; CMV: linear ulcers), caustic ingestion, or pill-induced esophagitis (eg, bisphosphonates, tetracycline, NSAIDs, iron, and potassium chloride). Eosinophilic esophagitis —infiltration of eosinophils in the esophagus often in patients with atopy. Etiology is multifactorial. Food allergens → dysphagia, food impaction. Esophageal rings and linear furrows often seen on endoscopy.
Esophageal strictures	Associated with caustic ingestion, acid reflux, and esophagitis.
Plummer-Vinson syndrome	Triad of d ysphagia, i ron deficiency anemia, e sophageal webs. ↑ risk of esophageal s quamous cell carcinoma (" P lumber d ies"). May be associated with glossitis.
Mallory-Weiss syndrome	Partial thickness, l ongitudinal l acerations of gastroesophageal junction, confined to mucosa/submucosa, due to severe vomiting. Often presents with hematemesis +/- abdominal/back pain. Usually found in patients with alcohol use disorder, bulimia nervosa.
Esophageal varices	Dilated submucosal veins (red arrows in B) in lower 1/3 of esophagus 2° to portal hypertension. Common in patients with cirrhosis, may be source of life-threatening hematemesis.
Distal esophageal spasm	Formerly called diffuse esophageal spasm. Spontaneous, nonperistaltic (uncoordinated) contractions of the esophagus with normal LES pressure. Presents with dysphagia and anginalike chest pain. Barium swallow may reveal "corkscrew" esophagus. Manometry is diagnostic. Treatment includes nitrates and CCBs.
Scleroderma esophageal involvement	Esophageal smooth muscle atrophy → ↓ LES pressure and distal esophageal dysmotility → acid reflux and dysphagia → stricture, Barrett esophagus, and aspiration. Part of CREST syndrome.
Esophageal perforation	Most commonly iatrogenic following esophageal instrumentation. Noniatrogenic causes include spontaneous rupture, foreign body ingestion, trauma, malignancy. May present with pneumomediastinum (arrows in C). Subcutaneous emphysema may be due to dissecting air (signs include crepitus in the neck region or chest wall). Boerhaave syndrome —transmural, usually distal esophageal rupture due to violent retching.



Barrett esophagus

Specialized intestinal metaplasia (arrow in **A**)—replacement of nonkeratinized stratified squamous epithelium with intestinal epithelium (nonciliated columnar with goblet cells [arrows in **B**]) in distal esophagus. Due to chronic gastroesophageal reflux disease (GERD). Associated with ↑ risk of esophageal adenocarcinoma.



Esophageal cancer

Typically presents with progressive dysphagia (first solids, then liquids) and weight loss. Aggressive course due to lack of serosa in esophageal wall, allowing rapid extension. Poor prognosis due to advanced disease at presentation.

CANCER	PART OF ESOPHAGUS AFFECTED	RISK FACTORS	PREVALENCE
Squamous cell carcinoma	Upper 2/3	Alcohol, hot liquids, caustic strictures, smoking, achalasia	More common worldwide
Adenocarcinoma	Lower 1/3	Chronic GERD, Barrett esophagus, obesity, tobacco smoking	More common in A merica

Gastritis

Acute gastritis

Erosions can be caused by:

- NSAIDs—↓ PGE₂ → ↓ gastric mucosa protection
- **Burns (Curling ulcer)**—hypovolemia → mucosal ischemia
- **Brain injury (Cushing ulcer)**—↑ vagal stimulation → ↑ ACh → ↑ H⁺ production

Especially common among patients with alcohol use disorder and those taking daily NSAIDs (eg, for rheumatoid arthritis)
Burned by the **Curling** iron

Always **Cushion** the **brain**

Chronic gastritis

Mucosal inflammation, often leading to atrophy (hypochlorhydria → hypergastrinemia) and intestinal metaplasia (↑ risk of gastric cancers)

H pylori

Most common. ↑ risk of peptic ulcer disease, MALT lymphoma

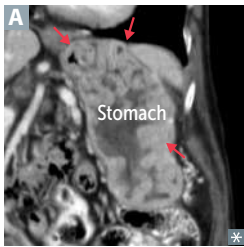
Affects antrum first and spreads to body of stomach

Autoimmune

Autoantibodies (T-cell induced) to the H⁺/K⁺-ATPase on parietal cells and to intrinsic factor. ↑ risk of pernicious anemia

Affects body/fundus of stomach

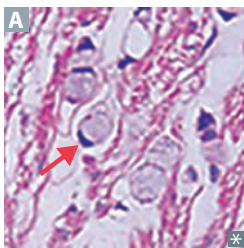
Ménétrier disease



Hyperplasia of gastric mucosa → hypertrophied rugae (“**wavy**” like brain gyri **A**). Causes excess mucus production with resultant protein loss and parietal cell atrophy with ↓ acid production. Precancerous.

Presents with **W**eight loss, **A**norexia, **V**omiting, **E**pigastric pain, **E**dema (due to protein loss; pronounce “**WAVEE**”).

Gastric cancer



Most commonly gastric adenocarcinoma; lymphoma, GI stromal tumor, carcinoid (rare). Early aggressive local spread with node/liver metastases. Often presents late, with **W**eight loss, **E**arly satiety, **A**bdominal **P**ain, **O**bstuction, and in some cases acanthosis **N**igricans or Leser-Trélat sign (**WEAPON**).

- Intestinal—associated with *H pylori*, dietary nitrosamines (smoked foods common in East Asian countries), tobacco smoking, achlorhydria, chronic gastritis. Commonly on lesser curvature; looks like ulcer with raised margins.
- Diffuse—not associated with *H pylori*; most cases due to E-cadherin mutation; signet ring cells (mucin-filled cells with peripheral nuclei) **A**; stomach wall grossly thickened and leathery (linitis plastica).

Virchow node—involvement of left supraclavicular node by metastasis from stomach.

Krukenberg tumor—metastasis to ovaries (typically bilateral). Abundant mucin-secreting, signet ring cells.

Sister Mary Joseph nodule—subcutaneous periumbilical metastasis.

Blumer shelf—palpable mass on digital rectal exam suggesting metastasis to rectouterine pouch (pouch of Douglas).

Peptic ulcer disease

	Gastric ulcer	Duodenal ulcer
PAIN	Can be g reater with meals—weight loss	D ecreases with meals—weight gain
H. PYLORI INFECTION	~ 70%	~ 90%
MECHANISM	↓ mucosal protection against gastric acid	↓ mucosal protection or ↑ gastric acid secretion
OTHER CAUSES	NSAIDs	Zollinger-Ellison syndrome
RISK OF CARCINOMA	↑ Biopsy margins to rule out malignancy	Generally benign Not routinely biopsied

Ulcer complications

Hemorrhage

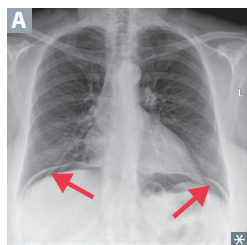
Gastric, duodenal (posterior > anterior). Most common complication. Ruptured gastric ulcer on the **l**esser curvature of stomach → bleeding from **l**eft gastric artery. An ulcer on the posterior wall of duodenum → bleeding from gastroduodenal artery.

Obstruction

Pyloric channel, duodenal.

Perforation

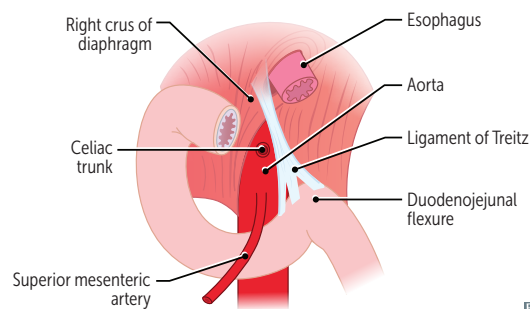
Duodenal (anterior > posterior). Anterior duodenal ulcers can perforate into the anterior abdominal cavity, potentially leading to pneumoperitoneum. May see free air under diaphragm (pneumoperitoneum) **A** with referred pain to the shoulder via irritation of phrenic nerve.



Acute gastrointestinal bleeding

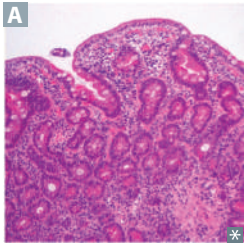
Upper GI bleeding—originates **proximal** to ligament of Treitz (suspensory ligament of duodenum). Usually presents with hematemesis and/or melena. Associated with peptic ulcer disease, variceal hemorrhage.

Lower GI bleeding—originates **distal** to ligament of Treitz. Usually presents with hematochezia. Associated with IBD, diverticulosis, angiodysplasia, hemorrhoids, anal fissure, cancer.



Malabsorption syndromes

Celiac disease



Can cause diarrhea, steatorrhea, weight loss, weakness, vitamin and mineral deficiencies. Screen for fecal fat (eg, Sudan stain).

Also called gluten-sensitive enteropathy, celiac sprue. Autoimmune-mediated intolerance of gliadin (gluten protein found in wheat, barley, rye). Associated with HLA-DQ2, HLA-DQ8, northern European descent.

Primarily affects distal duodenum and/or proximal jejunum → malabsorption and steatorrhea.

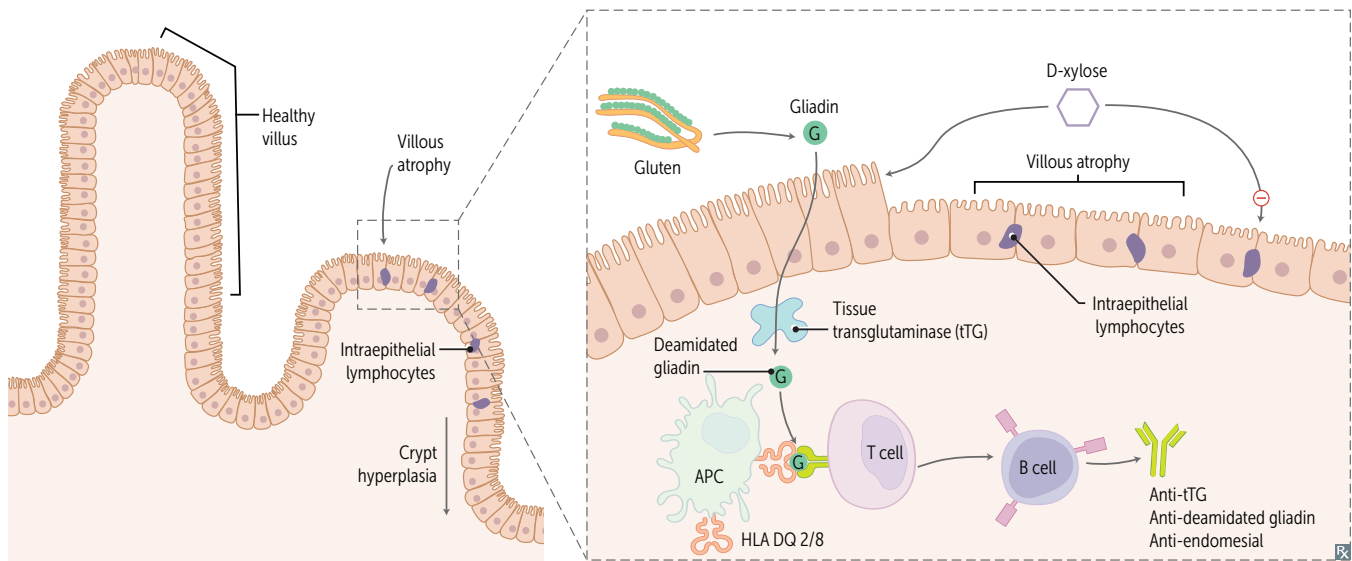
Treatment: gluten-free diet.

Associated with dermatitis herpetiformis, ↓ bone density, moderately ↑ risk of malignancy (eg, T-cell lymphoma).

D-xylose test: abnormal.

Serology: ⊕ IgA anti-tissue transglutaminase (IgA tTG), anti-endomysial, and anti-deamidated gliadin peptide antibodies.

Histology: villous atrophy, crypt hyperplasia **A**, intraepithelial lymphocytosis.



Lactose intolerance

Lactase deficiency. Normal-appearing villi, except when 2° to injury at tips of villi (eg, viral enteritis). Osmotic diarrhea with ↓ stool pH (colonic bacteria ferment lactose).

Lactose hydrogen breath test: ⊕ for lactose malabsorption if post-lactose breath hydrogen value increases > 20 ppm compared with baseline.

Pancreatic insufficiency

Due to chronic pancreatitis, cystic fibrosis, obstructing cancer. Causes malabsorption of fat and fat-soluble vitamins (A, D, E, K) as well as vitamin B₁₂.

↓ duodenal bicarbonate (and pH) and fecal elastase.

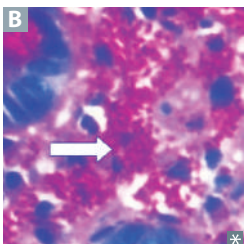
D-xylose test: normal.

Tropical sprue

Similar findings as celiac sprue (affects small bowel), but responds to antibiotics. Cause is unknown, but seen in residents of or recent visitors to tropics.

↓ mucosal absorption affecting duodenum and jejunum but can involve ileum with time. Associated with megaloblastic anemia due to folate deficiency and, later, B₁₂ deficiency.

Whipple disease

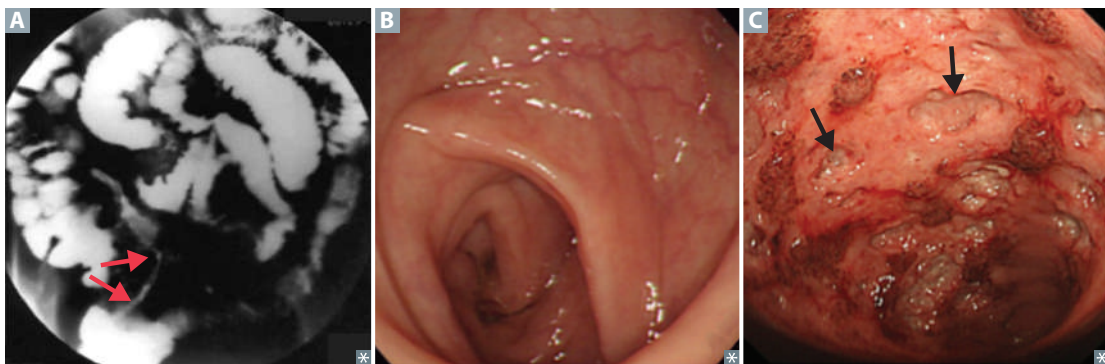


Infection with *Tropheryma whipplei* (intracellular gram ⊕); PAS ⊕ foamy macrophages in intestinal lamina propria **B**, mesenteric nodes. Cardiac symptoms, Arthralgias, and Neurologic symptoms are common. Diarrhea/steatorrhea occur later in disease course. Most common in older males.

PASs the foamy Whipped cream in a CAN.

Inflammatory bowel diseases

	Crohn disease	Ulcerative colitis
LOCATION	Any portion of the GI tract, usually the terminal ileum and colon. Skip lesions, rectal sparing.	Colitis = colon inflammation. Continuous colonic lesions, always with rectal involvement.
GROSS MORPHOLOGY	Transmural inflammation → fistulas. Cobblestone mucosa, creeping fat, bowel wall thickening (“string sign” on small bowel follow-through A), linear ulcers, fissures.	Mucosal and submucosal inflammation only. Friable mucosa with superficial and/or deep ulcerations (compare normal B with diseased C). Loss of haustra → “lead pipe” appearance on imaging.
MICROSCOPIC MORPHOLOGY	Noncaseating granulomas, lymphoid aggregates.	Crypt abscesses/ulcers, bleeding, no granulomas.
COMPLICATIONS	Malabsorption/malnutrition, colorectal cancer (↑ risk with pancolitis). Fistulas (eg, enterovesical fistulae, which can cause recurrent UTI and pneumaturia), phlegmon/abscess, strictures (causing obstruction), perianal disease.	Fulminant colitis, toxic megacolon, perforation.
INTESTINAL MANIFESTATION	Diarrhea that may or may not be bloody.	Bloody diarrhea (usually nocturnal and with pain).
EXTRINTESTINAL MANIFESTATIONS	Rash (pyoderma gangrenosum, erythema nodosum), eye inflammation (episcleritis, uveitis), oral ulcerations (aphthous stomatitis), arthritis (peripheral, spondylitis). Kidney stones (usually calcium oxalate), gallstones. May be ⊕ for anti- <i>Saccharomyces cerevisiae</i> antibodies (ASCA).	1° sclerosing cholangitis. Associated with MPO-ANCA/p-ANCA.
TREATMENT	Glucocorticoids, azathioprine, antibiotics (eg, ciprofloxacin, metronidazole), biologics (eg, infliximab, adalimumab).	5-aminosalicylic acid preparations (eg, mesalamine), 6-mercaptopurine, infliximab, colectomy.
DISEASE ACTIVITY	Fecal calprotectin used to monitor activity and distinguish from noninflammatory diseases (irritable bowel).	



Microscopic colitis

Inflammatory disease of colon that causes chronic watery diarrhea. Most common in older females. Colonic mucosa appears normal on endoscopy. Histology shows lymphocytic infiltrate in lamina propria with intraepithelial lymphocytosis or thickened subepithelial collagen band.

Irritable bowel syndrome

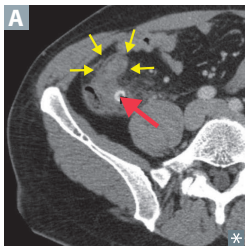
Recurrent abdominal pain associated with ≥ 2 of the following:

- Related to defecation
- Change in stool frequency
- Change in form (consistency) of stool

No structural abnormalities. Most common in middle-aged females. Chronic symptoms may be diarrhea-predominant, constipation-predominant, or mixed. Pathophysiology is multifaceted. May be associated with fibromyalgia and mood disorders (anxiety, depression).

First-line treatment is lifestyle modification and dietary changes.

Appendicitis



Acute inflammation of the appendix (yellow arrows in **A**), can be due to obstruction by fecalith (red arrow in **A**) (in adults) or lymphoid hyperplasia (in children).

Proximal obstruction of appendiceal lumen \rightarrow closed-loop obstruction \rightarrow \uparrow intraluminal pressure \rightarrow stimulation of visceral afferent nerve fibers at T8-T10 \rightarrow initial diffuse periumbilical pain \rightarrow inflammation extends to serosa and irritates parietal peritoneum. Pain localized to RLQ/McBurney point (1/3 the distance from right anterior superior iliac spine to umbilicus). Nausea, fever; may perforate \rightarrow peritonitis. May elicit psoas, obturator, and Rovsing (severe RLQ pain with palpation of LLQ) signs; guarding and rebound tenderness on exam.

Treatment: appendectomy.

Diverticula of the GI tract

Diverticulum

Blind pouch **A** protruding from the alimentary tract that communicates with the lumen of the gut. Most diverticula (esophagus, stomach, duodenum, colon) are acquired and are termed “false diverticula.”

“True” diverticulum—all gut wall layers outpouch (eg, Meckel).

“False” diverticulum or pseudodiverticulum—only mucosa and submucosa outpouch. Occur especially where vasa recta perforate muscularis externa.

Diverticulosis

Many false diverticula of the colon **B**, commonly sigmoid. Common (in $\sim 50\%$ of people > 60 years). Caused by \uparrow intraluminal pressure and focal weakness in colonic wall. Associated with obesity and diets low in fiber, high in total fat/red meat.

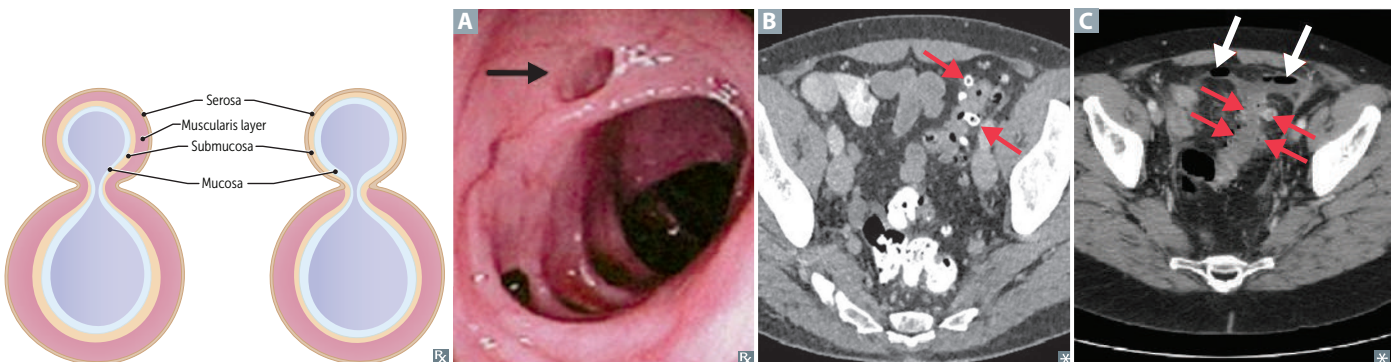
Often asymptomatic or associated with vague discomfort.

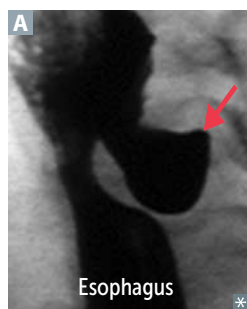Complications include diverticular bleeding (painless hematochezia), diverticulitis.

Diverticulitis

Inflammation of diverticula with wall thickening (red arrows in **C**) classically causing LLQ pain, fever, leukocytosis. Treat with supportive care (uncomplicated) or antibiotics (complicated).

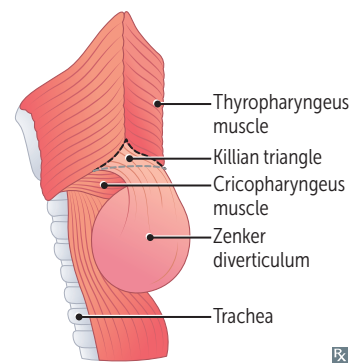
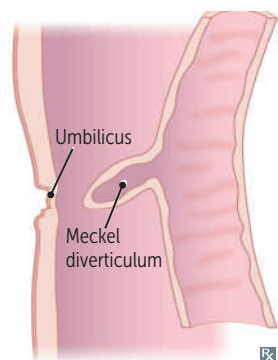
Complications: abscess, fistula (colovesical fistula \rightarrow pneumaturia), obstruction (inflammatory stenosis), perforation (white arrows in **C**) (\rightarrow peritonitis). Hematochezia is rare.



Zenker diverticulum

Pharyngoesophageal **false** diverticulum **A**.

Esophageal dysmotility causes herniation of mucosal tissue at an area of weakness between the thyropharyngeal and cricopharyngeal parts of the inferior pharyngeal constrictor (Killian triangle). Presenting symptoms: dysphagia, obstruction, gurgling, aspiration, foul breath, neck mass. Most common in older males.

**Meckel diverticulum**

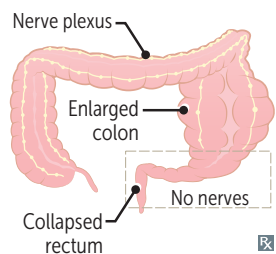
True diverticulum. Persistence of the vitelline (omphalomesenteric) duct. May contain ectopic acid-secreting gastric mucosa and/or pancreatic tissue. Most common congenital anomaly of GI tract. Can cause hematochezia/melena (less common), RLQ pain, intussusception, volvulus, or obstruction near terminal ileum.

Diagnosis: ^{99m}Tc -pertechnetate scan (also called Meckel scan) for uptake by heterotopic gastric mucosa.

The rule of **2**'s:

- 2** times as likely in males.
- 2** inches long.
- 2** feet from the ileocecal valve.
- 2**% of population.

Commonly presents in first **2** years of life.
May have **2** types of epithelia (gastric/pancreatic).

Hirschsprung disease

Congenital megacolon characterized by lack of ganglion cells/enteric nervous plexuses (Auerbach and Meissner plexuses) in distal segment of colon. Due to failure of neural crest cell migration. Associated with loss of function mutations in *RET*.

Presents with bilious emesis, abdominal distention, and failure to pass meconium within 48 hours → chronic constipation. Normal portion of the colon proximal to the aganglionic segment is dilated, resulting in a “transition zone.”

Risk ↑ with Down syndrome.

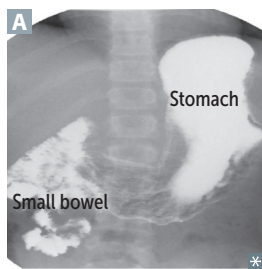
Explosive expulsion of feces (squirt sign)
→ empty rectum on digital exam.

Diagnosed by absence of ganglion cells on rectal suction biopsy.

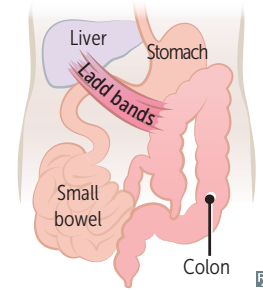
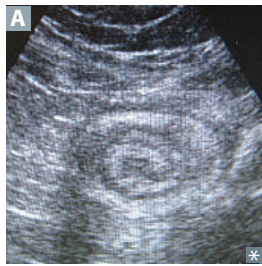
↑ AChE (acetylcholinesterase) in hypertrophied nerve fibers in lamina propria.

Treatment: resection.

RET mutation in the **REcTum**.

Malrotation

Anomaly of midgut rotation during fetal development → improper positioning of bowel (small bowel clumped on the right side) **A**, formation of fibrous bands (Ladd bands). Can lead to volvulus, duodenal obstruction.

**Intussusception**

Telescoping of a proximal bowel segment into a distal segment, most commonly at ileocecal junction. Typically seen in infants; rare in adults.

Usually idiopathic in children, less frequently due to an identifiable lead point. Idiopathic form is associated with recent viral infections (eg, adenovirus), rotavirus vaccine → Peyer patch hypertrophy may act as a lead point.

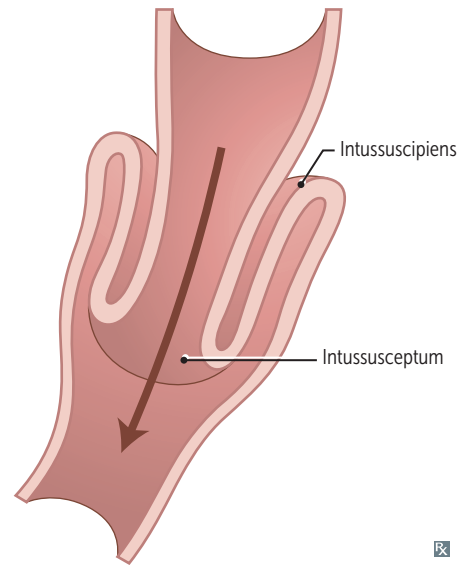
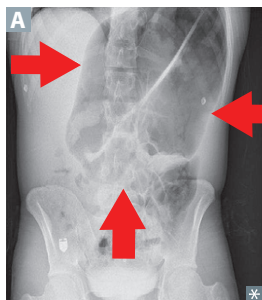
Common lead points:

- Children—Meckel diverticulum, small bowel wall hematoma (IgA vasculitis).
- Adults—intraluminal mass/tumor.

Causes small bowel obstruction and vascular compromise → intermittent abdominal pain, vomiting, bloody “currant jelly” stools.

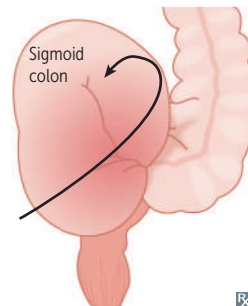
Physical exam—sausage shaped mass in right abdomen, patient may draw their legs to chest to ease pain.

Imaging—ultrasound/CT may show “target sign” **A**.

**Volvulus**

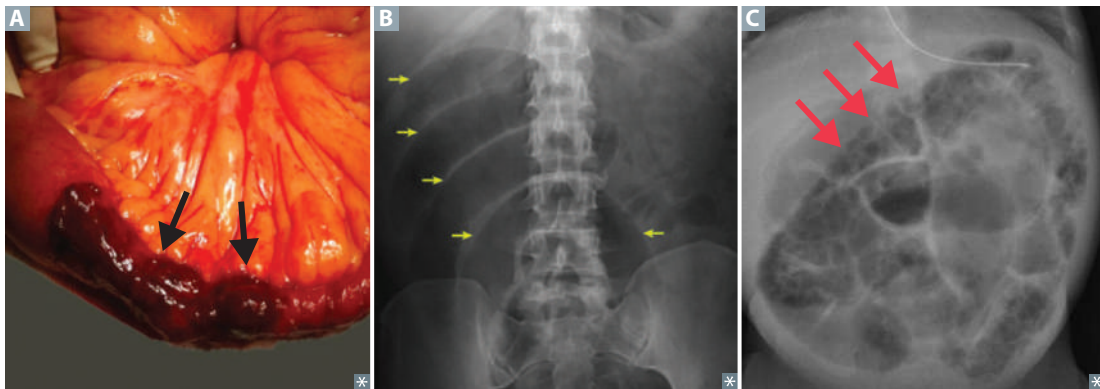
Twisting of portion of bowel around its mesentery; can lead to obstruction and infarction. Can occur throughout the GI tract.

- Gastric volvulus more common with anatomic abnormalities (paraesophageal hernia), and presents with severe abdominal pain, dry heaving, and inability to pass nasogastric tube
- Midgut volvulus more common in infants and children (minors)
- Sigmoid volvulus (coffee bean sign on x-ray **A**) more common in seniors (older adults)



Other intestinal disorders

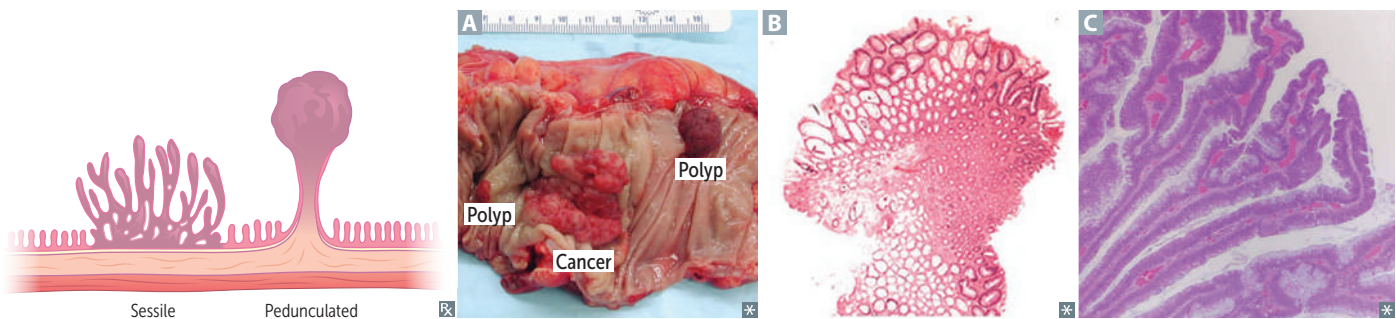
Acute mesenteric ischemia	Critical blockage of intestinal blood flow (often embolic occlusion of SMA) → small bowel necrosis A → abdominal pain out of proportion to physical findings. May see red “currant jelly” stools.
Angiodysplasia	Tortuous dilation of vessels B → hematochezia. Most often found in the right-sided colon. More common in older patients. Confirmed by angiography. Associated with end-stage renal disease, von Willebrand disease, aortic stenosis.
Chronic mesenteric ischemia	“Intestinal angina”: atherosclerosis of celiac artery, SMA (most commonly affected), or IMA → intestinal hypoperfusion → postprandial epigastric pain → food aversion and weight loss.
Colonic ischemia	Crampy abdominal pain followed by hematochezia. Commonly occurs at watershed areas (splenic flexure, rectosigmoid junction). Typically affects older adults. Thumbprint sign on imaging due to mucosal edema/hemorrhage.
Ileus	Intestinal hypomotility without obstruction → constipation and ↓ flatus; distended/tympanic abdomen with ↓ bowel sounds. Associated with abdominal surgeries, opiates, hypokalemia, sepsis. No transition zone on imaging. Treatment: bowel rest, electrolyte correction, cholinergic drugs (stimulate intestinal motility).
Necrotizing enterocolitis	Seen in premature, formula-fed infants with immature immune system. Necrosis of intestinal mucosa (most commonly terminal ileum and proximal colon), which can lead to pneumatosis intestinalis (arrows in C), pneumoperitoneum, portal venous gas.
Small bowel obstruction	Normal flow of intraluminal contents is interrupted → fluid accumulation and intestinal dilation proximal to blockage and intestinal decompression distal to blockage. Presents with abrupt onset of abdominal pain, nausea, vomiting, abdominal distension. Compromised blood flow due to excessive dilation or strangulation may lead to ischemia, necrosis, or perforation. Most commonly caused by intraperitoneal adhesions (fibrous band of scar tissue), tumors, and hernias (in rare cases, meconium plug in newborns → meconium ileus). Upright abdominal x-ray shows air-fluid levels. Management: gastrointestinal decompression, volume resuscitation, bowel rest.



Colonic polyps

Growths of tissue within the colon **A**. Grossly characterized as flat, sessile, or pedunculated on the basis of protrusion into colonic lumen. Generally classified by histologic type.

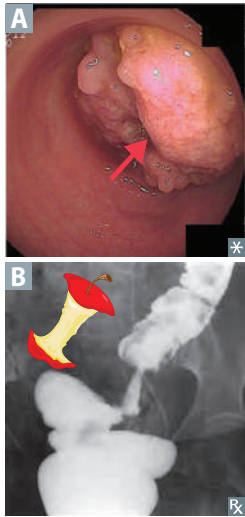
HISTOLOGIC TYPE	CHARACTERISTICS
Generally nonneoplastic	
Hamartomatous polyps	Solitary lesions do not have significant risk of transformation. Growths of normal colonic tissue with distorted architecture. Associated with Peutz-Jeghers syndrome and juvenile polyposis.
Hyperplastic polyps	Most common; generally smaller and predominantly located in rectosigmoid region. Occasionally evolves into serrated polyps and more advanced lesions.
Inflammatory pseudopolyps	Due to mucosal erosion in inflammatory bowel disease.
Mucosal polyps	Small, usually < 5 mm. Look similar to normal mucosa. Clinically insignificant.
Submucosal polyps	May include lipomas, leiomyomas, fibromas, and other lesions.
Potentially malignant	
Adenomatous polyps	Neoplastic, via chromosomal instability pathway with mutations in <i>APC</i> and <i>KRAS</i> . Tubular B histology has less malignant potential than villous C (“villous histology is villainous”); tubulovillous has intermediate malignant potential. Usually asymptomatic; may present with occult bleeding.
Serrated polyps	Neoplastic. Characterized by CpG island methylator phenotype (CIMP; cytosine base followed by guanine, linked by a phosphodiester bond). Defect may silence mismatch repair gene (eg, <i>MLH1</i>) expression. Mutations lead to microsatellite instability and mutations in <i>BRAF</i> . “Saw-tooth” pattern of crypts on biopsy. Up to 20% of cases of sporadic CRC.

**Polyposis syndromes**

Familial adenomatous polyposis	Autosomal dominant mutation of <i>APC</i> tumor suppressor gene on chromosome 5q21-q22. 2-hit hypothesis. Thousands of polyps arise starting after puberty; pancolonic; always involves rectum. Prophylactic colectomy or else 100% progress to CRC.
Gardner syndrome	FAP + osseous and soft tissue tumors (eg, osteomas of skull or mandible), congenital hypertrophy of retinal pigment epithelium, impacted/supernumerary teeth.
Turcot syndrome	FAP or Lynch syndrome + malignant CNS tumor (eg, medulloblastoma, glioma). Turcot = Turban.
Peutz-Jeghers syndrome	Autosomal dominant syndrome featuring numerous hamartomatous polyps throughout GI tract, along with hyperpigmented macules on mouth, lips, hands, genitalia. Associated with ↑ risk of breast and GI cancers (eg, colorectal, stomach, small bowel, pancreatic).
Juvenile polyposis syndrome	Autosomal dominant syndrome in children (typically < 5 years old) featuring numerous hamartomatous polyps in the colon, stomach, small bowel. Associated with ↑ risk of CRC.

Lynch syndrome

Formerly called hereditary nonpolyposis colorectal cancer (HNPCC). Autosomal dominant mutation of mismatch repair genes (eg, *MLH1*, *MSH2*) with subsequent microsatellite instability. ~ 80% progress to CRC. Proximal colon is always involved. Associated with endometrial, ovarian, and skin cancers.

Colorectal cancer**DIAGNOSIS**

Iron deficiency anemia in males (especially > 50 years old) and postmenopausal females raises suspicion.

Screening:

- Average risk: screen at age 45 with colonoscopy (polyp seen in **A**); alternatives include flexible sigmoidoscopy, fecal occult blood testing (FOBT), fecal immunochemical testing (FIT), FIT-fecal DNA, CT colonography.
- Patients with a first-degree relative who has colon cancer: screen at age 40 with colonoscopy, or 10 years prior to the relative's presentation.
- Patients with IBD: screen 8 years after onset.

“Apple core” lesion seen on barium enema x-ray **B**.

CEA tumor marker: good for monitoring recurrence, should not be used for screening.

EPIDEMIOLOGY

Most patients are > 50 years old. ~ 25% have a family history.

PRESENTATION

Rectosigmoid > ascending > descending.

Most are asymptomatic. Right side (cecal, ascending) associated with occult bleeding; left side (rectosigmoid) associated with hematochezia and obstruction (narrower lumen → ↓ stool caliber).

Ascending—exophytic mass, iron deficiency anemia, weight loss.

Descending—infiltrating mass, partial obstruction, colicky pain, hematochezia.

Can present with *S bovis* (*gallolyticus*) bacteremia/endocarditis or as an episode of diverticulitis.

RISK FACTORS

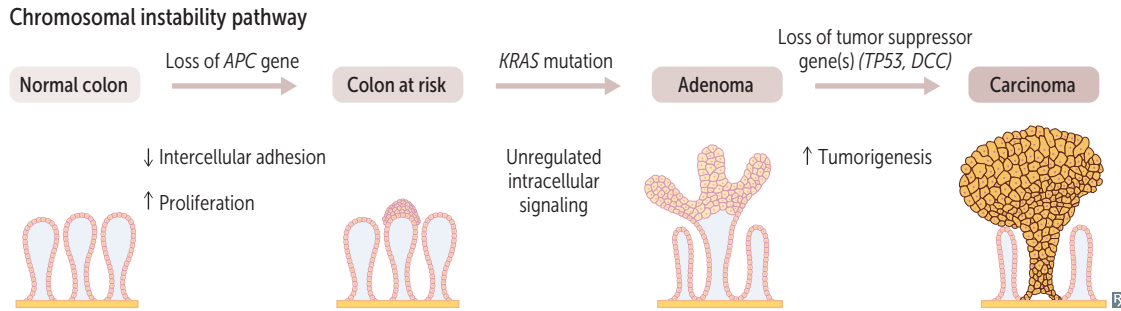
Adenomatous and serrated polyps, familial cancer syndromes, IBD, tobacco use, diet of processed meat with low fiber.

Molecular pathogenesis of colorectal cancer

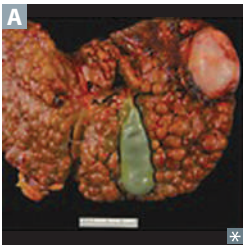Chromosomal instability pathway: mutations in *APC* cause FAP and most sporadic cases of CRC via adenoma-carcinoma sequence.

Microsatellite instability pathway: mutations or methylation of mismatch repair genes (eg, *MLH1*) cause Lynch syndrome and some sporadic CRC via serrated polyp pathway. Usually leads to right-sided CRC.

Overexpression of COX-2 has been linked to colorectal cancer, NSAIDs may be chemopreventive.



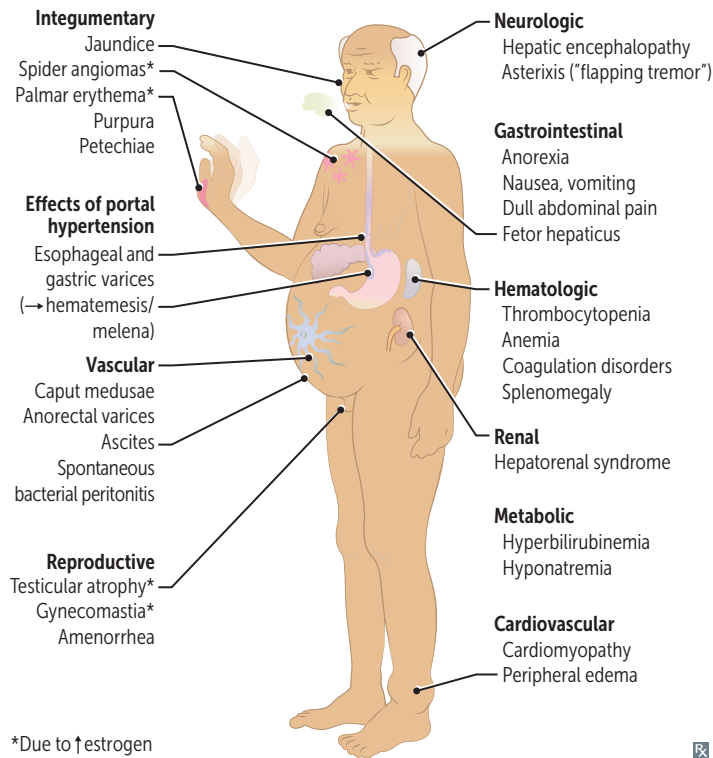
Cirrhosis and portal hypertension



Cirrhosis—diffuse bridging fibrosis (via stellate cells) and regenerative nodules disrupt normal architecture of liver; ↑ risk for hepatocellular carcinoma. Can lead to various systemic changes

A. Etiologies include alcohol, nonalcoholic steatohepatitis, chronic viral hepatitis, autoimmune hepatitis, biliary disease, genetic/metabolic disorders.

Portal hypertension—↑ pressure in portal venous system. Etiologies include cirrhosis (most common cause in developed countries), vascular obstruction (eg, portal vein thrombosis, Budd-Chiari syndrome), schistosomiasis.



Spontaneous bacterial peritonitis Also called 1° bacterial peritonitis. Common and potentially fatal bacterial infection in patients with cirrhosis and ascites. Often asymptomatic, but can cause fevers, chills, abdominal pain, ileus, or worsening encephalopathy. Commonly caused by gram ⊖ organisms (eg, *E coli*, *Klebsiella*) or less commonly gram ⊕ *Streptococcus*.
 Diagnosis: paracentesis with ascitic fluid absolute neutrophil count (ANC) > 250 cells/mm³.
 Empiric first-line treatment is 3rd generation cephalosporin (eg, cefotaxime).

Serum markers of liver pathology

ENZYMES RELEASED IN LIVER DAMAGE

Aspartate aminotransferase and alanine aminotransferase	↑ in most liver disease: ALT > AST ↑ in alcoholic liver disease: AST > ALT (ratio usually > 2:1, AST does not typically exceed 500 U/L in alcoholic hepatitis). Make a toAST with alcohol AST > ALT in nonalcoholic liver disease suggests progression to advanced fibrosis or cirrhosis ↑↑↑ aminotransferases (>1000 U/L): differential includes drug-induced liver injury (eg, acetaminophen toxicity), ischemic hepatitis, acute viral hepatitis, autoimmune hepatitis
Alkaline phosphatase	↑ in cholestasis (eg, biliary obstruction), infiltrative disorders, bone disease
γ-glutamyl transpeptidase	↑ in various liver and biliary diseases (just as ALP can), but not in bone disease (located in canalicular membrane of hepatocytes like ALP); associated with alcohol use

FUNCTIONAL LIVER MARKERS

Bilirubin	↑ in various liver diseases (eg, biliary obstruction, alcoholic or viral hepatitis, cirrhosis), hemolysis
Albumin	↓ in advanced liver disease (marker of liver's biosynthetic function)
Prothrombin time	↑ in advanced liver disease (↓ production of clotting factors, thereby measuring the liver's biosynthetic function)
Platelets	↓ in advanced liver disease (↓ thrombopoietin, liver sequestration) and portal hypertension (splenomegaly/splenic sequestration)

Reye syndrome Rare, often fatal childhood hepatic encephalopathy. Associated with viral infection (especially VZV and influenza) that has been treated with aspirin. Aspirin metabolites ↓ β-oxidation by reversible inhibition of mitochondrial enzymes. Findings: mitochondrial abnormalities, fatty liver (microvesicular fatty changes), hypoglycemia, vomiting, hepatomegaly, coma.

Avoid aspirin (**ASA**) in children, except in Kaw**ASA**ki disease. Salicylates aren't a ray (**Reye**) of sun**SHINE** for kids:
Steatosis of liver/hepatocytes
Hypoglycemia/**H**epatomegaly
Infection (VZV, influenza)
Not awake (coma)
Encephalopathy

Alcoholic liver disease**Hepatic steatosis**

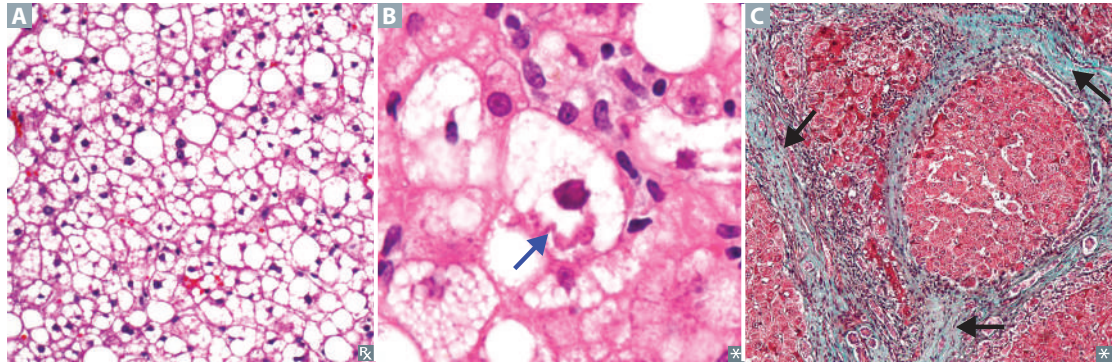
Macrovesicular fatty change **A** that may be reversible with alcohol cessation.

Alcoholic hepatitis

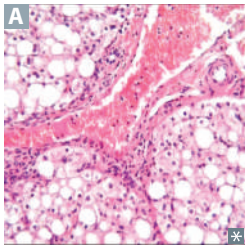
Requires sustained, long-term consumption. Swollen and necrotic hepatocytes with neutrophilic infiltration. Mallory bodies **B** (intracytoplasmic eosinophilic inclusions of damaged keratin filaments).

Alcoholic cirrhosis

Final and usually irreversible form. Sclerosis around central vein (arrows in **C**) may be seen in early disease. Regenerative nodules surrounded by fibrous bands in response to chronic liver injury → portal hypertension and end-stage liver disease.

**Nonalcoholic fatty liver disease**

Metabolic syndrome (insulin resistance); obesity → fatty infiltration of hepatocytes **A** → cellular “ballooning” and eventual necrosis. May cause cirrhosis and HCC. Independent of alcohol use.

**Autoimmune hepatitis**

Chronic inflammatory liver disease. More common in females. May be asymptomatic or present with fatigue, nausea, pruritus. Often ⊕ for anti-smooth muscle or anti-liver/kidney microsomal-1 antibodies. Labs: ↑ ALT and AST. Histology: portal and periportal lymphoplasmacytic infiltrate.

Hepatic encephalopathy

Cirrhosis → portosystemic shunts → ↓ NH_3 metabolism → neuropsychiatric dysfunction (reversible), which may range from disorientation/asterixis (mild) to difficult arousal or coma (severe).

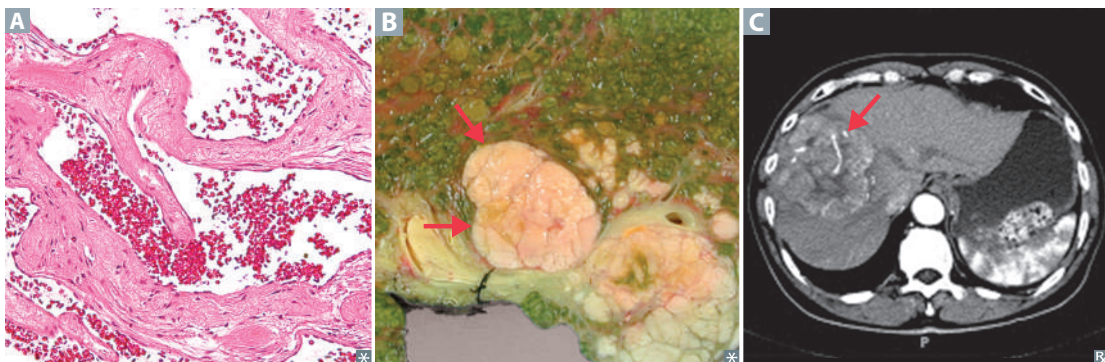
Triggers:

- ↑ NH_3 production and absorption (due to GI bleed, constipation, infection).
- ↓ NH_3 removal (due to renal failure, diuretics, bypassed hepatic blood flow post-TIPS).

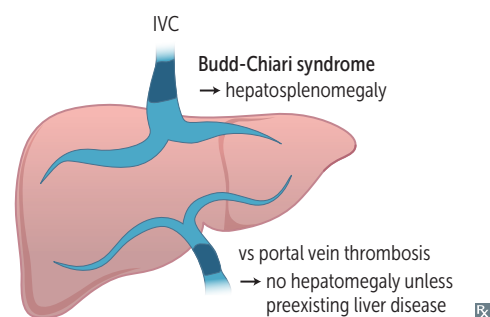
Treatment: lactulose (↑ NH_4^+ generation) and rifaximin (↓ NH_3 -producing gut bacteria).

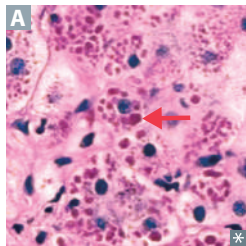
Liver tumors

Hepatic hemangioma	Also called cavernous hemangioma. Most common benign liver tumor (venous malformation) A ; typically occurs at age 30–50 years. Biopsy contraindicated because of risk of hemorrhage.
Focal nodular hyperplasia	Second most common benign liver tumor; occurs predominantly in females aged 35–50 years. Hyperplastic reaction of hepatocytes to an aberrant dystrophic artery. Marked by central stellate scar. Usually asymptomatic and detected incidentally.
Hepatic adenoma	Rare, benign tumor, often related to oral contraceptive or anabolic steroid use; may regress spontaneously or rupture (abdominal pain and shock).
Hepatocellular carcinoma	Also called hepatoma. Most common 1° malignant liver tumor in adults B . Associated with HBV (+/– cirrhosis) and all other causes of cirrhosis (including HCV, alcoholic and nonalcoholic fatty liver disease, autoimmune disease, hemochromatosis, Wilson disease, α_1 -antitrypsin deficiency) and specific carcinogens (eg, aflatoxin from <i>Aspergillus</i>). Findings: anorexia, jaundice, tender hepatomegaly. May lead to decompensation of previously stable cirrhosis (eg, ascites) and portal vein thrombosis. Spreads hematogenously. Diagnosis: ultrasound (screening) or contrast CT/MRI C (confirmation); biopsy if diagnosis is uncertain.
Hepatic angiosarcoma	Rare, malignant tumor of endothelial origin; associated with exposure to arsenic, vinyl chloride.
Metastases	Most common malignant liver tumors overall; 1° sources include GI, breast, lung cancers. Metastases are rarely solitary.



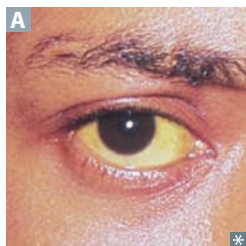Budd-Chiari syndrome Hepatic venous outflow tract obstruction (eg, due to thrombosis, compression) with centrilobular congestion and necrosis → congestive liver disease (hepatomegaly, ascites, varices, abdominal pain, liver failure). Absence of JVD. Associated with hypercoagulable states, polycythemia vera, postpartum state, HCC. May cause nutmeg liver (mottled appearance).



α_1 -antitrypsin deficiency

Misfolded gene product protein aggregates in hepatocellular ER → cirrhosis with PAS ⊕ globules **A** in liver. Codominant trait. Often presents in young patients with liver damage and dyspnea without a history of tobacco smoking.

In lungs, ↓ α_1 -antitrypsin → uninhibited elastase in alveoli → ↓ elastic tissue → panacinar emphysema.

Jaundice

Abnormal yellowing of the skin and/or sclera **A** due to bilirubin deposition. Hyperbilirubinemia 2° to ↑ production or ↓ clearance (impaired hepatic uptake, conjugation, excretion).

HOT Liver—common causes of ↑ bilirubin level:

- H**emolysis
- O**bststruction
- T**umor
- L**iver disease

Conjugated (direct) hyperbilirubinemia

Biliary tract obstruction: gallstones, cholangiocarcinoma, pancreatic or liver cancer, liver fluke. Biliary tract disease:

- 1° sclerosing cholangitis
- 1° biliary cholangitis

Excretion defect: Dubin-Johnson syndrome, Rotor syndrome.

Unconjugated (indirect) hyperbilirubinemia

Hemolytic, benign (neonates), Crigler-Najjar, Gilbert syndrome.

β -glucuronidase—lysosomal enzyme that deconjugates direct bilirubin. Also found in the intestinal brush border and in breast milk, sometimes leading to neonatal unconjugated hyperbilirubinemia. May lead to pigment stone formation.

Mixed hyperbilirubinemia

Both direct and indirect hyperbilirubinemia. Hepatitis, cirrhosis.

Benign neonatal hyperbilirubinemia

Formerly called physiologic neonatal jaundice. Mild unconjugated hyperbilirubinemia caused by:

- ↑ fetal RBC turnover (↑ hematocrit and ↓ fetal RBC lifespan).
- Immature newborn liver (↓ UDP-glucuronosyltransferase activity).
- Sterile newborn gut (↓ conversion to urobilinogen → ↑ deconjugation by intestinal β -glucuronidase → ↑ enterohepatic circulation).

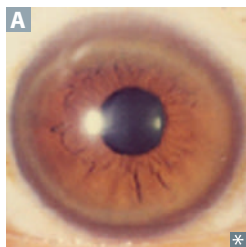
Occurs in nearly all newborns after first 24 hours of life and usually resolves without treatment in 1–2 weeks. Exaggerated forms:

Breastfeeding failure jaundice—insufficient breast milk intake → ↓ bilirubin elimination in stool → ↑ enterohepatic circulation.

Breast milk jaundice—↑ β -glucuronidase in breast milk → ↑ deconjugation → ↑ enterohepatic circulation.

Severe cases may lead to kernicterus (deposition of unconjugated, lipid-soluble bilirubin in the brain, particularly basal ganglia).

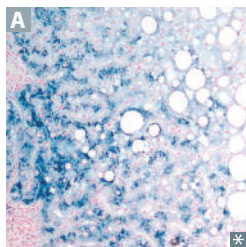
Treatment: phototherapy (non-UV) isomerizes unconjugated bilirubin to water-soluble form.

Wilson disease

Also called hepatolenticular degeneration. Autosomal recessive mutations in hepatocyte copper-transporting ATPase (*ATP7B* gene; chromosome 13) → ↓ copper incorporation into apoceruloplasmin and excretion into bile → ↓ serum ceruloplasmin. Copper accumulates, especially in liver, brain (eg, basal ganglia), cornea, kidneys; ↑ urine copper.

Presents before age 40 with liver disease (eg, hepatitis, acute liver failure, cirrhosis), neurologic disease (eg, dysarthria, dystonia, tremor, parkinsonism), psychiatric disease, Kayser-Fleischer rings (deposits in Descemet membrane of cornea) **A**, hemolytic anemia, renal disease (eg, Fanconi syndrome).

Treatment: chelation with penicillamine or trientine, oral zinc. Liver transplant in acute liver failure related to Wilson disease.

Hemochromatosis

Autosomal recessive. Mutation in *HFE* gene, located on chromosome 6. Leads to abnormal (low) hepcidin production, ↑ intestinal iron absorption. Iron overload can also be 2° to chronic transfusion therapy (eg, β-thalassemia major). Iron accumulates, especially in liver, pancreas, skin, heart, pituitary, joints. Hemosiderin (iron) can be identified on liver MRI or biopsy with Prussian blue stain **A**.

Presents after age 40 when total body iron > 20 g; iron loss through menstruation slows progression in females. Classic triad of cirrhosis, diabetes mellitus, skin pigmentation (“bronze diabetes”). Also causes restrictive cardiomyopathy (classic) or dilated cardiomyopathy (reversible), hypogonadism, arthropathy (calcium pyrophosphate deposition; especially metacarpophalangeal joints). HCC is common cause of death.

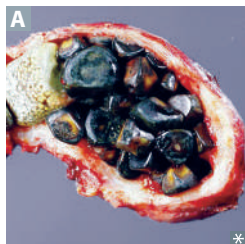
Treatment: repeated phlebotomy, iron (**Fe**) chelation with deferasirox, deferoxamine, deferiprone.

Biliary tract disease

May present with pruritus, jaundice, dark urine, light-colored stool, hepatosplenomegaly. Typically with cholestatic pattern of LFTs (↑ conjugated bilirubin, ↑ cholesterol, ↑ ALP, ↑ GGT).

	PATHOLOGY	EPIDEMIOLOGY	ADDITIONAL FEATURES
Primary sclerosing cholangitis 	Unknown cause of concentric “onion skin” bile duct fibrosis → alternating strictures and dilation with “beading” of intra- and extrahepatic bile ducts on ERCP A , magnetic resonance cholangiopancreatography (MRCP).	Classically in middle-aged males with ulcerative colitis.	Associated with ulcerative colitis. MPO-ANCA/p-ANCA ⊕. ↑ IgM. Can lead to 2° biliary cirrhosis. ↑ risk of cholangiocarcinoma and gallbladder cancer.
Primary biliary cholangitis	Autoimmune reaction → lymphocytic infiltrate +/- granulomas → destruction of lobular bile ducts.	Classically in middle-aged females.	Antimitochondrial antibody ⊕, ↑ IgM. Associated with other autoimmune conditions (eg, Hashimoto thyroiditis, rheumatoid arthritis, celiac disease). Treatment: ursodiol.
Secondary biliary cirrhosis	Extrahepatic biliary obstruction → ↑ pressure in intrahepatic ducts → injury/fibrosis and bile stasis.	Patients with known obstructive lesions (gallstones, biliary strictures, pancreatic carcinoma).	May be complicated by acute cholangitis.

Cholelithiasis and related pathologies



↑ cholesterol and/or bilirubin, ↓ bile salts, and gallbladder stasis all cause sludge or stones.

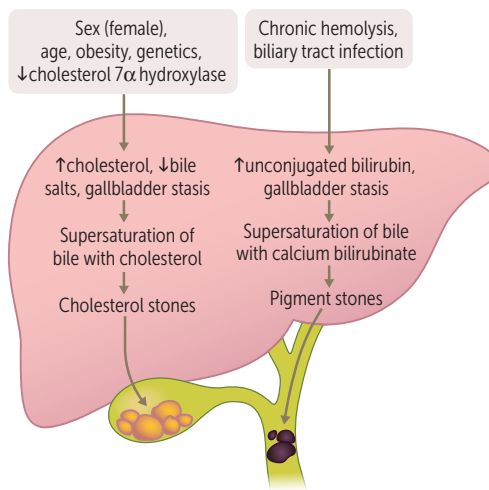
2 types of stones:

- Cholesterol stones (radiolucent with 10–20% opaque due to calcifications)—80% of stones. Associated with obesity, Crohn disease, advanced age, estrogen therapy, multiparity, rapid weight loss, medications (eg, fibrates), race (↑ incidence in White and Native American populations).
- Pigment stones **A** (black = radiopaque, Ca²⁺ bilirubinate, hemolysis; brown = radiolucent, infection). Associated with Crohn disease, chronic hemolysis, alcoholic cirrhosis, advanced age, biliary infections, total parenteral nutrition (TPN).

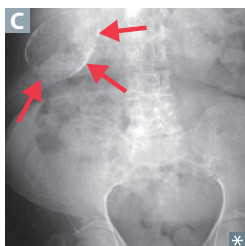
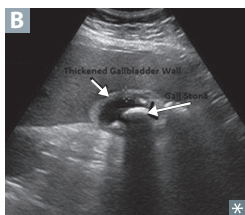
Most common complication is cholecystitis; can also cause acute pancreatitis, acute cholangitis.

Diagnose with ultrasound. Treat with elective cholecystectomy if symptomatic.

Risk factors (**5 F**'s): female, fat (obesity), fertile (multiparity), forty, fair.

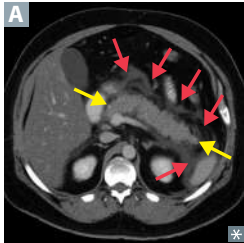


RELATED PATHOLOGIES	CHARACTERISTICS
Biliary colic	Associated with nausea/vomiting and dull RUQ pain. Neurohormonal activation (eg, by CCK after a fatty meal) triggers contraction of gallbladder, forcing stone into cystic duct. Labs are normal, ultrasound shows cholelithiasis.
Choledocholithiasis	Presence of gallstone(s) in common bile duct, often leading to elevated ALP, GGT, direct bilirubin, and/or AST/ALT.
Cholecystitis	Acute or chronic inflammation of gallbladder. Calculous cholecystitis —most common type; due to gallstone impaction in the cystic duct resulting in inflammation and gallbladder wall thickening (arrows in B); can produce 2° infection. Acalculous cholecystitis —due to gallbladder stasis, hypoperfusion, or infection (CMV); seen in critically ill patients. Murphy sign: inspiratory arrest on RUQ palpation due to pain. Pain may radiate to right shoulder (due to irritation of phrenic nerve). ↑ ALP if bile duct becomes involved (eg, acute cholangitis). Diagnose with ultrasound or cholescintigraphy (HIDA scan). Failure to visualize gallbladder on HIDA scan suggests obstruction. Gallstone ileus —fistula between gallbladder and GI tract → stone enters GI lumen → obstructs at ileocecal valve (narrowest point); can see air in biliary tree (pneumobilia). Rigler triad: radiographic findings of pneumobilia, small bowel obstruction, gallstone (usually in iliac fossa).
Porcelain gallbladder	Calcified gallbladder due to chronic cholecystitis; usually found incidentally on imaging C . Treatment: prophylactic cholecystectomy generally recommended due to ↑ risk of gallbladder cancer (mostly adenocarcinoma).
Acute cholangitis	Also called ascending cholangitis. Infection of biliary tree usually due to obstruction that leads to stasis/bacterial overgrowth. Charcot triad of cholangitis includes jaundice, fever, RUQ pain. Reynolds pentad is Charcot triad plus altered mental status and shock (hypotension).



Cholangiocarcinoma

Malignant tumor of bile duct epithelium. Most common location is convergence of right and left hepatic ducts. Risk factors include 1° sclerosing cholangitis, liver fluke infections. Usually presents late with fatigue, weight loss, abdominal pain, jaundice. Imaging may show biliary tract obstruction. Histology: infiltrating neoplastic glands associated with desmoplastic stroma.

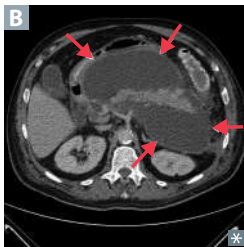
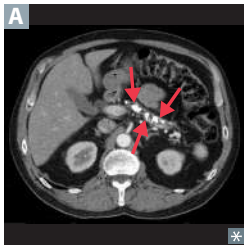
Acute pancreatitis

Autodigestion of pancreas by pancreatic enzymes (**A** shows pancreas [yellow arrows] surrounded by edema [red arrows]).

Causes: **I**diopathic, **G**allstones, **E**thanol, **T**rauma, **S**teroids, **M**umps, **A**utoimmune disease, **S**corpion sting, **H**ypercalcemia/**H**ypertriglyceridemia (> 1000 mg/dL), **E**RCP, **D**rugs (eg, sulfa drugs, NRTIs, protease inhibitors). **I GET SMASHED**.

Diagnosis by 2 of 3 criteria: acute epigastric pain often radiating to the back, ↑ serum amylase or lipase (more specific) to 3× upper limit of normal, or characteristic imaging findings.

Complications: pseudocyst **B** (lined by granulation tissue, not epithelium), abscess, necrosis, hemorrhage, infection, organ failure (ALI/ARDS, shock, renal failure), hypocalcemia (precipitation of Ca²⁺ soaps).

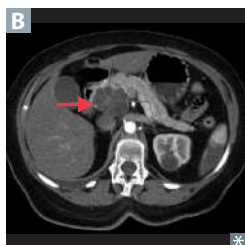
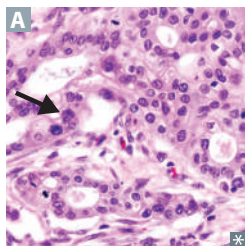
**Chronic pancreatitis**

Chronic inflammation, atrophy, calcification of the pancreas **A**. Major risk factors include alcohol use disorder and genetic predisposition (eg, cystic fibrosis); can be idiopathic. Complications include pancreatic insufficiency and pseudocysts.

Pancreatic insufficiency (typically when <10% pancreatic function) may manifest with steatorrhea, fat-soluble vitamin deficiency, diabetes mellitus.

Amylase and lipase may or may not be elevated (almost always elevated in acute pancreatitis).

Pancreatic adenocarcinoma



Very aggressive tumor arising from pancreatic ducts (disorganized glandular structure with cellular infiltration **A**); often metastatic at presentation, with average survival ~ 1 year after diagnosis. Tumors more common in pancreatic head **B** (lead to obstructive jaundice). Associated with CA 19-9 tumor marker (also CEA, less specific).

Risk factors:

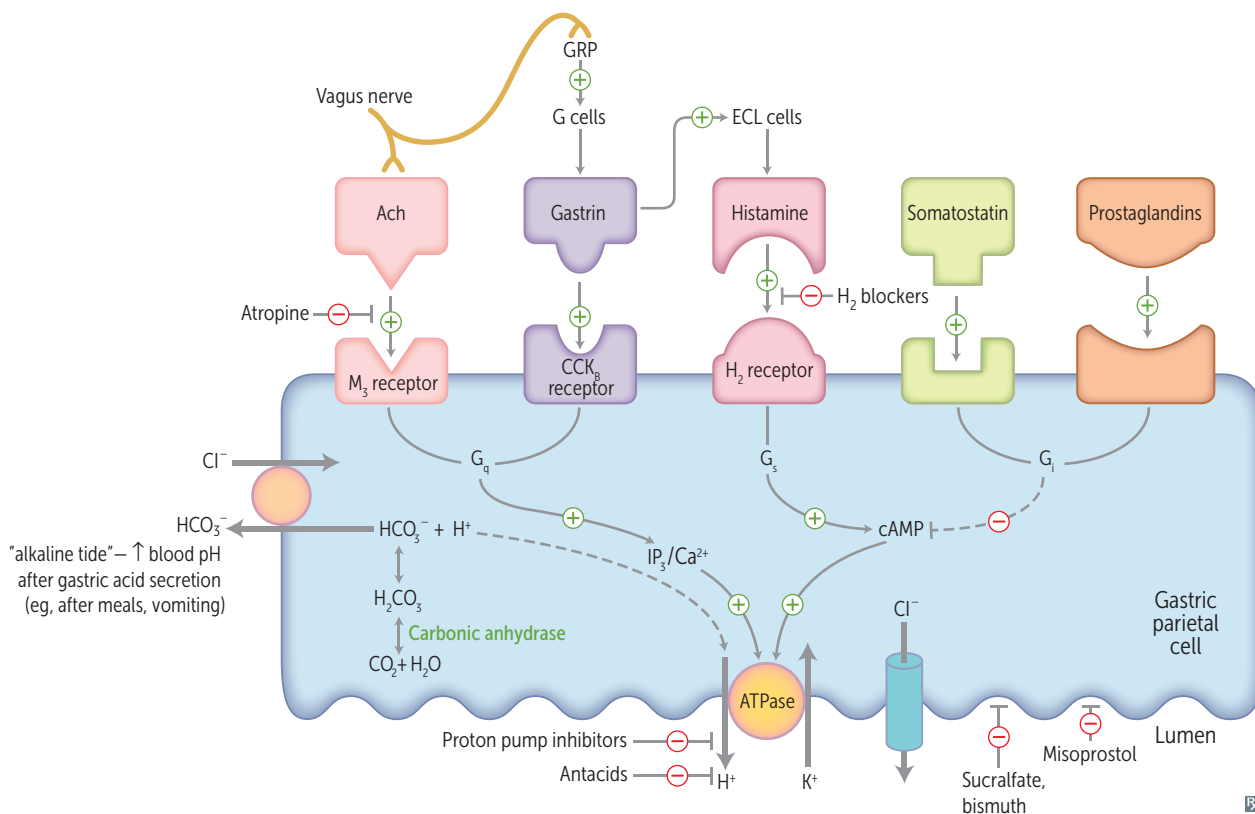
- Tobacco smoking (strongest risk factor)
- Chronic pancreatitis (especially > 20 years)
- Diabetes
- Age > 50 years

Often presents with:

- Abdominal pain radiating to back
- Weight loss (due to malabsorption and anorexia)
- Migratory thrombophlebitis—redness and tenderness on palpation of extremities (Trousseau syndrome)
- Obstructive jaundice with palpable, nontender gallbladder (Courvoisier sign)

▶ GASTROINTESTINAL—PHARMACOLOGY

Acid suppression therapy



H₂-blockers Cimetidine, famotidine, nizatidine. Take H₂ blockers before you **dine**. Think “**table for 2**” to remember H₂.

MECHANISM	Reversible block of histamine H ₂ -receptors → ↓ H ⁺ secretion by parietal cells.
CLINICAL USE	Peptic ulcer, gastritis, mild esophageal reflux.
ADVERSE EFFECTS	Cimetidine is a potent inhibitor of cytochrome P-450 (multiple drug interactions); it also has antiandrogenic effects (prolactin release, gynecomastia, impotence, ↓ libido in males); can cross blood-brain barrier (confusion, dizziness, headaches) and placenta. Cimetidine ↓ renal excretion of creatinine. Other H ₂ blockers are relatively free of these effects.

Proton pump inhibitors Omeprazole, lansoprazole, esomeprazole, pantoprazole, dexlansoprazole.

MECHANISM	Irreversibly inhibit H ⁺ /K ⁺ -ATPase in stomach parietal cells.
CLINICAL USE	Peptic ulcer, gastritis, esophageal reflux, Zollinger-Ellison syndrome, component of therapy for <i>H pylori</i> , stress ulcer prophylaxis.
ADVERSE EFFECTS	↑ risk of <i>C difficile</i> infection, pneumonia, acute interstitial nephritis. Vitamin B ₁₂ malabsorption; ↓ serum Mg ²⁺ /Ca ²⁺ absorption (potentially leading to increased fracture risk in older adults).

Antacids Can affect absorption, bioavailability, or urinary excretion of other drugs by altering gastric and urinary pH or by delaying gastric emptying. All can cause hypokalemia.

Aluminum hydroxide	Constipation, Hypophosphatemia, Osteodystrophy, Proximal muscle weakness, Seizures	Aluminum amount of feces CHOPS
Calcium carbonate	Hypercalcemia (milk-alkali syndrome), rebound acid ↑	Can chelate and ↓ effectiveness of other drugs (eg, tetracycline)
Magnesium hydroxide	Diarrhea, hyporeflexia, hypotension, cardiac arrest	Mg²⁺ = Must go 2 the bathroom

Bismuth, sucralfate

MECHANISM	Bind to ulcer base, providing physical protection and allowing HCO ₃ ⁻ secretion to reestablish pH gradient in the mucous layer. Sucralfate requires acidic environment, not given with PPIs/H ₂ blockers.
CLINICAL USE	↑ ulcer healing, travelers' diarrhea (bismuth). Bismuth also used in quadruple therapy for <i>H pylori</i> .

Misoprostol

MECHANISM	PGE ₁ analog. ↑ production and secretion of gastric mucous barrier, ↓ acid production.
CLINICAL USE	Prevention of NSAID-induced peptic ulcers (NSAIDs block PGE ₁ production). Also used off-label for induction of labor (ripens cervix).
ADVERSE EFFECTS	Diarrhea. Contraindicated in patients of childbearing potential (abortifacient).

Octreotide

MECHANISM	Long-acting somatostatin analog; inhibits secretion of various splanchnic vasodilatory hormones.
CLINICAL USE	Acute variceal bleeds, acromegaly, VIPoma, carcinoid tumors.
ADVERSE EFFECTS	Nausea, cramps, steatorrhea. ↑ risk of cholelithiasis due to CCK inhibition.

Sulfasalazine

MECHANISM	A combination of sulfapyridine (antibacterial) and 5-aminosalicylic acid (anti-inflammatory). Activated by colonic bacteria.
CLINICAL USE	Ulcerative colitis, Crohn disease (colitis component).
ADVERSE EFFECTS	Malaise, nausea, sulfonamide toxicity, reversible oligospermia.

Loperamide

MECHANISM	Agonist at μ -opioid receptors; slows gut motility. Poor CNS penetration (low addictive potential).
CLINICAL USE	Diarrhea.
ADVERSE EFFECTS	Constipation, nausea.

Antiemetics

All act centrally in chemoreceptor trigger zone of area postrema.

DRUG	MECHANISM	CLINICAL USE	ADVERSE EFFECTS
Ondansetron, granisetron	5-HT ₃ -receptor antagonists Also act peripherally (↓ vagal stimulation)	Nausea and vomiting after chemotherapy, radiotherapy, or surgery	Headache, constipation, QT interval prolongation, serotonin syndrome
Prochlorperazine, metoclopramide	D ₂ -receptor antagonists Metoclopramide also causes ↑ gastric emptying and ↑ LES tone	Nausea and vomiting Metoclopramide is also used in gastroparesis (eg, diabetic), persistent GERD	Extrapyramidal symptoms, hyperprolactinemia, anxiety, drowsiness, restlessness, depression, GI distress
Aprepitant, fosaprepitant	NK ₁ (neurokinin-1) receptor antagonists NK ₁ receptor = substance P receptor	Chemotherapy-induced nausea and vomiting	Fatigue, GI distress

Orlistat

MECHANISM	Inhibits gastric and pancreatic lipase → ↓ breakdown and absorption of dietary fats. Taken with fat-containing meals.
CLINICAL USE	Weight loss.
ADVERSE EFFECTS	Abdominal pain, flatulence, bowel urgency/frequent bowel movements, steatorrhea; ↓ absorption of fat-soluble vitamins.

Anticonstipation drugs

DRUG	MECHANISM	ADVERSE EFFECTS
Bulk-forming laxatives Methylcellulose, psyllium	Soluble fibers that draw water into gut lumen, forming viscous liquid that promotes peristalsis	Bloating
Osmotic laxatives Lactulose, magnesium citrate, magnesium hydroxide, polyethylene glycol	Provide osmotic load to draw water into GI lumen Lactulose also treats hepatic encephalopathy: gut microbiota degrades lactulose into metabolites (lactic acid, acetic acid) that promote nitrogen excretion as NH_4^+ by trapping it in colon	Diarrhea, dehydration; may be misused by patients with bulimia
Stimulant laxatives Bisacodyl, senna	Enteric nerve stimulation → colonic contraction	Diarrhea
Emollient laxatives Docusate	Surfactants that ↓ stool surface tension, promoting water entry into stool	Diarrhea
Lubiprostone	Chloride channel activator → ↑ intestinal fluid secretion	Diarrhea, nausea

Hematology and Oncology

“You’re always somebody’s type! (blood type, that is)”

—BloodLink

“The best blood will at some time get into a fool or a mosquito.”

—Austin O’Malley

“A life touched by cancer is not a life destroyed by cancer.”

—Drew Boswell, *Climbing the Cancer Mountain*

“Without hair, a queen is still a queen.”

—Prajakta Mhadnak

“Blood can circulate forever if you keep donating it.”

—Anonymous

When studying hematology, pay close attention to the many cross connections to immunology. Make sure you master the different types of anemias. Be comfortable interpreting blood smears. When reviewing oncologic drugs, focus on mechanisms and adverse effects rather than details of clinical uses, which may be lower yield.

Please note that solid tumors are covered in their respective organ system chapters.

▶ Embryology	412
▶ Anatomy	414
▶ Physiology	418
▶ Pathology	422
▶ Pharmacology	443

▶ HEMATOLOGY AND ONCOLOGY—EMBRYOLOGY

Fetal erythropoiesis

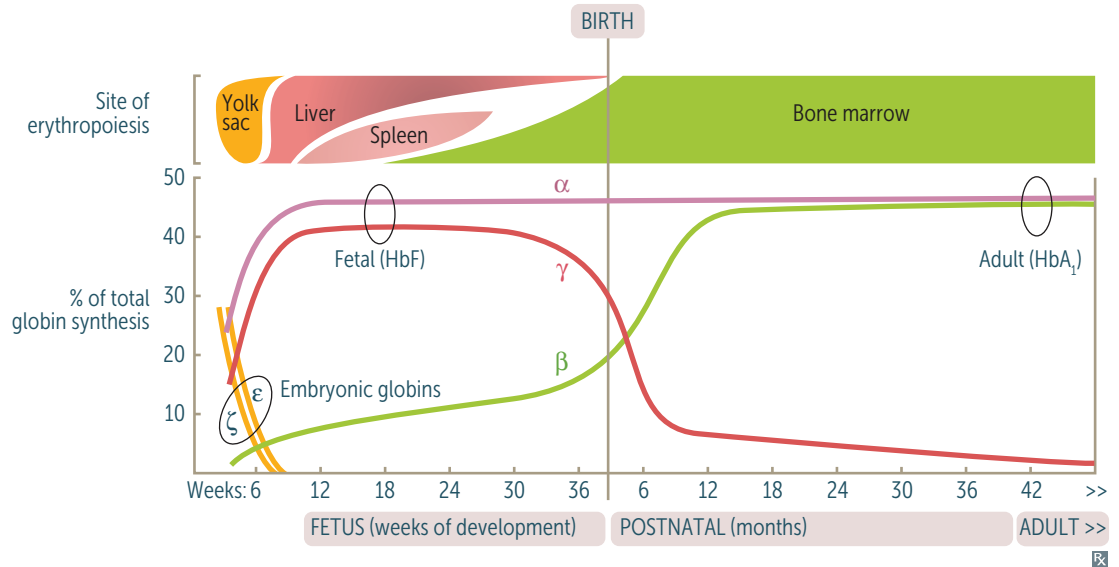
- Fetal erythropoiesis occurs in:
- **Yolk sac** (3–8 weeks)
 - **Liver** (6 weeks–birth)
 - **Spleen** (10–28 weeks)
 - **Bone marrow** (18 weeks to adult)

Young liver synthesizes blood.

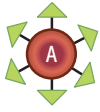
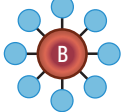
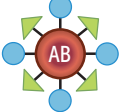

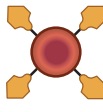










Hemoglobin development

Embryonic globins: ζ and ϵ .
 Fetal hemoglobin (HbF) = $\alpha_2\gamma_2$.
 Adult hemoglobin (HbA₁) = $\alpha_2\beta_2$.
 HbF has higher affinity for O₂ due to less avid binding of 2,3-BPG, allowing HbF to extract O₂ from maternal hemoglobin (HbA₁ and HbA₂) across the placenta. HbA₂ ($\alpha_2\delta_2$) is a form of adult hemoglobin present in small amounts.

From fetal to adult hemoglobin:
Alpha always; **gamma** goes, **beta** becomes.



Blood groups

	ABO classification				Rh classification	
	A	B	AB	O	Rh ⁺	Rh ⁻
RBC type						
Group antigens on RBC surface	A 	B 	A & B 	NONE	Rh (D) 	NONE
Antibodies in plasma	Anti-B  IgM	Anti-A  IgM	NONE	Anti-A  Anti-B  IgG (predominantly), IgM	NONE	Anti-D  IgG
Clinical relevance						
Compatible RBC types to receive	A, O	B, O	AB, A, B, O	O	Rh ⁺ , Rh ⁻	Rh ⁻
Compatible RBC types to donate to	A, AB	B, AB	AB	A, B, AB, O	Rh ⁺	Rh ⁺ , Rh ⁻

Anti-Kell antibody

Complex blood group system with high immunogenicity.

Anti-Kell antibodies (usually IgG) of a Kell-positive pregnant patient may cause hemolytic disease of the newborn when produced following previous sensitization to the Kell antigen and transferred through the placenta. Targets fetal RBC precursors (↓ RBC production) and mature RBCs (↑ hemolysis), resulting in severe fetal anemia.

Anti-Kell antibodies may also be associated with hemolytic transfusion reactions.

Hemolytic disease of the fetus and newborn

Also called erythroblastosis fetalis.

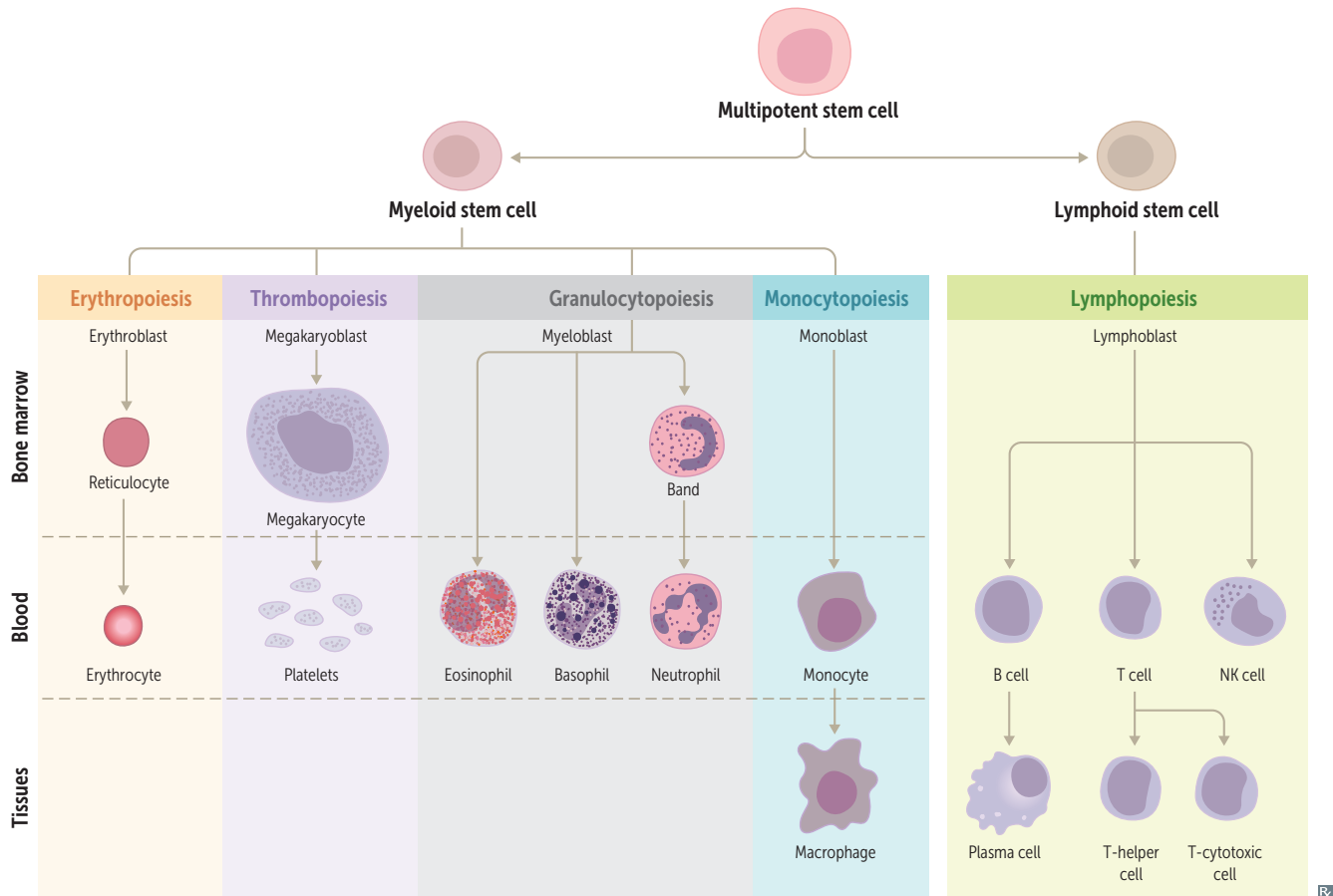
Rh hemolytic disease

ABO hemolytic disease

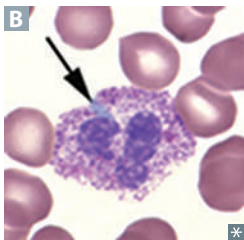
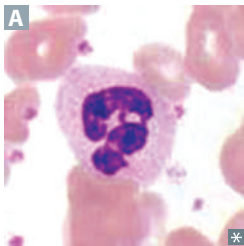
INTERACTION	Rh ⁻ pregnant patient; Rh ⁺ fetus.	Type O pregnant patient; type A or B fetus.
MECHANISM	First pregnancy: patient exposed to fetal blood (often during delivery) → formation of maternal anti-D IgG. Subsequent pregnancies: anti-D IgG crosses placenta → attacks fetal and newborn RBCs → hemolysis.	Preexisting pregnant patient anti-A and/or anti-B IgG antibodies cross the placenta → attack fetal and newborn RBCs → hemolysis.
PRESENTATION	Hydrops fetalis, jaundice shortly after birth, kernicterus.	Mild jaundice in the neonate within 24 hours of birth. Unlike Rh hemolytic disease, can occur in firstborn babies and is usually less severe.
TREATMENT/PREVENTION	Prevent by administration of anti-D IgG to Rh ⁻ pregnant patients during third trimester and early postpartum period (if fetus Rh ⁺). Prevents maternal anti-D IgG production.	Treatment: phototherapy or exchange transfusion.

▶ HEMATOLOGY AND ONCOLOGY—ANATOMY

Hematopoiesis



Neutrophils



Acute inflammatory response cells. Phagocytic.

Multilobed nucleus **A**. Specific granules contain leukocyte alkaline phosphatase (LAP), collagenase, lysozyme, and lactoferrin. Azurophilic granules (lysosomes) contain proteinases, acid phosphatase, myeloperoxidase, and β -glucuronidase.

Inflammatory states (eg, bacterial infection) cause neutrophilia and changes in neutrophil morphology, such as left shift, toxic granulation (dark blue, coarse granules), Döhle bodies (light blue, peripheral inclusions, arrow in **B**), and cytoplasmic vacuoles.

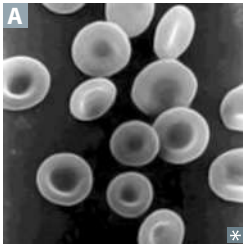
Neutrophil chemotactic agents: C5a, IL-8, LTB₄, 5-HETE (leukotriene precursor), kallikrein, platelet-activating factor, N-formylmethionine (bacterial proteins).

Hypersegmented neutrophils (nucleus has 6+ lobes) are seen in vitamin B₁₂/folate deficiency.

Left shift— \uparrow neutrophil precursors (eg, band cells, metamyelocytes) in peripheral blood.

Reflects states of \uparrow myeloid proliferation (eg, inflammation, CML).

Leukoerythroblastic reaction—left shift accompanied by immature RBCs. Suggests bone marrow infiltration (eg, myelofibrosis, metastasis).

Erythrocytes

Carry O_2 to tissues and CO_2 to lungs. Anucleate and lack organelles; biconcave **A**, with large surface area-to-volume ratio for rapid gas exchange. Life span of ~120 days in healthy adults; 60–90 days in neonates. Source of energy is glucose (90% used in glycolysis, 10% used in HMP shunt). Membranes contain Cl^-/HCO_3^- antiporter, which allow RBCs to export HCO_3^- and transport CO_2 from the periphery to the lungs for elimination.

Erythro = red; *cyte* = cell.

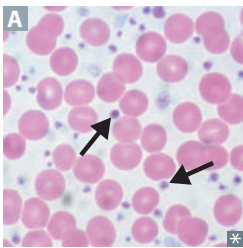
Erythrocytosis = polycythemia = ↑ Hct.

Anisocytosis = varying sizes.

Poikilocytosis = varying shapes.

Reticulocyte = immature RBC; reflects erythroid proliferation.

Bluish color (polychromasia) on Wright-Giemsa stain of reticulocytes represents residual ribosomal RNA.

Thrombocytes (platelets)

Involved in 1° hemostasis. Anucleate, small cytoplasmic fragments **A** derived from megakaryocytes. Life span of 8–10 days (pl8lets). When activated by endothelial injury, aggregate with other platelets and interact with fibrinogen to form platelet plug. Contain dense granules (Ca^{2+} , ADP, Serotonin, Histamine; **CASH**) and α granules (vWF, fibrinogen, fibronectin, platelet factor 4). Approximately 1/3 of platelet pool is stored in the spleen.

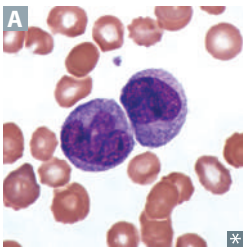
Thrombocytopenia or ↓ platelet function results in petechiae.

vWF receptor: GpIb.

Fibrinogen receptor: GpIIb/IIIa.

Thrombopoietin stimulates megakaryocyte proliferation.

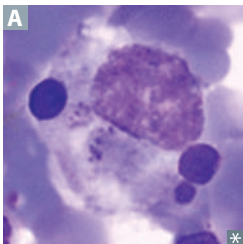
Alfa granules contain vWF, fibrinogen, fibronectin, platelet factor four.

Monocytes

Found in blood, differentiate into macrophages in tissues.

Large, kidney-shaped nucleus **A**. Extensive “frosted glass” cytoplasm.

Mono = one (nucleus); *cyte* = cell.

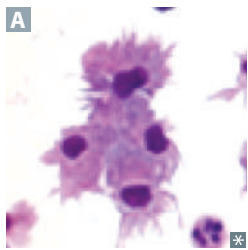
Macrophages

A type of antigen-presenting cell. Phagocytose bacteria, cellular debris, and senescent RBCs. Long life in tissues. Differentiate from circulating blood monocytes **A**. Activated by γ -interferon. Can function as antigen-presenting cell via MHC II. Also engage in antibody-dependent cellular cytotoxicity. Important cellular component of granulomas (eg, TB, sarcoidosis), where they may fuse to form giant cells.

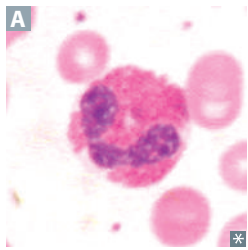
Macro = large; *phage* = eater.

Macrophage naming varies by specific tissue type (eg, Kupffer cells in liver, histiocytes in connective tissue, osteoclasts in bone, microglial cells in brain).

Lipid A from bacterial LPS binds CD14 on macrophages to initiate septic shock.

Dendritic cells

Highly phagocytic antigen-presenting cells (APCs) **A**. Function as link between innate and adaptive immune systems (eg, via T-cell stimulation). Express MHC class II and Fc receptors on surface. Can present exogenous antigens on MHC class I (cross-presentation).

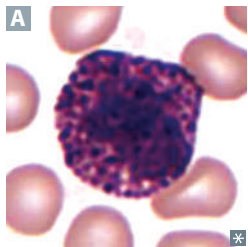
Eosinophils

Defend against helminthic infections (major basic protein). Bilobate nucleus. Packed with large eosinophilic granules of uniform size **A**. Highly phagocytic for antigen-antibody complexes. Produce histaminase, major basic protein (MBP, a helminthotoxin), eosinophil peroxidase, eosinophil cationic protein, and eosinophil-derived neurotoxin.

Eosin = pink dye; *philic* = loving.

Causes of eosinophilia (**PACMAN Eats**):

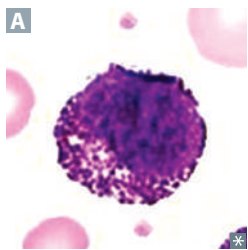
- P**arasites
- A**sthma
- C**hronic adrenal insufficiency
- M**yeloproliferative disorders
- A**llergic processes
- N**eoplasia (eg, Hodgkin lymphoma)
- E**osinophilic granulomatosis with polyangiitis

Basophils

Mediate allergic reaction. Densely basophilic granules **A** contain heparin (anticoagulant) and histamine (vasodilator). Leukotrienes synthesized and released on demand.

Basophilic—stains readily with **basic** stains.

Basophilia is uncommon, but can be a sign of myeloproliferative disorders, particularly CML.

Mast cells

Mediate local tissue allergic reactions. Contain basophilic granules **A**. Originate from same precursor as basophils but are not the same cell type. Can bind the Fc portion of IgE to membrane. Activated by tissue trauma, C3a and C5a, surface IgE cross-linking by antigen (IgE receptor aggregation) → degranulation → release of histamine, heparin, tryptase, and eosinophil chemotactic factors.

Involved in type I hypersensitivity reactions.

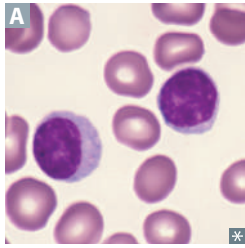
Cromolyn sodium prevents mast cell degranulation (used for asthma prophylaxis).

Vancomycin, opioids, and radiocontrast dye can elicit IgE-independent mast cell degranulation.

Mastocytosis—rare; proliferation of mast cells in skin and/or extracutaneous organs. Associated with *c-KIT* mutations and ↑ serum tryptase.

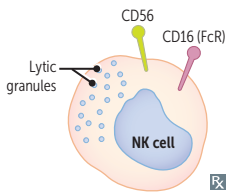
↑ histamine → flushing, pruritus, hypotension, abdominal pain, diarrhea, peptic ulcer disease.

Lymphocytes



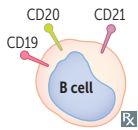
Refer to B cells, T cells, and natural killer (NK) cells. B cells and T cells mediate adaptive immunity. NK cells are part of the innate immune response. Round, densely staining nucleus with small amount of pale cytoplasm **A**.

Natural killer cells



Important in innate immunity, especially against intracellular pathogens. NK cells are larger than B and T cells, with distinctive cytoplasmic lytic granules (containing perforin and granzymes) that, when released, act on target cells to induce apoptosis. Distinguish between healthy and infected cells by identifying cell surface proteins (induced by stress, malignant transformation, or microbial infections). Induce **apoptosis** (natural **killer**) in cells that do not express class I MHC cell surface molecules, eg, virally infected cells in which these molecules are downregulated.

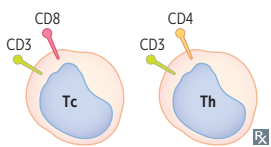
B cells



Mediate humoral immune response. Originate from stem cells in bone marrow and matures in marrow. Migrate to peripheral lymphoid tissue (follicles of lymph nodes, white pulp of spleen, unencapsulated lymphoid tissue). When antigen is encountered, B cells differentiate into plasma cells (which produce antibodies) and memory cells. Can function as an APC.

B = bone marrow.

T cells



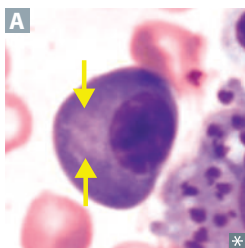
Mediate cellular immune response. Originate from stem cells in the bone marrow, but mature in the thymus. Differentiate into cytotoxic T cells (express CD8, recognize MHC I), helper T cells (express CD4, recognize MHC II), and regulatory T cells. CD28 (costimulatory signal) necessary for T-cell activation. Most circulating lymphocytes are T cells (80%).

T = thymus.

CD4+ helper T cells are the primary target of HIV.

Rule of 8: MHC II × CD4 = 8;
MHC I × CD8 = 8.

Plasma cells

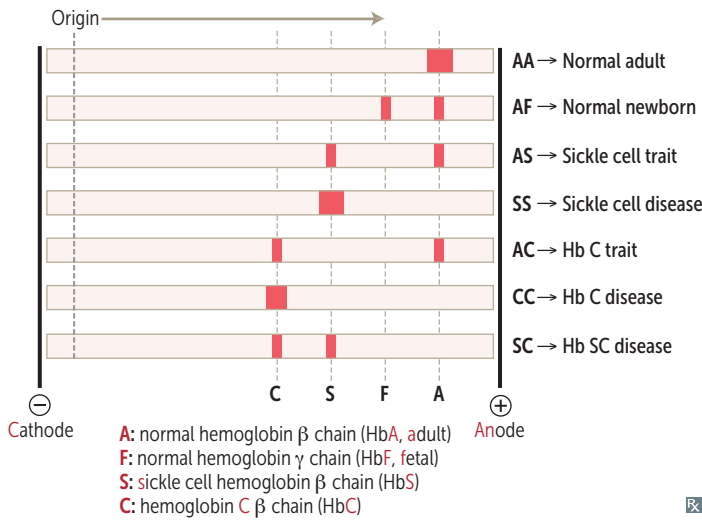


Produce large amounts of antibody specific to a particular antigen. “Clock-face” chromatin distribution and eccentric nucleus, abundant RER, and well-developed Golgi apparatus (arrows in **A**). Found in bone marrow and normally do not circulate in peripheral blood.

Multiple myeloma is a plasma cell dyscrasia.

▶ HEMATOLOGY AND ONCOLOGY—PHYSIOLOGY

Hemoglobin electrophoresis



During gel electrophoresis, hemoglobin migrates from the negatively charged cathode to the positively charged anode. HbA migrates the farthest, followed by HbF, HbS, and HbC. This is because the missense mutations in HbS and HbC replace glutamic acid \ominus with valine (neutral) and lysine \oplus , respectively, making HbC and HbS more positively charged than HbA.

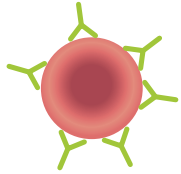

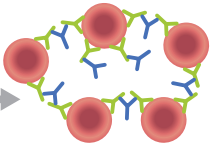
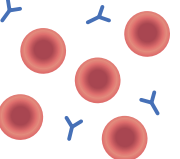
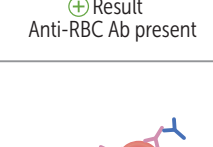
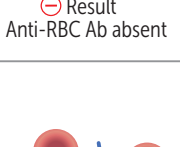

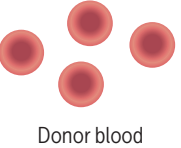
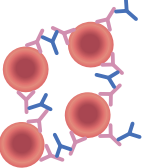
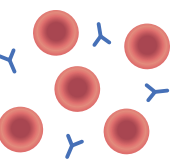
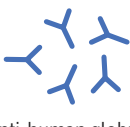
A Fat Santa Claus can't (cathode → anode) go far.

Coombs test

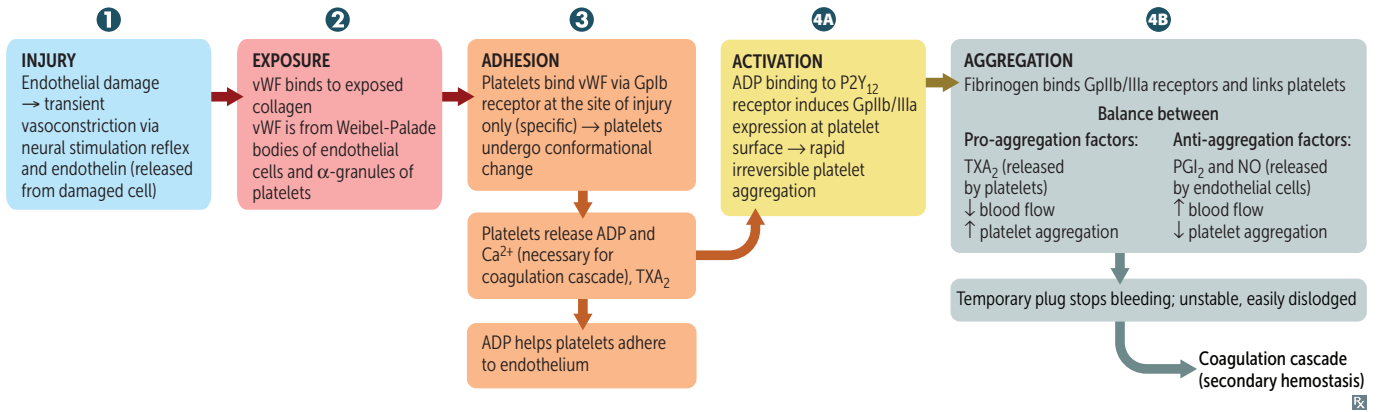
Also called antiglobulin test. Detects the presence of antibodies against circulating RBCs.

Direct Coombs test—anti-Ig antibody (Coombs reagent) added to patient's RBCs. RBCs agglutinate if RBCs are coated with Ig. Used for AIHA diagnosis.

Indirect Coombs test—normal RBCs added to patient's serum. If serum has anti-RBC surface Ig, RBCs agglutinate when Coombs reagent is added. Used for pretransfusion testing.

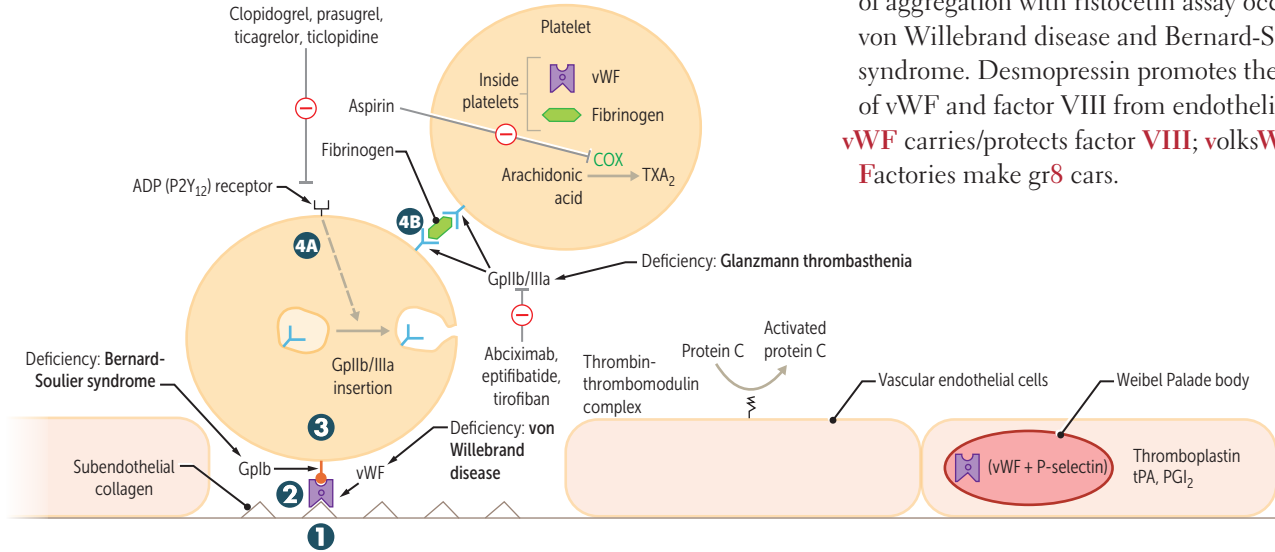
	Patient component	Reagent(s)	⊕ Result (agglutination)	⊖ Result (no agglutination)
Direct Coombs	 RBCs +/- anti-RBC Ab	 Anti-human globulin (Coombs reagent)	 ⊕ Result Anti-RBC Ab present	 ⊖ Result Anti-RBC Ab absent
			 ⊕ Result Anti-RBC Ab present	 ⊖ Result Anti-RBC Ab absent
Indirect Coombs	 Patient serum +/- anti-donor RBC Ab	 Donor blood	 ⊕ Result Anti-donor RBC Ab present	 ⊖ Result Anti-donor RBC Ab absent
		 Anti-human globulin (Coombs reagent)		

Platelet plug formation (primary hemostasis)



Thrombogenesis

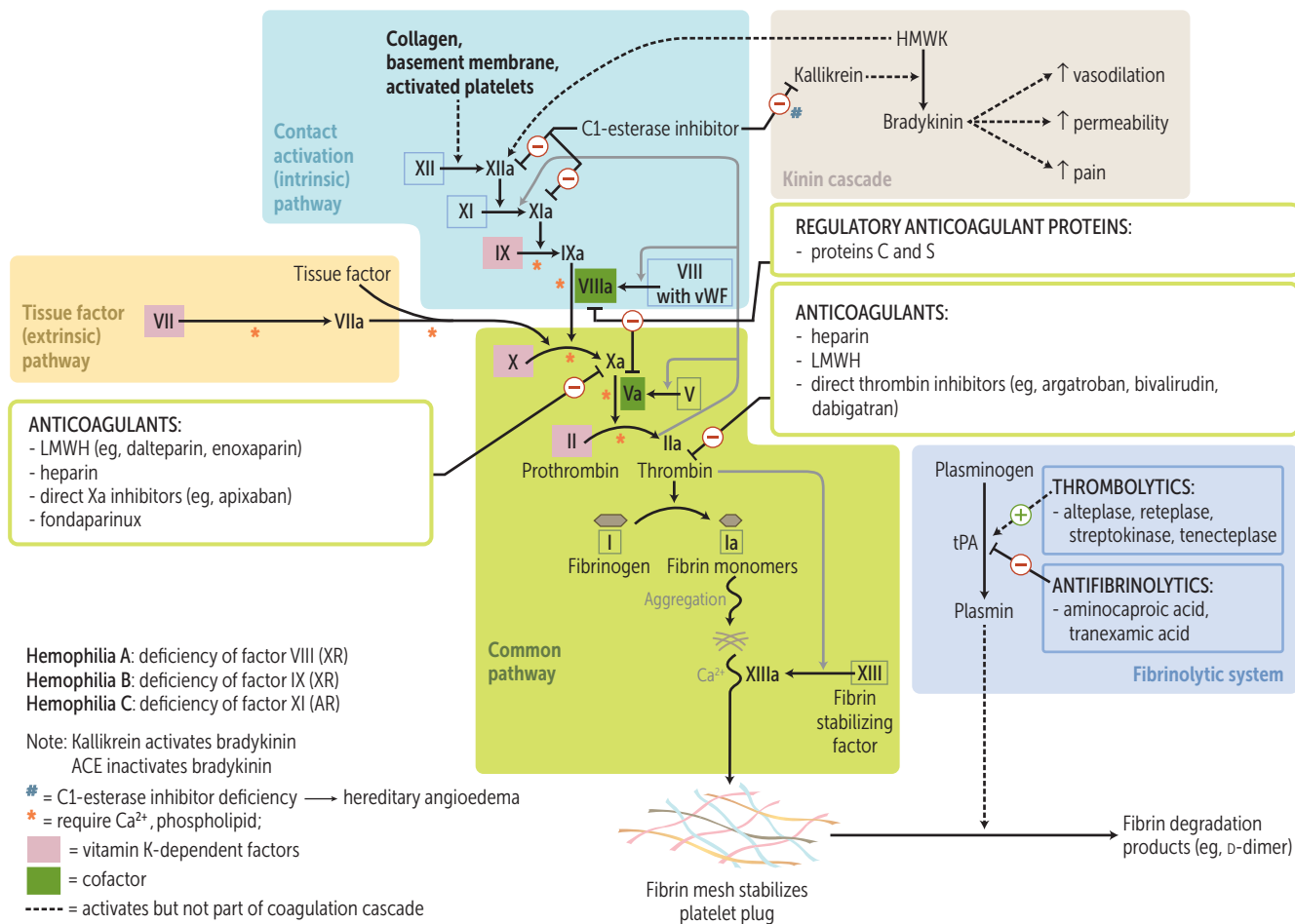
Formation of insoluble fibrin mesh. Aspirin irreversibly inhibits cyclooxygenase, thereby inhibiting TXA₂ synthesis. Clopidogrel, prasugrel, ticagrelor, and ticlopidine inhibit ADP-induced expression of GpIIb/IIIa by blocking P2Y₁₂ receptor. Abciximab, eptifibatide, and tirofiban inhibit GpIIb/IIIa directly. Ristocetin activates vWF to bind GpIb. Failure of aggregation with ristocetin assay occurs in von Willebrand disease and Bernard-Soulier syndrome. Desmopressin promotes the release of vWF and factor VIII from endothelial cells. **vWF** carries/protects factor **VIII**; **volksWagen** **F**actories make **gr8** cars.



Coagulation and kinin pathways

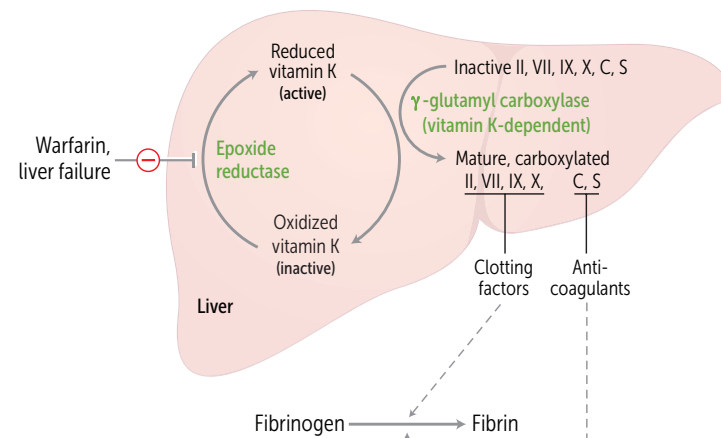
PT monitors extrinsic and common pathway, reflecting activity of factors I, II, V, VII, and X.

PTT monitors intrinsic and common pathway, reflecting activity of all factors except VII and XIII.

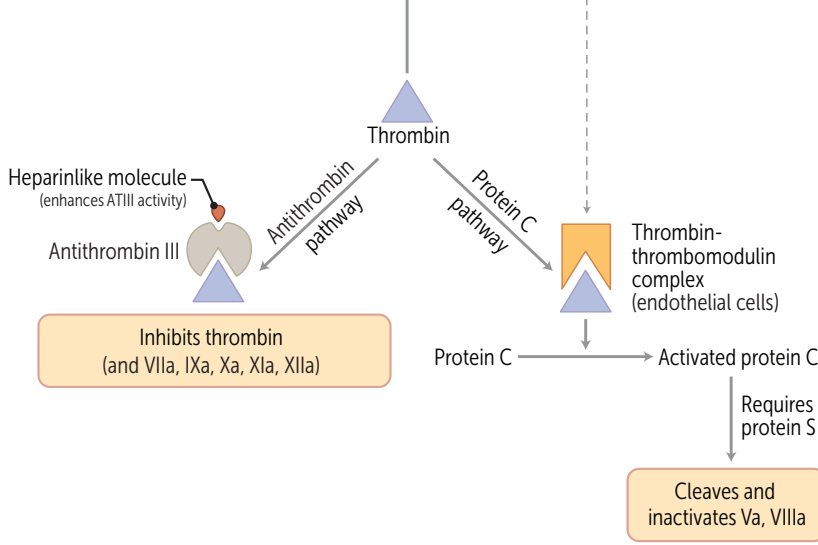


Vitamin K–dependent coagulation

Procoagulation



Anticoagulation



Vitamin K deficiency—↓ synthesis of factors II, VII, IX, X, protein C, protein S.

Warfarin inhibits vitamin K epoxide reductase. Vitamin K administration can potentially reverse inhibitory effect of warfarin on clotting factor synthesis (delayed). FFP or PCC administration reverses action of warfarin immediately and can be given with vitamin K in cases of severe bleeding.

Neonates lack enteric bacteria, which produce vitamin K. Early administration of vitamin K overcomes neonatal deficiency/coagulopathy.

Factor VII (seven)—shortest half-life.

Factor II (two)—longest (too long) half-life.

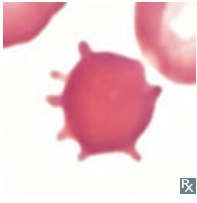
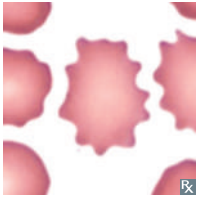
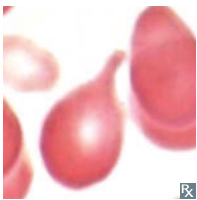
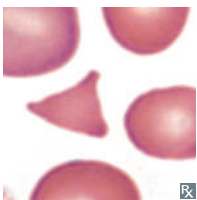

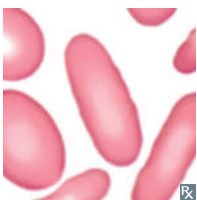
Antithrombin inhibits thrombin (factor IIa) and factors VIIa, IXa, Xa, XIa, XIIa.

Heparin enhances the activity of antithrombin. Principal targets of antithrombin: thrombin and factor Xa.


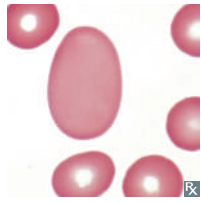


Factor V Leiden mutation produces a factor V resistant to inhibition by activated protein C. tPA is used clinically as a thrombolytic.

▶ HEMATOLOGY AND ONCOLOGY—PATHOLOGY

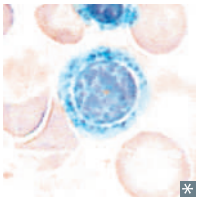


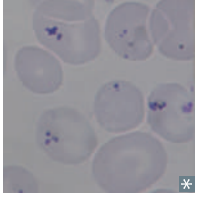

RBC morphology

TYPE	EXAMPLE	ASSOCIATED PATHOLOGY	NOTES
Acanthocytes ("spur cells")		Liver disease, abetalipoproteinemia, vitamin E deficiency	Projections of varying size at irregular intervals (acanthocytes are asymmetric).
Echinocytes ("burr cells")		Liver disease, ESRD, pyruvate kinase deficiency	Smaller and more uniform projections than acanthocytes (echinocytes are even).
Dacryocytes ("teardrop cells")		Bone marrow infiltration (eg, myelofibrosis)	RBC "sheds a tear" because it's mechanically squeezed out of its home in the bone marrow
Schistocytes ("helmet" cells)		MAHAs (eg, DIC, TTP/HUS, HELLP syndrome), mechanical hemolysis (eg, heart valve prosthesis)	Fragmented RBCs
Degmacytes ("bite cells")		G6PD deficiency	Due to removal of Heinz bodies by splenic macrophages (they "deg" them out of/bite them off of RBCs)
Elliptocytes		Hereditary elliptocytosis	Caused by mutation in genes encoding RBC membrane proteins (eg, spectrin)

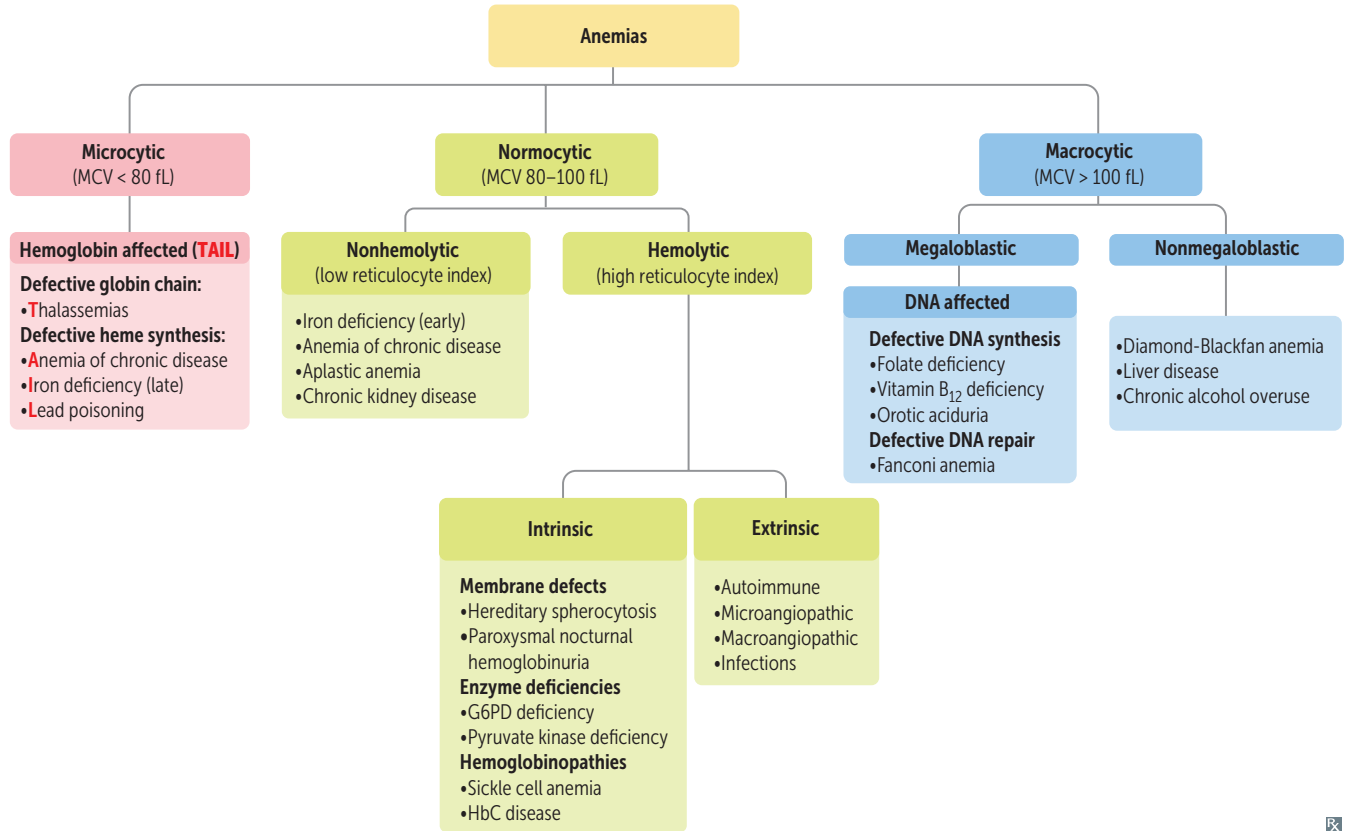
RBC morphology (continued)

TYPE	EXAMPLE	ASSOCIATED PATHOLOGY	NOTES
Spherocytes		Hereditary spherocytosis, autoimmune hemolytic anemia	Small, spherical cells without central pallor ↓ surface area-to-volume ratio
Macro-ovalocytes		Megaloblastic anemia (also hypersegmented PMNs)	
Target cells		H bc disease, A splenia, L iver disease, T halassemia	“ HALT ,” said the hunter to his target ↑ surface area-to-volume ratio
Sickle cells		Sickle cell anemia	Sickling occurs with low O ₂ conditions (eg, high altitude, acidosis)

RBC inclusions

TYPE	EXAMPLE	ASSOCIATED PATHOLOGY	NOTES
Bone marrow			
Iron granules		Sideroblastic anemias (eg, lead poisoning, myelodysplastic syndromes, chronic alcohol overuse)	Perinuclear mitochondria with excess iron (forming ring in ringed sideroblasts) Require Prussian blue stain to be visualized
Peripheral smear			
Howell-Jolly bodies		Functional hyposplenia (eg, sickle cell disease), asplenia	Basophilic nuclear remnants (do not contain iron) Usually removed by splenic macrophages
Basophilic stippling		Sideroblastic anemias, thalassemias	Basophilic ribosomal precipitates (do not contain iron)
Pappenheimer bodies		Sideroblastic anemia	Basophilic granules (contain iron)
Heinz bodies		G6PD deficiency	Denatured and precipitated hemoglobin (contain iron) Phagocytic removal of Heinz bodies → bite cells Requires supravital stain (eg, crystal violet) to be visualized

Anemias



ⓧ

Reticulocyte production index

Also called corrected reticulocyte count. Used to correct falsely elevated reticulocyte count in anemia. Measures appropriate bone marrow response to anemic conditions (effective erythropoiesis). High RPI (> 3) indicates compensatory RBC production; low RPI (< 2) indicates inadequate response to correct anemia. Calculated as:

$$RPI = \% \text{ reticulocytes} \times \left(\frac{\text{actual Hct}}{\text{normal Hct}} \right) / \text{maturation time}$$

**Microcytic,
hypochromic anemias**

MCV < 80 fL.

Iron deficiency

↓ iron due to chronic bleeding (eg, GI loss, menorrhagia), malnutrition, absorption disorders, GI surgery (eg, gastrectomy), or ↑ demand (eg, pregnancy) → ↓ final step in heme synthesis.
 Labs: ↓ iron, ↑ TIBC, ↓ ferritin, ↑ free erythrocyte protoporphyrin, ↑ RDW, ↓ RI. Microcytosis and hypochromasia (↑ central pallor) **A**.
 Symptoms: fatigue, conjunctival pallor **B**, pica (persistent craving and compulsive eating of nonfood substances), spoon nails (koilonychia).
 May manifest as glossitis, cheilosis, **Plummer-Vinson syndrome** (triad of iron deficiency anemia, esophageal webs, and dysphagia).

α-thalassemia

α-globin gene deletions on chromosome 16 → ↓ α-globin synthesis. May have *cis* deletion (deletions occur on same chromosome) or *trans* deletion (deletions occur on separate chromosomes). Normal is αα/αα. Often ↑ RBC count, in contrast to iron deficiency anemia.

# OF α-GLOBIN GENES DELETED	DISEASE	CLINICAL OUTCOME
1 (α α/α -)	α-thalassemia minima	No anemia (silent carrier)
2 (α -/α -; <i>trans</i>) or (α α/- -; <i>cis</i>)	α-thalassemia minor	Mild microcytic, hypochromic anemia; <i>cis</i> deletion may worsen outcome for the carrier's offspring
3 (- -/- α)	Hemoglobin H disease (HbH); excess β-globin forms β ₄	Moderate to severe microcytic hypochromic anemia
4 (- -/- -)	Hemoglobin Barts disease; no α-globin, excess γ-globin forms γ ₄	Hydrops fetalis; incompatible with life

β-thalassemia

Point mutation in splice sites or Kozak consensus sequence (promoter) on chromosome 11 → ↓ β-globin synthesis (β⁺) or absent β-globin synthesis (β⁰). ↑ prevalence in people of Mediterranean descent.

# OF β-GLOBIN GENES MUTATED	DISEASE	CLINICAL OUTCOME
1 (β/β ⁺ or β/β ⁰)	β-thalassemia minor	Mild microcytic anemia. ↑ HbA ₂ .
2 (β ⁺ /β ⁺ or β ⁺ /β ⁰)	β-thalassemia intermedia	Variable anemia, ranging from mild/asymptomatic to severe/transfusion-dependent.
2 (β ⁰ /β ⁰)	β-thalassemia major (Cooley anemia)	Severe microcytic anemia with target cells and ↑ anisopoikilocytosis requiring blood transfusions (↑ risk of 2° hemochromatosis), marrow expansion ("crew cut" on skull x-ray) → skeletal deformities, extramedullary hematopoiesis → HSM. ↑ risk of parvovirus B19-induced aplastic crisis. ↑ HbF and HbA ₂ , becomes symptomatic after 6 months when HbF declines (HbF is protective). Chronic hemolysis → pigmented gallstones.
1 (β ⁺ /HbS or β ⁰ /HbS)	Sickle cell β-thalassemia	Mild to moderate sickle cell disease depending on whether there is ↓ (β ⁺ /HbS) or absent (β ⁰ /HbS) β-globin synthesis.

Microcytic, hypochromic anemias (continued)**Lead poisoning**

Lead inhibits ferrochelatase and ALA dehydratase → ↓ heme synthesis and ↑ RBC protoporphyrin.
Also inhibits rRNA degradation → RBCs retain aggregates of rRNA (basophilic stippling).

Symptoms of **LEAD** poisoning:

- **L**ead **L**ines on gingivae (Burton lines) and on metaphyses of long bones **D** on x-ray.
- **E**ncephalopathy and **E**rythrocyte basophilic stippling.
- **A**bdominal colic and sideroblastic **A**nemia.
- **D**rops—wrist and foot drop.

Treatment: chelation with succimer, EDTA, dimercaprol.

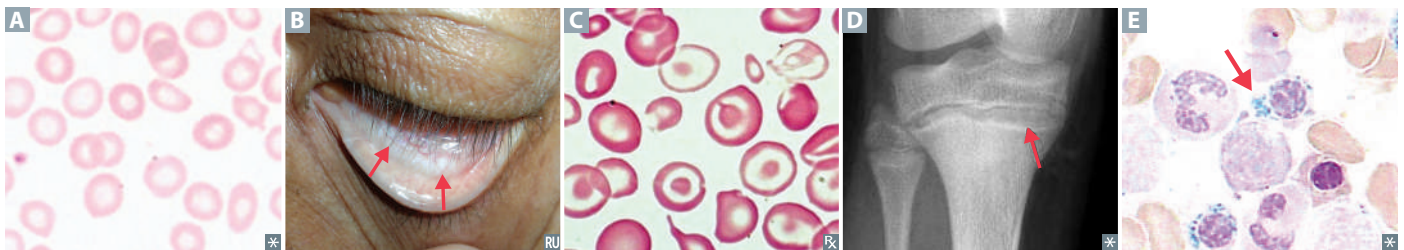
Exposure risk ↑ in old houses (built before 1978) with chipped paint (children) and workplace (adults).

Sideroblastic anemia

Causes: genetic (eg, X-linked defect in ALA synthase gene), acquired (myelodysplastic syndromes), and reversible (alcohol is most common; also lead poisoning, vitamin B₆ deficiency, copper deficiency, drugs [eg, isoniazid, linezolid]).

Lab findings: ↑ iron, normal/↓ TIBC, ↑ ferritin. Ringed sideroblasts (with iron-laden, Prussian blue–stained mitochondria) seen in bone marrow **E**. Peripheral blood smear: basophilic stippling of RBCs. Some acquired variants may be normocytic or macrocytic.

Treatment: pyridoxine (B₆, cofactor for ALA synthase).

**Interpretation of iron studies**

	Iron deficiency	Chronic disease	Hemochromatosis	Pregnancy/OCP use
Serum iron	↓	↓	↑	—
Transferrin or TIBC	↑	↓ ^a	↓	↑
Ferritin	↓	↑	↑	—
% transferrin saturation (serum iron/TIBC)	↓↓	—/↓	↑↑	↓

↑↓ = 1° disturbance.

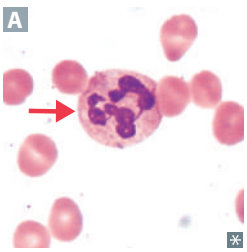
Transferrin—**t**ransports iron in blood.

TIBC—indirectly measures transferrin.

Ferritin—1° iron storage protein of body.

^aEvolutionary reasoning—pathogens use circulating iron to thrive. The body has adapted a system in which iron is stored within the cells of the body and prevents pathogens from acquiring circulating iron.

Macrocytic anemias MCV > 100 fL.

	DESCRIPTION	FINDINGS
Megaloblastic anemia 	Impaired DNA synthesis → maturation of nucleus of precursor cells in bone marrow delayed relative to maturation of cytoplasm. Causes: vitamin B ₁₂ deficiency, folate deficiency, medications (eg, hydroxyurea, phenytoin, methotrexate, sulfa drugs).	RBC macrocytosis, hypersegmented neutrophils (arrow in A), glossitis.
Folate deficiency	Causes: malnutrition (eg, chronic alcohol overuse), malabsorption, drugs (eg, methotrexate, trimethoprim, phenytoin), ↑ requirement (eg, hemolytic anemia, pregnancy).	↑ homocysteine, normal methylmalonic acid. No neurologic symptoms (vs B ₁₂ deficiency).
Vitamin B₁₂ (cobalamin) deficiency	Causes: pernicious anemia, malabsorption (eg, Crohn disease), pancreatic insufficiency, gastrectomy, insufficient intake (eg, veganism), <i>Diphyllobothrium latum</i> (fish tapeworm).	↑ homocysteine, ↑ methylmalonic acid. Neurologic symptoms: reversible dementia, subacute combined degeneration (due to involvement of B ₁₂ in fatty acid pathways and myelin synthesis): spinocerebellar tract, lateral corticospinal tract, dorsal column dysfunction. Folate supplementation in vitamin B ₁₂ deficiency can correct the anemia, but worsens neurologic symptoms. Historically diagnosed with the Schilling test, a test that determines if the cause is dietary insufficiency vs malabsorption. Anemia 2° to insufficient intake may take several years to develop due to liver's ability to store B ₁₂ (vs folate deficiency, which takes weeks to months).
Orotic aciduria	Inability to convert orotic acid to UMP (de novo pyrimidine synthesis pathway) because of defect in UMP synthase. Autosomal recessive. Presents in children as failure to thrive, developmental delay, and megaloblastic anemia refractory to folate and B ₁₂ . No hyperammonemia (vs ornithine transcarbamylase deficiency—↑ orotic acid with hyperammonemia).	Orotic acid in urine. Treatment: uridine monophosphate or uridine triacetate to bypass mutated enzyme.
Nonmegaloblastic anemia	Macrocytic anemia in which DNA synthesis is normal. Causes: chronic alcohol overuse, liver disease.	RBC macrocytosis without hypersegmented neutrophils.
Diamond-Blackfan anemia	A congenital form of pure red cell aplasia (vs Fanconi anemia, which causes pancytopenia). Rapid-onset anemia within 1st year of life due to intrinsic defect in erythroid progenitor cells.	↑ % HbF (but ↓ total Hb). Short stature, craniofacial abnormalities, and upper extremity malformations (triphalangal thumbs) in up to 50% of cases.

Normocytic, normochromic anemias

Normocytic, normochromic anemias are classified as nonhemolytic or hemolytic. The hemolytic anemias are further classified according to the cause of the hemolysis (intrinsic vs extrinsic to the RBC) and by the location of hemolysis (intravascular vs extravascular). Hemolysis can lead to ↑ in LDH, reticulocytes, unconjugated bilirubin, pigmented gallstones, and urobilinogen in urine.

Intravascular hemolysis

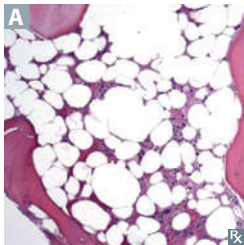
Findings: ↓ haptoglobin, ↑ schistocytes on blood smear. Characteristic hemoglobinuria, hemosiderinuria, and urobilinogen in urine. Notable causes are mechanical hemolysis (eg, prosthetic valve), paroxysmal nocturnal hemoglobinuria, microangiopathic hemolytic anemias.

Extravascular hemolysis

Mechanism: macrophages in spleen clear RBCs. Findings: splenomegaly, spherocytes in peripheral smear (most commonly due to hereditary spherocytosis and autoimmune hemolytic anemia), no hemoglobinuria/hemosiderinuria. Can present with urobilinogen in urine.

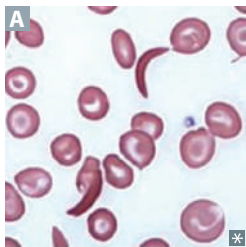
Nonhemolytic, normocytic anemias

	DESCRIPTION	FINDINGS
Anemia of chronic disease	Inflammation (eg, ↑ IL-6) → ↑ hepcidin (released by liver, binds ferroportin on intestinal mucosal cells and macrophages, thus inhibiting iron transport) → ↓ release of iron from macrophages and ↓ iron absorption from gut. Associated with conditions such as chronic infections, neoplastic disorders, chronic kidney disease, and autoimmune diseases (eg, SLE, rheumatoid arthritis).	↓ iron, ↓ TIBC, ↑ ferritin. Normocytic, but can become microcytic. Treatment: address underlying cause of inflammation, judicious use of blood transfusion, consider erythropoiesis-stimulating agents such as EPO (eg, in chronic kidney disease).
Aplastic anemia	Failure or destruction of hematopoietic stem cells. Causes (reducing volume from inside diaphysis): <ul style="list-style-type: none"> ▪ Radiation ▪ Viral agents (eg, EBV, HIV, hepatitis viruses) ▪ Fanconi anemia (autosomal recessive DNA repair defect → bone marrow failure); normocytosis or macrocytosis on CBC ▪ Idiopathic (immune mediated, 1° stem cell defect); may follow acute hepatitis ▪ Drugs (eg, benzene, chloramphenicol, alkylating agents, antimetabolites) 	↓ reticulocyte count, ↑ EPO. Pancytopenia characterized by anemia, leukopenia, and thrombocytopenia (vs aplastic crisis, which causes anemia only). Normal cell morphology, but hypocellular bone marrow with fatty infiltration A . Symptoms: fatigue, malaise, pallor, purpura, mucosal bleeding, petechiae, infection. Treatment: withdrawal of offending agent, immunosuppressive regimens (eg, antithymocyte globulin, cyclosporine), bone marrow allograft, RBC/platelet transfusion, bone marrow stimulation (eg, GM-CSF).

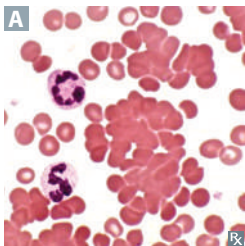


Intrinsic hemolytic anemias

	DESCRIPTION	FINDINGS
Hereditary spherocytosis	<p>Primarily autosomal dominant. Due to defect in proteins interacting with RBC membrane skeleton and plasma membrane (eg, ankyrin, band 3, protein 4.2, spectrin).</p> <p>Small, round RBCs with no central pallor. ↓ surface area/dehydration → ↑ MCHC → premature removal by spleen (extravascular hemolysis).</p>	<p>Splenomegaly, pigmented gallstones, aplastic crisis (parvovirus B19 infection).</p> <p>Labs: ↓ mean fluorescence of RBCs in eosin 5-maleimide (EMA) binding test, ↑ fragility in osmotic fragility test (RBC hemolysis with exposure to hypotonic solution). Normal to ↓ MCV with abundance of RBCs.</p> <p>Treatment: splenectomy.</p>
Paroxysmal nocturnal hemoglobinuria	<p>Hematopoietic stem cell mutation → ↑ complement-mediated intravascular hemolysis, especially at night. Acquired PIGA mutation → impaired GPI anchor synthesis for decay-accelerating factor (DAF/CD55) and membrane inhibitor of reactive lysis (MIRL/CD59), which protect RBC membrane from complement.</p>	<p>Triad: Coombs ⊖ hemolytic anemia (mainly intravascular), pancytopenia, venous thrombosis (eg, Budd-Chiari syndrome).</p> <p>Pink/red urine in morning. Associated with aplastic anemia, acute leukemias.</p> <p>Labs: CD55/59 ⊖ RBCs on flow cytometry.</p> <p>Treatment: eculizumab (targets terminal complement protein C5).</p>
G6PD deficiency	<p>X-linked recessive. G6PD defect → ↓ NADPH → ↓ reduced glutathione → ↑ RBC susceptibility to oxidative stress (eg, sulfa drugs, antimalarials, fava beans) → hemolysis.</p> <p>Causes extravascular and intravascular hemolysis.</p>	<p>Back pain, hemoglobinuria a few days after oxidant stress.</p> <p>Labs: ↓ G6PD activity (may be falsely normal during acute hemolysis), blood smear shows RBCs with Heinz bodies and bite cells.</p> <p>“Stress makes me eat bites of fava beans with Heinz ketchup.”</p>
Pyruvate kinase deficiency	<p>Autosomal recessive. Pyruvate kinase defect → ↓ ATP → rigid RBCs → extravascular hemolysis. Increases levels of 2,3-BPG → ↓ hemoglobin affinity for O₂.</p>	<p>Hemolytic anemia in a newborn.</p> <p>Labs: blood smear shows burr cells.</p>
Sickle cell anemia	<p>Point mutation in β-globin gene → single amino acid substitution (glutamic acid → valine). Mutant HbA is termed HbS. Causes extravascular and intravascular hemolysis.</p> <p>Pathogenesis: low O₂, high altitude, or acidosis precipitates sickling (deoxygenated HbS polymerizes) → anemia, vaso-occlusive disease. Newborns are initially asymptomatic because of ↑ HbF and ↓ HbS.</p> <p>Heterozygotes (sickle cell trait) have resistance to malaria.</p> <p>Sickle cells are crescent-shaped RBCs A.</p> <p>“Crew cut” on skull x-ray due to marrow expansion from ↑ erythropoiesis (also seen in thalassemias).</p>	<p>Complications:</p> <ul style="list-style-type: none"> ▪ Aplastic crisis (transient arrest of erythropoiesis due to parvovirus B19). ▪ Autosplenectomy (Howell-Jolly bodies) → ↑ risk of infection by encapsulated organisms (eg, <i>S pneumoniae</i>). ▪ Splenic infarct/sequestration crisis. ▪ <i>Salmonella</i> osteomyelitis. ▪ Painful vaso-occlusive crises: dactylitis (painful swelling of hands/feet), priapism, acute chest syndrome (respiratory distress, new pulmonary infiltrates on CXR, common cause of death), avascular necrosis, stroke. ▪ Sickling in renal medulla (↓ Po₂) → renal papillary necrosis → hematuria. <p>Hb electrophoresis: ↓↓ HbA, ↑ HbF, ↑↑ HbS.</p> <p>Treatment: hydroxyurea (↑ HbF), hydration.</p>
HbC disease	<p>Glutamic acid-to-lycine (lysine) mutation in β-globin. Causes extravascular hemolysis.</p>	<p>HbSC (1 of each mutant gene) milder than HbSS.</p> <p>Blood smear in homozygotes: hemoglobin c crystals inside RBCs, target cells.</p>



Extrinsic hemolytic anemias

	DESCRIPTION	FINDINGS
Autoimmune hemolytic anemia 	<p>A normocytic anemia that is usually idiopathic and Coombs ⊕. Two types:</p> <ul style="list-style-type: none"> ▪ Warm AIHA—chronic anemia in which primarily IgG causes extravascular hemolysis. Seen in SLE and CLL and with certain drugs (eg, β-lactams, α-methyl dopa). “Warm weather is Good.” ▪ Cold AIHA—acute anemia in which primarily IgM + complement cause RBC agglutination and extravascular hemolysis upon exposure to cold → painful, blue fingers and toes. Seen in CLL, <i>Mycoplasma pneumoniae</i> infections, infectious mononucleosis. 	<p>Spherocytes and agglutinated RBCs A on peripheral blood smear.</p> <p>Warm AIHA treatment: steroids, rituximab, splenectomy (if refractory).</p> <p>Cold AIHA treatment: cold avoidance, rituximab.</p>
Microangiopathic hemolytic anemia	<p>RBCs are damaged when passing through obstructed or narrowed vessels. Causes intravascular hemolysis.</p> <p>Seen in DIC, TTP/HUS, SLE, HELLP syndrome, hypertensive emergency.</p>	<p>Schistocytes (eg, “helmet cells”) are seen on peripheral blood smear due to mechanical destruction (<i>schisto</i> = to split) of RBCs.</p>
Macroangiopathic hemolytic anemia	<p>Prosthetic heart valves and aortic stenosis may also cause hemolytic anemia 2° to mechanical destruction of RBCs.</p>	<p>Schistocytes on peripheral blood smear.</p>
Hemolytic anemia due to infection	<p>↑ destruction of RBCs (eg, malaria, <i>Babesia</i>).</p>	

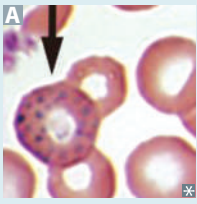

Leukopenias

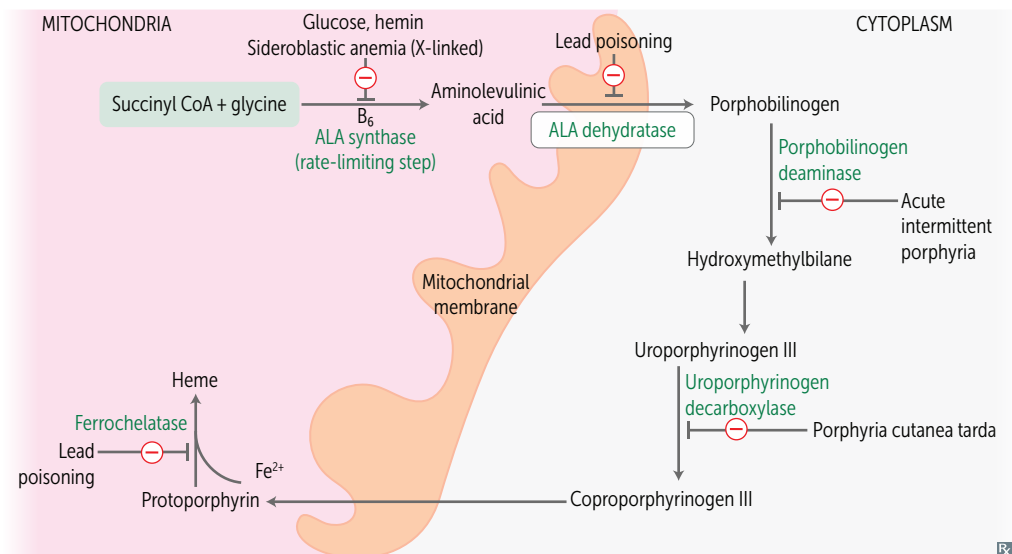
CELL TYPE	CELL COUNT	CAUSES
Neutropenia	Absolute neutrophil count < 1500 cells/mm ³ Severe infections typical when < 500 cells/mm ³	Sepsis/postinfection, drugs (including chemotherapy), aplastic anemia, SLE, radiation, congenital
Lymphopenia	Absolute lymphocyte count < 1500 cells/mm ³ (< 3000 cells/mm ³ in children)	HIV, DiGeorge syndrome, SCID, SLE, glucocorticoids ^a , radiation, sepsis, postoperative
Eosinopenia	Absolute eosinophil count < 30 cells/mm ³	Cushing syndrome, glucocorticoids ^a

^aGlucocorticoids cause neutrophilia, despite causing eosinopenia and lymphopenia. Glucocorticoids ↓ activation of neutrophil adhesion molecules, impairing migration out of the vasculature to sites of inflammation. In contrast, glucocorticoids sequester eosinophils in lymph nodes and cause apoptosis of lymphocytes.

Heme synthesis, porphyrias, and lead poisoning

The porphyrias are hereditary or acquired conditions of defective heme synthesis that lead to the accumulation of heme precursors. Lead inhibits specific enzymes needed in heme synthesis, leading to a similar condition.

CONDITION	AFFECTED ENZYME	ACCUMULATED SUBSTRATE	PRESENTING SYMPTOMS
Lead poisoning 	Ferrochelatase and ALA dehydratase	Protoporphyrin, ALA (blood)	Microcytic anemia (basophilic stippling in peripheral smear A), ringed sideroblasts in bone marrow), GI and kidney disease. Children—exposure to lead paint → mental deterioration. Adults—environmental exposure (eg, batteries, ammunition) → headache, memory loss, demyelination (peripheral neuropathy).
Acute intermittent porphyria	Porphobilinogen deaminase (autosomal dominant mutation)	Porphobilinogen, ALA	Symptoms (5 P 's): <ul style="list-style-type: none"> ▪ Painful abdomen ▪ Port wine-colored Pee ▪ Polyneuropathy ▪ Psychological disturbances ▪ Precipitated by factors that ↑ ALA synthase (eg, drugs [CYP450 inducers], alcohol, starvation) Treatment: hemin and glucose.
Porphyria cutanea tarda 	Uroporphyrinogen decarboxylase	Uroporphyrin (tea-colored urine)	Blistering cutaneous photosensitivity and hyperpigmentation B . Most common porphyria. Exacerbated with alcohol consumption. Causes: familial, hepatitis C . Treatment: phlebotomy, sun avoidance, antimalarials (eg, hydroxychloroquine).



Iron poisoning

	Acute	Chronic
FINDINGS	High mortality rate associated with accidental ingestion by children (adult iron tablets may look like candy).	Seen in patients with 1° (hereditary) or 2° (eg, chronic blood transfusions for thalassemia or sickle cell disease) hemochromatosis.
MECHANISM	Cell death due to formation of free radicals and peroxidation of membrane lipids.	
SYMPTOMS/SIGNS	Abdominal pain, vomiting, GI bleeding. Radiopaque pill seen on x-ray. May progress to anion gap metabolic acidosis and multiorgan failure. Leads to scarring with GI obstruction.	Arthropathy, cirrhosis, cardiomyopathy, diabetes mellitus and skin pigmentation (“bronze diabetes”), hypogonadism.
TREATMENT	Chelation (eg, deferoxamine, deferasirox), gastric lavage.	Phlebotomy (patients without anemia) or chelation.

Coagulation disorders

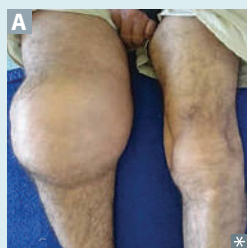PT—tests function of common and extrinsic pathway (factors I, II, V, VII, and X). Defect → ↑ **PT** (Play **Tennis outside [extrinsic pathway]**).

INR (international normalized ratio) = patient PT/control PT. 1 = normal, > 1 = prolonged. Most common test used to follow patients on warfarin, which prolongs INR.

PTT—tests function of common and **intrinsic** pathway (all factors except VII and XIII). Defect → ↑ **PTT** (Play **Table Tennis inside**).

Coagulation disorders can be due to clotting factor deficiencies or acquired factor inhibitors (most commonly against factor VIII). Diagnosed with a mixing study, in which normal plasma is added to patient’s plasma. Clotting factor deficiencies should correct (the PT or PTT returns to within the appropriate normal range), whereas factor inhibitors will not correct.

DISORDER	PT	PTT	MECHANISM AND COMMENTS
Hemophilia A, B, or C	—	↑	<p>Intrinsic pathway coagulation defect (↑ PTT).</p> <ul style="list-style-type: none"> ▪ A: deficiency of factor VIII; X-linked recessive. Pronounce “hemophilia eight.” ▪ B: deficiency of factor IX; X-linked recessive. ▪ C: deficiency of factor XI; autosomal recessive. <p>Hemorrhage in hemophilia—hemarthroses (bleeding into joints, eg, knee A), easy bruising, bleeding after trauma or surgery (eg, dental procedures). Treatment: desmopressin, factor VIII concentrate, emicizumab (A); factor IX concentrate (B); factor XI concentrate (C).</p>
Vitamin K deficiency	↑	↑	<p>General coagulation defect. Bleeding time normal. ↓ activity of factors II, VII, IX, X, protein C, protein S.</p>



Platelet disorders

All platelet disorders have ↑ bleeding time (BT), mucous membrane bleeding, and microhemorrhages (eg, petechiae, epistaxis). Platelet count (PC) is usually low, but may be normal in qualitative disorders.

DISORDER	PC	BT	NOTES
Bernard-Soulier syndrome	–/↓	↑	Autosomal recessive defect in adhesion. ↓ GpIb → ↓ platelet-to-vWF adhesion. Labs: abnormal ristocetin test, B ig platelets.
Glanzmann thrombasthenia	–	↑	Autosomal recessive defect in aggregation. ↓ GpIIb/IIIa (↓ integrin $\alpha_{IIb}\beta_3$) → ↓ platelet-to-platelet aggregation and defective platelet plug formation. Labs: blood smear shows no platelet clumping.
Immune thrombocytopenia	↓	↑	Destruction of platelets in spleen. Anti-GpIIb/IIIa antibodies → splenic macrophages phagocytose platelets. May be idiopathic or 2° to autoimmune disorders (eg, SLE), viral illness (eg, HIV, HCV), malignancy (eg, CLL), or drug reactions. Labs: ↑ megakaryocytes on bone marrow biopsy, ↓ platelet count. Treatment: glucocorticoids, IVIG, rituximab, TPO receptor agonists (eg, eltrombopag, romiplostim), or splenectomy for refractory ITP.
Uremic platelet dysfunction	–	↑	In patients with renal failure, uremic toxins accumulate and interfere with platelet adhesion.

Thrombotic microangiopathies

Disorders overlap significantly in symptomatology. May resemble DIC, but do not exhibit lab findings of a consumptive coagulopathy (eg, ↑ PT, ↑ PTT, ↓ fibrinogen), as etiology does not involve widespread clotting factor activation.

	Thrombotic thrombocytopenic purpura	Hemolytic-uremic syndrome
EPIDEMIOLOGY	Typically females	Typically children
PATHOPHYSIOLOGY	Inhibition or deficiency of ADAMTS13 (a vWF metalloprotease) → ↓ degradation of vWF multimers → ↑ large vWF multimers → ↑ platelet adhesion and aggregation (microthrombi formation)	Predominately caused by Shiga toxin–producing <i>Escherichia coli</i> (STEC) infection (serotype O157:H7), which causes profound endothelial dysfunction.
PRESENTATION	Triad of thrombocytopenia (↓ platelets), microangiopathic hemolytic anemia (↓ Hb, schistocytes, ↑ LDH), acute kidney injury (↑ Cr)	
DIFFERENTIATING SYMPTOMS	Triad + fever + neurologic symptoms	Triad + bloody diarrhea
LABS	Normal PT and PTT helps distinguish TTP and HUS (coagulation pathway is not activated) from DIC (coagulation pathway is activated)	
TREATMENT	Plasma exchange, glucocorticoids, rituximab	Supportive care

Mixed platelet and coagulation disorders

DISORDER	PC	BT	PT	PTT	NOTES
von Willebrand disease	—	↑	—	—/↑	Intrinsic pathway coagulation defect: ↓ vWF → ↑ PTT (vWF carries/protects factor VIII). Defect in platelet plug formation: ↓ vWF → defect in platelet-to-vWF adhesion. Most are autosomal dominant. Mild but most common inherited bleeding disorder. No platelet aggregation with ristocetin cofactor assay. Treatment: desmopressin, which releases vWF stored in endothelium.
Disseminated intravascular coagulation	↓	↑	↑	↑	Widespread clotting factor activation → thromboembolic state with excessive clotting factor consumption → ↑ thromboses, ↑ hemorrhages (eg, blood oozing from puncture sites). May be acute (life-threatening) or chronic (if clotting factor production can compensate for consumption). Causes: heat S troke, S nake bites, S epsis (gram ⊖), T rauma, O bstetric complications, acute P ancreatitis, m alignancy, n ephrotic syndrome, t ransfusion (SSSTOP making n ew thrombi). Labs: schistocytes, ↑ fibrin degradation products (D-dimers), ↓ fibrinogen, ↓ factors V and VIII.

Hereditary thrombophilias Autosomal dominant disorders resulting in hypercoagulable state (↑ tendency to develop thrombosis).

DISEASE	DESCRIPTION
Antithrombin deficiency	Has no direct effect on the PT, PTT, or thrombin time but diminishes the increase in PTT following standard heparin dosing. Can also be acquired: renal failure/nephrotic syndrome → antithrombin loss in urine → ↓ inhibition of factors IIa and Xa.
Factor V Leiden	Production of mutant factor V (guanine → adenine DNA point mutation → Arg506Gln mutation near the cleavage site) that is resistant to degradation by activated protein C. Complications include DVT, cerebral vein thrombosis, recurrent pregnancy loss.
Protein C or S deficiency	↓ ability to inactivate factors Va and VIIIa. ↑ risk of warfarin-induced skin necrosis. Together, protein C Cancels, and protein S Stops, coagulation.
Prothrombin G20210A mutation	Point mutation in 3' untranslated region → ↑ production of prothrombin → ↑ plasma levels and venous clots.

Blood transfusion therapy

COMPONENT	DOSAGE EFFECT	CLINICAL USE
Packed RBCs	↑ Hb and O ₂ binding (carrying) capacity	Acute blood loss, severe anemia
Platelets	↑ platelet count (↑ ~ 5000/mm ³ /unit)	Stop significant bleeding (thrombocytopenia, qualitative platelet defects)
Fresh frozen plasma/ prothrombin complex concentrate	↑ coagulation factor levels; FFP contains all coagulation factors and plasma proteins; PCC generally contains factors II, VII, IX, and X, as well as protein C and S	Cirrhosis, immediate anticoagulation reversal
Cryoprecipitate	Contains fibrinogen, factor VIII, factor XIII, vWF, and fibronectin	Coagulation factor deficiencies involving fibrinogen and factor VIII
Albumin	↑ intravascular volume and oncotic pressure	Post-paracentesis, therapeutic plasmapheresis

Blood transfusion risks include infection transmission (low), transfusion reactions, iron overload (may lead to 2° hemochromatosis), hypocalcemia (citrate is a Ca²⁺ chelator), and hyperkalemia (RBCs may lyse in old blood units).

Leukemia vs lymphoma

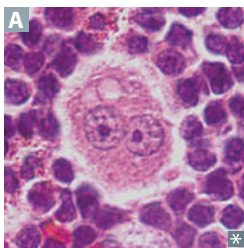
Leukemia	Lymphoid or myeloid neoplasm with widespread involvement of bone marrow. Tumor cells are usually found in peripheral blood.
Lymphoma	Discrete tumor mass arising from lymph nodes. Variable clinical presentation (eg, arising in atypical sites, leukemic presentation).

Hodgkin vs non-Hodgkin lymphoma**Hodgkin****Non-Hodgkin**

Both may have constitutional (“B”) signs/symptoms: low-grade fever, night sweats, weight loss.	
Localized, single group of nodes with contiguous spread (stage is strongest predictor of prognosis). Better prognosis.	Multiple lymph nodes involved; extranodal involvement common; noncontiguous spread. Worse prognosis.
Characterized by Reed-Sternberg cells.	Majority involve B cells; rarely of T-cell lineage.
Bimodal distribution: young adults, > 55 years.	Can occur in children and adults.
Associated with EBV.	May be associated with autoimmune diseases and viral infections (eg, HIV, EBV, HTLV).

Hodgkin lymphoma

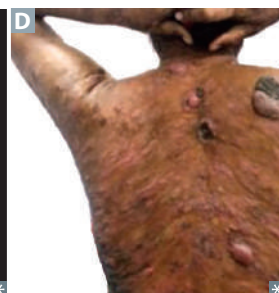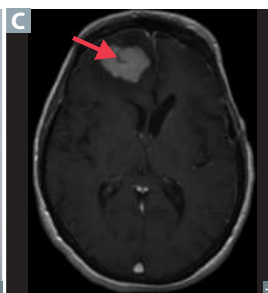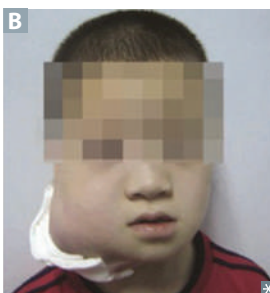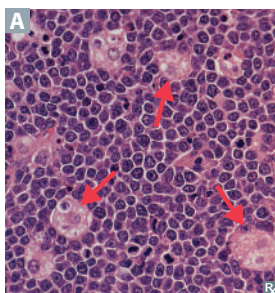
Contains Reed-Sternberg cells: distinctive tumor giant cells; bilobed nucleus with the 2 halves as mirror images (“owl eyes” **A**). RS cells are CD15+ and CD30+ B-cell origin. 2 owl eyes × 15 = 30.

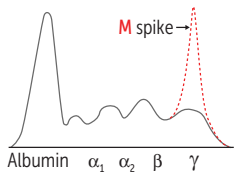


SUBTYPE	NOTES
Nodular sclerosis	Most common
Mixed cellularity	Eosinophilia; seen in immunocompromised patients
Lymphocyte rich	Best prognosis (the rich have better bank accounts)
Lymphocyte depleted	Worst prognosis (the poor have worse bank accounts); seen in immunocompromised patients

Non-Hodgkin lymphoma

TYPE	OCCURS IN	GENETICS	COMMENTS
Neoplasms of mature B cells			
Burkitt lymphoma	Adolescents or young adults	t(8;14)—translocation of <i>c-myc</i> (8) and heavy-chain Ig (14)	“ Starry sky ” appearance (StarBurst), sheets of lymphocytes with interspersed “tingible body” macrophages (arrows in A). Associated with EBV. Jaw lesion B in endemic form in Africa; pelvis or abdomen in sporadic form.
Diffuse large B-cell lymphoma	Usually older adults, but 20% in children	Mutations in <i>BCL-2</i> , <i>BCL-6</i>	Most common type of non-Hodgkin lymphoma in adults.
Follicular lymphoma	Adults	t(14;18)—translocation of heavy-chain Ig (14) and <i>BCL-2</i> (18)	Indolent course with painless “waxing and waning” lymphadenopathy. Bcl-2 normally inhibits apoptosis.
Mantle cell lymphoma	Adult males >> adult females	t(11;14)—translocation of cyclin D1 (11) and heavy-chain Ig (14), CD5+	Very aggressive, patients typically present with late-stage disease.
Marginal zone lymphoma	Adults	t(11;18)	Associated with chronic inflammation (eg, Sjögren syndrome, chronic gastritis [MALT lymphoma; may regress with <i>H pylori</i> eradication]).
Primary central nervous system lymphoma	Adults	EBV related; associated with HIV/AIDS	Considered an AIDS-defining illness. Variable presentation: confusion, memory loss, seizures. CNS mass (often single, ring-enhancing lesion on MRI) in immunocompromised patients C , needs to be distinguished from toxoplasmosis via CSF analysis or other lab tests.
Neoplasms of mature T cells			
Adult T-cell lymphoma	Adults	Caused by HTLV (associated with IV drug use)	Adults present with cutaneous lesions; common in Japan (T -cell in T okyo), West Africa, and the Caribbean. Lytic bone lesions, hypercalcemia.
Mycosis fungoides/Sézary syndrome	Adults		Mycosis fungoides: skin patches and plaques D (cutaneous T-cell lymphoma), characterized by atypical CD4+ cells with “cerebriform” nuclei and intraepidermal neoplastic cell aggregates (Pautrier microabscess). May progress to Sézary syndrome (T-cell leukemia).



Plasma cell disorders

Characterized by monoclonal immunoglobulin (paraprotein) overproduction due to plasma cell disorder.

Labs: serum protein electrophoresis (SPEP) or free light chain (FLC) assay for initial tests (M spike on SPEP represents overproduction of a monoclonal Ig fragment). For urinalysis, use 24-hr urine protein electrophoresis (UPEP) to detect light chain, as routine urine dipstick detects only albumin.

Confirm with bone marrow biopsy.

Multiple myeloma

Overproduction of IgG (55% of cases) > IgA.

Clinical features: **CRAB**

- **H**yper**C**alcemia (\uparrow secretion of cytokines [eg, IL-1, TNF- α , RANK-L] by malignant plasma cells \rightarrow \uparrow osteoclast activity)
- **R**enal involvement
- **A**nemia
- **B**one lytic lesions (“punched out” on X-ray **A**) \rightarrow back pain.

Peripheral blood smear shows rouleaux formation **B** (RBCs stacked like poker chips).

Urinalysis shows Ig light chains (Bence Jones proteinuria) with \ominus urine dipstick.

Bone marrow analysis shows > 10% monoclonal plasma cells with clock-face chromatin **C** and intracytoplasmic inclusions containing IgG.

Complications: \uparrow infection risk, 1 $^\circ$ amyloidosis (AL).

Waldenstrom macroglobulinemia

Overproduction of IgM (**macro**globulinemia because IgM is the **largest** Ig).

Clinical features:

- Peripheral neuropathy
- No CRAB findings
- Hyperviscosity syndrome:
 - Headache
 - Blurry vision
 - Raynaud phenomenon
 - Retinal hemorrhages

Bone marrow analysis shows > 10% small lymphocytes with intranuclear pseudoinclusions containing IgM (lymphoplasmacytic lymphoma).

Complication: thrombosis.

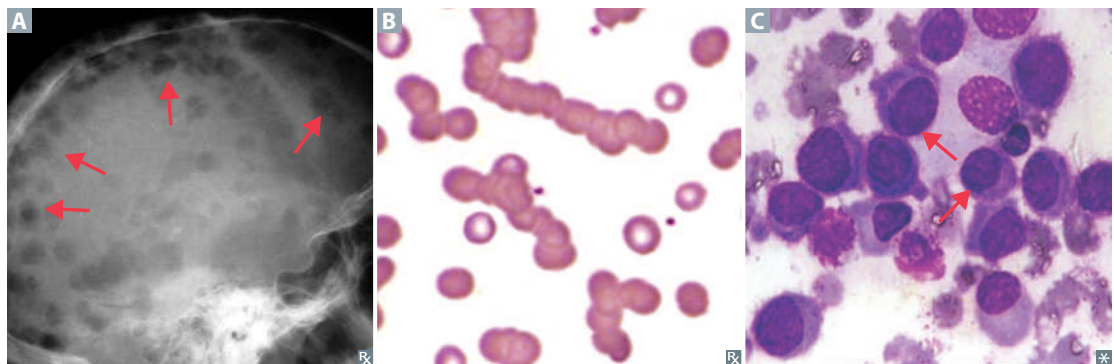
Monoclonal gammopathy of undetermined significance

Overproduction of any Ig type.

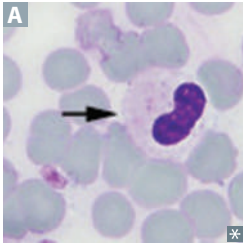
Usually asymptomatic. No CRAB findings.

Bone marrow analysis shows < 10% monoclonal plasma cells.

Complication: 1–2% risk per year of transitioning to multiple myeloma.



Myelodysplastic syndromes



Stem cell disorders involving ineffective hematopoiesis → defects in cell maturation of nonlymphoid lineages. Bone marrow blasts < 20% (vs > 20% in AML). Caused by de novo mutations or environmental exposure (eg, radiation, benzene, chemotherapy). Risk of transformation to AML. More common in older adults.

Pseudo-Pelger-Huët anomaly—neutrophils with bilobed (“duet”) nuclei **A**. Associated with myelodysplastic syndromes or drugs (eg, immunosuppressants).

Leukemias

Unregulated growth and differentiation of WBCs in bone marrow → marrow failure → anemia (↓ RBCs), infections (↓ mature WBCs), and hemorrhage (↓ platelets). Usually presents with ↑ circulating WBCs (malignant leukocytes in blood), although some cases present with normal/↓ WBCs.

Leukemic cell infiltration of liver, spleen, lymph nodes, and skin (leukemia cutis) possible.

TYPE	NOTES
------	-------

Lymphoid neoplasms**Acute lymphoblastic leukemia/lymphoma**

Most frequently occurs in children; less common in adults (worse prognosis). T-cell ALL can present as mediastinal mass (presenting as SVC-like syndrome). Associated with Down syndrome. Peripheral blood and bone marrow have ↑↑↑ lymphoblasts **A**.

TdT+ (marker of pre-T and pre-B cells), CD10+ (marker of pre-B cells).

Most responsive to therapy.

May spread to CNS and testes.

t(12;21) → better prognosis; t(9;22) (Philadelphia chromosome) → worse prognosis.

Chronic lymphocytic leukemia/small lymphocytic lymphoma

Age > 60 years. Most common adult leukemia. CD20+, CD23+, CD5+ B-cell neoplasm. Often asymptomatic, progresses slowly; smudge cells **B** in peripheral blood smear; autoimmune hemolytic anemia. **CLL = Crushed Little Lymphocytes** (smudge cells).

Richter transformation—CLL/SLL transformation into an aggressive lymphoma, most commonly diffuse large B-cell lymphoma (DLBCL).

Hairy cell leukemia

Adult males. Mature B-cell tumor. Cells have filamentous, hairlike projections (fuzzy appearing on LM **C**). Peripheral lymphadenopathy is uncommon.

Causes marrow fibrosis → dry tap on aspiration. Patients usually present with massive splenomegaly and pancytopenia.

Stains **TRAP** (Tartrate-Resistant Acid Phosphatase) ⊕ (**TRAP**ped in a **hairy** situation). TRAP stain largely replaced with flow cytometry. Associated with *BRAF* mutations.

Treatment: purine analogs (cladribine, pentostatin).

Myeloid neoplasms**Acute myelogenous leukemia**

Median onset 65 years. Auer rods **D**; myeloperoxidase ⊕ cytoplasmic inclusions seen mostly in APL (formerly M3 AML); ↑↑↑ circulating myeloblasts on peripheral smear. May present with leukostasis (capillary occlusion by malignant, nondistensible cells → organ damage).

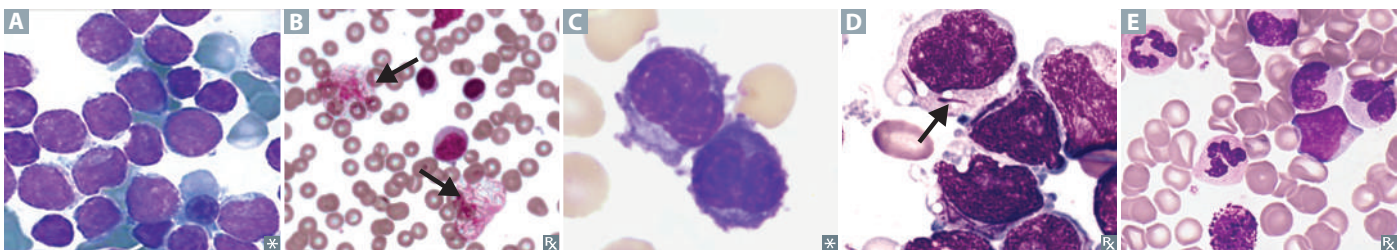
Risk factors: prior exposure to alkylating chemotherapy, radiation, benzene, myeloproliferative disorders, Down syndrome (typically acute megakaryoblastic leukemia [formerly M7 AML]).

APL: t(15;17), responds to all-*trans* retinoic acid (vitamin A) and arsenic trioxide, which induce differentiation of promyelocytes; DIC is a common presentation.

Chronic myelogenous leukemia

Peak incidence: 45–85 years; median age: 64 years. Defined by the Philadelphia chromosome (t[9;22], *BCR-ABL*) and myeloid stem cell proliferation. Presents with dysregulated production of mature and maturing granulocytes (eg, neutrophils, metamyelocytes, myelocytes, basophils **E**) and splenomegaly. May accelerate and transform to AML or ALL (“blast crisis”).

Responds to *BCR-ABL* tyrosine kinase inhibitors (eg, imatinib).



Myeloproliferative neoplasms

Malignant hematopoietic neoplasms with varying impacts on WBCs and myeloid cell lines.

Polycythemia vera

Primary polycythemia. Disorder of ↑ RBCs, usually due to acquired JAK2 mutation. May present as intense itching after shower (aquagenic pruritus). Rare but classic symptom is erythromelalgia (severe, burning pain and red-blue coloration) due to episodic blood clots in vessels of the extremities **A**. Associated with hyperviscosity and thrombosis (eg, PE, DVT, Budd-Chiari syndrome).

↓ EPO (vs 2° polycythemia, which presents with endogenous or artificially ↑ EPO).

Treatment: phlebotomy, hydroxyurea, ruxolitinib (JAK1/2 inhibitor).

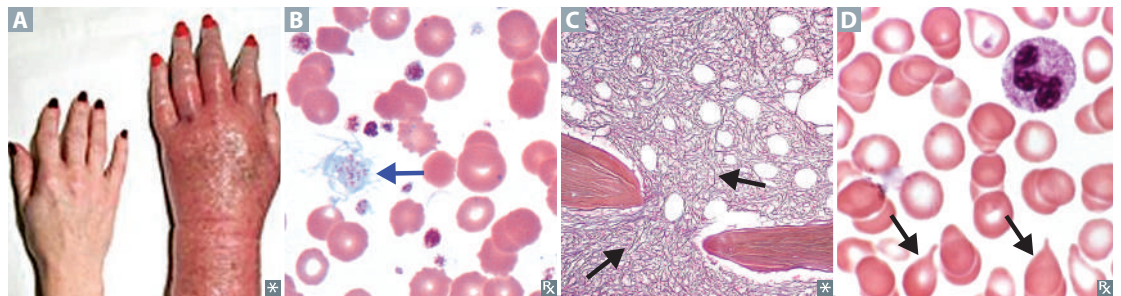
Essential thrombocythemia

Characterized by massive proliferation of megakaryocytes and platelets. Symptoms include bleeding and thrombosis. Blood smear shows markedly increased number of platelets, which may be large or otherwise abnormally formed **B**. Erythromelalgia may occur.

Myelofibrosis

Atypical megakaryocyte hyperplasia → ↑ TGF-β secretion → ↑ fibroblast activity → obliteration of bone marrow with fibrosis **C**. Associated with massive splenomegaly and “teardrop” RBCs **D**. “Bone marrow **cries** because it’s fibrosed and is a dry tap.”

	RBCs	WBCs	PLATELETS	PHILADELPHIA CHROMOSOME	JAK2 MUTATIONS
Polycythemia vera	↑	↑	↑	⊖	⊕
Essential thrombocythemia	—	—	↑	⊖	⊕ (30–50%)
Myelofibrosis	↓	Variable	Variable	⊖	⊕ (30–50%)
CML	↓	↑	↑	⊕	⊖



Leukemoid reaction vs chronic myelogenous leukemia

	Leukemoid reaction	Chronic myelogenous leukemia
DEFINITION	Reactive neutrophilia > 50,000 cells/mm ³	Myeloproliferative neoplasm ⊕ for BCR-ABL
NEUTROPHIL MORPHOLOGY	Toxic granulation, Döhle bodies, cytoplasmic vacuoles	Pseudo-Pelger-Huët anomaly
LAP SCORE	↑	↓ (LAP enzyme ↓ in malignant neutrophils)
EOSINOPHILS AND BASOPHILS	Normal	↑

Polycythemia

	PLASMA VOLUME	RBC MASS	O ₂ SATURATION	EPO LEVELS	ASSOCIATIONS
Relative	↓	–	–	–	Dehydration, burns.
Appropriate absolute	–	↑	↓	↑	Lung disease, congenital heart disease, high altitude, obstructive sleep apnea.
Inappropriate absolute	–	↑	–	↑	Exogenous EPO (athlete misuse, also called “blood doping”), androgen supplementation. Inappropriate EPO secretion: malignancy (eg, RCC, HCC).
Polycythemia vera	↑	↑↑	–	↓	EPO ↓ in PCV due to negative feedback suppressing renal EPO production.

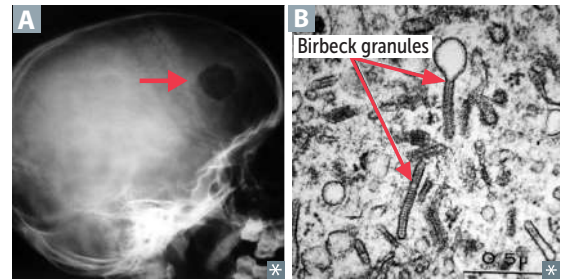
↑↓ = 1° disturbance

Chromosomal translocations

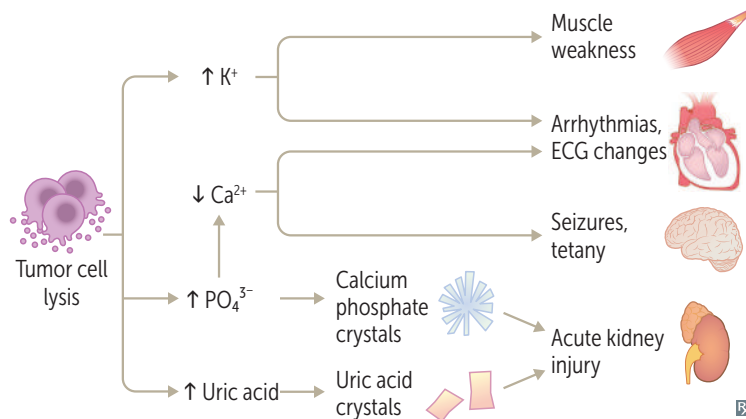
TRANSLOCATION	ASSOCIATED DISORDER	NOTES
t(8;14)	Burkitt (Burk-8) lymphoma (<i>c-myc</i> activation)	The Ig heavy chain genes on chromosome 14 are constitutively expressed. When other genes (eg, <i>c-myc</i> and <i>BCL-2</i>) are translocated next to this heavy chain gene region, they are overexpressed.
t(11;14)	Mantle cell lymphoma (cyclin D1 activation)	
t(11;18)	Marginal zone lymphoma	
t(14;18)	Follicular lymphoma (<i>BCL-2</i> activation)	
t(15;17)	APL (formerly M3 type of AML)	
t(9;22) (Philadelphia chromosome)	CML (<i>BCR-ABL</i> hybrid), ALL (less common); Philadelphia CreaML cheese	

Langerhans cell histiocytosis

Collective group of proliferative disorders of Langerhans cells (antigen-presenting cells normally found in the skin). Presents in a child as lytic bone lesions **A** and skin rash or as recurrent otitis media with a mass involving the mastoid bone. Cells are functionally immature and do not effectively stimulate primary T cells via antigen presentation. Cells express S-100 and CD1a. Birbeck granules (“tennis rackets” or rod shaped on EM) are characteristic **B**.



Tumor lysis syndrome



Oncologic emergency triggered by massive tumor cell lysis, seen most often with lymphomas/leukemias. Usually caused by treatment initiation, but can occur spontaneously with fast-growing cancers. Release of K⁺ → hyperkalemia, release of PO₄³⁻ → hyperphosphatemia, hypocalcemia due to Ca²⁺ sequestration by PO₄³⁻. ↑ nucleic acid breakdown → hyperuricemia → acute kidney injury. Prevention and treatment include aggressive hydration, allopurinol, rasburicase.

▶ HEMATOLOGY AND ONCOLOGY—PHARMACOLOGY

Heparin

MECHANISM	Activates antithrombin, which ↓ action primarily of factors IIa (thrombin) and Xa. Short half-life.
CLINICAL USE	Immediate anticoagulation for pulmonary embolism (PE), acute coronary syndrome, MI, deep venous thrombosis (DVT). Used during pregnancy (does not cross placenta). Monitor PTT.
ADVERSE EFFECTS	Bleeding (reverse with protamine sulfate), heparin-induced thrombocytopenia (HIT), osteoporosis (with long-term use), drug-drug interactions, type 4 renal tubular acidosis. <ul style="list-style-type: none"> ▪ HIT type 1—mild (platelets > 100,000/mm³), transient, nonimmunologic drop in platelet count that typically occurs within the first 2 days of heparin administration. Not clinically significant. ▪ HIT type 2—development of IgG antibodies against heparin-bound platelet factor 4 (PF4) that typically occurs 5–10 days after heparin administration. Antibody-heparin-PF4 complex binds and activates platelets → removal by splenic macrophages and thrombosis → ↓↓ platelet count. Highest risk with unfractionated heparin. Treatment: discontinue heparin, start alternative anticoagulant (eg, argatroban). Fondaparinux safe to use (does not interact with PF4).
NOTES	Low-molecular-weight heparins (eg, enoxaparin, dalteparin) act mainly on factor Xa. Fondaparinux acts only on factor Xa. Both are not easily reversible. Unfractionated heparin used in patients with renal insufficiency (low-molecular-weight heparins should be used with caution because they undergo renal clearance).

Warfarin

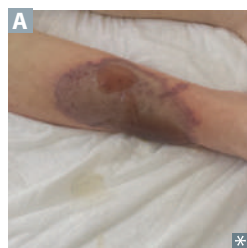MECHANISM

Inhibits vitamin K epoxide reductase by competing with vitamin K → inhibition of vitamin K–dependent γ -carboxylation of clotting factors II, VII, IX, and X and proteins C and S. Metabolism affected by polymorphisms in the gene for vitamin K epoxide reductase complex (*VKORC1*). In laboratory assay, has effect on **extrinsic** pathway and \uparrow **PT**. Long half-life.
“The **ex-President** went to **war**(farin).”

CLINICAL USE

Chronic anticoagulation (eg, venous thromboembolism prophylaxis and prevention of stroke in atrial fibrillation). Not used in pregnant patients (because warfarin, unlike heparin, crosses placenta). Monitor PT/INR.

ADVERSE EFFECTS



Bleeding, teratogenic effects, skin/tissue necrosis **A**, drug-drug interactions (metabolized by cytochrome P-450 [*CYP2C9*]).

Initial risk of hypercoagulation: protein C has shorter half-life than factors II and X. Existing protein C depletes before existing factors II and X deplete, and before warfarin can reduce factors II and X production → hypercoagulation. Skin/tissue necrosis within first few days of large doses believed to be due to small vessel microthrombosis.

Heparin “bridging”: heparin frequently used when starting warfarin. Heparin’s activation of antithrombin enables anticoagulation during initial, transient hypercoagulable state caused by warfarin. Initial heparin therapy reduces risk of recurrent venous thromboembolism and skin/tissue necrosis.

For reversal of warfarin, give vitamin K. For rapid reversal, give FFP or PCC.

Heparin vs warfarin

	Heparin	Warfarin
ROUTE OF ADMINISTRATION	Parenteral (IV, SC)	Oral
SITE OF ACTION	Blood	Liver
ONSET OF ACTION	Rapid (seconds)	Slow, limited by half-lives of normal clotting factors
DURATION OF ACTION	Hours	Days
MONITORING	PTT (intrinsic pathway)	PT/INR (extrinsic pathway)
CROSSES PLACENTA	No	Yes (teratogenic)

Direct coagulation factor inhibitors

DRUG	MECHANISM	CLINICAL USE	ADVERSE EFFECTS
Bivalirudin, argatroban, dabigatran	Directly inhibit thrombin (factor IIa)	Venous thromboembolism, atrial fibrillation. Can be used in HIT, when heparin is BAD for the patient	Bleeding (reverse dabigatran with idarucizumab) Dabigatran is the only oral agent in class Do not require lab monitoring
Apixaban, edoxaban, rivaroxaban	Directly inhibit factor Xa	Treatment and prophylaxis for DVT and PE; stroke prophylaxis in patients with atrial fibrillation	Bleeding (reverse with andexanet alfa) Oral agents that do not usually require lab monitoring

Anticoagulation reversal

ANTICOAGULANT	REVERSAL AGENT	NOTES
Heparin	Protamine sulfate	⊕ charged peptide that binds ⊖ charged heparin
Warfarin	Vitamin K (slow) +/- FFP or PCC (rapid)	
Dabigatran	Idarucizumab	Monoclonal antibody Fab fragments
Direct factor Xa inhibitors	Andexanet alfa	Recombinant modified factor Xa (inactive)

Antiplatelets

All work by ↓ platelet aggregation.

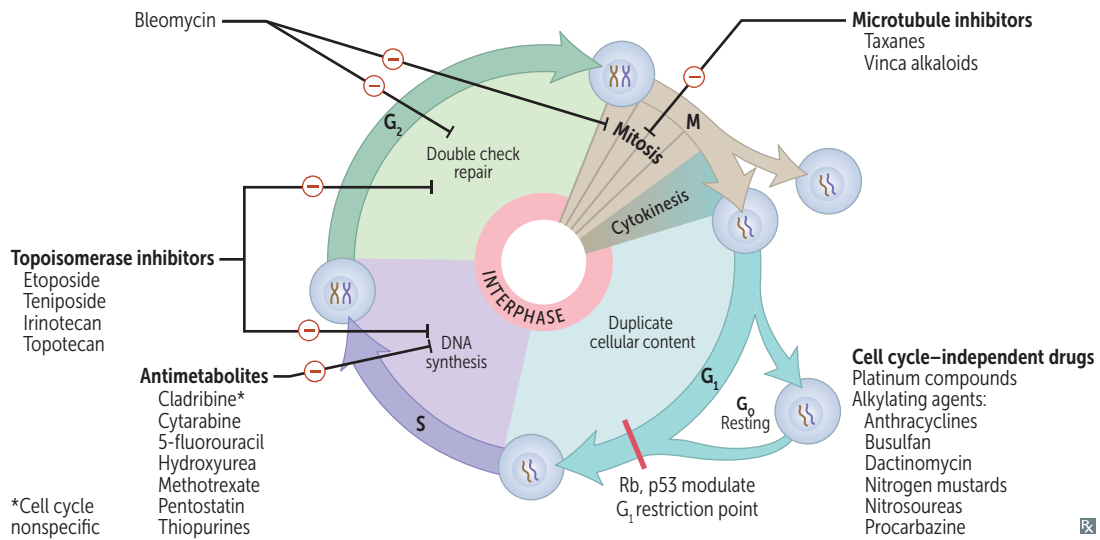
DRUG	MECHANISM	CLINICAL USE	ADVERSE EFFECTS
Aspirin	Irreversibly blocks COX → ↓ TXA ₂ release	Acute coronary syndrome; coronary stenting. ↓ incidence or recurrence of thrombotic stroke	Gastric ulcers, tinnitus, allergic reactions, renal injury
Clopidogrel, prasugrel, ticagrelor, ticlopidine	Block ADP (P2Y ₁₂) receptor → ↓ ADP-induced expression of GpIIb/IIIa	Same as aspirin; dual antiplatelet therapy	Neutropenia (ticlopidine); TTP may be seen
Abciximab, eptifibatide, tirofiban	Block GpIIb/IIIa (fib rinogen receptor) on activated platelets. Abciximab is made from monoclonal antibody Fab fragments	Unstable angina, percutaneous coronary intervention	Bleeding, thrombocytopenia
Cilostazol, dipyridamole	Block phosphodiesterase → ↓ cAMP hydrolysis → ↑ cAMP in platelets	Intermittent claudication, stroke prevention, cardiac stress testing, prevention of coronary stent restenosis	Nausea, headache, facial flushing, hypotension, abdominal pain

Thrombolytics

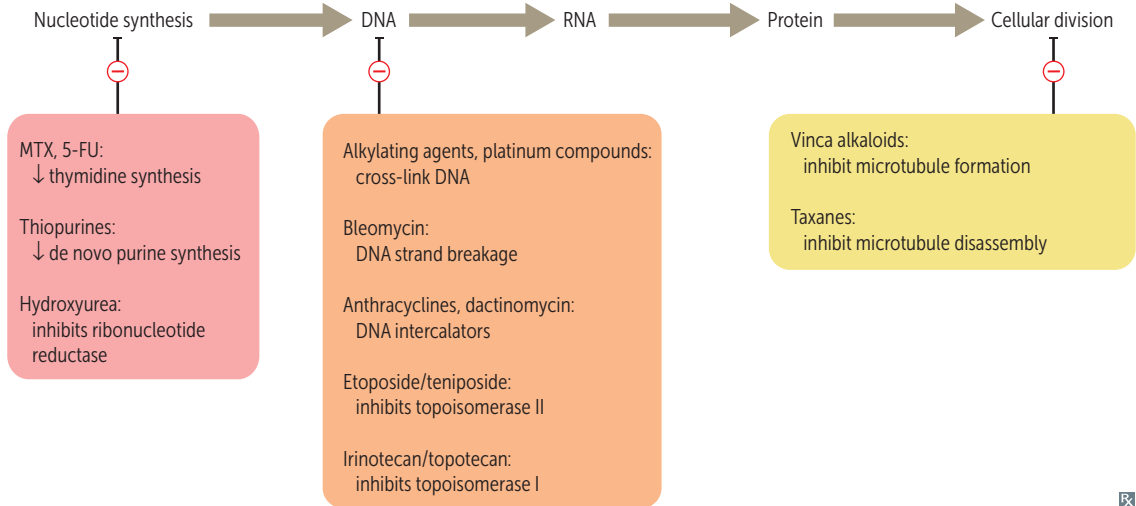
Alteplase (tPA), reteplase (rPA), streptokinase, tenecteplase (TNK-tPA).

MECHANISM	Directly or indirectly aid conversion of plasminogen to plasmin, which cleaves thrombin and fibrin clots. ↑ PT, ↑ PTT, no change in platelet count.
CLINICAL USE	Early MI, early ischemic stroke, direct thrombolysis of severe PE.
ADVERSE EFFECTS	Bleeding. Contraindicated in patients with active bleeding, history of intracranial bleeding, recent surgery, known bleeding diatheses, or severe hypertension. Nonspecific reversal with antifibrinolytics (eg, aminocaproic acid, tranexamic acid), platelet transfusions, and factor corrections (eg, cryoprecipitate, FFP, PCC).

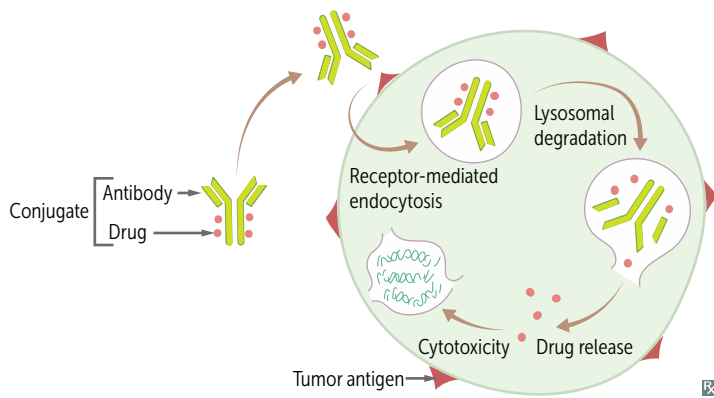
Cancer therapy—cell cycle



Cancer therapy—targets



Antibody-drug conjugates



Formed by linking monoclonal antibodies with cytotoxic chemotherapeutic drugs. Antibody selectivity against tumor antigens allows targeted drug delivery to tumor cells while sparing healthy cells → ↑ efficacy and ↓ toxicity.
 Example: ado-trastuzumab emtansine (T-DM1) for HER2 ⊕ breast cancer.

Antitumor antibiotics

All are cell cycle nonspecific, except bleomycin which is G₂/M phase specific.

DRUG	MECHANISM	CLINICAL USE	ADVERSE EFFECTS
Bleomycin	Induces free radical formation → breaks in DNA strands	Testicular cancer, Hodgkin lymphoma	Pulmonary fibrosis, skin hyperpigmentation
Dactinomycin (actinomycin D)	Intercalates into DNA, preventing RNA synthesis	Wilms tumor, Ewing sarcoma, rhabdomyosarcoma	Myelosuppression
Anthracyclines Doxorubicin, daunorubicin	Generate free radicals Intercalate in DNA → breaks in DNA → ↓ replication Inhibit topoisomerase II	Solid tumors, leukemias, lymphomas	Dilated cardiomyopathy (often irreversible; prevent with dexrazoxane), myelosuppression

Antimetabolites

All are S-phase specific except cladribine, which is cell cycle nonspecific.

DRUG	MECHANISM	CLINICAL USE	ADVERSE EFFECTS
Thiopurines Azathioprine, 6-mercaptopurine	Purine (thiol) analogs → ↓ de novo purine synthesis AZA is converted to 6-MP, which is then activated by HGPRT	Rheumatoid arthritis, IBD, SLE, ALL; steroid-refractory disease Prevention of organ rejection Weaning from glucocorticoids	Myelosuppression; GI, liver toxicity 6-MP is inactivated by xanthine oxidase (↑ toxicity with allopurinol or febuxostat)
Cladribine, pentostatin	Purine analogs → multiple mechanisms (eg, inhibition of ADA, DNA strand breaks)	Hairy cell leukemia	Myelosuppression
Cytarabine (arabinofuranosyl cytidine)	Pyrimidine analog → DNA chain termination Inhibits DNA polymerase	Leukemias (AML), lymphomas	Myelosuppression
5-Fluorouracil	Pyrimidine analog bioactivated to 5-FdUMP → thymidylate synthase inhibition → ↓ dTMP → ↓ DNA synthesis Capecitabine is a prodrug	Colon cancer, pancreatic cancer, actinic keratosis, basal cell carcinoma (topical) Effects enhanced with the addition of leucovorin	Myelosuppression, palmar- plantar erythrodysesthesia (hand-foot syndrome)
Hydroxyurea	Inhibits ribonucleotide reductase → ↓ DNA synthesis	Myeloproliferative disorders (eg, CML, polycythemia vera), sickle cell disease (↑ HbF)	Severe myelosuppression, megaloblastic anemia
Methotrexate	Folic acid analog that competitively inhibits dihydrofolate reductase → ↓ dTMP → ↓ DNA synthesis	Cancers: leukemias (ALL), lymphomas, choriocarcinoma, sarcomas Nonneoplastic: ectopic pregnancy, medical abortion (with misoprostol), rheumatoid arthritis, psoriasis, IBD, vasculitis	Myelosuppression (reversible with leucovorin “rescue”), hepatotoxicity, mucositis (eg, mouth ulcers), pulmonary fibrosis, folate deficiency (teratogenic), nephrotoxicity

Alkylating agents		All are cell cycle nonspecific.	
DRUG	MECHANISM	CLINICAL USE	ADVERSE EFFECTS
Busulfan	Cross-links DNA	Used to ablate patient's bone marrow before bone marrow transplantation	Severe myelosuppression (in almost all cases), pulmonary fibrosis, hyperpigmentation
Nitrogen mustards Cyclophosphamide, ifosfamide	Cross-link DNA Require bioactivation by liver	Solid tumors, leukemia, lymphomas, rheumatic disease (eg, SLE, granulomatosis with polyangiitis)	Myelosuppression, SIADH, Fanconi syndrome (ifosfamide), hemorrhagic cystitis and bladder cancer (prevent with mesna)
Nitrosoureas Carmustine, lomustine	Cross-link DNA Require bioactivation by liver Cross blood-brain barrier → CNS entry	Brain tumors (including glioblastoma multiforme) Put nitro in your Mustang and travel the globe	CNS toxicity (convulsions, dizziness, ataxia)
Procarbazine	Mechanism unknown Weak MAO inhibitor	Hodgkin lymphoma, brain tumors	Myelosuppression, pulmonary toxicity, leukemia, disulfiram-like reaction
Temozolomide	DNA methylation	Glioblastoma multiforme	Myelosuppression

Platinum compounds		Cisplatin, carboplatin, oxaliplatin.	
MECHANISM	Cross-link DNA. Cell cycle nonspecific.		
CLINICAL USE	Solid tumors (eg, testicular, bladder, ovarian, GI, lung), lymphomas.		
ADVERSE EFFECTS	Nephrotoxicity (eg, Fanconi syndrome; prevent with amifostine), peripheral neuropathy, ototoxicity.		

Microtubule inhibitors		All are M-phase specific.	
DRUG	MECHANISM	CLINICAL USE	ADVERSE EFFECTS
Taxanes Docetaxel, paclitaxel	Hyper stabilize polymerized microtubules → prevent mitotic spindle breakdown	Various tumors (eg, ovarian and breast carcinomas)	Myelosuppression, neuropathy, hypersensitivity Taxes stabilize society
Vinca alkaloids Vincristine, vinblastine	Bind β -tubulin and inhibit its polymerization into microtubules → prevent mitotic spindle formation	Solid tumors, leukemias, Hodgkin and non-Hodgkin lymphomas	Vin cr istine (cr isps the nerves): neurotoxicity (axonal neuropathy), constipation (including ileus) Vin bl astine (bl asts the marrow): myelosuppression

Topoisomerase inhibitors

All cause ↑ DNA degradation resulting in cell cycle arrest in S and G₂ phases.

DRUG	MECHANISM	CLINICAL USE	ADVERSE EFFECTS
Irinotecan, topotecan	Inhibit topoisomerase I “-tecone”	Colon, ovarian, small cell lung cancer	Severe myelosuppression, diarrhea
Etoposide, teniposide	Inhibit topoisomerase II “-bothside”	Testicular, small cell lung cancer, leukemia, lymphoma	Myelosuppression, alopecia

Tamoxifen

MECHANISM	Selective estrogen receptor modulator with complex mode of action: antagonist in breast tissue, partial agonist in endometrium and bone. Blocks the binding of estrogen to ER in ER ⊕ cells.
CLINICAL USE	Prevention and treatment of breast cancer, prevention of gynecomastia in patients undergoing prostate cancer therapy.
ADVERSE EFFECTS	Hot flashes, ↑ risk of thromboembolic events (eg, DVT, PE) and endometrial cancer.

Anticancer monoclonal antibodies Work against extracellular targets to neutralize them or to promote immune system recognition (eg, ADCC by NK cells). Eliminated by macrophages (not cleared by kidneys or liver).

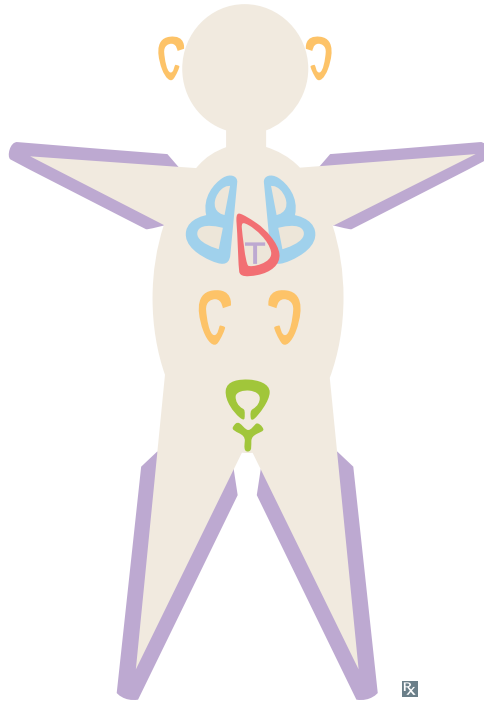
AGENT	TARGET	CLINICAL USE	ADVERSE EFFECTS
Alemtuzumab	CD52	Chronic lym phocytic leukemia (CLL), multiple sclerosis.	↑ risk of infections and autoimmunity (eg, ITP)
Bevacizumab	VEGF (inhibits blood vessel formation)	Colorectal cancer (CRC), renal cell carcinoma (RCC), non–small cell lung cancer (NSCLC), angioproliferative retinopathy	Hemorrhage, blood clots, impaired wound healing
Cetuximab, panitumumab	EGFR	Metastatic CRC (wild-type RAS), head and neck cancer	Rash, elevated LFTs, diarrhea
Rituximab	CD20	Non-Hodgkin lymphoma, CLL, rheumatoid arthritis, ITP, TTP, AIHA, multiple sclerosis	Infusion reaction due to cytokine release following interaction of rituximab with its target on B cells
Trastuzumab	HER2 (“ trust HER ”)	Breast cancer, gastric cancer	Dilated cardiomyopathy (often reversible)
Pembrolizumab, nivolumab, cemiplimab	PD-1	Various tumors (eg, NSCLC, RCC, melanoma, urothelial carcinoma)	↑ risk of autoimmunity (eg, dermatitis, enterocolitis, hepatitis, pneumonitis, endocrinopathies)
Atezolizumab, durvalumab, avelumab	PD-L1		
Ipilimumab	CTLA-4		

Anticancer small molecule inhibitors

AGENT	TARGET	CLINICAL USE	ADVERSE EFFECTS
Alectinib, crizotinib	ALK	Non–small cell lung cancer	Edema, rash, diarrhea
Erlotinib, gefitinib, afatinib	EGFR	Non–small cell lung cancer	Rash, diarrhea
Imatinib, dasatinib, nilotinib	BCR-ABL (also other tyrosine kinases [eg, c-KIT])	CML, ALL, GISTs	Myelosuppression, ↑ LFTs, edema, myalgias
Ruxolitinib	JAK1/2	Polycythemia vera	Bruises, ↑ LFTs
Bortezomib, ixazomib, carfilzomib	Proteasome (induce arrest at G2-M phase via accumulation of abnormal proteins → apoptosis)	Multiple myeloma, mantle cell lymphoma	Peripheral neuropathy, herpes zoster reactivation (↓ T-cell activation → ↓ cell-mediated immunity)
Vemurafenib, encorafenib, dabrafenib	BRAF	Melanoma Often co-administered with MEK inhibitors (eg, trametinib)	Rash, fatigue, nausea, diarrhea
Palbociclib	Cyclin-dependent kinase 4/6 (induces arrest at G1-S phase → apoptosis)	Breast cancer	Myelosuppression, pneumonitis
Olaparib	Poly(ADP-ribose) polymerase (↓ DNA repair)	Breast, ovarian, pancreatic, and prostate cancers	Myelosuppression, edema, diarrhea

Chemotoxicity amelioration

DRUG	MECHANISM	CLINICAL USE
Amifostine	Free radical scavenger	Nephrotoxicity from platinum compounds
Dexrazoxane	Iron chelator	Cardiotoxicity from anthracyclines
Leucovorin (folinic acid)	Tetrahydrofolate precursor	Myelosuppression from methotrexate (leucovorin “rescue”); also enhances the effects of 5-FU
Mesna	Sulfhydryl compound that binds acrolein (toxic metabolite of cyclophosphamide/ifosfamide)	Hemorrhagic cystitis from cyclophosphamide/ifosfamide
Rasburicase	Recombinant uricase that catalyzes metabolism of uric acid to allantoin	Tumor lysis syndrome
Ondansetron, granisetron	5-HT ₃ receptor antagonists	Acute nausea and vomiting (usually within 1-2 hr after chemotherapy)
Prochlorperazine, metoclopramide	D ₂ receptor antagonists	
Aprepitant, fosaprepitant	NK ₁ receptor antagonists	
Filgrastim, sargramostim	Recombinant G(M)-CSF	Neutropenia
Epoetin alfa	Recombinant erythropoietin	Anemia

Key chemotoxicities

Cisplatin, Carboplatin → ototoxicity

Vincristine → peripheral neuropathy

Bleomycin, Busulfan → pulmonary fibrosis

Doxorubicin, Daunorubicin → cardiotoxicity

Trastuzumab → cardiotoxicity

Cisplatin, Carboplatin → nephrotoxicity

CYclophosphamide → hemorrhagic cystitis

Nonspecific common toxicities of nearly all cytotoxic chemotherapies include myelosuppression (neutropenia, anemia, thrombocytopenia), GI toxicity (nausea, vomiting, mucositis), alopecia.

Musculoskeletal, Skin, and Connective Tissue

“Rigid, the skeleton of habit alone upholds the human frame.”

—Virginia Woolf, *Mrs. Dalloway*

“Beauty may be skin deep, but ugly goes clear to the bone.”

—Redd Foxx

“The finest clothing made is a person’s own skin, but, of course, society demands something more than this.”

—Mark Twain

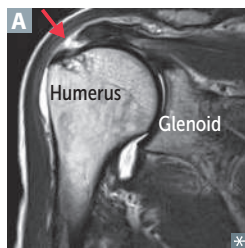
“To thrive in life you need three bones. A wishbone. A backbone. And a funny bone.”

—Reba McEntire

This chapter provides information you will need to understand common anatomic dysfunctions, orthopedic conditions, rheumatic diseases, and dermatologic conditions. Be able to interpret 3D anatomy in the context of radiologic imaging. For the rheumatic diseases, create instructional cases that include the most likely presentation and symptoms: risk factors, gender, important markers (eg, autoantibodies), and other epidemiologic factors. Doing so will allow you to answer higher order questions that are likely to be asked on the exam.

▶ Anatomy and Physiology	454
▶ Pathology	467
▶ Dermatology	485
▶ Pharmacology	498

▶ MUSCULOSKELETAL, SKIN, AND CONNECTIVE TISSUE—ANATOMY AND PHYSIOLOGY

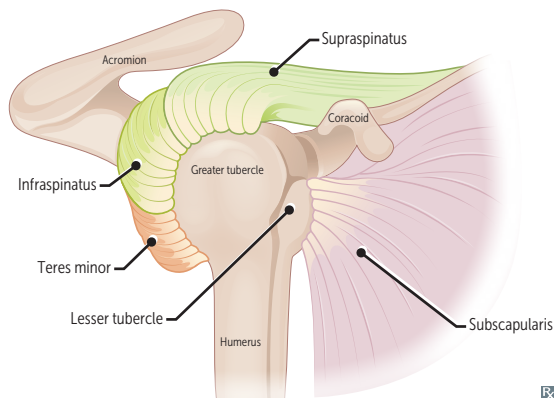
Rotator cuff muscles

Shoulder muscles that form the rotator cuff:

- **S**upraspinatus (suprascapular nerve)—abducts arm initially (before the action of the deltoid); most common rotator cuff injury (trauma or degeneration and impingement → tendinopathy or tear [arrow in **A**]), assessed by “empty/full can” test
- **I**nfraspinatus (suprascapular nerve)—externally rotates arm; pitching injury
- **t**eres minor (axillary nerve)—adducts and externally rotates arm
- **S**ubscapularis (upper and lower subscapular nerves)—internally rotates and adducts arm

Innervated primarily by C5-C6.

SItS (small t is for teres minor).

**Arm abduction**

DEGREE	MUSCLE	NERVE
0°–15°	Supraspinatus	Suprascapular
15°–90°	Deltoid	Axillary
> 90°	Trapezius	Accessory
> 90°	S erratus A nterior	L ong T horacic (SALT)

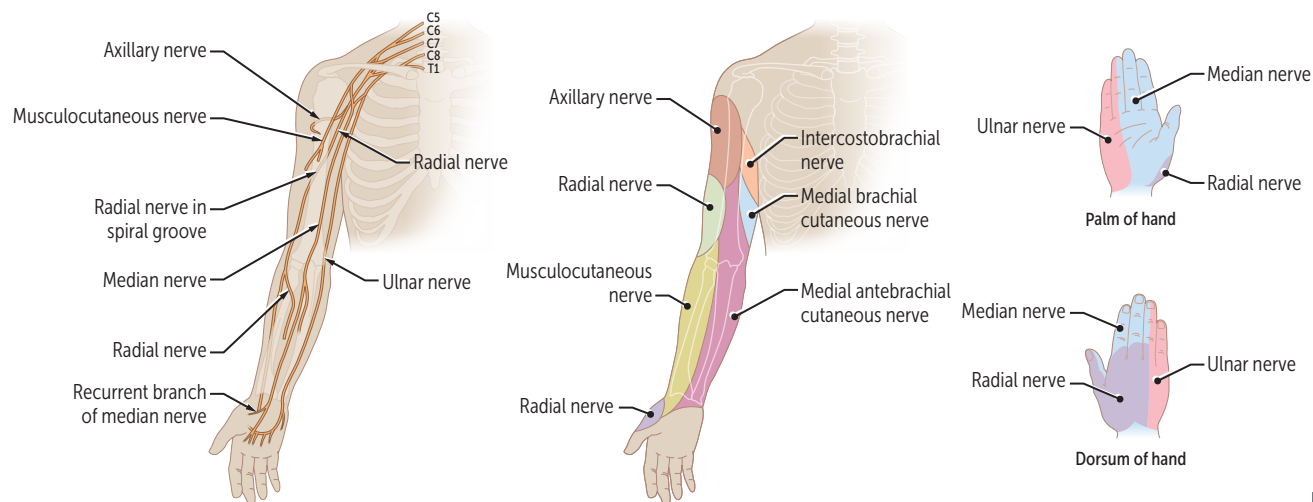
Upper extremity nerves

NERVE	CAUSES OF INJURY	PRESENTATION
Axillary (C5-C6)	Fractured surgical neck of humerus Anterior dislocation of humerus	Flattened deltoid Loss of arm abduction at shoulder (> 15°) Loss of sensation over deltoid and lateral arm
Musculocutaneous (C5-C7)	Upper trunk compression	↓ biceps (C5-6) reflex Loss of forearm flexion and supination Loss of sensation over radial and dorsal forearm
Radial (C5-T1)	Compression of axilla, eg, due to crutches or sleeping with arm over chair (“Saturday night palsy”) Midshaft fracture of humerus Repetitive pronation/supination of forearm, eg, due to screwdriver use (“finger drop”)	Injuries above the elbow cause loss of sensation over posterior arm/forearm and dorsal hand, wrist drop (loss of elbow, wrist, and finger extension) with ↓ grip strength (wrist extension necessary for maximal action of flexors) Injuries below the elbow cause distal paresthesias without wrist drop Tricep function and posterior arm sensation spared in midshaft fracture

Upper extremity nerves (continued)

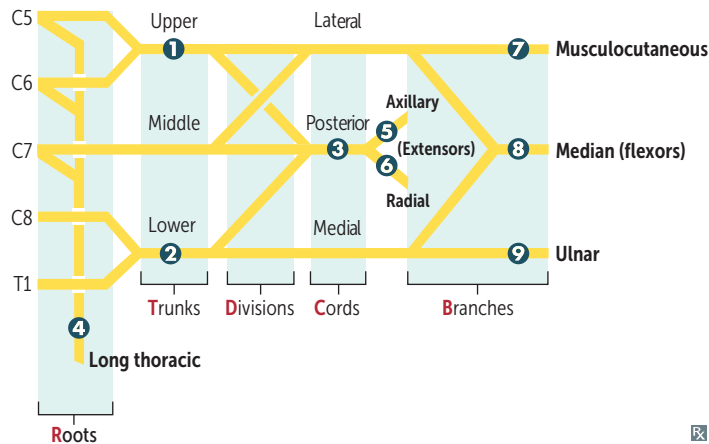
NERVE	CAUSES OF INJURY	PRESENTATION
Median (C5-T1)	Supracondylar fracture of humerus → proximal lesion of the nerve Carpal tunnel syndrome and wrist laceration → distal lesion of the nerve	“Ape hand” and “Hand of benediction” Loss of wrist flexion and function of the lateral two L umbricals, O pponens pollicis, A bductor pollicis brevis, F lexor pollicis brevis (LOAF) Loss of sensation over thenar eminence and dorsal and palmar aspects of lateral 3 1/2 fingers with proximal lesion
Ulnar (C8-T1)	Fracture of medial epicondyle of humerus (proximal lesion) Fractured hook of hamate (distal lesion) from fall on outstretched hand Compression of nerve against hamate as the wrist rests on handlebar during cycling	“Ulnar claw” on digit extension Radial deviation of wrist upon flexion (proximal lesion) ↓ flexion of ulnar fingers, abduction and adduction of fingers (interossei), thumb adduction, actions of ulnar 2 lumbrical muscles Loss of sensation over ulnar 1 1/2 fingers including hypothenar eminence
Recurrent branch of median nerve (C5-T1)	Superficial laceration of palm	“Ape hand” Loss of thenar muscle group: opposition, abduction, and flexion of thumb No loss of sensation

Humerus fractures, proximally to distally, follow the **ARM** (Axillary → Radial → Median) nerves



Brachial plexus lesions



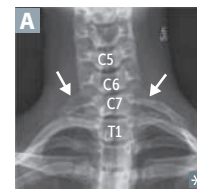
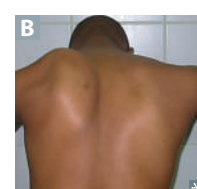
- 1 Erb palsy ("waiter's tip")
- 2 Klumpke palsy (claw hand)
- 3 Wrist drop
- 4 Winged scapula
- 5 Deltoid paralysis
- 6 "Saturday night palsy" (wrist drop)
- 7 Difficulty flexing elbow, variable sensory loss
- 8 Decreased thumb function, "hand of benediction"
- 9 Intrinsic muscles of hand, claw hand



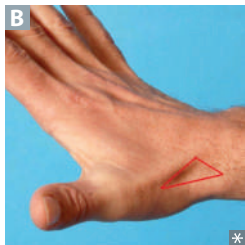
Divisions of brachial plexus:

Remember
To
Drink
Cold
Beer

Trunks of brachial plexus and the subclavian artery pass between anterior and middle scalene muscles. Subclavian vein passes anteromedial to the scalene triangle.

CONDITION	INJURY	CAUSES	MUSCLE DEFICIT	FUNCTIONAL DEFICIT	PRESENTATION
Erb palsy ("waiter's tip")	Traction or tear of upper trunk : C5-C6 roots	Infants—lateral traction on neck during delivery Adults—trauma leading to neck traction (eg, falling on head and shoulder in motorcycle accident)	D eltoid, s upraspinatus I nfra s pinatus, s upraspinatus B iceps brachii H erb gets DIBs on t ips	Abduction (arm hangs by side) Lateral rotation (arm medially rotated) Flexion, supination (arm extended and pronated)	
Klumpke palsy	Traction or tear of lower trunk : C8-T1 roots	Infants—upward force on arm during delivery Adults—trauma (eg, grabbing a tree branch to break a fall)	Intrinsic hand muscles: lumbricals, interossei, thenar, hypothenar	Claw hand: lumbricals normally flex MCP joints and extend DIP and PIP joints	
Thoracic outlet syndrome	Compression of lower trunk and subclavian vessels, most commonly within the scalene triangle	Cervical/anomalous first ribs (arrows in A), Pancoast tumor	Same as Klumpke palsy	Atrophy of intrinsic hand muscles; ischemia, pain, and edema due to vascular compression	
Winged scapula	Lesion of long thoracic nerve, roots C5-C7 (" w ings of h eaven")	Axillary node dissection after mastectomy, stab wounds	Serratus anterior	Inability to anchor scapula to thoracic cage → cannot abduct arm above horizontal position B	

Wrist region

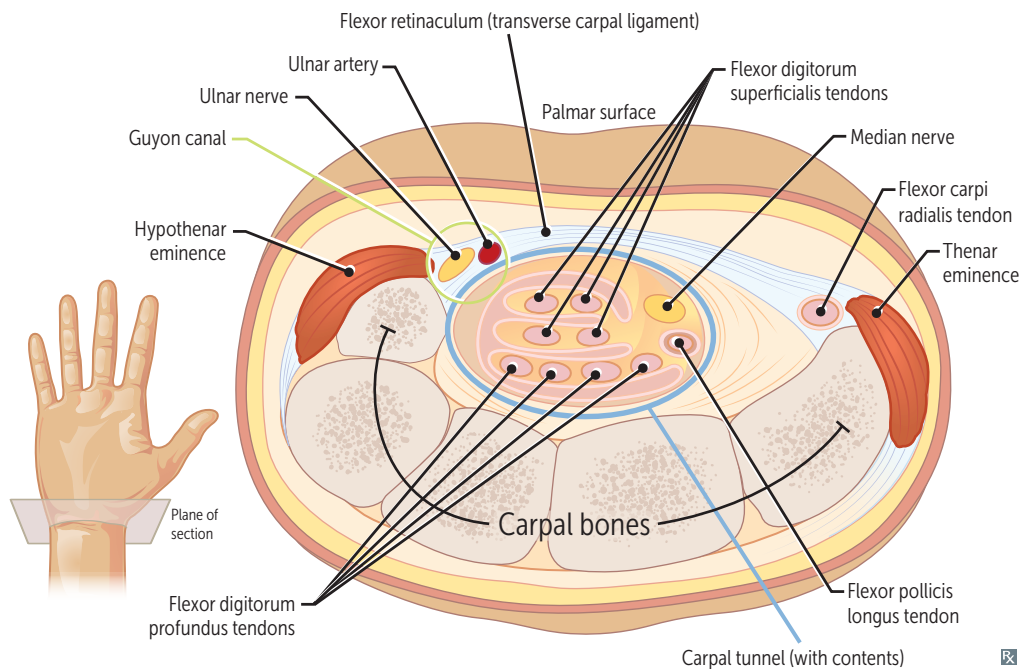
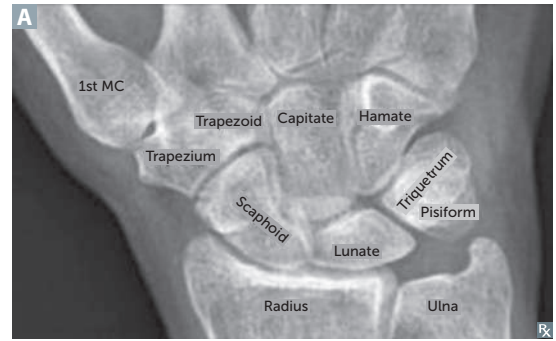


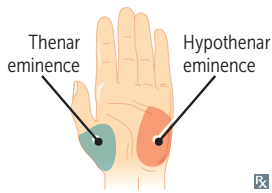
Scaphoid, lunate, triquetrum, pisiform, hamate, capitate, trapezoid, trapezium **A**. (So long to pinky, here comes the thumb)

Scaphoid (palpable in anatomic snuff box **B**) is the most commonly fractured carpal bone, typically due to a fall on an outstretched hand. Complications of proximal scaphoid fractures include avascular necrosis and nonunion due to retrograde blood supply from a branch of the radial artery. Occult fracture not always seen on initial x-ray.

Dislocation of lunate may impinge median nerve and cause carpal tunnel syndrome.

Fracture of the hook of the hamate can cause ulnar syndrome.



Hand muscles

Thenar (median)—**O**pponens pollicis, **A**bductor pollicis brevis, **F**lexor pollicis brevis, superficial head (deep head by ulnar nerve).

Hypothenar (ulnar)—**O**pponens digiti minimi, **A**bductor digiti minimi, **F**lexor digiti minimi brevis.

- ☒ Dorsal interossei (ulnar)—abduct the fingers.
- Palmar interossei (ulnar)—adduct the fingers.
- Lumbricals (1st/2nd, median; 3rd/4th, ulnar)—flex at the MCP joint, extend PIP and DIP joints.

Both groups perform the same functions:

Oppose, **A**bduct, and **F**lex (**OAF**).

DAB = **D**orsals **AB**duct.

PAD = **P**almars **AD**duct.

Distortions of the hand

At rest, a balance exists between the extrinsic flexors and extensors of the hand, as well as the intrinsic muscles of the hand—particularly the lumbrical muscles (flexion of MCP, extension of DIP and PIP joints).

“Clawing”—seen best with **distal** lesions of median or ulnar nerves. Remaining extrinsic flexors of the digits exaggerate the loss of the lumbricals → fingers extend at MCP, flex at DIP and PIP joints.

Deficits less pronounced in **proximal** lesions; deficits present during voluntary flexion of the digits.


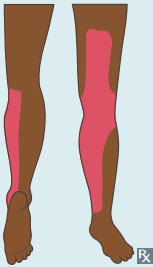
SIGN	“Ulnar claw”	“Hand of benediction”	“Median claw”	“OK gesture”
PRESENTATION				
CONTEXT	Extending fingers/at rest	Making a fist	Extending fingers/at rest	Making a fist
LOCATION OF LESION	Distal ulnar nerve	Proximal median nerve	Distal median nerve	Proximal ulnar nerve

Note: Atrophy of the thenar eminence can be seen in median nerve lesions, while atrophy of the hypothenar eminence can be seen in ulnar nerve lesions.

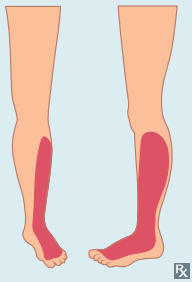
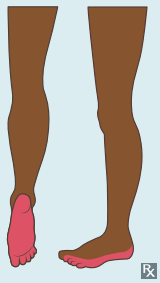
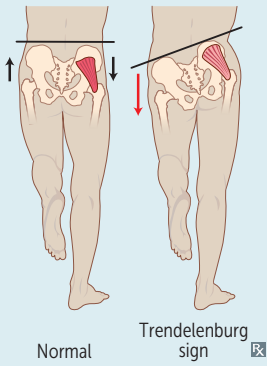
Actions of hip muscles

ACTION	MUSCLES
Abductors	Gluteus medius, gluteus minimus
Adductors	Adductor magnus, adductor longus, adductor brevis
Extensors	Gluteus maximus, semitendinosus, semimembranosus, long head of biceps femoris
Flexors	Iliopsoas (iliacus and psoas), rectus femoris, tensor fascia lata, pectineus, sartorius
Internal rotation	Gluteus medius, gluteus minimus, tensor fascia latae
External rotation	Iliopsoas, gluteus maximus, piriformis, obturator internus, obturator externus

Lower extremity nerves

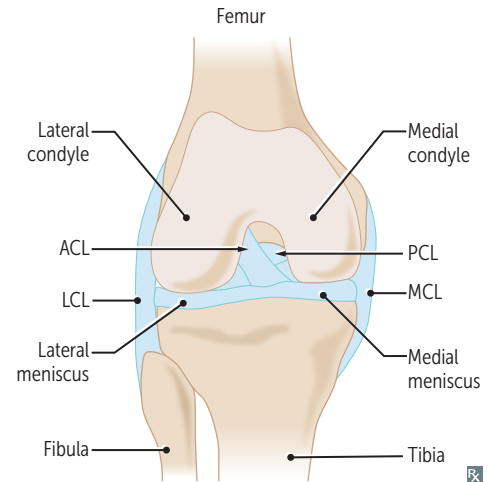
NERVE	INNERVATION	CAUSE OF INJURY	PRESENTATION/COMMENTS
Iliohypogastric (T12-L1)	Sensory—suprapubic region Motor—transversus abdominis and internal oblique	Abdominal surgery	Burning or tingling pain in surgical incision site radiating to inguinal and suprapubic region
Genitofemoral nerve (L1-L2)	Sensory—scrotum/labia majora, medial thigh Motor—cremaster	Laparoscopic surgery	↓ upper medial thigh and anterior thigh sensation beneath the inguinal ligament (lateral part of the femoral triangle); absent cremasteric reflex
Lateral femoral cutaneous (L2-L3)	Sensory—anterior and lateral thigh	Tight clothing, obesity, pregnancy, pelvic procedures	↓ thigh sensation (anterior and lateral) Meralgia paresthetica —compression of lateral femoral cutaneous nerve → tingling, numbness, burning pain in anterolateral thigh
Obturator (L2-L4) 	Sensory—medial thigh Motor—obturator externus, adductor longus, adductor brevis, gracilis, pectineus, adductor magnus	Pelvic surgery	↓ thigh sensation (medial) and adduction
Femoral (L2-L4) 	Sensory—anterior thigh, medial leg Motor—quadriceps, iliacus, pectineus, sartorius	Pelvic fracture	↓ leg extension (↓ patellar reflex)
Sciatic (L4-S3)	Motor—semitendinosus, semimembranosus, biceps femoris, adductor magnus	Herniated disc, posterior hip dislocation	Splits into common peroneal and tibial nerves

Lower extremity nerves (continued)

NERVE	INNERVATION	CAUSE OF INJURY	PRESENTATION/COMMENTS
<p>Common (fibular) peroneal (L4-S2)</p> 	<p>Superficial peroneal nerve:</p> <ul style="list-style-type: none"> ▪ Sensory—dorsum of foot (except webspace between hallux and 2nd digit) ▪ Motor—peroneus longus and brevis <p>Deep peroneal nerve:</p> <ul style="list-style-type: none"> ▪ Sensory—webspace between hallux and 2nd digit ▪ Motor—tibialis anterior 	<p>Trauma or compression of lateral aspect of leg, fibular neck fracture</p>	<p>PED = Peroneal Everts and Dorsiflexes; if injured, foot drop Loss of sensation on dorsum of foot Foot drop—inverted and plantarflexed at rest, loss of eversion and dorsiflexion; “steppage gait”</p>
<p>Tibial (L4-S3)</p> 	<p>Sensory—sole of foot Motor—biceps femoris (long head), triceps surae, plantaris, popliteus, flexor muscles of foot</p>	<p>Knee trauma, Baker cyst (proximal lesion); tarsal tunnel syndrome (distal lesion)</p>	<p>TIP = Tibial Inverts and Plantarflexes; if injured, can't stand on TIPtoes Inability to curl toes and loss of sensation on sole; in proximal lesions, foot everted at rest with weakened inversion and plantar flexion</p>
<p>Superior gluteal (L4-S1)</p> 	<p>Motor—gluteus medius, gluteus minimus, tensor fascia latae</p>	<p>Iatrogenic injury during intramuscular injection to superomedial gluteal region (prevent by choosing superolateral quadrant, preferably anterolateral region)</p>	<p>Trendelenburg sign/gait—pelvis tilts because weight-bearing leg cannot maintain alignment of pelvis through hip abduction Lesion is contralateral to the side of the hip that drops, ipsilateral to extremity on which the patient stands</p>
<p>Inferior gluteal (L5-S2)</p>	<p>Motor—gluteus maximus</p>	<p>Posterior hip dislocation</p>	<p>Difficulty climbing stairs, rising from seated position; loss of hip extension</p>
<p>Pudendal (S2-S4)</p>	<p>Sensory—perineum Motor—external urethral and anal sphincters</p>	<p>Stretch injury during childbirth, prolonged cycling, horseback riding</p>	<p>↓ sensation in perineum and genital area; can cause fecal and/or urinary incontinence Can be blocked with local anesthetic during childbirth using ischial spine as a landmark for injection</p>

Knee exam

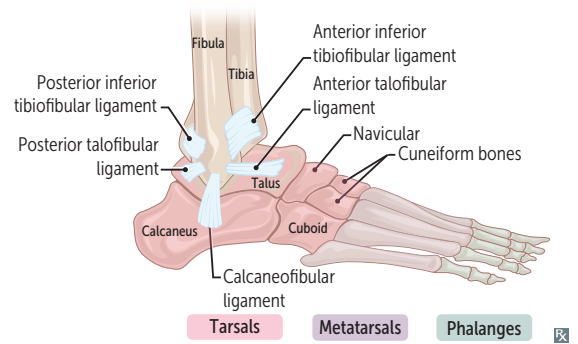
Lateral femoral condyle to anterior tibia: **ACL**.
 Medial femoral condyle to posterior tibia: **PCL**.
LAMP.



TEST	PROCEDURE	
Anterior drawer sign	Bending knee at 90° angle, ↑ anterior gliding of tibia (relative to femur) due to ACL injury Lachman test also tests ACL, but is more sensitive (↑ anterior gliding of tibia [relative to femur] with knee bent at 30° angle)	ACL tear
Posterior drawer sign	Bending knee at 90° angle, ↑ posterior gliding of tibia due to PCL injury	PCL tear
Abnormal passive abduction	Also called valgus stress test. Knee either extended or at ~ 30° angle, lateral (valgus) force → medial space widening of tibia → MCL injury	MCL tear
Abnormal passive adduction	Also called varus stress test. Knee either extended or at ~ 30° angle, medial (varus) force → lateral space widening of tibia → LCL injury	LCL tear
McMurray test	During flexion and extension of knee with rotation of tibia/foot (LIME): <ul style="list-style-type: none"> ▪ Pain, “popping” on internal rotation and varus force → Lateral meniscal tear (Internal rotation stresses lateral meniscus) ▪ Pain, “popping” on external rotation and valgus force → Medial meniscal tear (External rotation stresses medial meniscus) 	Lateral meniscal tear Medial meniscal tear

Ankle sprains

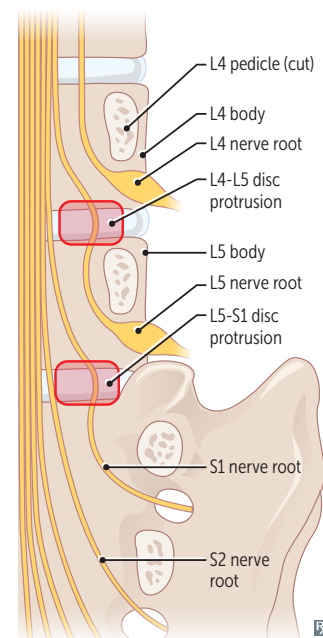
Anterior talofibular ligament—most common ankle sprain overall, classified as a low ankle sprain. Due to overinversion/supination of foot. **Always tears first.**
Anterior inferior tibiofibular ligament—most common high ankle sprain.



Signs of lumbosacral radiculopathy

Paresthesia and weakness related to specific lumbosacral spinal nerves. Intervertebral disc (nucleus pulposus) herniates posterolaterally through annulus fibrosus (outer ring) into spinal canal due to thin posterior longitudinal ligament and thicker anterior longitudinal ligament along midline of vertebral bodies. Nerve affected is usually below the level of herniation. ⊕ straight leg raise, ⊕ contralateral straight leg raise, ⊕ reverse straight leg raise (femoral stretch).

Disc level herniation	L3-L4	L4-L5	L5-S1
Nerve root affected	L4	L5	S1
Dermatome affected			
Clinical findings	Weakness of knee extension ↓ patellar reflex	Weakness of dorsiflexion Difficulty in heel walking	Weakness of plantar flexion Difficulty in toe walking ↓ Achilles reflex



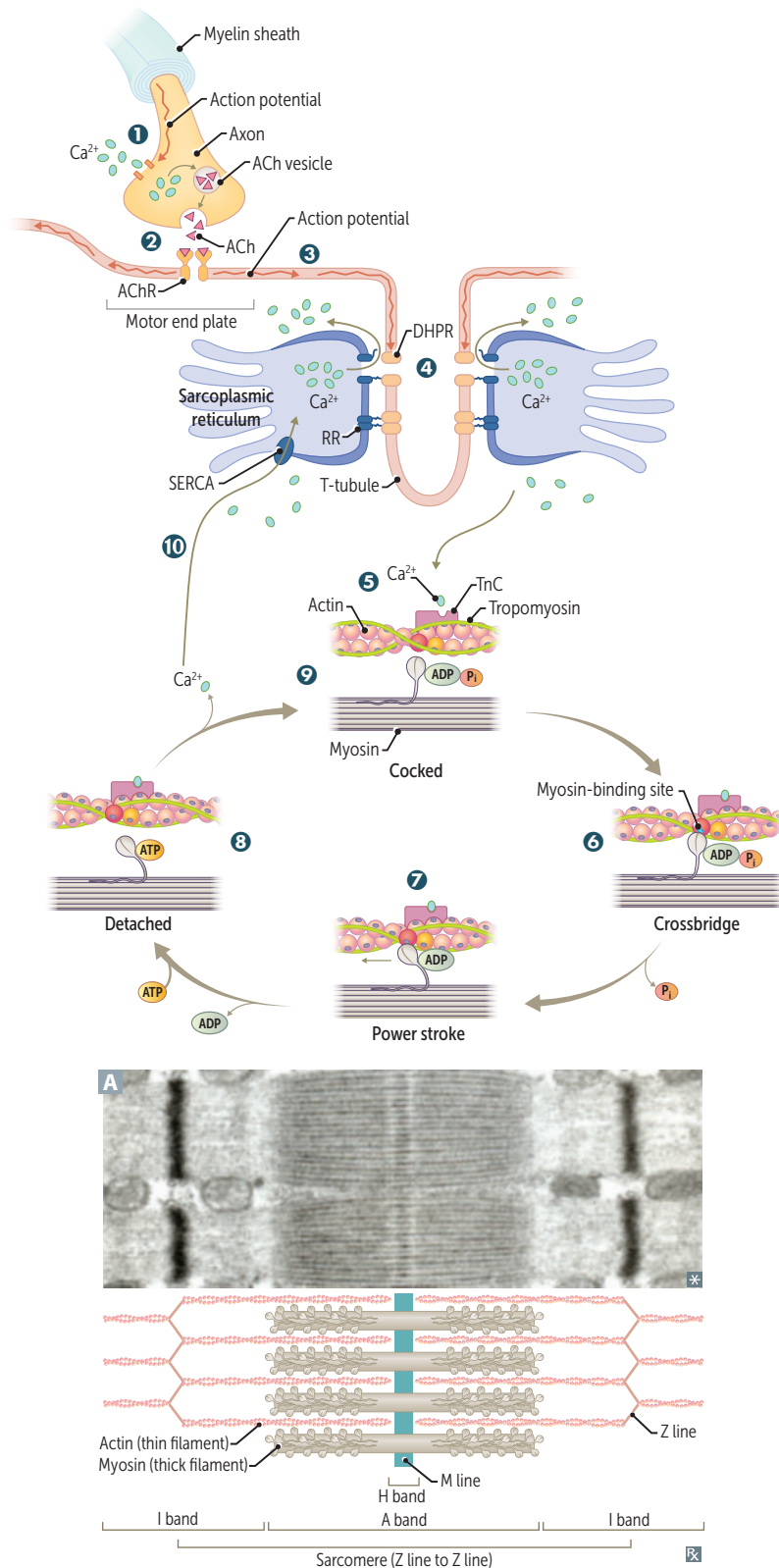
Neurovascular pairing

Nerves and arteries are frequently named together by the bones/regions with which they are associated. The following are exceptions to this naming convention.

LOCATION	NERVE	ARTERY
Axilla/lateral thorax	Long thoracic	Lateral thoracic
Surgical neck of humerus	Axillary	Posterior circumflex
Midshaft of humerus	Radial	Deep brachial
Distal humerus/cubital fossa	Median	Brachial
Popliteal fossa	Tibial	Popliteal
Posterior to medial malleolus	Tibial	Posterior tibial

Motoneuron action potential to muscle contraction

T-tubules are extensions of plasma membrane in contact with the sarcoplasmic reticulum, allowing for coordinated contraction of striated muscles.



- 1 Action potential opens presynaptic voltage-gated Ca^{2+} channels, inducing acetylcholine (ACh) release.
- 2 Postsynaptic ACh binding leads to muscle cell depolarization at the motor end plate.
- 3 Depolarization travels over the entire muscle cell and deep into the muscle via the T-tubules.
- 4 Membrane depolarization induces conformational changes in the voltage-sensitive dihydropyridine receptor (DHPR) and its mechanically coupled ryanodine receptor (RR) \rightarrow Ca^{2+} release from the sarcoplasmic reticulum (buffered by calsequestrin) into the cytoplasm.
- 5 Tropomyosin is blocking myosin-binding sites on the actin filament. Released Ca^{2+} binds to troponin C (TnC), shifting tropomyosin to expose the myosin-binding sites.
- 6 Myosin head binds strongly to actin (crossbridge). P_i released, initiating power stroke.
- 7 During the power stroke, force is produced as myosin pulls on the thin filament **A**. Muscle shortening occurs, with shortening of **H** and **I** bands and between **Z** lines (**HI**, I'm wearing short**Z**). The A band remains the same length (**A** band is **A**lways the same length). ADP is released at the end of the power stroke.
- 8 Binding of new ATP molecule causes detachment of myosin head from actin filament. Ca^{2+} is re-sequestered.
- 9 ATP hydrolysis into ADP and P_i results in myosin head returning to high-energy position (cocked). The myosin head can bind to a new site on actin to form a crossbridge if Ca^{2+} remains available.
- 10 Reuptake of calcium by sarco(endo)plasmic reticulum Ca^{2+} ATPase (SERCA) \rightarrow muscle relaxation.

Types of skeletal muscle fibers

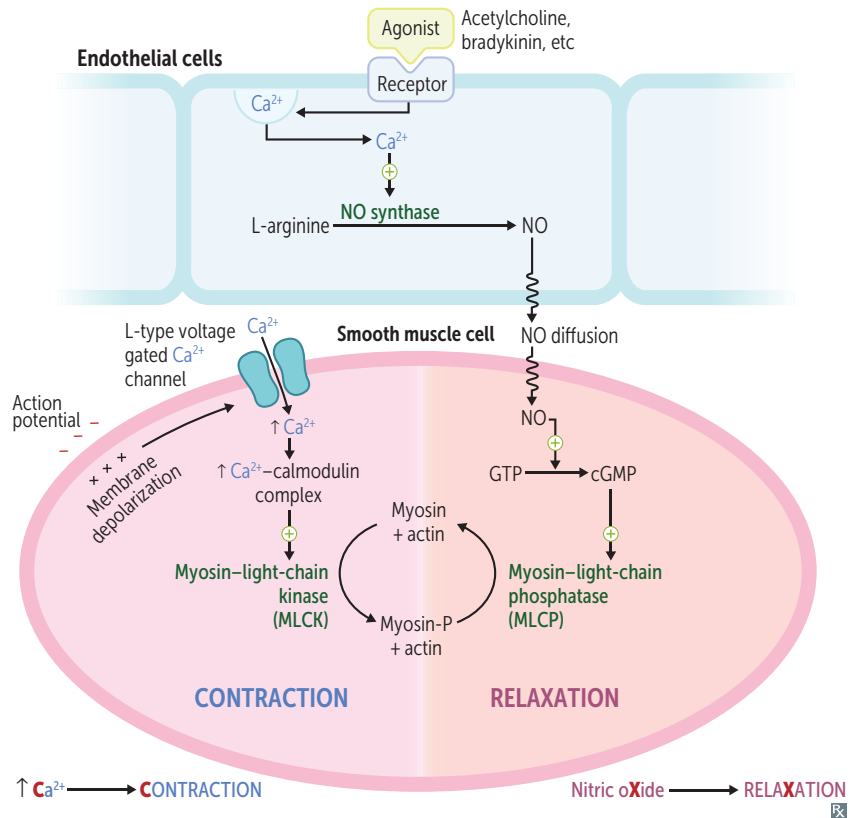
Muscle fiber type grouping commonly occurs due to reinnervation of denervated muscle fibers in peripheral nerve damage.

	Type I	Type II
CONTRACTION VELOCITY	Slow	Fast
FIBER COLOR	Red	White
PREDOMINANT METABOLISM	Oxidative phosphorylation → sustained contraction	Anaerobic glycolysis
MITOCHONDRIA, MYOGLOBIN	↑	↓
TYPE OF TRAINING	Endurance training	Weight/resistance training, sprinting
NOTES	Think “1 slow red ox”	Think “2 fast white antelopes”

Skeletal muscle adaptations

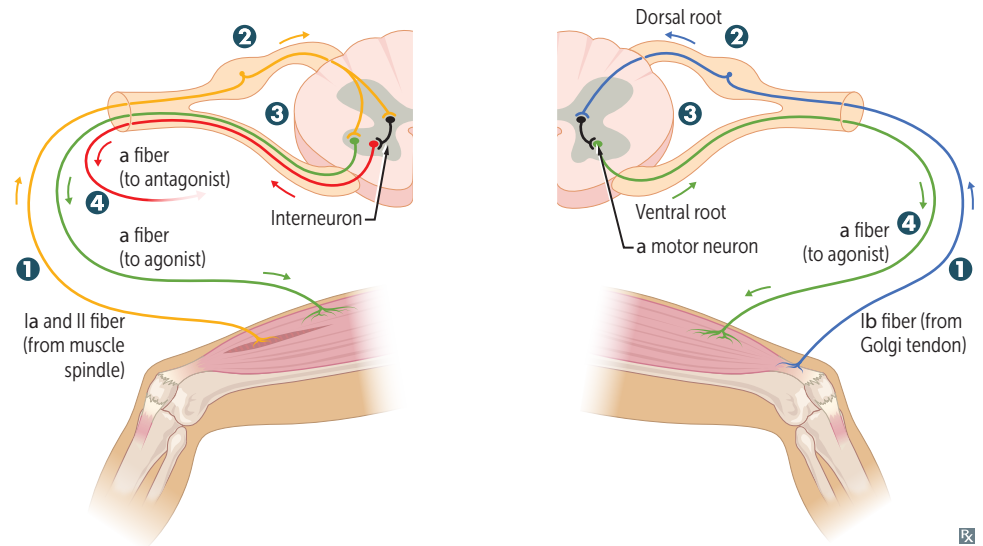
	Atrophy	Hypertrophy
MYOFIBRILS	↓ (removal via ubiquitin-proteasome system)	↑ (addition of sarcomeres in parallel)
MYONUCLEI	↓ (selective apoptosis)	↑ (fusion of satellite cells, which repair damaged myofibrils; absent in cardiac muscles)

Vascular smooth muscle contraction and relaxation



Muscle proprioceptors Specialized sensory receptors that relay information about muscle dynamics.

	Muscle stretch receptors	Golgi tendon organ
PATHWAY	<p>① ↑ length and speed of stretch → ② via dorsal root ganglion (DRG) → ③ activation of inhibitory interneuron and α motor neuron → ④ simultaneous inhibition of antagonist muscle (prevents overstretching) and activation of agonist muscle (contraction).</p>	<p>① ↑ tension → ② via DRG → ③ activation of inhibitory interneuron → ④ inhibition of agonist muscle (reduced tension within muscle and tendon)</p>
LOCATION/INNERVATION	Body of muscle/type Ia and II sensory axons	Tendons/type Ib sensory axons
ACTIVATION BY	↑ muscle stretch. Responsible for deep tendon reflexes	↑ muscle tension



Bone formation

Endochondral ossification

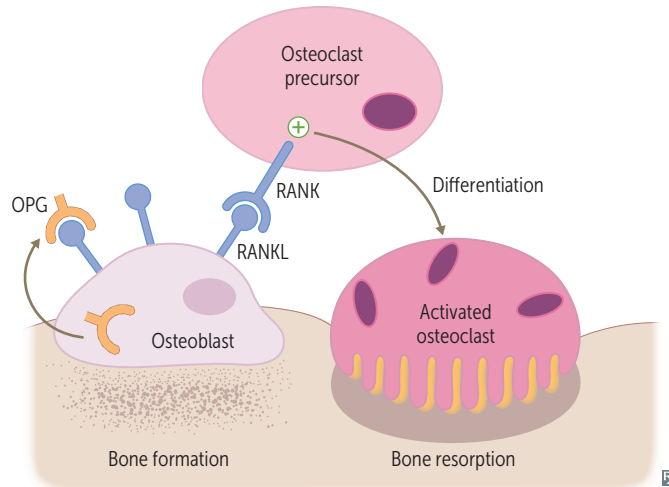
Bones of axial skeleton, appendicular skeleton, and base of skull. Cartilaginous model of bone is first made by chondrocytes. Osteoclasts and osteoblasts later replace with woven bone and then remodel to lamellar bone. In adults, woven bone occurs after fractures and in Paget disease. Defective in achondroplasia.

Membranous ossification

Bones of calvarium, facial bones, and clavicle. Woven bone formed directly without cartilage. Later remodeled to lamellar bone.

Cell biology of bone

Osteoblast	B uilds b one by secreting collagen and catalyzing mineralization in alkaline environment via ALP. Differentiates from mesenchymal stem cells in periosteum. Osteoblastic activity measured by bone ALP, osteocalcin, propeptides of type I procollagen.
Osteoclast	Dissolves (“ crushes ”) bone by secreting H ⁺ and collagenases. Differentiates from a fusion of monocyte/macrophage lineage precursors. RANK receptors on osteoclasts are stimulated by RANKL (RANK ligand, expressed on osteoblasts). OPG (osteoprotegerin, a RANKL decoy receptor) binds RANKL to prevent RANK-RANKL interaction → ↓ osteoclast activity.
Parathyroid hormone	At low, intermittent levels, exerts anabolic effects (building bone) on osteoblasts and osteoclasts (indirect). Chronically ↑ PTH levels (1° hyperparathyroidism) cause catabolic effects (osteitis fibrosa cystica).
Estrogen	Inhibits apoptosis in bone-forming osteoblasts and induces apoptosis in bone-resorbing osteoclasts. Causes closure of epiphyseal plate during puberty. Estrogen deficiency (surgical or postmenopausal) → ↑ cycles of remodeling and bone resorption → ↑ risk of osteoporosis.

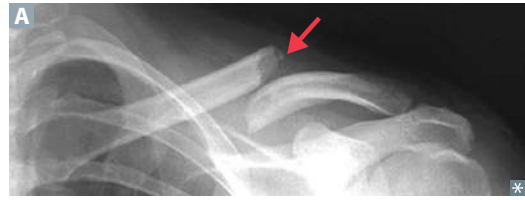**▶ MUSCULOSKELETAL, SKIN, AND CONNECTIVE TISSUE—PATHOLOGY****Overuse injuries of the elbow**

Medial epicondylitis (golfer's elbow)	Repetitive flexion or idiopathic → pain near medial epicondyle.
Lateral epicondylitis (tennis elbow)	Repetitive exten sion (backhand shots) or idiopathic → pain near lateral epicondyle.

Clavicle fractures

Common in children and as birth trauma.

Usually caused by a fall on outstretched hand or by direct trauma to shoulder. Weakest point at the junction of middle and lateral thirds; fractures at the middle third segment are most common **A**. Presents as shoulder drop, shortened clavicle (lateral fragment is depressed due to arm weight and medially rotated by arm adductors [eg, pectoralis major]).

**Wrist and hand injuries****Guyon canal syndrome**

Compression of ulnar nerve at wrist. Classically seen in cyclists due to pressure from handlebars.

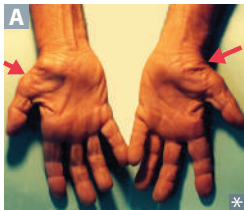May also be seen with fracture/dislocation of the hook of hamate.

Carpal tunnel syndrome

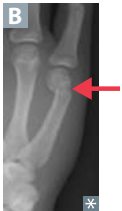Entrapment of median nerve in carpal tunnel (between transverse carpal ligament and carpal bones) → nerve compression → paresthesia, pain, and numbness in distribution of median nerve. Thenar eminence atrophies **A** but sensation spared, because palmar cutaneous branch enters hand external to carpal tunnel.

Suggested by ⊕ Tinel sign (percussion of wrist causes tingling) and Phalen maneuver (90° flexion of wrist causes tingling).

Associated with pregnancy (due to edema), rheumatoid arthritis, hypothyroidism, diabetes, acromegaly, dialysis-related amyloidosis; may be associated with repetitive use.

**Metacarpal neck fracture**

Also called boxer's fracture. Common fracture caused by direct blow with a closed fist (eg, from punching a wall). Most commonly seen in the 5th metacarpal **B**.

**Iliopsoas abscess**

Collection of pus in iliopsoas compartment. May spread from blood (hematogenous) or from adjacent structures (eg, vertebral osteomyelitis, tuberculous spondylitis [also called Pott disease], pyelonephritis). Associated with Crohn disease, diabetes, and immunocompromised states.

Staphylococcus aureus most commonly isolated, but may also occur 2° to tuberculosis.

Findings: flank pain, fever, flank bulge, inguinal mass, ⊕ psoas sign (hip extension exacerbates lower abdominal pain).

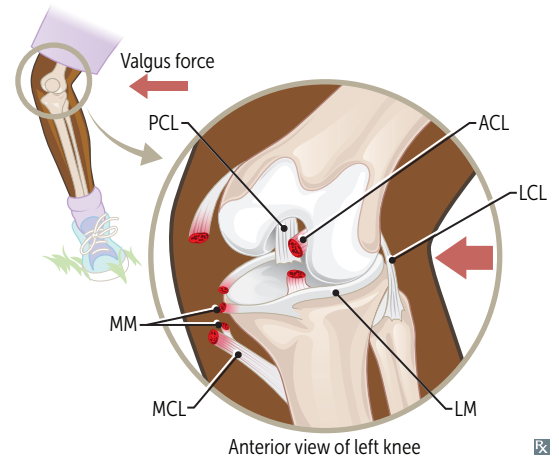
Labs: leukocytosis. Imaging (CT/MRI) will show focal hypodense lesion within the muscle plane.

Treatment: antibiotics based on culture, CT-guided percutaneous drainage (PCD), or surgical drainage.

Common knee conditions

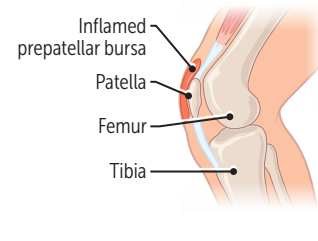
“Unhappy triad”

Common injury in contact sports due to lateral force impacting the knee when foot is planted on the ground. Consists of damage to the ACL **A**, MCL, and medial meniscus (attached to MCL). However, lateral meniscus involvement is more common than medial meniscus involvement in conjunction with ACL and MCL injury. Presents with acute pain and signs of joint instability.



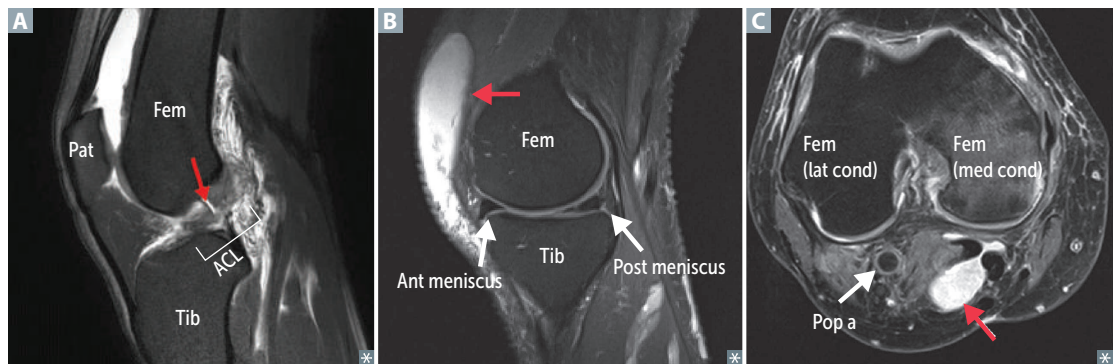
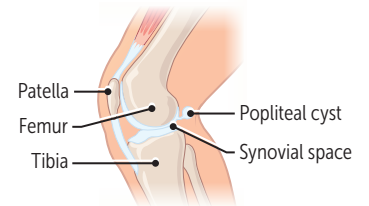
Prepatellar bursitis

Inflammation of the prepatellar bursa in front of the kneecap (red arrow in **B**). Can be caused by repeated trauma or pressure from excessive kneeling (also called “housemaid’s knee”).



Popliteal cyst

Also called Baker cyst. Popliteal fluid collection (red arrow in **C**) in gastrocnemius-semimembranosus bursa commonly communicating with synovial space and related to chronic joint disease (eg, osteoarthritis, rheumatoid arthritis).



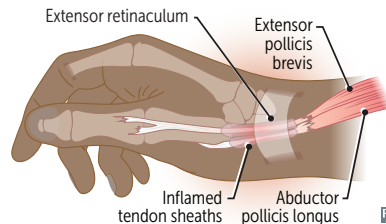
Common musculoskeletal conditions

Costochondritis

Inflammation of costochondral or costosternal junctions, may be due to minor trauma. Presents with pleuritic chest pain and focal tenderness to palpation. More common in younger female patients. May mimic myocardial infarction, pleuritis, or pulmonary embolism. Treatment: analgesics, stretching therapy.

De Quervain tenosynovitis

Noninflammatory thickening of abductor pollicis longus and extensor pollicis brevis tendons → pain or tenderness at radial styloid.
⊕ Finkelstein test (pain at radial styloid with active or passive stretch of thumb tendons).
↑ risk in new mothers (lifting baby), golfers, racquet sport players, “thumb” texters.



Dupuytren contracture

Caused by fibroblastic proliferation and thickening of superficial palmar fascia. Typically involves the fascia at the base of the ring and little fingers. Unknown etiology; most frequently seen in males > 50 years old of Northern European descent.

Ganglion cyst

Fluid-filled swelling overlying joint or tendon sheath, most commonly at dorsal side of wrist. Arises from herniation of dense connective tissue. Usually resolves spontaneously.

Iliotibial band syndrome

Overuse injury of lateral knee that occurs primarily in runners. Pain develops 2° to friction of iliotibial band against lateral femoral epicondyle.

Limb compartment syndrome

↑ pressure within fascial compartment of a limb → venous outflow obstruction and arteriolar collapse → anoxia, necrosis, rhabdomyolysis → acute tubular necrosis. Causes include significant long bone fractures (eg, tibia), reperfusion injury, animal venoms. Presents with severe pain and tense, swollen compartments with passive stretch of muscles in the affected compartment. Increased serum creatine kinase and motor deficits are late signs of irreversible muscle and nerve damage. **5 Ps:** pain, pallor, paresthesia, pulselessness, paralysis.

Medial tibial stress syndrome

Also called shin splints. Common cause of shin pain and diffuse tenderness in runners and military recruits. Caused by bone resorption that outpaces bone formation in tibial cortex.

Plantar fasciitis

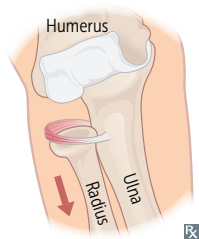
Inflammation of plantar aponeurosis characterized by heel pain (worse with first steps in the morning or after period of inactivity) and tenderness. Associated with obesity, prolonged standing or jumping (eg, dancers, runners), and flat feet. Heel spurs often coexist.

Temporomandibular disorders

Group of disorders that involve the temporomandibular joint (TMJ) and muscles of mastication. Multifactorial etiology; associated with TMJ trauma, poor head and neck posture, abnormal trigeminal nerve pain processing, psychological factors. Present with dull, constant unilateral facial pain that worsens with jaw movement, otalgia, headache, TMJ dysfunction (eg, limited range of motion).

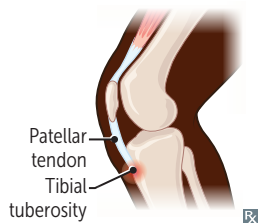
Childhood musculoskeletal conditions

Radial head subluxation



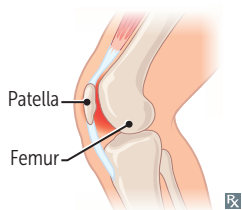
Also called nursemaid's elbow. Common elbow injury in children < 5 years. Caused by a sudden pull on the arm → immature annular ligament slips over head of radius. Injured arm held in slightly flexed and pronated position.

Osgood-Schlatter disease



Also called traction apophysitis. Overuse injury caused by repetitive strain and chronic avulsion of the secondary ossification center of proximal tibial tubercle. Occurs in adolescents after growth spurt. Common in running and jumping athletes. Presents with progressive anterior knee pain.

Patellofemoral syndrome



Overuse injury that commonly presents in young, female athletes as anterior knee pain. Exacerbated by prolonged sitting or weight-bearing on a flexed knee.

Developmental dysplasia of the hip

Abnormal acetabulum development in newborns. Risk factor is breech presentation. Results in hip instability/dislocation. Commonly tested with Ortolani and Barlow maneuvers (manipulation of newborn hip reveals a "clunk"). Confirmed via ultrasound (x-ray not used until ~4–6 months because cartilage is not ossified).

Legg-Calvé-Perthes disease

Idiopathic avascular necrosis of femoral head. Commonly presents between 5–7 years with insidious onset of hip pain that may cause child to limp. More common in males (4:1 ratio). Initial x-ray often normal.

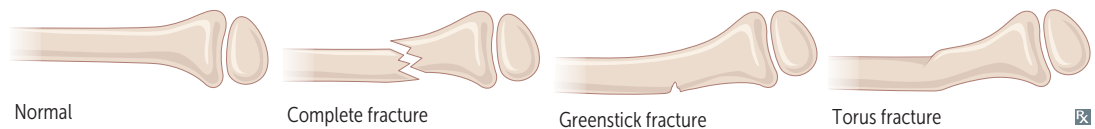
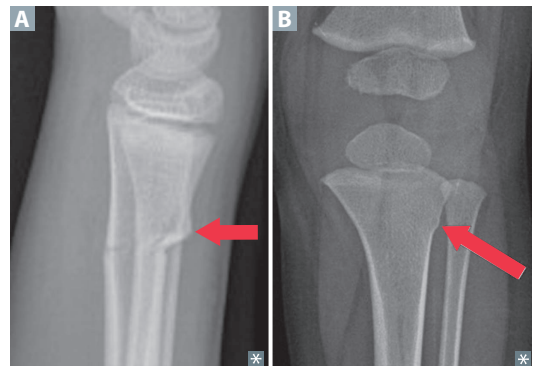
Slipped capital femoral epiphysis

Classically presents in an obese young adolescent with hip/knee pain and altered gait. Increased axial force on femoral head → epiphysis displaces relative to femoral neck (like a scoop of ice cream slipping off a cone). Diagnosed via x-ray.

Common pediatric fractures

Greenstick fracture Incomplete fracture extending partway through width of bone **A** following bending stress; bone fails on tension side; compression side intact (compare to torus fracture). Bone is bent like a **green twig**.

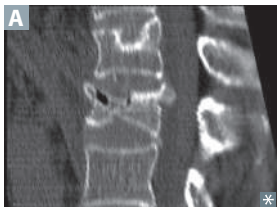Torus (buckle) fracture Axial force applied to immature bone → cortex buckles on compression (concave) side and fractures **B**. Tension (convex) side remains solid (intact).



Achondroplasia

Failure of longitudinal bone growth (endochondral ossification) → short limbs. Membranous ossification is not affected → large head relative to limbs. Constitutive activation of fibroblast growth factor receptor (FGFR3) actually inhibits chondrocyte proliferation. > 85% of mutations occur sporadically; autosomal dominant with full penetrance (homozygosity is lethal). Associated with ↑ paternal age. Most common cause of short-limbed dwarfism.

Osteoporosis



Trabecular (spongy) and cortical bone lose mass despite normal bone mineralization and lab values (serum Ca^{2+} and PO_4^{3-}).

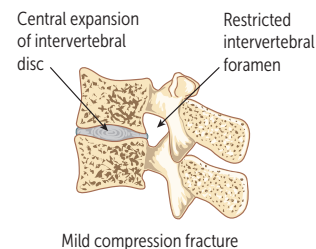
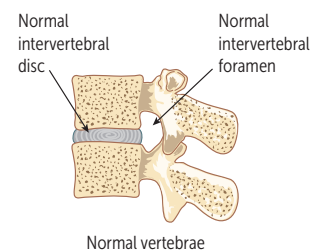
Most commonly due to ↑ bone resorption (↑ osteoclast number and activity) related to ↓ estrogen levels and old age. Can be 2° to drugs (eg, steroids, alcohol, anticonvulsants, anticoagulants, thyroid replacement therapy) or other conditions (eg, hyperparathyroidism, hyperthyroidism, multiple myeloma, malabsorption syndromes, anorexia).

Diagnosed by bone mineral density measurement by DEXA (dual-energy x-ray absorptiometry) at the lumbar spine, total hip, and femoral neck, with a T-score of ≤ -2.5 or by a fragility fracture (eg, fall from standing height, minimal trauma) at hip or vertebra. One-time screening recommended in females ≥ 65 years old.

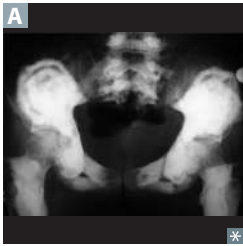
Prophylaxis: regular weight-bearing exercise and adequate Ca^{2+} and vitamin D intake throughout adulthood.

Treatment: bisphosphonates, teriparatide, SERMs, rarely calcitonin; denosumab (monoclonal antibody against RANKL).

Can lead to **vertebral compression fractures** **A**—acute back pain, loss of height, kyphosis. Also can present with fractures of femoral neck, distal radius (Colles fracture).



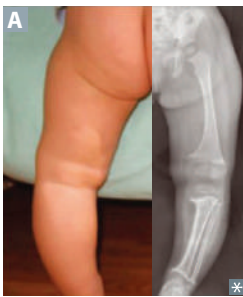Osteopetrosis



Failure of normal bone resorption due to defective osteoclasts → thickened, dense bones that are prone to fracture. Mutations (eg, carbonic anhydrase II) impair ability of osteoclast to generate acidic environment necessary for bone resorption. Overgrowth of cortical bone fills marrow space → pancytopenia, extramedullary hematopoiesis. Can result in cranial nerve impingement and palsies due to narrowed foramina.

X-rays show diffuse symmetric sclerosis (bone-in-bone, “stone bone” **A**). Bone marrow transplant is potentially curative as osteoclasts are derived from monocytes.

Osteomalacia/rickets

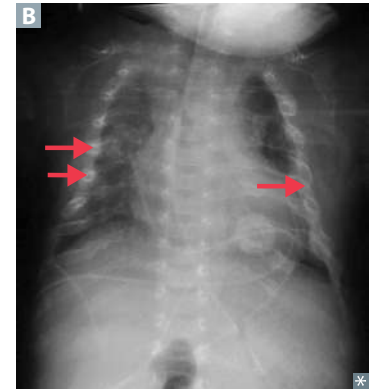


Defective mineralization of osteoid (osteomalacia) or cartilaginous growth plates (rickets, only in children). Most commonly due to vitamin D deficiency.

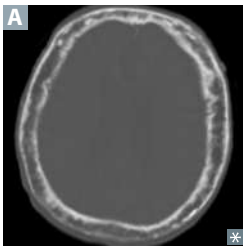
X-rays show osteopenia and pseudofractures in osteomalacia, epiphyseal widening and metaphyseal cupping/fraying in rickets. Children with rickets have pathologic bow legs (genu varum **A**), beadlike costochondral junctions (rachitic rosary **B**), craniotabes (soft skull).

↓ vitamin D → ↓ serum Ca²⁺ → ↑ PTH secretion → ↓ serum PO₄³⁻.

Hyperactivity of osteoblasts → ↑ ALP.



Osteitis deformans



Also called Paget disease of bone. Common, localized disorder of bone remodeling caused by ↑ osteoclastic activity followed by ↑ osteoblastic activity that forms poor-quality bone. Serum Ca²⁺, phosphorus, and PTH levels are normal. ↑ ALP. Mosaic pattern of woven and lamellar bone (osteocytes within lacunae in chaotic juxtapositions); long bone chalk-stick fractures. ↑ blood flow from ↑ arteriovenous shunts may cause high-output heart failure. ↑ risk of osteosarcoma.

Hat size can be increased due to skull thickening **A**; hearing loss is common due to skull deformity.

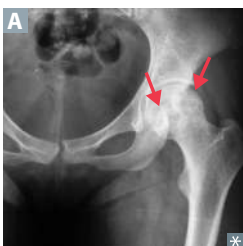
Stages of Paget disease:

- Early destructive (lytic): osteoclasts
- Intermediate (mixed): osteoclasts + osteoblasts
- Late (sclerotic/blastic): osteoblasts

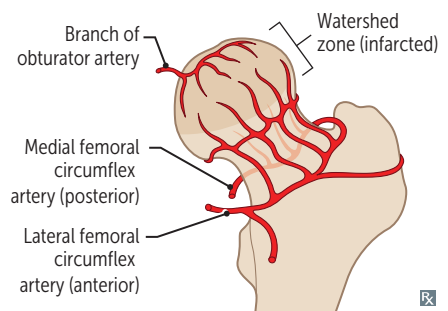
May enter quiescent phase.

Treatment: bisphosphonates.

Avascular necrosis of bone



Infarction of bone and marrow, usually very painful. Most common site is femoral head (watershed zone) **A** (due to insufficiency of medial circumflex femoral artery). Causes include glucocorticoids, chronic Alcohol overuse, Sickle cell disease, Trauma, SLE, “the Bends” (caisson/decompression disease), LEgg-Calvé-Perthes disease (idiopathic), Gaucher disease, Slipped capital femoral epiphysis—**CASTS Bend LEGS**.



Lab values in bone disorders

DISORDER	SERUM Ca ²⁺	PO ₄ ³⁻	ALP	PTH	COMMENTS
Osteoporosis	—	—	—	—	↓ bone mass
Osteopetrosis	—/↓	—	—	—	Dense, brittle bones. Ca ²⁺ ↓ in severe, malignant disease
Paget disease of bone	—	—	↑	—	Abnormal “mosaic” bone architecture
Osteitis fibrosa cystica Primary hyperparathyroidism	↑	↓	↑	↑	“Brown tumors” due to fibrous replacement of bone, subperiosteal thinning Idiopathic or parathyroid hyperplasia, adenoma, carcinoma
Secondary hyperparathyroidism	↓	↑	↑	↑	Often as compensation for CKD (↓ PO ₄ ³⁻ excretion and production of activated vitamin D)
Osteomalacia/rickets	↓	↓	↑	↑	Soft bones; vitamin D deficiency also causes 2° hyperparathyroidism
Hypervitaminosis D	↑	↑	—	↓	Caused by oversupplementation or granulomatous disease (eg, sarcoidosis)

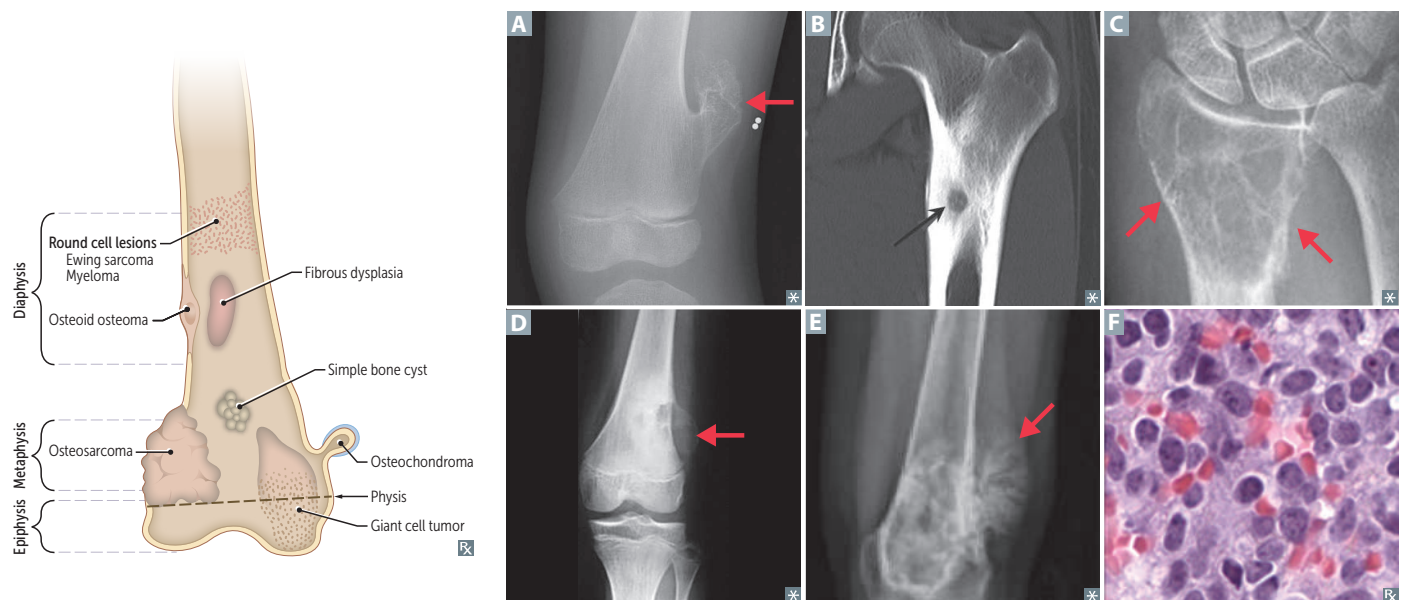
↑ ↓ = 1° change.

Primary bone tumors Metastatic disease is more common than 1° bone tumors. Benign bone tumors that start with **o** are more common in **boys**.

TUMOR TYPE	EPIDEMIOLOGY	LOCATION	CHARACTERISTICS
Benign tumors			
Osteochondroma	Most common benign bone tumor Males < 25 years old	Metaphysis of long bones	Lateral bony projection of growth plate (continuous with marrow space) covered by cartilaginous cap A Rarely transforms to chondrosarcoma
Osteoma	Middle age	Surface of facial bones	Associated with Gardner syndrome
Osteoid osteoma	Adults < 25 years old Males > females	Cortex of long bones	Presents as bone pain (worse at night) that is relieved by NSAIDs Bony mass (< 2 cm) with radiolucent osteoid core B
Osteoblastoma	Males > females	Vertebrae	Similar histology to osteoid osteoma Larger size (> 2 cm), pain unresponsive to NSAIDs
Chondroma		Medulla of small bones of hand and feet	Benign tumor of cartilage
Giant cell tumor	20–40 years old	Epiphysis of long bones (often in knee region)	Locally aggressive benign tumor Neoplastic mononuclear cells that express RANKL and reactive multinucleated giant (osteoclastlike) cells. “Osteoclastoma” “Soap bubble” appearance on x-ray C

Primary bone tumors (continued)

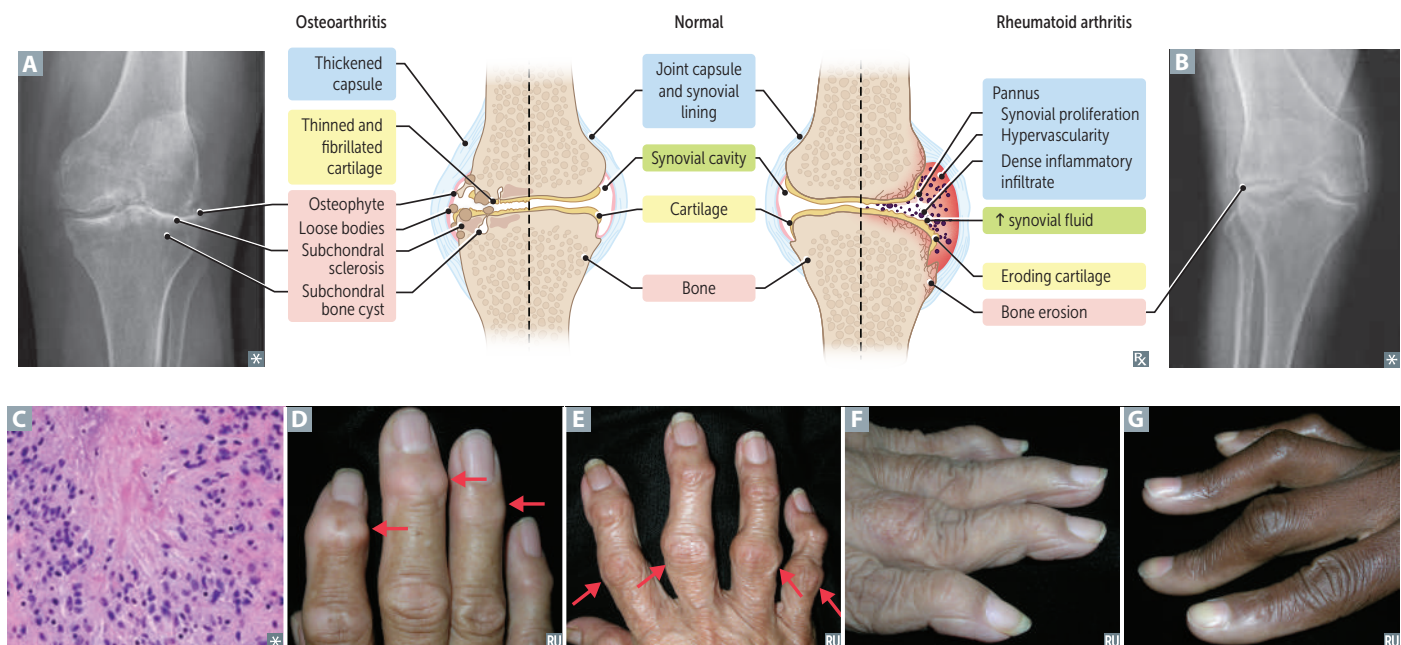
TUMOR TYPE	EPIDEMIOLOGY	LOCATION	CHARACTERISTICS
Malignant tumors			
Osteosarcoma (osteogenic sarcoma)	Accounts for 20% of 1° bone cancers. Peak incidence of 1° tumor in males < 20 years. Less common in older adults; usually 2° to predisposing factors, such as Paget disease of bone, bone infarcts, radiation, familial retinoblastoma, Li-Fraumeni syndrome.	Metaphysis of long bones (often in knee region).	Pleomorphic osteoid-producing cells (malignant osteoblasts). Presents as painful enlarging mass or pathologic fractures. Codman triangle D (from elevation of periosteum) or sunburst pattern on x-ray E (think of an osteocod [bone fish] swimming in the sun). Aggressive. 1° usually responsive to treatment (surgery, chemotherapy), poor prognosis for 2°.
Chondrosarcoma	Most common in adults > 50 years old.	Medulla of pelvis, proximal femur and humerus.	Tumor of malignant chondrocytes. Lytic (> 50%) cases with intralesional calcifications, endosteal erosion, cortex breach.
Ewing sarcoma	Most common in White patients, generally males < 15 years old.	Diaphysis of long bones (especially femur), pelvic flat bones.	Anaplastic small blue cells of neuroectodermal (mesenchymal) origin (resemble lymphocytes) F . Differentiate from conditions with similar morphology (eg, lymphoma, chronic osteomyelitis) by testing for t(11;22) (fusion protein EWS-FLI1). “Onion skin” periosteal reaction. Aggressive with early metastases, but responsive to chemotherapy. 11 + 22 = 33 (Patrick Ewing’s jersey number).



Osteoarthritis vs rheumatoid arthritis

	Osteoarthritis A	Rheumatoid arthritis B
PATHOGENESIS	Mechanical—wear and tear destroys articular cartilage (degenerative joint disorder) → inflammation with inadequate repair. Chondrocytes mediate degradation and inadequate repair.	Autoimmune—inflammation C induces formation of pannus (proliferative granulation tissue), which erodes articular cartilage and bone.
PREDISPOSING FACTORS	Age, female, obesity, joint trauma.	Female, HLA-DR4 (4-walled “rheum”), tobacco smoking. ⊕ rheumatoid factor (IgM antibody that targets IgG Fc region; in 80%), anti-cyclic citrullinated peptide antibody (more specific).
PRESENTATION	Pain in weight-bearing joints after use (eg, at the end of the day), improving with rest. Asymmetric joint involvement. Knee cartilage loss begins medially (“bowlegged”). No systemic symptoms.	Pain, swelling, and morning stiffness lasting > 1 hour, improving with use. Symmetric joint involvement. Systemic symptoms (fever, fatigue, weight loss). Extraarticular manifestations common.*
JOINT FINDINGS	Osteophytes (bone spurs), joint space narrowing (asymmetric), subchondral sclerosis and cysts. Synovial fluid noninflammatory (WBC < 2000/mm ³). Development of Heberden nodes D (at DIP) and Bouchard nodes E (at PIP), and 1st CMC; not MCP.	Erosions, juxta-articular osteopenia, soft tissue swelling, subchondral cysts, joint space narrowing (symmetric). Deformities: cervical subluxation, ulnar finger deviation, swan neck F , boutonniere G . Involves MCP, PIP, wrist; not DIP or 1st CMC.
TREATMENT	Activity modification, acetaminophen, NSAIDs, intra-articular glucocorticoids.	NSAIDs, glucocorticoids, disease-modifying agents (eg, methotrexate, sulfasalazine), biologic agents (eg, TNF- α inhibitors).

*Extraarticular manifestations include rheumatoid nodules (fibrinoid necrosis with palisading histiocytes) in subcutaneous tissue and lung (+ pneumoconiosis → Caplan syndrome), interstitial lung disease, pleuritis, pericarditis, anemia of chronic disease, neutropenia + splenomegaly (Felty syndrome), AA amyloidosis, Sjögren syndrome, scleritis, carpal tunnel syndrome.



Gout**FINDINGS**

Acute inflammatory monoarthritis caused by precipitation of monosodium urate crystals in joints **A**. Risk factors: male sex, hypertension, obesity, diabetes, dyslipidemia, alcohol use.

Strongest risk factor is hyperuricemia, which can be caused by:

- Underexcretion of uric acid (90% of patients)—largely idiopathic, potentiated by renal failure; can be exacerbated by alcohol and certain medications (eg, thiazide diuretics).
- Overproduction of uric acid (10% of patients)—Lesch-Nyhan syndrome, PRPP excess, ↑ cell turnover (eg, tumor lysis syndrome), von Gierke disease.

Crystals are needle shaped and ⊖ birefringent under polarized light (yellow under parallel light, blue under perpendicular light **B**). Serum uric acid levels may be normal during an acute attack.

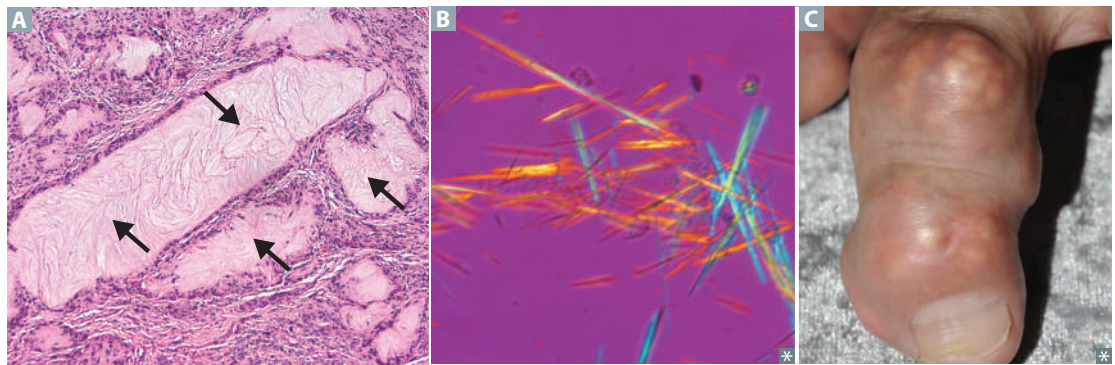
SYMPTOMS

Asymmetric joint distribution. Joint is swollen, red, and painful. Classic manifestation is painful MTP joint of big toe (podagra). Tophus formation **C** (often on external ear, olecranon bursa, or Achilles tendon). Acute attack tends to occur after a large meal with foods rich in purines (eg, red meat, seafood), trauma, surgery, dehydration, diuresis, or alcohol consumption (alcohol [beer > spirits] metabolites compete for same excretion sites in kidney as uric acid → ↓ uric acid secretion and subsequent buildup in blood).

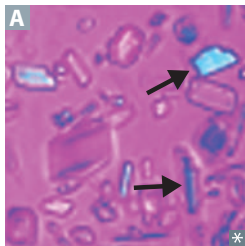
TREATMENT

Acute: NSAIDs (eg, indomethacin), glucocorticoids, colchicine.

Chronic (preventive): xanthine oxidase inhibitors (eg, allopurinol, febuxostat).



Calcium pyrophosphate deposition disease



Formerly called pseudogout. Deposition of calcium pyrophosphate crystals within the joint space. Occurs in patients > 50 years old; both sexes affected equally. Usually idiopathic, sometimes associated with hemochromatosis, hyperparathyroidism, joint trauma.

Pain and swelling with acute inflammation (pseudogout) and/or chronic degeneration (pseudo-osteoarthritis). Most commonly affected joint is the knee.

Chondrocalcinosis (cartilage calcification) on x-ray.

Crystals are rhomboid and weakly ⊕ birefringent under polarized light (blue when parallel to light) **A**.

Acute treatment: NSAIDs, colchicine, glucocorticoids.

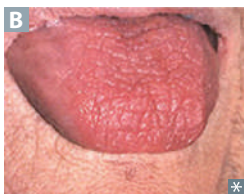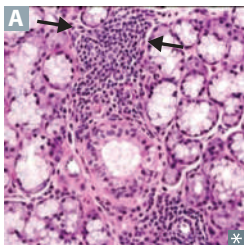
Prophylaxis: colchicine.

The **blue P's** of CPPD—**blue** (when parallel), **positive** birefringence, calcium **pyrophosphate**, **pseudogout**.

Systemic juvenile idiopathic arthritis

Systemic arthritis seen in < 16 year olds. Usually presents with daily spiking fevers, salmon-pink macular rash, arthritis (commonly 2+ joints). Associated with anterior uveitis. Frequently presents with leukocytosis, thrombocytosis, anemia, ↑ ESR, ↑ CRP. Treatment: NSAIDs, steroids, methotrexate, TNF inhibitors.

Sjögren syndrome



Autoimmune disorder characterized by destruction of exocrine glands (especially lacrimal and salivary) by lymphocytic infiltrates **A**. Predominantly affects females 40–60 years old.

Findings:

- Inflammatory joint pain
- Keratoconjunctivitis sicca (decreased tear production and subsequent corneal damage) → gritty or sandy feeling in eyes
- Xerostomia (↓ saliva production) → mucosal atrophy, fissuring of the tongue **B**
- Presence of antinuclear antibodies, rheumatoid factor (can be positive in the absence of rheumatoid arthritis), antiribonucleoprotein antibodies: SS-A (anti-Ro) and/or SS-B (anti-La)
- Bilateral parotid enlargement

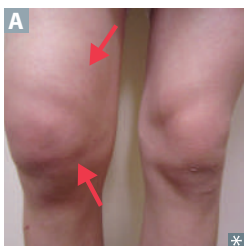Anti-SSA and anti-SSB may also be seen in SLE.

A common 1° disorder or a 2° syndrome associated with other autoimmune disorders (eg, rheumatoid arthritis, SLE, systemic sclerosis).

Complications: dental caries; mucosa-associated lymphoid tissue (MALT) lymphoma (may present as parotid enlargement); ↑ risk of giving birth to baby with neonatal lupus.

Focal lymphocytic sialadenitis on labial salivary gland biopsy can confirm diagnosis.

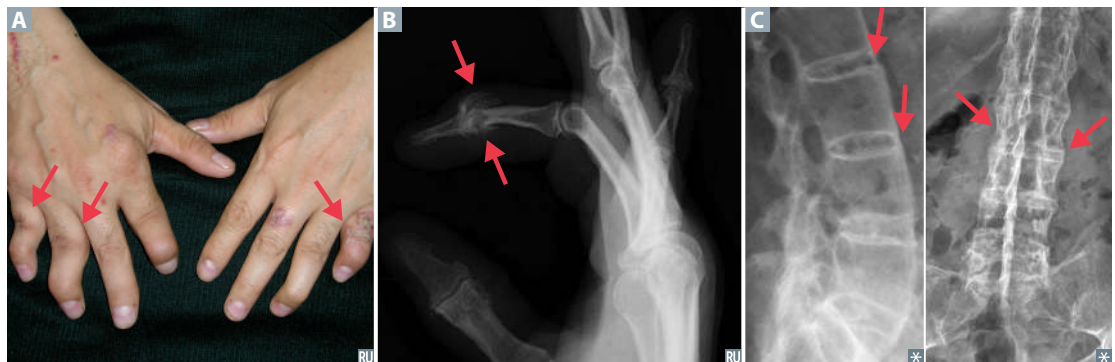Septic arthritis



S aureus, *Streptococcus*, and *Neisseria gonorrhoeae* are common causes. Usually unilateral. Affected joint is swollen **A**, red, and painful. Synovial fluid purulent (WBC > 50,000/mm³). Treatment: antibiotics, aspiration, and drainage (+/- debridement) to prevent irreversible joint damage.

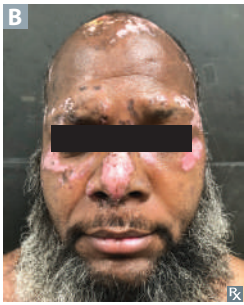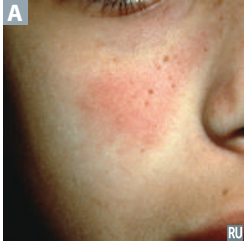Disseminated gonococcal infection—STI that presents as either purulent arthritis (eg, knee) or triad of polyarthralgia, tenosynovitis (eg, hand), dermatitis (eg, pustules).

Seronegative spondyloarthritis	Arthritis without rheumatoid factor (no anti-IgG antibody). Strong association with HLA-B27 (MHC class I serotype). Subtypes (PAIR) share variable occurrence of inflammatory back pain (associated with morning stiffness, improves with exercise), peripheral arthritis, enthesitis (inflamed insertion sites of tendons, eg, Achilles), dactylitis (“sausage fingers”), uveitis.	
Psoriatic arthritis	Associated with skin psoriasis and nail lesions. Asymmetric and patchy involvement A . Dactylitis and “pencil-in-cup” deformity of DIP on x-ray B .	Seen in fewer than 1/3 of patients with psoriasis.
Ankylosing spondylitis	Symmetric involvement of spine and sacroiliac joints → ankylosis (joint fusion), uveitis, aortic regurgitation.	Bamboo spine (vertebral fusion) C . Costovertebral and costosternal ankylosis may cause restrictive lung disease. Monitor degree of reduced chest wall expansion to assess disease severity. More common in males, with age of onset usually 20–40 years.
Inflammatory bowel disease	Crohn disease and ulcerative colitis are often associated with spondyloarthritis.	
Reactive arthritis	Classic triad: <ul style="list-style-type: none"> ▪ Conjunctivitis ▪ Urethritis ▪ Arthritis 	“Can’t see , can’t pee , can’t bend my knee .” Associated with infections by <i>Shigella</i> , <i>Campylobacter</i> , <i>E coli</i> , <i>Salmonella</i> , <i>Chlamydia</i> , <i>Yersinia</i> . “She C ought E very S tudent C heating Y esterday and over r eacted.”



Systemic lupus erythematosus

Systemic, remitting, and relapsing autoimmune disease. Organ damage primarily due to a type III hypersensitivity reaction and, to a lesser degree, a type II hypersensitivity reaction. Associated with deficiency of early complement proteins (eg, C1q, C4, C2) → ↓ clearance of immune complexes. Classic presentation: rash, joint pain, and fever in a female of reproductive age. ↑ prevalence in Black, Caribbean, Asian, and Hispanic populations in the US.



Libman-Sacks Endocarditis (LSE in SLE).

Lupus nephritis (glomerular deposition of DNA-anti-DNA immune complexes) can be nephritic or nephrotic (causing hematuria or proteinuria). Most common and severe type is diffuse proliferative.

Common causes of death in SLE: renal disease (most common), infections, cardiovascular disease (accelerated CAD). Lupus patients die with redness in their cheeks.

In an anti-SSA ⊕ pregnant patient, ↑ risk of newborn developing **neonatal lupus** → congenital heart block, periorbital/diffuse rash, transaminitis, and cytopenias at birth.

RASH OR PAIN:

Rash (malar **A** or discoid **B**)

Arthritis (nonerosive)

Serositis (eg, pleuritis, pericarditis)

Hematologic disorders (eg, cytopenias)

Oral/nasopharyngeal ulcers (usually painless)

Renal disease

Photosensitivity

Antinuclear antibodies

Immunologic disorder (anti-dsDNA, anti-Sm, antiphospholipid)

Neurologic disorders (eg, seizures, psychosis)

Mixed connective tissue disease

Features of SLE, systemic sclerosis, and/or polymyositis. Associated with anti-U1 RNP antibodies (speckled ANA).

Antiphospholipid syndrome

1° or 2° autoimmune disorder (most commonly in SLE).

Diagnosed based on clinical criteria including history of thrombosis (arterial or venous) or spontaneous abortion along with laboratory findings of lupus anticoagulant, anticardiolipin, anti-β₂ glycoprotein I antibodies.

Treatment: systemic anticoagulation.

Anticardiolipin antibodies can cause false-positive VDRL/RPR.

Lupus anticoagulant can cause prolonged PTT that is not corrected by the addition of normal platelet-free plasma.

Polymyalgia rheumatica

SYMPTOMS	Pain and stiffness in proximal muscles (eg, shoulders, hips), often with fever, malaise, weight loss. Does not cause muscular weakness. More common in females > 50 years old; associated with giant cell (temporal) arteritis.
FINDINGS	↑ ESR, ↑ CRP, normal CK.
TREATMENT	Rapid response to low-dose glucocorticoids.

Fibromyalgia

Most common in females 20–50 years old. Chronic, widespread musculoskeletal pain associated with “tender points,” stiffness, paresthesias, poor sleep, fatigue, cognitive disturbance (“fibro fog”). Normal inflammatory markers like ESR. Treatment: regular exercise, antidepressants (TCAs, SNRIs), neuropathic pain agents (eg, gabapentin).

**Polymyositis/
dermatomyositis**

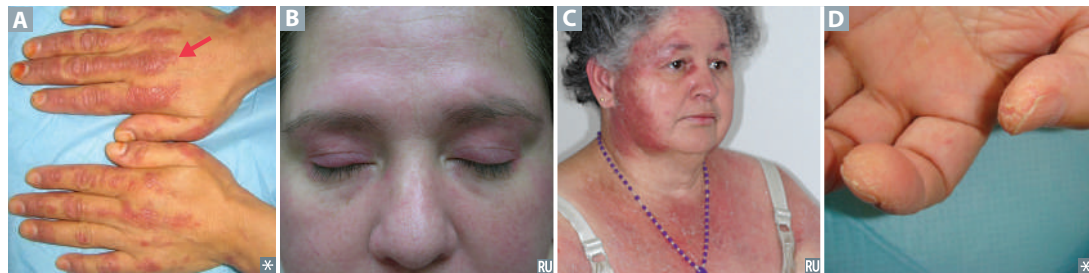Nonspecific: ⊕ ANA, ↑ CK. Specific: ⊕ anti-Jo-1 (histidyl-tRNA synthetase), ⊕ anti-SRP (signal recognition particle), ⊕ anti-Mi-2 (helicase).

Polymyositis

Progressive symmetric proximal muscle weakness, characterized by endomysial inflammation with CD8+ T cells. Most often involves shoulders.

Dermatomyositis

Clinically similar to polymyositis, but also involves Gottron papules **A**, photodistributed facial erythema (eg, heliotrope [violaceous] edema of the eyelids **B**), “shawl and face” rash **C**, mechanic’s hands (thickening, cracking, irregular “dirty”-appearing marks due to hyperkeratosis of digital skin **D**). ↑ risk of occult malignancy. Perimysial inflammation and atrophy with CD4+ T cells.

**Myositis ossificans**

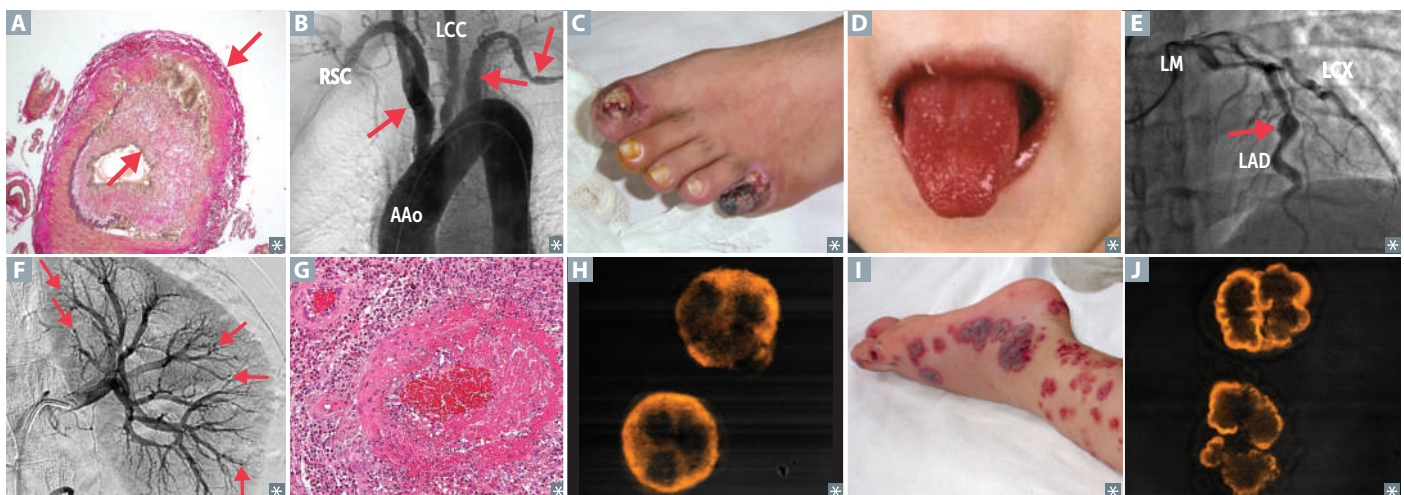
Heterotopic ossification involving skeletal muscle (eg, quadriceps). Associated with blunt muscle trauma. Presents as painful soft tissue mass. Imaging: eggshell calcification. Histology: metaplastic bone surrounding area of fibroblastic proliferation. Benign, but may be mistaken for sarcoma.

Vasculitides

	EPIDEMIOLOGY/PRESENTATION	NOTES
Large-vessel vasculitis		
Giant cell (temporal) arteritis	Females > 50 years old. Unilateral headache, possible temporal artery tenderness, jaw claudication. May lead to irreversible blindness due to anterior ischemic optic neuropathy. Associated with polymyalgia rheumatica.	Most commonly affects branches of carotid artery. Focal granulomatous inflammation A . ↑↑ ESR. IL-6 levels correlate with disease activity. Treat with high-dose glucocorticoids prior to temporal artery biopsy to prevent blindness.
Takayasu arteritis	Usually Asian females < 40 years old. “Pulseless disease” (weak upper extremity pulses), fever, night sweats, arthritis, myalgias, skin nodules, ocular disturbances.	Granulomatous thickening and narrowing of aortic arch and proximal great vessels B . ↑ ESR. Treatment: glucocorticoids.
Medium-vessel vasculitis		
Buerger disease (thromboangiitis obliterans)	Heavy tobacco smoking history, males < 40 years old. Intermittent claudication. May lead to gangrene C , autoamputation of digits, superficial nodular phlebitis. Raynaud phenomenon is often present.	Segmental thrombosing vasculitis with vein and nerve involvement. Treatment: smoking cessation.
Kawasaki disease	Usually Asian children < 4 years old. Bilateral nonexudative bulbar Conjunctivitis, Rash (polymorphous → desquamating), Adenopathy (cervical), Strawberry tongue (oral mucositis) D , Hand-foot changes (edema, erythema), fever.	Formerly called mucocutaneous lymph node syndrome. CRASH and burn on a Kawasaki . May develop coronary artery aneurysms E ; thrombosis or rupture can cause death. Treatment: IV immunoglobulin and aspirin.
Polyarteritis nodosa	Usually middle-aged males. Hepatitis B seropositivity in 30% of patients. Fever, weight loss, malaise, headache. GI: abdominal pain, melena. Hypertension, neurologic dysfunction, cutaneous eruptions, renal damage.	Typically involves renal and visceral vessels, not pulmonary arteries. Different stages of transmural inflammation with fibrinoid necrosis. Innumerable renal microaneurysms F and spasms on arteriogram (string of pearls appearance). Treatment: glucocorticoids, cyclophosphamide.
Small-vessel vasculitis		
Behçet syndrome	↑ incidence in people of Turkish and eastern Mediterranean descent. Recurrent aphthous ulcers, genital ulcerations, uveitis, erythema nodosum. Can be precipitated by HSV or parvovirus. Flares last 1–4 weeks.	Immune complex vasculitis. Associated with HLA-B51.
Cutaneous small-vessel vasculitis	Occurs 7–10 days after certain medications (penicillins, cephalosporins, sulfonamides, phenytoin, allopurinol) or infections (eg, HCV, HIV). Palpable purpura, no visceral involvement.	Immune complex–mediated leukocytoclastic vasculitis; late involvement indicates systemic vasculitis.

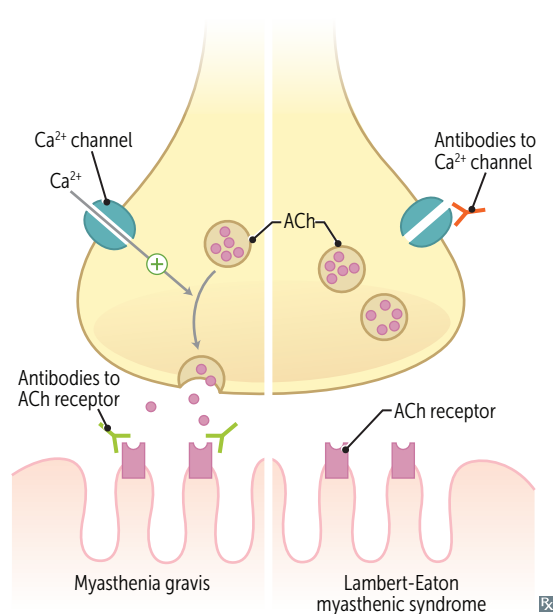
Vasculitides (continued)

	EPIDEMIOLOGY/PRESENTATION	NOTES
Small-vessel vasculitis (continued)		
Eosinophilic granulomatosis with polyangiitis	Asthma, sinusitis, skin nodules or purpura, peripheral neuropathy (eg, wrist/foot drop). Can also involve heart, GI, kidneys (pauci-immune glomerulonephritis).	Formerly called Churg-Strauss syndrome. Granulomatous, necrotizing vasculitis with eosinophilia G . MPO-ANCA/p-ANCA, ↑ IgE level.
Granulomatosis with polyangiitis	Upper respiratory tract: perforation of nasal septum, chronic sinusitis, otitis media, mastoiditis. Lower respiratory tract: hemoptysis, cough, dyspnea. Renal: hematuria, red cell casts.	Triad: <ul style="list-style-type: none"> ▪ Focal necrotizing vasculitis ▪ Necrotizing granulomas in lung and upper airway ▪ Necrotizing glomerulonephritis PR3-ANCA/c-ANCA H (anti-proteinase 3). CXR: large nodular densities. Treatment: glucocorticoids in combination with rituximab or cyclophosphamide.
Immunoglobulin A vasculitis	Most common childhood systemic vasculitis. Often follows URI. Classic triad: <ul style="list-style-type: none"> ▪ Hinge pain (arthralgias) ▪ Stomach pain (abdominal pain associated with intussusception) ▪ Palpable purpura on buttocks/legs I 	Formerly called Henoch-Schönlein purpura. Vasculitis 2° to IgA immune complex deposition. Associated with IgA nephropathy (Berger disease). Treatment: supportive care, possibly glucocorticoids.
Microscopic polyangiitis	Necrotizing vasculitis commonly involving lung, kidneys, and skin with pauci-immune glomerulonephritis and palpable purpura. Presentation similar to granulomatosis with polyangiitis but without nasopharyngeal involvement.	No granulomas. MPO-ANCA/p-ANCA J (anti-myeloperoxidase). Treatment: cyclophosphamide, glucocorticoids.
Mixed cryoglobulinemia	Often due to viral infections, especially HCV. Triad of palpable purpura, weakness, arthralgias. May also have peripheral neuropathy and renal disease (eg, glomerulonephritis).	Cryoglobulins are immunoglobulins that precipitate in the Cold. Vasculitis due to mixed IgG and IgM immune complex deposition.

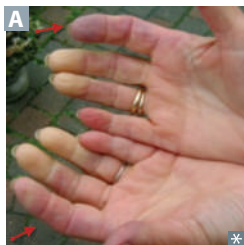


Neuromuscular junction diseases

	Myasthenia gravis	Lambert-Eaton myasthenic syndrome
FREQUENCY	Most common NMJ disorder	Uncommon
PATHOPHYSIOLOGY	Autoantibodies to postsynaptic ACh receptor	Autoantibodies to presynaptic Ca ²⁺ channel → ↓ ACh release; L comes before M
CLINICAL	Fatigable muscle weakness—ptosis; diplopia; proximal weakness; respiratory muscle involvement → dyspnea; bulbar muscle involvement → dysphagia, difficulty chewing Spared reflexes Worsens with muscle use	Proximal muscle weakness, autonomic symptoms (dry mouth, constipation, impotence) Hyporeflexia Improves with muscle use
ASSOCIATED WITH	Thymoma, thymic hyperplasia	Small cell lung cancer
ACH E INHIBITOR ADMINISTRATION	Reverses symptoms (pyridostigmine for treatment)	Minimal effect

**Raynaud phenomenon**

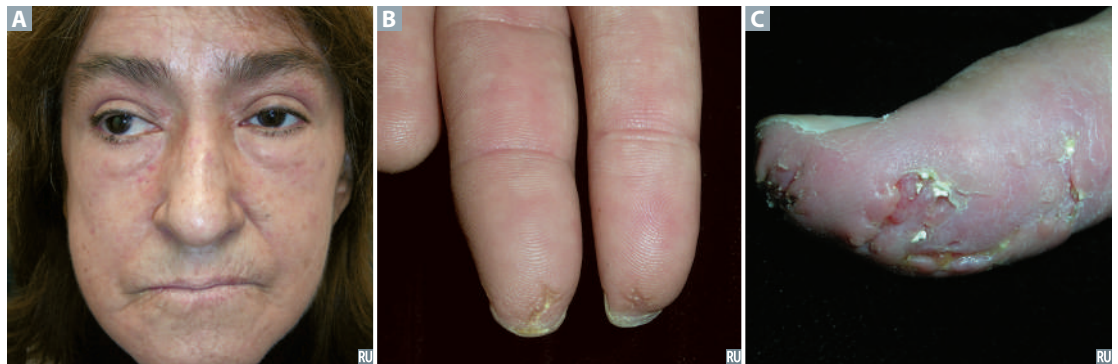↓ blood flow to skin due to arteriolar (small vessel) vasospasm in response to cold or stress: color change from white (ischemia) to blue (hypoxia) to red (reperfusion). Most often in the fingers **A** and toes. Called **Raynaud disease** when 1° (idiopathic), **Raynaud syndrome** when 2° to a disease process such as mixed connective tissue disease, SLE, or CREST syndrome (limited form of systemic sclerosis). Digital ulceration (critical ischemia) seen in 2° Raynaud syndrome. Treat with calcium channel blockers.



Scleroderma

Systemic sclerosis. Triad of autoimmunity, noninflammatory vasculopathy, and collagen deposition with fibrosis. Commonly sclerosis of skin, manifesting as puffy, taut skin **A** without wrinkles, fingertip pitting **B**. Can involve other systems, eg, renal (scleroderma renal crisis; treat with ACE inhibitors), pulmonary (interstitial fibrosis, pulmonary HTN), GI (↓ peristalsis and LES tone → dysphagia, heartburn), cardiovascular. 75% female. 2 major types:

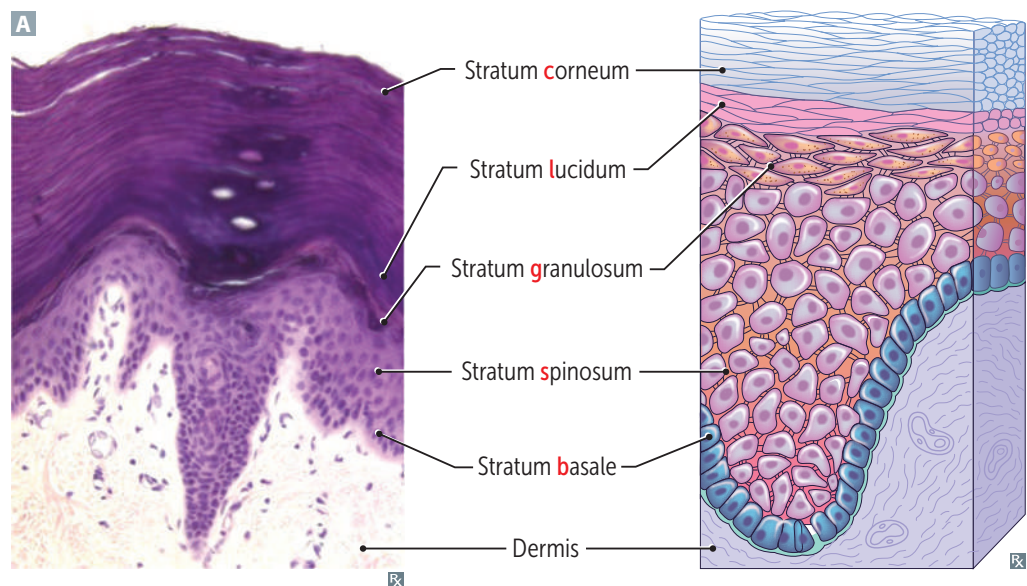
- **Diffuse scleroderma**—widespread skin involvement, rapid progression, early visceral involvement. Associated with anti-Scl-70 antibody (anti-DNA topoisomerase-I antibody) and anti-RNA polymerase III.
- **Limited scleroderma**—limited skin involvement confined to fingers and face. Also with **CREST** syndrome: **C**alcinosis cutis **C**, anti-**C**entromere antibody, **R**aynaud phenomenon, **E**sophageal dysmotility, **S**clerodactyly, and **T**elangiectasia. More benign clinical course.



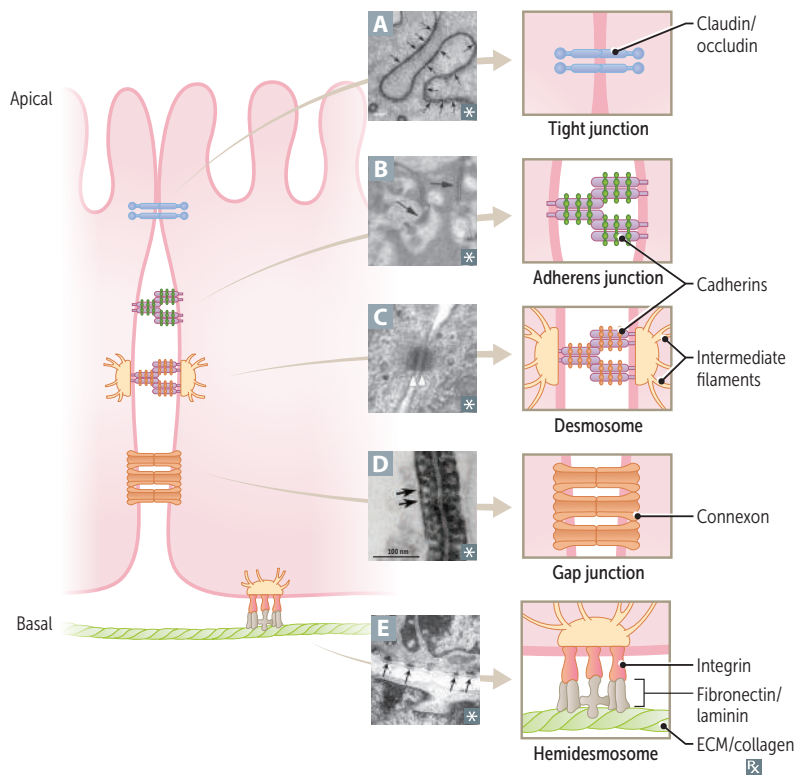
▶ MUSCULOSKELETAL, SKIN, AND CONNECTIVE TISSUE—DERMATOLOGY

Skin layers

Skin has 3 layers: epidermis, dermis, subcutaneous fat (hypodermis, subcutis).
Epidermal layers: **c**ome, **l**et's **g**et **s**unburned.



Epithelial cell junctions



Tight junctions (zonula occludens) **A**—prevents paracellular movement of solutes; composed of claudins and occludins.

Adherens junction (belt desmosome, zonula adherens) **B**—forms “belt” connecting actin cytoskeletons of adjacent cells with **cadherins** (Ca^{2+} -dependent **adhesion** proteins). Loss of E-cadherin promotes metastasis.

Desmosome (spot desmosome, macula adherens) **C**—structural support via intermediate filament interactions. Autoantibodies to desmoglein 1 and/or 3 → pemphigus vulgaris.

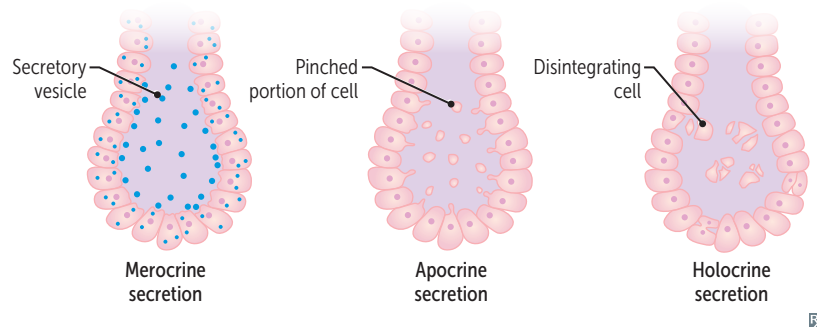
Gap junction **D**—channel proteins called connexons permit electrical and chemical communication between cells.

Hemidesmosome **E**—connects keratin in basal cells to underlying basement membrane. Autoantibodies → **bullous** pemphigoid. (Hemidesmosomes are down “**bullow**.”)

Integrins—membrane proteins that maintain **integrity** of basolateral membrane by binding to collagen, laminin, and fibronectin in basement membrane.

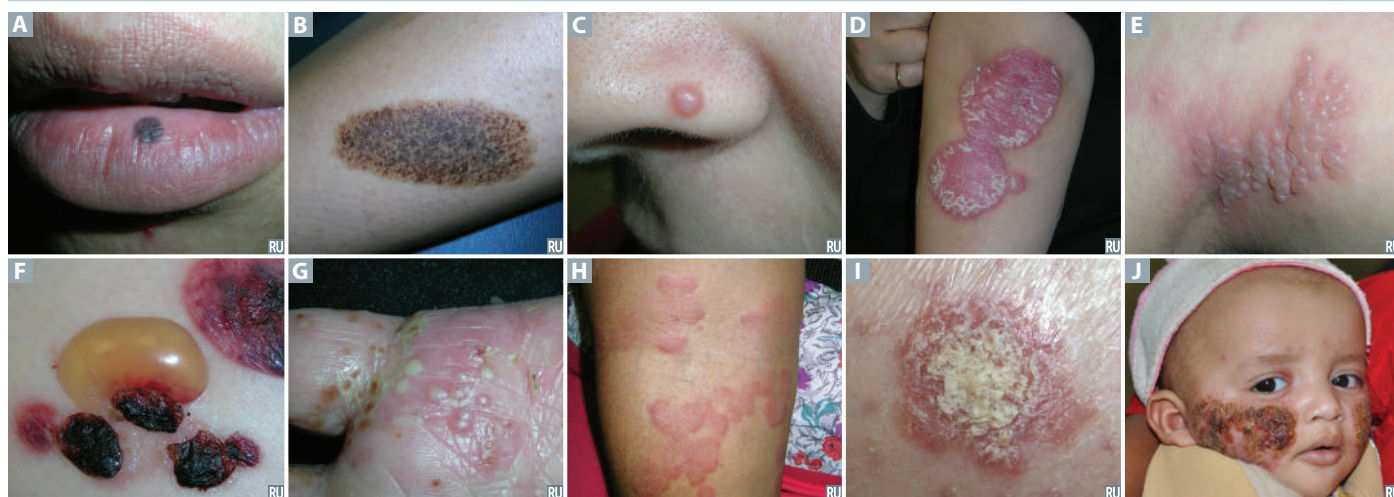Exocrine glands

Glands that produce substances other than hormones (vs endocrine glands, which secrete hormones) that are released through ducts to the exterior of the body. Can be merocrine (eg, salivary and sweat glands), apocrine (eg, mammary glands), or holocrine (eg, sebaceous glands).



Dermatologic macroscopic terms

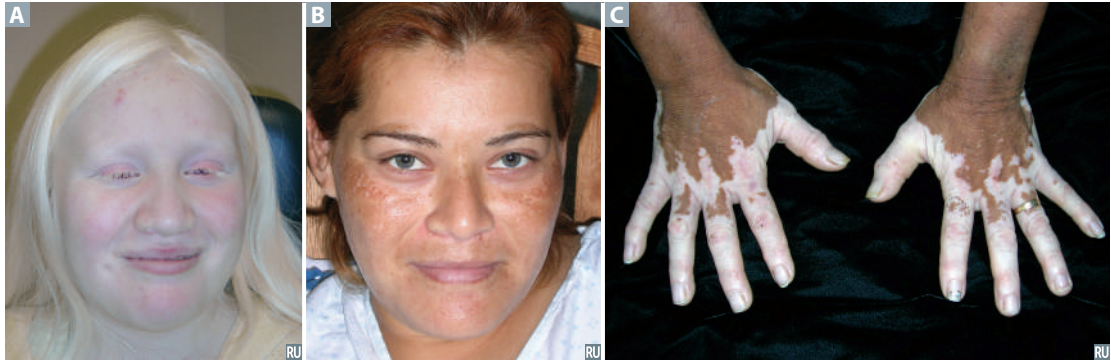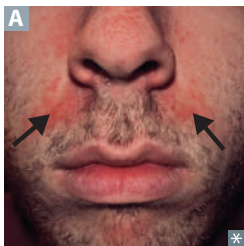LESION	CHARACTERISTICS	EXAMPLES
Macule	Flat lesion with well-circumscribed change in skin color < 1 cm	Freckle (ephelis), labial macule A
Patch	Macule > 1 cm	Large birthmark (congenital nevus) B
Papule	Elevated solid skin lesion < 1 cm	Mole (nevus) C , acne
Plaque	Papule > 1 cm	Psoriasis D
Vesicle	Small fluid-containing blister < 1 cm	Chickenpox (varicella), shingles (zoster) E
Bulla	Large fluid-containing blister > 1 cm	Bullous pemphigoid F
Pustule	Vesicle containing pus	Pustular psoriasis G
Wheal	Transient smooth papule or plaque	Hives (urticaria) H
Scale	Flaking off of stratum corneum	Eczema, psoriasis, SCC I
Crust	Dry exudate	Impetigo J

**Dermatologic microscopic terms**

LESION	CHARACTERISTICS	EXAMPLES
Dyskeratosis	Abnormal premature keratinization	Squamous cell carcinoma
Hyperkeratosis	↑ thickness of stratum corneum	Psoriasis, calluses
Parakeratosis	Retention of nuclei in stratum corneum	Psoriasis, actinic keratosis
Hypergranulosis	↑ thickness of stratum granulosum	Lichen planus
Spongiosis	Epidermal accumulation of edematous fluid in intercellular spaces	Eczematous dermatitis
Acantholysis	Separation of epidermal cells	Pemphigus vulgaris
Acanthosis	Epidermal hyperplasia (↑ spinosum)	Acanthosis nigricans, psoriasis

Pigmented skin disorders

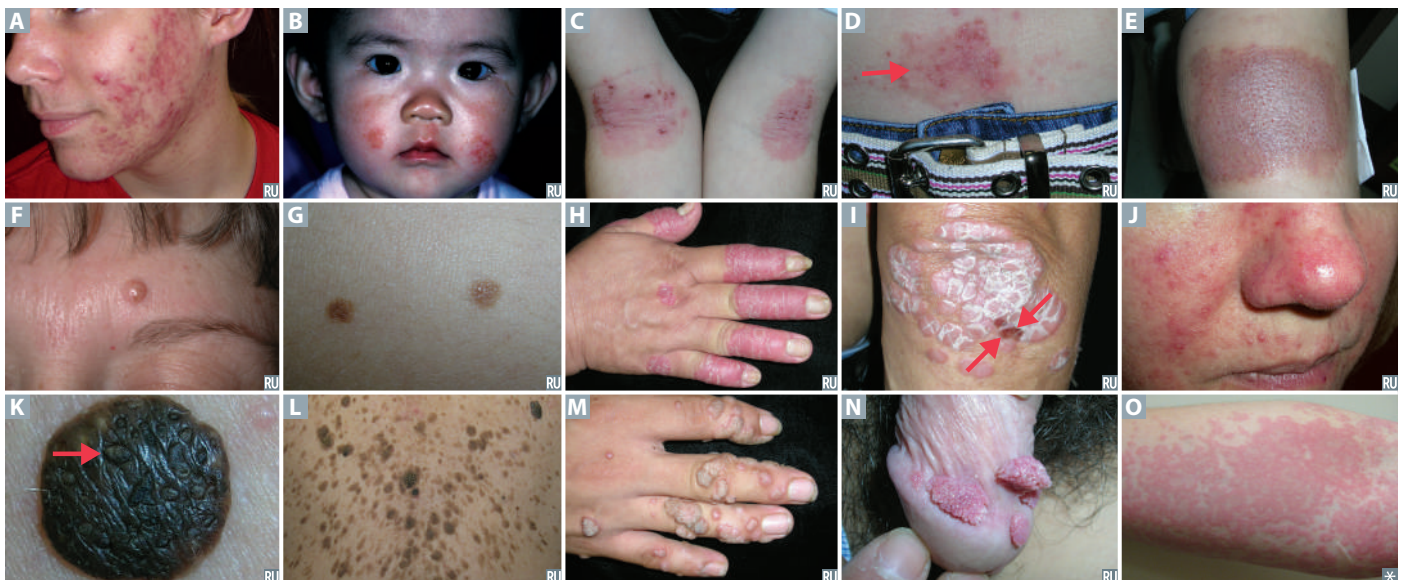Albinism	Normal melanocyte number with ↓ melanin production A due to ↓ tyrosinase activity or defective tyrosine transport. ↑ risk of skin cancer.
Melasma (chloasma)	Acquired hyperpigmentation associated with pregnancy (“mask of pregnancy” B) or OCP use. More common in patients with darker skin tones.
Vitiligo	Irregular patches of complete depigmentation C . Caused by destruction of melanocytes (believed to be autoimmune). Associated with other autoimmune disorders.
Waardenburg syndrome	Patchy depigmentation of skin, hair, and irises that can be associated with deafness. Caused by defects in the differentiation of neural crest cells into melanocytes.

**Seborrheic dermatitis**

Erythematous, well-demarcated plaques **A** with greasy yellow scales in areas rich in sebaceous glands, such as scalp, face, and periocular region. Common in both infants (cradle cap) and adults, associated with Parkinson disease. Sebaceous glands are not inflamed, but play a role in disease development. Possibly associated with *Malassezia* spp. Treatment: topical antifungals and glucocorticoids.

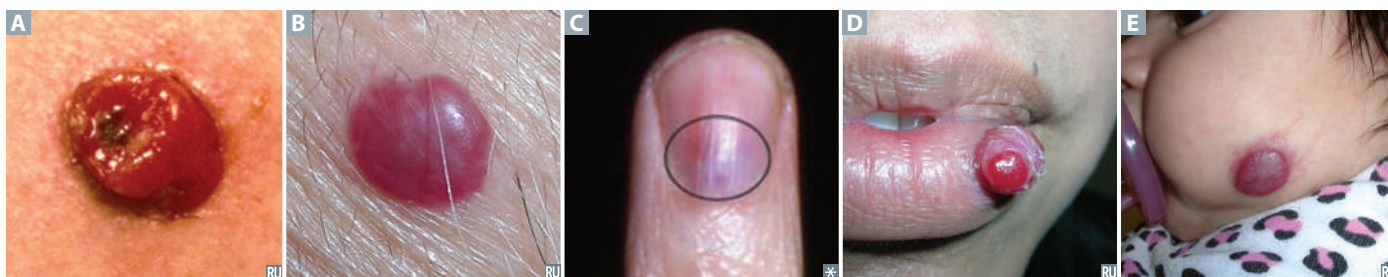
Common skin disorders

Acne	Multifactorial etiology—↑ sebum/androgen production, abnormal keratinocyte desquamation, <i>Cutibacterium acnes</i> colonization of the pilosebaceous unit (comedones), and inflammation (papules/pustules A , nodules, cysts). Treatment: retinoids, benzoyl peroxide, and antibiotics.
Atopic dermatitis (eczema)	Type I hypersensitivity reaction. Pruritic eruption, commonly on skin flexures. Associated with other atopic diseases (asthma, allergic rhinitis, food allergies); ↑ serum IgE. Mutations in filaggrin gene predispose (via skin barrier dysfunction). Often appears on face in infancy B and then in antecubital fossa C in children and adults.
Allergic contact dermatitis	Type IV hypersensitivity reaction secondary to contact allergen (eg, nickel D , poison ivy, neomycin E).
Melanocytic nevus	Common mole. Benign, but melanoma can arise in congenital or atypical moles. Intradermal nevi are papular F . Junctional nevi are flat macules G .
Pseudofolliculitis barbae	Foreign body inflammatory facial skin disorder characterized by firm, hyperpigmented papules and pustules that are painful and pruritic. Located on cheeks, jawline, and neck. Commonly occurs as a result of shaving (“razor bumps”), primarily affects Black males.
Psoriasis	Papules and plaques with silvery scaling H , especially on knees and elbows. Acanthosis with parakeratotic scaling (nuclei still in stratum corneum), Munro microabscesses. ↑ stratum spinosum, ↓ stratum granulosum. Auspitz sign (I)—pinpoint bleeding spots from exposure of dermal papillae when scales are scraped off. Associated with nail pitting and psoriatic arthritis.
Rosacea	Inflammatory facial skin disorder characterized by erythematous papules and pustules J , but no comedones. May be associated with facial flushing in response to external stimuli (eg, alcohol, heat). Complications include ocular involvement, rhinophyma (bulbous deformation of nose).
Seborrheic keratosis	Flat, greasy, pigmented squamous epithelial proliferation of immature keratinocytes with keratin-filled cysts (horn cysts) K . Looks “stuck on.” Lesions occur on head, trunk, and extremities. Common benign neoplasm of older persons. Leser-Trélat sign L —rapid onset of multiple seborrheic keratoses, indicates possible malignancy (eg, GI adenocarcinoma).
Verrucae	Warts; caused by low-risk HPV strains. Soft, tan-colored, cauliflowerlike papules M . Epidermal hyperplasia, hyperkeratosis, koilocytosis. Condyloma acuminatum on anus or genitals N .
Urticaria	Hives. Pruritic wheals that form after mast cell degranulation O . Characterized by superficial dermal edema and lymphatic channel dilation.



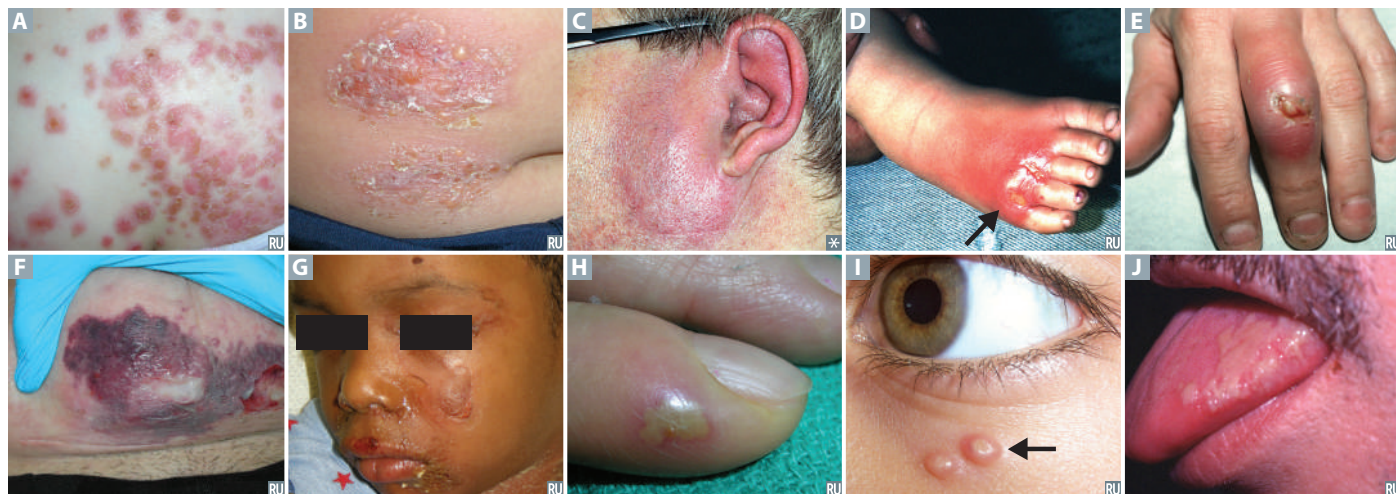Vascular tumors of skin

Angiosarcoma	Rare blood vessel malignancy typically occurring in the head, neck, and breast areas. Usually in older adults, on sun-exposed areas. Associated with radiation therapy and chronic postmastectomy lymphedema. Stewart-Treves syndrome —cutaneous angiosarcoma developing after chronic lymphedema. Hepatic angiosarcoma associated with vinyl chloride and arsenic exposures. Very aggressive and difficult to resect due to delay in diagnosis.
Bacillary angiomatosis	Benign capillary skin papules A found in patients with AIDS. Caused by <i>Bartonella</i> infections. Frequently mistaken for Kaposi sarcoma, but has neutrophilic infiltrate.
Cherry hemangioma	Benign capillary hemangioma B commonly appearing in middle-aged adults. Does not regress. Frequency ↑ with age.
Glomus tumor	Benign, painful, red-blue tumor, commonly under fingernails C . Arises from modified smooth muscle cells of the thermoregulatory glomus body.
Kaposi sarcoma	Endothelial malignancy most commonly affecting the skin, mouth, GI tract, respiratory tract. Classically seen in older Eastern European males, patients with AIDS, and organ transplant patients. Associated with HHV-8 and HIV. Lymphocytic infiltrate, unlike bacillary angiomatosis.
Pyogenic granuloma	Polypoid lobulated capillary hemangioma D that can ulcerate and bleed. Associated with trauma and pregnancy.
Strawberry (infantile) hemangioma	Benign capillary hemangioma of infancy E . Appears in first few weeks of life (1/200 births); grows rapidly and regresses spontaneously by 5–8 years old.



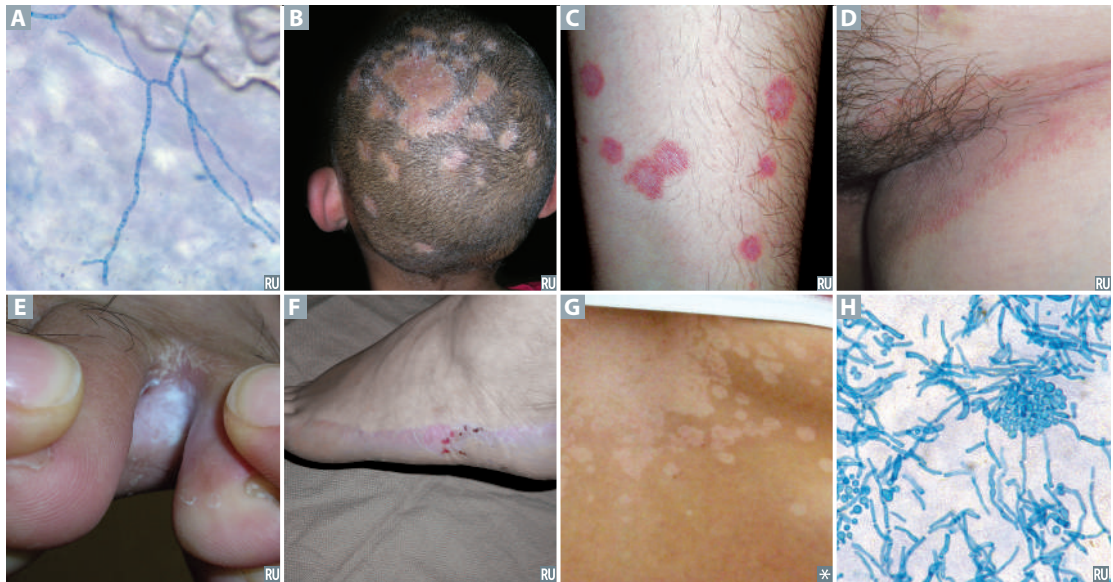Skin infections

Bacterial infections	
Impetigo	Skin infection involving superficial epidermis. Usually from <i>S aureus</i> or <i>S pyogenes</i> . Highly contagious. Honey-colored crusting A . Bullous impetigo B has bullae and is usually caused by <i>S aureus</i> .
Erysipelas	Infection involving upper dermis and superficial lymphatics, usually from <i>S pyogenes</i> . Presents with well-defined, raised demarcation between infected and normal skin C .
Cellulitis	Acute, painful, spreading infection of deeper dermis and subcutaneous tissues. Usually from <i>S pyogenes</i> or <i>S aureus</i> . Often starts with a break in skin from trauma or another infection D .
Abscess	Collection of pus from a walled-off infection within deeper layers of skin E . Offending organism is almost always <i>S aureus</i> .
Necrotizing fasciitis	Deeper tissue injury, usually from anaerobic bacteria or <i>S pyogenes</i> . Pain may be out of proportion to exam findings. Results in crepitus from methane and CO ₂ production. “Flesh-eating bacteria.” Causes bullae and skin necrosis → violaceous color of bullae, surrounding skin F . Surgical emergency.
Staphylococcal scalded skin syndrome	Exotoxin destroys keratinocyte attachments in stratum granulosum only (vs toxic epidermal necrolysis, which destroys epidermal-dermal junction). Characterized by fever and generalized erythematous rash with sloughing of the upper layers of the epidermis G that heals completely. ⊕ Nikolsky sign (separation of epidermis upon manual stroking of skin). Commonly seen in newborns and children/adults with renal insufficiency.
Viral infections	
Herpes	Herpes virus infections (HSV-1 and HSV-2) of skin can occur anywhere from mucosal surfaces to normal skin. These include herpes labialis, herpes genitalis, herpetic whitlow H (finger).
Molluscum contagiosum	Umbilicated papules I caused by a poxvirus. While frequently seen in children, it may be sexually transmitted in adults.
Varicella zoster	Causes varicella (chickenpox) and zoster (shingles). Varicella presents with multiple crops of lesions in various stages from vesicles to crusts. Zoster is a reactivation of the virus in dermatomal distribution (unless it is disseminated).
Hairy leukoplakia	Irregular, white, painless plaques on lateral tongue that cannot be scraped off J . EBV mediated. Occurs in patients living with HIV, organ transplant recipients. Contrast with thrush (scrapable) and leukoplakia (precancerous).



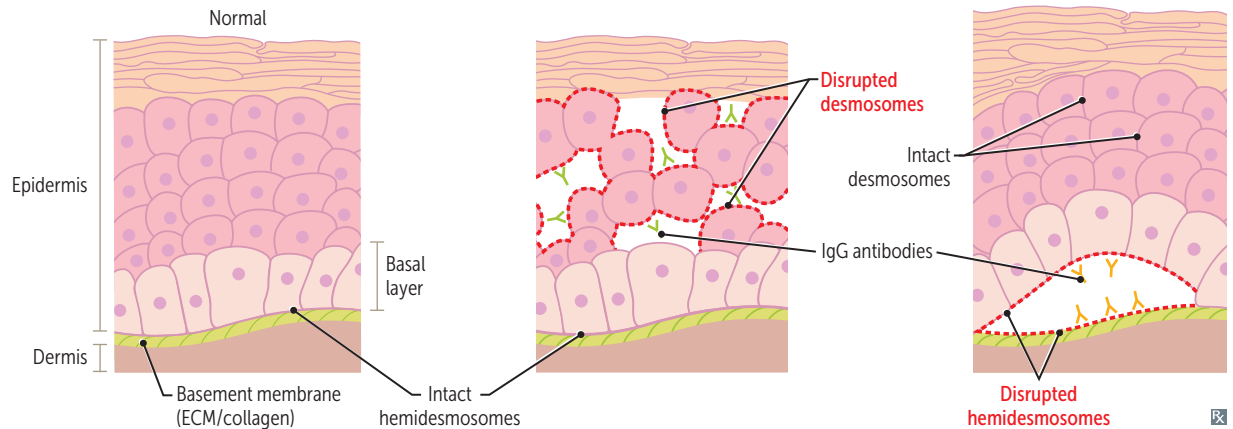
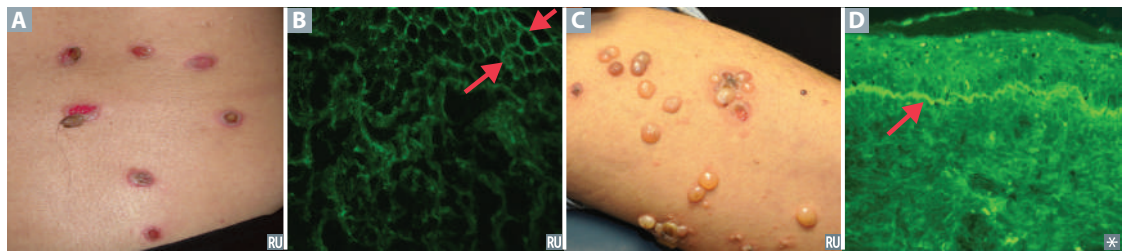
Cutaneous mycoses

Tinea (dermatophytes)	Clinical name for dermatophyte (cutaneous fungal) infections. Dermatophytes include <i>Microsporum</i> , <i>Trichophyton</i> , and <i>Epidermophyton</i> . Branching septate hyphae visible on KOH preparation with blue fungal stain A . Associated with pruritus.
Tinea capitis	Occurs on head, scalp. Associated with lymphadenopathy, alopecia, scaling B .
Tinea corporis	Occurs on body (usually torso). Characterized by enlarging erythematous, scaly rings (“ringworm”) with central clearing C . Can be acquired from contact with infected pets or farm animals.
Tinea cruris	Occurs in inguinal area (“jock itch”) D . Often does not show the central clearing seen in tinea corporis.
Tinea pedis	Three varieties (“athlete’s foot”): <ul style="list-style-type: none"> ▪ Interdigital E; most common ▪ Moccasin distribution F ▪ Vesicular type
Tinea unguium	Onychomycosis; occurs on nails.
Tinea (pityriasis) versicolor	Caused by <i>Malassezia</i> spp. (<i>Pityrosporum</i> spp.), a yeastlike fungus (not a dermatophyte despite being called tinea). Degradation of lipids produces acids that inhibit tyrosinase (involved in melanin synthesis) → hypopigmentation G ; hyperpigmentation and/or pink patches can also occur due to inflammatory response. Less pruritic than dermatophytes. Can occur any time of year, but more common in summer (hot, humid weather). “Spaghetti and meatballs” appearance on microscopy H . Treatment: selenium sulfide, topical and/or oral antifungal medications.



Autoimmune blistering skin disorders

	Pemphigus vulgaris	Bullous pemphigoid
PATHOPHYSIOLOGY	Potentially fatal. Most commonly seen in older adults. Type II hypersensitivity reaction. IgG antibodies against desmoglein-1 and/or desmoglein-3 (component of desmosomes, which connect keratinocytes in the stratum spinosum).	Less severe than pemphigus vulgaris. Most commonly seen in older adults. Type II hypersensitivity reaction. IgG antibodies against hemidesmosomes (epidermal basement membrane; antibodies are “ bulow ” the epidermis).
GROSS MORPHOLOGY	Flaccid intraepidermal bullae A caused by acantholysis (separation of keratinocytes, “row of tombstones” on H&E stain); oral mucosa is involved. Nikolsky sign ⊕.	Tense blisters C containing eosinophils; oral mucosa spared. Nikolsky sign ⊖.
IMMUNOFLUORESCENCE	Reticular pattern around epidermal cells B .	Linear pattern at epidermal-dermal junction D .



Epidermolysis bullosa simplex

Autosomal dominant defect in keratin filament assembly → cytoskeleton disruption → epithelial fragility. Presents early in life with friction-induced skin blistering that primarily affects palms and soles. Heals without scarring. Skin biopsy: intraepidermal cleavage.

Other blistering skin disorders**Dermatitis herpetiformis**

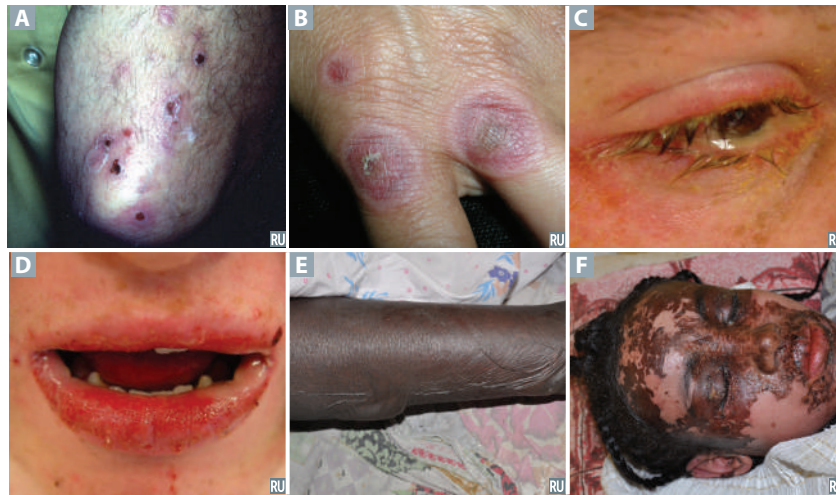Pruritic papules, vesicles, and bullae (often found on elbows, knees, buttocks) **A**. Deposits of IgA at tips of dermal papillae. Associated with celiac disease. Treatment: dapsone, gluten-free diet.

Erythema multiforme

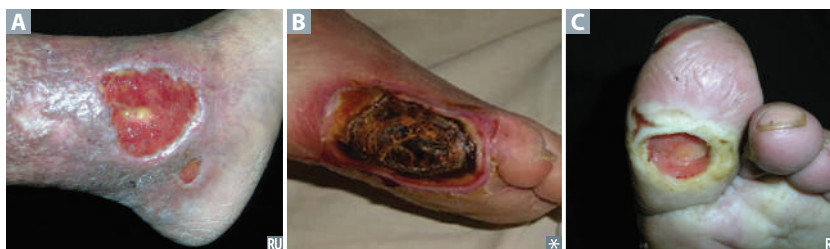Associated with infections (eg, *Mycoplasma pneumoniae*, HSV), drugs (eg, sulfa drugs, β -lactams, phenytoin). Presents with multiple types of lesions—macules, papules, vesicles, target lesions (look like targets with multiple rings and dusky center showing epithelial disruption) **B**.

Stevens-Johnson syndrome

Characterized by fever, bullae formation and necrosis, sloughing of skin at dermal-epidermal junction (\oplus Nikolsky), high mortality rate. Typically mucous membranes are involved **C D**. Targetoid skin lesions may appear, as seen in erythema multiforme. Usually associated with adverse drug reaction. **Toxic epidermal necrolysis (TEN)** **E F** is more severe form of SJS involving $> 30\%$ body surface area. 10–30% involvement denotes SJS-TEN.

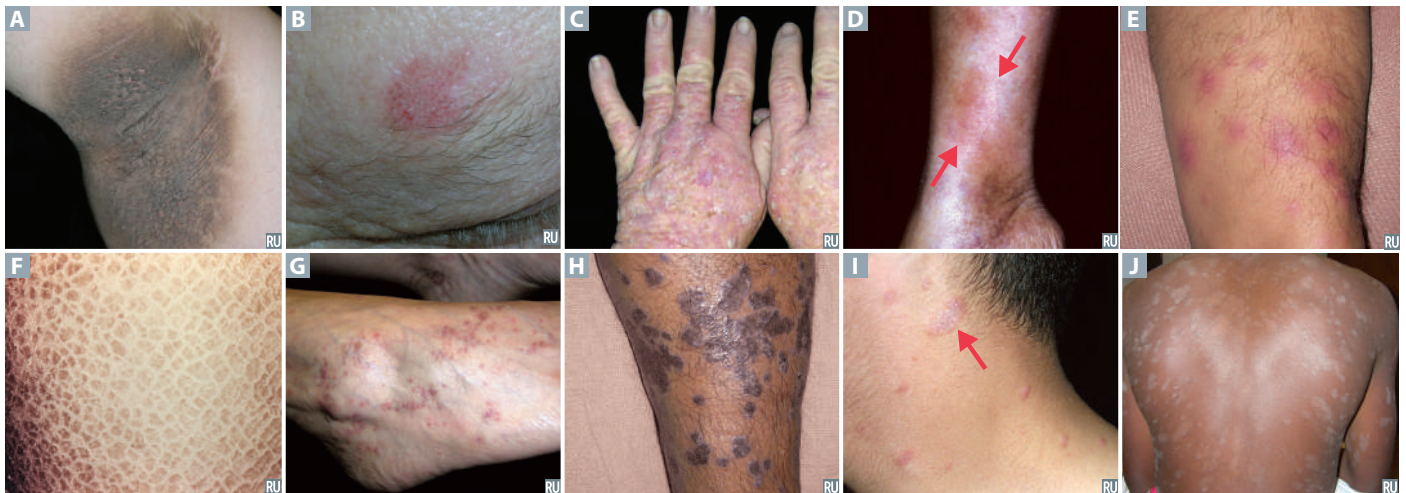**Lower extremity ulcers**

	Venous ulcer	Arterial ulcer	Neuropathic ulcer
ETIOLOGY	Chronic venous insufficiency; most common ulcer type	Peripheral artery disease (eg, atherosclerotic stenosis)	Peripheral neuropathy (eg, diabetic foot)
LOCATION	Gaiter area (ankle to midcalf), typically over malleoli	Distal toes, anterior shin, pressure points	Bony prominences (eg, metatarsal heads, heel)
APPEARANCE	Irregular border, shallow, exudative A	Symmetric with well-defined punched-out appearance B	Hyperkeratotic edge with undermined borders C
PAIN	Mild to moderate	Severe	Absent
ASSOCIATED SIGNS	Telangiectasias, varicose veins, edema, stasis dermatitis (erythematous eczematous patches)	Signs of arterial insufficiency including cold, pale, atrophic skin with hair loss and nail dystrophy, absent pulses	Claw toes, Charcot joints, absent reflexes



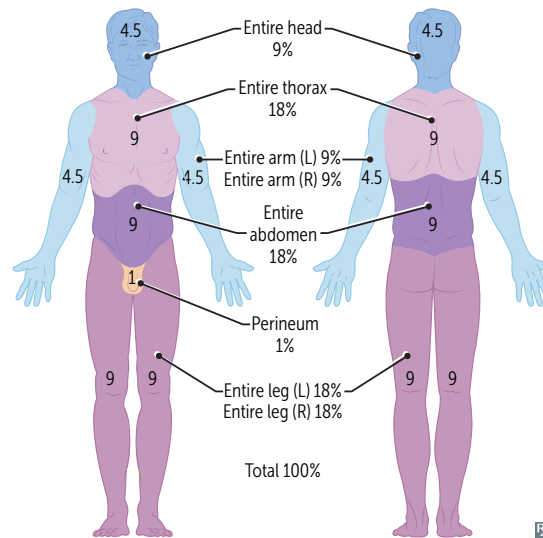
Miscellaneous skin disorders

Acanthosis nigricans	Epidermal hyperplasia causing symmetric, hyperpigmented thickening of skin, especially in axilla or on neck A . Associated with insulin resistance (eg, diabetes, obesity, Cushing syndrome, PCOS), visceral malignancy (eg, gastric adenocarcinoma).
Actinic keratosis	Premalignant lesions caused by sun exposure. Small, rough, erythematous or brownish papules or plaques B C . Risk of squamous cell carcinoma is proportional to degree of epithelial dysplasia.
Erythema nodosum	Painful, raised inflammatory lesions of subcutaneous fat (panniculitis), usually on anterior shins. Often idiopathic, but can be associated with sarcoidosis, coccidioidomycosis, histoplasmosis, TB, streptococcal infections D , leprosy E , inflammatory bowel disease.
Ichthyosis vulgaris	Disorder of keratinization resulting in diffuse scaling of the skin F most commonly on the extensor side of extremities and the trunk. Manifests in infancy or early childhood.
Lichen Planus	P ruritic, p urple, p olygonal p lanar p apules and p laques are the 6 P 's of lichen P lanus G H . Mucosal involvement manifests as Wickham striae (reticular white lines) and hypergranulosis. Sawtooth infiltrate of lymphocytes at dermal-epidermal junction. Associated with hepatitis C.
Pityriasis rosea	"Herald patch" I followed days later by other scaly erythematous plaques, often in a "Christmas tree" distribution on trunk J . Multiple pink plaques with collarette scale. Self-resolving in 6–8 weeks.
Sunburn	Acute cutaneous inflammatory reaction due to excessive UV irradiation. Causes DNA mutations, inducing apoptosis of keratinocytes. UVB is dominant in sun B urn, UVA in t A nning and photo A ging. Exposure to UVA and UVB ↑ risk of skin cancer.



Body surface area

Approximated by the rule of 9's. The extent of a burn injury can be estimated as a percentage of the body surface area.

**Burn classification**

DEPTH	INVOLVEMENT	APPEARANCE	SENSATION
Superficial burn	Epidermis only	Similar to sunburn; localized, dry, blanching redness with no blisters	Painful
Superficial partial-thickness burn	Epidermis and papillary dermis	Blisters, blanches with pressure, swollen, warm	Painful to temperature and air
Deep partial-thickness burn	Epidermis and reticular dermis	Blisters (easily unroofed), does not blanch with pressure	Painless; perception of pressure only
Full-thickness burn	Epidermis and full-thickness dermis	White, waxy, dry, inelastic, leathery, does not blanch with pressure	Painless; perception of deep pressure only
Deeper injury burn	Epidermis, dermis, and involvement of underlying tissue (eg, fascia, muscle)	White, dry, inelastic, does not blanch with pressure	Painless; some perception of deep pressure

Skin cancer

Basal cell carcinoma more common above **upper lip**.

Squamous cell carcinoma more common below **lower lip**.

Sun exposure strongly predisposes to skin cancer.

**Basal cell carcinoma**

Most common skin cancer. Found in sun-exposed areas of body (eg, face). Locally invasive, but rarely metastasizes. Waxy, pink, pearly nodules, commonly with telangiectasias, rolled borders **A**, central crusting or ulceration. BCCs also appear as nonhealing ulcers with infiltrating growth **B** or as a scaling plaque (superficial BCC) **C**. Basal cell tumors have “palisading” (aligned) nuclei **D**.

Keratoacanthoma

Seen in middle-aged and older adults. Rapidly growing, resembles squamous cell carcinoma. Presents as dome-shaped nodule with keratin-filled center. Grows rapidly (4-6 weeks) and may spontaneously regress **E**.

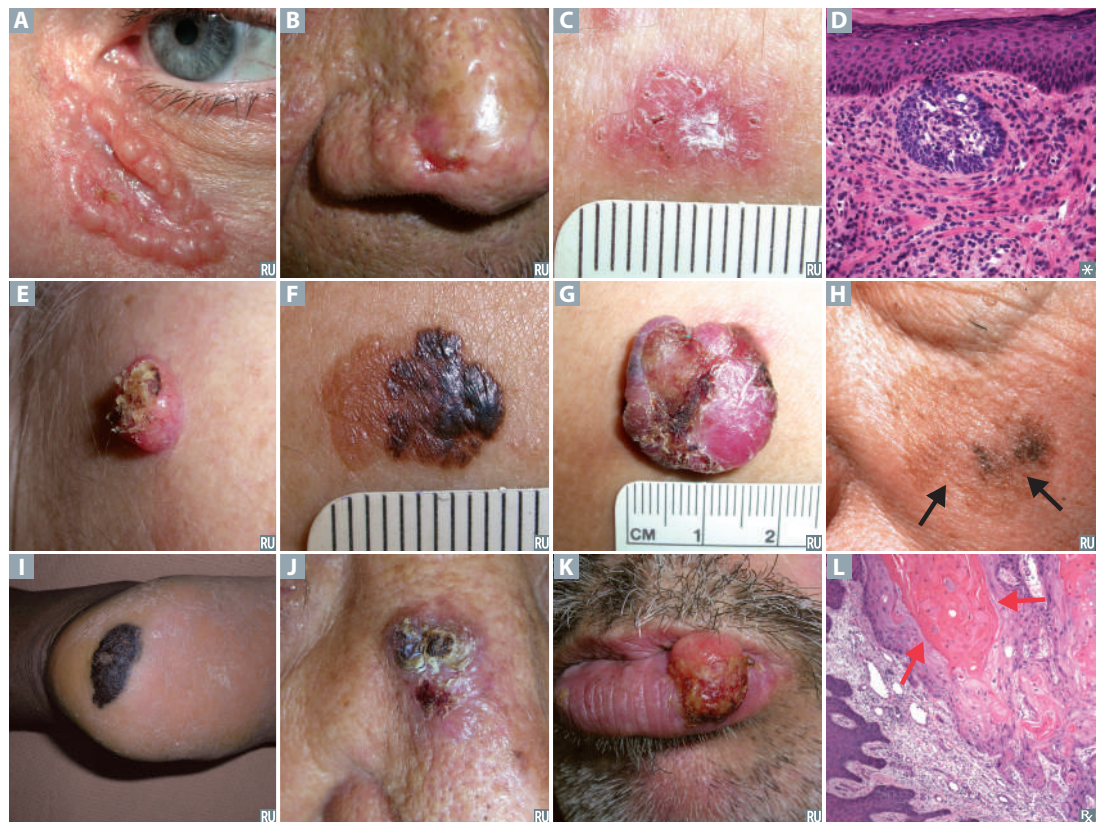Melanoma

Common tumor with significant risk of metastasis. S-100 tumor marker. Associated with dysplastic nevi; people with lighter skin tones are at ↑ risk. Depth of tumor (Breslow thickness) correlates with risk of metastasis. Look for the **ABCDEs**: **A**symmetry, **B**order irregularity, **C**olor variation, **D**iameter > 6 mm, and **E**volution over time. At least 4 different types of melanoma, including superficial spreading **F**, nodular **G**, lentigo maligna **H**, and acral lentiginous (highest prevalence in people with darker skin tones) **I**. Often driven by activating mutation in BRAF kinase. Primary treatment is excision with appropriately wide margins. Advanced melanoma also treated with immunotherapy (eg, ipilimumab) and/or BRAF inhibitors (eg, vemurafenib).

Squamous cell carcinoma

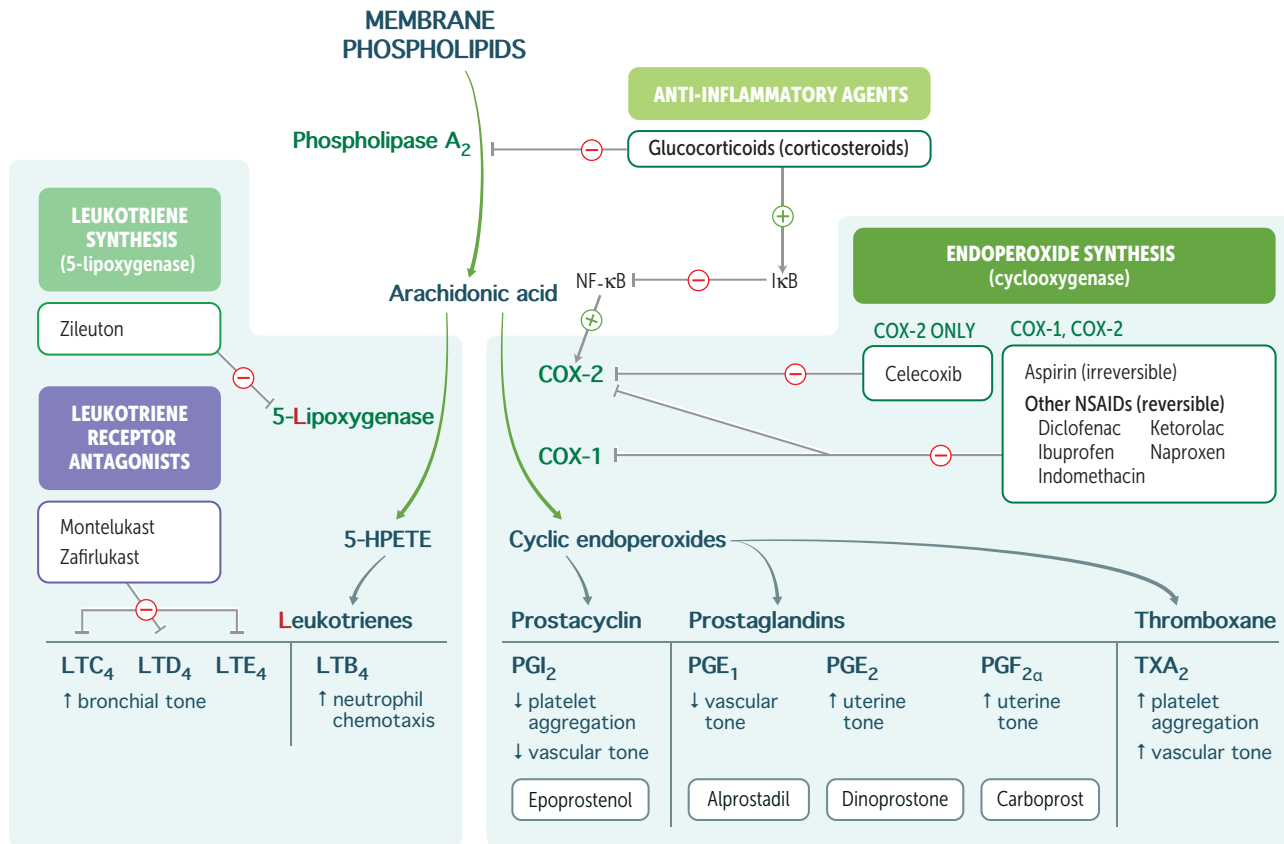
Second most common skin cancer. Associated with immunosuppression, chronic nonhealing wounds, and occasionally arsenic exposure. **Marjolin ulcer**—SCC arising in chronic wounds or scars; usually develops > 20 years after insult. Commonly appears on face **J**, lower lip **K**, ears, hands. Locally invasive, may spread to lymph nodes, and will rarely metastasize. Ulcerative red lesions. Histopathology: keratin “pearls” **L**.

Actinic keratosis, a scaly plaque, is a precursor to squamous cell carcinoma.



▶ MUSCULOSKELETAL, SKIN, AND CONNECTIVE TISSUE—PHARMACOLOGY

Arachidonic acid pathways



LTB₄ is a **neutrophil** chemotactic agent.

PGI₂ inhibits platelet aggregation and promotes vasodilation.

Neutrophils arrive “B4” others.

Platelet-Gathering Inhibitor.

Acetaminophen

MECHANISM

Reversibly inhibits cyclooxygenase, mostly in CNS. Inactivated peripherally.

CLINICAL USE

Antipyretic, analgesic, but not anti-inflammatory. Used instead of aspirin to avoid Reye syndrome in children with viral infection.

ADVERSE EFFECTS

Overdose produces hepatic necrosis; acetaminophen metabolite (NAPQI) depletes glutathione and forms toxic tissue byproducts in liver. N-acetylcysteine is antidote—regenerates glutathione.

Aspirin

MECHANISM	NSAID that irreversibly inhibits cyclooxygenase (both COX-1 and COX-2) by covalent acetylation → ↓ synthesis of TXA ₂ and prostaglandins. ↑ bleeding time. No effect on PT, PTT. Effect lasts until new platelets are produced.
CLINICAL USE	Low dose (< 300 mg/day): ↓ platelet aggregation. Intermediate dose (300–2400 mg/day): antipyretic and analgesic. High dose (2400–4000 mg/day): anti-inflammatory.
ADVERSE EFFECTS	Gastric ulceration, tinnitus (CN VIII), allergic reactions (especially in patients with asthma or nasal polyps). Chronic use can lead to acute kidney injury, interstitial nephritis, GI bleeding. Risk of Reye syndrome in children treated with aspirin for viral infection. Toxic doses cause respiratory alkalosis early, but transitions to mixed metabolic acidosis-respiratory alkalosis. Treatment of overdose: NaHCO ₃ .

Celecoxib

MECHANISM	Reversibly and selectively inhibits the cyclooxygenase (COX) isoform 2 (“ Selecoxib ”), which is found in inflammatory cells and vascular endothelium and mediates inflammation and pain; spares COX-1, which helps maintain gastric mucosa. Thus, does not have the corrosive effects of other NSAIDs on the GI lining. Spares platelet function as TXA ₂ production is dependent on COX-1.
CLINICAL USE	Rheumatoid arthritis, osteoarthritis.
ADVERSE EFFECTS	↑ risk of thrombosis, sulfa allergy.

Nonsteroidal anti-inflammatory drugs

Ibuprofen, naproxen, indomethacin, ketorolac, diclofenac, meloxicam, piroxicam.

MECHANISM	Reversibly inhibit cyclooxygenase (both COX-1 and COX-2). Block prostaglandin synthesis.
CLINICAL USE	Antipyretic, analgesic, anti-inflammatory. Indomethacin is used to close a PDA.
ADVERSE EFFECTS	Interstitial nephritis, gastric ulcer (prostaglandins protect gastric mucosa), renal ischemia (prostaglandins vasodilate afferent arteriole), aplastic anemia.

Leflunomide

MECHANISM	Reversibly inhibits dihydroorotate dehydrogenase, preventing pyrimidine synthesis. Suppresses T-cell proliferation.
CLINICAL USE	Rheumatoid arthritis, psoriatic arthritis.
ADVERSE EFFECTS	Diarrhea, hypertension, hepatotoxicity, teratogenicity.

Bisphosphonates

Alendronate, ibandronate, risedronate, zoledronate.

MECHANISM	Pyrophosphate analogs; bind hydroxyapatite in bone, inhibiting osteoclast activity.
CLINICAL USE	Osteoporosis, hypercalcemia, Paget disease of bone, metastatic bone disease, osteogenesis imperfecta.
ADVERSE EFFECTS	Esophagitis (if taken orally, patients are advised to take with water and remain upright for 30 minutes), osteonecrosis of jaw, atypical femoral stress fractures.

Teriparatide

MECHANISM	Recombinant PTH analog. ↑ osteoblastic activity when administered in pulsatile fashion.
CLINICAL USE	Osteoporosis. Causes ↑ bone growth compared to antiresorptive therapies (eg, bisphosphonates).
ADVERSE EFFECTS	↑ risk of osteosarcoma (avoid use in patients with Paget disease of the bone or unexplained elevation of alkaline phosphatase). Avoid in patients who have had prior cancers or radiation therapy. Transient hypercalcemia.

Gout drugs

Chronic gout drugs (preventive)

Allopurinol Competitive inhibitor of xanthine oxidase → ↓ conversion of hypoxanthine and xanthine to urate. Also used in lymphoma and leukemia to prevent tumor lysis–associated urate nephropathy. ↑ concentrations of xanthine oxidase active metabolites, azathioprine, and 6-MP.

Pegloticase Recombinant uricase catalyzing uric acid to allantoin (a more water-soluble product).

Febuxostat Inhibits xanthine oxidase. Think, “febu-**xo**-stat makes **X**anthine **O**xidase **st**atic.”

Probenecid Inhibits reabsorption of uric acid in proximal convoluted tubule (also inhibits secretion of penicillin). Can precipitate uric acid calculi or lead to sulfa allergy.

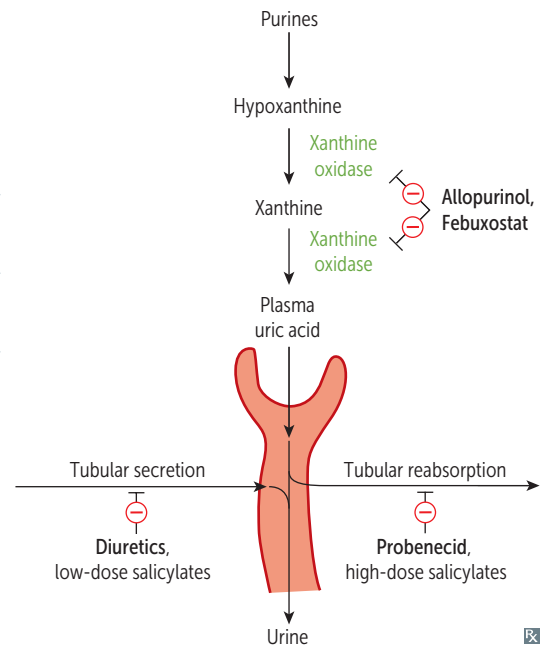
Acute gout drugs

NSAIDs Any NSAID. Use salicylates with caution (may decrease uric acid excretion, particularly at low doses).

Glucocorticoids Oral, intra-articular, or parenteral.

Colchicine Binds and stabilizes tubulin to inhibit microtubule polymerization, impairing neutrophil chemotaxis and degranulation. Acute and prophylactic value. GI, neuromyopathic adverse effects. Can also cause myelosuppression, nephrotoxicity.

All painful flares are preventable.



TNF- α inhibitors

DRUG	MECHANISM	CLINICAL USE	ADVERSE EFFECTS
Etanercept	Fusion protein (decoy receptor for TNF- α + IgG ₁ Fc), produced by recombinant DNA. Etanercept intercepts TNF.	Rheumatoid arthritis, psoriasis, ankylosing spondylitis.	Predisposition to infection, including reactivation of latent TB, since TNF is important in granuloma formation and stabilization.
Infliximab, adalimumab, certolizumab, golimumab	Anti-TNF- α monoclonal antibody.	Inflammatory bowel disease, rheumatoid arthritis, ankylosing spondylitis, psoriasis.	Can also lead to drug-induced lupus.

Imiquimod

MECHANISM	Binds toll-like receptor 7 (TLR-7) of macrophages, monocytes, and dendritic cells to activate them → topical antitumor immune response modifier.
CLINICAL USE	Anogenital warts, actinic keratosis.
ADVERSE EFFECTS	Itching, burning pain at site of application, rashes.

Neurology and Special Senses

“We are all now connected by the Internet, like neurons in a giant brain.”
—Stephen Hawking

“Exactly how [the brain] operates remains one of the biggest unsolved mysteries, and it seems the more we probe its secrets, the more surprises we find.”
—Neil deGrasse Tyson

“It’s not enough to be nice in life. You’ve got to have nerve.”
—Georgia O’Keeffe

“I not only use all the brains that I have, but all that I can borrow.”
—Woodrow Wilson

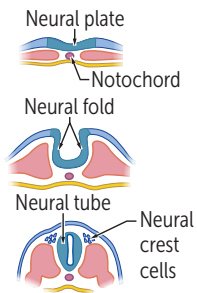
“The chief function of the body is to carry the brain around.”
—Thomas Edison

“I opened two gifts this morning. They were my eyes.”
—Hilary Hinton “Zig” Ziglar

Understand the difference between the findings and underlying anatomy of upper motor neuron and lower motor neuron lesions. Know the major motor, sensory, cerebellar and visual pathways and their respective locations in the CNS. Connect key neurological associations with certain pathologies (eg, cerebellar lesions, stroke manifestations, Brown-Séquard syndrome). Recognize common findings on MRI/CT (eg, ischemic and hemorrhagic stroke) and on neuropathology (eg, neurofibrillary tangles and Lewy bodies). High-yield medications include those used to treat epilepsy, Parkinson disease, migraine, and pain (eg, opioids).

▶ Embryology	504
▶ Anatomy and Physiology	507
▶ Pathology	528
▶ Otology	551
▶ Ophthalmology	553
▶ Pharmacology	564

▶ NEUROLOGY—EMBRYOLOGY

Neural development

Notochord induces overlying ectoderm to differentiate into neuroectoderm and form neural plate. Notochord becomes nucleus pulposus of intervertebral disc in adults.

Neural plate gives rise to neural tube and neural crest cells.

Lateral walls of neural tube are divided into alar and basal plates.

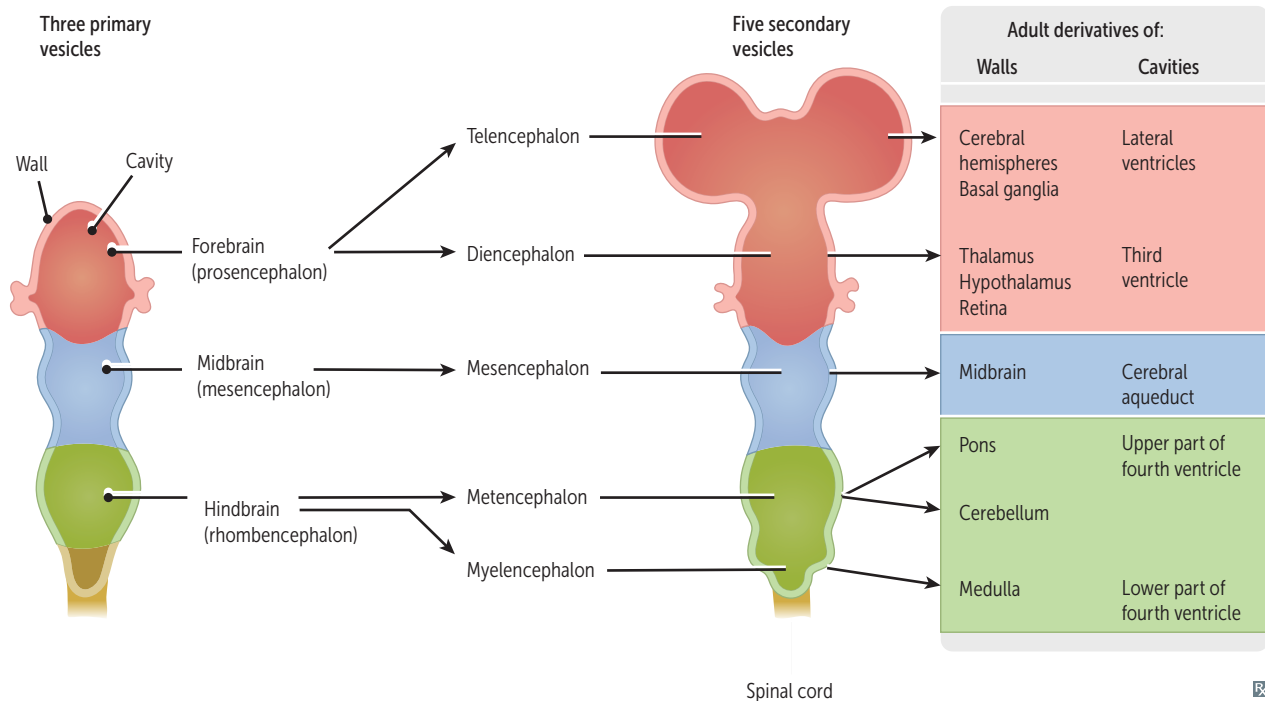
Alar plate (dorsal): sensory; induced by bone morphogenetic proteins (BMPs)

Basal plate (ventral): motor; induced by sonic hedgehog (SHH)

Same orientation as spinal cord

Regionalization of neural tube

Telencephalon is the 1st part. **D**iencephalon is the **2nd** part. The rest are arranged alphabetically: **m**esencephalon, **m**etencephalon, **m**yelencephalon.

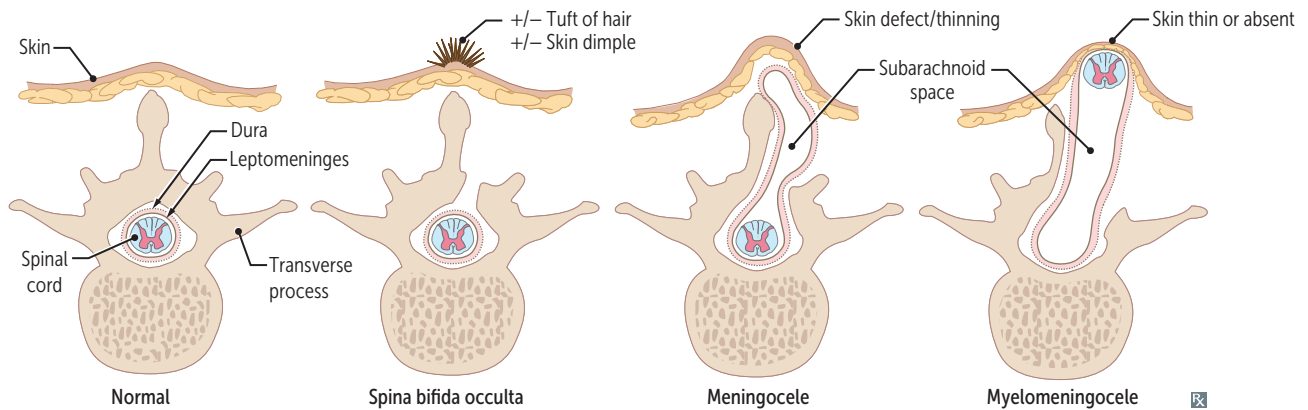
**Central and peripheral nervous systems origins**

Neuroepithelia in neural tube—CNS neurons, CNS glial cells (astrocytes, oligodendrocytes, ependymal cells).

Neural crest—PNS neurons (dorsal root ganglia, autonomic ganglia [sympathetic, parasympathetic, enteric]), PNS glial cells (Schwann cells, satellite cells), adrenal medulla.

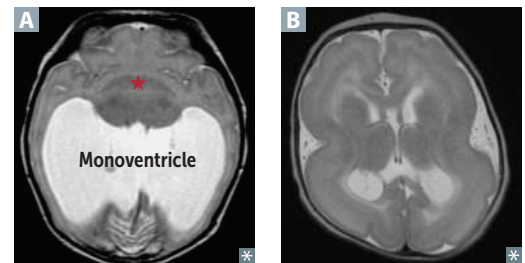
Mesoderm—**m**icroglia (like **m**acrophages).

Neural tube defects	Neuropores fail to fuse by the 4th week of development → persistent connection between amniotic cavity and spinal canal. Associated with diabetes and folate deficiency during pregnancy. ↑ α-fetoprotein (AFP) in amniotic fluid and serum (except spina bifida occulta = normal AFP). ↑ acetylcholinesterase (AChE) in amniotic fluid is a helpful confirmatory test.
Spina bifida occulta	Failure of caudal neuropore to close, but no herniation. Usually seen at lower vertebral levels. Dura is intact. Associated with tuft of hair or skin dimple at level of bony defect.
Meningocele	Meninges (but no neural tissue) herniate through bony defect.
Myelomeningocele	Meninges and neural tissue (eg, cauda equina) herniate through bony defect.
Myeloschisis	Also called rachischisis. Exposed, unfused neural tissue without skin/meningeal covering.
Anencephaly	Failure of rostral neuropore to close → no forebrain, open calvarium. Clinical findings: polyhydramnios (no swallowing center in brain).



Brain malformations Often incompatible with postnatal life. Survivors may be profoundly disabled.

Holoprosencephaly Failure of forebrain (prosencephalon) to divide into 2 cerebral hemispheres; developmental field defect usually occurring at weeks 3–4 of development. Associated with *SHH* mutations. May be seen in Patau syndrome (trisomy 13), fetal alcohol syndrome. Presents with midline defects: monoventricle **A**, fused basal ganglia (star in **A**), cleft lip/palate, hypotelorism, cyclopia, proboscis. ↑ risk for pituitary dysfunction (eg, diabetes insipidus).



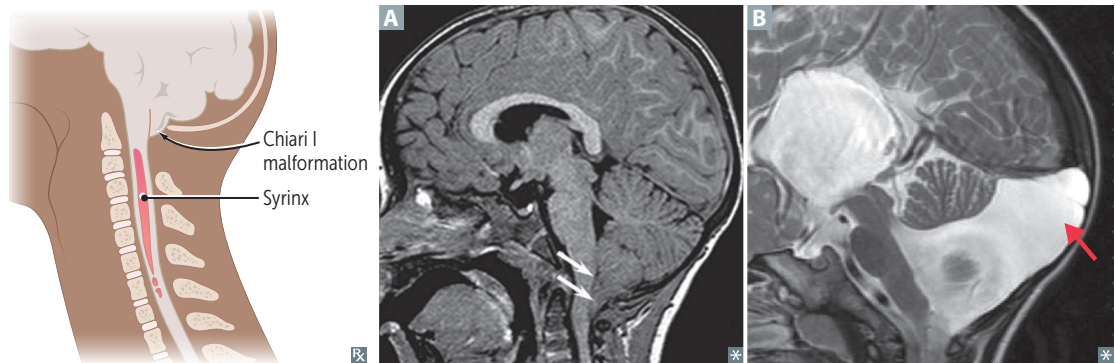Lissencephaly Failure of neuronal migration → smooth brain surface that lacks sulci and gyri **B**. Associated with microcephaly, facial anomalies, hydrocephalus.

Posterior fossa malformations

Chiari I malformation Ectopia of cerebellar **tonsils** inferior to foramen magnum (**1** structure) **A**. Usually asymptomatic in childhood, manifests in adulthood with headaches and cerebellar symptoms. Associated with spinal cavitations (eg, syringomyelia).

Chiari II malformation Herniation of **cerebellum** (vermis and tonsils) and **medulla** (**2** structures) through foramen magnum → noncommunicating hydrocephalus. More severe than Chiari I, usually presents early in life with dysphagia, stridor, apnea, limb weakness. Associated with myelomeningocele (usually lumbosacral).

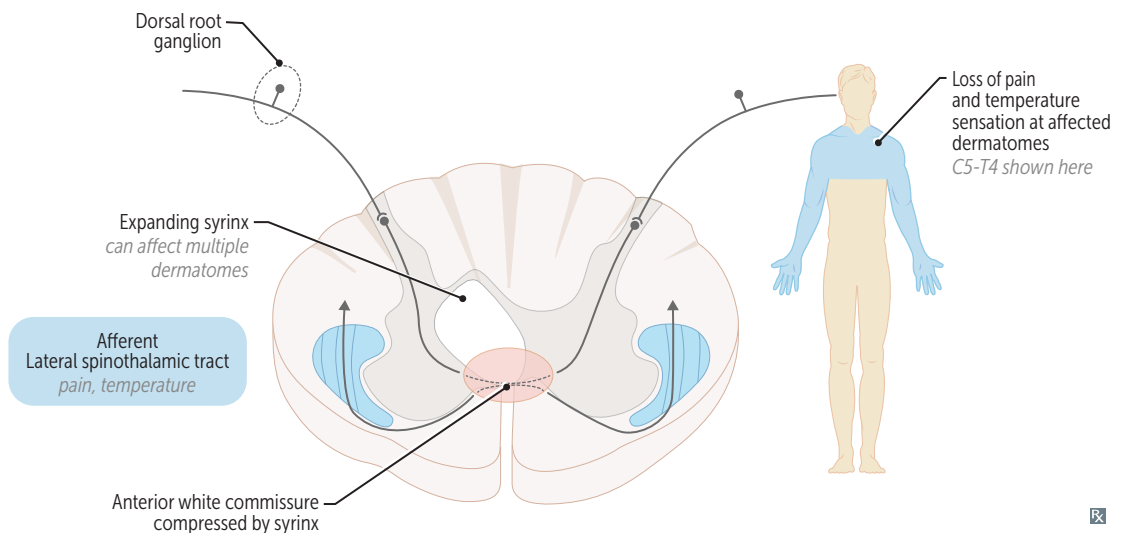
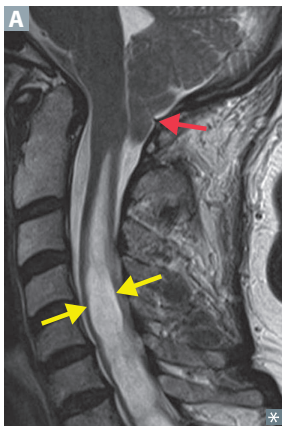
Dandy-Walker malformation Agenesis of cerebellar vermis → cystic enlargement of 4th ventricle (arrow in **B**) that fills the enlarged posterior fossa. Associated with noncommunicating hydrocephalus, spina bifida.



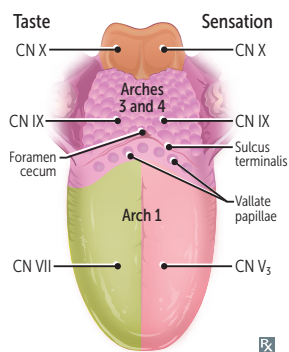
Syringomyelia

Cystic cavity (syrinx) within central canal of spinal cord (yellow arrows in **A**). Fibers crossing in anterior white commissure (spinothalamic tract) are typically damaged first. Results in a “cape-like,” bilateral, symmetrical loss of pain and temperature sensation in upper extremities (fine touch sensation is preserved).

Associated with Chiari I malformation (red arrow in **A** shows low-lying cerebellar tonsils), scoliosis and other congenital malformations; acquired causes include trauma and tumors. Most common location cervical > thoracic >> lumbar. **Syrinx** = tube, as in “syringe.”



Tongue development



1st pharyngeal arch forms anterior 2/3 of tongue (sensation via CN V₃, taste via CN VII).

3rd and 4th pharyngeal arches form posterior 1/3 of tongue (sensation and taste mainly via CN IX, extreme posterior via CN X).

Motor innervation is via CN XII to hyoglossus (retracts and depresses tongue), **genioglossus** (**protrudes** tongue), and **styloglossus** (draws sides of tongue upward to create a trough for swallowing).

Motor innervation is via CN X to palatoglossus (elevates posterior tongue during swallowing).

Taste—CN VII, IX, X (solitary nucleus).

Pain—CN V₃, IX, X.

Motor—CN X, XII.

The **genie** comes **out** of the lamp in **style**.

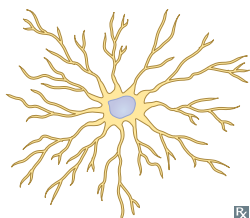
CN **10** innervates palatenglossus.

▶ NEUROLOGY—ANATOMY AND PHYSIOLOGY

Neurons

Signal-transmitting cells of the nervous system. Permanent cells—do not divide in adulthood. Signal-relaying cells with dendrites (receive input), cell bodies, and axons (send output). Cell bodies and dendrites can be seen on Nissl staining (stains RER). RER is not present in the axon. Neuron markers: neurofilament protein, synaptophysin.

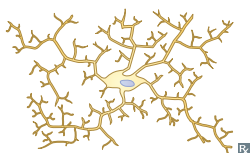
Astrocytes



Most common glial cell type in CNS. Physical support, repair, removal of excess neurotransmitter, component of blood-brain barrier, glycogen fuel reserve buffer. Reactive gliosis in response to neural injury.

Derived from neuroectoderm. Astrocyte marker: GFAP.

Microglia



Phagocytic scavenger cells of CNS. Activation in response to tissue damage → release of inflammatory mediators (eg, nitric oxide, glutamate). Not readily discernible by Nissl stain.

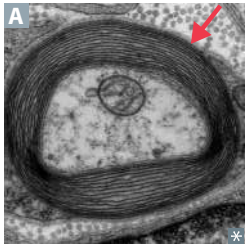
Derived from mesoderm. HIV-infected microglia fuse to form multinucleated giant cells in CNS in HIV-associated dementia.

Ependymal cells

Ciliated simple columnar glial cells lining ventricles and central canal of spinal cord. Apical surfaces are covered with cilia (which circulate CSF) and microvilli (which help with CSF absorption).

Derived from neuroectoderm. Specialized ependymal cells (choroid plexus) produce CSF.

Myelin

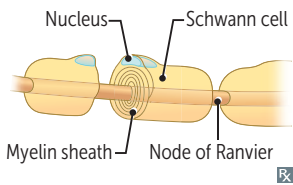


↑ conduction velocity of signals transmitted down axons → saltatory conduction of action potential at the nodes of Ranvier, where there are high concentrations of Na⁺ channels.
 In CNS (including CN II), myelin is synthesized by oligodendrocytes; in PNS (including CN III-XII), myelin is synthesized by Schwann cells.

Myelin (arrow in **A**) wraps and insulates axons:
 ↓ membrane capacitance, ↑ membrane resistance, ↑ space (length) constant, ↓ time constant.

CNS: Oligodendrocytes.
 PNS: Schwann cells. **COPS**

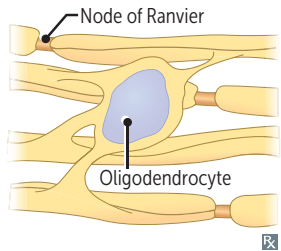
Schwann cells



Promote axonal regeneration. Derived from neural crest.

Each “Schwone” cell myelinates only **1** PNS axon.
 Injured in Guillain-Barré syndrome.
 Schwann cell marker: S100.

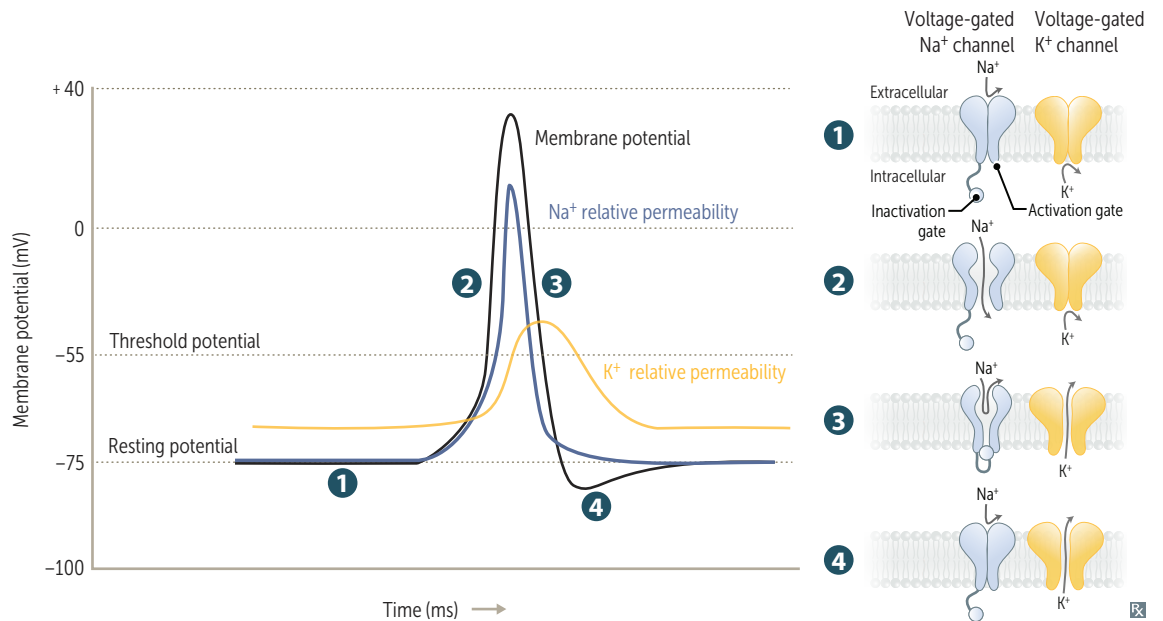
Oligodendrocytes



Myelinate axons of neurons in CNS. Each oligodendrocyte can myelinate many axons (~ 30). Predominant type of glial cell in white matter.

Derived from neuroectoderm.
 “Fried egg” appearance histologically.
 Injured in multiple sclerosis, progressive multifocal leukoencephalopathy (PML), leukodystrophies.

Neuron action potential

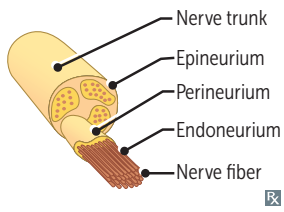


- ❶ Resting membrane potential: membrane is more permeable to K^+ than Na^+ at rest. Voltage-gated Na^+ and K^+ channels are closed.
- ❷ Membrane depolarization: Na^+ activation gate opens \rightarrow Na^+ flows inward.
- ❸ Membrane repolarization: Na^+ inactivation gate closes at peak potential, thus stopping Na^+ inflow. K^+ activation gate opens \rightarrow K^+ flows outward.
- ❹ Membrane hyperpolarization: K^+ activation gates are slow to close \rightarrow excess K^+ efflux and brief period of hyperpolarization. Voltage-gated Na^+ channels switch back to resting state. Na^+/K^+ pump restores ions concentration.

Sensory receptors

RECEPTOR TYPE	SENSORY NEURON FIBER TYPE	LOCATION	SENSES
Free nerve endings	Aδ —fast, myelinated fibers C —slow, unmyelinated A Delta plane is fast, but a tax C is slow	All tissues except cartilage and eye lens; numerous in skin	Pain, temperature
Meissner corpuscles	Large, myelinated fibers; adapt quickly	Glabrous (hairless) skin	Dynamic, fine/light touch, low-frequency vibration, skin indentation
Pacinian corpuscles	Large, myelinated fibers; adapt quickly	Deep skin layers, ligaments, joints	High-frequency vibration, pressure
Merkel discs	Large, myelinated fibers; adapt slowly	Finger tips, superficial skin	Pressure, deep static touch (eg, shapes, edges)
Ruffini corpuscles	Large, myelinated fiber intertwined among collagen fiber bundles; adapt slowly	Finger tips, joints	Stretch, joint angle change

Peripheral nerve

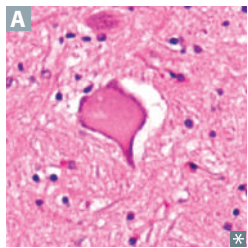


Endoneurium—thin, supportive connective tissue that ensheathes and supports individual myelinated nerve fibers. May be affected in Guillain-Barré syndrome.

Endo = inner
Peri = around
Epi = outer

Perineurium (blood-nerve permeability barrier)—surrounds a fascicle of nerve fibers.
Epineurium—dense connective tissue that surrounds entire nerve (fascicles and blood vessels).

Chromatolysis

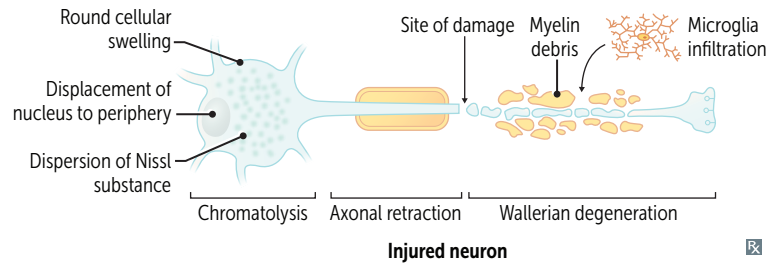


Reaction of neuronal cell body to axonal injury. Changes reflect ↑ protein synthesis in effort to repair the damaged axon. Characterized by:

- Round cellular swelling **A**
- Displacement of the nucleus to the periphery
- Dispersion of Nissl substance throughout cytoplasm

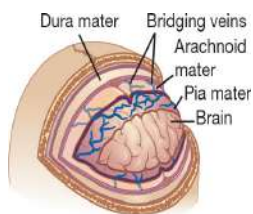
Wallerian degeneration—disintegration of the axon and myelin sheath distal to site of axonal injury with macrophages removing debris.

Proximal to the injury, the axon retracts, and the cell body sprouts new protrusions that grow toward other neurons for potential reinnervation. Serves as a preparation for axonal regeneration and functional recovery.



Neurotransmitter changes with disease

	LOCATION OF SYNTHESIS	ANXIETY	DEPRESSION	SCHIZOPHRENIA	ALZHEIMER DISEASE	HUNTINGTON DISEASE	PARKINSON DISEASE
Acetylcholine	Basal nucleus of Meynert (forebrain)				↓	↓	↑
Dopamine	Ventral tegmentum, SNc (midbrain)		↓	↑		↑	↓
GABA	Nucleus accumbens (basal ganglia)	↓				↓	
Norepinephrine	Locus ceruleus (pons)	↑	↓				
Serotonin	Raphe nuclei (brainstem)	↓	↓				↓

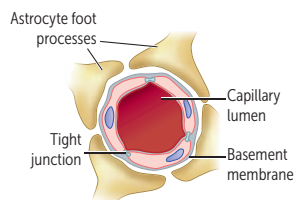
Meninges

Three membranes that surround and protect the brain and spinal cord:

- Dura mater—thick outer layer closest to skull. Derived from mesoderm.
- Arachnoid mater—middle layer, contains weblike connections. Derived from neural crest.
- Pia mater—thin, fibrous inner layer that firmly adheres to brain and spinal cord. Derived from neural crest.

CSF flows in the subarachnoid space, located between arachnoid and pia mater.

Epidural space—potential space between dura mater and skull/vertebral column containing fat and blood vessels. Site of blood collection associated with middle meningeal artery injury.

Blood-brain barrier

Prevents circulating blood substances (eg, bacteria, drugs) from reaching the CSF/CNS. Formed by 4 structures:

- Tight junctions between nonfenestrated capillary endothelial cells
- Basement membrane
- Pericytes
- Astrocyte foot processes

Glucose and amino acids cross slowly by carrier-mediated transport mechanisms.

Nonpolar/lipid-soluble substances cross rapidly via diffusion.

Circumventricular organs with fenestrated capillaries and no blood-brain barrier allow molecules in blood to affect brain function (eg, area postrema—vomiting after chemotherapy; OVLT [organum vasculosum lamina terminalis]—osmoreceptors) or neurosecretory products to enter circulation (eg, neurohypophysis—ADH release).

BBB disruption (eg, stroke) → vasogenic edema. Hyperosmolar agents (eg, mannitol) can disrupt the BBB → ↑ permeability of medications.

Vomiting center

Coordinated by nucleus tractus solitarius (NTS) in the medulla, which receives information from the chemoreceptor trigger zone (CTZ, located within area postrema (pronounce “puke”-strema) in 4th ventricle), GI tract (via vagus nerve), vestibular system, and CNS.

CTZ and adjacent vomiting center nuclei receive input through 5 major receptors: histamine (H_1), muscarinic (M_1), neurokinin (NK-1), dopamine (D_2), and serotonin ($5-HT_3$).

- $5-HT_3$, D_2 , and NK-1 antagonists used to treat chemotherapy-induced vomiting.
- H_1 and M_1 antagonists treat motion sickness; H_1 antagonists treat hyperemesis gravidarum.

Sleep physiology

Sleep cycle is regulated by the circadian rhythm, which is driven by suprachiasmatic nucleus (SCN) of the hypothalamus. Circadian rhythm controls nocturnal release of ACTH, prolactin, melatonin, norepinephrine: SCN → norepinephrine release → pineal gland → ↑ melatonin. SCN is regulated by environment (eg, light).

Two stages: rapid-eye movement (REM) and non-REM.

Alcohol, benzodiazepines, and barbiturates are associated with ↓ REM sleep and N3 sleep; norepinephrine also ↓ REM sleep.

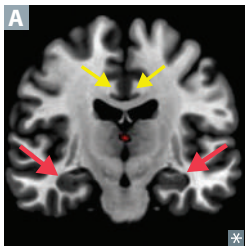
Benzodiazepines are useful for night terrors and sleepwalking by ↓ N3 and REM sleep.

SLEEP STAGE (% OF TOTAL SLEEP TIME IN YOUNG ADULTS)	DESCRIPTION	EEG WAVEFORM AND NOTES
Awake (eyes open)	Alert, active mental concentration.	Beta (highest frequency, lowest amplitude).
Awake (eyes closed)		Alpha .
Non-REM sleep		
Stage N1 (5%)	Light sleep.	Theta .
Stage N2 (45%)	Deeper sleep; when bruxism (“ t woth” [tooth] grinding) occurs.	Sleep spindles and K complexes.
Stage N3 (25%)	Deepest non-REM sleep (slow-wave sleep); sleepwalking , night terrors, and bedwetting occur (w ee and f lee in N3).	Delta (lowest frequency, highest amplitude), deepest sleep stage.
REM sleep (25%)	Loss of motor tone, ↑ brain O ₂ use, variable pulse/BP, ↑ ACh. REM is when dreaming, nightmares, and penile/clitoral tumescence occur; may serve memory processing function. Extraocular movements due to activity of PPRF (paramedian pontine reticular formation/conjugate gaze center). Occurs every 90 minutes, and duration ↑ through the night.	Beta . Changes in older adults: ↓ REM, ↓ N3, ↑ sleep latency, ↑ early awakenings. Changes in depression: ↑ REM sleep time, ↓ REM latency, ↓ N3, repeated nighttime awakenings, early morning awakening (terminal insomnia). Change in narcolepsy: ↓ REM latency. At night, BATS Drink Blood .

Hypothalamus	Maintains homeostasis by regulating T hirst and water balance, controlling A dеноhypophysis (anterior pituitary) and N eurohypophysis (posterior pituitary) release of hormones produced in the hypothalamus, and regulating H unger, A utonomic nervous system, T emperature, and S exual urges (TAN HATS). Inputs (areas not protected by blood-brain barrier): OVLT (senses change in osmolarity), area postrema (found in dorsal medulla, responds to emetics).	
Lateral nucleus	Hunger. Destruction → anorexia, failure to thrive (infants). Stimulated by ghrelin, inhibited by leptin.	L ateral injury makes you lean .
Ventromedial nucleus	Satiety. Destruction (eg, craniopharyngioma) → hyperphagia. Stimulated by leptin.	V entromedial injury makes you very massive .
Anterior nucleus	Cooling, parasympathetic.	A/C = A nterior C ooling.
Posterior nucleus	Heating, sympathetic.	H eating controlled by p osterior nucleus (“ hot pot ”).
Suprachiasmatic nucleus	Circadian rhythm.	SCN is a Sun-C ensing N ucleus.
Supraoptic and paraventricular nuclei	Synthesize ADH and oxytocin.	SAD POX : S upraoptic = ADH , P araventricular = OXY tocin. ADH and oxytocin are carried by neurophysins down axons to posterior pituitary, where these hormones are stored and released.
Preoptic nucleus	Thermoregulation, sexual behavior. Releases GnRH.	Failure of GnRH-producing neurons to migrate from olfactory pit → Kallmann syndrome.

Thalamus	Major relay for all ascending sensory information except olfaction.			
NUCLEI	INPUT	SENSES	DESTINATION	MNEMONIC
Ventral posterolateral nucleus	Spinothalamic and dorsal columns/medial lemniscus	V ibration, p ain, p ressure, p roprioception (conscious), l ight touch, t emperature	1° somatosensory cortex (parietal lobe)	
Ventral posteromedial nucleus	Trigeminal and gustatory pathway	F ace sensation, taste	1° somatosensory cortex (parietal lobe)	V ery p retty m akeup goes on the f ace
Lateral geniculate nucleus	CN II, optic chiasm, optic tract	Vision	1° visual cortex (occipital lobe)	L ateral = l ight (vision)
Medial geniculate nucleus	Superior olive and inferior colliculus of tectum	Hearing	1° auditory cortex (temporal lobe)	M edial = m usic (hearing)
Ventral anterior and ventral lateral nuclei	Basal ganglia, cerebellum	Motor	M otor cortices (frontal lobe)	V enus a stronauts v ow to l ove m oving

Limbic system



Collection of neural structures involved in emotion, long-term memory, olfaction, behavior modulation, ANS function.

Consists of hippocampus (red arrows in **A**), amygdalae, mammillary bodies, anterior thalamic nuclei, cingulate gyrus (yellow arrows in **A**), entorhinal cortex. Responsible for feeding, fleeing, fighting, feeling, and sex.

The famous **5 F**'s.

Dopaminergic pathways

Commonly altered by drugs (eg, antipsychotics) and movement disorders (eg, Parkinson disease).

PATHWAY	SYMPTOMS OF ALTERED ACTIVITY	NOTES
Mesocortical	↓ activity → “negative” symptoms (eg, anergia, apathy, lack of spontaneity)	Antipsychotics have limited effect
Mesolimbic	↑ activity → “positive” symptoms (eg, delusions, hallucinations)	1° therapeutic target of antipsychotics → ↓ positive symptoms (eg, in schizophrenia)
Nigrostriatal	↓ activity → extrapyramidal symptoms (eg, dystonia, akathisia, parkinsonism, tardive dyskinesia)	Motor control (pronounce “nigro stride atal”) Significantly affected by antipsychotics and Parkinson disease
Tuberoinfundibular	↓ activity → ↑ prolactin → ↓ libido, sexual dysfunction, galactorrhea, gynecomastia (in males)	

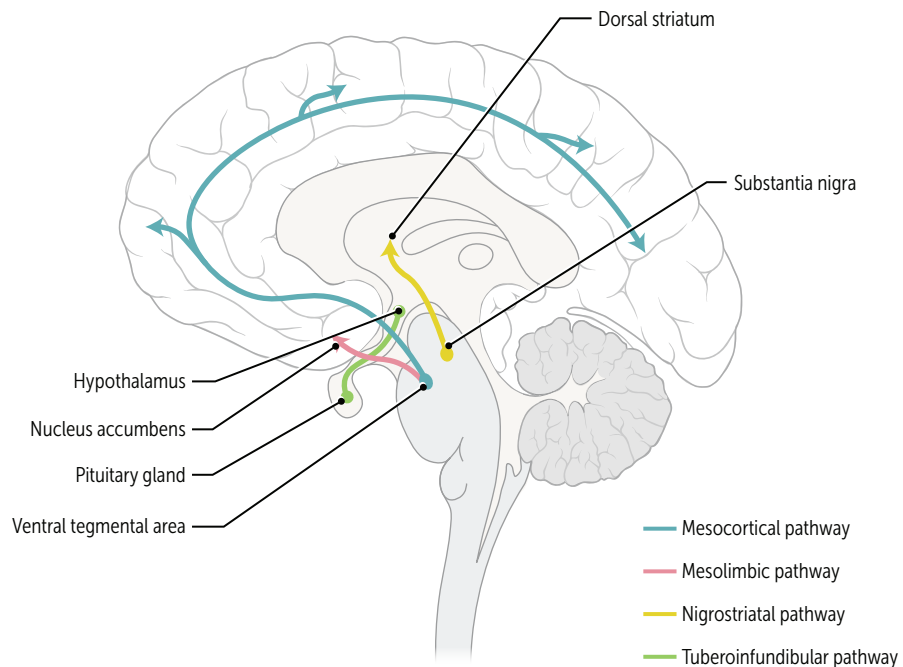
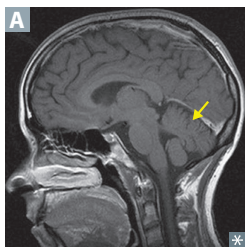


FIG 3-1

Cerebellum



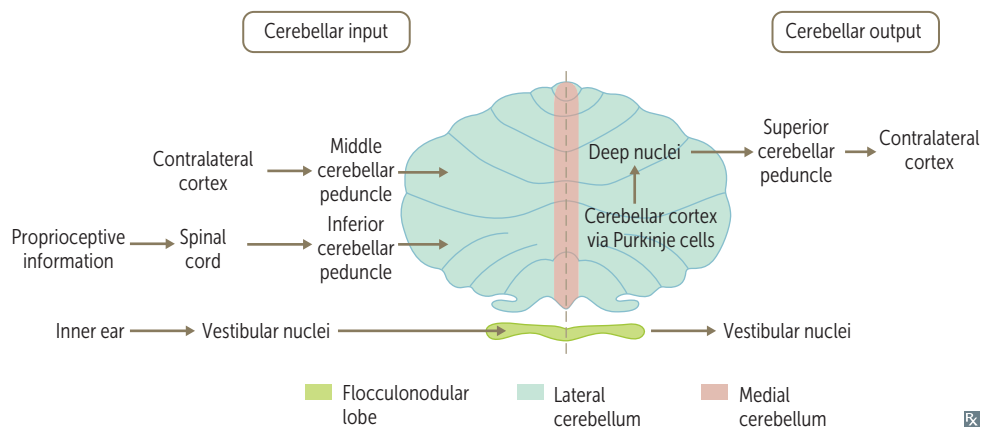
Modulates movement; aids in coordination and balance **A**.

- Ipsilateral (unconscious) proprioceptive information via inferior cerebellar peduncle from spinal cord
- Deep nuclei (lateral → medial)—dentate, emboliform, globose, fastigial (**d**on't eat **g**reasy **f**oods)

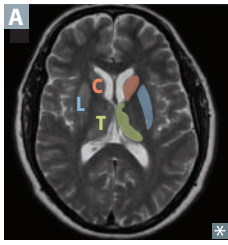
Lateral lesions—affect voluntary movement of extremities (**lateral** structures); when injured, propensity to fall toward injured (ipsilateral) side.

Medial lesions (eg, vermis, fastigial nuclei, flocculonodular lobe)—truncal ataxia (wide-based cerebellar gait), nystagmus, head tilting. Generally result in bilateral motor deficits affecting axial and proximal limb musculature (**medial** structures).

Tests: rapid alternating movements (pronation/supination), finger-to-nose, heel-to-shin, gait, look for intention tremor.



Basal ganglia



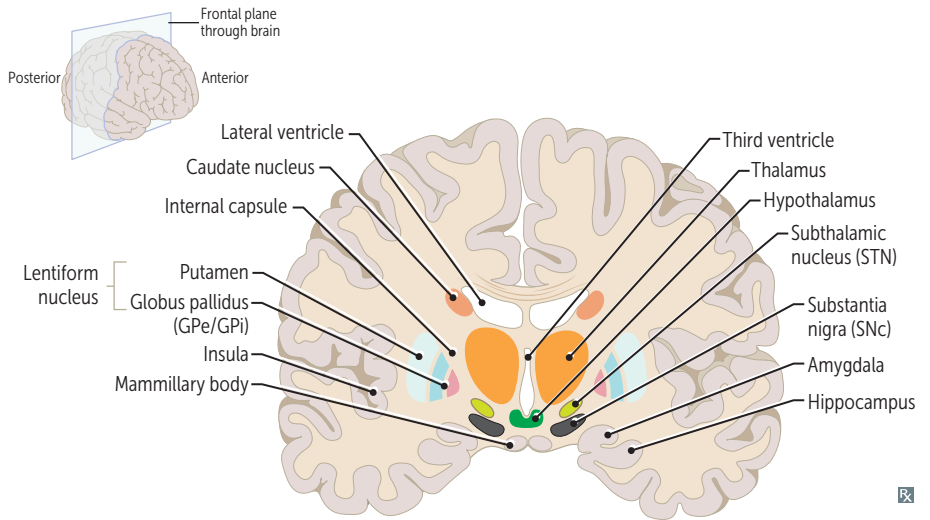
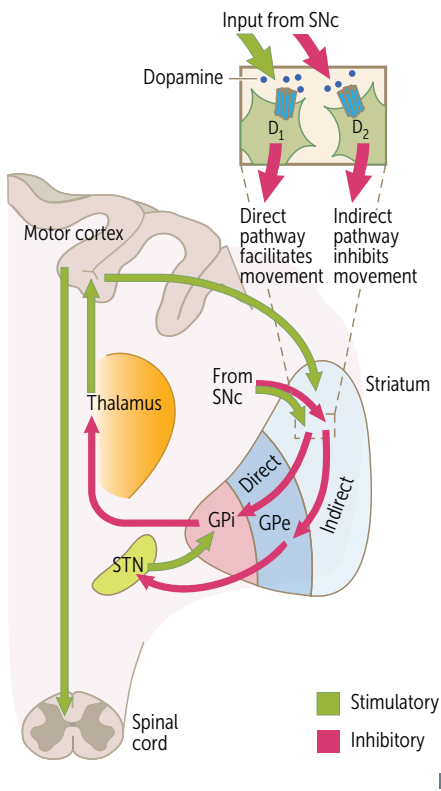
Important in voluntary movements and adjusting posture **A**.
 Receives cortical input, provides negative feedback to cortex to modulate movement.
 Striatum = putamen (motor) + **C**audate nucleus (cognitive).
Lentiform = putamen + globus pallidus.

D₁ Receptor = DIRect pathway.
Indirect (**D₂**) = **I**nhibitory.

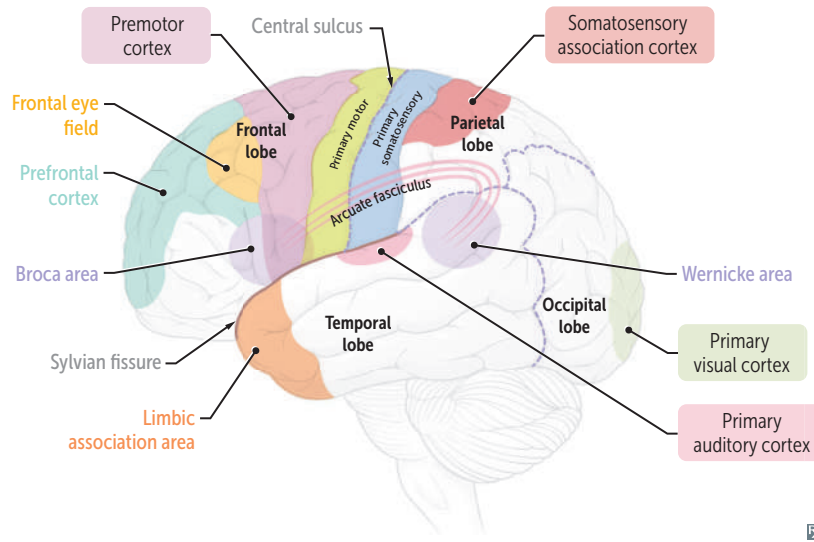
Direct (excitatory) pathway—cortical input (via glutamate) stimulates GABA release from the striatum, which inhibits GABA release from GPi, disinhibiting (activating) the **T**halamus → ↑ motion.

Indirect (inhibitory) pathway—cortical input (via glutamate) stimulates GABA release from the striatum, which inhibits GABA release from GPe, disinhibiting (activating) the STN. STN input (via glutamate) stimulates GABA release from GPi, inhibiting the **T**halamus → ↓ motion.

Dopamine from SNc (nigrostriatal pathway) stimulates the direct pathway (by binding to **D₁** receptor) and inhibits the indirect pathway (by binding to **D₂** receptor) → ↑ motion.



Cerebral cortex regions



Cerebral perfusion

Relies on tight autoregulation. Primarily driven by PCO_2 (PO_2 also modulates perfusion in severe hypoxia).

Also relies on a pressure gradient between mean arterial pressure (MAP) and intracranial pressure (ICP). \downarrow blood pressure or \uparrow ICP \rightarrow \downarrow cerebral perfusion pressure (CPP).

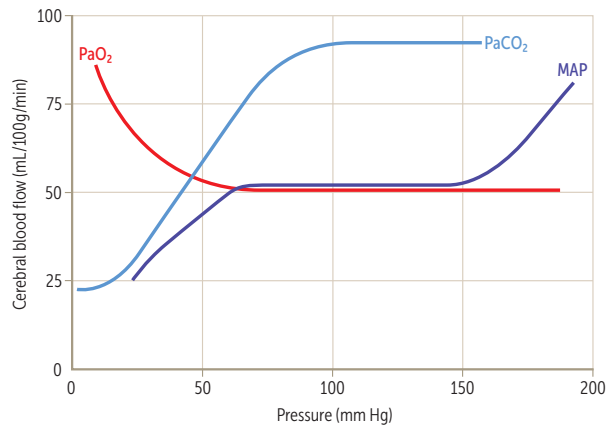
Cushing reflex—triad of hypertension, bradycardia, and respiratory depression in response to \uparrow ICP.

Therapeutic hyperventilation \rightarrow $\downarrow PCO_2$ \rightarrow vasoconstriction \rightarrow \downarrow cerebral blood flow \rightarrow \downarrow ICP. May be used to treat acute cerebral edema (eg, 2° to stroke) unresponsive to other interventions.

CPP = MAP – ICP. If CPP = 0, there is no cerebral perfusion \rightarrow brain death (coma, absent brainstem reflexes, apnea).

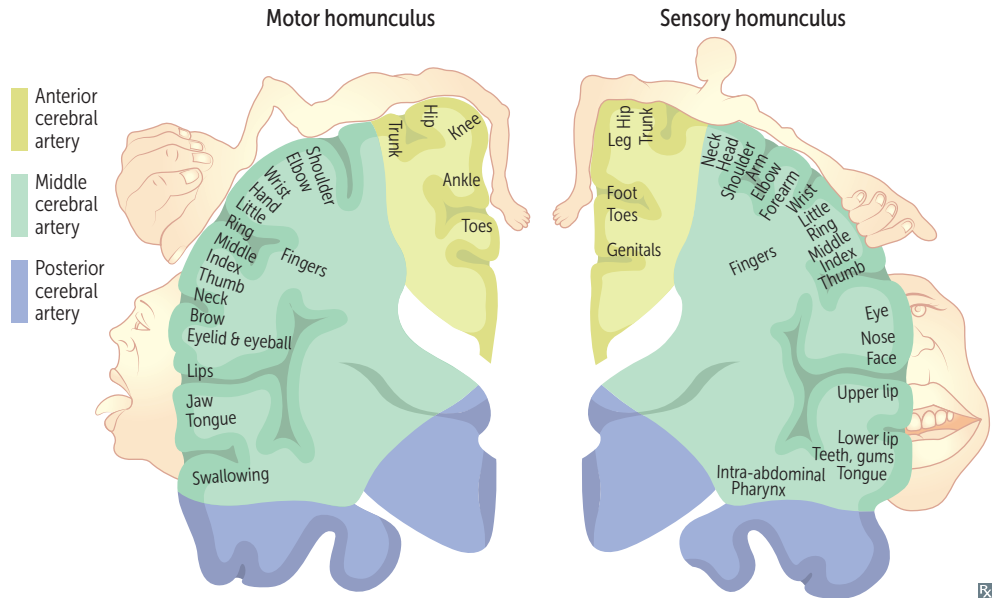
Hypoxemia increases CPP only if $PO_2 < 50$ mm Hg.

CPP is directly proportional to PCO_2 until $PCO_2 > 90$ mm Hg.

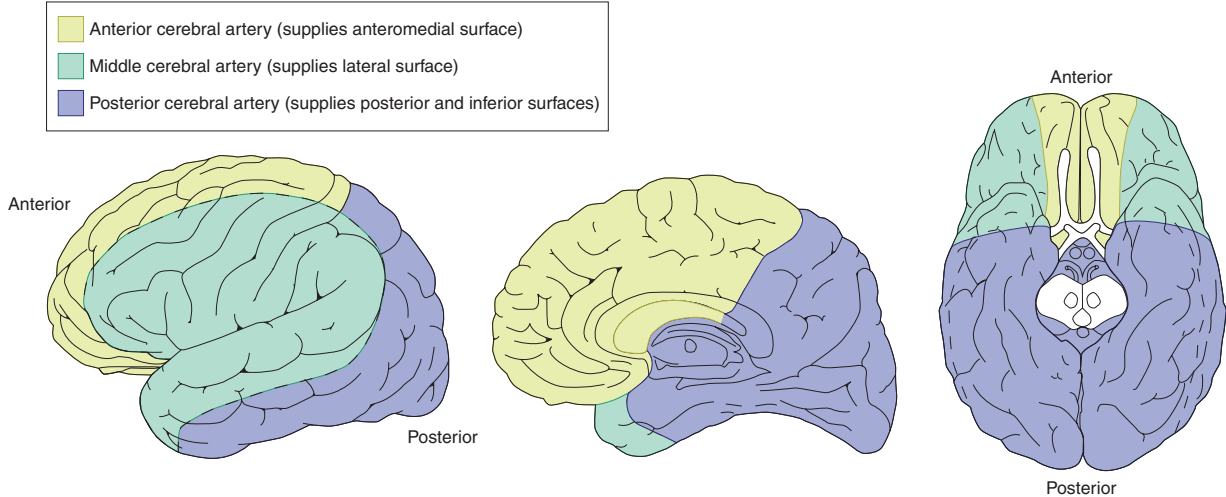


Homunculus

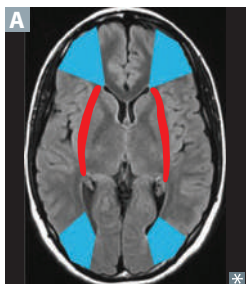
Topographic representation of motor and sensory areas in the cerebral cortex. Distorted appearance is due to certain body regions being more richly innervated and thus having ↑ cortical representation.



Cerebral arteries—cortical distribution



Watershed zones



Cortical border zones occur between anterior and middle cerebral arteries and posterior and middle cerebral arteries (blue areas in **A**). Internal border zones occur between the superficial and deep vascular territories of the middle cerebral artery (red areas in **A**).

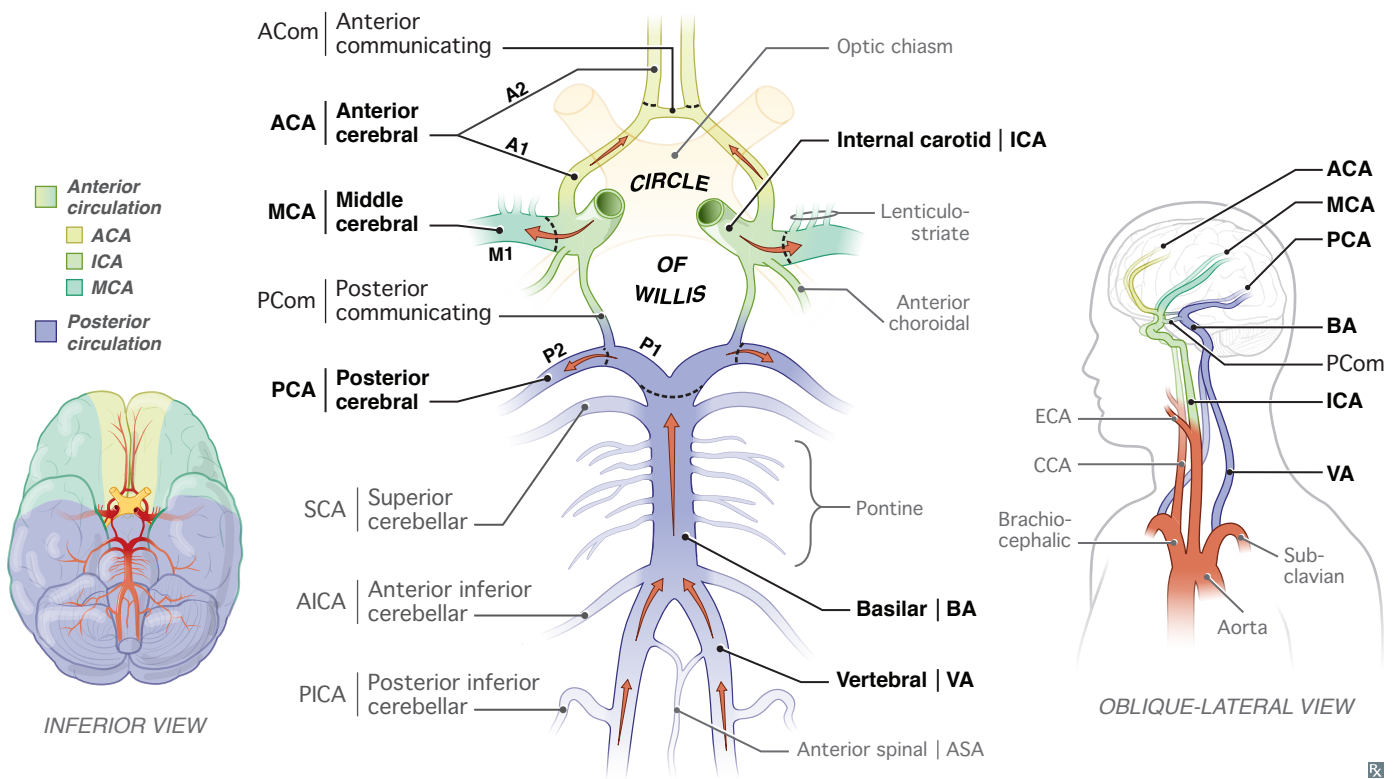
Common locations for brain metastases.

Infarct due to severe hypoperfusion:

- ACA-MCA watershed infarct—proximal upper and lower extremity weakness (“man-in-a-barrel syndrome”).
- PCA-MCA watershed infarct—higher-order visual dysfunction.

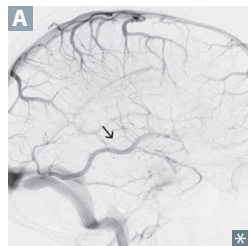
Circle of Willis

System of anastomoses between anterior and posterior blood supplies to brain.

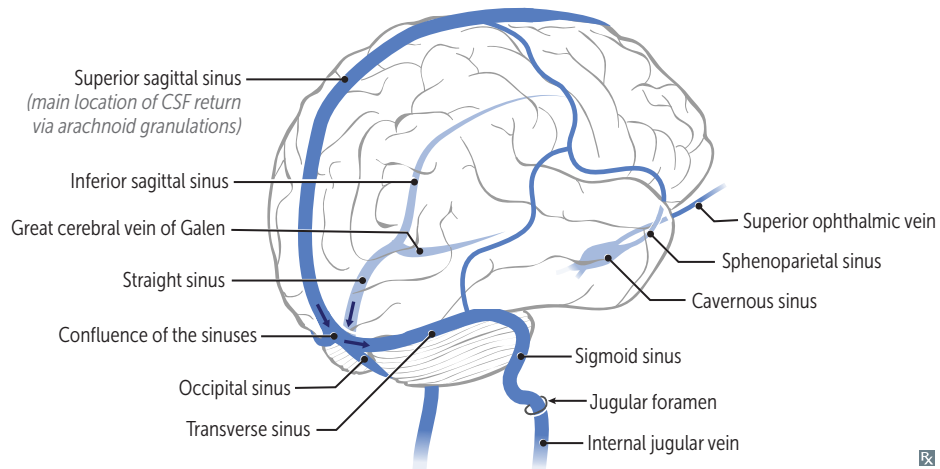


Dural venous sinuses

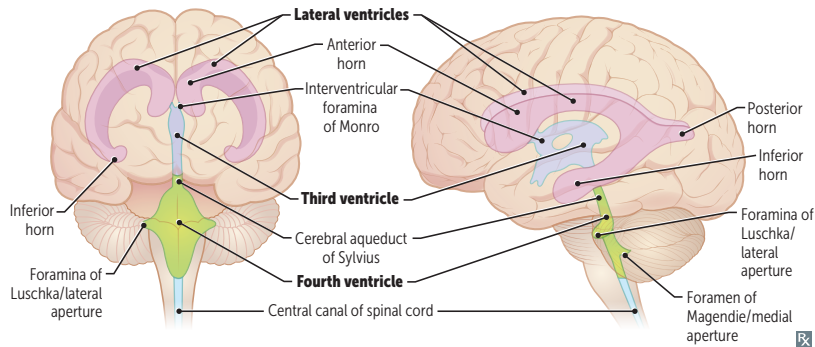
Large venous channels **A** that run through the periosteal and meningeal layers of the dura mater. Drain blood from cerebral veins (arrow) and receive CSF from arachnoid granulations. Empty into internal jugular vein.



Venous sinus thrombosis—presents with signs/symptoms of ↑ ICP (eg, headache, seizures, papilledema, focal neurologic deficits). May lead to venous hemorrhage. Associated with hypercoagulable states (eg, pregnancy, OCP use, factor V Leiden).



Ventricular system



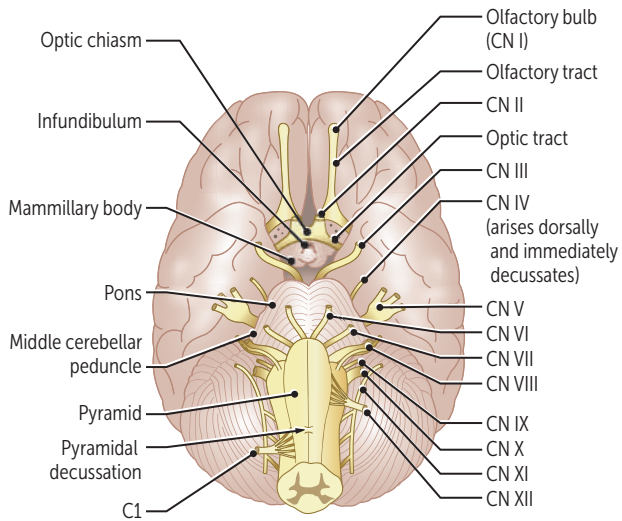
Lateral ventricles → 3rd ventricle via right and left interventricular foramina of Monro.
 3rd ventricle → 4th ventricle via cerebral aqueduct of Sylvius.

4th ventricle → subarachnoid space via:

- Foramina of **L**uschka = **l**ateral.
- Foramen of **M**agendie = **m**edial.

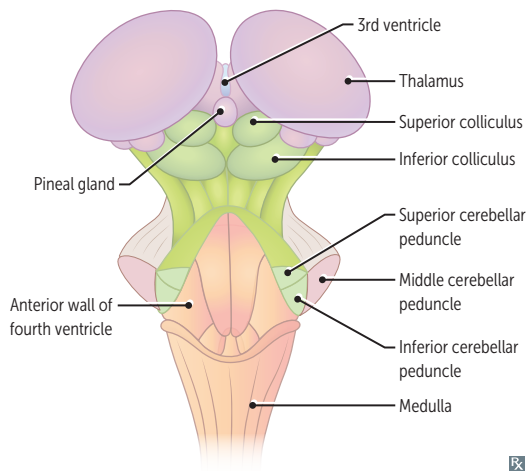
CSF made by choroid plexuses located in the lateral, third, and fourth ventricles. Travels to subarachnoid space via foramina of Luschka and Magendie, is reabsorbed by arachnoid granulations, and then drains into dural venous sinuses.

Brainstem—ventral view



- 4 CN are above pons (I, II, III, IV).
 - 4 CN exit the pons (V, VI, VII, VIII).
 - 4 CN are in medulla (IX, X, XI, XII).
 - 4 CN nuclei are medial (III, IV, VI, XII).
- “Factors of 12, except 1 and 2.”

Brainstem—dorsal view (cerebellum removed)



Pineal gland—melatonin secretion, circadian rhythms.

Superior colliculi—direct eye movements to stimuli (noise/movements) or objects of interest.

Inferior colliculi—auditory.

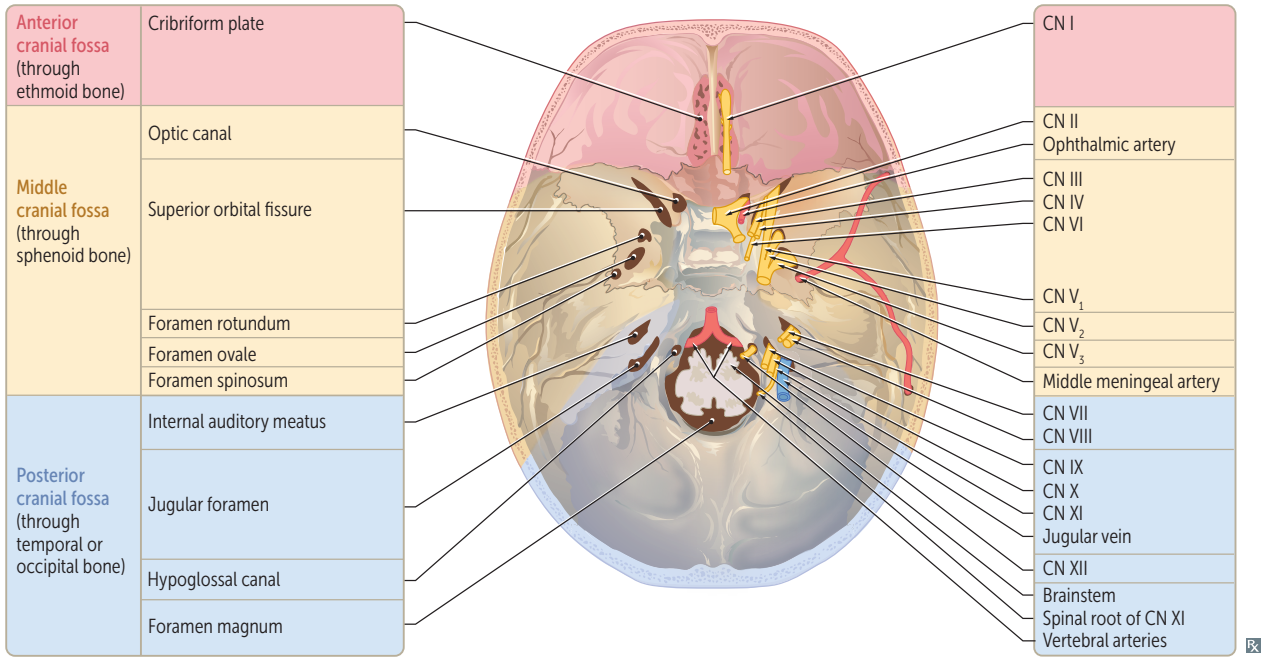
Your eyes are **above** your ears, and the superior colliculus (visual) is **above** the inferior colliculus (auditory).

Cranial nerve nuclei	<p>Located in tegmentum portion of brainstem (between dorsal and ventral portions):</p> <ul style="list-style-type: none"> ▪ Midbrain—nuclei of CN III, IV ▪ Pons—nuclei of CN V, VI, VII, VIII ▪ Medulla—nuclei of CN IX, X, XII ▪ Spinal cord—nucleus of CN XI 	<p>Lateral nuclei = sensory (alar plate). —Sulcus limitans— Medial nuclei = motor (basal plate).</p>
-----------------------------	--	--

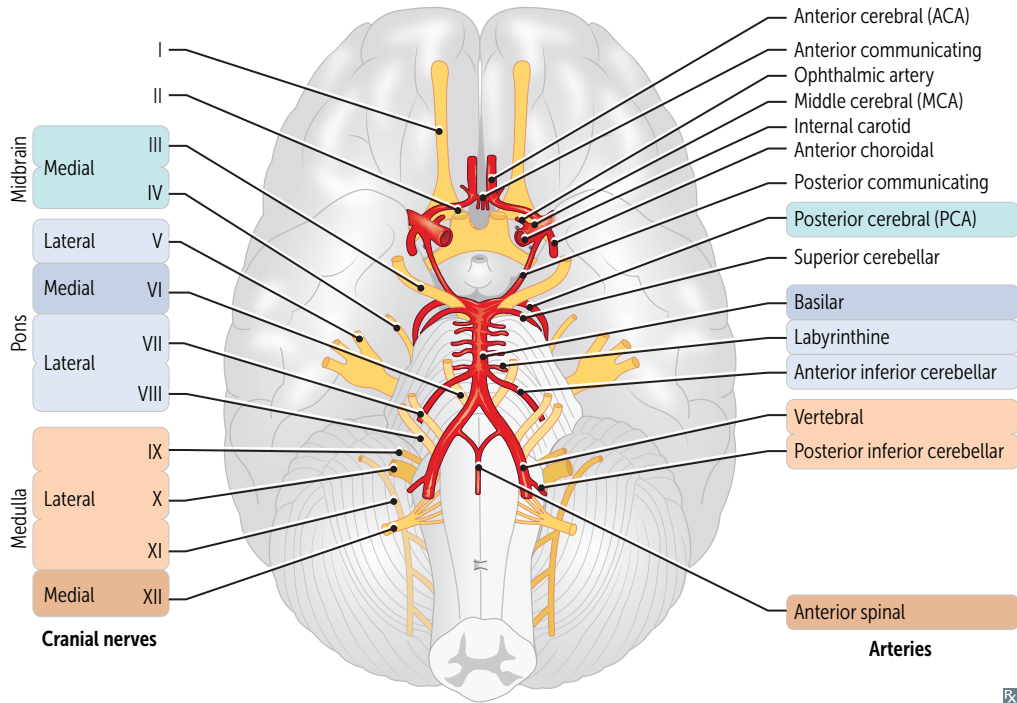
Vagal nuclei

NUCLEUS	FUNCTION	CRANIAL NERVES
Nucleus tractus solitarius	Visceral sensory information (eg, taste, baroreceptors, gut distention) May play a role in vomiting	VII, IX, X
Nucleus ambiguus	M otor innervation of pharynx, larynx, upper esophagus (eg, swallowing, palate elevation)	IX, X
Dorsal motor nucleus	Sends autonomic (parasympathetic) fibers to heart, lungs, upper GI	X

Cranial nerves and vessel pathways



Cranial nerves and arteries



Cranial nerves

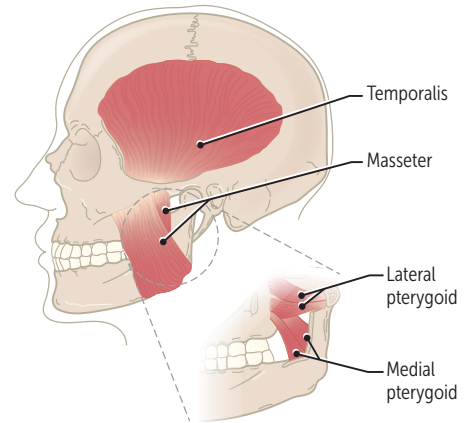
NERVE	CN	FUNCTION	TYPE	MNEMONIC
Olfactory	I	Smell (only CN without thalamic relay to cortex)	Sensory	Some
Optic	II	Sight	Sensory	Say
Oculomotor	III	Eye movement (SR, IR, MR, IO), pupillary constriction (sphincter pupillae), accommodation (ciliary muscle), eyelid opening (levator palpebrae)	Motor	Marry
Trochlear	IV	Eye movement (SO)	Motor	Money
Trigeminal	V	Mastication, facial sensation (ophthalmic, maxillary, mandibular divisions), somatosensation from anterior 2/3 of tongue, dampening of loud noises (tensor tympani)	Both	But
Abducens	VI	Eye movement (LR)	Motor	My
Facial	VII	Facial movement, eye closing (orbicularis oculi), auditory volume modulation (stapedius), taste from anterior 2/3 of tongue (chorda tympani), lacrimation, salivation (submandibular and sublingual glands are innervated by CN seven)	Both	Brother
Vestibulocochlear	VIII	Hearing, balance	Sensory	Says
Glossopharyngeal	IX	Taste and sensation from posterior 1/3 of tongue, swallowing, salivation (parotid gland), monitoring carotid body and sinus chemo- and baroreceptors, and elevation of pharynx/larynx (stylopharyngeus)	Both	Big
Vagus	X	Taste from supraglottic region, swallowing, soft palate elevation, midline uvula, talking, cough reflex, parasympathetics to thoracoabdominal viscera, monitoring aortic arch chemo- and baroreceptors	Both	Brains
Accessory	XI	Head turning, shoulder shrugging (SCM, trapezius)	Motor	Matter
Hypoglossal	XII	Tongue movement	Motor	Most

Cranial nerve reflexes

REFLEX	AFFERENT	EFFERENT
Accommodation	II	III
Corneal	V ₁ ophthalmic (nasociliary branch)	Bilateral VII (temporal branch—orbicularis oculi)
Cough	X	X (also phrenic and spinal nerves)
Gag	IX	X
Jaw jerk	V ₃ (sensory—muscle spindle from masseter)	V ₃ (motor—masseter)
Lacrimation	V ₁ (loss of reflex does not preclude emotional tears)	VII
Pupillary	II	III

Mastication muscles

3 muscles close jaw: **m**asseter, **t**emporalis, **m**edial pterygoid (**M**'s **m**unch).
Lateral pterygoid protrudes jaw.
All are innervated by mandibular branch of trigeminal nerve (CN V₃).

**Spinal nerves**

There are 31 pairs of spinal nerves: 8 cervical, 12 thoracic, 5 lumbar, 5 sacral, 1 coccygeal.
Nerves C1–C7 exit above the corresponding vertebrae (eg, C3 exits above the 3rd cervical vertebra).
C8 spinal nerve exits below C7 and above T1. All other nerves exit below (eg, L2 exits below the 2nd lumbar vertebra).

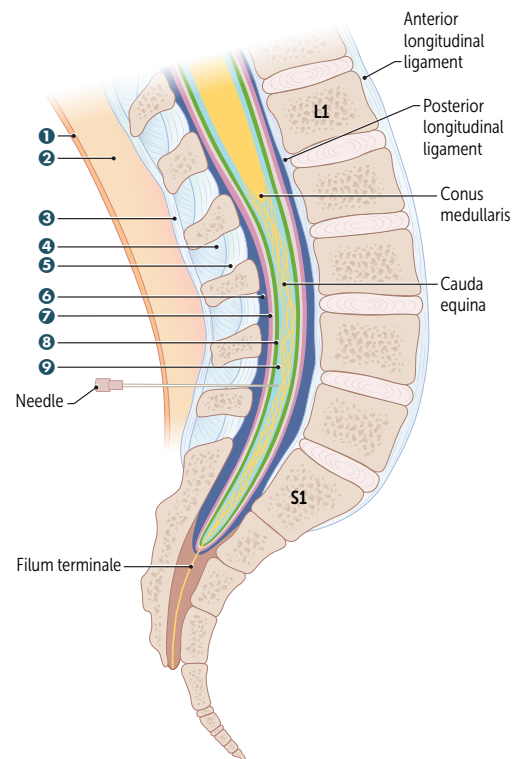
Spinal cord—lower extent

In adults, spinal cord ends at lower border of L1–L2 vertebrae. **S**ubarachnoid **s**pace (which contains the CSF) extends to lower border of **S**2 vertebra. Lumbar puncture is usually performed between L3–L4 or L4–L5 (level of cauda equina).

Goal of lumbar puncture is to obtain sample of CSF without damaging spinal cord. To **keep** the cord **alive**, keep the spinal needle between **L3** and **L5**.

Needle passes through:

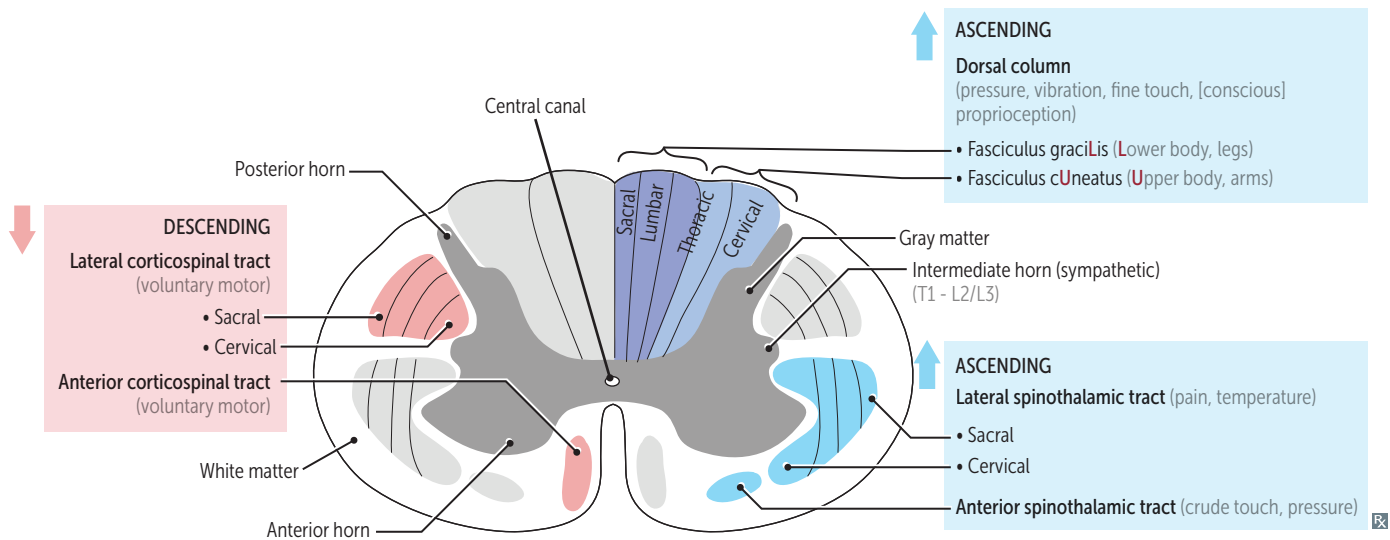
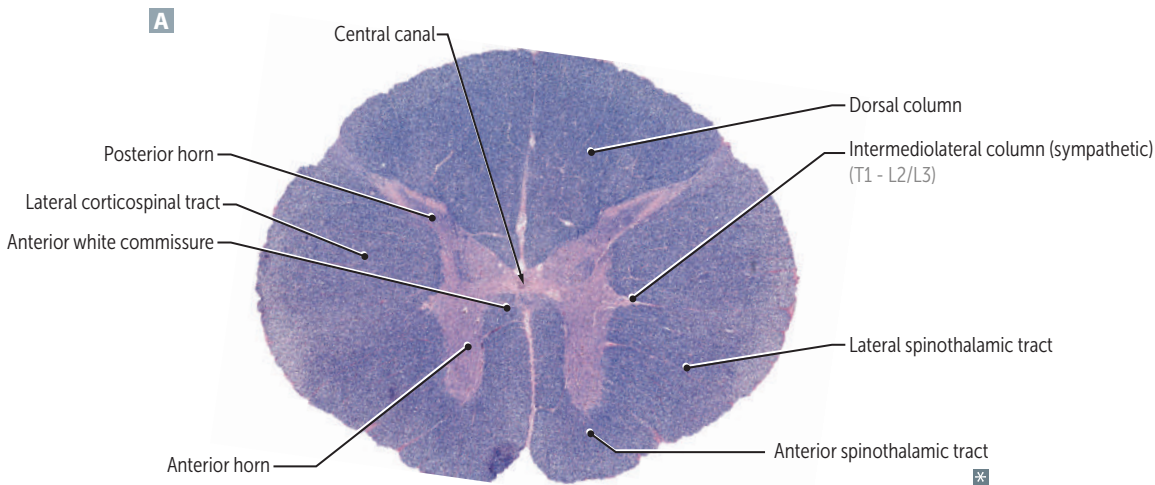
- 1 Skin
- 2 Fascia and fat
- 3 Supraspinous ligament
- 4 Interspinous ligament
- 5 Ligamentum flavum
- 6 Epidural space
(epidural anesthesia needle stops here)
- 7 Dura mater
- 8 Arachnoid mater
- 9 Subarachnoid space
(CSF collection occurs here)



Spinal cord and associated tracts

Legs (**l**umbosacral) are **l**ateral in **l**ateral corticospinal, spinothalamic tracts. Thoracic spinal cord section in **A**.

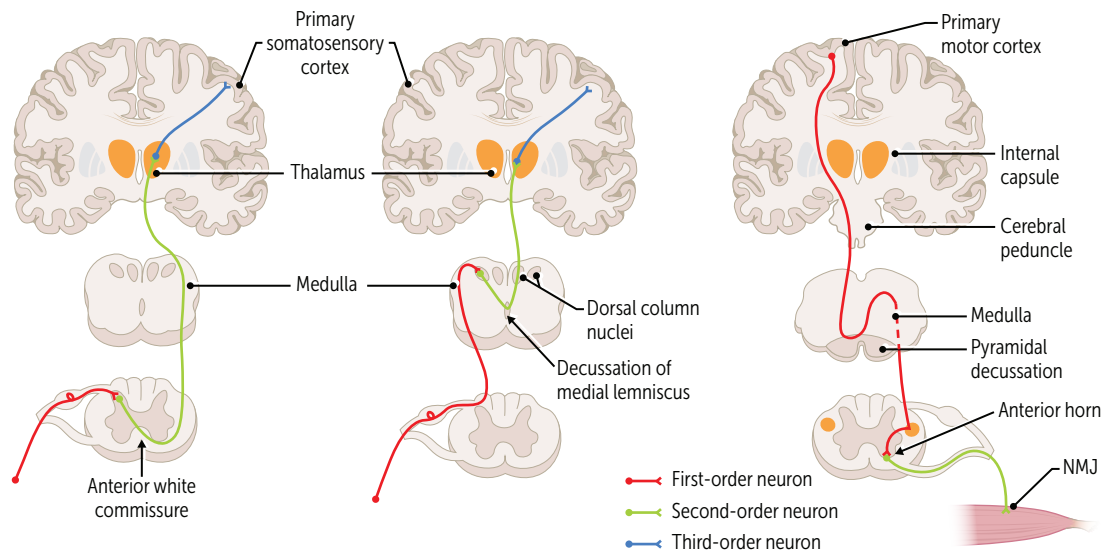
Dorsal columns are organized as you are, with hands at sides. “Arms outside, legs inside.”



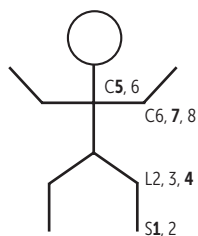
Spinal tract anatomy and functions

Spinothalamic tract and dorsal column (ascending tracts) synapse and then cross.
Corticospinal tract (descending tract) crosses and then synapses.

	Spinothalamic tract	Dorsal column	Corticospinal tract
FUNCTION	Pain, temperature	Pressure, vibration, fine touch, proprioception (conscious)	Voluntary movement
1ST-ORDER NEURON	Sensory nerve ending (A δ and C fibers) of pseudounipolar neuron in dorsal root ganglion → enters spinal cord	Sensory nerve ending of pseudounipolar neuron in dorsal root ganglion → enters spinal cord → ascends ipsilaterally in dorsal columns	UMN: 1° motor cortex → descends ipsilaterally (through posterior limb of internal capsule and cerebral peduncle), decussates at caudal medulla (pyramidal decussation) → descends contralaterally
1ST SYNAPSE	Posterior horn (spinal cord)	Nucleus gracilis, nucleus cuneatus (ipsilateral medulla)	Anterior horn (spinal cord)
2ND-ORDER NEURON	Decussates in spinal cord as the anterior white commissure → ascends contralaterally	Decussates in medulla → ascends contralaterally as the medial lemniscus	LMN: leaves spinal cord
2ND SYNAPSE	VPL (thalamus)	VPL (thalamus)	NMJ (skeletal muscle)
3RD-ORDER NEURON	Projects to 1° somatosensory cortex	Projects to 1° somatosensory cortex	



Clinical reflexes



Reflexes count up in order (main nerve root in **bold**):

- Achilles reflex** = S1, S2 (“buckle my shoe”)
- Patellar reflex** = L2-L4 (“kick the door”)
- Biceps and brachioradialis reflexes** = C5, C6 (“pick up sticks”)
- Triceps reflex** = C6, C7, C8 (“lay them straight”)

Additional reflexes:

- Cremasteric reflex** = L1, L2 (“testicles move”)
- Anal wink reflex** = S3, S4 (“winks galore”)

Reflex grading:

- 0: absent
- 1+: hypoactive
- 2+: normal
- 3+: hyperactive
- 4+: clonus

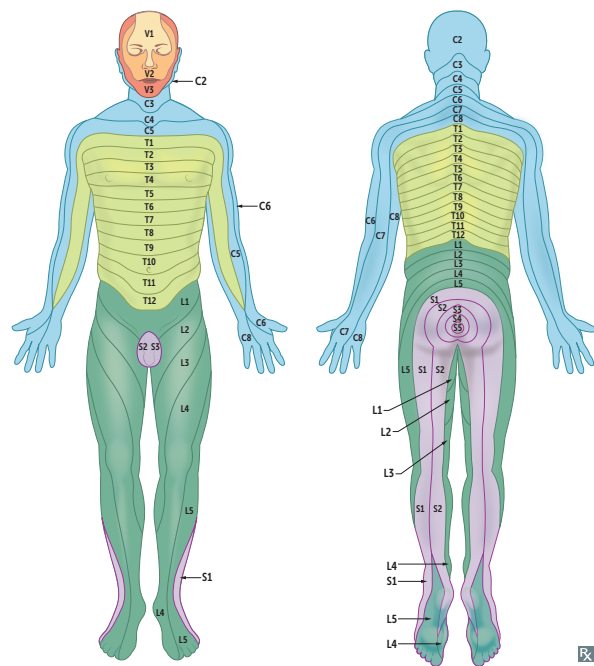
Primitive reflexes

CNS reflexes that are present in a healthy infant, but are absent in a neurologically intact adult. Normally disappear within 1st year of life. These primitive reflexes are inhibited by a mature/developing frontal lobe. They may reemerge in adults following frontal lobe lesions → loss of inhibition of these reflexes.

Moro reflex	“Hang on for life” reflex—abduct/extend arms when startled, and then draw together.
Rooting reflex	Movement of head toward one side if cheek or mouth is stroked (nipple seeking).
Sucking reflex	Sucking response when roof of mouth is touched.
Palmar reflex	Curling of fingers if palm is stroked.
Plantar reflex	Dorsiflexion of large toe and fanning of other toes with plantar stimulation. Babinski sign—presence of this reflex in an adult, which may signify a UMN lesion.
Galant reflex	Stroking along one side of the spine while newborn is in ventral suspension (face down) causes lateral flexion of lower body toward stimulated side.

Landmark dermatomes

DERMATOME	CHARACTERISTICS
C2	Posterior half of skull
C3	High turtleneck shirt Diaphragm and gallbladder pain referred to the right shoulder via phrenic nerve C3, 4, 5 keeps the diaphragm alive
C4	Low-collar shirt
C6	Includes thumbs Thumbs up sign on left hand looks like a 6
T4	At the nipple T4 at the teat pore
T7	At the xiphoid process 7 letters in xiphoid
T10	At the umbilicus (belly butten) Point of referred pain in early appendicitis
L1	At the Inguinal Ligament
L4	Includes the kneecaps Down on ALL 4 's
S2, S3, S4	Sensation of penile and anal zones S2, 3, 4 keep the penis off the floor



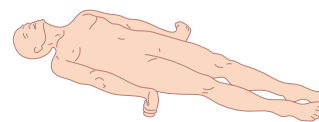
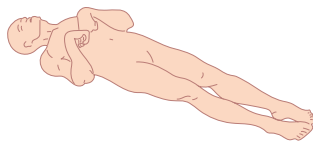
▶ NEUROLOGY—PATHOLOGY

Common brain lesions

AREA OF LESION	COMPLICATIONS
Prefrontal cortex	Frontal lobe syndrome —disinhibition, hyperphagia, impulsivity, loss of empathy, impaired executive function, akinetic mutism. Seen in frontotemporal dementia.
Frontal eye fields	Eyes look toward brain lesion (ie, away from side of hemiplegia). Seen in MCA stroke.
Paramedian pontine reticular formation	Eyes look away from brain lesion (ie, toward side of hemiplegia).
Dominant parietal cortex	Gerstmann syndrome —agraphia, acalculia, finger agnosia, left-right disorientation.
Nondominant parietal cortex	Hemispatial neglect syndrome —agnosia of the contralateral side of the world.
Basal ganglia	Tremor at rest, chorea, athetosis. Seen in Parkinson disease, Huntington disease.
Subthalamic nucleus	Contralateral hemiballismus.
Mammillary bodies	Bilateral lesions → Wernicke-Korsakoff syndrome (due to thiamine deficiency).
Amygdala	Bilateral lesions → Klüver-Bucy syndrome —disinhibition (eg, hyperphagia, hypersexuality, hyperorality). Seen in HSV-1 encephalitis.
Hippocampus	Bilateral lesions → anterograde amnesia (no new memory formation). Seen in Alzheimer disease.
Dorsal midbrain	Parinaud syndrome (often due to pineal gland tumors).
Reticular activating system	Reduced levels of arousal and wakefulness, coma.
Medial longitudinal fasciculus	Internuclear ophthalmoplegia (impaired adduction of ipsilateral eye; nystagmus of contralateral eye with abduction). Seen in multiple sclerosis.
Cerebellar hemisphere	Intention tremor, limb ataxia, loss of balance; damage to cerebellum → ipsilateral deficits; fall toward side of lesion. Cerebellar hemispheres are laterally located—affect lateral limbs.
Cerebellar vermis	Truncal ataxia (wide-based, “drunken sailor” gait), nystagmus, dysarthria. Degeneration associated with chronic alcohol overuse. Vermis is centrally located—affects central body.

Abnormal motor posturing

	Decorticate (flexor) posturing	Decerebrate (extensor) posturing
SITE OF LESION	Above red nucleus (often cerebral cortex)	Between red and vestibular nuclei (brainstem)
OVERACTIVE TRACTS	Rubrospinal and vestibulospinal tracts	Vestibulospinal tract
PRESENTATION	Upper limb flexion, lower limb extension	Upper and lower limb extension
NOTES	“Your hands are near the cor (heart)”	Worse prognosis



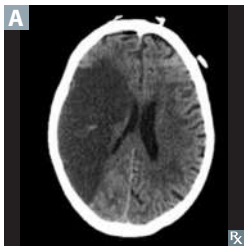
Ischemic brain disease/stroke

Irreversible neuronal injury begins after 5 minutes of hypoxia. Most **vulnerable: hippocampus** (CA1 region), **neocortex**, cerebellum (**Purkinje cells**), **watershed areas** (“**vulnerable hippos need pure water**”).

Stroke imaging: noncontrast CT to exclude hemorrhage (before tPA can be given). CT detects ischemic changes in 6–24 hr. Diffusion-weighted MRI can detect ischemia within 3–30 min.

TIME SINCE ISCHEMIC EVENT	12–24 HOURS	24–72 HOURS	3–5 DAYS	1–2 WEEKS	> 2 WEEKS
Histologic features	Eosinophilic cytoplasm + pyknotic nuclei (red neurons)	Necrosis + neutrophils	Macrophages (microglia)	Reactive gliosis (astrocytes) + vascular proliferation	Glial scar

Ischemic stroke



Ischemia → infarction → liquefactive necrosis.

3 types:

- **Thrombotic**—due to a clot forming directly at site of infarction (commonly the MCA **A**), usually over a ruptured atherosclerotic plaque.
- **Embolic**—due to an embolus from another part of the body. Can affect multiple vascular territories. Examples: atrial fibrillation, carotid artery stenosis, DVT with patent foramen ovale (paradoxical embolism), infective endocarditis.
- **Hypoxic**—due to systemic hypoperfusion or hypoxemia. Common during cardiovascular surgeries, tends to affect watershed areas.

Treatment: tPA (if within 3–4.5 hr of onset and no hemorrhage/risk of hemorrhage) and/or thrombectomy (if large artery occlusion). Reduce risk with medical therapy (eg, aspirin, clopidogrel); optimum control of blood pressure, blood sugars, lipids; smoking cessation; and treat conditions that ↑ risk (eg, atrial fibrillation, carotid artery stenosis).

Transient ischemic attack

Brief, reversible episode of focal neurologic dysfunction without acute infarction (⊖ MRI), with the majority resolving in < 15 minutes; ischemia (eg, embolus, small vessel stenosis). May present with amaurosis fugax (transient visual loss) due to retinal artery emboli from carotid artery disease.

Cerebral edema

Fluid accumulation in brain parenchyma → ↑ ICP. Types:

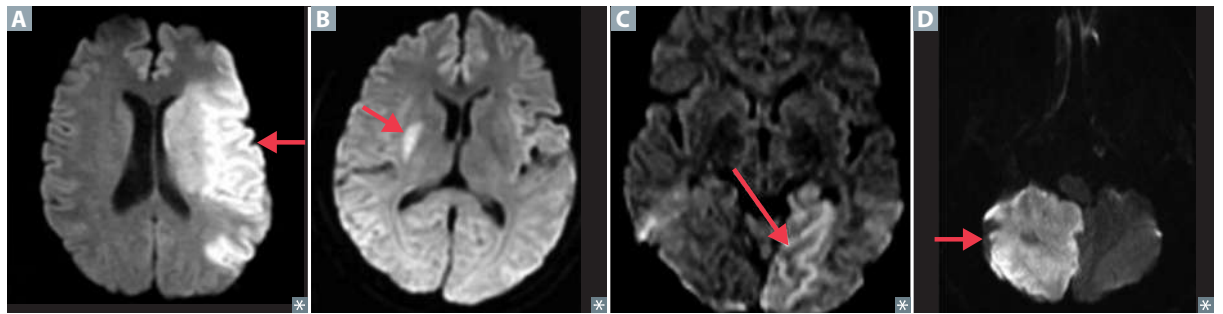
- **Cytotoxic edema**—intracellular fluid accumulation due to osmotic shift (eg, Na⁺/K⁺-ATPase dysfunction → ↑ intracellular Na⁺). Caused by ischemia (early), hyperammonemia, SIADH.
- **Vasogenic edema**—extracellular fluid accumulation due to disruption of BBB (↑ permeability). Caused by ischemia (late), trauma, hemorrhage, inflammation, tumors.

Effects of strokes

ARTERY	AREA OF LESION	SYMPTOMS	NOTES
Anterior circulation			
Anterior cerebral artery	Motor and sensory cortices—lower limb.	Contralateral paralysis and sensory loss—lower limb, urinary incontinence.	
Middle cerebral artery	Motor and sensory cortices A —upper limb and face. Temporal lobe (Wernicke area); frontal lobe (Broca area).	Contralateral paralysis and sensory loss—lower face and upper limb. Aphasia if in dominant (usually left) hemisphere. Hemineglect if lesion affects nondominant (usually right) hemisphere.	Wernicke aphasia is associated with right superior quadrant visual field defect due to temporal lobe involvement.
Lenticulo-striate artery	Striatum, internal capsule.	Contralateral paralysis. Absence of cortical signs (eg, neglect, aphasia, visual field loss).	Pure motor stroke (most common). Common location of lacunar infarcts B , due to microatheroma and hyaline arteriosclerosis (lipohyalinosis) 2° to unmanaged hypertension.
Posterior circulation			
Posterior cerebral artery	Occipital lobe C .	Contralateral hemianopia with macular sparing; alexia without agraphia (dominant hemisphere, extending to splenium of corpus callosum); prosopagnosia (nondominant hemisphere).	
Basilar artery	Pons, medulla, lower midbrain. Corticospinal and corticobulbar tracts. Ocular cranial nerve nuclei, paramedian pontine reticular formation.	If RAS spared, consciousness is preserved. Quadriplegia; loss of voluntary facial (except blinking), mouth, and tongue movements. Loss of horizontal, but not vertical, eye movements.	Locked-in syndrome (locked in the basement).
Anterior inferior cerebellar artery	Facial nerve nuclei. Vestibular nuclei. Spinothalamic tract, spinal trigeminal nucleus. Sympathetic fibers. Middle and inferior cerebellar peduncles. Inner ear.	Paralysis of face (LMN lesion vs UMN lesion in cortical stroke), ↓ lacrimation, ↓ salivation, ↓ taste from anterior 2/3 of tongue. Vomiting, vertigo, nystagmus ↓ pain and temperature sensation from contralateral body, ipsilateral face. Ipsilateral Horner syndrome. Ipsilateral ataxia, dysmetria. Ipsilateral sensorineural deafness, vertigo.	Lateral pontine syndrome. Facial nerve nuclei effects are specific to AICA lesions. Supplied by labyrinthine artery, a branch of AICA.

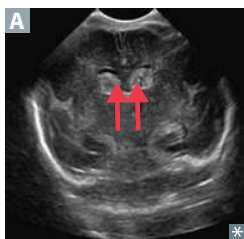
Effects of strokes (continued)

ARTERY	AREA OF LESION	SYMPTOMS	NOTES
Posterior inferior cerebellar artery	Nucleus ambiguus (CN IX, X, XI). Vestibular nuclei. Lateral spinothalamic tract, spinal trigeminal nucleus. Sympathetic fibers. Inferior cerebellar peduncle.	Dysphagia, hoarseness , ↓ gag reflex, hiccups. Vomiting, vertigo, nystagmus ↓ pain and temperature sensation from contralateral body, ipsilateral face. Ipsilateral Horner syndrome. Ipsilateral ataxia, dysmetria.	Lateral medullary (Wallenberg) syndrome. Nucleus ambiguus effects are specific to PICA lesions D . “Don’t pick a (PICA) lame horse (hoarseness) that can’t eat (dysphagia).”
Anterior spinal artery	Corticospinal tract. Medial lemniscus. Caudal medulla—hypoglossal nerve.	Contralateral paralysis—upper and lower limbs. ↓ contralateral proprioception. Ipsilateral hypoglossal dysfunction (tongue deviates ipsilaterally).	Medial Medullary syndrome —caused by infarct of paramedian branches of ASA and/or vertebral arteries. Ants love M&M’s .



Neonatal intraventricular hemorrhage

Bleeding into ventricles (arrows in **A** show blood in intraventricular spaces on ultrasound). Increased risk in premature and low-birth-weight infants. Originates in germinal matrix, a highly vascularized layer within the subventricular zone. Due to reduced glial fiber support and impaired autoregulation of BP in premature infants. Can present with altered level of consciousness, bulging fontanelle, hypotension, seizures, coma.



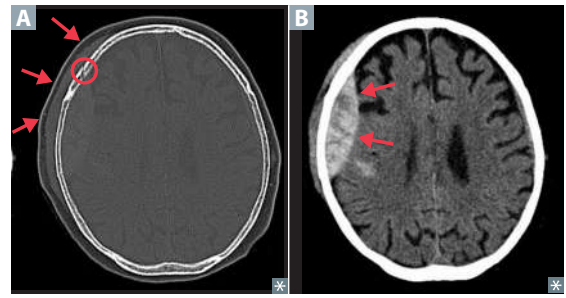
Intracranial hemorrhage

Epidural hematoma

Rupture of middle meningeal artery (branch of maxillary artery), often 2° to skull fracture (circle in **A**) involving the pterion (thinnest area of the lateral skull). Might present with transient loss of consciousness → recovery (“lucid interval”) → rapid deterioration due to hematoma expansion.

Scalp hematoma (arrows in **A**) and rapid intracranial expansion (arrows in **B**) under systemic arterial pressure → transtentorial herniation, CN III palsy.

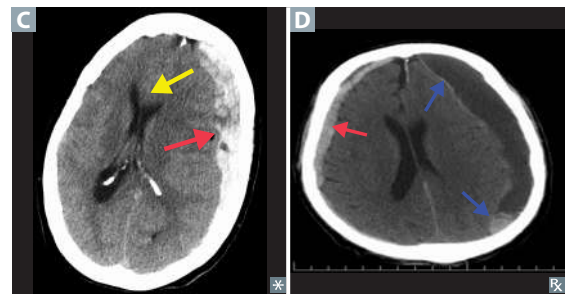
CT shows biconvex (lentiform), hyperdense blood collection **B** not crossing suture lines.



Subdural hematoma

Rupture of bridging veins. Can be acute (traumatic, high-energy impact → hyperdense on CT) or chronic (associated with mild trauma, cerebral atrophy, ↑ age, chronic alcohol overuse → hypodense on CT). Also seen in shaken babies.

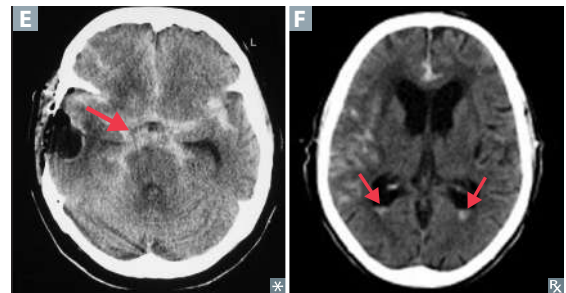
Crescent-shaped hemorrhage (red arrows in **C** and **D**) that **crosses suture lines**. Can cause midline shift (yellow arrow in **C**), findings of “acute on chronic” hemorrhage (blue arrows in **D**).



Subarachnoid hemorrhage

Bleeding **E F** due to trauma, or rupture of an aneurysm (such as a saccular aneurysm) or arteriovenous malformation. Rapid time course. Patients complain of “worst headache of my life.” Bloody or yellow (xanthochromic) lumbar puncture.

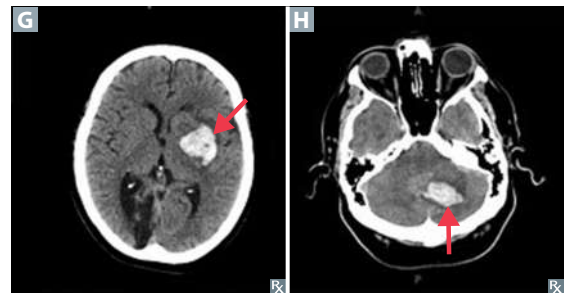
Vasospasm can occur due to blood breakdown or rebleed 3–10 days after hemorrhage → ischemic infarct; nimodipine used to prevent/reduce vasospasm. ↑ risk of developing communicating and/or obstructive hydrocephalus.



Intraparenchymal hemorrhage

Most commonly caused by systemic hypertension. Also seen with amyloid angiopathy (recurrent lobar hemorrhagic stroke in older adults), arteriovenous malformations, vasculitis, neoplasm. May be 2° to reperfusion injury in ischemic stroke.

Hypertensive hemorrhages (Charcot-Bouchard microaneurysm) most often occur in putamen of basal ganglia (lenticulostriate vessels **G**), followed by thalamus, pons, and cerebellum **H**.



Central poststroke pain

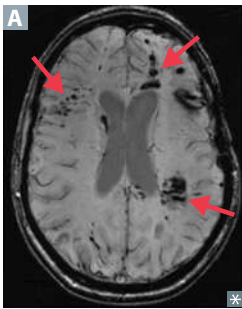
Neuropathic pain due to thalamic lesions. Initial paresthesias followed in weeks to months by allodynia (ordinarily painless stimuli cause pain) and dysesthesia (altered sensation) on the contralateral side. Occurs in 10% of stroke patients.

Phantom limb pain

Sensation of pain in a limb that is no longer present. Common after amputation. Associated with reorganization of 1° somatosensory cortex. Characterized by burning, aching, or electric shock-like pain.

Diffuse axonal injury

Traumatic shearing of white matter tracts during rapid acceleration and/or deceleration of the brain (eg, motor vehicle accident). Usually results in devastating neurologic injury, often causing coma or persistent vegetative state. MRI shows multiple lesions (punctate hemorrhages) involving white matter tracts **A**.

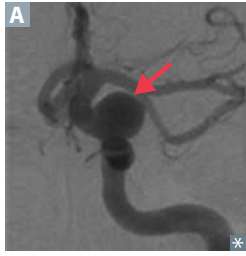**Aphasia**

Aphasia—higher-order language deficit (inability to understand/produce/use language appropriately); caused by pathology in dominant cerebral hemisphere (usually left).
Dysarthria—motor inability to produce speech (movement deficit).

TYPE	COMMENTS
Broca (expressive)	Broca area in inferior frontal gyrus of frontal lobe. Associated with defective language production. Patients appear frustrated, insight intact. Broca = broken boca (<i>boca</i> = mouth in Spanish).
Wernicke (receptive)	Wernicke area in superior temporal gyrus of temporal lobe. Associated with impaired language comprehension. Patients do not have insight. Wernicke is a word salad and makes no sense.
Conduction	Can be caused by damage to arcuate fasciculus .
Global	Broca and Wernicke areas affected.

Aneurysms

Abnormal dilation of an artery due to weakening of vessel wall.

Saccular aneurysm

Also called berry aneurysm **A**. Occurs at bifurcations in the circle of Willis. Most common site is junction of ACom and ACA. Associated with ADPKD, Ehlers-Danlos syndrome. Other risk factors: advanced age, hypertension, tobacco smoking.

Usually clinically silent until rupture (most common complication) → subarachnoid hemorrhage (“worst headache of my life” or “thunderclap headache”) → focal neurologic deficits. Can also cause symptoms via direct compression of surrounding structures by growing aneurysm.

- ACom—compression → bitemporal hemianopia (compression of optic chiasm); visual acuity deficits; rupture → ischemia in ACA distribution → contralateral lower extremity hemiparesis, sensory deficits.
- MCA—rupture → ischemia in MCA distribution → contralateral upper extremity and lower facial hemiparesis, sensory deficits.
- PCom—compression → ipsilateral CN III palsy → mydriasis (“blown pupil”); may also see ptosis, “down and out” eye.

Charcot-Bouchard microaneurysm

Common, associated with chronic hypertension; affects small vessels (eg, lenticulostriate arteries in basal ganglia, thalamus) and can cause hemorrhagic intraparenchymal strokes. Not visible on angiography.

Fever vs heat stroke

	Fever	Heat stroke
PATHOPHYSIOLOGY	Cytokine activation during inflammation (eg, infection)	Inability of body to dissipate heat (eg, exertion)
TEMPERATURE	Usually < 40°C (104°F)	Usually > 40°C (104°F)
COMPLICATIONS	Febrile seizure (benign, usually self-limiting)	CNS dysfunction (eg, confusion), rhabdomyolysis, acute kidney injury, ARDS, DIC
MANAGEMENT	Acetaminophen or ibuprofen for comfort (does not prevent future febrile seizures), antibiotic therapy if indicated	Rapid external cooling, rehydration and electrolyte correction

Seizures

Characterized by synchronized, high-frequency neuronal firing. Variety of forms.

Partial (focal) seizures

Affect single area of the brain. Most commonly originate in medial temporal lobe. Types:

- **Simple partial** (consciousness intact)—motor, sensory, autonomic, psychic
- **Complex partial** (impaired consciousness, automatisms)

Generalized seizures

Diffuse. Types:

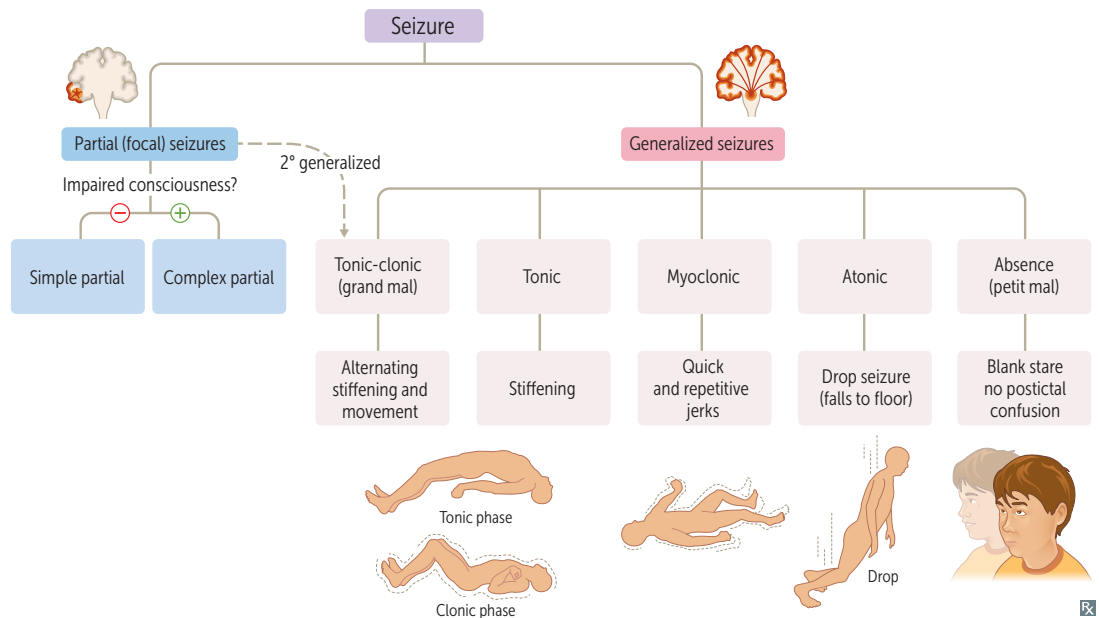
- **Absence** (petit mal)—3 Hz spike-and-wave discharges, short (usually 10 seconds) and frequent episodes of blank stare, no postictal confusion. Can be triggered by hyperventilation
- **Myoclonic**—quick, repetitive jerks; no loss of consciousness
- **Tonic-clonic** (grand mal)—alternating stiffening and movement, postictal confusion, urinary incontinence, tongue biting
- **Tonic**—stiffening
- **Atonic**—“drop” seizures (falls to floor); commonly mistaken for fainting

Epilepsy—disorder of recurrent, unprovoked seizures (febrile seizures are not epilepsy).

Status epilepticus—continuous (≥ 5 min) or recurring seizures without interictal return to baseline consciousness that may result in brain injury.

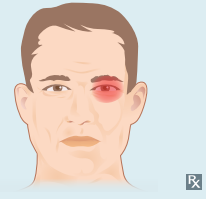
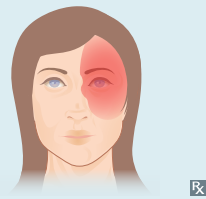
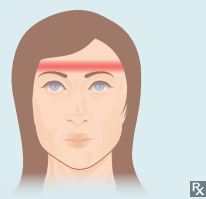
Causes of seizures by age:

- Children < 18 —genetic, infection (febrile), trauma, congenital, metabolic
- Adults 18–65—tumor, trauma, stroke, infection
- Adults > 65 —stroke, tumor, trauma, metabolic, infection



Headaches

Pain due to irritation of intra- or extracranial structures (eg, meninges, blood vessels). Primary headaches include cluster, migraine, and tension; migraine and tension headaches are more common in females. Secondary headaches include subarachnoid hemorrhage, meningitis, hydrocephalus, neoplasia, giant cell (temporal) arteritis.

CLASSIFICATION	LOCALIZATION	DURATION	DESCRIPTION	TREATMENT
Cluster^a 	Unilateral	15 min–3 hr; repetitive	Excruciating periorbital pain (“suicide headache”) with autonomic symptoms (eg, lacrimation, rhinorrhea, conjunctival injection). May present with Horner syndrome. More common in males.	Acute: sumatriptan, 100% O ₂ . Prophylaxis: verapamil.
Migraine 	Unilateral	4–72 hr	Pulsating pain with nausea, photophobia, and/or phonophobia. May have “aura.” Due to irritation of CN V, meninges, or blood vessels (release of vasoactive neuropeptides [eg, substance P, calcitonin gene-related peptide]).	Acute: NSAIDs, triptans, dihydroergotamine, antiemetics (eg, prochlorperazine, metoclopramide). Prophylaxis: lifestyle changes (eg, sleep, exercise, diet), β-blockers, amitriptyline, topiramate, valproate, botulinum toxin, anti-CGRP monoclonal antibodies. POUND —Pulsatile, One-day duration, Unilateral, Nausea, Disabling.
Tension 	Bilateral	> 30 min (typically 4–6 hr); constant	Steady, “bandlike” pain. No photophobia or phonophobia. No aura.	Acute: analgesics, NSAIDs, acetaminophen. Prophylaxis: TCAs (eg, amitriptyline), behavioral therapy.

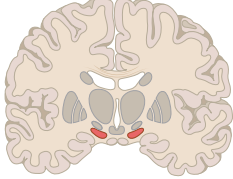

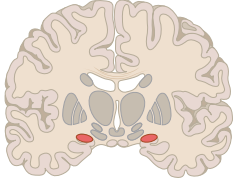
^aCompare with **trigeminal neuralgia**, which produces repetitive, unilateral, shooting/shocklike pain in the distribution of CN V. Triggered by chewing, talking, touching certain parts of the face. Lasts (typically) for seconds to minutes, but episodes often increase in intensity and frequency over time. First-line therapy: carbamazepine.

Movement disorders

DISORDER	PRESENTATION	CHARACTERISTIC LESION	NOTES
Akathisia	Restlessness and intense urge to move		Can be seen with neuroleptic use or as an adverse effect of Parkinson treatment
Asterixis	Extension of wrists causes “flapping” motion		Associated with hepatic encephalopathy, Wilson disease, and other metabolic derangements
Athetosis	Slow, snakelike, writhing movements; especially seen in the fingers	Basal ganglia	Seen in Huntington disease
Chorea	Sudden, jerky, purposeless movements	Basal ganglia	<i>Chorea</i> = dancing Seen in Huntington disease and in acute rheumatic fever (Sydenham chorea)
Dystonia	Sustained, involuntary muscle contractions		Writer’s cramp, blepharospasm, torticollis Treatment: botulinum toxin injection
Essential tremor	High-frequency tremor with sustained posture (eg, outstretched arms), worsened with movement or when anxious		Often familial Patients often self-medicate with alcohol, which ↓ tremor amplitude Treatment: nonselective β-blockers (eg, propranolol), barbiturates (primidone)
Intention tremor	Slow, zigzag motion when pointing/extending toward a target	Cerebellar dysfunction	
Resting tremor	Uncontrolled movement of distal appendages (most noticeable in hands); tremor alleviated by intentional movement	Substantia nigra (P arkinson disease)	Occurs at rest; “pill-rolling tremor” of Parkinson disease When you park your car, it is at rest
Hemiballismus	Sudden, wild flailing of one side of the body	Contralateral subthalamic nucleus (eg, lacunar stroke)	Pronounce “ H alf-of-body is going ballistic ”
Myoclonus	Sudden, brief, uncontrolled muscle contraction		Jerks; hiccups; common in metabolic abnormalities (eg, renal and liver failure), Creutzfeldt-Jakob disease
Restless legs syndrome	Uncomfortable sensations in legs causing irresistible urge to move them; relieved by movement; worse at rest/nighttime		Associated with iron deficiency, CKD, diabetes (especially with neuropathy) Treatment: dopamine agonists (pramipexole, ropinirole)

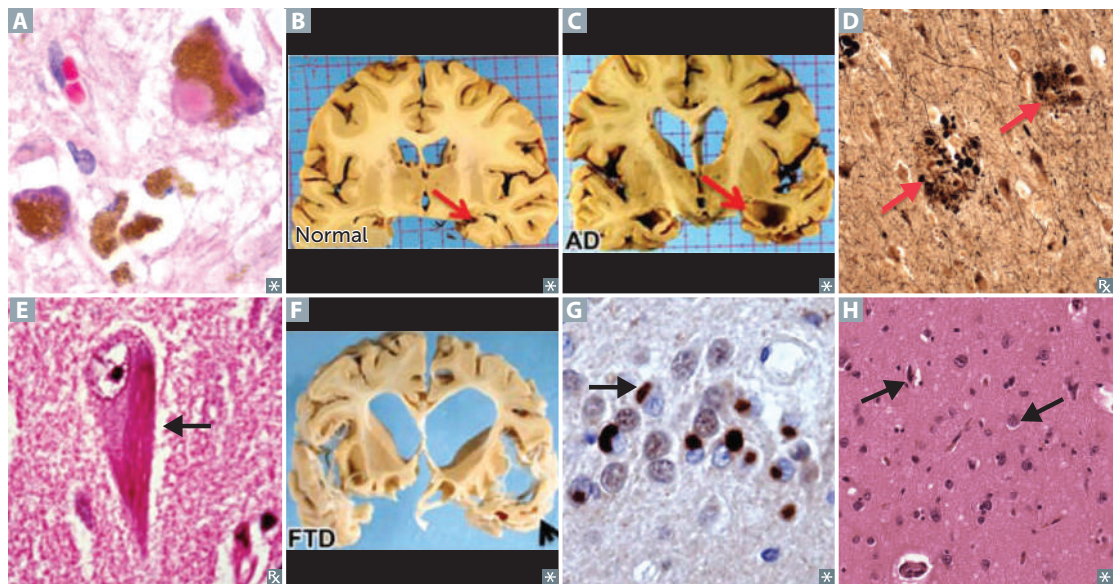
Neurodegenerative disorders

↓ in cognitive ability, memory, or function with intact consciousness.
Must rule out depression as cause of dementia (called pseudodementia). Other reversible causes of dementia: hypothyroidism, vitamin B₁₂ deficiency, neurosyphilis, normal pressure hydrocephalus.

DISEASE	DESCRIPTION	HISTOLOGIC/GROSS FINDINGS
Parkinson disease 	Parkinson TRAPSS your body: T remor (pill-rolling tremor at rest) R igidity (cogwheel) A kinesia (or bradykinesia) P ostural instability S huffling gait S mall handwriting (micrographia) Dementia is usually a late finding. MPTP, a contaminant in illegal drugs, is metabolized to MPP ⁺ , which is toxic to substantia nigra.	Loss of dopaminergic neurons (ie, depigmentation) of substantia nigra pars compacta. Lewy bodies: composed of α -synuclein (intracellular eosinophilic inclusions A).
Huntington disease 	Autosomal dominant trinucleotide (CAG) _n repeat expansion in the huntingtin (HTT) gene on chromosome 4 (4 letters) → toxic gain of function. Symptoms manifest between ages 20 and 50: chorea, athetosis, aggression, depression, dementia (sometimes initially mistaken for substance use). Anticipation results from expansion of CAG repeats. Caudate loses ACh and GABA .	Atrophy of caudate and putamen with ex vacuo ventriculomegaly. ↑ dopamine, ↓ GABA, ↓ ACh in brain. Neuronal death via NMDA-R binding and glutamate excitotoxicity.
Alzheimer disease 	Most common cause of dementia in older adults. Advanced age is the strongest risk factor. Down syndrome patients have ↑ risk of developing early-onset Alzheimer disease, as APP is located on chromosome 21. ↓ ACh. Associated with the following altered proteins: <ul style="list-style-type: none"> ▪ ApoE-2: ↓ risk of sporadic form ▪ ApoE-4: ↑ risk of sporadic form ▪ APP, presenilin-1, presenilin-2: familial forms (10%) with earlier onset ApoE-2 is “ protwo ctive”, apoE-4 is “ four ” Alzheimer disease.	Widespread cortical atrophy (normal cortex B ; cortex in Alzheimer disease C), especially hippocampus (arrows in B and C). Narrowing of gyri and widening of sulci. Senile plaques D in gray matter: extracellular β -amyloid core; may cause amyloid angiopathy → intracranial hemorrhage; A β (amyloid- β) synthesized by cleaving amyloid precursor protein (APP). Neurofibrillary tangles E : intracellular, hyperphosphorylated tau protein = insoluble cytoskeletal elements; number of tangles correlates with degree of dementia. Hirano bodies—intracellular eosinophilic proteinaceous rods in hippocampus.
Frontotemporal dementia	Formerly called Pick disease. Early changes in personality and behavior (behavioral variant), or aphasia (primary progressive aphasia). May have associated movement disorders.	Frontotemporal lobe degeneration F . Inclusions of hyperphosphorylated tau (round Pick bodies G) or ubiquitinated TDP-43.

Neurodegenerative disorders (continued)

DISEASE	DESCRIPTION	HISTOLOGIC/GROSS FINDINGS
Lewy body dementia	Visual hallucinations (“haLewycinations”), dementia with fluctuating cognition/alertness, REM sleep behavior disorder, and parkinsonism. Called Lewy body dementia if cognitive and motor symptom onset < 1 year apart, otherwise considered dementia 2° to Parkinson disease.	Intracellular Lewy bodies A primarily in cortex.
Vascular dementia	Result of multiple arterial infarcts and/or chronic ischemia. Step-wise decline in cognitive ability with late-onset memory impairment. 2nd most common cause of dementia in older adults.	MRI or CT shows multiple cortical and/or subcortical infarcts.
Creutzfeldt-Jakob disease	Rapidly progressive (weeks to months) dementia with myoclonus (“startle myoclonus”) and ataxia. Associated with periodic sharp waves on EEG and ↑ 14-3-3 protein in CSF. May be transmitted by contaminated materials (eg, corneal transplant, neurosurgical equipment). Fatal.	Spongiform cortex (vacuolation without inflammation). Prions (PrP ^c → PrP ^{sc} sheet [β-pleated sheet resistant to proteases]) H .
HIV-associated dementia	Subcortical dysfunction associated with advanced HIV infection. Characterized by cognitive deficits, gait disturbance, irritability, depressed mood.	Diffuse gray matter and subcortical atrophy. Microglial nodules with multinucleated giant cells.



Idiopathic intracranial hypertension

Also called pseudotumor cerebri. ↑ ICP with no obvious findings on imaging. Risk factors include **female** sex, **Tetracyclines**, **Obesity**, vitamin **A** excess, **Danazol (female TOAD)**. Associated with dural venous sinus stenosis. Findings: headache, tinnitus, diplopia (usually from CN VI palsy), no change in mental status. Impaired optic nerve axoplasmic flow → papilledema. Visual field testing shows enlarged blind spot and peripheral constriction. Lumbar puncture reveals ↑ opening pressure and provides temporary headache relief.

Treatment: weight loss, acetazolamide, invasive procedures for refractory cases (eg, CSF shunt placement, optic nerve sheath fenestration surgery for visual loss).

Hydrocephalus

↑ CSF volume → ventricular dilation +/- ↑ ICP.

Communicating**Communicating hydrocephalus**

↓ CSF absorption by arachnoid granulations (eg, arachnoid scarring post-meningitis) → ↑ ICP, papilledema, herniation.

Normal pressure hydrocephalus

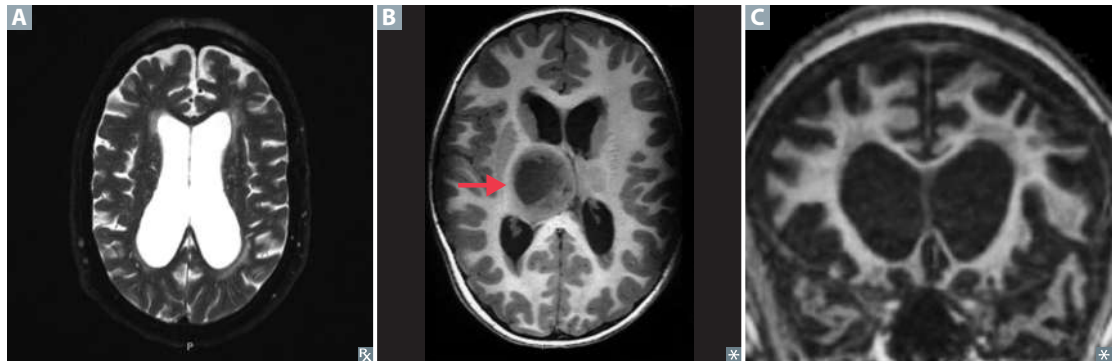
Affects older adults; idiopathic; CSF pressure elevated only episodically; does not result in increased subarachnoid space volume. Expansion of ventricles **A** distorts the fibers of the corona radiata → triad of **urinary incontinence**, **gait apraxia** (magnetic gait), and **cognitive dysfunction**. “**Wet, wobbly, and wacky**.” Symptoms potentially reversible with CSF drainage via lumbar puncture or shunt placement.

Noncommunicating (obstructive)**Noncommunicating hydrocephalus**

Caused by structural blockage of CSF circulation within ventricular system (eg, stenosis of aqueduct of Sylvius, colloid cyst blocking foramen of Monro, tumor **B**).

Hydrocephalus mimics**Ex vacuo ventriculomegaly**

Appearance of ↑ CSF on imaging **C**, but is actually due to ↓ brain tissue and neuronal atrophy (eg, Alzheimer disease, advanced HIV, frontotemporal dementia, Huntington disease). ICP is normal; NPH triad is not seen.



Multiple sclerosis

Autoimmune inflammation and demyelination of CNS (brain and spinal cord) with subsequent axonal damage. Can present with

- Optic neuritis (acute painful monocular visual loss, associated with relative afferent pupillary defect)
- Brainstem/cerebellar syndromes (eg, diplopia, ataxia, scanning speech, intention tremor, nystagmus/INO [bilateral > unilateral])
- Pyramidal tract demyelination (eg, weakness, spasticity)
- Spinal cord syndromes (eg, electric shock–like sensation along cervical spine on neck flexion, neurogenic bladder, paraparesis, sensory manifestations affecting the trunk or one or more extremity)

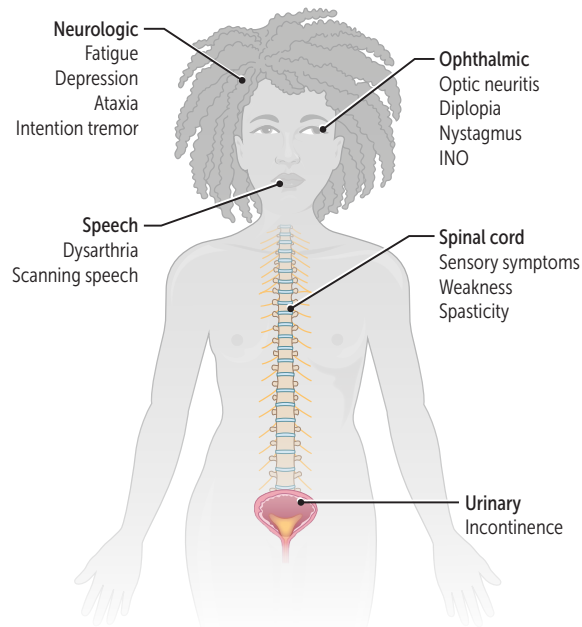
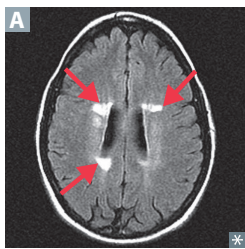
Symptoms may exacerbate with increased body temperature (eg, hot bath, exercise). Relapsing and remitting is most common clinical course. Most often affects females in their 20s and 30s; more common in individuals who grew up farther from equator and with low serum vitamin D levels.

FINDINGS

↑ IgG level and myelin basic protein in CSF. Oligoclonal bands aid in diagnosis. MRI is gold standard. Periventricular plaques **A** (areas of oligodendrocyte loss and reactive gliosis). Multiple white matter lesions disseminated in space and time.

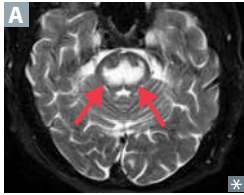
TREATMENT

Stop relapses and halt/slow progression with disease-modifying therapies (eg, β -interferon, glatiramer, natalizumab). Treat acute flares with IV steroids. Symptomatic treatment for neurogenic bladder (catheterization, muscarinic antagonists, botulinum toxin injection), spasticity (baclofen, GABA_B receptor agonists), pain (TCAs, anticonvulsants).



Other demyelinating and dysmyelinating disorders

Osmotic demyelination syndrome



Also called central pontine myelinolysis. Massive axonal demyelination in pontine white matter **A** 2° to rapid osmotic changes, most commonly iatrogenic correction of hyponatremia but also rapid shifts of other osmolytes (eg, glucose). Acute paralysis, dysarthria, dysphagia, diplopia, loss of consciousness. Can cause “locked-in syndrome.”

Correcting serum Na⁺ too fast:

- “From low to high, your pons will die” (osmotic demyelination syndrome)
- “From high to low, your brains will blow” (cerebral edema/herniation)

Acute inflammatory demyelinating polyneuropathy

Most common subtype of **Guillain-Barré syndrome**.

Autoimmune condition that destroys Schwann cells via inflammation and demyelination of motor fibers, sensory fibers, peripheral nerves (including CN III-XII). Likely facilitated by molecular mimicry and triggered by inoculations or stress. Despite association with infections (eg, *Campylobacter jejuni*, viruses [eg, Zika]), no definitive causal link to any pathogen.

Results in symmetric ascending muscle weakness/paralysis and depressed/absent DTRs beginning in lower extremities. Facial paralysis (usually bilateral) and respiratory failure are common. May see autonomic dysregulation (eg, cardiac irregularities, hypertension, hypotension) or sensory abnormalities. Most patients survive with good functional recovery.

↑ CSF protein with normal cell count (albuminocytologic dissociation).

Respiratory support is critical until recovery. Disease-modifying treatment: plasma exchange or IV immunoglobulins. No role for steroids.

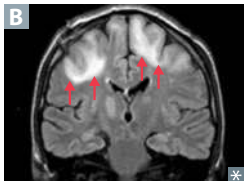Acute disseminated (postinfectious) encephalomyelitis

Multifocal inflammation and demyelination after infection or vaccination. Presents with rapidly progressive multifocal neurologic symptoms, altered mental status.

Charcot-Marie-Tooth disease

Also called hereditary motor and sensory neuropathy. Group of progressive hereditary nerve disorders related to the defective production of proteins involved in the structure and function of peripheral nerves or the myelin sheath. Typically autosomal dominant and associated with foot deformities (eg, pes cavus, hammer toe), lower extremity weakness (eg, foot drop), and sensory deficits (**C**an't **M**ove **T**oes). Most common type, CMT1A, is caused by *PMP22* gene duplication.

Progressive multifocal leukoencephalopathy



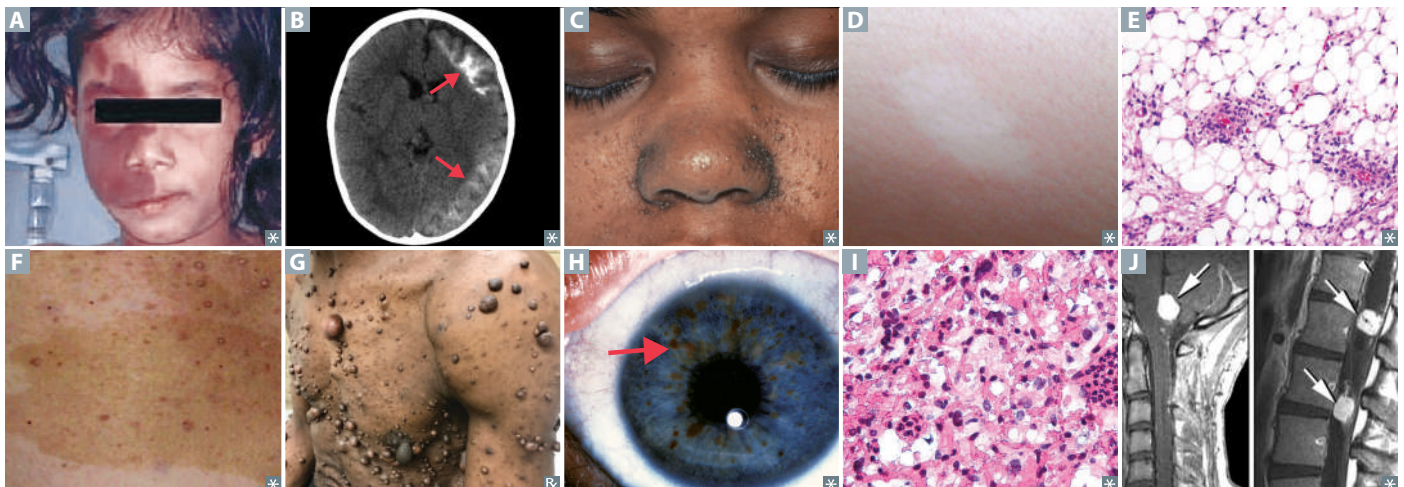
Demyelination of CNS **B** due to destruction of oligodendrocytes (2° to reactivation of latent JC virus infection). Associated with severe immunosuppression (eg, lymphomas and leukemias, AIDS, organ transplantation). Rapidly progressive, usually fatal. Predominantly involves parietal and occipital areas; visual symptoms are common. ↑ risk associated with natalizumab.

Other disorders

Krabbe disease, metachromatic leukodystrophy, adrenoleukodystrophy.

Neurocutaneous disorders

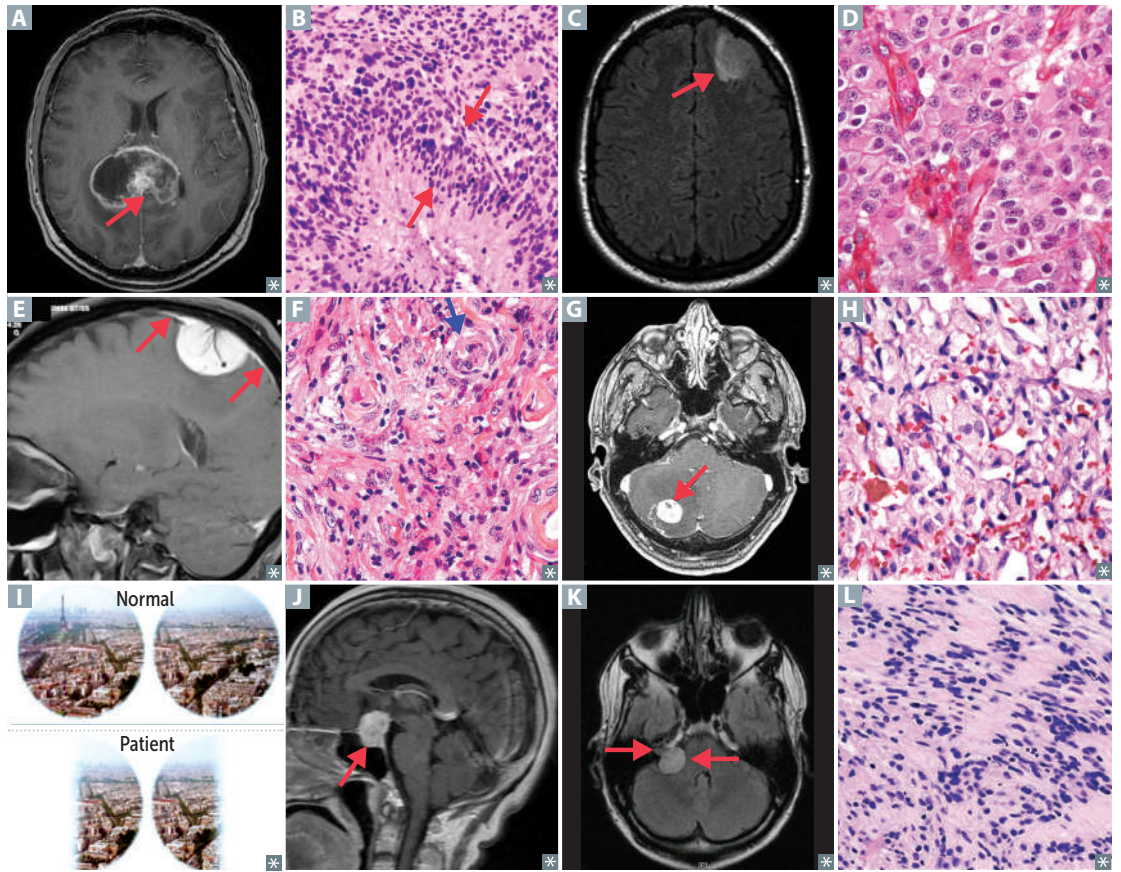
DISORDER	GENETICS	PRESENTATION	NOTES
Sturge-Weber syndrome	Congenital nonhereditary anomaly of neural crest derivatives. Somatic mosaicism of an activating mutation in one copy of the <i>GNAQ</i> gene.	Capillary vascular malformation → port-wine stain A (nevus flammeus or non-neoplastic birthmark) in CN V ₁ /V ₂ distribution; ipsilateral leptomeningeal angioma with calcifications B → seizures/epilepsy; intellectual disability; episcleral hemangioma → ↑ IOP → early-onset glaucoma.	Also called encephalotrigeminal angiomatosis.
Tuberous sclerosis	AD, variable expression. Mutation in tumor suppressor genes <i>TSC1</i> on chromosome 9 (hamartin), <i>TSC2</i> on chromosome 16 (tuberin; pronounce “twoberin”).	Hamartomas in CNS and skin, angiofibromas C , mitral regurgitation, ash-leaf spots D , cardiac rhabdomyoma, intellectual disability, renal angiomyolipoma E , seizures, shagreen patches.	↑ incidence of subependymal giant cell astrocytomas and ungual fibromas.
Neurofibromatosis type I	AD, 100% penetrance. Mutation in <i>NF1</i> tumor suppressor gene on chromosome 17 (encodes neurofibromin, a negative RAS regulator).	Café-au-lait spots F , Intellectual disability, Cutaneous neurofibromas G , Lisch nodules (pigmented iris hamartomas H), Optic gliomas, Pheochromocytomas, Seizures/focal neurologic Signs (often from meningioma), bone lesions (eg, sphenoid dysplasia).	Also called von Recklinghausen disease. 17 letters in “von Recklinghausen.” CICLOPSS .
Neurofibromatosis type II	AD. Mutation in <i>NF2</i> tumor suppressor gene (merlin) on chromosome 22.	Bilateral vestibular schwannomas, juvenile cataracts, meningiomas, ependymomas.	<i>NF2</i> affects 2 ears, 2 eyes.
von Hippel-Lindau disease	AD. Deletion of <i>VHL</i> gene on chromosome 3p. pVHL ubiquitinates hypoxia-inducible factor 1α.	Hemangioblastomas (high vascularity with hyperchromatic nuclei I) in retina, brainstem, cerebellum, spine J ; Angiomas; bilateral Renal cell carcinomas; Pheochromocytomas.	Numerous tumors, benign and malignant. HARP . VHL = 3 letters = chromosome 3 ; associated with RCC (also 3 letters).



Adult primary brain tumors

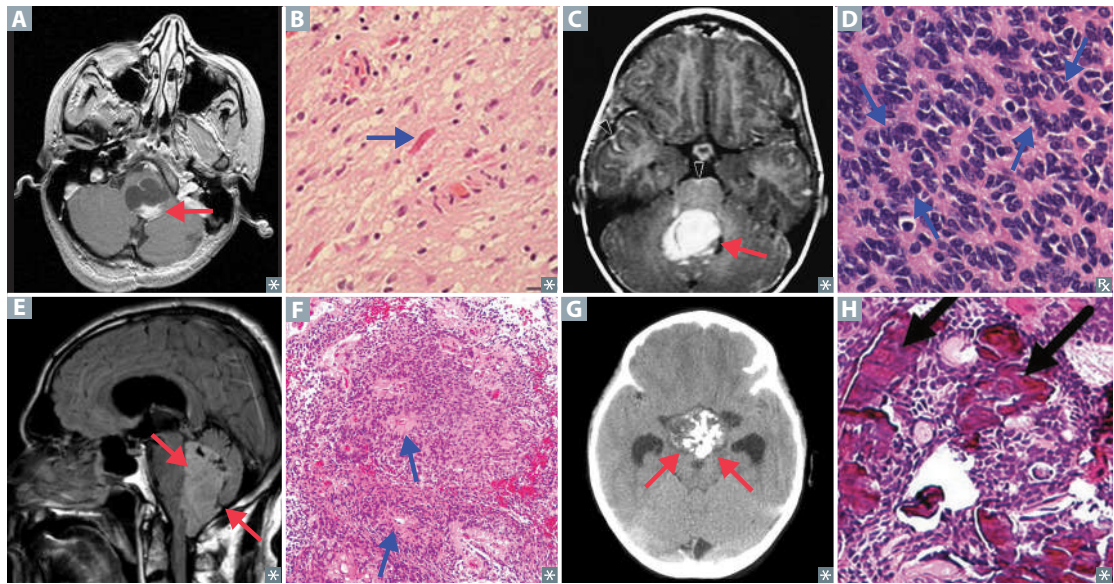
TUMOR	DESCRIPTION	HISTOLOGY
Glioblastoma	Grade IV astrocytoma. Common, highly malignant 1° brain tumor with ~ 1-year median survival. Found in cerebral hemispheres. Can cross corpus callosum (“butterfly glioma” A). Associated with <i>EGFR</i> amplification.	Astrocyte origin, GFAP ⊕. “Pseudopalisading” pleomorphic tumor cells B border central areas of necrosis, hemorrhage, and/or microvascular proliferation.
Oligodendroglioma	Relatively rare, slow growing. Most often in frontal lobes C . Often calcified.	Oligodendrocyte origin. “Fried egg” cells—round nuclei with clear cytoplasm D . “Chicken-wire” capillary pattern.
Meningioma	Common, typically benign. Females > males. Occurs along surface of brain or spinal cord. Extra-axial (external to brain parenchyma) and may have a dural attachment (“tail” E). Often asymptomatic; may present with seizures or focal neurologic signs. Resection and/or radiosurgery.	Arachnoid cell origin. Spindle cells concentrically arranged in a whorled pattern F ; psammoma bodies (laminated calcifications).
Hemangioblastoma	Most often cerebellar G . Associated with von Hippel-Lindau syndrome when found with retinal angiomas. Can produce erythropoietin → 2° polycythemia.	Blood vessel origin. Closely arranged, thin-walled capillaries with minimal intervening parenchyma H .
Pituitary adenoma	May be nonfunctioning (silent) or hyperfunctioning (hormone-producing). Nonfunctional tumors present with mass effect (eg, bitemporal hemianopia [due to pressure on optic chiasm I]). Pituitary apoplexy → hypopituitarism. Prolactinoma classically presents as galactorrhea, amenorrhea, ↓ bone density due to suppression of estrogen in females and as ↓ libido, infertility in males. Treatment: dopamine agonists (eg, bromocriptine, cabergoline), transsphenoidal resection.	Hyperplasia of only one type of endocrine cells found in pituitary. Most commonly from lactotrophs (prolactin) J → hyperprolactinemia. Less commonly, from somatotrophs (GH) → acromegaly, gigantism; corticotrophs (ACTH) → Cushing disease. Rarely, from thyrotrophs (TSH), gonadotrophs (FSH, LH).
Schwannoma	Classically at the cerebellopontine angle K , benign, involving CNs V, VII, and VIII, but can be along any peripheral nerve. Often localized to CN VIII in internal acoustic meatus → vestibular schwannoma (can present as hearing loss and tinnitus). Bilateral vestibular schwannomas found in NF-2. Resection or stereotactic radiosurgery.	Schwann cell origin, S-100 ⊕. Biphasic, dense, hypercellular areas containing spindle cells alternating with hypocellular, myxoid areas L .

Adult primary brain tumors (continued)

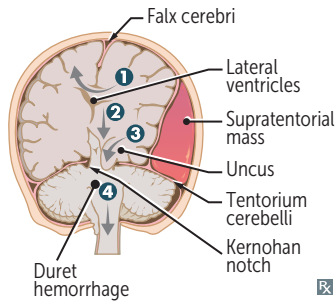


Childhood primary brain tumors

TUMOR	DESCRIPTION	HISTOLOGY
Pilocytic astrocytoma	Low-grade astrocytoma. Most common 1° brain tumor in childhood. Usually well circumscribed. In children, most often found in posterior fossa A (eg, cerebellum). May be supratentorial. Benign; good prognosis.	Astrocyte origin, GFAP ⊕. Bipolar neoplastic cells with hairlike projections. Associated with microcysts and Rosenthal fibers (eosinophilic, corkscrew fibers B). Cystic + solid (gross).
Medulloblastoma	Most common malignant brain tumor in childhood. Commonly involves cerebellum C . Can compress 4th ventricle, causing noncommunicating hydrocephalus → headaches, papilledema. Can involve the cerebellar vermis → truncal ataxia. Can send “drop metastases” to spinal cord.	Form of primitive neuroectodermal tumor (PNET). Homer-Wright rosettes (small blue cells surrounding central area of neuropil D). Synaptophysin ⊕.
Ependymoma	Most commonly found in 4th ventricle E . Can cause hydrocephalus. Poor prognosis.	Ependymal cell origin. Characteristic perivascular pseudorosettes F . Rod-shaped blepharoplasts (basal ciliary bodies) found near the nucleus.
Craniopharyngioma	Most common childhood supratentorial tumor. May be confused with pituitary adenoma (both cause bitemporal hemianopia). Associated with a high recurrence rate.	Derived from remnants of Rathke pouch (ectoderm). Calcification is common G H . Cholesterol crystals found in “motor oil”-like fluid within tumor.
Pineal gland tumors	Most commonly extragonadal germ cell tumors. ↑ incidence in males. Present with obstructive hydrocephalus (compression of cerebral aqueduct), Parinaud syndrome (compression of dorsal midbrain)—triad of upward gaze palsy, convergence-retraction nystagmus, and light-near dissociation.	Similar to testicular seminomas.



Herniation syndromes



- 1** Cingulate (subfalcine) herniation under falx cerebri Can compress anterior cerebral artery.

- 2** Central/downward transtentorial herniation Caudal displacement of brainstem → rupture of paramedian basilar artery branches → Duret hemorrhages. Usually fatal.


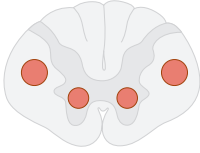
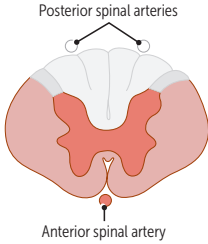
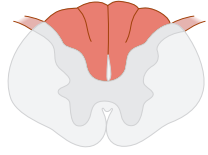


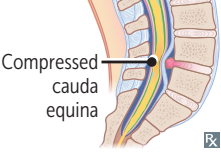
- 3** Uncal transtentorial herniation Uncus = medial temporal lobe. Early herniation → ipsilateral blown pupil (unilateral CN III compression), contralateral hemiparesis. Late herniation → coma, Kernohan phenomenon (misleading contralateral blown pupil and ipsilateral hemiparesis due to contralateral compression against Kernohan notch).

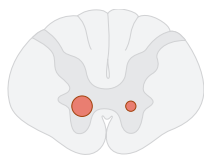- 4** Cerebellar tonsillar herniation into the foramen magnum Coma and death result when these herniations compress the brainstem.

Motor neuron signs

SIGN	UMN LESION	LMN LESION	COMMENTS
Weakness	+	+	L ower motor neuron (LMN) = everything l owered (less muscle mass, ↓ muscle tone, ↓ reflexes, downgoing toes)
Atrophy	–	+	
Fasciculations	–	+	U pper motor neuron (UMN) = everything u p (tone, DTRs, toes)
Reflexes	↑	↓	
Tone	↑	↓	Fasciculations = muscle twitching
Babinski	+	–	Positive Babinski is normal in infants
Spastic paresis	+	–	
Flaccid paralysis	–	+	
Clasp knife spasticity	+	–	

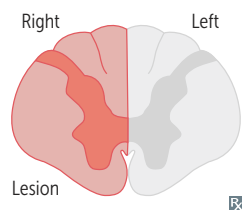
Spinal lesions

AREA AFFECTED	DISEASE	CHARACTERISTICS
	Spinal muscular atrophy	Congenital degeneration of anterior horns. LMN symptoms only, symmetric weakness. “Floppy baby” with marked hypotonia (flaccid paralysis) and tongue fasciculations. Autosomal recessive SMN1 mutation → defective snRNP assembly. SMA type 1 is called Werdnig-Hoffmann disease .
	Amyotrophic lateral sclerosis	Also called Lou Gehrig disease . Combined UMN (corticobulbar/corticospinal) and LMN (medullary and spinal cord) degeneration. No sensory or bowel/bladder deficits. Can be caused by defect in superoxide dismutase 1. LMN deficits: flaccid limb weakness, fasciculations, atrophy, bulbar palsy (dysarthria, dysphagia, tongue atrophy). UMN deficits: spastic limb weakness, hyperreflexia, clonus, pseudobulbar palsy (dysarthria, dysphagia, emotional lability). Fatal (most often from respiratory failure). Treatment: “ri Lou zole”.
	Complete occlusion of anterior spinal artery	Spares dorsal columns and Lissauer tract; mid-thoracic ASA territory is watershed area, as artery of Adamkiewicz supplies ASA below T8. Can be caused by aortic aneurysm repair. Presents with UMN deficit below the lesion (corticospinal tract), LMN deficit at the level of the lesion (anterior horn), and loss of pain and temperature sensation below the lesion (spinothalamic tract).
	Tabes dorsalis	Caused by 3° syphilis. Results from degeneration/demyelination of dorsal columns and roots → progressive sensory ataxia (impaired proprioception → poor coordination). ⊕ Romberg sign and absent DTRs. Associated with Charcot joints, shooting pain, Argyll Robertson pupils.
	Syringomyelia	Syrinx expands and damages anterior white commissure of spinothalamic tract (2nd-order neurons) → bilateral symmetric loss of pain and temperature sensation in capelike distribution. Seen with Chiari I malformation. Can affect other tracts.
	Vitamin B₁₂ deficiency	Subacute combined degeneration (SCD)—demyelination of S pinocerebellar tracts, lateral C orticospinal tracts, and D orsal columns. Ataxic gait, paresthesia, impaired position/vibration sense (⊕ Romberg sign), UMN symptoms.
	Cauda equina syndrome	Compression of spinal roots L2 and below, often due to intervertebral disc herniation or tumor. Radicular pain, absent knee and ankle reflexes, loss of bladder and anal sphincter control, saddle anesthesia.

Poliomyelitis

Caused by poliovirus (fecal-oral transmission). Replicates in lymphoid tissue of oropharynx and small intestine before spreading via bloodstream to CNS. Infection causes destruction of cells in anterior horn of spinal cord (LMN death).

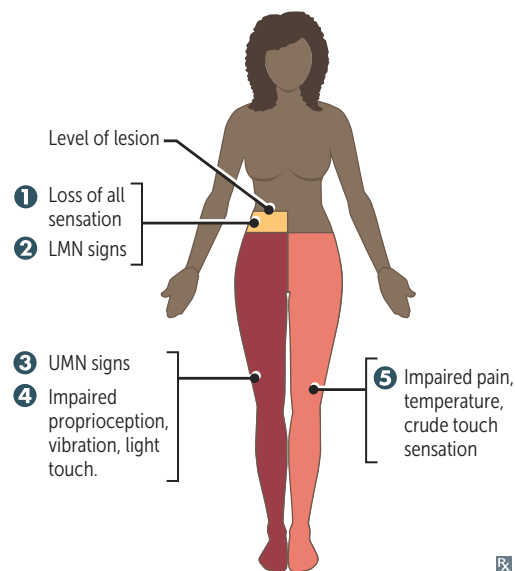
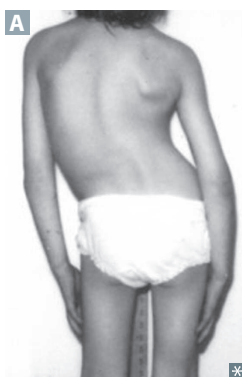Signs of LMN lesion: asymmetric weakness (vs symmetric weakness in spinal muscular atrophy), hypotonia, flaccid paralysis, fasciculations, hyporeflexia, muscle atrophy. Respiratory muscle involvement leads to respiratory failure. Signs of infection: malaise, headache, fever, nausea, etc. CSF shows ↑ WBCs (lymphocytic pleocytosis) and slight ↑ of protein (with no change in CSF glucose). Virus recovered from stool or throat.

Brown-Séquard syndrome

Hemisection of spinal cord. Findings:

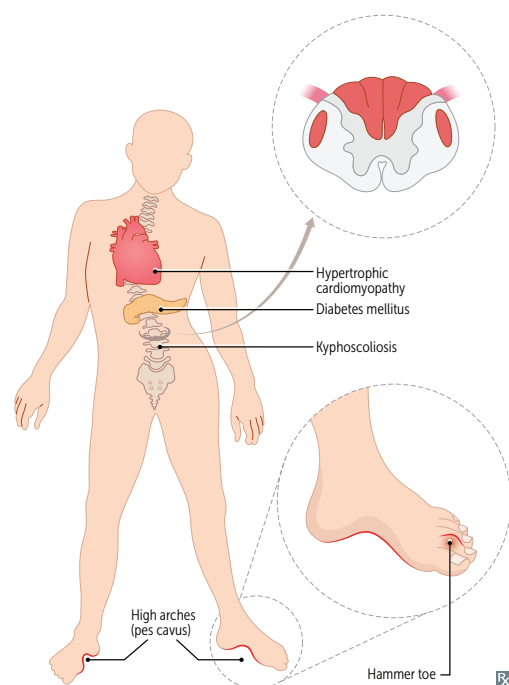
- 1 Ipsilateral loss of all sensation **at** level of lesion
- 2 Ipsilateral LMN signs (eg, flaccid paralysis) **at** level of lesion
- 3 Ipsilateral UMN signs **below** level of lesion (due to corticospinal tract damage)
- 4 Ipsilateral loss of proprioception, vibration, and light (2-point discrimination) touch **below** level of lesion (due to dorsal column damage)
- 5 Contralateral loss of pain, temperature, and crude (non-discriminative) touch **below** level of lesion (due to spinothalamic tract damage)

If lesion occurs above T1, patient may present with ipsilateral Horner syndrome due to damage of oculosympathetic pathway.

**Friedreich ataxia**

Autosomal recessive trinucleotide repeat disorder ($(GAA)_n$) on chromosome 9 in gene that encodes frataxin (iron-binding protein). Leads to impairment in mitochondrial functioning. Degeneration of lateral corticospinal tract (spastic paralysis), spinocerebellar tract (ataxia), dorsal columns (↓ vibratory sense, proprioception), and dorsal root ganglia (loss of DTRs). **Staggering** gait, frequent **falling**, nystagmus, dysarthria, pes cavus, hammer toes, **diabetes mellitus**, **hypertrophic cardiomyopathy** (cause of death). Presents in childhood with kyphoscoliosis **A**.

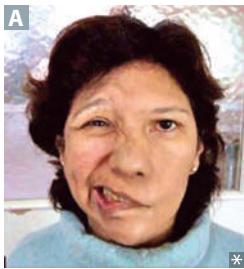Friedreich is **fratastic (frataxin)**: he's your favorite **frat** brother, always **staggering** and **falling** but has a **sweet, big heart**. Ataxic **GAAit**.



Common cranial nerve lesions

CN V motor lesion	Jaw deviates toward side of lesion due to unopposed force from the opposite pterygoid muscle.
CN X lesion	Uvula deviates away from side of lesion. Weak side collapses and uvula points away.
CN XI lesion	Weakness turning head to contralateral side of lesion (SCM). Shoulder droop on side of lesion (trapezius).
CN XII lesion	LMN lesion. Tongue deviates toward side of lesion (“lick your wounds”) due to weakened tongue muscles on affected side.

Facial nerve lesions

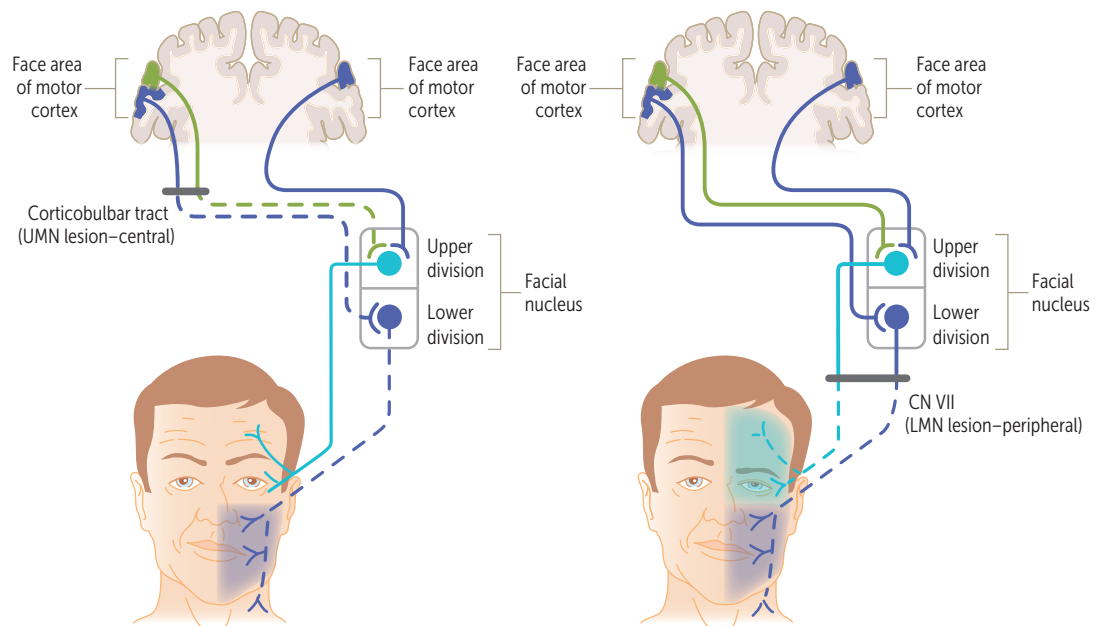


Bell palsy is the most common cause of peripheral facial palsy **A**. Usually develops after HSV reactivation. Treatment: glucocorticoids +/- acyclovir. Most patients gradually recover function, but aberrant regeneration can occur. Other causes of peripheral facial palsy include Lyme disease, herpes zoster (Ramsay Hunt syndrome), sarcoidosis, tumors (eg, parotid gland), diabetes mellitus.

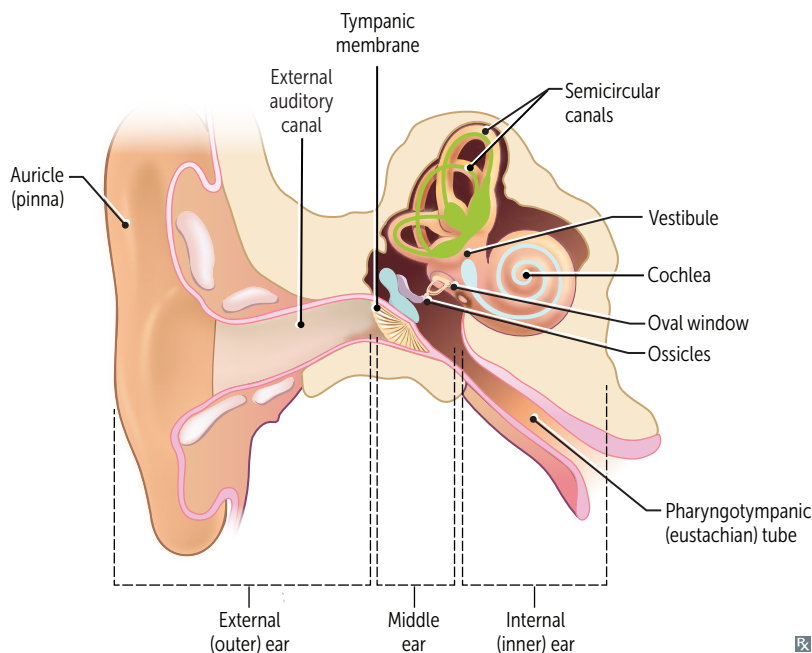
Upper motor neuron lesion

Lower motor neuron lesion

LESION LOCATION	Motor cortex, connection from motor cortex to facial nucleus in pons	Facial nucleus, anywhere along CN VII
AFFECTED SIDE	Contralateral	Ipsilateral
MUSCLES INVOLVED	Lower muscles of facial expression	Upper and lower muscles of facial expression
FOREHEAD INVOLVED?	Spared, due to bilateral UMN innervation	Affected
OTHER SYMPTOMS	Variable; depends on size of lesion	Incomplete eye closure (dry eyes, corneal ulceration), hyperacusis, loss of taste sensation to anterior tongue



▶ NEUROLOGY—OTOLOGY

Auditory anatomy and physiology**Outer ear**

Visible portion of ear (pinna), includes auditory canal and tympanic membrane. Transfers sound waves via vibration of tympanic membrane.

Middle ear

Air-filled space with three bones called the ossicles (malleus, incus, stapes). Ossicles conduct and amplify sound from tympanic membrane to inner ear.

Inner ear

Snail-shaped, fluid-filled cochlea. Contains basilar membrane that vibrates 2° to sound waves. Vibration transduced via specialized hair cells → auditory nerve signaling → brainstem.

Each frequency leads to vibration at specific location on basilar membrane (tonotopy):

- Low frequency heard at apex near helicotrema (wide and flexible).
- High frequency heard best at base of cochlea (thin and rigid).

Otitis externa

Inflammation of external auditory canal. Most commonly due to *Pseudomonas*. Associated with water exposure (swimmer's ear), ear canal trauma/occlusion (eg, hearing aids).

Presents with otalgia that worsens with ear manipulation, pruritus, hearing loss, discharge.

Malignant (necrotizing) otitis externa—invasive infection causing osteomyelitis. Complication of otitis externa mostly seen in older patients with diabetes. Presents with severe otalgia and otorrhea. Physical exam shows granulation tissue in ear canal.

Otitis media

Inflammation of middle ear. Most commonly due to nontypeable *Haemophilus influenzae*, *Streptococcus pneumoniae*, *Moraxella catarrhalis*. Associated with eustachian tube dysfunction, which promotes overgrowth of bacterial colonizers of upper respiratory tract.

Usually seen in children < 2 years old. Presents with fever, otalgia, hearing loss. Physical exam shows bulging, erythematous tympanic membrane that may rupture.

Mastoiditis—infection of mastoid process of temporal bone. Complication of acute otitis media due to continuity of middle ear cavity with mastoid air cells. Presents with postauricular pain, erythema, swelling. May lead to brain abscess.

Common causes of hearing loss

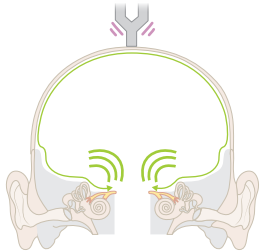
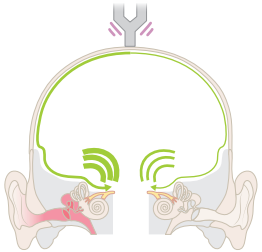
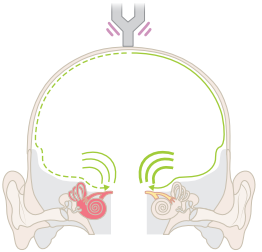
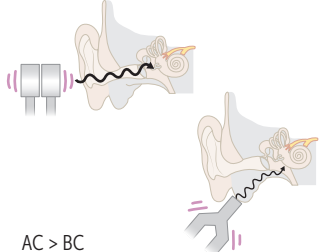
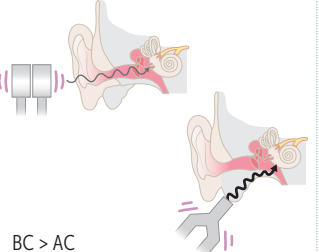
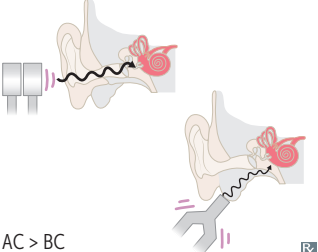
Noise-induced hearing loss

Damage to stereociliated cells in organ of Corti. Loss of high-frequency hearing first. Sudden extremely loud noises can produce hearing loss due to tympanic membrane rupture.

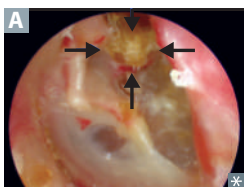
Presbycusis

Aging-related progressive bilateral/symmetric sensorineural hearing loss (often of higher frequencies) due to destruction of hair cells at the cochlear base (preserved low-frequency hearing at apex).

Diagnosing hearing loss

	Normal	Conductive	Sensorineural
Weber test Tuning fork on vertex of skull	 <p>No localization</p>	 <p>Localizes to affected ear ↓ transmission of background noise</p>	 <p>Localizes to unaffected ear ↓ transmission of all sound</p>
Rinne test Tuning fork in front of ear (air conduction, AC), Tuning fork on mastoid process (bone conduction, BC)	 <p>AC > BC</p>	 <p>BC > AC</p>	 <p>AC > BC</p>

Cholesteatoma



Abnormal growth of keratinized squamous epithelium in middle ear **A** (“skin in wrong place”). Usually acquired, but can be congenital. 1° acquired results from tympanic membrane retraction pockets that form due to eustachian tube dysfunction. 2° acquired results from tympanic membrane perforation (eg, due to otitis media) that permits migration of squamous epithelium to middle ear. Classically presents with painless otorrhea. May erode ossicles → conductive hearing loss.

Vertigo

Sensation of spinning while actually stationary. Subtype of “dizziness,” but distinct from “lightheadedness.” Peripheral vertigo is more common than central vertigo.

Peripheral vertigo

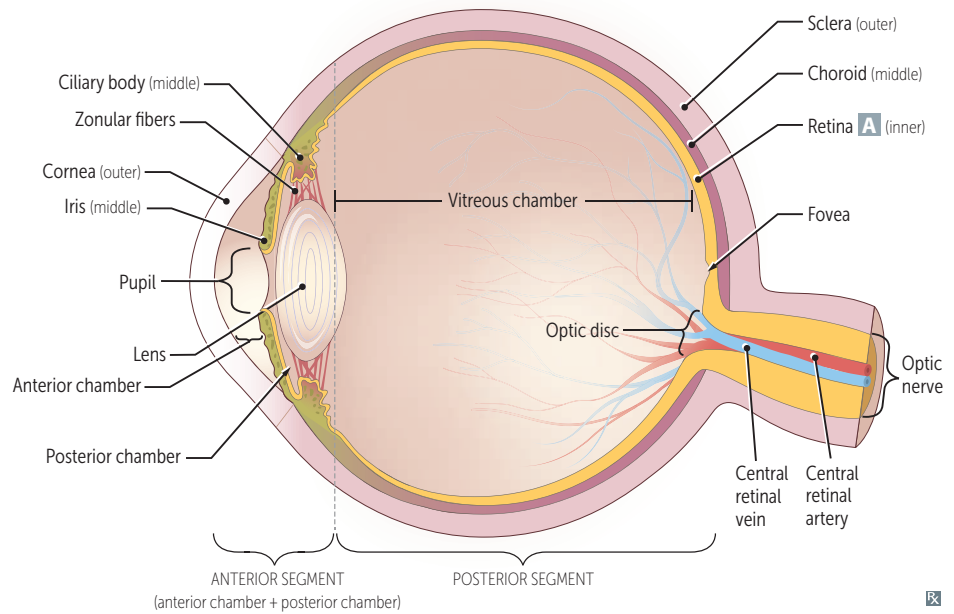
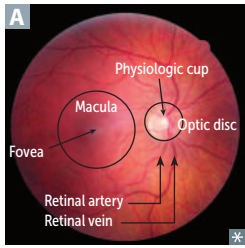
Due to inner ear pathologies such as semicircular canal debris (benign paroxysmal positional vertigo), vestibular neuritis, **Ménière disease**—endolymphatic hydrops (↑ endolymph in inner ear) → triad of vertigo, sensorineural hearing loss, tinnitus (“**men** wear **vests**”). Findings: mixed horizontal-torsional nystagmus (never purely torsional or vertical) that does not change direction and is suppressible with visual fixation.

Central vertigo

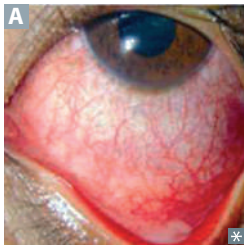
Brain stem or cerebellar lesion (eg, stroke affecting vestibular nuclei, demyelinating disease, or posterior fossa tumor). Findings: nystagmus of any direction that is not suppressible with visual fixation, neurologic findings (eg, diplopia, ataxia, dysmetria).

▶ NEUROLOGY—OPHTHALMOLOGY

Normal eye anatomy



Conjunctivitis



Inflammation of the conjunctiva → red eye **A**.

Allergic—itchy eyes, bilateral.

Bacterial—pus; treat with antibiotics.

Viral—most common, often adenovirus; sparse mucous discharge, swollen preauricular node, ↑ lacrimation; self-resolving.

Refractive errors

Common cause of impaired vision, correctable with glasses.

Hyperopia

Also called “farsightedness.” Eye too short for refractive power of cornea and lens → light focused behind retina. Correct with convex (converging) lenses.

Myopia

Also called “nearsightedness.” Eye too long for refractive power of cornea and lens → light focused in front of retina. Correct with concave (diverging) lenses.

Astigmatism

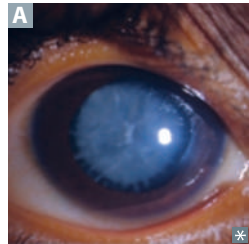
Abnormal curvature of cornea → different refractive power at different axes. Correct with cylindrical lens.

Lens disorders

Presbyopia

Aging-related impaired accommodation (focusing on near objects), primarily due to ↓ lens elasticity. Patients often need reading glasses or magnifiers.

Cataract



Painless, often bilateral, opacification of lens **A**. Can result in glare and ↓ vision, especially at night, and loss of the red reflex.

Acquired risk factors: ↑ age, tobacco smoking, alcohol overuse, excessive sunlight, prolonged glucocorticoid use, diabetes mellitus, trauma, infection.

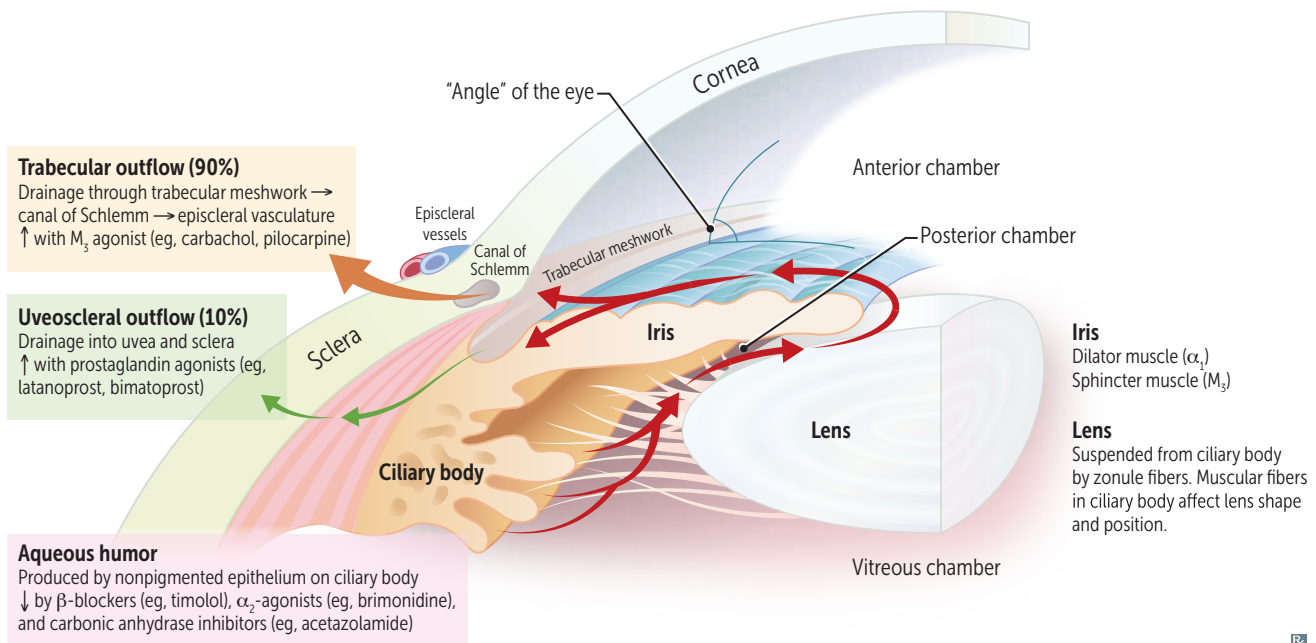
Congenital risk factors: classic galactosemia, galactokinase deficiency, trisomies (13, 18, 21), TORCH infections (eg, rubella), Marfan syndrome, Alport syndrome, myotonic dystrophy, NF-2.

Treatment: surgical removal of lens and replacement with an artificial lens.

Lens dislocation

Also called ectopia lentis. Displacement or malposition of lens. Usually due to trauma, but may occur in association with systemic diseases (eg, Marfan syndrome, homocystinuria).

Aqueous humor pathway



Glaucoma

Optic neuropathy causing progressive vision loss (peripheral → central). Usually, but not always, accompanied by ↑ intraocular pressure (IOP). Etiology is most often 1°, but can be 2° to an identifiable cause (eg, uveitis, glucocorticoids). Funduscopy: optic disc cupping (normal **A** vs thinning of outer rim of optic disc **B**). Treatment: pharmacologic or surgical lowering of IOP.

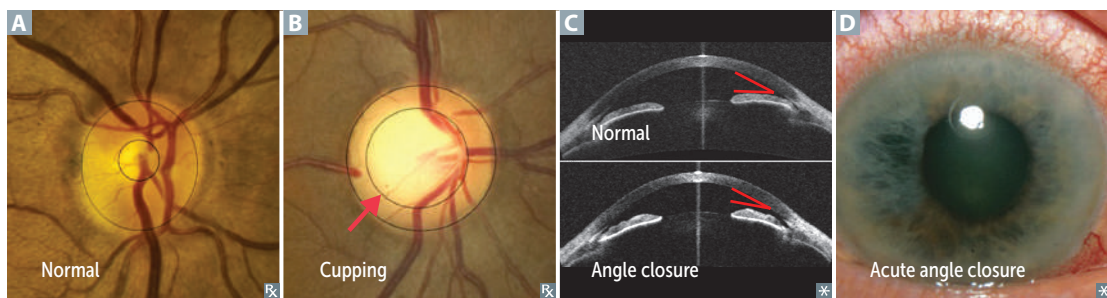
Open-angle glaucoma

Anterior chamber angle is open (normal). Most common type in US. Associated with ↑ resistance to aqueous humor drainage through trabecular meshwork. Risk factors: ↑ age, race (↑ incidence in Black population), family history, diabetes mellitus. Typically asymptomatic and discovered incidentally.

Angle-closure glaucoma

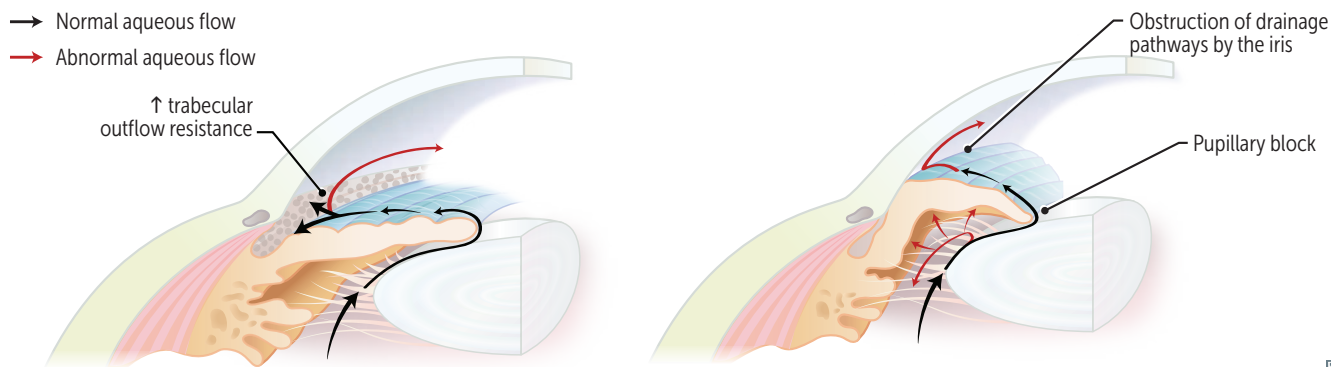
Anterior chamber angle is narrowed or closed **C**. Associated with anatomic abnormalities (eg, anteriorly displaced lens resting against central iris) → ↓ aqueous flow through pupil (pupillary block) → pressure buildup in posterior chamber → peripheral iris pushed against cornea → obstruction of drainage pathways by the iris. Usually chronic and asymptomatic, but may develop acutely.

Acute angle-closure glaucoma—complete pupillary block causing abrupt angle closure and rapid ↑ IOP. Presents with severe eye pain, conjunctival erythema **D**, sudden vision loss, halos around lights, headache, fixed and mid-dilated pupil, nausea and vomiting. Hurts in a hurry with halos, a headache, and a “half-dilated” pupil. True ophthalmic emergency that requires immediate management to prevent blindness. Mydriatic agents are contraindicated.



Open-angle glaucoma

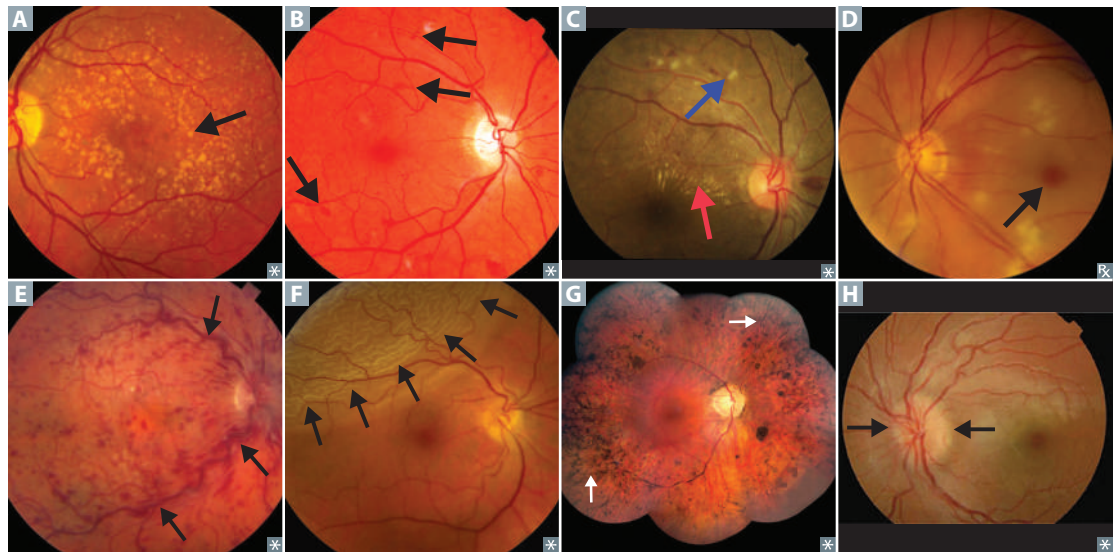
Angle-closure glaucoma



Retinal disorders

Age-related macular degeneration	<p>Degeneration of macula (central area of retina) → loss of central vision (scotomas). Two types:</p> <ul style="list-style-type: none"> ▪ Dry (most common)—gradual ↓ in vision with subretinal deposits (drusen, arrow in A). ▪ Wet—rapid ↓ in vision due to bleeding 2° to choroidal neovascularization. Distortion of straight lines (metamorphopsia) is an early symptom.
Diabetic retinopathy	<p>Chronic hyperglycemia → ↑ permeability and occlusion of retinal vessels. Two types:</p> <ul style="list-style-type: none"> ▪ Nonproliferative (most common)—microaneurysms, hemorrhages (arrows in B), cotton-wool spots, hard exudates. Vision loss mainly due to macular edema. ▪ Proliferative—retinal neovascularization due to chronic hypoxia. Abnormal new vessels may cause vitreous hemorrhage and tractional retinal detachment.
Hypertensive retinopathy	<p>Chronic hypertension → spasm, sclerosis, and fibrinoid necrosis of retinal vessels. Funduscopy: arteriovenous nicking, microaneurysms, hemorrhages, cotton-wool spots (blue arrow in C), hard exudates (may form macular “star,” red arrow in C). Presence of papilledema is indicative of hypertensive emergency and warrants immediate lowering of blood pressure.</p>
Retinal artery occlusion	<p>Blockage of central or branch retinal artery usually due to embolism (carotid artery atherosclerosis > cardiogenic); less commonly due to giant cell arteritis. Presents with acute, painless monocular vision loss. Funduscopy: cloudy retina with “cherry-red” spot at fovea D, identifiable retinal emboli (eg, cholesterol crystals appear as small, yellow, refractile deposits in arterioles).</p>
Retinal vein occlusion	<p>Central retinal vein occlusion is due to 1° thrombosis; branch retinal vein occlusion is due to 2° thrombosis at arteriovenous crossings (sclerotic arteriole compresses adjacent venule causing turbulent blood flow). Funduscopy: retinal hemorrhage and venous engorgement (“blood and thunder” appearance; arrows in E), retinal edema in affected areas.</p>
Retinal detachment	<p>Separation of neurosensory retina from underlying retinal pigment epithelium → loss of choroidal blood supply → hypoxia and degeneration of photoreceptors. Two types:</p> <ul style="list-style-type: none"> ▪ Rhegmatogenous (most common)—due to retinal tears; often associated with posterior vitreous detachment (↑ risk with advanced age, high myopia), less frequently traumatic. ▪ Nonrhegmatogenous—tractional or exudative (fluid accumulation). <p>Commonly presents with symptoms of posterior vitreous detachment (eg, floaters, light flashes) followed by painless monocular vision loss (“dark curtain”). Funduscopy: opacification and wrinkling of detached retina F, change in vessel direction. Surgical emergency.</p>
Retinitis pigmentosa	<p>Group of inherited dystrophies causing progressive degeneration of photoreceptors and retinal pigment epithelium. May be associated with abetalipoproteinemia. Early symptoms: night blindness (nyctalopia) and peripheral vision loss. Funduscopy: triad of optic disc pallor, retinal vessel attenuation, and retinal pigmentation with bone spicule-shaped deposits G.</p>
Papilledema	<p>Optic disc swelling (usually bilateral) due to ↑ ICP (eg, 2° to mass effect). Results from impaired axoplasmic flow in optic nerve. Funduscopy: elevated optic disc with blurred margins H.</p>

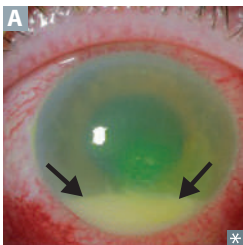
Retinal disorders (continued)

**Leukocoria**

Loss (whitening) of the red reflex. Important causes in children include retinoblastoma **A**, congenital cataract.

**Uveitis**

Inflammation of uvea; specific name based on location within affected eye. Anterior uveitis: iritis; posterior uveitis: choroiditis and/or retinitis. May have hypopyon (accumulation of pus in anterior chamber **A**) or conjunctival redness. Associated with systemic inflammatory disorders (eg, sarcoidosis, Behçet syndrome, juvenile idiopathic arthritis, HLA-B27-associated conditions).



Pupillary control

Miosis

Constriction, parasympathetic:

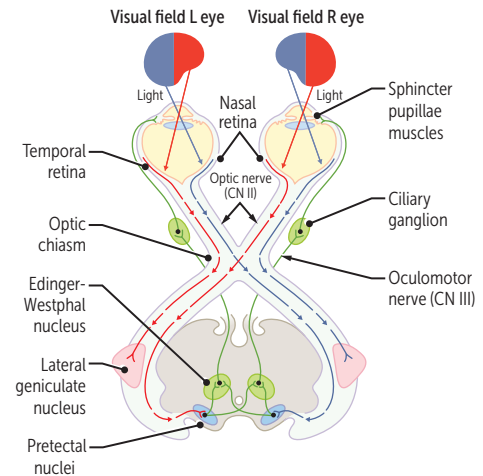
- 1st neuron: Edinger-Westphal nucleus to ciliary ganglion via CN III
- 2nd neuron: short ciliary nerves to sphincter pupillae muscles

Short ciliary nerves **shorten** the pupil diameter.

Pupillary light reflex

Light in either retina sends a signal via CN II to pretectal nuclei (dashed lines in image) in midbrain that activates bilateral Edinger-Westphal nuclei; pupils constrict bilaterally (direct and consensual reflex).

Result: illumination of 1 eye results in bilateral pupillary constriction.



Mydriasis

Dilation, sympathetic:

- 1st neuron: hypothalamus to ciliospinal center of Budge (C8–T2)
- 2nd neuron: exit at T1 to superior cervical ganglion (travels along cervical sympathetic chain near lung apex, subclavian vessels)
- 3rd neuron: plexus along internal carotid, through cavernous sinus; enters orbit as long ciliary nerve to pupillary dilator muscles. Sympathetic fibers also innervate smooth muscle of eyelids (minor retractors) and sweat glands of forehead and face.

Long ciliary nerves make the pupil diameter **longer**.

Relative afferent pupillary defect

Also called Marcus Gunn pupil. Extent of pupillary constriction differs when light is shone in one eye at a time due to unilateral or asymmetric lesions of afferent limb of pupillary reflex (eg, retina, optic nerve). When light shines into a normal eye, constriction of the ipsilateral eye (direct reflex) and contralateral eye (consensual reflex) is observed. When light is swung from a normal eye to an affected eye, both pupils dilate instead of constricting.

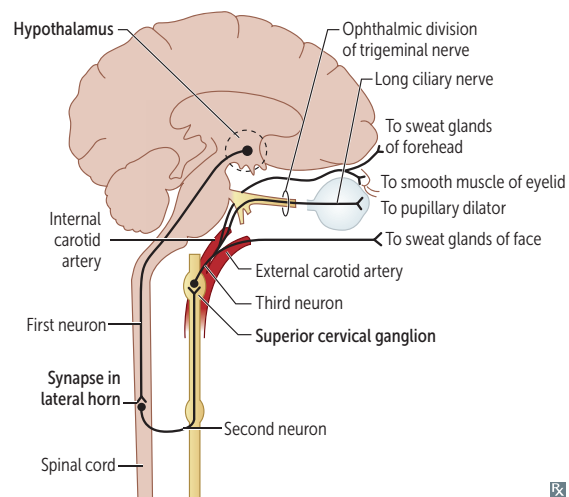
Horner syndrome

Sympathetic denervation of face:

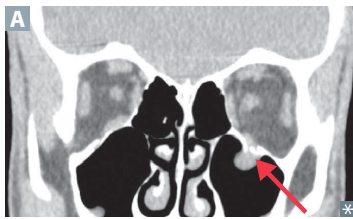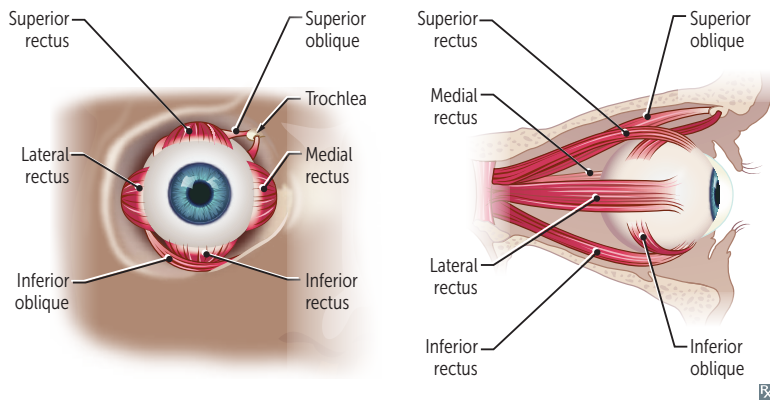
- Ptosis (slight drooping of eyelid: superior tarsal muscle)
- Miosis (pupil constriction)
- Anhidrosis (absence of sweating) and flushing of affected side of face

Associated with lesions along the sympathetic chain:

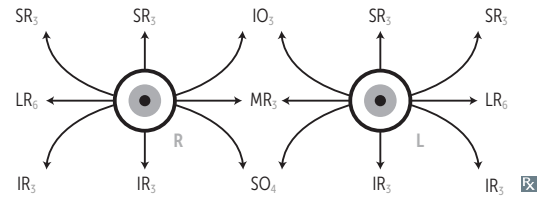
- 1st neuron: pontine hemorrhage, lateral medullary syndrome, spinal cord lesion above T1 (eg, Brown-Séquard syndrome, late-stage syringomyelia)
- 2nd neuron: stellate ganglion compression by Pancoast tumor
- 3rd neuron: carotid dissection (painful); anhidrosis is usually absent



Ocular motility



CN **VI** innervates the **Lateral Rectus**.
 CN **IV** innervates the **Superior Oblique**.
 CN **III** innervates the **Rest**.
 The “chemical formula” **LR₆SO₄R₃**.



Obliques go **O**pposite (left SO and IO tested with patient looking right)

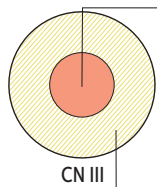
IOU: **IO** tested looking **U**p

Blowout fracture—orbital floor fracture; usually caused by direct trauma to eyeball or intraorbital rim. ↑ risk of IR muscle **A** and/or orbital fat entrapment. May lead to infraorbital nerve injury

Cranial nerve III, IV, VI palsies**CN III damage**

CN III has both motor (central) and parasympathetic (peripheral) components. Common causes include:

- Ischemia → pupil sparing (motor fibers affected more than parasympathetic fibers)
- Uncal herniation → coma
- PCom aneurysm → sudden-onset headache
- Cavernous sinus thrombosis → proptosis, involvement of CNs IV, V₁/V₂, VI
- Midbrain stroke → contralateral hemiplegia

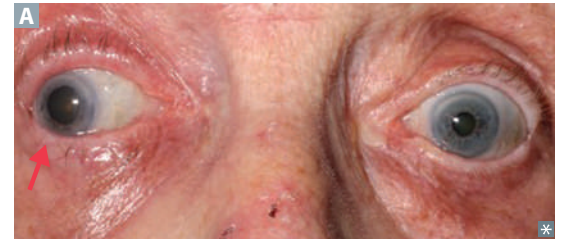


Motor output to extraocular muscles—affected primarily by vascular disease (eg, diabetes mellitus: glucose → sorbitol) due to ↓ diffusion of oxygen and nutrients to the interior (**m**iddle) fibers from compromised vasculature that resides on outside of nerve. Signs: ptosis, “down-and-out” gaze. **A**.

Parasympathetic output—fibers on the **p**eriphery are first affected by compression (eg, PCom aneurysm, uncal herniation). Signs: diminished or absent pupillary light reflex, “blown pupil” often with “down-and-out” gaze **A**.

Motor = **m**iddle (central)

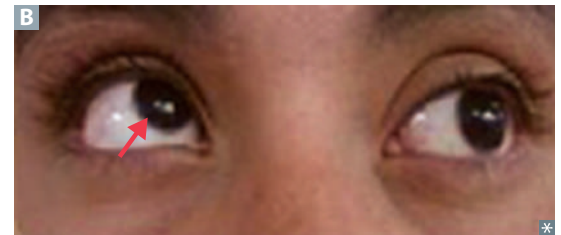
Parasympathetic = **p**eripheral

**CN IV damage**

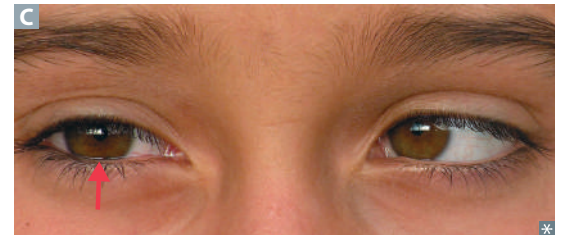Pupil is higher in the affected eye **B**.

Characteristic head tilt to contralateral/unaffected side to compensate for lack of intorsion in affected eye.

Can't see the **f**loor with CN **I**V damage (eg, difficulty going down stairs, reading).

**CN VI damage**

Affected eye unable to abduct **C** and is displaced medially in primary position of gaze.

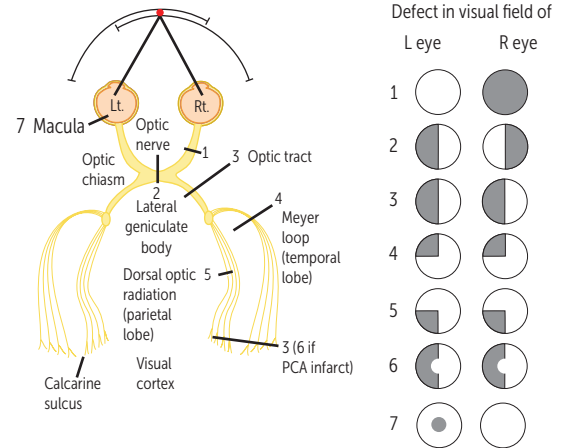


Visual field defects

1. Right anopia (monocular vision loss)
2. Bitemporal hemianopia (pituitary lesion, chiasm)
3. Left homonymous hemianopia
4. Left upper quadrantanopia (right temporal lesion, MCA)
5. Left lower quadrantanopia (right parietal lesion, MCA)
6. Left hemianopia with macular sparing (right occipital lesion, PCA)
7. Central scotoma (eg, macular degeneration)

Ventral optic radiation (Meyer loop)—lower retina; loops around inferior horn of lateral ventricle.

Dorsal optic radiation—superior retina; takes shortest path via internal capsule.



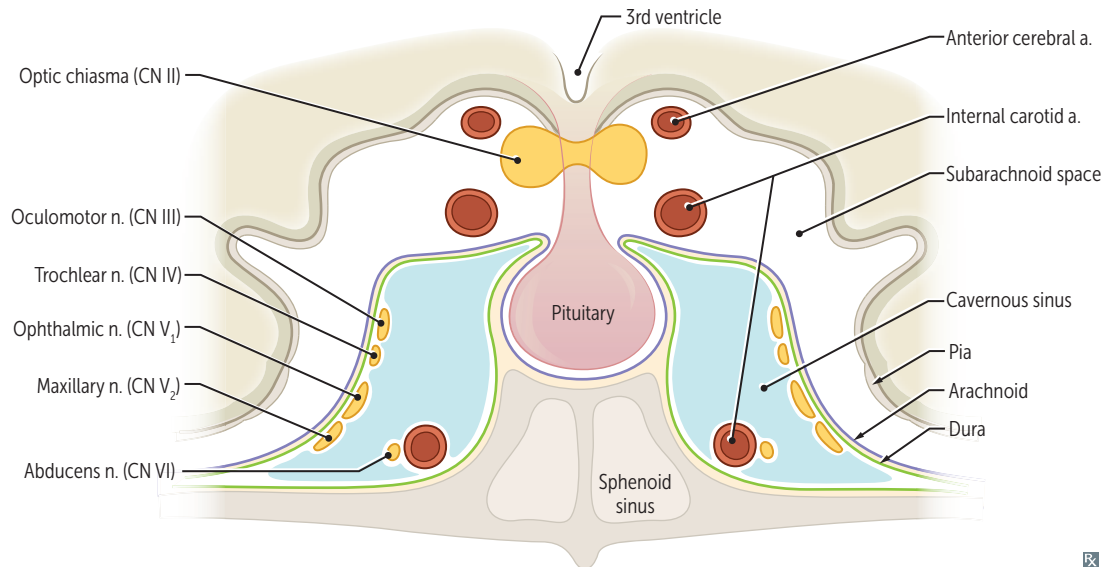
Note: When an image hits 1° visual cortex, it is upside down and left-right reversed.

Cavernous sinus

Collection of venous sinuses on either side of pituitary. Blood from eye and superficial cortex → cavernous sinus → internal jugular vein.

CNs III, IV, V₁, V₂, and VI plus postganglionic sympathetic pupillary fibers en route to orbit all pass through cavernous sinus. Cavernous portion of internal carotid artery is also here.

Cavernous sinus syndrome—presents with variable ophthalmoplegia (eg, CN III and CN VI), ↓ corneal sensation, Horner syndrome and occasional decreased maxillary sensation. 2° to pituitary tumor mass effect, carotid-cavernous fistula, or cavernous sinus thrombosis related to infection (spread due to lack of valves in dural venous sinuses).



Internuclear ophthalmoplegia

Medial longitudinal fasciculus (MLF): pair of tracts that interconnect CN VI and CN III nuclei. Coordinates both eyes to move in same horizontal direction. Highly myelinated (must communicate quickly so eyes move at same time). Lesions may be unilateral or bilateral (latter classically seen in multiple sclerosis, stroke).

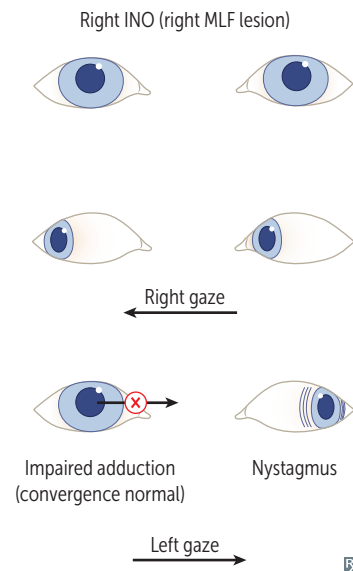
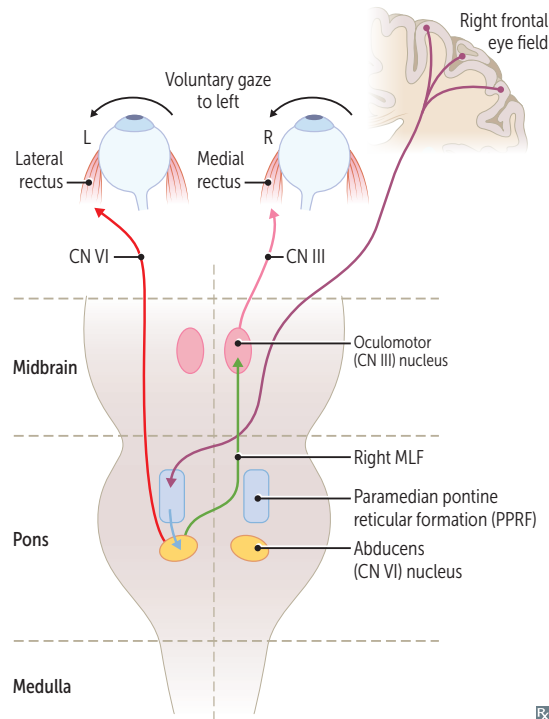
Lesion in MLF = internuclear ophthalmoplegia (INO), a conjugate horizontal gaze palsy. Lack of communication such that when CN VI nucleus activates ipsilateral lateral rectus, contralateral CN III nucleus does not stimulate medial rectus to contract. Abducting eye displays nystagmus (CN VI overfires to stimulate CN III). Convergence normal.

MLF in MS.

When looking left, the left nucleus of CN VI fires, which contracts the left lateral rectus and stimulates the contralateral (right) nucleus of CN III via the right MLF to contract the right medial rectus.

Directional term (eg, right INO, left INO) refers to the eye that is unable to adduct.

INO = Ipsilateral adduction failure, Nystagmus Opposite.



▶ NEUROLOGY—PHARMACOLOGY

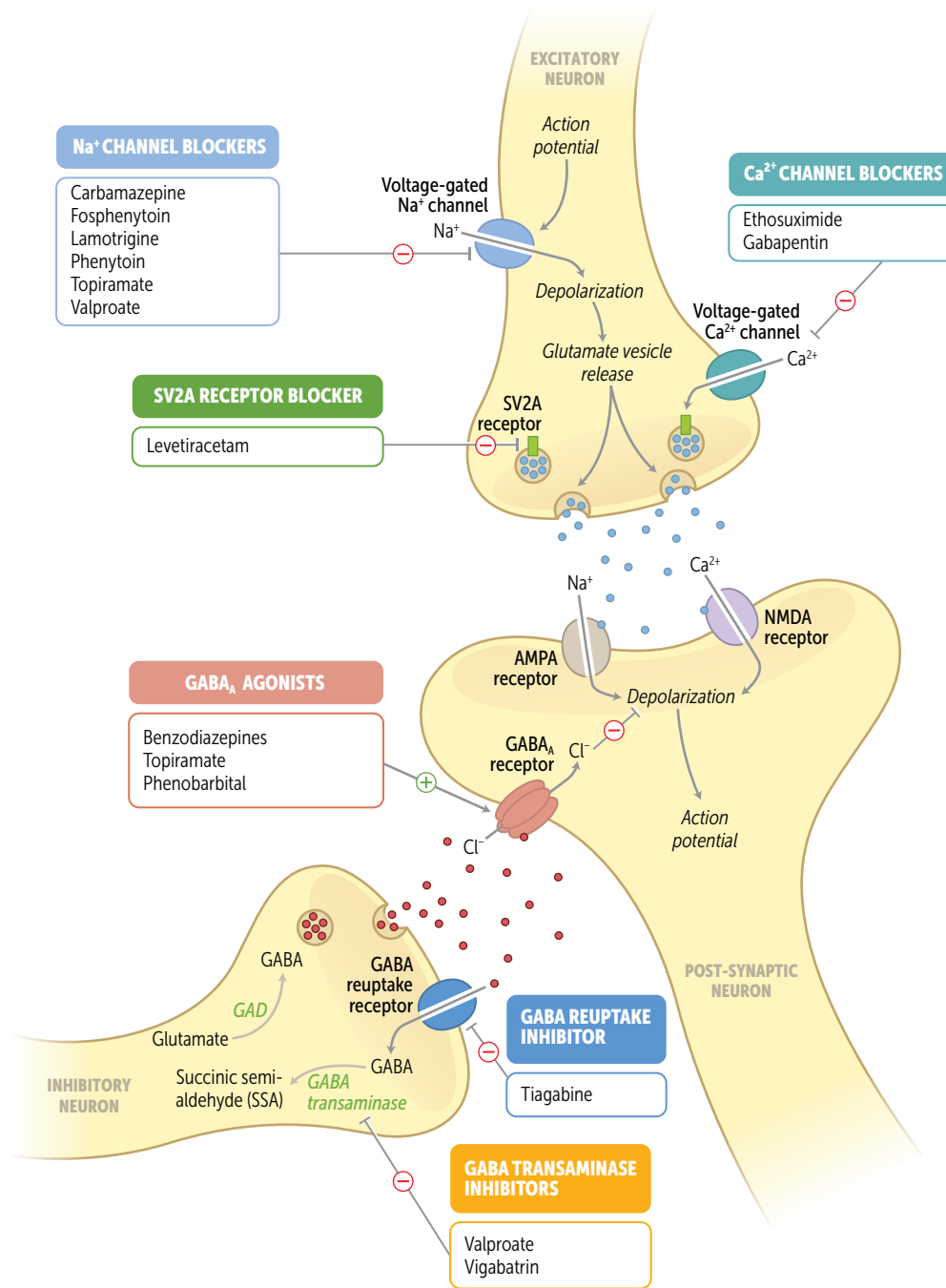
Epilepsy therapy

	PARTIAL (FOCAL) [†]	1° GENERALIZED		STATUS EPILEPTICUS	MECHANISM	ADVERSE EFFECTS	NOTES
		TONIC-CLONIC	ABSENCE				
Benzodiazepines				** ✓	↑ GABA _A action	Sedation, tolerance, dependence, respiratory depression	Also for eclampsia seizures (1st line is MgSO ₄)
Carbamazepine	* ✓				Blocks Na ⁺ channels	Diplopia, ataxia, blood dyscrasias (agranulocytosis, aplastic anemia), liver toxicity, teratogenesis (cleft lip/palate, spina bifida), induction of cytochrome P-450, SIADH, SJS	1st line for trigeminal neuralgia
Ethosuximide			* ✓		Blocks thalamic T-type Ca ²⁺ channels	EFGHIJ —Ethosuximide causes F atigue, G I distress, H eadache, I tching (and urticaria), S J	Sucks to have silent (absence) seizures
Gabapentin	✓				Primarily inhibits high-voltage-activated Ca ²⁺ channels; designed as GABA analog	Sedation, ataxia	Also used for peripheral neuropathy, postherpetic neuralgia
Lamotrigine	✓	✓	✓		Blocks voltage-gated Na ⁺ channels, inhibits the release of glutamate	SJS (must be titrated slowly), hemophagocytic lymphohistiocytosis (black box warning)	
Levetiracetam	✓	✓			SV2A receptor blocker; may modulate GABA and glutamate release, inhibit voltage-gated Ca ²⁺ channels	Neuropsychiatric symptoms (eg, personality change), fatigue, drowsiness, headache	
Phenobarbital	✓	✓		✓	↑ GABA _A action	Sedation, tolerance, dependence, induction of cytochrome P-450, cardiorespiratory depression	1st line in neonates (“phenobabyl”)
Phenytoin, fosphenytoin	✓			*** ✓	Blocks Na ⁺ channels; zero-order kinetics	PPHENYTOIN : cytochrome P -450 induction, P seudolymphoma, H irsutism, E nlarged gums, N ystagmus, Y ellow-brown skin, T eratogenicity (fetal hydantoin syndrome), O steopenia, I nhibited folate absorption, N europathy. Rare: SJS, DRESS syndrome, drug-induced lupus. Toxicity leads to diplopia, ataxia, sedation.	
Topiramate	✓	✓			Blocks Na ⁺ channels, ↑ GABA action	Sedation, slow cognition, kidney stones , skinny (weight loss), sight threatened (glaucoma), speech (word-finding) difficulties	Also used for migraine prophylaxis
Valproate	✓	* ✓	✓		↑ Na ⁺ channel inactivation, ↑ GABA concentration by inhibiting GABA transaminase	VALPPROaTTE : V omiting, A lopecia, L iver damage (hepatotoxic), P ancreatitis, P -450 inhibition, R ash, O besity (weight gain), T remor, T eratogenesis (neural tube defects). E pigastric pain (GI distress).	Also used for myoclonic seizures, bipolar disorder, migraine prophylaxis
Vigabatrin	✓				↑ GABA. Irreversible GABA transaminase inhibitor	Permanent visual loss (black box warning)	V ision loss with GABA transaminase i nhibitor

* = Common use, ** = 1st line for acute, *** = 1st line for recurrent seizure prophylaxis.

[†] Includes partial simple/complex and 2° generalized seizures.

Epilepsy therapy (continued)



Barbiturates

Phenobarbital, pentobarbital, thiopental, secobarbital.

MECHANISM

Facilitate GABA_A action by ↑ **duration** of Cl⁻ channel opening, thus ↓ neuron firing (barbiturates ↑ **duration**).

CLINICAL USE

Sedative for anxiety, seizures, insomnia, induction of anesthesia (thiopental).

ADVERSE EFFECTS

Respiratory and cardiovascular depression (can be fatal); CNS depression (can be exacerbated by alcohol use); dependence; drug interactions (induces cytochrome P-450).
Overdose treatment is supportive (assist respiration and maintain BP).
Contraindicated in porphyria.

Benzodiazepines

Diazepam, lorazepam, triazolam, temazepam, oxazepam, midazolam, chlordiazepoxide, alprazolam.

MECHANISM

Facilitate GABA_A action by ↑ **frequency** of Cl⁻ channel opening (“**fren**zodiazepines” ↑ **frequency**).
↓ REM sleep. Most have long half-lives and active metabolites (exceptions [**ATOM**]: **A**lprazolam, **T**riazolam, **O**xazepam, and **M**idazolam are short acting → higher addictive potential).

CLINICAL USE

Anxiety, panic disorder, spasticity, status epilepticus (lorazepam, diazepam, midazolam), eclampsia, detoxification (eg, alcohol withdrawal/DTs; long-acting chlordiazepoxide and diazepam are preferred), night terrors, sleepwalking, general anesthetic (amnesia, muscle relaxation), hypnotic (insomnia). **L**orazepam, **O**xazepam, and **T**emazepam can be used for those with liver disease who drink a **LOT** due to minimal first-pass metabolism.

ADVERSE EFFECTS

Dependence, additive CNS depression effects with alcohol and barbiturates (all bind the GABA_A receptor). Less risk of respiratory depression and coma than with barbiturates. Treat overdose with flumazenil (competitive antagonist at GABA benzodiazepine receptor). Can precipitate seizures by causing acute benzodiazepine withdrawal.

Insomnia therapy

AGENT	MECHANISM	ADVERSE EFFECTS	NOTES
Nonbenzodiazepine hypnotics	Examples: Z olpidem, Z aleplon, es Z opiclone Act via the BZ ₁ subtype of GABA receptor	Ataxia, headaches, confusion Cause only modest day-after psychomotor depression and few amnesic effects (vs older sedative-hypnotics)	These ZZZs put you to sleep Short duration due to rapid metabolism by liver enzymes; effects reversed by flumazenil ↓ dependency risk and ↓ sleep cycle disturbance (vs benzodiazepine hypnotics)
Suvorexant	O rexin (hypocretin) receptor antagonist	CNS depression (somnia), headache, abnormal sleep-related activities	Contraindications: narcolepsy, combination with strong CYP3A4 inhibitors Not recommended in patients with liver disease Limited risk of dependency
Ramelteon	M elatonin receptor agonist: binds MT ₁ and MT ₂ in suprachiasmatic nucleus	Dizziness, nausea, fatigue, headache	No known risk of dependency

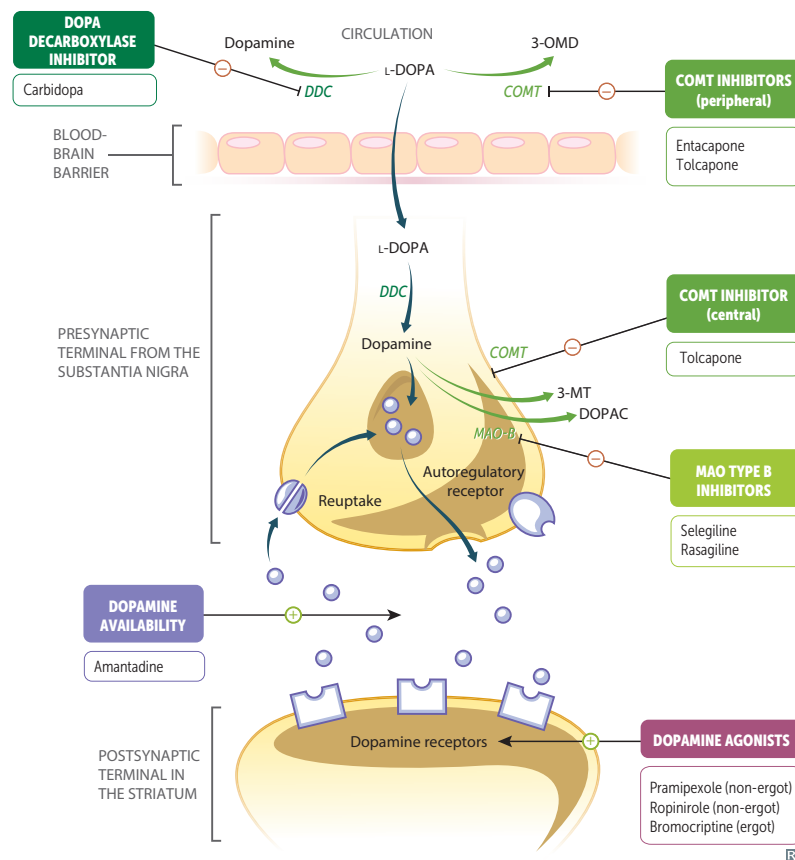
Triptans**Sumatriptan**

MECHANISM	5-HT _{1B/1D} agonists. Inhibit trigeminal nerve activation, prevent vasoactive peptide release, induce vasoconstriction.
CLINICAL USE	Acute migraine, cluster h eadache attacks. A sumo wrestler trips and falls on their h ead.
ADVERSE EFFECTS	Coronary vasospasm (contraindicated in patients with CAD or vasospastic angina), mild paresthesia, serotonin syndrome (in combination with other 5-HT agonists).

Parkinson disease therapy

The most effective treatments are non-ergot dopamine agonists which are usually started in younger patients, and levodopa (with carbidopa) which is usually started in older patients. Deep brain stimulation of the STN or GPi may be helpful in advanced disease.

STRATEGY	AGENTS
Dopamine agonists	Non-ergot (preferred)—pramipexole, ropinirole; toxicity includes nausea, impulse control disorder (eg, gambling), postural hypotension, hallucinations, confusion, sleepiness, edema. Ergot—bromocriptine; rarely used due to toxicity.
↑ dopamine availability	Amantadine (↑ dopamine release and ↓ dopamine reuptake); mainly used to reduce levodopa-induced dyskinesias; toxicity = peripheral edema, livedo reticularis, ataxia.
↑ L-DOPA availability	Agents prevent peripheral (pre-BBB) L-DOPA degradation → ↑ L-DOPA entering CNS → ↑ central L-DOPA available for conversion to dopamine. <ul style="list-style-type: none"> Levodopa (L-DOPA)/carbidopa—carbidopa blocks peripheral conversion of L-DOPA to dopamine by inhibiting DOPA decarboxylase. Also reduces adverse effects of peripheral L-DOPA conversion into dopamine (eg, nausea, vomiting). Entacapone and tolcapone prevent peripheral L-DOPA degradation to 3-O-methyldopa (3-OMD) by inhibiting COMT. Used in conjunction with levodopa.
Prevent dopamine breakdown	Agents act centrally (post-BBB) to inhibit breakdown of dopamine. <ul style="list-style-type: none"> Selegiline, rasagiline—block conversion of dopamine into DOPAC by selectively inhibiting MAO-B, which is more commonly found in the Brain than in the periphery. Tolcapone—crosses BBB and blocks conversion of dopamine to 3-methoxytyramine (3-MT) in the brain by inhibiting central COMT.
Curb excess cholinergic activity	Benz tropine, tri hexyphenidyl (Antimuscarinic; improves tremor and rigidity but has little effect on bradykinesia in Parkinson disease). Tri Parking my Mercedes- Benz .



Carbidopa/levodopa

MECHANISM	↑ dopamine in brain. Unlike dopamine, L-DOPA can cross BBB and is converted by DOPA decarboxylase in the CNS to dopamine. Carbidopa, a peripheral DOPA decarboxylase inhibitor that cannot cross BBB, is given with L-DOPA to ↑ bioavailability of L-DOPA in the brain and to limit peripheral adverse effects.
CLINICAL USE	Parkinson disease.
ADVERSE EFFECTS	Nausea, hallucinations, postural hypotension. With progressive disease, L-DOPA can lead to “on-off” phenomenon with improved mobility during “on” periods, then impaired motor function during “off” periods when patient responds poorly to L-DOPA or medication wears off.

Neurodegenerative disease therapy

DISEASE	AGENT	MECHANISM	NOTES
Alzheimer disease	Donepezil, rivastigmine, galantamine	AChE inhibitor	1st-line treatment Adverse effects: nausea, dizziness, insomnia; contraindicated in patients with cardiac conduction abnormalities Dona Riva dances at the gala
	Memantine	NMDA receptor antagonist; helps prevent excitotoxicity (mediated by Ca ²⁺)	Used for moderate to advanced dementia Adverse effects: dizziness, confusion, hallucinations
Amyotrophic lateral sclerosis	Riluzole	↓ neuron glutamate excitotoxicity	↑ survival Treat Lou Gehrig disease with riLou zole
Huntington disease	Tetrabenazine	Inhibit vesicular monoamine transporter (VMAT) → ↓ dopamine vesicle packaging and release	May be used for Huntington chorea and tardive dyskinesia

Anesthetics—general principles

CNS drugs must be lipid soluble (cross the blood-brain barrier) or be actively transported.

Drugs with ↓ solubility in blood = rapid induction and recovery times.

Drugs with ↑ solubility in lipids = ↑ potency.

MAC = **M**inimum **A**lveolar **C**oncentration (of inhaled anesthetic) required to prevent 50% of subjects from moving in response to noxious stimulus (eg, skin incision). Potency = 1/MAC.

Examples: nitrous oxide (N₂O) has ↓ blood and lipid solubility, and thus fast induction and low potency. Halothane has ↑ lipid and blood solubility, and thus high potency and slow induction.

Inhaled anesthetics

Desflurane, halothane, enflurane, isoflurane, sevoflurane, methoxyflurane, N₂O.

MECHANISM

Mechanism unknown.

EFFECTS

Myocardial depression, respiratory depression, postoperative nausea/vomiting, ↑ cerebral blood flow and ICP, ↓ cerebral metabolic demand.

ADVERSE EFFECTS

Hepatotoxicity (halothane), **nephrotoxicity** (methoxyflurane), proconvulsant (enflurane, epileptogenic), expansion of trapped gas in a body cavity (N₂O).

Malignant hyperthermia—rare, life-threatening condition in which inhaled anesthetics or succinylcholine induce severe muscle contractions and hyperthermia. Susceptibility is often inherited as autosomal dominant with variable penetrance. Mutations in ryanodine receptor (RYR1) cause ↑ Ca²⁺ release from sarcoplasmic reticulum.

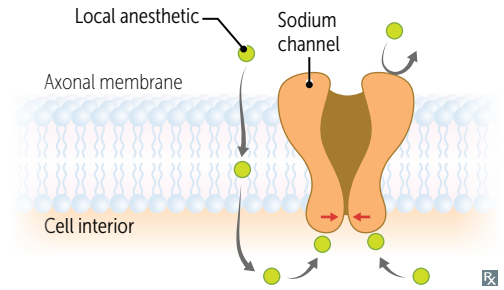
Treatment: dantrolene (a ryanodine receptor antagonist).

Intravenous anesthetics

AGENT	MECHANISM	ANESTHESIA USE	NOTES
Thiopental	Facilitates GABA _A (barbiturate)	Anesthesia induction, short surgical procedures	↓ cerebral blood flow. High lipid solubility Effect terminated by rapid redistribution into tissue, fat
Midazolam	Facilitates GABA _A (benzodiazepine)	Procedural sedation (eg, endoscopy), anesthesia induction	May cause severe postoperative respiratory depression, ↓ BP, anterograde amnesia
Propofol	Potentiates GABA _A	Rapid anesthesia induction, short procedures, ICU sedation	May cause respiratory depression, ↓ BP
Ketamine	NMDA receptor antagonist	Dissociative anesthesia Sympathomimetic	↑ cerebral blood flow Emergence reaction possible with disorientation, hallucination, vivid dreams

Local anesthetics

Esters—procaine, tetracaine, benzocaine, chlorprocaine.
Amides—lidocaine, mepivacaine, bupivacaine, ropivacaine, prilocaine (amides have 2 i's in name).

**MECHANISM**

Block neurotransmission via binding to voltage-gated Na^+ channels on inner portion of the channel along nerve fibers. Most effective in rapidly firing neurons. 3° amine local anesthetics penetrate membrane in uncharged form, then bind to ion channels as charged form.
Can be given with vasoconstrictors (usually epinephrine) to enhance block duration of action by \downarrow systemic absorption.
In infected (acidic) tissue, alkaline anesthetics are charged and cannot penetrate membrane effectively \rightarrow need more anesthetic.
Order of loss: (1) pain, (2) temperature, (3) touch, (4) pressure.

CLINICAL USE

Minor surgical procedures, spinal anesthesia. If allergic to esters, give amides.

ADVERSE EFFECTS

CNS excitation, severe cardiovascular toxicity (bupivacaine), hypertension, hypotension, arrhythmias (cocaine), methemoglobinemia (benzocaine, prilocaine).

Neuromuscular blocking drugs

Muscle paralysis in surgery or mechanical ventilation. Selective for N_m nicotinic receptors at neuromuscular junction but not autonomic N_n receptors.

Depolarizing neuromuscular blocking drugs

Succinylcholine—strong N_m nicotinic receptor agonist; produces sustained depolarization and prevents muscle contraction.

Reversal of blockade:

- Phase I (prolonged depolarization)—no antidote. Block potentiated by cholinesterase inhibitors.
- Phase II (repolarized but blocked; N_m nicotinic receptors are available, but desensitized)—may be reversed with cholinesterase inhibitors.

Complications include hypercalcemia, hyperkalemia, malignant hyperthermia. \uparrow risk of prolonged muscle paralysis in patients with pseudocholinesterase deficiency.

Nondepolarizing neuromuscular blocking drugs

Atracurium, cisatracurium, pancuronium, rocuronium, tubocurarine, vecuronium—competitive N_m nicotinic receptor antagonist.

Reversal of blockade—sugammadex or cholinesterase inhibitors (eg, neostigmine, edrophonium). Anticholinergics (eg, atropine, glycopyrrolate) are given with cholinesterase inhibitors to prevent muscarinic effects (eg, bradycardia).

Skeletal muscle relaxants

DRUG	MECHANISM	CLINICAL USE	NOTES
Baclofen	GABA _B receptor agonist in spinal cord	Muscle spasticity, dystonia, multiple sclerosis	Acts on the back (spinal cord) May cause sedation
Cyclobenzaprine	Acts within CNS, mainly at the brainstem	Muscle spasms	C entrally acting Structurally related to TCAs May cause anticholinergic adverse effects, sedation
Dantrolene	Prevents release of Ca ²⁺ from sarcoplasmic reticulum of skeletal muscle by inhibiting the ryanodine receptor	Malignant hyperthermia (toxicity of inhaled anesthetics and succinylcholine) and neuroleptic malignant syndrome (toxicity of antipsychotics)	Acts d irectly on muscle
Tizanidine	α ₂ agonist, acts centrally	Muscle spasticity, multiple sclerosis, ALS, cerebral palsy	

Opioid analgesics

MECHANISM	Act as agonists at opioid receptors (μ = β-endorphin, δ = enkephalin, κ = dynorphin) to modulate synaptic transmission—close presynaptic Ca ²⁺ channels, open postsynaptic K ⁺ channels → ↓ synaptic transmission. Inhibit release of ACh, norepinephrine, 5-HT, glutamate, substance P.
EFFICACY	Full agonist: morphine, heroin, meperidine (long acting), methadone, codeine (prodrug; activated by CYP2D6), fentanyl. Partial agonist: buprenorphine. Mixed agonist/antagonist: nalbuphine, pentazocine, butorphanol. Antagonist: naloxone, naltrexone, methylnaltrexone.
CLINICAL USE	Moderate to severe or refractory pain, diarrhea (loperamide, diphenoxylate), acute pulmonary edema, maintenance programs for opiate use disorder (methadone, buprenorphine + naloxone), neonatal abstinence syndrome (methadone, morphine).
ADVERSE EFFECTS	Nausea, vomiting, pruritus (histamine release), opiate use disorder, respiratory depression, constipation, sphincter of Oddi spasm, miosis (except meperidine → mydriasis), additive CNS depression with other drugs. Tolerance does not develop to miosis and constipation. Treat toxicity with naloxone and prevent relapse with naltrexone once detoxified.

Tramadol

MECHANISM	Very weak opioid agonist; also inhibits the reuptake of norepinephrine and serotonin.
CLINICAL USE	Chronic pain.
ADVERSE EFFECTS	Similar to opioids; decreases seizure threshold; serotonin syndrome.

Mixed agonist and antagonist opioid analgesics

DRUG	MECHANISM	CLINICAL USE	NOTES
Pentazocine	κ -opioid receptor agonist and μ -opioid receptor weak antagonist or partial agonist.	Analgesia for moderate to severe pain.	Can cause opioid withdrawal symptoms if patient is also taking full opioid agonist (due to competition for opioid receptors).
Butorphanol	κ -opioid receptor agonist and μ -opioid receptor partial agonist.	Severe pain (eg, migraine, labor).	Causes less respiratory depression than full opioid agonists. Use with full opioid agonist can precipitate withdrawal. Not easily reversed with naloxone.

Capsaicin

Naturally found in hot peppers.

MECHANISM	Excessive stimulation and desensitization of nociceptive fibers → ↓ substance P release → ↓ pain.
CLINICAL USE	Musculoskeletal and neuropathic pain.

Glaucoma therapy

↓ IOP via ↓ amount of aqueous humor (inhibit synthesis/secretion or ↑ drainage).
 “ $\beta\alpha$ D humor may not be politically correct.”

DRUG CLASS	EXAMPLES	MECHANISM	ADVERSE EFFECTS
β-blockers	Timolol, betaxolol, carteolol	↓ aqueous humor synthesis	No pupillary or vision changes
α-agonists	Epinephrine (α_1), apraclonidine, brimonidine (α_2)	↓ aqueous humor synthesis via vasoconstriction (epinephrine) ↓ aqueous humor synthesis (apraclonidine, brimonidine) ↑ outflow of aqueous humor via uveoscleral pathway	Mydriasis (α_1); do not use in closed-angle glaucoma Blurry vision, ocular hyperemia, foreign body sensation, ocular allergic reactions, ocular pruritus
Diuretics	Acetazolamide	↓ aqueous humor synthesis via inhibition of carbonic anhydrase	No pupillary or vision changes
Prostaglandins	Bimatoprost, latanoprost (PGF _{2α})	↑ outflow of aqueous humor via ↓ resistance of flow through uveoscleral pathway	Darkens color of iris (browning), eyelash growth
Cholinomimetics (M₃)	Direct: pilocarpine, carbachol Indirect: physostigmine, echothiophate	↑ outflow of aqueous humor via contraction of ciliary muscle and opening of trabecular meshwork Use pilocarpine in acute angle closure glaucoma—very effective at opening meshwork into canal of Schlemm	Miosis (contraction of pupillary sphincter muscles) and cyclospasm (contraction of ciliary muscle)

Psychiatry

“Words of comfort, skillfully administered, are the oldest therapy known to man.”

—Louis Nizer

“Psychiatry at its best is what all medicine needs more of—humanity, art, listening, and sympathy.”

—Susannah Cahalan

“The sorrow which has no vent in tears may make other organs weep.”

—Henry Maudsley

“I have schizophrenia. I am not schizophrenia. I am not my mental illness. My illness is a part of me.”

—Jonathan Harnisch

This chapter encompasses overlapping areas in psychiatry, psychology, sociology, and psychopharmacology. High-yield topics include schizophrenia, mood disorders, eating disorders, personality disorders, somatic symptom disorders, substance use disorders, and antipsychotics. Know the DSM-5 criteria for diagnosing common psychiatric disorders.

▶ Psychology	576
▶ Pathology	579
▶ Pharmacology	596

▶ PSYCHIATRY—PSYCHOLOGY

Classical conditioning	Learning in which a natural response (salivation) is elicited by a conditioned, or learned, stimulus (bell) that previously was presented in conjunction with an unconditioned stimulus (food).	Usually elicits involuntary responses. Pavlov's classical experiments with dogs—ringing the bell provoked salivation.
-------------------------------	---	--

Operant conditioning	Learning in which a particular action is elicited because it produces a punishment or reward. Usually elicits voluntary responses.
-----------------------------	---

Reinforcement	Target behavior (response) is followed by desired reward (positive reinforcement) or removal of aversive stimulus (negative reinforcement).
----------------------	---

Punishment	Repeated application of aversive stimulus (positive punishment) or removal of desired reward (negative punishment) to extinguish unwanted behavior.
-------------------	---

Extinction	Discontinuation of reinforcement (positive or negative) eventually eliminates behavior. Can occur in operant or classical conditioning.
-------------------	---

Skinner operant conditioning quadrants:

		Increase behavior	Decrease behavior
Remove a stimulus	Add a stimulus	Positive reinforcement	Positive punishment
	Remove a stimulus	Negative reinforcement	Negative punishment

Transference and countertransference

Transference	Patient projects feelings about formative or other important persons onto physician (eg, psychiatrist is seen as parent).
---------------------	---

Countertransference	Physician projects feelings about formative or other important persons onto patient (eg, patient reminds physician of younger sibling).
----------------------------	---

Ego defenses	Thoughts and behaviors (voluntary or involuntary) used to resolve conflict and prevent undesirable feelings (eg, anxiety, depression).
---------------------	--

IMMATURE DEFENSES	DESCRIPTION	EXAMPLE
Acting out	Subconsciously coping with stressors or emotional conflict using actions rather than reflections or feelings.	A patient skips therapy appointments after deep discomfort from dealing with his past.
Denial	Avoiding the awareness of some painful reality.	A patient with cancer plans a full-time work schedule despite being warned of significant fatigue during chemotherapy.
Displacement	Redirection of emotions or impulses to a neutral person or object (vs projection).	After being reprimanded by her principal, a frustrated teacher returns home and criticizes her wife's cooking instead of confronting the principal directly.
Dissociation	Temporary, drastic change in personality, memory, consciousness, or motor behavior to avoid emotional stress. Patient has incomplete or no memory of traumatic event.	A survivor of sexual abuse sees the abuser and suddenly becomes numb and detached.

Ego defenses (continued)

IMMATURE DEFENSES	DESCRIPTION	EXAMPLE
Fixation	Partially remaining at a more childish level of development (vs regression).	A college student studying for a stressful exam begins sucking her thumb.
Idealization	Expressing extremely positive thoughts of self and others while ignoring negative thoughts.	A patient boasts about his physician and his accomplishments while ignoring any flaws.
Identification	Largely unconscious assumption of the characteristics, qualities, or traits of another person or group.	A resident starts putting her stethoscope in her pocket like her favorite attending, instead of wearing it around her neck like before.
Intellectualization	Using facts and logic to emotionally distance oneself from a stressful situation.	A patient diagnosed with cancer discusses the pathophysiology of the disease.
Isolation (of affect)	Separating feelings from ideas and events.	Describing murder in graphic detail with no emotional response.
Passive aggression	Demonstrating hostile feelings in a nonconfrontational manner; showing indirect opposition.	A disgruntled employee is repeatedly late to work, but won't admit it is a way to get back at the manager.
Projection	Attributing an unacceptable internal impulse to an external source (vs displacement).	A man who wants to cheat on his wife accuses his wife of being unfaithful.
Rationalization	Asserting plausible explanations for events that actually occurred for other reasons, usually to avoid self-blame.	An employee who was recently fired claims that the job was not important anyway.
Reaction formation	Replacing a warded-off idea or feeling with an emphasis on its opposite (vs sublimation).	A stepfather treats a child he resents with excessive nurturing and overprotection.
Regression	Involuntarily turning back the maturational clock to behaviors previously demonstrated under stress (vs fixation).	A previously toilet-trained child begins bedwetting again following the birth of a sibling.
Repression	Involuntarily withholding an idea or feeling from conscious awareness (vs suppression).	A 20-year-old does not remember going to counseling during his parents' divorce 10 years earlier.
Splitting	Believing that people are either all good or all bad at different times due to intolerance of ambiguity. Common in borderline personality disorder.	A patient says that all the nurses are cold and insensitive, but the physicians are warm and friendly.
MATURE DEFENSES		
Sublimation	Replacing an unacceptable wish with a course of action that is similar to the wish but socially acceptable (vs reaction formation).	A teenager's aggression toward her parents because of their high expectations is channeled into excelling in sports.
Altruism	Alleviating negative feelings via unsolicited generosity, which provides gratification (vs reaction formation).	A mafia boss makes a large donation to charity.
Suppression	Intentionally withholding an idea or feeling from conscious awareness (vs repression); temporary.	An athlete focuses on other tasks to prevent worrying about an important upcoming match.
Humor	Lightheartedly expressing uncomfortable feelings to shift the internal focus away from the distress.	A nervous medical student jokes about the boards.

Mature adults wear a **SASH**.

Grief

Natural feeling that occurs in response to the death of a loved one. Symptoms and trajectory vary for each individual, are specific to each loss, and do not follow a fixed series of stages. In addition to guilt, sadness, and yearning, patients may experience somatic symptoms, hallucinations of the deceased, and/or transient episodes of wishing they had died with or instead of their loved one.

Typical acute grief is time limited (adaptations within 6 months) and is not a disorder.

Complicated grief (**persistent complex bereavement disorder**) can be diagnosed if thoughts are persistent and prolonged, significantly impair functioning, and do not meet criteria for another disorder (eg, major depressive disorder [MDD]).

Normal infant and child development

Milestone dates are ranges that have been approximated and vary by source. Children not meeting milestones may need assessment for potential developmental delay.

AGE	MOTOR	SOCIAL	VERBAL/COGNITIVE
Infant	Parents	Start	Observing,
0–12 mo	<p>Primitive reflexes disappear—Moro, rooting, palmar, Babinski (Mr. Peanut Butter)</p> <p>Posture—lifts head up prone (by 1 mo), rolls and sits (by 6 mo), crawls (by 8 mo), stands (by 10 mo), walks (by 12–18 mo)</p> <p>Picks—passes toys hand to hand (by 6 mo), Pincer grasp (by 10 mo)</p> <p>Points to objects (by 12 mo)</p>	<p>Social smile (by 2 mo)</p> <p>Stranger anxiety (by 6 mo)</p> <p>Separation anxiety (by 9 mo)</p>	<p>Orients—first to voice (by 4 mo), then to name and gestures (by 9 mo)</p> <p>Object permanence (by 9 mo)</p> <p>Oratory—says “mama” and “dada” (by 10 mo)</p>
Toddler	Child	Rearing	Working,
12–36 mo	<p>Cruises, takes first steps (by 12 mo)</p> <p>Climbs stairs (by 18 mo)</p> <p>Cubes stacked (number = age (yr) × 3)</p> <p>Cutlery—feeds self with fork and spoon (by 20 mo)</p> <p>Kicks ball (by 24 mo)</p>	<p>Recreation—parallel play (by 24–36 mo)</p> <p>Rapprochement—moves away from and returns to parent (by 24 mo)</p> <p>Realization—core gender identity formed (by 36 mo)</p>	<p>Words—uses 50-200 words (by 2 yr), uses 300+ words (by 3 yr)</p>
Preschool	Don't	Forget, they're still	Learning!
3–5 yr	<p>Drive—tricycle (3 wheels at 3 yr)</p> <p>Drawings—copies line or circle, stick figure (by 4 yr)</p> <p>Dexterity—hops on one foot by 4 yr (“4 on one foot”), uses buttons or zippers, grooms self (by 5 yr)</p>	<p>Freedom—comfortably spends part of day away from parent (by 3 yr)</p> <p>Friends—cooperative play, has imaginary friends (by 4 yr)</p>	<p>Language—understands 1000 (3 zeros) words (by 3 yr), uses complete sentences and prepositions (by 4 yr)</p> <p>Legends—can tell detailed stories (by 4 yr)</p>

▶ PSYCHIATRY—PATHOLOGY

Child abuse

	Physical abuse	Sexual abuse	Emotional abuse
SIGNS	<p>Nonaccidental trauma (eg, fractures, bruises, burns). Injuries often in different stages of healing or in patterns resembling possible implements of injury. Includes abusive head trauma (shaken baby syndrome), characterized by subdural hematomas or retinal hemorrhages.</p> <p>Caregivers may delay seeking medical attention for the child or provide explanations inconsistent with the child's developmental stage or pattern of injury.</p>	<p>STIs, UTIs, and genital, anal, or oral trauma. Most often, there are no physical signs; sexual abuse should not be excluded from a differential diagnosis in the absence of physical trauma.</p> <p>Children often exhibit sexual knowledge or behavior incongruent with their age.</p>	<p>Babies or young children may lack a bond with the caregiver but are overly affectionate with less familiar adults. They may be aggressive toward children and animals or unusually anxious.</p> <p>Older children are often emotionally labile and prone to angry outbursts. They may distance themselves from caregivers and other children. They can experience vague somatic symptoms for which a medical cause cannot be found.</p>
EPIDEMIOLOGY	<p>40% of deaths related to child abuse or neglect occur in children < 1 year old.</p>	<p>Peak incidence 9–12 years old.</p>	<p>~80% of young adult victims of child emotional abuse meet the criteria for ≥ 1 psychiatric illness by age 21.</p>

Child neglect

Failure to provide a child with adequate food, shelter, supervision, education, and/or affection. Most common form of child maltreatment. Signs: poor hygiene, malnutrition, withdrawal, impaired social/emotional development, failure to thrive. As with child abuse, suspected child neglect must be reported to local child protective services.

Vulnerable child syndrome

Parents perceive the child as especially susceptible to illness or injury (vs factitious disorder imposed on another). Usually follows a serious illness or life-threatening event. Can result in missed school or overuse of medical services.

Childhood and early-onset disorders

Attention-deficit hyperactivity disorder	Onset before age 12, but diagnosis can only be established after age 4. Characterized by hyperactivity, impulsivity, and/or inattention in ≥ 2 settings (eg, school, home, places of worship). Normal intelligence, but commonly coexists with difficulties in school. Often persists into adulthood. Commonly coexists with oppositional defiant disorder. Treatment: stimulants (eg, methylphenidate) +/- behavioral therapy; alternatives include atomoxetine and α_2 -agonists (eg, clonidine, guanfacine).
Autism spectrum disorder	Onset in early childhood. Social and communication deficits, repetitive/ritualized behaviors, restricted interests. May be accompanied by intellectual disability and/or above average abilities in specific skills (eg, music). More common in males. Associated with \uparrow head and/or brain size.
Conduct disorder	Repetitive, pervasive behavior violating societal norms or the basic rights of others (eg, aggression toward people and animals, destruction of property, theft). After age 18, often reclassified as antisocial personality disorder. Treatment: psychotherapy (eg, cognitive behavioral therapy [CBT]).
Disruptive mood dysregulation disorder	Onset before age 10. Severe, recurrent temper outbursts out of proportion to situation. Child is constantly angry and irritable between outbursts. Treatment: CBT, stimulants, antipsychotics.
Intellectual disability	Global cognitive deficits (vs specific learning disorder) that affect reasoning, memory, abstract thinking, judgment, language, learning. Adaptive functioning is impaired, leading to major difficulties with education, employment, communication, socialization, independence. Treatment: psychotherapy, occupational therapy, special education.
Intermittent explosive disorder	Onset after age 6. Recurrent verbal or physical outbursts representing a failure to control aggressive impulses. Outbursts last < 30 minutes and are out of proportion to provocation and may lead to legal, financial, or social consequences. Episodes are not premeditated and may provide an immediate sense of relief, followed by remorse. Treatment: psychotherapy, SSRIs.
Oppositional defiant disorder	Pattern of anger and irritability with argumentative, vindictive, and defiant behavior toward authority figures lasting ≥ 6 months. Treatment: psychotherapy (eg, CBT).
Selective mutism	Onset before age 5. Anxiety disorder lasting ≥ 1 month involving refraining from speech in certain situations despite speaking in other, usually more comfortable situations. Development (eg, speech and language) not typically impaired. Interferes with social, academic, and occupational tasks. Commonly coexists with social anxiety disorder. Treatment: behavioral, family, and play therapy; SSRIs.
Separation anxiety disorder	Overwhelming fear of separation from home or attachment figure lasting ≥ 4 weeks. Can be normal behavior up to age 3–4. May lead to factitious physical complaints to avoid school. Treatment: CBT, play therapy, family therapy.
Specific learning disorder	Onset during school-age years. Inability to acquire or use information from a specific subject (eg, math, reading, writing) near age-expected proficiency for ≥ 6 months despite focused intervention. General functioning and intelligence are normal (vs intellectual disability). Treatment: academic support, counseling, extracurricular activities.
Tourette syndrome	Onset before age 18. Sudden, recurrent, nonrhythmic, stereotyped motor (eg, grimacing, shrugging) and vocal (eg, grunting, throat clearing) tics that persist for > 1 year. Coprolalia (involuntary obscene speech) found in some patients. Associated with OCD and ADHD. Treatment: psychoeducation, behavioral therapy. For intractable and distressing tics: tetrabenazine, antipsychotics, α_2 -agonists.

Orientation Patients' ability to know the date and time, where they are, and who they are (order of loss: time → place → person). Common causes of loss of orientation: alcohol, drugs, fluid/electrolyte imbalance, head trauma, hypoglycemia, infection, nutritional deficiencies, hypoxia.

Amnesias

Retrograde amnesia	Inability to remember things that occurred before a CNS insult.
Anterograde amnesia	Inability to remember things that occurred after a CNS insult (↓ acquisition of new memory).
Korsakoff syndrome	Amnesia (anterograde > retrograde) and disorientation caused by vitamin B ₁ deficiency. Associated with disruption and destruction of the limbic system, especially mammillary bodies and anterior thalamus. Seen in chronic alcohol use as a late neuropsychiatric manifestation of Wernicke encephalopathy. Confabulations are characteristic.

Dissociative disorders

Depersonalization/derealization disorder	Persistent feelings of detachment or estrangement from one's own body, thoughts, perceptions, and actions (depersonalization) or one's environment (derealization). Intact reality testing (vs psychosis).
Dissociative amnesia	Inability to recall important personal information, usually following severe trauma or stress. May be accompanied by dissociative fugue (abrupt, unexpected travelling away from home).
Dissociative identity disorder	Formerly called multiple personality disorder. Presence of ≥ 2 distinct identities or personality states, typically with distinct memories and patterns of behavior. More common in females. Associated with history of sexual abuse, PTSD, depression, substance use, borderline personality disorder, somatic symptom disorders.

Delirium

“Waxing and waning” level of consciousness with acute onset, ↓ attention span, ↓ level of arousal. Characterized by disorganized thinking, hallucinations (often visual), misperceptions (eg, illusions), disturbance in sleep-wake cycle, cognitive dysfunction, agitation. Reversible.

Usually 2° to other identifiable illness (eg, CNS disease, infection, trauma, substance use/withdrawal, metabolic/electrolyte disturbances, hemorrhage, urinary/fecal retention), or medications (eg, anticholinergics), especially in older adults.

Most common presentation of altered mental status in inpatient setting, especially in the ICU or during prolonged hospital stays.

Delirium = changes in **sensorium**.
 EEG may show diffuse background rhythm slowing.
 Treatment: identification and management of underlying condition. Orientation protocols (eg, keeping a clock or calendar nearby), ↓ sleep disturbances, and ↑ cognitive stimulation to manage symptoms.
 Antipsychotics (eg, haloperidol) as needed.
 Avoid unnecessary restraints and drugs that may worsen delirium (eg, anticholinergics, benzodiazepines, opioids).

Psychosis

Distorted perception of reality characterized by delusions, hallucinations, and/or disorganized thought/speech. Can occur in patients with psychiatric illness or another medical condition, or secondary to substance or medication use.

Delusions

False, fixed, idiosyncratic beliefs that persist despite evidence to the contrary and are not typical of a patient's culture or religion (eg, a patient who believes that others are reading his thoughts). Types include erotomanic, grandiose, jealous, persecutory, somatic, mixed, and unspecified.

Disorganized thought

Speech may be incoherent (“word salad”), tangential, or derailed (“loose associations”).

Hallucinations

Perceptions in the absence of external stimuli (eg, seeing a light that is not actually present). Contrast with misperceptions (eg, illusions) of real external stimuli. Types include:

- Auditory—more commonly due to psychiatric illness (eg, schizophrenia) than neurologic disease.
- Visual—more commonly due to neurologic disease (eg, dementia), delirium, or drug intoxication than psychiatric illness.
- Tactile—common in alcohol withdrawal and stimulant use (eg, “cocaine crawlies,” a type of delusional parasitosis).
- Olfactory—often occur as an aura of temporal lobe epilepsy (eg, burning rubber) and in brain tumors.
- Gustatory—rare, but seen in epilepsy.
- Hypnagogic—occurs while going to sleep. Sometimes seen in narcolepsy.
- Hypnopompic—occurs while waking from sleep (“get **pomped** up in the morning”). Sometimes seen in narcolepsy.

Contrast with illusions, which are misperceptions of real external stimuli (eg, mistaking a shadow for a black cat).

Mood disorder

Characterized by an abnormal range of moods or internal emotional states and loss of control over them. Severity of moods causes distress and impairment in social and occupational functioning. Includes major depressive, bipolar, dysthymic, and cyclothymic disorders. Episodic superimposed psychotic features (delusions, hallucinations, disorganized speech/behavior) may be present at any time during mood changes.

Schizophrenia spectrum disorders

Schizophrenia	<p>Chronic illness causing profound functional impairment. Symptom categories include:</p> <ul style="list-style-type: none"> ▪ Positive—excessive or distorted functioning (eg, hallucinations, delusions, unusual thought processes, disorganized speech, bizarre behavior) ▪ Negative—diminished functioning (eg, flat or blunted affect, apathy, anhedonia, alogia, social withdrawal) ▪ Cognitive—reduced ability to understand or make plans, diminished working memory, inattention <p>Diagnosis requires ≥ 2 of the following active symptoms, including ≥ 1 from symptoms #1–3:</p> <ol style="list-style-type: none"> 1. Delusions 2. Hallucinations, often auditory 3. Disorganized speech 4. Disorganized or catatonic behavior 5. Negative symptoms <p>Symptom onset ≥ 6 months prior to diagnosis; requires ≥ 1 month of active symptoms over the past 6 months.</p>	<p>Associated with altered dopaminergic activity, \uparrow serotonergic activity, and \downarrow dendritic branching. Ventriculomegaly on brain imaging. Lifetime prevalence—1.5% (males $>$ females). Presents earlier in males (late teens to early 20s) than in females (late 20s to early 30s). \uparrow suicide risk.</p> <p>Heavy cannabis use in adolescence is associated with \uparrow incidence and worsened course of psychotic, mood, and anxiety disorders.</p> <p>Treatment: atypical antipsychotics (eg, risperidone) are first line.</p> <p>Negative symptoms often persist after treatment, despite resolution of positive symptoms.</p>
<p>Brief psychotic disorder—≥ 1 positive symptom(s) lasting between 1 day and 1 month, usually stress-related.</p>		
<p>Schizophreniform disorder—≥ 2 symptoms lasting 1–6 months.</p>		
Schizoaffective disorder	<p>Shares symptoms with both schizophrenia and mood disorders (MDD or bipolar disorder). To differentiate from a mood disorder with psychotic features, patient must have ≥ 2 weeks of psychotic symptoms without a manic or depressive episode.</p>	
Delusional disorder	<p>≥ 1 delusion(s) lasting > 1 month, but without a mood disorder or other psychotic symptoms. Daily functioning, including socialization, may be impacted by the pathological, fixed belief but is otherwise unaffected. Can be shared by individuals in close relationships (folie à deux).</p>	
Schizotypal personality disorder	<p>Cluster A personality disorder that also falls on the schizophrenia spectrum. May include brief psychotic episodes (eg, delusions) that are less frequent and severe than in schizophrenia.</p>	
Manic episode		
<p>Distinct period of abnormally and persistently elevated, expansive, or irritable mood and \uparrow activity or energy. Diagnosis requires marked functional impairment with ≥ 3 of the following for ≥ 1 week, or any duration if hospitalization is required (people with mania DIG FAST):</p> <ul style="list-style-type: none"> ▪ Distractibility ▪ Impulsivity/Indiscretion—seeks pleasure without regard to consequences (hedonistic) ▪ Grandiosity—inflated self-esteem ▪ Flight of ideas—racing thoughts ▪ \uparrow goal-directed Activity/psychomotor Agitation ▪ \downarrow need for Sleep ▪ Talkativeness or pressured speech 		

Hypomanic episode	<p>Similar to a manic episode except mood disturbance is not severe enough to cause marked impairment in social and/or occupational functioning or to necessitate hospitalization. Abnormally ↑ activity or energy usually present. No psychotic features. Lasts ≥ 4 consecutive days.</p>
Bipolar disorder	<p>Bipolar I—≥ 1 manic episode +/- a hypomanic or depressive episode (may be separated by any length of time). Bipolar II—a hypomanic and a depressive episode (no history of manic episodes). Patient's mood and functioning usually normalize between episodes. Use of antidepressants can destabilize mood. High suicide risk. Treatment: mood stabilizers (eg, lithium, valproate, carbamazepine, lamotrigine), atypical antipsychotics. Cyclothymic disorder—milder form of bipolar disorder fluctuating between mild depressive and hypomanic symptoms. Must last ≥ 2 years with symptoms present at least half of the time, with any remission lasting ≤ 2 months.</p>
Major depressive disorder	<p>Recurrent episodes lasting ≥ 2 weeks characterized by ≥ 5 of 9 diagnostic symptoms including depressed mood or anhedonia (or irritability in children). SIG E CAPS:</p> <ul style="list-style-type: none"> ▪ Sleep disturbances ▪ ↓ Interest in pleasurable activities (anhedonia) ▪ Guilt or feelings of worthlessness ▪ ↓ Energy ▪ ↓ Concentration ▪ Appetite/weight changes ▪ Psychomotor retardation or agitation ▪ Suicidal ideation <p>Screen for previous manic or hypomanic episodes to rule out bipolar disorder. Treatment: CBT and SSRIs are first line; alternatives include SNRIs, mirtazapine, bupropion, electroconvulsive therapy (ECT), ketamine. Responses to a significant loss (eg, bereavement, natural disaster, disability) may resemble a depressive episode. Diagnosis of MDD is made if criteria are met.</p>
MDD with psychotic features	<p>MDD + hallucinations or delusions. Psychotic features are typically mood congruent (eg, depressive themes of inadequacy, guilt, punishment, nihilism, disease, or death) and occur only in the context of major depressive episode (vs schizoaffective disorder). Treatment: antidepressant with atypical antipsychotic, ECT.</p>
Persistent depressive disorder	<p>Also called dysthymia. Often milder than MDD; ≥ 2 depressive symptoms lasting ≥ 2 years (≥ 1 year in children), with any remission lasting ≤ 2 months.</p>
MDD with seasonal pattern	<p>Formerly called seasonal affective disorder. Major depressive episodes occurring only during a particular season (usually winter) in ≥ 2 consecutive years and in most years across a lifetime. Atypical symptoms common. Treatment: standard MDD therapies + light therapy.</p>
Depression with atypical features	<p>Characterized by mood reactivity (transient improvement in response to a positive event), hypersomnia, hyperphagia, leaden paralysis (heavy feeling in arms and legs), long-standing interpersonal rejection sensitivity. Most common subtype of depression. Treatment: CBT and SSRIs are first line. MAO inhibitors are effective but not first line because of their risk profile.</p>

Peripartum mood disturbances	Onset during pregnancy or within 4 weeks of delivery. ↑ risk with history of mood disorders.	
Postpartum blues	50–85% incidence rate. Characterized by depressed affect, tearfulness, and fatigue starting 2–3 days after delivery. Usually resolves within 2 weeks. Treatment: supportive. Follow up to assess for possible MDD with peripartum onset.	
MDD with peripartum onset	10–15% incidence rate. Formerly called postpartum depression. Meets MDD criteria with onset either during pregnancy or within 4 weeks after delivery. Treatment: CBT and SSRIs are first line.	
Postpartum psychosis	0.1–0.2% incidence rate. Characterized by mood-congruent delusions, hallucinations, and thoughts of harming the baby or self. Risk factors include first pregnancy, family history, bipolar disorder, psychotic disorder, recent medication change. Treatment: hospitalization and initiation of atypical antipsychotic; if insufficient, ECT may be used.	
Electroconvulsive therapy	Rapid-acting method to treat refractory depression, depression with psychotic symptoms, catatonia, and acute suicidality. Induces tonic-clonic seizure under anesthesia and neuromuscular blockade. Adverse effects include disorientation, headache, partial anterograde/retrograde amnesia usually resolving in 6 months. No absolute contraindications. Safe in pregnant individuals and older adults.	
Risk factors for suicide death	<p>Sex (male)</p> <p>Age (young adult or older adult)</p> <p>Depression</p> <p>Previous attempt (highest risk factor)</p> <p>Ethanol or drug use</p> <p>Rational thinking loss (psychosis)</p> <p>Sickness (medical illness)</p> <p>Organized plan</p> <p>No spouse or other social support</p> <p>Stated future intent</p>	<p>SAD PERSONS are more likely to die from suicide.</p> <p>Most common method in US is firearms; access to guns ↑ risk of suicide death.</p> <p>Women try more often; men die more often.</p> <p>Other risk factors include recent psychiatric hospitalization and family history of suicide death.</p> <p>Protective factors include effective care for comorbidities; medical, familial, or community connectedness; cultural/religious beliefs encouraging self-preservation; and strong problem-solving skills.</p>
Anxiety disorders	Inappropriate experiences of fear/worry and their physical manifestations incongruent with the magnitude of the stressors. Symptoms are not attributable to another medical condition (eg, psychiatric disorder, hyperthyroidism) or substance use. Includes panic disorder, phobias, generalized anxiety disorder, and selective mutism.	

Panic disorder

Recurrent panic attacks involving intense fear and discomfort +/- a known trigger. Attacks typically peak in 10 minutes with ≥ 4 of the following: palpitations, paresthesias, depersonalization or derealization, abdominal pain, nausea, intense fear of dying, intense fear of losing control, lightheadedness, chest pain, chills, choking, sweating, shaking, shortness of breath. Strong genetic component. \uparrow risk of suicide.

Diagnosis requires attack followed by ≥ 1 month of ≥ 1 of the following:

- Persistent concern of additional attacks
- Worrying about consequences of attack
- Behavioral change related to attacks

Symptoms are systemic manifestations of fear.

Treatment: CBT, SSRIs, and venlafaxine are first line. Benzodiazepines occasionally used in acute setting.

Phobias

Severe, persistent (≥ 6 months) fear or anxiety due to presence or anticipation of a specific object or situation. Person often recognizes fear is excessive. Treatment: CBT with exposure therapy.

Social anxiety disorder—exaggerated fear of embarrassment in social situations (eg, public speaking, using public restrooms). Treatment: CBT, SSRIs, venlafaxine. For performance type (eg, anxiety restricted to public speaking), use β -blockers or benzodiazepines as needed.

Agoraphobia—irrational fear, anxiety, and/or avoidance while facing or anticipating ≥ 2 specific situations (eg, public transportation, open/closed spaces, lines/crowds, being outside of home alone). Symptoms stem from the concern that help or escape may be unavailable. Associated with panic disorder. Treatment: CBT, SSRIs.

Generalized anxiety disorder

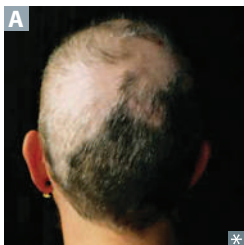Excessive anxiety and worry about different aspects of daily life (eg, work, school, children) for most days of ≥ 6 months. Associated with ≥ 3 of the following for adults (≥ 1 for kids): difficulty Concentrating, Restlessness, Irritability, Muscle tension, fatigue (low Energy), Sleep disturbance (anxiety over CRIMES). Treatment: CBT, SSRIs, SNRIs are first line. Buspirone, TCAs, benzodiazepines are second line.

Obsessive-compulsive disorders

Obsessions (recurring intrusive thoughts, feelings, or sensations) that cause severe distress, relieved in part by compulsions (performance of repetitive, often time-consuming actions). Ego-dystonic: behavior inconsistent with one's beliefs and attitudes (vs obsessive-compulsive personality disorder, ego-syntonic). Associated with Tourette syndrome. Treatment: CBT and SSRIs; clomipramine and venlafaxine are second line.

Body dysmorphic disorder—preoccupation with minor or imagined defects in appearance.

Causes significant emotional distress and repetitive appearance-related behaviors (eg, mirror checking, excessive grooming). Common in eating disorders. Treatment: CBT.

Trichotillomania

Compulsively pulling out one's hair. Causes significant distress and persists despite attempts to stop. Presents with areas of thinning hair or baldness on any area of the body, most commonly the scalp

A. Remaining hair shafts are of different lengths (vs alopecia). Incidence highest in childhood but spans all ages. Treatment: psychotherapy.


Trauma and stress-related disorders

Adjustment disorder Emotional or behavioral symptoms (eg, anxiety, outbursts) that occur within 3 months of an identifiable psychosocial stressor (eg, divorce, illness) lasting < 6 months once the stressor has ended. Symptoms do not meet criteria for another psychiatric illness. If symptoms persist > 6 months after stressor ends, reevaluate for other explanations (eg, MDD, GAD). Treatment: CBT is first line; antidepressants and anxiolytics may be considered.

Post-traumatic stress disorder Experiencing, witnessing, or discovering that a loved one has experienced a life-threatening situation (eg, serious injury, sexual assault) → persistent **H**yperarousal, **A**voidance of associated stimuli, intrusive **R**e-experiencing of the event (eg, nightmares, flashbacks), changes in cognition or mood (eg, fear, horror, **D**istress) (having PTSD is **HARD**). Disturbance lasts > 1 month with significant distress or impaired functioning. Treatment: CBT, SSRIs, and venlafaxine are first line. Prazosin can reduce nightmares.

Acute stress disorder—lasts between 3 days and 1 month. Treatment: CBT; pharmacotherapy is usually not indicated.

Diagnostic criteria by symptom duration



Personality disorders

Inflexible, maladaptive, and rigidly pervasive patterns of behavior causing subjective distress and/or impaired functioning; person is usually not aware of problem (egosyntonic). Usually present by early adulthood. Contrast with **personality traits**—nonpathologic enduring patterns of perception and behavior.

Three clusters:

- Cluster A—odd or eccentric (remember as “weird”); inability to develop meaningful social relationships. No psychosis; genetic association with schizophrenia.
- Cluster B—dramatic, emotional, or erratic (remember as “wild”); genetic association with mood disorders and substance use.
- Cluster C—anxious or fearful (remember as “worried”); genetic association with anxiety disorders.

Cluster A**Paranoid**

Pervasive distrust (**accusatory**), suspiciousness, hypervigilance, and a profoundly cynical view of the world.

Schizoid

Prefers social withdrawal and solitary activities (vs avoidant), limited emotional expression, indifferent to others’ opinions (**aloof**).

Schizotypal

Eccentric appearance, odd beliefs or magical thinking, interpersonal **awkwardness**. Included on the schizophrenia spectrum. Pronounce “**schizo-type-al**” for **odd-type** thoughts.

Cluster B**Antisocial**

Disregard for the rights of others with lack of remorse (**bad**). Involves criminality, impulsivity, hostility, and manipulation (sociopath). Males > females. Must be ≥ 18 years old with evidence of conduct disorder onset before age 15. If patient is < 18, diagnosis is conduct disorder.

Borderline

Unstable mood and interpersonal relationships, fear of abandonment, impulsivity, self-mutilation, suicidality, sense of emotional emptiness (**borderline**). Females > males. Splitting is a major defense mechanism. Treatment: dialectical behavior therapy.

Histrionic

Attention-seeking, dramatic speech and emotional expression, shallow and labile emotions, sexually provocative. May use physical appearance to draw attention (**flamboyant**).

Narcissistic

Grandiosity, sense of entitlement; lacks empathy and requires excessive admiration; often demands the “best” and reacts to criticism with rage and/or defensiveness (must be the **best**). Fragile self-esteem. Often envious of others.

Cluster C**Avoidant**

Hypersensitive to rejection and criticism, socially inhibited, timid (**cowardly**), feelings of inadequacy, desires relationships with others (vs schizoid).

Obsessive-compulsive

Preoccupation with order, perfectionism, and control (**obsessive-compulsive**); egosyntonic: behavior consistent with one’s own beliefs and attitudes (vs OCD).

Dependent

Excessive need for support (**clingy**), submissive, low self-confidence. Patients often get stuck in abusive relationships.

Malingering	Symptoms are intentional, motivation is intentional. Patient consciously fakes, profoundly exaggerates, or claims to have a disorder in order to attain a specific 2° (external) gain (eg, avoiding work, obtaining compensation). Poor compliance with treatment or follow-up of diagnostic tests. Complaints cease after gain (vs factitious disorder).
Factitious disorders	Symptoms are intentional, motivation is unconscious. Patient consciously creates physical and/or psychological symptoms in order to assume “sick role” and to get medical attention and sympathy (1° [internal] gain).
Factitious disorder imposed on self	Formerly called Munchausen syndrome. Chronic factitious disorder with predominantly physical signs and symptoms. Characterized by a history of multiple hospital admissions and willingness to undergo invasive procedures. More common in females and healthcare workers.
Factitious disorder imposed on another	Formerly called Munchausen syndrome by proxy. Illness in an individual being cared for (most often a child, also seen in disabled or older adults) is directly caused (eg, physically harming a child) or fabricated (eg, lying about a child’s symptoms) by the caregiver. Form of child/elder abuse.
Somatic symptom and related disorders	Symptoms are unconscious, motivation is unconscious. Category of disorders characterized by physical symptoms causing significant distress and impairment. Symptoms not intentionally produced or feigned.
Somatic symptom disorder	≥ 1 bodily complaints (eg, abdominal pain, fatigue) lasting months to years. Associated with excessive, persistent thoughts and anxiety about symptoms. May co-occur with medical illness. Treatment: regular office visits with the same physician in combination with psychotherapy.
Conversion disorder	Also called functional neurologic symptom disorder. Unexplained loss of sensory or motor function (eg, paralysis, blindness, mutism), often following an acute stressor; patient may be aware of but indifferent toward symptoms (“la belle indifférence”); more common in females, adolescents, and young adults.
Illness anxiety disorder	Preoccupation with acquiring or having a serious illness, often despite medical evaluation and reassurance; minimal to no somatic symptoms.

Malingering vs factitious disorder vs somatic symptom disorders

	Malingering	Factitious disorder	Somatic symptom disorders
SYMPTOMS	Intentional	Intentional	Unconscious
MOTIVATION	Intentional	Unconscious	Unconscious

Eating disorders

Most common in young women.

Anorexia nervosa

Intense fear of weight gain, overvaluation of thinness, and body image distortion leading to caloric restriction and severe weight loss resulting in inappropriately low body weight (BMI < 18.5 kg/m² for adults). May present with hypothyroidism, amenorrhea, osteoporosis, lanugo.

Binge-eating/purging type—recurring purging behaviors (eg, laxative or diuretic abuse, self-induced vomiting) or binge eating over the last 3 months.

Restricting type—primary disordered behaviors include dieting, fasting, and/or over-exercising. No recurring purging behaviors or binge eating over the last 3 months.

Refeeding syndrome—often occurs in significantly malnourished patients with sudden ↑ caloric intake → ↑ insulin → ↓ PO₄³⁻, ↓ K⁺, ↓ Mg²⁺ → cardiac complications, rhabdomyolysis, seizures.

Treatment: nutritional rehabilitation, psychotherapy, olanzapine.

Bulimia nervosa

Recurring episodes of binge eating with compensatory purging behaviors at least weekly over the last 3 months. BMI often normal or slightly overweight (vs anorexia). Associated with parotid gland hypertrophy (may see ↑ serum amylase), enamel erosion, Mallory-Weiss syndrome, electrolyte disturbances (eg, ↓ K⁺, ↓ Cl⁻), metabolic alkalosis, dorsal hand calluses from induced vomiting (Russell sign).

Treatment: psychotherapy, nutritional rehabilitation, antidepressants (eg, SSRIs). Bupropion is contraindicated due to seizure risk.

Binge-eating disorder

Recurring episodes of binge eating without purging behaviors at least weekly over the last 3 months. ↑ diabetes risk. Most common eating disorder in adults.

Treatment: psychotherapy (first line); SSRIs; lisdexamfetamine.

Pica

Recurring episodes of eating non-food substances (eg, ice, dirt, hair, paint chips) over ≥ 1 month that are not culturally or developmentally recognized as normal. May provide temporary emotional relief. Common in children and during pregnancy. Associated with malnutrition, iron deficiency anemia, developmental disabilities, emotional trauma.

Treatment: psychotherapy and nutritional rehabilitation (first line); SSRIs (second line).

Gender dysphoria

Significant incongruence between one's gender identity and one's gender assigned at birth, lasting > 6 months and leading to persistent distress. Individuals experience marked discomfort with their assigned gender, which interferes with social, academic, and other areas of function. Individuals may pursue multiple domains of gender affirmation, including social, legal, and medical.

Transgender—any individual who transiently or persistently experiences incongruence between their gender identity and their gender assigned at birth. Some individuals who are transgender will experience gender dysphoria. Nonconformity to one's assigned gender itself is not a mental disorder.

Sexual dysfunction

Includes sexual desire disorders (hypoactive sexual desire or sexual aversion), sexual arousal disorders (erectile dysfunction), orgasmic disorders (anorgasmia, premature ejaculation), sexual pain disorders (genito-pelvic pain/penetration disorder).

Differential diagnosis includes (**PENIS**):

- **P**ychological (if nighttime erections still occur)
- **E**ndocrine (eg, diabetes, low testosterone)
- **N**eurogenic (eg, postoperative, spinal cord injury)
- **I**nsufficient blood flow (eg, atherosclerosis)
- **S**ubstances (eg, antihypertensives, antidepressants, ethanol)

Sleep terror disorder	Periods of inconsolable terror with screaming in the middle of the night. Most common in children. Occurs during slow-wave/deep (stage N3) non-REM sleep with no memory of the arousal episode, as opposed to nightmares that occur during REM sleep (remembering a scary dream). Triggers include emotional stress, fever, and lack of sleep. Usually self limited.
Enuresis	Nighttime urinary incontinence ≥ 2 times/week for ≥ 3 months in person > 5 years old. First-line treatment: behavioral modification (eg, scheduled voids, nighttime fluid restriction) and positive reinforcement. For refractory cases: bedwetting alarm, oral desmopressin (ADH analog; preferred over imipramine due to fewer adverse effects).
Narcolepsy	Excessive daytime sleepiness (despite awakening well-rested) with recurrent episodes of rapid-onset, overwhelming sleepiness ≥ 3 times/week for the last 3 months. Due to \downarrow orexin (hypocretin) production in lateral hypothalamus and dysregulated sleep-wake cycles. Associated with: <ul style="list-style-type: none">▪ Hypnagogic (just before going to sleep) or hypnopompic (just before awakening; get pumped up in the morning) hallucinations.▪ Nocturnal and narcoleptic sleep episodes that start with REM sleep (sleep paralysis).▪ Cataplexy (loss of all muscle tone following strong emotional stimulus, such as laughter). Treatment: good sleep hygiene (scheduled naps, regular sleep schedule), daytime stimulants (eg, amphetamines, modafinil) and/or nighttime sodium oxybate (GHB).
Substance use disorder	Maladaptive pattern of substance use involving ≥ 2 of the following in the past year: <ul style="list-style-type: none">▪ Tolerance▪ Withdrawal▪ Intense, distracting cravings▪ Using more, or longer, than intended▪ Persistent desire but inability to cut down▪ Time-consuming substance acquisition, use, or recovery▪ Impaired functioning at work, school, or home▪ Social or interpersonal conflicts▪ Reduced recreational activities▪ > 1 episode of use involving danger (eg, unsafe sex, driving while impaired)▪ Continued use despite awareness of harm In the case of appropriate medical treatment with prescribed medications (eg, opioid analgesics, sedatives, stimulants), symptoms of tolerance and withdrawal do not indicate a substance use disorder.
Gambling disorder	Persistent, recurrent, problematic gambling that cannot be better explained as a manic episode. Diagnosis made if patient meets ≥ 4 of the following criteria: <ul style="list-style-type: none">▪ Is preoccupied with gambling▪ Requires more gambling to reach desired level of excitement▪ Has failed efforts to limit, cut back, or stop gambling▪ Becomes restless or irritable when limiting or attempting to stop gambling▪ Gambles to escape or relieve feelings of helplessness, guilt, anxiety, or depression▪ After losing money gambling, continues gambling in an attempt to recover losses▪ Lies to conceal the extent of gambling▪ Puts at risk or has lost significant relationship, career, or academic pursuits because of gambling▪ Relies on money from others to fix financial collapse due to gambling Treatment: psychotherapy.

Transtheoretical model of change

STAGE	FEATURES	MOTIVATIONAL STRATEGIES
Precontemplation	Denies problem and its consequences.	Encourage introspection. Use patient's personal priorities in explaining risks. Affirm your availability to the patient.
Contemplation	Acknowledges problem but is ambivalent or unwilling to change.	Discuss pros of changing and cons of maintaining current behavior. Suggest means to support behavior changes.
Preparation/ determination	Committed to and planning for behavior change.	Employ motivational interviewing. Encourage initial changes, promote expectations for positive results, provide resources to assist in planning.
Action/willpower	Executes a plan and demonstrates a change in behavior.	Assist with strategies for self-efficacy, contingency management, and coping with situations that trigger old behaviors.
Maintenance	New behaviors become sustained, integrate into personal identity and lifestyle.	Reinforce developing habits. Evaluate and mitigate relapse risk. Praise progress.
Relapse	Regression to prior behavior (does not always occur).	Varies based on degree of regression. Encourage return to changes. Provide reassurance that change remains possible.

Psychiatric emergencies

	CAUSE	MANIFESTATION	TREATMENT
Serotonin syndrome	Any drug that ↑ 5-HT. Psychiatric drugs: MAO inhibitors, SSRIs, SNRIs, TCAs, vilazodone, vortioxetine, bupirone Nonpsychiatric drugs: tramadol, ondansetron, triptans, linezolid, MDMA, dextromethorphan, meperidine, St. John's wort	3 A's: ↑ activity (neuromuscular; eg, clonus, hyperreflexia, hypertonia, tremor, seizure), a utonomic instability (eg, hyperthermia, diaphoresis, diarrhea), a ltered mental status	Benzodiazepines and supportive care; cyproheptadine (5-HT ₂ receptor antagonist) if no improvement Prevention: avoid simultaneous serotonergic drugs, and allow a washout period between them
Hypertensive crisis	Eating tyramine-rich foods (eg, aged cheeses, cured meats, wine, chocolate) while taking MAO inhibitors, insufficient washout period when switching antidepressants to or from MAO inhibitors	Hypertensive crisis (tyramine displaces other neurotransmitters [eg, NE] in the synaptic cleft → ↑ sympathetic stimulation)	Phentolamine
Neuroleptic malignant syndrome	Antipsychotics (typical > atypical) + genetic predisposition	Malignant FEVER: Myoglobinuria, F ever, E ncephalopathy, V itals unstable, ↑ E nzymes (eg, CK), muscle R igidity ("lead pipe")	Dantrolene, dopaminergics (eg, bromocriptine, amantadine), benzodiazepines; discontinue causative agent
Delirium tremens	Alcohol withdrawal; occurs 2–4 days after last drink Classically seen in hospital setting when inpatient cannot drink	Altered mental status, hallucinations, autonomic hyperactivity, anxiety, seizures, tremors, psychomotor agitation, insomnia, nausea	Longer-acting benzodiazepines
Acute dystonia	Typical antipsychotics, anticonvulsants (eg, carbamazepine), metoclopramide	Sudden onset of muscle spasms, stiffness, and/or oculogyric crisis occurring hours to days after medication use; can lead to laryngospasm requiring intubation	Benzotropine or diphenhydramine
Lithium toxicity	↑ lithium dosage, ↓ renal elimination (eg, acute kidney injury), medications affecting clearance (eg, ACE inhibitors, thiazide diuretics, NSAIDs) Narrow therapeutic window	Nausea, vomiting, slurred speech, hyperreflexia, seizures, ataxia, nephrogenic diabetes insipidus	Discontinue lithium, hydrate aggressively with isotonic sodium chloride, consider hemodialysis
Tricyclic antidepressant toxicity	TCA overdose	Respiratory depression, hyperpyrexia, prolonged QT Tricyclic's: convulsions, coma, cardiotoxicity (arrhythmia due to Na ⁺ channel inhibition)	Supportive treatment, monitor ECG, NaHCO ₃ (prevents arrhythmia), activated charcoal

Psychoactive drug intoxication and withdrawal

DRUG	INTOXICATION	WITHDRAWAL
Depressants		
	Nonspecific: mood elevation, ↓ anxiety, sedation, behavioral disinhibition, respiratory depression.	Nonspecific: anxiety, tremor, seizures, insomnia.
Alcohol	Emotional lability, slurred speech, ataxia, coma, blackouts. Serum γ -glutamyltransferase (GGT)—sensitive indicator of alcohol use. AST value is 2×ALT value (“ ToAST 2 ALcohol ”). Treatment: supportive (eg, fluids, antiemetics).	Treatment: longer-acting benzodiazepines. <div style="text-align: center;"> <p>Time from last drink (hours)</p> </div>
Barbiturates	Low safety margin, marked respiratory depression. Treatment: symptom management (eg, assist respiration, ↑ BP).	Delirium, life-threatening cardiovascular collapse.
Benzodiazepines	Greater safety margin. Ataxia, minor respiratory depression. Treatment: flumazenil (benzodiazepine receptor antagonist, but rarely used as it can precipitate seizures).	Seizures, sleep disturbance, depression.
Opioids	Pupillary constriction (pinpoint pupils), ↓ GI motility, respiratory and CNS depression, euphoria, ↓ gag reflex, seizures. Most common cause of drug overdose death. Overdose treatment: naloxone.	Dilated pupils, diarrhea (“flulike” symptoms), rhinorrhea, yawning, nausea, stomach cramps, sweating, piloerection (“cold turkey”), lacrimation. Treatment: symptom management, methadone, buprenorphine.
Inhalants	Disinhibition, euphoria, slurred speech, disturbed gait, disorientation, drowsiness. Effects often have rapid onset and resolution. Perinasal/perioral rash with repeated use.	Irritability, dysphoria, sleep disturbance, headache.
Stimulants		
	Nonspecific: mood elevation, ↓ appetite, psychomotor agitation, insomnia, cardiac arrhythmias, tachycardia, anxiety.	Nonspecific: post-use “crash,” including depression, lethargy, ↑ appetite, sleep disturbance, vivid nightmares.
Amphetamines	Euphoria, grandiosity, pupillary dilation, prolonged wakefulness, hyperalertness, hypertension, paranoia, fever, fractured teeth. Skin excoriations with methamphetamine use. Severe: cardiac arrest, seizures. Treatment: benzodiazepines for agitation and seizures.	
Caffeine	Palpitation, agitation, tremor, insomnia.	Headache, difficulty concentrating, flulike symptoms.

Psychoactive drug intoxication and withdrawal (continued)

DRUG	INTOXICATION	WITHDRAWAL
Cocaine	Impaired judgment, pupillary dilation, diaphoresis, hallucinations (including tactile), paranoia, angina, sudden cardiac death. Chronic use may lead to perforated nasal septum due to vasoconstriction and resulting ischemic necrosis. Treatment: benzodiazepines; use of β -blockers or mixed α -/ β -blockers (eg, labetalol) for hypertension and tachycardia is controversial as first-line therapy.	Restlessness, hunger, severe depression, sleep disturbance.
Nicotine	Restlessness.	Irritability, anxiety, restlessness, ↓ concentration, ↑ appetite/weight. Treatment: nicotine replacement therapy (eg, patch, gum, lozenge); bupropion/varenicline.
Hallucinogens		
Lysergic acid diethylamide	Perceptual distortion (visual, auditory), depersonalization, anxiety, paranoia, psychosis, flashbacks (usually nondisturbing), mydriasis.	
Cannabis/cannabinoids	Euphoria, anxiety, paranoid delusions, perception of slowed time, impaired judgment, social withdrawal, ↑ appetite, dry mouth, conjunctival injection, hallucinations.	Irritability, anxiety, depression, insomnia, restlessness, ↓ appetite.
MDMA	Also called ecstasy. Euphoria, hallucinations, disinhibition, hyperactivity, ↑ thirst, bruxism, distorted sensory and time perception, mydriasis. Life-threatening effects include hypertension, tachycardia, hyperthermia, hyponatremia, serotonin syndrome.	Depression, fatigue, change in appetite, difficulty concentrating, anxiety.
Phencyclidine	Violence, nystagmus, impulsivity, psychomotor agitation, miosis, tachycardia, hypertension, analgesia, psychosis, delirium, seizures.	
Alcohol use disorder	Diagnosed using criteria for substance use disorder. Complications: vitamin B ₁ (thiamine) deficiency, alcoholic cirrhosis, hepatitis, pancreatitis, peripheral neuropathy, testicular atrophy. Treatment: naltrexone (reduces cravings), acamprosate, disulfiram (to condition the patient to abstain from alcohol use). Support groups such as Alcoholics Anonymous are helpful in sustaining abstinence and supporting patient and family.	
Wernicke-Korsakoff syndrome	Results from vitamin B ₁ deficiency. Symptoms can be precipitated by administering dextrose before vitamin B ₁ . Triad of confusion, ophthalmoplegia, ataxia (Wernicke encephalopathy). May progress to irreversible memory loss, confabulation, personality change (Korsakoff syndrome). Treatment: IV vitamin B ₁ (before dextrose).	

▶ PSYCHIATRY—PHARMACOLOGY

Psychotherapy

Behavioral therapy	Teaches patients how to identify and change maladaptive behaviors or reactions to stimuli (eg, systematic desensitization for specific phobia).
Cognitive behavioral therapy	Teaches patients to recognize distortions in their thought processes, develop constructive coping skills, and ↓ maladaptive coping behaviors → greater emotional control and tolerance of distress (eg, recognizing triggers for alcohol consumption).
Dialectical behavioral therapy	Designed for use in borderline personality disorder, but can be used in other psychiatric conditions as well (eg, depression).
Interpersonal therapy	Focused on improving interpersonal relationships and communication skills.
Motivational interviewing	Enhances intrinsic motivation to change by exploring and resolving ambivalence. Used in substance use disorder and weight loss.
Supportive therapy	Utilizes empathy to help individuals during a time of hardship to maintain optimism or hope.

Preferred medications for selected psychiatric conditions

PSYCHIATRIC CONDITION	PREFERRED DRUGS
ADHD	Stimulants (methylphenidate, amphetamines)
Alcohol withdrawal	Benzodiazepines (eg, chlordiazepoxide, lorazepam, diazepam)
Bipolar disorder	Carbamazepine, atypical antipsychotics, lithium, lamotrigine, valproate. Character a little less variable
Bulimia nervosa	SSRIs
Depression	SSRIs
Generalized anxiety disorder	SSRIs, SNRIs
Obsessive-compulsive disorder	SSRIs, venlafaxine, clomipramine
Panic disorder	SSRIs, venlafaxine, benzodiazepines
PTSD	SSRIs, venlafaxine, prazosin (for nightmares)
Schizophrenia	Atypical antipsychotics
Social anxiety disorder	SSRIs, venlafaxine Performance only: β-blockers, benzodiazepines
Tourette syndrome	Antipsychotics (eg, fluphenazine, risperidone), tetrabenazine

Central nervous system stimulants

Methylphenidate, dextroamphetamine, methamphetamine, lisdexamfetamine.

MECHANISM

↑ catecholamines in the synaptic cleft, especially norepinephrine and dopamine.

CLINICAL USE

ADHD, narcolepsy, binge-eating disorder.

ADVERSE EFFECTS

Nervousness, agitation, anxiety, insomnia, anorexia, tachycardia, hypertension, weight loss, tics, bruxism.

Antipsychotics

Typical (1st-generation) antipsychotics—haloperidol, pimozide, trifluoperazine, fluphenazine, thioridazine, chlorpromazine.

Atypical (2nd-generation) antipsychotics—aripiprazole, asenapine, clozapine, olanzapine, quetiapine, iloperidone, paliperidone, risperidone, lurasidone, ziprasidone.

MECHANISM	Block dopamine D ₂ receptor (↑ cAMP). Atypical antipsychotics also block serotonin 5-HT ₂ receptor. Aripiprazole is a D ₂ partial agonist.
CLINICAL USE	Schizophrenia (typical antipsychotics primarily treat positive symptoms; atypical antipsychotics treat both positive and negative symptoms), disorders with concomitant psychosis (eg, bipolar disorder), Tourette syndrome, OCD, Huntington disease. Clozapine is used for treatment-resistant psychotic disorders or those with persistent suicidality (cloze to the edge).
ADVERSE EFFECTS	<p>Antihistaminic (sedation), anti-α₁-adrenergic (orthostatic hypotension), antimuscarinic (dry mouth, constipation) (anti-HAM). Use with caution in dementia.</p> <p>Metabolic: weight gain, hyperglycemia, dyslipidemia. Highest risk with clozapine and olanzapine (obesity).</p> <p>Endocrine: hyperprolactinemia → galactorrhea, oligomenorrhea, gynecomastia.</p> <p>Cardiac: QT prolongation.</p> <p>Neurologic: neuroleptic malignant syndrome.</p> <p>Ophthalmologic: chlorpromazine—corneal deposits; thioridazine—retinal deposits.</p> <p>Clozapine—agranulocytosis (monitor WBCs clozely), seizures (dose related), myocarditis.</p> <p>Extrapyramidal symptoms—ADAPT:</p> <ul style="list-style-type: none"> ▪ Hours to days: Acute Dystonia (muscle spasm, stiffness, oculogyric crisis). Treatment: benztropine, diphenhydramine. ▪ Days to months: <ul style="list-style-type: none"> ▪ Akathisia (restlessness). Treatment: β-blockers, benztropine, benzodiazepines. ▪ Parkinsonism (bradykinesia). Treatment: benztropine, amantadine. ▪ Months to years: Tardive dyskinesia (chorea, especially orofacial). Treatment: benzodiazepines, botulinum toxin injections, valbenazine, deutetrabenazine.
NOTES	<p>Lipid soluble → stored in body fat → slow to be removed from body.</p> <p>Typical antipsychotics have greater affinity for D₂ receptor than atypical antipsychotics → ↑ risk for hyperprolactinemia, extrapyramidal symptoms, neuroleptic malignant syndrome.</p> <p>High-potency typical antipsychotics: haloperidol, trifluoperazine, pimozide, fluphenazine (Hal tries pie to fly high)—more neurologic adverse effects (eg, extrapyramidal symptoms).</p> <p>Low-potency typical antipsychotics: chlorpromazine, thioridazine (cheating thieves are low)—more antihistaminic, anti-α₁-adrenergic, antimuscarinic effects.</p>

Lithium

MECHANISM	Not established; possibly related to inhibition of phosphoinositol cascade.
CLINICAL USE	Mood stabilizer for bipolar disorder; treats acute manic episodes and prevents relapse.
ADVERSE EFFECTS	Tremor, hypothyroidism, hyperthyroidism, mild hypercalcemia, polyuria (causes nephrogenic diabetes insipidus), teratogenesis (causes Ebstein anomaly). Narrow therapeutic window requires close monitoring of serum levels. Almost exclusively excreted by kidneys; most is reabsorbed at PCT via Na ⁺ channels. Thiazides, ACE inhibitors, NSAIDs, and other drugs affecting clearance are implicated in lithium toxicity.

LiTHIUM:

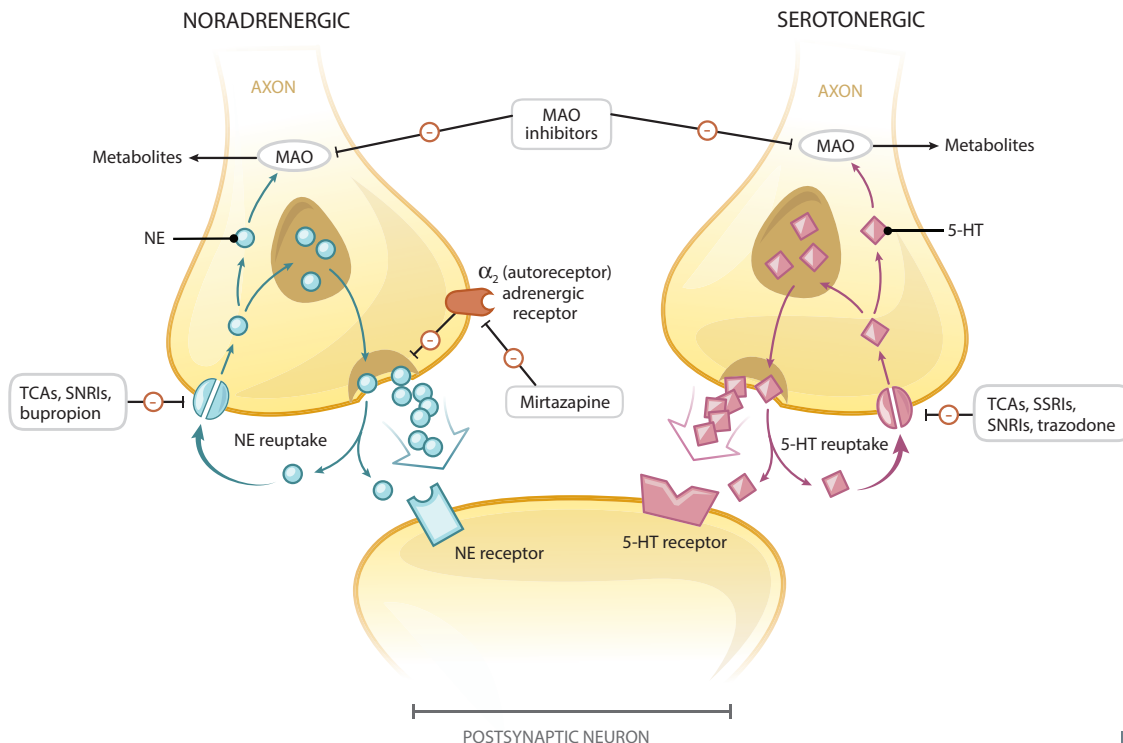
Low **T**h thyroid (hypothyroidism)
H heart (Ebstein anomaly)
Insipidus (nephrogenic diabetes insipidus)
Unwanted **M**ovements (tremor)

Buspirone

MECHANISM	Partial 5-HT _{1A} receptor agonist.
CLINICAL USE	Generalized anxiety disorder. Does not cause sedation, addiction, or tolerance. Begins to take effect after 1–2 weeks. Does not interact with alcohol (vs barbiturates, benzodiazepines).

I get **anxious** if the **bus** doesn't arrive at **one**, so I take **buspirone**.

Antidepressants



Selective serotonin reuptake inhibitors

Fluoxetine, fluvoxamine, paroxetine, sertraline, escitalopram, citalopram.

MECHANISM	Inhibit 5-HT reuptake.	It normally takes 4–8 weeks for antidepressants to show appreciable effect.
CLINICAL USE	Depression, generalized anxiety disorder, panic disorder, OCD, bulimia, binge-eating disorder, social anxiety disorder, PTSD, premature ejaculation, premenstrual dysphoric disorder.	
ADVERSE EFFECTS	Fewer than TCAs. Serotonin syndrome, GI distress, SIADH, sexual dysfunction (anorgasmia, erectile dysfunction, ↓ libido), mania precipitation if underlying bipolar disorder.	

Serotonin-norepinephrine reuptake inhibitors

Venlafaxine, desvenlafaxine, duloxetine, levomilnacipran, milnacipran.

MECHANISM	Inhibit 5-HT and NE reuptake.
CLINICAL USE	Depression, generalized anxiety disorder, diabetic neuropathy. Venlafaxine is also indicated for social anxiety disorder, panic disorder, PTSD, OCD. Duloxetine and milnacipran are also indicated for fibromyalgia.
ADVERSE EFFECTS	↑ BP, stimulant effects, sedation, sexual dysfunction, nausea.

Tricyclic antidepressants

Amitriptyline, nortriptyline, imipramine, desipramine, clomipramine, doxepin, amoxapine.

MECHANISM	TCAs inhibit 5-HT and NE reuptake.
CLINICAL USE	MDD, peripheral neuropathy, chronic neuropathic pain, migraine prophylaxis, OCD (clomipramine), nocturnal enuresis (imipramine).
ADVERSE EFFECTS	Sedation, α_1 -blocking effects including postural hypotension, and atropine-like (anticholinergic) adverse effects (tachycardia, urinary retention, dry mouth). 3° TCAs (amitriptyline) have more anticholinergic effects than 2° TCAs (nortriptyline). Can prolong QT interval. Tri-CyClic's: C onvulsions, C oma, C ardiotoxicity (arrhythmia due to Na ⁺ channel inhibition); also respiratory depression, hyperpyrexia. Confusion and hallucinations are more common in older adults due to anticholinergic adverse effects (2° amines [eg, nortriptyline] better tolerated). Treatment: NaHCO ₃ to prevent arrhythmia.

Monoamine oxidase inhibitors

Tranylcypromine, phenelzine, isocarboxazid, selegiline (selective MAO-B inhibitor). (MAO takes pride in Shanghai).

MECHANISM	Nonselective MAO inhibition → ↑ levels of amine neurotransmitters (norepinephrine, 5-HT, dopamine).
CLINICAL USE	Atypical depression, anxiety. Parkinson disease (selegiline).
ADVERSE EFFECTS	CNS stimulation; hypertensive crisis, most notably with ingestion of tyramine. Contraindicated with SSRIs, TCAs, St. John's wort, meperidine, dextromethorphan, pseudoephedrine, linezolid (to avoid precipitating serotonin syndrome). Wait 2 weeks after stopping MAO inhibitors before starting serotonergic drugs or stopping dietary restrictions.

Atypical antidepressants

Bupropion	Inhibits NE and DA reuptake. Also used for smoking cessation. Toxicity: stimulant effects (tachycardia, insomnia), headache, seizures in patients with bulimia and anorexia nervosa. ↓ risk of sexual adverse effects and weight gain compared to other antidepressants.
Mirtazapine	α_2 -antagonist (↑ release of NE and 5-HT), potent 5-HT ₂ and 5-HT ₃ receptor antagonist, and H ₁ antagonist. Toxicity: sedation (which may be desirable in depressed patients with insomnia), ↑ appetite, weight gain (which may be desirable in underweight patients), dry mouth.
Trazodone	Primarily blocks 5-HT ₂ , α_1 -adrenergic, and H ₁ receptors; also weakly inhibits 5-HT reuptake. Used primarily for insomnia, as high doses are needed for antidepressant effects. Toxicity: sedation, nausea, priapism, postural hypotension. Think tra ZZZ obone due to sedative and male-specific adverse effects.
Varenicline	Nicotinic ACh receptor partial agonist. Used for smoking cessation. Toxicity: sleep disturbance. Varen icline helps nicotine cravings decline .
Vilazodone	Inhibits 5-HT reuptake; 5-HT _{1A} receptor partial agonist. Used for MDD. Toxicity: headache, diarrhea, nausea, anticholinergic effects. May cause serotonin syndrome if taken with other serotonergic agents.
Vortioxetine	Inhibits 5-HT reuptake; 5-HT _{1A} receptor agonist and 5-HT ₃ receptor antagonist. Used for MDD. Toxicity: nausea, sexual dysfunction, sleep disturbances, anticholinergic effects. May cause serotonin syndrome if taken with other serotonergic agents.
Opioid detoxification and relapse prevention	Injection drug use ↑ risk for HBV, HCV, HIV, skin and soft tissue infections, bacteremia, right-sided infective endocarditis.
Methadone	Long-acting oral opiate used for heroin detoxification or long-term maintenance therapy.
Buprenorphine	Partial opioid agonist. Sublingual form (film) used to suppress withdrawal and for maintenance therapy. Partial agonists can precipitate withdrawal symptoms in opioid-dependent individuals or when administered shortly after use of a full agonist.
Naloxone	Short-acting opioid antagonist given IM, IV, or as a nasal spray to treat acute opioid overdose, particularly to reverse respiratory and CNS depression.
Naltrexone	Long-acting oral opioid antagonist used after detoxification to prevent relapse. May help alcohol and nicotine cessation, weight loss. Use nalt rex one for the long trex back to sobriety.

Renal

“But I know all about love already. I know precious little still about kidneys.”

—Aldous Huxley, *Antic Hay*

“This too shall pass. Just like a kidney stone.”

—Hunter Madsen

“Playing dead is difficult with a full bladder.”

—Diane Lane

▶ Embryology	602
▶ Anatomy	604
▶ Physiology	605
▶ Pathology	618
▶ Pharmacology	631

Being able to understand and apply renal physiology will be critical for the exam. Important topics include electrolyte disorders, acid-base derangements, glomerular disorders (including histopathology), acute and chronic kidney disease, urine casts, diuretics, ACE inhibitors, and AT II receptor blockers. Renal anomalies associated with various congenital defects are also high-yield associations to think about when evaluating pediatric vignettes.

▶ RENAL—EMBRYOLOGY

Kidney embryology

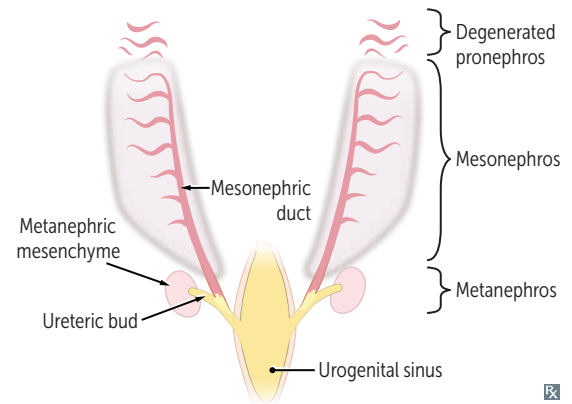
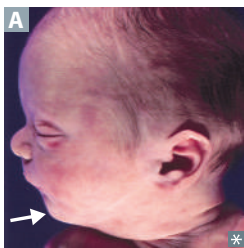
Pronephros—week 4 of development; then degenerates.

Mesonephros—week 4 of development; functions as interim kidney for 1st trimester; persists in the male genital system as Wolffian duct, forming ductus deferens and epididymis.

Metanephros—permanent; first appears in week 5 of development; nephrogenesis is normally completed by week 36 of gestation.

- Ureteric bud (metanephric diverticulum)—derived from caudal end of mesonephric duct; gives rise to ureter, pelvises, calyces, collecting ducts; fully canalized by week 10 of development
- Metanephric mesenchyme (ie, metanephric blastema)—ureteric bud interacts with this tissue; interaction induces differentiation and formation of glomerulus through to distal convoluted tubule (DCT)
- Aberrant interaction between these 2 tissues may result in several congenital malformations of the kidney (eg, renal agenesis, multicystic dysplastic kidney)

Ureteropelvic junction—last to canalize
→ congenital obstruction. Can be unilateral or bilateral. Most common pathologic cause of prenatal hydronephrosis. Detected by prenatal ultrasound.

**Potter sequence**

Oligohydramnios → compression of developing fetus → limb deformities, facial anomalies (eg, low-set ears and retrognathia **A**, flattened nose), compression of chest and lack of amniotic fluid aspiration into fetal lungs → pulmonary hypoplasia (cause of death).

Caused by chronic placental insufficiency or reduced renal output, including ARPKD, obstructive uropathy (eg, posterior urethral valves), bilateral renal agenesis.

Babies who can't "Pee" in utero develop **P**otter sequence.

POTTER sequence associated with:

Pulmonary hypoplasia

Oligohydramnios (trigger)

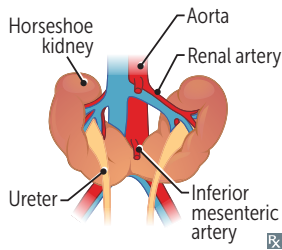
Twisted face

Twisted skin

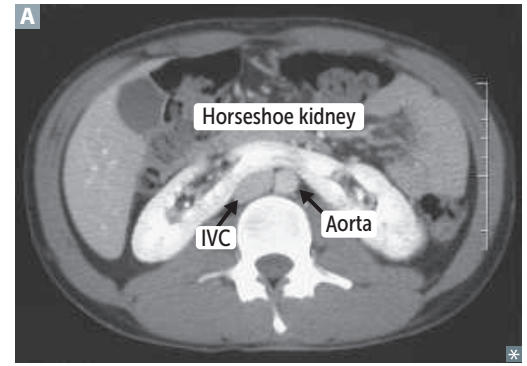
Extrernity defects

Renal failure (in utero)

Horseshoe kidney



Inferior poles of both kidneys fuse abnormally **A**. As they ascend from pelvis during fetal development, horseshoe kidneys get trapped under inferior mesenteric artery and remain low in the abdomen. Kidneys can function normally, but associated with hydronephrosis (eg, ureteropelvic junction obstruction), renal stones, infection, ↑ risk of renal cancer. Higher incidence in chromosomal aneuploidy (eg, Turner syndrome, trisomies 13, 18, 21).



Congenital solitary functioning kidney

Condition of being born with only one functioning kidney. Majority asymptomatic with compensatory hypertrophy of contralateral kidney, but anomalies in contralateral kidney are common. Often diagnosed prenatally via ultrasound.

Unilateral renal agenesis

Ureteric bud fails to develop and induce differentiation of metanephric mesenchyme → complete absence of kidney and ureter.

Multicystic dysplastic kidney

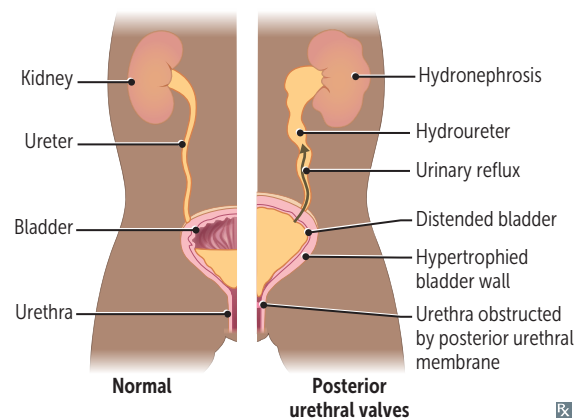
Ureteric bud develops, but fails to induce differentiation of metanephric mesenchyme → nonfunctional kidney consisting of cysts and connective tissue. Predominantly nonhereditary and usually unilateral; bilateral leads to Potter sequence.

Duplex collecting system

Bifurcation of ureteric bud before it enters the metanephric blastema creates a Y-shaped bifid ureter. Duplex collecting system can alternatively occur through two ureteric buds reaching and interacting with metanephric blastema. Strongly associated with vesicoureteral reflux and/or ureteral obstruction, ↑ risk for UTIs. Frequently presents with hydronephrosis.

Posterior urethral valves

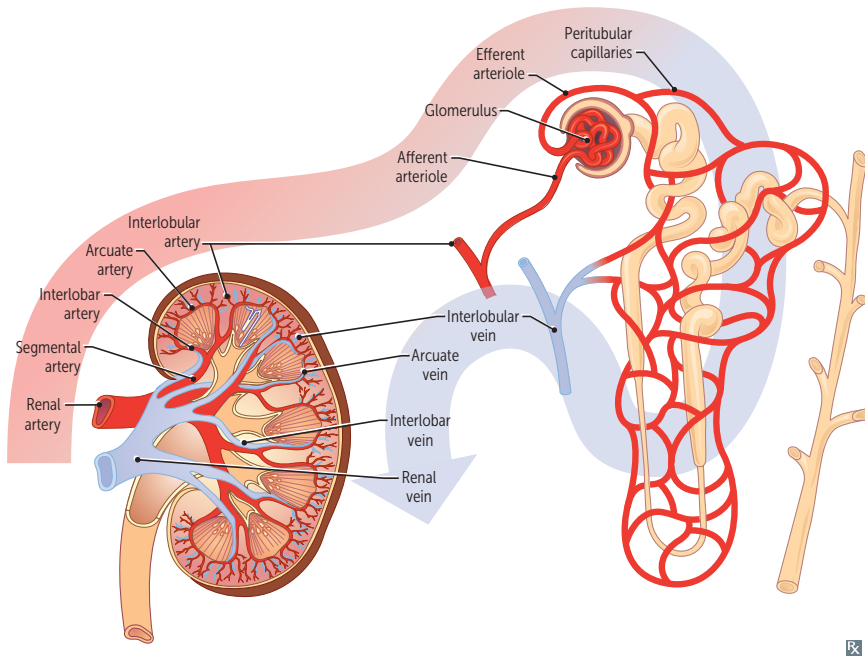
Membrane remnant in posterior (prostatic) urethra in males; its persistence can lead to urethral obstruction. Diagnosed prenatally by bilateral hydronephrosis and dilated or thick-walled bladder on ultrasound. Severe obstruction in fetus associated with oligohydramnios. Most common cause of bladder outlet obstruction in male infants.



Vesicoureteral reflux

Retrograde flow of urine from bladder toward upper urinary tract. Can be 1° due to abnormal/insufficient insertion of the ureter within the vesicular wall (ureterovesical junction [UVJ]) or 2° due to abnormally high bladder pressure resulting in retrograde flow via the UVJ. ↑ risk of recurrent UTIs.

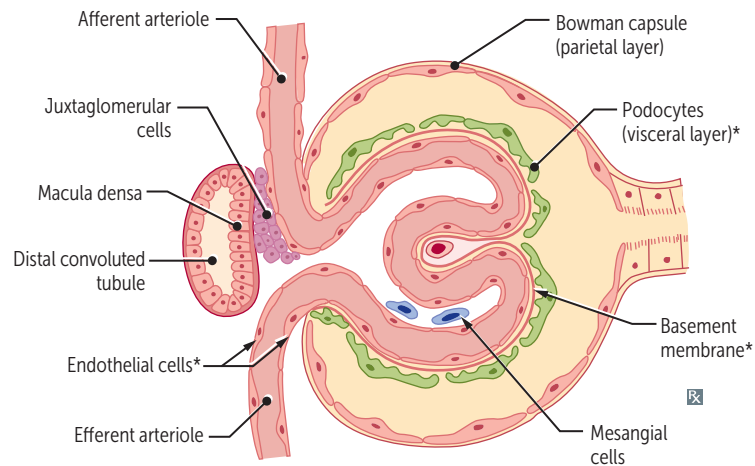
► RENAL—ANATOMY

Renal blood flow

Left renal vein receives two additional veins: left suprarenal and left gonadal veins.

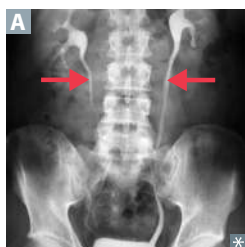
Renal medulla receives significantly less blood flow than the renal cortex. This makes medulla very sensitive to hypoxia and vulnerable to ischemic damage.

Left kidney is taken during living donor transplantation because it has a longer renal vein.

Glomerular anatomy

*Components of glomerular filtration barrier.

Course of ureters



Course of ureter **A**: arises from renal pelvis, travels under gonadal arteries → **over** common iliac artery → **under** uterine artery/vas deferens (retroperitoneal).

Gynecologic procedures (eg, ligation of uterine or ovarian vessels) may damage ureter → ureteral obstruction or leak.

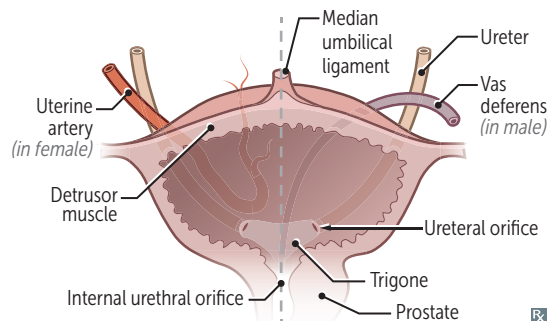
Bladder contraction compresses the intramural ureter, preventing urine reflux.

Blood supply to ureter:

- Proximal—renal arteries
- Middle—gonadal artery, aorta, common and internal iliac arteries
- Distal—internal iliac and superior vesical arteries


3 common points of ureteral obstruction: ureteropelvic junction, pelvic inlet, ureterovesical junction.

Water (ureters) flows **over** the iliacs and **under** the bridge (uterine artery or vas deferens).



► RENAL—PHYSIOLOGY

Fluid compartments



HIKIN: **HI**gh **K**⁺ **IN**tracellularly.

60–40–20 rule (% of body weight for average person):

- 60% total body water
- 40% ICF, mainly composed of K⁺, Mg²⁺, organic phosphates (eg, ATP)
- 20% ECF, mainly composed of Na⁺, Cl⁻, HCO₃⁻, albumin

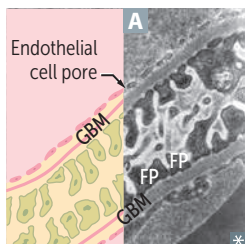
Plasma volume can be measured by radiolabeling albumin.

Extracellular volume can be measured by inulin or mannitol.

Serum osmolality = 275–295 mOsm/kg H₂O.

Plasma volume = TBV × (1 – Hct).

Glomerular filtration barrier



Responsible for filtration of plasma according to size and charge selectivity.

Composed of

- Fenestrated capillary endothelium
- Basement membrane with type IV collagen chains and heparan sulfate
- Visceral epithelial layer consisting of podocyte foot processes (FPs) **A**

Charger barrier—glomerular filtration barrier contains ⊖ charged glycoproteins that prevent entry of ⊖ charged molecules (eg, albumin).

Size barrier—fenestrated capillary endothelium (prevents entry of > 100 nm molecules/blood cells); podocyte foot processes interpose with glomerular basement membrane (GBM); slit diaphragm (prevents entry of molecules > 40–50 nm).

Renal clearance

$C_x = (U_x V)/P_x =$ volume of plasma from which the substance is completely cleared in the urine per unit time.

If $C_x < \text{GFR}$: net tubular reabsorption and/or not freely filtered.

If $C_x > \text{GFR}$: net tubular secretion of X.

If $C_x = \text{GFR}$: no net secretion or reabsorption.

$C_x =$ clearance of X (mL/min).

$U_x =$ urine concentration of X (eg, mg/mL).

$P_x =$ plasma concentration of X (eg, mg/mL).

$V =$ urine flow rate (mL/min).

Glomerular filtration rate

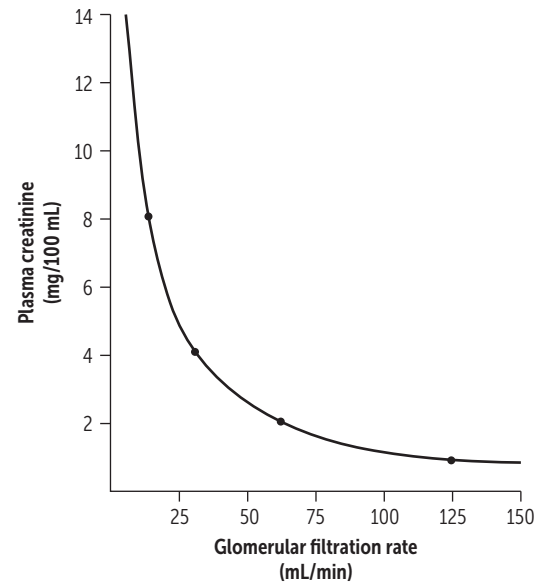
Inulin clearance can be used to calculate GFR because it is freely filtered and is neither reabsorbed nor secreted.

$$C_{\text{inulin}} = \text{GFR} = U_{\text{inulin}} \times V / P_{\text{inulin}} = K_f [(P_{\text{CC}} - P_{\text{BS}}) - (\pi_{\text{CC}} - \pi_{\text{BS}})]$$

(P_{CC} = glomerular capillary hydrostatic pressure; P_{BS} = Bowman space hydrostatic pressure; π_{CC} = glomerular capillary oncotic pressure; π_{BS} = Bowman space oncotic pressure; π_{BS} normally equals zero; K_f = filtration coefficient).

Normal GFR \approx 100 mL/min.

Creatinine clearance is an approximate measure of GFR. Slightly overestimates GFR because creatinine is moderately secreted by renal tubules.

**Renal blood flow autoregulation**

Autoregulatory mechanisms help maintain a constant RBF and GFR to protect the kidney from rapid increases or decreases in renal perfusion pressure that could cause renal injury or decrease glomerular filtration. Mechanisms:

Myogenic: \uparrow arterial pressure \rightarrow stretch of afferent arteriole \rightarrow mechanical activation of vascular smooth muscle \rightarrow vasoconstriction of afferent arteriole \rightarrow \downarrow RBF.

Tubuloglomerular: \uparrow NaCl or tonicity of the filtrate sensed by macula densa cells \rightarrow paracrine-driven vasoconstriction of afferent arteriole \rightarrow \downarrow RBF.

Effective renal plasma flow

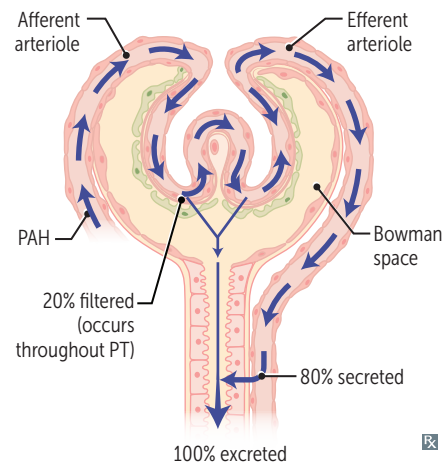
Effective renal plasma flow (eRPF) can be estimated using *para*-aminohippuric acid (PAH) clearance. Between filtration and secretion, there is nearly 100% excretion of all PAH that enters the kidney.

$$\text{eRPF} = U_{\text{PAH}} \times V / P_{\text{PAH}} = C_{\text{PAH}}$$

$$\text{Renal blood flow (RBF)} = \text{RPF} / (1 - \text{Hct}).$$

Usually 20–25% of cardiac output, remaining constant due to autoregulation.

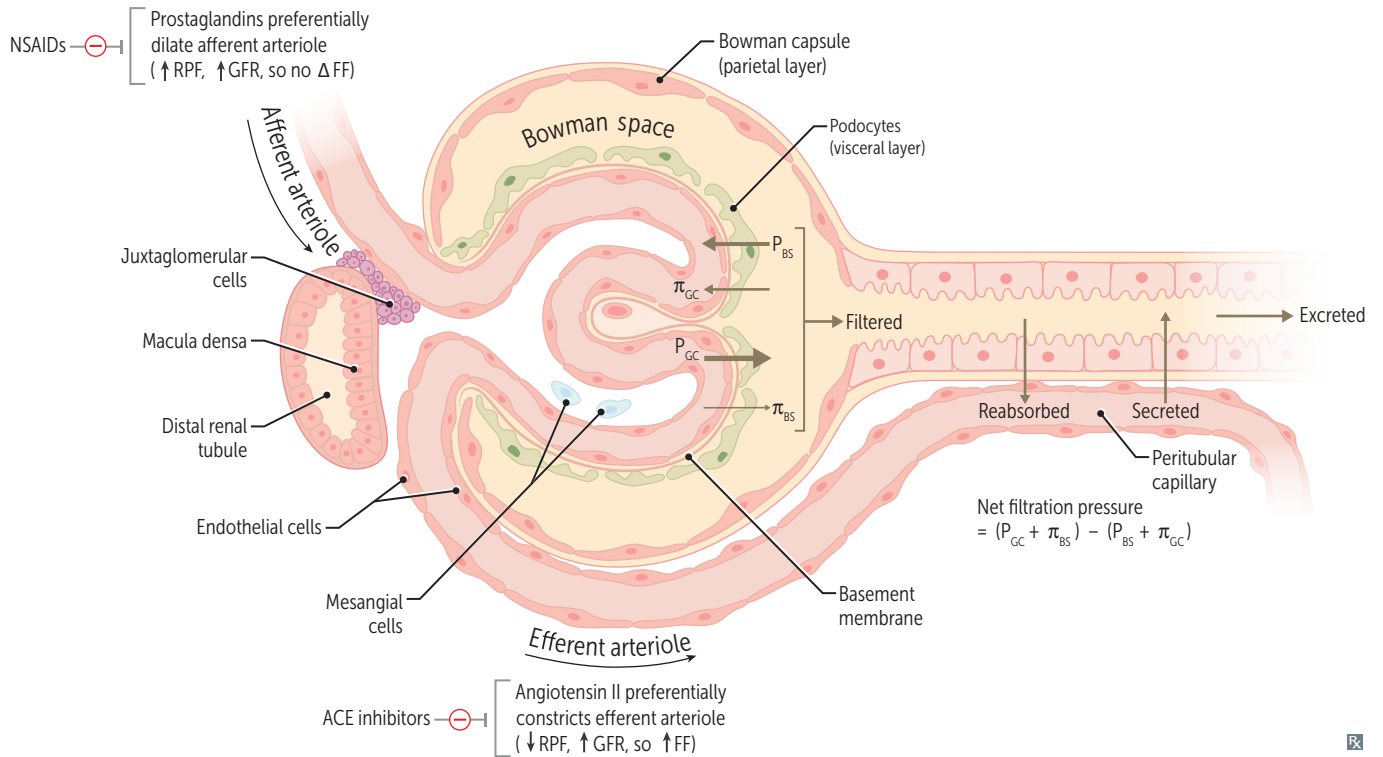
eRPF underestimates true renal plasma flow (RPF) slightly.



Filtration

Filtration fraction (FF) = GFR/RPF.
 Normal FF = 20%.
 Filtered load (mg/min) = GFR (mL/min) × plasma concentration (mg/mL).

GFR can be estimated with creatinine clearance.
 RPF is best estimated with PAH clearance.
Prostaglandins **D**ilate **A**fferent arteriole (**PDA**).
Angiotensin II **C**onstricts **E**fferent arteriole (**ACE**).



Changes in glomerular dynamics

	GFR	RPF	FF (GFR/RPF)
Afferent arteriole constriction	↓	↓	—
Efferent arteriole constriction	↑	↓	↑
↑ plasma protein concentration	↓	—	↓
↓ plasma protein concentration	↑	—	↑
Constriction of ureter	↓	—	↓
Dehydration	↓	↓↓	↑

Calculation of reabsorption and secretion rate

Filtered load = $GFR \times P_x$.

Excretion rate = $V \times U_x$.

Reabsorption rate = filtered – excreted.

Secretion rate = excreted – filtered.

Fe_{Na} = fractional excretion of sodium.

$$Fe_{Na} = \frac{Na^+ \text{ excreted}}{Na^+ \text{ filtered}} = \frac{V \times U_{Na}}{GFR \times P_{Na}} = \frac{P_{Cr} \times U_{Na}}{U_{Cr} \times P_{Na}} \text{ where } GFR = \frac{U_{Cr} \times V}{P_{Cr}}$$

Glucose clearance

Glucose at a normal plasma level (range 60–120 mg/dL) is completely reabsorbed in proximal convoluted tubule (PCT) by Na^+ /glucose cotransport.

In adults, at plasma glucose of ~ 200 mg/dL, glucosuria begins (threshold). At rate of ~ 375 mg/min, all transporters are fully saturated (T_m).

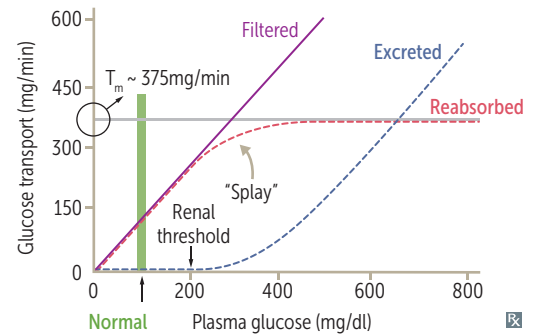
Normal pregnancy is associated with ↑ GFR.

With ↑ filtration of all substances, including glucose, the glucose threshold occurs at lower plasma glucose concentrations → glucosuria at normal plasma glucose levels.

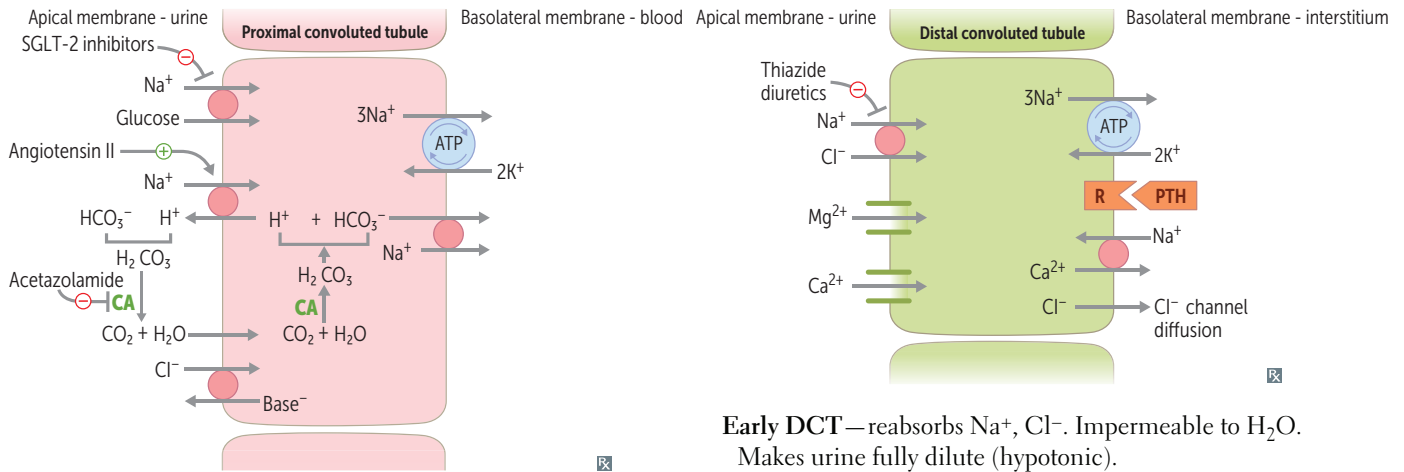
Sodium-glucose cotransporter 2 (SGLT2) inhibitors (eg, -flozin drugs) result in glucosuria at plasma concentrations < 200 mg/dL.

Glucosuria is an important clinical clue to diabetes mellitus.

Splay phenomenon— T_m for glucose is reached gradually rather than sharply due to the heterogeneity of nephrons (ie, different T_m points); represented by the portion of the titration curve between threshold and T_m .



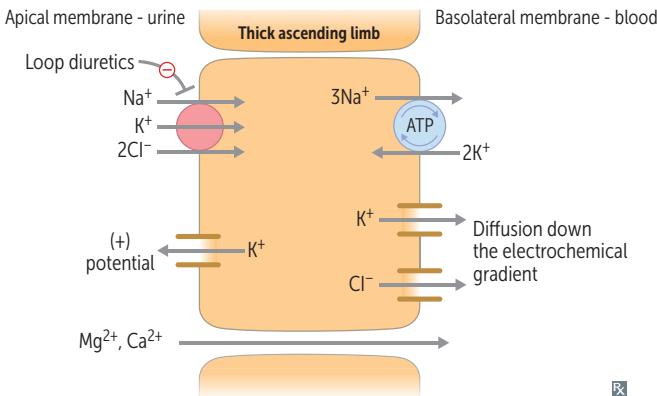
Nephron transport physiology



Early PCT—contains brush border. Reabsorbs all glucose and amino acids and most HCO₃⁻, Na⁺, Cl⁻, PO₄³⁻, K⁺, H₂O, and uric acid. Isotonic absorption. Generates and secretes NH₃, which enables the kidney to secrete more H⁺.

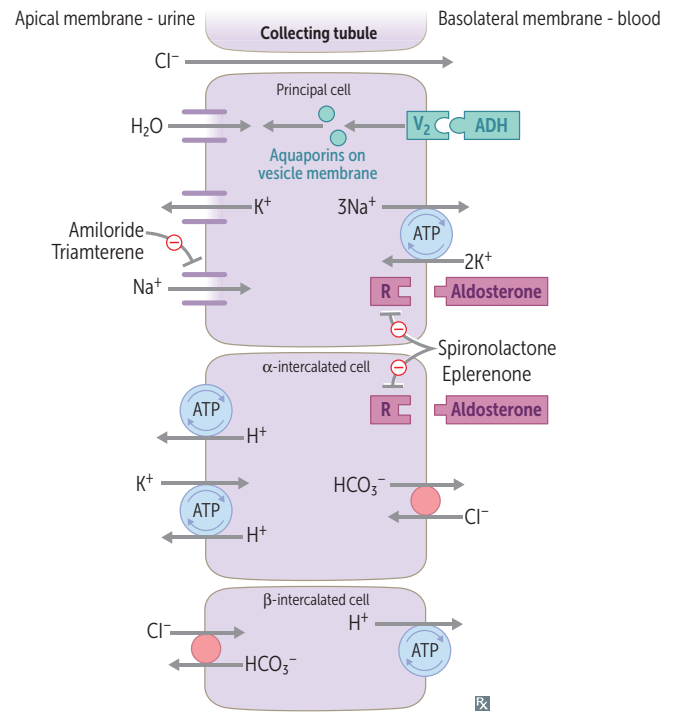
PTH—inhibits Na⁺/PO₄³⁻ cotransport → ↑ PO₄³⁻ excretion.
 AT II—stimulates Na⁺/H⁺ exchange → ↑ Na⁺, H₂O, and HCO₃⁻ reabsorption (permitting contraction alkalosis).
 65–80% Na⁺ and H₂O reabsorbed.

Thin descending loop of Henle—passively reabsorbs H₂O via medullary hypertonicity (impermeable to Na⁺).
 Concentrating segment. Makes urine hypertonic.

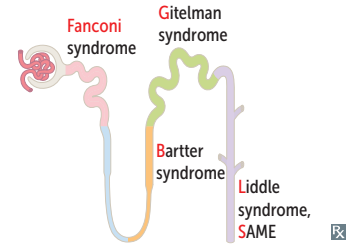


Thick ascending loop of Henle—reabsorbs Na⁺, K⁺, and Cl⁻. Indirectly induces paracellular reabsorption of Mg²⁺ and Ca²⁺ through ⊕ lumen potential generated by K⁺ backleak. Impermeable to H₂O. Makes urine less concentrated as it ascends.
 10–20% Na⁺ reabsorbed.

Early DCT—reabsorbs Na⁺, Cl⁻. Impermeable to H₂O.
 Makes urine fully dilute (hypotonic).
 PTH—↑ Ca²⁺/Na⁺ exchange → ↑ Ca²⁺ reabsorption.
 5–10% Na⁺ reabsorbed.



Collecting tubule—reabsorbs Na⁺ in exchange for secreting K⁺ and H⁺ (regulated by aldosterone).
 Aldosterone—acts on mineralocorticoid receptor → mRNA → protein synthesis. In principal cells: ↑ apical K⁺ conductance, ↑ Na⁺/K⁺ pump, ↑ epithelial Na⁺ channel (ENaC) activity → lumen negativity → K⁺ secretion. In α-intercalated cells: lumen negativity → ↑ H⁺ ATPase activity → ↑ H⁺ secretion → ↑ HCO₃⁻/Cl⁻ exchanger activity.
 ADH—acts at V₂ receptor → insertion of aquaporin H₂O channels on apical side, and UT1 receptor → urea reabsorption.
 3–5% Na⁺ reabsorbed.

Renal tubular defects Order: **Fanconi's BaGeLS**

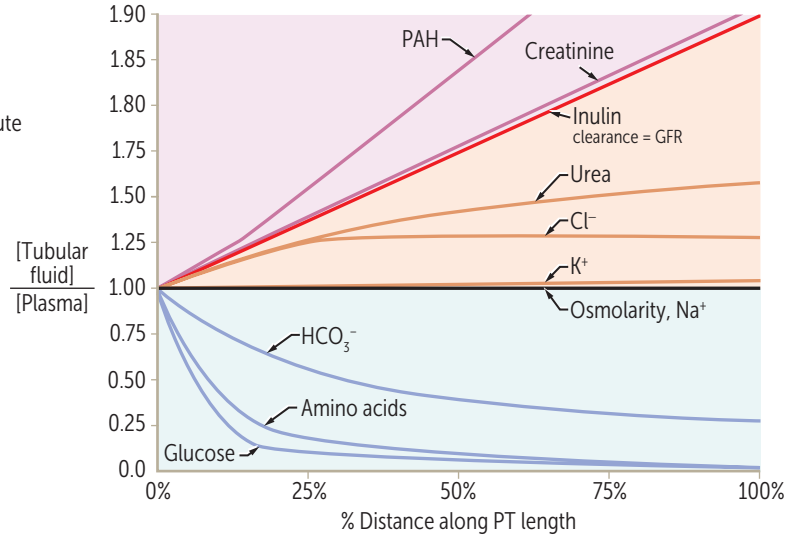
	DEFECTS	EFFECTS	CAUSES	NOTES
Fanconi syndrome	Generalized reabsorption defect in PCT → ↑ excretion of amino acids, glucose, HCO_3^- , and PO_4^{3-} , and all substances reabsorbed by the PCT	Metabolic acidosis (proximal RTA), hypophosphatemia, hypokalemia	Hereditary defects (eg, Wilson disease, tyrosinemia, glycogen storage disease), ischemia, multiple myeloma, drugs (eg, ifosfamide, cisplatin, tenofovir, expired tetracyclines), lead poisoning	Growth retardation and rickets/osteopenia common due to hypophosphatemia Volume depletion also common
Bartter syndrome	Reabsorption defect in thick ascending loop of Henle (affects $\text{Na}^+/\text{K}^+/\text{2Cl}^-$ cotransporter)	Metabolic alkalosis, hypokalemia, hypercalciuria	Autosomal recessive	Presents similarly to chronic loop diuretic use
Gitelman syndrome	Reabsorption defect of NaCl in DCT	Metabolic alkalosis, hypomagnesemia, hypokalemia, hypocalciuria	Autosomal recessive	Presents similarly to chronic thiazide diuretic use Less severe than Bartter syndrome
Liddle syndrome	Gain of function mutation → ↓ Na^+ channel degradation → ↑ Na^+ reabsorption in collecting tubules	Metabolic alkalosis, hypokalemia, hypertension, ↓ aldosterone	Autosomal dominant	Presents similarly to hyperaldosteronism, but aldosterone is nearly undetectable Treatment: amiloride
Syndrome of Apparent Mineralocorticoid Excess	Cortisol activates mineralocorticoid receptors; 11β -HSD converts cortisol to cortisone (inactive on these receptors) Hereditary 11β -HSD deficiency → ↑ cortisol → ↑ mineralocorticoid receptor activity	Metabolic alkalosis, hypokalemia, hypertension ↓ serum aldosterone level; cortisol tries to be the SAME as aldosterone	Autosomal recessive Can acquire disorder from glycyrrhetic acid (present in licorice), which blocks activity of 11β -hydroxysteroid dehydrogenase	Treatment: K^+ -sparing diuretics (↓ mineralocorticoid effects) or corticosteroids (exogenous corticosteroid ↓ endogenous cortisol production → ↓ mineralocorticoid receptor activation)

Relative concentrations along proximal tubule

$[TF/P] > 1$
when solute is reabsorbed less quickly than water or when solute is secreted

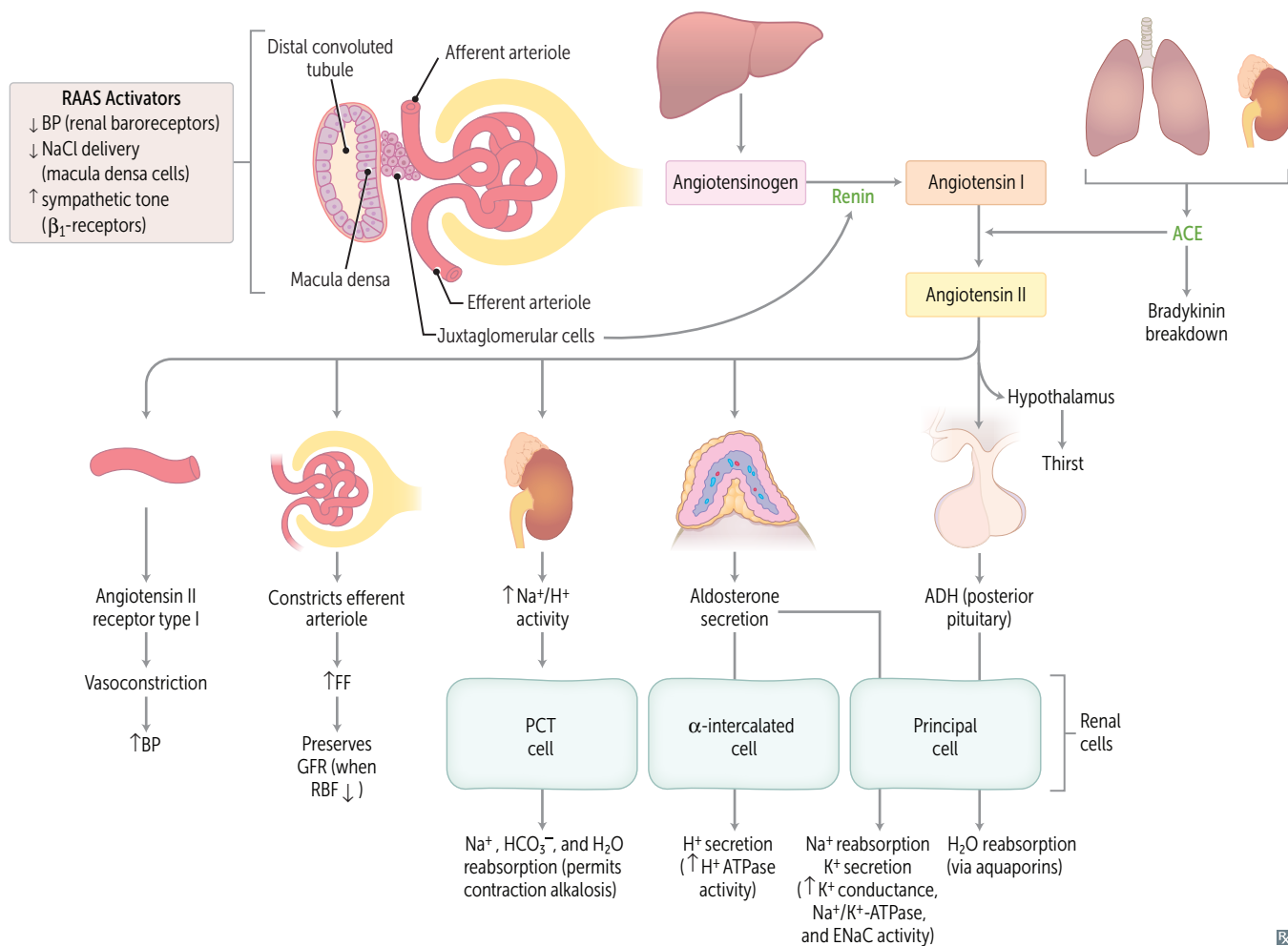
$[TF/P] = 1$
when solute and water are reabsorbed at the same rate

$[TF/P] < 1$
when solute is reabsorbed more quickly than water



Tubular inulin ↑ in concentration (but not amount) along the PT as a result of water reabsorption. Cl⁻ reabsorption occurs at a slower rate than Na⁺ in early PCT and then matches the rate of Na⁺ reabsorption more distally. Thus, its relative concentration ↑ before it plateaus.

Renin-angiotensin-aldosterone system

**Renin**

Secreted by JG cells in response to ↓ renal perfusion pressure (detected in afferent arteriole), ↑ renal sympathetic discharge (β_1 effect), and ↓ NaCl delivery to macula densa cells.

ACE

Catalyzes conversion of angiotensin I to angiotensin II. Located in many tissues but conversion occurs most extensively in the lung. Produced by vascular endothelial cells in the lung.

AT II

Helps maintain blood volume and blood pressure. Affects baroreceptor function; limits reflex bradycardia, which would normally accompany its pressor effects.

ANP, BNP

Released from atria (ANP) and ventricles (BNP) in response to ↑ volume; inhibits renin-angiotensin-aldosterone system; relaxes vascular smooth muscle via cGMP → ↑ GFR, ↓ renin. Dilates afferent arteriole, promotes natriuresis.

ADH (vasopressin)

Primarily regulates serum osmolality; also responds to low blood volume states. Stimulates reabsorption of water in collecting ducts. Also stimulates reabsorption of urea in collecting ducts to maximize corticopapillary osmotic gradient.

Aldosterone

Primarily regulates ECF volume and Na⁺ content; ↑ release in hypovolemic states. Responds to hyperkalemia by ↑ K⁺ excretion.

Juxtaglomerular apparatus

Consists of mesangial cells, JG cells (modified smooth muscle of afferent arteriole), and the macula densa (NaCl sensor located at the DCT). JG cells secrete renin in response to ↓ renal blood pressure and ↑ sympathetic tone (β_1). Macula densa cells sense ↓ NaCl delivery to DCT → ↑ renin release → efferent arteriole vasoconstriction → ↑ GFR.

JGA maintains GFR via renin-angiotensin-aldosterone system.
 β -blockers ↓ BP by ↓ CO and inhibiting β_1 -receptors of the JGA → ↓ renin release.

Kidney hormone functions

Erythropoietin	Released by interstitial cells in peritubular capillary bed in response to hypoxia.	Stimulates RBC proliferation in bone marrow. Administered for anemia secondary to chronic kidney disease. ↑ risk of HTN.
Calciferol (vitamin D)	PCT cells convert 25-OH vitamin D ₃ to 1,25-(OH) ₂ vitamin D ₃ (calcitriol, active form). Increases calcium absorption in small bowel.	$ \begin{array}{ccc} 25\text{-OH D}_3 & \xrightarrow{\quad 1\alpha\text{-hydroxylase} \quad} & 1,25\text{-(OH)}_2\text{ D}_3 \\ \text{(calcidiol)} & & \text{(calcitriol)} \\ & \uparrow & \\ & \oplus & \\ & \text{PTH} & \end{array} $
Prostaglandins	Paracrine secretion vasodilates afferent arterioles to ↑ RBF.	NSAIDs block renal-protective prostaglandin synthesis → constriction of afferent arteriole and ↓ GFR; this may result in acute kidney injury in low renal blood flow states.
Dopamine	Secreted by PT cells, promotes natriuresis. At low doses; dilates interlobular arteries, afferent arterioles, efferent arterioles → ↑ RBF, little or no change in GFR. At higher doses; acts as vasoconstrictor.	

Hormones acting on kidney

Atrial natriuretic peptide

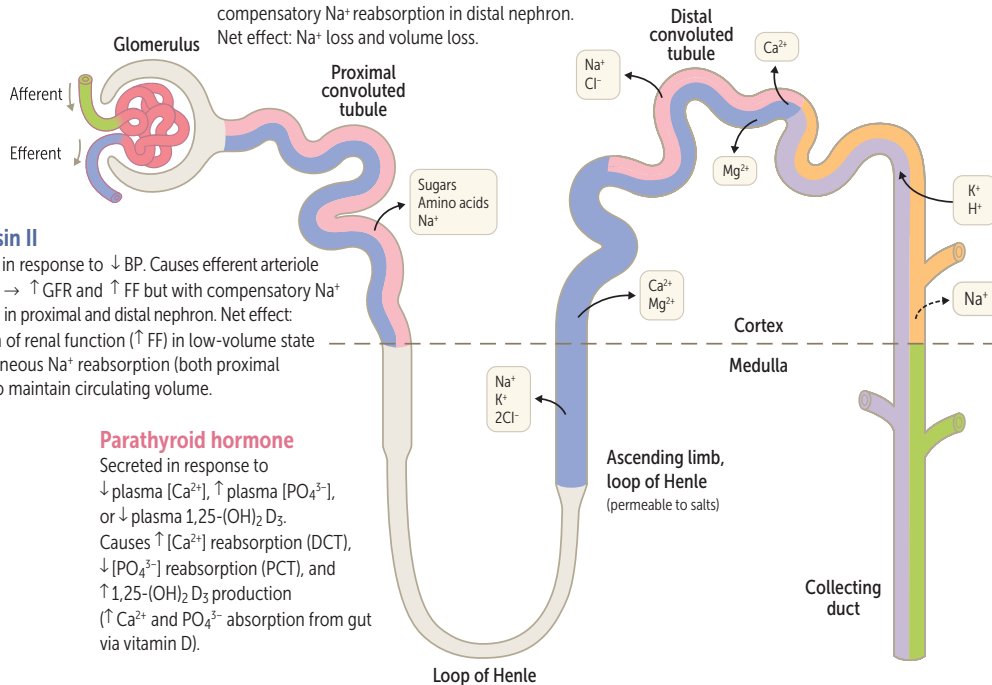
Secreted in response to \uparrow atrial pressure. Causes indirect afferent arteriole dilation (through inhibition of NE). Causes \uparrow GFR and \uparrow Na^+ filtration with no compensatory Na^+ reabsorption in distal nephron. Net effect: Na^+ loss and volume loss.

Angiotensin II

Synthesized in response to \downarrow BP. Causes efferent arteriole constriction \rightarrow \uparrow GFR and \uparrow FF but with compensatory Na^+ reabsorption in proximal and distal nephron. Net effect: preservation of renal function (\uparrow FF) in low-volume state with simultaneous Na^+ reabsorption (both proximal and distal) to maintain circulating volume.

Parathyroid hormone

Secreted in response to \downarrow plasma $[\text{Ca}^{2+}]$, \uparrow plasma $[\text{PO}_4^{3-}]$, or \downarrow plasma $1,25\text{-(OH)}_2\text{D}_3$. Causes \uparrow $[\text{Ca}^{2+}]$ reabsorption (DCT), \downarrow $[\text{PO}_4^{3-}]$ reabsorption (PCT), and \uparrow $1,25\text{-(OH)}_2\text{D}_3$ production (\uparrow Ca^{2+} and PO_4^{3-} absorption from gut via vitamin D).



Aldosterone

Secreted in response to \downarrow blood volume (via AT II) and \uparrow plasma $[\text{K}^+]$; causes \uparrow Na^+ reabsorption, \uparrow K^+ secretion, \uparrow H^+ secretion.

ADH (vasopressin)

Secreted in response to \uparrow plasma osmolarity and \downarrow blood volume. Binds to receptors on principal cells, causing \uparrow number of aquaporins and \uparrow H_2O reabsorption. \uparrow reabsorption of urea in collecting ducts to maximize corticopapillary osmotic gradient.

Potassium shifts

SHIFTS K^+ INTO CELL (CAUSING HYPOKALEMIA)

Hypo-osmolarity

Alkalosis (low K^+)

β -adrenergic agonist (\uparrow $\text{Na}^+/\text{K}^+\text{-ATPase}$)

Insulin (\uparrow $\text{Na}^+/\text{K}^+\text{-ATPase}$)

Insulin shifts K^+ into cells

SHIFTS K^+ OUT OF CELL (CAUSING HYPERKALEMIA)

Digoxin (blocks $\text{Na}^+/\text{K}^+\text{-ATPase}$)

HyperOsmolarity

Lysis of cells (eg, crush injury, rhabdomyolysis, tumor lysis syndrome)

Acidosis

β -blocker

High blood Sugar (insulin deficiency)

Succinylcholine (\uparrow risk in burns/muscle trauma)

Hyperkalemia? **DO LABSS**

Electrolyte disturbances

ELECTROLYTE	LOW SERUM CONCENTRATION	HIGH SERUM CONCENTRATION
Sodium	Nausea, malaise, stupor, coma, seizures	Irritability, stupor, coma
Potassium	U waves and flattened T waves on ECG, arrhythmias, muscle cramps, spasm, weakness	Wide QRS and peaked T waves on ECG, arrhythmias, muscle weakness
Calcium	Tetany, seizures, QT prolongation, twitching (eg, Chvostek sign), spasm (eg, Trousseau sign)	Stones (renal), bones (pain), groans (abdominal pain), thrones (↑ urinary frequency), psychiatric overtones (anxiety, altered mental status)
Magnesium	Tetany, torsades de pointes, hypokalemia, hypocalcemia (when $[Mg^{2+}] < 1.0$ mEq/L)	↓ DTRs, lethargy, bradycardia, hypotension, cardiac arrest, hypocalcemia
Phosphate	Bone loss, osteomalacia (adults), rickets (children)	Renal stones, metastatic calcifications, hypocalcemia

Features of renal disorders

CONDITION	BLOOD PRESSURE	PLASMA RENIN	ALDOSTERONE	SERUM Mg^{2+}	URINE Ca^{2+}
SIADH	—/↑	↓	↓	—	—
Primary hyperaldosteronism	↑	↓	↑	—	—
Renin-secreting tumor	↑	↑	↑	—	—
Bartter syndrome	—	↑	↑	—	↑
Gitelman syndrome	—	↑	↑	↓	↓
Liddle syndrome, syndrome of apparent mineralocorticoid excess	↑	↓	↓	—	—

↑ ↓ = important differentiating feature.

Acid-base physiology

Metabolic acid-base disorders cause HCO_3^- alterations. Respiratory acid-base disorders cause PCO_2 alterations.

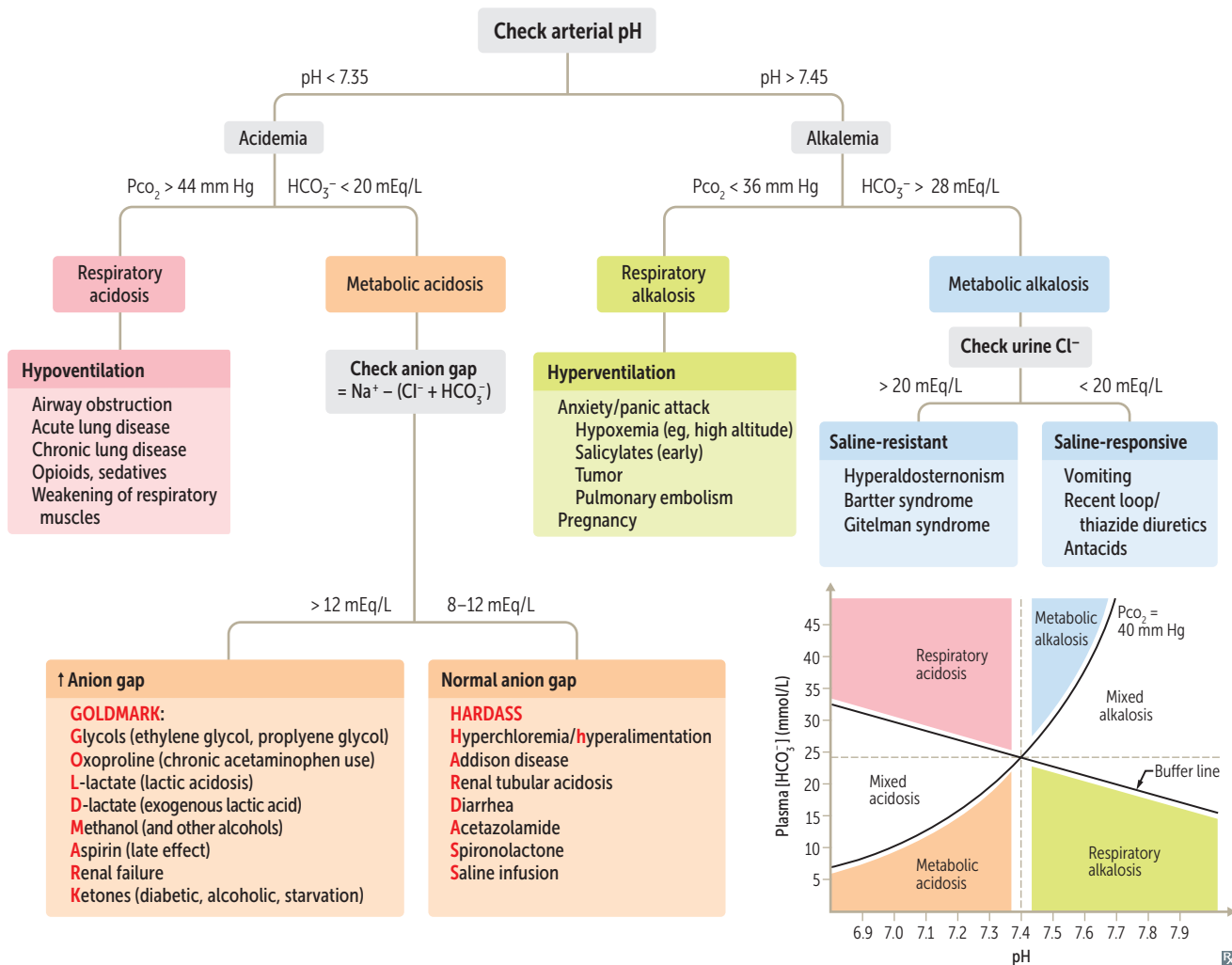
	pH	PCO_2	$[\text{HCO}_3^-]$	COMPENSATORY RESPONSE
Metabolic acidosis	↓	↓	↓	Hyperventilation (immediate)
Metabolic alkalosis	↑	↑	↑	Hypoventilation (immediate)
Respiratory acidosis	↓	↑	↑	↑ renal $[\text{HCO}_3^-]$ reabsorption (delayed)
Respiratory alkalosis	↑	↓	↓	↓ renal $[\text{HCO}_3^-]$ reabsorption (delayed)

Key: ↓ ↑ = compensatory response.

$$\text{Henderson-Hasselbalch equation: } \text{pH} = 6.1 + \log \frac{[\text{HCO}_3^-]}{0.03 \text{ PCO}_2}$$

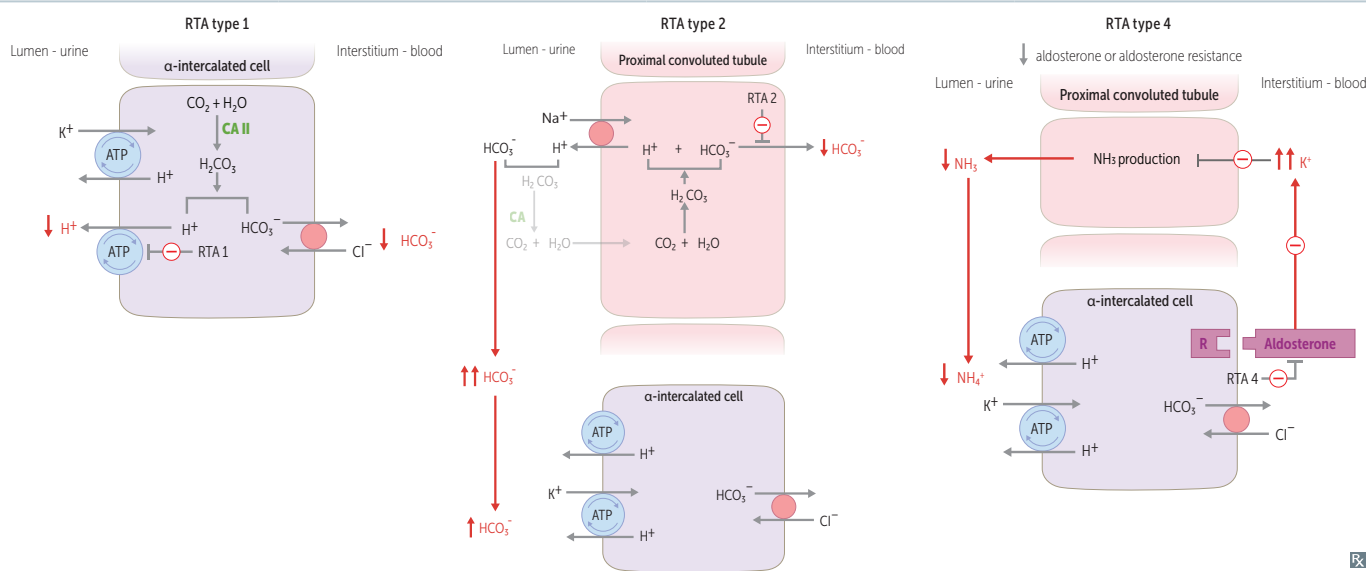
Predicted respiratory compensation for a simple metabolic acidosis can be calculated using the Winters formula. If measured $\text{PCO}_2 >$ predicted $\text{PCO}_2 \rightarrow$ concomitant respiratory acidosis; if measured $\text{PCO}_2 <$ predicted $\text{PCO}_2 \rightarrow$ concomitant respiratory alkalosis:

$$\text{PCO}_2 = 1.5 [\text{HCO}_3^-] + 8 \pm 2$$

Acidosis and alkalosis

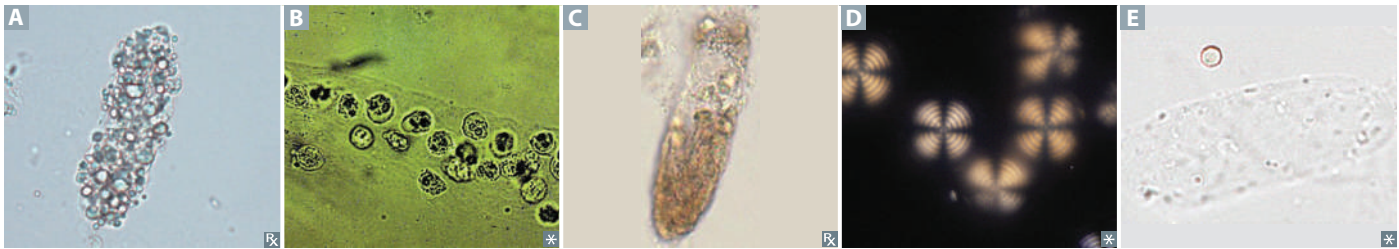
Renal tubular acidosis

	Distal renal tubular acidosis (RTA type 1)	Proximal renal tubular acidosis (RTA type 2)	Hyperkalemic tubular acidosis (RTA type 4)
DEFECT	Inability of α -intercalated cells to secrete H^+ \rightarrow no new HCO_3^- is generated \rightarrow metabolic acidosis	Defect in PCT HCO_3^- reabsorption \rightarrow \uparrow excretion of HCO_3^- in urine \rightarrow metabolic acidosis Urine can be acidified by α -intercalated cells in collecting duct, but not enough to overcome $\uparrow HCO_3^-$ excretion	Hypoaldosteronism or aldosterone resistance; hyperkalemia \rightarrow $\downarrow NH_3$ synthesis in PCT \rightarrow $\downarrow NH_4^+$ excretion
URINE pH	> 5.5	< 5.5 when plasma HCO_3^- below reduced resorption threshold > 5.5 when filtered HCO_3^- exceeds resorptive threshold	< 5.5 (or variable)
SERUM K^+	\downarrow	\downarrow	\uparrow
CAUSES	Amphotericin B toxicity, analgesic nephropathy, congenital anomalies (obstruction) of urinary tract, autoimmune diseases (eg, SLE)	Fanconi syndrome, multiple myeloma, carbonic anhydrase inhibitors	\downarrow aldosterone production (eg, diabetic hyporeninism, ACE inhibitors, ARB, NSAIDs, heparin, cyclosporine, adrenal insufficiency) or aldosterone resistance (eg, K^+ -sparing diuretics, nephropathy due to obstruction, TMP-SMX)
ASSOCIATIONS	\uparrow risk for calcium phosphate kidney stones (due to \uparrow urine pH and \uparrow bone turnover related to buffering)	\uparrow risk for hypophosphatemic rickets (in Fanconi syndrome)	



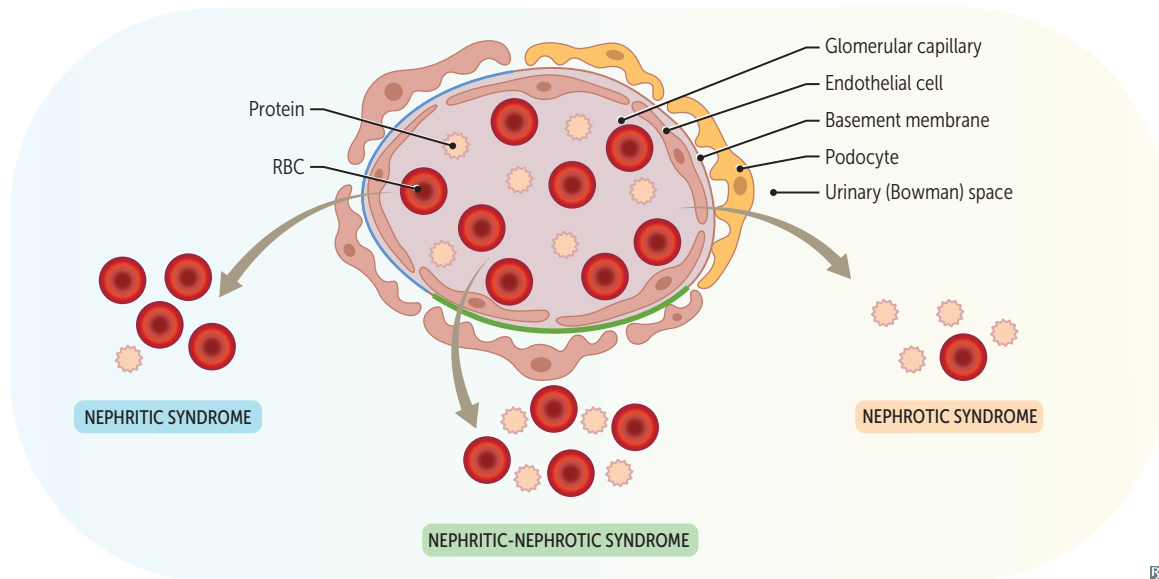
▶ RENAL—PATHOLOGY

Casts in urine	Presence of casts indicates that hematuria/pyuria is of glomerular or renal tubular origin. Bladder cancer, kidney stones → hematuria, no casts. Acute cystitis → pyuria, no casts.
RBC casts A	Glomerulonephritis, hypertensive emergency.
WBC casts B	Tubulointerstitial inflammation, acute pyelonephritis, transplant rejection.
Granular casts C	Acute tubular necrosis (ATN). Can be “muddy brown” in appearance.
Fatty casts (“oval fat bodies”)	Nephrotic syndrome. Associated with “Maltese cross” sign D .
Waxy casts	End-stage renal disease/chronic kidney disease.
Hyaline casts E	Nonspecific, can be a normal finding with dehydration, exercise, or diuretic therapy. Form via solidification of Tamm-Horsfall mucoprotein (uromodulin), secreted by renal tubular cells to prevent UTIs.

**Nomenclature of glomerular disorders**

TYPE	CHARACTERISTICS	EXAMPLE
Focal	< 50% of glomeruli are involved	Focal segmental glomerulosclerosis
Diffuse	> 50% of glomeruli are involved	Diffuse proliferative glomerulonephritis
Proliferative	Hypercellular glomeruli	Membranoproliferative glomerulonephritis
Membranous	Thickening of glomerular basement membrane (GBM)	Membranous nephropathy
Primary glomerular disease	1° disease of the kidney specifically impacting the glomeruli	Minimal change disease
Secondary glomerular disease	Systemic disease or disease of another organ system that also impacts the glomeruli	SLE, diabetic nephropathy

Glomerular diseases



TYPE	ETIOLOGY	CLINICAL PRESENTATION	EXAMPLES
Nephritic syndrome	Glomerular inflammation → GBM damage → loss of RBCs into urine → dysmorphic RBCs, hematuria	Hematuria, RBC casts in urine ↓ GFR → oliguria, azotemia ↑ renin release, HTN Proteinuria often in the subnephrotic range (< 3.5 g/day) but in severe cases may be in nephrotic range	<ul style="list-style-type: none"> ▪ Infection-associated glomerulonephritis ▪ Goodpasture syndrome ▪ IgA nephropathy (Berger disease) ▪ Alport syndrome ▪ Membranoproliferative glomerulonephritis
Nephrotic syndrome	Podocyte damage → impaired charge barrier → proteinuria	Massive proteinuria (> 3.5 g/day) with edema, hypoalbuminemia → ↑ hepatic lipogenesis → hypercholesterolemia Frothy urine with fatty casts Associated with hypercoagulable state due to antithrombin III loss in urine and ↑ risk of infection (loss of IgGs in urine and soft tissue compromise by edema)	May be 1° (eg, direct podocyte damage) or 2° (podocyte damage from systemic process): <ul style="list-style-type: none"> ▪ Focal segmental glomerulosclerosis (1° or 2°) ▪ Minimal change disease (1° or 2°) ▪ Membranous nephropathy (1° or 2°) ▪ Amyloidosis (2°) ▪ Diabetic glomerulonephropathy (2°)
Nephritic-nephrotic syndrome	Severe GBM damage → loss of RBCs into urine + impaired charge barrier → hematuria + proteinuria	Nephrotic-range proteinuria (> 3.5 g/day) and concomitant features of nephritic syndrome	Can occur with any form of nephritic syndrome, but is most common with: <ul style="list-style-type: none"> ▪ Diffuse proliferative glomerulonephritis ▪ Membranoproliferative glomerulonephritis

Nephritic syndrome	Nephritic syndrome = inflammatory process.
Infection-associated glomerulonephritis	<p>Formerly called post-infectious glomerulonephritis.</p> <p>Type III hypersensitivity reaction. Associated with hypocomplementemia (due to consumption). Children: most commonly caused by group A streptococcus (poststreptococcal glomerulonephritis). Seen ~2–4 weeks after pharyngeal or skin infection. ⊕ strep serologies. Usually resolves spontaneously.</p> <p>Adults: in addition to group A streptococcus, can also be caused by staphylococcus. Seen during infection; infection site is variable but usually not upper respiratory tract. Must be identified on culture as no serologic test available. May progress to renal insufficiency.</p> <ul style="list-style-type: none"> ▪ LM—glomeruli enlarged and hypercellular A ▪ IF—granular (“starry sky”) appearance (“lumpy-bumpy”) B due to IgG, IgM, and C3 deposition along GBM and mesangium ▪ EM—subepithelial IC humps
IgA nephropathy (Berger disease)	<p>Episodic hematuria that usually occurs concurrently with respiratory or GI tract infections (IgA is secreted by mucosal linings). Renal pathology of IgA vasculitis (HSP).</p> <ul style="list-style-type: none"> ▪ LM—mesangial proliferation ▪ IF—IgA-based IC deposits in mesangium; EM—mesangial IC deposition
Rapidly progressive (crescentic) glomerulonephritis	<p>Poor prognosis, rapidly deteriorating renal function (days to weeks).</p> <ul style="list-style-type: none"> ▪ LM—crescent moon shape C. Crescents consist of fibrin and plasma proteins (eg, C3b) with glomerular parietal cells, monocytes, macrophages <p>Several disease processes may result in this pattern which may be delineated with IF.</p> <ul style="list-style-type: none"> ▪ Linear IF due to antibodies to GBM and alveolar basement membrane: Goodpasture syndrome—hematuria/hemoptysis; type II hypersensitivity reaction. Treatment: plasmapheresis ▪ Negative IF/Pauci-immune (no IgC3 deposition): granulomatosis with polyangiitis—PR3-ANCA/c-ANCA, eosinophilic granulomatosis with polyangiitis or Microscopic polyangiitis—MPO-ANCA/p-ANCA ▪ Granular IF—PSGN or DPGN
Diffuse proliferative glomerulonephritis	<p>Often due to SLE (think “wire lupus”). DPGN and MPGN often present as nephrotic syndrome and nephritic syndrome concurrently.</p> <ul style="list-style-type: none"> ▪ LM—“wire looping” of capillaries D ▪ IF—granular; EM—subendothelial, sometimes subepithelial or intramembranous IgG-based ICs often with C3 deposition

Nephritic syndrome (continued)**Alport syndrome**

Mutation in type IV collagen → irregular thinning and thickening and splitting of glomerular basement membrane.

Most commonly X-linked dominant. Eye problems (eg, retinopathy, anterior lenticonus), glomerulonephritis, sensorineural deafness; “can’t see, can’t pee, can’t hear a bee.”

- EM—“basket-weave” appearance due to irregular thickening of GBM

Membrano-proliferative glomerulonephritis

MPGN is a nephritic syndrome that often co-presents with nephrotic syndrome.

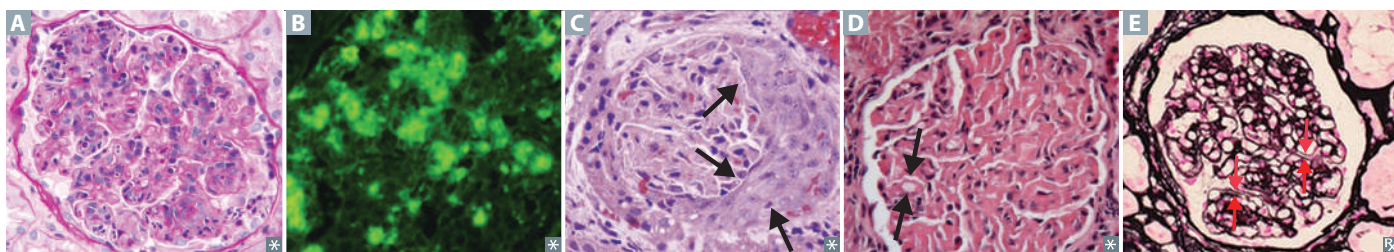
Type I may be 2° to hepatitis B or C infection. May also be idiopathic.

- Subendothelial IC deposits with granular IF

Type II is associated with C3 nephritic factor (IgG autoantibody that stabilizes C3 convertase → persistent complement activation → ↓ C3 levels).

- Intramembranous deposits, also called dense deposit disease

Both types: mesangial ingrowth → GBM splitting → “tram-track” on H&E and PAS **E** stains.



Nephrotic syndrome

Nephrotic syndrome—massive proteinuria (> 3.5 g/day)

Minimal change disease

Also called lipoid nephrosis. Most common cause of nephrotic syndrome in children. Often 1° (idiopathic) and may be triggered by recent infection, immunization, immune stimulus (4 I's of MCD). Rarely, may be 2° to lymphoma (eg, cytokine-mediated damage).

1° disease has excellent response to glucocorticoids.

- LM—Normal glomeruli (lipid may be seen in PT cells)
- IF— \ominus
- EM—effacement of podocyte foot processes **A**

Focal segmental glomerulosclerosis

Higher prevalence in Black people.

Can be 1° (idiopathic) or 2° to other conditions (eg, HIV infection, sickle cell disease, heroin use, obesity, interferon treatment, or congenital malformations).

1° disease has inconsistent response to steroids. May progress to CKD.

- LM—segmental sclerosis and hyalinosis **B**
- IF—often \ominus but may be \oplus for nonspecific focal deposits of IgM, C3, C1
- EM—effacement of foot processes similar to minimal change disease

Membranous nephropathy

Also called membranous glomerulonephritis.

Can be 1° (eg, antibodies to phospholipase A₂ receptor) or 2° to drugs (eg, NSAIDs, penicillamine, gold), infections (eg, HBV, HCV, syphilis), SLE, or solid tumors. ↑ risk for thromboembolism (eg, DVT, renal vein thrombosis).

1° disease has poor response to steroids. May progress to CKD.

- LM—diffuse capillary and GBM thickening **C**
- IF—granular due to immune complex (IC) deposition
- EM—“Spike and dome” appearance of subepithelial deposits

Amyloidosis

Kidney is the most commonly involved organ (systemic amyloidosis). Associated with chronic conditions that predispose to amyloid deposition (eg, AL amyloid, AA amyloid, prolonged dialysis).

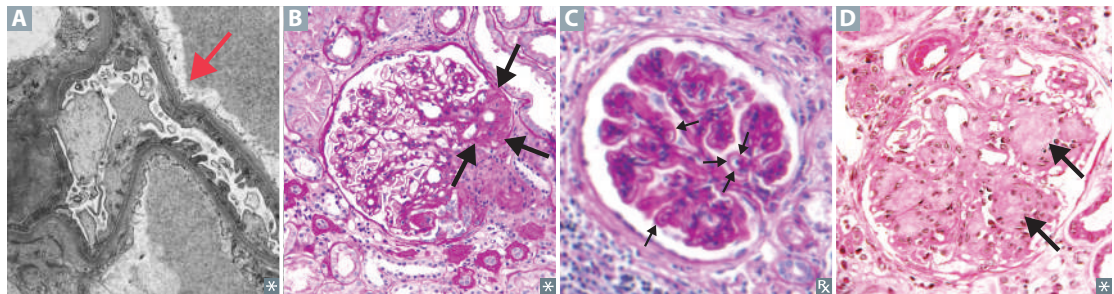
- LM—Congo red stain shows apple-green birefringence under polarized light due to amyloid deposition in the mesangium

Diabetic glomerulonephropathy

Most common cause of ESRD in the United States.

Hyperglycemia → nonenzymatic glycation of tissue proteins → mesangial expansion; GBM thickening and ↑ permeability. Hyperfiltration (glomerular HTN and ↑ GFR) → glomerular hypertrophy and glomerular scarring (glomerulosclerosis) → further progression of nephropathy.

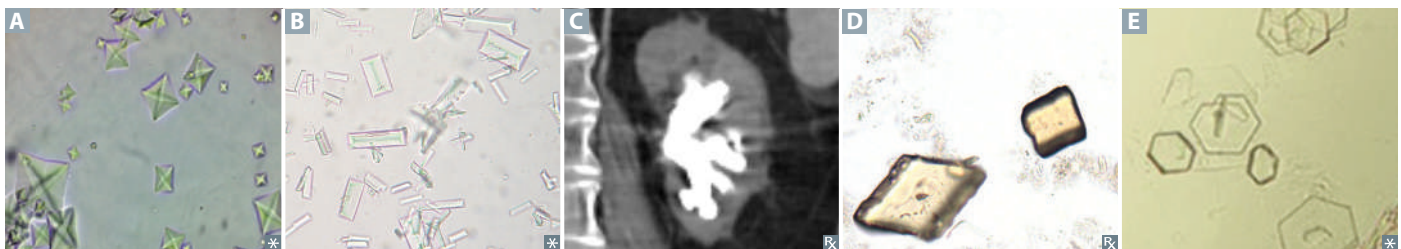- LM—Mesangial expansion, GBM thickening, eosinophilic nodular glomerulosclerosis (Kimmelstiel-Wilson lesions **D**)

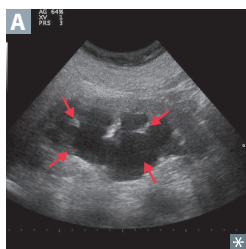


Kidney stones

Can lead to severe complications such as hydronephrosis, pyelonephritis, and acute kidney injury. Obstructed stone presents with unilateral flank tenderness, colicky pain radiating to groin, hematuria. Treat and prevent by encouraging fluid intake. Radiolucent stones: I can't **c** (see) **u** (you) (**c**ystine and **u**ric acid).

CONTENT	PRECIPITATES WITH	X-RAY FINDINGS	CT FINDINGS	URINE CRYSTAL	NOTES
Calcium	Calcium oxalate: hypocitraturia	Radiopaque	Radiopaque	Shaped like envelope A or dumbbell	Calcium stones most common (80%); calcium oxalate more common than calcium phosphate stones. Can result from ethylene glycol (antifreeze) ingestion, vitamin C overuse, hypocitraturia (associated with ↓ urine pH), malabsorption (eg, Crohn disease). Treatment: thiazides, citrate, low-sodium diet.
	Calcium phosphate: ↑ pH	Radiopaque	Radiopaque	Wedge-shaped prism	Treatment: low-sodium diet, thiazides.
Ammonium magnesium phosphate (struvite)	↑ pH	Radiopaque	Radiopaque	Coffin lid (“sarcophagus”) B	Account for 15% of stones. Caused by infection with urease ⊕ bugs (eg, <i>Proteus mirabilis</i> , <i>Staphylococcus saprophyticus</i> , <i>Klebsiella</i>) that hydrolyze urea to ammonia → urine alkalinization. Commonly form staghorn calculi C . Treatment: eradication of underlying infection, surgical removal of stone.
Uric acid	↓ pH	Radiolucent	Visible	Rhomboid D or rosettes	About 5% of all stones. Risk factors: ↓ urine volume, arid climates, acidic pH. Strong association with hyperuricemia (eg, gout). Often seen in diseases with ↑ cell turnover (eg, leukemia). Treatment: alkalization of urine, allopurinol.
Cystine	↓ pH	Faintly radiopaque	Moderately radiopaque	Hexagonal E	Hereditary (autosomal recessive) condition in which Cystine-reabsorbing PCT transporter loses function, causing cystinuria. Transporter defect also results in poor reabsorption of Ornithine, Lysine, Arginine (COLA). Cystine is poorly soluble, thus stones form in urine. Usually begins in childhood. Can form staghorn calculi. Sodium cyanide nitroprusside test ⊕. “Sixtine” stones have six sides. Treatment: low sodium diet, alkalization of urine, chelating agents (eg, tiopronin, penicillamine) if refractory.

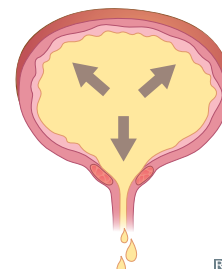
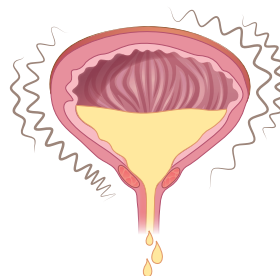
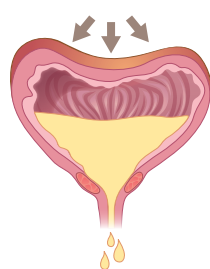


Hydronephrosis

Distention/dilation of renal pelvis and/or calyces **A**. Usually caused by urinary tract obstruction (eg, renal stones, severe BPH, congenital obstructions, locally advanced cervical cancer, injury to ureter); other causes include retroperitoneal fibrosis, vesicoureteral reflux. Dilation occurs proximal to site of pathology. Serum creatinine becomes elevated if obstruction is bilateral or if patient has an obstructed solitary kidney. Leads to compression and possible atrophy of renal cortex and medulla.

Urinary incontinence

Mixed incontinence has features of both stress and urgency incontinence.

Stress incontinence**Urgency incontinence****Overflow incontinence****MECHANISM**

Outlet incompetence (urethral hypermobility or intrinsic sphincter deficiency) → leak with ↑ intra-abdominal pressure (eg, sneezing, lifting)
⊕ bladder stress test (directly observed leakage from urethra upon coughing or Valsalva maneuver)

Detrusor overactivity → leak with urge to void immediately

Incomplete emptying (detrusor underactivity or outlet obstruction) → leak with overfilling, ↑ postvoid residual on catheterization or ultrasound

ASSOCIATIONS

Obesity, pregnancy, vaginal delivery, prostate surgery

UTI

Polyuria (eg, diabetes), bladder outlet obstruction (eg, BPH), spinal cord injury

TREATMENT

Pelvic floor muscle strengthening (Kegel) exercises, weight loss, pessaries

Kegel exercises, bladder training (timed voiding, distraction or relaxation techniques), antimuscarinics (eg, oxybutynin for overactive bladder), mirabegron

Catheterization, relieve obstruction (eg, α-blockers for BPH)

Acute cystitis

Inflammation of urinary bladder. Presents as suprapubic pain, dysuria, urinary frequency, urgency.

Systemic signs (eg, high fever, chills) are usually absent.

Risk factors include female sex (short urethra), sexual intercourse, indwelling catheter, diabetes mellitus, impaired bladder emptying.

Causes:

- *E coli* (most common)
- *Staphylococcus saprophyticus*—seen in sexually active young women (*E coli* is still more common in this group)
- *Klebsiella*
- *Proteus mirabilis*—urine has ammonia scent

Labs: ⊕ leukocyte esterase. ⊕ nitrites (indicates presence of Enterobacteriaceae). Sterile pyuria (pyuria with ⊖ urine cultures) could suggest urethritis by *Neisseria gonorrhoeae* or *Chlamydia trachomatis*.

Treatment: antibiotics (eg, TMP-SMX, nitrofurantoin).

Pyelonephritis**Acute pyelonephritis**

Neutrophils infiltrate renal interstitium **A**. Affects cortex with relative sparing of glomeruli/vessels.

Presents with fevers, flank pain (costovertebral angle tenderness), nausea/vomiting, chills.

Causes include ascending UTI (*E coli* is most common), hematogenous spread to kidney. Presents with WBCs in urine +/- WBC casts. CT would show striated parenchymal enhancement **B**.

Risk factors include indwelling urinary catheter, urinary tract obstruction, vesicoureteral reflux, diabetes mellitus, pregnancy (progesterone-mediated ↓ in uterine tone and compression by gravid uterus).

Complications include chronic pyelonephritis, renal papillary necrosis, perinephric abscess (with possible posterior spread to adjacent psoas muscle), urosepsis.

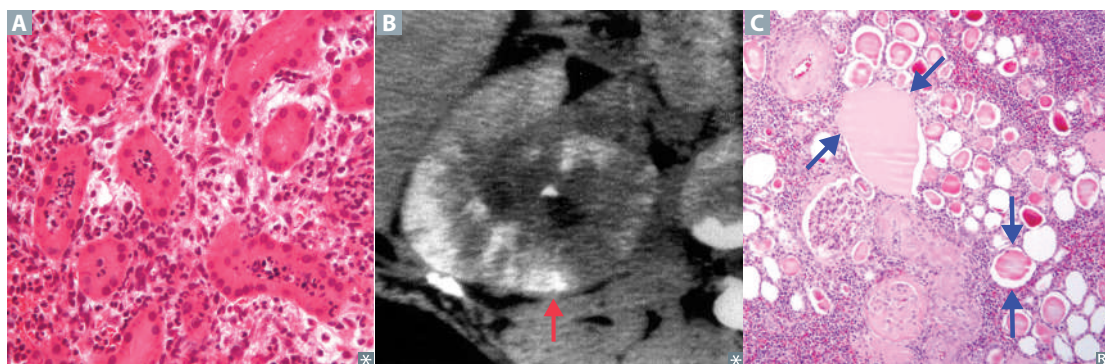
Treatment: antibiotics.

Chronic pyelonephritis

The result of recurrent or inadequately treated episodes of acute pyelonephritis. Typically requires predisposition to infection such as vesicoureteral reflux or chronically obstructing kidney stones.

Coarse, asymmetric corticomedullary scarring, blunted calyces. Tubules can contain eosinophilic casts resembling thyroid tissue **C** (thyroidization of kidney).

Xanthogranulomatous pyelonephritis—rare; grossly orange nodules that can mimic tumor nodules; characterized by widespread kidney damage due to granulomatous tissue containing foamy macrophages. Associated with *Proteus* infection.



Acute kidney injury

	Prerenal azotemia	Intrinsic renal failure	Postrenal azotemia
ETIOLOGY	Hypovolemia ↓ cardiac output ↓ effective circulating volume (eg, HF, liver failure)	Tubules and interstitium: ▪ Acute tubular necrosis (ischemia, nephrotoxins) ▪ Acute interstitial nephritis Glomerulus: ▪ Acute glomerulonephritis Vascular: ▪ Vasculitis ▪ Malignant hypertension ▪ TTP-HUS	Stones BPH Neoplasm Congenital anomalies
PATHOPHYSIOLOGY	↓ RBF → ↓ GFR → ↑ reabsorption of Na ⁺ /H ₂ O and urea	In ATN, patchy necrosis → debris obstructing tubules and fluid backflow → ↓ GFR	Outflow obstruction (bilateral)
URINE OSMOLALITY (mOsm/kg)	>500	<350	Varies
URINE Na ⁺ (mEq/L)	<20	>40	Varies
FE _{Na}	<1%	>2%	Varies
SERUM BUN/Cr	>20	<15	Varies

Acute interstitial nephritis

Also called tubulointerstitial nephritis. Acute interstitial renal inflammation. Pyuria (classically eosinophils) and azotemia occurring after administration of drugs that act as haptens, inducing hypersensitivity (eg, diuretics, NSAIDs, penicillin derivatives, proton pump inhibitors, rifampin, quinolones, sulfonamides). Less commonly may be 2° to other processes such as systemic infections (eg, *Mycoplasma*) or autoimmune diseases (eg, Sjögren syndrome, SLE, sarcoidosis).

Associated with fever, rash, pyuria, hematuria, and costovertebral angle tenderness, but can be asymptomatic.

Remember these **5 P'S**:

- **P**ee (diuretics)
- **P**ain-free (NSAIDs)
- **P**enicillins and cephalosporins
- **P**roton pump inhibitors
- Rifam**P**in
- **S**ulfa drugs

Acute tubular necrosis

Most common cause of acute kidney injury in hospitalized patients. Spontaneously resolves in many cases. Can be fatal, especially during initial oliguric phase. ↑ FE_{Na}.

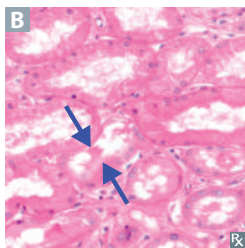
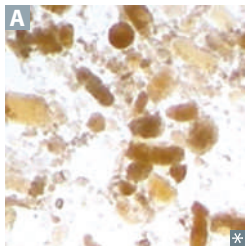
Key finding: granular casts (often muddy brown in appearance) **A**.

3 stages:

1. Inciting event
2. Maintenance phase—oliguric; lasts 1–3 weeks; risk of hyperkalemia, metabolic acidosis, uremia
3. Recovery phase—polyuric; BUN and serum creatinine fall; risk of hypokalemia and renal wasting of other electrolytes and minerals

Can be caused by ischemic or nephrotoxic injury:

- Ischemic—2° to ↓ renal blood flow (eg, prerenal azotemia). Results in death of tubular cells that may slough into tubular lumen **B** (PT and thick ascending limb are highly susceptible to injury).
- Nephrotoxic—2° to injury resulting from toxic substances (eg, aminoglycosides, radiocontrast agents, lead, cisplatin, ethylene glycol), myoglobinuria (rhabdomyolysis), hemoglobinuria. PTs are particularly susceptible to injury.



Diffuse cortical necrosis

Acute generalized cortical infarction of both kidneys. Likely due to a combination of vasospasm and DIC.

Associated with obstetric catastrophes (eg, placental abruption), septic shock.

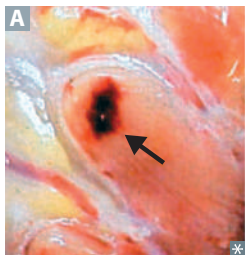
Renal papillary necrosis

Sloughing of necrotic renal papillae **A** → gross hematuria. May be triggered by recent infection or immune stimulus.

Associated with:

- Sickle cell disease or trait
- Acute pyelonephritis
- Analgesics (eg, NSAIDs)
- Diabetes mellitus

SAAD papa with **papillary** necrosis.



Consequences of renal failure

Decline in renal filtration can lead to excess retained nitrogenous waste products and electrolyte disturbances.

Consequences (**MAD HUNGER**):

- **M**etabolic **A**cidosis
- **D**yslipidemia (especially ↑ triglycerides)
- **H**igh potassium
- **U**remia
- **N**a⁺/H₂O retention (HF, pulmonary edema, hypertension)
- **G**rowth retardation and developmental delay
- **E**rythropoietin deficiency (anemia)
- **R**enal osteodystrophy

2 forms of renal failure: acute (eg, ATN) and chronic (eg, hypertension, diabetes mellitus, congenital anomalies).

Incremental reductions in GFR define the stages of chronic kidney disease.

Normal phosphate levels are maintained during early stages of CKD due to ↑ levels of fibroblast growth factor 23 (FGF23), which promotes renal excretion of phosphate. “**FGF23** fights **f**(ph)osphate.”

Uremia—syndrome resulting from high serum urea. Can present with **P**ericarditis, **E**ncephalopathy (seen with asterixis), **A**norexia, **N**ausea (pronounce “**Ure-PEAN**” [European]).

Renal osteodystrophy

Hypocalcemia, hyperphosphatemia, and failure of vitamin D hydroxylation associated with chronic kidney disease → 2° hyperparathyroidism → 3° hyperparathyroidism (if 2° poorly managed). High serum phosphate can bind with Ca^{2+} → tissue deposits → ↓ serum Ca^{2+} . ↓ $1,25\text{-(OH)}_2\text{D}_3$ → ↓ intestinal Ca^{2+} absorption. Causes subperiosteal thinning of bones.

Renal cyst disorders**Autosomal dominant polycystic kidney disease**

Numerous cysts in cortex and medulla **A** causing bilateral enlarged kidneys ultimately destroy kidney parenchyma. Presents with combinations of flank pain, hematuria, hypertension, urinary infection, progressive renal failure in ~ 50% of individuals.

Mutation in *PKD1* encoding polycystin protein (85% of cases, chromosome 16) or *PKD2* (15% of cases, chromosome 4). Complications include chronic kidney disease and hypertension (caused by ↑ renin production). Associated with berry aneurysms, mitral valve prolapse, benign hepatic cysts, diverticulosis.

Treatment: If hypertension or proteinuria develops, treat with ACE inhibitors or ARBs.

Autosomal recessive polycystic kidney disease

Mutation in *PKHD1* encoding fibrocystin. Cystic dilation of collecting ducts **B**. Often presents in infancy. Associated with congenital hepatic fibrosis. Significant oliguric renal failure in utero can lead to Potter sequence. Concerns beyond neonatal period include systemic hypertension, progressive renal insufficiency, and portal hypertension from congenital hepatic fibrosis.

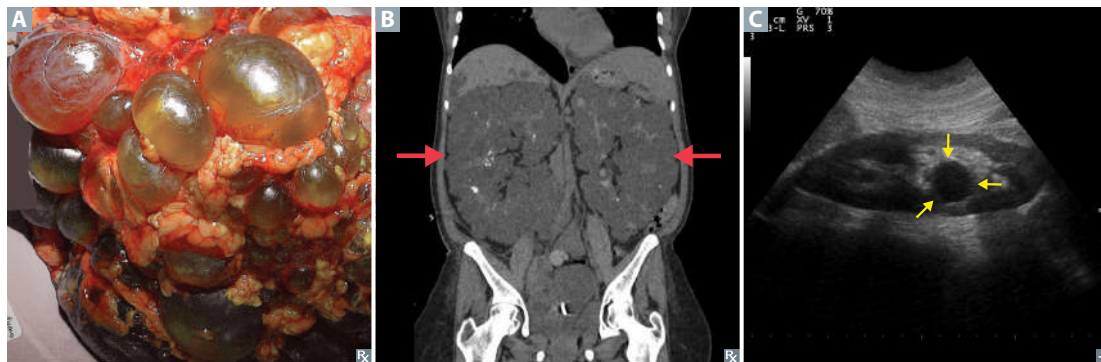Autosomal dominant tubulointerstitial kidney disease

Also called medullary cystic kidney disease. Causes tubulointerstitial fibrosis and progressive renal insufficiency with inability to concentrate urine. Medullary cysts usually not visualized; smaller kidneys on ultrasound. Poor prognosis.

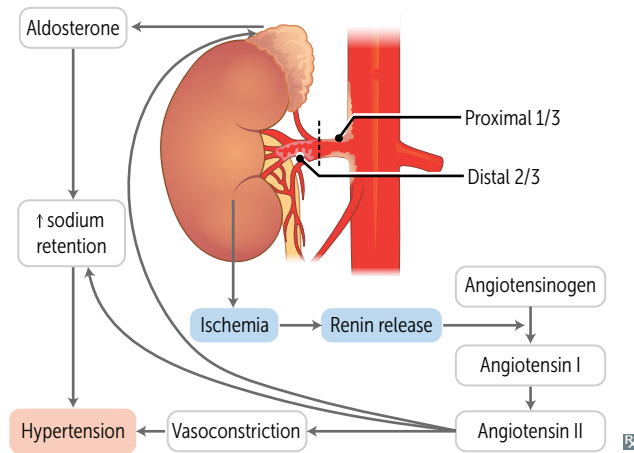
Simple vs complex renal cysts

Simple cysts are filled with ultrafiltrate (anechoic on ultrasound **C**). Very common and account for majority of all renal masses. Found incidentally and typically asymptomatic.

Complex cysts, including those that are septated, enhanced, or have solid components on imaging require follow-up or removal due to possibility of renal cell carcinoma.



Renovascular disease



Unilateral or bilateral renal artery stenosis (RAS) → ↓ renal perfusion → ↑ renin → ↑ angiotensin → HTN. Most common cause of 2° HTN in adults.

Main causes of RAS:

- Atherosclerotic plaques: proximal 1/3 of renal artery, usually in older males, smokers.
- Fibromuscular dysplasia: distal 2/3 of renal artery or segmental branches, usually young or middle-aged females

For unilateral RAS, affected kidney can atrophy → asymmetric kidney size. Renal venous sampling will show ↑ renin in affected kidney, ↓ renin in unaffected kidney.

For bilateral RAS, patients can have a sudden rise in creatinine after starting an ACE inhibitor, ARB, or renin inhibitor, due to their interference on RAAS-mediated renal perfusion.

Can present with severe/refractory HTN, flash pulmonary edema, epigastric/flank bruit. Patients with RAS may also have stenosis in other large vessels.

Renal cell carcinoma

Polygonal clear cells **A** filled with accumulated lipids and carbohydrate. Often golden-yellow **B** due to ↑ lipid content.

Originates from PCT → invades renal vein (may develop varicocele if left sided) → IVC → hematogenous spread → metastasis to lung and bone.

Manifests with flank pain, palpable mass, hematuria (classic triad) as well as anemia, 2° polycythemia (less common), fever, weight loss.

Treatment: surgery/ablation for localized disease. Immunotherapy (eg, ipilimumab) or targeted therapy for metastatic disease, rarely curative. Resistant to radiation and chemotherapy.

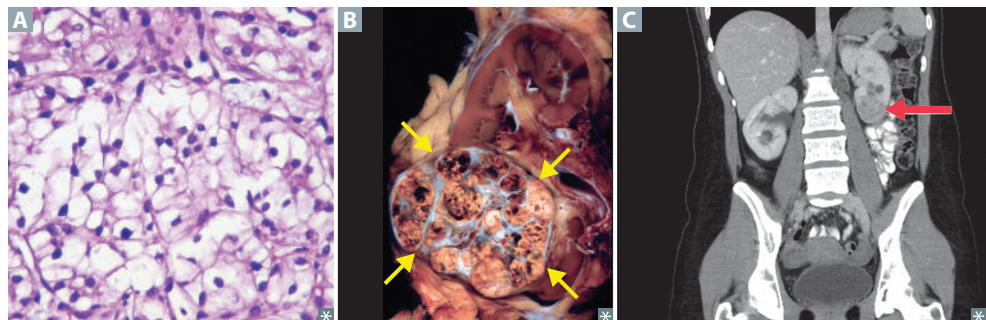
Most common 1° renal malignancy **C**.

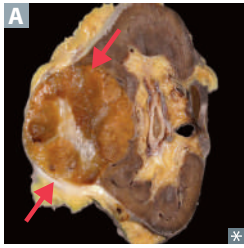
Most common in males 50–70 years old, ↑ incidence with tobacco smoking and obesity.

Associated with paraneoplastic syndromes, eg, PTHrP, Ectopic EPO, ACTH, Renin (“PEAR”-aneoplastic).

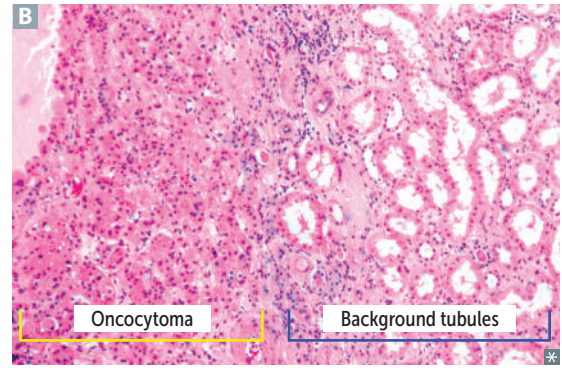
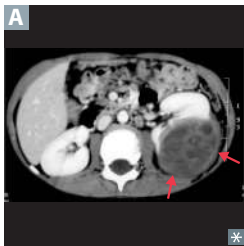
Clear cell (most common subtype) associated with gene deletion on chromosome 3 (sporadic, or inherited as von Hippel-Lindau syndrome).

RCC = 3 letters = chromosome 3 = associated with VHL (also 3 letters).



Renal oncocytoma

Benign epithelial cell tumor arising from collecting ducts (arrows in **A** point to well-circumscribed mass with central scar). Large eosinophilic cells with abundant mitochondria without perinuclear clearing **B** (vs chromophobe renal cell carcinoma). Presents with painless hematuria, flank pain, abdominal mass. Often resected to exclude malignancy (eg, renal cell carcinoma).

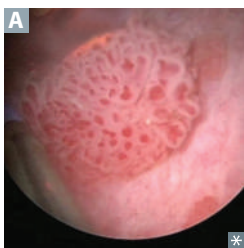
**Nephroblastoma**

Also called Wilms tumor. Most common renal malignancy of early childhood (ages 2–4). Contains embryonic glomerular structures. Most often present with large, palpable, unilateral flank mass **A** and/or hematuria and possible HTN.

Can be associated with loss-of-function mutations of tumor suppressor genes *WT1* or *WT2* on chromosome **11** (**W11**ms tumor).

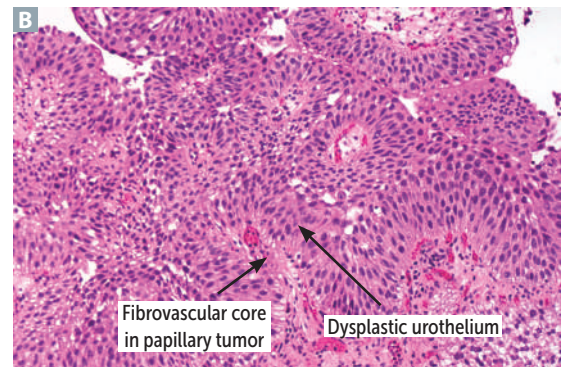
May be a part of several syndromes:

- **WAGR complex**—Wilms tumor, **A**niridia (absence of iris), **G**enitourinary malformations, **R**ange of developmental delays (*WT1* deletion)
- **Denys-Drash syndrome**—Wilms tumor, **D**iffuse mesangial sclerosis (early-onset nephrotic syndrome), **D**ysgenesis of gonads (male pseudohermaphroditism), *WT1* mutation
- **Beckwith-Wiedemann syndrome**—Wilms tumor, macroglossia, organomegaly, hemihyperplasia (imprinting defect causing genetic overexpression, associated with *WT2* mutation), omphalocele

Urothelial carcinoma of the bladder

Also called transitional cell carcinoma. Most common tumor of urinary tract system (can occur in renal calyces, renal pelvis, ureters, and bladder) **A B**. Can be suggested by painless hematuria (no casts).

Associated with problems in your **Pee SAC**: **P**henacetin, tobacco **S**moking, **A**romatic amines (found in dyes), **C**yclophosphamide.

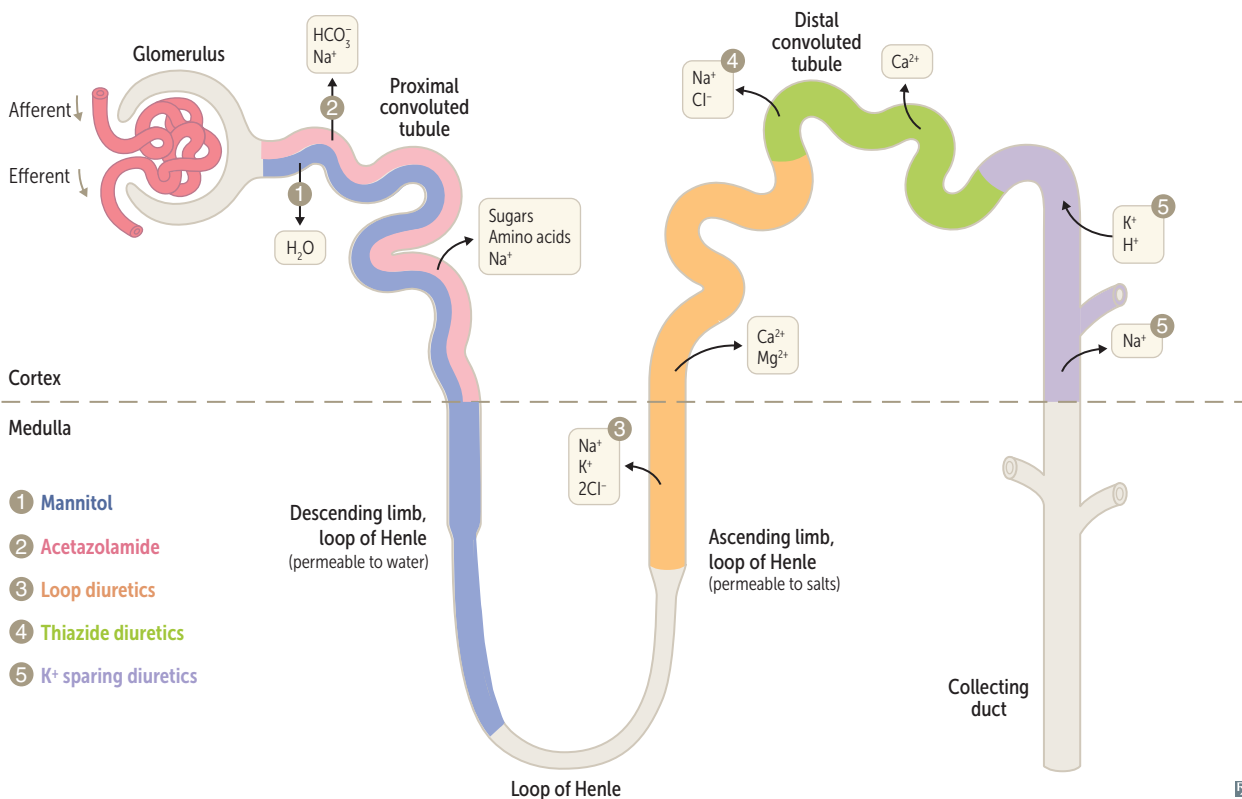
**Squamous cell carcinoma of the bladder**

Chronic irritation of urinary bladder → squamous metaplasia → dysplasia and squamous cell carcinoma.

Risk factors include **4 S**'s: *Schistosoma haematobium* infection (Middle East), chronic cystitis (“systitis”), **s**moking, chronic nephrolithiasis (**s**tones). Presents with painless hematuria (no casts).

▶ RENAL—PHARMACOLOGY

Diuretics site of action

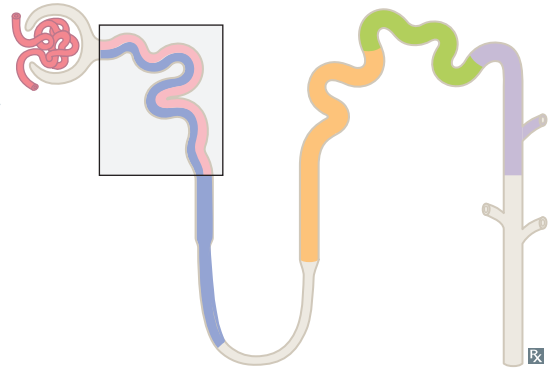


Mannitol

MECHANISM	Osmotic diuretic. ↑ serum osmolality → fluid shift from interstitium to intravascular space → ↑ urine flow, ↓ intracranial/intraocular pressure.
CLINICAL USE	Drug overdose, elevated intracranial/intraocular pressure.
ADVERSE EFFECTS	Dehydration, hypo- or hypernatremia, pulmonary edema. Contraindicated in anuria, HF.

Acetazolamide

MECHANISM	Carbonic anhydrase inhibitor. Causes self-limited NaHCO_3 diuresis and \downarrow total body HCO_3^- stores. Alkalinizes urine.
CLINICAL USE	Glaucoma, metabolic alkalosis, altitude sickness (by offsetting respiratory alkalosis), idiopathic intracranial hypertension.

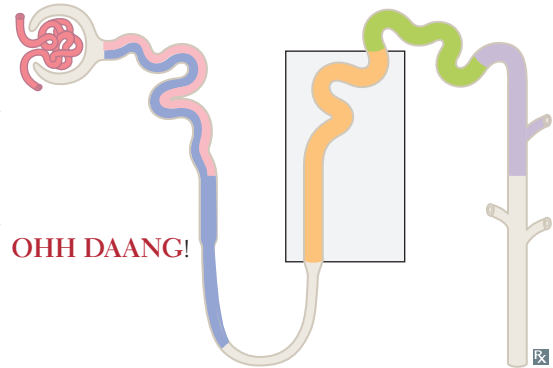


ADVERSE EFFECTS	Proximal renal tubular acidosis (type 2 RTA), paresthesias, NH_3 toxicity, sulfa allergy, hypokalemia. Promotes calcium phosphate stone formation (insoluble at high pH).
-----------------	--

“**Acid**”azolamide causes **acidosis**.

Loop diuretics**Furosemide, bumetanide, torsemide**

MECHANISM	Sulfonamide loop diuretics. Inhibit cotransport system ($\text{Na}^+/\text{K}^+/\text{2Cl}^-$) of thick ascending limb of loop of Henle. Abolish hypertonicity of medulla, preventing concentration of urine. Associated with \uparrow PGE (vasodilatory effect on afferent arteriole); inhibited by NSAIDs. \uparrow Ca^{2+} excretion. L oops l ose Ca^{2+} .
CLINICAL USE	Edematous states (HF, cirrhosis, nephrotic syndrome, pulmonary edema), hypertension, hypercalcemia.
ADVERSE EFFECTS	O tototoxicity, H ypokalemia, H ypomagnesemia, D ehydration, A llergy (sulfa), metabolic A lkalosis, N ephritis (interstitial), G out.



OHH DAANG!

Ethacrynic acid

MECHANISM	Nonsulfonamide inhibitor of cotransport system ($\text{Na}^+/\text{K}^+/\text{2Cl}^-$) of thick ascending limb of loop of Henle.
CLINICAL USE	Diuresis in patients allergic to sulfa drugs.
ADVERSE EFFECTS	Similar to furosemide, but more ototoxic .

Loop earrings hurt your **ears**.

Thiazide diuretics

Hydrochlorothiazide, chlorthalidone, metolazone.

MECHANISM

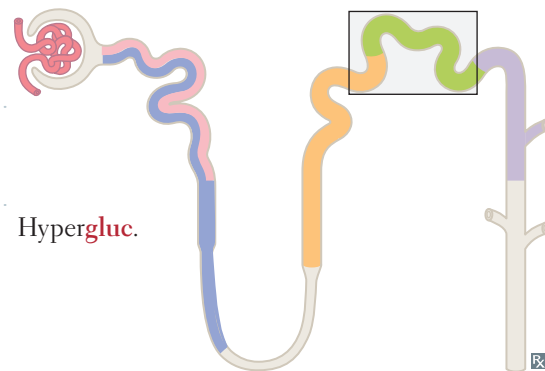
Inhibit NaCl reabsorption in early DCT → ↓ diluting capacity of nephron. ↓ Ca²⁺ excretion.

CLINICAL USE

Hypertension, HF, idiopathic hypercalciuria, nephrogenic diabetes insipidus, osteoporosis.

ADVERSE EFFECTS

Hypokalemic metabolic alkalosis, hyponatremia, hyperglycemia, hyperlipidemia, hyperuricemia, hypercalcemia. Sulfa allergy.



Potassium-sparing diuretics

Spironolactone, Eplerenone, Amiloride, Triamterene.

Keep your SEAT.

MECHANISM

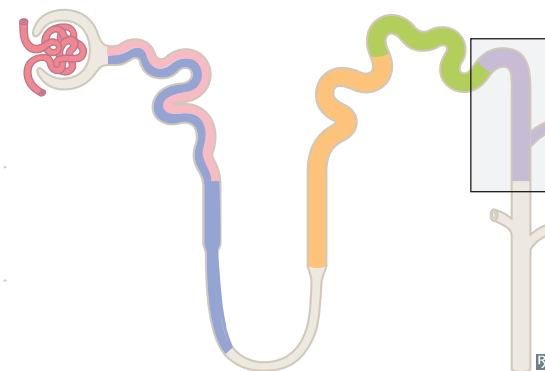
Spironolactone and eplerenone are competitive aldosterone receptor antagonists in cortical collecting tubule. Triamterene and amiloride block Na⁺ channels at the same part of the tubule.

CLINICAL USE

Hyperaldosteronism, K⁺ depletion, HF, hepatic ascites (spironolactone), nephrogenic DI (amiloride), antiandrogen (spironolactone).

ADVERSE EFFECTS

Hyperkalemia (can lead to arrhythmias), endocrine effects with spironolactone (eg, gynecomastia, antiandrogen effects), metabolic acidosis.



Diuretics: electrolyte changes

Urine NaCl

↑ with all diuretics (concentration varies based on potency of diuretic effect). Serum NaCl may decrease as a result.

Urine K⁺

↑ especially with loop and thiazide diuretics, excluding K⁺-sparing diuretics.

Blood pH

↓ (**acidemia**): carbonic anhydrase inhibitors: ↓ HCO₃⁻ reabsorption. K⁺ sparing: aldosterone blockade prevents K⁺ secretion and H⁺ secretion. Additionally, hyperkalemia leads to K⁺ entering all cells (via H⁺/K⁺ exchanger) in exchange for H⁺ exiting cells.

↑ (**alkalemia**): loop diuretics and thiazides cause alkalemia through several mechanisms:

- Volume contraction → ↑ AT II → ↑ Na⁺/H⁺ exchange in PCT → ↑ HCO₃⁻ reabsorption (“contraction alkalosis”)
- K⁺ loss leads to K⁺ exiting all cells (via H⁺/K⁺ exchanger) in exchange for H⁺ entering cells
- In low K⁺ state, H⁺ (rather than K⁺) is exchanged for Na⁺ in cortical collecting tubule → alkalosis and “paradoxical aciduria”

Urine Ca²⁺

↑ with loop diuretics: ↓ paracellular Ca²⁺ reabsorption → hypocalcemia.

↓ with thiazides: enhanced Ca²⁺ reabsorption.

Angiotensin-converting enzyme inhibitors

Captopril, enalapril, lisinopril, ramipril.

MECHANISM	Inhibit ACE → ↓ AT II → ↓ GFR by preventing constriction of efferent arterioles. ↑ renin due to loss of negative feedback. Inhibition of ACE also prevents inactivation of bradykinin, a potent vasodilator.	
CLINICAL USE	Hypertension, HF (↓ mortality), proteinuria, diabetic nephropathy. Prevent unfavorable heart remodeling as a result of chronic hypertension.	In chronic kidney disease (eg, diabetic nephropathy), ↓ intraglomerular pressure, slowing GBM thickening.
ADVERSE EFFECTS	Cough, A ngioedema (both due to ↑ bradykinin; contraindicated in C1 esterase inhibitor deficiency), T eratogen (fetal renal malformations), ↑ C reatinine (↓ GFR), H yperkalemia, and H ypotension. Used with caution in bilateral renal artery stenosis because ACE inhibitors will further ↓ GFR → renal failure.	Captopril's CATCHH .

Angiotensin II receptor blockers

Losartan, candesartan, valsartan.

MECHANISM	Selectively block binding of angiotensin II to AT ₁ receptor. Effects similar to ACE inhibitors, but ARBs do not increase bradykinin.	
CLINICAL USE	Hypertension, HF, proteinuria, or chronic kidney disease (eg, diabetic nephropathy) with intolerance to ACE inhibitors (eg, cough, angioedema).	
ADVERSE EFFECTS	Hyperkalemia, ↓ GFR, hypotension; teratogen.	

Aliskiren

MECHANISM	Direct renin inhibitor, blocks conversion of angiotensinogen to angiotensin I. Aliskiren kills renin .	
CLINICAL USE	Hypertension.	
ADVERSE EFFECTS	Hyperkalemia, ↓ GFR, hypotension, angioedema. Relatively contraindicated in patients already taking ACE inhibitors or ARBs and contraindicated in pregnancy.	

Reproductive

“Life is always a rich and steady time when you are waiting for something to happen or to hatch.”

—E.B. White, *Charlotte’s Web*

“Love is only a dirty trick played on us to achieve continuation of the species.”

—W. Somerset Maugham

“I liked that in obstetrics you end up with twice the number of patients you started with.”

—Adam Kay

“Life is a sexually transmitted disease and the mortality rate is one hundred percent.”

—R.D. Laing

Organizing the reproductive system by key concepts such as embryology, endocrinology, pregnancy, and oncology can help with understanding this complex topic. Study the endocrine and reproductive chapters together, because mastery of the hypothalamic-pituitary-gonadal axis is key to answering questions on ovulation, menstruation, disorders of sexual development, contraception, and many pathologies.

Embryology is a nuanced subject that spans multiple organ systems. Approach it from a clinical perspective. For instance, make the connection between the presentation of DiGeorge syndrome and the 3rd/4th pharyngeal pouch, and between the Müllerian/Wolffian systems and disorders of sexual development.

As for oncology, don’t worry about remembering screening or treatment guidelines. It is more important to recognize the clinical presentation (eg, signs and symptoms) of reproductive cancers and their associated labs, histopathology, and risk factors. In addition, some of the testicular and ovarian cancers have distinct patterns of hCG, AFP, LH, or FSH derangements that serve as helpful clues in exam questions.

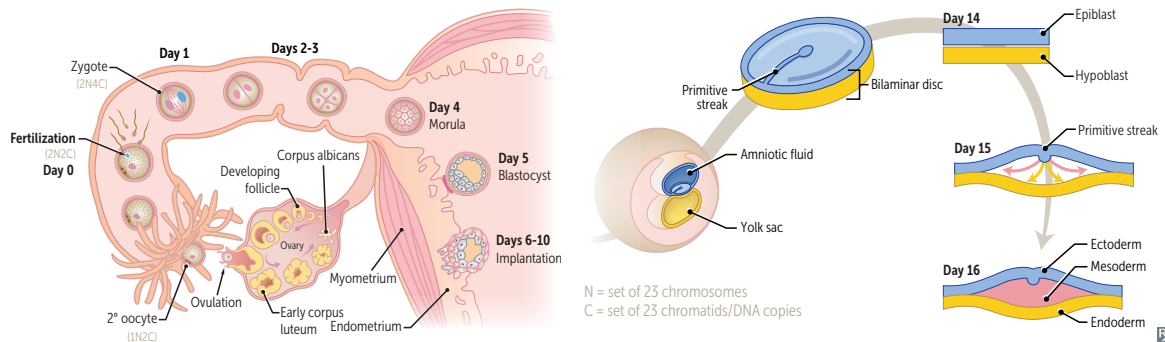
▶ Embryology	636
▶ Anatomy	648
▶ Physiology	653
▶ Pathology	661
▶ Pharmacology	679

► REPRODUCTIVE—EMBRYOLOGY

Important genes of embryogenesis

GENE	LOCATION	FUNCTION	NOTES
Sonic hedgehog (SHH) gene	Zone of polarizing activity at base of limb buds	Anterior-posterior axis patterning, CNS development	Mutations → holoprosencephaly
Wnt-7 gene	Apical ectodermal ridge at distal end of each limb	Dorsal-ventral axis patterning, limb development	“Wnt-7”
Fibroblast growth factor (FGF) gene	Apical ectodermal ridge	Limb lengthening (via mitosis of mesoderm)	“Look at that Fetus, Growing Fingers”
Homeobox (Hox) genes	Multiple	Segmental organization in cranial-caudal direction, transcription factor coding	Mutations → appendages in wrong locations. Isotretinoin → ↑ Hox gene expression

Early embryonic development



Week 1

hCG secretion begins around the time of blastocyst implantation. Blastocyst “sticks” on day six.

Week 2

Formation of bilaminar embryonic disc; two layers = epiblast, hypoblast.

Week 3

Formation of trilaminar embryonic disc via gastrulation (epiblast cell invagination through primitive streak); three layers = endoderm, mesoderm, ectoderm.
Notochord arises from midline mesoderm and induces overlying ectoderm (via SHH) to become neural plate, which gives rise to neural tube via neurulation.


Week 4

Heart begins to beat (four chambers). Cardiac activity visible by transvaginal ultrasound.
Upper and lower limb buds begin to form (four limbs).

Week 8

Genitalia have male/female characteristics (pronounce “geneightalia”).

Embryologic derivatives



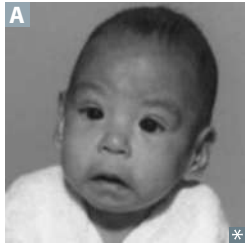Ectoderm		External/outer layer
Surface ectoderm	Epidermis; adenohypophysis (from Rathke pouch); lens of eye; epithelial linings of oral cavity, sensory organs of ear, and olfactory epithelium; anal canal below the pectinate line; parotid, sweat, mammary glands.	Craniopharyngioma —benign Rathke pouch tumor with cholesterol crystals, calcifications.
Neural tube	Brain (neurohypophysis, CNS neurons, oligodendrocytes, astrocytes, ependymal cells, pineal gland), retina, spinal cord.	Neuroectoderm—think CNS.
Neural crest	E nterochromaffin cells, L eptomeninges (arachnoid, pia), M elanocytes, O dontoblasts, P NS ganglia (cranial, dorsal root, autonomic), A drenal medulla, S chwann cells, S piral membrane (aorticopulmonary septum), E ndocardial cushions (also derived partially from mesoderm), S kull bones.	ELMO PASSES Neural crest—think PNS and non-neural structures nearby.
Mesoderm	Muscle, bone, connective tissue, serous linings of body cavities (eg, peritoneum, pericardium, pleura), spleen (develops within foregut mesentery), cardiovascular structures, lymphatics, blood, wall of gut tube, proximal vagina, kidneys, adrenal cortex, dermis, testes, ovaries, microglia, dura mater, tracheal cartilage. Notochord induces ectoderm to form neuroectoderm (neural plate); its only postnatal derivative is the nucleus pulposus of the intervertebral disc.	M iddle/“meat” layer. Mesodermal defects = VACTERL association: V ertebral defects A nal atresia C ardiac defects T racheo- E sophageal fistula R enal defects L imb defects (bone and muscle)
Endoderm	Gut tube epithelium (including anal canal above the pectinate line), most of urethra and distal vagina (derived from urogenital sinus), luminal epithelial derivatives (eg, lungs, liver, gallbladder, pancreas, eustachian tube, thymus, parathyroid, thyroid follicular and parafollicular [C] cells).	“ E nternal” layer.

Teratogens Most susceptible during organogenesis in embryonic period (before week 8 of development). Before implantation, “all-or-none” effect. After week 8 (fetal period), growth and function affected.

TERATOGEN	EFFECT ON FETUS
Medications	
ACE inhibitors	Renal failure, oligohydramnios, hypocalvaria.
Alkylating agents	Multiple anomalies (eg, ear/facial abnormalities, absence of digits).
Aminoglycosides	Ototoxicity. “A mean guy hit the baby in the ear.”
Antiepileptic drugs	Neural tube defects, cardiac defects, cleft palate, skeletal abnormalities (eg, phalanx/nail hypoplasia, facial dysmorphism). Most commonly due to valproate, carbamazepine, phenytoin, phenobarbital; high-dose folate supplementation recommended.
Diethylstilbestrol	Vaginal clear cell adenocarcinoma, congenital Müllerian anomalies.
Fluoroquinolones	Cartilage damage.
Folate antagonists	Neural tube defects. Most commonly due to trimethoprim, methotrexate.
Isotretinoin	Craniofacial (eg, microtia, dysmorphism), CNS, cardiac, and thymic defects. Contraception mandatory. Pronounce “isoteratinoin” for its teratogenicity.
Lithium	Ebstein anomaly.
Methimazole	Aplasia cutis congenita (congenital absence of skin, typically on scalp).
Tetracyclines	Discolored teeth, inhibited bone growth. Pronounce “teethracyclines.”
Thalidomide	Limb defects (eg, phocomelia—flipperlike limbs). Pronounce “thallimdomide.”
Warfarin	Bone and cartilage deformities (stippled epiphyses, nasal and limb hypoplasia), optic nerve atrophy, cerebral hemorrhage. Use heparin during pregnancy (does not cross placenta).
Substance use	
Alcohol	Fetal alcohol syndrome.
Cocaine	Preterm birth, low birth weight, fetal growth restriction (FGR). Cocaine → vasoconstriction.
Tobacco smoking	Preterm birth, low birth weight (leading cause in resource-rich countries), FGR, sudden infant death syndrome (SIDS), ADHD. Nicotine → vasoconstriction, CO → impaired O ₂ delivery.
Other	
Iodine lack or excess	Congenital hypothyroidism.
Maternal diabetes	Caudal regression syndrome, cardiac defects (eg, transposition of great arteries, VSD), neural tube defects, macrosomia, neonatal hypoglycemia (due to islet cell hyperplasia), polycythemia, respiratory distress syndrome.
Maternal PKU	Fetal growth restriction, microcephaly, intellectual disability, congenital heart defects.
Methylmercury	Neurotoxicity. ↑ concentration in top-predator fish (eg, shark, swordfish, king mackerel, tilefish).
X-rays	Microcephaly, intellectual disability. Effects minimized by use of lead shielding.

Types of errors in morphogenesis

Agensis	Absent organ due to absent primordial tissue.
Aplasia	Absent organ despite presence of primordial tissue.
Hypoplasia	Incomplete organ development; primordial tissue present.
Disruption	2° breakdown of tissue with normal developmental potential (eg, amniotic band syndrome).
Deformation	Extrinsic mechanical distortion (eg, congenital torticollis); occurs during fetal period.
Malformation	Intrinsic developmental defect (eg, cleft lip/palate); occurs during embryonic period.
Sequence	Abnormalities result from a single 1° embryologic event (eg, oligohydramnios → Potter sequence).
Field defect	Disturbance of tissues that develop in a contiguous physical space (eg, holoprosencephaly).

Fetal alcohol syndrome

One of the leading preventable causes of intellectual disability in the US. 2° to maternal alcohol use during pregnancy. Newborns may present with developmental delay, microcephaly, facial abnormalities **A** (eg, smooth philtrum, thin vermilion border, small palpebral fissures, flat nasal bridge), limb dislocation, heart defects. Holoprosencephaly may occur in more severe presentations. One mechanism is due to impaired migration of neuronal and glial cells.

Neonatal abstinence syndrome

Complex disorder involving CNS, ANS, and GI systems. 2° to maternal substance use (most commonly opioids) during pregnancy. Newborns may present with uncoordinated sucking reflexes, irritability, high-pitched crying, tremors, tachypnea, sneezing, diarrhea, and possibly seizures.

Treatment (for opioid use): methadone, morphine, buprenorphine.

Universal screening for substance use is recommended in all pregnant patients.

Placenta

1° site of nutrient and gas exchange between mother and fetus.

Fetal component**Cytotrophoblast**

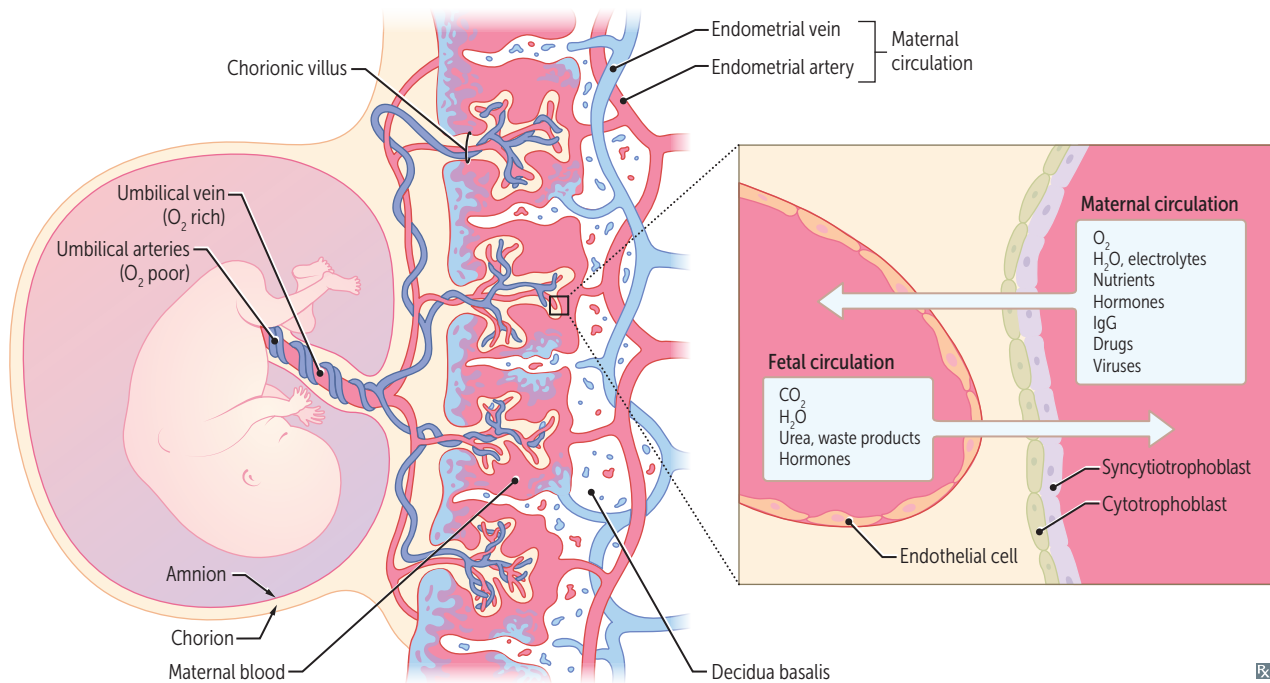
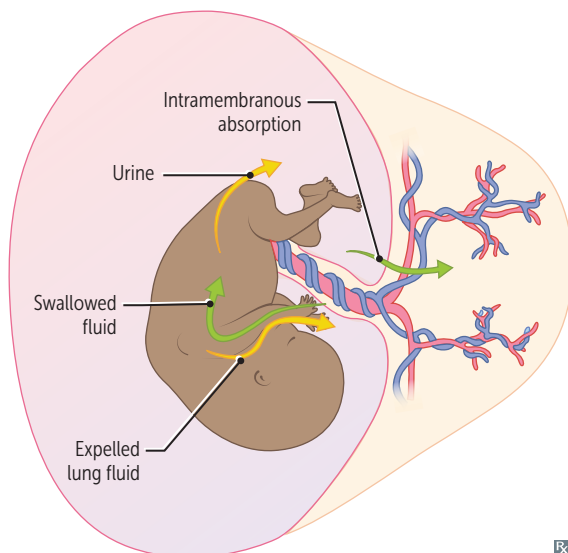
Inner layer of chorionic villi; **creates** cells.

Syncytiotrophoblast

Outer layer of chorionic villi; **synthesizes** and secretes hormones, eg, hCG (structurally similar to LH; stimulates corpus luteum to secrete progesterone during first trimester). Lacks MHC I expression → ↓ chance of attack by maternal immune system.

Maternal component**Decidua basalis**

Derived from endometrium. Maternal blood in lacunae.

**Amniotic fluid**

Derived from fetal urine (mainly) and fetal lung liquid.

Cleared by fetal swallowing (mainly) and intramembranous absorption.

Polyhydramnios—too much amniotic fluid.

May be idiopathic or associated with fetal malformations (eg, esophageal/duodenal atresia, anencephaly; both result in inability to swallow amniotic fluid), maternal diabetes, fetal anemia, multifetal gestation.

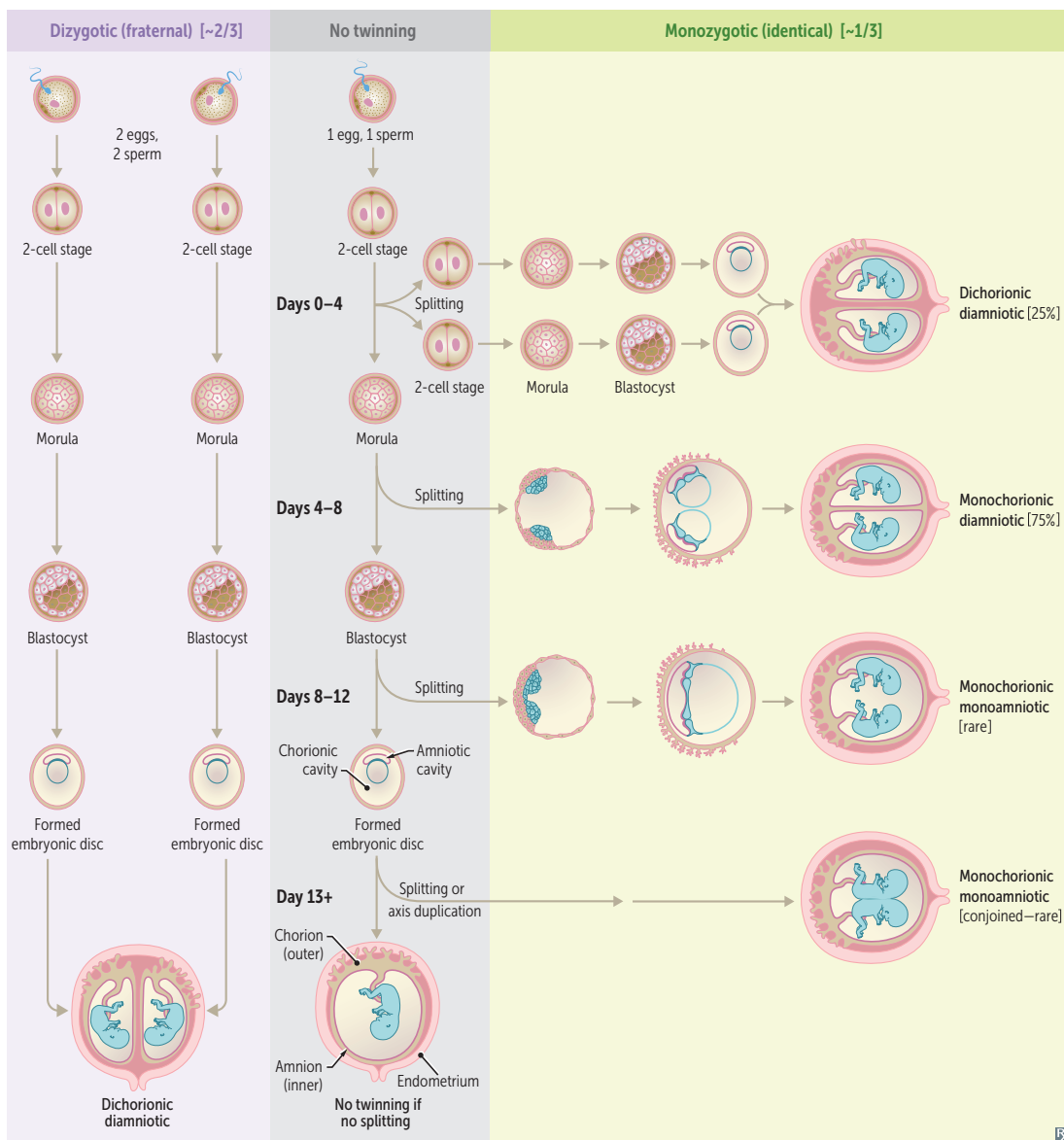
Oligohydramnios—too little amniotic fluid.

Associated with placental insufficiency, bilateral renal agenesis, posterior urethral valves (in males); these result in inability to excrete urine. Profound oligohydramnios can cause Potter sequence.

Twinning

Dizygotic (“fraternal”) twins arise from 2 eggs that are separately fertilized by 2 different sperm (always 2 zygotes) and will have 2 separate amniotic sacs and 2 separate placentas (chorions). Monozygotic (“identical”) twins arise from 1 fertilized egg (1 egg + 1 sperm) that splits in early pregnancy. The timing of splitting determines chorionicity (number of chorions) and amnionicity (number of amnions) (take **separate** cars or **share** a **CAB**):

- Splitting 0–4 days: **separate** chorion and amnion (di-di)
- Splitting 4–8 days: **shared** Chorion (mo-di)
- Splitting 8–12 days: **shared** chorion and **Amnion** (mo-mo)
- Splitting 13+ days: **shared** chorion, amnion, and **Body** (mo-mo; conjoined)



Twin-twin transfusion syndrome

Occurs in monochorionic twin gestations. Unbalanced arteriovenous anastomoses between twins in shared placenta → net blood flow from one twin to the other.
 Donor twin → hypovolemia and oligohydramnios (“stuck twin” appearance).
 Recipient twin → hypervolemia and polyhydramnios.

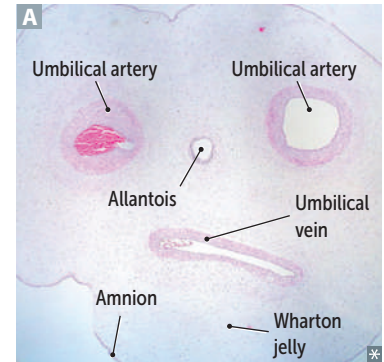
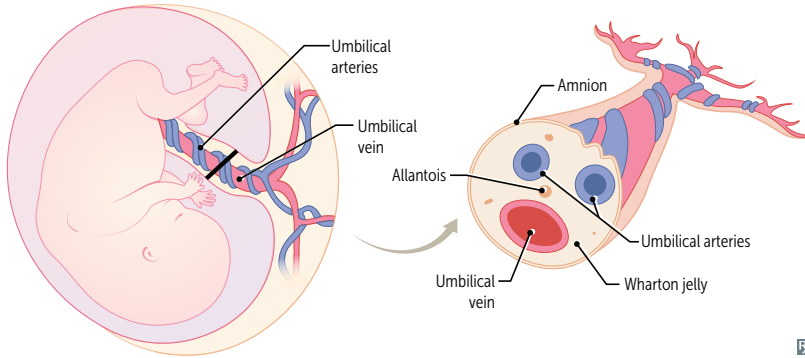
Umbilical cord

Two umbilical arteries return deoxygenated blood from fetal internal iliac arteries to placenta **A**.

One umbilical vein supplies oxygenated blood from placenta to fetus; drains into IVC via liver or via ductus venosus.

Single umbilical artery (2-vessel cord) is associated with congenital and chromosomal anomalies.

Umbilical arteries and vein are derived from allantois.



Urachus

Allantois forms from yolk sac and extends into cloaca. Intra-abdominal remnant of allantois is called the urachus, a duct between fetal bladder and umbilicus. Failure of urachus to involute can lead to anomalies that may increase risk of infection and/or malignancy (eg, adenocarcinoma) if not treated.

Obliterated urachus is represented by the median umbilical ligament after birth, which is covered by median umbilical fold of the peritoneum.

Patent urachus

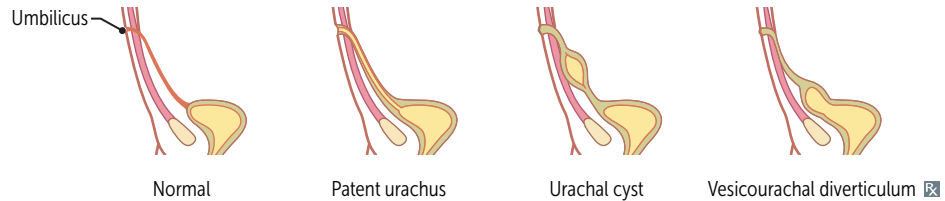
Total failure of urachus to obliterate → urine discharge from umbilicus.

Urachal cyst

Partial failure of urachus to obliterate; fluid-filled cavity lined with uroepithelium, between umbilicus and bladder. Cyst can become infected and present as painful mass below umbilicus.

Vesicourachal diverticulum

Slight failure of urachus to obliterate → outpouching of bladder.



Vitelline duct

Also called omphalomesenteric duct. Connects yolk sac to midgut lumen. Obliterates during week 7 of development.

Patent vitelline duct

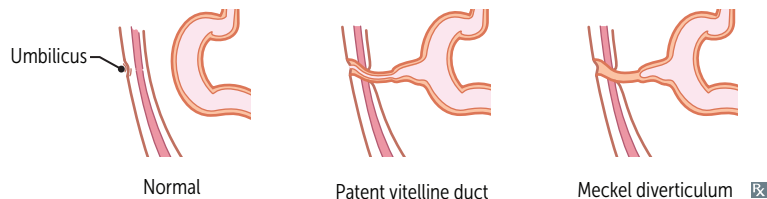
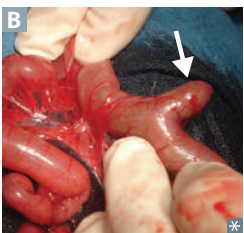
Total failure of vitelline duct to obliterate → meconium discharge from umbilicus.

Vitelline duct cyst

Partial failure of vitelline duct to obliterate. ↑ risk for volvulus.

Meckel diverticulum

Slight failure of vitelline duct to obliterate → outpouching of ileum (true diverticulum, arrow in **B**). Usually asymptomatic. May have heterotopic gastric and/or pancreatic tissue → melena, hematochezia, abdominal pain.



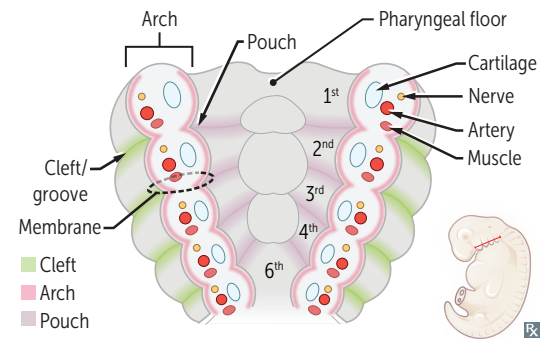
Pharyngeal apparatus Composed of pharyngeal (branchial) clefts, arches, pouches.
 Pharyngeal clefts—derived from ectoderm. Also called pharyngeal grooves.
 Pharyngeal arches—derived from mesoderm (muscles, arteries) and neural crest (bones, cartilage).
 Pharyngeal pouches—derived from endoderm.

CAP covers outside to inside:

Clefts = ectoderm

Arches = mesoderm + neural crest

Pouches = endoderm



Pharyngeal cleft derivatives

1st cleft develops into external auditory meatus.

2nd through 4th clefts form temporary cervical sinuses, which are obliterated by proliferation of 2nd arch mesenchyme.

Pharyngeal cleft cyst—persistent cervical sinus; presents as lateral neck mass anterior to sternocleidomastoid muscle that does not move with swallowing (vs thyroglossal duct cyst).

Pharyngeal arch derivatives

When at the restaurant of the golden **arches**, children tend to first **chew** (1), then **smile** (2), then **swallow** **stylishly** (3) or **simply swallow** (4), and then **speak** (6).

ARCH	NERVES*	MUSCLES	CARTILAGE	NOTES
1st pharyngeal arch	CN V ₃ chew	Muscles of m astication (temporalis, m asseter, lateral and m edial pterygoids), m ylorhyoid, anterior belly of digastric, tensor tympani, anterior 2/3 of tongue, tensor veli palatini	M axillary process → m axilla, zygomatic bone M andibular process → m eckel cartilage → m andible, m alleus and incus, sphenomandibular ligament	Pierre Robin sequence —micrognathia, glossoptosis, cleft palate, airway obstruction Treacher Collins syndrome —autosomal dominant neural crest dysfunction → craniofacial abnormalities (eg, zygomatic bone and mandibular hypoplasia), hearing loss, airway compromise
2nd pharyngeal arch	CN VII (seven) smile (facial expression)	Muscles of facial expression, s tapedius, s tylohyoid, platysma, posterior belly of digastric	Reichert cartilage: s tapes, s tyloid process, l esser horn of hyoid, s tylohyoid ligament	
3rd pharyngeal arch	CN IX swallow stylishly	S tylopharyngeus	Greater horn of hyoid	
4th and 6th pharyngeal arches	4th arch: CN X (superior laryngeal branch) simply swallow 6th arch: CN X (recurrent/inferior laryngeal branch) speak	4th arch: most pharyngeal constrictors; cricothyroid, levator veli palatini 6th arch: all intrinsic muscles of larynx except cricothyroid	A rytenoids, C ricoid, C orniculate, C uneiform, T hyroid (used to sing and ACCCT)	Arches 3 and 4 form posterior 1/3 of tongue Arch 5 makes no major developmental contributions

*Sensory and motor nerves are not pharyngeal arch derivatives. They grow into the arches and are derived from neural crest (sensory) and neuroectoderm (motor).

Pharyngeal pouch derivatives

Ear, tonsils, bottom-to-top: 1 (**ear**), 2 (**tonsils**), 3 dorsal (**bottom** = **inferior** parathyroids), 3 ventral (**to** = **thymus**), 4 (**top** = **superior** parathyroids).

POUCH	DERIVATIVES	NOTES
1st pharyngeal pouch	Middle ear cavity, eustachian tube, mastoid air cells	1st pouch contributes to endoderm-lined structures of ear
2nd pharyngeal pouch	Epithelial lining of palatine tonsil	
3rd pharyngeal pouch	Dorsal wings → inferior parathyroids Ventral wings → thymus	Third pouch contributes to thymus and both inferior parathyroids Structures from 3rd pouch end up below those from 4th pouch
4th pharyngeal pouch	Dorsal wings → superior parathyroids Ventral wings → ultimopharyngeal body → parafollicular (C) cells of thyroid	4th pharyngeal pouch forms para“ 4 ”llicular cells

Orofacial clefts

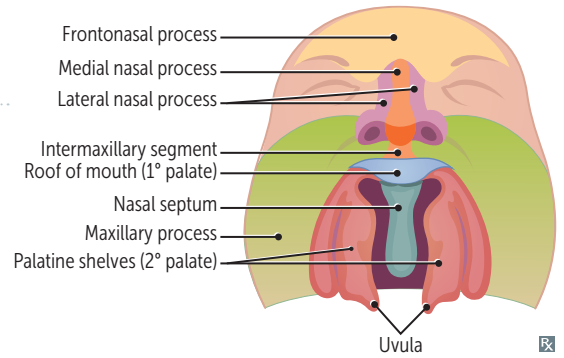
Cleft lip and cleft palate have distinct, multifactorial etiologies, but often occur together.

Cleft lip

Due to failure of fusion of the intermaxillary segment (merged medial nasal processes) with the maxillary process (formation of 1° palate).

Cleft palate

Due to failure of fusion of the two lateral palatine shelves or failure of fusion of lateral palatine shelf with the nasal septum and/or 1° palate (formation of 2° palate).



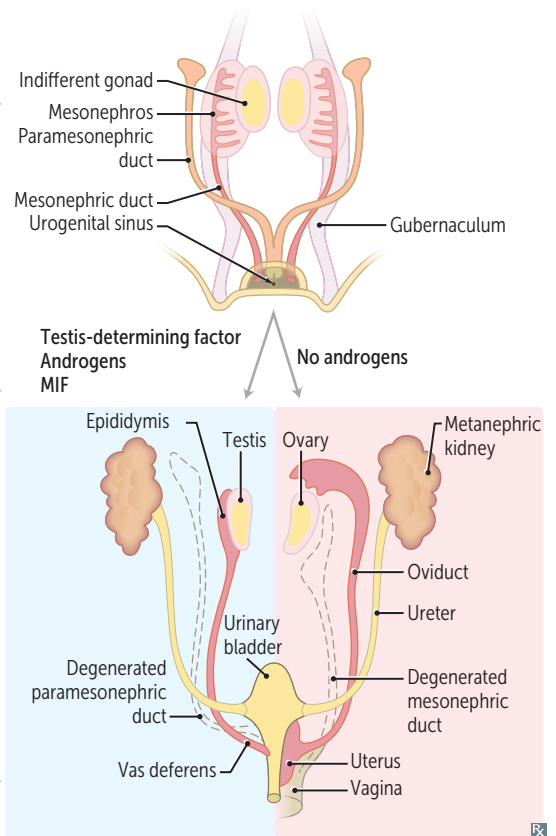
Genital embryology

Female

Default development. Mesonephric duct degenerates and paramesonephric duct develops.

Male

SRY gene on Y chromosome—produces testis-determining factor → testes development. Sertoli cells secrete Müllerian inhibitory factor (MIF, also called antimüllerian hormone) that suppresses development of paramesonephric ducts. Leydig cells secrete androgens that stimulate development of mesonephric ducts.



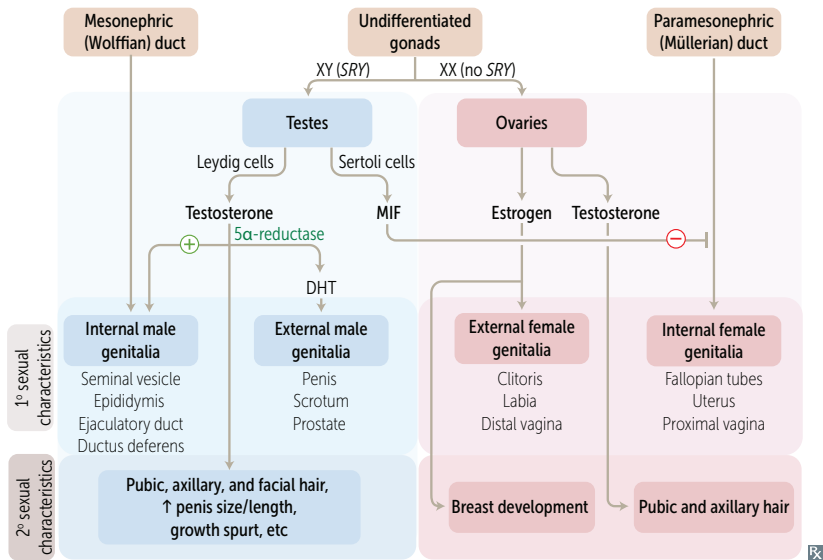
Paramesonephric (Müllerian) duct

Develops into female internal structures—fallopian tubes, uterus, proximal vagina (distal vagina from urogenital sinus). Male remnant is appendix testis. **Müllerian agenesis (Mayer-Rokitansky-Küster-Hauser syndrome)**—1° amenorrhea with absent uterus, blind vaginal pouch, normal female external genitalia and 2° sexual characteristics (functional ovaries). Associated with urinary tract anomalies (eg, renal agenesis).

Mesonephric (Wolffian) duct

Develops into male internal structures (except prostate)—**S**eminal vesicles, **E**pididymis, **E**jaculatory duct, **D**uctus deferens (**SEED**). Female remnant is Gartner duct.

Sexual differentiation



Absence of Sertoli cells or lack of Müllerian inhibitory factor \rightarrow develop both male and female internal genitalia and male external genitalia (streak gonads)

5 α -reductase deficiency— inability to convert testosterone into DHT \rightarrow male internal genitalia, atypical external genitalia until puberty (when \uparrow testosterone levels cause masculinization)

In the testes:

Leydig leads to male (internal and external) sexual differentiation.

Sertoli shuts down female (internal) sexual differentiation.

Uterine (Müllerian duct) anomalies

\downarrow fertility and \uparrow risk of complicated pregnancy (eg, spontaneous abortion, prematurity, FGR, malpresentation). Contrast with normal uterus **A**.

Septate uterus

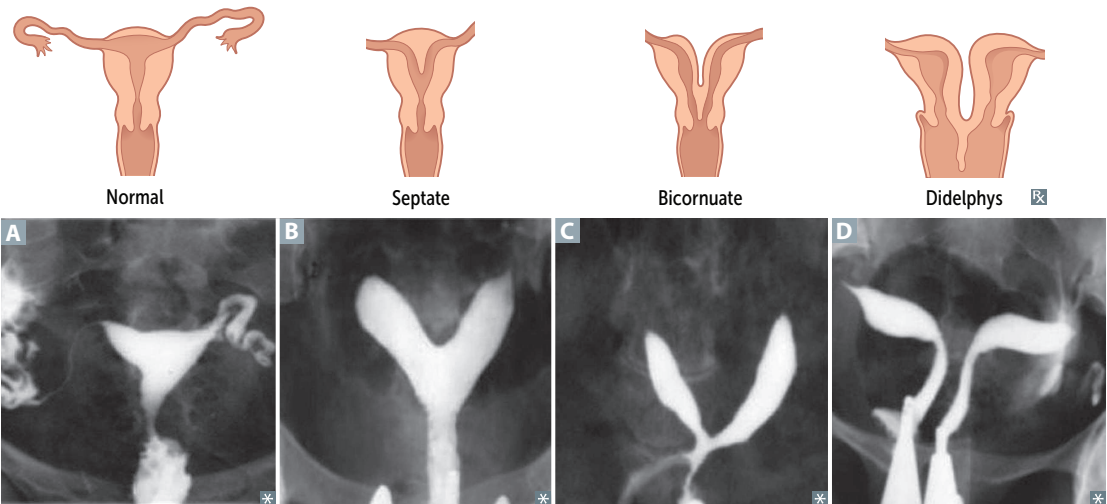
Incomplete resorption of septum **B**. Common anomaly. Treat with septoplasty.

Bicornuate uterus

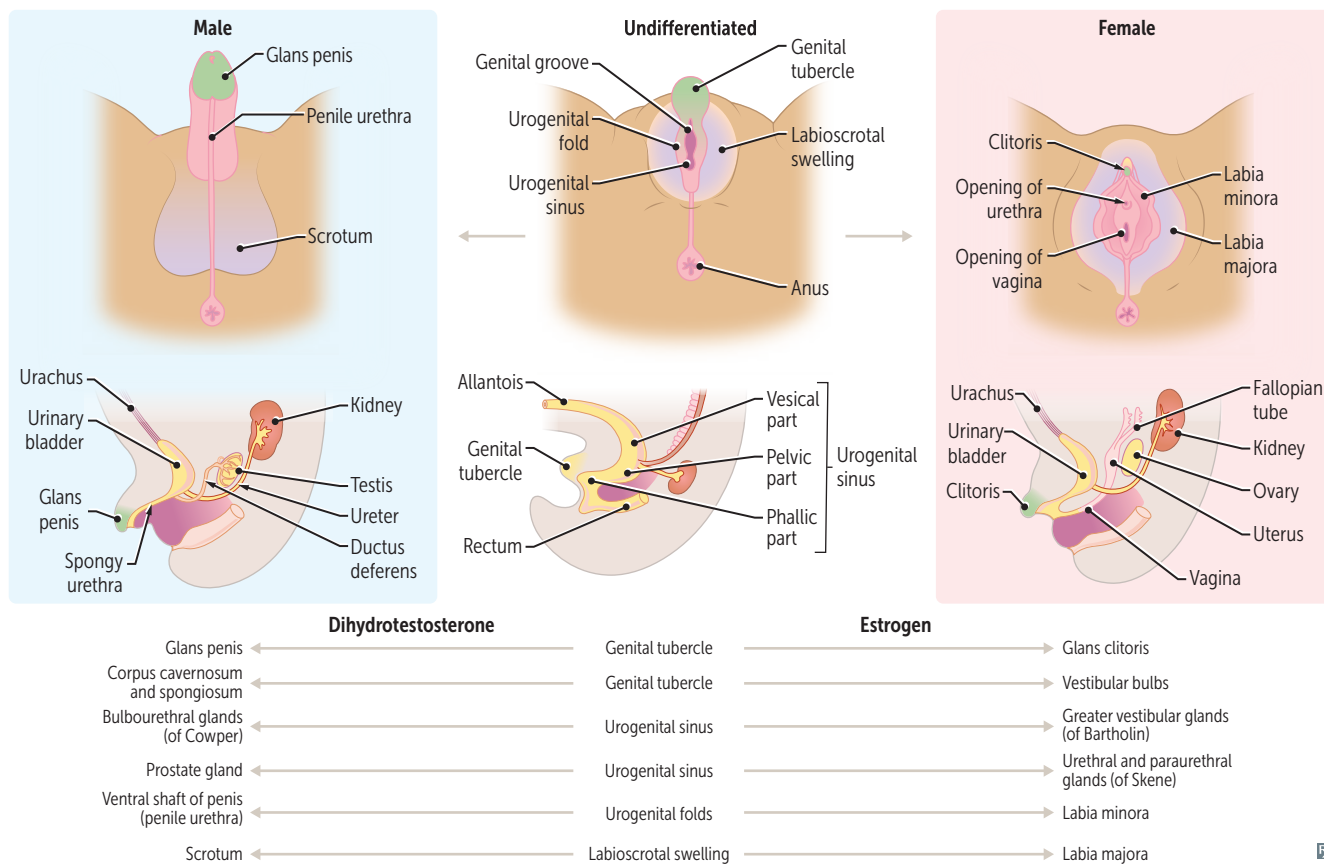
Incomplete fusion of Müllerian ducts **C**.

Uterus didelphys

Complete failure of fusion \rightarrow double uterus, cervix, vagina **D**.

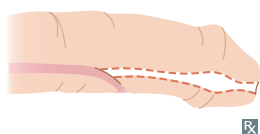


Male/female genital homologs



Congenital penile abnormalities

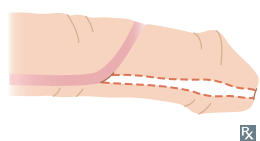
Hypospadias



Abnormal opening of penile urethra on ventral (**u**nder) surface due to failure of **u**rethral folds to fuse.

Hypospadias is more common than epispadias. Associated with inguinal hernia, cryptorchidism, chordee (downward or upward bending of penis). Can be seen in 5 α -reductase deficiency.

Epispadias



Abnormal opening of penile urethra on dorsal (**t**op) surface due to faulty positioning of genital **t**ubercle.

Exstrophy of the bladder is associated with **e**pispadias.

Descent of testes and ovaries

	DESCRIPTION	MALE REMNANT	FEMALE REMNANT
Gubernaculum	Band of fibrous tissue	Anchors testes within scrotum	Ovarian ligament + round ligament of uterus
Processus vaginalis	Evagination of peritoneum	Forms tunica vaginalis Persistent patent processus vaginalis → hydrocele	Obliterated

► REPRODUCTIVE—ANATOMY**Gonadal drainage****Venous drainage**

Left ovary/testis → left gonadal vein → left renal vein → IVC.

Right ovary/testis → right gonadal vein → IVC.
Because the left testicular vein enters the left renal vein at a 90° angle, flow is less laminar on left than on right → left venous pressure > right venous pressure → varicocele more common on the left.

“Left gonadal vein takes the longer way.”

Lymphatic drainage

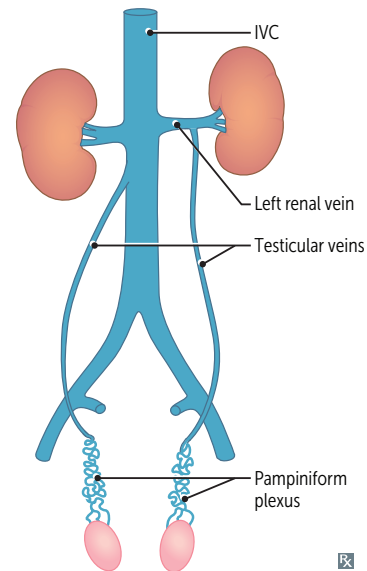
Ovaries/testes/fundus of uterus → para-aortic lymph nodes.

Body of uterus/cervix/superior part of bladder → external iliac nodes.

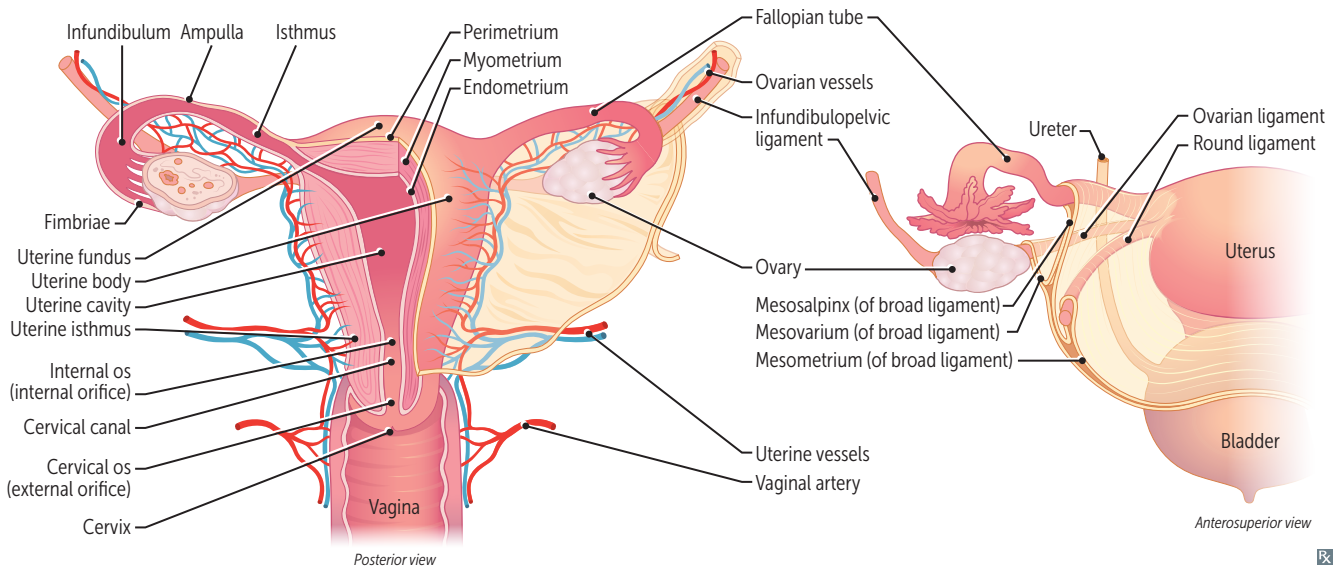
Prostate/cervix/corpus cavernosum/proximal vagina/inferior part of bladder → internal iliac nodes.

Distal vagina/vulva/scrotum/distal anus → superficial inguinal nodes.

Clitoris/glans penis → deep inguinal nodes.

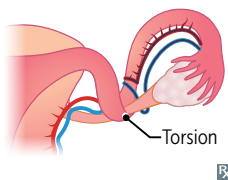


Female reproductive anatomy



LIGAMENT	CONNECTS	STRUCTURES CONTAINED	NOTES
Infundibulopelvic ligament	Ovary to lateral pelvic wall	Ovarian vessels	Also called suspensory ligament of ovary Ovarian vessel ligation during oophorectomy risks damaging the ureter
Ovarian ligament	Ovary to uterine horn		Derivative of gubernaculum
Round ligament	Uterine horn to labia majora		Travels through inguinal canal Derivative of gubernaculum
Broad ligament	Uterus to lateral pelvic wall	Ovary, fallopian tube, round ligament	Fold of peritoneum comprising the mesometrium, mesovarium, and mesosalpinx
Cardinal ligament	Cervix to lateral pelvic wall	Uterine vessels	Condensation at the base of broad ligament Uterine vessel ligation during hysterectomy risks damaging the ureter
Uterosacral ligament	Cervix to sacrum		

Adnexal torsion



Twisting of ovary and fallopian tube around infundibulopelvic ligament and ovarian ligament → compression of ovarian vessels in infundibulopelvic ligament → blockage of lymphatic and venous outflow. Continued arterial perfusion → ovarian edema → complete blockage of arterial inflow → necrosis, local hemorrhage. Associated with ovarian masses. Presents with acute pelvic pain, adnexal mass, nausea/vomiting. Surgical emergency.

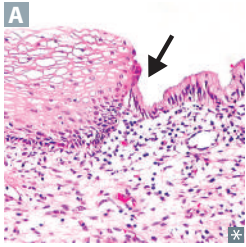
Pelvic organ prolapse

Herniation of pelvic organs to or beyond the vaginal walls (anterior, posterior) or apex. Associated with multiparity, ↑ age, obesity. Presents with pelvic pressure, bulging sensation or tissue protrusion from vagina, urinary frequency, constipation, sexual dysfunction.

- Anterior compartment prolapse—bladder (cystocele). Most common type.
- Posterior compartment prolapse—rectum (rectocele) or small bowel (enterocele).
- Apical compartment prolapse—uterus, cervix, or vaginal vault.

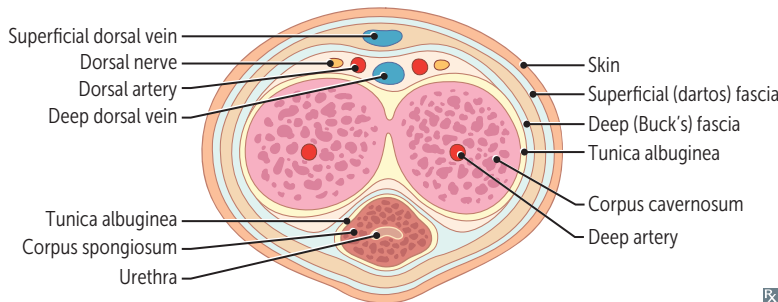
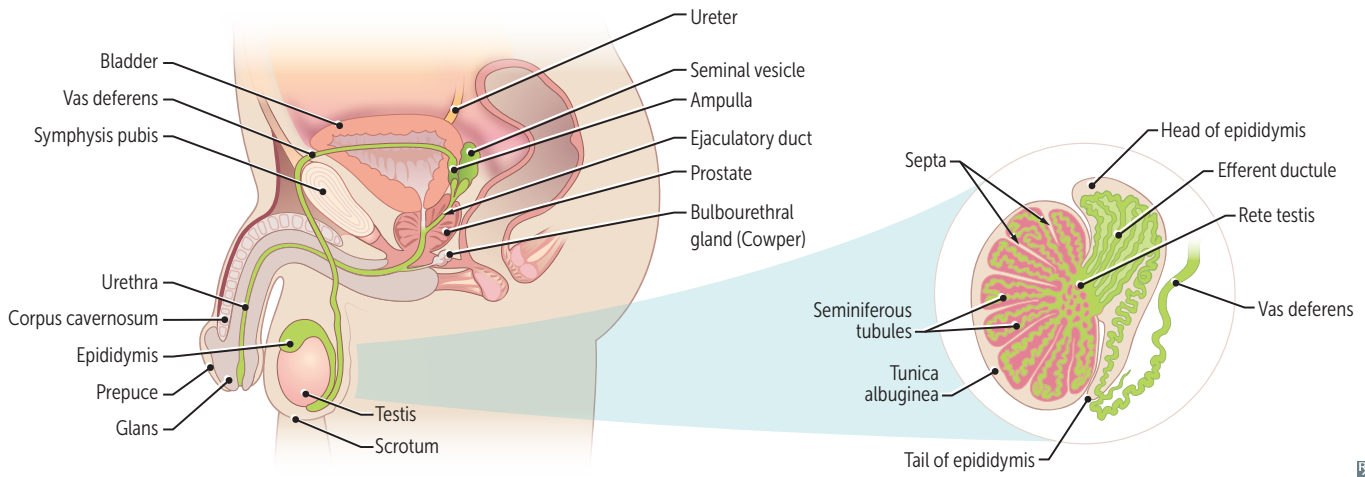
Uterine procidentia—herniation involving all 3 compartments.

Female reproductive epithelial histology



TISSUE	HISTOLOGY/NOTES
Vulva	Stratified squamous epithelium
Vagina	Stratified squamous epithelium, nonkeratinized
Ectocervix	Stratified squamous epithelium, nonkeratinized
Transformation zone	Squamocolumnar junction A (most common area for cervical cancer; sampled in Pap test)
Endocervix	Simple columnar epithelium
Uterus	Simple columnar epithelium with long tubular glands in proliferative phase; coiled glands in secretory phase
Fallopian tube	Simple columnar epithelium, ciliated
Ovary, outer surface	Simple cuboidal epithelium (germinal epithelium covering surface of ovary)

Male reproductive anatomy



Pathway of sperm during ejaculation—

- S**EVEN UP:
- S**eminiferous tubules
- E**pididymis
- V**as deferens
- E**jaculatory ducts
- (N**othing)
- U**rethra
- P**enis

Genitourinary trauma Most commonly due to blunt trauma (eg, motor vehicle collision).

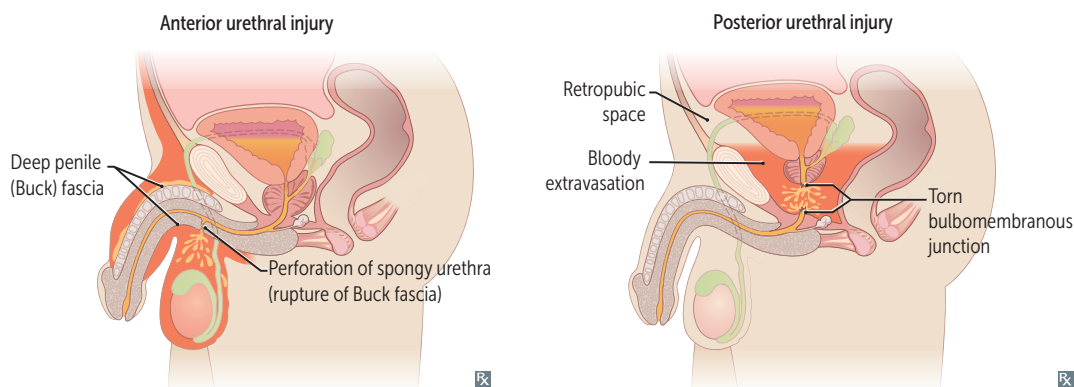
Renal injury Presents with bruises, flank pain, hematuria. Caused by direct blows or lower rib fractures.

Bladder injury Presents with hematuria, suprapubic pain, difficulty voiding.

- Superior bladder wall (dome) injury—direct trauma to full bladder (eg, seatbelt) → abrupt ↑ intravesical pressure → dome rupture (weakest part) → intraperitoneal urine accumulation. Peritoneal absorption of urine → ↑ BUN, ↑ creatinine.
- Anterior bladder wall or neck injury—pelvic fracture → perforation by bony spicules → extraperitoneal urine accumulation (retropubic space).

Urethral injury Occurs almost exclusively in males. Presents with blood at urethral meatus, hematuria, difficulty voiding. Urethral catheterization is relatively contraindicated.

- Anterior urethral injury—perineal straddle injury → disruption of bulbar (spongy) urethra → scrotal hematoma. If Buck fascia is torn, urine escapes into perineal space.
- Posterior urethral injury—pelvic fracture → disruption at bulbomembranous junction (weakest part) → urine leakage into retropubic space and high-riding prostate.



Autonomic innervation of male sexual response

Erection—**p**arasympathetic nervous system (pelvic splanchnic nerves, S2-S4):

- NO → ↑ cGMP → smooth muscle relaxation → vasodilation → proerectile.
- Norepinephrine → ↑ $[Ca^{2+}]_{in}$ → smooth muscle contraction → vasoconstriction → antierectile.

Emission—**s**ympathetic nervous system (hypogastric nerve, T11-L2).

Expulsion—visceral and **s**omatic nerves (pudendal nerve).

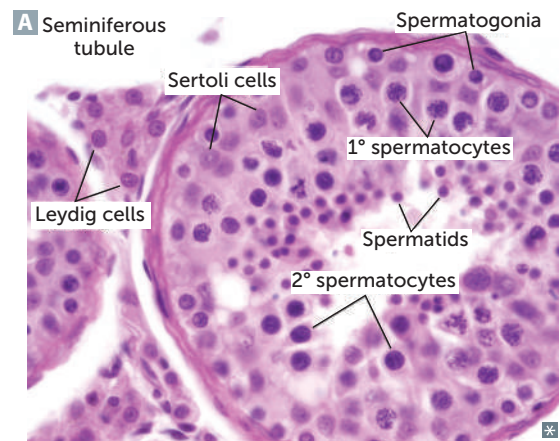
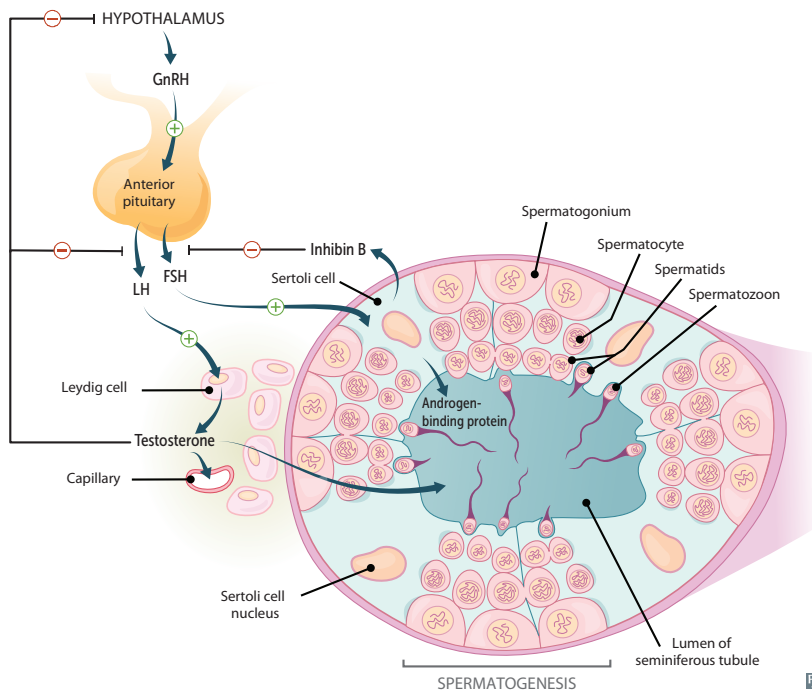
Point, **s**queeze, and **s**hoot.

S2, 3, 4 keep the penis off the **f**loor.

PDE-5 inhibitors (eg, sildenafil) → ↓ cGMP breakdown.

Seminiferous tubules

CELL	FUNCTION	LOCATION/NOTES
Spermatogonia	Maintain germ cell pool and produce 1° spermatocytes	Line seminiferous tubules A Germ cells
Sertoli cells	Secrete inhibin B → inhibit FSH Secrete androgen-binding protein → maintain local levels of testosterone Produce MIF Tight junctions between adjacent Sertoli cells form blood-testis barrier → isolate gametes from autoimmune attack Support and nourish developing spermatozoa Regulate spermatogenesis Temperature sensitive; ↓ sperm production and ↓ inhibin B with ↑ temperature	Line seminiferous tubules Non-germ cells Convert testosterone and androstenedione to estrogens via aromatase Sertoli cells are temperature sensitive, line seminiferous tubules, support sperm synthesis, and inhibit FSH Homolog of female granulosa cells ↑ temperature seen in varicocele, cryptorchidism
Leydig cells	Secrete testosterone in the presence of LH; testosterone production unaffected by temperature	Interstitial Endocrine cells Homolog of female theca interna cells



▶ REPRODUCTIVE—PHYSIOLOGY

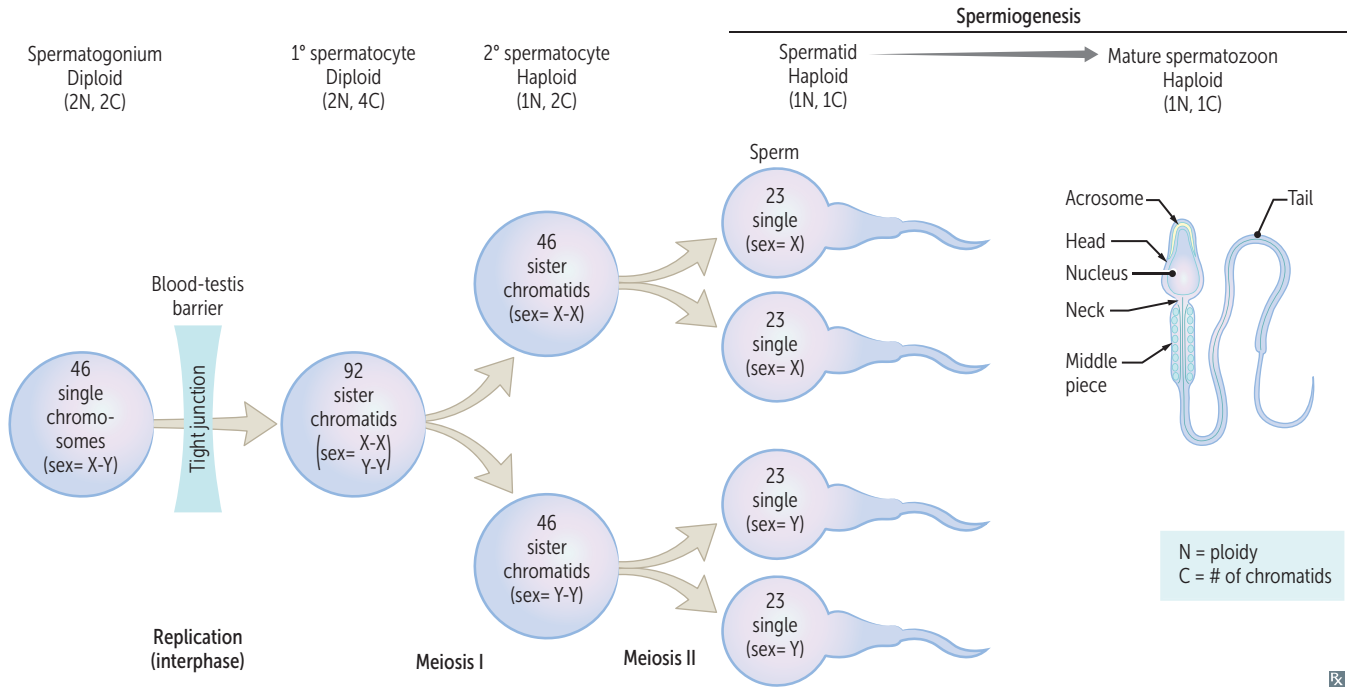
Spermatogenesis

Begins at puberty with spermatogonia. Full development takes 2 months. Occurs in seminiferous tubules. Produces spermatids that undergo spermiogenesis (loss of cytoplasmic contents, gain of acrosomal cap) to form mature spermatozoa.

“Gonium” is going to be a sperm; “zoon” is “zooming” to egg.

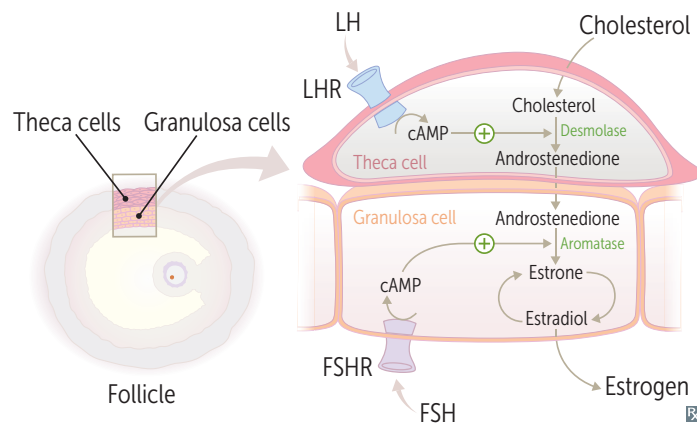
Tail mobility impaired in ciliary dyskinesia/ Kartagener syndrome → infertility.

Tail mobility normal in cystic fibrosis (in CF, absent vas deferens → infertility).



Estrogen

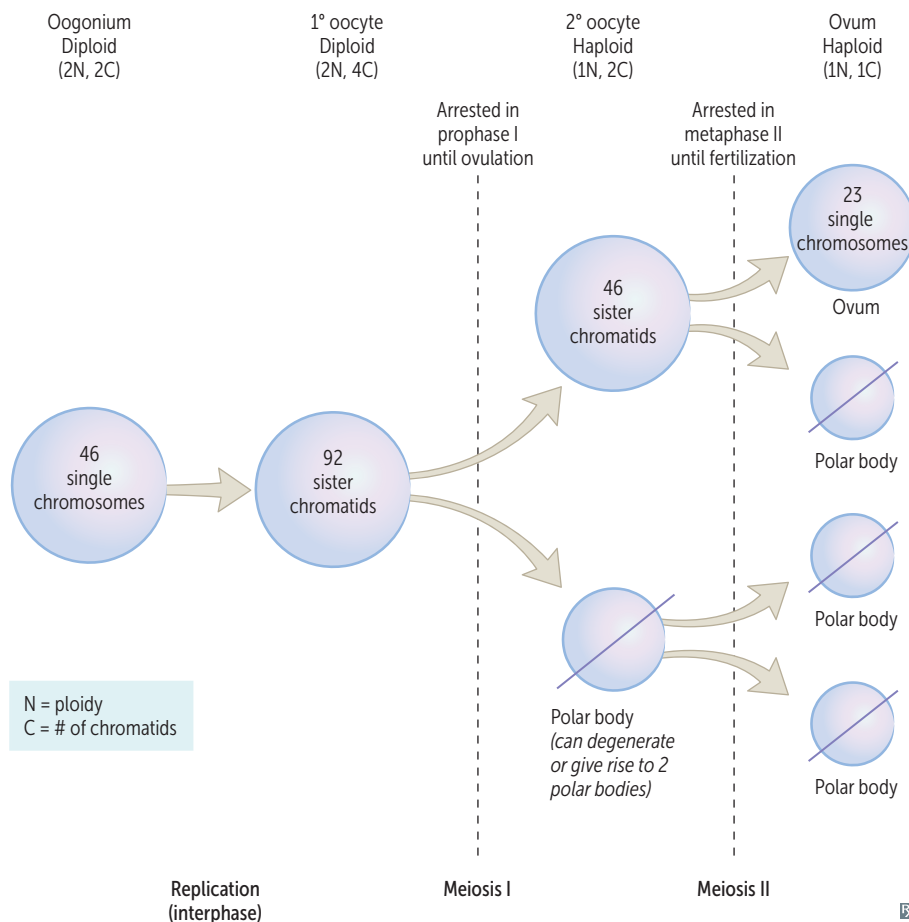
SOURCE	Ovary (17β -estradiol), placenta (estriol), adipose tissue (estrone via aromatization).	Potency: estradiol > estrone > estriol.
FUNCTION	<p>Development of internal/external genitalia, breasts, female fat distribution.</p> <p>Growth of follicle, endometrial proliferation, \uparrow myometrial excitability.</p> <p>Upregulation of estrogen, LH, and progesterone receptors; feedback inhibition of FSH and LH, then LH surge; stimulation of prolactin secretion, \downarrow prolactin action on breasts.</p> <p>\uparrow transport proteins, SHBG; \uparrow HDL; \downarrow LDL.</p>	<p>Pregnancy:</p> <ul style="list-style-type: none"> 50-fold \uparrow in estradiol and estrone 1000-fold \uparrow in estriol (indicator of fetal well-being) <p>Estrogen receptors expressed in cytoplasm; translocate to nucleus when bound by estrogen.</p>

**Progesterone**

SOURCE	Corpus luteum, placenta, adrenal cortex, testes.	Fall in estrogen and progesterone after delivery disinhibits prolactin \rightarrow lactation. \uparrow progesterone is indicative of ovulation.
FUNCTION	<p>During luteal phase, prepares uterus for implantation of fertilized egg:</p> <ul style="list-style-type: none"> Stimulation of endometrial glandular secretions and spiral artery development Production of thick cervical mucus \rightarrow inhibits sperm entry into uterus Prevention of endometrial hyperplasia \uparrow body temperature \downarrow estrogen receptor expression \downarrow gonadotropin (LH, FSH) secretion <p>During pregnancy:</p> <ul style="list-style-type: none"> Maintenance of endometrial lining and pregnancy \downarrow myometrial excitability \rightarrow \downarrow contraction frequency and intensity \downarrow prolactin action on breasts 	<p>Progesterone is pro-gestation.</p> <p>Prolactin is pro-lactation.</p>

Oogenesis

1° oocytes begin meiosis I during fetal life and complete meiosis I just prior to ovulation. Meiosis I is arrested in **prophase I (one)** for years until **ovulation (1° oocytes)**. Meiosis II is arrested in **metaphase II (two)** until **fertilization (2° oocytes)**. If fertilization does not occur within 1 day, the 2° oocyte degenerates.



Ovulation

Follicular rupture and 2° oocyte release. Caused by sudden LH release (LH surge) at **midcycle**. Estrogen normally inhibits LH release, but high estrogen at midcycle transiently stimulates LH release → LH surge → ovulation.

Mittelschmerz (“**middle hurts**”)—pain with ovulation. Associated with peritoneal irritation from normal bleeding upon follicular rupture. Typically unilateral and mild, but can mimic acute appendicitis.

Menstrual cycle

Follicular phase can fluctuate in length.

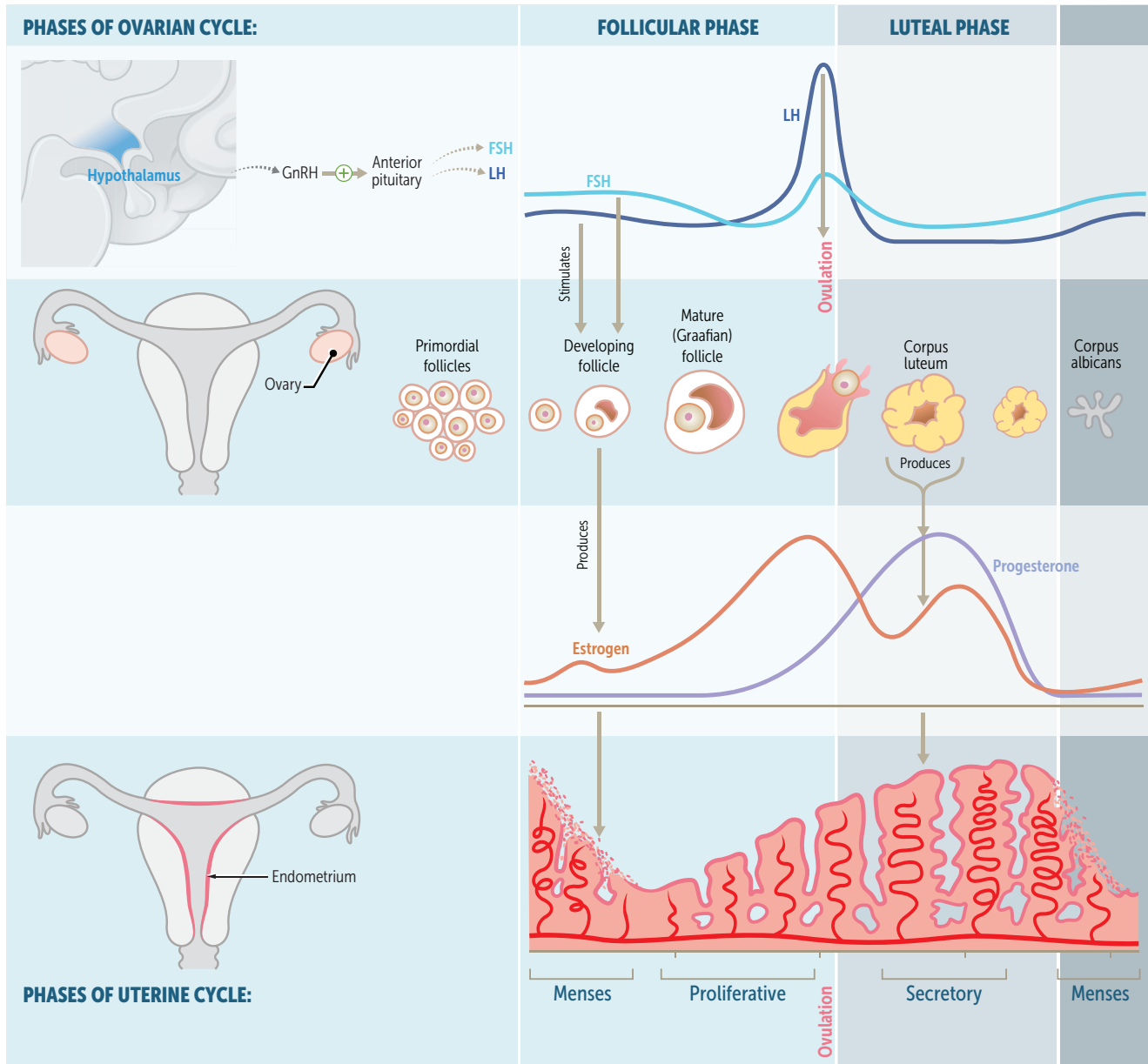
Follicular growth is fastest during 2nd week of the follicular phase.

Luteal phase is a fixed 14 days, after which menstruation occurs.

Estrogen stimulates endometrial proliferation.

Progesterone maintains endometrium to support implantation.

↓ progesterone → ↓ fertility.



Abnormal uterine bleeding

Deviation from normal menstruation volume, duration, frequency, regularity, or intermenstrual bleeding.

Causes (**PALM-COEIN**):

- Structural: **P**olyp, **A**denomyosis, **L**eiomyoma, **M**alignancy/hyperplasia
- Nonstructural: **C**oagulopathy, **O**vulatory, **E**ndometrial, **I**atrogenic, **N**ot yet classified

Terms such as dysfunctional uterine bleeding, menorrhagia, metrorrhagia, polymenorrhea, and oligomenorrhea are no longer recommended.

Pregnancy

Fertilization (conception) most commonly occurs in upper end of fallopian tube (the ampulla). Occurs within 1 day of ovulation. Implantation in the uterine wall occurs 6 days after fertilization. Syncytiotrophoblasts secrete hCG, which is detectable in blood 1 week after fertilization and on home urine tests 2 weeks after fertilization.

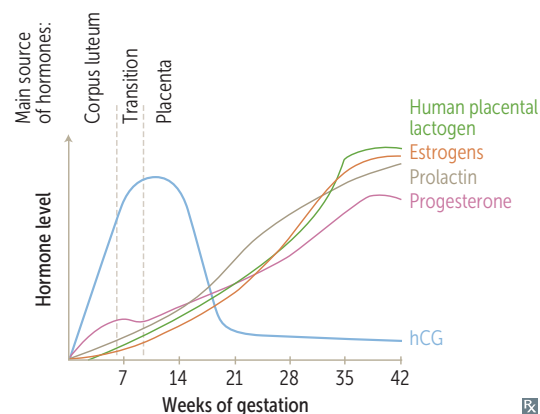
Embryonic/developmental age—time since fertilization. Used in embryology.

Gestational age—time since first day of last menstrual period. Used clinically.

Gravidity (“gravida”)—number of pregnancies.

Parity (“para”)—number of pregnancies that resulted in live births.

Placental hormone secretion generally increases over the course of pregnancy, but hCG peaks at 8–10 weeks of gestation.



Physiologic changes in pregnancy

Maternal changes that nurture the developing fetus and prepare the mother for labor and delivery. Mediated by ↑ hormones (eg, estrogen, progesterone) and mechanical effects of gravid uterus.

CARDIOVASCULAR	↓ SVR (↓ afterload) and ↑ blood volume (↑ preload) → ↑ SV → ↑ CO → ↑ placental perfusion. ↑ HR is the major contributor to ↑ CO in late pregnancy. Hemodilution → ↓ oncotic pressure → peripheral edema.
ENDOCRINE	↑ insulin resistance and secretion → ↑ lipolysis and fat utilization (to preserve glucose and amino acids for fetus). Pituitary enlargement (lactotroph hyperplasia). ↑ TBG, ↑ CBG, ↑ SHBG.
GASTROINTESTINAL	↓ GI motility, ↓ LES tone, gallbladder stasis; predispose to constipation, GERD, gallstones.
HEMATOLOGIC	Dilutional anemia (↑↑ plasma volume, ↑ RBC mass), hypercoagulable state (to ↓ blood loss at delivery). ↑ micronutrient requirements predispose to deficiency (eg, iron, folate).
MUSCULOSKELETAL	Lordosis (to realign gravity center), joint laxity (to facilitate fetal descent).
SKIN	Hyperpigmentation (eg, melasma, linea nigra, areola darkening), striae gravidarum (stretch marks), vascular changes (eg, spider angiomas, palmar erythema, varicosities).
RENAL	Vasodilation → ↑ renal plasma flow → ↑ GFR → ↓ BUN and ↓ creatinine. Mild glucosuria, proteinuria. Hydronephrosis and hydroureter (more prominent on the right) predispose to pyelonephritis.
RESPIRATORY	Respiratory center stimulation → chronic hyperventilation (↑ V _T , unchanged RR) → mild respiratory alkalosis (to ↑ fetal CO ₂ elimination).

Human chorionic gonadotropin







SOURCE	Syncytiotrophoblast of placenta.
FUNCTION	Maintains corpus luteum (and thus progesterone) for first 8–10 weeks of gestation by acting like LH (otherwise no luteal cell stimulation → abortion). Luteal-placental shift is complete after 8–10 weeks; placenta synthesizes its own estriol and progesterone and corpus luteum degenerates. Used to detect pregnancy because it appears early in urine (see above). Has identical α subunit as LH, FSH, TSH (states of \uparrow hCG can cause hyperthyroidism). β subunit is unique (pregnancy tests detect β subunit). hCG is \uparrow in multifetal gestation, hydatidiform moles, choriocarcinomas, and Down syndrome; hCG is \downarrow in ectopic/failing pregnancy, Edwards syndrome, and Patau syndrome.

Human placental lactogen

Also called human chorionic somatomammotropin.

SOURCE	Syncytiotrophoblast of placenta.
FUNCTION	Promotes insulin resistance to supply growing fetus with glucose and amino acids. Concurrently stimulates insulin secretion; inability to overcome insulin resistance → gestational diabetes.

Apgar score

	Score 2	Score 1	Score 0
A ppearance	 Pink	 Extremities blue	 Pale or blue
P ulse	≥ 100 bpm	< 100 bpm	No pulse
G rimace	Cries and pulls away	Grimaces or weak cry	No response to stimulation
A ctivity	 Active movement	 Arms, legs flexed	 No movement
R espiration	Strong cry	Slow, irregular	No breathing

Assessment of newborn vital signs following delivery via a 10-point scale evaluated at 1 minute and 5 minutes. **Apgar** score is based on **a**ppearance, **p**ulse, **g**rimace, **a**ctivity, and **r**espiration. Apgar scores < 7 may require further evaluation. If Apgar score remains low at later time points, there is \uparrow risk the child will develop long-term neurologic damage.

Low birth weight

Defined as < 2500 g. Caused by prematurity or FGR. Associated with \uparrow risk of SIDS and with \uparrow overall mortality.

Lactation

After parturition and delivery of placenta, rapid ↓ in estrogen and progesterone disinhibits prolactin → initiation of lactation. Suckling is required to maintain milk production and ejection, since ↑ nerve stimulation → ↑ oxytocin and prolactin.

Prolactin—induces and maintains lactation and ↓ reproductive function.

Oxytocin—assists in milk letdown; also promotes uterine contractions.

Breast milk is the ideal nutrition for infants < 6 months old. Contains immunoglobulins (conferring passive immunity; mostly IgA), macrophages, lymphocytes. Breast milk reduces infant infections and is associated with ↓ risk for child to develop asthma, allergies, diabetes mellitus, and obesity. Guidelines recommend exclusively breastfed infants get vitamin D and possibly iron supplementation.

Breastfeeding facilitates bonding with the child. Breastfeeding or donating milk ↓ risk of breast and ovarian cancers.

Menopause

Diagnosed by amenorrhea for 12 months. ↓ estrogen production due to age-linked decline in number of ovarian follicles. Average age at onset is 51 years (earlier in people who smoke tobacco).

Usually preceded by 4–5 years of abnormal menstrual cycles. Source of estrogen (estrone) after menopause becomes peripheral conversion of androgens, ↑ androgens → hirsutism.

↑↑ FSH is specific for menopause (loss of negative feedback on FSH due to ↓ estrogen).

Hormonal changes: ↓ estrogen, ↑↑ FSH, ↑ LH (no surge), ↑ GnRH.

Causes **HAVOCS**: **H**ot flashes (most common), **A**trophy of the **V**agina, **O**steoporosis, **C**oronary artery disease, **S**leep disturbances.

Menopause before age 40 suggests 1° ovarian insufficiency (premature ovarian failure); may occur in females who have received chemotherapy and/or radiation therapy.

Androgens

Testosterone, dihydrotestosterone (DHT), androstenedione.

SOURCE

DHT and testosterone (testis), **and**rostenedione (**ad**renal)

Potency: DHT > testosterone > androstenedione.

FUNCTION

Testosterone:

- Differentiation of epididymis, vas deferens, seminal vesicles (internal genitalia, except prostate)
- Growth spurt: penis, seminal vesicles, sperm, muscle, RBCs
- Deepening of voice
- Closing of epiphyseal plates (via estrogen converted from testosterone)
- Libido

DHT:

- Early—differentiation of penis, scrotum, prostate
- Late—prostate growth, balding, sebaceous gland activity

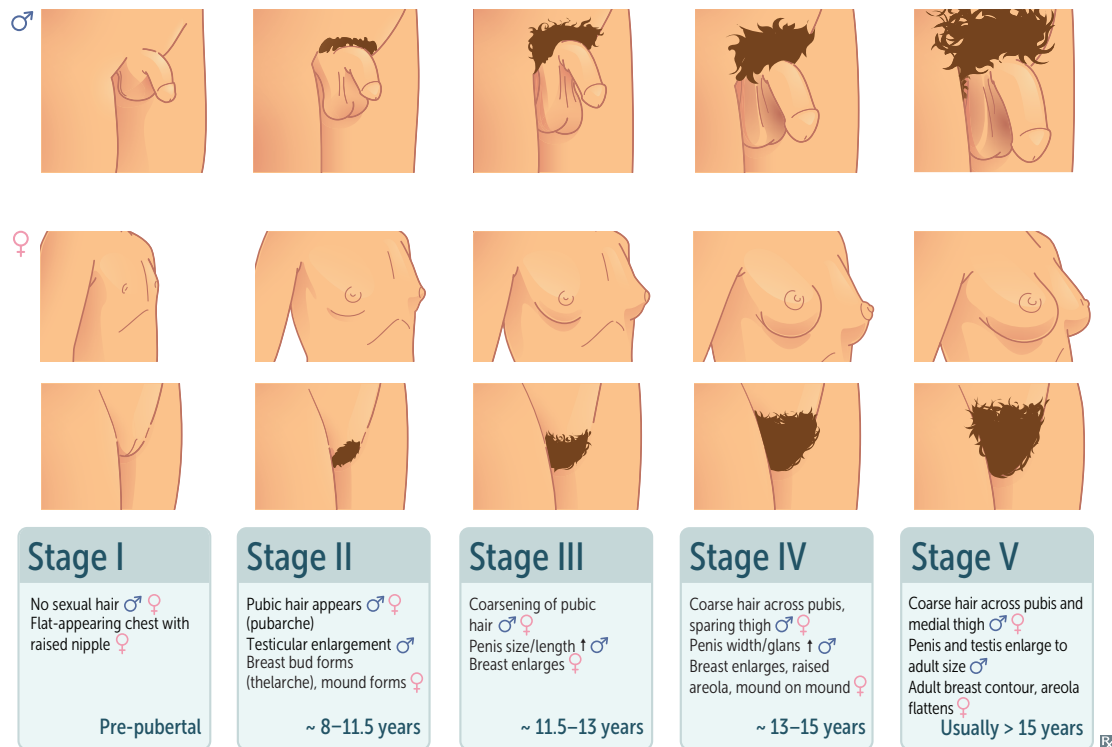
Testosterone is converted to DHT by

5α-reductase, which is inhibited by finasteride. In the male, **and**rogens are converted to **est**rogens by **aromatase** (primarily in adipose tissue and testes).

Anabolic-androgenic steroid use—↑ fat-free mass, muscle strength, performance. Suspect in males who present with changes in behavior (eg, aggression), acne, gynecomastia, erythrocytosis (↑ risk of thromboembolism), small testes (exogenous testosterone → hypothalamic-pituitary-gonadal axis inhibition → ↓ intratesticular testosterone → ↓ testicular size, ↓ sperm count, azoospermia). Females may present with virilization (eg, hirsutism, acne, breast atrophy, male pattern baldness).

Tanner stages of sexual development

Tanner stage is assigned independently to genitalia, pubic hair, and breast (eg, a person can have Tanner stage 2 genitalia, Tanner stage 3 pubic hair). Earliest detectable secondary sexual characteristic is breast bud development in females, testicular enlargement in males.



Precocious puberty

Appearance of 2° sexual characteristics (eg, pubarche, thelarche) before age 8 years in females and 9 years in males. ↑ sex hormone exposure or production → ↑ linear growth, somatic and skeletal maturation (eg, premature closure of epiphyseal plates → short stature). Types include:

- Central precocious puberty (↑ GnRH secretion): idiopathic (most common; early activation of hypothalamic-pituitary gonadal axis), CNS tumors.
- Peripheral precocious puberty (GnRH-independent; ↑ sex hormone production or exposure to exogenous sex steroids): congenital adrenal hyperplasia, estrogen-secreting ovarian tumor (eg, granulosa cell tumor), Leydig cell tumor, McCune-Albright syndrome.

Delayed puberty

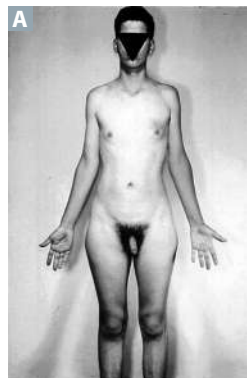Absence of 2° sexual characteristics by age 13 years in females and 14 years in males. Causes:

- Hypergonadotropic (1°) hypogonadism: Klinefelter syndrome, Turner syndrome, gonadal injury (eg, chemotherapy, radiotherapy, infection).
- Hypogonadotropic (2°) hypogonadism: constitutional delay of growth and puberty (“late blooming”), Kallman syndrome, CNS lesions.

▶ REPRODUCTIVE—PATHOLOGY

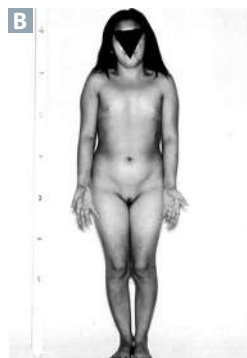Sex chromosome disorders

Aneuploidy most commonly due to meiotic nondisjunction.

Klinefelter syndrome

Male, 47,XXY.
Small, firm testes; infertility (azoospermia); tall stature with eunuchoid proportions (delayed epiphyseal closure → ↑ long bone length); gynecomastia; female hair distribution **A**.
May present with developmental delay.
Presence of inactivated X chromosome (Barr body). Common cause of hypogonadism seen in infertility workup. ↑ risk of breast cancer.

Dysgenesis of seminiferous tubules
→ ↓ inhibin B → ↑ FSH.
Abnormal Leydig cell function → ↓ testosterone
→ ↑ LH.

Turner syndrome

Female, 45,XO.
Short stature (associated with *SHOX* gene, preventable with growth hormone therapy), ovarian dysgenesis (streak ovary), broad chest with widely spaced nipples **B**, bicuspid aortic valve, coarctation of the aorta (femoral < brachial pulse), lymphatic defects (result in webbed neck or cystic hygroma; lymphedema in feet, hands), horseshoe kidney, high-arched palate, shortened 4th metacarpals.
Most common cause of 1° amenorrhea. No Barr body.

Menopause before menarche.
↓ estrogen leads to ↑ LH, FSH.
Sex chromosome (X, or rarely Y) loss often due to nondisjunction during meiosis or mitosis.
Meiosis errors usually occur in paternal gametes
→ sperm missing the sex chromosome.
Mitosis errors occur after zygote formation → loss of sex chromosome in some but not all cells
→ mosaic karyotype (eg. 45,X/46XX).
(45,X/46,XY) mosaicism associated with increased risk for gonadoblastoma.
Pregnancy is possible in some cases (IVF, exogenous estradiol-17β and progesterone).

Double Y males

47, XYY.
Phenotypically normal (usually undiagnosed), very tall. Normal fertility. May be associated with severe acne, learning disability, autism spectrum disorders.

Other disorders of sex development	Formerly called intersex states. Discrepancy between phenotypic sex (external genitalia, influenced by hormonal levels) and gonadal sex (testes vs ovaries, corresponds with Y chromosome).
46,XX DSD	Ovaries present, but external genitalia are virilized or atypical. Most commonly due to congenital adrenal hyperplasia (excessive exposure to androgens early in development).
46,XY DSD	Testes present, but external genitalia are feminized or atypical. Most commonly due to androgen insensitivity syndrome (defect in androgen receptor).
Ovotesticular DSD	46,XX > 46,XY. Both ovarian and testicular tissue present (ovotestis); atypical genitalia.

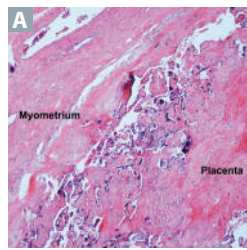
Diagnosing disorders by sex hormones	Testosterone	LH	Diagnosis
	↑	↑	Androgen insensitivity syndrome
	↑	↓	Testosterone-secreting tumor, exogenous androgenic steroids
	↓	↑	Hypergonadotropic (1°) hypogonadism
	↓	↓	Hypogonadotropic (2°) hypogonadism

Diagnosing disorders by physical characteristics	Uterus	Breasts	Diagnosis
	⊕	⊖	Hypergonadotropic (1°) hypogonadism in genotypic female Hypogonadotropic (2°) hypogonadism in genotypic female
	⊖	⊕	Müllerian agenesis in genotypic female Androgen insensitivity syndrome in genotypic male

Aromatase deficiency	Inability to synthesize endogenous estrogens. Autosomal recessive. During fetal life, DHEA produced by fetal adrenal glands cannot be converted to estrogen by the placenta and is converted to testosterone peripherally → virilization of both female infant (atypical genitalia) and mother (acne, hirsutism; fetal androgens can cross placenta).
Androgen insensitivity syndrome	Defect in androgen receptor resulting in female-appearing genetic male (46,XY DSD); female external genitalia with scant axillary and pubic hair, rudimentary vagina; uterus and fallopian tubes absent due to persistence of anti-Müllerian hormone from testes. Patients develop normal functioning testes (often found in labia majora; surgically removed to prevent malignancy). ↑ testosterone, estrogen, LH (vs sex chromosome disorders).
5α-reductase deficiency	Autosomal recessive; sex limited to genetic males (46,XY DSD). Inability to convert testosterone to DHT. Atypical genitalia until puberty, when ↑ testosterone causes masculinization/↑ growth of external genitalia. Testosterone/estrogen levels are normal; LH is normal or ↑. Internal genitalia are normal.
Kallmann syndrome	Failure to complete puberty; a form of hypogonadotropic hypogonadism. Defective migration of neurons and subsequent failure of olfactory bulbs to develop → ↓ synthesis of GnRH in the hypothalamus; hyposmia/anosmia; ↓ GnRH, FSH, LH, testosterone. Infertility (low sperm count in males; amenorrhea in females).

Placental disorders

Placenta accreta spectrum

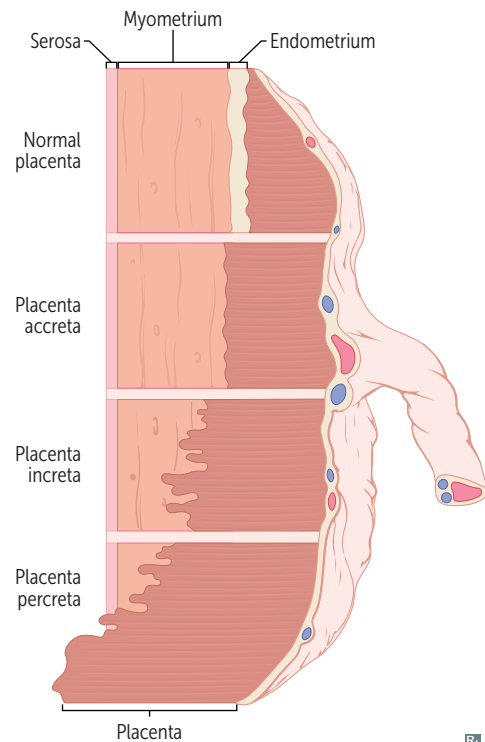


Formerly called morbidly adherent placenta.

Abnormal invasion of trophoblastic tissue into uterine wall **A**. Risk factors: prior C-section or other uterine surgery (areas of uterine scarring impair normal decidualization), placenta previa, ↑ maternal age, multiparity. Three types depending on depth of trophoblast invasion:

- **Placenta accreta**—attaches to myometrium (instead of overlying decidua basalis) without invading it. Most common type.
- **Placenta increta**—partially invades **into** myometrium.
- **Placenta percreta**—completely invades (“**perforates**”) through myometrium and serosa, sometimes extending into adjacent organs (eg, bladder → hematuria).

Presents with difficulty separating placenta from uterus after fetal delivery and severe postpartum hemorrhage upon attempted manual removal of placenta (often extracted in pieces).



Placenta previa

Attachment of placenta over internal cervical os (a “**preview**” of the placenta is visible through cervix). Risk factors: prior C-section, multiparity.

Presents with painless vaginal bleeding in third trimester.

Low-lying placenta—located < 2 cm from, but not covering, the internal cervical os.

Vasa previa

Fetal vessels run over, or < 2 cm from, the internal cervical os. Risk factors: velamentous insertion of umbilical cord (inserts in chorioamniotic membrane rather than placenta → fetal vessels travel to placenta unprotected by Wharton jelly), bilobed or succenturiate placenta.

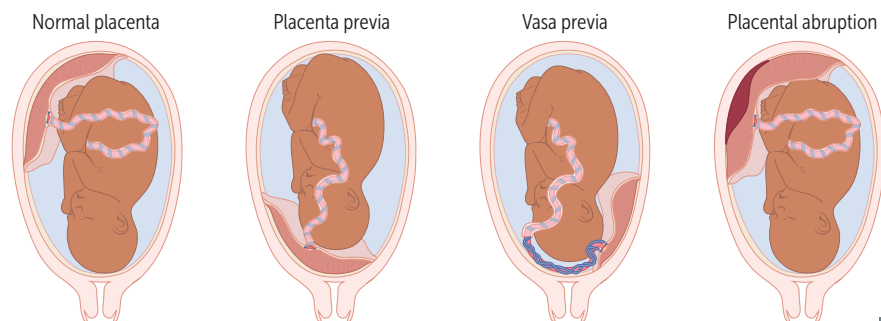
Presents with painless vaginal bleeding (fetal blood from injured vessels) upon rupture of membranes accompanied by fetal heart rate abnormalities (eg, bradycardia). May lead to fetal death from exsanguination.

Placental abruption

Also called abruption placentae. Premature separation of placenta from uterus prior to fetal delivery.

Risk factors: maternal hypertension, preeclampsia, smoking, cocaine use, abdominal trauma.

Presents with **abrupt**, painful vaginal bleeding in third trimester; can lead to maternal hypovolemic shock (due to hemorrhage) and DIC (due to release of tissue factor from injured placenta), fetal distress (eg, hypoxia). May be life threatening for both mother and fetus.



Uterine rupture

Full-thickness disruption of uterine wall. Risk factors: prior C-section (usually occurs during labor in a subsequent pregnancy), abdominal trauma.

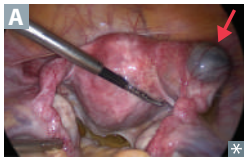Presents with painful vaginal bleeding, fetal heart rate abnormalities (eg, bradycardia), easily palpable fetal parts, loss of fetal station. May be life threatening for both mother and fetus.

Postpartum hemorrhage

Greater-than-expected blood loss after delivery. Leading cause of maternal mortality worldwide.

Etiology (**4 T's**): **T**one (uterine atony → soft, boggy uterus; most common), **T**rauma (eg, lacerations, incisions, uterine rupture), **T**issue (retained products of conception), **T**hrombin (coagulopathy).

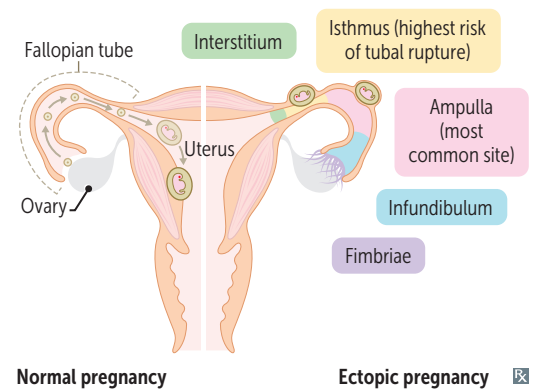
Treatment: uterine massage, oxytocin. If refractory, surgical ligation of uterine or internal iliac arteries (fertility is preserved since ovarian arteries provide collateral circulation).

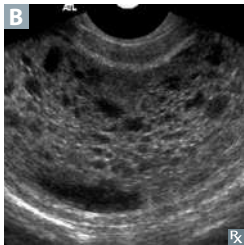
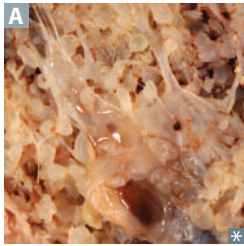
Ectopic pregnancy

Implantation of fertilized ovum in a site other than the uterus, most often in ampulla of fallopian tube **A**. Risk factors: tubal pathologies (eg, scarring from salpingitis [PID] or surgery), previous ectopic pregnancy, IUD, IVF.

Presents with first-trimester bleeding and/or lower abdominal pain. Often clinically mistaken for appendicitis. Suspect in patients with history of amenorrhea, lower-than-expected rise in hCG based on dates. Confirm with ultrasound, which may show extraovarian adnexal mass.

Treatment: methotrexate, surgery.

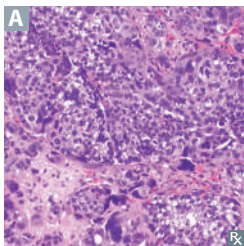


Hydatidiform mole

Cystic swelling of chorionic villi and proliferation of chorionic epithelium (only trophoblast). Presents with vaginal bleeding, emesis, uterine enlargement more than expected, pelvic pressure/pain. Associated with hCG-mediated sequelae: hyperthyroidism, theca lutein cysts, hyperemesis gravidarum, early preeclampsia (before 20 weeks of gestation).

Treatment: dilation and curettage +/- methotrexate. Monitor hCG.

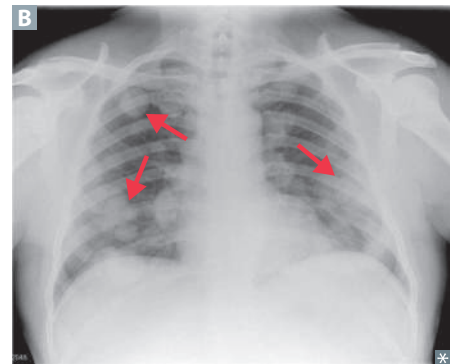
	Complete mole	Partial mole
KARYOTYPE	46,XX (most common); 46,XY	69,XXX; 69,XXY; 69,XYY
COMPONENTS	Most commonly enucleated egg + single sperm (subsequently duplicates paternal DNA)	2 sperm + 1 egg
HISTOLOGY	Hydropic villi, circumferential and diffuse trophoblastic proliferation	Only some villi are hydropic, focal/minimal trophoblastic proliferation
FETAL PARTS	No	Yes (partial = fetal parts)
STAINING FOR P57 PROTEIN	⊖ (paternally imprinted)	⊕ (maternally expressed) Partial mole is P57 positive
UTERINE SIZE	↑	—
hCG	↑↑↑↑	↑
IMAGING	“Honeycombed” uterus or “clusters of grapes” A , “snowstorm” B on ultrasound	Fetal parts
RISK OF INVASIVE MOLE	15–20%	< 5%
RISK OF CHORIOCARCINOMA	2%	Rare

Choriocarcinoma

Rare malignancy of trophoblastic tissue **A** (cytotrophoblasts, syncytiotrophoblasts), without chorionic villi present. Most commonly occurs after an abnormal pregnancy (eg, hydatidiform mole, abortion); can occur nongestationally in gonads.

Presents with abnormal uterine bleeding, hCG-mediated sequelae, dyspnea, hemoptysis. Hematogenous spread to lungs → “cannonball” metastases **B**.

Treatment: methotrexate.



Hypertension in pregnancy

Gestational hypertension	BP > 140/90 mm Hg after 20 weeks of gestation. No preexisting hypertension. No proteinuria or end-organ damage. Hypertension prior to 20 weeks of gestation suggests chronic hypertension. Treatment: antihypertensives (H ydralazine, α - m ethyldopa, l abetalol, n ifedipine), deliver at 37–39 weeks. H ypertensive m oms l ove n ifedipine.	
Preeclampsia	New-onset hypertension with either proteinuria or end-organ dysfunction after 20 weeks' gestation (onset of preeclampsia < 20 weeks of gestation may suggest molar pregnancy). Caused by abnormal placental spiral arteries → endothelial dysfunction, vasoconstriction, ischemia. Risk factors: history of preeclampsia, multifetal gestation, chronic hypertension, diabetes, chronic kidney disease, autoimmune disorders (eg, antiphospholipid syndrome), obesity, age > 35 years. Complications: placental abruption, coagulopathy, renal failure, pulmonary edema, uteroplacental insufficiency; may lead to eclampsia and/or HELLP syndrome. Treatment: antihypertensives, IV magnesium sulfate (to prevent seizure); definitive is delivery. Prophylaxis: aspirin.	
Eclampsia	Preeclampsia with seizures. Death due to stroke, intracranial hemorrhage, ARDS. Treatment: IV magnesium sulfate, antihypertensives, immediate delivery.	
HELLP syndrome	Preeclampsia with thrombotic microangiopathy of the liver. H emolysis, E levated L iver enzymes, L ow P latelets. May occur in the absence of hypertension and proteinuria. Blood smear shows schistocytes. Can lead to hepatic subcapsular hematomas (rupture → severe hypotension) and DIC (due to release of tissue factor from injured placenta). Treatment: immediate delivery.	
Supine hypotensive syndrome	Also called aortocaval compression syndrome. Seen at > 20 weeks of gestation. Supine position → compression of abdominal aorta and IVC by gravid uterus → ↓ placental perfusion (can lead to pregnancy loss) and ↓ venous return (hypotension). Relieved by left lateral decubitus position.	
Gynecologic tumor epidemiology	Incidence (US)—endometrial > ovarian > cervical; cervical cancer is more common worldwide due to lack of screening or HPV vaccination. Prognosis: C ervical (best prognosis, diagnosed < 45 years old) > E ndometrial (middle-aged, about 55 years old) > O varian (worst prognosis, > 65 years).	CEO s often go from best to worst as they get older.

Vulvar pathology**Non-neoplastic**

Bartholin cyst and abscess Due to blockage of Bartholin gland duct causing accumulation of gland fluid. May lead to abscess 2° to obstruction and inflammation **A**. Usually in reproductive-age females.

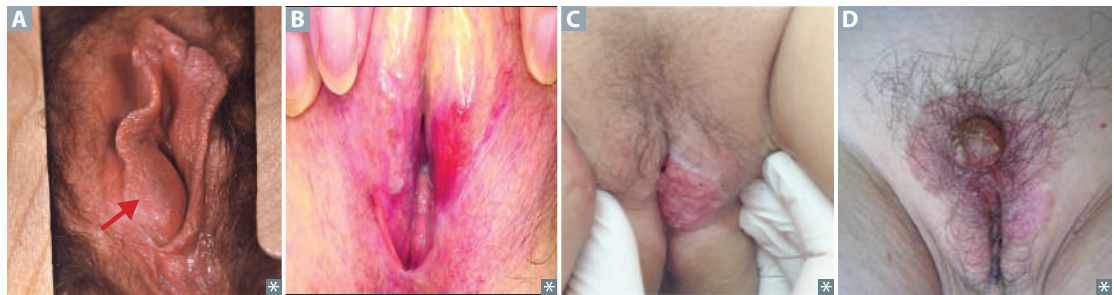Lichen sclerosus Chronic, progressive inflammatory disease characterized by porcelain-white plaques **B** that can be hemorrhagic, eroded, or ulcerated. May extend to anus producing figure-eight appearance. ↑ incidence in prepubertal and peri-/postmenopausal females. Presents with intense pruritus, dyspareunia, dysuria, dyschezia. Benign, but slightly ↑ risk for SCC.

Lichen simplex chronicus Hyperplasia of vulvar squamous epithelium. Presents with leathery, thick vulvar skin with enhanced skin markings due to chronic rubbing or scratching. Benign, no risk of SCC.

Neoplastic

Vulvar carcinoma Carcinoma from squamous epithelial lining of vulva **C**. Rare. Presents with leukoplakia, biopsy often required to distinguish carcinoma from other causes.
 HPV-related vulvar carcinoma—associated with high-risk HPV types 16, 18. Risk factors: multiple partners, early coitarche. Usually in reproductive-age females.
 Non-HPV vulvar carcinoma—usually from long-standing lichen sclerosus. Females > 70 years old.

Extramammary Paget disease Intraepithelial adenocarcinoma. Carcinoma in situ, low risk of underlying carcinoma (vs Paget disease of the breast, which is always associated with underlying carcinoma). Presents with pruritus, erythema, crusting, ulcers **D**.



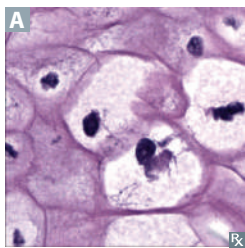
Imperforate hymen Incomplete degeneration of the central portion of the hymen. Accumulation of vaginal mucus at birth → self-resolving bulge in introitus. If untreated, leads to 1° amenorrhea, cyclic abdominal pain, hematocolpos (accumulation of menstrual blood in vagina → bulging and bluish hymenal membrane).

Vaginal tumors

Squamous cell carcinoma Usually 2° to cervical SCC; 1° vaginal carcinoma rare.

Clear cell adenocarcinoma Arises from vaginal adenosis (persistence of glandular columnar epithelium in proximal vagina), found in females who had exposure to diethylstilbestrol in utero.

Sarcoma botryoides Embryonal rhabdomyosarcoma variant. Affects females < 4 years old; spindle-shaped cells; desmin ⊕. Presents with clear, grapelike, polypoid mass emerging from vagina.

Cervical pathology**Dysplasia and carcinoma in situ**

Disordered epithelial growth; begins at basal layer of squamocolumnar junction (transformation zone) and extends outward. Classified as CIN 1, CIN 2, or CIN 3 (severe, irreversible dysplasia or carcinoma in situ), depending on extent of dysplasia. Associated with HPV-16 and HPV-18, which produce both the E6 gene product (inhibits *TP53*) and E7 gene product (inhibits *pRb*) (6 before 7; P before R). Koilocytes (cells with wrinkled “raisinoid” nucleus and perinuclear halo **A**) are pathognomonic of HPV infection. May progress slowly to invasive carcinoma if left untreated. Typically asymptomatic (detected with Pap smear) or presents as abnormal vaginal bleeding (often postcoital).

Risk factors: multiple sexual partners, HPV, smoking, early coitarche, DES exposure, immunocompromise (eg, HIV, transplant).

Invasive carcinoma

Often squamous cell carcinoma. Pap smear can detect cervical dysplasia before it progresses to invasive carcinoma. Diagnose via colposcopy and biopsy. Lateral invasion can block ureters → hydronephrosis → renal failure.

Primary ovarian insufficiency

Also called premature ovarian failure.

Premature atresia of ovarian follicles in females of reproductive age. Most often idiopathic; associated with chromosomal abnormalities (eg, Turner syndrome, fragile X syndrome premutation), autoimmunity. Need karyotype screening. Patients present with signs of menopause after puberty but before age 40. ↓ estrogen, ↑ LH, ↑ FSH.

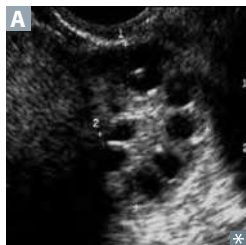
Most common causes of anovulation

Pregnancy, polycystic ovarian syndrome, obesity, HPO axis abnormalities/immaturity, premature ovarian failure, hyperprolactinemia, thyroid disorders, eating disorders, competitive athletics, Cushing syndrome, adrenal insufficiency, chromosomal abnormalities (eg, Turner syndrome).

Functional hypothalamic amenorrhea

Also called exercise-induced amenorrhea. Severe caloric restriction, ↑ energy expenditure, and/or stress → functional disruption of pulsatile GnRH secretion → ↓ LH, FSH, estrogen. Pathogenesis includes ↓ leptin (due to ↓ fat) and ↑ cortisol (stress, excessive exercise).

Associated with eating disorders and “female athlete triad” (↓ calorie availability/excessive exercise, ↓ bone mineral density, menstrual dysfunction).

Polycystic ovarian syndrome

Hyperinsulinemia and/or insulin resistance hypothesized to alter hypothalamic hormonal feedback response → ↑ LH:FSH, ↑ androgens (eg, testosterone) from theca interna cells, ↓ rate of follicular maturation → unruptured follicles (cysts) + anovulation. Common cause of ↓ fertility in females.

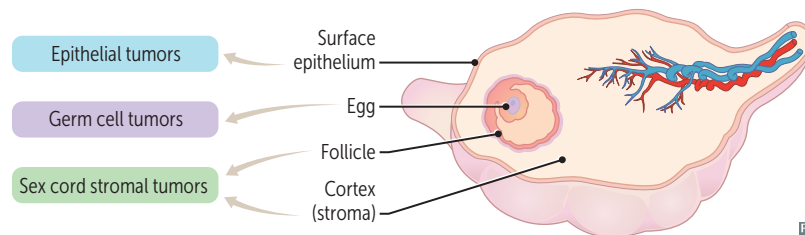
Diagnosed based on ≥ 2 of the following: cystic/enlarged ovaries on ultrasound **A**, oligo-/anovulation, hyperandrogenism (eg, hirsutism, acne). Associated with obesity, acanthosis nigricans. ↑ risk of endometrial cancer 2° to unopposed estrogen from repeated anovulatory cycles.

Treatment: cycle regulation via weight reduction (↓ peripheral estrone formation), OCPs (prevent endometrial hyperplasia due to unopposed estrogen); clomiphene (ovulation induction); spironolactone, finasteride, flutamide to treat hirsutism.

Primary dysmenorrhea Painful menses, caused by uterine contractions to ↓ blood loss → ischemic pain. Mediated by prostaglandins. Treatment: NSAIDs, acetaminophen, hormonal contraceptives.

Ovarian cysts	Usually asymptomatic, but may rupture, become hemorrhagic, or lead to adnexal torsion.
Follicular cyst	Functional (physiologic) cyst. Most common ovarian mass in young females. Caused by failure of mature follicle to rupture and ovulate. May produce excess estrogen. Usually resolves spontaneously.
Corpus luteal cyst	Functional cyst. Caused by failure of corpus luteum to involute after ovulation. May produce excess progesterone. Usually resolves spontaneously.
Theca lutein cyst	Also called hyperreactio luteinalis. Caused by hCG overstimulation. Often bilateral/multiple. Associated with gestational trophoblastic disease (eg, hydatidiform mole, choriocarcinoma).

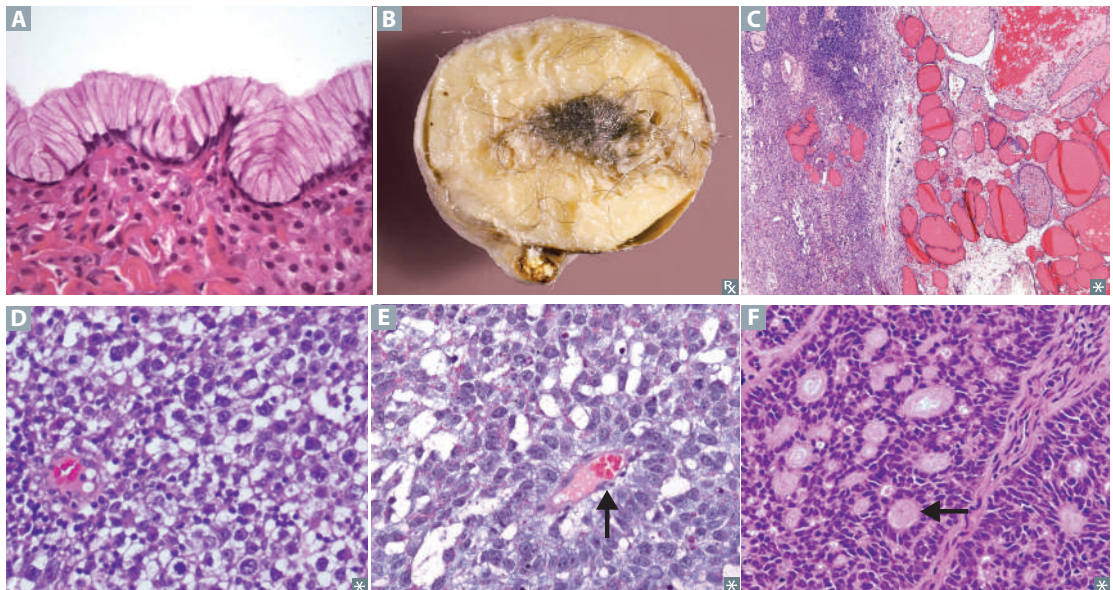
Ovarian tumors Most common adnexal mass in females > 55 years old. Present with abdominal distention, bowel obstruction, pleural effusion.
 Risk ↑ with advanced age, ↑ number of lifetime ovulations (early menarche, late menopause, nulliparity), endometriosis, genetic predisposition (eg, *BRCA1/BRCA2* mutations, Lynch syndrome).
 Risk ↓ with previous pregnancy, history of breastfeeding, OCPs, tubal ligation.
 Epithelial tumors are typically serous (lined by serous epithelium natively found in fallopian tubes, and often bilateral) or mucinous (lined by mucinous epithelium natively found in cervix). Monitor response to therapy/relapse by measuring CA 125 levels (not good for screening).
 Germ cell tumors can differentiate into somatic structures (eg, teratomas), or extra-embryonic structures (eg, yolk sac tumors), or can remain undifferentiated (eg, dysgerminoma).
 Sex cord stromal tumors develop from embryonic sex cord (develops into theca and granulosa cells of follicle, Sertoli and Leydig cells of seminiferous tubules) and stromal (ovarian cortex) derivatives.



TYPE	CHARACTERISTICS
Epithelial tumors	
Serous cystadenoma	Benign. Most common ovarian neoplasm. Lined by fallopian tube–like epithelium.
Mucinous cystadenoma	Benign. Multiloculated, large. Lined by mucus-secreting epithelium A .
Brenner tumor	Usually benign. Nests of urothelial-like (bladderlike) epithelium with “coffee bean” nuclei.
Serous carcinoma	Most common malignant ovarian neoplasm. Psammoma bodies.
Mucinous carcinoma	Malignant. Rare. May be metastatic from appendiceal or other GI tumors. Can result in pseudomyxoma peritonei (intraperitoneal accumulation of mucinous material).

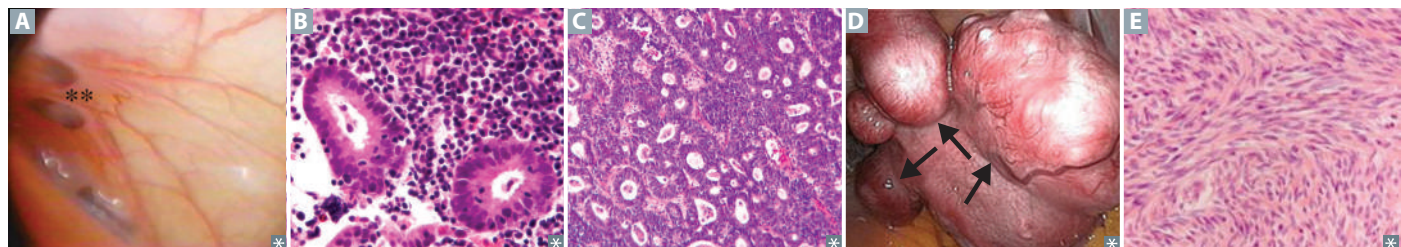
Ovarian tumors (continued)

TYPE	CHARACTERISTICS
Germ cell tumors	
Mature cystic teratoma	Also called dermoid cyst. Benign. Most common ovarian tumor in young females. Cystic mass with elements from all 3 germ layers (eg, teeth, hair, sebum) B . May be painful 2° to ovarian enlargement or torsion. Monodermal form with thyroid tissue (struma ovarii C) may present with hyperthyroidism. Malignant transformation rare (usually to squamous cell carcinoma).
Immature teratoma	Malignant, aggressive. Contains fetal tissue, neuroectoderm. Commonly diagnosed before age 20. Typically represented by immature/embryoniclike neural tissue.
Dysgerminoma	Malignant. Most common in adolescents. Equivalent to male seminoma but rarer. Sheets of uniform “fried egg” cells D . Tumor markers: ↑ hCG, ↑ LDH.
Yolk sac tumor	Also called endodermal sinus tumor. Malignant, aggressive. Yellow, friable (hemorrhagic) mass. 50% have Schiller-Duval bodies (resemble glomeruli, arrow in E). Tumor marker: ↑ AFP. Occurs in children and young adult females.
Sex cord stromal tumors	
Fibroma	Benign. Bundle of spindle-shaped fibroblasts. Meigs syndrome —triad of ovarian fibroma, ascites, pleural effusion. “Pulling” sensation in groin.
Thecoma	Benign. May produce estrogen. Usually presents as abnormal uterine bleeding in a postmenopausal female.
Sertoli-Leydig cell tumor	Benign. Gray to yellow-brown mass. Resembles testicular histology with tubules/cords lined by pink Sertoli cells. May produce androgens → virilization (eg, hirsutism, male pattern baldness, clitoral enlargement).
Granulosa cell tumor	Most common malignant sex cord stromal tumor. Predominantly occurs in females in their 50s. Often produces estrogen and/or progesterone. Presents with postmenopausal bleeding, endometrial hyperplasia, sexual precocity (in preadolescents), breast tenderness. Histology shows Call-Exner bodies (granulosa cells arranged haphazardly around collections of eosinophilic fluid, resembling primordial follicles; arrow in F). Tumor marker: ↑ inhibin. “Give Granny a Call .”

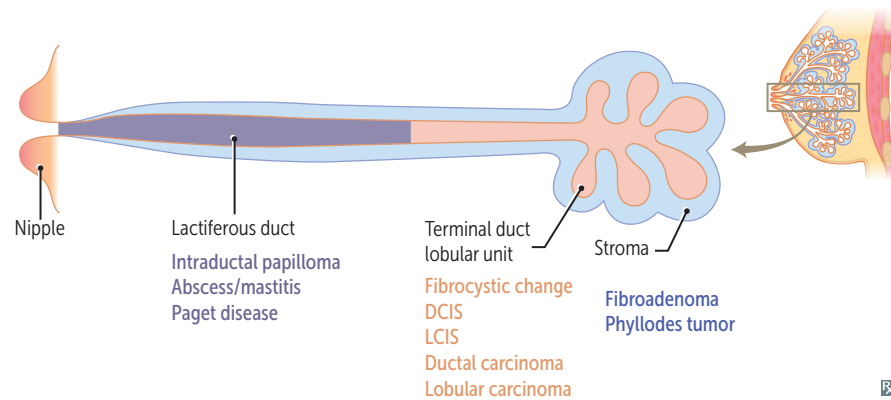


Uterine conditions

TYPE	CHARACTERISTICS
Non-neoplastic uterine conditions	
Adenomyosis	Extension of endometrial tissue (glandular) into uterine myometrium. Caused by hyperplasia of basal layer of endometrium. Presents with dysmenorrhea, abnormal uterine bleeding, and uniformly enlarged, soft, globular uterus. Treatment: GnRH agonists, hysterectomy, excision of an organized adenomyoma.
Asherman syndrome	Adhesions and/or fibrosis of the endometrium. Presents with ↓ fertility, recurrent pregnancy loss, abnormal uterine bleeding, pelvic pain. Often associated with dilation and curettage of intrauterine pregnancy.
Endometrial hyperplasia	Abnormal endometrial gland proliferation usually stimulated by excess estrogen. ↑ risk for endometrial carcinoma (especially with nuclear atypia). Presents as postmenopausal vaginal bleeding. ↑ risk with anovulatory cycles, hormone replacement therapy, PCOS, granulosa cell tumors.
Endometriosis	Endometriumlike glands/stroma outside endometrial cavity, most commonly in the ovary (frequently bilateral), pelvis, peritoneum (yellow-brown “powder burn” lesions [oval structures above and below asterisks in A]). In ovary, appears as endometrioma (blood-filled “chocolate cysts”). May be due to retrograde flow, metaplastic transformation of multipotent cells, transportation of endometrial tissue via lymphatic system. Presents with pelvic pain (dysmenorrhea, dyspareunia, dysuria, dyschezia), abnormal uterine bleeding, infertility; normal-sized uterus. Treatment: NSAIDs, OCPs, progestins, GnRH agonists, danazol, laparoscopic removal.
Endometritis	Inflammation of endometrium B associated with retained products of conception following delivery, miscarriage, abortion, or with foreign body (eg, IUD). Retained material is nidus for bacteria from vagina or GI tract. Chronic endometritis shows plasma cells on histology. Treatment: gentamicin + clindamycin +/- ampicillin.
Uterine neoplasms	
Endometrial carcinoma	Most common gynecologic malignancy. Presents with irregular vaginal bleeding. Two types: Endometrioid C —most cases caused by unopposed estrogen exposure due to obesity, but also associated with early menarche, late menopause, nulliparity. Histology shows abnormally arranged endometrial glands. Early pathogenic events include loss of PTEN or mismatch repair proteins. Serous —associated with endometrial atrophy in postmenopausal females. Aggressive. Psammoma bodies often seen on histology. Characterized by formation of papillae and tufts.
Leiomyoma (fibroid)	Most common tumor in females. Often presents with multiple discrete tumors D . ↑ incidence in Black patients. Benign smooth muscle tumor; malignant transformation to leiomyosarcoma is rare. Estrogen sensitive; tumor size ↑ with pregnancy and ↓ with menopause. Peak occurrence at 20–40 years of age. May be asymptomatic, cause abnormal uterine bleeding, or result in miscarriage. Severe bleeding may lead to iron deficiency anemia. Whorled pattern of smooth muscle bundles with well-demarcated borders on histology E .
Leiomyosarcoma	Malignant proliferation of smooth muscle arising from myometrium; arises de novo (not from leiomyomas), usually in postmenopausal females. Exam shows single lesion with areas of necrosis.



Breast pathology



Benign breast diseases

Fibrocystic changes

Most common in premenopausal females 20–50 years old. Present with premenstrual breast pain or lumps; often bilateral and multifocal. Nonproliferative lesions include simple cysts (fluid-filled duct dilation, blue dome), papillary apocrine change/metaplasia, stromal fibrosis. Risk of cancer is usually not increased. Proliferative lesions include

- **Sclerosing adenosis**—acini and stromal fibrosis, associated with calcifications. Slight ↑ risk for cancer.
- **Epithelial hyperplasia**—cells in terminal ductal or lobular epithelium. ↑ risk of carcinoma with atypical cells.

Inflammatory processes

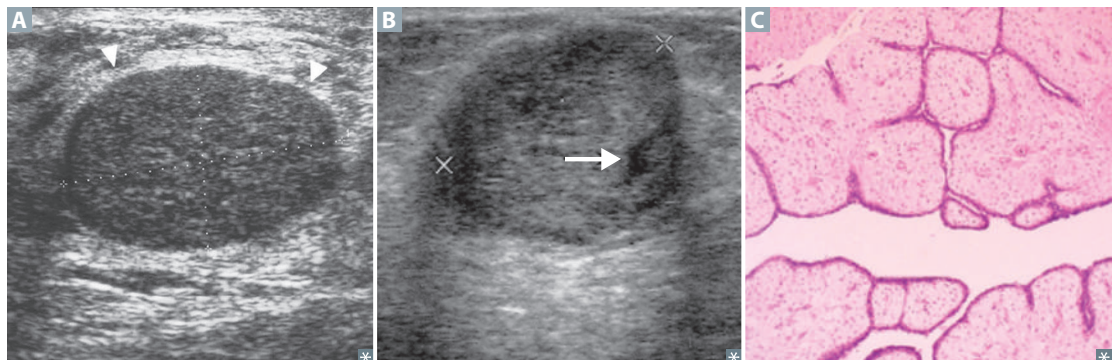
Fat necrosis—benign, usually painless, lump due to injury to breast tissue. Calcified oil cyst on mammography; necrotic fat and giant cells on biopsy. Up to 50% of patients may not report trauma.
Lactational mastitis—occurs during breastfeeding, ↑ risk of bacterial infection through cracks in nipple. *S aureus* is most common pathogen. Treat with antibiotics and continue breastfeeding.

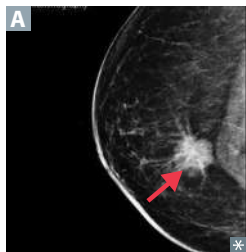
Benign tumors

Fibroadenoma—most common in females < 35 years old. Small, well-defined, mobile mass **A**. Tumor composed of fibrous tissue and glands. ↑ size and tenderness with ↑ estrogen (eg, pregnancy, prior to menstruation). Risk of cancer is usually not increased.
Intraductal papilloma—small fibroepithelial tumor within lactiferous ducts, typically beneath areola. Most common cause of nipple discharge (serous or bloody). Slight ↑ risk for cancer.
Phyllodes tumor—large mass **B** of connective tissue and cysts with “leaflike” lobulations **C**. Most common in 5th decade. Some may become malignant.

Gynecomastia

Breast enlargement in males due to ↑ estrogen compared with androgen activity. Physiologic in newborn, pubertal, and older males, but may persist after puberty. Other causes include cirrhosis, hypogonadism (eg, Klinefelter syndrome), testicular tumors, drugs (eg, spironolactone).



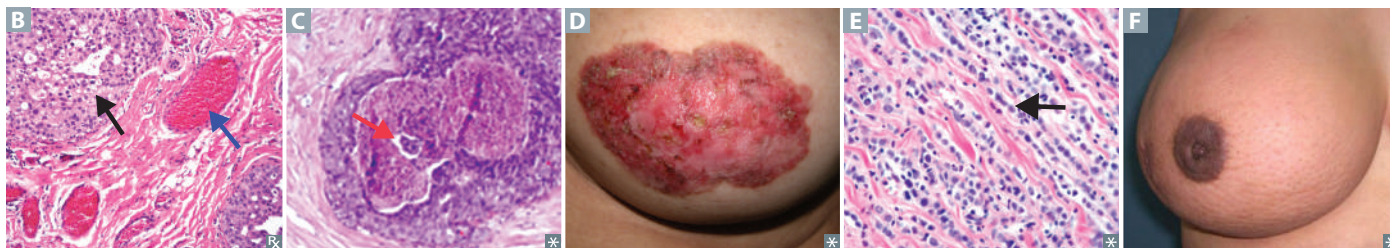Breast cancer

Commonly postmenopausal. Often presents as a palpable hard mass **A** most often in upper outer quadrant. Invasive cancer can become fixed to pectoral muscles, deep fascia, Cooper ligaments, and overlying skin → nipple retraction/skin dimpling.

Usually arises from terminal duct lobular unit. Amplification/overexpression of estrogen/progesterone receptors or HER2 (an EGF receptor) is common; triple negative (ER ⊖, PR ⊖, and HER2 ⊖) form more aggressive.

Risk factors in females: ↑ age; history of atypical hyperplasia; family history of breast cancer; race (White patients at highest risk, Black patients at ↑ risk for triple ⊖ breast cancer); *BRCA1/BRCA2* mutations; ↑ estrogen exposure (eg, nulliparity); postmenopausal obesity (adipose tissue converts androstenedione to estrone); ↑ total number of menstrual cycles; absence of breastfeeding; later age of first pregnancy; alcohol intake. In males: *BRCA2* mutation, Klinefelter syndrome. Axillary lymph node metastasis most important prognostic factor in early-stage disease.

TYPE	CHARACTERISTICS	NOTES
Noninvasive carcinomas		
Ductal carcinoma in situ	Fills ductal lumen (black arrow in B indicates neoplastic cells in duct; blue arrow shows engorged blood vessel). Arises from ductal atypia. Often seen early as microcalcifications on mammography.	Early malignancy without basement membrane penetration. Usually does not produce a mass. Comedocarcinoma —Subtype of DCIS. Cells have high-grade nuclei with extensive central necrosis C and dystrophic calcification.
Paget disease	Extension of underlying DCIS/invasive breast cancer up the lactiferous ducts and into the contiguous skin of nipple → eczematous patches over nipple and areolar skin D .	Paget cells = intraepithelial adenocarcinoma cells.
Lobular carcinoma in situ	↓ E-cadherin expression. No mass or calcifications → incidental biopsy finding.	↑ risk of cancer in either breast (vs DCIS, same breast and quadrant).
Invasive carcinomas		
Invasive ductal	Firm, fibrous, “rock-hard” mass with sharp margins and small, glandular, ductlike cells in desmoplastic stroma.	Most common type of invasive breast cancer.
Invasive lobular	↓ E-cadherin expression → orderly row of cells (“single file” E) and no duct formation. Often lacks desmoplastic response.	Often bilateral with multiple lesions in the same location. Lines of cells = Lobular.
Medullary	Large, anaplastic cells growing in sheets with associated lymphocytes and plasma cells.	Well-circumscribed tumor can mimic fibroadenoma.
Inflammatory	Dermal lymphatic space invasion → breast pain with warm, swollen, erythematous skin around exaggerated hair follicles (peau d’orange) F .	Poor prognosis (50% survival at 5 years). Often mistaken for mastitis or Paget disease. Usually lacks a palpable mass.

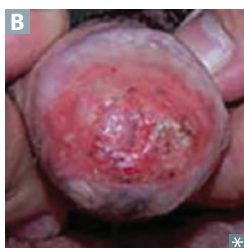

Penile pathology**Peyronie disease**

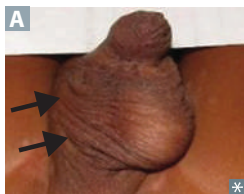Abnormal curvature of penis **A** due to fibrous plaque within tunica albuginea. Associated with repeated minor trauma during intercourse. Can cause pain, anxiety, erectile dysfunction. Consider surgical repair or treatment with collagenase injections once curvature stabilizes. Distinct from penile fracture (rupture of tunica albuginea due to forced bending).

Ischemic priapism

Painful sustained erection lasting > 4 hours. Associated with sickle cell disease (sickled RBCs block venous drainage of corpus cavernosum vascular channels), medications (eg, sildenafil, trazodone). Treat immediately with corporal aspiration, intracavernosal phenylephrine, or surgical decompression to prevent ischemia.

Squamous cell carcinoma

Seen in the US, but more common in Asia, Africa, South America. Most common type of penile cancer. Precursor in situ lesions: Bowen disease (in penile shaft, presents as leukoplakia “white plaque”), erythroplasia of Quey^rrat (carcinoma in situ of the glans **B**, presents as erythroplakia “red plaque”), Bowenoid papulosis (carcinoma in situ of unclear malignant potential, presenting as reddish papules). Associated with uncircumcised males and HPV-16.

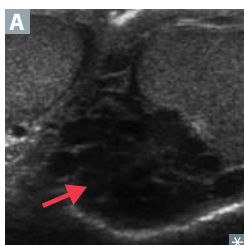Cryptorchidism

Descent failure of one **A** or both testes. Impaired spermatogenesis (since sperm develop best at temperatures < 37°C) → subfertility. Can have normal testosterone levels (Leydig cells are mostly unaffected by temperature). Associated with ↑ risk of germ cell tumors. Prematurity ↑ risk of cryptorchidism. ↓ inhibin B, ↑ FSH, ↑ LH; testosterone ↓ in bilateral cryptorchidism, normal in unilateral. Most cases resolve spontaneously; otherwise, orchiopexy performed before 2 years of age.

Testicular torsion

Rotation of testicle around spermatic cord and vascular pedicle. Commonly presents in males 12–18 years old. Associated with congenital inadequate fixation of testis to tunica vaginalis → horizontal positioning of testes (“bell clapper” deformity). May occur after an inciting event (eg, trauma) or spontaneously. Characterized by acute, severe pain, high-riding testis, and absent cremasteric reflex. ⊖ Prehn sign.

Treatment: surgical correction (orchiopexy) within 6 hours, manual detorsion if surgical option unavailable in timeframe. If testis is not viable, orchiectomy. Orchiopexy, when performed, should be bilateral because the contralateral testis is at risk for subsequent torsion.

Varicocele

Dilated veins in pampiniform plexus due to ↑ venous pressure; most common cause of scrotal enlargement in adult males. Most often on left side because of ↑ resistance to flow from left gonadal vein drainage into left renal vein. Right-sided varicocele may indicate IVC obstruction (eg, from RCC invading right renal vein). Can cause infertility because of ↑ temperature. Diagnosed by standing clinical exam/Valsalva maneuver (distension on inspection and “bag of worms” on palpation; augmented by Valsalva) or ultrasound **A**. Does not transilluminate. Treatment: consider surgical ligation or embolization if associated with pain or infertility.

Extragenadal germ cell tumors

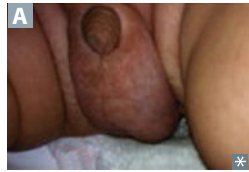Arise in midline locations. In adults, most commonly in retroperitoneum, mediastinum, pineal, and suprasellar regions. In infants and young children, sacrococcygeal teratomas are most common.

Benign scrotal lesions

Testicular masses that can be transilluminated (vs solid testicular tumors).

Congenital hydrocele

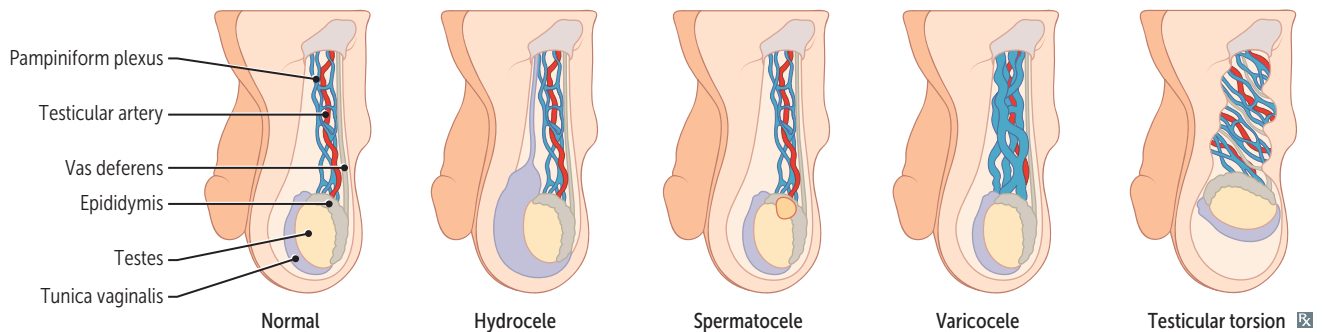
Common cause of scrotal swelling **A** in infants, due to incomplete obliteration of processus vaginalis. Most spontaneously resolve within 1 year.

**Acquired hydrocele**

Scrotal fluid collection usually 2° to infection, trauma, tumor. If bloody → hemocele. Noncommunicating hydrocele.

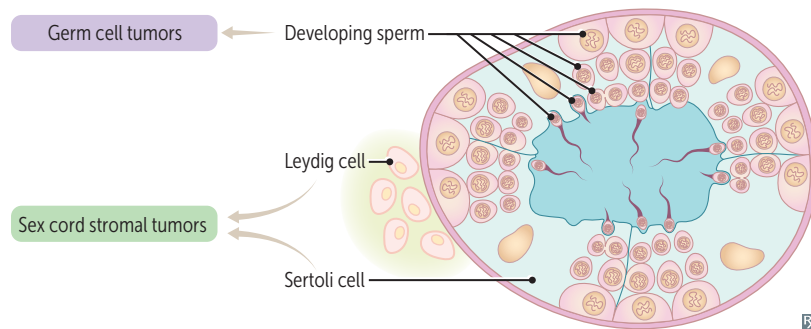
Spermatocele

Cyst due to dilated epididymal duct or rete testis. Paratesticular fluctuant nodule.

**Testicular tumors**

Germ cell tumors account for ~95% of all testicular tumors. Arise from germ cells that produce sperm. Most often occur in young males. Risk factors: cryptorchidism, Klinefelter syndrome. Can present as mixed germ cell tumors. Do not transilluminate. Usually not biopsied (risk of seeding scrotum), removed via radical orchiectomy.

Sex cord stromal tumors develop from embryonic sex cord (develops into Sertoli and Leydig cells of seminiferous tubules, theca and granulosa cells of follicle) derivatives. 5% of all testicular tumors. Mostly benign.



Testicular tumors (continued)

TYPE	CHARACTERISTICS
Germ cell tumors	
Seminoma	Malignant. Painless, homogenous testicular enlargement. Most common testicular tumor. Analogous to ovarian dysgerminoma. Does not occur in infancy. Large cells in lobules with watery cytoplasm and “fried egg” appearance on histology, ↑ placental alkaline phosphatase (PLAP). Highly radiosensitive. Late metastasis, excellent prognosis.
Embryonal carcinoma	Malignant. Painful, hemorrhagic mass with necrosis. Often glandular/papillary morphology. “Pure” embryonal carcinoma is rare; most commonly mixed with other tumor types. May present with metastases. May be associated with ↑ hCG and normal AFP levels when pure (↑ AFP when mixed). Worse prognosis than seminoma.
Teratoma	M ature teratoma may be m alignant in adult m ales. Benign in children and females.
Yolk sac tumor	Also called endodermal sinus tumor. Malignant, aggressive. Yellow, mucinous. Analogous to ovarian yolk sac tumor. Schiller-Duval bodies resemble primitive glomeruli. ↑ AFP is highly characteristic. Most common testicular tumor in children < 3 years old.
Choriocarcinoma	Malignant. Disordered syncytiotrophoblastic and cytotrophoblastic elements. Hematogenous metastases to lungs and brain. ↑ hCG. May produce gynecomastia, symptoms of hyperthyroidism (β subunit of hCG is similar to β subunit of TSH).
Non-germ cell tumors	
Leydig cell tumor	Mostly benign. Golden brown color; contains Reinke crystals (eosinophilic cytoplasmic inclusions). Produces androgens or estrogens → precocious puberty, gynecomastia.
Sertoli cell tumor	Also called androblastoma (arises from sex cord stroma). Mostly benign.
Primary testicular lymphoma	Malignant, aggressive. Typically diffuse large B-cell lymphoma. Often bilateral. Most common testicular cancer in males > 60 years old.

Hormone levels in germ cell tumors

	SEMINOMA	YOLK SAC TUMOR	CHORIOCARCINOMA	TERATOMA	EMBRYONAL CARCINOMA
PLAP	↑	–	–	–	–
AFP	–	↑↑	–	–/↑	–/↑ (when mixed)
β-hCG	–/↑	–/↑	↑↑	–	↑

Epididymitis and orchitis

Most common causes:

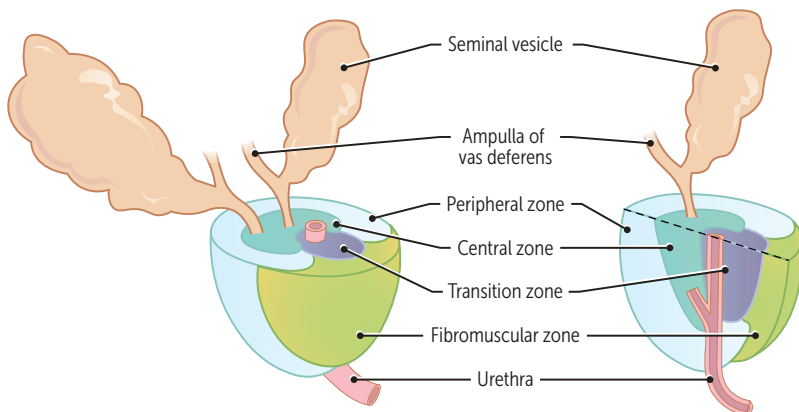
- *C trachomatis* and *N gonorrhoeae* (young males)
- *E coli* and *Pseudomonas* (older males, associated with UTI and BPH)
- Autoimmune (eg, granulomas involving seminiferous tubules)

Epididymitis

Inflammation of epididymis. Presents with localized pain and tenderness over posterior testis.
⊕ Prehn sign (pain relief with scrotal elevation). May progress to involve testis.

Orchitis

Inflammation of testis. Presents with testicular pain and swelling. Mumps orchitis ↑ infertility risk.
Rare in males < 10 years old.

Benign prostatic hyperplasia

Common in males > 50 years old. Characterized by smooth, elastic, firm nodular enlargement (hyperplasia not hypertrophy) of transition zone, which compress the urethra into a vertical slit. Not premalignant.

Often presents with ↑ frequency of urination, nocturia, difficulty starting and stopping urine stream, dysuria. May lead to distention and hypertrophy of bladder, hydronephrosis, UTIs. ↑ total PSA, with ↑ fraction of free PSA. PSA is made by prostatic epithelium stimulated by androgens.

Treatment: α_1 -antagonists (terazosin, tamsulosin), which cause relaxation of smooth muscle; 5α -reductase inhibitors (eg, finasteride); PDE-5 inhibitors (eg, tadalafil); surgical resection (eg, TURP, ablation).

Prostatitis

Characterized by dysuria, frequency, urgency, low back pain. Warm, tender, enlarged prostate. Acute bacterial prostatitis—in older males most common bacterium is *E coli*; in young males consider *C trachomatis*, *N gonorrhoeae*.

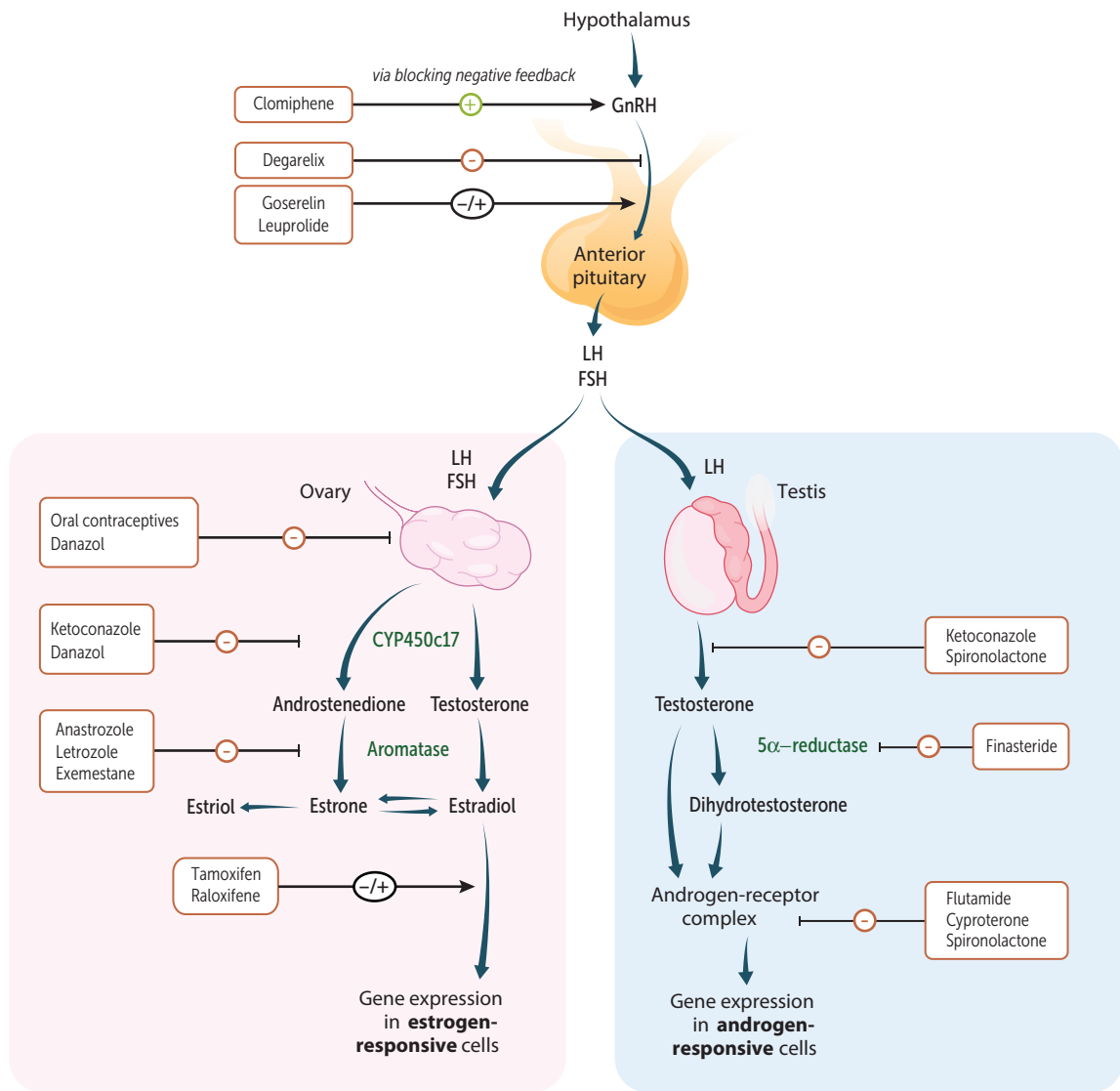
Chronic prostatitis—either bacterial or nonbacterial (eg, 2° to previous infection, nerve problems, chemical irritation).

Prostatic adenocarcinoma

Common in males > 50 years old. Arises most often from posterior lobe (peripheral zone) of prostate gland and is most frequently diagnosed by ↑ PSA and subsequent needle core biopsies (transrectal, ultrasound-guided). Histologically graded using Gleason grade, which is based on glandular architecture and correlates closely with metastatic potential. Prostatic acid phosphatase (PAP) and PSA are useful tumor markers (↑ total PSA, with ↓ fraction of free PSA). Osteoblastic metastases in bone may develop in late stages, as indicated by lower back pain and ↑ serum ALP and PSA. Metastasis to the spine often occurs via Batson (vertebral) venous plexus.

▶ REPRODUCTIVE—PHARMACOLOGY

Control of reproductive hormones



Gonadotropin-releasing hormone analogs

Leuprolide, goserelin, nafarelin, histrelin.

MECHANISM

Act as GnRH agonists when used in pulsatile fashion. When used in continuous fashion, first transiently act as GnRH agonists (tumor flare), but subsequently act as GnRH antagonists (downregulate GnRH receptor in pituitary → ↓ FSH and ↓ LH → ↓ estrogen in females and ↓ testosterone in males). Can be used in **lieu** of GnRH.

CLINICAL USE

Uterine fibroids, endometriosis, precocious puberty, prostate cancer, infertility. **Pulsatile** for pregnancy, **continuous** for cancer.

ADVERSE EFFECTS

Hypogonadism, ↓ libido, erectile dysfunction, nausea, vomiting.

Degarelix**MECHANISM**

GnRH antagonist. No start-up flare.

CLINICAL USE

Prostate cancer.

ADVERSE EFFECTS

Hot flashes, liver toxicity.

Estrogens

Ethinyl estradiol, DES, mestranol.

MECHANISM

Bind estrogen receptors.

CLINICAL USE

Hypogonadism or ovarian failure, menstrual abnormalities (combined OCPs), hormone replacement therapy in postmenopausal females.

ADVERSE EFFECTS

↑ risk of endometrial cancer (when given without progesterone), bleeding in postmenopausal patients, clear cell adenocarcinoma of vagina in females exposed to DES in utero, ↑ risk of thrombi. Contraindications—ER ⊕ breast cancer, history of DVTs, tobacco use in females > 35 years old.

Selective estrogen receptor modulators**Clomiphene**

Antagonist at estrogen receptors in hypothalamus. Prevents normal feedback inhibition and ↑ release of LH and FSH from pituitary, which stimulates ovulation. Used to treat infertility due to anovulation (eg, PCOS). May cause hot flashes, ovarian enlargement, multiple simultaneous pregnancies, visual disturbances.

Tamoxifen

Antagonist at breast, partial agonist at uterus, bone. Hot flashes, ↑ risk of thromboembolic events (especially with tobacco smoking), and endometrial cancer. Used to treat and prevent recurrence of ER/PR ⊕ breast cancer and to prevent gynecomastia in patients undergoing prostate cancer therapy.

Raloxifene

Antagonist at breast, uterus; agonist at bone; hot flashes, ↑ risk of thromboembolic events (especially with tobacco smoking), but no increased risk of endometrial cancer (vs tamoxifen, so you can “**relax**”); used primarily to treat osteoporosis.

Aromatase inhibitors

Anastrozole, letrozole, exemestane.

MECHANISM

Inhibit peripheral conversion of androgens to estrogen.

CLINICAL USE

ER ⊕ breast cancer in postmenopausal females.

Hormone replacement therapy	Used for relief or prevention of menopausal symptoms (eg, hot flashes, vaginal atrophy), osteoporosis (↑ estrogen, ↓ osteoclast activity). Unopposed estrogen replacement therapy ↑ risk of endometrial cancer, progesterone/progestin is added. Possible increased cardiovascular risk.
Progestins	Levonorgestrel, medroxyprogesterone, etonogestrel, norethindrone, megestrol.
MECHANISM	Bind progesterone receptors, ↓ growth and ↑ vascularization of endometrium, thicken cervical mucus.
CLINICAL USE	Contraception (forms include pill, intrauterine device, implant, depot injection), endometrial cancer, abnormal uterine bleeding. Progestin challenge: presence of bleeding upon withdrawal of progestins excludes anatomic defects (eg, Asherman syndrome) and chronic anovulation without estrogen.
Antiprogestins	Mifepristone, ulipristal.
MECHANISM	Competitive inhibitors of progestins at progesterone receptors.
CLINICAL USE	Termination of pregnancy (mifepristone with misoprostol); emergency contraception (ulipristal).
Combined contraception	Progestins and ethinyl estradiol; forms include pill, patch, vaginal ring. Estrogen and progestins inhibit LH/FSH and thus prevent estrogen surge. No estrogen surge → no LH surge → no ovulation. Progestins cause thickening of cervical mucus, thereby limiting access of sperm to uterus. Progestins also inhibit endometrial proliferation → endometrium is less suitable to the implantation of an embryo. Adverse effects: breakthrough menstrual bleeding, breast tenderness, VTE, hepatic adenomas. Contraindications: people > 35 years old who smoke tobacco (↑ risk of cardiovascular events), patients with ↑ risk of cardiovascular disease (including history of venous thromboembolism, coronary artery disease, stroke), migraine (especially with aura), breast cancer, liver disease.
Copper intrauterine device	
MECHANISM	Produces local inflammatory reaction toxic to sperm and ova, preventing fertilization and implantation; hormone free.
CLINICAL USE	Long-acting reversible contraception. Most effective emergency contraception.
ADVERSE EFFECTS	Heavier or longer menses, dysmenorrhea. Insertion contraindicated in active PID (IUD may impede PID resolution).
Tocolytics	Medications that relax the uterus; include terbutaline (β ₂ -agonist action), nifedipine (Ca ²⁺ channel blocker), indomethacin (NSAID). Used to ↓ contraction frequency in preterm labor and allow time for administration of glucocorticoids (to promote fetal lung maturity) or transfer to appropriate medical center with obstetrical care.

Danazol

MECHANISM	Synthetic androgen that acts as partial agonist at androgen receptors.
CLINICAL USE	Endometriosis, hereditary angioedema.
ADVERSE EFFECTS	Weight gain, edema, acne, hirsutism, masculinization, ↓ HDL levels, hepatotoxicity, idiopathic intracranial hypertension.

Testosterone, methyltestosterone

MECHANISM	Agonists at androgen receptors.
CLINICAL USE	Treat hypogonadism and promote development of 2° sex characteristics.
ADVERSE EFFECTS	Virilization in females; testicular atrophy in males. Premature closure of epiphyseal plates. ↑ LDL, ↓ HDL.

Antiandrogens

DRUG	MECHANISM	CLINICAL USE	ADVERSE EFFECTS
Abiraterone	17 α -hydroxylase/17,20-lyase inhibitor (↓ steroid synthesis)	Prostate cancer	Hypertension, hypokalemia (↑ mineralocorticoids)
Finasteride	5 α -reductase inhibitor (↓ conversion of testosterone to DHT)	BPH, male-pattern baldness	Gynecomastia, sexual dysfunction
Flutamide, bicalutamide	Nonsteroidal competitive inhibitors at androgen receptor (↓ steroid binding)	Prostate cancer	Gynecomastia, sexual dysfunction
Ketoconazole	17 α -hydroxylase/17,20-lyase inhibitor	Prostate cancer	Gynecomastia
Spirolactone	Androgen receptor and 17 α -hydroxylase/17,20-lyase inhibitor	PCOS	Amenorrhea

Tamsulosin

MECHANISM	α_1 -antagonist selective for $\alpha_{1A/D}$ receptors in prostate (vs vascular α_{1B} receptors) → ↓ smooth muscle tone → ↑ urine flow.
CLINICAL USE	BPH.

Minoxidil

MECHANISM	Direct arteriolar vasodilator.
CLINICAL USE	Androgenetic alopecia (pattern baldness), severe refractory hypertension.

Respiratory

“Whenever I feel blue, I start breathing again.”

—L. Frank Baum

“Until I feared I would lose it, I never loved to read. One does not love breathing.”

—Scout, *To Kill a Mockingbird*

“Love is anterior to life, posterior to death, initial of creation, and the exponent of breath.”

—Emily Dickinson

“Love and a cough cannot be concealed.”

—Anne Sexton

Group key respiratory, cardiovascular, and renal concepts together for study whenever possible. Respiratory physiology is challenging but high yield, especially as it relates to the pathophysiology of respiratory diseases. Develop a thorough understanding of normal respiratory function. Know obstructive vs restrictive lung disorders, ventilation/perfusion mismatch, lung volumes, mechanics of respiration, and hemoglobin physiology. Lung cancers and other causes of lung masses are also high yield. Be comfortable reading basic chest x-rays, CT scans, and PFTs.

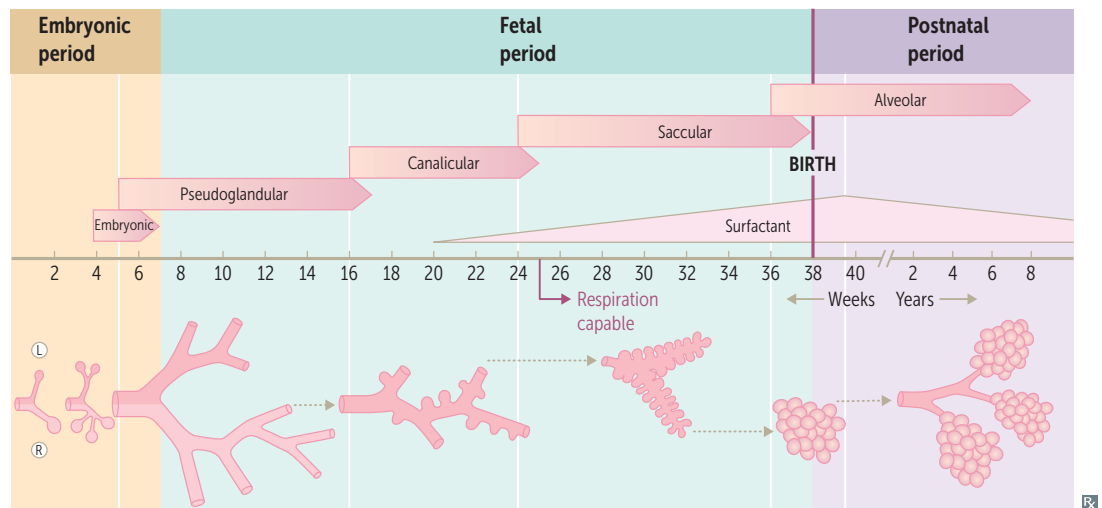
▶ Embryology	684
▶ Anatomy	686
▶ Physiology	688
▶ Pathology	696
▶ Pharmacology	710

▶ RESPIRATORY—EMBRYOLOGY

Lung development

Occurs in five stages. Begins with the formation of lung bud from distal end of respiratory diverticulum during week 4 of development. **Every pulmonologist can see alveoli.**

STAGE	STRUCTURAL DEVELOPMENT	NOTES
Embryonic (weeks 4–7)	Lung bud → trachea → bronchial buds → mainstem bronchi → secondary (lobar) bronchi → tertiary (segmental) bronchi.	Errors at this stage can lead to tracheoesophageal fistula.
Pseudoglandular (weeks 5–17)	Endodermal tubules → terminal bronchioles. Surrounded by modest capillary network.	Respiration impossible, incompatible with life.
Canalicular (weeks 16–25)	Terminal bronchioles → respiratory bronchioles → alveolar ducts. Surrounded by prominent capillary network.	Airways increase in diameter. Pneumocytes develop starting at week 20. Respiration capable at week 25.
Saccular (week 24–birth)	Alveolar ducts → terminal sacs. Terminal sacs separated by 1° septae.	
Alveolar (week 36–8 years)	Terminal sacs → adult alveoli (due to 2° septation).	In utero, “breathing” occurs via aspiration and expulsion of amniotic fluid → ↑ pulmonary vascular resistance through gestation. At birth, air replaces fluid → ↓ pulmonary vascular resistance.

**Choanal atresia**

Blockage of posterior nasal opening. Often associated with bony abnormalities of the midface. Most often unilateral. When bilateral, represents an emergency and presents with upper airway obstruction, noisy breathing, and/or cyanosis that worsens during feeding and improves with crying. Diagnosed by failure to pass nasopharyngeal tube and confirmed with CT scan.

Often part of multiple malformation syndromes, such as **CHARGE** syndrome:

- **C**oloboma of eye
- **H**ear defects
- **A**tresia of choanae
- **R**estricted growth and development
- **G**enitourinary defects
- **E**ar defects

Lung malformations

Pulmonary hypoplasia Poorly developed bronchial tree with abnormal histology. Associated with congenital diaphragmatic hernia (usually left-sided), bilateral renal agenesis (Potter sequence).

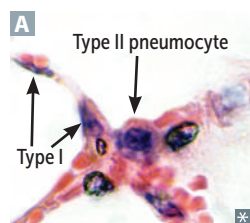
Bronchogenic cysts Caused by abnormal budding of the foregut and dilation of terminal or large bronchi. Discrete, round, sharply defined, fluid-filled densities on CXR (air-filled if infected). Generally asymptomatic but can drain poorly → airway compression, recurrent respiratory infections.

Club cells

Nonciliated; low columnar/cuboidal with secretory granules. Located in bronchioles. Degrade toxins via cytochrome P-450; secrete component of surfactant; progenitor cells for club and ciliated cells.

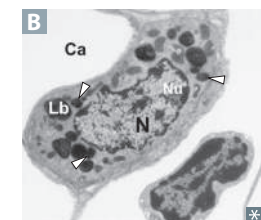
Alveolar cell types**Type I pneumocytes**

Squamous. 97% of alveolar surfaces. Thinly line the alveoli **A** for optimal gas exchange.

**Type II pneumocytes**

Cuboidal and clustered **A**. 2 functions:

1. Serve as stem cell precursors for 2 cell types (type I and type II pneumocytes); proliferate during lung damage.
2. Secrete surfactant from lamellar bodies (arrowheads in **B**).



Surfactant—↓ alveolar surface tension, ↓ alveolar collapse, ↓ lung recoil, and ↑ compliance.

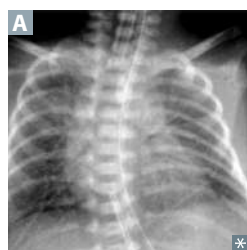
Composed of multiple lecithins, mainly dipalmitoylphosphatidylcholine (DPPC). Synthesis begins ~20 weeks of gestation and achieves mature levels ~35 weeks of gestation. Glucocorticoids important for fetal surfactant synthesis and lung development.

$$\text{Collapsing pressure (P)} = \frac{2 (\text{surface tension})}{\text{radius}}$$

Law of Laplace—alveoli have ↑ tendency to collapse on expiration as radius ↓.

Alveolar macrophages

Phagocytose foreign materials; release cytokines and alveolar proteases. Hemosiderin-laden macrophages may be found in the setting of pulmonary edema or alveolar hemorrhage.

Neonatal respiratory distress syndrome

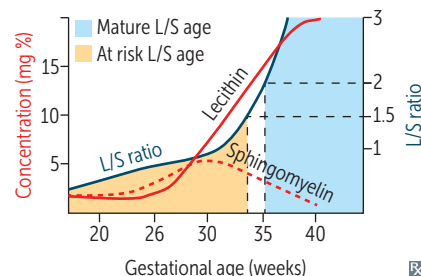
Surfactant deficiency → ↑ surface tension → alveolar collapse (“ground-glass” appearance of lung fields) **A**.

Risk factors: prematurity, diabetes during pregnancy (due to ↑ fetal insulin), C-section delivery (↓ release of fetal glucocorticoids; less stressful than vaginal delivery).

Treatment: maternal glucocorticoids before birth; exogenous surfactant for infant.

Therapeutic supplemental O₂ can result in **R**etinopathy of prematurity, **I**ntraventricular hemorrhage, **B**ronchopulmonary dysplasia (**RIB**).

Screening tests for fetal lung maturity: lecithin-sphingomyelin (L/S) ratio in amniotic fluid (≥ 2 is healthy; < 1.5 predictive of NRDS), foam stability index, surfactant-albumin ratio. Persistently low O₂ tension → risk of PDA.



► RESPIRATORY—ANATOMY

Respiratory tree**Conducting zone**

Large airways consist of nose, pharynx, larynx, trachea, and bronchi. Airway resistance highest in the large- to medium-sized bronchi. Small airways consist of bronchioles that further divide into terminal bronchioles (large numbers in parallel → least airway resistance).

Warms, humidifies, and filters air but does not participate in gas exchange → “anatomic dead space.” Cartilage and goblet cells extend to the end of bronchi.

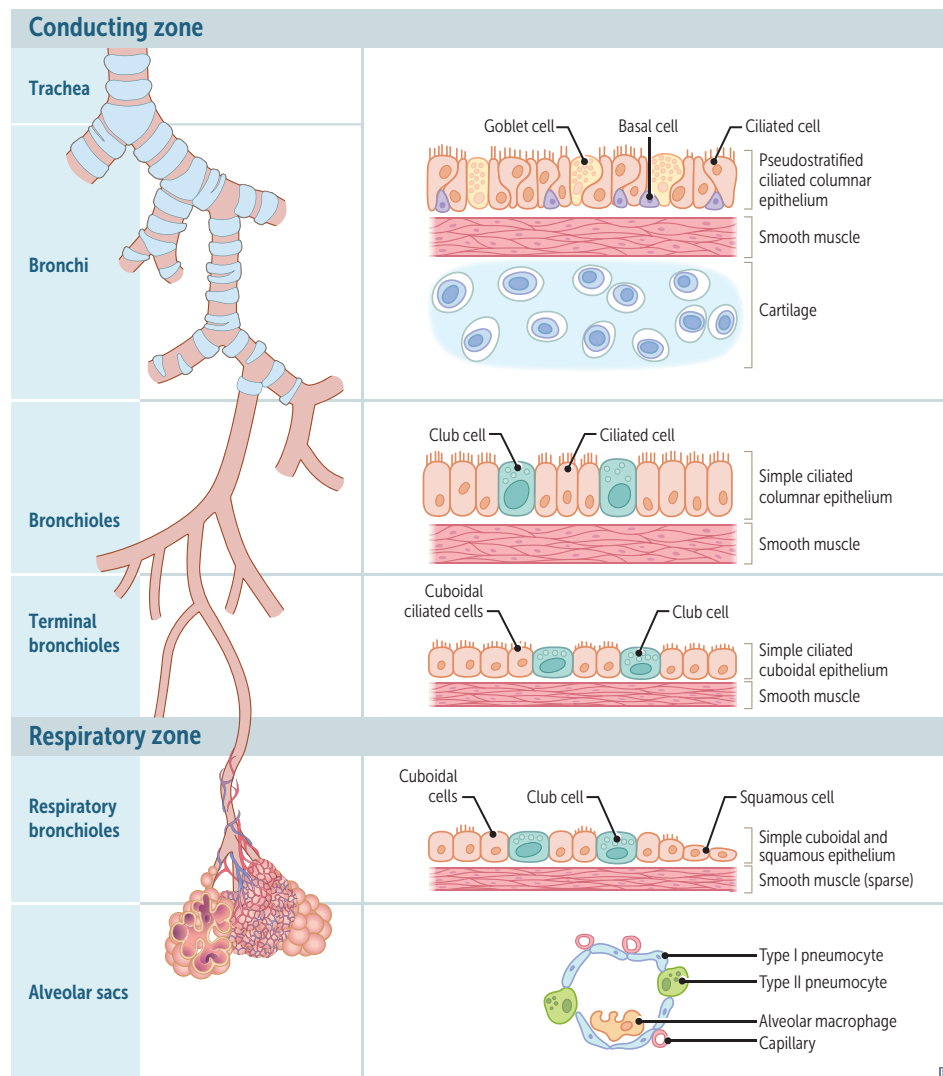
Pseudostratified ciliated columnar cells primarily make up epithelium of bronchus and extend to beginning of terminal bronchioles, then transition to cuboidal cells. Clear mucus and debris from lungs (mucociliary escalator).

Airway smooth muscle cells extend to end of terminal bronchioles (sparse beyond this point).

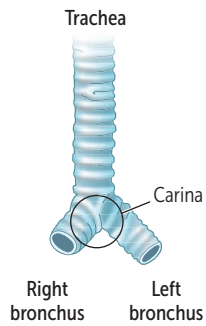
Respiratory zone

Lung parenchyma; consists of respiratory bronchioles, alveolar ducts, and alveoli. Participates in gas exchange.

Mostly cuboidal cells in respiratory bronchioles, then simple squamous cells up to alveoli. Cilia terminate in respiratory bronchioles. Alveolar macrophages clear debris and participate in immune response.



Lung anatomy

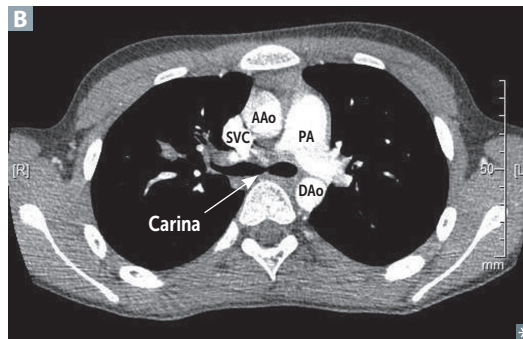
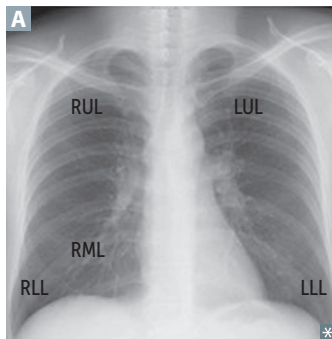
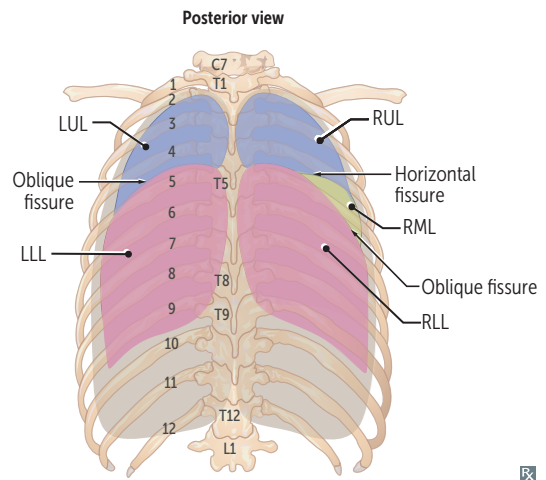
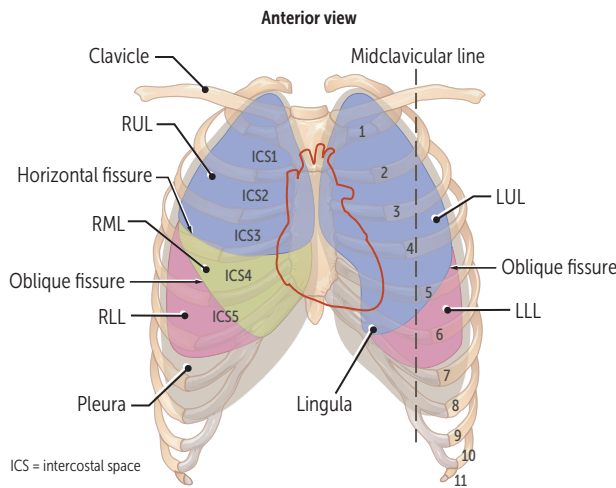


Right lung has 3 lobes; **Left** has **less lobes** (2) and **lingula** (homolog of right middle lobe). Instead of a middle lobe, left lung has a space occupied by the heart **A**.

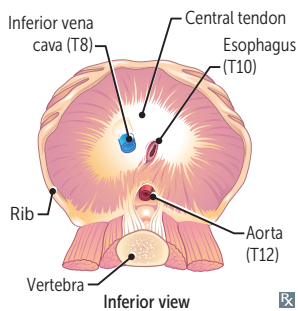
Relation of the pulmonary artery to the bronchus at each lung hilum is described by **RALS**—**R**ight **A**nterior; **L**eft **S**uperior. Carina is posterior to ascending aorta and anteromedial to descending aorta **B**.

Right lung is a more common site for inhaled foreign bodies because right main stem bronchus is wider, more vertical, and shorter than the left. If you aspirate a peanut:

- While supine—usually enters superior segment of right lower lobe.
- While lying on right side—usually enters right upper lobe.
- While upright—usually enters right lower lobe.



Diaphragm structures



Structures perforating diaphragm:

- At T8: IVC, right phrenic nerve
- At T10: esophagus, vagus (CN 10; 2 trunks)
- At T12: aorta (red), thoracic duct (white), azygos vein (blue) (“At T-1-2 it’s the **red, white, and blue**”)

Diaphragm innervated by C3-5 (phrenic). Pain from diaphragm irritation can be referred to shoulder (C5) and trapezius ridge (C3, 4). Phrenic nerve injury causes elevation of the ipsilateral hemidiaphragm on x-ray.

Number of letters = T level:

- T8: vena cava (**IVC**)
- T10: (**O**)esophagus
- T12: **aortic** hiatus

I ate (**8**) **ten** eggs at **twelve**.

C3, 4, 5 keeps the diaphragm **alive**.

Other bifurcations:

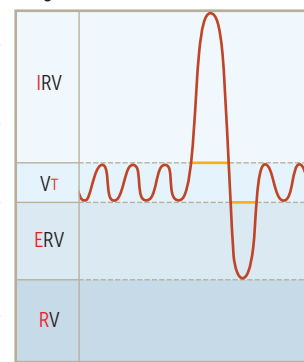
- The **C**ommon **C**arotid **bifour**cates at **C4**.
- The **T**rachea **bifour**cates at **T4**.
- The abdominal aorta **bifour**cates at **L4**.

► RESPIRATORY—PHYSIOLOGY

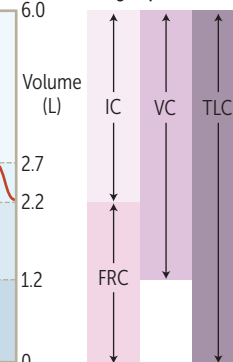
Lung volumes and capacities

Note: a capacity is a sum of ≥ 2 physiologic volumes. There are 4 volumes and 4 capacities.

Tidal volume	Air that moves into lung with each quiet inspiration, 6–8 mL/kg, typically ~500 mL.
Inspiratory reserve volume	Air that can still be breathed in after normal inspiration
Expiratory reserve volume	Air that can still be breathed out after normal expiration
Residual volume	Air in lung after maximal expiration; RV and any lung capacity that includes RV cannot be measured by spirometry
Inspiratory capacity	IRV + V _T Air that can be breathed in after normal exhalation
Functional residual capacity	RV + ERV Volume of gas in lungs after normal expiration; outward pulling force of chest wall is balanced with inward collapsing force of lungs
Vital capacity	IRV + V _T + ERV Maximum volume of gas that can be expired after a maximal inspiration
Total lung capacity	IRV + V _T + ERV + RV = VC + RV Volume of gas present in lungs after a maximal inspiration

Lung volumes (LITER)

IRV = inspiratory reserve volume
V_T = tidal volume
ERV = expiratory reserve volume
RV = residual volume

Lung capacities

IC = inspiratory capacity
FRC = functional residual capacity
VC = vital capacity
TLC = total lung capacity

Work of breathing

Refers to the energy expended or O₂ consumed by respiratory muscles to produce the ventilation needed to meet the body's metabolic demand. Comprises the work needed to overcome both elastic recoil and airway resistance (ie, work = force × distance = pressure × volume). Minimized by optimizing respiratory rate (RR) and V_T. ↑ in restrictive diseases (↑ work to overcome elastic recoil achieved with ↑ RR and ↓ V_T) and obstructive diseases (↑ work to overcome airway resistance achieved with ↓ RR and ↑ V_T).

Determination of physiologic dead space

$$V_D = V_T \times \frac{P_{aCO_2} - P_{eCO_2}}{P_{aCO_2}}$$

V_D = physiologic dead space = anatomic dead space of conducting airways plus alveolar dead space; apex of healthy lung is largest contributor of alveolar dead space. V_D = volume of inspired air that does not take part in gas exchange.

P_{aCO₂} = arterial P_{CO₂}.

P_{eCO₂} = expired air P_{CO₂}.

Physiologic dead space—approximately equivalent to anatomic dead space in normal lungs. May be greater than anatomic dead space in lung diseases with ventilation/perfusion mismatch.

Ventilation

Minute ventilation Abbreviated as V_E . Total volume of gas entering lungs per minute.

$$V_E = V_T \times RR$$

Alveolar ventilation Abbreviated as V_A . Volume of gas that reaches alveoli each minute.

$$V_A = (V_T - V_D) \times RR$$

Normal values:

- RR = 12–20 breaths/min
- V_T = 500 mL/breath
- V_D = 150 mL/breath

Lung and chest wall

Because of historical reasons and small pressures, pulmonary pressures are always presented in cm H_2O .

Elastic recoil

Tendency for lungs to collapse inward and chest wall to spring outward.

At FRC, airway and alveolar pressures equal atmospheric pressure (P_B ; called zero), and intrapleural pressure is negative (preventing atelectasis). The inward pull of the lung is balanced by the outward pull of the chest wall. System pressure is atmospheric. Pulmonary vascular resistance (PVR) is at a minimum.

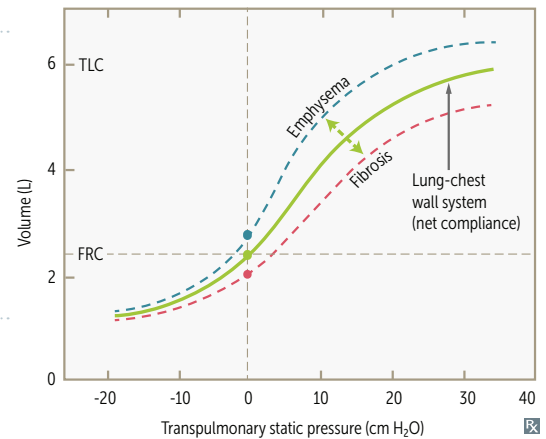
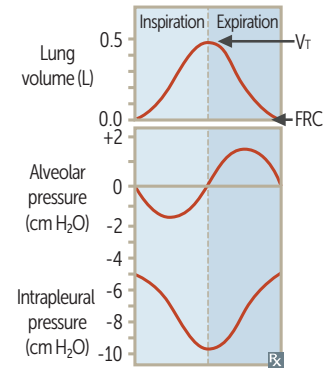
Compliance

Change in lung volume for a change in pressure ($\Delta V/\Delta P$). Inversely proportional to wall stiffness and increased by surfactant.

- ↑ compliance = lung easier to fill (eg, emphysema, older adults)
- ↓ compliance = lung more difficult to fill (eg, pulmonary fibrosis, pneumonia, ARDS, pulmonary edema)

Hysteresis

Lung inflation follows a different pressure-volume curve than lung deflation due to need to overcome surface tension forces in inflation.



Pulmonary circulation

Normally a low-resistance, high-compliance system. A ↓ in P_{AO_2} causes hypoxic vasoconstriction that shifts blood away from poorly ventilated regions of lung to well-ventilated regions of lung.

Perfusion limited— O_2 (normal health), CO_2 , N_2O . Gas equilibrates early along the length of the capillary. Exchange can be ↑ only if blood flow ↑.

Diffusion limited— O_2 (emphysema, fibrosis), CO . Gas does not equilibrate by the time blood reaches the end of the capillary.

O_2 diffuses slowly, while CO_2 diffuses very rapidly across the alveolar membrane. Disease states that lead to diffusion limitation (eg, pulmonary fibrosis) are more likely to cause early hypoxia than hypercapnia.

Chronic hypoxic vasoconstriction may lead to pulmonary hypertension +/- cor pulmonale.

Diffusion (J) = $A \times D_k \times \frac{P_1 - P_2}{\Delta_x}$ where

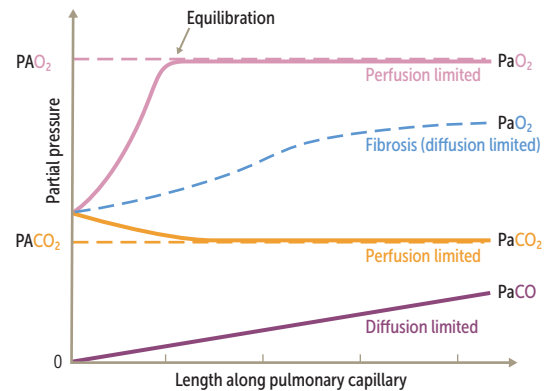
A = area, Δ_x = alveolar wall thickness,

D_k = diffusion coefficient of gas,

$P_1 - P_2$ = difference in partial pressures.

- A ↓ in emphysema.
- Δ_x ↑ in pulmonary fibrosis.

DLCO is the extent to which CO passes from air sacs of lungs into blood.



P_a = partial pressure of gas in pulmonary capillary blood
 P_A = partial pressure of gas in alveolar air

**Pulmonary vascular resistance**

$$PVR = \frac{P_{\text{pulm artery}} - P_{\text{L atrium}}}{\dot{Q}}$$

Remember: $\Delta P = \dot{Q} \times R$, so $R = \Delta P / \dot{Q}$

$$R = \frac{8\eta l}{\pi r^4}$$

$P_{\text{pulm artery}}$ = pressure in pulmonary artery

$P_{\text{L atrium}} \approx$ pulmonary artery occlusion pressure (also called pulmonary capillary wedge pressure)

\dot{Q} = cardiac output (mL/min)

R = resistance

η = viscosity of blood ("stickiness")

l = vessel length

r = vessel radius

Ventilation/perfusion mismatch

Ideally, ventilation (V) is matched to perfusion (Q) per minute (ie, \dot{V}/\dot{Q} ratio = 1) for adequate gas exchange.

Lung zones:

- \dot{V}/\dot{Q} at apex of lung = 3 (wasted ventilation)
- \dot{V}/\dot{Q} at base of lung = 0.6 (wasted perfusion)

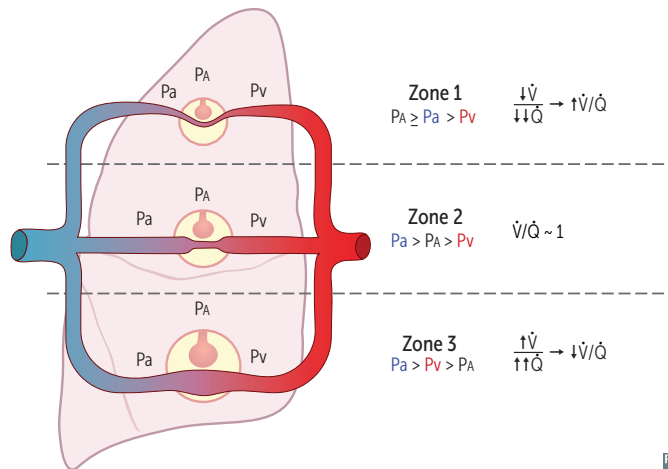
Both ventilation and perfusion are greater at the base of the lung than at the apex of the lung.

With exercise (\uparrow cardiac output), there is vasodilation of apical capillaries $\rightarrow \dot{V}/\dot{Q}$ ratio approaches 1.

Certain organisms that thrive in high O_2 (eg, TB) flourish in the apex.

$\dot{V}/\dot{Q} = 0$ = “airway” obstruction (shunt). In shunt, 100% O_2 does not improve P_{aO_2} (eg, foreign body aspiration).

$\dot{V}/\dot{Q} = \infty$ = blood flow obstruction (physiologic dead space). Assuming $< 100\%$ dead space, 100% O_2 improves P_{aO_2} (eg, pulmonary embolus).



Alveolar gas equation

$$P_{AO_2} = P_{iO_2} - \frac{P_{aCO_2}}{RQ}$$

$$\approx 150 \text{ mm Hg}^a - \frac{P_{aCO_2}}{0.8}$$

^aAt sea level breathing room air

P_{AO_2} = alveolar PO_2 (mm Hg)
 P_{iO_2} = PO_2 in inspired air (mm Hg)
 P_{aCO_2} = arterial PCO_2 (mm Hg)
 RQ = respiratory quotient = CO_2 produced/
 O_2 consumed

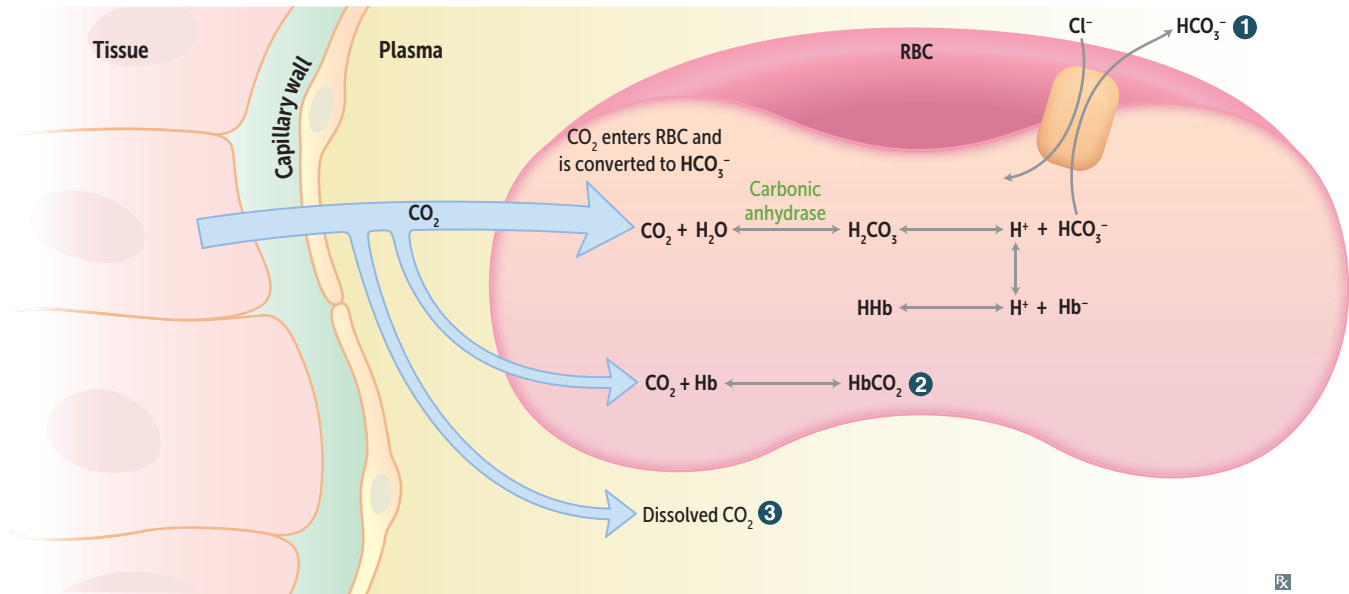
A-a gradient = $P_{AO_2} - P_{aO_2}$. Normal A-a gradient estimated as $(\text{age}/4) + 4$ (eg, for a person < 40 years old, gradient should be < 14).

Carbon dioxide transport

CO₂ is transported from tissues to lungs in 3 forms:

- 1 HCO₃⁻ (70%). HCO₃⁻/Cl⁻ transporter on RBC membrane allows HCO₃⁻ to diffuse out to plasma and Cl⁻ to diffuse into RBC (chloride shift) via facilitated diffusion countertransport
- 2 Carbaminohemoglobin or HbCO₂ (21–25%). CO₂ bound to Hb at N-terminus of globin (not heme). CO₂ favors deoxygenated form (O₂ unloaded).
- 3 Dissolved CO₂ (5–9%).

In lungs, oxygenation of Hb promotes dissociation of H⁺ from Hb. This shifts equilibrium toward CO₂ formation; therefore, CO₂ is released from RBCs (Haldane effect). Majority of blood CO₂ is carried as HCO₃⁻ in the plasma.



Hypoxia and hypoxemia

Hypoxia

↓ O₂ delivery to tissues. Commonly due to ↓ cardiac output, hypoxemia, ischemia, anemia, CO/cyanide poisoning. Mechanism of hypoxia:

NORMAL A-a GRADIENT

↓ inspired oxygen tension (P_IO₂)—
P_IO₂ = F_IO₂ × (P_B - P_{H₂O}); most commonly due to ↓ P_B in high altitude

Hypoventilation (due to increased P_aCO₂)—
P_AO₂ = P_IO₂ - P_aCO₂ / R_Q (eg, CNS depression, obesity hypoventilation syndrome, muscular weakness)

INCREASED A-a GRADIENT

Diffusion limitation (eg, fibrosis)

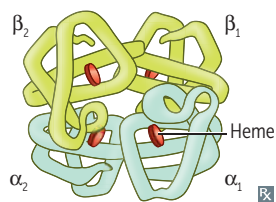
Ṡ/Q mismatch—normal perfusion in areas of decreased ventilation

Right-to-left shunt—normal perfusion in areas of no ventilation. Can be anatomic (eg, intracardiac shunt) or physiologic (eg, perfusion of nonventilated alveoli in ARDS)

Hypoxemia

Insufficient oxygenation of blood (↓ P_aO₂).

Hemoglobin



Normal adult hemoglobin (Hb) is composed of 4 polypeptide subunits (2 α and 2 β) that each bind one O_2 molecule. Hb is an allosteric protein that exhibits positive cooperativity when binding to O_2 , such that:

- Oxygenated Hb has high affinity for O_2 (300 \times).
- Deoxygenated Hb has low affinity for $O_2 \rightarrow$ promotes release/unloading of O_2 .

The protein component of hemoglobin acts as buffer for H^+ ions. Myoglobin is composed of a single polypeptide chain associated with one heme moiety. Higher affinity for oxygen than Hb.

Oxygen content of blood

$$O_2 \text{ content} = (O_2 \text{ bound to hemoglobin}) + (O_2 \text{ solubilized in plasma}) = (1.34 \times Hb \times SaO_2) + (0.003 \times PaO_2).$$

SaO_2 = percent saturation of arterial blood with O_2 .

0.003 = solubility constant of O_2 ; PaO_2 = partial pressure of O_2 in arterial blood.

Normally 1 g Hb can bind 1.34 mL O_2 ; normal Hb amount in blood is 15 g/dL.

O_2 binding (carrying) capacity \approx 20 mL O_2 /dL of blood.

With \downarrow Hb there is \downarrow O_2 content of arterial blood, but no change in O_2 saturation and PaO_2 .

O_2 delivery to tissues = cardiac output \times O_2 content of blood.

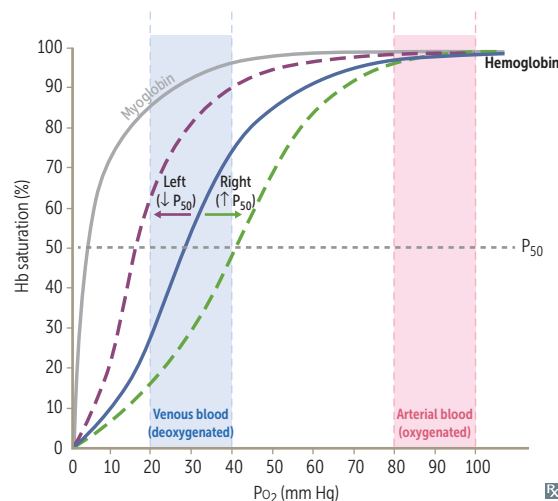
	Hb CONCENTRATION	SaO_2	PaO_2	TOTAL O_2 CONTENT
CO poisoning	Normal	\downarrow (CO competes with O_2)	Normal	\downarrow
Anemia	\downarrow	Normal	Normal	\downarrow
Polycythemia	\uparrow	Normal	Normal	\uparrow
Methemoglobinemia	Normal	\downarrow (Fe^{3+} poor at binding O_2)	Normal	\downarrow
Cyanide toxicity	Normal	Normal	Normal	Normal

Oxyhemoglobin dissociation curve

Shifts in oxyhemoglobin dissociation curve (ODC) reflect local tissue oxygen needs. Can be helpful (meets metabolic needs) or harmful (in toxicities, pathophysiologic situations).

Right shift in ODC reflects \downarrow Hb affinity for $O_2 \rightarrow \uparrow$ O_2 unloading at tissue. Physiologically occurs with \uparrow O_2 needs: exercise, \downarrow pH, \uparrow temperature/fever, hypoxia (\uparrow 2,3-BPG); at the cellular level, caused by \uparrow H^+ and \uparrow CO_2 created by tissue metabolism (Bohr effect).

Left shift in ODC reflects \uparrow Hb affinity for $O_2 \rightarrow \downarrow$ O_2 unloading at tissue. Physiologically occurs with \downarrow O_2 needs (\downarrow temperature) and pregnancy (fetal Hb has higher O_2 affinity than adult Hb, and \uparrow O_2 binding due to \downarrow affinity for 2,3-BPG \rightarrow left shift, driving O_2 across placenta to fetus). Pathologically occurs with \uparrow CO, \uparrow MetHb, genetic mutation (\downarrow 2,3-BPG). **Left is lower.**



ODC has sigmoidal shape due to positive cooperativity (ie, tetrameric Hb molecule can bind 4 O_2 molecules and has higher affinity for each subsequent O_2 molecule bound). Myoglobin is monomeric and thus does not show positive cooperativity; curve lacks sigmoidal appearance.

Response to high altitude

Constant F_{IO_2} but $\downarrow P_B \rightarrow \downarrow$ atmospheric oxygen (P_{IO_2}) $\rightarrow \downarrow P_{aO_2} \rightarrow \uparrow$ ventilation $\rightarrow \downarrow P_{aCO_2}$ \rightarrow respiratory alkalosis \rightarrow altitude sickness (headaches, nausea, fatigue, lightheadedness, sleep disturbance).

Chronic \uparrow in ventilation.

\uparrow erythropoietin $\rightarrow \uparrow$ Hct and Hb (due to chronic hypoxia).

\uparrow 2,3-BPG (binds to Hb \rightarrow rightward shift of oxyhemoglobin dissociation curve $\rightarrow \uparrow O_2$ release).

Cellular changes (\uparrow mitochondria).

\uparrow renal excretion of HCO_3^- to compensate for respiratory alkalosis (can augment with acetazolamide).

Chronic hypoxic pulmonary vasoconstriction $\rightarrow \uparrow$ pulmonary vascular resistance \rightarrow pulmonary hypertension, right ventricular hypertrophy (RVH).

Response to exercise

\uparrow HR and \uparrow SV $\rightarrow \uparrow \dot{Q} \rightarrow \uparrow$ pulmonary blood flow $\rightarrow \uparrow \dot{V}/\dot{Q}$ ratio from base to apex (becoming more uniform).

\uparrow cellular respiration $\rightarrow \uparrow CO_2$ production and \downarrow pH at tissues \rightarrow right shift of ODC \rightarrow tissue offloading of more $O_2 \rightarrow \uparrow O_2$ consumption. \uparrow RR to meet $\uparrow O_2$ demand and remove excess CO_2 .

P_{aO_2} and P_{aCO_2} are maintained by homeostatic mechanisms.

$\downarrow P\bar{v}O_2$ due to $\uparrow O_2$ consumption.

$\uparrow P\bar{v}CO_2$ due to $\uparrow CO_2$ production.

Methemoglobin

Iron in Hb is normally in a reduced state (ferrous Fe^{2+} ; “just the **2** of **us**”). Oxidized form of Hb (ferric, Fe^{3+}) does not bind O_2 as readily as Fe^{2+} , but has \uparrow affinity for cyanide \rightarrow tissue hypoxia from $\downarrow O_2$ saturation and $\downarrow O_2$ content.

This Fe^{3+} form is called methemoglobinemia.

While typical concentrations are 1–2%, methemoglobinemia will occur at higher levels and may present with cyanosis (does not improve with supplemental O_2) and with chocolate-colored blood.

Dapsone, local anesthetics (eg, benzocaine), and nitrites (eg, from dietary intake or polluted water sources) cause poisoning by oxidizing Fe^{2+} to Fe^{3+} .

Methemoglobinemia can be treated with **methylene blue** and vitamin C.

Cyanide vs carbon monoxide poisoning

Both inhibit aerobic metabolism via inhibition of complex IV of ETC (cytochrome c oxidase) → hypoxia that does not fully correct with supplemental O₂ and ↑ anaerobic metabolism.

Cyanide

Carbon monoxide

EXPOSURE

Synthetic product combustion, amygdalin ingestion (found in apricot seeds), cyanide ingestion (eg, in suicide attempts), fire victims.

Motor exhaust, gas heaters, fire victims.

PRESENTATION

Headache, dyspnea, drowsiness, seizure, coma. May have cherry red skin. Breath may have bitter almond odor.

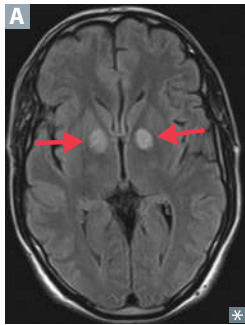
Headache, vomiting, confusion, visual disturbances, coma. May have cherry-red skin with bullous skin lesions. Multiple victims may be involved (eg, family due to faulty furnace).

LABS

Normal PaO₂. Elevated lactate → anion gap metabolic acidosis.

Normal PaO₂. Elevated carboxyhemoglobin on co-oximetry.

Classically associated with bilateral globus pallidus lesions on MRI **A**, although can rarely be seen with cyanide toxicity.



EFFECT ON OXYGEN-HEMOGLOBIN CURVE

Curve normal. Oxygen saturation may appear normal initially. Despite ample O₂ supply, it cannot be used due to ineffective oxidative phosphorylation.

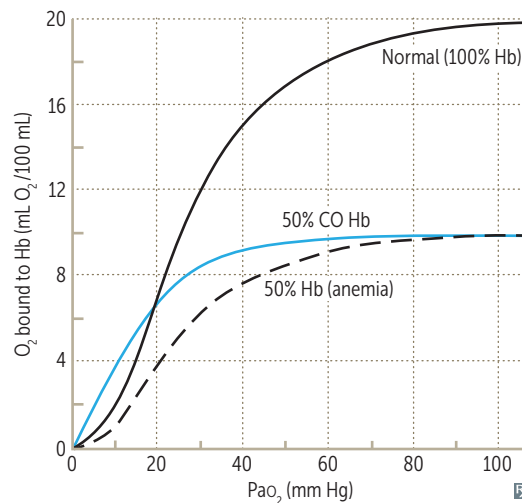
Left shift in ODC → ↑ affinity for O₂ → ↓ O₂ unloading in tissues.

Binds competitively to Hb with > 200× greater affinity than O₂ to form carboxyhemoglobin → ↓ %O₂ saturation of Hb.

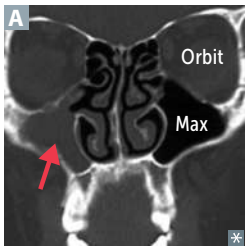
TREATMENT

Decontamination (eg, remove clothing).
 Hydroxocobalamin (binds cyanide → cyanocobalamin → renal excretion).
 Nitrites (oxidize Hb → methemoglobin → binds cyanide → cyanomethemoglobin → ↓ toxicity).
 Sodium thiosulfate (↑ cyanide conversion to thiocyanate → renal excretion).

100% O₂.
 Hyperbaric oxygen if severe.



► RESPIRATORY—PATHOLOGY

Rhinosinusitis

Obstruction of sinus drainage into nasal cavity → inflammation and pain over affected area.

Typically affects maxillary sinuses, which drain against gravity due to ostia located superomedially (red arrow points to fluid-filled right maxillary sinus in **A**).

Superior meatus—drains posterior ethmoid; middle meatus—drains frontal, maxillary, and anterior ethmoid; inferior meatus—drains nasolacrimal duct.

Acute rhinosinusitis is most commonly caused by viruses (eg, rhinovirus); may lead to superimposed bacterial infection, most commonly nontypeable *H influenzae*, *S pneumoniae*, *M catarrhalis*.

Paranasal sinus infections may extend to the orbits, cavernous sinus, and brain, causing complications (eg, orbital cellulitis, cavernous sinus syndrome, meningitis).

Epistaxis

Nose bleed. Most commonly occurs in anterior segment of nostril (**Kiesselbach plexus**). Life-threatening hemorrhages occur in posterior segment (sphenopalatine artery, a branch of maxillary artery). Common causes include foreign body, trauma, allergic rhinitis, and nasal angiofibromas (common in adolescent males).

Kiesselbach drives his **Lexus** with his **LEGS**: superior **L**abial artery, anterior and posterior **E**thmoidal arteries, **G**reater palatine artery, **S**phenopalatine artery.

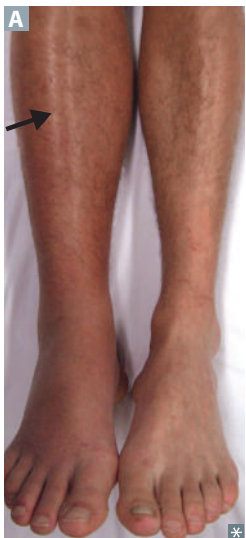Head and neck cancer

Mostly squamous cell carcinoma. Risk factors include tobacco, alcohol, HPV-16 (oropharyngeal), EBV (nasopharyngeal). Field cancerization: carcinogen damages wide mucosal area → multiple tumors that develop independently after exposure.

Nasopharyngeal carcinoma may present with unilateral nasal obstruction, discharge, epistaxis.

Eustachian tube obstruction may lead to otitis media +/- effusion, hearing loss.

Laryngeal papillomatosis—also called recurrent respiratory papillomatosis. Common benign laryngeal tumor (eg, vocal cords), especially in children. Associated with HPV-6 and HPV-11.

Deep venous thrombosis

Blood clot within a deep vein → swelling, redness **A**, warmth, pain. Predisposed by Virchow triad (**SHE**):

- **S**tasis (eg, post-op, long drive/flight)
- **H**ypercoagulability (eg, defect in coagulation cascade proteins, such as factor V Leiden; oral contraceptive use; pregnancy)
- **E**ndothelial damage (exposed collagen triggers clotting cascade)

Most pulmonary emboli arise from proximal deep veins of lower extremity (iliac, femoral, popliteal veins).

D-dimer test may be used clinically to rule out DVT if disease probability is low or moderate (high sensitivity, low specificity).

Imaging test of choice is compression ultrasound with Doppler.

Use unfractionated heparin or low-molecular weight heparins (eg, enoxaparin) for prophylaxis and acute management.

Use direct anticoagulants (eg, rivaroxaban, apixaban) for treatment and long-term prevention.

Pulmonary emboli

Obstruction of the pulmonary artery or its branches by foreign material (usually thrombus) that originated elsewhere. Affected alveoli are ventilated but not perfused (\dot{V}/\dot{Q} mismatch). May present with sudden-onset dyspnea, pleuritic chest pain, tachypnea, tachycardia, hypoxemia, respiratory alkalosis. Large emboli or saddle embolus **A** may cause sudden death due to clot preventing blood from filling LV and increased RV size further compromising LV filling (obstructive shock). CT pulmonary angiography is imaging test of choice for PE (look for filling defects) **B**. ECG may show sinus tachycardia or, less commonly, S1Q3T3 abnormality.

Lines of Zahn **C** are interdigitating areas of pink (platelets, fibrin) and red (RBCs) found only in thrombi formed before death; help distinguish pre- and postmortem thrombi.

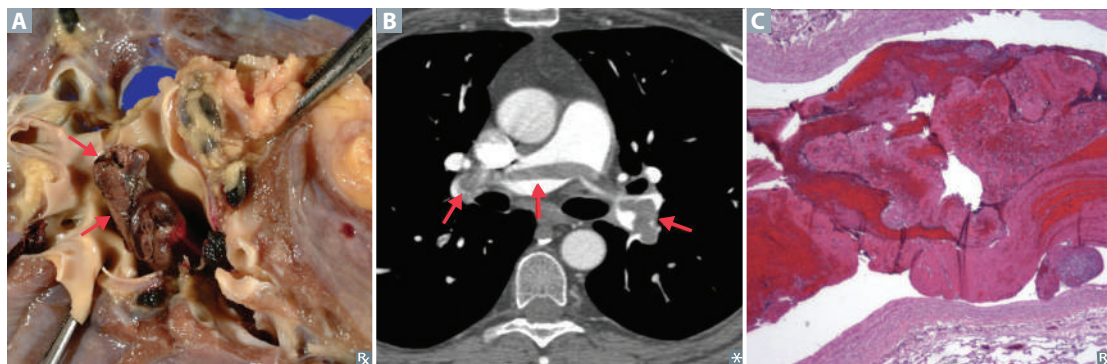
Treatment: anticoagulation (eg, heparin, direct thrombin/factor Xa inhibitors), IVC filter (if anticoagulation is contraindicated).

Types: **F**at, **A**ir, **T**hrombus, **B**acteria, **A**mniotic fluid, **T**umor. An embolus moves like a **FAT BAT**.

Fat emboli—associated with long bone fractures and liposuction; classic triad of hypoxemia, neurologic abnormalities, petechial rash.

Air emboli—nitrogen bubbles precipitate in ascending divers (caisson disease/decompression sickness); treat with hyperbaric O₂; or, can be iatrogenic 2° to invasive procedures (eg, central line placement).

Amniotic fluid emboli—typically occurs during labor or postpartum, but can be due to uterine trauma. Can lead to DIC. Rare, but high mortality.

**Mediastinal pathology**

Normal mediastinum contains heart, thymus, lymph nodes, esophagus, and aorta.

Mediastinal masses

Some pathologies (eg, lymphoma, lung cancer, abscess) can occur in any compartment, but there are common associations:

- Anterior—**4 T**'s: **t**hyroid (substernal goiter), **t**hymic neoplasm, **t**eratoma, "**t**errible" lymphoma.
- Middle—esophageal carcinoma, metastases, hiatal hernia, bronchogenic cysts.
- Posterior—neurogenic tumor (eg, neurofibroma), multiple myeloma.

Mediastinitis

Inflammation of mediastinal tissues. Commonly due to postoperative complications of cardiothoracic procedures (≤ 14 days), esophageal perforation, or contiguous spread of odontogenic/retropharyngeal infection.

Chronic mediastinitis—also called fibrosing mediastinitis; due to \uparrow proliferation of connective tissue in mediastinum. *Histoplasma capsulatum* is common cause.

Clinical features: fever, tachycardia, leukocytosis, chest pain, and sternal wound drainage.

Pneumomediastinum

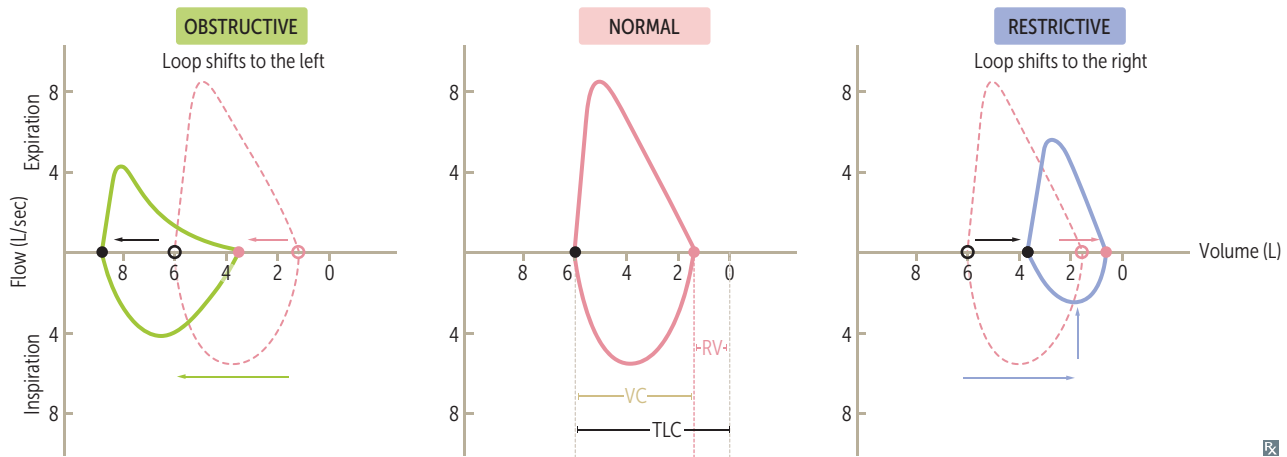
Presence of gas (usually air) in the mediastinum. Can either be spontaneous (due to rupture of pulmonary bleb) or 2° (eg, trauma, iatrogenic, Boerhaave syndrome).

Ruptured alveoli allow tracking of air into the mediastinum via peribronchial and perivascular sheaths.

Clinical features: chest pain, dyspnea, voice change, subcutaneous emphysema, \oplus Hamman sign (crepitus on cardiac auscultation).

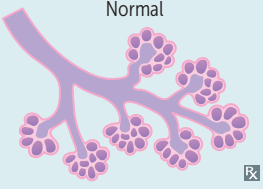

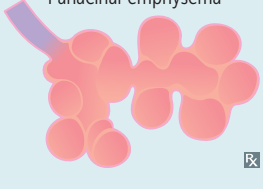
Flow-volume loops

FLOW-VOLUME PARAMETER	Obstructive lung disease	Restrictive lung disease
RV	↑	↓
FRC	↑	↓
TLC	↑	↓
FEV ₁	↓↓	↓
FVC	↓	↓
FEV ₁ /FVC	↓ FEV ₁ decreased more than FVC	Normal or ↑ FEV ₁ decreased proportionately to FVC



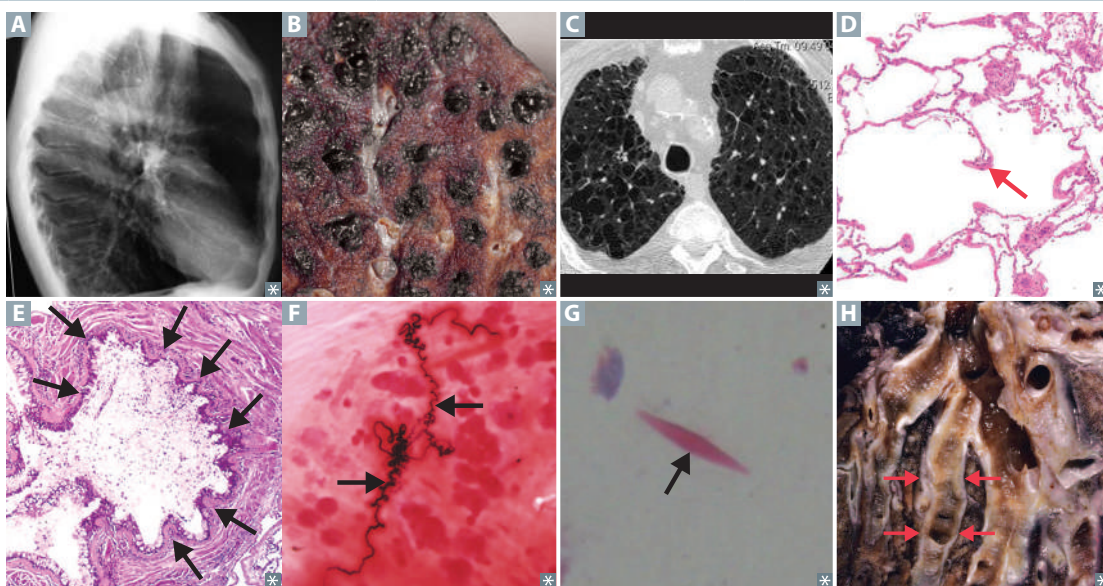
Obstructive lung diseases

Obstruction of air flow (↑ FRC, ↑ RV, ↑ TLC) → air trapping in lungs with premature airway closure at high lung volumes (↓↓ FEV₁, ↓ FVC ↓ FEV₁/FVC ratio). Leads to \dot{V}/\dot{Q} mismatch.

TYPE	PRESENTATION	PATHOLOGY	OTHER
Emphysema	Barrel-shaped chest A , expiration is prolonged and/or through pursed lips (increases airway pressure and prevents airway collapse).	Centriacinar—affects respiratory bronchioles while sparing distal alveoli, associated with tobacco smoking B C . Frequently in upper lobes (smoke rises up) . Panacinar—affects respiratory bronchioles and alveoli, associated with α_1 -antitrypsin deficiency. Frequently in lower lobes. Enlargement of air spaces ↓ recoil, ↑ compliance, ↓ DLCO from destruction of alveolar walls (arrow in D) and ↓ blood volume in pulmonary capillaries. Imbalance of proteases and antiproteases → ↑ elastase activity → ↑ loss of elastic fibers → ↑ lung compliance.	CXR: ↑ AP diameter, flattened diaphragm, ↑ lung field lucency. Chronic inflammation is mediated by CD8+ T cells, neutrophils, and macrophages.
Normal			
Centriacinar emphysema			
Panacinar emphysema			

Obstructive lung diseases (continued)

TYPE	PRESENTATION	PATHOLOGY	OTHER
Chronic bronchitis	Wheezing, crackles, cyanosis (hypoxemia due to shunting), dyspnea, CO ₂ retention, 2° polycythemia.	Hypertrophy and hyperplasia of mucus-secreting glands in bronchi → Reid index (thickness of mucosal gland layer to thickness of wall between epithelium and cartilage) > 50%.	Diagnostic criteria: productive cough for ≥ 3 months in a year for > 2 consecutive years. DLCO may be normal.
Asthma	Asymptomatic baseline with intermittent episodes of coughing, wheezing, tachypnea, dyspnea, hypoxemia, ↓ inspiratory/ expiratory ratio, mucus plugging E . Severe attacks may lead to pulsus paradoxus. Triggers: viral URIs, allergens, stress.	Hyperresponsive bronchi → reversible bronchoconstriction. Smooth muscle hypertrophy and hyperplasia, Curschmann spirals F (shed epithelium forms whorled mucous plugs), and Charcot-Leyden crystals G (eosinophilic, hexagonal, double-pointed crystals formed from breakdown of eosinophils in sputum). DLCO normal or ↑.	Type I hypersensitivity reaction. Diagnosis supported by spirometry +/- methacholine challenge. NSAID-exacerbated respiratory disease is a combination of COX inhibition (leukotriene overproduction → airway constriction), chronic sinusitis with nasal polyps, and asthma symptoms.
Bronchiectasis	Daily purulent sputum, recurrent infections (most often <i>P aeruginosa</i>), hemoptysis, digital clubbing.	Chronic necrotizing infection of bronchi or obstruction → permanently dilated airways.	Associated with bronchial obstruction, poor ciliary motility (eg, tobacco smoking, Kartagener syndrome), cystic fibrosis (arrows in H show dilated airway with mucus plug), allergic bronchopulmonary aspergillosis, pulmonary infections (eg, <i>M avium</i>).



Restrictive lung diseases

May lead to ↓ lung volumes (↓ FVC and TLC). PFTs: normal or ↑ FEV₁/FVC ratio. Patient presents with short, shallow breaths.

Types:

- Altered respiratory mechanics (extrapulmonary, normal D_{LCO}, normal A-a gradient):
 - Respiratory muscle weakness—polio, myasthenia gravis, Guillain-Barré syndrome, ALS
 - Chest wall abnormalities—scoliosis, severe obesity
- Diffuse parenchymal lung diseases, also called interstitial lung diseases (pulmonary, ↓ D_{LCO}, ↑ A-a gradient):
 - Pneumoconioses (eg, coal workers' pneumoconiosis, silicosis, asbestosis)
 - Sarcoidosis: bilateral hilar lymphadenopathy, noncaseating granulomas; ↑ ACE and Ca²⁺
 - Idiopathic pulmonary fibrosis
 - Granulomatosis with polyangiitis
 - Pulmonary Langerhans cell histiocytosis (eosinophilic granuloma)
 - Hypersensitivity pneumonitis
 - Drug toxicity (eg, bleomycin, busulfan, amiodarone, methotrexate)
 - Acute respiratory distress syndrome
 - **Radiation-induced lung injury**—associated with proinflammatory cytokine release (eg, TNF-α, IL-1, IL-6). May be asymptomatic but most common symptoms are dry cough and dyspnea +/- low-grade fever. Acute radiation pneumonitis develops within 3–12 weeks (exudative phase); radiation fibrosis may develop after 6–12 months.

Idiopathic pulmonary fibrosis

Progressive fibrotic lung disease of unknown etiology. May involve multiple cycles of lung injury, inflammation, and fibrosis. Associated with cigarette smoking, environmental pollutants, genetic defects.

Findings: progressive dyspnea, fatigue, nonproductive cough, crackles, clubbing. Imaging shows peripheral reticular opacities with traction bronchiectasis +/- “honeycomb” appearance of lung (advanced disease). Histologic pattern: usual interstitial pneumonia.

Complications: pulmonary hypertension, right heart failure, arrhythmias, coronary artery disease, respiratory failure, lung cancer.

Hypersensitivity pneumonitis

Mixed type III/IV hypersensitivity reaction to environmental antigens. Often seen in farmers and bird-fanciers. Acutely, causes dyspnea, cough, chest tightness, fever, headache. Often self-limiting if stimulus is removed. Chronically, leads to irreversible fibrosis with noncaseating granuloma, alveolar septal thickening, traction bronchiectasis.

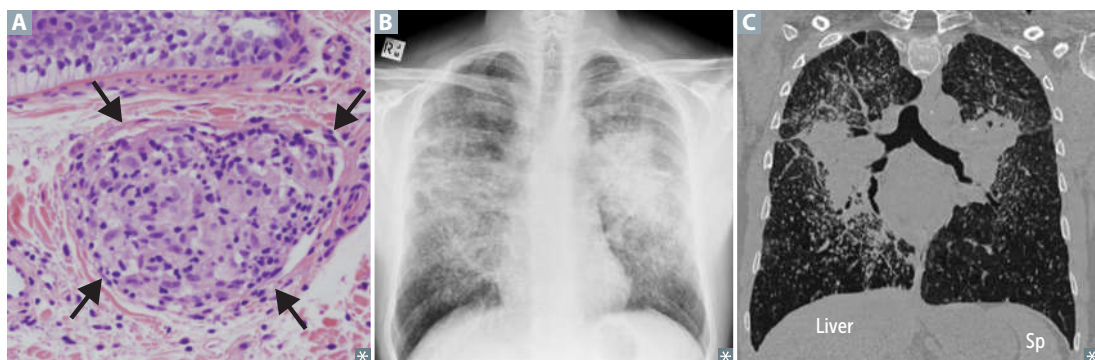Sarcoidosis

Characterized by immune-mediated, widespread noncaseating granulomas **A**, elevated serum ACE levels, and elevated CD4/CD8 ratio in bronchoalveolar lavage fluid. More common in Black females. Often asymptomatic except for enlarged lymph nodes. CXR shows bilateral adenopathy and coarse reticular opacities **B**; CT of the chest better demonstrates the extensive hilar and mediastinal adenopathy **C**.

Associated with Bell palsy, uveitis, granulomas (noncaseating epithelioid, containing microscopic Schaumann and asteroid bodies), lupus pernio (skin lesions on face resembling lupus), interstitial fibrosis (restrictive lung disease), erythema nodosum, rheumatoid arthritis–like arthropathy, hypercalcemia (due to \uparrow 1α -hydroxylase–mediated vitamin D activation in macrophages).

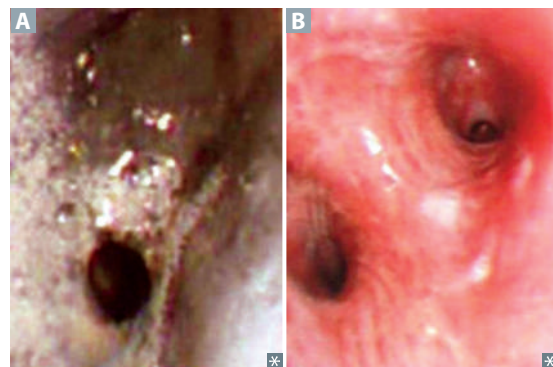
Associated with granulomas (noncaseating epithelioid, containing microscopic **S**chaumann and **A**steroid bodies), **R**heumatoid arthritis–like arthropathy, \uparrow **C**alcium, **O**cular uveitis, **I**nterstitial fibrosis, vitamin **D** activation (due to \uparrow 1α -hydroxylase in macrophages), **S**kin changes (eg, lupus pernio, erythema nodosum) (**SARCOIDS**).

Treatment: glucocorticoids (if symptomatic).

**Inhalation injury and sequelae**

Complication of inhalation of noxious stimuli (eg, smoke). Caused by heat, particulates ($< 1 \mu\text{m}$ diameter), or irritants (eg, NH_3) \rightarrow chemical tracheobronchitis, edema, pneumonia, ARDS. Many patients present 2 $^\circ$ to burns, CO inhalation, cyanide poisoning, or arsenic poisoning. Singed nasal hairs or soot in oropharynx common on exam.

Bronchoscopy shows severe edema, congestion of bronchus, and soot deposition (**A**, 18 hours after inhalation injury; **B**, resolution at 11 days after injury).



Pneumoconioses

Asbestos is from the **roof** (was common in insulation), but affects the **base** (lower lobes). **Silica, coal,** and **berries** are from the **base** (earth), but affect the **roof** (upper lobes).

Asbestos-related disease

Asbestos causes asbestosis (pulmonary fibrosis), pleural disease, malignancies. Associated with shipbuilding, roofing, plumbing. “Ivory white,” calcified, supradiaphragmatic **A** and pleural **B** plaques are pathognomonic. Risk of bronchogenic carcinoma > risk of mesothelioma. ↑ risk of Caplan syndrome (rheumatoid arthritis and pneumoconioses with intrapulmonary nodules).

Affects lower lobes.

Asbestos (ferruginous) bodies are golden-brown fusiform rods resembling dumbbells **C**, found in alveolar sputum sample, visualized using Prussian blue stain, often obtained by bronchoalveolar lavage. ↑ risk of pleural effusions.

Berylliosis

Associated with exposure to beryllium in aerospace and manufacturing industries. Granulomatous (noncaseating) **D** on histology and therefore occasionally responsive to glucocorticoids. ↑ risk of cancer and cor pulmonale.

Affects upper lobes.

Coal workers' pneumoconiosis

Prolonged coal dust exposure → macrophages laden with carbon → inflammation and fibrosis. Also called black lung disease. ↑ risk of Caplan syndrome.

Affects upper lobes.

Small, rounded nodular opacities seen on imaging.

Anthracosis—asymptomatic condition found in many urban dwellers exposed to sooty air.

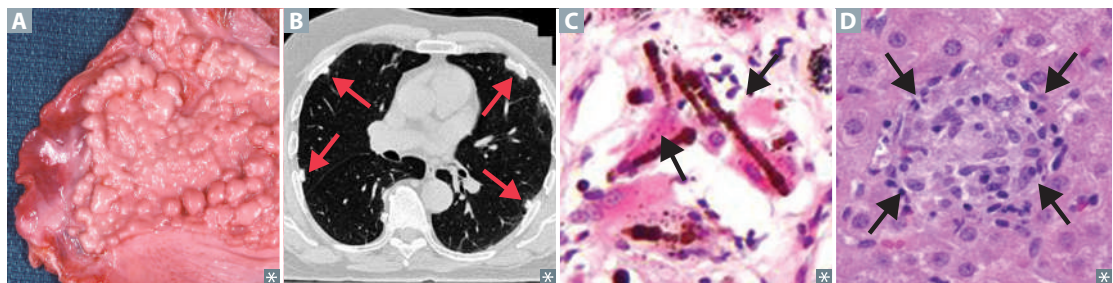
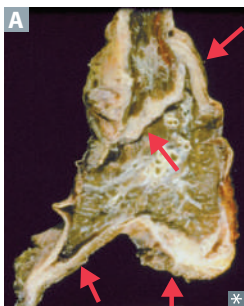Silicosis

Associated with sandblasting, foundries, mines. Macrophages respond to silica and release fibrogenic factors, leading to fibrosis. It is thought that silica may disrupt phagolysosomes and impair macrophages, increasing susceptibility to TB. ↑ risk of cancer, cor pulmonale, and Caplan syndrome.

Affects upper lobes.

“Eggshell” calcification of hilar lymph nodes on CXR.

The **silly egg sandwich I found is mine!**

**Mesothelioma**

Malignancy of the pleura associated with asbestosis. May result in hemorrhagic pleural effusion (exudative), pleural thickening **A**.

Histology may show psammoma bodies.

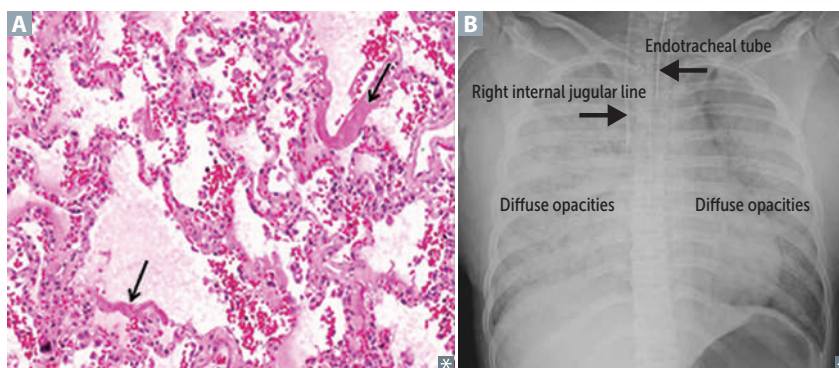
EM may show polygonal tumor cells with microvilli, desmosomes, tonofilaments.

Calretinin and cytokeratin 5/6 ⊕ in almost all mesotheliomas, ⊖ in most carcinomas.

Tobacco smoking is not a risk factor.

Acute respiratory distress syndrome

PATHOPHYSIOLOGY	Alveolar insult → release of pro-inflammatory cytokines → neutrophil recruitment, activation, and release of toxic mediators (eg, reactive oxygen species, proteases, etc) → capillary endothelial damage and ↑ vessel permeability → leakage of protein-rich fluid into alveoli → formation of intra-alveolar hyaline membranes (arrows in A) and noncardiogenic pulmonary edema (normal PCWP) → ↓ compliance and \dot{V}/\dot{Q} mismatch → hypoxic vasoconstriction → ↑ pulmonary vascular resistance. Loss of surfactant also contributes to alveolar collapse.
CAUSES	Sepsis (most common), aspiration pneumonia, trauma, pancreatitis.
DIAGNOSIS	Diagnosis of exclusion with the following criteria (ARDS): <ul style="list-style-type: none"> ▪ A Abnormal chest X-ray (bilateral lung opacities) B ▪ Respiratory failure within 1 week of alveolar insult ▪ Decreased P_{aO_2}/F_{IO_2} (ratio < 300, hypoxemia due to ↑ intrapulmonary shunting and diffusion abnormalities) ▪ Symptoms of respiratory failure are not due to HF/fluid overload
CONSEQUENCES	Impaired gas exchange, ↓ lung compliance; pulmonary hypertension.
MANAGEMENT	Treat the underlying cause. Mechanical ventilation: ↓ tidal volume, ↑ PEEP (keeps alveoli open during expiration).

**Sleep apnea**

Repeated cessation of breathing > 10 seconds during sleep → disrupted sleep → daytime somnolence. Diagnosis confirmed by sleep study.
Nocturnal hypoxia → systemic and pulmonary hypertension, arrhythmias (atrial fibrillation/flutter), sudden death.
Hypoxia → ↑ EPO release → ↑ erythropoiesis.

Obstructive sleep apnea

Respiratory effort against airway obstruction. P_{aO_2} is usually normal during the day. Associated with obesity, loud snoring, daytime sleepiness. Usually caused by excess parapharyngeal/oropharyngeal tissue in adults, adenotonsillar hypertrophy in children. Treatment: weight loss, CPAP, dental devices, hypoglossal nerve stimulation, upper airway surgery.

Central sleep apnea

Impaired respiratory effort due to **C**NS injury/toxicity, **C**ongestive HF, opioids. May be associated with **C**heyne-Stokes respirations (oscillations between apnea and hyperpnea). Treatment: positive airway pressure.

Obesity hypoventilation syndrome

Also called Pickwickian syndrome. Obesity ($BMI \geq 30 \text{ kg/m}^2$) → hypoventilation → ↑ P_{aCO_2} during waking hours (retention); ↓ P_{aO_2} and ↑ P_{aCO_2} during sleep. Treatment: weight loss, positive airway pressure.

Pulmonary hypertension

Elevated mean pulmonary artery pressure (> 20 mm Hg) at rest. Results in arteriosclerosis, medial hypertrophy, intimal fibrosis of pulmonary arteries, plexiform lesions. \uparrow pulmonary vascular resistance \rightarrow \uparrow RV pressure \rightarrow RVH, RV failure.

ETIOLOGIES

Pulmonary arterial hypertension

Often idiopathic. Females $>$ males. Heritable PAH can be due to an inactivating mutation in *BMPR2* gene (normally inhibits vascular smooth muscle proliferation); poor prognosis. Pulmonary vasculature endothelial dysfunction results in \uparrow vasoconstrictors (eg, endothelin) and \downarrow vasodilators (eg, NO and prostacyclins). Other causes include drugs (eg, amphetamines, cocaine), connective tissue disease, HIV infection, portal hypertension, congenital heart disease, schistosomiasis.

Left heart disease

Causes include systolic/diastolic dysfunction and valvular disease.

Lung diseases or hypoxia

Destruction of lung parenchyma (eg, COPD), lung inflammation/fibrosis (eg, interstitial lung diseases), hypoxic vasoconstriction (eg, obstructive sleep apnea, living in high altitude).

Chronic thromboembolic

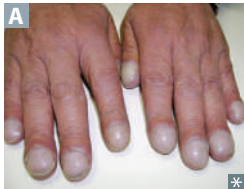Recurrent microthrombi \rightarrow \downarrow cross-sectional area of pulmonary vascular bed.

Multifactorial

Causes include hematologic, systemic, and metabolic disorders, along with compression of the pulmonary vasculature by a tumor.

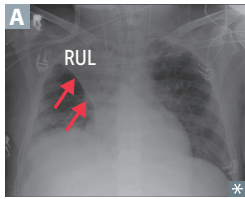
Physical findings in select lung diseases

ABNORMALITY	BREATH SOUNDS	PERCUSSION	FREMITUS	TRACHEAL DEVIATION
Pleural effusion	\downarrow	Dull	\downarrow	None if small Away from side of lesion if large
Atelectasis	\downarrow	Dull	\downarrow	Toward side of lesion
Simple pneumothorax	\downarrow	Hyperresonant	\downarrow	None
Tension pneumothorax	\downarrow	Hyperresonant	\downarrow	Away from side of lesion
Consolidation (lobar pneumonia, pulmonary edema)	Bronchial breath sounds; late inspiratory crackles, egophony, whispered pectoriloquy	Dull	\uparrow	None

Digital clubbing

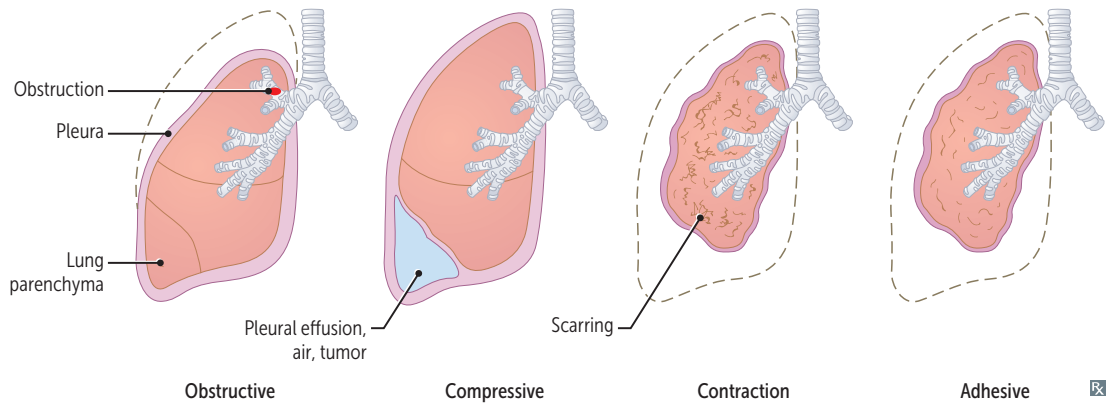
Increased angle between nail bed and nail plate ($> 180^\circ$) **A**. Pathophysiology not well understood; in patients with intrapulmonary shunt, platelets and megakaryocytes become lodged in digital vasculature \rightarrow local release of PDGF and VEGF. Can be hereditary or acquired. Causes include respiratory diseases (eg, idiopathic pulmonary fibrosis, cystic fibrosis, bronchiectasis, lung cancer), cardiovascular diseases (eg, cyanotic congenital heart disease), infections (eg, lung abscess, TB), and others (eg, IBD). Not typically associated with COPD or asthma.

Atelectasis



Alveolar collapse (right upper lobe collapse against mediastinum in **A**). Multiple causes:

- Obstructive—airway obstruction prevents new air from reaching distal airways, old air is resorbed (eg, foreign body, mucous plug, tumor)
- Compressive—external compression on lung decreases lung volumes (eg, space-occupying lesion, pleural effusion)
- Contraction (cicatrization)—scarring of lung parenchyma that distorts alveoli (eg, sarcoidosis)
- Adhesive—due to lack of surfactant (eg, NRDS in premature babies)



Pleural effusions

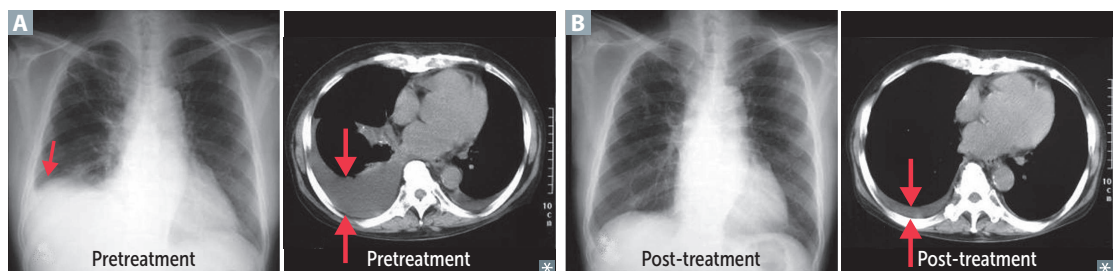
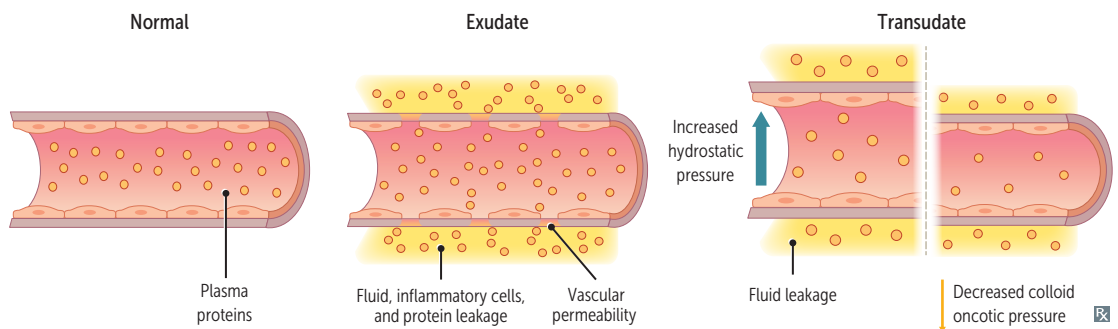
Excess accumulation of fluid **A** between pleural layers → restricted lung expansion during inspiration. Can be treated with thoracentesis to remove/reduce fluid **B**. Based on the Light's criteria, fluid is consistent with an exudate if pleural fluid protein/serum protein > 0.5, pleural fluid LDH/serum LDH > 0.6, or pleural fluid LDH > 2/3 upper limit of normal serum LDH.

Exudate

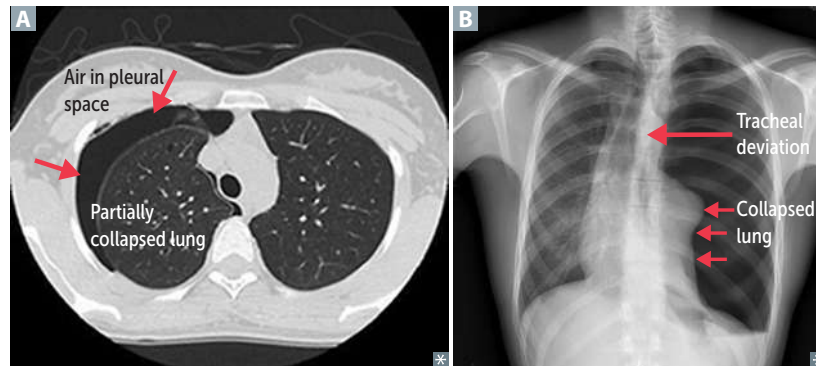
Cloudy fluid (cellular). Due to infection (eg, pneumonia, tuberculosis), malignancy, connective tissue disease, lymphatic (chylothorax), trauma. Often requires drainage due to ↑ risk of infection.

Transudate

Clear fluid (hypocellular). Due to ↑ hydrostatic pressure (eg, HF, Na⁺ retention) and/or ↓ oncotic pressure (eg, nephrotic syndrome, cirrhosis).

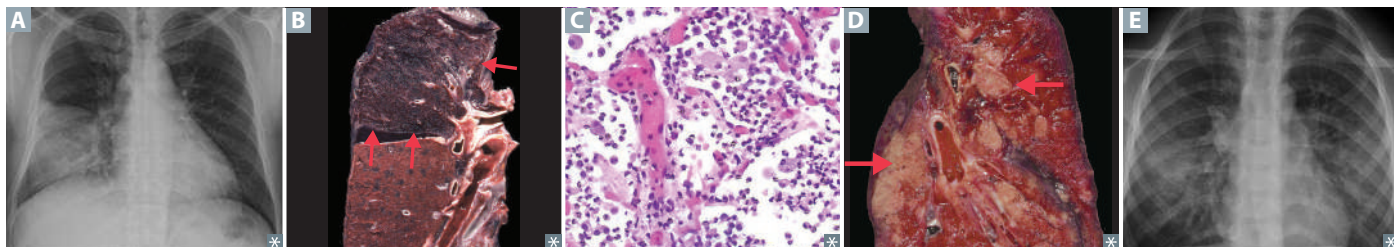


Pneumothorax	Accumulation of air in pleural space A . Dyspnea, uneven chest expansion. Chest pain, ↓ tactile fremitus, hyperresonance, and diminished breath sounds, all on the affected side.
Primary spontaneous pneumothorax	Due to rupture of apical subpleural bleb or cysts. Occurs most frequently in tall, thin, young males. Associated with tobacco smoking.
Secondary spontaneous pneumothorax	Due to diseased lung (eg, bullae in emphysema, Marfan syndrome, infections), mechanical ventilation with use of high pressures → barotrauma.
Traumatic pneumothorax	Caused by blunt (eg, rib fracture), penetrating (eg, gunshot), or iatrogenic (eg, central line placement, lung biopsy, barotrauma due to mechanical ventilation) trauma.
Tension pneumothorax	Can be from any of the above. Air enters pleural space but cannot exit. Increasing trapped air → tension pneumothorax. Trachea deviates away from affected lung B . May lead to increased intrathoracic pressure → mediastinal displacement → kinking of IVC → ↓ venous return → ↓ cardiac output, obstructive shock (hypotension, tachycardia), jugular venous distention. Needs immediate needle decompression and chest tube placement.



Pneumonia

TYPE	TYPICAL ORGANISMS	CHARACTERISTICS
Lobar pneumonia	<i>S pneumoniae</i> (most common), <i>Legionella</i> , <i>Klebsiella</i>	Intra-alveolar exudate → consolidation A ; may involve entire lobe B or the whole lung.
Bronchopneumonia	<i>S pneumoniae</i> , <i>S aureus</i> , <i>H influenzae</i> , <i>Klebsiella</i>	Acute inflammatory infiltrates C from bronchioles into adjacent alveoli; patchy distribution involving ≥ 1 lobe D .
Interstitial (atypical) pneumonia	<i>Mycoplasma</i> , <i>Chlamydomphila pneumoniae</i> , <i>Chlamydomphila psittaci</i> , <i>Legionella</i> , <i>Coxiella burnetii</i> , viruses (RSV, CMV, influenza, adenovirus)	Diffuse patchy inflammation localized to interstitial areas at alveolar walls; CXR shows bilateral multifocal opacities E . Generally follows a more indolent course (“walking” pneumonia).
Cryptogenic organizing pneumonia	Etiology unknown. ⊖ sputum and blood cultures, often responds to glucocorticoids but not to antibiotics.	Formerly called bronchiolitis obliterans organizing pneumonia (BOOP). Noninfectious pneumonia characterized by inflammation of bronchioles and surrounding structure.
Aspiration pneumonia	Aspiration of oropharyngeal or gastric contents → pulmonary infection. Risk factors: altered mental status (↓ cough reflex or glottic closure), dysphagia, neurologic disorders (eg, stroke), invasive tubes (eg, nasogastric tube).	Presents days after aspiration event in dependent lung segment. More common in RLL if sitting up and RUL if lying down due to bronchial anatomy. Can progress to abscess. Aspiration (chemical) pneumonitis —presents hours after aspiration event. Due to gastric acid-mediated inflammation. Presents with infiltrates in lower lobe(s) and resolves with supportive treatment.



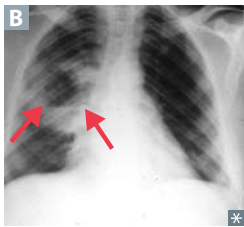
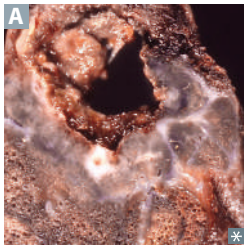Natural history of lobar pneumonia

	Congestion	Red hepatization	Gray hepatization	Resolution
DAYS	1–2	3–4	5–7	8+
FINDINGS	Red-purple, partial consolidation of parenchyma Exudate with mostly bacteria	Red-brown consolidation Exudate with fibrin, bacteria, RBCs, WBCs Reversible	Uniformly gray Exudate full of WBCs, lysed RBCs, and fibrin	Enzymatic digestion of exudate by macrophages

The diagram illustrates the natural history of lobar pneumonia in five stages: Normal, Congestion, Red hepatization, Gray hepatization, and Resolution. Each stage shows a cross-section of a lung lobe and a magnified view of an alveolus.

- Normal:** Shows a healthy alveolus with macrophages, capillaries, and WBCs.
- Congestion:** Shows bacteria and exudate entering the alveolus.
- Red hepatization:** Shows RBCs and fibrin entering the alveolus, creating a red-brown consolidation.
- Gray hepatization:** Shows the exudate becoming uniformly gray due to lysed RBCs and fibrin.
- Resolution:** Shows the exudate being digested by macrophages, returning the lung to normal.

Lung abscess



Localized collection of pus within parenchyma **A**. Caused by aspiration of oropharyngeal contents (especially in patients predisposed to loss of consciousness [eg, alcohol overuse, epilepsy]) or bronchial obstruction (eg, cancer).

Air-fluid levels **B** often seen on CXR; presence suggests cavitation. Due to anaerobes (eg, *Bacteroides*, *Fusobacterium*, *Peptostreptococcus*) or *S aureus*.

Treatment: antibiotics, drainage, or surgery.

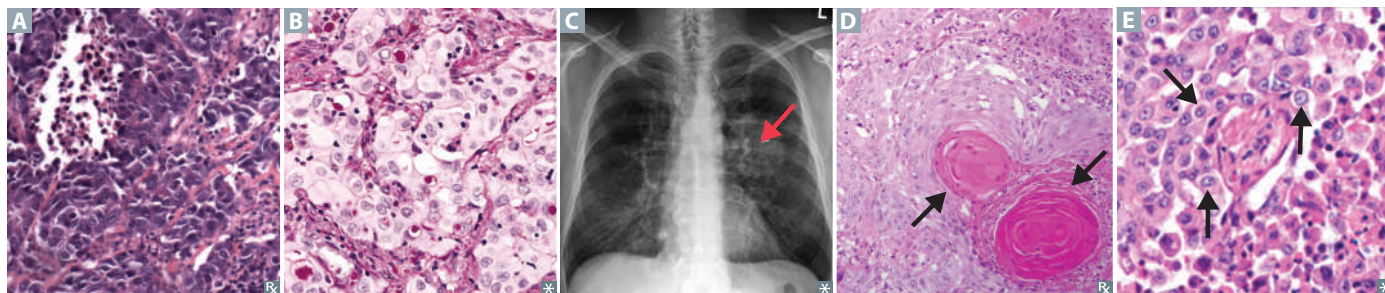
Lung abscess 2° to aspiration is most often found in right lung. Location depends on patient's position during aspiration: RLL if upright, RUL or RML if recumbent.

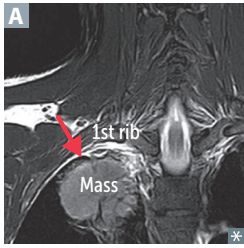
Lung cancer

Leading cause of cancer death.
 Presentation: cough, hemoptysis, bronchial obstruction, wheezing, pneumonic “coin” lesion on CXR or noncalcified nodule on CT.
 Sites of metastases from lung cancer: **liver** (jaundice, hepatomegaly), **adrenals**, **bone** (pathologic fracture), **brain**; “Lung ‘mets’ Love affective **boneheads** and **brainiacs**.”
 In the lung, metastases (usually multiple lesions) are more common than 1° neoplasms. Most often from breast, colon, prostate, and bladder cancer.

SPHERE of complications: **S**uperior vena cava/thoracic outlet syndromes, **P**ancoast tumor, **H**orner syndrome, **E**ndocrine (paraneoplastic), **R**ecurrent laryngeal nerve compression (hoarseness), **E**ffusions (pleural or pericardial).
 Risk factors include tobacco smoking, secondhand smoke, radiation, environmental exposures (eg, radon, asbestos), pulmonary fibrosis, family history.
Squamous and **s**mall cell carcinomas are **s**entral (central) and often caused by **s**moking.

TYPE	LOCATION	CHARACTERISTICS	HISTOLOGY
Small cell			
Small cell (oat cell) carcinoma	Central	Undifferentiated → very aggressive. May cause neurologic paraneoplastic syndromes (eg, Lambert-Eaton myasthenic syndrome, paraneoplastic myelitis, encephalitis, subacute cerebellar degeneration) and endocrine paraneoplastic syndromes (Cushing syndrome, SIADH). Amplification of <i>myc</i> oncogenes common. Managed with chemotherapy +/- radiation.	Neoplasm of neuroendocrine Kulchitsky cells → small dark blue cells A . Chromogranin A ⊕, neuron-specific enolase ⊕, synaptophysin ⊕.
Non-small cell			
Adenocarcinoma	Peripheral	Most common 1° lung cancer. Most common subtype in people who do not smoke. More common in females than males. Activating mutations include <i>KRAS</i> , <i>EGFR</i> , and <i>ALK</i> . Associated with hypertrophic osteoarthropathy (clubbing). Bronchioloalveolar subtype (adenocarcinoma in situ): CXR often shows hazy infiltrates similar to pneumonia; better prognosis.	Glandular pattern, often stains mucin ⊕ B . Bronchioloalveolar subtype: grows along alveolar septa → apparent “thickening” of alveolar walls. Tall, columnar cells containing mucus.
Squamous cell carcinoma	C entral	Hilar mass C arising from bronchus; c avitation; c igarettes; hyper calc emia (produces PTHrP).	Keratin pearls D and intercellular bridges (desmosomes).
Large cell carcinoma	Peripheral	Highly anaplastic undifferentiated tumor. Strong association with tobacco smoking. May produce hCG → gynecomastia. Less responsive to chemotherapy; removed surgically. Poor prognosis.	Pleomorphic giant cells E .
Bronchial carcinoid tumor	Central or peripheral	Excellent prognosis; metastasis rare. Symptoms due to mass effect or carcinoid syndrome (flushing, diarrhea, wheezing).	Nests of neuroendocrine cells; chromogranin A ⊕.

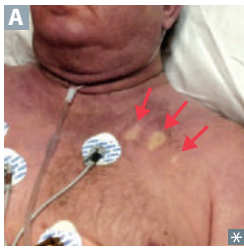


Pancoast tumor

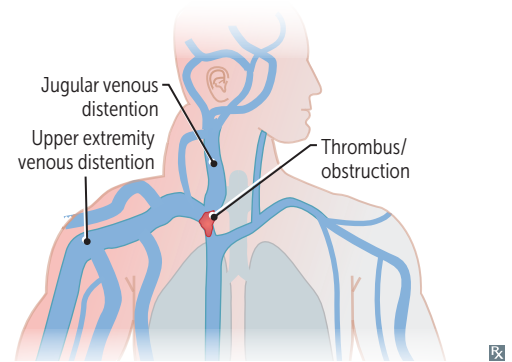
Also called superior sulcus tumor. Carcinoma that occurs in the apex of lung **A** may cause Pancoast syndrome by invading/compressing local structures.

Compression of locoregional structures may cause array of findings:

- Recurrent laryngeal nerve → hoarseness
- Stellate ganglion → Horner syndrome (ipsilateral ptosis, miosis, anhidrosis)
- Superior vena cava → SVC syndrome
- Brachiocephalic vein → brachiocephalic syndrome (unilateral symptoms)
- Brachial plexus → shoulder pain, sensorimotor deficits (eg, atrophy of intrinsic muscles of the hand)
- Phrenic nerve → hemidiaphragm paralysis (hemidiaphragm elevation on CXR)

Superior vena cava syndrome

Obstruction of the SVC (eg, thrombus, tumor) impairs blood drainage from the head (“facial plethora”; note blanching after fingertip pressure in **A**), neck (jugular venous distension, laryngeal/pharyngeal edema), and upper extremities (edema). Commonly caused by malignancy (eg, mediastinal mass, Pancoast tumor) and thrombosis from indwelling catheters. Medical emergency. Can raise intracranial pressure (if obstruction is severe) → headaches, dizziness, ↑ risk of aneurysm/rupture of intracranial arteries.

**▶ RESPIRATORY—PHARMACOLOGY****H₁-blockers**

Also called antihistamines. Reversible inhibitors of H₁ histamine receptors. May function as neutral antagonists or inverse agonists.

First generation

Diph~~e~~nhydramine, dimenhydrinate, chlorpheniramine, doxylamine.

Names usually contain “-en/-ine” or “-en/-ate.”

CLINICAL USE

Allergy, motion sickness, vomiting in pregnancy, sleep aid.

ADVERSE EFFECTS

Sedation, antimuscarinic, anti- α -adrenergic.

Second generation

Loratadine, fexofenadine, desloratadine, cetirizine.

Names usually end in “-adine.” Setirizine (cetirizine) is second-generation agent.

CLINICAL USE

Allergy.

ADVERSE EFFECTS

Far less sedating than 1st generation because of ↓ entry into CNS.

Dextromethorphan

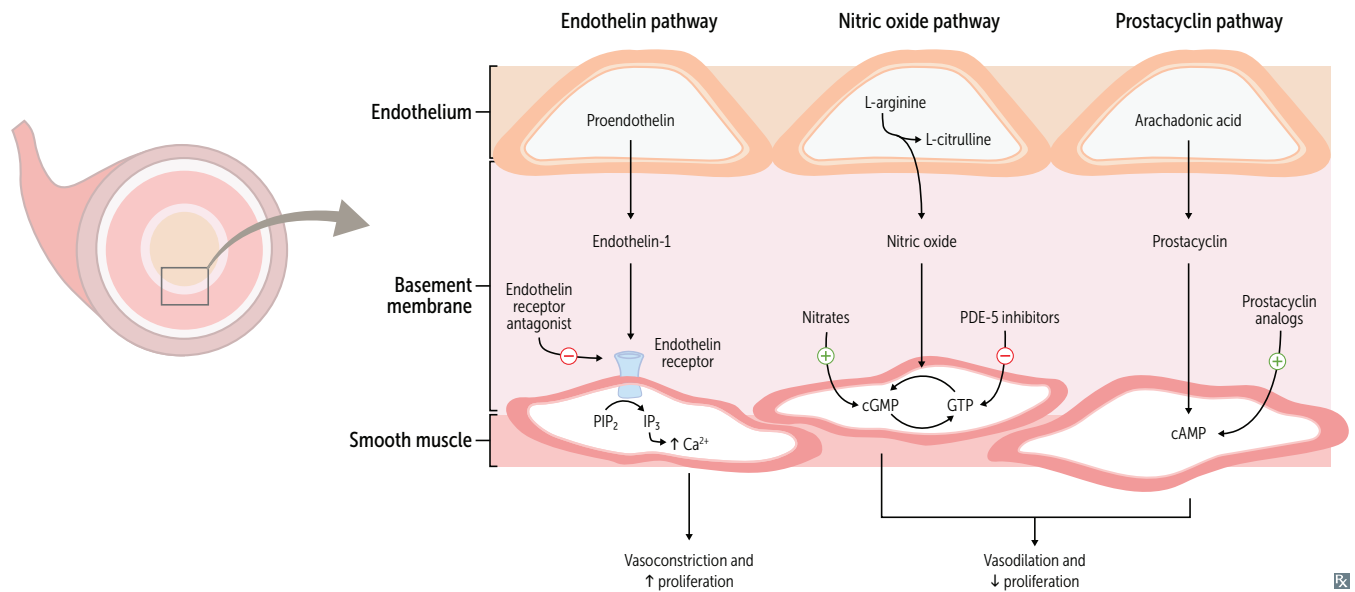
Antitussive (antagonizes NMDA glutamate receptors). Synthetic codeine analog. Has mild opioid effect when used in excess. Naloxone can be given for overdose. Mild abuse potential. May cause serotonin syndrome if combined with other serotonergic agents.

Pseudoephedrine, phenylephrine

MECHANISM	Activation of α -adrenergic receptors in nasal mucosa → local vasoconstriction.
CLINICAL USE	Reduce hyperemia, edema (used as nasal decongestants); open obstructed eustachian tubes.
ADVERSE EFFECTS	Hypertension. Rebound congestion (rhinitis medicamentosa) if used more than 4–6 days. Associated with tachyphylaxis. Can also cause CNS stimulation/anxiety (pseudoephedrine).

Pulmonary hypertension drugs

DRUG	MECHANISM	CLINICAL NOTES
Endothelin receptor antagonists	Competitively antagonizes endothelin-1 receptors → ↓ pulmonary vascular resistance.	Hepatotoxic (monitor LFTs). Example: bosentan.
PDE-5 inhibitors	Inhibits PDE-5 → ↑ cGMP → prolonged vasodilatory effect of NO.	Also used to treat erectile dysfunction. Contraindicated when taking nitroglycerin or other nitrates (due to risk of severe hypotension). Example: sildenafil.
Prostacyclin analogs	PGI ₂ (prostacyclin) with direct vasodilatory effects on pulmonary and systemic arterial vascular beds. Inhibits platelet aggregation.	Adverse effects: flushing, jaw pain. Examples: epoprostenol, iloprost.



Asthma drugs

Bronchoconstriction is mediated by (1) inflammatory processes and (2) parasympathetic tone; therapy is directed at these 2 pathways.

Inhaled β_2 -agonists

Albuterol, salmeterol, formoterol—relax bronchial smooth muscle. Can cause tremor, arrhythmia. Albuterol is short-acting, used for acute symptoms. Salmeterol and formoterol are long-acting.

Inhaled glucocorticoids

Fluticasone, budesonide—inhibit the synthesis of virtually all cytokines. Inactivate NF- κ B, the transcription factor that induces production of TNF- α and other inflammatory agents. 1st-line therapy for chronic asthma. Use a spacer or rinse mouth after use to prevent oral thrush.

Muscarinic antagonists

Tiotropium, ipratropium—competitively block muscarinic receptors, preventing bronchoconstriction. Also used for COPD. Tiotropium is long acting.

Antileukotrienes

Montelukast, zafirlukast—block leukotriene receptors (CysLT1). Especially good for aspirin-induced and exercise-induced asthma.

Zileuton—5-lipoxygenase inhibitor. \downarrow conversion of arachidonic acid to leukotrienes. Hepatotoxic.

Anti-IgE monoclonal therapy

Omalizumab—binds mostly unbound serum IgE and blocks binding to Fc ϵ RI. Used in allergic asthma with \uparrow IgE levels resistant to inhaled glucocorticoids and long-acting β_2 -agonists.

Methylxanthines

Theophylline—likely causes bronchodilation by inhibiting phosphodiesterase \rightarrow \uparrow cAMP levels due to \downarrow cAMP hydrolysis. Limited use due to narrow therapeutic index (cardiotoxicity, neurotoxicity); metabolized by cytochrome P-450. Blocks actions of adenosine.

PDE-4 Inhibitors

Roflumilast—inhibits phosphodiesterase \rightarrow \uparrow cAMP \rightarrow bronchodilation, \downarrow airway inflammation. Used in COPD to reduce exacerbations.

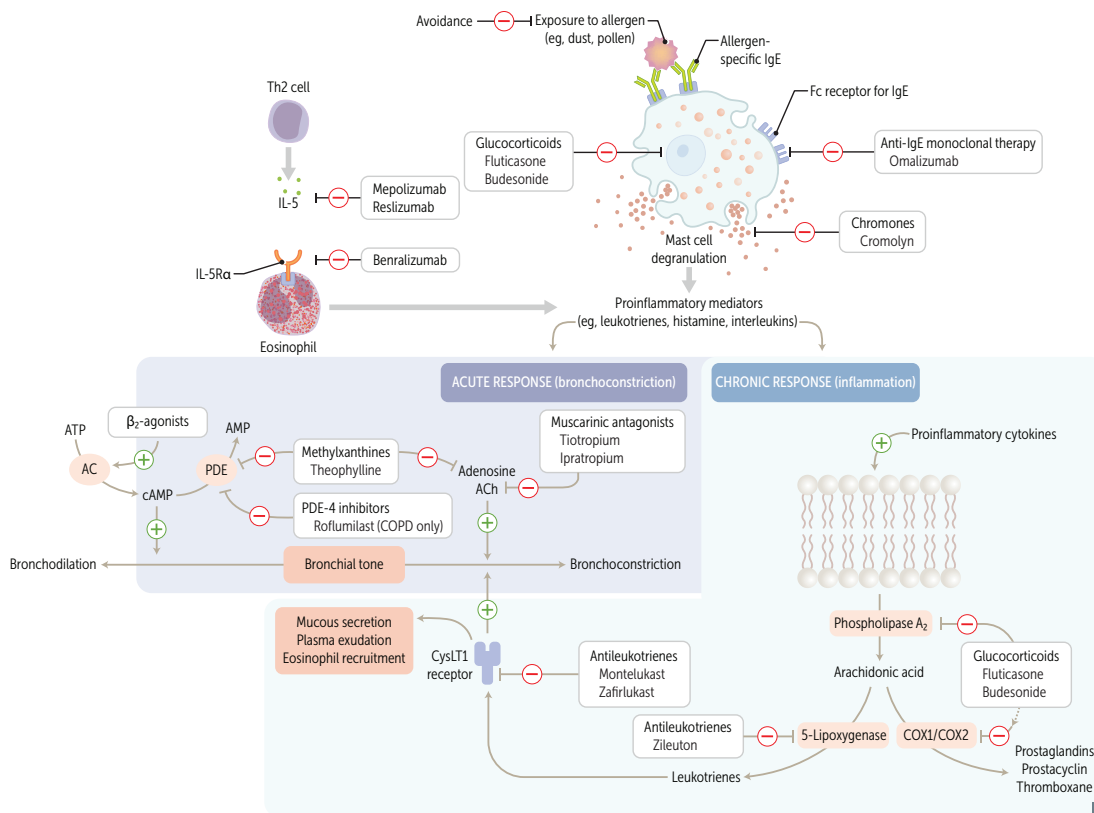
Chromones

Cromolyn—prevents mast cell degranulation. Prevents acute asthma symptoms. Rarely used.

Anti-IL-5 monoclonal therapy

Prevents eosinophil differentiation, maturation, activation, and survival mediated by IL-5 stimulation. For maintenance therapy in severe eosinophilic asthma.

Mepolizumab, reslizumab—against IL-5. **Benralizumab**—against IL-5 receptor α .



Rapid Review

“Study without thought is vain: thought without study is dangerous.”
—Confucius

“It is better, of course, to know useless things than to know nothing.”
—Lucius Annaeus Seneca

“For every complex problem there is an answer that is clear, simple, and wrong.”
—H. L. Mencken

The following tables represent a collection of high-yield associations between diseases and their clinical findings, treatments, and key associations. They can be quickly reviewed in the days before the exam.

▶ Classic Presentations	714
▶ Classic Labs/ Findings	720
▶ Classic/Relevant Treatments	724
▶ Key Associations	728
▶ Equation Review	732
▶ Easily Confused Medications	734

► CLASSIC PRESENTATIONS

CLINICAL PRESENTATION	DIAGNOSIS/DISEASE	PAGE
Gout, intellectual disability, self-mutilating behavior in a boy	Lesch-Nyhan syndrome (HGPRT deficiency, X-linked recessive)	35
Situs inversus, chronic ear infections, sinusitis, bronchiectasis, infertility	Primary ciliary dyskinesia or Kartagener syndrome (dynein arm defect affecting cilia)	47
Blue sclera, multiple fractures, dental problems, conductive hearing loss	Osteogenesis imperfecta (type I collagen defect)	49
Elastic skin, hypermobility of joints, ↑ bleeding tendency	Ehlers-Danlos syndrome (type V collagen defect, type III collagen defect seen in vascular subtype of ED)	49
Arachnodactyly, lens dislocation (upward and temporal), aortic dissection, hyperflexible joints	Marfan syndrome (fibrillin defect)	50
Arachnodactyly, pectus deformity, lens dislocation (downward)	Homocystinuria (autosomal recessive)	50
Café-au-lait spots (unilateral), polyostotic fibrous dysplasia, precocious puberty, multiple endocrine abnormalities	McCune-Albright syndrome (G_s -protein activating mutation)	55
Meconium ileus in neonate, recurrent pulmonary infections, nasal polyps, pancreatic insufficiency, infertility/subfertility	Cystic fibrosis (<i>CFTR</i> gene defect, chromosome 7, $\Delta F508$)	58
Calf pseudohypertrophy	Muscular dystrophy (most commonly Duchenne, due to X-linked recessive frameshift mutation of dystrophin gene)	59
Child uses arms to stand up from squat	Duchenne muscular dystrophy (Gowers sign)	59
Slow, progressive muscle weakness in boys	Becker muscular dystrophy (X-linked non-frameshift deletions in dystrophin; less severe than Duchenne)	59
Infant with cleft lip/palate, microcephaly or holoprosencephaly, polydactyly, cutis aplasia	Patau syndrome (trisomy 13)	61
Infant with microcephaly, rocker-bottom feet, clenched hands, and structural heart defect	Edwards syndrome (trisomy 18)	61
Single palmar crease, intellectual disability	Down syndrome	61
Microcephaly, high-pitched cry, intellectual disability	Cri-du-chat (cry of the cat) syndrome	62
Confusion, ophthalmoplegia/nystagmus, ataxia	Wernicke encephalopathy (add confabulation/memory loss for Korsakoff syndrome)	64
Dilated cardiomyopathy/high-output heart failure, edema, alcoholism or malnutrition	Wet beriberi (thiamine [vitamin B_1] deficiency)	64
Burning feet syndrome	Vitamin B_5 deficiency	65
Dermatitis, dementia, diarrhea	Pellagra (niacin [vitamin B_3] deficiency)	65
Swollen gums, mucosal bleeding, poor wound healing, petechiae, corkscrew hairs	Scurvy (vitamin C deficiency: can't hydroxylate proline/lysine for collagen synthesis); tea and toast diet	67
Bowlegs (children), bone pain, and muscle weakness	Rickets (children), osteomalacia (adults); vitamin D deficiency	68
Hemorrhagic disease of newborn with ↑ PT, ↑ aPTT	Vitamin K deficiency	69

CLINICAL PRESENTATION	DIAGNOSIS/DISEASE	PAGE
Intellectual disability, musty body odor, hypopigmented skin, eczema	Phenylketonuria	82
Bluish-black connective tissue, ear cartilage, sclerae; urine turns black on prolonged exposure to air	Alkaptonuria (homogentisate oxidase deficiency; ochronosis)	82
Myopathy (infantile hypertrophic cardiomyopathy), exercise intolerance	Pompe disease (lysosomal α -1,4-glucosidase deficiency)	85
Infant with hypoglycemia, hepatomegaly	Cori disease (debranching enzyme deficiency) or Von Gierke disease (glucose-6-phosphatase deficiency, more severe)	85
Chronic exercise intolerance with myalgia, fatigue, painful cramps, myoglobinuria	McArdle disease (skeletal muscle glycogen phosphorylase deficiency)	85
“Cherry-red spots” on macula	Tay-Sachs (ganglioside accumulation; no hepatosplenomegaly); Niemann-Pick disease (sphingomyelin accumulation; hepatosplenomegaly); central retinal artery occlusion	86, 556
Hepatosplenomegaly, pancytopenia, osteoporosis, avascular necrosis of femoral head, bone crises	Gaucher disease (glucocerebrosidase [β -glucosidase] deficiency)	86
Achilles tendon xanthoma	Familial hypercholesterolemia (\downarrow LDL receptor signaling)	92
Recurrent <i>Neisseria</i> infection	Terminal complement deficiencies (C5-C9)	105
Male child, recurrent infections, no mature B cells	Bruton disease (X-linked agammaglobulinemia)	114
Anaphylaxis following blood transfusion	IgA deficiency	114
Recurrent cold (noninflamed) abscesses, eczema, high serum IgE, \uparrow eosinophils	Hyper-IgE syndrome (Job syndrome: neutrophil chemotaxis abnormality)	114
Late separation (>30 days) of umbilical cord, no pus, recurrent skin and mucosal bacterial infections	Leukocyte adhesion deficiency (type 1; defective LFA-1 integrin)	115
Recurrent infections and granulomas with catalase \oplus organisms	Chronic granulomatous disease (defect of NADPH oxidase)	115
Fever, vomiting, diarrhea, desquamating rash following use of nasal pack or tampon	Staphylococcal toxic shock syndrome	133
“Strawberry tongue”	Scarlet fever (sandpaper rash); Kawasaki disease (lymphadenopathy, high fever for 5 days)	134, 482
Colon cancer associated with infective endocarditis	<i>Streptococcus bovis</i>	135
Flaccid paralysis in newborn after ingestion of honey	<i>Clostridium botulinum</i> infection (floppy baby syndrome)	136
Abdominal pain, diarrhea, leukocytosis, recent antibiotic use	<i>Clostridioides difficile</i> infection	136
Tonsillar pseudomembrane with “bull’s neck” appearance	<i>Corynebacterium diphtheria</i> infection	137
Back pain, fever, night sweats	Pott disease (vertebral TB)	138
Adrenal insufficiency, fever, DIC	Waterhouse-Friderichsen syndrome (meningococcemia)	140, 355
Red “currant jelly” sputum in patients with alcohol overuse or diabetes	<i>Klebsiella pneumoniae</i> pneumonia	143
Large rash with bull’s-eye appearance	Erythema migrans from <i>Ixodes</i> tick bite (Lyme disease: <i>Borrelia</i>)	144

CLINICAL PRESENTATION	DIAGNOSIS/DISEASE	PAGE
Ulcerated genital lesion	Nonpainful, indurated: chancre (1° syphilis, <i>Treponema pallidum</i>) Painful, with exudate: chancroid (<i>Haemophilus ducreyi</i>)	145, 180
Smooth, moist, painless, wartlike white lesions on genitals	Condylomata lata (2° syphilis)	145
Pupil accommodates but doesn't react to light	Neurosyphilis (Argyll Robertson pupil)	145
Fever, chills, headache, myalgia following antibiotic treatment for syphilis	Jarisch-Herxheimer reaction (due to host response to sudden release of bacterial antigens)	146
Dog or cat bite resulting in infection (cellulitis, osteomyelitis)	<i>Pasteurella multocida</i> (cellulitis at inoculation site)	147
Atypical "walking pneumonia" with x-ray looking worse than the patient	<i>Mycoplasma pneumoniae</i> infection	148
Rash on palms and soles	Coxsackie A, 2° syphilis, Rocky Mountain spotted fever	148
Black eschar on face of patient with diabetic ketoacidosis and/or neutropenia	<i>Mucor</i> or <i>Rhizopus</i> fungal infection	150
Chorioretinitis, hydrocephalus, intracranial calcifications	Congenital toxoplasmosis	153
Pruritus, serpiginous rash after walking barefoot	Hookworm (<i>Ancylostoma</i> spp, <i>Necator americanus</i>)	156
Child with fever later develops red rash on face that spreads to body	Erythema infectiosum/fifth disease ("slapped cheeks" appearance, caused by parvovirus B19)	161
Fever, cough, conjunctivitis, coryza, diffuse rash	Measles	167
Small, irregular red spots on buccal/lingual mucosa with blue-white centers	Koplik spots (measles [rubeola] virus)	167
Bounding pulses, wide pulse pressure, diastolic heart murmur, head bobbing	Aortic regurgitation	298
Systolic ejection murmur (crescendo-decrescendo), narrow pulse pressure, pulsus parvus et tardus	Aortic stenosis	298
Continuous "machinelike" heart murmur	PDA (close with indomethacin; keep open with PGE analogs)	298
Chest pain on exertion	Angina (stable: with moderate exertion; unstable: with minimal exertion or at rest)	310
Chest pain with ST depressions on ECG	Angina (⊖ troponins) or NSTEMI (⊕ troponins)	310
Chest pain, pericardial effusion/friction rub, persistent fever following MI	Dressler syndrome (autoimmune-mediated post-MI fibrinous pericarditis, 2 weeks to several months after acute episode)	316
Distant heart sounds, distended neck veins, hypotension	Beck triad of cardiac tamponade	319
Painful, raised red lesions on pads of fingers/toes	Osler nodes (infective endocarditis, immune complex deposition)	320
Painless erythematous lesions on palms and soles	Janeway lesions (infective endocarditis, septic emboli/microabscesses)	320
Splinter hemorrhages in fingernails	Infective endocarditis	320
Retinal hemorrhages with pale centers	Roth spots (infective endocarditis)	320
Telangiectasias, recurrent epistaxis, skin discoloration, arteriovenous malformations, GI bleeding, hematuria	Hereditary hemorrhagic telangiectasia (Osler-Weber-Rendu syndrome)	323

CLINICAL PRESENTATION	DIAGNOSIS/DISEASE	PAGE
Polyuria (water diuresis), polydipsia	Primary polydipsia, diabetes insipidus (central, nephrogenic)	344
No lactation postpartum, absent menstruation, cold intolerance	Sheehan syndrome (severe postpartum hemorrhage leading to pituitary infarction)	345
Heat intolerance, weight loss, palpitations	Hyperthyroidism	346
Cold intolerance, weight gain, brittle hair	Hypothyroidism	346
Cutaneous/dermal edema due to deposition of mucopolysaccharides in connective tissue	Myxedema (caused by hypothyroidism, Graves disease [pretibial])	346
Facial muscle spasm upon tapping	Chvostek sign (hypocalcemia)	350
Carpal spasm upon inflation of BP cuff	Trousseau sign (hypocalcemia)	350
Rapid, deep, labored breathing/hyperventilation	Diabetic ketoacidosis (Kussmaul respirations)	353
Skin hyperpigmentation, orthostatic hypotension, fatigue, weakness, muscle aches, weight loss, GI disturbances	Chronic 1° adrenal insufficiency (Addison disease) → ↑ ACTH, ↑ MSH	355
Shock, altered mental status, vomiting, abdominal pain, weakness, fatigue in patient under glucocorticoid therapy	Acute adrenal insufficiency (adrenal crisis)	355
Pancreatic, pituitary, parathyroid tumors	MEN1 (autosomal dominant <i>MEN1</i> mutation)	358
Thyroid and parathyroid tumors, pheochromocytoma	MEN2A (autosomal dominant <i>RET</i> mutation)	358
Thyroid tumors, pheochromocytoma, ganglioneuromatosis, Marfanoid habitus	MEN2B (autosomal dominant <i>RET</i> mutation)	358
Cutaneous flushing, diarrhea, bronchospasm, heart murmur	Carcinoid syndrome (↑ urinary 5-HIAA)	359
Jaundice, palpable distended non-tender gallbladder	Courvoisier sign (distal malignant obstruction of biliary tree)	377, 407
Vomiting blood following gastroesophageal lacerations	Mallory-Weiss syndrome (alcohol use disorder, bulimia nervosa)	386
Dysphagia (esophageal webs), glossitis, iron deficiency anemia	Plummer-Vinson syndrome (may progress to esophageal squamous cell carcinoma)	386
Enlarged, hard left supraclavicular node	Virchow node (abdominal metastasis)	388
Hematemesis, melena	Upper GI bleeding (eg, peptic ulcer disease)	389
Hematochezia	Lower GI bleeding (eg, colonic diverticulosis)	389
Arthralgias, adenopathy, cardiac and neurological symptoms, diarrhea	Whipple disease (<i>Tropheryma whipplei</i>)	390
Severe RLQ pain with palpation of LLQ	Rovsing sign (acute appendicitis)	392
Severe RLQ pain with deep tenderness	McBurney sign (acute appendicitis)	392
Hamartomatous GI polyps, hyperpigmented macules on mouth, feet, hands, genitalia	Peutz-Jeghers syndrome (inherited, benign polyposis can cause bowel obstruction; ↑ breast/GI cancer risk)	396
Multiple colon polyps, osteomas/soft tissue tumors, impacted/supernumerary teeth	Gardner syndrome (subtype of FAP)	396
Severe jaundice in neonate	Crigler-Najjar syndrome (congenital unconjugated hyperbilirubinemia)	403
Golden brown rings around peripheral cornea	Wilson disease (Kayser-Fleischer rings due to copper accumulation)	404

CLINICAL PRESENTATION	DIAGNOSIS/DISEASE	PAGE
Female, fat (obese), fertile (multiparity), forty, fair	Cholelithiasis (gallstones)	405
Painless jaundice with enlarged gallbladder	Cancer of the pancreatic head obstructing bile duct	407
Bluish line on gingiva	Burton line (lead poisoning)	427
Short stature, café-au-lait spots, thumb/radial defects, ↑ incidence of tumors/leukemia, aplastic anemia	Fanconi anemia (genetic loss of DNA crosslink repair; often progresses to AML)	429
Red/pink urine, fragile RBCs	Paroxysmal nocturnal hemoglobinuria	430
Painful blue fingers/toes, hemolytic anemia	Cold agglutinin disease (autoimmune hemolytic anemia caused by <i>Mycoplasma pneumoniae</i> , infectious mononucleosis, CLL)	431
Petechiae, mucosal bleeding, prolonged bleeding time	Platelet disorders (eg, Glanzmann thrombasthenia, Bernard Soulier, HUS, TTP, ITP, uremic platelet dysfunction)	434
Fever, night sweats, weight loss	B symptoms of malignancy	436
Skin patches/plaques, Pautrier microabscesses, atypical T cells	Mycosis fungoides (cutaneous T-cell lymphoma) or Sézary syndrome (mycosis fungoides + malignant T cells in blood)	437
Neonate with arm paralysis following difficult birth, arm in “waiter’s tip” position	Erb-Duchenne palsy (superior trunk [C5–C6] brachial plexus injury)	456
Anterior drawer sign ⊕	Anterior cruciate ligament injury	462
Bone pain, bone enlargement, arthritis	Osteitis deformans (Paget disease of bone, ↑ osteoblastic and osteoclastic activity)	473
Swollen, hard, painful finger joints in an elderly individual, pain worse with activity	Osteoarthritis (osteophytes on PIP [Bouchard nodes], DIP [Heberden nodes])	476
Sudden swollen/painful big toe joint, tophi	Gout/podagra (hyperuricemia)	477
Dry eyes, dry mouth, arthritis	Sjögren syndrome (autoimmune destruction of exocrine glands)	478
Urethritis, conjunctivitis, arthritis in a male	Reactive arthritis associated with HLA-B27	479
“Butterfly” facial rash, arthritis, cytopenia, and fever in a young female	Systemic lupus erythematosus	480
Cervical lymphadenopathy, desquamating rash, coronary aneurysms, red conjunctivae and tongue, hand-foot changes	Kawasaki disease (mucocutaneous lymph node syndrome, treat with IVIG and aspirin)	482
Palpable purpura on buttocks/legs, joint pain, abdominal pain (child), hematuria	Immunoglobulin A vasculitis (Henoch-Schönlein purpura, affects skin and kidneys)	483
Painful fingers/toes changing color from white to blue to red with cold or stress	Raynaud phenomenon (vasospasm in extremities)	484
Dark purple skin/mouth nodules in a patient with AIDS	Kaposi sarcoma, associated with HHV-8	490
Pruritic, purple, polygonal planar papules and plaques (6 P’s)	Lichen planus	495
Truncal ataxia, nystagmus, head tilting, fall towards injured side	Cerebellar lesion (lateral affects voluntary movement of extremities; medial affects axial and proximal movement)	515
Dorsiflexion of large toe with fanning of other toes upon plantar scrape	Babinski sign (UMN lesion)	527, 547

CLINICAL PRESENTATION	DIAGNOSIS/DISEASE	PAGE
Hyperphagia, hypersexuality, hyperorality	Klüver-Bucy syndrome (bilateral amygdala lesion)	528
Resting tremor, athetosis, chorea	Basal ganglia lesion	528
Dysphagia, hoarseness, ↓ gag reflex, nystagmus, ipsilateral Horner syndrome	Lateral medullary (Wallenberg) syndrome (posterior inferior cerebellar artery lesion)	531
Lucid interval after traumatic brain injury	Epidural hematoma (middle meningeal artery rupture; branch of maxillary artery)	532
“Worst headache of my life”	Subarachnoid hemorrhage	532
Resting tremor, rigidity, akinesia, postural instability, shuffling gait, micrographia	Parkinson disease (loss of dopaminergic neurons in substantia nigra pars compacta)	538
Chorea, dementia, caudate degeneration	Huntington disease (autosomal dominant CAG repeat expansion)	538
Urinary incontinence, gait apraxia, cognitive dysfunction	Normal pressure hydrocephalus	540
Nystagmus, intention tremor, scanning speech, bilateral internuclear ophthalmoplegia	Multiple sclerosis	541
Rapidly progressive limb weakness that ascends following GI/upper respiratory infection	Guillain-Barré syndrome (acute inflammatory demyelinating polyneuropathy)	542
Café-au-lait spots, Lisch nodules (iris hamartoma), cutaneous neurofibromas, pheochromocytomas, optic gliomas	Neurofibromatosis type I	543
Vascular birthmark (port-wine stain) of the face	Nevus flammeus (benign, but associated with Sturge-Weber syndrome)	543
Renal cell carcinoma (bilateral), hemangioblastomas, angiomas, pheochromocytoma	von Hippel-Lindau disease (deletion of <i>VHL</i> on chromosome 3p)	543
Bilateral vestibular schwannomas	Neurofibromatosis type II	543
Hyperreflexia, hypertonia, Babinski sign present	UMN damage	547
Hyporeflexia, hypotonia, atrophy, fasciculations	LMN damage	547
Staggering gait, frequent falls, nystagmus, hammer toes, diabetes mellitus, hypertrophic cardiomyopathy	Friedreich ataxia	549
Unilateral facial drooping involving forehead	LMN facial nerve (CN VII) palsy; UMN lesions spare the forehead	550
Episodic vertigo, tinnitus, sensorineural hearing loss	Ménière disease	552
Ptosis, miosis, anhidrosis	Horner syndrome (sympathetic chain lesion)	559
Conjugate horizontal gaze palsy, horizontal diplopia	Internuclear ophthalmoplegia (damage to MLF; may be unilateral or bilateral)	563
“Waxing and waning” level of consciousness (acute onset), ↓ attention span, ↓ level of arousal	Delirium (usually 2° to other cause)	581
Polyuria, renal tubular acidosis type II, growth retardation, electrolyte imbalances, hypophosphatemic rickets	Fanconi syndrome (multiple combined dysfunction of the proximal convoluted tubule)	610
Periorbital and/or peripheral edema, proteinuria (> 3.5g/day), hypoalbuminemia, hypercholesterolemia	Nephrotic syndrome	619
Hereditary nephritis, sensorineural hearing loss, retinopathy, anterior lenticonus	Alport syndrome (mutation in type IV collagen)	621

CLINICAL PRESENTATION	DIAGNOSIS/DISEASE	PAGE
Wilms tumor, macroglossia, organomegaly, hemihyperplasia, omphalocele	Beckwith-Wiedemann syndrome (<i>WT2</i> mutation)	630
Streak ovaries, congenital heart disease, horseshoe kidney, cystic hygroma, short stature, webbed neck, lymphedema	Turner syndrome (45,XO)	661
Ovarian fibroma, ascites, pleural effusion	Meigs syndrome	671
Red, itchy, swollen rash of nipple/areola	Paget disease of the breast (sign of underlying neoplasm)	674
Fibrous plaques in tunica albuginea of penis with abnormal curvature	Peyronie disease (connective tissue disorder)	675
Hypoxemia, polycythemia, hypercapnia	Chronic bronchitis (hypertrophy and hyperplasia of mucus-secreting glands, “blue bloater”)	698
Pink complexion, dyspnea, hyperventilation	Emphysema (“pink puffer,” centriacinar [smoking] or panacinar [α_1 -antitrypsin deficiency])	698
Bilateral hilar adenopathy, uveitis	Sarcoidosis (noncaseating granulomas)	701

► CLASSIC LABS/FINDINGS

LAB/DIAGNOSTIC FINDING	DIAGNOSIS/DISEASE	PAGE
Colonies of <i>Pseudomonas</i> in lungs	Cystic fibrosis (autosomal recessive mutation in <i>CFTR</i> gene → fat-soluble vitamin deficiency and mucous plugs)	58
↓ AFP in amniotic fluid/maternal serum	Down syndrome, Edwards syndrome	61
↑ β -hCG, ↓ PAPP-A on first trimester screening	Down syndrome	61
↑ serum homocysteine, ↑ methylmalonic acid, ↓ folate	Vitamin B ₁₂ deficiency	67
Anti-histone antibodies	Drug-induced SLE	113
↓ T cells, ↓ PTH, ↓ Ca ²⁺ , absent thymic shadow on CXR	Thymic aplasia (DiGeorge syndrome, velocardiofacial syndrome)	114
Recurrent infections, eczema, thrombocytopenia	Wiskott-Aldrich syndrome	115
Large granules in phagocytes, immunodeficiency	Chédiak-Higashi disease (congenital failure of phagolysosome formation)	115
Optochin sensitivity	Sensitive: <i>S pneumoniae</i> ; resistant: viridans streptococci (<i>S mutans</i> , <i>S sanguis</i>)	132
Novobiocin response	Sensitive: <i>S epidermidis</i> ; resistant: <i>S saprophyticus</i>	132
Bacitracin response	Sensitive: <i>S pyogenes</i> (group A); resistant: <i>S agalactiae</i> (group B)	132
Branching gram ⊕ rods with sulfur granules	<i>Actinomyces israelii</i>	137
Hilar lymphadenopathy, peripheral granulomatous lesion in middle or lower lung lobes (can calcify)	Ghon complex (1° TB: <i>Mycobacterium bacilli</i>)	138
“Thumb sign” on lateral neck x-ray	Epiglottitis (<i>Haemophilus influenzae</i>)	140
Bacteria-covered vaginal epithelial cells	“Clue cells” (<i>Gardnerella vaginalis</i>)	147
Dilated cardiomyopathy with apical atrophy, megacolon, megaesophagus	Chagas disease (<i>Trypanosoma cruzi</i>)	155
Atypical lymphocytes, heterophile antibodies	Infectious mononucleosis (EBV infection)	162

LAB/DIAGNOSTIC FINDING	DIAGNOSIS/DISEASE	PAGE
Narrowing of upper trachea and subglottis (Steeple sign) on x-ray	Croup (parainfluenza virus)	167
Eosinophilic inclusion bodies in cytoplasm of hippocampal and cerebellar neurons	Negri bodies of rabies	169
Ring-enhancing brain lesion on CT/MRI in AIDS	<i>Toxoplasma gondii</i> (multiple), CNS lymphoma (may be solitary)	174
Psammoma bodies	Meningiomas, papillary thyroid carcinoma, mesothelioma, papillary serous carcinoma of the endometrium and ovary	225
“Boot-shaped” heart on x-ray	Tetralogy of Fallot (due to RVH)	304
Rib notching (inferior surface, on x-ray)	Coarctation of the aorta	305
“Delta wave” on ECG, short PR interval, supraventricular tachycardia	Wolff-Parkinson-White syndrome (bundle of Kent bypasses AV node)	313
Electrical alternans (alternating amplitude on ECG)	Cardiac tamponade	319
Granuloma with giant cells after pharyngeal infection	Aschoff bodies (rheumatic fever)	321
Empty-appearing nuclei with central clearing of thyroid cells	“Orphan Annie” eyes nuclei (papillary carcinoma of the thyroid)	349
“Brown” tumor of bone	Hyperparathyroidism or osteitis fibrosa cystica (deposited hemosiderin from hemorrhage gives brown color)	351, 474
Hypertension, hypokalemia, metabolic alkalosis	1° hyperaldosteronism (eg, Conn syndrome)	356
Mucin-filled cell with peripheral nucleus	“Signet ring” cells (diffuse gastric carcinoma)	388
Anti-transglutaminase/anti-gliadin/anti-endomysial antibodies	Celiac disease (diarrhea, weight loss)	390
Narrowing of bowel lumen on barium x-ray	“String sign” (Crohn disease)	391
“Lead pipe” appearance of colon on abdominal imaging	Ulcerative colitis (loss of haustra)	391
Thousands of polyps on colonoscopy	Familial adenomatous polyposis (autosomal dominant, mutation of APC gene)	396
“Apple core” lesion on barium enema x-ray	Colorectal cancer (usually left-sided)	397
Eosinophilic cytoplasmic inclusion in liver cell	Mallory body (alcoholic liver disease)	400
Triglyceride accumulation in liver cell vacuoles	Fatty liver disease (alcoholic or metabolic syndrome)	400
Anti-smooth muscle antibodies (ASMAs), anti-liver/kidney microsomal-1 (anti-LKM1) antibodies	Autoimmune hepatitis	400
“Nutmeg” appearance of liver	Chronic passive congestion of liver due to right heart failure or Budd-Chiari syndrome	401
Antimitochondrial antibodies (AMAs)	1° biliary cholangitis (female, cholestasis, portal hypertension)	404
Low serum ceruloplasmin	Wilson disease (hepatolenticular degeneration; Kayser-Fleischer rings due to copper accumulation)	404
Migratory thrombophlebitis (leading to migrating DVTs and vasculitis)	Trousseau syndrome (adenocarcinoma of pancreas)	407
Hypersegmented neutrophils	Megaloblastic anemia (vitamin B ₁₂ deficiency: neurologic symptoms; folate deficiency: no neurologic symptoms)	414, 428

LAB/DIAGNOSTIC FINDING	DIAGNOSIS/DISEASE	PAGE
Basophilic nuclear remnants in RBCs	Howell-Jolly bodies (due to splenectomy or nonfunctional spleen)	424
Basophilic stippling of RBCs	Lead poisoning or sideroblastic anemia	424
Hypochromic, microcytic anemia	Iron deficiency anemia, lead poisoning, thalassemia (fetal hemoglobin sometimes present)	426, 427
“Hair on end” (“crew cut”) appearance on x-ray	β -thalassemia, sickle cell disease (marrow expansion)	426, 430
Anti-GpIIb/IIIa antibodies	Immune thrombocytopenia	434
High level of D-dimers	DVT, DIC	435, 696
Giant B cells with bilobed nucleus with prominent inclusions (“owl’s eye”)	Reed-Sternberg cells (Hodgkin lymphoma)	436
Sheets of medium-sized lymphoid cells with scattered pale, tingible body-laden macrophages (“starry sky” histology)	Burkitt lymphoma (t[8:14] <i>c-myc</i> activation, associated with EBV; “starry sky” made up of malignant cells)	437
Lytic (“punched-out”) bone lesions on x-ray	Multiple myeloma	438
Monoclonal spike on serum protein electrophoresis	Multiple myeloma (usually IgG or IgA) Waldenström macroglobulinemia (IgM) Monoclonal gammopathy of undetermined significance	438
Stacks of RBCs	Rouleaux formation (high ESR, multiple myeloma)	438
Azurophilic peroxidase \oplus granular inclusions in granulocytes and myeloblasts	Auer rods (APL)	440
WBCs that look “smudged”	CLL	440
“Tennis racket”-shaped cytoplasmic organelles (EM) in Langerhans cells	Birbeck granules (Langerhans cell histiocytosis)	442
“Soap bubble” in femur or tibia on x-ray	Giant cell tumor of bone (generally benign)	474
Raised periosteum (creating a “Codman triangle”)	Aggressive bone lesion (eg, osteosarcoma, Ewing sarcoma)	475
“Onion skin” periosteal reaction	Ewing sarcoma (malignant small blue cell tumor)	475
Anti-IgG antibodies	Rheumatoid arthritis (systemic inflammation, joint pannus, boutonniere and swan neck deformities)	476
Rhomboid crystals, \oplus birefringent	Pseudogout (calcium pyrophosphate dihydrate crystals)	477
Needle-shaped, \ominus birefringent crystals	Gout (monosodium urate crystals)	477
\uparrow uric acid levels	Gout, Lesch-Nyhan syndrome, tumor lysis syndrome, loop and thiazide diuretics	477
“Bamboo spine” on x-ray	Ankylosing spondylitis (chronic inflammatory arthritis: HLA-B27)	479
Antinuclear antibodies (ANAs: anti-Smith and anti-dsDNA)	SLE (type III hypersensitivity)	480
Antineutrophil cytoplasmic antibodies (ANCA)	Microscopic polyangiitis, eosinophilic granulomatosis with polyangiitis, and primary sclerosing cholangitis (MPO-ANCA/p-ANCA); granulomatosis with polyangiitis (PR3-ANCA/c-ANCA)	483

LAB/DIAGNOSTIC FINDING	DIAGNOSIS/DISEASE	PAGE
Anticentromere antibodies	Limited scleroderma (CREST syndrome)	485
Anti-topoisomerase antibodies	Diffuse scleroderma	485
Anti-desmoglein (anti-desmosome) antibodies	Pemphigus vulgaris	493
Antihemidesmosome antibodies	Bullous pemphigoid	493
Keratin pearls on a skin biopsy	Squamous cell carcinoma	497
↑ AFP in amniotic fluid/maternal serum	Dating error, anencephaly, spina bifida (open neural tube defects)	505
Bloody or yellow tap on lumbar puncture	Xanthochromia (due to subarachnoid hemorrhage)	532
Eosinophilic cytoplasmic inclusion in neuron	Lewy body (Parkinson disease and Lewy body dementia)	538, 539
Extracellular amyloid deposition in gray matter of brain	Senile plaques (Alzheimer disease)	538
Depigmentation of neurons in substantia nigra	Parkinson disease (basal ganglia disorder: rigidity, resting tremor, bradykinesia)	538
Protein aggregates in neurons from hyperphosphorylation of tau protein	Neurofibrillary tangles (Alzheimer disease) and Pick bodies (Pick disease)	538
Silver-staining spherical aggregation of tau proteins in neurons	Pick bodies (frontotemporal dementia: progressive dementia, changes in personality)	538
Pseudopalisading pleomorphic tumor cells on brain biopsy	Glioblastoma multiforme	544
Small blue cells surrounding central area of neuropil	Homer-Wright rosettes (neuroblastoma, medulloblastoma)	546
“Waxy” casts with very low urine flow	Chronic end-stage renal disease	618
WBC casts in urine	Acute pyelonephritis, transplant rejection, tubulointerstitial inflammation	618
RBC casts in urine	Glomerulonephritis	618
Anti-glomerular basement membrane antibodies	Goodpasture syndrome (glomerulonephritis and hemoptysis)	620
Cellular crescents in Bowman capsule	Rapidly progressive (crescentic) glomerulonephritis	620
“Wire loop” glomerular capillary appearance on light microscopy	Diffuse proliferative glomerulonephritis (usually seen with lupus)	620
Linear appearance of IgG deposition on glomerular and alveolar basement membranes	Goodpasture syndrome	620
“Lumpy bumpy” appearance of glomeruli on immunofluorescence	Poststreptococcal glomerulonephritis (due to deposition of IgG, IgM, and C3)	620
Necrotizing vasculitis (lungs) and necrotizing glomerulonephritis	Granulomatosis with polyangiitis (PR3-ANCA/c-ANCA) and Goodpasture syndrome (anti-basement membrane antibodies)	620
“Tram-track” appearance of capillary loops of glomerular basement membranes on light microscopy	Membranoproliferative glomerulonephritis	621
Nodular hyaline deposits in glomeruli	Kimmelstiel-Wilson nodules (diabetic nephropathy)	622
Podocyte fusion or “effacement” on electron microscopy	Minimal change disease (child with nephrotic syndrome)	622
“Spikes” on basement membrane, “domelike” subepithelial deposits	Membranous nephropathy (nephrotic syndrome)	622

LAB/DIAGNOSTIC FINDING	DIAGNOSIS/DISEASE	PAGE
Thyroidlike appearance of kidney	Chronic pyelonephritis (usually due to recurrent infections)	625
Granular casts in urine	Acute tubular necrosis (eg, ischemia or toxic injury)	627
hCG elevated	Multifetal gestation, hydatidiform moles, choriocarcinomas, Down syndrome	658
Dysplastic squamous cervical cells with “raisinoid” nuclei and hyperchromasia	Koilocytes (HPV: predisposes to cervical cancer)	669
Sheets of uniform “fried egg” cells, ↑ hCG, ↑ LDH	Dysgerminoma	671
Glomeruluslike structure surrounding vessel in germ cells	Schiller-Duval bodies (yolk sac tumor)	671
Disarrayed granulosa cells arranged around collections of eosinophilic fluid	Call-Exner bodies (granulosa cell tumor of the ovary)	671
“Chocolate cyst” of ovary	Endometriosis (frequently involves both ovaries)	672
Mammary gland (“blue domed”) cyst	Fibrocystic change of the breast	673
Rectangular, crystal-like, cytoplasmic inclusions in Leydig cells	Reinke crystals (Leydig cell tumor)	677
Thrombi made of white/red layers	Lines of Zahn (arterial thrombus, layers of platelets/RBCs)	697
Hexagonal, double-pointed, needlelike crystals in bronchial secretions	Bronchial asthma (Charcot-Leyden crystals: eosinophilic granules)	699
Desquamated epithelium casts in sputum	Curschmann spirals (bronchial asthma; can result in whorled mucous plugs)	699
“Honeycomb lung” on x-ray or CT	Idiopathic pulmonary fibrosis	700
Iron-containing nodules in alveolar septum	Ferruginous bodies (asbestosis: ↑ chance of lung cancer)	702
Bronchogenic apical lung tumor on imaging	Pancoast tumor (can compress cervical sympathetic chain and cause Horner syndrome)	710

► CLASSIC/RELEVANT TREATMENTS

CONDITION	COMMON TREATMENT(S)	PAGE
Ethylene glycol/methanol intoxication	Fomepizole (alcohol dehydrogenase competitive inhibitor)	70
Chronic hepatitis B or C	IFN- α (HBV and HCV); ribavirin, simeprevir, sofosbuvir (HCV)	119, 201
<i>Streptococcus bovis</i>	Penicillin prophylaxis; evaluation for colon cancer if linked to infective endocarditis	135
<i>Clostridium botulinum</i>	Human botulinum immunoglobulin	136
<i>Clostridium tetani</i>	Antitoxin and wound debridement	136
<i>Clostridioides difficile</i>	Oral vancomycin or fidaxomicin Refractory cases: repeat regimen or fecal microbiota transplant	136
<i>Neisseria gonorrhoeae</i>	Ceftriaxone (add azithromycin or doxycycline to cover likely concurrent <i>C trachomatis</i>)	140

CONDITION	COMMON TREATMENT(S)	PAGE
<i>Neisseria meningitidis</i>	Penicillin/ceftriaxone, rifampin/ciprofloxacin/ceftriaxone (prophylaxis)	140
<i>Haemophilus influenzae</i> (B)	Amoxicillin ± clavulanate (mucosal infections), ceftriaxone (meningitis), rifampin (prophylaxis)	140
<i>Legionella pneumophila</i>	Macrolides (eg, azithromycin) or fluoroquinolones	141
<i>Pseudomonas aeruginosa</i>	Piperacillin-tazobactam, cephalosporins (3rd/4th gen), monobactams, fluoroquinolones, carbapenems	141
<i>Treponema pallidum</i>	Penicillin G	145
<i>Chlamydia trachomatis</i>	Azithromycin or doxycycline (+ ceftriaxone for gonorrhea coinfection), oral erythromycin to treat chlamydial conjunctivitis in infants	146
<i>Candida albicans</i>	Topical azoles (vaginitis); nystatin, fluconazole, caspofungin (oral); fluconazole, caspofungin, amphotericin B (esophageal or systemic)	150
<i>Cryptococcus neoformans</i>	Induction with amphotericin B and flucytosine, maintenance with fluconazole (in AIDS patients)	150
<i>Sporothrix schenckii</i>	Itraconazole, oral potassium iodide (only for cutaneous/lymphocutaneous)	151
<i>Pneumocystis jirovecii</i>	TMP-SMX (prophylaxis and treatment in immunosuppressed patients, CD4 < 200/mm ³), pentamidine, dapsone, atovaquone	151
<i>Toxoplasma gondii</i>	Sulfadiazine + pyrimethamine	153
Malaria	Chloroquine, mefloquine (chloroquine resistant cases), atovaquone/proguanil, primaquine (for liver hypnozoite)	154
<i>Trichomonas vaginalis</i>	Metronidazole (patient and partner[s])	155
<i>Streptococcus pyogenes</i>	Penicillin	184
<i>Streptococcus pneumoniae</i>	Penicillin/cephalosporin (systemic infection, pneumonia), vancomycin (meningitis)	184, 187
<i>Staphylococcus aureus</i>	MSSA: nafcillin, oxacillin, dicloxacillin (antistaphylococcal penicillins); MRSA: vancomycin, daptomycin, linezolid, ceftaroline	185, 187, 192
Enterococci	Vancomycin, aminopenicillins/cephalosporins. VRE: daptomycin, linezolid, tigecycline, streptogramins	187, 190
<i>Rickettsia rickettsii</i>	Doxycycline, chloramphenicol	189
<i>Mycobacterium tuberculosis</i>	RIPE (rifampin, isoniazid, pyrazinamide, ethambutol)	193
Recurrent UTI prophylaxis	TMP-SMX	195
Influenza	Oseltamivir, zanamivir	198
CMV	Ganciclovir, foscarnet, cidofovir	199
HIV pre-exposure prophylaxis	Tenofovir + emtricitabine	200
Patent ductus arteriosus	Close with NSAIDs (eg, indomethacin, ibuprofen) or acetaminophen; keep open with PGE analogs	289
Stable angina	Sublingual nitroglycerin	310

CONDITION	COMMON TREATMENT(S)	PAGE
Hypercholesterolemia	Statin (first-line)	326
Hypertriglyceridemia	Fibrate	326
Arrhythmia in damaged cardiac tissue	Class IB antiarrhythmic (lidocaine, mexiletine)	328
Prolactinoma	Bromocriptine (dopamine agonists)	336
Diabetes insipidus	Desmopressin (central); hydrochlorothiazide, indomethacin, amiloride (nephrogenic)	344
SIADH	Fluid restriction, IV hypertonic saline, tolvaptan, demeclocycline	344
Diabetic ketoacidosis/hyperosmolar hyperglycemic state	Fluids, insulin, K ⁺	353
Pheochromocytoma	α-antagonists (eg, phenoxybenzamine) then β-blockers)	357
Carcinoid syndrome symptom control	Octreotide, telotristat	359
Diabetes mellitus type 1	Dietary intervention (low carbohydrate) + insulin replacement	360
Diabetes mellitus type 2	Dietary intervention, hypoglycemic agents, and insulin (if refractory)	360
Gestational Diabetes	Dietary intervention and exercise, add insulin (if refractory to nutritional therapy)	360
Crohn disease	Glucocorticoids, infliximab, azathioprine	391
Ulcerative colitis	5-ASA preparations (eg, mesalamine), 6-mercaptopurine, infliximab, colectomy	391
Sickle cell disease	Hydroxyurea (↑ fetal hemoglobin)	430
Chronic myelogenous leukemia	BCR-ABL tyrosine kinase inhibitors (eg, imatinib)	440
Acute promyelocytic leukemia (M3)	All- <i>trans</i> retinoic acid, arsenic trioxide	440
Drug of choice for anticoagulation in pregnancy	Low-molecular-weight heparin	443
Immediate anticoagulation	Heparin	443
Long-term anticoagulation	Warfarin, dabigatran, direct factor Xa inhibitors	444
Heparin reversal	Protamine sulfate	445
Warfarin reversal	Vitamin K (slow) +/- fresh frozen plasma or prothrombin complex concentrate (rapid)	445
Dabigatran reversal	Idarucizumab	445
Direct factor Xa inhibitor reversal	Andexanet alfa	445
HER2 ⊕ breast cancer	Trastuzumab	450
Hemorrhagic cystitis from cyclophosphamide/ifosfamide	Mesna	451
Nephrotoxicity from platinum compounds	Amifostine	451
Cardiotoxicity from anthracyclines	Dexrazoxane	451
Myelosuppression from methotrexate	Leucovorin	451
Osteoporosis	Calcium/vitamin D supplementation (prophylaxis); bisphosphonates, PTH analogs, SERMs, calcitonin, denosumab (treatment)	472
Osteomalacia/rickets	Vitamin D supplementation	473
Chronic gout	Xanthine oxidase inhibitors (eg, allopurinol, febuxostat)	477

CONDITION	COMMON TREATMENT(S)	PAGE
Acute gout attack	NSAIDs, colchicine, glucocorticoids	477
Buerger disease	Smoking cessation	482
Kawasaki disease	IVIG, aspirin	482
Giant cell arteritis	High-dose glucocorticoids	482
Granulomatosis with polyangiitis	Cyclophosphamide, glucocorticoids	483
Neural tube defect prevention	Prenatal folic acid	505
Migraine	Abortive therapies (eg, sumatriptan, NSAIDs); prophylaxis (eg, propranolol, topiramate, anti-CGRP antibodies, amitriptyline)	536
Trigeminal neuralgia (tic douloureux)	Carbamazepine	536
Multiple sclerosis	Disease-modifying therapies (eg, β -interferon, glatiramer, natalizumab, alemtuzumab, rituximab); for acute flares, use IV steroids	541
Tonic-clonic seizures	Levetiracetam, phenytoin, valproate, carbamazepine	564
Absence seizures	Ethosuximide	564
Malignant hyperthermia	Dantrolene	572
ADHD	Methylphenidate, amphetamines, behavioral therapy, atomoxetine, guanfacine, clonidine	580, 596
Schizophrenia	Atypical antipsychotics	583, 596
Anorexia	Nutrition, psychotherapy, SSRIs	590
Bulimia nervosa	Nutrition rehabilitation, psychotherapy, SSRIs	590
Alcohol use disorder	Disulfiram, acamprosate, naltrexone, supportive care	595
Alcohol withdrawal	Long-acting benzodiazepines	596
Bipolar disorder	Mood stabilizers (eg, lithium, valproate, carbamazepine), atypical antipsychotics	596
Depression	SSRIs (first-line)	596
Generalized anxiety disorder	SSRIs, SNRIs (first line); buspirone (second line)	596
Hyperaldosteronism	Spironolactone	633
Benign prostatic hyperplasia	α_1 -antagonists, 5 α -reductase inhibitors, PDE-5 inhibitors, TURP	678
Infertility	Leuprolide, GnRH (pulsatile), clomiphene	680
Breast cancer in postmenopausal woman	Aromatase inhibitor (anastrozole)	680
ER/PR \oplus breast cancer	Tamoxifen	680
Uterine fibroids	Leuprolide, GnRH (continuous)	680
Prostate adenocarcinoma	Flutamide, GnRH (continuous), degarelix, ketoconazole	680, 682
Medical abortion	Mifepristone	681
Erectile dysfunction	Sildenafil	711
Pulmonary arterial hypertension (idiopathic)	Sildenafil, bosentan, epoprostenol, iloprost	711

► KEY ASSOCIATIONS

DISEASE/FINDING	MOST COMMON/IMPORTANT ASSOCIATIONS	PAGE
Mitochondrial inheritance	Disease occurs in both males and females, inherited through females only	57
Intellectual disability	Down syndrome, fragile X syndrome	60, 61
Vitamin deficiency (USA)	Folate (pregnant women are at high risk; body stores only 3- to 4-month supply; prevents neural tube defects)	66
Lysosomal storage disease	Gaucher disease	86
HLA-DR3	DM type 1, SLE, Graves disease, Hashimoto thyroiditis, Addison disease	98
HLA-DR4	DM type 1, rheumatoid arthritis, Addison disease	98
Bacteria associated with gastritis, peptic ulcer disease, and gastric malignancies (eg, adenocarcinoma, MALToma)	<i>H pylori</i>	144
Opportunistic respiratory infection in AIDS	<i>Pneumocystis jirovecii</i> pneumonia	151
Helminth infection (US)	<i>Enterobius vermicularis</i>	156
Viral encephalitis affecting temporal lobe	HSV-1	162
Infection 2° to blood transfusion	Hepatitis C	170
Food poisoning (exotoxin mediated)	<i>S aureus</i> , <i>B cereus</i>	175
Healthcare-associated pneumonia	<i>S aureus</i> , <i>Pseudomonas</i> , other gram negative rods	176
Bacterial meningitis (> 6 months old)	<i>S pneumoniae</i>	177
Bacterial meningitis (newborns 0–6 months old)	Group B streptococcus/ <i>E coli</i> / <i>Listeria monocytogenes</i> (newborns)	177
Osteomyelitis	<i>S aureus</i> (most common overall)	177
Osteomyelitis in sickle cell disease	<i>Salmonella</i> and <i>S aureus</i>	177
Osteomyelitis with injection drug use	<i>S aureus</i> , <i>Pseudomonas</i> , <i>Candida</i>	177
UTI	<i>E coli</i> , <i>Staphylococcus saprophyticus</i> (young women)	179
Sexually transmitted disease coinfecting with <i>N gonorrhoeae</i>	<i>C trachomatis</i>	180
Pelvic inflammatory disease	<i>C trachomatis</i> (subacute), <i>N gonorrhoeae</i> (acute)	182
Metastases to bone	Prostate, breast > kidney, thyroid, lung	221
Metastases to brain	Lung > breast > melanoma, colon, kidney	221
Metastases to liver	Colon >> stomach > pancreas	221
S3 heart sound	↑ ventricular filling pressure (eg, mitral regurgitation, HF), common in dilated ventricles	294
S4 heart sound	Stiff/hypertrophic ventricle (aortic stenosis, restrictive cardiomyopathy)	294
Holosystolic murmur	VSD, tricuspid regurgitation, mitral regurgitation	297
Ejection click	Aortic stenosis	298
Mitral valve stenosis	Rheumatic heart disease	298
Opening snap	Mitral stenosis	298

DISEASE/FINDING	MOST COMMON/IMPORTANT ASSOCIATIONS	PAGE
Heart murmur, congenital	Mitral valve prolapse	298
Cyanotic heart disease (early; less common)	Tetralogy of Fallot, transposition of great arteries, truncus arteriosus, total anomalous pulmonary venous return, tricuspid atresia	304
Late cyanotic shunt (uncorrected left to right becomes right to left)	Eisenmenger syndrome (caused by ASD, VSD, PDA; results in pulmonary hypertension/polycythemia)	305
Congenital cardiac anomaly	VSD > ASD > PDA	305
Hypertension, 2°	Renal artery stenosis, chronic kidney disease (eg, polycystic kidney disease, diabetic nephropathy), hyperaldosteronism	306
Aortic aneurysm, thoracic	Marfan syndrome (idiopathic cystic medial degeneration)	308
Aortic aneurysm, abdominal	Atherosclerosis, smoking is major risk factor	308
Aortic aneurysm, ascending or arch	3° syphilis (syphilitic aortitis), vasa vasorum destruction	308
Sites of atherosclerosis	Abdominal aorta > coronary artery > popliteal artery > carotid artery	308
Aortic dissection	Hypertension	309
Chronic arrhythmia with no discrete P waves	Atrial fibrillation (associated with high risk of emboli)	313
Right heart failure due to a pulmonary cause	Cor pulmonale	318
Heart valve in infective endocarditis	Mitral > aortic, tricuspid (injectable drug use)	320
Infective endocarditis presentation associated with bacterium	<i>S aureus</i> (acute, injection drug use, tricuspid valve), viridans streptococci (subacute, dental procedure), <i>S bovis</i> (colon cancer), gram negative (HACEK), culture negative (<i>Coxiella</i> , <i>Bartonella</i>)	320
Cardiac 1° tumor (kids)	Rhabdomyoma, often seen in tuberous sclerosis	323
Cardiac tumor (adults)	Metastasis, myxoma (90% in left atrium; “ball valve”)	323
Congenital adrenal hyperplasia, hypotension	21-hydroxylase deficiency	341
Hypopituitarism	Pituitary adenoma (usually benign tumor)	345
Congenital hypothyroidism (cretinism)	Thyroid dysgenesis/dyshormonogenesis, iodine deficiency	347
Thyroid cancer	Papillary carcinoma (childhood irradiation)	349
Hypoparathyroidism	Accidental excision during thyroidectomy	350
1° hyperparathyroidism	Adenomas, hyperplasia, carcinoma	351
2° hyperparathyroidism	Hypocalcemia of chronic kidney disease	351
Cushing syndrome	<ul style="list-style-type: none"> ▪ Iatrogenic (from glucocorticoid therapy) ▪ Adrenocortical adenoma (secretes excess cortisol) ▪ ACTH-secreting pituitary adenoma (Cushing disease) ▪ Paraneoplastic (due to ACTH secretion by tumors) 	354
1° hyperaldosteronism	Adrenal hyperplasia or adenoma	356
Tumor of the adrenal medulla (kids)	Neuroblastoma (malignant)	356
Tumor of the adrenal medulla (adults)	Pheochromocytoma (usually benign)	357
Refractory peptic ulcers and high gastrin levels	Zollinger-Ellison syndrome (gastrinoma of duodenum or pancreas), associated with MEN1	358, 359

DISEASE/FINDING	MOST COMMON/IMPORTANT ASSOCIATIONS	PAGE
Esophageal cancer	Squamous cell carcinoma (worldwide); adenocarcinoma (US)	387
Acute gastric ulcer associated with CNS injury	Cushing ulcer (\uparrow intracranial pressure stimulates vagal gastric H^+ secretion)	388
Acute gastric ulcer associated with severe burns	Curling ulcer (greatly reduced plasma volume results in sloughing of gastric mucosa)	388
Bilateral ovarian metastases from gastric carcinoma	Krukenberg tumor (mucin-secreting signet ring cells)	388
Chronic atrophic gastritis (autoimmune)	Predisposition to gastric carcinoma (can also cause pernicious anemia)	388
Alternating areas of transmural inflammation and normal colon	Skip lesions (Crohn disease)	391
Site of diverticula	Sigmoid colon	392
Diverticulum in pharynx	Zenker diverticulum (diagnosed by barium swallow)	393
Hepatocellular carcinoma	HBV (+/- cirrhosis) or other causes of cirrhosis (eg, alcoholic liver disease, hemochromatosis), aflatoxins	401
Congenital conjugated hyperbilirubinemia (black liver)	Dubin-Johnson syndrome (inability of hepatocytes to secrete conjugated bilirubin into bile)	403
Hereditary harmless jaundice	Gilbert syndrome (benign congenital unconjugated hyperbilirubinemia)	403
Wilson disease	Hereditary <i>ATP7B</i> mutation (copper buildup in liver, brain, cornea, kidneys)	404
Hemochromatosis	Multiple blood transfusions or hereditary <i>HFE</i> mutation (can result in heart failure, "bronze diabetes," and \uparrow risk of hepatocellular carcinoma)	404
Pancreatitis (acute)	Gallstones, alcohol	406
Pancreatitis (chronic)	Alcohol (adults), cystic fibrosis (kids)	406
Microcytic anemia	Iron deficiency, thalassemias	426
Autosplenectomy (fibrosis and shrinkage)	Sickle cell anemia (hemoglobin S)	430
Bleeding disorder with GpIb deficiency	Bernard-Soulier syndrome (defect in platelet adhesion to von Willebrand factor)	434
Bleeding disorder with GpIIb/IIIa deficiency	Glanzmann thrombasthenia (defect in platelet-to-platelet aggregation)	434
Hereditary bleeding disorder	von Willebrand disease	435
Hereditary thrombophilia	Factor V Leiden	435
DIC	Severe sepsis, obstetric complications, cancer, burns, trauma, major surgery, acute pancreatitis, APL	435
Malignancy associated with noninfectious fever	Hodgkin lymphoma	436
Type of Hodgkin lymphoma (most common)	Nodular sclerosis	436
t(14;18)	Follicular lymphoma (<i>BCL-2</i> activation, anti-apoptotic oncogene)	437, 442
t(8;14)	Burkitt lymphoma (<i>c-myc</i> fusion, transcription factor oncogene)	437, 442

DISEASE/FINDING	MOST COMMON/IMPORTANT ASSOCIATIONS	PAGE
Type of non-Hodgkin lymphoma (most common)	Diffuse large B-cell lymphoma	437
1° bone tumor (adults)	Multiple myeloma	438
Age ranges for patient with ALL/CLL/AML/CML	ALL: child, CLL: adult > 60, AML: adult ~ 65, CML: adult 45–85	440
Malignancy (kids)	Leukemia, brain tumors	440, 546
Death in CML	Blast crisis	440
t(9;22)	Philadelphia chromosome, CML (<i>BCR-ABL</i> oncogene, tyrosine kinase activation), more rarely associated with ALL	440, 442
Vertebral compression fracture	Osteoporosis	472
HLA-B27	Psoriatic arthritis, ankylosing spondylitis, IBD-associated arthritis, reactive arthritis	479
Death in SLE	Lupus nephropathy	480
Giant cell arteritis	Risk of ipsilateral blindness due to occlusion of ophthalmic artery; polymyalgia rheumatica	482
Recurrent inflammation/thrombosis of small/medium vessels in extremities	Buerger disease (strongly associated with tobacco)	482
Tumor of infancy	Strawberry hemangioma (grows rapidly and regresses spontaneously by childhood)	490
Actinic keratosis	Precursor to squamous cell carcinoma	495
Herald patch	Pityriasis rosea	495
Cerebellar tonsillar herniation	Chiari I malformation	506
Atrophy of the mammillary bodies	Wernicke-Korsakoff syndrome (with bilateral lesions)	528
Epidural hematoma	Rupture of middle meningeal artery (trauma; lentiform shaped)	532
Subdural hematoma	Rupture of bridging veins (crescent shaped)	532
Dementia	Alzheimer disease, multiple infarcts (vascular dementia)	538, 539
Demyelinating disease in young women	Multiple sclerosis	541
Brain tumor (adults)	Supratentorial: metastasis, astrocytoma (including glioblastoma multiforme), meningioma, schwannoma	544
Pituitary tumor	Prolactinoma, somatotrophic adenoma	545
Brain tumor (children)	Infratentorial: medulloblastoma (cerebellum) or supratentorial: craniopharyngioma	546
Mixed (UMN and LMN) motor neuron disease	Amyotrophic lateral sclerosis	548
Degeneration of dorsal column fibers	Tabes dorsalis (3° syphilis), subacute combined degeneration (dorsal columns, lateral corticospinal, spinocerebellar tracts affected)	548
Glomerulonephritis (adults)	Berger disease (IgA nephropathy)	620
Nephrotic syndrome (adults)	Membranous nephropathy	622
Nephrotic syndrome (children)	Minimal change disease	622

DISEASE/FINDING	MOST COMMON/IMPORTANT ASSOCIATIONS	PAGE
Kidney stones	<ul style="list-style-type: none"> ▪ Calcium = radiopaque ▪ Struvite (ammonium) = radiopaque (formed by urease ⊕ organisms such as <i>Proteus mirabilis</i>, <i>S saprophyticus</i>, <i>Klebsiella</i>) ▪ Uric acid = radiolucent ▪ Cystine = faintly radiopaque 	623
Renal tumor	Renal cell carcinoma: associated with VHL and cigarette smoking; paraneoplastic syndromes (EPO, renin, PTHrP, ACTH)	629
1° amenorrhea	Turner syndrome (45,XO or 45,XO/46,XX mosaic)	661
Neuron migration failure	Kallmann syndrome (hypogonadotropic hypogonadism and anosmia)	663
Clear cell adenocarcinoma of the vagina	DES exposure in utero	668
Ovarian tumor (benign, bilateral)	Serous cystadenoma	670
Ovarian tumor (malignant)	Serous carcinoma	670
Tumor in women	Leiomyoma (estrogen dependent, not precancerous)	672
Gynecologic malignancy	Endometrial carcinoma (most common in US); cervical carcinoma (most common worldwide)	672
Breast mass	Fibrocystic change, carcinoma (in postmenopausal women)	673
Breast tumor (benign, young woman)	Fibroadenoma	673
Breast cancer	Invasive ductal carcinoma	674
Testicular tumor	Seminoma (malignant, radiosensitive), ↑ PLAP	677
Obstruction of male urinary tract	BPH	678
Hypercoagulability, endothelial damage, blood stasis	Virchow triad (↑ risk of thrombosis)	696
Pulmonary hypertension	Idiopathic, heritable, left heart disease (eg, HF), lung disease (eg, COPD), hypoxemic vasoconstriction (eg, OSA), thromboembolic (eg, PE)	704
SIADH	Small cell carcinoma of the lung	709

► EQUATION REVIEW

TOPIC	EQUATION	PAGE
Volume of distribution	$V_d = \frac{\text{amount of drug in the body}}{\text{plasma drug concentration}}$	231
Half-life	$t_{1/2} = \frac{0.7 \times V_d}{CL}$	231
Drug clearance	$CL = \frac{\text{rate of elimination of drug}}{\text{plasma drug concentration}} = V_d \times K_e \text{ (elimination constant)}$	231
Loading dose	$LD = \frac{C_p \times V_d}{F}$	231

TOPIC	EQUATION	PAGE
Maintenance dose	$D = \frac{C_p \times CL \times \tau}{F}$	231
Therapeutic index	TI = median toxic dose/median effective dose = TD ₅₀ /ED ₅₀	235
Odds ratio (for case-control studies)	OR = $\frac{a/c}{b/d} = \frac{ad}{bc}$	260
Relative risk	RR = $\frac{a/(a+b)}{c/(c+d)}$	260
Attributable risk	AR = $\frac{a}{a+b} - \frac{c}{c+d}$	260
Relative risk reduction	RRR = 1 - RR	260
Absolute risk reduction	ARR = $\frac{c}{c+d} - \frac{a}{a+b}$	260
Number needed to treat	NNT = 1/ARR	260
Number needed to harm	NNH = 1/AR	260
Likelihood ratio +	LR+ = sensitivity/(1 - specificity) = TP rate/FP rate	261
Likelihood ratio -	LR- = (1 - sensitivity)/specificity = FN rate/TN rate	261
Sensitivity	Sensitivity = TP / (TP + FN)	262
Specificity	Specificity = TN / (TN + FP)	262
Positive predictive value	PPV = TP / (TP + FP)	262
Negative predictive value	NPV = TN / (FN + TN)	262
Cardiac output	CO = $\frac{\text{rate of O}_2 \text{ consumption}}{(\text{arterial O}_2 \text{ content} - \text{venous O}_2 \text{ content})}$ CO = stroke volume × heart rate	292 292
Mean arterial pressure	MAP = cardiac output × total peripheral resistance MAP = 2/3 diastolic + 1/3 systolic	292 292
Stroke volume	SV = EDV - ESV	292
Ejection fraction	EF = $\frac{SV}{EDV} = \frac{EDV - ESV}{EDV}$	292
Resistance	Resistance = $\frac{\text{driving pressure } (\Delta P)}{\text{flow } (Q)} = \frac{8\eta \text{ (viscosity)} \times \text{length}}{\pi r^4}$	293
Capillary fluid exchange	J _v = net fluid flow = K _f [(P _c - P _i) - σ(π _c - π _i)]	303
Reticulocyte production index	RPI = % reticulocytes × $\left(\frac{\text{actual Hct}}{\text{normal Hct}}\right)$ / maturation time	425
Renal clearance	C _x = (U _x V)/P _x	606
Glomerular filtration rate	C _{inulin} = GFR = U _{inulin} × V/P _{inulin} = K _f [(P _{GC} - P _{BS}) - (π _{GC} - π _{BS})]	606
Effective renal plasma flow	eRPF = U _{PAH} × $\frac{V}{P_{PAH}}$ = C _{PAH}	606

TOPIC	EQUATION	PAGE
Filtration fraction	$FF = \frac{GFR}{RPF}$	607
Fractional excretion of sodium	$Fe_{Na} = (Na^+ \text{ excreted} / Na^+ \text{ filtered})$	608
Henderson-Hasselbalch equation (for extracellular pH)	$pH = 6.1 + \log \frac{[HCO_3^-]}{0.03 P_{CO_2}}$	616
Winters formula	$P_{CO_2} = 1.5 [HCO_3^-] + 8 \pm 2$	616
Anion gap	$Na^+ - (Cl^- + HCO_3^-)$	616
Physiologic dead space	$V_D = V_T \times \frac{P_{aCO_2} - P_{eCO_2}}{P_{aCO_2}}$	688
Pulmonary vascular resistance	$PVR = \frac{P_{\text{pulm artery}} - P_{\text{L atrium}}}{\dot{Q}}$	690
Alveolar gas equation	$PAO_2 = PIO_2 - \frac{PaCO_2}{RQ}$	691

► EASILY CONFUSED MEDICATIONS

DRUG	CLINICAL USE/MECHANISM OF ACTION
Amiloride	K ⁺ -sparing diuretic
Amiodarone	Class III antiarrhythmic
Amlodipine	Dihydropyridine Ca ²⁺ channel blocker
Benztropine	Cholinergic antagonist
Bromocriptine	Dopamine agonist
Bupirone	Generalized anxiety disorder (5-HT _{1A} -receptor agonist)
Bupropion	Depression, smoking cessation (NE-DA reuptake inhibitor)
Cimetidine	H ₂ -receptor antagonist
Cetirizine	2nd-generation antihistamine
Chloramphenicol	Antibiotic (blocks 50S subunit)
Chlordiazepoxide	Long-acting benzodiazepine
Chlorpromazine	Typical antipsychotic
Chlorpropamide	1st-generation sulfonylurea
Chlorpheniramine	1st-generation antihistamine
Chlorthalidone	Thiazide diuretic
Clozapine	Atypical antipsychotic
Clomipramine	Tricyclic antidepressant
Clomiphene	Selective estrogen receptor modulator
Clonidine	α ₂ -agonist

DRUG	CLINICAL USE/MECHANISM OF ACTION
Doxepin	Tricyclic antidepressant
Doxazosin	α_1 -antagonist
Eplerenone	K ⁺ -sparing diuretic
Propafenone	Class IC antiarrhythmic
Fluoxetine	Selective serotonin reuptake inhibitor
Fluphenazine	Typical antipsychotic
Duloxetine	Serotonin-norepinephrine reuptake inhibitor
Mifepristone	Progesterone receptor antagonist
Misoprostol	PGE ₁ synthetic analog
Naloxone	Opioid receptor antagonist (treats toxicity)
Naltrexone	Opioid receptor antagonist (prevents relapse)
Nitroprusside	Hypertensive emergency (↑ cGMP/NO)
Nitroglycerin	Antianginal (↑ cGMP/NO)
Omeprazole	Proton pump inhibitor
Ketoconazole	Antifungal (inhibits fungal sterol synthesis)
Aripiprazole	Atypical antipsychotic
Anastrozole	Aromatase inhibitor
Rifaximin	Hepatic encephalopathy (↓ ammoniagenic bacteria)
Rifampin	Antimicrobial (inhibits DNA-dependent RNA polymerase)
Sertraline	Selective serotonin reuptake inhibitor
Selegiline	MAO-B inhibitor
Trazodone	Insomnia (blocks 5-HT ₂ , α_1 -adrenergic, and H ₁ receptors)
Tramadol	Chronic pain (weak opioid agonist)
Varenicline	Smoking cessation (nicotinic ACh receptor partial agonist)
Venlafaxine	Serotonin-norepinephrine reuptake inhibitor

SECTION IV

Abbreviations and Symbols

ABBREVIATION	MEANING
1st MC*	1st metacarpal
A-a	alveolar-arterial [gradient]
AA	Alcoholics Anonymous, amyloid A
AAMC	Association of American Medical Colleges
AAo*	ascending aorta
Ab	antibody
ABPA	allergic bronchopulmonary aspergillosis
AC	adenyl cyclase
ACA	anterior cerebral artery
Acetyl-CoA	acetyl coenzyme A
ACD	anemia of chronic disease
ACE	angiotensin-converting enzyme
ACh	acetylcholine
AChE	acetylcholinesterase
ACL	anterior cruciate ligament
ACom	anterior communicating [artery]
ACTH	adrenocorticotropic hormone
AD	Alzheimer disease, autosomal dominant
ADA	adenosine deaminase, Americans with Disabilities Act
ADH	antidiuretic hormone
ADHD	attention-deficit hyperactivity disorder
ADP	adenosine diphosphate
ADPKD	autosomal-dominant polycystic kidney disease
AFP	α -fetoprotein
Ag	antigen, silver
AICA	anterior inferior cerebellar artery
AIDS	acquired immunodeficiency syndrome
AIHA	autoimmune hemolytic anemia
AKI	acute kidney injury
AKT	protein kinase B
AL	amyloid light [chain]
ALA	aminolevulinic acid
ALI	acute lung injury
ALK	anaplastic lymphoma kinase
ALL	acute lymphoblastic (lymphocytic) leukemia
ALP	alkaline phosphatase
ALS	amyotrophic lateral sclerosis
ALT	alanine transaminase
AMA	American Medical Association, antimitochondrial antibody
AML	acute myelogenous (myeloid) leukemia
AMP	adenosine monophosphate
ANA	antinuclear antibody
ANCA	antineutrophil cytoplasmic antibody

ABBREVIATION	MEANING
ANOVA	analysis of variance
ANP	atrial natriuretic peptide
ANS	autonomic nervous system
Ant*	anterior
Ao*	aorta
AOA	American Osteopathic Association
AP	action potential, A & P [ribosomal binding sites]
APC	antigen-presenting cell, activated protein C
APL	Acute promyelocytic leukemia
Apo	apolipoprotein
APP	amyloid precursor protein
APRT	adenine phosphoribosyltransferase
aPTT	activated partial thromboplastin time
APUD	amine precursor uptake decarboxylase
AR	attributable risk, autosomal recessive, aortic regurgitation
ARB	angiotensin receptor blocker
ARDS	acute respiratory distress syndrome
Arg	arginine
ARPKD	autosomal-recessive polycystic kidney disease
ART	antiretroviral therapy
AS	aortic stenosis
ASA	anterior spinal artery
Asc*	ascending
Asc Ao*	ascending aorta
ASD	atrial septal defect
ASO	anti-streptolysin O
AST	aspartate transaminase
AT	angiotensin, antithrombin
ATN	acute tubular necrosis
ATP	adenosine triphosphate
ATPase	adenosine triphosphatase
ATTR	transthyretin-mediated amyloidosis
AV	atrioventricular
AZT	azidothymidine
BAL	British anti-Lewisite [dimeric caprol]
BBB	blood-brain barrier
BCG	bacille Calmette-Guérin
bd*	bile duct
BH ₄	tetrahydrobiopterin
BM	basement membrane
BOOP	bronchiolitis obliterans organizing pneumonia
BP	bisphosphate, blood pressure
BPG	bisphosphoglycerate
BPH	benign prostatic hyperplasia

*Image abbreviation only

ABBREVIATION	MEANING
BT	bleeding time
BUN	blood urea nitrogen
C*	caudate
Ca*	capillary
Ca ²⁺	calcium ion
CAD	coronary artery disease
CAF	common application form
cAMP	cyclic adenosine monophosphate
CBG	corticosteroid-binding globulin
CBSE	Comprehensive Basic Science Examination
CBSSA	Comprehensive Basic Science Self-Assessment
CBT	computer-based test, cognitive behavioral therapy
CCK	cholecystokinin
CCS	computer-based case simulation
CD	cluster of differentiation
CDK	cyclin-dependent kinase
cDNA	complementary deoxyribonucleic acid
CEA	carcinoembryonic antigen
CETP	cholesteryl-ester transfer protein
CF	cystic fibrosis
CFTR	cystic fibrosis transmembrane conductance regulator
CGD	chronic granulomatous disease
cGMP	cyclic guanosine monophosphate
CGRP	calcitonin gene-related peptide
C _H 1-C _H 3	constant regions, heavy chain [antibody]
ChAT	choline acetyltransferase
CHD*	common hepatic duct
χ ²	chi-squared
CI	confidence interval
CIN	candidate identification number, carcinoma in situ, cervical intraepithelial neoplasia
CIS	Communication and Interpersonal Skills
CK	clinical knowledge, creatine kinase
CKD	chronic kidney disease
CK-MB	creatine kinase, MB fraction
C _L	constant region, light chain [antibody]
CL	clearance
Cl ⁻	chloride ion
CLL	chronic lymphocytic leukemia
CMC	carpometaacarpal (joint)
CML	chronic myelogenous (myeloid) leukemia
CMV	cytomegalovirus
CN	cranial nerve
CN ⁻	cyanide ion
CNS	central nervous system
CNV	copy number variation
CO	carbon monoxide, cardiac output
CO ₂	carbon dioxide
CoA	coenzyme A
Coarct*	coarctation
COL1A1	collagen, type I, alpha 1
COL1A2	collagen, type I, alpha 2
COMT	catechol-O-methyltransferase
COP	coat protein

ABBREVIATION	MEANING
COPD	chronic obstructive pulmonary disease
CoQ	coenzyme Q
COVID-19	Coronavirus disease 2019
COX	cyclooxygenase
C _p	plasma concentration
CPAP	continuous positive airway pressure
CPR	cardiopulmonary resuscitation
Cr	creatinine
CRC	colorectal cancer
CREST	calcinosis, Raynaud phenomenon, esophageal dysfunction, sclerosis, and telangiectasias [syndrome]
CRH	corticotropin-releasing hormone
CRP	C-reactive protein
CS	clinical skills
C-section	cesarean section
CSF	cerebrospinal fluid
CT	computed tomography
CTP	cytidine triphosphate
CXR	chest x-ray
DA	dopamine
DAF	decay-accelerating factor
DAG	diacylglycerol
DAo*	descending aorta
dATP	deoxyadenosine triphosphate
DCIS	ductal carcinoma in situ
DCT	distal convoluted tubule
ddI	didanosine
DES	diethylstilbestrol
Desc Ao*	descending aorta
DEXA	dual-energy x-ray absorptiometry
DHAP	dihydroxyacetone phosphate
DHEA	dehydroepiandrosterone
DHF	dihydrofolic acid
DHT	dihydrotestosterone
DI	diabetes insipidus
DIC	disseminated intravascular coagulation
DIP	distal interphalangeal [joint]
DKA	diabetic ketoacidosis
DLCO	diffusing capacity for carbon monoxide
DM	diabetes mellitus
DNA	deoxyribonucleic acid
DNR	do not resuscitate
dNTP	deoxynucleotide triphosphate
DO	doctor of osteopathy
DPGN	diffuse proliferative glomerulonephritis
DPM	doctor of podiatric medicine
DPP-4	dipeptidyl peptidase-4
DPPC	dipalmitoylphosphatidylcholine
DS	double stranded
dsDNA	double-stranded deoxyribonucleic acid
dsRNA	double-stranded ribonucleic acid
DRG	dorsal root ganglion
d4T	didehydrodeoxythymidine [stavudine]
dTMP	deoxythymidine monophosphate
DTR	deep tendon reflex

*Image abbreviation only

ABBREVIATION	MEANING
DTs	delirium tremens
dUDP	deoxyuridine diphosphate
dUMP	deoxyuridine monophosphate
DVT	deep venous thrombosis
E*	euthromatin, esophagus
EBV	Epstein-Barr virus
ECA*	external carotid artery
ECF	extracellular fluid
ECFMG	Educational Commission for Foreign Medical Graduates
EKG	electrocardiogram
ECL	enterochromaffin-like [cell]
ECM	extracellular matrix
ECT	electroconvulsive therapy
ED ₅₀	median effective dose
EDRF	endothelium-derived relaxing factor
EDTA	ethylenediamine tetra-acetic acid
EDV	end-diastolic volume
EEG	electroencephalogram
EF	ejection fraction
EGF	epidermal growth factor
EHEC	enterohemorrhagic <i>E coli</i>
EIEC	enteroinvasive <i>E coli</i>
ELISA	enzyme-linked immunosorbent assay
EM	electron micrograph/microscopy
EMB	eosin–methylene blue
EPEC	enteropathogenic <i>E coli</i>
Epi	epinephrine
EPO	erythropoietin
EPS	extrapyramidal system
ER	endoplasmic reticulum, estrogen receptor
ERAS	Electronic Residency Application Service
ERCP	endoscopic retrograde cholangiopancreatography
ERP	effective refractory period
eRPF	effective renal plasma flow
ERT	estrogen replacement therapy
ERV	expiratory reserve volume
ESR	erythrocyte sedimentation rate
ESRD	end-stage renal disease
ESV	end-systolic volume
ETEC	enterotoxigenic <i>E coli</i>
EtOH	ethyl alcohol
EV	esophageal vein
F	bioavailability
FA	fatty acid
Fab	fragment, antigen-binding
FAD	flavin adenine dinucleotide
FADH ₂	reduced flavin adenine dinucleotide
FAP	familial adenomatous polyposis
F1,6BP	fructose-1,6-bisphosphate
F2,6BP	fructose-2,6-bisphosphate
FBPase	fructose biphosphatase
FBPase-2	fructose biphosphatase-2
Fc	fragment, crystallizable
FcR	Fc receptor

ABBREVIATION	MEANING
5f-dUMP	5-fluorodeoxyuridine monophosphate
Fe ²⁺	ferrous ion
Fe ³⁺	ferric ion
Fem*	femur
FENa	excreted fraction of filtered sodium
FEV ₁	forced expiratory volume in 1 second
FF	filtration fraction
FFA	free fatty acid
FGF	fibroblast growth factor
FGFR	fibroblast growth factor receptor
FGR	fetal growth restriction
FISH	fluorescence in situ hybridization
F _I O ₂	fraction of inspired oxygen
FIT	fecal immunochemical testing
FKBP	FK506 binding protein
fMet	formylmethionine
FMG	foreign medical graduate
FMN	flavin mononucleotide
FN	false negative
FP, FP*	false positive, foot process
FRC	functional residual capacity
F _{SH}	follicle-stimulating hormone
F _{SMB}	Federation of State Medical Boards
F _{TA} -ABS	fluorescent treponemal antibody—absorbed
F _{TD} *	frontotemporal dementia
5-FU	5-fluorouracil
FVC	forced vital capacity
GABA	γ-aminobutyric acid
GAG	glycosaminoglycan
Gal	galactose
GBM	glomerular basement membrane
GC	glomerular capillary
G-CSF	granulocyte colony-stimulating factor
GERD	gastroesophageal reflux disease
GFAP	glial fibrillary acid protein
GFR	glomerular filtration rate
GGT	γ-glutamyl transpeptidase
GH	growth hormone
GHB	γ-hydroxybutyrate
GHRH	growth hormone–releasing hormone
G ₁	G protein, I polypeptide
GI	gastrointestinal
GIP	gastric inhibitory peptide
GIST	gastrointestinal stromal tumor
GLUT	glucose transporter
GM	granulocyte macrophage
GM-CSF	granulocyte-macrophage colony stimulating factor
GMP	guanosine monophosphate
GnRH	gonadotropin-releasing hormone
Gp	glycoprotein
G6P	glucose-6-phosphate
G6PD	glucose-6-phosphate dehydrogenase
GPe	globus pallidus externa
G _{Pi}	globus pallidus interna

*Image abbreviation only

ABBREVIATION	MEANING
GPI	glycosyl phosphatidylinositol
GRP	gastrin-releasing peptide
G _s	G protein, S polypeptide
GSH	reduced glutathione
GSSG	oxidized glutathione
GTP	guanosine triphosphate
GTPase	guanosine triphosphatase
GU	genitourinary
H*	heterochromatin
H ⁺	hydrogen ion
H ₁ , H ₂	histamine receptors
H ₂ S	hydrogen sulfide
ha*	hepatic artery
HAV	hepatitis A virus
HAVAb	hepatitis A antibody
Hb	hemoglobin
HBcAb/HBcAg	hepatitis B core antibody/antigen
HBeAb/HBeAg	hepatitis B early antibody/antigen
HBsAb/HBsAg	hepatitis B surface antibody/antigen
HbCO ₂	carbaminohemoglobin
HBV	hepatitis B virus
HCC	hepatocellular carcinoma
hCG	human chorionic gonadotropin
HCO ₃ ⁻	bicarbonate
Hct	hematocrit
HCTZ	hydrochlorothiazide
HCV	hepatitis C virus
HDL	high-density lipoprotein
HDN	hemolytic disease of the newborn
HDV	hepatitis D virus
H&E	hematoxylin and eosin
HEV	hepatitis E virus
HF	heart failure
Hfr	high-frequency recombination [cell]
HFpEF	heart failure with preserved ejection fraction
HFrEF	heart failure with reduced ejection fraction
HGPRT	hypoxanthine-guanine phosphoribosyltransferase
HHb	deoxygenated hemoglobin
HHS	hyperosmolar hyperglycemic state
HHV	human herpesvirus
5-HIAA	5-hydroxyindoleacetic acid
HIT	heparin-induced thrombocytopenia
HIV	human immunodeficiency virus
HL	hepatic lipase
HLA	human leukocyte antigen
HMG-CoA	hydroxymethylglutaryl-coenzyme A
HMP	hexose monophosphate
HMWK	high-molecular-weight kininogen
HNPCC	hereditary nonpolyposis colorectal cancer
hnRNA	heterogeneous nuclear ribonucleic acid
H ₂ O ₂	hydrogen peroxide
HOCM	hypertrophic obstructive cardiomyopathy
HPA	hypothalamic-pituitary-adrenal [axis]
HPO	hypothalamic-pituitary-ovarian [axis]

ABBREVIATION	MEANING
HPV	human papillomavirus
HR	heart rate
HSP	Henoch-Schönlein purpura
HSV	herpes simplex virus
5-HT	5-hydroxytryptamine (serotonin)
HTLV	human T-cell leukemia virus
HTN	hypertension
HUS	hemolytic-uremic syndrome
HVA	homovanillic acid
IBD	inflammatory bowel disease
IBS	irritable bowel syndrome
IC	inspiratory capacity, immune complex
I _{Ca}	calcium current [heart]
I _f	funny current [heart]
ICA	internal carotid artery
ICAM	intercellular adhesion molecule
ICD	implantable cardioverter defibrillator
ICE	Integrated Clinical Encounter
ICF	intracellular fluid
ICP	intracranial pressure
ID	identification
ID ₅₀	median infective dose
IDL	intermediate-density lipoprotein
IF	immunofluorescence, initiation factor
IFN	interferon
Ig	immunoglobulin
IGF	insulinlike growth factor
I _K	potassium current [heart]
IL	interleukin
IM	intramuscular
IMA	inferior mesenteric artery
IMG	international medical graduate
IMP	inosine monophosphate
IMV	inferior mesenteric vein
I _{Na}	sodium current [heart]
INH	isoniazid
INO	internuclear ophthalmoplegia
INR	International Normalized Ratio
IO	inferior oblique [muscle]
IOP	intraocular pressure
IP ₃	inositol triphosphate
IPV	inactivated polio vaccine
IR	current × resistance [Ohm's law], inferior rectus [muscle]
IRV	inspiratory reserve volume
ITP	idiopathic thrombocytopenic purpura
IUD	intrauterine device
IV	intravenous
IVC	inferior vena cava
IVIG	intravenous immunoglobulin
JAK/STAT	Janus kinase/signal transducer and activator of transcription [pathway]
JGA	juxtaglomerular apparatus
JVD	jugular venous distention
JVP	jugular venous pulse

*Image abbreviation only

ABBREVIATION	MEANING
K ⁺	potassium ion
KatG	catalase-peroxidase produced by <i>M tuberculosis</i>
K _e	elimination constant
K _f	filtration constant
KG	ketoglutarate
Kid*	kidney
K _m	Michaelis-Menten constant
KOH	potassium hydroxide
L	left, lentiform, liver
LA	left atrial, left atrium
LAD	left anterior descending coronary artery
LAP	leukocyte alkaline phosphatase
Lat cond*	lateral condyle
Lb*	lamellar body
LCA	left coronary artery
LCAT	lecithin-cholesterol acyltransferase
LCC*	left common carotid artery
LCFA	long-chain fatty acid
LCL	lateral collateral ligament
LCME	Liaison Committee on Medical Education
LCMV	lymphocytic choriomeningitis virus
LCX	left circumflex coronary artery
LD	loading dose
LD ₅₀	median lethal dose
LDH	lactate dehydrogenase
LDL	low-density lipoprotein
LES	lower esophageal sphincter
LFA	leukocyte function-associated antigen
LFT	liver function test
LH	luteinizing hormone
Liv*	liver
LLL*	left lower lobe (of lung)
LLQ	left lower quadrant
LM	lateral meniscus, left main coronary artery, light microscopy
LMN	lower motor neuron
LOS	lipooligosaccharide
LPA*	left pulmonary artery
LPL	lipoprotein lipase
LPS	lipopolysaccharide
LR	lateral rectus [muscle]
LT	labile toxin, leukotriene
LUL*	left upper lobe (of lung)
LV	left ventricle, left ventricular
M ₁ -M ₅	muscarinic (parasympathetic) ACh receptors
MAC	membrane attack complex, minimum alveolar concentration
MALT	mucosa-associated lymphoid tissue
MAO	monoamine oxidase
MAP	mean arterial pressure, mitogen-activated protein
Max*	maxillary sinus
MC	midsystolic click, metacarpal
MCA	middle cerebral artery
MCAT	Medical College Admissions Test
MCHC	mean corpuscular hemoglobin concentration

ABBREVIATION	MEANING
MCL	medial collateral ligament
MCP	metacarpophalangeal [joint]
MCV	mean corpuscular volume
MD	maintenance dose
MDD	major depressive disorder
Med cond*	medial condyle
MELAS	mitochondrial encephalopathy, lactic acidosis, and stroke-like episodes
MEN	multiple endocrine neoplasia
MERS	Middle East respiratory syndrome
Mg ²⁺	magnesium ion
MgSO ₄	magnesium sulfate
MHC	major histocompatibility complex
MI	myocardial infarction
MIF	müllerian inhibiting factor
MIRL	membrane inhibitor of reactive lysis
MLCK	myosin light-chain kinase
MLF	medial longitudinal fasciculus
MMC	migrating motor complex
MMR	measles, mumps, rubella [vaccine]
MODY	maturity-onset diabetes of the young
6-MP	6-mercaptopurine
MPGN	membranoproliferative glomerulonephritis
MPO	myeloperoxidase
MPO-ANCA/ p-ANCA	myeloperoxidase/perinuclear antineutrophil cytoplasmic antibody
MR	medial rectus [muscle], mitral regurgitation
MRI	magnetic resonance imaging
miRNA	microribonucleic acid
mRNA	messenger ribonucleic acid
MRSA	methicillin-resistant <i>S aureus</i>
MS	mitral stenosis, multiple sclerosis
MSH	melanocyte-stimulating hormone
mtDNA	mitochondrial DNA
mTOR	mammalian target of rapamycin
MTP	metatarsophalangeal [joint]
MTX	methotrexate
MVO ₂	myocardial oxygen consumption
MVP	mitral valve prolapse
N*	nucleus
Na ⁺	sodium ion
NAAT	nucleic acid amplification test
NAD	nicotinamide adenine dinucleotide
NAD ⁺	oxidized nicotinamide adenine dinucleotide
NADH	reduced nicotinamide adenine dinucleotide
NADP ⁺	oxidized nicotinamide adenine dinucleotide phosphate
NADPH	reduced nicotinamide adenine dinucleotide phosphate
NBME	National Board of Medical Examiners
NBOME	National Board of Osteopathic Medical Examiners
NBPME	National Board of Podiatric Medical Examiners
NE	norepinephrine
NF	neurofibromatosis
NFAT	nuclear factor of activated T-cell
NH ₃	ammonia

*Image abbreviation only

ABBREVIATION	MEANING
NH ₄ ⁺	ammonium
NK	natural killer [cells]
N _M	muscarinic ACh receptor in neuromuscular junction
NMDA	N-methyl-d-aspartate
NMJ	neuromuscular junction
NMS	neuroleptic malignant syndrome
N _N	nicotinic ACh receptor in autonomic ganglia
NRMP	National Residency Matching Program
NNRTI	non-nucleoside reverse transcriptase inhibitor
NO	nitric oxide
N ₂ O	nitrous oxide
NPH	neutral protamine Hagedorn, normal pressure hydrocephalus
NPV	negative predictive value
NRTI	nucleoside reverse transcriptase inhibitor
NSAID	nonsteroidal anti-inflammatory drug
NSE	neuron-specific enolase
NSTEMI	non-ST-segment elevation myocardial infarction
Nu*	nucleolus
OAA	oxaloacetic acid
OCD	obsessive-compulsive disorder
OCP	oral contraceptive pill
ODC	oxygen-hemoglobin dissociation curve
OH	hydroxy
1,25-OH D ₃	calcitriol (active form of vitamin D)
25-OH D ₃	storage form of vitamin D
OPV	oral polio vaccine
OR	odds ratio
OS	opening snap
OSA	obstructive sleep apnea
OVL1	organum vasculosum of the lamina terminalis
P-body	processing body (cytoplasmic)
P-450	cytochrome P-450 family of enzymes
PA	posteroanterior, pulmonary artery
PABA	<i>para</i> -aminobenzoic acid
Paco ₂	arterial PCO ₂
PACO ₂	alveolar PCO ₂
PAH	<i>para</i> -aminohippuric acid
PAN	polyarteritis nodosa
Pao ₂	partial pressure of oxygen in arterial blood
PAO ₂	partial pressure of oxygen in alveolar blood
PAP	Papanicolaou [smear], prostatic acid phosphatase, posteromedial papillary muscle
PAPPA	pregnancy-associated plasma protein A
PAS	periodic acid-Schiff
Pat*	patella
Pb	Barometric (atmospheric) pressure
PBP	penicillin-binding protein
PC	platelet count, pyruvate carboxylase
PCA	posterior cerebral artery
PCC	prothrombin complex concentrate
PCL	posterior cruciate ligament
Pco ₂	partial pressure of carbon dioxide
PCom	posterior communicating [artery]

ABBREVIATION	MEANING
PCOS	polycystic ovarian syndrome
PCP	phencyclidine hydrochloride, <i>Pneumocystis jirovecii</i> pneumonia
PCR	polymerase chain reaction
PCT	proximal convoluted tubule
PCV13	pneumococcal conjugate vaccine
PCWP	pulmonary capillary wedge pressure
PDA	patent ductus arteriosus, posterior descending artery
PDE	phosphodiesterase
PDGF	platelet-derived growth factor
PDH	pyruvate dehydrogenase
PE	pulmonary embolism
PECAM	platelet-endothelial cell adhesion molecule
PECO ₂	expired air PCO ₂
PEP	phosphoenolpyruvate
PF	platelet factor
PFK	phosphofructokinase
PFK-2	phosphofructokinase-2
PFT	pulmonary function test
PG	phosphoglycerate
PH ₂ O	water pressure
P _i	plasma interstitial osmotic pressure, inorganic phosphate
PICA	posterior inferior cerebellar artery
PID	pelvic inflammatory disease
PiO ₂	PO ₂ in inspired air
PIP	proximal interphalangeal [joint]
PIP ₂	phosphatidylinositol 4,5-bisphosphate
PIP ₃	phosphatidylinositol 3,4,5-bisphosphate
PKD	polycystic kidney disease
PKR	interferon- α -induced protein kinase
PKU	phenylketonuria
PLAP	placental alkaline phosphatase
PLP	pyridoxal phosphate
PML	progressive multifocal leukoencephalopathy
PMN	polymorphonuclear [leukocyte]
P _{net}	net filtration pressure
PNET	primitive neuroectodermal tumor
PNS	peripheral nervous system
Po ₂	partial pressure of oxygen
PO ₄ ³⁻	phosphate
Pop*	popliteal artery
Pop a*	popliteal artery
Post*	posterior
PPAR	peroxisome proliferator-activated receptor
PPD	purified protein derivative
PPI	proton pump inhibitor
PPM	parts per million
PPSV23	pneumococcal polysaccharide vaccine
PPV	positive predictive value
PR3-ANCA/ c-ANCA	cytoplasmic antineutrophil cytoplasmic antibody
PrP	prion protein
PRPP	phosphoribosylpyrophosphate
PSA	prostate-specific antigen

*Image abbreviation only

ABBREVIATION	MEANING
PSS	progressive systemic sclerosis
PT	prothrombin time, proximal tubule
<i>PTEN</i>	phosphatase and tensin homolog
PTH	parathyroid hormone
PTHrP	parathyroid hormone–related protein
PTSD	post-traumatic stress disorder
PTT	partial thromboplastin time
PV	plasma volume, venous pressure, portal vein
pv*	pulmonary vein
PVC	polyvinyl chloride
PVR	pulmonary vascular resistance
R	correlation coefficient, right, R variable [group]
R ₃	Registration, Ranking, & Results [system]
RA	right atrium, right atrial
RAAS	renin-angiotensin-aldosterone system
RANK-L	receptor activator of nuclear factor- κ B ligand
RAS	reticular activating system
RBF	renal blood flow
RCA	right coronary artery
REM	rapid eye movement
RER	rough endoplasmic reticulum
Rh	<i>rhesus</i> antigen
RLL*	right lower lobe (of lungs)
RLQ	right lower quadrant
RML*	right middle lobe (of lung)
RNA	ribonucleic acid
RNP	ribonucleoprotein
ROS	reactive oxygen species
RPF	renal plasma flow
RPGN	rapidly progressive glomerulonephritis
RPR	rapid plasma reagin
RR	relative risk, respiratory rate
rRNA	ribosomal ribonucleic acid
RS	Reed-Sternberg [cells]
RSC*	right subclavian artery
RSV	respiratory syncytial virus
RTA	renal tubular acidosis
RUL*	right upper lobe (of lung)
RUQ	right upper quadrant
RV	residual volume, right ventricle, right ventricular
RVH	right ventricular hypertrophy
[S]	substrate concentration
SA	sinoatrial
SAA	serum amyloid–associated [protein]
SAM	S-adenosylmethionine
SARS	severe acute respiratory syndrome
SARS-CoV-2	severe acute respiratory syndrome coronavirus 2
SCC	squamous cell carcinoma
SCD	sudden cardiac death
SCID	severe combined immunodeficiency disease
SCJ	squamocolumnar junction
SCM	sternocleidomastoid muscle
SCN	suprachiasmatic nucleus
SD	standard deviation

ABBREVIATION	MEANING
SE	standard error [of the mean]
SEP	Spoken English Proficiency
SER	smooth endoplasmic reticulum
SERM	selective estrogen receptor modulator
SGLT	sodium-glucose transporter
SHBG	sex hormone–binding globulin
SIADH	syndrome of inappropriate [secretion of] antidiuretic hormone
SIDS	sudden infant death syndrome
SJS	Stevens-Johnson syndrome
SLE	systemic lupus erythematosus
SLL	small lymphocytic lymphoma
SLT	Shiga-like toxin
SMA	superior mesenteric artery
SMX	sulfamethoxazole
SNARE	soluble NSF attachment protein receptor
SNC	substantia nigra pars compacta
SNP	single nucleotide polymorphism
SNr	substantia nigra pars reticulata
SNRI	serotonin and norepinephrine receptor inhibitor
snRNA	small nuclear RNA
snRNP	small nuclear ribonucleoprotein
SO	superior oblique [muscle]
SOAP	Supplemental Offer and Acceptance Program
Sp*	spleen
spp	species
SR	superior rectus [muscle]
SS	single stranded
ssDNA	single-stranded deoxyribonucleic acid
SSPE	subacute sclerosing panencephalitis
SSRI	selective serotonin reuptake inhibitor
ssRNA	single-stranded ribonucleic acid
St*	stomach
ST	Shiga toxin
StAR	steroidogenic acute regulatory protein
STEMI	ST-segment elevation myocardial infarction
STI	sexually transmitted infection
STN	subthalamic nucleus
SV	splenic vein, stroke volume
SVC	superior vena cava
SVR	systemic vascular resistance
SVT	supraventricular tachycardia
T*	thalamus, trachea
t _{1/2}	half-life
T ₃	triiodothyronine
T ₄	thyroxine
TAPVR	total anomalous pulmonary venous return
TB	tuberculosis
TBG	thyroxine-binding globulin
TBV	total blood volume
3TC	dideoxythiacytidine [lamivudine]
TCA	tricarboxylic acid [cycle], tricyclic antidepressant
Tc cell	cytotoxic T cell
TCR	T-cell receptor
TDF	tenofovir disoproxil fumarate

*Image abbreviation only

ABBREVIATION	MEANING
TdT	terminal deoxynucleotidyl transferase
TE	tracheoesophageal
TFT	thyroid function test
TG	triglyceride
TGF	transforming growth factor
Th cell	helper T cell
THF	tetrahydrofolic acid
TI	therapeutic index
TIA	transient ischemic attack
Tib*	tibia
TIBC	total iron-binding capacity
TIPS	transjugular intrahepatic portosystemic shunt
TLC	total lung capacity
T_m	maximum rate of transport
TMP	trimethoprim
TN	true negative
TNF	tumor necrosis factor
TNM	tumor, node, metastases [staging]
TOP	topoisomerase
ToRCHeS	<i>Toxoplasma gondii</i> , rubella, CMV, HIV, HSV-2, syphilis
TP	true positive
tPA	tissue plasminogen activator
TPO	thyroid peroxidase, thrombopoietin
TPP	thiamine pyrophosphate
TPPA	<i>Treponema pallidum</i> particle agglutination assay
TPR	total peripheral resistance
TR	tricuspid regurgitation
TRAP	tartrate-resistant acid phosphatase
TRECs	T-cell receptor excision circles
TRH	thyrotropin-releasing hormone
tRNA	transfer ribonucleic acid
TSH	thyroid-stimulating hormone
TSI	triple sugar iron
TSS	toxic shock syndrome
TSST	toxic shock syndrome toxin
TTP	thrombotic thrombocytopenic purpura
TTR	transthyretin
TXA ₂	thromboxane A ₂
UDP	uridine diphosphate
UMN	upper motor neuron
UMP	uridine monophosphate

ABBREVIATION	MEANING
UPD	uniparental disomy
URI	upper respiratory infection
USMLE	United States Medical Licensing Examination
UTI	urinary tract infection
UTP	uridine triphosphate
UV	ultraviolet
V ₁ , V ₂	vasopressin receptors
V _A	alveolar ventilation
VC	vital capacity
V _d	volume of distribution
V _D	physiologic dead space
V(D)J	variable, (diversity), joining gene segments rearranged to form Ig genes
VDRL	Venereal Disease Research Laboratory
V _E	minute ventilation
VEGF	vascular endothelial growth factor
V _H	variable region, heavy chain [antibody]
VHL	von Hippel-Lindau [disease]
VIP	vasoactive intestinal peptide
VIPoma	vasoactive intestinal polypeptide-secreting tumor
V _J	light-chain hypervariable region [antibody]
V _L	variable region, light chain [antibody]
VLCFA	very-long-chain fatty acids
VLDL	very low density lipoprotein
VMA	vanillylmandelic acid
VMAT	vesicular monoamine transporter
V _{max}	maximum velocity
VPL	ventral posterior nucleus, lateral
VPM	ventral posterior nucleus, medial
VPN	vancomycin, polymyxin, nystatin [media]
\dot{V}/\dot{Q}	ventilation/perfusion [ratio]
VRE	vancomycin-resistant enterococcus
VSD	ventricular septal defect
V _T	tidal volume
VTE	venous thromboembolism
vWF	von Willebrand factor
VZV	varicella-zoster virus
VMAT	vesicular monoamine transporter
XR	X-linked recessive
XXXY	normal complement of sex chromosomes for female/male
ZDV	zidovudine [formerly AZT]

*Image abbreviation only