

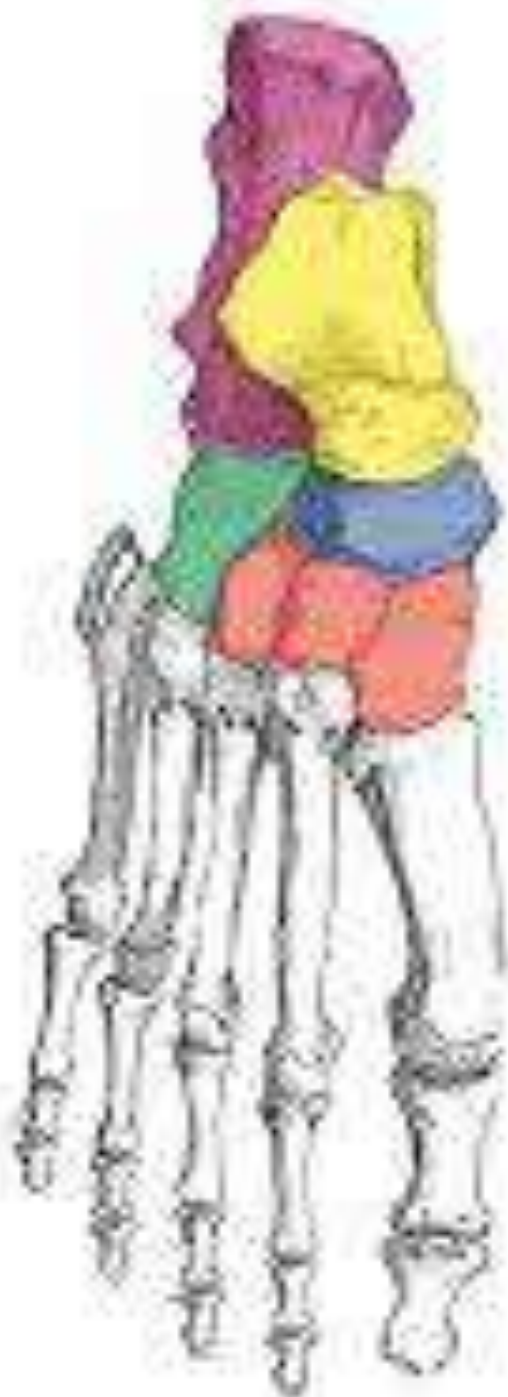Foot Radiology

Dr Ehsan Ullah

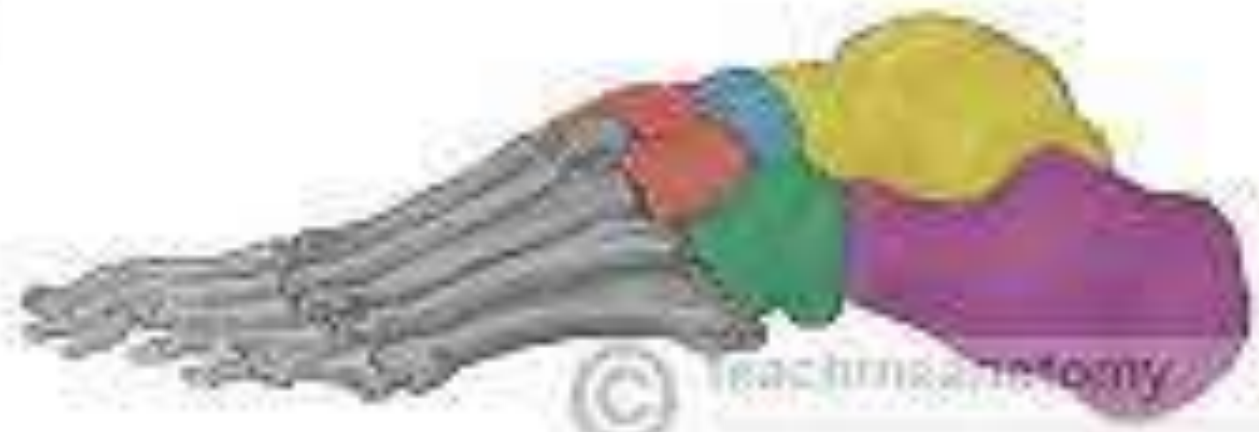Clinical Skills Lab

Khyber Girls Medical College,
Peshawar





- Calcaneus
- Talus
- Navicular
- Cuboid
- Cuneiforms

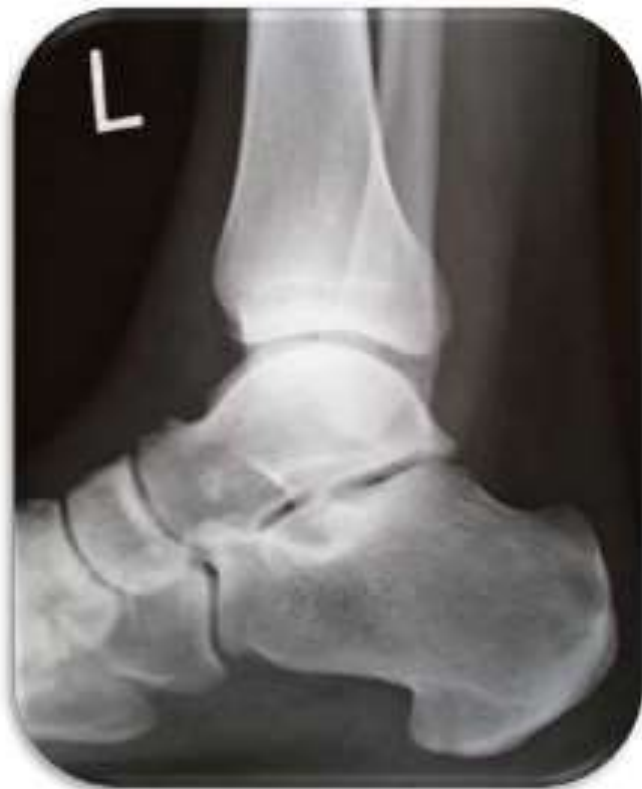

Foot series X-rays

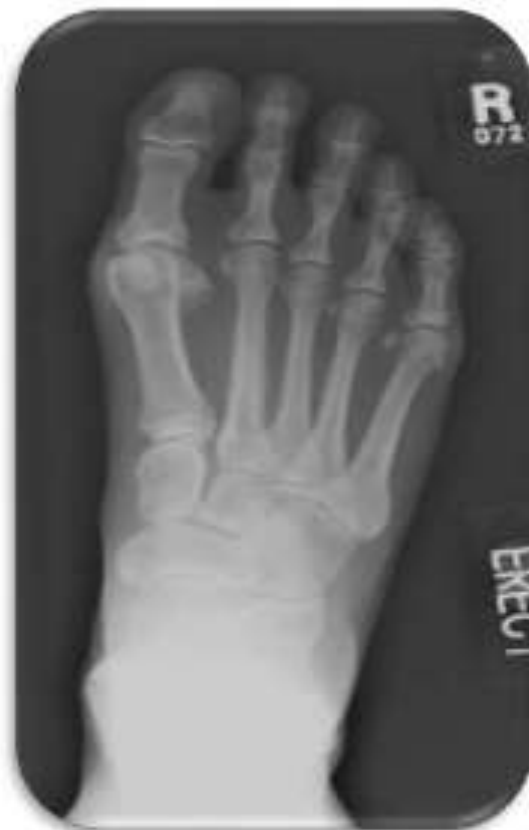Foot & Ankle
Orthopedics



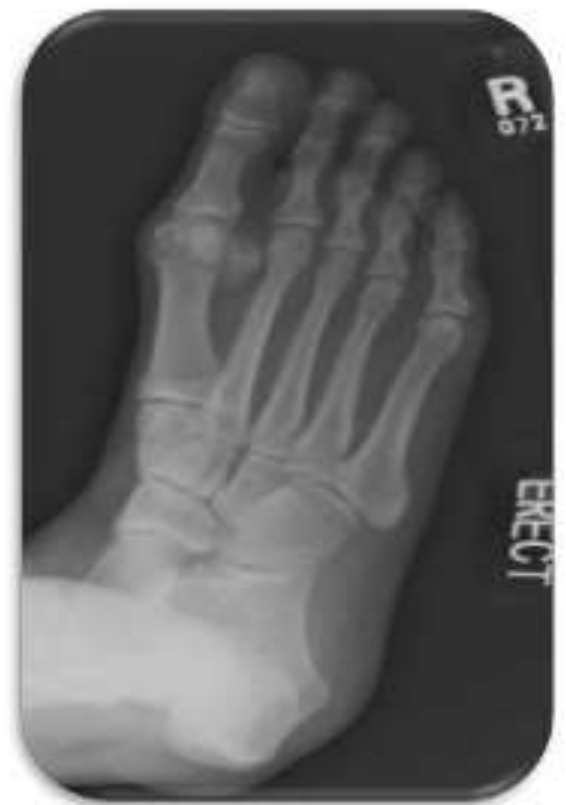Lateral



AP

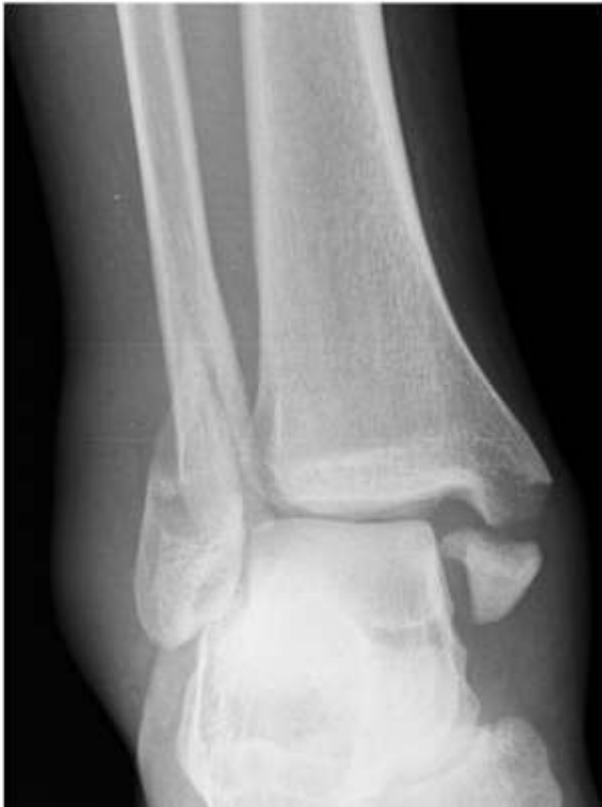

Oblique

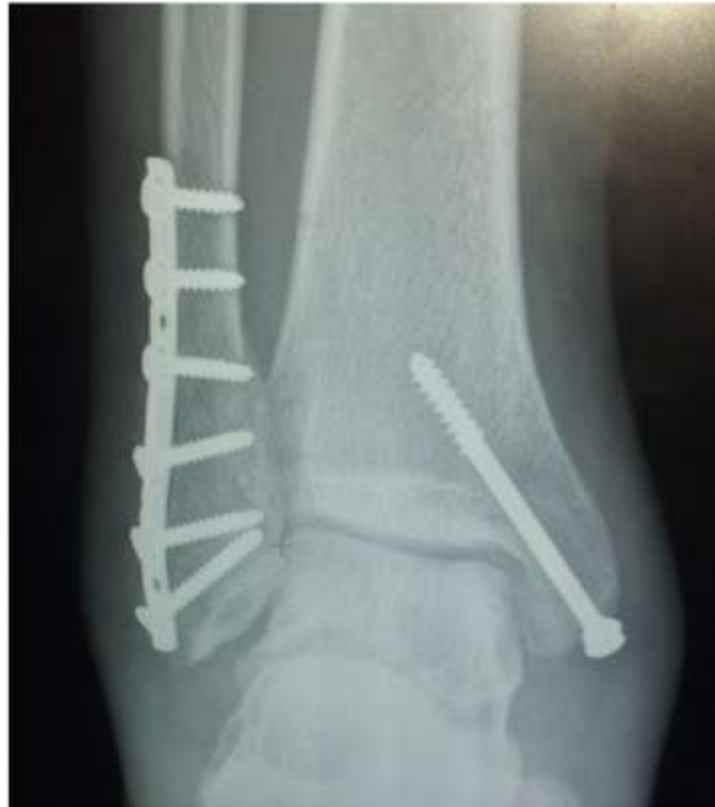

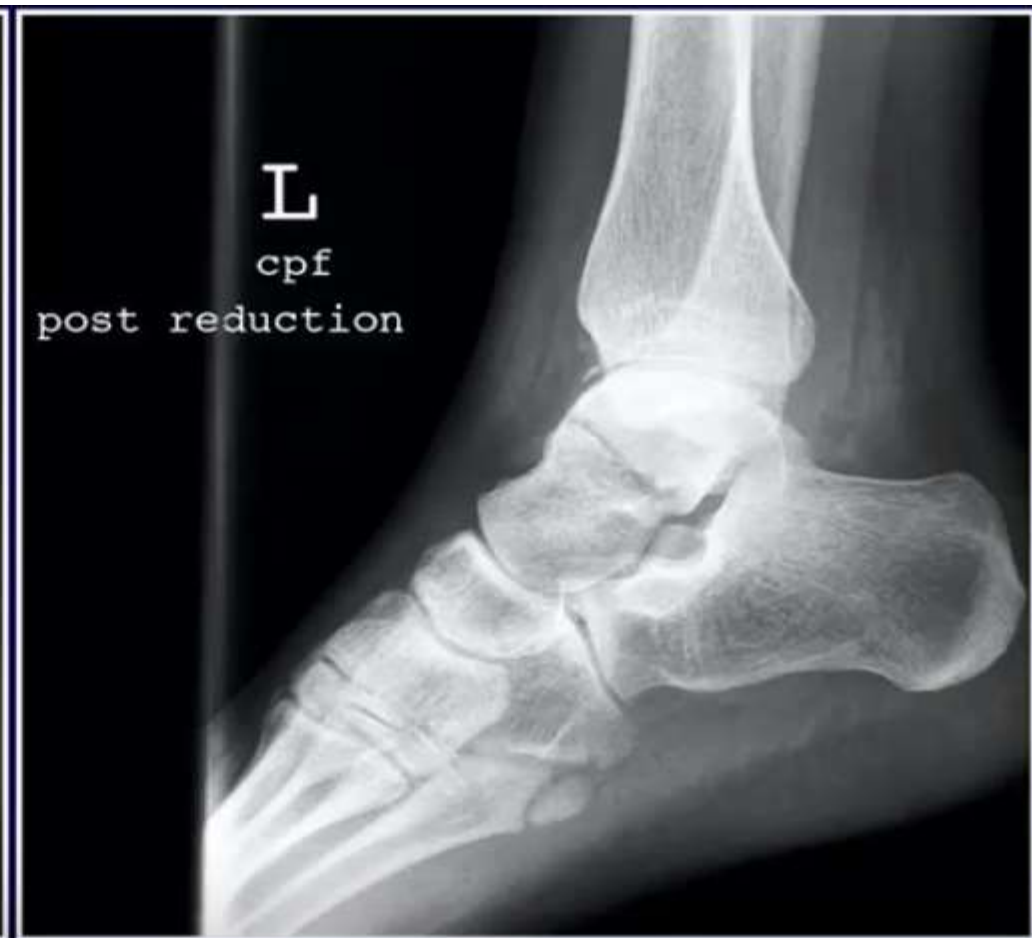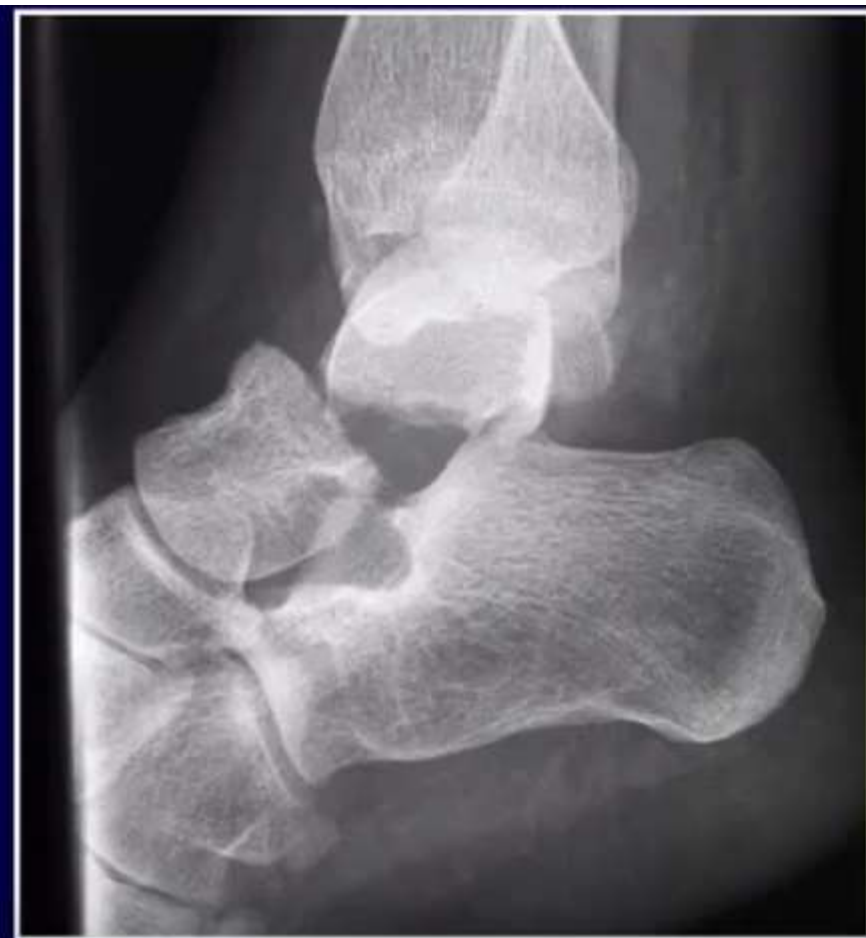Activity 1

BEFORE

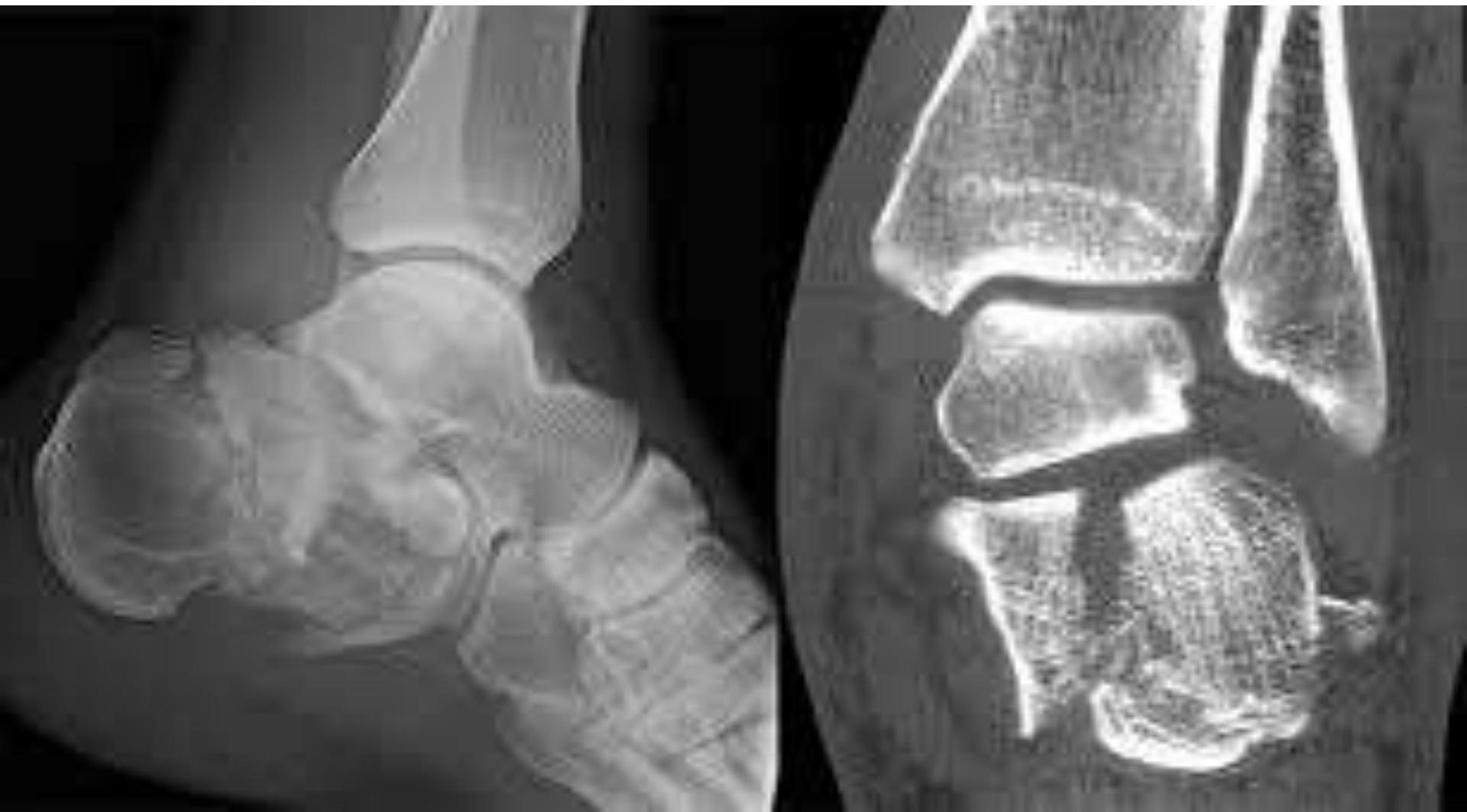

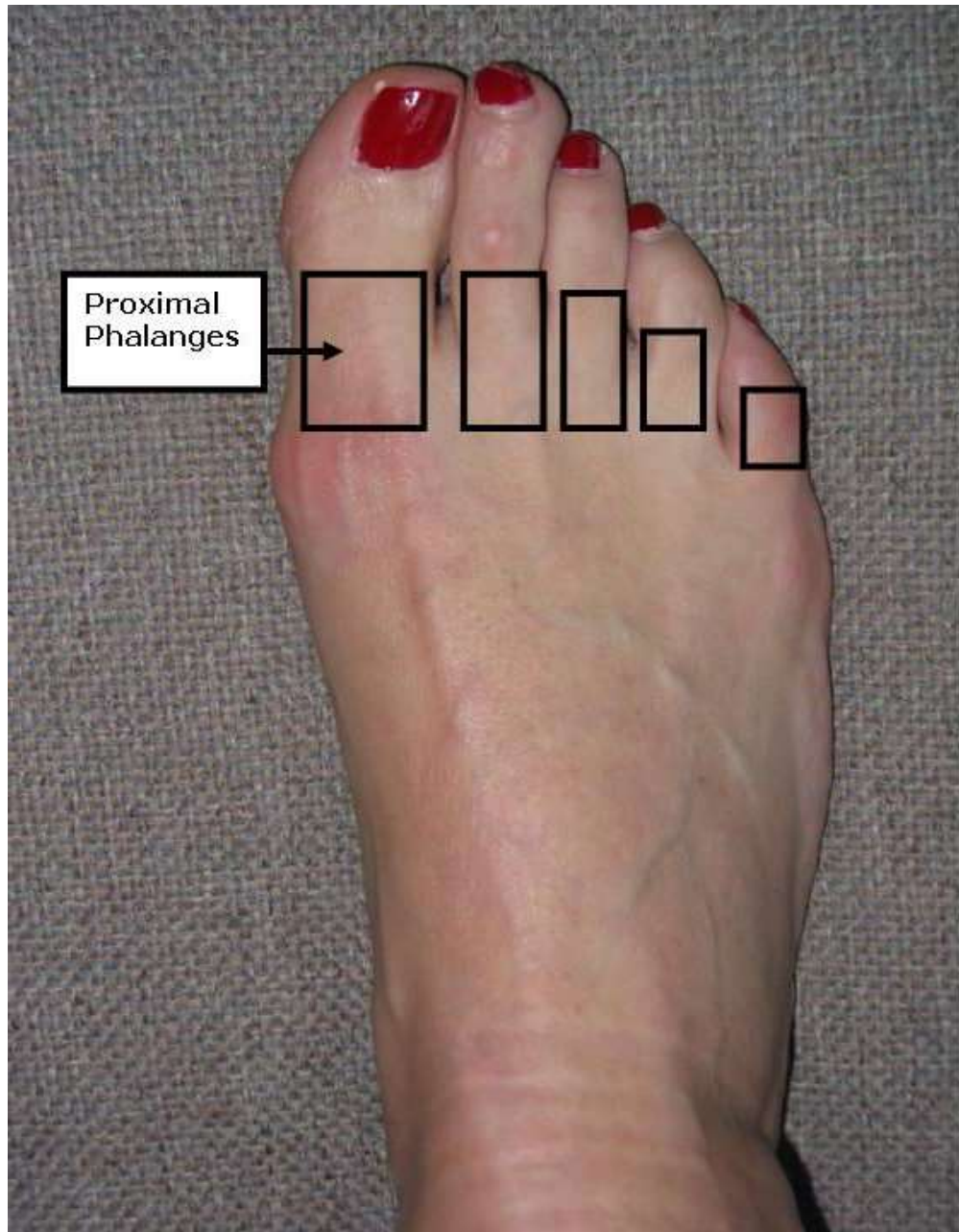
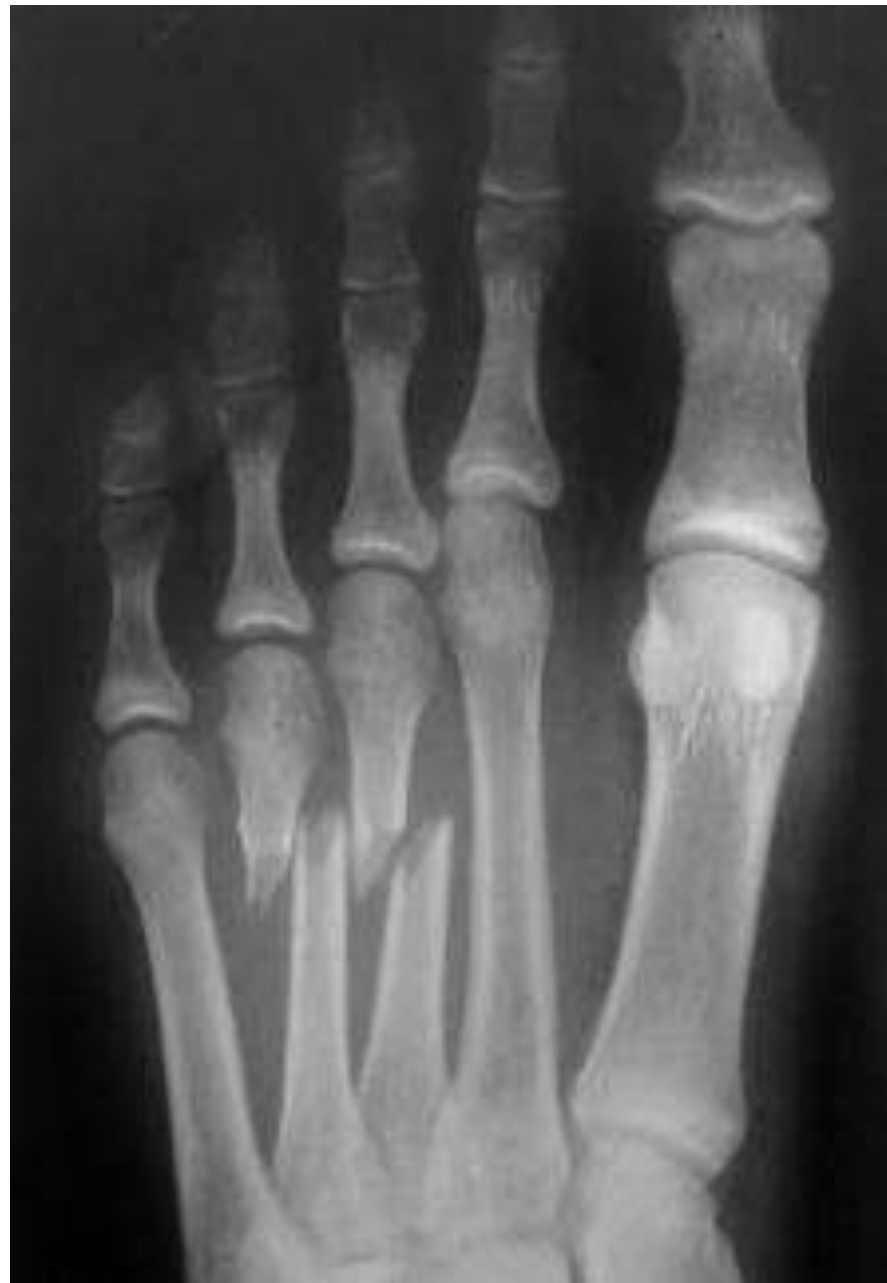AFTER



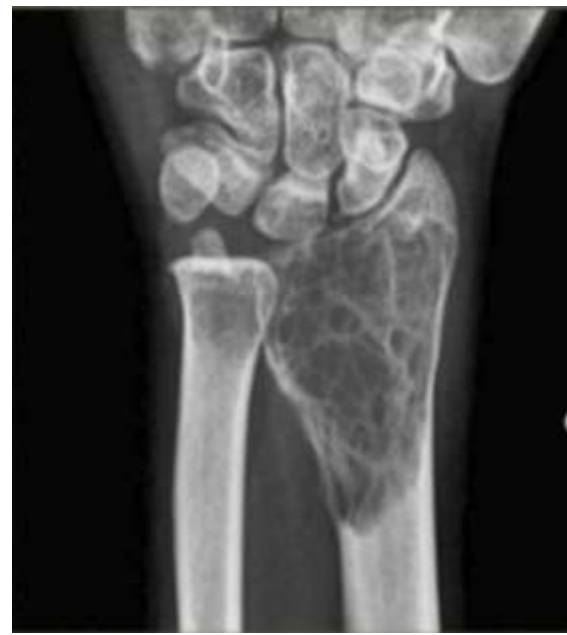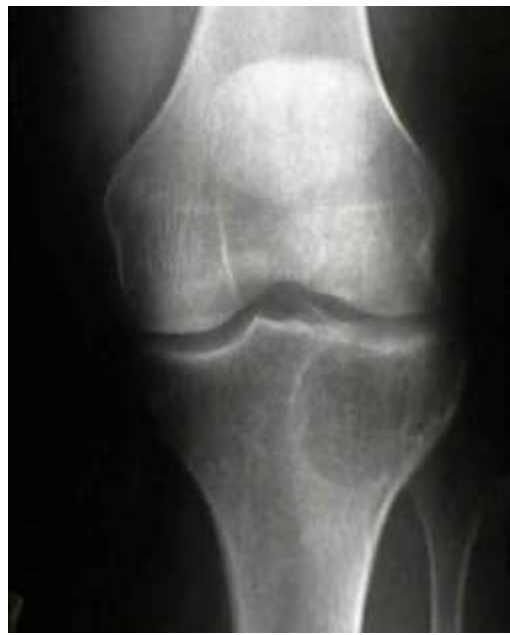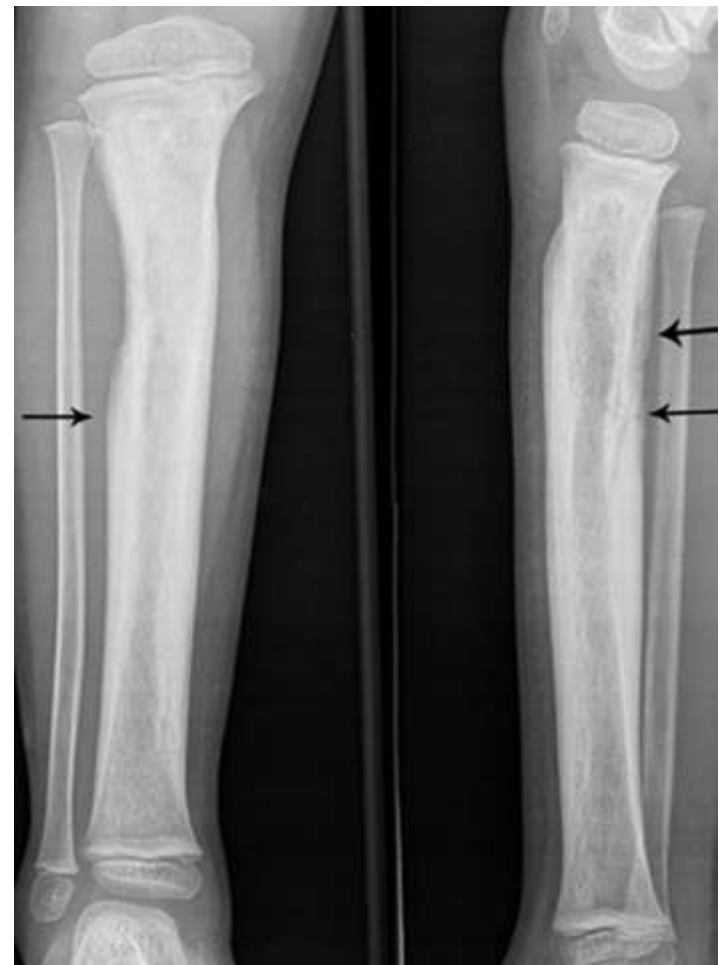
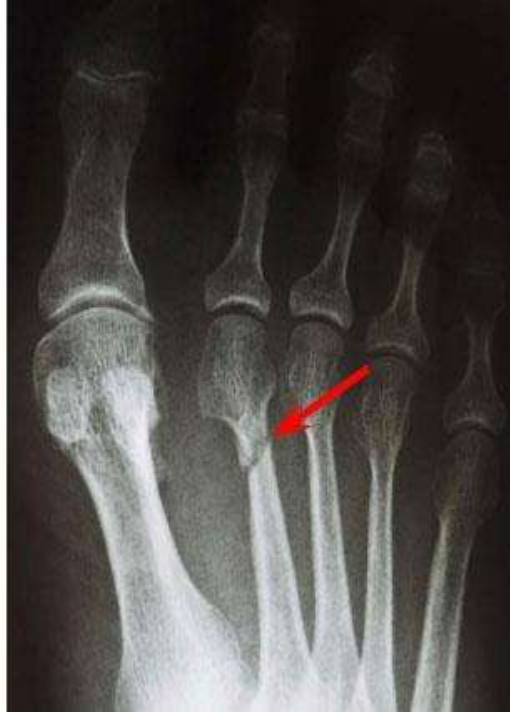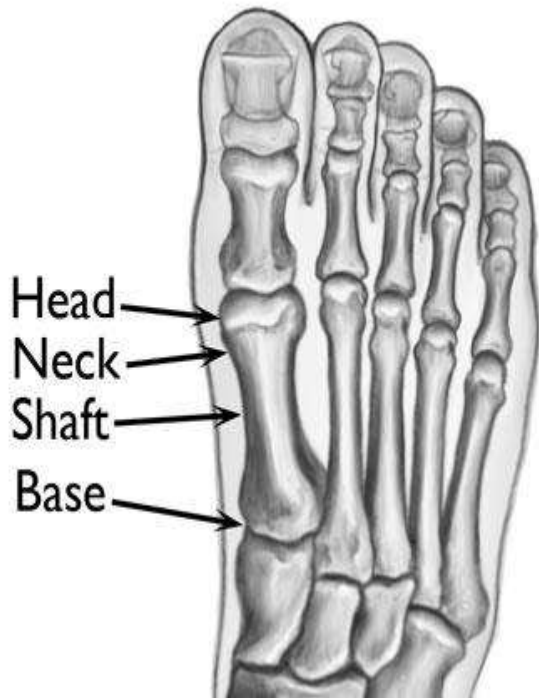


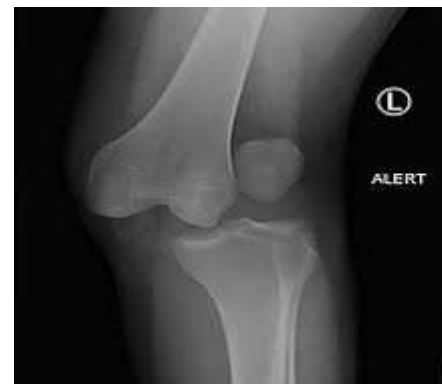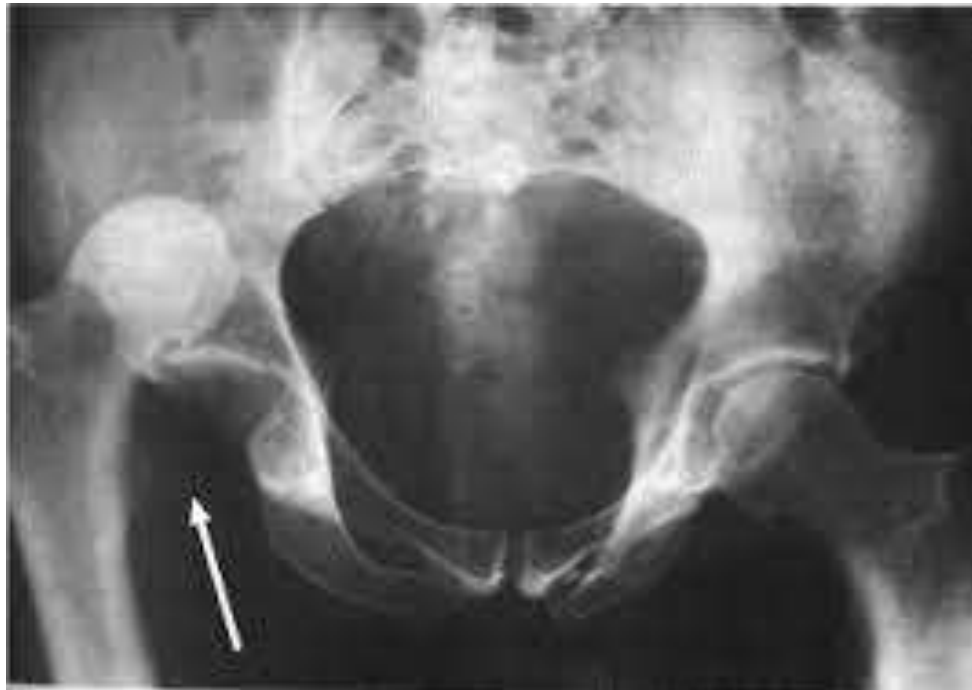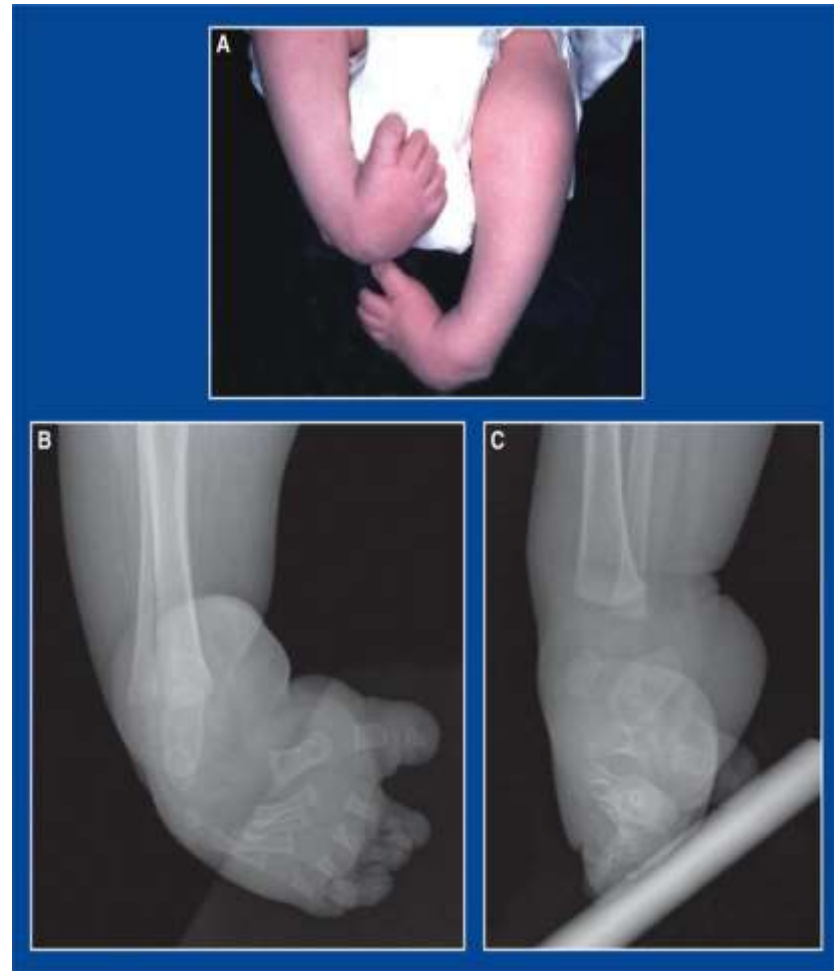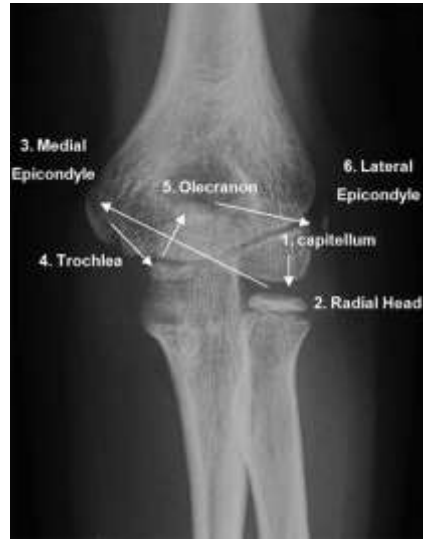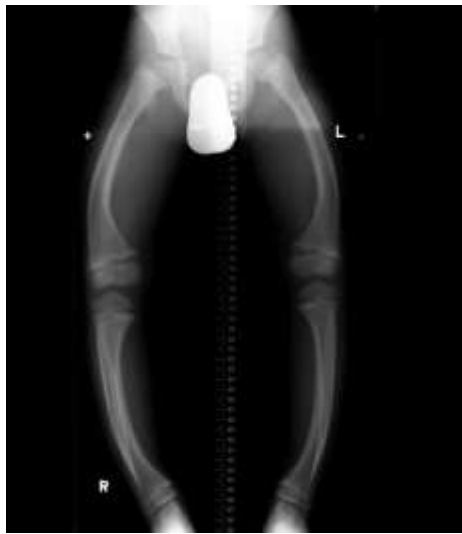Activity 2





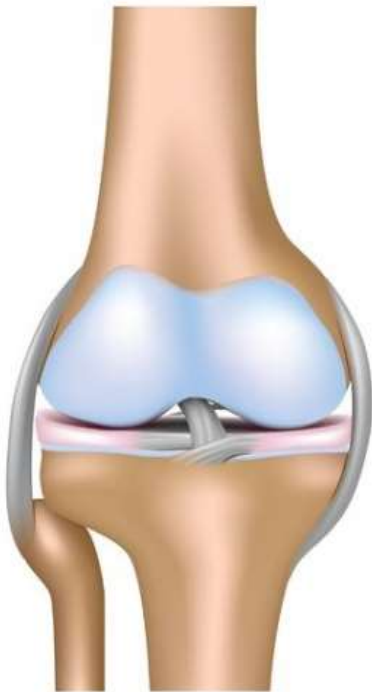




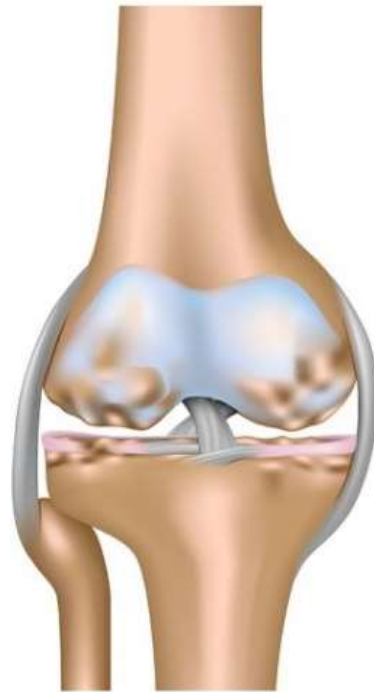

FITROAD

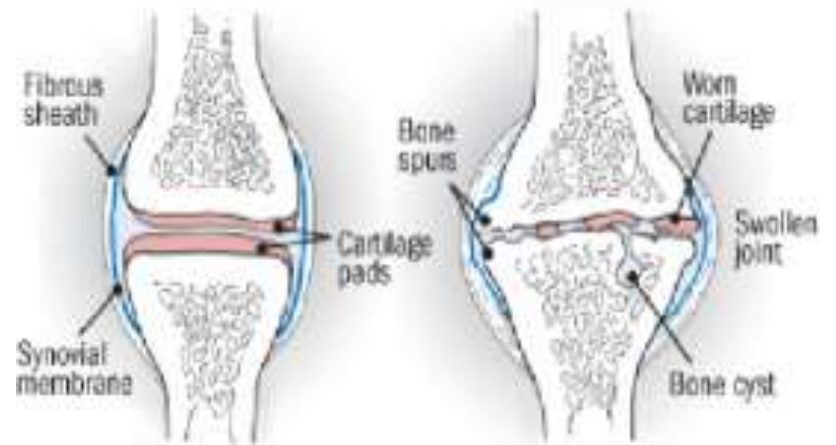
- Fractures
- Infections
- Tumors
- Rickets
- Ossifications
- Abnormalities
- Dislocations

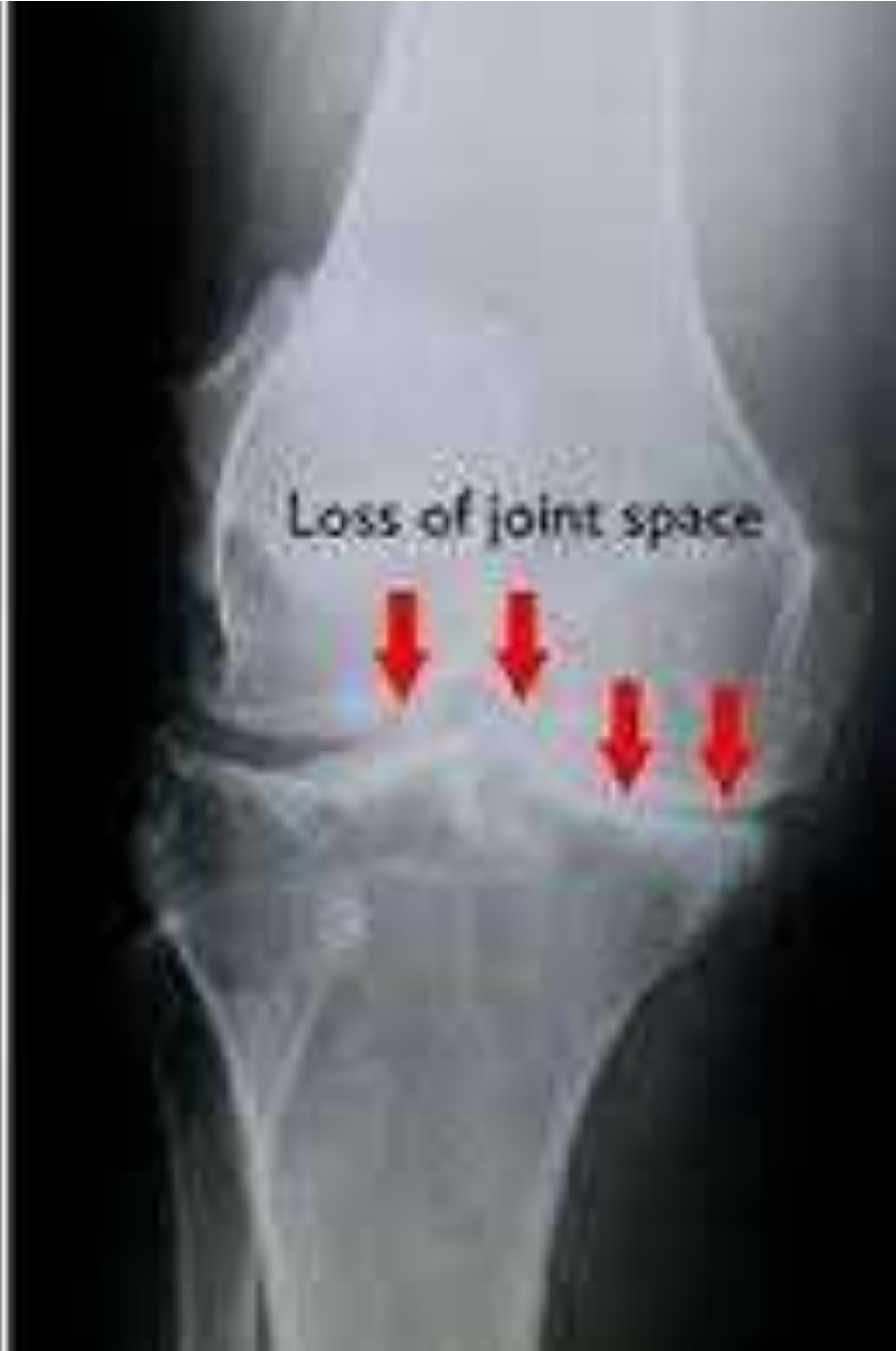
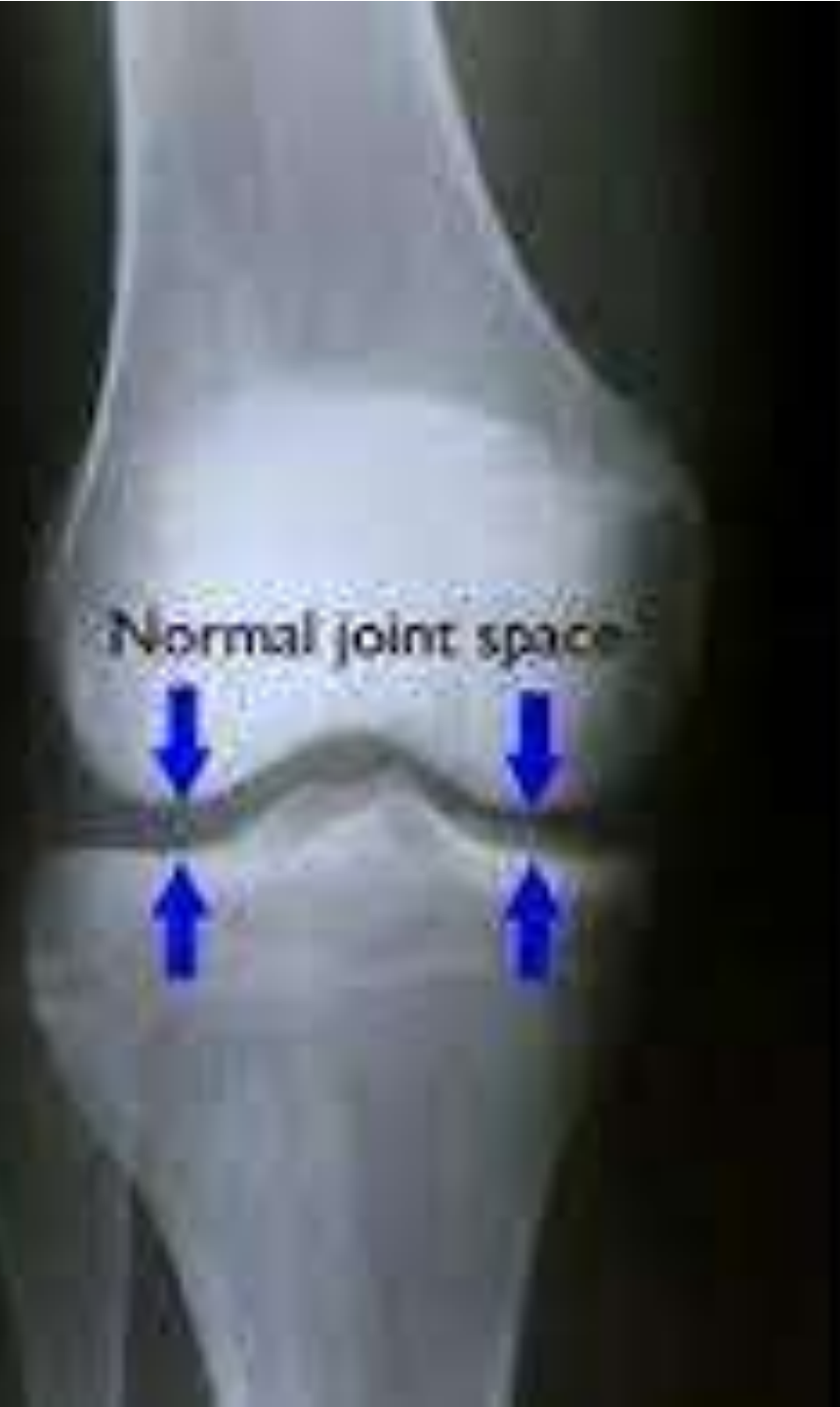
Healthy knee joint

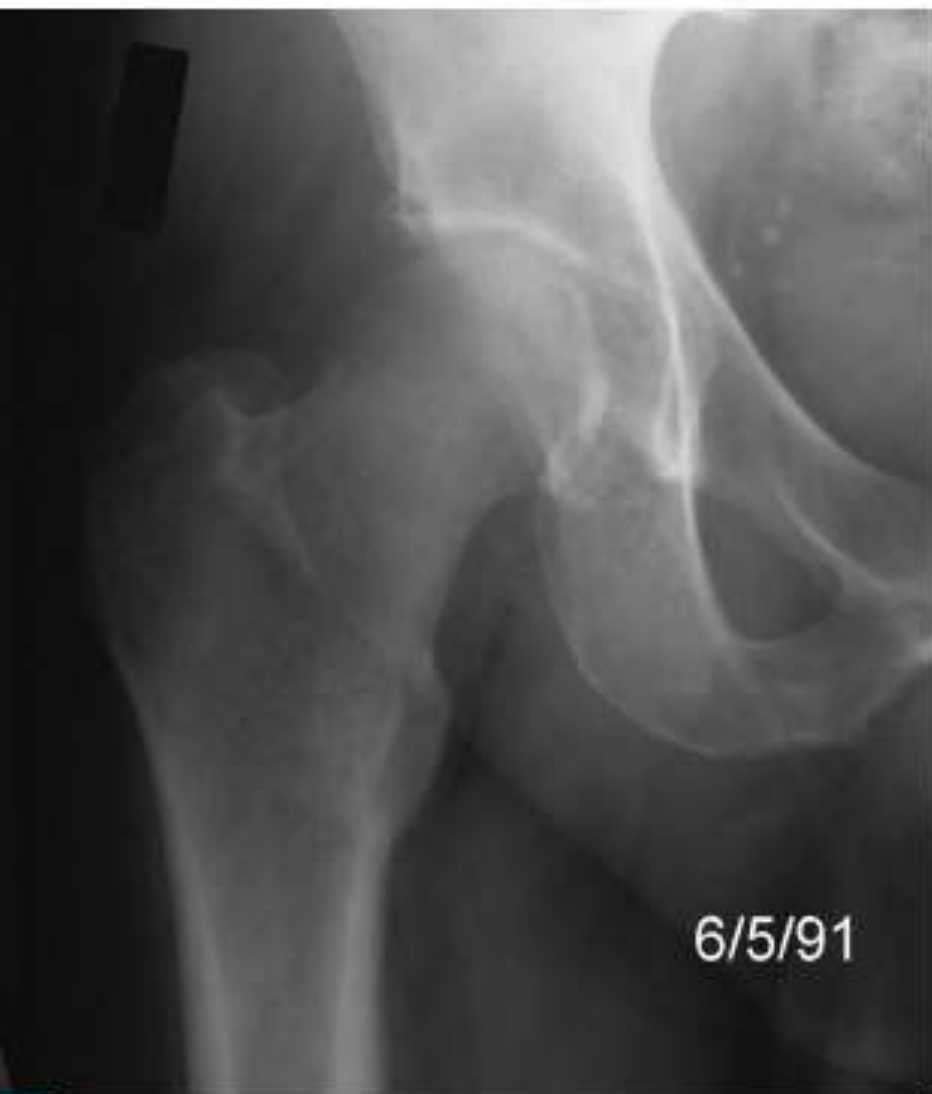

Osteoarthritis

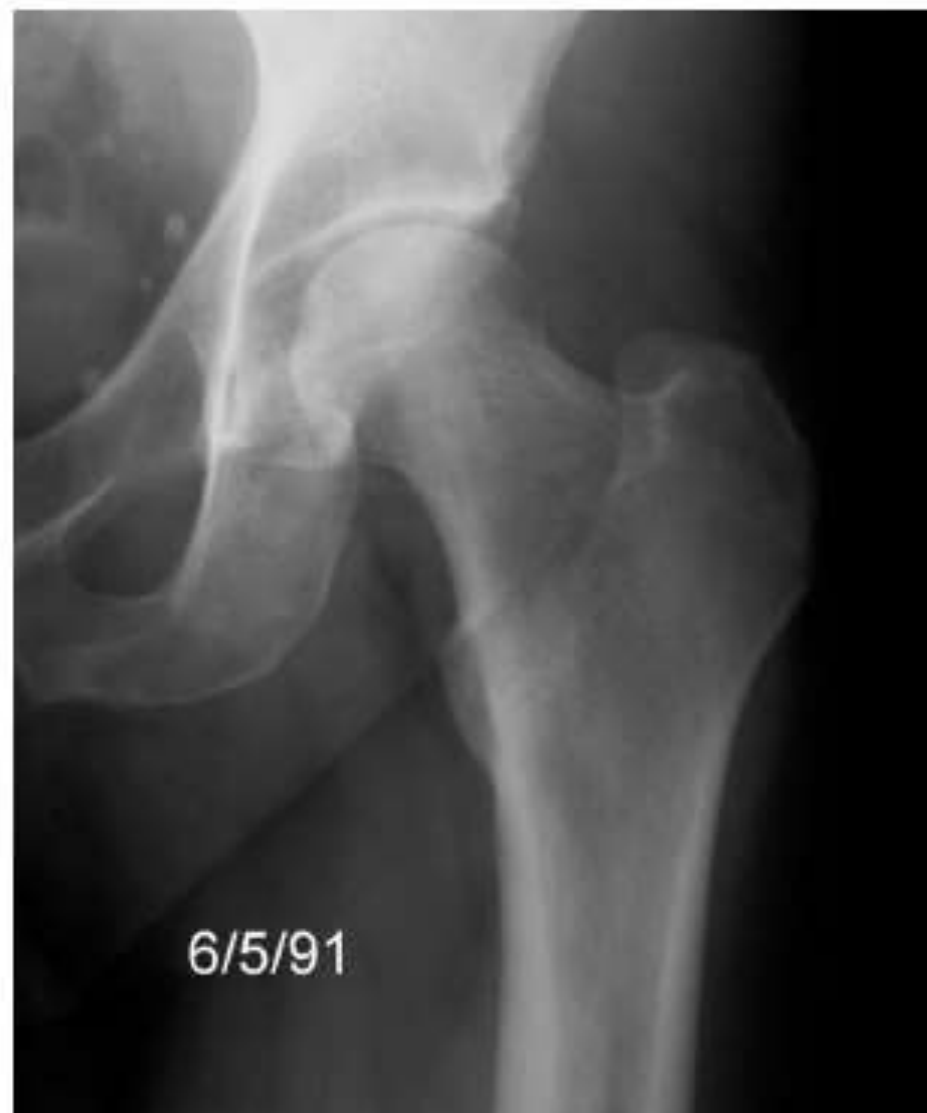



Local
osteoporosis



Normal



Any
Questions?

Thank
you