

# HEART BLOCK

*By*

*Dr Gul Muhammad*



# Learning Objectives

- What is heart block?
- What are the types of heart block?
- What are the causes of heart block?
- What will be the treatment of heart block
- How do you know about the artificial or external pace maker?



# HEART BLOCK OR CARDIAC BLOCL

**Definition:** partial or complete obstruction in cardiac impulses within conducting system is called heart block

**Types;**

1. Sinu-atrial

Atrio-ventricular

Bundle branch block

1<sup>st</sup> degree

2<sup>nd</sup> degree

Complete heart block

Mobitz' type-1

Mobitz' type-2



# Sinoatrial block

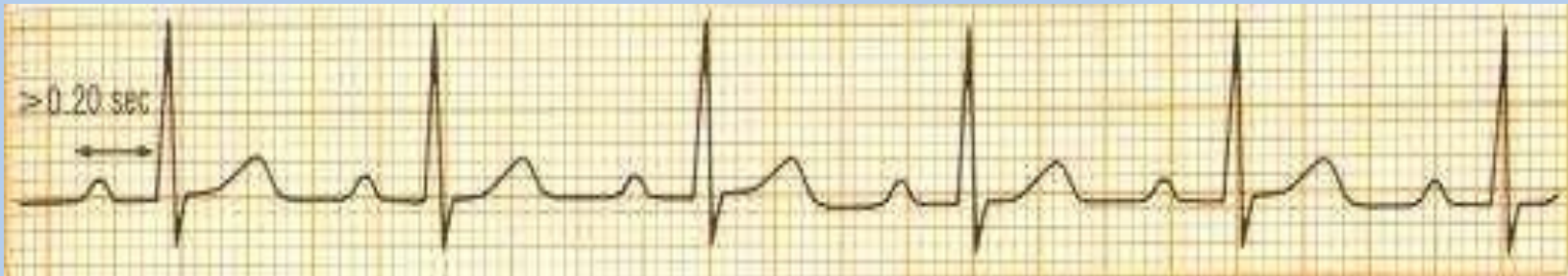- ❖ SA block is a disorder of impulse conduction. Unlike sinus arrest, the SA node continues to fire, but the **impulse is not conducted** to the atrial myocardium.
- ❖ It is therefore also referred to as **SA exit block**. SA block can be differentiated from sinus arrest based on pause duration.



# Heart Block

## First Degree Heart Block

(Just the prolongation of PR interval)



Heart Rate	Rhythm	P Wave	PR Interval (sec.)	QRS (Sec.)
Norm.	Regular	Before each QRS, Identical	> .20	<.12



# Heart Block

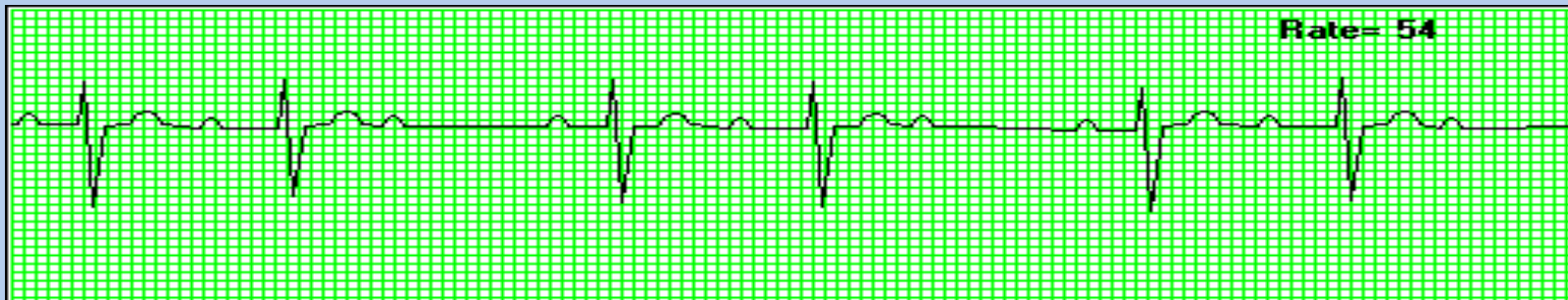
## – First Degree Heart Block

- **P-wave for every QRS**
- **Rhythm is regular**
- **Rate may vary**
- *Av Node hold each impulse longer than normal before conducting normally through the ventricles*
- *Prolonged PR interval*
  - *– Looks just like normal sinus rhythm*



# Heart Block

## Second Degree Heart Block Mobitz Type I (Wenckebach)



Heart Rate	Rhythm	P Wave	PR Interval (sec.)	QRS (Sec.)
Norm. can be slow	Irregular	Present but some not followed by QRS	Progressively longer	<.12



# Heart Block

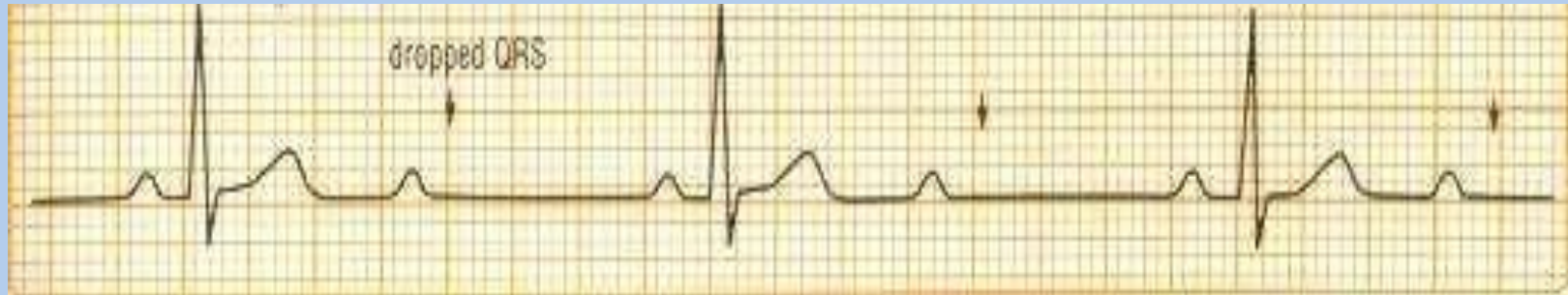- **Second Degree Heart Block**
- **Mobitz Type I (Wenckebach)**
  - *Some p-waves are not followed by QRS complexes*
  - **Rhythm is irregular**
    - **R-R interval is in a pattern of grouped beating**
  - **Rate 60-100 bpm**
  - *Intermittent Block at the AV Node*
    - *Progressively prolonged p-r interval until a QRS is blocked completely*





# Heart Block

## Second Degree Heart Block Mobitz Type II (Classical)



Heart Rate	Rhythm	P Wave	PR Interval (sec.)	QRS (Sec.)
Usually slow	Regular or irregular	2 3 or 4 before each QRS, Identical	.12 - .20	<.12 depends



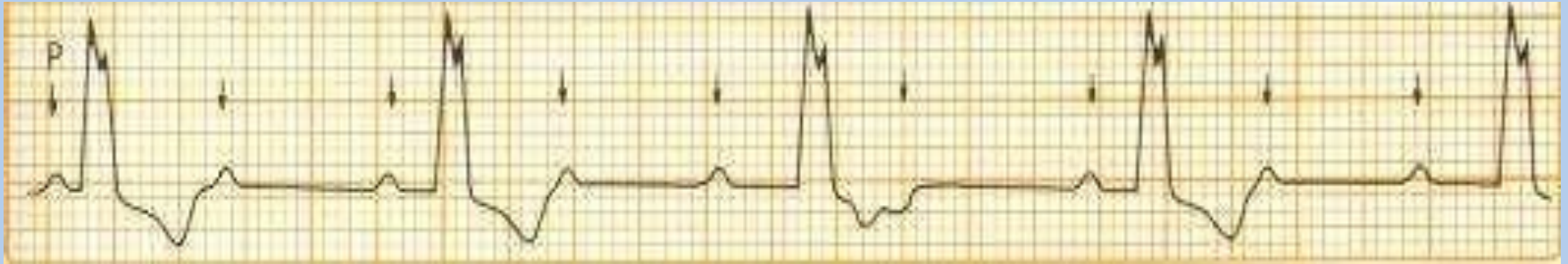# Heart Block

- **Second Degree Heart Block**
- **Mobitz Type II (Classical)**
  - *More p-waves than QRS complexes*
  - *Rhythm is irregular*
  - *Atrial rate 60-100 bpm; Ventricular rate 30-100 bpm (depending on the ratio on conduction)*
  - *Intermittent block at the AV node*
    - *AV node normally conducts some beats while blocking others*



# Heart Block

## Third Degree Heart Block (Complete)



Heart Rate	Rhythm	P Wave	PR Interval (sec.)	QRS (Sec.)
30 – 60	Regular	Present but no correlation to QRS may be hidden	Varies	<.12 depends

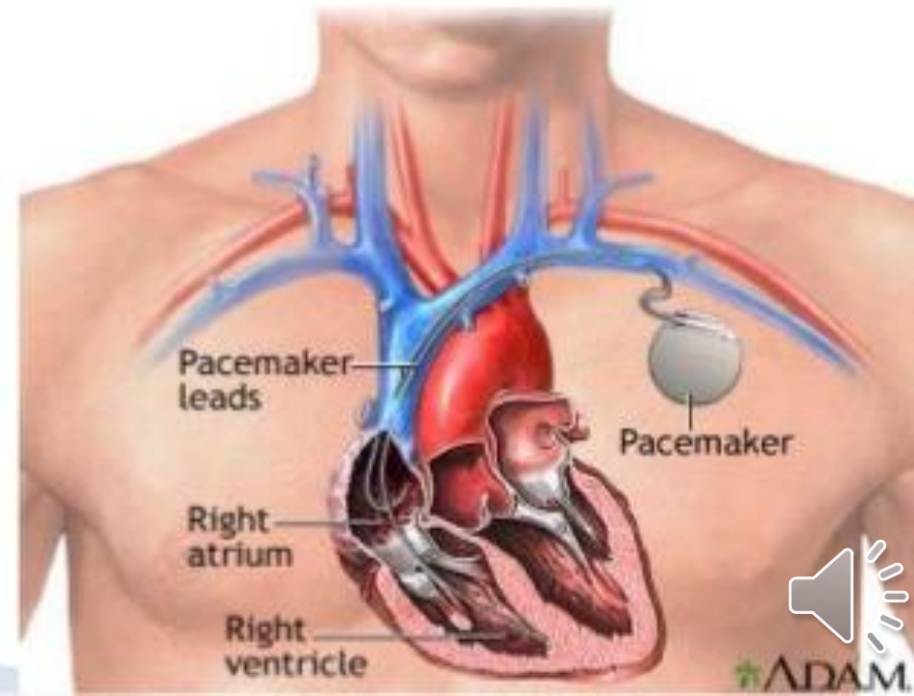
# Heart Block

- **Third Degree Heart Block (Complete)**
  - *There are more p-waves than QRS complexes*
  - Both P-P and R-R intervals are regular
  - Atrial rate within normal range; Ventricular rate between 20-60 bpm
  - *The block at the AV node is complete*
    - *There is no relationship between the p-waves and QRS complexes*



# PACEMAKER

- ▶ Pacemakers is an electronic device used to pace the heart when the normal conduction pathway is damaged or diseased.



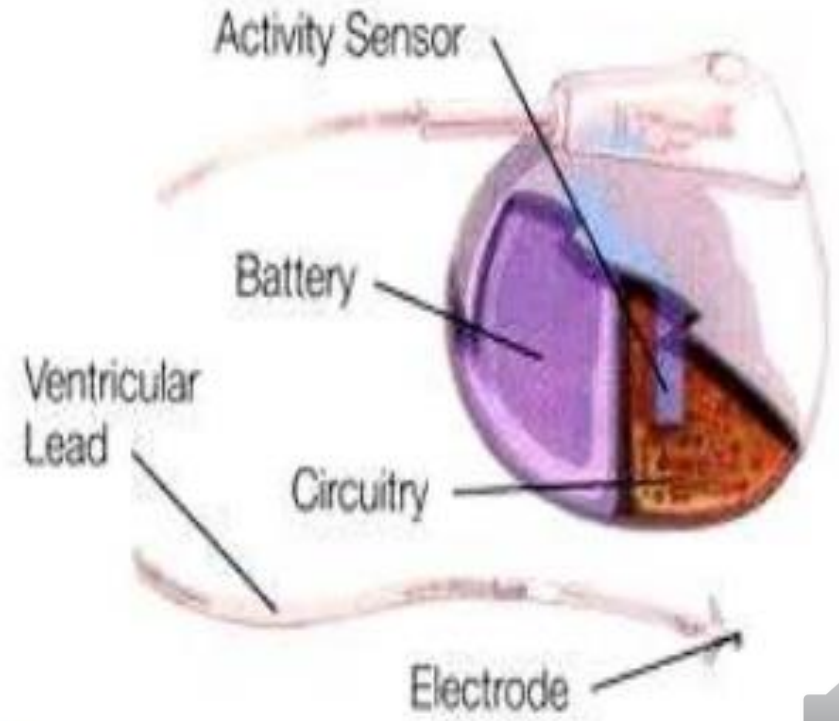
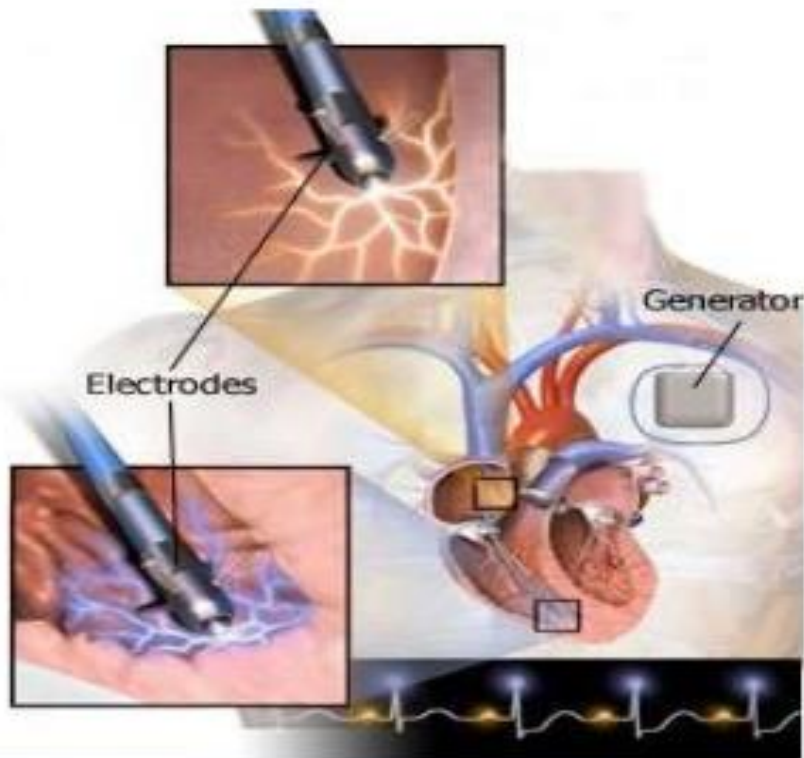
# Temporary pacemaker

- ▶ It is one that has the power source outside the body.



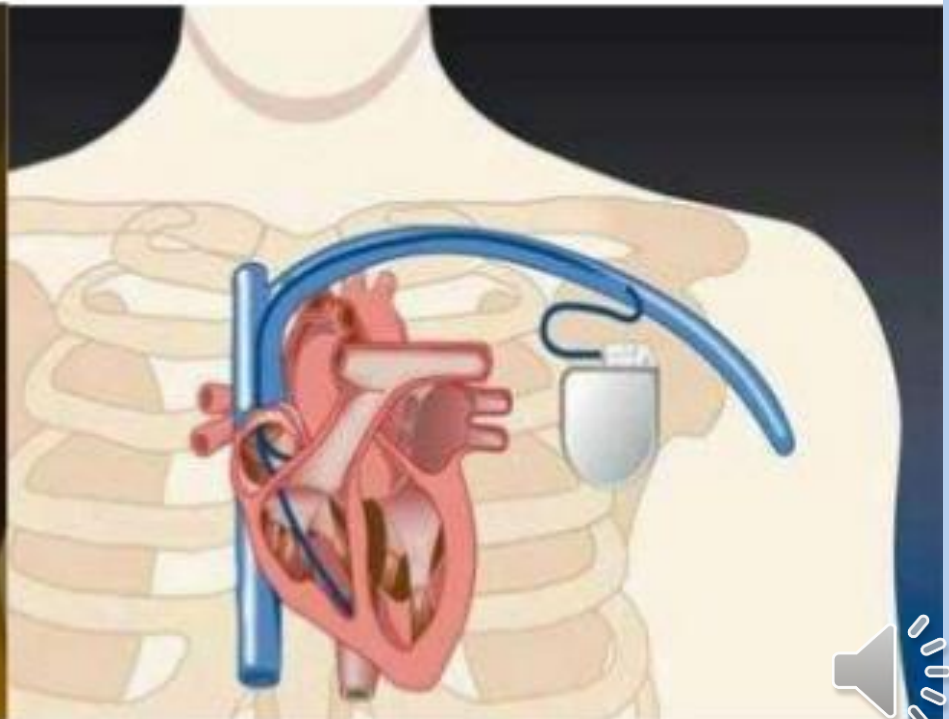
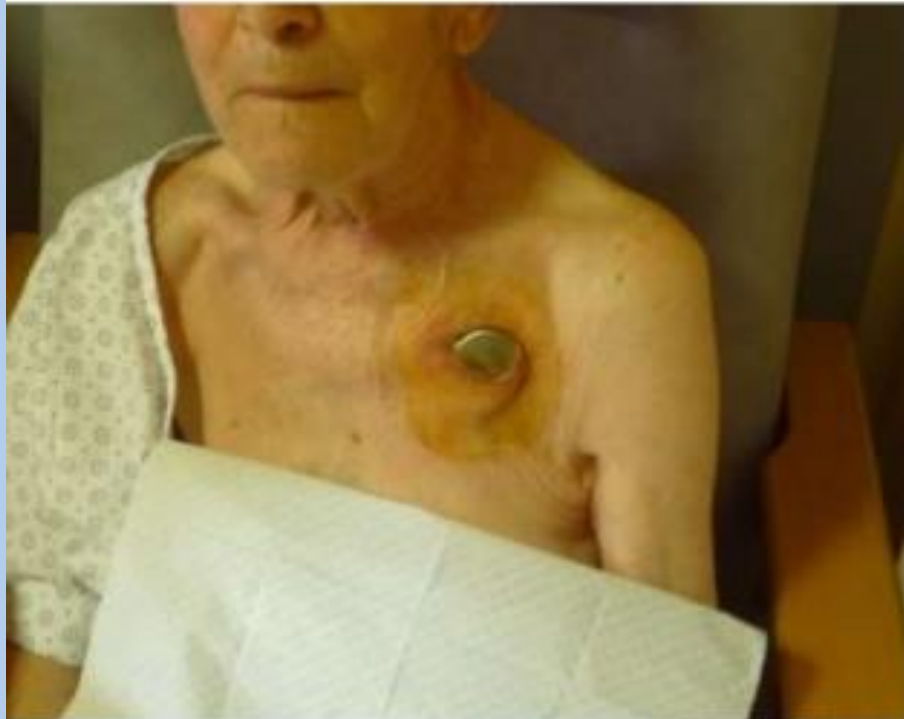# COMPONENTS OF PACEMAKER

- ▶ Pulse generator
- ▶ Pacemaker electrodes



# Permanent pacemaker

- ▶ Implanted totally in the body.
- ▶ Power source is implanted subcutaneously usually over the pectoral muscle on the patient non dominant side.

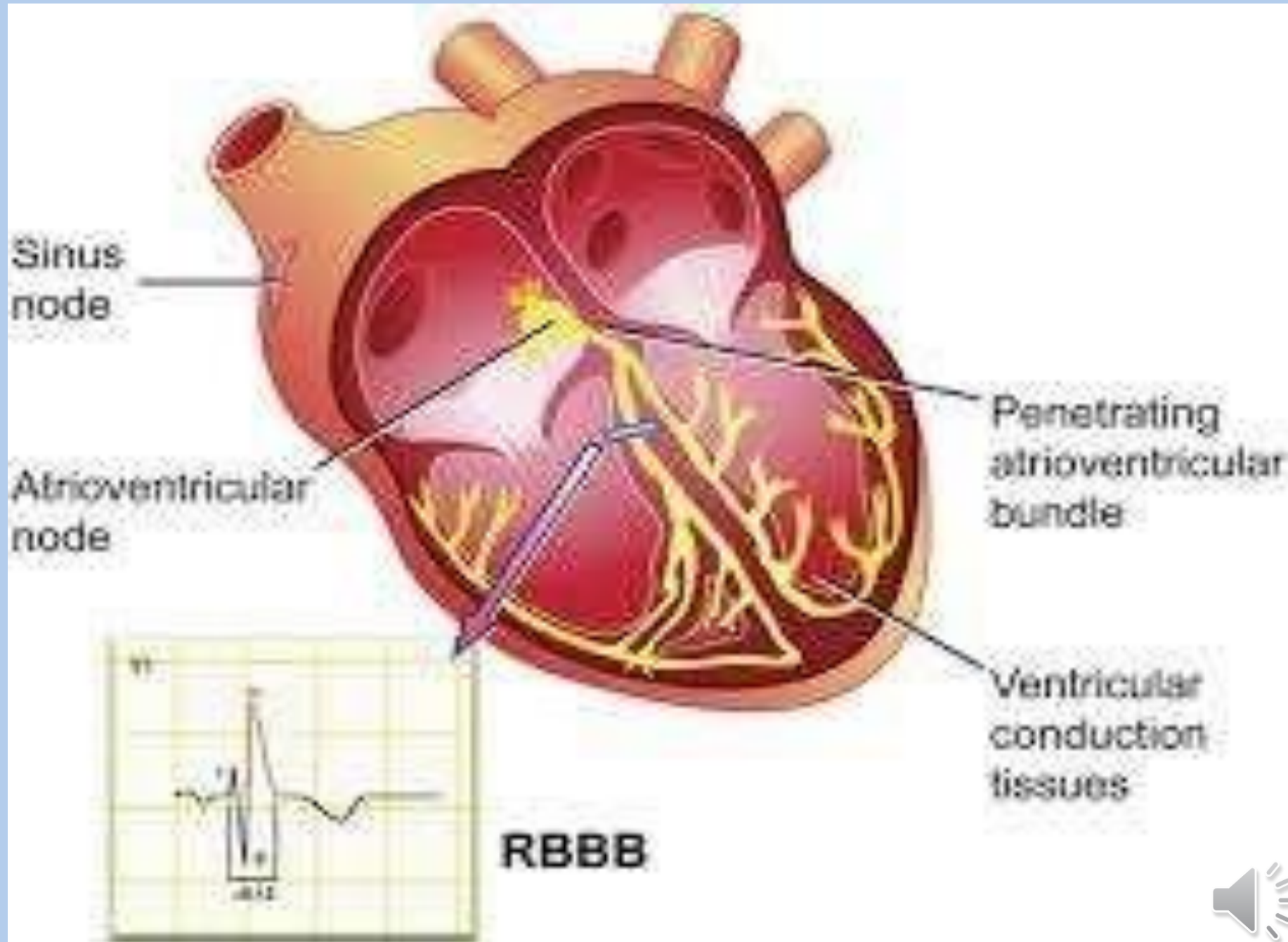




# Bundle branch block

- **BBB refers to failure or delay of impulse conduction through one or more branches of the His bundle**
- **Block in a bundle branch results in delay in depolarization of the region of ventricular myocardium supplied by it,**
- **resulting in a QRS complex of abnormal (wide and bizarre) morphology.**
- **Causes: Structural heart disease, Hyperkalaemia, Hypocalcaemia.**



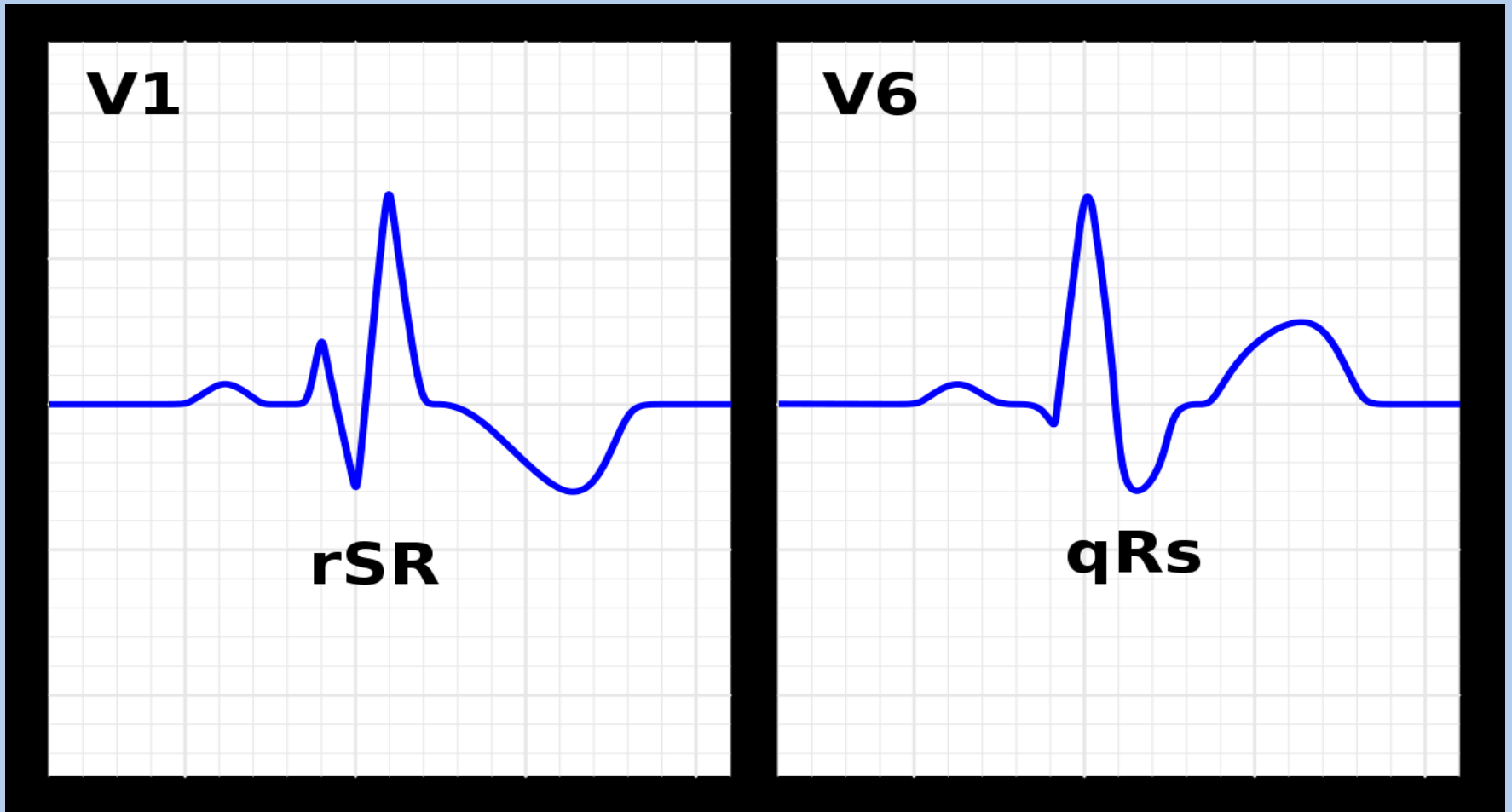


# Right bundle branch

- **The right bundle branch connects the AV junction to the right ventricle (RV). It is a discrete structure that runs most of its course just beneath the endocardial surface. It is therefore susceptible to damage from disease affecting the RV, such as pulmonic stenosis and pulmonary hypertension causing right bundle branch block (RBBB).**



# RBBB



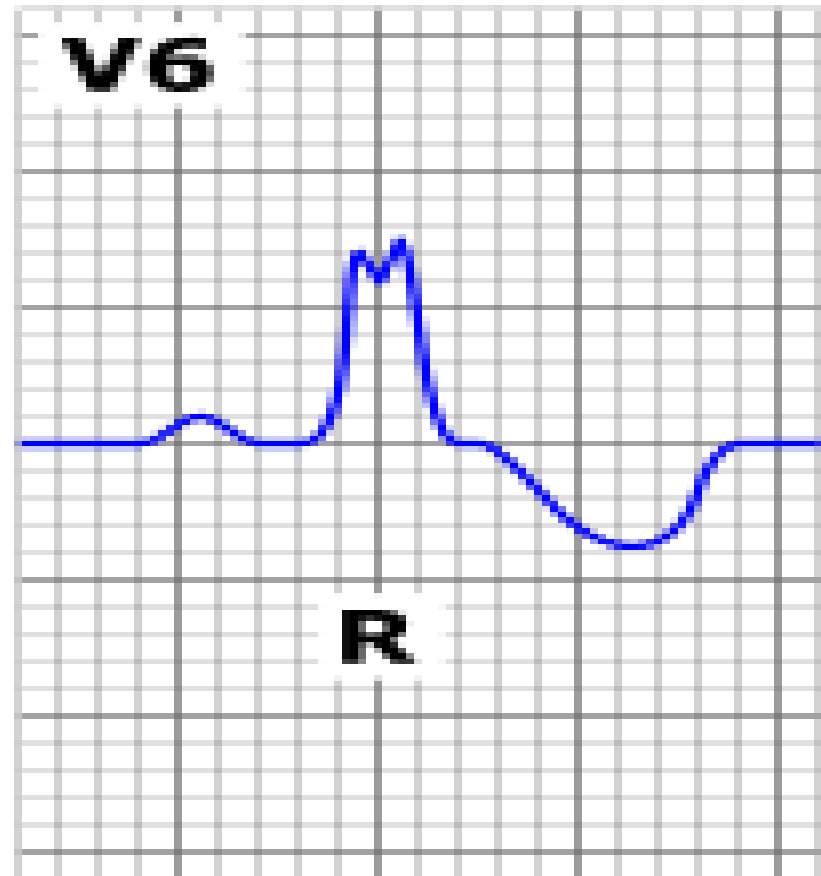
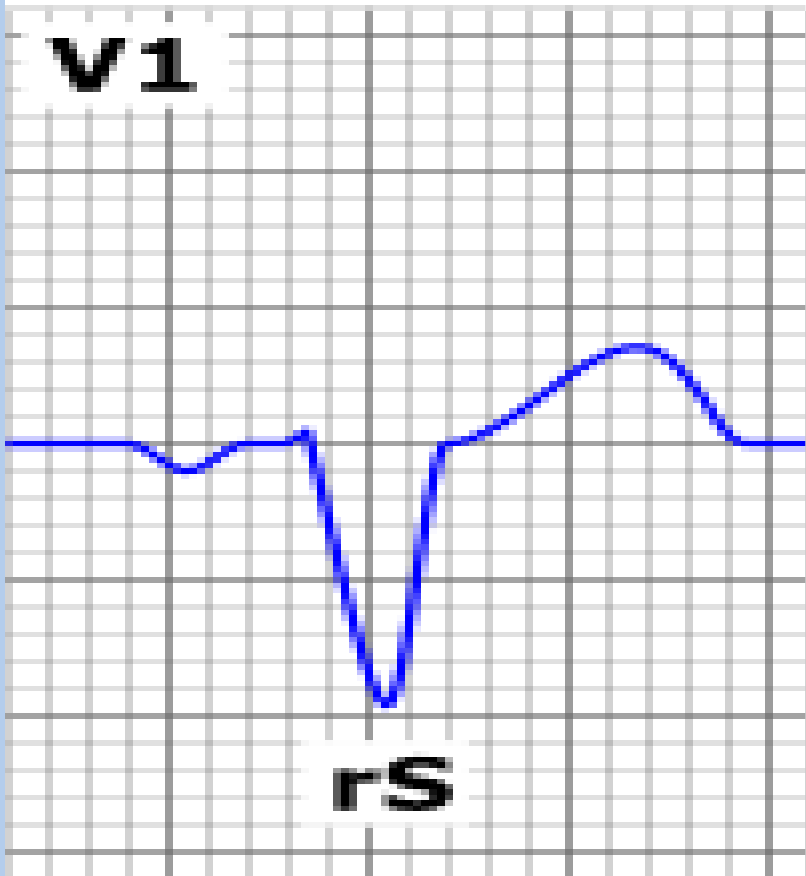
## 2. Left bundle branch block

- **The left bundle branch is larger than the right, with ~~div~~ into anterior and posterior fascicles. Left bundle branch block (LBBB) can occur at the proximal main branch or at both fascicles (bifascicular block).**
- **Because of the large size and extensive nature of the left bundle branch, lesions that result in block are also usually extensive, such as myocardial disease.**



# LBBB

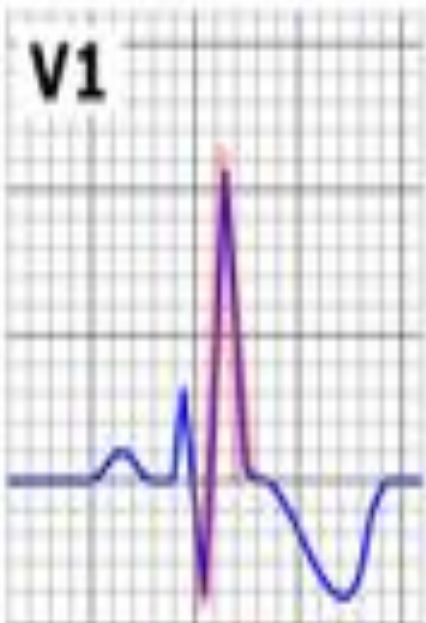
## Left bundle branch block characteristics



# Bundle Branch Block

## RBBB

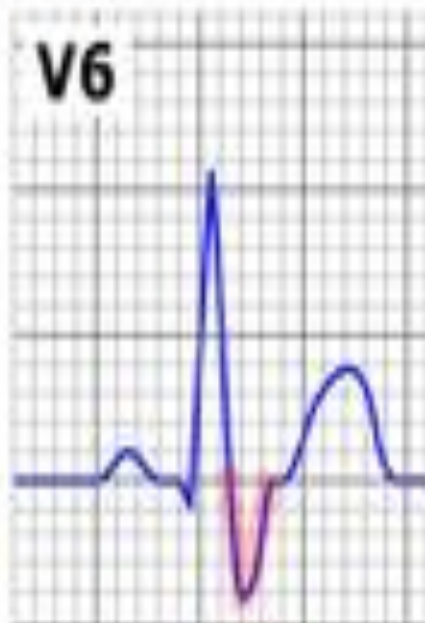
V1



rSR'

Anterior

V6

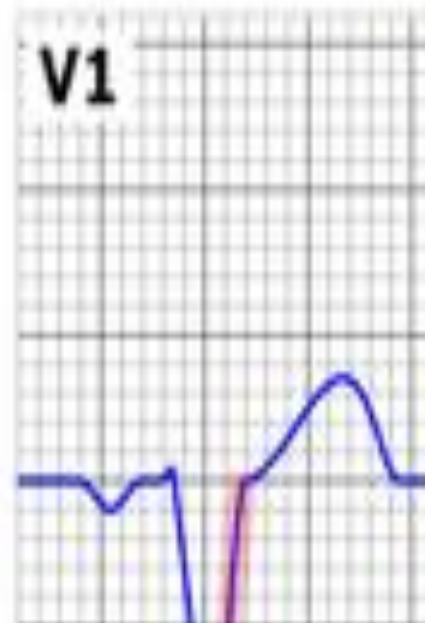

qRs

Lateral

## LBBB

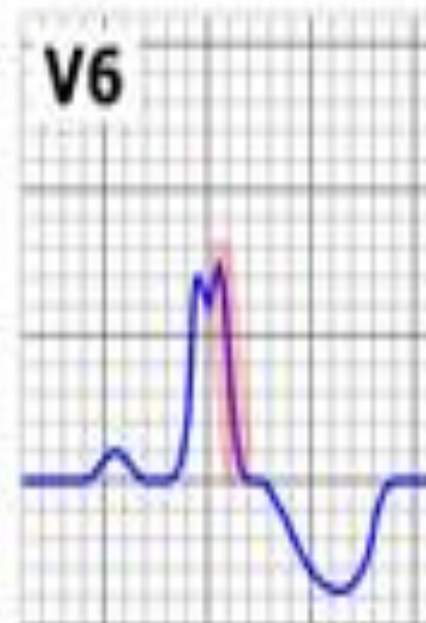V1



rS

Anterior

V6



R

Lateral



**THANK YOU**

