

Clinical Anatomy FLASH CARDS

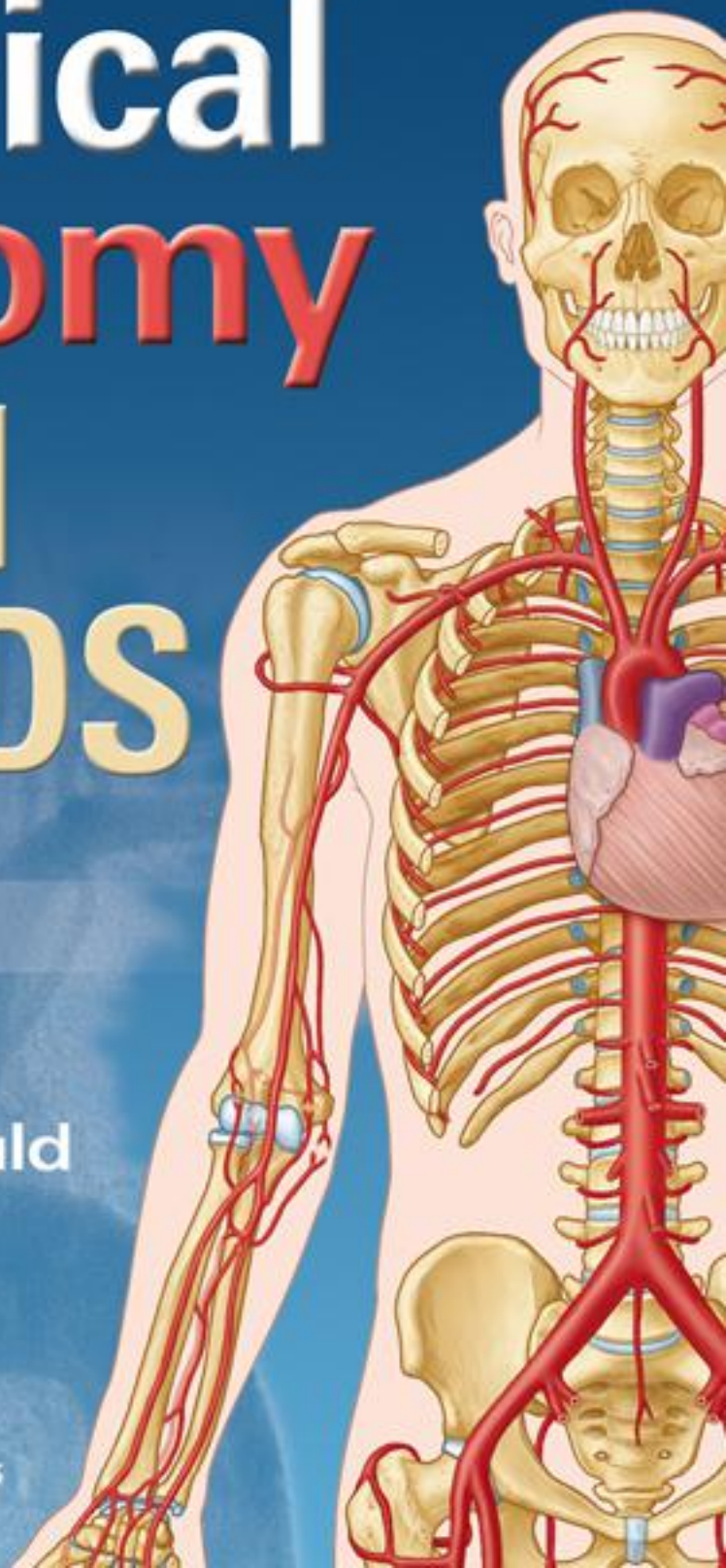
Second Edition

Douglas J. Gould



Wolters Kluwer
Health

Lippincott
Williams & Wilkins



Moore's Clinical Anatomy Flash Cards

Second Edition

Douglas J. Gould, PhD

Professor, Department of
Biomedical Sciences
Oakland University William Beaumont
School of Medicine
Rochester, Michigan



Wolters Kluwer | Lippincott Williams & Wilkins
Health

Philadelphia • Baltimore • New York • London
Buenos Aires • Hong Kong • Sydney • Tokyo

Acquisitions Editor: Crystal Taylor
Product Director: Julie Montalbano
Product Manager: Lauren Pecarich
Marketing Manager: Joy Fisher Williams
Production Project Manager: David Orzechowski
Designer: Teresa Mallon
Compositor: Absolute Service, Inc.
Printer: C & C Offset Printing Co., Ltd.

Copyright © 2014 Lippincott Williams & Wilkins, a Wolters Kluwer business

351 West Camden Street
Baltimore, MD 21201

Two Commerce Square
2001 Market Street
Philadelphia, PA 19103

All rights reserved. This book is protected by copyright. No part of this book may be reproduced in any form or by any means, including photocopying, or utilized by any information storage and retrieval system without written permission from the copyright owner.

The publisher is not responsible (as a matter of product liability, negligence, or otherwise) for any injury resulting from any material contained herein. This publication contains information relating to general principles of medical care that should not be construed as specific instructions for individual patients. Manufacturers' product information and package inserts should be reviewed for current information, including contraindications, dosages, and precautions.

Printed in China

The publishers have made every effort to trace the copyright holders for borrowed material. If they have inadvertently overlooked any, they will be pleased to make the necessary arrangements at the first opportunity.

To purchase additional copies of this book, call our customer service department at **(800) 638-3030** or fax orders to **(301) 223-2320**. International customers should call **(301) 223-2300**.

Visit Lippincott Williams & Wilkins on the Internet: <http://www.LWW.com>. Lippincott Williams & Wilkins customer service representatives are available from 8:30 am to 6:00 pm, EST.

07 08 09 10 11

1 2 3 4 5 6 7 8 9 10

Contents

Preface

Introduction

1 Thorax

2 Abdomen

3 Pelvis and Perineum

4 Back

5 Lower Limb

6 Upper Limb

7 Head

8 Neck

9 Cranial Nerves

Preface

C*linical Anatomy Flash Cards* were created to serve as the premier ancillary learning resource for the study of clinically relevant anatomy. The cards are designed for use by all undergraduate, graduate, and professional level students of anatomy; surgical residents; and practicing clinicians in need of a comprehensive review. The flash cards are organized around the popular “blue boxes” from *Clinically Oriented Anatomy*, 7th Edition, by Moore and Dalley.

The front of each card features an image from *Clinically Oriented Anatomy*, with 5 to 10 structures indicated for identification; the answers are provided on the back of the card. Approximately 150 muscles are labeled with red numbers on the front of the cards with corresponding attachment, innervation, and action information detailed on the back. Clinically relevant blue boxes, modified from *Clinically Oriented Anatomy*, appear on the back of most cards and serve to reinforce the anatomy pictured on the front. Approximately 90% of the blue box topics from *Clinically Oriented Anatomy* are covered in this set.

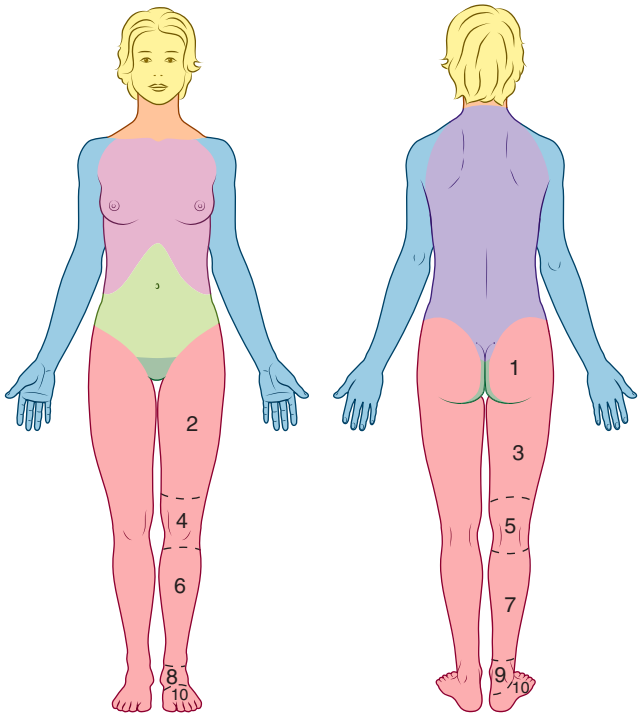
I am confident that these cards will greatly benefit all students learning clinically relevant anatomy. The cards will further reinforce a love and fascination with the human form that all health professions students and professionals undoubtedly already possess.

Douglas J. Gould, PhD

Introduction

- I.1** Major Regions of the Body and Parts of the Lower Limb
- I.2** Structure of the Skin
- I.3** Parts of a Long Bone
- I.4** Newborn Skull
- I.5** Muscular System
- I.6** Cardiovascular System
- I.7** Lymphatic System
- I.8** Nervous System

Major Regions of the Body and Parts of the Lower Limb



Major Regions of the Body and Parts of the Lower Limb

Major parts of the body

Head

Back

Lower limb

Neck

Abdomen

Upper limb

Thorax

Pelvis/perineum

Regions of lower limb

1 = Gluteal region

6 = Anterior leg region

2 = Anterior thigh region

7 = Posterior leg region

3 = Posterior thigh region

8 = Anterior talocrural (ankle) region

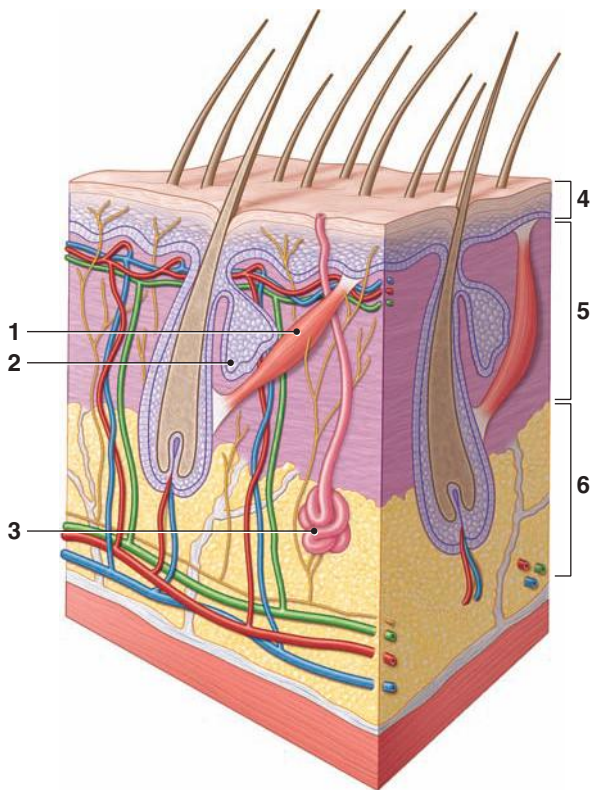
4 = Anterior knee region

9 = Posterior talocrural region

5 = Posterior knee region

10 = Foot region

Structure of the Skin

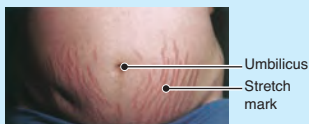


Structure of the Skin

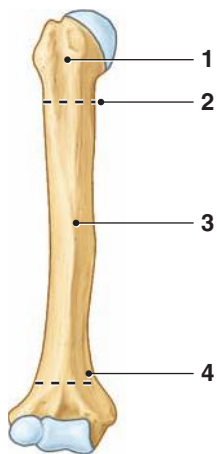
1. arrector muscle of hair
2. sebaceous gland
3. sweat gland
4. epidermis
5. dermis
6. superficial fascia

The capillary beds in the dermis affect the skin color and are an excellent diagnostic tool—cyanosis is a bluing of the skin resulting from a lack of oxygen in the blood. Erythema is a reddening of the skin resulting from engorged capillary beds. Jaundice, a yellowing of the skin, may indicate liver failure.

Tension lines in the skin are created by the orientation of the collagen fibers in the dermis. The strong yet flexible dermis may be stretched too much, resulting in stretch marks.



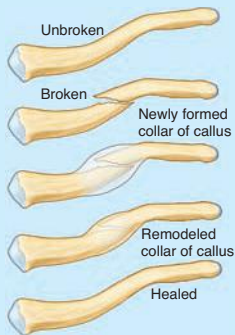
Parts of a Long Bone



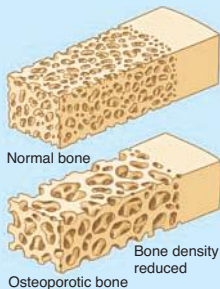
Parts of a Long Bone

1. epiphysis
2. epiphyseal plate
3. diaphysis
4. metaphysis

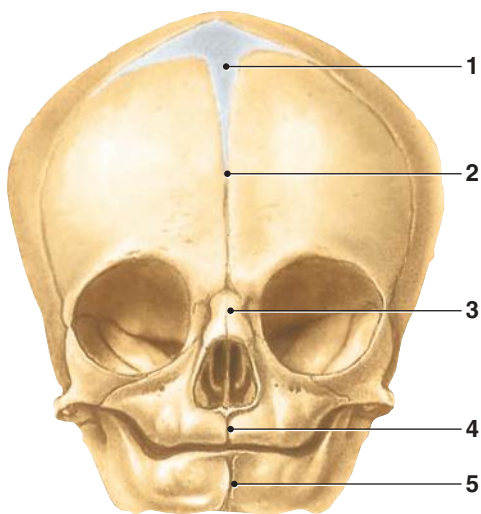
Bones are dynamic living organs capable of great change in response to trauma, age, and use. After a bone fracture, the broken ends must be reduced (brought together) in order that a fibroblast-produced collagen collar is produced, which is later replaced by bone.



Osteoporosis occurs as part of the aging process, whereby bones lose their organic and inorganic components, causing atrophy of the skeleton.



Newborn Skull

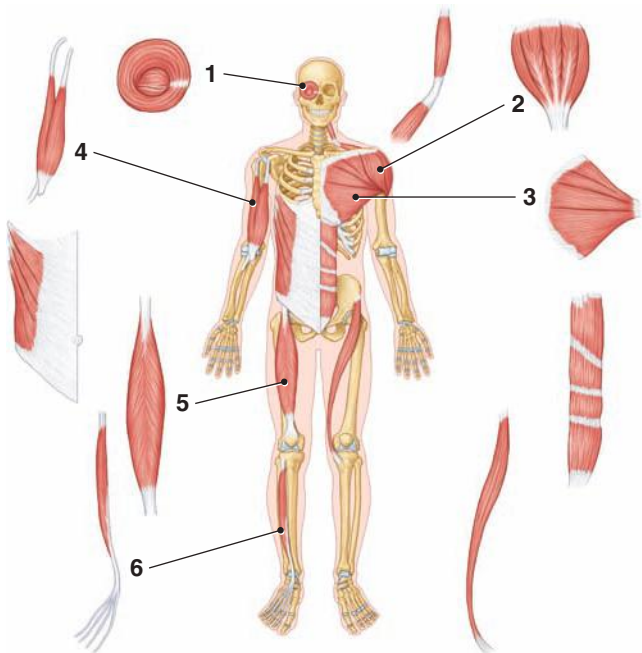


Newborn Skull

- 1.** anterior fontanelle
- 2.** frontal suture
- 3.** internasal suture
- 4.** intermaxillary suture
- 5.** mandibular symphysis

The sutural joints of the newborn skull are not yet joined; they are filled with areas of fibrous tissue called fontanelles. The fontanelles, of which the anterior fontanelle (soft spot) is the most prominent, may serve as a diagnostic tool. Bulging may indicate increased intracranial pressure, whereas depression may indicate dehydration.

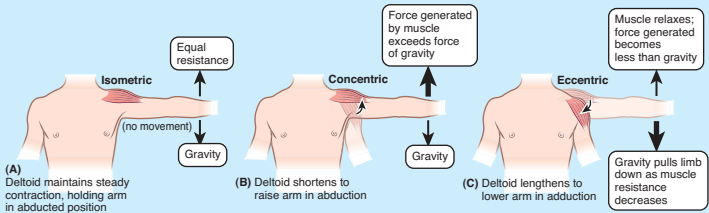
Muscular System



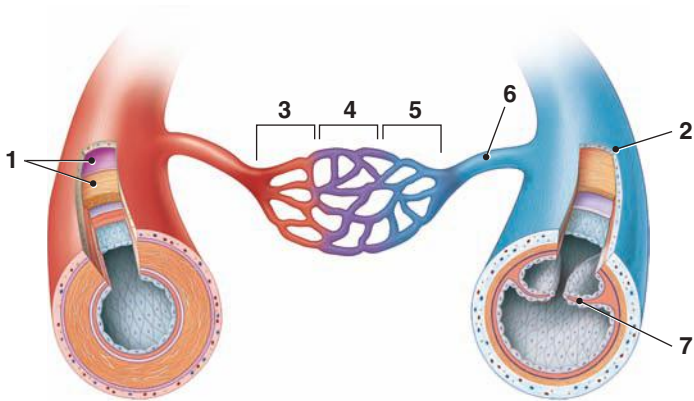
Muscular System

1. circular (orbicularis oculi)
2. multipennate (deltoid)
3. convergent (pectoralis major)
4. fusiform (biceps brachii)
5. bipennate (rectus femoris)
6. unipennate (extensor digitorum longus)

Muscles may be pulled or strained by excessive eccentric contraction (controlled lengthening), producing soreness.



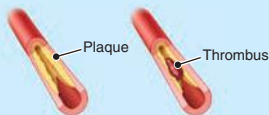
Cardiovascular System



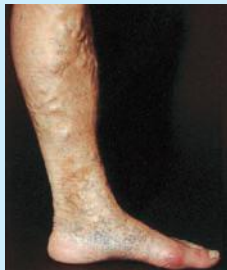Cardiovascular System

1. tunica media
2. tunica adventitia
3. arteriole
4. capillary bed
5. venule
6. vein
7. cusps of valve

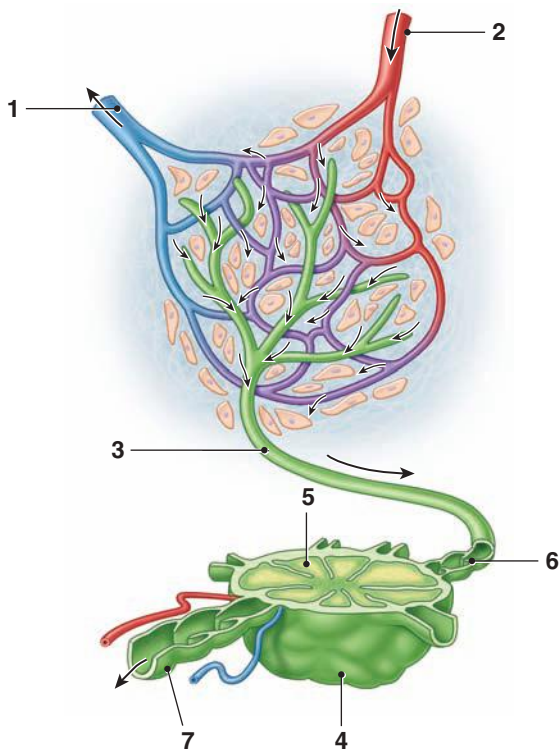
Arteriosclerosis (hardening of the arteries) is a thickening and loss of elasticity of the arterial wall. Atherosclerosis is associated with the buildup of fat in the arterial wall—such plaque formation may lead to turbulent blood flow and thrombosis.



Varicose veins are the result of a loss of elasticity of veins, often as a result of aging, and incompetent valves.



Lymphatic System



Lymphatic System

1. venule
2. arteriole
3. afferent lymphatic vessels
4. lymph node
5. follicle
6. lymphatic valve
7. efferent lymphatic vessel

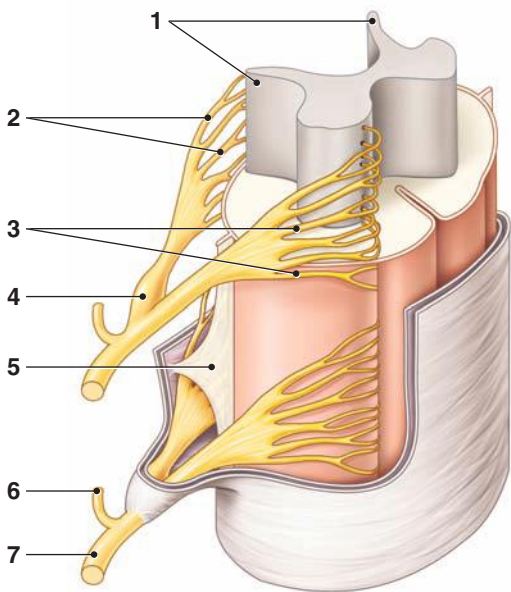
Metastasizing cancer is spread throughout the body by:

1. direct seeding of serous membranes,
2. hematogenous spread, and
3. lymphogenous spread.

Lymphogenic spread is the most common route for the initial spread of carcinomas. Carcinomas, derived from epithelium, represent the most common type of cancer.

During infection, lymphangitis may occur—the lymph nodes may enlarge and become tender and the lymphatic channels may appear red under the skin. Lymphangitis has the potential to lead to septicemia if left untreated.

Nervous System



Nervous System

1. posterior gray horns
2. posterior rootlets
3. anterior root
4. spinal ganglion
5. denticulate ligament
6. posterior primary ramus
7. anterior primary ramus

After CNS injury, regeneration is typically blocked by the presence of an astrocytic scar.

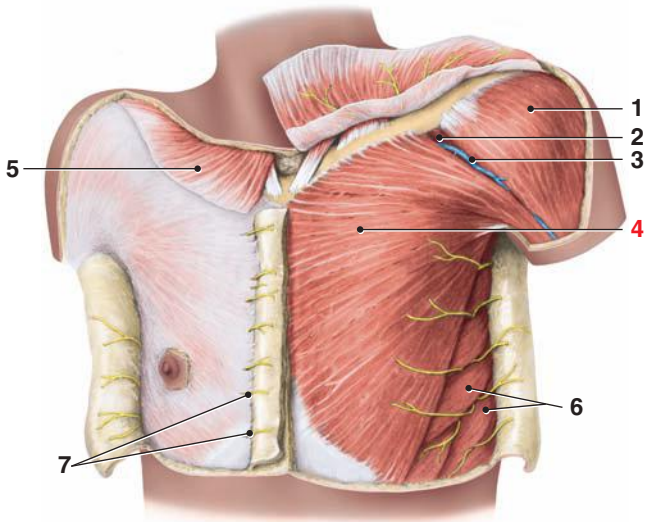
Regeneration and reestablishment of function is more possible in the PNS, provided the nerve cell body is still intact, the epineurial sheath is present, and there is functioning target tissue.

1 • Thorax

- 1.1** Male Pectoral Region
- 1.2** Bony Thorax
- 1.3** Atypical Ribs
- 1.4** Typical Ribs
- 1.5** Lateral View of the Sternum
- 1.6** Anterior View of the Sternum
- 1.7** Thoracic Apertures
- 1.8** Spinal Nerves in the Thoracic Region
- 1.9** Intercostal Space
- 1.10** Vertebral Ends of Intercostal Space
- 1.11** Thoracic Wall
- 1.12** Internal Aspect of Thoracic Wall
- 1.13** Superficial Breast
- 1.14** Mammary Glands
- 1.15** Lymphatic Drainage of the Breast
- 1.16** Thoracic Contents In Situ
- 1.17** Pleurae
- 1.18** Pleural Cavity, Anterior View
- 1.19** Lungs, Mediastinal Surface
- 1.20** Lungs, Lateral Surface
- 1.21** Bronchial Tree
- 1.22** Tertiary Bronchi
- 1.23** Pulmonary Arteries
- 1.24** Lymphatic Drainage of the Lungs
- 1.25** Innervation of the Lungs
- 1.26** Transverse Pericardial Sinus
- 1.27** Pericardium
- 1.28** Right Atrium
- 1.29** Left Ventricle
- 1.30** Left Atrium

- 1.31** Right Ventricle
- 1.32** Semilunar Valves
- 1.33** Heart, Anterior View
- 1.34** Heart, Posterior View
- 1.35** Anterior Surface of the Heart
- 1.36** Posterior Surface of the Heart
- 1.37** Veins of the Heart
- 1.38** Conduction System of the Heart
- 1.39** Mediastinum, Right Side
- 1.40** Mediastinum, Left Side
- 1.41** Superior Mediastinum, Superficial Dissection
- 1.42** Superior Mediastinum, Thymus Removed
- 1.43** Arch of the Aorta
- 1.44** Superior Mediastinum, Tracheal Bifurcation
- 1.45** Superior Mediastinum, Nerves
- 1.46** Esophagus
- 1.47** Thoracic Duct
- 1.48** Azygos System of Veins

Male Pectoral Region



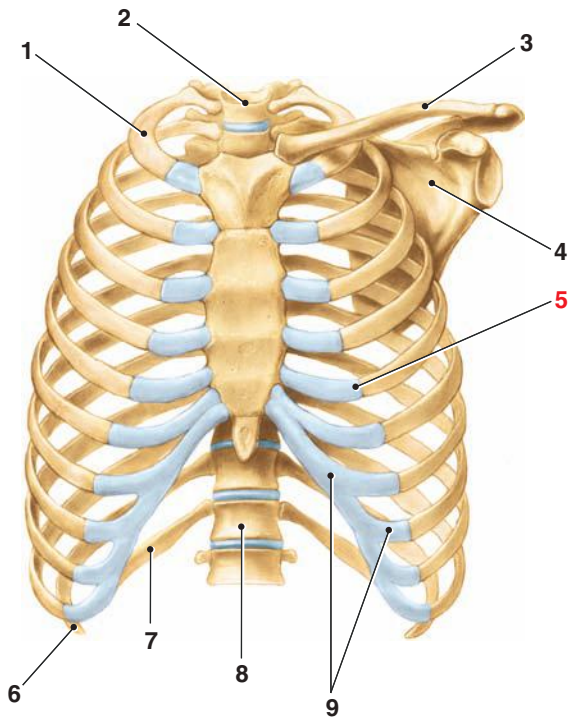
Male Pectoral Region

1. deltoid
2. deltopectoral triangle
3. cephalic vein
4. pectoralis major
5. platysma
6. serratus anterior
7. anterior cutaneous nerves

Pectoralis Major

- proximal attachment: clavicular head—anterior surface of medial half of clavicle; sternocostal head—anterior surface of sternum, superior six costal cartilages, aponeurosis of external oblique
- distal attachment: lateral lip of intertubercular groove of humerus
- innervation: lateral and medial pectoral nerves
- main action: adducts and medially rotates the humerus

Bony Thorax



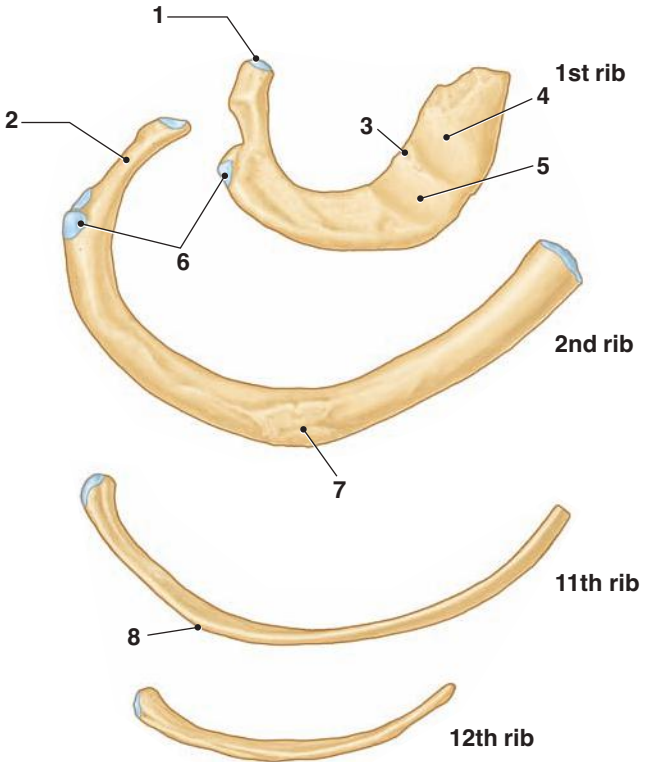
Bony Thorax

1. 1st rib
2. 1st thoracic vertebra
3. clavicle
4. scapula
5. costochondral joint
6. 11th rib
7. 12th rib
8. 12 thoracic vertebra
9. costal margin

Costochondral Joints

- primary cartilaginous joints
- articulation of lateral end of costal cartilage with sternal end of rib
- cartilage and bone bound together by periosteum
- normally no movement permitted at these joints

Atypical Ribs



Atypical Ribs

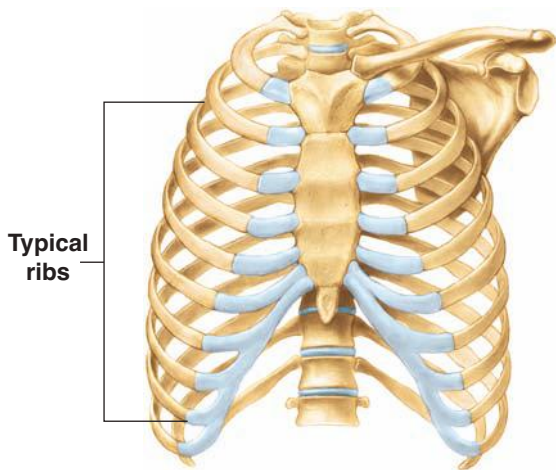
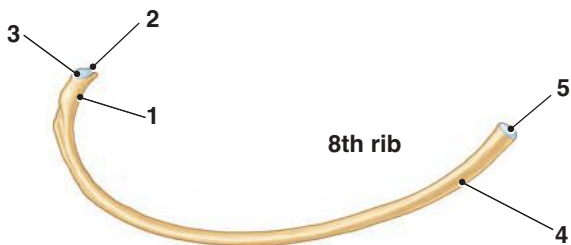1. single facet on head
2. neck
3. scalene tubercle
4. groove for subclavian vein
5. groove for subclavian artery
6. tubercle
7. tuberosity for serratus anterior
8. angle

The atypical ribs—1st, 2nd, and 10th to 12th—differ from typical ribs in several ways. The 1st and 2nd ribs possess tubercles for muscle attachment, while the 11th and 12th ribs have no necks or tubercles.

The short, broad 1st rib is well protected by the clavicle and is rarely broken. However, when it is broken, injury to the brachial plexus and subclavian vessels may occur.

Lower rib fractures may injure internal organs, such as the spleen and liver, or may tear the diaphragm.

Typical Ribs



Typical Ribs

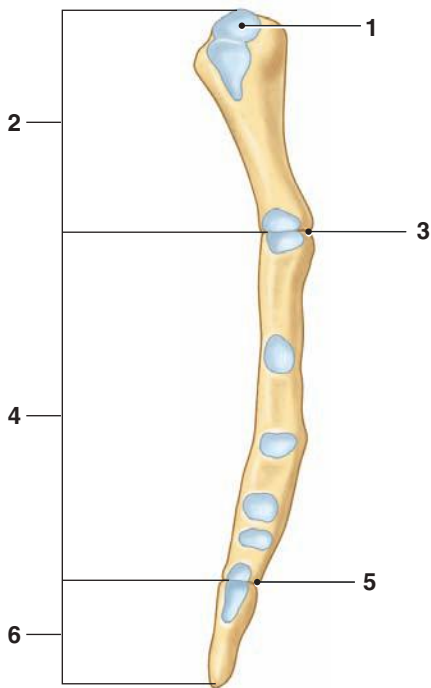
1. neck
2. head
3. articular facet
4. body (shaft)
5. sternal end

Typical ribs, 3 to 9, all have a head with 2 facets, a neck and tubercle, and a body with a costal angle.

The middle ribs are the most commonly fractured, usually as a result of a blow or crushing injury. The weakest part of the rib is just anterior to its angle; however, trauma may fracture a rib anywhere, and its broken end may injure internal organs.

Rib fractures are painful because the broken parts move during respiration, coughing, laughing, and sneezing.

Lateral View of the Sternum



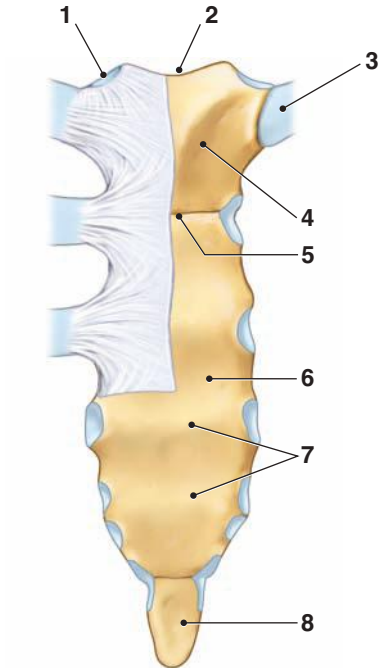
Lateral View of the Sternum

1. clavicular notch
2. manubrium
3. sternal angle
4. body of sternum
5. xiphisternal joint
6. xiphoid process

Note the costal notches along the lateral extent of the sternum for articulation with the heads of the ribs.

The xiphoid process is typically cartilaginous until approximately age 40. The partial ossification of the xiphoid process often manifests itself as a lump in the pit of the stomach. Many individuals who were unaware of their xiphoid process up to this point fear that they have developed a tumor, such as stomach cancer, and consult their physician.

Anterior View of the Sternum

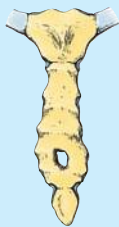

Anterior View of the Sternum

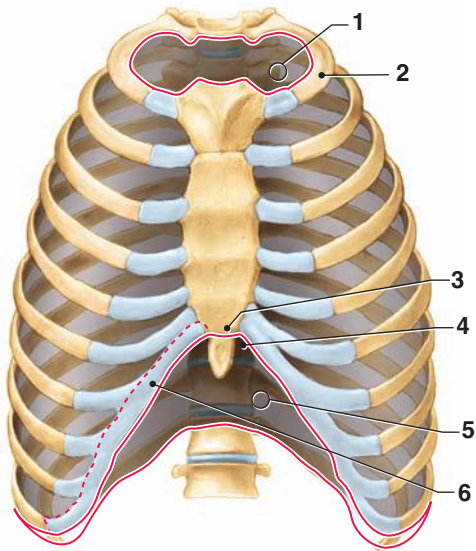
1. clavicular notch
2. jugular notch
3. costal cartilage of 1st rib
4. manubrium
5. sternal angle
6. body
7. transverse ridges
8. xiphoid process

The subcutaneous and easily accessible sternum is a typical site for harvest of bone marrow for transplantation or biopsy. During a sternal puncture, a wide-bore needle is inserted into the sternum and a sample of red bone marrow is removed.

A sternal foramen results from incomplete fusion of the fetal sternal plates. It may be mistaken for a bullet wound on a medical image.



Thoracic Apertures



Thoracic Apertures

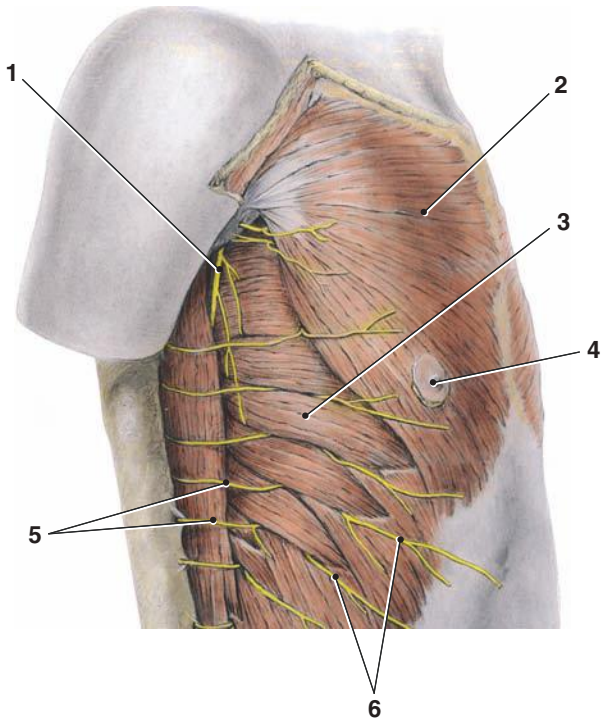
1. superior thoracic aperture
2. 1st rib
3. xiphisternal joint
4. infrasternal angle
5. inferior thoracic aperture
6. costal margin

The superior thoracic aperture (thoracic inlet) is bounded by the T1 vertebra, the 1st pair of ribs and their costal cartilages, and the manubrium.

The inferior thoracic aperture (thoracic outlet) is bounded by the T12 vertebra, the 11th and 12th ribs, the costal cartilages of ribs 7 to 10, and the xiphisternal joint.

Clinicians often refer to the superior thoracic aperture as the thoracic outlet because of the arteries and T1 spinal nerves that emerge through this aperture. Thoracic outlet syndrome refers to structures that emerge through the superior thoracic aperture being affected by obstructions in the root of the neck and manifesting themselves most typically in the upper limb.

Spinal Nerves in the Thoracic Region

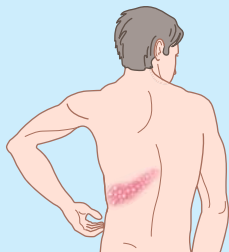

Spinal Nerves in the Thoracic Region

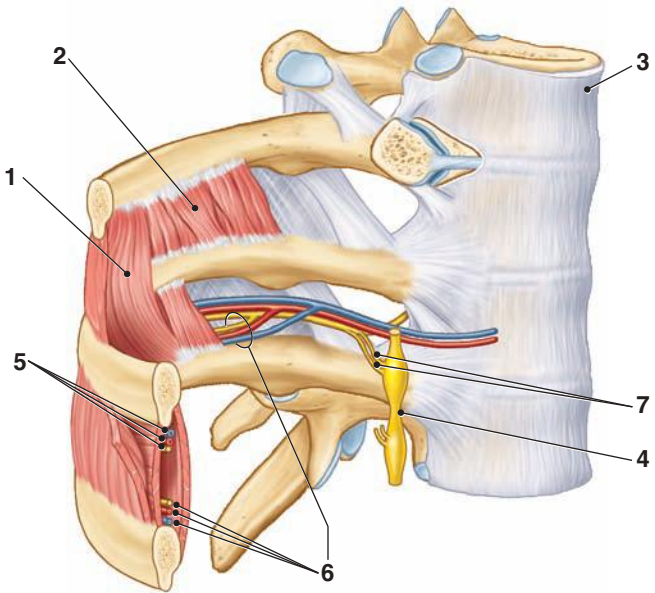
1. long thoracic nerve
2. pectoralis major
3. serratus anterior
4. nipple
5. posterior branches of lateral cutaneous nerves
6. anterior branches of lateral cutaneous nerves

Lateral cutaneous nerve branches contribute to dermatomes: a strip of skin innervated by one spinal cord level.

Herpes zoster infections cause skin lesions called shingles. Herpes zoster is a viral disease of the spinal ganglia caused by reactivation of the chickenpox virus. The painful, red-skinned area exhibits skin eruptions. Herpes zoster is primarily a sensory neuropathy, although motor weakness may occur.



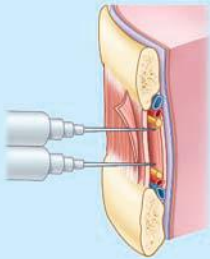
Intercostal Space



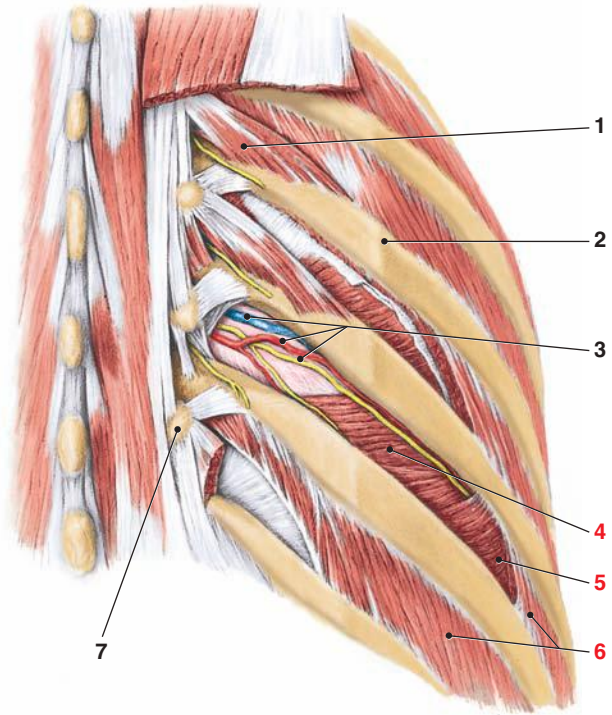
Intercostal Space

1. subcostal
2. innermost intercostal
3. anterior longitudinal ligament
4. sympathetic trunk
5. intercostal vessels and nerve
6. collateral branches of intercostal vessels and nerve
7. rami communicantes

An intercostal nerve block produces anesthesia of an intercostal space by introduction of an anesthetic agent around the intercostal nerve and the nerve collaterals.



Vertebral Ends of Intercostal Space



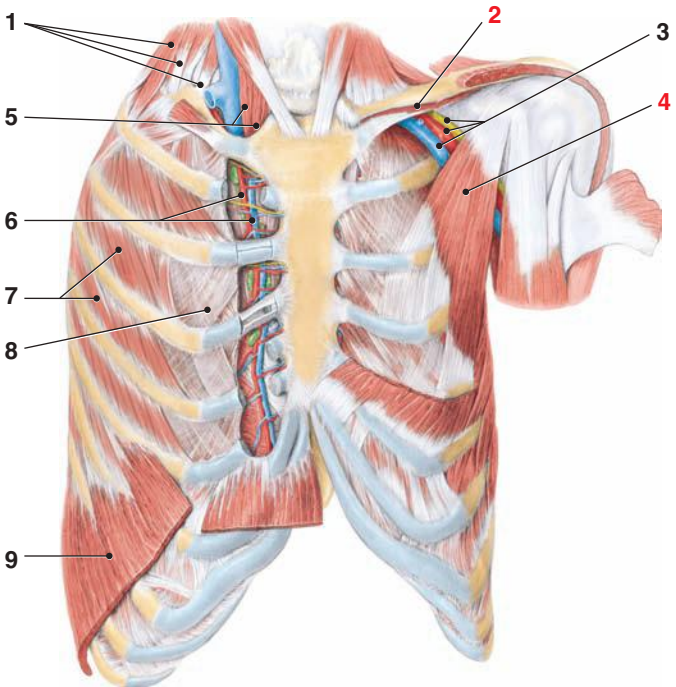
Vertebral Ends of Intercostal Space

1. levator costarum
2. angle of 8th rib
3. intercostal vein, artery, and nerve
4. innermost intercostal
5. internal intercostal
6. external intercostal
7. tip of transverse process

Innermost Intercostal, Internal Intercostal, and External Intercostal

- superior attachment: inferior border of ribs above
- inferior attachment: superior border of ribs below
- innervation: intercostal nerves
- main action: keep intercostal spaces rigid and move the ribs during respiration

Thoracic Wall



Thoracic Wall

1. posterior, middle, and anterior scaleni
2. subclavius
3. brachial plexus, axillary artery, and vein
4. pectoralis minor
5. sternothyroid and sternohyoid
6. internal thoracic artery and vein
7. external intercostal
8. internal intercostal
9. external oblique

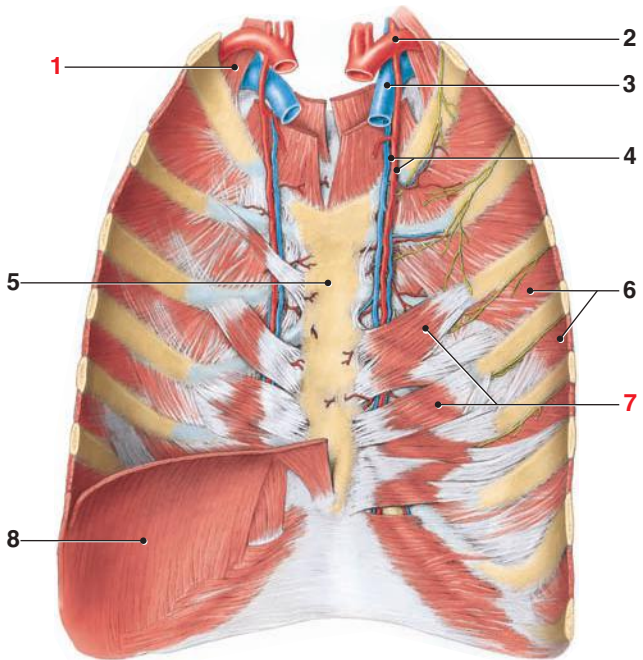
Subclavius

- proximal attachment: 1st rib and its costal cartilage
- distal attachment: inferior surface of middle third of clavicle
- innervation: nerve to subclavius
- main action: stabilizes and depresses clavicle

Pectoralis Minor

- proximal attachment: 3rd to 5th ribs
- distal attachment: coracoid process of scapula
- innervation: medial pectoral nerve
- main action: stabilizes scapula by drawing it inferiorly and anteriorly against the thoracic wall

Internal Aspect of Thoracic Wall



Internal Aspect of Thoracic Wall

1. anterior scalene
2. subclavian artery
3. right brachiocephalic vein
4. internal thoracic vein and artery
5. sternum
6. internal intercostal
7. transversus thoracis
8. diaphragm

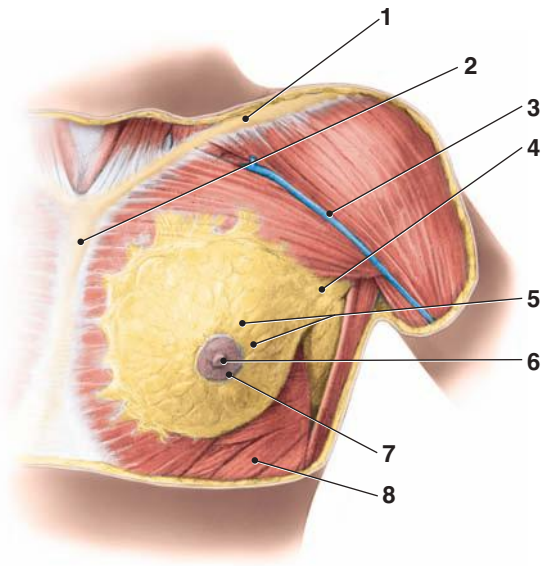
Anterior Scalene

- superior attachment: transverse process C4–C6 vertebrae
- inferior attachment: 1st rib
- innervation: cervical spinal nerves C4–C6
- main action: flex neck

Transverse Thoracic

- superior attachment: posterior surface of lower sternum
- inferior attachment: internal surface of costal cartilages 2 to 6
- innervation: intercostal nerves
- main action: weakly depresses ribs

Superficial Breast



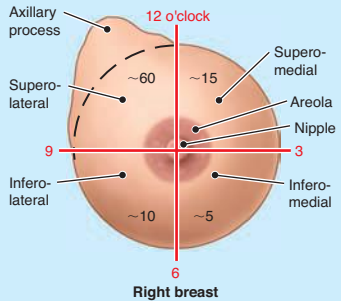
Superficial Breast

1. clavicle
2. sternum
3. cephalic vein
4. axillary tail
5. fat lobules
6. nipple
7. areola
8. serratus anterior

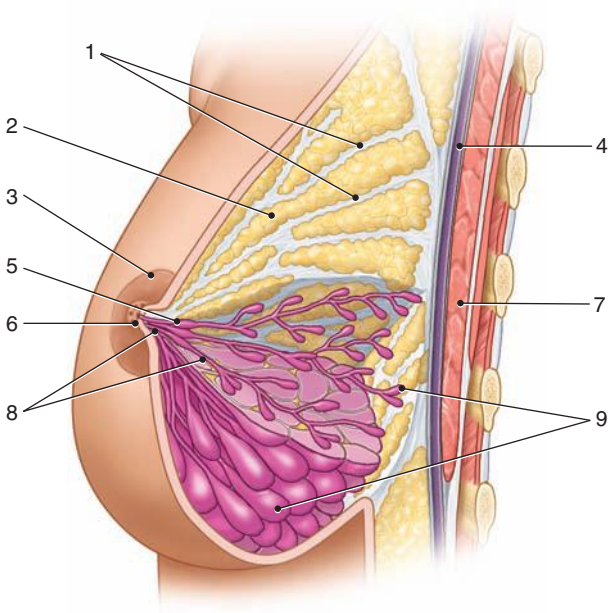
The nonlactating breast consists mainly of fat.

The breast is divided into four quadrants for the anatomical location and description of cysts and tumors.

If possible, surgical incisions of the breast are made in the inferior quadrants, as they are less vascular.



Mammary Glands



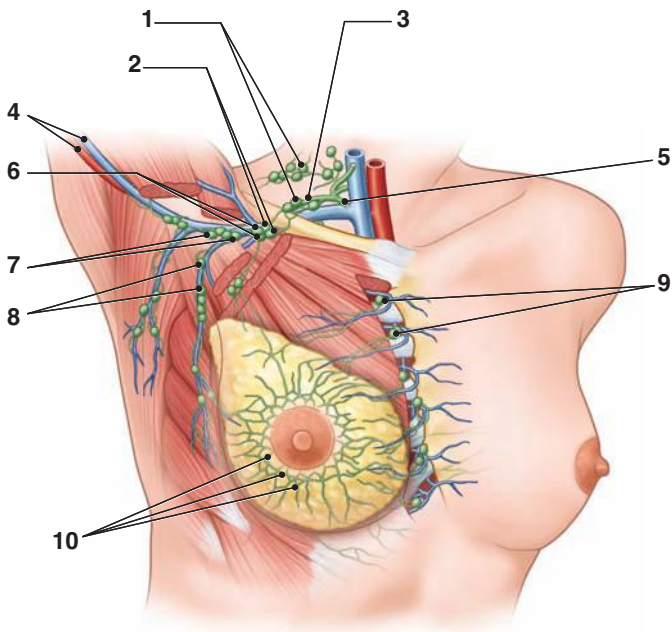
Mammary Glands

1. suspensory ligaments
2. fat
3. areola
4. retromammary space
5. lactiferous sinus
6. nipple
7. pectoralis major
8. lactiferous ducts
9. mammary gland

In multiparous women, the breasts often become large and pendulous. In elderly women, the breasts are usually small because of a decrease in fat and glandular tissue.

Changes such as branching of the lactiferous ducts occur during menstrual periods and pregnancy. Mammary glands are prepared for secretion by midpregnancy, but they don't actually produce milk until shortly after the baby is born. Colostrum, a premilk fluid rich in proteins, immune agents, and growth factor, may be secreted from the nipples during the last trimester of pregnancy and during the initial episodes of nursing.

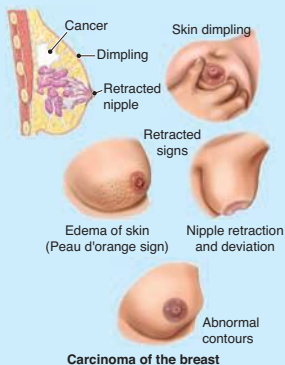
Lymphatic Drainage of the Breast



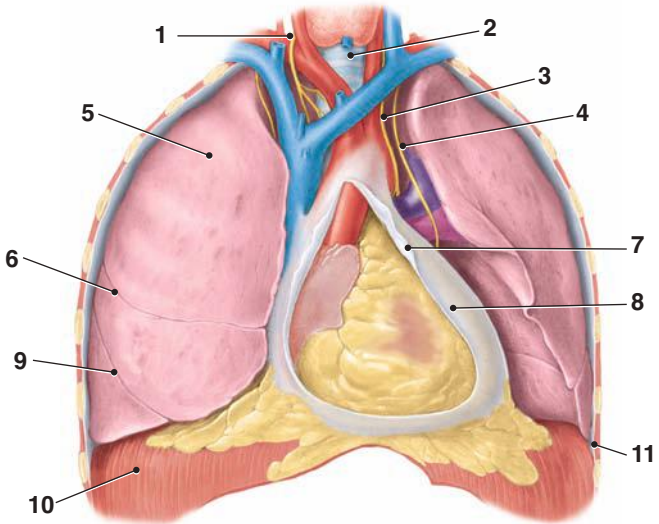
Lymphatic Drainage of the Breast

1. supraclavicular lymph nodes
2. infraclavicular lymph nodes
3. subclavian trunk
4. axillary vein and artery
5. right lymphatic duct
6. apical lymph nodes
7. central lymph nodes
8. pectoral lymph nodes
9. parasternal lymph nodes
10. subareolar lymphatic plexus

Knowledge of the lymphatic drainage of the breast is important, as metastatic cancer cells typically pass through the lymphatic system. Carcinoma of the breast may be indicated by deviation of the nipple; thick, leathery skin; prominent or puffy skin between dimpled pores (peau d'orange sign); large dimples caused by traction on the suspensory ligaments; or inversion of the nipple caused by subareolar breast cancer.



Thoracic Contents In Situ

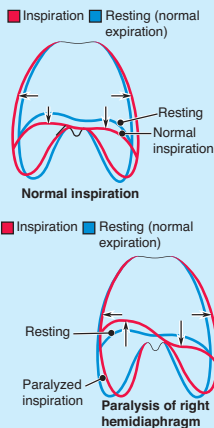


Thoracic Contents In Situ

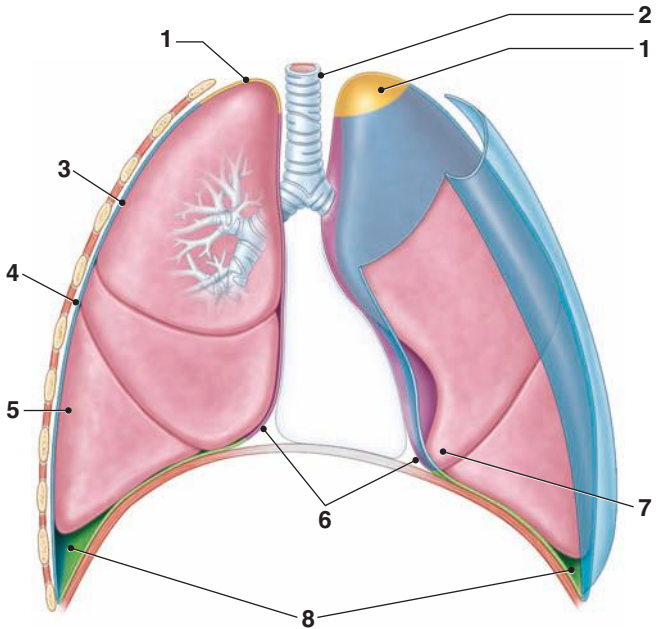
1. right vagus nerve
2. trachea
3. left vagus nerve
4. phrenic nerve
5. superior lobe of left lung
6. horizontal fissure
7. parietal layer of serous pericardium
8. fibrous pericardium
9. oblique fissure
10. diaphragm
11. costodiaphragmatic recess

Each phrenic nerve supplies half of the diaphragm with motor innervation.

Hemiparalysis of the diaphragm from phrenic nerve injury results in paradoxical movement. Instead of descending during inspiration, the paralyzed half ascends in response to increased intraabdominal pressure, while the paralyzed half descends during expiration in response to increased intrathoracic pressure.



Pleurae

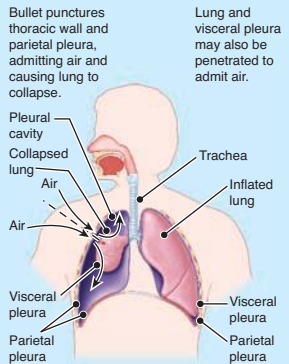


Pleurae

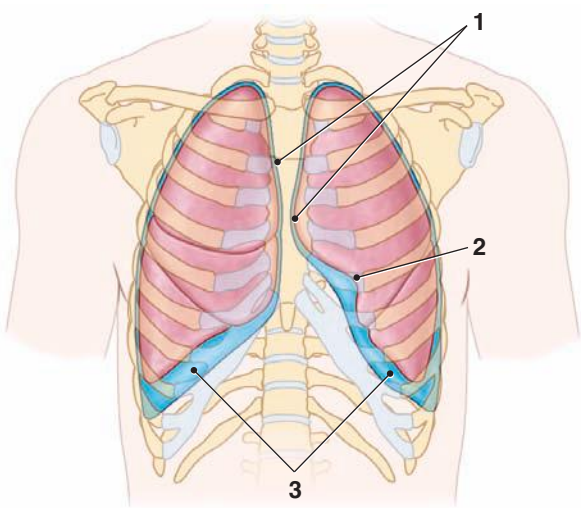
1. cervical pleura
2. trachea
3. costal pleura
4. pleural cavity
5. visceral pleura
6. mediastinal layer of parietal pleura
7. lingula
8. costodiaphragmatic recess

The cervical pleura and apex of the lung are subject to injury from wounds to the base of the neck because they extend through the thoracic inlet. The costal and diaphragmatic pleurae are subject to injury where they extend below the costal margin.

Negative pressure in the pleural cavity keeps the lung inflated. If the surface tension holding the visceral and parietal pleura is compromised, the lung will collapse.



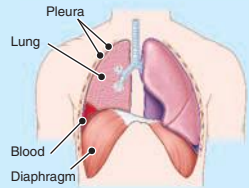
Pleural Cavity, Anterior View



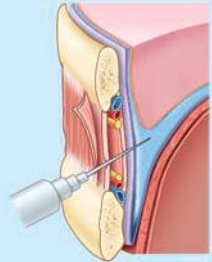
Pleural Cavity, Anterior View

1. costomediastinal recess
2. cardiac notch
3. costodiaphragmatic recess

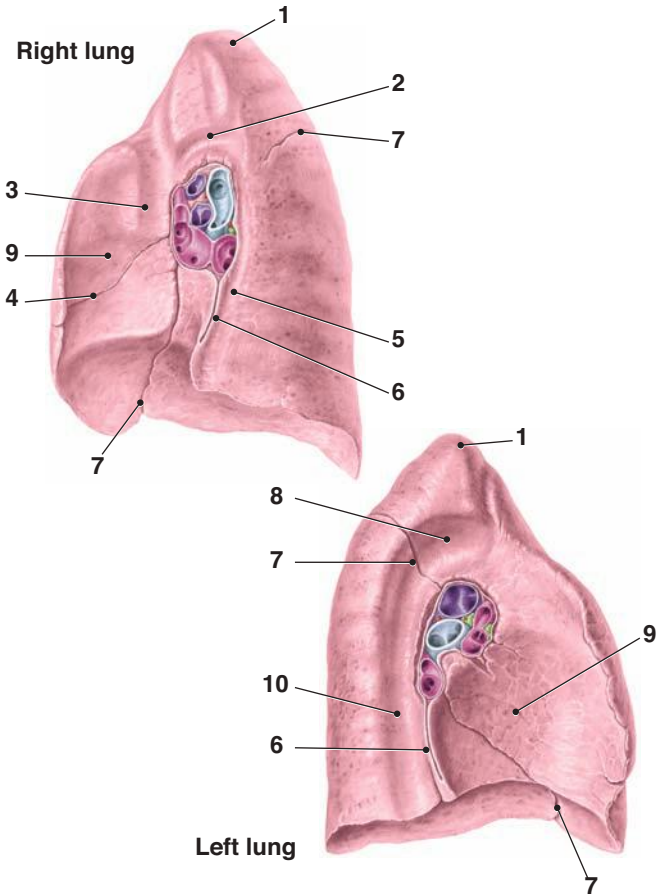
Entry of air (pneumothorax), fluid (hydrothorax), or blood (hemothorax) into the pleural cavity may collapse the lung.



Insertion of a hypodermic needle through an intercostal space into the pleural cavity (thoracocentesis) is sometimes necessary to remove fluid, blood, or pus. Care must be taken to avoid damaging neurovascular elements.



Lungs, Mediastinal Surface



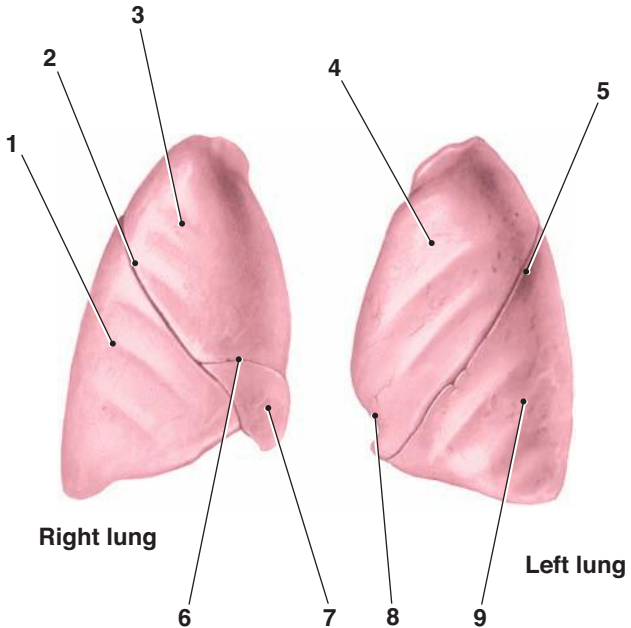
Lungs, Mediastinal Surface

1. apex
2. groove for arch of Azygos vein
3. groove for superior vena cava
4. horizontal fissure
5. groove for esophagus
6. pulmonary ligament
7. oblique fissure
8. groove for arch of aorta
9. cardiac impression
10. groove for descending aorta

The embalmed lung shows impressions of the structures with which it comes in contact.

In the root of the lung, the artery is superior, the bronchus is posterior, one vein is anterior, and the other is inferior.

Lungs, Lateral Surface

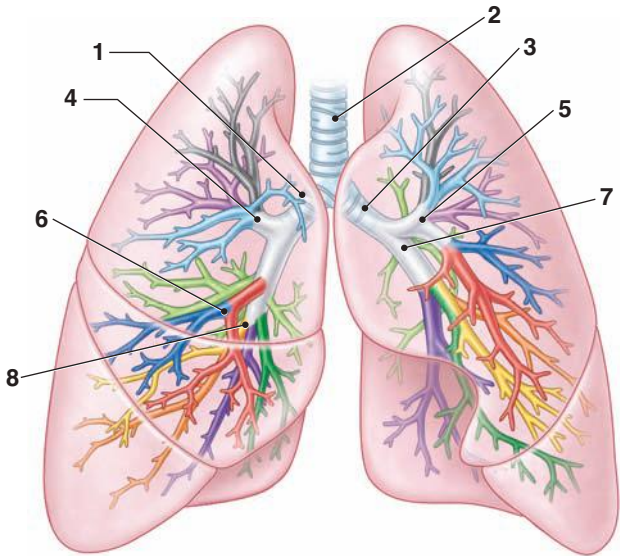


Lungs, Lateral Surface

1. inferior lobe
2. oblique fissure
3. superior lobe
4. superior lobe
5. oblique fissure
6. horizontal fissure
7. middle lobe
8. cardiac notch
9. inferior lobe

Occasionally, an extra fissure divides a lung, or a fissure is absent. The most common accessory lobe is the azygos lobe, which appears in the right lung in approximately 1% of people.

Bronchial Tree

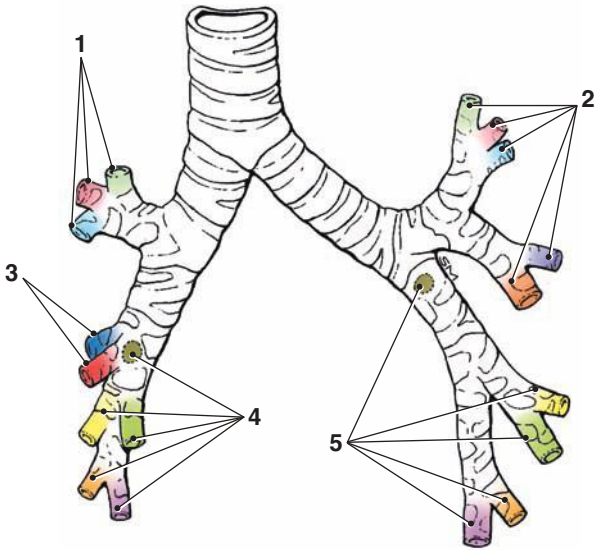


Bronchial Tree

1. right main bronchus
2. trachea
3. left main bronchus
4. right superior lobar bronchus
5. left superior lobar bronchus
6. right middle lobar bronchus
7. left inferior lobar bronchus
8. right lower lobar bronchus

Because the right bronchus is wider and shorter and runs more vertically than the left bronchus, foreign material is more likely to enter and lodge in it or one of its bronchi. A bronchoscope is inserted into the trachea to examine the bronchial tree.

Tertiary Bronchi

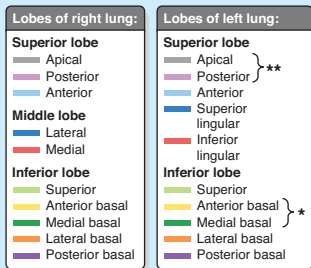


Tertiary Bronchi

1. superior lobe, right lung
 - apical, posterior, anterior
2. superior lobe, left lung
 - apical, posterior, anterior
 - superior lingular, inferior lingular
3. middle lobe, right lung
 - lateral, medial
4. inferior lobe, right lung
 - superior, anterior basal, medial basal, lateral basal, posterior basal
5. inferior lobe left lung
 - superior, anterior basal, medial basal, lateral basal, posterior basal

There are 10 tertiary bronchi in each lung. Each tertiary bronchus supplies a bronchopulmonary segment.

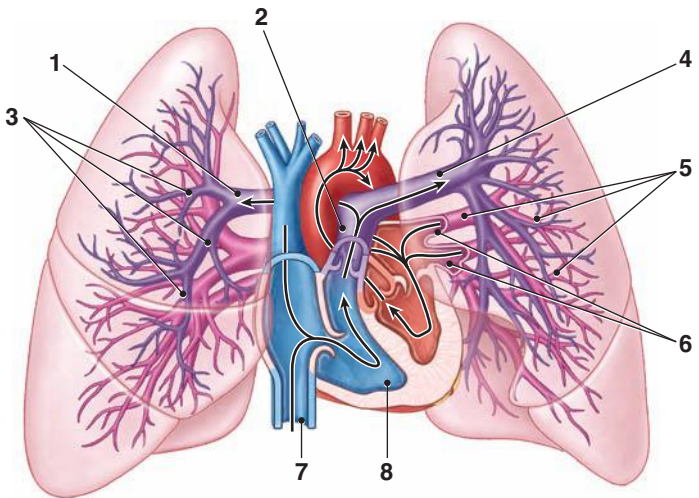
Bronchial and pulmonary disorders, such as tumors and abscesses, often localize in a bronchopulmonary segment, which may be surgically resected. Resection of a bronchopulmonary segment is called segmentectomy. A lobe resection is a lobectomy, and removal of an entire lung is a pneumonectomy.



** Typically combine into apicoposterior segment

* Often combined into anteromedial basal segment

Pulmonary Arteries



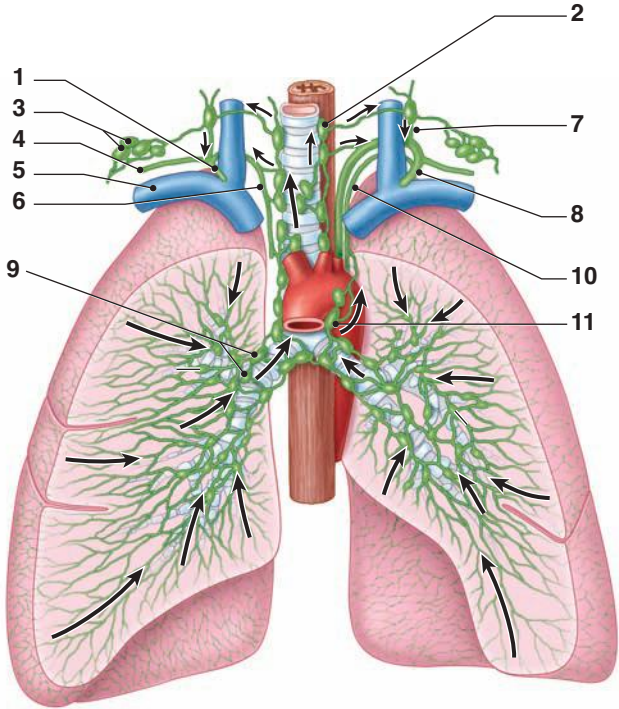
Pulmonary Arteries

1. right pulmonary artery
2. pulmonary trunk
3. lobar and segmental arteries
4. left pulmonary artery
5. lobar and segmental veins
6. left pulmonary veins
7. inferior vena cava
8. right ventricle

The pulmonary arteries carry poorly oxygenated blood to the lungs for oxygenation.

Acute respiratory distress results from a major decrease in the oxygenation of blood owing to a blockage of blood flow to the lung, which may lead to death in only a few minutes. Obstruction of a pulmonary artery (pulmonary embolism) by a blood clot (embolism) may lead to partial or complete loss of blood flow to the lung.

Lymphatic Drainage of the Lungs



Lymphatic Drainage of the Lungs

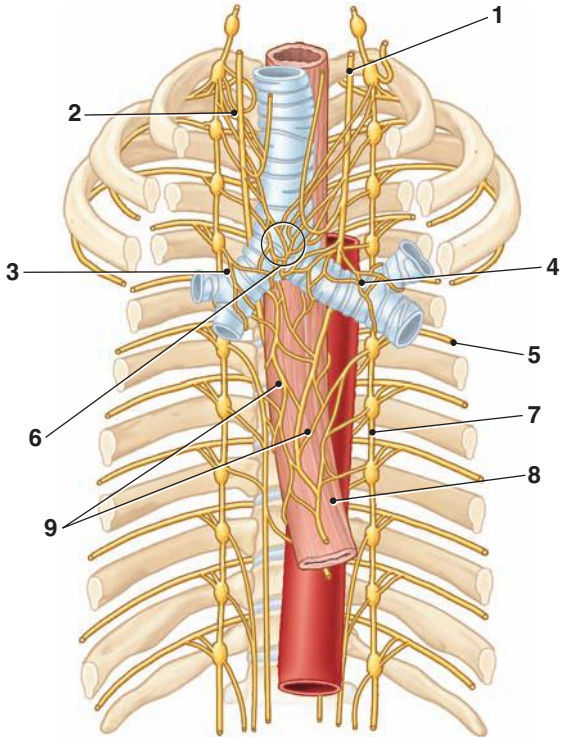
1. right lymphatic duct
2. tracheal node
3. supraclavicular nodes
4. right subclavian lymphatic trunk
5. right subclavian vein
6. right bronchomediastinal trunk
7. left jugular lymphatic trunk
8. thoracic duct
9. bronchopulmonary nodes
10. left bronchomediastinal trunk
11. aortic arch node

The superficial lymphatic drainage of the lung drains to the bronchopulmonary nodes. Deep lymphatic drainage passes to the root of the lung and into the tracheobronchial nodes, then to the bronchomediastinal trunk and into the right lymphatic and thoracic ducts.

Pleural adhesion may cause the lymphatic vessels of the lung to drain into axillary nodes.

The bronchopulmonary nodes are an early site of tumor metastases in bronchogenic carcinoma; subsequently, the supraclavicular nodes enlarge. They are often called sentinel nodes because their enlargement alerts physicians that a metastatic cancer may be present in the thorax or abdomen.

Innervation of the Lungs



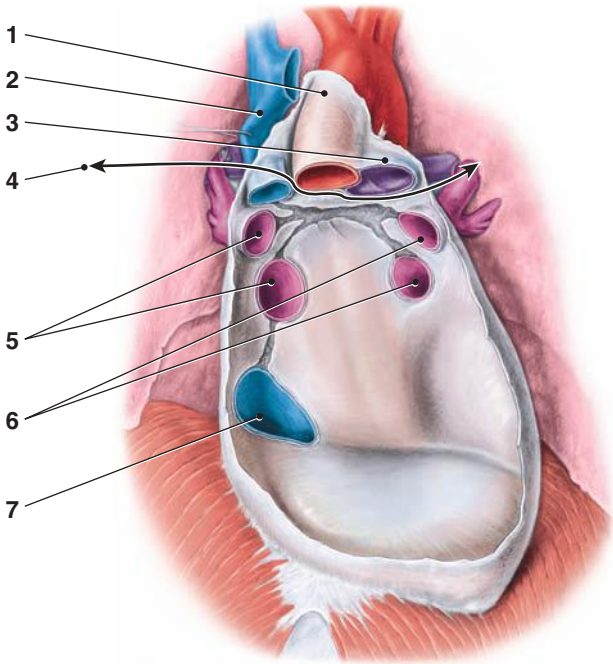
Innervation of the Lungs

1. left vagus nerve
2. right vagus nerve
3. right pulmonary plexus
4. left pulmonary plexus
5. intercostal nerve
6. cardiac plexus
7. sympathetic trunk
8. esophagus
9. esophageal plexus

The pulmonary plexuses receive sympathetic contributions from the sympathetic trunks and parasympathetic contributions from the right and left vagus nerves. Branches from the pulmonary plexuses follow bronchi and vasculature into the lungs. The visceral pleura is insensitive to pain, while the parietal pleura is highly sensitive to pain.

The parietal pleura is supplied by branches of the intercostal and phrenic nerves. Irritation of the pleura may produce local pain or pain referred to the dermatome supplied by the same spinal cord segment.

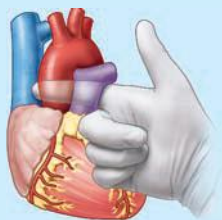
Transverse Pericardial Sinus



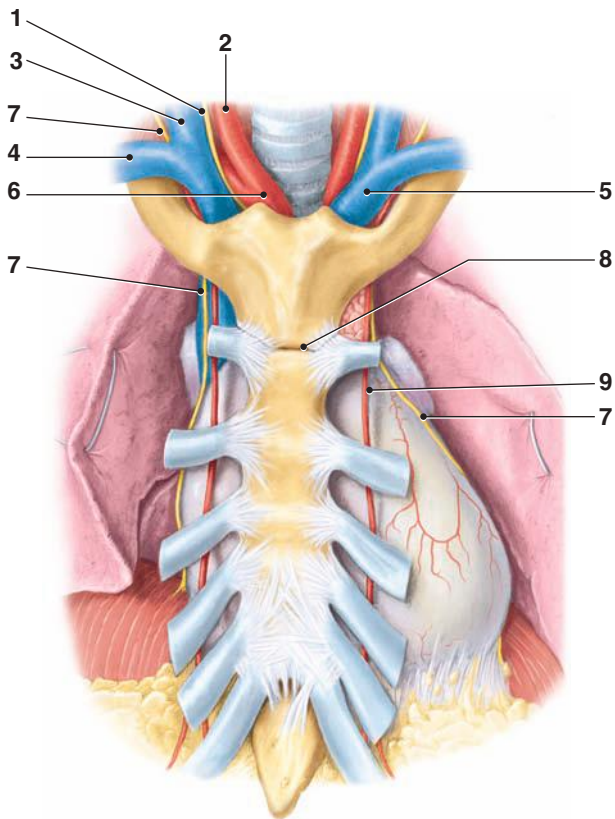
Transverse Pericardial Sinus

1. aorta
2. superior vena cava
3. pulmonary trunk
4. transverse pericardial sinus
5. right pulmonary veins
6. left pulmonary veins
7. inferior vena cava

After the pericardial sac is opened anteriorly, a finger can be passed through the transverse pericardial sinus posterior to the ascending aorta and pulmonary trunk and a surgical clamp or ligature can be placed to control blood flow out of these major arteries during cardiac surgery.



Pericardium



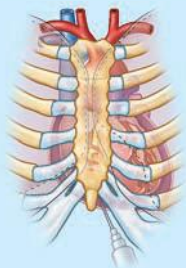Pericardium

1. vagus nerve
2. common carotid artery
3. internal jugular vein
4. subclavian vein
5. left brachiocephalic vein
6. brachiocephalic trunk
7. phrenic nerve
8. sternal angle
9. internal thoracic artery

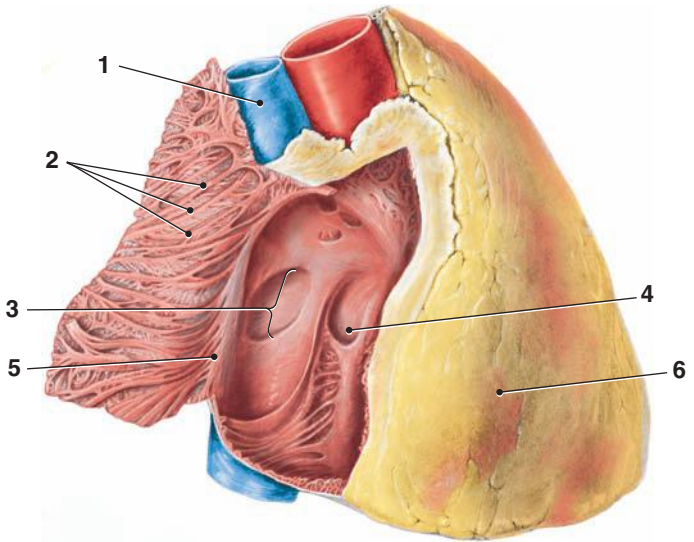
Inflammation of the pericardium, or pericarditis, may cause chest pain and pericardial friction rub, which can be detected during auscultation.

A chronically inflamed pericardium may cause pericardial effusion, and a decrease in the efficiency of the heart due to compression caused by the increased fluid in the pericardial cavity—cardiac tamponade.

Drainage of fluid from the pericardial cavity, pericardiocentesis, is usually necessary to relieve cardiac tamponade.



Right Atrium

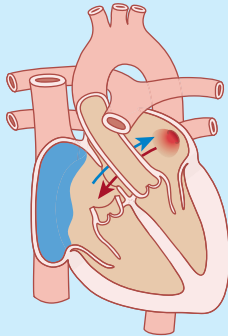


Right Atrium

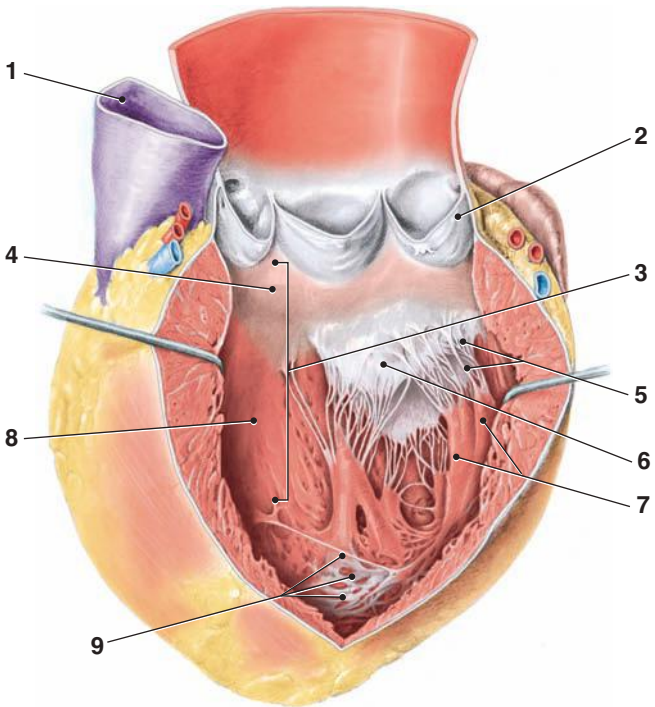
1. superior vena cava
2. pectinate muscles
3. oval fossa
4. opening of coronary sinus
5. crista terminalis
6. right ventricle

The oval fossa is the remnant of the oval foramen, an embryological right-to-left shunt for blood during development.

Congenital incomplete closure of the oval foramen is present in 15% to 25% of adults. It typically causes no clinically significant abnormalities. Significant atrial septal defects may allow blood to be shunted from the left atrium into the right atrium, eventually overloading the pulmonary circulation.



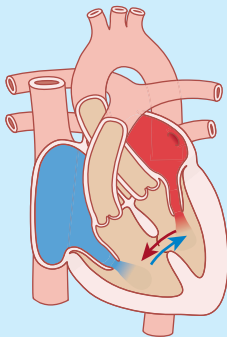
Left Ventricle



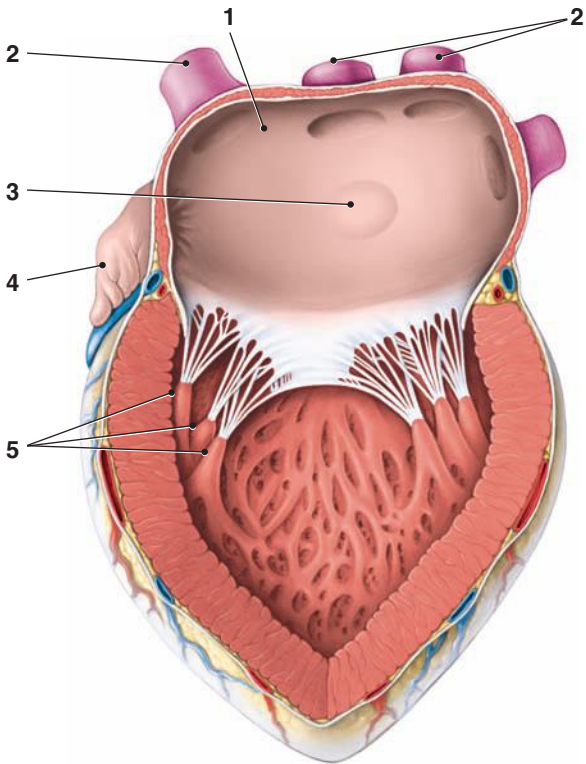
Left Ventricle

1. pulmonary trunk
2. left cusp of aortic valve
3. aortic vestibule
4. membranous part of interventricular septum
5. tendinous cords
6. anterior cusp of mitral valve
7. anterior papillary muscle
8. muscular part of interventricular septum
9. trabeculae carneae

The membranous part of the interventricular septum is the most common site of ventricular septal defects (VSDs). A VSD causes a left-to-right shunt of blood through the defect, which may result in pulmonary hypertension and cardiac failure.



Left Atrium



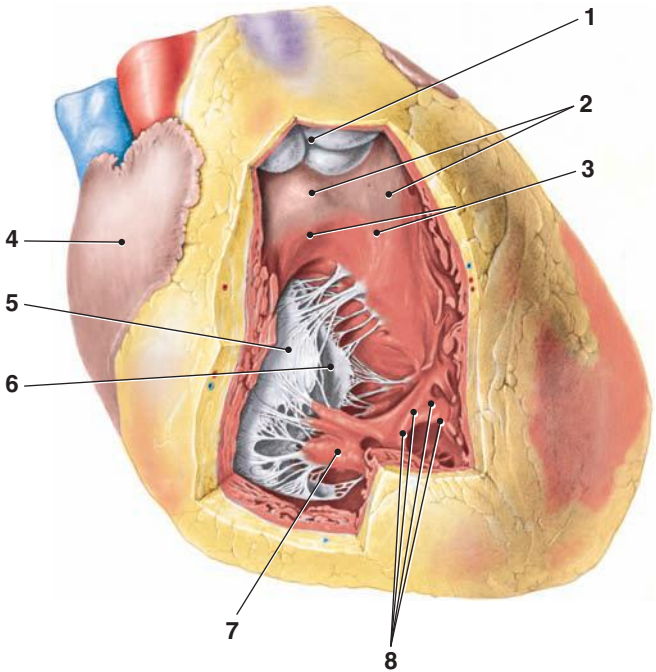
Left Atrium

1. interatrial septum
2. pulmonary veins
3. oval fossa
4. left auricle
5. papillary muscle

Except for that of the auricle, the wall of the left atrium is smooth.

Thrombi (clots) form on the walls of the left atrium in certain types of heart disease. If the thrombi detach or pieces break off, they may pass into the systemic circulation and occlude peripheral arteries. Occlusion of an artery supplying the brain results in a stroke, or cerebrovascular accident.

Right Ventricle



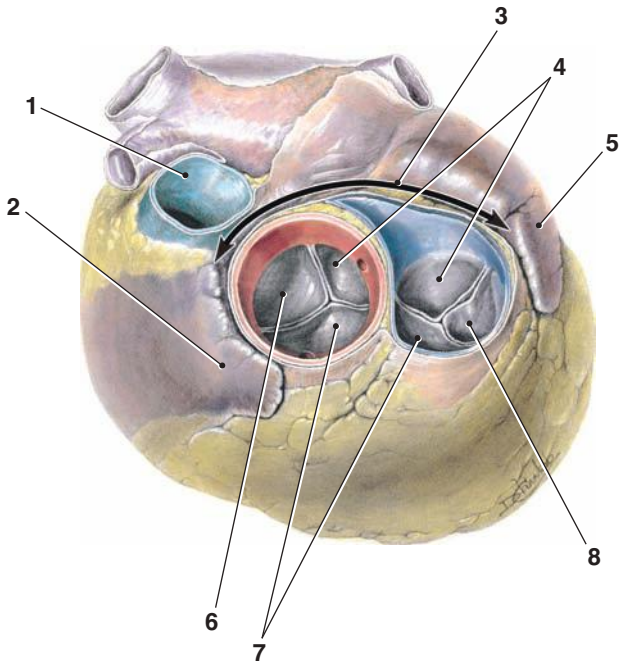
Right Ventricle

1. cusps of pulmonary valve
2. conus arteriosus
3. supraventricular crest
4. right atrium
5. anterior valve cusp
6. septal cusp
7. anterior papillary muscle
8. septomarginal trabecula (moderator band)

In compensatory hypertrophy, the myocardium responds to increased demands by increasing the size of its muscle fibers.

Cardiac muscle cells do not divide; therefore, muscle cells that degenerate—as in the case of a myocardial infarct, an area of myocardial necrosis—are not replaced.

Semilunar Valves



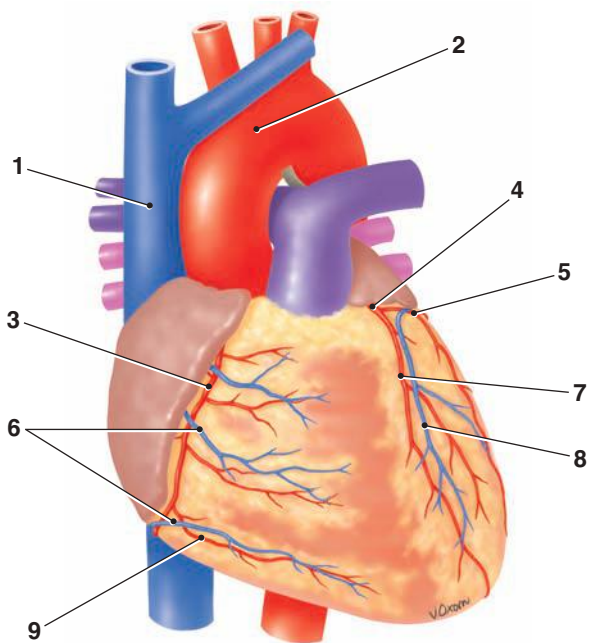
Semilunar Valves

1. superior vena cava
2. right auricle
3. transverse pericardial sinus
4. left cusps
5. left auricle
6. posterior cusp of aortic valve
7. right cusps
8. anterior cusp of pulmonary valve

Disorders involving the valves of the heart disturb the efficiency of the heart. Valvular heart disease produces either stenosis (narrowing) or insufficiency. Stenosis is the failure of a valve to open fully, slowing blood flow from the chamber. Insufficiency or regurgitation is a failure of the valve to close completely.

Damaged or defective heart valves are often replaced surgically in a procedure called valvuloplasty.

Heart, Anterior View



Heart, Anterior View

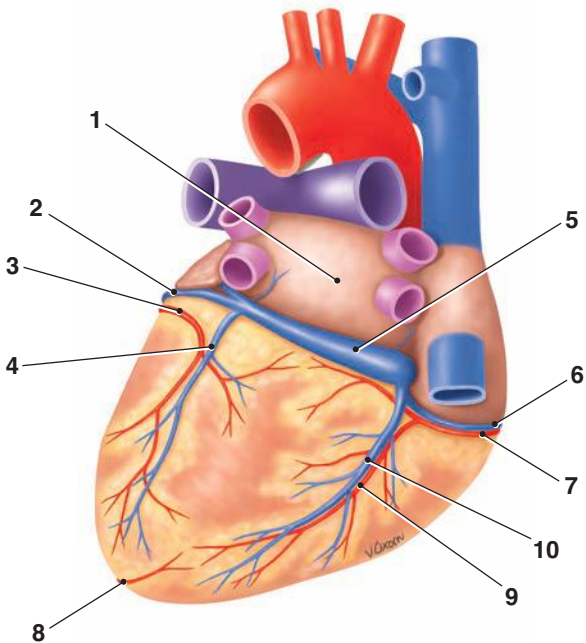
1. superior vena cava
2. arch of the aorta
3. right coronary artery
4. left coronary artery
5. circumflex branch
6. anterior cardiac veins
7. anterior interventricular artery
8. great cardiac vein
9. right marginal artery

In most cases, the right and left coronary arteries share equally in supplying blood to the heart.

Coronary artery disease (CAD) is a leading cause of death; CAD results in decreased blood flow to the heart. Coronary atherosclerosis is the slow buildup of lumen-occluding plaque in a coronary artery.

An area of myocardium that has undergone necrosis constitutes a myocardial infarction. The three most common sites of coronary artery occlusion are the anterior interventricular (40% to 50%), the right coronary (30% to 40%), and the circumflex branch (15% to 20%).

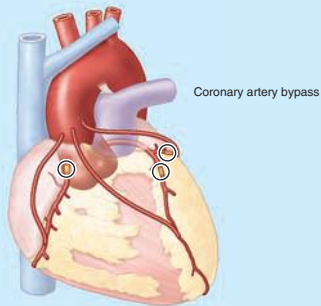
Heart, Posterior View



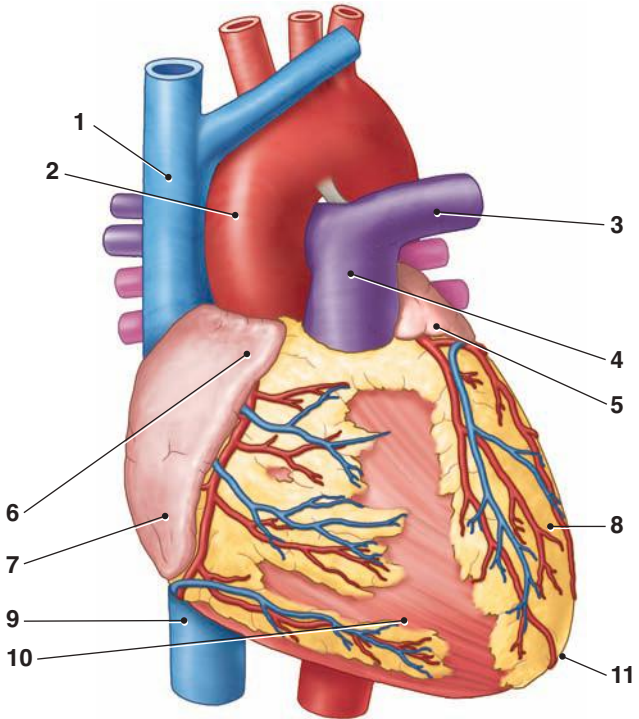
Heart, Posterior View

1. left atrium
2. great cardiac vein
3. circumflex branch
4. left posterior ventricular vein
5. coronary sinus
6. small cardiac vein
7. right coronary artery
8. anterior interventricular artery
9. posterior interventricular artery
10. middle cardiac vein

Some patients with an obstruction of the coronary circulation and severe angina (pain originating in the heart from ischemia of the myocardium) undergo coronary bypass surgery, which involves using a segment of an artery or vein to link the proximal and distal portions of the obstructed coronary artery to provide a detour around the stenotic portion.



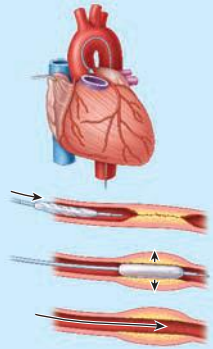
Anterior Surface of the Heart



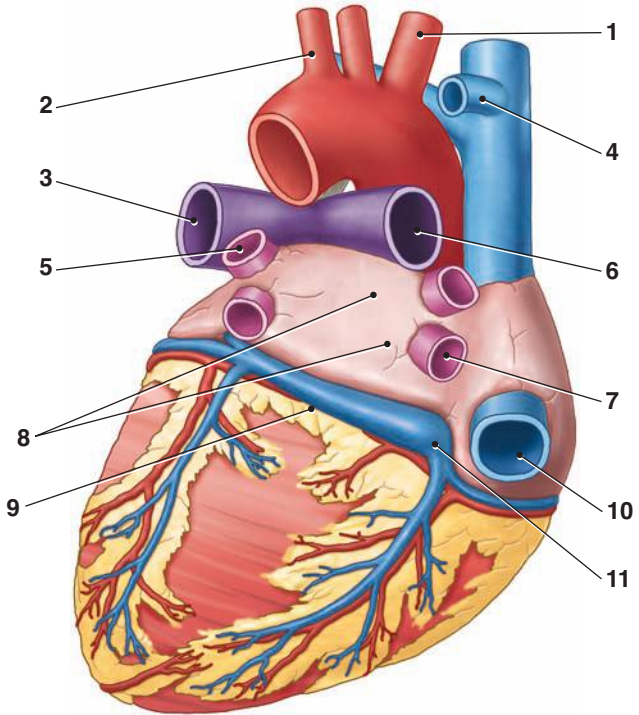
Anterior Surface of the Heart

1. superior vena cava
2. ascending aorta
3. left pulmonary artery
4. pulmonary trunk
5. left auricle
6. right auricle
7. right atrium
8. left ventricle
9. inferior vena cava
10. right ventricle
11. apex

In some patients, blockage of the coronary arteries is relieved by percutaneous transluminal coronary angioplasty, which involves passing a catheter with an inflatable balloon into the obstructed artery. When the obstruction is reached, the balloon is inflated to flatten the atherosclerotic plaque and stretch the vessel to increase the size of the lumen.



Posterior Surface of the Heart

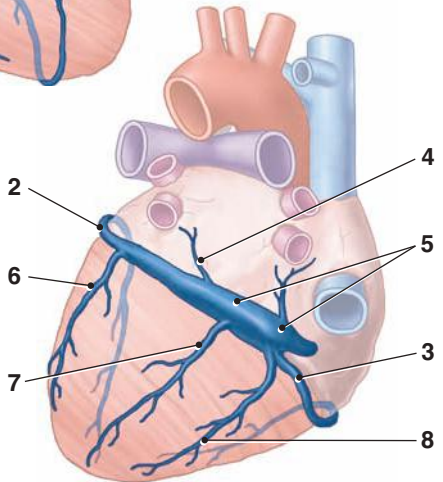
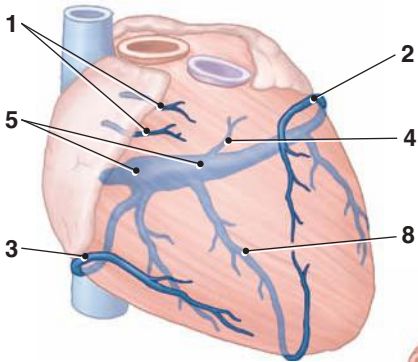


Posterior Surface of the Heart

1. brachiocephalic trunk
2. left subclavian artery
3. left pulmonary artery
4. arch of azygos vein
5. left superior pulmonary vein
6. right pulmonary artery
7. right inferior pulmonary vein
8. left atrium
9. coronary sulcus
10. inferior vena cava
11. coronary sinus

The left atrium forms the greater part of the posterior aspect of the heart. The anterior wall of the oblique pericardial sinus is seen between the pulmonary veins and inferior vena cava.

Veins of the Heart



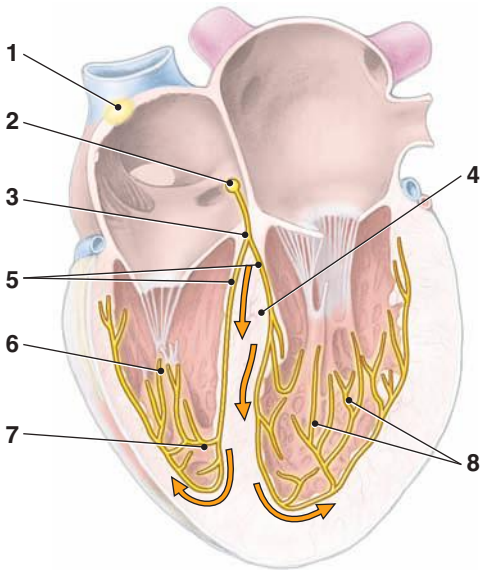
Veins of the Heart

1. anterior cardiac vein
2. great cardiac vein
3. small cardiac vein
4. oblique vein of the left atrium
5. coronary sinus
6. left marginal vein
7. left posterior ventricular vein
8. middle cardiac vein

Most venous drainage of the heart empties into the coronary sinus before it reaches the right atrium. Anterior cardiac veins end directly in the right atrium. The smallest cardiac veins begin in capillary beds and empty directly into the heart chambers (primarily the atria).

Reversal of flow in the anterior and smallest cardiac veins may allow luminal blood to flow directly to the myocardium, providing some collateral circulation.

Conduction System of the Heart



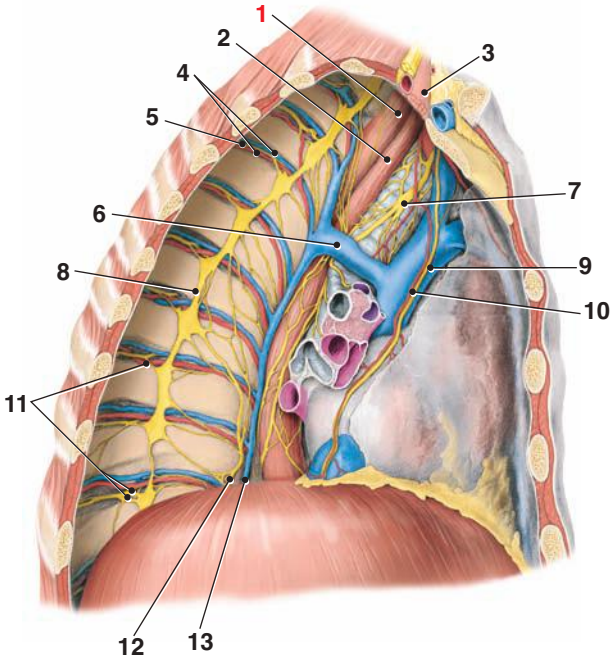
Conduction System of the Heart

1. sinoatrial node
2. atrioventricular node
3. atrioventricular bundle
4. muscular interventricular septum
5. bundle branches (right and left)
6. anterior papillary muscle
7. septomarginal trabecula
8. subendocardial branches

The sinoatrial node is the pacemaker of the heart because it initiates muscle contraction and determines the heart rate.

Damage to the conduction system of the heart (often by compromised blood supply) leads to disturbances of muscle contraction. Damage to the atrioventricular node results in heart block because the atrial excitation wave does not reach the ventricles. The ventricles therefore contract at their own slower rate. In some patients with heart block, an artificial cardiac pacemaker is inserted subcutaneously. The pacemaker is connected directly to the trabecula carneae of the right ventricle.

Mediastinum, Right Side



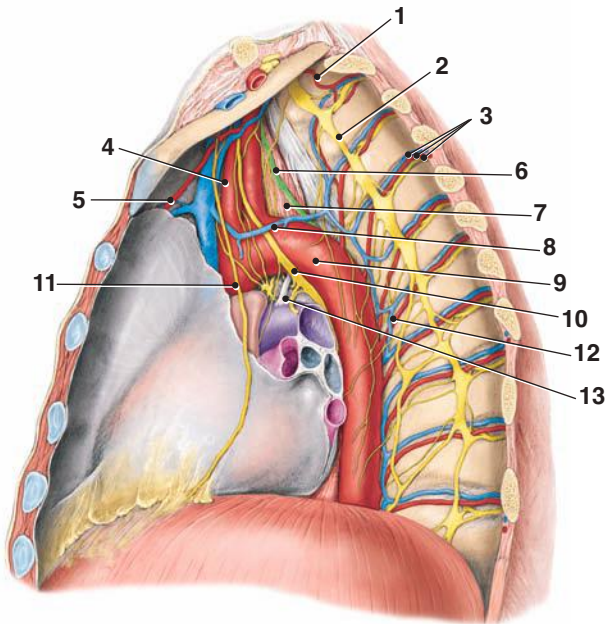
Mediastinum, Right Side

1. longus coli
2. esophagus
3. anterior scalene
4. posterior intercostal vein and artery
5. intercostal nerve
6. azygos vein
7. right vagus nerve
8. sympathetic trunk
9. right phrenic nerve
10. pericardiophrenic artery
11. rami communicantes
12. greater splanchnic nerve
13. azygos vein

Longus Coli

- superior attachment: anterior tubercle of the atlas; bodies of C1–C3 and transverse processes of C3–C6 vertebrae
- inferior attachment: bodies of C5–T3 vertebrae; transverse processes of C3–C5 vertebrae
- innervation: anterior rami of C2–C6 spinal nerves
- main action: flexes neck; rotation toward opposite side if acting unilaterally

Mediastinum, Left Side



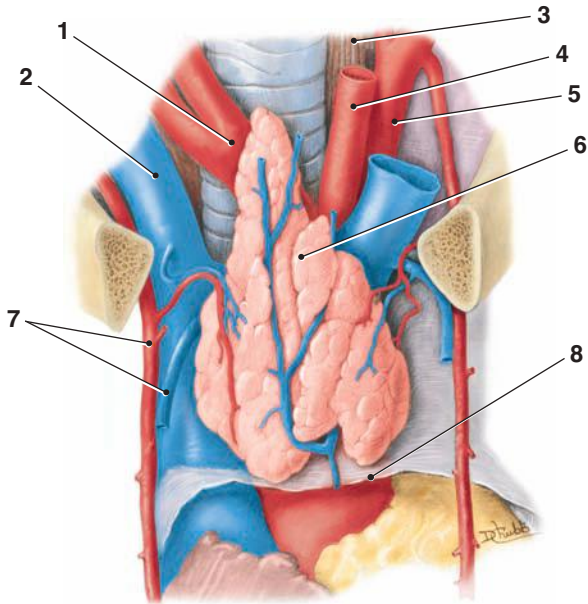
Mediastinum, Left Side

1. supreme intercostal artery
2. sympathetic trunk
3. intercostal vein, artery, and nerve
4. common carotid artery
5. internal thoracic artery
6. thoracic duct
7. esophagus
8. left superior intercostal vein
9. arch of aorta
10. vagus nerve
11. left phrenic nerve
12. accessory hemiazygos vein
13. ligamentum arteriosum

Using an endoscope (mediastinoscope), surgeons can see much of the mediastinum and conduct minor surgical procedures. The endoscope is inserted through a small incision at the root of the neck.

Physicians sometimes observe widening of the mediastinum when viewing radiographs. Any structure may contribute to widening of the mediastinum; it is typically a sign of some pathological process within the region.

Superior Mediastinum, Superficial Dissection



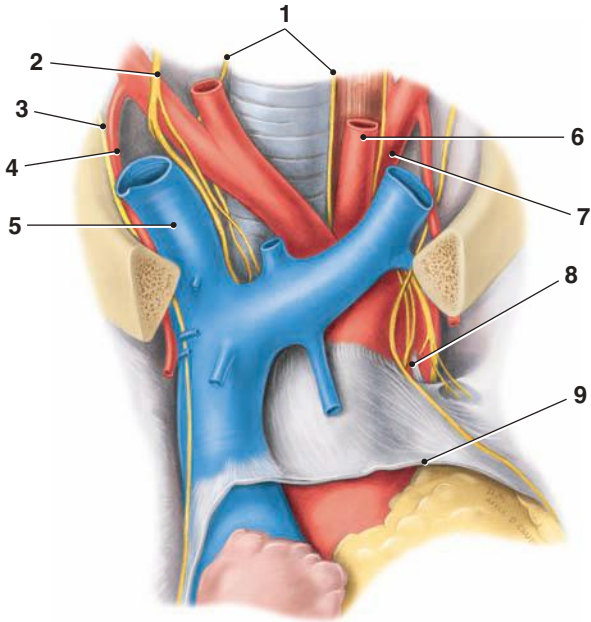
Superior Mediastinum, Superficial Dissection

1. brachiocephalic artery
2. right brachiocephalic vein
3. esophagus
4. left common carotid artery
5. left subclavian artery
6. thymus
7. internal thoracic artery and vein
8. cut edge of fibrous pericardium

The thymus regresses after puberty and is largely replaced by fat and fibrous tissue.

In the infant, the thymus is a prominent feature of the superior mediastinum. In some infants, the thymus may compress the trachea. Even after the thymus becomes diminished after puberty, it still continues to produce T lymphocytes.

Superior Mediastinum, Thymus Removed



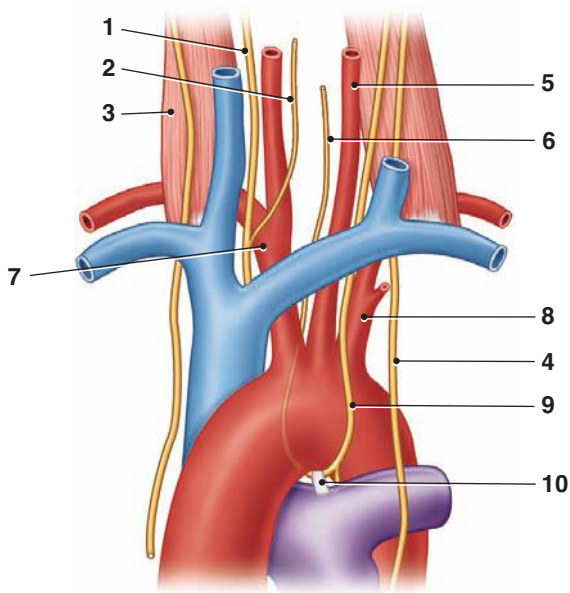
Superior Mediastinum, Thymus Removed

- 1.** recurrent laryngeal nerves
- 2.** right vagus nerve
- 3.** phrenic nerve
- 4.** internal thoracic artery
- 5.** right brachiocephalic vein
- 6.** left common carotid artery
- 7.** left subclavian artery
- 8.** ligamentum arteriosum
- 9.** cut edge of fibrous pericardium

The fibrous pericardium fuses with the proximal aspects of the great vessels.

The distal part of the ascending aorta receives a strong thrust of blood when the left ventricle contracts. Because the distal part of the ascending aorta lacks reinforcement from fibrous pericardium, an aneurysm (a localized dilation) may develop.

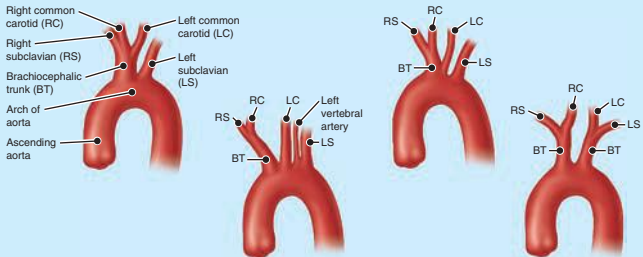
Arch of the Aorta



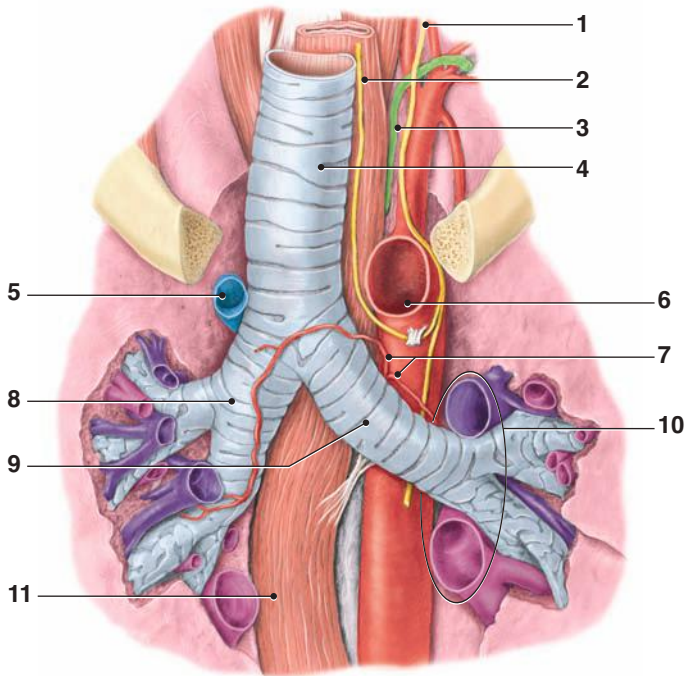
Arch of the Aorta

1. right vagus nerve
2. right recurrent laryngeal nerve
3. anterior scalene muscle
4. left phrenic nerve
5. left common carotid artery
6. left recurrent laryngeal nerve
7. brachiocephalic trunk
8. left subclavian artery
9. left vagus nerve
10. ligamentum arteriosum

The usual pattern of branches of the arch of the aorta is present in approximately 65% of people. Variations in the origin of the branches are fairly common.



Superior Mediastinum, Tracheal Bifurcation

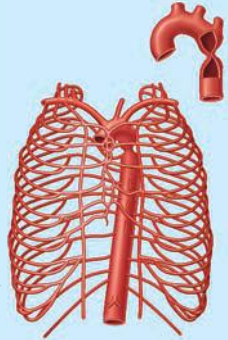


Superior Mediastinum, Tracheal Bifurcation

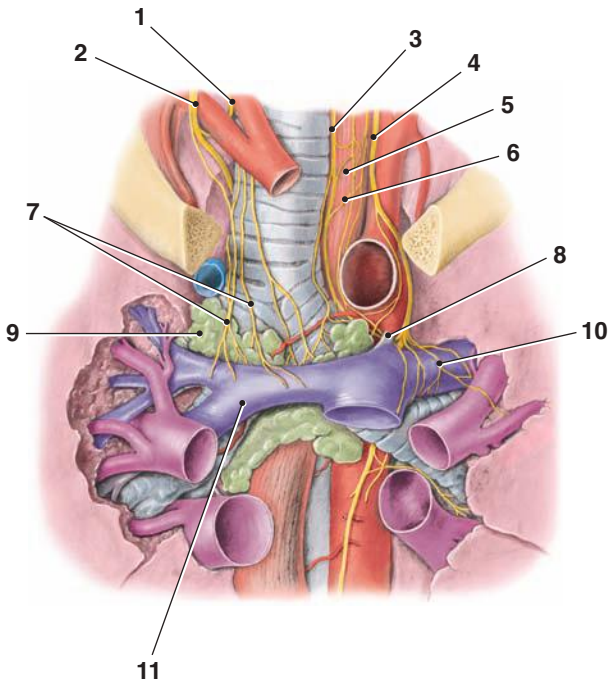
1. left vagus nerve
2. left recurrent laryngeal nerve
3. thoracic duct
4. trachea
5. arch of azygos vein
6. arch of aorta
7. bronchial arteries
8. right main bronchus
9. left main bronchus
10. root of lung
11. esophagus

In coarctation of the aorta, the arch of the aorta, or descending aorta, has an abnormal narrowing (stenosis) that diminishes the caliber of the aortic lumen, producing an obstruction to blood flow to the inferior part of the body. The most common site is near the ligamentum arteriosum.

Coarctation of the aorta



Superior Mediastinum, Nerves



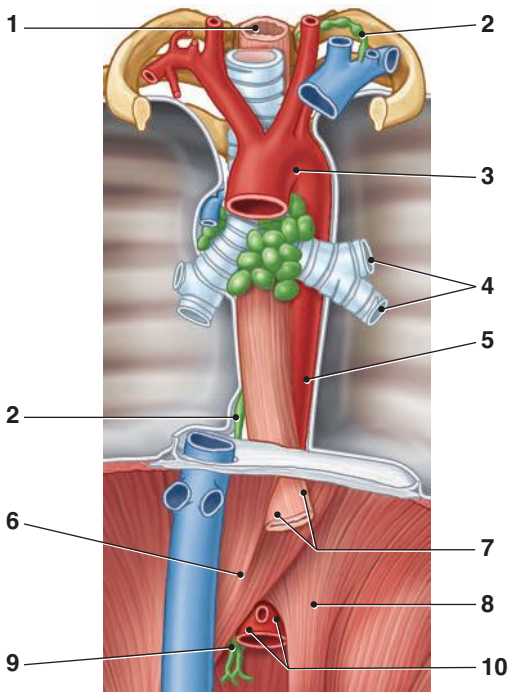
Superior Mediastinum, Nerves

1. right recurrent laryngeal nerve
2. right vagus nerve
3. left recurrent laryngeal nerve
4. left vagus nerve
5. esophagus
6. cervical cardiac nerves
7. cardiac plexus
8. ligamentum arteriosum
9. lymph nodes
10. anterior pulmonary plexus
11. right pulmonary artery

The recurrent laryngeal nerves supply all intrinsic muscles of the larynx except one, the cricothyroid.

Any diagnostic procedure or disease process in the superior mediastinum may injure the recurrent laryngeal nerves and affect the voice. The left recurrent laryngeal nerve, as a result of its course through the region, may be compromised in a bronchogenic or esophageal carcinoma, enlargement of mediastinal lymph nodes, or an aneurysm of the arch of the aorta.

Esophagus



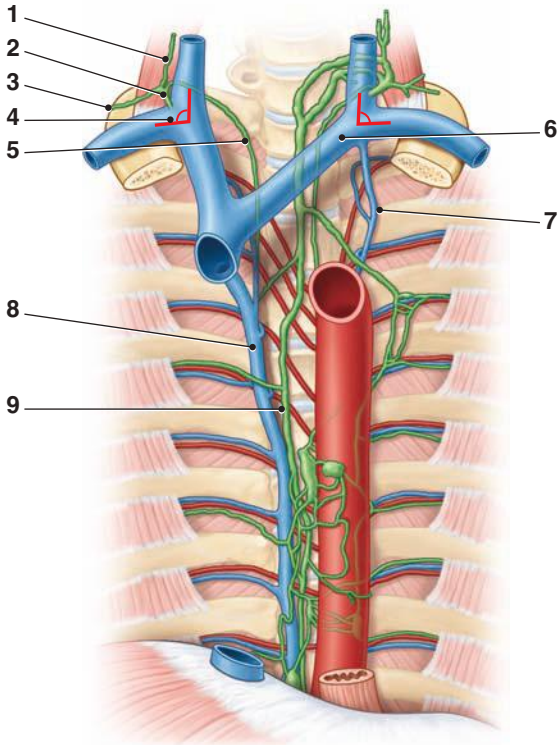
Esophagus

1. esophagus
2. thoracic duct
3. arch of aorta
4. left bronchi
5. descending aorta
6. right crus of diaphragm
7. esophageal hiatus
8. left crus of diaphragm
9. chyle cistern
10. aortic hiatus

The esophagus is compressed by three structures: (1) the arch of the aorta, (2) the left primary bronchus, and (3) the diaphragm.

The sites of compression of the esophagus by adjacent structures indicate where swallowed foreign objects are most likely to lodge and where a stricture may develop after accidental drinking of a caustic liquid.

Thoracic Duct



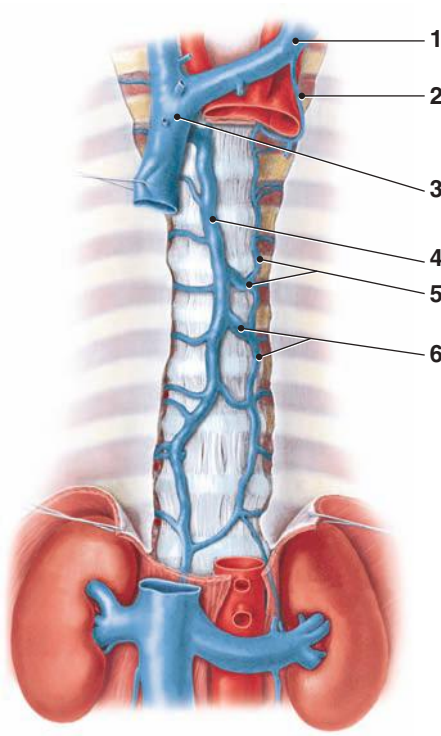
Thoracic Duct

1. jugular trunk
2. right lymphatic duct
3. subclavian trunk
4. right venous angle
5. bronchomediastinal trunk
6. left brachiocephalic vein
7. left superior intercostal vein
8. azygos vein
9. thoracic duct

Variations in the thoracic duct are common because of its embryological formation. Occasionally, there are two lymphatic ducts for a short distance.

Laceration of the thoracic duct during surgical or investigative procedures of the thorax results in lymph escaping into the thoracic cavity. The fluid may be removed by a needle tap or thoracocentesis, and, in some cases, it may be necessary to ligate the duct.

Azygos System of Veins



Azygos System of Veins

1. left brachiocephalic vein
2. left superior intercostal vein
3. superior vena cava
4. azygos vein
5. accessory hemiazygos vein
6. hemiazygos vein

The highly variable azygos system of veins drains the back, thoracoabdominal walls, and thoracic viscera.

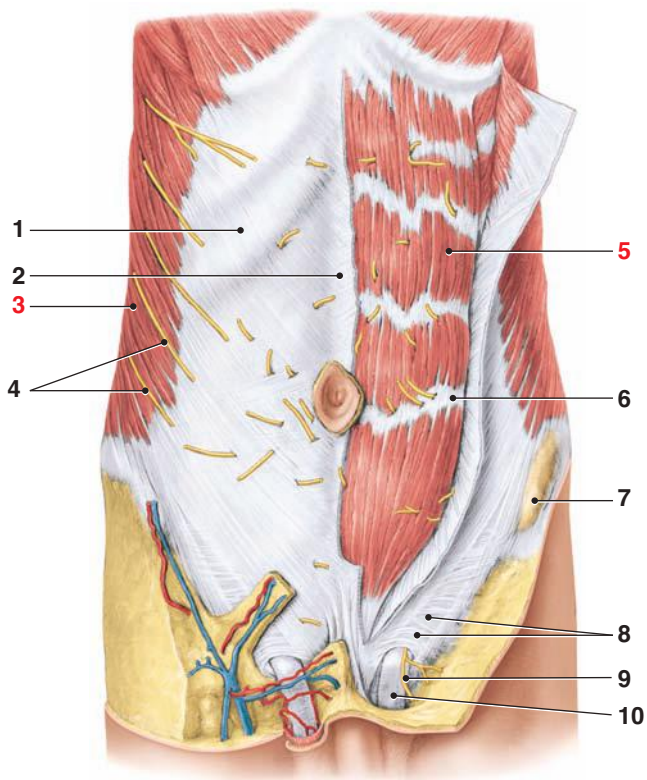
The azygos system of veins offers an alternative route for venous drainage from the thoracic, abdominal, and back regions when obstruction of either the superior or inferior vena cava occurs.

2 • Abdomen

- 2.1** Anterior Abdominal Wall, Superficial Dissection
- 2.2** Anterior Abdominal Wall, Musculature
- 2.3** Trunk
- 2.4** Drainage of the Anterior Abdominal Wall
- 2.5** Neurovascular Elements, Penis and Spermatic Cord
- 2.6** Inguinal Canal of the Female
- 2.7** Posterior Aspect of Anterolateral Abdominal Wall
- 2.8** Inguinal Region of the Male
- 2.9** Inguinal Region of the Male, Musculature
- 2.10** Spermatic Cord
- 2.11** Scrotum
- 2.12** Anterior Abdominal Wall, Deep Dissection
- 2.13** Testis and Epididymis
- 2.14** Peritoneal Cavity
- 2.15** Greater Omentum
- 2.16** Posterior Wall of Peritoneal Cavity
- 2.17** Stomach and Omenta
- 2.18** Omental Bursa
- 2.19** Porta Hepatis and Gallbladder
- 2.20** Stomach
- 2.21** Diaphragm, Inferior View
- 2.22** Internal Aspect of the Stomach
- 2.23** Duodenum, Anterior View
- 2.24** Duodenum, Posterior View
- 2.25** Superior Mesenteric Artery
- 2.26** Appendix
- 2.27** Inferior Mesenteric Artery
- 2.28** Colon
- 2.29** Spleen
- 2.30** Pancreas

- 2.31** Bile and Pancreatic Ducts
- 2.32** Liver, Anterior View
- 2.33** Liver, Superior View
- 2.34** Hepatic Arteries
- 2.35** Gallbladder
- 2.36** Portal System
- 2.37** Viscera of Posterior Abdominal Wall
- 2.38** Kidney
- 2.39** Kidney, Internal View
- 2.40** Posterior Abdominal Wall
- 2.41** Nerves of the Diaphragm
- 2.42** Aortic Plexus

Anterior Abdominal Wall, Superficial Dissection



Anterior Abdominal Wall, Superficial Dissection

1. anterior layer of rectus sheath
2. linea alba
3. external oblique
4. lateral abdominal cutaneous branches
5. rectus abdominis
6. tendinous intersection
7. anterior superior iliac spine
8. intercrural fibers
9. ilioinguinal nerve
10. spermatic cord

Rectus Abdominis

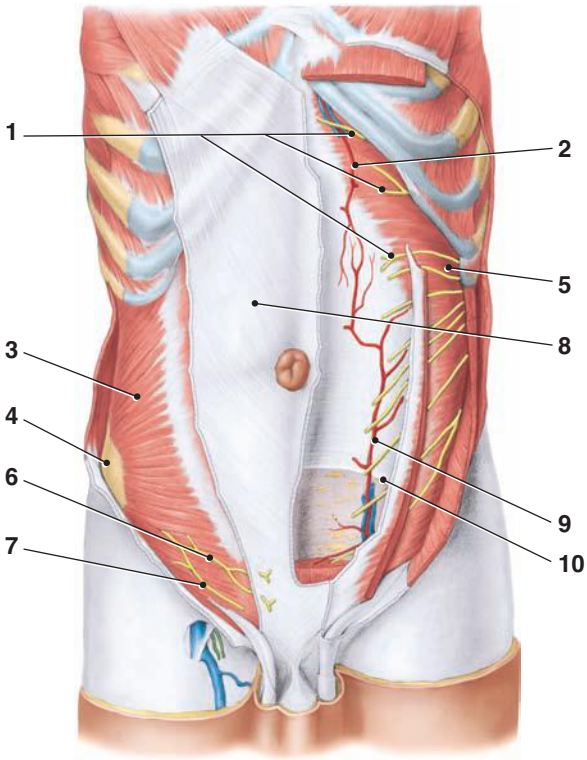
- proximal attachment: pubic symphysis and crest
- distal attachment: xiphoid process, 5th to 7th costal cartilages
- innervation: thoracoabdominal nerves
- main action: flexes trunk, compresses viscera

External Oblique

- proximal attachment: 5th to 12th ribs
- distal attachment: linea alba, pubic tubercle, iliac crest
- innervation: thoracoabdominal nerves
- main action: flexes and rotates trunk, compresses viscera

The muscles of the abdominal wall contract involuntarily and are rigid when the abdomen is touched or an underlying organ is inflamed; this is the guarding reflex.

Anterior Abdominal Wall, Musculature



Anterior Abdominal Wall, Musculature

1. thoracoabdominal nerves
2. superior epigastric artery
3. internal oblique
4. anterior superior iliac spine
5. transverse abdominal
6. iliohypogastric nerve
7. ilioinguinal nerve
8. rectus sheath
9. inferior epigastric artery
10. arcuate line

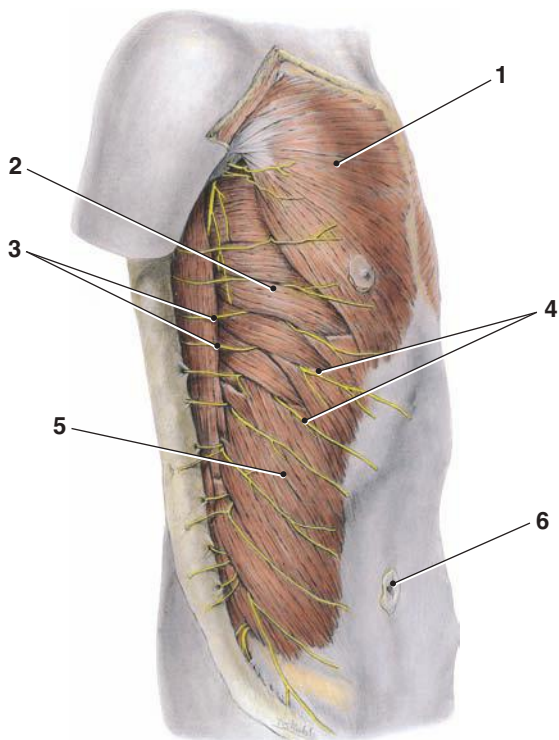
Internal Oblique

- proximal attachment: thoracolumbar fascia, iliac crest, inguinal ligament
- distal attachment: 10th to 12th ribs, linea alba, pecten pubis
- innervation: thoracoabdominal nerves
- main action: flexes, rotates trunk; compresses viscera

Transverse Abdominal

- proximal attachment: 7th to 12th costal cartilages, thoracolumbar fascia, iliac crest, inguinal ligament
- distal attachment: linea alba, pubic crest, pecten pubis
- innervation: thoracoabdominal nerves
- main action: compresses viscera

Trunk



Trunk

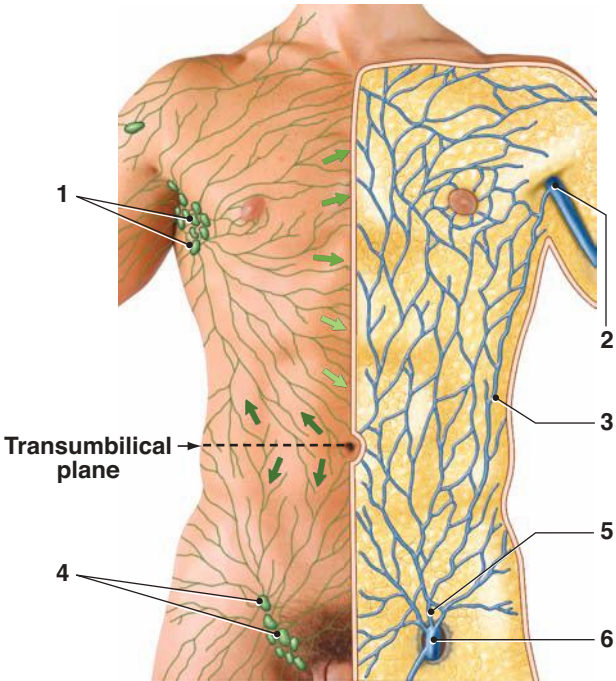
1. pectoralis major
2. serratus anterior
3. posterior branches of lateral cutaneous nerves
4. anterior branches of lateral cutaneous nerves
5. external oblique
6. umbilicus

The nerves of the abdominal wall innervate the musculature segmentally and run obliquely and horizontally across the abdomen. Care must be taken to not damage them during surgical procedures. Abdominal incisions are typically made in line with the cleavage lines of the skin and with the muscle fibers that must be passed through in order to preserve function.

Drainage of the Anterior Abdominal Wall

Lymphatic drainage

Venous drainage



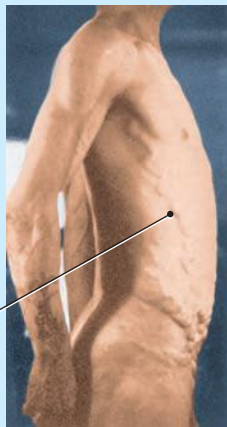
Drainage of the Anterior Abdominal Wall

1. axillary lymph nodes
2. axillary vein
3. thoracoepigastric vein
4. superficial inguinal lymph nodes
5. superficial epigastric vein
6. femoral vein

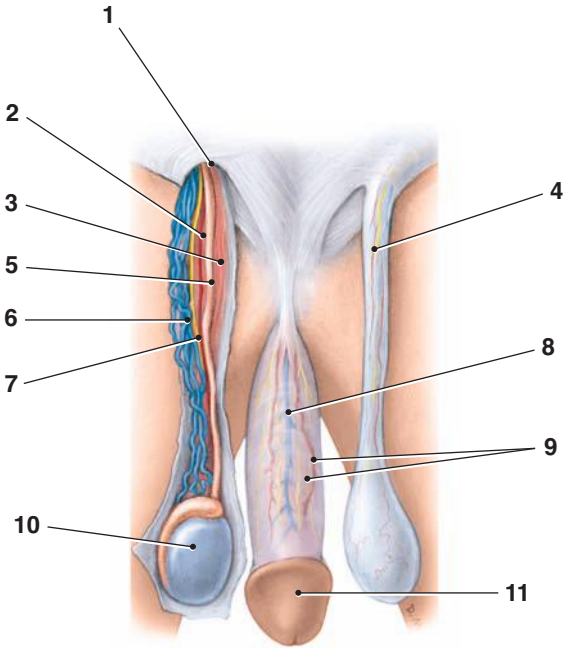
Lymph superior to the transumbilical plane drains to the axillary lymph nodes, while lymph inferior to the plane drains to the superficial inguinal lymph nodes.

When flow in the superior or inferior vena cava is blocked, anastomoses between their tributaries, like the thoracoepigastric vein, may provide collateral circulation, allowing the obstruction to be bypassed.

Thoracoepigastric vein



Neurovascular Elements, Penis and Spermatic Cord

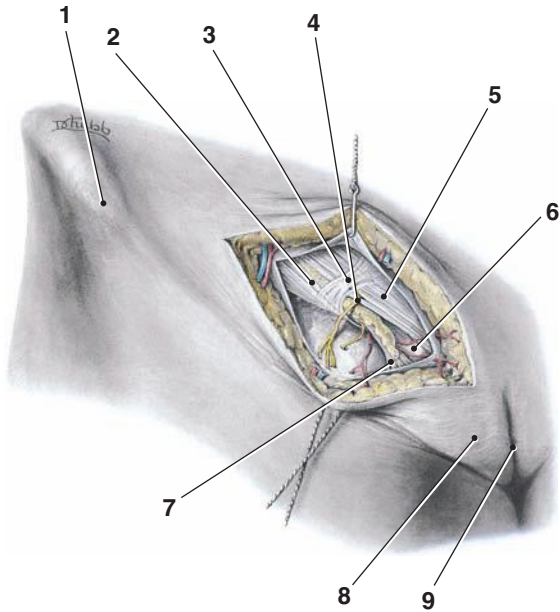


Neurovascular Elements, Penis and Spermatic Cord

1. superficial inguinal ring
2. testicular artery
3. cremaster
4. genitofemoral nerve
5. ductus deferens
6. pampiniform plexus of veins
7. ilioinguinal nerve
8. dorsal vein of the penis
9. dorsal artery and nerve of the penis
10. testis
11. glans penis

The testes are undescended in approximately 3% of full-term and 30% of premature infants. Cryptorchism is a condition in which the testis (often unilateral) is not descended or is not retractable. There is a greatly increased risk of malignancy in the undescended testis.

Inguinal Canal of the Female



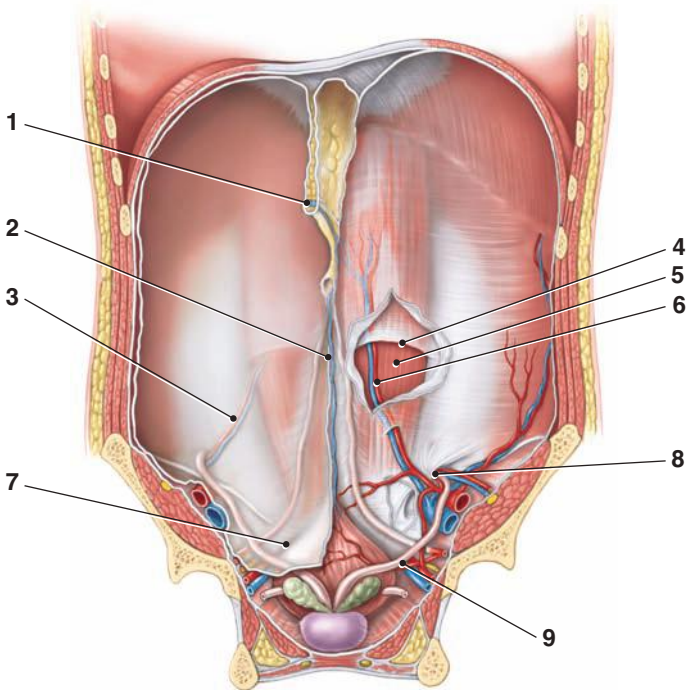
Inguinal Canal of the Female

1. anterior superior iliac spine
2. lateral crus of aponeurosis of external oblique
3. intercrural fibers
4. ilioinguinal nerve
5. medial crus of aponeurosis of external oblique
6. pubic tubercle
7. round ligament of the uterus
8. labium majus
9. pudendal cleft

Indirect inguinal hernias may occur in women, although they are 20 times more common in men. A persistent processus vaginalis in females forms a small peritoneal pouch—the canal of Nuck, which may extend into the labium majus and form cysts in the inguinal canal.

Metastatic uterine cancer cells can spread from the uterus to the labium majus and from there to the superficial inguinal nodes.

Posterior Aspect of Anterolateral Abdominal Wall



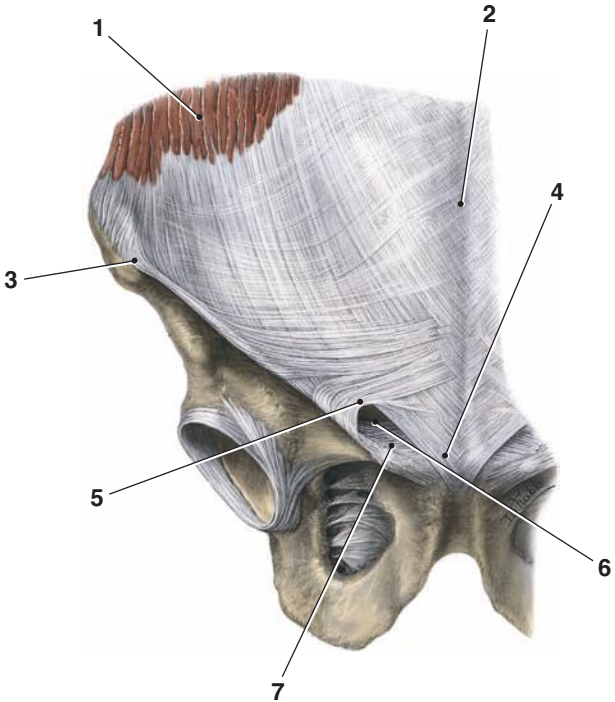
Posterior Aspect of Anterolateral Abdominal Wall

1. round ligament of the liver
2. median umbilical fold
3. lateral umbilical fold
4. arcuate line
5. rectus abdominis
6. inferior epigastric vein and artery
7. suprapubic fossa
8. deep inguinal ring
9. ductus deferens

An external suprapubic hernia leaves the peritoneal cavity through the suprapubic fossa, medial to a direct inguinal hernia. The iliohypogastric nerve is in danger of injury during repair of this hernia.

Before birth, the umbilical vein carries blood from the placenta to the fetus. This vein is patent for some time after birth and is used for umbilical vein catheterization.

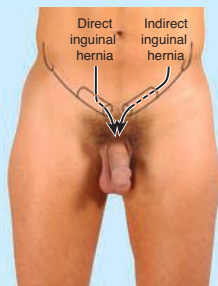
Inguinal Region of the Male



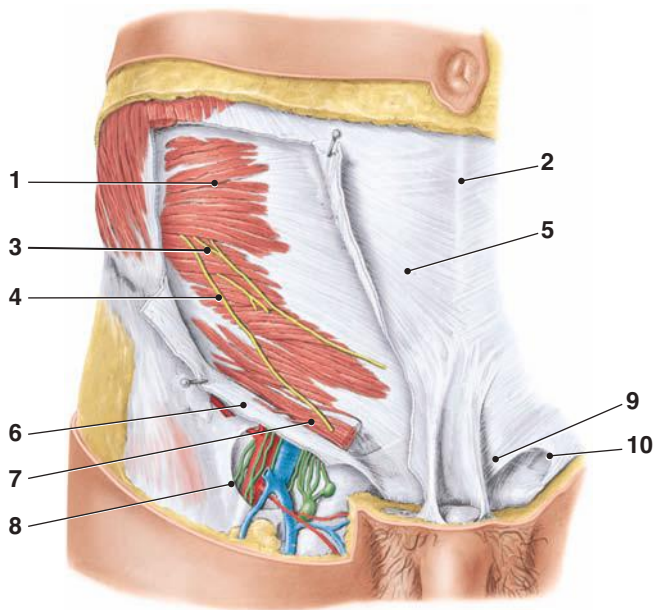
Inguinal Region of the Male

1. external oblique
2. linea alba
3. anterior superior iliac spine
4. medial crus
5. intercrural fibers
6. superficial inguinal ring
7. lacunar ligament

An inguinal hernia is a protrusion of parietal peritoneum and viscera through an opening from the cavity in which they belong. An indirect inguinal hernia follows the inguinal canal, entering the deep inguinal ring and exiting via the superficial inguinal ring. A direct inguinal hernia enters the canal through its posterior wall.



Inguinal Region of the Male, Musculature



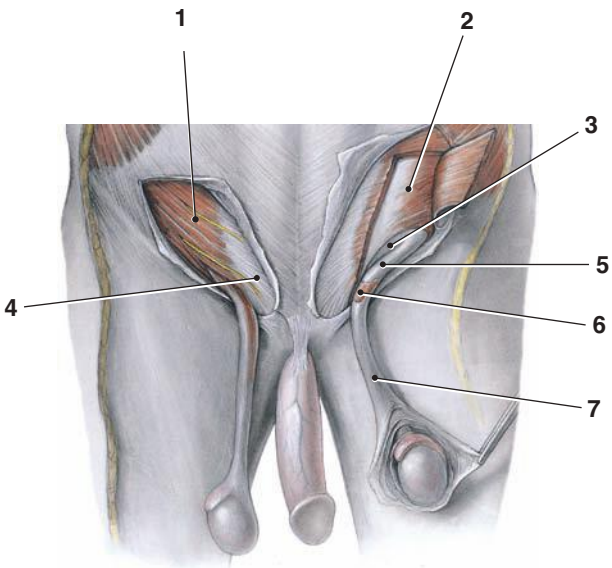
Inguinal Region of the Male, Musculature

1. internal oblique
2. linea alba
3. iliohypogastric nerve
4. ilioinguinal nerve
5. rectus sheath
6. inguinal ligament
7. cremaster
8. saphenous opening
9. medial crus
10. lateral crus

The conjoint tendon is formed by the fusion of the aponeurosis of the internal oblique and transverse abdominal muscles.

Contraction of the cremaster is elicited by stroking the skin on the medial aspect of the superior part of the thigh. The ilioinguinal and genitofemoral nerves supply this area of skin while the genitofemoral nerve supplies the cremaster muscle. Rapid elevation of the ipsilateral testicle is the cremasteric reflex.

Spermatic Cord



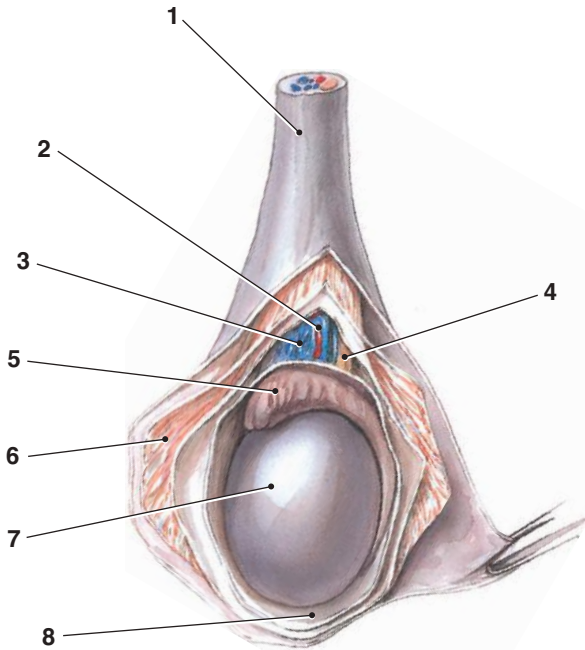
Spermatic Cord

1. internal oblique
2. transverse abdominal
3. transversalis fascia
4. conjoint tendon
5. internal spermatic fascia
6. cremaster
7. external spermatic fascia

Torsion (twisting) of the spermatic cord is a surgical emergency because the testicle may die. The torsion obstructs the venous drainage, causing edema, hemorrhage, and subsequent arterial obstruction.



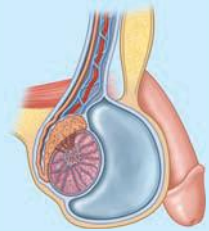
Scrotum



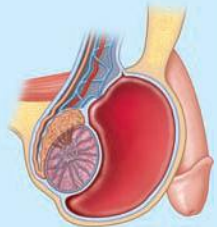
Scrotum

1. spermatic cord
2. testicular artery
3. pampiniform plexus of veins
4. ductus deferens
5. epididymis
6. cremaster and fascia
7. tunica vaginalis (visceral layer)
8. tunica vaginalis (parietal layer)

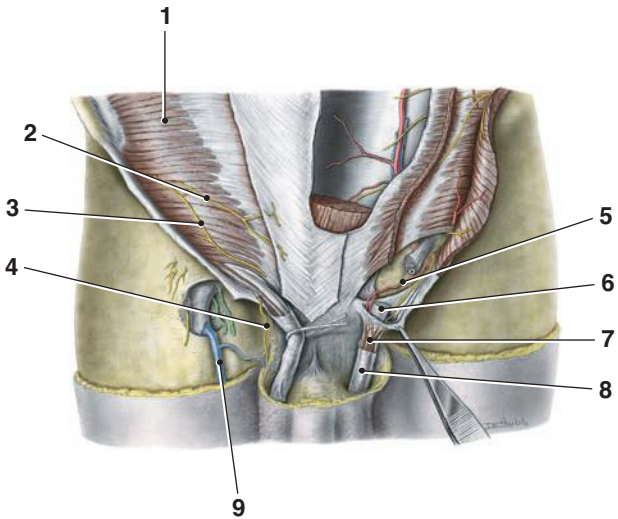
A hydrocele is excess fluid in a persistent processus vaginalis. It may be contained within the scrotum (hydrocele of the testis) or in the spermatic cord (hydrocele of the cord).



A hematocele of the testis is a collection of blood in the tunica vaginalis from trauma or rupture of the testicular artery.



Anterior Abdominal Wall, Deep Dissection



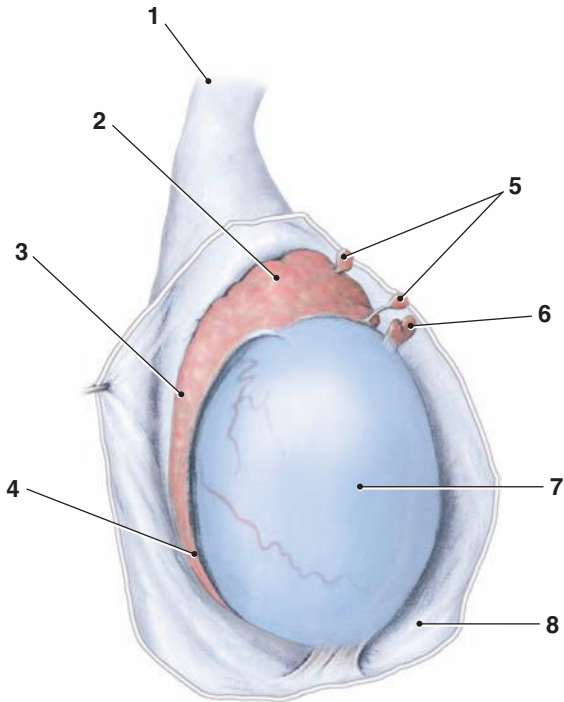
Anterior Abdominal Wall, Deep Dissection

1. internal oblique
2. iliohypogastric nerve
3. ilioinguinal nerve
4. genital branch of genitofemoral nerve
5. cremasteric artery
6. internal spermatic fascia
7. cremaster
8. external spermatic fascia
9. great saphenous vein

Coverings of the spermatic cord include the internal spermatic fascia, derived from the transversalis fascia; the cremaster muscle and fascia, from the internal oblique; and the external spermatic fascia, from the external oblique aponeurosis.

The anterior third of the scrotum is supplied by the ilioinguinal nerve (L1), while the posterior two-thirds is supplied by the perineal and posterior femoral cutaneous nerves (S3). Therefore, for anesthesia of the scrotum, it is necessary to inject more superiorly to anesthetize the anterior surface than the posterior surface.

Testis and Epididymis

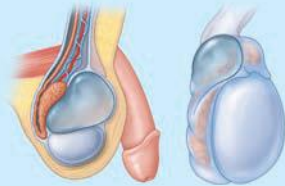


Testis and Epididymis

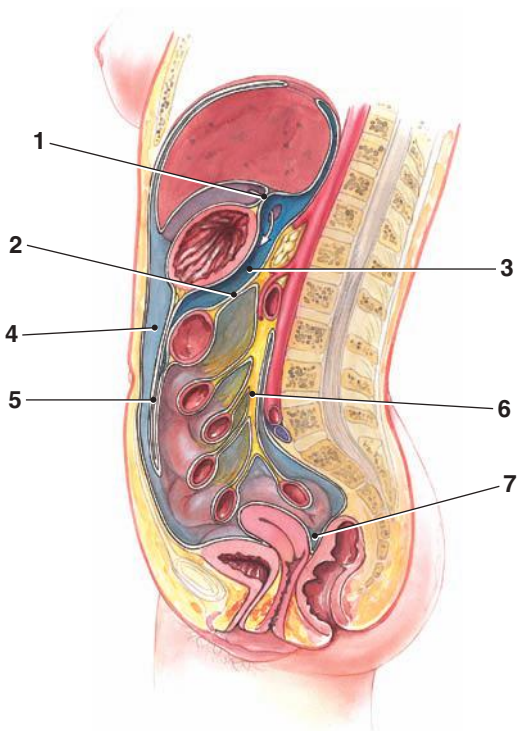
1. spermatic cord
2. head of the epididymis
3. body of the epididymis
4. tail of the epididymis
5. appendix of epididymis
6. appendix of testis
7. testis covered by the visceral layer of tunica vaginalis
8. parietal layer of tunica vaginalis

A spermatocele is a cyst in the epididymis, usually near its head. An epididymal cyst is a collection of fluid anywhere in the epididymis.

The appendix of the testis is a remnant of the paramesonephric duct. The appendices of the epididymis are remnants of the mesonephric duct. Both are rare unless pathological changes occur.



Peritoneal Cavity



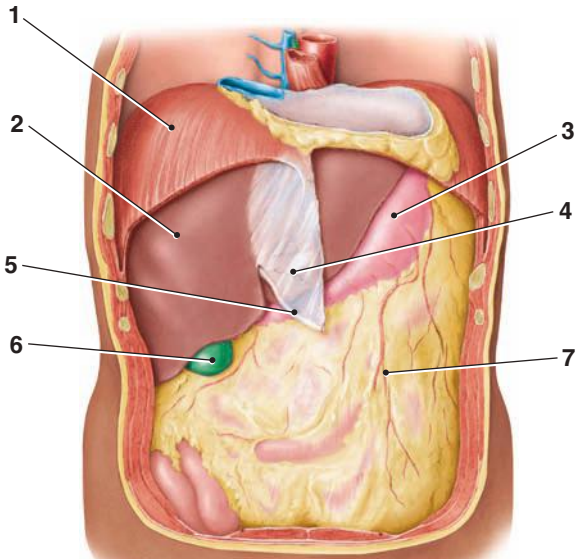
Peritoneal Cavity

1. lesser omentum
2. transverse mesocolon
3. omental bursa
4. greater sac
5. greater omentum
6. mesentery of small intestine
7. rectouterine pouch

Peritonitis is inflammation of the peritoneal cavity. It may occur as a result of trauma, infection, or surgery. The inflamed peritoneum becomes sticky with fibrin that may be replaced by fibrous connective tissue during healing, forming adhesions, which may have to be surgically removed if they compromise proper function of the viscera.

Surgical puncture of the peritoneum is sometimes necessary to remove excess fluid (ascites) that accumulates during inflammation, to introduce anesthetic agents (intraperitoneal injection), or to conduct peritoneal dialysis.

Greater Omentum

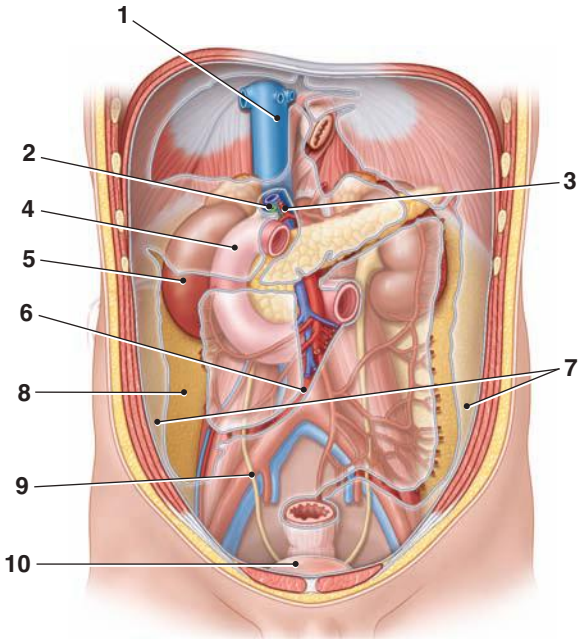


Greater Omentum

1. diaphragm
2. right lobe of liver
3. stomach
4. falciform ligament
5. round ligament of liver
6. fundus of gallbladder
7. greater omentum

The greater omentum prevents the visceral peritoneum from adhering to the parietal peritoneum, cushions the abdominal organs against injury, and insulates against loss of body heat. The normally mobile greater omentum forms adhesions in response to inflammation to wall off the affected area.

Posterior Wall of Peritoneal Cavity

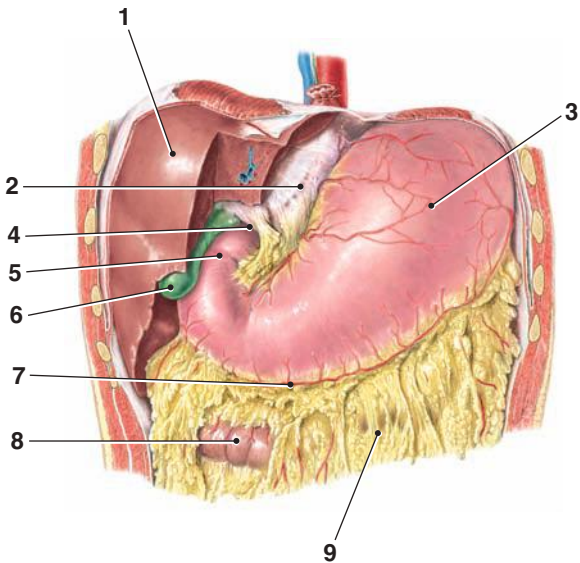


Posterior Wall of Peritoneal Cavity

1. inferior vena cava
2. bile duct
3. hepatic artery
4. duodenum
5. right kidney
6. root of mesentery of small intestine
7. paracolic gutters
8. site of ascending colon
9. right ureter
10. uterus

The paracolic gutters provide pathways for the flow of ascitic fluid and the spread of intraperitoneal infections and tumor cells. When a person is standing, purulent material may travel along the gutters into the pelvis, where absorption of toxins is slow.

Stomach and Omenta



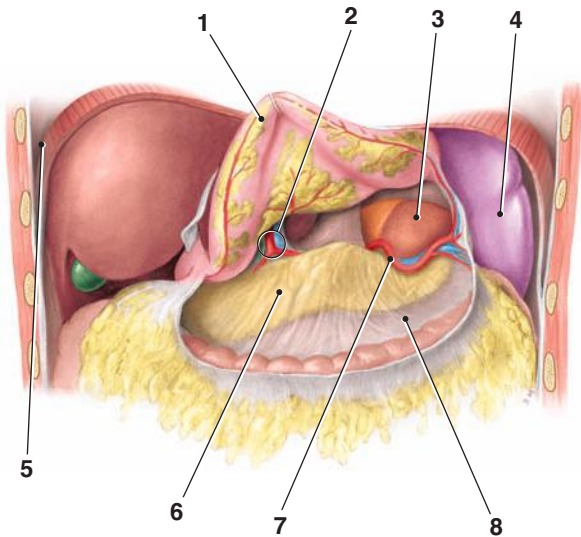
Stomach and Omenta

1. liver
2. lesser omentum
3. stomach
4. omental (epiploic) foramen
5. duodenum
6. gallbladder
7. right gastroepiploic (epiploic) artery
8. transverse colon
9. greater omentum

Perforation of a duodenal ulcer, rupture of the gallbladder, or perforation of the appendix may lead to the formation of a circumscribed collection of purulent exudate in the subphrenic recess (space between the inferior surface of the diaphragm and the liver).

Although it is uncommon, a loop of small intestine may pass through the omental foramen into the omental bursa and be strangulated by the edges of the foramen.

Omental Bursa



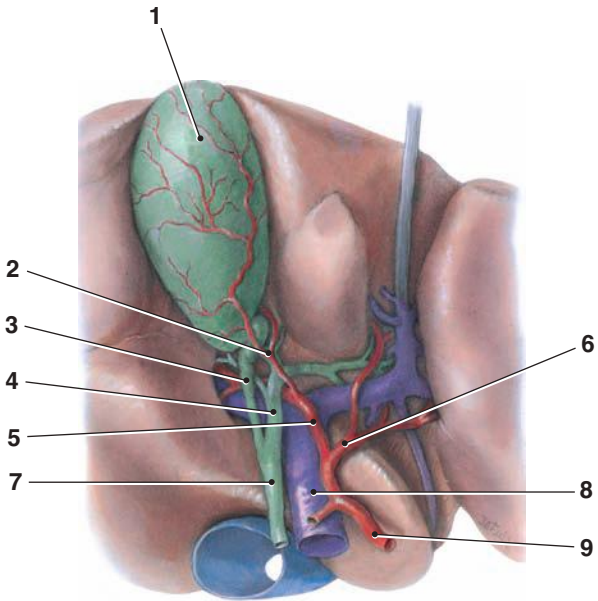
Omental Bursa

1. greater curvature of stomach
2. portal triad
3. left kidney
4. spleen
5. costodiaphragmatic recess
6. body of pancreas
7. splenic artery
8. transverse mesocolon

The figure shows the opened omental bursa.

Perforation of the posterior wall of the stomach results in the passage of its contents into the omental bursa. An inflamed or injured pancreas may pass pancreatic fluid into the bursa, forming a pancreatic pseudocyst.

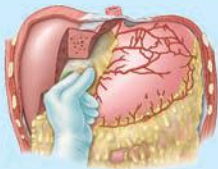Porta Hepatis and Gallbladder



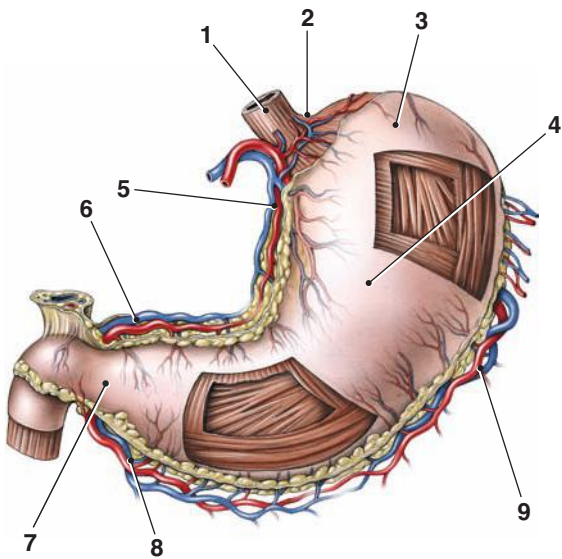
Porta Hepatis and Gallbladder

1. gallbladder
2. cystic artery
3. cystic duct
4. common hepatic duct
5. right hepatic artery
6. left hepatic artery
7. bile duct
8. hepatic portal vein
9. hepatic artery

The cystic artery must be ligated or clamped during cholecystectomy, or removal of the gallbladder. Flow through the cystic artery can be controlled by compressing the hepatic artery in the hepatoduodenal ligament.



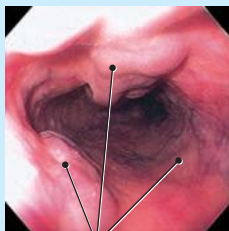
Stomach



Stomach

1. esophagus
2. cardiac notch
3. fundus
4. body
5. left gastric artery and vein
6. right gastric artery and vein
7. pyloric canal
8. right gastroepiploic artery and vein
9. left gastroepiploic artery and vein

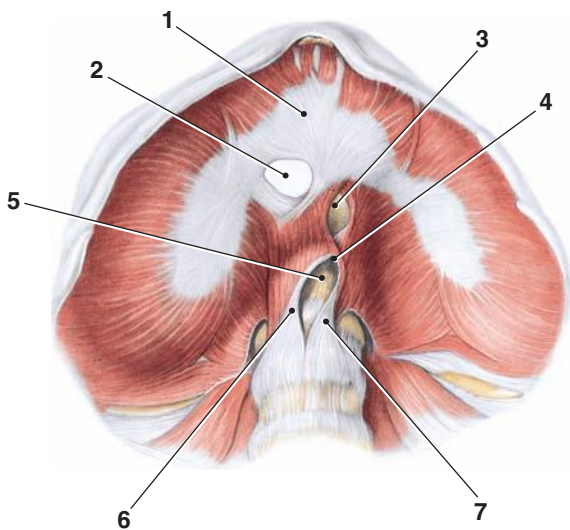
Esophageal varices are dilated esophageal veins that may rupture in cases of portal hypertension, as they drain to both the portal and systemic systems.



View through esophagoscope
of esophageal varices

Pyrosis (heartburn) is usually the result of regurgitation of gastric fluid and/or food into the lower esophagus (gastroesophageal reflux disorder or GERD).

Diaphragm, Inferior View

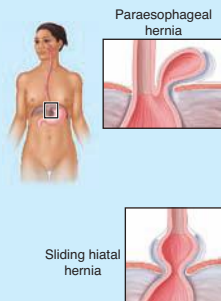


Diaphragm, Inferior View

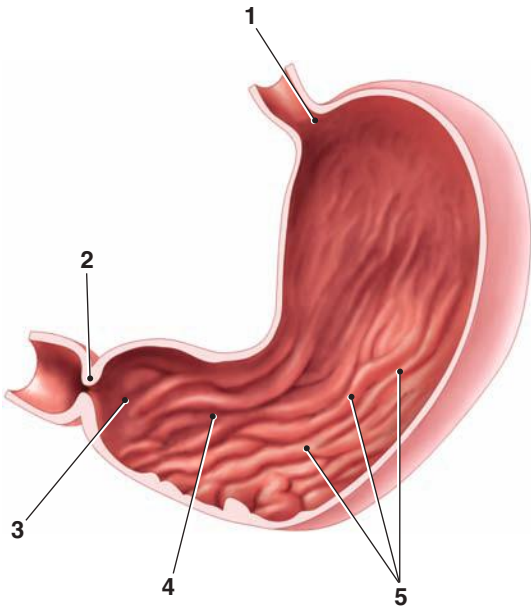
1. central tendon
2. caval opening
3. esophageal hiatus
4. median arcuate ligament
5. aortic hiatus
6. right crus
7. left crus

A hiatal hernia is protrusion of part of the stomach into the mediastinum through the esophageal hiatus of the diaphragm. In a paraesophageal hernia, a pouch of peritoneum, often with the fundus of the stomach, protrudes. In a sliding hiatal hernia, the esophagus, cardia, and part of the fundus protrude.

In a congenital diaphragmatic hernia, part of the stomach and intestine protrude through a posterior defect in the diaphragm.



Internal Aspect of the Stomach

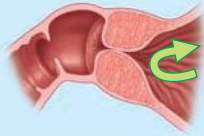

Internal Aspect of the Stomach

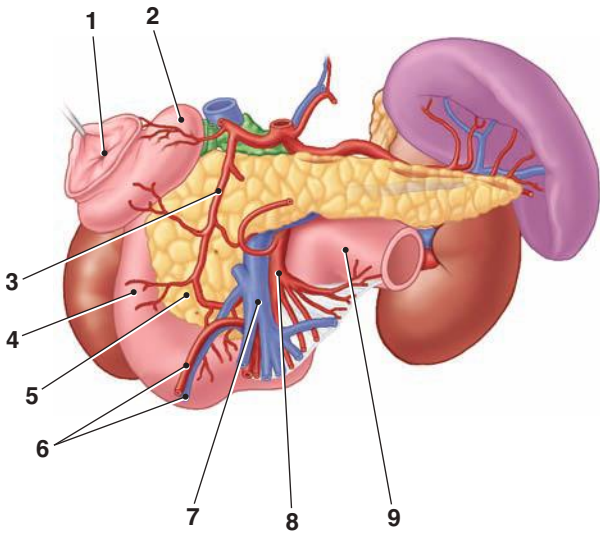
1. cardiac orifice of the stomach
2. pyloric sphincter
3. pyloric canal
4. pyloric antrum
5. gastric folds (rugae)

Pylorospasm (spasmodic contraction of the pylorus) is characterized by failure of the pyloric sphincter to relax so that food does not pass easily from the stomach to duodenum. This occurs most often in infants; the result is overfilling of the stomach and vomiting.

Congenital hypertrophic pyloric stenosis is a marked thickening of the pyloric sphincter. The resulting stenosis of the pyloric canal interferes with normal stomach emptying.



Duodenum, Anterior View



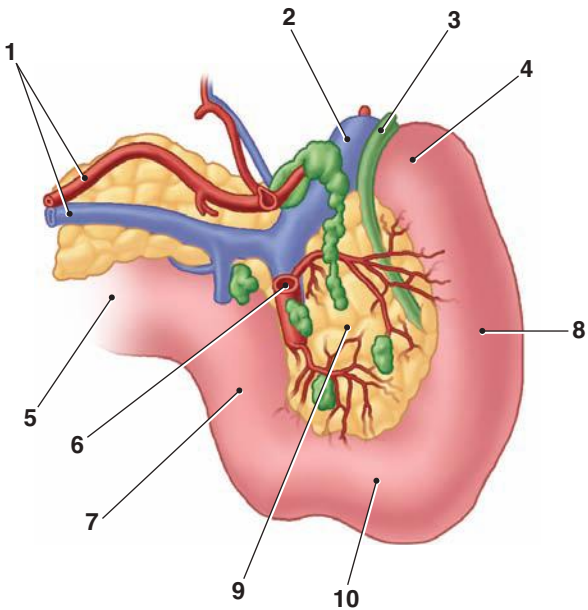
Duodenum, Anterior View

1. pylorus
2. 1st part of duodenum
3. gastroduodenal artery
4. 2nd part of duodenum
5. head of the pancreas
6. right colic artery and vein
7. superior mesenteric vein
8. superior mesenteric artery
9. jejunum

Duodenal ulcers are inflammatory erosions of the duodenal mucosa. The ulcer may perforate the duodenal wall, leading to peritonitis or erosion of the posteriorly related gastroduodenal artery, resulting in severe hemorrhage.

The shared blood supply to the duodenum and head of the pancreas makes it impossible to remove the entire pancreas in a pancreatectomy. A rim of the pancreas is retained along the medial border of the duodenum to preserve the blood supply.

Duodenum, Posterior View

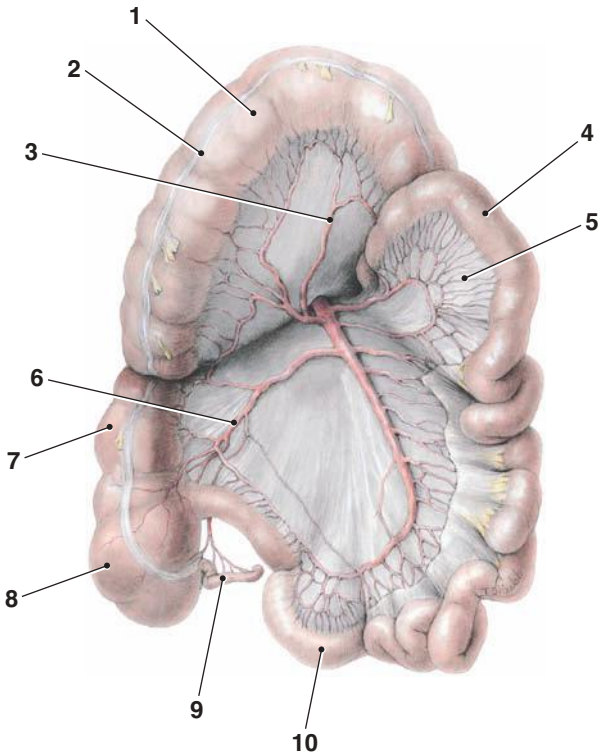


Duodenum, Posterior View

1. splenic artery and vein
2. portal vein
3. bile duct
4. 1st part of the duodenum
5. jejunum
6. superior mesenteric artery
7. 4th part of the duodenum
8. 2nd part of the duodenum
9. head of the pancreas
10. 3rd part of the duodenum

The secondarily retroperitoneal portions of the duodenum (parts 2 and 3) are easily mobilized during surgery because fusion fascia (embryological mesentery) fixes them to the posterior abdominal wall. Parts 1 and 4 remain mesenterized in the adult.

Superior Mesenteric Artery

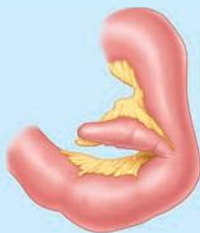

Superior Mesenteric Artery

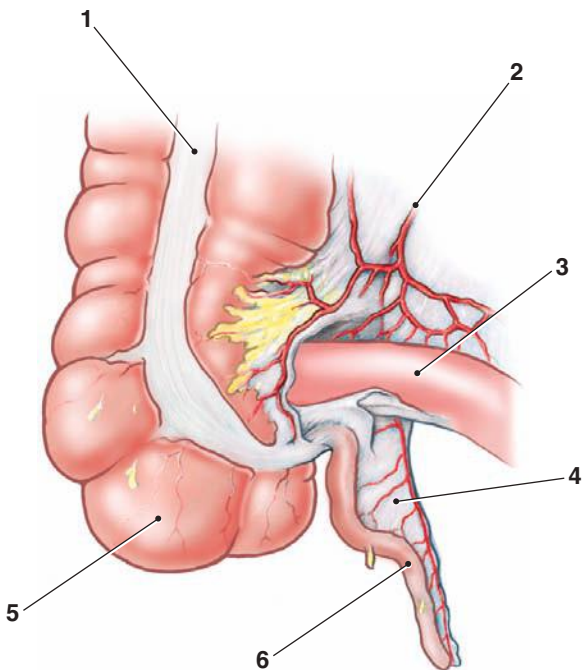
1. transverse colon
2. tenia coli
3. middle colic artery
4. jejunum
5. vasa recta
6. ileocolic artery
7. ascending colon
8. cecum
9. appendix
10. ileum

Occlusion of the vasa recta results in ischemia of the part of the intestine concerned, which may result in necrosis and ileus (obstruction of the intestine) of the paralytic type.

An ileal diverticulum is a remnant of the proximal part of the yolk stalk. The diverticulum may become inflamed and produce pain that mimics appendicitis.



Appendix



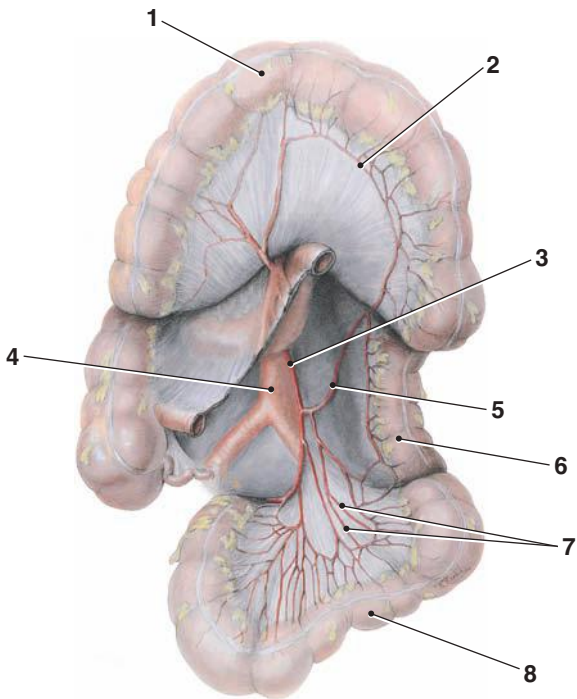
Appendix

1. tenia coli
2. ileocolic artery
3. ileum
4. mesoappendix
5. cecum
6. appendix

Inflammation of the appendix, or appendicitis, is a common cause of an acute abdomen. An appendectomy may be necessary to remove the inflamed appendix to ameliorate pain and prevent rupture.

When the inferior part of the ascending colon (normally secondarily retroperitoneal) has a mesentery, volvulus of the colon, or an obstruction of intestine resulting from twisting, may occur. Suturing of the tenia coli to the abdominal wall, or cecopexy, may alleviate the problem.

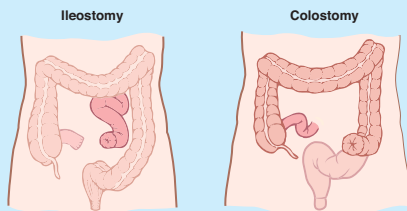
Inferior Mesenteric Artery



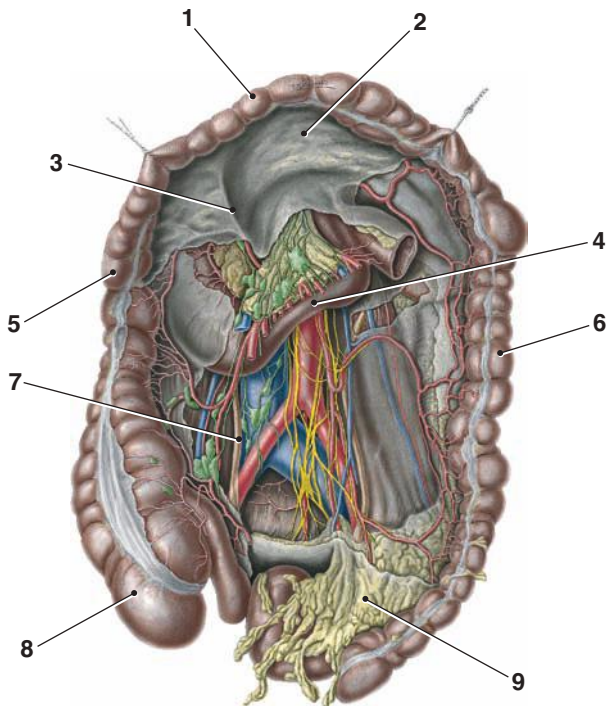
Inferior Mesenteric Artery

1. transverse colon
2. marginal artery
3. inferior mesenteric artery
4. aorta
5. left colic artery
6. descending colon
7. sigmoid arteries
8. sigmoid colon

Colitis is severe inflammation of the colon and rectum. In some cases, a colectomy is performed, during which the terminal ileum, colon, rectum, and anal canal are removed. An ileostomy is constructed to establish an opening between the ileum and the skin. Sometimes, a colostomy is performed to create an opening into the colon.



Colon

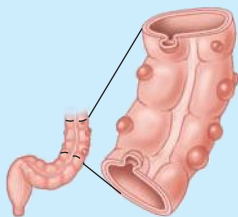
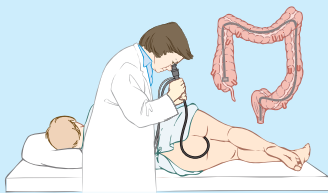


Colon

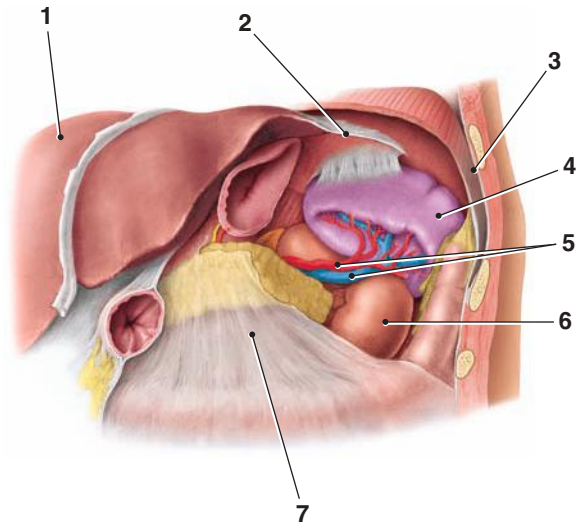
1. transverse colon
2. transverse mesocolon
3. middle colic artery
4. 3rd part of duodenum
5. ascending colon
6. descending colon
7. right ureter
8. cecum
9. sigmoid mesocolon

The interior of the colon can be observed in a colonoscopy using an elongated flexible endoscope inserted into the anus.

Diverticulosis is a disorder in which false diverticula develop along the colon. They are extensions of the mucous membrane, commonly found along the sigmoid colon. They project through the muscular wall and may inflame and rupture.



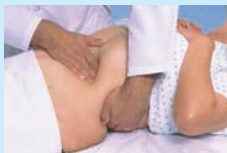Spleen



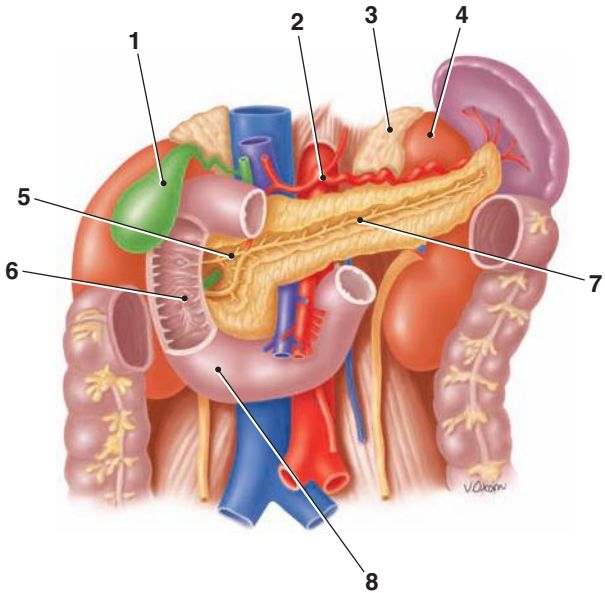
Spleen

1. liver
2. left triangular ligament
3. costodiaphragmatic recess
4. spleen
5. splenic artery and vein
6. left kidney
7. transverse mesocolon

Broken ribs or a sudden increase in intraabdominal pressure may cause rupture of the spleen and profuse bleeding. Total or partial removal of the spleen is performed to prevent excessive blood loss subsequent to injury. The spleen enlarges (splenomegaly) in response to a variety of conditions; the enlarged spleen can be detected by palpation below the costal margin.



Pancreas



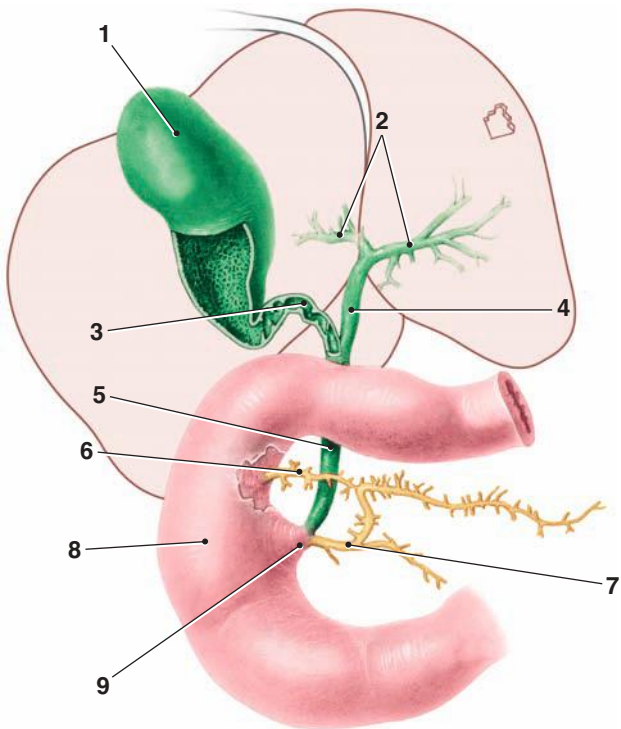
Pancreas

1. gallbladder
2. celiac artery
3. left suprarenal gland
4. left kidney
5. accessory pancreatic duct
6. major duodenal papilla
7. main pancreatic duct
8. duodenum

The friable pancreas may rupture because of extreme traumatic force, causing pancreatic juices to enter the gland and invade adjacent organs, causing great pain.

Pancreatic cancer is difficult to identify and treat because of its location and quick metastasis to the liver, which results in a low survival rate. Pancreatic cancer may be indicated by jaundice and/or back pain.

Bile and Pancreatic Ducts

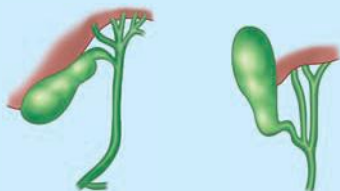


Bile and Pancreatic Ducts

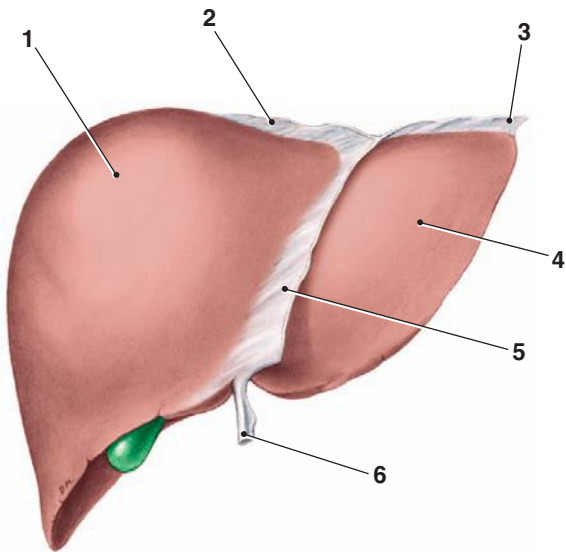
1. gallbladder
2. right and left hepatic ducts
3. cystic duct
4. common hepatic duct
5. bile duct
6. accessory pancreatic duct
7. main pancreatic duct
8. 2nd part of duodenum
9. hepatopancreatic ampulla

A gallstone may lodge in the hepatopancreatic ampulla, block the biliary and pancreatic duct systems, and cause bile to back up into the pancreas, producing pancreatitis. An accessory pancreatic duct may compensate for the obstruction of the main duct.

Accessory (aberrant) hepatic ducts are common and are in positions of danger during cholecystectomy.



Liver, Anterior View



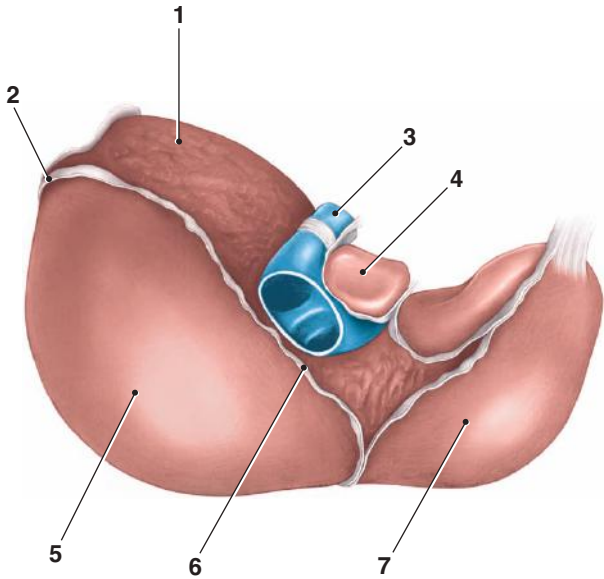
Liver, Anterior View

1. right lobe
2. coronary ligament
3. left triangular ligament
4. left lobe
5. falciform ligament
6. round ligament of the liver

The large, friable liver is easily injured, especially by a broken rib. Liver lacerations often cause considerable hemorrhage and pain. In such instances, the damaged segment of liver may be removed via a segmentectomy.

A needle inserted into the right 10th intercostal space near the midaxillary line is used to obtain hepatic tissue for biopsy. The patient is asked to hold his or her breath in full expiration to lessen the risk of damaging the lung.

Liver, Superior View



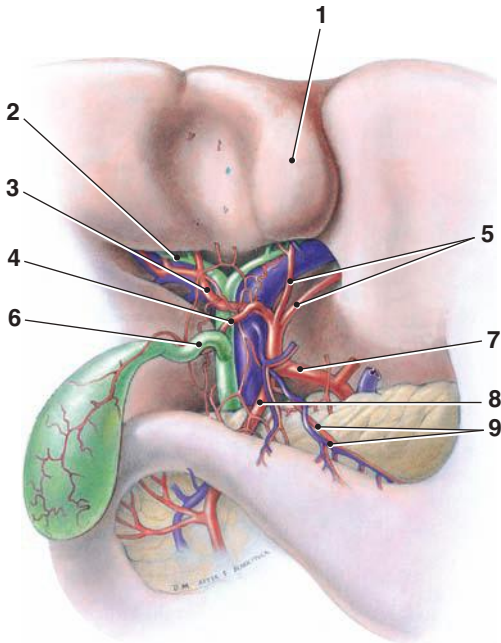
Liver, Superior View

1. bare area
2. right triangular ligament
3. inferior vena cava
4. caudate lobe
5. right lobe
6. coronary ligament
7. left lobe

Hepatic cirrhosis is characterized by replacement of hepatocytes with fat and fibrous tissue. It is most commonly seen in alcoholics (alcoholic cirrhosis), the most common cause of portal hypertension.

Hepatomegaly, or enlargement of the liver, may be caused by hepatic engorgement (such as from congestive heart failure), bacterial or viral disease, or tumor. An enlarged liver may cause pain and may be palpable below the costal margin in the right upper quadrant.

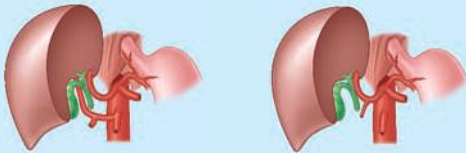
Hepatic Arteries



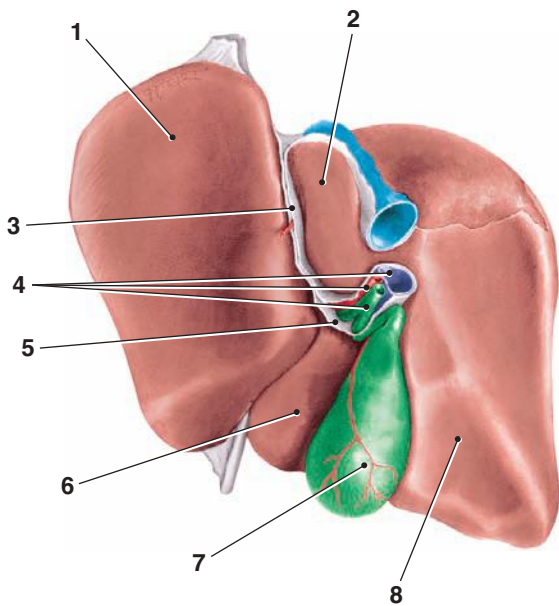
Hepatic Arteries

1. quadrate lobe of liver
2. right hepatic duct
3. right hepatic branch
4. cystic artery
5. middle and left hepatic branches
6. cystic duct
7. common hepatic artery
8. gastroduodenal artery
9. right gastric artery and vein

Variations in the relations of the hepatic arteries to surrounding structures are fairly common. Aberrant hepatic arteries are also possible: the right hepatic branch often comes off the superior mesenteric, while the left branch often comes off of the left gastric artery.



Gallbladder

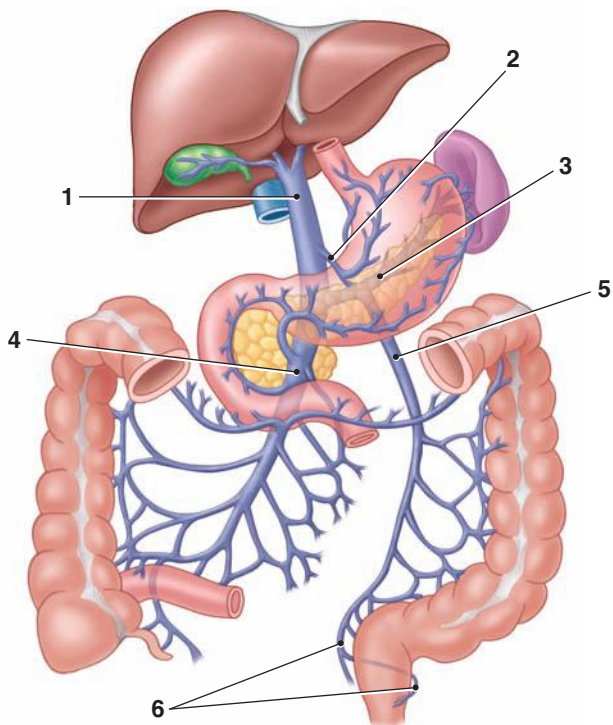


Gallbladder

1. left lobe
2. caudate lobe
3. lesser omentum
4. portal vein, hepatic artery, bile duct
5. porta hepatis
6. quadrate lobe
7. gallbladder
8. right lobe

A gallstone is a concretion in the gallbladder, cystic duct, or bile duct composed chiefly of cholesterol crystals. The distal end of the hepatopancreatic ampulla and the infundibulum of the gallbladder are common sites for impaction of gallstones. Gallstones may block drainage of bile, causing inflammation, jaundice, and pain. The gallbladder may be removed via laparoscopic cholecystectomy.

Portal System

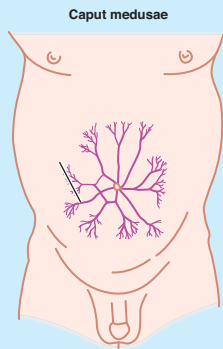


Portal System

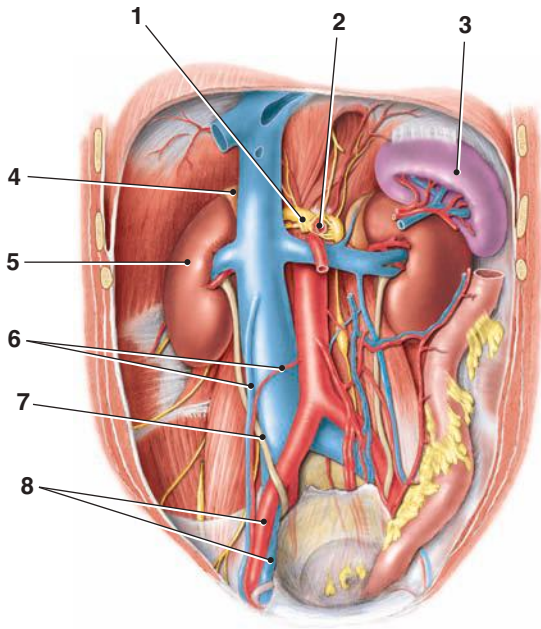
1. hepatic portal vein
2. right gastric vein
3. splenic vein
4. superior mesenteric vein
5. inferior mesenteric vein
6. superior rectal veins

When scarring and fibrosis from cirrhosis obstruct the portal vein, pressure in the portal vein rises and produces portal hypertension. The blood then flows into the systemic system at places of portal-systemic anastomosis, producing varicose veins. Caput medusae is caused by the veins of the anterior abdominal wall becoming dilated from portal hypertension.

A common method for reducing portal hypertension is to divert blood from the portal system to the systemic venous system by creating a communication between the portal vein and the inferior vena cava.



Viscera of Posterior Abdominal Wall



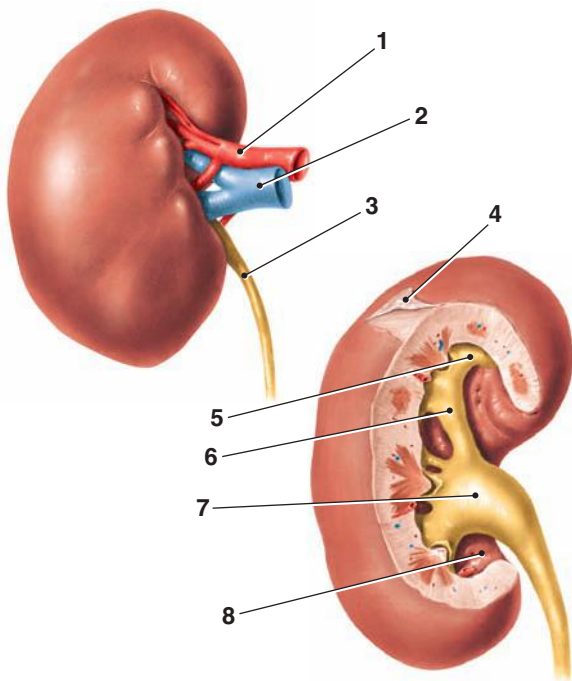
Viscera of Posterior Abdominal Wall

1. celiac ganglion
2. celiac trunk
3. spleen
4. right suprarenal gland
5. right kidney
6. right testicular artery and vein
7. right ureter
8. right external iliac artery and vein

Nephroptosis (dropped kidney) is the result of an abnormally mobile kidney. In nephroptosis, when a person is standing, the ureter, which is of normal length (unlike in ectopic kidney), may become coiled and/or kinked.

Renal transplantation is a well-established operation to replace failing kidneys. The transplanted kidney is placed in the iliac fossa for support.

Kidney



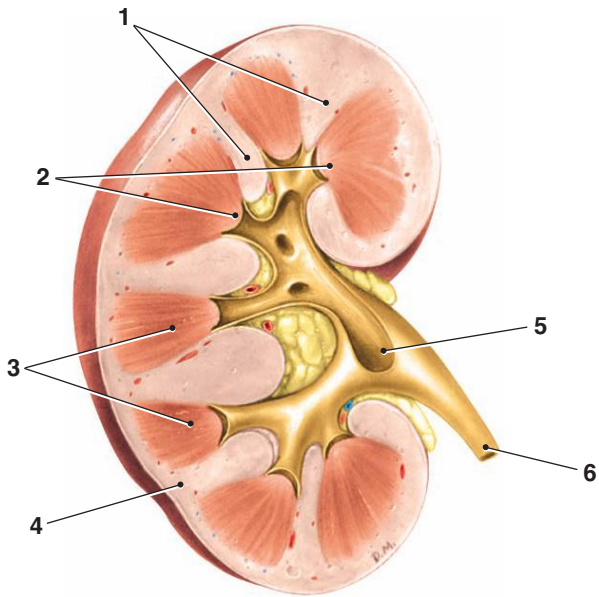
Kidney

1. renal artery
2. renal vein
3. ureter
4. fibrous capsule
5. minor calyx
6. major calyx
7. renal pelvis
8. renal sinus

Cysts in the kidney are common. Polycystic disease is an important cause of kidney failure.

A renal calculus (kidney stone) may form and lodge in the calices of the kidneys, ureter (ureteric calculus), or urinary bladder. The calculi may block the normal passage of urine and cause intermittent pain referred to the lumbar and groin regions.

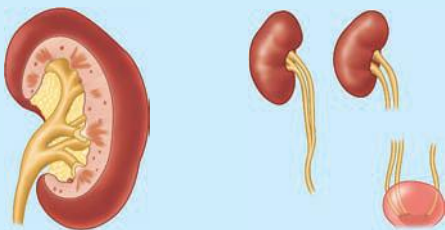
Kidney, Internal View



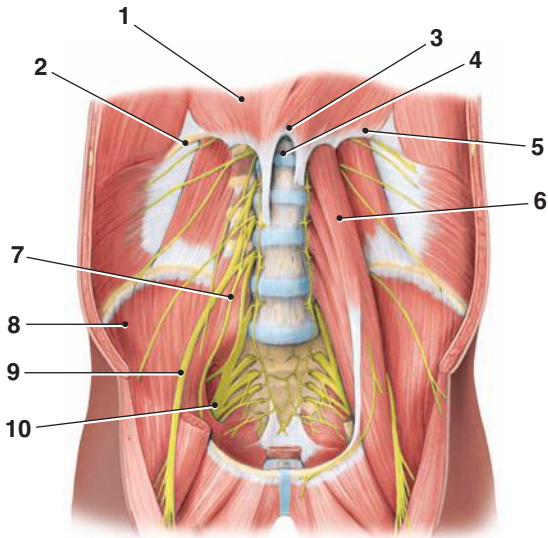
Kidney, Internal View

1. renal columns
2. renal papilla
3. renal pyramids
4. renal cortex
5. renal pelvis
6. ureter

Anomalies resulting from altered embryological development of the kidney and ureter are common. A bifid renal pelvis and ureter may be unilateral or bilateral. Other anomalies include ectopic kidneys, horseshoe kidneys, and retrocaval ureters.



Posterior Abdominal Wall



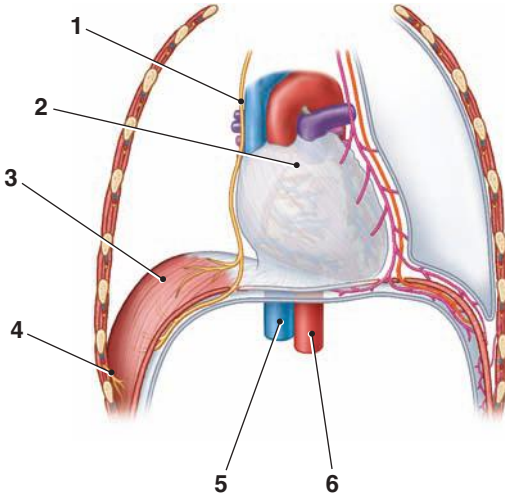
Posterior Abdominal Wall

1. diaphragm
2. 12th rib
3. median arcuate ligament
4. aortic opening
5. lateral arcuate ligament
6. psoas major
7. obturator nerve
8. iliacus
9. femoral nerve
10. sciatic nerve

Pain from the diaphragm is referred to the shoulder region (diaphragmatic pleura or peritoneum) or to the costal margin and anterior abdominal wall (peripheral parts of the diaphragm). Contraction of the psoas and iliacus (iliopsoas) causes pain from diseased viscera that lie against the posterior abdominal wall.

A psoas abscess may result from tuberculosis in the lumbar region, causing the spread of pus throughout the region.

Nerves of the Diaphragm

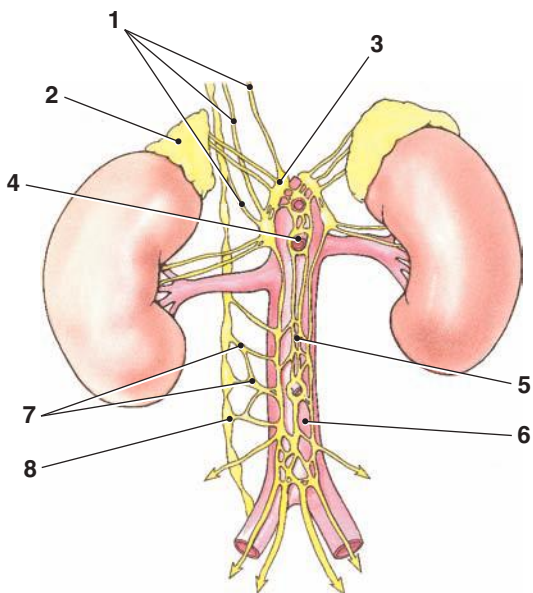


Nerves of the Diaphragm

1. phrenic nerve
2. pericardium
3. diaphragm
4. intercostal nerve
5. inferior vena cava
6. abdominal aorta

Hiccups are spasmodic contractions of the diaphragm that cause sudden inhalation followed by abrupt closure of the glottis. Irritation of the phrenic nerve may result in hiccups. Each nerve supplies motor innervation to one hemidiaaphragm; section of the nerve results in complete paralysis of the diaphragm ipsilateral to the lesion.

Aortic Plexus

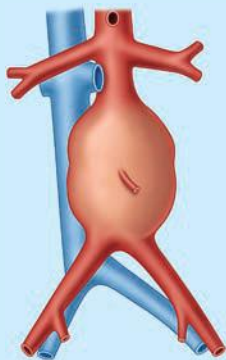


Aortic Plexus

1. greater, lesser, and least thoracic splanchnic nerves
2. suprarenal gland
3. celiac ganglia
4. superior mesenteric ganglia and artery
5. intermesenteric plexus
6. abdominal aorta
7. lumbar splanchnic nerves
8. sympathetic ganglia and trunk

A partial lumbar sympathectomy (removal of two or more lumbar sympathetic ganglia) is done in some patients with arterial disease of the lower limbs.

A local enlargement of the abdominal aorta (aortic aneurysm) results from a weakness of the arterial wall. Acute rupture of the aneurysm has nearly a 90% mortality rate.



3 • Pelvis and Perineum

- 3.1** Bony Pelvis, Superior View
- 3.2** Bony Pelvis, Oblique View
- 3.3** Bony Pelvis, Medial View
- 3.4** Pelvic Ligaments
- 3.5** Floor of the Female Pelvis
- 3.6** Obturator Internus and Piriformis
- 3.7** Pelvic Diaphragm
- 3.8** Sacral Plexus
- 3.9** Female Pelvic Vessels
- 3.10** Ureter
- 3.11** Arteries of the Male Pelvis
- 3.12** Arteries of the Female Pelvis
- 3.13** Urinary Bladder, Male
- 3.14** Urinary Bladder, Female
- 3.15** Male Pelvis, Sagittal View
- 3.16** Seminal Vesicles and Prostate
- 3.17** Prostatic Urethra
- 3.18** Vagina
- 3.19** Female Pelvis, Superior View
- 3.20** Uterus
- 3.21** Uterus and Pelvic Diaphragm
- 3.22** Lumbosacral Plexus
- 3.23** Uterine Tubes
- 3.24** Female Pelvic Viscera
- 3.25** Rectum
- 3.26** Perineal Body
- 3.27** Male Urethra
- 3.28** Anal Canal

3.29 Male Urogenital System

3.30 Penis

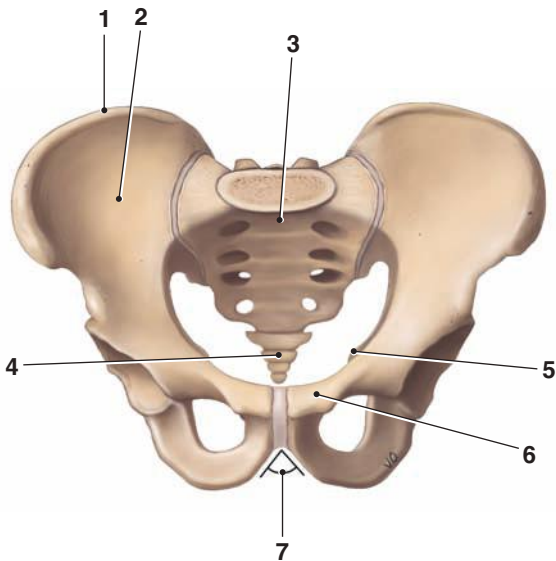
3.31 Bulbospongiosus and Ischiocavernosus

3.32 Clitoris

3.33 Female Perineum

3.34 Vaginal Vestibule

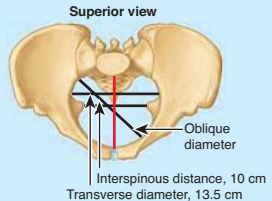
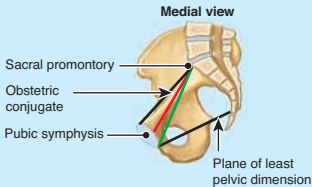
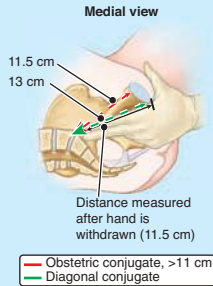
Bony Pelvis, Superior View



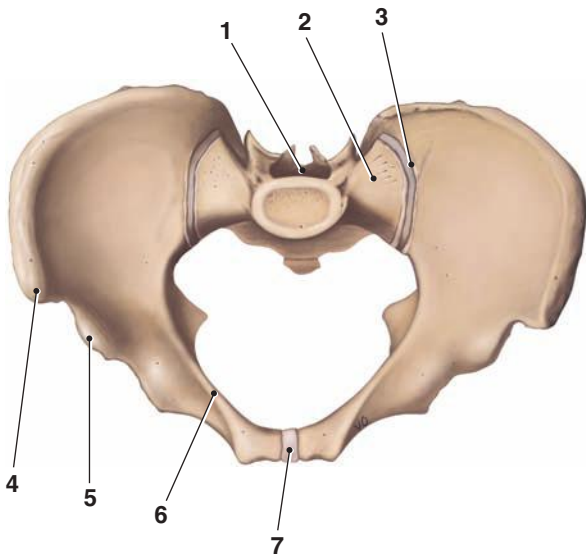
Bony Pelvis, Superior View

1. iliac crest
2. iliac fossa
3. sacral promontory
4. coccyx
5. ischial spine
6. pubic tubercle
7. subpubic angle

Minimum diameters (conjugates) of the true pelvis are important in obstetrics. The minimum obstetric (true) conjugate should be over 11 cm for vaginal delivery. The diagonal conjugate is measured by palpating the sacral promontory. Because of the relaxation of pelvic ligaments, the interspinous distance is not fixed.



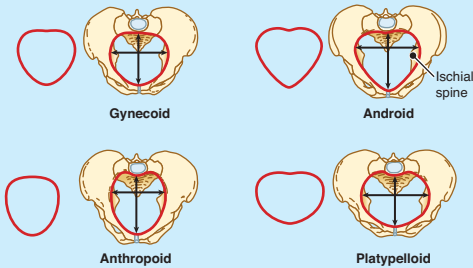
Bony Pelvis, Oblique View



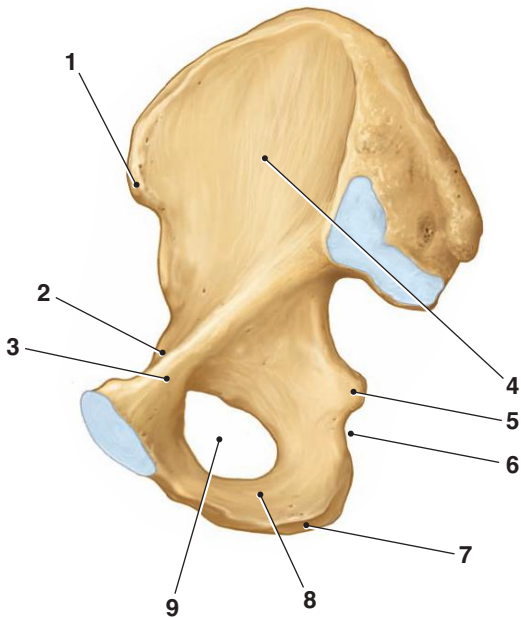
Bony Pelvis, Oblique View

1. sacral canal
2. ala of sacrum
3. sacroiliac joint
4. anterior superior iliac spine
5. anterior inferior iliac spine
6. pecten pubis
7. pubic symphysis

Anatomical differences between male and female pelvises are important for parturition and useful in forensic medicine. Android and anthropoid are most common in males, android and gynecoid in white females, and gynecoid and anthropoid in black females. Platypelloid is uncommon in both sexes.



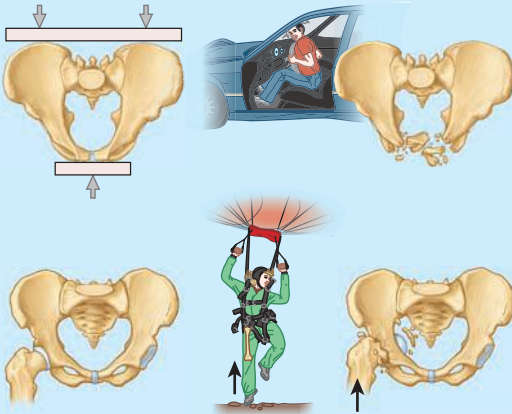
Bony Pelvis, Medial View



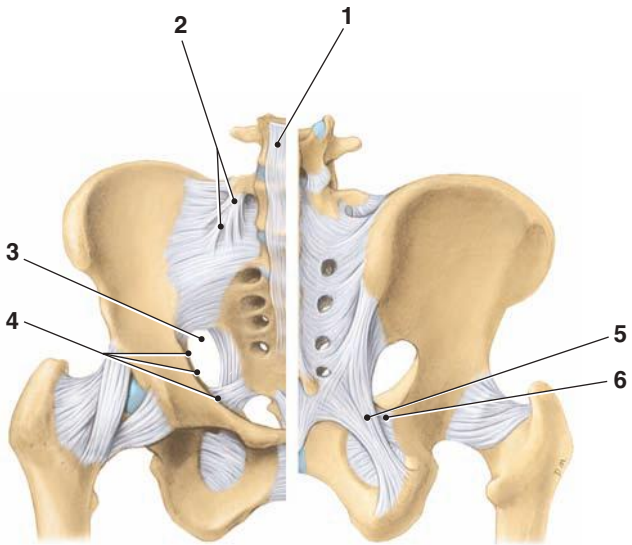
Bony Pelvis, Medial View

1. anterior superior iliac spine
2. pecten pubis
3. superior ramus of pubis
4. iliac fossa
5. ischial spine
6. lesser sciatic notch
7. ischial tuberosity
8. ischiopubic ramus
9. obturator foramen

Anteroposterior compression of the pelvis occurs during crush accidents, which commonly produce fractures of the pubic rami. The ilia and acetabula may be broken during lateral compression of the pelvis.



Pelvic Ligaments

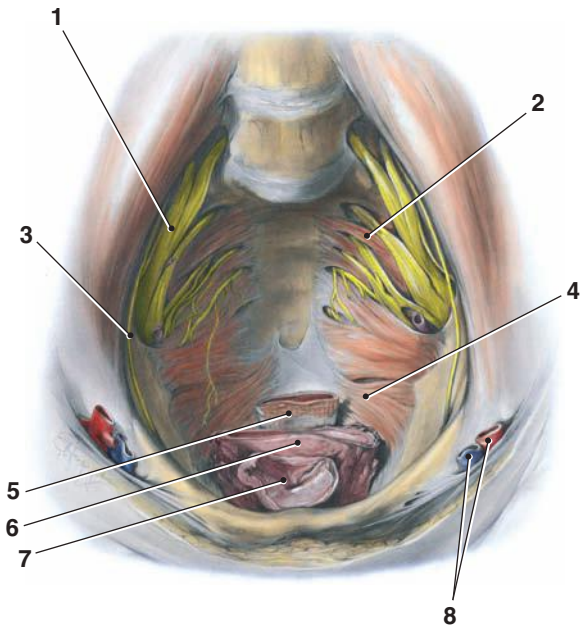


Pelvic Ligaments

1. anterior longitudinal ligament
2. anterior sacroiliac ligament
3. greater sciatic foramen
4. pelvic brim
5. sacrotuberous ligament
6. sacrospinous ligament

The circumference of the lesser pelvis increases and the pubic symphysis becomes more flexible in pregnant females because the hormone relaxin causes the pelvic ligaments to relax. This relaxation permits as much as a 10% to 15% increase in pelvic diameters (except the true conjugate) and contributes to a lordotic posture.

Floor of the Female Pelvis



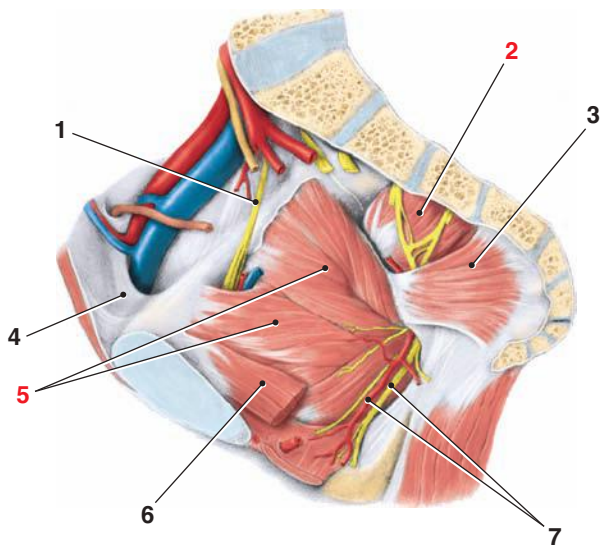
Floor of the Female Pelvis

1. lumbosacral trunk
2. piriformis
3. obturator nerve
4. pubococcygeus
5. rectum
6. vagina
7. urinary bladder
8. femoral artery and vein

The floor of the pelvis may be injured during childbirth. The pubococcygeus, the main part of the levator ani, is most often damaged, and the injury may lead to urinary incontinence.

Prenatal training (e.g., Lamaze) may allow relaxation of the muscles of the pelvic floor while increasing intraabdominal pressure, preventing injury during childbirth.

Obturator Internus and Piriformis



Obturator Internus and Piriformis

1. obturator nerve
2. piriformis
3. coccygeus
4. lacunar ligament
5. obturator internus
6. pubococcygeus
7. perineal artery and nerve

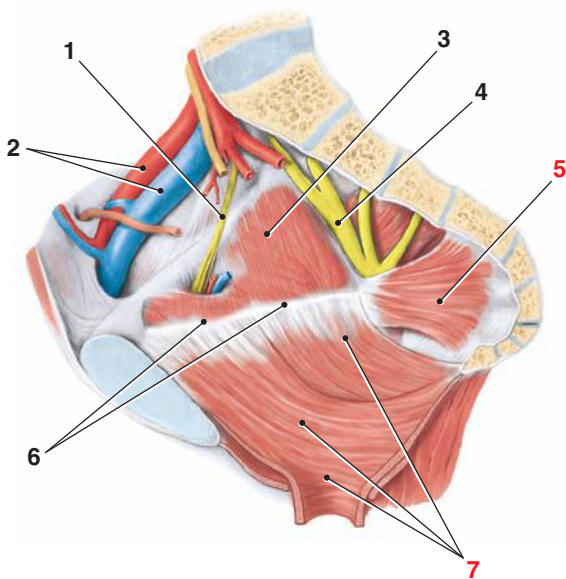
Piriformis

- proximal attachment: 2nd to 4th sacral segments, margin of greater sciatic notch, and sacrotuberous ligament
- distal attachment: greater trochanter of femur
- innervation: anterior rami (S1–S2)
- main action: rotates thigh laterally, abducts thigh, holds head of femur in acetabulum

Obturator Internus

- proximal attachment: ilium, ischium, obturator membrane
- distal attachment: greater trochanter of femur
- innervation: nerve to obturator internus (L5–S2)
- main action: rotates thigh laterally, holds head of femur in acetabulum

Pelvic Diaphragm



Pelvic Diaphragm

1. obturator nerve
2. external iliac artery and vein
3. obturator internus
4. lumbosacral trunk
5. coccygeus
6. tendinous arch of levator ani
7. levator ani (iliococcygeus, pubococcygeus, puborectalis)

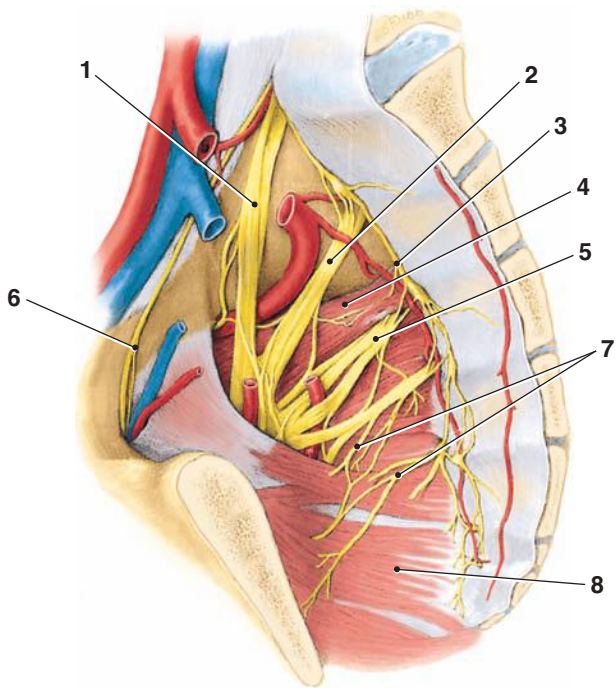
Coccygeus

- proximal attachment: ischial spine
- distal attachment: sacrum and coccyx
- innervation: S4–S5
- main action: forms part of pelvic diaphragm, supports pelvic viscera

Levator Ani (Iliococcygeus, Pubococcygeus, Puborectalis)

- proximal attachment: pubis, tendinous arch of obturator fascia, and ischial spine
- distal attachment: perineal body, coccyx, anococcygeal ligament, prostate or vagina, rectum, and anal canal
- innervation: S4 and pudendal nerve
- main action: forms part of pelvic diaphragm, supports pelvic viscera

Sacral Plexus

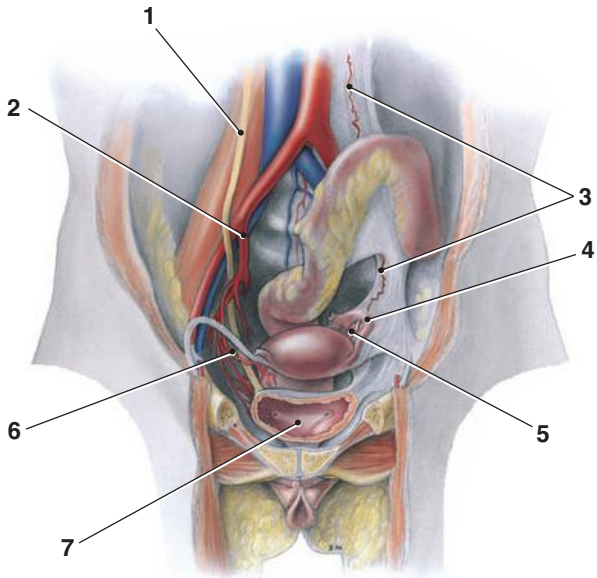


Sacral Plexus

1. lumbosacral trunk
2. anterior ramus (S1)
3. sympathetic trunk
4. piriformis
5. anterior ramus (S2)
6. obturator nerve
7. pelvic splanchnics
8. levator ani

During childbirth, the fetal head may compress the nerves of the sacral plexus, producing pain in the lower limbs. The obturator nerve is vulnerable to injury during surgery and may cause pain and sensory loss in the adductor compartment of the thigh.

Female Pelvic Vessels



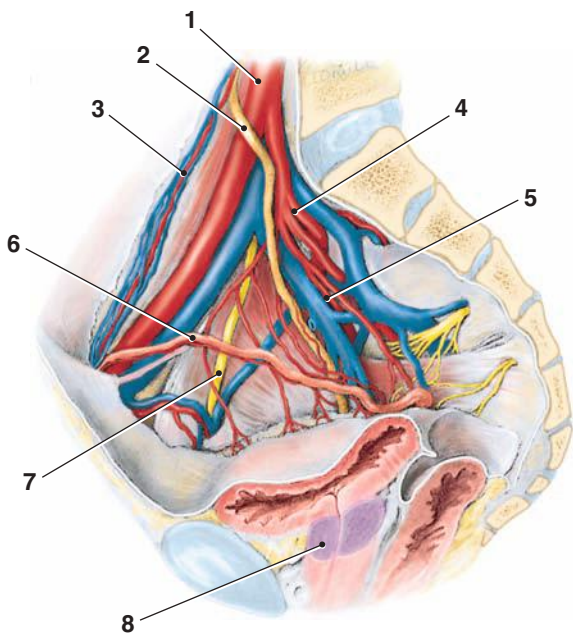
Female Pelvic Vessels

1. right ureter
2. internal iliac artery
3. ovarian artery
4. uterine tube
5. ovary
6. uterine artery
7. trigone of urinary bladder

The ureter lies close to several pelvic arteries and is in danger of damage during a hysterectomy, when the uterine artery is clamped, or during an ovariectomy, when the ovarian arteries are ligated.

The collateral circulation in the pelvis allows for ligation of the internal iliac artery to control pelvic hemorrhage without completely interrupting the blood supply to pelvic structures.

Ureter



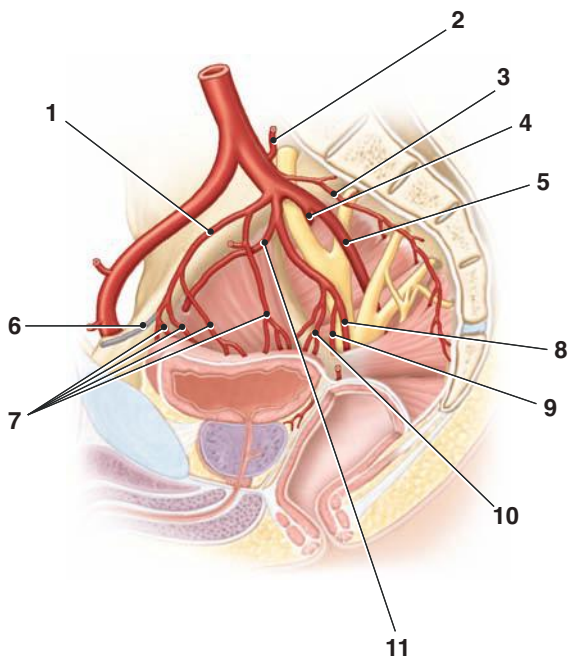
Ureter

1. common iliac artery
2. ureter
3. testicular artery
4. superior gluteal artery
5. internal pudendal artery
6. ductus deferens
7. obturator nerve
8. prostate

The ureter is in danger of damage during surgery as a result of inadvertent interruption of the blood supply. Traction on the ureter during surgery may lead to rupture.

Obstruction of the ureters, such as from ureteric calculi, may cause pain and obstruction of urinary flow. Obstruction most often occurs where the ureter is constricted: (1) at the junction of the ureter and the renal pelvis, (2) where the ureter crosses the pelvic brim, and (3) as it passes through the bladder wall.

Arteries of the Male Pelvis

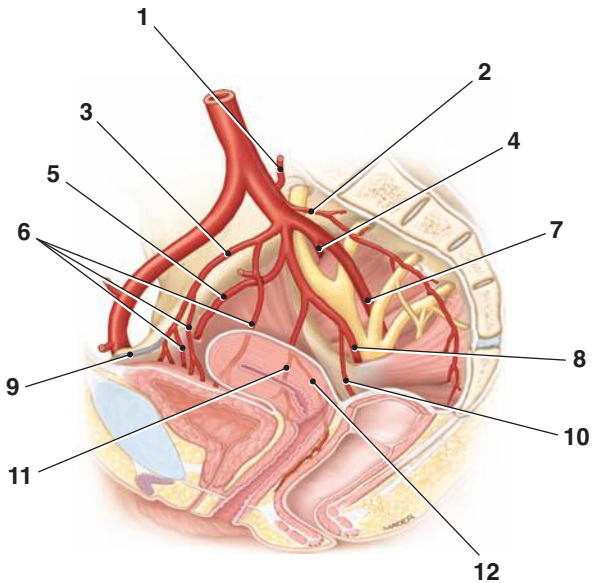


Arteries of the Male Pelvis

1. umbilical artery
2. iliolumbar artery
3. lateral sacral artery
4. superior gluteal artery
5. inferior gluteal artery
6. obliterated umbilical artery
7. superior vesical arteries
8. internal pudendal artery
9. middle rectal artery
10. inferior vesical artery
11. obturator artery

The internal iliac artery is the main blood supply to the pelvic organs, gluteal muscles, and perineum.

Arteries of the Female Pelvis

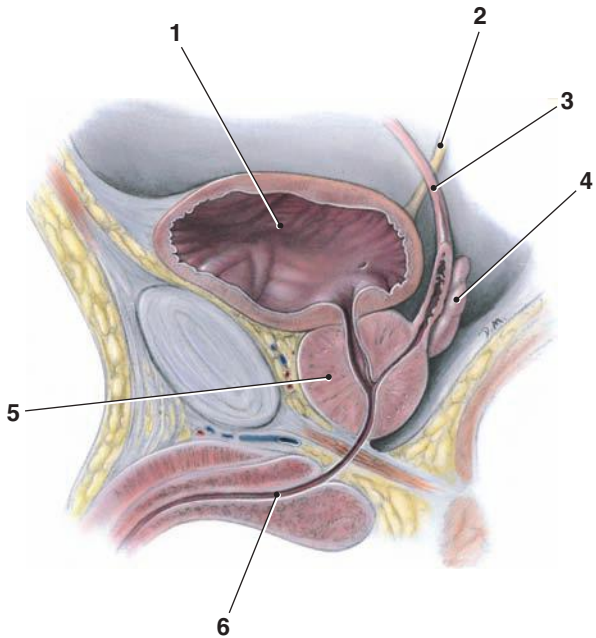


Arteries of the Female Pelvis

1. iliolumbar artery
2. lateral sacral artery
3. umbilical artery
4. superior gluteal artery
5. obturator artery
6. superior vesical arteries
7. inferior gluteal artery
8. internal pudendal artery
9. obliterated umbilical artery
10. middle rectal artery
11. uterine artery
12. vaginal artery

The internal iliac artery is the main blood supply to the pelvic organs, gluteal muscles, and perineum.

Urinary Bladder, Male

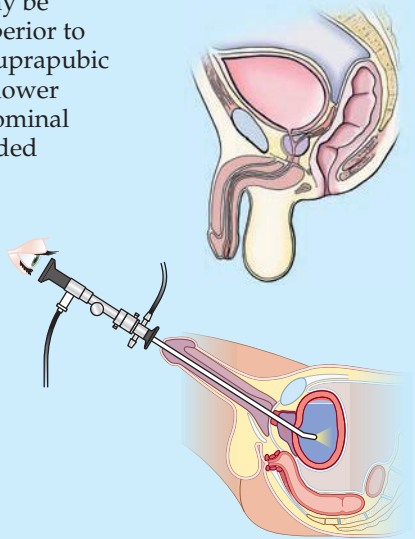


Urinary Bladder, Male

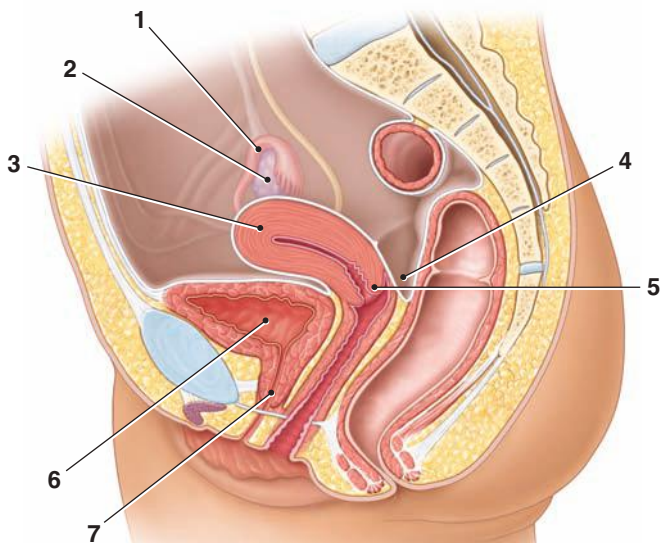
1. urinary bladder
2. ureter
3. ductus deferens
4. seminal vesicle
5. prostate
6. spongy urethra

The distended bladder may be approached surgically superior to the pubic symphysis—a suprapubic cystostomy. Injuries to the lower aspect of the anterior abdominal wall may affect the distended bladder and lead to the extravasation of urine.

A cystoscope can be used to examine the interior aspect of the bladder. High-frequency electrical current emitted through the cystoscope can be used to remove tumors from the bladder.



Urinary Bladder, Female

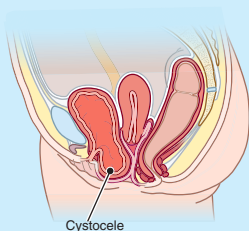


Urinary Bladder, Female

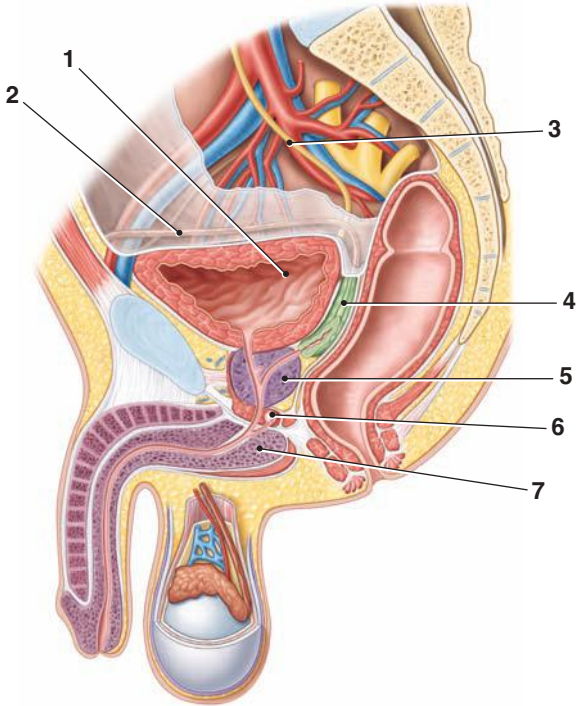
1. uterine tube
2. ovary
3. uterus
4. rectouterine pouch
5. cervix
6. urinary bladder
7. urethra

Injury to the pelvic floor may result in a cystocele, or herniation of the bladder into the vaginal wall.

The short, distensible female urethra allows easy passage of catheters and cystoscopes into the bladder; these characteristics also make bladder infections more common than in males.



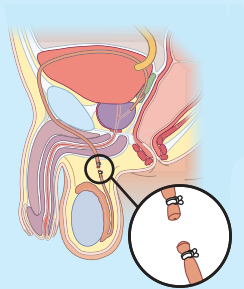
Male Pelvis, Sagittal View



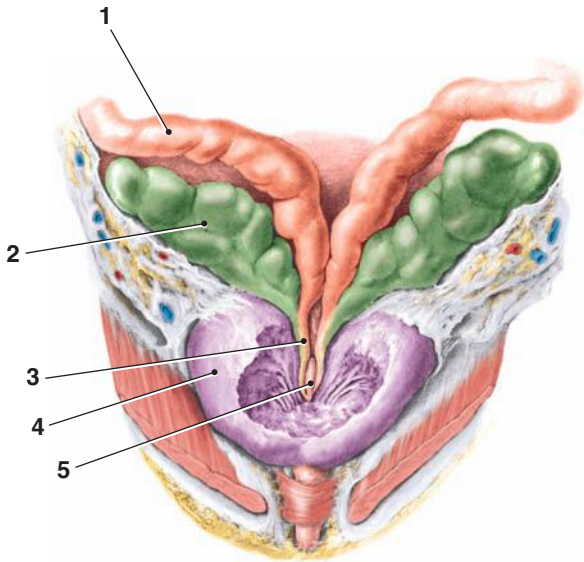
Male Pelvis, Sagittal View

1. urinary bladder
2. ductus deferens
3. ureter
4. seminal vesicle
5. prostate
6. bulbourethral gland
7. bulb of penis

The common method of male sterilization is a deferentectomy (vasectomy), during which part of the ductus deferens is ligated.



Seminal Vesicles and Prostate

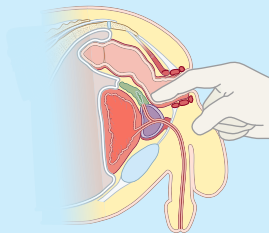


Seminal Vesicles and Prostate

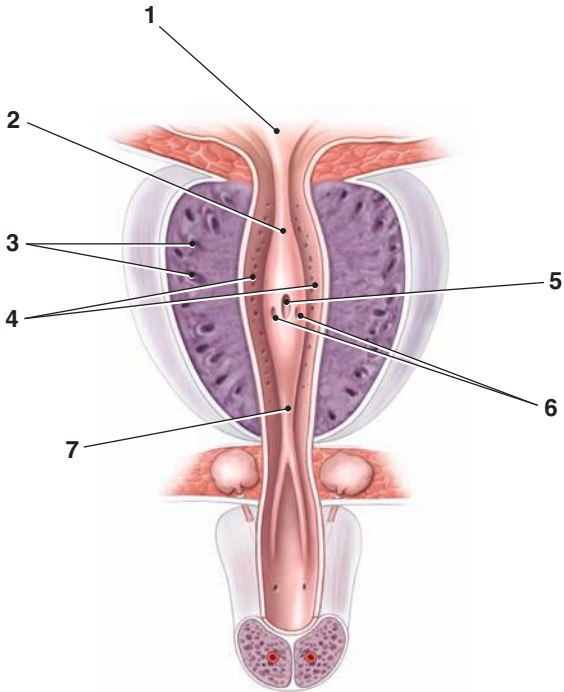
1. ductus deferens
2. seminal vesicle
3. ejaculatory duct
4. prostate
5. prostatic utricle

Abscesses in the seminal vesicles may rupture and allow pus to enter the peritoneal cavity.

Rectal examination allows for palpation of the seminal vesicles and the prostate. Benign hypertrophy of the prostate is common after middle age; it can impede urination and lead to nocturia, dysuria, and urgency of urination. The malignant prostate feels hard upon palpation.



Prostatic Urethra

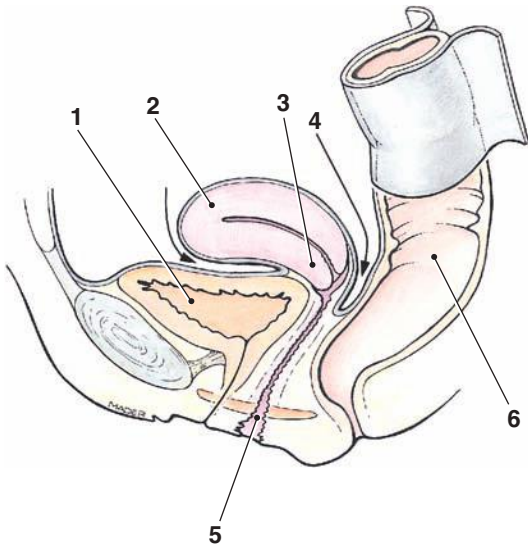


Prostatic Urethra

1. internal urethral orifice
2. seminal colliculus
3. cut surface of prostate
4. prostatic sinus
5. prostatic utricle
6. openings of ejaculatory ducts
7. urethral crest

The prostatic utricle is an embryological remnant of the uterus and vagina in the male.

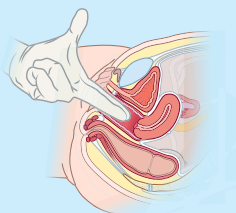
Vagina



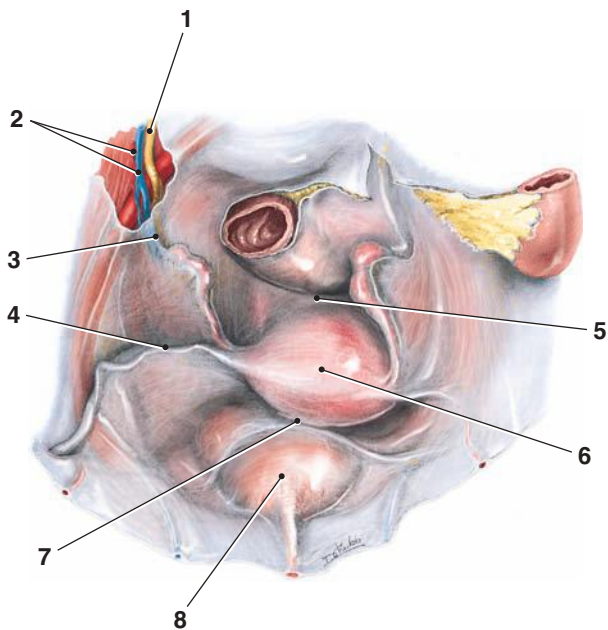
Vagina

1. urinary bladder
2. uterus
3. cervix
4. rectouterine pouch
5. vagina
6. rectum

The highly distensible, thin-walled vagina's central location within the pelvis allows for digital palpation of many pelvic structures, such as the cervix, ischial spines, sacral promontory, arteries, and ovaries.



Female Pelvis, Superior View

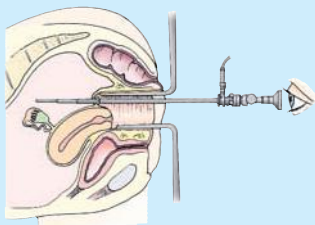
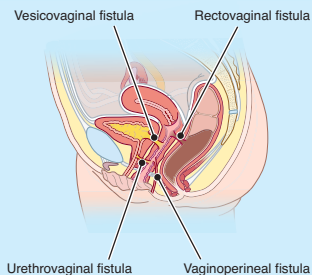


Female Pelvis, Superior View

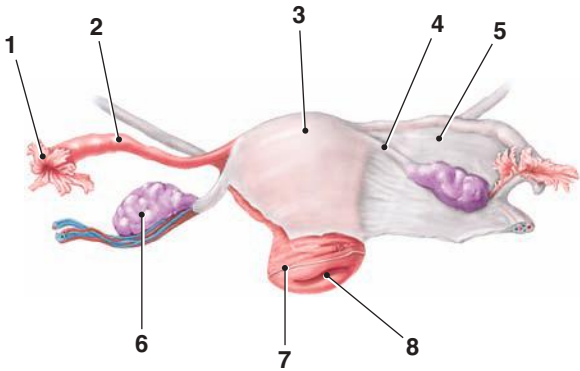
1. ureter
2. ovarian artery and vein
3. suspensory ligament of the ovary
4. round ligament of the uterus
5. rectouterine pouch
6. uterus
7. vesicouterine pouch
8. urinary bladder

Because the vagina is close to adjacent pelvic organs, trauma may result in weakness, necrosis, or tears that may subsequently form fistulas between the vagina and the adjacent structure.

A culdoscope can be inserted into the vagina to examine the ovaries or uterine tubes. A pelvic abscess in the rectouterine pouch can be drained by culdocentesis through the vaginal fornix.



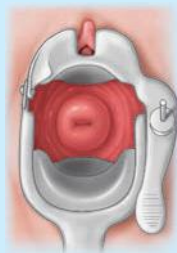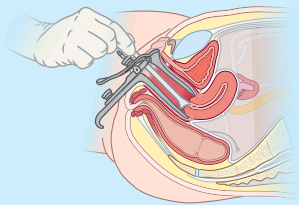
Uterus



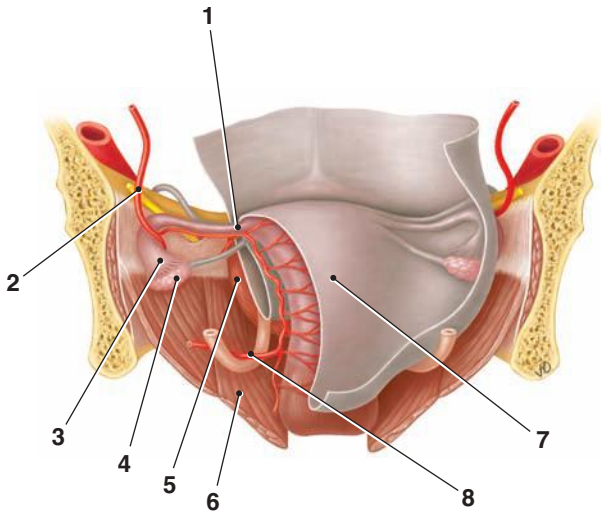
Uterus

1. fimbriae of uterine tube
2. ampulla of uterine tube
3. uterus
4. ligament of the ovary
5. mesosalpinx
6. ovary
7. cervix of the uterus
8. external ostium of the uterus

A vaginal speculum is used to distend the vagina to harvest cervical cells from the external ostium of the cervix for examination. This procedure, a Papanicolaou (Pap) smear, has greatly reduced mortality from cervical cancer.



Uterus and Pelvic Diaphragm

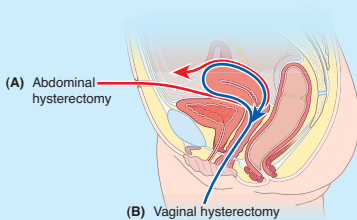


Uterus and Pelvic Diaphragm

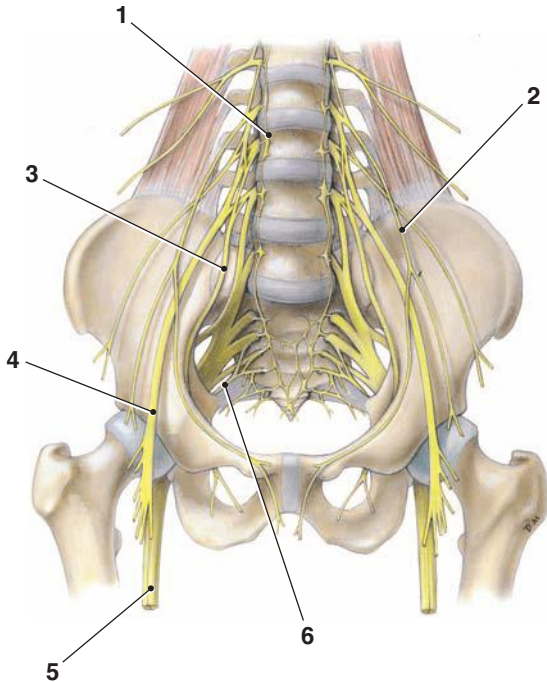
1. isthmus of the uterine tube
2. left ovarian artery
3. infundibulum
4. left ovary
5. urinary bladder
6. levator ani
7. uterus
8. uterine artery

The uterus is typically anteverted and anteflexed. An increase in intraabdominal pressure presses the uterus against the bladder; it may be in a less common position (e.g., retroverted), which may lead to prolapse and/or high-risk pregnancy.

Owing to the frequency of uterine and cervical cancer, hysterectomy, or excision of the uterus, is a relatively common procedure.



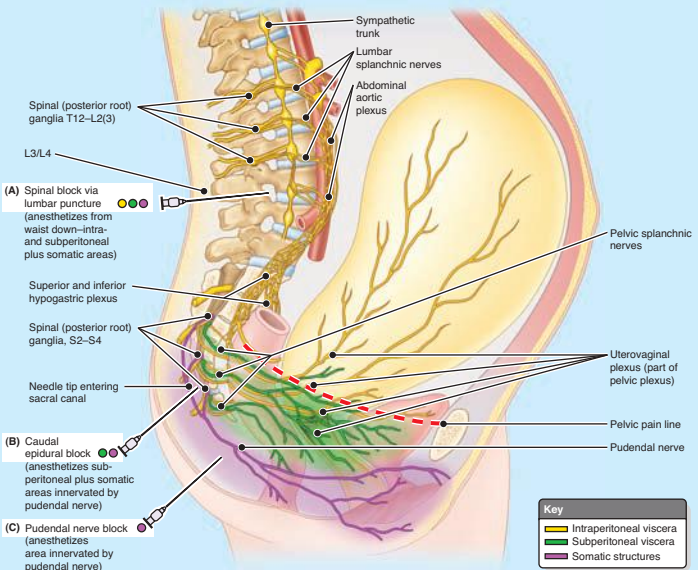
Lumbosacral Plexus



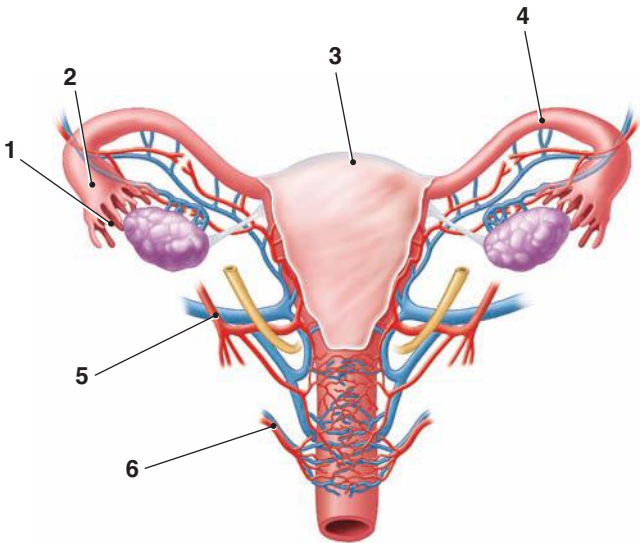
Lumbosacral Plexus

1. sympathetic trunk
2. genitofemoral nerve
3. obturator nerve
4. femoral nerve
5. sciatic nerve
6. pudendal nerve

To reduce pain and discomfort during childbirth, general or regional anesthesia may be used. Types of regional anesthesia include spinal, pudendal nerve, and caudal epidural blocks.



Uterine Tubes



Uterine Tubes

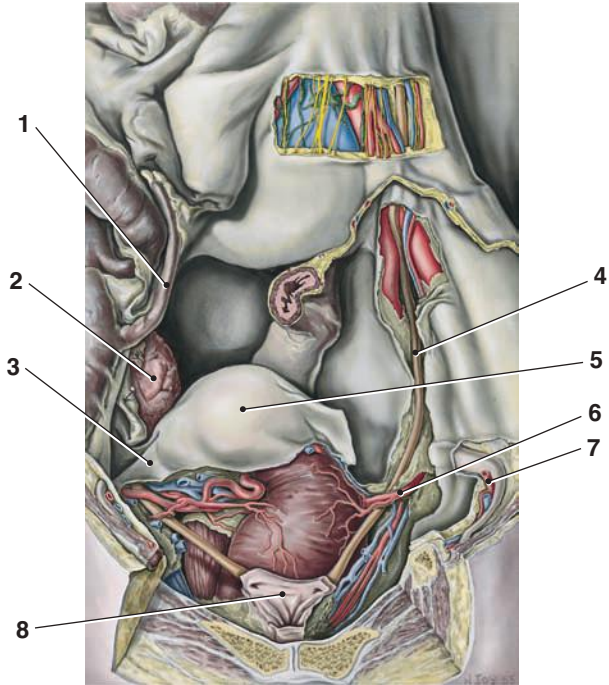
1. fimbriae
2. infundibulum
3. fundus of the uterus
4. ampulla
5. uterine artery
6. vaginal artery

Patency of the uterine tubes may be determined by radiography, hysterosalpingography, or use of an endoscope during a hysteroscopy.

Ligation of the uterine tubes is a surgical method of birth control. Abdominal tubal ligation is done through a suprapubic incision, while laparoscopic tubal ligation is done with a laparoscope.

The blastocyst may implant in the mucosa of the uterine tube (usually the ampulla), resulting in an ectopic tubal pregnancy.

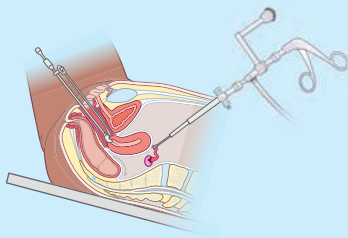
Female Pelvic Viscera



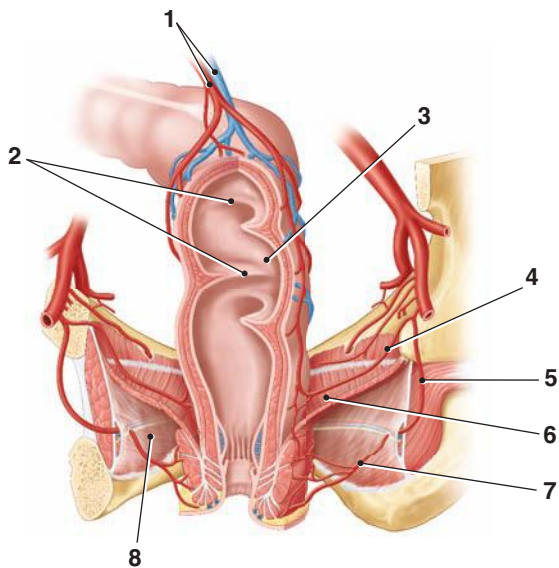
Female Pelvic Viscera

1. appendix
2. ovary
3. broad ligament of the uterus
4. ureter
5. uterus
6. uterine artery
7. inferior epigastric artery
8. trigone of the urinary bladder

Laparoscopy entails inserting a laparoscope into the peritoneal cavity through a small incision near the umbilicus. It allows for visual examination of the pelvic viscera and for diagnosing pathologies (e.g., ovarian cysts, endometriosis, and ectopic pregnancies).



Rectum



Rectum

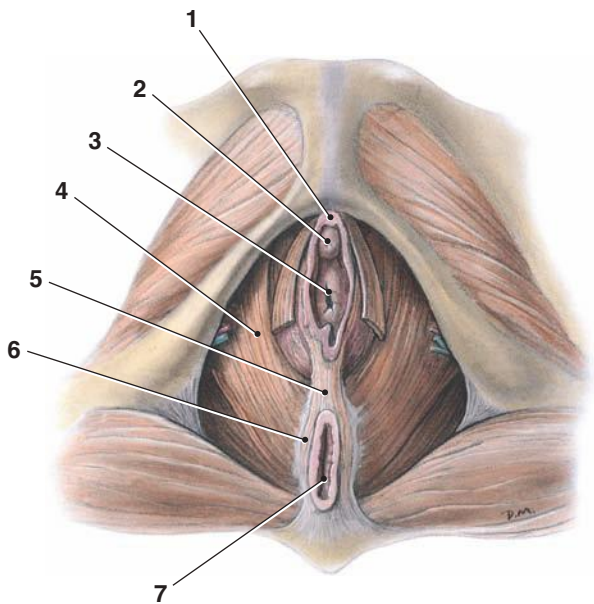
1. superior rectal artery and vein
2. transverse rectal folds
3. rectal ampulla
4. middle rectal artery
5. internal pudendal artery
6. levator ani
7. inferior rectal artery
8. obturator internus

Rectal prolapse may occur when the supportive fat in the ischioanal fossa disappears, as in starvation.

The rectum allows for palpation of nearby pelvic structures (e.g., prostate, cervix, sacrum, ischial spines, ureters, iliac lymph nodes). A proctoscope may be used to examine the inside of the rectum.

During resection of the rectum in males, the plane of the rectovesical septum is followed to avoid damage to the prostate and urethra.

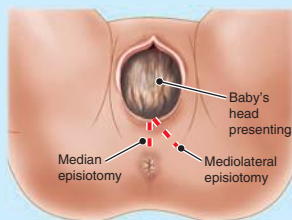
Perineal Body



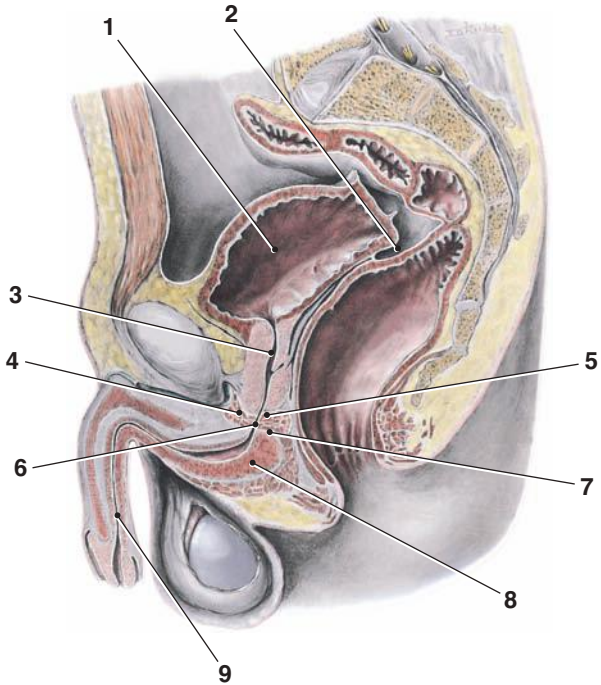
Perineal Body

1. clitoris
2. urethral orifice
3. vaginal orifice
4. levator ani
5. perineal body
6. external anal sphincter
7. anus

The pelvic viscera may prolapse if the perineal body is damaged during childbirth, trauma, disease, or infection. An episiotomy is routinely performed during childbirth to enlarge the vaginal orifice. The median episiotomy incises the perineal body, while a mediolateral episiotomy avoids the perineal body.



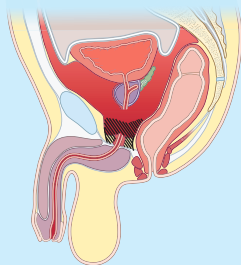
Male Urethra



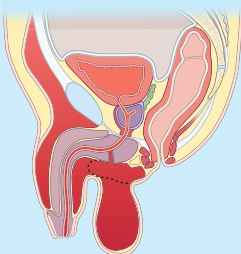
Male Urethra

1. urinary bladder
2. rectovesical pouch
3. prostatic urethra
4. deep transversus perinei
5. external urethral sphincter
6. membranous urethra
7. perineal membrane
8. bulb of the penis
9. spongy urethra

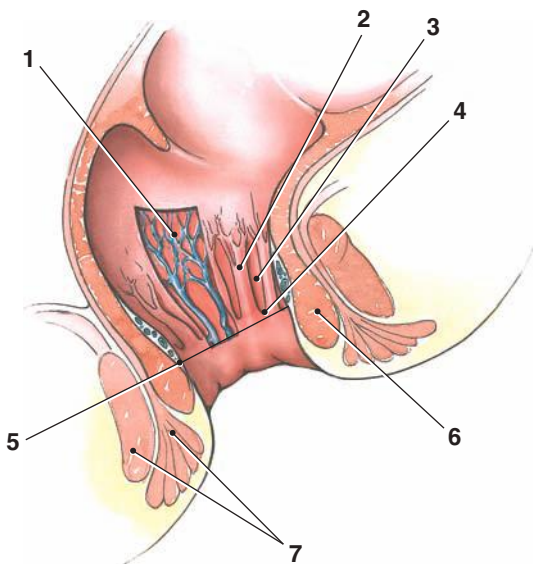
Rupture of the membranous urethra may result in extravasation of urine and blood into the deep pouch and, eventually, extraperitoneally around the prostate and bladder.



Straddle injuries cause rupture of the spongy urethra and urine extravasation in the bulb of the penis, allowing urine to enter the superficial perineal space.



Anal Canal



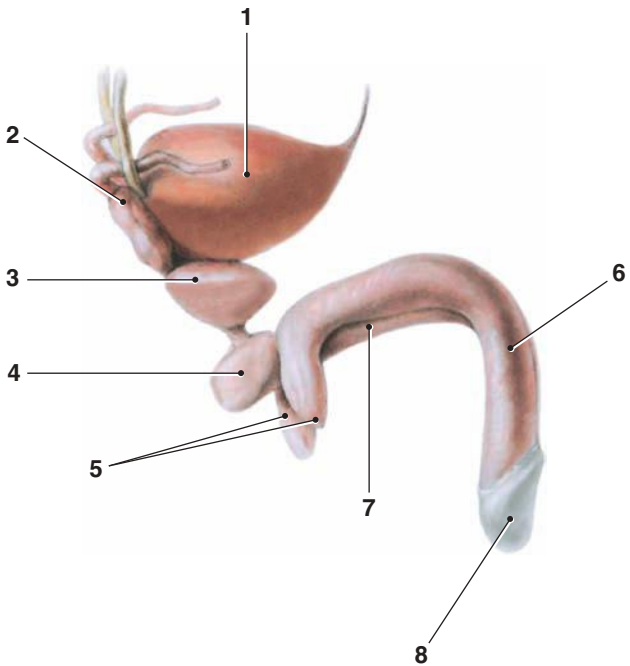
Anal Canal

1. internal rectal venous plexus
2. anal column
3. anal sinus
4. anal valve
5. pectinate line
6. internal anal sphincter
7. external anal sphincter

The pectinate line indicates the transition from visceral (above) and parietal (below) with respect to arterial supply, venous and lymphatic drainage, and innervation.

Internal hemorrhoids are prolapses of rectal mucosa containing the dilated veins of the internal rectal venous plexus.

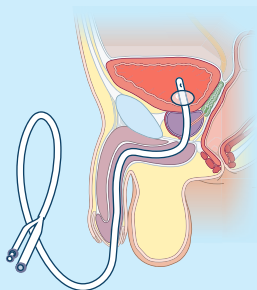
Male Urogenital System



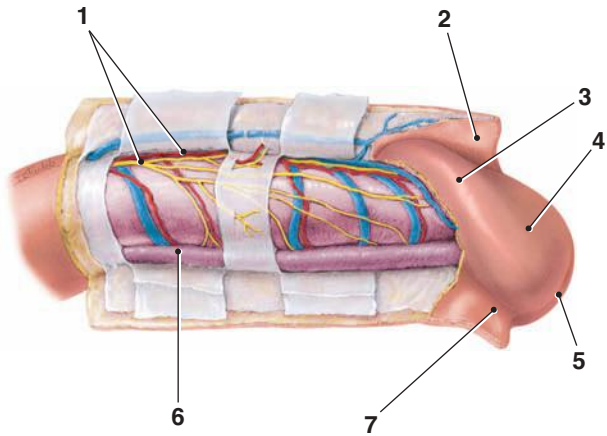
Male Urogenital System

1. urinary bladder
2. seminal vesicle
3. prostate
4. bulb of the penis
5. left and right crura
6. corpora cavernosum
7. corpus spongiosum
8. glans penis

Urethral catheterization is done to remove urine (uncontaminated), to irrigate the bladder, and to explore and dilate using a urethral sound.



Penis

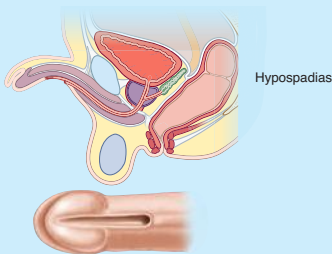


Penis

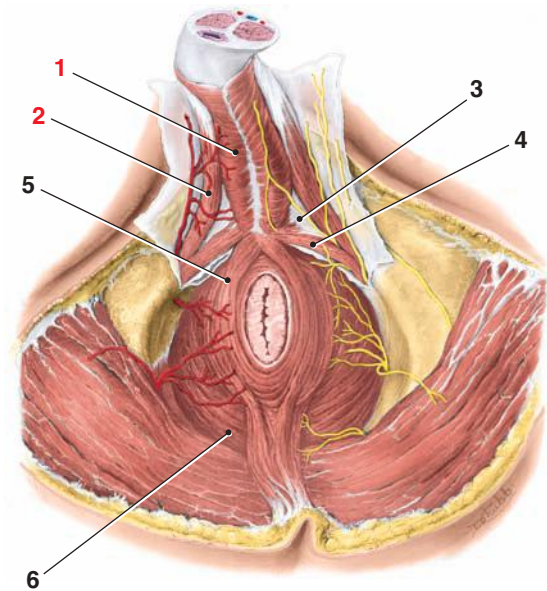
1. dorsal nerve and artery of the penis
2. prepuce (foreskin)
3. corona of glans penis
4. glans penis
5. external urethral orifice
6. corpus spongiosum
7. frenulum of penis

Hypospadias is a common congenital anomaly of the penis in which the external urethral orifice is on the urethral aspect of the penis or in the perineum. It results from the failure of embryological tissue to fuse properly.

Circumcision is the surgical excision of the prepuce.



Bulbospongiosus and Ischiocavernosus



Bulbospongiosus and Ischiocavernosus

1. bulbospongiosus
2. ischiocavernosus
3. perineal membrane
4. superficial transverse perinei
5. external anal sphincter
6. levator ani

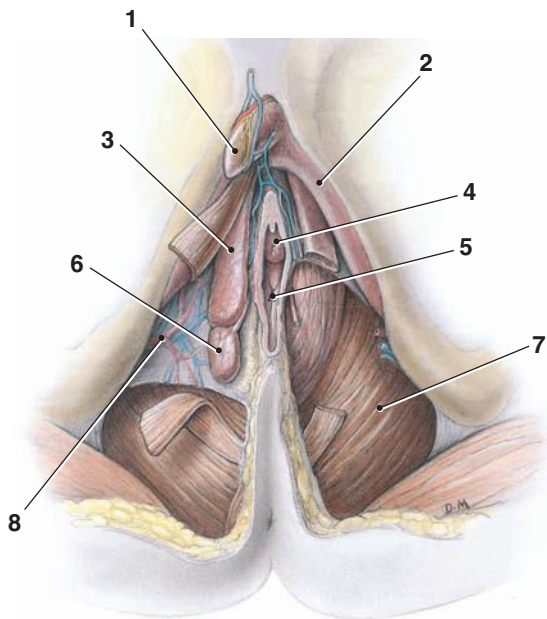
Bulbospongiosus

- proximal attachment: male, median raphe and perineal body; female, perineal body
- distal attachment: corpus spongiosum
- innervation: perineal nerve (from pudendal)
- main action: assists in erection

Ischiocavernosus

- proximal attachment: ischiopubic ramus and ischial tuberosity
- distal attachment: crus of penis or clitoris
- innervation: perineal nerve (from pudendal)
- main action: assists in erection

Clitoris



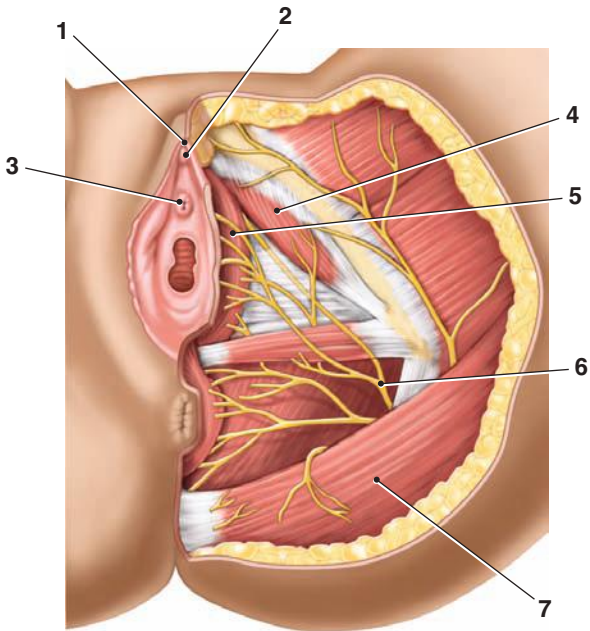
Clitoris

1. glans clitoris
2. crus of the clitoris
3. bulb of the vestibule
4. external urethral orifice
5. vaginal orifice
6. greater vestibular gland
7. levator ani
8. perineal branches of internal pudendal vessels

The highly vascular bulbs of the vestibule are susceptible to injury that may result in vulvar hematomas in the labia majora.

When infected, the greater vestibular glands may become palpable. The glands may be infected because of blockage of the duct or a pathogenic organism; they are the site of origin of most vulvar adenocarcinomas.

Female Perineum

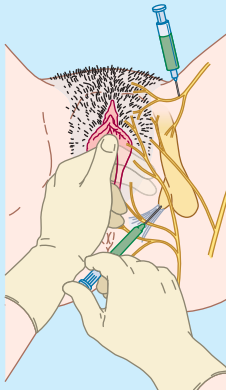


Female Perineum

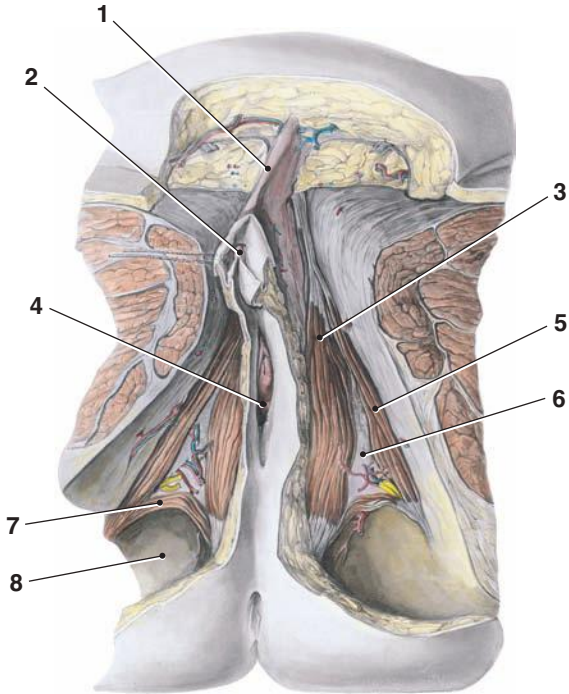
1. prepuce of the clitoris
2. glans clitoris
3. external urethral orifice
4. ischiocavernosus
5. bulb of the vestibule (covered by bulbospongiosus)
6. pudendal nerve
7. gluteus maximus

Female circumcision is the removal of the prepuce and often all or part of the clitoris and labia minora. It is a form of mutilation.

To relieve pain during childbirth, pudendal nerve block anesthesia may be performed by injecting an anesthetic agent into the tissues surrounding the nerve.



Vaginal Vestibule



Vaginal Vestibule

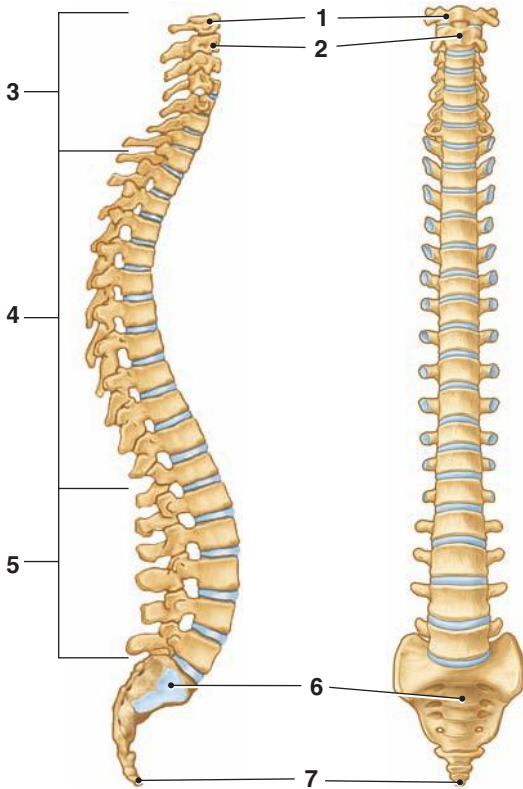
1. suspensory ligament of the clitoris
2. glans clitoris
3. bulbospongiosus
4. vaginal orifice
5. ischiocavernosus
6. perineal membrane
7. superficial transverse perinei
8. ischioanal fossa

The superficial transverse perinei, bulbospongiosus, and external anal sphincter can all be strengthened using Kegel exercises to help support and prevent postpartum prolapse of the pelvic viscera and prevent urinary incontinence.

4 • Back

- 4.1** Vertebral Column
- 4.2** Curvatures of the Vertebral Column
- 4.3** Typical Vertebra
- 4.4** Cervical Vertebra
- 4.5** Atlas
- 4.6** Axis
- 4.7** Craniovertebral Joints
- 4.8** Lumbar Vertebrae
- 4.9** Sacrum, Posterior View
- 4.10** Sacrum, Anterior View
- 4.11** Cervical Spine
- 4.12** Intervertebral Disk
- 4.13** Ligaments of the Vertebral Column
- 4.14** Articulated Vertebrae
- 4.15** Lumbar Region of the Vertebral Column
- 4.16** Dural Sac
- 4.17** Spinal Cord
- 4.18** Spinal Cord Blood Supply
- 4.19** Spinal Cord and Prevertebral Structures
- 4.20** Superficial and Intermediate Layers of Intrinsic Back Muscles
- 4.21** Deep Layer of Intrinsic Back Muscles I
- 4.22** Deep Layer of Intrinsic Back Muscles II
- 4.23** Deep Back Muscles
- 4.24** Intermediate Back
- 4.25** Superficial Back
- 4.26** Suboccipital Triangle

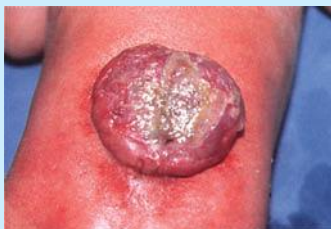Vertebral Column



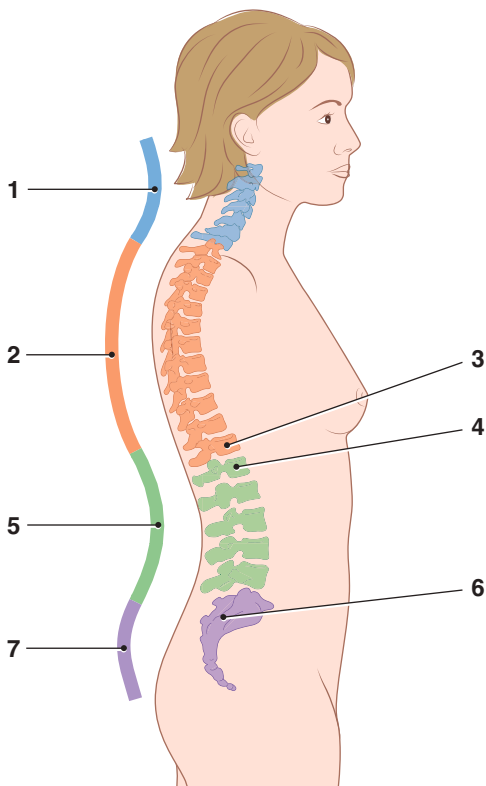
Vertebral Column

1. atlas
2. axis
3. cervical vertebrae
4. thoracic vertebrae
5. lumbar vertebrae
6. sacrum
7. coccyx

A common congenital anomaly of the vertebral column is spina bifida. In spina bifida occulta, the neural arches, usually L5 and/or S1, fail to fuse. It is often asymptomatic. Spina bifida cystica is more serious; it involves herniation of the meninges and/or neural tissue.



Curvatures of the Vertebral Column

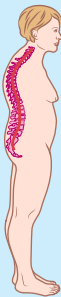

Curvatures of the Vertebral Column

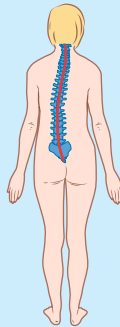
1. cervical lordosis
2. thoracic kyphosis
3. T12
4. L1
5. lumbar lordosis
6. sacrum
7. sacral kyphosis

Abnormal curvature of the vertebral column may result from a developmental anomaly or pathological process. Excess thoracic kyphosis (humpback or dowager's hump) is often caused by osteoporosis. Excess lumbar lordosis (sway back) is often seen in the late stages of pregnancy. Scoliosis (crooked back) is a common deformity of the vertebral column in pubertal girls.

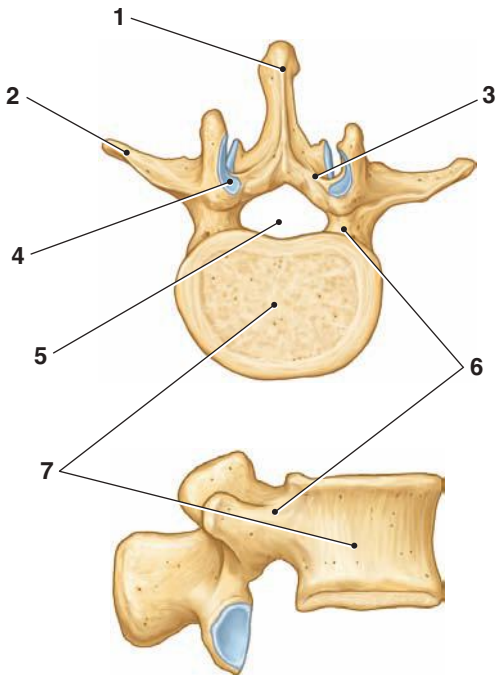
Kyphosis



Scoliosis



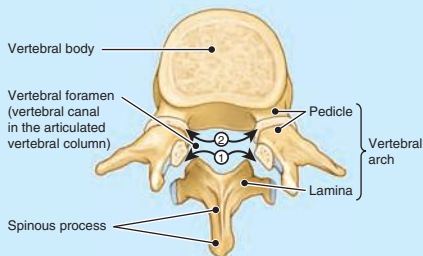
Typical Vertebra



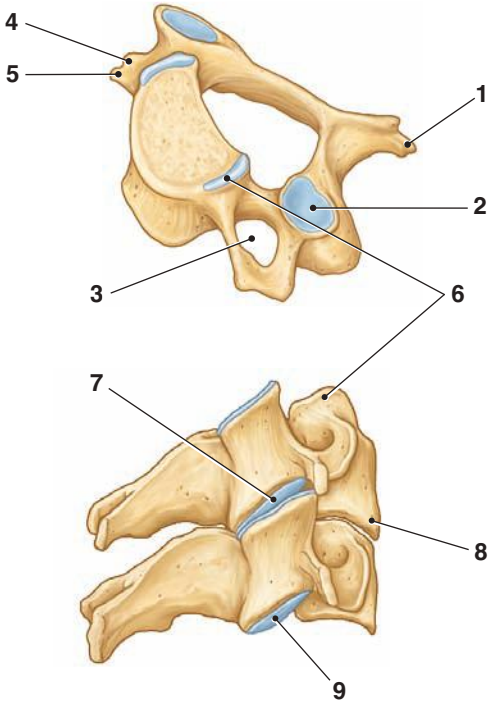
Typical Vertebra

1. spinous process
2. transverse process
3. lamina
4. superior articular facet
5. vertebral foramen
6. pedicle
7. vertebral body

A laminectomy is the surgical removal of one or more spinous processes and the adjacent laminae. The term is also used to denote removal of all or part of the vertebral arch by transecting the pedicles. Laminectomies provide access to the contents of the vertebral canal.



Cervical Vertebra

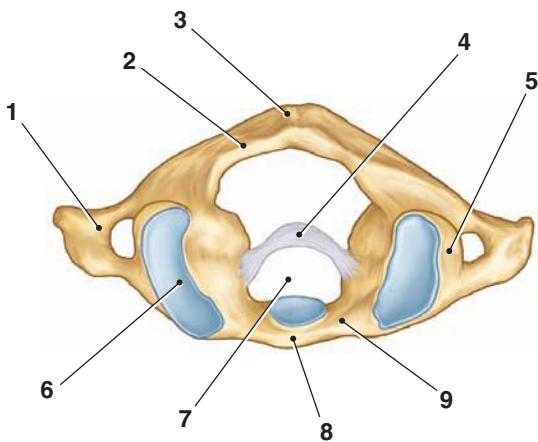


Cervical Vertebra

1. bifid spinous process
2. superior articular facet
3. transverse foramen
4. posterior tubercle
5. anterior tubercle
6. superior lip
7. zygapophysial joint
8. inferior lip
9. inferior articular facet

Because of their more horizontal articular facets, cervical vertebrae are less tightly interlocked than the rest. As a result, cervical vertebrae are more easily dislocated than fractured.

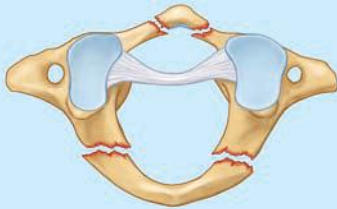
Atlas



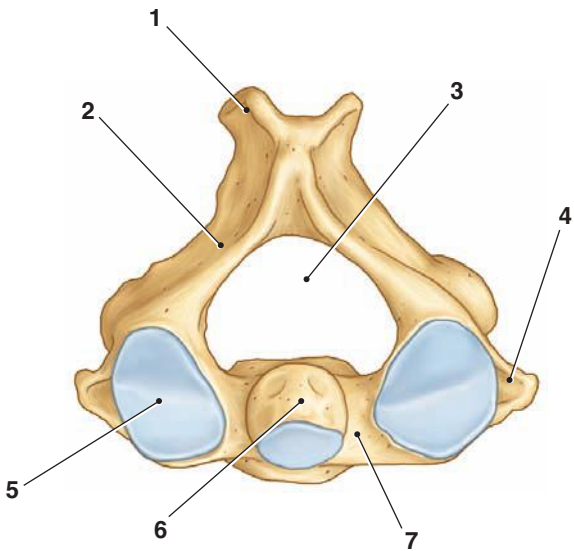
Atlas

1. transverse process
2. posterior arch
3. posterior tubercle
4. transverse ligament
5. lateral mass
6. superior articular facet
7. foramen for dens
8. anterior tubercle
9. anterior arch

Vertical force may compress the lateral masses between the occipital condyles and the axis, driving them apart and fracturing one or both of the arches, resulting in a Jefferson (burst) fracture of C1.



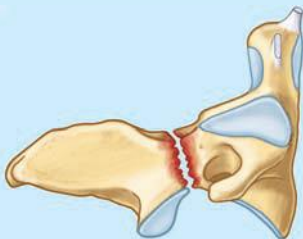Axis



Axis

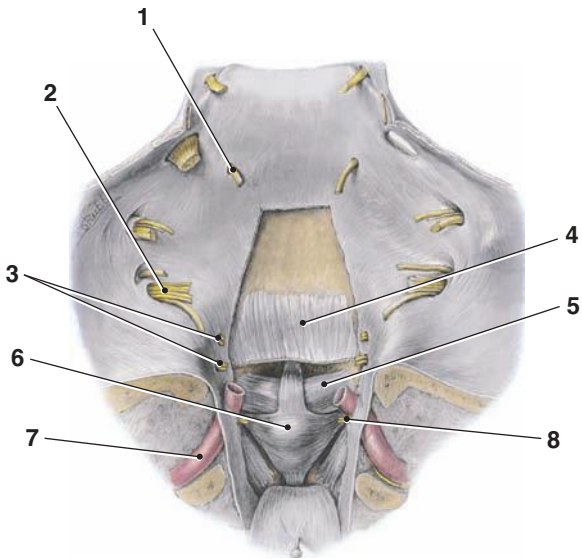
1. bifid spinous process
2. lamina
3. vertebral foramen
4. transverse process
5. superior articular process
6. dens of axis
7. body

Fractures of the vertebral arch of the axis are relatively common, often occurring between the articulating processes. Traumatic spondylolysis of C2 (hangman's fracture) typically results from hyperextension, as may occur in whiplash or hanging.



Rupture of the transverse ligament of the axis sets the dens free, causing atlantoaxial subluxation, which may lead to spinal cord or brainstem compression. Fracture of the dens is typically less severe, as the transverse ligament holds the fractured dens in place.

Craniovertebral Joints



Craniovertebral Joints

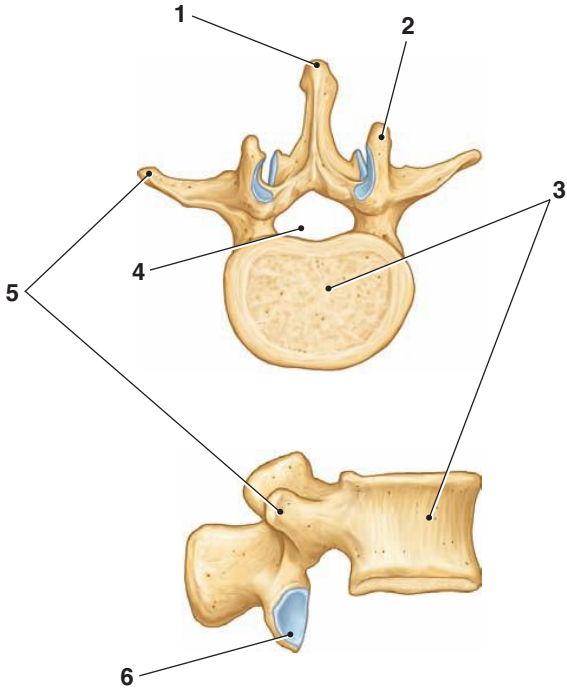
1. cranial nerve VI
2. cranial nerve X
3. cranial nerve XII
4. tectorial membrane
5. alar ligament
6. cruciform ligament
7. vertebral artery
8. C1 spinal nerve

The alar ligaments are weaker than the transverse ligament of the atlas and are relatively easy to tear, which results in an increase in the range of movement to the contralateral side.

Atlantoaxial rotation may compress the C2 spinal nerve and ganglion, causing severe pain and headaches.

The winding course of the vertebral arteries through the neck becomes significant when blood flow is reduced, as in atherosclerosis, possibly causing dizziness and light-headedness during prolonged turning of the head.

Lumbar Vertebrae

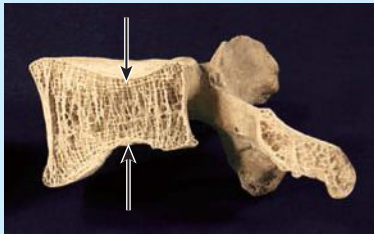


Lumbar Vertebrae

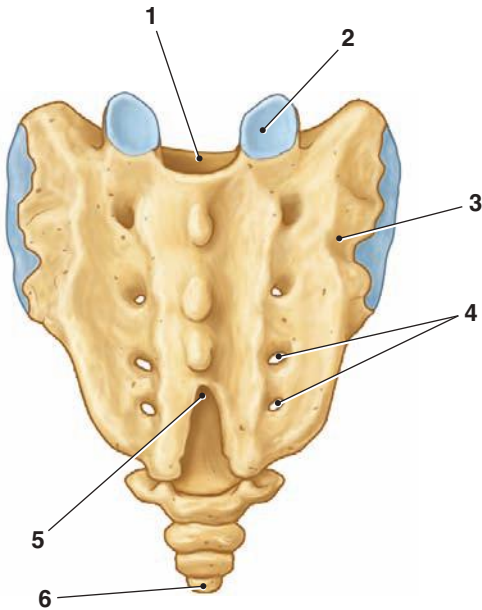
1. spinous process
2. superior articulating process
3. body
4. vertebral foramen
5. transverse process
6. inferior articulating process

Lumbar spinal stenosis is a narrowing of the vertebral foramen in one or more lumbar vertebrae. The narrowing may be related to disk bulging and may compress spinal nerve roots.

Beginning in middle age, overall bone density and strength decrease. Articular surfaces of vertebral bodies bow inward, causing the IV disk to become more convex, often leading to altered mechanics, loss of height, and bony or cartilaginous outgrowths.



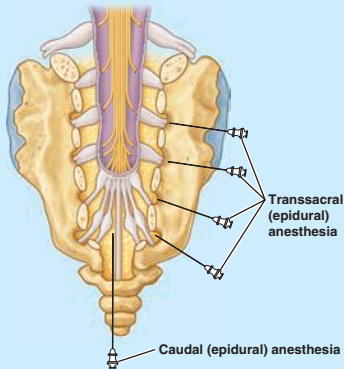
Sacrum, Posterior View



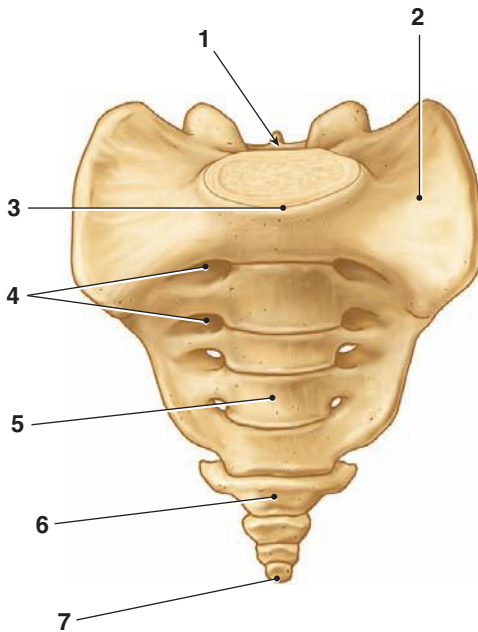
Sacrum, Posterior View

1. sacral canal
2. superior articulating facet
3. sacral tuberosity
4. posterior sacral foramina
5. sacral hiatus
6. tip of coccyx

Caudal epidural anesthesia entails injection of a local anesthetic into the fat of the sacral canal that surrounds the sacral nerves. This can be accomplished by several routes, including the sacral hiatus and the posterior sacral foramina (transsacral epidural anesthesia).



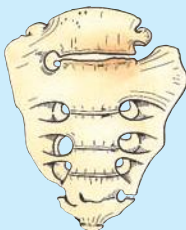
Sacrum, Anterior View



Sacrum, Anterior View

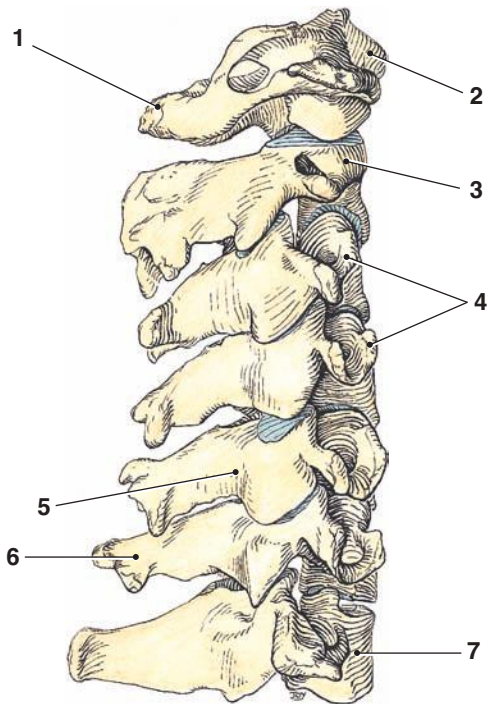
1. sacral canal
2. ala
3. promontory
4. anterior sacral foramina
5. S4
6. base of coccyx
7. apex of coccyx

In hemisacralization and sacralization, part or all, respectively, of the L5 vertebra is incorporated into the sacrum. In lumbarization of the S1 vertebra, S1 is partly or completely separate from the sacrum.



A fall onto the lower back may cause painful subperiosteal bruising or fracture of the coccyx or a fracture–dislocation of the sacrococcygeal joint.

Cervical Spine

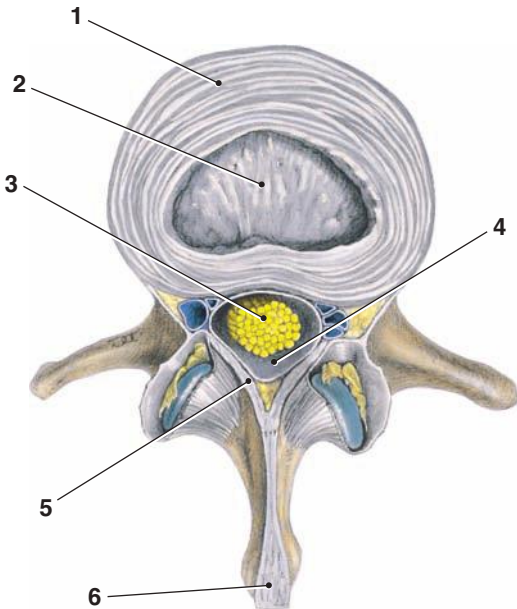


Cervical Spine

1. posterior tubercle of the atlas
2. anterior tubercle of the atlas
3. axis
4. anterior tubercles of transverse processes
5. lamina
6. spinous processes
7. C7

A relatively common anomaly is a cervical rib. The developmental costal element of C7 may be abnormally enlarged, often bilaterally. It may press on structures emerging from the superior thoracic aperture, causing thoracic outlet syndrome.

Intervertebral Disk

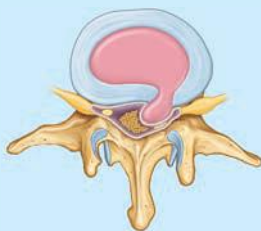
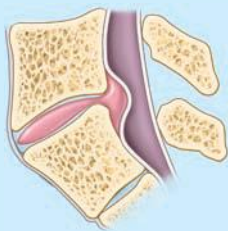


Intervertebral Disk

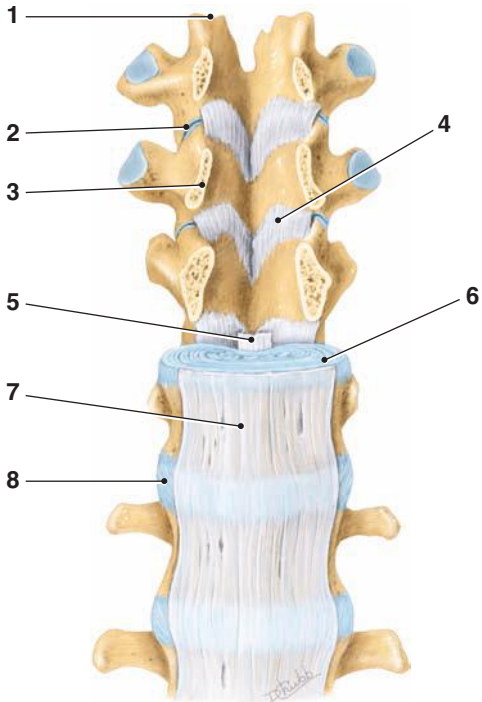
1. annulus fibrosus
2. hyaline end plate (nucleus pulposus removed)
3. cauda equina
4. subarachnoid space
5. ligamentum flavum
6. supraspinous ligament

The nuclei pulposi lose their turgor with age, and they become stiffer and more resistant to deformation, while the annuli fibrosi thicken and develop fissures and cavities.

Herniation of the nucleus pulposus into or through the annulus fibrosus is a well-recognized cause of lower back and lower limb pain. It is typically caused by hyperflexion of the vertebral column and is often called a slipped or ruptured disk.



Ligaments of the Vertebral Column



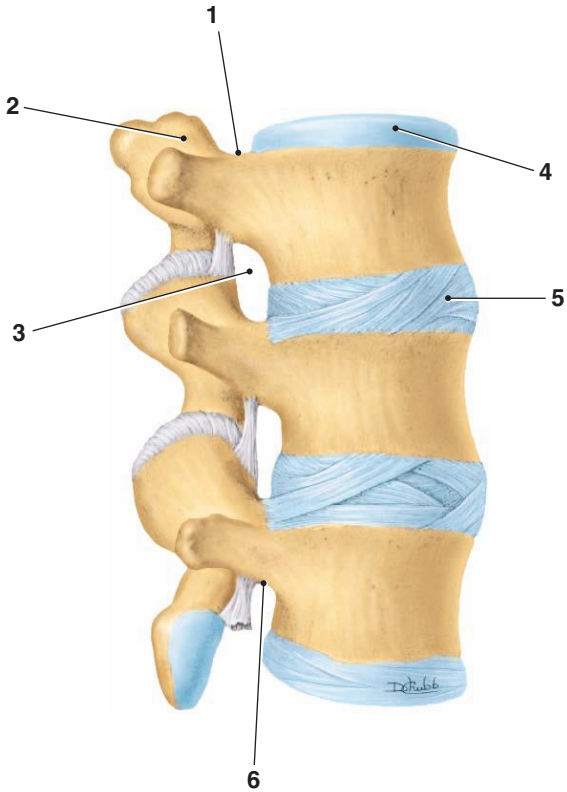
Ligaments of the Vertebral Column

1. superior articular process
2. zygapophysial joint
3. pedicle
4. ligamentum flavum
5. posterior longitudinal ligament
6. annulus fibrosus
7. anterior longitudinal ligament
8. IV disk

When the zygapophysial joints are injured or develop osteophytes, the related spinal nerves are often affected, causing pain along the dermatomes and spasm in the muscles of the associated myotomes.

Denervation of the articular branches of the nerves innervating the joint is a standard treatment for back pain caused by disease of the zygapophysial joints.

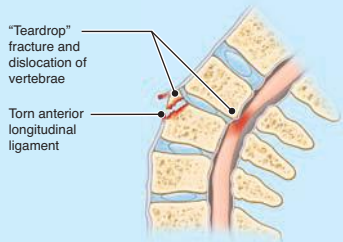
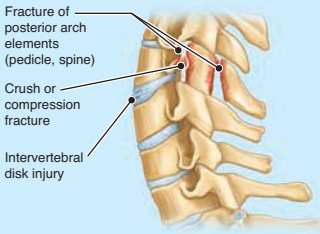
Articulated Vertebrae



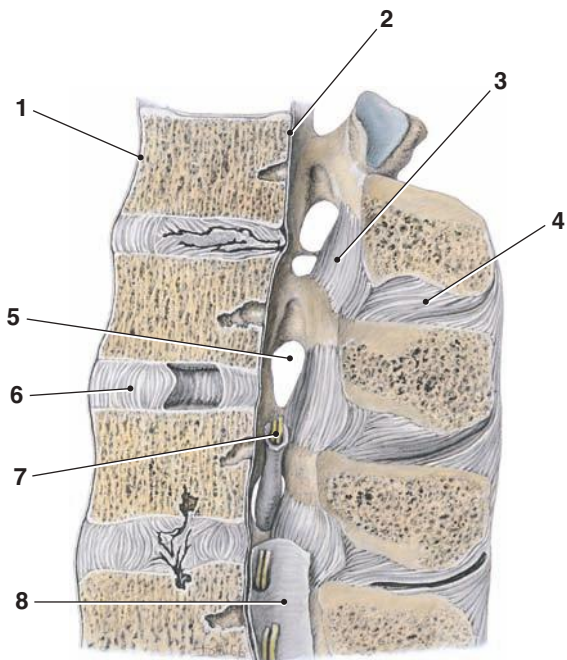
Articulated Vertebrae

1. superior vertebral notch
2. superior articular process
3. intervertebral foramen
4. intervertebral disk
5. annulus fibrosus
6. inferior vertebral notch

Excessive or sudden violent movement of the vertebral column may result in fractures, dislocations, and fracture-dislocations. Injuries may result from hyperflexion or hyperextension and typically occur in the more mobile cervical and thoracic regions of the column.



Lumbar Region of the Vertebral Column

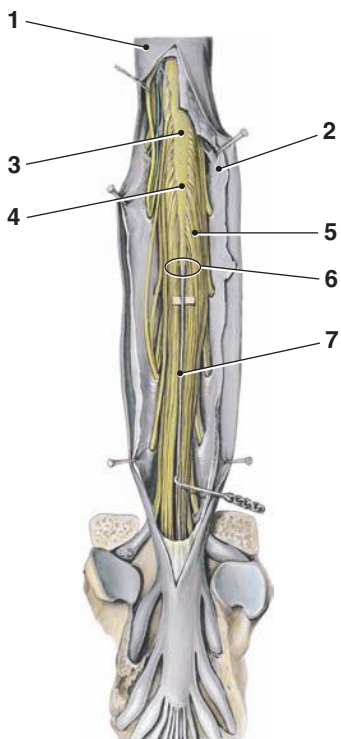


Lumbar Region of the Vertebral Column

1. anterior longitudinal ligament
2. posterior longitudinal ligament
3. ligamentum flavum
4. interspinous ligament
5. intervertebral foramen
6. annulus fibrosus
7. anterior and posterior nerve roots
8. dura mater

The lumbar spinal nerves increase in size from superior to inferior, while the intervertebral foramina decrease in diameter. This increases the chance that these nerve roots will be compressed if the nucleus pulposus herniates.

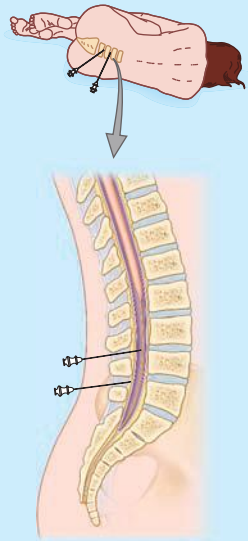
Dural Sac



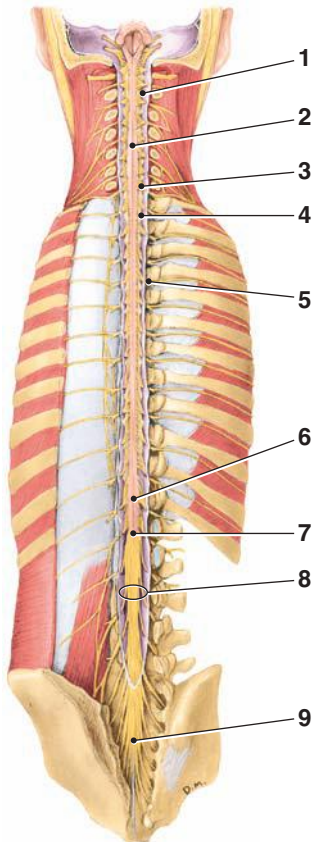
Dural Sac

1. dura mater
2. arachnoid mater
3. spinal cord
4. medullary cone
5. posterior rootlets
6. cauda equina
7. terminal filament

Lumbar spinal puncture (spinal tap) is performed for extraction of cerebrospinal fluid from the lumbar cistern for examination of the cellular composition, pressure, and chemical constituents. A spinal block entails introduction of an anesthetic into the cerebrospinal fluid through a lumbar puncture.



Spinal Cord

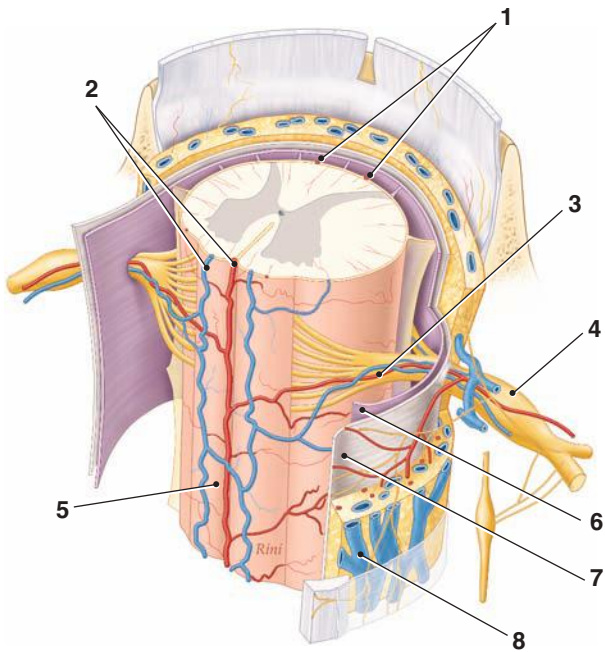


Spinal Cord

1. arachnoid mater
2. spinal cord (cervical enlargement)
3. posterior rootlets
4. denticulate ligament
5. spinal nerve
6. spinal cord (lumbar enlargement)
7. medullary cone
8. cauda equina
9. terminal filament

A narrow vertebral canal in the cervical region is dangerous because a minor fracture or dislocation may damage the cord. Encroachment of the vertebral canal by protruding IV disks, swollen ligamenta flava, or osteoarthritis may exert pressure on nerve roots. Transection of the cord results in loss of sensation and movement inferior to the damage.

Spinal Cord Blood Supply

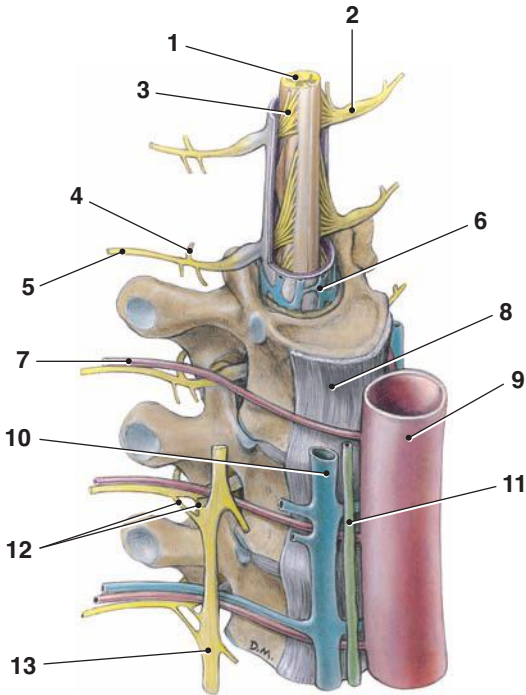


Spinal Cord Blood Supply

1. posterior spinal arteries and veins
2. anterior spinal artery and vein
3. anterior segmental medullary artery
4. spinal nerve
5. pia mater
6. arachnoid mater
7. dura mater
8. internal vertebral venous plexus

Fractures, dislocations, and fracture–dislocations may interfere with the blood supply to the spinal cord from the spinal and medullary arteries. Deficiency of blood supply (ischemia) to the cord affects its function and can lead to muscle weakness and paralysis.

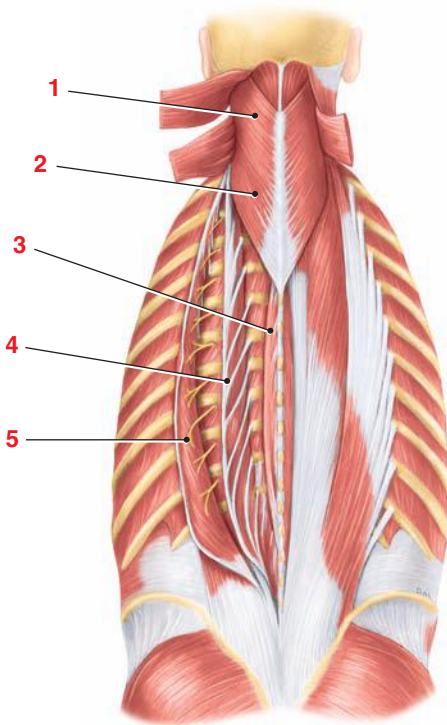
Spinal Cord and Prevertebral Structures



Spinal Cord and Prevertebral Structures

- 1.** spinal cord
- 2.** spinal nerve
- 3.** anterior rootlets
- 4.** posterior ramus
- 5.** anterior ramus
- 6.** internal vertebral venous plexus
- 7.** posterior intercostal artery
- 8.** anterior longitudinal ligament
- 9.** aorta
- 10.** azygos vein
- 11.** thoracic duct
- 12.** rami communicans
- 13.** sympathetic trunk

Superficial and Intermediate Layers of Intrinsic Back Muscles



Superficial and Intermediate Layers of Intrinsic Back Muscles

1. splenius capitis
2. splenius cervicis
3. spinalis
4. longissimus
5. iliocostalis

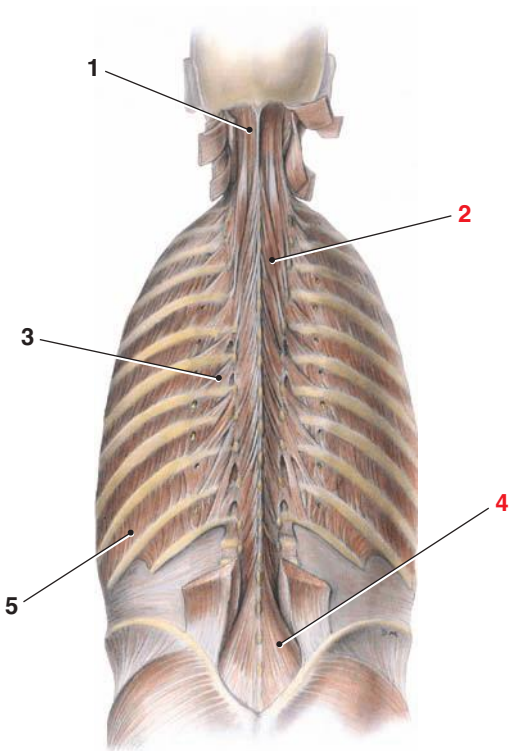
Splenius

- proximal attachment: nuchal ligament and spinous processes of C7–T3/T4
- distal attachment: capitis, mastoid process, and superior nuchal line; cervicis, transverse processes of C1–C3/C4
- innervation: posterior rami of spinal nerves
- main action: alone, lateral flexion of head and neck; together, extend head and neck

Erector Spinae

- proximal attachment: iliac crest, sacrum, sacral, and lumbar spinous processes; supraspinous ligament
- distal attachment: iliocostalis, angles of ribs, and cervical transverse processes; longissimus, ribs between tubercles and angles, transverse processes of thoracic and cervical vertebrae and mastoid process; spinalis, spinous processes to skull
- innervation: posterior rami of spinal nerves
- main action: alone, laterally flex vertebral column; together, extend vertebral column and head

Deep Layer of Intrinsic Back Muscles I



Deep Layer of Intrinsic Back Muscles I

1. semispinalis capitis
2. semispinalis
3. levator costarum
4. multifidus
5. external intercostal

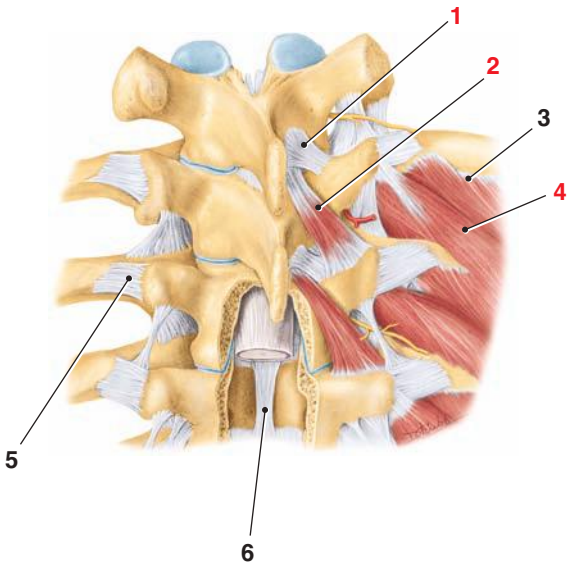
Semispinalis

- proximal attachment: thoracic and cervical transverse processes
- distal attachment: occipital bone, spinous processes of thoracic and cervical vertebrae
- innervation: posterior rami of spinal nerves
- main action: contralateral rotation and extension of head and thoracic and cervical regions of vertebral column

Multifidus

- proximal attachment: sacrum and ilium, transverse processes of T1–T5 and articular processes of C4–C7
- distal attachment: spinous processes
- innervation: posterior rami of spinal nerves
- main action: stabilizes vertebrae during local movements of column

Deep Layer of Intrinsic Back Muscles II



Deep Layer of Intrinsic Back Muscles II

1. rotatores breves
2. rotatores longi
3. external intercostal
4. levator costarum
5. lateral costotransverse ligament
6. posterior longitudinal ligament

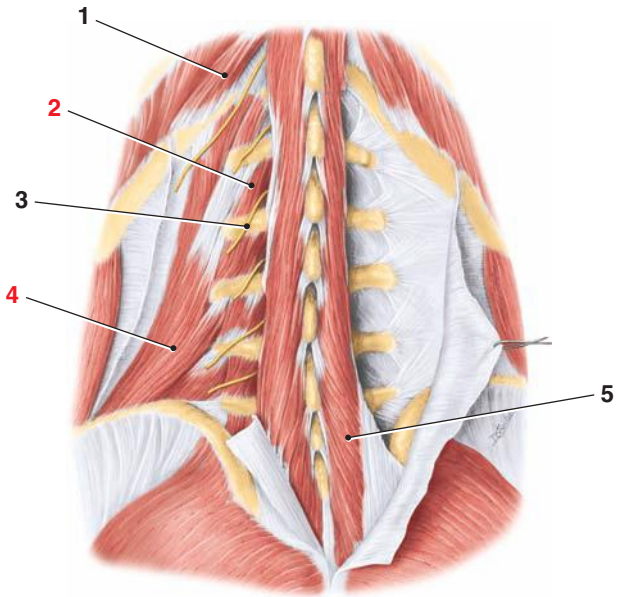
Rotatores

- proximal attachment: transverse processes
- distal attachment: junction of lamina and transverse processes of vertebra of origin or spinous process above
- innervation: posterior rami of spinal nerves
- main action: stabilize vertebrae and assist with extension and rotation of vertebral column

Levator Costarum

- proximal attachment: transverse processes C7–T11
- distal attachment: between angle and tubercle of ribs
- innervation: posterior rami of C8–T11
- main action: elevates ribs, assists with lateral bending of vertebral column

Deep Back Muscles



Deep Back Muscles

1. levator costarum
2. intertransversarii
3. posterior ramus
4. quadratus lumborum
5. multifidus

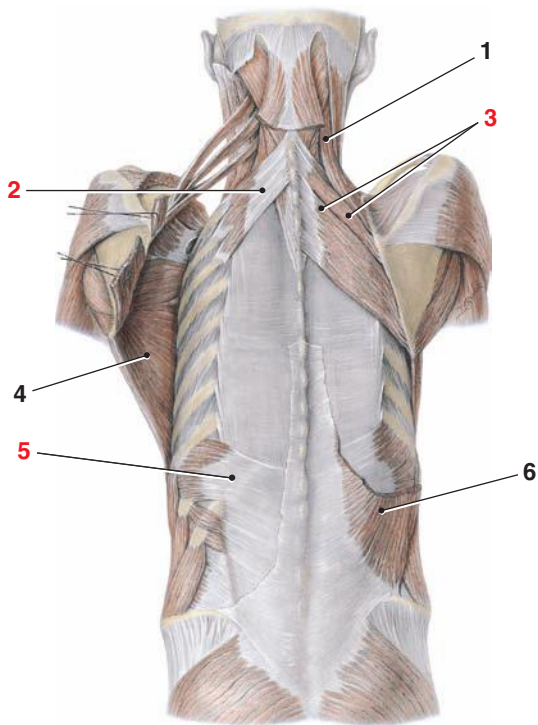
Intertransversarii

- proximal attachment: transverse processes of cervical and lumbar vertebrae
- distal attachment: transverse processes of adjacent vertebrae
- innervation: anterior and posterior rami of spinal nerves
- main action: assist in lateral flexion and stabilization of vertebral column

Quadratus Lumborum

- proximal attachment: 12th rib and transverse processes of lumbar vertebrae
- distal attachment: iliolumbar ligaments and iliac crest
- innervation: anterior branches of T12–L4 nerves
- main action: extends and laterally flexes vertebral column; fixes 12th rib during inspiration

Intermediate Back



Intermediate Back

1. levator scapulae
2. serratus posterior superior
3. rhomboid major and minor
4. serratus anterior
5. serratus posterior inferior
6. latissimus dorsi (cut)

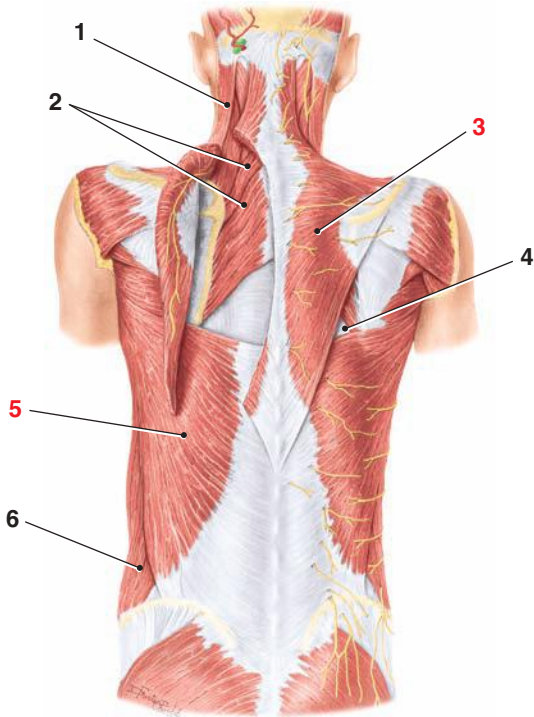
Serratus Posterior

- proximal attachment: superior, nuchal ligament and C7–T3 spinous processes; inferior, T11–L2 spinous processes
- distal attachment: superior, ribs 2 to 4; inferior, ribs 8 to 12
- innervation: superior, intercostal nerves 2 to 5; inferior, T9–T12 spinal nerves
- main action: superior, elevate ribs; inferior, depress ribs

Rhomboids

- proximal attachment: minor, nuchal ligament and C7–T1 spinous processes; major, T2–T5 spinous processes
- distal attachment: medial border of scapula
- innervation: dorsal scapular nerve
- main action: retract and rotate scapula

Superficial Back



Superficial Back

1. levator scapulae
2. rhomboid minor and major
3. trapezius
4. triangle of auscultation
5. latissimus dorsi
6. external oblique

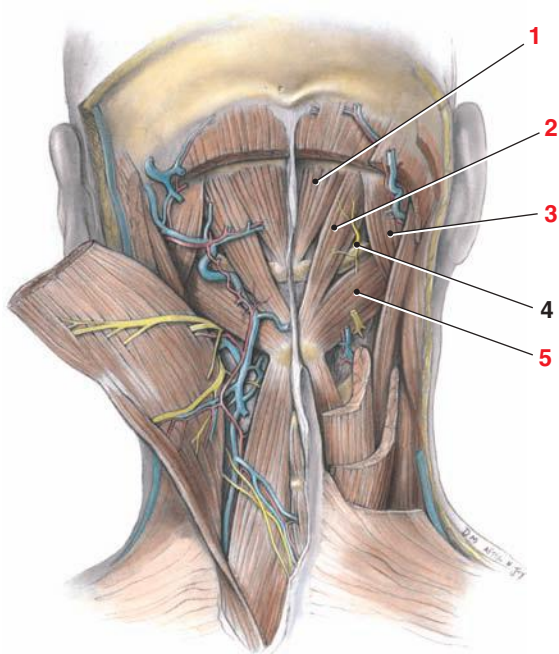
Trapezius

- proximal attachment: superior nuchal line, external occipital protuberance, nuchal ligament, and C7–T12 spinous processes
- distal attachment: clavicle, acromion, and spine of scapula
- innervation: spinal accessory nerve
- main action: elevates, retracts, and rotates scapula

Latissimus Dorsi

- proximal attachment: spinous processes of lower 6 thoracic vertebrae, thoracolumbar fascia, iliac crest, and inferior 3 to 4 ribs
- distal attachment: floor of intertubercular groove of humerus
- innervation: thoracodorsal nerve
- main action: extends, adducts, and medially rotates humerus

Suboccipital Triangle



Suboccipital Triangle

1. rectus capitis posterior minor
2. rectus capitis posterior major
3. superior oblique
4. C1, posterior ramus (suboccipital nerve)
5. inferior oblique

Rectus Capitis Posterior

- proximal attachment: major, C2 spinous process; minor, C1 posterior arch
- distal attachment: inferior nuchal line
- innervation: suboccipital nerve
- main action: postural and proprioceptive

Superior and Inferior Oblique

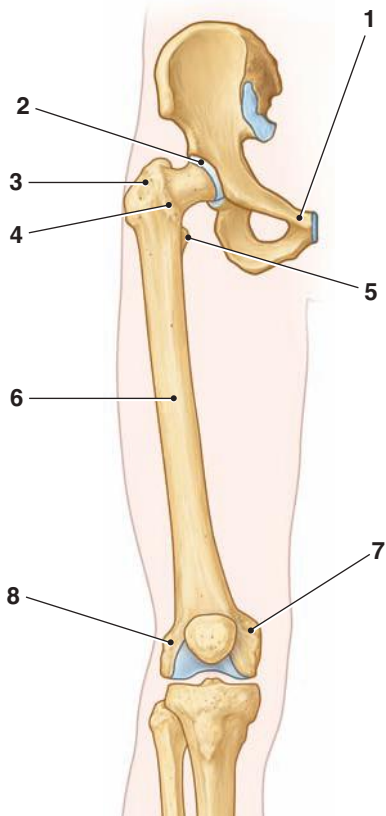
- proximal attachment: inferior, C1 posterior arch; superior, C1 transverse process
- distal attachment: inferior, C1 transverse process; superior, between nuchal lines
- innervation: suboccipital nerve
- main action: postural and proprioceptive

5 • Lower Limb

- 5.1** Femur, Anterior View
- 5.2** Femur, Posterior View
- 5.3** Tibia, Anterior View
- 5.4** Tibia, Posterior View
- 5.5** Bones of the Foot, Dorsal View
- 5.6** Bones of the Foot, Medial View
- 5.7** Veins of the Lower Limb
- 5.8** Sensory Innervation of the Lower Limb
- 5.9** Inguinal Region
- 5.10** Inguinal Lymph Nodes
- 5.11** Muscles of the Inguinal Region
- 5.12** Anterior Thigh
- 5.13** Quadriceps
- 5.14** Lateral Thigh
- 5.15** Femoral Artery
- 5.16** Femoral Vein
- 5.17** Medial Thigh
- 5.18** Gluteal Region
- 5.19** Muscles of the Gluteal Region
- 5.20** Posterior Thigh
- 5.21** Muscles of the Posterior Thigh
- 5.22** Muscles of the Posterior Thigh, Deep Dissection
- 5.23** Popliteal Fossa
- 5.24** Muscles of the Popliteal Fossa
- 5.25** Fascia of the Lower Limb
- 5.26** Anterior Leg
- 5.27** Muscles of the Anterior Leg
- 5.28** Lateral Leg
- 5.29** Muscles of the Lateral Leg
- 5.30** Posterior Leg

- 5.31** Posterior Leg, Deep Dissection
- 5.32** Muscles of the Posterior Compartment of the Leg
- 5.33** Deep Dissection of the Posterior Compartment of the Leg
- 5.34** Dorsum of the Foot
- 5.35** Plantar Surface of the Foot
- 5.36** Medial Aspect of the Ankle
- 5.37** Arteries of the Sole of the Foot
- 5.38** Muscles of the Sole of the Foot, Layer 1
- 5.39** Muscles of the Sole of the Foot, Layer 2
- 5.40** Muscles of the Sole of the Foot, Layer 3
- 5.41** Hip Joint
- 5.42** Patella
- 5.43** Knee
- 5.44** Knee Joint, Posterior View
- 5.45** Open Knee Joint
- 5.46** Knee Joint, Lateral View
- 5.47** Ligaments of the Ankle, Lateral View
- 5.48** Ligaments of the Ankle, Posterior View
- 5.49** Toes, Superior View
- 5.50** Toes, Inferior View
- 5.51** Ligaments of the Foot

Femur, Anterior View



Femur, Anterior View

1. pubic tubercle
2. head of femur
3. greater trochanter
4. intertrochanteric line
5. lesser trochanter
6. femur
7. adductor tubercle
8. lateral epicondyle

The neck of the femur is often fractured, especially in older females, secondary to osteoporosis; two examples of femoral neck fracture include the transcervical and intertrochanteric. Fractures of the greater trochanter, or shaft of the femur, occur during more active years; examples include spiral fracture.

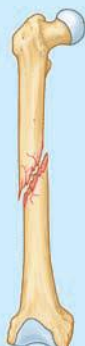Transcervical



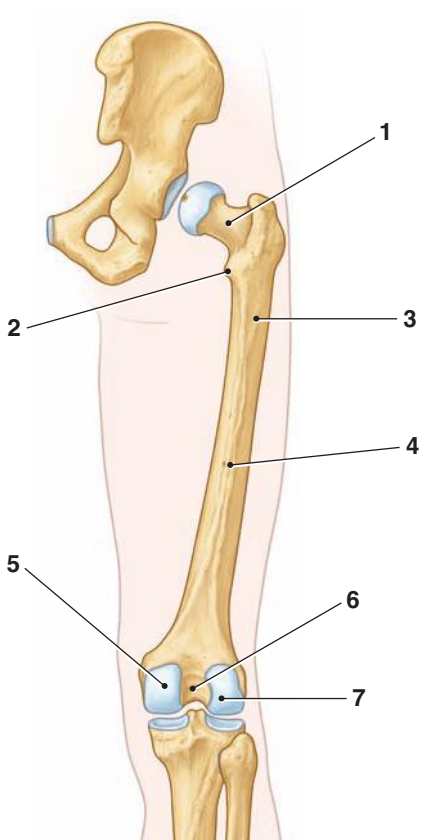
Intertrochanteric



Spiral



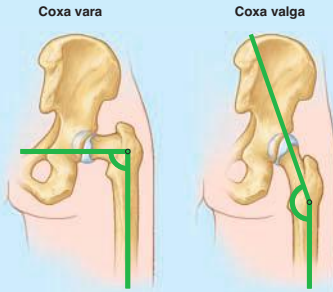
Femur, Posterior View



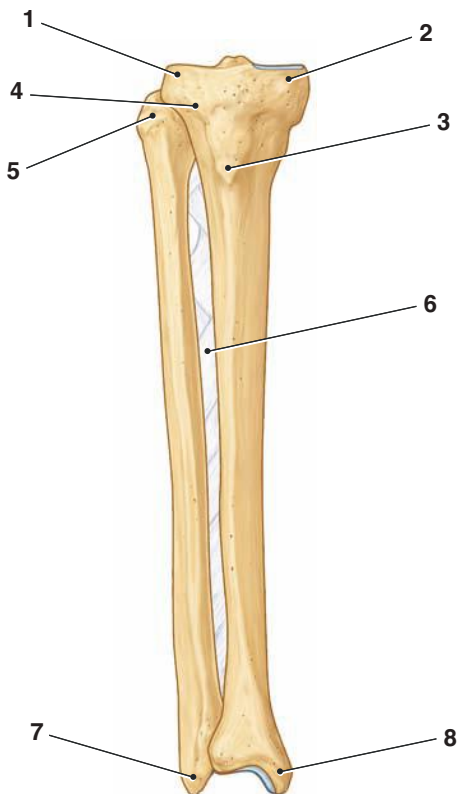
Femur, Posterior View

1. neck of the femur
2. lesser trochanter
3. gluteal tuberosity
4. linea aspera
5. medial femoral condyle
6. intercondylar fossa
7. lateral femoral condyle

The angle of inclination between the long axis of the femoral neck and the shaft varies with age, sex, development, and pathological processes (e.g., rickets). When the angle is decreased, the condition is coxa vara; when it is increased, it is coxa valga.



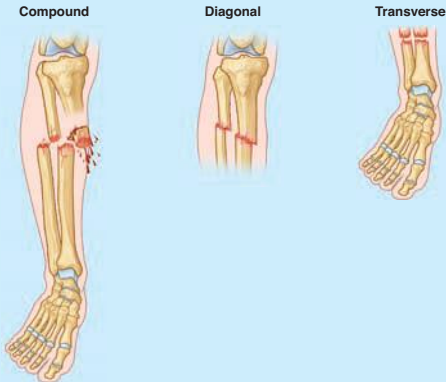
Tibia, Anterior View



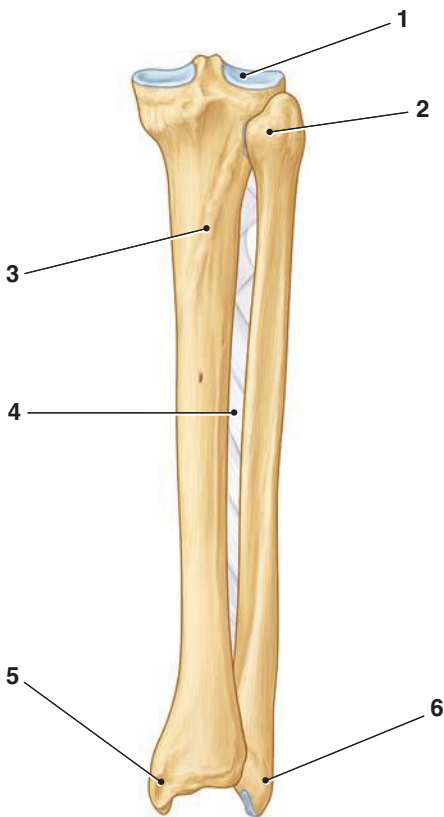
Tibia, Anterior View

1. lateral condyle
2. medial condyle
3. tibial tuberosity
4. anterolateral (Gerdy's) tubercle
5. head of the fibula
6. interosseous membrane
7. lateral malleolus
8. medial malleolus

The tibial shaft is most narrow and has the poorest blood supply at the junction of its middle and inferior thirds. It is also the most common site for a compound fracture. Transverse stress (march) fractures occur in unconditioned hikers. Diagonal fractures occur as a result of severe torsion. Boot-top fractures may occur during skiing when the leg is forced against the rigid boot.



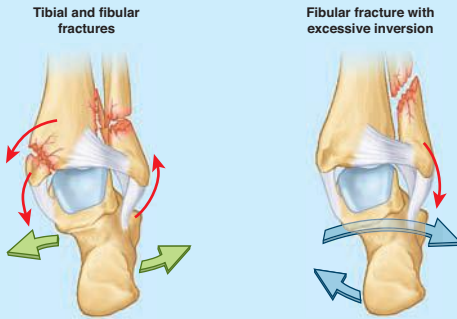
Tibia, Posterior View



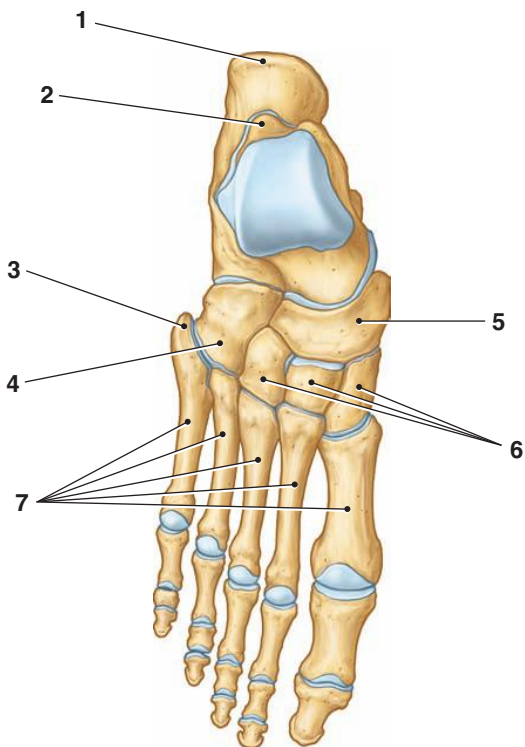
Tibia, Posterior View

1. lateral tibial plateau
2. head of the fibula
3. soleal line
4. interosseous membrane
5. medial malleolus
6. lateral malleolus

Fracture of the fibula commonly occurs a few centimeters proximal to the lateral malleolus and is usually associated with fracture–dislocations of the ankle joint. Malleolar fractures are relatively common in soccer and basketball players.



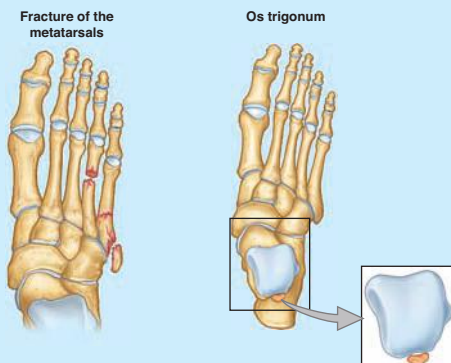
Bones of the Foot, Dorsal View



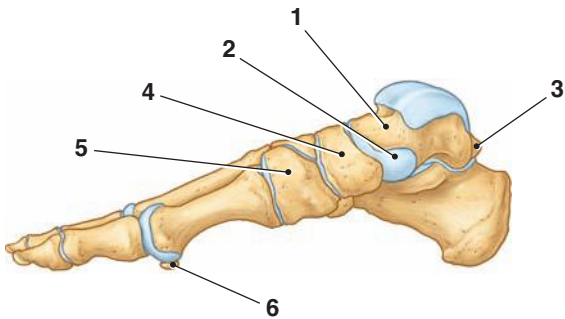
Bones of the Foot, Dorsal View

1. calcaneal tuberosity
2. lateral tubercle
3. tuberosity of the 5th metatarsal
4. cuboid
5. navicular
6. cuneiforms
7. metatarsals

Metatarsal fractures may occur during trauma to the foot. They also occur in dancers (dancer's fracture) or from prolonged walking (fatigue fracture). Sudden inversion of the foot may cause avulsion of the tuberosity of the 5th metatarsal. During ossification of the talus, the lateral tubercle occasionally fails to unite with the body, resulting in an accessory ossicle—an os trigonum.



Bones of the Foot, Medial View

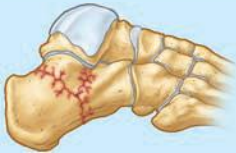

Bones of the Foot, Medial View

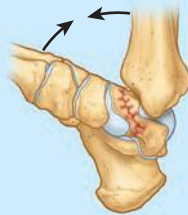1. neck of the talus
2. head of the talus
3. lateral tubercle
4. navicular
5. 1st cuneiform
6. medial sesamoid

A disabling comminuted fracture of the calcaneus may occur during a hard fall onto the heel. Fracture of the talar neck may occur during forceful dorsiflexion of the ankle. Fracture of the sesamoid bones of the great toe may occur during a crush injury, creating gait disturbances.

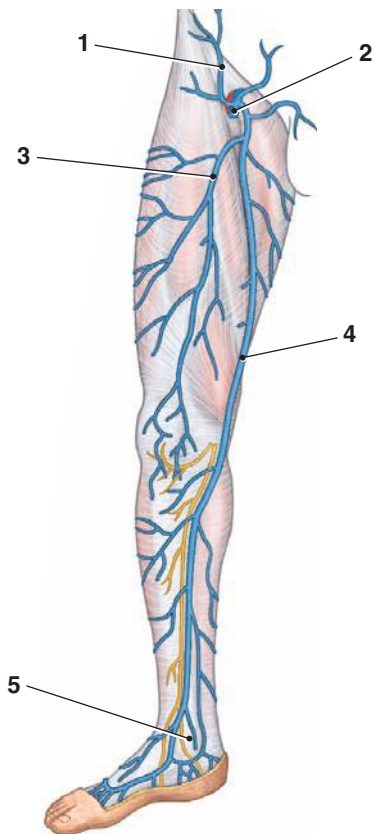
Comminuted fracture
of the calcaneus



Fracture of the
talar neck



Veins of the Lower Limb

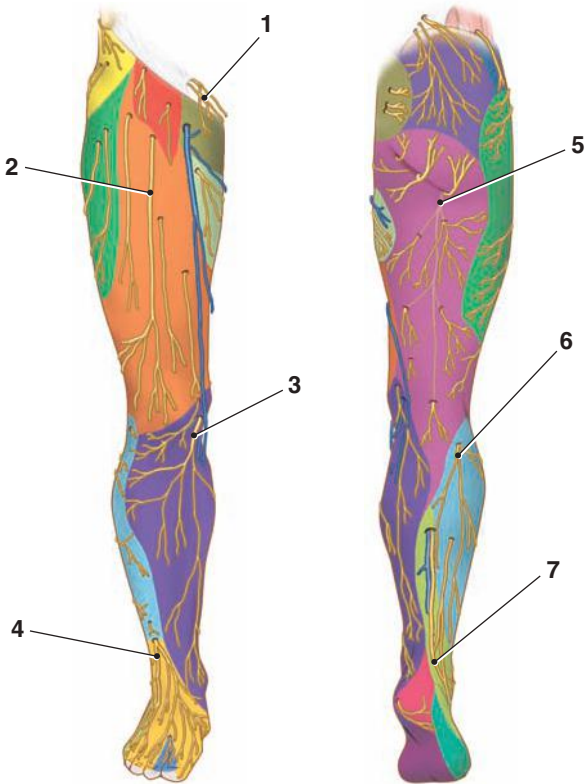


Veins of the Lower Limb

1. superficial circumflex iliac vein
2. femoral vein
3. lateral femoral cutaneous vein
4. great saphenous vein
5. medial malleolus

The great saphenous vein and its tributaries may become varicose. Varicose veins form when the valves that prevent backflow from deep veins become incompetent. Because of its accessibility, size, and structure, the great saphenous vein is often used for the graft in coronary arterial bypass. During saphenous cutdown, an incision is made anterior to the medial malleolus to locate the great saphenous vein for prolonged infusion of therapeutic agents.

Sensory Innervation of the Lower Limb

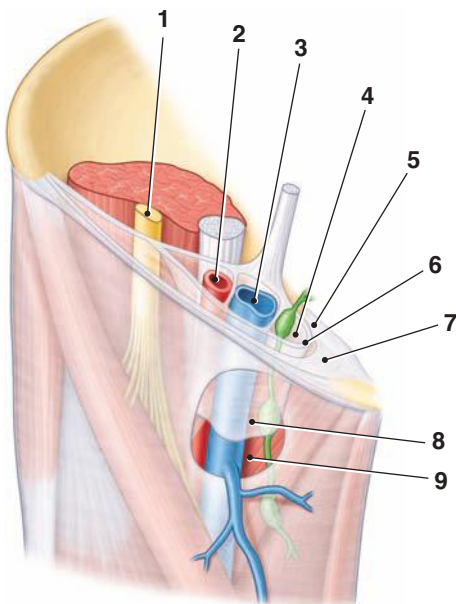


Sensory Innervation of the Lower Limb

1. ilioinguinal nerve
2. anterior femoral cutaneous nerve
3. saphenous nerve
4. superficial fibular nerve
5. posterior femoral cutaneous nerve
6. lateral sural cutaneous nerve
7. sural nerve

The highly variable cutaneous nerves of the lower limb may be anesthetized if necessary. Injecting an anesthetic agent 4 to 6 cm posterior to the ASIS blocks the iliohypogastric and ilioinguinal nerves. The femoral nerve can be blocked 2 cm inferior to the inguinal ligament.

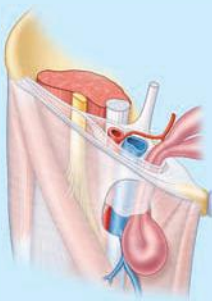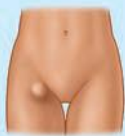Inguinal Region



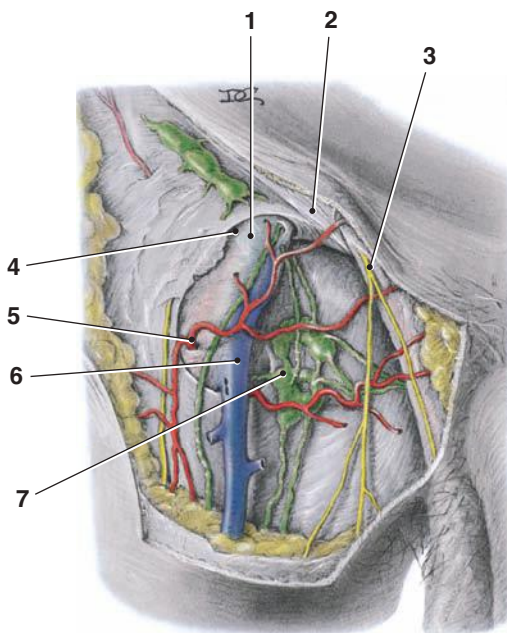
Inguinal Region

1. femoral nerve
2. femoral artery
3. femoral vein
4. femoral canal
5. pectineal ligament
6. femoral ring
7. lacunar ligament
8. femoral sheath
9. saphenous opening

The femoral ring is the usual originating site of a femoral hernia, a protrusion of abdominal viscera through the ring and into the canal. A femoral hernia appears as a tender mass in the femoral triangle inferolateral to the pubic tubercle; it may become strangulated because of the sharp lacunar ligament.



Inguinal Lymph Nodes

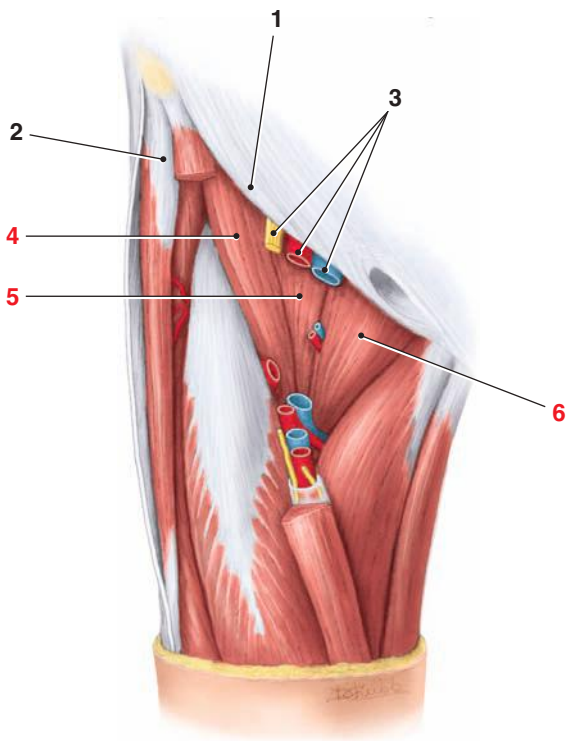


Inguinal Lymph Nodes

1. femoral sheath
2. inguinal ligament
3. ilioinguinal nerve
4. saphenous opening
5. superficial epigastric artery
6. great saphenous vein
7. superficial inguinal lymph nodes

Lymph nodes enlarge when diseased—lymphadenopathy. The superficial inguinal lymph nodes are in the superficial fascia and are easily palpated when enlarged, indicating a possible pathological process in the trunk inferior to the umbilicus, both lower limbs, and/or the uterus.

Muscles of the Inguinal Region



Muscles of the Inguinal Region

1. inguinal ligament
2. tensor fascia lata
3. femoral nerve, artery, and vein
4. iliacus
5. psoas major
6. pectineus

Iliacus

- proximal attachment: iliac crest and fossa, sacrum and sacroiliac ligaments
- distal attachment: psoas major and lesser trochanter
- innervation: femoral nerve
- main action: flexes and stabilizes hip

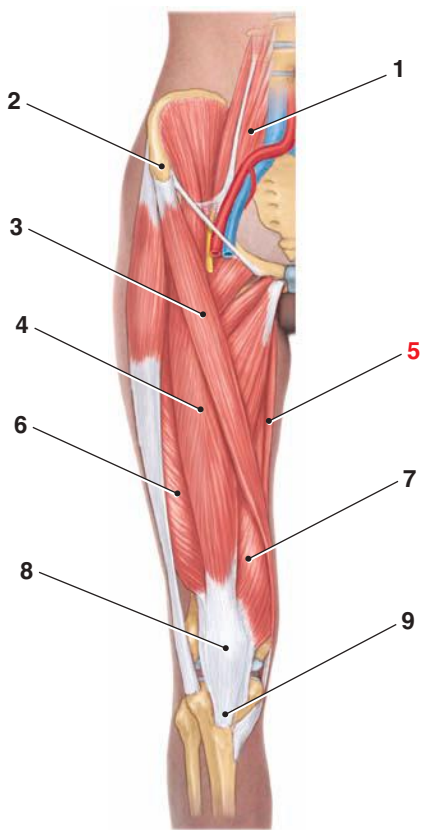
Psoas Major

- proximal attachment: T12–L5 vertebrae
- distal attachment: lesser trochanter
- innervation: L1–L3
- main action: flexes and stabilizes hip

Pectineus

- proximal attachment: pubis
- distal attachment: pectineal line of femur
- innervation: femoral nerve
- main action: adducts and flexes the thigh

Anterior Thigh



Anterior Thigh

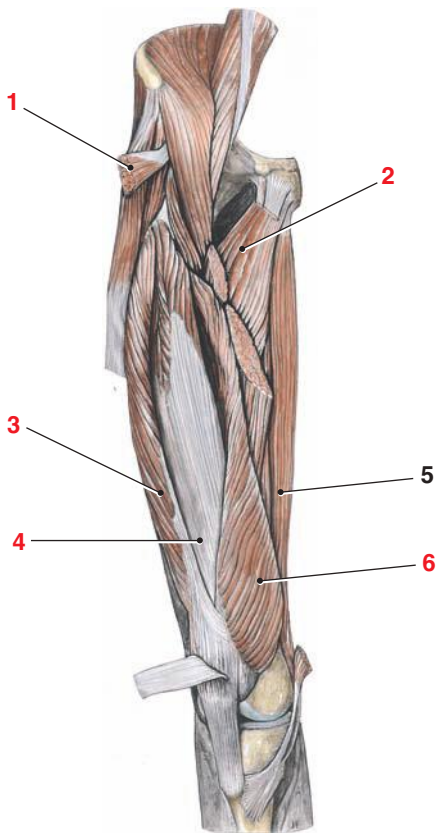
1. psoas major
2. anterior superior iliac spine
3. sartorius
4. rectus femoris
5. gracilis
6. vastus lateralis
7. vastus medialis
8. patella
9. patellar ligament

A common sports injury is contusion of the iliac crest near the anterior superior iliac spine, or hip pointer. Charley horse refers to a cramp in the thigh, usually in the rectus femoris. Paralysis of the quadriceps produces gait disturbances and the inability to extend the leg against resistance. A psoas abscess may pass into the thigh, causing severe pain referred to the hip, thigh, or knee and should be considered when the proximal thigh is edematous.

Gracilis

- proximal attachment: pubis
- distal attachment: proximal tibia
- innervation: obturator nerve
- main action: adducts thigh and flexes leg

Quadriceps



Quadriceps

1. rectus femoris (cut)
2. adductor brevis
3. vastus lateralis
4. vastus intermedius
5. gracilis
6. vastus medialis

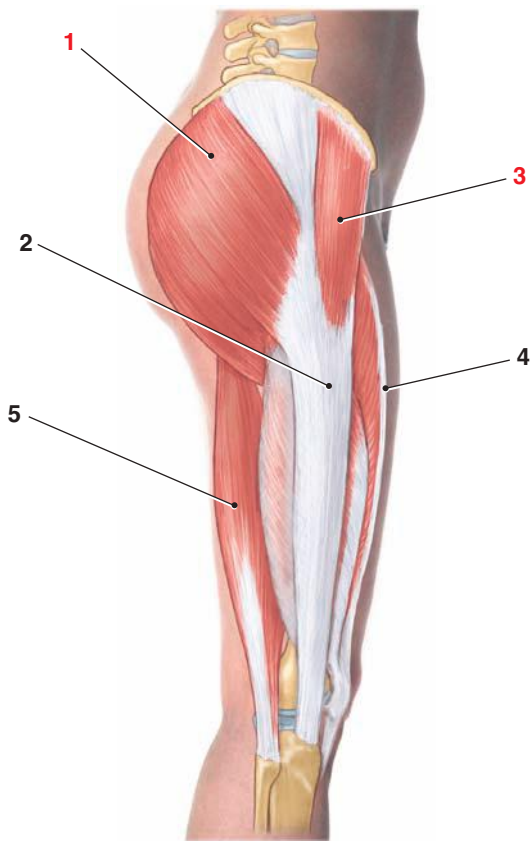
Adductor Brevis

- proximal attachment: pubis
- distal attachment: pectineal line and linea aspera
- innervation: obturator nerve
- main action: adducts thigh

Quadriceps Femoris

- proximal attachment: rectus femoris, anterior superior iliac spine; vastus lateralis, greater trochanter; vastus intermedius, femur; vastus medialis, intertrochanteric line and linea aspera
- distal attachment: patellar ligament to tibial tuberosity
- innervation: femoral nerve
- main action: extends leg, steadies and flexes hip

Lateral Thigh



Lateral Thigh

1. gluteus maximus
2. iliotibial tract
3. tensor fascia lata
4. rectus femoris
5. biceps femoris

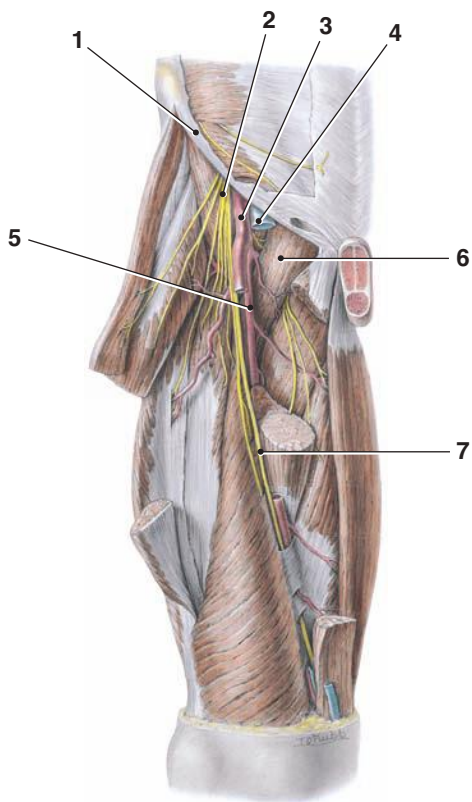
Gluteus Maximus

- proximal attachment: ilium, sacrum, coccyx, sacrotuberous ligament
- distal attachment: iliotibial tract and gluteal tuberosity
- innervation: inferior gluteal nerve
- main action: extends and steadies thigh, some lateral rotation

Tensor Fascia Lata

- proximal attachment: anterior superior iliac spine and iliac crest
- distal attachment: iliotibial tract
- innervation: superior gluteal nerve
- main action: abducts, medially rotates and flexes thigh, steadies trunk on thigh

Femoral Artery

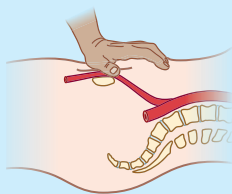


Femoral Artery

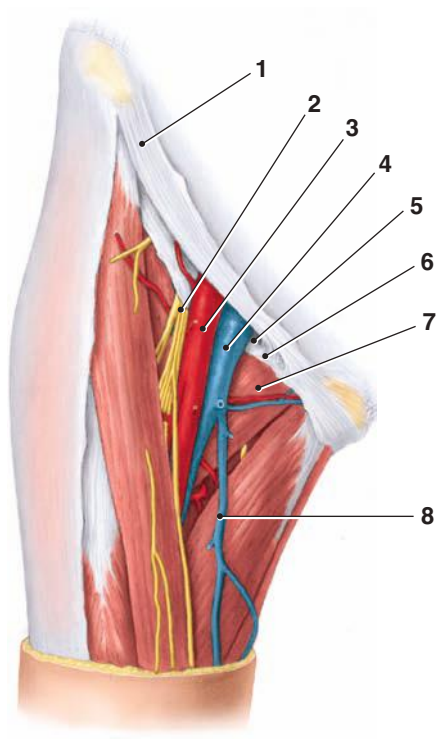
1. inguinal ligament
2. femoral nerve
3. femoral artery
4. femoral vein
5. deep femoral artery
6. pectineus
7. saphenous nerve

The proximal portion of the femoral artery is easily accessible for palpation, compression, and cannulation. The superficial location also makes it vulnerable to traumatic injury, such as laceration.

Compression of the femoral artery



Femoral Vein



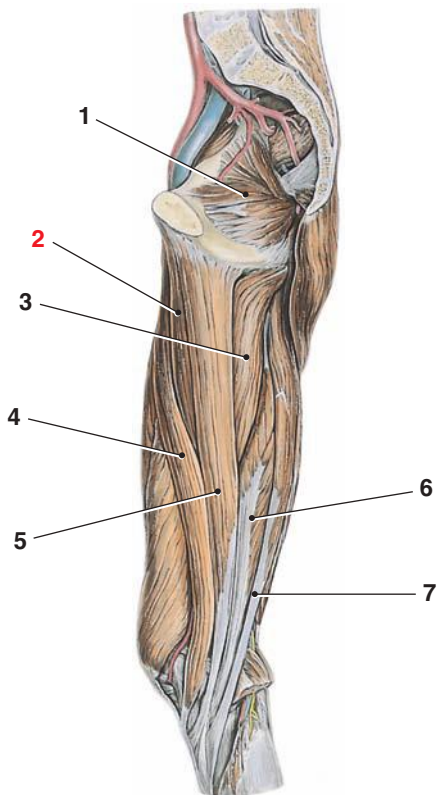
Femoral Vein

1. inguinal ligament
2. femoral nerve
3. femoral artery
4. femoral vein
5. femoral ring
6. lacunar ligament
7. pectineus
8. great saphenous vein

A saphenous varix is a local dilation of the terminal portion of the great saphenous vein that may cause edema in the femoral triangle and may be confused with other groin swellings, such as a psoas abscess.

The femoral vein can be located by palpating the pulsations of the femoral artery, which is immediately lateral to the vein. The vein can be cannulized for access to the right side of the heart and pulmonary trunk.

Medial Thigh



Medial Thigh

1. obturator internus
2. adductor longus
3. adductor magnus
4. sartorius
5. gracilis
6. semimembranosus
7. semitendinosus

The gracilis may be transplanted to replace damaged muscles elsewhere in the body.

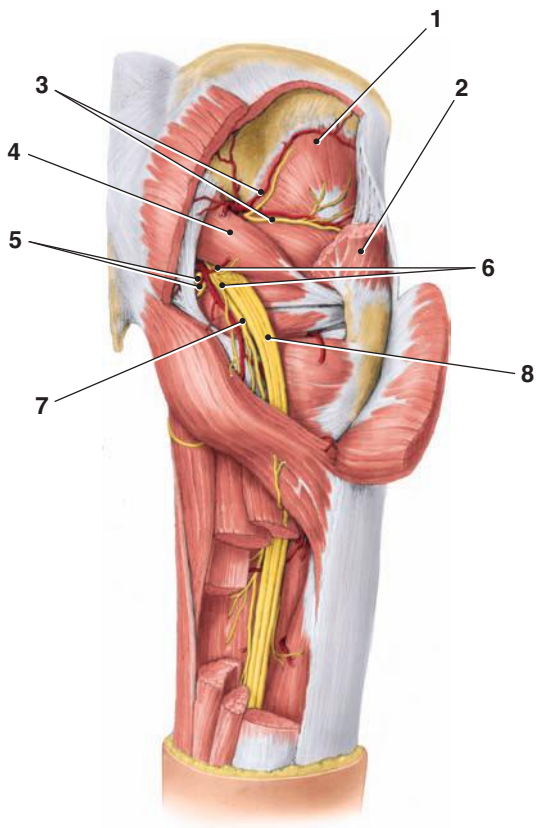
A groin pull usually refers to straining of the proximal aspect of the anteromedial thigh musculature, such as occurs in sporting activities requiring a quick start.

Rider's strain affects the adductor longus muscle, as occurs in horseback riders. The proximal tendons of these muscles ossify because of the active adduction needed to stay on the horse.

Adductor Longus

- proximal attachment: pubis
- distal attachment: linea aspera
- innervation: obturator nerve
- main action: adducts thigh

Gluteal Region

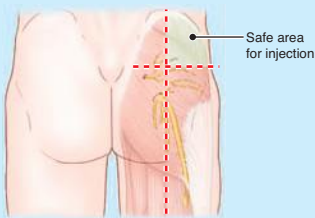


Gluteal Region

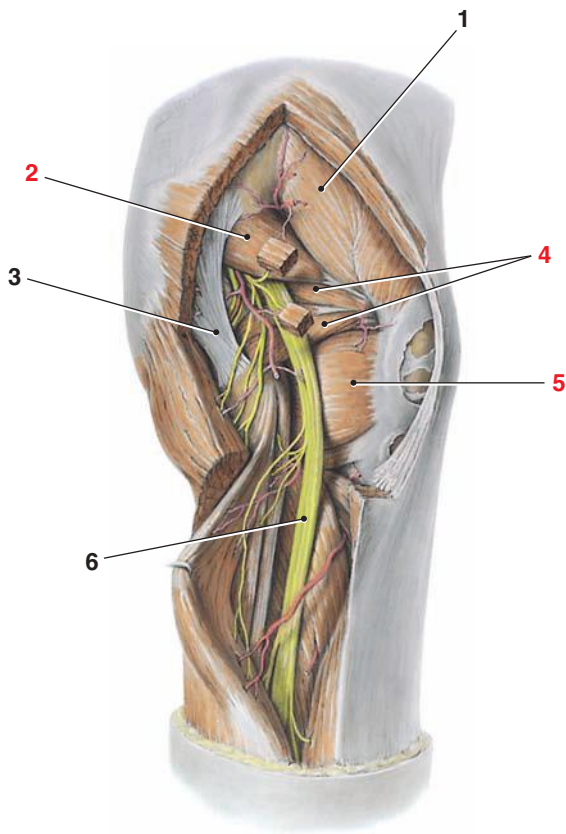
1. gluteus minimus
2. gluteus medius (cut)
3. superior gluteal artery and nerve
4. piriformis
5. pudendal nerve and internal pudendal artery
6. inferior gluteal artery and nerve
7. posterior femoral cutaneous nerve
8. sciatic nerve

Injury to the superior gluteal nerve results in a disabling gluteus medius limp to compensate for weakened abduction of the limb and/or a gluteal gait—a compensatory list of the body to the weakened side, observed as a positive Trendelenburg sign.

The gluteal region is a common site for intramuscular injection. Injections into the gluteal region are made in the superolateral quadrant to avoid damaging neurovascular elements.



Muscles of the Gluteal Region



Muscles of the Gluteal Region

1. gluteus medius
2. piriformis
3. sacrotuberous ligament
4. superior and inferior gemellus
5. quadratus femoris
6. sciatic nerve

Piriformis

- proximal attachment: sacrum and sacrotuberous ligament
- distal attachment: greater trochanter
- innervation: S1–S2
- main action: laterally rotates thigh

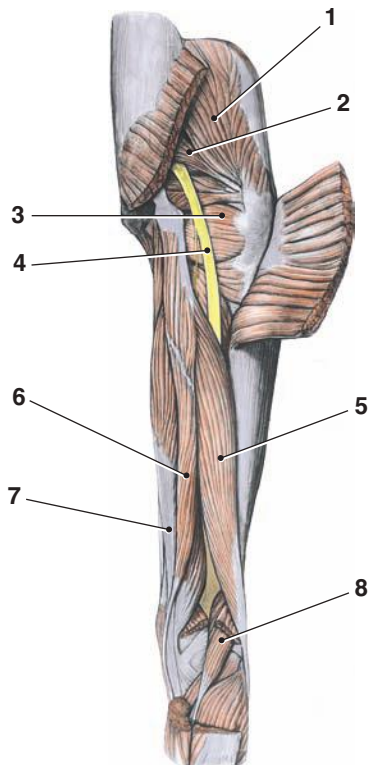
Gemelli

- proximal attachment: superior, ischial spine; inferior, ischial tuberosity
- distal attachment: greater trochanter
- innervation: L5–S1
- main action: laterally rotates thigh

Quadratus Femoris

- proximal attachment: ischial tuberosity
- distal attachment: intertrochanteric crest
- innervation: L5–S1
- main action: laterally rotates thigh

Posterior Thigh



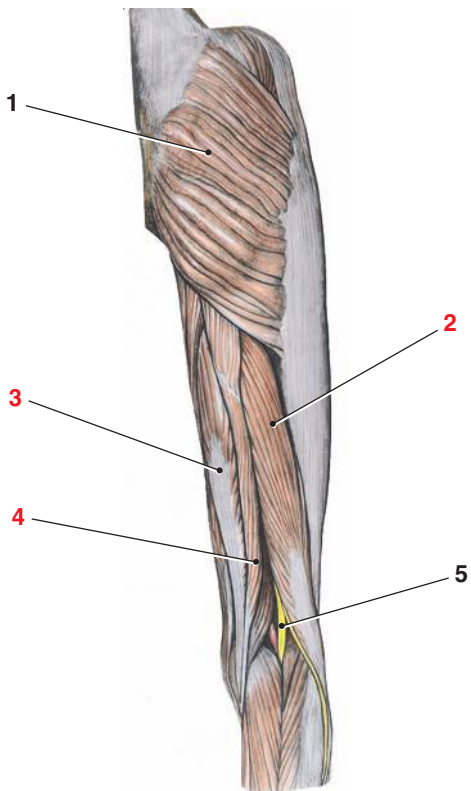
Posterior Thigh

1. gluteus medius
2. piriformis
3. quadratus femoris
4. sciatic nerve
5. biceps femoris
6. semitendinosus
7. semimembranosus
8. plantaris

Hamstring strains are common in active individuals. Violent exertion may tear the tendinous attachment to the ischial tuberosity.

Hypertrophy and spasm of the piriformis may result in pain in the buttocks and/or radiating down the limb from compression of the sciatic nerve. The sciatic nerve may be blocked by injection of an anesthetic agent between the posterior superior iliac spine and the greater trochanter.

Muscles of the Posterior Thigh



Muscles of the Posterior Thigh

1. gluteus maximus
2. biceps femoris
3. semimembranosus
4. semitendinosus
5. tibial nerve

Biceps Femoris

- proximal attachment: long head, ischial tuberosity; short head, linea aspera
- distal attachment: head of the fibula
- innervation: long head, tibial division of sciatic; short head, common fibular division of sciatic
- main action: flexes and rotates leg laterally, extends thigh

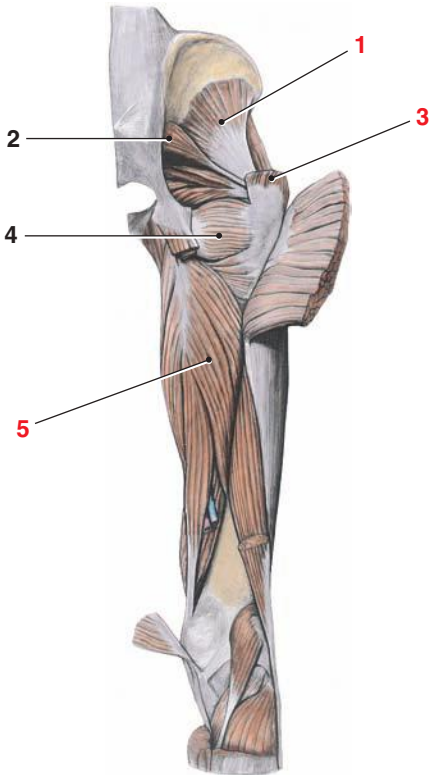
Semitendinosus

- proximal attachment: ischial tuberosity
- distal attachment: tibia
- innervation: tibial division of sciatic
- main action: extends thigh, flexes and rotates leg medially

Semimembranosus

- proximal attachment: ischial tuberosity
- distal attachment: tibia
- innervation: tibial division of sciatic
- main action: extends thigh, flexes and rotates leg medially

Muscles of the Posterior Thigh, Deep Dissection



Muscles of the Posterior Thigh, Deep Dissection

1. gluteus minimus
2. piriformis
3. gluteus medius (cut)
4. quadratus femoris
5. adductor magnus

Gluteus Minimus

- proximal attachment: external aspect of ilium
- distal attachment: greater trochanter
- innervation: superior gluteal nerve
- main action: abducts and medially rotates thigh

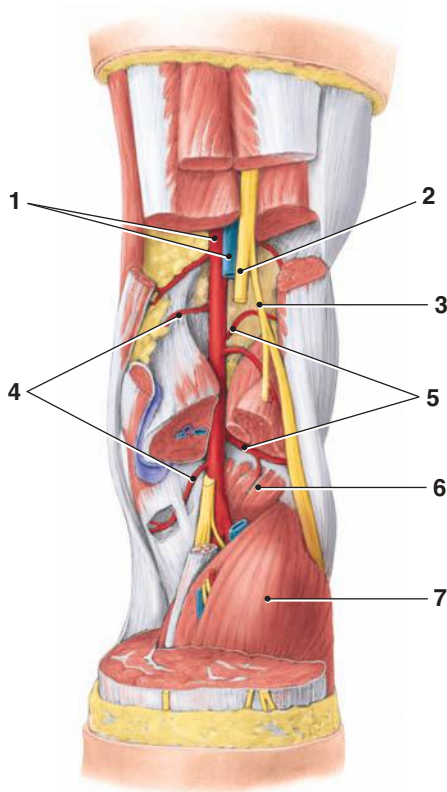
Gluteus Medius

- proximal attachment: external aspect of ilium
- distal attachment: greater trochanter
- innervation: superior gluteal nerve
- main action: abducts and medially rotates thigh, steadies pelvis when opposite leg is raised

Adductor Magnus

- proximal attachment: ischial tuberosity, rami of pubis and ischium
- distal attachment: gluteal tuberosity, linea aspera, adductor tubercle
- innervation: adductor part, obturator nerve; hamstring part, tibial division of the sciatic
- main action: adducts, flexes, and extends thigh

Popliteal Fossa



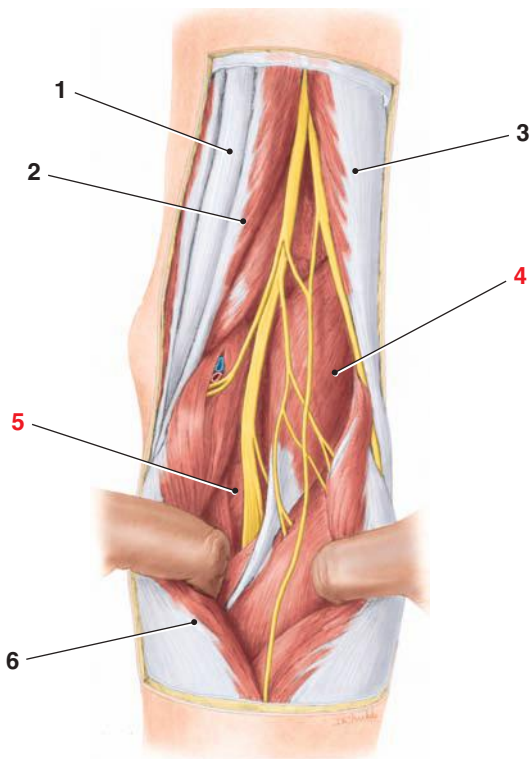
Popliteal Fossa

1. popliteal artery and vein
2. tibial nerve
3. common fibular nerve
4. superior and inferior medial genicular arteries
5. superior and inferior lateral genicular arteries
6. popliteus
7. soleus

The strong popliteal fascia limits expansion from regional abscesses and tumors, which may cause severe pain.

A popliteal aneurysm usually causes pain and edema in the popliteal fossa; as the artery lies deep in the fossa, the pulse and the source of the pain may be difficult to detect.

Muscles of the Popliteal Fossa



Muscles of the Popliteal Fossa

1. semimembranosus
2. semitendinosus
3. biceps femoris
4. plantaris
5. popliteus
6. gastrocnemius

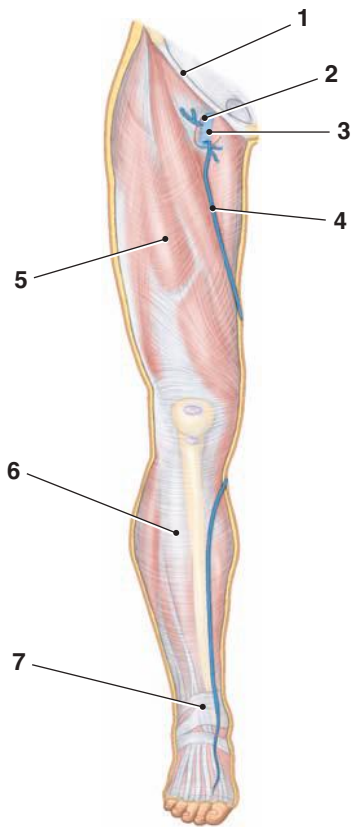
Plantaris

- proximal attachment: distal femur
- distal attachment: calcaneus via calcaneal tendon
- innervation: tibial nerve
- main action: plantar-flexes ankle

Popliteus

- proximal attachment: lateral condyle of femur and lateral meniscus
- distal attachment: proximal tibia
- innervation: tibial nerve
- main action: unlocks knee

Fascia of the Lower Limb

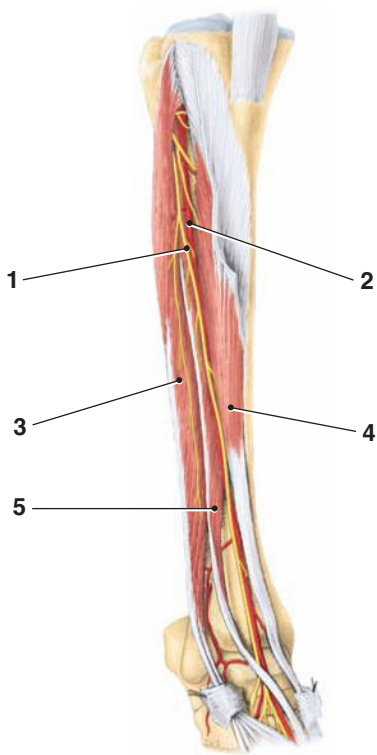


Fascia of the Lower Limb

1. inguinal ligament
2. saphenous opening
3. cribriform fascia
4. great saphenous vein
5. fascia lata
6. crural fascia
7. extensor retinacula

The fascial compartments of the lower limb are formed by deep extensions of the investing fascia, forming closed spaces. Trauma to muscles or vessels in the compartments causes increased pressure, which may produce compartment syndromes resulting from a decrease in arterial perfusion of the tissues.

Anterior Leg



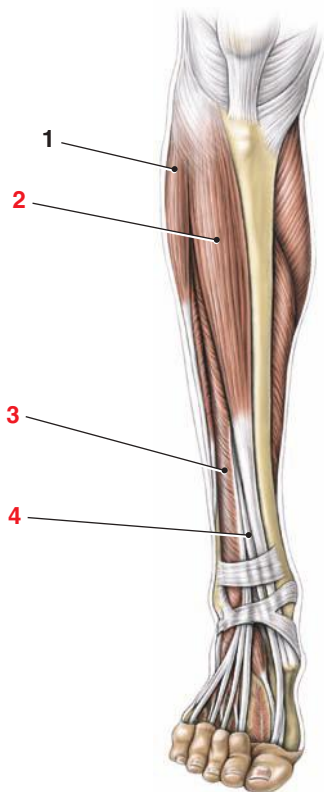
Anterior Leg

1. deep fibular nerve
2. anterior tibial artery
3. extensor digitorum longus
4. tibialis anterior
5. extensor hallucis longus

Shin splints (anterior compartment syndrome), or edema and pain in the anterior compartment of the leg, results from repetitive microtrauma to the tibialis anterior.

Compression of the deep fibular nerve from tight-fitting ski boots or shoes may cause pain in the anterior compartment of the leg and into the dorsum of the foot.

Muscles of the Anterior Leg



Muscles of the Anterior Leg

1. fibularis longus
2. tibialis anterior
3. extensor digitorum longus
4. extensor hallucis longus

Tibialis Anterior

- proximal attachment: tibia
- distal attachment: medial cuneiform and 1st metatarsal
- innervation: deep fibular nerve
- main action: dorsiflexion and inversion

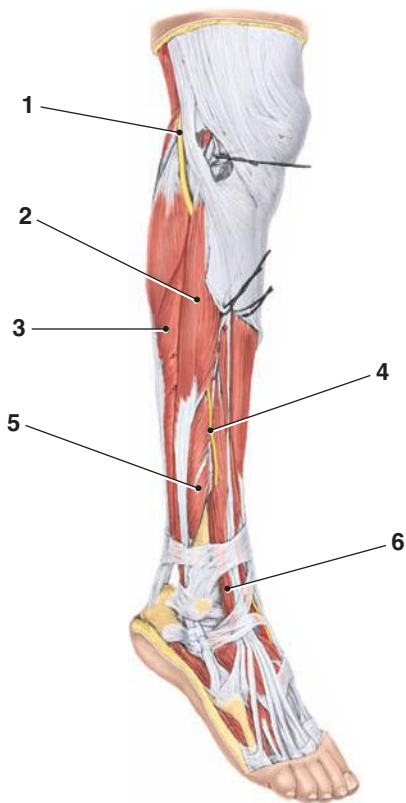
Extensor Digitorum Longus

- proximal attachment: tibia and interosseous membrane
- distal attachment: middle and distal phalanges of lateral four toes
- innervation: deep fibular nerve
- main action: extends lateral four toes; dorsiflexion

Extensor Hallucis Longus

- proximal attachment: fibula and interosseous membrane
- distal attachment: distal phalanx of great toe
- innervation: deep fibular nerve
- main action: extends great toe; dorsiflexion

Lateral Leg



Lateral Leg

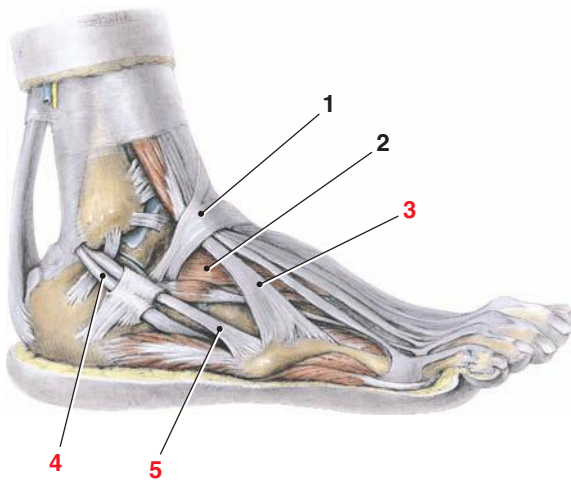
1. common fibular nerve
2. fibularis longus
3. soleus
4. superficial fibular nerve
5. fibularis brevis
6. fibularis tertius

Damage to the common fibular nerve results in flaccid paralysis of the muscles of the anterior and lateral compartments of the leg, causing foot drop and inversion of the foot and gait disturbances.

The superficial fibular nerve may be damaged in ankle sprains, causing pain along the lateral aspect of the leg and ankle. It may be anesthetized anywhere along its course to produce anesthesia on the dorsum of the foot.

Violent inversion of the foot may avulse the tuberosity of the 5th metatarsal, the attachment of the fibularis brevis, leading to inversion of the foot.

Muscles of the Lateral Leg



Muscles of the Lateral Leg

1. inferior extensor retinaculum
2. extensor digitorum brevis
3. fibularis tertius
4. fibularis longus
5. fibularis brevis

Fibularis Tertius

- proximal attachment: fibula and interosseous membrane
- distal attachment: 5th metatarsal
- innervation: deep fibular nerve
- main action: dorsiflexes ankle and everts foot

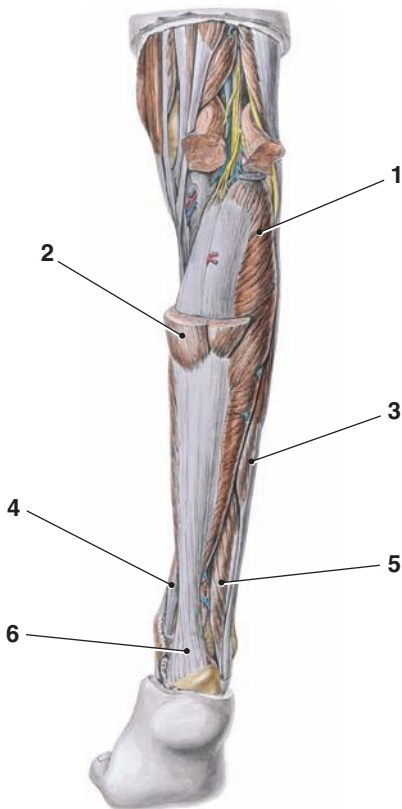
Fibularis Longus

- proximal attachment: fibula
- distal attachment: 1st metatarsal and medial cuneiform
- innervation: superficial fibular nerve
- main action: evert foot

Fibularis Brevis

- proximal attachment: fibula
- distal attachment: tuberosity of 5th metatarsal
- innervation: superficial fibular nerve
- main action: evert foot

Posterior Leg



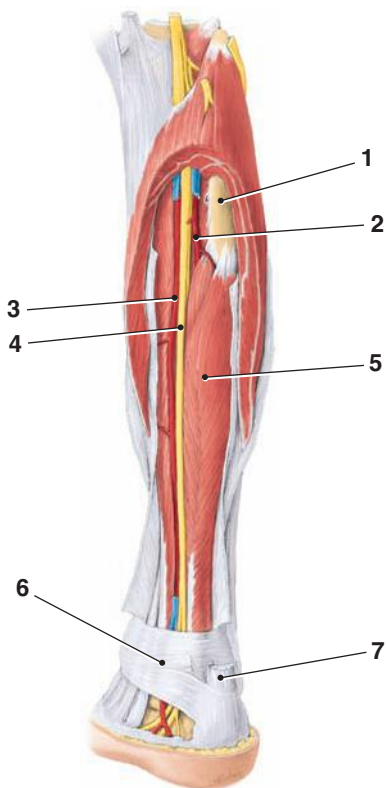
Posterior Leg

1. soleus
2. gastrocnemius (cut)
3. fibularis longus
4. flexor digitorum longus
5. fibularis brevis
6. calcaneal tendon

Calcaneal tendinitis, a common running injury, often results from repetitive activities in inactive people. Rupture of the tendon may occur during forceful plantar flexion, causing the inability to raise the heel from the ground. The calcaneal tendon reflex is used to test the S1 and S2 nerve roots.

Gastrocnemius strain (tennis leg) is a painful injury resulting from tearing of the medial belly of the muscle, usually from overstretching in full extension of the knee and dorsiflexion of the ankle.

Posterior Leg, Deep Dissection

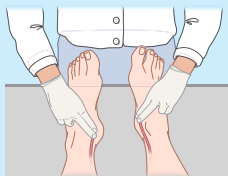

Posterior Leg, Deep Dissection

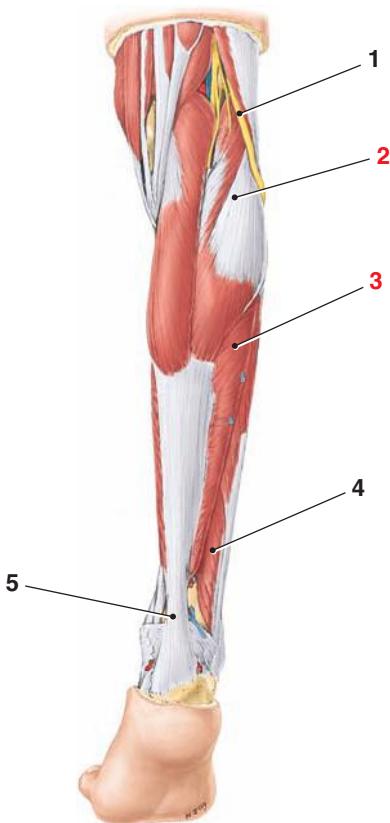
1. fibula
2. fibular artery
3. posterior tibial artery
4. tibial nerve
5. flexor hallucis longus
6. flexor retinaculum
7. calcaneal tendon (cut)

Calcaneal bursitis, or inflammation of the bursa of the calcaneal tendon between the tendon and the calcaneus, causes pain over the heel.

The posterior tibial pulse can be palpated between the medial malleolus and the calcaneal tendon for examination of individuals with peripheral arterial disease.



Muscles of the Posterior Compartment of the Leg



Muscles of the Posterior Compartment of the Leg

1. common fibular nerve
2. gastrocnemius
3. soleus
4. fibularis brevis
5. calcaneal tendon

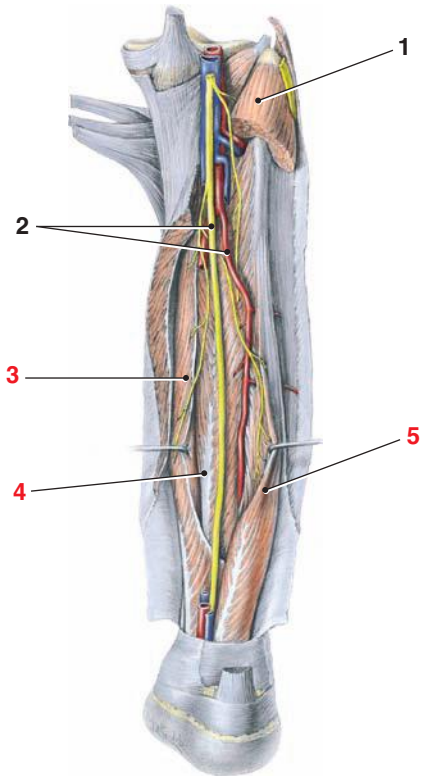
Gastrocnemius

- proximal attachment: distal femur
- distal attachment: calcaneus via calcaneal tendon
- innervation: tibial nerve
- main action: plantar-flexes ankle

Soleus

- proximal attachment: proximal tibia and fibula
- distal attachment: calcaneus via calcaneal tendon
- innervation: tibial nerve
- main action: plantar-flexes ankle

Deep Dissection of the Posterior Compartment of the Leg



Deep Dissection of the Posterior Compartment of the Leg

1. soleus (cut)
2. tibial nerve and fibular artery
3. flexor digitorum longus
4. tibialis posterior
5. flexor hallucis longus

Flexor Digitorum Longus

- proximal attachment: posterior tibia and fibula
- distal attachment: distal phalanges of lateral four toes
- innervation: tibial nerve
- main action: flexes lateral four toes, plantar-flexes ankle

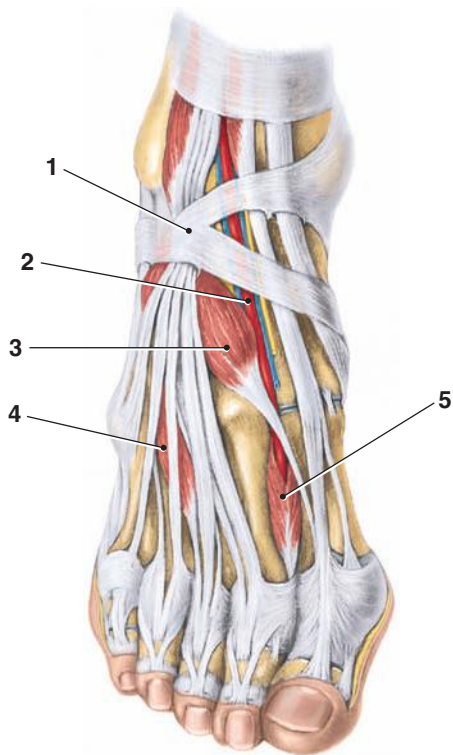
Tibialis Posterior

- proximal attachment: tibia, fibula, and interosseous membrane
- distal attachment: navicular, cuneiform, cuboid, bases of metatarsals 2 to 4
- innervation: tibial nerve
- main action: plantar-flexes ankle and inverts foot

Flexor Hallucis Longus

- proximal attachment: fibula and interosseous membrane
- distal attachment: distal phalanx of great toe
- innervation: tibial nerve
- main action: flexes great toe

Dorsum of the Foot

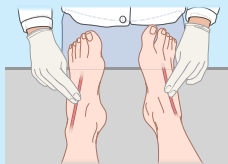


Dorsum of the Foot

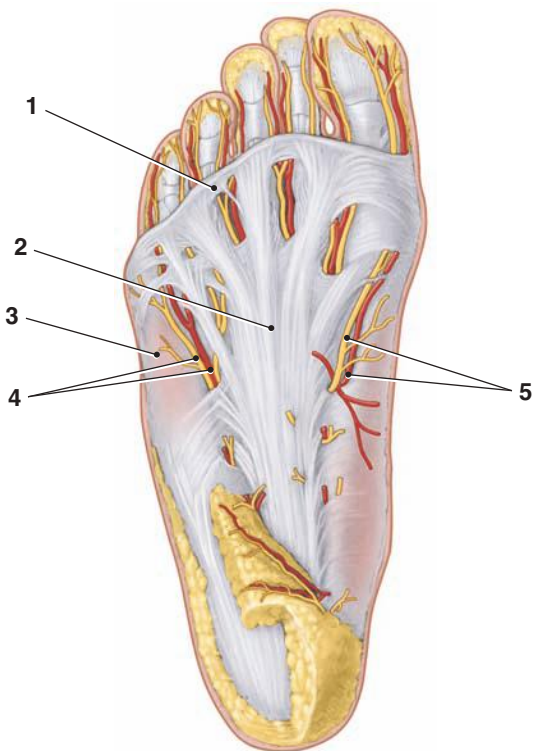
1. inferior extensor retinaculum
2. dorsalis pedis artery
3. extensor hallucis brevis
4. extensor digitorum brevis
5. 1st dorsal interosseous

A hematoma resulting from trauma to the extensor digitorum brevis produces edema near the ankle that is often confused with an ankle sprain.

The pulse of the dorsalis pedis artery may be palpated along a line from the extensor retinaculum along the extensor hallucis longus tendons in patients needing examination of the peripheral vascular system.



Plantar Surface of the Foot



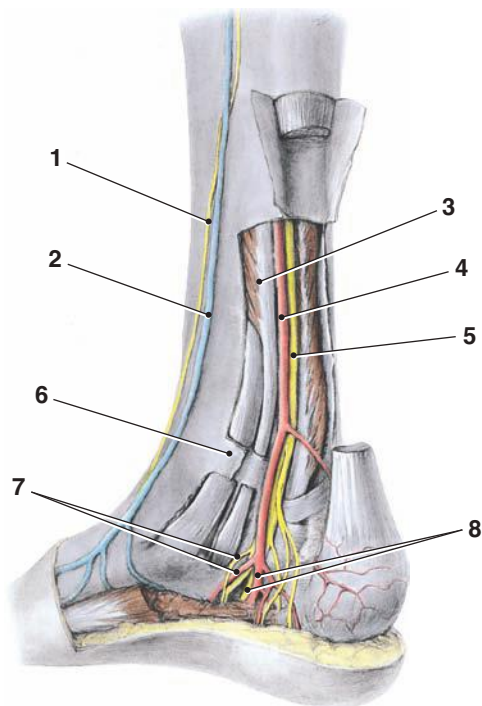
Plantar Surface of the Foot

1. superficial transverse metatarsal ligament
2. plantar aponeurosis
3. plantar fascia
4. lateral plantar nerve and artery
5. medial plantar nerve and artery

Plantar fasciitis, or inflammation of the plantar aponeurosis, results from high-impact exercise and causes pain over the heel and medial aspect of the foot.

The plantar reflex is routinely tested in neurological examinations (L4–S2). The lateral aspect of the sole is stroked from the heel to the base of the great toe. Toe flexion is normal. Dorsiflexion (a positive Babinski sign) indicates brain injury or disease, except in infants.

Medial Aspect of the Ankle



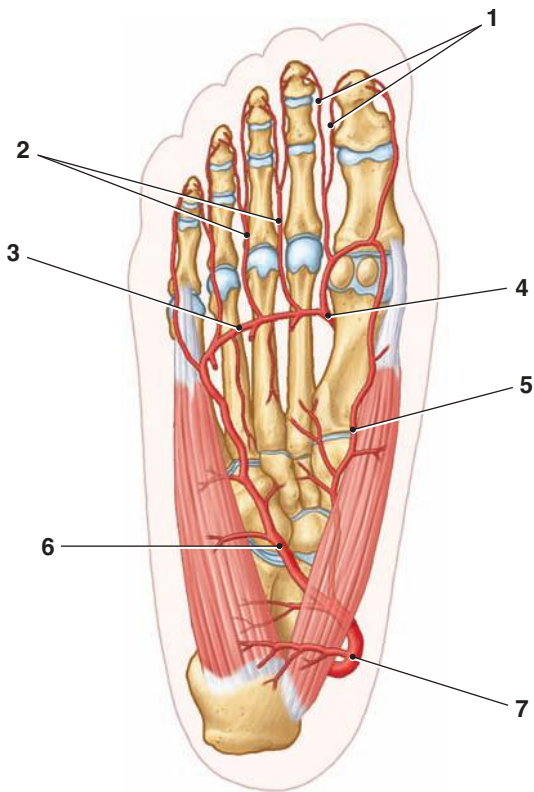
Medial Aspect of the Ankle

1. saphenous nerve
2. great saphenous vein
3. flexor digitorum longus
4. posterior tibial artery
5. tibial nerve
6. flexor retinaculum
7. medial plantar nerve and artery
8. lateral plantar artery and nerve

Compressive irritation of the medial plantar nerve as it passes deep to the flexor retinaculum or deep to the abductor hallucis may cause pain or paresthesia along the medial aspect of the foot. Medial plantar nerve compression is often called jogger's foot because of its frequency in runners.

Tarsal tunnel syndrome is compression of the tibial nerve deep to the flexor retinaculum, resulting in heel pain.

Arteries of the Sole of the Foot

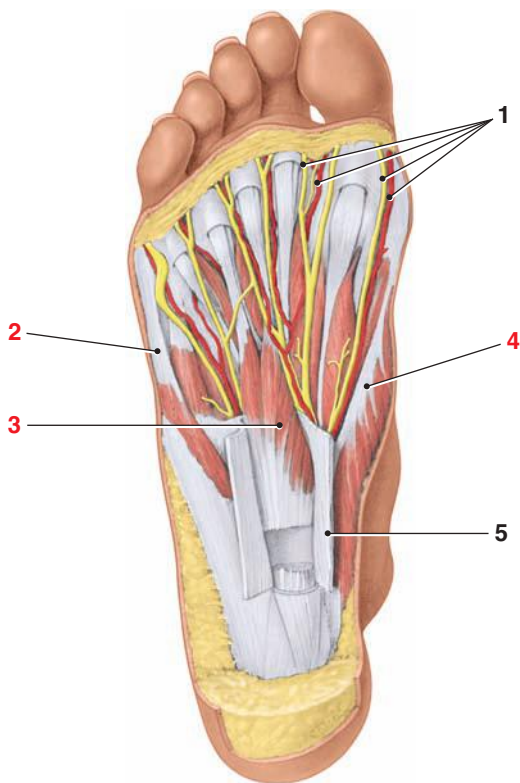


Arteries of the Sole of the Foot

1. plantar digital arteries
2. plantar metatarsal arteries
3. plantar arch
4. deep plantar artery
5. medial plantar artery
6. lateral plantar artery
7. posterior tibial artery

Puncture wounds of the sole of the foot involving the plantar arch result in severe bleeding from both cut ends. Ligature is difficult because of the depth and the structures surrounding it.

Muscles of the Sole of the Foot, Layer 1



Muscles of the Sole of the Foot, Layer 1

1. plantar digital nerves and arteries
2. abductor digiti minimi
3. flexor digitorum brevis
4. abductor hallucis
5. plantar aponeurosis (reflected)

Abductor Digiti Minimi

- proximal attachment: calcaneus and plantar aponeurosis
- distal attachment: proximal phalanx of 5th toe
- innervation: lateral plantar nerve
- main action: abducts and flexes 5th toe

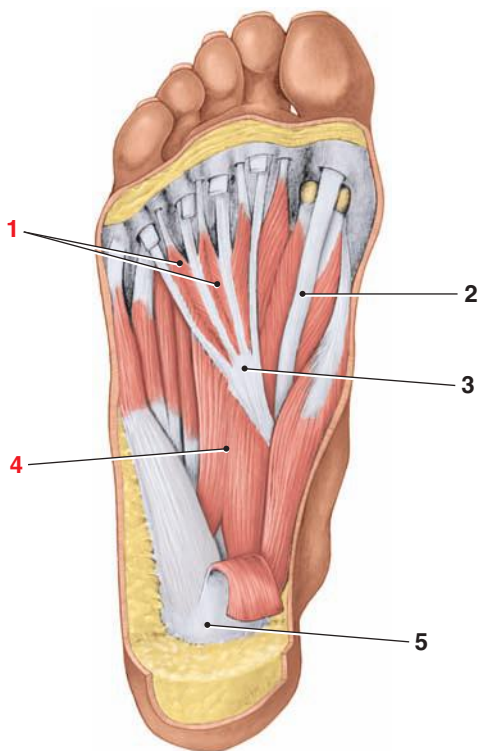
Flexor Digitorum Brevis

- proximal attachment: calcaneus and plantar aponeurosis
- distal attachment: middle phalanges of lateral four toes
- innervation: medial plantar nerve
- main action: flexes lateral four toes

Abductor Hallucis

- proximal attachment: calcaneus, flexor retinaculum, and plantar aponeurosis
- distal attachment: proximal phalanx of 1st toe
- innervation: medial plantar nerve
- main action: abducts and flexes 1st toe

Muscles of the Sole of the Foot, Layer 2



Muscles of the Sole of the Foot, Layer 2

1. lumbricals
2. tendon of flexor hallucis longus
3. tendons of flexor digitorum longus
4. quadratus plantae
5. calcaneus

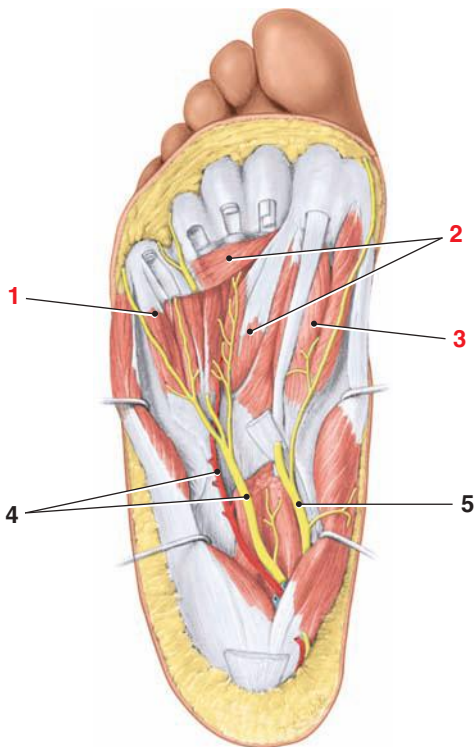
Lumbricals

- proximal attachment: tendons of flexor digitorum longus
- distal attachment: extensor expansion over lateral four toes
- innervation: medial one, medial plantar nerve; lateral three, lateral plantar nerve
- main action: flex proximal phalanges and extend middle and distal phalanges of lateral four toes

Quadratus Plantae

- proximal attachment: calcaneus
- distal attachment: tendon of flexor digitorum longus
- innervation: lateral plantar nerve
- main action: assists flexor digitorum longus in flexing lateral four toes

Muscles of the Sole of the Foot, Layer 3



Muscles of the Sole of the Foot, Layer 3

1. flexor digiti minimi
2. adductor hallucis
3. flexor hallucis brevis
4. lateral plantar artery and nerve
5. medial plantar nerve

Flexor Digiti Minimi

- proximal attachment: 5th metatarsal
- distal attachment: proximal phalanx of 5th toe
- innervation: lateral plantar nerve
- main action: flexes proximal phalanx of 5th toe

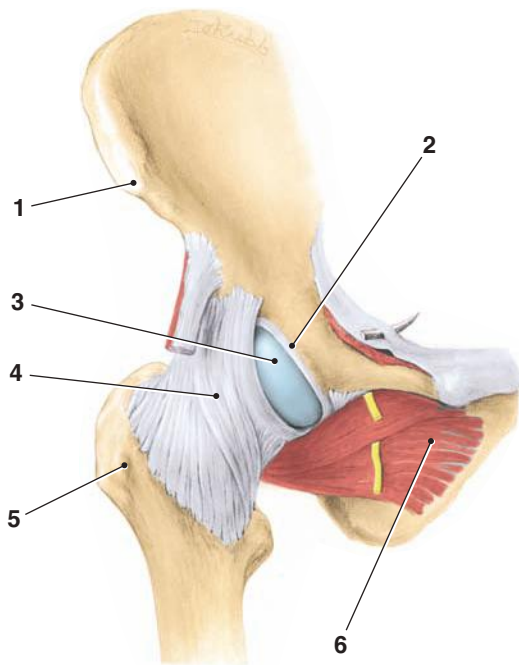
Adductor Hallucis

- proximal attachment: oblique head, metatarsals 2 to 4; transverse head, plantar ligaments
- distal attachment: proximal phalanx of 1st toe
- innervation: lateral plantar nerve
- main action: adducts 1st toe

Flexor Hallucis Brevis

- proximal attachment: cuboid and lateral cuneiform
- distal attachment: proximal phalanx of 1st toe
- innervation: medial plantar nerve
- main action: flexes proximal phalanx of 1st toe

Hip Joint



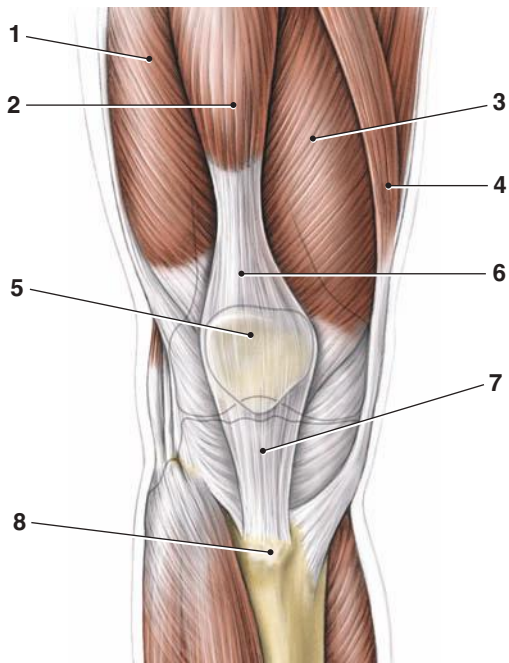
Hip Joint

1. anterior superior iliac spine
2. acetabular labrum
3. head of the femur
4. iliofemoral ligament
5. greater trochanter
6. obturator externus

Hip replacement is surgical implantation of a metal prosthesis in place of a diseased or traumatized hip.

Congenital dislocation of the hip joint is common, particularly in girls. Acquired dislocation is uncommon, although posterior dislocation may occur when a flexed knee strikes the dashboard in an automobile accident, driving the head of the femur posteriorly out of the acetabulum.

Patella



Patella

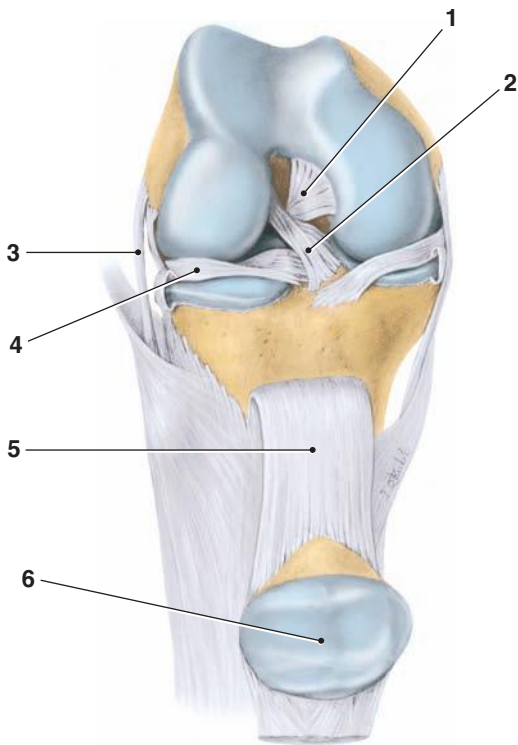
1. vastus lateralis
2. rectus femoris
3. vastus medialis
4. sartorius
5. patella
6. quadriceps tendon
7. patellar ligament
8. tibial tuberosity

Patellar fractures may occur from a direct blow to the patella or during sudden contraction of the quadriceps. Ossification abnormalities of the patella may give rise to bipartite or tripartite patella, which may be confused with a fracture on a radiograph.

The patellar tendon reflex (L2–L4) is initiated by tapping the patellar ligament, stimulating contraction of the quadriceps.

Patellar dislocation is most common in women because of the greater Q angle. It almost always occurs laterally.

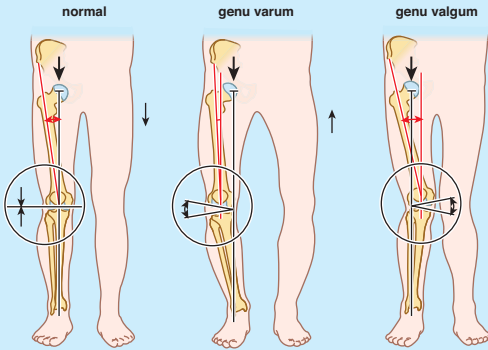
Knee



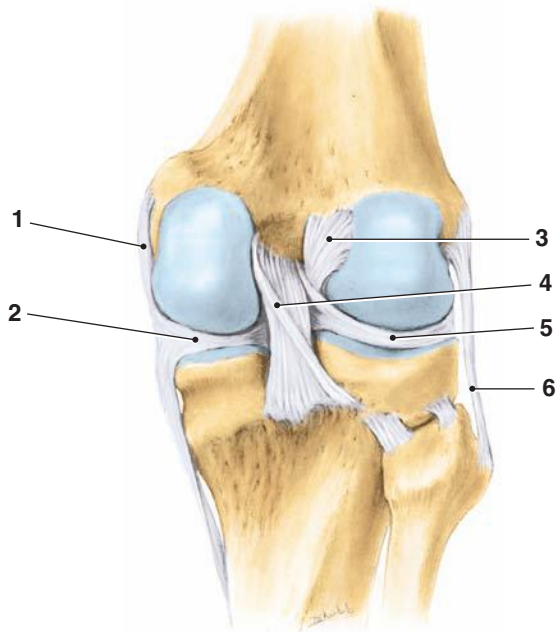
Knee

1. posterior cruciate ligament
2. anterior cruciate ligament
3. fibular collateral ligament
4. lateral meniscus
5. patellar ligament
6. patella

The angle between the femur and tibia is the Q angle. A small Q angle (the femur is abnormally vertical) is genu varum (bowleg), which may result in arthrosis. A large Q angle is genu valgum (knock knee), which may result in arthrosis and excessive stress on the knee joint.



Knee Joint, Posterior View



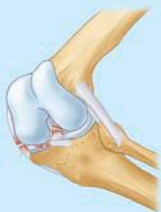Knee Joint, Posterior View

1. tibial collateral ligament
2. medial meniscus
3. anterior cruciate ligament
4. posterior cruciate ligament
5. lateral meniscus
6. fibular collateral ligament

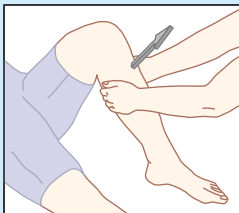
The firm attachment of the tibial collateral ligament to the medial meniscus means they are frequently damaged together; combined with an injury to the anterior cruciate from a blow to the lateral aspect of the knee, the result is the unhappy triad of injuries.

Anterior cruciate ligament ruptures allow the tibia to slide anteriorly relative to the femur—**anterior drawer sign**. Posterior cruciate ligament ruptures allow the tibia to slide posteriorly relative to the femur—**posterior drawer sign**.

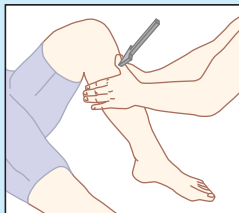
Unhappy triad



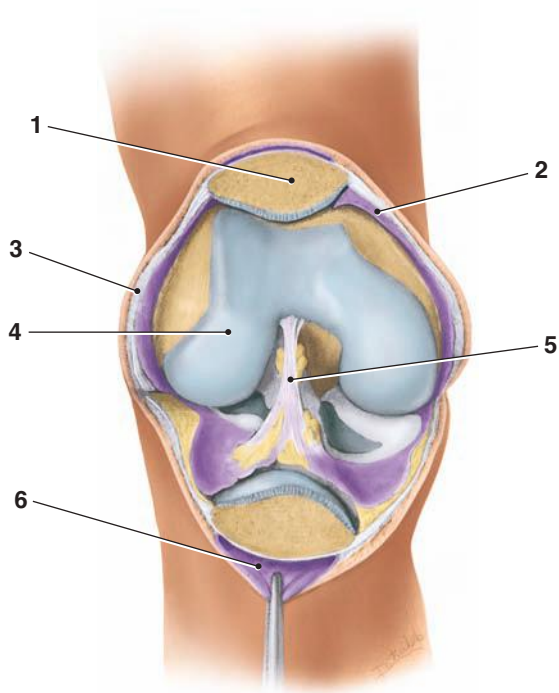
Anterior drawer sign



Posterior drawer sign



Open Knee Joint

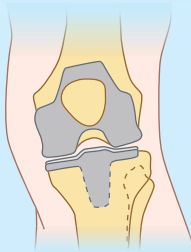
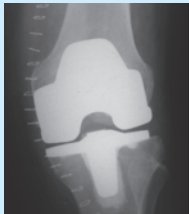

Open Knee Joint

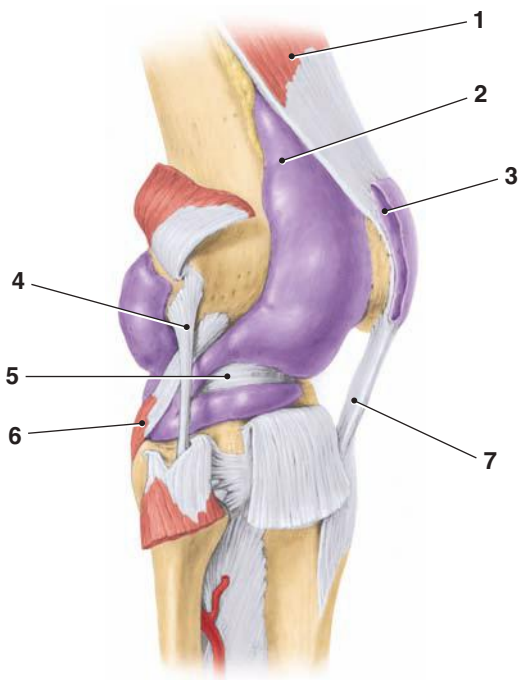
1. patella
2. synovial fold
3. joint capsule
4. articular cartilage
5. infrapatellar synovial fold
6. prepatellar bursa

Arthroscopy is endoscopic visualization of the interior of the knee cavity with minimal disruption of tissue, allowing for debridement, removal of torn menisci and loose bodies, ligament repair, and fluid removal. Excess fluid may also be directly aspirated from the flexed knee with a needle.

If a person's knee is osteoarthritic, an artificial knee may be inserted.



Knee Joint, Lateral View



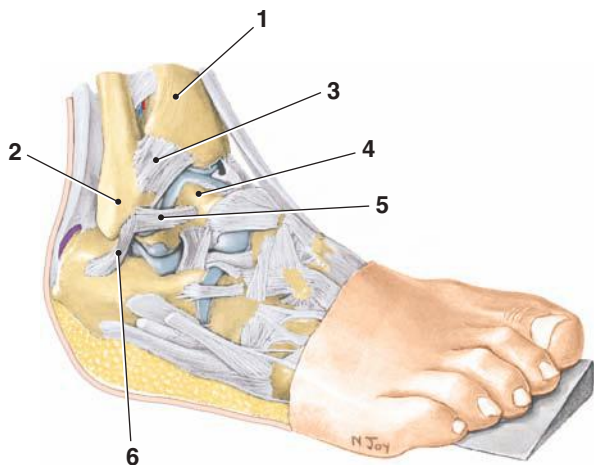
Knee Joint, Lateral View

1. quadriceps femoris
2. suprapatellar bursa
3. prepatellar bursa
4. fibular collateral ligament
5. lateral meniscus
6. popliteus
7. patellar ligament

Housemaid's knee is bursitis of the prepatellar bursa, resulting from compressive forces or a direct blow to the knee, causing inflammation. Infrapatellar bursitis is common in individuals such as roofers and floor tilers who must work on their knees. Suprapatellar bursitis is typically caused by a bacterial infection.

Popliteal cysts are abnormal fluid-filled sacs of synovial membrane in the popliteal fossa. They are usually a complication of chronic knee joint effusion.

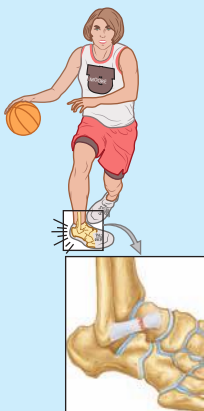Ligaments of the Ankle, Lateral View



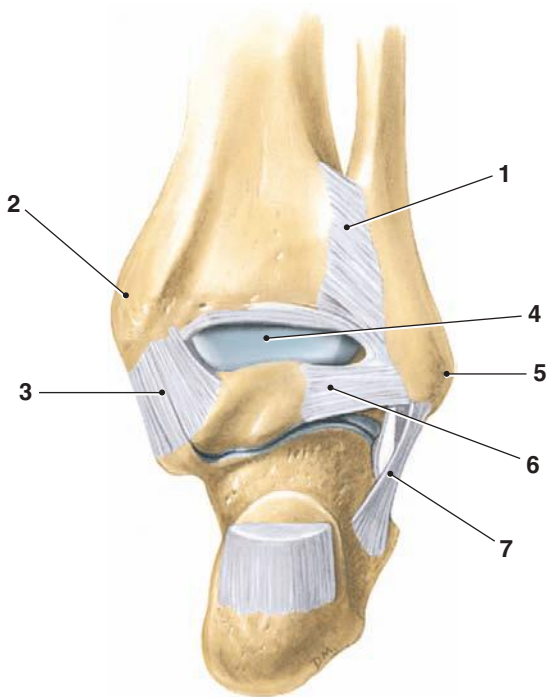
Ligaments of the Ankle, Lateral View

1. tibia
2. lateral malleolus
3. anterior inferior tibiofibular ligament
4. talus
5. anterior talofibular ligament
6. calcaneofibular ligament

The ankle is the most frequently injured joint in the body. Ankle sprains are most often inversion injuries. The lateral ligaments are weaker than the medial and are injured more often as they are the ligaments that resist inversion.



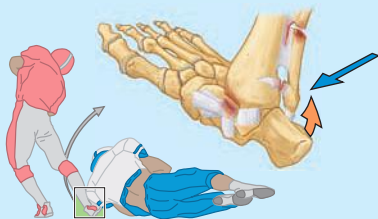
Ligaments of the Ankle, Posterior View



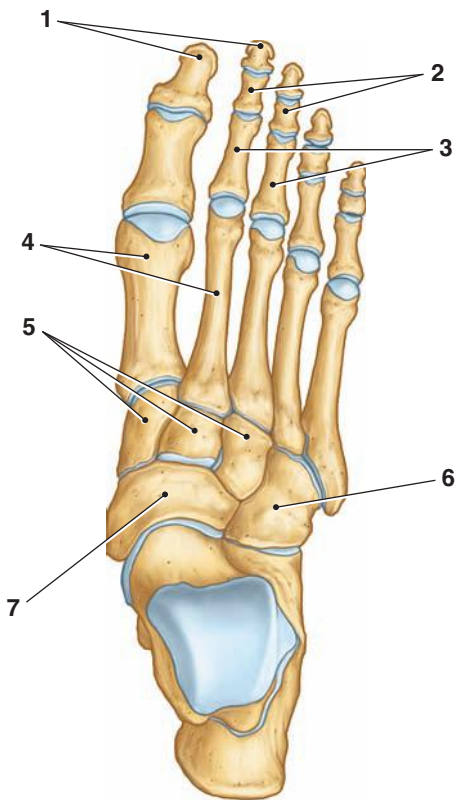
Ligaments of the Ankle, Posterior View

1. posterior tibiofibular ligament
2. medial malleolus
3. deltoid ligament
4. talus
5. lateral malleolus
6. posterior talofibular ligament
7. calcaneofibular ligament

A Pott fracture–dislocation of the ankle occurs when the foot is forcibly everted. The medial malleolus is torn away by the strong medial ligament, causing the talus to move laterally, shearing off the lateral malleolus or breaking the fibula.



Toes, Superior View

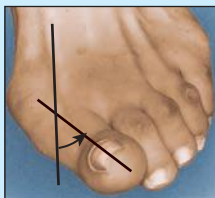

Toes, Superior View

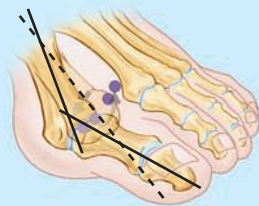1. distal phalanges
2. middle phalanges
3. proximal phalanges
4. metatarsals
5. cuneiforms
6. cuboid
7. navicular

Hallux valgus is characterized by lateral deviation of the great toe. The sesamoid bones are displaced and lie between the heads of the 1st and 2nd metatarsals, causing inability to move the great toe away from the 2nd toe. Hallux valgus often results in the formation of a bunion and corns.

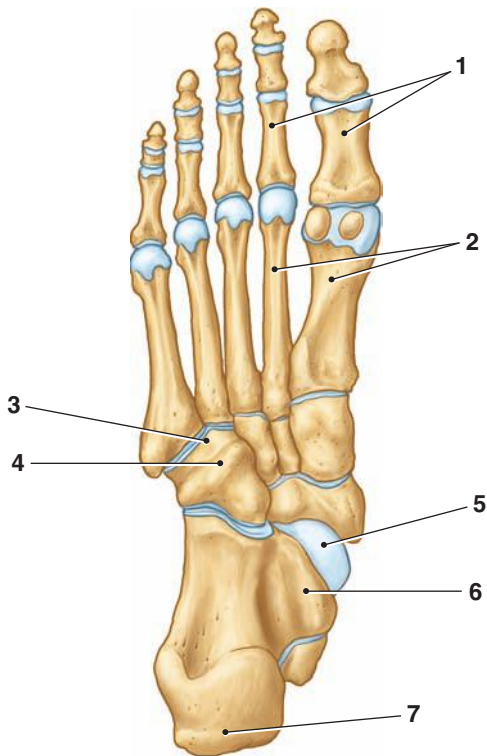
Hallux valgus with
bunion and corns



Displacement of
sesamoid bones



Toes, Inferior View

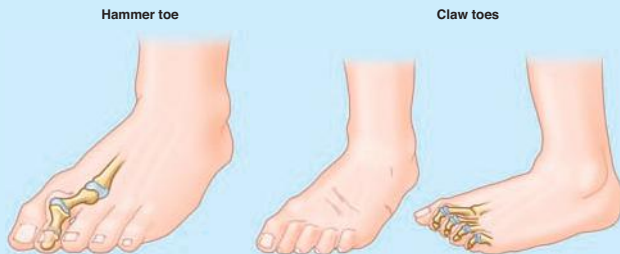

Toes, Inferior View

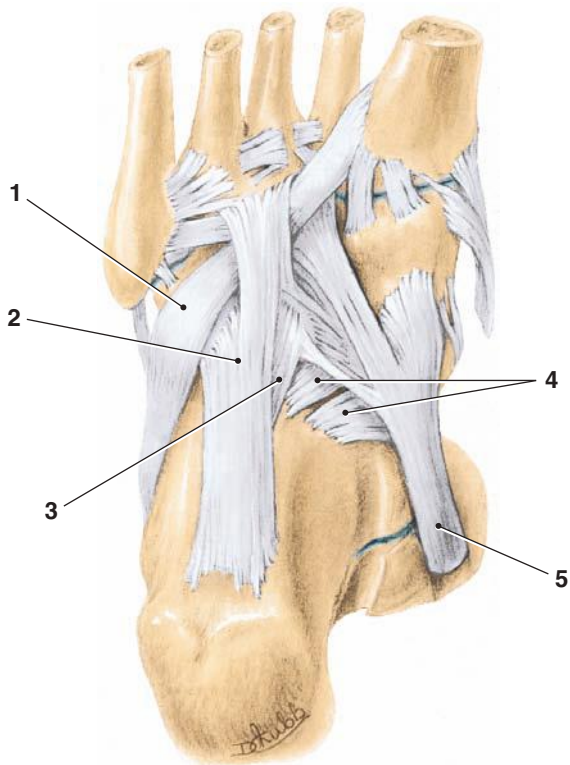
1. proximal phalanges
2. metatarsals
3. groove for fibularis longus
4. tuberosity of the cuboid
5. head of the talus
6. sustentaculum tali
7. calcaneal tuberosity

In hammer toe, the proximal phalanx is permanently dorsiflexed at the metatarsophalangeal joint, and the middle phalanx is plantar-flexed at the proximal interphalangeal joint, often as a result of muscle weakness.

Claw toes are characterized by hyperextension of the metatarsophalangeal joints and flexion of the distal interphalangeal joints.



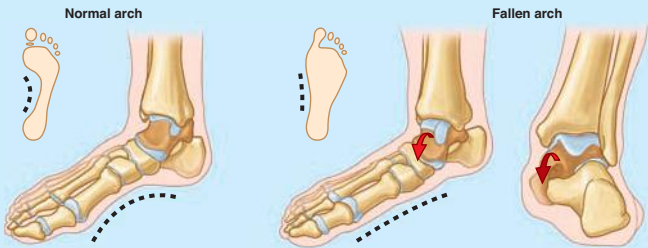
Ligaments of the Foot



Ligaments of the Foot

1. tendon of fibularis longus
2. long plantar ligament
3. plantar calcaneocuboid ligament (short plantar ligament)
4. plantar calcaneonavicular ligament (spring ligament)
5. tendon of tibialis posterior

Pes planus (flatfoot) can be either flexible (normal when not bearing weight) or rigid (flat when not bearing weight). Flexible flatfoot usually results from loose or degenerated ligaments. Rigid flatfeet are most likely the result of bone deformity or are acquired, commonly as a result of dysfunction of the tibialis posterior.

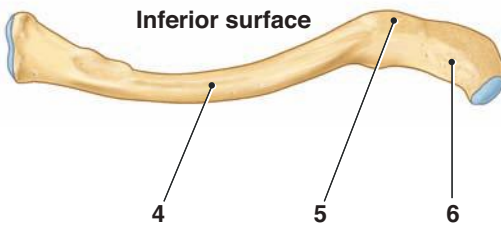
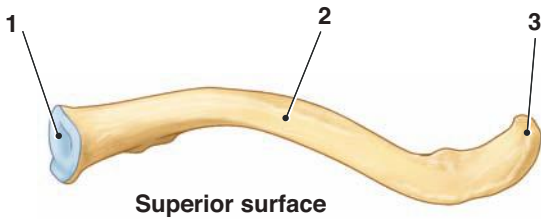


6 • Upper Limb

- 6.1** Clavicle
- 6.2** Scapula
- 6.3** Humerus
- 6.4** Radius and Ulna
- 6.5** Carpal Bones
- 6.6** Bones of the Hand
- 6.7** Serratus Anterior
- 6.8** Superficial Muscles of the Back
- 6.9** Deltoid and Serratus Anterior
- 6.10** Anterior Wall of the Axilla
- 6.11** Rotator Cuff Muscles 1
- 6.12** Rotator Cuff Muscles 2
- 6.13** Transverse Section through the Shoulder Joint
- 6.14** Axillary Artery
- 6.15** Veins of the Axilla
- 6.16** Axillary Lymph Nodes
- 6.17** Brachial Plexus, General Form
- 6.18** Brachial Plexus
- 6.19** Brachial Plexus, Axillary Vein Removed
- 6.20** Anterior Arm
- 6.21** Deep Anterior Arm
- 6.22** Posterior Shoulder
- 6.23** Medial Arm
- 6.24** Arm, Deep Dissection
- 6.25** Lateral Arm
- 6.26** Veins of the Cubital Fossa
- 6.27** Elbow, Posterior View
- 6.28** Dorsum of the Hand
- 6.29** Finger
- 6.30** Arteries of the Forearm

- 6.31** Superficial Forearm Musculature
- 6.32** Intermediate Forearm Musculature
- 6.33** Deep Forearm Musculature
- 6.34** Median Nerve in the Cubital Fossa
- 6.35** Ulnar Nerve at the Elbow
- 6.36** Radial Nerve at the Elbow
- 6.37** Palmar Aponeurosis
- 6.38** Arteries of the Hand
- 6.39** Anterior Wrist
- 6.40** Superficial Palm
- 6.41** Intermediate Palm
- 6.42** Sternoclavicular Joint
- 6.43** Acromioclavicular Joint
- 6.44** Anterior Aspect of the Shoulder Joint
- 6.45** Rotator Cuff
- 6.46** Glenoid Cavity
- 6.47** Ligaments of the Elbow Joint
- 6.48** Head of the Radius
- 6.49** Lateral Aspect of the Hand
- 6.50** Superficial Posterior Forearm Musculature
- 6.51** Deep Posterior Forearm Musculature

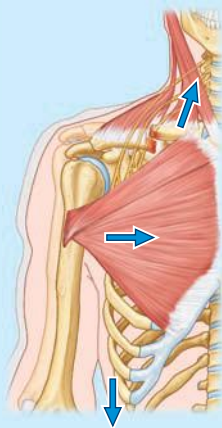
Clavicle



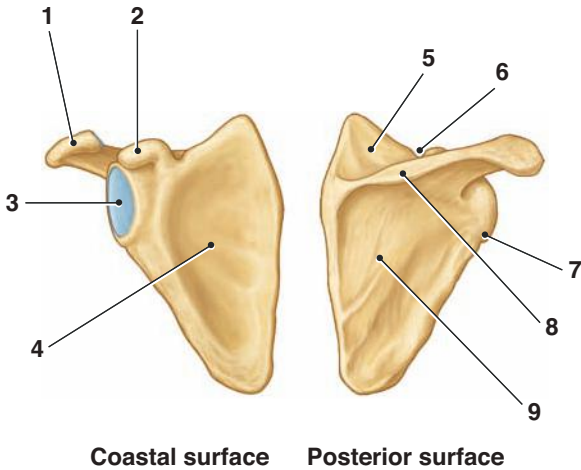
Clavicle

1. sternal end
2. shaft
3. acromial end
4. subclavian groove
5. conoid tubercle
6. trapezoid line

The clavicle, the first bone to ossify, is highly variable in shape and size and is one of the most commonly fractured bones. Fracture is usually evident by the palpable elevation of the medial portion from action of the sternocleidomastoid and dropping of the shoulder from the unsupported weight of the upper limb.



Scapula

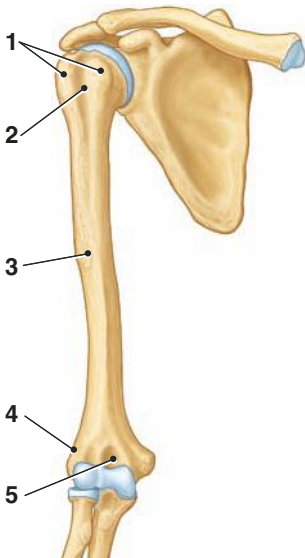


Scapula

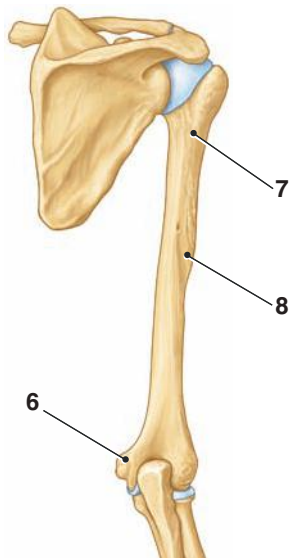
1. acromion
2. coracoid process
3. glenoid cavity
4. subscapular fossa
5. supraspinous fossa
6. suprascapular notch
7. infraglenoid tubercle
8. spine of the scapula
9. infraspinous fossa

Fracture of the scapula, usually the result of severe trauma, requires little treatment because the scapula is covered in muscles.

Humerus



Anterior view



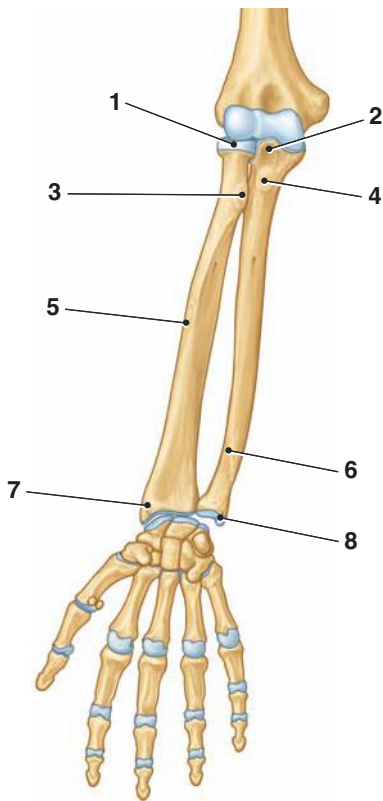
Posterior view

Humerus

1. greater and lesser tubercles
2. intertubercular groove
3. deltoid tuberosity
4. lateral epicondyle
5. coronoid fossa
6. medial epicondyle
7. surgical neck
8. radial groove

Most humeral fractures occur at the surgical neck during falls, resulting in an impacted fracture: One bone fragment is driven into another. A fall on the acromion may result in an avulsion fracture, in which the greater tubercle is pulled away from the humerus. A direct blow to the arm may result in a transverse or spiral fracture of the shaft, while an intercondylar fracture may be caused by a fall on a flexed elbow.

Radius and Ulna

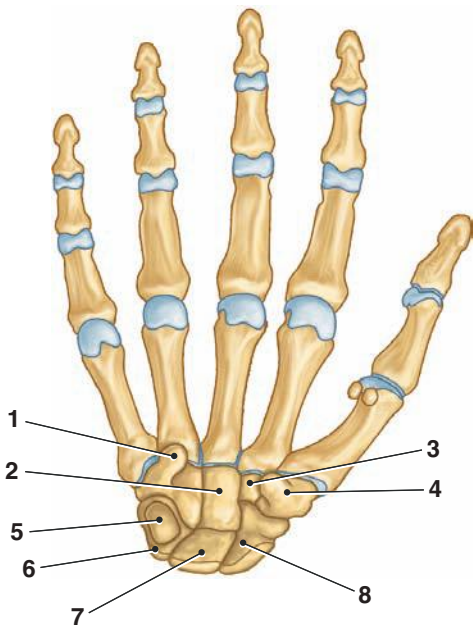


Radius and Ulna

1. head of the radius
2. coronoid process
3. tuberosity of the radius
4. tuberosity of the ulna
5. pronator tuberosity
6. pronator crest
7. styloid process of the radius
8. styloid process of the ulna

A Colles fracture is a transverse fracture of the distal radius, often accompanied by an avulsed styloid process of the ulna. It is a result of attempting to break a fall with the outstretched limb. The result is posterior angulation of the forearm just proximal to the wrist—a dinner fork deformity.

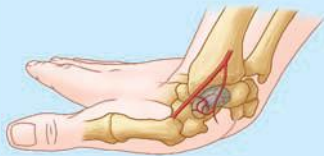Carpal Bones



Carpal Bones

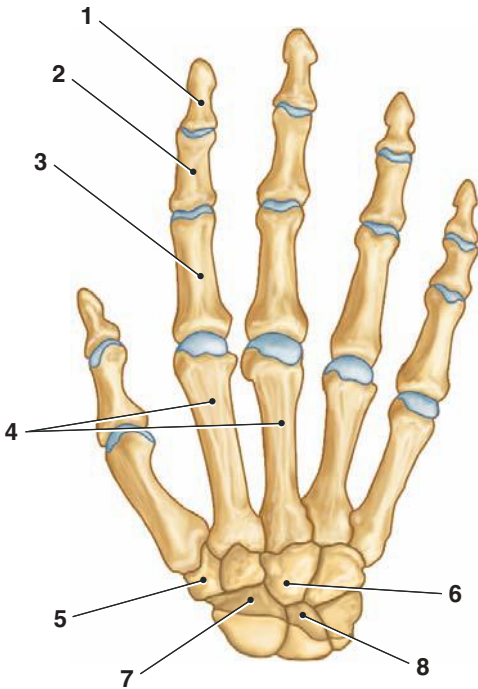
1. hook of the hamate
2. capitate
3. trapezoid
4. trapezium
5. pisiform
6. triquetrum
7. lunate
8. scaphoid

The scaphoid is the most frequently fractured carpal bone. Such fractures result from a fall on the palm with the wrist abducted. Healing is slow because of the poor blood supply to the proximal scaphoid.



Fracture of the hamate may result in disunion of the fractured parts because of the traction of the attached musculature and may involve the ulnar nerve and artery.

Bones of the Hand



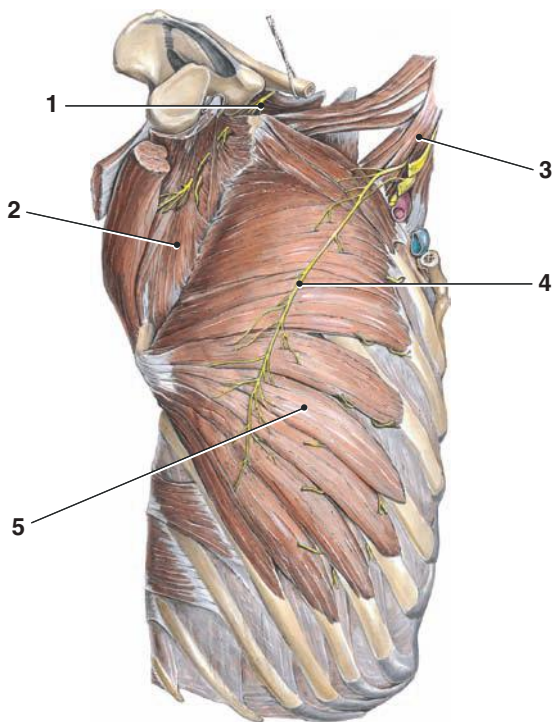
Bones of the Hand

1. distal phalanx
2. middle phalanx
3. proximal phalanx
4. metacarpals
5. trapezium
6. capitate
7. scaphoid
8. lunate

Metacarpal fractures are relatively stable and heal quickly. Fracture of the 5th metacarpal, a boxer's fracture, occurs when an unskilled person punches someone, causing the head of the bone to rotate over the distal shaft.

Crushing injuries of the phalanges are common and are extremely painful.

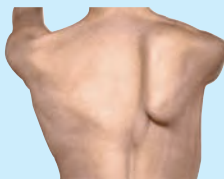Serratus Anterior



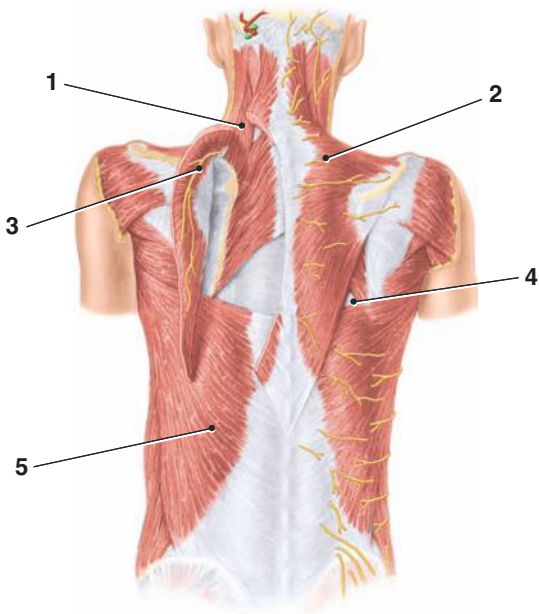
Serratus Anterior

1. spinal accessory nerve
2. subscapularis
3. middle scalene
4. long thoracic nerve
5. serratus anterior

When serratus anterior is paralyzed by injury of the long thoracic nerve, the medial border of the scapula moves laterally and posteriorly away from the thoracic wall, producing a winged scapula.



Superficial Muscles of the Back



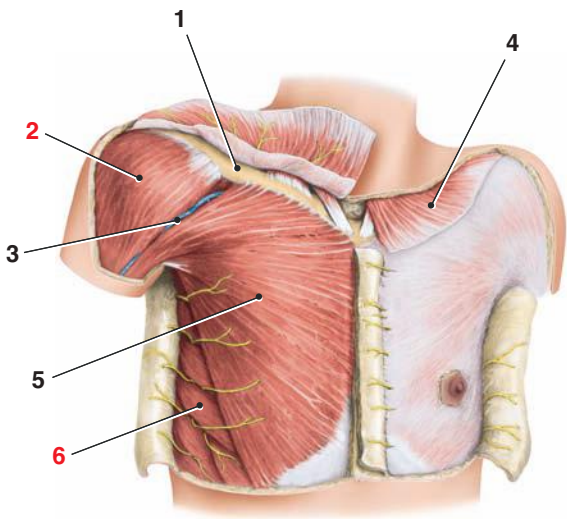
Superficial Muscles of the Back

1. levator scapulae
2. trapezius
3. spinal accessory nerve
4. triangle of auscultation
5. latissimus dorsi

The triangle of auscultation is a good place to examine the posterior aspect of the lungs with a stethoscope, as the thick back musculature is deficient in this region.

Injury to the thoracodorsal nerve, as occurs during surgery on scapular lymph nodes or the axilla, causes paralysis of the latissimus dorsi. The person is then unable to raise the trunk with the upper limbs or use an axillary crutch.

Deltoid and Serratus Anterior



Deltoid and Serratus Anterior

1. clavicle
2. deltoid
3. cephalic vein
4. platysma
5. pectoralis major
6. serratus anterior

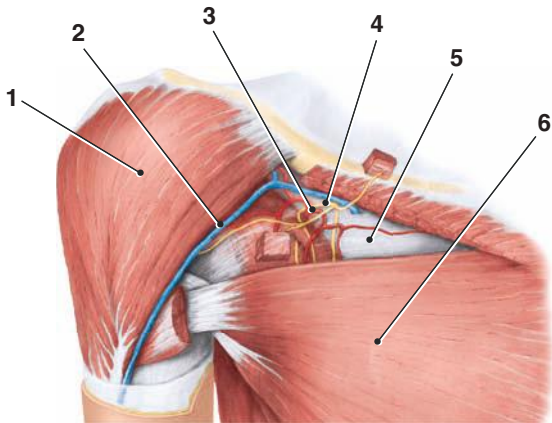
Deltoid

- proximal attachment: clavicle, acromion and spine of scapula
- distal attachment: deltoid tuberosity
- innervation: axillary nerve
- main action: anterior part flexes and medially rotates arm; middle part abducts arm; posterior part extends and laterally rotates arm

Serratus Anterior

- proximal attachment: ribs 1 to 8
- distal attachment: medial border of scapula
- innervation: long thoracic nerve
- main action: protracts and rotates scapula, holds it against thoracic wall

Anterior Wall of the Axilla

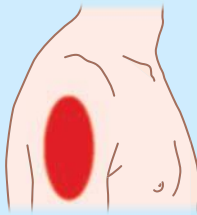

Anterior Wall of the Axilla

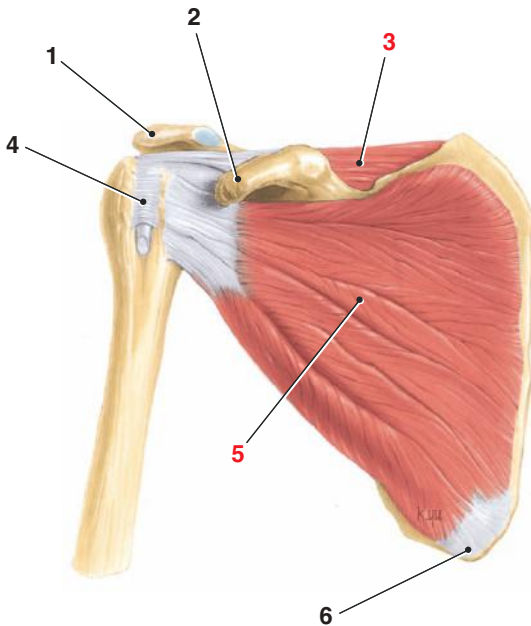
1. deltoid
2. cephalic vein
3. thoracoacromial artery
4. lateral pectoral nerve
5. clavipectoral fascia
6. pectoralis major

The deltoid atrophies when the axillary nerve is damaged, as happens during fracture of the proximal humerus, dislocation of the glenohumeral joint, or incorrect use of crutches. Loss of sensation over the proximal arm accompanies atrophy of the deltoid.

Area of anesthesia



Rotator Cuff Muscles 1



Rotator Cuff Muscles 1

1. acromion
2. coracoid process
3. supraspinatus
4. transverse humeral ligament
5. subscapularis
6. inferior angle

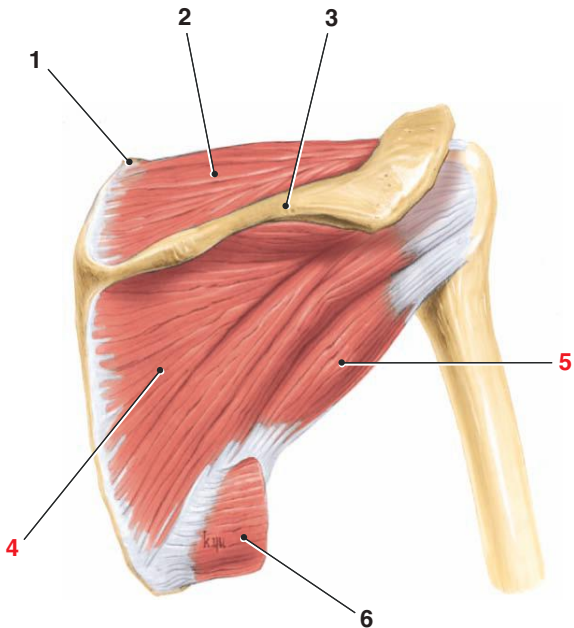
Supraspinatus

- proximal attachment: supraspinous fossa
- distal attachment: greater tubercle of humerus
- innervation: suprascapular nerve
- main action: abducts arm

Subscapularis

- proximal attachment: subscapular fossa
- distal attachment: lesser tubercle of humerus
- innervation: upper and lower subscapular nerves
- main action: medially rotates and adducts arm

Rotator Cuff Muscles 2



Rotator Cuff Muscles 2

1. superior angle
2. supraspinatus
3. spine of scapula
4. infraspinatus
5. teres minor
6. teres major (cut)

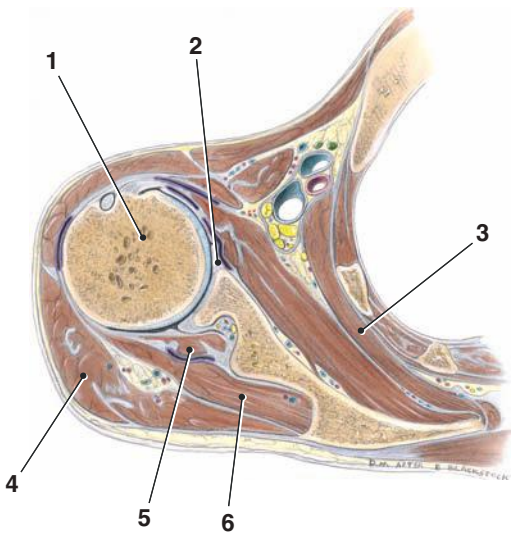
Infraspinatus

- proximal attachment: infraspinous fossa
- distal attachment: greater tubercle of humerus
- innervation: suprascapular nerve
- main action: laterally rotates arm

Teres Minor

- proximal attachment: superior part of lateral border of scapula
- distal attachment: greater tubercle of humerus
- innervation: axillary nerve
- main action: laterally rotates arm

Transverse Section through the Shoulder Joint



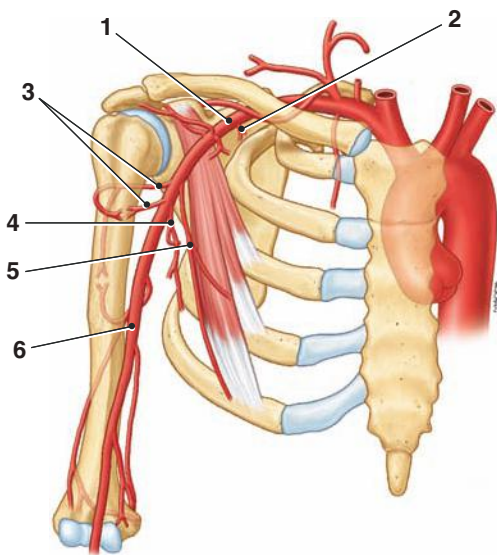
Transverse Section through the Shoulder Joint

1. head of the humerus
2. glenoid labrum
3. serratus anterior
4. deltoid
5. teres minor
6. infraspinatus

An injury to the shoulder of a child may produce a fracture–dislocation of the proximal humeral epiphysis because the joint capsule is stronger than the epiphyseal plate.

Injury or disease may damage the musculotendinous rotator cuff, producing instability of the glenohumeral joint.

Axillary Artery



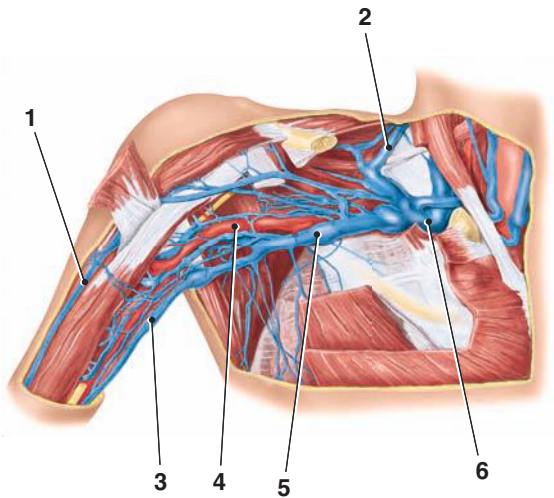
Axillary Artery

1. thoracoacromial artery
2. superior thoracic artery
3. posterior and anterior circumflex humeral arteries
4. subscapular artery
5. lateral thoracic artery
6. brachial artery

The axillary artery can be compressed against the humerus or the first rib to control profuse bleeding from a penetrating wound. Branches of the axillary artery contribute to the extensive anastomoses around the scapula, which may protect the limb during occlusion or compression of the primary arterial pathways.

Aneurysm of the axillary artery may compress the trunks of the brachial plexus, leading to pain and anesthesia in the areas supplied by the affected nerves.

Veins of the Axilla



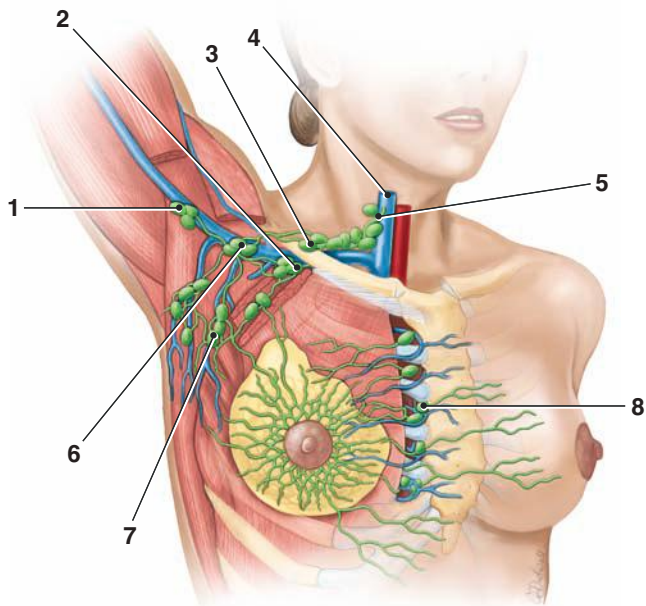
Veins of the Axilla

1. cephalic vein
2. external jugular vein
3. basilic vein
4. axillary artery
5. axillary vein
6. subclavian vein

Wounds in the axilla often involve the axillary vein, owing to its large size and superficial position. A wound to the proximal portion causes profuse bleeding and a risk of air entering and producing air emboli.

Subclavian vein puncture involves passing a catheter into the proximal aspect of the axillary vein, as its superficial location makes it easily accessible.

Axillary Lymph Nodes

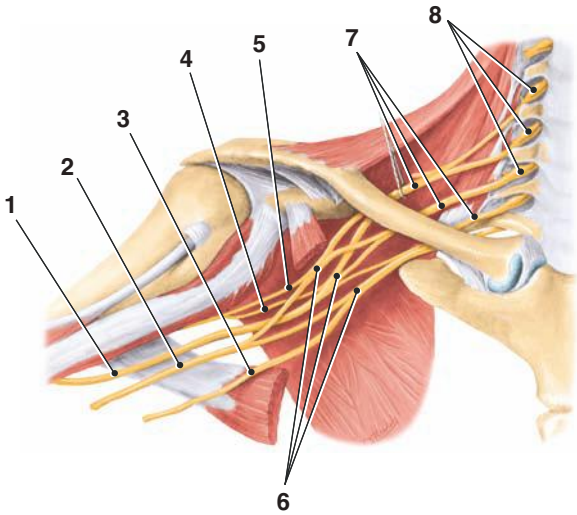


Axillary Lymph Nodes

1. humeral lymph nodes
2. apical lymph nodes
3. supraclavicular lymph nodes
4. internal jugular vein
5. right lymphatic duct
6. central lymph nodes
7. pectoral lymph nodes
8. parasternal lymph nodes

An infection in the upper limb can cause the axillary lymph nodes to enlarge—lymphangitis—resulting in pain and tenderness. Dissection of the axillary lymph nodes is useful in determining the degree to which a cancer, such as breast cancer, has metastasized. Care must be taken when removing the axillary lymph nodes not to damage the long thoracic or thoracodorsal nerves.

Brachial Plexus, General Form

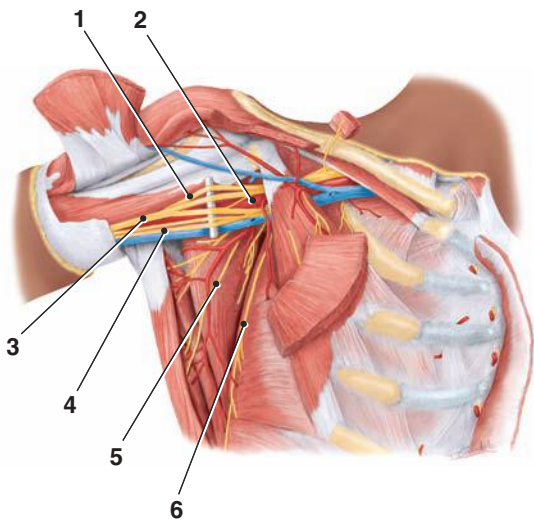


Brachial Plexus, General Form

1. radial nerve
2. median nerve
3. ulnar nerve
4. axillary nerve
5. musculocutaneous nerve
6. lateral, posterior, and medial cords
7. superior, middle, and inferior trunks
8. roots

Variations in the form of the brachial plexus are common. They may include contributions from additional anterior rami such as C4 or T2 or alterations in the branches, divisions, cords, and/or trunks. Alterations may affect the relationship with the 1st rib, scalene muscles, or axillary artery, which can lead to a host of clinical considerations.

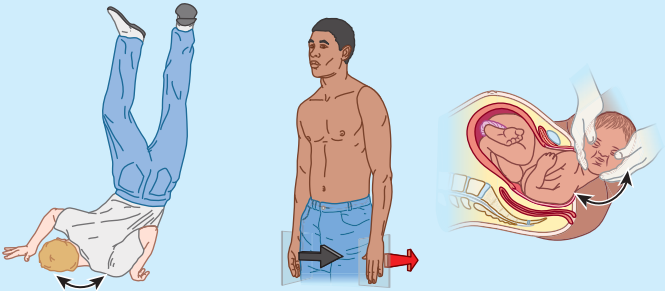
Brachial Plexus



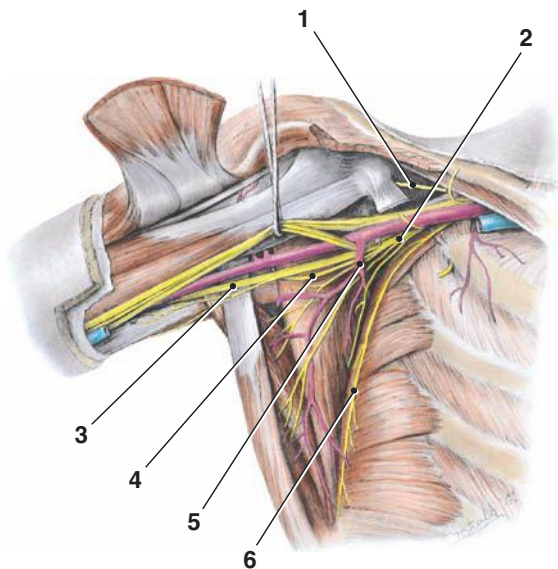
Brachial Plexus

1. musculocutaneous nerve
2. axillary artery
3. median nerve
4. ulnar nerve
5. thoracodorsal nerve
6. long thoracic nerve

Injuries to the superior parts of the brachial plexus usually result from an excessive increase in the angle between the neck and shoulder, as occurs during a fall or excessive stretching during delivery. Injury to the superior parts of the plexus is apparent by the characteristic waiter's tip position, in which the limb is medially rotated, the shoulder adducted, and the elbow extended.



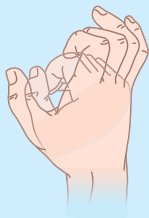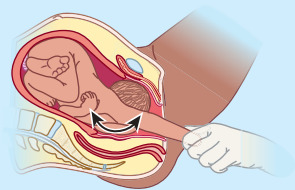
Brachial Plexus, Axillary Vein Removed



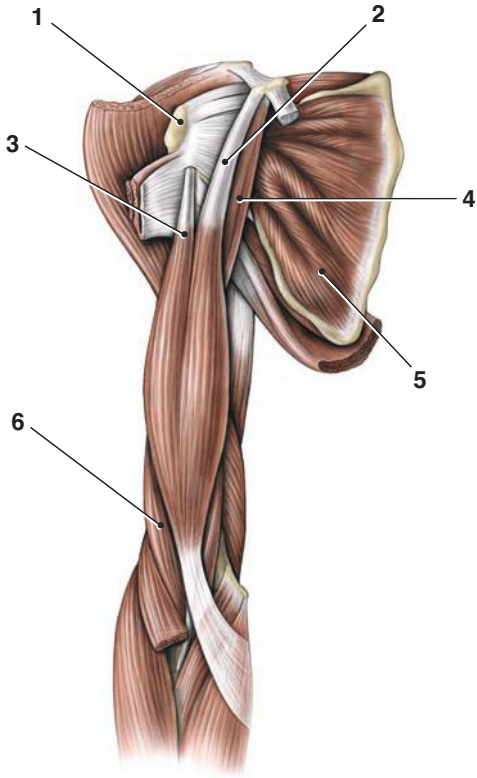
Brachial Plexus, Axillary Vein Removed

1. suprascapular nerve
2. posterior cord
3. radial nerve
4. axillary nerve
5. subscapular trunk
6. long thoracic nerve

Injuries to the inferior parts of the brachial plexus occur when the upper limb is pulled superiorly, as in grasping something to break a fall or as a baby's upper limb is pulled during delivery. The intrinsic muscles of the hand are involved, resulting in claw hand.



Anterior Arm

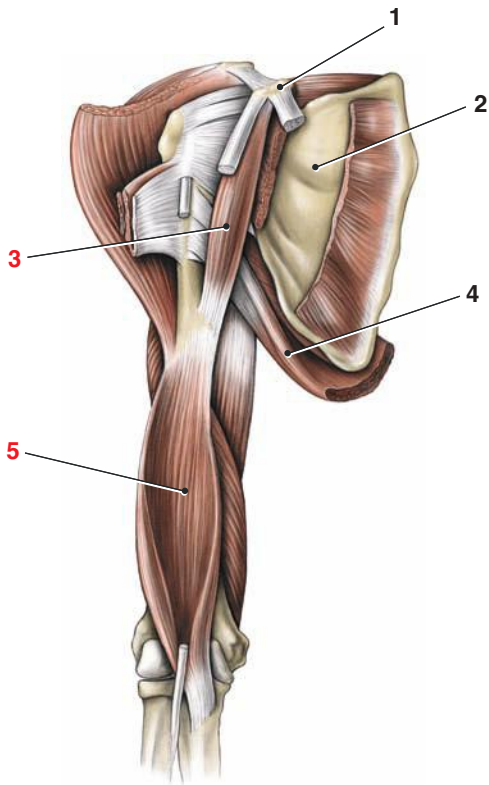


Anterior Arm

1. greater tubercle
2. short head of the biceps brachii
3. long head of the biceps brachii
4. coracobrachialis
5. subscapularis
6. brachialis

Biceps tendonitis—inflammation of the tendon of the long head—is the result of repetitive movement of the tendon in the intertubercular groove, as occurs in sports that involve throwing. The tendon may rupture as it is torn from the supraglenoid tubercle, often as the result of chronic inflammation. The tendon of the long head can be dislocated from the intertubercular groove, causing extreme pain.

Deep Anterior Arm



Deep Anterior Arm

1. coracoid process
2. subscapular fossa
3. coracobrachialis
4. latissimus dorsi
5. brachialis

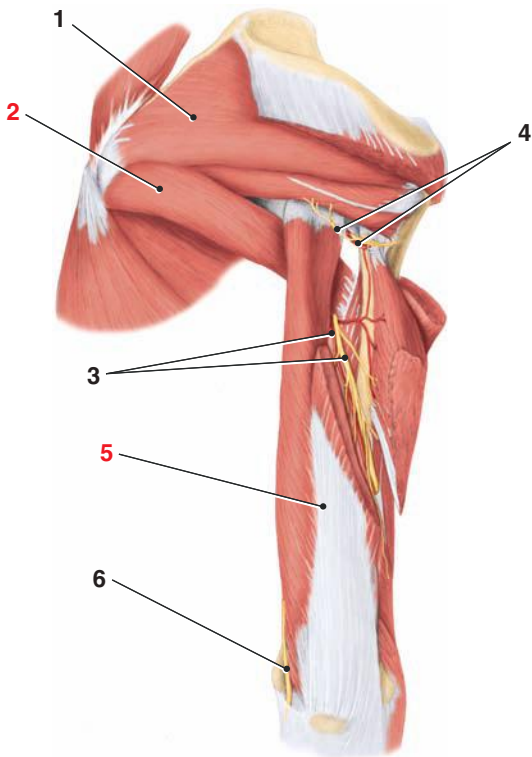
Coracobrachialis

- proximal attachment: coracoid process
- distal attachment: humerus
- innervation: musculocutaneous nerve
- main action: flexes and adducts arm

Brachialis

- proximal attachment: distal humerus
- distal attachment: coronoid process of ulna
- innervation: musculocutaneous nerve
- main action: flexes forearm

Posterior Shoulder



Posterior Shoulder

1. infraspinatus
2. teres major
3. radial nerve and deep artery of arm
4. axillary nerve and posterior circumflex humeral artery
5. triceps brachii
6. ulnar nerve

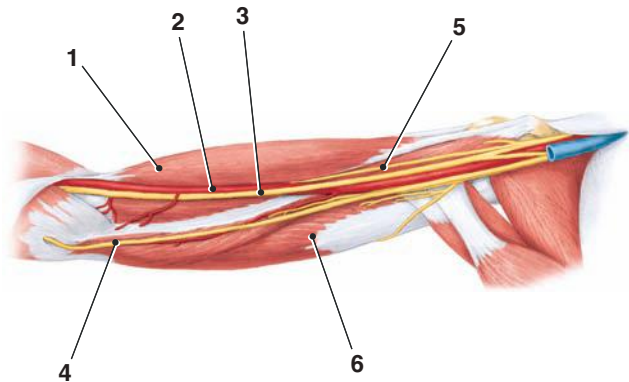
Teres Major

- proximal attachment: inferior angle of scapula
- distal attachment: lesser tubercle of humerus
- innervation: lower subscapular nerve
- main action: adducts and medially rotates arm

Triceps Brachii

- proximal attachment: long head, infraglenoid tubercle; lateral head, humerus, superior to radial groove; medial head, humerus, inferior to radial groove
- distal attachment: olecranon process
- innervation: radial nerve
- main action: extends forearm

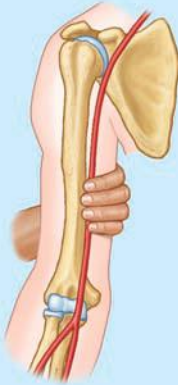Medial Arm



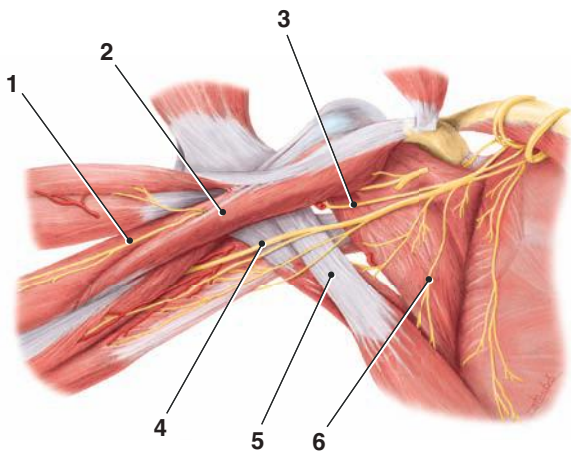
Medial Arm

1. biceps brachii
2. brachial artery
3. median nerve
4. ulnar nerve
5. musculocutaneous nerve
6. triceps brachii

The best place to compress the brachial artery to control hemorrhage is medial to the humerus near the middle of the arm. Compressing distal to the origin of the deep artery of the arm allows for collateral circulation around the elbow to keep tissues adequately perfused.



Arm, Deep Dissection

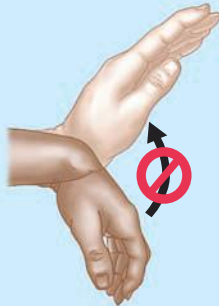

Arm, Deep Dissection

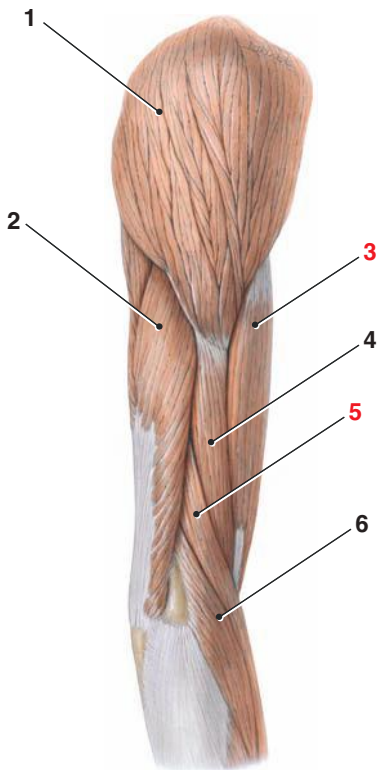
1. musculocutaneous nerve
2. coracobrachialis
3. axillary nerve
4. radial nerve
5. latissimus dorsi
6. thoracodorsal nerve

Musculocutaneous nerve injury results in paralysis of the muscles in the anterior compartment of the arm, hence weakening of elbow flexion and supination and loss of sensation over the lateral forearm.

Injury to the radial nerve may result in wrist drop as a result of the unopposed actions of the flexor muscles.



Lateral Arm



Lateral Arm

1. deltoid
2. triceps brachii
3. biceps brachii
4. brachialis
5. brachioradialis
6. extensor carpi radialis longus

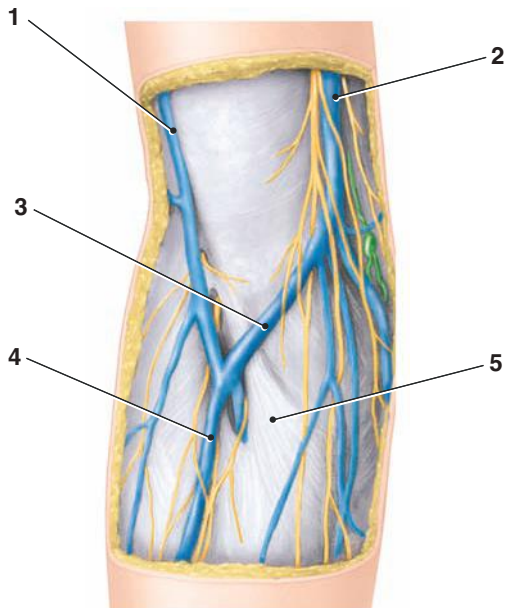
Biceps Brachii

- proximal attachment: short head, coracoid process; long head, supraglenoid tubercle
- distal attachment: tuberosity of radius
- innervation: musculocutaneous nerve
- main action: supinates and flexes forearm

Brachioradialis

- proximal attachment: lateral supraepicondylar ridge of humerus
- distal attachment: distal end of radius
- innervation: radial nerve
- main action: flexes forearm

Veins of the Cubital Fossa

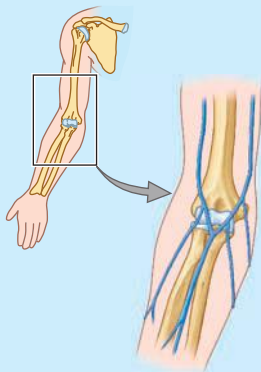


Veins of the Cubital Fossa

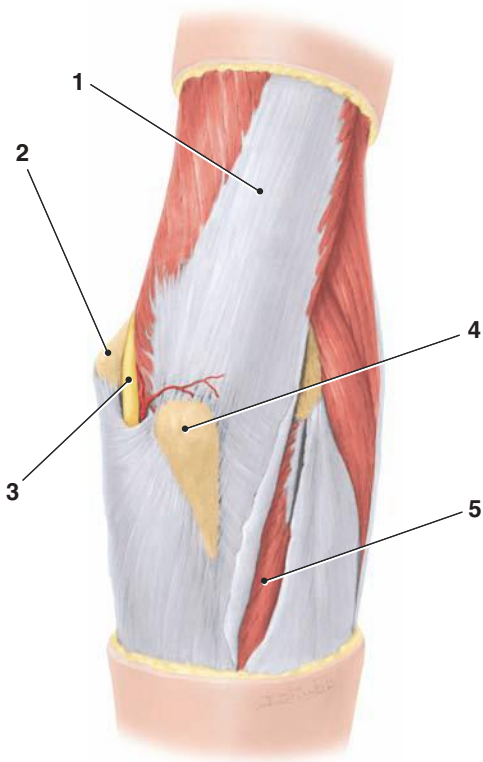
1. cephalic vein
2. basilic vein
3. median cubital vein
4. median vein of the forearm
5. bicipital aponeurosis

The median cubital vein is the vein commonly selected for venipuncture because of its accessibility and superficial relationship to the bicipital aponeurosis, which supplies some protection to the underlying brachial artery.

The pattern of veins in the fossa varies greatly, so it is important to identify which vein lies on the bicipital aponeurosis for venipuncture.



Elbow, Posterior View

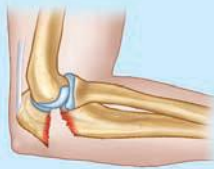

Elbow, Posterior View

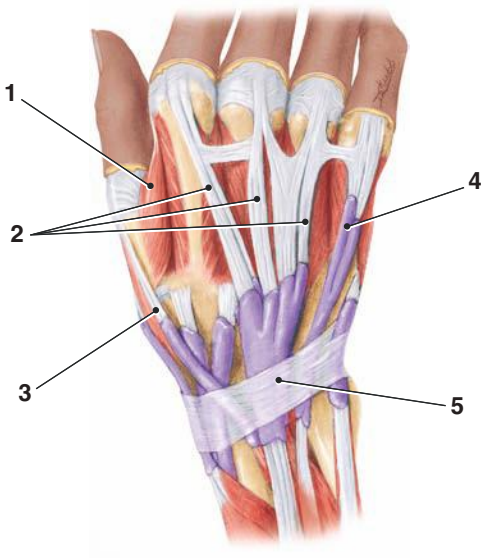
1. triceps tendon
2. medial epicondyle
3. ulnar nerve
4. olecranon
5. anconeus

Repetitive use of the superficial extensor muscles of the forearm may cause elbow tendonitis, or tennis elbow. Repeated forceful flexion and extension of the wrist strain the attachment of the common extensor tendon at the lateral epicondyle.

Fracture of the olecranon, or a fractured elbow, is often caused by a fall. The triceps brachii pulls the avulsed piece of bone in this painful and debilitating injury.



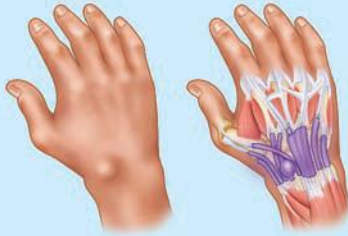
Dorsum of the Hand



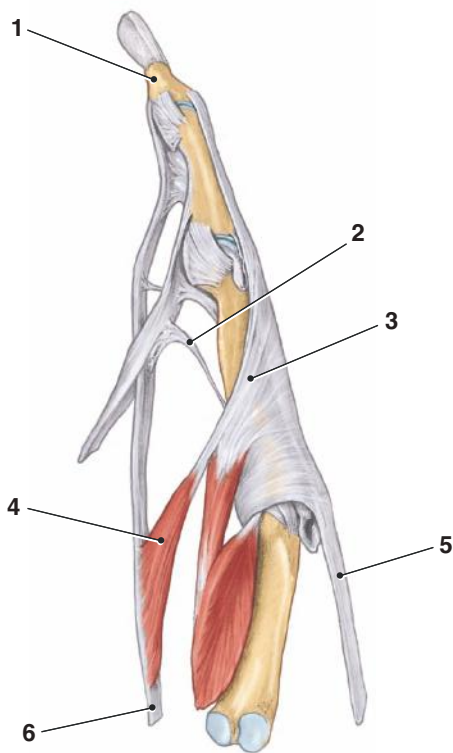
Dorsum of the Hand

1. 1st dorsal interosseous
2. extensor digitorum tendons
3. extensor pollicis longus tendon
4. extensor digiti minimi
5. extensor retinaculum

Occasionally, a cyst appears on the dorsum of the hand, clinically known as a ganglion cyst. These cysts are often associated with the synovial sheaths of the long extensor tendons as they cross the wrist.



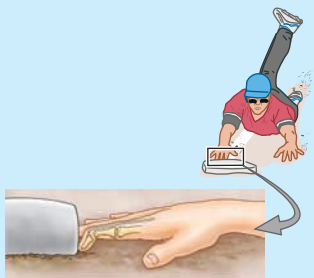
Finger



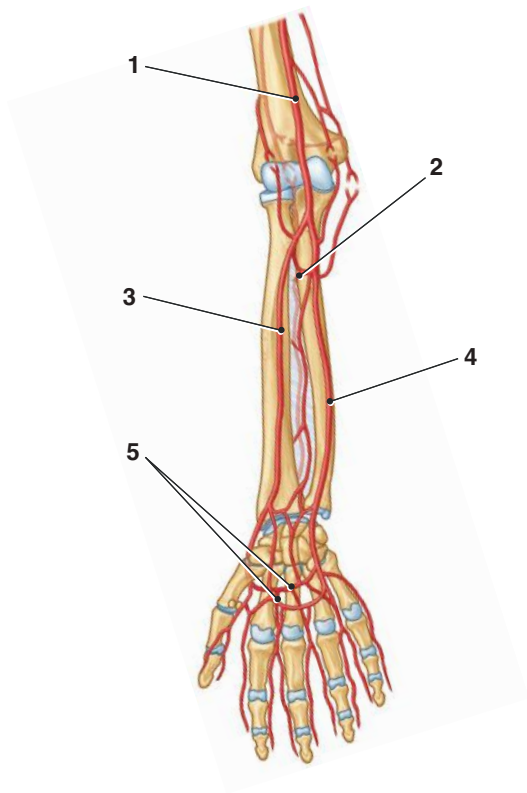
Finger

1. distal phalanx
2. vincula longa
3. extensor expansion
4. lumbrical
5. extensor digitorum
6. flexor digitorum profundus

Sudden severe tension on a long extensor tendon may avulse part of its attachment to the phalanx, commonly resulting in a mallet or baseball finger. Extension of the distal interphalangeal joint is not possible, which causes the finger to resemble a mallet.



Arteries of the Forearm

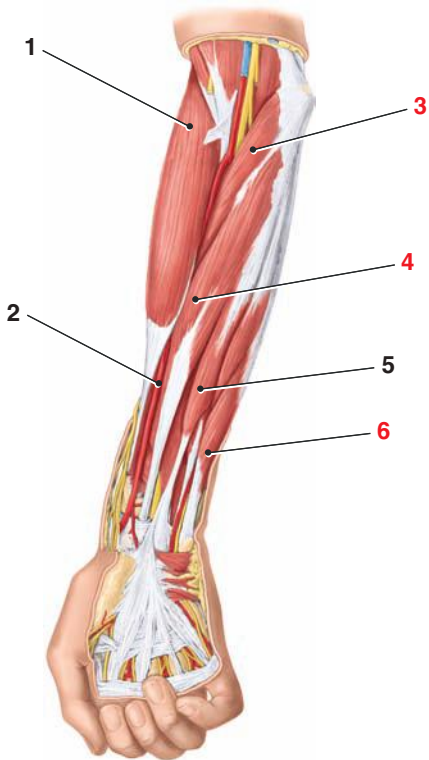


Arteries of the Forearm

1. brachial artery
2. common interosseous artery
3. radial artery
4. ulnar artery
5. deep and superficial palmar arches

Sometimes the brachial artery divides at a more proximal level than usual, in which case the radial and ulnar arteries begin in the arm. In a small percentage of people, the ulnar and/or radial artery descends superficial to the muscles, and care must be taken to not mistake it for a vein when drawing blood. The superficial arteries are also subject to laceration.

Superficial Forearm Musculature



Superficial Forearm Musculature

1. brachioradialis
2. radial artery
3. pronator teres
4. flexor carpi radialis
5. palmaris longus
6. flexor carpi ulnaris

Pronator Teres

- proximal attachment: medial epicondyle of humerus
- distal attachment: pronator tuberosity of radius
- innervation: median nerve
- main action: pronates forearm and flexes elbow

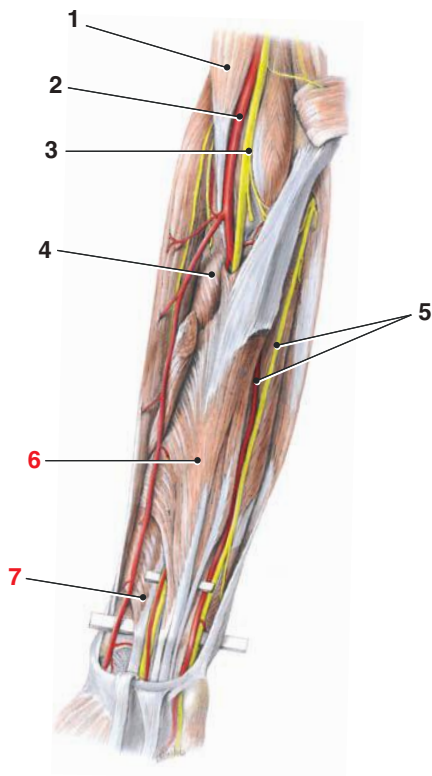
Flexor Carpi Radialis

- proximal attachment: medial epicondyle of humerus
- distal attachment: base of 2nd metacarpal
- innervation: median nerve
- main action: flexes wrist and abducts hand

Flexor Carpi Ulnaris

- proximal attachment: medial epicondyle of humerus
- distal attachment: pisiform and 5th metacarpal
- innervation: ulnar nerve
- main action: flexes wrist and adducts hand

Intermediate Forearm Musculature



Intermediate Forearm Musculature

1. biceps brachii
2. brachial artery
3. median nerve
4. supinator
5. ulnar nerve and artery
6. flexor digitorum superficialis
7. flexor pollicis longus

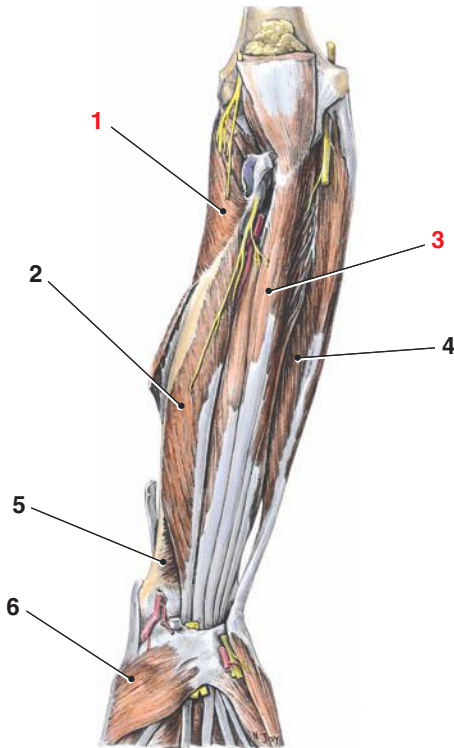
Flexor Digitorum Superficialis

- proximal attachment: medial epicondyle of humerus, ulna, and radius
- distal attachment: middle phalanges of medial four digits
- innervation: median nerve
- main action: flexes proximal interphalangeal joints

Flexor Pollicis Longus

- proximal attachment: radius
- distal attachment: base of distal phalanx of thumb
- innervation: anterior interosseous nerve (median nerve)
- main action: flexes phalanges of 1st digit

Deep Forearm Musculature



Deep Forearm Musculature

1. supinator
2. flexor pollicis longus
3. flexor digitorum profundus
4. flexor carpi ulnaris
5. pronator quadratus
6. opponens pollicis

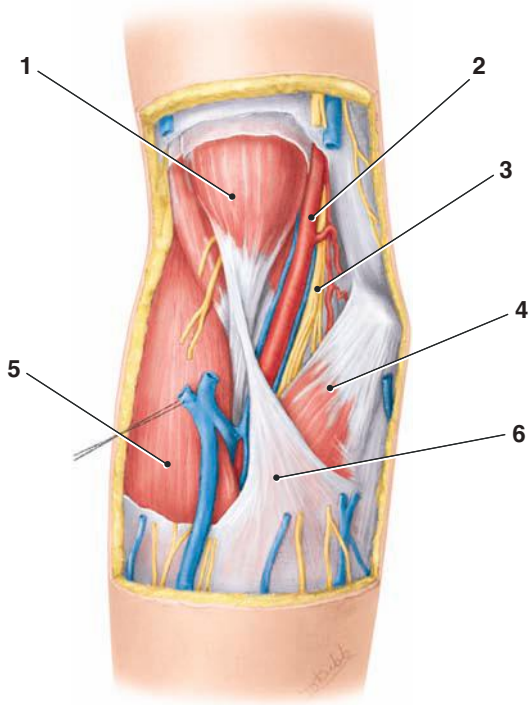
Supinator

- proximal attachment: lateral epicondyle of humerus, supinator fossa, and ulna
- distal attachment: proximal radius
- innervation: deep branch of radial nerve
- main action: supinates forearm

Flexor Digitorum Profundus

- proximal attachment: proximal ulna and interosseous membrane
- distal attachment: distal phalanges of medial four digits
- innervation: medial part, ulnar nerve; lateral part, median nerve
- main action: flexes distal interphalangeal joint of medial four digits

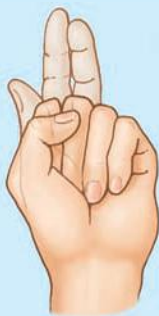Median Nerve in the Cubital Fossa



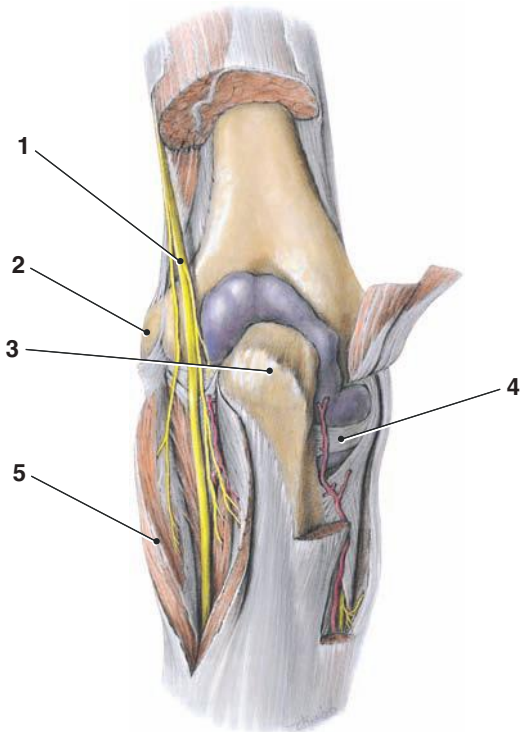
Median Nerve in the Cubital Fossa

1. biceps brachii
2. brachial artery
3. median nerve
4. pronator teres
5. brachioradialis
6. bicipital aponeurosis

When the median nerve is injured or entrapped (as in pronator syndrome) at the elbow, the hand forms the hand of benediction upon attempting to make a fist—the 2nd and 3rd digits remain partially extended.



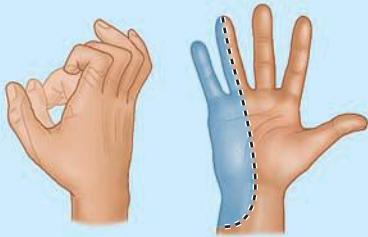
Ulnar Nerve at the Elbow



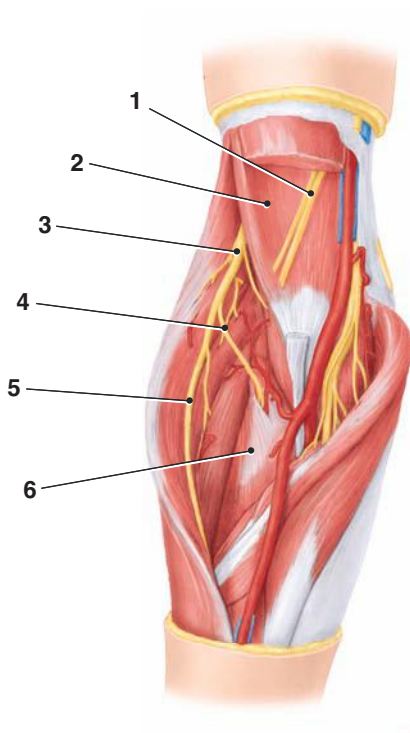
Ulnar Nerve at the Elbow

1. ulnar nerve
2. medial epicondyle
3. olecranon
4. annular ligament
5. flexor carpi ulnaris

The ulnar nerve is commonly damaged or compressed (as in cubital tunnel syndrome) as it passes posterior to the medial epicondyle. After injury to the ulnar nerve, the person has difficulty making a fist; the characteristic claw hand appearance is due to extensive muscle failure combined with sensory loss over the medial aspect of the palm.



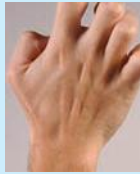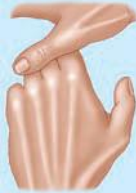Radial Nerve at the Elbow



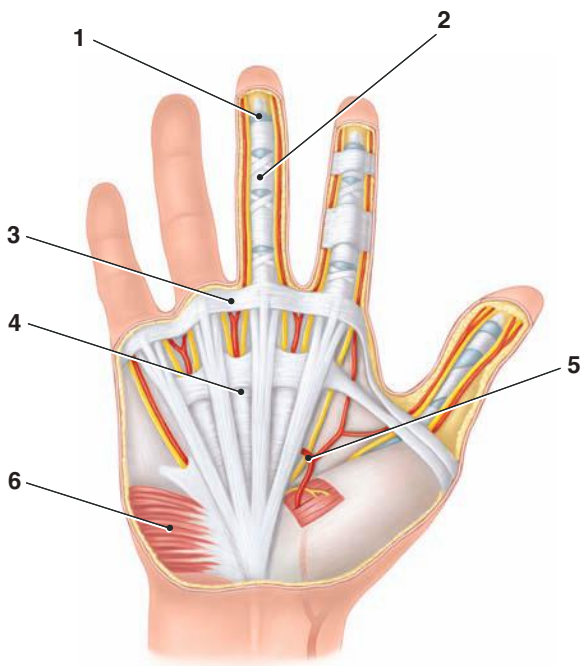
Radial Nerve at the Elbow

1. musculocutaneous nerve
2. brachialis
3. radial nerve
4. deep branch of the radial nerve
5. superficial branch of the radial nerve
6. supinator

A deep wound to the forearm may damage the deep branch of the radial nerve, causing inability to extend the thumb and metacarpophalangeal joints. The integrity of the nerve is easily tested by asking the patient to extend the metacarpophalangeal joints against resistance.



Palmar Aponeurosis



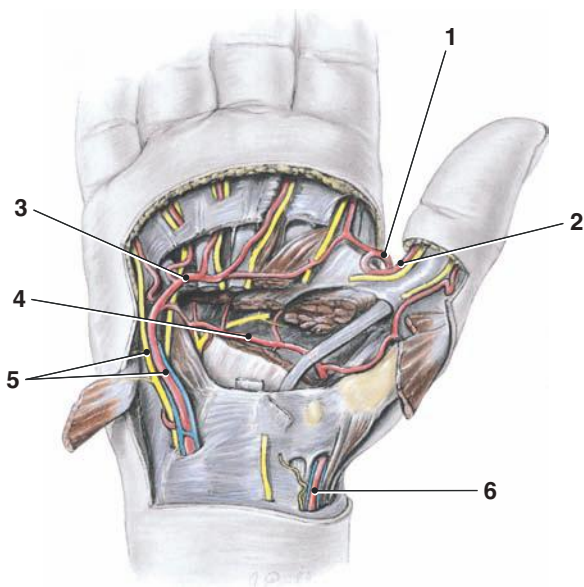
Palmar Aponeurosis

1. synovial sheath
2. fibrous digital sheath
3. superficial transverse metacarpal ligament
4. palmar aponeurosis
5. superficial palmar arch
6. palmaris brevis

Dupuytren contracture is a disease of the palmar fascia resulting in progressive shortening, thickening, and fibrosis of the aponeurosis. The palm is drawn inward, and the 4th and 5th digits are pulled into flexion.

Hand infections usually appear on the dorsum of the hand due to the strong aponeurosis limiting swelling in the palm. Injuries to the fingers may cause inflammation of the tendons and their synovial sheaths, causing swelling and pain upon movement.

Arteries of the Hand



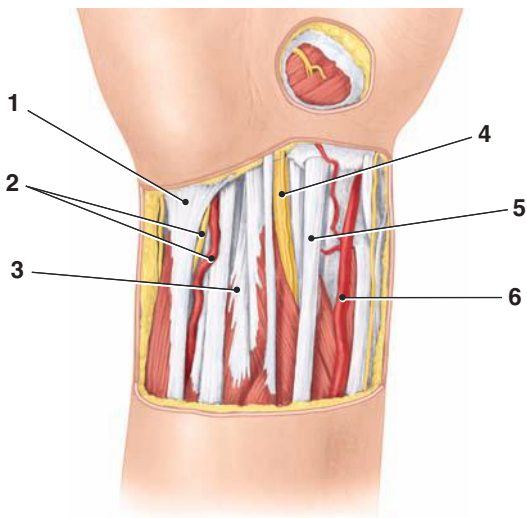
Arteries of the Hand

1. dorsalis pollicis artery
2. princeps pollicis artery
3. superficial palmar arch
4. deep palmar arch
5. ulnar nerve and artery
6. radial artery

Bleeding is usually profuse and difficult to control when the palmar arches are lacerated. Often, because of the extensive branching and anastomoses of the arteries in the hand, it is necessary to compress the brachial artery in the arm to limit the bleeding.

Raynaud syndrome is characterized by idiopathic ischemia of the fingers. It is sometimes necessary to perform a presynaptic sympathectomy to limit vasoconstriction and restore blood flow to the fingers.

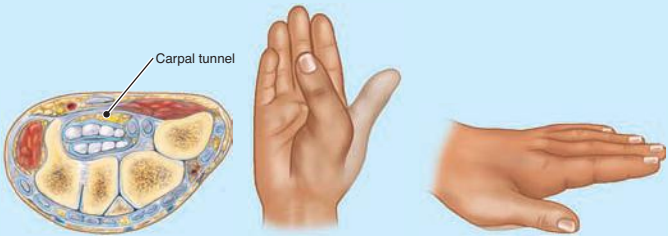
Anterior Wrist



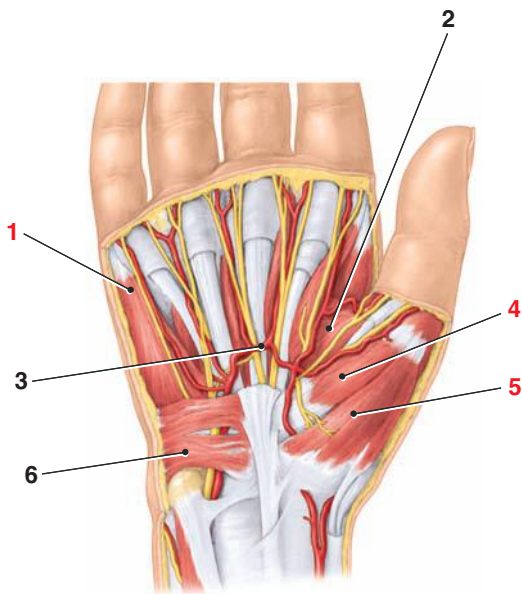
Anterior Wrist

1. flexor carpi ulnaris
2. ulnar nerve and artery
3. flexor digitorum superficialis
4. median nerve
5. flexor carpi radialis
6. radial artery

Carpal tunnel syndrome results from anything that limits the space in the carpal tunnel. It is characterized by loss of sensation over the lateral palm, inability to oppose the thumb, and thenar wasting owing to the compromised function of the median nerve. Severance of the flexor retinaculum, or carpal tunnel release, may be necessary to relieve pressure on the nerve.



Superficial Palm



Superficial Palm

1. abductor digiti minimi
2. adductor pollicis
3. superficial palmar arch
4. flexor pollicis brevis
5. abductor pollicis brevis
6. palmaris brevis

Abductor Digiti Minimi

- proximal attachment: pisiform
- distal attachment: proximal phalanx of digit 5
- innervation: deep branch of ulnar nerve
- main action: abducts digit 5

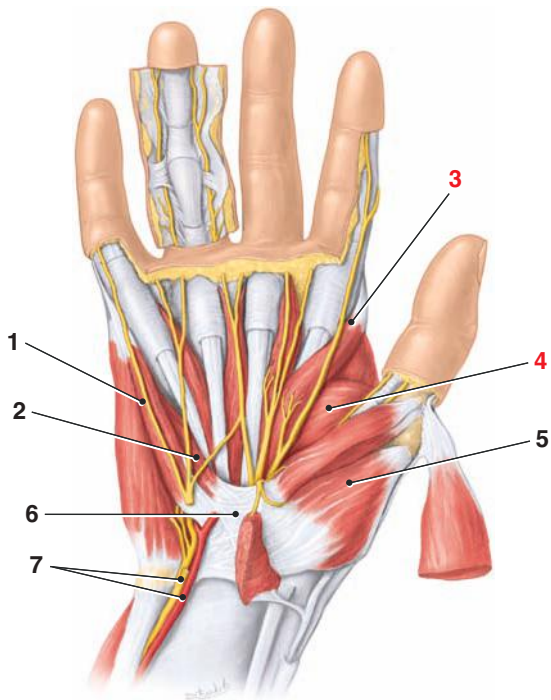
Flexor Pollicis Brevis

- proximal attachment: flexor retinaculum and trapezium
- distal attachment: proximal phalanx of thumb
- innervation: recurrent branch of median nerve
- main action: flexes thumb

Abductor Pollicis Brevis

- proximal attachment: flexor retinaculum, scaphoid, and trapezium
- distal attachment: proximal phalanx of thumb
- innervation: recurrent branch of median nerve
- main action: abducts thumb

Intermediate Palm



Intermediate Palm

1. flexor digiti minimi
2. opponens digiti minimi
3. 1st lumbrical
4. adductor pollicis
5. opponens pollicis
6. flexor retinaculum
7. ulnar nerve and artery

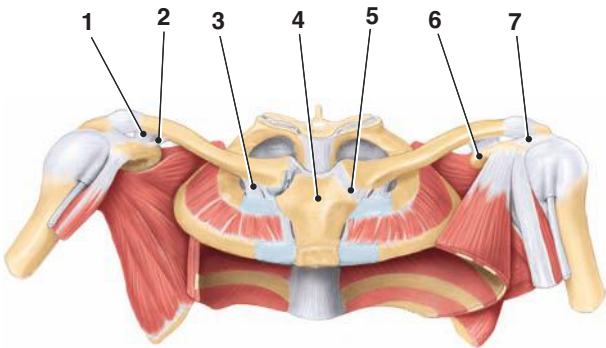
Lumbricals

- proximal attachment: tendons of flexor digitorum profundus
- distal attachment: extensor expansions of digits
- innervation: 1 and 2, median nerve; 3 and 4, deep branch of ulnar nerve
- main action: flex the metacarpophalangeal joints and extend interphalangeal joints

Adductor Pollicis

- proximal attachment: oblique head, 2nd and 3rd metacarpals and capitate; transverse head, 3rd metacarpal
- distal attachment: proximal phalanx of thumb
- innervation: deep branch of ulnar nerve
- main action: adducts the thumb

Sternoclavicular Joint

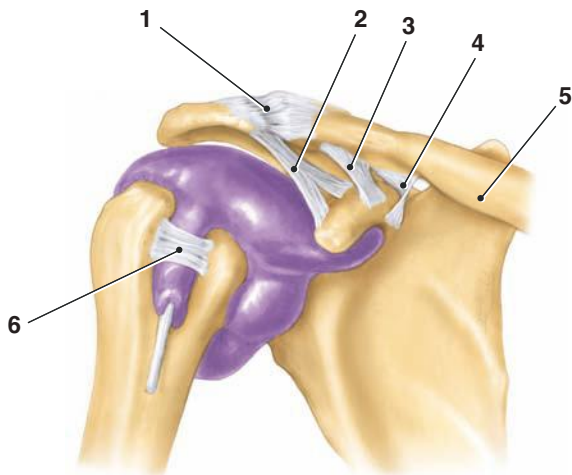


Sternoclavicular Joint

1. trapezoid ligament
2. conoid ligament
3. costoclavicular ligament
4. manubrium
5. anterior sternoclavicular ligament
6. coracoid process
7. coracoacromial ligament

Dislocation of the sternoclavicular joint is rare, owing to the strength of the ligaments and the direction that forces are applied. Ankylosis of the joint (stiffening or fixation) may limit the movement of the shoulder. Often, a piece of the clavicle is removed to restore function.

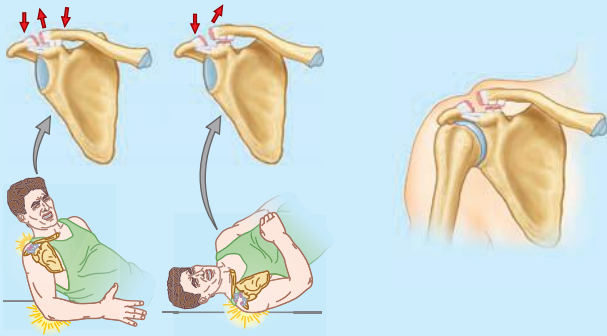
Acromioclavicular Joint



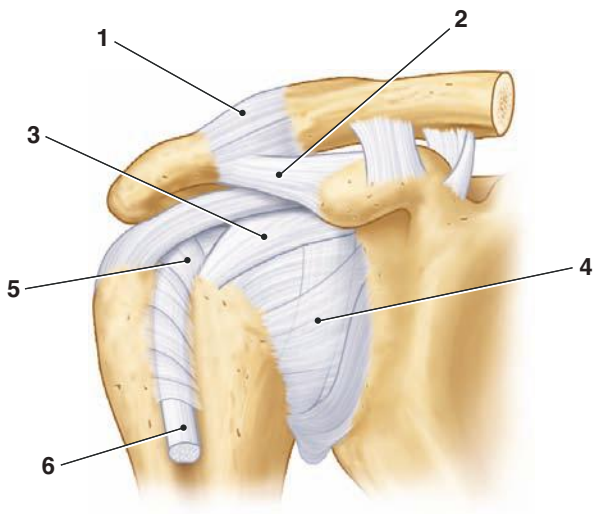
Acromioclavicular Joint

1. superior acromioclavicular ligament
2. coracoacromial ligament
3. trapezoid ligament
4. conoid ligament
5. clavicle
6. transverse humeral ligament

Dislocation of the acromioclavicular joint, or shoulder separation, is relatively common in sports or falls that jar the shoulder. Rupture of the coracoacromial ligament is evidenced by a prominent acromion and the upper limb falling.



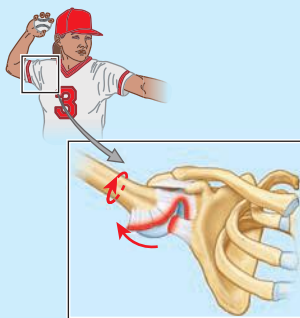
Anterior Aspect of the Shoulder Joint



Anterior Aspect of the Shoulder Joint

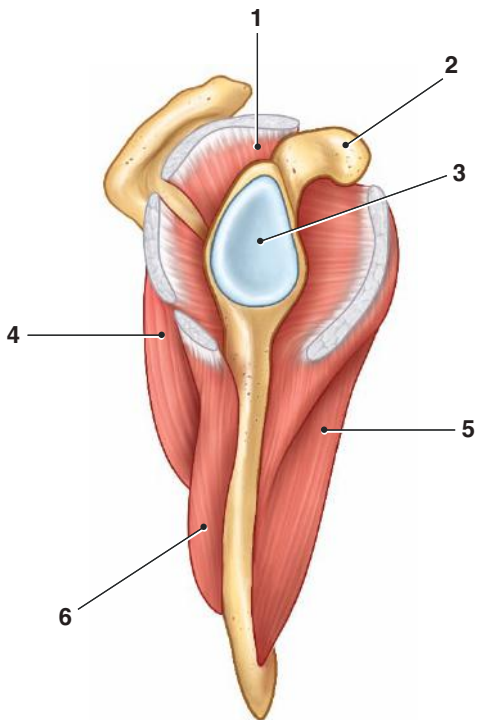
1. acromioclavicular ligament
2. coracoacromial ligament
3. coracohumeral ligament
4. fibrous capsule
5. transverse humeral ligament
6. tendon of the long head of the biceps brachii

Most dislocations of the glenohumeral joint occur downward because ligamentous and muscular support elsewhere is strong. Anterior dislocations are caused by excessive extension and lateral rotation of the humerus.



Adhesive capsulitis (frozen shoulder) is caused by fibrosis and scarring in the glenohumeral joint. Symptoms include difficulty abducting the arm.

Rotator Cuff



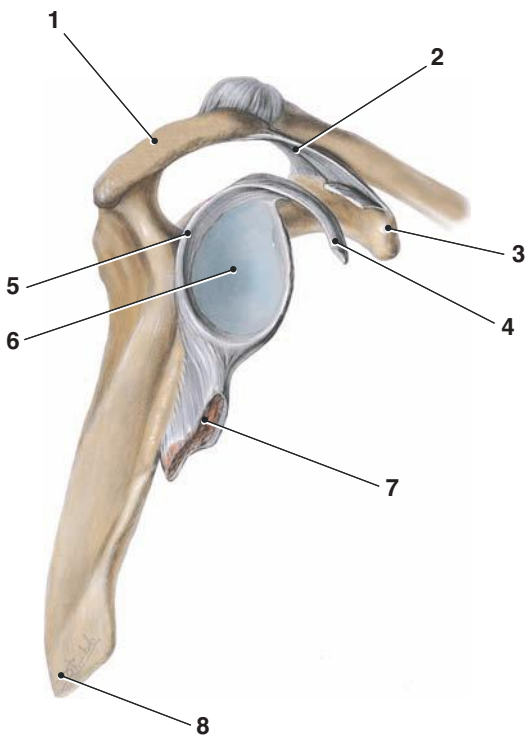
Rotator Cuff

1. supraspinatus
2. coracoid process
3. glenoid cavity
4. infraspinatus
5. subscapularis
6. teres minor

Calcific supraspinatus tendonitis is caused by inflammation and calcification of the subacromial bursa and the tendon of supraspinatus; pain and limitation of movement result.

The musculotendinous rotator cuff is commonly injured in sports, resulting in shoulder pain and instability of the joint.

Glenoid Cavity

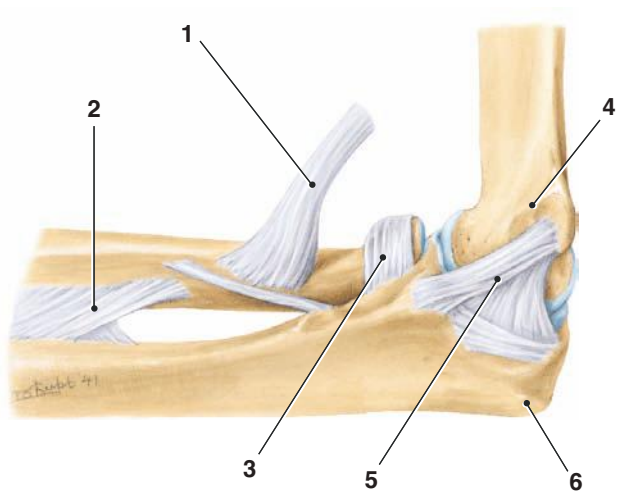


Glenoid Cavity

1. acromion
2. coracoacromial ligament
3. coracoid process
4. tendon of the long head of the biceps brachii
5. glenoid labrum
6. glenoid cavity
7. long head of the triceps brachii (cut)
8. inferior angle of the scapula

Tearing of the glenoid labrum is a common injury in athletes who throw a ball or have shoulder instability. The tear results from sudden contraction of the biceps or forceful subluxation of the humeral head. It causes pain upon throwing.

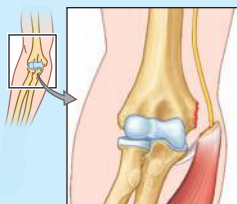
Ligaments of the Elbow Joint



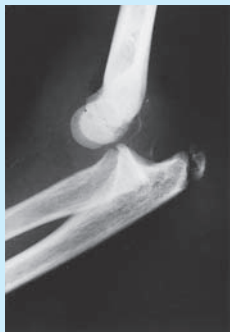Ligaments of the Elbow Joint

1. biceps brachii tendon
2. interosseous membrane
3. anular ligament
4. medial epicondyle
5. ulnar collateral ligament
6. olecranon

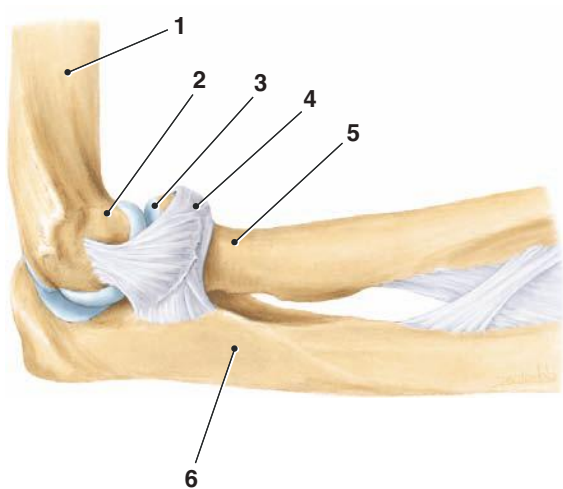
Avulsion of the medial epicondyle may occur in children, typically from a fall. Traction injury to the ulnar nerve is a frequent complication.



Posterior dislocation of the elbow may occur in children when they fall on their hands with their elbows flexed.



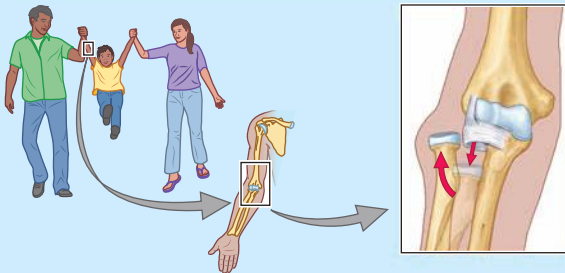
Head of the Radius



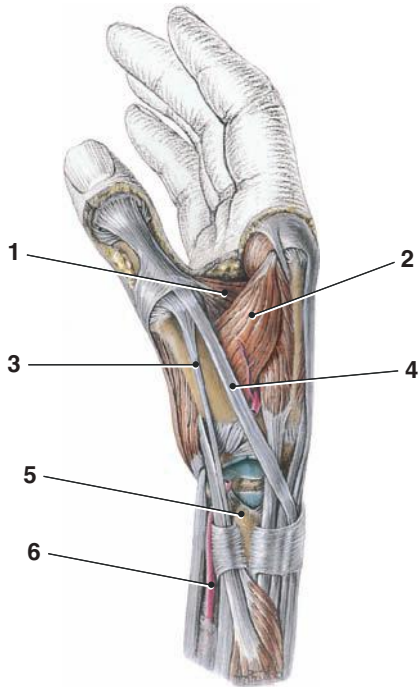
Head of the Radius

1. humerus
2. capitulum
3. head of the radius
4. anular ligament
5. neck of the radius
6. ulna

Subluxation and dislocation of the head of the radius, also known as nursemaid's elbow or pulled elbow, is common in children who are suddenly lifted by the upper limb.



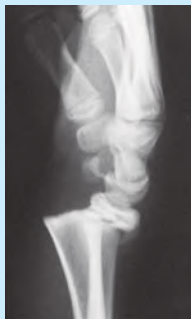Lateral Aspect of the Hand



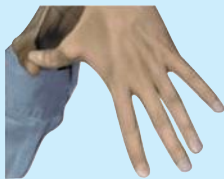Lateral Aspect of the Hand

1. adductor pollicis
2. 1st dorsal interosseous
3. extensor pollicis brevis
4. extensor pollicis longus
5. styloid process of the radius
6. radial artery

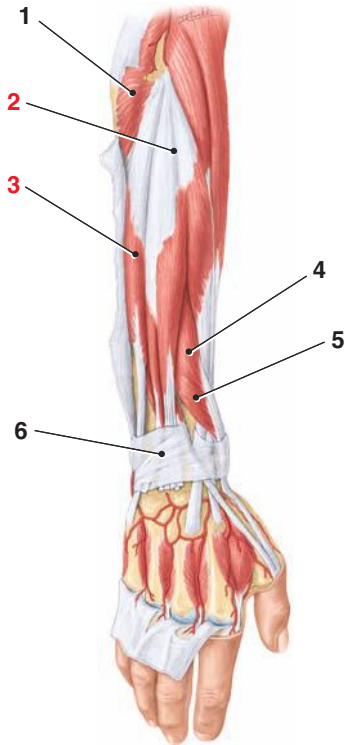
Fracture–separation of the distal radial epiphysis is common in children because of frequent falls.



Skier's thumb refers to the chronic laxity of the collateral ligament of the 1st metacarpophalangeal joint, resulting in hyperabduction. Bull rider's thumb is a sprain of the radial collateral ligament and fracture of the proximal phalanx of the thumb.



Superficial Posterior Forearm Musculature



Superficial Posterior Forearm Musculature

1. anconeus
2. extensor digitorum
3. extensor carpi ulnaris
4. abductor pollicis longus
5. extensor pollicis brevis
6. extensor retinaculum

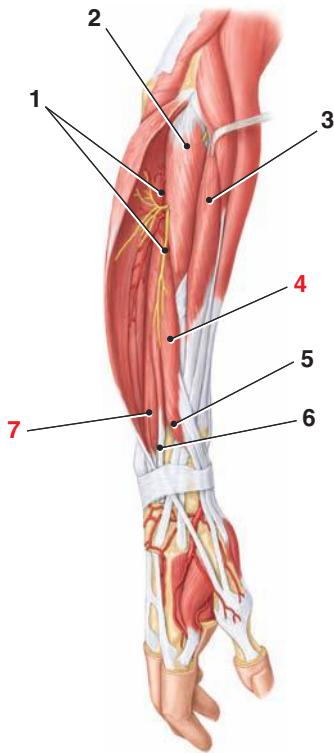
Extensor Digitorum

- proximal attachment: lateral epicondyle of humerus
- distal attachment: extensor expansions of medial four digits
- innervation: posterior interosseous nerve (radial nerve)
- main action: extends medial four digits and wrist

Extensor Carpi Ulnaris

- proximal attachment: lateral epicondyle of humerus
- distal attachment: 5th metacarpal
- innervation: posterior interosseous nerve (radial nerve)
- main action: extends and adducts wrist

Deep Posterior Forearm Musculature



Deep Posterior Forearm Musculature

1. posterior interosseous artery and nerve
2. supinator
3. extensor carpi radialis brevis
4. abductor pollicis longus
5. extensor pollicis brevis
6. extensor pollicis longus
7. extensor indicis

Abductor Pollicis Longus

- proximal attachment: ulna, radius, and interosseous membrane
- distal attachment: 1st metacarpal
- innervation: posterior interosseous nerve
- main action: abducts thumb

Extensor Indicis

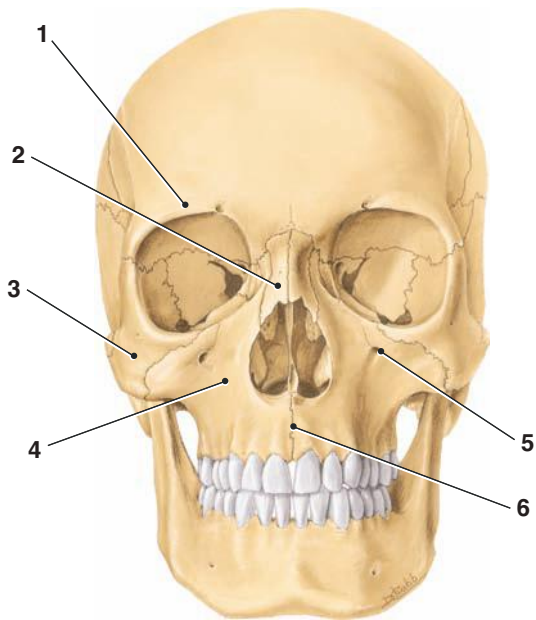
- proximal attachment: ulna and interosseous membrane
- distal attachment: extensor expansion of 2nd digit
- innervation: posterior interosseous nerve
- main action: extends 2nd digit

7 • Head

- 7.1** Skull, Anterior View
- 7.2** Skull, Lateral View
- 7.3** Skull, Inferior View
- 7.4** Scalp
- 7.5** Cranial Base, Internal View
- 7.6** Dural Folds
- 7.7** Dural Sinuses
- 7.8** Tentorial Notch
- 7.9** Meninges
- 7.10** Brain
- 7.11** Subarachnoid Spaces and Ventricles
- 7.12** Arterial Supply to the Brain
- 7.13** Facial Musculature, Lateral View
- 7.14** Facial Nerve on the Face
- 7.15** Nerves of the Face
- 7.16** Arteries of the Face
- 7.17** Veins of the Face
- 7.18** Parotid Gland
- 7.19** Orbit
- 7.20** Eyelids
- 7.21** Conjunctiva
- 7.22** Retina
- 7.23** Anterior Aspect of the Eye
- 7.24** Eye
- 7.25** Extraocular Muscles 1
- 7.26** Extraocular Muscles 2
- 7.27** Extraocular Muscles 3
- 7.28** Arteries of the Orbit
- 7.29** Infratemporal Fossa
- 7.30** Temporomandibular Joint

- 7.31** Temporalis
- 7.32** Deep Temporal Region
- 7.33** Oral Cavity
- 7.34** Muscles of the Oral Cavity
- 7.35** Hard Palate
- 7.36** Teeth
- 7.37** Tongue
- 7.38** Salivary Glands
- 7.39** Nasal Septum
- 7.40** Nasal Cavity
- 7.41** Paranasal Sinuses
- 7.42** External Ear
- 7.43** Middle Ear

Skull, Anterior View



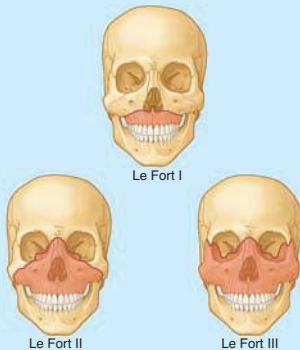
Skull, Anterior View

1. superciliary arch
2. nasal bone
3. zygomatic bone
4. maxilla
5. infraorbital foramen
6. intermaxillary suture

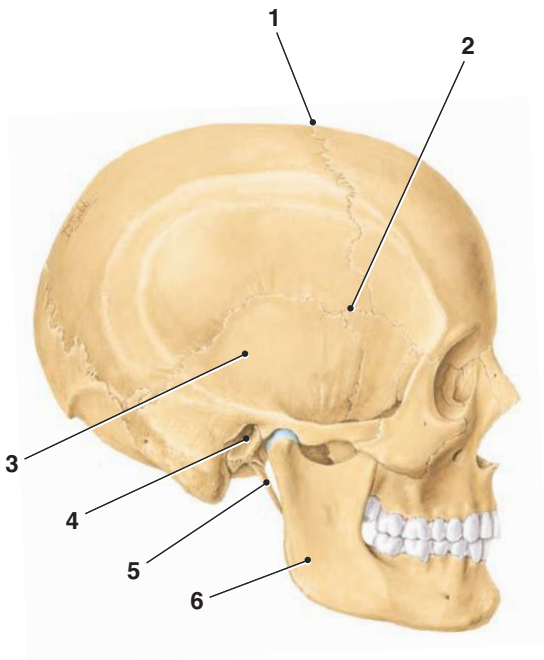
A blow to the superciliary arch may cause a laceration and a black eye.

Malar flush refers to the redness of the skin over the zygomatic prominence. It is associated with fever.

The three common maxillary fractures as described by Le Fort are numbered I, II, and III.



Skull, Lateral View

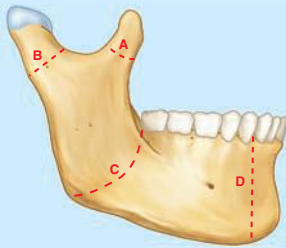


Skull, Lateral View

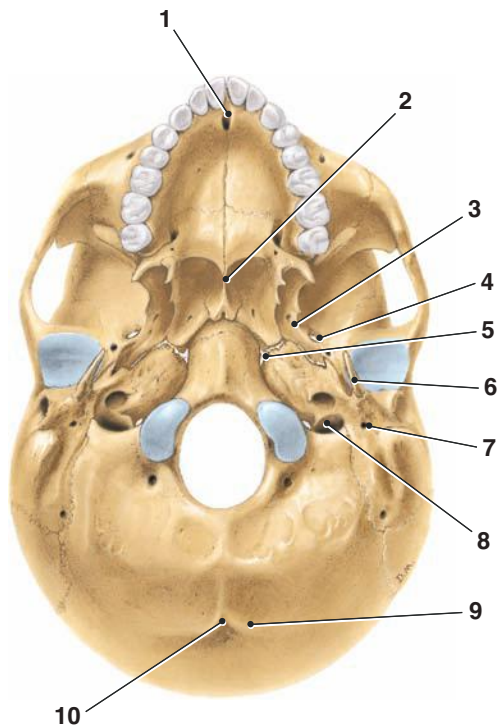
1. bregma
2. pterion
3. temporal bone – squamous portion
4. external auditory meatus
5. styloid process
6. mandible – angle

Fractures of the mandible usually occur in pairs, frequently on opposite sides. **A**, fracture of the coronoid process; **B**, fracture of the neck; **C**, fracture of the angle; **D**, fracture of the body.

Extraction of teeth causes resorption of alveolar bone. The mandible shrinks, occasionally leaving the mental foramen open and the nerves exposed to pain from dentures.



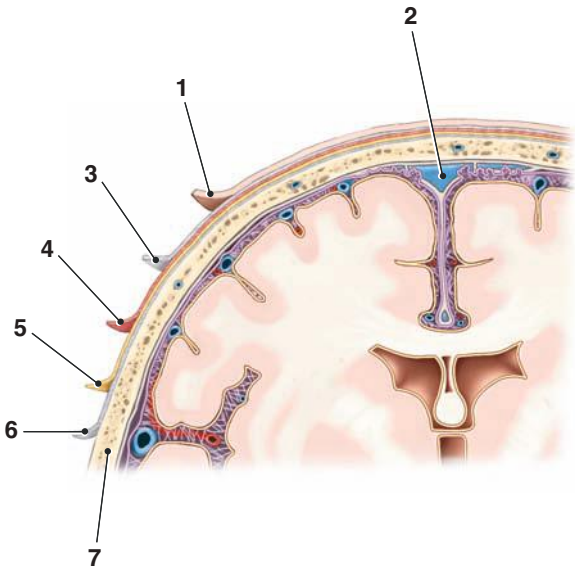
Skull, Inferior View



Skull, Inferior View

1. incisive foramen
2. vomer
3. lateral pterygoid plate
4. foramen ovale
5. foramen lacerum
6. styloid process
7. stylomastoid foramen
8. jugular foramen
9. superior nuchal line
10. external occipital protuberance

Scalp

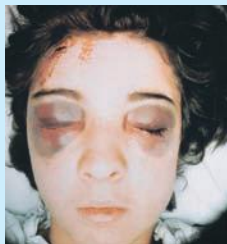

Scalp

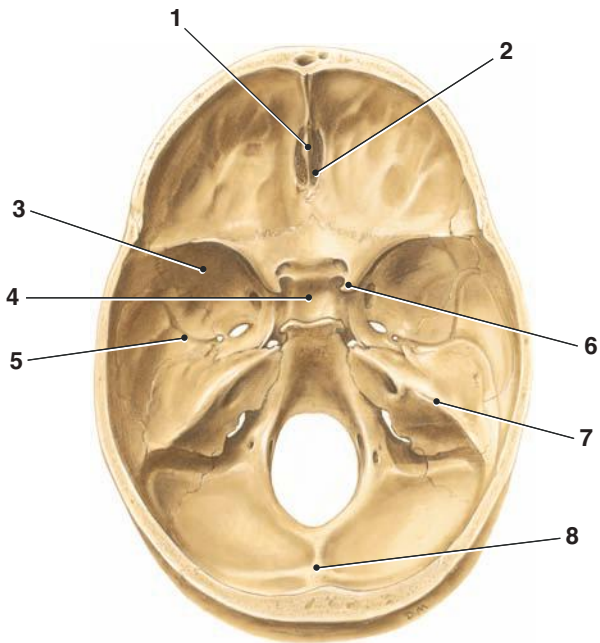
1. skin
2. superior sagittal sinus
3. connective tissue
4. aponeurosis
5. loose areolar tissue
6. pericranium
7. skull

Superficial scalp wounds do not gape owing to the strength of the epicranial aponeurosis. Wounds that lacerate the aponeurosis gape widely.

Blood or pus spreads easily in the loose areolar layer of the scalp and may pass anteriorly into the eyelids, causing black eyes.



Cranial Base, Internal View

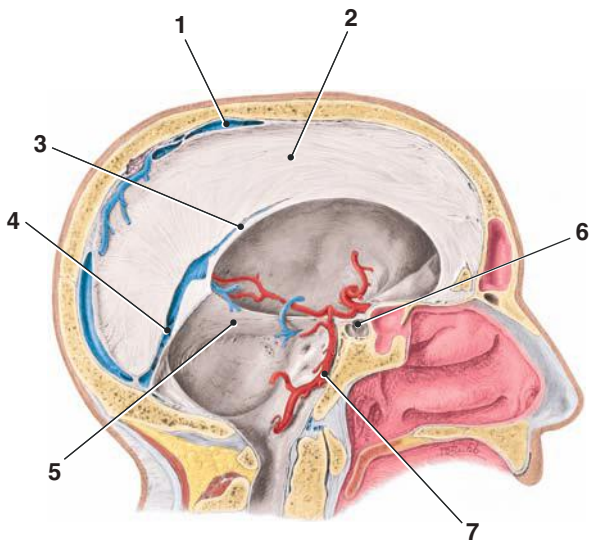


Cranial Base, Internal View

1. crista galli
2. cribriform plate
3. greater wing of the sphenoid
4. body of the sphenoid bone
5. groove for the middle meningeal artery
6. anterior clinoid process
7. petrous ridge
8. internal occipital protuberance

A blow to the head can detach the periosteal layer of dura mater from the calvaria. The dura is firmly attached to the bone in the cranial base, and a fracture that tears the dura often results in leakage of cerebrospinal fluid.

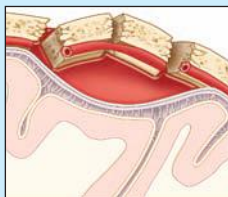
Dural Folds



Dural Folds

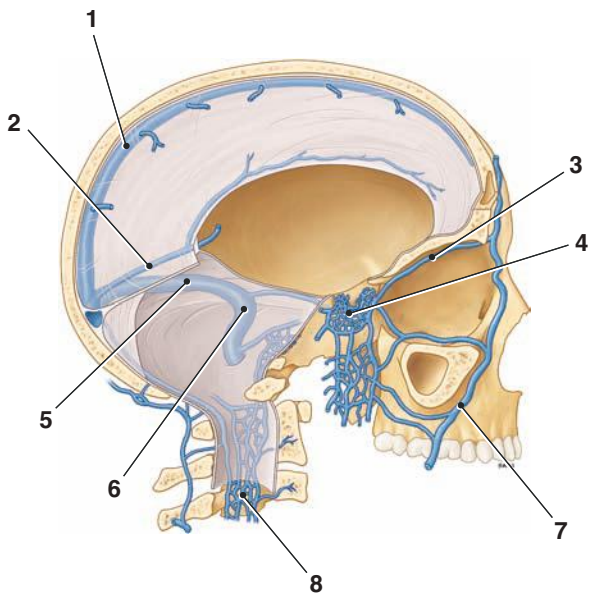
1. superior sagittal sinus
2. cerebral falx
3. inferior sagittal sinus
4. straight sinus
5. cerebellar tentorium
6. sellar diaphragm
7. basilar artery

Extradural or epidural hemorrhage originates in an artery. Typically, the middle meningeal artery is torn by a blow to the head.



Many headaches originate in the dura, which is sensitive to pain caused by stretching. Sensation to the dura is mediated by CN V in the anterior and middle cranial fossae and by CN X in the posterior cranial fossa.

Dural Sinuses



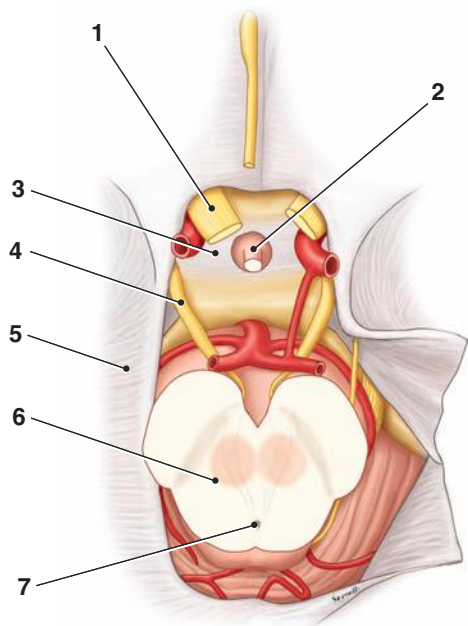
Dural Sinuses

1. superior sagittal sinus
2. straight sinus
3. superior ophthalmic vein
4. cavernous sinus
5. transverse sinus
6. sigmoid sinus
7. facial vein
8. vertebral venous plexus

The cerebral veins and dural sinuses may become occluded. Infection may pass from the facial vein into the cavernous sinus via the superior ophthalmic veins or from the vertebral venous plexus into the dural sinuses.

Fractures of the cranial base may tear the internal carotid artery as it passes through the cavernous sinus, causing compression of cranial nerve VI and/or the structures in the wall of the wall of the sinus, which include CNs III, IV, V₁, and V₂.

Tentorial Notch



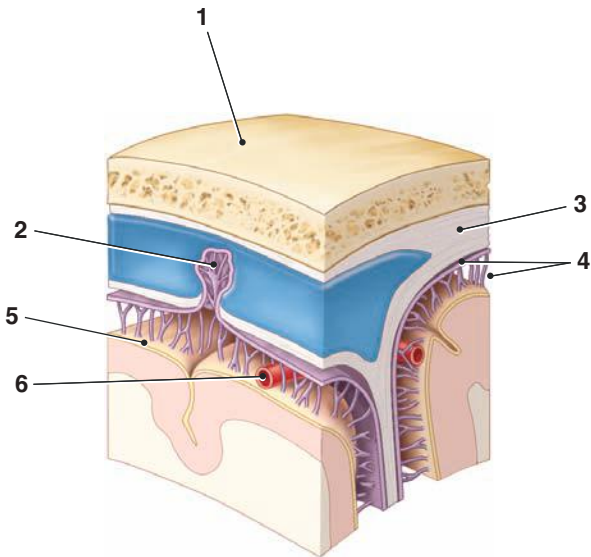
Tentorial Notch

1. optic nerve
2. infundibulum
3. sellar diaphragm
4. oculomotor nerve
5. cerebellar tentorium
6. midbrain
7. cerebral aqueduct

Parts of the temporal lobe may herniate through the tentorial notch. The tentorium may lacerate the temporal lobe and damage the oculomotor nerve, causing paralysis of extraocular muscles.

Pituitary tumors may extend superiorly through the sellar diaphragm, producing endocrine disturbances.

Meninges

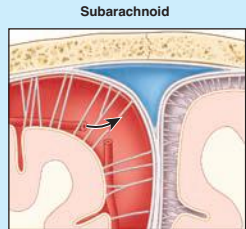
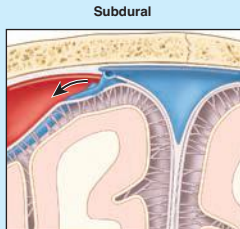


Meninges

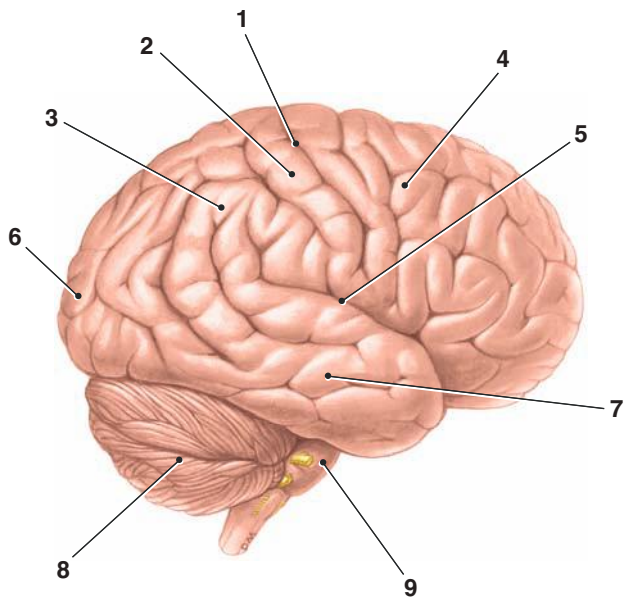
1. calvaria
2. arachnoid granulation
3. dura mater
4. arachnoid mater and subarachnoid space
5. pia mater
6. cerebral artery

Inflammation of the leptomeninges (arachnoid and pia) results from pathogenic organisms.

A dural border hematoma (subdural hematoma) is caused by extravasated blood between the dura and arachnoid, typically from tearing of a cerebral vein. A subarachnoid hemorrhage is extravasation of blood (usually arterial) into the subarachnoid space.



Brain

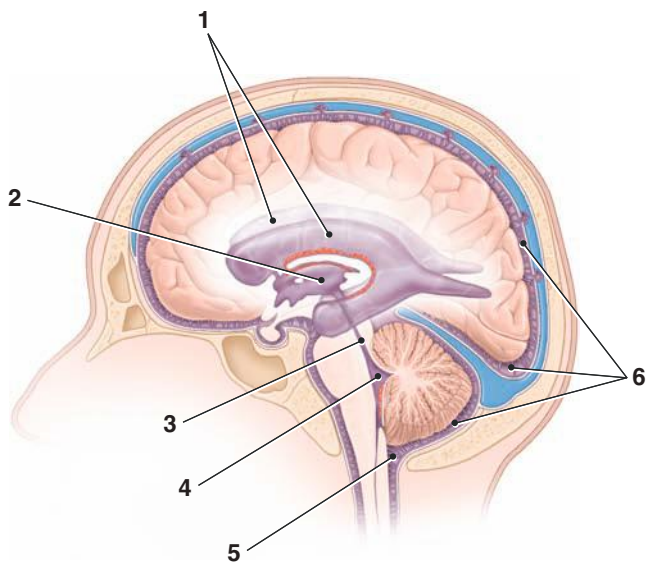


Brain

1. central sulcus
2. postcentral gyrus
3. parietal lobe
4. frontal lobe
5. lateral fissure
6. occipital lobe
7. temporal lobe
8. cerebellum
9. pons

Cerebral concussion is loss of consciousness after a head injury. Cerebral contusion results when the pia is stripped from the surface of the brain, allowing blood to enter the subarachnoid space. Cerebral lacerations result in bleeding into the brain, causing compression.

Subarachnoid Spaces and Ventricles

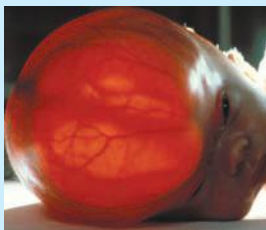

Subarachnoid Spaces and Ventricles

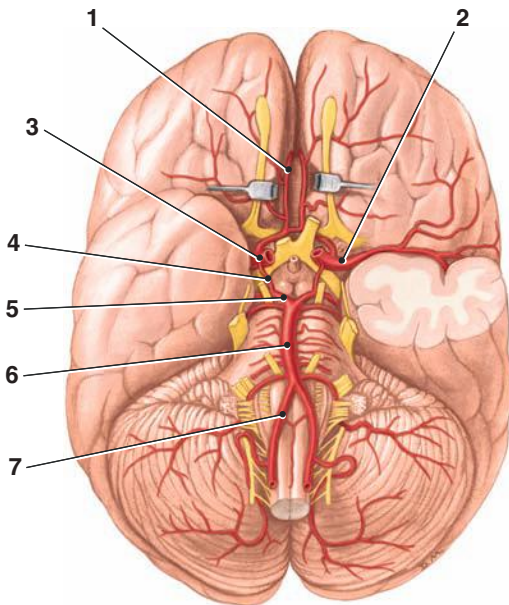
1. lateral ventricles
2. 3rd ventricle
3. cerebral aqueduct
4. 4th ventricle
5. posterior cerebellomedullary cistern
6. subarachnoid space

Cerebrospinal fluid may be obtained from the posterior cerebellomedullary cistern through a cisternal puncture.

Excessive cerebrospinal fluid dilates the ventricles (hydrocephalus), thins the cerebral cortex, and separates the bones of the calvaria in infants.



Arterial Supply to the Brain



Arterial Supply to the Brain

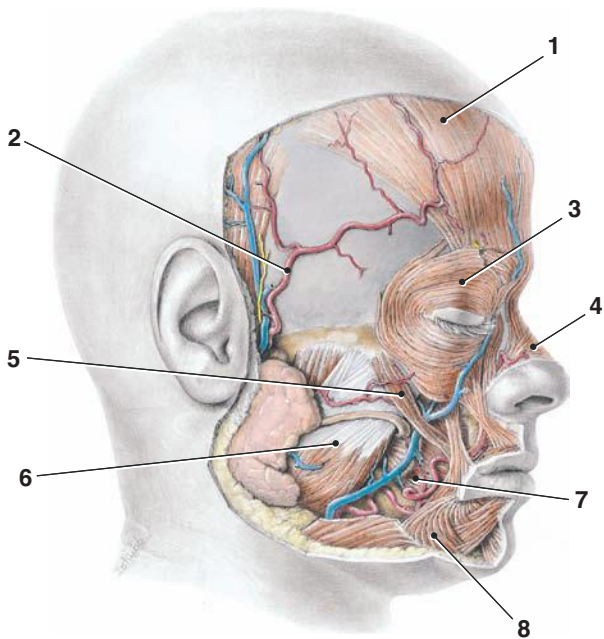
1. anterior cerebral artery
2. middle cerebral artery
3. internal carotid artery
4. posterior communicating artery
5. posterior cerebral artery
6. basilar artery
7. vertebral artery

Sudden occlusion of part of the highly variable cerebral arterial circle leads to a stroke, the result of impaired blood flow, which is evidenced by impaired neurological function.

An atherosclerotic plaque at the bend of a cerebral artery may give rise to an embolus, which can lodge in an artery, causing an acute cortical infarction.

Transient ischemic attacks are short-term ischemic episodes leading to an ambiguous list of symptoms, such as staggering, dizziness, and fainting.

Facial Musculature, Lateral View



Facial Musculature, Lateral View

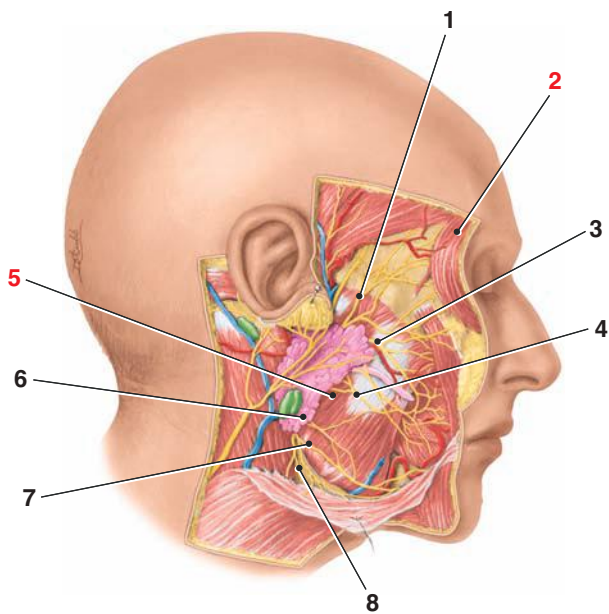
1. frontal belly of occipitofrontalis
2. superficial temporal artery
3. orbicularis oculi
4. nasalis
5. zygomaticus major
6. masseter
7. buccinator
8. depressor anguli oris

The function of the nasalis muscle in flaring the nostrils is a useful diagnostic tool in determining a true mouth breather with a chronic nasal obstruction.

Injury to the facial nerve produces paralysis of the facial muscles (Bell palsy) on that side, causing the face to droop.



Facial Nerve on the Face



Facial Nerve on the Face

1. temporal branch of the facial nerve
2. orbicularis oculi
3. zygomatic branch of the facial nerve
4. buccal branch of the facial nerve
5. masseter
6. parotid gland
7. mandibular branch of the facial nerve
8. cervical branch of the facial nerve

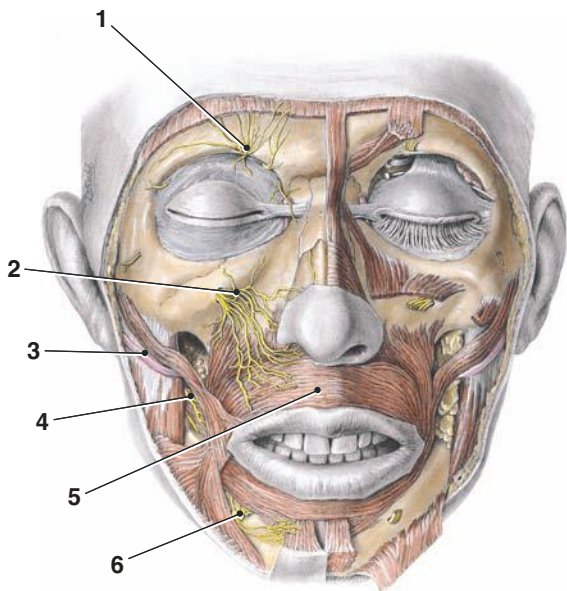
Orbicularis Oculi

- proximal attachment: margin of orbit, lacrimal bone, medial palpebral ligament
- distal attachment: skin around margin of orbit and tarsal plate
- innervation: facial nerve
- main action: closes eyelid

Masseter

- proximal attachment: zygomatic arch
- distal attachment: ramus of mandible and coronoid process
- innervation: mandibular nerve
- main action: elevates and protrudes mandible

Nerves of the Face



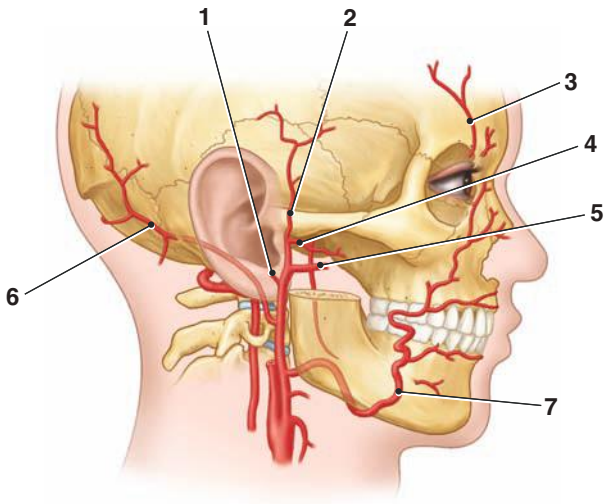
Nerves of the Face

1. supraorbital nerve
2. infraorbital nerve
3. parotid duct
4. buccal nerve
5. orbicularis oris
6. mental nerve

In cases of injury or surgery, it may be necessary to anesthetize the mental, buccal, infraorbital, or supraorbital nerves near their point of emergence onto the face.

Trigeminal neuralgia (tic douloureux) is a sensory disorder of the trigeminal nerve whose origin is unknown. It causes excruciating pain over the face. Lesions of the trigeminal nerve cause widespread anesthesia over the face and paralysis of the muscles of mastication.

Arteries of the Face



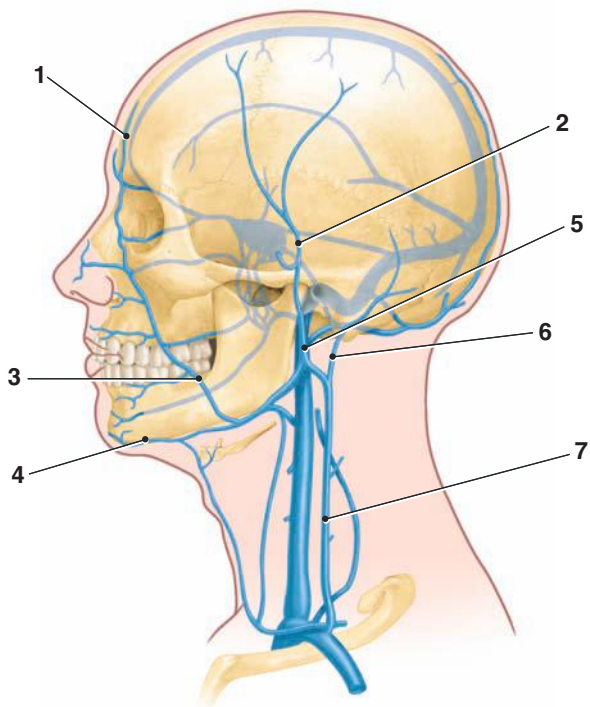
Arteries of the Face

1. posterior auricular artery
2. superficial temporal artery
3. supraorbital artery
4. transverse facial artery
5. maxillary artery
6. occipital artery
7. facial artery

The facial artery may be compressed to limit bleeding; a pulse can be taken where it crosses the mandible.

The scalp has a rich blood supply with extensive anastomoses, which cause profuse and difficult-to-control bleeding after injury and provide a good blood supply to promote healing after repair.

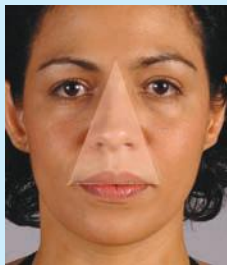
Veins of the Face



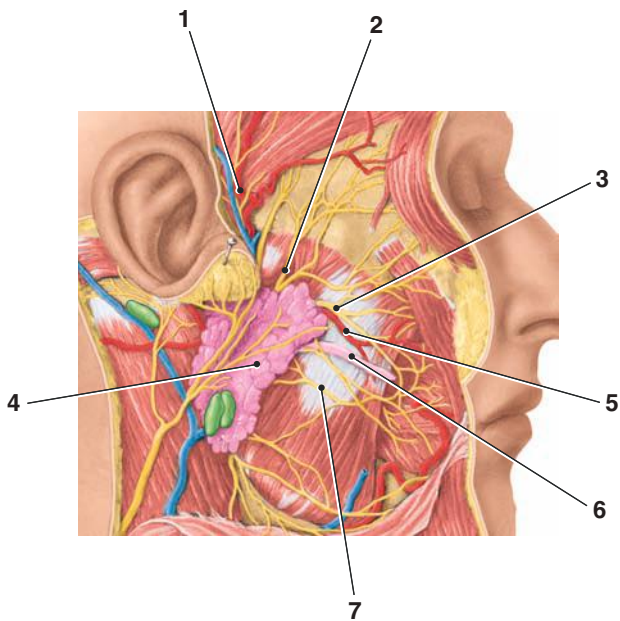
Veins of the Face

1. supraorbital vein
2. superficial temporal vein
3. facial vein
4. submental vein
5. retromandibular vein
6. posterior auricular vein
7. external jugular vein

The danger triangle of the face is an area in which infection may produce inflammation of the facial vein. In thrombophlebitis of the facial vein, or inflammation of the facial vein with thrombus formation, pieces of the clot may pass into the cavernous sinus and produce thrombophlebitis there.



Parotid Gland

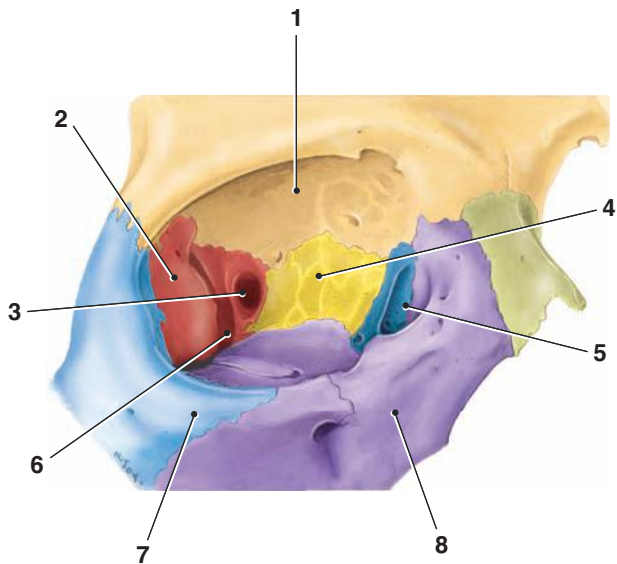


Parotid Gland

1. superficial temporal artery
2. temporal branches of the facial nerve
3. zygomatic branches of the facial nerve
4. parotid gland
5. transverse facial artery
6. parotid duct
7. buccal branches of the facial nerve

Surgical excision of part of the parotid gland is part of the treatment of tumors. Care must be taken to avoid the facial nerve branches in the gland. The gland may become infected by a virus, such as in mumps, or bacteria, which may cause an abscess. Both cause considerable pain and may compromise function of the facial nerve branches.

Orbit



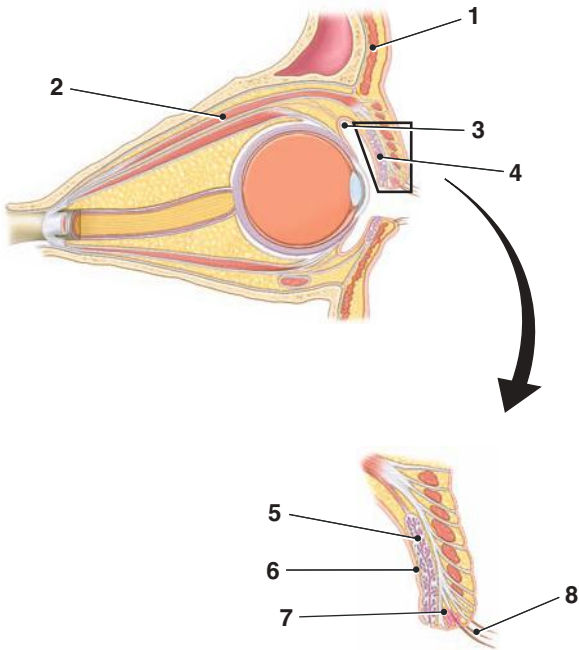
Orbit

1. frontal bone
2. sphenoid bone
3. optic canal
4. ethmoid bone
5. fossa for lacrimal sac
6. superior orbital fissure
7. zygomatic bone
8. maxillary bone

A blow to the orbit is most likely to fracture the relatively thin inferior and medial walls, leading to a blowout fracture, with the strong bony margin intact.

Tumors in the orbit produce exophthalmos, or protrusion of the eye. Tumors may enter through the sinuses or the fissures of the orbit. Tumors are likely to compress the eye and orbital contents.

Eyelids



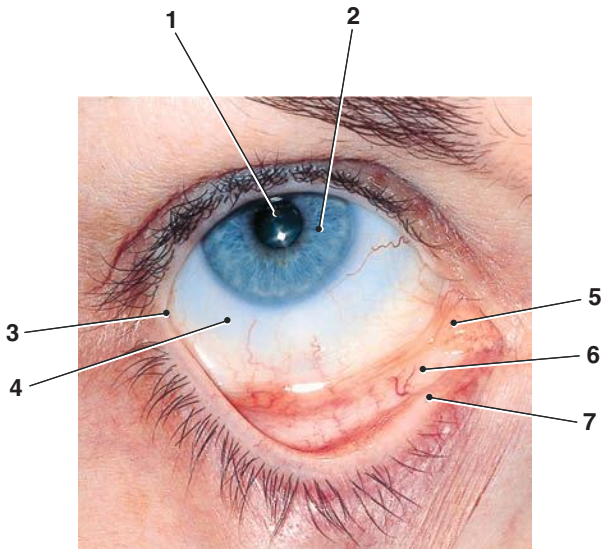
Eyelids

1. orbicularis oculi
2. levator palpebrae superioris
3. superior conjunctival fornix
4. superior tarsal plate
5. tarsal glands
6. palpebral conjunctiva
7. ciliary glands
8. eyelashes

The thin skin of the eyelid swells readily. Periorbital ecchymosis (extravasation of blood) into the eyelid may occur after a blow to the eye. Any of the glands of the eyelid may become inflamed and swollen, resulting in a sty (ciliary glands) or chalazia (sebaceous or tarsal glands).

A lesion of the oculomotor nerve causes paralysis of the levator palpebrae superioris, and the eyelid droops (ptosis). Damage to the facial nerve, which supplies the orbicularis oculi, prevents the eyelids from closing fully; the cornea dries out as a result.

Conjunctiva



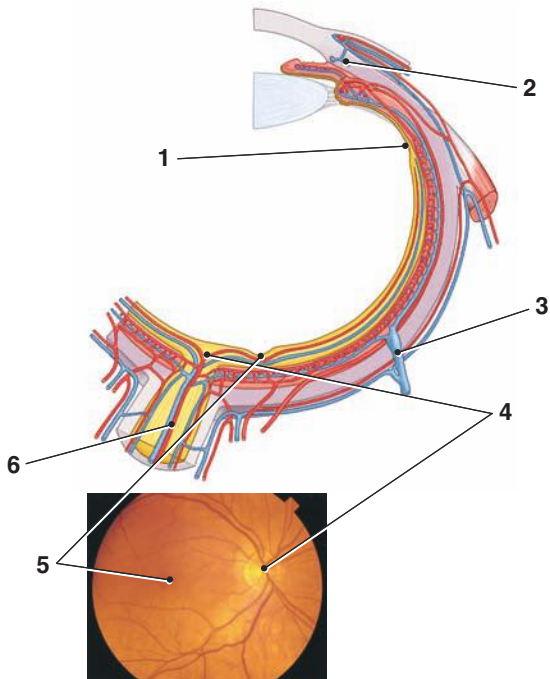
Conjunctiva

1. pupil
2. iris
3. lateral canthus
4. bulbar conjunctiva (covering sclera)
5. plica semilunaris
6. palpebral conjunctiva
7. inferior lacrimal papilla and punctum

The conjunctiva is colorless except when its vessels are dilated (bloodshot eyes) or inflamed from infection (conjunctivitis, or pinkeye).

Subconjunctival hemorrhage produces red patches deep to and within the bulbar conjunctiva.

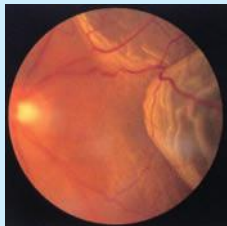
Retina



Retina

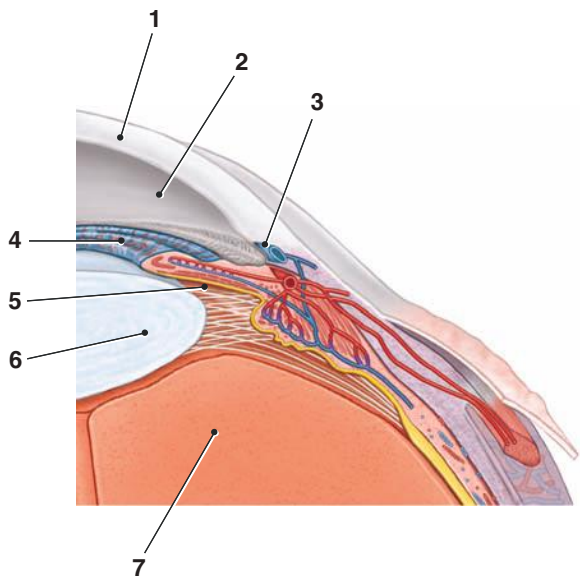
1. ora serrata
2. scleral venous sinus
3. vorticosae vein
4. optic disk
5. macula lutea
6. central artery and vein of the retina

A detached retina usually results from seepage of fluid between the neural and pigment layers of the retina following trauma to the eye.



An increase in cerebrospinal fluid pressure slows venous return from the retina, causing edema of the retina. The edema is viewed during ophthalmoscopy as a swelling of the optic disk (papilledema).

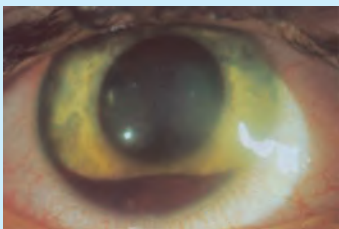
Anterior Aspect of the Eye



Anterior Aspect of the Eye

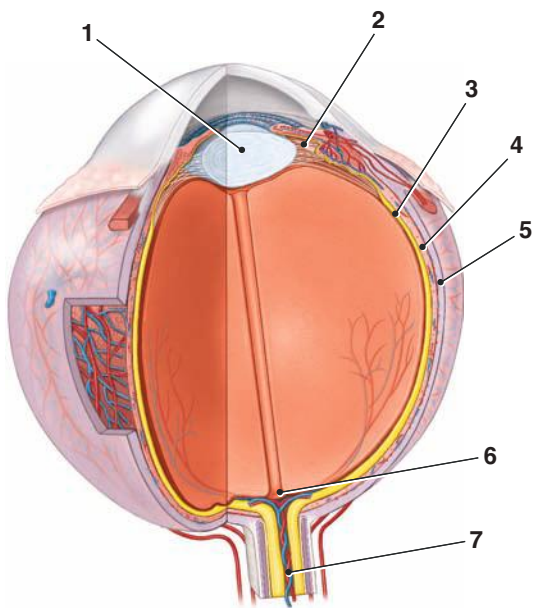
1. cornea
2. anterior chamber
3. scleral venous sinus
4. iris
5. posterior chamber
6. lens
7. vitreous body

Hyphema, or hemorrhage into the anterior chamber of the eye, usually results from trauma.



When drainage of aqueous humor through the scleral venous sinus decreases, pressure builds up in the anterior and posterior chambers (glaucoma). Blindness can result if the pressure is not reduced.

Eye



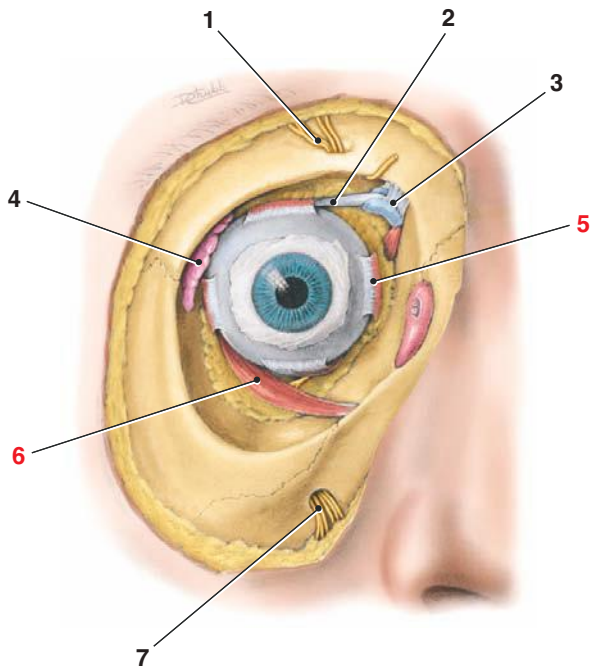
Eye

1. lens
2. ciliary process
3. retina
4. choroid
5. sclera
6. optic disk
7. central artery and vein of the retina

As people age, their lenses become flat and less flexible, reducing the focusing power (presbyopia). Loss of transparency of the lens causes cloudiness, or cataracts. Transplanting the lens and the cornea if it, too, becomes opaque or scarred are common procedures.

Blockage of the central artery of the retina results in blindness, as it is an end artery with no anastomoses.

Extraocular Muscles 1



Extraocular Muscles 1

1. supraorbital nerve
2. superior oblique
3. trochlea
4. lacrimal gland
5. medial rectus
6. inferior oblique
7. infraorbital nerve

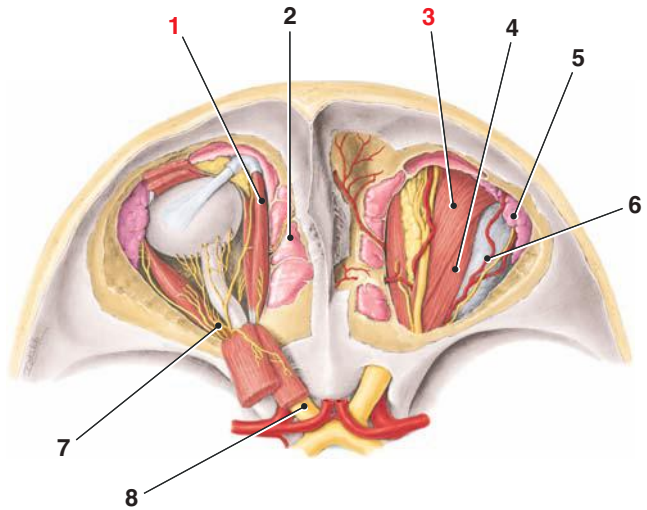
Medial Rectus

- proximal attachment: common tendinous ring
- distal attachment: sclera
- innervation: oculomotor nerve
- main action: adducts eyeball

Inferior Oblique

- proximal attachment: floor of the orbit
- distal attachment: sclera
- innervation: oculomotor nerve
- main action: abducts, elevates, and laterally rotates (extorts) eyeball

Extraocular Muscles 2



Extraocular Muscles 2

1. superior oblique
2. anterior ethmoid air cells
3. levator palpebrae superioris
4. superior rectus
5. lacrimal gland
6. lacrimal artery
7. ciliary ganglion
8. optic nerve

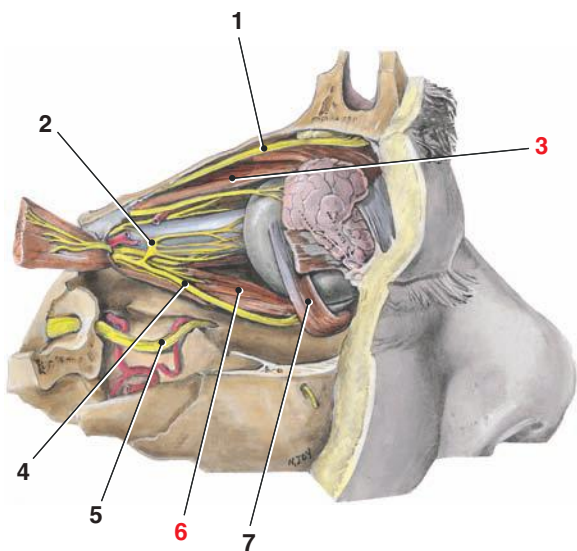
Superior Oblique

- proximal attachment: sphenoid
- distal attachment: sclera, after passing through the trochlea
- innervation: trochlear nerve
- main action: abducts, depresses, and medially rotates (intorts) the eyeball

Levator Palpebrae Superioris

- proximal attachment: sphenoid bone
- distal attachment: tarsal plate and skin of upper eyelid
- innervation: oculomotor nerve (superior tarsal muscle by sympathetics)
- main action: elevates superior eyelid

Extraocular Muscles 3



Extraocular Muscles 3

1. frontal nerve
2. ciliary ganglion
3. superior rectus
4. oculomotor nerve
5. maxillary nerve
6. inferior rectus
7. inferior oblique

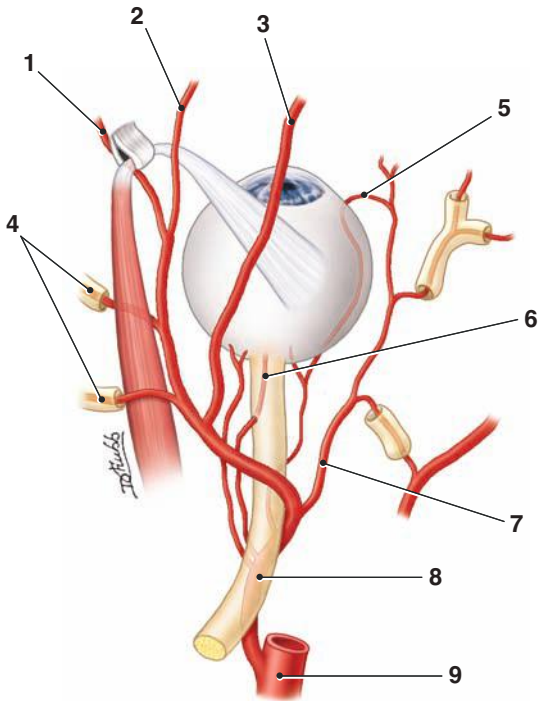
Superior Rectus

- proximal attachment: common tendinous ring
- distal attachment: sclera
- innervation: oculomotor nerve
- main action: elevates, adducts, and medially rotates (intorts) eyeball

Inferior Rectus

- proximal attachment: common tendinous ring
- distal attachment: sclera
- innervation: oculomotor nerve
- main action: depresses, adducts, and laterally rotates (extorts) eyeball

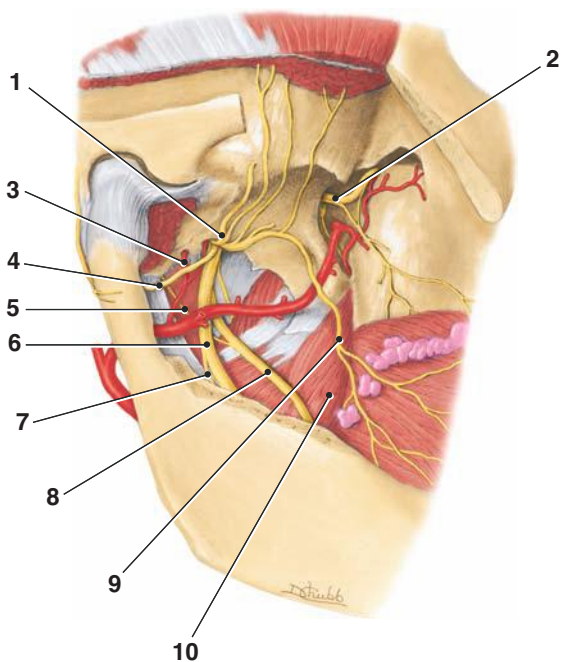
Arteries of the Orbit



Arteries of the Orbit

1. dorsal nasal artery
2. supratrochlear artery
3. supraorbital artery
4. anterior and posterior ethmoidal arteries
5. anterior ciliary artery
6. central artery of the retina
7. lacrimal artery
8. ophthalmic artery
9. internal carotid artery

Infratemporal Fossa



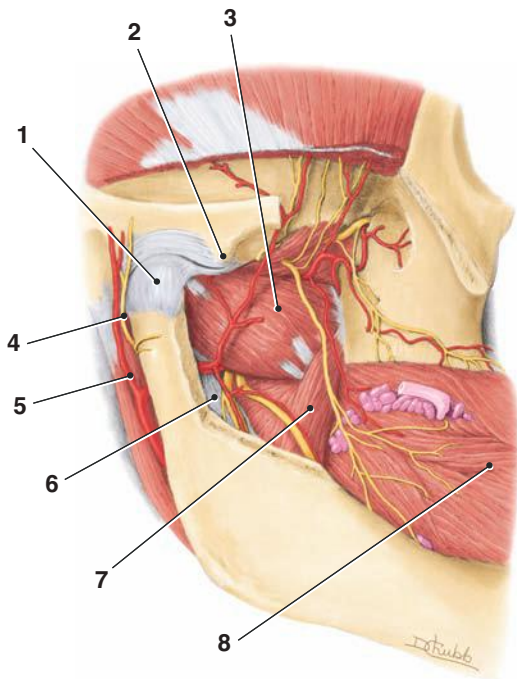
Infratemporal Fossa

1. mandibular nerve
2. maxillary nerve
3. middle meningeal artery
4. auriculotemporal nerve
5. chorda tympani
6. inferior alveolar nerve
7. nerve to mylohyoid
8. lingual nerve
9. buccal nerve
10. medial pterygoid

A needle is passed through the mandibular notch into the infratemporal fossa to anesthetize the mandibular nerve as it emerges from the cranial cavity.

An anesthetic agent is injected around the mandibular foramen to block the inferior alveolar nerve, thus blocking sensation from the lower lip, mucosa, gingivae, and skin of the chin.

Temporomandibular Joint

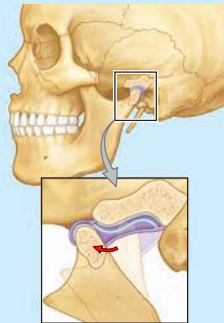


Temporomandibular Joint

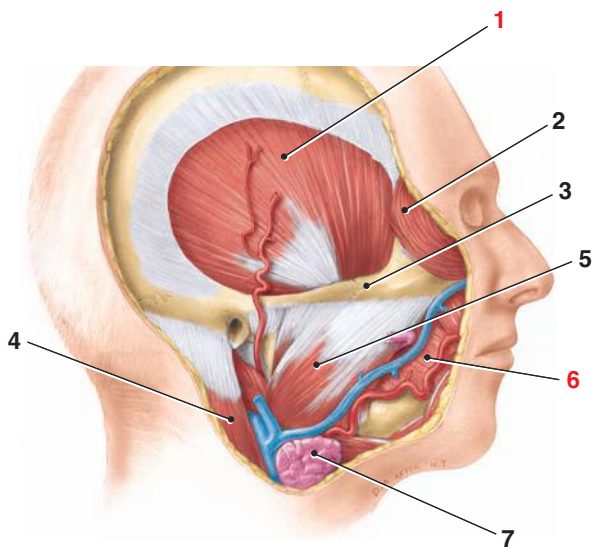
1. capsule of temporomandibular joint
2. articular tubercle
3. lateral pterygoid muscle
4. auriculotemporal nerve
5. superficial temporal artery
6. sphenomandibular ligament
7. medial pterygoid
8. buccinator

The temporomandibular joint dislocates during excessive opening of the jaw or as a result of trauma. Most dislocations occur anteriorly because of the pull of the lateral pterygoid and the strength of the lateral ligament and postglenoid tubercle.

The temporomandibular joint may become arthritic, leading to problems with dental occlusion and joint clicking (crepitus).



Temporalis



Temporalis

1. temporalis
2. orbicularis oculi
3. zygomatic arch
4. sternocleidomastoid
5. masseter
6. buccinator
7. submandibular gland

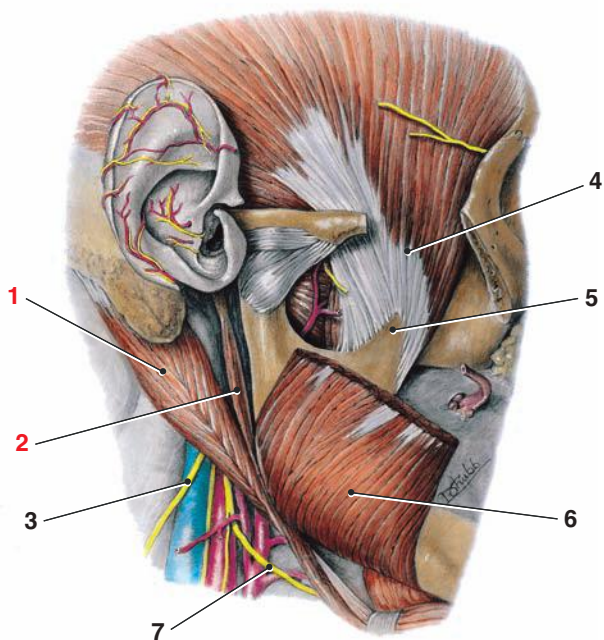
Temporalis

- proximal attachment: temporal fossa
- distal attachment: coronoid process of mandible
- innervation: mandibular nerve
- main action: elevates mandible

Buccinator

- proximal attachment: mandible, pterygomandibular raphe, and maxilla
- distal attachment: angle of mouth
- innervation: facial nerve
- main action: presses cheek against molar teeth

Deep Temporal Region



Deep Temporal Region

1. posterior belly of digastric
2. stylohyoid
3. spinal accessory nerve
4. temporalis
5. coronoid process of mandible
6. masseter
7. hypoglossal nerve

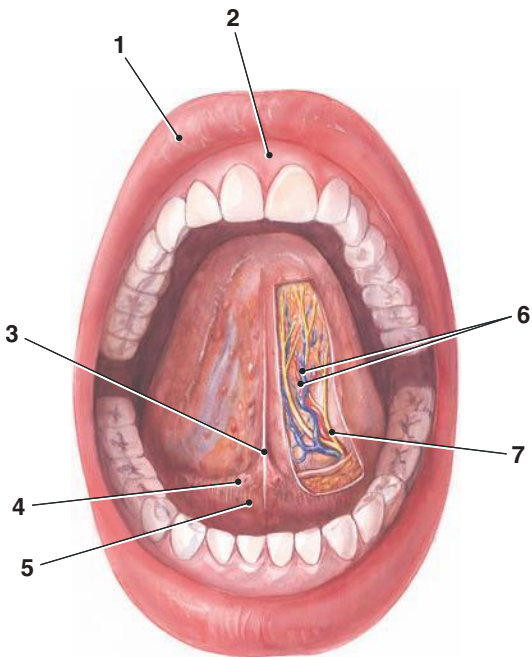
Digastric

- proximal attachment: anterior belly, digastric fossa; posterior belly, mastoid notch
- distal attachment: hyoid bone
- innervation: anterior belly, nerve to mylohyoid; posterior belly, facial nerve
- main action: elevates and steadies hyoid, depresses mandible

Stylohyoid

- proximal attachment: styloid process
- distal attachment: hyoid bone
- innervation: facial nerve
- main action: elevates and retracts hyoid bone

Oral Cavity



Oral Cavity

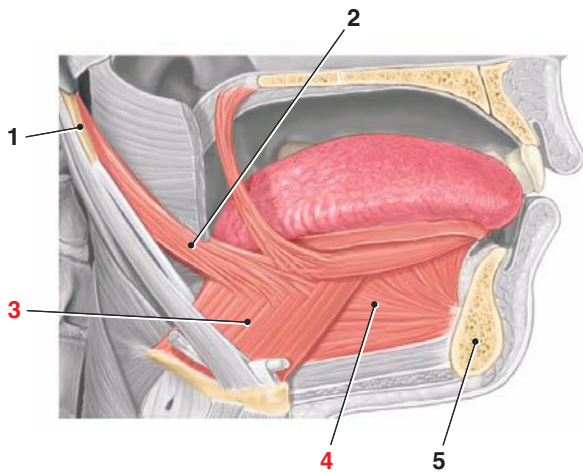
1. lips
2. gingiva
3. frenulum of tongue
4. opening of the submandibular duct
5. sublingual fold
6. deep lingual artery and vein
7. lingual nerve

Inflammation of the gingiva, or gingivitis, may lead to periodontitis if left untreated.

The deep lingual veins provide a rapid (<1 minute) entry for drugs, such as nitroglycerin for treatment of angina pectoris.

An overlarge lingual frenulum (tongue-tie) interferes with tongue movement and therefore speech. Frenectomy may be performed to free the tongue.

Muscles of the Oral Cavity



Muscles of the Oral Cavity

1. styloid process
2. styloglossus
3. hyoglossus
4. genioglossus
5. mandible

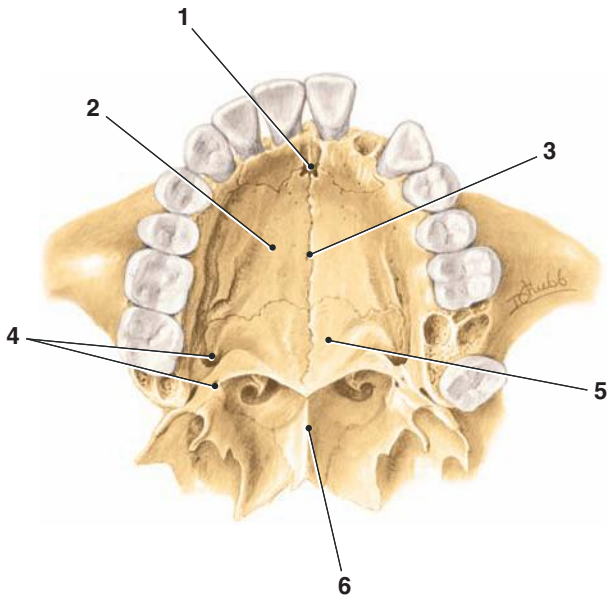
Hyoglossus

- proximal attachment: hyoid bone
- distal attachment: tongue
- innervation: hypoglossal nerve
- main action: depresses and retracts tongue

Genioglossus

- proximal attachment: mental spine of mandible
- distal attachment: tongue and hyoid bone
- innervation: hypoglossal nerve
- main action: depresses and protrudes tongue

Hard Palate

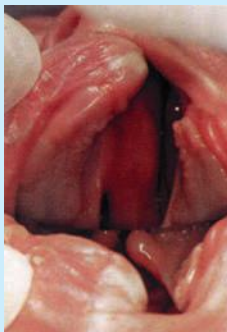

Hard Palate

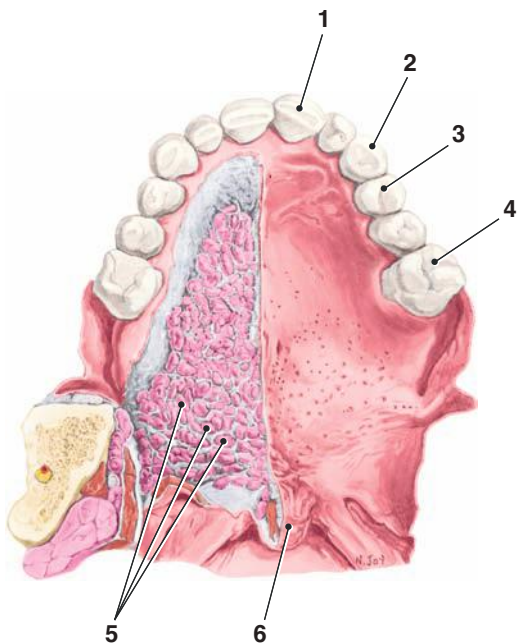
1. incisive fossa
2. palatine process of the maxilla
3. intermaxillary suture
4. greater and lesser palatine foramen
5. horizontal plate of the palatine bone
6. vomer

The nasopalatine nerves can be blocked bilaterally by injection into the incisive fossa. The greater palatine nerve can be blocked by injection into the greater palatine foramen.

Cleft palate occurs when the lateral palatine processes fail to fuse with each other and/or the nasal septum. It is often associated with a cleft lip.



Teeth



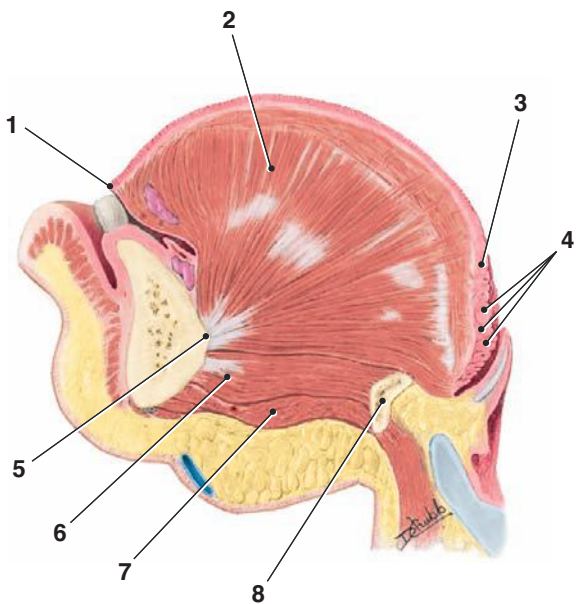
Teeth

1. incisor
2. canine
3. premolar
4. molar
5. palatine glands
6. uvula

Decay of the hard tissues of the tooth results in the formation of dental caries (cavities). A toothache occurs when neglected dental caries invade and inflame tissues in the pulp cavity (pulpitis).

Tooth extraction is performed if the tooth is impacted or too badly damaged to be restored.

Tongue



Tongue

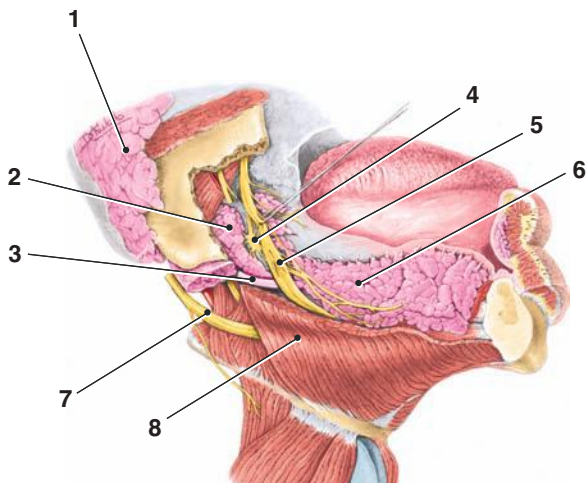
1. apex of the tongue
2. genioglossus
3. foramen cecum
4. lingual tonsils
5. superior mental spine of mandible
6. geniohyoid
7. mylohyoid
8. hyoid

Touching the posterior part of the tongue initiates the gag reflex, verifying the function of cranial nerves IX (afferent limb) and X (efferent limb).

Trauma may injure the hypoglossal nerve, resulting in paralysis and atrophy. The tongue deviates to the paralyzed side upon protrusion because of the action of the unaffected genioglossus.

The embryonic thyroglossal duct begins at the foramen cecum. Aberrant thyroid glandular tissue may be found anywhere along its migratory path, or a remnant of the duct may remain in the form of a thyroglossal duct cyst.

Salivary Glands



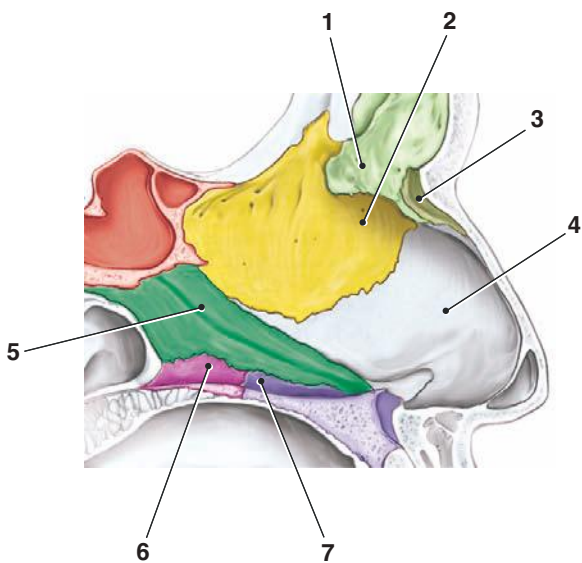
Salivary Glands

1. parotid gland
2. submandibular gland
3. submandibular duct
4. submandibular ganglion
5. lingual nerve
6. sublingual gland
7. hypoglossal nerve
8. mylohyoid

It is sometimes necessary to remove the submandibular gland because of a stone (calculus) in its duct or a tumor in the gland.

In a sialography, contrast is injected into the submandibular duct to reveal the duct and some of the secretory units of the gland.

Nasal Septum



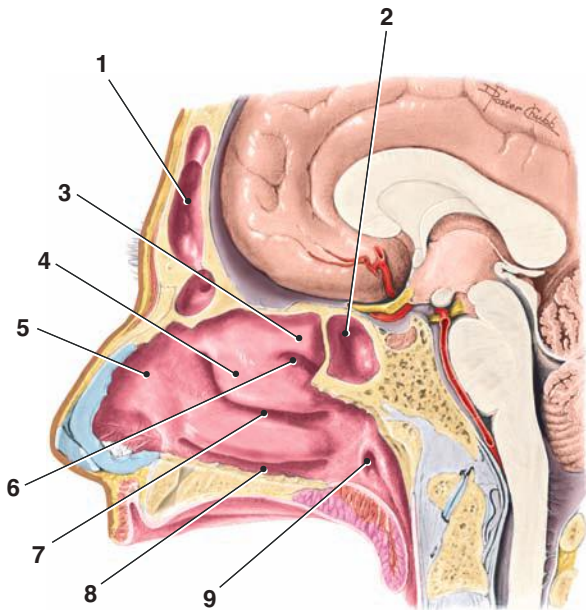
Nasal Septum

1. crista galli
2. perpendicular plate of the ethmoid
3. nasal bone
4. septal nasal cartilage
5. vomer
6. nasal crest of the palatine bone
7. nasal crest of the maxilla

Epistaxis (nosebleed) and deformation of the nose are common in fractures of the nasal bones. Severe blows may result in fracture of the cribriform plate of the ethmoid bone.

The nasal septum is usually deviated to one side or the other, typically as the result of trauma. Deviation can be corrected if it is severe and interferes with breathing or exacerbates snoring.

Nasal Cavity

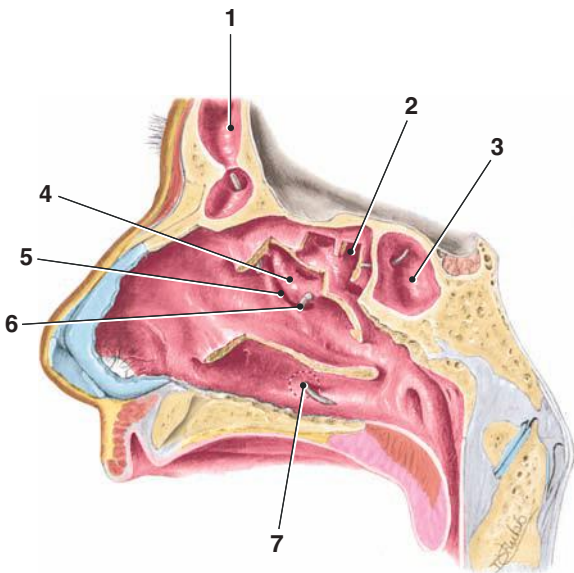


Nasal Cavity

1. frontal sinus
2. sphenoid sinus
3. superior concha
4. middle concha
5. atrium
6. superior meatus
7. middle meatus
8. inferior meatus
9. pharyngeal opening of the pharyngotympanic (auditory) tube

The nasal mucosa becomes swollen and inflamed (rhinitis) during severe respiratory infections and allergic reactions. Infections may spread to nearby regions and structures, such as the sinuses, resulting in sinusitis and pain.

Paranasal Sinuses



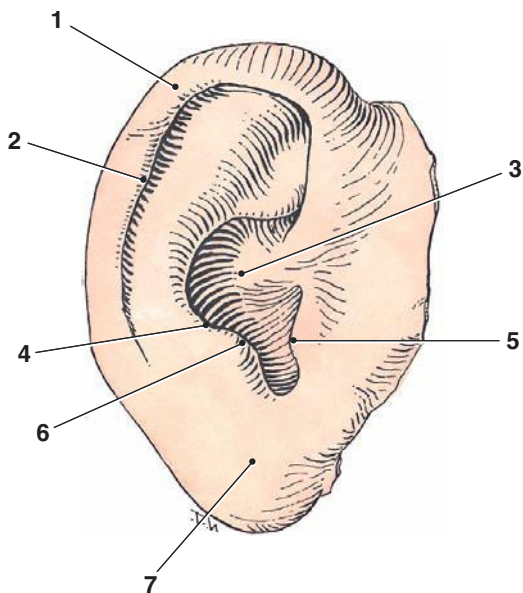
Paranasal Sinuses

1. frontal sinus
2. posterior ethmoid air cells
3. sphenoid sinus
4. ethmoidal bulla
5. semilunar hiatus
6. opening of the maxillary sinus
7. opening of the nasolacrimal duct

If nasal drainage is blocked, infections of the ethmoid air cells may enter the medial wall of the orbit, perhaps causing blindness if severe.

The ostia of the maxillary sinuses are small and high on their superomedial walls, making drainage difficult. Because of the close relationship of the molars to the sinus, pain from inflammation of the sinus is often perceived as a toothache. Transillumination is used to examine the sinuses.

External Ear



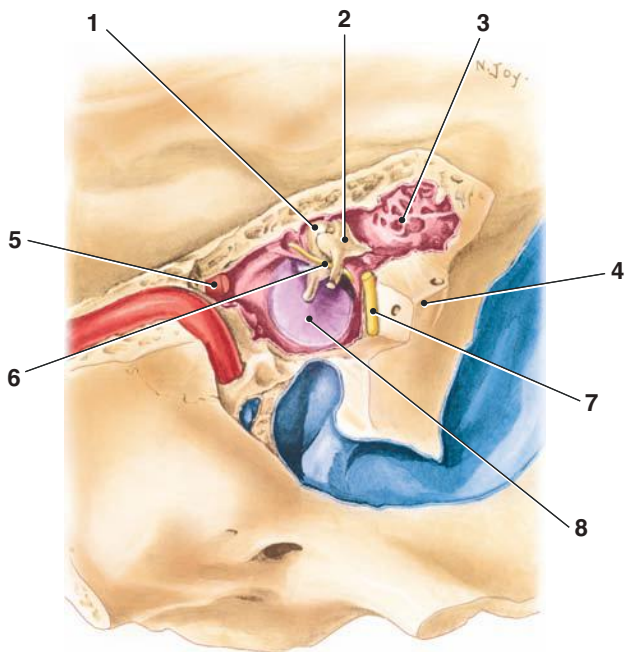
External Ear

1. helix
2. auricular tubercle
3. concha
4. antihelix
5. tragus
6. antitragus
7. lobe

Bleeding within the auricle resulting from trauma may produce an auricular hematoma. If untreated, it may interfere with the blood supply to the cartilage and cause deformation of the auricle – as seen in cases of “cauliflower ear” in boxing and cage fighting.

Examination of the external acoustic meatus is done by straightening out the canal and inserting an otoscope, allowing for detection of otitis externa (inflammation of the meatus).

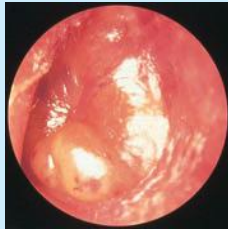
Middle Ear



Middle Ear

1. malleus
2. incus
3. aditus to mastoid antrum
4. mastoid process
5. tensor tympani
6. chorda tympani
7. facial nerve
8. tympanic membrane

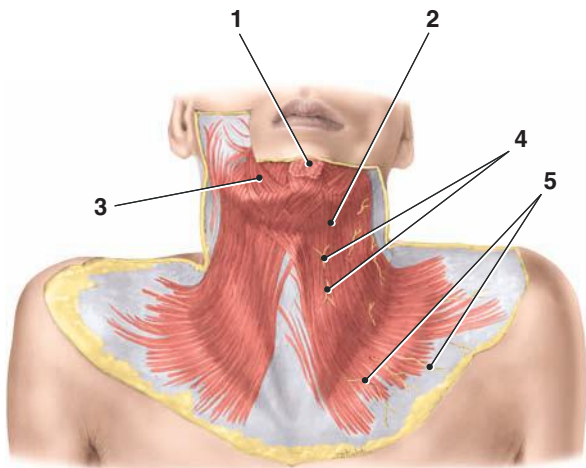
Otitis media, an ear infection, is secondary to an upper respiratory tract infection. The bulging, red tympanic membrane may perforate (rupture) as a result of pressure from infection or from trauma. Infection may spread into the mastoid antrum and mastoid air cells (mastoiditis).



8 • Neck

- 8.1** Platysma
- 8.2** Neck, Lateral View
- 8.3** Posterior Triangle Musculature
- 8.4** Arteries of the Neck
- 8.5** Veins of the Neck
- 8.6** Lateral Aspect of the Neck
- 8.7** Posterior Triangle Region
- 8.8** Prevertebral Region
- 8.9** Prevertebral Musculature
- 8.10** Hyoid Muscles 1
- 8.11** Hyoid Muscles 2
- 8.12** Thyroid Gland
- 8.13** Root of the Neck
- 8.14** Anterior Neck, Deep Dissection
- 8.15** Laryngeal Skeleton
- 8.16** Larynx, Superior View
- 8.17** Larynx, Medial View
- 8.18** Nerves of the Larynx
- 8.19** Muscles of the Larynx
- 8.20** Trachea and Larynx
- 8.21** Internal Aspect of the Pharynx
- 8.22** Pharyngeal Musculature
- 8.23** Posterior Aspect of the Pharynx
- 8.24** Tonsils
- 8.25** Internal Pharynx and Esophagus

Platysma

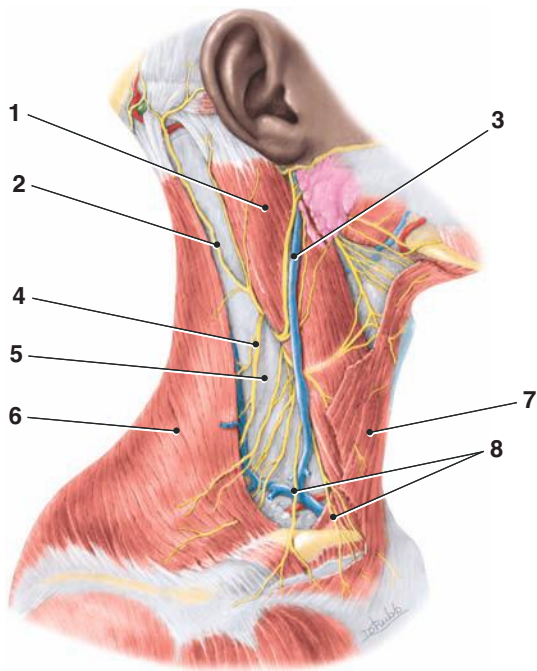


Platysma

1. mentalis
2. platysma
3. depressor anguli oris
4. transverse cervical nerve branches
5. supraclavicular nerve branches

Paralysis of the platysma, which results from injury to the facial nerve, causes the skin of the neck to fall away in folds.

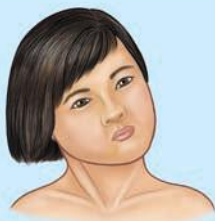Neck, Lateral View



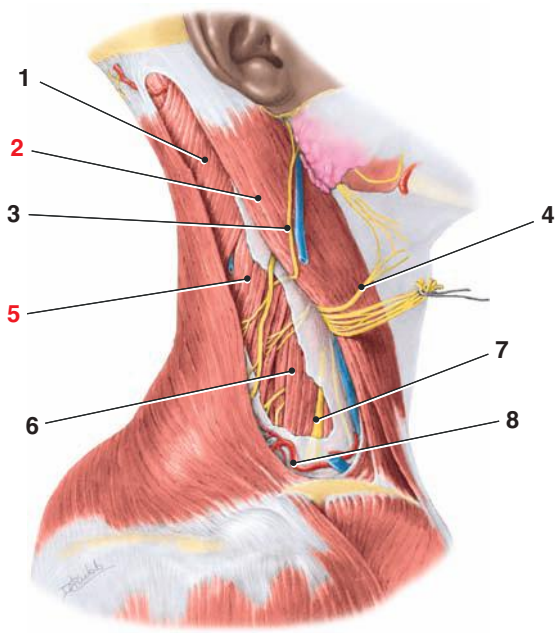
Neck, Lateral View

1. sternocleidomastoid
2. lesser occipital nerve
3. external jugular vein
4. spinal accessory nerve
5. prevertebral layer of deep cervical fascia
6. trapezius
7. platysma
8. supraclavicular nerves

Torticollis is a contraction of the cervical muscles that produces a twisting of the neck and slanting of the head. The most common type results from a fibrous tumor in the sternocleidomastoid shortly after birth. Spasmodic torticollis (cervical dystonia) is caused by abnormal tonicity of the cervical musculature.



Posterior Triangle Musculature



Posterior Triangle Musculature

1. splenius capitis
2. sternocleidomastoid
3. great auricular nerve
4. transverse cervical nerve
5. levator scapulae
6. middle scalene
7. brachial plexus
8. transverse cervical artery

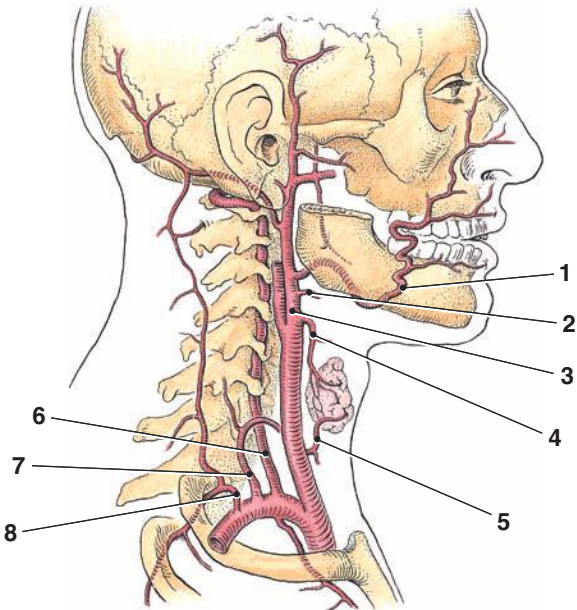
Sternocleidomastoid

- proximal attachment: mastoid process and superior nuchal line
- distal attachment: sternal head, manubrium; clavicular head, clavicle
- innervation: spinal accessory nerve
- main action: tilts head to one side, flexes neck

Levator Scapulae

- proximal attachment: transverse processes of C1–C4 vertebrae
- distal attachment: medial border of scapula
- innervation: dorsal scapular nerve
- main action: elevates and rotates scapula

Arteries of the Neck



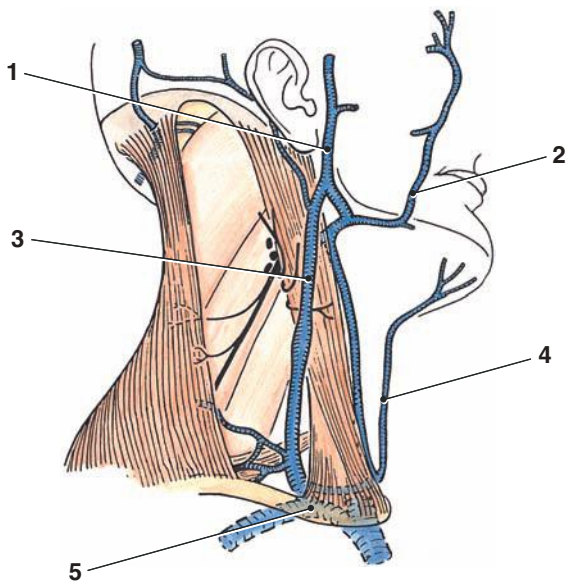
Arteries of the Neck

1. facial artery
2. lingual artery
3. external carotid artery
4. superior thyroid artery
5. inferior thyroid artery
6. vertebral artery
7. thyrocervical trunk
8. costocervical trunk

Ligation of the external carotid artery is sometimes necessary to control bleeding from one of its branches.

Accumulation of atherosclerotic plaque in the internal carotid artery may lead to a transient ischemic attack or a stroke. Carotid occlusion can be relieved by opening the artery at its origin and stripping off the plaque, a carotid endarterectomy.

Veins of the Neck



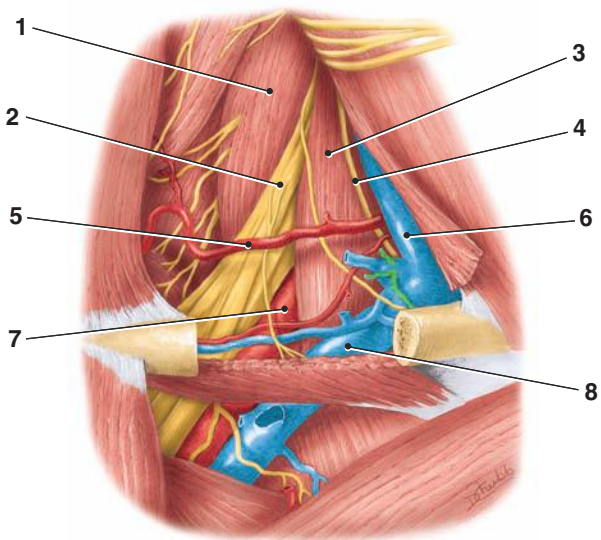
Veins of the Neck

1. retromandibular vein
2. facial vein
3. external jugular vein
4. anterior jugular vein
5. subclavian vein

The external jugular vein may serve as an internal barometer: When venous pressure rises, as in heart failure, the vein becomes prominent throughout its course.

When the external jugular vein is severed, its lumen is held open by deep cervical fascia, allowing air to enter. This action produces a churning noise in the thorax and cyanosis. A venous air embolism may fill the right side of the heart with froth, resulting in dyspnea.

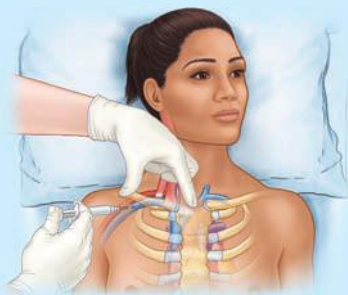
Lateral Aspect of the Neck



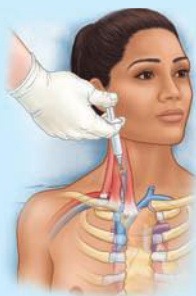Lateral Aspect of the Neck

1. middle scalene
2. brachial plexus
3. anterior scalene
4. phrenic nerve
5. transverse cervical artery
6. internal jugular vein
7. subclavian artery
8. subclavian vein

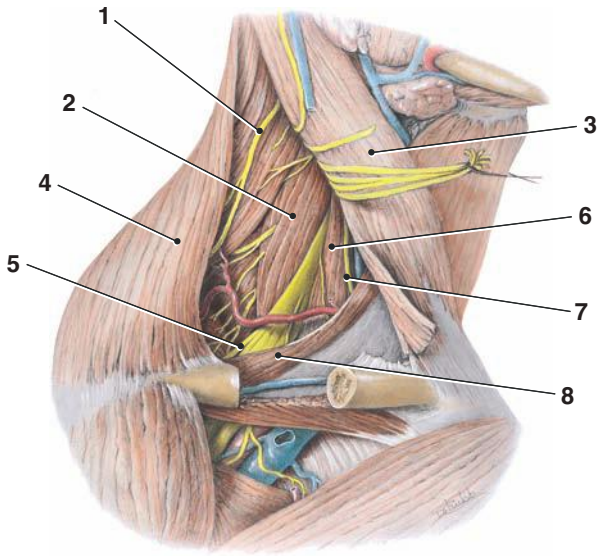
The subclavian vein is a common point of entry for central line placement. Central lines are inserted to administer nutrient fluids and medications and to measure central venous pressure.



The right internal jugular vein is the route of insertion of a catheter that is passed into the right side of the heart to measure pressures.



Posterior Triangle Region



Posterior Triangle Region

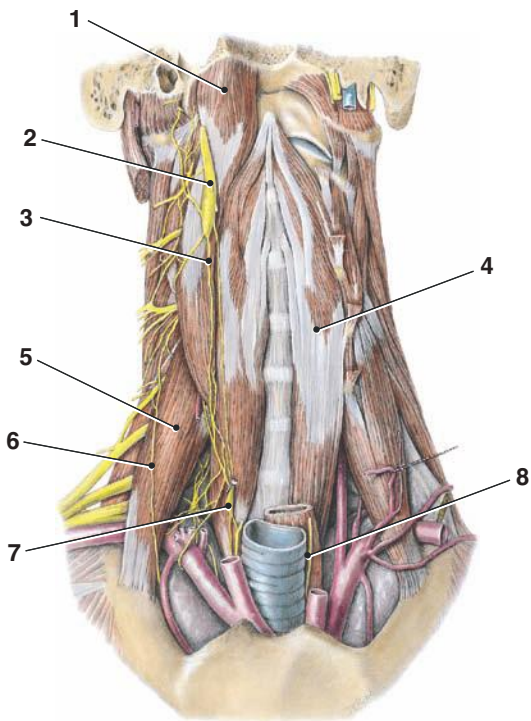
1. spinal accessory nerve
2. middle scalene
3. sternocleidomastoid
4. trapezius
5. suprascapular nerve
6. anterior scalene
7. phrenic nerve
8. inferior belly of omohyoid

Severance or blocking of the phrenic nerve results in paralysis of the corresponding half of the diaphragm.

A cervical nerve block along the posterior border of the middle third of the sternocleidomastoid is used to anesthetize the region before neck surgery.

The supraclavicular nerve is often injured in fractures of the clavicle. This results in inability to rotate the humerus laterally, producing the waiter's tip position.

Prevertebral Region



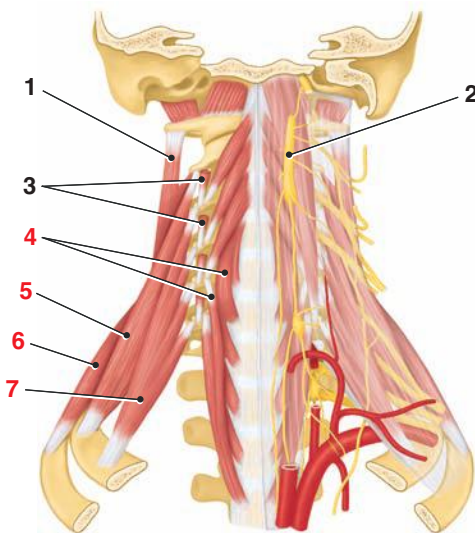
Prevertebral Region

1. longus capitis
2. superior cervical ganglion
3. sympathetic trunk
4. longus coli
5. anterior scalene
6. phrenic nerve
7. sympathetic ganglion
8. recurrent laryngeal nerve

Anesthetic injected around the cervicothoracic ganglion (inferior cervical ganglion fused with the first thoracic ganglion) may relieve vascular spasms involving the brain and upper limb.

A lesion of the cervical sympathetic trunk results in Horner's syndrome, which is characterized by miosis, ptosis, enophthalmos, and anhidrosis.

Prevertebral Musculature



Prevertebral Musculature

1. levator scapulae
2. superior cervical ganglion
3. longus capitis (cut)
4. longus colli
5. middle scalene
6. posterior scalene
7. anterior scalene

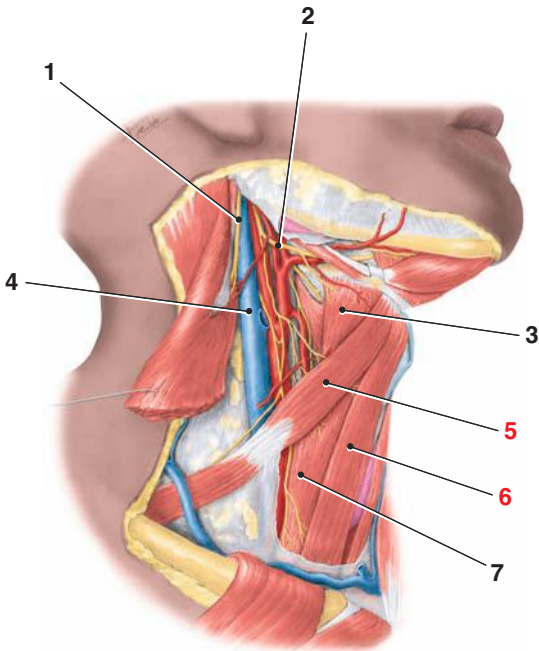
Longus Colli

- proximal attachment: vertebrae C1–C6
- distal attachment: vertebrae C3–T5
- innervation: anterior rami C2–C6
- main action: flexes neck with rotation when acting unilaterally

Scalenes

- proximal attachment: posterior, vertebrae C4–C6; middle, vertebrae C2–C7; anterior, vertebrae C4–C6
- distal attachment: posterior, 2nd rib; middle, 1st rib; anterior, 1st rib
- innervation: posterior, anterior rami C7–C8; middle, anterior rami cervical spinal nerves; anterior, cervical spinal nerves C4–C6
- main action: flexes and rotates neck laterally, elevates 1st two ribs

Hyoid Muscles 1



Hyoid Muscles 1

1. spinal accessory nerve
2. hypoglossal nerve
3. thyrohyoid
4. internal jugular vein
5. omohyoid
6. sternohyoid
7. sternothyroid

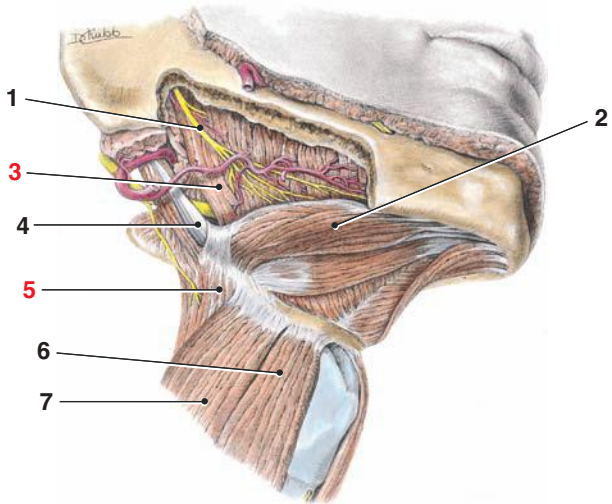
Omohyoid

- proximal attachment: scapula
- distal attachment: hyoid bone
- innervation: C1–C3 via ansa cervicalis
- main action: depresses, retracts, and steadies hyoid bone

Sternohyoid

- proximal attachment: manubrium and clavicle
- distal attachment: hyoid bone
- innervation: C1–C3 via ansa cervicalis
- main action: depresses hyoid bone after swallowing

Hyoid Muscles 2



Hyoid Muscles 2

1. nerve to mylohyoid
2. anterior belly of digastric
3. mylohyoid
4. tendon of digastric
5. thyrohyoid
6. sternohyoid
7. omohyoid

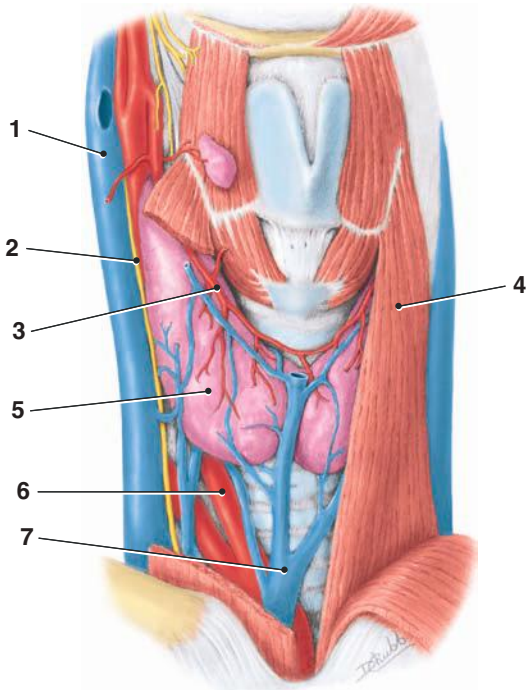
Mylohyoid

- proximal attachment: mandible
- distal attachment: hyoid bone
- innervation: nerve to mylohyoid
- main action: elevates hyoid bone, floor of mouth, and tongue

Thyrohyoid

- proximal attachment: thyroid cartilage
- distal attachment: hyoid bone
- innervation: C1 via hypoglossal
- main action: depresses hyoid and elevates larynx

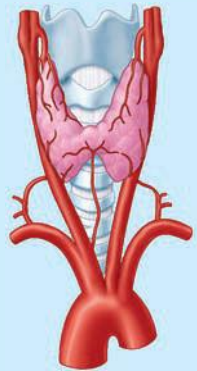
Thyroid Gland



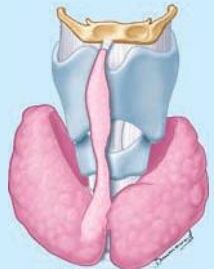Thyroid Gland

1. internal jugular vein
2. vagus nerve
3. superior thyroid artery
4. sternothyroid
5. thyroid gland
6. common carotid artery
7. inferior thyroid vein

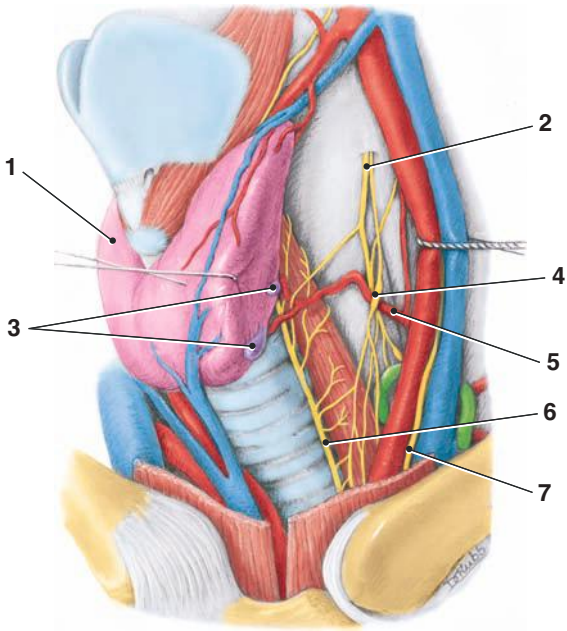
In approximately 10% of people, an unpaired thyroid ima artery is present. It must be considered during surgery in the region.



Approximately 50% of thyroid glands have a pyramidal lobe extending superiorly from the isthmus of the gland.



Root of the Neck



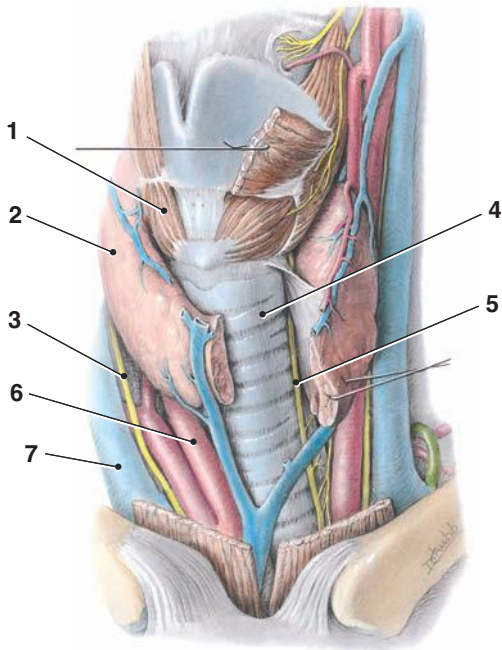
Root of the Neck

1. thyroid gland
2. sympathetic trunk
3. parathyroid glands
4. middle cervical ganglion
5. inferior thyroid artery
6. left recurrent laryngeal nerve
7. vagus nerve

Care must be taken not to remove the aberrantly positioned parathyroid glands during surgery. Removal results in tetany, a severe neurological syndrome that may result in death.

Near the inferior pole of the thyroid gland, the right recurrent laryngeal nerve is closely related to the inferior thyroid artery. Therefore, the artery is ligated lateral to the gland to prevent damaging the nerve. The left recurrent laryngeal nerve is further from danger in this region.

Anterior Neck, Deep Dissection



Anterior Neck, Deep Dissection

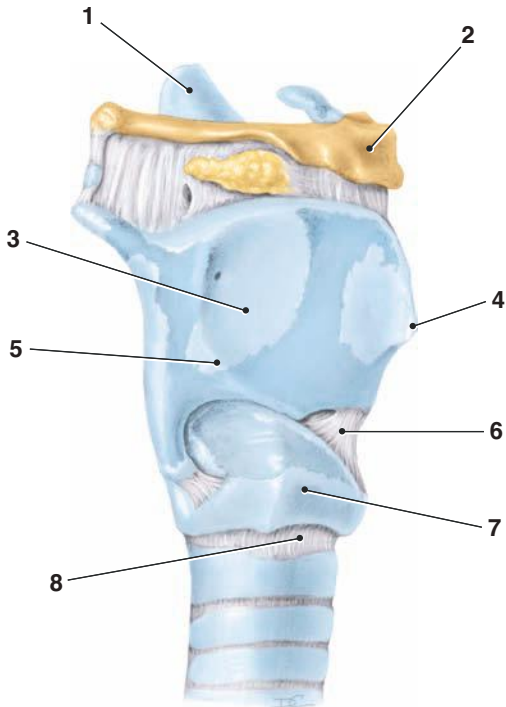
1. cricothyroid muscle
2. thyroid gland
3. vagus nerve
4. trachea
5. recurrent laryngeal nerve
6. common carotid artery
7. internal jugular vein

Enlargement of the thyroid gland that is neither neoplastic nor inflammatory—goiter— results from iodine deficiency. The enlarged gland may compress nearby structures.

Surgical procedures sometimes necessitate the removal of the thyroid gland, a thyroidectomy.



Laryngeal Skeleton



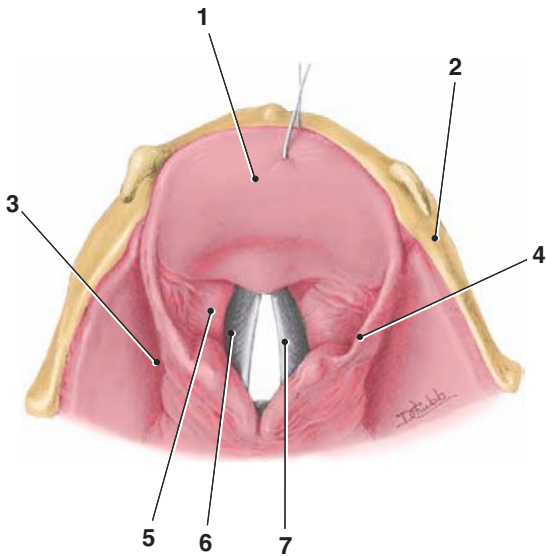
Laryngeal Skeleton

1. epiglottis
2. body of hyoid
3. lamina of thyroid cartilage
4. laryngeal prominence
5. oblique line of the thyroid
6. middle cricothyroid ligament
7. arch of the cricoid cartilage
8. cricotracheal ligament

Fractures of the hyoid occur in persons who are strangled. The result is inability to elevate the hyoid, which makes swallowing and maintenance of the separation of the alimentary and respiratory tracts difficult, perhaps producing aspiration pneumonia.

Laryngeal fractures are common. They may produce submucous hemorrhage and edema, respiratory obstruction, hoarseness, and the inability to speak.

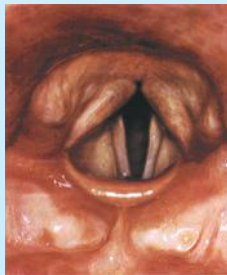Larynx, Superior View



Larynx, Superior View

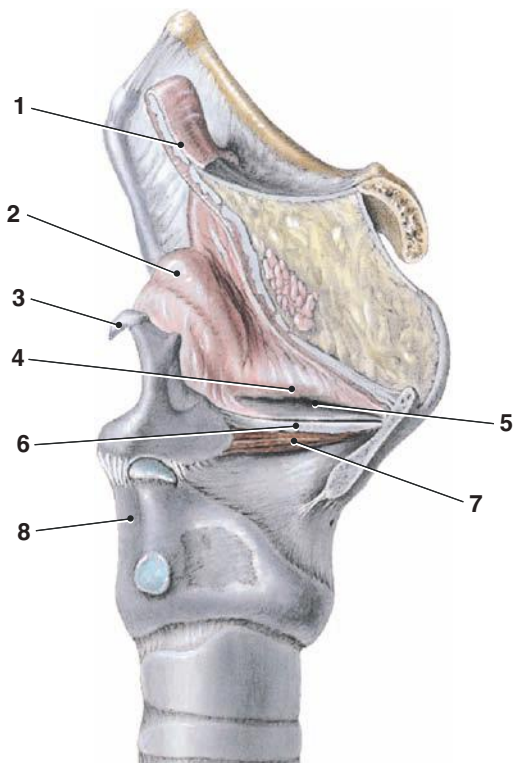
1. epiglottis
2. greater horn of the hyoid bone
3. piriform recess
4. aryepiglottic fold
5. vestibular fold
6. ventricle of the larynx
7. vocal fold

Laryngoscopy is the procedure used to examine the interior of the larynx.



In the Valsalva maneuver, the vestibular and vocal folds are tightly adducted at the end of deep inspiration. Contraction of the abdominal muscles increases intrathoracic and intra-abdominal pressures, thereby impeding venous return to the heart.

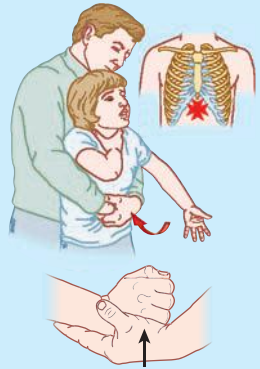
Larynx, Medial View



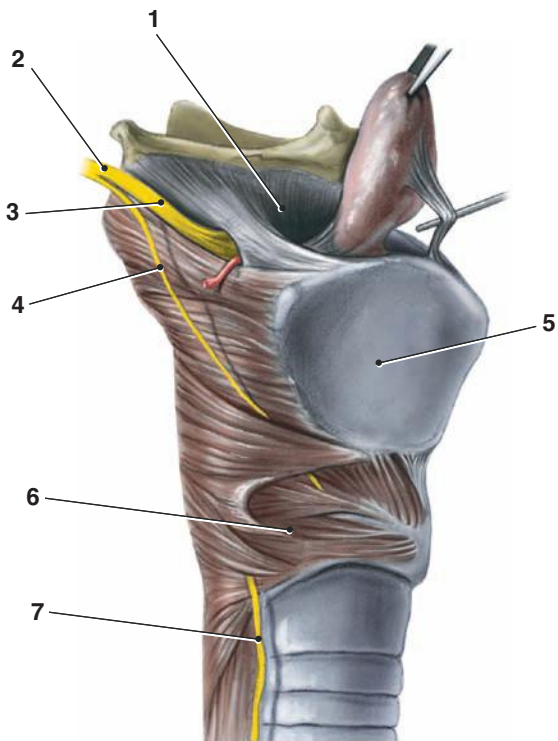
Larynx, Medial View

1. epiglottis
2. cuneiform tubercle
3. corniculate cartilage
4. vestibular fold
5. ventricle of the larynx
6. vocal ligament
7. vocalis
8. lamina of the cricoid cartilage

Sudden compression of the abdomen (Heimlich maneuver) causes the diaphragm to elevate and compress the lungs, expelling air to dislodge food from the larynx during choking.



Nerves of the Larynx

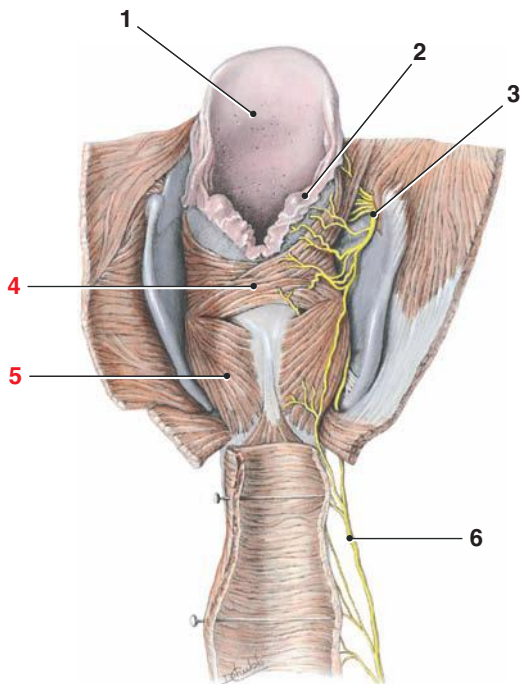


Nerves of the Larynx

1. thyrohyoid membrane
2. superior laryngeal nerve
3. internal laryngeal nerve
4. external laryngeal nerve
5. lamina of thyroid cartilage
6. cricopharyngeus
7. recurrent laryngeal nerve

Injury to the recurrent laryngeal nerve paralyzes the vocal fold and hoarsens the voice. Bilateral damage to the recurrent laryngeal nerves paralyzes both vocal folds; they remain adducted. Damage to the external laryngeal nerve results in a monotone voice, as the cricothyroid muscle cannot vary the tension of the vocal fold.

Muscles of the Larynx



Muscles of the Larynx

1. epiglottis
2. aryepiglottic fold
3. internal laryngeal nerve
4. oblique and transverse arytenoids
5. posterior cricoarytenoid
6. recurrent laryngeal nerve

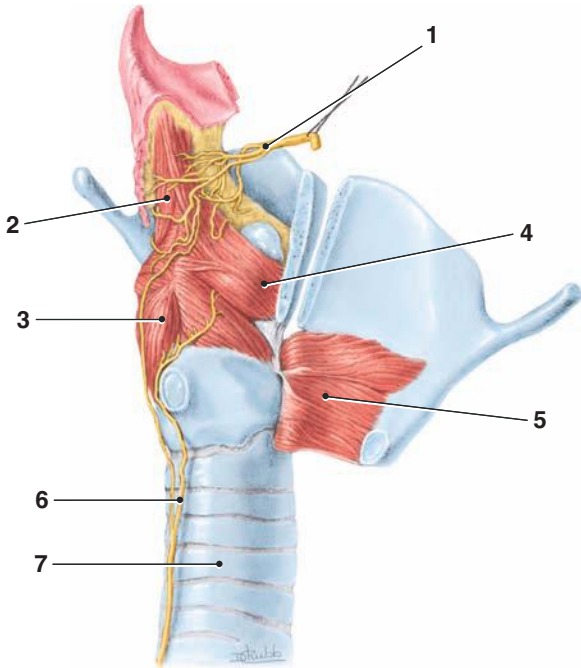
Oblique and Transverse Arytenoids

- proximal attachment: ipsilateral arytenoid cartilage
- distal attachment: contralateral arytenoid cartilage
- innervation: recurrent laryngeal nerve
- main action: approximates arytenoid cartilages

Posterior Cricoarytenoid

- proximal attachment: cricoid cartilage
- distal attachment: arytenoid cartilage
- innervation: recurrent laryngeal nerve
- main action: abducts vocal fold

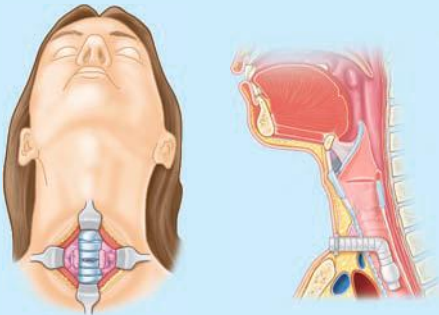
Trachea and Larynx



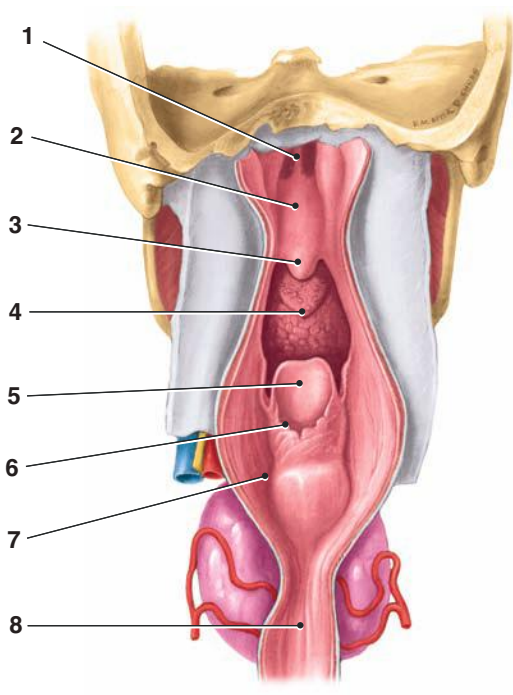
Trachea and Larynx

1. internal branch of superior laryngeal nerve
2. aryepiglotticus
3. posterior cricoarytenoid
4. thyroarytenoid
5. cricothyroid
6. right recurrent laryngeal nerve
7. trachea

An incision through the anterior wall of the trachea (tracheostomy) allows for insertion of a tracheostomy tube, which establishes an airway in patients with upper respiratory failure.



Internal Aspect of the Pharynx

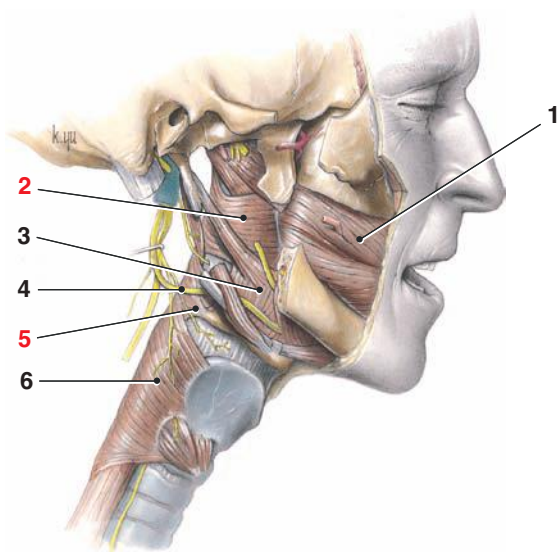


Internal Aspect of the Pharynx

1. nasal septum
2. soft palate
3. uvula
4. foramen cecum
5. epiglottis
6. aryepiglottic fold
7. piriform recess
8. esophagus

Ingested objects may lodge at the inferior end of the nasopharynx or in the piriform recess. Care must be taken when removing them from the piriform recess, as the internal laryngeal nerve lies immediately beneath the mucosa.

Pharyngeal Musculature



Pharyngeal Musculature

1. buccinator
2. superior pharyngeal constrictor
3. hyoglossus
4. hypoglossal nerve
5. middle pharyngeal constrictor
6. inferior pharyngeal constrictor

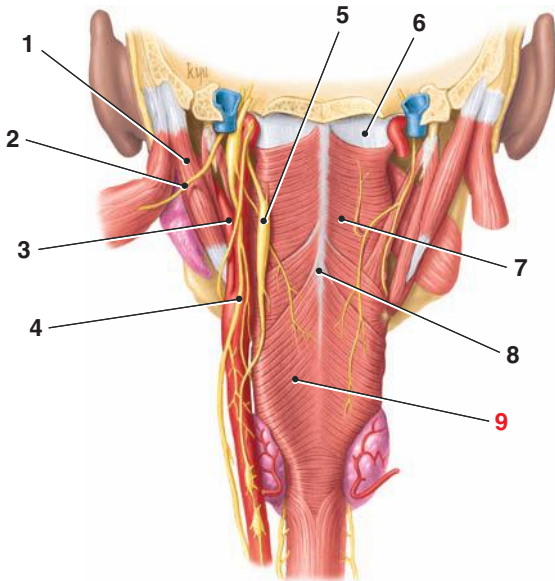
Superior Pharyngeal Constrictor

- proximal attachment: pterygoid hamulus, pterygomandibular raphe, mandible, tongue
- distal attachment: pharyngeal raphe
- innervation: vagus nerve through pharyngeal plexus
- main action: constricts pharyngeal wall during swallowing

Middle Pharyngeal Constrictor

- proximal attachment: stylohyoid ligament and hyoid bone
- distal attachment: pharyngeal raphe
- innervation: vagus nerve through pharyngeal plexus
- main action: constricts pharyngeal wall during swallowing

Posterior Aspect of the Pharynx



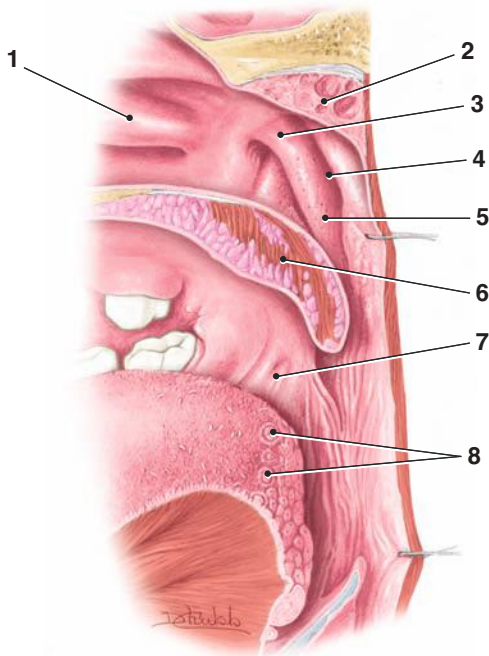
Posterior Aspect of the Pharynx

1. posterior belly of the digastric
2. spinal accessory nerve
3. external carotid artery
4. vagus nerve
5. superior cervical ganglion
6. pharyngobasilar fascia
7. superior pharyngeal constrictor
8. pharyngeal raphe
9. inferior pharyngeal constrictor

Inferior Pharyngeal Constrictor

- proximal attachment: thyroid and cricoid cartilage
- distal attachment: pharyngeal raphe and cricoid cartilage
- innervation: vagus nerve through pharyngeal plexus
- main action: constricts pharyngeal wall during swallowing, acts as superior esophageal sphincter

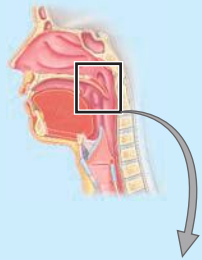
Tonsils



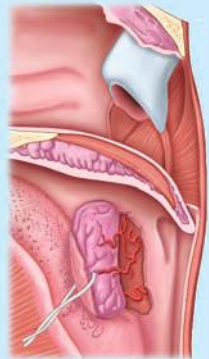Tonsils

1. inferior nasal concha
2. pharyngeal tonsil
3. torus tubarius
4. pharyngeal recess
5. salpingopharyngeal fold
6. soft palate
7. tonsillar fossa
8. vallate papilla

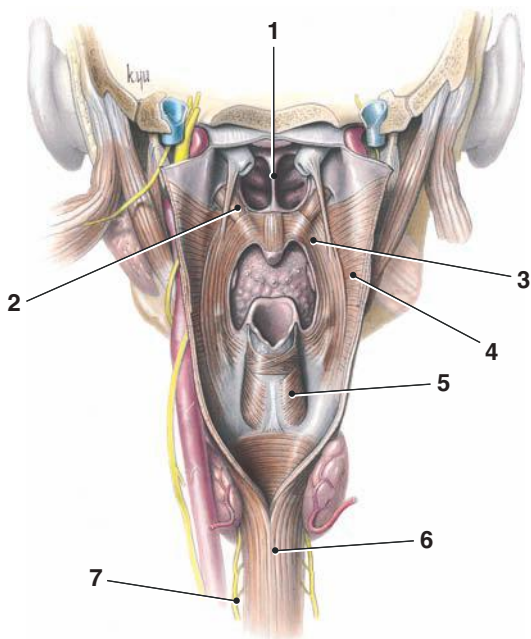
Tonsillectomy is performed by removing the palatine tonsil and its fascia from the tonsillar fossa.



Inflammation of the pharyngeal tonsils (adenoids) is adenoiditis. Inflamed adenoids interfere with nasal breathing, and infection may spread to the middle ear through the nearby pharyngotympanic (auditory) tubes.



Internal Pharynx and Esophagus

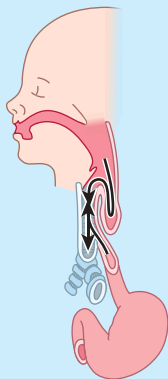


Internal Pharynx and Esophagus

1. nasal septum
2. levator palati
3. palatopharyngeus
4. superior pharyngeal constrictor
5. posterior cricoarytenoid
6. esophagus
7. recurrent laryngeal nerve

Tracheoesophageal fistulas result from abnormalities in partitioning of the esophagus and trachea during development. The most common type involves the superior part of the esophagus ending as a blind-ended pouch, with the inferior end communicating with the trachea.

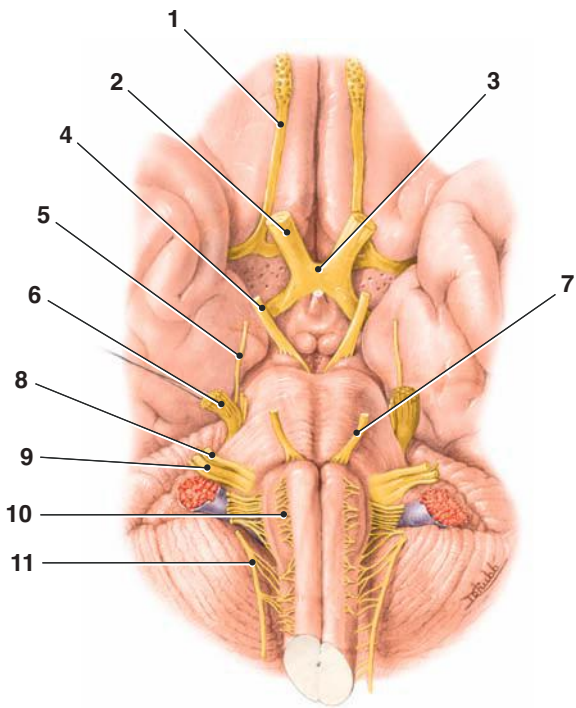
Esophagoscopy is used to diagnose esophageal cancer, the most common complaint of which is dysphagia.



9 • Cranial Nerves

- 9.1** Cranial Nerves
- 9.2** Cranial Base
- 9.3** Olfactory Nerve: CN I
- 9.4** Optic Nerve: CN II
- 9.5** Oculomotor Nerve: CN III; Trochlear Nerve: CN IV
- 9.6** Trigeminal Nerve: CN V
- 9.7** Abducent Nerve: CN VI
- 9.8** Facial Nerve: CN VII
- 9.9** Vestibulocochlear Nerve: CN VIII
- 9.10** Glossopharyngeal Nerve: CN IX
- 9.11** Vagus Nerve: CN X
- 9.12** Spinal Accessory Nerve: CN XI
- 9.13** Hypoglossal Nerve: CN XII

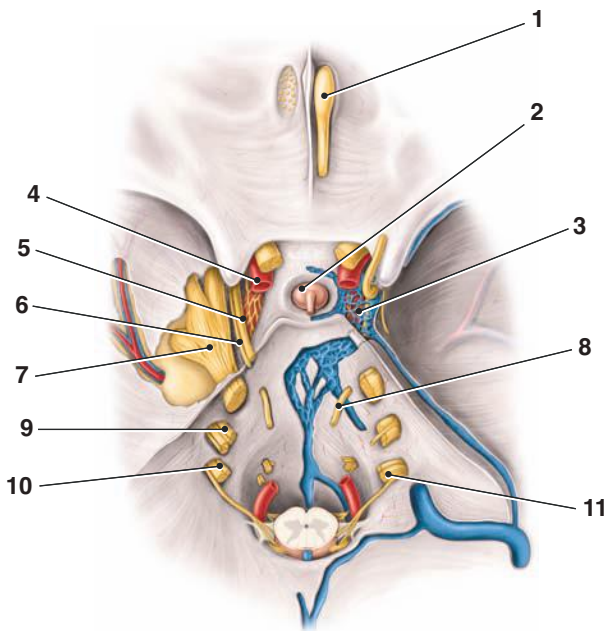
Cranial Nerves



Cranial Nerves

- 1.** olfactory tract
- 2.** optic nerve
- 3.** optic chiasm
- 4.** oculomotor nerve
- 5.** trochlear nerve
- 6.** trigeminal nerve
- 7.** abducent nerve
- 8.** facial nerve
- 9.** vestibulocochlear nerve
- 10.** hypoglossal nerve
- 11.** spinal accessory nerve

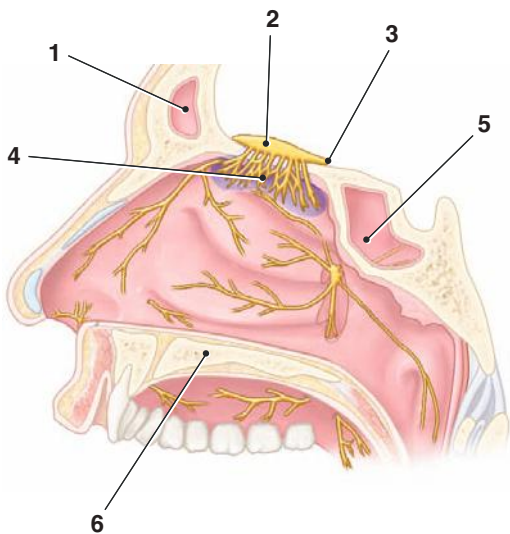
Cranial Base



Cranial Base

1. olfactory bulb
2. hypophysis
3. cavernous sinus
4. internal carotid artery
5. oculomotor nerve
6. trochlear nerve
7. trigeminal ganglion
8. abducent nerve
9. facial nerve
10. glossopharyngeal nerve
11. vagus nerve

Olfactory Nerve: CN I

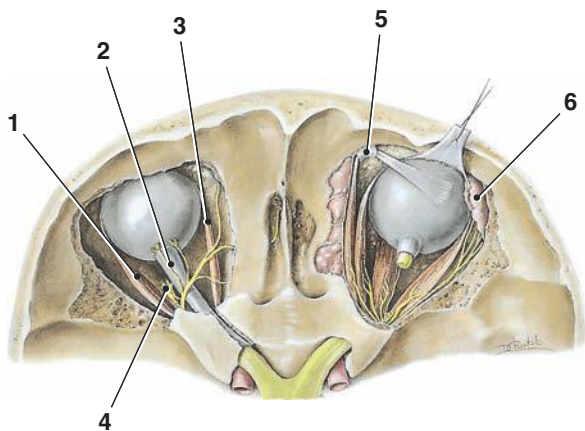


Olfactory Nerve: CN I

1. frontal sinus
2. olfactory bulb
3. olfactory tract
4. olfactory nerves
5. sphenoid sinus
6. hard palate

Injury to the nasal mucosa, olfactory nerve fibers, olfactory bulbs, or olfactory tracts and/or aging may result in loss of the sense of smell (anosmia). Temporal lobe lesions may cause olfactory hallucinations.

Optic Nerve: CN II



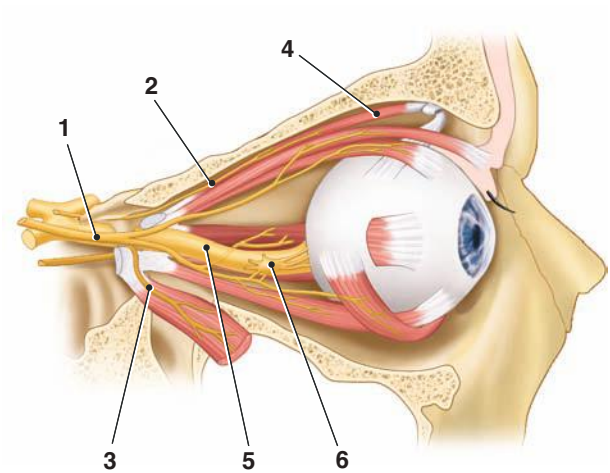
Optic Nerve: CN II

1. lateral rectus
2. optic nerve
3. medial rectus
4. ciliary ganglion
5. trochlea
6. lacrimal gland

The optic nerves are actually central nervous system tracts and are therefore susceptible to the effects of demyelinating diseases, such as multiple sclerosis. Optic neuritis is a lesion of the optic nerve that causes diminution of visual acuity. It may be caused by inflammatory, degenerative, demyelinating, or toxic disorders.

Visual field defects result from lesions that affect different parts of the visual pathway. The visual field loss indicates the location of the lesion.

Oculomotor Nerve: CN III; Trochlear Nerve: CN IV



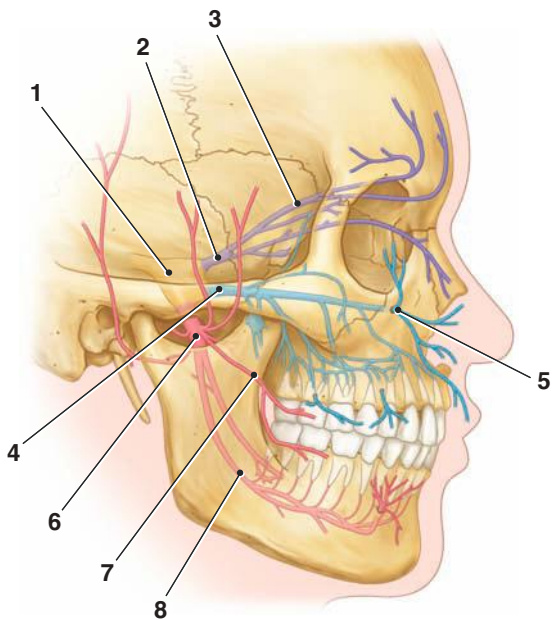
Oculomotor Nerve: CN III; Trochlear Nerve: CN IV

1. oculomotor nerve
2. trochlear nerve
3. abducent nerve
4. superior oblique
5. optic nerve
6. ciliary ganglion

A lesion or compression of the oculomotor nerve, such as from an aneurysm of the posterior cerebral or superior cerebellar arteries, results in ipsilateral oculomotor palsy, the first symptoms of which are dilation of the pupil and a slowed pupillary constriction in response to light.

The trochlear nerve is rarely injured alone. The characteristic sign of trochlear nerve injury is diplopia from paralysis of the superior oblique.

Trigeminal Nerve: CN V

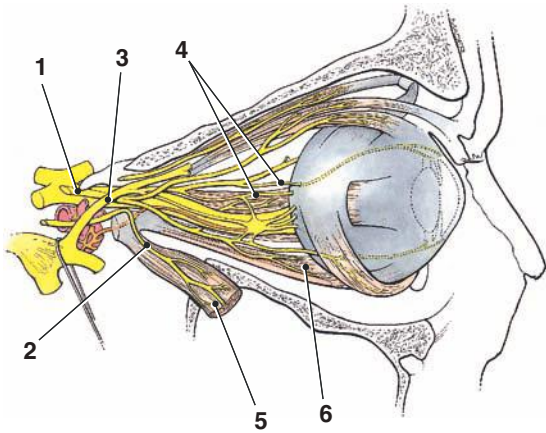


Trigeminal Nerve: CN V

1. trigeminal ganglion
2. ophthalmic nerve
3. frontal nerve
4. maxillary nerve
5. infraorbital nerve
6. mandibular nerve
7. buccal nerve
8. inferior alveolar nerve

Injury to CN V causes paralysis of the muscles of mastication, loss of sensation in the face, and loss of the corneal and sneezing reflexes. Branches of the maxillary nerve and the inferior alveolar nerve are commonly anesthetized during dental procedures.

Abducent Nerve: CN VI



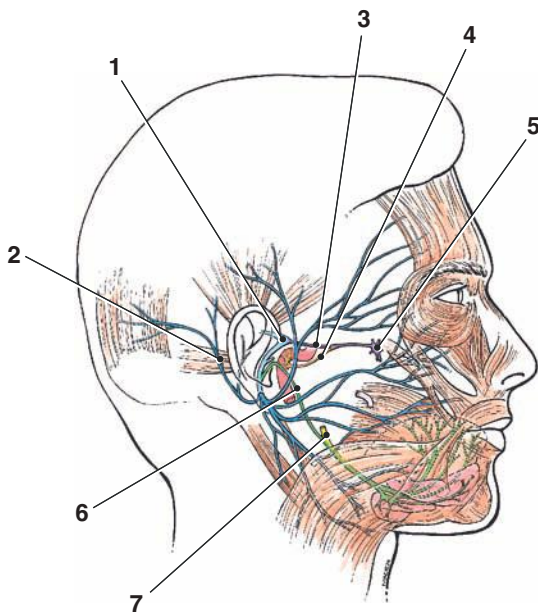
Abducent Nerve: CN VI

1. oculomotor nerve
2. abducent nerve
3. ophthalmic nerve
4. long ciliary nerves
5. lateral rectus
6. inferior rectus

Compression of the abducent nerve causes paralysis of the lateral rectus, resulting in medial deviation (strabismus) of the affected eye because the action of the medial rectus is unopposed.



Facial Nerve: CN VII

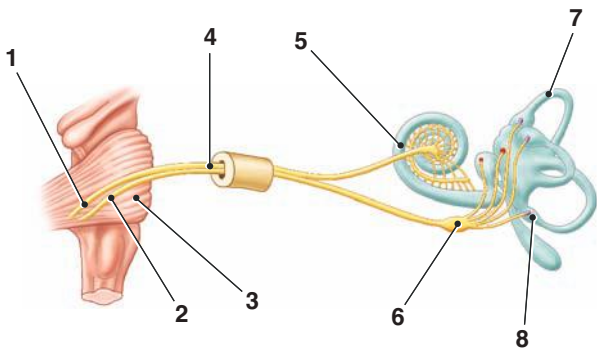


Facial Nerve: CN VII

1. geniculate ganglion
2. posterior auricular nerve
3. greater petrosal nerve
4. deep petrosal nerve
5. pterygopalatine ganglion
6. chorda tympani
7. lingual nerve

A lesion of the facial nerve may result in paralysis of facial muscles (Bell palsy), loss of taste from the anterior two-thirds of the tongue, and/or altered secretion of the lacrimal and salivary glands. The functions lost give a good indication of the location of the lesion.

Vestibulocochlear Nerve: CN VIII



Vestibulocochlear Nerve: CN VIII

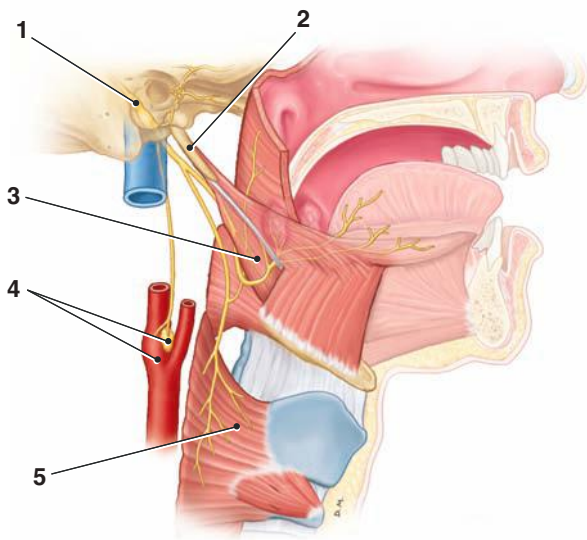
1. cochlear nerve
2. vestibular nerve
3. pons
4. vestibulocochlear nerve
5. cochlear duct
6. vestibular ganglion
7. semicircular duct (canal)
8. ampulla of semicircular duct (canal)

Lesions of CN VIII may cause tinnitus, vertigo, and hearing deficits.

There are two kinds of deafness: conductive, which involves the external or middle ear, and sensorineural, which results from disease in the cochlea or the central auditory pathway.

Vertigo is a hallucination of movement that usually results from peripheral nerve lesion of CN VIII.

Glossopharyngeal Nerve: CN IX



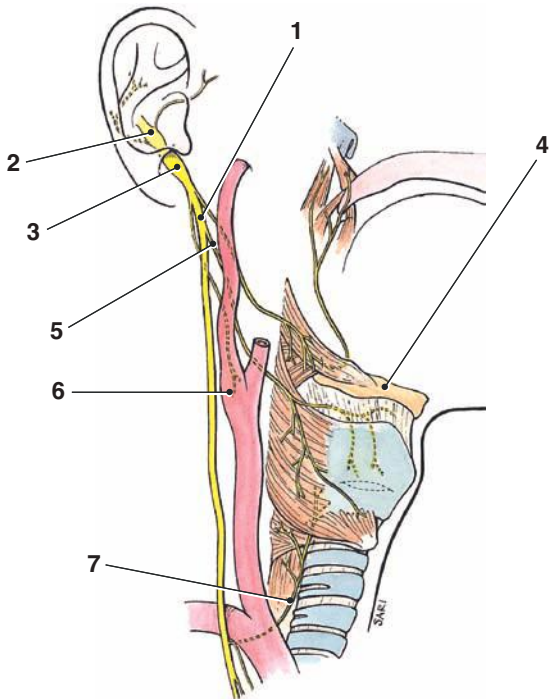
Glossopharyngeal Nerve: CN IX

1. glossopharyngeal nerve
2. styloid process
3. stylopharyngeus
4. carotid body and sinus
5. inferior pharyngeal constrictor

Lesions of the glossopharyngeal nerve lead to the absence of taste on the posterior third of the tongue, and the gag reflex is absent on the side of the lesion. In addition, a noticeable change in swallowing may occur.

Glossopharyngeal neuralgia involves the sudden onset of pain initiated by swallowing, protruding the tongue, talking, or touching the palatine tonsil.

Vagus Nerve: CN X

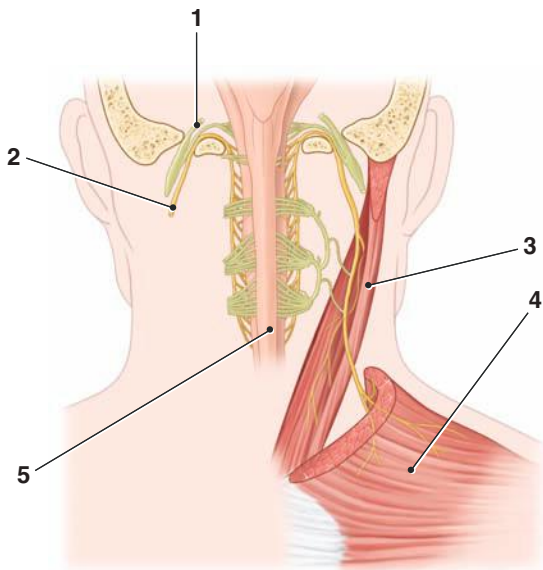


Vagus Nerve: CN X

1. vagus nerve
2. superior ganglion
3. inferior ganglion
4. hyoid bone
5. superior laryngeal nerve
6. carotid sinus
7. right recurrent laryngeal nerve

Injury to pharyngeal branches of CN X results in dysphagia. Injury to the superior laryngeal nerve results in anesthesia of the superior aspect of the larynx and paralysis of the cricothyroid muscle. Injury to the recurrent laryngeal nerve produces dysphonia (one nerve injured) or aphonia (when both nerves are injured).

Spinal Accessory Nerve: CN XI

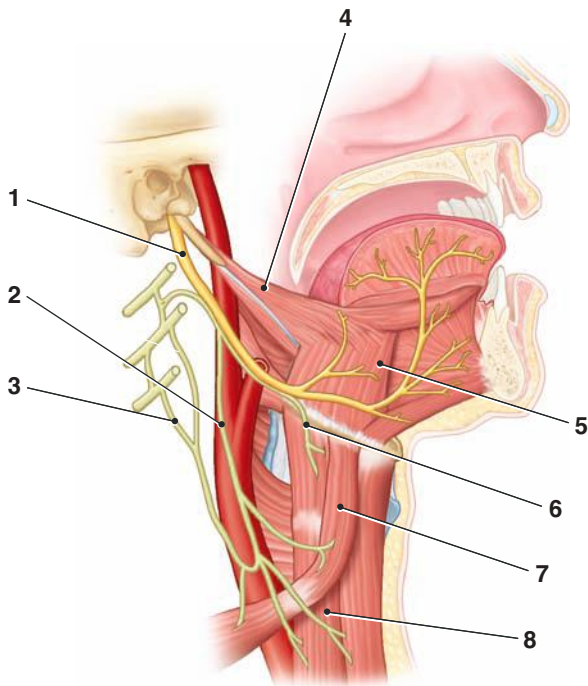


Spinal Accessory Nerve: CN XI

1. vagus nerve
2. spinal accessory nerve
3. sternocleidomastoid
4. trapezius
5. spinal cord

Injury to the spinal accessory nerve, as may occur during surgical procedures in the neck, produces paralysis of the sternocleidomastoid and trapezius.

Hypoglossal Nerve: CN XII



Hypoglossal Nerve: CN XII

1. hypoglossal nerve
2. ansa cervicalis superior root
3. ansa cervicalis inferior root
4. styloglossus
5. hyoglossus
6. C1 nerve to thyrohyoid
7. superior belly of omohyoid
8. sternothyroid

Injury to the hypoglossal nerve paralyzes the ipsilateral half of the tongue. When the tongue protrudes, it deviates toward the paralyzed side because of the unopposed action of the genio-glossus muscle on the normal side.