

MUSCLES OF FASCIAL EXPRESSIONS

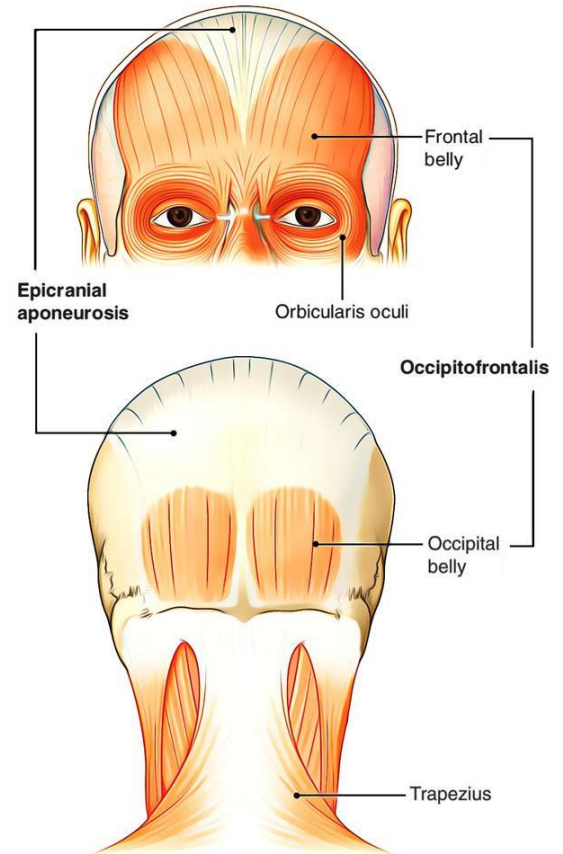
LAIBA AREEJ
ROLL#5

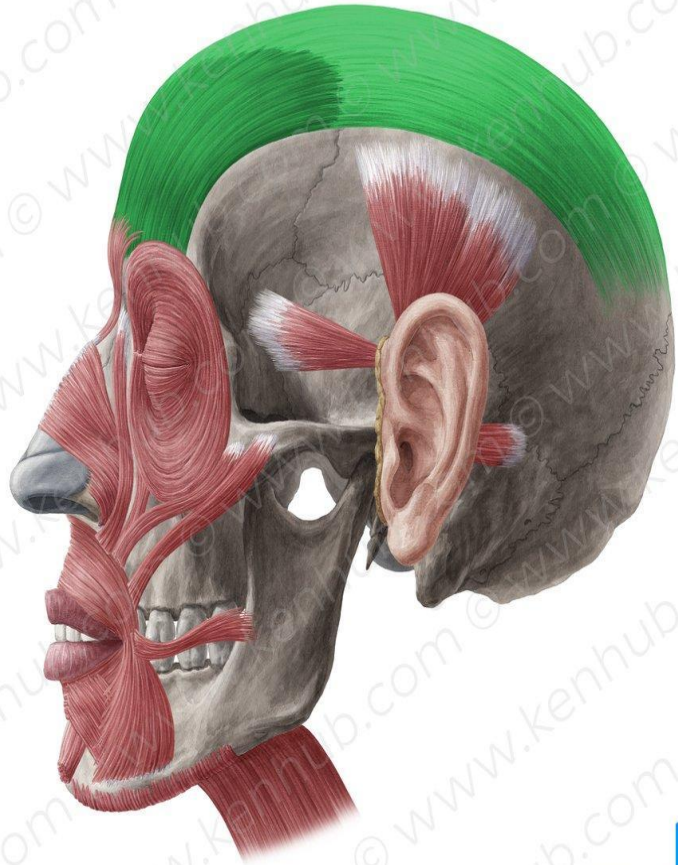OCCIPITAL FRONTALIS

ORIGIN: Supraciliary arches

External occipital protuberance

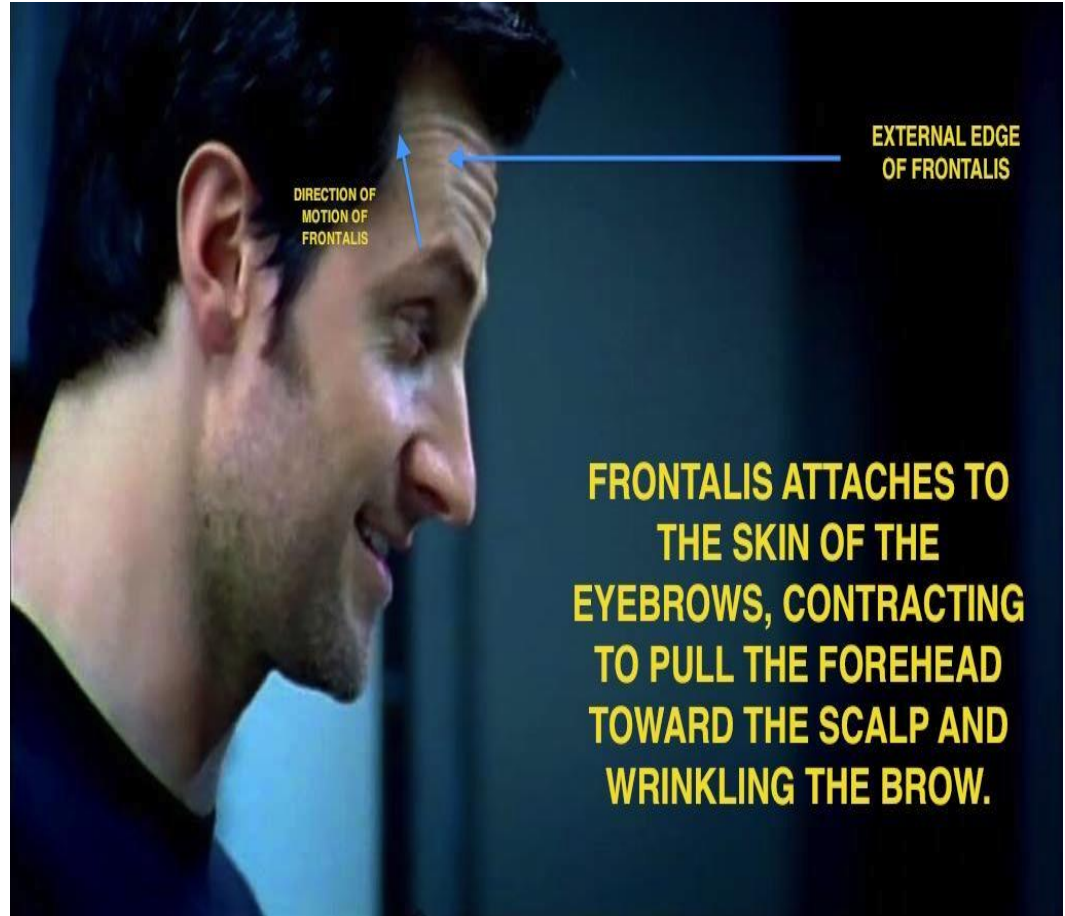
INSERTION: Epicranial aponeurosis





© www.kenhub.com

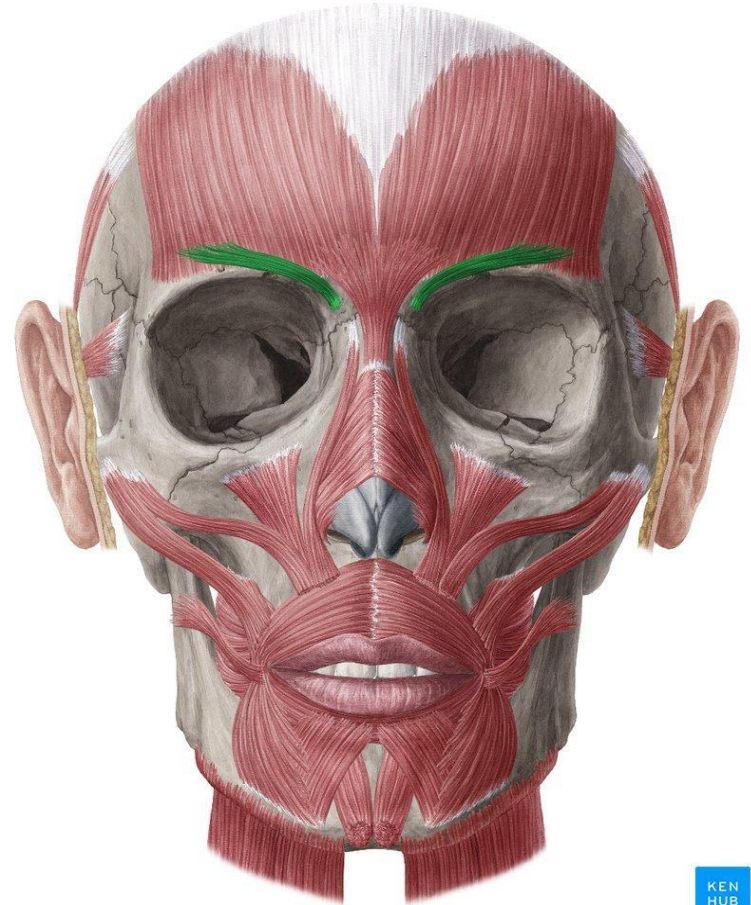
KEN
HUB



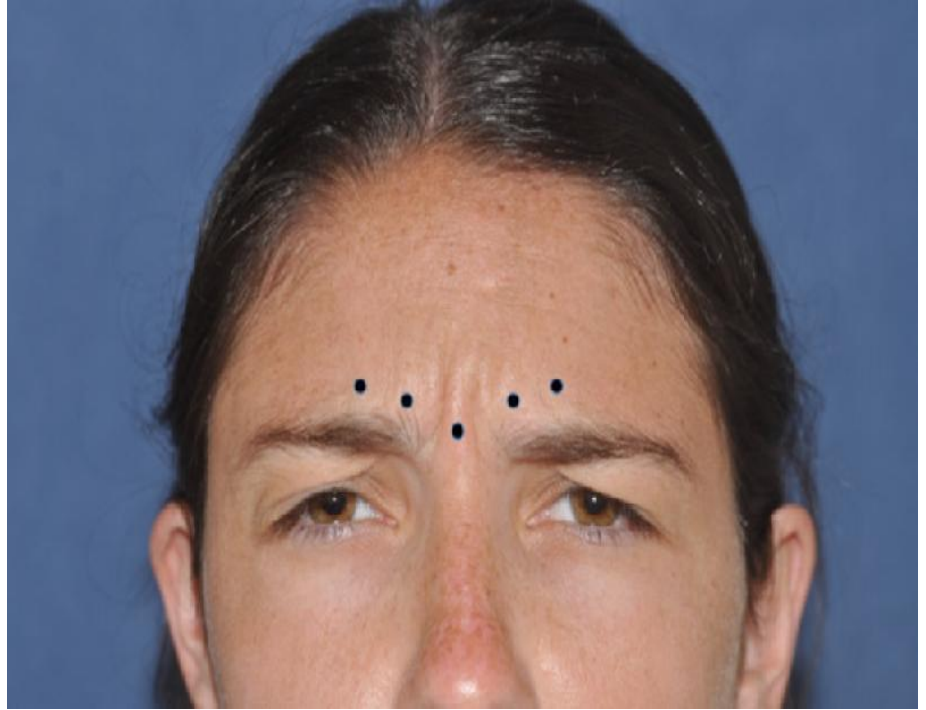CORRUGATOR SUPERCILLI

ORIGIN: Supraciliary arches

INSERTION: Skin of eyebrow



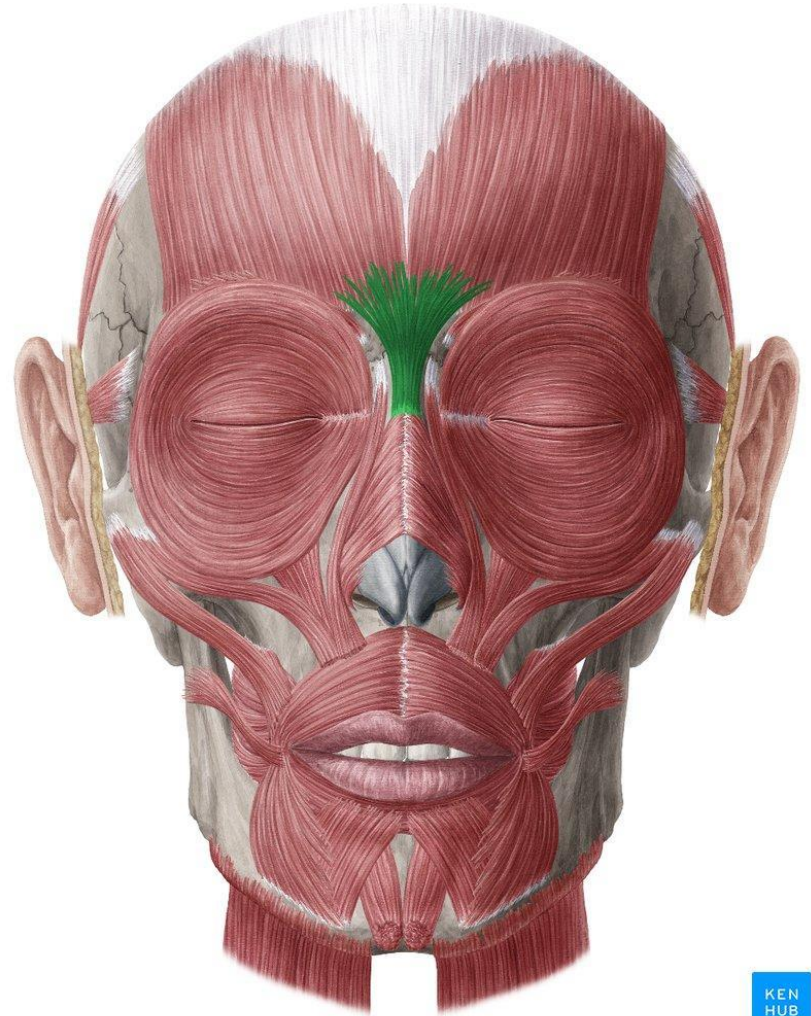ACTION: Vertical wrinkle
Of forehead



PROCERUS

ORIGIN: Upper part of nasal bone

INSERTION: Skin of glabella



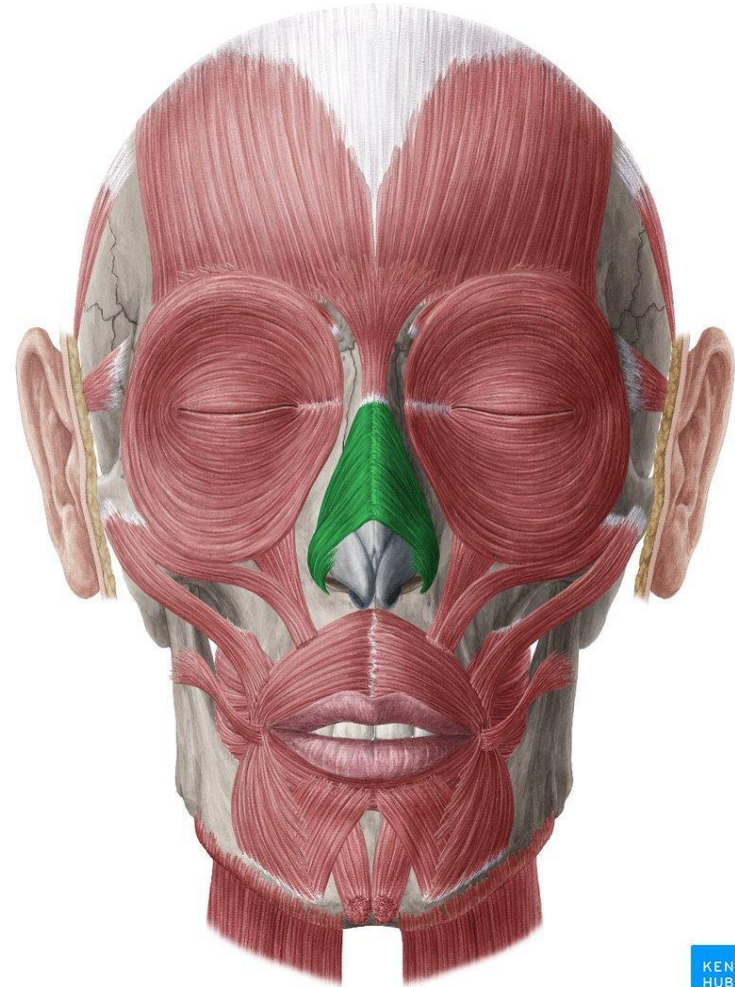


wiseGEEK

NASALIS

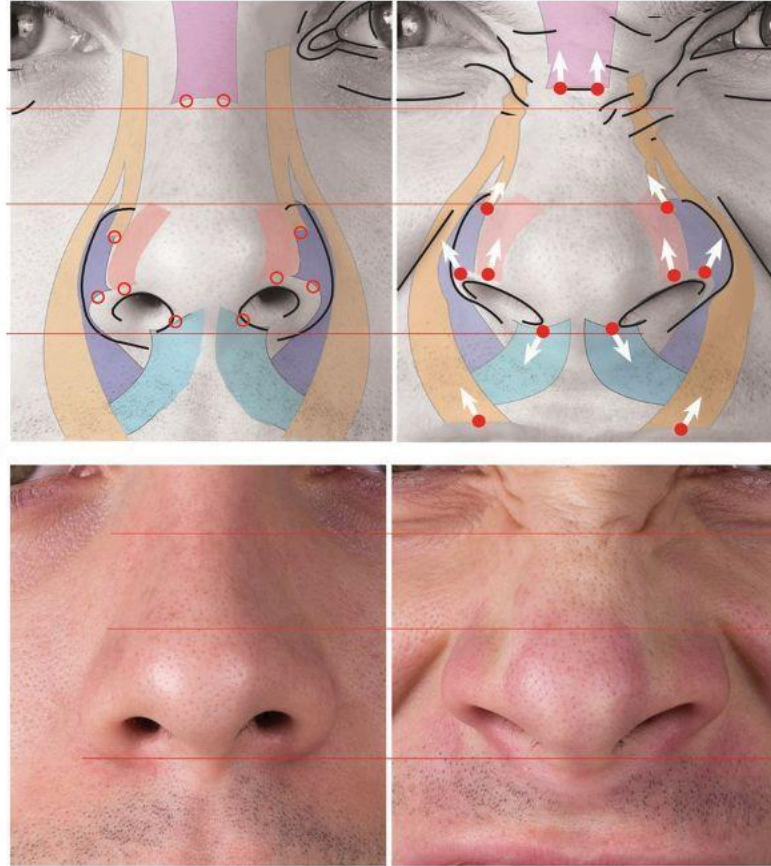
ORIGIN: Frontal part of maxilla

INSERTION: Skin near the margin of nostrils



NASAL DILATOR MUSCLES

NASALIS (alar portion) DILATOR NARIS ANTERIOR, DEPRESSOR SEPTI NASI



Story for illustration purpose:



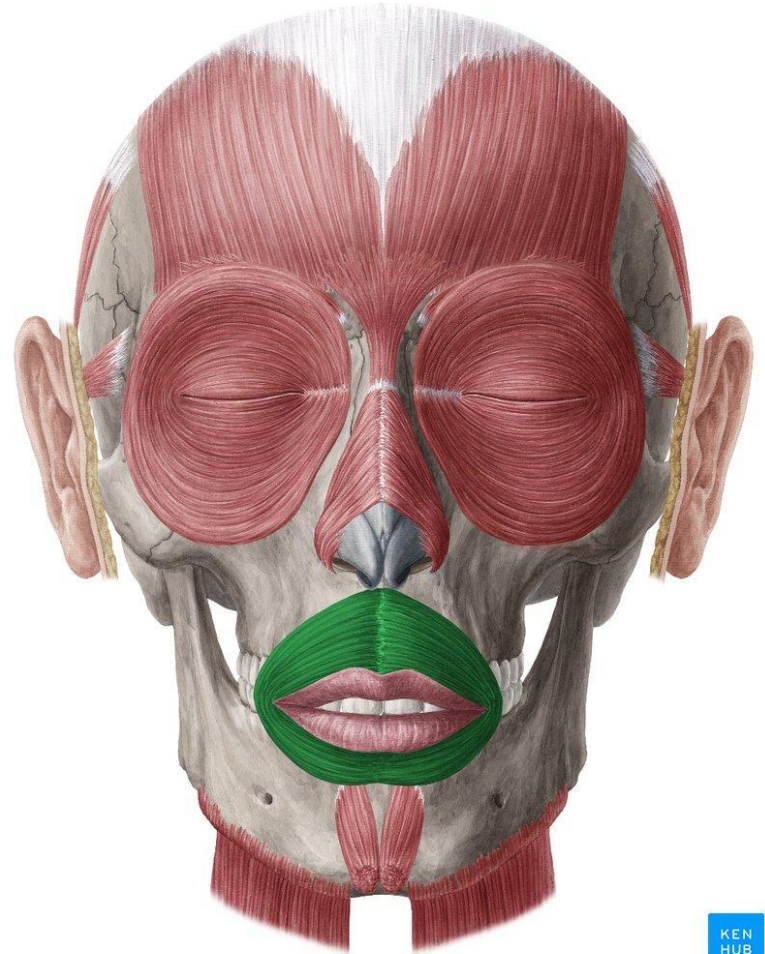
ORBICULARIS ORIS

ORIGIN: Maxilla

Mandible

INSERTION: Skin surrounding the lips

corners

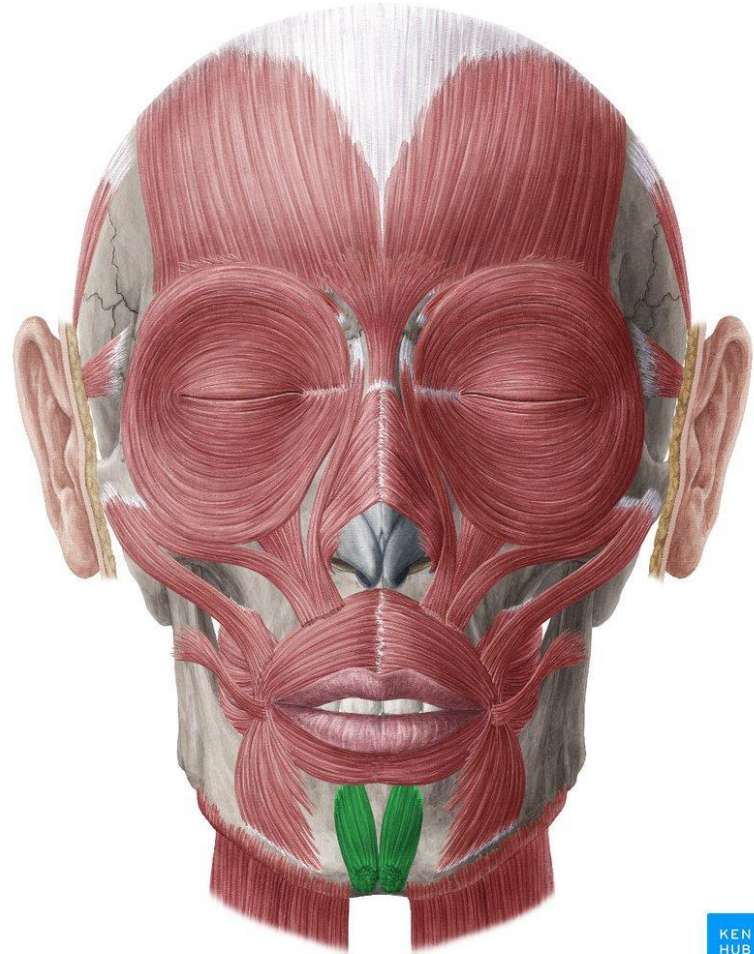




MENTALIS

ORIGIN: Incisive fossa
of mandible

INSERTION: Skin of chin

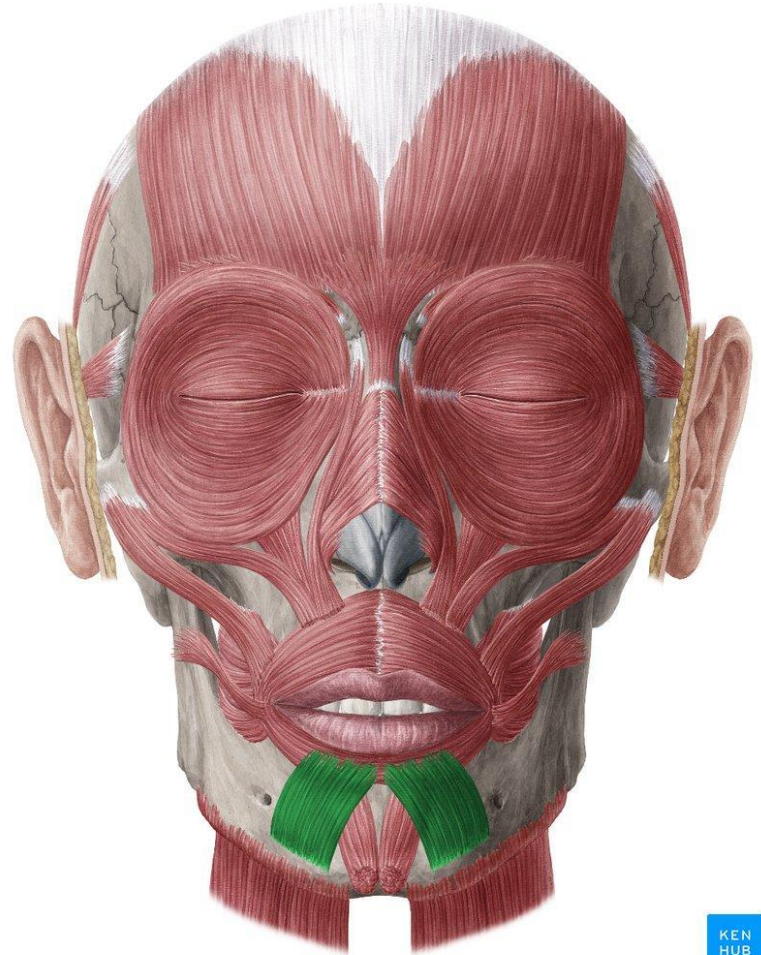




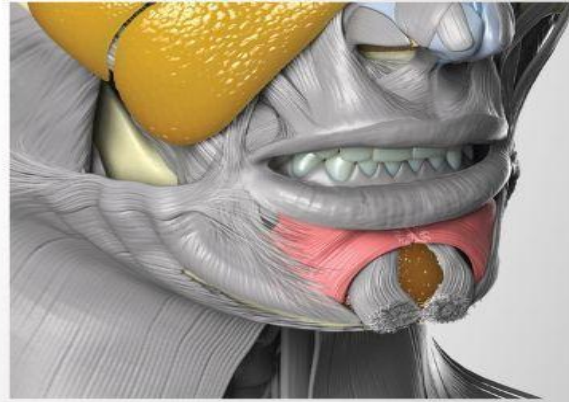
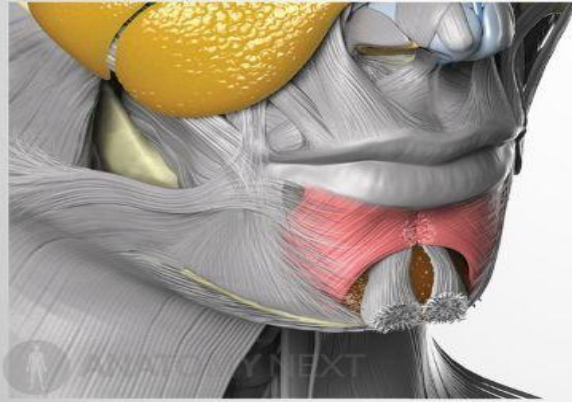
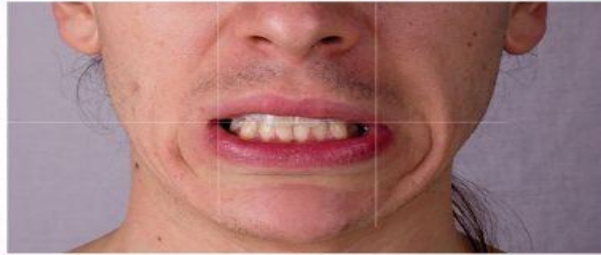
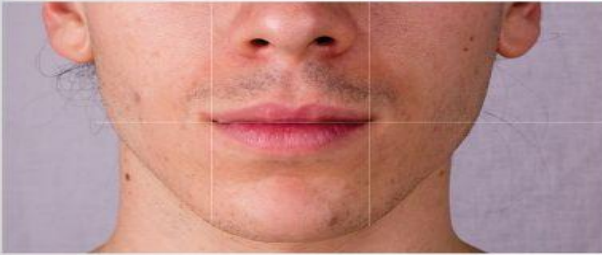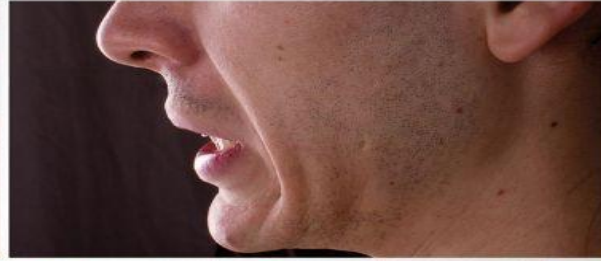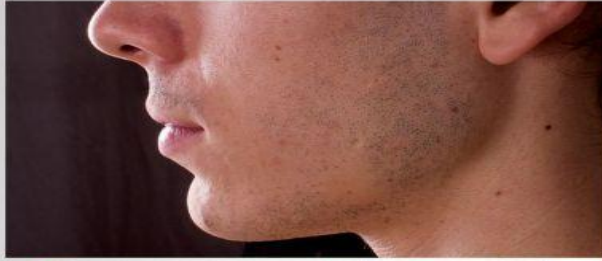DEPRESSOR LABII INFERIORIS

ORIGIN: Oblique line of
mandible

INSERTION: Lower lip



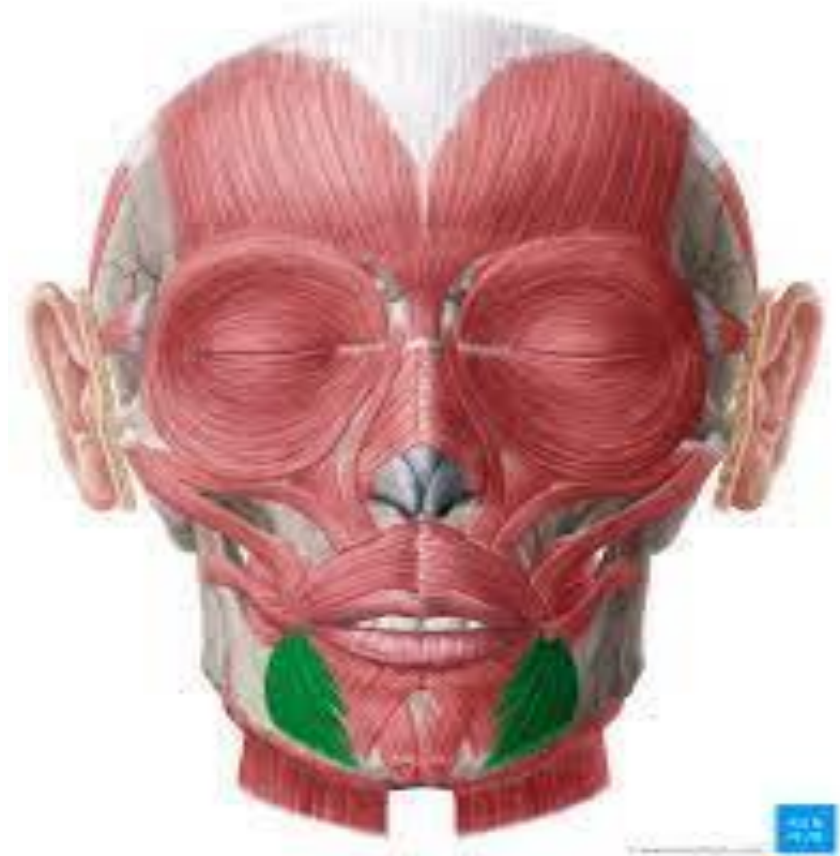depressor labii inferioris



DEPRESSOR ANGULI ORIS

ORIGIN: oblique line of
mandible

INSERTION: Angle of
mouth





LEVATOR LABII SUPERIORIS

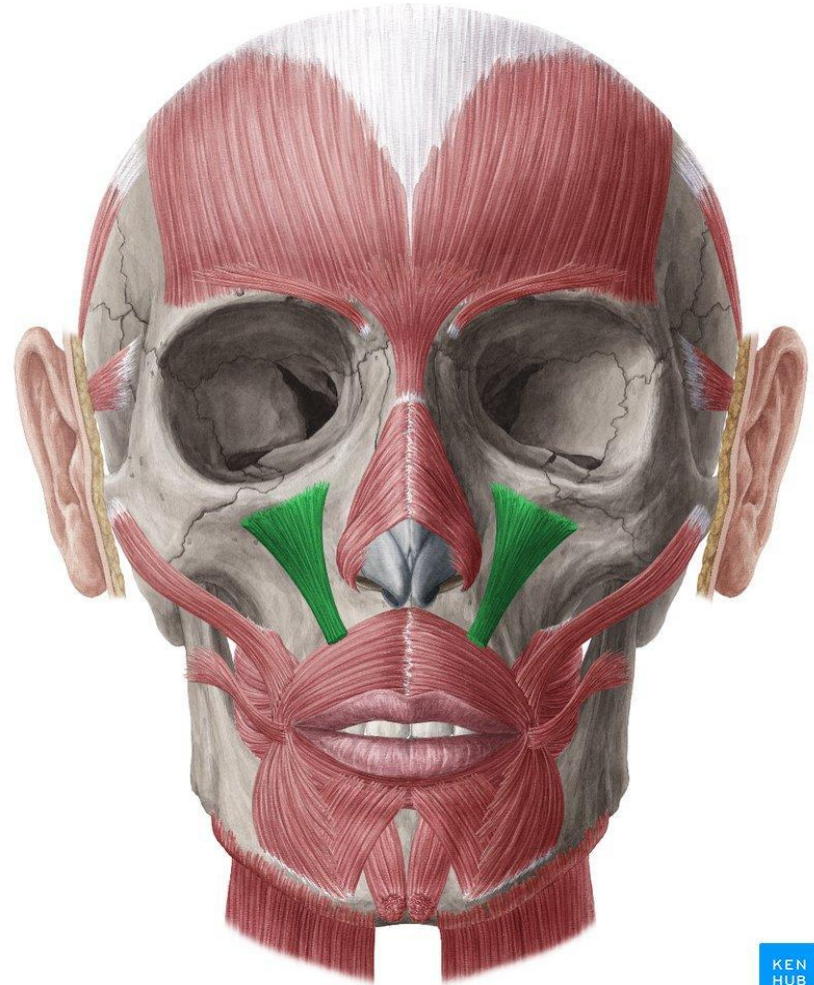
ORIGIN:

Angular head: Frontal process of maxilla

Infraorbital head : Inferior margin of orbit

Zygomatic head; Zygomatic bone

INSERTION: Upper lip

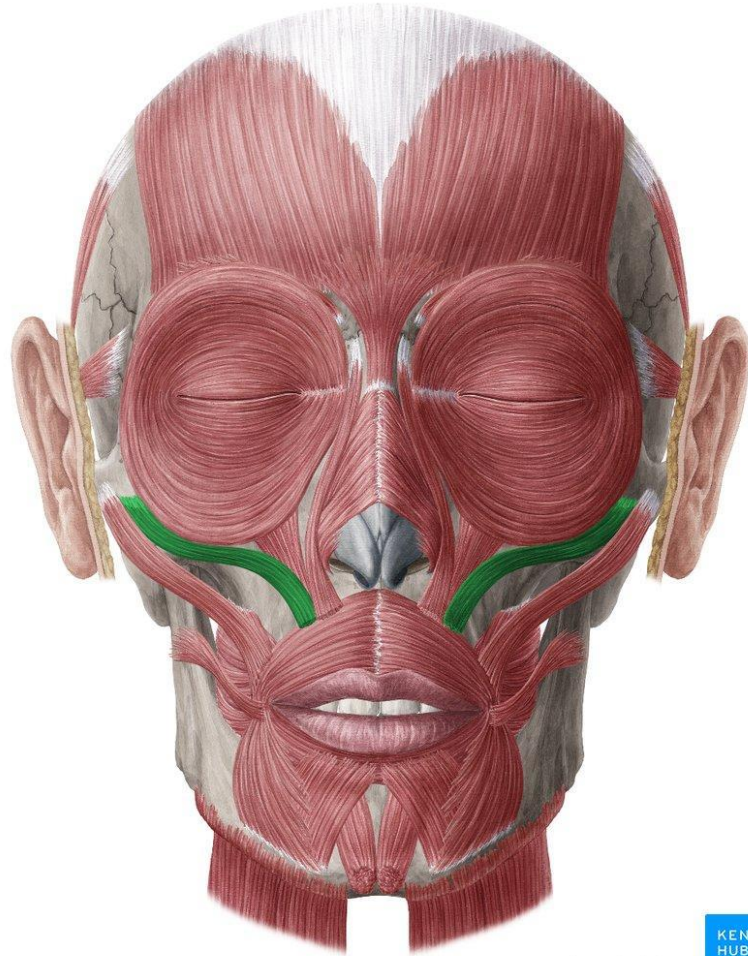


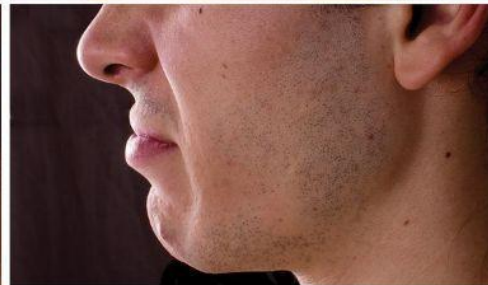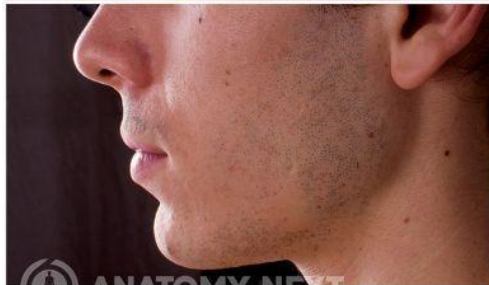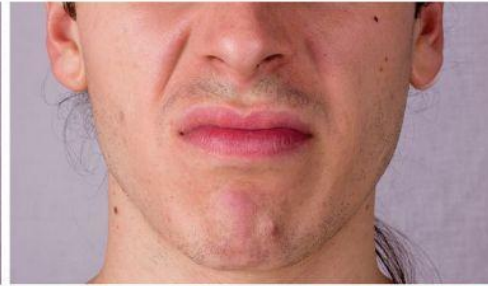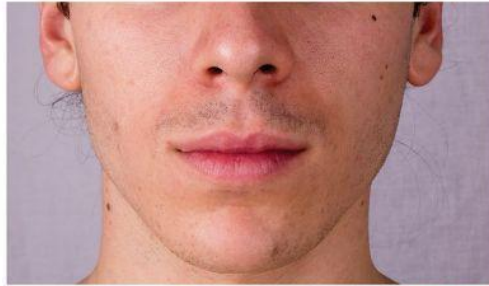
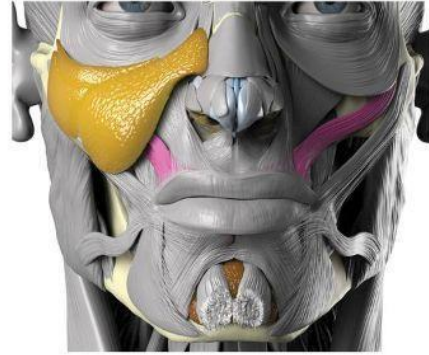
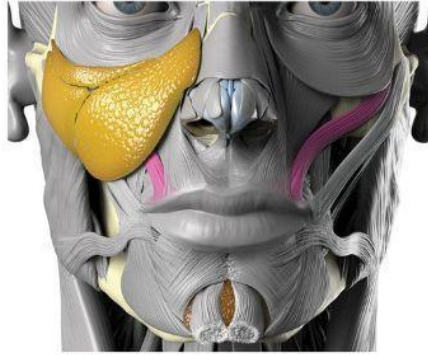


ZYGOMATIC MINOR

ORIGIN: Lateral part of
zygomatic bone

INSERTION: Upper lips

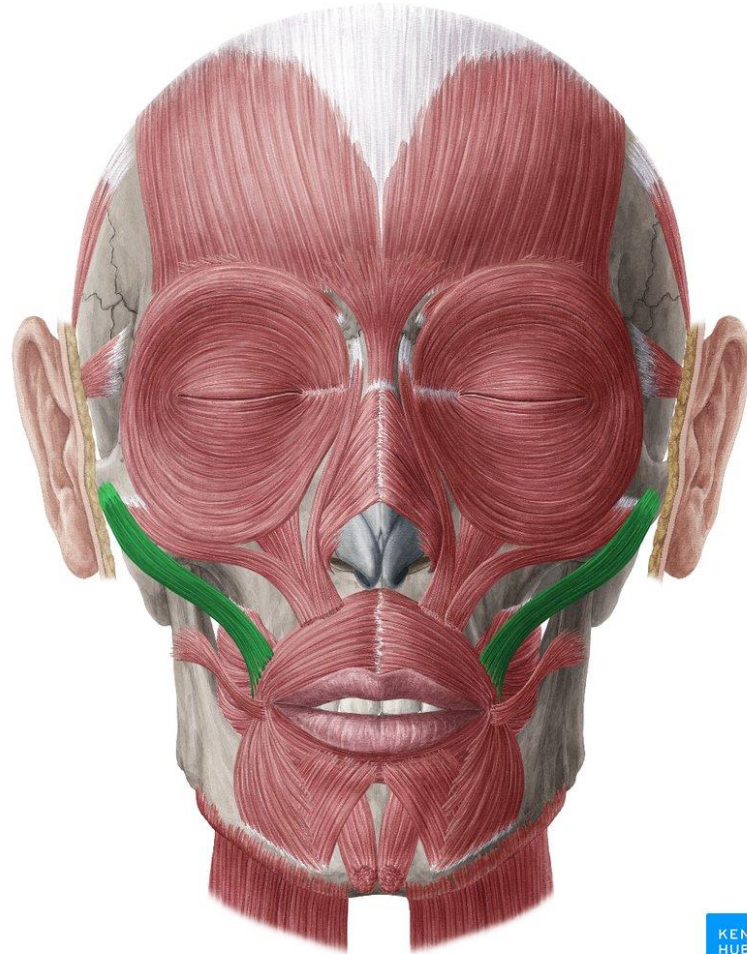


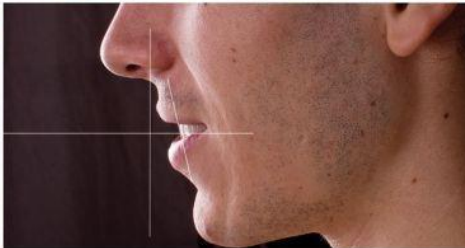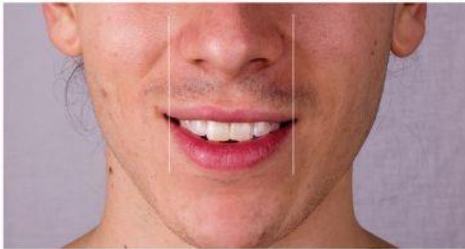
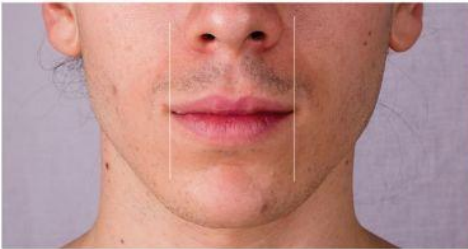
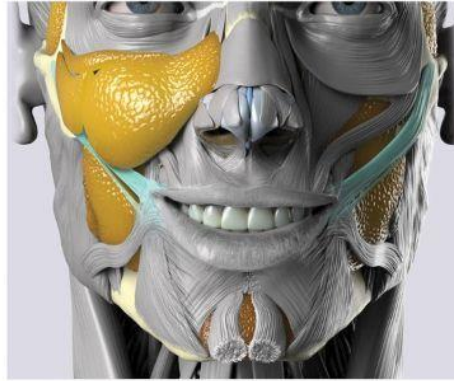

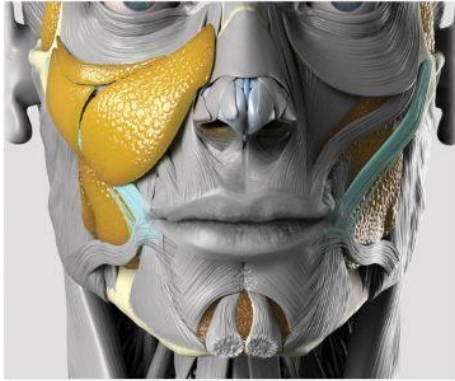
ZYGOMATIC MAJOR

ORIGIN: Zygomatic
bone

INSERTION: Angle of
mouth

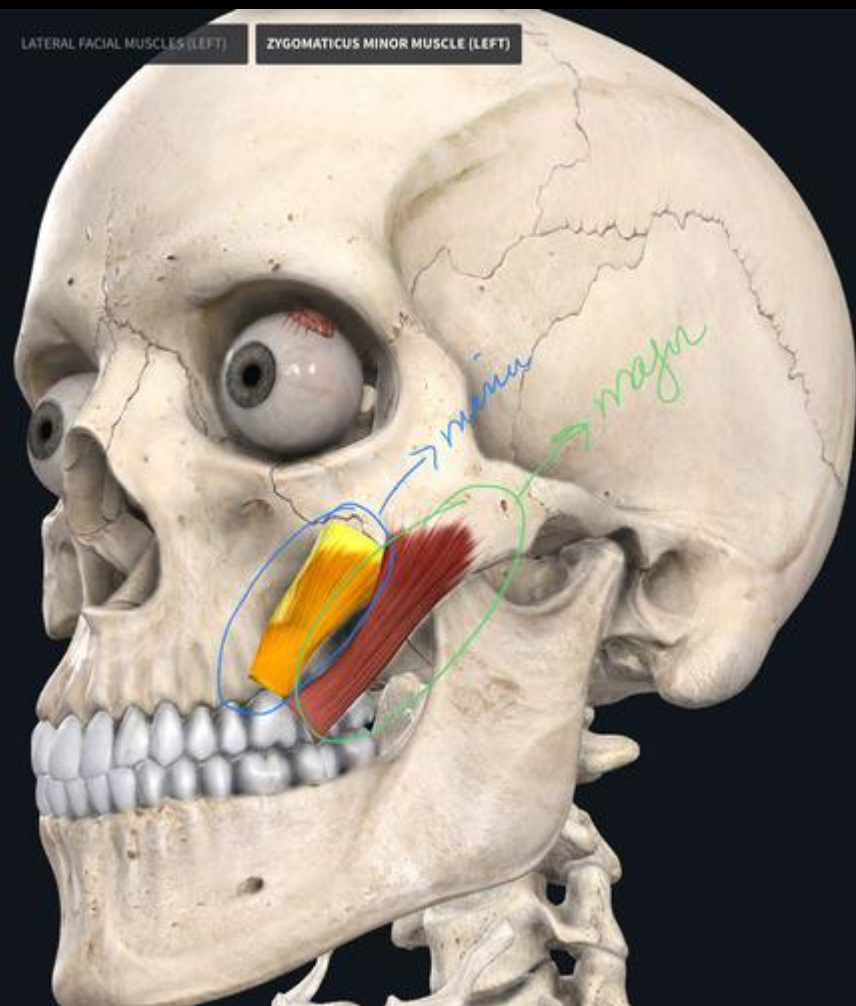




FACIAL MUSCLES

LATERAL FACIAL MUSCLES (LEFT)

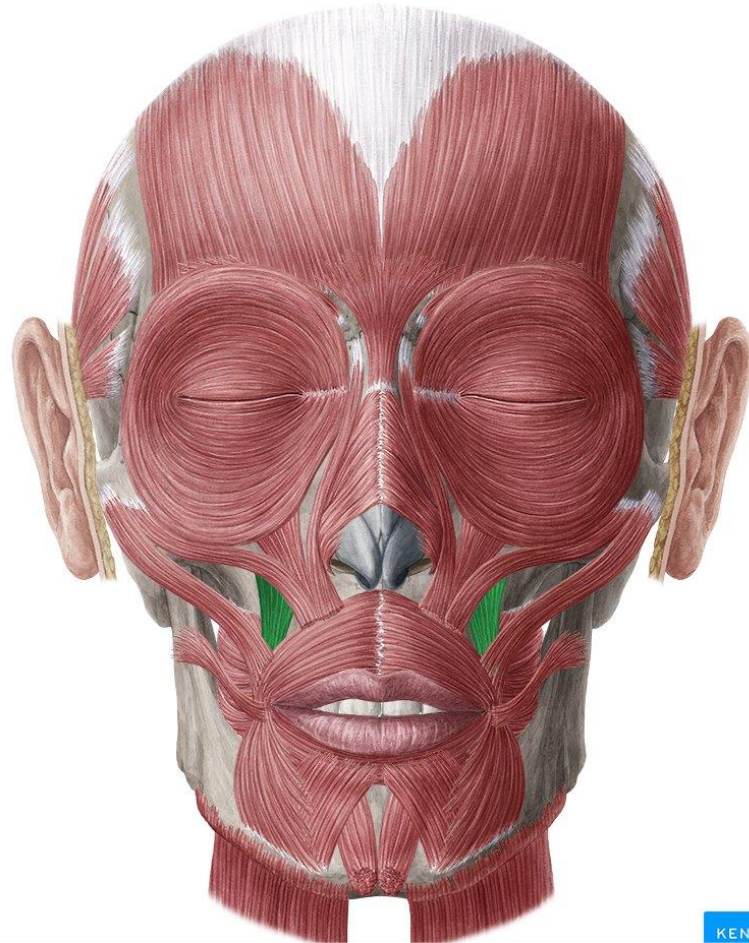ZYGOMATICUS MINOR MUSCLE (LEFT)



LEVATOR ANGULI ORIS

ORIGIN: Canine fossa of maxilla

INSERTION: Angle of mouth



ACTION

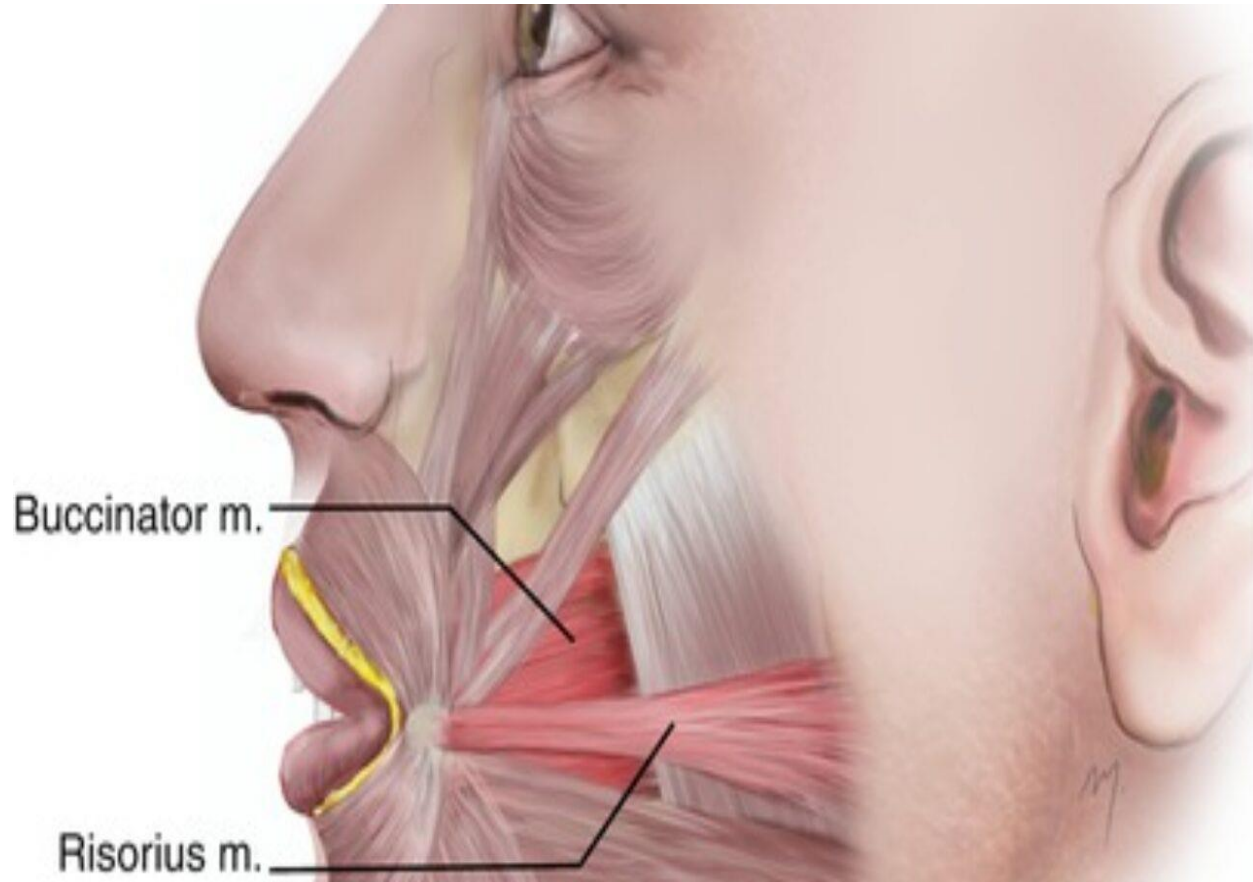
Lift the angle of mouth
producing expression of
a smile



RISORIUS

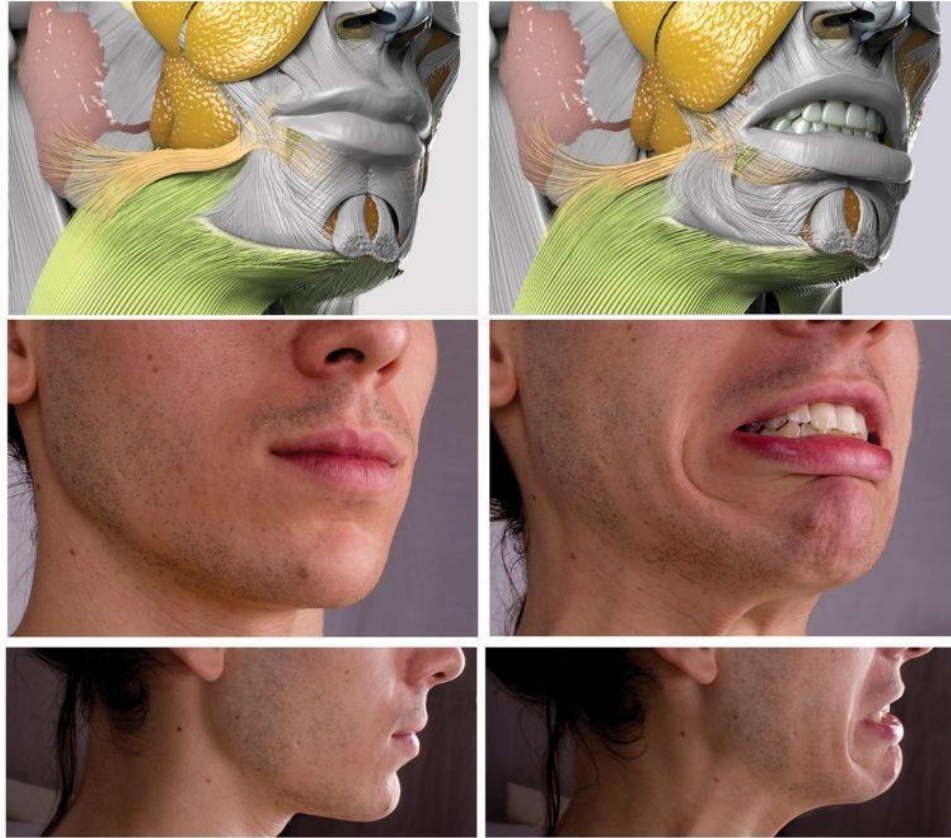ORIGIN: Zygomatic bone
bone

INSERTION: Angle of mouth



ACTION

Pull the corner of mouth
laterally



BUCCINATOR

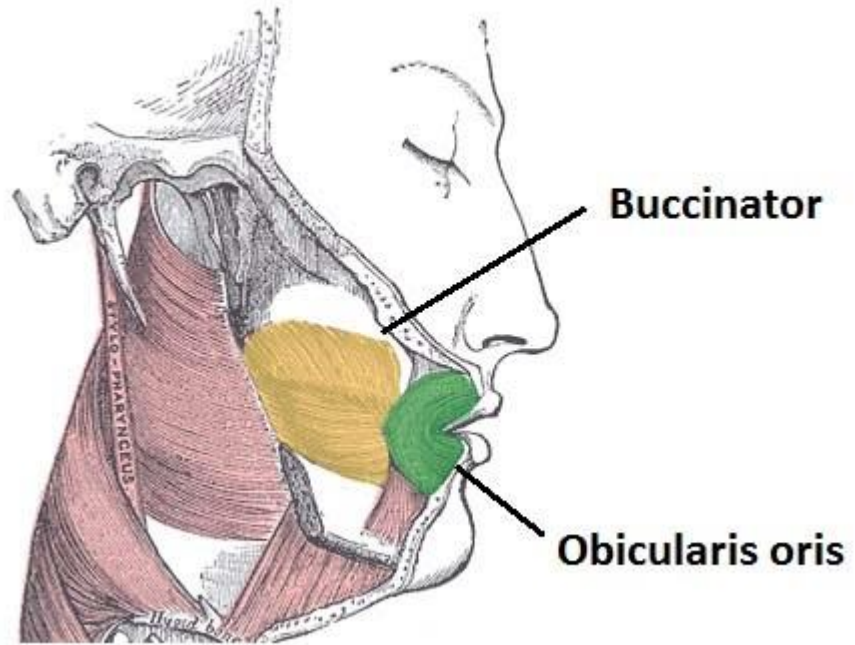
ORIGIN: Superior part -
alveolar process of maxilla

Inferior part -
alveolar process of mandible

INSERTION : Lower fibers
cross to insert into upper lip

Upper fiber cross
to insert into lower lips

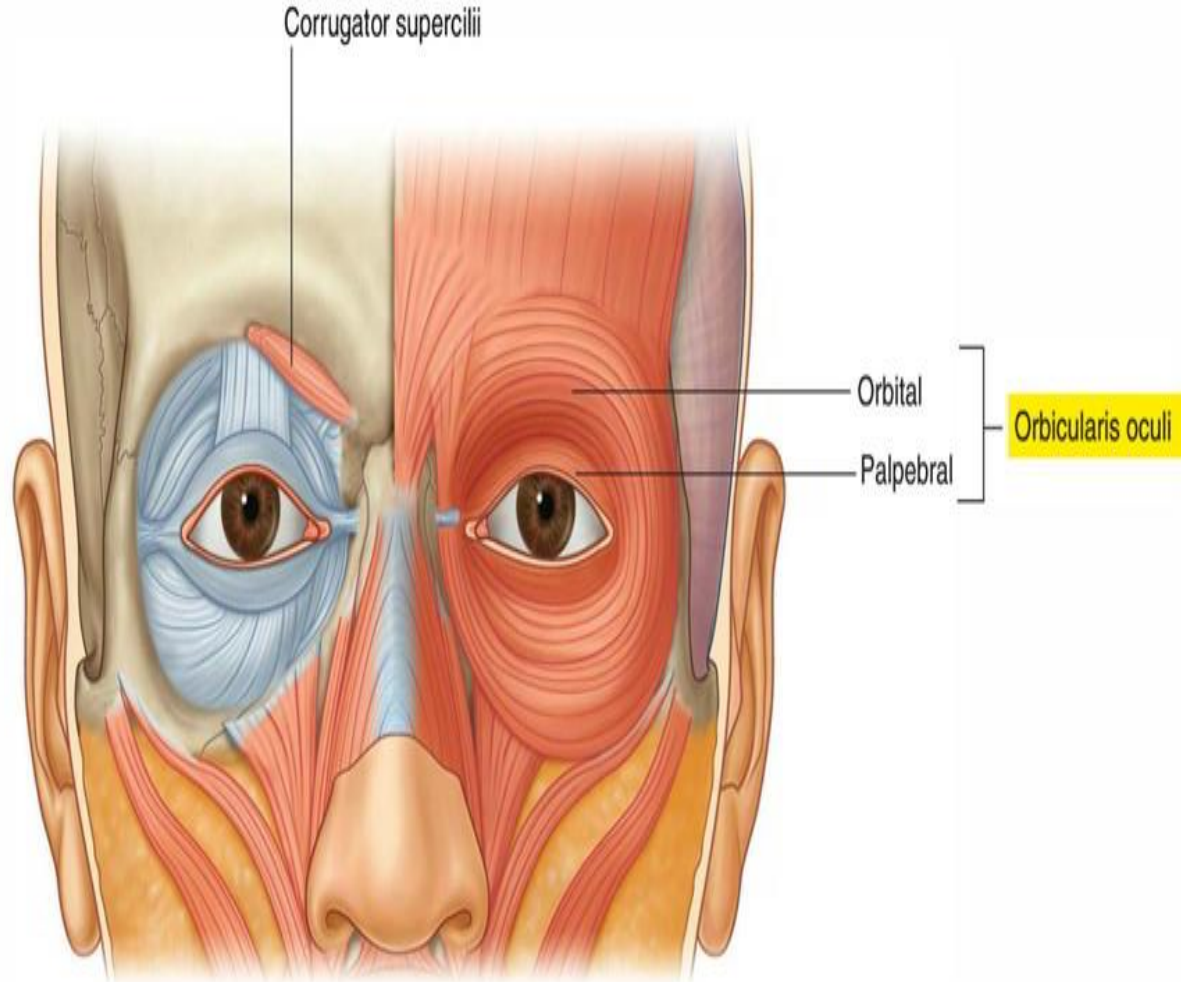
ACTION : Compresses cheek
against teeth



ORBICULARIS OCULI

ORIGIN: Medial orbital margin and zygomatic bone

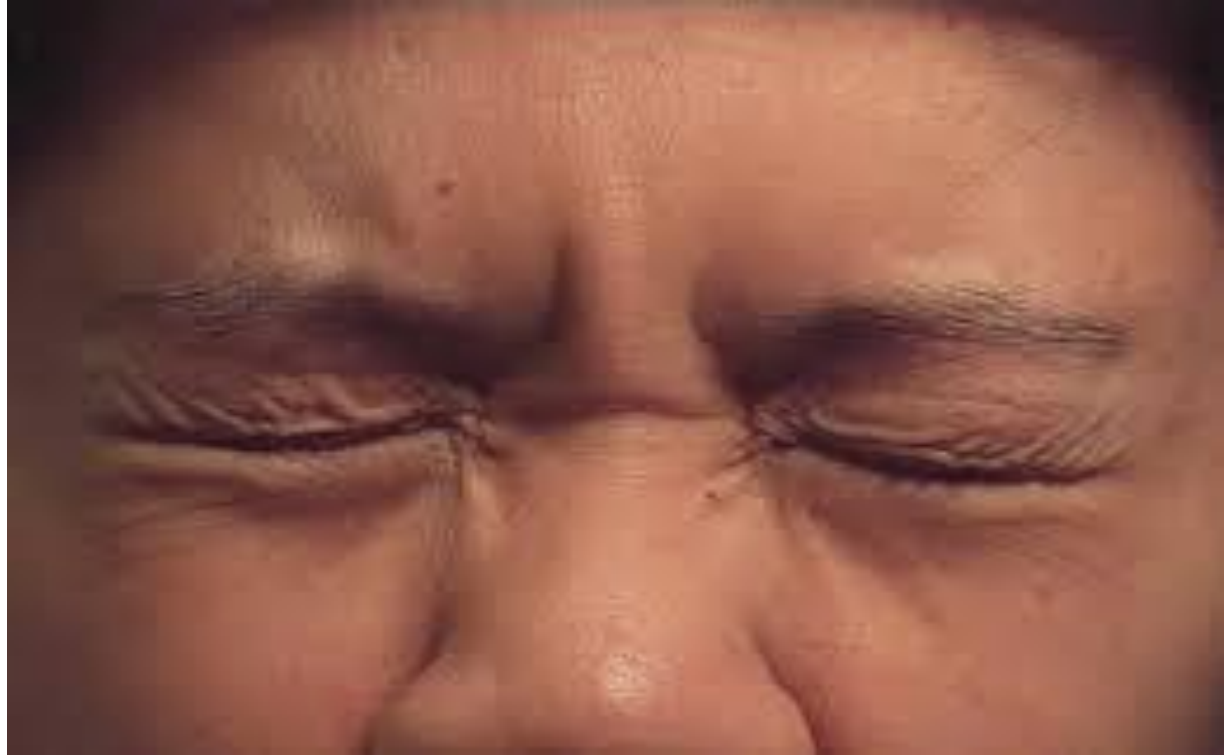INSERTION: Skin surrounding eye



ACTION

Depresses eyelid

Assist in pumping tears
from eye





**Thank
You**