

OSTEOLOGY OF FEMUR BONE

DR NAJMA ATTAULLAH

LECTURER KGMC

The Femur

- **The Femur** is the longest, heaviest and strongest bone of the body, present in the thigh.
- It's around 18 inches (45 long),
 - i.e., about quarter of the height of the individual.
- At the upper end it articulates with the hip bone to create the hip joint.
- At the lower end it articulates with the patella and tibia.
- The femur conducts body weight from the hip bone to the tibia in standing position.

PARTS

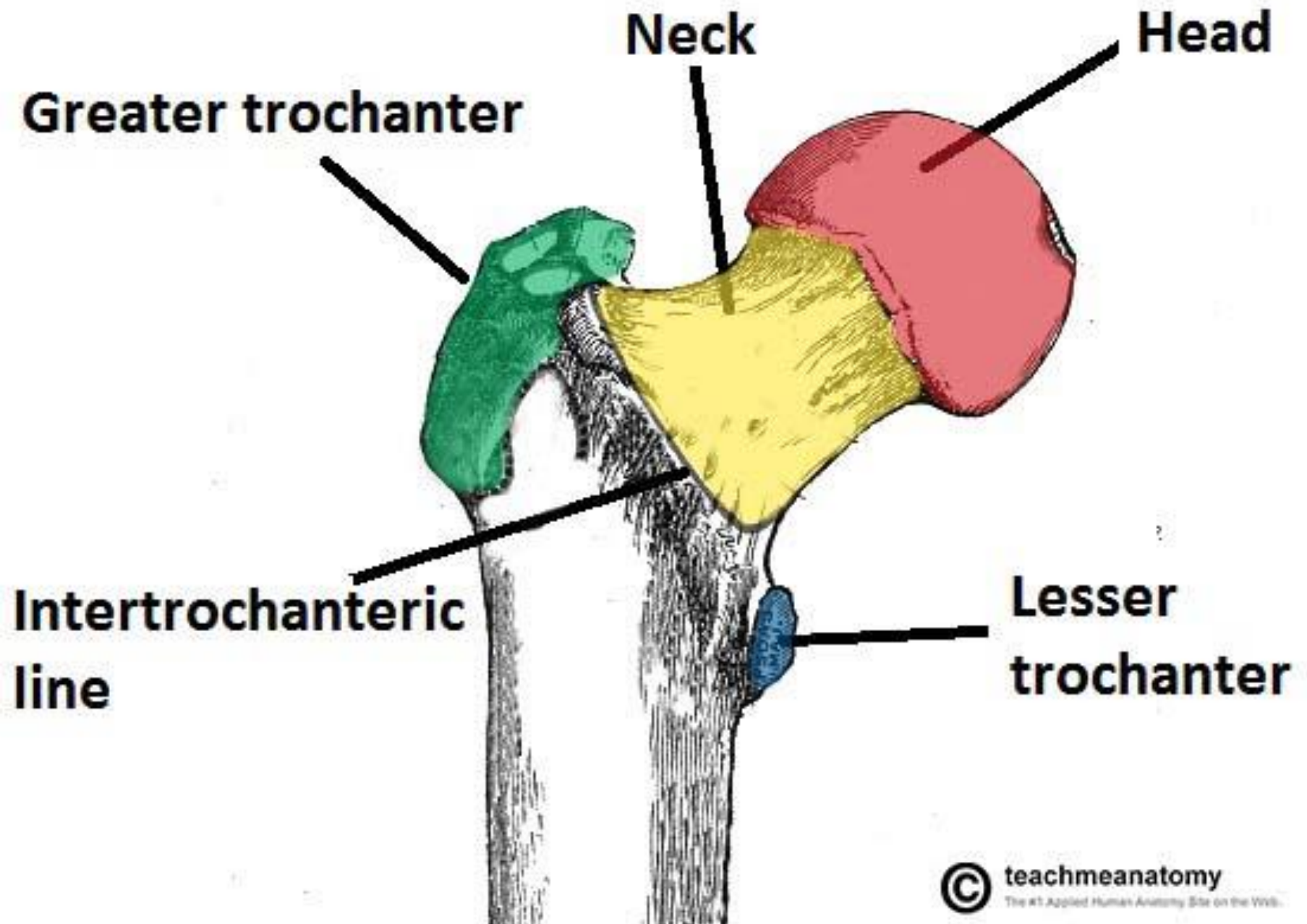
- The femur is composed of 3 parts:
 - Upper end,
 - Shaft .
 - Lower end.
- The upper end contains:
 - The head,
 - The neck .
 - The lesser and greater trochanter.
- The shaft of the femur is gradually convex anteriorly with maximum convexity in the middle third where the shaft is narrowest.
- The lower end of the femur is enlarged to create
 - Medial condyle.
 - Lateral condyle.
 - Intercondylar fossa
 - Both condyles project backwards and are divided by the intercondylar fossa.
- The most notable points on the condyles are named epicondyles.

SIDE DETERMINATION

- The upper end bears a rounded head whereas the lower end is widely expanded to form two large condyles.
- The head is directed medially.
- The cylindrical shaft is convex forwards

ANATOMICAL POSITION

- The head is directed medially upwards and slightly forwards.
- The shaft is directed obliquely downwards and medially so that the lower surfaces of the two condyles of the femur lie in the same horizontal plane.



JOINTS OF FEMUR.

- FEMURO- ACETABULAR JOINT. (Hip Joint)
- FEMURO – TIBIAL JOINT. (Knee Joint)
- ARTICULATES WITH PATELLA.

HEAD

- It creates about two-third of a sphere and articulates with the acetabulum of the hip bone to create the hip joint.
- It is covered with cartilage except a central pit, fovea.

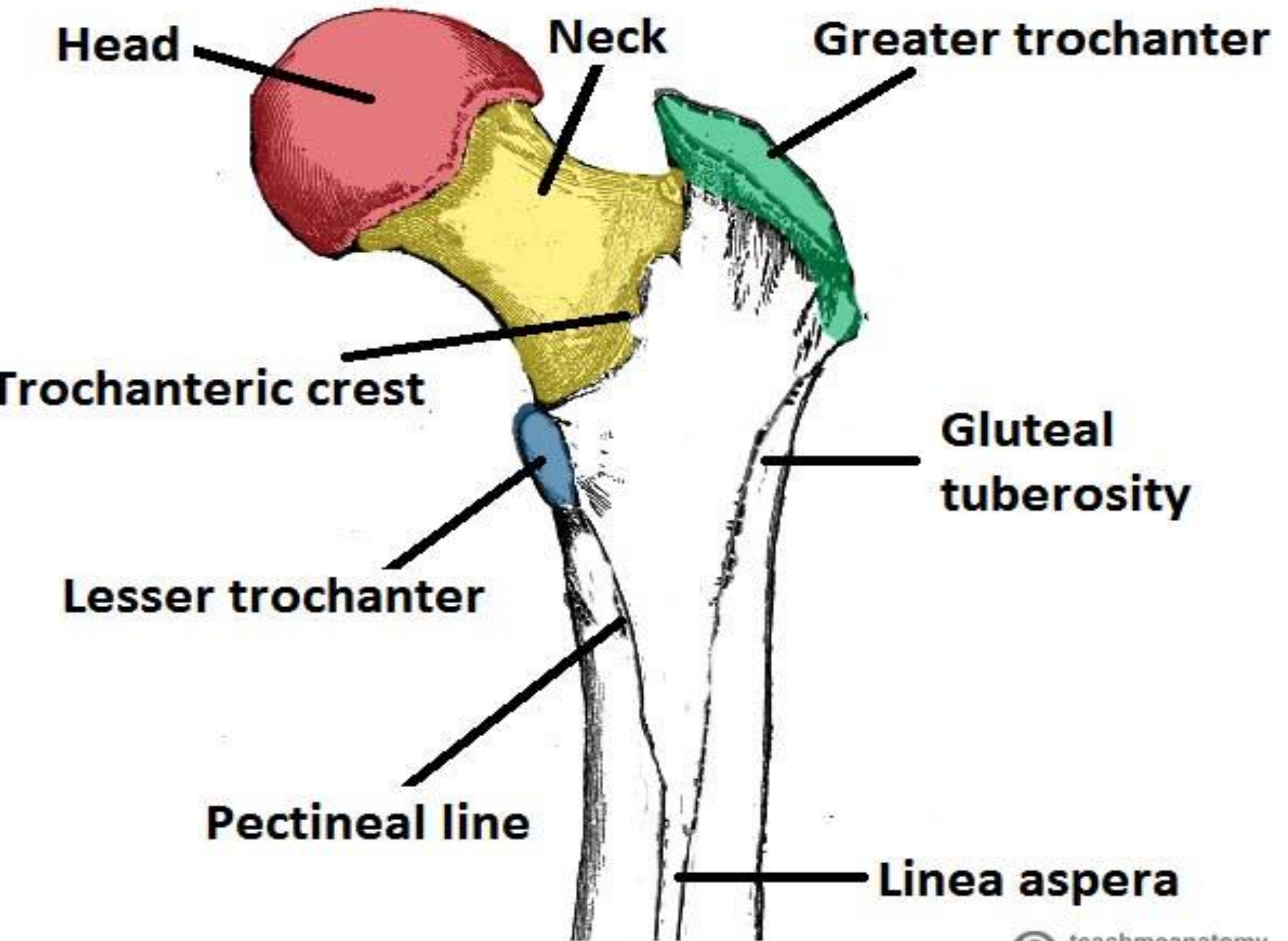
It presents a small pit, the fovea, just below and behind the center, where ligament of the head of femur (ligamentum teres femoris) attaches.

NECK

- It is 5 cm long and attaches the head with all the shaft.
- It is directed upward, medially, and somewhat forwards.
- The angle between its lower border and the medial border of shaft is termed neck-shaft angle($110-120^{\circ}$).

NECK

- Two borders and two surfaces
- UPPER BORDER....meets the shaft at greater trochanter...
- LOWER BORDER.....meets the shaft at lesser trochanter...
- ANTERIOR SURFACE....Meets the shaft at intertrochanteric line
- POSTERIOR SURFACE....meets the shaft at inter trochanteric crest.



GREATER TROCHANTER

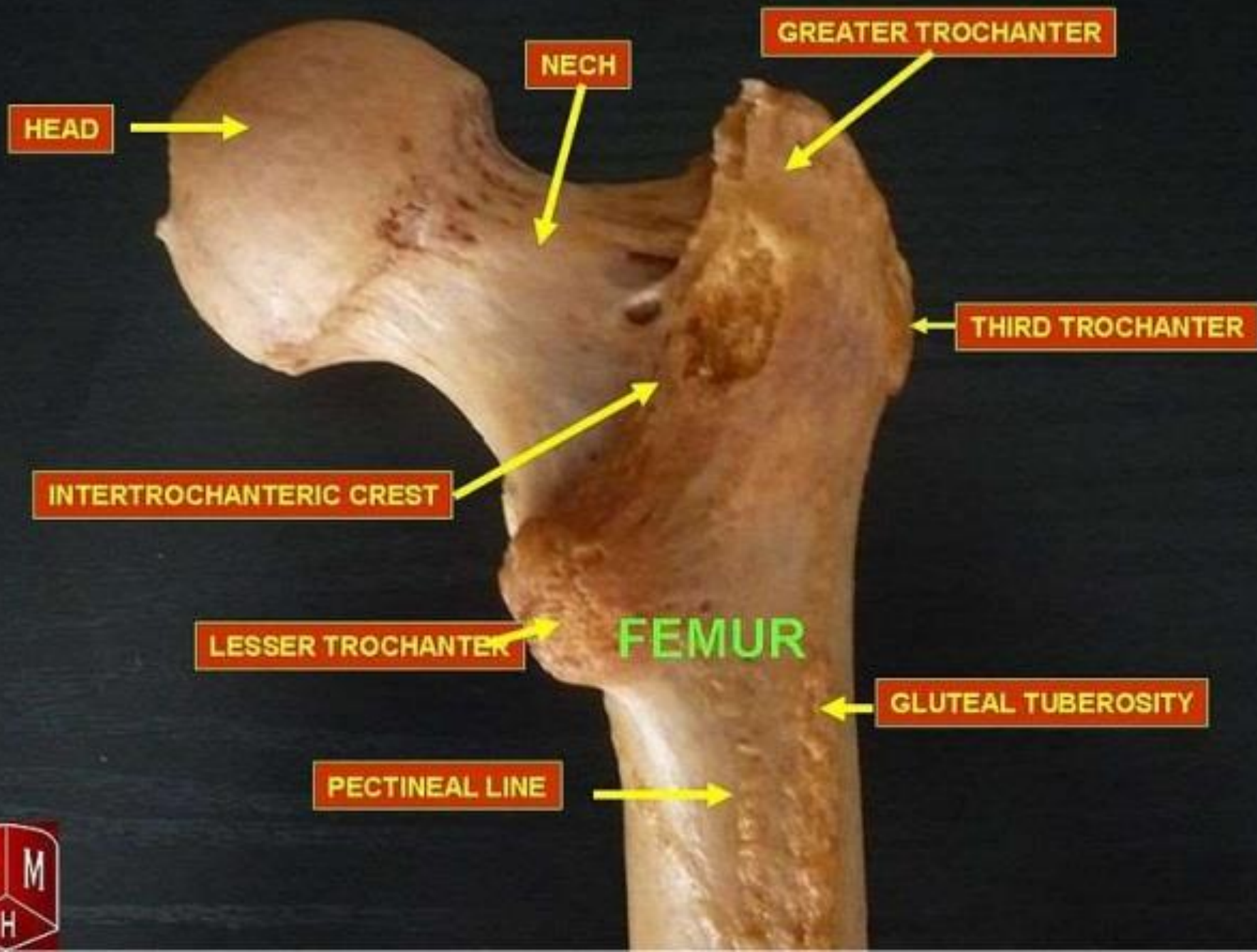
- It's a quadrilateral elevation, projecting upward from the lateral aspect of the junction of neck and shaft.
- Its upper & posterior part is bent backwards & medially and overhangs the neck.
- Its lateral surface has an oblique rough ridge which separates 2 smooth areas.

Greater trochanter

- It has the following features:
 - Its lateral surface is convex.
 - Its upper & posterior borders are free.
 - Its highest point is in its posterosuperior angle.
 - Its medial surface has a deep depression called the trochanteric fossa for insertion of obturator externus.
 - Its posterior part presents the apex or tip of greater trochanter, which gives connection to the piriformis.

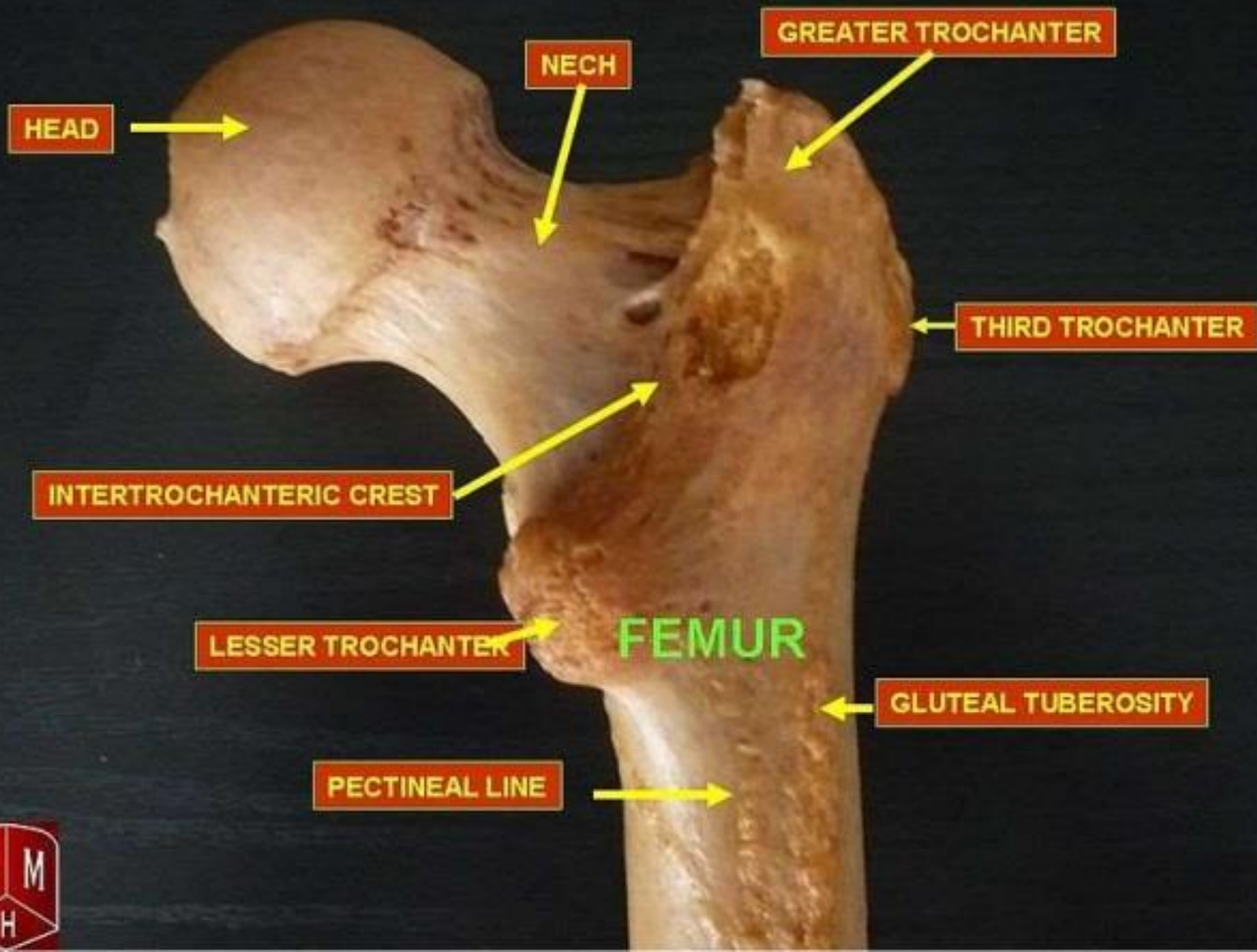
Greater trochanter

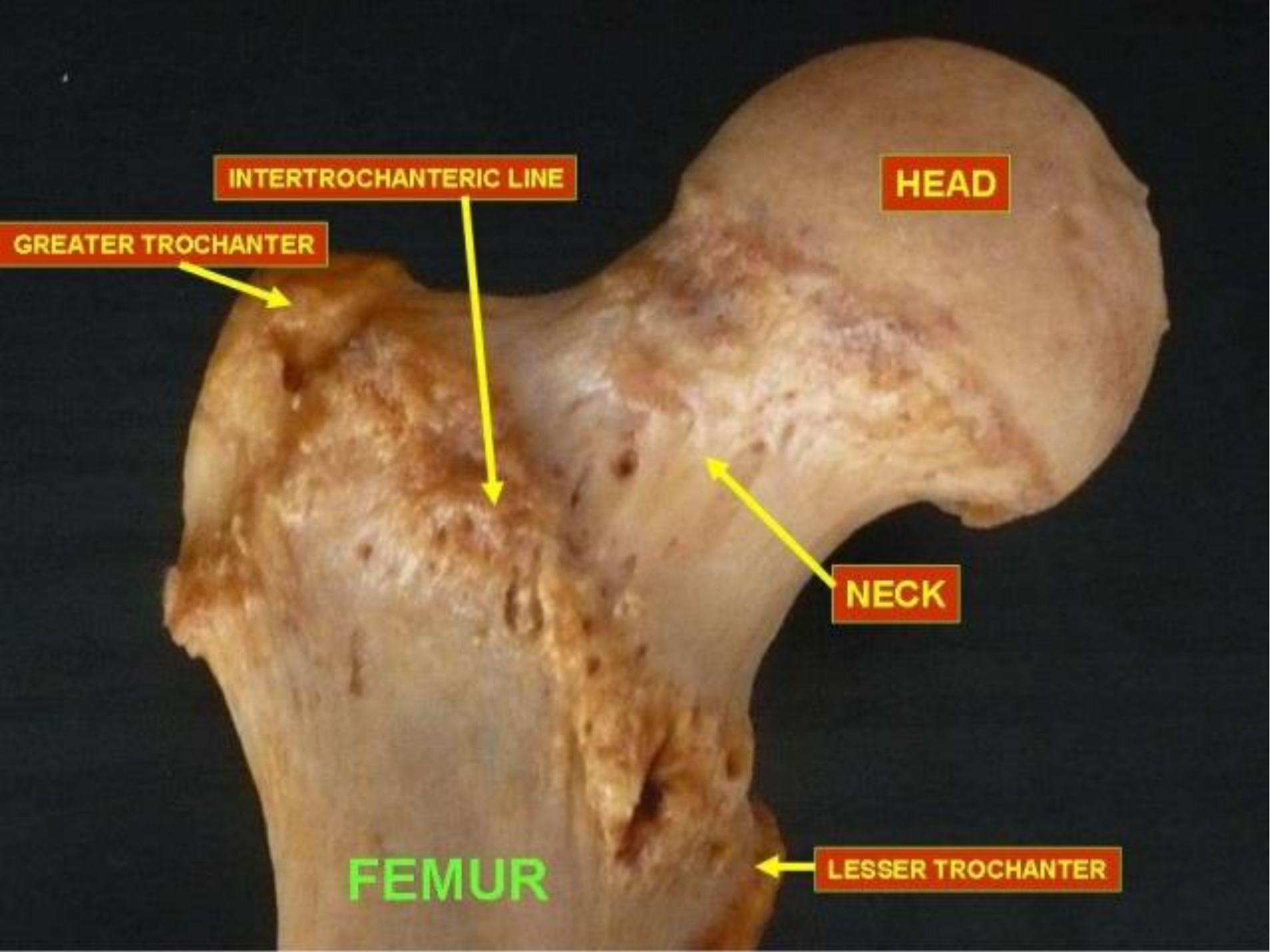
- A shallow depression above and in front of trochanteric fossa for insertion of obturator internus together with the gemellus superior and gemellus inferior.
- It is quadrilateral and split diagonally by an oblique ridge into the upper and lower triangular regions.
 - The ridge gives connection to the gluteus medius muscle.
- The triangular regions- anterior and posterior to the ridge are associated with the trochanteric bursae of the gluteus medius and gluteus maximus, respectively.



LESSER TROCHANTER

- It is a conical projection rising from the posteromedial surface of the neck-shaft angle. It is directed medially.
 - Its apex gives connection to the [psoas major](#).
 - [Iliacus](#) is connected to its base on the front.
- Three lines radiate from the lesser trochanter
 - One runs upwards & medially below the neck.
 - 2nd is pectineal line; it runs downwards & gives attachment to the aponeurosis of the pectineal muscle.
 - 3rd line runs upwards & laterally and forms the lower half of the “**Intertrochanteric crest**”





HEAD

INTERTROCHANTERIC LINE

NECK

LESSER TROCHANTER

FEMUR

GREATER TROCHANTER

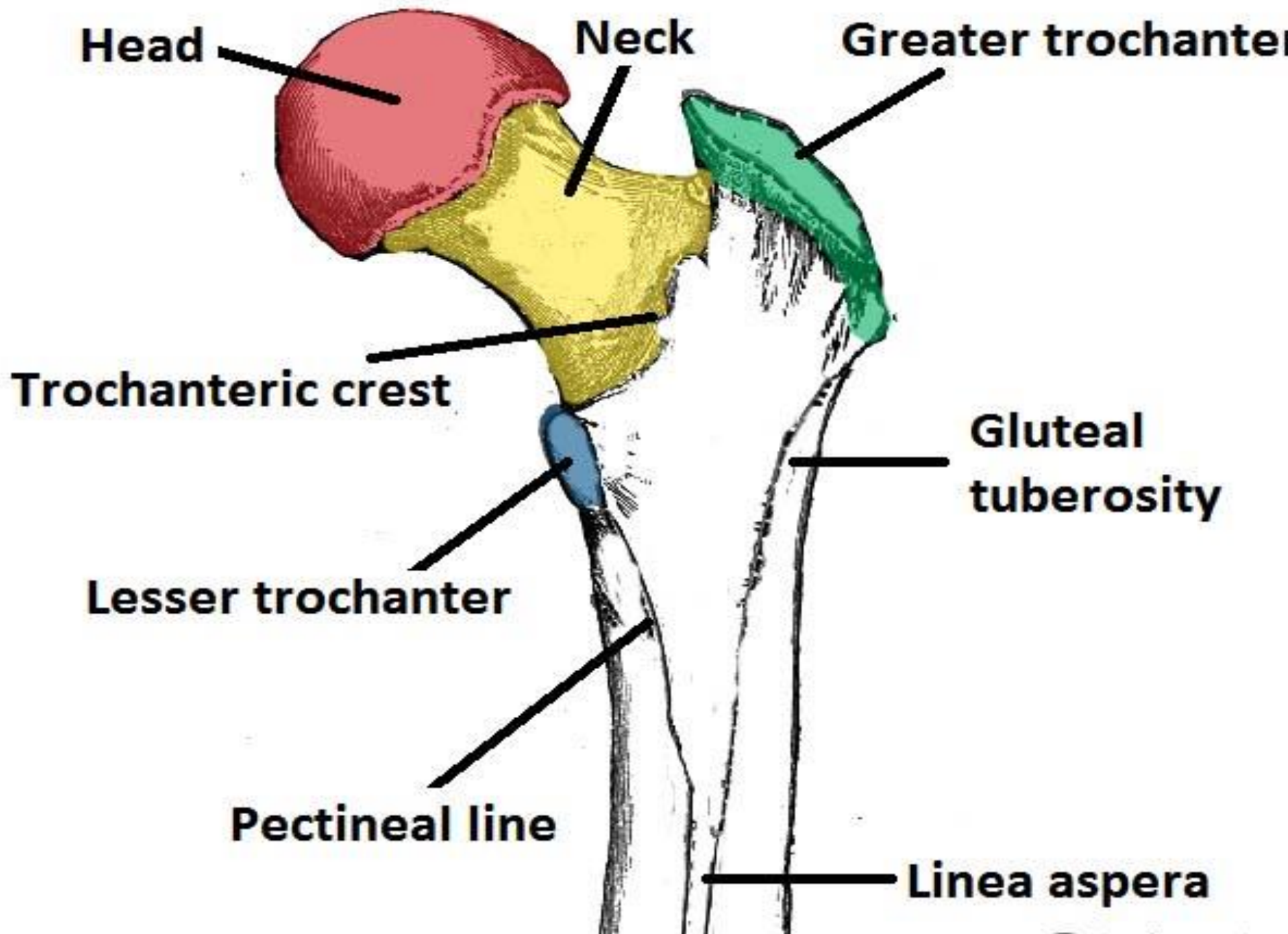
Bony ridges in between trochanters

- **Intertrochanteric line**

- **Intertrochanteric crest**

TROCHANTERIC LINE

- A ridge of bone that runs in an inferomedial direction on the anterior surface of the femur, connecting the two trochanters together.
 - After it passes the lesser trochanter on the posterior surface, it is known as the pectineal line of femur.
 - It continues downward and medially below the lesser trochanter on the posterior aspect of femur as spiral line.
- It gives connection to :
 - 2 ligaments and
 - Capsule of the hip joint.
 - Iliofemoral ligament (strongest ligament in the body).
 - 2 muscles:
 - Vastus lateralis to its upper end.
 - Vastus medialis to its lower end.



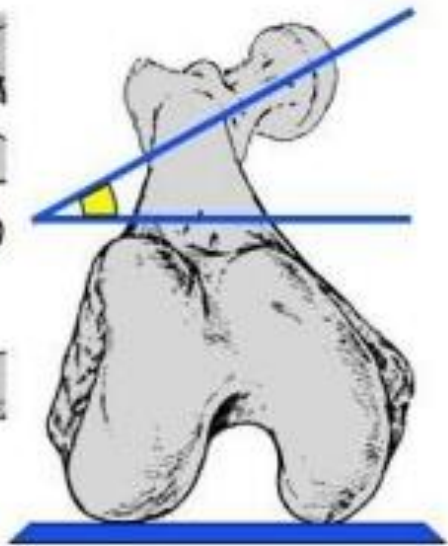
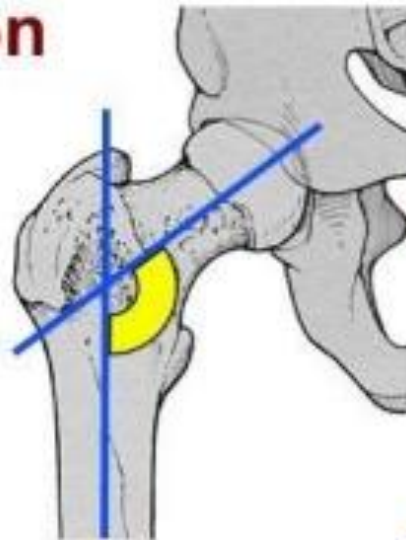
TROCHANTERIC CREST

- This is a ridge of bone that connects the two trochanters together. It is located on the posterior surface of the femur.
- There is a rounded tubercle on its superior half, this is called the quadrate tubercle.
 - It gives insertion to the quadratus femoris.

Femur Neck Angles

1. Angle of inclination

- $=125^\circ$ is normal
- $>125^\circ$ is coxa valga
- $<125^\circ$ is coxa vara

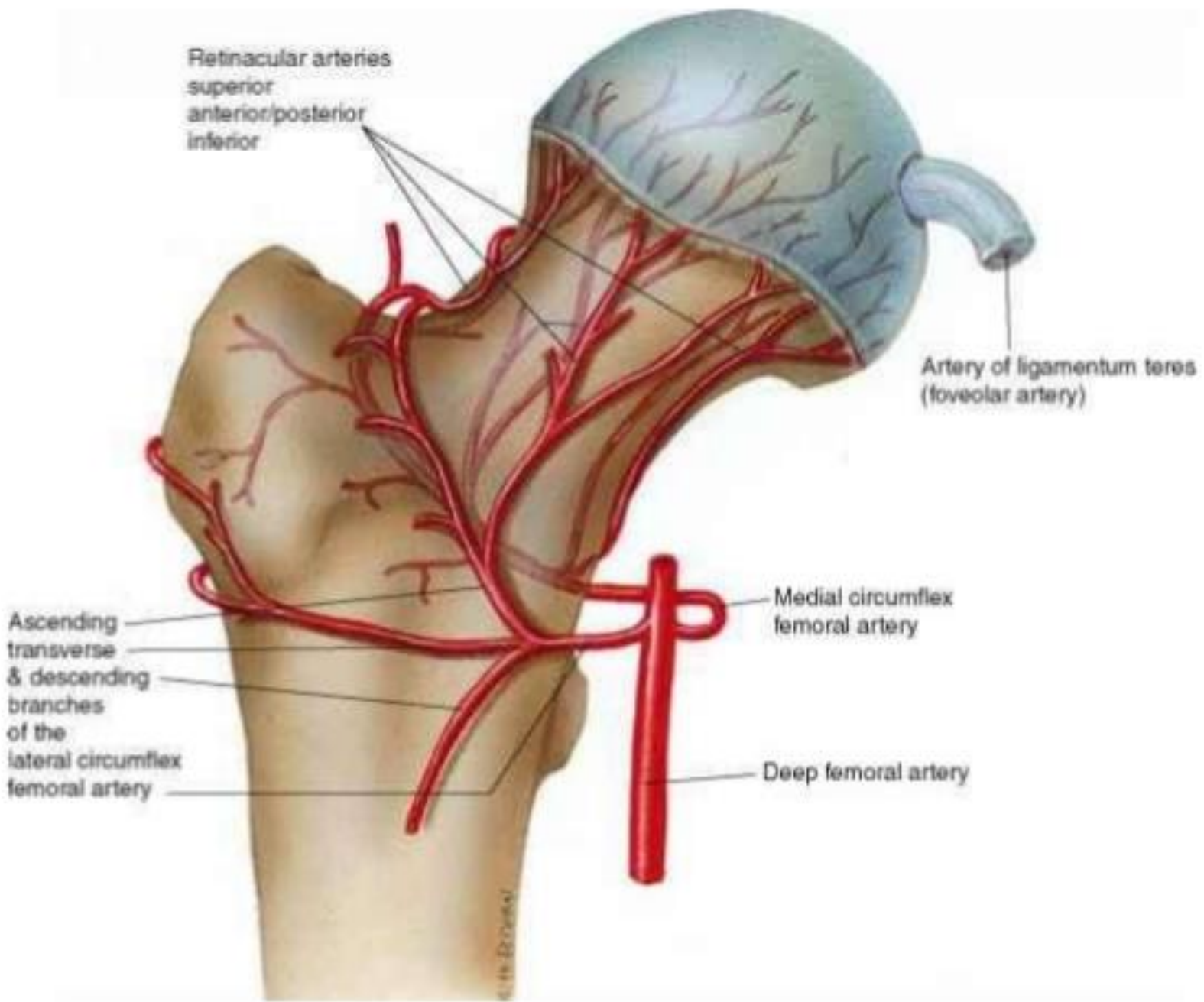


2. Angle of torsion

- 12 to 14° is normal
- Head forward is anteversion or internal femoral torsion (toeing in) – common & usually outgrown in children
- Head back is retroversion (toeing out)

Blood supply of the head of the femur

- Blood ascends upwards from the shaft along the cancellous bone.
- Blood from the vessels in the capsule of the hip joint; reflected to the neck in longitudinal bands called capsular retinaculae (retinacular supply). These arise from the lateral femoral circumflex artery.
- Blood from the artery in the ligament teres.



Retinacular arteries
superior
anterior/posterior
inferior

Artery of ligamentum teres
(foveolar artery)

Ascending
transverse
& descending
branches
of the
lateral circumflex
femoral artery

Medial circumflex
femoral artery

Deep femoral artery

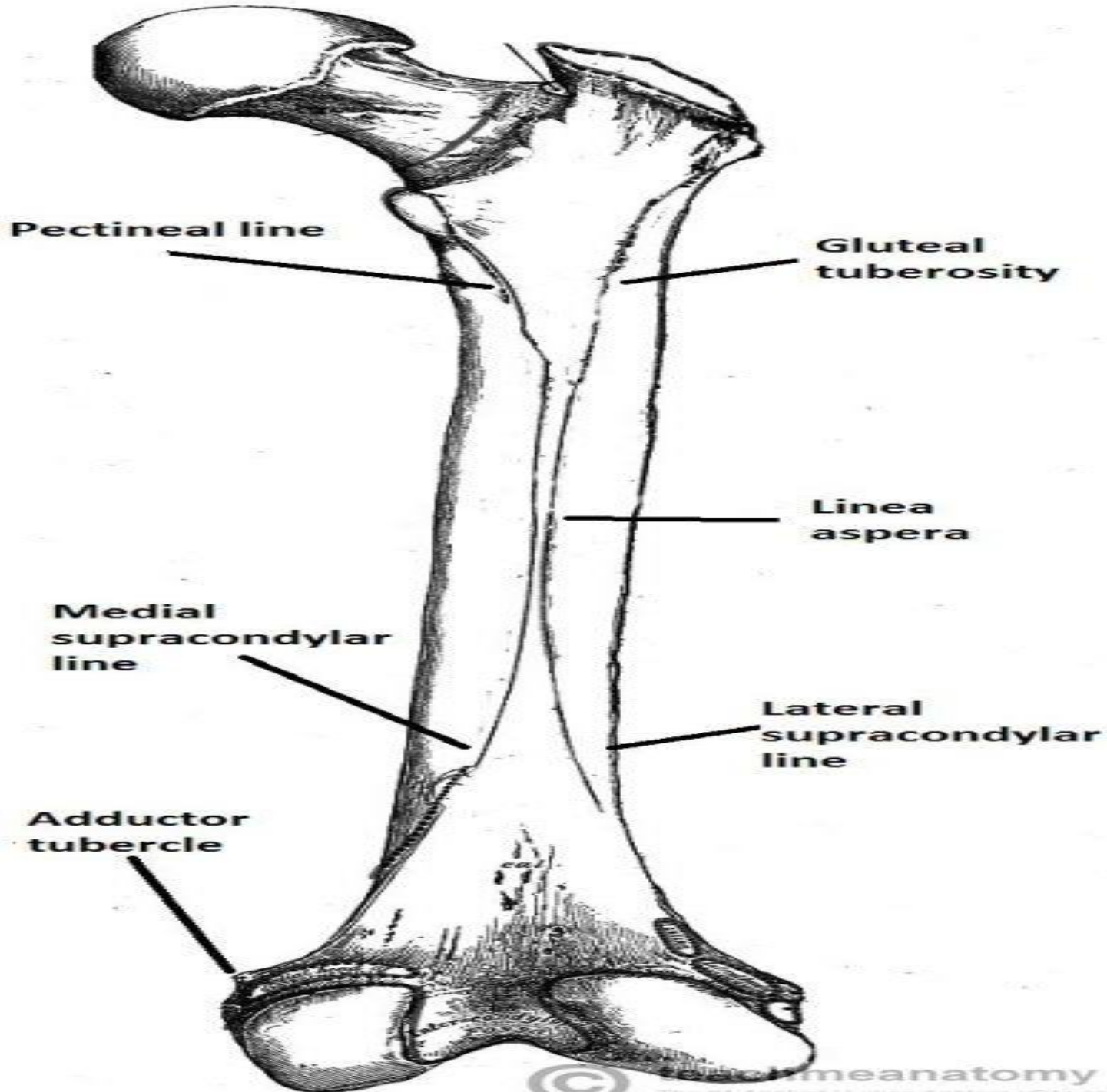
© H. B. DeGruy

FEATURES OF THE SHAFT OF FEMUR

- Essentially the shaft of femur presents:
- Cylindrical in the mid, expands in upper $1/3^{\text{rd}}$ and flattened in lower $1/3^{\text{rd}}$.
- **3 surfaces:**
 - Anterior ,
 - Medial , and
 - Lateral
 - Upper posterior, and
 - Lower posterior (popliteal surface).

The Shaft

- On the posterior surface of the femoral shaft, there are roughened ridges of bone, these are called the **linea aspera** .
- Proximally, the medial border of the linea aspera becomes the **pectineal line**.
- The lateral border becomes the **gluteal tuberosity**, where the gluteus maximus attaches.
- Distally, the linea aspera widens and forms the floor of the **popliteal fossa**, the medial and lateral borders form the medial and lateral supracondylar lines.
- The medial supracondylar line stops at the **adductor tubercle**, where the adductor magnus attaches.



Gluteal tuberosity

- The lateral ridge of the linea aspera is very rough, and runs almost vertically upward to the base of the greater trochanter.
- It is termed the **gluteal tuberosity**, and gives attachment to part of the Glutæus maximus: its upper part is often elongated into a roughened crest, on which a more or less well-marked, rounded tubercle, the third trochanter.

Left femur (posterior view)

greater trochanter

intertrochanteric crest

Lesser trochanter

Spiral line

Gluteal tuberosity

Medial lip of linea aspera

lateral lip of linea aspera

linea aspera

lateral surface

medial surface

medial supracondylar line

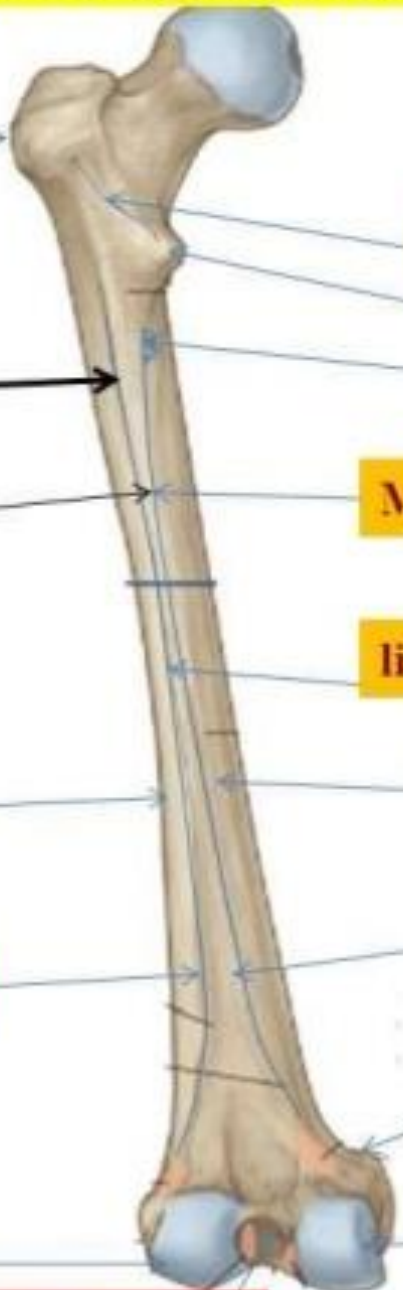
lateral supracondylar line

Adductor tubercle

lateral condyle

medial condyle

Intercondylar notch



The Distal end

- The distal end is characterised by the presence of the medial and lateral condyles, which articulate with the tibia and patella, forming the knee joint.
- **Medial and lateral condyles**
- **Medial and lateral epicondyles**

FEMUR

PATELLAR SURFACE

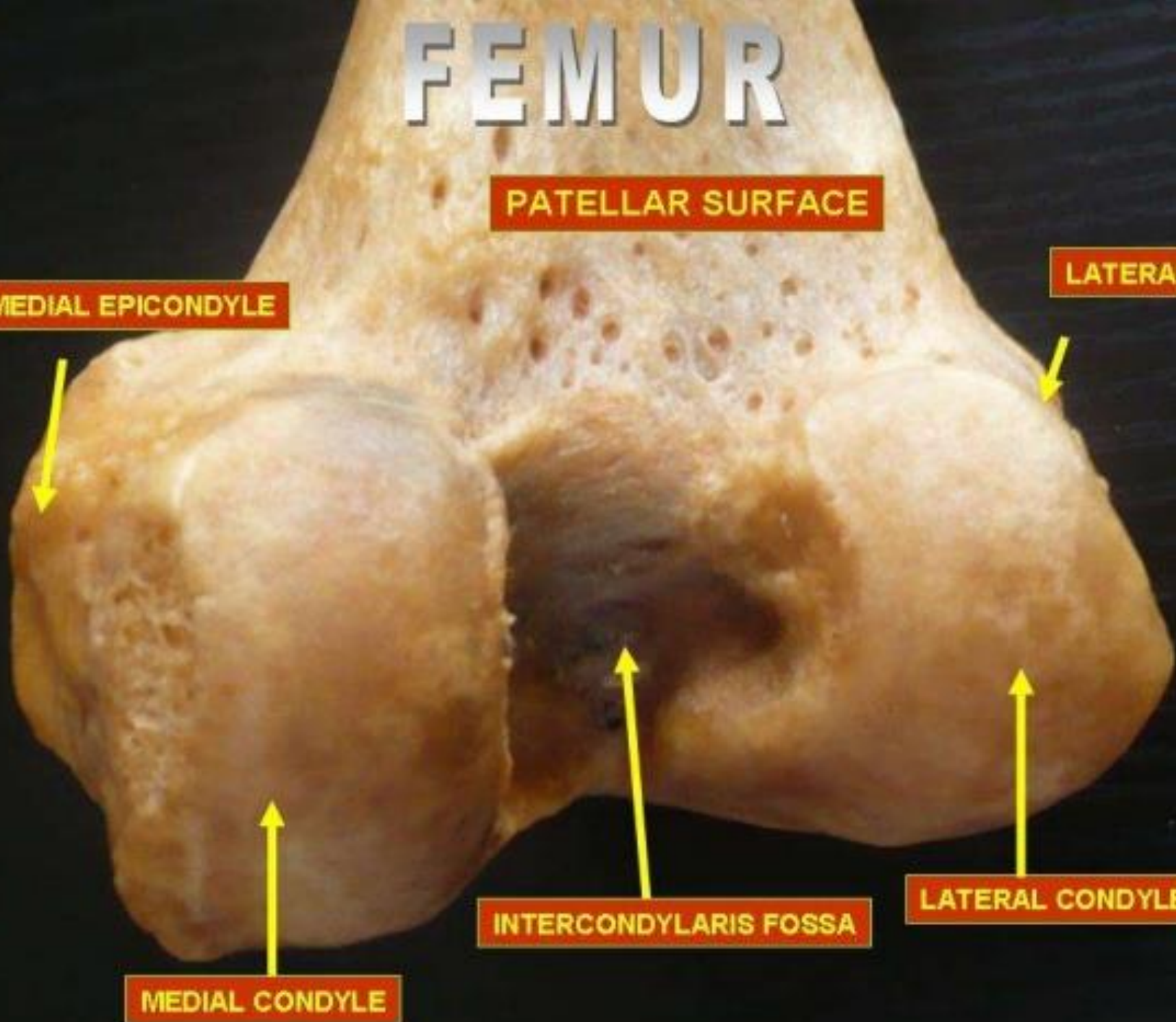
MEDIAL EPICONDYLE

LATERAL EPICONDYLE

INTERCONDYLARIS FOSSA

LATERAL CONDYLE

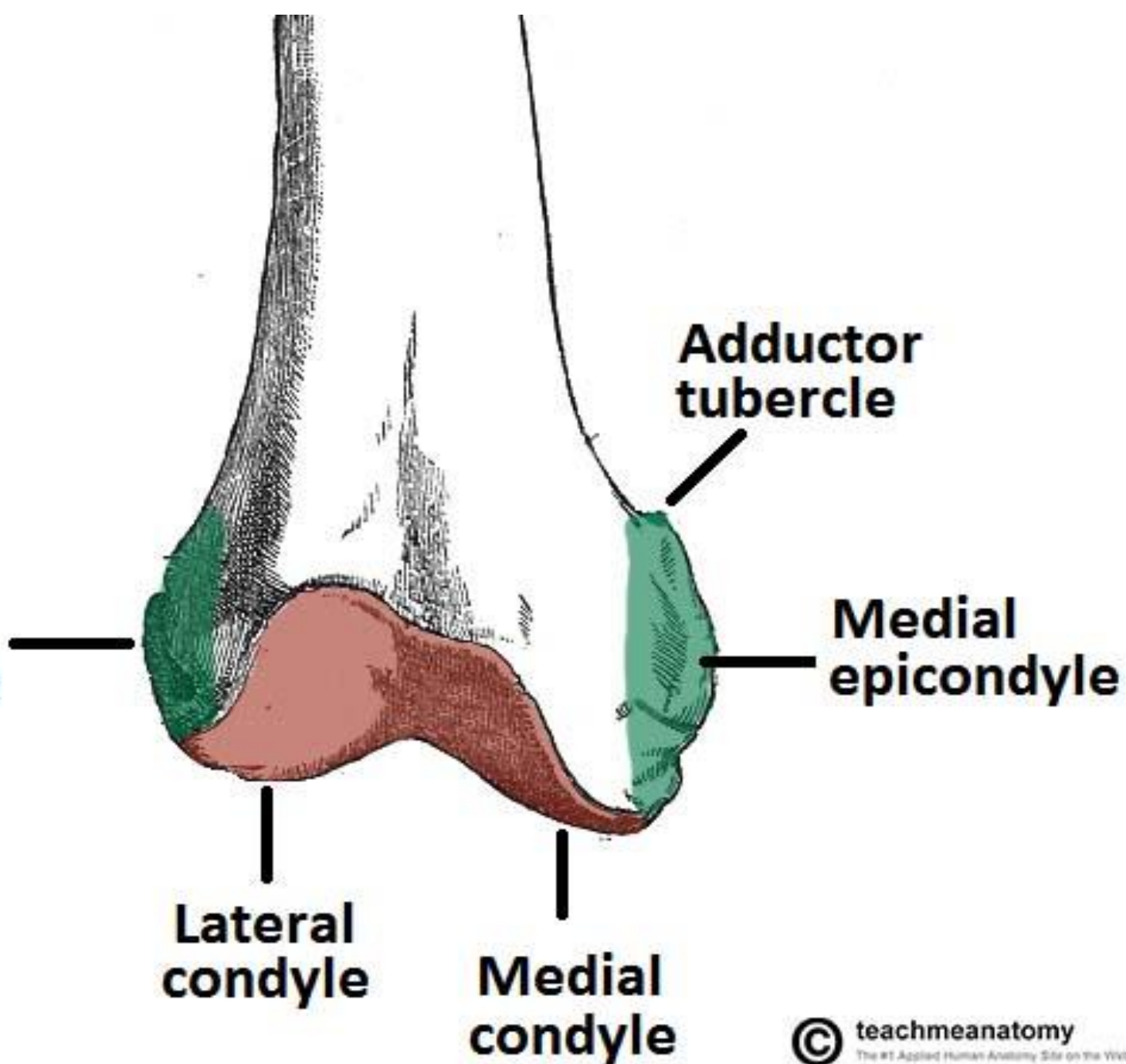
MEDIAL CONDYLE



Medial Condyle

- Its most notable point is named medial epicondyle, which gives connection to the upper end of **medial collateral ligament**.
- A projection posterosuperior to the medial epicondyle is known as adductor tubercle, which gives insertion to the ischial head of adductor magnus.
- Its lateral surface creates medial boundary of intercondylar fossa.

**Lateral
epicondyle**

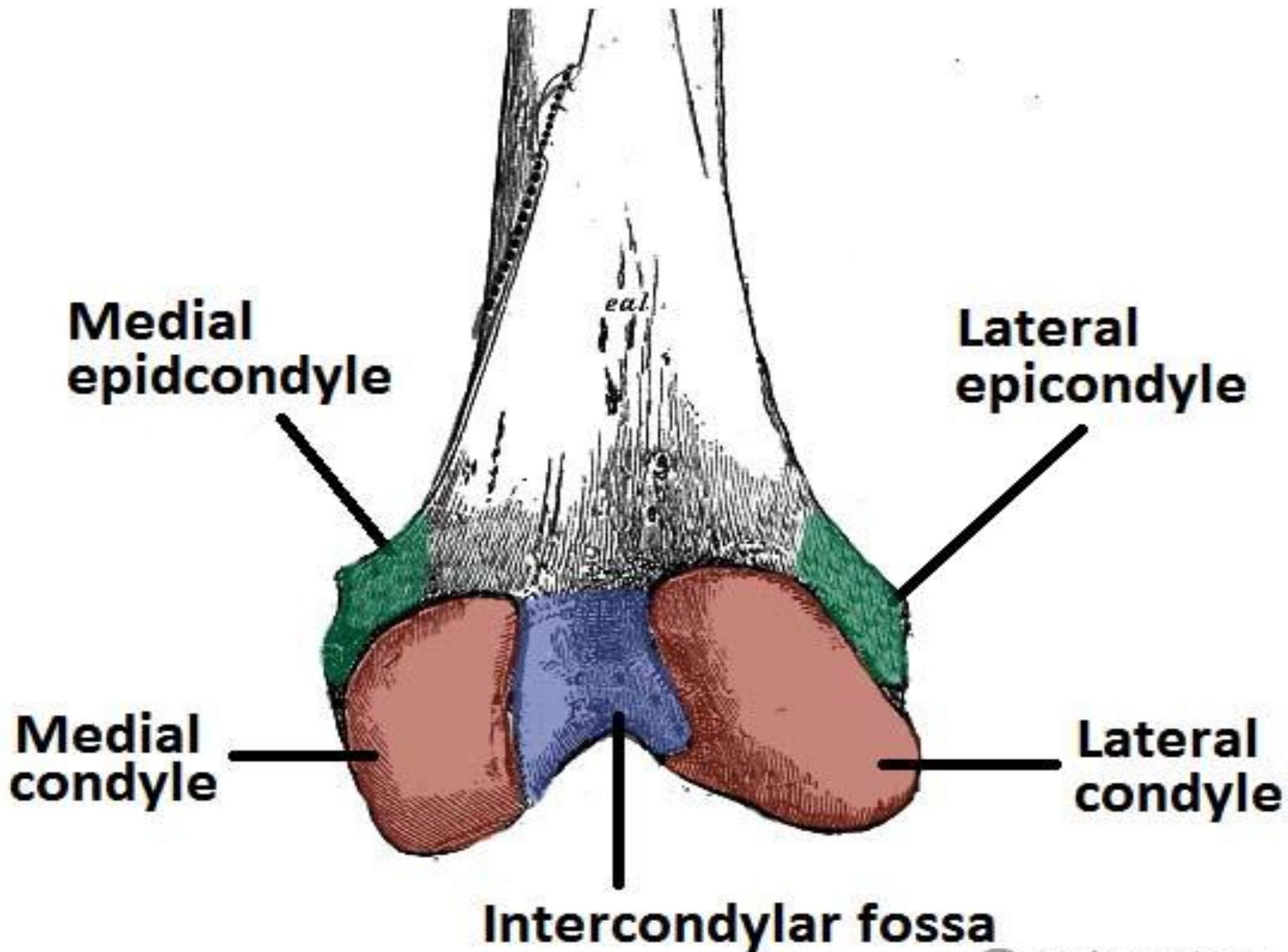


Lateral Condyle

- It's stouter and more powerful in relation to the medial condyle but less notable.
- Its lateral surface presents a bulge referred to as lateral epicondyle which gives connection to the fibular collateral ligament of the [knee joint](#).
- Smooth opinion above and behind the lateral epicondyle there is an origin to the lateral head of gastrocnemius.
- A groove below and behind the lateral epicondyle gives connection to [popliteus](#) in its anterior part. Tendon of popliteus takes up the posterior part of the groove during total flexion in the [knee joint](#).
- Its medial surface creates the lateral boundary of intercondylar fossa.

Intercondylar fossa

- **Intercondylar fossa** – A depression found on the posterior surface of the femur, it lies in between the two condyles. It contains two facets for attachment of internal knee ligaments.
- **Facet for attachment of the posterior cruciate ligament** – Found on the medial wall of the intercondylar fossa, it is a large rounded flat face, where the posterior cruciate ligament of the knee attaches.
- **Facet for attachment of anterior cruciate ligament** – Found on the lateral wall of the intercondylar fossa, it is smaller than the facet on the medial wall, and is where the anterior cruciate ligament of the knee attaches.



ARTICULAR SURFACE

on distal end of femur

- The lower end of femur presents a V-shaped articular surface having the anterior, inferior, and posterior surfaces of both condyles.
- The apex of 'V' is referred to as patellar surface which inhabits the anterior surfaces of 2 condyles and articulates with the [patella](#).
- The patellar surface is saddle-shaped. Its lateral portion is wider and extends to a higher level in relation to the medial portion, corresponding to articular outermost layer of the patella.

Clinical Relevance: Proximal Femur Fractures

- Fractures of the proximal femur can broadly be classified into two main groups:
- **Intracapsular Fracture**
- Intracapsular fractures are more common in the elderly, especially **women**. They are a result of a minor trip or stumble. This fracture occurs within the **capsule** of the hip joint. It can damage the medial **femoral circumflex artery** – and cause avascular necrosis of the femoral head.
 - The distal fragment is pulled **upwards** and rotated **laterally**. This manifests clinically as a shorter leg length, with the toes pointing laterally
- **Extracapsular Fractures**
- Extracapsular fractures are more common in young and middle aged people. In these fractures, the blood supply to the head of femur is **intact**, and so no avascular necrosis can occur. Like the subcapital fracture, the leg is shortened and laterally rotated.

CLINICAL SIGNIFICANCE

- **FRACTURE NECK OF FEMUR**

- It's quite common in aged especially in women because of osteoporotic changes in the neck.

- **TYPES OF FRACTURE**

- The fracture might be intracapsular (subcapital, transverse cervical) or extracapsular (basal, intertrochanteric, and subtrochanteric).

- In intracapsular fracture, the retinacular vessels- the main source of blood supply to the head- are injured. This results in delayed healing or nonunion of fracture, or even avascular necrosis of the head of femur.

- In intracapsular fracture of the neck of femur, the affected limb is shortened and characteristically held in laterally rotated position with the toes pointing laterally.

Clinical Relevance: Fractures of the Femoral Shaft

- Fractures of the **femoral shaft** are relatively uncommon, and require a lot of force. They are usually a consequence of a **traumatic** injury, such as a vehicular accident.
- They can often occur as a **spiral** fracture, which causes leg **shortening**. The loss of leg length is due the bony fragments overriding, pulled by their attached muscles.
- As the method of injury is typically high energy, the surrounding soft tissues may also be damaged. As in any fracture, it is important to assess the **neurovascular supply** to the affected limb, as the femoral nerve or artery may have been damaged in the injury.


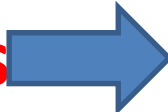


OSSIFICATION

- The femur ossifies from 5 centers:
- 1 primary and 4 secondary centers.
 - The primary center appears in the midshaft.
 - 3 secondary centers show up in the upper end
 - 1 secondary center in the lower end.

CLINICAL SIGNIFICANCE

- Medicolegal importance of ossification center at the lower end of femur:
- The secondary center at the lower end of femur is exceptional in the meaning it seems during beginning/ just before arrival (ninth month of IUL).
- It is of medicolegal significance because its look in radiograph signifies maturity of the fetus.

MUSCLE ATTACHMENT (INSERTION ON FEMUR)

- **Iliacus and psoas major** (iliopsoas)  Lesser trochanter
- **Pectineus**  Pectineal line, linea aspera
- **Obturator externus**  Trochanteric fossa of femur
- **Obturator internus**  Medial surface of the greater trochanter

MUSCLES ATTACHMENT

- **Superior and inferior gemelli**..... Medial surface of the greater trochanter (via tendon of obturator internus)
- **Piriformis**Apex of the greater trochanter (lateral and superior to the insertion of obturator internus)
- **Gluteus maximus** Iliotibial tract, gluteal tuberosity
- **Gluteus medius** Lateral aspect of the greater trochanter
- **Gluteus minimus** Anterior aspect of the greater trochanter

MUSCLES ATTACHMENT

- **Quadratus femoris** Intertrochanteric crest
- **Adductor magnus** Adductor part: Gluteal tuberosity, Linea aspera (medial lip), Medial supracondylar line
- **Adductor brevis** Linea aspera (medial lip)
- **Adductor longus** Linea aspera of the femur (medial lip)

ORIGIN ON FEMUR

- **Vastus lateralis** Linea aspera, greater trochanter
- **Vastus intermedius** Anterior surface of the femoral shaft
- **Vastus medialis** Intertrochanteric line

ORIGIN ON FEMUR

- **Biceps femoris brevis (short head)** Linea aspera (lateral lip), Lateral supracondylar line
- **Gastrocnemius Lateral head:** Posterolateral surface of lateral femoral condyle
- **Medial head:** Medial femoral condyle, Popliteal surface of femoral shaft
- **Popliteus** Lateral femoral condyle, Posterior horn of lateral meniscus of knee joint



Thank
you!