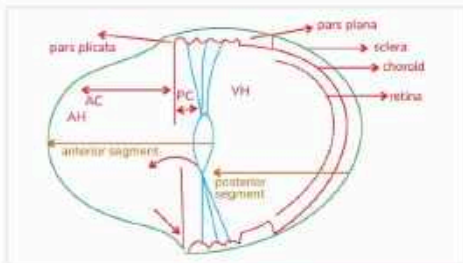


- A basic diagram of the eye is drawn, where the white part is the sclera which continues as cornea anteriorly. Behind cornea, lies the Iris that gives color to the eye. The opening in the Iris is the pupil. The junction between the sclera and cornea is known as Limbus. Above the sclera, there lies another tissue, the episclera. The episclera is a continuation of the sclera and is the outermost layer of the sclera. Above the episclera lies the Tenon's capsule.
- Conjunctiva is a thin mucus membrane covering the ocular surface but does not cover the cornea.

### Parts of the conjunctiva

00:04:00

- The bulbar conjunctiva
- The fornix
- Palpebral conjunctiva (the part of the conjunctiva covering the upper lid and the lower lid).



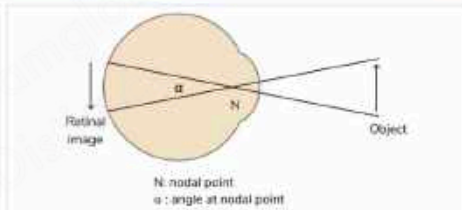
- The whole eyeball is divided into two segments, the anterior segment, and the posterior segment. The anterior segment is further divided into the anterior chamber and the posterior chamber. The anterior and posterior chambers are filled with aqueous humor. Behind the lens lies the vitreous cavity filled with vitreous humor, which is a gel.
- Aqueous humor is formed in the ciliary processes.
- The rough part of the ciliary body is called "pars plicata"

which is rough due to the ciliary process. This is the place where the aqueous is formed. The plain part of the ciliary body is called "pars plana".

- The aqueous after being formed in the ciliary process goes into the posterior chamber and through the pupil, it comes into the anterior chamber. From the anterior chamber it goes into the peripheral space in between the Iris and the cornea, the angle of the anterior chamber. The angle on the inside is corresponding to the limbus outside.
- The angle also has channels known as trabecular meshworks. From there, the Aqueous goes into the Schlemm's canal. It eventually goes into the episcleral venous system.

### Mechanism of vision

00:10:27



- When parallel light rays fall on the cornea, there is the bending of the light rays called as refraction. The major refracting surfaces are the cornea and the lens.
- The parallel light rays falling on the cornea are first bent at the cornea and then at the lens. The first point where the parallel light rays fall is situated just behind the lens and is known as the nodal point of the eye (N). At the nodal point, the image becomes inverted and falls on the retina. This image is then made straight by our brain.



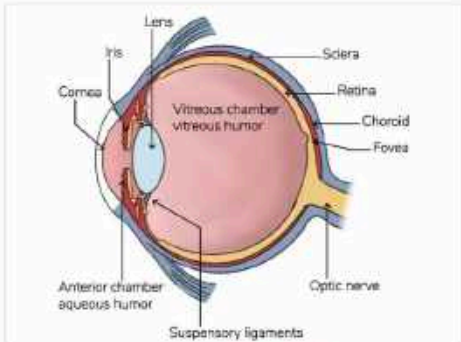
### Important Information

- Nodal point:** It is the optical center of the eye. It is also the first focal point that is situated just behind the lens.

### Structure of the eye

00:13:10

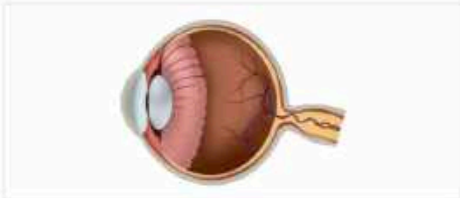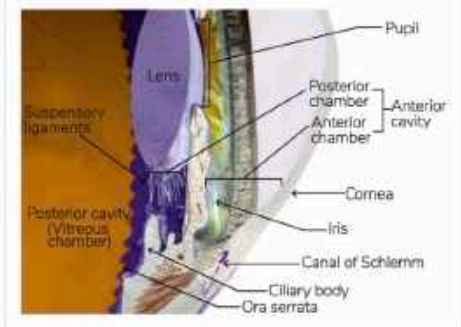
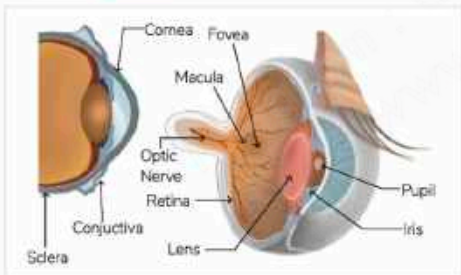




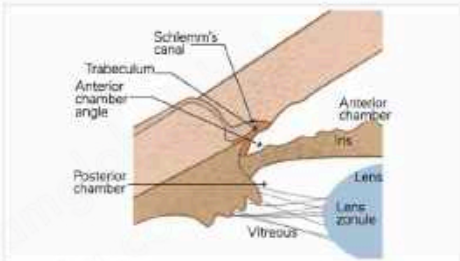
- The shape of the eye is an **oblate spheroid**. Capacity varies from 6 to 7 ml.
- All the nerve fibers from the retina aggregate at the **disc** and form the **optic nerve**.

Refer Image 1.1

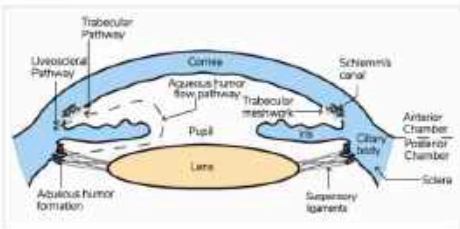
- Corresponding to the optic disc, the scotoma is called the **blind spot**. Any non-seeing area surrounded by a seeing area is called a **scotoma**.



- The retina is the innermost layer but does not extend up to the anterior part and stops at the ciliary body (*pars plana*). The most peripheral part of the retina is labelled as **ora serrata**.

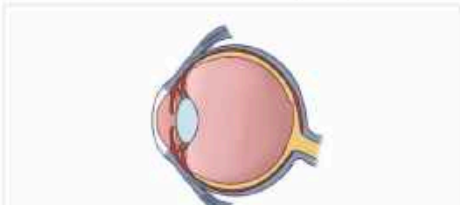


- In the diagram above, the Iris, the anterior chamber, the cornea, and the angle can be seen. The anterior chamber angle has the trabecule. The Schlemm's canal can also be seen.

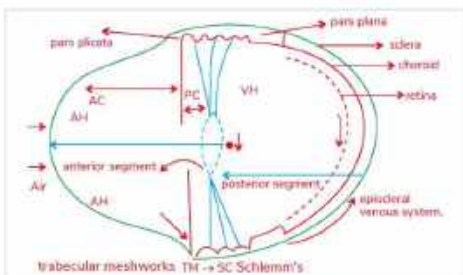


#### Outflow of aqueous humor

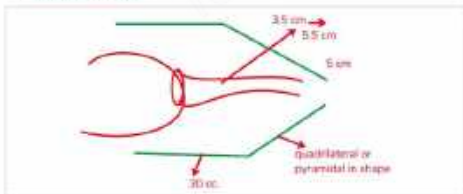
- The aqueous that is formed in the posterior chamber goes through the pupil into the anterior chamber, and through the **trabecular meshwork**. When it passes through the **uveosclera**, it is called the **uveoscleral pathway**.



- In the above-drawn diagram of the eye, the red part represents the vascular layer, the yellow part represents the retina, and the nerve fibres forming the optic nerve can be seen. The outermost blue layer is the sclera. The muscles can be seen to be attached to the sclera. The white part represents the cornea.



- Both the cornea, and the lens are avascular. These get their nutrition from the aqueous humor.
- More aqueous humor in the eye raises intraocular pressure. When this is happening, it presses more on the optic disc. This will lead to damage of the optic nerve or glaucoma. However, there are cases when the patient is glaucomatous, but their intraocular pressure is normal (normal tension glaucoma).
- All the nerve fibres have aggregated into the optic disc, crossing the retina, the choroid, and the sclera, and then entering into the orbital cavity. Part of the sclera at the optic disc where it is exiting is actually sieve-like and is called lamina cribrosa.

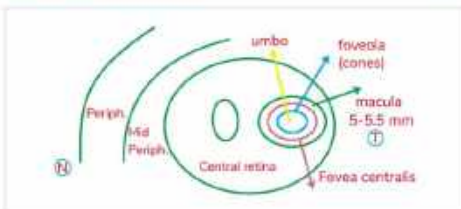


- The capacity of the orbit is 30 cc.
- The shape of the orbit is quadrilateral or pyramidal. The length of the optic nerve is 3.5 to 5.5 cms (If multiple options from this range is given in the question, then the correct option would be 5 cm).
- The axial length of the eye is 24 mm. The axial length is measured through ultrasound. Ultrasound in the eye can either be A scan or B scan.
- A scan is used for axial length measurements.
- B scan is used to see the posterior segment of the eye.
- The depth of the anterior chamber which is the area in between the iris and the cornea is 2.4-2.5 mm.

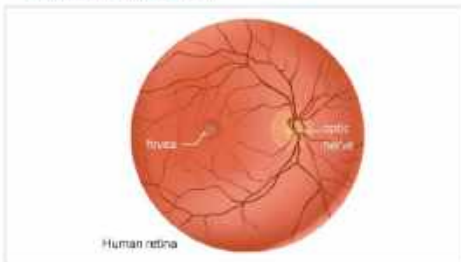
- Anisometropia: When the difference between the refractive power of both eyes is more than 2.5 D.

## Basis about the Retina

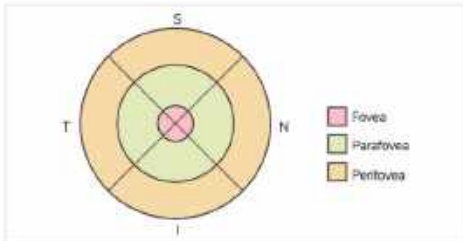
06/31/00



- Retina consists of the following.
  - Central retina
  - The optic disc, from where the nerve is existing and,
  - The macula, which is responsible for the central vision. Macula is 5 to 5.5 mm. It is also known as Macula Lutea because it is yellowish in colour.
- Inside the macula lies the most sensitive part of the retina, the fovea centralis. Inside it lies another area, known as a foveola (it only has cones). There is a very small depression at the center, the umbra.
  - Periphery
  - Mid Periphery.
- The disc is nasal, and the macula is temporal. The most peripheral part of the retina, the ora serrata, is serrated. The thinnest part of the retina is the fovea.
- The distance of the disc from the foveola is 2 DD or 3 mm.
- The central vision is checked through visual acuity charting. Peripheral testing is done through perimetry or peripheral vision field charting tests.



- A blind spot is an absolute scotoma and is a negative scotoma. Absolute scotoma means under any condition (even if the size of the object is changed), the patient will not be able to see it. Negative scotoma means that it is an empty space and positive scotoma means that there is a black patch in front of the eyes.



- In the slide above, the area around the fovea, the **parafovea**, and the **perifovea**, can be seen.

### Instruments to see the Retina

00:45:21

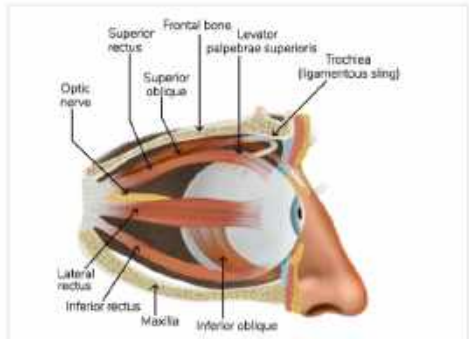


- The **retinoscope** is an instrument that is used for doing the **refraction of the eye**. The retina is examined through an **ophthalmoscope** or a **fundoscopy**.

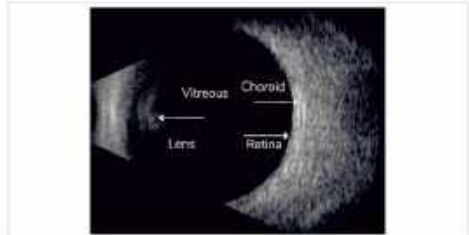
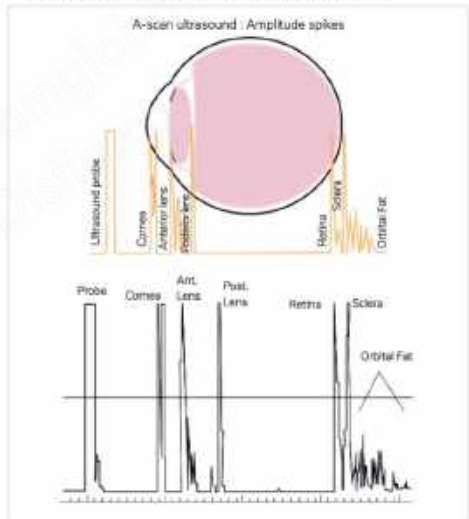
### Direct Ophthalmoscope



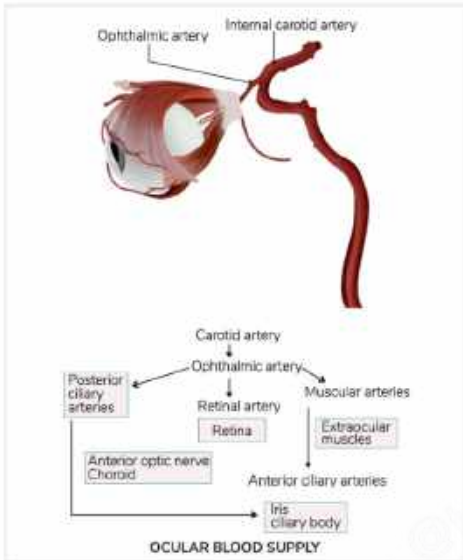
### Indirect Ophthalmoscope



- The slide above shows how the eyeball is placed in the orbital cavity. The muscles holding it on can also be seen.



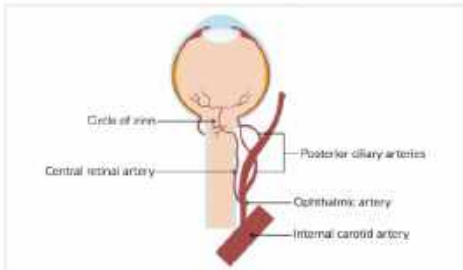
- The slide above shows a **B-scan**, showing the lens, vitreous, choroid, and, retina. This can be used to see structures behind the lens, the posterior segment of the eye.



- The main artery supplying blood to the eye is the ophthalmic artery. The **ophthalmic artery** is a branch of the **internal carotid artery**.

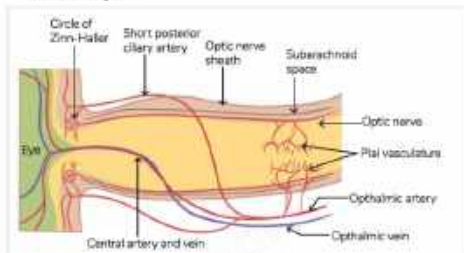
The ophthalmic artery is divided into three main branches.

- Posterior ciliary arteries:** These supply the short and long; the short one will supply the choroid and optic nerve; the long one will go to the iris and the ciliary body.
- Retinal artery**
- Muscular arteries:** The muscular arteries supplying the extraocular muscles are anterior ciliary arteries.



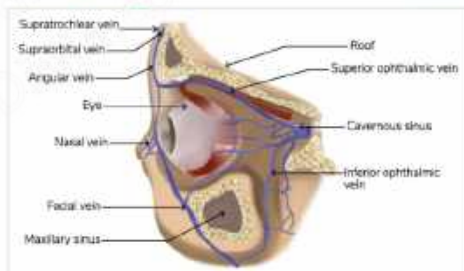
- In the slide above, the **internal carotid artery** can be seen. The ophthalmic artery originates from the internal carotid artery. The ophthalmic artery gives out one branch as the posterior

ciliary artery. The short posterior ciliary artery will supply choroid and the long one will further move anteriorly. The central retinal artery is another branch of the ophthalmic artery which pierces the optic nerve and goes through it to enter the eye.

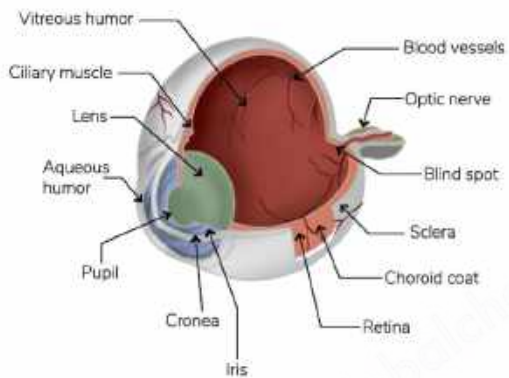


- Part of the optic disc is supplied by the anastomosis of the short posterior ciliary artery which is supplying the choroid and retina. This anastomosis is called the **circle of Zinn-Haller**, and is supplying an area of the optic disc.

**Venous Drainage**



- In the slide above, the **superior ophthalmic vein** and the **inferior ophthalmic vein** can be seen draining into the **cavernous sinus**.



Telegram: @teambaluchay  
www.Distia.co



## PREVIOUS YEAR QUESTIONS



Q. Evisceration is removal of which layer of eyeball?

(FMGE JUNE 2019)

- A. **Middle and inner layer**
- B. Outer and middle
- C. Outer and inner
- D. All the layers

Q. Corneal transparency is decided by

(FMGE JUNE 2021)

- A. **Keratan sulphate**
- B. Chondroitin sulphate
- C. Heparan sulphate
- D. Hyaluronic acid

Q. Which layer of cornea helps in maintaining hydration of stroma of cornea?

(NEET JAN 2020)

- A. Descemet's membrane
- B. **Endothelium**
- C. Epithelium
- D. Stroma

Q. All of the following are features of corneal epithelium except,


(AIIMS JUNE 2019)

- A. Lined by stratified squamous epithelium
- B. **Bowman's membrane regenerates**
- C. Apical cells have microvilli
- D. Mitosis is limited to limbus

Telegram: @teamlab  
www.DrBha.co



## Crossword Puzzle 1



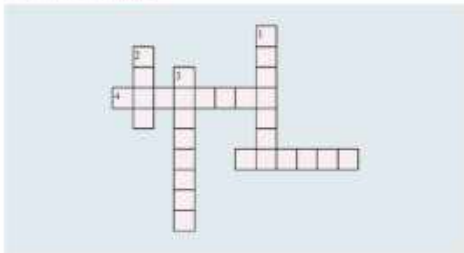
### Across

- The superior ophthalmic vein and the inferior ophthalmic vein drains into the ----- sinus.
- The main artery supplying blood to the eye is the ----- artery.

### Down

- A blind spot is an absolute scotoma and is also a ----- scotoma.
- Part of the optic disc is supplied by the ----- of the short posterior ciliary artery, called the circle of Zinn-Haller.
- Ophthalmic artery is a branch of the internal ----- artery.

## Crossword Puzzle 2



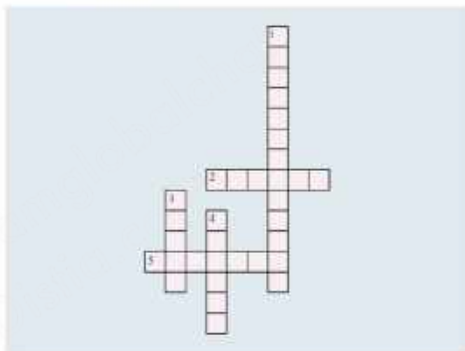
### Across

- scotoma means under any condition (even if the size of the object is changed), the patient will not be able to see the object.
- Inside the ----- lies the most sensitive part of the retina, the fovea centralis.

### Down

- Inside the fovea centralis lies another area, known as ----- (it only has cones).
- There is a very small depression at the centre called the -----.
- Negative scotoma means that it is an empty space and ----- scotoma means that there is a black patch in front of the eyes.

## Crossword Puzzle 3



### Across

- The shape of the human eye is called an ----- spheroid.
- The most peripheral part of the retina, the ora -----, is serrated.

### Down

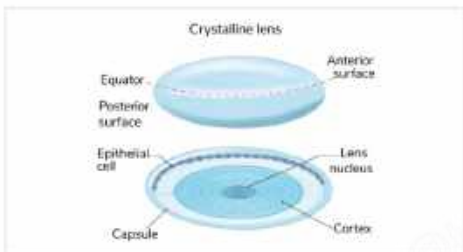
- The shape of the orbit is ----- or pyramidal.
- The thinnest part of the retina is the -----.
- The bending of the light rays is more at the -----.





00101:44

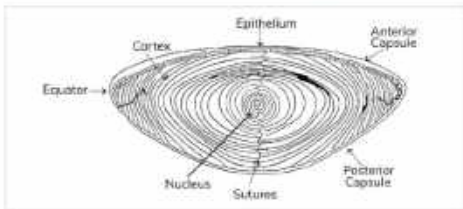
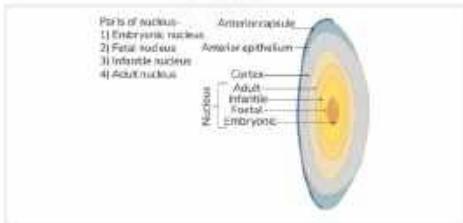
- The shape of the lens is biconvex.
- The equatorial diameter of the lens is around **9-10 mm**.
- The refractive power of the lens is 16-17 dioptres (However, this can differ slightly since physiological values differ from person to person).
- The refractive index of the lens is 1.39.
- This refractive index is maximum at the centre of the lens, and it is 1.4-1.41.



### Nucleus and Its Parts

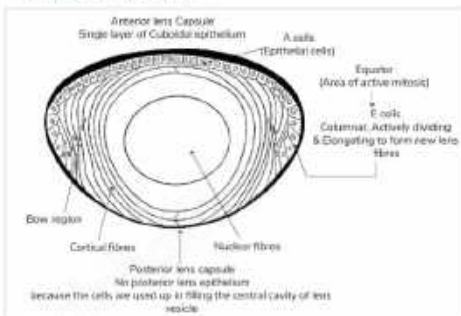
00108:38

- Embryonic (0-3 months)
- Foetal (3-8 months)
- Infantile (Pre-puberty)
- Adult (Post-puberty)

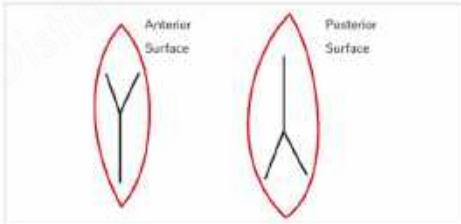


- Anterior epithelial cells are of two types
  - A cells: They are cuboidal and reside at the centre.
  - E cells: They are columnar and reside at the equator.

- Lens fibres are formed from E cells. While formation, there is a **microscopic gap left behind in the intersection, called sutures**, as shown below



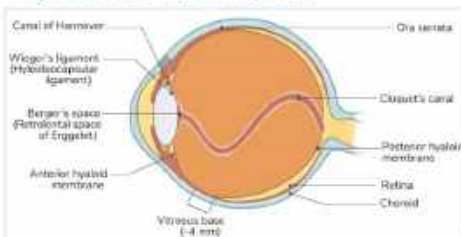
- These sutures look like a straight 'Y' from the anterior surface and an inverted 'Y' from the posterior surface as shown below



### Location of the Lens

0617:02

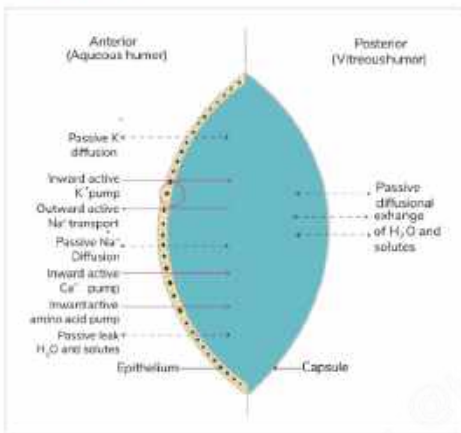
- The lens is supported by suspensory ligaments.
- The anterior, most condensed part of the vitreous is called the Hyaloid membrane.
- Thus, the lens resides in the posterior chamber, in space called Patellar Fossa.
- The strong adhesion between the most posterior part of the lens and the Hyaloid membrane is called the **Wiegert's Ligament or Hylo-Capsular Ligament**.



## Physiology

00:12:35

- Lens is avascular.
- The primary metabolism of the lens is anaerobic i.e., 80% or more of the glucose is metabolised anaerobically.
- Since hydration can cause cataract, there exists a mechanism that prevents water from getting into the lens known as **Pump Leak Theory**.



## Lens Protein

00:16:27

Lens protein is Sequestered Antigen. They are broadly divided into two categories:

- Water Soluble Proteins
- Water Insoluble Proteins

### Water Soluble Proteins

- They are mainly **Crystallines**, which in turn are of 3 types:
  - $\alpha$
  - $\beta$
  - $\gamma$
- Crystalline Gamma or CRY-G gene is responsible for congenital cataracts.
- Another type of soluble proteins are **High-Molecular weight proteins (HMW)** - 1, 2.

### Water Insoluble Proteins

- They are mainly **albuminoids**.
- We can also further classify water insoluble proteins as Urea-soluble and Urea-Insoluble.
- Cytoskeletal Proteins are one of the main urea-soluble proteins. E.g.: - Vimentin.
- Major Intrinsic protein (MIP) is a Urea Insoluble protein.
- HMW-3,4 are water-insoluble proteins and any increase in the same will cause cataract formation.
- HMW 4 individually is responsible for nuclear cataract.

## Cataract

00:19:07

- **Definition:** Any opacity in the lens that hinders the optical homogeneity of the lens is known as cataract.
- **Classification:** A cataract can be congenital or acquired.

### Congenital

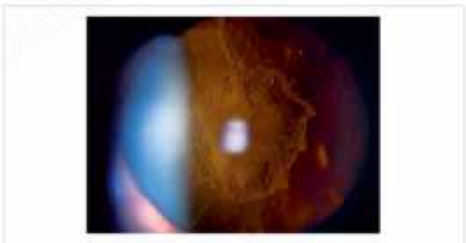
Infantile  $\rightarrow$  <1 year  
Developmental  $\rightarrow$  >>1 year

### Acquired Cataract

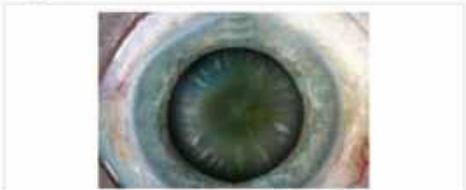- This can be classified in 3 ways:
  - Anatomically
  - Maturity
  - Etiologically

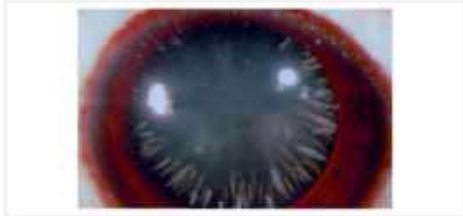### Anatomically

- We classify based on where the cataract starts from in the anatomy of an eye.
  - Anterior Subcapsular (ASC)
  - Anterior Cortical
  - Nuclear Cataract
  - Posterior Cortical Cataract
  - Posterior Subcapsular Cataract (PSC)/Cupuliform Cataract
  - Anterior Polar Cataract
  - Posterior Polar Cataract



- PSC forms due to dysplasia of E cells that migrate posteriorly. **Wedl cells/Bladder cells** are E cells that are responsible for formation of PSC.
- Posterior Polar Cataracts typically have **onion ring patterns**, as shown below:
- ASC is formed due to fibrous metaplasia of anterior epithelial cells.
- The image below depicts Cortical Cataracts with radial spokes:



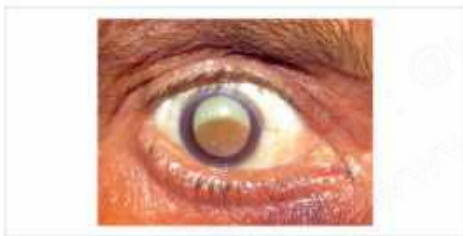

- It is also called **Cuneiform Cataract**,

#### Maturity

00:46:48

- We can classify according to maturity as:
  - Immature
  - Mature
  - Hyper-mature
- Hyper-mature cataract can cause 2 types of degenerative changes:
  - **Morgagnian Cataract**: Liquefaction of the cortex causing nucleus to float, Wrinkling of capsule.



#### Etiological

00:36:14

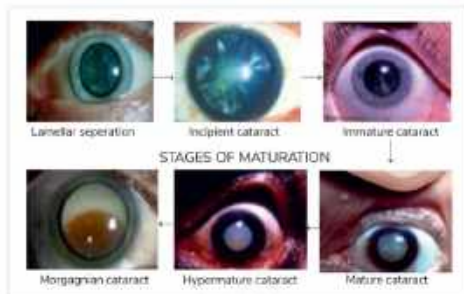- They are classified based on aetiology as
  - Senile (Most common cataract)
  - Metabolic
  - Complicated/Secondary
  - Toxic
  - Traumatic
  - Radiational
  - Associated with systemic disease (pre-Senile) <50 years of age
- **Senile cataract**: They are further divided as Cortical, Nuclear and Sub-Capsular.

00:54:23

- **Cortical Cataract**: It occurs primarily due to hydration.
  - Water collects between the fibres, forming clefts and vacuoles. This gives rise to different stages of hydration.
  - Stage I - Stage of lamellar separation
  - Stage II - Incipient stage (Cuneiform cataract)
  - Stage III - Intumescent (Maximum hydration)

→ Stage IV - Mature Cataract

→ Stage V - Hyper-mature Cataract → Morgagnian  
→ Sclerotic



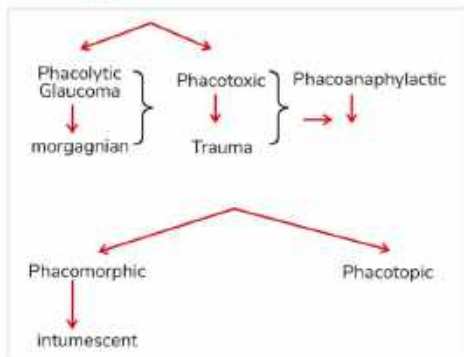
→ The most common complication of the morgagnian cataract is **Phacolytic Glaucoma**.

→ If the TM blockage occurs due to trauma and not morgagnian, then it is **Phacotoxic/ Lens Particle Glaucoma**.

→ **Phacocanaphylactic Glaucoma**- due to immune reaction.

→ The type of glaucoma due to intumescent cataract is called **Phacomorphic Glaucoma-SACG**

→ The most common complication of Hyper-mature sclerotic is **subluxation of lens i.e., partial dislocation of lens**.



- **Nuclear cataract**: The mechanism is Nuclear Sclerosis. Sclerosis can be caused due to increase in insoluble protein and decrease in soluble protein, denaturation of the protein (dehydrational crisis), deposition of pigments such as **melanin and urochrome**.

Cataract can be :

1. Yellow - Xanthopsia (Yellow vision)
2. Amber

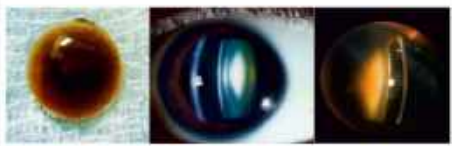### 3. Brown - Brunescence

#### 4. Black - Nigra

#### Free radical Scavenger

004748

- There exists an antioxidant system in lenses that prevents oxidative/free-radical injury.
  - Superoxide Dismutase (SOD)
  - Catalase
  - Glutathione Reductase
  - Vitamin C
  - Vitamin E
  - Anaerobic condition of the lens:
- Vitamin A is not present in the lens.



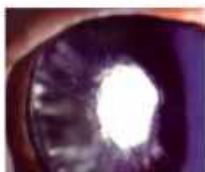- **'Second sight of old age'** is improvement in near glasses/presbyopic glasses. 'Second sight of old age' is improvement in near glasses/presbyopic glasses.

- This happens when a patient develops nuclear sclerosis.
  - Subcapsular
    1. Anterior Subcapsular (ASC) due to fibrous dysplasia of anterior epithelial cells
    2. Posterior Subcapsular (PSC): The pupil dilates at night, giving rise to scattering of light that causes glare, especially while driving.
      - dysplasia of E cells or Wedl cells or bladder cells
      - During the day, there is Miosis that leads to decrease in visual acuity and difficulty in near vision.

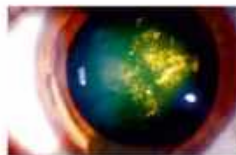
- **PSC is the lenticular opacity that causes maximum diminution of vision**

- Associated with systemic disease (Pre-Senile) 013558

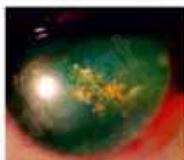- Any cataract that is developed within the age of 50 years.
  - They are divided into different categories as:
    - Diabetes Mellitus (DM) aka metabolic cataract
    - Myotonic Dystrophy (MD),
    - Atopic Dermatitis
    - Neurofibromatosis-Type 2
  - Atopic dermatitis is associated with shield cataract which is a kind of ASC.



- The image below depicts a **Christmas-Tree Cataract** which is associated with Myotonic Dystrophy. It involves the cortical part and can be a PSC too.



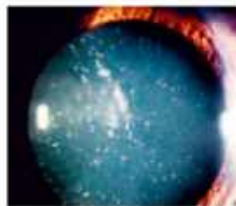- It has polychromatic needle-like opacities.



- Ocular Features of Myotonic Dystrophy: The 5Ps
  - Ptosis
  - Presenile Cataract (Christmas-free cataract)
  - Intraocular Pressure (IOP): Low
  - Pigmentary Retinopathy- salt and pepper fundus
  - Pupil: Miotic reacting slowly to light.

#### • Metabolic Cataract 010635

- Diabetes Mellitus (DM)
  - It occurs due to sorbitol accumulation. Sorbitol is hyperosmotic and any hydration will lead to cataract.
  - The enzyme responsible for the Sorbitol pathway is NADPH-dependent Aldose Reductase.
  - It can be a **Snowflake/Snowstorm cataract**.



- Snowflake/Snowstorm is more common in Type-1 DM.
- Frequent changes of Presbyopic glasses are caused by:
  - Early cataracts (Intumescent cataracts)
  - Late Glaucoma (Late stage of Primary Open-Angle Glaucoma (POAG) can crescent with fluctuating refractive errors.

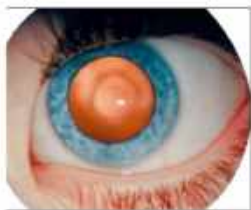- DM

[In case of Hyperglycemia we see myopic shift  
Vice versa, in case of hypoglycemia, we observe  
hypermetropic shift (towards lesser curvature)]

o Galactosemia

→ It can occur due to 2 enzyme deficiencies, and they are:

- Galactokinase - This deficiency causes Lamellar cataract.
- Galactose-Phosphate-Uridyl Transferase (GPUT) - This deficiency causes Oil-Droplet Cataract as shown below:



→ It is also known as reversible cataract

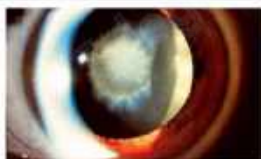
o Chalcosis

→ It means copper alloy in the eye.

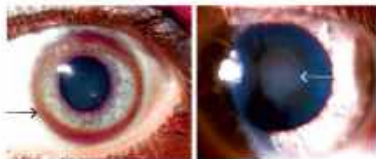→ It is caused due to:

- Wilson's disease
- Any copper-containing foreign body.

→ The image below depicts a Sunflower cataract



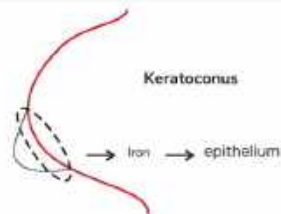
→ Kayser-Fleischer Ring (KF-Ring) is copper disposition in Descemet's membrane in the cornea. It is reversible (fading).



→ It starts superiorly and inferiorly to make a circle.

→ 95-100% patients with neurological complications will present with KF-ring whereas only 65-67% of patients with Hepatic involvement will present with KF-ring.

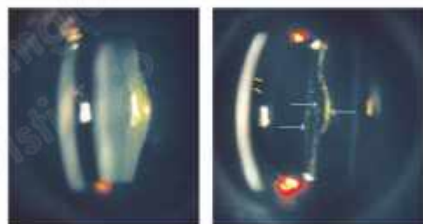
→ Fleischer's Ring is an iron deposition on the epithelium layer and appears in patients with Keratoconus.



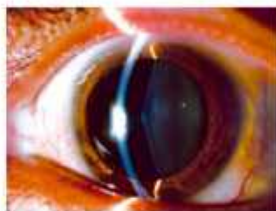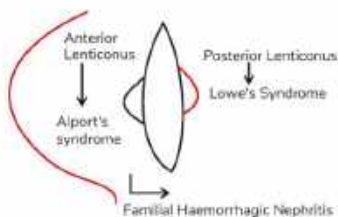
o Lowe's Syndrome/ Oculo-Cerebro-Renal Syndrome

o The features in lens

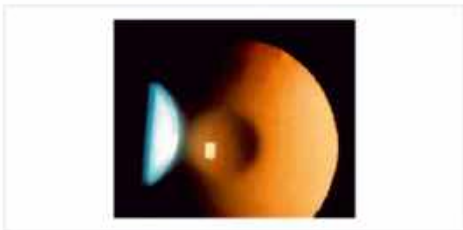
- Microphakia (lens size < 9mm)
- Cataract (amino-acid metabolism error)
- Posterior Lenticonus (conical protrusion of lens posteriorly)
- Glaucoma



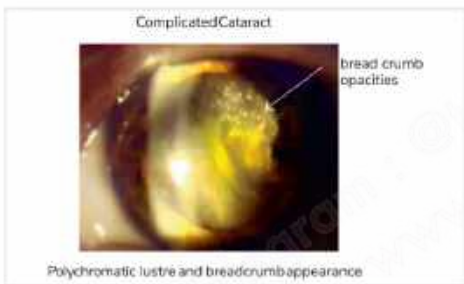
- Anterior Lenticonus is seen in Alport's syndrome, which is Familial Haemorrhagic Nephritis.



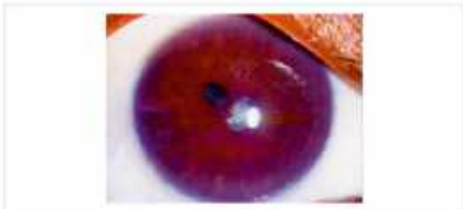- Anterior Lenticulus is more common in males.
- Oil-Globule Reflex, as shown below, is observed in anterior lenticulus when seen through a slit lamp, in retro illumination.



- Complicated Cataract/Secondary Cataract 02/07/01
  - The pathognomonic feature of complicated cataract is polychromatic lustre.




- Most common type of complicated cataract is Posterior secondary cataract (PSC).
- Etiologies
  - Most common cause of complicated cataract is Chronic Anterior Uveitis.



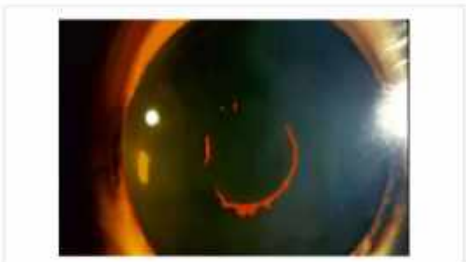- High Myopia (mostly PSC)
- Hereditary Fundus Dystrophy - it can lead to:
  - Retinitis Pigmentosa (RP)
  - Leber's Amaurosis
  - Gyrate atrophy
  - Stickler syndrome

- Toxic Cataract 01/31/01
  - It can be caused by
    - Steroids - It disturbs the osmotic balance in the lens.
    - Phenothiazines
    - Long-Acting Miotics such as Echothiophate, Phospholine Iodide, DFP.
    - Amiodarone
    - Busulfan
    - Gold
    - Chloroquine
  - An easy mnemonic to remember the drugs and respective cataracts is shown above. **B-S-C causes PSC and the rest of the drugs on the list cause ASC.**
  - The most common complication of topical steroids in the eye is Glaucoma (OAG) due to deposition of Mucopolysaccharides in TM.
  - The most common complication of systemic steroids is cataract (PSC)

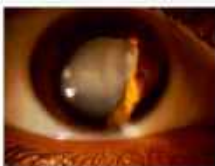- Traumatic Cataract 01/07/22
  - Perforating/Penetrating: It can lead to cataract if it hits the lens.
  - Blunt Trauma: It is also called concussion injury.
  - Features of Blunt Trauma
    - **Rosette-shaped Cataract:** It is a cortical cataract that starts from the posterior cortex.



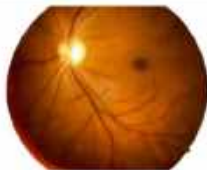- **Vossius Ring:** Pigment deposition on the anterior capsule of the lens.



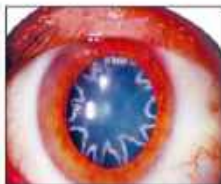- **Iridodialysis:** Disinsertion of iris from its root causing a **D-shaped pupil**.



→ **Berlin's Edema:** Edema at the macular of the retina. Also called commotio retinae. There is a **cherry red spot** that is shown below.



○ **Electric Shock:** It leads to Stellate ASC that causes electric cataract.



- **Radiational cataract** 01/03/13
  - All electromagnetic radiations can cause cataracts and most commonly cause PSC.
  - We further divide it as:
    - Infrared radiation - It is seen in glass factories and leads to Glass-Blower's cataract. It can be cortical changes/PSC.
    - Ionizing Radiation - It can lead to PSC (most common).
  - We can get a radiational cataract after CT scan or when exposed to microwave traditions but not after an MRI



### Important Information

- The enzyme responsible for the Sorbitol pathway is NADPH-dependent Aldose Reductase.
- Kayser-Fleischer Ring (KF-Ring) is copper disposition in descemet's membrane in the cornea and is reversible (fading).
- 95-100% patients with neurological complications will present with KF-ring whereas only 65-67% of patients with Hepatic involvement will present with KF-ring.

### Presenile Cataract

- Cataracts in less than 50 years of age.
- **Causes of presenile cataracts are –**
  1. Diabetes mellitus
  2. Myotonic dystrophy
  3. Atopic dermatitis
  4. Neurofibromatosis type 2 (NF2)

### Myotonic Dystrophy

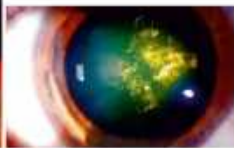
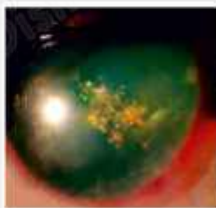- It is one of the most common muscular dystrophies.

### Ocular features of myotonic dystrophy: 5P's

1. **Ptoisis**- Drooping of the eyelid
2. **Presenile cataract**- Christmas tree cataract.
3. **IOP**- Because of the myopathy there is low intraocular pressure.
4. **Pupil**-Miotic pupil, Slow reacting
5. **Pigmentary retinopathy**- Also called as "Salt and Pepper" fundus.

### Christmas Tree Cataract

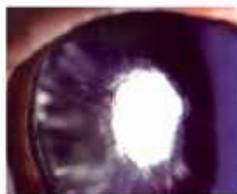
- These are polychromatic needle like opacities.
- It can involve cortical or posterior subcapsular area



### Atopic Dermatitis

#### Shield Cataract

- It involves the whole pupillary area.
- It is an anterior sub capsular part opacity.



Shield Cataract

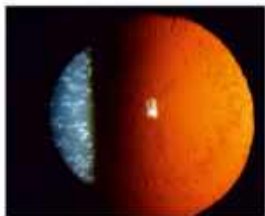### Neurofibromatosis Type 2 (NF2)

- It is a posterior sub-capsule cataract.
- **Most common ocular feature of NF2 is PSC.**
- **Most common ocular feature of NF1 is Lisch Nodules.**

## Clinical Features

015624

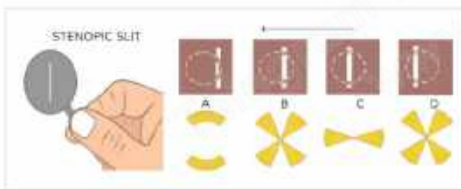
- The blurring of vision occurs.
- Diminished vision: The normal vision is 6/6. If the cataract is nucleus centred, it can lead to day blindness called **hamarlopia**.
- Cortical changes: Diminished Vision at night
  - **Polyopia**: Can be seen in incipient cataracts.



- **Glare**: The glare is mainly a feature of the PSC Posterior Subcapsular Cataract. It is very prominent at night.
- **Coloured Halos**: Can be caused by

1. Cataracts
2. Acute congestive glaucoma
3. Mucopurulent conjunctivitis

## Fincham's Test



- Fincham's test, in which a stenoptic slit is passed over the pupil, can distinguish between the halos of acute congestive glaucoma and immature cataract.
- Halos break in immature cataract but not in acute congestive glaucoma.

## Treatment of the Cataract

029656

There is no medical treatment or prevention of cataracts. The only option is surgery. These surgeries are explained in detail below as

- **ICCE**: Intracapsular cataract extraction, the capsule is removed along with the lens.
- **ECCE**: Extracapsular cataract extraction, the posterior capsule is not removed.
- **SICS**: Small-Incision Cataract Surgery, it can be manual or with the help of Phacoemulsification.
- **FLCS**: Femto Laser Cataract Extraction.

## Methods

- Forceps Extraction: Arrugas forceps.
- Cryo extraction: The best method of extraction.
- Wire Vectis method.
- Indian smith method.

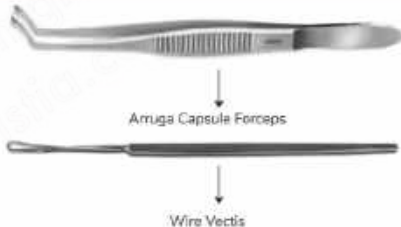


## Important Information

### Pre-Operative Assessment

#### Systemic Condition

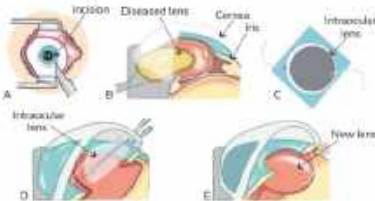
- **Sugar Level**: DM (Diabetes mellitus).
- **Hypertension**: Make the blood pressure normal for the surgery.
- **Respiratory System**: The patient should not have a cough or upper respiratory infections because if the patient coughs after or during the surgery, it will be harmful.
- **History of Myocardial infarction or Stroke**: Surgeons have to wait for 4-6 months.



## ECCE Extracapsular Cataract Extraction

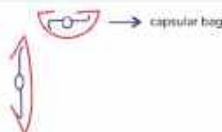
001128

### Extracapsular cataract extraction



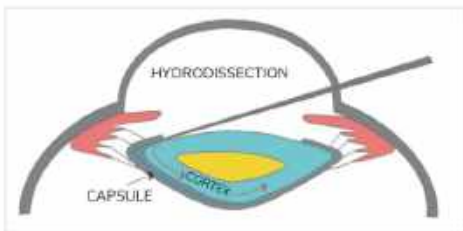
## ECCE WITH PCIOI.

- Extracapsular cataract extraction and posterior chamber intraocular lens.

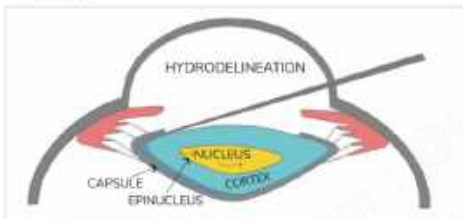




- **Procedure:** The surgeon makes an incision of 8mm on the limbus and some part of the anterior capsule and the whole of the posterior capsule is left; this is called the capsular bag. In this bag, the intraocular lens is placed.



- Water is injected under the margin of the anterior capsule, it is called **hydro dissection**.
- Avoid Hydro dissection in the case of Posterior Polar Cataract.

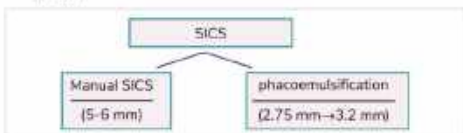


- **Hydro delineation** can also be done.
- During cataract surgery, hydro delineation is the process of forcing fluid into the mass of the nucleus to separate an outer shell (or several shells) of the lens of the eye from the centre compact mass of inner nuclear material (also known as endonucleus).
- The nucleus needs to be removed through pressure counter pressure in this case.
- Clearing the bag with irrigation aspiration I/A is necessary before placement of the intraocular lens with radial suture.
- IOL is made up of PMMA Poly methyl Methacrylate.

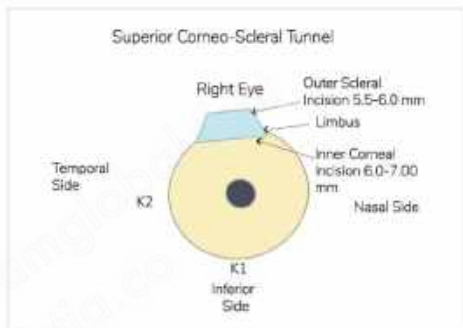
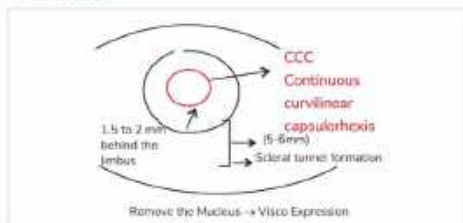
### SICS Small Incision Cataract Surgery

02:18:55

- There are two salient features of SICS
  1. Small Incisions.
  2. Suture less Surgery - The incision is made in different planes.
- These two features ensure no postoperative astigmatism, and the patient can have their normal vision back as early as 2 weeks.



### Manual SICS



- These incisions will form a scleral tunnel formation.
- Round Smooth opening CCC (**Continuous curvilinear capsulorhexis**)

Q. If the capsule is not visible, what should be done?

Ans. The capsule can be stained if it is not visible in the case of mature white cataracts, Trypan Blue is used to stain the capsule. Before that, an air bubble needs to be put in, which protects the endothelial from this dye.

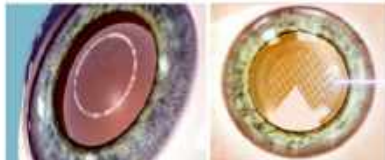### Phacoemulsification

02:28:32

- The incision of 2.75 - 3.2 mm in length with a partial thickness on the cornea is made.
- The frequency of the Phaco probe is 40KHz.
- In phacoemulsification, foldable IOL is used. They are made up of acrylic, which is mostly used, and silicone.

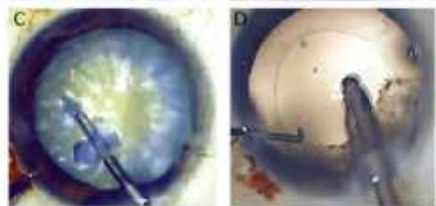
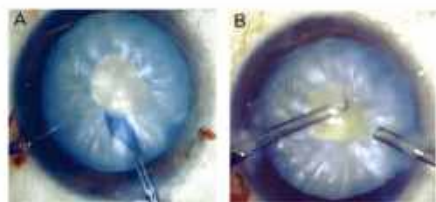
### MICS

- MICS stands for minimal incision cataract surgery.
- The procedure is the same as that of phacoemulsification, but the incision is further less which is ranging from 1.8 - 2.4 mm.
- **Phakonit:** This is a term where phacoemulsification is done at 0.9mm. After this rollable IOL is used, these are ultrathin which are made up of hydrogel.

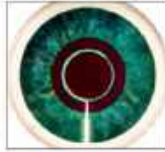

Capsulotomy

Lens Fragmentation



Shape may be irregular



Near to perfect roundness

- Viscoelastic will be used throughout the surgery. It is either HPMC Hydroxypropyl methylcellulose 2% or 1% Sodium Hyaluronate (with or without chondroitin sulphate)



### Important Information

Irrigating Fluids

RL: Ringer lactate ± adrenaline

BSS: Isotonic

Q. Which is the ideal fluid used for Irrigation and aspiration?

Ans. The ideal Fluid for irrigation and aspiration is Basal salt solution plus (plus means it has glutathione). The composition of BSS is chlorides of sodium, potassium, and calcium, mainly isotonic.

**PLACS Femto Laser Assisted Cataract Extraction** 02-46/46

- It is called a Neodymium glass (Nd: Glass) laser.
- Since it is Femto, the pulse duration of this laser's  $10^{-15}$ .
- Wavelength is 1054 nm.
- The Femto laser used in has three ways
  - Making the incision through the laser.
  - CCC
  - Lens fragmentation.



### Important Information

- Use of phenylephrine on a hypertension patient should be avoided.

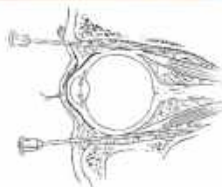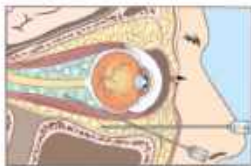Q. Which are the steps most important that prevent infection during cataract surgery?

Ans. The most important step is washing the eye with Povidone Iodine 5% w/v eye drops to prevent endophthalmitis.

### Local Anaesthesia

There are three types of local anaesthesia that can be administered

1. TOPICAL (0.5% proparacaine, but this will not have Akinesia),
2. PERIBULBAR INJECTION
3. RETROBULBAR INJECTION

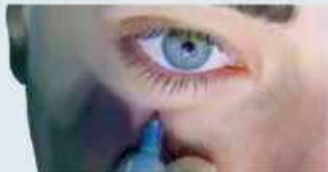

## Peribulbar and Retrobulbar Anesthesia

Peribulbar	Retrobulbar
<ul style="list-style-type: none"> <li>Peribulbar anaesthesia is injected in orbit around the equator of the eyeball.</li> </ul>	<ul style="list-style-type: none"> <li>Retrobulbar anaesthesia is injected in orbit further behind the eyeball, near the nerves that control eye movement and sensation.</li> </ul>
<ul style="list-style-type: none"> <li>It is given in extraconal space.</li> </ul>	<ul style="list-style-type: none"> <li>It is given in the intraconal space.</li> </ul>
<ul style="list-style-type: none"> <li>26G needle 1 inch long.</li> </ul>	<ul style="list-style-type: none"> <li>26G needle 1 ½ inch Long.</li> </ul>

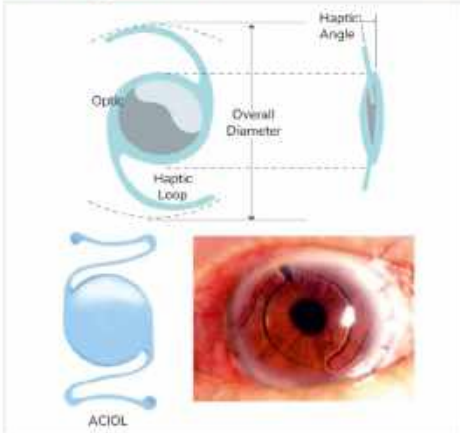
**What is injected:** Lidocaine 2% and bupivacaine 0.75% (bupivacaine will sustain the effect more) along with that hyaluronidase (optional) for a better spread on the tissue. With or without epinephrine.

The injections are given in the supraorbital nerve block and the second one between the medial ⅓ and lateral ⅓.



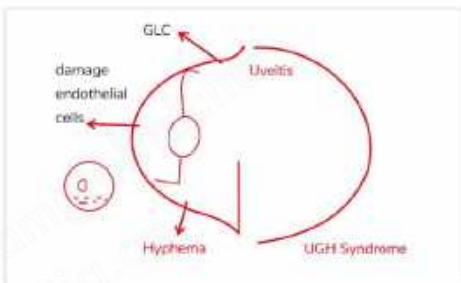
## Different Types of IOLs

02:55:48

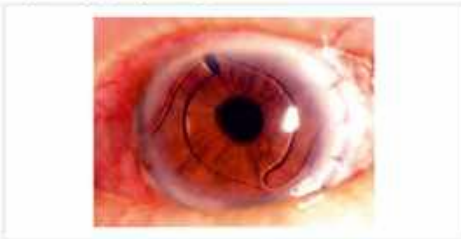

## Other options

1. **ACIOLs.**
  2. **Iris Claw Lenses.**
  3. **Scleral fixated lenses** (best option).
- ACIOLs is the least preferred IOL.
    1. IOL damages the cornea leading to corneal oedema and damage to the endothelial cells.
    2. ACIOL can lead to UGH syndrome.
      - Blocking the angle and causing glaucoma or bleeding leading to hyphema (collection of blood in the anterior chamber of the eye) called Uveitis glaucoma hyphema (UGH) syndrome.



- The opening is called Peripheral iridectomy. (When it is done with laser it is called Iridotomy and surgically it is called Iridectomy.)
- It is done to remove any blockage of the pupil due to the lens and to release fluid that has built up behind the iris. Overall to prevent pupillary block glaucoma.



## Plate Haptic Lens



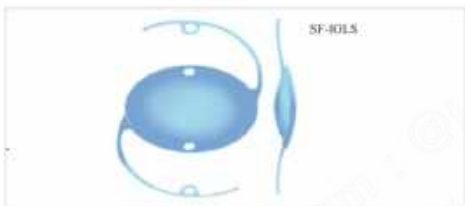- These are Iris-supported lenses, a very famous one is named **WORST IOL.**

- They are also called Iris claw lenses.
- It is used when an appropriate posterior capsular support is lacking.

### Posterior Chamber IOL (PCIOL)



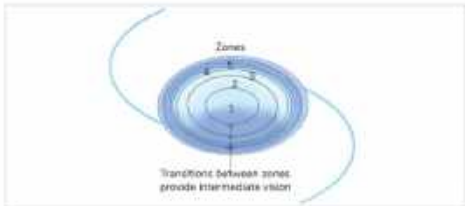
- Dialing holes are used while putting in the intraocular lens inside, these holes are used to attach the dialer in these holes.
- Dialing means properly adjusting.



- The hole in the haptic is to pass the suture through the sclera.
- The above image shows a scleral fixated lens.
- This is a C- Shaped haptic and there is also another type J-shaped.

### Some Specific IOL'S

- **Multifocal IOLs**



- **TORIC IOLs:** When a patient has significant cylindrical power
- The 3 dots in the image are used to define at which axis the lens should be put.



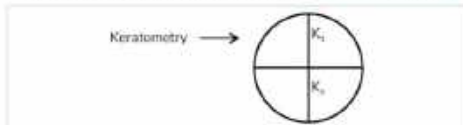
### Important Information

- Marking the axis operatively should be done in a sitting or standing position.
- **HEPARIN-COATED IOLs:** If the eye is prone to a lot of inflammation,
- **BLUE LIGHT BLOCKING IOLs:** The cataract lens blocks blue light and this lens will have no influence on colour perception.
- **ASPHERIC IOLs:** The vision quality is even better because it negates the factor of spherical aberration.

### Biometry

00.06.16

- Biometry is a method to calculate the IOL power.
  - Biometry needs two measurements
1. Axial Length (AL)
  2. Keratometry
- The axial length can be measured with **A-Scan Ultrasound**.



- **IOL Master:** It is a very accurate precision tool used for non-contact measurement of the axial length, Keratometry, anterior chamber depth, and white-to-white measurement.

### Formulas

There are four generations of formulas for Biometry

- **1st Generation: SRK (Sanders Retzlaff and Kraff)**
  - $P = A - 2.5 L - 0.9 K$
  - Where;
    - P = The actual implanted IOL power
    - A = The A-constant
    - L = The axial length
    - K = The average keratometer reading.
  - It was best calculated if the AL was between 22 to 24.5.

- **2nd Generation: SRK 2**

→ SRK/T; That is 24.5mm to 26.0mm

- **3rd Generation: SRK/T**

- Formula: Hoffer, Holladay 1

- **For Smaller eyes**

→ For adult eyes Hoffer-Q (<22mm)

- **4th Generation**

- These were not based on keratometry reading.
- They were based on AC depth which is measured through the IOL master and the white-to-white measurement.
- Formula: Hoffer Q, Holladay 2, Haigis, Barrett.
- **For longer eyes**

- For congenital cataract in children the best formula is SRK/T.


Q. What will be the formula for a case of a post-Lasik patient?

Ans. Lasik is laser surgery to alter the curvature of the cornea.  
The best formula is Haigis.

Telegram : @teanglobalchat  
www.Distia.co



## Crossword Puzzle 1



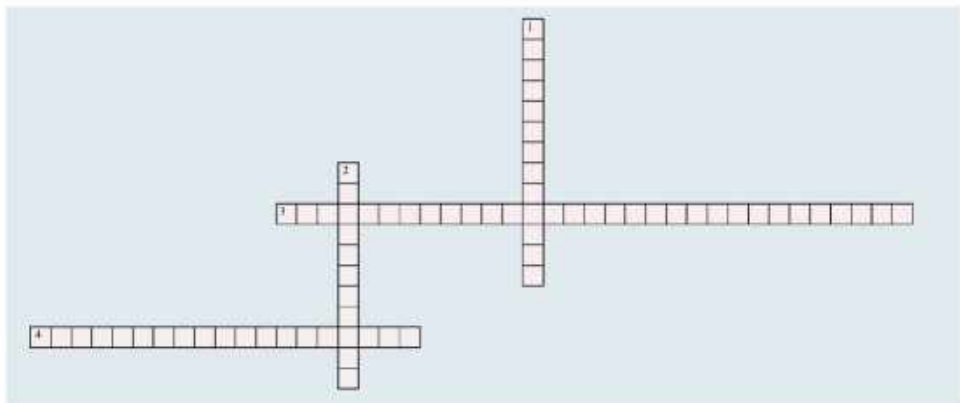
### Down

1. These are Iris-supported lenses, a very famous one is named \_\_\_\_\_.
2. \_\_\_\_\_ is the measurement of the corneal radius of curvature.
3. The vision quality in \_\_\_\_\_ is even better because it negates the factor of spherical aberration.
5. Most prominent ocular feature in Marfan is \_\_\_\_\_.

### Across

4. A nuclear cataract will need more power in \_\_\_\_\_.
6. Checking the health of the cornea is called \_\_\_\_\_.
7. \_\_\_\_\_ is used in the Fincham's Test.

## Crossword Puzzle 2

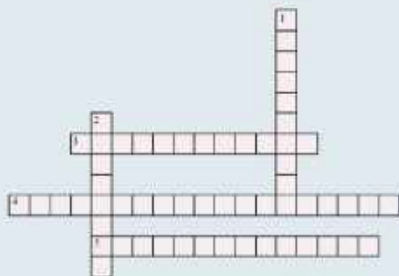


**Down**

1. Avoid the use of \_\_\_\_\_ on a hypertension patient.
2. \_\_\_\_\_ is the measurement of the corneal radius of curvature.

**Across**

3. ICCE stands for \_\_\_\_\_.
4. A nuclear cataract will need more power in \_\_\_\_\_.

**Crossword Puzzle 3****Down**

1. \_\_\_\_\_ lens opacities that affect the Y Sutural cataract sutures of the fetal lens nucleus and are usually very slow to progress.
2. Vitamin D deficiency, as well as rubella infection, causes \_\_\_\_\_.

**Across**

3. Any reduction in the substance of urine is \_\_\_\_\_.
4. \_\_\_\_\_ is a familial condition inheritance is autosomal dominant.
5. \_\_\_\_\_ syndrome shows blood in the urine.



### Complications of Cataract Surgery

00:00:30

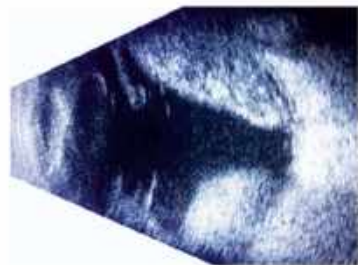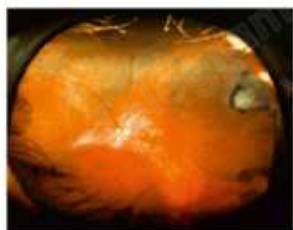
- The complications of cataract surgery can be divided into three types:
  - Operative complications
  - Acute post-operative complications
  - Chronic post-operative complications

### Operative Complications

#### 1. Posterior Capsular Tear

- This can be of two types -
  - Without vitreous loss : It has less complications.
  - With vitreous loss: This condition can lead to more complications like -
    - Cystoid macular edema (CME)
    - Retinal detachment
    - Endophthalmitis
    - Glaucoma

#### 2. Supra-Choroidal Haemorrhage



- Etiology:** This can occur while giving anesthesia or due to sudden changes in intraocular pressure (IOP).

- It happens due to the puncturing and bleeding of short-posterior ciliary arteries.
- Expulsive hemorrhage:** If the hemorrhage becomes severe, it can lead to the extrusion of the intraocular contents.

- This expulsive hemorrhage can lead to:**

Iris prolapses.



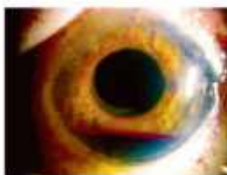
Vitreous prolapse.



Loss of red reflex.

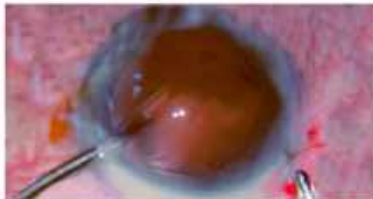- Short posterior ciliary artery supplying choroid is the source of bleeding.
- Management:** Immediately stop the surgery and re-suture everything. Don't drain the blood during this acute phase, instead wait for 7 days.
- If it doesn't resolve in a week, then a sclerotomy is done.
- For glaucoma: Glaucoma management is done
- Systemic and topical steroids may be continued after the surgery

#### 3. UGH Syndrome (Uveitis Glaucoma Hypheama)



- It is mainly a complication of AC IOL (Anterior chamber intraocular lens).

#### 4. DM (Descemet Membrane) detachment



Descemet's detachment

- Descemetopexy is done to manage this complication.
- Inject the air and due to pressure the Descemet membrane will reattach.



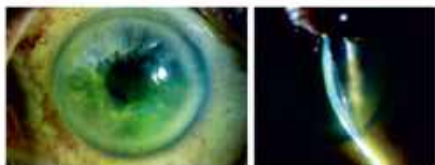## Acute Postoperative Complications

00:07:56

- These are the following acute postoperative complications:

### 1. Shallow Anterior Chamber

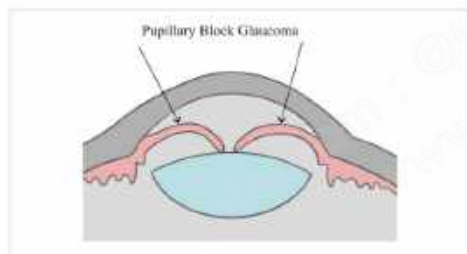
- Etiology:** This can happen due to
  - a. **Leak:** This can be confirmed by doing the Seidel test.



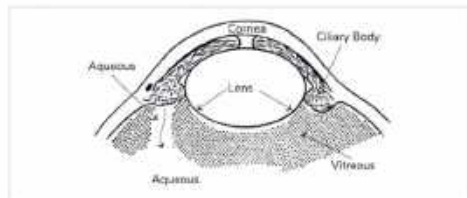
- o **Seidel Test:** Put the fluorescein dye and in the area of aqueous leakage the fluorescein dilutes.

### b. Pupillary block glaucoma:

- o The aqueous is collected in the posterior chamber due to the blockade and thus the pressure created pushes the iris forward causing **iris bombe** which ultimately results in glaucoma.
- o It results in a shallow anterior chamber.



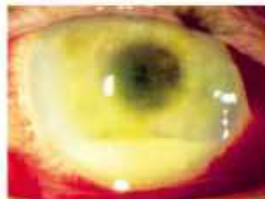### c. Malignant/ Ciliary block glaucoma: It is also known as aqueous misdirection syndrome.



- o The aqueous is collected in the vitreous cavity in this condition.
- o The aqueous accumulated posteriorly will push the anterior chamber forward making the chamber shallow.
- o **Treatment:** **Atropine** is given to relieve the pressure by expanding the ciliary ring and breaking the blockade so that the aqueous can flow anteriorly.

### d. Cilio-choroidal detachment

## 2. Endophthalmitis



- It is the **purulent inflammation** of intraocular fluids usually due to infection.
- Etiology:** The most common etiological factor that causes the acute onset of endophthalmitis is **Staphylococcus epidermidis**.
- The **hallmark feature of endophthalmitis is progressive vitritis**.
- Clinical features:** All these signs and symptoms rapidly progresses.
  - o Worsening of vision
  - o Redness
  - o Pain
  - o Photophobia
  - o Blepharospasm
  - o Discharge
- Two eyes are never operated simultaneously as postoperative there can be infection and diminishing of the vision in both eyes.
- Minimal 2 weeks interval should be there before the surgery of other eye
- On examination:**
  - o There is a progressive diminution of vision.
  - o Lid swelling
  - o Chemosis
  - o Corneal edema
  - o Hypopyon: It is the presence of pus cells in the anterior chamber.
  - o All the signs of anterior uveitis may be present.
  - o Vitritis: Hallmark
    - There are lot of inflammatory cells and exudates in the vitreous due to which media is hazy
  - o Fundal glow is absent in severe and late cases.
  - o Retinal peri phlebitis

### Treatment:

- According to EVS (endophthalmitis vitrectomy study)
- Check the Vision: As per the vision, treatment can be of two types:

- If there is **no hand movement** then the treatment is pars plana vitrectomy.
- For pars plana vitrectomy, entry from vitreous is through pars plana i.e., the eye is entered 3.5 mm from the limbus so as to avoid damage to zonules and lens.
- If there is **hand movement** or better vision then the patient is treated conservatively.
- The **treatment of choice for endophthalmitis is intravitreal antibiotic injections**. The antibiotics given are **ceftazidime and vancomycin**. Also, small doses of **dexamethasone** is given to control the inflammation.
- Systemic antibiotics that are given due to their higher ocular penetration are **quinolones**.
- Management of associated **uveitis** is done by giving **cycloplegics and topical steroids** under the cover.



### Important Information

- The most common pathogen that causes post-traumatic endophthalmitis is **Bacillus cereus**.
- Antibiotics that are contraindicated to be given by intra vitreal injection are **gentamycin and amikacin** as they are toxic to the macula.
- In case of fungal infection, **Amphotericin B and Voriconazole** can be given intravitreally.
- The most common fungus that causes endophthalmitis and lids infection is **Candida albicans**.
- The most common fungus that causes orbital cellulitis is **Mucormycosis**.
- The most common fungus that causes keratitis is **aspergillus fumigatus**.

### Chronic Postoperative Complications

06/25/04

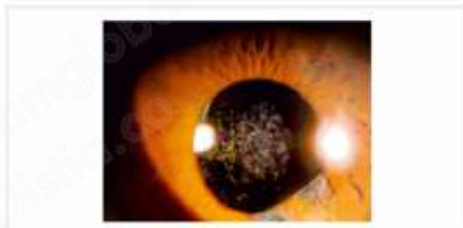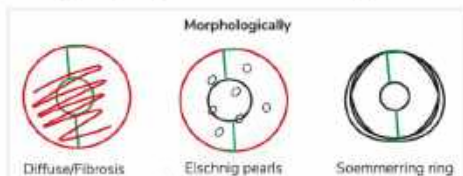
#### 1. Endophthalmitis

- In this case, it will be late onset usually after 9 months.
- **Etiology:** It is caused by **Propionibacterium acne**.
  - If it is present in the bag and causes infection at a later stage then the condition is called saccular ophthalmitis.
- **Clinical features:**
  - Painless condition
  - Mildly progressive diminution of vision.
- **On examination:**
  - All the signs of low-grade anterior uveitis are seen.
  - Mild vitritis
- **Treatment:**
  - Use aqueous and vitreous culture, confirm the diagnosis and an intravitreal antibiotic is given i.e., **vancomycin**.
  - Systemic quinolones are given, preferably, **moxifloxacin** is given.
  - Management of associated uveitis is done by giving cycloplegics and topical steroids under the cover.

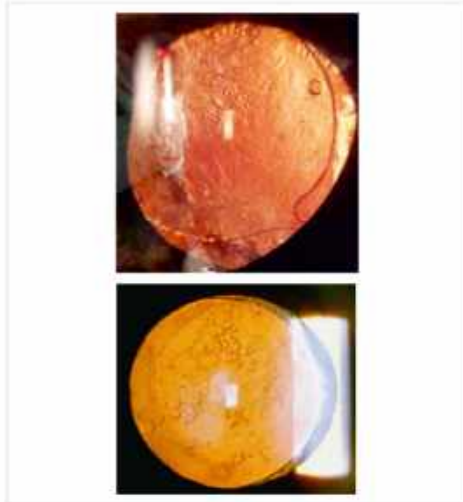
- Other cause of slow onset is fungal.

#### 2. Posterior capsular opacification/ after cataract/ secondary cataract

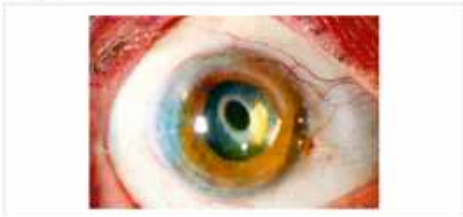- It is the **most common long-term complication** of cataract surgery.
- In this condition even after surgery, the posterior capsule on which the lens is put is getting opaque
- **Morphologically this is divided into three types:**



- a. **Diffuse/Fibrosis:** This is caused due to fibrous metaplasia of the epithelial cell.



- b. **Circular opacities: Elschnig pearls** - These are the migrated epithelial cells.



- c. **Soemmerring ring (Fibrotic ring at the periphery)**; This is due to the proliferation of the residual cells.

- **Clinical Features:** Blurring of vision and later results in the diminution of vision.
- **Treatment:** Cut at the center to clear the visual axis  
The treatment of choice is NdYAG laser posterior capsulotomy.

#### Important Question

Q. Which IOL will have the least chance of causing posterior capsular opacification?

- The answer is **hydrophobic acrylic**.

#### 3. Cystoid Macular Edema

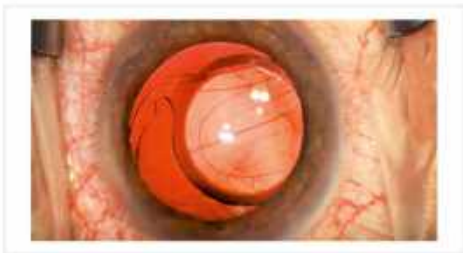- It is called cystoid macular edema because cystoid spaces are filled with fluid
- Any CME after cataract surgery is called as Irvine Gass syndrome
- Treatment of CME is systemic CA inhibitors and topical NSAIDs

#### 4. Anterior capsular contraction and fibrosis

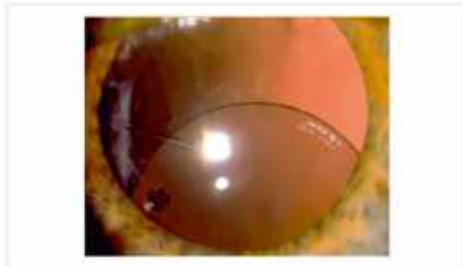
- Cut and make the central opening in the anterior capsule.
- It is managed by **NdYAG anterior capsulotomy**.

#### 5. Displacement of IOLs

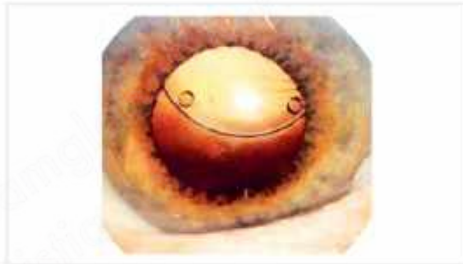- Lens can get displaced either up, down, or lateral.



- IOL displaced lateral



- IOL displaced downwards- sunset syndrome



- IOL displaced upwards- sunrise syndrome

#### 6. Dysphotopsia

- These are some annoying visual phenomenon like flash of light, dark shadow due to mono focal IOLs.

#### 7. Refractive Surprise

- It is a **significant residual refractive error**.
- **Treatment:** There are three options for treatment -
  - Prescribe specs or contact lenses.
  - Exchange of the IOLs.
  - **Piggyback IOLs**: if one IOL is put in capsular bag now put the other IOL is put in ciliary sulcus

#### Congenital Cataract

06/40/33

##### This can be of two types:

- **Developmental:** It occurs in children >1 year, affecting adult and infantile nuclei.
- **Infantile:** It occurs in babies <1 year of age affecting embryonic and foetal nuclei.

##### Etiology: (Bilateral)

- **TORCHS:** It stands for toxoplasmosis, rubella, cytomegalovirus, herpes, and syphilis. Any of these infections in the first trimester can cause congenital cataract.

- Radiation exposure in the first trimester.
- Use of teratogenic drugs in the first trimester.
- Metabolic causes: These are as follows
  - Galactosemia
  - Fabry's disease
  - Lowe's syndrome
- Hepatic disorders like Wilson's disease
- Chromosomal disorders like Down's syndrome- blue dot /punctate cataract
- **Genetic:** There is a positive family history of the disease, and the inheritance is autosomal dominant.
- **Birth trauma and some cases of ROP (retinopathy of prematurity) can cause unilateral congenital cataracts.**

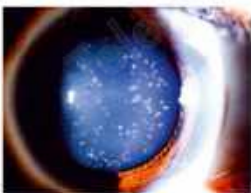


### Important Information

- **Blue dot cataract** or punctate cataract is a feature of Down's syndrome.
- The most common congenital cataract is the **blue dot cataract**.
- The most common congenital cataract causing **marked diminution of vision** is **lamellar cataract**.
- Genes that are responsible for congenital cataracts are the **CRY-G gene (crystalline gamma)**, **Cx gene (connexins)**, and **MIP gene (major intrinsic protein)**.

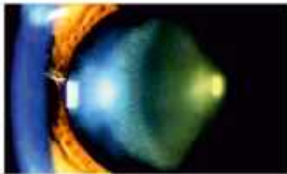
## Types of congenital cataracts

### 1. Blue dot cataract

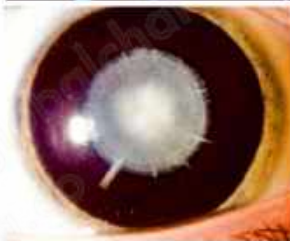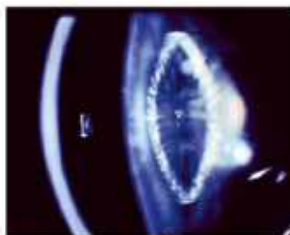


- This is the most common type of congenital cataract.
- **Bluish dots** are seen on the lens as cataract opacities.
- It is also a feature of Down syndrome.
- Both **nucleus and the cortex of the lens** are affected.

### 2. Cataracta pulverulenta



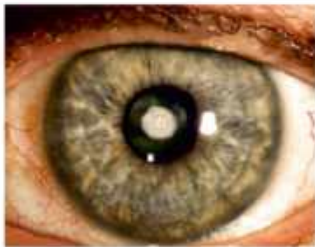### 3. Lamellar/zonular cataract



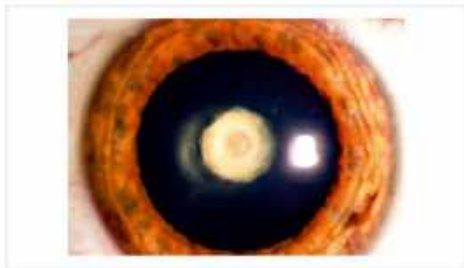
- Due to some environmental insult, one lamella can develop cataracts, but the adjacent areas are clear.
- Over this cataract, there can be small spoke-like opacities called the **RIDERS**.
- **Etiology:** This condition can develop due to **vitamin D deficiency** or **rubella infection**.
- This only involves the **foetal nucleus**.
- This is the **most common infantile cataract**.
- This is the **most common congenital cataract causing marked diminution of vision**

### 4. Anterior polar cataract

- It starts from anterior pole
- This is generally associated with the **persistent pupillary membrane**.

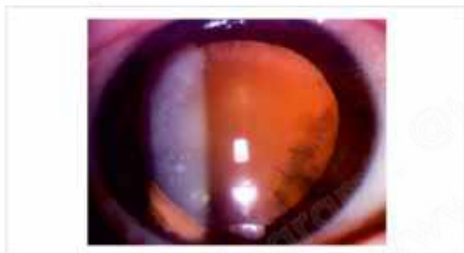

### 5. Posterior polar cataract



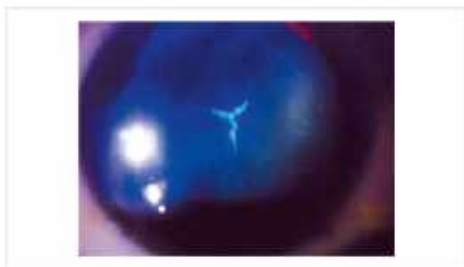- This can be associated with remnants of hyaloid tissues known as **Mittendorf dots**.
- An **onion ring appearance** is seen.

### 6. Coronary cataract



- **Peripheral cortical opacities** are seen in this condition.

### 7. Sutural cataract



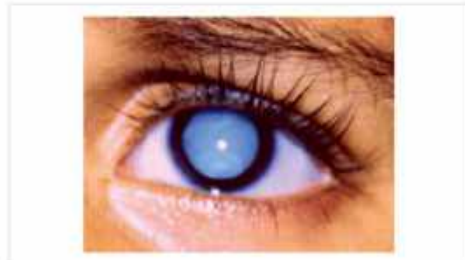- The **opacities are only seen along the sutures**.
- From the front, it looks like **Y** and from the back, it looks like an **inverted Y**.

### 8. Wilson disease causes sunflower cataract

### 9. Galactosemia causing oil droplet cataract

### 10. Total congenital cataract

- Whole lens is opaque when the child is born.



#### Clinical Features

**Leukocoria:** It is also known as the **white eye reflex**.

#### Investigation:

- First a detailed eye examination is to be done.
  - **Ocular:** A scan and B scan are done.
  - **Systemic:** It is not done in unilateral cataracts or bilateral cataracts with positive family history. It is done to find other causes of cataracts. This can be of two types:
    - **Serum analysis:** In this glucose level, galactokinase level, calcium, phosphorus levels, and TORCHS titre levels are checked.
    - **Urine analysis:**
      - Reducing substance in the urine then diagnosis is **galactosemia**.
      - **Amino acids** in the urine indicate **Lowes's syndrome**.
      - If **sediments** are detected in the urine, then it is **Fabry's disease**.
      - Detection of **copper** in the urine indicated **Wilson's disease**.
      - **Blood** in the urine indicates **Alport's syndrome (Familial hemorrhagic Nephritis)**.

#### Treatment of congenital cataract

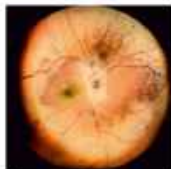- **The ideal time to operate:**
  - It should not be done before 1 month of age due to the high chances of developing inflammatory glaucoma.
  - After 1 month of age, it should be done as soon as possible.
  - **Unilateral:** In this case amblyopia will be deeper and difficult to treat, so the treatment should be done as soon as possible.
  - **Bilateral:** In this case, the treatment should be done after 6 weeks of age.
- **Dhane's criteria**
- **P** indicates power:
  - If the child is <2 years, under correct the P value by 20%.

o If the child is 2-8 years old, then under correct by 10%.

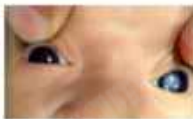- **Treatment of choice:** It is lens aspiration with primary posterior capsulotomy with anterior vitrectomy.

#### Congenital rubella syndrome:

- The triad of this disease is CHD - cataract, heart defects, and deafness.
- The most common type of cataract is the **nuclear pearly cataract**.
- **Ocular features of rubella:** They are-
  - o Microphthalmos: When the axial length is <21 mm or at 1 year the axial length is <19mm.
  - o Rubella keratitis.
  - o Angle anomaly leading to glaucoma.
  - o **Nuclear pearly cataract:** This is the **second most common ocular feature**.
  - o **Pigmented retinopathy:** Salt and pepper fundus is seen due to diffuse chorioretinitis. This is the **most common ocular feature**.



**Signs and Symptoms**  
Diffuse Pigmentary Retinopathy  
Salt-and-pepper Retinopathy



**Cataract**



Fundus photo of the patient with Rubella

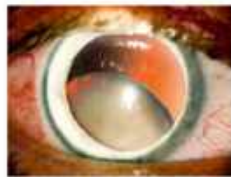


#### Important Information

- **Differential diagnosis of salt and pepper fundus:**  
**These are -**
  - o Rubella
  - o Syphilis
  - o Myotonic dystrophy
  - o Retinitis pigmentosa: A variant of this condition is sine pigmento.
  - o Leber's amaurosis

#### Subluxation of Lens

01/15/35



- It is the **partial dislocation** where a part of the lens is still in the **patellar fossa**.

#### Etiology:

- It can be of two types -
  - o **Acquired:**
    - The most common cause is trauma.
    - Buphthalmos: Enlargement of the eyeball
    - High myopia
    - Pseudo exfoliation syndrome
    - Chronic uveitis
    - Hyper mature nuclear sclerotic cataract
  - o **Genetic:** It is called **ectopia lentis**. This can be of three types -
    - **Simple EL:** Displace of lens takes place.
    - It includes familial EL which is autosomal dominant.
    - **Ectopia lentes et pupillae:** The pupil is also displaced in the opposite direction of lens displacement.
    - **EL associated with systemic diseases**

#### EL associated with systemic diseases

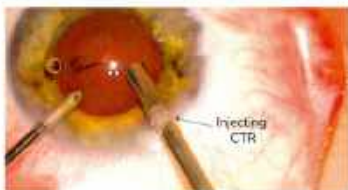
- **Murfan's syndrome:** It is a superio-temporal ectopia lentes.
- Patient is tall, hands and fingers are long, arachnodactyly.
- **Homocystinuria:** It is inferio-nasal ectopia lentes.
- **Wiel Marchesani syndrome:** It has an inferior subluxation and microspherophakia (small, spherical lenses). The patient is short stature with stubby fingers.
- **Ehler-Danlos syndrome:** The subluxation has no specific direction. Also, a blue sclera is seen which is a very thin sclera such that the underlying uveal tissues are visible.
- Sulfite oxidase deficiency
- Hyperlysinemia
- **Stickler syndrome:** It is disorder of collagen production. The most common ocular feature is **retinal detachment**.

### Ocular features of Marfan's Syndrome

- Axial myopia
- **Megalocornea**: It is the most prominent feature.
- Cornea plana
- **Ectopia lentis which is superio-temporal**: It is the most common feature.
- Hypoplasia of dilator pupillae.
- Lattice degeneration of the retina.
- Rhegmatogenous retinal detachments.

### Management

- Spectacle correction from **phakic area** or **aphakic area**, whichever is more.
- **Surgery**



Capsular tension rings in PXF

- If subluxation is  $< 9$  o'clock hours; Usage of capsular tension rings or CRS (capsular ring segments) is done.
- It will help to support the capsular bag where there is no support from the suspensory ligament.
- If subluxation is  $> 9$  o'clock hours; Removal of the lens is done i.e., ICCE.



# PREVIOUS YEAR QUESTIONS




- Q. Most common cause of blindness in India?  
(FMGE JUNE 2019)
- A. **Cataract**  
B. Refractive error  
C. Trachoma  
D. Glaucoma
- Q. A patient with VA  $>1/60$ , but  $<3/60$  in his better eye. What type of blindness does he have?  
(FMGE JUNE 2021)
- A. Low vision  
B. Economic blindness  
C. **Social blindness**  
D. Manifest blindness
- Q. A person comes with right eye 6/60 and left eye 3/60. He should be categorized into which type of blindness?  
(FMGE DEC 2019)
- A. Manifest  
B. Social  
C. **Economic**  
D. No blindness
- Q. Most sensitive to radiation is, (JIPMER MAY 2019)
- A. Retina  
B. Optic nerve  
C. **Lens**  
D. Cornea
- Q. Intraocular lens is implanted in a young adult after cataract surgery which was uneventful. When will you remove the IOL?  
(AIIMS MAY 2019)
- A. Remove after 10 years  
B. Remove after presbyopia  
C. After secondary cataract develops  
D. **Never removed**
- Q. Advantage of lens over spectacles? (FMGE DEC 2019)
- A. **Less prismatic effects**  
B. Protection from UV rays  
C. Decrease infection  
D. Decrease inflammation
- Q. A 60-year-old man underwent phacoemulsification surgery and placement of foldable IOL of left eye a year back has come back with complaints of hazy vision now in that eye. There is no associated redness or pain or watering of eye. The probable cause (JIPMER MAY 2018)
- A. **Posterior capsular opacification**  
B. Cystoid macular edema  
C. Neovascular glaucoma  
D. Chorioretinitis
- Q. A 10-year-old child is diagnosed with amblyopia in one eye. What will be the best treatment? (FMGE JUNE 2021)
- A. Observation  
B. Penalisation  
C. **Occlusion**  
D. None of the above





## Crossword Puzzle 1




### Across

- \_\_\_\_\_ dye is used in the Seidel test.
- The hallmark feature of endophthalmitis is progressive \_\_\_\_\_.

### Down

- \_\_\_\_\_ are the systemic antibiotics given in endophthalmitis.
- \_\_\_\_\_ is the treatment of Descemet membrane detachment.

## Crossword Puzzle 2




### Across

- The most common fungus that causes keratitis is \_\_\_\_\_.
- \_\_\_\_\_ have the least chance of causing posterior capsular opacification.

### Down

- \_\_\_\_\_ and amphotericin B are the fungal drugs that can be given intravitreally.
- \_\_\_\_\_ is the most common pathogen that causes post-traumatic endophthalmitis.

### Crossword Puzzle 3



#### Across

1. cataract \_\_\_\_\_ is a feature of Down's syndrome.
4. \_\_\_\_\_ is the spoke-like opacities seen in lamellar cataracts.
5. Refractive surprise can be treated by specs, exchange of the IOLs or \_\_\_\_\_ IOLs.

#### Down

2. \_\_\_\_\_ appearance is seen in the posterior polar cataract.
3. R in TORCHS stands for \_\_\_\_\_.

Telegram : @teamlab  
www.Disha.co



### Types of Lasers

- Lasers for eyes, based on their mechanisms, are classified into three types:
  - Photo disruptive laser
  - Photocoagulative laser
  - Photo ablative laser

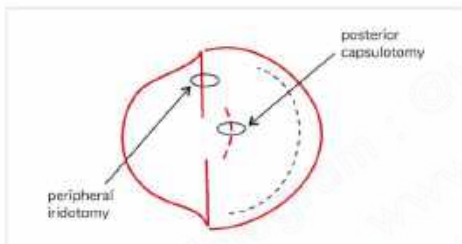
### Photodisruptive Lasers

00:01:24

- Photo disruptive lasers are used for cutting a hole in the eye, such as Nd: YAG.

### Nd: YAG

- Nd: YAG is used for cutting the posterior capsule, and this procedure is called posterior capsulotomy. So, one application of this laser is **laser posterior capsulotomy**.



- Another indication is its use in the peripheral eye, known as **peripheral iridotomy**.

### Femto-Laser

00:02:53

- Femto-laser is another photo disruptive laser.
- Femto-laser is used in **cataract surgery** and **refractive surgery**.
- The basis for all refractive surgery, especially laser-assisted ones, is to alter the cornea's curvature, which is called **keratomileusis**. It is known that the more curvature, the more refractive power which is myopia.
- If a patient already has myopia, more curvature is unwanted. The correct way would be to flatten the central cornea.
- In the case of hypermetropia, the correct way would be to bulge the central cornea.
- The altering of curvature of the cornea as per the need of the patient is called **keratomileusis**. The common surgery is LASIK surgery.
- In LASIK surgery, Femto-laser is used to raise the flap.
- The second application of Femto is the **SMILE procedure**, where we focus the Femto laser directly on the stroma,

cutting a piece of stroma as per the requirement, making a small incision, and removing that piece. SMILE stands for **Small Incision Lenticule Extraction**.

### Photocoagulative Lasers

00:05:33

- This is the second type of laser.
- One of its applications is on the trabecular meshwork i.e., **trabeculoplasty** in open-angle glaucoma.
- The second application : instead vascular diseases of the retina.
- Photocoagulative lasers are:
  - Argon
  - Diode
  - Double frequency Nd: YAG (the wavelength here is half of the Nd: YAG).
  - Simple Nd: YAG is photo disruptive, but in case of double frequency, it becomes Photocoagulative.)

### Photo ablative Lasers

00:06:59

- Photo ablative lasers primarily refer to **Excimer lasers**.
- Argon Fluoride** is used for the eye, and the indication for this is **refractive surgery**.

Q. What is the wavelength of the laser used in LASIK surgery?

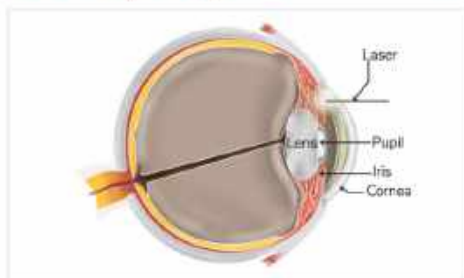
00:07:44

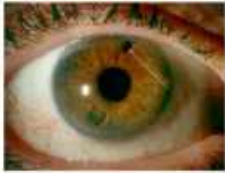Ans. The wavelength of Argon Fluoride is 193 nm.

- The wavelengths of the rest of the lasers are as follows:
  - The wavelength of Nd: YAG is an infrared range of 1064 nm.
  - The wavelength of the Femto-laser is 1054 or 1053 nm.
- The wavelength of Photocoagulative lasers are as follows:
  - Argon: 514 nm
  - Diode: 780 nm to 850 nm
  - Double frequency Nd: YAG: 532 nm

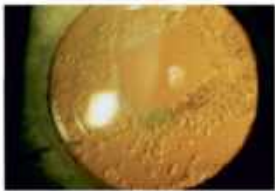### Slides Showing Laser Application

00:09:07





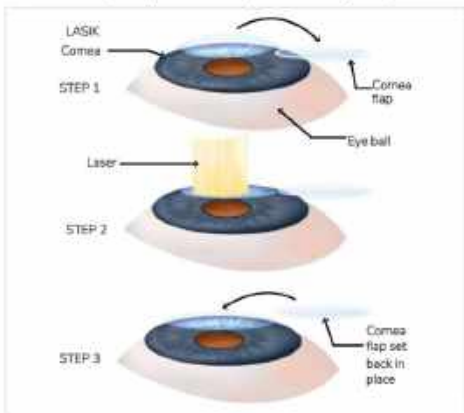
- The peripheral iridotomy is carried out on the peripheral iris, and the laser used here is Nd: YAG.



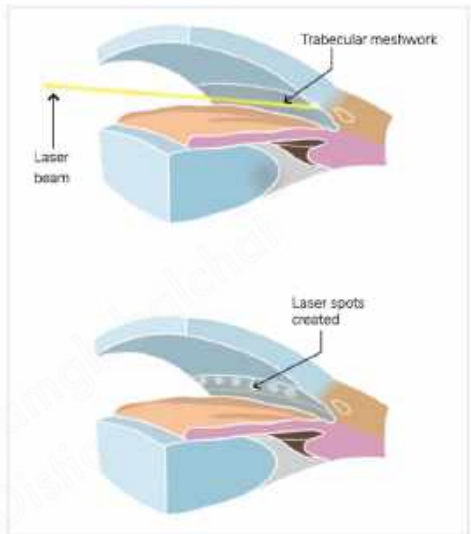
- This image shows, the posterior capsule is opacified, and there are Elschnig pearls. The central part is cut and Nd: YAG posterior capsulotomy is done.



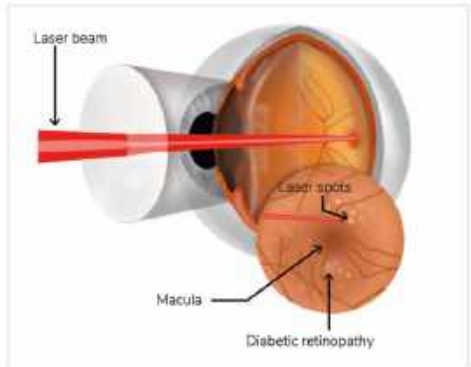
- Here, the capsule has been cut with the laser. Femto-laser CCC (Continuous Curvilinear Capsulorhexis) is used. Afterward, the capsule is easily removed surgically.



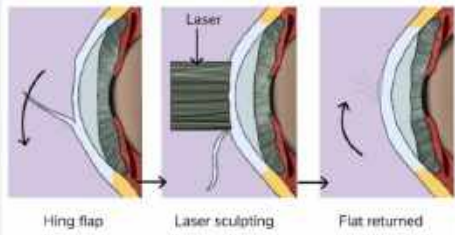
- The above diagram shows how a LASIK procedure is done by raising the corneal flap, applying the laser in the corneal stroma, and putting the flap back. Raising the flap can be done by microkeratome or Femto-laser.



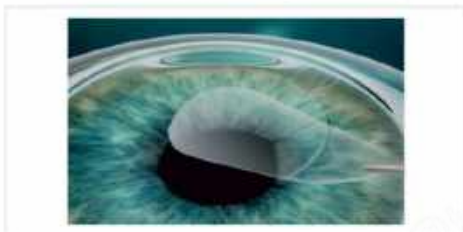
- It's evident from the slides that the laser is applied to the trabecular meshwork, and the laser spots are visible. The laser is focused through the lens.



- In the above slide, a laser beam is focussed on the retina in case of Photocoagulative procedures, such as diabetic retinopathy, CRVO, sickle cell, etc.




- In this image, it can be seen how LASIK surgery works. There is a flap, and the laser is applied to the rest of the cornea. There is sculpting, and the flap returns to its position.



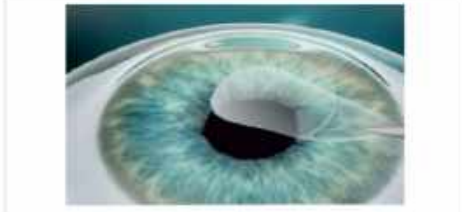#### The treatment steps

- Lenticule; It is a piece of corneal stroma which is cut by the FEMTO laser.
1. Step 1: Lenticule creation
    - A thin lenticule and small incision are created inside the intact cornea.



#### 2. Step 2: Lenticule removal

- The lenticule is removed through the incision with minimal disruption to the corneal biomechanics.



#### 3. Step 3: Impairment is corrected

- Removing the lenticule changes the shape of the cornea, thereby achieving the desired refractive correction.




- In the above diagram, the SMILE procedure is being done. In step 1, there's a creation of the lenticule by the laser; secondly, the lenticule is removed.
- In the third step, there's a correction of impairment by changing the shape of the cornea. Lenticule is a piece of the corneal stroma cut by the Femto laser and then removed.



# CROSS WORD PUZZLES



## Crossword Puzzle 1



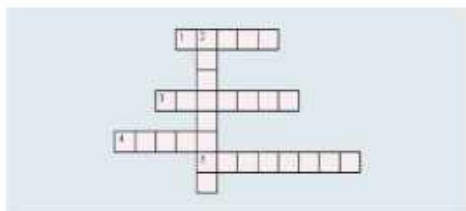
### Across

- \_\_\_\_\_ is a piece of the corneal stroma that the Femto laser has cut.
- The two major indications for Nd: YAG; posterior capsulotomy and peripheral \_\_\_\_\_.

### Down

- \_\_\_\_\_ laser is a cutting laser type that forms a hole such as Nd:YAG.
- Cutting the posterior capsule is called posterior \_\_\_\_\_.
- Laser beam is focussed on the \_\_\_\_\_ in case of Photocoagulative procedures such as diabetic retinopathy.

## Crossword Puzzle 2



### Across


- \_\_\_\_\_ laser is used in cataract surgery for capsular axis and lens fragmentation.
- \_\_\_\_\_ lasers are of many types, for example, Xenon Fluoride, Argon Fluoride, etc.
- For the eye, \_\_\_\_\_ Fluoride Excimer laser is used.

- When the posterior capsule is opacified, there are \_\_\_\_\_ pearls.

### Down

- The wavelength of Nd: YAG is an \_\_\_\_\_ range of 1064 nm.

## Crossword Puzzle 3



### Across

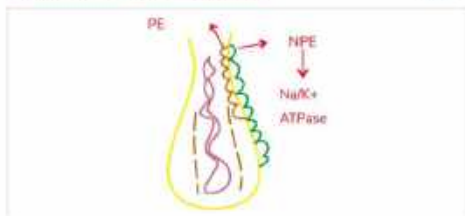
- \_\_\_\_\_ procedure is done by raising the corneal flap.
- In LASIK surgery, a \_\_\_\_\_ laser is used to raise the flap.
- In the SMILE procedure, the Femto laser is focused directly on the \_\_\_\_\_.

### Down

- The altering of cornea curvature as per patients' need is called \_\_\_\_\_.
- Argon and Diode are the names of \_\_\_\_\_ lasers. \_\_\_\_\_ conjunctivitis.
- \_\_\_\_\_ causes lid retraction.

## Formation of Aqueous Humour

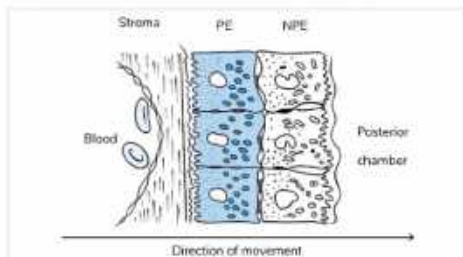
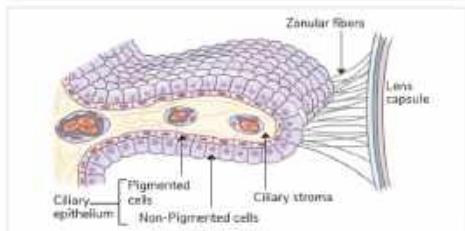
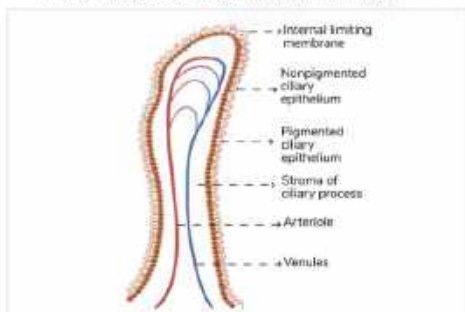
(00:01:00)



- Aqueous is formed from the ciliary processes.
- Aqueous humour is formed from the **non-pigmented epithelium**, which has **Na/K+ ATPase pump** and is responsible for the process of secretion of aqueous humour.
- Non pigmented epithelium has tight junctions so it is a part of blood aqueous barrier

### Process

- Diffusion
- Ultrafiltration
- **Secretion: It is an energy dependent process, maximum aqueous is formed by secretion.**
- Direction of movement of aqueous is Blood → Stroma → PE → NPE → Posterior chamber maximum formation.



- **Rate of formation of Aqueous humour: 2.3 microlitre per min**
- **Hypersecretory glaucoma:** Due to increased formation of aqueous
  - Seen in epidemic dropsy.
- Volume of aqueous humor: 0.31ml
  - Anterior Chamber - 0.25ml
  - Posterior Chamber - 0.06ml

### Constituents in aqueous, more than plasma are.

- **Lactate:** due to anaerobic glycolysis
- **Ascorbate:** Antioxidant
- Chloride
- Pyruvate

### Blood Aqueous Barrier

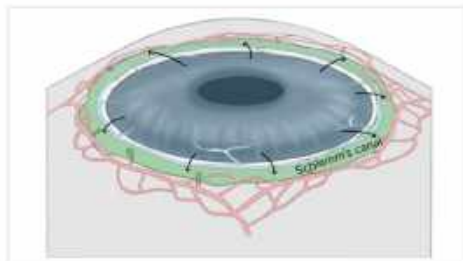
(00:11:34)

- The blood-aqueous barrier is formed by
  - **Non-pigmented epithelium (Tight junction)**
  - **Vascular endothelium of iris,**
 → Eg. Aqueous flare in UVEITIS.

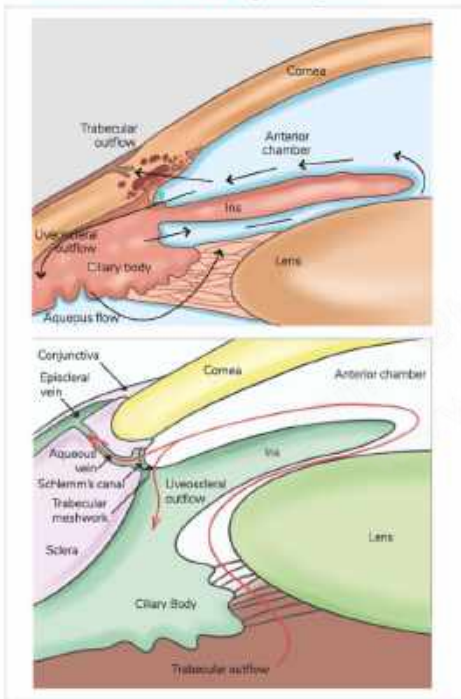
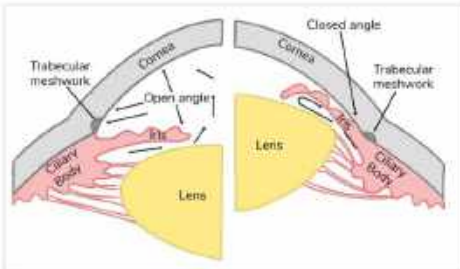
### Outflow of Aqueous

- Conventional/ Trabecular flow (90%)
- Uveo-sclera (10%)

### Conventional Outflow (90%)



- Aqueous humour is formed by ciliary process in posterior chamber → through pupil enters anterior chamber → angle of anterior chamber (space between iris and cornea) → trabecular meshwork → Schlemm's canal → collector channels in sclera → aqueous vein of Ascher → reabsorbed in episcleral vein → superior and inferior ophthalmic vein → cavernous sinus
- Therefore, any pathology in the cavernous sinus can cause more pressure in the episcleral venous system.
  - This leads to post trabecular cause of glaucoma.
- **Trabecular outflow is an IOP dependent process.**



#### Uveo-Scleral Outflow (10%)

- A small proportion of the aqueous (4%) drains from Uvea (root of iris) → suprachoroidal space → absorbed in sclera by the pores/ long posterior ciliary vessels.
- **It is non-IOP dependent.**

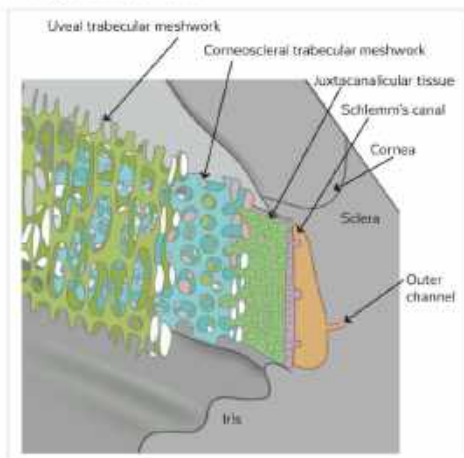
#### Important Information

- Facility of aqueous outflow i.e., measuring how easily the aqueous is flowing through the outflow system → **Tonography.**
  - It is depicted as C value 0.22-0.28 ul/min/mmHg.

#### Different type of impaired drainage

Open angle glaucoma	Angle closure glaucoma
<ul style="list-style-type: none"> <li>• Primary Open-angle glaucoma.</li> <li>• It is due to blockage of trabecular meshwork</li> </ul>	<ul style="list-style-type: none"> <li>• In Closed-angle glaucoma, the angle gets obliterated and the aqueous is unable to reach the angle at all.</li> <li>• E.g. pupillary block: lens is touching the iris → aqueous cannot flow and gets collected in posterior chamber and pushes the iris forward and blocks the angle.</li> </ul>

#### Trabecular Meshwork



- It has 3 parts:
  - Uveal trabecular meshwork
  - Corneoscleral trabecular meshwork



- o Juxtacanalicular trabecular meshwork (besides Schlemm's canal)
- Maximum resistance in TM is seen in juxtacanalicular trabecular meshwork.
- Trabecular Meshwork secrete glycosaminoglycans (GAG).
- It has contractile properties due to actin and myosin.



### Important Information

- Most common complication of steroids in the eye is glaucoma.
- This steroid induced glaucoma is primarily due to increased secretion of GAG.
- Antiglaucoma drug: **Netarsudil**, it increases the contractile property of trabecular meshwork and increases the trabecular outflow.

### Glaucoma

00032/09

- Glaucoma is a group of conditions that have in common- A chronic progressive optic neuropathy that results in characteristic morphological changes at the optic nerve head and in retinal nerve fibre layer.
- **IOP is a key modifiable factor.**

### Mechanism of optic nerve damage

<b>Mechanical Theory</b> ↓ ↑ IOP ↓ Mechanical damage of optic nerve	<b>Vascular Theory</b> ↓ Due to Less blood supply
---	---

### Classification

Refer Table 5.1

### Primary Open-Angle Glaucoma

#### Risk Factor

- IOP high, Difference of IOP between two eyes is  $\geq 4$  mmHg
- Age > 40 years
- Positive family history
- **Genes responsible for glaucoma**
  - o Myocillin – MYOC gene
  - o Optineurin gene – OPTN gene
  - o WDR-36
- High Myopia (> 6 D)
- Race → More common in blacks
- **DM → No increased risk of glaucoma**

#### Pathogenesis

- Any mechanical or vascular cause leads to decrease in axoplasmic flow

- It causes compromise in nutrition leading to oxidative injury which cause apoptosis of retinal ganglionic cells.
- Thinning of optic nerve → astrocytes/ glial cells proliferation → leads to alteration in extracellular matrix of lamina cribrosa → remodelling in optic nerve head → leads to cupping of optic disc.
- Lamina cribrosa is a sieve like part of optic disc and sclera

### Clinical Feature

- Headache/ Eye ache: Main complaint
- Visual acuity is normal in the initial stage.
- Colour vision is not affected.

### On Examination

#### 3 salient features:

- IOP Changes
- Fundus Changes : Along with damage of optic nerve, there will be change in optic nerve head
- Visual field defect

#### IOP Changes

- **Normal IOP- 10-21 mmHg**
- Normal diurnal variation is 5 mmHg.
- If diurnal variation is 5-8 mmHg- glaucoma suspect.
- If diurnal variation is  $\geq 8$  mmHg- glaucoma.
- IOP is more in the morning because of more cortisol levels in the morning.
- Other factors causing short term fluctuations of IOP
  - o Max in a prone position. Prone > supine > sitting.
  - o Exercise decreases IOP except during head stand.
  - o Drinking water increases IOP.
  - o General anaesthesia decreases IOP except Ketamine
  - o Steroids increases IOP- Steroid responders:
    - Mild responders: < 6 mmHg
    - Moderate responders: 6-15 mmHg
    - Severe responders: pressure rises > 15 mmHg (avoid steroids in these patients)

### Ocular Hypertension:

- Increased IOP (No damage in the optic nerve)
- No Fundus findings
- No visual Field effects.

### Normal-Tension Glaucoma (NTG)

- IOP is normal.
- Fundus changes Present
- Visual field defect present
- Etiology explained by vascular theory of axonal loss.

#### Association:

- Nocturnal Hypotension patient (associated with early morning surge in blood pressure)
- Sleep Apnoea patient.

- Migraine patient.
- Significant positive family history



## Important Information

### How to measure IOP

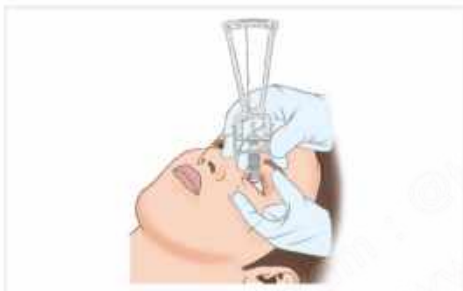- IOP is measured by tonometry.

### Tonometry: 2 types

00:59:00

#### • Indentation tonometry

1. Schiøtz tonometer: Frieden Wald nomogram chart is used to record the value.
2. Reading depends on scleral rigidity and therefore it is less reliable.
  - Scleral rigidity is less in children, myopic patients.
  - Scleral rigidity is more in hypermetropic patients.



#### • Applanation tonometry

- Applanation tonometer is based on Imbert Fick Law,  $P = \text{Force}/\text{Area}$
- Applanation tonometer divides into
  - Variable force Applanation tonometer (Area is fixed and the area is 3,06 mm diameter) – E.g., Goldman applanation tonometer.
  - Fixed force Applanation tonometer (force is fixed)
  - Applanation is more reliable than indentation tonometry.

### Goldman applanation tonometer:



- Fluorescein dye is applied before placing the applanation tonometer.
- Two semicircles are seen when we touch the cornea.



- Reading is measured when the inner margin of two semicircles touches each other.

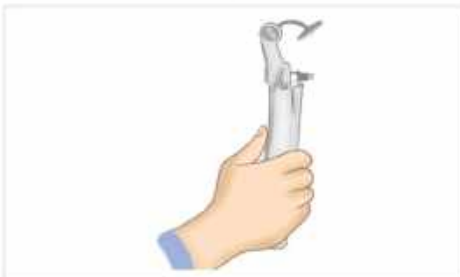

- Disadvantage: IOP measurement depends on Central cornea Thickness (CCT).
- Thick Cornea → IOP is overestimated
- Thin Cornea → IOP is underestimated
- 10 microns change in CCT means 0,7mmHg of IOP change.

#### Variable force tonometers:

- Variable force means that area is fixed but the amount of force needed to applanate that area is directly proportional to IOP.

  1. Goldmann applanation tonometer → Goldstandard
  2. Perkins (hand held version of goldmann)



3. Draeger (measures Wide range of IOP)  
Draeger Tonometer
  - Draeger tonometer is similar to Perkins
  - It has a different set of prisms
  - It operates with a motor

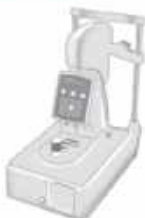o Types of transpalpebral tonometer

→ If patient is having keratoprosthesis i.e., when keratoplasty is unsuccessful, some artificial material is used to maintain transparency in cornea.

Refer Table 5.2



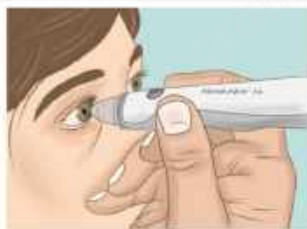4. Pulsair (non-contact tonometer)



5. Airpuff (non-contact tonometer)

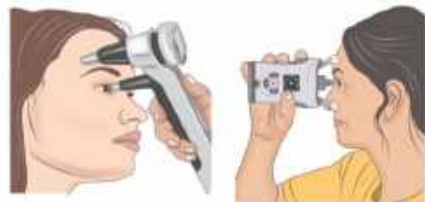6. Grolmanns (non-contact tonometer)

7. Tonopen (based on both indentation and applanation)



8. Mac kay marg (based on both indentation and applanation)

9. Rebound tonometer.

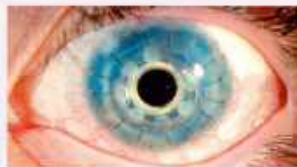

10. Transpalpebral Tonometer

- It is not directly put on cornea, eyes should be closed

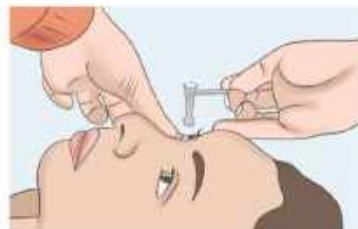 Important Information

- Tonometer of choice in infants is Tonopen > perkins
- Tonometer of choice in scarred and irregular cornea is Tonopen > Mac kay marg
- Tonopen is used in patients with bandage contact lenses.
- Rebound tonometer (Home tonometer) is used for self-measurement of IOP.
- Transpalpebral tonometer is used in keratoprosthesis



Fixed force tonometer:

- Here the force is fixed but the area is inversely proportional to the IOP.
- MaklaKov tonometer



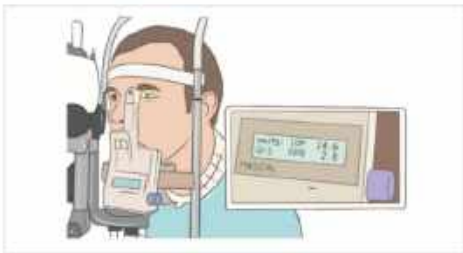• Barraquer tonometer



## Latest Tonometer

### Contact

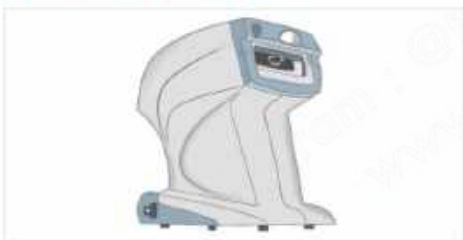- Pascal DCT (Dynamic Contour Tonometry)



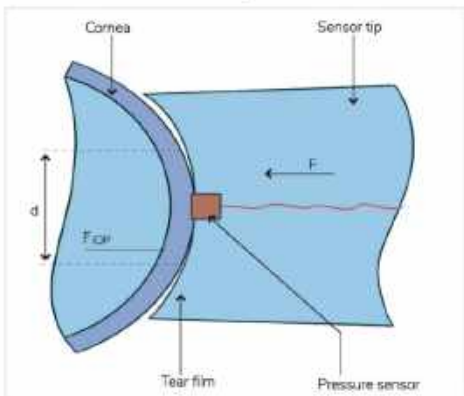
- Reading does not depend on Central corneal Thickness.
- This is the choice of instrument in Refractive surgery and post-Lasik patients.
- It can also be used in patients with keratoconus

### Non-contact

- Ocular response analyser (ORA)



- ORA is based on corneal Hysteresis.



- Puff of air is applanating the cornea, due to which cornea is bending in.
- Take the pressure when it is applanated and also measure the pressure when it is coming back.
- It measures the biomechanical property of the cornea when taking the difference of reading between cornea applanates in and when it bends out.
- If the difference is smaller the risk of glaucoma is higher.
- Low value means, more risk of progression of glaucoma

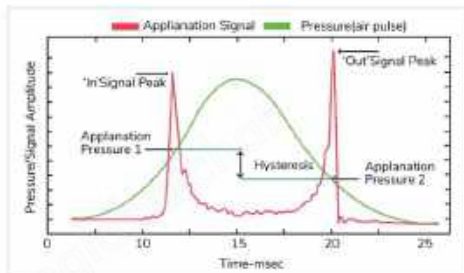


Table 5.1

### Congenital/Developmental Glaucoma

#### Types:

- True Congenital Glaucoma
- Infantile Glaucoma: in child < 3 years of age
- Juvenile Glaucoma: from 3 years of age to adolescents
  - Sclera within 3 years is very soft. So, more pressure in the eyeball causes expansion of the eyeball called **Buphthalmos**. Seen in True Congenital Glaucoma and Infantile Glaucoma

### Acquired Glaucoma

#### Types

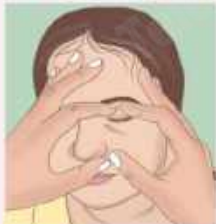- Primary : No known cause
  - Primary Open angle glaucoma
    - Ocular hypertension
    - Normal tension Glaucoma
  - Primary angle closure glaucoma
    - With pupillary block
    - Without pupillary block
- Secondary : Known cause
  - Secondary Open angle glaucoma
    - Pre-trabecular
    - Trabecular
    - Post-trabecular
  - Secondary angle closure glaucoma
    - With pupillary block
    - Without pupillary block

Table 5.2

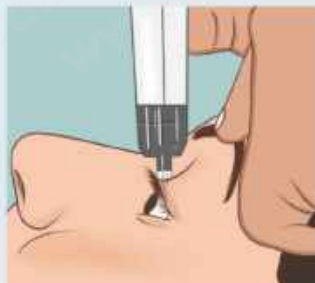#### Digital

- Soft
- Firm (Normal)
- Hard

Technique of digital tonometry



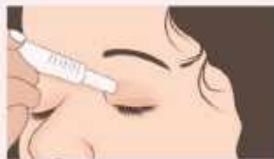#### Diaton



#### Proview

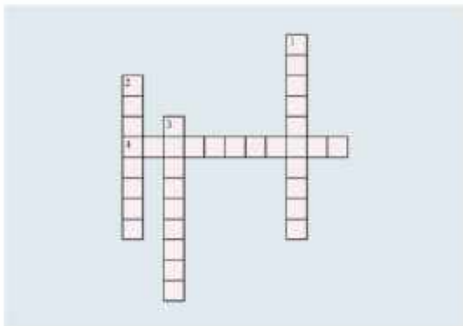


The proview eye pressure monitor (Bausch & Lomb, Rochester, NY)





## Crossword Puzzle 1



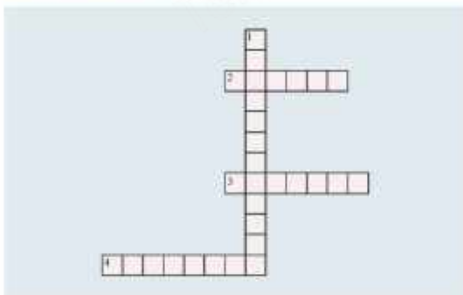
### Across

4. Unconventional outflow also called as

### Down

1. recording measurements of IP with a tonometer
2. increased Intraocular pressure within the eyeball,
3. A maximum formation of aqueous humour process

## Crossword Puzzle 2



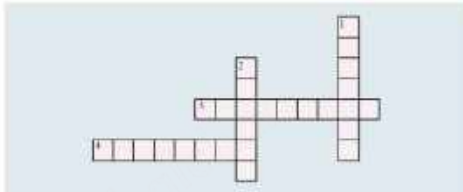
### Across

2. Under normal conditions, production of aqueous humor is \_\_\_\_\_ balanced with drainage in healthy individuals,
3. Latanoprost (\_\_\_\_\_), travoprost, tafuprost and bimatoprost are PGF<sub>2α</sub> selective agonists.
4. Parasympathetic activation of the M<sub>3</sub> receptor in the eye will increase aqueous humor \_\_\_\_\_.

### Down

1. is a carbonic anhydrase inhibitor (CAI) that causes less ocular irritation.

## Crossword Puzzle 3



### Across

3. A condition of the lens of the eyes that causes them become to opaque
4. The condition of pus in the back of the chamber of the eye.

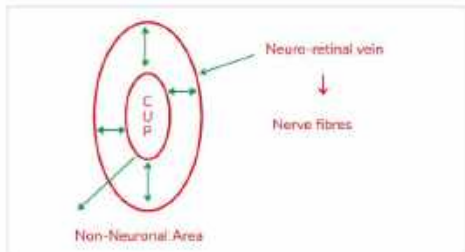
### Down

1. U-group of conditions affecting the front of the eye.
2. The nerve layer that lines the back of the eye are

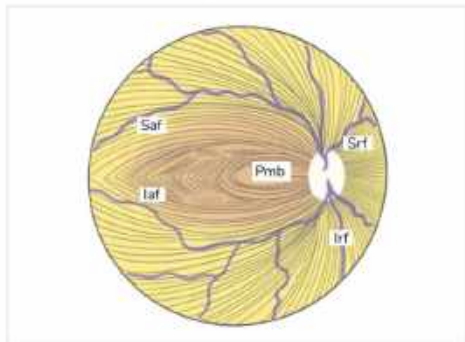
## Fundus Changes

## Cupping of Disc

00:06:12

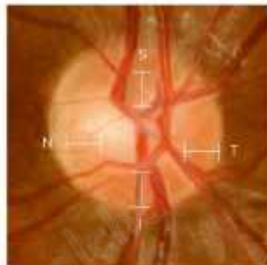

- The nerve fibre occupies the Neuro-retinal rim.
- Cup is considered a non-neuronal area.
- Normal ratio of the cup and the whole disc is called **CD ratio**, i.e.  $\leq 0.3$ .
- If C:D ratio increases, it is called cupping.
- Area of cup is increasing i.e., non neuronal area is increasing.
- It is remodeling of lamina cribrosa due to proliferation of astrocytes and glial cells.
- A patient is suspected with glaucoma if the C:D ratio is more than 0.7.
- Cupping of glaucoma is first vertically oval as 1<sup>st</sup> damage in glaucoma occurs in arcuate fibres.

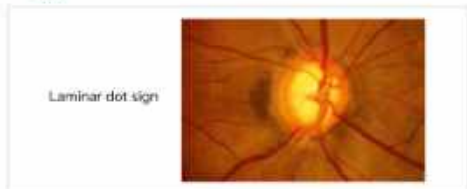

## ISNT Rules

00:10:00



- The neuroretinal rim in normal eyes shows a characteristic configuration. It is usually broadest in the inferior rim, followed by the superior and nasal rims, and thinnest in the temporal disc region.
- This pattern of rim width is known as the **ISNT rule** (**i**nferior  $\geq$  **s**uperior  $\geq$  **n**asal  $\geq$  **t**emporal).
- When there is cupping, there is damage of arcuate fibers.
- The size of cup has increased so I is lesser so glaucoma does not follow ISNT rule.
- If the cupping happens only inferiorly, outer rim is lost and it is called notching neuroretinal rim
- When the whole cup is involved, it is called thinning of neuroretinal rim.
- Inferior arcuate fibers are damaged first.
- Lamina cribrosa is a sieve like opening in sclera and all the nerve fibers are passing through this opening.
- When the nerve fibers are damaged these opening are visible.
- The visible opening of the lamina cribrosa is k/a **laminar dot sign**.



## Type of Fundus Changes

00:13:30

Refer Table 6.1

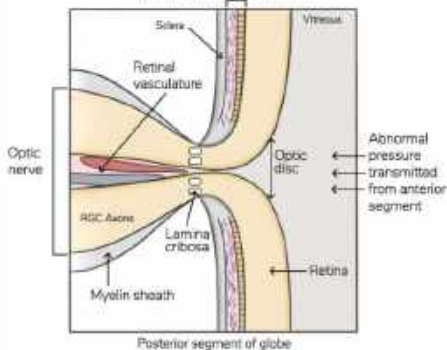
- Cupping is only seen when substantial amount of damage happens, then Scotomas are seen



## Important Information

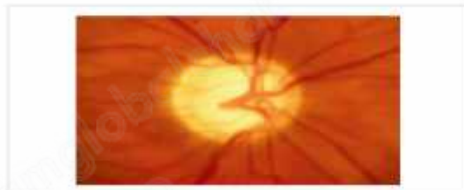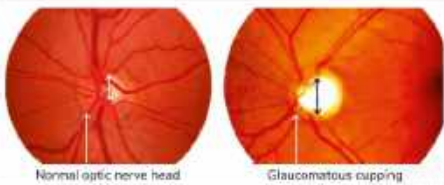
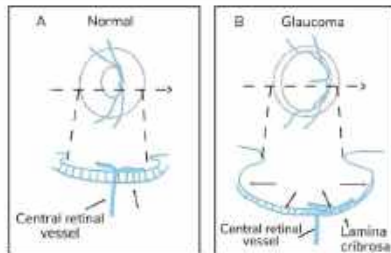
- Glaucoma is never bilaterally symmetrical.

### Pigment epithelium and choroid



### Vascular Changes

#### Nasal Shifting of Vessel

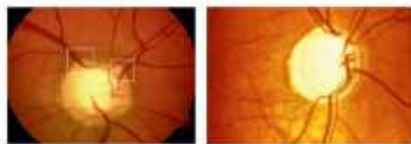
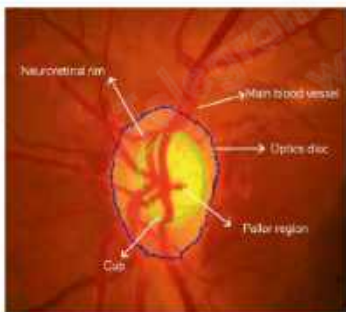


- Ratio is more than 0.7

- When glaucoma progresses, retinal blood vessels shift nasally.

#### Bayoneting Sign

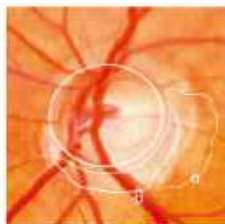- The retinal vessels can disappear as they turn sharply into the cup in severe cases of glaucoma with loss of retinal tissue. This is called bayoneting cupping.



#### Splinter Haemorrhage

- Flame shaped haemorrhage

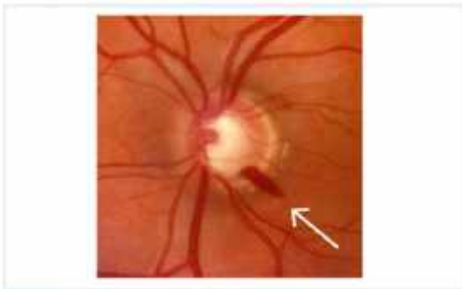
#### Peripapillary Changes



- There is some notching of neuroretinal rim

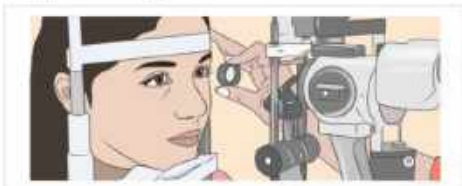

- In peripapillary, there is beta zone and alpha zone.
- Beta zone is more associated with glaucoma.
- Blind spot is an absolute scotoma.
- Alpha zone is mainly due to chorioretinal atrophic areas.



#### Ideal Investigation for Fundus Changes

- Slit Lamp Bimicroscopy: It is a investigation of choice.
- Lens is put in front of patients eye and changes in retina is appreciated through the lens.



#### Type of Lenses

Contact	Non-contact	
Goldman three mirror	Convex	Concave (Hruby Lens)
	+60	-58.60
	+78	
	+90 (best)	



#### NFL Assessment

1. OCT (Optical coherence tomography)
  - o Media should be clear.
  - o Optical Coherence Tomography (OCT) is a non-invasive diagnostic technique that renders an in vivo cross-sectional view of the retina.
  - o For assessing Nerve Fibre Layer Thickness.
  - o It is useful for Glaucoma suspects patients or in any case of glaucoma.
  - o Glaucoma suspect: IOP more than 21, +/- fundus, +/- visual field defects (generally not there), positive family history
  - o Follow up should be done on yearly basis

Refer Image 6.1

Refer Image 6.2

- This is an OCT graph
- Here thickness is with same age normal person.
- Green: Within limits
- Yellow: Borderline
- Red: Outside the limit

2. Scanning Laser Ophthalmoscopy
  - o To assess the nerve fibre layer
3. Scanning laser polarimetry

#### Visual Field Defect

003697

- It is a three-dimensional representation of differential light sensitivity i.e., against particular background or luminescence how much luminescence of target is increased so it is visible to the patient

#### Extent of the visual field.

- Temporarily, it is 90 to 100 degrees, inferiorly 70 degrees, nasally 60 degrees, and superiorly 50 degrees.
- The extent of your visual field is maximum Temporarily and minimum superiorly.

#### Scotoma

004004

- Area of reduced sensitivity or total absence but surrounded by normal area

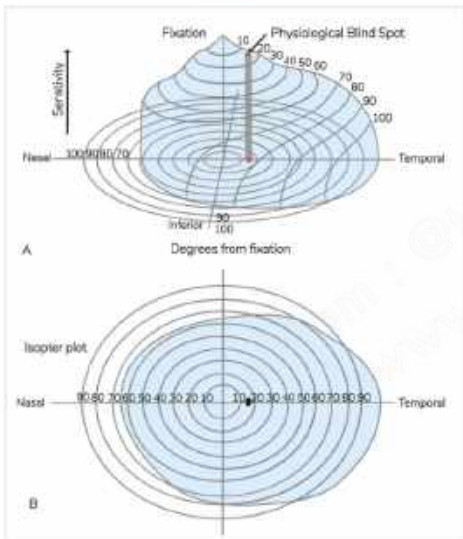
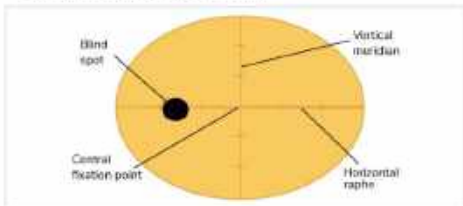
#### Isopter

- Line joining the corresponding area of same light sensitivity

#### Blind Spot

- Is a physiological scotoma.
- Located between 10-to-20-degree isopters

- Projection of retina is always crossed.
- Normally optic disc is nasal to the macula so blind spot is temporally placed.
- Blind spot is an absolute scotoma.
- Blind spot is a negative scotoma.

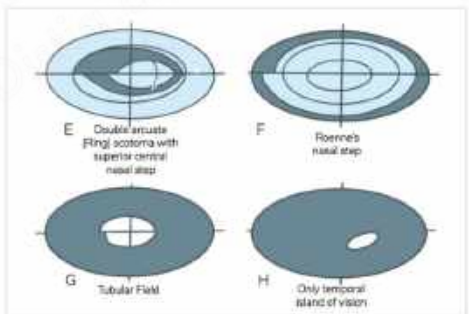
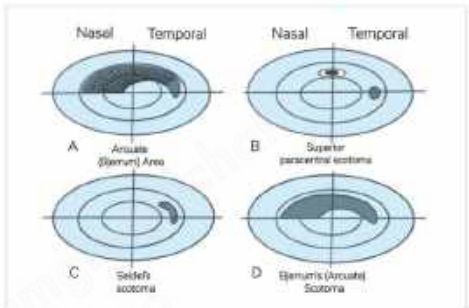


- Sensitivity is maximum where the patient is fixing i.e., at the foveal area.

### Visual Field Defect in Primary Open Angle Glaucoma

Early	Late
<ul style="list-style-type: none"> <li>• <b>Paracentral scotoma:</b> Earliest visual field defect is <b>Paracentral scotoma in Bjerrum's area</b></li> <li>• <b>Seidel scotoma:</b> Paracentral scotomas in the Bjerrum area merging with the blind spot</li> <li>• <b>Nasal step:</b> Scotoma on the nasal side</li> </ul>	<ul style="list-style-type: none"> <li>• <b>Arcuate Scotoma</b></li> <li>• <b>Double arcuate Scotoma</b></li> <li>• <b>Central and Temporal island of vision:</b> Seen just before the blindness</li> </ul>

- **Bjerrum Area** – Area in visual field where the first scotoma corresponds to arcuate fibre.
- **Earliest visual field defect is Paracentral scotoma in Bjerrum's area.**
- **When inferior field is also involved it is called double scotoma.**
- **Temporal island of vision stays till last.**
- **Superior arcuate scotoma is also called as Bjerrum's scotoma**
- **Double arcuate scotoma is also called as ring scotoma**

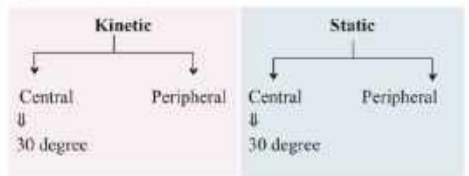


- **First visual field change:** Iopter contraction not involving blind spot i.e., outer extent of visual field is lesser hence it is called **barring of blind spot**

### Perimetry

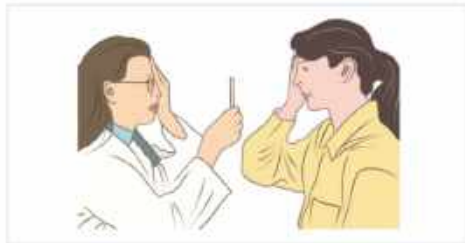- Perimetry is visual field testing.

#### Type of Perimetry



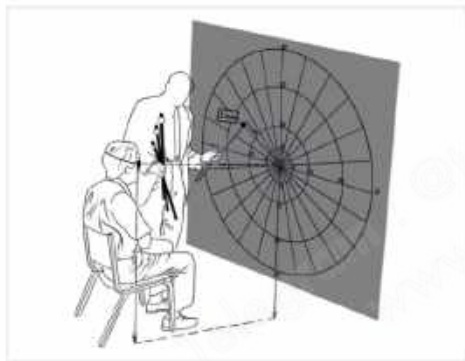
## Kinetic Perimetry

### 1. Confrontation test



- Doctor compare the patients field of vision with his own

### 2. Bjerrum Screen



- It Checks central visual field
- Put a black screen in front of patient 2m away, one eye is closed and patient is given one target, the other is moved from periphery and field is charted
- It is a subject test where patients attention is required

### 3. Lester Perimetry

- Used for peripheral field chart-kinetic method

## Static Perimetry

1. Humphrey field analyser
2. Octopus

### Humphrey field analyser

31.5 Ash. → Luminescence

Sensitivity → dB (decibel)

1/Luminescence

- Sensitivity is inversely proportional to luminescence.
- Sensitivity at the blind spot is 0.
- Sensitivity is maximum at center/fovea i.e., it can be upto 39-40 dB.

- There are some fixation factors to make sure patient is looking at center.



- Computer screen will show if person is fixing properly or not, what is false -ve or false +ve.
- Patient focus on one target (there are multiple white target on screen).
- Whenever patient feels any light is on, he will press the button. This is how light sensitivity is tested against particular background.
- Differential light sensitivity - How much luminescence should be increased in target so that patient can see that.
- If there is damage in optic nerve, sensitivity will be less..
- If it is in pattern of glaucomatous damage, it will confirm glaucoma.

### Chart of automated perimetry

- Age is very important as everything is compared with same age i.e., what is normal for that age.
- Birth date


### Reliability indices

- Shows fixation losses - How many times patient removed his eyes from center, False +ve, False -ve.
  - Test duration.
  - If any reliability i.e., false +ve or false -ve is > 33% then test is not reliable.
1. Grey scale
  2. Total deviation - Compared with age
  3. Pattern deviation - E.g., in cataract, there will be overall decreased sensitivity so taking care of all factors are plotted in graph.
  4. Probability deviation and probability pattern

### Global indices

- Glaucoma Hemifield test; Compare superior and inferior filed.
- VFI - Normal is 100, then what is normal field for patient when compared to 100.

- MD - Tells overall deviation from normal.
- PSD - Tells localized defect.



Refer Image 6.3

### Testing Pattern

- It can be of 3 types
- -2 means the testing points are not at the vertical or horizontal meridian.

30-2 ↓ Checking 30 degrees	24-2 ↓ Checking 24 degrees	10-2 ↓ Checking 10-degree
----------------------------------	----------------------------------	---------------------------------

### Testing Algorithm

00:42:00

#### Type of Testing Algorithm

##### 1. Threshold Perimetry

- A high intensity of luminescence is given, when patient responds, starts decreasing it
- Monitoring glaucoma.

##### 2. Suprathreshold Perimetry

- In suprathreshold perimetry, stimuli are presented above the estimated detection threshold of a normal visual field of that age.
- Quick screening.

##### 3. Fast algorithm

- SITA Standard (Swedish Interactive Thresholding Algorithm)  
→ 4 values are checked at threshold level, it is compared between data base of normal and data base of glaucoma patient
- SITA Fast  
→ SITA Fast, a new rapid perimetric threshold test.
- Fast Pac
- TOP (Tendency Oriented Perimetry)

### High Sensitivity Field Modalities

01:24:00

- Done to catch some early changes
- It is done to catch some specific group of ganglion cells and test it

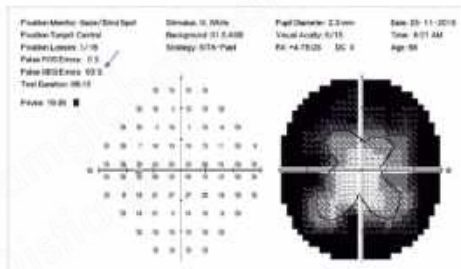
#### 1. SWAP

- Short Wavelength Automated Perimetry
- Stimulus is blue, Background is yellow.
- This test is does not hold much reliability in cataract as cataract has decreasing sensitivity to blue light.

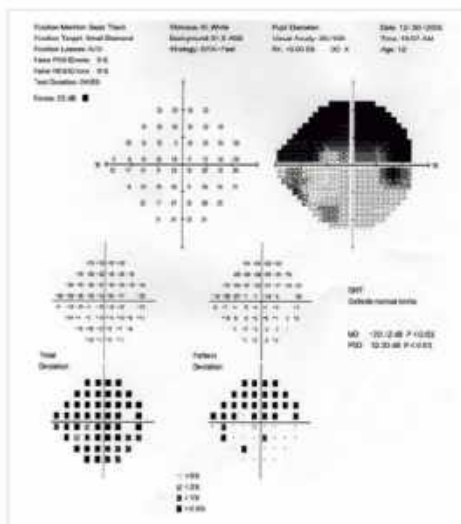
#### 2. FDT

- Frequency doubling technology.
- It catch hold of magnocellular layer and ganglion cells.


### Refer Image 6.4




- Grey scale: it shows clover leaf pattern
- 63% is false negative so it is not reliable



- Shows superior arcuate scotoma



- Shows Inferior arcuate scotoma



- Decreased sensitivity in inferonasal part
- This is inferior nasal step, this is an early change glaucoma

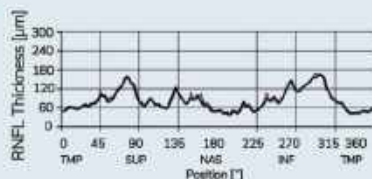
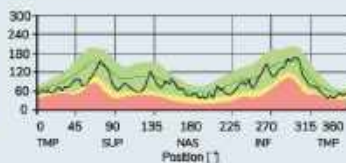
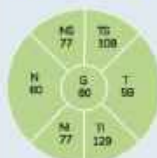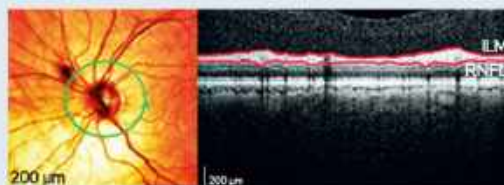
Refer Image 6.5

Table 6.1

Disc Changes	Peripapillary changes	Vascular changes	Retinal Nerve Fibre layer defect
<ul style="list-style-type: none"> <li>The C:D ratio is greater than 0.3.</li> <li>Two eyes differ by 0.2.</li> <li>Notching of neuroretinal rim</li> <li>Slowly thinning in the neuroretinal rim.</li> <li>Visible opening of lamina cribrosa, i.e., Lamellar dot sign.</li> </ul>	<ul style="list-style-type: none"> <li>They are prominent for <math>\beta</math> zone.</li> </ul>	<ul style="list-style-type: none"> <li>Nasal shifting of the vessel.</li> <li>Bayonetting sign (sharp bending of the vessel)</li> <li>A splinter haemorrhage</li> </ul>	<ul style="list-style-type: none"> <li>Slit shape/wedge shape defect</li> </ul>

## Follow-Up #3 Apr/27/2010

IR 30° ART + OCT ART (2) Q:25 [HR]

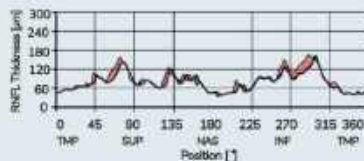
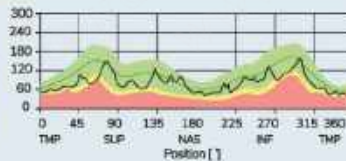
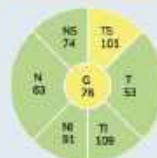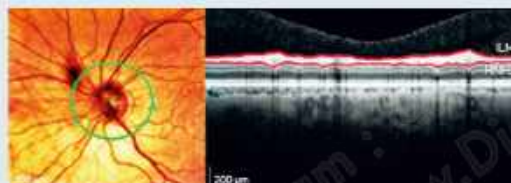


Classification

Within Normal Limits

## Follow-Up #31 May/7/2012

IR 30° ART + OCT ART (37) Q:30 [HR]

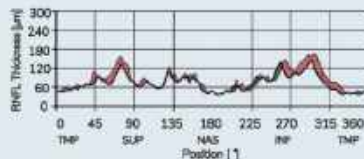
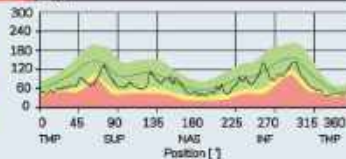
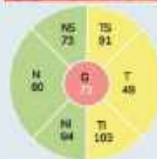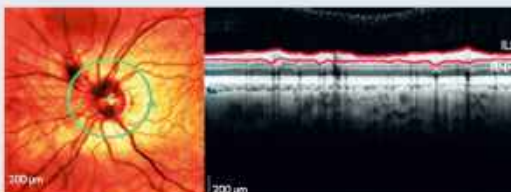


Classification

Borderline

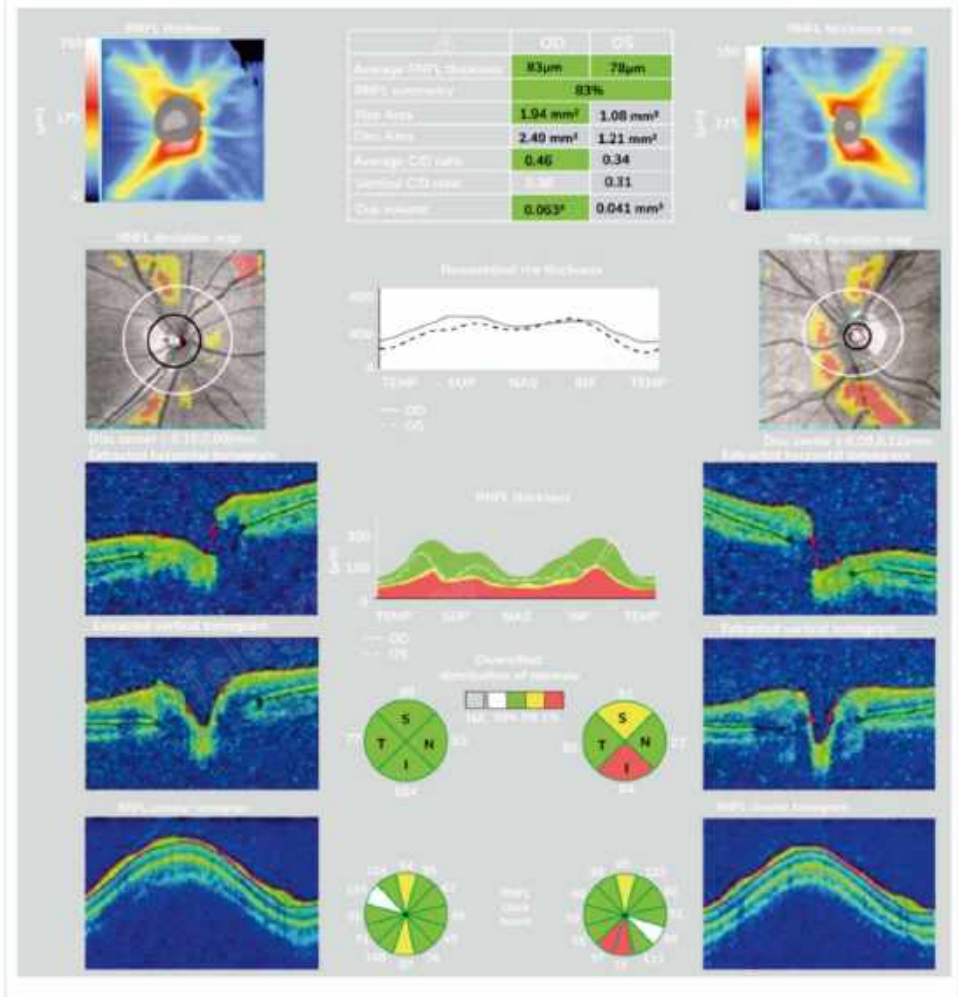
## Follow-Up #32 Mon/8/2012

IR 30° ART + OCT ART (84) Q:33 [I-IR]



Classification

Outside Normal Limits



## Parameters - Central 24-2 Threshold Test

Reliability Indexes →  
 Fixation Monitor: Gaze/Blind Spot  
 Fixation Target: Central  
 Fixation Losses: 1/13  
 False POS Errors: 1.8  
 False NEG Errors: 0.5  
 Test Duration: 04:05  
 Focus: 36 dB


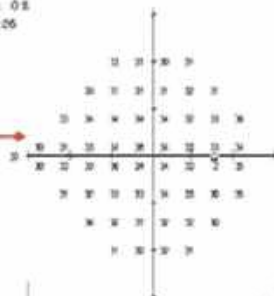
## Stimulus

Stimulus: White  
 Background: 21.5 ASD  
 Strategy: S/TA - Standards

Pupil Diameter: 4.6 mm  
 Visual Acuity: R: +0.50 DS OC X

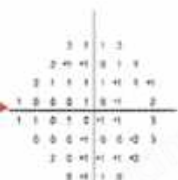
Date: 01-31-2011  
 Time: 2:18 PM  
 Age: 22

## Numerical Sensitivity Plot →



## ← Grayscale Map

## Numerical Total Deviation Map →



Total Deviation

## Numerical Pattern Deviation Map



Pattern Deviation

GHT ← Glaucoma Hemifield Test  
Within normal limits

VF1: 100%

MD: +0.20 dB ← Mean Deviation

PSD: 1.21 dB ← Pattern Standard Deviation

## Probability Total Deviation Map →



## ← Probability Pattern Deviation Map



□ < 5%  
 ◻ < 2%  
 ■ < 1%  
 ■ < 0.5%

Visual Field Laboratory  
 University of Iowa  
 College of Medicine  
 Iowa City, IA  
 (319) 355-1611





## Centrocaecal scotoma

Fixation Monitor: Gaze/Windback  
 Fixation Target: Central  
 Fixation Location: 1/13  
 Fixation PDS Error: 0.2  
 Fixation NDC Error: 3.2  
 Test Duration: 04:45  
 Fixure: OFF

Stimulus: H: White  
 Background: 31.8 ASB  
 Strategy: NTA-Fast

Pupil Diameter:  
 Visual Acuity:  
 NA DS EC: 8


Date: 01-07-99  
 Time: 15:14  
 Age: 25



Size7  
 Outside normal limits

MD: -5.60 dB P < 0.5%  
 PSD: 7.07 dB P < 0.5%

Total  
 Deviation:



Pattern  
 Deviation:



○ P < 5%  
 ◐ P < 2%  
 ◑ P < 1%  
 ◒ P < 0.5%

## Superior Arcuate Scotoma


Fixation Monitor: Gaze Track  
 Fixation Target: Small Diamond  
 Fixation Losses: 0/0  
 False POS Errors: 0 %  
 False NEG Errors: 0 %  
 Test Duration: 04:59

Stimulus III, White  
 Background: 31.5 ASB  
 Strategy: SITA-Fast

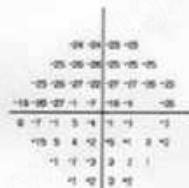Pupil Diameter  
 Visual Acuity: 20/100  
 Rx: +0.00 DS DC X

Date: 12-30-2006  
 Time: 10:07 AM  
 Age: 12


Fovea 22 dB ■



Total  
 Deviation



Pattern  
 Deviation



□ < 0.5%  
 □ < 2%  
 ■ < 1%  
 ■ < 0.5%

GH

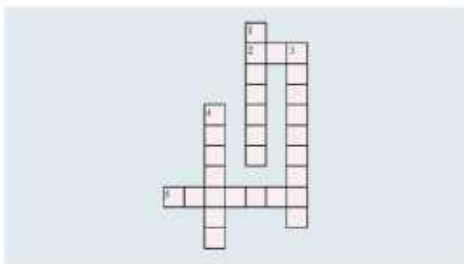
Outside normal limits

MD -20.12 dB P < 0.05

PSD 12.30 dB P < 0.05



## Crossword Puzzle 1




### Across

2. Is considered is non-neuronal area
5. Glaucoma is not bilateral

### Down

1. Damages the optic nerve and causes gradual loss of vision called
3. Is the systematic measurement of visual field function.
4. Is a test to measure the pressure inside your eyes

## Crossword Puzzle 2



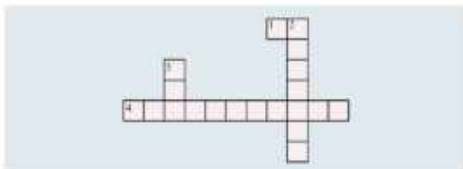
### Across

2. Visual field is a diagnostic test to measure visual fields or perimetry.
3. Perimetry techniques that utilize the evaluation of RNFL.

### Down

1. The patient looks directly at your eye or nose and tests each quadrant in the patient's visual field

## Crossword Puzzle 3



### Across

1. Normal ratio of the cup and the whole disk is called—ratio
4. The extent of your visual field is maximum in

### Down

2. The visible opening of the liminal fibrosabn is a lamina
3. is the outer space apart from the cup called a notching of the neuroretinal rim.

### Primary angle closure Glaucoma

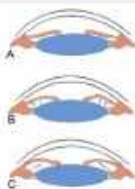
- Angle is a peripheral space between iris and cornea
- This space is occluded the most when the pupil is dilated.
- **Maximum closure of angle occurs in mid dilated pupil.**

#### Risk Factors:

- Small eye; Very common in the nanophthalmos (<20mm of Axial length) or hypermetropia – shallow anterior chamber/narrow angle
- More common in females.
- More prevalent in families exact gene is not defined.

#### Mechanisms:

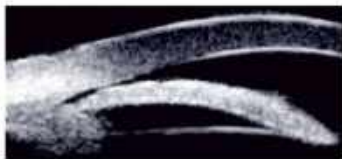- With Pupillary Block
- Without Pupillary Block (Plateau iris)
- Combined mechanism



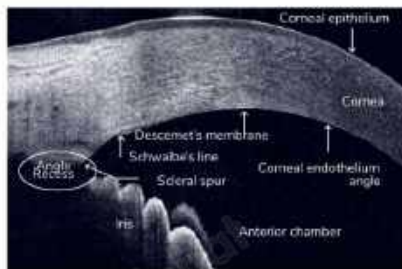
- For any relative pupillary block means the aqueous cannot flow anteriorly and it gets collected in the posterior chamber. Which results in **Iris bombe**.



- Anterior lens vault: part of lens anterior to the angle of AC. If it is big it will cause pupillary block due to
  - Increased lens vault
  - Increased lens thickness
- Anterior iris convexity leads to iridocorneal apposition.



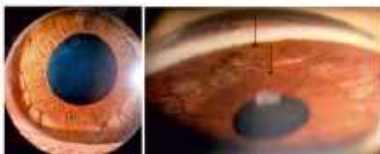- The above image shows iridocorneal touch.



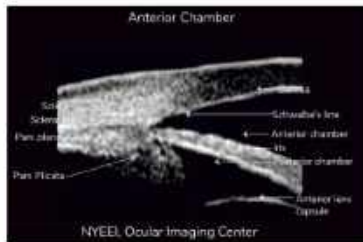

- The anterior most part of the angle is the **Descemet's membrane of cornea**.

### Plateau Iris

06/08/31



#### Plateau Iris



NYEEL Ocular Imaging Center

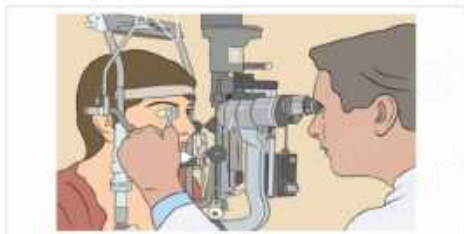- Plateau iris is anteriorly rotated ciliary body any rotation will push the iris anterior and make it more flatter.
- Peripheral anterior chamber is shallow and the central anterior chamber is deep.
- It is caused by a narrowing of the anterior chamber angle induced by insertion of the iris anteriorly on the ciliary body or anterior displacement of the ciliary body, which affects the location of the peripheral iris about the trabecular meshwork (i.e., placing them in apposition).

### Anterior chamber angle assessment

00:10:23


- Gonioscopy
- Van-Herick Method.
- Grading the angle Shaffer system.
- Ultrasound bimicroscopy (UBM)-50MHz.
  - o Structures behind the iris can be seen
- AS-OCT: Non-Contact Method.
  - o Structures behind the iris can not be seen.

### Gonioscopy



- It is **bimicroscopic visualisation** of the angle of the anterior chamber. It will not need dilation of the pupil.

#### Normal Angle Structures

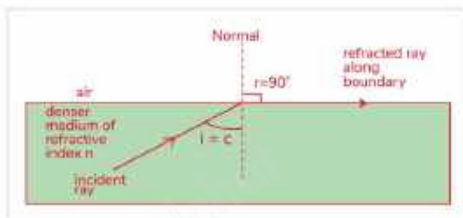


- From anterior to posterior, the normal angle structures are as follows:
  - o Schwalbe's line : Anterior most structure
  - o Non- Pigmented trabecular meshwork.
  - o Pigmented Trabecular meshwork.
  - o Scleral spur.
  - o Ciliary body band.
  - o Iris.

- If the **post-trabecular structures** are not visible more than 180 degrees these are called **Occludable angles**.

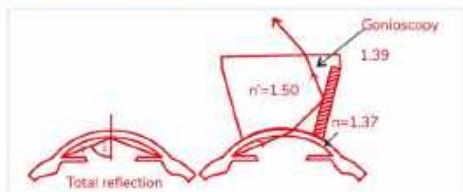
### Critical Angle

- The critical angle is defined as the angle of incidence in the optically denser medium for which the angle of refraction in the optically less dense medium is  $90^\circ$



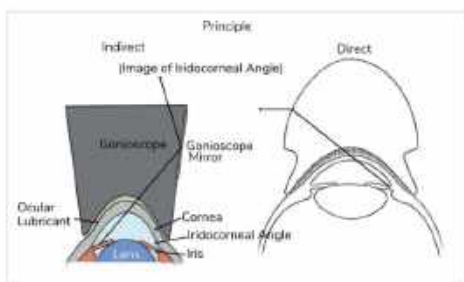
- Whenever light is travelling from denser to lighter medium it will deviate away from the Normal.
- If the angle of incidence keeps increasing when the refractive ray is  $90^\circ$  degrees to the normal which means above the angle of incidence it is not going to refract and there will be total internal reflection.
- The **critical angle of the cornea is 46 Degrees**.

### Principles of Gonioscopy



- The angle structure is not visible to the examiner because of the total internal reflection inside the **anterior chamber**.
- To avoid this the density of the medium should be changed so the **Gonio lens** is used as it has a more refractive index (air it is 1 and for aqueous humour is 1.33)

Indirect	Direct
1. Goldmann lenses	1. Koeppel
• Single mirror	2. Swan - Jacob use used for
• Two mirror	
• Three mirror	
2. Zeiss	
3. Susman	
4. Posner - Rutch	



• **Gonio lenses are of two types:**

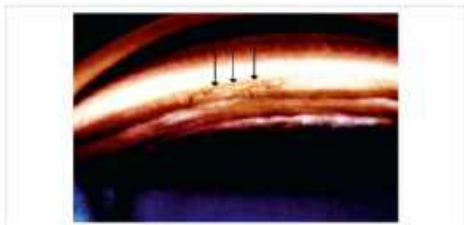- **Indirect lens:** Where a mirror is used and with help of the reflected light the structures are seen. Since it is a mirrored image it is crucial to remember the placement is opposite.
- **Direct lens:** In case of a surgical procedure such as goniotomy especially in small children direct lens is used. E.g., Koeppel, Swan-jacob

**How to record**

- Remember it is an **inverse view in the case of the indirect lens.**
- **Iris pattern: Flat, Convex or Concave.**
- **Indentation Gonioscopy: To distinguish between oppositional and synechiae angle closure.**
  - Synechiae is adhesion between cornea and iris.
  - Indentation gonioscopy is done by pressing to see whether the angle is opening or not
  - If it is not opening adhesions is formed and if it is opening, adhesions are not formed.

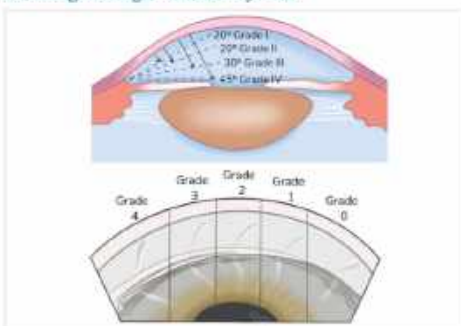


- The image shows peripheral anterior synechiae



- The above image shows the neovascularisation of the blood vessels in the angle structures.

**Grading the angle - Shaffer System**



- To grade the angle during the gonioscopy there are various methods. One of the important ones is grading the angle **Shaffer system.**
- It is important to understand that the angle in degree between two imaginary lines is tangential to the inner surface of trabecular meshwork and the anterior surface of the iris (1/3rd distance from the periphery).

ACA in degrees	ACA grade	Angle status	Visible structures
0	0	Closed	No structures visible
≤10	1	Extremely narrow	Schwalbe's line
11-19	2	Narrow	Trabecular meshwork
20-34	3	Open	Scleral spur
35-45	4	Wide open	Ciliary body

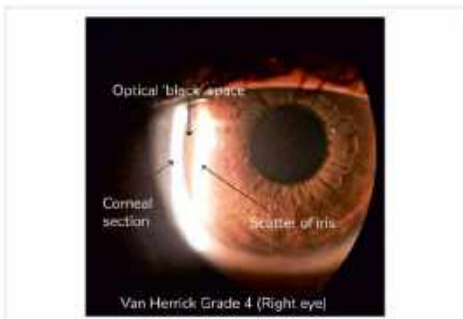
ACA= Anterior Chamber Angle

**VAN Herick grading: Ratio of PACD and PCT**

Width of the empty space (LACD) as compared to the corneal thickness	VAN Herick Grade	Angle status
No black space observed	0	Closed
<1/4 Corneal thickness	1	Extremely narrow
1/4 of corneal thickness	2	Narrow
>1/4 to 1/2 of corneal thickness	3	Open
≥1 of corneal thickness	4	Wide open

LACD= Limbal Anterior Chamber Depth

- The Van Herick technique is an eye examination method used to determine the size of the anterior chamber angle of the eye using the ratio of the anterior chamber depth and corneal section gives the status of the angle as per the chart given above.



#### Classification according to the natural history 00:28:19

- Staging according to the natural history:

#### PACS: Primary Angle Closure Suspect

- TTC (Iridotrabecular contact) or occludable angles of more than 3 quadrants on gonioscopy.
- No peripheral anterior synechiae.
- Intraocular pressure is normal.
- Patient is at risk of developing glaucoma

#### Refer Diagram 7.1

- Eclipse sign of PACS Convex iris lens diaphragm.
- T/t: Prophylactic PI in both eyes with lens extraction. Peripheral iridotomy is done with a NdYAG laser.

#### PAC: Primary Angle Closure

- TTC Occludable angle >3 quadrants.
- PAS +/- (by indentation gonioscopy).
- Raised IOP.
- T/t: Prophylactic PI, control IOP.

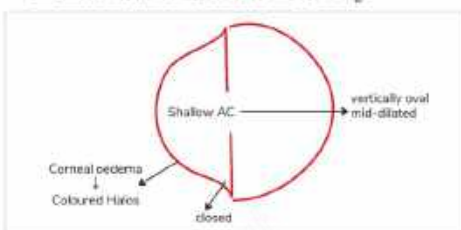
#### APAC: Acute Primary Angle Closure [Fellow eye: Occludable Angles] or Acute congestive Glaucoma.

##### Precipitating Factors:

- Darkness
- Prone position
- Mydriasis
- Emotional stress
- Medications: Topiramate: CB Effusion or sympathomimetics,

#### Clinical features: All 360 degree is closed

- Redness and Photophobia.
- Blepharospasm.
- High IOP up to 60mmHg.
- Pain is associated with nausea and vomiting.

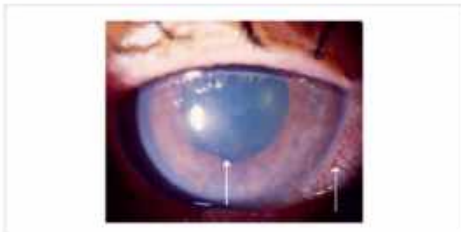

#### Observations:

- Corneal oedema due to high pressure.
- Coloured Halos.
- Shallow AC
- Angle 360 degrees closed.
- The pupil is vertically oval and mid-dilated.
- Cupping: Seen in recurrent attacks, it is not appreciated in acute attacks

#### Treatment of choice:

- Supine position.
- Decrease the pressure with I.V Mannitol (if IOP is higher than 50 mmHg)/ Acetazolamide.
- After that Pilocarpine simultaneously.
- Topical steroids to control inflammation.
- 10% topical glycerine for corneal oedema.
- Lens extraction.



#### Resolved APAC

- DM folds: These are seen due to sudden pressure drop after such high IOP after treatment with mannitol or acetazolamide
- Iris atrophy
- Irregular pupil: Due to damage of iris sphincter
- Glaucomaflecken: These are epithelial cell infarcts
- Cataract
- Cupping +/-

### • Vogts triad

- Dispersion of pigment on the cornea.
- Glaucomaflecken
- Iris atrophy



### PACG: Primary Angle Closure Glaucoma

- Occludable angles.
- PAS
- High IOP
- Optic Neuropathy (when the optic nerve is damaged it will be called glaucoma).

### Chronic Glaucoma

00:46:37

#### Clinical Features:

- Raised IOP
- Fundus changes present.
- Visual Field defects present.
- In gonioscopy, angles are closed/creeping angle closure.

#### Tests:

- **Angle assessment:** Gonioscopy shows creeping angle closure.
- **DRPPT: Darkroom Prone Provocative Test.** If the pressure difference is  $>8\text{mmHg}$  it is an indication.
- If the result is positive, then **PI** is recommended. If patent PI is already there, then the cause is **plateau iris**. Then lens extraction should be done.
- Treatment of choice PAC is PI.
- The drug of choice for PACG is Latanoprost.

### Absolute Glaucoma

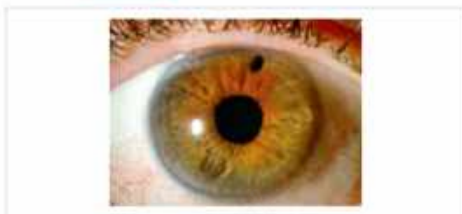- It is a painful blind eye.
- 100% cupping.
- The eye is stony hard as it is not responding to any treatment.
- All the nerve fibres are damaged.

#### Treatment of choice:

- **Cyclotherapy:** Ciliary process area is 2.5mm from the limbus. By using laser or cryo damage some of the ciliary process. Therefore, aqueous is formed less and pressure is controlled.

### ○ Other modalities:

- Retrobulbar injection of absolute alcohol suppresses the **ciliary ganglion**. (This is not the choice of treatment because the effect is not long-lasting).
- If nothing works, the eye is removed it is called **Evisceration**.



### ○ PI

- It is done in both eyes
- 11 – 1 o'clock position should be chosen. So it will be covered with lids
- It is done on the thinnest part of the iris **Crypts of iris**.
- **NdYAG laser** is used.
- Pilocarpine is always used before doing the laser
- While focusing the NdYAG laser the **Abraham lens** is used it is 66D. (Wise lens of 103D can be used as well).



### Secondary Glaucoma

It can be:

#### Open angle glaucoma

- **Pre trabecular:** Causes NVG, ICE syndrome or it could be epithelial ingrowths in the angle.
- **Trabecular:** Pigmentary glaucoma, PEX syndrome, Uveitis, Haemorrhage, Phacolytic.
- **Post trabecular:** All the causes of increased **episcleral venous pressure**.
  - Carotico Cavernous Fistulas.
  - Sturge-Weber syndrome (SWS).
  - TED (thyroid eye disease.)

#### Angle Closure glaucoma:

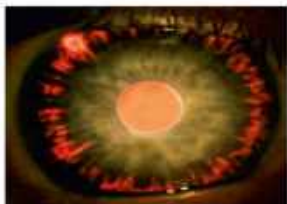
- **With pupillary block:**
  - Phacomorphic
  - Phacolytic : Due to dislocation of lens
  - Secclusio pupillae.



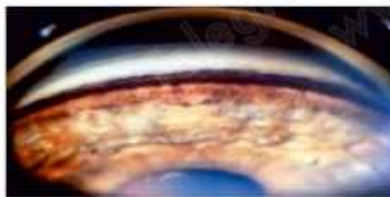
- **Without pupillary block:**
  - ICE syndrome.
  - PAS in advanced NVG.

#### Pigmentary Glaucoma:

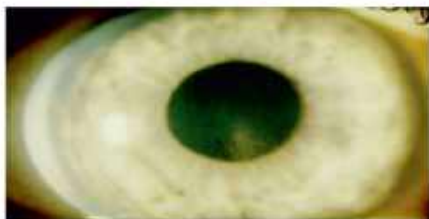- **Secondary open-angle glaucoma** known as **pigmentary glaucoma** is characterised by severe homogeneous trabecular meshwork pigmentation, Iris transillumination defects, and pigment along the corneal endothelium (krukenberg spindles in cornea). **More common in males and young myopes.**
- There is a common history of person coming from gym or heavy workout seen with pigmentary glaucoma
- It is the pigment dispersion from iris flowing through aqueous blocking the DM causing the open angle glaucoma



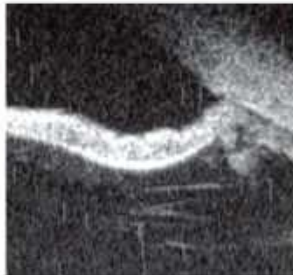- The image above shows **transillumination defects**.



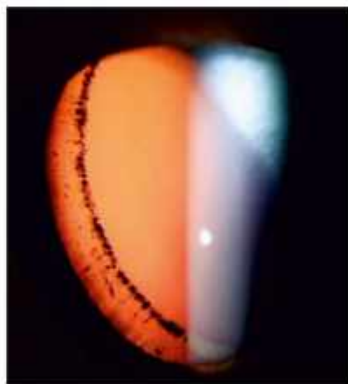
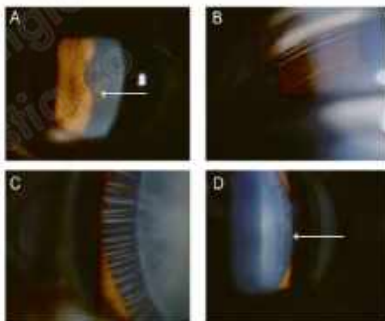
- The image shows **pigment on trabecular meshwork**.



- The image shows **krukenberg spindles (KPs)**



- The ultrasound biomicroscopy image shows: **Concave configuration of the iris**
- Therefore, **pigmentary glaucoma** also known as **reverse glaucoma**.
- If it is concave it will rub against the suspensory ligament which will cause release of pigments.



- The image shows **Scheie / zentmayer's line**

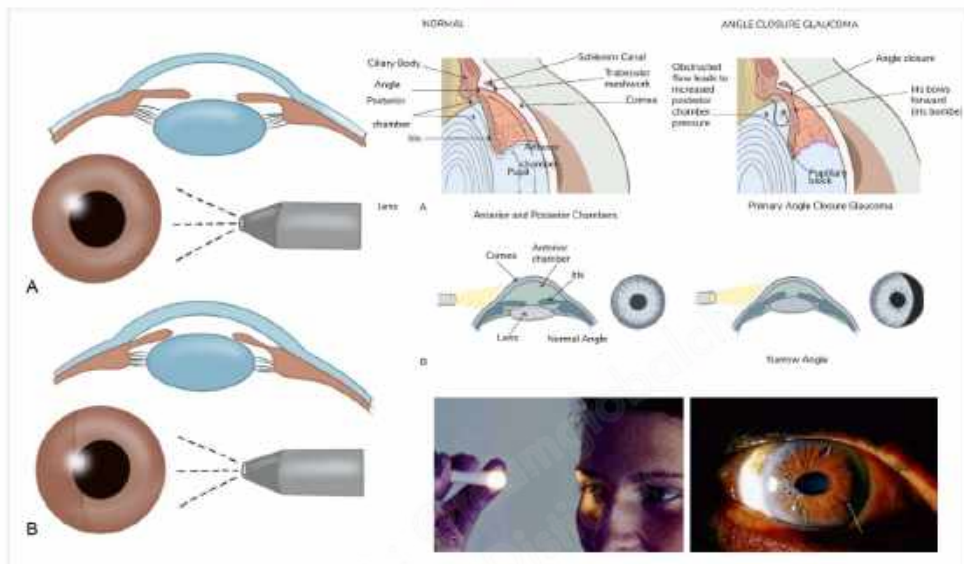
- Any pigment dispersion at equatorial area near the zonula insertion is called Scheie/zentamayer's line
- **Treatment:**
  - Medical therapy with antiglaucoma drugs
  - ALT: Argon Laser Trabeculoplasty
  - It is more effective in pigmentary glaucoma

**Pseudoexfoliation syndrome:** Most common secondary glaucoma.

- **Sampolesi's line:** It is an extra pigment line anterior to Schwalbe's line. Which can be seen in pigmentary glaucoma and pseudoexfoliation syndrome.


Telegram : @teamglobalchat  
www.Distia.co

Diagram 7.1





## Crossword Puzzle 1



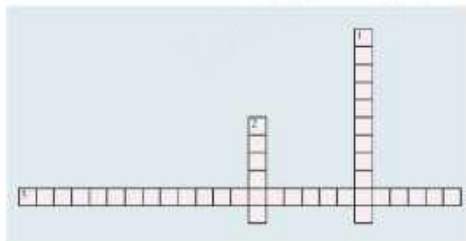
### Across

- Blind shrink eye is called \_\_\_\_\_.
- Retrolubar injection of absolute alcohol suppresses the \_\_\_\_\_.

### Down

- The removal of the eye is called \_\_\_\_\_.

## Crossword Puzzle 2



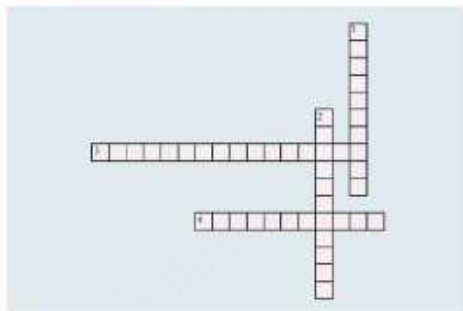
### Across

- Most common secondary glaucoma.

### Down

- While focusing the NdYAG laser the \_\_\_\_\_ was used.
- The thinnest part of the iris \_\_\_\_\_.

## Crossword Puzzle 3



### Across

- If the post-trabecular structures are not visible more than 180 degrees these are called \_\_\_\_\_.
- Drug of choice for PACG is \_\_\_\_\_.

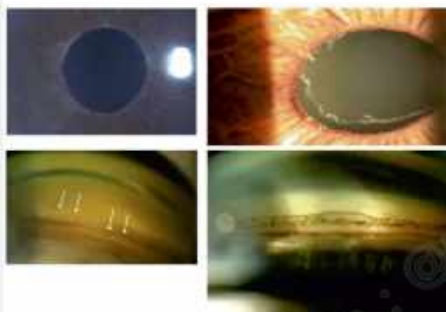
### Down

- Peripheral iridotomy is done with a \_\_\_\_\_.
- Treatment of choice PAC is \_\_\_\_\_.

### Pseudoexfoliation Syndrome (PEX)

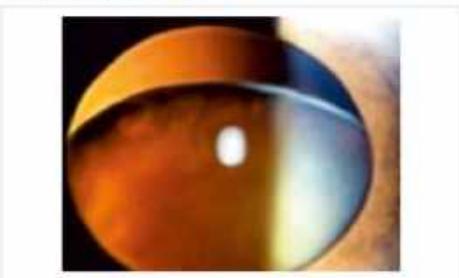00:00:17

- It is the **most common secondary glaucoma**.
- **Dandruff-like grey-white fibrillary material** gets deposited in the lens capsule, suspensory ligaments, and back of the cornea, and they block the trabecular meshwork.
- This material is some abnormal extracellular matrix metabolism tissue that's why it's called **pseudoexfoliation**.
- This leads to **secondary open-angle glaucoma (SOAG)**.



Sampaesi line  
Increased pigmentation anterior to Schwalbe's line in pseudoexfoliation syndrome

- More pigmentation is seen in the trabecular meshwork and an extra line in front of Schwalbe's line known as the **Sampaesi line**.
- **Etiology**: It is genetic in origin and associated with the **LOXL1 gene in chromosome no. 15**.
- Usually seen in age groups **>50 years**.
- It causes the **weakening of suspensory ligaments** which leads to subluxation of the lens.



- This is why it causes challenges during cataract surgery.

It can also be associated with some systemic diseases like

- Hearing loss
- Some CVS disorders
- More homocysteine levels are seen in the plasma and aqueous humor. (It precipitates more in folate deficiency).

### Sites of Deposition

- **These are the places where the dandruff-like material can be deposited**
  - Back of the cornea-Krukenberg spindles
  - Pupillary border - this causes loss of pupillary ruff.
  - On the lens - there is a clear area due to the absence of deposition known as the **Hoarfrost sign**.
  - Trabecular meshwork - this causes **secondary open-angle glaucoma**.

### Treatment

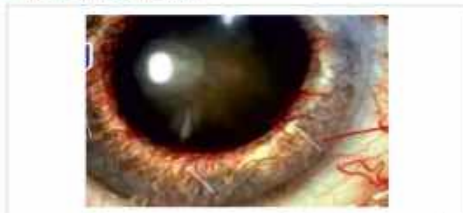- **Treatment can be of two types**
  - Medical
  - Argon laser trabeculoplasty (ALT)

### Lens Induced Glaucoma

This can be of 4 types

- **Phacolytic glaucoma**: It is seen in **morgagnian cataracts** It is a **SOAG**.
- **Phacotoxic glaucoma**: It is caused **due to trauma and is also known as lens particle glaucoma**. It is Secondary open angle glaucoma - SOAG.
- **Phacomorphic**: It is caused due to **intumescent cataracts causing pupillary block** (It is Secondary angle-closure glaucoma - SACG).
- **Phacocanaphylactic**: It is also known as **Phacogenic** and is caused due to the **immune reaction towards the lens protein**. It is Secondary open angle glaucoma - SOAG.

### Neovascular Glaucoma

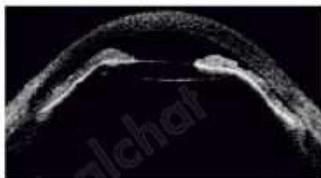

- Its **pathology starts with hypoxia in the retina** and to compensate for the situation there is new vascularization formation by the release of angiogenic factors like **vascular endothelial growth factor (VEGF)**.

- This VEGF reaches the anterior segment of the eye which causes neovascularization of the iris known as **Rubescens Iridis**.
- This will be grown further into the angle causing **open-angle glaucoma**.
- However, new vascularization is a combination of blood vessels and fibrous tissue, and these fibrous tissues will contract and this closes the angle.
- So, later it becomes an **angle closure glaucoma**.
- **Etiology-Vascular Diseases** like Diabetes Mellitus, CRVO etc.



- Thus, it is also called **aqueous misdirection syndrome**,

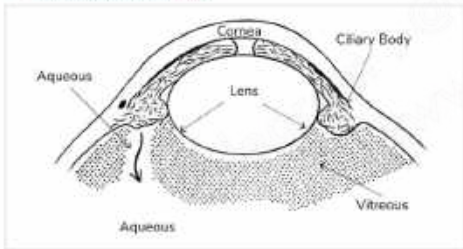


### Treatment

- The **treatment of choice** is pan-retinal photocoagulation (PRP) to treat hypoxia.
- Anti-glaucoma drugs are also given.
- Adjunctive treatment is given as **intravitreal anti-VEGF drugs**.

### Malignant Glaucoma

- It is also known as **Ciliary block glaucoma**.
- It is called malignant because it **doesn't respond to normal anti-glaucoma treatment**.



OCT of the anterior segment in malignant glaucoma: shallowing of the anterior chamber, peripheral iridocorneal touch, forward shift of the IOL.

- OCT shows a shallow anterior chamber and peripheral iridocorneal touch.

### Etiology

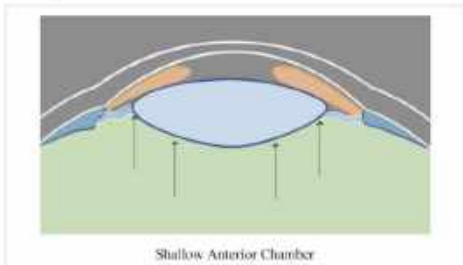
- After intraocular surgery
- Most common after Trabeculectomy

### Treatment

1. The **first line of treatment is atropine**. It dilates the ciliary ring and relaxes the ciliary muscles which causes stretching of zonules will pull back the lens, thus opening the block.
2. **NdYAG anterior hyaloidotomy**: Multiple openings are made in the anterior hyaloid membrane which releases the pressure.
3. **Pars plana vitrectomy**: We enter from pars plana which is 3.5mm from the limbus.

### Pathogenesis

- After any intraocular procedure, anterior rotation of the ciliary processes takes place. This causes **cilio-lenticular touch**.
- The aqueous starts collecting in the vitreous cavity.
- Now, the pressure rises due to the blockage, and it results in a very shallow anterior chamber.



### Important Point

- Malignant glaucoma is most common after trabeculectomy.
- **Inverse glaucoma**: When glaucoma is treated by mydriatics. Two major examples are:
  - Malignant glaucoma
  - Microspherophakia (it is caused by pupillary block)

### Glaucoma Associated with Uveitis

#### This is of three types

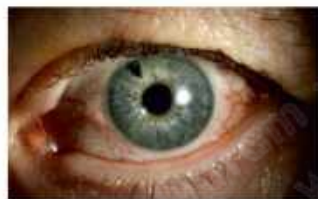1. **Angle-closure glaucoma with a pupillary block**: This is due to **posterior synechiae**.
2. **Angle-closure glaucoma without a pupillary block**: This is due to **anterior synechiae**.

3. **Open-angle glaucoma:** This is caused by the blocking/inflammation of the trabecular meshwork by aqueous cells.

#### **Uveitis with Open-Angle Glaucoma**

- It is called **glaucomatocyclitic crisis** or **PSS (Posner-Schlossman Syndrome)**.
- Another term for this condition is **Hypertensive uveitis** (There is high intraocular pressure).
- **Etiology: It is commonly seen in young males. This can be due to**
  - **HLA-BW 54 association has been documented.**
  - **CMV or H. Pylori infection.**
- Signs of uveitis is minimum so it can be misdiagnosed as angle closure glaucoma because pressure is very high but keratic precipitates are minimum.
- **Pathogenesis:** It is caused due to **trabeculitis and blocking of trabecular meshwork happening due to uveitis.**

#### **Findings**



- **On examination**
  - The KPs are few.
  - Dilated pupil.
  - No posterior synechiae
  - **Intraocular pressure: it is >40 mmHg.**
  - **Mild redness**

#### **Treatment**

- The **treatment of choice** is anti-glaucoma drugs and once IOP is under control, steroids are given. Thus, steroids are given **under anti-glaucoma cover.**

#### **Steroid-Induced Glaucoma**

00:32:09

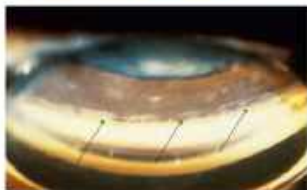
- **It is open-angle glaucoma.**

#### **Pathogenesis**

- It is an altered function of the extracellular matrix. This results in the deposition of **mucopolysaccharides or GAGs (glycosaminoglycans)** in the trabecular meshwork.
- Steroids are not given in high responders.

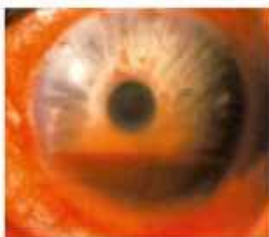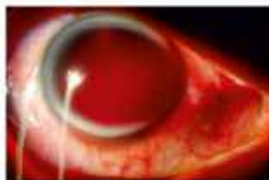
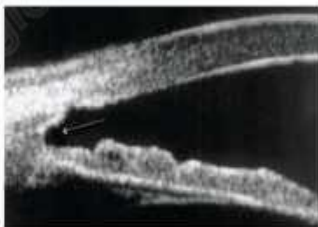#### **Traumatic Glaucoma**

**It is caused by blunt trauma. It results in**



Typical angle appearance of an angle recession. Torn iris processes (arrows), a whitened and increasingly visible scleral spur, and a localized depression in the trabecular meshwork are seen.

1. **Angle-recession glaucoma:** The recession is due to a tear in the ciliary body and the glaucoma is due to associated damage in the trabecular meshwork.



2. **Hyphema:** This can cause corneal staining (irreversible) and glaucoma.
  - Hyphema can be partial or complete as shown in image above.

The different ways Hyphema can block the trabecular meshwork are

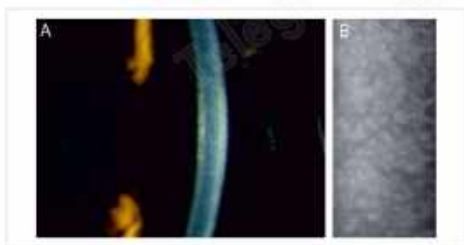
1. **Red cell glaucoma:** In this, the RBC blocks the trabecular meshwork.
2. **Haemolytic glaucoma:** The macrophages engulf the RBCs and block the trabecular meshwork.
3. **Hemosiderotic glaucoma:** Hemoglobin and iron blocks the trabecular meshwork.
4. **Ghost cell glaucoma:** The RBCs lose their iron and hemoglobin and become ghost cells. These ghost cells travel anteriorly and block the trabecular meshwork. It is seen in the vitreous hemorrhage.

### ICE Syndrome (Irido-Corneo-Endothelial Syndrome)

- In normal circumstances, the endothelial cells of the cornea never proliferate. However, in this case, the endothelial cells start proliferating and encroach the angle resulting in its closure.
- This is called **proliferative endotheliopathy with secondary glaucoma**.
- It is more common in **middle-aged women**.
- It commonly has a unilateral presentation.
- Sometimes it has been associated with **viral infections like HSV**.

This disease has three main forms

1. **Chandler's syndrome:** This is the **most common form of ICE syndrome**.
  - Corneal oedema is seen in this disease.



- The cornea has a **hammered silver appearance**. (As seen in the diagram)
2. **Progressive iris atrophy:** The prominent feature is iris atrophy.
    - It has an appearance of **pseudopolycolia**.
    - **Corectopia:** When pupils are not centrally placed.
  3. **Cogan Reese syndrome:** **Naevus nodules and iris cysts are seen**.

### Treatment of Glaucoma

004211

There are 3 types of treatments: Medical, Laser and Surgery

**Medical:** Antiglaucoma drugs which can be either topical or systemic

- The drugs either decrease the formation of aqueous or increase the drainage to ultimately decrease the IOP.
  - Target IOP: It prevents the progression of visual field defects without compromising the quality of life.
  - **This is of two types**
- a. **Topical: There are six types**
    - i. **Beta-blockers:** These decrease the formation of aqueous.
      - For example: Timolol, betaxolol, levobunolol, etc.
      - These are **contra-indicated in asthma**.
      - **Nasolacrimal duct obstruction is caused by Timolol**.
      - **Side effects:** Corneal anesthesia and Blepharo conjunctivitis.
    - ii. **Alpha agonists:** They have dual action i.e decreasing the aqueous formation and increasing the drainage (uveoscleral outflow).
      - For example - **Adrenaline/epinephrine, dipivefrin, brimonidine, and apraclonidine**. The last two are selective alpha agonists and can be given to hypertension and heart disease patients.
      - **Brimonidine causes drowsiness**.
      - **Brimonidine is contraindicated in children because it causes sleep apnea and heart blocks in children**.
      - **Brimonidine can be given in pregnancy**.
      - **Apraclonidine can cause lid retraction**.
      - **Adrenaline cause conjunctival pigmentation or deposits**.
      - **Specific side effect of adrenaline is cystoid macular edema**.
      - **Adrenaline is C/I in aphakic glaucoma**.
    - iii. **Miotics:** These increase the trabecular outflow and open the angle blockage.
      - For example - **Pilocarpine**.
      - **Side effects of pilocarpine:** It causes spasms of the ciliary muscles leading to **pseudo myopia**. In severe cases, it can lead to retinal detachment.
      - It also leads to a shallow anterior chamber.
      - It can also cause iris cysts.
      - It increases the capillary permeability leading to uveitis. Thus, it is **contraindicated in uveitis**.
    - iv. **PGF2a agonists:** It increases the uveoscleral outflow.
      - These are also contraindicated in uveitis and asthma.
      - For example - **Latanoprost, bimatoprost, travoprost, tafuprost, and unoprostone isopropyl**.
      - **Latanoprost cause heterochromia iridis (difference of iris color between the 2 eyes)**.
      - **Bimatoprost can increase both outflows: trabecular outflow and uveoscleral outflow**
      - **Side effects: hypertrichosis**

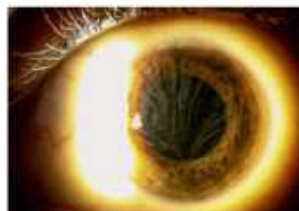

v. **Topical carbonic anhydrase inhibitors:** These decrease the formation of aqueous.

- For example - **Dorzolamide** and **brinzolamide**.
- These are contraindicated in sulphu allergies.

vi. **Newer anti-glaucoma drugs:** These are-

- **Netarsudil:** This increases the contractile property of the trabecular meshwork, thus increasing the trabecular outflow and it also decreases the aqueous production.
- It also decreases episcleral venous pressure.
- This is given as 0.02% O.D.
- This is a **Rho-kinase inhibitor** and is available by the name of **Rhopressa**.



- **Side effect:** Netarsudil causes **vortex keratopathy** (causes deposition in cornea in a whorl like pattern) It is also known as **cornea verticillata**.
- **Latanoprostene bunod:** This increases the uveoscleral outflow as well as trabecular outflow through NO.

**b. Systemic: These are of 2 types**

i) **Carbonic anhydrase inhibitor:** For example, **acetazolamide** and **methazolamide**.

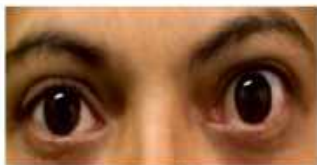- **Side effects:** These cause tingling and numbness, constipation, renal stress, and a bad metallic taste.
- Contraindicated in sulfa allergy.

ii) **Hyperosmotic agents:** These draw the aqueous out of the eye.

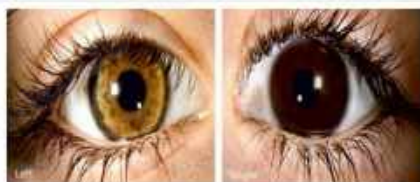- For example: **I/V mannitol** (CI in heart disease), **glycerol** (CI in diabetes), **isosorbide**, and **urea**.

## Important Information

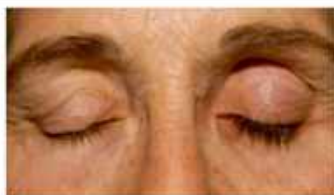- **Target IOP:** It is the IOP which prevents the progression of visual field defects without compromising the quality of life.



Lid retraction




Hypertrichosis



Hypertrichosis



## Crossword Puzzle 1



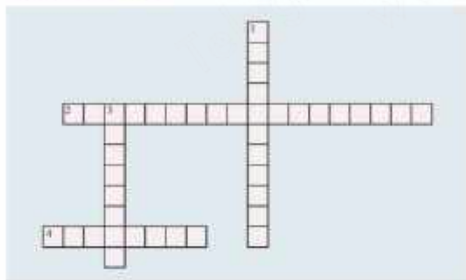
### Across

- The aetiology of neovascular glaucoma is CRVA and \_\_\_\_\_.
- Malignant glaucoma is also known as \_\_\_\_\_ glaucoma.
- \_\_\_\_\_ is caused due to intumescent cataracts causing the pupillary block.

### Down

- The three drugs that increase trabecular outflow are pilocarpine, latanoprostene bunod, and \_\_\_\_\_.

## Crossword Puzzle 2



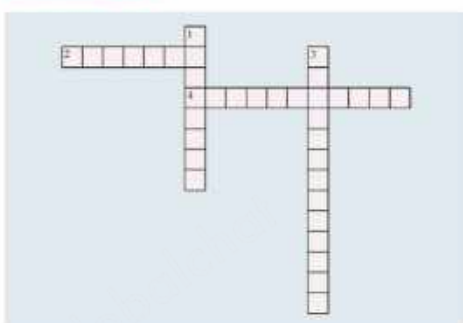
### Across

- Uveitis with open-angle glaucoma is also called \_\_\_\_\_ crisis.
- \_\_\_\_\_ syndrome is the most common form of ICE syndrome.

### Down

- Ghost cell glaucoma is caused by the RBCs that lose their iron and \_\_\_\_\_.
- The first line of treatment for malignant glaucoma is \_\_\_\_\_.

## Crossword Puzzle 3



### Across

- \_\_\_\_\_ causes nasolacrimal duct obstruction.
- \_\_\_\_\_ miotic drug leads to pseudo myopia.

### Down

- A side effect of beta-blockers is \_\_\_\_\_ conjunctivitis.
- \_\_\_\_\_ causes lid retraction.

Laser Treatment for Glaucoma is divided into-

1. Open-angle glaucoma
2. Angle-closure glaucoma

### ACG

- Angle-closure glaucoma is a **peripheral iridotomy** by **NdyAG**.
- We should always use prophylactic peripheral iridotomy in the other eye. So it means even if the other eye is not suffering from acute angle closure we have to do peripheral iridotomy on the other eye as well.
- For angle closure, if it is a plateau iris, then peripheral iridotomy is not effective, so in that case, perform **laser iridoplasty**. They give peripheral burns by using a photo-coagulative laser. Iris contract and angle opens.

### OAG

- Blockage in the trabecular meshwork **trabeculoplasty** using photo coagulative laser increases inter-meshwork distance.

### Type of Trabeculoplasty

ALT (Argon Laser Trabeculoplasty)

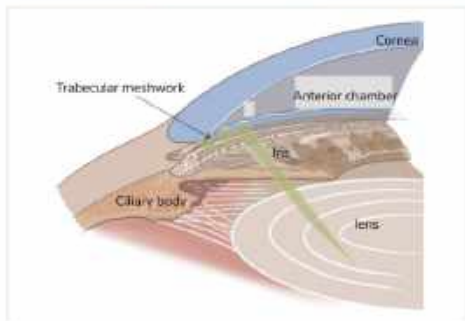
- Wavelength (514 nm)

SLT (Selective Laser Trabeculoplasty)

- Double frequency NdyAG (532 nm)

MLT (Micropulse Laser Trabeculoplasty)

- Given for short duration



### Management of absolute glaucoma

- Cyclophotocoagulation for absolute glaucoma and refractory glaucoma. (like neovascular glaucoma, malignant glaucoma)
- Cyclophotocoagulation can be done either endoscopically or over the sclera i.e. called transscleral.



### Types

Cryo	DLCP <ul style="list-style-type: none"> <li>• Diode 810nm</li> </ul>
------	--

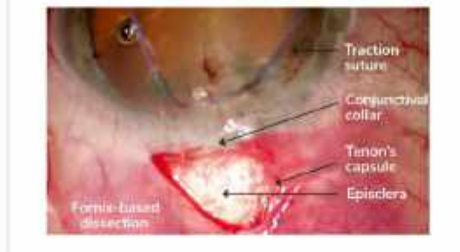
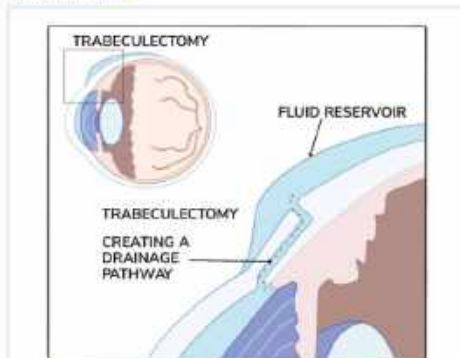
### Glaucoma Surgery

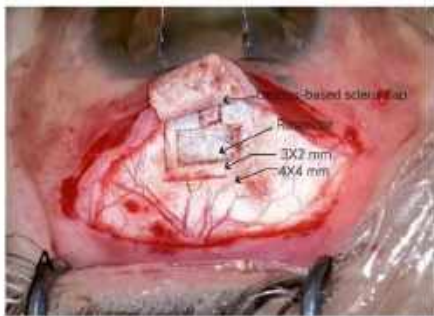
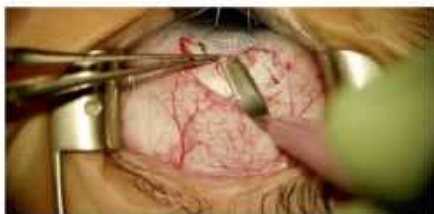#### Types of Glaucoma surgery

- Penetrating
- Non-Penetrating

Penetrating Trabeculectomy, MIGS	Non-Penetrating Deep sclerectomy Viscocannulostomy
-------------------------------------	--

### Trabeculectomy





- The Trabecular meshwork was resected, and creating a fistula between the sub conjunctival space and the anterior chamber.

#### Prevent closure of fistula

- Antimitotic drugs (MMC and 5FU)
- Implant for aqueous drainage (**Seton Surgery**) or GDD

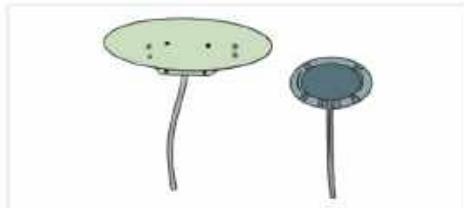#### Glaucoma Drainage Devices: GDD

##### Or seton surgery

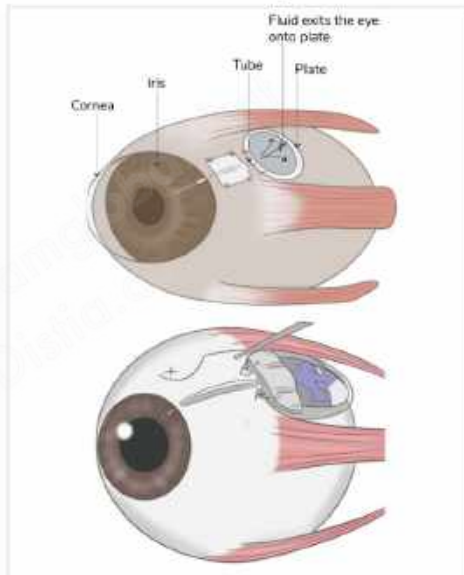
- Express mini shunt: Not using TM punch, no PI done, it is made up of **titanium** (MRI compatible)
- AGV-Ahmed Glaucoma Valve: Silicon tube and valve with polypropylene body



- Molteno implant: silicone tubes with polypropylene plates



- Baerveldt: both of silicone tube and plate



#### MIGS (Minimum incision glaucoma surgery)

- In mild to moderate glaucoma with modest target pressure goal.
- Commonly done with cataract surgery.
- This is mainly done in combination with phacoemulsification.

MIGS can divide into two:

Refer Table 9.1

#### Congenital Glaucoma

1. PCG: Primary Congenital Glaucoma
2. SCG: Secondary Congenital Glaucoma

### Primary Congenital Glaucoma

- Primary congenital is generally considered sporadic.
- If it is hereditary, it is autosomal recessive.
- More common in males than females.

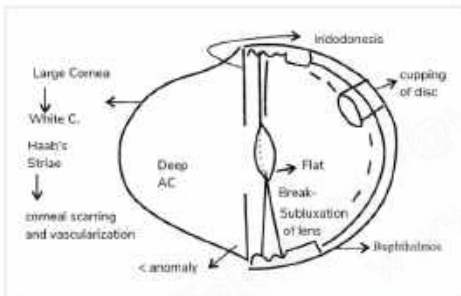
### Type of Primary Congenital glaucoma

True Congenital	Infantile	Juvenile
• The child is born with it.	• $\leq 3$ yrs of age	• $> 3$ yrs of age

- Buphthalmos is enlargement of eyeball.
- The child's sclera being very soft, any pressure generated by the pressure inside the eyeball causes scleral stretching.

### Pathogenesis

- Trabeculodysgenesis.
- Commonly due to anteriorly located iris insertion



### Clinical feature

- Presence of watery eyes
- Photophobia
- Blepharospasm

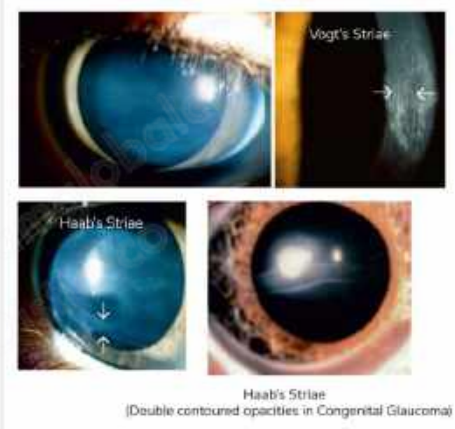
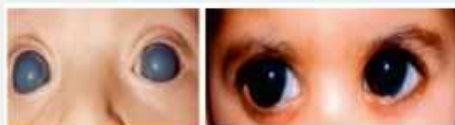### on examination:

- Buphthalmos leads to large cornea, white cornea, haab's striae.
- Haab's striae later leads to corneal scarring and vascularization.
- Deep Anterior chamber
- Angle anomaly
- Iridodonesis
- Flat lens
- Breaking of suspensory ligaments leads to subluxation of lens
- Cupping of disc.
- D/D of large cornea is megalocornea.

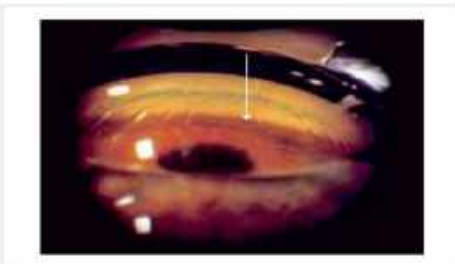
### Under GA examination:

- GA lowers IOP

- Therefore, prefer a conscious sedated child
- Corneal diameter in 1yr child is  $> 12\text{mm}$  is significant finding
- Anterior segment examination
- Optic disc examination: to check Cup disc asymmetry
- Gonioscopy: to check angle



- Losch ness monster phenomenon: on gonioscopy tuft of blood vessels are seen k/as Losch Ness Monster Phenomenon



### Treatment:

- Goniotomy is a TOC (Use a lens called a goniolens to see the structure of the front part of the eye.) cut in TM is given.
- If cornea is hazy we do trabeculotomy. Here we go through schelmm's canal and cut is given in TM and SC
- Second choice of treatment is Trabeculectomy + Trabeculotomy



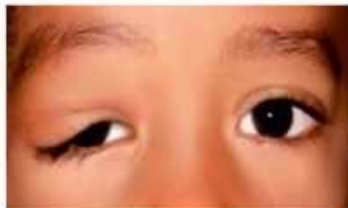Intraoperative view of eye's drainage system as a goniotomy is being performed



Goniotomy-removal of the surface layer of the drain

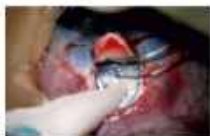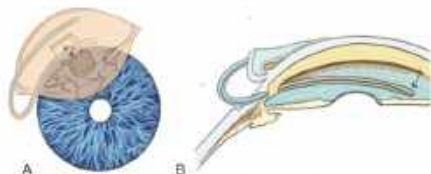
- **NF-1**

- Glaucoma is due to angle anomalies.
- Associated with plexiform Neurofibroma (s-shaped lid)



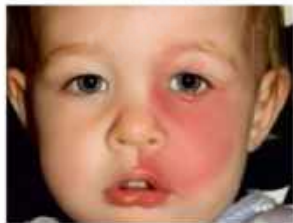- **Aniridia**

- Rudimentary frill of iris
- Mutation in PAX-6 gene
- May be associated with Wilms tumour



#### Conditions of Secondary congenital Glaucoma

- **Sturge weber syndrome**

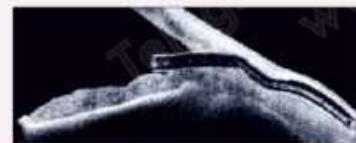
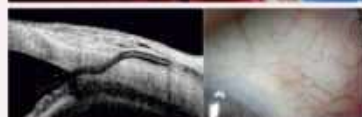
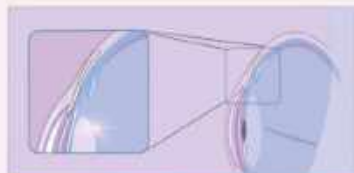- Hemangioma on the face
- Hemangioma in the brain
- Glaucoma

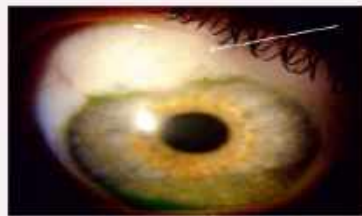Table 9.1

**With bleb formation**

- A trap door that allows fluid to drain out of the eye
- By using (Xen-gel implant)



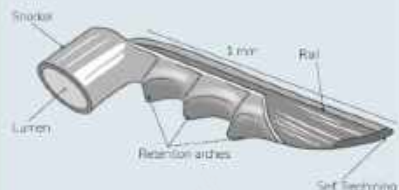
- Placed [subconjunctivally with MMC]
- Made of Gelatin



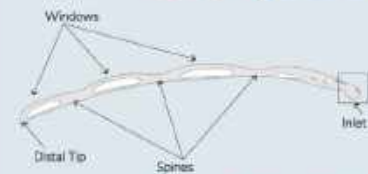
**No bleb formation**

Types:

- I-stent is open in schlemm's canal



- I-stent supra opens in supra choroidal space
- Hydrus : open in schlemm's canal



- Cypass Microstent (increases the Uveo-scleral outflow)



# PREVIOUS YEAR QUESTIONS




- Q. A 50-year-old male with family history of glaucoma presents with headache. IOP is 22 and 24, angles open on gonioscopy, no field defects noted. True statement regarding management of this patient, (JIPMER MAY 2018)
- A. Normal tension glaucoma - treat it  
B. POAG - to be treated  
C. **Ocular hypertension - no intervention**  
D. Ocular hypertension - to be treated
- Q. A 2 year old child with watering of eyes with bilateral proptosis and photophobia, what may be the diagnosis? (AIIMS NOV 2018)
- A. **Congenital glaucoma**  
B. Retinoblastoma  
C. Congenital endothelial dystrophy  
D. Megalocornea
- Q. A 50-year-old male with family history of glaucoma presents with headache. IOP is 22 and 24, angles open on gonioscopy, no field defects noted. True statement regarding management of this patient (JIPMER MAY 2018)
- A. Normal tension glaucoma - treat it  
B. POAG - to be treated  
C. **Ocular hypertension - no intervention**  
D. Ocular hypertension - to be treated
- Q. All are drugs given in primary open angle glaucoma except, (INICET Nov 2020)
- A. Latanoprost  
B. Pilocarpine  
C. Physostigmine  
D. **Phenylephrine**
- Q. A patient of Primary open angle glaucoma with a known case of bronchial asthma. What is the Drug of choice? (NEET Sep 2021)
- A. **Latanoprost**  
B. Carboprost  
C. Apristadii  
D. Gemeprost
- Q. Beta blockers should be avoided in all the conditions except, (FMGE June 2021)
- A. **Glaucoma**  
B. Peripheral vascular disease  
C. Diabetes  
D. COPD
- Q. The ocular hypotensive agent causing apnoea in infants is, (NEET JAN 2019)
- A. Latanoprost  
B. Timolol  
C. Betaxolol  
D. **Brimonidine**
- Q. What is the DOC for decreasing IOP by increased uveoscleral outflow in a patient with increased IOP and optic disc changes with ciliary congestion? (NEET Jan 2020)
- A. **Latanoprost**  
B. Dorzolamide  
C. Pilocarpine  
D. Timolol
- Q. Which of the following are true? (AIIMS NOV 2019)
- A. Latanoprost is used with caution in patients of bronchial asthma  
B. **Topiramate can cause bilateral angle closure glaucoma**  
C. Methazolamide causes decrease in ocular blood flow  
D. Central scotoma is seen in open angle glaucoma
- Q. All are drugs which lower IOP except? (AIIMS NOV 2019)
- A. Clonidine  
B. Mannitol  
C. **Dexamethasone**  
D. Acetazolamide
- Q. Intravenous mannitol is indicated in? (NEET JAN 2019)
- A. Primary open angle glaucoma  
B. **Acute angle closure attack**  
C. Normal tension glaucoma  
D. Sympathetic ophthalmitis
- Q. Which one of the procedures involves using glaucoma drainage device? (NEET JAN 2019)
- A. **Seton operation**  
B. Deep sclerectomy  
C. Visco canalostomy  
D. Trabeculectomy





## Crossword Puzzle



### Across

2. Stretching of the sclera and enlargement of eyeball =
4. Cornea is too hazy surgery choice is =

### Down

1. angle malformation called =
3. type of glaucoma surgery =

Telegram: @amglobalchat  
www.Distia.co

**The shape of the cornea**

- Aspherical : Curvature gradually decreases
- Diameter - 11.5 mm to 12 mm
- Refractive index - 1.37
- Power: 43D - 45D
- Thickness - 500-600 microns or 0.5 to 0.6mm and at the limbus it is 1mm
- Average thickness- 540 microns

**Structure of Cornea**

- Epithelium - uppermost layer
- Bowman's layer
- Stroma
- Dua's layer
- Descemet membrane
- Endothelium

**Upper layer - epithelial layer**

- Multilayer consisting of a single layer of columnar cells.
- These Columnar cells are called basal cells.
- Next are two-three layers of wing cells.
- The uppermost two layers are non keratinized stratified squamous epithelium.
- Above this layer is microvilli or micropliae.
  - Microvilli helps to increase the surface area, helping in attachment of tear film to cornea.
- These basal cells are attached to the basement membrane with the help of hemidesmosomes
- So in corneal dystrophy there is recurrent erosions and the problem lies in hemidesmosomes.

**Second layer - bowman's membrane**

- It is part of stroma.
  - It is acellular but it is not basement membrane.
- It does not regenerate.

**The third layer, the thickest layer, majority part includes - stroma.**

- Consists of 200-300 collagen lamellae.
- It is Type-I collagen.
- A ground substance composed of - Glycosaminoglycans (GAGs).
- GAGs - keratin sulphate and chondroitin sulphate.
- Other components includes fibroblasts/ keratocytes.
- 90% of thickness is due to stroma

**Fourth layer- Dua's layer**

- It is Acellular.
- It is one of the Strongest and toughest layer.

**Descemet membrane**

- Two parts - Banded and non-banded parts.
- Banded part - laid down in uterus.
- Non-banded part - secreted by endothelial cells, it is regenerative.
- No elastic tissues.

◦ Therefore, the break leads to **haabs striae, Vogt's striae**

- On gonioscopy: Schwalbe's line is seen.

**Endothelium**

- Single layer of polygonal cells.
- It does not regenerate.
- Main role of endothelium is to keep cornea in a dehydrated state.
- Therefore number of endothelial cells are very critical for cornea.



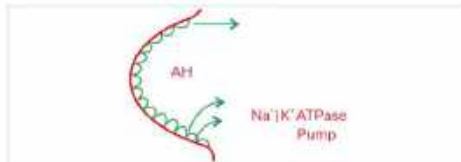
**Important Information**

- Cornea is the most densely innervated tissue in body.
- Sensory supply: Ophthalmic division of trigeminal → nasociliary nerve → long posterior ciliary nerve → supplies cornea
- Long posterior ciliary nerve forms plexus at three levels
  - Intra epithelial plexus
  - Sub epithelial plexus.
  - Stromal plexus
- Neurotrophic keratitis- Due to fifth nerve lesion, there will be no growth factors or neuropeptides which compromise with the health of epithelium → leads to keratitis.
- Neuroparalytic keratitis - Due to seventh nerve palsy → lagophthalmos due to affected orbicularis oculi → exposure keratitis.

**Physiology of Cornea**

001530

- Avascular
- Dehydrated
- Primary metabolism - Aerobic metabolism
- Nutrition from - Aqueous humour



- Endothelial cells does not allow water in the cornea i.e., the barrier function of the cornea.
- Pump function by Sodium Potassium ATPase pump and barrier function helps to keep the cornea in dehydrated state.
- Whenever endothelium is not functioning well, hydration occurs leading to edema in the cornea.

**Number of endothelial cell (normal range)**

- Adults - 2500 to 3000 cells/mm square
- Children - 3500 to 4000 cells/mm square

- When endothelium is damaged, adjacent endothelial cells change its shape, enlarges themselves and cover the space.
  - **Pleomorphism:** changing of shape.
  - **Polymegathism:** Enlarging
- If <math><500</math> cells/mm square leads to
  - Stromal edema
  - Epithelial edema
  - Blister like elevation filled with fluid **Bullous keratopathy**
    - Sign of corneal decompensation-it indicates extreme hydration.
  - It is a sign of corneal decompensation number of epithelial cells can be checked with specular microscopy.



### Important Information

- Any activation of anaerobic glycolysis leads to lactic acid formation. Which will further leads to metabolic acidosis, which will cause inhibition of sodium potassium pump. This leads to corneal oedema.

### Factors responsible for transparency of cornea

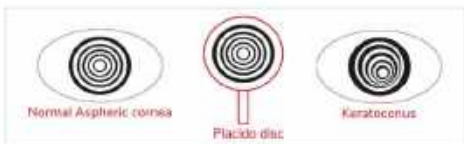- Regular arrangement of corneal epithelium.
- Regular arrangement of stromal lamellae.
- There is no scattering of light because distance between two lamellae is less than half of wavelength of light.
- This is assisted by GAGs - keratin sulphate and chondroitin sulphate
- Endothelium takes care of the pumping function and barrier function. Which keeps cornea in dehydrated state
- Normal IOP, less than stromal pressure.
- Stromal pressure - 53-55mmHg in acute closure glaucoma - IOP is more than stromal pressure leading to epithelial edema.
- Avascularity

### Investigation related to Cornea

0025:57

**Keratometry** - Measuring the central optical zone of 3 metres, i.e., curvature of cornea both horizontal and vertical

### Keratometry or placido's disc



- It is important to access the overall surface of cornea
- Placido's disc: It is cardboard disc with black and white rings with central hole
- It is shown in front of eye and image of rings will fall on cornea.
  - Regular spacing seen in normal cornea.
  - Rings are closer in steeper cornea.
  - Rings are far apart in flatter cornea.

### Corneal topography

- Steep cornea
- Name of instrument is **Orbscan**, it is based on the principle of placido's disc



### Corneal tomography

- 3-D image of both anterior and posterior cornea.
- Normally only anterior surface of cornea is assessed but in this both anterior and posterior surface is assessed
- it is important because initial changes in keratoconus starts from posterior

### Penta Cam

- 3-D image of both anterior and posterior cornea.
- Based on scheinplugg imaging (rotating camera)
- It is a non-invasive imaging device used in ophthalmology.
- Used to measure the anterior and posterior curvature of the cornea, the thickness of (pachymetry), and the anterior chamber depth.
- It generates a three-dimensional image of the eye and is used in the diagnosis and treatment of various eye conditions such as **glaucoma, cataracts, and keratoconus**.
- Axial map- colour coded, steeper part of cornea will be warmer colours (red colour), flatter areas are depicted by cooler colors (blue).
- Corneal thickness measured. Thinner cornea- warm colours, thicker cornea- cool colours
- Measures pupillary diameters.
- Uses of Penta cam:
  - Assessment and screening of keratoconus
  - Preop assessment for patient undergoing, corneal refractive surgeries.

### Other uses

- 1 Pentacam HR - It helps in preop assessment of patients for intraocular phakic IOLs.
- 2 Pentacam AXL - It measures the axial length.
  - It is helpful for IOL power calculation and in assessment of corneal ectasia.
- 3 Pachymetry - To measure the thickness of cornea
- 4 Specular microscopy: To examine endothelial cells in high magnification.
  - It is used to see number per mm square and its morphology to see if there is any polymorphism or polymegathism or if there is any corneal guttae.

○ Corneal guttae: These are seen as empty spaces on specular microscopy.

○ These are affected cells seen in Fuchs endothelial dystrophy.

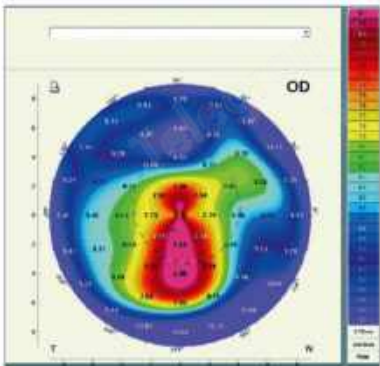
- 5 Aesthesiometer - It has a long filament which is kept on decreasing by 0.5 mm and keeps on touching to see at what length patient show blinking reflex.



○ If it shows at shorter length then sensation is less, if it is showing at longer length it is ok.

- 6 Microbiological investigation - Staining and culture


### Keratoconus



Refer Image 10.1

- **Regular astigmatism:** uniform steepening along a single corneal meridian that can be fully corrected with a cylindrical lens (BCVA of 20/20 or better)
- **Expected topography:** symmetric "bow-tie" along a single meridian

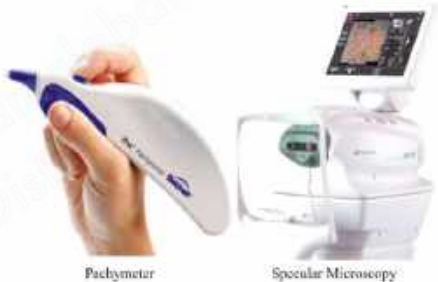Refer Image 10.2



Endothelial cells

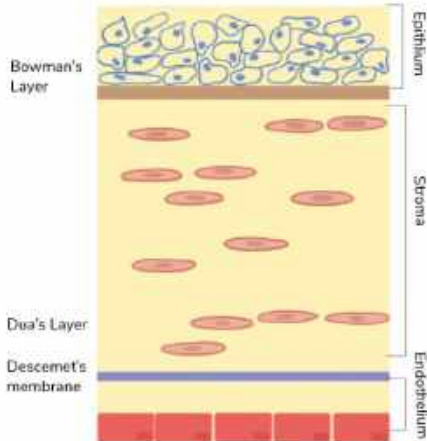
### Pachymeter

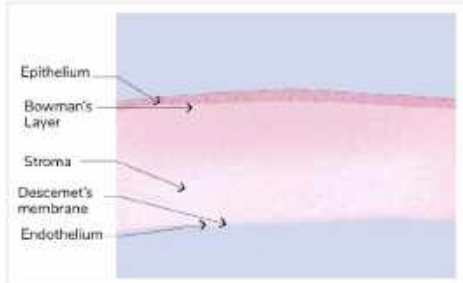
- It is a device used to measure corneal thickness.



Pachymeter

Specular Microscopy





## Ulcer

064130

- Ulcers is the breach in the epithelium along with infiltration and necrosis

## Organisms That Can Penetrate Intact Epithelium

- **N** - Neisseria gonorrhoea
- **N** - N. meningitis
- **L** - Listeria
- **D** - Diphtheria
- **H** - Hemophilous
- **S** - Shigella

## Keratitis

064256

- Inflammation of the cornea leads to ulcer formation, necrosis, infiltration & neovascularization.

## Pannus

- Any superficial vascularization and some degenerative change.

## Clinical Features

- Pain
- Redness (Ciliary congestion)
- Photophobia
- Discharge
- Blurring of vision
- Blepharospasm
- It is seen either due to ulcer formation or in immuno-compromised patient.

## Bacterial Keratitis

Q. What is the most common etiology?

Ans. Staph aureus

Q. Most common bacteria causing keratitis in India?

Ans. Staphylococcus epidermidis

Q. Most common infection after refractive surgery?

Ans. Mycobacterium chelonae (Atypical mycobacterium)

Q. Which bacterial infection resembles fungal keratitis?

Ans. Nocardia

- Ulcer is dry and rough

## Other causes

- Streptococcus/ Pneumococcus
- Pyogen

## Pneumococcus causes

- Ulcus serpens also called hypopyon corneal ulcer

## Clinical Features

- Pain
- Redness (Ciliary congestion)
- Photophobia
- Discharge
- Blurring of vision
- Blepharospasm

## On Examination

- Fluorescein stain positive ulcer
- Hypopyon: Pus cells in the anterior chamber
- It is a sterile hypopyon
- Stromal edema
- DM folds

## Any keratitis can be associated with uveitis

## KPs are found due to anterior uveitis- 3Types

- Perforating
  - Pseudomonas : It can cause corneal perforation in 48 hrs.
  - Pseudomonas release exotoxins which have collagenolytic effect causing perforation
  - Thinning cause perforation, it will not remain open as iris will seal the perforation which is called as Leucoma adherens.
- Localized
  - Tt → Healing → Corneal opacity
- Sloughing U/ulcer
  - Infection by virulent organism can lead to sloughing which is continuously replaced by inflammatory exudates which will lead to pseudo cornea
  - Pseudo cornea can complicate as anterior staphylocoma

## Investigations

- Microbiological investigations: Corneal Scraping - Kimura Spatula
- Conjunctival swab
- Contact lens cases.
- Staining
  - Gram stain
  - Giemsa stain
  - AFB - Acid fast stain for mycobacterium and nocardia
- Culture
  - Blood agar
  - Chocolate agar

- Lowenstein Jensen for mycobacterium and nocardia.
- Cooked Meal broth for anaerobic bacterium.

### Treatment of Bacterial Keratitis

The treatments for bacterial keratitis are mentioned below.

- **Empirical monotherapy** - This is a very effective treatment. Moxifloxacin achieves the best penetration.
- Gatifloxacin, Besifloxacin also can be used
- Choose antibiotic according to culture sensitivity
- If patient is not responding, despite culture sensitivity, start duo therapy.
- **Duo therapy** - This therapy uses fortified antibiotics eyedrops. It takes care of both gram-positive and negative stains. The combination of two drugs is given - cefazoline with gentamicin or cefuroxime with gentamycin.
- Antibiotic ointment at night
- Subconjunctival injection of antibiotics - If compliance is poor
- Cycloplegics and mydriatics.
- Oral anti-inflammatory drugs.
- Lubricating eye drops
- Vitamin A and C contain supplements for healing for ulcer.
- If there is risk of systemic involvement with *Neisseria meningitidis*/N. Gonorrhoea or *H. influenzae* starts with antibiotics
- If corneal thinning - Tetracycline, Doxycycline (Oral)
- It has anticholinergase effect.



### Important Information

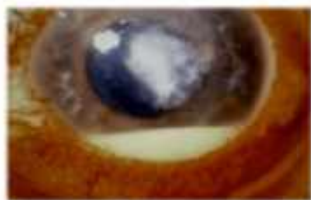
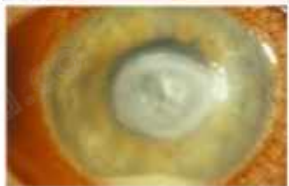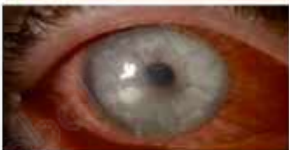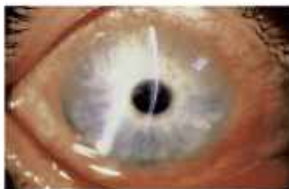If there is any infective epithelial involved / ulcer, use of bandage is avoided, and secondly, no use of steroids.

### Management of Non-Healing Ulcer

Management of non-healing ulcers is done in the following ways.

- Debridement - This process means removing the necrotic tissue helps in healing of epithelium.
- High water content means more oxygen transmissibility through lens.
- Another way to manage it is by using lubricating eye drops.
- Chemical cauterization : It acts as a local antiseptic
  - Trichloroacetic acid (TCA), carbolic acid
- Bandage contact lens (high water content soft contact lens) - It can be soft or semisoft.
- Hard lens are not used.
- Surgical means - This is amniotic membrane grafting, buccal mucus membrane grafting.
- For persistent defect: Gundersen conjunctival flapping i.e., putting conjunctival flap over the cornea.
- Management of impending perforation
  - Antiglaucoma drugs to decrease IOP.

- Cyanoacrylate glue: use to treat corneal perforation < 2mm
- > 2mm : use therapeutic keratoplasty.
- Bandage contact lens



Bacterial corneal ulcer

### Keratomycosis

- Fungus ids of two types
- Yeasts → *Candida albicans*, more in temperate regions and colder regions
- Filamentous fungi : Septate and non pigmented, affect more in tropical countries
  - *Aspergillus* and *Fusarium*

Q. Which is the most common fungus infecting cornea?

Ans. *Aspergillus fumigatus* is the most common fungal infection in the cornea.

- *Fusarium*

Q. Why will you get fungal keratitis?

Ans. Trauma by vegetative matter causes fungal keratitis.

- It is more common in agricultural hosts
- Any cause of low immunity

Q. What is the most common fungal infection for Endophthalmitis?

Ans. Candida

Q. What is the most common fungus infecting lids?

Ans. Candida albicans

Q. What is the most common cause of orbital cellulitis?

Ans. Mucormycosis

- Lots of cases after Covid due to steroids misuse.
- It is called black fungus due to necrosis of tissue

### Clinical Features

- Pain
- Redness (Ciliary congestion)
- Photophobia
- Discharge
- Blurring of vision
- Compared to bacterial infection signs are more than symptoms
- On examination
- Unsterile - Fungus enters anterior chamber.
- Satellite nodules are infective and have immune reaction.
- Fungus can cause associated uveitis
- KPs are present
- IOP is high

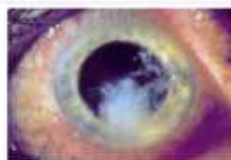### Investigation

- Firstly, there is staining of the culture.
  - **SDA** - It stands for Sabouraud dextrose agar.  
→ With the use of this agar media, the culture reporting should be given in one week.
  - **PDA**
- 10% KOH is used.
- Can be seen through light or a simple microscope
- Confocal biomicroscopy - The hyphae of fungi can be observed through this.
- Grocott-Gomori methamine silver stain can be used
- Calcofluor white - A widely used stain for detecting fungi and bacteria.
- Gram stain, Giemsa stain
- PCR - Polymerase chain reaction method.

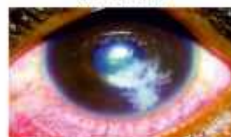### Treatment

- Drug of choice for treatment of fungal keratitis is - Natamycin 5% (most effective against filamentous fungi).
- Start 1 hourly for 2 days then reduce, also give 2 hourly at night

- If it is responding, taper it in 7 days.
- If not responding, add 1% voriconazole with natamycin.
- Econazole - 1%.
- 0.15% Amphotericin can be used
- Silver Sulfadiazine cream can also be used in fungal keratitis.
- For recalcitrant fungal keratitis Caspofungin can be used
- For severe cases
  - Systemic
    - Fluconazole  
(most effective against candida)
    - Voriconazole
  - Subconjunctival injection of Fluconazole
  - Intra cameral (inside the chamber) - Voriconazole, Amphotericin B.
  - If corneal thinning - Tetracycline, Doxycycline (Oral)
  - In case of severe thinning: Therapeutic keratoplasty is done
  - For uveitis: Cycloplegics can be used



Unsterile ulcer



Hyphae

### Viral Keratitis

@12532

- Herpes infection is the most common, found in the cornea.
- HSV is more common than HZO (Shingles).
- The most common infectious cause of corneal blindness in developed countries is **Herpetic Eye DS**.
- Herpes Simplex (HSV 1) viruses are mostly transmitted through sores, saliva, or surfaces near or in the mouth.
- This infection occurs above the waist.
  - Primary infection - It causes minimal corneal involvement.
  - It is self-limiting
  - Cause blepharo conjunctivitis (minimum corneal involvement)
  - Secondary infection - It is recurrent and has severe corneal involvement.
  - It is dormant in trigeminal ganglion
- HSV 2 is caused below the waist.
- In case of neonatorum ophthalmitis, neonatal conjunctivitis is caused by HSV-2

## Clinical features

- Pain
- Redness
- Photophobia
- Discharge
- Blurring of vision
- Pathognomic features of viral keratitis show decreased corneal sensation.
  - Though sensation is less, pain is still a feature.
  - On examination observe- superficial punctate keratitis.
  - Formation of linear ulcers : Dendritic ulcer can be seen again.
  - There has knob ends filled with viruses.
  - A dendritic ulcer is a feature of Herpes simplex.
  - It can progress as geographical ulcer (amoeboid).
  - Steroids are contraindicated in dendritic ulcer as it can lead to perforated corneal ulcer.
- Margin (Virus laden cells) take rose Bengal stain and base take fluorescein stain
- Stromal involvement
  - Direct infection leads to necrotic keratitis (necrosis, infiltration)
  - Immune mediated hypersensitivity reaction leading to interstitial keratitis
  - It is type III hypersensitivity reaction
  - Necrotic keratitis - Necrosis, infiltration, edema
- Endothelial involvement
  - Endothelitis can be due to direct infection or majority it is hypersensitivity reaction (Type IV)
  - It involves central endothelial cells in a disc shape manner i.e., Disciform keratitis
  - It is endothelitis in a disc shape manner.
  - It only involves central cornea leading to edema.

## Investigation of Viral Infection

- Most of the time, diagnosis is clinical.
- PCR - Polymerase Chain Reaction is one of the investigation methods.
- Giemsa stain: Multinucleated giant cells seen
- HIV serological tests - No use in recurrent infections.

## Treatment

- Topical therapy is given. 0.15% ganciclovir gel, to be given five times.
- Topical acyclovir ointment with- 3% is used 5 hourly per day 0.15% Ganciclovir gel
- Trifluridine (frequency - 9 times to 5 times).
- Acyclovir and tetracycline is only available in ointment form.
- Tetracycline and atropine - 1%

## Others

- Idoxuridine
- Vidarabine
- Associated uveitis: Give cycloplegics
- IOP control if raised
- A topical steroid is given under an antiviral cover if the epithelium is healed and not involved (Under anti-viral cover)
- This is mainly for the hypersensitive reaction of stroma and endothelium.
- IOP control; avoid PG analogs in case of managing IOP. It promotes herpes activity.
- Systemic antiviral drugs are those which inhibit viral replication.
  - The viral infection depends on whether it requires a therapeutic dose of Acyclovir.
  - These drugs are given in both stromal keratitis and endothelial involvement.
  - If epithelial is involved prophylactic dose of acyclovir is used.
  - Therapeutic dose given: 400 mg tab 5 times a day
  - Prophylactic dose: 400 mg B.D
  - Prophylactic valacyclovir: 500mg O.D

## Causes of Decreased Corneal Sensation

01:44:45

### The causes of decreased corneal sensation.

- Leprosy
  - Viral keratitis - It is the infection of the cornea
  - Diabetes
  - Chronic degenerative condition of the cornea, like - band-shaped keratopathy
  - Absolute glaucoma
    - Phthisis bulbi
    - Section of trigeminal nerve
  - Varicella zoster
    - Two types- one causes chickenpox, and the other causes herpes zoster. (shingles)
- ### Herpeszoster ophthalmicus
- Either there is a skin lesion, eye lesion, and trigeminal neuralgia.
  - It follows dermatome of trigeminal nerve.
  - Hutchinson's rule - The eye will be involved if the nose tip is involved in skin lesion. As it indicates nasociliary nerve involvement (Ophthalmic branch of Trigeminal).
  - Vesicles are present on the nose. Whenever there is the involvement of the nose and skin lesions, this is called Hutchinson's sign.
  - Zoster infection is mainly found in immunocompromised patients.
  - In Elderly
  - Shingles can be early indicator of HIV



### Ocular Manifestations

- Acute
- Chronic Eye Disease
- Relapsing eye disease

### Acute Infection

#### Other features

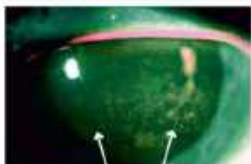- Uveitis
- Episcleritis
- Scleritis
- Blepharo conjunctivitis (Lid and corneal involvement)
- Acute retinal necrosis
- Cranial nerve palsies
  - All three nerves i.e., 3,4,6 are involved
  - Most common nerve involved in herpes zoster: Frontal nerve

### Chronic Eye Disease

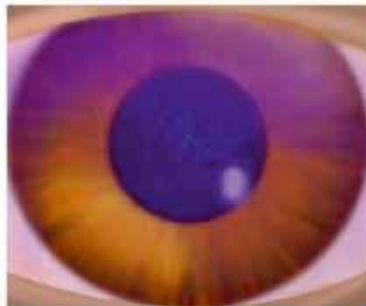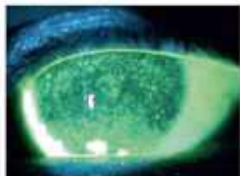- It can lead to neurokeratitis, mucus plaque, scleritis, and lipid keratopathy.
- Mucus plaque keratitis - managed through acetylcysteine eye drops, mucus stains to rose Bengal.
- Lipid keratopathy
  - Irregular deposition of lipids around the cornea
    - Primary - Idiopathic
    - Secondary- Cause is not known
  - The most common cause is herpes
- Relapsing eye disease - Reactivation after several years.
- Investigation - not generally required, but PCR can be used.

### Treatment

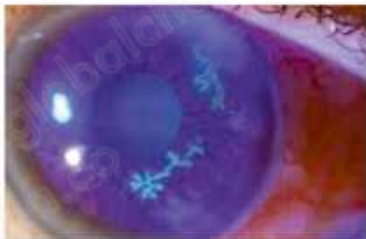- Topical treatment is the form of a cream that can be applied in any place.
- Systemic drugs used are - Oral acyclovir- 800mg, 5 times a day
- Another drug used is Valacyclovir - 1000mg TDS
- Therapy should not exceed more than 14 days (7-10 days).
- If it exceeds that, and patient is not healing it is because of the toxicity of antivirals. Also called Methherpetic keratitis.
- Start lubricating eye drops, stop antiviral.



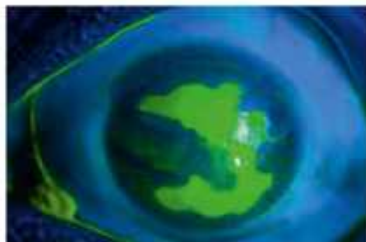
Superficial punctate keratitis



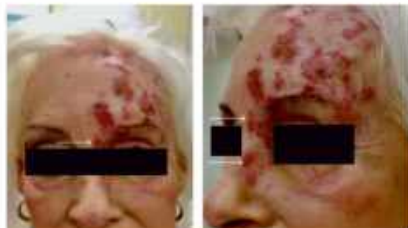Dendritic ulcer



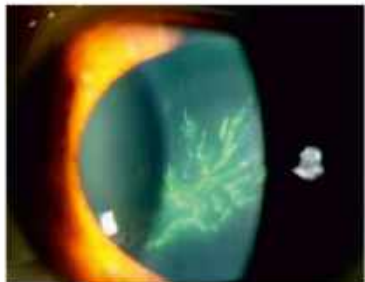Dendritic ulcer-linear



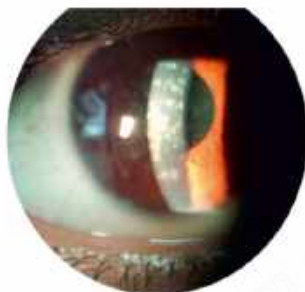
Geographical ulcer



HZO-skin lesion



Dendritic - Pseudo dendritis



Nummular keratitis

#### Acanthamoeba Keratitis

013934

- It is a free living protozoa.
- It feeds on fungi and bacteria.

#### Clinical Features

- Rare infection
- Happens in soft contact lens users.
  - After washing their lens with tap water
  - Swimming with contact lens and without swimming goggles.
- Pain is disproportionately more.
- Pain is more due to perineural invasion, i.e., radial perineuritis.
- On examination, **typical ring lesions** and pseudo dendrites can be observed.
- Limbitis is also a feature with Stromal edema and infiltration.

Q. Which is the most common infection after contact lens use?

Ans. Pseudomonas

Q. Soft contact lens users prone to develop?

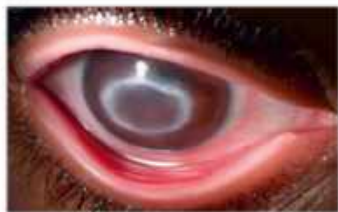Ans. Acanthamoeba keratitis

#### Investigation

- It includes staining and culture investigation
- The stains used are the following:
  - Calcofluor White
  - Acridine Orange
  - PAS
  - Giemsa and gram stain
- Culture media: It includes non-nutrient agar with e.coli
  - 2 forms - Cystic and trophozoite
- PCR
- Confocal microscopy : Bright spot double walled cysts

#### Treatment

- PHMB (Polyhexa Methylene Biguanide); This is a drug of choice, and is a form of eye drop. It is one hourly drug.
- Add with chlorhexidine drug, given one hourly.
- Diamedines (Propamide Isethionate)
- Neomycin - It acts only on trophozoites. It is also modality of treatment.
- Voriconazole is also effective.
- NSAIDS for pain can be used



Ring lesion of acanthamoeba keratitis

#### Interstitial Keratitis

02.07.14

- It is only stromal keratitis.
- It means epithelium and endothelium normal.

#### Different Etiologies

- Interstitial keratitis is divided into syphilitic and non-syphilitic.
- Syphilitic
  - Generally they are congenital where the infection is transplacental.
  - They are cognitive.
- Non-syphilitic
  - It includes Leprosy, TB, Sarcoidosis, HSV, HZO, Onchocerciasis
  - Acanthamoeba may present as Interstitial keratitis.
  - Cogao syndrome -It is an autoimmune disease.
  - It is an interstitial keratitis with sensory neural deafness.
  - RP with deafness is called as Ushers syndrome.
- Inflammation in the stroma leads to new vascularization and bleeding.

- The pink patch (due to neovascularization) is called the salmon patch. It is a feature of syphilis.
- Later ghost vessels are also seen.
- Most of interstitial keratitis is immune mediated.

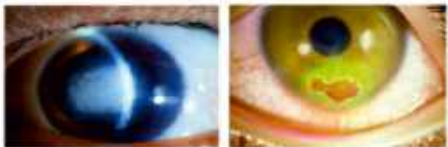### Treatment

Following treatments are done for interstitial keratitis.

- Topical steroids.
- May need systemic steroids and immunosuppressive drugs
- Topical cycloplegic
- Systemic penicillin has no role in syphilitic interstitial keratitis.

### Ocular features of syphilis

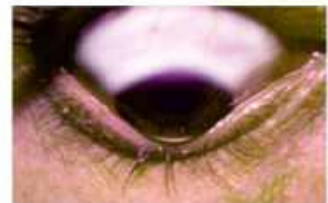- Interstitial keratitis
- Granulomatous anterior uveitis
- Argyll Robertson pupil
- Cataract
- Salt and pepper fundus due to diffuse chorioretinitis
  - Most common cause is syphilis.
- Optic neuropathy



### Keratoconus

- It is a conical protrusion of cornea.

02:14:29



V Shaped Deformity

### It occurs due to the following reasons

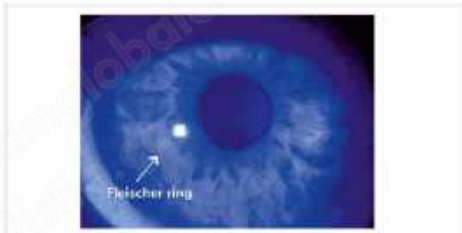
- Ectatic dystrophy of the cornea leads to its conical protrusion
- Genetic disease
- Progresses slowly
- Mode of inheritance - autosomal dominant
- Myopia + irregular Astigmatism is seen due to keratoglobus where whole cornea is protruded

### Clinical features

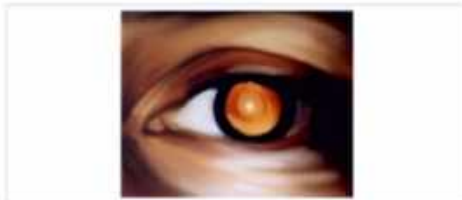- Diminishing of vision
- Frequent change of glasses (in young patients)
- In high Astigmatism, chances of unocular diplopia

### Findings

- **Fleischer's ring** - Iron deposition at the base of cone at epithelial layer can be seen through the slit lamp.



- **Munsun's sign** - v-shaped deformity of the lower lid on down gaze can be seen in the torch light.
- **Oil droplet reflex** - seen through a distant direct ophthalmoscope.
- Dark reflex seen just at the base of cone.



- Retinoscopy - objective refraction method, reflex looks like a cross, also called scissor's reflex.
- **Corneal topography** - Initial stage shows regular astigmatism and a bow-tie appearance.
  - Soon, this leads to an asymmetrical appearance.
  - This progresses as irregular astigmatism and asymmetrical appearance
  - Investigation of choice - Pentacam (Corneal tomography)

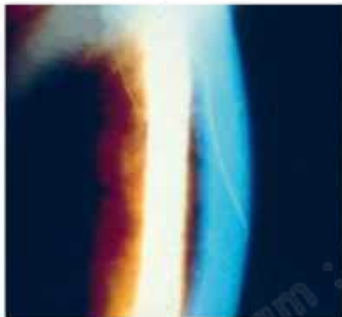**Form fruste Keratoconus** : Early case caught on tomography

- Vogt's striae - On excessive stretching, there is break in elastic membrane.

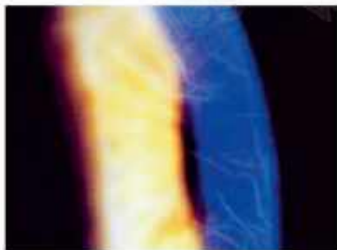
- Vertical striae
- Seen In congenital glaucoma
- Horizontal striae - Hobbs striae



Vogt Striae



Prominent corneal nerves



#### Causes of Thickening of Corneal Nerves

02/24/37

- Old age - With growing age, thickening of the endothelium and epithelial basement membranes take place.
- Interstitial keratitis in Cogan syndrome

#### Treatment

- The person in case of eye infection should avoid eye rubbing.
- Use spectacles, or toric soft contact lens. Astigmatism vision correction is much easier using toric lenses.
- Soft lens takes the shape of cornea itself so irregular surface stays irregular.
- But if it is replaced with rigid gas permeable lens or semi soft lens, irregular surface is replaced by regular surface.
- Choice of contact lens - RGP lens
- If it is a progressive case of Astigmatism, opt for Corneal collagen cross-linking with riboflavin (C3R) treatment.
- Dresden's protocol-put on riboflavin eye drops for 30 minutes (3-5 minutes) while exposed to UV rays.
- For displaced or eccentric cone use INTACS.
- INTACS (Intracorneal ring segment) - It is used to alter curvature of cornea.
- Create the channel by laser or manually put these rings.
- INTACS are used when position is eccentric and it is non progressive
- Use C3R in progressive case.
- If nothing works, replace the cornea with a healthy cornea.
- Keratoplasty
  - PK (Replace full thickness)
  - DALK

#### Associations of Keratoconus

02/30/29

- It can be either ocular or systemic.
- Systemic
  - Can be seen in Ehler danlos syndrome.
  - It also includes Osteogenesis imperfecta.
  - Down syndrome.
- Ocular
  - Vernal keratoconjunctivitis.
  - Atopic keratoconjunctivitis and Blue sclera.

Image 10.1

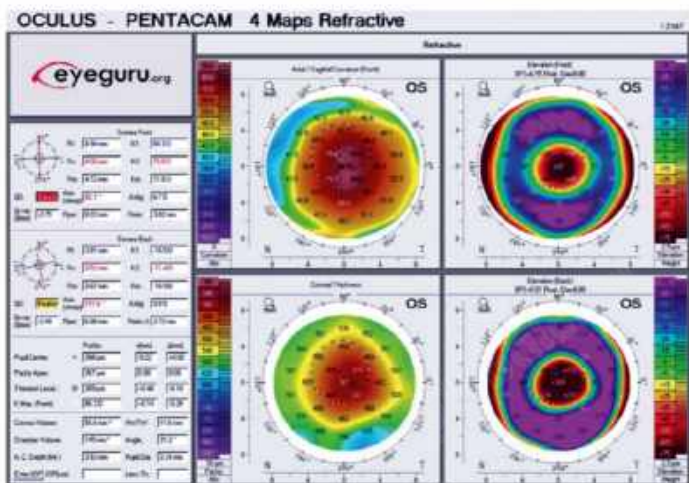
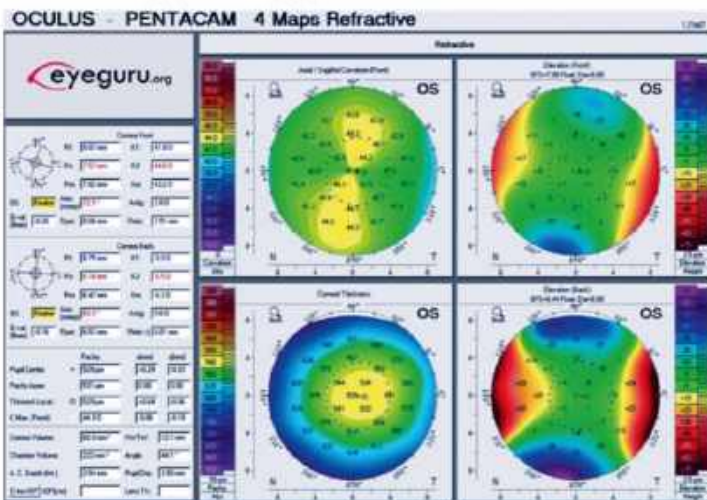


Image 10.2

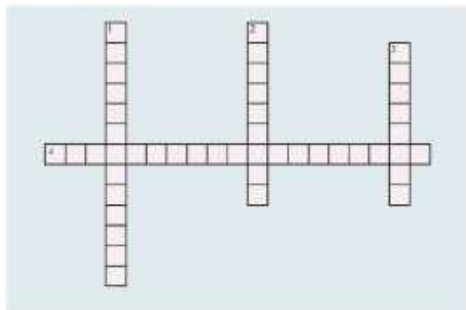




# CROSS WORD PUZZLES



## Crossword Puzzle 1



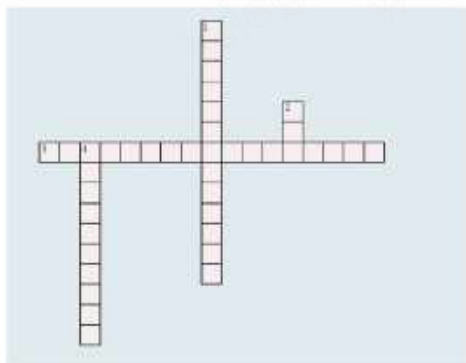
### Across

4. Chemical cauterization for non-healing ulcers is \_\_\_\_\_.

### Down

1. An example of acid-fast stain is \_\_\_\_\_.
2. Treatment of fungal keratitis is \_\_\_\_\_.
3. Treatment of bacterial keratitis is \_\_\_\_\_.

## Crossword Puzzle 2



### Across

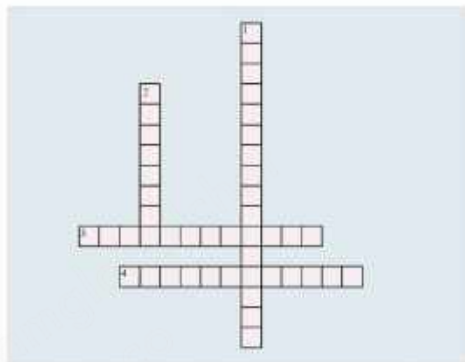
3. \_\_\_\_\_ shows regular astigmatism and a bow-tie appearance in the initial stage.

### Down

1. \_\_\_\_\_ is a cone-shaped structure of the eye.
2. \_\_\_\_\_ treatment is Corneal collagen cross-linking.

4. \_\_\_\_\_ eye drops are used for treating corneal nerves.

## Crossword Puzzle 3



### Across

3. \_\_\_\_\_ is a pink patch in this disease.
4. \_\_\_\_\_ is a chronic eye disease.

### Down

1. Hereditary disorder that makes tumors enlarge along your nerves is \_\_\_\_\_.
2. Corneal topography investigation is done by \_\_\_\_\_.

### Keratoplasty

- Keratoplasty is the replacement of diseased cornea by donor /healthy cornea
- It is obtained from the cadaveric eyes.
- Ideally, the donor cornea must be extracted within 6 hours of the death with relaxation for up to 12 hours.

#### The two methods of tissue removal are-

- Whole eye excision
- Corneoscleral button extraction

Blood test is done to exclude the contraindications.

### Important Information

- Recent studies showed that the tissue can be safely extracted about 24 hours of death. But the timeline of within 6 hours is the best, between 6 and 12 hours is safe, and between 12 to 24 hours is allowable.

### Contraindications for cornea donation

00/02/19

Absolute contraindications	Relative contraindications
<ol style="list-style-type: none"> <li>1. Death due to an unknown cause</li> <li>2. Systemic infections                             <ul style="list-style-type: none"> <li>• HIV</li> <li>• Hepatitis</li> <li>• Congenital rubella</li> <li>• TB</li> <li>• Syphilis</li> </ul> </li> <li>3. CNS infections                             <ul style="list-style-type: none"> <li>• Multiple sclerosis</li> <li>• Rabies</li> <li>• Creutzfeldt-Jakob disease</li> </ul> </li> <li>4. Most haematological malignancies</li> </ol>	<ol style="list-style-type: none"> <li>1. History of                             <ul style="list-style-type: none"> <li>• Intraocular surgery: Due to compromising endothelial cell count</li> <li>• Intraocular tumours</li> </ul> </li> </ol>

### Tests before keratoplasty

- Blood tests for infections, malignancies, or disease biomarkers.
- Examination of all the three layers of donor cornea.
  - One of the criteria to approve a cornea for transplantation is endothelial cell count; at least 1500 to 2000 cells/mm<sup>2</sup>
  - Prerequisite for healthy cornea - Specular microscopy to see endothelial cell count.
  - Check if stroma is clear or cloudy or if there is any epithelial defect.

### Storage of cornea after removal

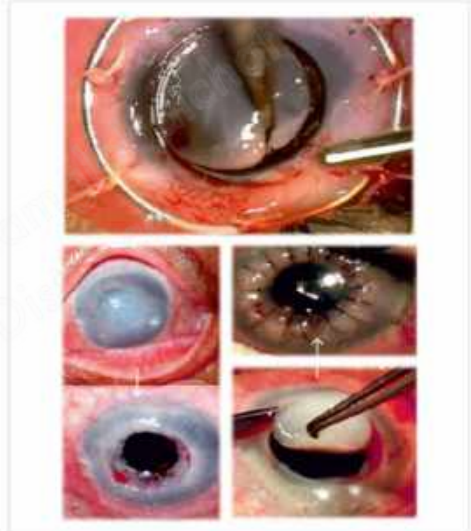
Refer Table 11.1

### Classification of Keratoplasty

06/09/19

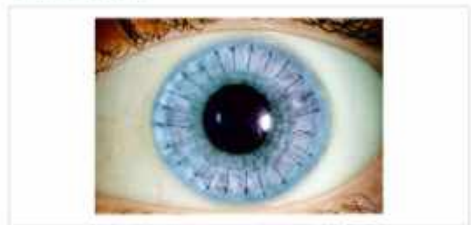- 2 types:
  - Penetrating keratoplasty/ full thickness keratoplasty
  - Lamellar keratoplasty

### Penetrating keratoplasty (PK)



- Penetrating keratoplasty is a replacement of full thickness of cornea with healthy cornea.
- Ideal size of the graft - 0.25 mm larger than cornea of the host, That amounts to ideal size of 7.5mm.
- Most common infection after PK is Staph. Epidermidis.
- Indications of Penetrating Keratoplasty

Refer Table 11.2



## Post-op complications of Penetrating Keratoplasty

### • Early:

- Infection (most common: staphylococcus epidermidis)
- Glaucoma
- Shallow anterior chamber
- Loose or protruding sutures
- Persistent epithelial defects
- Descemet membrane detachment
- **Ureter's zavalia syndrome (rare)** - a triad of **iris atrophy, fixed dilated pupil and secondary glaucoma.**

### • Late:

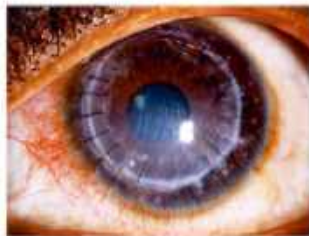- **Astigmatism (most common late complications)**
- Glaucoma
- Graft rejection

## Graft rejection

00:16:24

### Signs of graft rejection

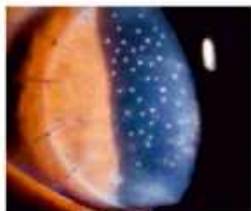
- Corneal edema (most common)
- Ciliary congestion
- Uveitis



- Keratic precipitates on the corneal graft but not on the peripheral recipient cornea
- Corneal vascularization
- Stromal infiltrates

### Types of graft rejection

1. Epithelial graft rejection: **Kayes dots**
2. Subepithelial rejection: **Kraclmer spots**

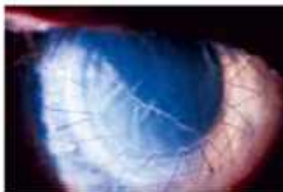

Kraclmer Spots

Subepithelial infiltrates seen in corneal stromal graft rejection

### 3. Stromal haze

### 4. Endothelial graft rejection; **Khodadoust line**



Khodadoust Line

Corneal graft endothelial rejection line composed of inflammatory cells.



## Important Information

### Cornea is immune privileged

- Corneal graft rejection is uncommon as they are less prone to adverse immune reactions due to avascularity, absence of lymphatic structures, minimal MHC expression.
- HLA matching does not have much role.

### Gender-biased graft compatibility

- A cornea from a male donor can be used only for male patients, while cornea from a female donor is compatible with both.

### • Lamellar Keratoplasty (LK)

- Lamellar keratoplasty is a partial thickness replacement. It is of two types based on the layers involved.


#### 1. Anterior lamellar keratoplasty:

- It is the replacement of the anterior portion of the cornea without disturbing the endothelium, as there is high chance of endothelium graft rejection. There are two types based on the thickness of the stroma involved.
- **Superficial Anterior LK:** Includes less than or equal to one-third of stroma replaced.
  - Done in pterygium and limbal dermoid.
- **Deep anterior LK:** replaces more than one-third of the stroma.

#### 2. Posterior lamellar/ Deep endothelial lamellar keratoplasty

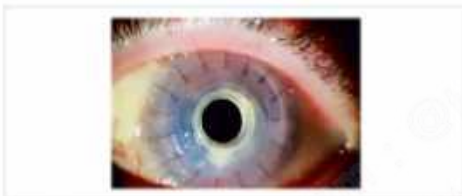- This type replaces the endothelium with or without a part of the stroma. It is of two types.
- **Descemet stripping automated endothelial keratoplasty (DSAEK)** replaces a part of stroma along with Descemet membrane and endothelium.
- **Descemet membrane endothelial keratoplasty:** does not involve stroma. only Descemet membrane and endothelium is removed and exchanged..





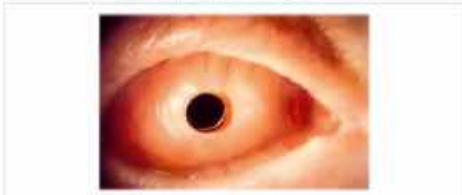### Keratoprosthesis

- It is a surgical procedure where a diseased cornea is replaced by an artificial cornea after one or two failed corneal transplants. It is of two types.
  - Boston keratoprosthesis**
    - It is a collar button design keratoplasty and the most used type worldwide.



- Osteo-odonto keratoprosthesis**

- It is also called **tooth in eye** surgery, ideal for patients with end-stage corneal inflammatory diseases.
- Removal of tooth is followed by drilling a hole and fitting optics into it.
- After growing in patient's buccal mucosa cheek for a month, it is implanted in the eye.



### Corneal degeneration

00:26:30

- Age related degeneration can be arcus senilis (most important), cornea farinata, crocodile shagreen

#### Arcus Senilis

- It is an **age-related degeneration** characterized by round white opacity in cornea due to lipid deposition.
- There is clear space between arcus and limbus called as lucid interval of Vogt.

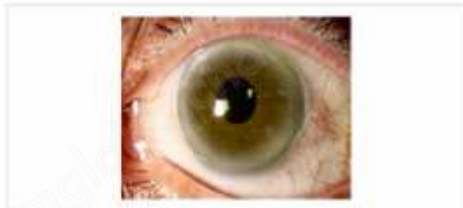- Lipid deposition in the stroma or bowman membrane starts as superior and inferior arc and completes the circle gradually.
- Round opacity at a young age is called arcus juvenilis, caused by dyslipidaemia.**



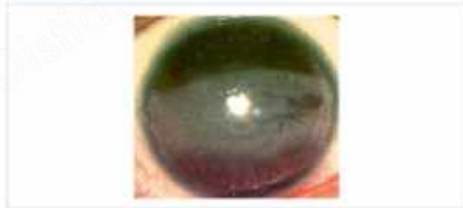### Important Information

#### Unilateral arcus senilis

- Commonly, arcus senilis is bilateral affecting both the eyes. But if the opacity occurs in a single eye, it indicates a **contralateral carotid artery stenosis**.



### Band Shaped Keratopathy (BSK)



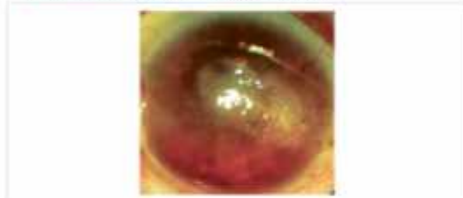
- Band shaped keratopathy** : Calcium deposition in subepithelial, bowman's membrane and anterior stromal layers.

#### Causes

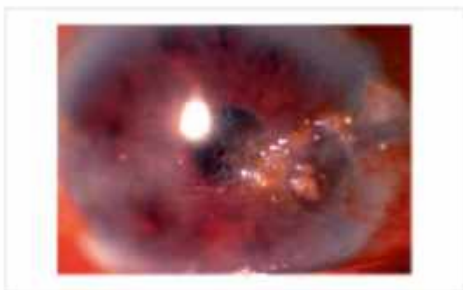
- Idiopathic (MC), generally age-related.
- Ocular diseases - chronic uveitis, uveitis in JRA (Juvenile rheumatoid arthritis), Phthisis bulbi absolute glaucoma.
- Metabolic causes: Hypercalcemia - Sarcoidosis, vitamin D toxicity, and hyperthyroidism.

#### Spheroidal degeneration

- Also known as Labrador keratopathy/ Climatic droplet keratopathy (CDK)/ Actinic degeneration



- Amber-coloured proteinaceous granules deposition mainly actin.
- This deposition replace bowman's membrane in anterior stroma



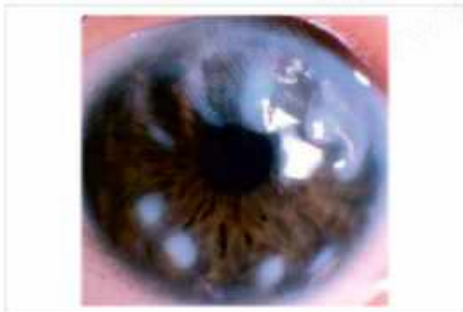#### Causes

- UV exposure (Common in tropical countries) – PRIMARY CAUSE
- Inflammation or infection- SECONDARY CAUSE

#### Treatment

- Avoid sun exposure.
- Removal of deposits through superficial keratectomy.
- Lamellar keratoplasty.

#### Salzmann Nodular Degeneration



- Hyaline deposits usually seen above the Bowman's membrane.
- These deposition can be easily peeled off.

#### Causes

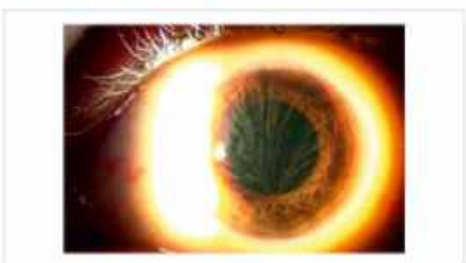- Chronic irritation, such as trachoma, chronic blepharitis and dry eye.

#### Treatment

- Lubrication
- Manual or excimer superficial keratectomy.

#### Vortex keratopathy or cornea verticillata

06/35/31



- Deposition of drugs in whirl-like pattern radiating from a single point is characteristic of vortex keratopathy.
- It is also called as Cornea Verticillata.
- It is seen in a whirl like manner because its all deposited in epithelium and epithelium when it renews itself from stem cells migrate in this manner

#### Causes

- Chloroquine.
- Amiodarone (dose related).
- Tamoxifen.
- Indomethacin
- Fabry's disease.



#### Important Information

- Chlorpromazine deposits on endothelial cells. (it is not a cause of vortex keratopathy)

#### Lipid Keratopathy

- It is an irregular deposition of fat, cholesterol, and phospholipids in stroma.

#### Types

- Primary lipid keratopathy (Idiopathic) → It happens spontaneously and there is no vascularization
- Secondary lipid keratopathy → causes corneal vascularization resulting from infection with herpes simplex virus or herpes zoster ophthalmicus.

#### Conditions related to cornea.

##### Corneal Opacities

06/38/30

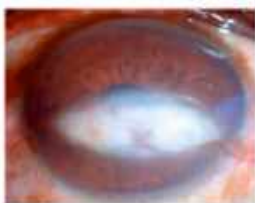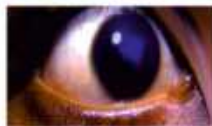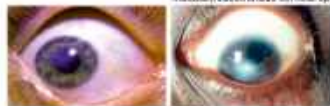It is seen when there is breach in Bowman's membrane and stroma is involved.

##### 3 types:

- **Nebular:** <math>1/3^{rd}</math> of stroma gets involved – faint white in colour
- **Macular:** <math>1/3^{rd}</math> to <math>2/3^{rd}</math> of stroma gets involved – little darker than nebular

- **Leucoma:**  $>2/3^{rd}$  to full thickness involved – dense white
- Diminution of vision is more in nebular because of scattering of light. Which disturbs normal function of cornea. Whereas leucoma obstructs the light.

-OPTICAL IRIDECTOMY: central incision/leucomatous corneal opacity



#### Management:

- Optical iridectomy: when it covers the pupil.
- Penetrating / lamellar keratoplasty
- Corneal tattooing by brown or black : When it is not covering the pupil.
- Color the cornea black or brown
  - Brown colour by applying gold and black colour by applying platinum.
  - And wash with hydrazine hydrate which helps to fix it
  - Apply bandage

#### Corneal Dystrophies

004599

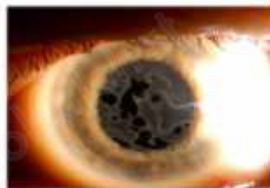
- It is described as any idiopathic spontaneous change with no inflammation.
- These are Corneal opacifying disorders
- It is a Genetic disease
- Bilateral symmetrical and generally progressive. **Exception - Posterior polymorphous dystrophy is unilateral.**

#### Classification according to layers involved:

- Epithelial/ sub epithelial corneal dystrophy involves (basement membrane)
- Epistromal corneal dystrophy involves (bowman's membrane and anterior stroma)
- Stromal corneal dystrophy
- Endothelial corneal dystrophy

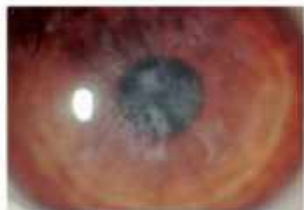#### Epithelial and subepithelial dystrophy/ epithelium basement membrane dystrophy

- Presents with recurrent erosions, due to defective hemidesmosomes attachment.
- Sometime asymptomatic
- **They are of 2 types-**
  - Microcystic/ map dot/ fingerprint dystrophy
  - Meesmans dystrophy: intra epithelial cysts.
- **Treatment**
  - For meesmans- Lubricants, bandage contact lens.
  - For microcystic - anterior stromal puncture (stimulates scarring of bowman's membrane), PTK (Photo therapeutic keratectomy) – Removing epithelium by excimer laser.



#### Bowman's membrane dystrophy

- Clinical feature - Recurrent erosion
- 2types: Rees buckler dystrophy and Thiel Behnke.
- Rees buckler dystrophy seen as Reticular pattern subepithelial opacities.
- Histology: **Bowman's layer is replaced by connective tissue**



- **Thiel Behnke dystrophy:** Bowman's membrane is replaced by fibrofatty tissue.
- **Histology: Saw tooth appearance/ honeycomb appearance**
- **Treatment -** lubricating eye drops, bandage and contact lenses.

### Stromal Dystrophy

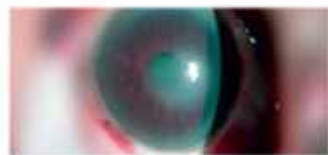00:53:18

Refer Table 11.3

- **Treatment:** Replace the cornea by **penetrating keratoplasty**

### Endothelial dystrophy

01:50:14



- **Clinical features:** Present with corneal oedema, due to dysfunction of endothelial.
- **Treatment -** Hypertonic saline eye drops (5% NaCl), hairdryer to dehydrate the cornea.
  - In case of bullae rupture- bandage contact lens, antibiotics and cycloplegics
  - Keratoplasty: penetrating keratoplasty / posterior lamellar keratoplasty

- **Types -** Fuchs endothelial dystrophy, posterior polymorphous dystrophy

### Fuchs endothelial dystrophy

- Common in females,
- Associated with open angle glaucoma.
- There is Accelerated and bilateral endothelial cell loss
- On specular microscopy beaten bronze endothelium is seen which later leads to bullous keratopathy
- In central cornea, protuberances or excrescences are seen from Descemet membrane which is called corneal guttata.
- **Corneal guttate** is a feature of Fuchs endothelial dystrophy.
- **Posterior polymorphous dystrophy**
  - It is **unilateral**
  - Metaplasia of endothelial cell
  - Seen in early childhood.
  - **Associated with glaucoma and Alport syndrome.**

Telegram: @teanglab  
www.Distia.co

Table 11.1


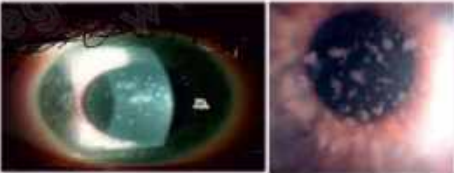
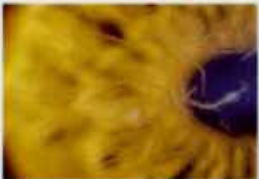
## Storage

Short term	Intermediate term	Long term
<p><b>For 48 hours</b></p> <ul style="list-style-type: none"> <li>Moist chamber (whole eye)</li> <li>Temperature is 2 to 8 °C</li> <li>In MK media (Mc Carey Kaufmann media)</li> <li>It mainly contains Tc-199, 5% dextrose</li> </ul> <p><b>For up to four days</b></p>	<p><b>Stored about two weeks</b></p> <p><b>Media used</b></p> <ul style="list-style-type: none"> <li>K-Sol</li> <li>Dexsol</li> <li>Lysol</li> <li>Optisol (hybrid of Ksol and dexsol) - most commonly used media</li> <li>Optisol GS (GS- gentamycin and streptomycin)</li> </ul> <p><b>A notable ingredient</b></p> <p>Chondroitin sulphate - antioxidant which helps to store for a longer period of time</p>	<p><b>For definite period (30 days)</b></p> <ul style="list-style-type: none"> <li>Organ culture</li> </ul> <p><b>For indefinite period</b></p> <ul style="list-style-type: none"> <li>Maximum one year</li> <li>Uses cryopreservation (T= -190 degree centigrade).</li> <li>Main preservative: glycerine.</li> </ul>

Table 11.2

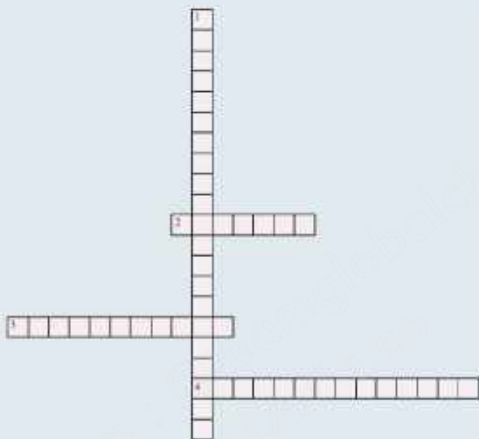
Optical (for improving vision)	Therapeutic	Cosmetic	Tectonic
<ul style="list-style-type: none"> <li>Keratoconus</li> <li>Corneal dystrophy</li> <li>Phakic keratopathy</li> <li>Pseudophakic keratopathy</li> <li>Bullous keratopathy</li> <li>Corneal degeneration</li> </ul>	<ul style="list-style-type: none"> <li>Infections resistant to other treatments</li> </ul>	<ul style="list-style-type: none"> <li>Improve aesthetics of the eye.</li> </ul>	<p>There Is Extremely Thin Comes And Distorted Integrity</p> <ul style="list-style-type: none"> <li>Descemetocoele</li> <li>Anterior staphyloma</li> </ul>

Table 11.3

Dystrophies	Features
<ul style="list-style-type: none"> <li>Granular</li> </ul>	<ul style="list-style-type: none"> <li>Decrease visual acuity feature.</li> <li>Hyaline deposit in stroma</li> <li>Sugar granules with clear cornea in between</li> <li>Stain: Masson Trichrome stain</li> </ul>  <p>2 Types</p> <ul style="list-style-type: none"> <li>Type 1 (classic)</li> <li>Type 2 (Avellino dystrophy): hyaline + amyloid deposits</li> <li>Combined granular and lattice dystrophy</li> </ul>
<ul style="list-style-type: none"> <li>Macular</li> </ul>	<ul style="list-style-type: none"> <li>Least common dystrophy</li> <li>Mucopolysaccharide depositions/GAG deposition.</li> <li>Space between opacities is Cloudy cornea.</li> <li>Autosomal recessive (MC in ICELAND)</li> <li>Gene responsible is <i>CHST6</i></li> <li>Stain - Alcian blue or Colloidal iron</li> </ul> 
<ul style="list-style-type: none"> <li>Lattice</li> </ul>	<ul style="list-style-type: none"> <li>Type 1 - classic form, most common stromal dystrophy.</li> <li>Type 2 - gelsolin form, associated with systemic amyloidosis.</li> <li>Stain - Congo red stain</li> </ul> 
<ul style="list-style-type: none"> <li>Schnyder crystalline dystrophy</li> </ul>	<ul style="list-style-type: none"> <li>Associated with disorders of lipid metabolism.</li> <li>Deposits of cholesterol and phospholipids seen in stroma.</li> <li>Stain - Oil red O stain</li> </ul>



## Crossword Puzzle 1 Keratoplasty



### Across

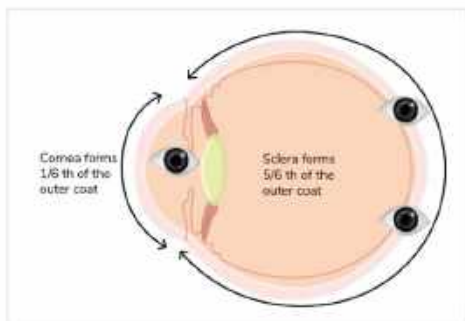
2. hybrid of ksol and dexisol
3. the most common late complication of penetrating keratoplasty
4. round opacity in young age

### Down

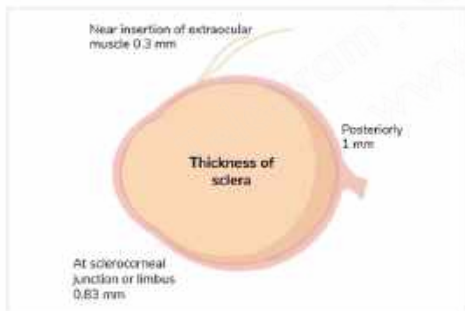
1. minimum cell count for a cornea transplant



Sclera is the white part of eye which is toughest in nature



- Scattering all wavelengths of light, therefore the sclera is opaque
- Most radioresistant structure of eye: Sclera
- **Most radiosensitive structure of eye: Lens**

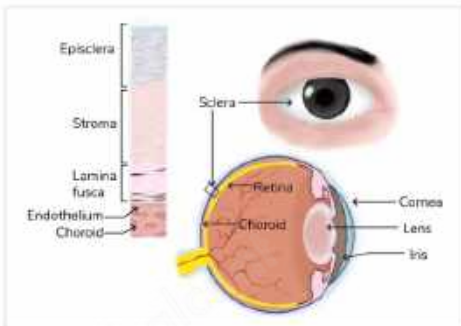


- Sclera thinnest at muscle insertion posteriorly
- **Most common site of scleral (globe) rupture: posterior to the site of muscle insertion**

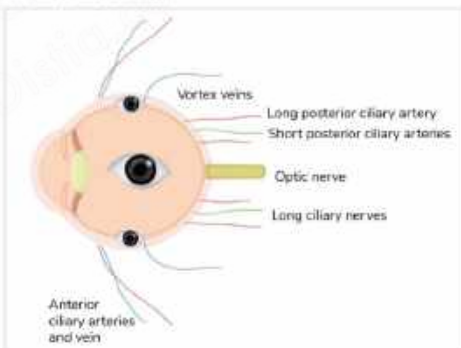
### Different Layers of Sclera

(1693-5)

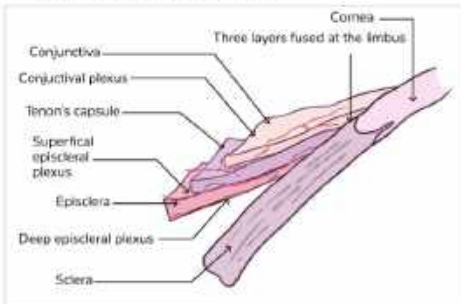
1. Episclera: thin vascularized connective tissue. It has collagen fibres, fibroblasts, blood vessels and nerves.
2. Sclera proper: Relatively avascular. It is dense tissue so it has collagen fibres, elastic fibres, fibroblasts and proteoglycans.
3. Lamina fusca: innermost layer. It is a loose connective tissue. It has melanocytes (migrated from choroid)



- Anterior ciliary artery is near the insertion of the recti. Every recti has two anterior ciliary artery except lateral rectus which has one ciliary artery. Anterior ciliary arteries are muscular branches.



- At the limbal area, the three layers (conjunctiva, tenon's capsule and episclera) fuse together.



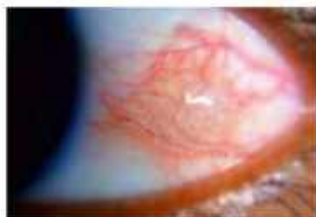

## Scleral Inflammation

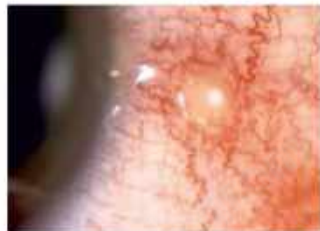001033

- **Episcleritis**
  - No pain
- **Scleritis**
  - Pain due to long and short ciliary nerves

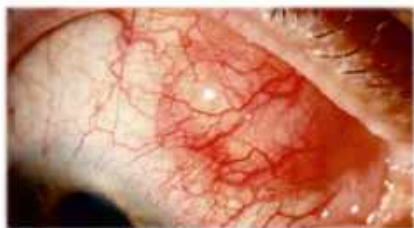### Nodular Episcleritis



### Phlyctenular Keratoconjunctivitis



### Scleritis



- **Phenylephrine test** is used to differentiate between Nodular episcleritis, scleritis and phlyctenular keratoconjunctivitis.
- **Phenylephrine test:**
  - Put 1% phenylephrine to this type of patient. If blood vessels are blanching, then it is conjunctival congestion (phlyctenular keratoconjunctivitis)

- If not blanched, increase upto 10% phenylephrine, if it blanches with 10% it is Episcleritis.
- Even after increasing upto 10%, if not blanched, then it is identified as scleritis.
- Episclera of two types: Deep and superficial episcleral plexus.
  - In case of episcleritis, it mainly affects superficial episcleral plexus
- In case of conjunctivitis, conjunctival plexus is mainly affected.

### Episcleritis

001525

- Inflammation of episclera
- Benign and recurrent disease
- Mainly affects middle age people (female > male)
- It is a self-limiting disease. Treated by its own
- Clinical features:
  - Discomfort
  - Grittiness
- On examination:
  - Nodular type- nodule near limbus
  - Diffuse type
- Confirmatory test: Phenylephrine test
- Management:
  - Cold compressors
  - Refrigerated lubricants
  - Oral NSAIDs (most preferable: ibuprofen or indomethacin)
  - Weak topical steroids

**Association in episcleritis:** Ocular (dry eye and contact lens wear) and systemic (crohns disease, ulcerative colitis, herpes zoster oëcus, rheumatoid arthritis).

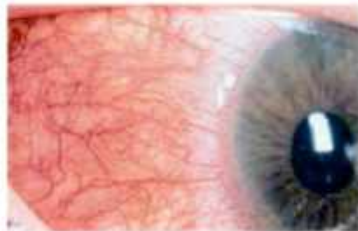
### Scleritis

001937

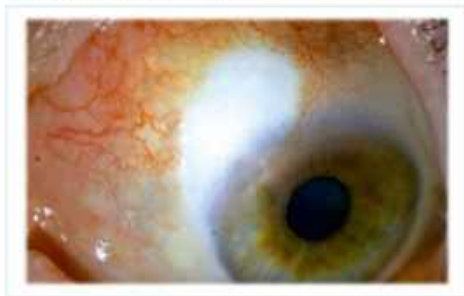
- Inflammation of sclera associated with edema and cellular infiltration
- Most commonly, it is immune mediated

Refer Flow Chart 12.1

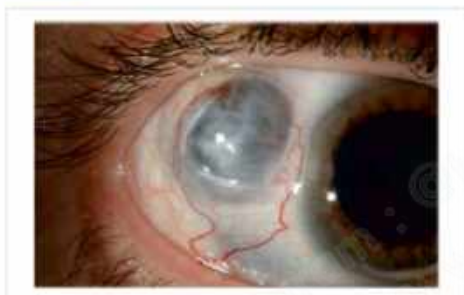
### Diffuse Scleritis



## Necrotizing with Inflammation



## Necrotizing without Inflammation: Scleromalacia Perforans



## Anterior scleritis

002406

- Most common in 5<sup>th</sup> decade mainly in females
- Non-necrotising anterior scleritis:
  - Clinical features: Pain, tenderness, discomfort, grittiness
  - **Phenylephrine test: not blanching**
  - On examination: Nodular or diffuse with congestion
  - Treatment:
    - Cold compressors
    - Refrigerated lubricants
    - Topical steroids
    - Systemic NSAIDs
    - Systemic steroids
- Necrotising anterior scleritis:
  - With inflammation: Aggressive form of scleritis, managed by systemic immunotherapy
  - Without inflammation: Scleromalacia perforans

## Scleromalacia Perforans

002900

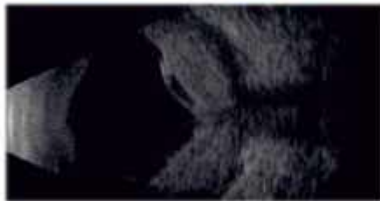
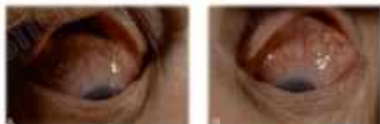- It is a disease of long standing Rheumatoid arthritis
- The necrotic patch slowly causes scleral thinning which leads to exposed uveal tissue
- Mostly perforation doesn't occur. Only if IOP raised, then perforation may occur.

- No effective treatment
- Early case is treated as same as anterior scleritis
  - Topical systemic steroids
  - Topical/systemic anti collagenase
  - Topical cyclosporine
- Protection of eye from trauma

## Posterior scleritis

063026

- It is a potentially blinding condition
- Generally diagnosed late
- Age of onset: <40years
- Clinical features:
  - Choroidal folds
  - Uveal effusion with choroidal detachment
  - Exudative retinal detachment
  - Disc edema
  - If orbit involves due to scleritis causes inflammation of the muscles (Myositis) -severe pain
  - Mild proptosis
- **IOC: USG- B scan shows T' sign**
  - T-sign denotes vertical limb is the optic nerve and T is the fluid accumulated between the tenon's capsule and sclera.
- Other investigations: CT or MRI



- Treatment:
  - Topical & systemic steroids
  - Immuno-suppressants / Immunomodulators:
    - Rituximab (particularly effective in treating scleritis)
    - Cyclosporine
    - Tacrolimus
    - Cyclophosphamide
    - Azathioprine

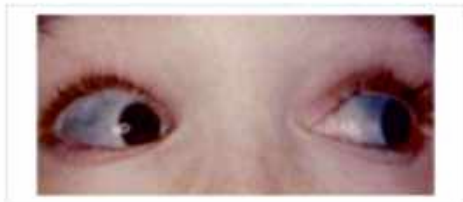### Systemic associations of scleritis:

- Rheumatoid arthritis
- Granulomatosis with polyangiitis
- PAN
- Relapsing polychondritis
- Crohn's diseases

### Blue Sclera

00:17:59

- Thin sclera where underlying uveal tissues are visible
- Causes:
  - Osteogenesis imperfecta



- Ehler-Danlos syndrome

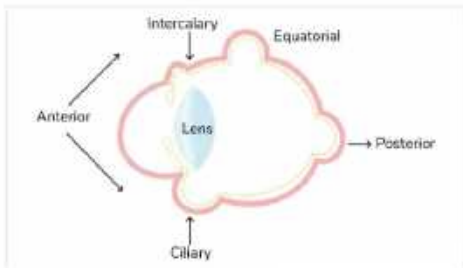

- Scleromalacia perforans
- Marfans syndrome
- Hallermann-streiff syndrome (spontaneous reabsorption of lens)

### Staphyloma

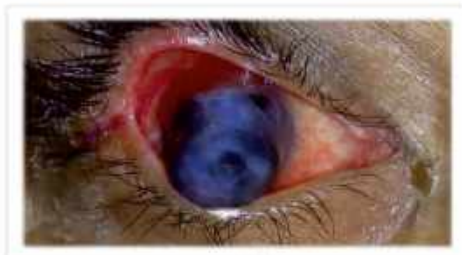00:19:58

- Ectasia of eye ball along with herniation of uveal tissue



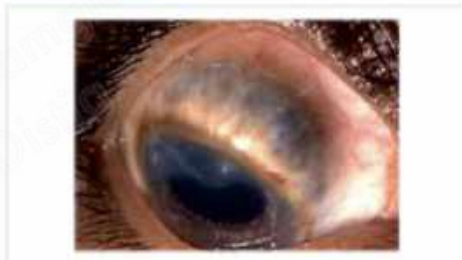- Classification:

- Anterior
  - Causes: Pseudocornea

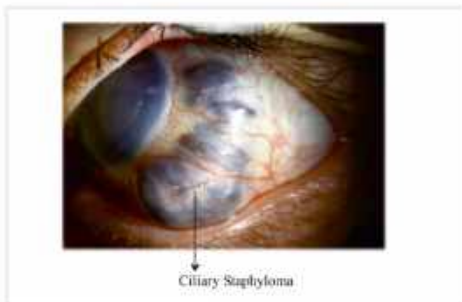

- Intercalary
  - Causes: Peripheral corneal ulcer

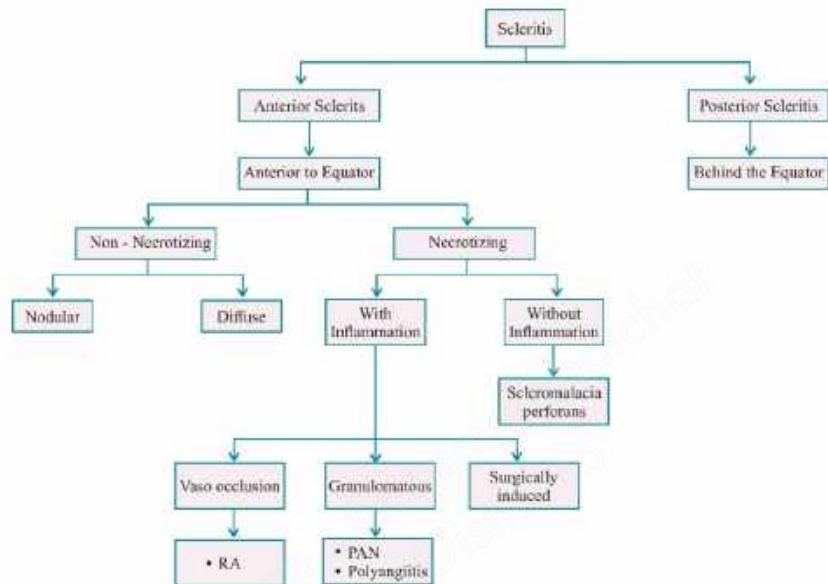
### Intercalary Staphyloma

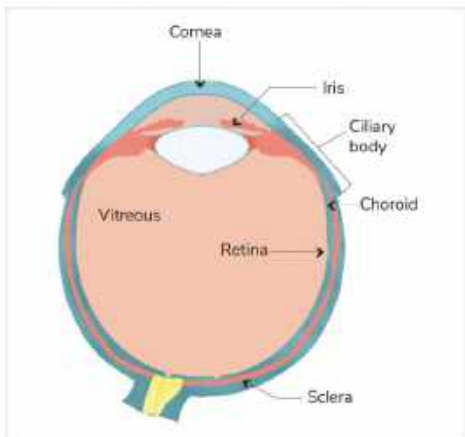


- Equatorial
  - Causes: Scleritis
- Posterior:
  - Most common type
  - Cause: pathological myopia
- Ciliary
  - Causes: Scleritis
  - Other causes: Trauma, absolute glaucoma



Flow Chart 12.1





- Uveal tissue - Iris, ciliary body, Choroid
- Uveitis is an inflammation of the **uveal tissue**

### Classification

000935

#### Anatomical classification

- It is according to the Standardisation of Uveitis nomenclature (SUN)
  - Anterior Uveitis:** Involves Iris and pars plicata, so it is also called as **iritidocyclitis**
  - Intermediate Uveitis:** Primarily involves Pars plana so k/a **Pars planitis** and also involves **peripheral part of retina, Vitreous.**
  - Posterior Uveitis:** Involves the choroid and retina so k/a **Chorioretinitis**
  - Pan Uveitis:** All 3 involved

#### According to SUN: Classification based on time of inflammatory activity

- Acute Uveitis:** < 3 months duration, Sudden onset
- Chronic Uveitis:** > 3 months duration
- Recurrent:** Repeated episodes with inactive periods
- Remission:** No inflammation in ≥ 3 months

#### Etiological classification: Given by IUSG (International Uveitis Study Group)

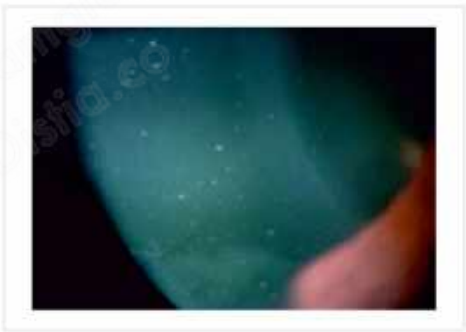- Infectious- Bacterial, Viral, Fungal, Protozoal
- Non-Infectious cause
  - With Systemic association
  - Without systemic association

c. **Masquerade Syndrome:** All situations or condition which are mimicking an inflammatory etiology. It can be Neoplastic or non-neoplastic

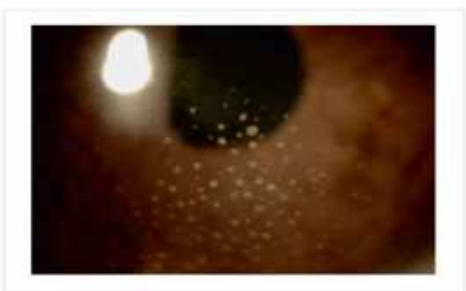
### Anterior Uveitis

000704

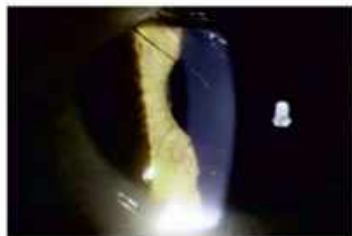- It is also called **iritidocyclitis**
- Most common type of uveitis
- **Clinical Features:** Pain, redness, photophobia, blepharospasm and discharge (serous discharge), blurring and diminishment of vision (due to haze in aqueous humor).
- **O/E**
  - Keratic precipitates: Are proteinaceous or cellular deposits at back of the cornea (hallmark).



- KPs are fine and grey in non-Granulomatous uveitis. Keratic precipitates are generally Lymphocytes
- **Mutton fat KPs** (Large with greasy look) seen in Granulomatous Uveitis. Mutton fat KPs are generally macrophages



→ KPs are mostly present in the lower cornea due to convection current in aqueous humor and this imaginary triangular area in the lower cornea is k/a **Arlt's triangle**



- **Aqueous cells:** Sign of active inflammation
- After long standing inflammation, these KPs can get pigmented.



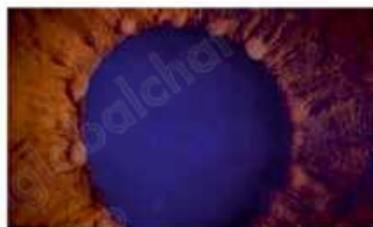- **Aqueous Flare:** Haziness in the anterior chamber. Haziness is due to leakage of proteins from the inflamed tissue
- Aqueous flare is seen due to - Tyndall effect or scattering of light
- In iris and pars plicata, due to inflammation, there is increased capillary permeability.
- Leakage will cause edema in iris and such an iris is called muddy iris.



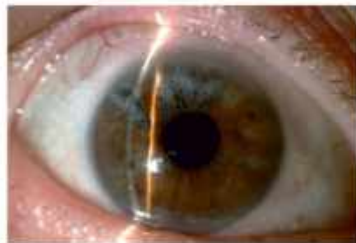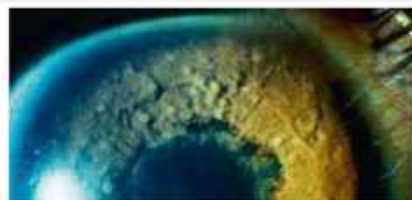○ Miosis: Due to release of toxins from the inflamed tissue

### Important Information

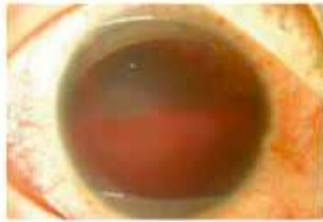- In Uveitis the pupil is constricted
  - In Angle closure Glaucoma there will be mid dilated pupil
- Nodules on the iris
- It can be at the pupillary border k/a Koeppe's nodules (seen in granulomatous and non granulomatous uveitis).



→ Busacca nodules are seen at the base of iris. It is seen in granulomatous uveitis

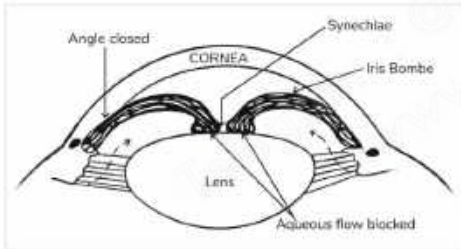


- Sectoral iris Atrophy is typical feature of herpes infection
- Diffused iris Atrophy is a feature of Fuchs heterochromic cyclitis

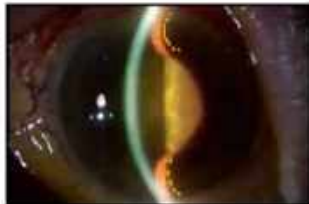

- **Hyphema is blood in anterior chamber. It is typical of herpetic uveitis.**

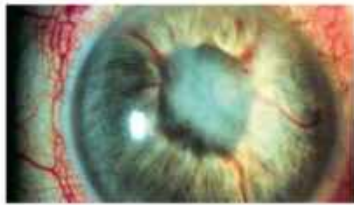- **Festooned shape pupil:** feature of Acute anterior uveitis
- Other features - If the treatment is not started inflammation progresses which causes adherence of iris to lens which is called posterior synechiae.
- So during dilatation, the adherent part will not move. This type of pupil is called Festooned pupil.
- **Seclusio pupillae/ Ring Synechiae:** When the adhesion is present along the pupillary border. Aqueous can not flow anteriorly so there is pupillary block.



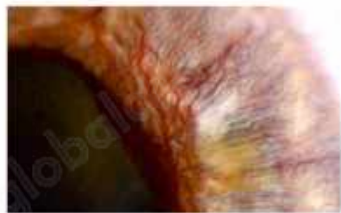- Due to pupillary block it gets collected in anterior chamber which pushes iris forward. It will lead to Iris Bombe, which will adhere to cornea leading to Peripheral anterior Synechiae leading to Angle closure glaucoma



- **Occlusio pupillae:** When it is covering the whole surface of the lens



- Cyclitic membrane



- Pseudo Rubeosis Iridis - Radially dilated blood vessels.
- **Mc complication is Secondary glaucoma**



### Important Information

#### • IOP changes

- In Acute uveitis: Increase IOP
- In Chronic uveitis: there is ciliary shutdown (aqueous formed by ciliary processes) which results in decrease IOP

#### Systemic associations of anterior uveitis

##### 1. Infectious

- a. Herpes infection: Varicella Zoster, HSV
- b. TB
- c. Syphilis
- d. Leprosy

##### 2. Non-infectious causes

- a. Sarcoidosis
- b. Behcet's Disease
- c. HLA B27 associated arthritis
- d. IBD (UC > Crohn's)
- e. Drug induced Pilocarpine, PG analogues

##### 3. Masquerades: Can be neoplastic or non neoplastic

- Neoplastic include: Lymphomas, Anterior segment Melanoma, retino blastoma and Metastasis
- Non neoplastic: Intra ocular foreign body, Old RD, PDS, Coats disease

## Investigations

- Ocular: USG-B-Scan, FFA, OCT
- Systemic investigation
  - Hemogram
  - Syphilis: VDRL, TPHA
  - Sarcoidosis: Serum ACE levels
  - Chest X ray
  - LFT, KFT
  - Glucose in serum and urine
  - TB - Montoux test, Gold Quantiferon test
  - X-ray spine - HLA associated arthritis or uveitis.



## Important Information

### HLA typing

- HLA B27 - Arthritis
- HLA B5 - Behcets
- HLA B51 - Behcets
- HLA DR4 - VKH syndrome, sympathetic ophthalmitis

## Treatment

- TOC: Topical steroids
  - Prednisolone for severe uveitis
  - Diffuprednate
  - Loteprednol
- Cycloplegics- Topical
  - Cycloplegics give rest to ciliary muscles.
  - Therefore, relieves pain.
  - Prevents posterior synechiae by keeping iris mobile.
  - Breaks posterior synechiae.
  - Improves blood supply- Leads to better healing.
- Luminate program: study to find non-steroidal treatment of uveitis
  - Non-steroidal treatment - Voclosporin (Immuno modulator)**
- If chronic vision threatening Uveitis
  - Monoclonal antibodies: Adalimumab- TNF inhibitor, Infliximab
  - Interferon alpha.

## Intermediate Uveitis

00:40:14

- Inflammation of vitreous, peripheral retina and pars plana.
- It is a **Chronic disease with insidious onset**.
- No gender predilection.

## Etiology

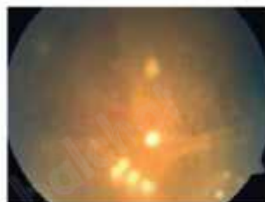
- Infectious**: TB, Leprosy, Syphilis, Toxocariasis.
- Non-infectious**: Sarcoidosis, MS.
- Idiopathic**: >75 percentage - Pars planitis.

## Clinical features

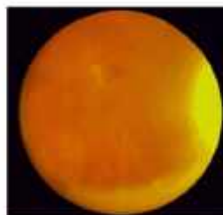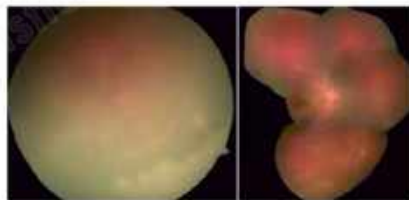- Blurring of vision.
- Diminution of vision.
- Floater.

## On examination

- Retrolental flares- Inflammatory cells behind lens.
- Few KP's
- Snowballs- Inflammatory exudate floating in vitreous.



- Snow banking**, (Pathognomonic feature,) - Inflammatory fibrovascular plaque/membrane on pars plana generally seen inferiorly.



Snow banking

- Periphlebitis (Inflammation of veins)

## Investigation

- Ocular: USG B scan, OCT, FFA for CME.
- Systemic: Hemogram, LFT, KFT, Chest X ray, - for TB, sarcoidosis Blood sugar, HIV, VDRL, CT scan, MRI for brain and spinal cord.



### Treatment

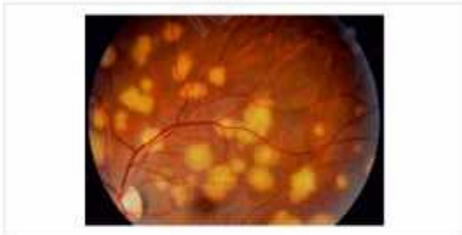- In mild cases it is self-limiting.
- Indications of treatment: vision less than 6/12.
- **4 step approach/Step ladder approach**
  - **Step 1. Local steroids**
    - Sub tenon Injection of Triamcinolone acetonide.
    - Intravitreal steroids: Intravitreal Triamcinolone acetonide - high IOP. Slow release by Intravitreal implants loaded with Dexamethasone is given to prevent rise of IOP.
  - **Step 2. Systemic steroids:** Tapering dose of Prednisolone.
  - **Step 3. Immunosuppressive therapy:** Methotrexate, Cyclosporine, tocilizumab in children, Adalimumab.
  - Cryotherapy is given in snow banking area, to damage its blood supply. But the side effect is retinal detachment.
  - **Step 4. Pars plana vitrectomy helps to manage complications like RD, vitreous hemorrhage.**
    - It decreases the bulk of inflammation.
    - After PPV, patient starts responding to steroids.
- **Modified Kaplan approach: 5 steps.**
  - Step 1. Local steroids.
  - Step 2. Systemic steroids.
  - Step 3. Immunosuppressive.
  - Step 4. Laser or cryotherapy for peripheral retina.
  - Step 5. PPV.

### Posterior uveitis/Retinochoroiditis/Chorioretinitis

100/54/44

#### Components

- Choroiditis



- Retinitis
- Retinal vasculitis
  - **Periphlebitis (most common)**
  - Peri arteritis.
- Retinal vasculitis causes perivascular cuffing, hemorrhage.

#### Etiology

- **Infectious:** Bacterial - TB, Syphilis
  - Parasitic - Toxocariasis, Toxoplasmosis,
  - Viral - HSV, HZO, HIV.
- **Non-infectious:** Sarcoidosis, VKH syndrome, Sympathetic ophthalmitis, Multiple Evanescent White-dot Syndrome.

### Investigation

- **Ocular:** USG B scan, OCT, FFA
- **Systemic:** Hemogram, LFT, KFT, Chest X ray, Blood sugar, HIV, VDRL, CT scan, MRI for brain and spinal cord.

### Treatment

- Local steroids.
- Systemic steroids.
- Immunosuppressive according to the etiology agent.

### Diseases Associated with Uveitis

01/01/47

#### Arthritis associated with Uveitis

- HLA B 27 positive and Seronegative: RF negative
- Type: Non granulomatous anterior uveitis.
- Chronic uveitis: Juvenile rheumatoid arthritis or juvenile idiopathic arthritis.
  - Juvenile idiopathic arthritis means age < 16 years
- **Types of juvenile idiopathic arthritis**
  - **Pauci articular:** Less than 4 joints involved.
  - **Polyarticular:** More than or equal to 4 joints involved.
  - **Systemic onset/ Still's disease.**
- **Types of Pauci articular Arthritis**
  - Type I - early onset,
  - Type II - late onset.

- **Type I/ Pauciarticular/ seronegative JRA is associated with uveitis**
- **Type II/ Pauciarticular/ seronegative JRA**
  - **Most common in girls**
  - ANA positive
  - RF negative
  - This condition is also known as **white Uveitis** because no redness present.
  - Atypical presentation of anterior uveitis
- **Examples of acute anterior uveitis.**
  - Ankylosing spondylitis.
  - Reiter's syndrome.
  - Psoriatic arthritis.

#### Reiter's syndrome

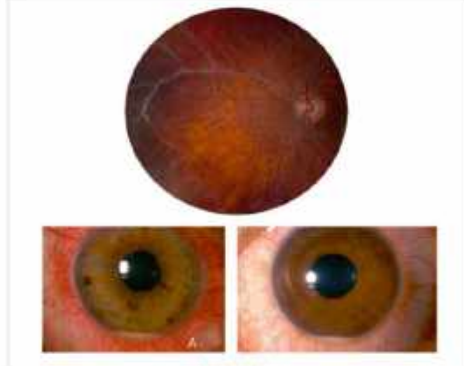
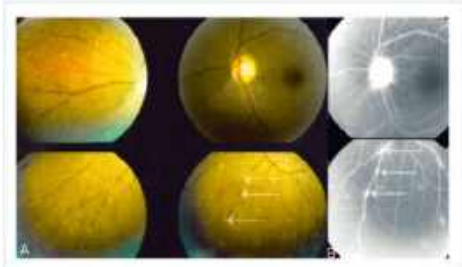
- **Triad of Reiter's syndrome**
  - **Urethritis.**
  - **Arthritis.**
  - **Conjunctivitis.**
- Other ocular features of Reiter's syndrome are Acute anterior uveitis, Scleritis, Episcleritis.
- It is precipitated by Shigella, Salmonella, campylobacter, and chlamydia infections.

#### Ankylosing spondylitis

- **Ocular features:** Acute anterior uveitis(main), Scleritis, Episcleritis.

### Sarcoidosis

- It is a non-caseating granulomatous inflammation primarily involves lungs.
- **Ocular features**
  - Sarcoid nodules on sclera or episclera
  - Interstitial keratitis
  - Band shaped keratopathy because of hypercalcemia.
  - Uveitis: Granulomatous pan Uveitis.
  - Candle wax dripping: Segmental or nodular periphlebitis. (Important feature)
  - Venous sheathing - Feature of peri phlebitis.



### Uveitis in bowel disease

- Ulcerative colitis (Most common): Present with episcleritis, scleritis, conjunctivitis and AAU (non granulomatous AU)
- Crohn's disease.
- Whipple's disease.

### Uveitis associated with renal disease

- TINU: Tubulo interstitial nephritis with uveitis.
  - Type: B/L non granulomatous anterior uveitis.

### Viral uveitis

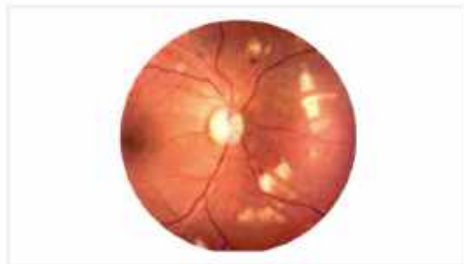01:33:30

- HIV
- Herpes
- HIV
  - Most common ocular feature HIV induced microangiopathy.
    - Hemorrhages.
    - Micro aneurysm (< 100 micron)
    - Soft exudates: Axonal debris (most common).
    - Hard exudates - Leaked lipid.

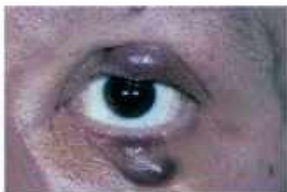- Lander's sign: Pre retinal (Posterior hyaloid membrane of vitreous and retina)
- Heerfordt syndrome: Sarcoidosis with Uveo-parotitis.
- Lofgren syndrome: Sarcoidosis with. Anterior uveitis, Bilateral hilar lymphadenopathy, Erythema nodosum.

### Behcet's disease

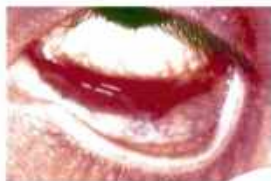- It is an Autoimmune disease.
- Obliterative vasculitis due to circulating immune complexes.
- C/F: Ulcers in mouth, genital ulcers, positive skin test and eye involvement.
- Also known as transient hypopyon syndrome.
- Type of uveitis-non granulomatous pan uveitis.
- HLA association: HLA-B5, HLA-B51
- Generally, it is relapsing and repeating condition with spontaneous recovery without treatment.



- Other ocular features
- In lid
  - Kaposi sarcoma.

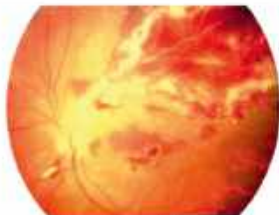

- Blepharitis - Inflammation of lid margin
- Multiple Molluscum.
- HZO
- In conjunctiva
  - Kaposi sarcoma



- Squamous cell carcinoma.
- In cornea
  - HZO keratitis
  - HSV keratitis
  - Fungal keratitis
  - Kerato Conjunctivitis Sicca
- In iris
  - Anterior uveitis
- Microangiopathy: Asymptomatic and disappears by itself. It is associated with decreased CD4 count.
- In orbit
  - Orbital cellulitis (aspergillus)
  - B cell lymphoma.
- Opportunistic infection of HIV.
- 1. **Most common CMV retinitis.**

→ Features of CMV retinitis : pizza margarita appearance, hemorrhages, sauce and cheese retinopathy



Sauce + Cheese Retinopathy

- CMV retinitis strongly associated with low CD 4 count.
- Other features of CMV retinitis are vitritis, arthritis, Optic neuritis.

2. Pneumocystis carinii/ cryptococcal choroiditis.
3. HZO causes acute retinal necrosis
4. Protozoal infection: Toxoplasmosis

#### • Treatment

- Anti-retroviral therapy
- MC ocular side effects of HAART is immune recovery uveitis.
- Vitritis is most common type of immune recovery uveitis.
- Intravitreal ganciclovir implant or oral ganciclovir.
- Steroids for immune recovery uveitis.

#### HERPES

- Acute retinal necrosis.
  - Caused by VZV in adults
  - Caused by HSV in young
- Pan uveitis with peripheral retinal necrosis.
- **Treatment**
  - Acyclovir—oral
  - Oral valacyclovir
  - Intravitreal ganciclovir
  - Steroids under antiviral cover- in severe cases
- Anterior uveitis caused by HSV or VZV.
  - **Features:** Sectoral iris atrophy, hyphema, stellate Kps.
  - **Treatment:** Topical steroids, topical cycloplegics, oral antivirals.

#### Bacterial uveitis

01/09/20

- TB
- Syphilis
- Leprosy

#### TB

- It causes granulomatous pan uveitis.
- Most common ocular feature of TB – Uveitis (Koeppel's nodules)
- Most common allergic manifestation of TB – Phlyctenular keratoconjunctivitis

## Syphilis

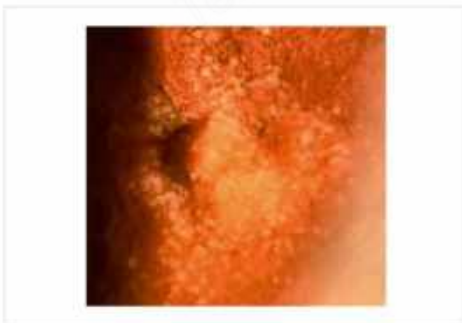
- It can present either as anterior uveitis or posterior Uveitis in secondary syphilis.
- That can be either granulomatous or non-granulomatous.
- **Typical finding of syphilis is Iris roseola.**
  - Iris roseola: Dilated capillaries which develops into nodules.



- Posterior uveitis causes chorioretinitis and it appears as salt and pepper fundus.
- Treatment: Penicillin

## Leprosy

- Seen in lepromatous infection.
- Ocular features are due to direct bacterial infiltration.
- It causes chronic granulomatous anterior uveitis.
- Pathognomonic feature of Leprosy is iris pearls. (size < 0.5mm)
- Iris pearls mainly contains bacteria.



- **Other features:** Thickened corneal nerves; decreased corneal sensation, iris atrophy, retinal pearls, scleritis, and episcleritis, madrosis (cause of loss of lateral 1/3rd of eye) 7th nerve palsy - Lagophthalmos.
- **Treatment**
  - Systemic: Dapsone or Rifampicin
  - Anterior uveitis: Topical steroids.



## Important Information

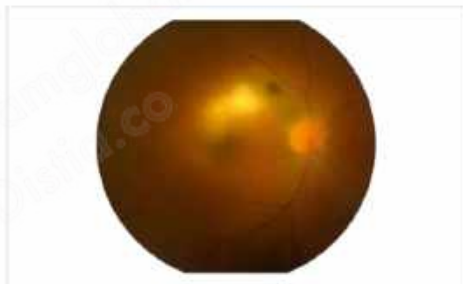- Leprosy cause madrosis
- Leprosy can also cause 7th nerve palsy, resulting in lagophthalmos.

004938

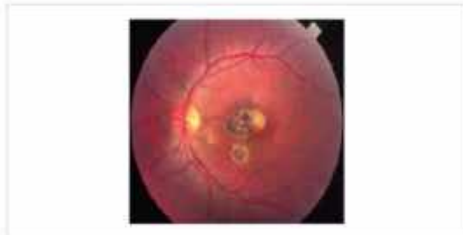## Parasitic uveitis

### • Toxoplasmosis Gondii

- Definitive host: Cat
- Intermediate host: Human
- Person can get infected from fecal matter of cats.
- Ocular features: granulomatous or non-granulomatous uveitis.
- Primarily it is posterior uveitis then spreads to anterior.
- In active inflammation headlight in fog appearance is seen due to intense vitritis.



- On healing, it mainly involves the macular area.

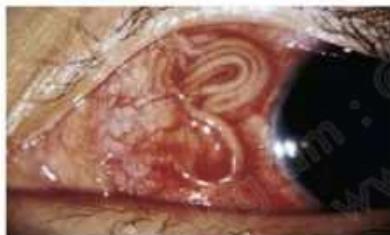
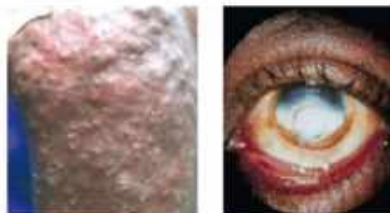
- On healing, there is punched out lesion with pigmented margins.
- **Treatment**
  - Triple therapy: Pyrimethamine + Sulfadiazine + Cindamycin.
  - Steroids under the cover of the above drugs.
  - Intravitreal Cindamycin with dexamethasone.

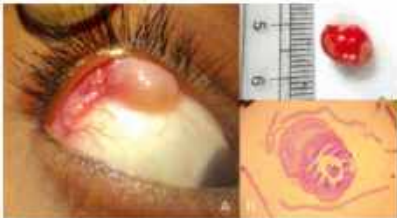### • Onchocerciasis

- Oncoerca volvulus nematode.
- It is also known as river blindness.

- Caused by vector black fly (*Simulium*) present near river.
- It is not a disease of India.
- It causes non granulomatous, either anterior or posterior uveitis.
- Cause of blindness is sclerosing keratitis.
- Cornea becomes opaque like sclera.
- **Treatment:** Ivermectin (only kills the microfilaria)- TOC
- Prophylactic steroids to control inflammation.
- IV Suramin is effective against adult worm.
- Mazzotti reaction - Severe inflammation leading to life threatening complications.



- **Cysticercosis**
  - Caused by **Caused by cysticercosis cellulosae** -- larvae of *Taenia solium*.
  - Cysticercosis calcifies - one of the causes of intraocular calcification.
  - It affects eyes, muscles, and brain.
  - Eye involvement - Conjunctival cyst.



- Cyst in anterior chamber- Free floating.
- Intense vitritis.

- Cyst and larvae in sub retinal space.
- Cyst can also present in extraocular muscles. **MC in superior rectus muscle.** Leads to pain, swelling and restriction of movements.
- **Treatment:** systemic steroids for inflammation.
- Albendazole under steroid cover.
- Surgical removal of cyst.

#### • **Toxocariasis**

- **Mo ocular parasitic infection of children**
- D/D of leukocoria
- Caused by *Toxocara Canis* (round worm of dogs).
- It causes anterior uveitis, Posterior uveitis (mainly chorioretinitis), chronic endophthalmitis (leads to leukocoria and strabismus) and vitritis.

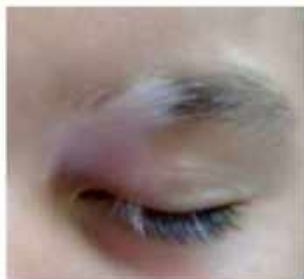#### **Vogt Koyanagi Harada Syndrome**

02.02.20

- It is **idiopathic autoimmune disease**.
- Inflammation of the melanocyte containing tissues.
- It primarily involves Uvea, ear, and meninges.
- It causes granulomatous pan uveitis.

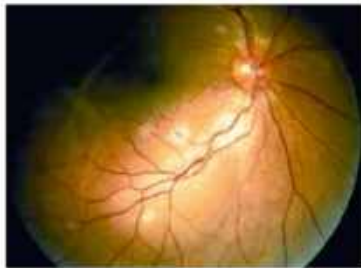
#### **Systemic features**

- Encephalitis.
- Vestibular dysfunction.
- Tinnitus.
- Alopecia.
- Vitiligo.
- Poliosis- Greying of eyelash.



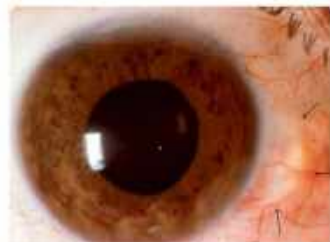#### **4 phases of VKH syndrome**

- **Phase I: Prodromal phase.**
  - Presents with neurological and auditory manifestations.
- **Phase II: Acute uveitis phase.**
  - Presents with granulomatous pan uveitis.
  - In posterior uveitis later it leads to exudative retinal detachment.

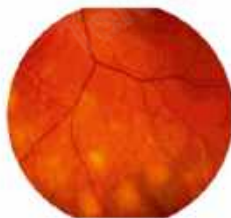

• **Phase III: Convalescent phase.**

- Perilimbal depigmentation k/as **Sugriva's sign**



- Choroidal depigmentation k/as **sunset fundus**



• **Phase IV: Chronic recurrent phase**

- It manifests as anterior uveitis

**Treatment**

- IV methylprednisolone
- Then shift to oral steroids
- In steroid resistant cases we use **infliximab**.



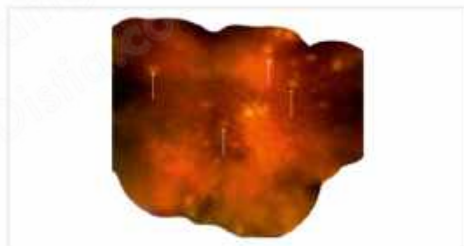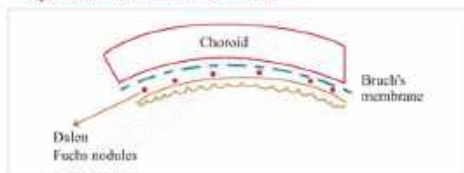
**Important Information**

- Uveitis associated with encephalitis is seen in **VKH syndrome**.

**Sympathetic Ophthalmitis**

02.09.07

- Injury in one eye causes uveitis in the other eye k/as **sympathetic ophthalmitis**
- It is caused by **perforating injury**.
- Traumatized eye is known as exciting eye and the other eye is known as sympathizing eye.
- This is due to autoimmune reaction towards uveal tissue.
- Antigen responsible is **retinal S antigen**.
- **Duration:** It never appears before 2 weeks. Maximum chances are that it manifests between 2 weeks to 3 months.
- It causes of **granulomatous pan uveitis**.
- **Dalen Fuchs nodules** are present between retinal pigment epithelium and bruch's membrane.



- **Sunset glow fundus** due to chorio-retinal scarring in SO.
- First sign in SO is **Retrolental flare**.
- First symptom in SO is **Difficulty in near vision or decreased accommodation**.
- Dangerous area of eye is **ciliary body**.
- Any trauma to ciliary body is big risk for sympathetic ophthalmitis.

**Treatment**

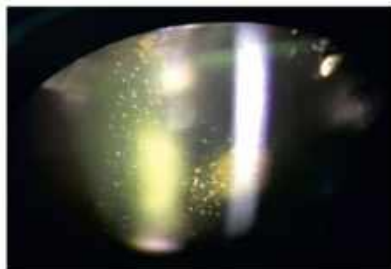
- High dose of oral steroids to prevent the sympathetic ophthalmitis in other eye.
- Anterior uveitis: Topical steroids are used.
- For high risk - Early immunosuppressive therapy.
- If traumatized eye is irreparable & eye needs to be removed.
- Never do enucleation.
- On scooping, uveal tissue is left behind so autoimmune reaction may happen and eye cannot be saved.
- If we need to remove the injured eye always do **enucleation**.
  - Enucleation means the removal of an eyeball with maximum part of optic nerve.

### Fuchs Heterochromatic Cyclitis

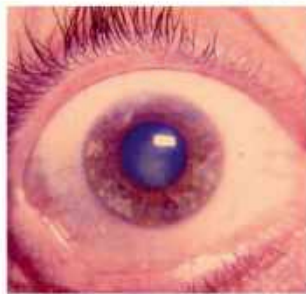- Heterochromia iridis - Different iris color
- Involved eyes is hypochromic.
- It is unilateral.
- It is chronic non granulomatous uveitis. Primarily involves anterior uvea and may also involves posterior uvea.

#### Clinical features of anterior uveitis: atypical

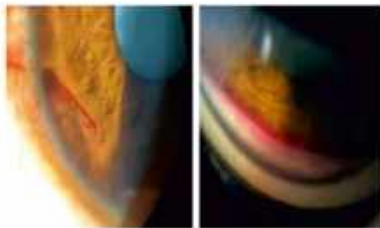
- No pain, redness, photophobia
- On examination - Stellate KPs with feathery ends



- Russel bodies
- Diffuse iris atrophy. Therefore, no posterior synechiae.



- Heterochromia iridis
- Posterior subcapsular cataract. (MC)
- Exposed iris blood vessels.
- Bleeding in angle during paracentesis on gonioscopy k/as Amsler's sign.
- Treatment - No role of steroids or cycloplegics
- Aim - to manage complications.



**Complication:** Secondary Glaucoma

#### Complicated cataract

##### Posterior uveitis findings

- No CME
- Generally, present with peripheral choroiditis.
- Retrolental flare present.

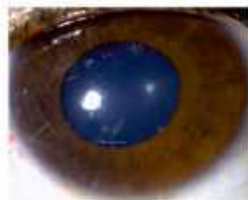

#### Important Information

- IOL is contraindicated in JRA because it will aggravate the inflammation.
- IOL is tolerated in Fuchs Heterochromic Cyclitis

### Ophthalmia Nodosum

02:24:30



- It is intense granulomatous inflammation with a very big nodule on the iris
- It occurs due to caterpillar hair in the eye.



## PREVIOUS YEAR QUESTIONS



Q. Iritis is seen in all except?

A. SLE

**B. Rheumatoid Arthritis**

C. Behcet's disease

D. Psoriatic arthritis

E. Ulcerative colitis

(INICET NOV 2020)

Q. Which out of them is a prerequisite for development of sympathetic ophthalmitis?  
(NEET JAN 2020)

**A. Penetrating trauma to eye**

B. Blunt ocular trauma

C. Chemical

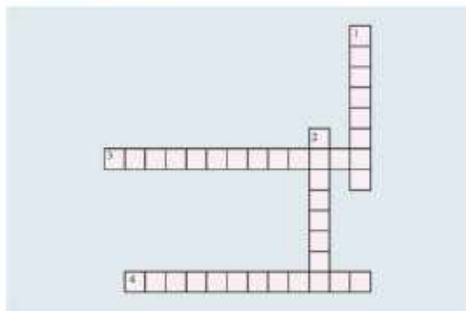
D. Infection

Telegram: @teanglobalchat  
www.Distia.co





## Crossword Puzzle 1



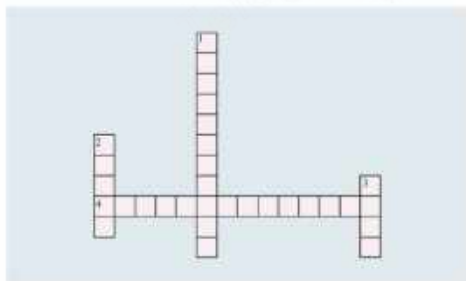
### Across

- Retina is derived from \_\_\_\_\_.
- \_\_\_\_\_ is the condition in which eyes are not formed

### Down

- Any failure in the closure of the choroidal fissure leads to a form of \_\_\_\_\_.
- Primary vitreous is derived from \_\_\_\_\_.

## Crossword Puzzle 2



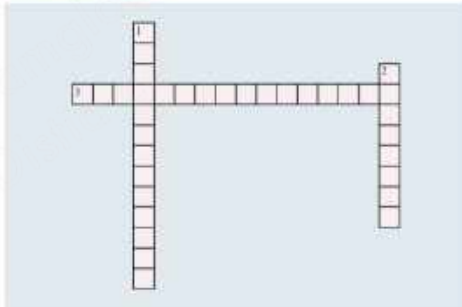
### Across

- Myelination of the optic nerve starts with the lateral geniculate body till \_\_\_\_\_.

### Down

- Formation of the eye starts with the thickening of \_\_\_\_\_.
- Optical nerve hypoplasia is a condition in which the size of the disc is \_\_\_\_\_.
- \_\_\_\_\_ gene plays important role in the development of the eye

## Crossword Puzzle 3



### Across

- Optic stalk has got a gap and this gap is called \_\_\_\_\_.

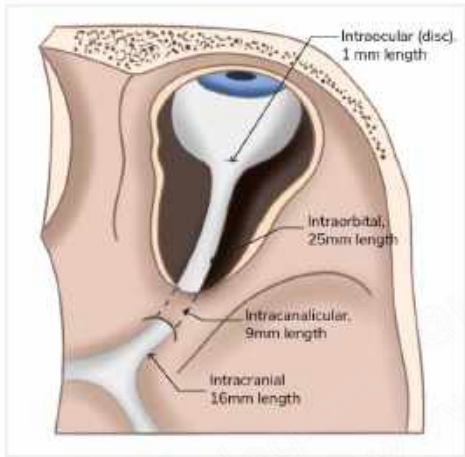
### Down

- Optic nerve is derived from \_\_\_\_\_.
- Temporal parts of sclera are derived from \_\_\_\_\_.

Four parts of the Optic Nerve

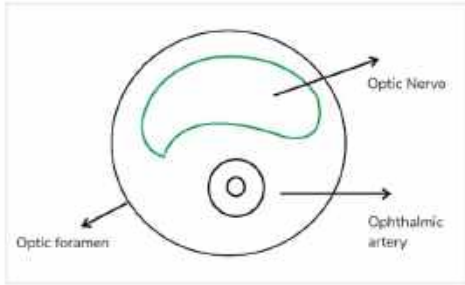
1. Intraocular
2. Intra-orbital
3. Intra-canalicular
4. Intracranial

000009



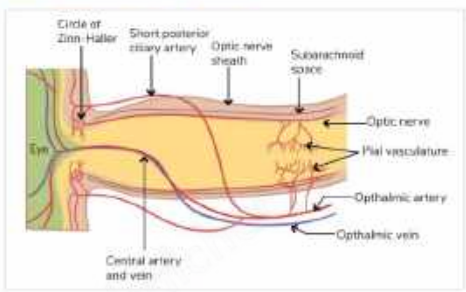
Optic Foramen

000026



- What are the structures passing through the optic foramen?
  - The two main structures that pass through the optic foramen are the eye's main nerve and the eye's main artery
    - Optic nerve
    - Ophthalmic artery

Blood Supply of the Optic Nerve



- The blood supply of the optic nerve can be divided into two sources:
  - The circle of **Haller and Zinn**: This is an anastomosis of short posterior ciliary arteries. There are around 15-20 of these.
  - The second source is the **central retinal artery**. This artery enters 1 cm behind the optic disc. This supplies the inner 6 layers.

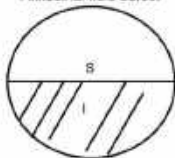
Optic Nerve Dysfunction

- Optic nerve dysfunction can also be called **optic nerve disease**.
- It is thus described as a pathological condition of the optic nerve, where **nerve impulse transmission is hampered**.

Clinical feature optic nerve dysfunction

1. Decreased visual activity.
2. Relative Afferent Pupillary Defect (RAPD)- First sign of optic nerve disorder.
3. Dyschromatopsia (Affected colour vision)
4. Decrease in brightness.
5. Decreased contrast sensitivity is also observed.
6. Visual field defects. Visual field defects can be of the following type:
  - **Central scotoma**: It is the most common type of scotoma because the macular fibres are more sensitive to the damage.
  - **Centrocecal scotoma**: The scotoma that involves both the disc and the macula.
  - **Altitudinal field defect**: This is when either the superior or the inferior field is affected. The diagram below shows that the inferior field is affected.

Altitudinal field defect



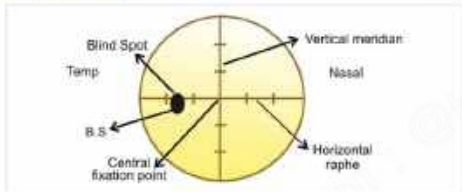
## RAPD

### Relative Afferent Pupillary Defect (RAPD)/Marcus Gunn Pupil.

- Thus, in such a case, the initial reaction is normal. It is only when the comparison begins that one can see the defect.
- It is therefore considered relative and to be an early sign of optic nerve disease.
- This is also called the **Marcus Gunn Pupil**.
- It is tested by a **Swinging Flashlight Test (S.F.T)**.

## Field Charting

00:14:27



- This shows a **Field Chart of the Left Eye**.
- The retinal coordinates and the field coordinates are opposites.
- Thus, when talking about the left eye, the disc will be nasal, the macula will be temporal, and it will become the opposite on the field chart. The disc will become temporal, hence it is a field chart of the left eye.

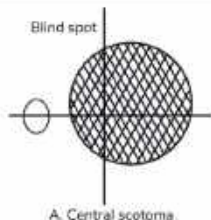


## Important Information

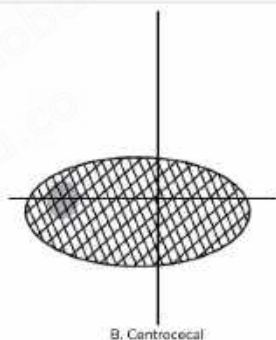
- Whenever a field chart is being talked about, one is to picture that the patient is seated beside. Thus, the orientation of the field chart of the doctor and the patient remain the same.
- **Blind Spot**
  - It is an **absolute type of scotoma**. In any condition, even if the target size or the illumination is changed, it is not possible to see any object because it corresponds to the optic disc. For these reasons, the blind spot is considered to be an absolute scotoma. A relative scotoma is when one is able to see in special conditions, which is not the case here, hence absolute.
  - Positive means if there is a black patch in front of the eye in case of a blind spot. However, if one does not see

anything that is just blank or empty, it is called negative. The **blind spot is an absolute negative scotoma**.

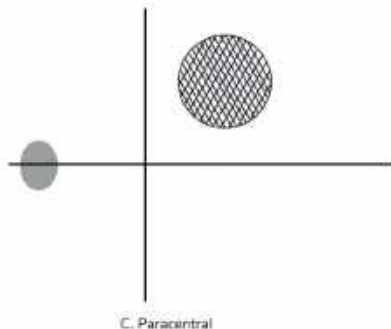
- In optic neuropathy, central scotoma is when the central 30-degree area is infected. It involves central fixation.

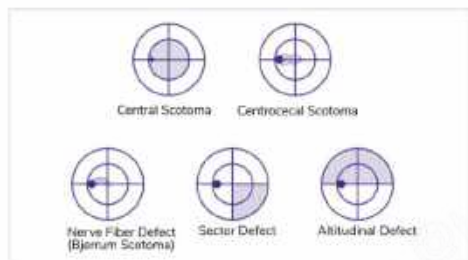
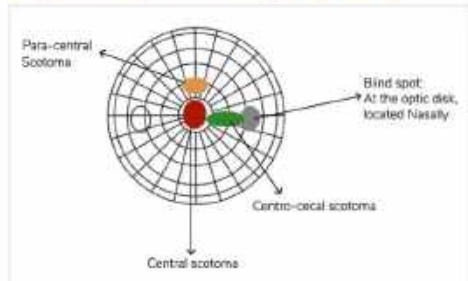


- As for the centrocecal scotoma, it is observed that the scotoma exists in the blind spot as well as in the macula.

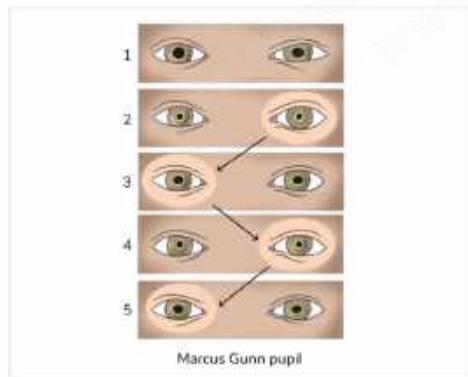


- When the scotoma is a little away, it is known as a **para-central scotoma**.





**Relative Afferent Pupillary Defect (RAPD)**



- It is also known as the Marcus Gunn Pupil.
- The arrows here depict the torchlight swinging from one eye to the other.
- The pupil constricts when the torch is on the left eye. When the torch is then shifted to the right eye, no constriction takes place. When it is back to the left eye, there is constriction again. No constriction is then again observed when it is back to the right eye.

- Optic neuropathy can be broadly classified as
  - **Inflammatory**  
→ Inflammation can be a cause of optic nerve disease. This is usually called optic neuritis.
  - **Glaucomatous**
  - **Ischemic**
  - **Hereditary**
  - **Nutritional or Toxic**  
→ Toxicity amounts from drugs, which can cause optic toxicity.
  - **Disc Oedema**
  - **Papilledema**  
→ This condition is caused due to increase in intracranial tension.
  - **Traumatic Optic Neuropathy**

**Optic Neuritis**

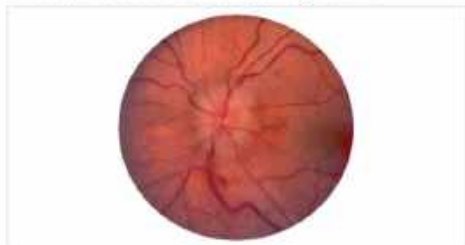- Optic neuritis is a optic nerve disease. The features are decreased visual activity, RAPD, Dyschromatopsia, decrease in brightness, decreased contrast sensitivity, nerve fibre bundle defect, and visual field defects.

**Classification of Optic Neuritis**

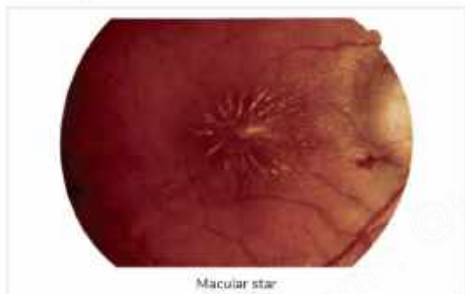
**A. Anatomical type**

- This can further be of three types.
  1. **Papillitis** 00:24:45
    - Papilla is the optic disc, there is a blurred disc margin due to leakage and increased capillary permeability.
  2. **Retrobulbar neuritis**
    - Bulb means the eyeball. Retrobulbar means behind the eyeball.
  3. **Neuro-retinitis**
    - Here the optic nerve is involved but along with the papillitis, the macular area and the retina are also involved.
    - Thus neuro-retinitis is papillitis with macular star.
- However, for retrobulbar neuritis, no fundus changes are visible. This is because the fundus is normal. There is decreased visual capacity, RAPD, and all the other features that are specific to nerve disorders.
  - a. RAPD
  - b. Pain on eye elevation due to SR
  - Superior rectus fibres are originating from the annulus of Zinn. The annulus of Zinn is the tendinous ring crossing the superior orbital fissure. Some fibres are attached to the Myelin Sheath of the optic nerve.

- The below picture shows papillitis. In retrobulbar neuritis case, this would have looked absolutely normal.



- Below picture elaborates the condition of neuro-retinitis.



#### B. Etiological type

00:29:38

- Etiologically, optic neuritis (that is the inflammatory type) can be divided into the following types:
  - Demyelinating disease
    - Demyelinating disease happens when there is a loss of myelin sheath.
  - Para-infectious
    - Para-infectious can be defined as viral infections in children or after immunization. This is accompanied by spontaneous recovery.
  - Infectious
    - Syphilis or Herpes Zoster.
  - Non-infectious
  - Non-infectious - all auto-immune diseases like SLE or PAN come under this type.

#### Demyelinating diseases

- There is loss of myelin sheath

#### Pathogenesis of Demyelinating disease:

- There is a loss of myelin of the nerve fibre, due to phagocytosis by macrophages and the microglial cells.
- So, the astrocytes are going to cause the lay down of the fibrous tissue which looks like plaques.

- When there is plaque formation, the nerve conduction is disturbed.
- Involving the visual system, the three main types:
  - Multiple sclerosis
  - Devic's Disease / Neuromyelitis Optica (NMO):
    - Here, the optic nerve is involved, and the spinal cord is involved. This is optic neuritis with Transverse myelitis.
  - Schilder's disease:
    - This disease is progressive in nature with no improvements involving the optic nerve and optic tract. It is thus defined as **optic neuritis without improvement**.

#### Multiple sclerosis

- This disease is not progressive in nature and the vision improves after some time.
- It is usually seen in middle aged women.
- It is idiopathic and it involves the central nervous system white matter.

#### Clinical features

- Ocular manifestations
  - Optic neuritis- Retrobulbar neuritis (Main presentation)/ Papillitis or Neuroretinitis
  - Inter nuclear ophthalmoplegia- lesion of the medial longitudinal fasciculus
  - Nystagmus
  - Patients suffering from multiple sclerosis will first complain about the decrease in visual acuity. It can be anything around 6/18 to 6/60.
  - RAPD, decreased colour sensitivity.
  - Along with these features, there is also the presence of pain and discomfort around the eyes.
  - Signs: The visual field defect, such as central scotoma, centrocecal, and altitudinal scotoma, can all be present.
  - After the condition worsening for about two-three weeks, it starts to improve. The vision is then recovered to around 6/9.
- Uhthoff's phenomenon.**
  - This is when there is a worsening of visual symptoms after exercise.
- Pulfrich's phenomenon.**
  - This happens when the nerve conduction speeds of the two eyes are different, and there is a discrepancy. Because of this discrepancy, there are some difficulties, such as difficulty in stereopsis. This can be experienced during daily activities like driving, catching a flight, and any such activity that needs three-dimensional vision.
- Hermitte's sign** is a condition that is unrelated to the eye. For multiple sclerosis patients, it's the electrical sensation on neck flexion.

## • Treatment of Multiple Sclerosis

00:41:55

- The indication of treatment is that only when the patient is having a visual acuity of less than 6/12 in the first week of the disease. The treatment is started with steroids
- Give a bolus dose of IV Methylprednisolone (the dose here should be 1gm daily). for three days.
- Oral steroids for the next 11 days (the dose should be 1mg/kg/day), these have to tapering doses.
- When the patient is not responding to steroids, i.e., steroid resistant, Give methotrexate.
- Newer modalities can involve the following:
  - a) Interferon beta-1a
  - b) Glatiramer acetate, an immune modulator
  - c) Monoclonal antibodies include natalizumab and alemtuzumab. Monoclonal antibodies are very helpful in cases of relapse.

## Ischemic optic neuropathy

00:45:06

- If this involves the papilla and causes papillitis type of a picture, it is called anterior ischemic optic neuropathy (AION). This is named so because it involves the optic disc.
- If it does not involve the disc and has more of a retro-bulbar pattern, it is called posterior ischemic optic neuropathy (PION). This type is primarily retro-bulbar.
- Whenever there is ischemia, there is blockage of the blood supply from some arteries.
- The arteries that are blocked in the posterior ischemic optic neuropathy (PION), are mostly the Pial branches. These are direct branches from the ophthalmic artery. These pial branches or capillary plexus is causing ischemia of the retrolaminar part of the optic nerve.

00:50:27

## • AION

- It is due to the **blockage of the short posterior ciliary artery** which is supplying the outer four layers and the choroid.

## Anterior Ischemic Optic Neuropathy (AION)

00:56:14

- Anterior ischemic optic neuropathy (AION) can be arteritic or non-arteritic.
- The etiology of the arteritis is giant cell arteritis.
- However, for non-arteritic, the cause is unknown. The major risk factor is hypertension. People with long-standing hypertension, have fluctuation of blood pressure. These patients can suffer from nocturnal hypotension. This in turn causes ischemia in patients.

## Other risk factors

- If there is a small eye and a small disc, there is a small C/D ratio, it is like a compartment syndrome.

## • Presentation in Arteritic AION

### ○ Ocular Presentation:

1. Decreased visual acuity, leading to sudden but painful and diminished vision. Generally, the patient complains of pain around the eyes. This could be due to arteritis even if it may not be due to ischemia or optic neuritis
2. Relative Afferent Pupillary Defect (RAPD).
3. Decreased brightness and dyschromatopsia.
4. Decreased contrast sensitivity.  
→ **The visual field defects in ischemic is always altitudinal.**  
→ Short posterior ciliary arteries have segmentation and supply in a segment form. When it blocks, initially it can be seen on the disc that superior or inferior margin is blurred. The field defect is altitudinal.

### ○ Systemic presentation

- Jaw claudication
- Temporal tenderness
- Headache

### ○ Investigation

- Raised ESR
- Raised CRP

### ○ Examination of the fundus

- **More white and pale due to ischaemia**
- **Blurred disc margin**

## • Presentation in Non-arteritic AION

00:56:28

### ○ Presentation: Primarily due to nocturnal hypotension

- Sudden diminution of vision, but painless
- Visual acuity is slightly reduced (usually seen in the morning after waking up)
- Along with all the features of optic nerve disease (decreased colour sensitivity, decreased brightness sensitivity, and all the optic nerve functions).
  - **Altitudinal field defect.**
- Compartment syndrome - Thus it is very important to observe the other eye and see the fundus.

### ○ Examination of the fundus

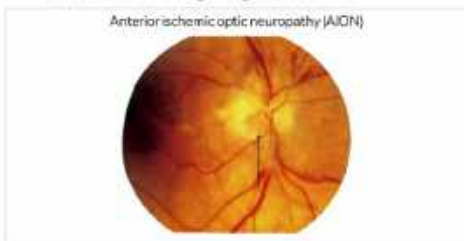- In non-arteritic, the disc is generally hyperaemic with a blurred margin. Though there is ischemia there is a hyperaemic disc (paradox).



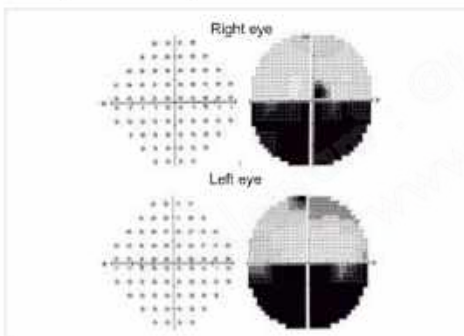
## Important Information

- Amaurosis fugax: This is the transient loss of vision. This means that the vision that is gone will come back. This happens in a curtain-like manner. The patient will first complain that there is loss of vision in the superior field, and will gradually not be able to see the central and then the inferior field. When the vision gets back, the inferior comes first, then the central, and lastly, the superior- as if the curtain is down and then up again.
- It is seen in arteritic AION

- **Treatment** 01/00/08
  - IV steroids given for a period of 3 days, followed by tapering doses of oral steroids, which can be tapered up to the next 3 days.
  - Steroids are given even when there is no inflammation because it is reducing vasogenic oedema.



- There is oedema but the margins are not visible initially in the upper and lower parts. Slowly it becomes blurred everywhere but initially it is segmented.

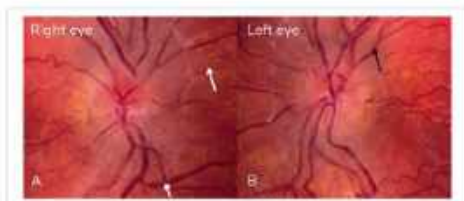


- It is an altitudinal field defect.

### Hereditary Optic Neuropathy 01/00/97

- Leber's Hereditary Optic Neuropathy (LHON).
- Miscellaneous
- **Leber's Hereditary Optic Neuropathy (LHON)**
  - It is a genetic disease. The mutation is in maternal mitochondrial DNA.
  - **Clinical Features**
    - The patient presents with all the signs of optic nerve dysfunction in one eye.
    - If it started in the right eye. Thus all the features of optic nerve disease can be seen in the right eye, followed by the left eye.
    - Then there is optic atrophy in the right eye, followed by the left eye. This progress cannot be stopped, and it is all genetically controlled.

- **Variations in LHON**
  - RAPD is absent
  - Pupillary reactions are normal
  - Telangiectatic vessels in and around the optic disc.
  - Thickening of the retinal nerve fibre layer around the disc which is called pseudo-oedema.



- Here, the white arrow shows what pseudo-oedema is. The black arrows show the new blood vessels, which are permanently dilated.

### Miscellaneous Hereditary Optic Neuropathy

- Kjer type
- Behr Syndrome
- Wolfram Syndrome: Diabetes insipidus, Diabetes mellitus, Optic atrophy, and Deafness (DIDMOAD).

### Nutritional or Toxic Optic Neuropathy 01/06/25

- This was called Toxic Amblyopia which is a partial loss of vision due to drugs.
  - The field defect here is centrocecal. It is the cyanide element in tobacco that is causing all the damage.

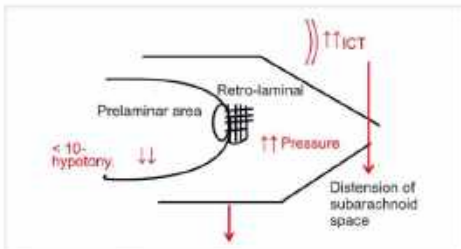
  - Tobacco
  - Ethambutol
  - Isoniazid.
  - Chloroquine.
  - Ethyl alcohol.
  - Methyl alcohol.
    - Methyl alcohol is more dangerous as it causes very acute damage in very little time. It directly damages the ganglion cells.
    - In case of ethyl alcohol, the damage is chronic. The person is not eating anything but is drinking. This causes vitamin B 12 deficiency which leads to optic nerve disease or optic neuropathy.
    - Hydroxocobalamin supplements, Injectables or oral, is the treatment of choice.
    - In ethyl alcohol damage, all the B vitamins- B1 or thiamine, B2 or riboflavin, B6 or pyridoxine, B3 or niacin are deficient and hence lead to optic neuropathy. Folic acid deficiency is also observed.
  - vigabatrin
  - This causes constriction of the visual field.
  - Digitalis

## Chloroquine

1. It causes **posterior subcapsular cataract**.
2. It can lead to optic neuritis.
3. It can affect the macula, causing a maculopathy that looks like a bull's eye, which is why it is called **bull's eye maculopathy**.
  - If you look at the retina, there are alternate areas of hyper and hypopigmentation. Hypo means retinal pigment epithelial atrophy. Darker colour means pigmentation.
  - Some other causes of bull's eye maculopathy are hydroxychloroquine, cone dystrophy, and Batten-Mayo syndrome. The Batten Mayo syndrome is a Cerebro-macular degeneration.
4. Vortex keratopathy, the drug is deposited in a whorl-like manner. It is also called **Cornea verticillata**.

## Disc Edema

- Thus disc oedema means any oedema around the disc. When this happens due to increased ICT, it is called papilloedema.
- **Clinical features:**
  - Visual acuity is normal and therefore vision is not diminished. However, there may be some transient blurring of vision.
  - Pupillary reactions are normal.
  - Colour and brightness are normal.
  - Contrast sensitivity is normal.
  - Visual field defect
    - Oedema around the disc looks like enlargement of the blind spot. Gradual pressure by the this oedema will cause damage to optic nerve, which leads to constriction of visual field.
- Examination:
  - The first sign papilloedema or disc oedema is **venous dilatation**.
  - There is a blurring of the disc margin.
- **Patho-physiology**
  - Any decrease in pre-laminal pressure or any increase in pressure in the retro-laminal area.
  - This causes an imbalance of pressure.
  - distension of the sub retinoid space.



- This disturbance in the pressure gradient in the lamina cribrosa will lead to axoplasmic stasis. This means that there will be swelling of axons, which will in turn, cause pressure on veins.
- The veins will be dilated and there will be leakage.

## • Etiology

### 1. Intra-ocular Cause

- Any cause of hypotony. Pressure will be less in the eye when eye suddenly opens due to trauma, surgery, or in the case for chronic uveitis. Chronic uveitis can lead to ciliary shut down.

### 2. Intra-orbital Cause

- There is more pressure in orbit.
- Tumours, inflammation (also called pseudo-tumour in orbit) or even thyroid eye disease (TED). Any of the causes where the pressure is more in the orbit can lead to disc oedema.

### 3. Intra-cranial Cause

- Increased intra-cranial tension. It is called papilloedema. More pressure around the brain can be caused by encephalitis, meningitis, any abscess or space-occupying lesion.
- **Idiopathic intracranial hypertension (IIH)**.

- This is called **benign intracranial hypertension** or **pseudotumor cerebri**.
- With the rise in intracranial tension, it can press on the sixth nerve, causing horizontal diplopia.
- Investigations: No space-occupying lesions can be seen. Thus the CT and MRI will come out to be normal. CSF composition is also normal.
- The pathophysiology of this condition is that either CSF is formed more from the choroid plexus or it is drained less from the retinoid villi.
- Thus, there is an imbalance between formation and reabsorption.
- **Etiology of Idiopathic Intracranial Hypertension**
  - Obesity.
  - Vitamin A toxicity, known as hypervitaminosis A.
  - OCPs.
  - Tetracycline.
  - Sleep apnoea
- 4. **Systemic cause** of more pressure or disc oedema.
  - Uncontrolled or malignant hypertension.
  - Severe anaemias, as it leads to hypoxia causing dilatation of the vessels.

## Stages of Papilloedema

### 1. Early stage.

- Visual acuity is absolutely normal. there is only transient obscuration



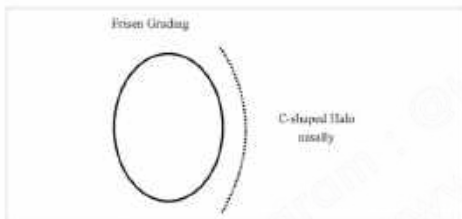
- Blurring of the disc margin, which starts nasally.
  - The visual field is normal.
2. **Established papilledema.**
- There is a transient disturbance of vision.
  - Blurring all around along with even elevation of the disc. Enlargement of blind spot (field defect).
  - The retinal-choroidal folds due to the oedema are called **Paton's lines**.
  - Haemorrhage and exudate.

### 3. Chronic papilledema.

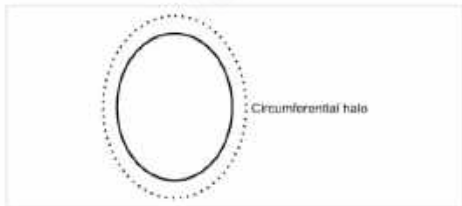
- Visual acuity starts decreasing.
- Constriction of visual field defect.
- Fundus examination shows blurring and disc elevation.
- Optico-ciliary shunt vessels are seen.

### 4. Atrophic papilledema.

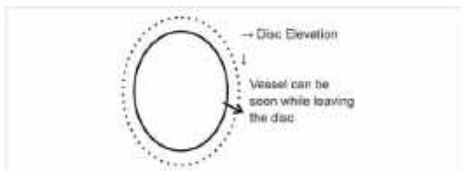
- This is secondary optic atrophy.
  - The vision is markedly reduced.
- Frisen Grading of papilledema**
- Grade 1 Only nasal halo is seen, which is C-shaped.



- Grade 2: Circumferential halo.



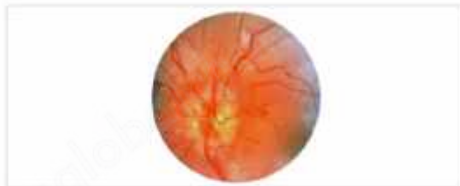- Grade 3: Obscuration of blood vessels. This happens because the oedema causes the blood vessels to appear hidden. So, along with the circumferential halo, there is also disc elevation, i.e., oedema has increased further.



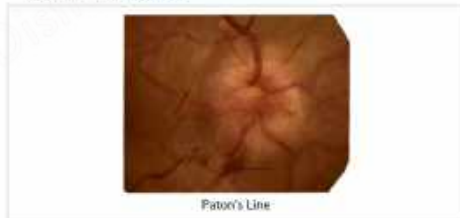- Grade 4: When one vessel is obscured on the disc.



- Grade 5: All vessels are obscured.
- In the below diagram, there is papilledema, dilated veins, blurred disc margin.



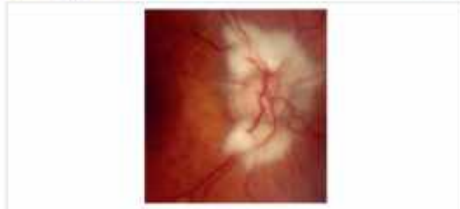- Diagram below shows established papilledema and the arrows indicate Paton's line. The dilated veins and the haemorrhage are seen.




- **Treatment:**
  - Treat the cause.
- **Investigation:**
  - Ultrasound-B scan. - Optic nerve sheath diameter(ONSD) is increased in the case of papilledema.
  - MRI shows any space-occupying lesions
  - Lumbar puncture is only done when there is no presence of space-occupying lesions.

### Pseudo-papilledema

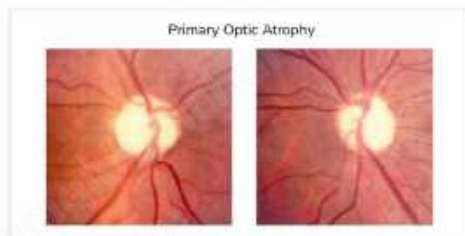
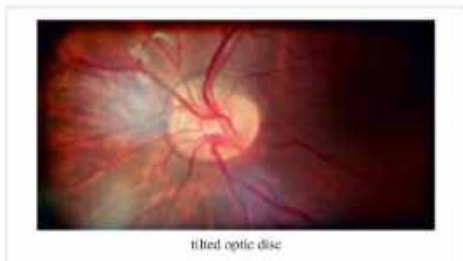
11/1/08



- Myelinated nerve fibres are seen, causing blurring of the disc margin.
- This condition can be termed as **pseudo-papillitis** or **pseudo-papilledema** when there is the blurring of the disc margin but the cause is neither papillitis nor is it papilledema.
- **Causes**
  - a) Myelinated nerve fibres.
  - b) Drusens
  - c) Hypermetropia .
  - d) Tilted optic disc



- A clear depiction of the enlargement of the blind spot is made.



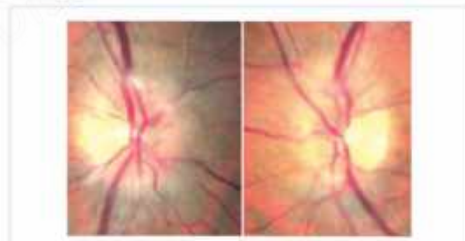

### Optic Atrophy

01:41:00

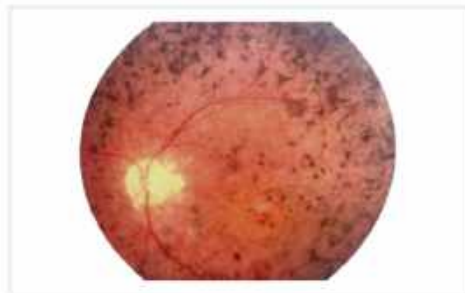
- In optic atrophy, the nerve fibres are damaged. Complete atrophy thus means that all nerve fibres are damaged. The patient then turns blind. Since there is no vision, there will be no pupillary action.
- The distinct features are:
  - TAPD: Total Afferent Pupillary defect.
  - There is no PL (perception of light).
  - All nerve fibres are damaged.
- **Classification of optic atrophy**

- The disc is **chalky white** in colour, that it is **Primary optic atrophy**.

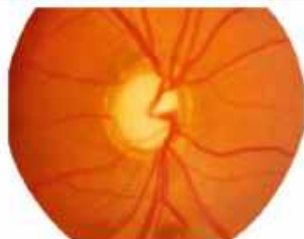Refer Table 14.1



- Secondary optic atrophy with a blurred disc margin. However, in the first picture, the disc colour seems normal. It slowly changes to a dirty white colour. The **reason for a blurred disc margin in this condition is gliosis**.



- Consecutive optic atrophy. There is a clear presence of **retinitis pigmentosa**.
- Triad of pale waxy disc, arterial attenuation and bony spicules

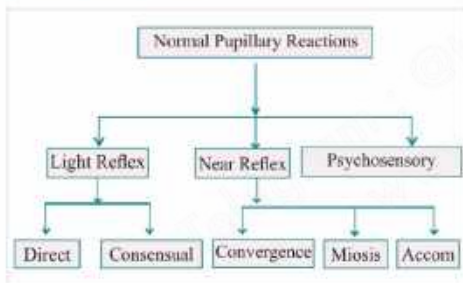


Glaucomatous Optic Nerve

- C/D ratio is almost 0.7-0.8. There is nasal shifting of vessels, and the bending of vessels.

### Normal Pupillary Reactions

01:58:00



1. **Light Reflex:** When light is shown into the eye, there is constriction of the pupil. When for the same eye, it is called direct and when it is for the opposite eye, it is called consensual light reflex.
2. **Near Reflex:** The three components of near reflex are convergence, miosis, and accommodation.
3. **Psycho-sensory Reflex:** Any anxiety causes dilatation of the pupil.

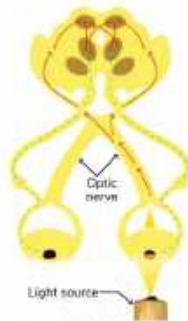


### Important Information

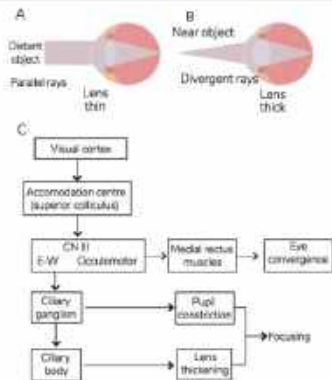
- Iris sphincter has a parasympathetic supply, and dilator pupillae has sympathetic supply.
- This is why anxiety is causing dilatation of the pupil.

### Pathways of Normal Pupillary Reactions

01:53:20



- The light reflex is thus travelling from the optic nerve to the optic chiasma and then to the tract.
- It is then going to finally come to the pretectal nucleus, which will later innovate both Edinger-Westphal nuclei.
- This is the mechanism behind the consensual light reflex because from every pretectal it goes to both EWN. This is the afferent pathway.
- The Efferent pathway starts from the third nerve. This leads to inferior division of third nerve.
- From inferior division it goes to nerve to inferior oblique(IO). From nerve to inferior oblique, it goes to ciliary ganglion. It then goes to short ciliary nerves, and this is what innervates the iris sphincter.
- Near Reflex



- o Near reflex starts in the visual cortex.
- o When looking from far to near, the information from the visual cortex will be going in the superior colliculus, which is the accommodation centre.

- From here it goes into the third nerve which through the medial rectus, causes convergence.
- When it then passes through the ciliary ganglion and short ciliary nerves, the Iris sphincter will cause miosis. Then it passes to the ciliary muscles leading to accommodation.

### Abnormal Pupillary Reactions

01:58:50

#### 1. RAPD.

- The relative afferent pupillary defect is also called Marcus Gunn Pupil.
- This is diagnosed by the Swinging Flashlight Test.
- Problem starts in optic nerve
- Initially there is normal reaction but on comparison defect can be seen and there is dilation in both eyes instead of constriction.

#### 2. TAPD.

- This is a feature of optic atrophy.

#### 3. ARP.

- Argyll Robertson Pupil, also known as light near dissociation.
- Light reflex is absent here, and near reflex is present.
  - Mnemonic: ARP - Accommodation Reflex Present.
- Such a condition, when observed in neurosyphilis is called the Argyll Robertson pupil.
- Lesion is seen in internuncial neurons i.e., between pretectal nucleus and Edinger Westphal nucleus
- Position of pupil: Bilaterally miotic and irregular
- This means that it will not dilate in the dark. LR is also absent so there is no constriction in light. However, the pupils will react to accommodation.
- The **supranuclear adrenergic fibres being damaged hinders the process of dilatation**, It is a continuous parasympathetic stimulation.

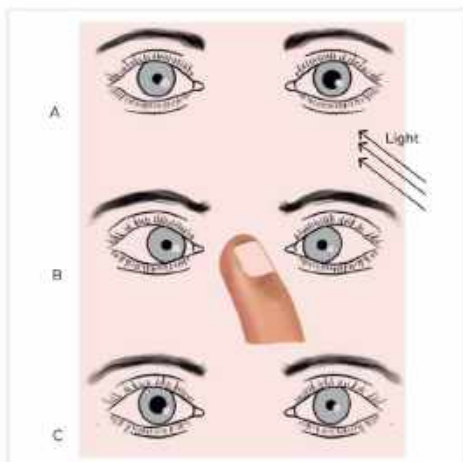
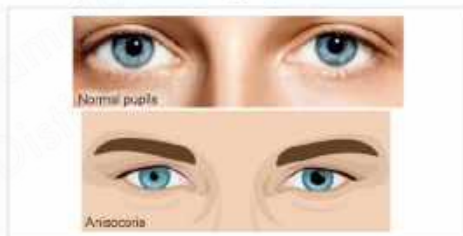

#### • Pseudo-ARP

- When there is a light near dissociation, but the pupil is not miotic and is mainly dilated and fixed, this is called pseudo-ARP.
- This is a feature of dorsal membrane syndrome or Perinaud's syndrome.

#### 4. Adie's Pupil.

- Adie's pupil is also called the Tonic pupil.
- When light is shown to the eye, the iris is moving very slowly and it stops in the mid-dilating position. It then takes time to come to the normal state.
- It is more common in middle-aged women.
- It is a unilateral condition and therefore, the patient will observe Anisocoria- unequal pupil. **When there is a difference in pupil size of around 0.4-0.5 mm, it is Anisocoria.**
  - a. Because of the mid-dilated pupil, the patient experiences photophobia.
  - b. On examination - a sluggish or absent light reflex is observed in such patients.
  - c. Tendon reflexes like knee jerks are also affected. This is called Holmes-Adie's Pupil
  - d. Vermiform movement of eyes.
- Here lesion is in the efferent pathway- either in the short ciliary nerves or in the ciliary ganglion.



- When light is being shown to the left eye, there is almost no reaction in this case.

- When something is shown near a stimulus, pupil constriction takes place.
- However, when the stimulus is removed, the pupil on this side still remains constricted, which proves that it is tonic in nature.
- In order to confirm Holmes Adie's pupil, a small concentration of 0.125 pilocarpine is used. If it is an Adie's pupil, constriction will take place.
- This happens due to denervation hypersensitivity.
- For such patients, it is suggested that glasses be worn when stepping outside to manage photophobia.

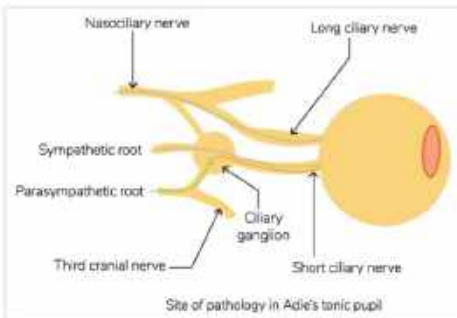
### 5. Horner's Syndrome

- Lesions in the sympathetic chain.
- **Clinical features**
  - a) **Miosis:** This because the sympathetic chain supplies dilator pupillae, which causes uninhibited action of the iris sphincter.
  - b) **Ptosis:** It is the drooping of the eyelid. LPS is one of the retractors of the lid and is supplied by the third nerve. Mullers, or superior tarsal muscle, is the other retractor and is supplied by the sympathetic. The ptosis is mild because it is the mullers that is hampered in function.
  - c) **Enophthalmos:** This is apparent in form.
  - d) **Anhidrosis:** When the lesion is before the superior cervical ganglion, the sudomotor fibres travelling along the external carotid artery (are along the sympathetic chain). can get damaged. So, anhidrosis is not seen in postganglionic lesions. Thus there is a loss of sweating.
  - e) **Loss of Cilio-spinal reflex:** When there is pinching on the nape or one side of the body, face, or upper trunk, and any trauma that causes dilatation of pupil, this is called Cilio-spinal reflex.
- **Horner's is congenital or acquired?**
  - It is both congenital and acquired.
  - The presence of heterochromia iridis indicates it is congenital.

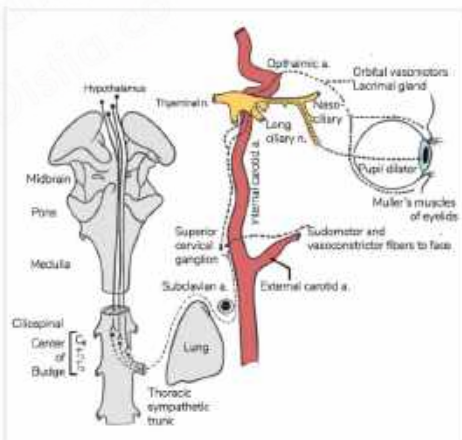
### Sympathetic Pathway

02.11.20

- The sympathetic chain starts from the hypothalamus.
- It travels down the brain, pons, medulla and midbrain, and comes to the ciliospinal centre of budge (C8, T1, T2).
- Now the fibres are going to cross the apex of the lung. This is important because any Pancoast tumour can be a cause of Horner's.
- This sympathetic chain will now synapse at the superior cervical ganglion.
- It comes in the central pathway, pre-ganglionic path and then to the post-ganglionic pathway.
- It goes into the cavernous sinus and then reaches the eye.
- Finally, through the long ciliary nerve to the dilator pupillae.



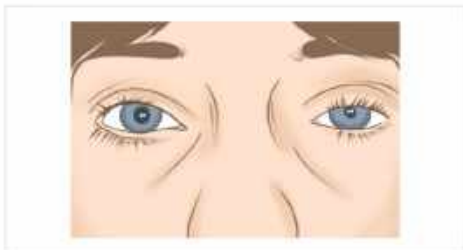- Here, the ciliary ganglion can be seen. There is a synapse of only parasympathetic fibres.
- The short ciliary nerve is supplying the iris sphincter (efferent pathway of light reflex).
- The sympathetic is passing through the ciliary ganglion.
- Nasociliary and long ciliary nerves supply the dilator pupillae.



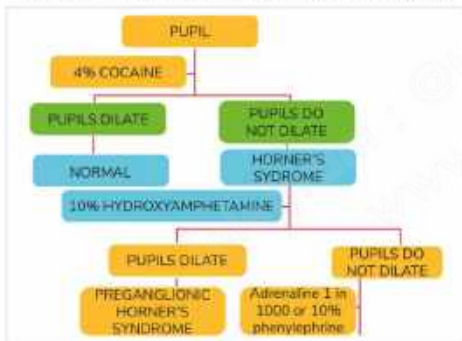
### Lesions and Causes

1. Central lesions (first order neurons)
  - Brainstem diseases: Tumour, vascular, demyelinating
  - Spinal cord tumours
2. Preganglionic
  - Pancoast tumour
  - Carotid and Aortic aneurysms
  - Neck lesions
3. Postganglionic lesion
  - Atherosclerosis Of ICA

- Nasopharyngeal tumours
- Cavemous sinus pathology
- Cluster headaches



- Here, the patient has one pupil that is normal size, and the other is a miotic pupil with ptosis.
- For **Horner's patients**, when they are sitting in the dark, there may be no movement of the pupil for 5-7 seconds, but then it slowly starts dilation, which is called **dilatation lag**.



- For diagnosing Horner's, 4% cocaine is given to the pupil.
  - If the pupil dilates, it is normal.
  - If no dilation is seen, it is Horner's.
  - This is because cocaine blocks the reuptake of noradrenaline (NA).
- Now use 10% Hydroxy amphetamine.
  - If the pupil dilates, it is preganglionic.
  - If not, it is post-ganglionic.
- To check again, very low concentration of adrenaline is used. If it responds to that, it is a postganglionic lesion.

#### Q. Approach to a case of Anisocoria.

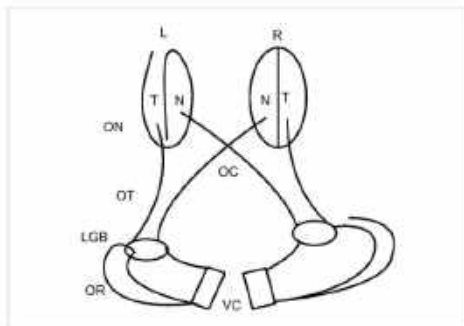
02/31/18

- Anisocoria is when there is a difference of pupil size by at least 0.4-0.5 mm in the two eyes.
- It is a lesion of efferent pathway.
- When there is a patient of different pupil size. The difference can either be more in the dark or more in light.

- When the difference is more in light, the one that is dilated is the abnormal pupil.
- If it more in the dark, the smaller pupil is abnormal.
- When the larger pupil is abnormal, the first step is a slit lamp examination.
- If there is an iris sphincter tear it can be due to trauma.
- However, if it is normal, constrict the pupil.
- This can be started with 0.125% concentration of Pilocarpine.
- On giving pilocarpine, if there is constriction, it is Adie's pupil, if not, the dose of Pilocarpine is increased to 1%.
- If there is constriction, then it is normal.
- If there is still no constriction, then the diagnosis is pharmacological mydriases.
- Now, when dealing with the one that was more in dark, which means that the smaller pupil was abnormal. Slit lamp examination is conducted.
- There can be presence of posterior synechiae causing uveitis.
- But if it is normal, cocaine is used for dilation.
  - If dilation happens, it is normal. (it can be a case of physiological miosis).
  - If not, there is a dilatation lag, which means it is Horner's.
  - Sometimes it can be a physiological miosis.
- For the purpose of differentiation, Hydroxy amphetamine is used.
  - If dilation takes place, it is a preganglionic lesion, and if no dilation takes place, it is post ganglionic lesion.

#### Lesions of visual pathway

02/31/18

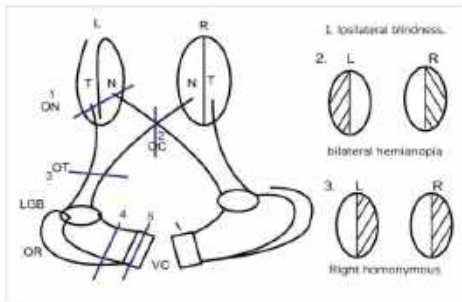


#### • Description

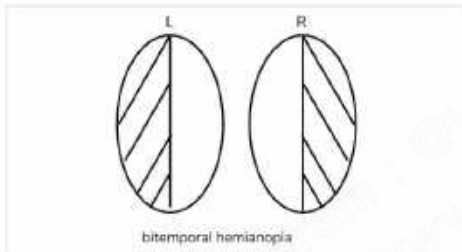
- L is the left retina and R is the right retina.
- T stands for temporal and N stands for nasal.
- ON - Optic Nerve.
- OC - Optic Chiasma.
- OT - Optic Tract.
- LGB - Lateral Geniculate Body.
- OR - Optic Radiations.

o VC-Visual Cortex.

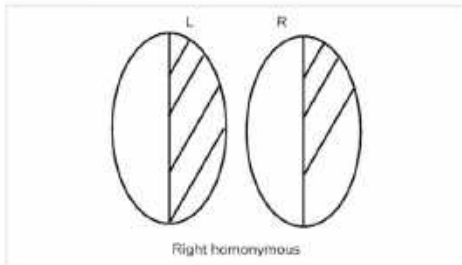
- The visual field coordinates are opposite to the retinal field coordinates. The projection of the retina is always crossed.



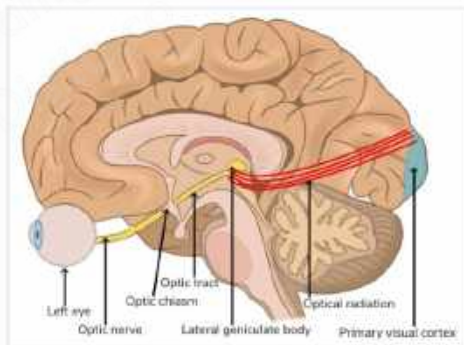
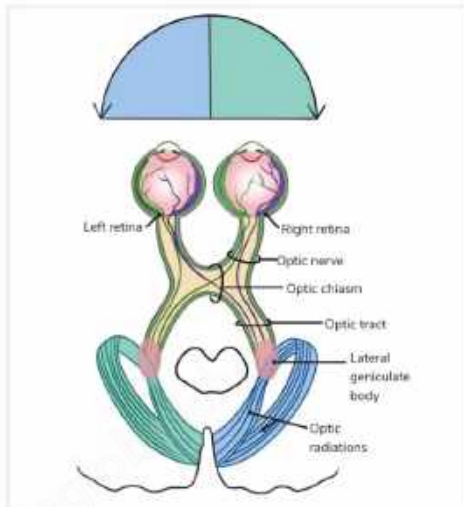
- Lesion 1: Ipsilateral blindness.**



- Lesion 2:** The lesion is at the decussation of the nasal fibre, it will lead **bitemporal hemianopia**.



- Lesion 3: Right homonymous hemianopia.**
- Lesion 4:** It shows radiation lesion which results in **Right Homonymous hemianopia**. It can be both congruous and incongruous if it is anterior it will be incongruous but towards the parietal lobe it becomes more congruous.
- Lesion 5: Cortical lesions** which result in Right Homonymous hemianopia. They are always congruous.



**Important Information**

- The only lesions that are **Heteronymous** are chiasmal lesions.
- Chiasma can be affected in Pituitary Adenomas, craniopharyngioma and Aneurysm circle of Willis.

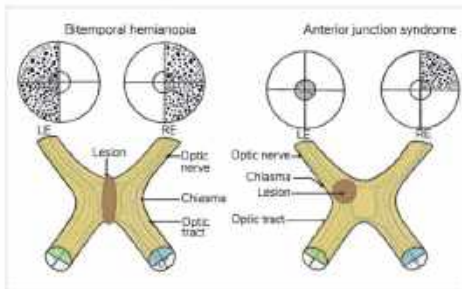
**Chiasmal Lesion**

02:42:47

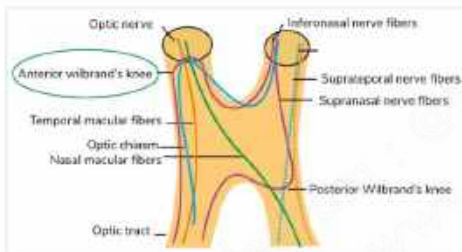
Chiasmal lesions are divided into three categories.

- Anterior junction syndrome.**
- Central lesion: Bitemporal hemianopias may be associated with see-saw nystagmus.**
- Posterior junction syndrome:** These primarily involved Macular fibres, which is why they are heteronymous macular hemianopia.

## Anterior Junction Syndrome



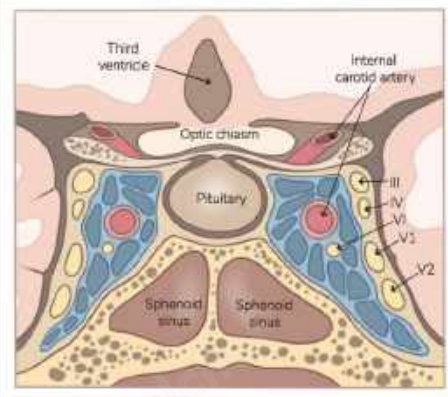
- When lesion is at the junction of the nerve and chiasma, some part of the nerve is involved causing **central scotoma**,
- And when the whole nerve is damaged the patient will get blindness on one side.



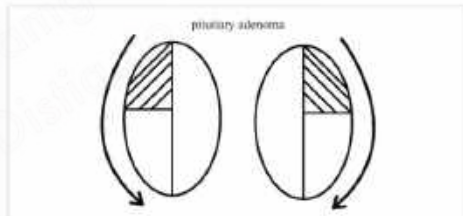
- The fibres that are inferonasal detour towards the opposite side before entering the chiasma this called **Anterior Willbrand's knee**. So, because of the lesion, it will damage the anterior Willbrand's knee which is in Inferonasal. The field effect will be just the opposite which is **superior temporal**.



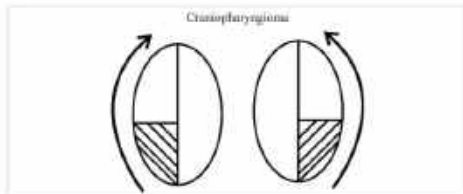
- The above image shows the visual field of Bitemporal hemianopia.



- Nerves passing along walls is 3, 4 and 5 and 6th nerve is passing along the internal carotid artery.



- Pituitary adenoma is present below the optic chiasma so the lower fibre will get affected first, so, superior defects will be first to occur.
- Superior to inferior leading to bitemporal hemianopia

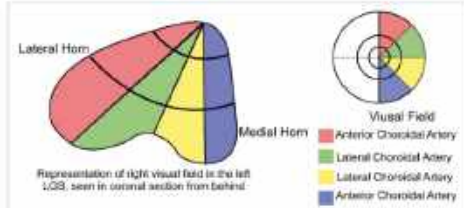
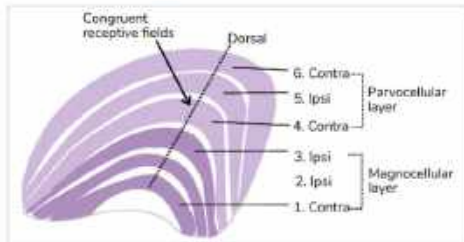
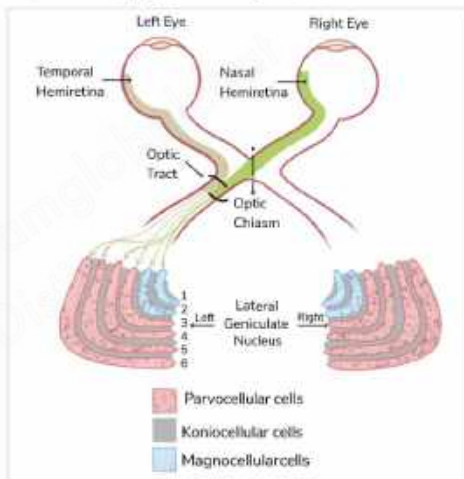


- In Craniopharyngioma it will be opposite to the Pituitary adenoma, i.e. inferior defects will be first to occur.
- Inferior to superior
- Post-Fixed Chiasma: Anterior junction syndrome (crossing after Pituitary gland)
- Pre-fixed chiasma: Posterior junction syndrome (crossing before Pituitary gland)
- In normal optic chiasma, central lesions are seen (crossing at Pituitary gland)

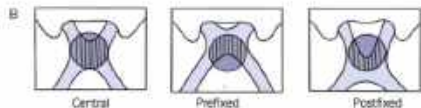
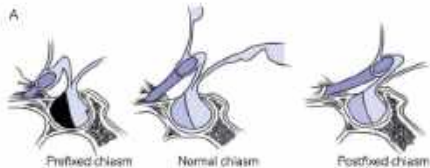


## Lateral Geniculate Body

- The lateral geniculate body has six layers which are divided into the following ways:
  - Layers 1-2 are called **magnocellular**. The role of the magnocellular is to perceive motion and gross details.
  - Layers 3-6 are called **parvocellular**. They are mainly responsible for colour vision except for blue colour and fine details.
- The interlamellar area between each layer is called **koniocellular**. It is responsible for the perception of blue colour.
- Layers 1, 4 and 6 have contralateral supply and 2, 3 and 5 have ipsilateral supply (which is temporal).



Representation of right visual field in the left VCB, seen in coronal section from behind.



## Optic Tract Lesion

1. **Incongruous homonymous hemianopsia.**

2. **Wernicke's Hemianopic pupil** (half of pupil is responding, half is not):

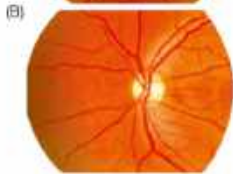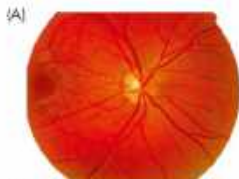00:52:16



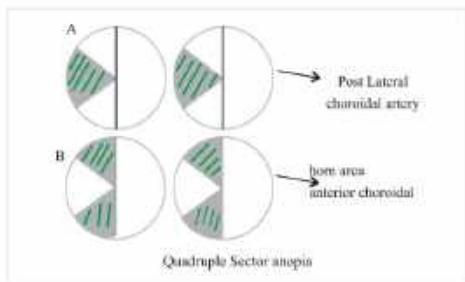
## Important Information

- In optic radiation lesions, and visual cortical lesions i.e. cortical blindness it can be observed that pupillary reactions are normal.

3. Bow tie optic atrophy: In contralateral disc where nasal fibres and nasal macular fibres are involved



- This image depicts the blood supply and what is the field that is responsible for it. (Anterior choroidal is the branch of the middle cerebral artery.)
- Two horns are supplied by anterior choroidal artery.



- Hilum is supplied by posterolateral choroidal artery
- In the above image figure (a) shows When the posterolateral choroidal artery is blocked it will result in a key hole VFD.
- Figure (b) shows when the horn area which is when the anterior choroidal artery is blocked, will cause a lesion called **Quadruple Sector anopia**.

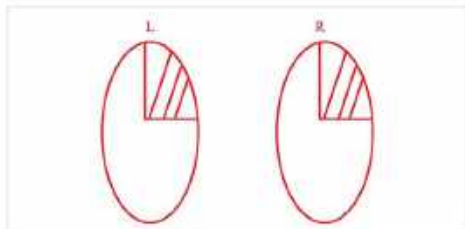
### Optic Radiation Lesion

0305:47

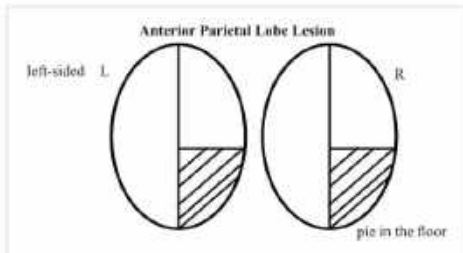
- In optic radiations initially, the fibres pass through the temporal and parietal lobe and later on it comes to the deep parietal lobe.
- So, these fibres passing through the temporal lobe are inferior fibres, these loop around the temporal horn which is called the **Meyers loop**.
- The fibres passing through the parietal lobe are superior fibres and they are called **Baum's loop**.

### Temporal Lobe Lesion

- Features of the Temporal lobe lesions
  - In the left temporal lobe lesion the patient will get right-sided superior quadrantanopia which is also called **pie-in-the-sky**, and vice versa.
  - Formed hallucinations:** In this case, the patient hallucinates that they can see clear faces and formations.
  - Gustatory hallucinations.**
- It is an incongruous lesion.



### Anterior Parietal Lobe Lesion



- Features of Anterior parietal lobe lesion
  - In left-sided parietal lobe lesions the patient will get right-sided inferior quadrantanopia which is also called **pie in the floor**.
  - Acalculia: Inability to calculate.
  - Agraphia: Inability to write.
- It is an incongruous lesion.

### Posterior Partial Lobe Lesions

- Features of Posterior partial lobe lesions
  - Congruous homonymous hemianopia.
  - Defective optokinetic nystagmus**
    - OKN is a physiological nystagmus.
    - It follows saccadic movement and pursuit
    - Saccadic: Fast abrupt movement to refix object on fovea
    - Pursuit: Slow following movement
    - Cogam's dictum: It can be either symmetrical or asymmetrical. If it is asymmetrical with homonymous hemianopia it is parietal lobe lesions generally due to tumour. And if the defect is symmetrical it is occipital lobe lesions caused by trauma.

### Optokinetic Drum Test

- The OK drum test is for eliciting the optokinetic nystagmus and this test is totally an objective test.
  - To diagnose Malingering / functional blindness.
  - To assess the visual acuity in infants.

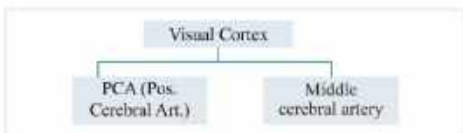
### Visual Cortex Lesion

0315:36

- Visual cortex can be of two types
  - The Primary Visual cortex:** Brodman Area 17. It is further divided into 6 layers.
    - Layer 4 is the thickest layer. It is divided into 4A, 4B, 4C $\alpha$ , and 4C $\beta$ .
    - **Maximum fibres terminate in layer 4 of the visual cortex.**
  - The Secondary Visual cortex:** Brodman area 18 and 19, it is also called the Visual association area.

### Blood Supply

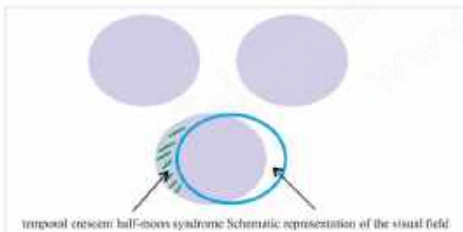
- It is supplied by 2 cerebral arteries: Posterior cerebral artery and Middle cerebral artery
- **Posterior cerebral arteries (PCA)** : When PCA is blocked the macula is spared. This is what is called Macula sparing hemianopia or also called Key hole vision.



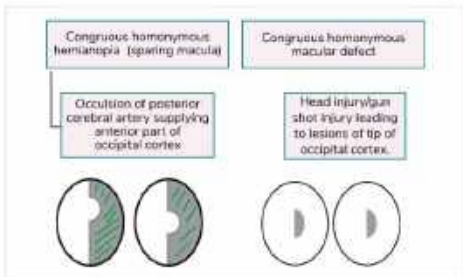
- **Middle cerebral artery (MCA)**: MCA supplies in the macular area, if MC is blocked, there is never total macular lesion because some branches of PCA also supplies macular area.

### Important Information


- Keyhole visual field defect is caused by an LGB lesion due to the blockage of **posterior choroidal arteries**.
- Keyhole vision is caused by the Occipital lobe lesion.
- Any trauma to the tip of the visual cortex (Calcarine fissure) will cause macular homonymous hemianopia.



- If it is little anterior or in front of tip, this represent most temporal extremity outside binocular single vision.



- The temporal crescent half-moon syndrome can be a visual field defect when the trauma is more in the front of the calcarine cortex.



### Occipital Lobe Lesion

03-22-33

- The occipital lobe lesion is 90% of the time caused due to strokes.
- Congruous homonymous hemianopia.
- The pupillary reactions are normal.
- No optic atrophy
- Unformed hallucinations.
- **Anton's syndrome**: It is cortical blindness with denial of blindness. It can be confirmed with visual evoked potential (flat VEP), VEP is an electrodiagnostic test which checks the activity from the ganglion to the visual cortex.
- **Riddoch Phenomenon**: Only perception of moving objects, static objects are not seen.

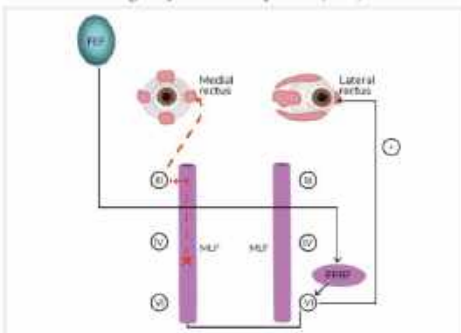
### Supra Nuclear Gaze Control

03-25-08

- Any control above the nucleus of the nerve. The supranuclear gaze is divided into two parts:
  - Horizontal Gaze centre.
  - Vertical gaze centre.

### Horizontal Gaze Centre

- The horizontal gaze centre is at pons, (**Paramedian pontine reticular formation**) also known as PPRF.
- PPRF is managed by the frontal eye field (FEF).



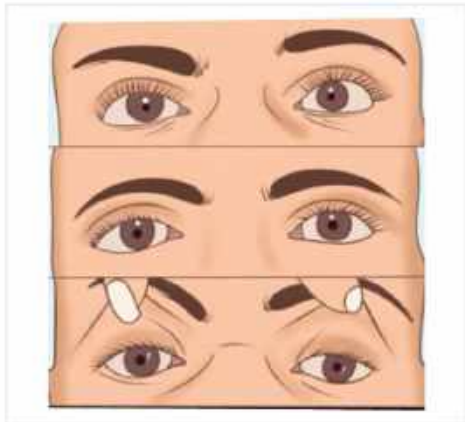
- The right PPRF will contract the right lateral rectus, which means the innervation is ipsilateral. For the other side the contra-lateral MLF is ordered and becomes the left MLF, which in turn orders the left medial rectus (the innervation is ipsilateral). One side PPRF and the other side MLF is contra-lateral.

- **PPRF Lesion:** Ipsilateral horizontal gaze palsy.
- **FEFLesion:** Contralateral horizontal gaze palsy.
- **MLF lesion:** It is also called **Internuclear ophthalmoplegia**.
  - It is characterized by defective ipsilateral adduction.
  - Contralateral abducting eye is showing **ataxic nystagmus** due to imbalance of impulse.
  - In unilateral INO convergence is normal.
  - Demyelination, stroke and tumours are the causes.
  - Bilateral INO - When patient is looking to the right then there is defective adduction in left eye and ataxic nystagmus.
  - In bilateral INO if associated with convergence deficit it is called **Wall-eyed bilateral internuclear ophthalmoplegia (WEBINO) syndrome**.
  - B/L exotropia with ataxic nystagmus.
  - **1 1/2 syndrome:** E.g., Lesion of right PPRF and right MLF is also gone so there is no horizontal gaze on right side which means no abduction on right and as right PPRF manages opposite side abduction so no abduction on left.
  - There is also defective right MLF lesion.
  - Right side there is no adduction and abduction
  - Left side, there is no adduction hence called one and a half syndrome.

#### Vertice Gaze Center

03:39:03

- The vertical gaze centre is managed from the frontal lobe from where it goes to the vertical gaze centre in the midbrain and simultaneously bilateral stimulation is given.



- **RiMLF:** In the midbrain, the main nuclei responsible for the vertical gaze is **RiMLF (Rostral interstitial nucleus of medial longitudinal fasciculus)**. And this gives order at the nuclear level so it will go to the nuclei of the 3 and 4 nerves (these nerves are responsible for vertical movements).
- **INC** (The interstitial nucleus of Cajal).
- **Posterior commissure**.

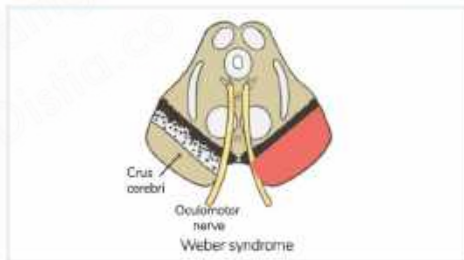
#### Parinaud Dorsal Midbrain Syndrome

**Features of Parinaud dorsal midbrain syndrome are:**

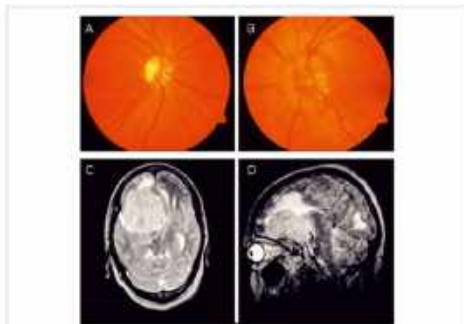
- Lid retraction which is called Collier's sign.
- Eyes are straight in the primary gaze
- Vertical gaze palsy.
- Pseudo-Argyll Robertson pupil : Dilated pupil with light near dissociation.
- Convergence retraction nystagmus: Any attempt to converge the eye will lead to retraction of eyeball
- Defective convergence.
- Causes can be demyelination, trauma, meningitis in children

#### Syndromes

03:45:03



1. **Weber syndrome:** It is the third nerve palsy with contralateral hemiplegia (cerebral peduncle is involved).
2. **Benedict syndrome:** It is the third nerve palsy with contralateral Hemi tremor (red nucleus involved).
3. **Millard-Gubler syndrome (MGS):** Palsy of CN VI with contralateral hemiplegia.



4. Foster-Kennedy Syndrome: It is seen in frontal lobe tumours or olfactory groove tumours. Initially in the patient, Ipsilateral optic atrophy and contralateral papilledema are seen.

## Nystagmus

002E3F

- Nystagmus is the involuntary oscillatory motion of the eye. It can be classified in two ways:

### Anatomically

- Jerky nystagmus has a slow phase and a fast phase.
  - It has saccadic movement
- Pendular nystagmus movement is equal in both directions.
- Mixed nystagmus : in a primary position, it is pendular but lateral gaze is jerky.

### Etiological

- Physiological Nystagmus:
  - OKN.
  - End-point nystagmus-Nystagmus at extreme of gaze (fine jerky nystagmus).
    - Fast phase is towards the direction of gaze
  - Vestibular nystagmus is a biphasic eye movement with slow and rapid phases of opposite directions. It happens due to the altered impulse from the vestibular nuclei to the horizontal gaze centre.
  - When cold water is put in ear, opposite side nystagmus is seen, when warm water is put in ear, same side nystagmus is seen (COWS).
  - It is jerky nystagmus
- Pathological Nystagmus:
  - **Congenital:**
    - The majority of congenital are due to sensory deprivation, this nystagmus is pendular. **Foveal reflex is formed within 5-6 months** when the light rays fall on the fovea. Any cause of opaque media causes nystagmus.

- Congenital motor nystagmus-Due to sensory deprivation, it is initially pendular but it can change into jerky sideways this is called mixed nystagmus.
- Spasmus Nutans is nystagmus with head nodding, and if it is idiopathic or neurological disorder it will resolve till the age of 3.

- **Acquired:** They are generally due to motor imbalance therefore they are jerky nystagmus. Fast phase is towards the side of lesions.

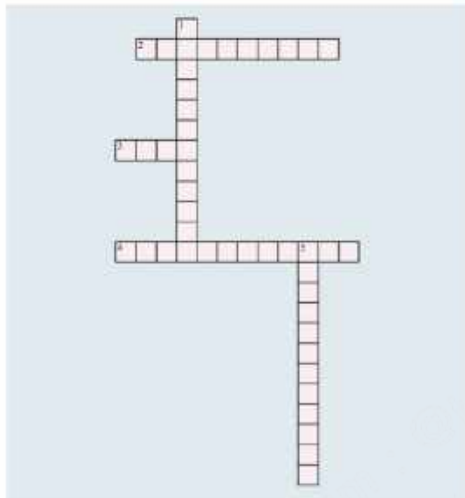
1. Ataxic nystagmus is a feature of INO.
  2. Latent nystagmus is a binocular horizontal oscillation that becomes apparent when 1 eye is covered. It is a feature of infantile esotropia. It is manifested by cover uncover test.
  3. Downbeat nystagmus is a jerky nystagmus with a fast phase downwards. It is mainly a feature of Arnold Chiari's malformation.
  4. Upbeat nystagmus is a jerky nystagmus with a fast phase upwards. Generally seen in posterior fossa lesion.
  5. Seesaw nystagmus is a feature of chiasma lesion seen in central chiasma lesion where the patient gets bi-temporal hemianopia. It is a Pendular nystagmus.
    - Eye which is up will intort
    - Eye which is down will extort
  6. **Convergence retraction nystagmus. It is a feature of Parinauds syndrome.**
  7. Bruns nystagmus is a feature of cerebellopontine angle tumor (in acoustic neuroma).
  8. Periodic alternating nystagmus (PAN) . It is seen in cerebellar lesions and phenytoin drug toxicity.
    - Horizontal jerk on one side, after sometime it changes its direction and now fast phase is on other side.
- It reverses the direction periodically

Table 14.1

Primary	Secondary	Consecutive	Glaucomatous
<ul style="list-style-type: none"> <li>• Idiopathic</li> <li>• Etiology lies in the retrolaminar area, Behind the lamina cribrosa till the brain.</li> <li>• On Fundoscopy-clear disc margin, chalky white in colour is seen.</li> <li>• Causes include neurosyphilis, multiple sclerosis, Leber's hereditary optic neuropathy, toxic/nutritional, and traumatic avulsion of the optic disc</li> </ul>	<ul style="list-style-type: none"> <li>• Etiology- Optic nerve.</li> <li>• On Fundoscopy-blurred disc margin, dirty white in colour is seen.</li> <li>• Causes include long-standing optic nerve disease or papilledema</li> </ul>	<ul style="list-style-type: none"> <li>• Etiology- retinal disease (wide spread).</li> <li>• On Fundoscopy-blurred disc margin, pale waxy disc is seen.</li> <li>• Causes include retinitis pigmentosa, central retinal artery occlusion and repeated sessions of pan-retinal-photocoagulation</li> </ul>	<ul style="list-style-type: none"> <li>• Etiology- Glaucoma.</li> <li>• On Fundoscopy, there is 100% cupping, nasal shifting of vessels, double-bending of vessels, lamina dot sign.</li> </ul>



## Crossword Puzzle 1




### Across

- When there is light, the pupil \_\_\_\_\_.
- There are \_\_\_\_\_ parts of the optic nerve.
- \_\_\_\_\_ in optic nerve disease is called optic neuritis.

### Down

- Part of the optic nerve going into the brain is called \_\_\_\_\_ part.
- The longest part of the optic nerve is the \_\_\_\_\_ part.

## Crossword Puzzle 2



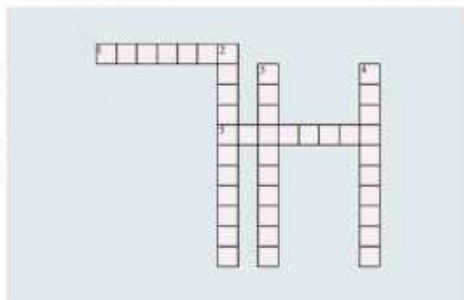
### Across

- When there is constriction of the eye where light falls it is called \_\_\_\_\_ reflex.
- The inner 6 layers are supplied by the \_\_\_\_\_ artery.
- Marcus Gunn Pupil is tested by the \_\_\_\_\_ Flashlight Test.

### Down

- The \_\_\_\_\_ part of the optic nerve is known as the intraocular part.
- \_\_\_\_\_ artery is the main artery of the eye.

## Crossword Puzzle 3



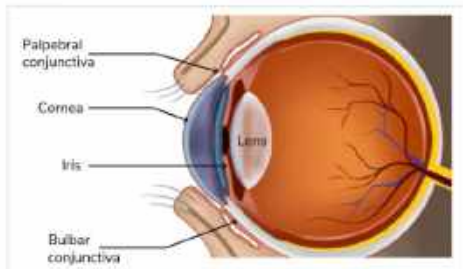
### Across

- The blind spot is an \_\_\_\_\_ scotoma.
- \_\_\_\_\_ is both congenital or acquired in nature.

### Down

- \_\_\_\_\_ is the condition where there is a difference of pupil size of eyes.
- \_\_\_\_\_ chain starts from hypothalamus.
- \_\_\_\_\_ optic neuropathy is passed through

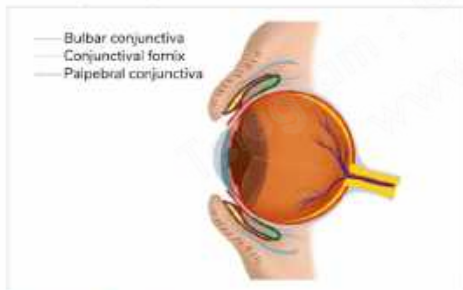Conjunctiva is a thin mucous membrane present on the ocular surface.



### Parts of Conjunctiva

00:03:41

- The Conjunctiva is divided into three parts which are the following:
  1. Bulbar conjunctiva
  2. Conjunctival fornix: Fold of conjunctiva reflecting on lids
  3. Palpebral conjunctiva



### Conjunctival Fornix

- Fornix is also called cul-de-sac.
- Conjunctival Fornix can be divided into 4 parts which are as follows:
  1. Superior (deepest)
  2. Lateral
  3. Medial
  4. Inferior



### Important Information

- Giant Fornix syndrome, generally seen in old age, is a condition with voluminous superior fornix, due to disinsertion levator palpebrae superioris.
- It is like a groove where foreign body can get entrapped

### Palpebral Conjunctiva

00:03:13

- The Palpebral conjunctiva extends from the mucocutaneous junction to the covering of the tarsal plate. There are four types of palpebral conjunctiva which are as follows:
  - o Marginal (covers 2mm)
  - o Tarsal
  - o Orbital
  - o Sulcus sub tarsalis



### Important Information

- Groove between marginal and tarsal is called sulcus tarsalis.
- When foreign body gets stuck in the sulcus sub tarsalis, it requires double eversion of the lid, which can be done by the Instrument known as the Desmarres retractor.

### Bulbar Conjunctiva

00:04:42

- Bulbar Conjunctiva covers the whole anterior sclera till the limbus, but it doesn't cover the cornea.
- At the limbus, it joins with the tenon capsule and episclera - ridges are created due to this fusion.
- These ridges are called rete ridges. The space between two rete ridges is called the palisades of Vogt. The palisade of Vogt contains limbal stem cells.
- It is the stem cells which is giving rise to continuous renewal of corneal epithelium through limbal stem cells.

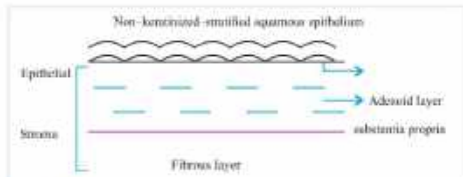
Q. What is the marker for limbal stem cells?

Ans: Marker is ABCG2.

### Histology of the Conjunctiva

00:05:15

- Conjunctiva can be divided into a 5-layered epithelium and a stroma.
- The stroma is divided into a loose connective tissue (Adenoid layer/substantia propria) The lower stroma layer is fibrous in nature.



### Epithelium

- The epithelium of the conjunctiva is a non-keratinized stratified squamous tissue. The basal cells of the epithelium can be cuboid. The rest of the 5 layers have polyhedral-shaped cells.



- The Epithelial cells also exhibit the following type of cells:
  - Goblet cells
  - Lymphocytes
  - Melanocytes (Reti ridges also have melanocytes)

### Clinical Question

**Q.** Where is the maximum number of goblet cells in eye?

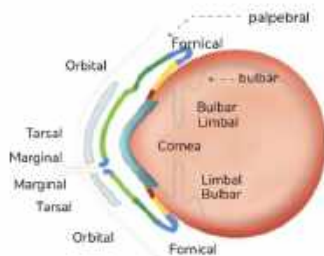
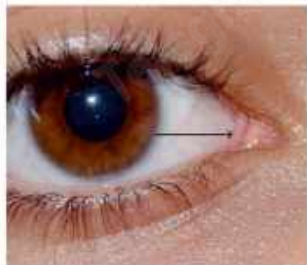**Ans:** Inferior fornix / Inero-nasally

**Q.** Where is the minimum number of goblet cells in eye?

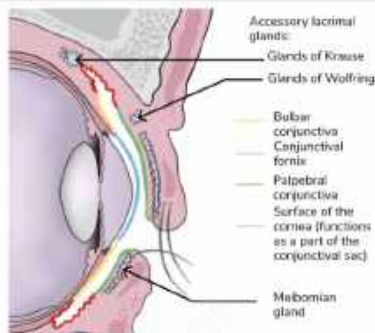
**Ans.** Superiorly

### Stroma

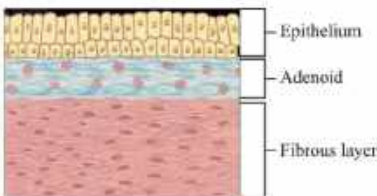
- The Stroma is loose connective tissue known as the substantia propria. The stroma layer has the blood vessels, lymphatics, and lymphoid tissue (lymphocytes and plasma cells).
- CALT (Conjunctiva associated lymphoid tissue): Broad term for all the Lymphoid tissue of the conjunctiva.
- The dense fibrous tissue present in the basal part of the stroma has collagen and elastic tissue. The nerves are also deeply present in this layer. This is the reason why we don't feel pain in mild conjunctiva.
- A fold of conjunctiva is synonymous with the nictitating membrane in lower animals. The first part is plica semilunaris, the collection of tears is lacus lacrimalis.
- This second part is the caruncle. It has the nasolacrimal duct.



### Accessory Lacrimal Gland

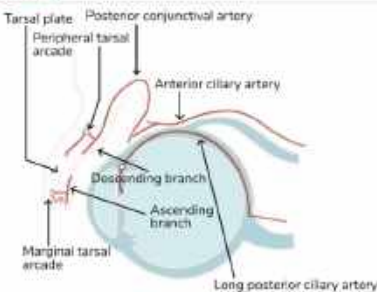


- Accessory lacrimal glands in the region of the conjunctiva are the **Glands of Krause, Glands of Wolfring, Meibomian glands, and islet**.



### Blood Supply

001533



- The anterior ciliary arteries supply blood to the bulbar conjunctiva.
- Anterior and posterior conjunctival arteries are supplying bulbar conjunctiva.
- The marginal and peripheral tarsal arcades supply palpebral and fornix parts of the conjunctiva. These arcades are supplied by median (branch of the ophthalmic artery) and lateral palpebral arteries (branch of the lacrimal artery).



## Important Information

- Conjunctiva is a tissue where there is lymphatic supply. Medially it drains into the submandibular and laterally into preauricular lymphatic nodes.
- In viral conjunctivitis, preauricular lymph nodes are enlarged.
- Sensory supply is by the 5th nerve.

### Conjunctivitis

00:18:00

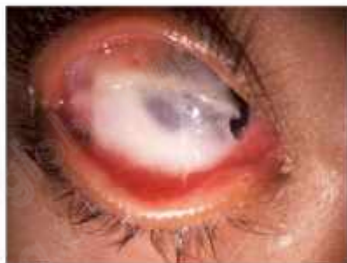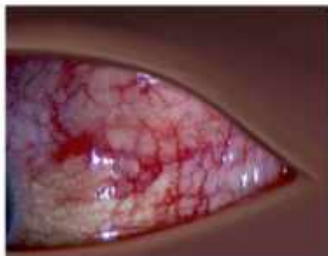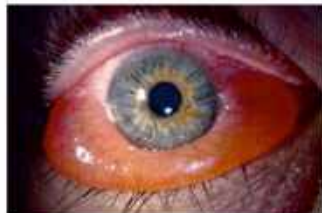- Inflammation of the conjunctiva is known as conjunctivitis.

### Clinical features

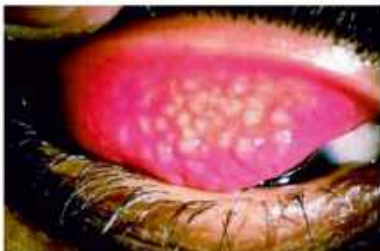- Redness
- Pain
- Photophobia
- Blepharospasm
- Discharge
- Foreign body sensation
- Pain, photophobia and blepharospasm is seen if there is corneal involvement.

### Types of Discharge

- Depending upon the etiology of conjunctivitis, there can be different types of discharge: BCVA
  - Bacterial is Mucopurulent / Moderate purulent / Severely Purulent. (in gonococcal infection)
  - Chlamydial is mucopurulent.
  - Viral is watery in nature.
  - Allergic conjunctivitis is watery.
- On examination
  - Redness: It can be of 2 types
    - Ciliary congestion: Mainly seen in corneal involvement, glaucoma, uveitis
    - Conjunctival congestion: If only conjunctival blood vessels are inflamed, it is branched
    - It is seen in all conjunctival pathologies
  - Chemosis
  - Follicles
  - Papilla
  - Subconjunctival hemorrhages
  - Pseudo membrane/ true membrane



- Pathologically conjunctivitis can be classified as:
  - Follicular → Characterised by the aggregations of lymphoid cells. The maximum aggregation is observed in the fornix region. However, this aggregation is only in lymphoid tissue.
  - Papillary → Epithelial hyperplasia along with aggregation of lymphocyte and plasma cells is observed along with the presence of a blood vessel at the centre.



## Important Information

- Adenoid tissue develops only after 2-3 years of birth. So, no follicle is present in the neonates.
- Giant papilla > 1 mm

## Treatment

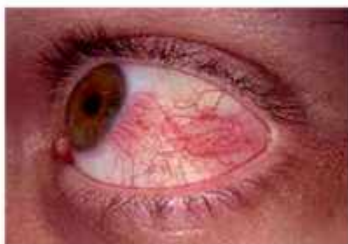- The various treatment methods depending upon the etiology of the conjunctivitis are:
  - Bacterial – Antibiotics
  - Chlamydial – Antibiotics
  - Viral – Antibiotics are given in this type to prevent secondary infection
  - Allergic – Anti-allergic / Mild steroids

## Types of Conjunctivitis

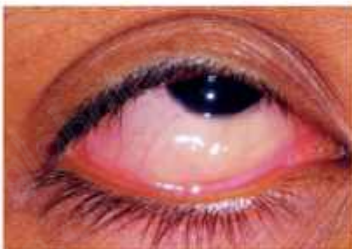00:26:09

### Acute Bacterial Conjunctivitis

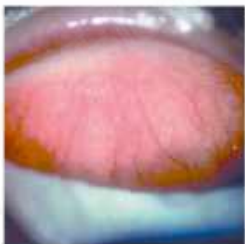
- Most common causative organisms: Staphylococcus aureus, Streptococcus pneumoniae, Haemophilus influenzae
- Clinical features – The signs exhibited by patients suffering from this type are the same as the general signs of conjunctivitis which include redness, pain, photophobia, discharge, etc.
- Treatment – Antibiotics
  - In severe cases like gonorrhoea it can lead to corneal involvement, corneal perforation – Start aggressive treatment with 3rd generation cephalosporins.
- Investigation – For investigating the causative agent of this type of conjunctivitis the following strategies can be used:
  - Microbiologically (staining and culture)
  - PCR (most accurate)
  - Immunofluorescence microscopy
  - Biopsy



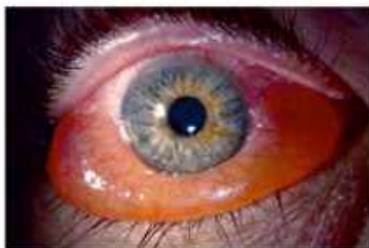Ciliary congestion



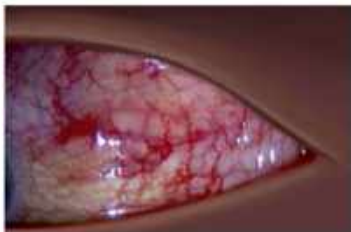Chemosis



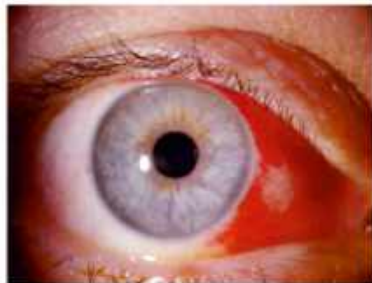Congestion in palpebral conjunctiva



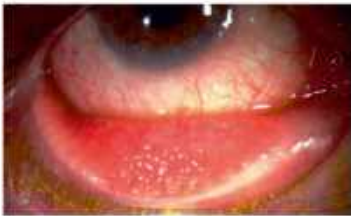Chemosis



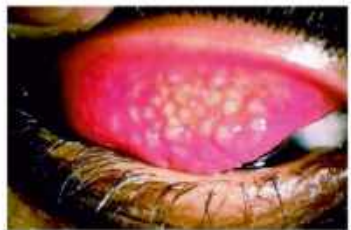Conjunctival congestion



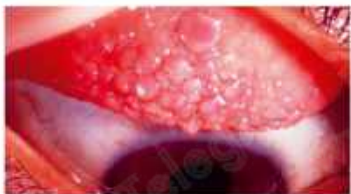Subconjunctival haemorrhage



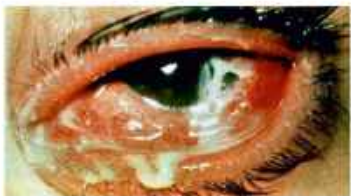Follicle in lower palpebral conjunctiva



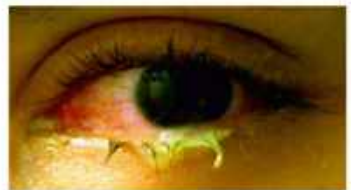Sago grain / follicles



Pappilla



Severely purulent discharge

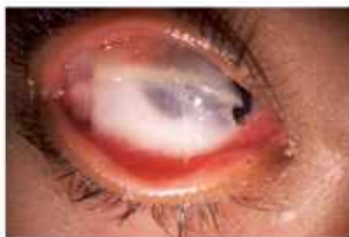

Purulent discharge

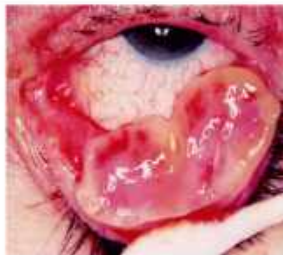- Gonorrhoea is the most dangerous infection in children.
- If there is systemic involvement, start 3rd generation cephalosporins.

### Pseudomembranous Conjunctivitis

06/32/35

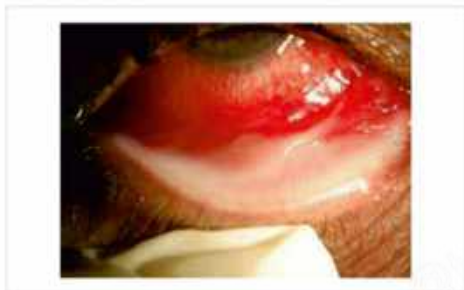

- Signs - The signs exhibited by patients suffering from this type are the same as the general signs of conjunctivitis which include redness, pain, photophobia, discharge, etc. However, a characteristic sign of this type of conjunctivitis is pseudomembrane formation which is mostly made of exudates and are adhering to the epithelial layer. The membrane **does not bleed** on peeling.
- The different causes that have been observed for pseudomembranous conjunctivitis are:
  - Bacterial Cause
    - Mild Diphtheria
    - Streptococcus haemolyticus
    - Staph aureus
    - Gonococcus
  - Viral cause
    - Severe Adenoviral
    - Herpes simplex
  - Chemical irritants
- Ligneous conjunctivitis: A type of pseudomembrane conjunctivitis
- It is a genetic condition where pseudo membrane is present in different parts of the body.

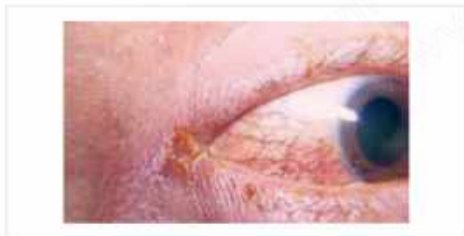

### Membranous Conjunctivitis

- In membranous conjunctiva the membrane bleeds on peeling.
  - Signs - The signs exhibited by patients suffering from this type are the same as the general signs of conjunctivitis which include redness, pain, photophobia, discharge, etc along with inflammatory membrane formation.
  - True membrane bleeds on peeling.
- Cause - *Corynebacterium diphtheriae* has been observed as a recurring cause for membranous conjunctivitis.
- Treatment - Anti-diphtheria serum has been found to be effective as a treatment method in this type of conjunctivitis.



### Angular Conjunctivitis



This type of conjunctivitis involves 2 cantha along with excoriation of the skin.

- Cause
  - *Moraxella axenfeld*
  - *M. lacunata*
  - *M. catarrhalis*
  - *Staph aureus*
- Treatment
  - Antibiotic eye drops
  - Zinc oxide solution: It inhibits proteolytic enzymes.

### Hemorrhagic Conjunctivitis

- Signs - The signs exhibited by patients suffering from this type are the same as the general signs of conjunctivitis which include redness, pain, photophobia, discharge, etc along with subconjunctival haemorrhages.

- Cause:
  - Bacterial:
    - *Pneumococcus*
    - *Haemophilus*
  - Viral:
    - Enterovirus - 70
    - Coxsackie - 24
    - Echovirus - 34
    - Adenovirus
- The various causes which can lead to subconjunctival haemorrhage are:
  - Trauma
  - Hypertension (Measure blood pressure 3 times a day)
  - Foreign body
  - Contact lens
  - Bleeding diathesis
  - Pertussis (Any cause of severe cough)

### Trachoma

90.42.43

- Trachoma is the chronic conjunctivitis in children which is caused by *Chlamydia trachomatis*. It has different strains which are A, B, Ba, and C strain.
- Trachoma is the world's leading cause of preventable and irreversible cause of blindness.
- Chlamydia can be involved in:
  - TRIC: Trachoma inclusion conjunctivitis
    - A, B, Ba, C strains in children
    - D to K strains in adults (adults inclusion conjunctivitis)
    - D to K strains also known as swimming pool conjunctivitis (adenovirus can also cause swimming pool conjunctivitis)
  - LGV: Lymphogranuloma venereum for which the strains are L1, L2 L3
- Common in 1-9 years of age.
- Trachoma has two stages of infection: The active inflammatory stage and the chronic cicatricial stage.

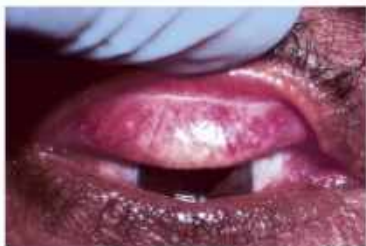#### In the Active-inflammatory stage:

- Signs: The signs are itching and mucopurulent discharge.
- On examination:
  - Follicles (sago grain like follicles) on the upper palpebral conjunctiva and upper limbus (Herbert follicles) are observed.
  - Corneal vascularisation can also occur which is known as pannus and forms rete ridges.
  - Corneal epithelial defects are also seen in this stage and papillary reaction also present.
  - In this stage there is both papillary and follicular reaction

#### Chronic Cicatricial stage:

- Signs: In this stage follicles in the upper palpebral cause scarring which is known as *Artt's line*.

- Scarring also occurs in the upper limbus and is known as the Herbert's pits.
- Pannus is also seen
- Type IV hypersensitivity reaction
- Cicatricial entropion, Trichiasis and Corneal opacity are also observed.



- WHO Grading
  - F - Grade 1:  $\geq 5$  follicles in the upper palpebral
  - I - Grade 2: Inflammatory
  - S - Grade 3: Scarring
  - T - Grade 4: Trichiasis
  - O - Grade 5: Corneal opacity
- **Complication** – Corneal ulcer which later leads to opacity.

#### Pathology of Trachoma

- Follicular and Papillary reaction
- Intracytoplasmic inclusion bodies
  - HP bodies – Halbersteidter Prowasek

#### Investigation of Choice

- PCR (IOC) - by tarsal and conjunctival scraping
- Mc coy cell culture
- Giemsa staining – HP bodies

#### Treatment

- The treatment method for trachoma is abbreviated as SAFE strategy, which are explained as follows:
  - Surgery- (for trichiasis and entropion) Bilamellar Tarsal Rotation
  - Antibiotics - Azithromycin (20 mg/kg in children and 1g/kg in adults), Tetracycline (1% ointment)
  - 1% tetracycline is less effective than azithromycin.
  - It has poor compliance.
  - In children it can lead to tooth staining.
  - Facial hygiene
  - Environmental cleanliness

#### Important Information

- Factors to employ the SAFE strategies in an area affected with trachoma are:
  - The prevalence of Trachoma follicles is observed in 1-9 years old children and if it is in more than 10% of children.
  - If the prevalence is 5% to 10%, then only FE strategy is employed.
  - If the prevalence is less than 5% then no action is taken.

#### Important Information

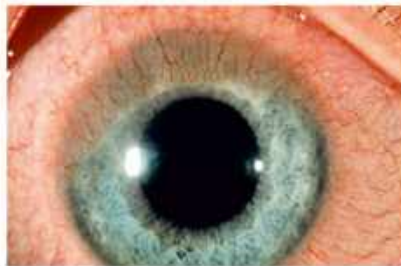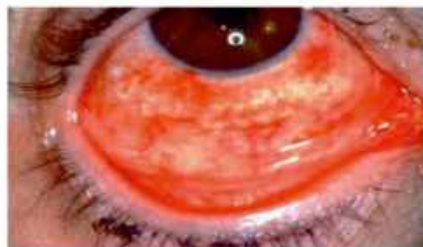- S – Surgery
- A – Antibiotics
- F – Facial Cleanliness
- E – Environmental improvement to reduce transmission

#### Additional Question

Q. What drug is of choice for blanket therapy of trachoma?

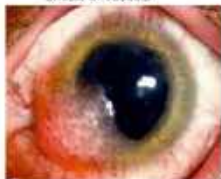Ans: Azithromycin

Other drugs that can be used for trachoma: Doxycycline and Erythromycin, Sulfacetamide eye drops



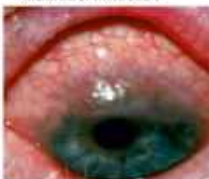## Pannus

Infiltration of cornea is ahead of vessels

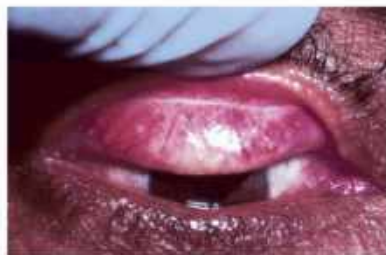

Progressive Pannus

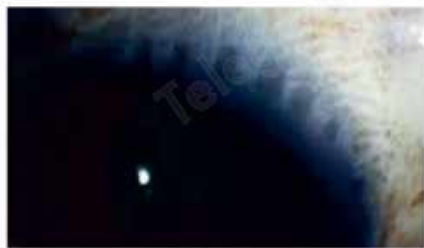Vessels extend beyond the area of infiltration



Regressive Pannus



Arlt's line



Herbert's pits

## Ophthalmia Neonatorum

01.02.24

- Also known as neonatal conjunctivitis
- Conjunctivitis within 1 month of age

### Causes

- Chlamydia (takes 1-3 weeks to manifest) – Most Common
- Gonorrhoea (manifests in 1<sup>st</sup> week) – Most Dangerous
- Herpes simplex virus 2
- Staph aureus
- H. influenzae
- Chemical conjunctivitis (within 24-hour manifest)
- NLD obstruction
- Chlamydia, gonorrhoea, HSV occurs due to vaginal delivery

## Side Note

- A most common cause of chemical conjunctivitis is 1% AgNO<sub>3</sub>, which is given in both eyes in case the mother has Gonorrhoea. (Creed's Method)

## Prophylaxis

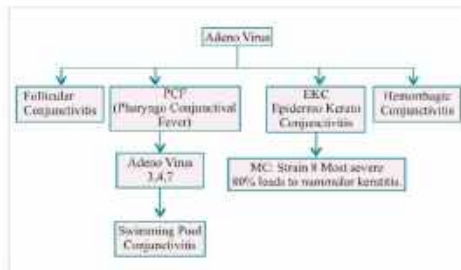
The treatment provided in this case are:

- 1% AgNO<sub>3</sub>,
- Povidone iodine
- Erythromycin
- IM Single dose benzyl penicillin - For gonorrhoeal infection.
- HSV infection can have systemic involvement hence it is needed to be treated vigorously.
- Investigate, do PCR and check for any encephalitis in any small children

## Viral Conjunctivitis

01.08.32

- Cause:
  - In 90% of cases of viral conjunctivitis, the cause is Adenovirus. However, it is also caused by other viral conditions like:
  - COVID-19 (Acute follicular conjunctivitis)
  - Herpes simplex
  - Systemic viral illness (Measles, Mumps, Varicella)
  - Molluscum contagiosum - it is mainly caused by varicella zoster.

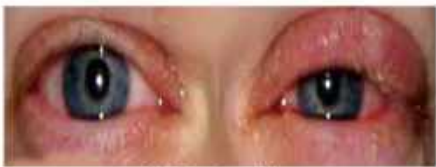

### Clinical features:

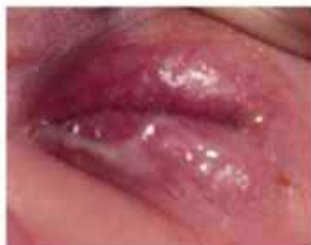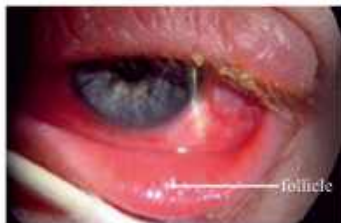- Redness - Conjunctival congestion
- Pain (if cornea is involved), all other features of conjunctivitis
- Watery discharge
- Sub-conjunctival haemorrhages.
- Preauricular lymphadenopathy
- Corneal involvement and keratitis

### Treatment:

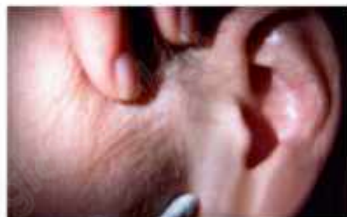- Antivirals only in case of HSV
- Antibiotics to prevent secondary bacterial infection



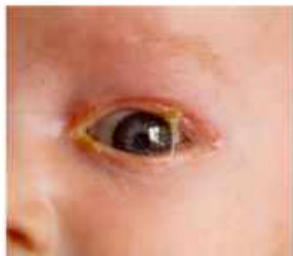Viral conjunctivitis



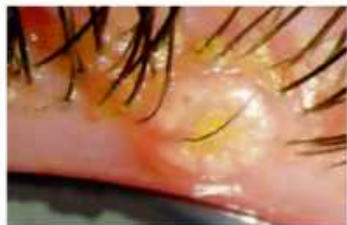Ophthalmia Neonatorum



Preauricular Lymphadenopathy



Neonatal Conjunctivitis




Molluscum Contagiosum

- Molluscum Contagiosum : It is viral infection caused by pox virus.
- Waxy-umbilicated nodule are seen.





## Crossword Puzzle 1




### Across

- Allergic conjunctivitis treated with \_\_\_\_\_ eyedrops.
- A growth on the conjunctiva is \_\_\_\_\_.

### Down

- An inflammation of the conjunctiva is \_\_\_\_\_.
- The bacterial conjunctivitis treated with \_\_\_\_\_ eye drops or ointment.

## Crossword Puzzle 2



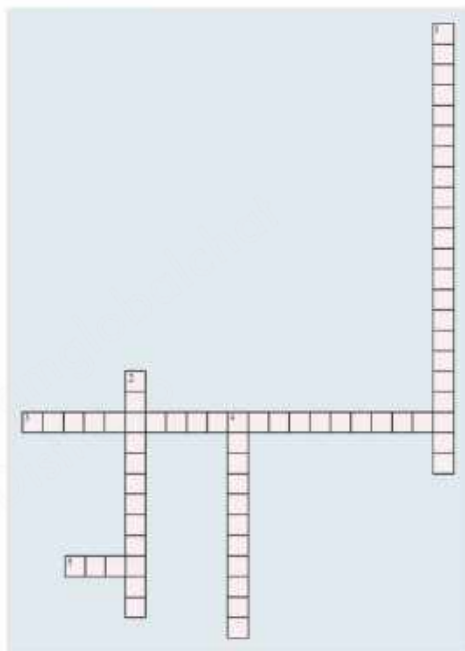
### Across

- \_\_\_\_\_ is the name of the membrane that covers the eyeball's front surface and lines the eyelids inside.
- A growth on the conjunctiva is \_\_\_\_\_.
- The function of the conjunctiva is to protect the eye from \_\_\_\_\_ and foreign bodies.

### Down

- \_\_\_\_\_ is a common condition that affects the conjunctiva.

## Crossword Puzzle 3



### Across

- Stroma is a type of \_\_\_\_\_.
- The number of conjunctival epithelial layers is \_\_\_\_\_.

### Down

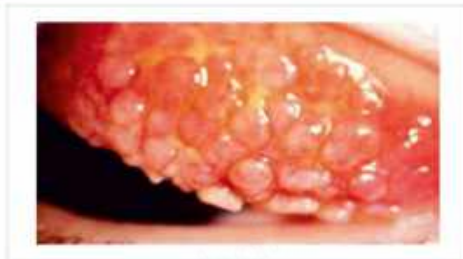- Blood vessel supplying to the bulbar conjunctiva is \_\_\_\_\_.
- A type of discharge in bacterial conjunctivitis is \_\_\_\_\_.
- The tissue in an eye having a lymphatic supply is \_\_\_\_\_.

# 16 CONJUNCTIVA PART-2

## Allergic Conjunctivitis

0030:06

- It is a form of ocular allergy that primarily presents irritation and excessive watering in the eyes due to immunoinductive agents.
- It can be acute, seasonal, or perennial allergic reactions. The types of allergic conjunctivitis are vernal keratoconjunctivitis, atopic & phlyctenular keratoconjunctivitis.



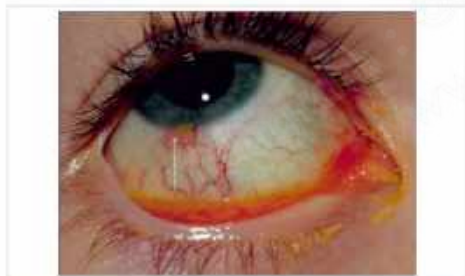## Phlyctenular Conjunctivitis

00:01:35

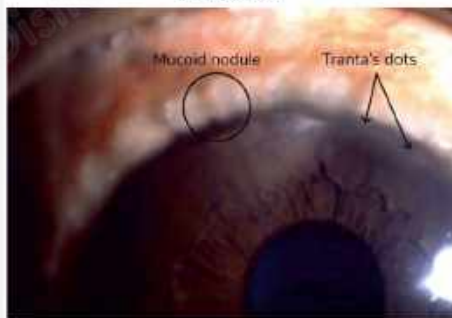
- Allergy caused by endogenous antigens → Staphylococcus aureus and tuberculosis infections.
- Presents watering and itching.
- Characteristic of phlyctenular conjunctivitis → nodule of phlycten near the limbus and conjunctival congestion
- Involvement of cornea leads to a **fascicular ulcer**, which later develops into ring ulcer.
- It is a type 4 hypersensitivity reaction → treated with steroids
- Recurrence of PC due to infection → antibiotics, such as tetracycline.

## Limbal form

- It develops horner trantas spots: white dots containing eosinophils
- When it involves the cornea, it forms the cupid's bow, also known as pseudogerontoxon.



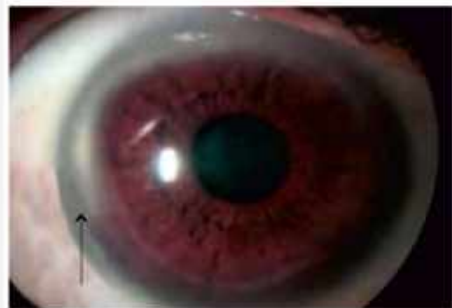Limbal vernal



## Vernal Conjunctivitis

00:05:12

- It is a type 1 hypersensitivity reaction caused by exogenous allergens, such as pollen, dust, etc.
- It is also known as Spring Catarrh
- Common in summer and male children.
- Presents itching, watering, and **ropy discharge containing mucin**.
- It **does not develop follicular reactions** but only papillary reactions.

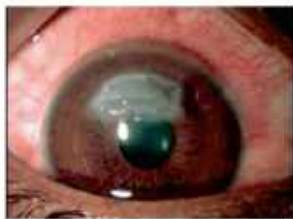

## Three forms of vernal conjunctivitis

Three forms are palpebral, limbal and mixed.

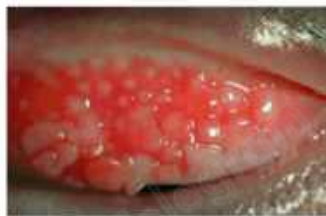## Palpebral form

- It is characterised by papillary reaction with cobblestone appearance



### Important Information

- **Gerontoxon** is another name for **arcus senilis**. The epithelial lesion in vernal conjunctivitis appears like arcus senilis. Hence the name.
- Later stages lead to shield ulcer: deposition of mucus and calcium phosphates in micro-erosions
- Maxwell Lyon's sign is a pseudomembrane formed due to excessive deposition of mucus on the papilla.



- It can lead to Keratoconus due to rubbing

#### Treatment

- Antiallergics:
  - Olopatadine and azelastine: Mast cell stabilisers and antihistamines
  - Mast cell stabiliser: Sodium cromoglycate and nedocromil sodium
  - Antihistamines: Apenastin and bepotastine.
- Topical steroids : Fluorometholone and loteprednol etabonate, when others do not work.
- Acetylcysteine to dissolve mucus

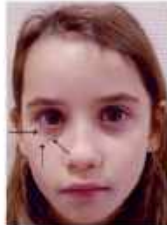#### Atopic Keratoconjunctivitis

00:15:00

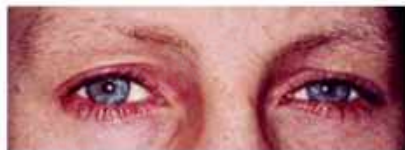- Common temperate regions and winters.
- Predominant in adults with no gender predilection.

#### Findings in Atopic keratoconjunctivitis

- Shield cataract
- Dennie morgan folds: Skin folds under the eyes due to excessive rubbing.



- Madarosis: Loss of eyebrows and eyelashes.
- Hertoghe's sign: Loss of lateral one-third eyebrows



#### Treatment for atopic keratoconjunctivitis

In case of severe allergic reactions: Immunomodulators such as cyclosporin and calcineurin inhibitors, such as tacrolimus.

#### Side notes:

Other causes of Hertoghe's sign

- Leprosy
- Myxedema

#### Xerophthalmia

00:20:22

It is a spectrum of ocular diseases due to Vitamin A deficiency.

#### WHO grading of xerophthalmia

The grading helps determine the severity of the condition. The signs are denoted by X and a subscript. They are

- $X_0$  → night blindness / nyctalopia: the earliest sign
- $X_1$  → conjunctival xerosis
- $X_2$  → bitots spot
- $X_3$  → corneal xerosis
- $X_{4a}$  → keratomalacia in less than one-third of the cornea
- $X_{4b}$  → keratomalacia in more than one-third of the cornea (keratomalacia is liquefactive necrosis of cornea)
- $X_5$  → corneal scarring
- $X_6$  → xerophthalmia fundus → white spotted fundus and decreased amplitude in electroretinogram

**Q:** why do we see decreased amplitude in ERG?

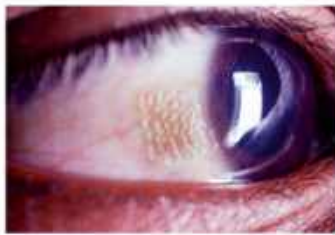**Ans.** ERG represents the activity of layers of rods and cones.

Since xerophthalmia affects rods and bipolar cells, ERG shows a dip in amplitude.

#### Side notes:

##### More about bitots spot

Bitots spot: is keratinised epithelia and infection by *Corynebacterium xerosis*. It is more common on the temporal side.



#### Pathological changes in xerophthalmia

- Loss of goblet cells
- Squamous metaplasia with keratinisation.

#### Treatment for xerophthalmia

- Child more than one year: One lakh IU of vitamin A on the 0<sup>th</sup>, 1<sup>st</sup>, and 14<sup>th</sup> day
- Less than one year: Half the dose
- Oral: Double the dose of injective vitamin A.

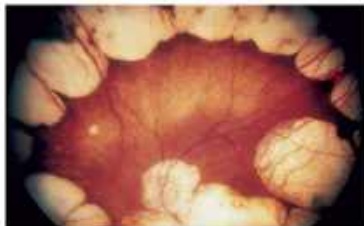
#### Local treatment for xerophthalmia

- Intense lubrication: Eyedrops containing methylcellulose derivatives or sodium hyaluronate
- Retinoic acid.

#### Side note:

##### Causes of nyctalopia

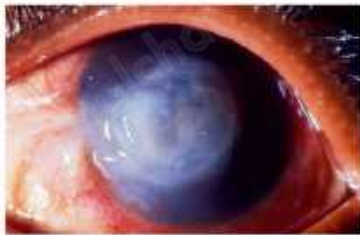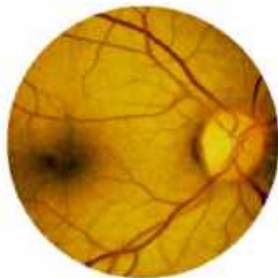- Xerophthalmia
- Retinitis pigmentosa
- High myopia
- Late stage of primary open-angle glaucoma
- Congenital stationary night blindness (CSNB)
- Choroidal dystrophy: choroideremia and gyrate atrophy



#### Side notes:

##### Two forms of CSNB

1. Fundus albi punctatus: night blindness with white spots in the fundus
2. Oguchi's disease: night blindness with pale spots on the fundus.



#### Side notes:

##### Causes of Hemeralopia:

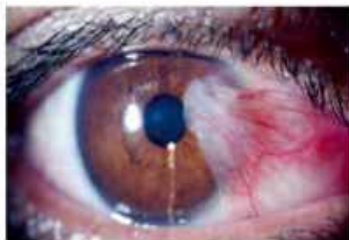
- Central corneal opacity
- Central lenticular opacity
- Congenital absence of cones

##### Mezov's phenomenon

Pale fundus restores its appearance when a person suffering from Oguchi's disease stays in darkness for about an hour. The cause of the phenomenon is the overstimulation of rods.

#### Pterygium

06:33:18



It is conjunctival degeneration characterised by triangular fibrovascular subepithelial ingrowth of bulbar conjunctiva over the limbus. It occurs commonly on the nasal side.

## Causes

- Exposure to UVB rays

## Side note:

What else does UVB cause?

In addition to pterygium, it can cause phot ophthalmia, also called snow blindness → UVB rays reflect off the snow and cause corneal epithelial erosion.

## Clinical features

- Cosmetic problems
- Astigmatism
- Diminished vision when it encroaches on pupils.

## Histopathology

- Elastotic degeneration of conjunctival stroma (similar to pinguecula).

## Structure of Pterygial Formation

- Body: part from the triangle's base to the border of the pupil.
- Head: apical part of pterygium that protrudes into the pupil. and
- Avascular halo: the region around the tip: the destruction of bowman's membrane by metalloproteinases.
- Stocker's line occurs due to iron deposition near the head.

## Pseudo Pterygium

- It is a scarring that appears like pterygium.
- How to differentiate it from pterygium?
  - Glass rod test: if the glass rod passes through scarring, it is pseudo-ptyerygium.

## Treatment

### 1. Bare sclera technique

- The recurrence rate after the bare sclera technique is 30 to 40%.
- Mitomycin C, an anti-mitotic drug administered preoperatively reduces the recurrence.

### 2. Autografting

- It is the most effective modality
- Procedure:
  - Cut a portion of the conjunctiva in the upper or superior temporal quadrant, including limbal stem cells:



Stitch it over the affected area: conjunctiva at excised region regenerates.

### 3. PERFECT

- It stands for Pterygium Extended Resection Followed by Extended Conjunctival Transplantation.
- It is a modified version of autografting wherein the conjunctiva excised is much larger.

## Pinguecula

06:45:00



It is a yellowish-white mound near the limbus formed by elastotic degeneration of conjunctival stroma

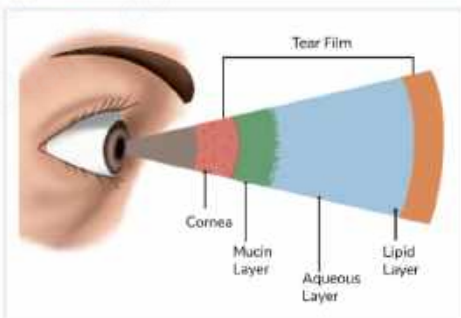
- It is commonly nasal.
- It does not extend on to the cornea.

## Treatment

- Not needed: if asymptomatic.
- Mild steroids or lubricants: if presents itching
- Excision is an option but not preferable.

## Dry Eye

06:46:20



- It is a condition caused by impaired functions of any layer of the tear film. It becomes a disease with the onset of ocular inflammation.
- Dysfunction of any of the three layers of tear film causes inadequate volume, unstable secretion, or dysfunction in the tear.

## Layers of Tear Film After Cornea

1. Mucin layer: formed of goblet cells of conjunctiva → helps spread tear over the ocular surface
2. Aqueous layer: thickest layer: formed of lacrimal and accessory lacrimal glands → lubrication.
3. Lipid layer: formed by meibomian glands → prevents evaporation of tear.

Keratoconjunctivitis sicca is the deficiency of the aqueous layer.

- KCS → Xerostomia primary: Primary Sjogren syndrome.
- Primary Sjogren syndrome + connective tissue disorder: secondary Sjogren syndrome

**Side note:**

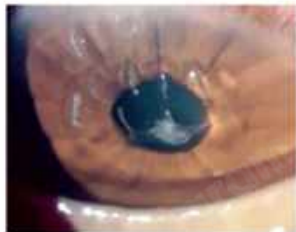00:50:10

**Ocular features of rheumatoid arthritis**

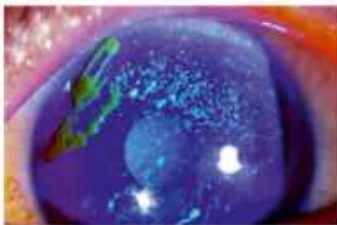
Rheumatoid arthritis is a connective tissue disorder, and its association with keratoconjunctivitis sicca leads to secondary Sjogren syndrome. Hence, patients with rheumatoid arthritis experience dry eye disorder.

**Clinical Manifestations of Dry Eye**

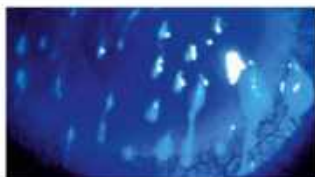- Burning sensation
- Gritty sensation of foreign bodies
- Excessive mucus deposition
- Diminished vision when precorneal tear film involved
- Tear meniscus height lesser than 0.25 mm.



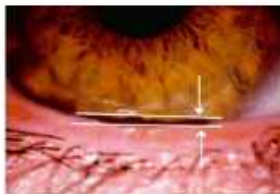
- Punctate epithelial keratitis



- Mucus filaments

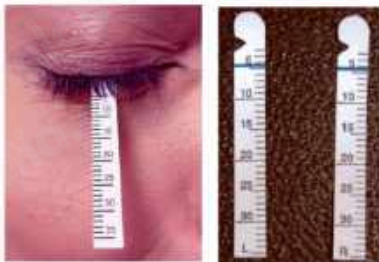

- Slit lamp examination



To visualise tear meniscus height, which is the length of a triangular cross-section between lower lid margin and cornea.

- Schirmer's test



- Schirmer's test 1

It involves placing Whatman paper No. 41 under the lower lid for 5 minutes:

Wet length of less than 5 mm indicates dry eye.

It measures both basal and reflex secretion.

- Schirmer's test 2

Measures only basal secretion using topical anaesthesia.

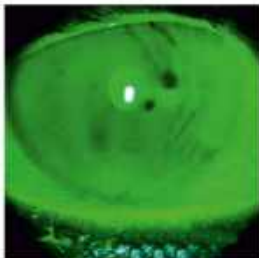


- Phenol red thread test

Yellow-colored thread is brought in contact with the eye for 15 seconds, and the length of the stain that turns red is measured.

Less than 6 mm indicates severe dry eye.

- **Tear film break-up time**



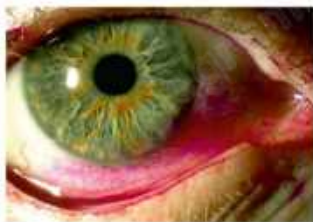- It is the time taken for a dry spot to appear from the last blink.
- Less than 10 seconds indicates severe dry eye.



### Important Information

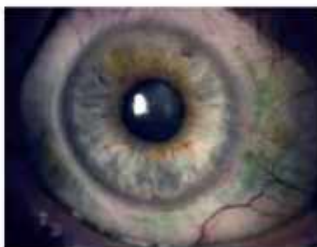- While Schirmer's and phenol red thread tests help diagnose aqueous layer dysfunction, TBUT helps diagnose deficiency in the meibomian and lipid layer.

- **Rose Bengal or lissamine green staining**



#### Medical

- Lubricating eye drops containing methylcellulose derivatives, polyvinyl alcohol with povidone, or hyaluronate derivatives.
- Acetylcysteine to dissolve mucus.
- Cyclosporin for inflammation
- Management of lid pathology



They help visualize dead cells and mucus.

- **Tear constituent**  
Low levels of lactoferrin indicate dry eye.
- **Tear meniscometry**  
Check the tear meniscus height
- **Impression cytology**  
Measures the number of goblet cells.
- **Tear osmolality measurement**  
A high value indicates a dry eye.

#### Treatment

Treatment is either medical or surgical

#### Surgical

##### Lacrimal punctal occlusion.

- For temporary measure Collagen plug that can be dissolved in a few weeks.  
Silicone plugs for prolonged occlusion.
- For permanent measure, thermal cautery of proximal canaliculi.

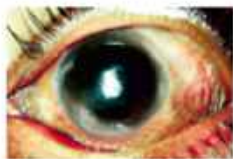

## PREVIOUS YEAR QUESTIONS



- Q. A patient presenting with diminishing vision in dim light with dry eyes and roughening of corneal surface. Which of the deficiency can be associated with it?

(NEET SEP 2021)



- A. Iron  
B. Protein  
C. **Retinoic acid**  
D. Niacin

- Q. The dosage of Vitamin A in keratomalacia in a 2-year-old boy who is 12 kg weight is? (NEET JAN 2019)

- A. **Vitamin A: 2 lakh in oral, 1st, 2nd, 14<sup>th</sup> day**  
B. Vitamin A: 1 lakh in oral, 1st, 2nd 14<sup>th</sup>  
C. Vitamin A: 2 lakhs in oral, 1st, 2nd, 3rd  
D. Vitamin A: 1 lakh in oral, 1st, 2nd, 3<sup>rd</sup>

- Q. Which is the most sensitive screening test for vitamin A deficiency? (FMGE DEC 2019)

- A. Serum retinol < 10 ug /decilitre  
B. Beta carotene < 50ug / decilitre  
C. Bitot's spots  
D. **Night blindness**

- Q. What is the treatment of choice for recurrent pterygium? (FMGE JUNE 2021)

- A. Simple excision  
B. Observation  
C. **Excision with conjunctival auto graft**  
D. Treatment with Mitomycin C

- Q. Herbert's pits are seen in? (JIPMER NOV 2018)

- A. Vernal conjunctivitis  
B. Atopic conjunctivitis  
C. Gonococcal conjunctivitis  
D. **Chlamydial conjunctivitis**

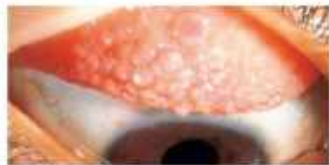- Q. What is the term given to a condition with an extra Layer of cilia posterior to grey line? (NEET JAN 2020)

- A. Tylosis  
B. Madarosis  
C. **Distichiasis**  
D. Trichiasis

- Q. Phlyctenular conjunctivitis is seen due to: (FMGE DEC 2019)

- A. Post fungal infection  
B. **Allergic reaction**  
C. Post protozoal  
D. Post tuberculoid

- Q. A female comes with 2-year history of contact lens use presents with eye pain, irritation and foreign body sensation. Identify the diagnosis? (NEET SEP 2021)

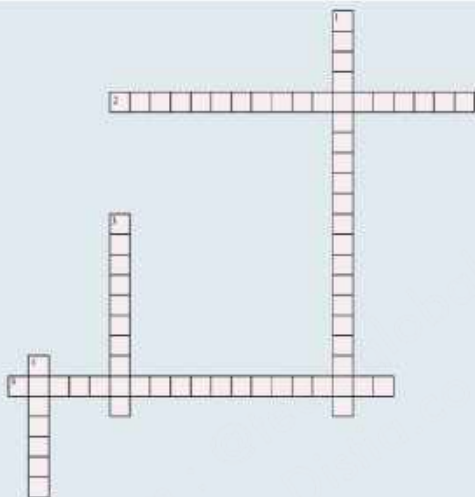


- A. Trachoma  
B. **Giant papillary conjunctivitis**  
C. Spring Cataract  
D. Acute follicular conjunctivitis





## Crossword Puzzle



### Across

2. Common symptoms in conjunctivitis.
5. Test to diagnose deficiency in meibomian and lipid layer.

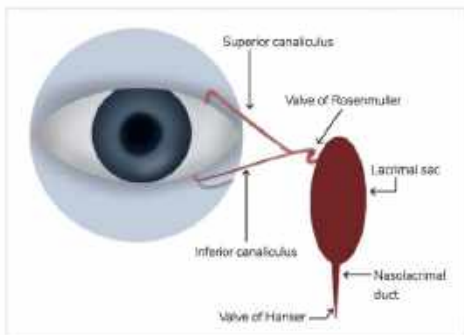
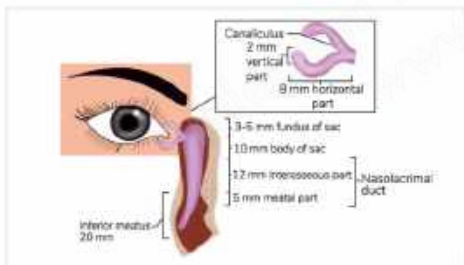
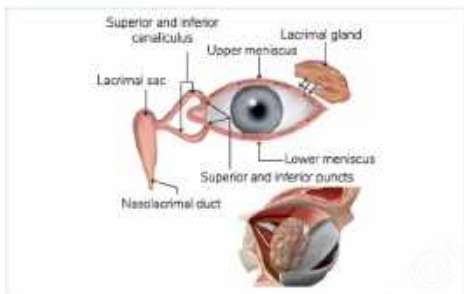
### Down

1. The most common conjunctivitis in summer and tropical regions.
3. The earliest sign of xerophthalmia.
4. Modified version of autografting with almost zero recurrence.

00:00:18

## Anatomy

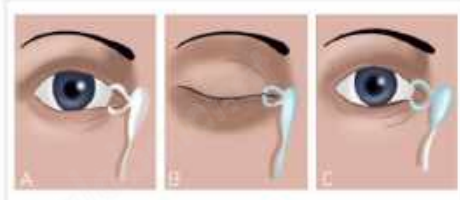- It consists of an upper lid and a lower lid with two puncta: **upper and lower punctum**.
- The upper and lower canaliculi join to form **common canaliculi** which open into the **lacrimal sac** and open into the **nasolacrimal duct**.



## Physiology of the Lacrimal Gland

00:04:37

- Tear is formed from lacrimal gland i.e., accessory lacrimal gland and main lacrimal gland.
- It lubricates the ocular surface, after lubricating some are evaporated and some tears are drained.
- **Blinking plays an important role in the drainage of the tear.**



- When eyes are open, there is a negative pressure in the lacrimal sac. This leads to the expansion of the lacrimal sac.
- Due to the negative pressure and capillary forces, the tear flows from the **puncta to the canaliculus**.
- Now when we close our eyes, due to the positive pressure developed in the lacrimal sac it pushes the tear into the nasolacrimal duct.

## Types of Watery

00:07:20

	Lacrimation	Epiphora
	Over-production	Over-flow
<b>Causes</b>	Anterior segment diseases like conjunctivitis, uveitis, keratitis, glaucoma Dry eye (paradoxical watering)	<ul style="list-style-type: none"> <li>• Malposition of lacrimal puncta</li> <li>• Obstruction (anatomical) in the drainage system</li> <li>• Functional obstructions like lacrimal pump failure</li> </ul>

## Symptoms of Lacrimal Blockage

00:11:36

The two main symptoms are.

- Epiphora
- Discharge : Any stagnancy can lead to infection which can lead to discharge

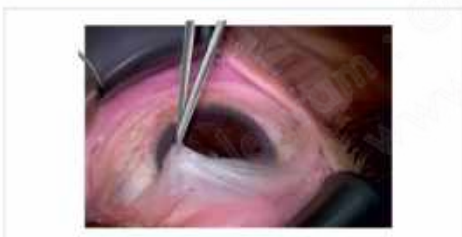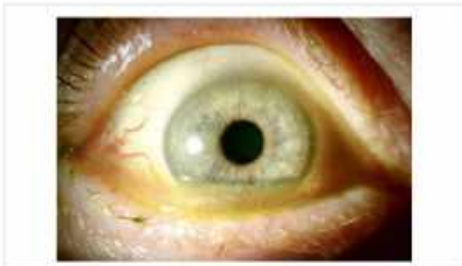## On Examination

### Meniscus Height of the Tear

- Under the slit lamp, check the meniscus height of the tear film.
- The height of lower meniscus has increased (the normal height is 0.2-0.4mm).
- **If there is drainage blockage it can go up to 0.6mm.**

### Conjunctivochalasis

- It is a loose conjunctiva that is not properly attached.
- It covers the puncta, and the tear cannot drain.

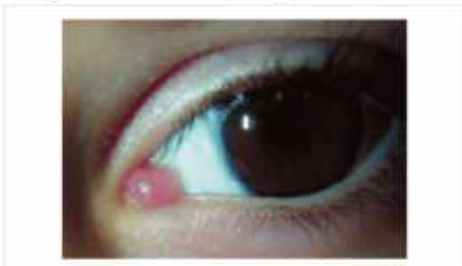

### Lacrimal Puncta

- Check for Stenosis of the puncta.
- Malposition of the puncta like ectropion.

### Caruncle

- Large caruncle which obstructs the puncta.



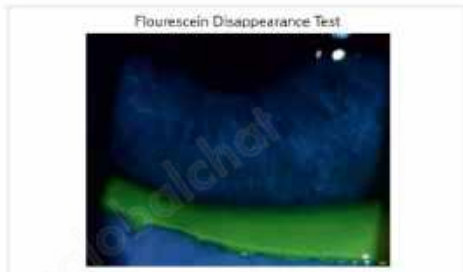## Regurgitation Test

- Press the medial canthus at the sac area. If there is a blockage in the nasolacrimal duct, **regurgitation** occurs.

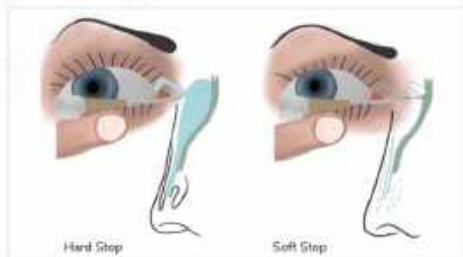
## Investigation

### Fluorescein Disappearance Test

- Fluorescein is put in the eye and waited for 5 to 10 minutes → we don't expect fluorescein after 10 mins.
- If fluorescein is present, there is some drainage issue in the eye.



## Syringing



- If it is a hard stop, then **the canaliculi are normal.**
- If it is a soft stop, then there is **an issue with the common canaliculi or lower canaliculi.**
- If lower canaliculi are blocked, **the water regurgitates from the lower puncta.**
- If the common canaliculi are blocked, **it regurgitates from both the puncta.**

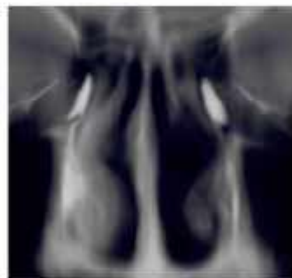
Saline does not reach the throat	Saline reaches the throat
Total obstruction of the nasolacrimal duct	Pump is patent, punctal stenosis, Mild lacrimal pump failure(mild), or partial obstruction
Regurgitation from both puncta	—

- If there is a hard stop with doubt of partial obstruction or pump failure, or punctal obstruction, the Jones dye test is done.

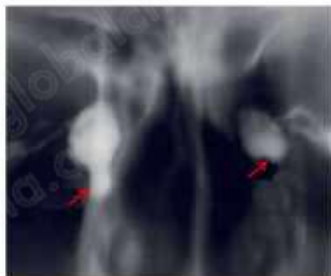
### Jones Dye Test

00:24:11

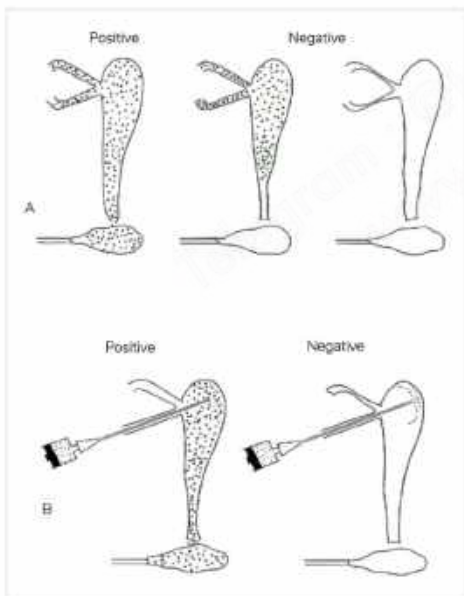
- The primary test differentiates it from hypersecretion.
- If fluorescein is present in the cotton test is positive and the inference, the inference is that it is a case of hypersecretion.
- If it is negative, we perform the secondary test.
- Fluorescein-stained saline indicates that fluorescein has entered the sac and this suggests that the upper lacrimal passage is normal.
- Inference: There may be partial obstruction of NLD distal to the sac.
- If no fluorescein is present in the saline, then the fluorescein has not entered the lacrimal sac. The upper lacrimal passage has an obstruction.
  - There is either a partial physical obstruction or pump failure.



Normal DCG



- The image shows the distended sac, obstruction in NLD and filling defect S/O lacrimal stone



### Dacryocystography (DCG Test)

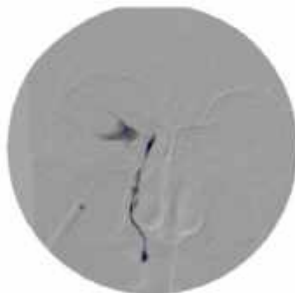00:32:25

- Detailed study of the lacrimal sac
- The radiopaque contrast is ethiodized oil.
- The oil is injected into the canaliculi and the magnified images are taken.
- Tumours or stones in the sac are found using this method.

### Dacryoscintillography or Nuclear Lacrimal Scintigraphy

00:33:33

- Labelling the tear with a radioactive substance.
- It is the study of the flow of tears in physiological conditions.
- This is the IOC for lacrimal pump failure.





Normal lacrimal Flow

Blockage  
Nasolacrimal Sac



R

L

#### CT/ MRI scan

- Pathology of the lacrimal sac
- Paranasal sinuses

00:05:25

#### Obstruction of Lacrimal Pathway

00:09:15

##### Congenital

- Nasolacrimal duct obstruction because of non canalization of NLD
- Dacryoceles

##### Acquired

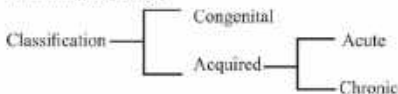
- Conjunctivochalasia
- Lacrimal punctal stenosis: Primary (no punctal eversion) or secondary (associated with punctal eversion)
- Catarrhal obstruction
- Dacryolithiasis: Any stone or tumor
- NLD obstruction

#### Dacryocystitis

- Inflammation of the lacrimal sac.

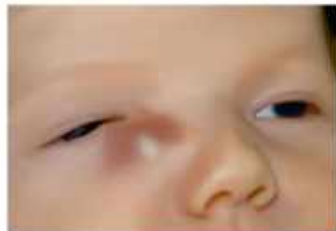00:02:15

Inflammation of L.sac

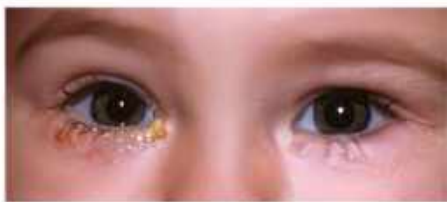

#### Congenital Dacryocystitis

00:02:40



- **Causes:**
  - Non-canalisation of the NLD just above the valve of Hasner
- **Symptoms:**
  - Child with Epiphora or discharge



#### Investigations:

- Fluorescein disappearance (highly specific) test or Regurgitation test

#### Differential Diagnosis:

- Congenital glaucoma
- Neonatal conjunctivitis
- Punctal atresia

#### Treatment:

- If the patient is less than 9 months, **Criggers massage is done**. Maximum success of **Criggers massage is within 6 months of age**.
- If the patient is greater than 9 months, **probing is done**. Success rate is till 18 months (2 years)
- If the child is older than 4 years, **DCR (dacryocystorhinostomy) surgery is done**.
- Another new modality of treatment is **intubation and balloon dilatation of NLD**.



#### Important Information

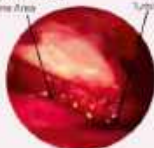##### Types of DCR:

- External DCR: Incision line is made below the medial canthal line along the medial crest
- Scar is seen
- Endoscopic Endonasal DCR

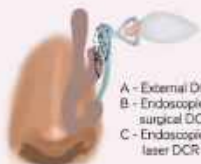

Exposed: orbital Bone Area

Probe Turbinate



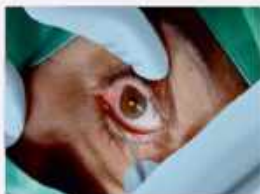- Endonasal Laser DCR



A - External DCR  
B - Endoscopic endonasal surgical DCR  
C - Endoscopic endonasal laser DCR

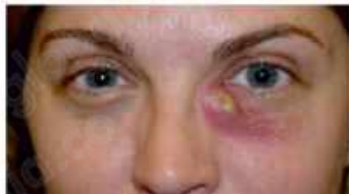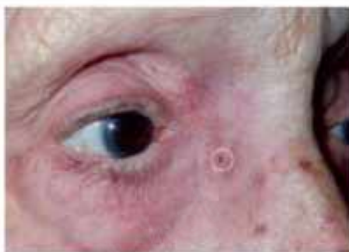Comparison of Rhinostomy size at surgery

- Trans canalicular laser DCR



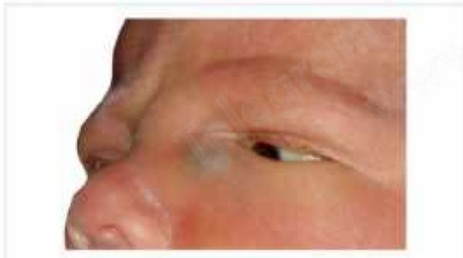- Laser used is diode: 980nm or Holmium-YAG laser

- This acute inflammation may lead to **lacrimal abscess** or **pre-septal cellulitis**.
- If any drainage is done, it may lead to **Lacrimal fistula formation**.
- **Fistula opens on the skin**



### Congenital Dacryocoele

00:51:20



- Amniotic fluid and mucous is trapped in the lacrimal sac due to imperforated Hasner valve.
- **Symptoms:**
  - Bluish cystic swelling
  - Epiphora
- **Treatments:**
  - Antibiotics
  - Probing if needed Usually, resolution is seen

- **Treatment:**

- Conservative treatment with Antibiotics/ anti-inflammatory
- DCR

### Chronic Acquired Dacryocystitis

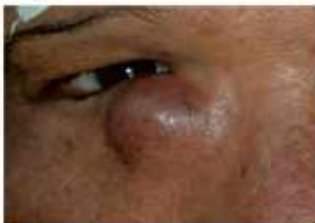00:56:01

- **More common in females than males.**
- **MC aetiology: Staph aureus**
- **C/P: epiphora, discharge and mucocele**
- **Sequelae:**
  - Mucocele formation can lead to Pyocoele formation which can lead to lacrimal fibrosis.

### Acute Acquired Dacryocystitis

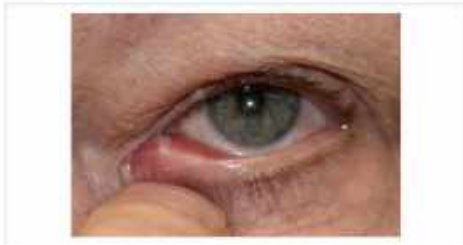00:53:00

- **Symptoms:**
  - Epiphora
  - Discharge
  - All signs of inflammation like redness, pain and tenderness.



- **Treatment:**

- Treatment for lacrimal fibrosis is DCT (Dacryocystectomy).

**Causes**

- Actinomyces Israeli: Anaerobic gram positive bacteria
- Herpes simplex virus

**Symptoms**

- Pouting of puncta (Hallmark of canaliculitis)
- Concretions inside canaliculi → that gets complicated as canalicular obstruction and scarring.

**Treatment**

- Broad-spectrum antibiotics
- Canaliculotomy: give linear incision and curettage the concretions.

**Important Information**

- Before any intraocular operation for cataract or glaucoma, if there is any doubt regarding blockage in lacrimal drainage system or if there is any infection, procedure will not be done till the it is managed as there will high chances of intraocular infection leading to endophthalmitis.



## PREVIOUS YEAR QUESTIONS

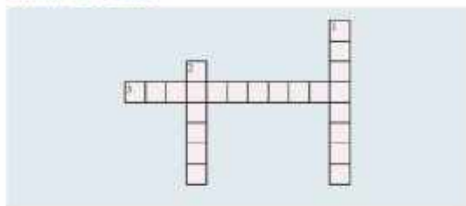


- Q. Lacrimal gland is supplied through parasympathetic system. It is supplied by which ganglion? (FMGE DEC 2019)
- A. Ciliary ganglion
  - B. Otic ganglion
  - C. **Pterygopalatine ganglion**
  - D. Submandibular ganglion
- Q. In canalicular blockage, which is true about Jones test findings? (JIPMER MAY 2018)
- A. First test positive, second test negative
  - B. First test negative, second test positive
  - C. Both positive
  - D. **Both negative**
- Q. A 3-month-old baby presents with mucous exuding from eye on pressing the lacrimal sac. what treatment should be given? (FMGE JUNE 2021)
- A. **Lacrimal sac massage**
  - B. Syringing
  - C. Probing
  - D. DCR
- Q. A 5-year-old child presents with chronic epiphora. what is the next step of management? (FMGE JUNE 2021)
- A. Lacrimal sac massage
  - B. Tarsal fracture
  - C. Lacrimal probing
  - D. **Dacryocystorhinostomy**





## Crossword Puzzle 1



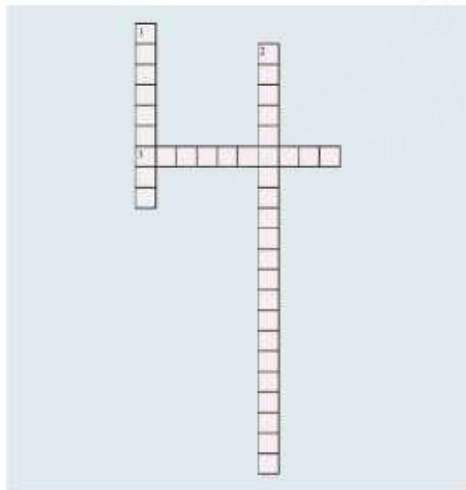
### Across

1. flow of tears

### Down

1. plays an important role in drainage of tear
2. paradoxical watering

## Crossword Puzzle 2



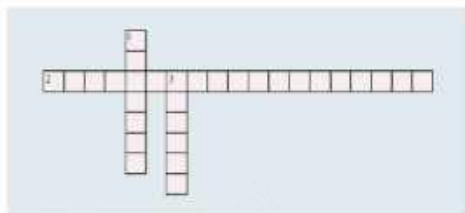
### Across

1. \_\_\_ oil is radioopaque contrast in DCG test

### Down

1. \_\_\_ massage is done for patients less than nine months suffering fro.
2. investigation of choice for lacrimal pump failure

## Crossword Puzzle 3



### Across

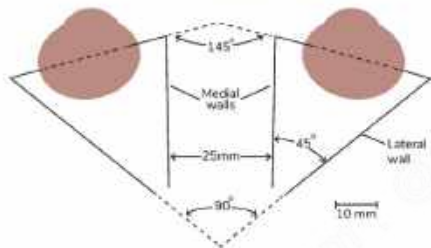
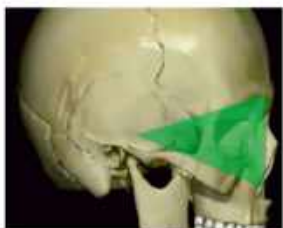1. loose conjunctiva that is not properly attached.

### Down

1. \_\_\_ of puncta is the hallmark of canaliculitis
3. bluish \_\_\_ swelling is seen in Congenital Dacryocoele

# 18 ORBIT

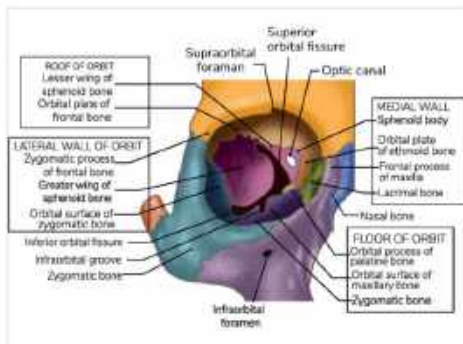
## Orbit



- The capacity of the orbit is 30cc.
- The shape of the orbit is quadrilateral or pyramidal.
- Medial walls are parallel to each other
- The angle between the medial and lateral walls of the orbit is 45 degrees.
- It is a divergent orbit.

### Bones Forming Orbit

00:01:52



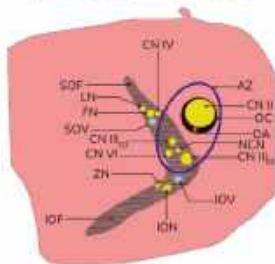
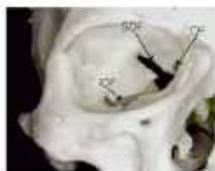The following bones form the orbit:

Boundaries	Bones
<b>Roof</b>	<ul style="list-style-type: none"> <li>• Frontal bone</li> <li>• Lesser wing of Sphenoid bone</li> </ul>
<b>Lateral</b>	<ul style="list-style-type: none"> <li>• Zygomatic bone</li> <li>• Greater wing of Sphenoid bone</li> </ul>
<b>Floor</b>	<ul style="list-style-type: none"> <li>• Zygomatic bone</li> <li>• Maxillary bone</li> <li>• Palatine bone</li> </ul>
<b>Medially</b>	<ul style="list-style-type: none"> <li>• Frontal process of maxillary bone</li> <li>• Lacrimal bone</li> <li>• Cribriform plate of ethmoid sinus (Lamina papyracea)</li> <li>• Body of sphenoid</li> </ul>

- The weakest wall of the orbit is the medial wall due to the cribriform plate of the ethmoid.
- Blowout fracture (fracture due to blunt trauma) means fracture floor of the orbit.
- The weakest part of the floor is the posteromedial part.

### Fissures and Structures Passing Through them

00:05:25

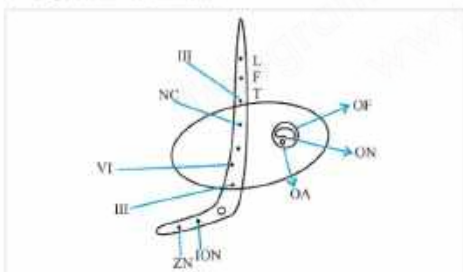


- Superior orbital fissure is present between the lesser wing of sphenoid and the greater wing of sphenoid
- Inferior orbital fissure is formed between greater wing of sphenoid and maxillary bone

- Orbital fissure is the part of the roof
- Supraorbital notch: Peribulbar anesthesia is given through this
- **Superior orbital fissure:** A bony cleft found at the orbital apex between the roof and lateral wall.
- **Structures passing through the superior orbital fissure are**
  - Oculomotor nerve,
  - Trochlear nerve,
  - Ophthalmic division of the trigeminal nerve (with its frontal, lacrimal, and nasociliary branch),
  - Abducens nerve
  - The ophthalmic veins (superior and inferior).
- **Inferior orbital fissure:** It is defined as a space between the lateral wall and floor of the orbit.
- **Structures passing through the Inferior orbital fissure are**
  - Maxillary nerve and its zygomatic branch,
  - The ascending branches form the pterygopalatine ganglion.
- **Optic foramen**
- **Structures passing through the Optic foramen are**
  - The optic nerve
  - The ophthalmic artery.

## Annulus of zen

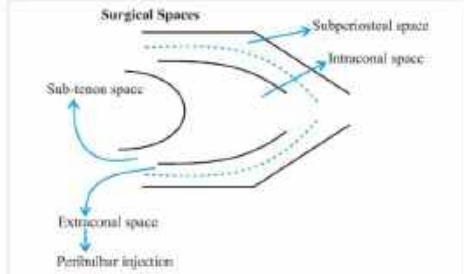
1. Origin of all 4 recti muscle



## Orbital Fascia

60/99/19

- It has two types:
  - **Periorbital fascia** - Periorbital fascia provides lining to the periosteum.
  - **Bulbar fascia aka Tenon's capsule**- Bulbar fascia forms the extraocular muscle sheaths.
  - Bulbar fascia gives rise to **medial and lateral check ligaments**, which help the eyeball's horizontal stability or lateral stability.
  - **The suspensory ligament of Lockwood** (forms the fascial sheath of all extraocular muscles except superiors,) provides vertical stability and prevents downward displacement of the eyeball.



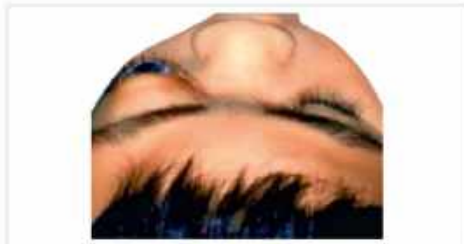- Intraconal surgical space is within the muscle cone.
  - Retrobulbar injection are given in intraconal space.
- Extracanal surgical space - Peribulbar injection are given here.
- Subperiosteal - Below periosteum
- Sub-tenon surgical space is between the tenon capsule and the eyeball.

## Proptosis

06/14/31

- It is the protrusion of the eyeball.
  - If the distance between the lateral orbital margin and the apex of the cornea is more than 21mm or the difference between the eyes is more than 2mm.
  - Proptosis is measured by exophthalmometer
  - Hertel's exophthalmometer is used in adults
  - Luedde exophthalmometer in children.
  - Naugle exophthalmometer - Non axial proptosis

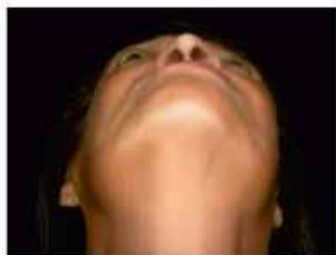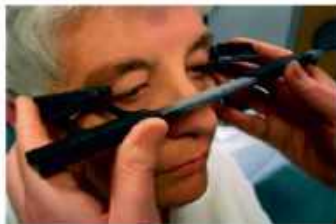## Clinical examination of the orbit



## A) Inspection

- **2 globe position**
  - Proptosis (Axial forward Protrusion of the globe)
  - "Nafziger Test" - Stand behind the patient & elevate the chin of the patient
- Eye outside supraorbital rim is protruded eye.
- Looking from above
  - Bring upper & Lower orbital margins in the same plane

- Look whether the cornea is coming out of this plane



- Worms view - seeing patient from front

### Classification of Proptosis

Proptosis is classified based on the following three conditions:

- Painful/Painless
- Unilateral/Bilateral
- Axial/Non-axial (Dystopia)

### Pseudoproptosis

- Eye is not protruded, distance between lateral & orbital margin & apex of cornea is normal.
- But still on looking one eye is normal & other is protruded

### Causes of Pseudoproptosis

There are various causes of Pseudoproptosis, which are as

- High myopia.
- Eyelid retraction.
  - Normal position of upper eyelid - just below limbus i.e., covering 2 mm of cornea.
  - Lower eyelid just touches the limbus.
  - Eyelid below normal level is ptosis & above normal level is called retraction
- Contralateral ptosis.
- Contralateral enophthalmos.
- Shallow orbit.

### Thyroid Eye Disease

06/21/09

- Also known as Grave's ophthalmopathy.
- Thyroid eye disease (TED) is an autoimmune disease.
- Thyroid eye disease is more common in females.
- Thyroid eye disease patients can have euthyroidism, hyperthyroidism, or hypothyroidism.
- Most common causes of proptosis is TED in adults



### Clinical Features

- **Proptosis**
  - It can be U/L/BL, Painful/Non-painful/ Axial/ Non-axial.
- **Optic neuropathy**
- **Myopathy**
- Soft tissue sign.
- Lid sign.

### Pathogenesis

- Thyroid eye disease (TED) is an autoimmune disease caused by antibodies against thyroid gland cells & orbital fibroblast.

It causes inflammation of the extraocular muscles,



It leads to the infiltration of inflammatory cells.



The multiplication of adipose cells results in increased secretion of GAGs.

- There is more pressure inside orbit ( normal capacity -33 cc) i.e., orbital pressure which will push the eye out causing proptosis
- This will also press on optic nerve leading to compression optic neuropathy.
- Optic neuropathy will manifest as all the sign of optic nerve disease.

### Treatment

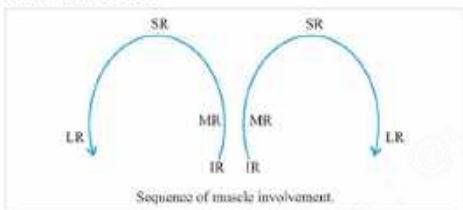
Thyroid eye disease can be treated by the following

- Systemic steroids.
- Immunosuppressors.
  - Tocilizumab → IL 6

- Infliximab → TNF  $\alpha$
- Adalimumab → TGF
- Teprotumumab
- Radiotherapy - Anti Inflammatory role.
- In very severe cases, surgery is performed. (decompression surgery).
  - In decompression surgery, the deep lateral wall of the orbit is broken first.
  - Followed by medial
  - Inferior
  - Lateral
- Myopathy (Restricted myopathy)
  - **Clinical features:** Symptoms in myopathy patients are Diplopia and Squint eye.
  - **Treatment:** Myopathy can be treated by Squint surgery.

Q. Which is the first muscle to be involved?

Ans: Inferior rectus



Q. Last muscle to involve

Ans: IO - Inferior oblique

Q. Which part of the muscle is involved?

Ans: Belly of muscle

Q. First defective movement detected in thyroid?

Ans: Elevation due to fibrosis of IR

- FDT - Force Duction Test is used to check fibrosis
  - In a patient with defective elevation, superior rectus is held with a forceps and moved upwards. If it moves along with forceps easily, it indicates superior rectus palsy. If it is stuck even with forceps movement, it indicates inferior rectus fibrosis.

#### Soft Tissue Signs

- There can be **conjunctival congestion**; Called as the **Goldzeiher sign**.
- There can be **chemosis** (conjunctival oedema), called the **Enroth sign**.
- There can be Superior limbic keratoconjunctivitis -
- It is a feature of thyroid eye disease.
- There can be mucous deposition.
- To treat this condition, adrenaline eye drops can be used.
- Acetylcysteine eye drops can also be used to dissolve the

- mucous
- Complications: Exposure Keratopathy.
- **Lid signs**
  - Lid retraction: Dalrymple sign.
  - Due to fibrosis of IR, there is rebound action of LPS & SR.
  - Lid lag: The Von-Graefe sign.
  - Decreased frequency of blinking: Stellwag sign
  - Mobius sign - difficulty in convergence

N → No Sign

O → Only sign → first → lid retraction

S → Soft tissue involvement

P → Proptosis

E → EOM. (Jed convergence mobius sign)

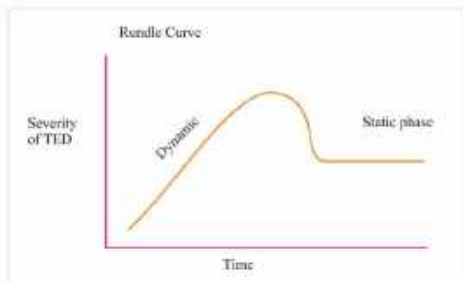
C → Corneal involvement

S → Loss of sight → Optic Neuropathy

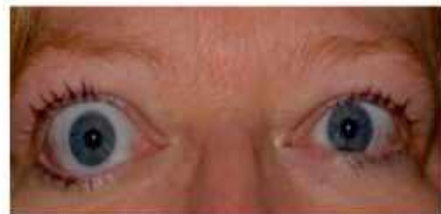**Treatment:** Recession of overacting muscle and resection of underacting muscle.

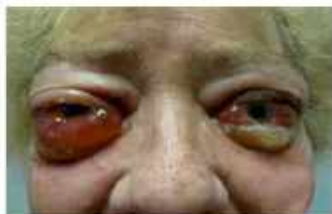#### Recession of LPS

- D → Decompress surgery
- S → Squint surgery
- L → Lid surgery
- **The Randle curve** is used to study the severity of **Thyroid eye disease**.

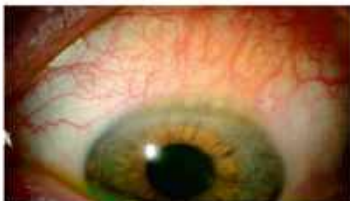

- Kocher's sign is a condition when the patient's eyelids are wide open, giving the patient the appearance of staring too intently at everything they see.

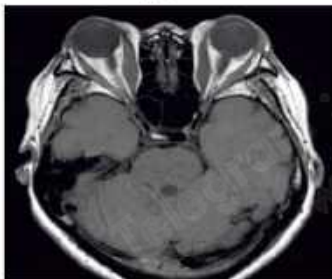




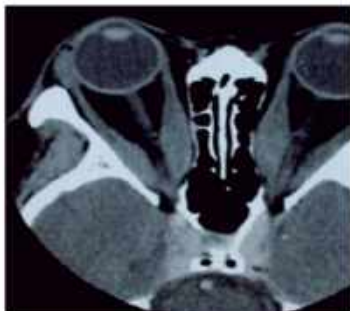Enroth Sign



SLK



MRI Thyroid Myopathy-Tendons spared, only belly of muscle is involved  
CT Scan: Thyroid Myopathy



### Orbital Cellulitis

- It is inflammation behind the orbital septum.
- Pre-septal cellulitis seen more commonly in children.
- It can occur due to any insect bite, mild trauma.

### Aetiology of Orbital Cellulitis

The following point describes the underlying causes of orbital cellulitis.

- Sinusitis: Ethmoid Sinusitis
- Dental cause
- Dacryocystitis
- Endogenous cause : Septicemia
- Exogenous cause: Inflammation & infection in orbit due to some trauma like fracture or surgery of orbit.

### Etiological Agents

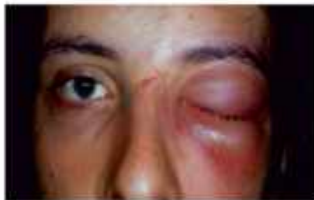The various agents causing orbital cellulitis and Pre septal cellulitis are

- Staphylococcus aureus infection (most common).
- Streptococcus pyogenes infection
- Haemophilus infection can lead to orbital cellulitis (most common in children)
- Fungal - Mucormycosis

### Clinical Features

Following are the features to identify the cases of orbital cellulitis:

- Unilateral proptosis
- Painful Proptosis
- Restriction of eye movements due to proptosis ( No nerve involvement)
- Decreased visual acuity
- Lid oedema / Conjunctival congestion / Chemosis
- Fever, Weakness, Malaise



### Complications

Orbital cellulitis, if not treated early, can lead to

- Disc edema

- RAPD due to optic nerve dysfunction
- Cavernous sinus thrombosis
- CRAO/CRVO (In case of fungal infection i.e., Mucormycosis)
- Intraorbital abscess formation or periorbital abscess formation.
  - Orbital cellulitis is an emergency - Immediately patient is admitted and start with IV antibiotic because risk of involving cavernous sinus.
  - 6th nerve is first involved in cavernous sinus so patient present with U/L OC, check abduction in other eye.

### Investigation

The following two techniques are used to diagnose orbital cellulitis:

- Computed tomography
- Magnetic resonance imaging

### Treatment

Orbital cellulitis can be treated by giving

- Intravenous antibiotics can be given to treat orbital cellulitis.
- Empirical therapy treats orbital cellulitis by giving Cefazidime, Vancomycin, and Metronidazole.



### Important Information

- Any inflammation in the front of the orbital septum is called Pre septal cellulitis. It is more common in children.
- The risk of cavernous sinus thrombosis is known as an ocular emergency.

### Rhino Orbital Cerebral Mucormycosis

01.02.20

#### Infection

- In immunocompromised patients, inhalation of mucor spores can lead to Rhino orbital cerebral mucormycosis.

#### Clinical Features

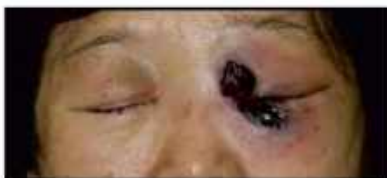There are certain features with the help of which rhino orbital cerebral mucormycosis can be identified.

- It is similar to orbital cellulitis.
- Black fungus is called so because it causes tissue ischemia, leading to tissue necrosis.
- There is a risk of complications like CRAO and CRVO.

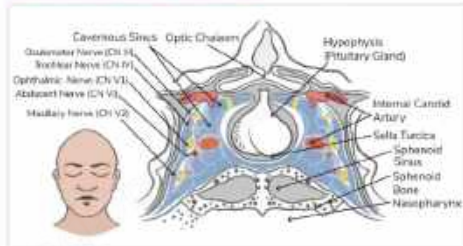
#### Treatment

Various medications are used to treat rhino orbital cerebral mucormycosis, such as

- Intravenous amphotericin B
- Intravenous Posaconazole



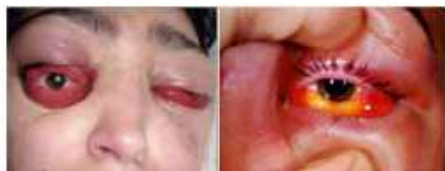### Cavernous Sinus Thrombosis



- The first sign of cavernous sinus thrombosis is 6th nerve palsy as it is present inside body of sinus.

#### Clinical Features

- 6th nerve palsy can be seen, defective abduction.
- Total restriction of eye movements can be seen due to the involvement of 3,4,6th nerves.
- 5th nerve sensory supply is also affected, resulting in blink reflex loss.
- Absent light reflex and absent accommodation reflex
- Bilateral painful proptosis is seen.
- Bilateral papilledema (swelling of the optic disc)
- Mastoid tenderness is also seen.



#### Treatment

To treat this cavernous sinus thrombosis

- Intravenous antibiotics are given.
- Intravenous anti-inflammatories are given.

### Superior Orbital Fissure Syndrome

01.07.22

- Superior orbital fissure syndrome (also known as Rochon-Duvigneaud syndrome) is a collection of symptoms caused by compression of structures anterior to the orbital apex.

- Nerves passing through superior orbital fissure will be affected in superior orbital fissure syndrome causing infection and inflammation.

### Symptoms

- Ophthalmoplegia - The eye cannot perform conjugate lateral gaze.
- Proptosis is bulging one or both of your eyes from their natural position.
- Loss of corneal sensation is observed because 3, 4, 5, and 6 nerves are involved.
- It is orbital apex syndrome when all these symptoms are associated with optic nerve involvement.

### Tolosa Hunt Syndrome

01:39:00

- It is a rare, idiopathic, non-specific granulomatous inflammation of the cavernous sinus orbital, SOF or orbital apex.

### Clinical Features

The clinical features associated with Tolosa syndrome are

- Diplopia (double vision or seeing double)
- Mild proptosis (Mild bulging of eyes)
- Pupillary movement is affected.

### Investigation

- CT or MRI scan.

### Treatment

- Systemic steroids and immunosuppressive drugs.

### Lacrimal Gland Tumor

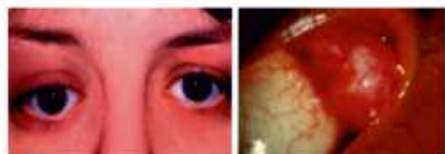01:10:26

- In this non-axial proptosis occurs, down, and nasal dystopia.

### Types

It is of two types:

Refer Table 18.1



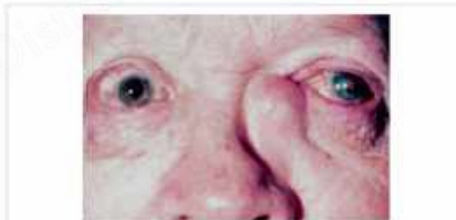- It is slowly progressive proptosis or swelling in the superolateral eyelid.
- In this condition, the lacrimal gland fossa develops a smooth, firm, non-tender mass leading to inferonasal dystopia.
- It involves the orbital part of the lacrimal gland.
- S shaped deformity of lid

### Treatment

- An excision biopsy is performed to treat pleomorphic lacrimal gland adenoma.

### Lacrimal Sac Tumor

- It is a superotemporal dystopia of the lacrimal gland.
- Most common benign tumor - Papilloma
- Most common malignant tumor - Squamous cell carcinoma




### Pulsating Proptosis

01:18:00

#### Etiology

- Carotico - cavernous fistula  
c-c fistula
- 1. Fracture Roof or orbit
- 2. NF-1



- Most common cause of pulsating proptosis is c-c fistula

#### Etiology

The various causes of Pulsating proptosis are.

- Carotico - cavernous fistula

It is mainly two types

**Direct fistula:** It is between the carotid artery and cavernous sinus.

- 75% of the cases are due to trauma.
- It is a triad of Pulsating proptosis, Chemosis, and Whoosh sounds.

### Important Information

- Pleomorphic adenoma and marked benign tumors are Epithelial benign lacrimal gland tumors.
- Pleomorphic adenocarcinoma, Mucoepidermoid, and adenoid cyst are examples of epithelial malignant lacrimal gland tumors.
- An adenoid cyst is the most dangerous tumor and most common.

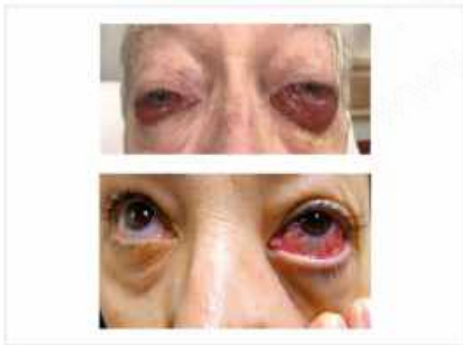- Most common malignant tumor - Adenoid cystic.
- Most dangerous tumor - Adenoid cystic (as it spreads very fast due to perineural invasion).



- Increased pressure in the cavernous sinus can lead to increased episcleral pressure leading to glaucoma. Venous stasis leads to arterial stasis causing retinopathy, and Anterior segment ischemia results in decreased blood supply to the cavernous sinus affecting function of 3, 4, 5, 6th nerve.
- Can lead to Post-ganglionic Horner's syndrome.
- Congestion and stasis cause conjunctival redness and typical appearance of dilated tortuous conjunctival blood vessels called as Cork screw vessels can be seen.
- **Investigation** - CT scan and MRI are used to investigate direct fistula.
  - Direct superior ophthalmic vein seen
- **Treatment:** Balloon tamponade or coil embolisation technique is used to treat direct fistula.

**Indirect fistula:** It is between the meningeal branches of the Internal carotid artery or External carotid artery with cavernous sinus i.e., Dural shunts.

- All the features are similar to direct but in minor form.
- **Investigation** - CT scan and MRI are used to investigate direct fistula.
- **Treatment:** It resolves spontaneously; no such specific treatment is required.



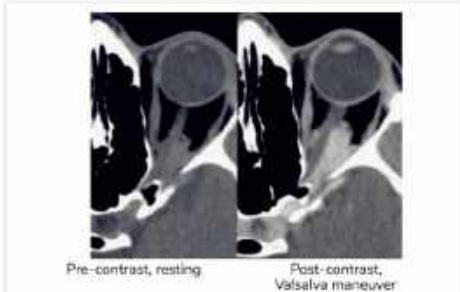
#### Intermittent Proptosis

01:27:00

- It changes with head posture e.g., if patient is lying supine he is fine but if he is lying laterally there is sudden feeling of eye coming out.
- **Orbital varices** are characteristic features of intermittent proptosis.

#### Orbital varices

1. Thin-walled, distensible and low flow veins
2. Increased with Valsalva, Coughing, change in head position
3. It can calcify and lead to Phlebolith formation.



- Investigation - CT shows ill defined mass.

#### Treatment

Intermittent proptosis can be treated by

- CO2 laser ablation technique can be used.
- Endovascular embolization
- Surgical excision procedure is difficult as it is very friable.

#### Additional Questions

**Q.** Most common intraocular malignancy

**Ans.** In children, retinoblastoma, and in adults, malignant choroidal melanoma.

**Q.** Most common intra-orbital primary malignant tumour.

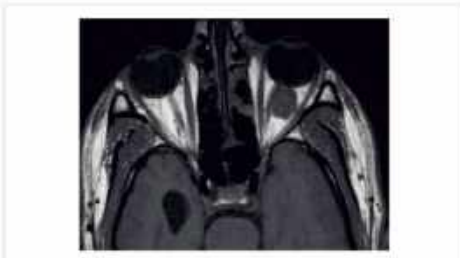**Ans.** In children, Rhabdomyosarcoma and in adults, Lymphoma (Non-Hodgkin's, B cell type)

**Q.** What is the most common intraorbital benign tumor?

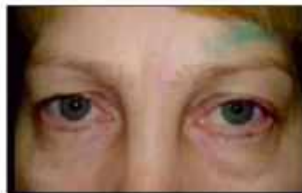**Ans.** In adults-Cavernous hemangioma and in children, capillary hemangioma > dermoid cyst.

#### Cavernous Hemangioma

01:30:26

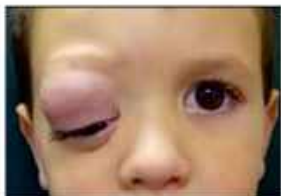

- Cavernous hemangioma is intraconal in location and encapsulated, so it is easily resected.
- Cavernous hemangioma is more common in middle-aged females.
- Axial proptosis can be seen during cavernous hemangioma.
- Treatment - Excision



### Rhabdomyosarcoma

01:31:45



- It is a connective tissue tumour, but has the capacity to differentiate as muscle cells.
- 90% of cases are seen in under 16 year of children
- Pathologically it is classified as
  - Embryonal (MC but undifferentiated)
  - Alveolar (aggressive)
  - Pleomorphic
  - Botryoid

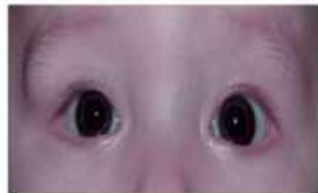### Treatment

To treat cavernous hemangioma, the following treatments can be used:

- Chemotherapy- Vincristine, Actinomycin D,
- Radiotherapy + CT
- Avoid exenteration

### Dermoid Cyst

01:36:15



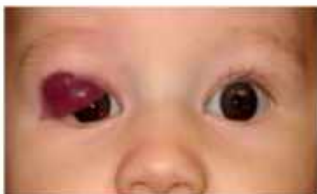- Small child with ICA bulge almost at the suture line.
- It is a choristoma (normal tissue at abnormal place)
- It is present along embryonic fissure.
- Most common supero-temporally → fronto zygomatic suture

### Treatment

- Surgical excision is done in Toto to treat the dermoid cyst.

### Capillary Hemangioma

01:35:50



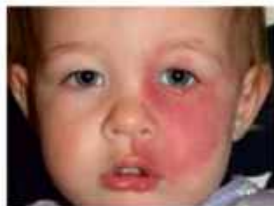- Capillary hemangioma is more common in female children.
- It is ill-defined.
- Capillary hemangioma is also called strawberry naevus of infancy.
- In Capillary hemangioma, non-axial proptosis occurs.

### Treatment

- Oral propranolol - Triamcinolone acetate can be given to treat Capillary hemangioma.
- Intralesional steroids can also be given to treat Capillary hemangioma.
- CO2 laser resection

### Sturge Weber Syndrome

01:37:52



- It is a phacomatosis.
- It is a triad of:
  - Naevus flammeus
  - It does not blanch
  - Capillary hemangioma in the brain
  - Glaucoma (due to increased episcleral pressures).

### Optic Nerve Meningioma

01:39:35

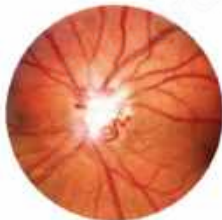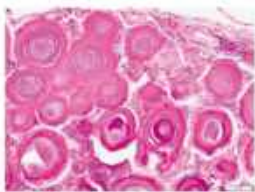- It is a tumour from the meningoepithelial cells from the arachnoid layer.
- 2/3rd of the cases are secondary tumours and the primary is an extension from intracranial meningioma.
- 1/3rd arise independently.
- Common in middle-aged females.
- More common in NF-2

### Clinical Feature

- The Hyot-Spencer triad includes vision loss, optic atrophy, and opto-ciliary shunt vessels.
- Proptosis- Late feature
- Restricted up gaze is seen due to involvement of SR.
- Transient loss of vision can be seen (Gaze evoked amaurosis fugax).
- Temporal fossa fullness due to the hyperostosis of sphenoid bone

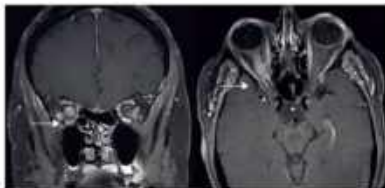### Pathology

- **Psammoma bodies:** Laminated calcified structures (Typical)
- Optico ciliary shunts:
- Blood vessels between ciliary system and retinal blood vessel.
- Near the disc due to high pressure (in CRVO) - It opens up and is called optico-ciliary shunt.
- It is not newly formed, vessels are there that open up.

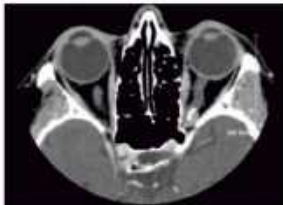

### Investigation On doing an MRI scan

- The coronal section gives a bull's eye appearance.
- In the axial section, it gives the Tram Track appearance.



- On CT - Tubular enlargement of optic nerve + Calcification



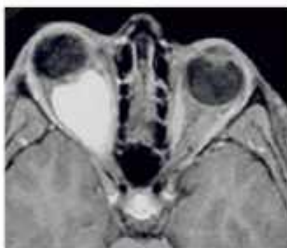### Treatment - Observation

- If not working, surgery is done

### Optic Nerve Glioma

01:46:30

- Glial cells are all non neuronal cells of nervous system like astrocytes, oligodendrocytes, neuroglial, microglial, ependymal.
- It is slow growing and unilateral.
- Optic nerve glioma is a tumor of astrocytes
- It is a tumor of childhood.
- Optic nerve glioma is more common in females.
- Optic nerve glioma is more common in patients with NF-1.



- Clinical features- All features of optic nerve disease.
- Later when size increases, it pushes the eye out causing proptosis.
- Pathologically, pilocytic astrocytoma (Spindle shaped cells) is the most common type of optic nerve glioma.
- Investigations
  - Fusiform enlargement of the optic nerve can be seen in CT/MRI.
- Treatment
  - Observation to preserve the nerve as long as possible.
  - Excision
  - Surgery

### Neurofibromatosis - 1 (Ocular Features)

01:48:00

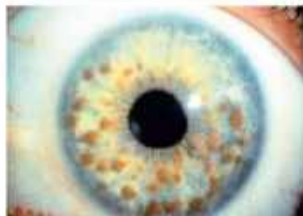- Neurofibromatosis type 1 is characterized by changes in skin coloring and the growth of tumors along nerves in the skin, brain, and other parts of the body.

### Mnemonic

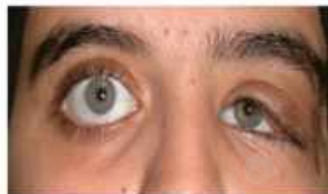- Orbit: Optic nerve glioma
- Cornea: Prominent corneal nerves

### Uvea: Lisch nodules (Most common)

- Lid: Neurofibroma leading to S-shaped deformity.
- Angle: Glaucoma
- Retina: Choroidal nevus and astrocytoma



- S shaped Deformity of lid is seen.



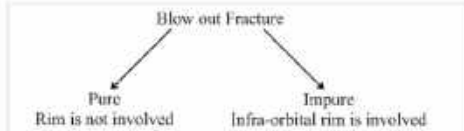
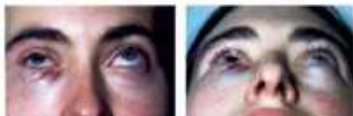### Neurofibromatosis - 2 (Ocular Features)

01:49:28

- The most common is PSC (Presenile; before 30 years)
- PSC: Posterior subcapsular cataract
- Optic nerve sheath meningioma
- Epiretinal membranes
- Ocular motor defects
- Less commonly: optic nerve glioma
- **Diagnosis: Bilateral acoustic neuroma, positive family history, and ocular features.**

### Blowout Fractures

01:50:25



- Fracture floor due to blunt trauma.
- Weakest part - Posteromedial.
- A fracture occurs due to the buckling effect.

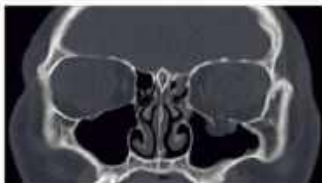
### Features

- Periorcular ecchymosis (black eye)
- Panda/raccoon eyes are seen due to fracture base of skull.
- Decreased sensation on the cheek due to damage to the infraorbital nerve.
- Ask the patient to close the eye and touch their cheek with cotton.
- Ask the patient to count whenever there is touch..
- On affected side, patient starts missing the count.
- Enophthalmos
- Diplopia - Edema, Hemorrhage, Entrapment of muscle (IR/IO) at fracture site, direct muscle injury.
- Subcutaneous emphysema if medial wall is affected.
- Pull on the muscle cause oculocardiac reflex.

### Investigation

To investigate blowout fractures, the following tests can be done

- CT Scan can be done (Tear drop sign is seen)
- Tear drop sign - Opacity against black background of maxillary sinus.



- The X-Ray (PNS) can also be done to investigate

### Treatment

- Antibiotics and anti-inflammatory drugs are used to treat blowout fractures.
- No improvement in diplopia or enophthalmos even after 10 days indicate muscle entrapment
- If a muscle is entrapped, surgery is performed in case of blowout fractures.

### Other indications of surgery

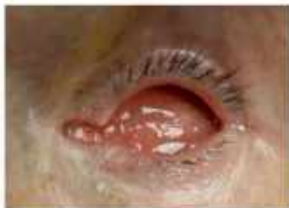- If Enophthalmos is > 2mm
- 1/2 floor is fractured.
- Surgery - Dislodge the muscle and do microplating.

## Surgeries to Remove the Eye

01:58:18

### Enucleation

- Enucleation is a surgical procedure that removes the entire globe and its intraocular contents, preserving all other periorbital and orbital structures.

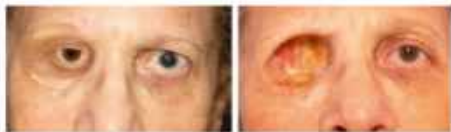

### Contraindication:

- Panophthalmitis as infection can spread to brain.
- Indication - Any painful blind eye, intraocular tumors like retinoblastoma, choroidal melanoma, Pthisis bulbi.
- To prevent formation of granulation tissue, an orbital implant is placed in the vacant space within 10 days of enucleation and after 4-6 weeks later a prosthesis is placed.
- Orbital implants can be put in same sitting if made of hydroxy apatite.

### Exenteration

- It is a procedure done to prevent the spread of malignancy/ infection in case of eyelid malignancy, orbital malignancy and mucormycosis.
- Removal of orbital contents, periosteum is stripped and lids are cut
- To make it cosmetically better, grafting is opted or spectacle prosthesis is used.



### Types:

- Partial exenteration:
  - When lids and orbital apex is preserved.
- Extended exenteration:
  - Total + Bone is also removed.

### Evisceration:

- The cornea is cut at the limbus and all the contents are scooped out. The left out sclera is stiched. This process is called Evisceration.
- But if the sclera is infected/inflamed, maximum part of the sclera is removed and a frill is left behind. This is called frill excision.
- Indications for frill excision - Panophthalmitis
- After evisceration either put scleral shells or any prosthesis.

### Indications:

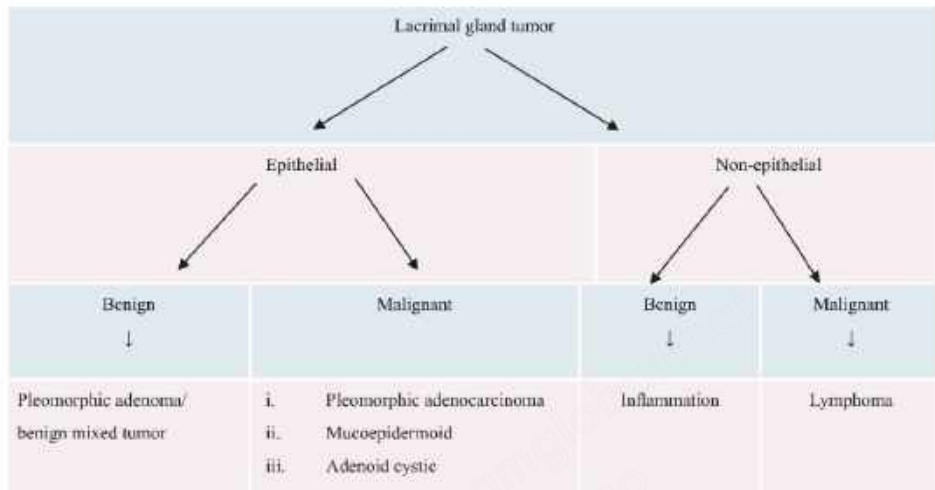
- Painful blind eye
- Better cosmesis
- Panophthalmitis
- Bleeding anterior staphylococci

### Contraindication:

- Malignancies
- Removing eye after perforating injury to prevent SO.

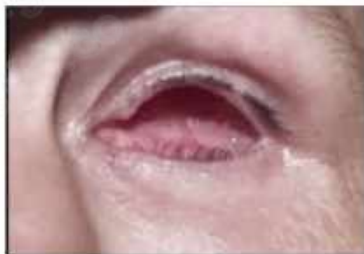

Table 18.1






# PREVIOUS YEAR QUESTIONS



- Q. Axial ptosis is seen in? (JIPMER Dec 2019)
- A. **Hyperthyroidism**
  - B. Optic nerve sheath Meningioma
  - C. Orbital floor fracture
  - D. Lacrimal gland tumour
- Q. What is the diagnosis for a patient with unilateral ptosis with bilateral 6th nerve palsy with chemosis and euthyroid status? (NEET Jan 2020)
- A. **Cavernous sinus thrombosis**
  - B. Thyroid ophthalmopathy
  - C. Retinoblastoma
  - D. Orbital pseudotumour
- Q. Levator palpebrae superioris is supplied by? (JIPMER Dec 2019)
- A. 2nd cranial nerve
  - B. **3rd CN**
  - C. 4th CN
  - D. 6th CN
- Q. 3-year-old child presents with drooping of upper lid since birth. O/E, the palpebral aperture height is 6 mm and with poor LPS function what is the procedure recommended? (NEET JAN 2019)
- A. Observation
  - B. Mullerectomy
  - C. Fasanella servat operation
  - D. **Frontalis Sling surgery**
- Q. Appropriate treatment for mild Congenital ptosis is, (FMGE DEC 2019)
- A. **LPS resection**
  - B. Antibiotics and hot compresses
  - C. Tarsal fracture
  - D. Wedge resection of conjunctiva
- Q. A lady presents with ptosis, on eating sipping fluid her ptosis decreases. What is the most likely diagnosis? (FMGE JUNE 2021)
- A. Mechanical ptosis
  - B. Horner's syndrome
  - C. **Complicated ptosis**
  - D. Blepharophimosis syndrome
- Q. A patient presents with complaints of itching of the lid and swelling for the past one month. O/E there are crusting, scaling with small ulcers at the eyelid margin. If untreated it can lead to (JIPMER MAY 2018)
- A. Orbital cellulitis
  - B. Chalazion
  - C. **Ectropion and epiphora**
  - D. Orbital abscess



## Crossword Puzzle 1



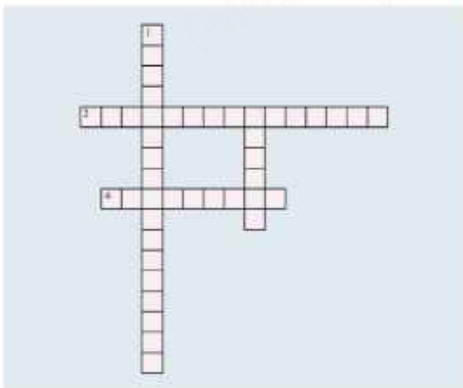
### Across

- The whoosh sound is the character of \_\_\_\_ type of Caroticocavernous fistula.
- The shape of the orbit is \_\_\_\_.

### Down

- The weakest part of the floor is \_\_\_\_.
- \_\_\_\_ fracture of the floor of the orbit.

## Crossword Puzzle 2



### Orbit and adnexa

#### Across

- \_\_\_\_ is the inability of the eye to perform conjugate lateral gaze.


- Any inflammation in the front of the orbital septum is called \_\_\_\_.

#### Down

- \_\_\_\_ inflammation behind the orbital septum.
- \_\_\_\_ emergency refers to the risk of cavernous sinus thrombosis.

## Crossword Puzzle 3

### Orbit and adnexa



#### Across

- \_\_\_\_ curve is used to study the severity of Thyroid eye disease.
- \_\_\_\_ soft tissue gives signs in case of chemosis.
- \_\_\_\_ can be caused by an infection or growth in the sinuses.

#### Down

- Inhalation of spores of mucor results in \_\_\_\_ disease.

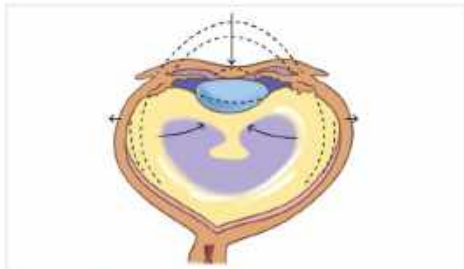


# 19 OCULAR INJURIES

- A wide terminology for a physical or chemical injury to the eye or eye socket.

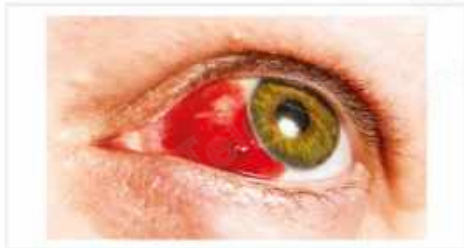## Globe Trauma, i.e., Blunt trauma:

00:01:06

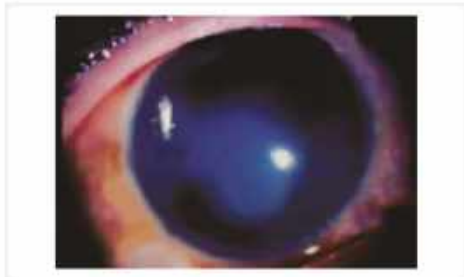

### Features of blunt trauma:

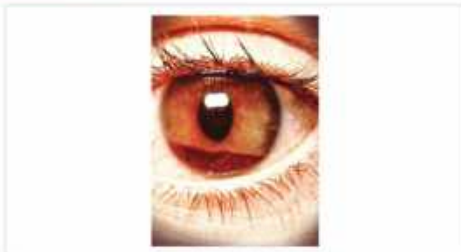- Subconjunctival Haemorrhage



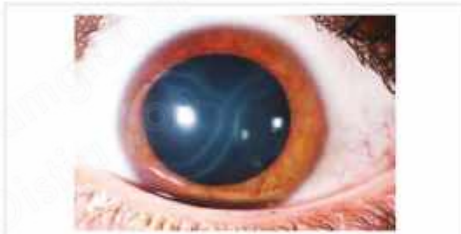- Corneal oedema



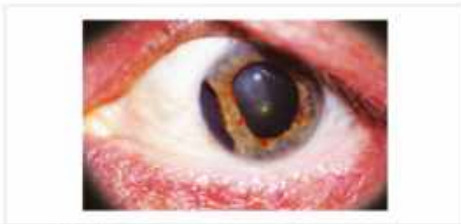
- Hyphema (blood in the anterior chamber), if untreated leads to corneal staining.



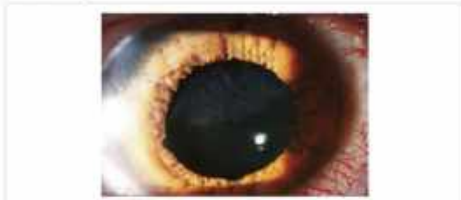- Descemet membrane tear



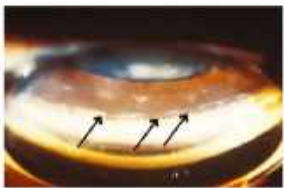
- On the iris:
  - Iridodialysis



- Iris sphincter tear

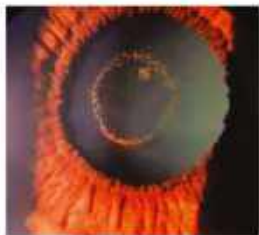

- In the angle:
  - Angle recession due to tear in ciliary body- leads to **angle recession glaucoma**.

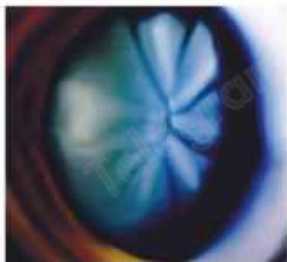

- **In the lens**

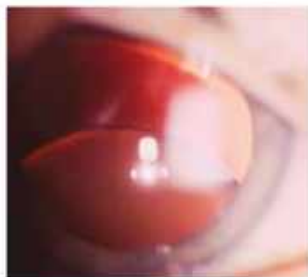- Vossius ring: In the shape of pupil



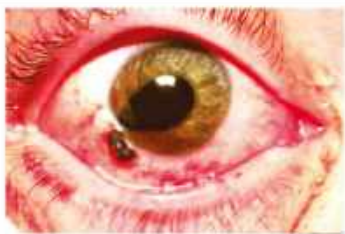
- Rosette shaped cataract



- Blunt trauma can cause subluxation of the lens.

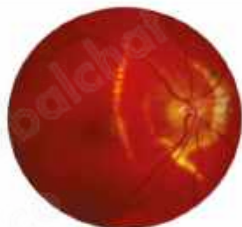

- Iris prolapse is a sign of globe rupture.

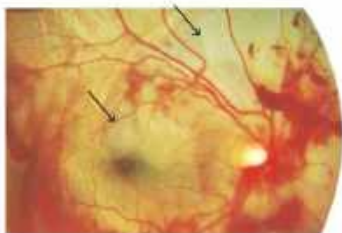

- **In the retina**

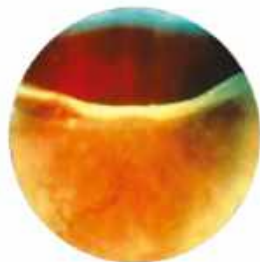- Choroidal rupture occurs behind the retina.



- Comotio Retinae, also known as Berlin's oedema.



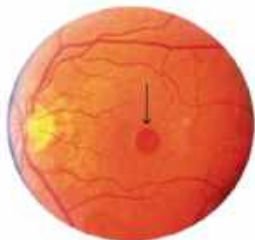
- Retinal dialysis – Disinsertion from ora serrata



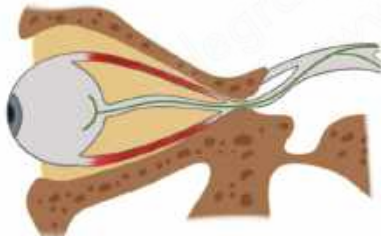
- Giant retinal tear – Horseshoe shaped



• **Macular hole**



- Trauma induced injury to the optic nerve occurring anywhere along the nerve's intraorbital to intracranial length



- Traumatic neuropathy with chorioretinal scarring.
  - Presents with decrease visual acuity, visual field defect, afferent pupillary defect, decrease color and decrease brightness.



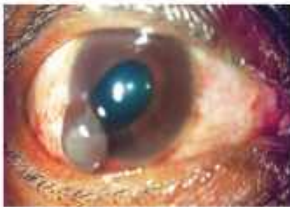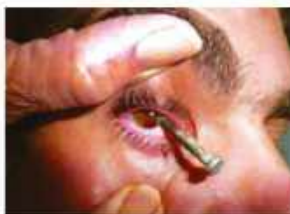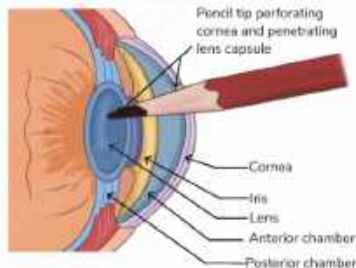
**Important Information**

- Hyphema could be dangerous as it might cause **Glaucoma**. Further, if left untreated for an extended period it can lead to a **Corneal staining** (it can cause permanent damage to the cornea and one might need cornea replacement).

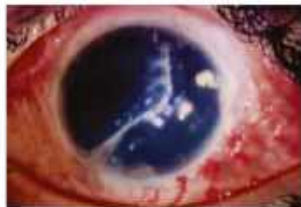**Penetrating Injury**

06/11/25

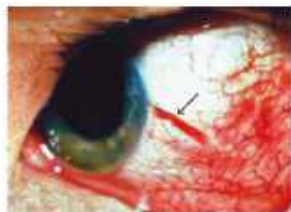- Penetrating injuries, by definition, enter the eye but do not exit—there is no exit wound.
- Entrance and exit wounds are present in perforating injuries.
- **Most common cause of penetrating injury in children is by sharpened pencil.**



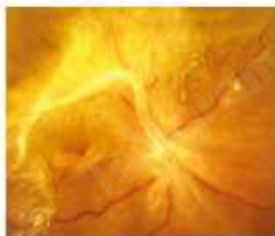- The image shows corneal tear with iris prolapse because of penetrating injury.



- Repaired laceration due to corneal tear.



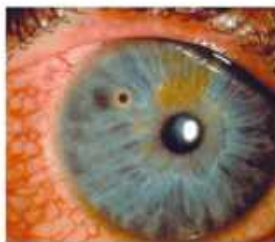Scleral laceration



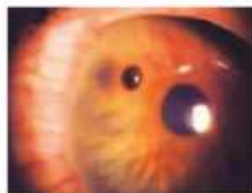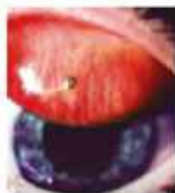## Foreign Bodies

### 1. Superficial foreign body

00:14:10



- In this case, it's an iron particle, the most commonly found due to chisel and hammer.



## Treatment:

- First, add some anaesthetic drops to the injured eyes.
- Then take a 26-gauge needle and scrape it out if it's not too deep.
- After that, apply the antibiotic ointment and bandage.

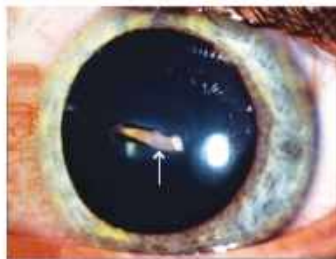
## 2. Intraocular foreign body

### • Any Intraocular foreign body (IOFB) has three effects:

1. **Mechanical effect:** cataract due to capsular injury, vitreous liquefaction and retinal haemorrhage and retinal tear.
2. **Infection:** give prophylactic intravitreal antibiotic injections.
3. **Toxic effects**

## IOFB are of two types:

Inert FB	Reactive FB
It is any substance that enters the eye and remains there, causing no further reaction.	It is any substance that enters the eye, causing reactions such as Siderosis and Chalcosis.
Examples of Inert FB: Glass, wood, plastic, rubber, gold, silver, platinum	Examples of Reactive FB: 1. Organic 2. Inorganic: iron [Siderosis], copper [Chalcosis]





#### Work up:

- Detailed examination including gonioscopy and funduscopy.

**IOC:** CT scan

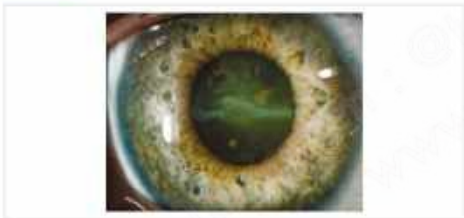#### Treatment:

- Magnetic removal for metallic FB
- Forceps removal through pars plana vitrectomy

**Q.** What should be the investigation of choice (IOC) in the case of metallic IOFB?

**Ans:** It should always be a CT scan and never MRI.

#### Siderosis

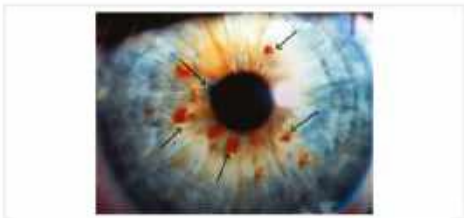

- It is a case of intraocular iron.
- Most common cause is chisel and hammer injury.

#### Signs of Siderosis.

- Lens deposits
- Iris pigmentation
- Retinal changes
- Decreased amplitude of b wave in ERG

In Siderosis, to check the progress, use Serial ERG for b waves, whether it diminished or not.

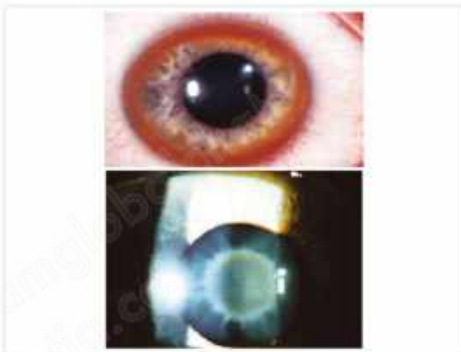


#### Important Information

- Copper is known as the most dangerous IOFB.
- Pure copper leads to Pithitis bulbi. And hence, known as the most dangerous IOFB.

#### Chalcosis

- It is a condition with Copper in the eye, leading to injury.
- Chalcosis is caused either due to foreign bodies or due to Wilson's disease.



- The golden brown ring found in the eyes is known as the **Kayser Fleischer ring**. And it is mainly Cu deposition in Descemet's membrane (DM) of cornea.
- Sunflower cataract is seen.

#### Chemical Injuries

06/27/25

- Chemical eye injuries are related to either an acidic or alkali material entering in the eye. Chemical (alkali and acid) injury to the conjunctiva and cornea is a serious ocular emergency that must be treated right away.

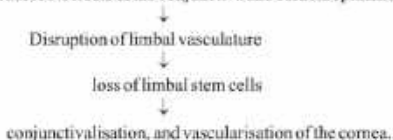
**Q.** What is more dangerous Alkali or acid?

**Ans.** Alkali is more dangerous because acid cause coagulation of the protein which creates a layer and stops it from reaching intraocular, whereas Alkali can easily penetrate the cornea and go intraocular.

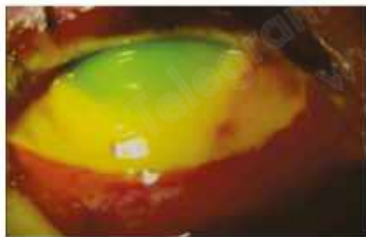
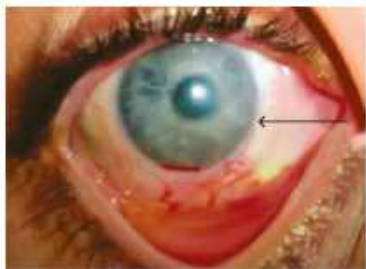
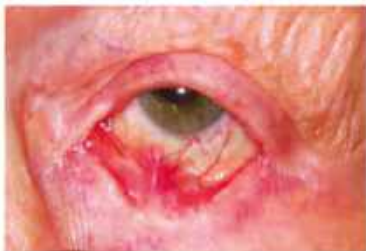- Alkali burn: Most common: severe damage due to rapid penetration
- MC: Ammonia
- Other: NaOH, Lime [CaO]
- Acid: Coagulates the surface proteins

#### Pathophysiology of Chemical injury

- It causes Necrosis of the conjunctiva and corneal epithelium.



- Deeper penetration leads to stromal opacification.
- Late effect: symblepharon, cicatricial entropion.



#### Treatment:

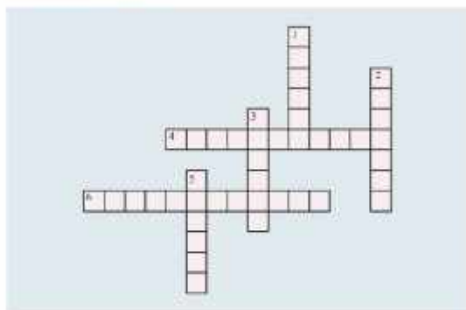
- The first and the most important step while treating a chemical injury is **Copius irrigation by double eversion of the lid**. Other steps are followed in the given order below:
  - Antibiotics
  - Cycloplegics
  - Steroids: for only initial seven days as it reduces collagen synthesis and impairs healing
  - Ascorbic acid: Promotes collagen synthesis and improves wound healing; 10% E/D 2hrly.
  - Citrate: Powerful inhibitor of neutrophils and hence controls inflammation. Also, it chelates extracellular calcium and hence inhibits collagenase 10% E/D 2 5, hourly for ten days.
  - Tetracycline: Collagenase inhibitor
  - Acetylcysteine 10%: Anti collagenase

#### Surgical Treatment

- Advancement of tenons capsul
- Limbal cell transplantation
- Amniotic membrane grafting
- Late: [For symblepharopl]
  - Division of bands in symblepharon
  - Conjunctival grafting
  - Mucous membrane grafting



## Crossword Puzzle 1



### Across

4. Causes subluxation of the lens
6. A sign of globe rupture

### Down

1. Most dangerous IOFB
2. Shape of the pupil in irido dialysis?
3. IOC in the case of metallic superficial FB
5. Color of Kysher Flesher ring

Telegram : @teamglobalcheer  
www.Distia.co

## Lids

- The horizontal length of the lid is around 28-30mm.
  - Any decrease in horizontal length is called **Blepharophimosis**.
- The vertical gap, the **palpebral fissure**, is the area between the open eyelids, around 8-10mm.
- The lateral canthus is normally 2mm above the medial canthus.
  - When it is more than 2mm, it is called as **Mongoloid slant**.
  - If it is reversed, i.e., the medial is above the lateral, it is called an **antimongoloid slant**.

### Basic Structure of the Lid

0042:10

- The lid is made up of mainly **thick connective tissue**, which is called **Tarsal plate**.
- The lid margin is divided by a **Grey line** into anterior lid margin and posterior lid margin.
- From anterior lid margin, eyelashes arise. These eyelashes have sebaceous glands i.e., Gland of Zeiss and Gland of Moll (modified sweat gland)
- Posterior lid margin has opening of meibomian glands
- Meibomian glands are located in the Tarsal.**
- This grey line divides the lids into two lamella: Anterior lamella and posterior lamella
  - Anterior Lamella** include **skin, subcutaneous tissue** and **orbicularis oculi**.
  - Posterior Lamella** includes **Tarsal plate - LPS, lower-lid retractors and conjunctiva**
- The space between supra orbital margin and infra orbital margin is filled by a thin connective tissue known as orbital septum

### Clinical Significance

0046:14

#### Anterior Lamella

##### Skin

- The subcutaneous tissue is loose, and the skin above is in excess. That condition of excessive skin is called **Dermatochalasia** which may mimic ptosis.
- It is a cause of **pseudo-ptosis**.
- The treatment for this condition is **blepharoplasty**.

##### Subcutaneous Tissue

- The subcutaneous tissue is very loose, so whatever swelling occurs near the eyes is too much.
- This is the plane where blood and oedema collect.

##### Orbicularis Oculi

- Orbicularis Oculi is responsible for the closure of the eye and Blepharospasm.
- It is supplied by VII nerve

- Orbicularis Oculi has two parts
  - Palpebral part
    - When it is in front of the tarsal, it is called **pre-tarsal**. It is responsible for **involuntary blinking**.
    - Normal frequency of blinking: 12-20/min
    - It is attached to the lacrimal sac, which helps in the lacrimal pump. This is called **horner's muscles**.
    - Riolen muscle is mainly responsible for the formation of grey line.
    - When it is in front of the septal, it is called **pre-septal**. It is responsible for voluntary blinking.
  - Orbital part: It is mainly responsible for forceful closure of the eyelids.
- Lagophthalmos**: Inability to close the eye.
  - It is a feature of 7th nerve palsy.
  - When the eyes is not closing, the cornea gets exposed, which leads to **exposure keratopathy**.
    - It can be the cause of blindness if not properly taken care of
  - This whole condition is called **Neuroparalytic keratitis**.
  - Neurotrophic keratitis: It is due to palsy of fifth nerve where the corneal epithelium is affected due to no sensory supply
  - Treatment: Patching, Gold weights (to droop the lids) or Tarsorrhaphy. (Stitching of two lids together)

### Posterior Lamella

#### Tarsal Plate

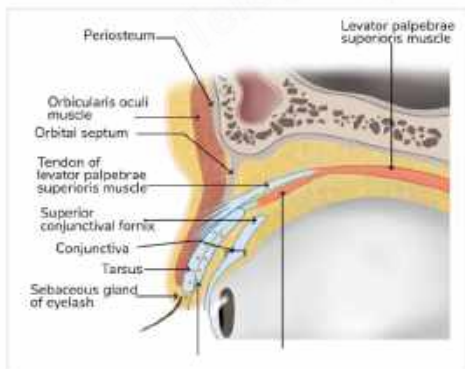
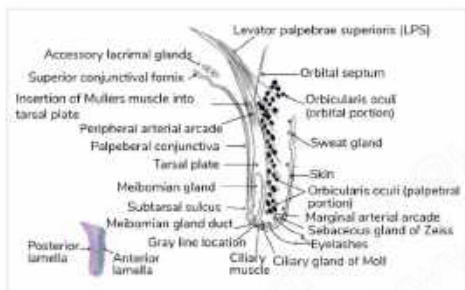
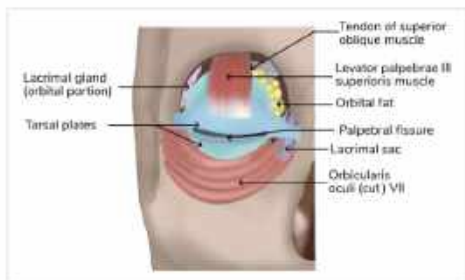
- The width at the upper lid is 8-10mm.
- The vertical length at the lower lid is 4mm.
- The two lids joins at medial and lateral canthus
  - These are Y shaped with 3 limbs, medial canthal and lateral canthal tendon
- The lateral canthal tendon (part of orbicularis oculi) is attached to Whitnall's tubercle.
- Muscles attached to the tarsal plate
  - Upper border: Mullers
  - Lower border: LPS

### Lid Retractors

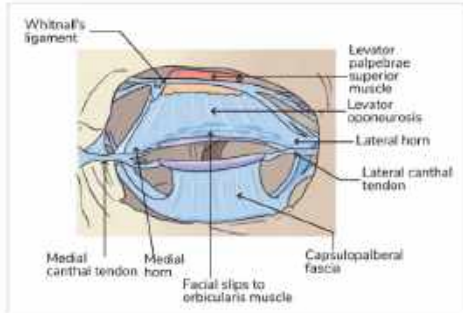
- They are divided into two parts
  - Upper lid retractors
    - Levator **palpebrae superioris muscle** (supplied by the 3rd nerve) and Müller's muscle/ Superior tarsal muscle (supplied by sympathetic supply).
  - Lower lid retractors
    - **Capsulo-palpebral fascia** originates from the sheath of the inferior rectus fascia.



- Inferior Tarsal muscles: Orbital septum arises from the periorbital fascia from the periosteum.
- This periorbital fascia gives rise to annulus of Zinn.

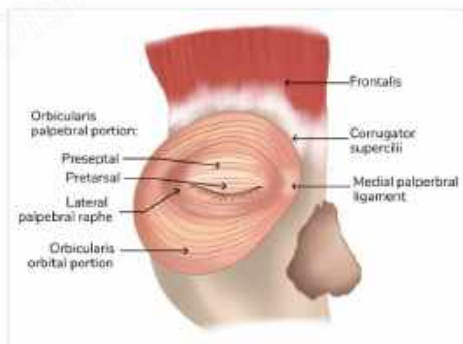


- LPS muscles
  - Origin: LPS arises from the lesser wing of the sphenoid above the optic foramen.
  - From here it moves in front then it is going to reach anteriorly, it will stop at Whitnarr's ligament and here it changes its direction from horizontal to vertical



- Insertion of LPS
  - The lower border of the tarsus.
  - Lateral orbital tubercle.
  - Medial horn (orbital septum).
  - Skin: Lid crease.
  - Conjunctival fornix.
  - Orbicularis Oculi.
  - The posterior lamina gives rise to the muller's muscle.

### Orbicularis Oculi



- There are striated skeletal muscles.

### Ptosis

00:33:32

- **Drooping** of the upper eyelid is called ptosis.
- Drooping of lower lid: When the sympathetic is gone, the inferior tarsal muscle supplied by it will be defective so the lower lid will rest at higher level.
- Normal position of lid: Upper lid covers 2mm of the limbus/ 1/6° of the cornea
  - Lower lid just touches the limbus
- When lid goes below its normal level its called ptosis but when lid goes above its normal level it is called retraction.

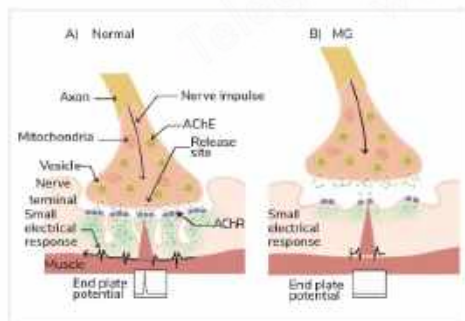
## Classification

- Congenital ptosis: They can be two types
  - Simple Congenital
  - Complicated Congenital: Blepharophimosis syndrome, Marcus Gunn Jaw Winking and double elevator palsy (DEP)
- Acquired ptosis
  - When it is caused due to nerve problems, it is called **Neurogenic**.
  - When it is caused due to muscle problems, it is **Myogenic**.
  - When it is caused due to an aponeurotic problem, called **Aponeurotic**. It is also the most common.
  - **Mechanical**.

## Acquired Ptosis

10/26/20

- Neurogenic
  - Causes - 3rd nerve palsy.
  - Horner's Syndrome.
- Myogenic Ptosis.
  - Causes - Myasthenia gravis
  - Lambert-Eaton syndrome
  - Chronic progressive external ophthalmoplegia (CPEO)
  - Myotonic dystrophy
- **Myasthenia gravis (MG)**: Myasthenia gravis is an autoimmune disease
  - Pathogenesis: there are antibodies against the Ach receptors so the potential generated is very minimal and there will be no proper muscle contraction



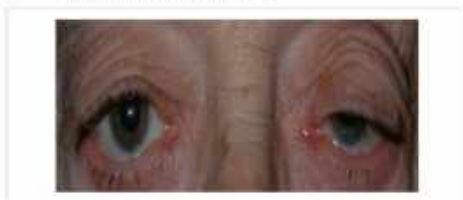- It affects mainly the skeletal muscles.
- Ocular feature: It only affects the LPS and EOM.
- **Clinical feature**: The presenting feature would be ptosis and diplopia.
- The first extraocular muscle to be affected is the **medial rectus**.
- It gets worst on prolonged upgaze and Worst at the end of the day.

## Tests for MG

- **Cogan Twitch Test**: The Cogan lid twitch is elicited by having the patient look in downgaze for 30-50 sec followed by upgaze, in primary gaze there will be twitching of the upper lid.
- **Fatigue ability test**: Ask the patient to look up for sometime which will lead to fatigueness of LPS causing drooping of the lid
- **Eye Peak Sign**: Ask the patient to close his eyes continuously for some time now orbicularis will get tired causing little opening of the eye.
- **Lab investigations**
  - **Tension Test** - Use 1mg of Neostigmine injection IM or 10mg Edrophonium IV. There will be an improvement in ptosis.
  - Tension is an anticholinesterase, it blocks the enzyme metabolising ACh so that ACh can stay longer at NMJ
  - **Ice pack test**: It also acts as anticholinesterase hence ptosis improves

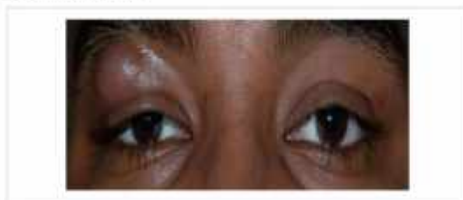## Aponeurotic Ptosis

- It is the most common ptosis.
- It is mainly caused due to the dehiscence of aponeurosis. This can be either
  - Post-operative
  - Involutional: That is in old age.



- Due to the dehiscence, there is a high lid crease.
- Lid crease is seen due to attachment of LPS to the skin so due to dehiscence it moves up

## Mechanical ptosis



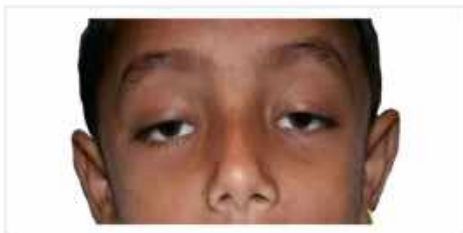- Mechanical ptosis is caused due to something or some swelling causing the lid to droop down
- Causes of mechanical ptosis

- Pushing mechanism, which includes tumour, Chalazion and neurofibroma.
- Pulling mechanism, which is happening due to conjunctiva cicatrization
- Conjunctiva cicatrization can be seen due to
  - Trachoma
  - Burns
  - S. Johnson syndrome
  - Cicatricial pemphigoid

## Congenital Ptosis

1003824

### Simple Congenital ptosis



- In simple congenital ptosis, there is the absence of lid crease.
- There is lid lag on the ptotic side due to defective LPS formation causing defective relaxation
- It is associated with hypertropia.

### Double elevator palsy

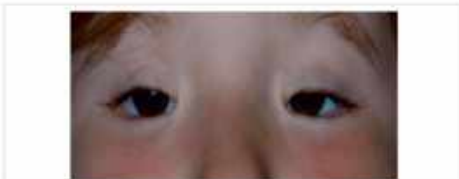- Double elevation palsy; LPS involvement with SR involvement
- Ptosis and hypertropia.

### Blepharophimosis syndrome

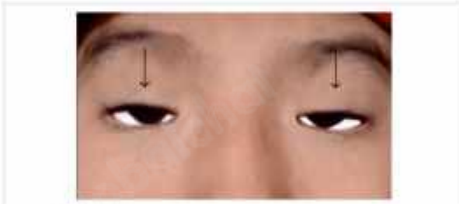
- Blepharophimosis syndrome is a genetic disorder
- The responsible gene is the FOXL-2 gene.
- It is an autosomal dominant condition.
- Clinical features:
  - Shorter horizontal length i.e Blepharophimosis.
  - Ptosis.
  - Congenital ectropion of the lower lid.
  - Telecanthus: Far apart medial canthus due to excessive soft tissue but the interpupillary distance is normal.

Telecanthus	Hypertelorism
Soft tissue problem	Bony defect
Interpupillary distance is normal	IPD is increased

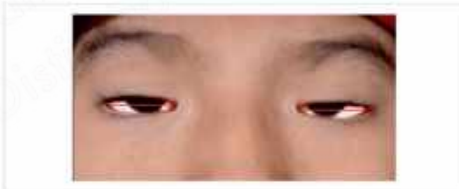- Epicanthus inversus: Extra fold of skin on medial canthus but when it arises from lower lid it is called as inversus



- In every congenital cases, visual axis is being covered i.e., fovea will not be formed properly causing amblyopia



- Congenital ptosis should be urgently treated.

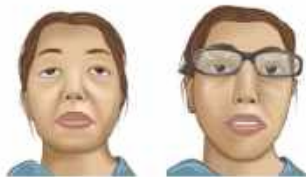

### Calculation of ptosis amount

- Upper lid covers 2 mm of cornea and lower lid just touches the limbus
- MRD1: Distance of the margin of the lid till the light reflex is called as MRD1 (Marginal reflex distance)
- MRD2: Distance between the lower lid and the light reflex is called MRD2.
- Amount of ptosis
  1. Palpebral fissure height: Normal - Ptotic eye
  2. Difference of MRD1 - Normal - Ptotic eye
  3. If both the eyes are drooped then it depends upon the amount of droop
  4. Amount of droop
    - Mild droop: 2mm (but distance from limbus is 4mm)
    - Moderate droop: 3mm (5mm from upper limbus)
    - Severe droop: 4mm.

### Treatment of Ptosis

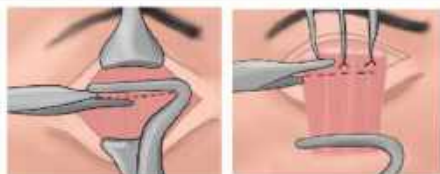- Neurogenic Ptosis: Nerves takes time to come back so wait for 5-6 months for it to revert back but in meantime use crutch Glasses to heal normally.



Before

After

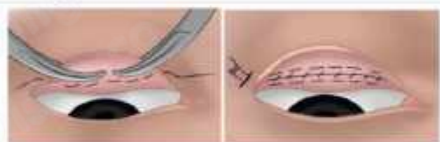- Surgery: For any muscle surgery, acting muscle **resection is the choice**.
  - In resection if the action of muscle is less it is cut and stitched, the fibre length decreases and action improves
- For overaction of muscle: The **surgery of choice is a recession**.
  - In recession, just push the attachment of muscle backwards
- In ptosis, there is underaction of retractors hence resection is done.
- Muscle that can undergo resection can be LPS or Muller's
- Limitation of Muller's: It has only 2mm of action so only mild ptosis can be improved.
- It is important to check the action of LPS, if the action of LPS is not enough and Muller's is also of no use then another muscle i.e., frontalis.
- **Sling operation is done, in this the upper lid is connected to frontalis.**
- LPS resection. To check the action of the LPS, the upper lid excursion is done and it is called Berke's method
- Upper lid excursion: Ask the patient to look down as much as possible, block the frontalis and then ask the patient to look up as much up.
  - So the distance the lower most and upper most position is called lid excursion
  - Normal upper lid excursion:  $\geq 12\text{mm}$
  - If it is less than 5 mm, LPS resection is not done.
- LPS resection can be done either with the skin route (called **Eversbusch operation**) or conjunctival route (**Blaskovics operation**).
- LPS resection is usually done for moderate ptosis.



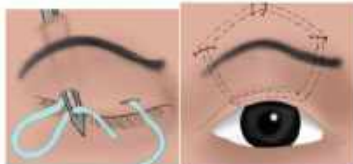Shortening of levator complex

Amount determined by levator function and severity of ptosis

- Indicated for any ptosis provided levator function is at least 5 mm
- Contraindicated in patients having severe ptosis with poor levator function
- Muller resection - For mild ptosis and there is a good levator function, the operation is called **Fasanella Servat operation**.
  - Main indication: Horners syndrome
  - Fasanella Servat operation: Cut the strip of lower border of Muller's, upper border of tarsal plate and overlying conjunctiva.



- Sling operation: Join the upper lid with frontalis muscle.
  - Material used: Silicone, Fascia Lata (choice of material)
  - It is mainly done in severe ptosis
  - Fox pentagon: Connecting upper lid with frontalis muscle



Attachment of tarsus to frontalis muscle with sling

#### Main indications

- Severe ptosis with poor levator function (4 mm or less)
- Marcus Gunn Jaw-Winking syndrome
- **Marcus Gunn Jaw winking syndrome (MGJWS)** is a congenital ptosis with an aberrant connection between the LPS (IIRD nerve) and lateral pterygoid muscle (Vth nerve)
- Treatment: Disinsertion of LPS along with sling operation.

#### Pseudoptosis

- In pseudoptosis cause is not due to any problem in retractors, it seems like the eyelid is drooping but it is not

00:37:07

### Causes of pseudoptosis

- Lack of support: Enophthalmos (eyeball inside), Phthisis Bulbi (blind shrunken eye) and microphthalmos
  - Microphthalmos: Small eye, less than 21mm of axial length
- Contralateral lid retraction.
- Ipsilateral hypotropia
- Brow ptosis: Excessive skin on the brow because of which lid is going down
- Dermatochalasia: Overhanging skin on the upper lids.

### Eyelid Tumours

00:58:58

#### Types of eyelid tumour

- The most common malignant eyelid tumour is **BCC (Basal cell carcinoma)**.
  - Most common site of BCC: Lower lid, medial canthus
- **Squamous cell carcinoma** is the second most common.
- Sebaceous cell carcinoma - May present as a recurrent chalazion.
  - Most common site for sebaceous cell carcinoma is upper lid
- Malignant Melanoma.
- Kaposi Sarcoma: Seen in HIV patients.

### Entropion

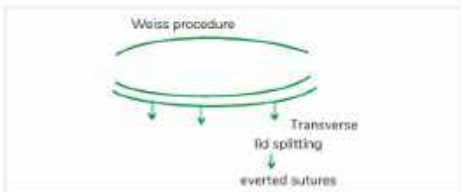
- Entropion is an inward turning of the eyelid margin.
- Depending on the capacity of inversion, it can be graded:
  - Grade 1: Only the posterior lid margin is inverted.
  - Grade 2: Intermarginal strip is inverted.
  - Grade 3: Anterior border is inverted.

#### Types of Entropion

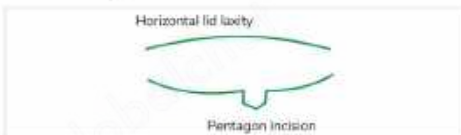
- Involutional entropion
- Cicatricial entropion
- Congenital
- Spastic entropion
- Involutional entropion; Causes of involutional entropion
  - **Overriding of pre-septal over pre-tarsal.**
  - **Disinsertion of lower eyelid retractors.** Plication of the lower lid retractor can be done it is called June's procedure.
  - **Horizontal lid laxity**- It can be identified with a
    - Pinch test: In this test it is checked that how far the lower lid can be pulled away from the eyeball. Normal value is 6-8mm, anything more than that is laxity
    - Snap test: When the pulled lid is left to snap back, it is observed how fast it goes back. It should snap back within a blink, if it takes more than 2 sec then it is laxity

#### Treatment

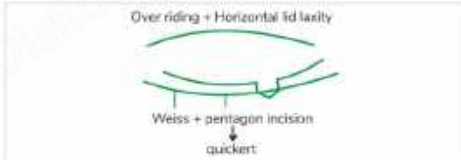
- Overriding of pre-septal over pre-tarsal: Transverse everting sutures or the Weiss procedure.
  - Weiss procedure: First there is transverse lid splitting and then everted sutures are given



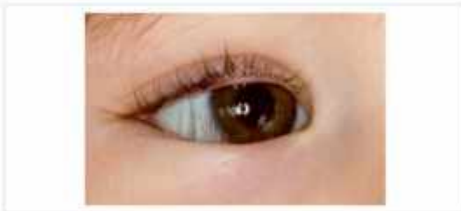- Disinsertion of lower eyelid retractors: Plication of the lower lid retractor can be done which is called Jones procedure.
- Horizontal lid laxity: Pentagon incision is given so that the laxity is less



- If there is overriding as well as horizontal laxity, then the Weiss procedure with pentagon incision should be done, which is called the **quickert procedure**

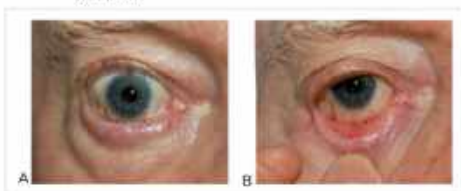

- Congenital entropion: The lower lid retractors are not well developed.

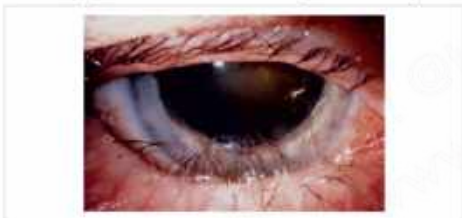

- Treatment: **Hotz procedure.**
  - Surgical excision of the elliptically shaped eyelid skin, and underlying orbicularis and later the skin is sutured with tarsal plate and lower lid retractors
- Cicatricial entropion: Scarring of conjunctiva and there can be inward rotation of eyeball
  - Causes of scarring: Cicatrizing condition of conjunctiva.
  - Treatment: Cut the scar and do grafting
    - Treat the cause
    - Tarsal fracture, after tarsal fracture put everting sutures

- Mucous membrane grafting can be done
- Grafts
- Treat trichiasis
- Surgery: Split at grey line and reposition the lower lid retractors



- **Spastic entropion:** There is long term patching which causes spasm of the muscle
  - Treatment: Use botulinum toxin
  - Treat the cause of spasm
  - Surgical intervention: Displaced fibres of orbicularis oculi cause the eye lashes of the lower lid to turn inwards so surgery is needed to correct the laxity of the lower eyelid



#### Ectropion

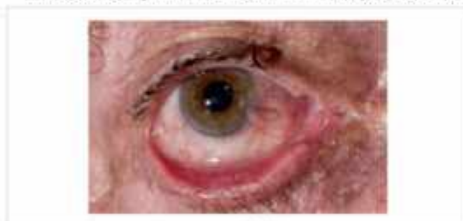01:12:09

- Ectropion: Outward turning of the lid margin.
- Grade 1: Punctal area is out.
- Grade 2: Palpebral conjunctiva is seen
- Grade 3: The fornix is seen
- Classification
  - Involutional: Due to old age
  - Cicatricial: Scarring on skin
  - Paralytic: Part of VII nerve palsy
  - Mechanical
  - Congenital: Rare
    - Seen in Blepharophimosis syndrome
    - Down syndrome

#### Involutional Ectropion

- It is seen due to horizontal lid laxity.
- A Pentagon incision is recommended.
- Along with horizontal lid laxity, there is also excessive skin.
- In this case, along with the pentagon incision, resection of the excessive skin is done. It is called the **Kuhnt Szymanowski procedure**.
- If there is only medial ectropion, then medial conjunctival plasty is done

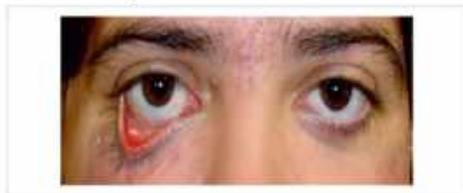- In medial conjunctival plasty, make the diamond shape cut at tarsal and conjunctiva
- If there is medial ectropion along with horizontal lid laxity then medial conjunctival plasty is done with lid excision, it is called as lazy T procedure or Byran-Smith Lazy T procedure.



#### Treatment

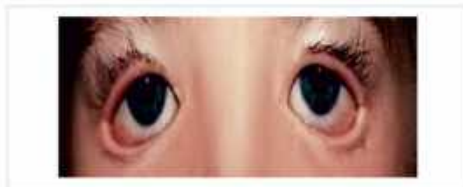- No horizontal lid laxity: Medial conjunctivoplasty (Excision of diamond-shaped of tarso-conjunctiva)
- Mild horizontal lid laxity: Lazy-T procedure (medial conjunctivoplasty with full thickness lid excision)
- Severe horizontal laxity: Bick procedure – removing full thickness wedge of lower lid at the lateral canthus (for ectropion and entropion)
- Modified Kuhnt: Szymanowski procedure: Incision parallel and ventral to the lower lid starting 1 cm medial to medial canthus and extending 4 cm beyond the lateral canthus

#### Cicatricial Ectropion



- There is scarring outside in the skin
- Causes: Trauma and burns.
- Treatment excision of the scar with Z-plasty.
  - Transposition of flaps.
  - Fress skin grafts.

#### Congenital ectropion



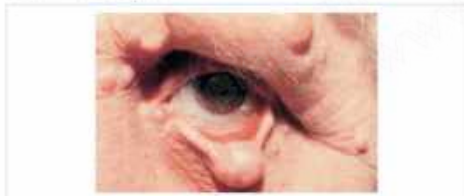- It is a condition where lower eyelid retractors are not developed.
- Treatment of choice is skin grafting.

### Paralytic ectropion

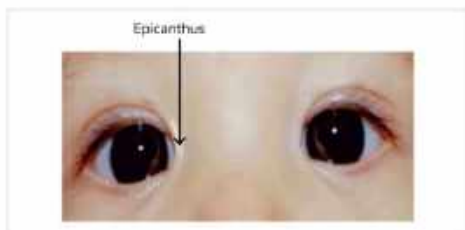


- There is facial nerve palsy.
- Treatment of choice
  - Temporary
    - Artificial tears and ointment.
    - If poor bells phenomenon, tarsorrhaphy can be done.
  - Permanent:
    - Medical canthoplasty.
    - Prosthetic devices; Silicone rings.

### Mechanical ectropion



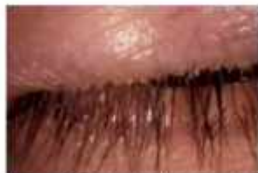- It is mainly caused due to eyelid tumours.
- Treatment is to treat the main cause.



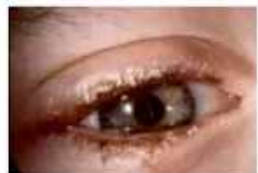### Blepharitis

- It is the inflammation of the lid margin.
- The lid margin can be anterior or posterior.

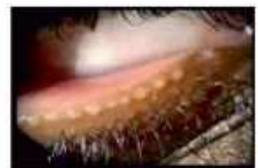- Anterior lid margin contains lashes and posterior lid margin contains meibomian glands
- Anterior blepharitis:
  - Squamous/seborrheic blepharitis: it is seen in patients of seborrheic dermatitis
  - Ulcerative/staphylococcal infection: Ulcer below the scales.
    - This condition is mainly associated with atopic dermatitis
- Posterior blepharitis/Meibomitis.
  - It is associated with acne rosacea.
  - There is meibomian gland dysfunction, there is decrease expression of the lipid from the gland affecting the lipid layer of tear film causing dry eye.
  - Clinical feature:
    - Burning sensation in the eye.
    - Mild photophobia.
    - Grittiness in the eye.
  - On examination
    - Mild redness
    - Squamous: Dandruff on the eyelashes.
    - Ulcer: Ulcer below the scales and crusting at the lid margin
    - Posterior: Oil globules at the opening of the meibomian gland.



Squamous blepharitis with dandruff on the lids



Crusting and ulcerative blepharitis



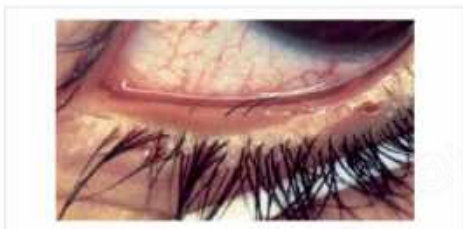Oil globules on the lower lid margin

001037

- Treatment
  - Lid hygiene: Wash eyelashes with diluted baby shampoo or sodium bicarbonate. Lid massage should also be done, it should always be towards the lid margin to express the lipid out in case of posterior blepharitis.
  - Medicine: For squamous, Antibiotic Steroid ointment, and in case of ulcer, only antibiotic ointment is given
  - Antibiotics like chloramphenicol or fusidic acid can be given
  - For meibomitis: Oral antibiotics like doxycycline 100mg bd for a week can be given
  - Newer modality: For posterior blepharitis - thermal pulsation
  - Manage the dry eye

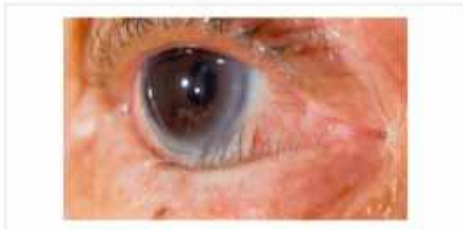
### Distichiasis

01:26:02



- It is a congenital anomaly with an extra layer of eyelashes.
- Treatment: Diathermy or Cryo (-20)

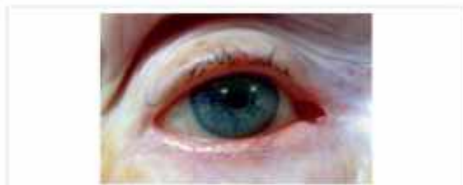
### Trichiasis



- It is the misdirection of the eyelash.
- If it is due to entropion it is called as pseudotrachiasis
- It is harmful to cornea and can cause corneal opacity
- Clinical features: Irritation, pain, lacrimation and blepharospasm.
- Complications
  - Punctate epithelial erosions.
  - Corneal ulcer
  - Pannus.
  - Pseudotrachiasis (entropion).

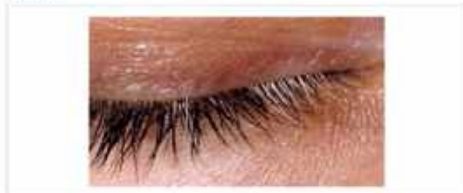- Treatment
  - Epilation
  - Diathermy/Cryo

### Madarosis



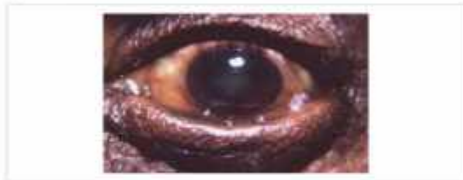- It is an overlapping term used both for the loss of eyelashes and the loss of the eyebrow.
- For loss of eyebrows there are systemic causes like leprosy and myxoedema
- Loss of eyelash: Causes
  - Local: Chronic blepharitis (most common), trachoma, tumours, burns.
  - Skin: Psoriasis generalised alopecia.
  - Systemic: Myxoedma leprosy.
  - Following removal, trichotillomania is lactogenic.
    - Trichotillomania is a psychiatric condition where person keeps pulling their eyebrows which can also lead to madarosis

### Poliosis



- Poliosis: Greying of eyelashes.
- Causes: It can be a complication of chronic blepharitis.
  - VKH syndrome
  - Waardenburg syndrome

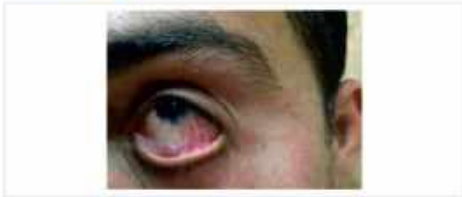### Tylosis



- Tylosis: Thickening of lid margin.
- It occurs due to chronic blepharitis

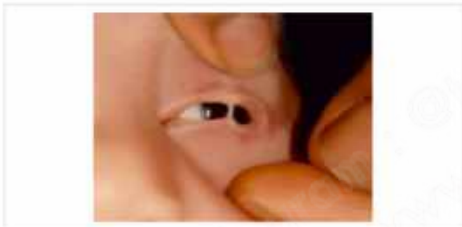

### Symblepharon



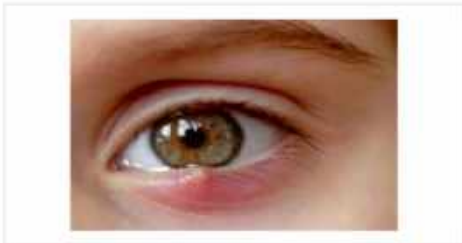- Symblepharon: Adhesion of palpebral and bulbar conjunctiva
- Causes: Scarring can be seen due to
  - Burns
  - Chemical injuries
  - Surgery
  - Ulcers

### Ankyloblepharon



- When there is adhesion between two lids, it is called **Ankyloblepharon**.
- Ablepharon: Absence of lids

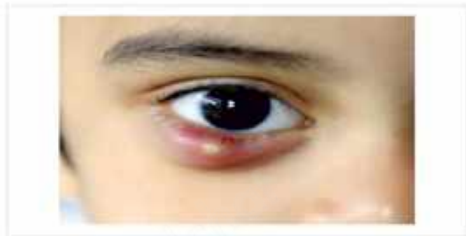### Hordeolum externum/Stye



- There is painful swelling on the anterior lid margin.
- Management: Hot fomentation and oral anti-inflammatory can be given.
  - Antibiotic ointment can be given

### Hordeolum internum

- It is the acute inflammation of meibomian gland
- It is a very painful condition.
- Management: Hot fomentation
  - Oral antibiotics
  - Oral anti-inflammatory




### Chalazion

- A chalazion is a painless bump on the eyelid caused by blocked oil glands.
- It is a lipogranulomatous inflammation of meibomian gland
- It can present as painless swelling on the lid.
- Treatment:
  - Incision and curettage
  - It should always be a vertical incision.
  - And if horizontal incision is given it can damage the ducts
  - Intralidial injection of TA (Triamcinolone acetonide)
- Most common cause of recurrent chalazion: Uncorrected mild refractive error
  - Other cause can be sebaceous cell carcinoma, most common site is upper lid



## Crossword Puzzle 1




### Across

3. LPS resection done with the conjunctival route \_\_\_\_\_.
4. LPS resection done with the skin route called \_\_\_\_\_.

### Down

1. For mild ptosis and there is a good levator function, the operation is called \_\_\_\_\_ operation.
2. \_\_\_\_\_ Upper lid is joined with frontalis muscle.

## Crossword Puzzle 2



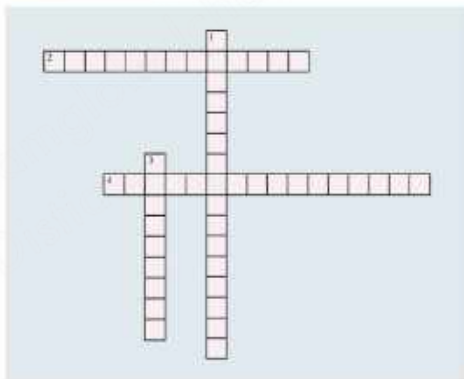
### Across

2. Posterior blepharitis is associated with \_\_\_\_\_.
3. Congenital lower lid retractors need to be better developed. It can be treated with \_\_\_\_\_.

### Down

1. When there is adhesion between two lids, it is called \_\_\_\_\_.

## Crossword Puzzle 3



### Across

2. \_\_\_\_\_ describes the incomplete or abnormal closure of the eyelids.
4. When the horizontal length of the eyelid decreases, it is called \_\_\_\_\_.

### Down

1. The vertical gap, the \_\_\_\_\_, is the area between the open eyelids, around 8-10mm.
3. \_\_\_\_\_ glands are located in the Tarsal.

- Refraction is the phenomenon of bending of light rays when it travels from one medium to another.

### Visual Perceptions

00:00:33

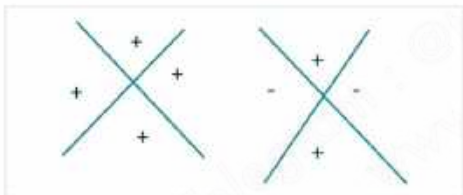
There are four types of visual perceptions:

- Light sense
- Form sense
- Color sense-Perception of colour
- Contrast sense-Sharpness of image

### Light Sense

00:01:49

- It is the perception of Light (PL) and projection of rays (PR).
- The '+' sign in the image below depicts that the light is perceived from that direction and the '-' sign shows that the light is not being recognized from that region (For ex. Glaucoma, RP)



### Form Sense

00:03:48

- Form sense is measured by visual acuity.
- Snellen's visual acuity chart is used to measure the visual acuity of an individual.

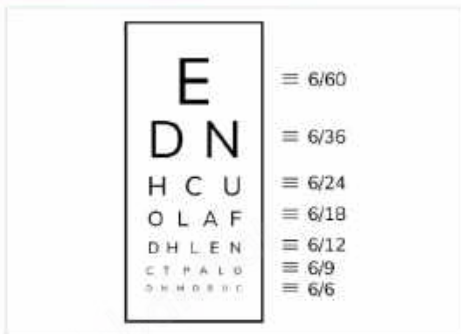
### VA Assessment

00:05:18

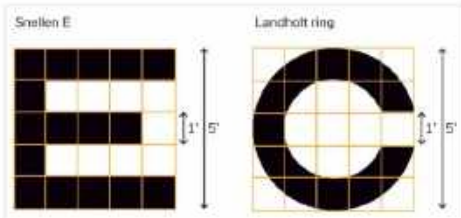
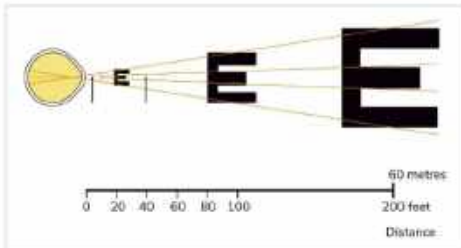
For adults or school-going children:

### Snellen Chart

- The image below shows the Snellen charts. The numbers on the right side of the alphabet show the measure of visual acuity.
- E.g., 6/6, 6/9, 6/36
- Here 6 is the numerator is the distance at which patient is sitting.
- Denominator is the vision of normal person.
- For example, if a person has 6/36 vision, it means that the person can read that alphabet only at a 6-meter distance while a normal person can read it at a distance of 36 meters.

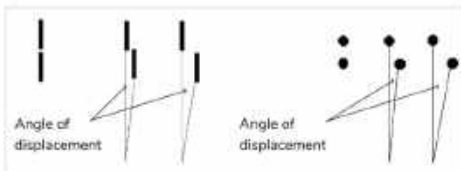


- The size of every letter in Snellen's box has significance.
- Every letter subtends an angle of 5 mins with the nodal point of the eye and every margin subtends an angle of 1 minute with the nodal point of the eye.
- Nodal point - First focal point which is considered normal optical center of eye just behind the lens.
- Angle subtended by every letter at nodal point is same.



- This angle subtended depends on the distance between the individual and the letter.
- The Minimal angle of resolution (MAR) is the angle subtended with the margin.

- The angle subtended by the letter is five times the minimum angle of resolution.
- If your patient cannot read at six meters, then we shift the patient to five meters and gradually decrease it till the patient can see. If he can see at a one-meter distance, then we say the visual acuity is 1/60.
- 1/60 is the minimum vision on Snellen's chart.
- Best acuity is 6/3
- Normal - 6/6
- If the patient still cannot see, then we check the finger count (finger count visual acuity), hand movement, and then the PL and PR.




### Hyperacuity or Stereo Acuity

- Hyper acuity / Stereo acuity – Measuring the resolution power of eye
- It is also called the vernier acuity.
- Hyperacuity is the ability to find the two nearest points and differentiate between them.
- This depends on the spacing of retinal receptors.
- Needs to have a 3D vision.
- For normal humans, 2-5 arc seconds
- Resolution of the eye → 576 megapixels
- VA Assessment
  - Adults / School going Childrens
    - Snellens chart
      - Far Vision
      - Near vision

### LOGMARS Chart or ETDRS Chart

- It is fixed number of letters in each line.
- It is done at a distance of four meters.
- It excludes or avoids crowding phenomenon or can also be used for patients with amblyopia.
- In amblyopia, the same letter in Snellen line which patient can not read, can be read independently.
- The most accurate method of checking visual acuity.



### Landolt's Broken Ring Test or Tumbling E test

Visual acuity test for illiterates.



- Near vision tests
- Jaegers test
- Snellen's can also be used
- Roman
- ETDRS/LOGMARS

### Jaeger's Chart/ Roman's Test



### For children less than one year:

- **Preferential Acuity Test**
  - Done with the Tellers chart or Keeler cards.
  - Show the cards to child and check whether he is interested in looking or not.
    - The minimum spatial frequency gives the idea of visual acuity.

- **OKN (Optokinetic) Drum Test**



- It is a drum with white and black stripes
- Main function - To attract the child and notice if the child is looking at the drum or not.
- Doctor observe whether child has optokinetic nystagmus or not.
- It is positive if vision is at least 3/60.
- Catford drum is used for the test. It is a drum with dots.

- **VER (Visually Evoked Response) Test**

- The visual activity from the ganglion to the visual cortex is viewed by showing a flash to the patient's eye.



Tellers Chart

**Tellers Chart:** The minimum spatial frequency detected gives the idea of visual acuity.

- **Keeler cards**

- These cards are printed with a circular patch to avoid identification of the grating by its edge
- They also have an 'empty' circle printed on the other side: This leads to a different visual response whereby the infant may look from one circle to the other before a definite fixation preference is made



- **Preschool [Subjective Tests]**

- CARDIFF Acuity test
- Sheridan Gardiner Test
- Allen-Picture test
- STYCAR TEST

- **Cardiff Acuity Test**

- For children up to one year of age, it is an objective test and for others, it is a subjective test.
- There are cards with images engraved.
- If the child is looking at those images then there is a visual activity.
- We can ask older children to recognize the images.



- **Sheridan Gardiner HOTV Test**

- It is used for the age group of 3-5 years.
- It is done at 6 meters and if the child cannot read at 6/60, then it is done at three meters.
- The chart consists of letters of different sizes.
- The main charts consists of letters HOTV of different size.



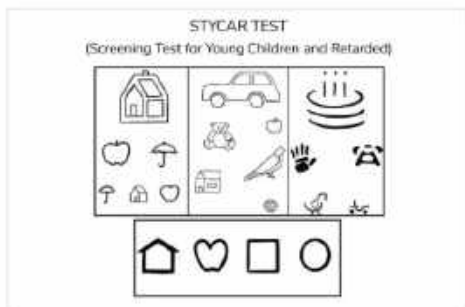
- **Allens Test Cards**

- Similar to the Sheridan Gardiner test.
- Patient is asked to identify the picture and observe if he can tell or not



### Stycar Test

- Screening test for young children and retarded.
- It is done at a distance of 10-20 feet.
- The main chart consists of pictures of eating items and toys.
- The child is given a key card and is asked to match it with the pictures shown in the main chart by the examiner.

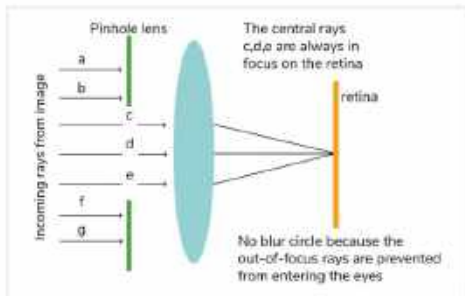


### Pin-Hole Test



- Pin hole is cutting all peripheral light rays so only central light rays can pass
- Checks whether the vision becomes better or worse after looking through the pinhole.
- If the vision gets better, then there is a refractive error in the eye.
- If the vision gets worse, there are central or macular issues/diseases.

### Size - 1mm to 1.2mm



### Stenopic Slit



- It is used to determine the site of iridectomy.
- It helps in detecting the axis of astigmatism. A width of 1mm and a length of 15mm.
- The vision becomes 6/6 at 6 years old.



### Important Information

- **Menace reflex test:** Blinking of an eye when there is bright light flashing in front of it. It can be seen only after 5 months of age.

### Contrast sensitivity

- Ability to distinguish any object against its background.
- Normal vision with decreased contrast sensitivity happens in amblyopia and some optic neuropathy.

### Tests for Contrast Sensitivity

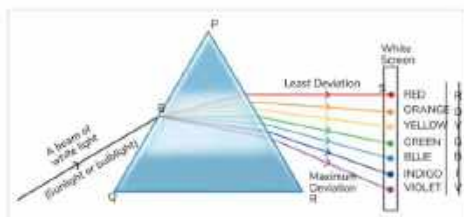
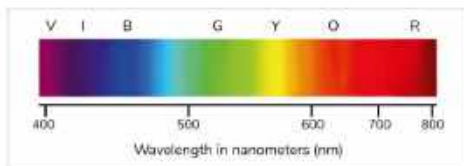
- Contrast sensitivity tests are helpful in the early diagnosis of **glaucoma**.

### Refer Table 21.1

### Color Sense

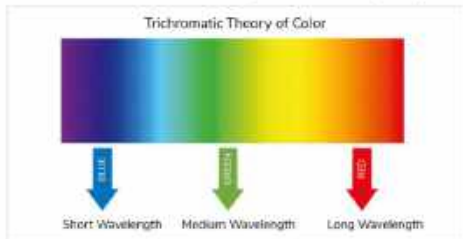
08/03/26

- Color perception starts earliest from **3 months** of age.
- Foveal maturation starts six weeks after birth and ends by 5-6 months.
- When white light is dispersed or scattered, the **VIBGYOR** is formed.



### Trichromatic Theory of Colour

- It is given by Young Helmholtz.
- There are three types of cones for color perception: large cones, small cones, and medium cones.
- Large cone - for red
- Medium cone - for green
- Small cone - blue color
- Combination of all three is responsible for color perception.



### Color Blindness

#### Classification of color blindness

##### Trichromats

- All three types of cones are present.
- Protanomaly: red weakness
- Deuteranomaly: green weakness
- Tritanomaly: blue weakness

##### Dichromats

- Only two types of cones are present.
- Protanopia: red blindness
- Deuteranopia: green blindness
- Tritanopia: blue blindness

##### Monochromats

- Only one type of cone is present and shades of grey are appreciated.

#### Congenital Color Blindness

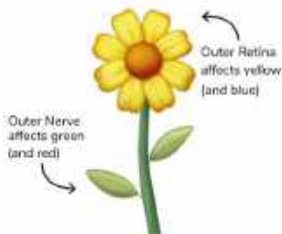
- It is an X-linked recessive disease
- It is mostly seen in males.
- It is not progressive i.e. it does not worsen with time.
- The visual acuity is normal.
- It is mostly red-green blindness.

#### Acquired Color Blindness

- The visual acuity is less and it can be progressive.
- Retinal diseases and optical neural pathway disorders can cause acquired color blindness.
- Kollner's Rule: If the optical neuropathway or inner retina is affected then the major issue is in red-green perception whereas if it is an outer retinal disease then it is a blue-yellow defect.

### KOLLNER'S RULE

Note: There are exceptions to the rule




- Exceptions to this rule: Stargardt's disease of the outer retina and Glaucoma of the inner retina.

#### Tests for Color Blindness

06:55:02

##### Ishihara Chart

- It can be 24 or 38-plated.
- Vision should be greater than 6/18.
- The first 12 plates are made such that everyone irrespective of whether diseased or normal can read.
- The next few plates are meant only for people with normal vision and the last few plates are meant only for people with color blindness.
- If a person can read less than nine plates, then the patient is colorblind (red-green blindness).



##### Hardy Rand Rittler Test



- It is used for detecting color blindness in children.
- The screening is done using shapes.

## Quantification of Color Blindness

00:57:20

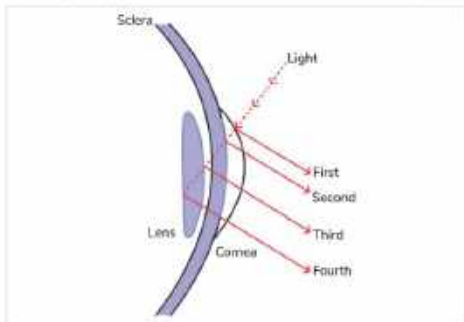


- Farnsworth-Munsell 100 hue test
  - There are only 85 caps
  - Arrange it in color progression
- Nagel's Anomaloscope : Used to quantify color blindness
- Edridge Green Lantern Test : Used for classification



## Purkinje Images

01:00:01



- They are the images formed on the major refracting surface of the eye i.e., cornea and lens.
- The image formed on the anterior surface of the cornea is Purkinje image- I, the posterior surface of the cornea is Purkinje image- II, the anterior surface of the lens is image- III, and the posterior surface of the lens is an image- IV.
- The images III and IV are absent in aphakia.
- The Purkinje image - IV is inverted.
- If pseudophakia or artificial lenses are inserted, all four images are obtained.
- IVth image is absent in mature cataract.
- Image 1 - It is used for Keratometry.

## Direct Ophthalmoscope

01:13:35

- It is also called Fundoscope.
- It has a 15x magnification and a field of 2 disc diameter.
- Virtual and erect images are formed.
- The central retina is examined.
- Right eye of the patient is examined by the right eye of the examiner and vice versa.
- Magnification= power of eye/4 = 60/4= 15 diopter.



## Indirect Ophthalmoscope

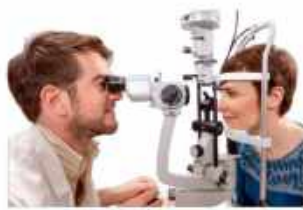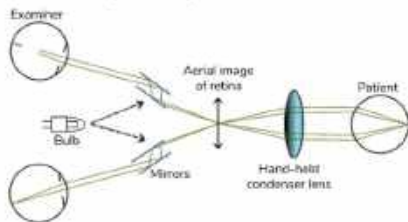
01:15:27



- It has a magnification of 3x or 5x and has a field of 8 disc diameter.
- It forms real and inverted images.
- It is used to examine the peripheral retina.
- Image is formed in between the lens and the examiner.
- Magnification=Power of eye/power of lens=60/20=3 diopter.

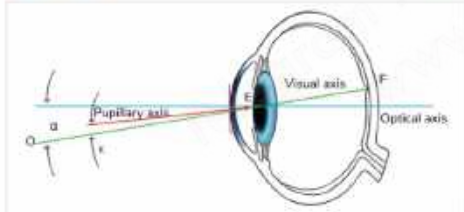


## How an indirect ophthalmoscope works



$$M_x = \frac{\text{Power of Eye}}{\text{Power of lens}} \times \text{Slit lamp magnification}$$

01/28/24



- The imaginary line that divides the eye into two halves is called the optic axis.
- The line passing through your fovea is the visual axis.
- The angle "alpha" is the angle formed between the visual axis and the optic axis.
- The imaginary line that divides the pupil into two halves is called the pupillary axis.
- The angle "kappa" is the angle between the pupillary axis and the visual axis.
- Angle kappa is a very small angle of 5 degrees.
- When a torch is pointed towards an eye, and it is a large positive kappa, then the reflex is more nasally. This is pseudoexotropia.
- Pseudoexotropia is seen in high hypermetropia.
- When there is a large negative kappa, then the reflex falls more temporally. This is pseudoesotropia.
- Pseudoesotropia is seen in high myopia.

## Refractive Errors

1. Myopia
2. Hypermetropia
3. Astigmatism
4. Anisometropia
5. Anisokonia

## Myopia

- The refractive power in the eye is more than required.
- The light rays focus in front of the retina.
- It is corrected by using a concave lens.

## Classification

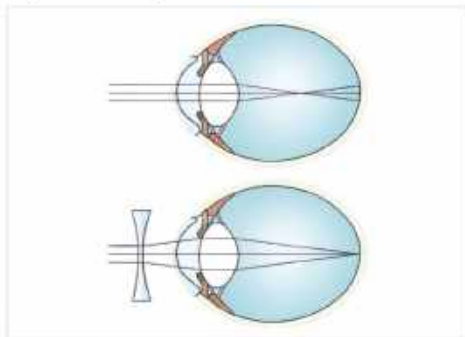
Myopia	Definition
Axial myopia	The axial length of the eye is more.
Curvature myopia	There is an increase in the curvature of the Cornea.
Index myopia	The refractive index of the lens is higher than the normal value.
Positional myopia	Anterior lens dislocation is observed in this type of myopia.

## Symptoms

- Blurred vision for far objects is seen in myopic patients.
- The eyes of patients with myopia are long, with a thin sclera and a deep anterior chamber.
- Ciliary muscle atrophy or damage can also be observed in such patients.
- Pathological myopia - Retinal changes
- Difficulty in far vision.

## Treatment

- Spectacles and contact lenses with corrected power can be used to treat the disorder. Refractive surgeries can also be performed on the patient.



## Hypermetropia

01/24/14

- The refractive power of the eye is less than required.
- The light rays focus behind the retina (small eye).
- It is corrected with a convex lens.

### Classification

1. Axial Hypermetropia: Lesser axial length
2. Curvature hypermetropia: lesser curvature of lens
3. Index hypermetropia: Index decreases due to old age
4. Positional hypermetropia: Posterior dislocation of lens

### Total Hypermetropia

- It can be Latent and manifest hypermetropia.
- Latent hypermetropia is due to the ciliary body and it is up to 1 dioptre.
- Manifest hypermetropia can either be due to facultative (can be overcome by accommodation) or absolute (cannot be overcome by accommodation)

### Symptoms

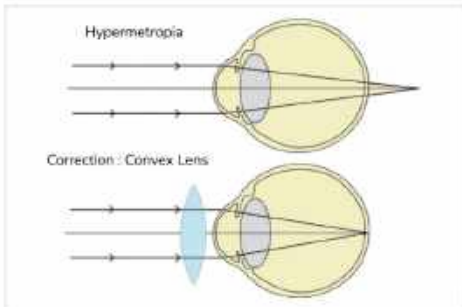
- Aesthenopic symptoms like headaches and blurred vision can be observed.
- Both far and near vision is affected in high hypermetropia cases.

### Examination

- Accommodative esotropia
- Pseudo myopia - Accommodation spasm.
- Small eye, more radius i.e., lesser curvature, shallow anterior chamber, narrow angles prone to closure and normal lens.
  - Retinal findings - Pseudo papillitis.

### Treatment

- Spectacles or contact lenses with corrected power may be used
- Contact Lenses
- IOL
- Refractory surgeries



## Important Information

- Concave lenses minify image, and convex lenses magnify the image.
- One dioptre is responsible for a 2 per cent change in image size.
- Effective power of the concave lens is more when it is closer to the eye and the effective power of the convex lens is more when it is farther from the eye.

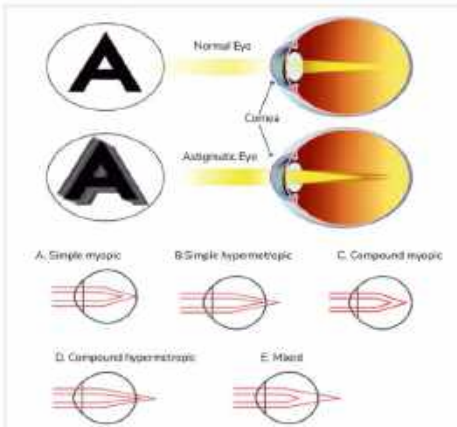
### Astigmatism

01/28/20

- Difference of refractive power between two principal axis.
- There are multiple focal points.

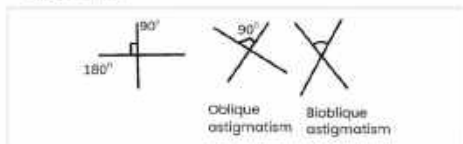
### Classification

Axis-I	Axis- II	Type of astigmatism
Normal	+	Simple hypermetropic
Normal	-	Simple myopic
+	+	Compound hypermetropic
-	-	Compound myopic
+	-	Mixed astigmatism

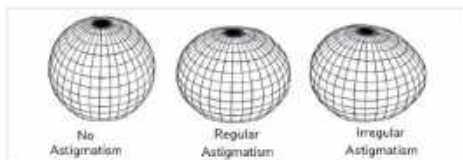
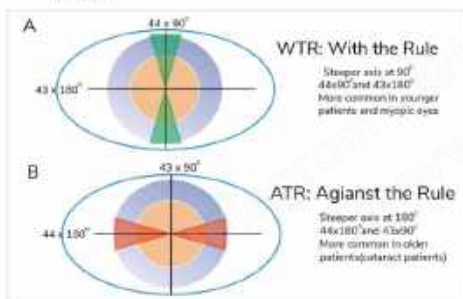


- Regular astigmatism is when both the axis are at 90 degrees and 180 degrees and are perpendicular to each other.

- If the two axis are perpendicular to each other but they are not at 90 degrees and 180 degrees with the eye, this is called Oblique astigmatism.
- If the angle is also less than 90 degrees, then it is bi-oblique astigmatism.



- When the power is constant over a single axis, then it is regular astigmatism.
- If there is variation in a single axis then it is irregular astigmatism.
- Irregular astigmatism is seen in keratoconus.
- With the rule: Vertical axis more curved than the horizontal axis.
  - Against the rule: If horizontal is more curved than vertical.



### Symptoms

- The patient complains of blurred vision and constant headaches.

### Treatment

- Cylindrical spectacles with the correct power can help correct this disorder or even toric contact lenses can be used.
- Refractive surgeries can also be performed.

### Anisometropia

02:00:44

- Difference of power of two eyes of more than 2.5 diopters.

### Aniseikonia

02:01:16

- Difference in an image size of two eyes.
- Physiological difference between image size is five percent and this helps in-depth perception.
- The image size difference of more than five percent leads to aniseikonia.
- It is measured by Eikonometer.
- Isekon glasses can help treat it.

### Aphakia

02:01:50

#### Examination on clinical feature

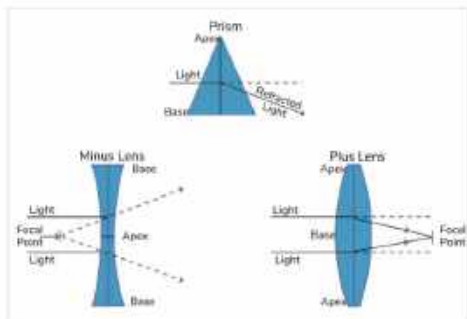
- There is no lens in the eye.
- It is a state of high hypermetropia.
- The vision is less by at least 15 to 16 diopters.
- Aesthenopic symptoms are seen.

#### Examination

- The eye has a deep anterior chamber.
- The nodal point of the eye moves forward. (normal position is 7.08mm from the anterior surface of the cornea).
- Support of the lens is lost - Iridodonesis and power of eye is 44 D instead of 59-60 D.
- No lens means no accommodation.

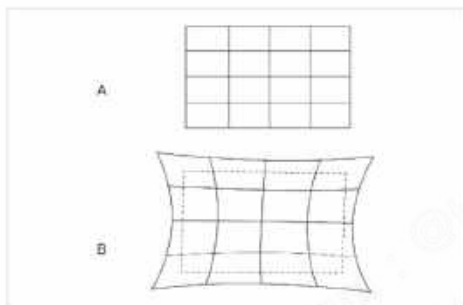
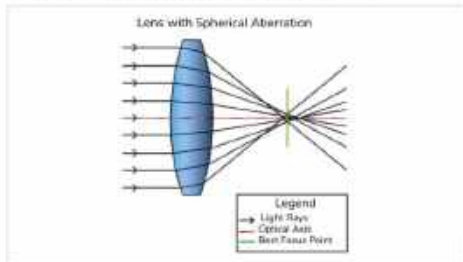
#### Treatment

- Spectacles or contact lenses with corrected power can be used.
- IOLS - Treatment of choice.
- Refractive surgeries.
- **Specks used for aphakia - +10D - +14 D**
- The problems caused due to spectacles (high convex lens) while treating aphakia :
  - Very high magnification of around 25- 30 % and due to this we cannot correct a unioocular aphakia with specs and it can lead to high aniseikonia which will further lead to diplopia.
  - High Spherical aberration (there is more bending from the periphery than the centre) hence person can not see straight so everything is parabola i.e., curved which can cause image distortions (Pincushion effect).
  - High prismatic effect leads to roving ring scotoma.
- This roving ring scotoma leads to Jack in box phenomenon.



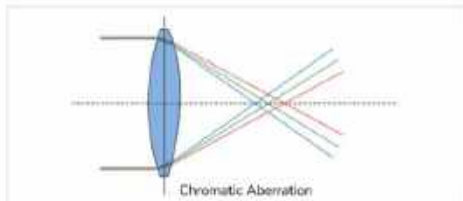
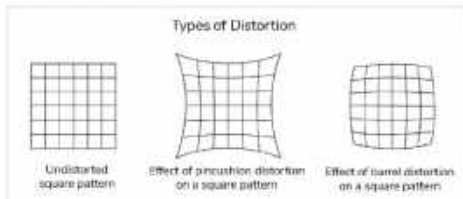
The spherical aberration can cause distortions:

- Pincushion effect on a square due to a convex lens.



Pin-cushion phenomenon: A, an object viewed through a plane glass; B, the same object viewed through a convex lens (pin-cushion effect). The dotted lines in B indicate normal size.

- Barrel effect on a square due to a concave lens.



- Chromatic aberration: Longer wavelength of the light bends less and shorter wavelength of light bends more.

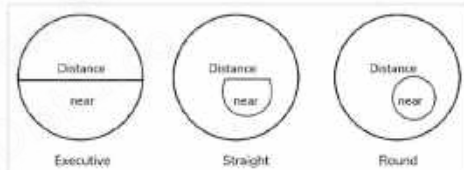
- Chromatic aberration: Different color of the light bends differently
- Spherical aberrations can be reduced by aspherical glasses where periphery is more flatter and center is more curved.



### Executive Bifocals

#2:18:20

- In patients after cataract surgery where lens is removed and IOLs are put, there will be no accommodation.
- Bifocals are used in corrections in pediatric aphakia or pseudophakia.



### Accommodation

#2:22:16

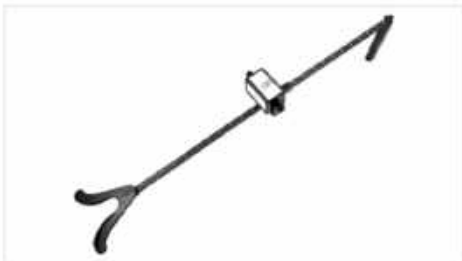- 1 - There is contraction of ciliary muscle.
  - 2 - Relaxation of zonules which is causing more curvature of the lens.
  - 3 - More the curvature, more the refractive power.
- The far point or punctum remotum is the farthest point a patient can see clearly.
  - The near point or punctum proximum is the nearest point where vision is most clear.
  - The range of accommodation is the difference between the far point and the near point.
    - $a = r - p$ , where  $a$  - accommodation,  $r$  - far point or punctum remotum and  $p$  - near point or punctum proximum.

○ Power at far point (at infinity for emmetropic eye) - 0.

- The amplitude of accommodation is the difference between the power at the near point and the power at the far point.
  - $A = P - R$ , where A - amplitude, R - far point or punctum remotum and P - near point or punctum proximum.
  - Power - 1/focal length in meters.
- For emmetropia, the power of the far point is infinity.
- In myopia, the far point is in front of the eye and for hypermetropia, the far point is behind the eye.

#### RAF Ruler

02:31:12



- It will be helpful to assess the near point of convergence and near point of accommodation.
- The point where the patient shows diplopia is the site of the near point of convergence.
- The near point of accommodation is the point where the blurring of vision is noticed.

#### Presbyopia


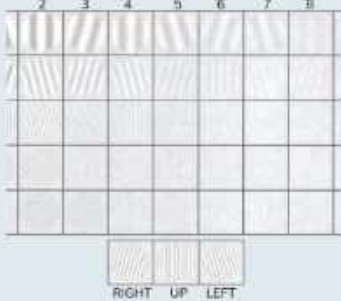

02:32:08

- Error of accommodation is presbyopia.
- Here presbyopic glasses are needed only for near vision.
- It happens around the age of 40 years for an emmetropic person, less than 40 years in hypermetropic patients, and more than 40 years for myopic patients.
- At 40 years, around +1 D spherical lens is used to correct it. With every year that passes around 0.5 D increase happens.
  - 40 years → +1.0 D spherical
  - 45 years → +1.5 D spherical
  - 50 years → +2.0 D
  - 55 years → +2.25 D
  - 60 years → +2.5 D
- Causes of frequent changes in presbyopic glasses:
  - Intumescent cataract or early cataract as swelling is different at different time so curvature is different
  - Late Glaucoma i.e., late stage of primary open angle glaucoma.
  - Diabetes: Due to hyperglycemia, there is a myopic shift and in hypoglycemia, there is hypermetropic shift.
  - So while doing refraction in patient it is very important to have blood sugar under control.

#### Retinoscopy

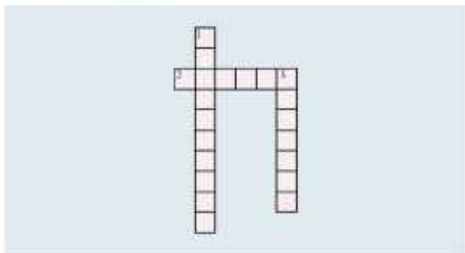
02:37:40

- It is an objective method to assess the refraction of the eye.
- It is used to assess refractive status in child or in a person who cannot respond properly.
- The distance between the examiner and the patient is around one meter.
- The line of light from the retinoscope is falling on the patient's eye.
- We move the line of light and see if the reflex is moving along i.e., with the movement or opposite (against the movement) to the line of light in both the perpendicular and parallel axis of the eye.
- Take lenses and check which lens helps you attain the point of neutralization. The point of neutralization is the point where there is no reflex observed when the light is moved.
- This lens reading at the point of neutralization is the retinoscopic reading.
- Now the correction factors are subtracted from the reading. This includes both the distance factor and the cycloplegic factor.
- Now if the distance is 1 meter then 1 D has to be subtracted and if the distance was 2/3rd of a meter then 1.5 D is subtracted from the retinoscopic reading.
- Now if the cycloplegic factor is atropine then 1 D is subtracted and if it is any other factor then 0.5 D is subtracted from the reading.
- On retinoscopy (from a distance of 1m)
  - If it is with the movement, then the patient is emmetropic, hypermetropic, or myopia less than one.
  - If the movement is against the light, then the myopia is greater than one.
  - If there is no movement, the myopia is one.

Test	Description
<p>Pelli-Robson Contrast sensitivity letter chart</p> <p>V R S K D R            N H C S O K            S C N O Z V            C N H Z O K            N O D V H R            C D N Z S V            K C H O D K</p>	<p>The contrast sensitivity test employs a single large letter size (20/60 optotype) with shifting levels of contrast between sets of letters.</p>
<p>Arden Gratings test</p> 	<p>Ask patient if he can see different lines separately.</p>
<p>Functional Acuity Contrast Test</p> <p>FUNCTIONAL ACUITY CONTRAST TEST</p> 	<p>Different contrast sensitivity and different spatial arrangement is seen in this chart.</p> <ul style="list-style-type: none"> <li>• Patient is asked to describe in each box.</li> <li>• It tells functional visual acuity.</li> </ul>
<p>SPARCS test (Spath-Richman contrast sensitivity test)</p> 	<p>It is generally done for illiterates.</p> <ul style="list-style-type: none"> <li>• It is a computerized method where patient is told to click at the box where they can see these gratings.</li> </ul>



## Crossword Puzzle 1



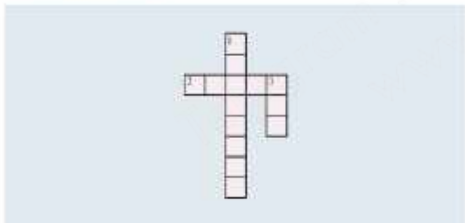
### Across:

- 2) \_\_\_\_\_ acuity is measured by form sense

### Down:

- 1) Stenoscopic slit is used to determine the site of \_\_\_\_\_  
3) The chart used for patients with amblyopia \_\_\_\_\_

## Crossword Puzzle 2



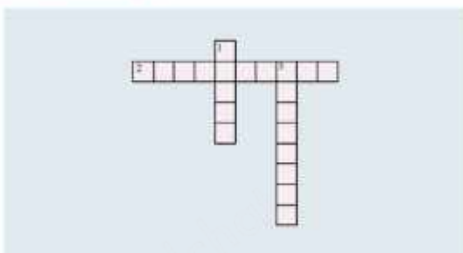
### Across

2. The reflex when light is flashed in front of eye \_\_\_\_\_

### Down

1. The sense which allows you to distinguish an object from the background, \_\_\_\_\_  
3. Color perception starts earliest from \_\_\_\_\_ months of age \_\_\_\_\_

## Crossword Puzzle 3



### Across

2. Red blindness is called \_\_\_\_\_

### Down

1. The angle between the pupillary axis and visual axis, \_\_\_\_\_  
3. The images formed on the major refracting surface of the eye, \_\_\_\_\_

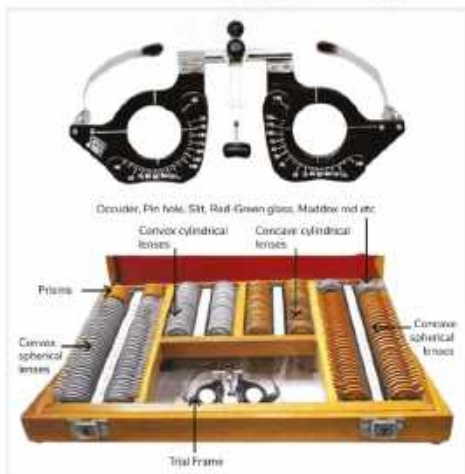
- Retinoscopy: Streak retinoscope



- A line of light is falling on the pupil, the axis of astigmatism is assessed very well.



- Plane mirror retinoscope on one side and concave on the other side.



- Against the movement - Choose golden lenses (concave lens).

- With the movement - Choose silver lens (convex lens).

### Spectacle prescription

00:01:16

- E.g., Give prescription on the basis of corrected reading.

$$\begin{array}{l}
 1. \quad \begin{array}{c} | \\ \hline +2 \\ \hline | \end{array} \quad \longrightarrow \quad +2 \text{ D Sph.} \\
 2. \quad \begin{array}{c} | \\ \hline -3 \\ \hline | \end{array} \quad \longrightarrow \quad -3 \text{ D Sph.} \\
 3. \quad \begin{array}{c} | \\ \hline -3 \\ \hline | \\ \hline -2 \\ \hline | \end{array} \quad \longrightarrow \quad \text{CM/WTR.} \\
 \qquad \qquad \qquad -2 \text{ Dsph} - 1 \text{ Deyl at } 180^\circ
 \end{array}$$

- How to write prescription for -3, -2
  - Pick any one number out of two like -3, -2 and give spherical to any number (-2) but the requirement is -3/-2 so -1 has to be given more at 90 so add power in cylindrical.

### Subjective Verification of Refraction

00:01:32

#### Spherical Lenses

- Refine the sphere first.
- Pinhole test: In the pinhole test, the first thing checked is whether the given spherical is correct. If the vision improves after a pinhole test, more refractive errors must be improved.
- Duo-chrome test: It is based on chromatic abbreviation. In this test, the patient is given red and green letters and asked which one is more prominent; if green is more prominent than red, there is some residual hypermetropia, and if red is more, then there is some residual myopia.
  - If both are clear, then it is emmetropic



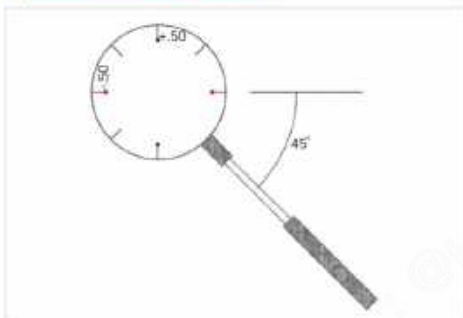
- Fogging test: Creating Cycloplegia without giving cycloplegics. In the first place, a high-power lens is taken and then slowly reduces the power to get the accurate point of the patient, and there would be no residual accommodations.



- It is done to exclude any factor of accommodation.



### Cylindrical correction refinement



- Jacksons Cross Cylinder, two combinations could be there that are  $-0.25$  and  $+0.25$  or  $-0.5$  and  $+0.5$ . Spherical is half and opposite to the cylindrical power.
- Astigmatic Dial or Astigmatic Fan test.
- Both these test is used to determine the axis and magnitude of astigmatism.

### Binocular Balancing

- Binocular balancing is done after refining individual eyes for spherical and cylindrical refraction. It is important to check whether the patient is comfortable when both eyes are opened. The following tests can do this:
  - Fogging Test
  - Duo-chrome Test

### Contact Lens

0018:57

#### Types of Contact Lenses

- Soft contact lens: It is made up of HEMA (Hydroxyethyl methacrylate). It is larger than cornea. It is available in various water content; those lenses with higher water content will have higher oxygen permeability and vice versa.
- Semi-soft contact lens: It is also known as rigid gas permeable. It is made of either silicon, fluoro-silicon, or cellulose acetate butyrate (CAB). It is smaller in size than Cornea, which makes oxygen permeability easier.

- Hard lens: It is not used nowadays because it is made up of polymethyl methacrylate (PMMA), which is not permeable to oxygen.
- Extended wear lens: It has high water content. It is not recommended for use.
- Oxygen transmissibility can be defined as  $DK/t$ , where  $D$  stands for the diffusion coefficient,  $K$  stands for the solubility coefficient, and  $t$  stands for thickness.

#### Determination of Contact Lens Power

- It is important to determine the lens power because it would not be the same as the power prescribed to the specs. Since the vertex distance gets reduced in the contact lens the power is adjusted accordingly with myopic and hypermetropic conditions.
- In myopia the power of the contact lens should be less than the specs. In the case of Hypermetropia, a contact lens of more power is used.

#### Indications of Contact Lenses

- Refractive uses include correcting the power.
- Cosmetic purposes, as it is used as an alternative to specs, and comes in various colors.
- Therapeutic purposes e.g., bandage contact lens is used in corneal ulcer, Rigid gas permeable lens are used in keratoconus.

#### Complications Associated with Lenses

- Hypersensitivity or allergic reaction to contact lenses can lead to giant papillary conjunctivitis.
- Overwearing syndrome can cause hypoxia of cornea which will lead to corneal edema.

### Amblyopia

00:29:23

Amblyopia is also known as the lazy eye, which means a decrease in best-corrected visual activity. It can be due to form deprivation, strabismus, or refractive error.

#### Types of Amblyopia

- Strabismic Amblyopia : When one eye is deviated, fovea of that eye is not working, it become dull and this causes amblyopia.
- Form deprivation amblyopia
  - Any cause of opaque media - at the cornea or cataract can lead to light not reaching the fovea so fovea is not formed which can lead to amblyopia.
- Refractive
  - High degree of anisometropia which is uncorrected
  - Ametropia
  - Meridional amblyopia- It can happen in any axis of astigmatism.

### Clinical Findings of Amblyopia

- Decrease in visual activity.
- Decreased contrast sensitivity.
- Decreased hyperacuity.
- Sunglass effect - Decreased brightness in the amblyopic eye.
- Crowding phenomenon : When the patient can read same letter in same size when presented individually (separated from line).

#### Crowding phenomenon

Amblyopes can discriminate smaller visual acuity symbols when presented singly



### Treatment

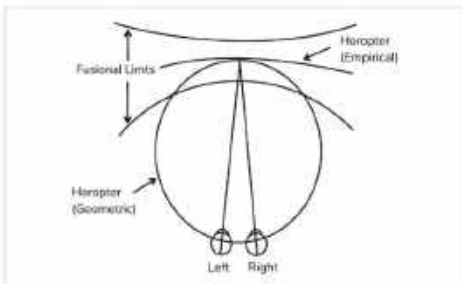
- Occlusion of the normal eye - Using patches to cover the normal eye or penalisation by atropine. This is done for about 4-6 hours a day. It is treatment of choice.



- As age increases it is difficult to treat amblyopia.
  - Criteria according to age
  - 1 year - 1:1 i.e., occlude for one day and open for one day.
  - 2 year - 2:1
  - 3 years - 3:1
  - 4 years - 4:1
  - 5 years - 5:1
  - 6 years - 6:1
- 
- Amblyopia treatment can be done upto 8 years of age but is most effective till 6 years of age.
  - Other methods
  - Carbidopa/levodopa
  - Using Cam Stimulators, stimulate the amblyopic eye various patterns are shown to activate the fovea.



- Pleoptics - To treat eccentric fixation by stimulating the fovea and blinding the eccentric point.
  - If fovea of one eye is working with eccentric point of another it is known as abnormal retinal correspondence.
  - On covering one eye, if the fovea of the other eye does not takes the center position, it is known as eccentric fixation.

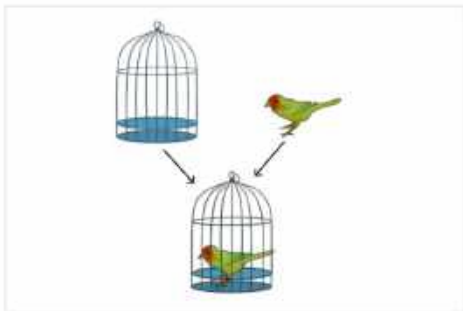

- Horopter - Area in space where points present are stimulating corresponding retinal points i.e., 2 eyes are seeing same thing together.
- Panum's fusional space: Area outside horopter where diplopia is not present

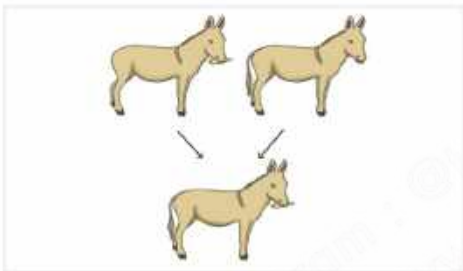
### Binocular Single Vision/Binocular Function

06:44:58

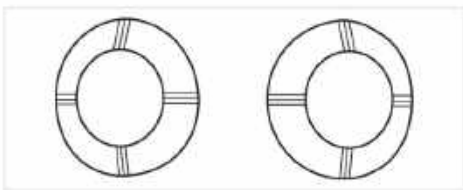
- It is the faculty of brain to fuse 2 retinal images as one.
- It gets developed after 5-6 years of age.
- It is divided into 3 grades:
  1. Simultaneous perception



2. Fusion : It is formed by 6 months.
- Fusion of 2 similar objects

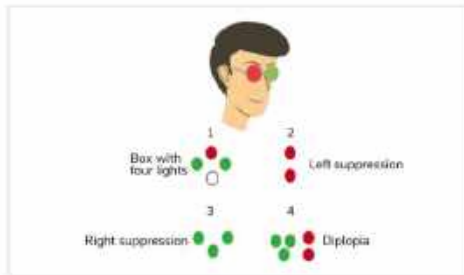


3. Stereopsis (Depth perception)
- Ability to obtain an impression of depth.
  - Superimposition of two pictures of same object taken from slightly different angles.
  - 5% difference of image size of both eyes is normal and this helps in 3D vision or in depth perception

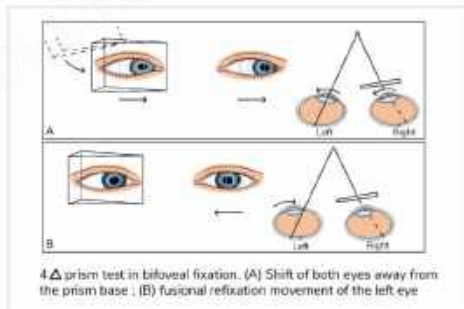


#### Tests To Check for Binocular Singular Vision

1. Worth Four Dots Test: An individual is given red-green glasses red, on the right side and green on the left side and is asked to see the box which contains four lights, that is one red, two greens, and white light.
- Diagnosis: If a person sees only two red lights, then he has left eye suppression, and if a person sees three green lights, then he has right eye suppression. However, if the person sees more than 4 lights, then he has Diplopia.



2. 4 Prism base out test: - Put prism base out in front of the eye.
- Put prism on right eye, eye will deviate towards the apex.
  - So as a part of conjugate movement left eye will also deviate on same side but if fovea of left eye is fine, it will come back for bifoveal fixation.
  - This recovery movement indicates there is bifoveal fixation.
  - So it also helps in diagnosis of very small amount of squint i.e. Microtropia which is a squint of less than equal to 5 degree.



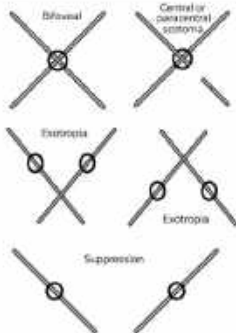
3. Bagolini Striated Glasses test: - Patient is made to wear these glasses.
- There is striations in glasses which is 135 degree in right eye and 45 degree in left eye.
  - Patient is asked to look at one point and interpretation is made basis on what patient see.
  - Image formed will be in opposite directions of striations.

#### Interpretations

1. Bifoveal - If a person sees cross at center.
2. Central/paracentral scotoma suppression : If a patient sees gap in one side.
3. Uncrossed diplopia (Esotropia): light seen before crossing.
4. Crossed diplopia: Light seen after crossing.
- Crossed diplopia is a feature of divergent squint
5. Right and left eye suppression.



- Random dot E test



- Lang test



- Random dot test

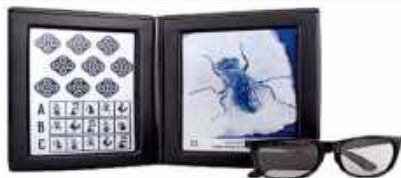#### 4. Synoptophore/Amblyoscope



- Diagnosis of binocular single vision in a child.
- Grades of BSV can be found.
- Orthoptic exercises : Improves binocular vision.
- Helps in convergence exercises.
- Type and amount of squint in an eye.

#### Tests Of Stereopsis

- Titmus fly test



- Frisby test : Do not need polaroid glasses.



- TNO test



## Refractive Surgery

### Basis of refractive surgery

- Keratomileusis: It is the alteration in curvature of cornea.
- More the curvature, more is the refractive power.
- So in myopia: For lesser curvature, flatten the cornea.
- For hypermetropia: Bulge the center of cornea

### Myopia

#### Incisional

- Radial Keratotomy: Leave optic zone of central 4 mm, peripheral cuts are made on cornea with diamond knife causing periphery to bulge and center to flatten.
  - o Results will be good within the 5 D of myopia.

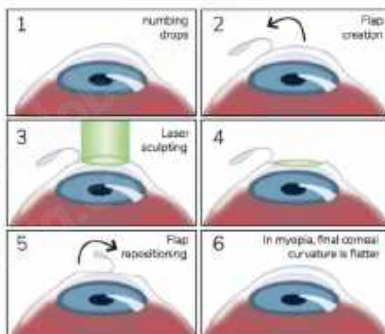


#### Laser Associated

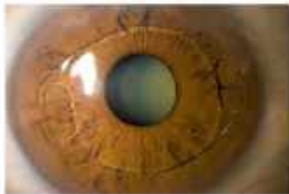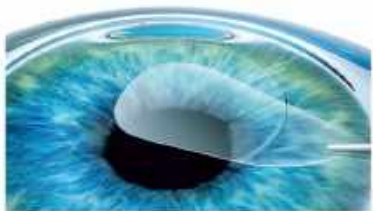
- Laser used: Excimer laser 193nm argon fluoride.
- Surface Ablation: The superficial stroma is dealt with here, It is done in case of low to moderate Myopia.
  - o Photorefractive keratotomy (PRK)- The epithelium is debride by alcohol, then the laser is given and eye is bandaged. The rehab time is longer and is not used now.
  - o LASEK- Laser Assisted Sub epithelial Keratotomy/Laser Epithelial Keratomileusis, It is done by raising the flap with alcohol.

- o Epi Lasik - Raising the flap by microkeratome.
- o Trans PRK- Flap is raised by laser.
- o For nebular corneal opacity, surface ablation procedures are done so that nebular opacity can be treated when superficial stroma is put under laser.
- LASIK: (Laser in situ Keratomileusis) It is done in case of moderate to high myopia, dealing with deeper stroma.
  - o I-Lasik
  - o Z-Lasik
  - o In I-LASIK and Z-LASIK: Raise the flap by Femto laser.
  - o Contura: Topo Guided Lasik
  - o Wavefront Guided Lasik : To treat Abberopia


### LASIK EYE SURGERY



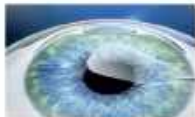- ReLEx (Refractive Lenticular Extraction) or SMILE : Cut small piece of corneal stroma by focusing the Femto laser on cornea.
- It is small incision lenticule extraction.
- After the piece of corneal stroma is cut, make 4mm incision.



### The Treatment Steps



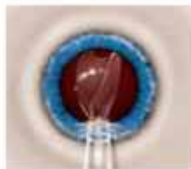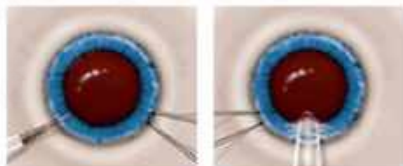
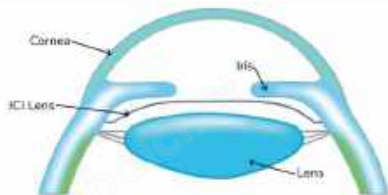
**Step 1**  
Lenticule creation  
A thin lenticule and small incision are created inside the intact cornea.



**Step 2**  
Lenticule removal  
The lenticule is removed through the incision with minimal disruption to the corneal biomechanics.



**Step 3**  
Impairment is corrected  
Removing the lenticule changes the shape of the cornea, thereby achieving the desired refractive correction.



### Important Question

**Q.** What is the age limit for Refractive Surgery?

**A.** A minimum of 18+ years is required to perform refractive surgery.

**Q.** How much can ablate the patient?

**A.** Stromal bed thickness should be minimum 275 microns.

**Q.** How to calculate ablation depth?

**A.** Munnerlyn formula

$$\text{Ablation depth } (\mu\text{m}) = 1/3 \times (\text{Optic zone in mm})^2 \times \text{Intended correction in diopter}$$

### New Procedures: Higher Myopia

- Clear lens extraction: Fucali's Operation is done for this type of extraction.
  - Immediately power of lens is reduced by 16-17D.
  - Complications - Posterior capsule tear, retinal detachment.
- Phakic IOL implantation: - Additional lens is put to counteract the refractive error. It is done with the help of an iris clip (Lobster claw) or it is put in ciliary sulcus and it is called ICL (Implantable Contact lens).

- Implantable Contact Lens (ICL): derived from collagen, known as Collamer.
  - Range of correction is very high i.e., -3 to -20.5

### Hypermetropia

06/19/18

#### Laser

- Surface Ablation
- LASIK
- Laser thermal keratoplasty: Holmium Laser is used in this procedure and is given as two rows of laser burns in the mid periphery. So the periphery will shrink and center will bulge.
  - It is done to correct low hypermetropia.
  - It can regress so procedure can be repeated.
- Radio frequency waves: Here radiofrequency waves are used cause burns.

## New procedures

- Phakic IOL.

## Astigmatism

01:21:58

### Incisional

- Arcuate keratotomy
  - It is also called as T cuts
  - Perpendicular cuts are made on steeper axis which becomes little flatter and opposite axis will slightly bulge which is known as Coupling effect
- Ruiz procedure: relaxing cuts are given to treat post operative astigmatism after keratoplasty. Either rectangular or trapezoid shaped cuts are given.

### Laser

- Surface Ablation
- LASIK

### Surgery

- Toric IOL Implantation

## Presbyopia

01:25:36

1. PreLEx: Presbyopic lens exchange. Put multifocal IOLs.
  - Disadvantage: Glare
2. Conductive Keratoplasty Radiofrequency waves are put at periphery and center bulges. This is based on the concept of monovision so brain learn to use one eye for near and one eye for far.

### Monovision

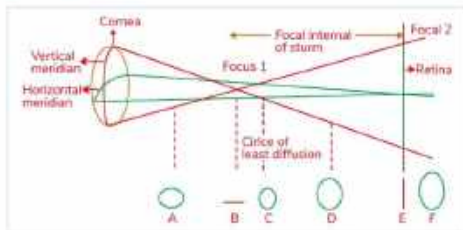
3. Laser induced
4. IOL based
5. Intracorneal inlays : Put intracorneal rings
6. Laser modification of natural lens by Femto laser (under research)

## Low Visual Aids

1. Late stage glaucoma or ARMD or macular disease.
2. Low visual aids: Gadgets used to magnify the image.
3. If the magnification is more, field and depth of focus is less.

## Surm's conoid

01:36:44



- Sturm's conoid: It is blurred effect of diffuse bundle of rays when it passes through an astigmatic lens.
- Focal interval: Distance between focal point 1 and focal point 2.
- More the focal interval, more the degree of astigmatism.
- Circle of least diffusion: It is the point where there is least blurring among all the focal points.

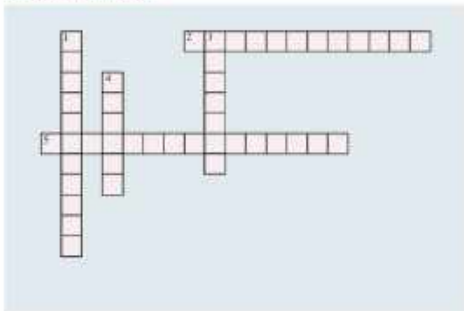
## Reduced Eye

01:35:28

- It is the simplified optical system of the eye where eye is considered as single surface and refraction is studied on that.
- All the values of power of lens, power of eye, power of cornea, index of lens, index of cornea is based on reduced eye.
- Concept of reduced eye is given by
  - Listing
  - Donders



## Crossword Puzzle 1



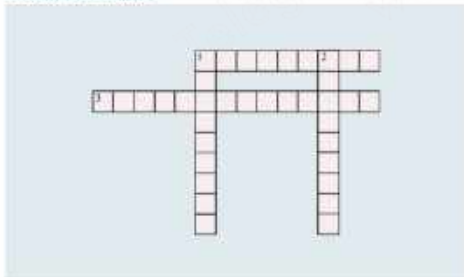
### Across

- Soft contact lens users are prone to \_\_\_\_\_.
- \_\_\_\_\_ is larger than the cornea.

### Down

- \_\_\_\_\_ is the most common infection.
- Oedema is caused by overwearing \_\_\_\_\_ lens.
- The distance between the lens and retina is \_\_\_\_\_.

## Crossword Puzzle 2



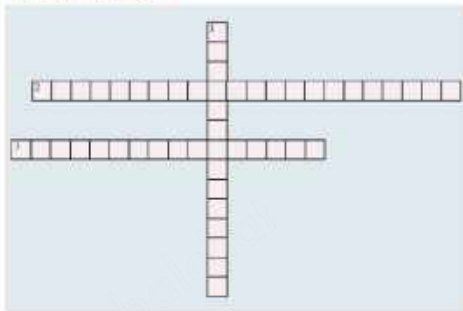
### Across

- \_\_\_\_\_ is a partial loss of vision.
- \_\_\_\_\_ decreased brightness in amblyopic eye.

### Down

- complete loss of vision is \_\_\_\_\_.
- to treat eccentric fixation \_\_\_\_\_

## Crossword Puzzle 3



### Across

- Derived from collagen \_\_\_\_\_.
- Clear lens extraction is done by \_\_\_\_\_.

### Down

- Reducing lenticule from a 4mm incision is known as \_\_\_\_\_.

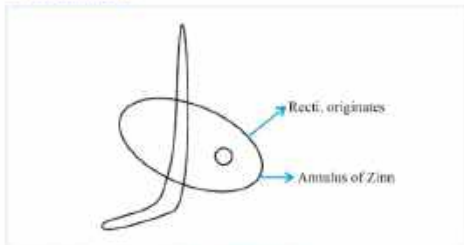


### Extraocular Muscles

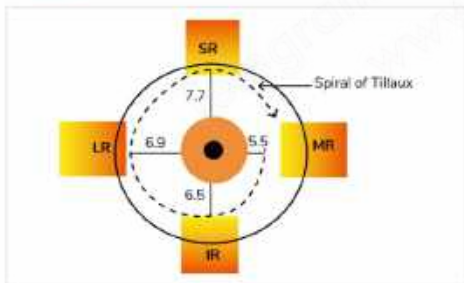
90/90/37

- The extraocular muscles are the muscles that control the movements of the eyes.
- Total six extraocular muscles are present in the eye: **Four recti muscles and two oblique muscles.**

#### 1. Recti muscles



- It originates from the **Annulus of Zinn**
- Annulus of Zinn is the tendinous ring located at the **apex of the orbit**.
- Insertion of recti muscle: **Anterior to the equator, Spiral of Tillaux**

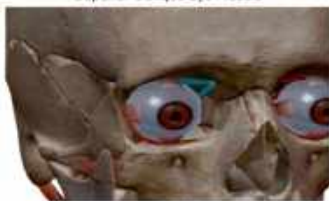

- Distance from limbus,
  - Medial Recti muscle: 5.5 mm
  - Inferior rectus muscle: 6.5 mm
  - Lateral rectus muscle: 6.9 mm
  - Superior rectus muscle: 7.7 mm
- The spiral ring shown with a dotted line is the **spiral of Tillaux**.

#### 2. Superior oblique muscle


- It originates from the **apex of the orbit, mainly from the body of sphenoid bone**.
- The superior oblique muscle passes through the **trochlea** where it acts as a **pulley** then it is inserted into the outer upper quadrant.

Superior Oblique Eye Muscle



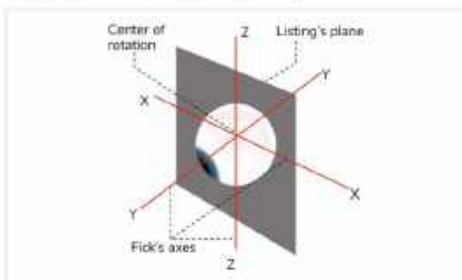
- Insertion is always posterior to the equator (posterior upper temporal quadrant)

#### 3. Inferior oblique muscle



- It originates (just behind the orbital ring) from maxilla.
- Insertion is lower temporal quadrant posterior to the equator.
- Movements of eye**
  - Elevation and depression
  - Abduction (away from nose) and adduction (towards the nose)
  - Intorsion ( $12^\circ$  inward rotation) and extorsion ( $12^\circ$  outward rotation)

#### Imaginary coronal plane passing through the centre of rotation



- The three-axis on which the eyeball is performing all six movements is called **Fick's axes**.
- The plane passing through the centre of rotation is called **Lister's plane**.
- X-axis shows elevation and depression
- Y-axis shows intorsion and extorsion
- Z-axis shows abduction and adduction

### Action of Different Muscles

0030719

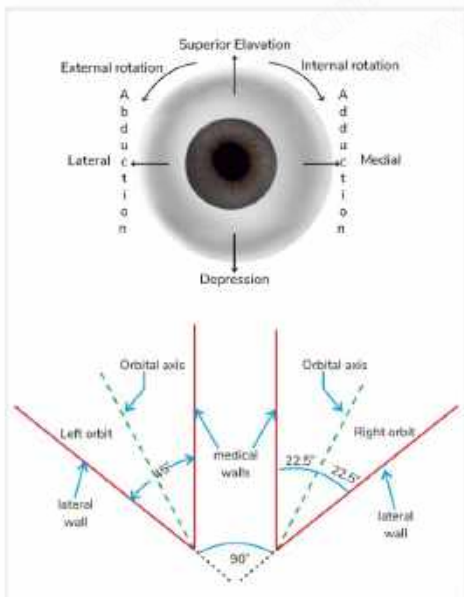
#### Horizontal

- Adduction is done by the **medial rectus muscle**, and abduction is done by the **lateral rectus muscle**.

#### Vertical

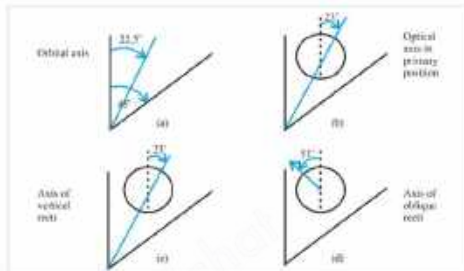
- IS: Superior are intorters
- RAD: Recti are adductors
- Vertical muscles: Superior rectus (SR), inferior rectus (IR), superior oblique (SO), and inferior oblique (IO).
- For vertical muscles, Adduction and abduction are always tertiary actions
- Elevation is also called **Sursum version** and depression is also called the **Deorsum version**.

Refer Table 23.1

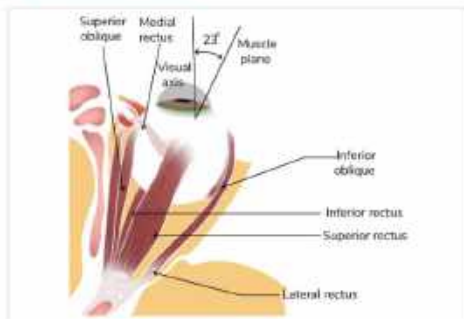


- Angle between lateral wall and medial wall is  $45^\circ$
- Any axis which is bisecting the two is  $22.5^\circ$  or  $23^\circ$  (orbital axis).

### Relationship of orbital axis with the eyeball

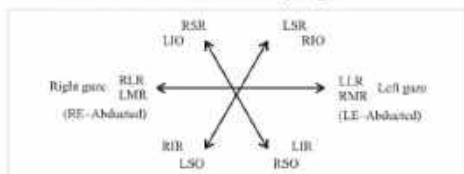


- Angle between the visual axis and the orbital axis is  $23^\circ$ .
- Superior rectus and inferior rectus are also aligned in the same line as the orbital axis and i.e., it forms an angle of  $23^\circ$  with the visual axis.
- When the eyeball is abducted at  $23^\circ$ , it comes in a straight line with vertical recti and in this position in the abducted eye, the action of elevation and depression is totally of recti.
- Angle formed between the oblique muscle and visual axis is  $51^\circ$ .
- When the eye is adducted at  $51^\circ$ , it comes in a straight line with oblique muscle. Therefore, the action of elevation and depression is of oblique.

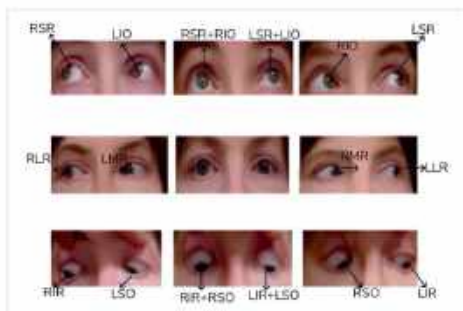

### Yoke muscles

- Yoke muscles are the **contralateral synergist**.



- Different gazes: Movement of both eye is denoted as version and movement of one eye is denoted as ductions
- There are 9 gazes



- Centre position is the primary gaze., supraversion is elevation and the infraversion is depression
- Movement of an eye towards the right is Dextro version and towards the left is Levo version.
- So there is dextro-elevation or dextro depression and levo elevation or levo depression
- Levo-elevation: Elevators are superior rectus and inferior oblique and levo means left eye is abducted so muscles involved are left superior rectus and right inferior oblique
- Muscles action in dextro-depression: Depressors are IR and SO and dextro means right eye is abducted so muscles involved are right inferior rectus and left superior oblique.
- Yoke muscles for right inferior rectus is left superior oblique
- Yoke muscle for right inferior oblique is left superior rectus

#### Herring Law

- It states that there is equal innervation in yoke muscles i.e., yoke muscles receive equal and simultaneous innervation.

#### Sherrington's law

- It's a law of equal but reciprocal innervation of agonist and antagonist.
- It means that two muscles in the same eye with opposite action (right eye, right superior rectus and right inferior rectus).

#### Squint/Strabismus

0001:23

- Misalignment of the visual axis.
- This condition is also called Heterotropia.

#### PSEUDO-STRABISMUS

- Pseudostrabismus is a condition when the eyes are well aligned but appear to be misaligned.
- Causes of pseudo-Isotropia:
  - Epicanthal folds
  - High myopia. High negative angle kappa

- Causes of Pseudo-Exotropia:
  - Telecanthus or hypertelorism
  - High hypermetropia (high positive angle kappa)
- In telecanthus there is normal inter pupillary distance but in hypertelorism it is more but both are far apart medial canthus with no actual deviation.

#### Classification of Strabismus

- It is divided into latent squint (phorias) and manifest (tropia).
- Latent squint is diagnosed by an uncover test by breaking the fusion reflex.
- Latent squint is further classified into esophoria, exophoria, and hyperphoria.
- Hyperphoria is a condition when the one eye is up and the other eye is down
  - It is protocol to mention the eye which is up.
  - if the left eye is up, it is left hyperphoria and right hypophoria
  - Similarly, if the right eye is up, it is right hyperphoria and left hypophoria.
- Exophoria: The eyes are divergent
- Esophoria: The eyes are convergent
- Manifest squint is further classified into esotropia, exotropia, and hypertropia
- Manifest squint can also be classified into
  - Concomitant squint: Esotropia or exotropia
  - Vertical squint are not concomitant
  - Inconcomitant squint:
    - Paralytic (paralysis of muscles)
    - Restrictive squint (fibrosis of muscles)
    - A-V pattern or pattern squint
    - Ocular motility defect.

#### Concomitant squint

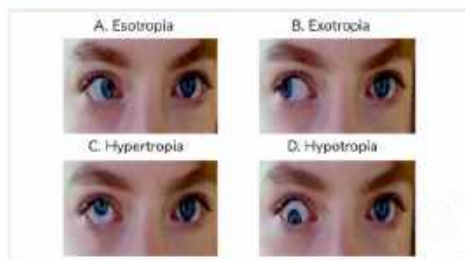- It's a type of manifest squint in which the amount of deviation remains same in all gazes.
- Primary deviation is equal to secondary deviation.
- Primary deviation is the amount of deviation in squinted eyes.
- Secondary deviation: It is the deviation of normal eye behind the cover
- When both fovea works together it is normal alignment and is called normal retinal retinal correspondence.
- Concomitant squint commonly occurs from early childhood or congenital squint.
- Eye movements are normal and no double vision (diplopia).
- There is no diplopia because of sensory adaptation as there is suppression (cortical inhibition)
- Eye gets deviated because of the abnormal retinal correspondence.

#### Etiology of Concomitant squint

- Sensory obstacles: Uncorrected refractive errors, high anisometropia, any disease of macula and any opaque media within 5-6 months of age.

- In small children, medial rectus muscle is very strong so the eye goes inwards
- After 8-9 years, in any non seeing eye, eye will start to drift outwards
- Moiar obstacle:** Abnormal accommodative convergence per accommodation ratio (AC/A ratio)
  - If the person is born with high AC/A ratio then per accommodation prism dioptre of convergence/dioptre of accommodation is more
  - Normal ratio:** 3-5:1
- Abnormality in the extraocular muscle.
- Congenital abnormality of size and shape of orbits.
- Central obstacle:** Defective development of fusion reflex.

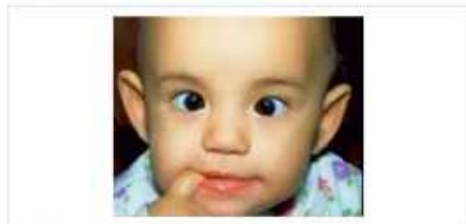## Esotropia



- It is a concomitant convergent squint
- Esotropia is divided into three types
  - Infantile esotropia
  - Accommodative esotropia
  - Non-accommodative esotropia.

### Infantile esotropia/ Essential infantile esotropia/ Congenital esotropia

- It manifests by six months of age.
- Amount of squint is large, about 30 prism dioptre.
- There will be alternate fixation in primary gaze (when the child looks straight either one eye can fix or the other eye can fix).



- There will be cross fixation in lateral gaze (when the child looks to the right with left eye).
- Latent Nystagmus:** Normally looking at child no nystagmus is seen, but when one eye is covered nystagmus is observed so nystagmus is manifested by covering the eye

- Jerky nystagmus: Fast phase towards the fixating eye.
- Dissociated vertical divergence (DVD):** Dissociated vertical deviation (DVD) is a condition characterised by a slow drift of the non-fixating eye while the other eye is fixating on a target.
  - DVD does not obey hering's law.
- Treatment:** By 6-8 months of age child starts to manifest i.e., child is not looking through both his fovea together
- Binocular single vision forms by 6-8 years but if the child is left as such he will never develop binocular single vision so to avoid amblyopia refraction and occlusion can be done
- Occlusion-** If amblyopia is found in one eye and vision is less, the treatment approach is to stimulate fovea by occluding the normal eye.
- Second treatment approach is to straighten the eye.
- Surgery
  - It should be planned at the correct time, so that binocular development will not be affected.
  - Both eye medial rectus recession (due to its overaction)
  - Lateral rectus resection.

### Accommodative Esotropia

- It is a condition developed due to activation of the accommodation reflex.
- It can be divided into refractive, non-refractive, and mixed type
- Refractive accommodative esotropia**
- Due to uncorrected high hypermetropia, accommodation is exerted. When too much of accommodation is exerted it will result in convergence squint.
- This convergent squint is same for far and near.
- Treatment: Treat hypermetropia
- Refractive correction- accommodation slowly relaxes and eyes become straight.

### Non-refractive accommodative esotropia

- Child is born with an increased AC/A ratio.
- As a result, the amount of squint will be more for near and convergence increases even further.
- Treatment:** Relax the accommodation by assisting accommodation or creating peripheral accommodation so that the central impulse is less
- Assist accommodation: Miotics like echothiophate.
  - Near glasses (bifocals).
- Usually surgery is not done but if needed- Bilateral medial rectus muscle recession can be done.

### Mixed accommodative esotropia

- High hypermetropia and increased AC/A ratio.
- Treatment
  - Refractive correction
  - Bifocals to relax accommodation
  - if surgery is needed : Bilateral medial rectus muscle recession

### Non-Accommodative Esotropia

- It can be stress induced, non-seeing eyes in children within 8 years, over correction exotropia
- **Convergence excess** is also a type of non-accommodative esotropia-normal AC/A ratio.
  - Near point of accommodation is normal
  - Esotropia: Only for near but ortho (straight eyes) for far vision.
  - There will be no refractive error.
- Treatment: Bilateral medial rectus muscle recession.

### Exotropia

- Exotropia is the condition when one or both eyes deviate.
- It can be congenital (very rare), primary exotropia, secondary exotropia, and consecutive exotropia.
- Primary exotropia manifests **within 2 years of age** that can be constant or intermittent.
- Secondary exotropia: Non seeing eye in adults.
- Consecutive exotropia: Overcorrection of esotropia

### Microtropia

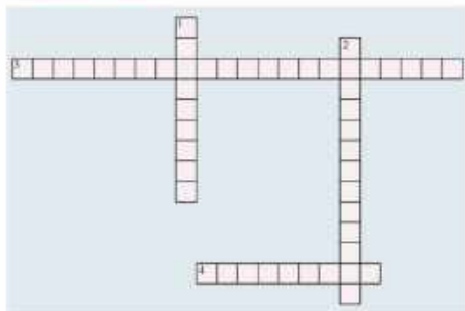
- Ultra small amount of squint is present (esotropia), about  $5^\circ$  of squint or 10 prism dioptre.
- Fixation can be foveal or extra foveal.
- 4 prism dioptre base out test is performed to check the fixation in microtropia.

Table 23.1

Function	SR	IR	SO	IO
Primary function	Elevation (Sursum version)	Depression (Deorsum version)	Intorsion	Extorsion
Secondary function	Intorsion	Extorsion	Depression	Elevation
Tertiary function	Adduction	Adduction	Abduction	Abduction



## Crossword Puzzle 1



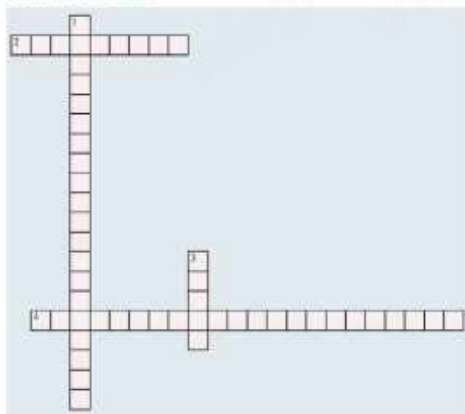
### Across

1. \_\_\_ is the conjugate movement of the eye.
4. \_\_\_ is the tertiary function of inferior rectus muscle.

### Down

1. \_\_\_ is the primary function of inferior oblique muscle.
2. \_\_\_ is the movement of an eye towards the right.

## Crossword Puzzle 2




### Across

2. \_\_\_ is the treatment of over-acting muscles.
4. \_\_\_ is the condition developed due to activation of the accommodation reflex.

### Down

1. \_\_\_ is the treatment of accommodative esotropia.
3. \_\_\_ ratio is increased in Non-refractive accommodative esotropia.

## Crossword Puzzle 3



### Across

3. \_\_\_ is one of the treatment approaches for accommodative esotropia.
4. \_\_\_ is revealed by viewing with one eye alone.

### Down

1. \_\_\_ is a condition characterized by a slow drift of the non-fixating eye while the other eye is fixating on a target.
2. \_\_\_ is the presence of a very small amount of squint, approximately 5° of squint or 10 prism dioptres.

**Inconcomitant Squints**

- This condition is just the **opposite of Concomitant squints**, where the degree of squint varies in different gazes.

**Important Points**

- Secondary (Paralytic) >> Primary
- In contrast to Concomitant squints, there is a **late presentation**.
- There is palsy of other muscles, which causes limited ocular movements (ocular movements are restricted).
- Diplopia** is also a very important feature of inconcomitant squints.

**Sequelae followed when there is palsy of a Muscle**

- Secondary **over-action of yoke**: According to **Herring's law** when there is palsy of one muscle, there has to be equal innervation in the yoke causing secondary over-action of the yoke muscle.
- Secondary **contracture**: Due to the palsy, there will be secondary contracture of the ipsilateral antagonist. It is only seen in the case of a long-standing deviation.
- Secondary inhibition of **contralateral antagonist**: When a contracture is taking place in the muscle, there will be secondary inhibition.

**Diplopia**

00095-83

- Diplopia means double vision.



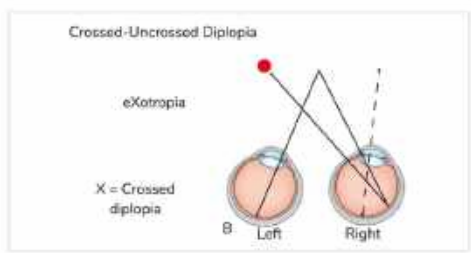
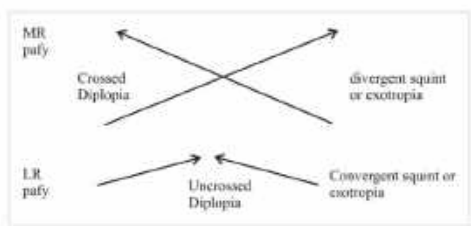
- There is two localization of one object.

**Classification**

- Diplopia can be classified in three ways.
  - First way**
    - Horizontal diplopia**

- Vertical diplopia**
  - Torsional diplopia**
- Second way**
    - Unioocular diplopia
    - Binocular diplopia

- The most common cause of unioocular diplopia** is subluxation of the lens.
  - Some other causes include polycoria or the case of multiple pupils.
  - Incipient cataract can also lead to unioocular diplopia.
- The most common causes of binocular diplopia.**
  - Paralytic squint
  - Restrictive causes: Thyroid eye disease and blowout fractures
  - Third way**
    - Crossed diplopia**
    - Uncrossed diplopia**
- In diplopia, one is a true image, and one is a false one. If the false image is on the squinted side, this condition is uncrossed. If the image is formed on the opposite side of the squinted eye, it is crossed.



- This is another method to figure out if it is crossed or uncrossed diplopia.

### Compensatory Head Posture

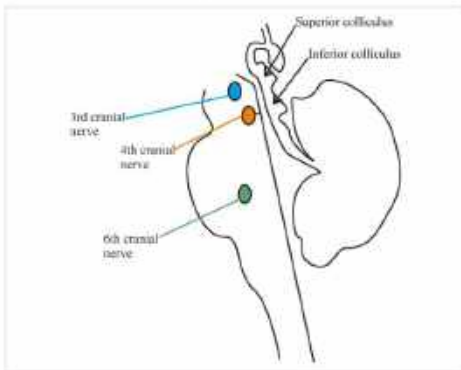
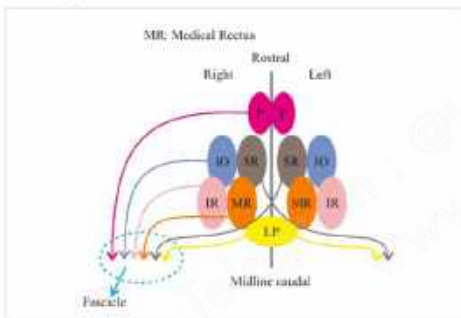
- In all of these diplopia, there is compensatory head posture.
- It is a motor adaptation to avoid diplopia.
- In the case of horizontal diplopia, the compensatory head posture becomes face turn.
- For vertical diplopia, the compensatory head posture is chin up and down.
- For torsional diplopia, the compensatory head posture becomes a head tilt.

### Paralytic Squint

001617

### Third Nerve Palsy

- The third nerve nucleus is present in the superior colliculus in the midbrain.
- This consists of two types of nuclei, the main nucleus and the accessory nucleus. The accessory nucleus is the **Edinger Westphal nucleus** and supplies the iris sphincter and the ciliary muscles.



- In the main nucleus at the level of the superior colliculus - the innervation of the superior rectus is contralateral. A single LPS subnuclei manages the both LPS. All of these different subnuclei are forming the fascicle.

- In the case of a nuclear lesion, there is contralateral superior rectus, and in both eye LPS is gone, there is ptosis. This is called Daroff's Rule.
- From the superior colliculus, the third cranial nerve arises. From the inferior, the fourth nerve arises, and from the Pons medulla, the sixth cranial nerve arises.

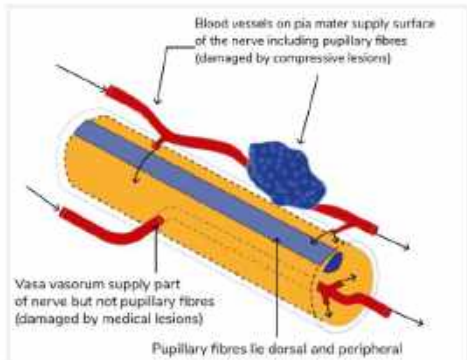
### Other features of third nerve palsy include the following.

1. The position of the eye is **down and out**.
  - o The action of muscles and innervation is LR6 & SO4, and the rest are supplied by the third nerve.
  - o When the third nerve is gone, the lateral rectus and superior oblique are still working. This is why the eye is down and out. The position of the eye is depressed and abducted.
2. Diplopia will happen in all gazes except down and out.
3. **Restricted** eye movements are seen.
4. Crossed diplopia is also observed.
5. **Ptosis** is present. Bilateral ptosis, when present, indicates a nuclear lesion, and single-eye ptosis means a one-sided lesion.
6. The pupillary and ciliary muscles are also innervated. This will cause mydriasis.
7. No accommodations is observed.
  - There will be non reactive, dilated fixed pupil
8. Direct and consensual reflex are absent in the same eye.
  - The Edinger Westphal does not work and hence does not stimulate the other Edinger Westphal. This means that both the direct and consensual reflexes do not work.

### Etiology of third nerve palsy

002308

- The etiology of third nerve palsy may be due to the following:
  - a. Medical causes: **Hypertension, diabetes mellitus**, etc
  - b. Surgical causes:
    - Trauma with **subdural hematoma**.
    - **Posterior communicating artery aneurysm**.
    - **Uncal herniation**.





- The pupillary fibres are lying dorsal and peripheral to the side
- The pupillary fibres are responsible for constriction, accommodation and miosis.
- These fibres present in the dorsal peripheral part are superficial and are supplied by pial blood vessels. The core of the nerve is supplied by **vasa vasorum**, which are not supplying the pupillary fibres. For diabetes and hypertension, these blood vessels are affected first.
- There is pupillary sparing in medical palsy. There will be no dilated fixed pupil, and all pupillary reactions are normal.
- For the surgical cause, the pupillary fibers are affected.

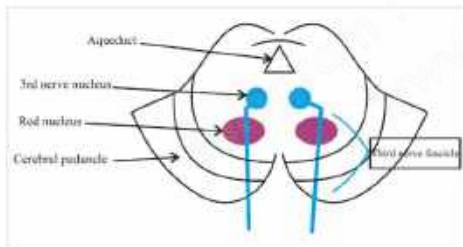
#### Pseudo-Von Graefe Sign

- When there is a surgical third nerve palsy, there can be aberrant regeneration of the nerves
- Von Graefe sign is when the eyes are moved from the upper to the lower levels. The lid keeps lagging behind due to retraction
- Pseudo-Von Graefe sign means that on looking down (inferior rectus), there is lid retraction(LPS).

#### Syndromes Related to Third Nerve Palsy

00:29:31

##### Weber's Syndrome



- It is due to the involvement of cerebral peduncle
- It is the third nerve palsy along with contralateral hemiplegia.

##### Benedict Syndrome

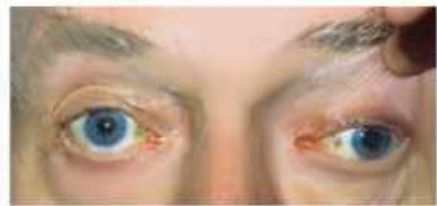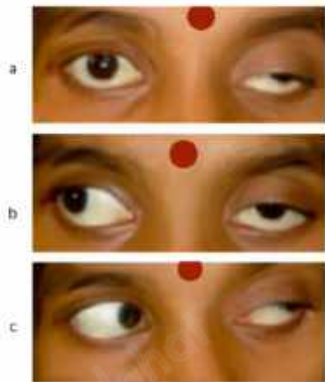
- It is the third nerve palsy with contralateral hemi-tremors due to the involvement of the red nucleus.

##### Nothnagel's Syndrome

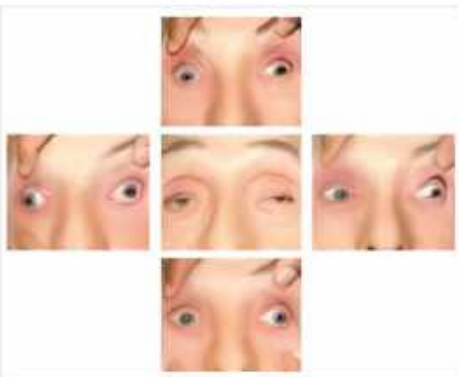- It is the condition where third nerve palsy seen with ipsilateral cerebellar ataxia.

##### Claude's Syndrome

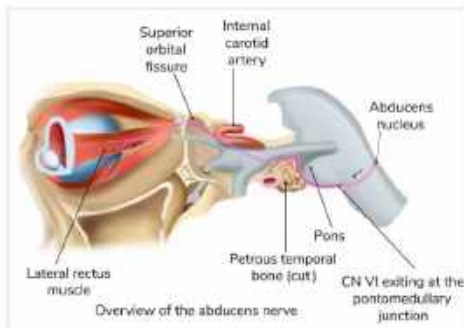
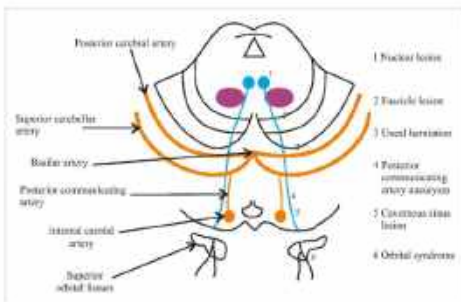
- It is the combination of Benedict's syndrome and Nothnagel's syndrome.
- There will be third nerve palsy, ipsilateral cerebellar ataxia, and contralateral hemi-tremors are present in this condition.



- The eye can be seen to be down and out on this slide. This also indicates third nerve palsy.



- In the slide above, the primary gaze can be seen to be different. **Bilateral ptosis** is observed. The left eye is down and out. This indicates a nuclear lesion.
- There is a defective elevation of the other eye.
- **Contralateral SR** is involved.

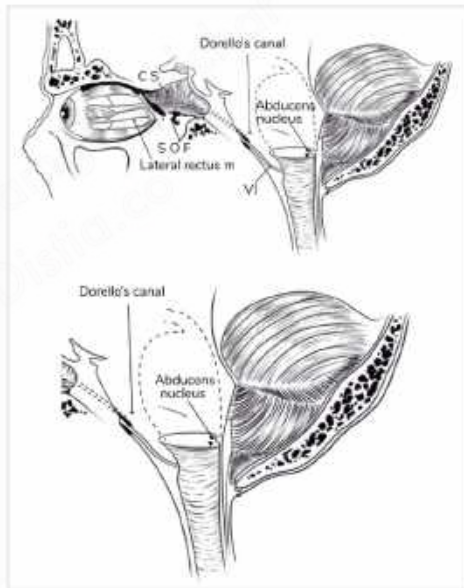


- In uncal herniation, only the fibres supplying the iris sphincter are affected; therefore, only mydriasis takes place.

### Treatment

00:35:32

- The sequence of treatment for concomitant squint
  - Refraction
  - Occlusion,
  - Orthoptic exercises to enhance **binocular single vision**, strength and convergence
  - Surgery
- For paralytic type, one has to wait for the palsy to resolve.
- If the palsy does not resolve, the only option for treatment is surgery.
- When waiting for the third nerve palsy to resolve, in order to soothe the patient in the meantime, certain steps are followed.
  - The waiting period is usually 6 to 9 months.
  - For ptosis, crutch glasses can be used.
  - Occlusion can be done for one eye in order to relieve diplopia.
  - Fresnel Prisms also be used for small squints.
  - For the contracture of ipsilateral antagonists, botulinum toxin injections can be used.
- If the condition does not seem to be improving, surgery is seen to be an option.



### Surgery

1. R-R surgery
  - This surgery states that the lateral rectus has to be loosened, and the medial rectus has to be tightened.
2. If the medial rectus has no power, transposition of fibre is done. Superior and inferior rectus fibres are taken and transposed in place of the medial rectus.

### Sixth Nerve Palsy

00:38:48

- It arises from the Pons and passes through an osteofibrous conduit located at the level of the petrous apex. This is known as Dorello's canal.

- After the abducens nucleus, it passes through the point to the medullary junction. Through the apex of the petrous bone, it is then passed into the cavernous sinus, the superior orbital fissure, and finally into the eye.
- Any increase in intracranial tension can cause sixth nerve to press against the petrous apex. This is why there is sixth nerve palsy in the case of papilloedema.

### Clinical Features of Sixth Nerve Palsy

00:40:52

- The position of the eye is going to be in **esotropia** because the sixth nerve supply is the lateral rectus.
- There will be defective or no abduction.
- The type of diplopia is horizontal.



## Important Information

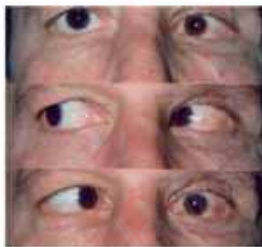Diplopia is always **maximum** in the direction of action of the paralyzed muscle.

- If the right eye is checked and there is **lateral rectus palsy**, the diplopia is maximum when looking towards the right.
- To avoid that, the compensatory head posture is the face turned to the affected side and the eye is going other side. This reflex is called Doll's eye reflex i.e., vestibulo ocular reflex (VOR).
- The type of diplopia is uncrossed diplopia.

### Etiology

00:44:07

- Most common: Diabetes, hypertension, and atherosclerosis.
- Trauma
- Less common causes: Multiple sclerosis and increased intracranial tension.
- In children, it can either be **acquired or congenital**.



Left VI nerve (abducens) paresis or paralysis. Left scotopia with major limitation of abduction, increasing on left gaze.

### Millard Gubler Syndrome

00:45:42

- This is a condition in which the patient has sixth nerve palsy, 7th nerve palsy, and contralateral hemiplegia or hemiparesis.

### Foville Syndrome

- This is a condition in which the patient has sixth nerve palsy, 7th nerve palsy, contralateral hemiplegia/hemiparesis, and Central Horner syndrome (PPRF may also be involved).

### Treatment

- Wait for period of 6 to 9 months
- Occlusion can be done to avoid diplopia
- Use prisms
- In case of medial rectus contracture, botulinum toxin is used.

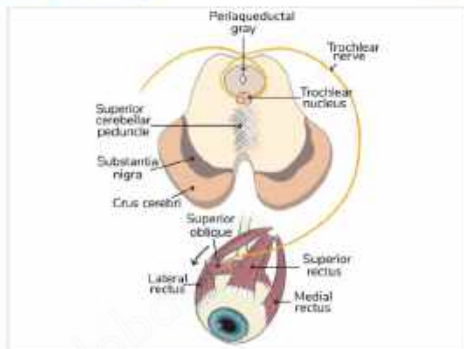
### Surgery

- Medial rectus recession is performed to treat contracture.
- Lateral rectus resection can be performed if there is some power left in the lateral rectus.

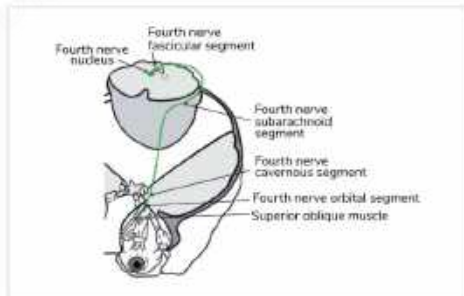
- If the lateral rectus is weak, transposition surgery is performed.

## Fourth Nerve Palsy

00:48:39



- The nucleus of the fourth nerve lies in the midbrain originating from the inferior colliculus.
- From there, it goes to the contralateral superior oblique. The innervation is contralateral.
- This is the only nerve to arise from the dorsal membrane.



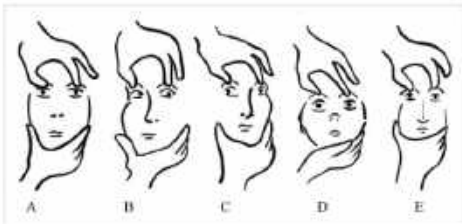
- The trochlear nucleus is present at inferior colliculus and trochlear supplies the contralateral superior oblique.
- From fourth nerve fascicular segment it is going into the subarachnoid segment, cavernous segment, orbital segment, through supraorbital fissure and supplies the superior oblique muscle.
- In the case of a nuclear lesion, there will be a contralateral superior oblique palsy, but when there is a lesion in the cavernous sinus or the superior orbital fissure, there will be ipsilateral superior oblique palsy.

### Etiology

- It is most commonly congenital in nature.

- Trauma.
- Hypertension and diabetes mellitus.

### DOLL'S EYE REFLEX



- The patient's head is moved in one direction, and the eyes move in the opposite direction. This is called as vestibular ocular reflex.
- It is a normal phenomenon in all individual.
- **Nerves involved in the doll's eye reflex include the third nerve, the sixth nerve, and the eighth nerve.**

### Clinical Features of Fourth Nerve Palsy

- The position of the eye: **Hypertropia**, extorsion and slightly adducted.
- Compensatory head posture: Tilting of head on the opposite side.
  - In the case of hypertropia, as there will be no depression, chin will be down with the face turned on the opposite side.
- There is a defective depression in the adducted position.
- Vertical diplopia maximum when looking down (Main action of SO is depression and diplopia is always maximum in direction of action of paralysed muscle ). This will be maximum when one is trying to climb down a flight of stairs.
- **Crossed diplopia** is also observed.

### Management

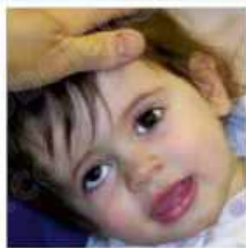- Wait for 6 to 9 months.
- Occlusion can be done to avoid diplopia.
- Botulinum toxin can be used in case of muscle overaction/contracture of inferior oblique.

### Surgery


- Knapp management
  - Inferior-oblique recession surgery can be done to manage the contracture,
  - Superior oblique tucking can also be done to strengthen the superior oblique muscle.
  - Both inferior-oblique recession surgery and superior-oblique tucking can also be done.



- The head tilt of the child can be seen on the left side with a right hypertropia.



- Once the head is tilted on the same side, the hypertropia increases.



- In primary gaze, the person has left hypertropia, which will increase on the right gaze (opposite gaze).
- When there is right head tilt, it is normal and hence this is the compensatory head posture.
- But in case of a same side head tilt, it again increases.



### Important Information

- In superior oblique palsy
  - **Hypertropia increases in opposite gaze and same-side head tilt.**



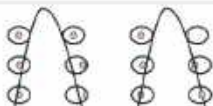
### Oculocephalic or Vestibuloocular reflex

- Pathway
  - Semi-circular canal → Eighth nerve (Ipsilateral) → Vestibular nucleus (Ipsilateral) → Sixth nerve (contralateral) → Left Lateral rectus, Right MLF → Right medial rectus.
  - There is third nerve involvement it is affected in brain stem lesions, Doll's eye reflex is not normal, the eye will not move at all
  - Nerves involved: Third, sixth and eight

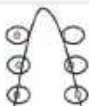### Pattern Squints

01/15/04

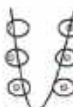- Pattern squints consist of an A pattern and a V pattern.
- **A PATTERN**
  - In this pattern, convergence is more up than down
  - It is seen when the difference of squint between upgaze and downgaze is more than equal to **10 PD**.
- **V PATTERN**
  - It is when the difference of squint between upgaze and downgaze is more than equal to **15 PD**.
  - The patient either has an exotropia or esotropia and, based on that, it has an A pattern or a V pattern.



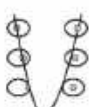
A Exotropia



A Esotropia



V Exotropia



V Esotropia

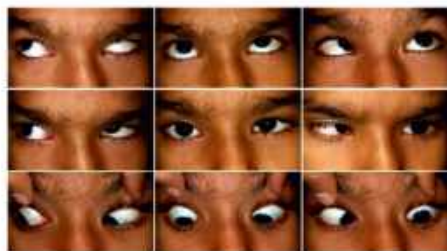- If the exotropia is more in downgaze then it is 'A' pattern and if the exotropia is more in upgaze then it is 'V' pattern.
- When Esotropia is more in upgaze it is 'A' pattern and if the esotropia is more in downgaze it is 'V' pattern.
- **Rectus muscles** are adductors, so in V pattern there is superior rectus under action and inferior rectus over action.
- In A pattern, there is superior rectus overaction and inferior rectus underaction.

### Ocular Motility Defects

01/18/13

#### Duane's Retraction Syndrome (DRS)

- In this condition, the sixth nerve nucleus is not formed properly i.e., there is **Hypoplastic sixth nerve nucleus** so the lateral rectus is supplied by the third nerve (Anomalous innervation of the lateral rectus by the third nerve).
- So there will always be co-contraction of the lateral and medial rectus. It does not obey **Sherrington's law**.
- **Clinical Features**
  - On adduction, there is upshoot and retraction of the globe.
  - Decreased palpebral fissure
  - Decreased convergence
- **DRS is classified by Huber's classification**
  - Type 1- Decreased abduction.
  - Type 2- Decreased adduction.
  - Type 3- Both abduction and adduction are affected.
- **Treatment**
  - LR resection is contraindicated as it increases the retraction.
  - Muscle transposition is the choice of treatment.



- In primary gaze, right eye seems okay, but in left eye palpebral fissure is small and eye is retracted and in left eye there is no abduction.
- So, according to **Huber's classification**, this is Type 1.

#### Brown's Syndrome

- Brown syndrome is the fibrosis of the superior oblique tendon sheath i.e., there is tight superior oblique tendon sheath.

- **Etiology**

- When it happens congenitally it is known as congenital click syndrome.
- Acquired: Inflammation and trauma of trochlea
- Rheumatoid arthritis or scleritis

- **Clinical Features**

- It has a restrictive pathology because of fibrosis.
- Hypotropia in the primary position (when the patient is looking straight).
- Defective elevation in the adducted position and normal elevation in the abducted position.
- A positive **forced duction test** is seen i.e., even with forceps when there is elevation in adducted position, there is restriction
- As there will be no elevation, compensatory head position of chin elevation is observed.

- **Treatment**

- If binocular single vision is fine, it will not be disturbed.
- For congenital cases, lengthening of the superior oblique is performed.

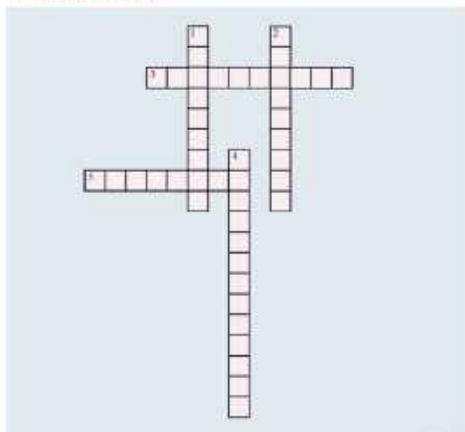
- **Strabismus Fixus**

01:28:00

- It means the two medial rectus are fibrosed leading to both eyes being convergent (fixed in convergence).
- In the case of lateral rectus fibrosis, both the eyes are fixed in divergence.



## Crossword Puzzle 1




### Across

- In ----- fixus, MR fibrosis is observed in both the eyes, leading to both eyes being convergent.
- In Brown's syndrome, lengthening of the ----- oblique is performed as a form of treatment.

### Down

- When the normal eye is covered, and there is ----- of the muscle, prevent it from taking the centre, in case of paralytic squints.
- For Duane's Retraction Syndrome (DRS), LR ----- is contraindicated.
- Muscle ----- is the choice of treatment for Duane's Retraction Syndrome (DRS).

## Crossword Puzzle 2



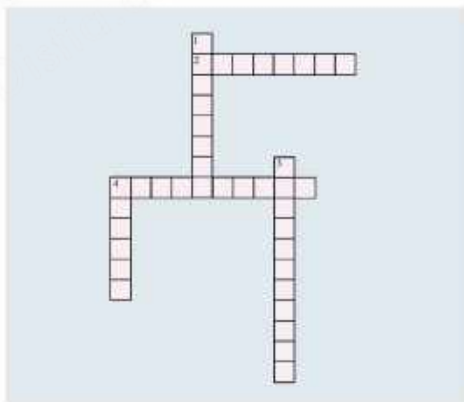
### Across

- According to ----- management, in the case of contracture, one can opt for inferior-oblique recession surgery.
- For treatment of ptosis during the waiting period, ----- glasses can be used.
- Gubler Syndrome is a condition in which the patient has sixth nerve palsy, 7th nerve palsy, and contralateral hemiplegia.
- Syndrome is a condition in which the patient has sixth nerve palsy, 7th nerve palsy, contralateral hemiplegia/hemiparesis, and Central Horner syndrome (PPRF may also be involved).

### Down

- The waiting period is usually 6 to 9 months before the treatment of ----- squints.

## Crossword Puzzle 3



### Across

- The nucleus of the fourth nerve lies in the midbrain originating from the ----- colliculus.
- For Duane's ----- Syndrome (DRS), the sixth nerve nucleus is not formed properly (Hypoplastic sixth nerve nucleus).

### Down

- means double vision.
- For the treatment ----- of ipsilateral antagonists, botulinum toxin injections can be used.
- In Doll's Eye -----, the patient's head is moved in one direction, and the eyes move in the opposite direction.

## History

009105

- History-taking can be very elaborate.
  - The time of deviation.
  - It is important to know the time because concomitant occurs early.
  - Whether the deviation is constant (problem of amblyopia) or intermittent.
  - Whether the patient has **Diplopia (any double vision in any gaze)**.
  - Any typical head posture.
  - Whether the patient is using specks (since when and what number) – gives an idea about the refractory status.
  - Old photographs are compared with the present ones.

## Examination

- Head posture.
- Ocular alignment (if it is normal or there is a squint).
- Ocular movements: All types of ocular movements should be seen.
  - **Ductions: Single-eye movements.**
  - **Versions: Both eyes moving together.**
  - All 9 gazes for far and near.
  - **Vergence: It is when 2 eyes moves in opposite directions (Convergence and Divergence).**
    - The convergence is checked by the **RAF rule** i.e., by finding out the near point of convergence
    - Ask the patient to look at box or ruler and then bring the ruler near to the patient so the point where the patient sees the double is the near point of convergence.
    - Whenever the patient sees the blurred, it is the near point of accommodation.
    - The normal value for the near point of convergence is 10cm.
- Visual acuity – to check the vision in the patient.
- Refraction – to see if this vision can be corrected to 6/6.
- Detailed anterior segment examination as any opaque media can lead to secondary squint
- Check for **Ptosis**.
- Pupils particularly should be properly checked.
- **Posterior segment examination**
  - Any problem in fovea or central retina can cause squint
  - Check for foveal fixation – if it is foveal fixation or Parafoveal fixation.
  - **Foveal fixation** – The star from the direct ophthalmoscope is projected and the patient is asked to look at it. If star projected is falling within 2° of fovea, then it is central fixation but if it is 2-5° away then it is **parafoveal fixation**.
  - Check for any pathology

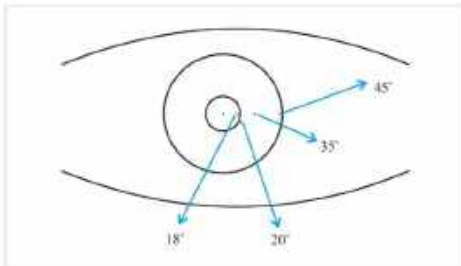
- Oculocephalic reflexes : for comatose patients.
- **To check whether there is squint present or not**
- Two tests are performed for squint.

### 1. Cover Test

- It is the test for manifest squint.
- If two eyes are straight and ocular alignment is normal then if one is covered there will be no movement i.e., there is no squint.
- Cover the normal eye and the movement of the uncovered eye is seen.
- The movement is always opposite to the type of squint.
- Primary deviation is the deviation of squinted eye
- Secondary deviation is the deviation of normal eye behind the cover
- If the cover test is normal, then the Uncover test is done.

### 2. Uncover Test

- The movement of the covered eye is seen while uncovering it.
- If occluders are translucent, movement can be seen through it
- This test is done to check **Phorias (Latent squint)**.
- It is seen due to breaking of the fusion reflex, therefore it is manifested.
- If there is no Latent squint, there will be no movement.
- **Esophoria – the movement is out.**
- In the normal eye, there is no movement.
- The movement will always be opposite to the squint.
- If the cover test or the uncover test is positive, then the next step is to check the amount of squint.
  - **The amount of squint is denoted either in degrees or prism dioptre and the prism dioptre is almost double of the degrees.**
- To know the amount of squint–Hirschberg Test
  - Show the torch light in front of the eye, the location of the reflex is seen.

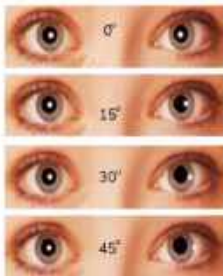


- And this test is known as Hirschberg test



## Hirschberg Test

Corneal reflections are usually symmetrical in absence of squint

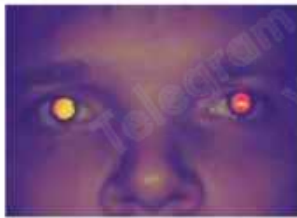

In esodeviation reflex fall on temporal cornea.

Roughly 1mm shift signifies 7° or 15 prism diopter.

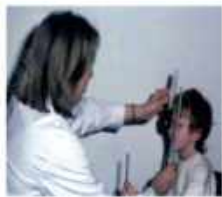- If the eye is outward, the reflex is going inwards and vice versa.
- Corneal reflections are usually symmetrical in the absence of a squint.
- In Esodeviation, the reflex falls on the temporal cornea.
- Roughly 1mm of displacement is around 7° of squint which is around 14-15 prism diopter.
- Prism Dioptre is either written as PD or ΔD.

## Bruckner Test



- This test only tells about the presence of a squint.
- This test is helpful to check for squint in infants. It can be done in bigger children as well.
- The light is shown to the eye normally the fundus shine equally in both eyes. If one reflex is brighter than the other, then the brighter one will be squinted.
- A brighter reflex means there is a squint.
- The dull reflex is normal.

## Prism Cover Test (PCT)

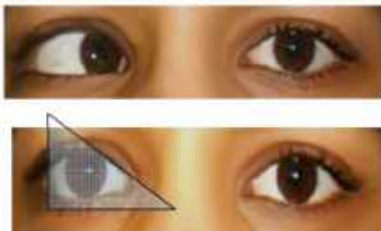


- The same cover test is done and the movement of the eye is seen. The prism of different strengths is placed.
- Prism Bar is the different prisms on the same scale.
- At what Prism Dioptre, there is no movement in the cover test that will be the exact amount of squint.
- How to place the prism?
  - The prism has an apex and a base. The base is always opposite to the direction of the squint.
  - If the patient has Esotropia and base out prism is placed to check the amount of squint.
- If the patient has Exotropia, the base is put in and the amount of squint is checked.

## Prism Reflection Test

00/25/12

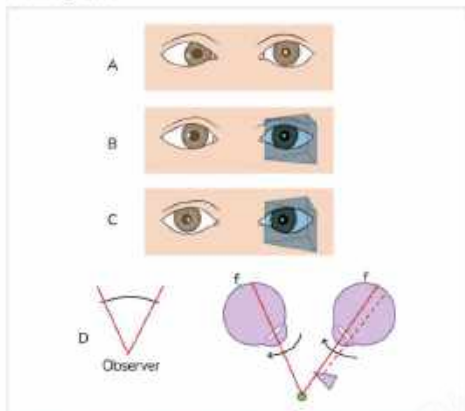
## Krimsky Test



- The right eye deviates inward on doing Hirschberg test it is seen that light reflex is at centre but in the affected eye light reflex is at pupillary border or out because the eye is deviated inwards

- When the eye is in, put the base out prism in front of squinted eye and keep observing the behaviour of normal eye
- Now observe at what prism strength, both eyes corneal reflex is at the centre.

### Krimsky Test



- **Krimsky test is the test where the same prism is put in front of the normal eye and is checked.**
- If the reflex is out, the eye is in so the prism base should be out.
- In the normal eye, the two reflexes are at the center.

### Synaptophore/Amblyoscope

00:28:27



- It is a differential image method.
- **It tells the amount of squint and the angle of squint.**
- It also helps in telling the grades of binocular single vision that the patient has.
- It can help to improve those grades but only if the patient is within 8 years of age - **orthoptic exercise**
- It can also help in the convergence axis.

### Important Information

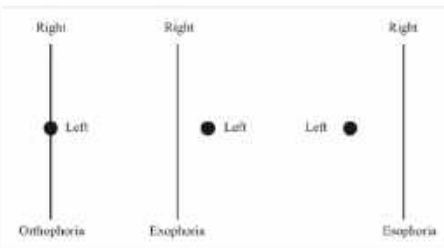
- Bruckner test tells about the presence of squint.
- The prism has an apex and a base. The base is always opposite to the direction of the squint.
- Krimsky test is when the prism is put in front of the normal eye.

### Subjective Tests

00:30:41

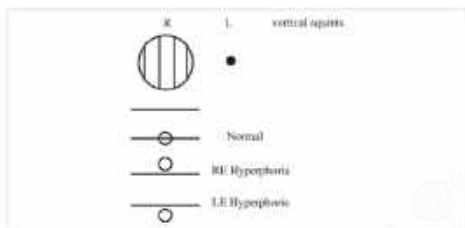
- These are done to catch the small degrees of Phorias.
- They are differential image tests.
- The tests are based on the Diplopia principle – the Diplopia of the patient is artificially created.

### Maddox Rod




- It is done for the far vision of up to 6m of distance.
- It is red-colored with a series of plano convex lenses.
- The patient is shown a spot of light and the lens is put in front of the eye. From the right eye, a line of light is seen and from the left eye, a spot of light is seen.
- The line of light will be vertical as the rod is placed horizontally and from normal eye a spot of light is seen.
- As the inference depends upon how the patient responds hence it is a subjective test.
- Now the 2 images is created, one is in line and other is spot so the different images are created hence called as differential image test.
- These 2 different images can not diffuse causing diplopia
- The patient is asked what does he/she see?

- **Orthophoria** – if the patient is normal, he sees line of the light and the spot of light is crossing the line of light.
- **Exophoria** – if the patient says that the line of light is left to the spot of light. Crossed diplopia is seen.
- **Esophoria** – if the line of light is on the right side towards the same side and the spot of light is on the left then it is uncrossed diplopia.
- In Maddox rod test, if the rod is placed vertically then the patient sees horizontal line of light and the spot of light in normal eye
- It is done for vertical squints
- If the line passes through then it is normal
- But if the light is passing below that means that the right eye is up showing right hyperphoria
- If the line of light is above that means that the right eye is below showing left hyperphoria.



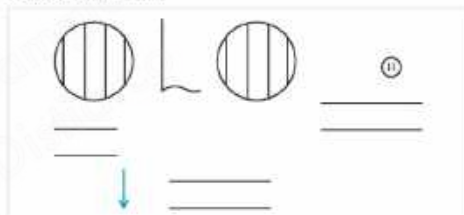
### Maddox Wing



- It is done for near vision.

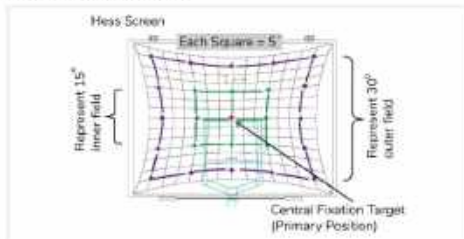
- In a Maddox wing the patient see through two eyepieces and there is a divider which will divide what the right eye will see and what the left eye will see, the right eye will only see the arrows and the left will only see the numbers.
- The red arrow is for the vertical and white arrow is for the horizontal.
- The patient is asked to what numbers the white and red arrows are pointing.
- **Esophoria** – If the patient says that the white arrow is on the right side. (Same side, uncrossed)
- **Exophoria** – if the white arrow is on the left side. (Crossed)
- **Left Hyperphoria** – vertical squints have crossed Diplopia. If the red arrow is pointed at upper numbers/upwards that means the right eye is hypo but it is known as Left Hyperphoria.
- **Right Hyperphoria** – if the red arrow is pointed at lower numbers (the right eye is up), it is Right Hyperphoria.
- Intorsion and Extorsion can also be checked

### Double Maddox Rod



- The Maddox rod is vertically put on both eyes, the patient sees horizontal lines.
- If there is no Torsion, both lines should be seen parallel (in normal eye).
- If one line is tilted, the movement of the corrective lens is done in ex cyclotorsion or incyclotorsion till both lines become parallel.
- The amount of correction needed in the lens to make the two lines parallel is noted.
- It helps to catch the torsion and the amount of torsion.
- It is very helpful to assess the superior oblique palsy.
- It does not differentiate between **Phorias** and **Tropias**.

### Hess Screen/Lees screen



- It is based on the Haploscopic principle.
- This test is done in concomitant squints.
- This is based on foveal projections.
- Procedure:
  - This test is performed with each eye fixating in turn.
  - The patient is seated 50cm away from the screen.
  - The patient wears red (right side) and green goggles (left side).
  - The eye which has to be tested should have green glass in front of it.
  - Red acts as fixator and green is indicator
  - The chart has an electronically operated board with small red lights.
  - The patient is asked to place green light in each of the points on a red light as illuminated.
  - Next, the goggles are changed. The green is not in front of the right eye.
- In the Hess chart, each square is 5°. The inward green square is 15° and the outer purple square is 30°.
- Also, the central fixation should be checked if it is correct or not.

#### Lees Screen



- In this, instead of the red-green goggles, the image is reflected on the mirror according to that the patient put markers
- Alternate illuminations occur and the mirror is in between.
- Both the eyes are tested like this.



#### Important Information

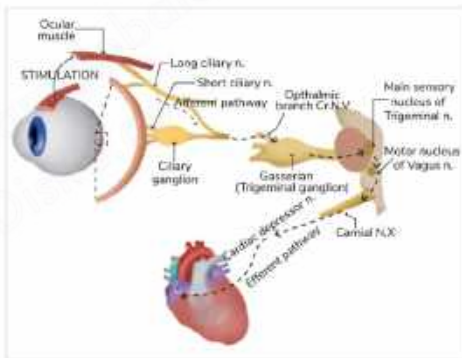
- Maddox rod is done for far vision.
- Maddox wing is done for near vision.
- Double Maddox rod does not differentiate between Phorias and Tropias.
- Hess screen and Lees screen tests are based on the Haploscopic principle.



- This test is done to check for near point accommodation and near point convergence in child.

#### Oculo-Cardiac Reflex

00-3230



- When the muscle is pulled, the reflex from the trigeminal ganglion (afferent) through the Ciliary ganglion goes to the motor nucleus of the Vagus nerve (efferent), and efferent nerve can cause cardiac depression.

#### Prevention

1. For squint surgery, Retrobulbar anesthesia is given so that it blocks the ciliary ganglion and helps to suppress the reflex.
2. Atropine.



#### Important Information

- Retrobulbar anesthesia is given to block the Ciliary ganglia and suppress the reflex.

#### Clinical Questions

**Q.** If you are operating the child with a squint and the child starts developing Bradycardia. What should be your next step?

**Ans:** The surgery should be immediately stopped.

**Q.** Where is the injection given in Retrobulbar anesthesia?

**Ans:** Intraconal space.

**Q.** What test is helpful in infants?

**Ans:** Bruckner test.

**Q.** Is Synaptophore a differential image method?

**Ans:** Yes.

Telegram : @teamglobalchat  
www.Distia.co



## PREVIOUS YEAR QUESTIONS

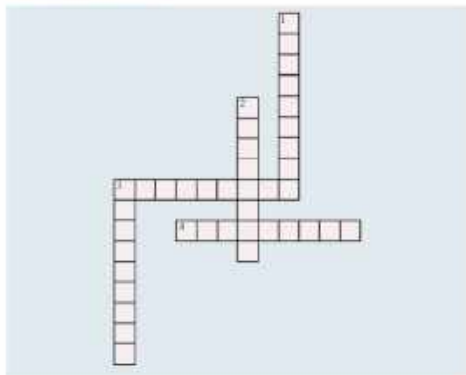


- Q. Levator palpebrae superioris is supplied by?  
(JIPMER DEC 2019)
- A. 2nd cranial nerve
  - B. 3rd CN**
  - C. 4th CN
  - D. 6th CN
- Q. A man with convergent squint in one eye has vision 6/60, and another eye has no squint with vision 6/60. What is the next step?  
(FMGE Dec 2019)
- A. MRI
  - B. Squint surgery
  - C. Botulinum toxin
  - D. Refraction**
- Q. Miotics are useful in which type of squint?  
(JIPMER NOV 2018)
- A. Paralytic squint
  - B. Accommodative squint**
  - C. Divergent squint
  - D. Congenital squint ointment after sometime
- Q. A kid comes in with left sided head tilt. when doctor corrects that, he notices right hypotropia which increases on dextroversion and right tilt head which muscle is paralyzed?  
(AIIMS JUNE 2020)
- A. Right superior oblique
  - B. Right superior rectus**
  - C. Left inferior oblique
  - D. Left superior oblique

Telegram: @teanglaanet  
www.Disha.co



## Crossword Puzzle 1




### Across

- \_\_\_\_\_ is the double vision.
- \_\_\_\_\_ is when the two eyes are moving together.

### Down

- \_\_\_\_\_ is when the two eyes are moving in opposite directions.
- \_\_\_\_\_ is also known as Latent squint.
- \_\_\_\_\_ is known as the single-eye movement.

## Crossword Puzzle 2



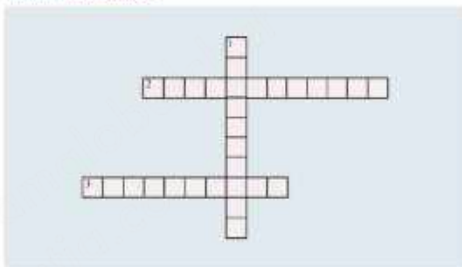
### Across

- \_\_\_\_\_ is when the movement is in.
- \_\_\_\_\_ is when the movement is down.

### Down

- \_\_\_\_\_ is also known as Amblyoscope.
- \_\_\_\_\_ is when the movement is out.

## Crossword Puzzle 3



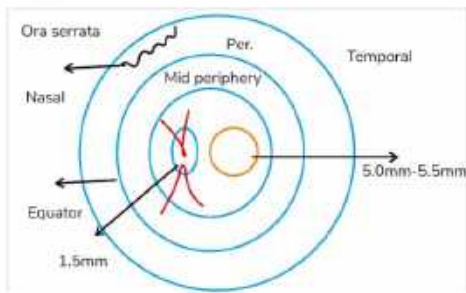
### Across

- \_\_\_\_\_ is when the patient sees a line of light and a spot of the light crossing the line of light.
- \_\_\_\_\_ is when the cross Diplopia is seen.

### Down

- \_\_\_\_\_ is when the uncrossed Diplopia is seen.

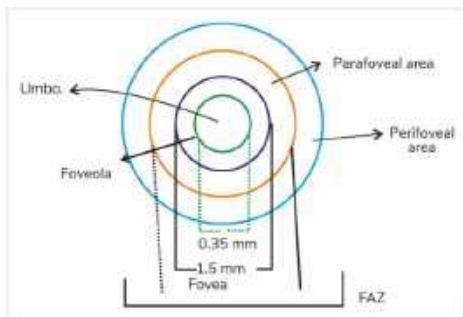
## Retina



- Retina is divided into 3 parts
  - Central retina:** It contains the **optic disc and macula**.
  - Mid-peripheral retina:** The equator is marked by the **vortex veins** that drain the choroid.
  - Peripheral retina:** It has **dentate process** called as **ora serrata**.
- The diameter of the optic disc is 1.5mm and the macula is 5.0 - 5.5 mm.
- Ora serrata is spanned by a 3 - 4mm of **vitreous** known as the **vitreous base**.
- Ora serrata is 6 - 6.5mm away from the limbus.
- Pars plicata is 2.0 - 2.5mm away from the limbus.
- Pars plana is 3.5 - 4mm away from the limbus. Intravitreal injections are given at pars plana.

## Macula

00:04:36



- It contains the **most sensitive part** of the retina called the **fovea centralis**.
- Inside the **fovea centralis** is the **foveola** and there is a **central depression** over the foveola known as the **umbo**.
- The diameter of **foveola** is 0.35mm and **fovea** is 1.5mm.
- There is **no blood supply** in the **fovea centralis** or the **foveola**, so this area is known as the **foveal avascular zone**.
- Outside the fovea centralis are two areas - the **parafoveal** (2.5mm in diameter) area and outside the parafoveal area is the **perifoveal area** (5.0-5.5mm in diameter).

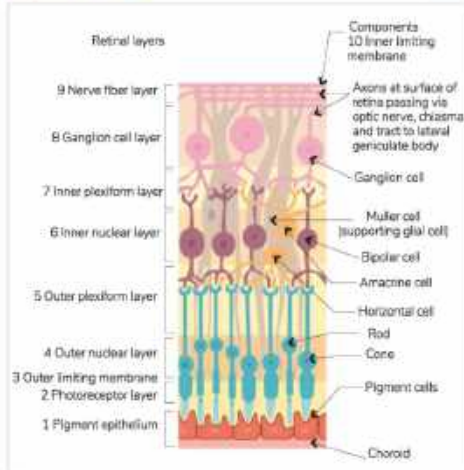


## Important Information

- The most sensitive part of the retina is the **fovea centralis**.
- The thinnest part of the retina is also the **fovea centralis**.
- The distance between the **temporal margin of the optic disc** and the **fovea centralis** is **2DD** (disc diameter) which is around **3mm**.
- The **vitreous base** is the **strongest adhesion to the retina**.

## Layers of Retina

00:09:29



There are 10 layers of the retina. These are (outermost to innermost)

- Retinal pigment epithelium: Outermost layer
  - Subretinal space



## 2. Photoreceptor layer: Layers of rods and cones

3. External limiting membrane
4. Outer nuclear
5. Outer plexiform
6. Inner nuclear
7. Inner plexiform
8. Ganglion cell layer
9. Nerve fibre layer
10. Internal limiting membrane

- Inside this is the condensed part of the vitreous known as the **hyaloid membrane**.
- The **retinal detachment** is the separation of the outermost layer i.e., retinal pigment epithelium from the rest of the layers up to the internal limiting membrane which is collectively called the **neurosensory retina (NSR)**.
- The retinal detachment happens along the **subretinal space**.
- The **innermost layer of the choroid is the Bruch's membrane**. It is a membrane between the choroid and the retinal pigment epithelium.

### Blood supply of retina

- The outer 4 layers are supplied by short posterior ciliary arteries and the inner 6 layers are supplied by the central retinal artery.

### Exudates

Exudates in the retina are of two types

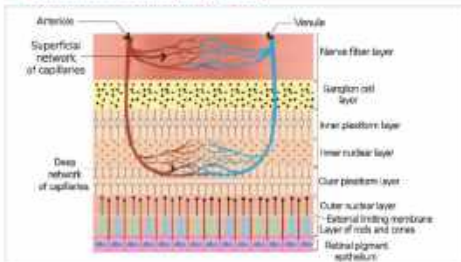
#### 1. **Hard exudates:** These have well-defined margins.

- These are **leaked lipids**.
- 2. **Soft exudates:** Their margins are ill-defined.
- These are also called **cotton wool spots**.
- These are the **axonal infarcts (dead axons)**.
- It is a more serious condition as it happens due to **hypoxia**.

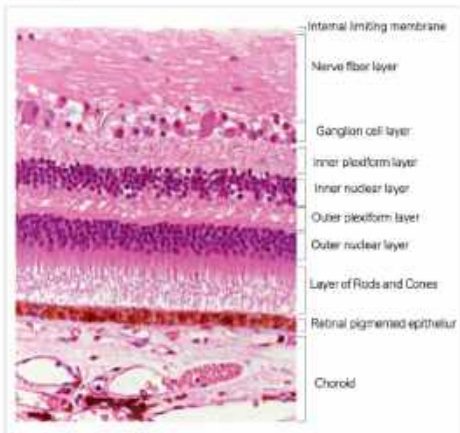
### Blood Retinal Barrier

There are two blood-retinal barriers:

1. **Inner:** It is the capillary integrity.
- When this barrier is broken, it causes leakage and thus leads to **cystoid macular oedema**.
2. **Outer:** It is made up of strong adhesion of retinal pigment epithelium.
- It prevents any choroidal leakage in the retinal layers.
- These strong adhesions are called **zonula occludens**.
- In case of breakage of the barrier (shallow detachment) there can be a mild collection of fluid and this condition is called **central serous retinopathy (CSR)**.



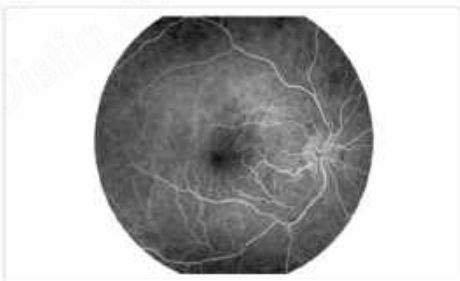
## Histology



### Investigations Related to the Retina

00:26:28

#### 1. Fundus Fluorescein Angiography (FFA)



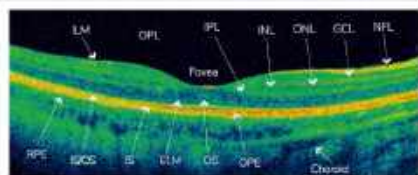
- After dilating the pupil and through examination, the **dye is injected into the antecubital vein**.
- A vial of **10% 5ml fluorescein** is injected into the blood which reaches from the arm to the retina.
- The **arm-retina time is 10-11 secs**.
- It is first going to appear in choroid.
- The choroid fluorescence fails to reach the foveal avascular zone as there is a dense collection of pigments in this area.
- The pigments present in the foveal or foveola are **melanin and xanthophyll**.
- **Findings:** It can show
  - a. **Hypofluorescence:** The causes are
    - Capillary non-perfusion (CNP) or capillary block.
    - Blocked fluorescence can be due to any haemorrhage or exudate present in that area.

- b. **Hyperfluorescence:** The causes are
  - o Leakage due to **breaking of the inner retinal barrier**
  - o Retinal pigment epithelial defect.

## 2. Indocyanine Green Angiography (ICG)

- The fluorescence is seen in the **infrared range**.
- ICG is **98% bound to plasma protein** thus it becomes a **big molecule** which is hard to leak out of the capillaries and **dye remains in the choroid circulation for a longer time**.
- It is the investigation of choice for **occult CNV (Choroidal Neovascularization)**.

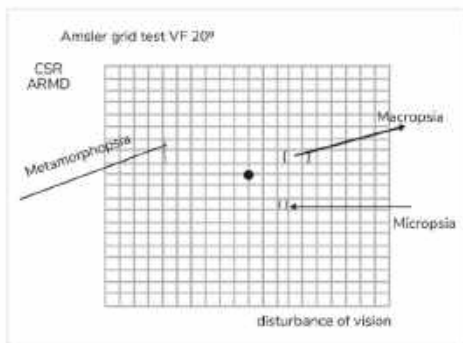
## 3. Optical Coherence Tomography (OCT)



NFL: Nerve fiber layer  
 OPL: Outer plexiform layer  
 INL: Inner nuclear layer  
 ONL: Outer nuclear layer  
 OLM: External limiting membrane  
 IS: Photoreceptor inner segment  
 OS: Photoreceptor outer segment  
 SIOS: Interface between IS and OS  
 RPE: Retinal pigment epithelium  
 OPR: Outer photoreceptor/RPE complex

- This test shows the **cross-sections of the different layers of retina with an accuracy of 10-15 microns**.
- It is based on the **principle of interferometry**. It uses light waves instead of sound waves.
- Thus the media has to be very clear, it **cannot be done in opaque media** (like in cataracts).

## 4. Amsler-Grid test

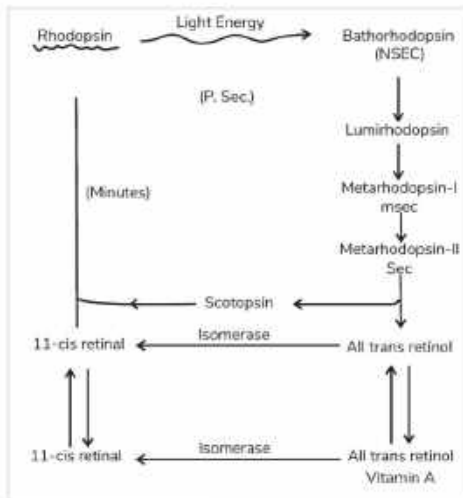


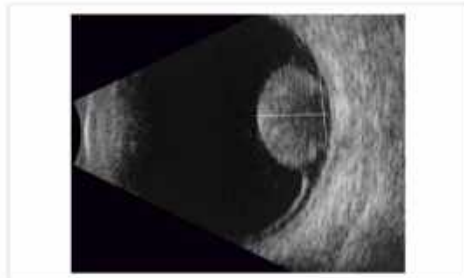
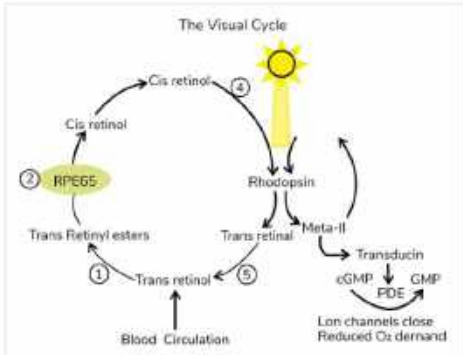
- It is a subjective test where the patient's visual field is tested.
- The patient is given a paper with several grids/squares and there is a dot present at the centre.
- The patient is asked to **hold the paper approximately 30 cm away from the eye** and then focus on the dot one eye at a time and then ask about the different squares.
- In this, **around 20° of the visual field is tested**, so any pathology in the macular area is detected by this test.
- The patient can see **wavy lines/distortion of the image which is known as metamorphopsia**.
- The square can look bigger which is known as **macropsia**.
- The square can appear smaller which is known as **micropsia**.
- These are the different disturbance of vision.
- This test is very useful in patients with **CSR or Age-related macular degeneration patients (ARMD)**.
- It is a very helpful **follow-up test**.

## 5. Photostress Test

- The principle of this test involves exposing the macula to a light source bright enough to bleach a significant proportion of the visual pigments.
- Return of normal retinal function and sensitivity depends on the regeneration of the visual pigments.
- The **normal value of PSRT is 30-50 secs**.
- In the case of a **macular lesion, PSRT increases to around 60 secs**.
- However, in the optic nerve lesion, the PSRT will be normal.
- **Photostress test is used to differentiate between macular lesion and optic nerve lesion**.

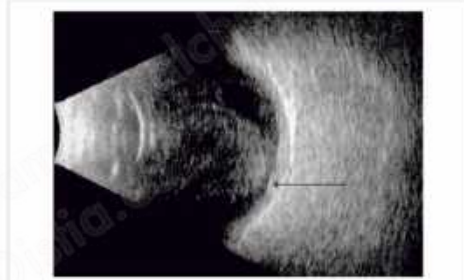
## WALD'S visual cycle





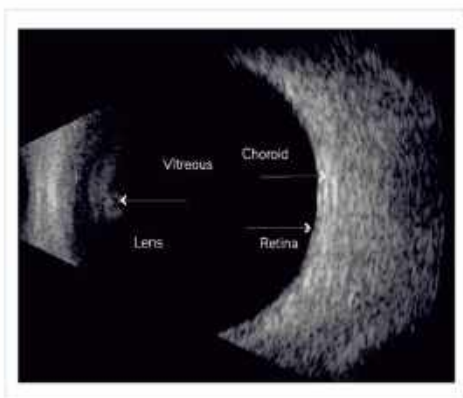
- A lesion with a collar button appearance seen is the **choroidal malignant melanoma**.

- The light that is directed to the patient's eyes converts the rhodopsin into:
  - Bathorhodopsin → Lumirhodopsin → Metarhodopsin I → Metarhodopsin II.
- The **metarhodopsin II** later causes the release of transducin which converts the cGMP to GMP with the help of the enzyme PDE (phosphodiesterase).
- Due to this, the sodium ion channels close and the nerve impulses generated goes from the optic nerve and reach the visual cortex. This is known as **hyperpolarisation**.
- Metarhodopsin II gets converted to Scotopsin and all-trans-retinal.
- Further, all-trans-retinal converts to all cis-retinal with the help of isomerase enzyme inside the RPE and along with scotopsin it regenerates the rhodopsin.

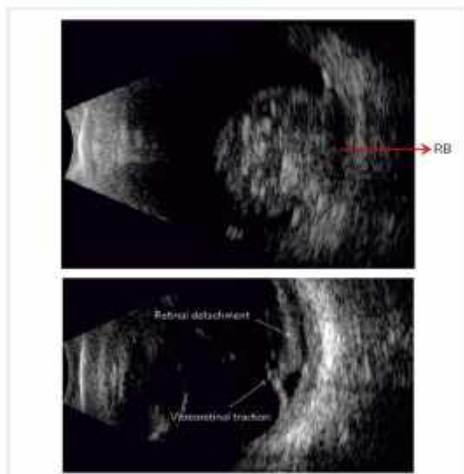


- A **vitreous haemorrhage** is seen.

## 6. USG B Scan

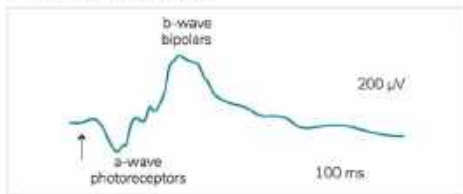


- It helps to visualize the **posterior segment of the eye**.

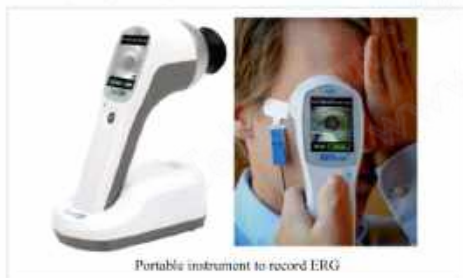

- This image shows the **retinal detachment** and the **peak** represents the **vitreoretinal traction**.
- The frequency of the ultrasound used is **7.5-10MHz**.

## 7. Electroretinogram (ERG)

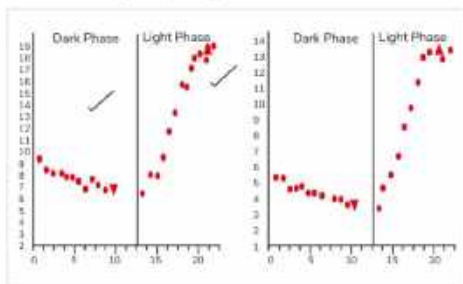


- When the light is shown to the eye, it gives the **activity of photoreceptor cells and bipolar cells**.
- Procedure: There are two electrodes, one is placed on the cornea/conjunctiva, the other is placed on the forehead and the electrical activity is taken.
- **Special ERGs**
  - a. Pattern ERGs: These indicate the **activity of ganglion cells** and thus it is helpful for the diagnosis of glaucoma.
  - b. Multifocal ERGs: These are **multiple recordings taken from different points of the central retina**.
    - This covers 40-50° of the visual field.
    - It is helpful in the diagnosis of **cone dystrophy and toxic neuropathy & maculopathy due to chloroquine and hydroxychloroquine**.



Portable instrument to record ERG

## 8. Electrooculogram (EOG)



- It measures the **standing potential of the eye**, i.e., the potential difference between the front and back of the eye.

- The **normal reading is 6mV**.
- Two cycles are recorded, **15 mins in the dark and 15 mins in the light** and the maximum potential in the light (Light peak) and minimum potential in the dark (dark trough) are noted.
- **Light peak/dark trough = ARDEN RATIO**.
- The normal value of the arden ratio is  $\geq 1.85$ .
- It is affected in RPE dystrophies.
- In **Best disease**, the arden ratio becomes  $< 1.5$ .
- This test is also helpful in the diagnosis of **Stargardt's disease and chloroquine toxicity**.
- **Flat EOG**: The arden ratio is  $< 1.25$



### Important Information

- The **photoreceptors** are end receptors.
- The **bipolar cells** are the first-order neurons.
- The **ganglion cells/optic nerve** is the second-order neuron.
- The **lateral geniculate body** is the third-order neuron.

### Retinal Pathologies

01:01:38

- Retinal pathologies are broadly classified as
  - Vascular diseases
  - Macular diseases
  - Hereditary fundus dystrophy
  - Retinal detachments
  - Retinoblastoma

### Vascular Diseases

#### Retinitis Prolifera

- Vascular diseases include diabetic retinopathy, hypertensive retinopathy, central retinal vein occlusion and retinopathy of prematurity, etc.

#### Pathogenesis

- Common pathogenesis in all vascular diseases includes
  - Any pathology (**diabetes, hypertension, microangiopathy**) in the blood vessel leads to **leakage** and leakage leads to **hypoxia**.
  - Any hypoxia leads to increased capillary permeability and further leads to more leakage.
  - Manifestations due to increased capillary permeability and more leakage in retina are
    - Edema
    - Hemorrhage
      - **Dot and blot hemorrhage**
      - **Flame shaped hemorrhage**
    - Hard exudates
  - Due to more increase in hypoxia, there is **release of chemotactic factors**
    - It will lead to **neovascularization**
  - Neovascularization in the retina can be categorized in two ways
    - **NVD**: Neuro vascularization at the disc.
    - **NVE**: Neovascularization elsewhere.

- So, any neovascularization can lead to 3 blinding complications
  - Vitreous hemorrhage
  - Tractional retinal detachment and
  - Neovascular glaucoma

#### Use of Laser Treatment

- Photo Coagulative laser that is used in treatment of retinitis proliferans.
- Panretinal photocoagulation (PRP) turns the hypoxia into anoxia and where there is anoxia, there is no release of chemotactic, neovascularization and no blinding complications.

#### Chemotactic Factors

01:08:09

- Different types of chemotactic factors are
  - Vascular endothelial growth factor (VEGF)
  - Basic fibroblast growth factor (bFGF)
  - Insulin like growth factor (IGF)
  - Platelet derived growth factor (PDGF)
  - Tumor necrosis factor  $\alpha$  (TNF $\alpha$ )
  - Transforming growth factor  $\alpha/\beta$  (TGF $\alpha/\beta$ )
- All these chemotactic factors assist in **angiogenesis**.
- **Statins** will stop **angiogenesis** like **endostatin** and **angiostatin**.

#### Diabetic Retinopathy

01:11:04

- **Pathogenesis**
  - Loss of pericyte
  - Thickening of basement membrane.
  - Because of loss of pericytes and the microangiopathy there will be **leakage, hypoxia and retinitis proliferans (pathogenesis)**.

#### Risk Factors

1. **Duration**
  - **Most important factor.**
2. **Glycemic control**
  - It is the **second most important factor.**
3. **Other factors**
  - i. **Hypertension should be controlled.**
  - ii. **Any associated nephropathy**
  - iii. **In case of pregnancy, it can also precipitate retinopathy.**

#### Clinical Features

- Clinical features of diabetic retinopathy can be divided into 3 stages.
  1. **Background diabetic retinopathy [BDR]**
  2. **Pre proliferative diabetic retinopathy [PPDR].**
  3. **Proliferative diabetic retinopathy [PDR].**

#### Background Diabetic Retinopathy (BDR)

- There is microaneurysm

- Micro aneurysm is present in nerve fiber layer
- There are all types of edema, all types of exudates, and all types of hemorrhages.

#### Pre proliferative diabetic retinopathy [PPDR]

- As hypoxia increases, along with BDR there are some additional features
  - **Increase the number of cotton wool spots (CWSs)**, if there is more hypoxia, more CWSs will be seen.
  - **Large blot hemorrhages** which indicates venous infarcts.
  - **Looping and beading of the veins or venules.**
  - **IRMA (Intraretinal microvascular abnormality)**; These are capillary shunt vessels.

#### Proliferative diabetic retinopathy (PDR)

- All the features of preproliferative along with neovascularization which could be NVD or NVE

#### ETDRS Classification

- The **diabetic retinopathy** can be divided into **NPDR (non proliferative)** and **PDR (proliferative)**.
- The NPDR can be divided into
  - **Very mild NPDR:** Only microaneurysm
  - **Mild NPDR:** Along with microaneurysm there are features of background diabetic retinopathy which means hemorrhage, exudate, edema.
  - **Moderate NPDR:** All the features of pre proliferative diabetic retinopathy.
  - **Severe NPDR:** It is described by 4:2:1 rule.
    - 4:2:1 rule;
    - **Divide the retina into four quadrants.**
    - Microaneurysms and hemorrhages seen in all four quadrants, OR
    - Looping and beading is seen in two quadrants, OR
    - IRMA even in one quadrant.
  - **Very severe NPDR:** When the patient meets two or more than two criteria of 4:2:1 rule, that is called very severe NPDR.
- According to **ETDRs classification**
  - PDR can be classified as mild to moderate or high risk, according to the amount of disc-area that has been covered by neovascularization.
  - Advance eye disease means all the three blinding complications-vitreous hemorrhage, tractional retinal detachment and neovascular glaucoma.

#### Treatment

- NPDR without cystoid macular edema (CME): A regular follow up is needed
- **Very mild NPDR:** Frequency follow-up is 12 monthly
- **Mild NPDR:** Frequency follow-up is 6-12 months.
- **Moderate NPDR:** Frequency follow-up is 6 months.

- **Severe NPDR:** Frequency follow-up is 4 months.
- **Very severe NPDR:** Frequency follow-up is 2-3 months.
- **NPDR with CME**
  - Check whether edema is very near to the center of the macula.
  - Clinically significant macular edema (CSMO): It is defined as any edema < 500 microns from the centre of fovea or any hard exudates within 500 microns from centre of fovea.
- For confirmation of CSMO: **FFA (Fundus fluorescein angiogram)** can be done to know whether CSMO is clinically significant or not.
- If it is clinically significant then the first line of treatment is
  - Intravitreal injection of anti-VEGF.
  - Anti-VEGF: Bevacizumab (Avastin) or **Aflibercept** or Ranibizumab (Lucentis).
  - After completion of first line treatment, any second line treatment should not be repeated until 6 months
  - Injections can be repeated thrice.
- Second line treatment: Laser, only after 6 months of this therapy.

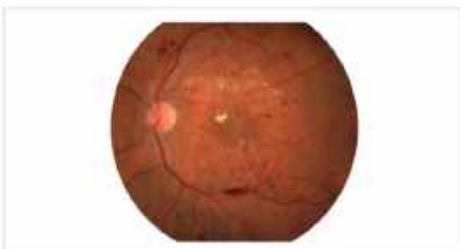#### Laser Photocoagulation

- It depends on **Angiographic findings**.
- In the case of NPDR with CME, focus should be on central macular edema which can be controlled by either giving focal or grid photocoagulation.
- Two rows of burns along arcuate blood vessels are given temporarily this is called **Grid photocoagulation**.
- The purpose is to **change the hypoxia to anoxia**.

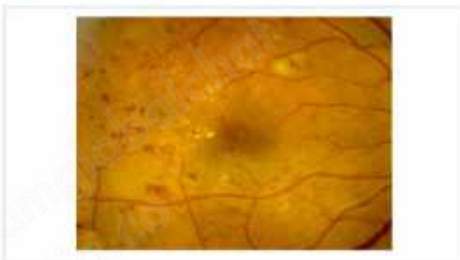#### Proliferative Diabetic Retinopathy

01:33:38

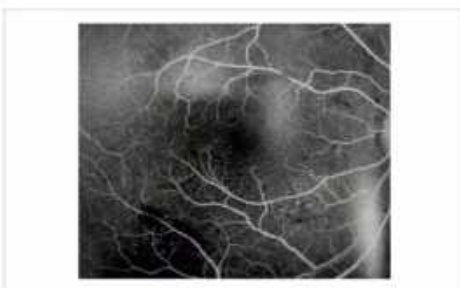
- First line of treatment is Laser photocoagulation i.e., panretinal photocoagulation (PRP).
- **Pan retinal means whole retina but spare the macular area.**
- Give a **temporal barrage** to make a boundary and not enter into the macular area.
- The PRP should start from the inferior part because if it starts from superior and there is a hemorrhage, the blood is going to settle down then the retina in the inferior part is not seen. So the procedure will be postponed.
- How many burns are given?
  - It depends upon **what type and how serious the disease is**.
  - Number of burns, especially in mild cases; starts with 2500 burns-3000 burns.
  - If it is a moderate or severe case, more burns can be given.
  - By giving these burns, anoxia will be created i.e., there will be damage to the nerve fiber layer and visual defects.
  - So, PRP can be repeated maximum two times and then shift to second line treatment.
  - If there are no desired effects after PRP then start anti-VEGF.
  - **Second line treatment is Intravitreal Anti-VEGF injections.**



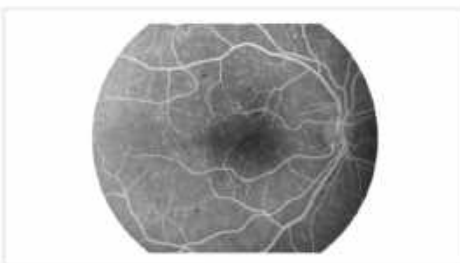
- There are **hard exudates, flame shaped hemorrhage and dot and blot hemorrhage**.



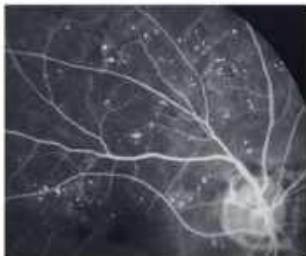- Cotton wool spots, hard exudates, dot and blot haemorrhages are seen (macular area focused)



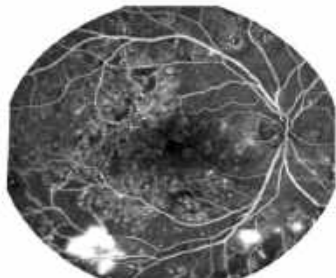
- Multiple hyper fluorescein, i.e., microaneurysm are seen



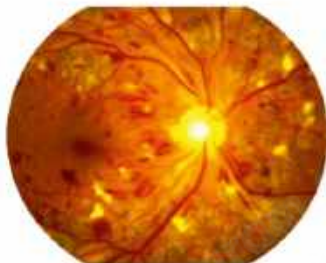- Dark spots are blocked fluorescence which can be hemorrhage, or exudates
- White dots are microaneurysms,



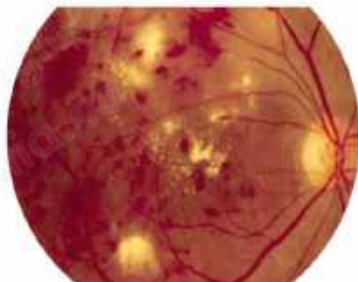
- Proliferative stage i.e., severe NPDR, where IRMA can be seen



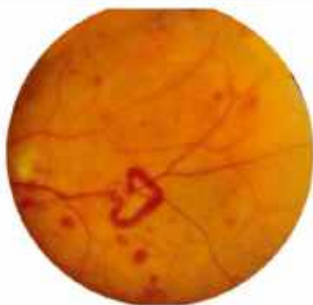
- All the white dots are microaneurysm i.e., there is tuft of new blood vessels when there is leakage that is NVE.
- This is a proliferative diabetic retinopathy.



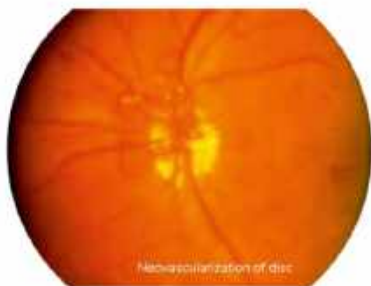- Number of cotton wool spots (CWS) have increased
- There are flame shaped hemorrhage and large dot and blot hemorrhage
- It is a preproliferative diabetic retinopathy/ moderate NPDR.



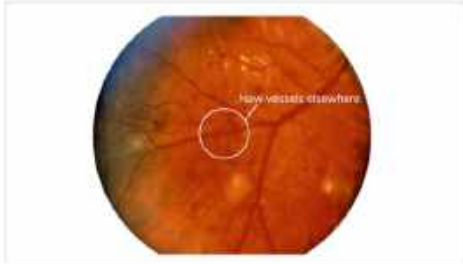- There are flame shaped hemorrhage, hard exudates, cotton wool spots, and there is a tuft of new blood vessels at the disc. This is the case of NVD.
- Hence it is proliferative diabetic retinopathy.



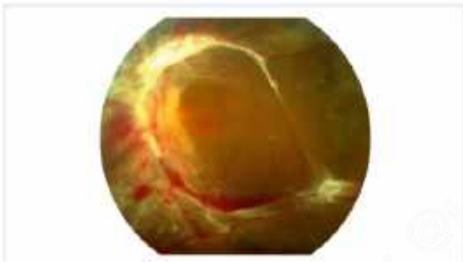
- There is looping of the vessels, blot hemorrhage, large dot hemorrhage and cotton wool spots.
- It is also a preproliferative diabetic retinopathy stage.



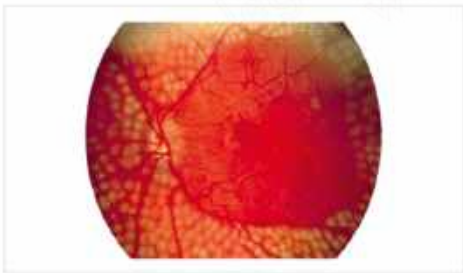
- The image shows neovascularization at the disc.
- It is a proliferative diabetic retinopathy.



- NVE, there is a tuft of new vessels which is at the periphery/ elsewhere.



- **Advanced eye disease:** Tractional retinal detachment.
- The image shows a **tractional band**.



- It is the case of pan retinal photocoagulation.

### Hypertensive Retinopathy

01:49:38

- Any long standing hypertension can cause effect in the retina called as hypertensive retinopathy.
- Keith-wagner Grading explained hypertensive retinopathy into four **grades**.

#### Grade I

- It is a generalized or diffused arterial attenuation.

#### Grade II

- Apart from this features of diffuse, there is focal arterial constriction or focal spasm.
- The A-V nipping changes are mainly due to the atherosclerosis plaque inside the artery, which presses on the vein, therefore the Salus sign can be seen.

#### Grade III

- Apart from all the features of grade II, there will be hemorrhage and exudates
- When the attenuation is so much, the artery looks like copper wire.

#### Grade IV

- **Grade IV is malignant hypertension.**
- There is increase in ICT, which causes papilledema.

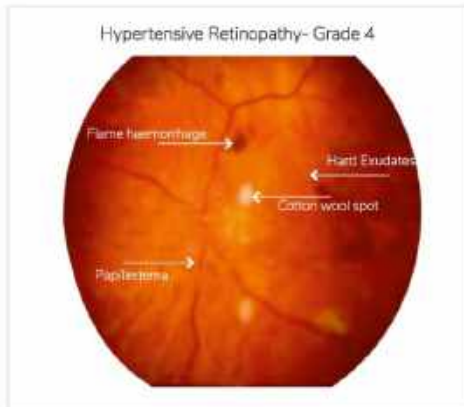
#### Atherosclerotic changes

- Bonnet sign is the banking of the vein.
- All these signs are seen due to atherosclerosis and effect in the vein.
- All these Gun, Bonnet and Salus sign are not hypertensive changes, they are mainly due to atherosclerotic changes.
- **In grade III, there is copper wire and grade IV, there is silver wire; these are atherosclerotic changes.**

#### Acute Hypertensive Crises

01:48:58

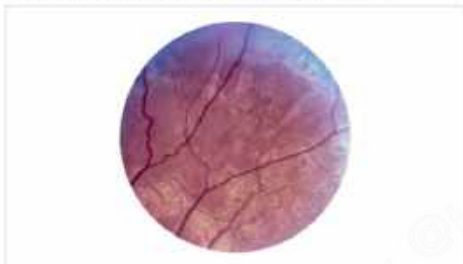- Due to very high pressure, the autoregulation is disturbed, then it causes blockage of vessels and Ischaemia.
- Due to this ischemia there are 2 findings present
  - Elschnig spots: These are choroidal infarcts.
  - Siegrist streaks: These are fibrinoid necrosis of choroidal blood vessels







- The image shows the periphery of the retina and there is hyperpigmented necrosis called as siegrist streaks.



- These are Elschnig spots (choroidal infarcts).

### Management

- Manage the blood pressure.

### CRVO

015621

- There is no exact known cause.

### Risk Factors

- A high intraocular pressure can block the central retinal vein.
- If the size of lamina cribosa is small, then there is a chance of occlusion at the optic disc as in hypermetropia.
- Hypertension
- Blood viscosity syndrome.
- Old age
- Smoking
- OCPs

### Pathogenesis

- There is a venous blockage/occlusion of the vein it causes increased venous pressure which causes extravasation leading to hypoxia which will lead to retinitis proliferans.
- It can be non-ischaemic or ischemic.
- If it is non-ischaemic then there are all the features of extravasation, leakage, edema, hemorrhage but because there is less hypoxia therefore no neovascularization.

- When it is ischaemic then there is retinitis proliferans, leading to neovascularization and all the complications of hypoxia.

### Clinical Features

- It can be divided into non-ischaemic and ischemic.

Non-Ischaemic	Ischaemic
Decreased Visual acuity	Markedly Decreased visual acuity < 6/60
Pupillary reaction is normal	Relative apparent pupillary defect
Cotton wool spots may be present	Increased number of cotton wool spots
Haemorrhage and exudates are present	Typical multiple flame shaped haemorrhages are present i.e., called as Splashed sauce appearance.
	100 day glaucoma
Visual field is normal	Visual field is affected

- Ischaemic
  - 100 day glaucoma is a neurovascular glaucoma of Ischaemic CRVO.
- Too much leakage may lead to cystoid macular edema; it is seen in both ischaemic and non-ischaemic.

### Investigation (CRVO)

- It is divided into non-ischaemic and Ischaemia.

Non-Ischaemic	Ischaemic
Leakage may be seen	Leakage and Capillary non-perfusion/blockage can be seen
ERG: Normal	Decreased b wave
OCT: Cystoid macular edema	CME present

### Treatment

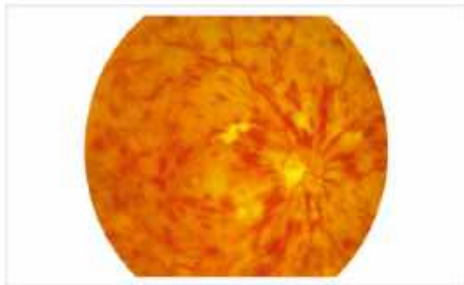
- Non-Ischaemic**
  - IVTA is done
  - In IVTA a very high risk of increase of IOP, therefore it has to be monitored.
- Ischaemic**
  - PRP and anti-VEGF injections can be given.

### Sequelae of CRVO

- If optic ciliary shunt is formed, it is a good sign which means the hypoxia will be not much therefore, the neovascularisation may be less.

### Branch Retinal Vein Occlusion (BRVO)

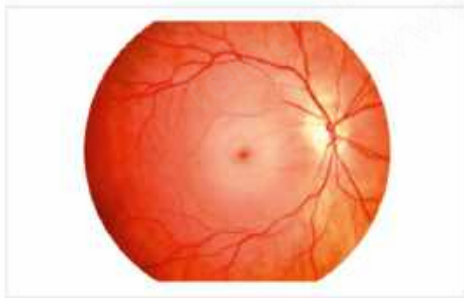- There is one quadrant or single branch of the vein involvement.
- The branches are occluded, there is extravasation and all the finding will be in that quadrant.
- It is mostly seen in superotemporal retina as AV crossings are more in this area, and therefore chances of blockage are more.
- Treatment: Photocoagulation in the affected area.



- The image shows multiple flame-shaped hemorrhages.
- CWS are also present
- It is the case of splashed sauce appearance

### Central Retinal Artery Occlusion

625658



- Cherry red spot is seen.
- There is attenuation of arteries and oedematous retina.

### Risk factors

- **Embolism:** Emboli can be cholesterol bodies called **Hollenhorst plaques**. It is common in heart disease patients/carotid artery disease patients Emboli can also be calcific.
- **Mucor mycosis**
- COVID-19
- **Vasculitis:** Polyarteritis nodosa, Systemic lupus erythematosus, Giant cell arteritis.

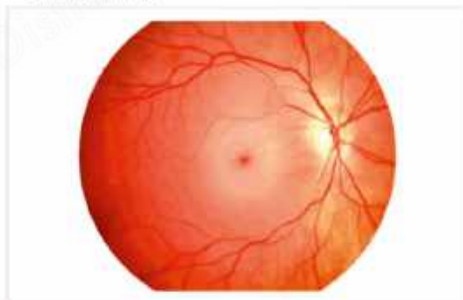
### Clinical Features

- Sudden painless loss of vision/Marked diminished vision.
  - Vision will be up to 6/60.
  - If PL is negative, it indicates giant cell arteritis.
- There is an acute blockage in the artery that leads to severe edema and the whole retina looks white.
- Marked attenuation of arteries, these are described as thread-like arteries.
- Interrupted blood column in the veins called as cattle truck appearance of blood flow. It is also called **BOX caring** and segmented flow.

### Cherry red spot

#### Differential Diagnosis of Cherry Red Spot

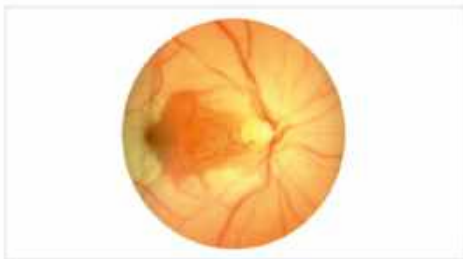- Blunt trauma leading to Berlin's edema also known as commotio retinae.
- Central retinal artery occlusion.
- **Storage disorders**
  - GM, gangliosidosis-Tay sachs disease.
  - GM, gangliosidosis is of two types type 1 and type 2, type 2 has a cherry red spot.
- Niemann Pick disease.
- Mucopolipidosis.
- Gauchers disease



### Important Information

- 14% of the population got dual blood supply to the macular area hence the patient suffering from the CRAO might still not be blind.
- One is central retinal artery, and the other artery is cilioretinal artery (branch of short posterior ciliary artery).
- So, if the cilioretinal artery is supplying then very small amount of field at the centre is retained which is called as Tunnel vision or tubular vision.
- Causes of Tunnel Vision
  - CRAO with Cilioretinal artery.
  - Bilateral occipital lobe lesion (rare).

- Late stage of retinitis pigmentosa.
- Drugs like Quinine toxicity.
- Vigabatrin



- Image shows cilioretinal artery
- It supplies papillo macular bundle.

### Treatment of CRAO

- It is an ocular emergency.
- Reopening of the artery should be done within 90 mins, to secure the retina and prevent permanent damage.
- Aim is to decrease the pressure so much, that emboli dislodge by themselves.
- It can be done by asking the patient to lie supine.
- Start with ocular massage.
- IV acetazolamide can decrease intraocular pressure.
- Vasodilation can be done by carbogen inhalation (ask the patient to breathe in bag) which causes respiratory acidosis.
- Sublingual iso-sorbate can also cause vasodilation.
- For vasculitis: IV Methylprednisolone is given intravenously.
- Role of thrombolytic therapy is very limited in central retinal artery occlusion.

### Retinopathy of Prematurity

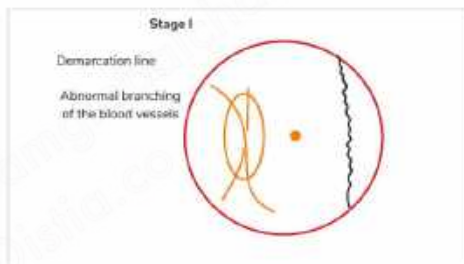
02/20/44

- If a pre-mature infant has any medical condition, and oxygen is to be given to the child then this child may develop some changes in the retina.
- Blood vessels in the retina develops very late and temporal vasculature keeps developing till 1 month of age.
- If the child is born prematurely and due to any reason oxygen is given, and since the blood vessels are still developing, they undergo a free radical injury hence it will lead to hypoxia.
- Oxygen acts as vasoconstrictor so it is going to accentuate the hypoxia and hypoxia will cause retinitis proliferans.
- This is also one of the reasons for ROP to starts from temporal area.
- First temporal retina is seen and checked. If that is normal then everything is fine.
- Pre-maturity is the most important factor to decide ROP in children.
- Prematurity is < 32 weeks and low birth weight is < 1500gm.
- In India: Criteria for high risk factors

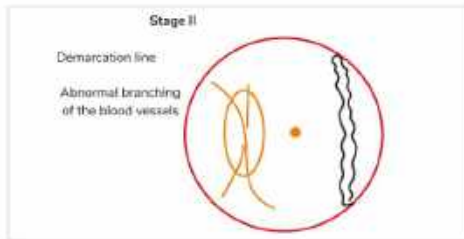
- Prematurity is < 34 weeks and low birth weight is < 2000gm.
- Supplemental oxygen is 100% oxygen.
- Ideal time for screening the child.
- Add 4 weeks to postnatal age and follow up for 1-3 weeks till the blood vessels have grown up to the periphery/zone 3.
- Screening with indirect ophthalmoscopy is done to see the periphery with scleral indentation (+ 28 D lens is used)
- Widefield retinal camera can also be used.
- Apnea should be monitored in child during screening.

### Clinical Features

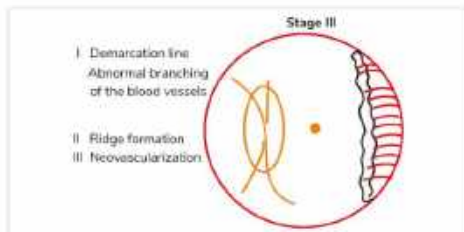
- **Stage I** : Demarcation line is seen due to abnormal branching of the blood vessels.
- It starts from temporal side



- **Stage II**: Ridge formation (it raise above the surface) occurs in stage II.

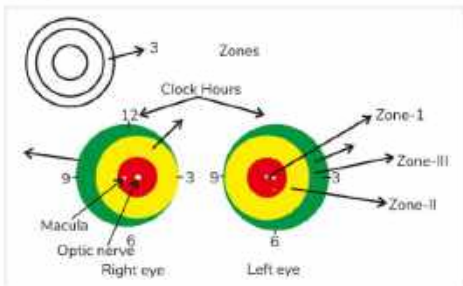


- **Stage III**: Neovascularization (new vessels in the hypoxic area, blood vessels are not developed)

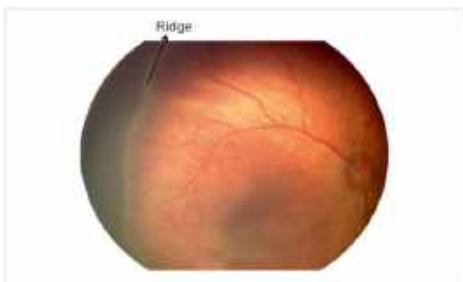
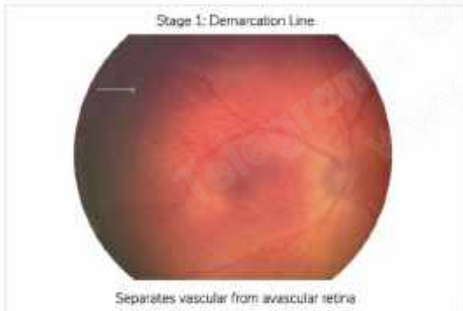


- **Stage IV:** Subtotal retinal detachment
- **Stage V:** Total retinal detachment

### Zones



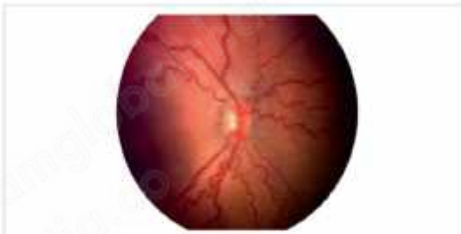- Retina is divided into 3 zones.
- First zone is a circle of 6mm.
- Zone 2: Tangential to the nasal area
- Zone 3: Whatever is left at the temporal crease instead of extreme.
- Zone I and II involvement is more serious than zone III.



- All these changes are across the temporal retina away from the disc.



- **Plus disease:**
  - It is the tortuosity of blood vessels at atleast 2 quadrants on the posterior pole
  - Any tortuosity indicates progression.



### Rush disease

- The rush disease is very aggressive and fast progresses from Stage I to Stage V.
- Any ROP can be divided into active disease and cicatricial disease.
- Cicatricial disease
  - After active disease, there can be complications like total and subtotal retinal detachment, vitreoretinal fibrosis.
  - Vitreoretinal fibrosis will cause dragging of macula and disc causing retrolental fibroplasia.
  - And this retrolental fibroplasia will lead to leukocoria (white eye reflex).

### Treatment of ROP

- Treatment of the child is started when he/she falls under threshold disease.
- It is given by IC-ROP.
- **Threshold disease:** It is stage III. Zones I and II should be involved.
- The extent should be 5 contiguous or 8 non-contiguous clock hours and along with that only if there is Plus disease. This is the definition of threshold disease.
- Treatment: Laser the hypoxic part of retina.
- **Pre-threshold disease:** This concept was given by the study **Early treatment Retinopathy of prematurity study (ET-ROP)**.
- ET-ROP has divided cases into two parts type I and type II.

- In type II: Child is only under observation.
- Type I: Immediate treatment is needed.
- Type I:
  - Zone I, any stage with plus disease.
  - Zone I, stage III without plus disease
  - Zone II, stage II, III with plus disease
  - This type needs immediate treatment.
- Type II:
  - Zone I, stage I, II without plus disease.
  - Zone II, stage III, without plus disease.
  - In this type, just put the child under observation.
- Treatment: Laser treatment of the hypoxic part (No PRP).
- Laser treatment in children is done through an indirect ophthalmoscope. It can be done in sitting position. A photo coagulative laser is used.
- Anti-VEGF: There is risk of recurrence.
- Pars plana vitrectomy: For tractional retinal detachment.
- Pathogenesis- There is inflammation and occlusion in the veins, which is finally leading to hypoxia. Therefore, this will lead to retinitis proliferans.
- Clinical feature- Sudden visual drop, decreased vision due to vitreous hemorrhage.
  - Floaters
- Examination- Inflammatory exudates are along the veins this is a sign of peri which is called venous sheathing. The patient will have a recurrent vitreous hemorrhage.
- It is generally common in young males.
- Investigation- On fundus fluorescein angiography (FFA), areas of capillary non-perfusion can be seen.
- Treatment- Periocular, intravitreal, or systemic steroids.
  - ATT may or may not be given.
  - Photocoagulation in the hypoxic area.

### Purtscher's Retinopathy

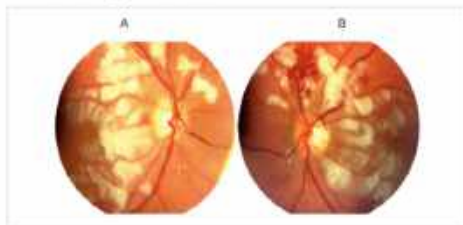
02:40:55

#### Pathogenesis

- Any trauma will lead to microvascular damage and that will lead to occlusions causing ischemia.
- This damage can also lead to embolism.
- Other causes: Fat/air embolism
- Acute pancreatitis

#### Clinical Features

- Sudden marked decrease in vision, it goes up to 6/60.
- On examination: Multiple cotton wool spots are seen around the disc.
- Purtscher's flecken: There are due to the small capillary infarcts.
- Haemorrhage is also seen.



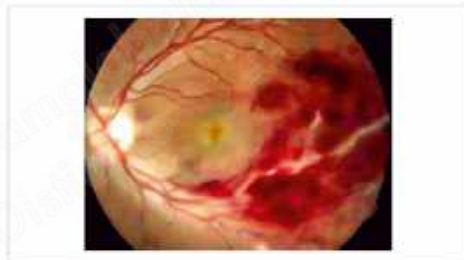#### Treatment

- No effective treatment

### Eales Disease

02:45:11

- It is also called Periphlebitis retinae.
- Primarily, there is inflammation around the veins mainly in the peripheral retina.
- Etiology- Hypersensitivity to tubercular antigen. It is type IV and type III hypersensitivity.

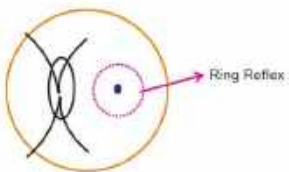


### Macular Disorders

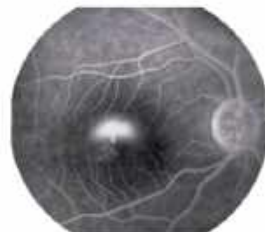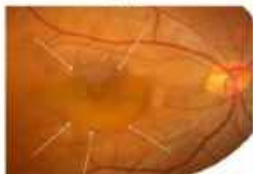02:48:11

#### CSR (Central Serous Chorioretinopathy)

- Breaking of the outer blood-retinal barrier is mainly the cause of fluid leaking from the choriocapillaris to the sub-retinal space.
- There is mild accumulation of fluid so there is very shallow retinal detachment.
- This shallow exudative retinal detachment is called as CSR.
- Clinical features: It is more common in young males.
  - The ratio between males to females is 3:1.
  - Disease has two forms one is acute form and another is chronic form (> 12 months).
- Risk factors: Any young male with type A personality, steroids, stress, H.pylori infection.
- Acute form: Disturbance of vision - Metamorphopsia (distortion of image) and micropsia may occur.
  - Mild diminution of vision is corrected by the plus lens (due to hypermetropia).
  - It is self-limiting.
- Examination: After examining the patient, a ring reflex is seen because fluid is accumulated and this causes a shallow retinal detachment.



CSR



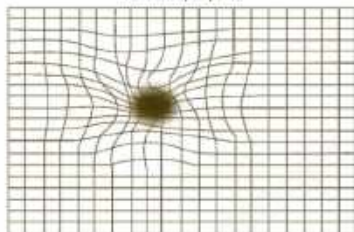
Mushroom shaped pattern - Smoke-stack appearance

- **Chronic form:** It persists for more than 12 months.
  - It causes damage of RPE and photoreceptors.
  - There is marked diminished vision or permanent diminished vision.

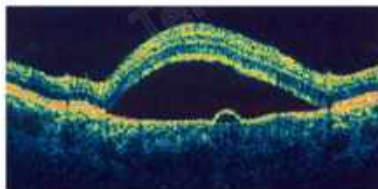
- **Treatment**

- Acute: Self-limiting, avoid steroids.
- Chronic:
  1. Photodynamic therapy is done.
    - If anything is very close to the fovea, photocoagulative laser can not be used as it will damage the fovea as well
    - Verteporfin is used, 30%-50% of the dose is used (in ARMD) it acts as a photosensitizer + 689 nm of diode.
  2. Sub threshold micropulse diode.

Metamorphopsia



CSR

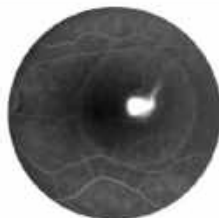

OCT, Optical coherence tomography

- **CME (Cystoid macular edema)**

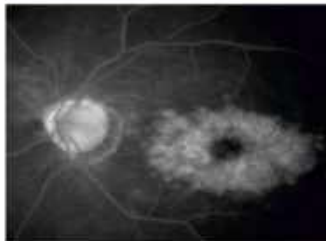
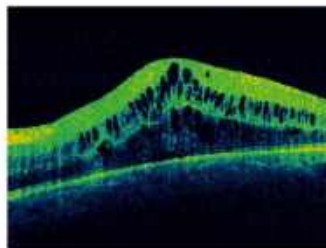
- It is called cystoid macular edema because the cystic spaces are filled with fluid.
- Etiology- Breaking of the inner blood-retinal barrier due to increased capillary permeability.
  - Inflammation, any cause of inter uveitis or posterior uveitis can lead to CME.
  - Vascular diseases
  - Degenerative disease: Retinitis pigmentosa are also causes of CME.
  - **Irvine gass syndrome:** CME after cataract surgery.
  - **Drugs:** Niacin, PG analogues, and epinephrine (given during aphakic glaucoma) may cause CME.

- **Fluorescein angiography:** Two patterns are seen.

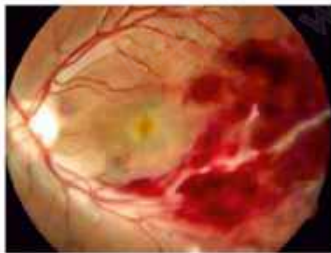


Enlarging Ink-blot pattern

- Clinical factors: Diminution of vision, metamorphopsia.
- Examination- Absent or dull foveal reflex.
- Investigation
  - Optical Coherence Tomography: Cystoid spaces filled with fluid.



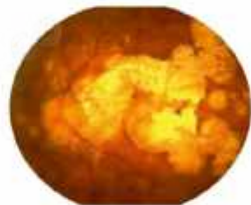
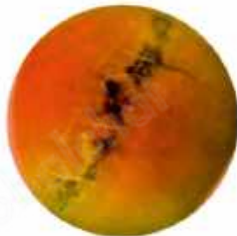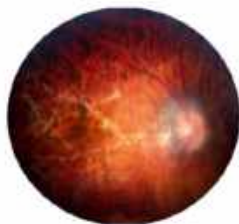- Angiography: This type of leakage shows flower petal pattern.
- **Treatment:** NSAIDs like Indomethacin, Steroids, Acetazolamide (CA inhibitors), laser treatment.



### Pathological Myopia

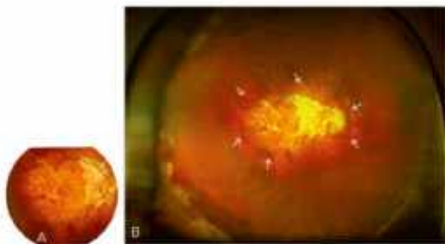
03/06/33

- Any myopia with fundus changes.
- Different pathological changes
  - When the choroidal blood vessels are more prominent due to attenuation of retinal pigment epithelium it is called a tigroid or tessellated fundus.
  - A greyish shadow around the disc is seen. This is peripapillary atrophy, also called annular crescent.
  - Too much stretching will lead to haemorrhage and pigments at the macula. This is called a "Foster Fuchs" spot, or Flecks.

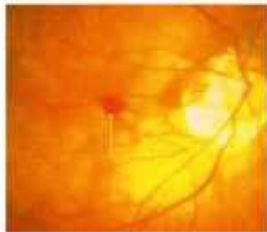

- There can be chorioretinal atrophy.
- At the peripheral retina, degeneration can be seen, called lattice degeneration.
- This degeneration can lead to hole formations. This is called rhegmatogenous retinal detachment.

posterior staphyloma



- Elongation of the eyeball can lead to posterior staphyloma.
- Excessive stretching can break bruch's membrane which are called lacquer cracks. This can lead to choroidal neovascularization or can lead to haemorrhage called coin haemorrhage.



#### Pathological myopia associated conditions

03:12:09

- Pathological myopia can be associated with
  - Primary open-angle glaucoma (POAG),
  - High-steroid responders.
  - Posterior subcapsular cataract (PSC) is common.
  - Macular hole formation.

#### Angioid Streaks

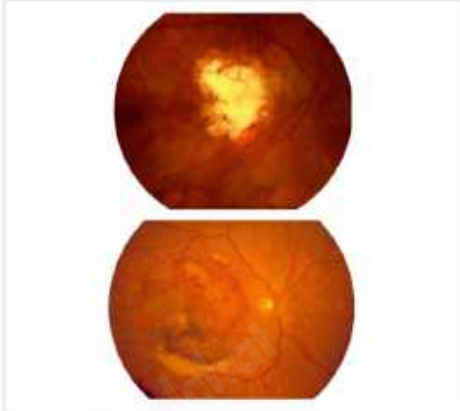
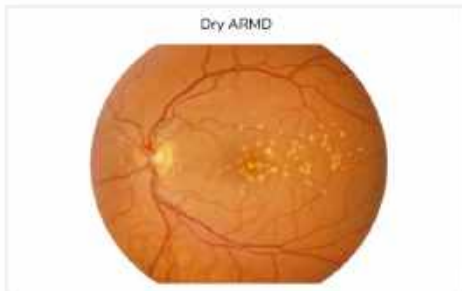- Angioid streaks are breaks in the Bruch's membrane due to collagen disorders.
- Etiology: **"PEPSP"**.
- **P** - Pseudoxanthoma elasticum (most common).
- **E** - Ehlers-Danlos syndrome.
- **P** - Paget's disease.
- **S** - Sickle cell disease.
- **I** - Incontinentia pigmenti.
- Angioid streaks are a very big risks for causing neovascularisation.
- These cracks will rupture and cause choroidal neovascularisation.

#### Age Related Macular Disease (AMRD)

03:15:27

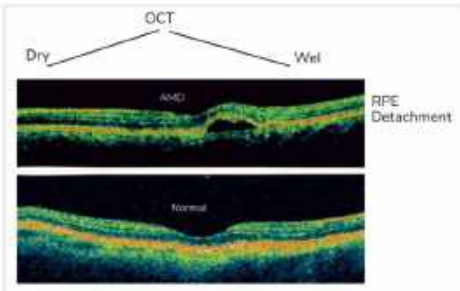
- AMRD means degenerative changes at the macula that lead to irreversible loss of vision.
- It generally starts from the 6<sup>th</sup> decade.
- This is a choroidal disorder.
- It is classified into dry ARMD and wet ARMD.

#### Dry ARMD vs wet ARMD

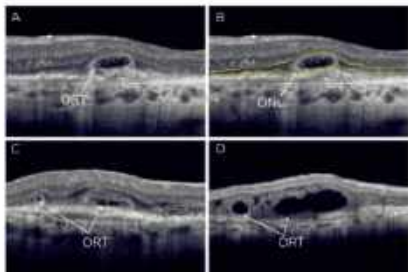


Dry ARMD (more common)	Wet ARMD
<ul style="list-style-type: none"> <li>• The first feature is dried up deposits at the macula (drusens).</li> </ul>	<ul style="list-style-type: none"> <li>• The first feature is retinal pigment epithelial (RPE) detachment.</li> </ul>
<ul style="list-style-type: none"> <li>• Geographical atrophy.</li> </ul>	<ul style="list-style-type: none"> <li>• Choroidal neovascularisation. It slowly percolates into the subretinal space. Thus, CNV is also called subretinal neovascularization</li> </ul>

#### Investigation of ARMD







- Optical coherence tomography (OCT).
- In wet OCT, RPE detachment is seen.
- In dry OCT, in outer nuclear layer, outer retinal tubulation (ORT) is seen.
- Fundus fluorescein angiography (FFA). RPE defects in dry ARMD can also be seen.
- In wet ARMD, a CNV membrane called the lacy pattern can be seen.
- In dry ARMD, fundus autofluorescence (FAF) is done. Here, the dye is not put in the eye, as only the fluorescence property of drusens is to be determined.
- Indocyanine green (ICG) angiography is done for occult conditions (not very clear).

● **Prophylaxis of ARMD**

- Prophylaxis includes antioxidants like lutein and zeaxanthin. These are the natural carotenoids present in the outer plexiform layer.
- Apart from these, prophylaxis also includes vitamin C, vitamin E, zinc, and copper.
- Stop smoking
- Avoid direct sunlight exposure.

● **Treatment of dry ARMD**

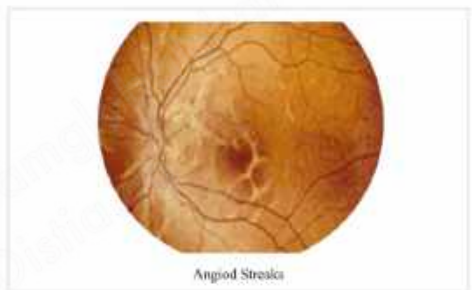- There is no effective treatment for dry ARMD.
- The Amsler grid can be monitored.
- Low-vision aids (LVA) can also be used.
- Never photocoagulate the drusens, as it will aggravate the disease.

● **Treatment of wet ARMD**

- Treatment will depend on the location of neovascular membrane.
- The neovascular membrane can be extrafoveal (more than 200 microns from the foveal avascular zone), juxtafoveal (less than 200 microns from the foveal avascular zone), or subfoveal (below the fovea).
- Laser photocoagulation can be used in cases of extrafoveal.
- However, in cases of juxtafoveal or subfoveal, laser

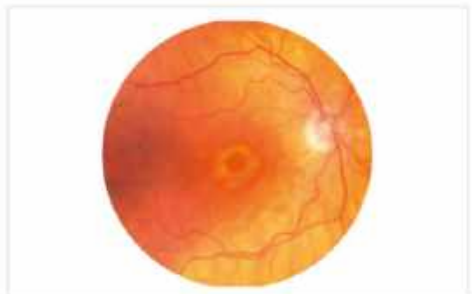
photocoagulation cannot be used. Instead, intravitreal anti-vascular endothelial growth factor (anti-VEGF) injections are used.

- Photodynamic therapy (PDT) uses a diode. Visudyne is put in, and after 5 minutes, 689 nanometers of diode are applied for 83 seconds.
- It leads to free radical induction, which will damage the blood vessel and cause thrombus formation on the neovascular membrane.
- The anti-VEGF injection is given at a dose of 0.05 mL.
  - Examples: Pegafenib, broclizumab (a newer therapy), bevacizumab (Avastin), ranibizumab (Lucentis), and aflibercept.

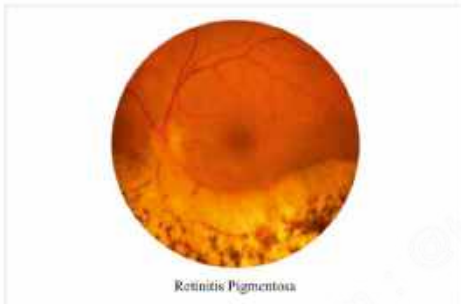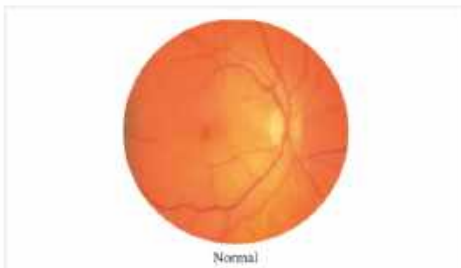


**Bull's-Eye Maculopathy**

03:30:58



- There is alternative hypo and hyperpigmentation.
- There is hyperpigmentation due to pigment melanin
- Hypopigmentation due to RPE damage.
- Causes: Chloroquine (a cumulative dose of more than or equal to 300 g)
  - Hydroxychloroquine (a cumulative dose of more than or equal to 1000 g)
  - Cone dystrophy
  - Batten mayo syndrome or Bultens disease (cerebromacular degeneration).



- Retinitis pigmentosa is a dystrophy of rods and cones, initially rods are affected.
- It is a genetic disease.
- Most commonly, it is sporadic.
- If it is hereditary, then all three modes of inheritance are possible, including autosomal dominant (AD), autosomal recessive (AR), and x-linked recessive inheritance.
- AR has the best prognosis, and x-linked recessive has the worst prognosis.
- **Clinical features:** Nyctalopia (night blindness) and impaired dark adaptation.
- **Examination:** TRIAD include pale waxy disc, attenuation of arteries, and pigmentary disturbance in the form of bone spicules.



- Perimetry: Typical disease involve mid periphery first.
  - The initial findings is ring scotoma in the early stage and tunnel vision in the late stage.
- **Electroretinography (ERG):** There's a decreased amplitude of both "a" and "b" waves.
- **OCT:** If there's an associated cystoid macular edema (CME).
- Dark adaptometry: Dark adaptation time is prolonged.
- In the late stages, changes in the electrooculogram (EOG) are seen.
- Decreased Arden ratio may be present.

#### Atypical retinitis pigmentosa

03/37/09

- Sectoral RP is when only one sector is involved.
- If it starts from the center, then it is called pericentric or inverse RP.
- When there is no bone spicule, then it is called RP sine pigmento.
- When instead of black salt and pepper presentation, there are white dots, it is called RP albescens.

#### Systemic association in retinitis pigmentosa

- The most common systemic association is Usher's syndrome. It is RP with deafness.
- Laurence-Moon-Bardet-Biedl syndrome (LMBBS). It involves RP, mental retardation, obesity, polydactyly, and paraplegia.
- Kearns-Sayer syndrome: It involves RP, heart block, and chronic progressive external ophthalmoplegia (Myopathy instead of CPEO).
- Refsum's disease: It is a defect in the phytanic acid metabolism. It is managed with a low phytanic acid diet.
- Bassen-Kornzweig syndrome involves RP, ucanthocytosis, abetalipoproteinemia, and ataxia. It is managed with a low-fat diet and vitamin supplements.

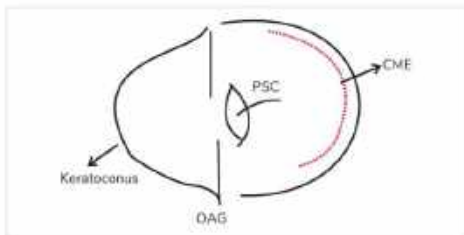
#### Treatment of retinitis pigmentosa

- There are not many effective treatments for RP.
- The treatable RP includes Refsum's disease and Bassen-Kornzweig syndrome.
- Regular follow-up (VF/ERG), a vitamin A supplement, a docosahexaenoic acid supplement (which helps to decrease the disease progression)
  - Newer therapies like gene therapy (in case the defect is localised in the RPE-65 gene).
  - In gene therapy, an adenovirus associated vector (AAV) based therapy, it is given as a single-dose intraocular suspension. The drug used is VORETIGENE NEPARVOVEX.
- A retinal implant (ARGUS-II) can also be performed.
- Low-vision aids (LVA).
- It can also lead to cone dystrophy

### Cone dystrophy

- Any unexplained decrease in central vision, along with photophobia and nystagmus.
- The fundus is normal on investigation.
- It is detected by a multifocal ERG.

### Ocular associations in retinitis pigmentosa

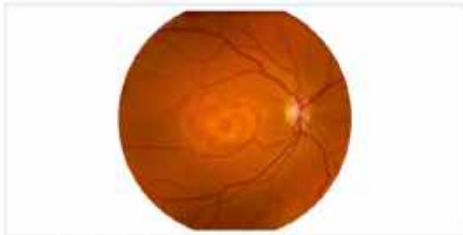

- It can be associated with
  - Keratoconus
  - Posterior subcapsular cataract (PSC)
  - Open-angle glaucoma (OAG)
  - CME

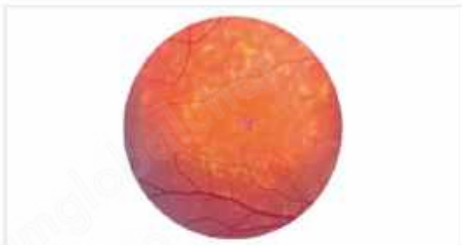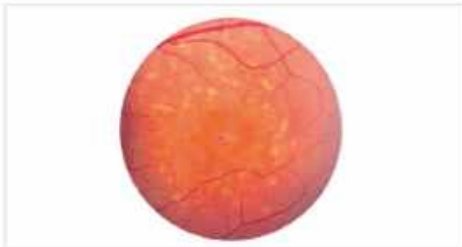### Stargardt Disease

03/48/23

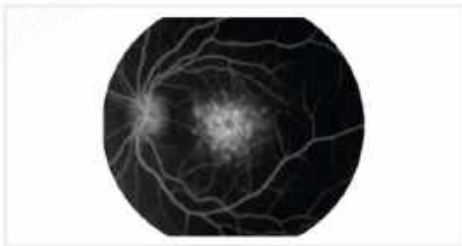
- It is also called juvenile macular dystrophy.
- It manifests after the first decade.
- It is a dystrophy of the RPE.
- Variant is Fundus flavi-maculatus.
- It is one of the most common macular dystrophies.
- The gene involved is STGD1 (autosomal recessive, most common), ABCA4.
- Clinical features of Stargardt disease
  - It manifests in initial decades.
  - There will be a gradual diminishing of central vision. The vision drops to less than 6/60.
  - There will be decreased color vision or impaired dark adaptation.
- Examination of Stargardt disease
  - Initially, there is a mottled appearance. There is a snail-line appearance.



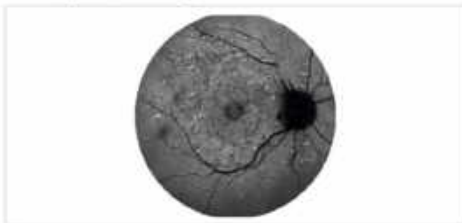- Later it gives a beaten-bronze appearance.



### Investigation of Stargardt disease



- FFA: A dye is injected, there is a dark background choroid fluorescence due to dense deposition of lipofuscin on the retinal pigment epithelium.
- Since there is no choroidal background fluorescence seen, it is called "dark choroid sign" or "silent choroid syndrome".
- Fundus autofluorescence: No dye is seen, all lipofuscin deposits are shining.

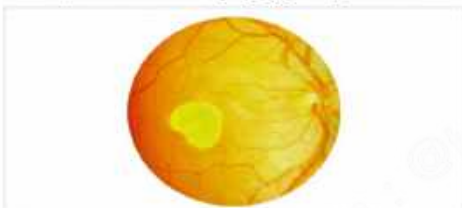


- o EOG abnormality.
- o ERG: Late changes may affect the ERG mainly photopic.
- **Treatment of Stargardt disease**
  - o Avoid bright sunlight. Use sunglasses
  - o **Avoid vitamin A, as it promotes lipofuscinosis.**

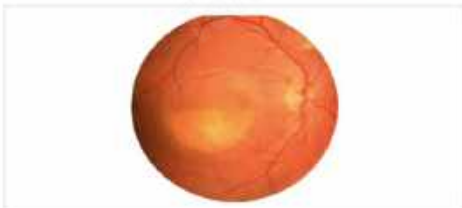### Best Vitelliform Macular Dystrophy

03:55:18

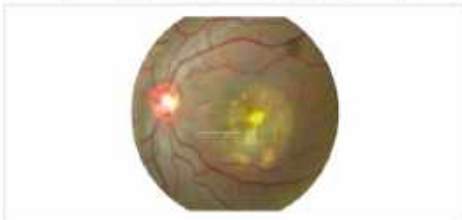- It is a dystrophy of the RPE.
- It is a childhood disease.
- It is autosomal dominant.
- Gene involved is Bestrophin gene.
- **Clinical features of the best vitelliform macular dystrophy**
  - o Initially, the vision is normal, but the vision will drop to less than 6/60 only in the late stages of the disease.
  - o **Pre-vitelliform stage:** The vision and fundus are normal, but the EOG is abnormal
  - o The vitelliform stage: It involves lipofuscin. Here, lipofuscin is collected giving egg yolk appearance.



- o **Pseudohypopyon stage:** Partial reabsorption and collection of lipofuscin in sub-retinal space are due to the breaking of RPE.



- o **Vitelliruptive stage:** Here, the visual acuity drops. The appearance is called a "scrambled egg" appearance.



- o **Atrophic stage.**

- The investigation is done by EOG.
  - o EOG arden value is less than 1.5
- Complications of best vitelliform macular dystrophy is choroidal neovascularisation
- Investigation
  - o EOG shows an Arden ration less than 1.5.
  - o FAF shows hyperfluorescence (in egg yolk).
  - Adult form of best vitelliform dystrophy is known as adult onset foveal vitelliform dystrophy.

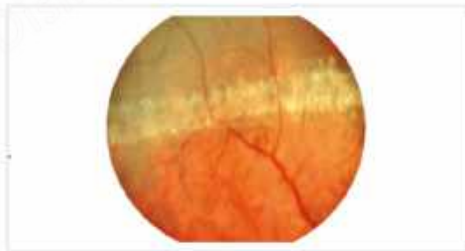### Retinal Detachment

04:00:17

- It is defined as the separation of the retinal pigment epithelium (RPE) from the neurosensory retina (NSR).
- Types of retinal detachment
  - o Rhegmatogenous retinal detachment
  - o Tractional retinal detachment
  - o Exudative retinal detachment.

### Rhegmatogenous retinal detachment

- It is the break in the retina which can either be a tear or a hole.
- Tear is due to traction (horseshoe-shaped) and hole is formed after any degeneration.
- The most common cause of traction is posterior vitreous detachment (PVD).



- The degeneration that leads to hole formation are lattice degeneration and snail track degeneration. Any break in continuity of retina cause fluid to enter from vitreous to sub retinal space causing retinal detachment.
- The cause of exudative retinal detachment is any choroidal cause leading to the accumulation of fluid in the sub-retinal space.
  - o Inflammatory causes like posterior scleritis
  - o Vascular causes: Central serous chorioretinopathy (CSR)
  - o Tumor
  - o Neovascularization
  - o Systemic causes: Pregnancy-induced hypertension, or renal hypertension.
- **The rhegmatogenous type is the most common type of retinal detachment.**

### Clinical features

- Diminution of vision.
- Visual field defects, if superior retina is detached, it is inferior field defect.
- Curtain falling in front of the eye in case of rhegmatogenous retinal detachment.



- Floaters: These are the opacities in the vitreous cavity.
- Photopsia: It is a flash of light in the visual field. It is due to traction on rods and cones.
- Grey reflex: when it is detached it appears greyish black



### Examination

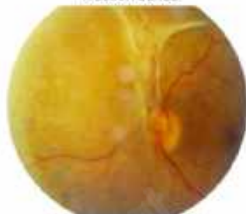- Rhegmatogenous retinal detachment
  - Retina has corrugated appearance.
  - Light mobility is undulating.
  - Floaters are present.
  - Photopsia.
  - Schaffer's sign; It is also called "Tobacco duct". It is the pigment dispersal in vitreous cavity. It is a sure indication of retinal detachment.
  - The Lincoff rule is applicable for fresh rhegmatous retinal detachment. It is governed by gravity and anatomical landmarks like the optic nerve (ON) and ora serrata.
  - Rhegmatogenous retinal detachment extends until ora serrata.

### Tractional Retinal Detachment

- When there is retinitis proliferans, neovascularization is seen in vitreous, new vessels with fibrous tissue will contract, pull the retina leading to tractional retinal detachment.

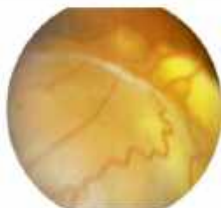- Typically it is concave, traction bands are seen and it is almost immobile.
- Due to the traction of rods and cones, photopsia can be seen.
- Floaters are not present.

Traction bands

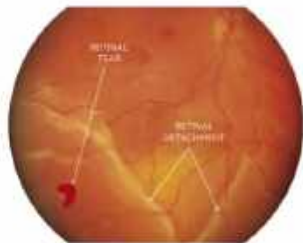


### Exudative Retinal Detachment

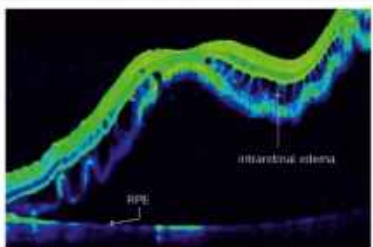
- It is a convex retinal detachment.
- It is very mobile as subretinal fluid will move according to the position of the head- **shifting fluid**.
- When the fluid is reabsorbed from the subretinal space, there may be some pigmented spots and these pigments are called as leopard spots.
- Floaters can be seen due to inflammatory causes.
- No photopsia.



Area of intraretinal exudates anterior to bullous retinal detachment



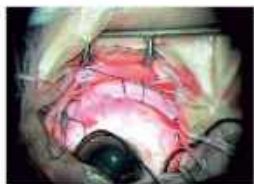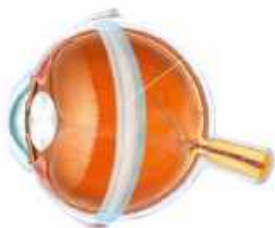- This image shows horseshoe retinal tear, demarcation line.
- It is a sign of any old retinal detachment.



- OCT indicates retinal detachment.

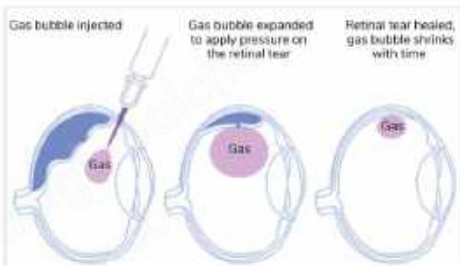
### Management

- Aim is to close or seal the retina.
- It can be done by "DACE" procedure.
- D - Drainage of retinal fluid
- A - Air in the vitreous
- C - Cryotherapy
- E - Encirclement band
- It can be done by putting a cryo corresponding to the location of break on the sclera and the temperature of the cryo is -72°C.
- When the position of the retina is changed because of the collection of fluid, first step is to drain the fluid, then inject air into the vitreous to repress the retina, and the last step is cryo to seal the break.
- Retinal seal can be reopened due to the eye movement, so it can be managed by-Buckling of sclera,
  - If multiple breaks are found on the retina, then whole encirclement band is put all over the sclera.

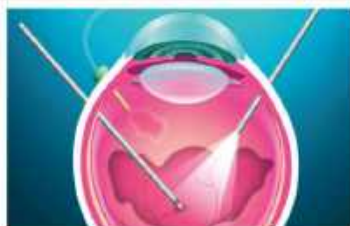

### • Pneumatic retinopexy (PR)

- There is a break in the superior quadrant and to close the break a gas is injected which will rise and cause the tamponade to close the break and therefore the resolution of retinal detachment.
- Patient should always be in erect position so that the gas can cause the tamponade.
- A gas bubble is used which is expanded.
- This expanded gas bubble will now put the pressure on the retinal tear and try to seal it.
- It will be reabsorbed after the definitive period.
- Cryo is used to seal the break and gas is maintaining the tamponade.

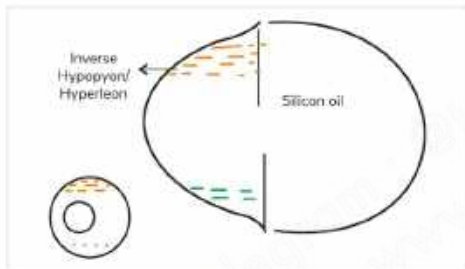


### • Pars Plana Vitrectomy



- If there is vitreous hemorrhage, traction bands then it is removed through pars plana vitrectomy.
- In this surgery, various vitreous substitutes are used.
- In vitreoretinal surgery, the pars plana vitrectomy (PPV) approach is frequently used to provide access to the posterior region for the controlled, closed-system treatment of diseases like retinal detachments, vitreous hemorrhage, etc.
- If the break is present on the superior quadrant, then pneumatic retinopexy is done.
- **Treatment for Tractional Retinal Detachment**
  - Cause of tractional detachment is retinitis proliferans.
  - If traction bands are already formed then the approach would be to cut the traction band by pars plana vitrectomy and repress the retina.
  - PRP can also be done.
  - Anti-VEGF injections can be given.

- **Treatment for Exudative Retinal Detachment**
  - Treat the cause.
  - On treating the cause like any tumor, any neovascularization, any exudate and exudative RD can be managed.
- **Vitreous substitutes**
  - Vitreous substitutes can be of two types: Gas and liquid.
  - Gas can be air but it collapses within 5 days.
  - Gas vitreous substitutes can be divided into non-expansile and expansile.
    - **Non-expansile: Air**
    - **Expansile: Sulfur hexafluoride (SF6)** – It will be reabsorbed but it stays still for 2 weeks.
      - Perfluorocarbon's (C2F6, and C3F8).
      - C3F8 is the best choice because it can stay for two months and then reabsorb within two months.
  - Liquid vitreous substitutes: Silicon oil and perfluorocarbons liquid (PFCL).



- Disadvantages: Silicon oil is removed by surgery after three months because it is not self-absorbing.
- Silicon oil can also lead to band-shaped keratopathy.
- Complication: Silicon oil can leak into the upper part of anterior chamber of the eye and lead to **inverse hypopyon or hyperlecon**.
- In heavy liquids, PFCL is preferred.

#### Retinoblastoma

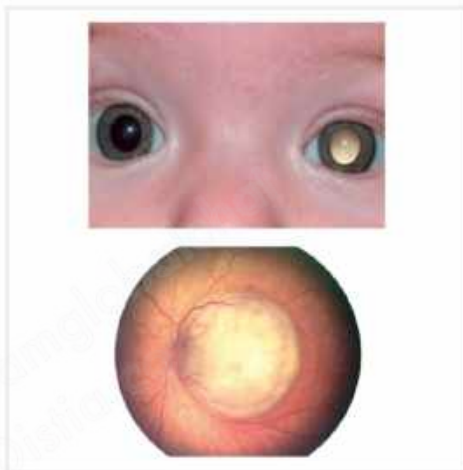
04/29/08

- It is the most common primary intraocular malignancy in children.

- It develops from the immature neuroectodermal cells of eye called retinoblasts.

#### Clinical features

- Most common age: **18 months** or within 3 years.
- The most common mode of presentation is **white eye reflex or leukocoria**.



- Second most common mode of presentation is **squint or strabismus**.
- Other presentations: **Glaucoma**
  - Pseudo uveitis: KPs cells are present but these are not inflammatory cells, these are mainly tumor cells which are called pseudo uveitis.
  - Pseudo hypopyon: These are not pus cells; these are tumor cells.
  - Orbital cellulitis.

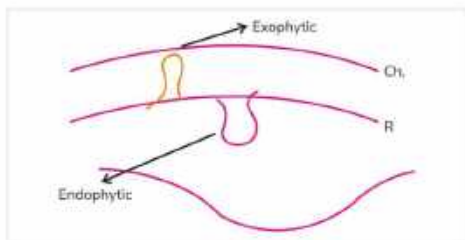


#### Important Information

##### Differential diagnosis of leukocoria

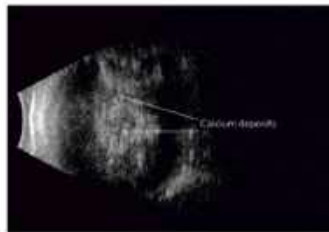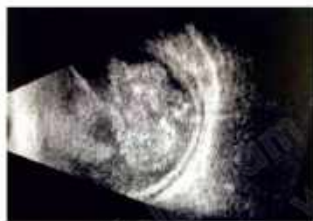- Congenital cataract – most common cause
- Cystic membrane
- Fungal endophthalmitis
- Central choroiditis mainly toxocarasis
- Central coloboma (condition in which some part of the eye is not formed).
- Retinopathy of prematurity
- Coats disease
  - It is Seen in small male children.
  - It is multiple microaneurysms.
- Persistent hyperplastic primary vitreous
- Retinal dysplasia
- Central retinal detachment

- All these causes together except retinoblastoma are collectively called as **pseudo-gliomas**.
- Any tumor that grows toward the vitreous is known as an **endophytic tumor** and toward the choroid is an **exophytic tumor**.



### Diagnosis

- First diagnosis: Ultrasound-B scan
  - Tumor can calcify hence it can be a cause intraocular calcification

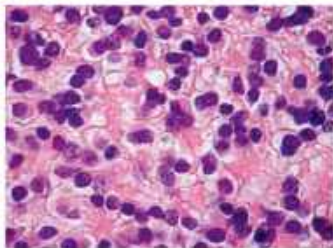
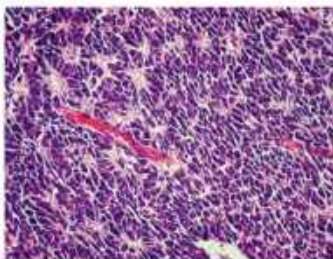
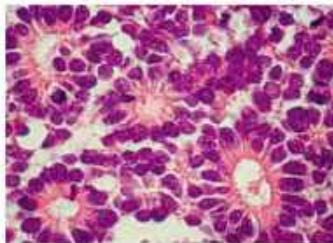


- CT scan helps to show intracranial extensions
- MRI is used to check associated pinealoma.
- **X-ray Rhese view:** It shows optic foramen.
  - If the tumor is present in the optic foramen, the most common mode of spread is through the optic nerve.
  - When it reaches the intracanalicular part of the optic nerve, it damage the bone and leads to the enlargement of optic foramen.
- Estimation of enzymes in aqueous humor

- Enzymes that are raised in retinoblastoma: Lactose dehydrogenase (LDH), Phosphoglucosomerase (PGI), and neuron-specific enolase (NSE).
- The investigation of choice is MRI-to avoid exposure of child to radiation.

### Pathology of tumor

- Pathology of the tumor is divided into gross and microscopic pathology.
- Gross in pathology, calcification and necrosis is seen.
- Microscopic pathology can be differentiated and undifferentiated retinoblastoma.



- The differentiated type has three forms
  - Flexner wintersteiner/Rosette are the columnar cells with central lumen
  - Pseudo rosette is called homer wright
  - Fluorettes.



## Genetics

080817

- RB gene is responsible for the pathology of retinoblastoma that is located at position 13 q 14 (tumor suppressor gene).
- Any mutation that occurs on the 14 band will result in retinoblastoma.
- If a mutation extends outside the 14 band, along with retinoblastoma patient also gets dysmorphic features (facial deformities – flat nasal bridge, frontal prominence), which is called 13 q syndrome.

## Trilateral Retinoblastoma

- Bilateral retinoblastoma with pinealoma is called trilateral retinoblastoma.
- The most common nonocular malignancy associated with retinoblastoma is osteosarcoma
- Inheritance of this retinoblastoma is autosomal dominant.

## Knudson's Two-Hit Hypothesis

- According to this hypothesis if a person have genotypically inherited one gene i.e., only one inactive allele of the retinoblastoma gene but the patient needs another mutation i.e., the patient needs two more mutations for retinoblastoma to manifest phenotypically.
- Possibilities
  - If both mutations occur in somatic cells, it will result in 60% non-hereditary cases
  - If the mutation occurs in somatic and germ cells it will result in 40% hereditary cases (as germ cell will transfer the problem to offspring).
  - Hereditary cases generally seen are bilateral, multicentric and are associated with osteosarcomas.
- Hereditary cases can be
  - Familial (30-33%): Family history is present.
  - Non-familial (6-10%): Family history is absent.
- Sporadic cases are non hereditary, non familial
- Sporadic case are around 90-94%.

## Staging of retinoblastoma

- An international classification for retinoblastoma (ICRB) is followed.
- It is mainly concerned with an intraocular tumor which is in stage-I.
- ICRB is divided into groups-
  - Group A- tumor size is less than 3 mm and away from the important structure i.e., macula and optic disc.
  - Group B- tumor size is more than 3 mm and near the important structure (macula and optic disc).
  - Group C- tumor with focal seeding in sub retinal space and vitreous within 3 mm from the tumor.
  - Group D- diffuse seeding in sub-retinal and vitreous greater than 3 mm of the tumor.
  - Group E- large tumor filling half of the globe.
- Stage II: Optic nerve involvement.
- Stage III: Stage of extraocular extension (tumor is in the orbit).
- Stage IV: Distant metastasis.

## Treatment

- Stage I, Group A: Focal therapy (cryotherapy or laser photocoagulation).
  - It damages the blood supply of tumor and tumor will regress.
- For stage I, group B, C, D: Along with focal therapy, chemotherapy is also used (Etoposide, Vincristine, and Carboplatin).
- For stage I, group E: Enucleation is done.
- Stage II: If there is the involvement of the optic nerve. So, along with enucleation, radiotherapy and chemotherapy is also done.
- Stage III: Extraocular extension. So, the treatment approach is exenteration to prevent the spread of tumors into the brain.
- Stage IV: Palliative therapy.



# PREVIOUS YEAR QUESTIONS



Q. Most radioresistant layer of retina? (JIPMER Nov 2019)

- A. Layer of rods and cones
- B. Outer plexiform layer
- C. **Retinal pigment epithelium**
- D. Ganglion cell layer

Q. Blood retinal barrier is formed by? (JIPMER Nov 2018)

- A. **Muller cells**
- B. Amacrine cell
- C. Bipolar cell
- D. Horizontal cell layer

Q. Rhegmatogenous retinal detachment is seen in which of the following conditions? (JIPMER DEC 2019)

- A. Diabetes
- B. **Myopia**
- C. Accelerated hypertension
- D. Complicated cataract

Q. Shifting fluid sign is seen in?

- A. **Exudative Retinal detachment**
- B. Tractional retinal detachment
- C. Rhegmatogenous retinal detachment
- D. Retinal hole

Q. ETDRS is done for? (AIIMS Nov 2019)

- A. Endothelial count
- B. Corneal topography
- C. Primary open angle glaucoma
- D. **Classification of diabetic retinopathy**

Q. A patient with hypertension and diabetes presents with blurred vision. Fluorescein angiography shows?

(AIIMS Nov 2019)

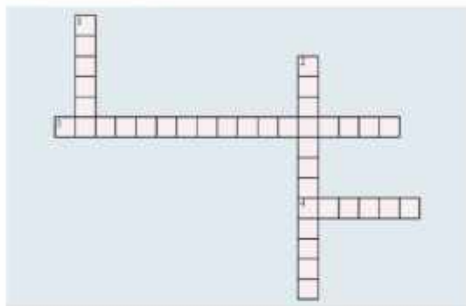
- A. **Macular edema**
- B. Sub macular edema
- C. Papilledema
- D. Pre macular hemorrhage

Q. Administration of which causes vitamin macular edema and cysts? (NEET Jan 2020)

- A. Vitamin A
- B. Vitamin D
- C. Vitamin E
- D. **Niacin**



## Crossword Puzzle 1



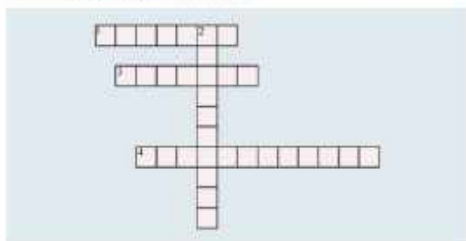
### Across

3. \_\_\_\_ is the treatment for stage IV retinoblastoma.
4. \_\_\_\_ is responsible for the pathology of retinoblastoma.

### Down

1. \_\_\_\_ tumor size is less than 3 mm and away from the important structures (the macula and the optic disc).
2. \_\_\_\_ is the most common nonocular malignancy associated with retinoblastoma.

## Crossword Puzzle 2



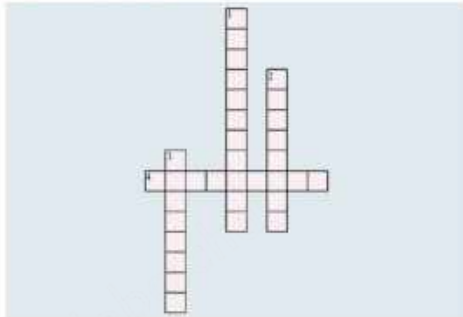
### Across

1. \_\_\_\_ cracks can also lead to coin hemorrhage.
3. \_\_\_\_ streaks are breaks in the Bruch's membrane due to collagen deposits.
4. \_\_\_\_ therapy (PDT) uses a diode. Visudyne is put in, and after 5 minutes, 689 nanometers of the diode are applied for 83 seconds.

### Down

2. \_\_\_\_ of the eyeball can lead to posterior staphy loma.

## Crossword Puzzle 3




### Across

4. CRAO is also called \_\_\_\_\_.

### Down

1. \_\_\_\_\_ is tortuosity of the blood vessels on the posterior retina.
2. \_\_\_\_\_ is the main cause of CRAO
3. \_\_\_\_\_ percent of the world's population may have a dual blood supply.

## Crossword Puzzle 4



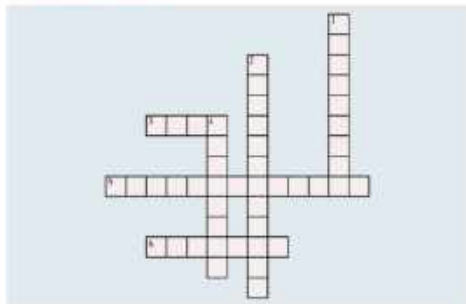
### Across

3. The peripheral retina has \_\_\_\_\_.
4. The pigments present in the FAZ are \_\_\_\_\_ and xanthophyll.

### Down

1. The most sensitive part of the retina is called the \_\_\_\_\_.
2. OCT cannot be done in \_\_\_\_\_ media.

### Crossword Puzzle 5



#### Down

1. \_\_\_\_\_ are mainly related to autoregulation.
2. \_\_\_\_\_ are related to inflammation.
4. \_\_\_\_\_ is the most important factor for the occurrence of retinopathy in diabetic patients.

#### Across

3. \_\_\_\_\_ exudates are present in the outer plexiform layer of the retina.
5. \_\_\_\_\_ is present in the nerve fiber layer.
6. \_\_\_\_\_ increases more, it will lead to release of chemotactic factors.

Telegram : @teamglobalchat  
www.Distia.co

## Vitreous

- Vitreous can be primary, secondary, or tertiary.

### Primary Vitreous

00:00:23

- The primary vitreous is the vitreous during embryonic development.
- It is mainly composed of hyaloid tissue i.e., hyaloid blood vessels along with mesodermal tissue.
- The primary vitreous later on regresses and gets replaced by the secondary vitreous.

### Secondary Vitreous

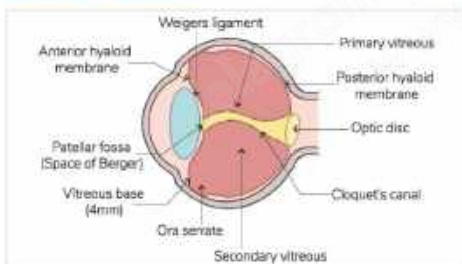
- It is the adult vitreous.
- It is composed of primarily hyaluronic acid and type II collagen.

### Tertiary Vitreous

- The tertiary vitreous is also known as the zonules of zinn.
- The secondary and tertiary vitreous develop from neuroectoderm whereas primary vitreous develops from the mesoderm.

### Anatomical Landmarks

00:02:48



- The condensed part just behind the lens is known as the anterior hyaloid membrane
- The vitreous spanning the ora serrata (3-4 mm of space) is the vitreous base
- Cloquet's canal is the remnant of the primary vitreous after regression.
- Posterior condensed part is posterior hyaloid membrane

### Types of remnants of the primary vitreous after regression:

- Floaters are the opacities in the vitreous cavity.
- If a very small bit is left behind, these appear as floaters and is known as Muscae Volitantes.
- Anterior persistent hyperplastic primary vitreous (PHPV): It is the larger chunk left behind the lens.

- Posterior persistent hyperplastic primary vitreous (PHPV): It is present near the optic disc.
- Mittendorf dots: They are present behind the lens.
- Bergmester Papilla: It is present near the optic disc.

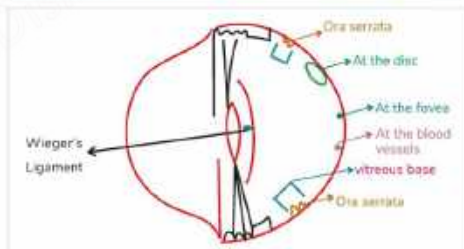
### Persistent hyperplastic primary vitreous

Refer Table 27.1

- Anterior PHPV: It is present behind the lens hence cause opaque media so the main problem with the patient or child will be amblyopia.
- Generally, it is unilateral and may be associated with microphthalmos.
- Anterior PHPV has a better visual prognosis.
- Posterior PHPV: It has poor prognosis
- There is no calcification in PHPV
- PHPV is also one of the causes of leucocoria

### Attachments of Vitreous

00:07:41



- Vitreous attachment can be
  - Vitreous base spanning the Ora serrata (anteriorly)
  - Weigert's ligament with the posterior capsule and the space is called as Berger space
  - At the disc
  - At the fovea
  - At the blood vessels
- The vitreous base at the Ora serrata is the strongest attachment.

### Floaters

00:10:17

- These are the opacities in the vitreous cavity.

### Different type of opacities can be:

- Retro lateral flare: Inflammatory cells
- Pigments

- Hemorrhage
- **Synchysis Scintillans**
  - These are **cholesterol bodies** generally seen in end-stage disease and are free-falling, when the patient is asked to look up and down
- **Asteroid bodies**
- It is also known as asteroid hyalosis.
  - It is composed of calcium and lipids.
  - It is more common in males.
  - It does not affect the vision, the visual acuity is normal.
  - Asteroid bodies are fixed and not free-falling.
  - It is associated with diabetes, hypertension, and high cholesterol.
  - Asteroid bodies may also be associated with hypermetropia and **NOT with myopia**.

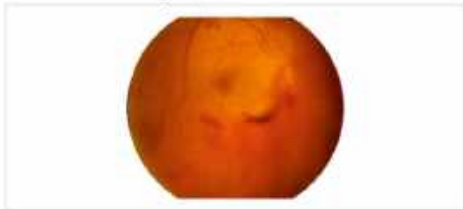#### Muscae Volitans

- These are the remnants of hyaloid tissue.

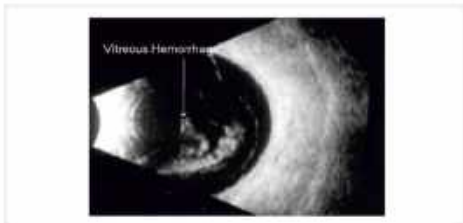
#### Identify the slide given



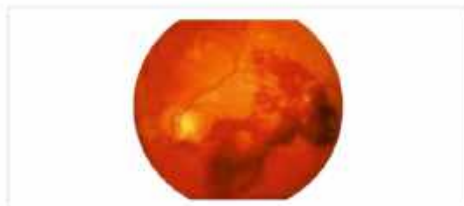
- Asteroid bodies because they appear fixed, but should be examined clinically.



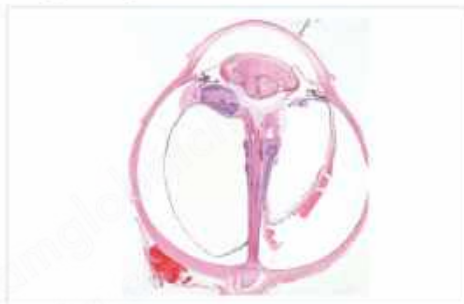
- Hemorrhage in the vitreous.



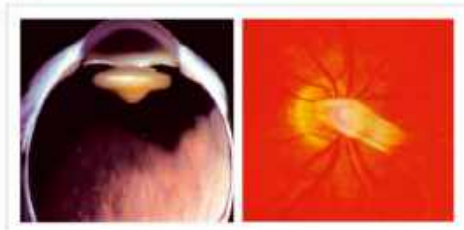
- B scan: The hyper echotic area is the vitreous hemorrhage.



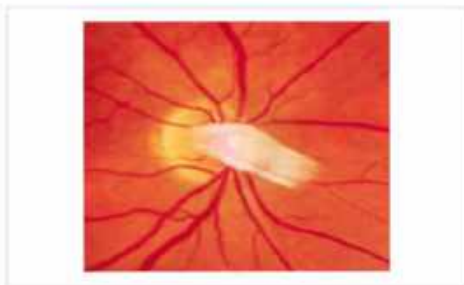- Big hemorrhagic clots in the vitreous.



- PHPV (Persistent Hyperplastic Primary Vitreous)

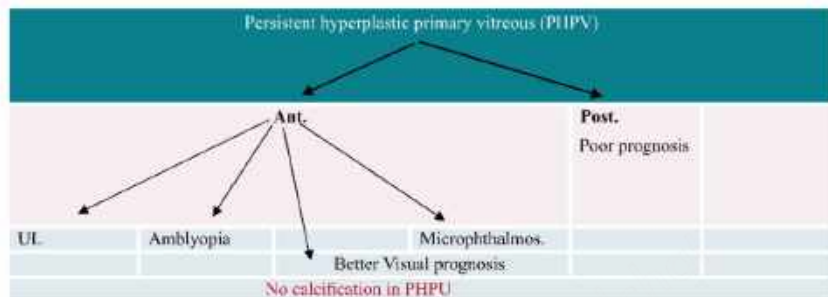


- **Mettendorf dots** and **Bergmiesster Papilla**: Both are remnants of hyaloid tissue.



- **Bergmiesster Papilla**

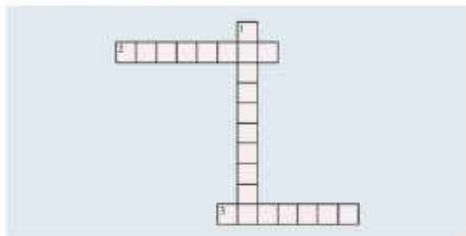
Table 27.1



Telegram: @teamglobal  
 www.Distia.co



## Crossword Puzzle 1




### Cross

1. Ligaments are in the tertiary vitreous.

### Down

2. Can be primary, secondary, or tertiary.
3. Tissue includes hyaloid blood vessels along with.

## Crossword Puzzle 2



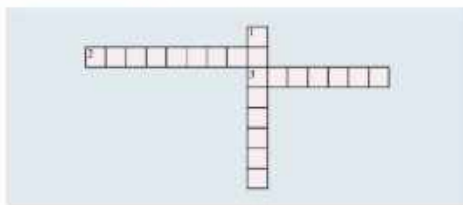
### Cross

2. Part is the anterior hyaloid membrane just behind the lens.

### Down

1. Canal is the remnant of the primary vitreous after regression
3. Serrata is the periphery.

## Crossword Puzzle 3



### Cross

1. Bodies may also be associated with hypermetropia and NOT with myopia.

### Down

2. Scintillans are cholesterol bodies generally seen in end-stage disease and are free-filling
3. Dust are the pigments seen due to the retinal break.



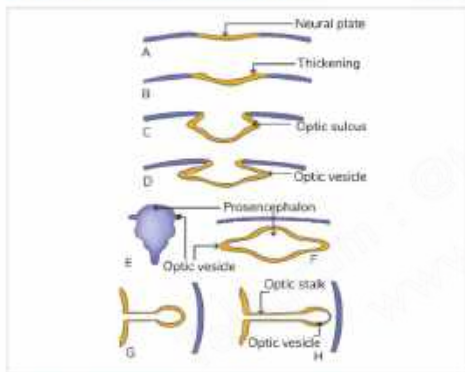
**Embryology of the eye**

06:06:19

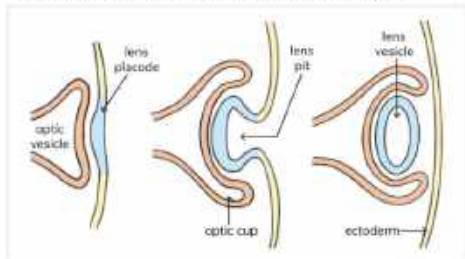
- Eye develops from the forebrain (prosencephalon).
- The development of eye starts at the 22<sup>nd</sup> day of gestation.
- PAX 6 gene plays an important role in the development of the eye.
- Any problem in PAX 6 gene leads to disorders of Anophthalmia (eyes not formed) and Microphthalmia (small eye less than 21 millimeters of axial length).
- Or in microphthalmia, eye size is less than 19 millimeters of axial length at one year of age.

**The main process of formation of the eye**

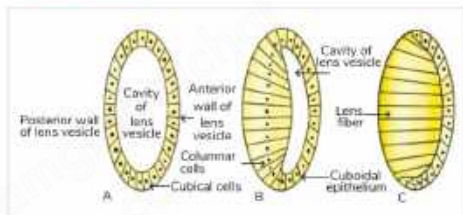
00:02:19



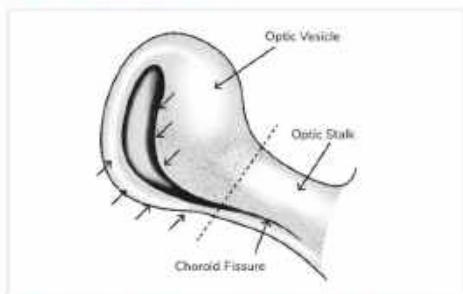
- It starts with the thickening of the neural plate.
- When this plate starts thickening it forms the optic sulcus, and later the optic vesicle.
- Slowly optic vesicle will form an optic stalk.
- Outside the wall of the forebrain is the surface ectoderm, the optic vesicle touches the surface ectoderm and the thickening of the part is called the **early lens placode**.
- Lens placode and optic vesicle slowly invaginate to form a lens pit, and the optic vesicle becomes the optical cup.



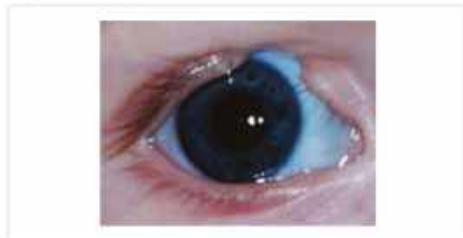- And this finally invaginates to form a lens vesicle from where the lens is formed.
- Hence though lens is an internal structure, it is derived from surface ectoderm. Initially, lens have both anterior and posterior epithelium cuboidal cells
- Slowly Posterior wall of the lens vesicle forms columnar cells and then change into lens fiber.
- Therefore, an adult lens has got a single layer of anterior epithelial cells.

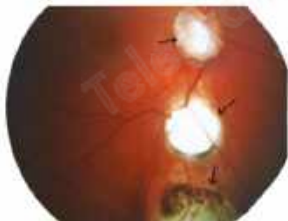
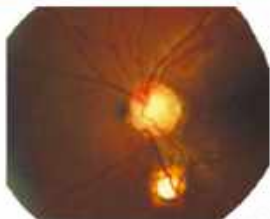
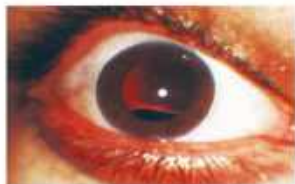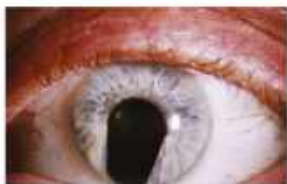- Optic stalk has got a gap and this gap is called a choroidal fissure, the ideal time for closure of a choroidal fissure is the 6<sup>th</sup> to 7<sup>th</sup> week of gestation.



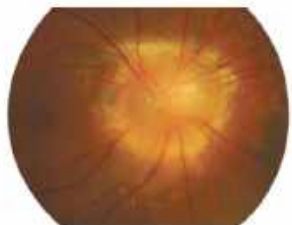- Any failure in the closure of the choroidal fissure leads to a form of coloboma. (absence of that structure). Different type of colobomas



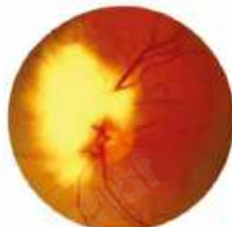

### Morning Glory Syndrome

- One of the colobomas is morning glory syndrome, which is the **dysplastic coloboma of the disc**. It occurs due to either incomplete closure of the choroidal fissure or some mesenchymal changes.

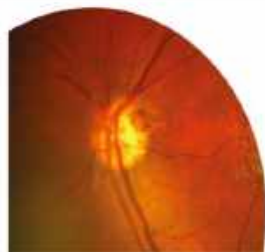

- This disc looks like funnel-shaped excavation of the disc blood vessels looks like spoke of wheel which resembles the flower i.e., **morning glory flower** therefore it is called **morning glory syndrome**.
- Atrophic changes around the disc and peripapillary chorio retinal pigmentary changes are seen.



Myelination of nerve fibers

- Myelination of the optic nerve starts with the lateral geniculate body till lamina cribrosa. Any defect in lamina cribrosa will lead to this myelination visible and this is myelinated nerve fiber. **Which is one of the causes of the enlargement of blind spots.**
- Myelination of the optic nerve starts at 7<sup>th</sup> month of IUL and just completed after birth.



- Optic nerve hypoplasia is a condition in which the size of the disc is small, and there are some peripapillary changes generally called as a **double ring sign**. And there will be a **small blind spot**. Steroids during pregnancy will cause optic nerve hypoplasia.

### Structures derived from Surface Ectoderm

06/1/22

SLLEEK (mnemonic)

- Skin of eyelids and appendages
- Lens
- Lacrimal gland
- Epithelium of the cornea
- Epithelium of conjunctiva

### Structures derived from neuroectoderm

0013:06

#### STORME (mnemonic)

- Secondary vitreous
- Tertiary vitreous
- Optic nerve
- Retina
- Smooth muscles of the iris (iris sphincter and dilator pupillae)
- Epithelium lining of iris and ciliary body

### Structures derived from mesoderm

0013:27

#### PSME (mnemonic)

- Primary vitreous (hyaloid tissue)
- Sclera-temporal part of sclera
- Extra ocular muscles
- Endothelial lining of the blood vessels

### Neural Crest

0014:38

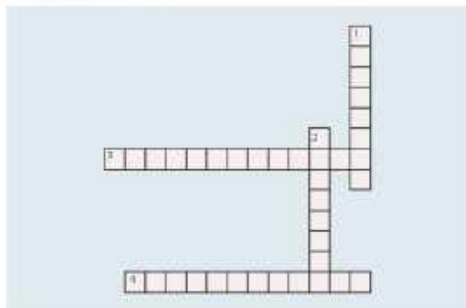
**Neural Part-** Myelin sheath (derived from oligodendrocytes) and ciliary ganglion

**Mesenchymal Part-** All coverings

- All Sclera-except the temporal part
- Choroid
- Corneal stroma
- Corneal endothelium
- Ciliary muscles
- Trabecular meshwork
- Stroma of ciliary body and iris
- Orbital bones



## Crossword Puzzle 1



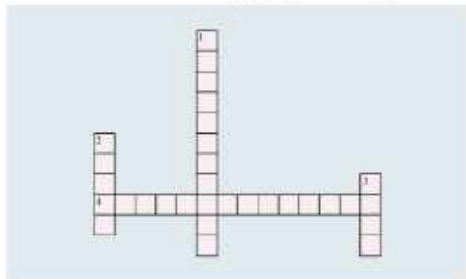
### Across

- Retina is derived from \_\_\_\_\_
- \_\_\_\_\_ is the condition in which eyes are not formed

### Down

- Any failure in the closure of the choroidal fissure leads to a form of \_\_\_\_\_
- Primary vitreous is derived from \_\_\_\_\_

## Crossword Puzzle 2



### Across

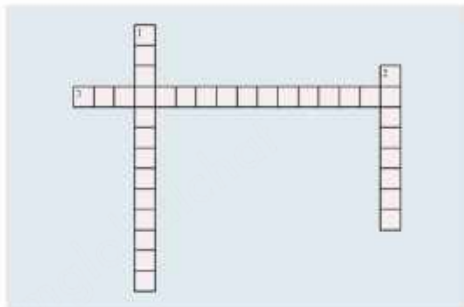
- Myelination of the optic nerve starts with the lateral geniculate body till \_\_\_\_\_

### Down

- Formation of the eye starts with the thickening of \_\_\_\_\_
- Optical nerve hypoplasia is a condition in which the size of the disc is \_\_\_\_\_

- \_\_\_\_\_ gene plays important role in the development of the eye

## Crossword Puzzle 3



### Across

- Optic stalk has got a gap and this gap is called \_\_\_\_\_

### Down

- Optic nerve is derived from \_\_\_\_\_
- Temporal parts of sclera are derived from \_\_\_\_\_

**Important Questions**

00:00:34

**Q.** Most common cause of blindness in India?**Ans:** Cataract**Q.** Most common cause of preventable blindness in India?**Ans:** Cataract > Trachoma**Q.** Most common cause of childhood blindness in India?**Ans:** Vitamin A deficiency**Q.** Second most common cause of blindness in India?**Ans:** Refractive error**Q.** Most common cause of ocular morbidity in India?**Ans:** Refractive error**Q.** Most common cause of blindness in world?**Ans:** Cataract**Q.** Most common cause of blindness in developed country?**Ans:** Glaucoma > ARMD (Age-Related Macular Degeneration)**Blindness**

00:00:28

- According to WHO, it is best corrected visual acuity (BCVA) in better eye less than equal to 3 by 60 (3/60) or visual field in the better eye of less than 10 degrees
- NPCB - VI (National program for control of blindness and visual impairment)
  - Initially, according to NCPB it was defined as best corrected visual acuity (BCVA) in better eye less than equal to 6 by 60 (6/60).
  - From 2017, criteria had changed because if the criteria for visual acuity is 6/60 then the number of blind people reported in India was too much so the criteria is changed according to WHO. Therefore it is defined as, best available or presenting visual acuity in the better eye less than equal to 3 by 60 (3/60) or visual field in the better eye of less than 10 degrees

**Q.** What is the prevalence of blindness in India?**Ans:** 0.36% (earlier-1%)**Q.** What is the incidence of cataract in India?**Ans:** 62.6%**School Screening Programme**

- Who check the visual acuity/ who perform the eye tests?
- School teachers
- What is the cut-off limit when the teacher refer the child to ophthalmologist?
- Ask the teacher to refer if the child is unable to read the last two lines i.e., any vision of < 6/9.

**Trachoma**

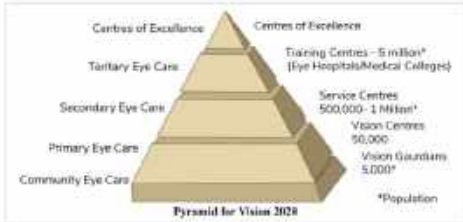00:00:49

- SAFE Strategy: WHO programme to control trachoma in a community.
  - Surgery: Trichiasis surgery > Entropion
  - Antibiotics : Oral azithromycin > topical tetracycline 1% ointment
    - Azithromycin: 1gm in adults
    - 20mg/kg in children
  - Facial hygiene
  - Environmental changes
- Criteria for SAFE strategy:
  - Prevalance of trachoma follicles
    - >10% : start SAFE strategy
    - 5% - 10% : Follow facial hygiene and environmental changes
    - <5%: Nothing is done

**Vision 2020**

00:11:50

- WHO programme to control 5 diseases:
  1. Cataract
  2. Trachoma
  3. Refractive errors
  4. Childhood blindness
  5. Onchocerciasis
- Human resource development
- Infrastructure development
- Onchocerciasis was not found in india. So, VISION 2020 in India was to eradicate the following 7 diseases:
  1. Cataract
  2. Trachoma
  3. Refractive errors
  4. Childhood blindness
  5. Glaucoma
  6. Corneal blindness
  7. Diabetic retinopathy



**Q.** What is the ratio of the ophthalmologist: Population according to the vision 2020?

**Ans.** 1:50,000

**Q.** What is the ratio of secondary service centre: Population?

**Ans.** 1:5 lakh

Telegram : @teamglobalchat  
www.Distia.co