



CONTENTS

CELL INJURY	1
Introduction to cell injury	1
Reversible cell injury	3
Irreversible cell injury	4
Types of necrosis	5
Apoptosis	8
Pyroptosis	11
Necroptosis	12
Free radical injury	12
cell Adaptation	13
pigmentation	17
INFLAMMATION	20
Introduction to inflammation & vascular changes	20
Intra vascular cellular changes	22
Extra vascular cellular changes	24
Oxygen dependent bacterial killing	25
oxygen independent killing & Neutrophil Extracellular trap	27
Preformed chemical mediators	27
Freshly formed mediators : Nitric oxide	29
Arachidonic acid metabolites	29
cytokines	31
chemical mediators in plasma : Kinin system	33
clotting system	34
chronic inflammation	38
wound healing	40
IMMUNITY 1	41
Introduction to immunity	41
B cell	42
T cell	44
NK cell	45
Immune system activation - Basic concepts	46
major histocompatibility complex	48
Hypersensitivity Reactions : type I	49
Type II HR	50
Type III HR	52
Type IV HR	52
IMMUNITY 2	54
Tolerance	54
Auto immune disorders introduction	55
SLE	56
Other autoimmune disorders	58
organ transplant/ graft	61
Graft vs Host disease	63
Immuno deficiency disorders	63



Medicalstudyzone.com



Medicalstudyzone.com

This PDF was created and uploaded by www.medicalstudyzone.com which is one the biggest free resources platform for medical students and healthcare professionals. You can access all medical Video Lectures, Books in PDF Format or kindle Edition, Paid Medical Apps and Softwares, Qbanks, Audio Lectures And Much More Absolutely for Free By visiting our Website <https://medicalstudyzone.com> all stuff are free with no cost at all.

Furthermore You can also request a specific Book In PDF Format OR Medical Video Lectures.

Amyloidosis	67
GENETICS	71
Introduction	71
Specific cytogenic disorders	74
single gene disorders	77
Non classical inheritance disorders	79
HEMATOLOGY : RED BLOOD CELLS	82
Hematopoiesis : Basic concepts	82
RBC Development & classification of Anemias	83
Iron Deficiency Anemia	86
Anemia of chronic disease	88
sideroblastic anemia	89
megaloblastic anemia	90
Summary table of microcytic hypochromic anemia	90
Hemolytic anemias : Basic concepts & classification	93
Hereditary spherocytosis	94
G6PD Deficiency	96
Hemoglobinopathies : sickle cell anemia	97
Beta thalassemia	101
Alpha thalassemia	105
paroxysmal Nocturnal Hemoglobinuria	106
Auto immune hemolytic anemia	108
Aplastic Anemia	110
HEMATOLOGY : WHITE BLOOD CELLS	112
Introduction to WBC disorders	112
Acute lymphoblastic leukemia	114
chronic lymphocytic leukemia	117
Acute myelogenous leukemia	119
chronic myelogenous leukemia	121
myeloproliferative disorders	123
Hodgkin's Lymphoma	125
myelodysplastic syndrome	128
Non - hodgkin lymphoma	129
Plasma cell disorders	132
multiple myeloma	134
Waldenstrom's disease & heavy chain disorders	137
PLATELETS & BLOOD TRANSFUSION	138
concepts of bleeding disorders	138
Introduction to platelet disorders	139
ITP	139
clotting factor disorders [hemophilias] & concept of factor inhibitors	143
HUS ; TTP	140
von willebrand Disease	145

DIC	141
Angiopathic Hemolytic anemia : Basic concepts	142
Blood transfusion	146
Blood grouping	149
GASTROINTESTINAL TRACT 152	
Introduction	152
Infantile Hypertrophic pyloric Stenosis	152
Hirschsprung disease	153
Esophagus applied anatomy : GERD	154
Alcohol induced Esophageal Disorders	156
Esophageal fistula	155
Achalasia cardia	156
Inflammatory Bowel Disease	166
Esophageal cancer	157
Stomach	158
Acute chronic gastritis	158
Peptic ulcer disease	159
Gastric tumors	161
Small intestine malabsorption disorders	163
carcinoid tumor	165
Intestinal polyps, colon & anal cancer	168
t.me/latestpgnotes	
RESPIRATORY SYSTEM 171	
Introduction	171
obstructive Lung Disease	172
Restrictive Lung disease	176
Infectious Lung Disease : pneumonia	179
Pulmonary tuberculosis & Lung abscess	181
Pulmonary HTN	183
Respiratory Distress Syndrome	184
Sarcoidosis	185
Lung tumor	187
mesothelioma & other pleural tumors	190
BREAST 193	
Introduction to Breast disorders	193
Basic concepts in Breast cancers & insitu breast cancer	197
Infiltrating Breast cancer	200
BONE DISORDERS 203	
Introduction to bone disorders	203
Specific individual tumors	204
Giant cell tumor	205
Chondrosarcoma	206
Ewing Sarcoma	208

NEOPLASIA	210
General concepts	210
Genetic basis of carcinogenesis 1	214
Genetic basis of carcinogenesis 2	218
Etiological factors of neoplasia	222
Diagnosis of tumors	225
paraneoplastic syndrome	227
CVS, BLOOD VESSELS & VASCULITIS	230
vasculitis	230
Angina	234
myocardial Infarction	235
chronic Ischemic Heart Disease	238
Rheumatic fever	238
Infective Endocarditis	240
cardiac tumors	242
KIDNEY & URINARY BLADDER	243
Basic concepts	243
Adult polycystic kidney	244
childhood polycystic kidney	245
medullary cystic kidney	246
medullary sponge kidney	246
Ectopic kidney	246
Horseshoe kidney	247
Nephritic syndrome	247
RPGN & Bergers Disease	248
membranous glomerulopathy	250
Anti-GBM Disorders	252
Nephrotic syndrome - Basic concepts	253
minimal change Disease	254
focal segmental Glomerulosclerosis	254
systemic disorders affecting glomerulus	255
Renal tumors : Renal cell carcinoma	256
Wilms tumor	258
Acquired cystic disease	259
Renal agenesis	259
LIVER, BILIARY SYSTEM & PANCREAS	260
Bilirubin metabolism	260
Cirrhosis	262
Tumors	267
CENTRAL NERVOUS SYSTEM	270
CNS Tumors	274
General Introduction	270
Neurodegenerative Disorders	270

GENITAL SYSTEM	278
Male genital tract : cryptorchidism & orchitis	278
Testicular tumors	278
prostate	281
Female genital tract : cervix	283
uterus	285
Ovaries	287

ENDOCRINOLOGY	292
Basic concepts	292
Thyroiditis	293
parathyroid	299
Hyperthyroidism & goitre	294
Thyroid tumor	297
Adrenal Gland	302

t.me/latestpgnotes

INTRODUCTION

CELL INJURY

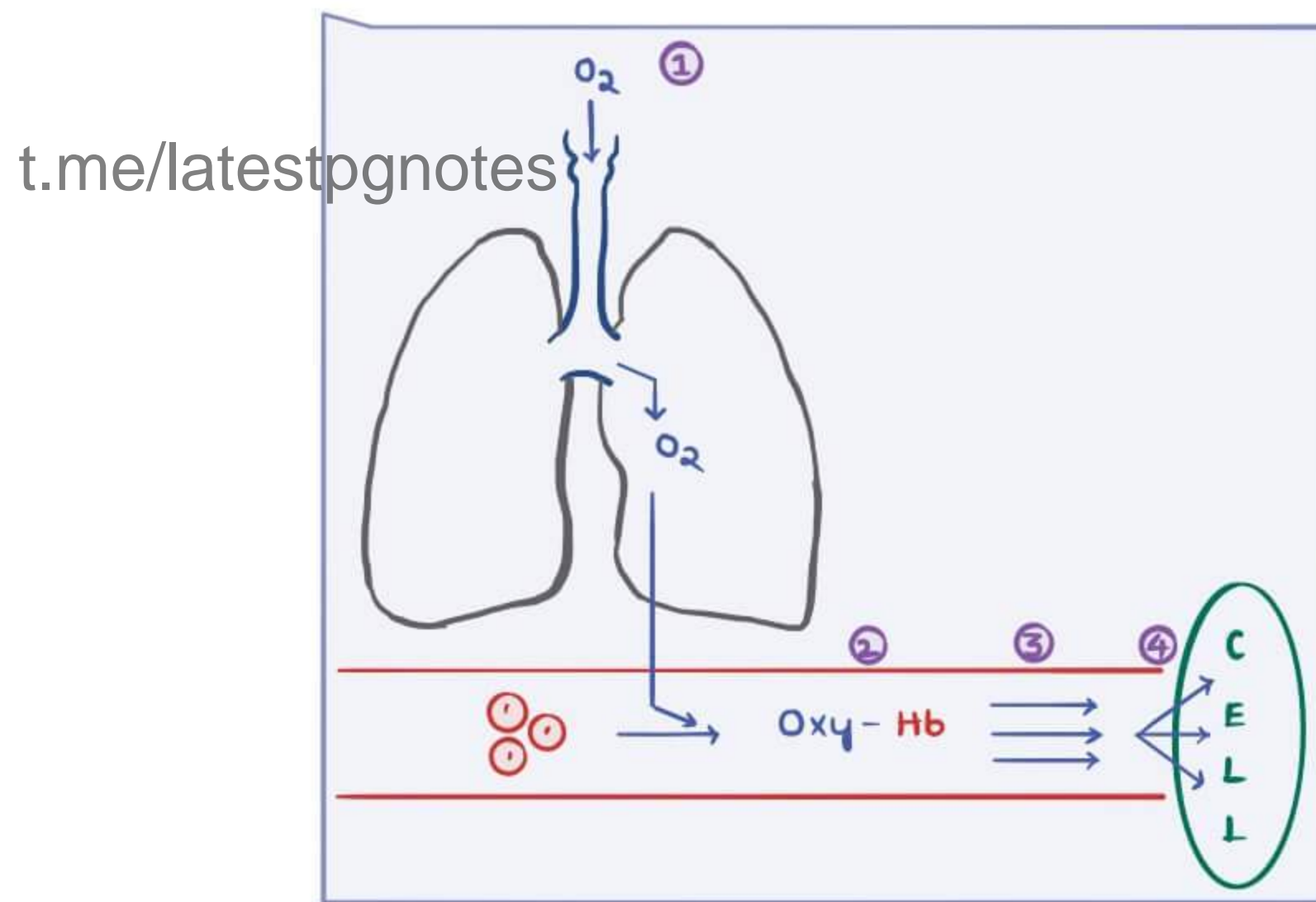
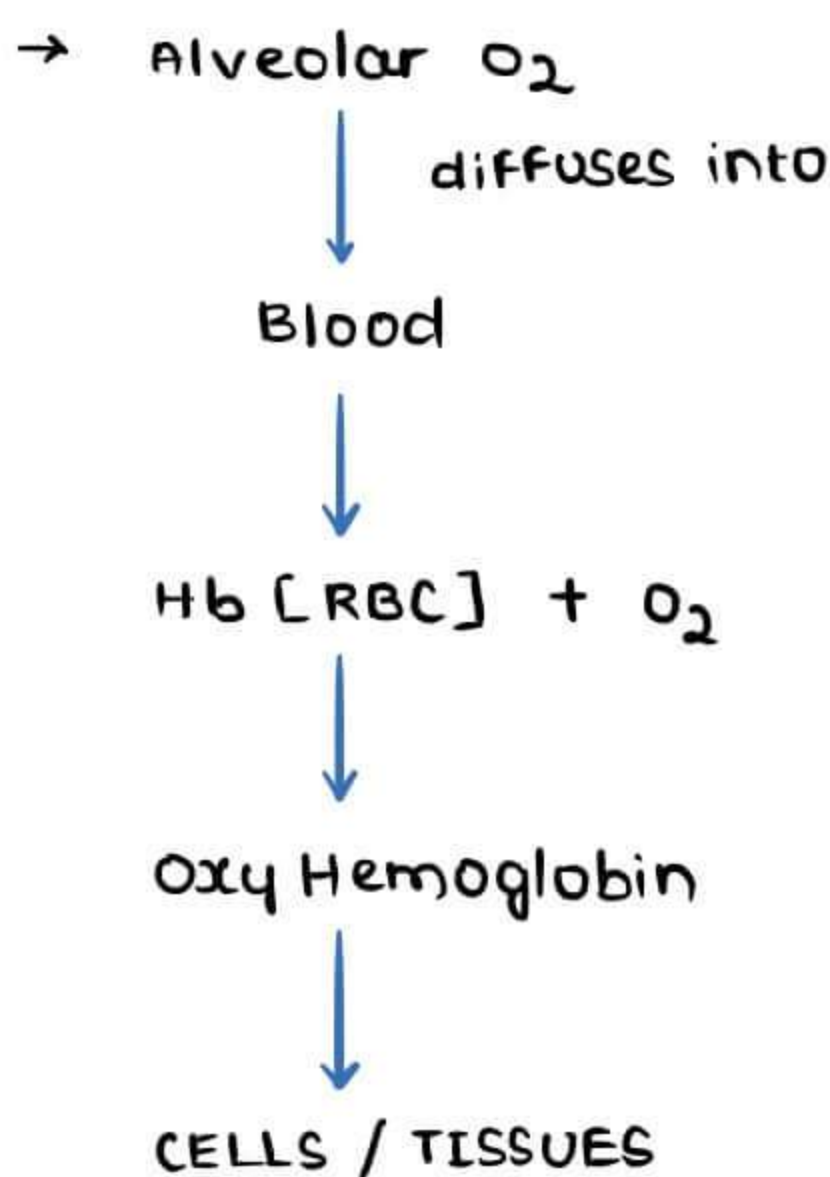
- disease taking place in the human body at microscopic level
- because tissues are not functioning normally
 - ↳ dit cell damage or not able to functⁿ properly

CAUSES OF CELL INJURY

1. PHYSICAL FACTOR
 - Eg: Temperature
 - ↳ too high temperature → burn injury
 - ↳ less than normal → sub zero temperature [frostbite]
2. EXPOSURE TO CHEMICALS
3. EXPOSURE TO INFECTIONS
4. GENETIC FACTORS

HYPOXIA

- mc cause of cell injury
- Hypo → Less } cell having less O₂ for utilizatⁿ
- oxia → Oxygen }



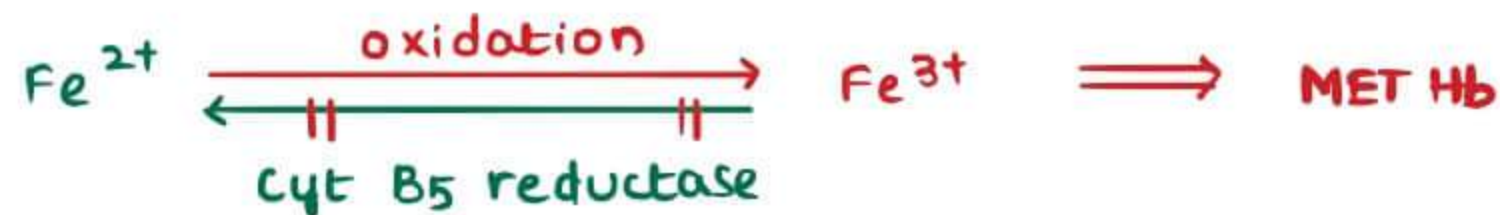
4 COMMON CAUSES OF HYPOXIA ['HASH' - mnemonic]

1. Hypoxic Hypoxia

- High altitudes
- COPD
- ILD [Interstitial Lung Disease]
- Right → Left shunt

2. Anemic Hypoxia

- dit ↓ functional Hb
 - Anemia
 - Altered Hb
 - ↳ CO poisoning → CO-Hb → Headache, Cherry-red color + nt
 - ↳ Met Hb



- Met Hb a/w NEWBORN on exposure to DRUGS like Nitrite, Sulfonamides & local anesthetics
- Met Hb also a/w \bar{c} individuals \bar{c} cytochrome B5 reductase deficiency
- Rx by IV Methylene Blue [Reducing agent]

3. Stagnant Hypoxia

- Ischemia [arterial obstructⁿ] - more common cause of stagnant hypoxia
- congestⁿ [venous obstructⁿ]

4. Histotoxic hypoxia

- cytochrome \leftarrow cyanide
 - a/w IV Nitroprusside longterm usage
 - cyanide poisoning a/w BRICK red discoloration
 - Rx by
 - B₁₂ [methylcobalamine]
 - Amyl nitrate
 - Sodium Thiosulfate

MOST COMMON CAUSE OF HYPOXIA → ISCHEMIA
t.me/latestpgnotes

SEVERITY OF INJURY AFFECTED BY

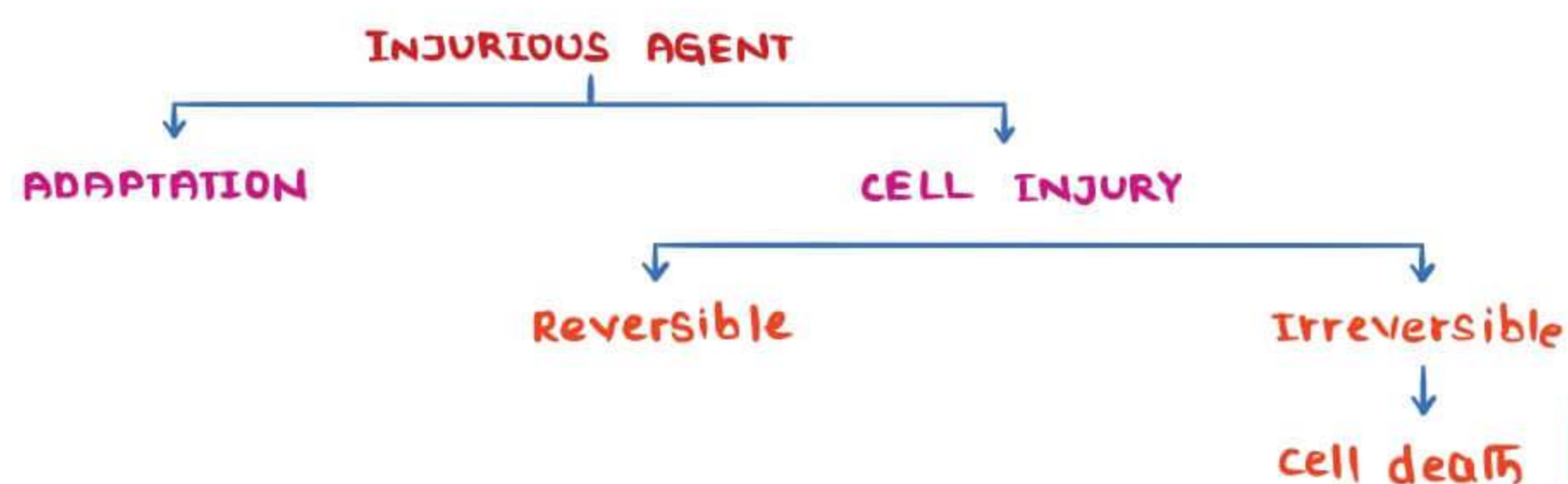
1. Nature of the cell
2. Duration

SENSITIVITY OF CELL IN BODY TO ANY KIND OF INJURY

Neuron [amin] > cardiac fibre [2amin] > skeletal muscle fibre > Fibroblast
 [most sensitive] [most resistant]

3. ORGANS [specific Areas more susceptible to ischemic damage]

- a. CNS
 - Purkinje cells in cerebellum
 - cerebral cortical neurons in layers 3, 5 & 6
- b. CARDIAC TISSUE → sub endocardial area
- c. GIT → Splenic flexure



REVERSIBLE CELL INJURY

↓ O₂ → mitochondria affected → ↓ ATP → AFFECTS

1. cell membrane
2. ER
3. Misc. changes

1. CELL MEMBRANE

↓ ATP → ↓ Na⁺ K⁺ Pump activity [↑ Na⁺ inside the cell]

↓

↑ water inside

↓

* CELLULAR SWELLING / HYDROPIIC CHANGE [1^o microscopic feature]

* BLEB FORMATION

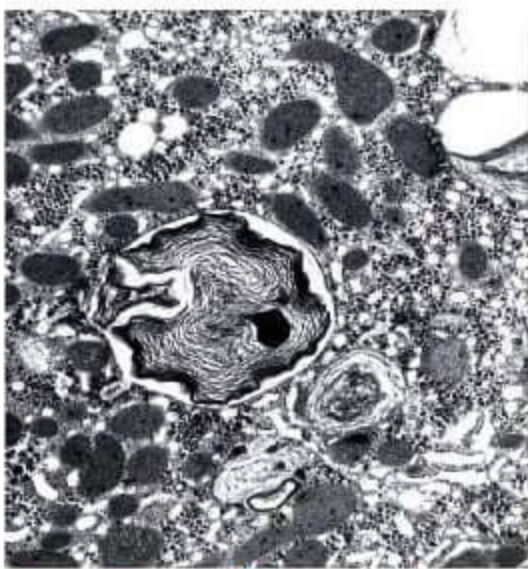
* LOSS OF MICROVILLI

* MYELIN FIGURES

↳ small & spiral fragments derived either from cell membrane or membrane of organelles

↳ made up of phospholipids [dit denaturatⁿ of PL]

↳ intracellular usually, can be seen extracellularly too



myeline figure

2. ER [ENDOPLASMIC RETICULUM] [particulary rough Endoplasmic Reticulum]

↓ ATP → Ribosomes break away → ↓ Protein Synthesis
 ↳ misfolded proteins accumulation

3. MISC. CHANGES

↓ O₂ → ↑ Glycolysis → ↑ Lactate → ACIDOSIS [↓ PH]

a. NUCLEUS



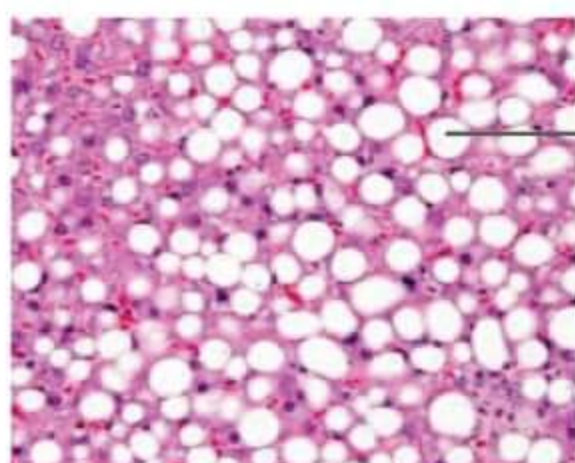
Homogenous appearance
of nucleus

Acidosis →



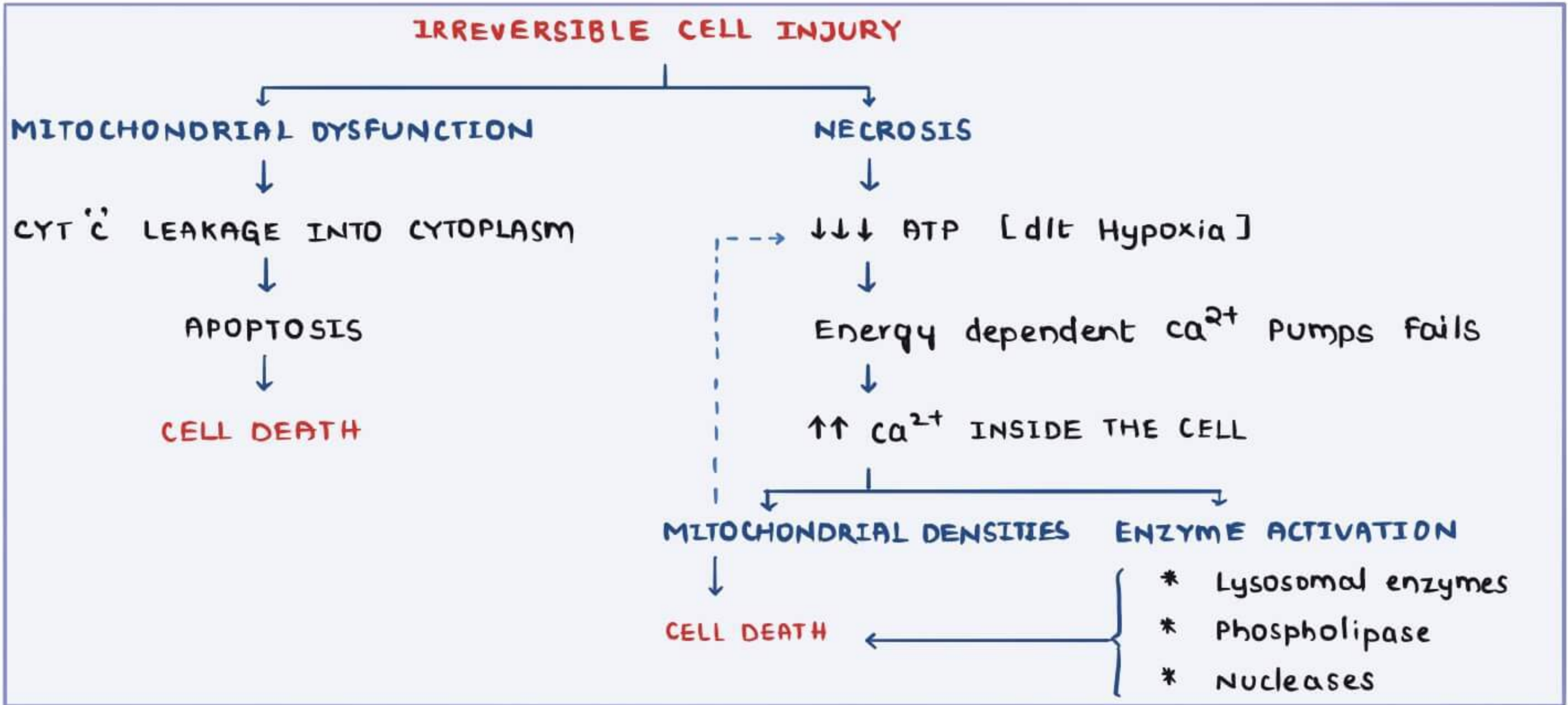
clumping of chromatin
[Patchy depositⁿ of chromatin material]

b. LIVER → FATTY CHANGE



Lipid
droplets

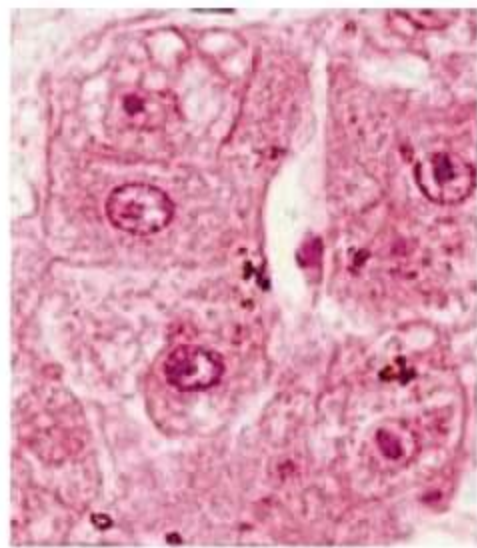
c. MITOCHONDRIAL / AMORPHOUS DENSITIES ← ↑ ca²⁺ accumulatiⁿ in mitochondria ← ↓ ATP



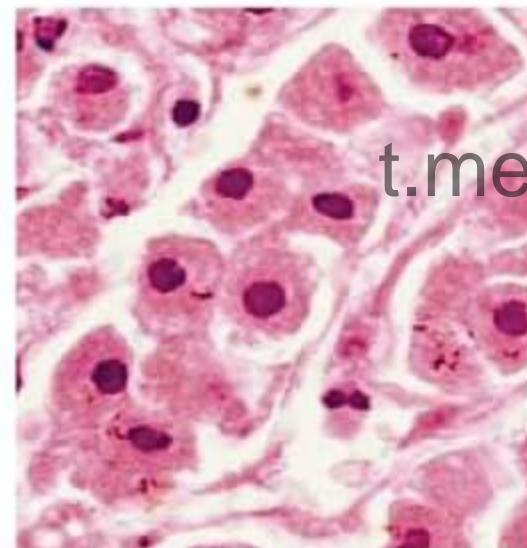
LYSOSOMAL ENZYME ACTIVATION [m.imp] → CELL DEATH

NUCLEASE ACTIVATⁿ  →

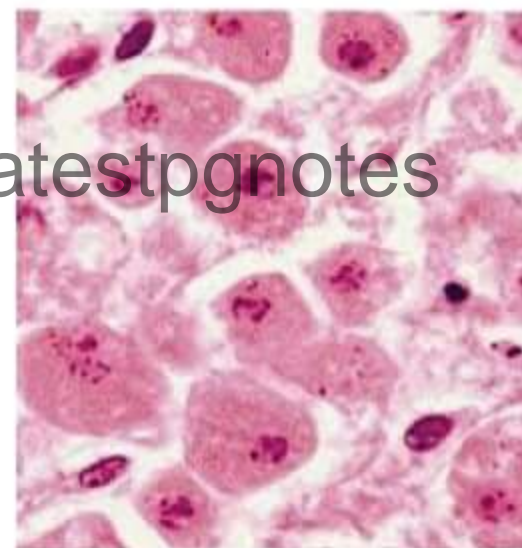
- Pyknosis [ink dot nucleus]
- ⊗ Karyorrhexis [Nuclear fragmentation]
- ⋯ Karyolysis [Total Breakdown of nucleus]



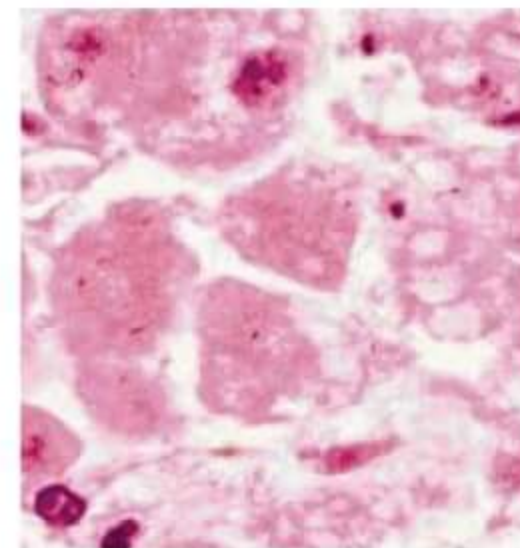
NORMAL



PYKNOSIS

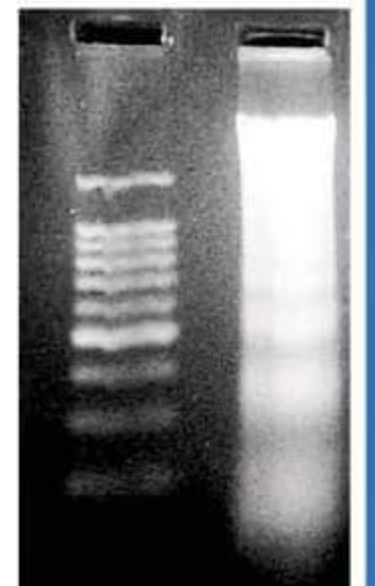


KARYORRHESIS



KARYOLYSIS

t.me/latestpnotes



STEP LADDER PATTERN SMEAR PATTERN

→ ON GEL ELECTROPHORESIS

- ↳ NORMAL NUCLEIC ACIDS → appear as Single band
- ↳ NECROTIC NUCLEIC ACIDS → appear as SMEAR PATTERN
- ↳ APOPTIC NUCLEIC ACIDS → appear as STEP LADDER PATTERN

PHOSPHOLIPASE ACTIVATION → cell membrane damage

Eg: cardiac cell [intracellular enzyme (Troponin)] 

REVERSIBLE CELL INJURY 

- cell becomes bigger
- no membrane damage
- enzymes won't leak out
- enzyme level normal in blood
- Seen in Angina

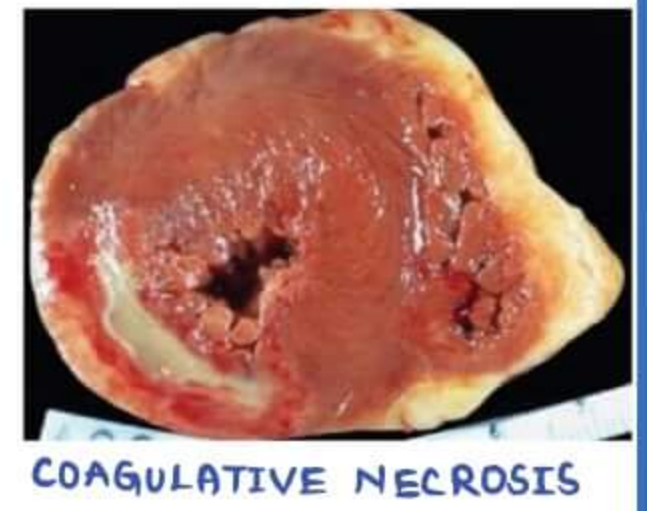IRREVERSIBLE CELL INJURY 

- membrane damage
- enzymes in cardiac cells leaks out
- ↑ enzyme level in blood
- Seen in MI

SUB TYPES

1. COAGULATIVE NECROSIS

- mc subtype of necrosis
- mc cause is ISCHEMIA
- denaturation or inactivation of hydrolytic enzymes
- a/w "TOMBSTONE APPEARANCE"
- commonly a/w ALL ORGANS except CNS
- ZENKER'S DEGENERATION
 - ↳ coagulative necrosis in skeletal muscle
 - ↳ a/w Typhoid

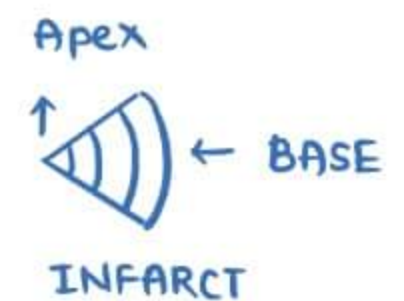



COAGULATIVE NECROSIS

- commonly a/w neutrophilic infiltratⁿ

→ INFARCT

- ↳ localized area formed dlt ischemia
- ↳ usually triangular in shape
- ↳ Apex of infarct pointing the direction of site of obstruction



↳ SUB TYPES

a. WHITE INFARCT

- Seen a/w organs i end arterial blood supply particularly in solid organs
- Eg: Heart, Kidneys

b. RED INFARCT

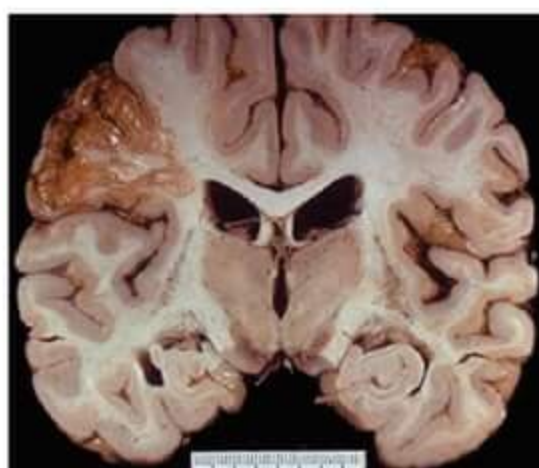- Seen in organs i loose connective tissues
- Seen in organs i dual blood supply like Lungs / Liver

2. LIQUEFACTIVE / COLLIQUATIVE NECROSIS

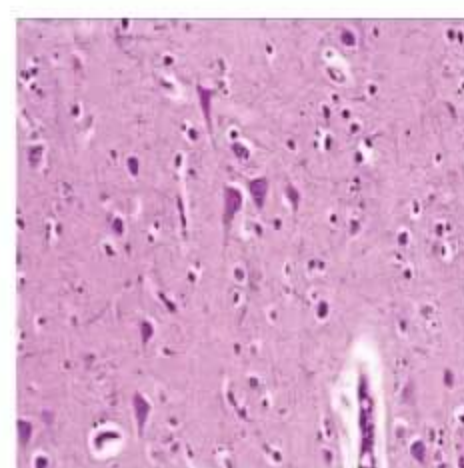
- Hydrolytic Enzymes Activation → Damage to tissue architecture

→ EXAMPLES

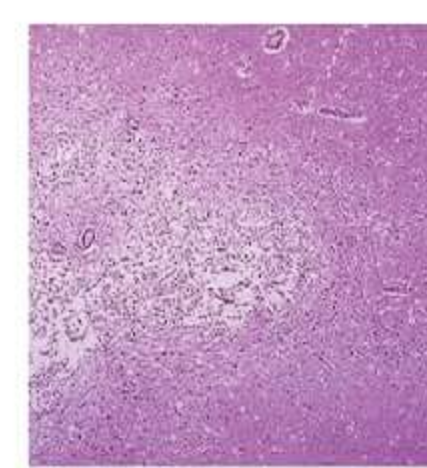
- CNS ISCHEMIA
- INFECTIONS [a/w pus formation] [a/w Staphylococcus aureus infections]



LIQUEFACTIVE NECROSIS



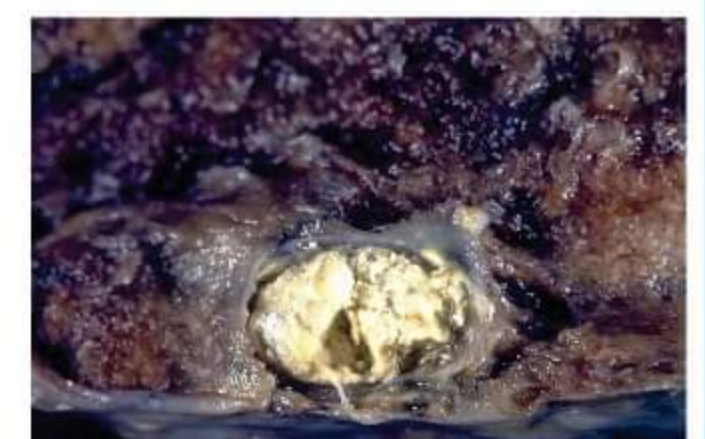NORMAL BRAIN TISSUE



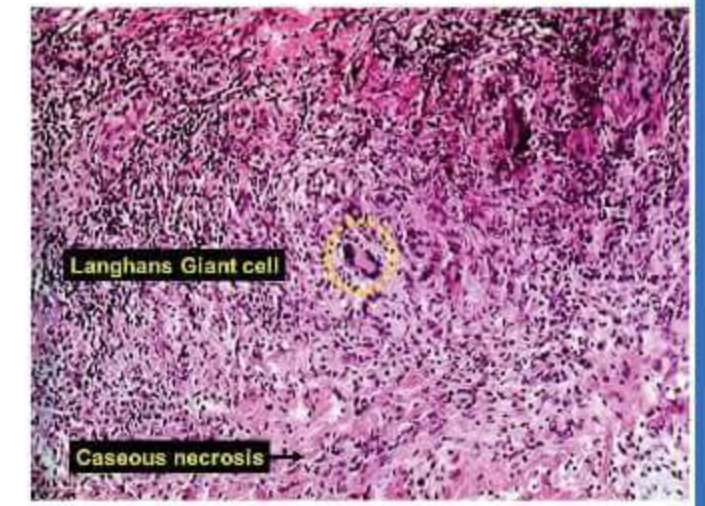
LIQUEFACTIVE NECROSIS

3. CASEOUS NECROSIS

- 'cheese-like' necrotic material
- structural outline not preserved
- coagulative Necrosis + Liquefactive necrosis
- coagulative necrosis is the predominant contributor



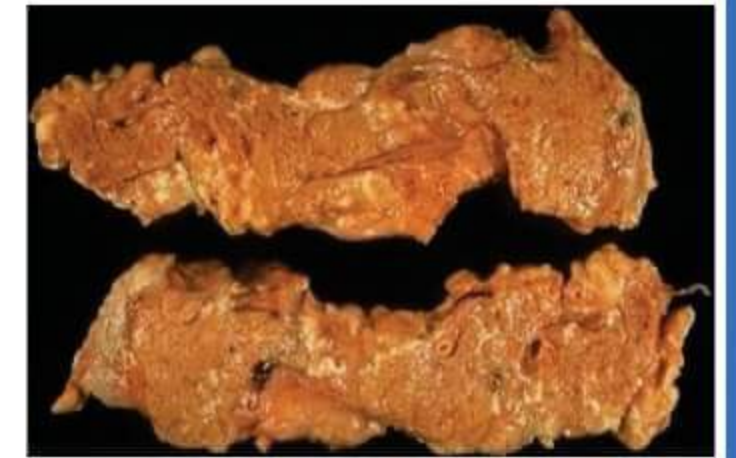- SEEN in a/w
 - ↳ TB
 - ↳ Fungi [Systemic]
 - ↳ Syphilis
- } NON - tubercular causes



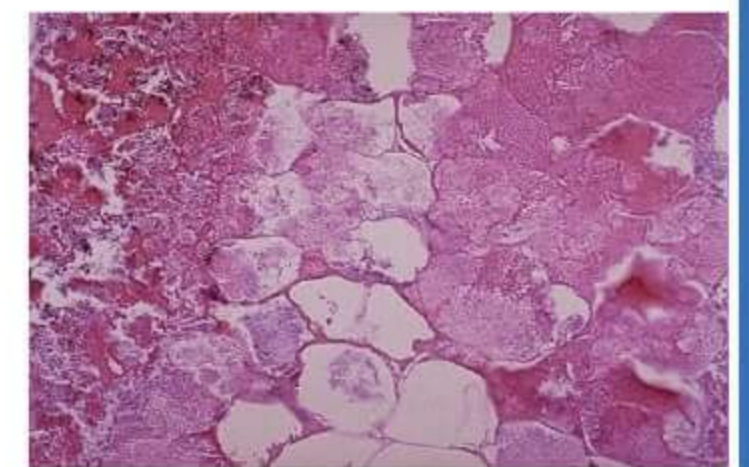
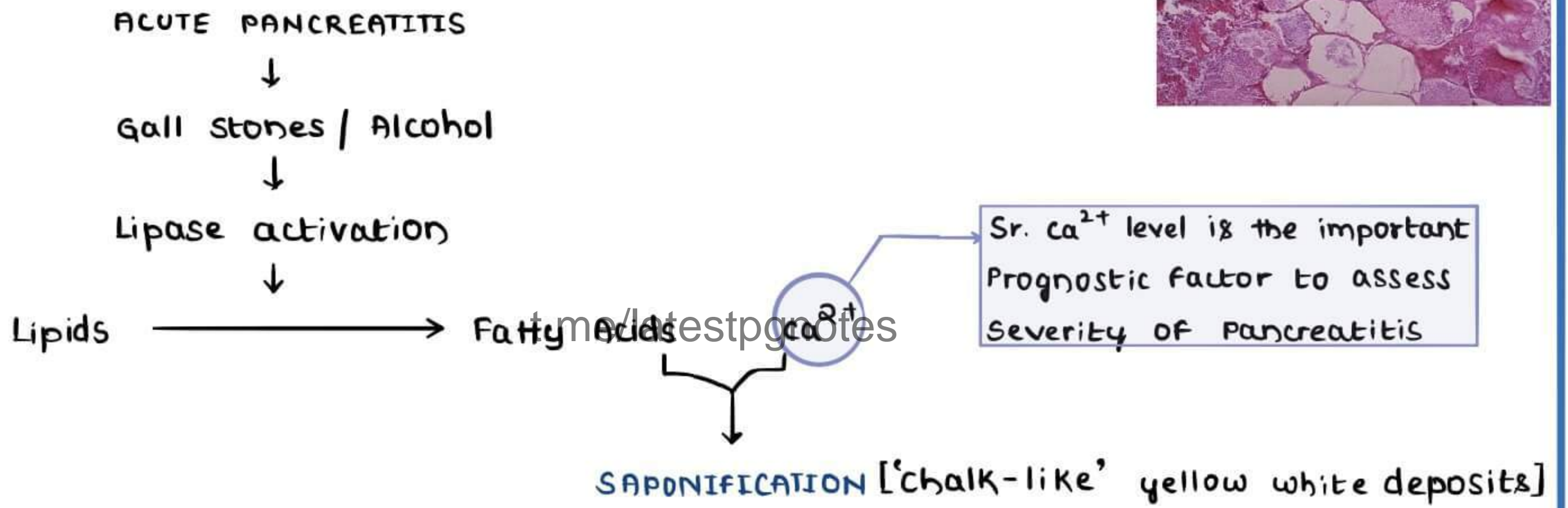
- Granulomatous Reaction + nt
- monocytes & Lymphocyte infiltration seen
- Langerhans Giant cells are a/w Tubercule [TB]

4. FAT NECROSIS

- a/w organs i high Fats or Lipase activation
- SEEN i
 - injury to breast tissue
 - injury to Omentum tissue
 - pancreatitis



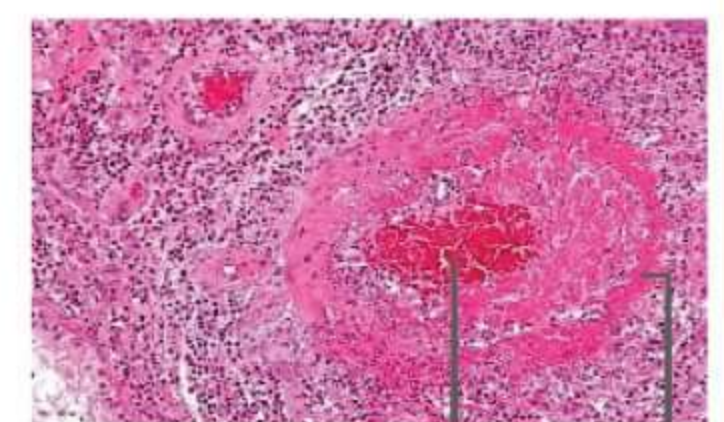
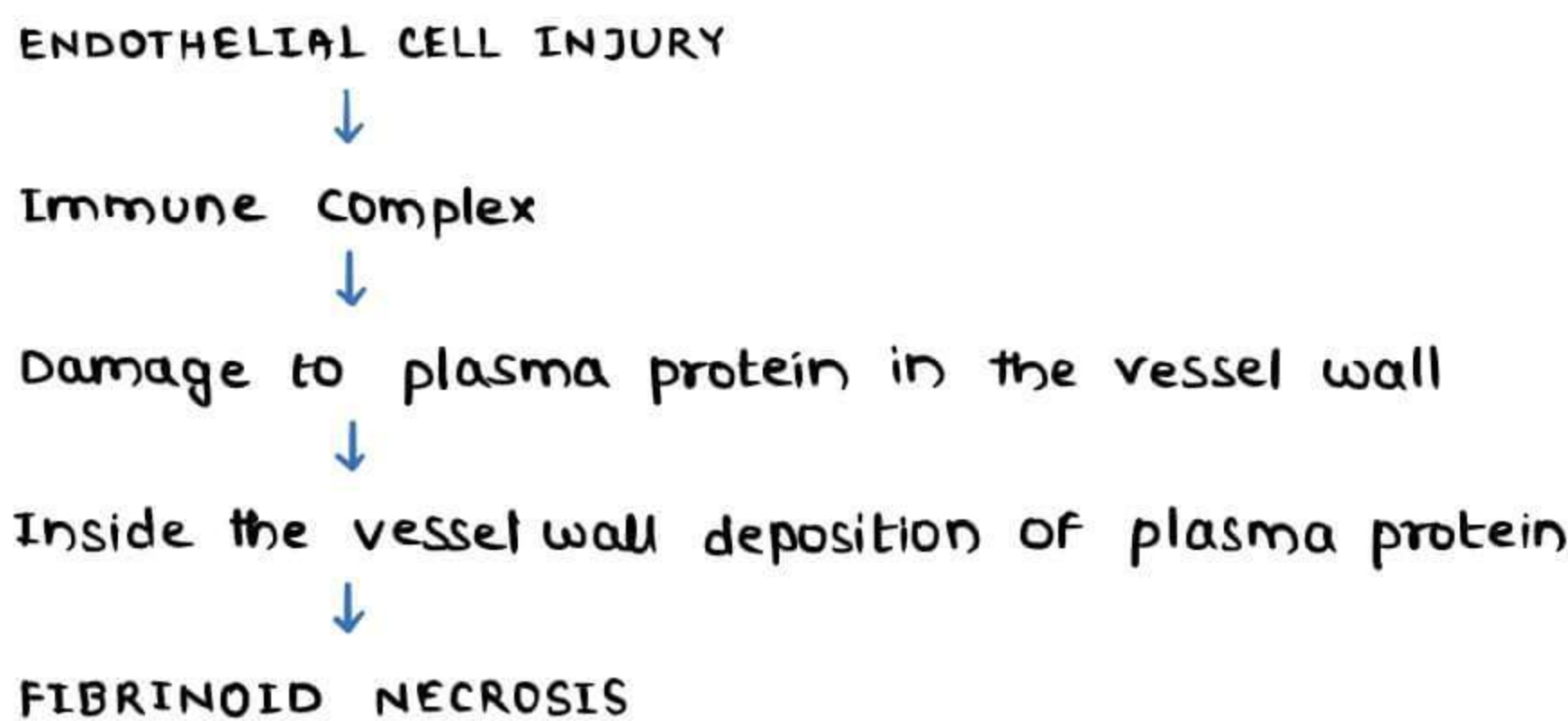
→ EXAMPLE



- In PANCREATITIS, there is involvement of
 - Pancreas → Liquefactive necrosis seen
 - Peri Pancreatic fat → Fat necrosis seen

5. FIBRINOID NECROSIS

→ PATHOGENESIS





Lumen
fibrinoid necrosis

→ SEEN a/w

- Malignant Hypertension
- ASchoff Body
- Immune complex disorders ~ Type 3 hypersensitivity Reaction [PAN/HSP]

GANGRENE

DRY GANGRENE	WET GANGRENE
 <ul style="list-style-type: none">→ Ischemia→ coagulative necrosis	 <ul style="list-style-type: none">→ Ischemia + secondary infectⁿ→ liquefactive necrosis <p>GAS GANGRENE</p> <ul style="list-style-type: none">→ subtype of wet gangrene→ a/w <i>Clostridium welchii</i>

t.me/latestpgnotes

APOPTOSIS

- APOPTOSIS = falling of leaves
- CASPASE DEPENDENT PROGRAMMED CELL DEATH
- controlled by Genes
- Affects Single cell or small group of cells

GENES ASSOCIATED WITH APOPTOSIS

PRO - APOPTOTIC GENES	ANTI - APOPTOTIC GENES	SENSORS
<ul style="list-style-type: none"> → BAK gene → BAX gene → P₅₃ gene [most imp] → corticosteroids → Bcl - X_S → Promotes apoptosis 	<ul style="list-style-type: none"> → Bcl - 2 gene [most imp] → Bcl - X_L gene → Mcl - 1 gene → Sex steroids → inhibits apoptosis 	<ul style="list-style-type: none"> → Bim gene → Bid gene → PUMA gene → NOXA gene → Balances apoptosis

- Bcl - 2 gene a/w Follicular lymphoma
- Mcl - 1 gene a/w development of resistance to chemotherapy
- Bcl - X_S gene

APOPTOSIS AFFECTS SINGLE CELL | SMALL GROUP OF CELLS

NECROSIS AFFECTS LARGE GROUP OF CELLS

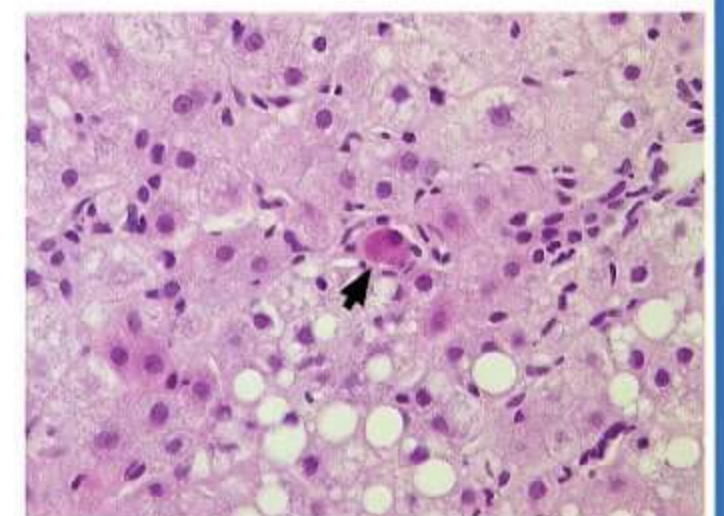
NECROSIS IS ALWAYS PATHOLOGICAL

APOPTOSIS CAN BE EITHER PHYSIOLOGICAL OR PATHOLOGICAL

t.me/latestpgnotes

PHYSIOLOGICAL APOPTOSIS SEEN IN

1. Embryogenesis
2. Females of Reproductive Age group [menstrual cycle]
3. Apoptosis of ↑↑↑ TLC after infection subsides
4. Self Reactive B & T cells



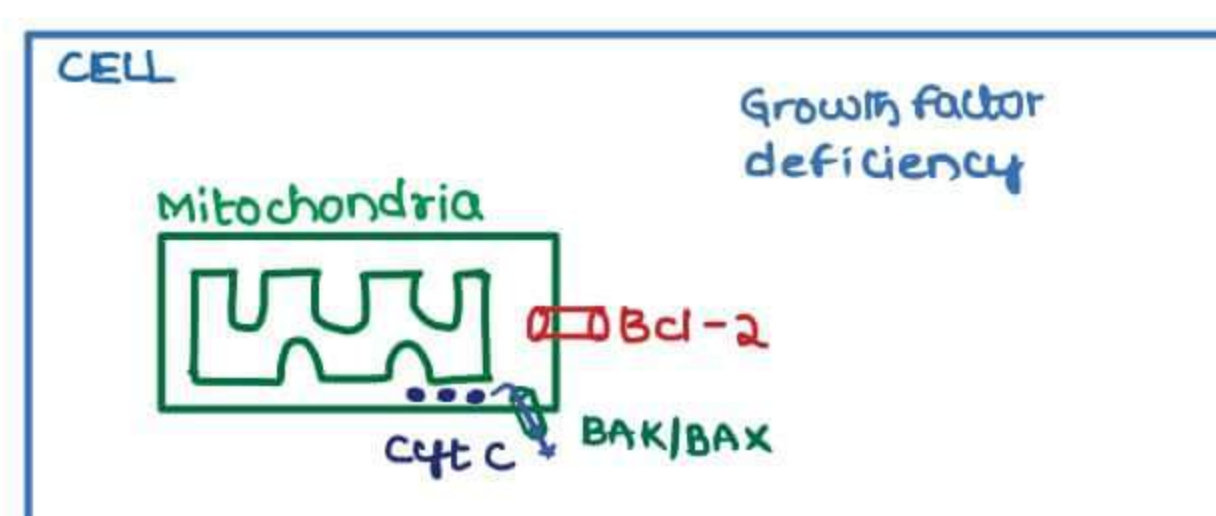
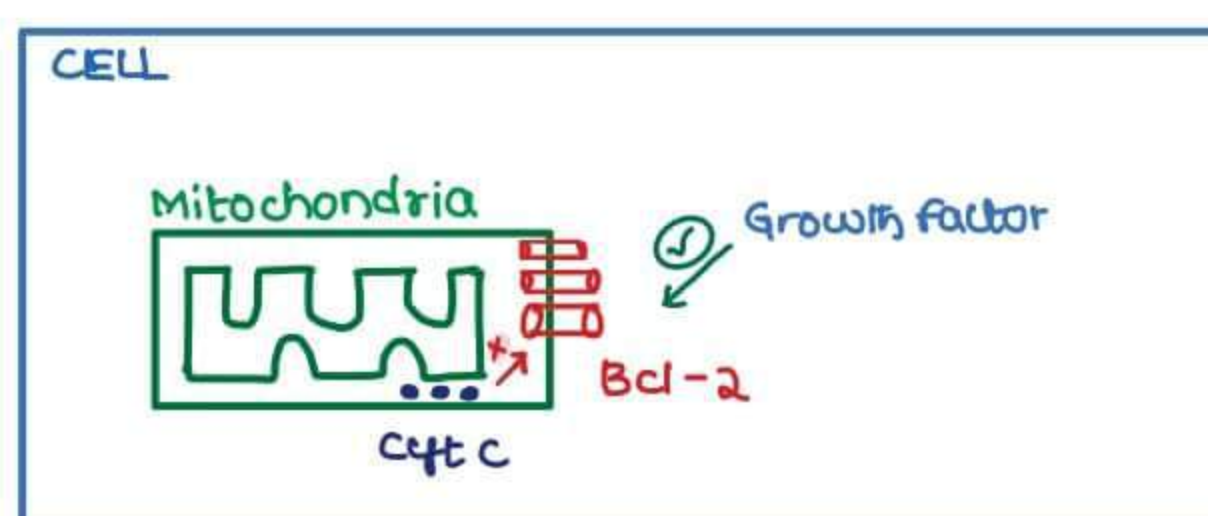
COUNCILMAN / APOPTOTIC BODY

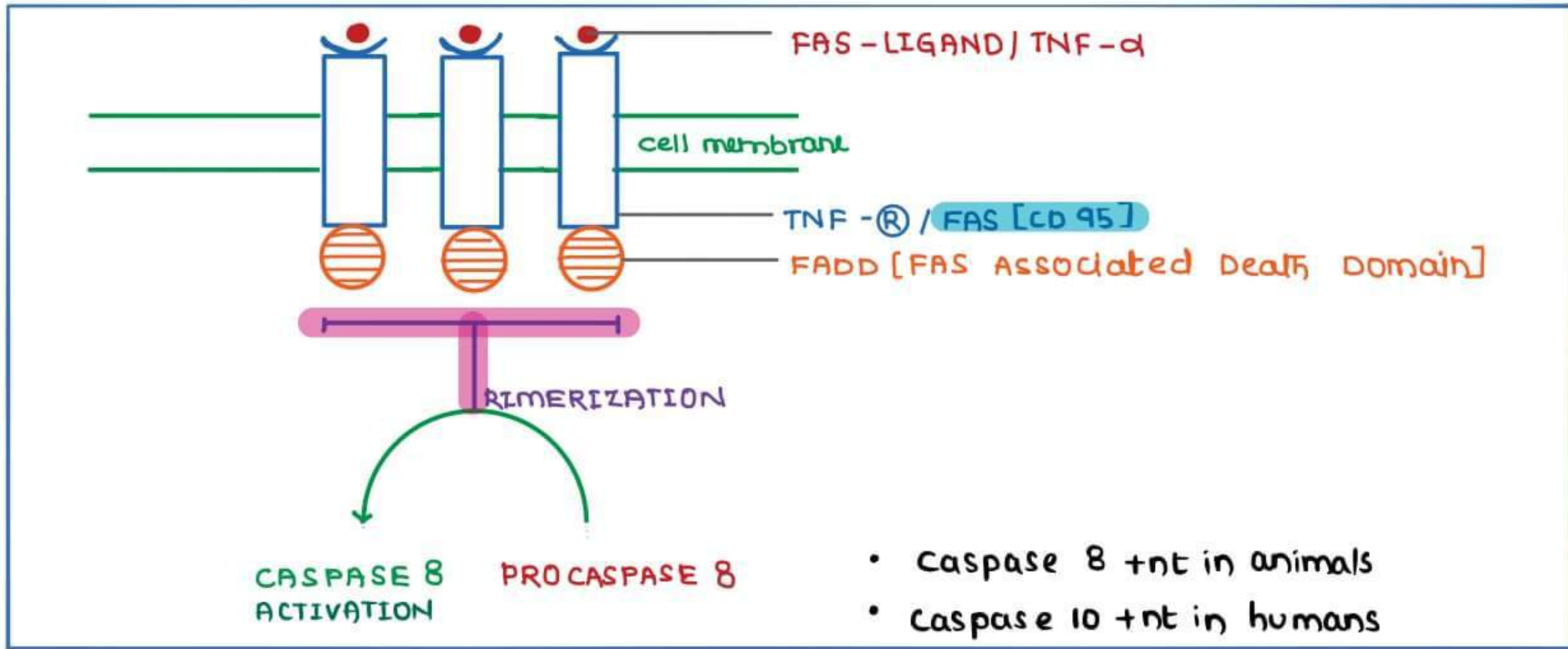
PATHOLOGICAL APOPTOSIS SEEN IN

1. DNA Damage
2. Duct obstruction [salivary glands | Pancreas]
3. viral infection of hepatocytes → COUNCILMANN BODIES [APOPTOTIC BODY]
4. Transplant rejection | Graft vs Host Disease
5. Retinitis Pigmentosa
 - Rods → responsible for DIM LIGHT VISION [Rods → RAAT]
 - cones → responsible for DAY LIGHT VISION [Cones → COLOR]
 - Excessive apoptosis of rods +nt → NIGHT BLINDNESS

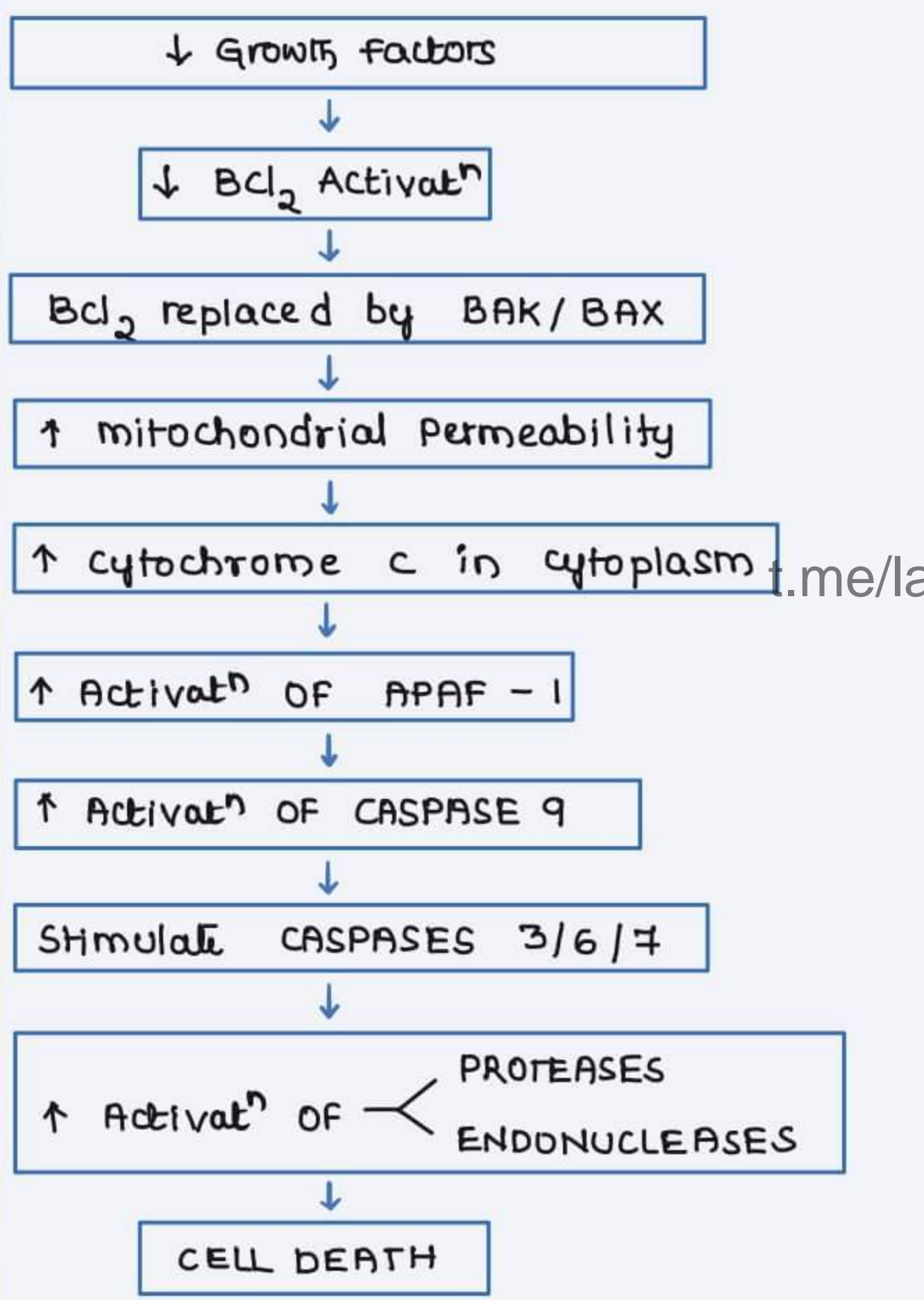
PATHWAYS OF APOPTOSIS

INTRINSIC / MITOCHONDRIAL PATHWAY

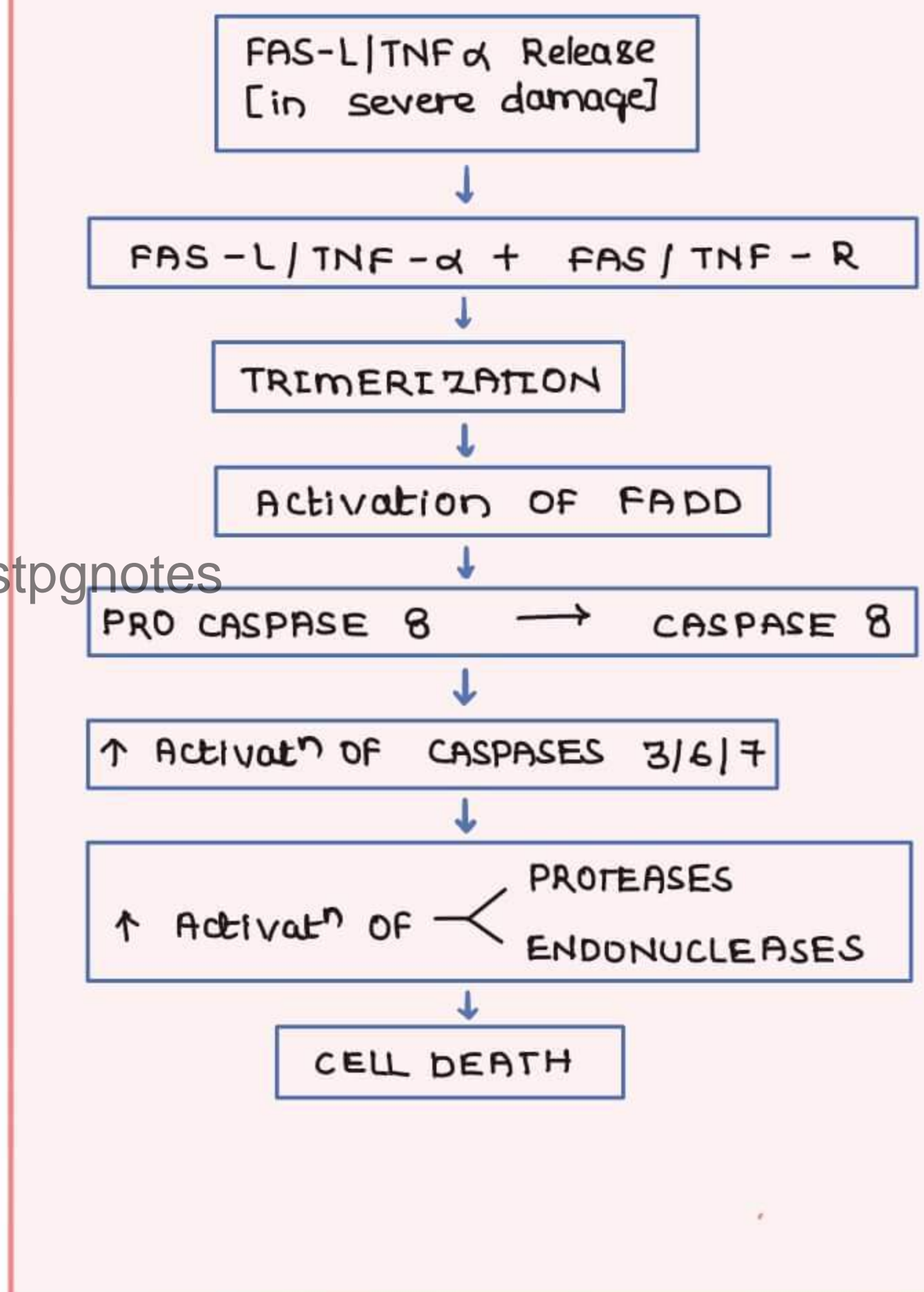




INTRINSIC / MITOCHONDRIAL PATHWAY



EXTRINSIC PATHWAY



APAF1 → Apoptosis Activating factor 1

CASPASES

→ **cystein** containing , **Protease** , Acting at **Aspartic Acid Residues**

→ INTRINSIC / MITOCHONDRIAL PATHWAY

- initiator caspases → CASPASE 9 [NINE]
- Executioner caspases → CASPASE 3/6/7

→ EXTRINSIC PATHWAY

- initiator caspases → CASPASE 8 [EIGHT]
- Executioner caspases → CASPASE 3/6/7

SALIENT FEATURES OF APOPTOSIS

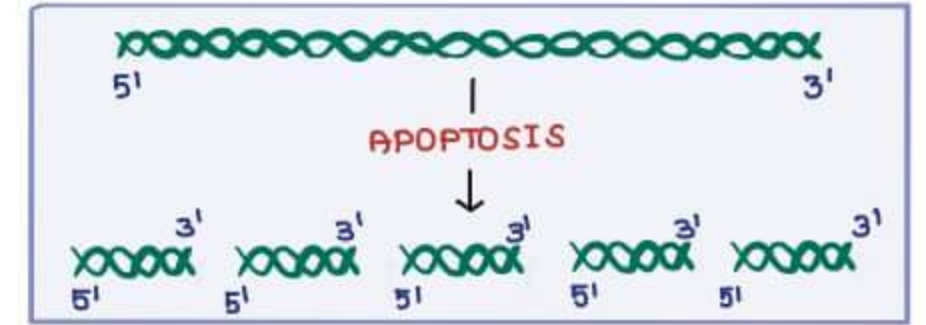
1. CELL SIZE

- cell size decreases [shrinkage]
- dlt structural protein destruction by proteases
- one of the earliest change

2. NO INFLAMMATION / CELL MEMBRANE INTACT [no phospholipase activation]

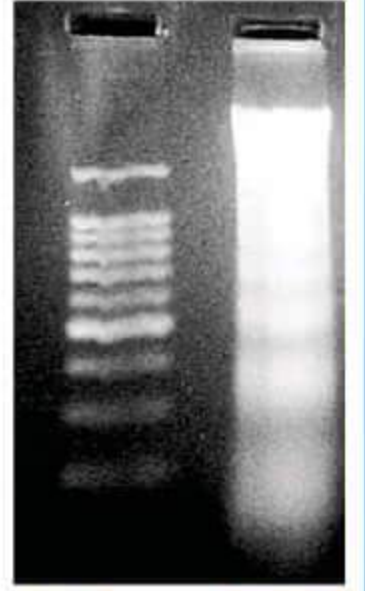
3. CHROMATIN CONDENSATION

- dlt Endonuclease activation
- Hallmark feature of apoptosis
- most characteristic feature of apoptosis



4. GEL ELECTROPHORESIS

- NORMAL NUCLEIC ACIDS → appear as single band
- NECROTIC NUCLEIC ACIDS → appear as smear pattern
- APOPTOTIC NUCLEIC ACIDS → appear as step ladder pattern

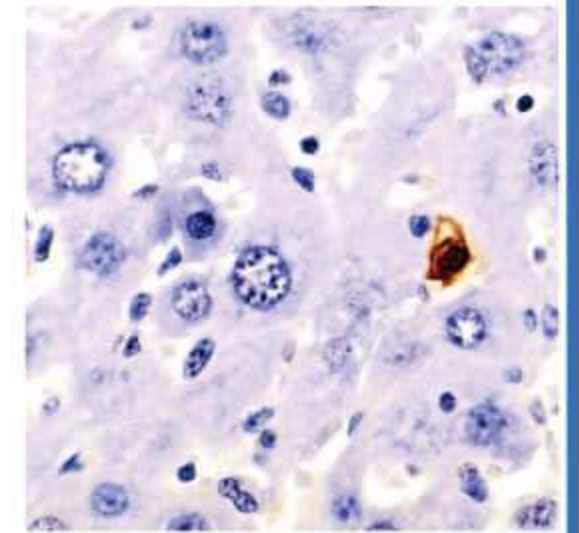


STEP LADDER PATTERN SMEAR PATTERN

5. TUNEL TECHNIQUE

- this technique uses dUTP
 - ↳ attaches at 3'OH
 - ↳ more amount of dye is attached in apoptosis
 - more intensified colour [Brown] occurs
 - can be picked up by light microscope

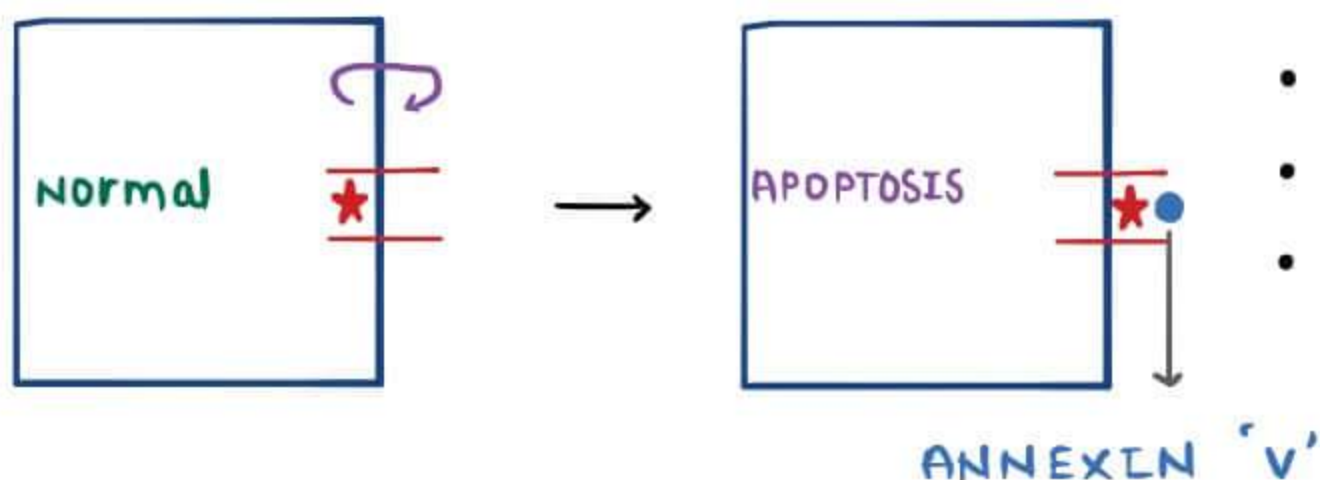
- 'TUNEL' stands for t.me/latestpnotes
 - T → Tdt [Terminal Deoxy nucleotide transferase]
 - U → dUTP
 - N → Nick
 - E → End
 - L → Labelling



TUNEL STAINING

6. STAINING done by 'ANNEXIN V'

FLIPPING CONCEPT



- attracts ↑ Phagocytic cells
 - NO time for enzyme leakage
 - cell membrane intact
- } NO INFLAMMATⁿ

- molecules that can flip over are [expression increases at the time of apoptosis]
 - Phosphatidyl serine
 - C1q
 - Thrombospondin

BOOSTER POINTS

- MCL-1 gene a/w development of resistance to chemotherapy
- In Traumatic Neuronal injury, AIF [Apoptosis Initiating factor] is secreted
 - ↳ no caspase activation
 - ↳ directly activates endonucleases & Proteases
- **Di** **A** **M** **I** **D** **I** **N** **O** **P** **H** **E** **N** **I** **D** **O** **L** **E** [DAPI] → dye useful for detectⁿ of Apoptosis

EXCESSIVE APOPTOSIS SEEN IN

- Neurodegenerative disorders
- virus infections

REDUCED APOPTOSIS SEEN IN

- Auto immune disorders

p53 GENE

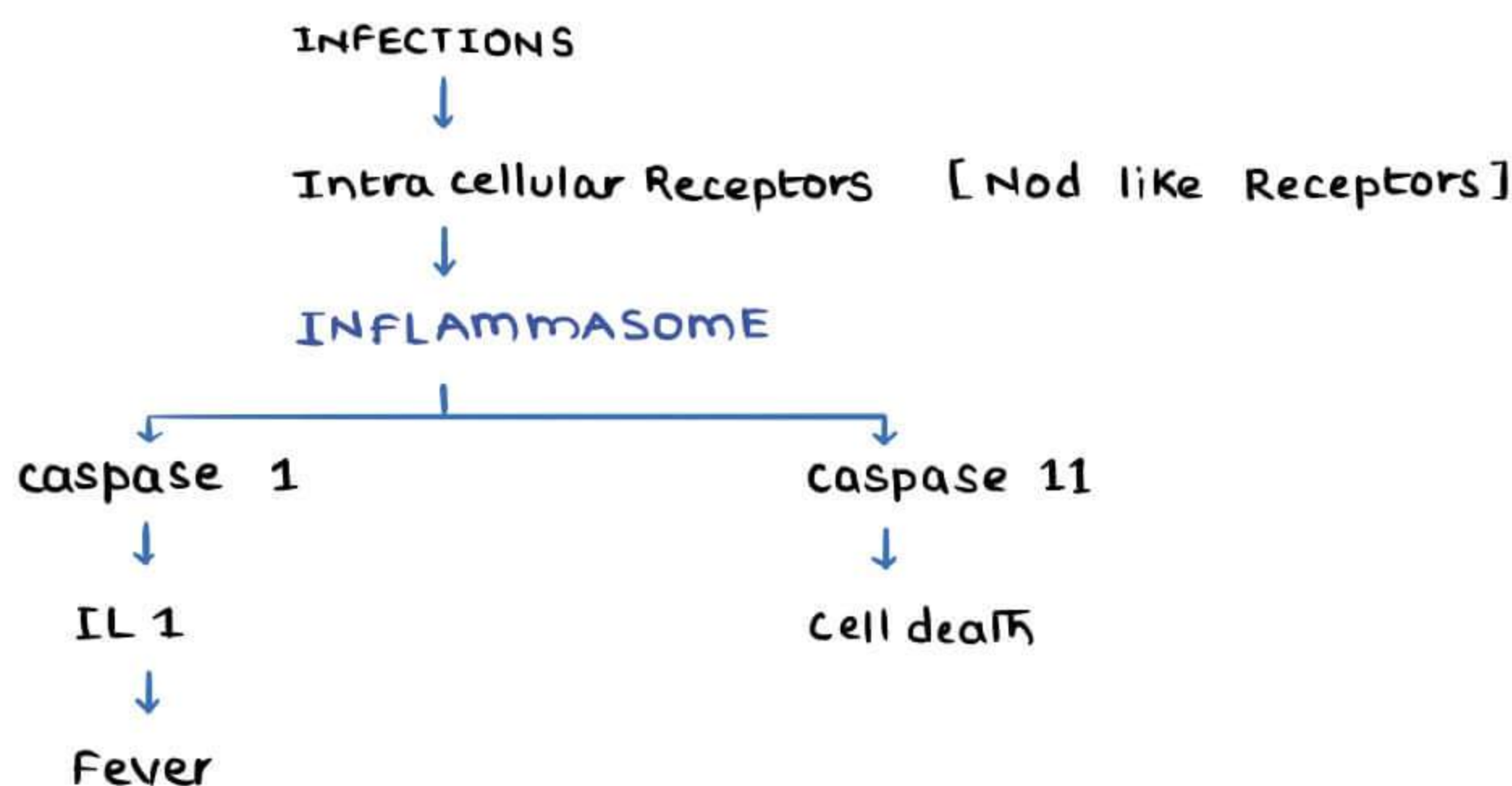
- activates during DNA damage

DNA damage $\xrightarrow{\text{p53 gene}}$ ↑ Apoptosis

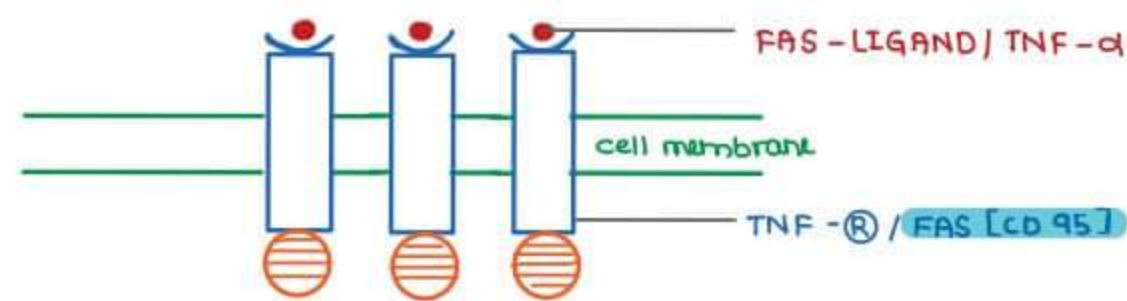
- Prevents the accumulation of altered cells → GUARDIAN OF GENOME
- located on chr 17p

t.me/latestpnotes

- mutation in p53 → ↑ cancers
 - around 50% of human cancers are d/t p53 mutation

PYROPTOSIS

- Overactivity of NLR → AUTO INFLAMMATORY SYNDROME
- MORPHOLOGICAL FEATURES
 - cellular swelling ⊕
 - Inflammation ⊕



↓
RIP 1/3 [Receptor associated Kinase]

↓
ROS [Reactive Oxygen Species]

↓
NO CASPASE ACTIVATION

- Lysosomal / mitochondrial damage
- ↓ ATP
- cm damage ⊕ / Inflammation ⊕

- caspase independent Programmed cell death
- NECROSIS + APOPTOSIS → PROGRAMMED NECROSIS

SEEN IN

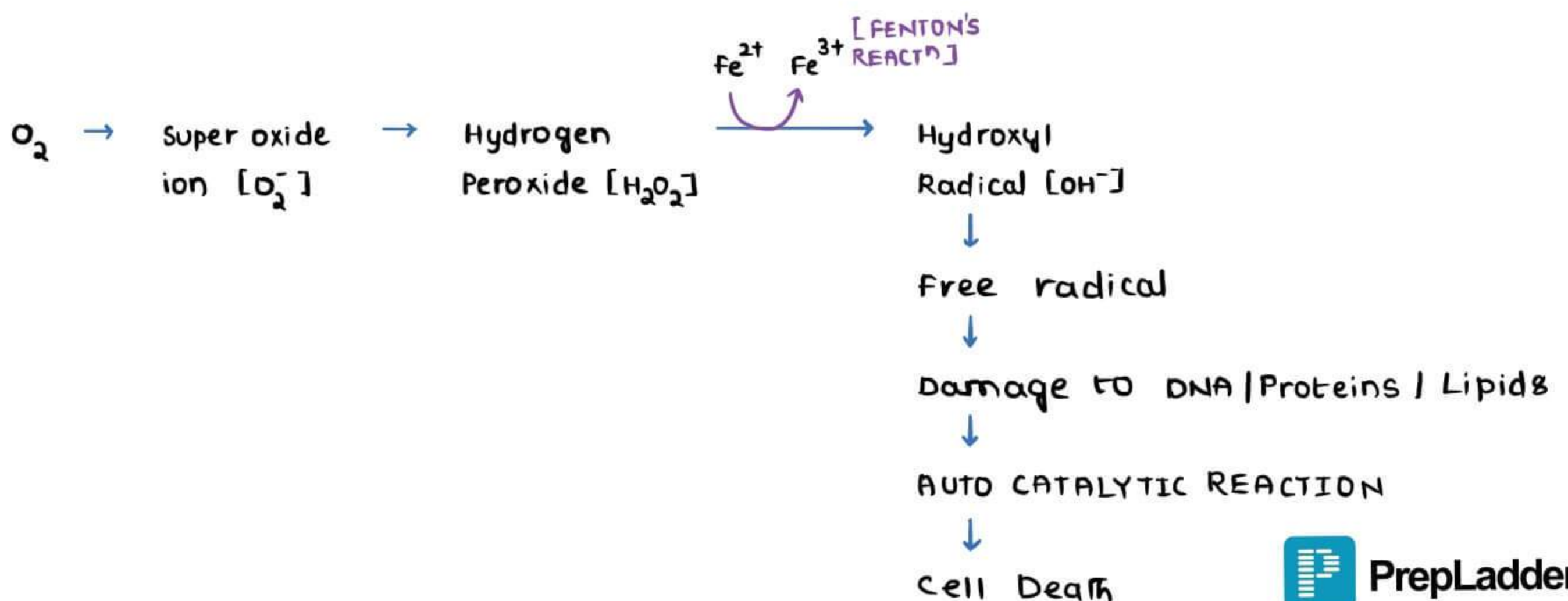
- PHYSIOLOGICAL → mammalian growth plate
- PATHOLOGICAL
 - ↳ Pancreatitis / Reperfusion injury I
 - ↳ Steatohepatitis / Parkinsonism

MICROBIOLOGY LINK

- cmv avoid apoptosis by forming ' FLIP PROTEIN ' → inhibit Caspase 8
- cmv destroyed by Necroptosis

FREE RADICAL INJURY

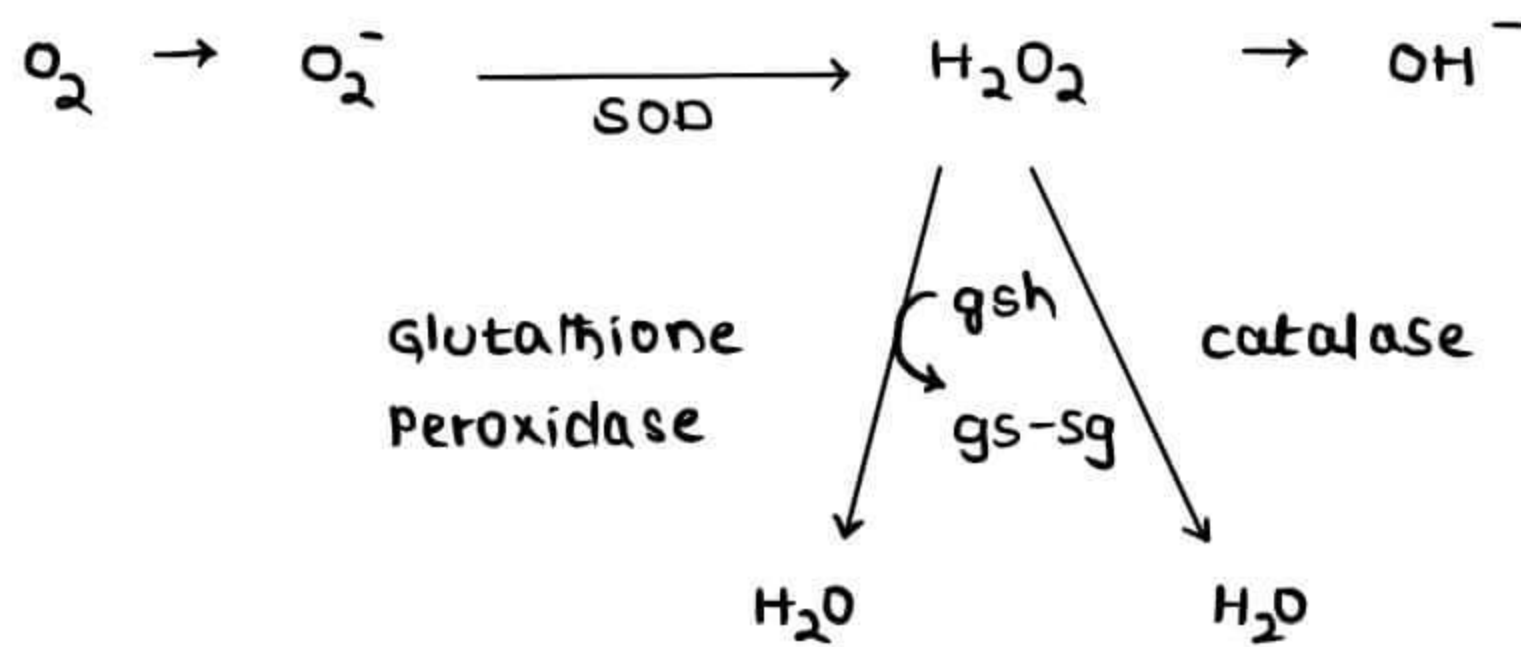
- Free radical have unpaired e⁻ in its structure
- highly reactive molecules
- FREE RADICAL FORMATION ASSOCIATED I
 - ↳ Radiation
 - ↳ Reperfusion injury
 - ↳ Heavy metal Injury [Cu/Fe]
 - ↳ Infections



- Most dangerous free radical → Hydroxyl radical
- Damage from free radicals can be prevented by → Anti oxidants

ANTI OXIDANTS

1. vitamin A, C, E
2. Plasma proteins
 - ↳ Transferrin [Fe]
 - ↳ ceruloplasmin [Cu]
3. Enzymes



- a. Superoxide dismutase [SOD]
- b. catalase
- c. Glutathione peroxidase

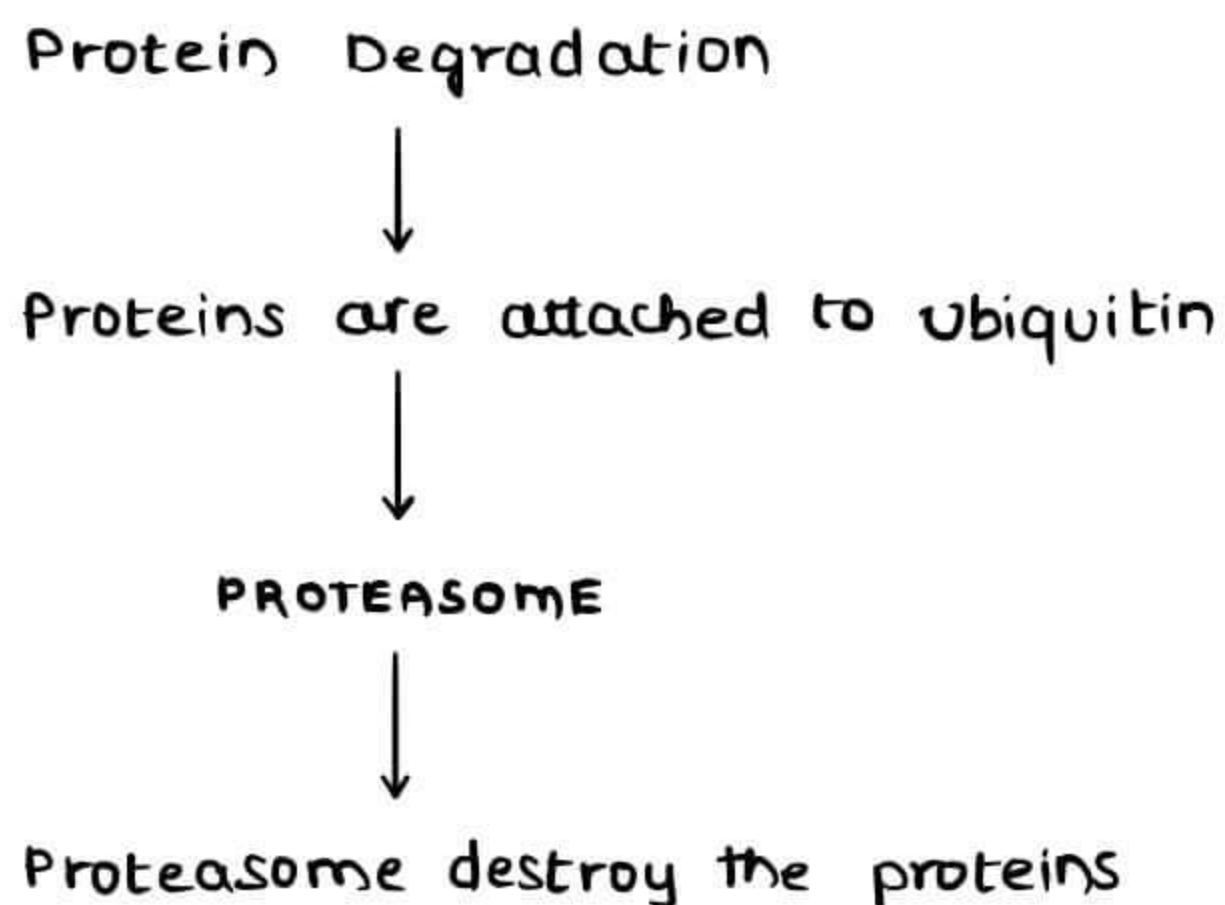
CELL ADAPTATION

SUB TYPES

t.me/latestpgnotes

1. ATROPHY

- A ≡ absent ; Trophy ≡ growth
- ↓ number & ↓ size of cells or tissues
- Reason



In short, UBIQUITIN ATTACHED PROTEINS ARE GOING TO BE DESTROYED BY PROTEASOME

→ PHYSIOLOGICAL ATROPHY

1. Atrophy of notochord
2. Atrophy of ductus arteriosus

→ **PATHOLOGICAL ATROPHY**

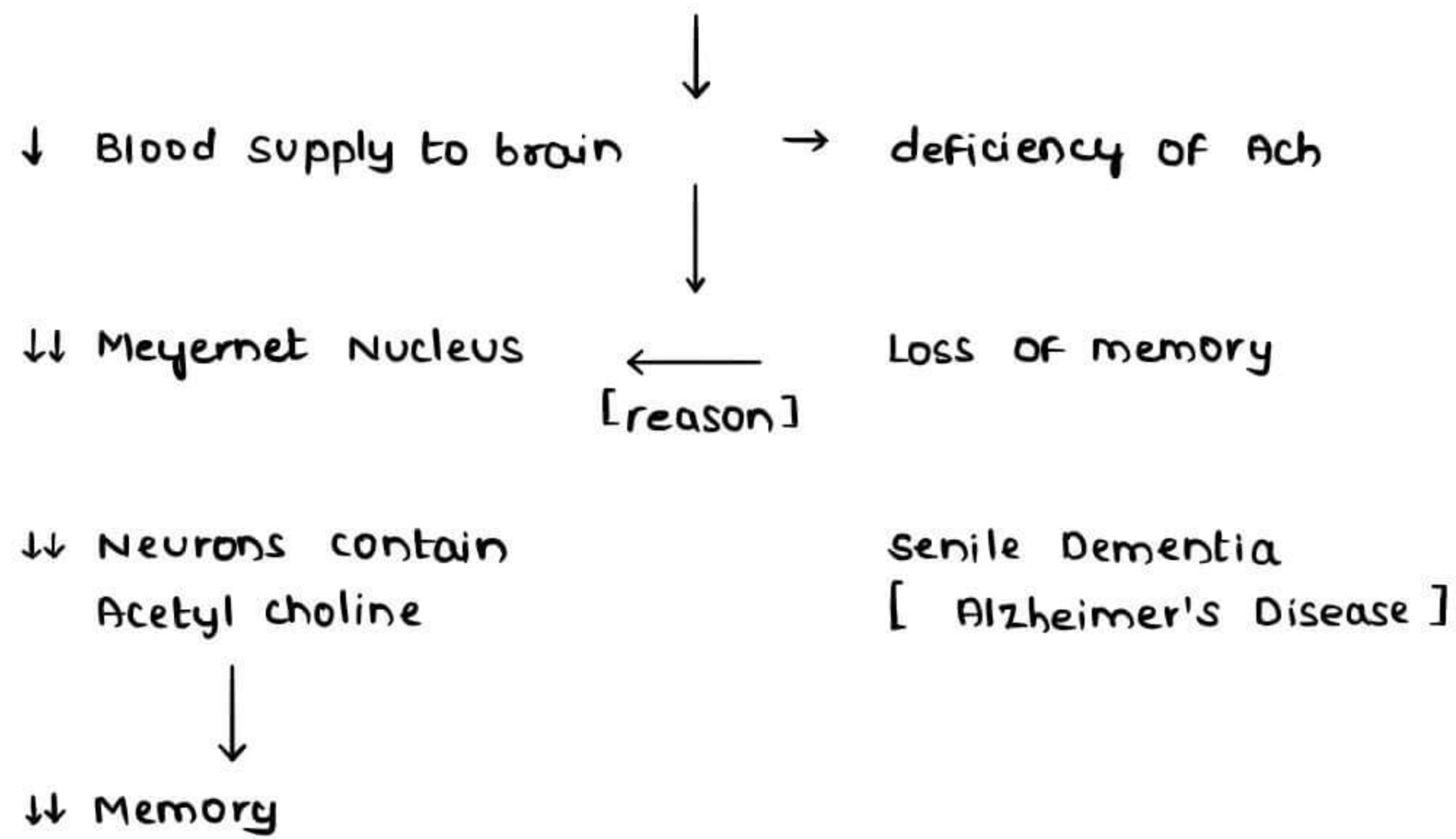
1. Malnutrition

2. Disuse atrophy

3. Senile atrophy

↳ dit old age, gradual deposition of lipids on blood vessels

↳ cerebral artery in brain going to develop atherosclerosis



4. **PRESSURE ATROPHY**

obstruction at urinary outflow level

t.me/latestpnotes

more urine accumulating inside the kidney

compression of cortical part of kidney

cortical part undergoes atrophy

→ SO ABSENCE OF GROWTH OF CELLS, either decrease in number or size of cells leads to atrophy

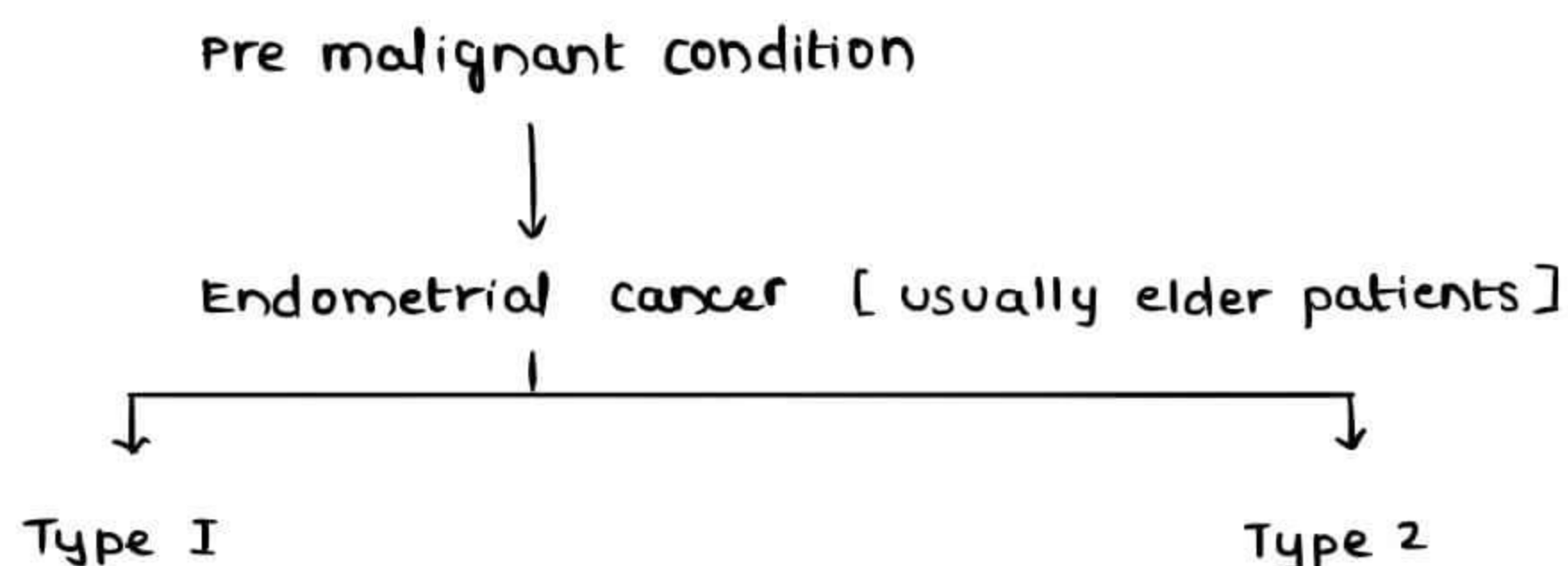
→ **NEW CONCEPT REGARDING ATROPHY**

↳ EARLIER considered as

→ TOTALLY BENIGN CONDITION

NOW considered SOME as

→ PRE MALIGNANT CONDITION



↑ Estrogen
[Females have
Endometrial hyperplasia]

Suffer from endometrial atrophy
Patients have P53 gene mutation



↑ risk of Type 2 Endometrial cancer

2. HYPERTROPHY

- Hyper \cong Excessive ; Trophy \cong growth
- ↑ size of individual cells
- dlt oversynthesis of structural protein
- Both Physiological & Pathological

→ PHYSIOLOGICAL

1. Pregnancy [Uterus, breast]
2. Puberty
3. Body builders

→ PATHOLOGICAL

1. Cardiac patients → particularly Hypertension
2. Stricture → narrowing of Lumen & Intestine



Area prior to it undergo hypertrophy

Heart pumps into Aorta

↓ t.me/latestpnotes

Pressure in left ventricle is more than pressure in Aorta



In case of HTN, LV have to exert more force



overtime, LV gets hypertrophy



Risk of cardiac failure

3. HYPERPLASIA

- Hyper \cong Increase ; Plasia \cong number
- ↑ number of cells
- Both Physiological & Pathological

→ PHYSIOLOGICAL

1. Pregnancy [Uterus & Breast tissue]
2. Puberty [Uterus & Breast tissue]

→ PATHOLOGICAL

1. Endometrial Hyperplasia [Pre - cancerous condition]
2. Prostatic Hyperplasia [Benign prostatic hyperplasia]

Androgen dependent [Testosterone not responsible]

↓ 5 α reductase

Di Hydro Testosterone [DHT]

↓

↑ NO. OF cells in the prostate

↓

clinical symptoms of patient

- ↳ elderly man
- ↳ delayed micturition
- ↳ problems in starting of stream
- ↳ stream is not of proper strength
- ↳ stream can't be controlled

↓

↑ Prostate size [Periurethral zone enlarges]

↓

compresses urethra

Important to know because of 2 reasons

↓

(i) IF patients symptoms

are seen in the help of DHT.me/latestpnotes for development of ca prostate

↓

Relief can be provided to the patient by ↓ concentratⁿ of DHT by FINASTERIDE [5 α -reductase inhibitor]

↓

↓ Size of prostate in elderly male patients & provides symptomatic relief

(ii) BPH is not a risk factor

for development of ca prostate [as this is a benign condition]

→ So, Hyperplasia may or may not be a pre cancerous condition like atrophy

4 METAPLASIA

→ Meta \cong Slightly altered ; Plasia \cong Number

→ change in number of cells in presence of stress

→ EPITHELIAL METAPLASIA

→ CONNECTIVE TISSUE METAPLASIA

1. Myositis Ossificans [muscle replaced by bone]

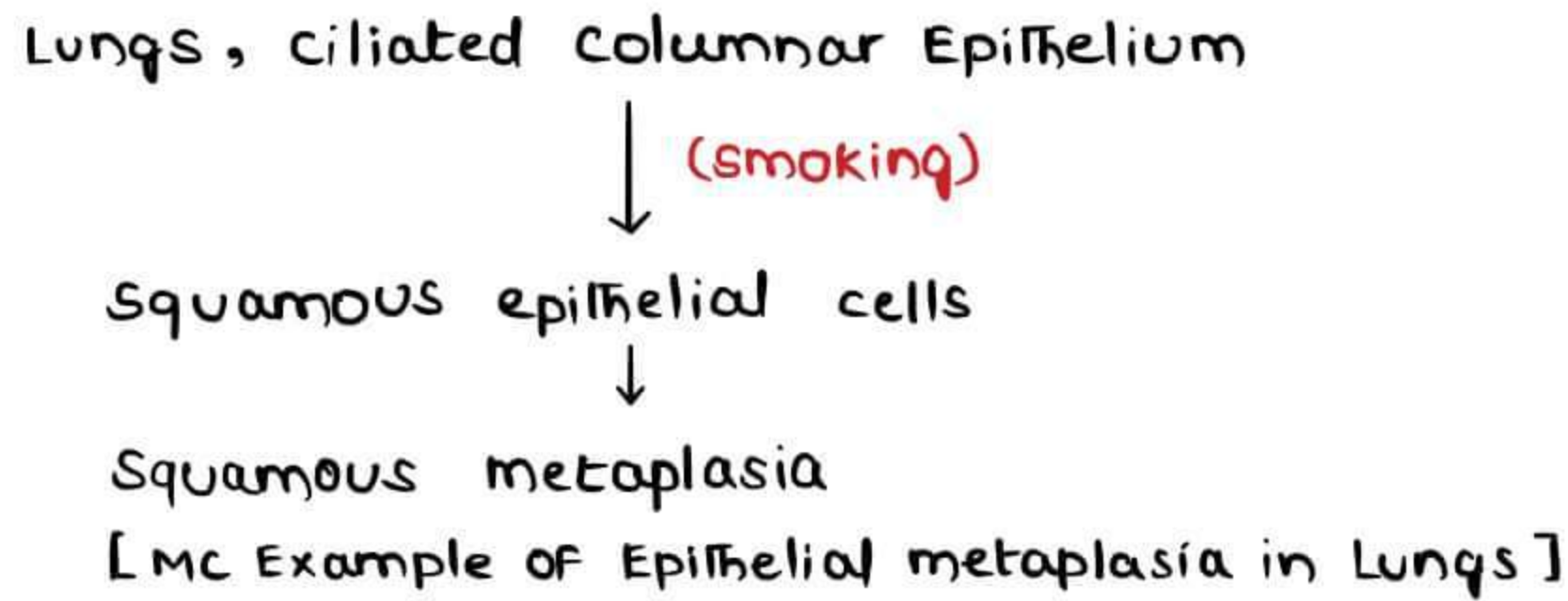
2. Barrett's oesophagus [intestinal columnar metaplasia]

→ Metaplasia is a reversible change

↳ metaplasia persisting for longer periods → cancer

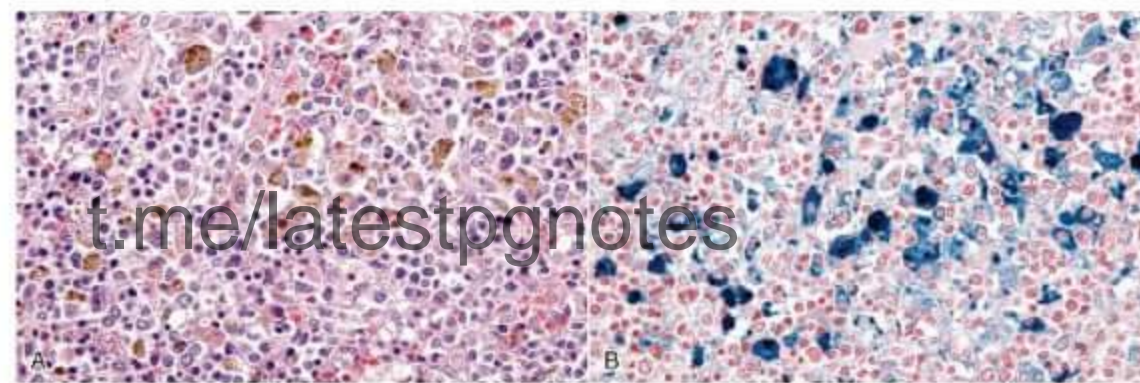
↳ Reversible metaplasia → Benign

- undifferentiated stem cells $\xrightarrow{\text{Stress}}$ New epithelium / connective tissue
- EPITHELIAL METAPLASIA



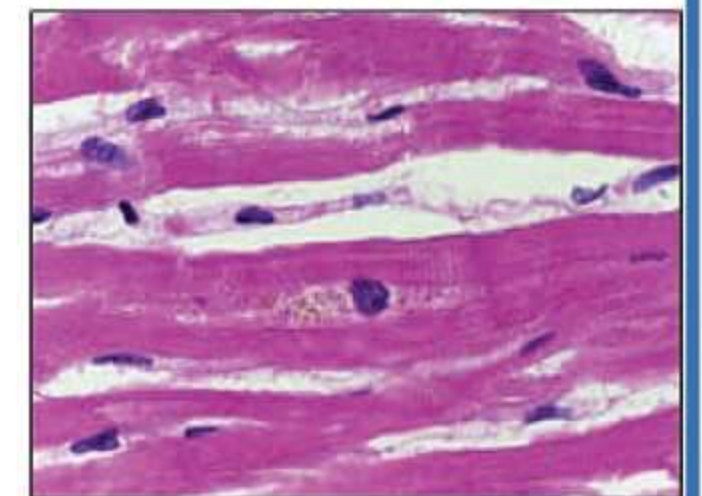PIGMENTATION

- MELANIN**
 - Endogenous black pigment
 - Provides Hair & Skin colour
 - derived from TYROSINE
- HEMOSIDERIN**
 - derived from Iron
 - present at Storage sites of Iron [Bone marrow]
 - detected by **PRUSSIAN BLUE**
 - ↳ Purple / violet granules
 - ↳ Reaction known as **PERLS RXN**



3. LIPOFUSCIN / LIPOCHROME

- PERI NUCLEAR BROWN pigment
- Lipid derived pigment
- accumulated by **LIPOD PEROXIDATION**
 - ↳ a/w free radical injury
- seen in
 1. Aging
 - WEAR & TEAR PIGMENT
 - BROWN ATROPHY
 2. PEM
 3. Cancer



- **AGING** is due to
 - 1. collagen - cross linking
 - 2. free radical injury [most accepted theory]
 - 3. DNA damage [or defect in DNA HELICASE]
 - 4. Telomere shortening

- **WERNER SYNDROME**
 - defect in DNA helicase → DNA damage
 - Pre mature aging

→ SIRTUINS

→ causes

- | | | |
|--------------------------|---|------------|
| 1. DNA alteration | } | ↑ Lifespan |
| 2. ↓ free radical injury | | |
| 3. ↓ Insulin resistance | → | ↓ DM |

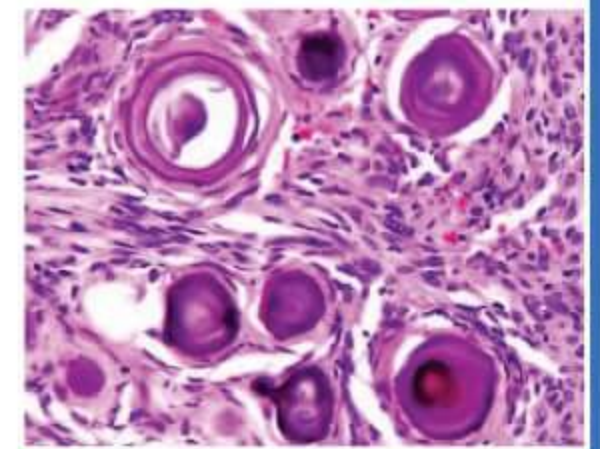
→ sirtulins increased by

1. ↓ calorie intake
2. Red wine consumption

4. CALCIFICATION

a. DYSTROPHIC CALCIFICATION

- s. Ca^{2+} → normal
- deposited in Dead / Degenerated tissues
- Ex:
 1. TB OF LN
 2. Cardiac valves [RHD]
 3. Atherosclerosis
 4. Tumors / cancers [PSAMMOMA BODIES]
 - M → meningioma
 - O → Papillary CA of ovaries
 - S → Papillary CA of Salivary gland
 - T → Papillary CA of Thyroid



PSAMMOMA BODIES

b. METASTATIC CALCIFICATION / latestpgnotes

- s. Ca^{2+} ↑↑↑
- deposited in Living tissues
- Ex:
 1. PTH ⤴
 - ↳ Parathyroid adenoma [mcc of Primary hyperparathyroidism]
 - ↳ chronic renal failure [secondary hyperparathyroidism]
 2. VIT D INTOXICATION
 - ↳ Granulomatous Disease

1- α Hydroxylase ↑
↓
↑ calcitriol

3. MILK - ALKALI SYNDROME

4. CANCER

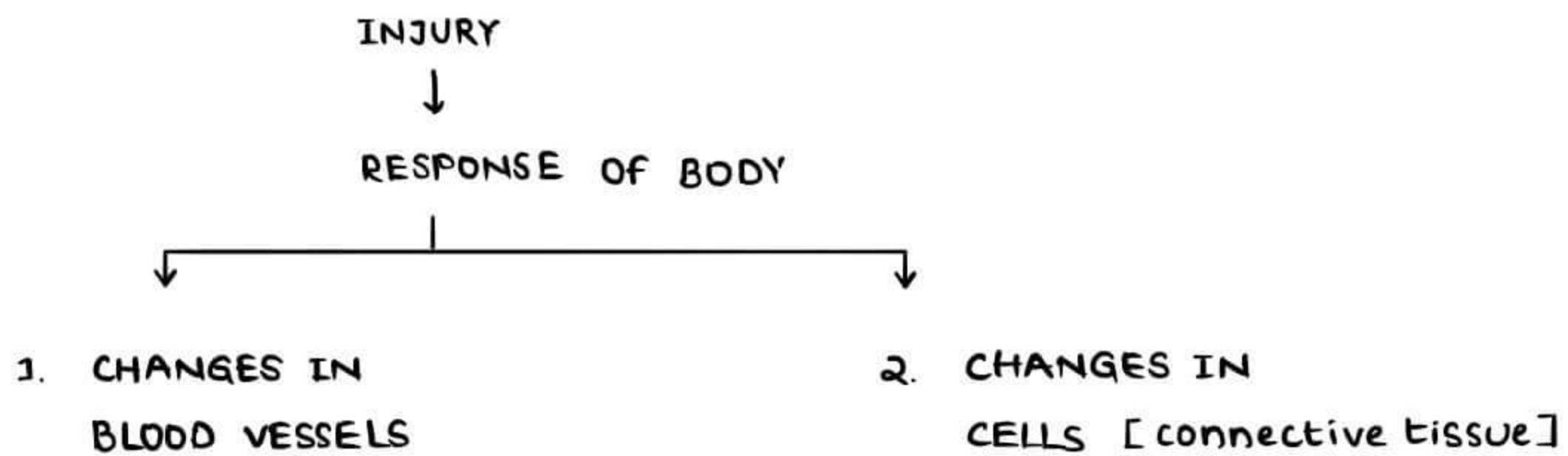
↓
osteolysis

↓
Metastatic calcification

- Ca^{2+} deposits in MITOCHONDRIA in majority OF cells EXCEPT in RENAL CELLS [deposits in Basement membrane]
- Ca^{2+} has predilection to deposit in following organs
 1. Lungs
 2. Gastric mucosa
 3. Kidneys
 4. Systemic arteries & Pulmonary veins
- Ca^{2+} will not directly affect Parathyroid glands
- Ca^{2+} → TETRACYCLINE [radio labelled]
 - ↓
 - used for the study OF BONE REMODELING

t.me/latestpgnotes

BASIC CONCEPTS



→ RESPONSE is usually protective, but some times harmful

CLASSIFICATION

→ mc type of Inflammation → CATARRHAL INFLAMMATION

SUB TYPES

1. ACUTE INFLAMMATION → Short duration
Neutrophils

2. CHRONIC INFLAMMATⁿ → Long duration
Mono nuclear WBCs [Lymphocytes | monocytes]

CARDINAL FEATURES OF INFLAMMATION

→ Described by **CELSUS**

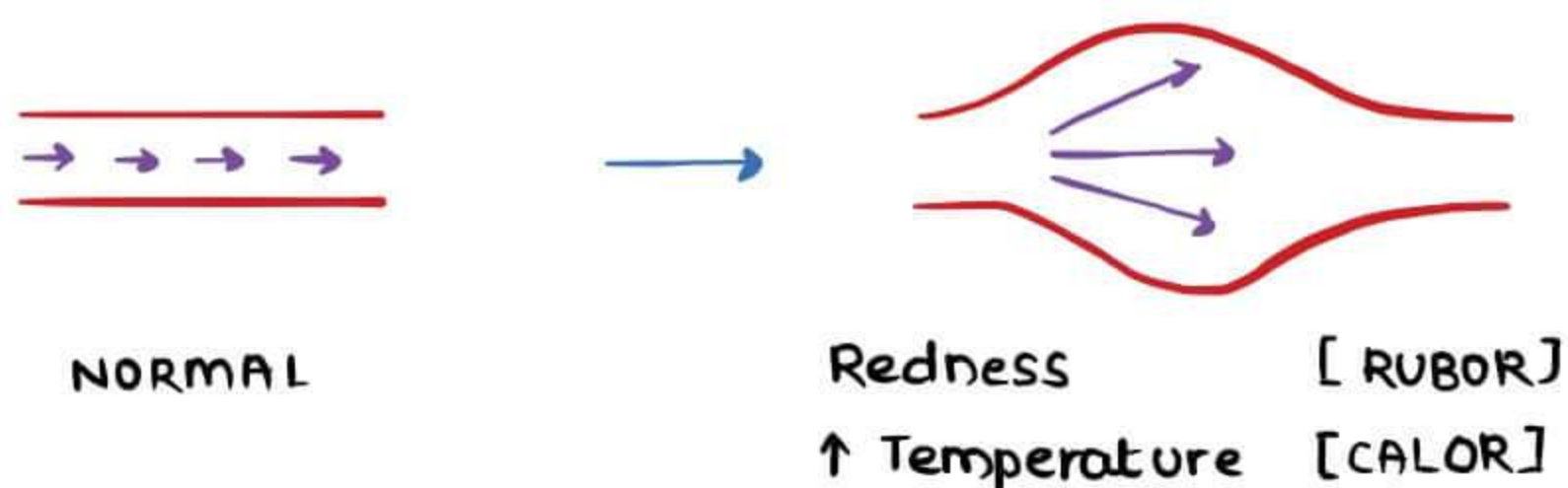
1. RUBOR - redness
2. CALOR - ↑ temp.
3. TUMOR - Swelling
4. DOLOR - Pain

→ **VIRCHOW** described LOSS OF FUNCTION / FUNCTIO LAESA

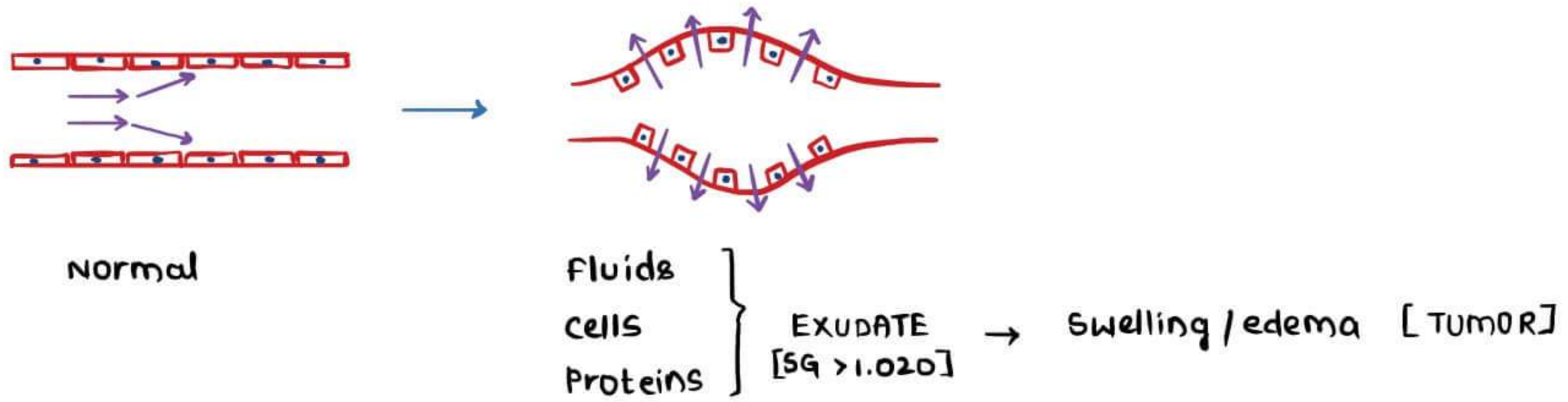
ACUTE INFLAMMATION

VASCULAR CHANGES

1. VASO CONSTRICTION → 1st change
2. VASO DILATION



3. ↑ VASCULAR PERMEABILITY



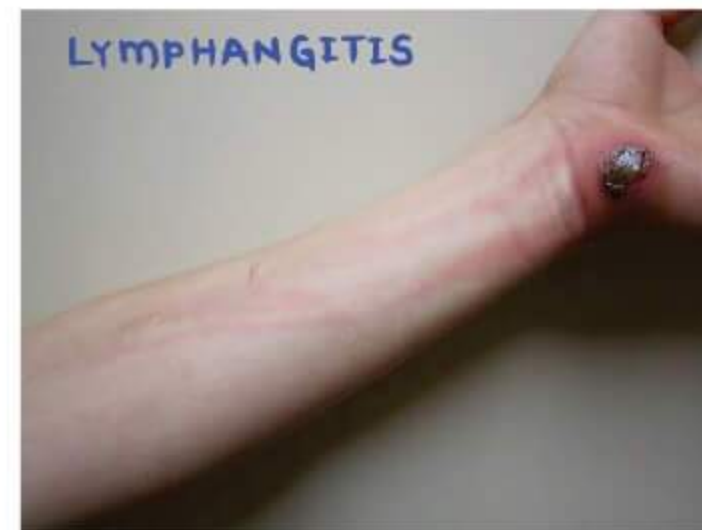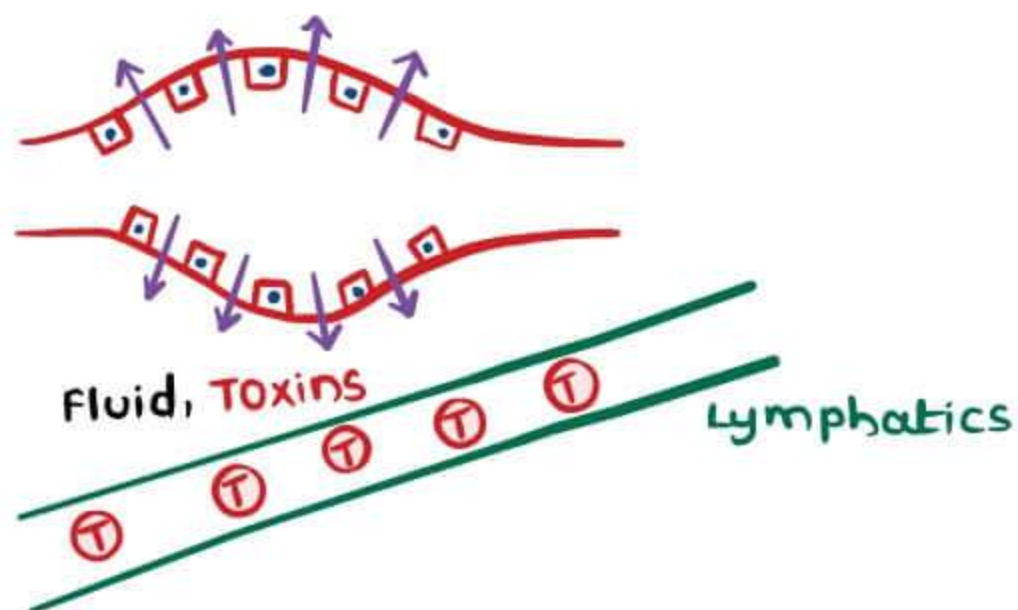
- most characteristic feature of acute inflammation
- mc mechanism responsible
- Endothelial cell contractⁿ typically involves
 - ↑ vascular permeability
 - Endothelial cell contraction
 - Small Blood vessels
 - ↳ Arterioles
 - ↳ capillaries
 - ↳ venules [mc involved]

MECHANISMS OF ↑ VASCULAR PERMEABILITY

- | | | |
|---------------------|--------------------------------|----------------------------|
| 1. EC CONTRACTION | → Immediate transient Response | → THORN PRICK |
| 2. DIRECT EC INJURY | → Immediate sustained Response | → SEVERE BURN / SEPTICEMIA |
| 3. EC RETRACTION | → delayed transient response | → BACTERIAL INFECTIONS |
| 4. EC DAMAGE | → Delayed Prolonged leakage | → LATE SUN BURN |

t.me/latestpgnotes

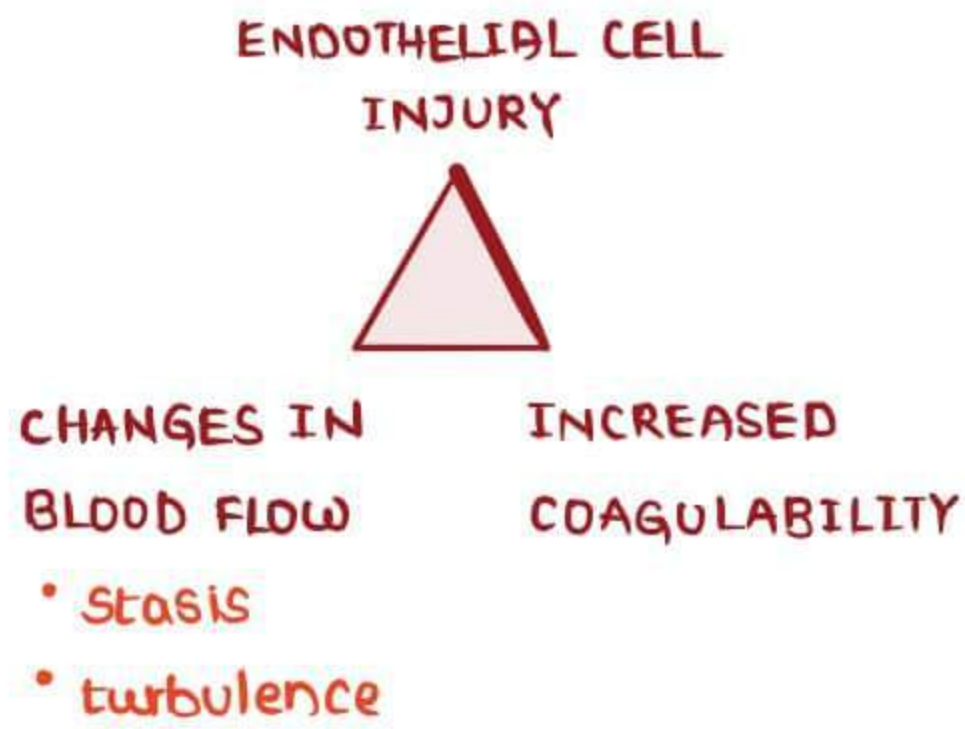
LYMPHANGITIS can occur



- Lymphatics drain excess extracellular contents
- along i Exudates, sometimes they also drain bacteria / toxins leading to lymphangitis
- mc bacterial infectⁿ responsible for lymphangitis → STREPTOCOCCUS PYOGENES

4. STASIS

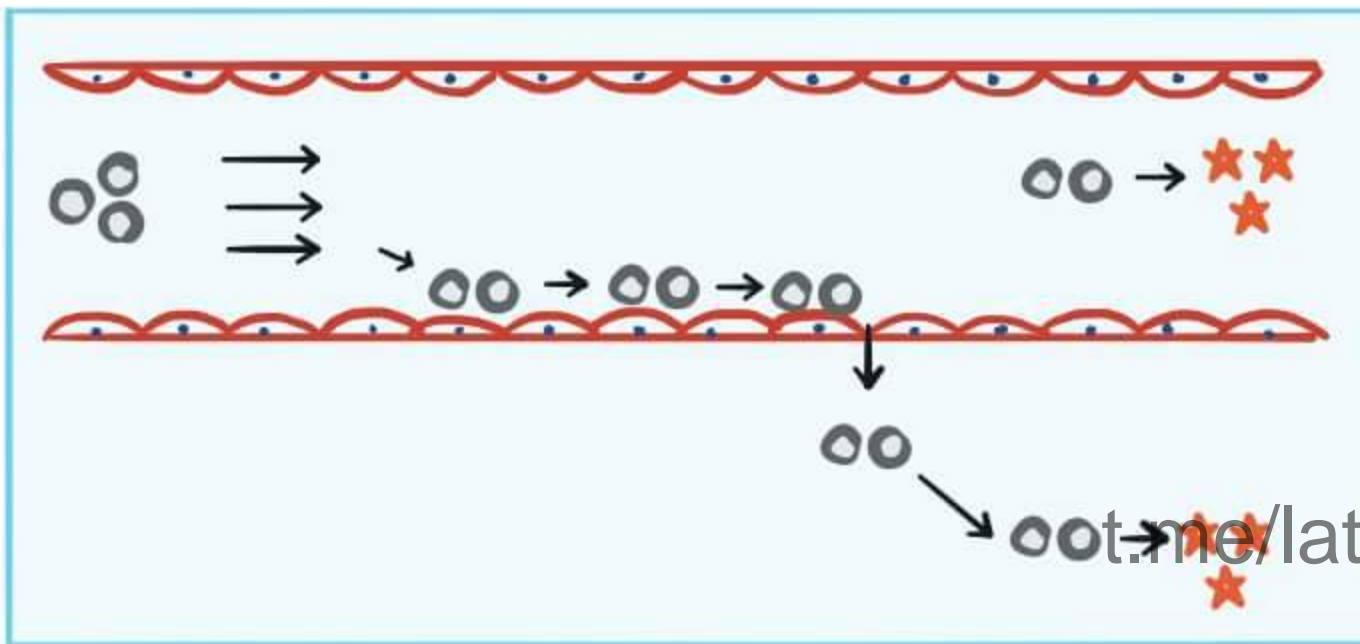
↑ vascular permeability → ↑ Hemoconcentratⁿ → ↓ Blood Flow → STASIS



VASCULAR CHANGES AT A GLANCE			
VASO CONSTRICT ⁿ	→	VASO DILATAT ⁿ	→
		INCREASED PERMEABILITY	→
			STASIS

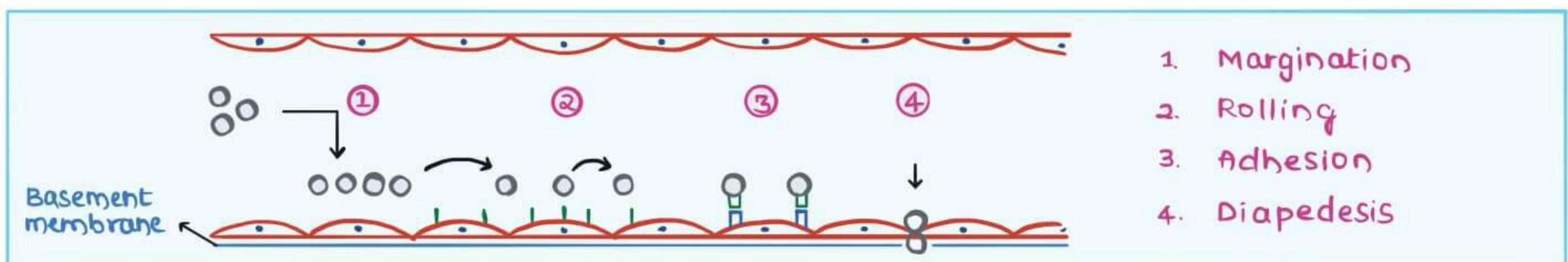
INTRA VASCULAR CELLULAR CHANGES

CELLULAR CHANGES



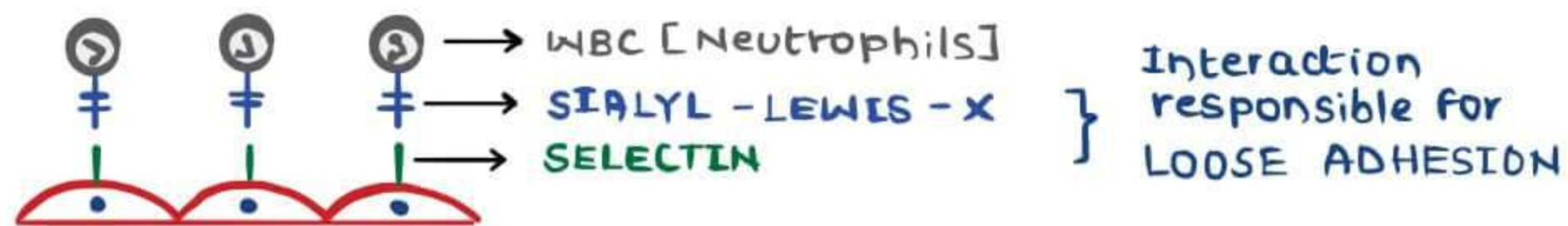- I. INTRA VASCULAR CELLULAR CHANGES
- II. EXTRA VASCULAR CELLULAR CHANGES

INTRA VASCULAR CELLULAR CHANGES



1. Margination
2. Rolling
3. Adhesion
4. Diapedesis

1. MARGINATION
2. ROLLING



→ Loose adhesion → ↓ Speed → ROLLING

→ **SELECTINS**

1. [Redacted] → expressed on surface of [Redacted]
2. [Redacted] → expressed on surface of [Redacted]
3. [Redacted] → expressed on surface of [Redacted]

↳ WEIBEL PALADE BODY

- intra cellular body in endothelial cells [Low energy state]
- contains Willebrand factor & Selectins

3. ADHESION



- ICAM - Inter cellular adhesion molecules
- VCAM - vascular cellular adhesion molecules
- Integrins → made of sub units known as CD 11a / LFA

4. TRANSMIGRATION / DIAPEDESIS

- occurs d/t
 - ↳ CD 31 [PECAM - Platelet Endothelial cell adhesⁿ molecule]
 - ↳ collagenase secreted by WBC & responsible for breaking of collagen of Basement membrane

LEUCOCYTE ADHESION DISORDERS [LAD]

- LAD I → Malfunctioning of INTEGRINS [LFA / CD 11] [firm adhesⁿ]
- LAD II → Malfunctioning of SELECTIN RECEPTORS [Sialyl - Lewis] [loose adhesⁿ]

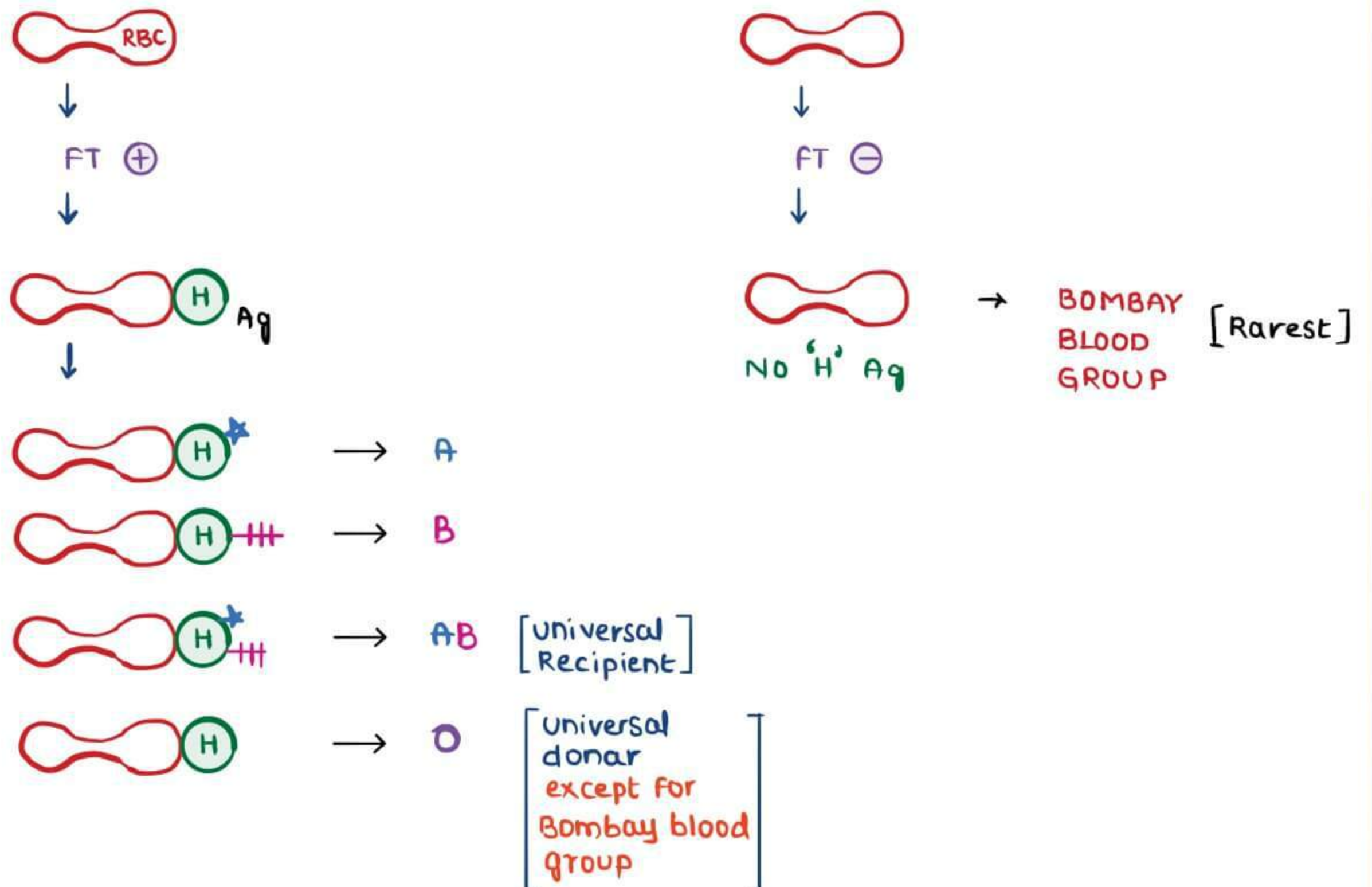
→ BOTH conditions lead to RECURRENT INFECTIONS
t.me/latestpgnotes

LAD I

→ H/o delayed separaⁿ of Umbilical cord

LAD II

→ Fucosyl transferase defect

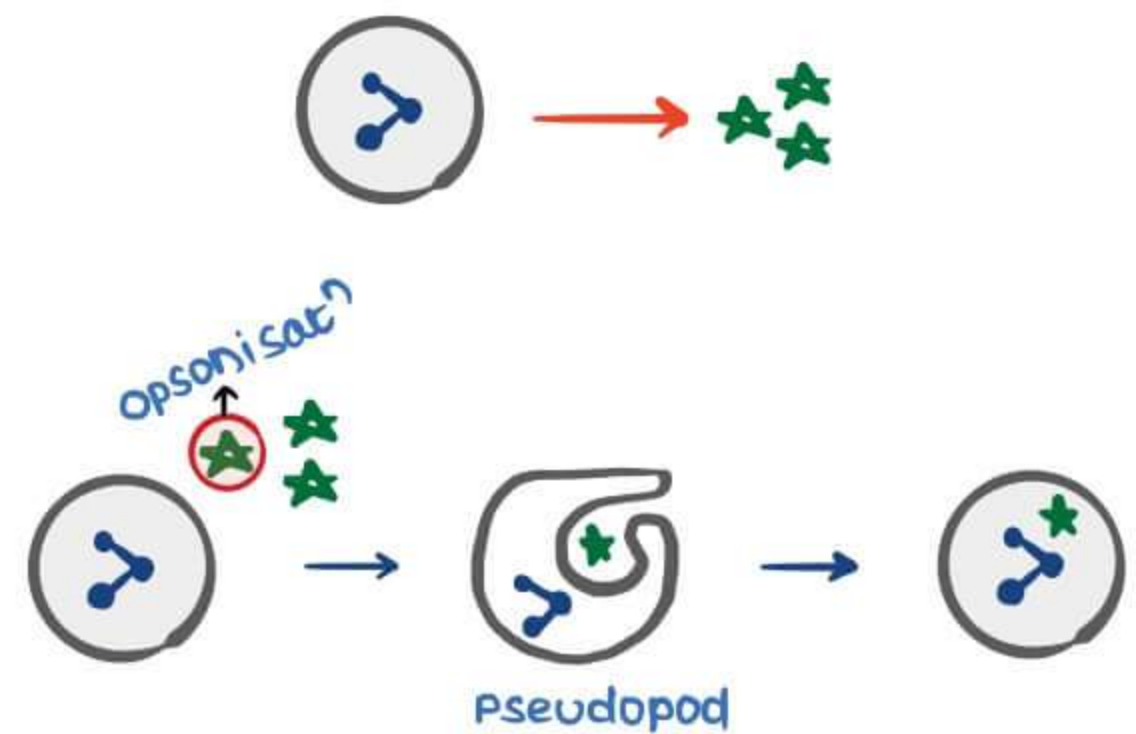
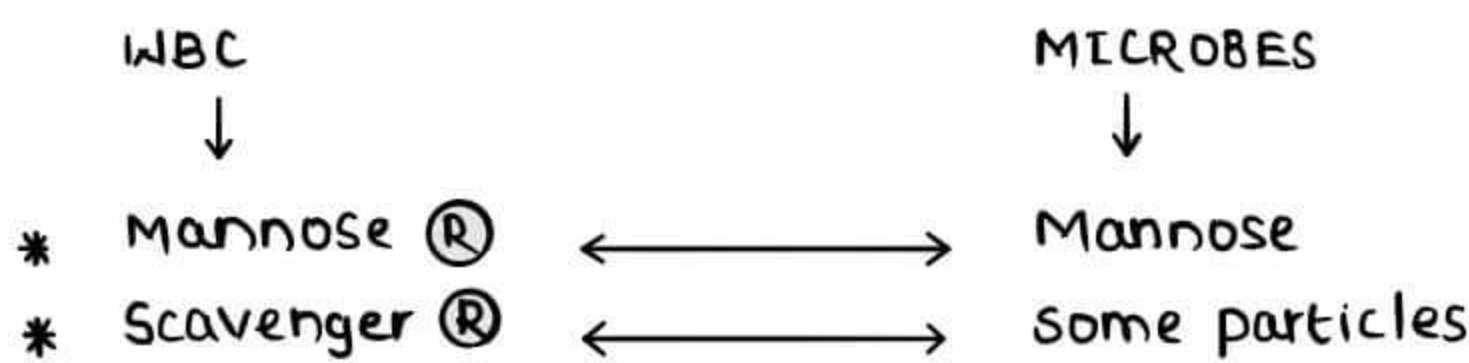


5. CHEMOTAXIS

- chemo = chemicals ; Taxis = slow movement
- UNIDIRECTIONAL MOVEMENT of WBC towards bacteria
- CHEMICALS RESPONSIBLE :
 - ↳ Bacterial Products
 - ↳ C_{5a} [complement protein]
 - ↳ IL - 8 [Interleukin]
 - ↳ LTB₄ [Leukotriene B₄]
- Exogenous
- Endogenous
- Major action of STEROIDS
- Chemotaxis Inhibition

6. LEUKOCYTE ACTIVATION

6a. RECOGNITION OF TARGET CELL



6b. ENGLUFMENT

- PSEUDOPDPE FORMATION
 - ↳ dlt Actin Polymerisation

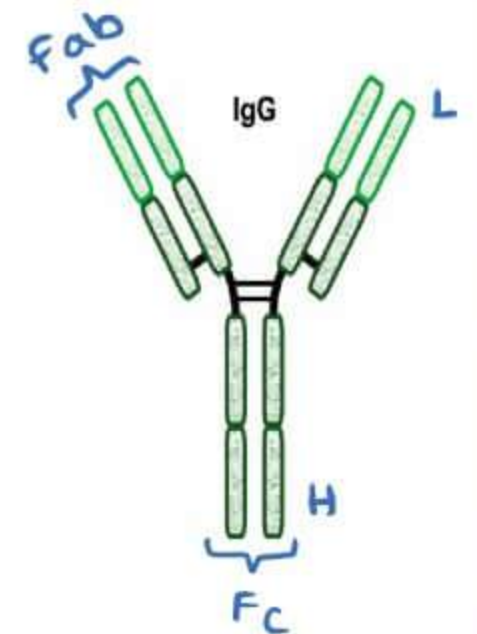
→ OPSONISATION

t.me/latestpgnotes

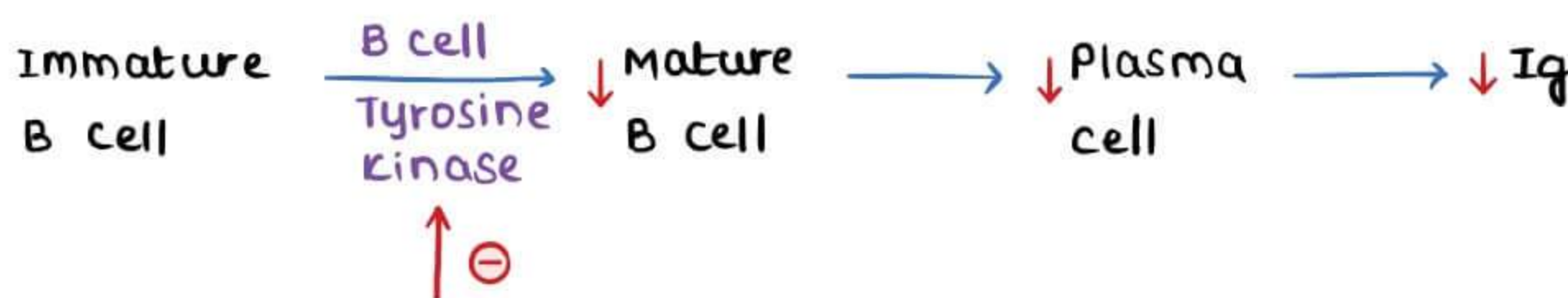
↳ Bacteria becomes tastier → PREFERENTIAL EATING

↳ OPSONINS

- chemicals r/f opsonisatⁿ
- Examples
 - ↳ F_c fragment of Ig G
 - ↳ C_{3b}
 - ↳ Fibrinogen / CRP



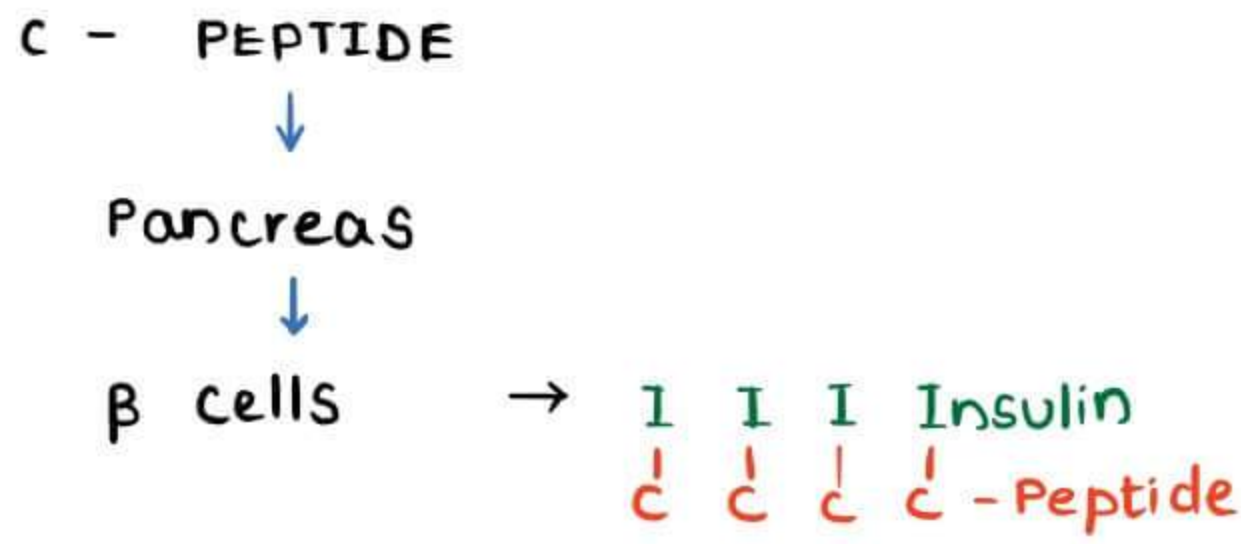
→ ANTIBODY FORMATION



BRUTON'S DISEASE

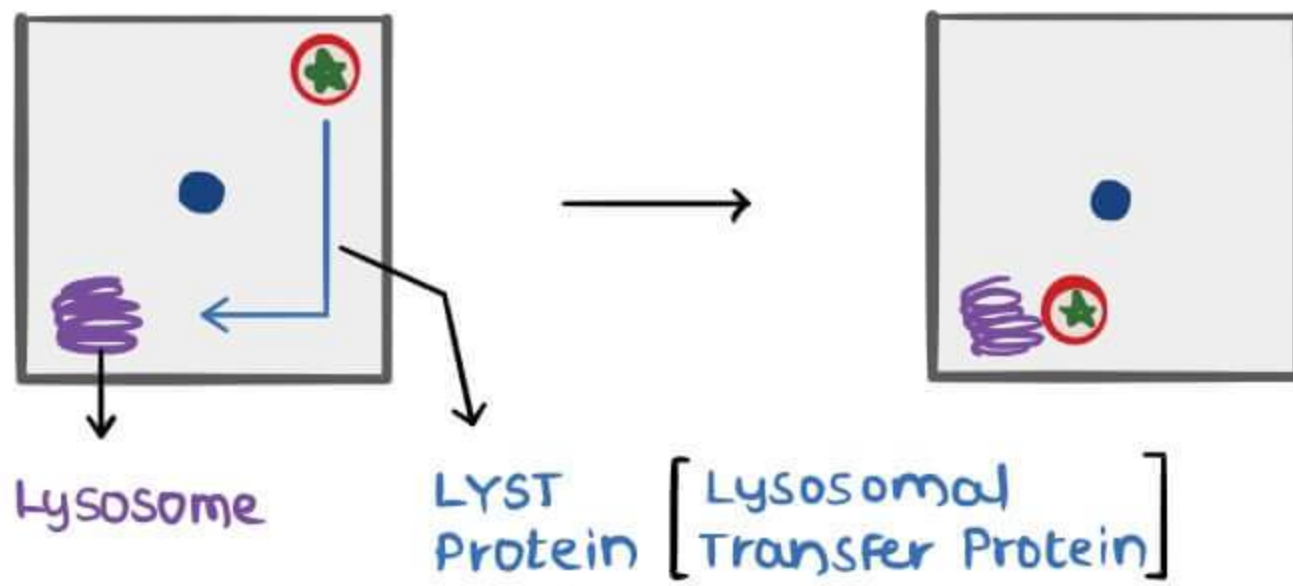
- x linked recessive disorder
- affects Boys
- B - cell defect
- Hypogamma globulinemia
- Defective Opsonisation

→ CRP [C-Reactive Peptide]
 ↳ CRP is different from C-Peptide



↳ C - RP
 → C = carbohydrate Ag [derived from Pneumococcus]

6C. KILLING OF BACTERIA



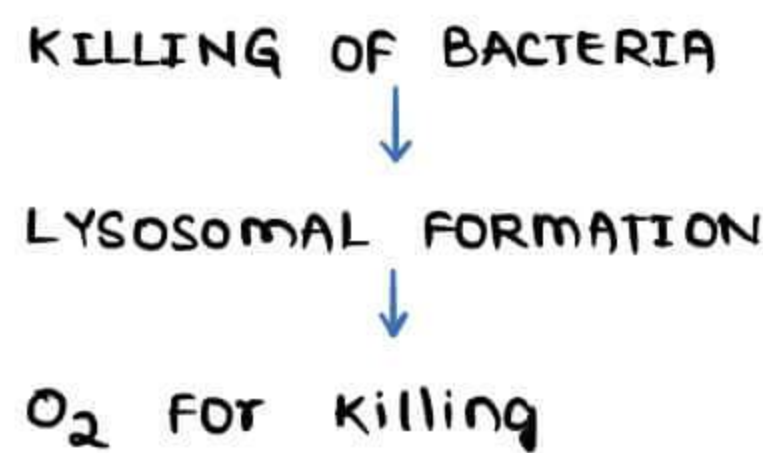
C	→ CNS features
HE	→ Hemorrhage
DI	→ Decreased Immunity
A	→ Albinism
K	

Defect

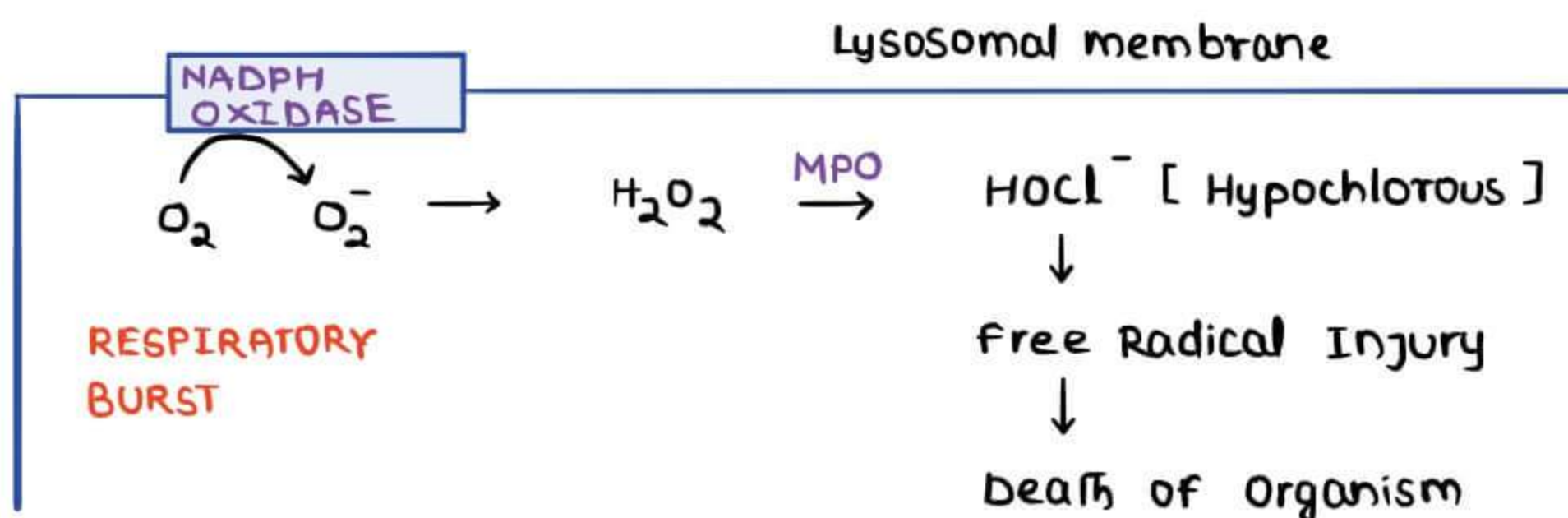
CHEDIAK - HIGASHI SYNDROME

- ↳ RECURRENT INFECTIONS
- ↳ ↓ melanin → ALBINISM
- ↳ ↓ myelin → NEUROLOGICAL CIF
- ↳ Platelet defects → BLEEDING ↑
- ↳ Peripheral smear shows
 → GIANT GRANULE INSIDE THE CELLS

OXYGEN DEPENDENT BACTERIAL KILLING



→ Most efficient bactericidal mechanism



NADPH OXIDASE / RESPIRATORY BURST OXIDASE & PHAGOCYTE OXIDASE

→ CHRONIC GRANULOMATOUS DISEASE

↳ d/t NADPH oxidase defect

↳ SUB TYPES

1. X LINKED RECESSIVE

→ gp 91 PHOX defect [membrane bound component]

2. AUTOSOMAL RECESSIVE

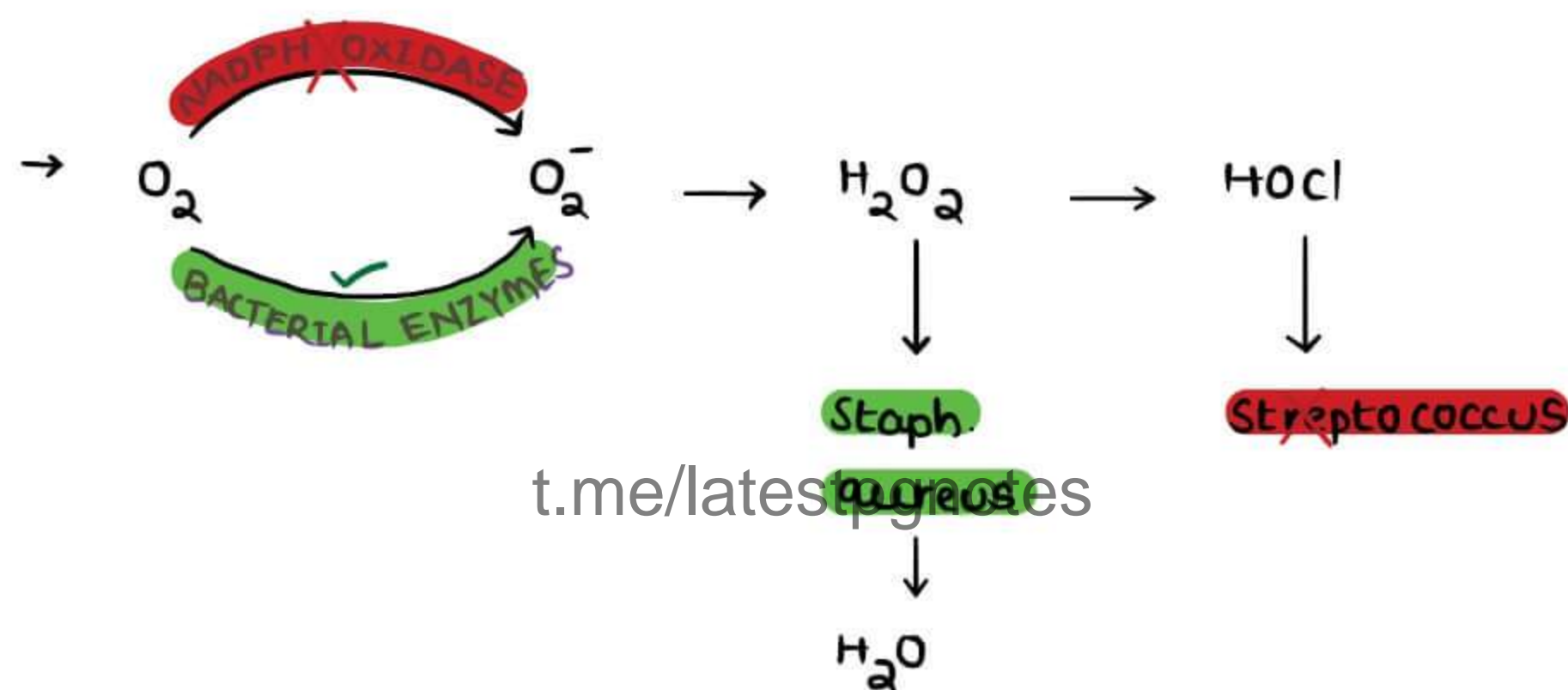
→ gp 47 PHOX defect } cytosomal component defect
gp 67 PHOX defect }

→ C/F

1. RECURRENT INFECTIONS

→ by catalase Positive organisms

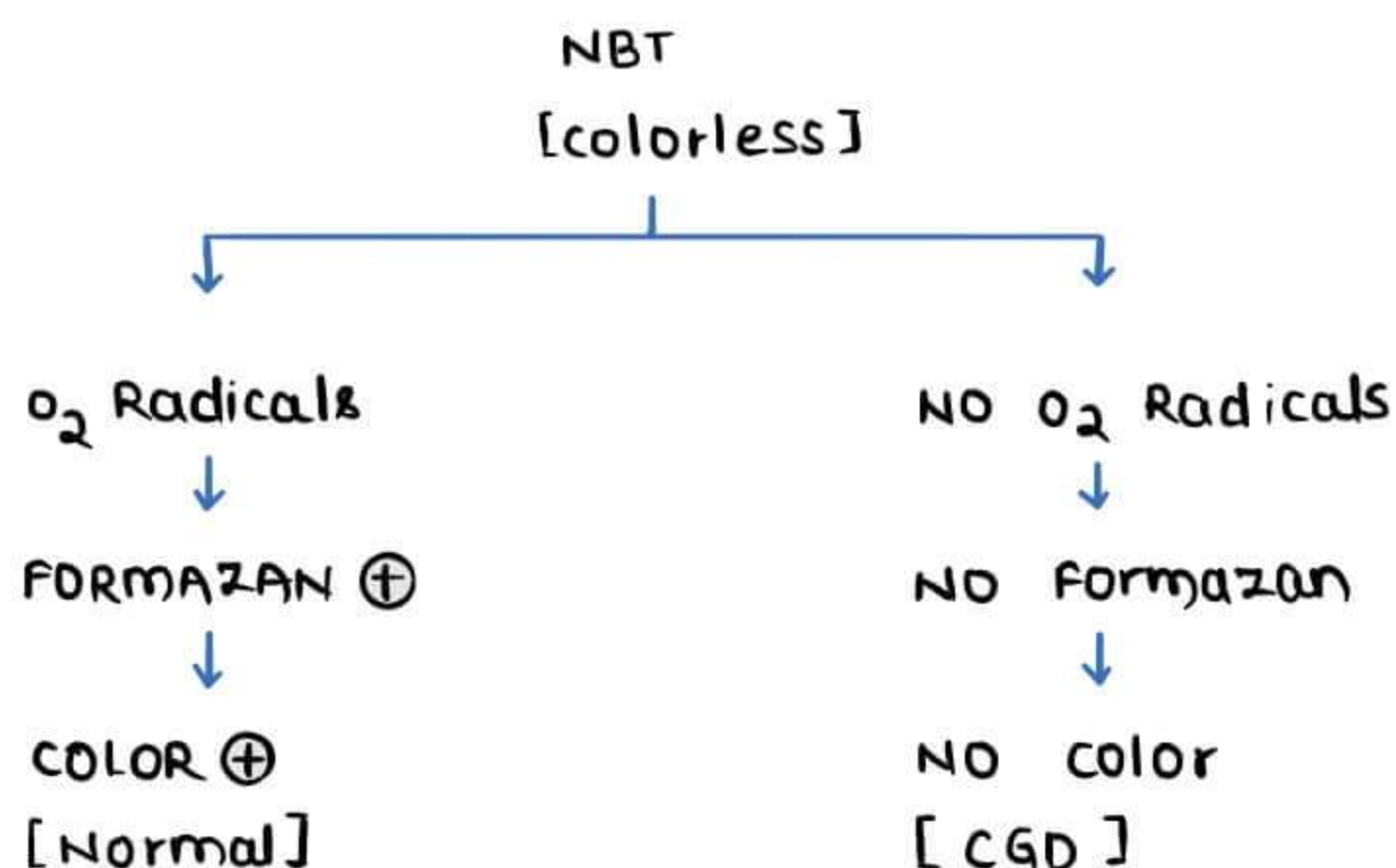
↳ Eg: Staphylococcus aureus
Pseudomonas
Nocardia



2. GRANULOMA FORMATION

→ DIAGNOSIS

1. NITRO - BLUE TETRAZOLIUM TEST [NBT TEST]



2. FLOW CYTOMETRY

→ done using DHR [Di Hydro Rhodamine]

→ Better test than NBT Test

OXYGEN INDEPENDENT KILLING

→ ACHIEVED IN THE HELP OF

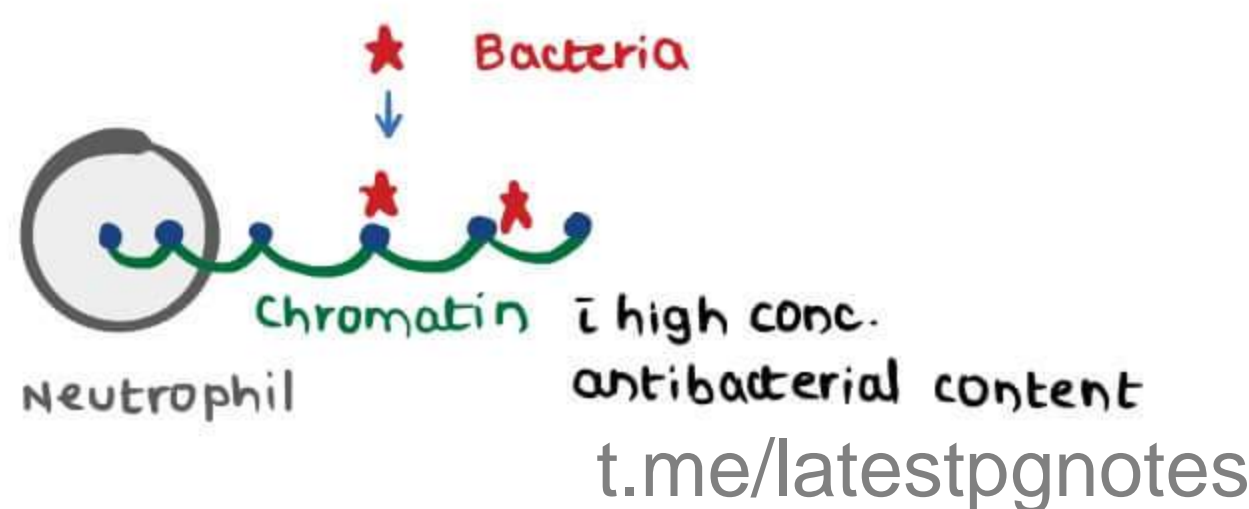
1. CATHELICIDIN
2. LYSOZYMES
3. LACTOFERRIN
4. MAJOR BASIC PROTEIN
 - abundant in EOSINOPHILS
 - σ /F parasitic killing

NEUTROPHIL EXTRA CELLULAR TRAP [NET]

→ NORMAL



→ SEPSIS → Platelet Activation → NET formation

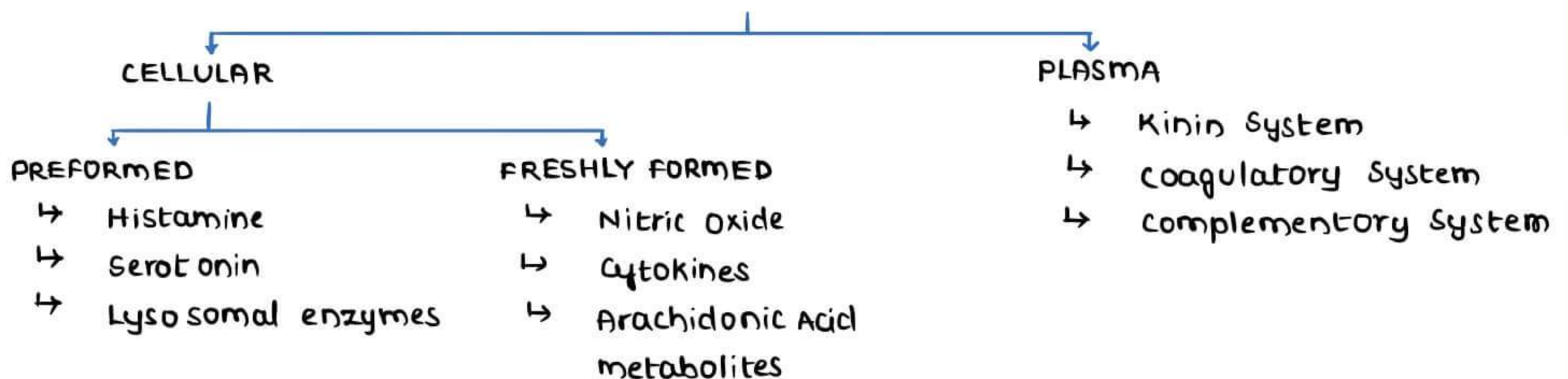


→ FEATURES

- ↳ Killing of Bacteria
- ↳ Killing of WBC
- ↳ Nuclear Ag exposure
 - Anti Nuclear Antibodies will be formed
 - ↑ risk of Auto immune disorders [SLE (commonly associated)]

PREFORMED CHEMICAL MEDIATORS

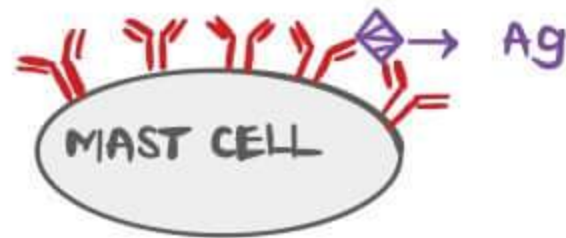
CHEMICAL MEDIATORS



CELLULAR PREFORMED MEDIATORS

HISTAMINE

- SOURCE → mast cells [Richest source] | Basophils | Platelets
- FUNCTIONS →
 1. vasodilatⁿ
 2. ↑ vascular permeability
 3. Itching
 4. Bronchospasm



- (H) RELEASE
 1. IgE crosslinking
 2. Physical factors → Temp.
 3. Viruses
 4. Anaphylotoxins
 - ↳ Bee venom / Insect venom
 - ↳ Proteins [C_{3a} / C_{4a} / C_{5a}]
 5. DRUGS
 - ↳ morphine [should be used cautiously in Asthmatics]
 - ↳ D-tubocurarine
 - ↳ Vancomycin
 - should give slow i.v.
 - Rapid injection → RED MAN SYNDROME

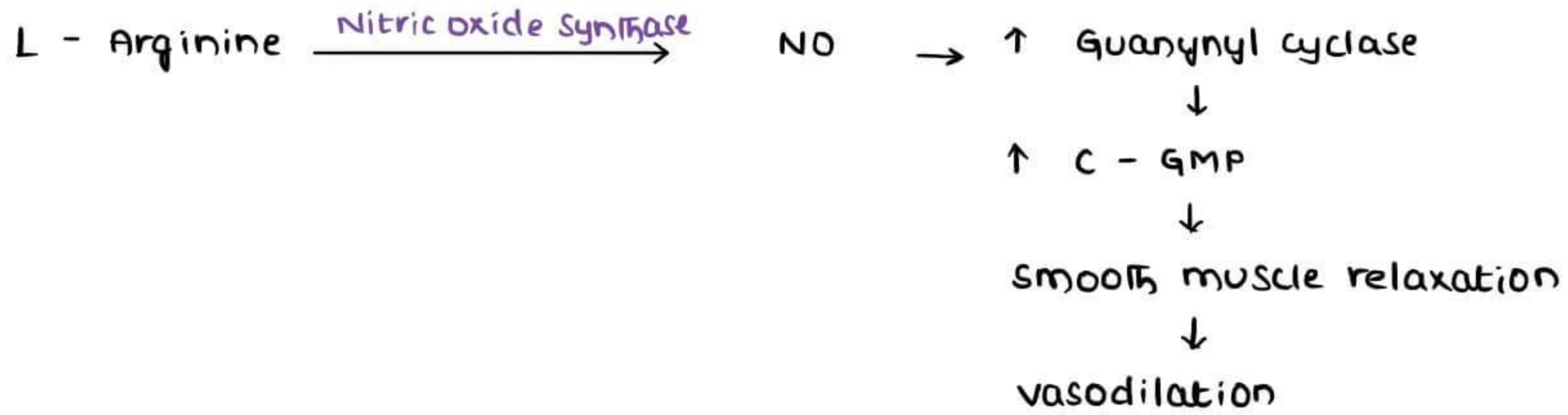
SEROTONIN [5 - HYDROXY TRYPTAMINE (5-HT)]

- SOURCE → GIT [Richest source, aka ENTERO CHROMAFFIN CELLS]
Platelets
CNS
- FUNCTIONS → Same as Histamine
 - Responsible for
 - ↳ vasoconstriction in small blood vessels
 - ↳ vasodilation in large blood vessels

LYSOSOMAL ENZYMES

- Responsible for oxygen dependent killing of Bacteria

1. NITRIC OXIDE [NO]



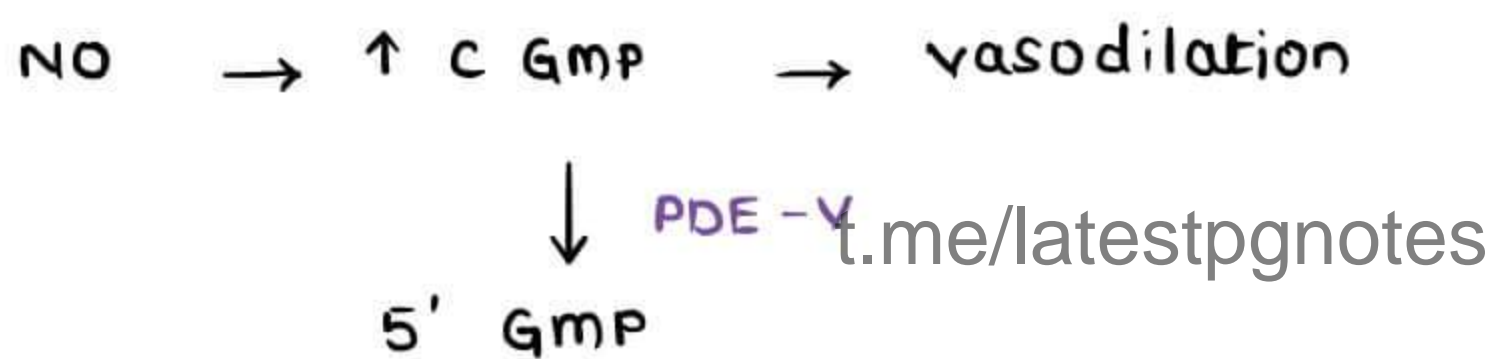
NO \rightarrow free radicals

NOS

\rightarrow ISOFORMS

- \rightarrow e NOS \rightarrow Endothelial cells
- \rightarrow i NOS \rightarrow Inducible / Inflammation
- \rightarrow n NOS \rightarrow Neurons

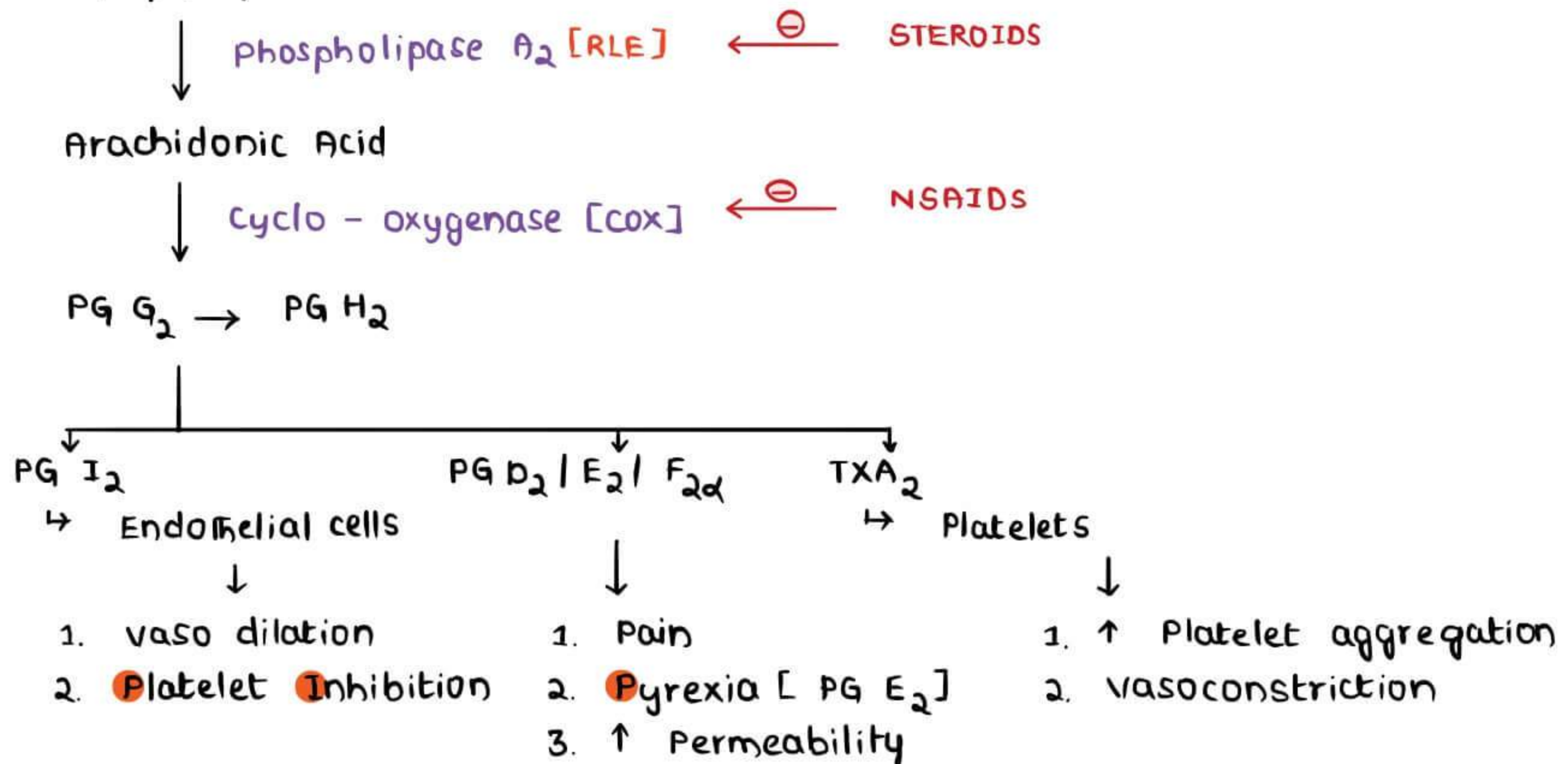
MOA



δ \rightarrow Impotency \rightarrow Rx by VIAGRA [PDE - V inhibitor] / SILDENAFIL

ARACHIDONIC ACID METABOLITES

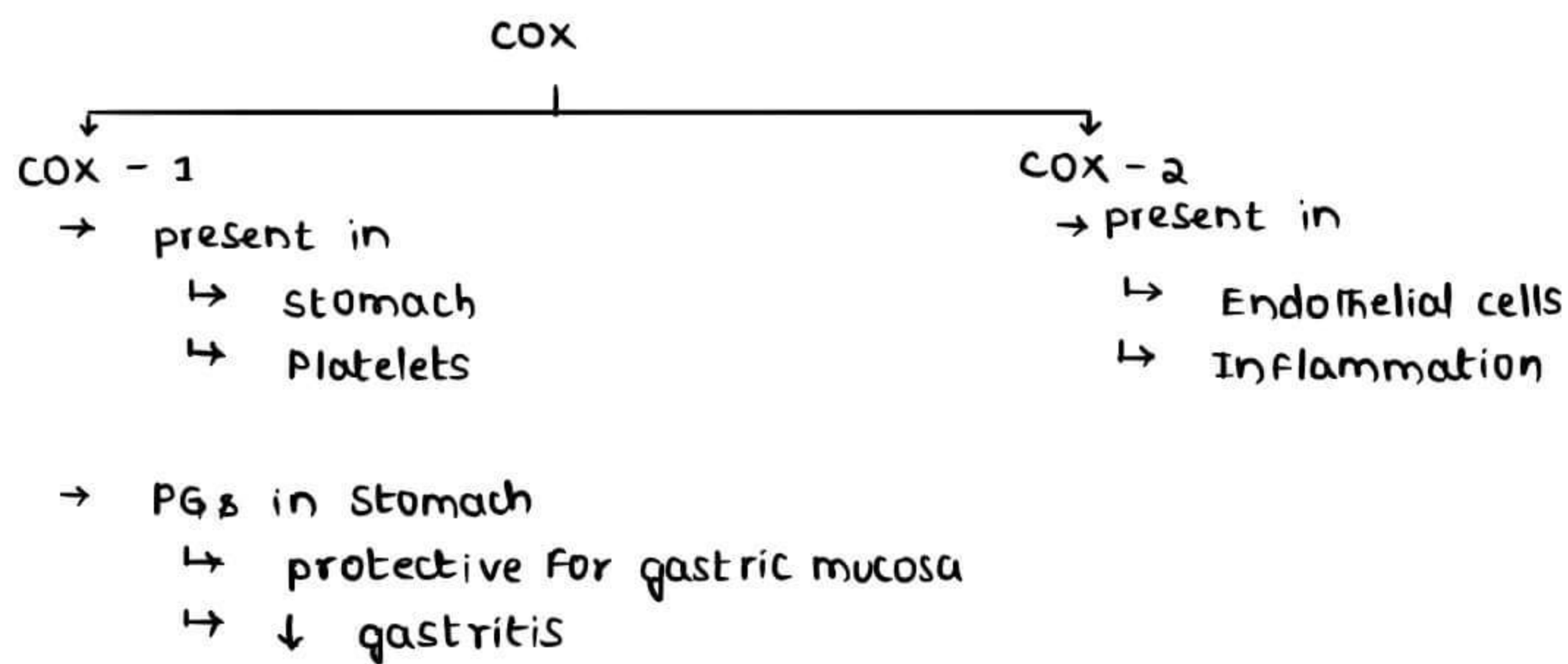
\rightarrow Phospholipids



→ CIP → ANTI - INFLAMMATORY DRUGS

1. Steroids
2. NSAIDs

→



→ NSAIDs

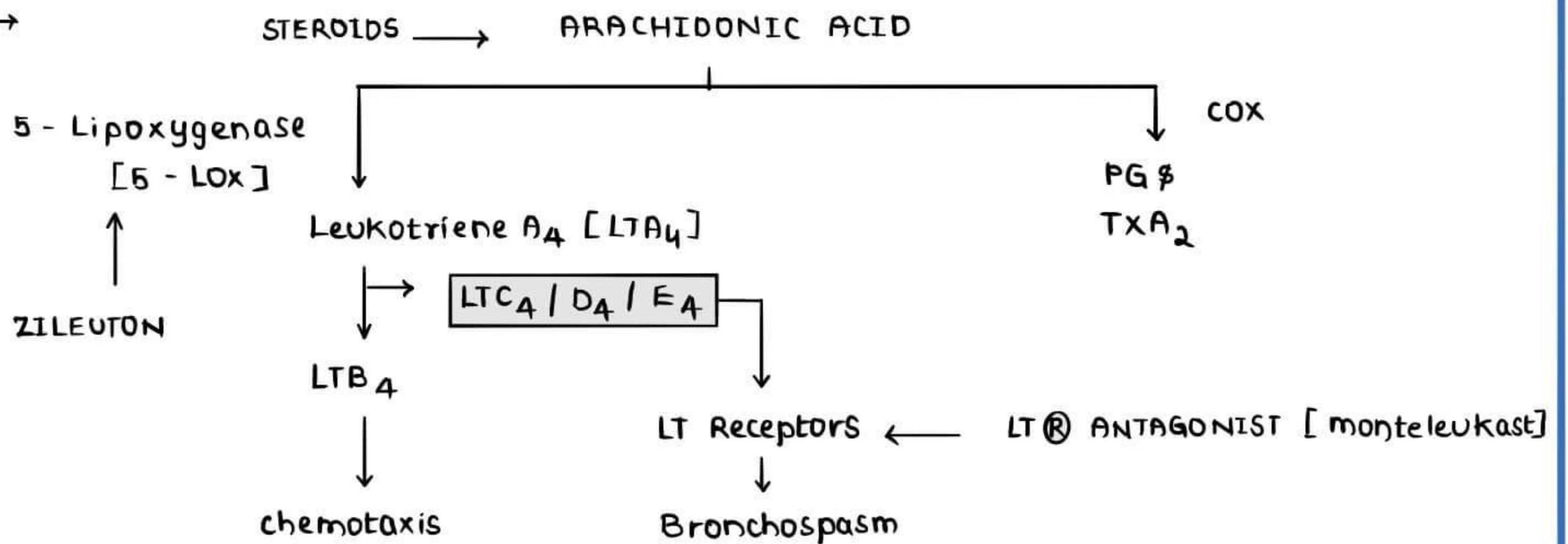
1. ⊖ COX 1 / COX 2 → NON - SELECTIVE

- ↳ Anti inflammatory
- ↳ ↑ gastritis
- ↳ ↓ TXA₂ & ↓ PGI₂ → balance maintained

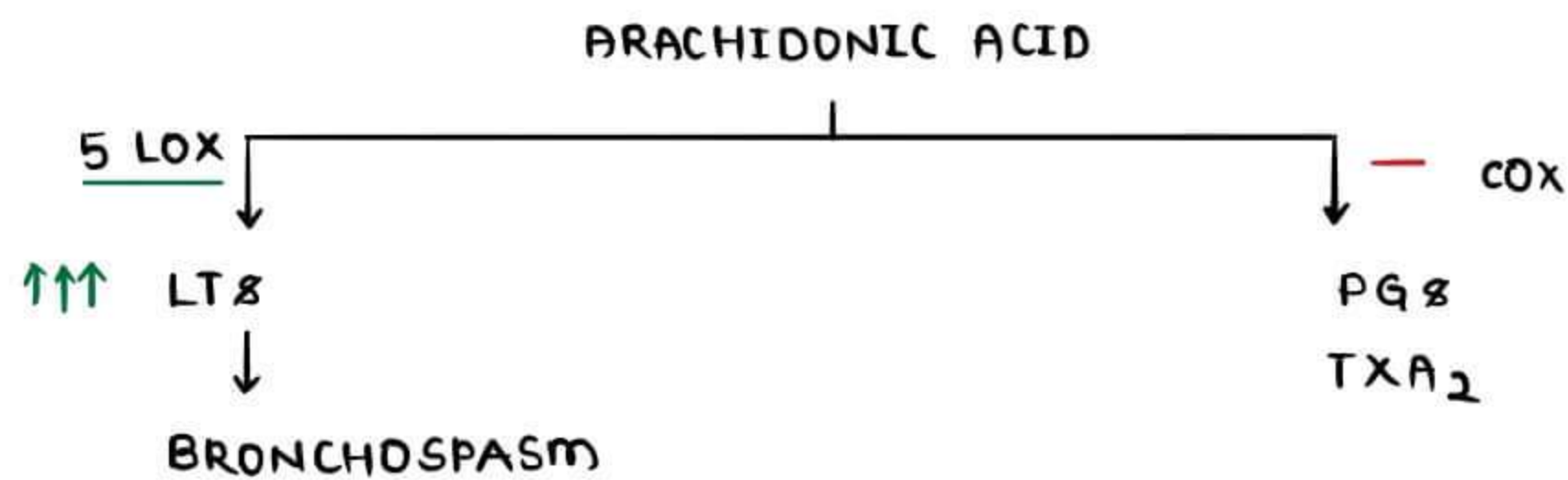
2. ⊖ COX 2 → SELECTIVE

- ↳ Anti inflammatory
- ↳ gastroprotective t.me/latestpgnotes
- ↳ ↓ PGI₂ & ↑ TXA₂ → ↑ myocardial infarctⁿ risk

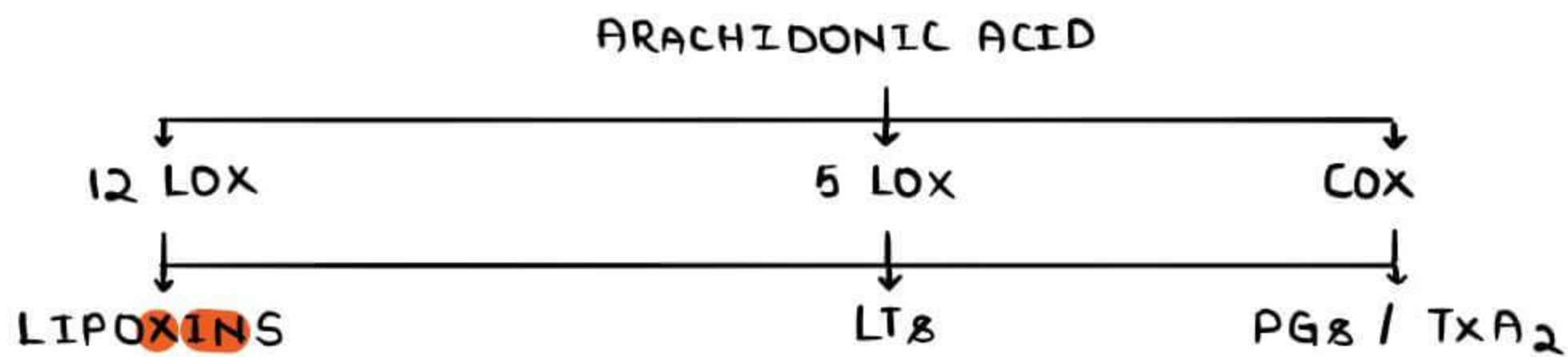
→



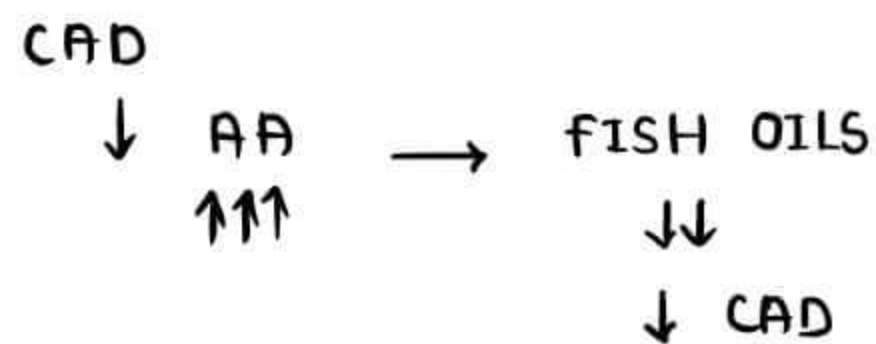
→ LTC₄ / D₄ / E₄ → SRS - A [Slow Reacting Substance - Anaphylaxis]
 → responsible for Asthma [LT induced]
 ↳ R₁ by monteleukast



- most prescribed drug for reducing the action of LT₈ → montelukast
- DRUG INDUCED ASTHMA → COX Inhibitors → NSAIDs



- ↓ Inflammation
- CAD [coronary Artery Disease]



CYTOKINES

- cyto = cells ; Kines = Peptides
- INCLUDES
 1. Interleukins
 2. TNF - α
 3. Interferons
- PLEIOTROPIC → more than one action by one cytokine
- REDUNDANCY → more than one cytokines having common action
- LOCAL EFFECTS
 - ↳ acts on Endothelial cells / Fibroblasts
- SYSTEMIC EFFECTS

IL 1 IL 6 TNF - α	}	acts on 1. Brain [central act ⁿ] ↳ ↓ appetite ↳ ↑ Sleep ↳ ↑ COX → fever 2. Bone marrow ↳ ↑↑↑ TLC ↳ ↑ neutrophils ↳ ↑ Lymphocytes ↳ ↑ Eosinophils
--------------------------------	---	---------------------------------------------------------------------------------------------------------------------------------------------------------------------------------------------

3. Liver

↳ Acute Phase Reactants

a. Positive APR

- Fibrinogen
- CRP
- Lectin
- Hepsidin
- Ferritin
- SAA Protein

b. Negative APR

- Albumin
- Transferrin

→ ESR [Erythrocyte Sedimentation Rate]

↳ ESR \propto serum Fibrinogen

- ↑ ESR → inflammation
- ↓ ESR → Afibrinogenemia

→ PYROGENIC CYTOKINES

↳ FEVER

→ caused by

- ↳ Exogenous → Bacterial toxins
- ↳ Endogenous → IL1 / IL6 / TNF- α
CNTF [Ciliary Neuro Tropic Factor]

→ eliminates viruses

→ O₂ dissociation curve shift to RIGHT

- ↳ ↑ O₂ → WBC/late Respiratory Burst → kills bacteria

→ SYSTEMIC INFLAMMATORY RESPONSE SYNDROME [SIRS]

↳ Diagnostic criteria [≥ 2 out of the following]

1. RR > 24/min
2. HR > 90/min
3. TLC > 12000 / μ l (or)
< 4000 / μ l (or)
> 10% band/stab cells
4. Temp > 38°C or < 36°C

→ SEPSIS

- ↳ SIRS + Documented Infection
- ↳ New Marker → PRO-CALCITONIN
- ↳ Old marker → C-RP

→ TNF- α [CACHETIN]

↳ ↓↓↓ Appetite

↓
cachexia

↓
cancer

chronic state

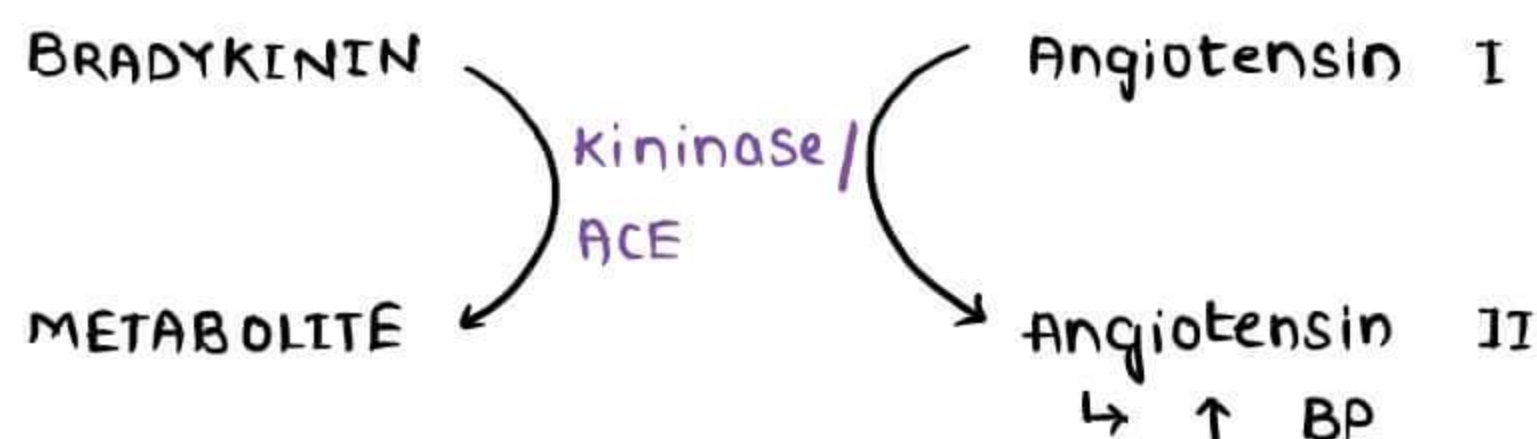
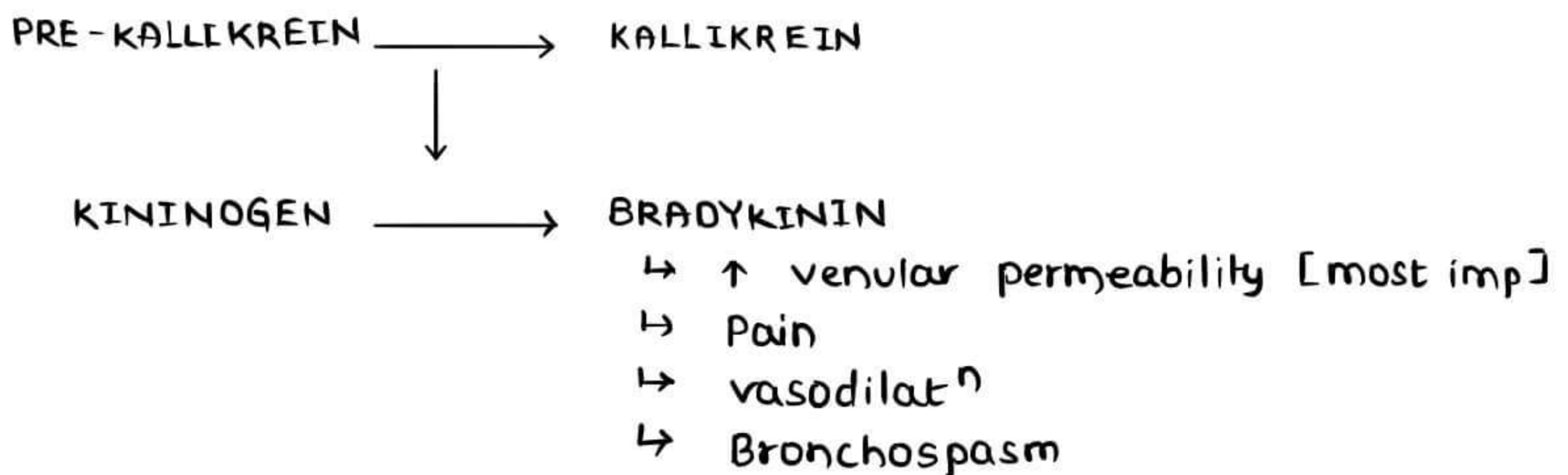
- MOST cytokines → ↑ Inflammation
 ↳ Exception → ANTI INFLAMMATORY CYTOKINES
- IL-10 } classical examples
 - TGF- β }
 - IL-6 } in some conditions
 - IL-4 }
 - Adiponectin }
- IL 1 → Systemic Effects of Inflammation
 IL 2 → Auto crine ; ↑ T-lymphocytes
 IL 4 } B cell proliferatⁿ & Differentiation
 IL 5 }
- IL 6 → Systemic Effects of Inflammation
 IL 7 → Normal functioning of B/T cell [defect causes SCID]
 IL 11 → ↑ Platelets
- IL 3 → Haematopoietic precursor cell proliferatⁿ
 IL 10 → Anti Inflammatory action

→ INTERFERONS [IFN]

	SOURCE	ACTION	CLINICAL USE
IFN α	→ Leucocytes	→ Anti viral	→ Virus R ₁
IFN β	→ Fibroblast	→ Immuno modulatory	→ Multiple sclerosis
IFN γ	→ T cells	→ macrophage activat ⁿ	→ Chr. granulomatous DS.

CHEMICAL MEDIATORS IN PLASMA : KININ SYSTEM

→ INJURY TO BLOOD VESSEL



- ACE INHIBITOR [↑ Bradykinin]
 - ↳ ↓ BP
 - ↳ S/E → Dry cough
 - ↳ Angioedema

COMPLEMENT SYSTEM

- group of > 20 proteins
- responsible for IMMUNITY
- regulates normal functions of body


→ SUB UNITS



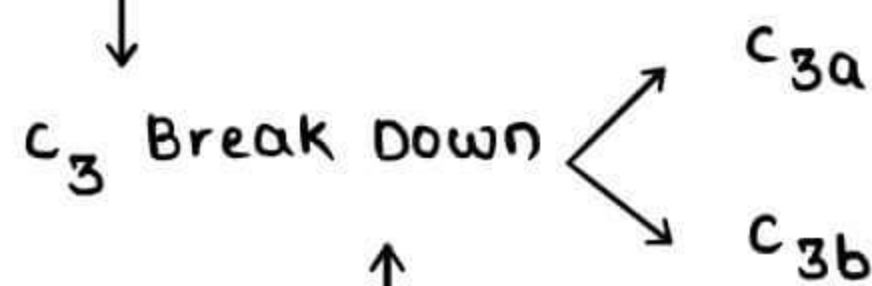
→ CLASSICAL PATHWAY

Ag - Ab [Ig M / G]

$C_1 \longrightarrow$ Activated C_1



t.me/latestpnotes



→ ALTERNATE PATHWAY

Endotoxin } C_3
 Ig A } +
 } factor B } C_{3bBb}

C_5 Breakdown

C_{5a}
 $C_{5b} + C_6 / C_7 / C_8 / C_9$

C_{5b6789} / C_{5b-9} complex

→ C_{5b-9} complex [MAC]

- ↳ MAC → Membrane Attack Complex
- ↳ causes Antigen destruction [main function of MAC]

→ Normal → ↓ Infections

DEFICIENCY	DISEASES
C ₁ / C ₂ / C ₄ [Early proteins]	↑ Autoimmune disorders [SLE]
C ₃	Severe pyogenic infections
C ₅ / C ₆ / C ₇ / C ₈ [Late proteins]	↑ Neisseria infection ↑ Toxoplasmosis
C ₉	NO DISEASE

→ REGULATORY C PROTEINS

1. C₁ INHIBITOR [Blocks the activation of C₁]

C₁ → Activated C₁ → ⊕ → ⊙ SYSTEM

→ C₁ Inhibitor Deficiency

↑↑↑ ⊙ Activation



Release of C_{3a} / C_{5a}



HEREDITARY ANGIOEDEMA

↳ F >>> [latestpgnotes](https://www.youtube.com/watch?v=latestpgnotes)

↳ Edema [Oral [mc] / Larynx / GIT] [Emergency]

↳ Non pitting edema

2. CD₄₆ / factor B / factor H

→ controls Alternate pathway

→ defect → +++ ⊙ System



Endothelial cell damage



ATYPICAL HEMOLYTIC UREMIC SYNDROME

3. CD₅₅ / CD₅₉

→ present on normal blood cell

→ defect → ↓ RBC / WBC / Platelets



Pancytopenia

→ PNH

[Paroxysmal Nocturnal Hemoglobinuria]

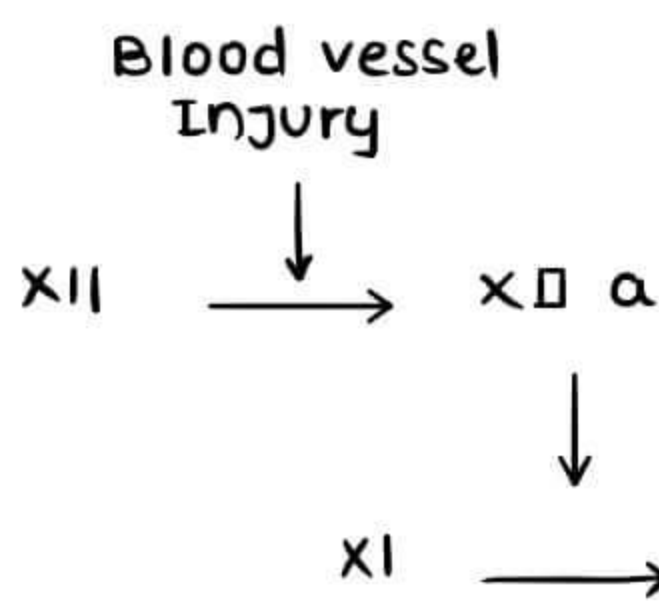


→ CD₅₅ / CD₅₉

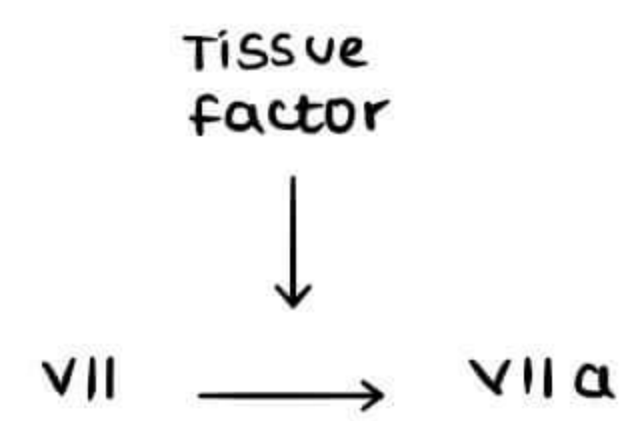
- C_{3a} → Anaphylotoxin
- C_{3b} → Opsonisation
- Anaphylotoxin
- C_{5a} → Chemotaxis
- C_{5b} → MAC [C_{5b-9}] → Antigenic destruction

COAGULATION CASCADE

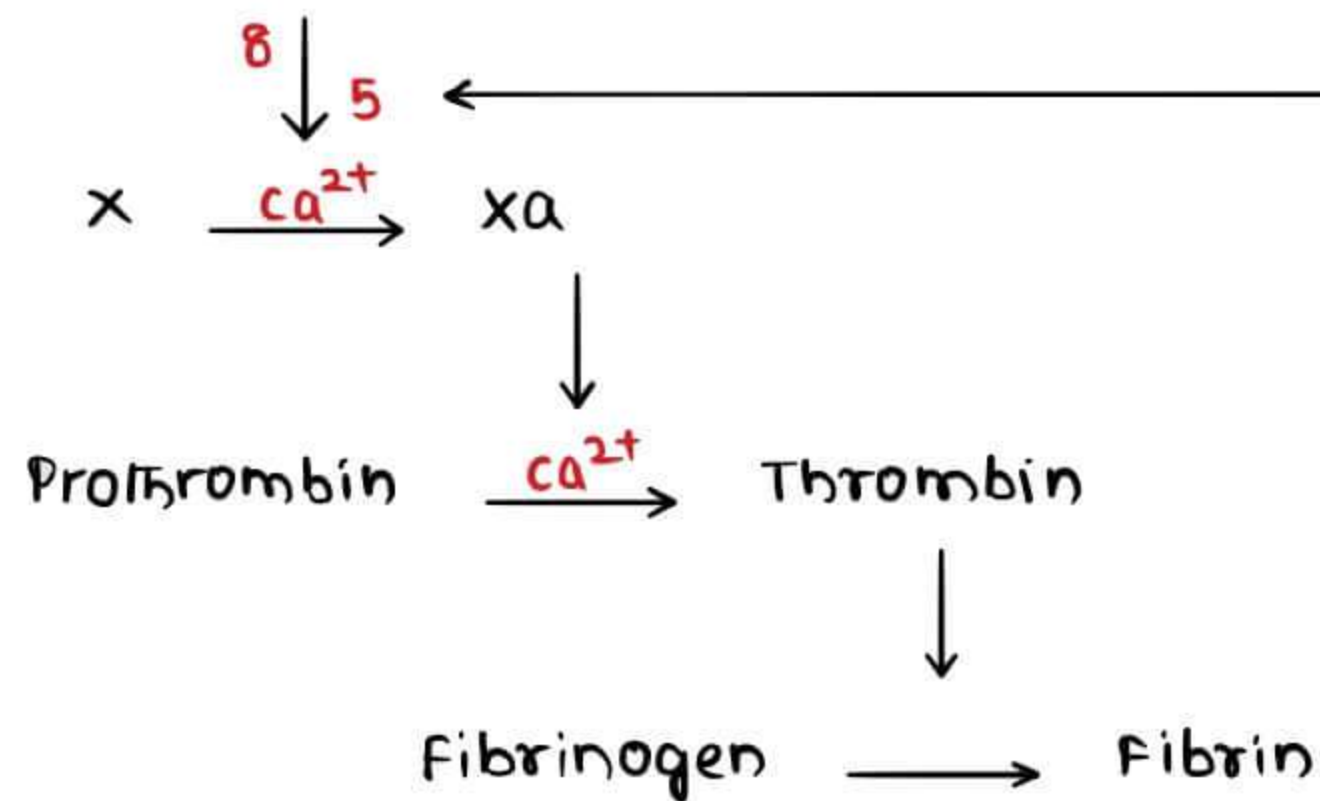
I INTRINSIC PATHWAY



EXTRINSIC PATHWAY



IX → t.m.a. test pgnotes



→ FIBRINOGEN [soluble] → FIBRIN [insoluble]

→ FIBRINOGEN
 → plasma protein
 → also required for Opsonisation

→ FIBRIN
 → plasma protein
 → required for chemotaxis

→ HEMOPHILIA

- ↑ Bleeding
- A → factor 8 Deficiency
- B → factor 9 Deficiency
- C → factor 11 Deficiency

→ PROTHROMBIN TIME [PT]

→ aPTT [ACTIVATED PARTIAL THROMBOPLASTIN TIME]

PERFORMED

- ↳ using Platelet free plasma
- ↳ at room temp.
- ↳ within 2 hrs
- ↳ Additives added
 - for PT → Tissue Thromboplastin
 - for aPTT → Kaolin / Silica
- ↳ Plastic tube / Syringes used

PT
↓
monitors
Extrinsic
Pathway

aPTT
↓
monitors
Intrinsic
Pathway

t.me/latestpnotes

→



Exception → IV

↓
vit. K required
for ACTIVATION

↓
γ carboxylatⁿ of
Glutamate

- ↳ vit K dependent clotting factors → 2/7/9/10
- ↳ vit K dependent anti clotting factors → Protein C/S

→ Ca²⁺

- co-factor for clotting
- ↓ Ca²⁺ → ↓ clotting
- used in

1. Blood Banks

- * ACD → Acid citrate Dextrose
- * CPD-A → citrate PO₄ Dextrose - Adenine
- * SAGM → Saline Adenine Glucose mannitol [⊕ cit./PO₄]

↳ citrate → ↓ Ca²⁺ → ↓ clotting



- ↳ SHELF LIFE
- ACD → 21 days [3 weeks]
 - CPD - A → 35 days [5 weeks]
 - SAGM → 42 days [6 weeks]

CHRONIC INFLAMMATION

- ongoing inflammation
- a/w tissue destruction → Hallmark feature
- a/w Repair or Healing

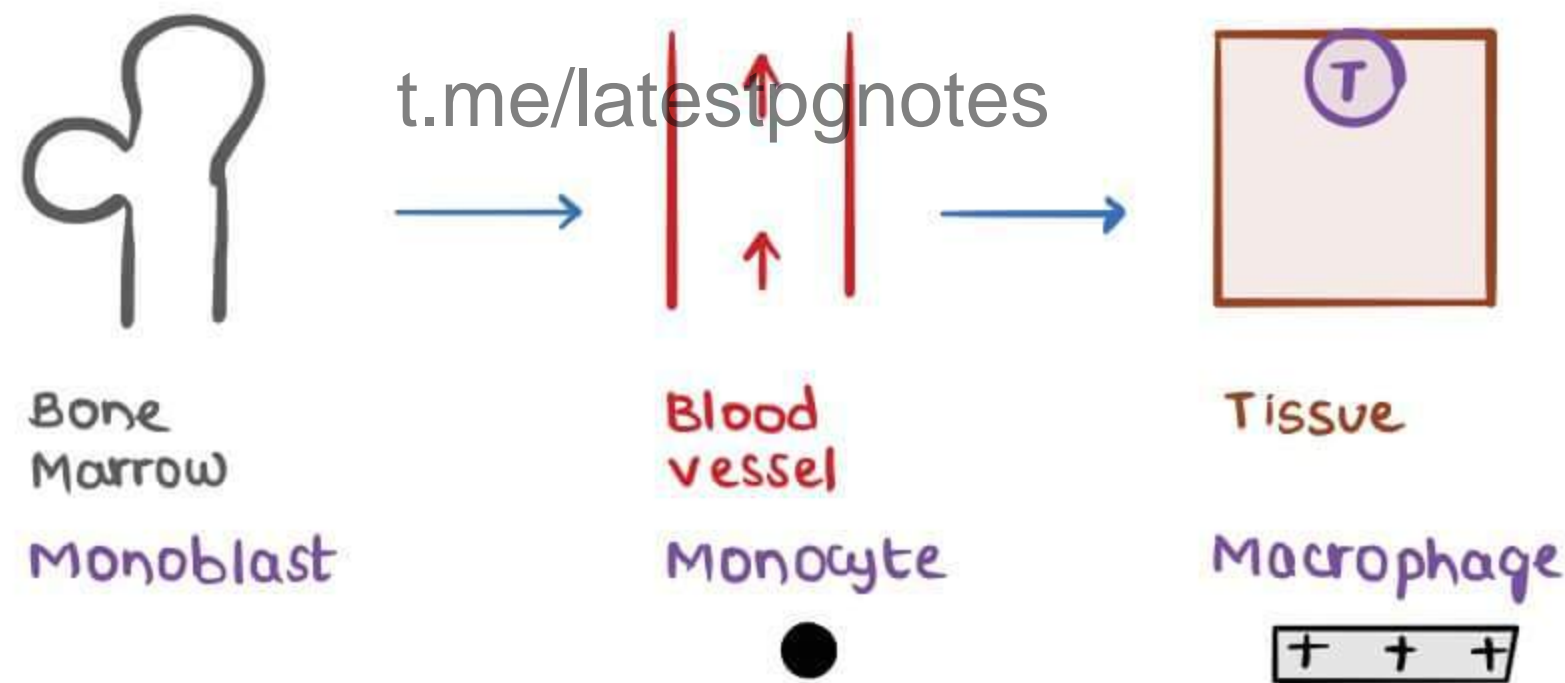
→ Longer Duration → NEUTROPHILS

↓
 MONO NUCLEAR WBC [monocyte / Lymphocyte]

CHEMOKINES

- 1. α → IL 8 → attack Neutrophils
- 2. β → MCP / EDOTAXIN → attract monocytes & Eosinophils
- 3. γ → LYMPHOTAXIN → attract Lymphocytes

→ In Acute inflammation → α chemokines predominate
 In chronic inflammation → β & γ chemokines predominate



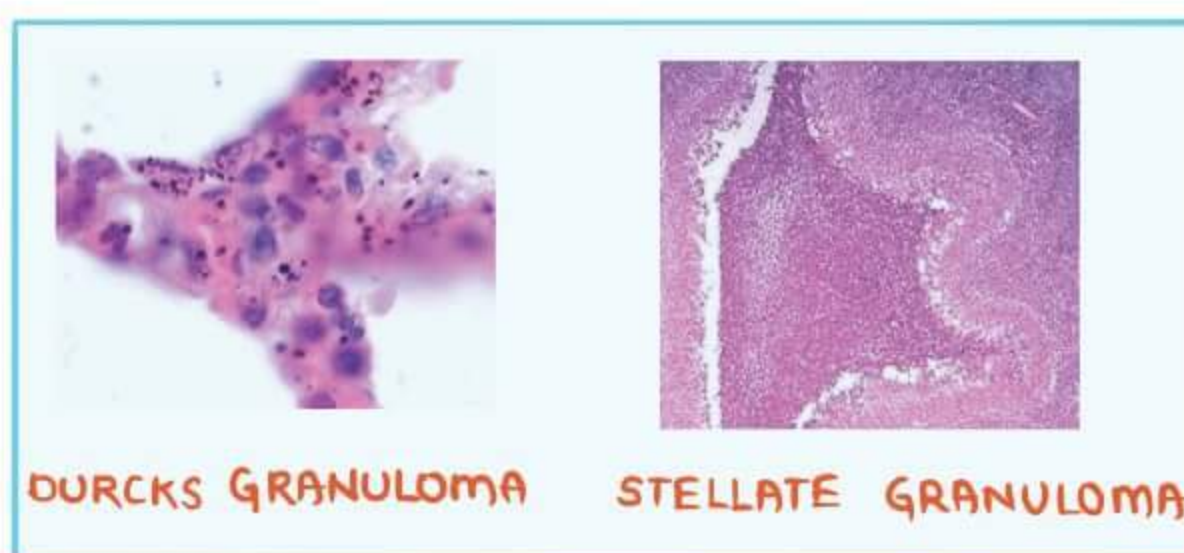
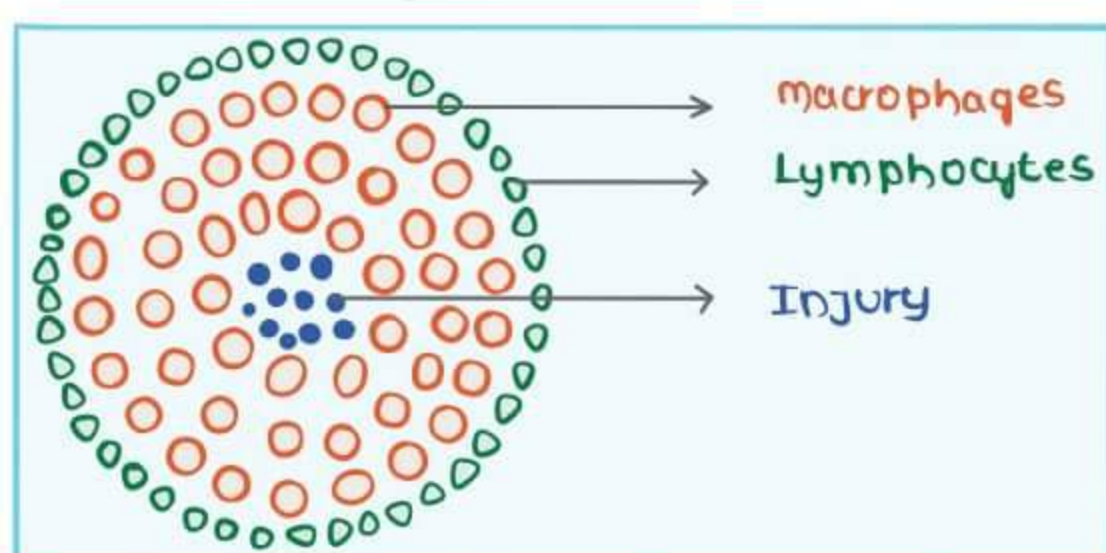
LIFE SPAN

MACROPHAGE NAMES IN DIFFERENT SITES

- 1. Kidney → Mesangial cell
- 2. Liver → Kupffer cell
- 3. Brain → Microglia
- 4. Bone → Osteoclast
- 5. Spleen → Littoral cell
- 6. Placenta → Hofbauer cell

GRANULOMATOUS INFLAMMATION

GRANULOMA



→ SEEN IN

- ↳ TB → CASEATING GRANULOMA
- ↳ Sarcoidosis → NON - CASEATING GRANULOMA
- ↳ Syphilis → GUMMA
- ↳ malaria → DURCK GRANULOMA
- ↳ cat scratch disease → STELLATE GRANULOMA
- ↳ IBD
 - crohn's disease → Granuloma ⊕
 - ulcerative colitis → NO granuloma
- ↳ GRANULOMATOUS VASCULITIS
 - Temporal Arteritis
 - Takayasu Arteritis
 - churg strauss syndrome
 - Granulomatosis & polyangitis

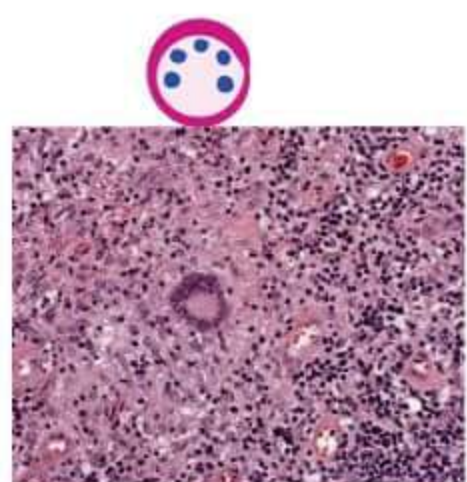
→ EPITHELOID CELLS [ACTIVATED MACROPHAGES]

- ↳ derivative of macrophages
- ↳ do not line the body cavities
- ↳ present inside the granuloma
- ↳ have SLIPPER SHAPED NUCLEUS
- ↳ secretory in function
- ↳ Fused to form 'GIANT CELL'

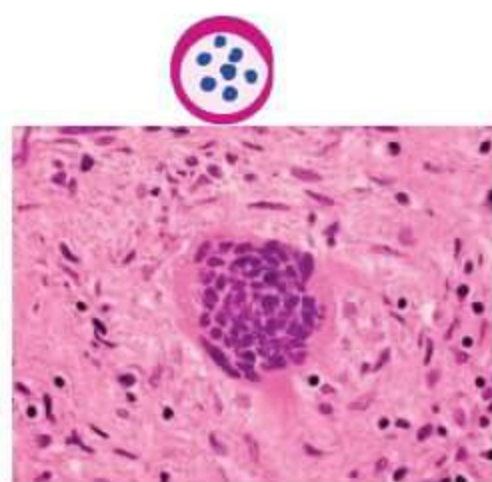
→ GIANT CELL - SUB TYPES

t.me/latestpgnotes

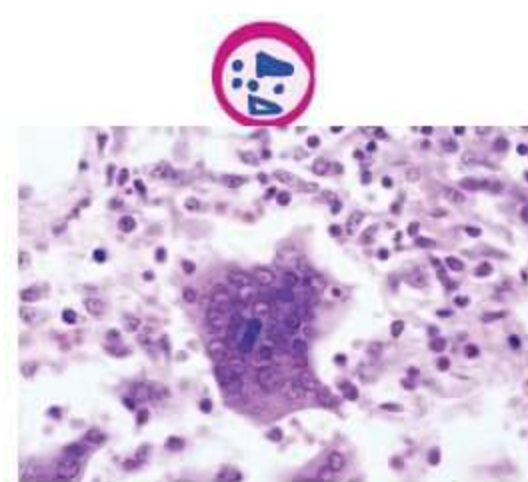1. LANGHANS GIANT CELLS	→ Seen in TB → LANGERHANS CELL → Normal
2. FOREIGN BODY GC	→ Seen in sutures & talc
3. WARTHIN - FINKELDEY GC	→ Seen in measles
4. REED - STERNBERG CELL / TUMOR GIANT CELL	→ OWL - EYE APPEARANCE → Seen in Hodgkin's Lymphoma
5. TOUTON CELLS	→ Fat droplets ⊕ → Seen in Xanthoma



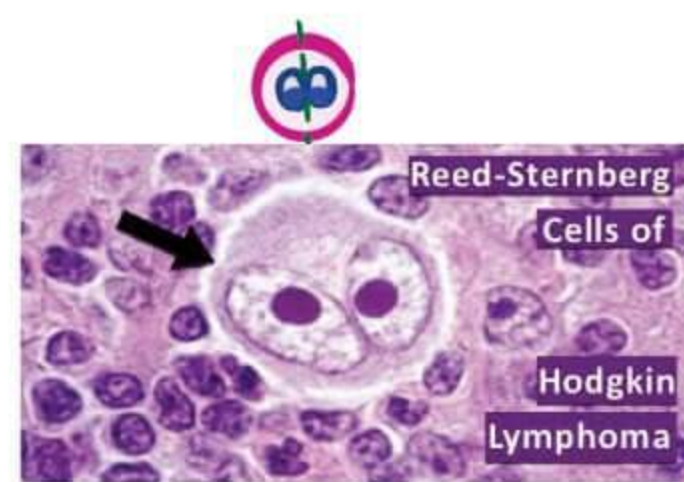
LANGHAN CELL



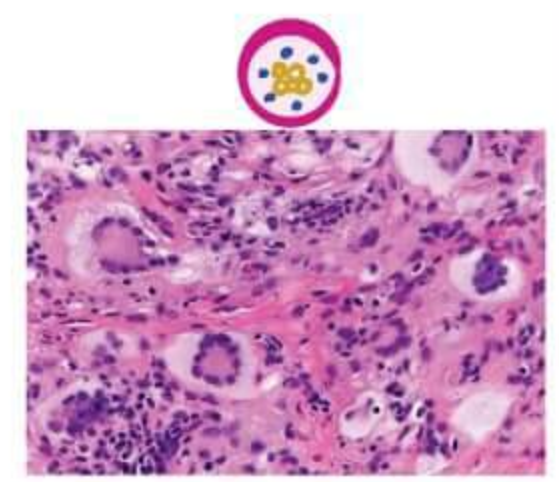
FBGC



WFGC



RS CELL



TOUTON CELL

→ GIANT CELLS PER SE ARE NOT DIAGNOSTIC

DAY	
0	→ Blood clot
1	→ Blood clot + Neutrophilic infiltrat ⁿ
2	→ Day 1 + Thin Epithelial layer
3	→ Granulation tissue ↳ macrophages ⊕ ↳ Fibrous tissues ⊕ ↳ Angiogenesis
4/5	→ GT + collagen deposit ⁿ [Type III]
14	→ ↑↑ collagen + Fibrous tissue

→ maximum angiogenesis seen at → DAY 5

→ COLLAGEN REMODELING

- ↳ 3-4 wks collagen III replaced by collagen I
- ↳ dit MMP [Matrix metallo Proteinases (zn)]

SUBTYPES

PRIMARY UNION

→ Seen in SHARP OBJECT INJURY

SECONDARY UNION

- Seen in BLUNT OBJECT INJURY
- more chance OF SCAR FORMATION

t.me/latestpgnotes

FIBROBLAST



MYO FIBROBLAST

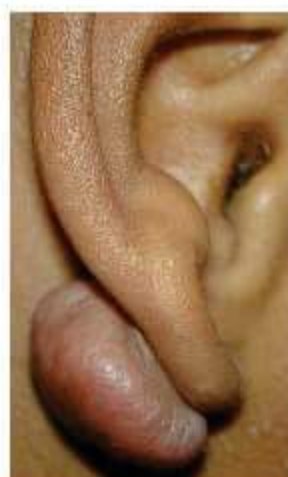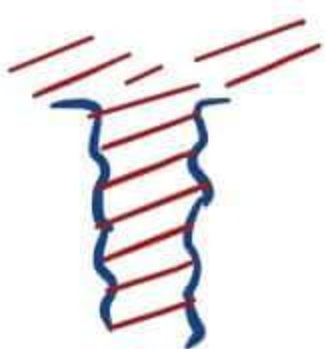
- has the contractⁿ ability
- ↓ SIZE OF SCAR
 - ↳ scar contractⁿ
 - ↳ wound contractⁿ

DELAYED WOUND HEALING

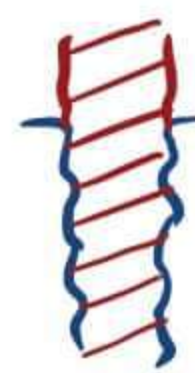
LOCAL FACTORS	SYSTEMIC FACTORS
<ul style="list-style-type: none"> → foreign body → persistent infections → Radiation 	<ul style="list-style-type: none"> → ↓ Immunity → DM → DRUGS [steroids]

EXCESSIVE | ABNORMAL HEALING

KELOID

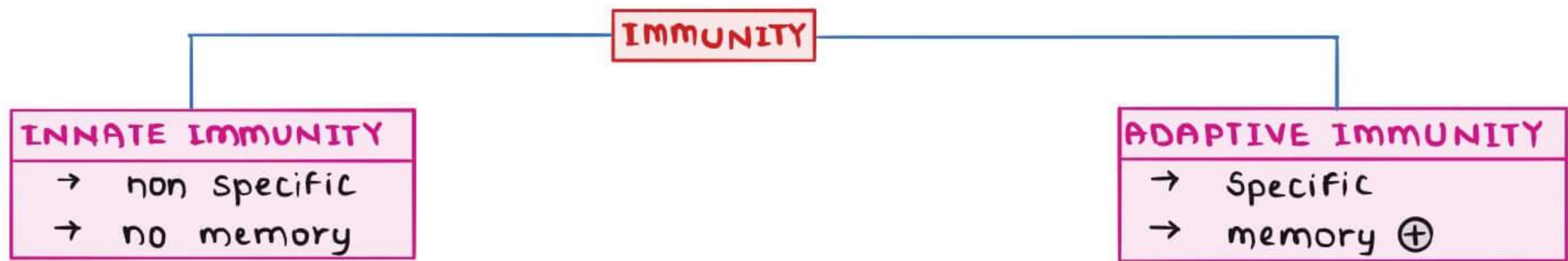


HYPERTROPHIC SCAR



- more common in AFRO AMERICANS [genetic predisposition]
- STEROIDS → causes ↓ fibroblast proliferatⁿ → ↓ SCAR SIZE

IMMUNITY 1 INTRODUCTION



INNATE IMMUNITY

1. BARRIERS

- Anatomical [skin]
- Physiological [secretions]

2. PROTEINS

- C-RP
- Lectin
- Complement proteins
- Surfactants

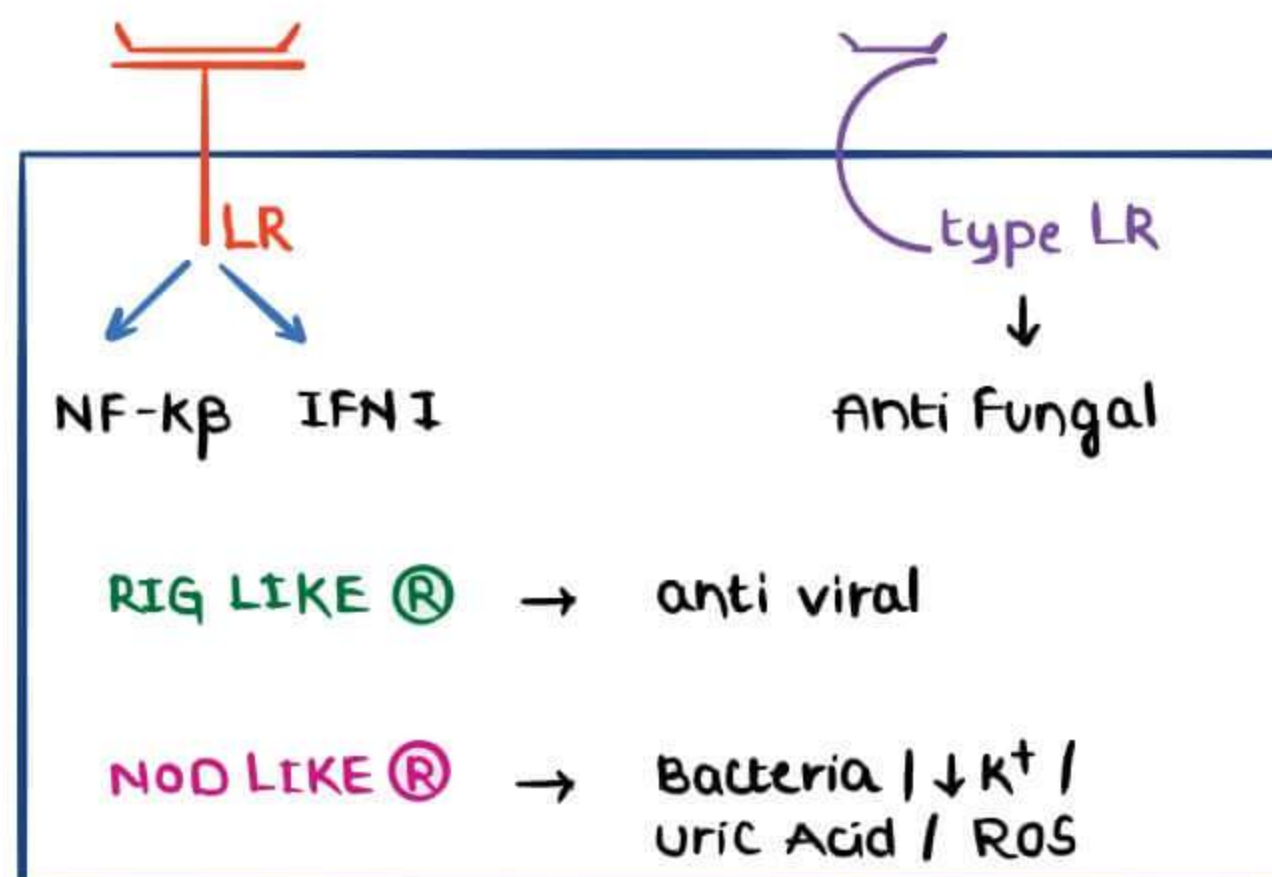
3. CELLS

- Neutrophils
- macrophages
- NK cell
 - ↳ Kills virus infected cells
 - ↳ Kills tumor cells

BACTERIA	→	PAMP [Pathogen Associated Molecular Patterns]
INFLAMMATION	→	DAMP [Damage Associated Molecular Patterns]

PATTERN RECOGNITION RECEPTORS

- recognises PAMP & DAMP t.me/latestpgnotes
- EXAMPLES



Nuclear factor κ B

- activatⁿ leads to more recruitment of WBC

IFN-1 → Anti viral

→ NOD LIKE RECEPTOR

- identifies Bacteria / $\downarrow K^+$ / Uric Acid / ROS [Reactive O₂ Species]
- acts by 'INFLAMMASOME'

INFLAMMASOME

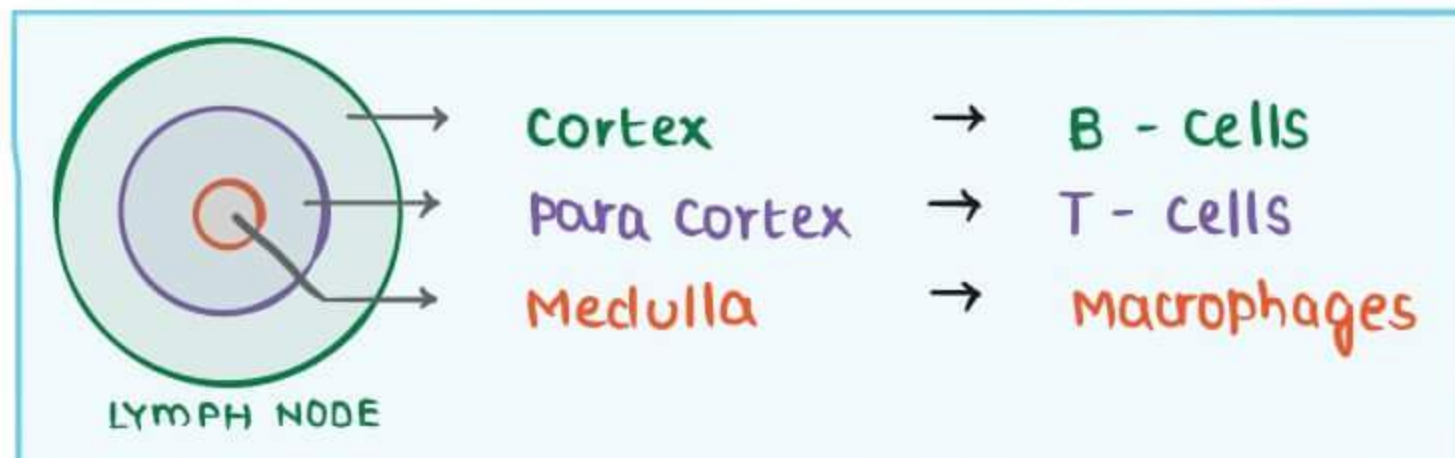
CASPASE 1 ⊕ → IL1 release → Fever
inflammation

ADAPTIVE IMMUNITY

- contributed by T cells / B cells
- **B CELLS** → PLASMA CELLS → Igs → HUMORAL IMMUNITY
- **T CELLS** → CELLULAR IMMUNITY
- HUMORAL IMMUNITY → effective against extra cellular microbes
- CELLULAR IMMUNITY → effective against Intracellular microbes

B CELLS

- Located in LN, Spleen, git, Tonsils

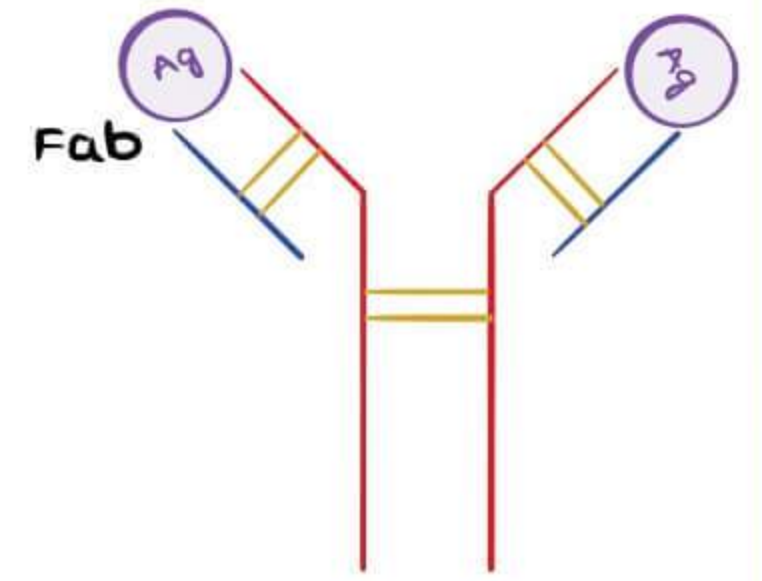


- GIT → mucosal Tissue → MALT → PEYER PATCHES → ILEUM
 - Enteric fever → ulceration of Peyer patches
- t.me/latestpgnotes

B CELL MARKERS

- CD 19/20/21/22/23
- CD 40 | $\frac{CD 80}{CD 86}$
- CD 19 → Pan B marker
- CD 20 → $\text{\textcircled{R}}$ for EBV
- CD 40
 - ↳ binds \bar{i} CD 40 - Ligand on T cells
 - ↳ responsible for B \leftrightarrow T cell interaction
 - ↳ helps in quality antibody formation
- $\frac{CD 80}{CD 86}$
 - ↳ aka B7
 - ↳ binds \bar{i} CD 28
 - ↳ responsible for normal CO-STIMULATORY SIGNAL

B CELL → PLASMA CELL → I_g SECRETION



IMMUNOGLOBULINS [I_g]

- LIGHT CHAINS → K, λ
- HEAVY CHAINS → γ, α, μ, δ, ε

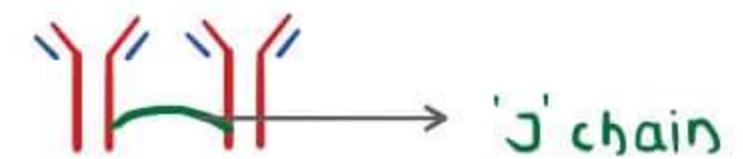IMMUNOGLOBULIN CLASSES [Based on heavy chains]

1. I_g G

- Concentration in body → maximum
- Cross placenta
- Complement activation
- Cell eater [opsonisation]

2. I_g A

- Forms
 - Monomer [serum]
 - Dimer [secretions & mucosa] [two monomers joined by 'J' chain]
- FIRST LINE OF DEFENCE
- activates ALTERNATE Ⓢ PATHWAY



3. I_g M

- Maximum size
- maximum molecular weight
- PENTAMERIC [mostly]
- MILLIONAIRE ANTIBODY
- component of PRIMARY IMMUNE RESPONSE [predominant component]
- MONOMERIC FORM as B-CELL Ⓢ

G	→ max. concentr ⁿ
A	
M	
D	
E	→ Lowest concentr ⁿ

4. I_g D → acts as B-cell Ⓢ

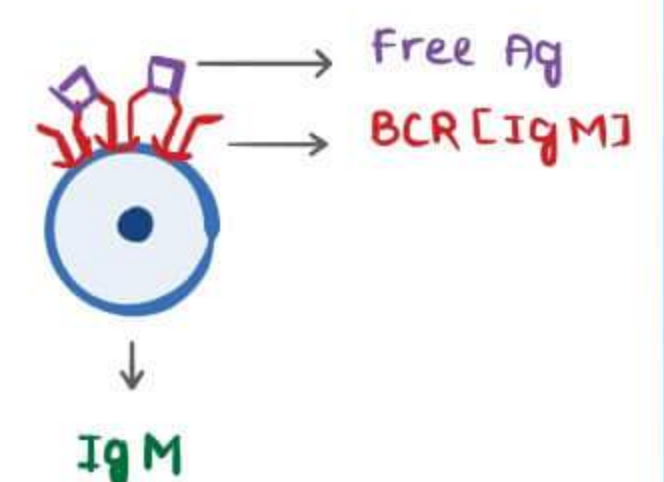
5. I_g E

- LOWEST CONCENTRATION
- attached on surface of MAST CELLS → Type 1 HSR
- Heat labile antibody

TYPES OF ANTIGENS

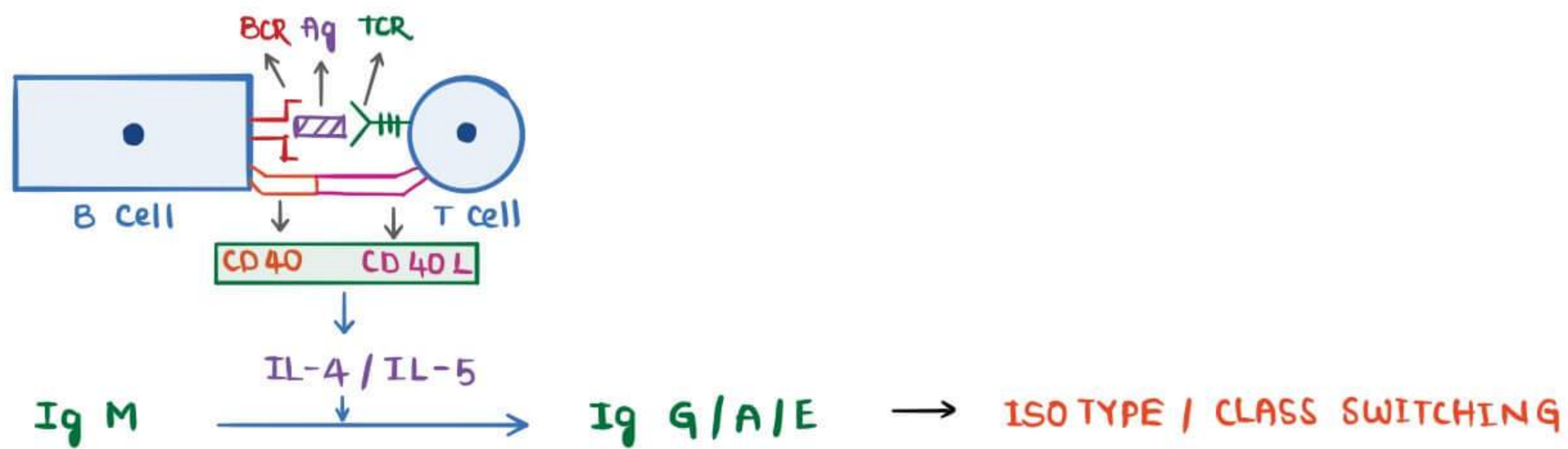
1. NON PROTEINACEOUS ANTIGENS

- FREE ANTIGENS
 - ↳ do not require support of any additional cells
 - ↳ aka THYMIC / T CELL INDEPENDENT ANTIGENS
 - ↳ interaction leads to I_g M production



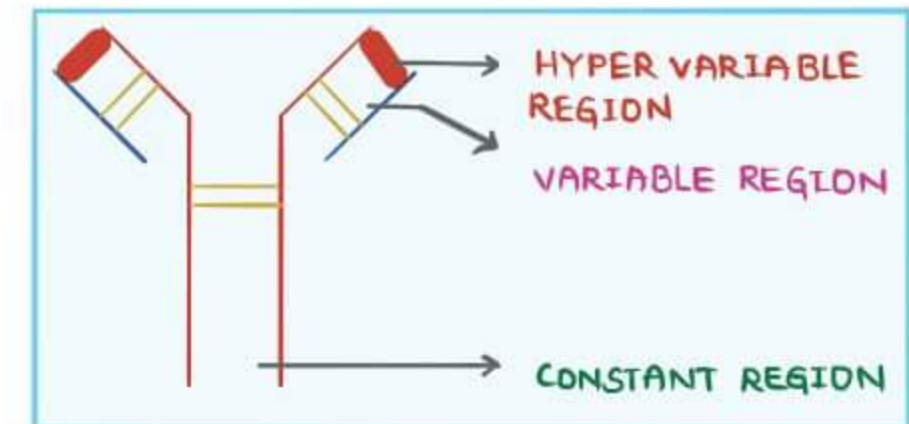
2. PROTEINACEOUS ANTIGENS / T-CELL DEPENDENT ANTIGENS

- requires the support of T-CELLS for proper activatⁿ of immune system



ISOTYPE / CLASS SWITCHING

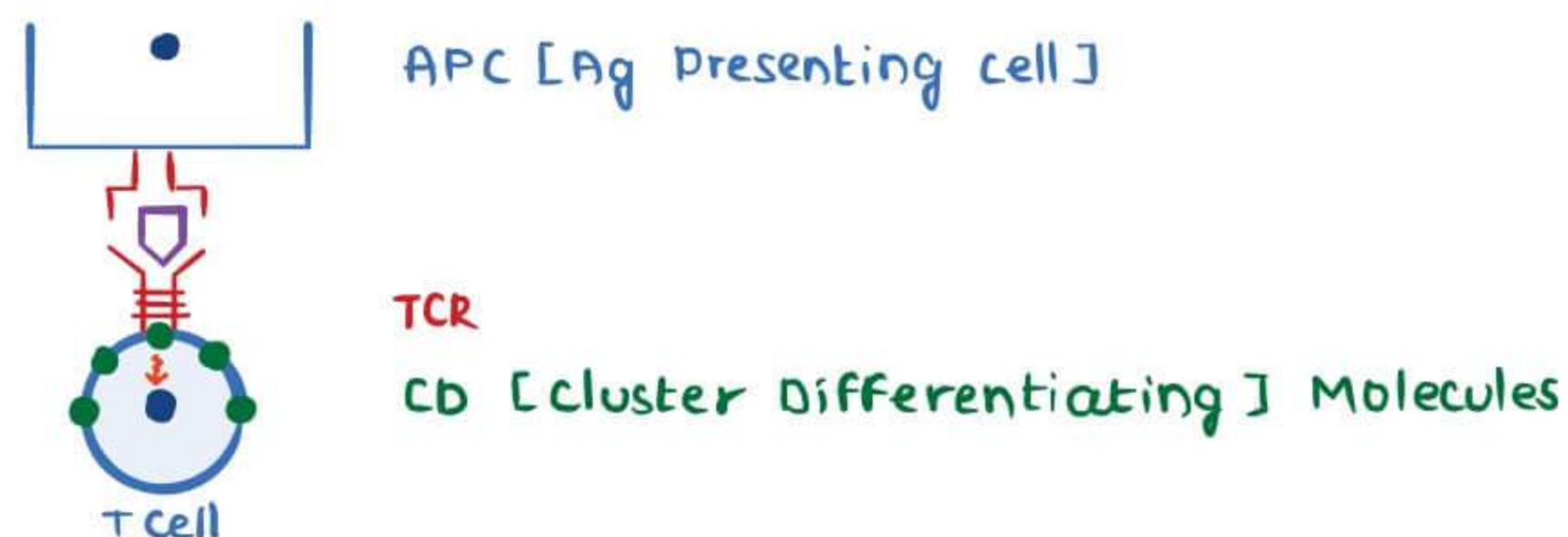
- ↳ Occurs d/t interactⁿ b/w CD 40 & CD 40 Ligand
- ↳ responsible for
 - * SOMATIC HYPERMUTATION
 - * AFFINITY MATURATION



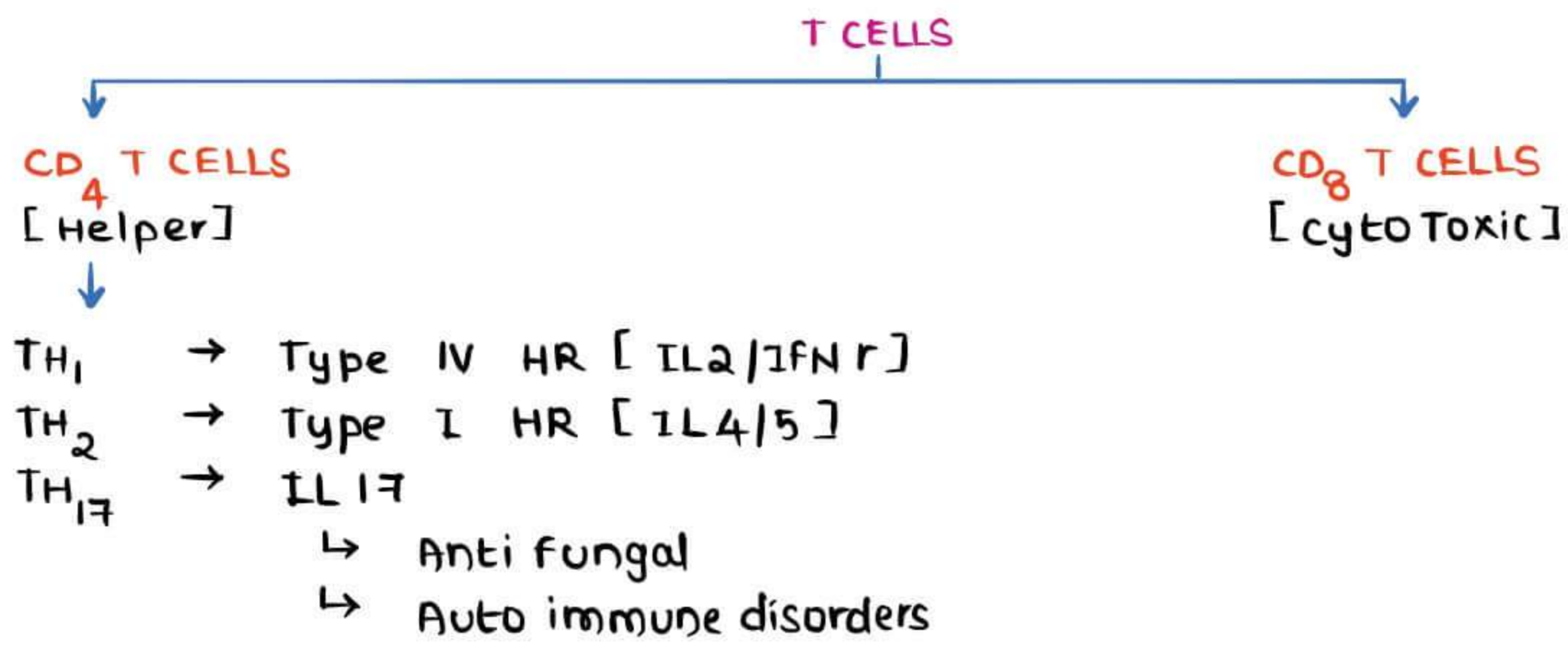
- ISOTYPE** → Different classes of Antibodies in same person
- ALLOTYPE** → Difference in Antibody taken from 2 different people
- IDIOTYPE** → variable part of Antibody different in same person

T CELL

- formed in Thymus
- present at
 - ↳ LN → Para cortex [PC]
 - ↳ Spleen → Peri arteriolar Lymphoid sheath [PALS]
 - ↳ GIT → Intra Epithelial lymphocytes [IELs]

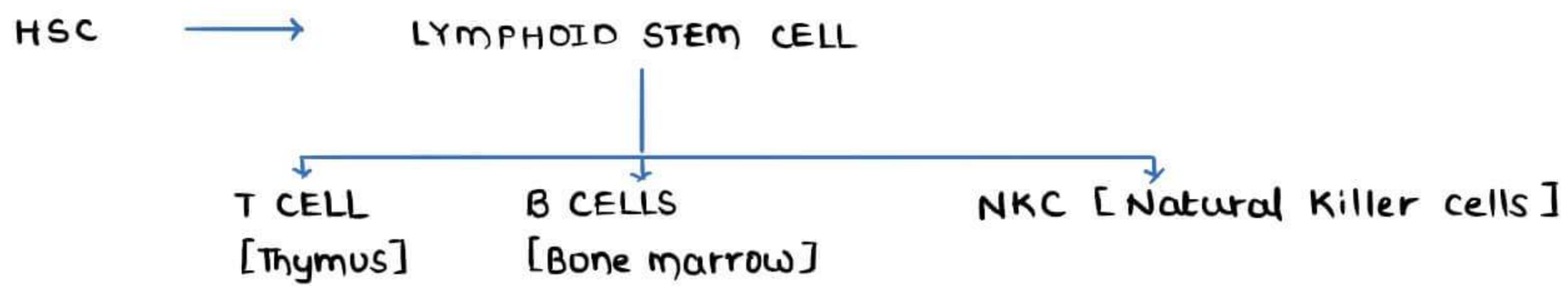


- T cell get activated by pre bound antigens, T Cells NEVER activated BY FREE ANTIGENS
- **CD MOLECULES USEFUL IN IDENTIFICATION OF CERTAIN CELLS**
 - ↳ CD 1/2/3/4/5/7/8 → T cell markers
 - ↳ CD 28 → CD stimulatory molecule
 - ↳ CD 40 L → i CD 40 → maintains proper quality of Ab
 - ↳ CD 3
 - Pan T cell marker
 - Significant in signal transductⁿ mechanism
 - activatⁿ of T-cell assisted by Calcineurin & IL-2



NK CELLS

LYMPHOCYTES

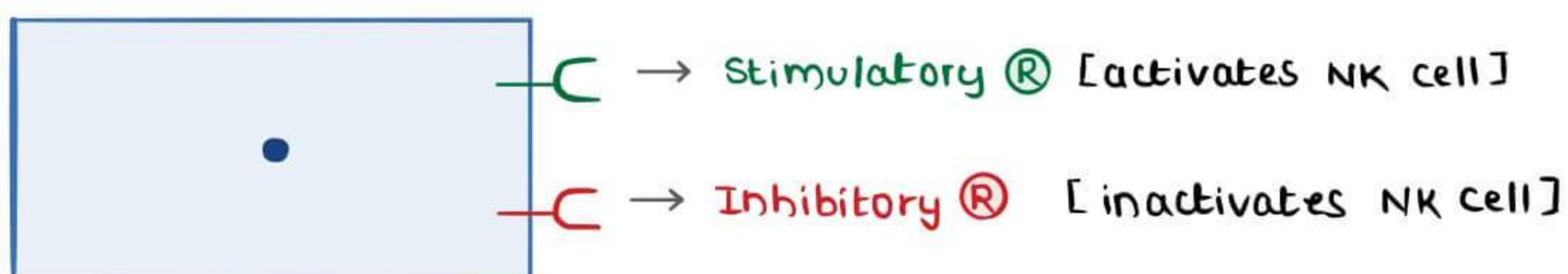


- NK cells → Component of INNATE IMMUNITY
- T & B cells → components of ADAPTIVE IMMUNITY

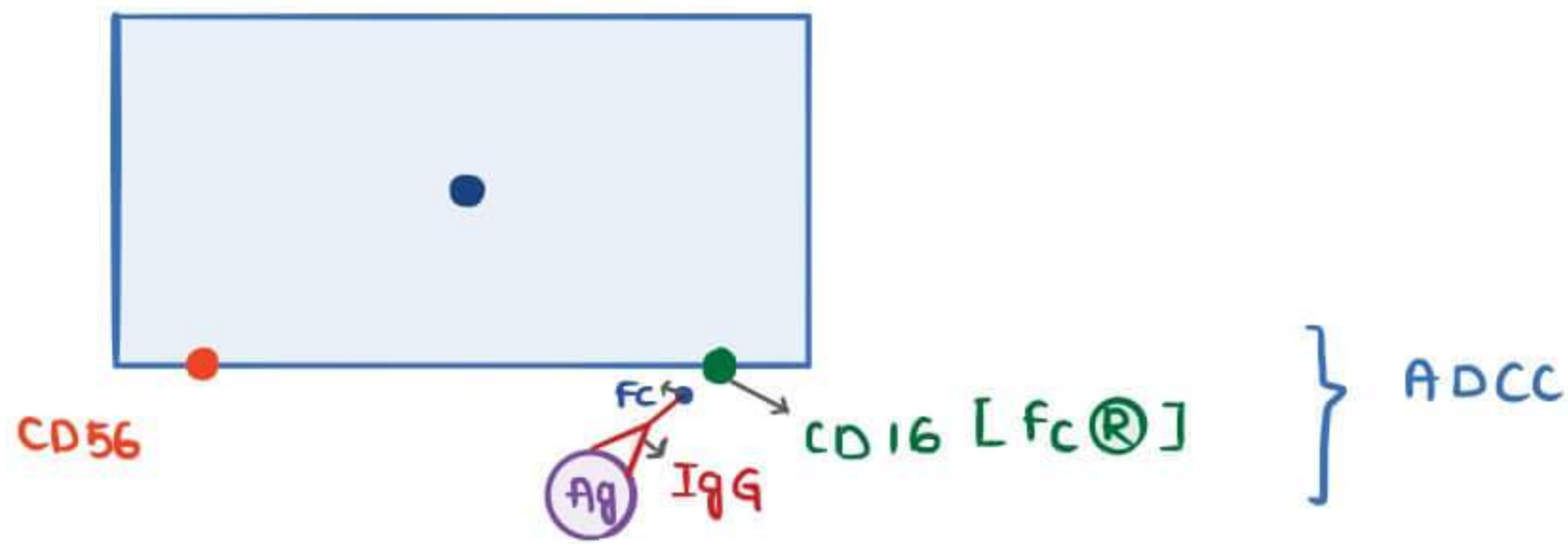
NK CELLS

t.me/latestpgnotes

- Ex. of INNATE LYMPHOID CELLS [ILCs]
 - ↳ no TCR
 - ↳ secretes cytokines like T cells
- earlier known as LARGE GRANULAR LYMPHOCYTES [LGL]
- kills virus infected cells & tumor cells



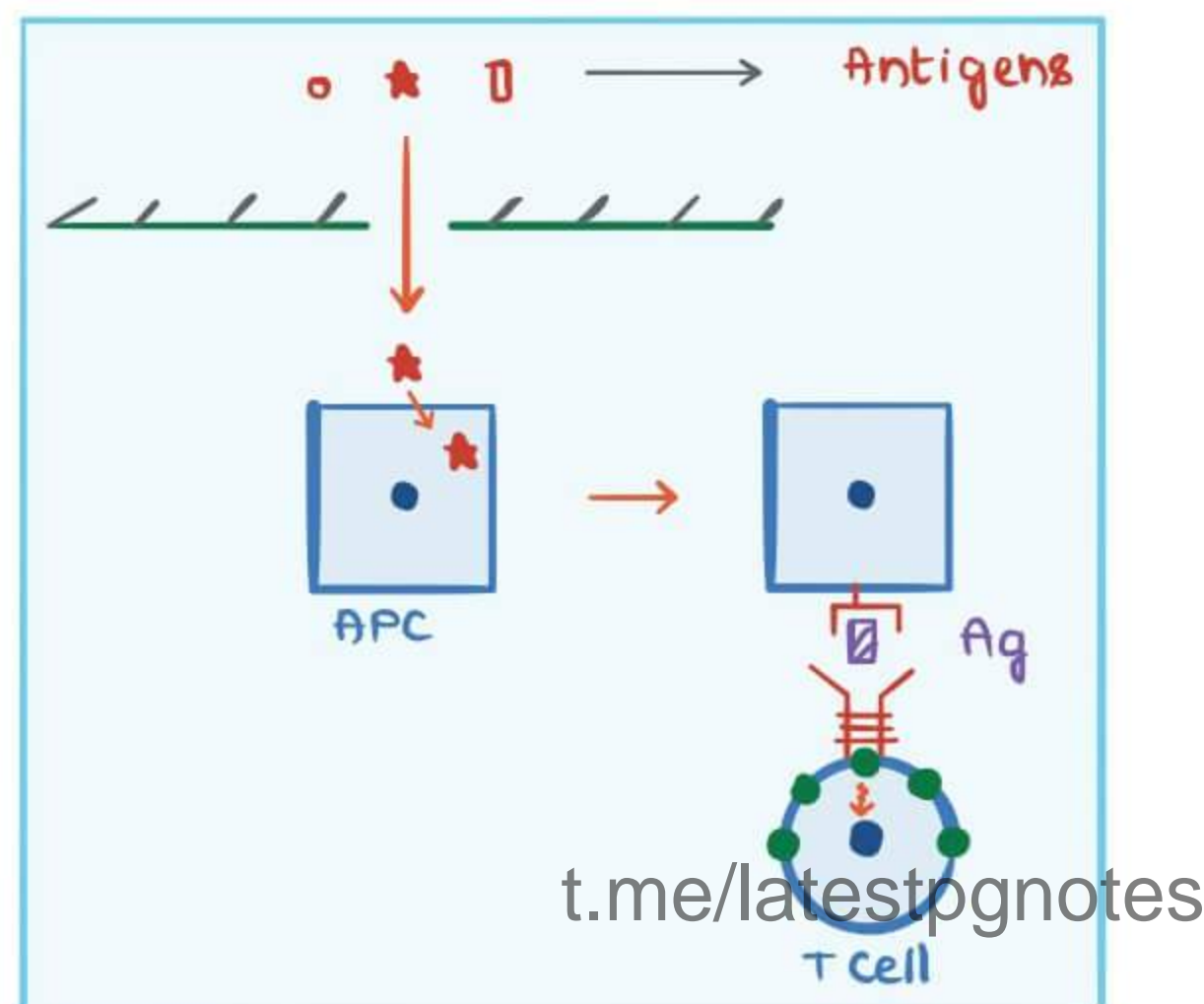
- almost all Normal cells have MHC - I expression
- MHC - I interacts with Inhibitory Ⓡ → NK cells inactivated
- In case of Virus infected cells / mutated [tumor] cells,
 - ↳ ↓ expression of MHC I [virus infected cells] (or)
 - ↳ ↑ expression of molecules overstimulating the Stimulatory Ⓡ [tumor cells]
 - ↳ both mechanisms activate NK cells & get destroyed



→ Fc of IgG + CD₁₆ [FcR] → activates NK cells → ADCC
 → ADCC → Antibody dependent cell mediated cytotoxicity

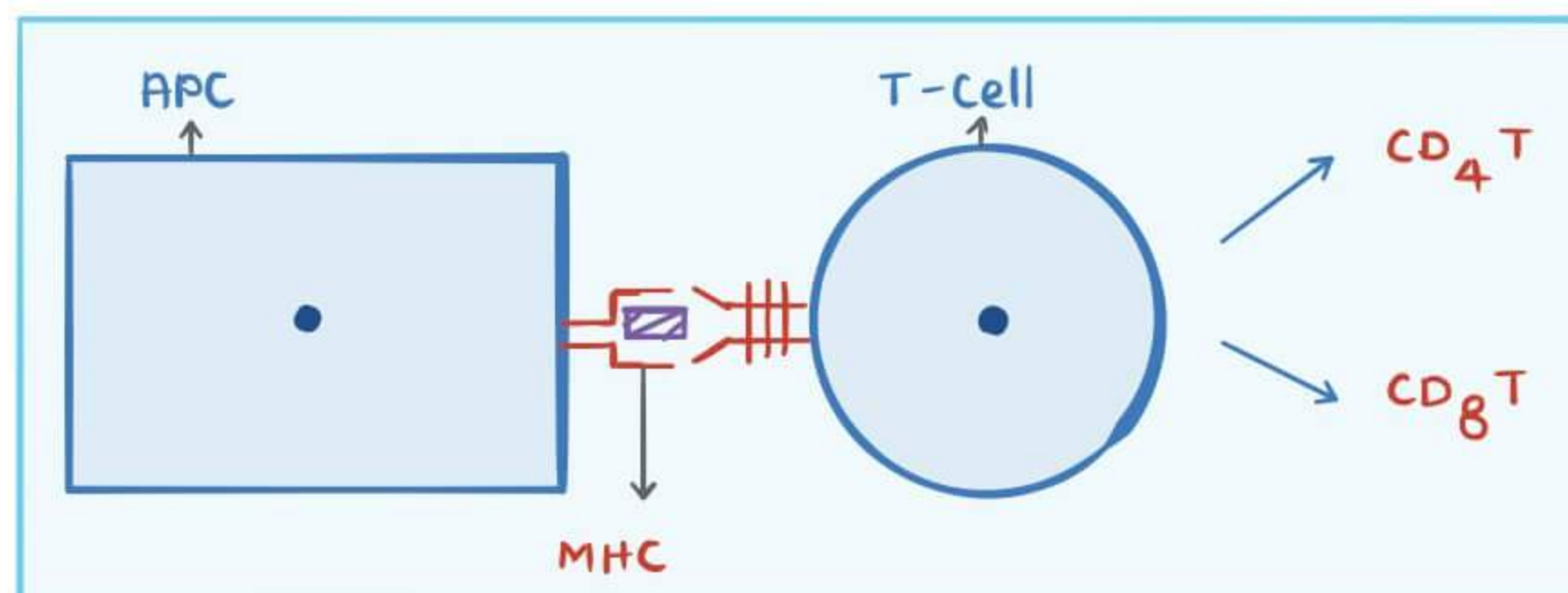
IMMUNE SYSTEM ACTIVATION

BASIC CONCEPTS



1. Entry of pathogen inside the body
2. Phagocytosis of pathogen by APC
3. Expression of Ag on the surface of APC & movement into circulation
4. T cell comes in contact & Antigenic peptide presented by APC & T cell activation
5. T cell activation leads to production of
 - a. EFFECTOR T-CELLS → deals & present infection
 - b. MEMORY T-CELLS → deals & later infections

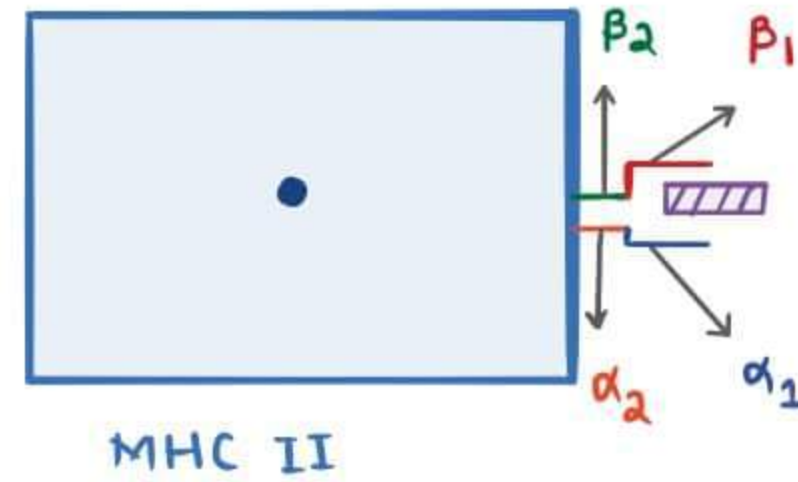
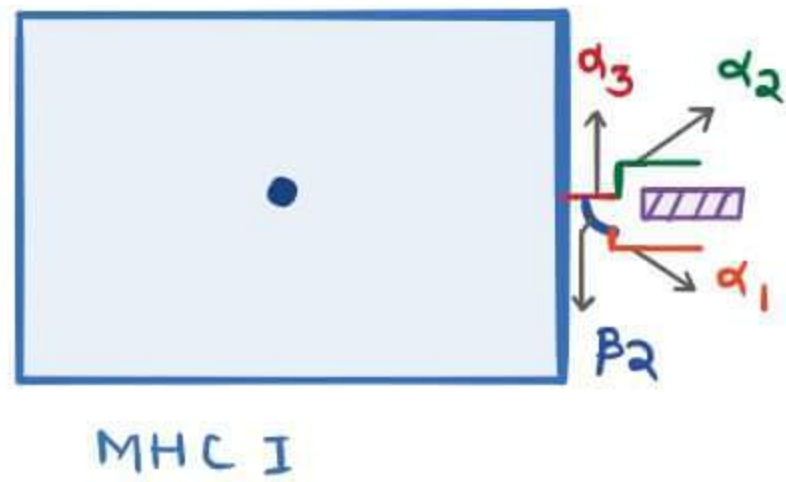
ANTIGEN PRESENTING CELLS [APCs]



→ MHC FUNCTIONS

- ↳ Let pathogenic Ag be expressed on Surface OF APC
- ↳ decision of activation of sub types of T cells done based on MHC
 - MHC I → always activates CD_8^T cells
 - MHC II → always activates CD_4^T cells
- CD_8^T cells are MHC I restricted cells
- CD_4^T cells are MHC II restricted cells
- NK cells are MHC unrestricted cells

→ STRUCTURE OF MHC



→ ANTIGEN BINDING CLEFT

- ↳ part of MHC molecule, where Ag binds
 - ↳ on MHC I, ABC made up of → α_1 & α_2 chains [distal α chains]
 - ↳ on MHC II, ABC made up of → α_1 & β_1 chains [distal α & β chains]
- t.me/latestpgnotes

→ TYPES OF APCs

1. PROFESSIONAL APCs [+++ MHC]

a. Dendritic cells

skin & interstitial tissue
Lymphnode & spleen

- LANGERHANS CELL [most important]
- FOLLICULAR DENDRITIC CELLS [acts as reservoir for HIV]

b. B - cells

c. Macrophages

2. NON PROFESSIONAL APCs [+ MHC]

a. Fibroblasts

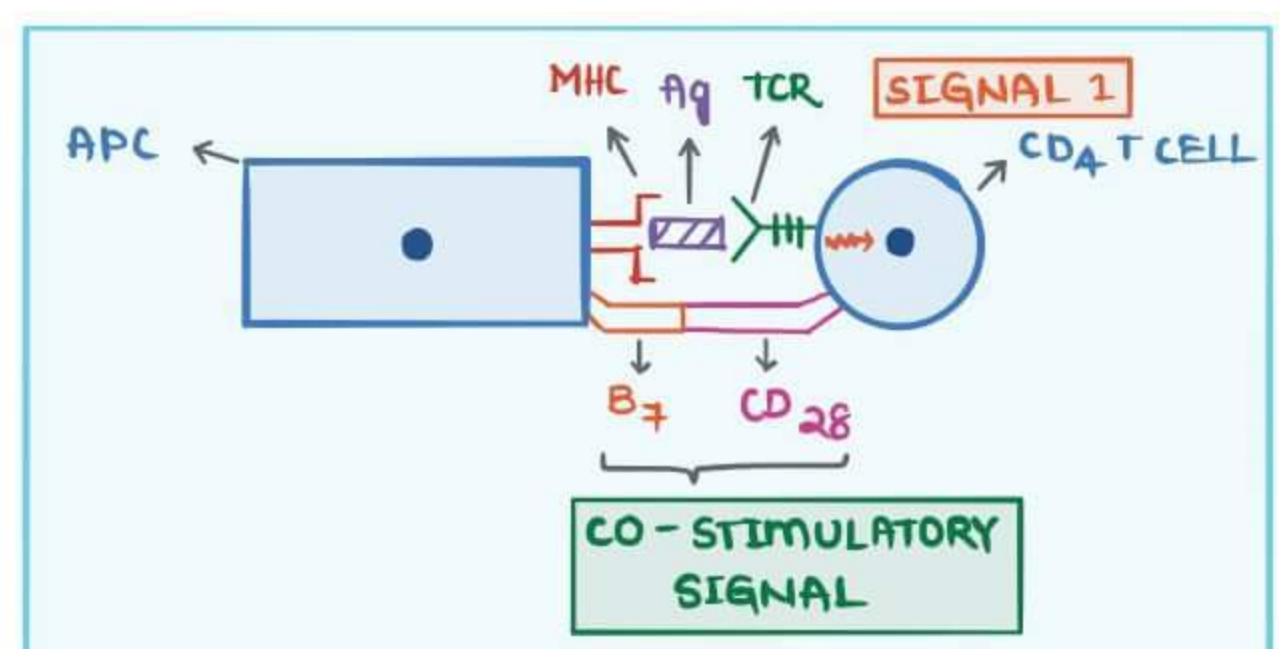
b. Endothelial cells

c. Thymic epithelial cells

ACTIVATION / INHIBITION OF T-CELLS

Ag → APC → Surface

CO-STIMULATORY SIGNAL IS MANDATORY FOR THE ACTIVATION OF T CELLS

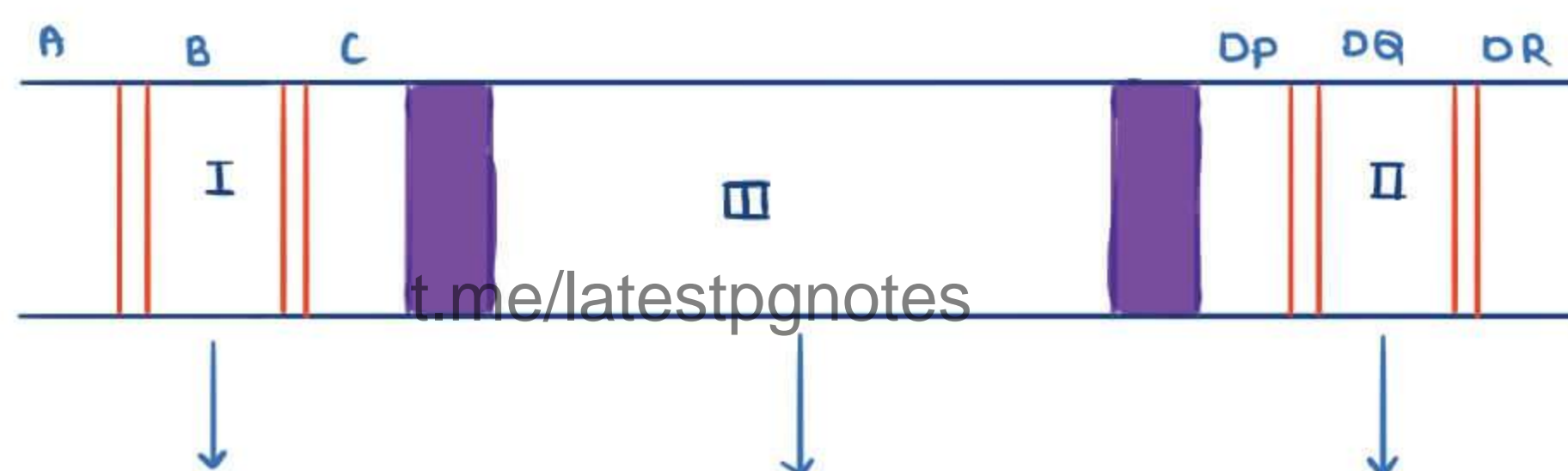


- **EXTERNAL AG**
 - ↳ provides Signal 1 & costimulatory signal → T-CELLS ACTIVATED
- **SELF AG**
 - ↳ provides Signal 1 & no co-stimulatory signal → T-CELL ANERGY
- **T-CELL ANERGY**
 - NON ACTIVATⁿ OF T cell in the presence of SELF Ag
 - helps in prevention OF Auto immune disorders
- **CO - STIMULATORY SIGNALS**
 - ↳ CD 28 interactⁿ → T cell activation [a/w external Ag]
 - ↳ CTLA 4 / PD 1 interactⁿ → T cell inhibition [a/w SELF Ag]

MAJOR HISTOCOMPATIBILITY COMPLEX [MHC]

- aka HLA [Human Leukocyte Antigen] COMPLEX [discovered on Leukocytes]
- these gene are located on CHROMOSOME 6p

CHROMOSOME 6p (short arm)



CODES FOR	MHC I	$C_2/C_4/\textcircled{P}$ TNF α $\alpha 1 \alpha$ OHase	MHC II
PRESENT ON	All nucleated cells Platelets		All APCs [Prof. APCs [Non - prof. APCs]
ACTIVATES	CD 8 T-cells		CD 4 T cells
DETECTED BY	ALLO ANTISERUM		MIXED LEUKOCYTE REACT ⁿ

USES OF MHCs

1. GENETIC ASSOCIATION OF DISEASE

- ↳ HLA - DR 3 / DR 4 → TYPE 1 DM
- ↳ HLA - B 27 → Ankylosing Spondylitis

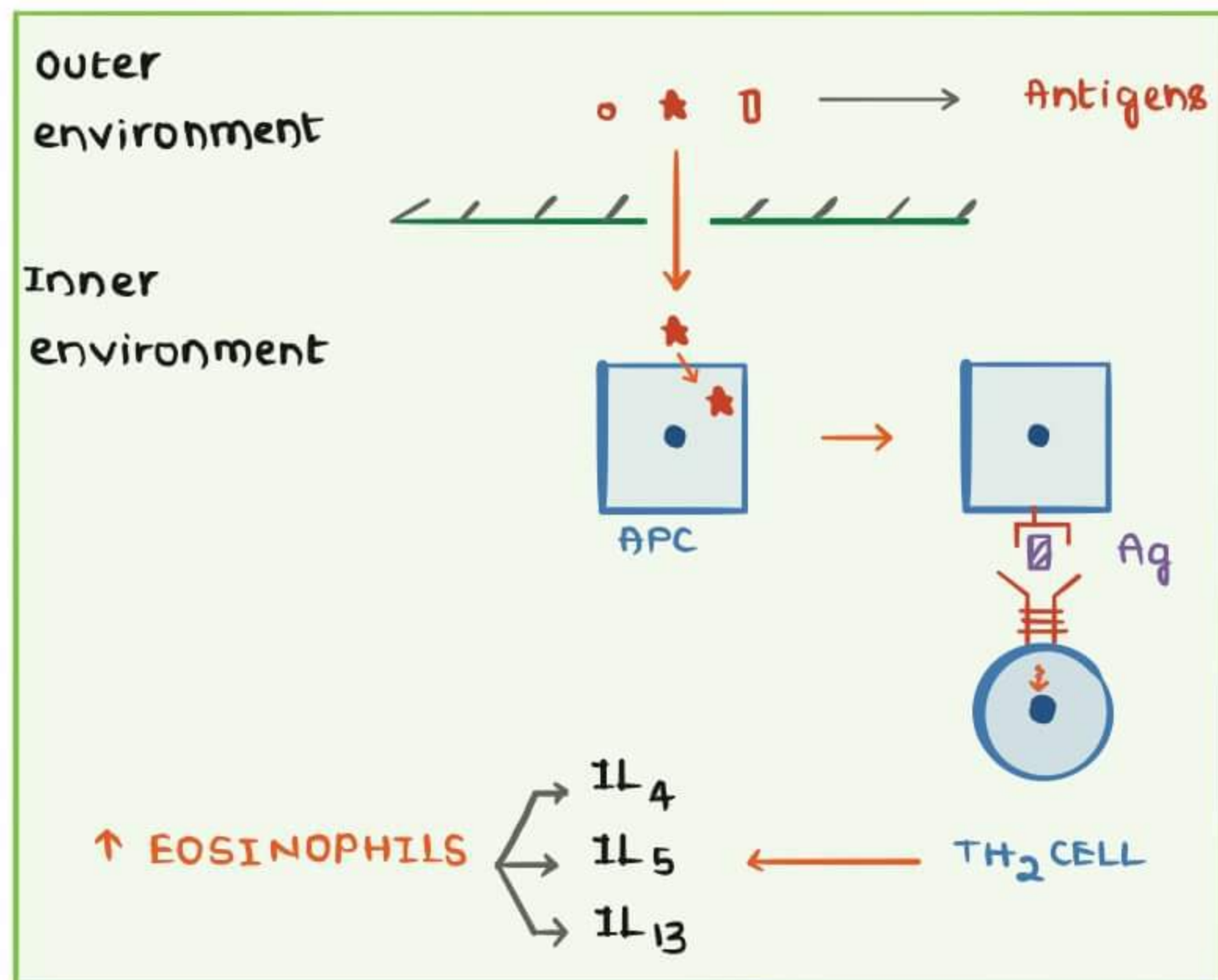
2. ORGAN TRANSPLANTATION

- ↳ HLA matching | gene matching done by TISSUE TYPING
- ↳ done i
 - mixed Leukocyte Reactⁿ
 - micro cytotoxicity Assay

3. PATERNITY DISPUTES

→ aka ANAPHYLACTIC / IMMEDIATE HR

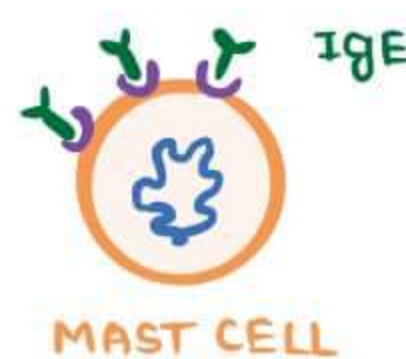
PATHOGENESIS



EOSINOPHILIA SEEN IN

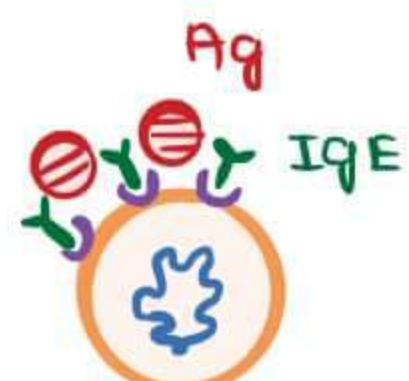
- Allergy
- parasitic infection
- Hodgkin's lymphoma
- Type 1 HR

FIRST EXPOSURE

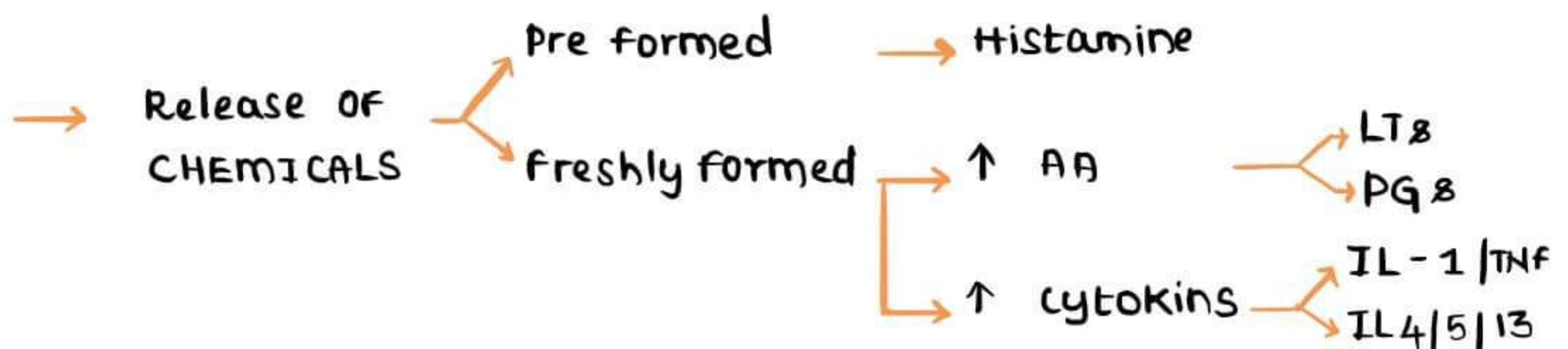


STAGE OF SENSITIZATION / PRIMING
[NO symptoms]

2nd OF REPEAT EXPOSURE



MAST CELL ACTIVATION



- Histamines } vasodilatⁿ
- PGs }
- Histamines } Broncho spasm
- LT8 }
- Histamines → Itching
- cytokines → ↑ inflammation

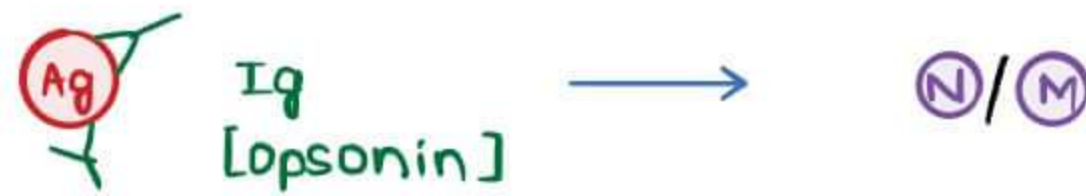
CLASSICAL EXAMPLE → BRONCHIAL ASTHMA

- cause of Attack
 - ↳ in India → Dust particles
 - ↳ in western countries → Pollen grains

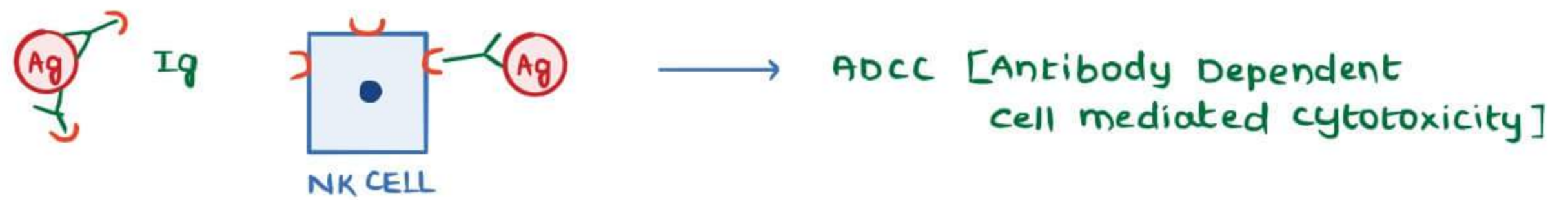MECHANISMS

A. OPSONISATION & PHAGOCYTOSIS

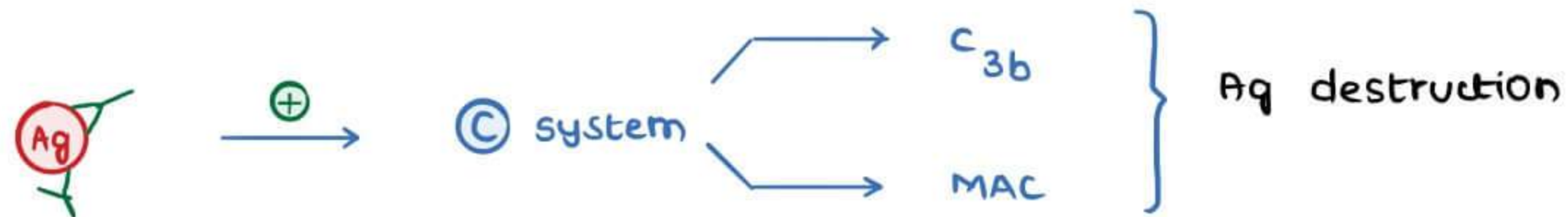
1. Direct Antibody mediated Opsonisation



2. ADCC [Antibody dependent cell mediated cytotoxicity]



3. via complement activation



EXAMPLES

- RH INCOMPATIBILITY
- BLOOD TRANSFUSION REACTION
- AUTO IMMUNE HEMOLYTIC ANEMIA
- AUTO IMMUNE THROMBOCYTOPENIA
- AUTO IMMUNE LEUCOPENIA

B. COMPLEMENT ACTIVATION & INDUCTION OF INFLAMMATION

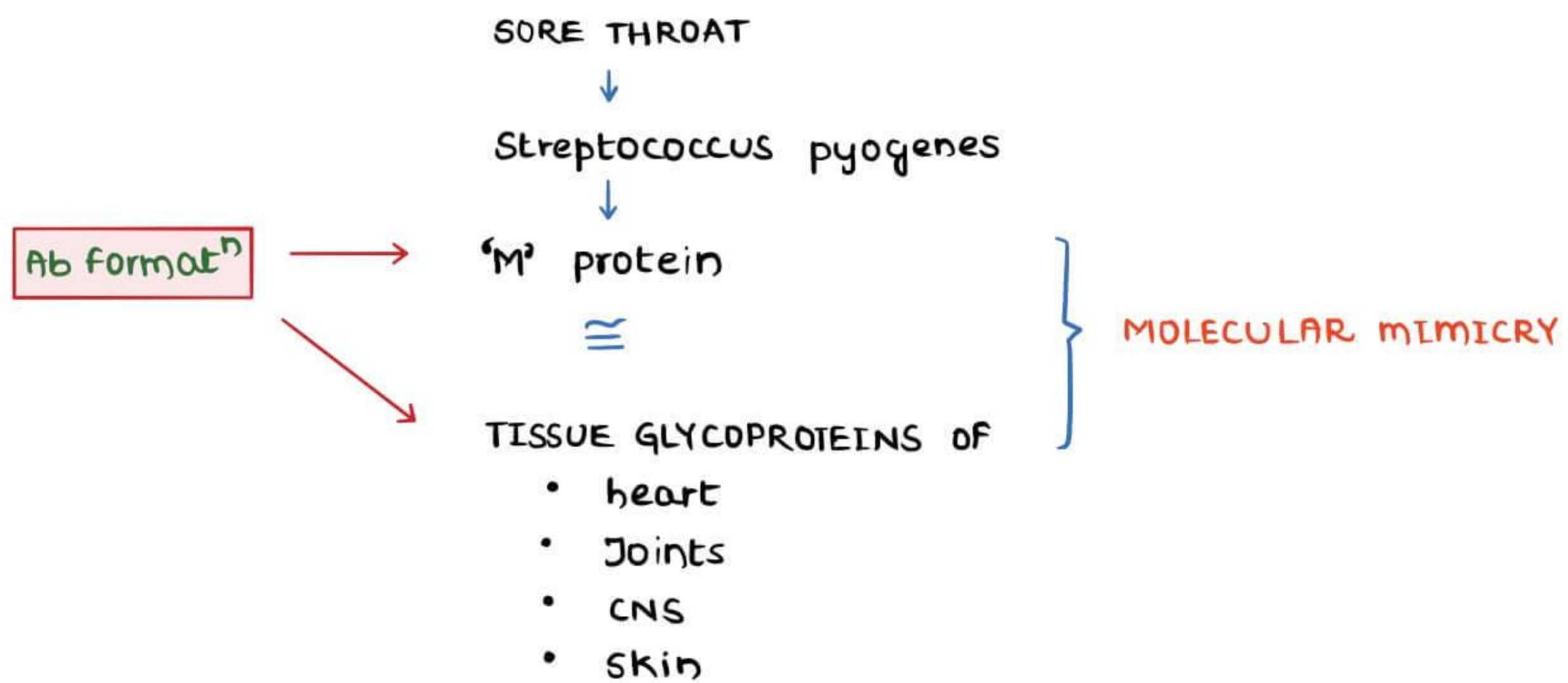
Ag + Ab formation

C System Activation



EXAMPLES

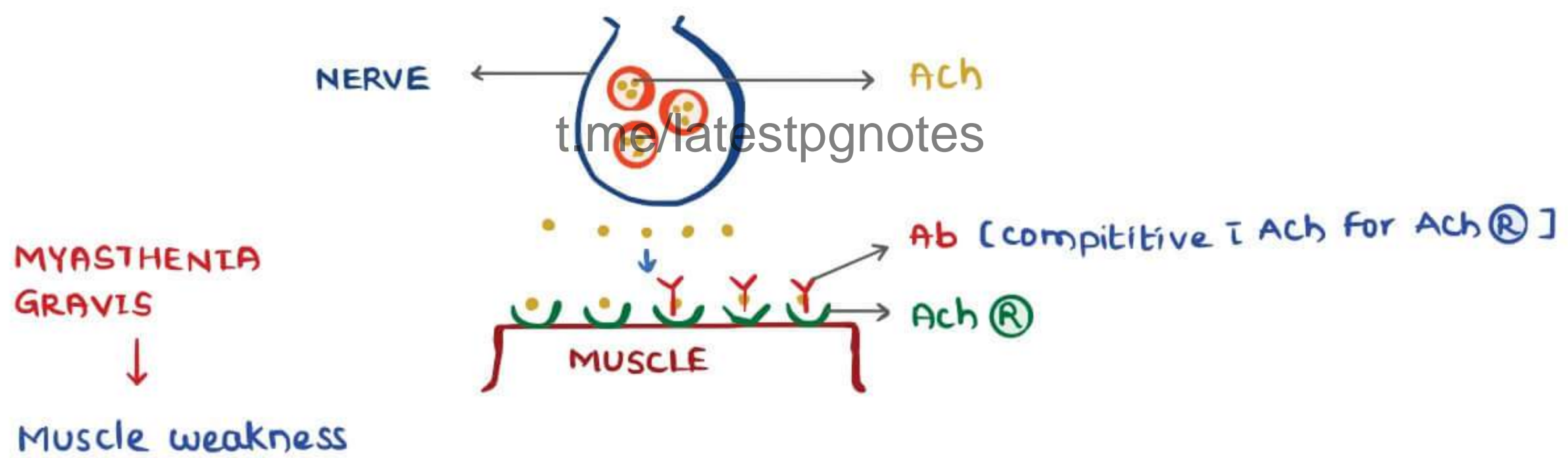
- ACUTE RHEUMATIC FEVER
- GOODPASTURE SYNDROME
- ANCA - mediated VASCULITIS



C. Ab INDUCED TISSUE DYSFUNCTION

EXAMPLES

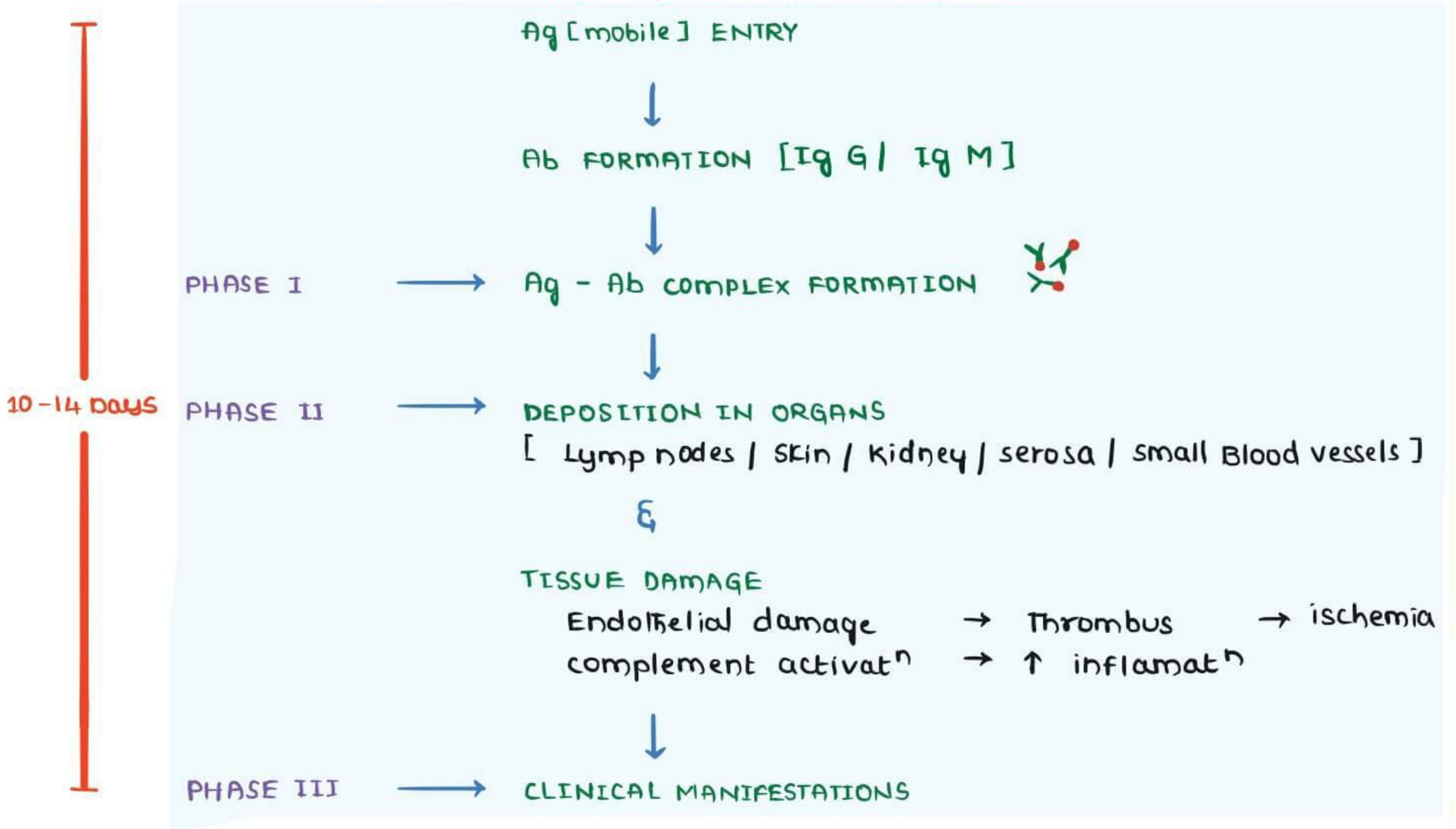
- MYASTHENIA GRAVIS
- GRAVES DISEASE
- PERNICIOUS ANEMIA
- INSULIN RESISTANT DIABETES



- TYPE 2 HR takes place by
 - A. Opsonisatⁿ & phagocytosis
 - B. Inflammation
 - C. Antibody induced Tissue dysfunction

→ EXAMPLES

- My → Myasthenia gravis
- Blood → Blood transfusion Reactions
- Group → Good pasture syndrome; Graves disease
- IS → Immune Hemolytic Anemia; Immune Thrombocytopenia
- R → Rheumatic Fever
- H → Hyper acute transplant rejection
- Positive → Pernicious anemia; Pemphigus vulgaris



© Activatⁿ occurs → ↓ Serum C₃ indicates Active Immune complex Disease

EXAMPLES

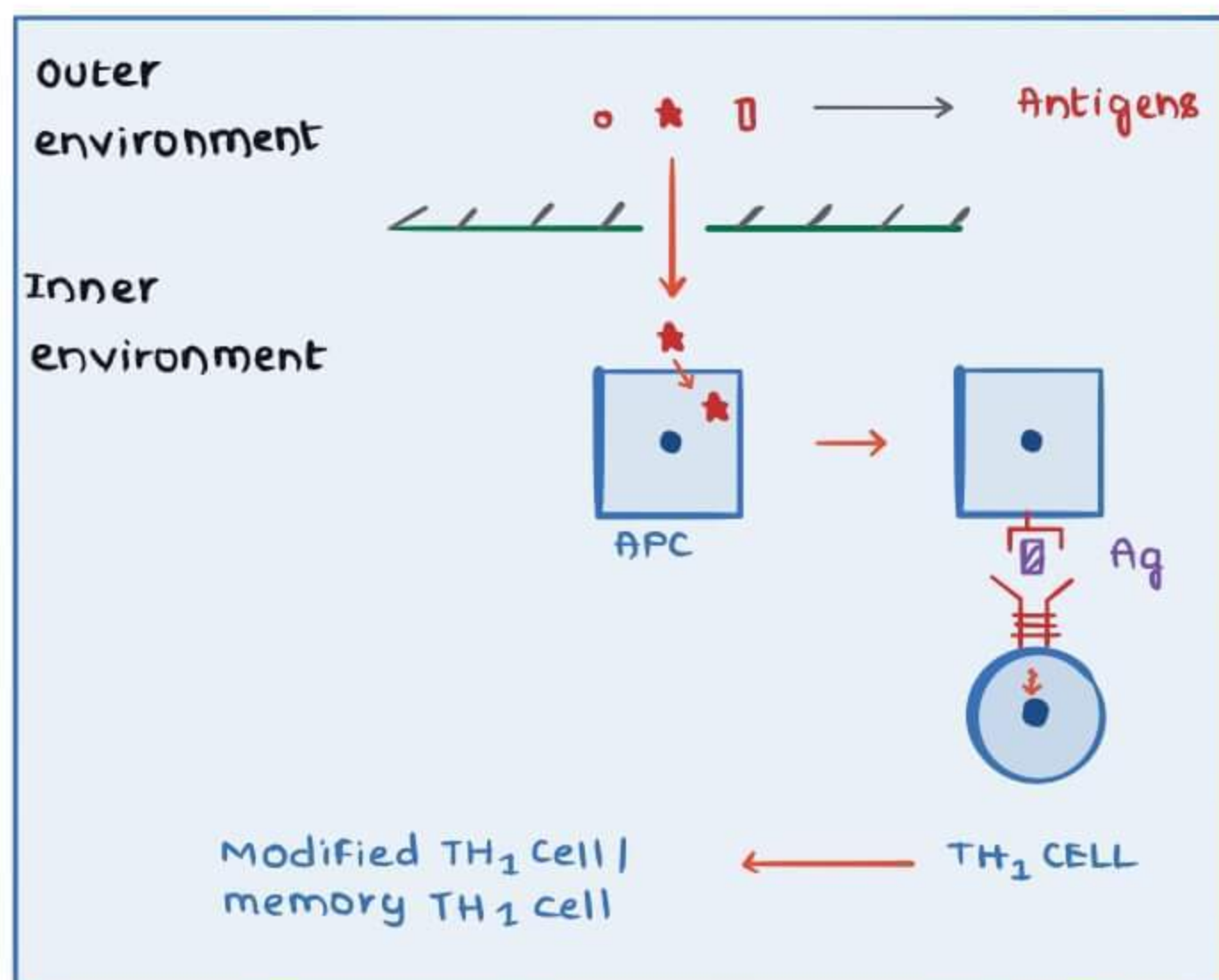
- S → Serum Sickness / SLE
- H → Henoch - Schonlein Purpura
- A → Arthus Reaction
- R → Reactive Arthritis
- P → Post streptococcal Glomerulonephritis / PAN

TYPE IV HR / CELL MEDIATED HR [do not utilize Ab]

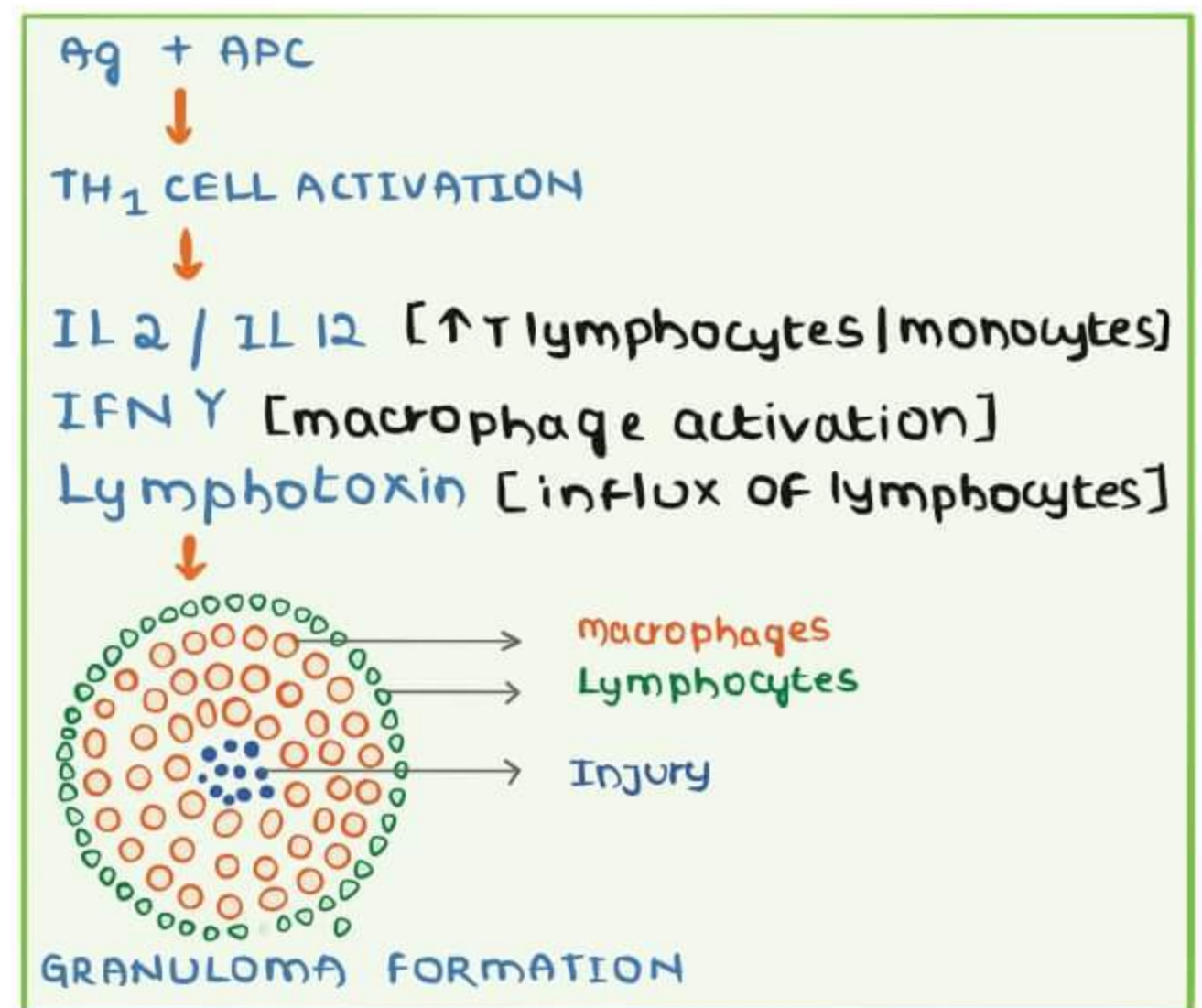
SUB TYPES

1. DELAYED TYPE

1st EXPOSURE

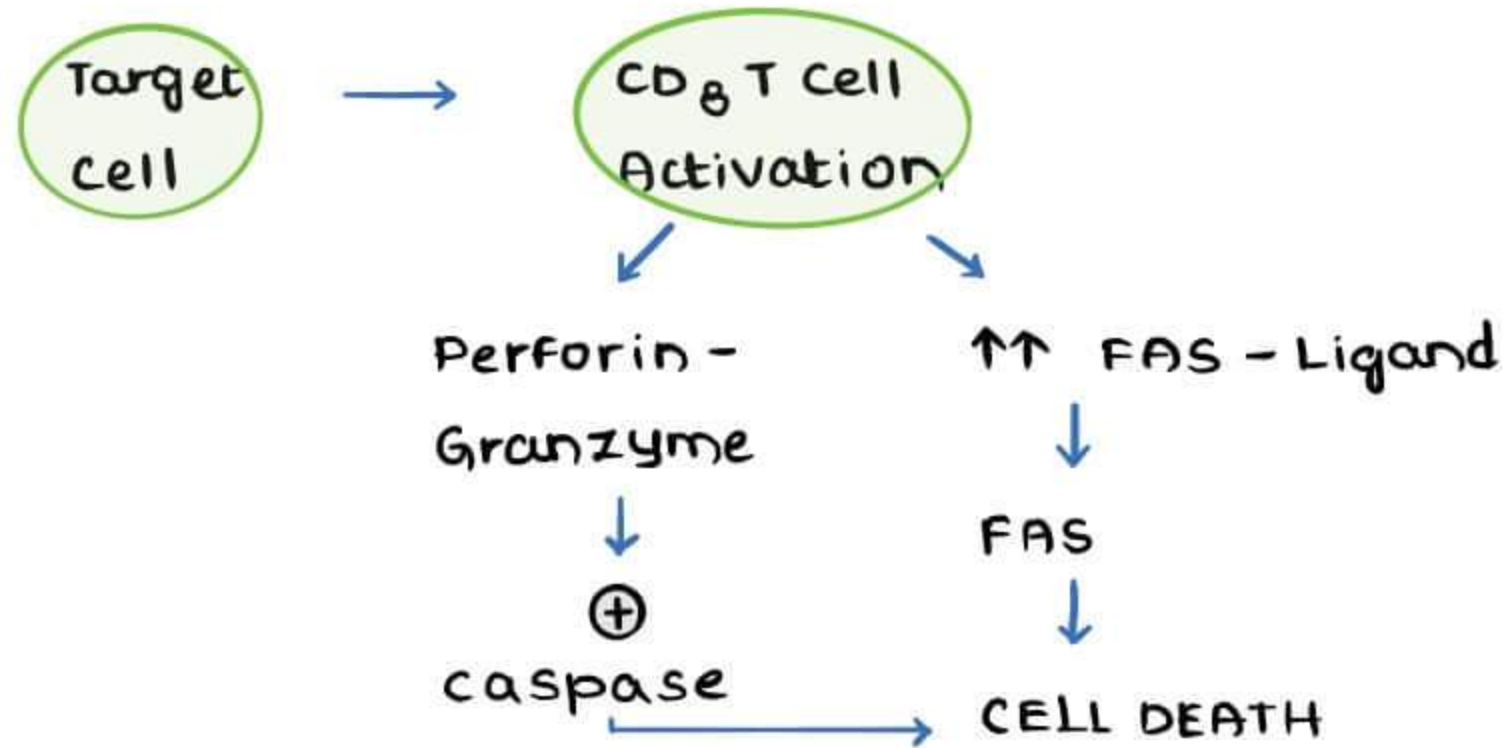


2nd EXPOSURE



EXAMPLES

R	}	Rheumatoid Arthritis
A		
m	→	multiple sclerosis
Chandra	→	contact dermatitis
Is	→	IBD
Psoriatic	→	Psoriasis
Diabetic ϵ_1	→	DM 1
TB	→	TB → mantoux test

2. MECHANISM OF CD_8 T CELL ACTIVATION

- CD_8 T - CELLS
- virus infected cell / cancer cells
- Graft Rejection

t.me/latestpgnotes

IMMUNITY 2 TOLERANCE

54

↓ RESPONSE OF IMMUNE SYSTEM TO ANTIGENS [SELF]

SUB TYPES

1. CENTRAL TOLERANCE
2. PERIPHERAL TOLERANCE

1. CENTRAL TOLERANCE

→ takes place in thymus / Bone marrow

→ Deletion

Negative selection

↓

Self reactive B/T cells

→ T - cells \ominus → AIRE Gene → alteration → AUTO IMMUNE
[Auto Immune Regulator Gene] POLY ENDOCRINOPATHY

→ RECEPTOR EDITING → Seen in B cells

2. PERIPHERAL TOLERANCE

a. ANERGY

→ functional hyporesponsiveness

→ mechanisms t.me/latestpgnotes

Self Ag $\xrightarrow{\oplus}$ $\frac{CTLA-4}{PD-1}$

↓ interactⁿ b/w B.7 & CD 28 → T CELL ANERGY

↓ interactⁿ b/w CD 40 & CD 40L → B CELL ANERGY

b. T - REGULATORY CELLS

CD₄ T CELLS $\begin{cases} \text{CD 25} \\ \text{foxp 3 gene} \end{cases}$

→ IL 10 / TGF β secreted

→ + CTLA - 4 & PD - 1

→ plays a role in ACCEPTANCE OF FETUS at pregnancy

→ CD 25 Defect → ↑ MULTIPLE SCLEROSIS

→ fox p3 Defect → ↑ IPEX SYNDROME

I → Immune dysregulatⁿ

P → Poly endocrinopathy

E → Enteropathy

X → XLinked Syndrome

C. APOPTOSIS OF SELF-REACTIVE B/T CELLS

- dit ↑ FAS - FAS-L
- Defect → AUTO IMMUNE LYMPHO PROLIFERATIVE SYNDROME [ALPS]

D. ANTIGEN SEQUESTRATION

→ Ag → IMMUNE PRIVILEGED SITES

B → Brain
E → Eye
T → Testis

→ Trauma in B/E/T → AUTO IMMUNE DISEASE

CENTRAL TOLERANCE	PERIPHERAL TOLERANCE
<ul style="list-style-type: none"> → ⊖ selection [AIRE gene] → ⊕ Editing 	<ul style="list-style-type: none"> → Anergy → T_{Reg} cells → Deletⁿ → FAS → Immune Priv. Sites

AUTO IMMUNE DISORDERS

ETIOLOGY

I. GENETIC FACTORS

- FAILURE OF TOLERANCE
- HLA - GENES DEFECTS → HLA B-27 [Ankylosing Spondylitis]
- NON HLA GENES DEFECTS
 - ↳ PTPN - 22 t.me/latestpgnotes
 - most important
 - Abnormal Lymphocyte activatⁿ & proliferatⁿ
 - DM, RA & others
 - ↳ NOD - 2 → IBD [Inflammatory Bowel Disease]
 - ↳ IL - 2 ⊕ → ↓ T_{Reg} cells

II. INFECTIONS

- ↑ co-stimulatory signals [APC]
- molecular mimicry → Rheumatic fever
- Polyclonal B cell Activation

⊕ ⊕ ⊕ ⊕ $\xrightarrow{\text{mutation}}$ AUTO ANTIBODIES

Example → EBV & HIV

- Spread of cryptic Epitope
- Infections → ↓ IL-2 → T_{Reg} cells

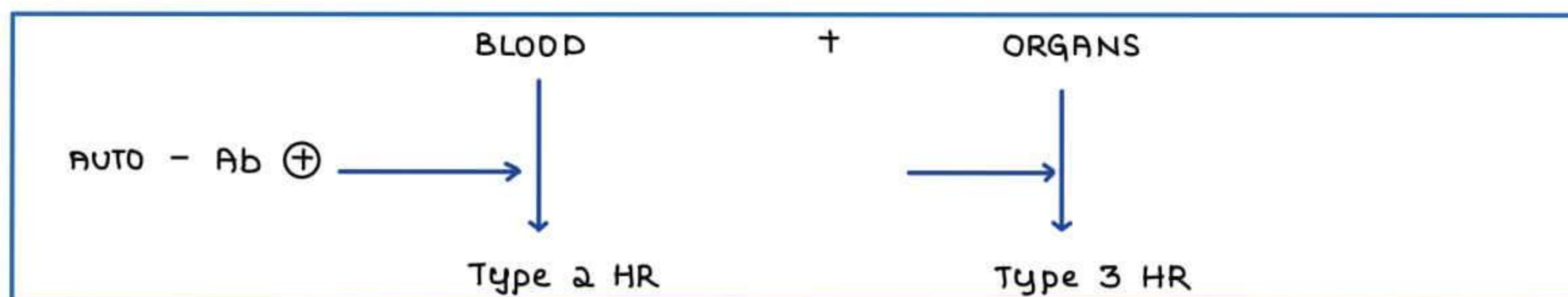
HYGIENE HYPOTHESIS → Disease

III MISCELLANEOUS

1. RELEASE OF SEQUESTERED Ag
2. SUN light [UV]
3. HORMONES [Estrogen | progesterone → ♀]
4. DRUGS
 - ↳ sulfonamide
 - ↳ Hydralazine
 - ↳ Isoniazid
 - ↳ Procainamide

SYSTEMIC LUPUS ERYTHEMATOSIS

MULTI SYSTEM DISORDER



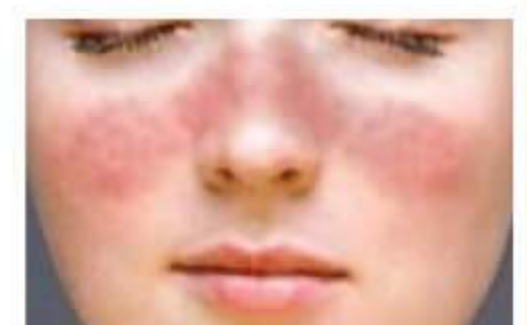RISK FACTORS

- ♀ >> ♂
- Reproductive age > extremes of age
- HLA - DR t.me/latestpgnotes
- UV Rays
- Drugs [sulfonamides]
- Infections → NETs [Neutrophil Extra cellular Traps]
- Complement Protein [C₁ | C₂ | C₄] deficiency

CRITERIA [> 4 out of 11 are essential for diagnosis]

- | | | |
|----------|---|--------------------------------------------------------|
| M | → | Malar Rash |
| D | → | Discoid Rash |
| S | → | Serositis |
| O | → | Oral ulcers |
| A | → | Arthritis |
| P | → | Photosensitivity |
| B | → | Blood Auto Ab |
| R | → | Renal disorders |
| A | → | ANA [Anti nuclear antibodies] |
| I | → | Immunological defects → Other Ab → Anti DNA Smith Ab |
| N | → | Neurological manifestations [Epilepsy / psychosis] |

- | | |
|---------------------------|-------------------------|
| → Oral cavity involvement | → Painless ulcers |
| → Joints involvements | → Non erosive Arthritis |
| → Skin involvement | → BUTTERFLY RASH |



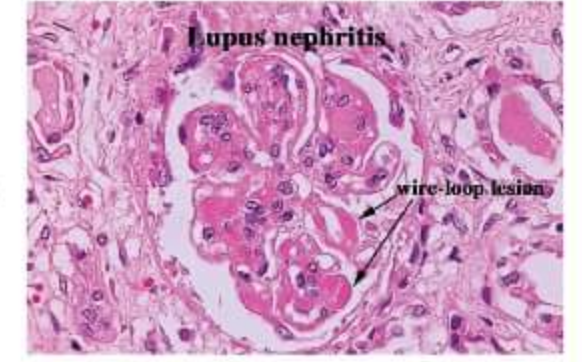

Butterfly Rash

[↑ in intensity on UV rays exposure]

→ Pulmonary involvement → Pleuritis [more common]
SHRINKING LUNG SYNDROME
[d/t weakness of diaphragm]

→ KIDNEY INVOLVEMENT

→ Type **IV** Glomerulonephritis / **Diffuse proliferative** Glomerulonephritis
→ mc sub type of glomerulonephritis
→ WIRE - LOOP LESIONS seen

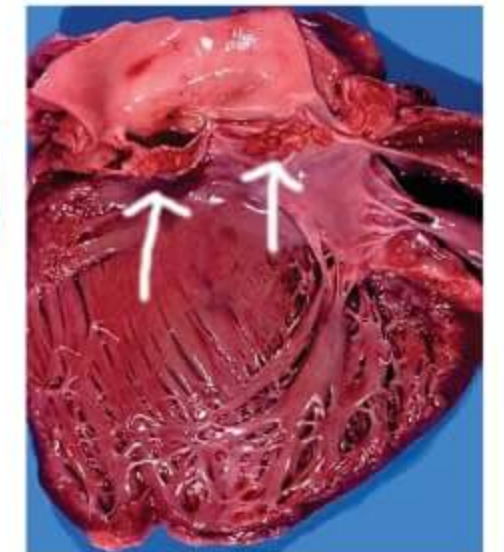


→ CARDIAC INVOLVEMENT

→ Pericarditis [more common]
→ Endocarditis → **LIBMAN-SACKS** ENDOCARDITIS [LSE → **SLE**]
→ **Lower** Surface of Mitral valve [Endocardium] involved more

→ SPLEEN INVOLVEMENT

→ ONION SKIN APPEARANCE in Blood vessels seen
→ d/t reactions to immune complexes



AUTO ANTIBODIES

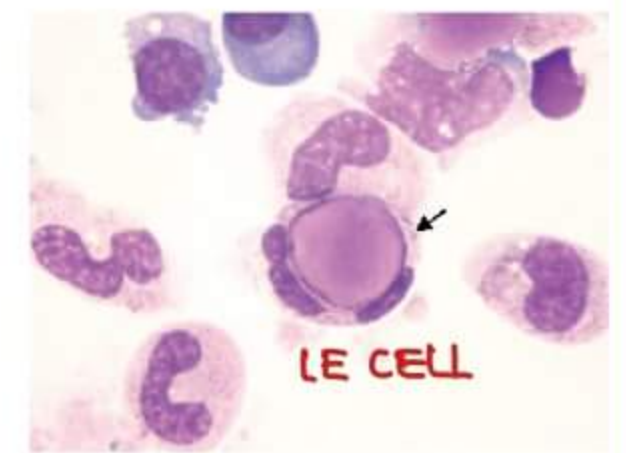
- ① ANTI NUCLEAR ANTIBODIES → most sensitive Test for Dx
- ② ANTI SMITH ANTIBODIES } most specific Test for Dx
- ③ ANTI - dsDNA ANTIBODIES } t.me/latestpgnotes
- ④ ANTI - RO ANTIBODY → a/w Neonatal lupus
→ high risk for congenital Heart Block
→ a/w sub acute cutaneous lupus
- ⑤ ANTI - **P** ANTIBODY → a/w **Psychosis**
- ⑥ ANTI - β_2 Glycoprotein Ab
→ seen in ♀ [reproductive age group]
→ presents \bar{c} Recurrent Abortion
→ induces prothrombotic state
- predisposed to
DVT [deep vein thrombosis]
HVT [Hepatic vein thrombosis]
stroke

→ aka ANTI PHOSPHOLIPID ANTIBODIES [APLA]
- responsible for APLA SYNDROME
- 1°
- 2° APLA m/cly a/w SLE

→ causes \uparrow aPTT [in vitro]
→ reacts \bar{c} CARDIOLIPIN Antigen
- responsible for false positive VDRL

→ DRVVT [DILUTE RUSSELL VIPER VENOM TEST]
→ detects auto Ab more specifically

→ LE CELL seen in SLE
→ Neutrophil / Macrophage \bar{c} damaged cell in it
→ present in vitro



TREATMENT → STEROIDS

DRUG INDUCED LUPUS

→ DRUGS RESPONSIBLE :

S → SULFONAMIDES [DAPSONE]
H → HYDRALAZINE
I → ISONIAZID
P → PROCAINAMIDE

→ H/O drug intake +nt
→ NO kidney / Brain involved
→ ANTI HISTONE ANTIBODIES +nt
→ a/w HLA DR 4
HLA DR 6

→ TREATMENT → withdrawal of offending drug

OTHER AUTO IMMUNE DISORDERS

SJOGREN SYNDROME

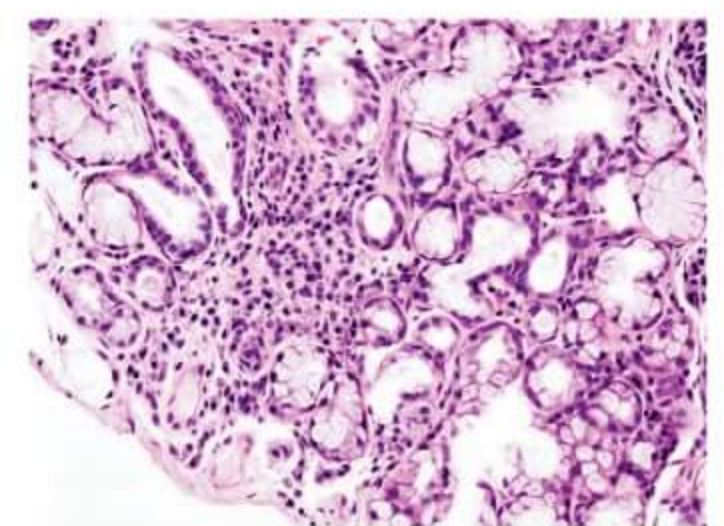
→ Lacrimal glands } damaged by } Fibrosis
salivary glands } Lymphocytic infiltratⁿ }

→ Dry eyes / Dry mouth syndrome → SICCA SYNDROME [1° / 2°]
→ a/w Rheumatoid Arthritis [cause of 2° sicca syndrome]

→ DIAGNOSIS

1. AUTO ANTIBODIES

↳ ANA ⊕
↳ ANTI - RO Ab [SS-A] ⊕
↳ ANTI - LA Ab [SS-B] ⊕
↳ ANTI - RO Ab a/w
→ Vasculitis
→ Renal Inflammation
→ Longer duration of disease



2. LIP BIOPSY

↳ confirmatory [IOC]
↳ Lymphocytic infiltratⁿ around glands & ducts

→ ↑ risk of MARGINAL ZONE LYMPHOMA



SYSTEMIC SCLEROSIS / SCLERODERMA

59

→ ↑ Fibrous tissue deposition → SKIN & OTHER ORGANS

VARIANTS

1. LINEAR SCLERODERMA / MORPHEA

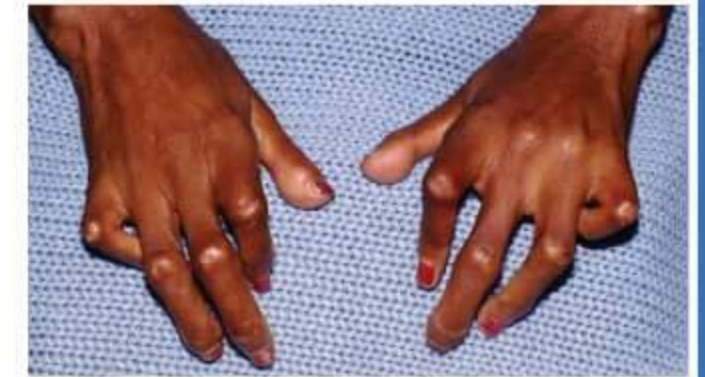- Patches of hard skin ⊕
- no other organ involvement

2. LIMITED SCLERODERMA

- Initially → Blood vessels [Raynaud's disease] ⊕
→ SKIN OF Fingers / SKIN OF FACE / Fore arm ⊕
- Later → Other organs ⊕
- a/w LATE VISCERAL INVOLVEMENT

CREST SYNDROME

- C → Calcinosis
- R → Raynaud's phenomenon
- E → Esophageal dysmotility
- S → Sclerodactyly
- T → Telangiectasia



- a/w ANTI - CENTROMERE Ab ⊕
- Limited Scleroderma → good prognosis
t.me/latestpgnotes

3. DIFFUSE SCLERODERMA

- SKIN + other organs involved early
- esophagus → Dysphagia
- GIT → malabsorptⁿ
- Cardiac → fibrosis
- Lungs → cause of Death
- Kidney
- ANTI - DNA TOPOISOMERASE Ab ⊕ [Anti - SCL 70 Ab ⊕]
 - Diffuse Scleroderma
 - Total Organ involvement
- ANTI ANA Ab ⊕
- ANTI RNA POLYMERASE III Ab ⊕
 - ↳ indicates Acute onset
 - ↳ a/w Renal involvement [scleroderma crisis]
 - ↳ ↑ risk of cancer

- R → Renal
- N → Neoplasia
- A → Acute Onset

4. MIXED CONNECTIVE TISSUE DISEASE

- Features OF SLE / SCLEROSIS / Sjogren syndrome ⊕
- ANTI - U₁ RNA Ab ⊕
- Less Renal involvement
- Better response to Steroids

5. DERMATOMYOSITIS

- SKIN + Muscles + Surrounding Blood vessels
- 1° or a/w cancers

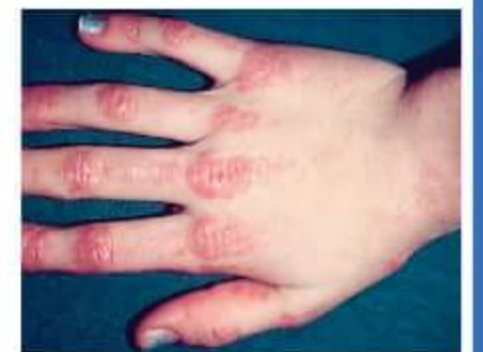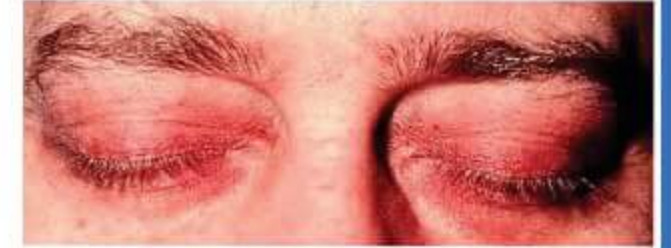→ C/F

SKIN

- HELIOTROPE RASH [on upper eye lid]
- GOTTRON PAPULES [seen on extensor surface]

MUSCLE

- proximal muscles involved predominantly
- distal muscles involved later
[↑ creatinine kinase value]



→ DIAGNOSIS

1. AUTO ANTI BODIES

- ANA ⊕
- ANTI - JO₁ Ab ⊕ → MECHANIC HANDS
- ANTI - Mi₂ Ab ⊕ → a/w skin features
- ANTI - P 155 Ab + } a/w Paraneoplastic Syndromes
- ANTI - P 140 Ab + } Juvenile variant

t.me/latestpnotes

2. BIOPSY → confirmatory

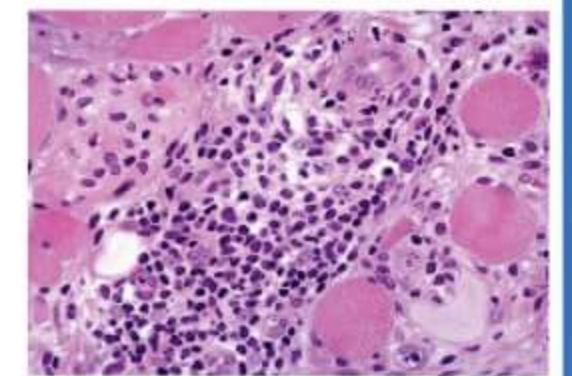
Dermato Myositis



PERI MYOIAL INFLAMMATION [CD₄Tc]

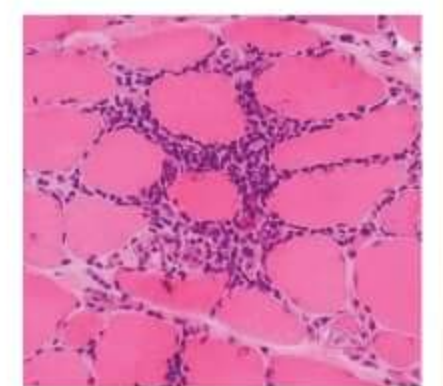


PERI FASCICULAR ATROPHY




6. POLYMYOSITIS

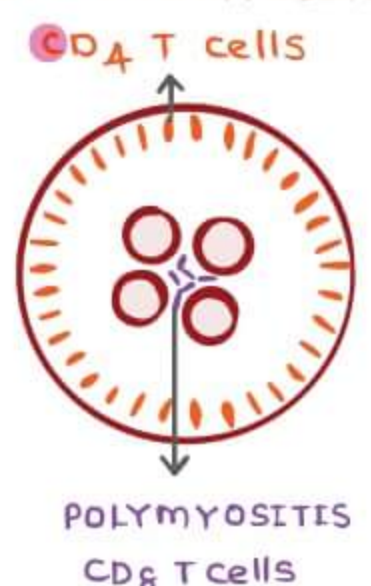- Skeletal muscle involved
- no skin involved
- BIOPSY → ENDOMYSIAL INFLAMMATION [CD₈T cells]



Ig G₄ RELATED DISEASE

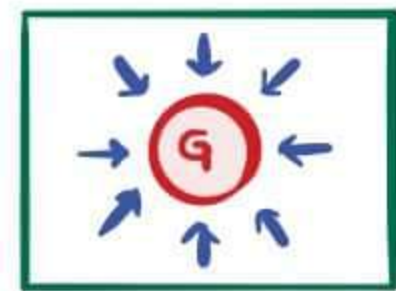

DERMATOMYOSITIS

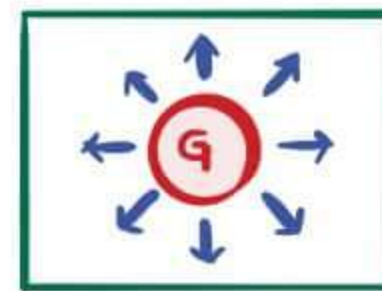


1. IDIOPATHIC RETRO PERITONEAL FIBROSIS / ORMOND DISEASE
2. RIEDEL THYROIDITIS
3. MIKULICZ SYNDROME
4. AUTO IMMUNE PANCREATITIS

→ R_t by RITUXIMAB

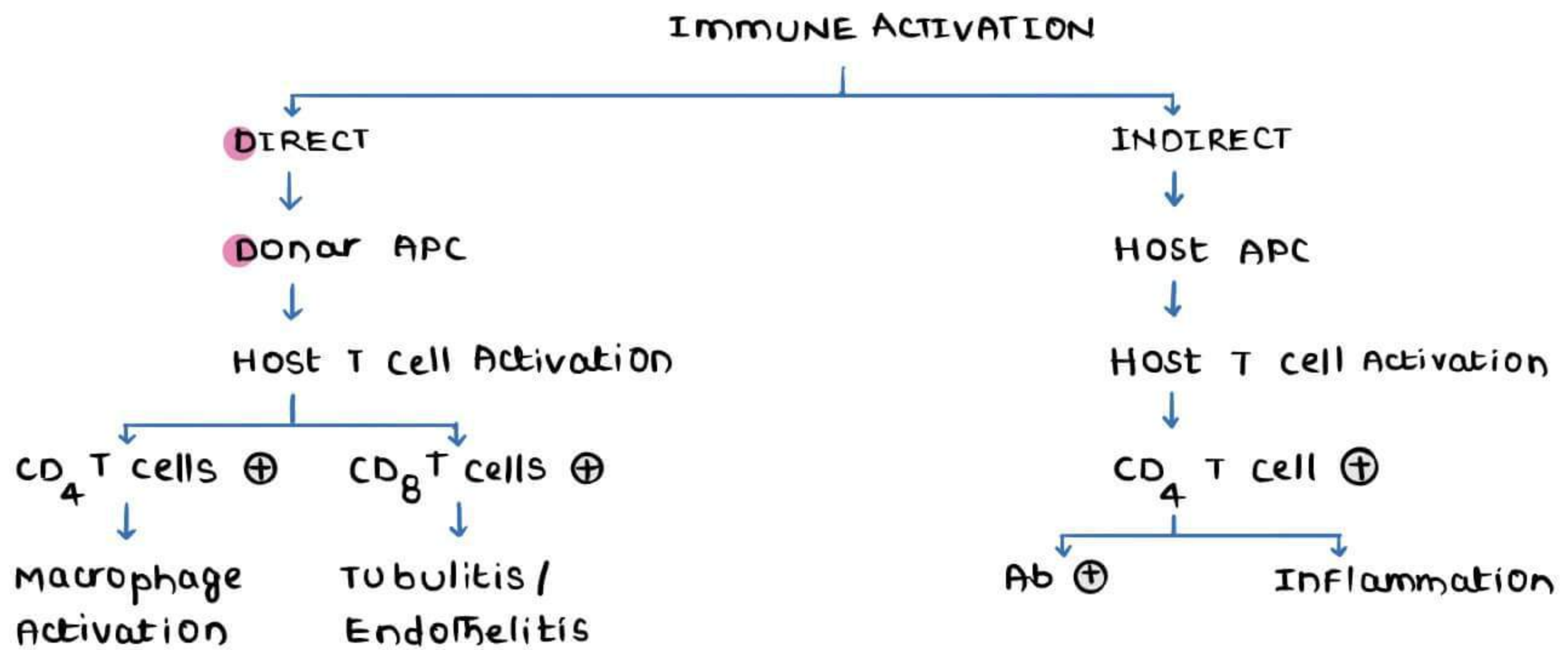


Transplant Rejection



Graft vs Host Disease

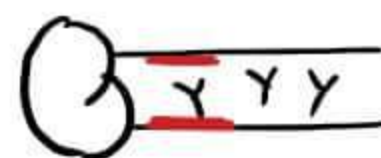
GRAFT REJECTION



SUBTYPES

1. HYPER ACUTE TRANSPLANT REJECTION → GREAT VESSELS

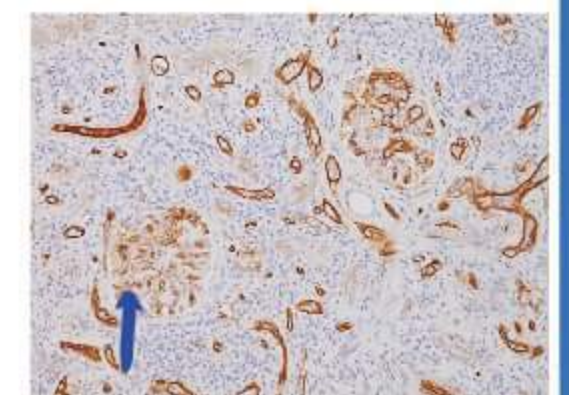
- d/t Preformed Ab t.me/latestpgnotes
 - ↳ multiparous ♀
 - ↳ previous recipient
 - ↳ prior blood transfusion
- ↳ Endothelial cell injury + Thrombus
- ↳ Neutrophilic infiltration



- cross matching should be done to check for preformed Ab
- Type 2 HR
- rejected in minutes to hrs

2. ACUTE TRANSPLANT REJECTION

- Type 2 ⊕ Type 4 HR
- rejected in days to weeks



SUB TYPES

a. ACUTE HUMORAL REJECTION

Ag + Ab → complement ⊕ → C₄d Deposition [marker] → Glomeruli damage vessel damage

b. ACUTE CELLULAR REJECTION

Direct Pathway → CD₄ / CD₈ T cells → Tubulitis [Type I HR] Endothelitis [Type II HR]

3. CHRONIC GRAFT REJECTION

- occurs in months to years
- Type 2 + Type 4 HR

→ CHRONIC HUMORAL

↓
Ab ⊕
↓
Graft vasculature

CHRONIC CELLULAR

↓
CD₄ T cell ⊕
↓
Inflammation

↘ ↙
Mononuclear infiltration
Glomerulopathy
↳ intimal thickening
↳ peritubular inflammatⁿ
↳ reduplication of Basement membrane

Interstitial fibrosis
Tubular Atrophy

↓ RISK OF REJECTION

1. HLA MATCHING

- HLA - A/B/C ; HLA - DRB1 ; HLA - DQ
- HLA - A/B/C & DRB1 considered predominantly
 - ↳ In Adults, at least 6 out of 8 alleles should be matched
 - ↳ In cord blood, 4/6 alleles should be matched
- Transplant rejection is maximum if HLA - DRB1 mismatch

2. SOURCE OF GRAFT

- | | |
|--------------|--------------------------------------------|
| → Auto Graft | → self ; skin / hair grafting |
| → Allo Graft | → Different person from same species |
| → ISO Graft | → Identical twin |
| → xeno Graft | → Different species ; valvular replacement |

3. DRUGS

T cell Activation

- | | |
|-----------------------------------------|-------------------------------|
| 1. ↓ inflammation | → steroids |
| 2. ↓ Lymphocyte proliferat ⁿ | → Mycophenolate mofetil [MMF] |
| 3. ↓ T cell Activat ⁿ | → Tacrolimus [calcineurin ⊖] |
| 4. IV Ig | |

B CELL ACTIVATION → B cell ⊕ → Ab ⊕ ← PLASMAPHERESIS

→ RESULT

↓↓↓ T - CELL
↓
POST TRANSPLANT LYMPHOMA [B cell Lymphoma]

- Immuno compromised host & Immuno Competent Graft
- **IMMUNOCOMPETENT GRAFT**
 - ↳ HSC [Hematopoietic stem cells] [mc]
 - ↳ Solid organs [Liver]
 - ↳ Unirradiated Blood Transfusion

SUB TYPES

ACUTE [< 100 days]	CHRONIC [> 100 days]
<ul style="list-style-type: none"> → Skin → Intestine → Liver 	<ul style="list-style-type: none"> → Rash [mc] → Bloody diarrhea → Jaundice
	<ul style="list-style-type: none"> → Fibrosis → Stricture ⊕ → Cholestatic Jaundice <ul style="list-style-type: none"> ↳ discolouratⁿ of urine ↳ pruritis → Thymic abnormality [in some]

- GRAFT → Destructⁿ of Leukemia cells → **GRAFT VS LEUKEMIA EFFECT**

IMMUNO DEFICIENCY DISORDERS**SUB TYPES**

t.me/latestpgnotes

1. PRIMARY DISORDERS

- LEUCOCYTE DISORDERS
- COMPLEMENT PROTEIN DEFECTS
- LYMPHOCYTE DEFECTS

2. ACQUIRED / SECONDARY DISORDERS**I PRIMARY DISORDERS****I LEUCOCYTE DISORDERS**

- LAD 1/2
- CHS
- CGD
- MPO Deficiency

II COMPLEMENT PROTEIN DEFECTS**III LYMPHOCYTE DEFECTS****1. DI - GEORGE SYNDROME**

Chr 22q deletion → TBX 1 gene defect → Failure of 3rd / 4th Pharyngeal pouch development

→ 22 q 11 Deletion Syndrome

1. DI - GEORGE SYNDROME
2. VELLO - CARDIAL FACIAL SYNDROME

C → Congenital cardiac Defects
 A → Abnormal facies
 T → T-cell Defects
 C → Cleft lip / cleft palate
 H → Hypocalcemia
 22

↳ a/w defective protectⁿ against intra cellular infectious organisms

2. BRUTON'S DISEASE

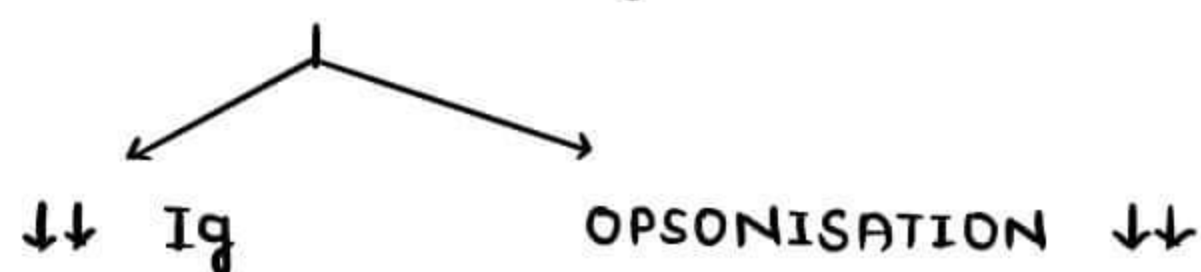
- B cell defect
- x-Linked
- Boys >>> girls affected
- BTK [B cell Tyrosine Kinase] Defect

↓ B CELLS → ↓ Plasma cells → ↓ Igs

→ aka X-LINKED AGAMMAGLOBULINEMIA

↓ B CELLS → AREAS → UNDER DEVELOPED
t.me/latestpgnotes

External Organisms
 [Extra cellular organisms]



- manifestations seen after 6 months of birth
- Pneumococcal / H. influenzae ↑
- Ig A → Enterovirus / Giardia ↑
- LIVE POLIO VACCINE administratⁿ → Paralytic poliomyelitis
- ECHO VIRUS → ↑ Encephalitis

3. COMMON VARIABLE IMMUNODEFICIENCY DISEASE [CVID]

B CELL MATURATⁿ → BAFF } ↓ T cell
 ICOS } Activatⁿ

BAFF → cytokine } require
 Inducible co Stimulator } for B cell
 maturatⁿ

↓↓ Igs in Blood

- ↑↑ sino pulmonary infections
- ↑ Bacteria / viruses / Giardia

→ **OD**

1. childhood / Adolescent onset
2. ♀ = ♂
3. defect in B cell maturation → B cell $\text{\textcircled{N}}$

Aq → ↑ no. of B cells
↓

4. Hyperplastic areas

- ↑ risk of → AUTO IMMUNE DISORDERS [RA]
- MALIGNANCIES [Lymphoid ; Gastric cancer]

4. IgA DEFICIENCY

- mc Ig deficiency
- ↑ respiratory / GIT / Urogenital infections
- ↑ Autoimmune disorders [SLE/RA]
- ↑ Allergies
 - ↳ during Blood transfusion → Anaphylaxis occurs

- ↓ Ig A ; ↓ Ig G₂/G₄

5. HYPER Ig M SYNDROME

t.me/latestpnotes



- ↑↑↑ Ig M → React \bar{c} Blood cells → autoimmune hemolytic anemia
 - Thrombocytopenia
 - leucopenia
- ↓ Ig G/A/E → ↓ Opsonisatⁿ → ↑ Bacterial infections
 - ↑ Fungal infections [Pneumocystis Jiroveci]
- x Linked >>> Autosomal Recessive

DEFECT IN CYTOKINE RECEPTOR	ENZYME DEFICIENCY
<ul style="list-style-type: none"> → X Linked → defect in γ chain unit → \downarrow IL-7 → \downarrow T cells & \downarrow Ig [sec. \downarrow] → \downarrow IL-15 → \downarrow NK cells 	<ul style="list-style-type: none"> → Adenosine deaminase defect → Autosomal recessive → Damage to T - Lymphocytes

→ Both B & T cells are defective → \uparrow Bacterial Infections
 \uparrow Viral / fungal infections

→ GENE THERAPY used for R_{γ}

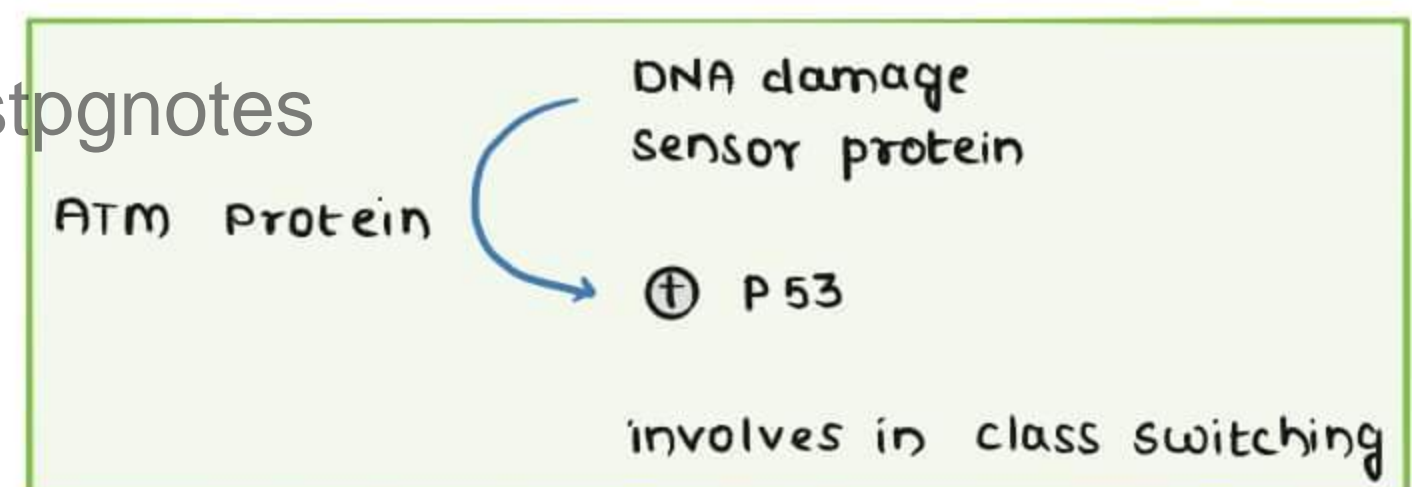
7. X - LINKED LYMPHOPROLIFERATIVE SYNDROME

→ SLAM protein [Surface molecule for Lymphocyte Activation molecules]
 ↳ requires for activatⁿ of B / T / NK cells
 ↳ defect causes \downarrow clearance of EBV
 ↳ Leads to Fulminant Infectious mononucleosis & B cell tumors

8. ATAXIA TELANGECTASIA

→ Ataxia
 → vascular malformations
 → neurological deficits t.me/latestpgnotes
 → \downarrow immunity [B / T cells]
 → \uparrow Tumors

→ GENE → chr 11



9. WISKOTT - ALDRICH SYNDROME

→ WASP GENE → X chromosome 'p' arm
 → Triad of
 ↳ Recurrent infections [\downarrow humoral & cellular immunity]
 ↳ \downarrow platelets
 ↳ Eczema

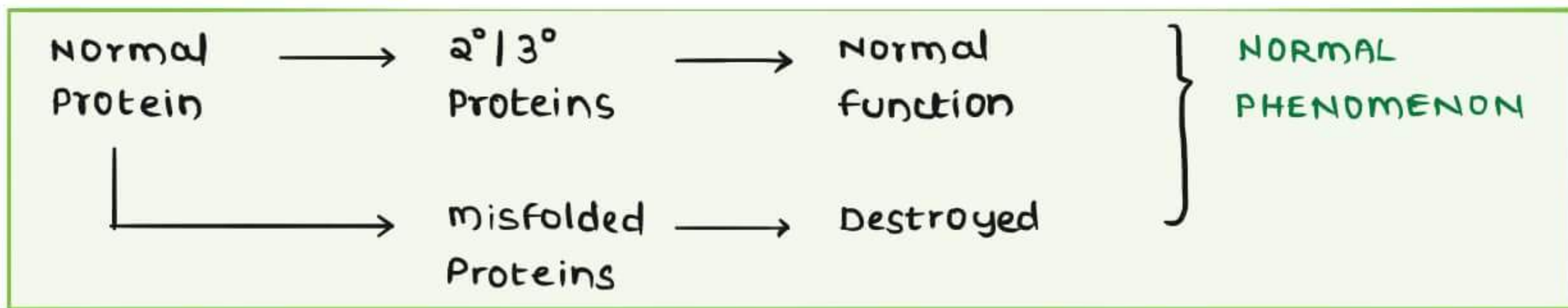
→ Ig M → \downarrow
 Ig A → \textcircled{N} / \uparrow
 Ig E → \uparrow

→ Peripheral Smear Shows → Small sized platelets

SECONDARY IMMUNODEFICIENCY DISORDERS

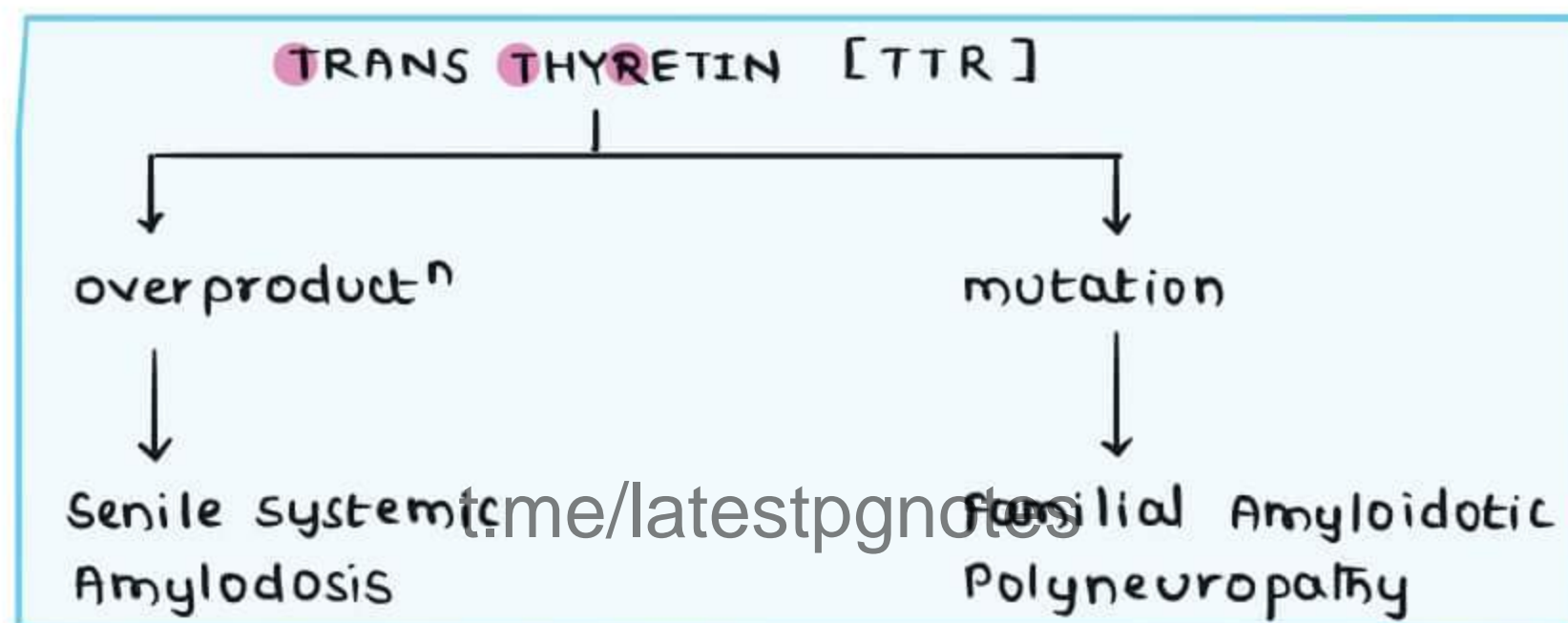
1. INFECTIONS [HIV]
2. PEM
3. MALIGNANCY / METASTASIS
4. \downarrow SPLEEN FUNCTION

- Group of conditions \bar{c} Extra cellular Fibrillar protein deposition
- alw Organomegaly
- pressure atrophy seen



→ **PATHOGENESIS**

- over production of misfolding proteins } not
- Altered / mutated protein \bar{c} \uparrow misfolding } destroyed



→ **AMYLOID PROTEIN**

- made up of
 - ↳ Fibrillary protein [95%]
 - ↳ P component [5%]

→ Structure → NON - BRANCHING FIBRILS

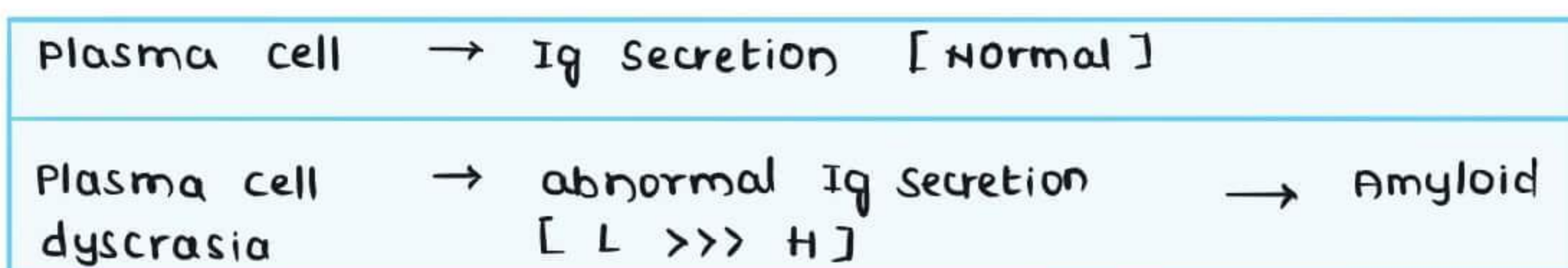
→ **CLASSIFICATION OF AMYLOIDOSIS**

- I. Generalised / systemic
- II Localised
- III Hereditary / familial

I GENERALISED / SYSTEMIC AMYLOIDOSIS

1. **PRIMARY AMYLOIDOSIS** [mc amyloidosis]

→ seen in **PLASMA CELL DYSCRASIA** [mc cause]



→ chemical Nature → AL [Amyloid Light chain]

2. SECONDARY AMYLOIDOSIS

68

→ Risk factors

↳ chronic inflammation [RA | TB]

↳ cancers [Hodgkin Lymphoma | Renal cell carcinoma]

→ mc cause of 2° amyloidosis in **Bharat** → **TB**

→ mc cause of 2° amyloidosis in US → RA

→ chronic Bronchitis not a/w Amyloidosis

→ ETIOLOGY

cytokines
[IL-1 | IL-6]



↑↑ SAA Protein [Serum Amyloid Associated Protein]

→ chemical nature → AA [Amyloid Associated Protein]

→ FAMILIAL MEDITERRANEAN FEVER

↳ "PYRIN" → Fever/serpiginosities

↳ Rx by COLCHICINE

3. CHRONIC RENAL FAILURE [CKD]

DIALYSIS [previous machines]



↑↑↑ β_2 - microglobulin



chemical nature → $A\beta_2$

4. LOCALISED AMYLOIDOSIS

a. ALZHEIMER'S DISEASE

APP
[Amyloid
precursor
protein]

α Secretase



DESTROYED

β /R secretase



β - PLAQUE



Neuronal damage



Dementia

- Chemical nature of Amyloid → A β
- gene for APP located on → chr. 21
- Down syndrome [Trisomy 21] has faster progression for developing dementia

b. MEDULLARY THYROID CANCER [MTC]

- Para follicular cells / 'c' cells secretes CALCITONIN
- Medullary thyroid cancer arises from 'c' cells

↑↑↑ 'c' → ↑↑↑ CALCITONIN

→ CALCITONIN

- ↳ ↑ calcitonin levels are used as a diagnostic marker in MTC
- ↳ ↑ calcitonin converts into amyloid
 - chemical nature of calcitonin → Acal

c. DIABETES MELLITIS TYPE 2

- α w Islet Associated Pancreatic Peptide [IAPP] / Amylin production
- chemical nature of Amyloid → A IAPP

5. HEREDITARY AMYLOIDOSIS

a. FAMILIAL MEDITERRANEAN FEVER

- chemical nature of Amyloid → AA

b. FAMILIAL AMYLOIDOTIC POLYNEUROPATHY

- chemical nature of Amyloid → ATTR [A - Amyloid; TTR - Transthyretin]
- ATTR is also seen in [t.me/latostpnotes](https://www.t.me/latostpnotes) SENILE SYSTEMIC AMYLOIDOSIS
- FAMILIAL AMYLOIDOTIC POLYNEUROPATHY α w MUTATED TRANSTHYRETIN
- SENILE SYSTEMIC AMYLOIDOSIS α w overproductⁿ OF NORMAL TTR

ORGANS AFFECTED IN AMYLOIDOSIS

1. CARDIAC TISSUE

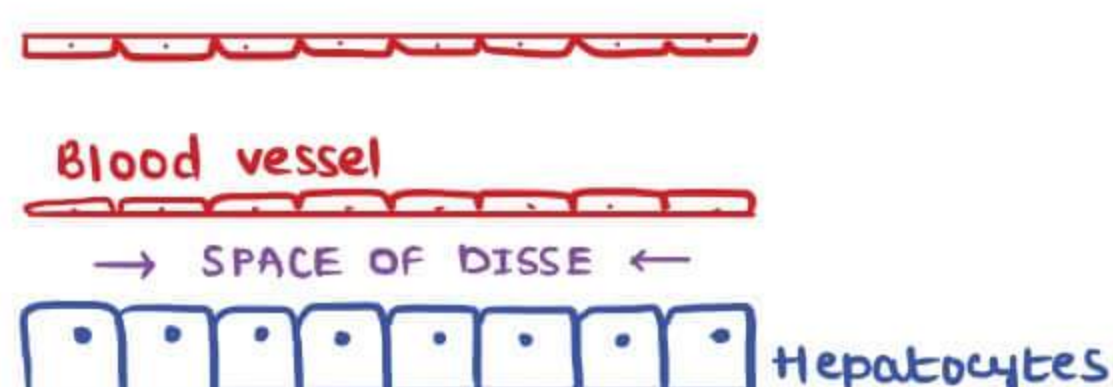
- α w more commonly \bar{t} 1^o amyloidosis
- Extra cellular amyloid deposited in Subendocardial tissue and interferes \bar{t} electric conduction of heart → ARRHYTHMIA occurs
- RESTRICTIVE CARDIOMYOPATHY occurs
 - mc cause of restrictive cardiopathy → Amyloidosis

2. KIDNEY

- MC & most seriously affected organ dlt amyloid deposition
- Amyloid deposition begins from Mesangium & involves other parts later
- CLINICAL FEATURES → urinary casts \oplus ; proteinuria \oplus ; Kidney size \uparrow

3. HEPATIC TISSUE

- hepatomegaly + nt
- 1st part inside the liver involved is 'SPACE OF DISSE'





5. JOINTS

- Knee joint involved
- Wrist joint involved → carpal tunnel syndrome

6. SKIN

- Perivascular area involved → PINCH PURPURA

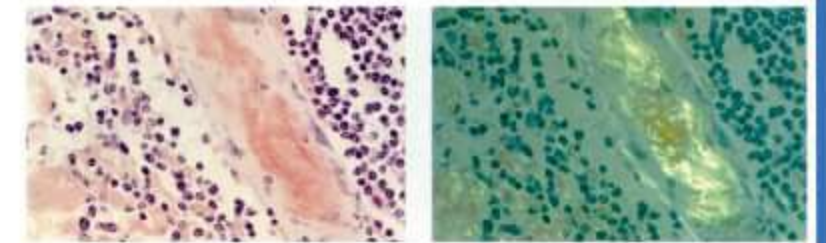
7. GIT

- Tongue involved → MACROGLOSSIA [↑ Tongue size] → Protrudes from mouth
- Oral / Rectal mucosa involved [easy areas to take Biopsy, rectal mucosa biopsy is preferred]
- ABDOMINAL FAT ASPIRATION [Preferred now a days for diagnosis of amyloidosis]

DIAGNOSIS OF AMYLOIDOSIS

1. STAINING

- congo red [mc used]
 - under normal light → Pink red appearance
 - under Polarised microscope → Apple green birefringens [characteristic]
- PAS ⊕
- THIOFLAVIN T & THIOFLAVIN S [provides secondary immunoflorescence]

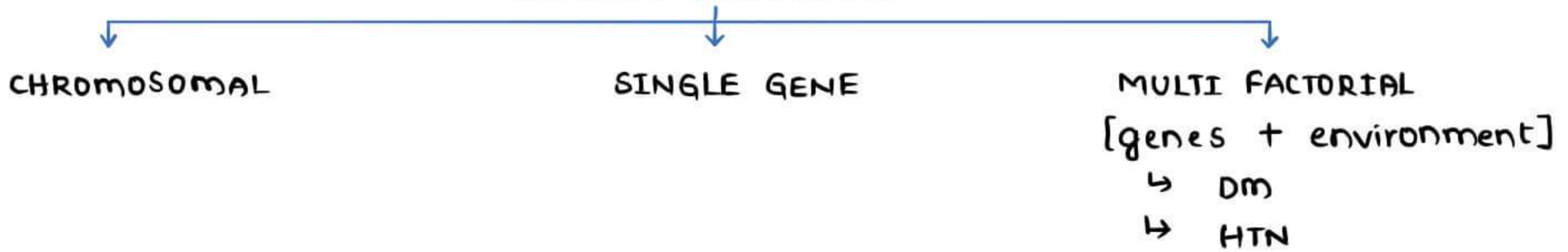


- 2. ELECTRON MICROSCOPY → Non-branching Fibrils are observed
- 3. SPECTROSCOPY & X-RAY CRYSTALLOGRAPHY → reveals β -plated structure
- 4. IMMUNO STAINING
- 5. SCINTIGRAPHY → done in the help of Serum Amyloid P
- 6. GROSS SPECIMEN → Shows waxy appearance
 - applying I_2 on it, gives Yellow color
 - if washed in dilute H_2SO_4 , it gives Blue/violet color

- Genetics → study of genes
- Genes → present on chromosomes
- Alleles → two different set of genes acquired from parents

- NO. OF genes discovered → 20,000
- % OF genes for coding proteins → 1.5%

GENETIC DISORDERS




CHROMOSOMAL DISORDERS

- sub divided based on
 1. Number
 - Diploid [2n] [normal cell]
 - Haploid [n] [gamete]
 - Aneuploidy [An = absent ; Euploidy = multiples of 'n']
 2. Structural Defect

t.me/latestpnotes

SUB TYPES OF CHROMOSOMES [based on centromere]

- | | |
|--------------------|----------------------------------|
| 1. METACENTRIC | → centromere right in the middle |
| 2. SUB-METACENTRIC | → centromere side of middle |
| 3. ACROCENTRIC | → centromere towards one end |
| 4. TELOCENTRIC | → centromere towards tip |
-
- Telocentric → not seen in humans
 - Sub metacentric → X chromosome
 - Acro centric → Y chromosome, chromosome 13/14/15/21/22



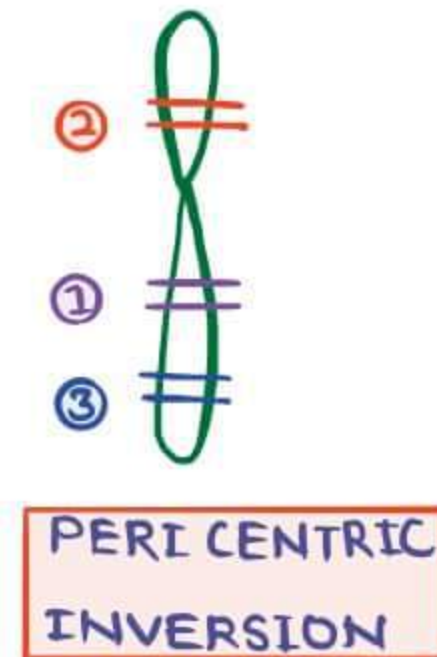
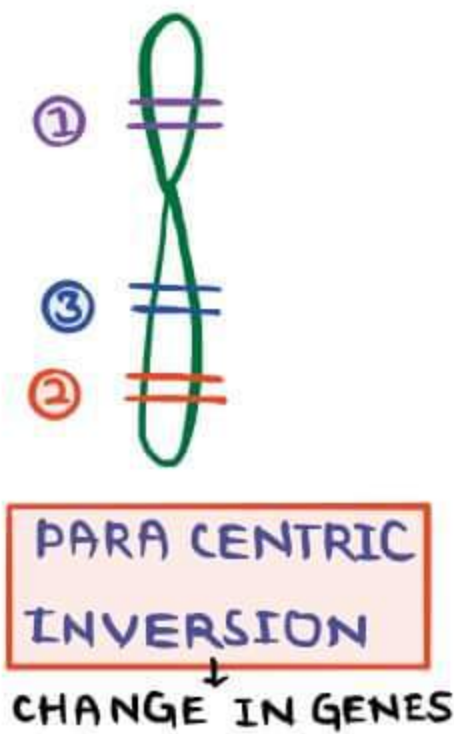
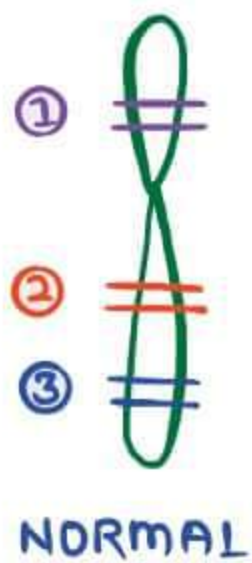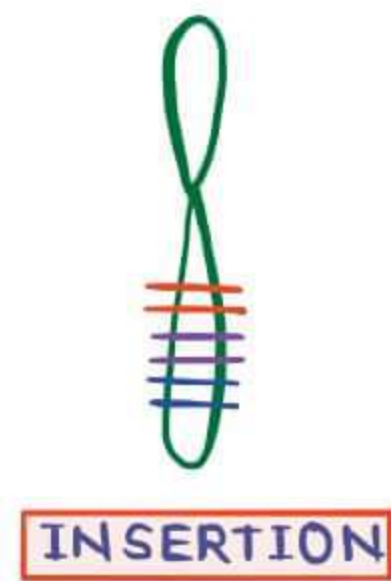

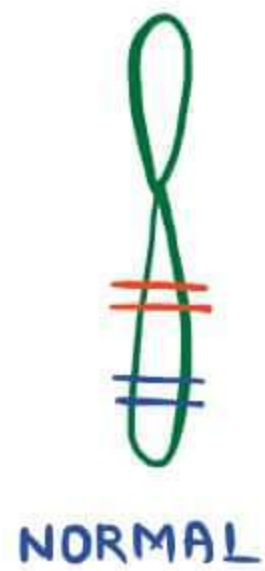
SUB TYPES OF CHROMOSOMES [based on sex determination]

- | | | |
|--------------------|------------------------------------------|-----------|
| 1. AUTOSOMES | → not a/w determinat ⁿ of sex | → 1 to 22 |
| 2. SEX CHROMOSOMES | → a/w sex determinat ⁿ | → X/Y |

KARYOTYPING

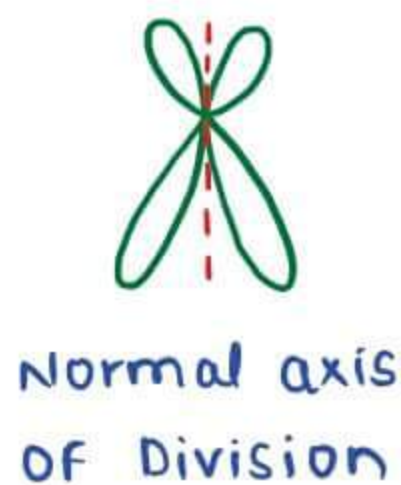
- study of chromosomes
- SAMPLES CAN BE TAKEN FROM
 - ↳ Amniotic cells
 - ↳ skin fibroblasts
 - ↳ Peripheral blood lymphocytes

- COLCHICINE added to sample → causes METAPHASIC ARREST
- mc banding pattern → 'G' Banding [Giemsa]
- CARNDY'S FIXATIVE → Methanol : Glacial acetic acid [3:1]

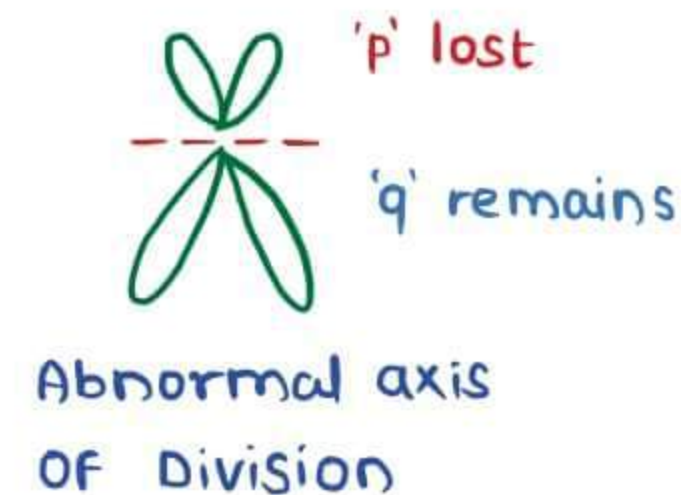


↳ inv (16) → AML - M₄

→ **ISOCHROMOSOME** - xq / 17q / 12p



t.me/latestpnotes



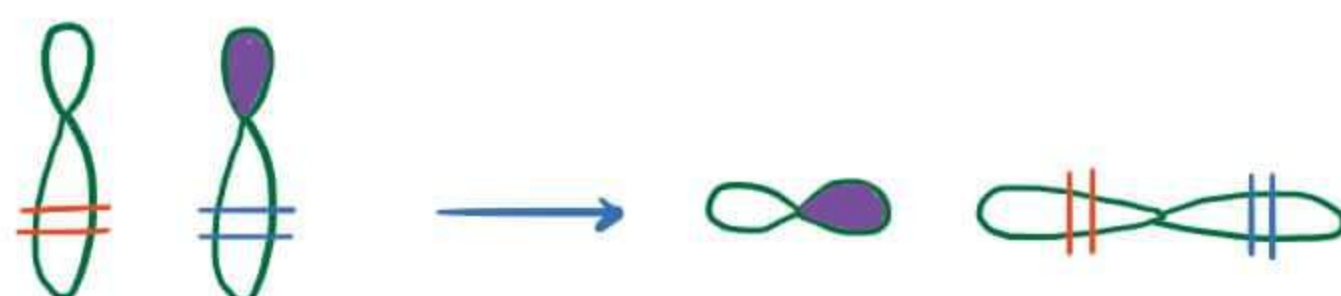
- ↳ Normal axis of division → vertical
- ↳ abnormal axis of division → perpendicular to normal division
- ↳ abnormal division leads to ISOCHROMOSOMES
- ↳ In ISOCHROMOSOME, the short arm [p] will be lost usually
- ↳ mc isochromosome observed in humans → xq
- ↳ mc isochromosome alw malignancy → 17q
- ↳ mc isochromosome alw testicular tumor → 12p

→ **TRANSLOCATION**



BALANCED TRANSLOCATION

- ↳ no genetic loss
- ↳ t [8;14] → Burkitt Lymphoma



ROBERTSONIAN TRANSLOCATION

- ↳ cell with lesser genetic material will be lost
- ↳ IF it affect Acrocentric chromosome, it can lead to DOWN SYNDROME [chr. 14|21]



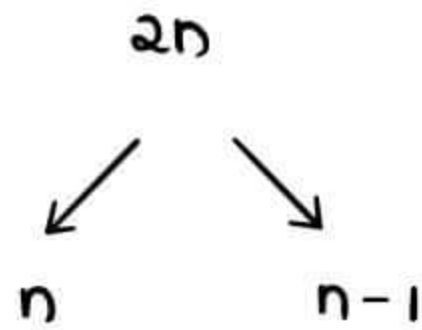
RING CHROMOSOME

- ↳ defect lies at edges of chromosome & two ends will fuse w each other
- ↳ involves 46X Y [X] → TURNER SYNDROME

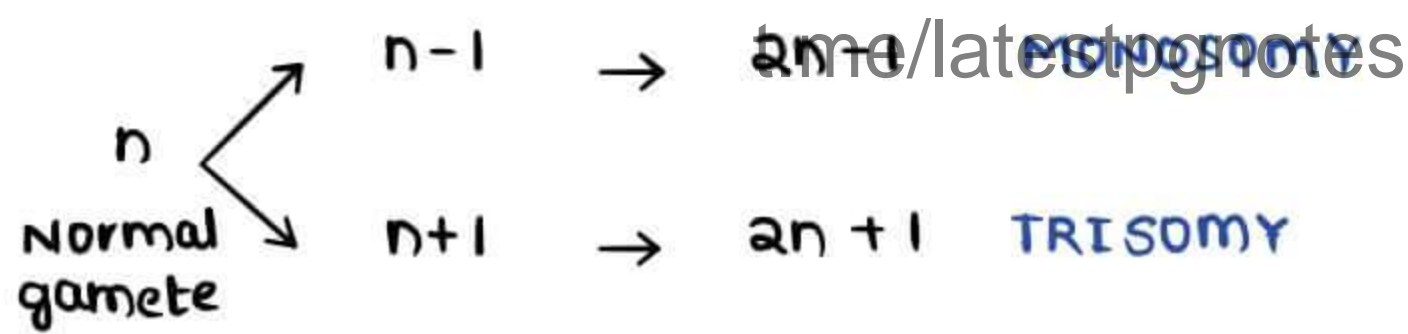
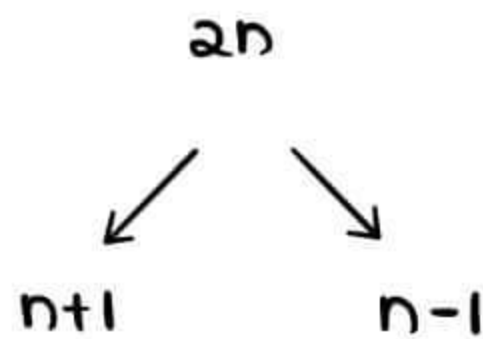
→ **ANEUPLOIDY**

→ due to

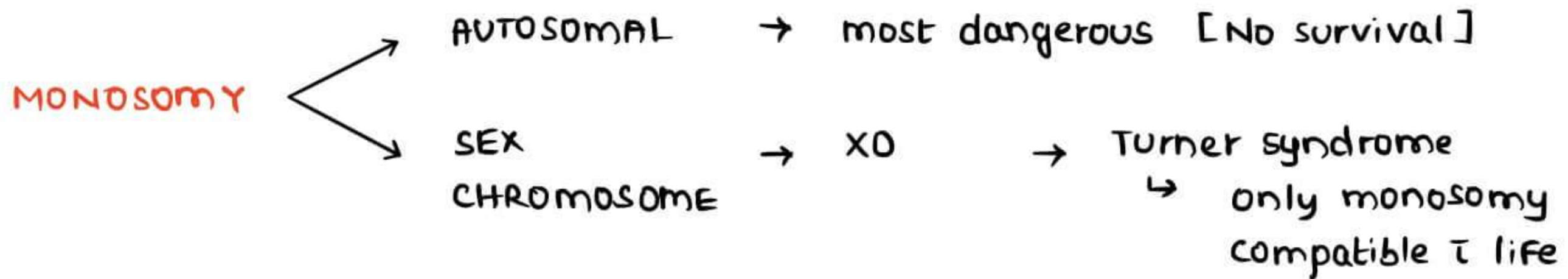
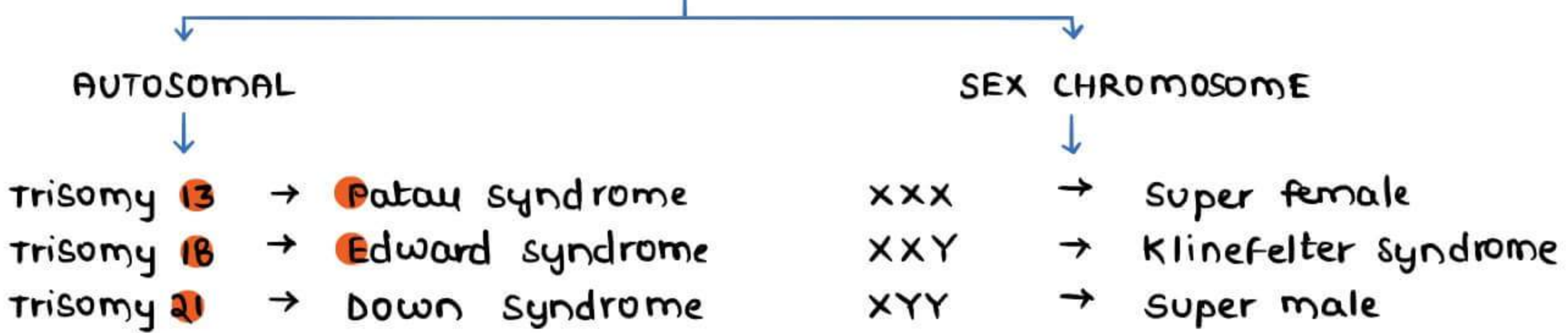
1. ANAPHASE LAG



2. MEIOTIC NON - DISJUNCTION



TRISOMY [mc - Trisomy 16]



DOWN SYNDROME

- Trisomy 21
- mc chromosomal disorder
- mc inheritable cause of mental retardation

→ GENETIC BASIS

1. MEIOTIC NON - DISJUNCTION

- ↳ mc cause
- ↳ a/w ↑ maternal age
- ↳ takes place at Meiosis I
 - all trisomies occurs dlt defect at meiosis I, Except for TRISOMY 18 [Edward syndrome] [occurs at meiosis II]

2. ROBERTSONIAN TRANSLOCATION → affects chr 14/21

3. MOSAICISM [MITOTIC NON - DISJUNCTION]

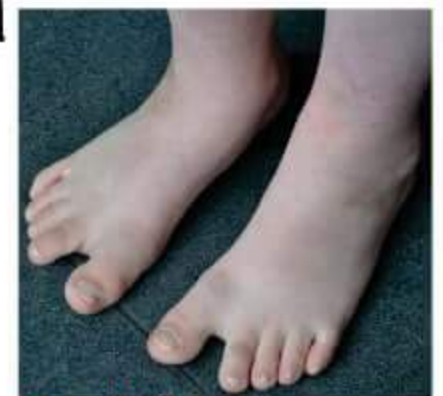- ↳ least common cause
- ↳ unequal distribution of chromosome at mitosis

→ CIF

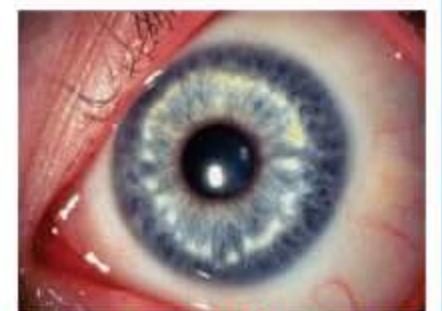- C** → Congenital cardiac defect
- H** → Hypotonia
- I** → Increased gap b/w great toe & second toe [SADDLE TOE]
- L** → Leukemia [ALL, AML - M7]
- D** → Duodenal atresia www.latestpnotes.com

- H** → Hirschsprung disease
- A** → Alzheimer's disease
- S** → Simian crease [single palmar crease]

- P** → Protruding Tongue
- R** → Rolling of Eyes
- O** → Occiput [flat]
- B** → Brushfield spots
- L** → Low nasal bridge
- E** → Epicanthal folds
- M** → Mongolian slant



Saddle toe



Brushfield Spots



Epicanthal folds

→ SCREENING

- ↳ Sporadic down syndrome
 - dlt meiotic non - disjunction
 - a/w ↑ Maternal age
 - chances of having 2nd baby i down syndrome are much lower

- ↳ Familial down syndrome
 - dlt Robertsonian translocatⁿ
 - chances of having 2nd baby i down syndrome are much higher

→ TRIPLE TEST

AFP
↓HCG
↑ESTRIOL
↓

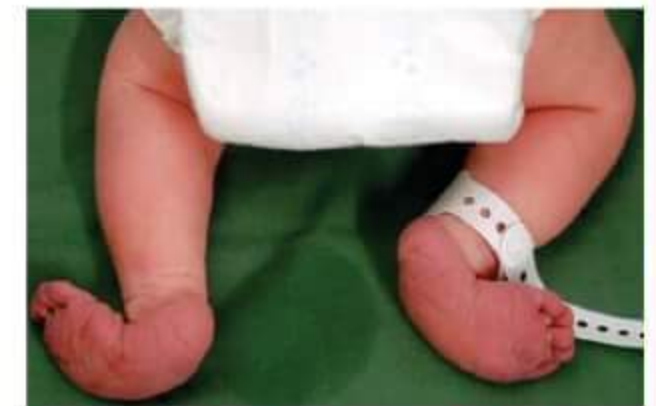→ QUAD TEST

Triple Test + Inhibin - α ↑

FEATURES OF OTHER TRISOMIES [13/18]

COMMON DEFECTS [13/18]

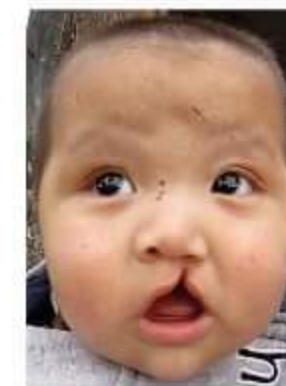- congenital cardiac defects
- Renal defects
- Mental Retardation
- Rocker Bottom Feet



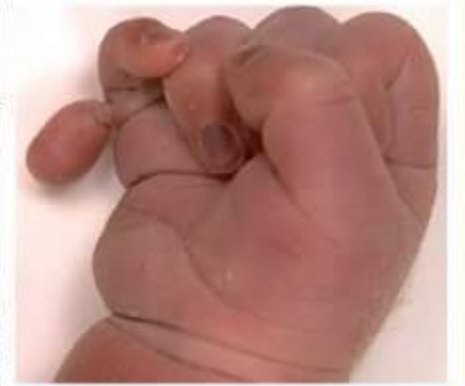Rocker Bottom foot

PATAU SYNDROME [13]

- Polydactyly
- Palate defects
- Eye defects
- microcephaly



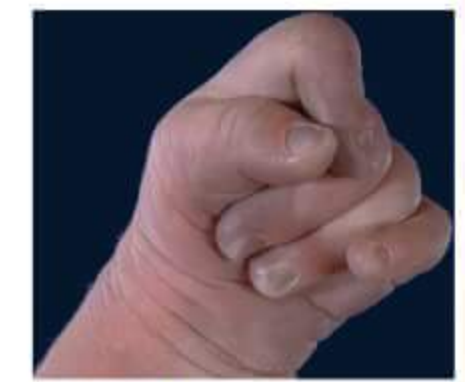Palate defects



Polydactyly

EDWARD SYNDROME [18]

- Extra / Prominent occiput
- micrognathia [small chin] me/latestpgnotes
- overlapping fingers



overlapping fingers

TURNER SYNDROME

- Loss of 'x' chromosome
 1. 45 XO [classical] [more common]
 2. 46 X τ [X]
 3. 46 X i [Xq]
 4. Mosaicism [46 XX / 45 XO]

→ CIF

↳ mc cause of primary amenorrhea

↳ C → Cardiac defects [Bicuspid aortic valve > coarctatⁿ of aorta]

L → Lymphedema [Hands & feet involved]

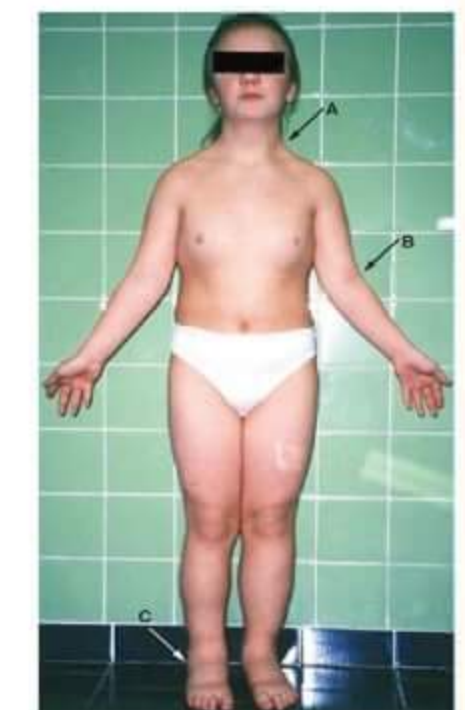O → Ovaries [streak] → ↓↓ fertility

W → Webbed neck [low neck hair line]

N → Nipples [widely spaced]

S → Short stature [SHOX gene defect]

↳ 'O' BARR BODY



KLINFELTER SYNDROME

- ♂ Phenotype → 47 XXY
- mc genetic cause of infertility
- CIF
 - ↳ tall stature
 - ↳ ↓ IQ
 - ↳ hypotonia
- '1' Barrbody
 - ↳ feminine manifestations
 - gynecomastia
 - testicular atrophy
 - ↳ ↓ Testosterone
 - ↳ ↑ FSH
 - ↳ ↑ LH
 - no 2° sexual characteristics
- ↑ Auto immune disorders [SLE]
- ↑ Cancers [Testicular tumors (teratoma) < Breast cancer [Ductal]]
- ↑ congenital cardiac defects [Mitral valve prolapse]

→ DEFECTIVE GAMETOGENESIS → a/w ↑↑ Age [Both sex]

t.me/latestpgnotes

↑ maternal age
↑ paternal age

→ Down Syndrome
→ M → Marfan syndrome
→ O → Osteogenesis imperfecta
→ N → Neurofibromatosis
→ A → Achondroplasia

LYON'S HYPOTHESIS

- only '1' X chromosome → active
- 2nd Inactivation → dit XIST gene [DNA methylation]
- takes place at the level OF BLASTOCYST

→ BARR BODY

↳ perinuclear structure observed in interphase

↳ NO. OF BARR BODIES [no. of X - 1]

- | | | |
|----------------------|-------|-----|
| 1. Normal Male | → XY | → 0 |
| 2. Normal Female | → XX | → 1 |
| 3. Turner Syndrome | → XO | → 0 |
| 4. Klinefelter synd. | → XXY | → 1 |
| 5. Super female | → XXX | → 2 |

classical Mendelian Inheritance

- | | |
|-------------|-----------------|
| Autosomal | Sex chromosomal |
| ↳ dominant | ↳ y Linked |
| ↳ Recessive | ↳ X Linked |
| | → XLR |
| | → XLD |

Non - Mendelian Inheritance

1. Genomic Imprinting
2. Mitochondrial Inheritance
3. Trinucleotide repeat expansion
4. Germline mosaicism

MENDELIAN INHERITANCE

ALLELES

↳ individual copies of genes of a trait coming from both parents & present on same locus

Ⓝ gene → 2 ALLELES [same locus]

HAIR COLOR	HOMOZYGOUS TRAIT	HETEROZYGOUS TRAIT
GENOTYPE	AA aa	Aa
	↓ ↓	↓
PHENOTYPE	A a	A
	[Black] [Brown]	[Black]

t.me/latestpnotes

- ↳ DOMINANT ALLELE → expressed even in heterozygous trait
- ↳ RECESSIVE ALLELE → expressed only in homozygous trait
- ↳ CO - DOMINANCE → Both alleles are expressed in heterozygous trait
 - ↳ EX: Blood grouping
 - HLA | MHC genes

AUTOSOMAL DOMINANT DISORDERS

- expressed in Heterozygous state
- 50% progeny affected
- Patient → at least 1 parent affected [vertical Inheritance]
- ♂ / ♀ equally affected
- Structural proteins are affected
- Loss of function mutation > Gain of function mutation
- Incomplete penetrance
- variable expressivity
- Pleiotropy [> 1 system involved] ; Ex: NF
- EXAMPLES

100
↓
80
↓
+ / + + / + + +

Vo	→	V WD; V HL Syndrome
Familial	→	F amilial adenomatous Polyposis ;
Hyperchol	→	F amilial H ypercholesterolemia
Poora	→	P olycystic Kidney Disease
D	→	D ystrophia myotonica
O	→	O steogenesis imperfecta
m	→	M arfan syndrome ; M EN
I	→	I ntermittent porphyria [Acute]
N	→	N eurofibromatosis 1
A	→	A chondroplasia
N	→	N eurofibromatosis 2
T	→	T uberous sclerosis
Hota	→	H untington's disease [gain of funct ⁿ mutat ⁿ]
Hai	→	H ereditary Spherocytosis

AUTOSOMAL RECESSIVE DISORDERS

- affects Enzymatic proteins [Inborn errors of metabolism]
- expressed in homozygous state [Early onset]
- complete penetrance
- ↑ in consanguineous marriage [parsi] muslims]
- Patient → Parents may be carriers
- Siblings have higher chances [Horizontal Inheritance]

100
↓
100

→ EXAMPLES

1. Inborn Errors of metabolism [glycogen & Lysosomal Disorders]
2. Friedrich's ataxia
3. Sickle cell anemia
4. Thalassemia
5. Wilson's disease [Cu]
6. Hemochromatosis [Fe]
7. Homocystinuria
8. Alkaptonuria

SEX LINKED DISORDERS

Y LINKED DISORDERS

- Only ♂ affected
- Patient → Sons
- Hair on pinna
- Y chromosome → acrocentric chromosome → ↓ Fertility

X LINKED DISORDERS [father to son transmission is 'zero']

XLR [X Linked Recessive]

- mc sex linked pattern of inheritance
- x linked genes → encodes enzyme genes
- more common in ♂
- ♀ → $X X^d$ → heterozygous [not common]
- EXAMPLES

Less	→	Lesch - Nyhan Syndrome
H	→	Hemophilia A & B
C	→	Color blindness [more i red] / CGD
G is	→	G6PD deficiency
Detected in	→	Duchenne muscular dystrophy
A	→	Agammaglobulinemia [Bruton Disease]
Fragile	→	Fragile X syndrome
Women	→	Wiskott - Aldrich Syndrome

XLD [X linked Dominant Disorders]

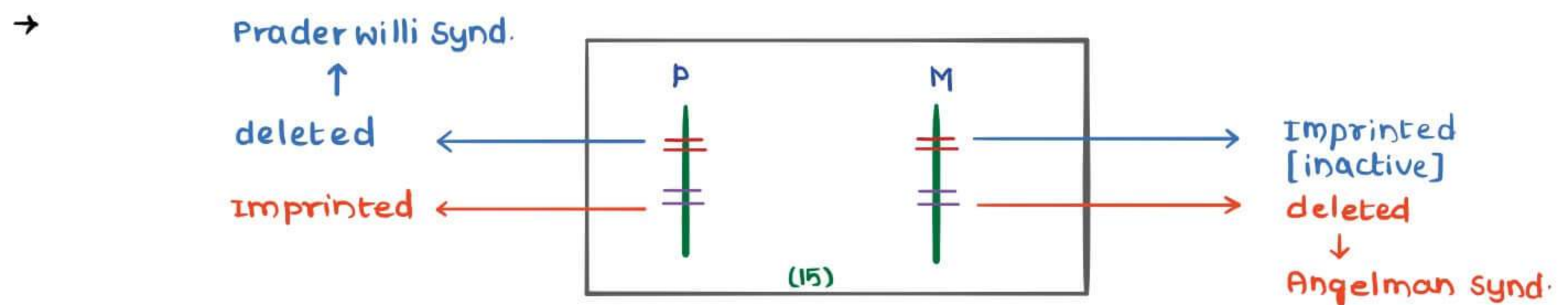
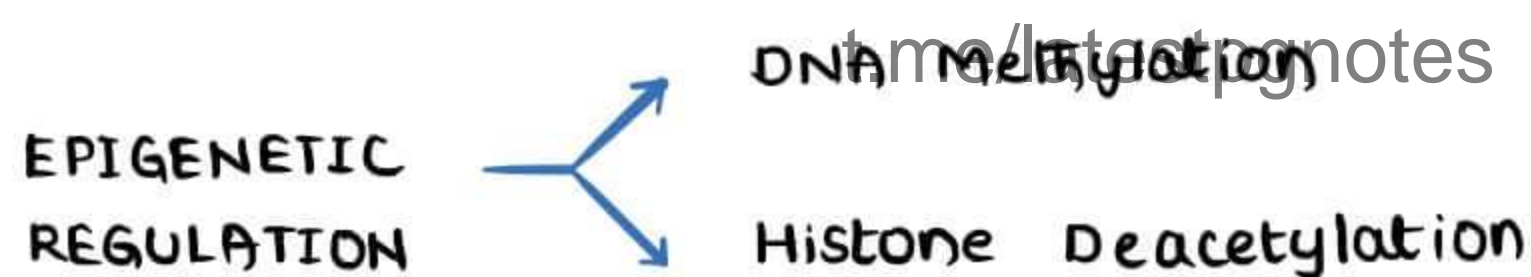
- affects ♂ → Daughters [xx^d → 50% Progeny]
- affects structural proteins
- less common
- EXAMPLES

A	→	Alport Syndrome
V	→	vit D resistant Rickets
I	}	Incontinentia Pigmenti
P		

NON CLASSICAL / NON MENDELIAN INHERITANCE DISORDERS

1. GENOMIC IMPRINTING

- DIFFERENTIAL GENE EXPRESSION based on PARENT OF ORIGIN
-



→ PRADER WILLI SYNDROME

↳ Normal → Maternal gene imprinted & paternal gene is active

↳ Etiology

1. in case of deletion of Paternal chromosome [mc cause]
2. uniparental Disomy [maternal chromosome]
3. ↓ SNORP [Small Nucleolar RNA Proteins]

↳ CIF

- Mental Retardation
- Obesity [dLE ↑ ghrelin]
- hypotonia
- hypogonadism

→ ANGELMAN SYNDROME [AMS]

→ Normal → Paternal gene imprinted & Maternal gene is active

→ Etiology

1. Deletion of maternal chromosome [mc cause]
2. Uniparental disomy [paternal chromosome]

→ CIF

S	→	Seizures	}	HAPPY PUPPETS
A	→	Ataxia		
R	→	Retardat ⁿ [Mental]		
I	→	Inappropriate laughter		

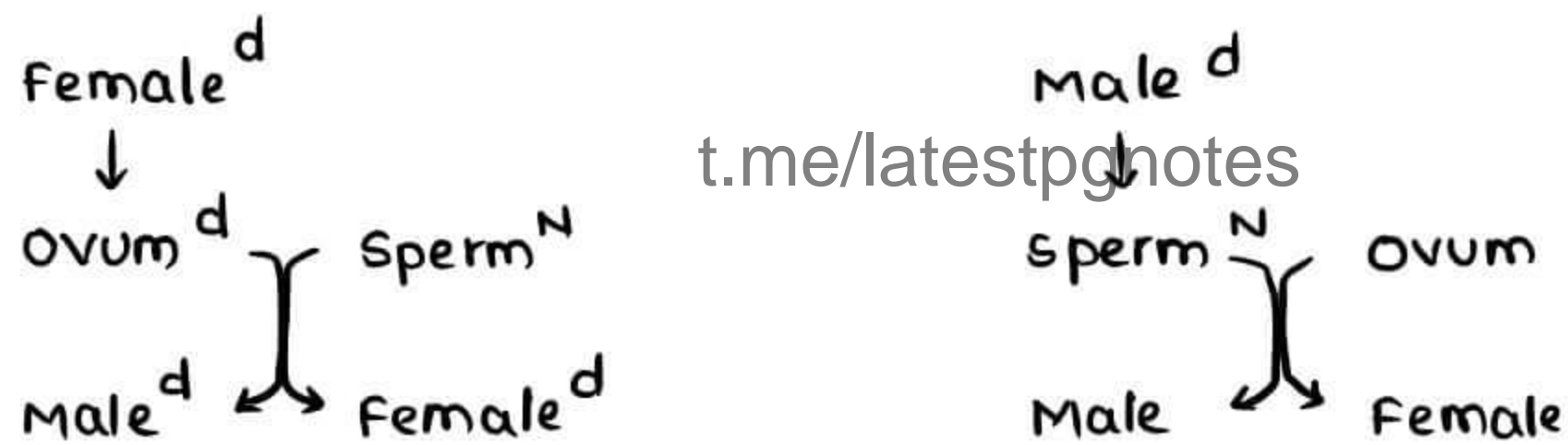
→ Genomic Imprinting seen in

1. PWS
2. AMS
3. Mc Cune Albright Dystrophy
4. Beckwith-wiedemann Syndrome

2. MITOCHONDRIAL / MATERNAL INHERITANCE

→ MATERNAL INHERITANCE

mt. DNA in ovum is preserved & in sperms not preserved



→ CLINICAL EXAMPLES

1. MELAS → Mitochondrial Encephalopathy, Lactic Acidosis, stroke
2. LEIGH'S DISEASE
3. NARP SYNDROME → Neuropathy, Ataxia, Retinitis Pigmentosa
4. LEBER'S OPTIC NEUROPATHY

→ governed by Law of POPULATION GENETICS

3. GERMLINE MOSAICISM

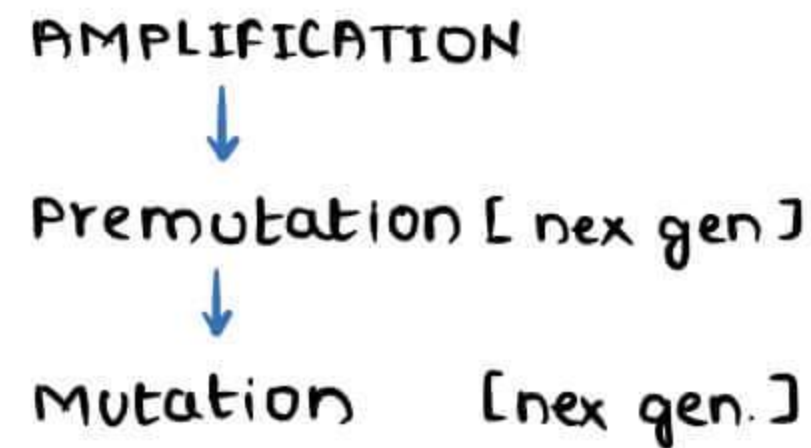
AD → 1 Affected parent → Normal
 → NO Affected parent → Rare

Person → N → Post zygotic mutatⁿ affecting gonadal cells → Progeny / next generation affected
 [>1 progeny]

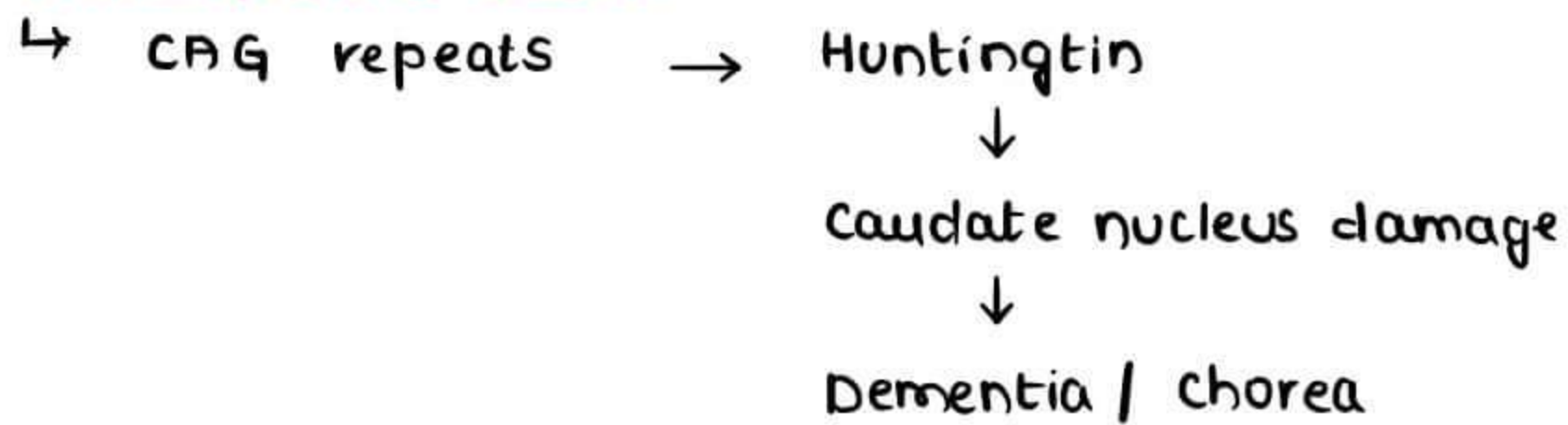
→ Seen in Osteogenesis imperfecta
 Tuberous sclerosis

4. TRIPLE REPEAT MUTATIONS

- Long nucleotide repeats [affects cytosine | guanosine]
- causes Neurodegenerative disease
- Dynamic in nature
 - ↳ Amplification of nucleotide repeats at the time of gametogenesis



→ HUNTINGTON'S DISEASE



- CAG repeats → Huntington's Disease
- GAA repeats → Friedrich Ataxia
- CTG repeats → Myotonic Dystrophy

→ FRAGILE X SYNDROME

- ↳ FMR - 1 gene mutation
- ↳ 2nd MCC of MR
- ↳ Large face
- ↳ Large mandible
- ↳ Large Testis [Macro orchidism]
- ↳ Large everted ears

- CGG Repeats takes place at OOOGENESIS

♂ → → → Grandson

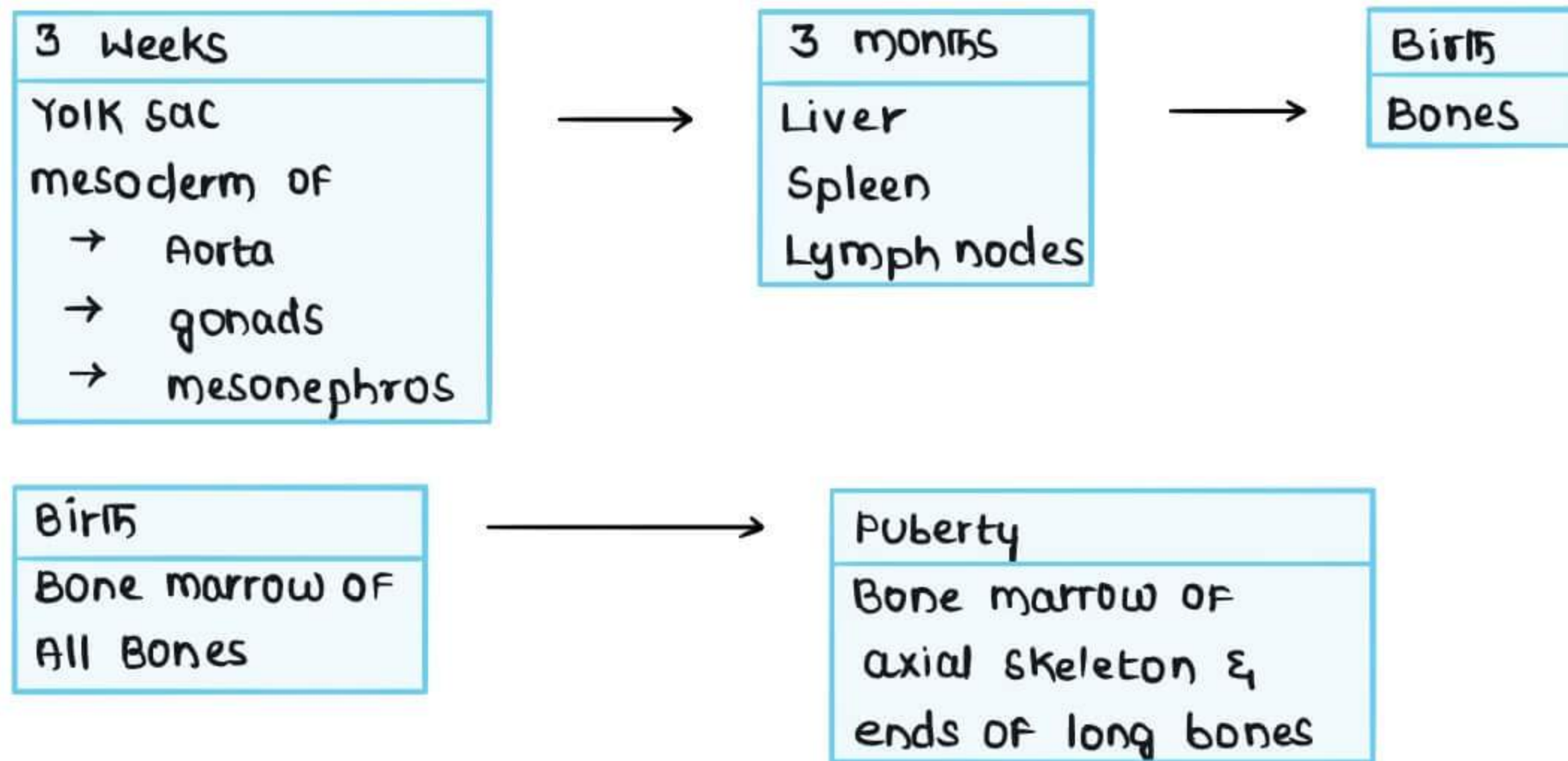
SHERMAN'S PARADOX

- ↳ chances of developing MR far more in grandson by ANTICIPATION
- ↳ Nuclear repeats → Premutation → Mutation [ANTICIPATION]

HEMATOLOGY HEMATOPOIESIS BASIC CONCEPTS

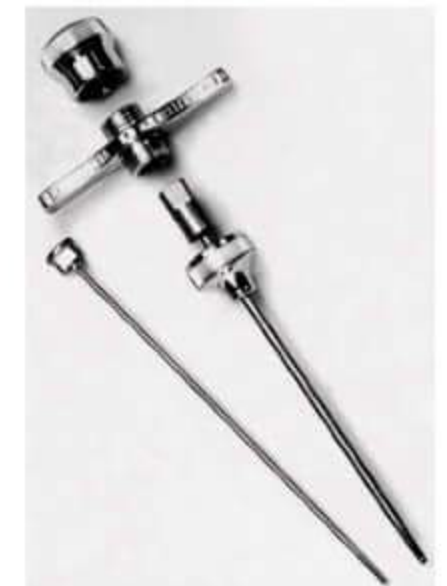- HEMATOPOIETIC STEM CELL [HSC]
 - ↳ pluripotent cell [can give rise to multiple types of cells]
 - ↳ self-renewable

- ERYTHROPOIESIS & HSC LOCATION



- Bm EXAMINATION

1. Bm Aspiratⁿ → by KLIMA/SALAH'S NEEDLE
2. Bm Biopsy → by ~~TREPHINE NEEDLES~~
JAMSHEDI'S NEEDLE

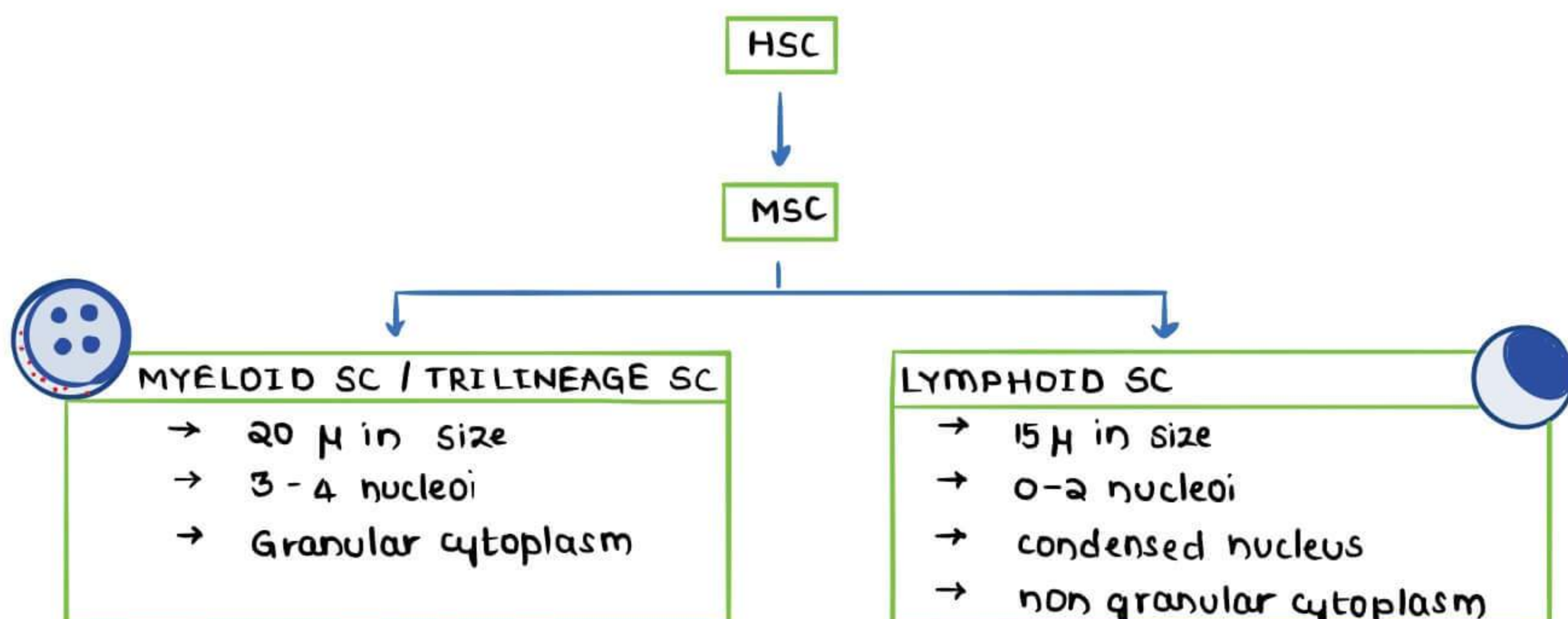


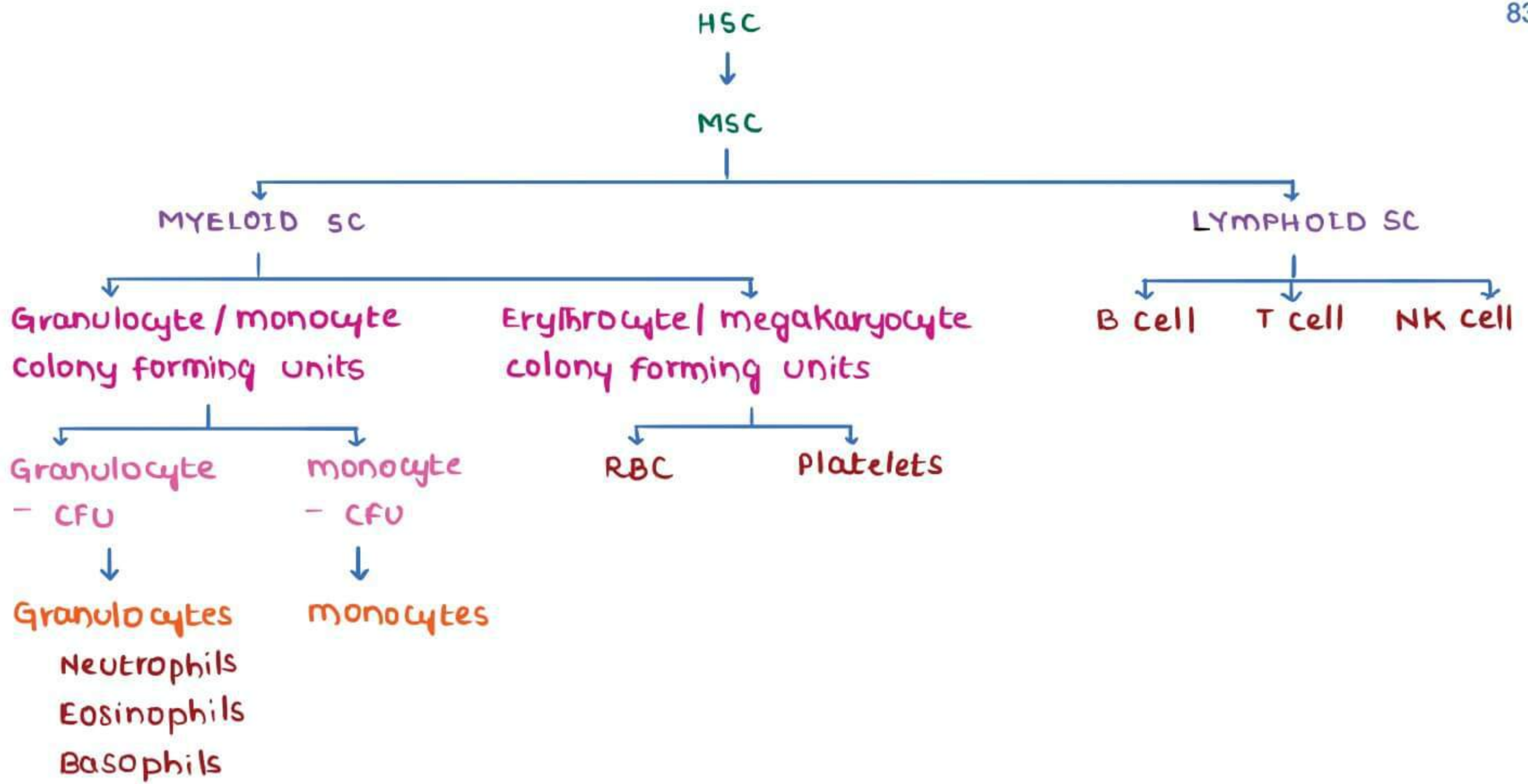
TREPHINE &
JAMSHEDI'S
NEEDLES

- Ideal Site of Bm BIOPSY

- ↳ Adults → posterior superior iliac spine [PSIS]
except in obese people [ASIS]
- ↳ CHILD → Anterior end [Tibia]

HEMATOPOIESIS / ERYTHROPOIESIS





- HSC / MSC
- From Myeloid / Lymphoid SC
- SELF RENEWABLE CELLS
- COMMITTED CELLS

→ FROM TOP TO BOTTOM OF Hierarchy Differentiation increases

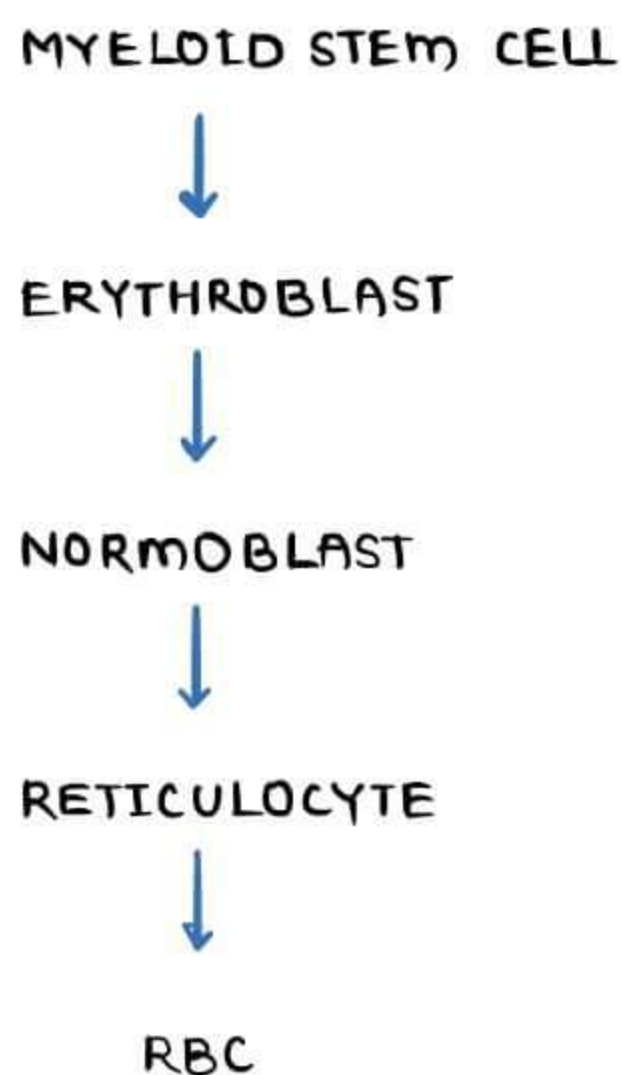
- ↳ highly differentiated cells affected by specified GF
 - ↳ RBC → Erythropoietin [EPO] ← DARBOPOIETIN
 - ↳ Platelets → IL 11 ← OPRELVKIN
 - ↳ Gm - CFU → Gm-CSF ← SARGRAMOSTIM
 - ↳ G - CFU → G-CSF ← FILGRASTIM

- PANCYTOPENIA Seen in
 - Aplastic Anemia
 - dit damage to HSC

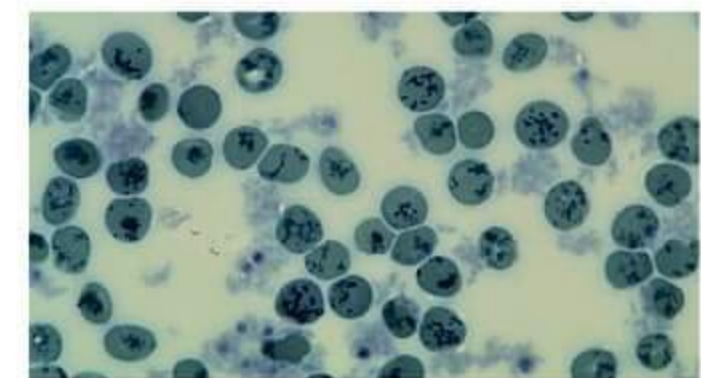
- MYELOPROLIFERATIVE DISORDERS → ↑ RBC / P / WBC

RBC DEVELOPMENT & CLASSIFICATION OF ANEMIA

DEVELOPMENT



- ↑ differentiation
 - ↓ size
 - ↓ size of nucleus
 - ↑ Hb concentration
- } NUCLEAR CYTOPLASMIC SYNCHRONY



SUPRA VITAL STAINING

- Hb detected firstly in Erythroblast [only by e⁻ microscope]

NORMOBLAST

- ↳ Early
- ↳ Intermediate → Hb can be detected by routine staining
- ↳ Late → Polychromatophilic cell
- ↳ Late → NUCLEUS EXTRUSION OCCURS while it converting to Reticulocyte

**RETICULOCYTE**

- mesh like appearance
- FIRST NON - NUCLEATED CELL
- detectⁿ requires SUPRA VITAL STAINING [detected Only in Living state]
 - ↳ New methylene blue [preferred]
 - ↳ Brilliant cresyl blue
 - ↳ Bm ACTIVITY → Reticulocyte count
 - ↳ Reticulocyte count Estimation gives Bm ACTIVITY aka 'POOR MAN'S Bm ASPIRATION'
- Normal → 0.5 - 2%

Increased Reticulocyte count

- Hemolytic anemia
- Fe / FA / B₁₂ Supplementation

Decreased Reticulocyte count

- Aplastic anemia / latest pgnoses
- deficiency of Fe / FA / B₁₂
- Leukemias / metastasis
- myelofibrosis

→ CORRECTED RETICULOCYTE COUNT

$$\frac{\text{Reticulocyte count} \times \text{Hb [Patient]}}{\text{Hb [normal]}}$$

used to estimate compensatory increase of reticulocytes in certain conditions

RBCs**NORMAL RBCs [N - 7-8 μ]**

- Biconcave shape
- more Hb at periphery than center
- Shape & Flexibility maintained by
 - ↳ Spectrin [most imp]
 - ↳ Band
 - ↳ Ankyrin



- Variation in size of RBC can be known as → ANISOCYTOSIS
- 11.5 - 14.5
- Central 1/3 rd Pallor

- MCV → 80 - 100 FL
- MCH → 27 - 33 pg
- MCHC → $\frac{MCH}{MCV}$ → 34 - 37 g/dl

→ B₁₂ deficiency | megaloblastic Anemia → MCHC → ⊖

- Hematocrit → 45% or 0.45
- Red cell Distribution width [RDW]

MCH → gives color of RBC → ↓ → hypochromic RBC

MCV

- 80 - 100 FL
- < 80 FL
 - ↳ S → Sideroblastic Anemia
 - ↳ I → Iron deficiency Anemia
 - ↳ T → Thalassemia
 - ↳ A → Anemia of chronic disease
 - ↳ L → Lead poisoning

- > 100 FL
 - ↳ L → Liver disease
 - ↳ H → Hypothyroidism
 - ↳ M → Myelodysplastic syndrome
 - ↳ C → Cytotoxic drugs
 - ↳ Cell Nutrient deficiency
 - ↳ B₁₂ deficiency
 - ↳ FA deficiency
 - ↳ Methotrexate
 - ↳ Alcohol
 - ↳ Phenytoin

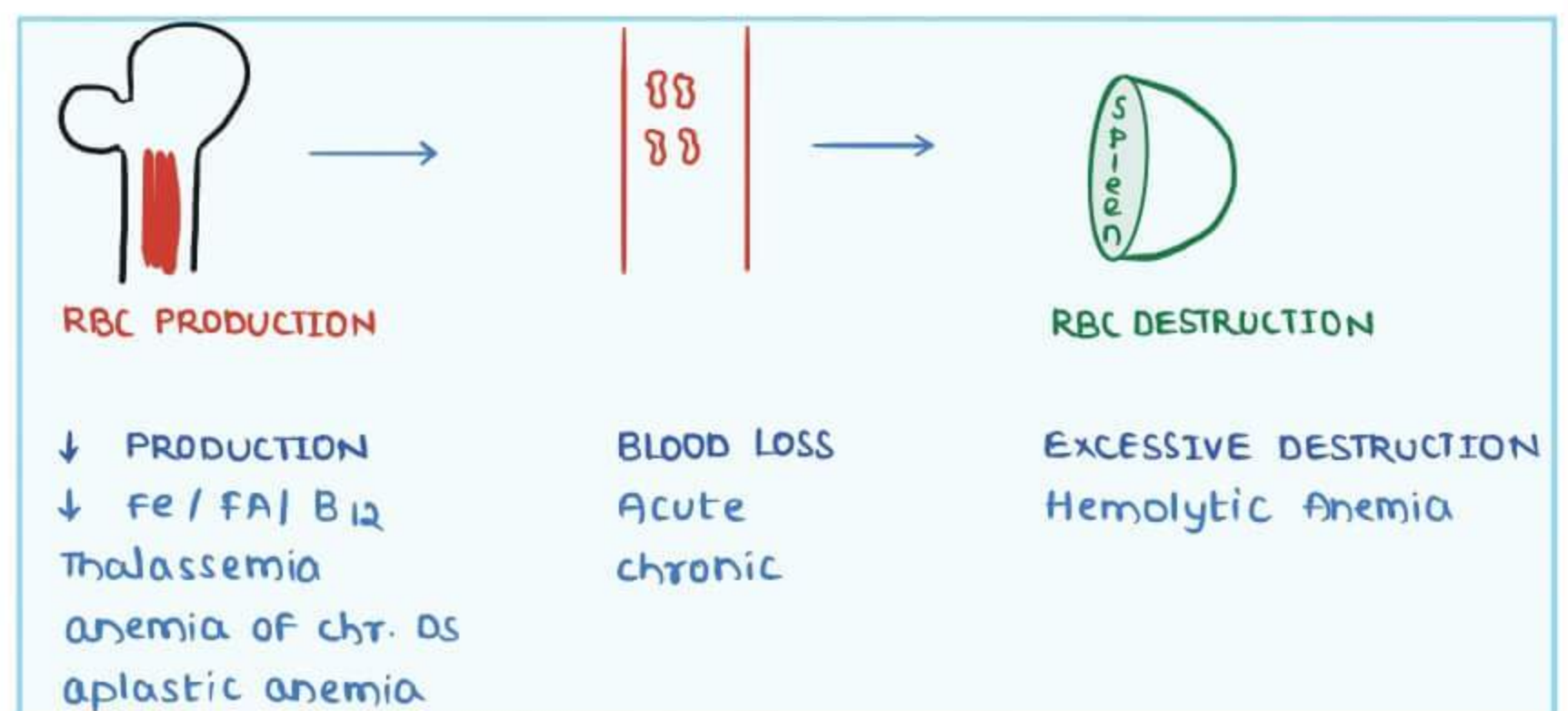
↳ ↓ B₁₂ } NUCLEAR CYTOPLASMIC
 ↳ ↓ FA } ASYNCHRONY

→ ↑ RBC size } MEGALOBLAST
 → Nucleus is immature } [> 110 FL]

ANEMIA - CLASSIFICATION

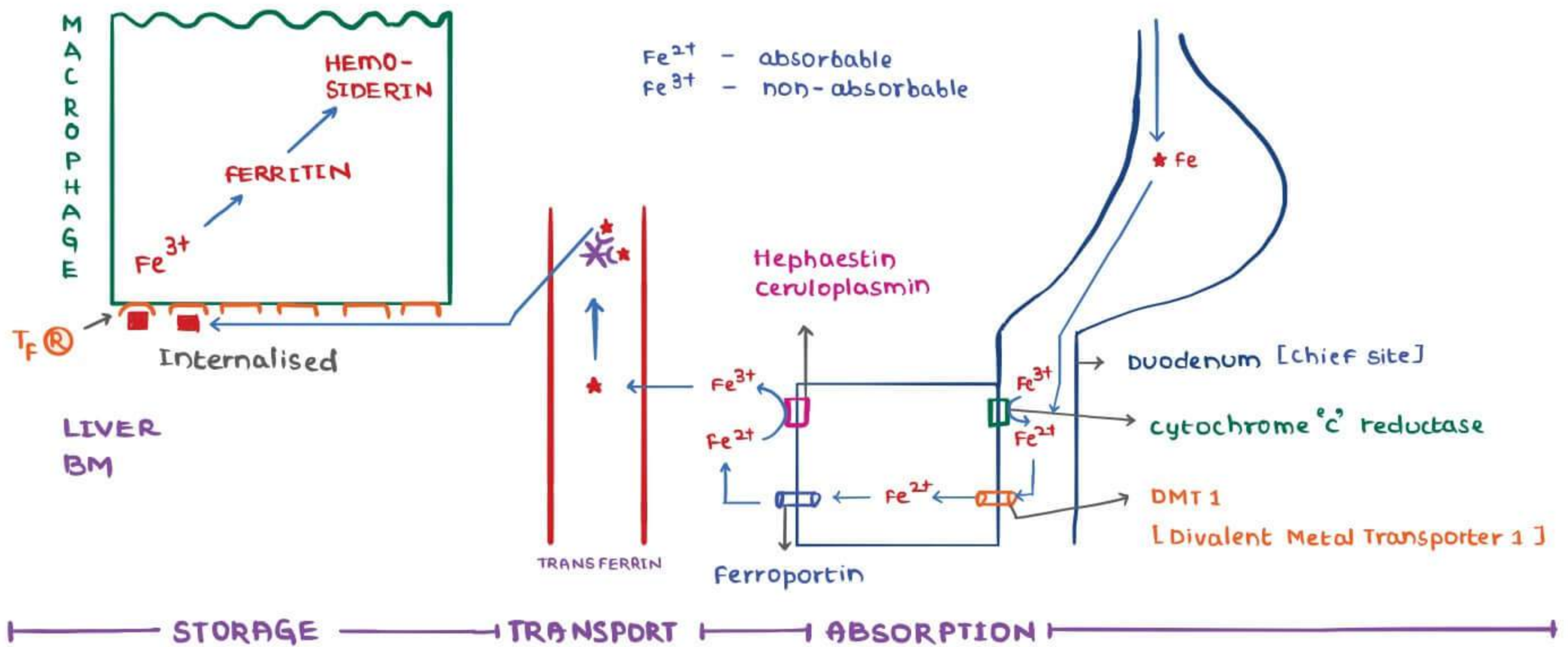
1. Size of RBC

- a. Microcytic Anemia
- b. macrocytic Anemia
- c. Normocytic Anemia
 - myelofibrosis
 - Radiation
 - metastasis
 - Renal disease



→ m.c.c of microcytic anemia

IRON METABOLISM



ABSORPTION

→ chief site → DUODENUM

↑ ABSORPTION

- ↳ HCl
- ↳ vitamin C
- ↳ Amino acid
- ↳ Sugars

↓ ABSORPTION

- ↳ Phytates [vegetables]
- ↳ carbonates
- ↳ tannins
- ↳ Tetracyclines

t.me/latestnotes

→ PURE VEGETARIANS HAVE HIGHER CHANCES OF IRON DEFICIENCY

TRANSPORT

→ SERUM IRON → Iron attached i transferrin [Tf]
 → N → 100 - 120 µg/dl

→ % TRANSFERRIN SATURATION

$$\frac{2}{6} \rightarrow 33\% \text{ or } 1/3$$

→ TOTAL IRON BINDING CAPACITY [TIBC]

→ N → 300 - 360 µg/dl

STORAGE

→ FERRITIN $\propto \frac{1}{\text{TRANSFERRIN}}$

→ BM FERRITIN \rightleftharpoons SERUM FERRITIN [indirect indicator of Fe storage]

→ Serum ferritin $\propto \frac{1}{\text{TRANSFERRIN}}$

IRON DEFICIENCY CAUSES

- ↓ Intake
- ↓ Absorption [Malabsorption, Diarrhea]
- ↑ requirement
 - ↳ growing children
 - ↳ reproductive age group
 - ↳ pregnancy
 - ↳ Lactation
- Blood loss
 - ↳ accidents / trauma
 - ↳ Hook worm infection
 - ↳ Peptic ulcer disease
 - ↳ colon cancer

STAGES OF IRON DEFICIENCY

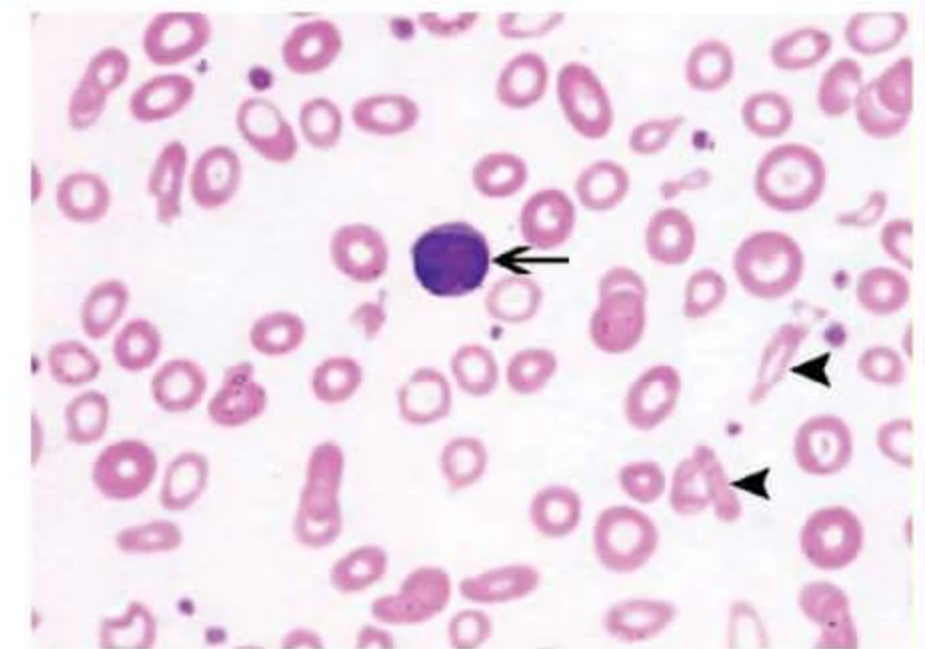
- I ↓ STORAGE IRON** → ↓ Bm IRON
→ ↓ Serum ferritin



II IRON DEFICIENT ERYTHROPOIESIS

- Serum Iron → ↓↓
→ % Tf Saturation → ↓
→ TIBC → ↑

III IRON DEFICIENCY ANEMIA t.me/latestpgnotes

- RBCs } MICROCYTIC
AFFECTED } HYPOCHROMIA
ANISOCYTOSIS
POIKILOCYTOSIS

**CLINICAL FEATURES**

- fatigue
- pallor
- Dyspnea
- palpitations
- Stunted growth
- Alopecia 
- Koilonychia 
- Pica


DIAGNOSIS**1. BM EXAMINATION**

- Gold standard
- ↓↓ staining ± prussian blue
- micro normoblasts ⊕

2. BLOOD

- ↓ Hb
- ↓ MCH / MCV / MCHC

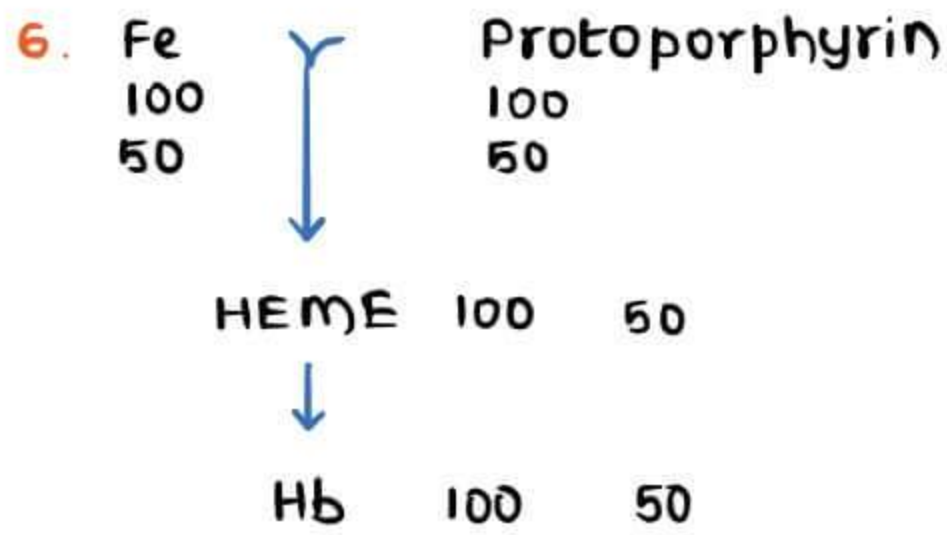
3. PERIPHERAL SMEAR

- microcytic hypochromic RBCs
- Anisocytosis
- Poikilocytosis, Target cells 

4. IRON PROFILE

- S. ferritin → ↓
- S. Iron → ↓
- % Tf saturation → ↓
- TIBC → ↑

5. $\frac{S.Tf}{\text{Log [S.ferritin]}}$ → > 1.5



FREE ERYTHROCYTE PROTOPORPHYRIN [FEP] → ↑↑↑

7. MENTZER INDEX → ↑ [> 13]

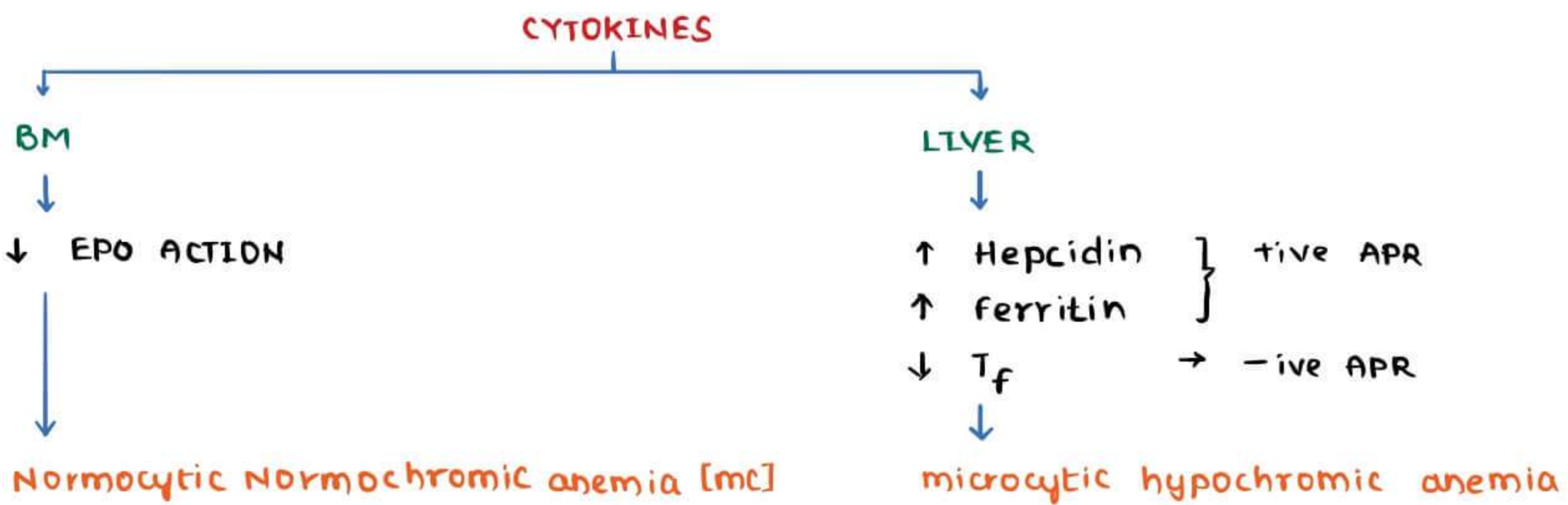
$\frac{MCV}{RBC \text{ count}}$

- IDA → ↓ Reticulocyte count
- Distinguishes b/w microcytic anemias [IDA vs Thalassemia Trait]
 - ↳ Thalassemia trait → ↓

→ Index for Anisocytosis → RED CELL DISTRIBUTION WIDTH
t.me/latestpgnotes

ANEMIA OF CHRONIC DISEASE

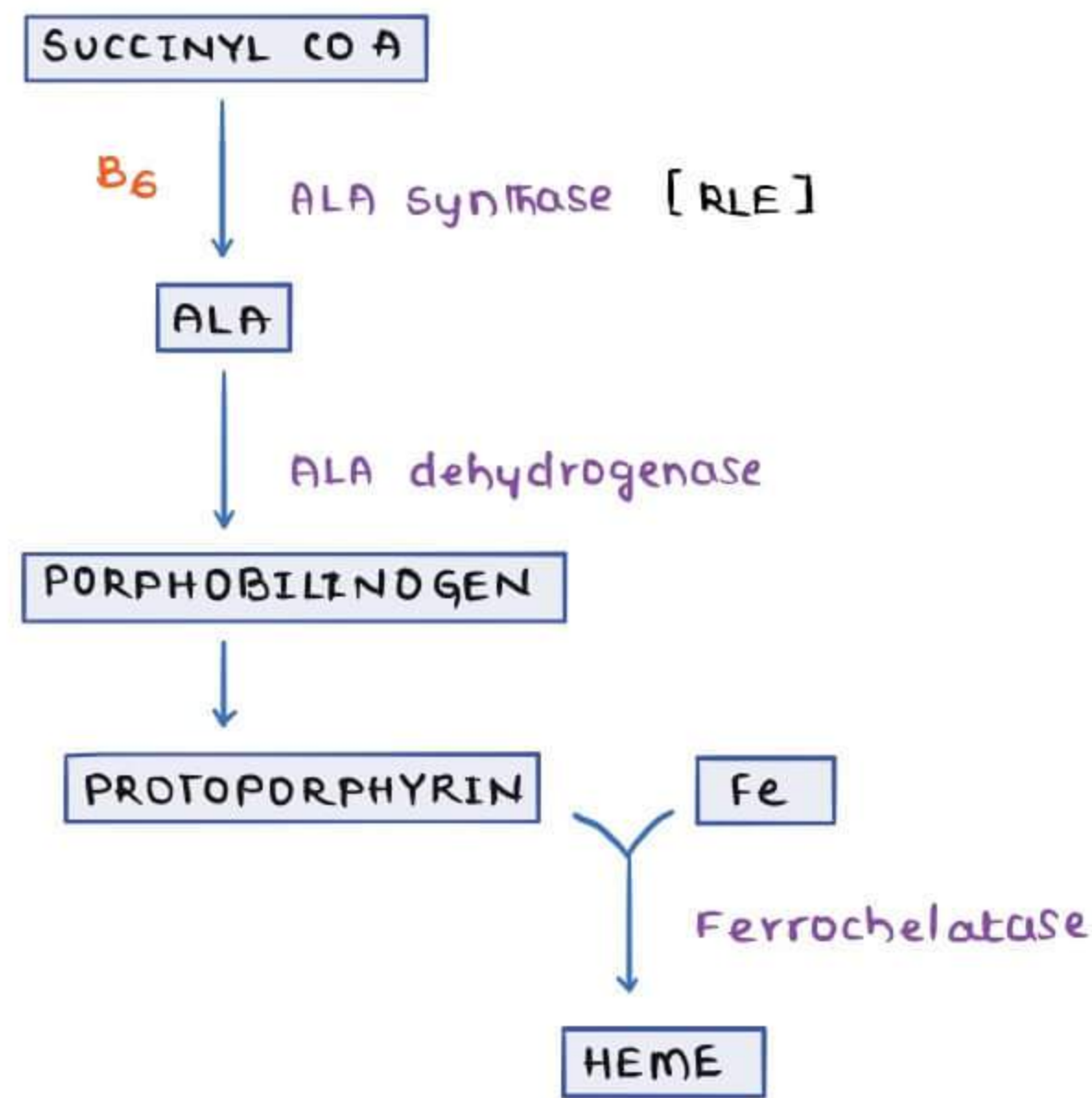
→ CHRONIC INFLAMMATION → IL1 | IL-6 | TNF-α



→ HEPCIDIN → inhibits Iron metabolism

	AACD	IDA
S. ferritin	↑↑	↓↓
% Tf saturat ⁿ	↓↓	↓↓
S. Iron	↓↓	↓↓
TIBC	↓↓	↑↑
$\frac{S.TfR}{\text{Log [ferritin]}}$	< 1.5	> 1.5

HEME METABOLISM



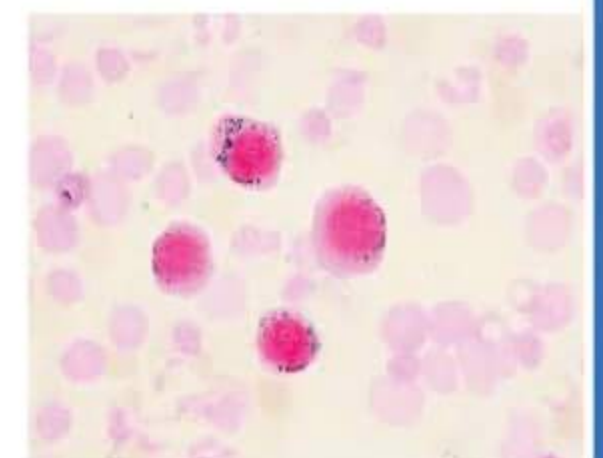
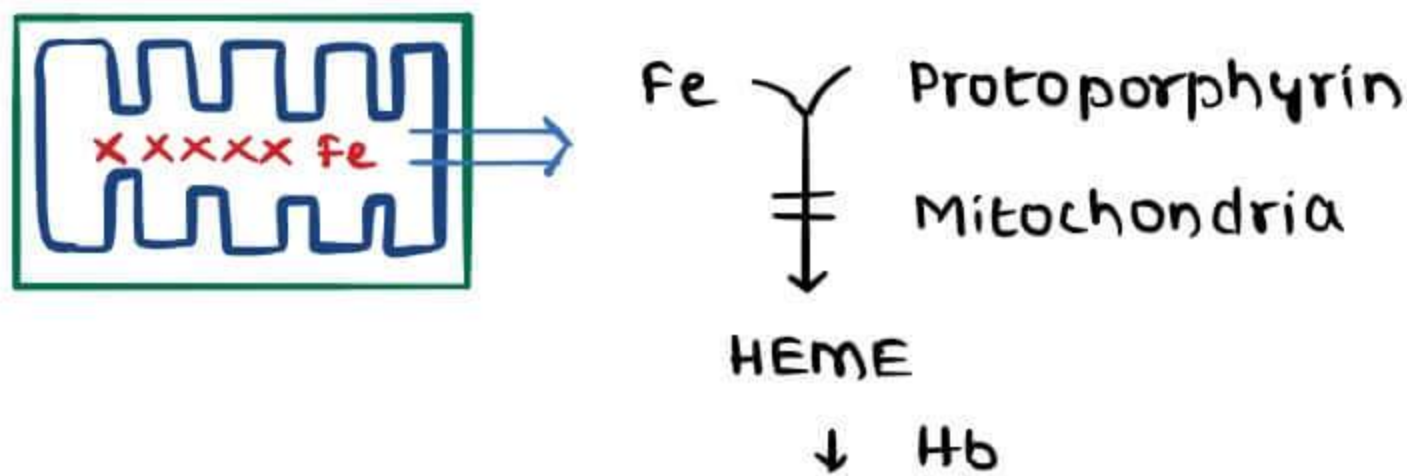
CAUSES

I. CONGENITAL → Enzyme defects

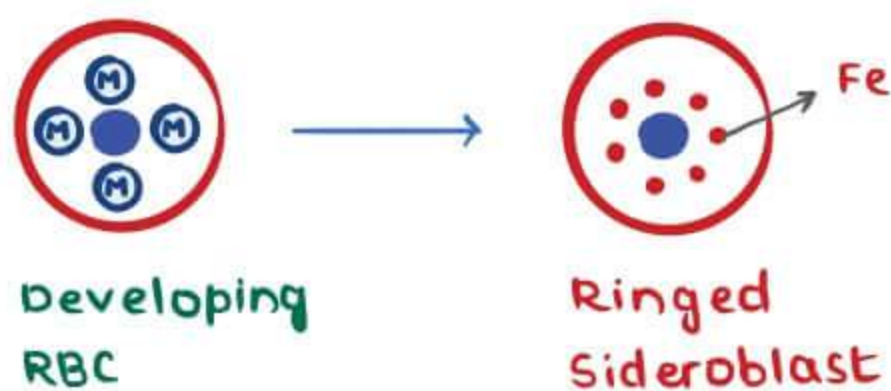
II. ACQUIRED [more common]

- B₆ deficiency
 - primary
 - Isoniazid / dietary
- Alcohol [mc]
- Lead poisoning
 - damages ALAD & Ferrochelatase

t.me/latestpnotes



RINGED SIDEROBLAST



Fe → damage to RBC precursor → Leakage of Iron → IRON OVERLOAD

- S. FERRITIN → ↑↑
- S. IRON → ↑↑
- % T_f SATURATION → ↑↑
- TIBC → ↓↓

SUMMARY TABLE OF MICROCYTIC HYPOCHROMIC ANEMIA

90

	IDA	AACD	SID. AN.	THAL. TRAIT
S. FERRETIN	↓	↑	↑	N
S. IRON	↓	↓	↑	N
% T _f SATURATION	↓	↓	↑	N
TIBC	↑↑	↓	↓↓	N

MEGALOBLASTIC ANEMIA

- Macrocytic Anemia → ↑ Size
- megaloblastic anemia → ↑ Size & N:C Asynchrony

ETIOLOGY

1. vit B₁₂ deficiency
2. FA deficiency
3. Drugs

VITAMIN B₁₂ DEFICIENCY

- Normal functioning requires → Intrinsic factor [parietal cells]
 → Pancreatic enzymes [duodenum]
 → Ileum [site]

Normal function [required for]

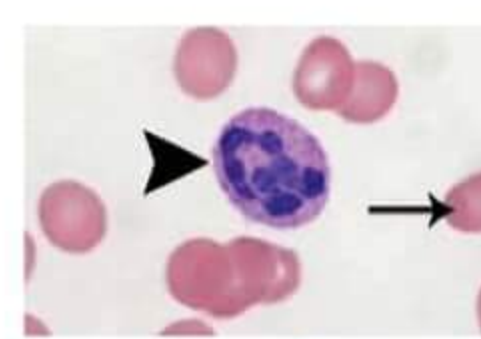
- rapid division of cells
- DNA synthesis t.me/latestpgnotes
- Homocysteine → methionine
- methyl malonyl CoA → Succinyl CoA [req. for myelin synthesis]

ETIOLOGICAL FACTORS

- ↓ Intake → VEGANS [x no milk]
- ↓ Absorptⁿ → ↓ IF
 pancreatic disease
 ileal disease
 fish tape worm [Diphyllobothrium latum] infectⁿ
- ↑ Requirement → Children
 → Pregnancy
 → Lactation
 → Blind loop syndrome [overgrowth of bacteria]

CLINICAL FEATURES

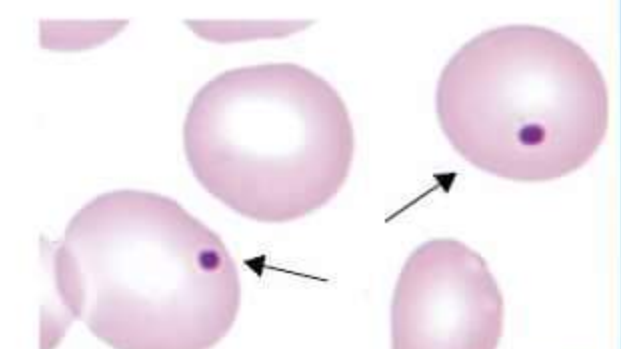
1. BLOOD/ Bm CHANGES
 - Pancytopenia
 - Dyserythropoiesis



Macro-ovalocyte



Basophilic stippling



Howel-Jolly Bodies

- RBC → MACRO - OVALOCYTOSIS [earliest manifestatⁿ]
 BASOPHILIC STIPPLING ⊕
 HOWEL JOLLY BODIES

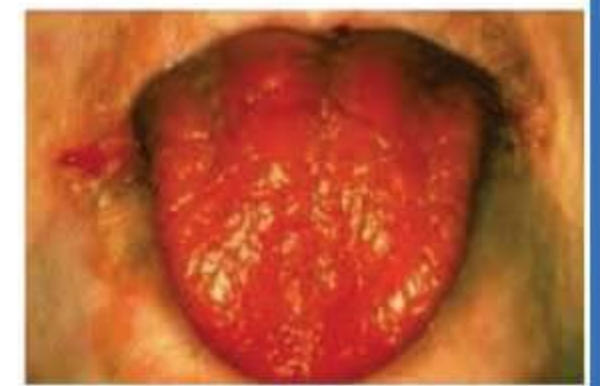
WBC

B₁₂ Def.Hypersegmented neutrophils
[> 5 nuclei]

PLATELETS → ↑↑ Size
→ Abnormal shape

2. GIT

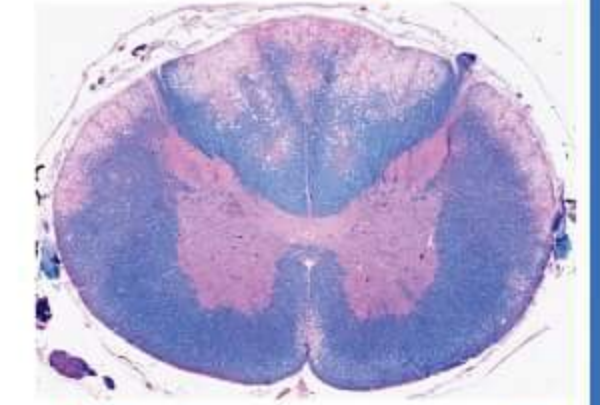
→ Mucosal Atrophy
→ Tongue → Smooth → BEEFY TONGUE



Beefy tongue

3. CNS

→ ↓ myelin
↳ peripheral neuropathy
Ascending / descending tract involvement → SUB ACUTE COMBINED
DEGENERATION OF SPINAL CORD
[also seen in neurosyphilis]

Sub acute combined
degeneratn of SC

CLINICAL FEATURES → Anemia + Jaundice + Neurological Features

DIAGNOSIS

1. BLOOD

→ ↑ MCV
→ ↑ MCH
→ ⊕ MCHC [mcv/mch]
→ Basophiles, stippling ⊕
→ Howell Jolly bodies ⊕
→ Hypersegmented neutrophils

2. SERUM VIT. B₁₂
S. Homocysteine
mm coA

→ ↓↓
→ ↑
→ methyl malonyemia [Blood]
→ methyl malonyluria [Urine]

3. BM

→ Hypercellular BM }
↓↓↓ Reticulocytes } INEFFECTIVE
ERYTHROPOIESIS

PERNICIOUS ANEMIA

→ Auto immune

↳ I → ↓ [IF + B₁₂] [most specific]
↳ II → Ileal ⊕
↳ III → parietal cells

→ ↓↓ B₁₂ absorptⁿ

→ Intestinalization occurs [predominant in fundus / Body] → ↑ Cancer

→ DIAGNOSIS → Auto Ab_s ⊕

→ SCHILLING TEST

→ done for CAUSE of B₁₂ deficiency→ not done for diagnosis of B₁₂ deficiency

→ TREATMENT

1. B₁₂ supplementation

- in pernicious anemia → Life time
- in other causes → for specific period

→ ON TREATMENT w B₁₂

- BLOOD PICTURE → Reversal
- NEUROLOGICAL C/F → no further aggravation / no reversal
- CANCER → higher than normal

2. FOLATE DEFICIENCY



Poly glutamate form
of folate [DIET]



mono glutamate form
absorbed in SI [JEJUNUM]

ETIOLOGY

- ↓ Intake
- ↓ absorptⁿ
- ↑ requirements
- Drugs which ↓ absorptⁿ
 - alcohol
 - Methotrexate & OCPs

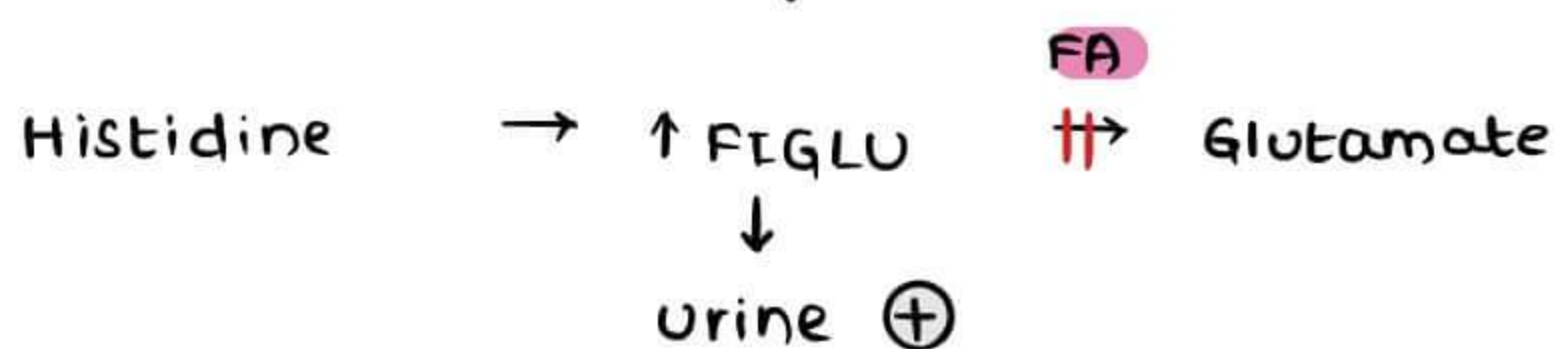
- Chr 21 → location for FA[®]
- t.me/latestpgnotes

CLINICAL FEATURES

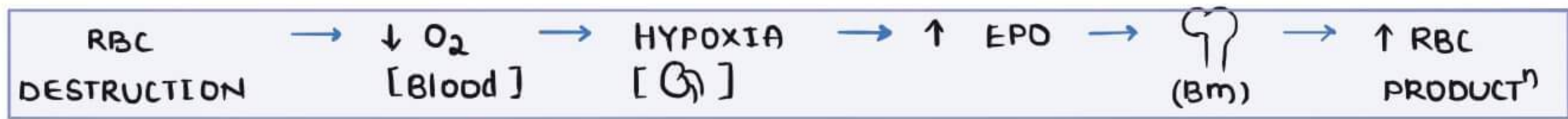
- megaloblastic anemia
- no neurological manifestations

DIAGNOSIS

1. S. folate → ↓↓
2. RBC folate → ↓↓ [Best test]
3. FIGLU TEST [Forminino glutamate]



- R₁ → vit B₁₂ + FA
never FA alone



ETIOLOGY

INTRA CORPUSCULAR HEMOLYTIC ANEMIAS

1. INHERITED

1. Hereditary spherocytosis
2. G6PD Deficiency
3. Thalassemia
4. Sickle cell anemia

2. ACQUIRED

PNH [Paroxysmal nocturnal Hemoglobinuria]

EXTRA CORPUSCULAR HEMOLYTIC ANEMIAS

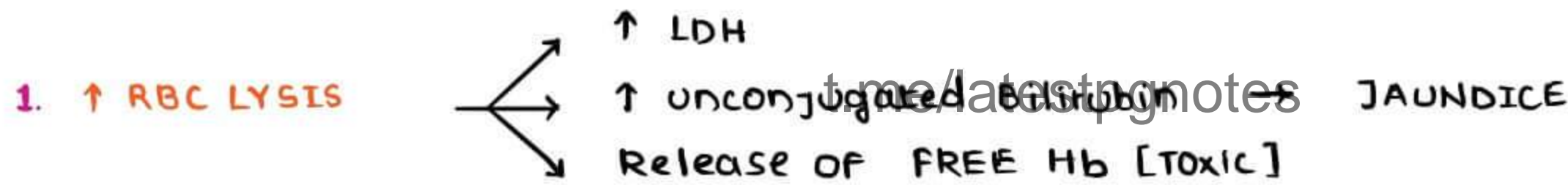
IMMUNE MECHANISM

1. ABO Incompatibility
2. Rh Incompatibility
3. autoimmune hemolytic anemia

NON - IMMUNE MECHANISM

1. Clostridium → Toxin
2. Snake venom → Toxin
3. Sequestration
4. mechanical damage
 - ↳ Angiopathic hemolytic anemia
 - ↳ march hemoglobinuria [Soldiers]

CLINICAL FEATURES



FREE Hb + Haptoglobin / Hemopexin → Haptoglobin-Hb → ↓ S. HAPTOGLOBIN

FREE Hb → Blood hemoglobinemia → urine hemoglobinuria [altered color urine]

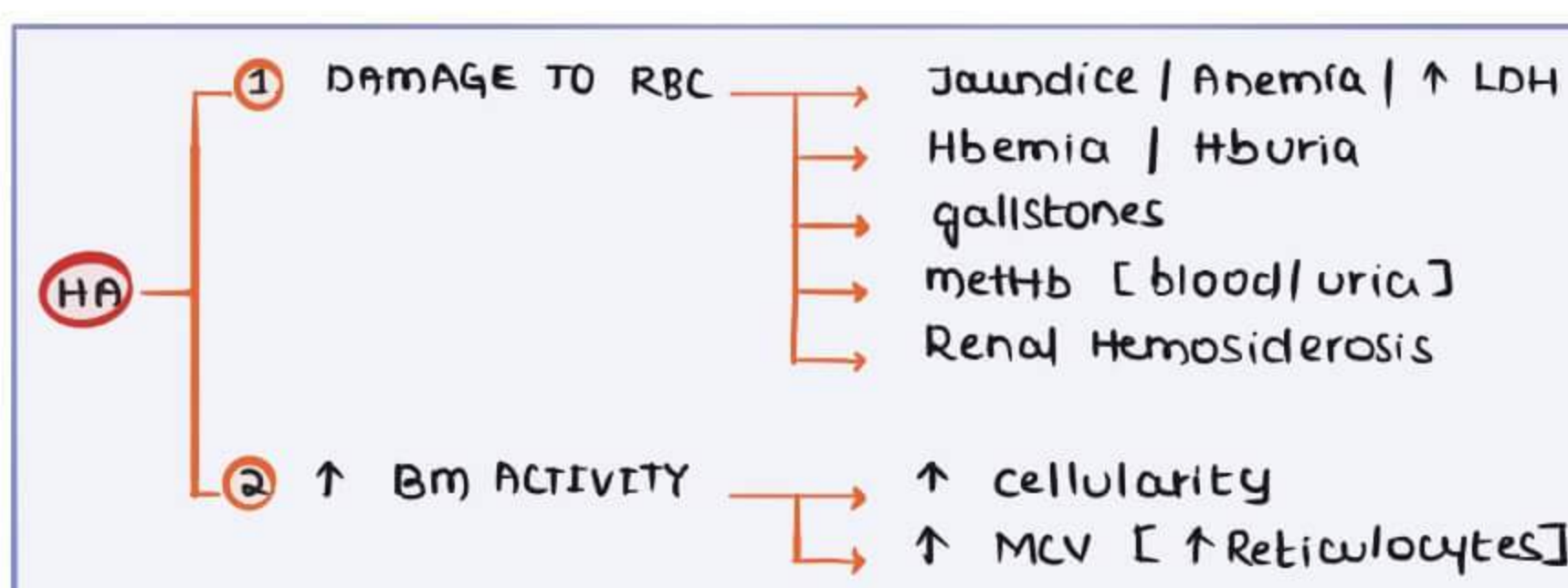
FREE Hb $\xrightarrow{Fe^{2+} \rightarrow Fe^{3+}}$ METHEMOGLOBIN → Methemoglobinemia & MethHburia



chronic Hemolytic anemia → ↑↑↑ UCB → Ca^{2+} Bilirubinate → PIGMENT GALL STONES

2. ↑ EPO → ↑ Bm activity [compensatory] → Hypercellular Bm & ↑ Reticulocytes [↑MCV]

EXCEPTION → in Fe/B₁₂/FA deficiency → no reticulocytosis



SITES OF RBC DAMAGE

**INSIDE SYSTEMIC CIRCULATION
[INTRAVASCULAR HA]**

- Hbemia ⊕ ⊕ ⊕
- Hburia ⊕ ⊕
- S. haptoglobin ↓↓↓
- no hepatomegaly
- no splenomegaly
- Ex:
G6PD DEFICIENCY
PNH

**INSIDE REC / SPLEEN
[EXTRA VASCULAR HA]**

- Hbemia ⊕
- Hburia ⊕
- S. haptoglobin ↓
- hepatomegaly ⊕
- splenomegaly ⊕
- Ex:
SICKLE CELL ANEMIA
HEREDITARY SPHEROCYTOSIS

INTRA CORPUSCULAR HEMOLYTIC ANEMIA

INHERITED

- 1. Membrane defects → HS / HE
- 2. Enzyme defects → G6PD DEFICIENCY
- 3. Hb defects → THALASSEMIA

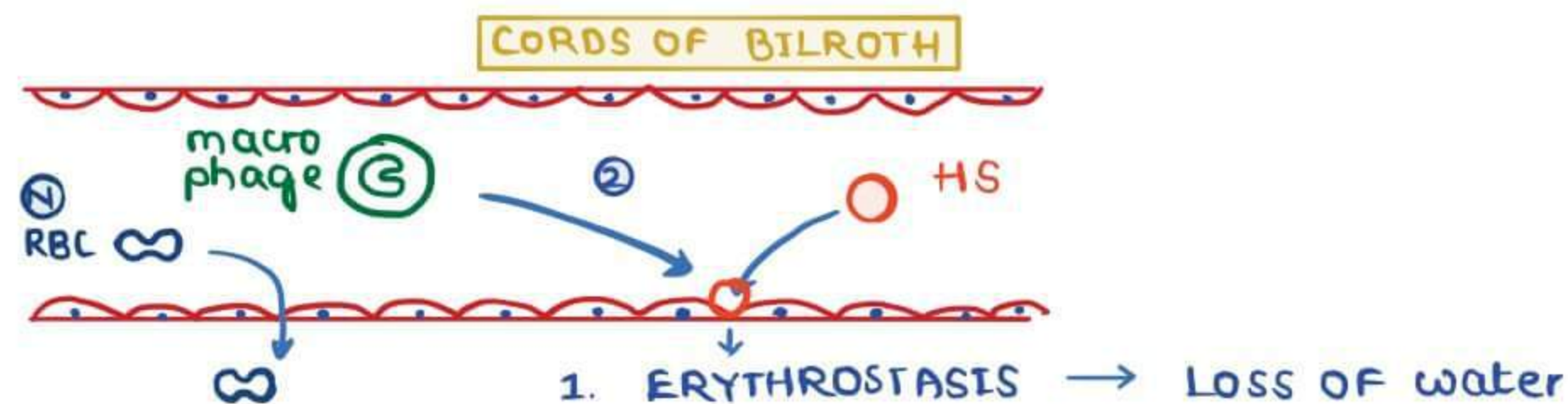
HEREDITARY SPHEROCYTOSIS

PATHO PHYSIOLOGY

- **NORMAL RBC**
 - Biconcave
 - Biconcavity is dlt → Spectrin | Ankyrin | Band 3 | Band 4-1
- **HEREDITARY SPHEROCYTOSIS**
 - membrane defect dlt Ankyrin > Band 3 > Spectrin



Small Blood vessels



- HS → Spherical RBC → 1. Loss of water → but can reach P. circulae^D
- 2. Eaten up by splenic macrophages
↳ leads to Extravascular hemolytic anemia

CLINICAL FEATURES

- Anemia [$t_{1/2} \downarrow\downarrow$]
- Jaundice
- Splenomegaly
- Autosomal dominant → H/o in family ⊕

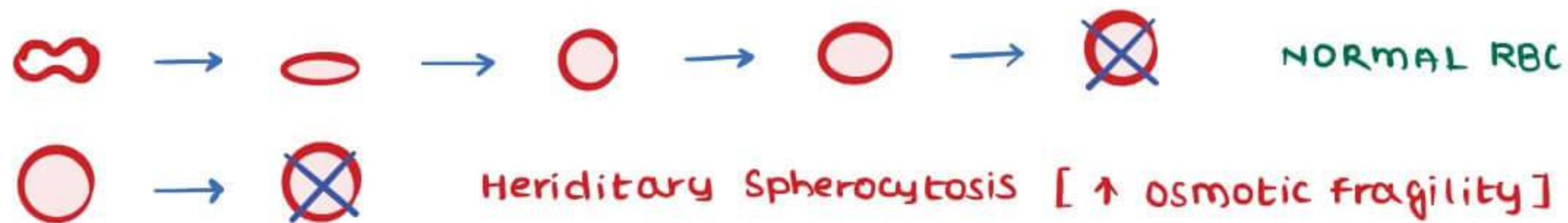
DIAGNOSIS**1. BM EXAMINATION**

→ ↑ cells / ↑ reticulocytes

2. BLOOD

- ↓ Hb | ↑ LDH | ↓ S. haptoglobin
- MCH → ⊕
- MCV → ↓
- MCHC → ↑↑↑ [$\frac{mch}{mcv}$]

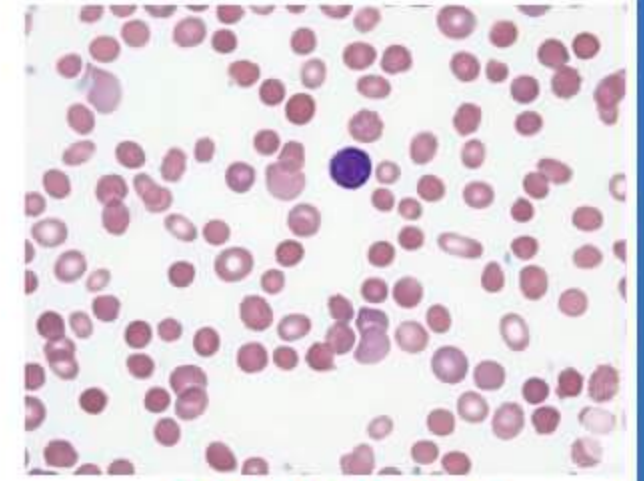
- **PI SMEAR** shows Spherocytes [no central pallor]
- **OSMOTIC FRAGILITY TEST** [RBC in hypotonic solution]



- **AUTOHEMOLYSER** [0.9% NaCl [Kept RBC for 48 hrs]]
 - ↳ ⊕ → < 4% RBC destructⁿ
 - ↳ HS → > 15% RBC destructⁿ

t.me/latestpgnotes→ **EKTACYTOMETRY**

- ↳ can detect the shearing stress OF RBC
- ↳ Recent test



SPHEROCYTES

TREATMENT**1. ELECTIVE SPLENECTOMY**

1. Severity of anemia → ↓
2. Shape of RBCs → no change [Spherical]
3. chance of infection → ↑ [by capsulated bacteria]
 - ↳ pneumococcus
 - ↳ H. influenzae

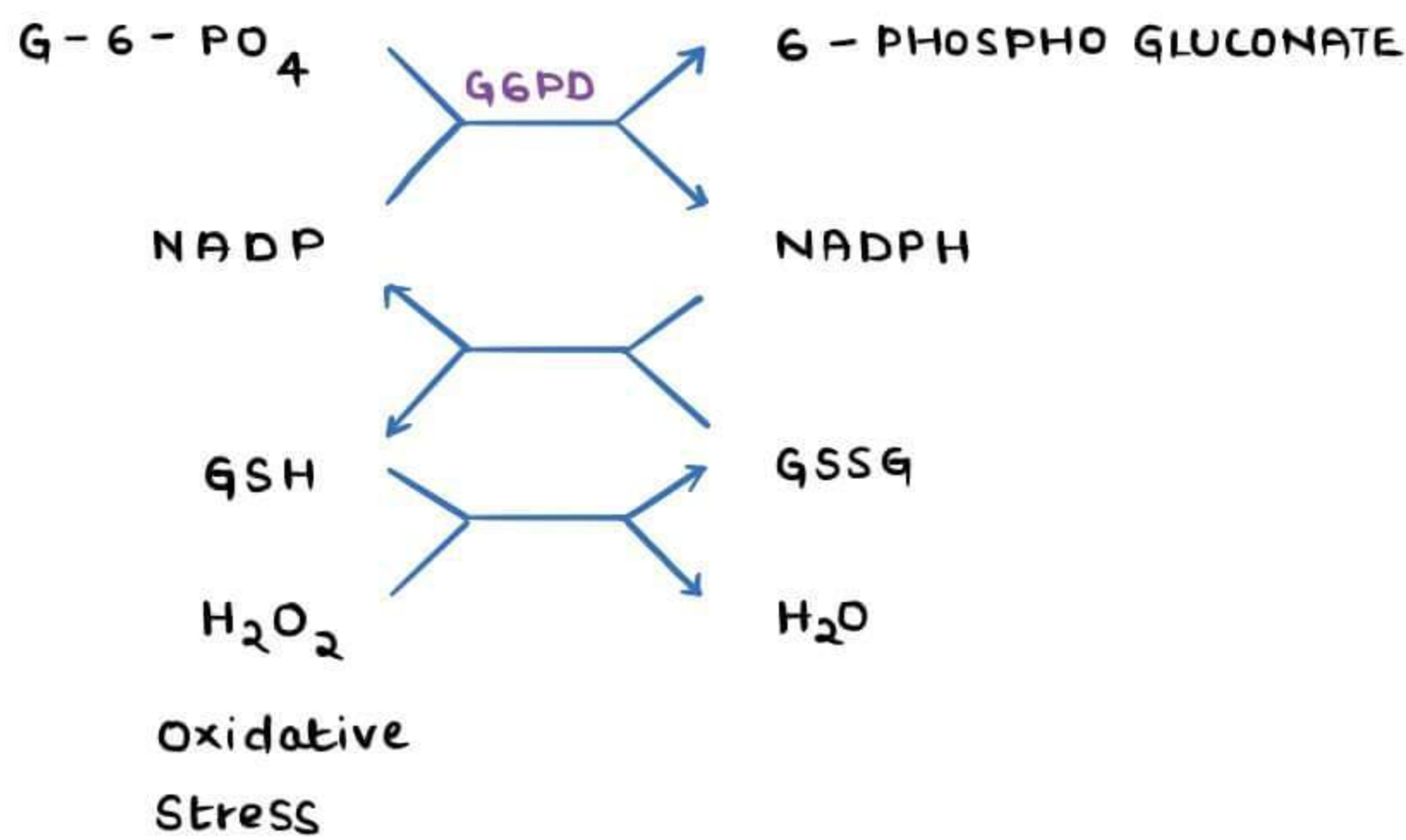
COMPLICATIONS**1. APLASTIC CRISIS**

↑ BMA → ↑ Erythroid precursors → Susceptible to Parvo virus

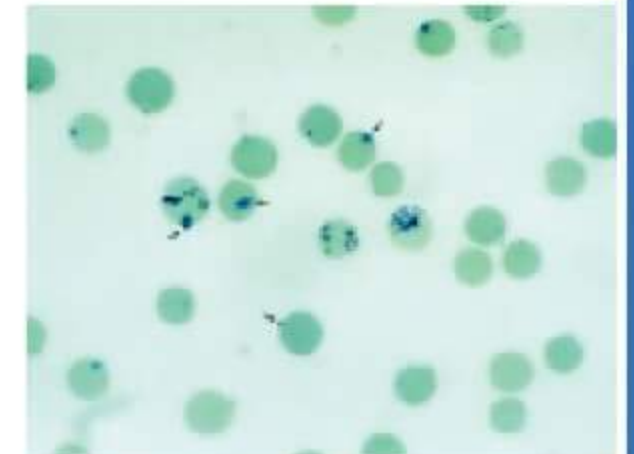
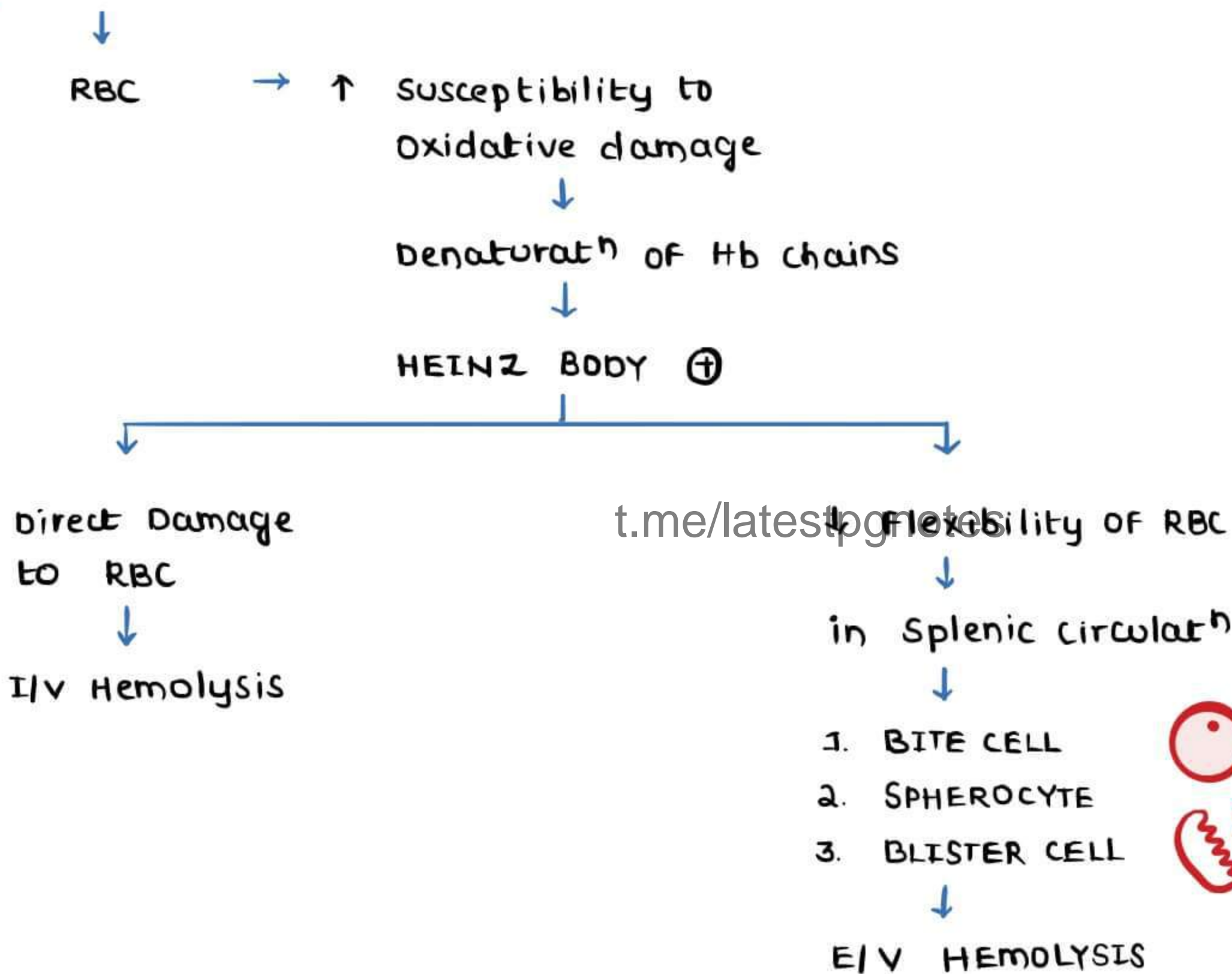
2. ↑ INFECTIONS [post splenectomy]

3. HS → Chronic Hemolysis → Pigment gallstones

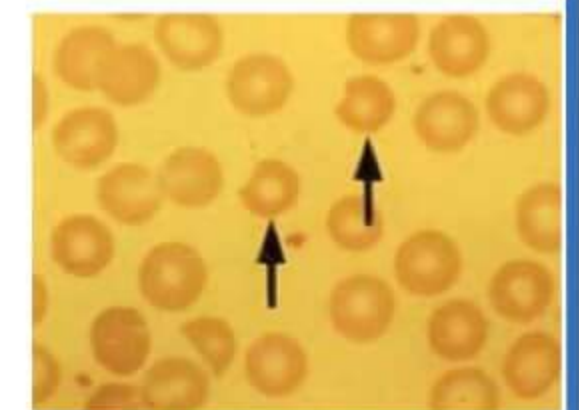
2. HEREDITARY ELLIPTOCYTOSIS [dit SPECTRIN defect]



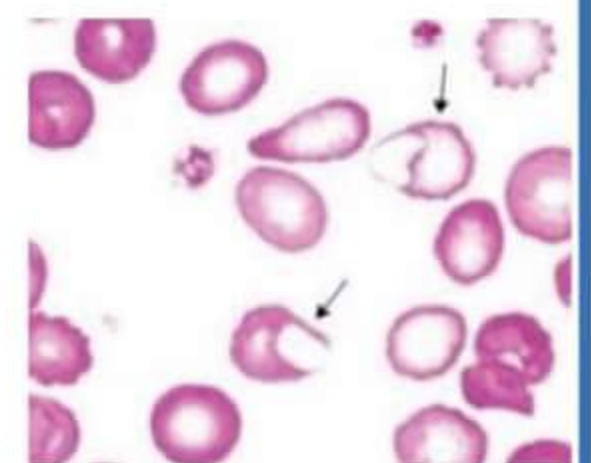
G-6-PD DEFECT



HEINZ BODIES



BITE CELLS



BLISTER CELLS

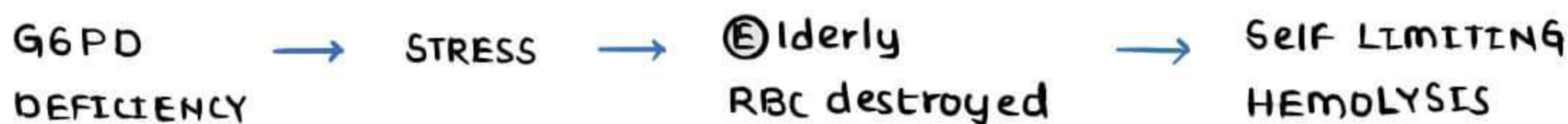
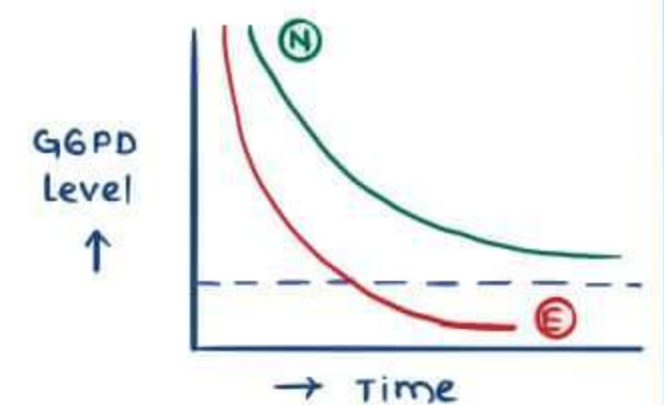
→ OXIDATIVE STRESS → HEMOLYSIS

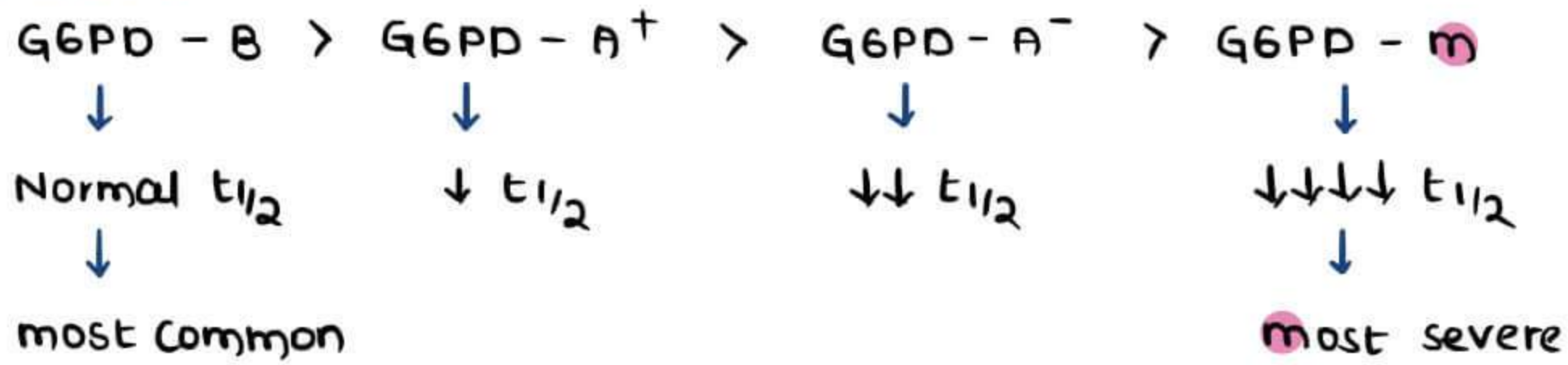


1. Infections [pneumonia / sepsis]
2. Drugs [Anti-malarials [primaquine], sulfa drugs, anti TB drugs]
3. Foods [Fava beans]

G6PD DEFICIENCY

- x Linked Recessive Disorder
- unstable enzyme
- ↓↓↓ t_{1/2}



VARIANTS**DIAGNOSIS**

1. HISTORY [♂ > ♀]

2. BLOOD → ↓ Hb
 → MCH → N
 → MCV → N
 → MCHC → N

→ PI smear

↳ Bite cells ⊕

↳ Blister cells ⊕

↳ Spherocytes ⊕

↳ Heinz Body ⊕

[visualised by crystal violet]

→ SPHEROCYTES IN PERIPHERAL SMEAR

DID

1. HS

2. G6PD Def

3. Infections [clostridium]

4. Auto Immune hemolytic anemia [mc]

3. G6PD LEVEL ESTIMATION

↳ Electrophoresis → Sub type

↳ Sodium nitrite

↓

Methemoglobin Reduction assay

→ G6PD DEFICIENCY → Rapid clearance of RBC

↳ P. falciparum → PROTECTIVE

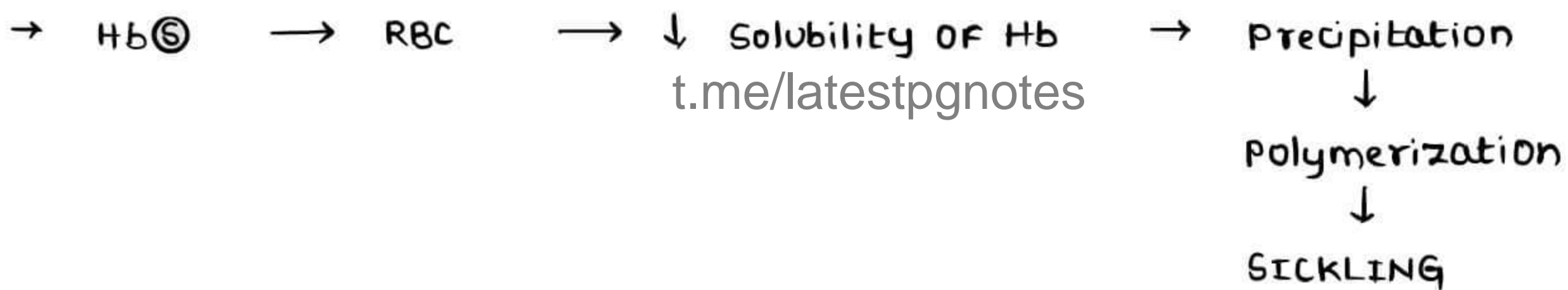
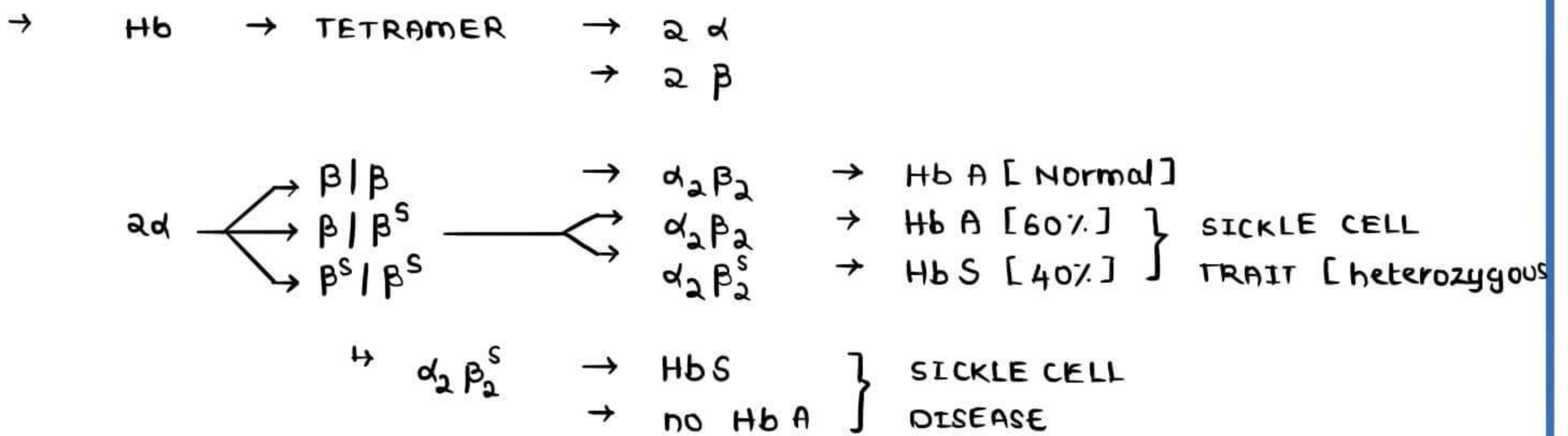
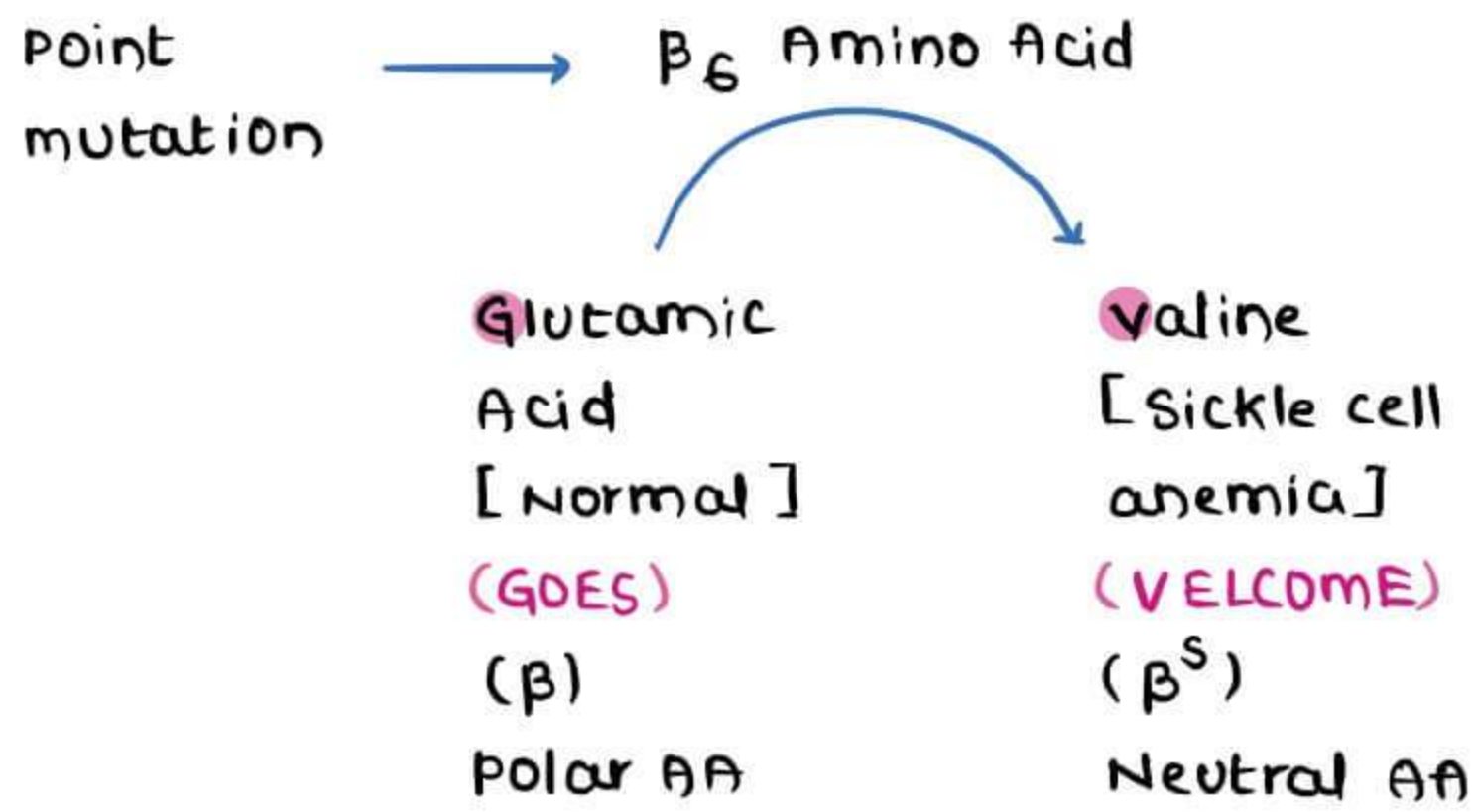
R_y → NO drugs required [self limiting]

HEMOGLOBINOPATHIES - SICKLE CELL ANEMIA**HB DEFECTS**

→ ↓ quantity → Thalassemia

→ ↓ quality → Sickle cell anemia

PATHOPHYSIOLOGY



FACTORS AFFECTING SICKLING

1. AMOUNT OF HbS [most important]

→ HbS → ↑ sickling [SCO >>> SCT]

→ HbF } ↓ sickling
→ HbA }

→ HYDROXYUREA } ↑↑ HbF → ↓ sickling
→ DECITABINE }

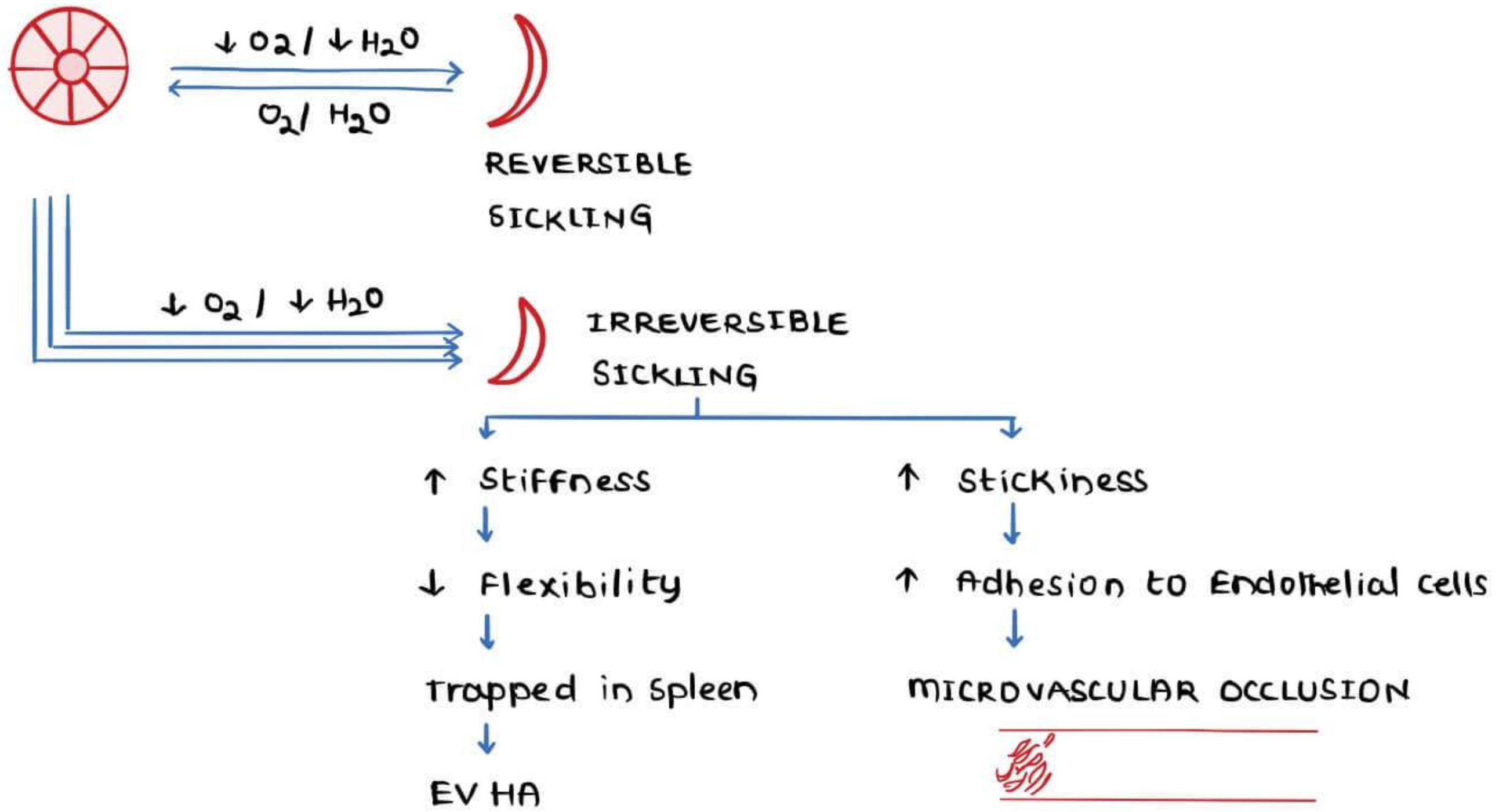
2. ACIDOSIS

3. EXERCISE

4. DEHYDRATION → ↑ MCHC

5. TIME OF RBC FOR CIRCULATION

↳ spleen / Bm → Sluggish flow → ↑ sickling





C/F

- Jaundice
- anemia
- splenomegaly
- retarded growth

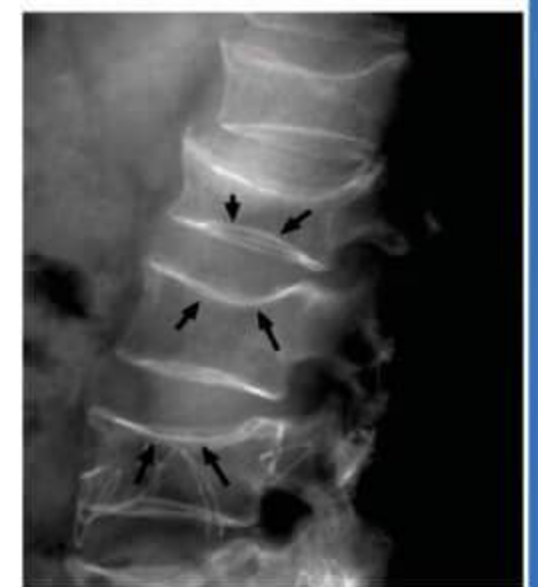COMPLICATIONS

1. VASO OCCLUSIVE CRISIS [med]atestpnotes

- Brain → coma / ↓ consciousness / Stroke
- Bones
 - ↳ small bones of hands & feet → HAND - FOOT SYNDROME
 - ↳ Long bones → Avascular necrosis of neck of femur
 - ↳ vertebral column

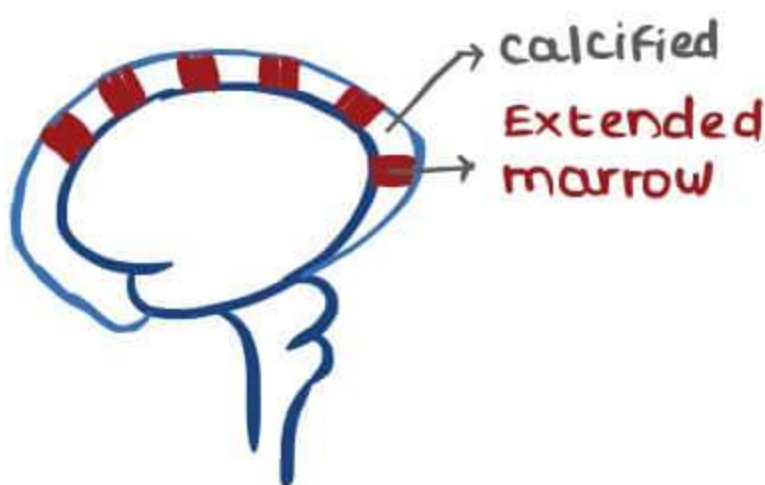


H - SHAPED VERTEBRA
 COD FISH VERTEBRA
 FISH MOUTH VERTEBRA

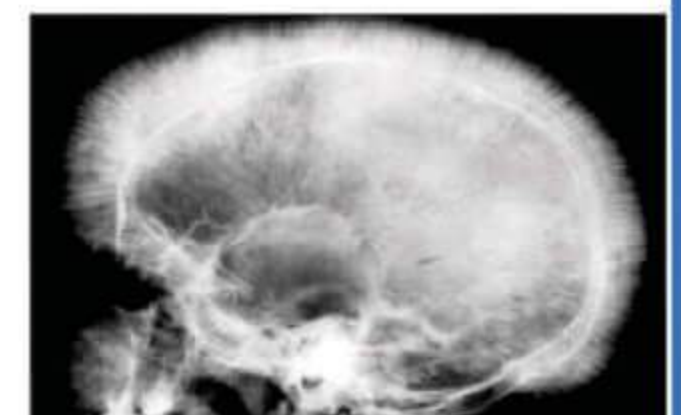

COD FISH VERTEBRA

→ **SKULL**



calcified area
 HAIR ON END APPEARANCE
 CREW CUT APPEARANCE



CREW CUT APPEARANCE

- SKIN → chronic non healing leg ulcers
- SPLEEN → ↑↑ size initially → congestive splenomegaly
 Later → Arterial occlusⁿ → ischemic damage → FIBROSIS OF SPLEEN [AUTO SPLENECTOMY]

→ PULMONARY CIRCULATION

→ ACUTE CHEST SYNDROME

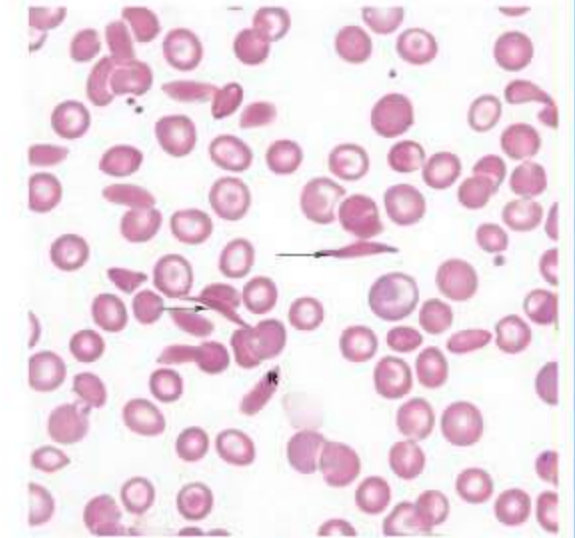
- ↳ pain in chest
- ↳ dyspnea
- ↳ ↓ O₂ in blood

→ ♂ → Painful erection → PRIAPISM

- 2. APLASTIC CRISIS → ↑ BMA → Parvo virus infection
- 3. HEMOLYTIC CRISIS → Infection → ↑↑ Splenic activity
- 4. SEQUESTRATION CRISIS → ↑↑↑ Splenic size → hypovolemia

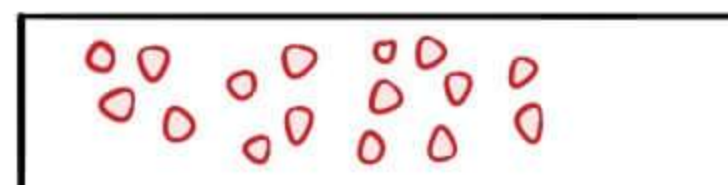
DIAGNOSIS

- 1. BM → ↑ cells / ↑ Reticulocyte count
- 2. BLOOD → ↑ LDH / ↑ S. Bilirubin
- ↑↑↑ TLC
- ↓↓↓ ESR



SICKLED CELLS

→ PERIPHERAL SMEAR shows → SICKLED CELLS ⊕



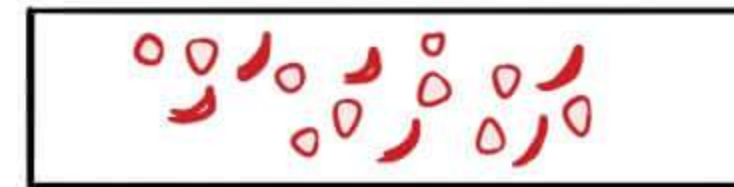
↓

Add DITHIONITE METABOLITE

TEST

↓

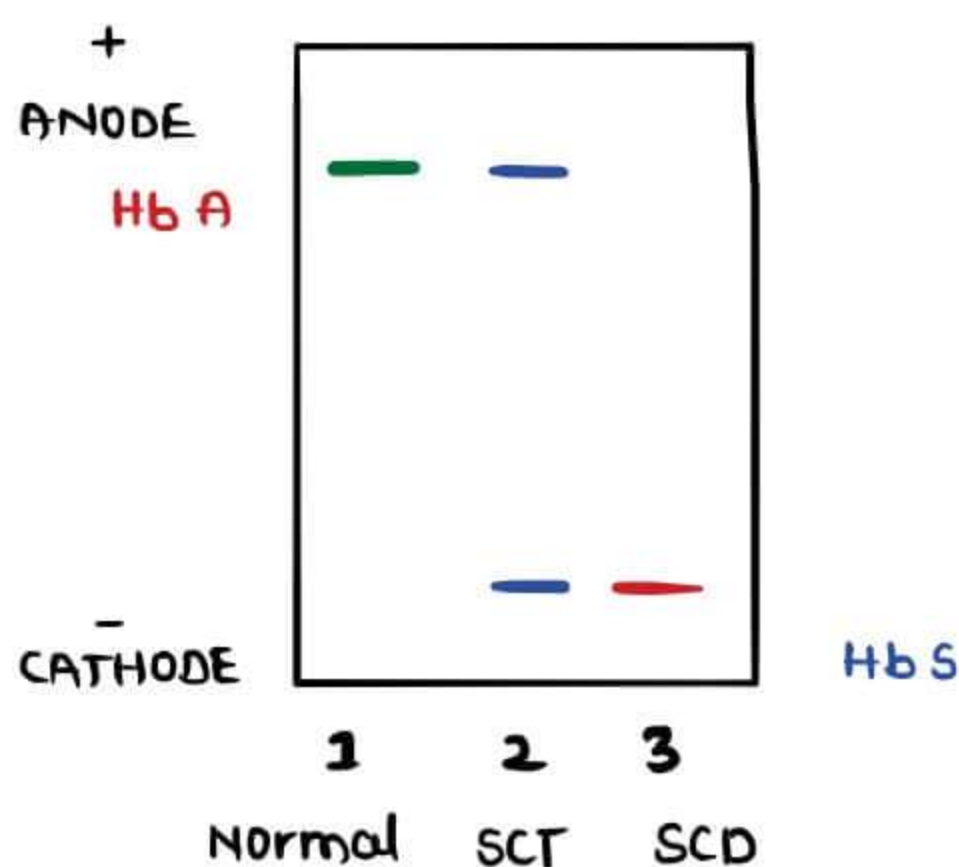
can't distinguish blw SCT/SCD



3. Hb ELECTROPHORESIS

Glutamic acid
[Polar] [HbA]

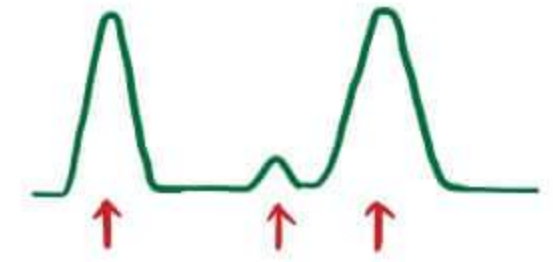
valine
[Neutral] [HbS]



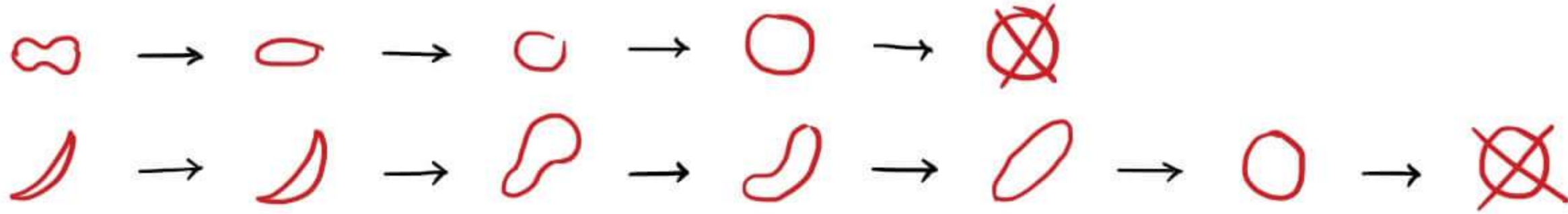
- require expertise
- quantification of different Hb types not possible

4. HPLC [HIGH PERFORMANCE LIQUID CHROMATOGRAPHY]

- can be differentiate the types OF Hb
- quantity of Hb can be known
- IOC FOR ALL TYPES OF HEMOGLOBINOPATHIES



5. OSMOTIC FRAGILITY TEST



- SCA → ↓ Osmotic Fragility
 - ↳ also seen in Hemoglobinopathies
 - Thalassemia
 - Severe IDA
 - HbC [β₆ → glutamic acid → Lysine]

6. X RAY → SKULL → HAIR ON END APPEARANCE
 → vertebra → FISH MOUTH APPEARANCE

TREATMENT

1. O₂
2. IVF
3. ANALGESICS
4. ANTIBIOTICS
5. HYDROXYURIA } ↑ HbF
- DESITAMINE }

t.me/latestpgnotes

MORTALITY COMMONLY DUE TO → SEPSIS

β THALASSEMIA

→ Quantitative disorder of Hb

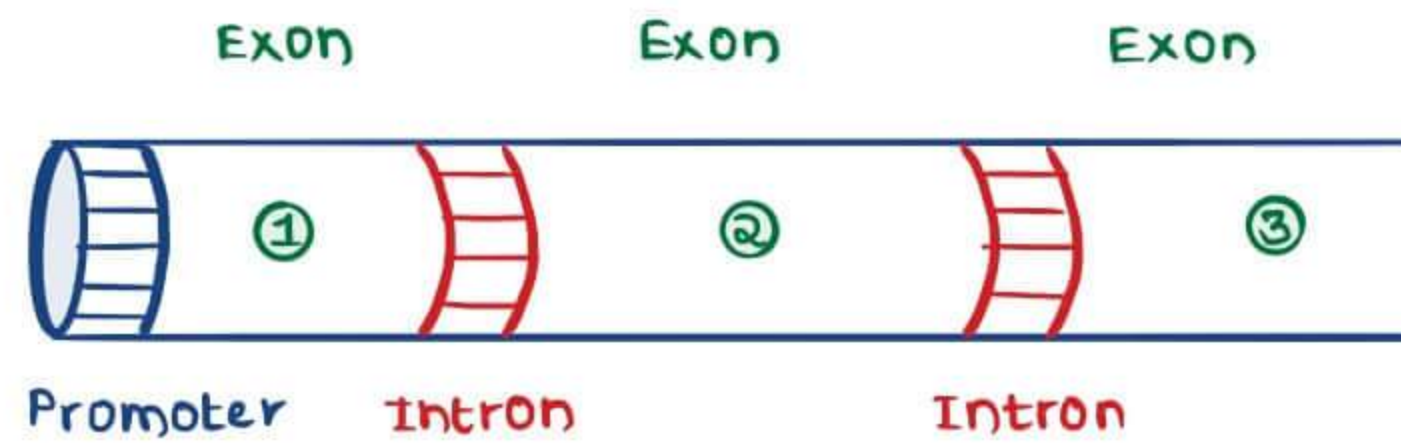
Hb → 2α → 4 α genes → Chr 16
 2β → 2 β genes → Chr 11

α THALASSEMIA → dit gene deletion
 β THALASSEMIA → dit gene mutation [more common]

β THALASSEMIA

NORMAL → Hb A / Hb F / Hb A₂
 [Adult] ↓ ↓ ↓
 α₂β₂ α₂γ₂ α₂δ₂
 95% 1% 3%

β → normal β chain formation
 β⁺ → partial β chain formatⁿ
 β⁰ → no β chain formatⁿ



SPLICING [introns removed]



RIBOSOMES



translation



β FORMATION

- INTRON → Intervening region
 EXON → Expressive sequence
 PROMOTOR → increases the no. of β chains

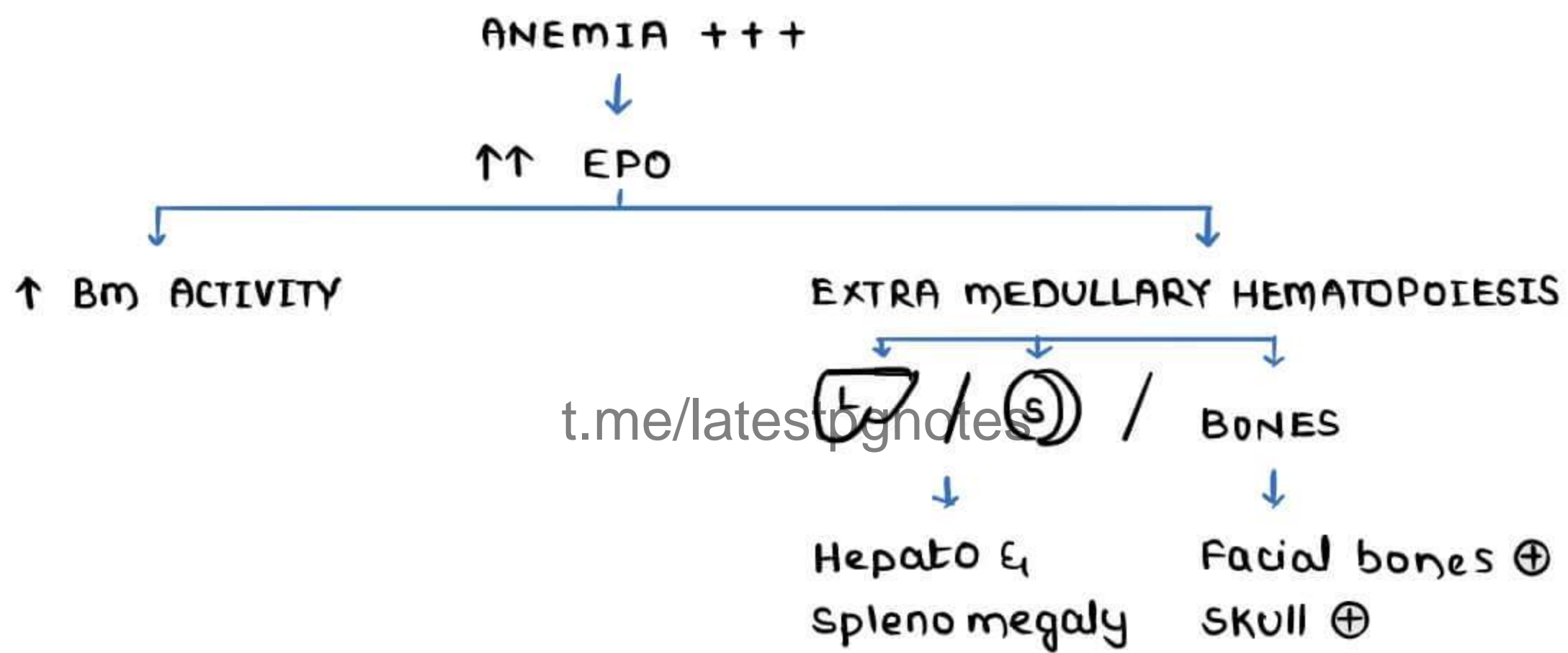
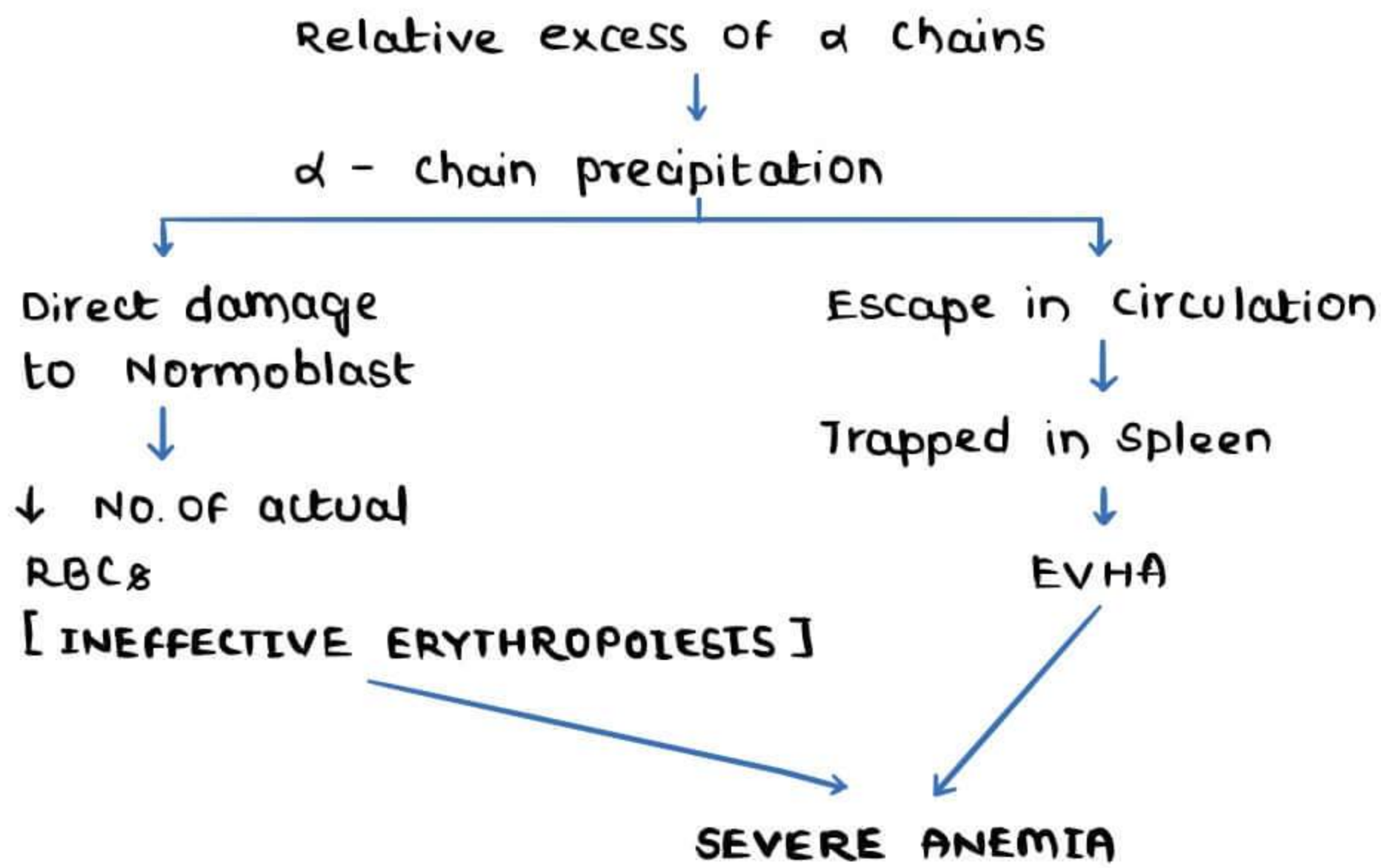
→ MUTATIONS

1. SPLICING MUTATIONS → β^+ >>> β^0
 [Intron > Exon] t.me/latestpgnotes
2. PROMOTER MUTATIONS → β^+
3. CHAIN TERMINATION MUTATION → β^0

CLINICAL POSSIBILITIES

- | | | |
|-------------------------------------------|------------|-----------------------------------------------------------------------------|
| β/β | → NORMAL | → 14 - 17 g/dl |
| 1. β/β^+ | → mild | → THALASSEMIA MINOR / THALASSEMIA TRAIT
↳ Hb > 10 g/dl
↳ Asymptomatic |
| 2. β^+/β^+ | → moderate | → THALASSEMIA INTERMEDIA
↳ Hb → 6 - 7 g/dl
↳ Blood transfusions ± |
| 3. β^0/β^+
β^0/β^0 | → severe | → THALASSEMIA MAJOR
↳ Hb < 6 g/dl
↳ multiple blood transfusions |

BONE MARROW



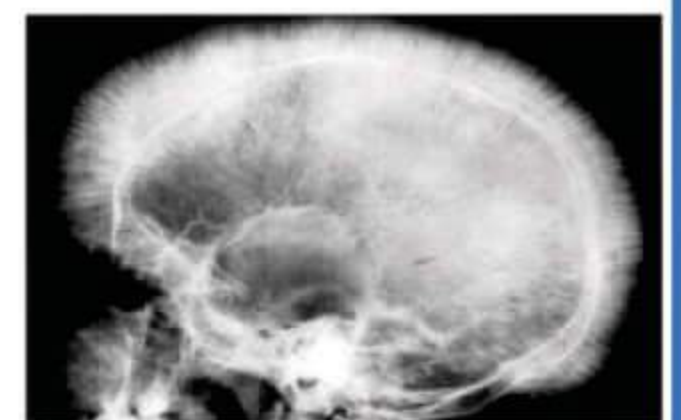FACIAL BONES INVOLVEMENT

- Frontal Bossing
- malocclusion of teeth

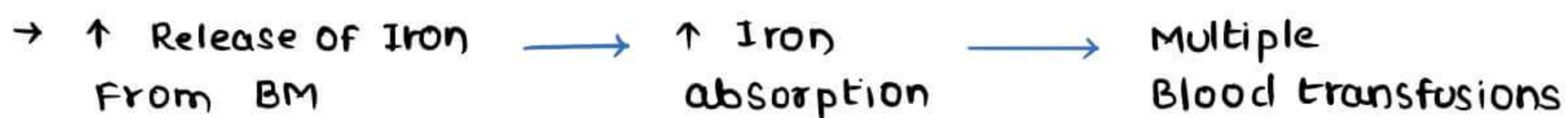
CHIPMUNK FACIES

SKULL INVOLVEMENT

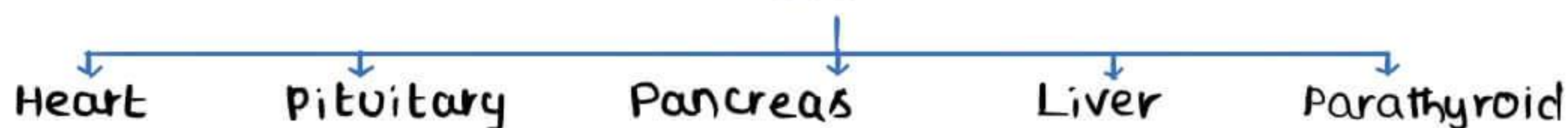
- CREWCUT / HAIR ON END APPEARANCE



CREWCUT APPEARANCE



IRON OVERLOAD



CIF

- Anemia +++
- Stunted growth
- chipmunk facies
- Hepato & Splenomegaly

DIAGNOSIS

1. BLOOD

→ ↓↓↓ Hb

MCV ↓↓

MCH ↓↓

MCHC ↓↓

→ PERIPHERAL SMEAR

↳ microcytosis

↳ anisocytosis

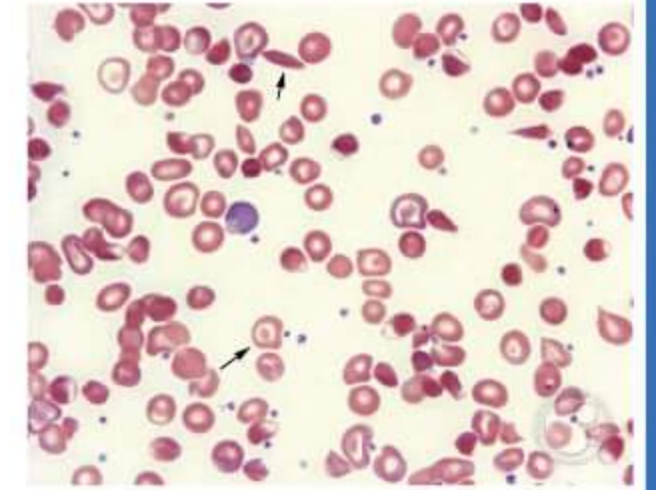
↳ poikilocytosis

↳ target cells

↳ basophilic stippling [dit abnormal RNA]

↳ ↑ Reticulocyte count [not proportional to severity of anemia]

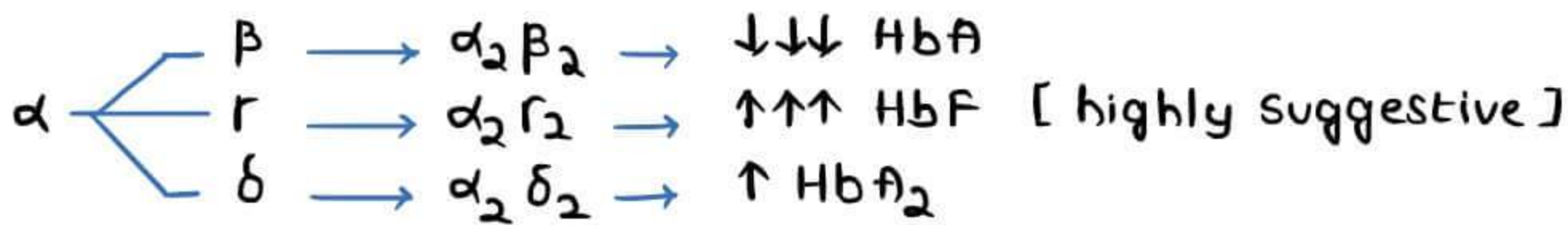
↳ Normoblasts ⊕



2. OSMOTIC FRAGILITY ↓↓↓

3. HPLC → IOC

t.me/latestpnotes



α : β RATIO → 1 : 1 [Normal]

30 : 1 [Thalassemia major]

THALASSEMIA TRAIT / MINOR

- ↓ Intensity
- mild anemia
- no H/O Blood transfusion
- P/SMEAR → Mild ⊕

♂ Thalassaemia major → do not marry
 ♀ T. trait T. trait → AR → Thalassaemia major [25%]

→ SCREENING

→ osmotic fragility → ↓

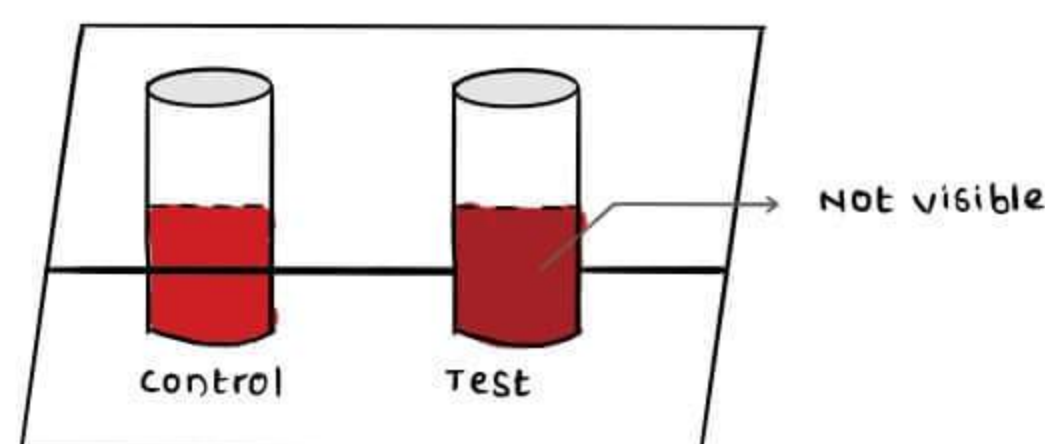


image @ 55:45

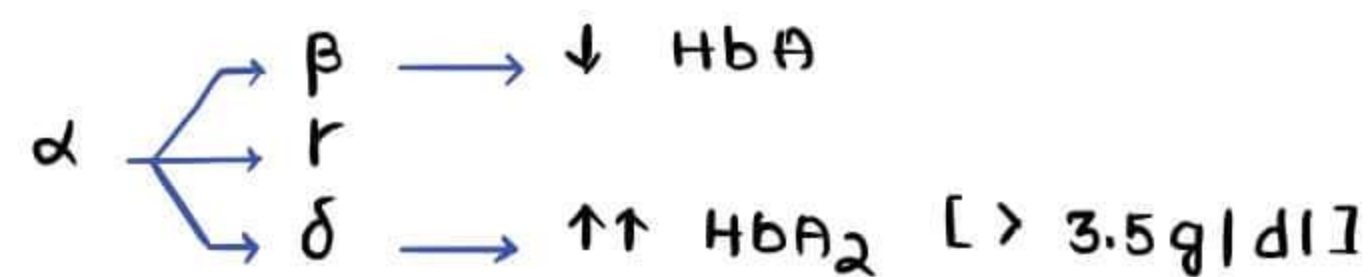
SCREENING

- Hypotonic saline [5ml]
- 0.2 ml Blood
- Wait for 30 minutes

NESTROF TEST

- NE → Naked Eye
- ST → Single tube
- R → Red cell
- OF → osmotic fragility
- TEST → Test

→ diagnosis confirmed by HPLC of Hb



→ THALASSEMIA TRAIT VS IDA by HPLC
other parameters

RDW	N	↑↑↑
mentzer index $\frac{MCV}{RBC\ count}$	< 13	> 13
HPLC	↑↑ HbA ₂	↓ HbA

ALPHA THALASSEMIA

→ dit GENE DELETION

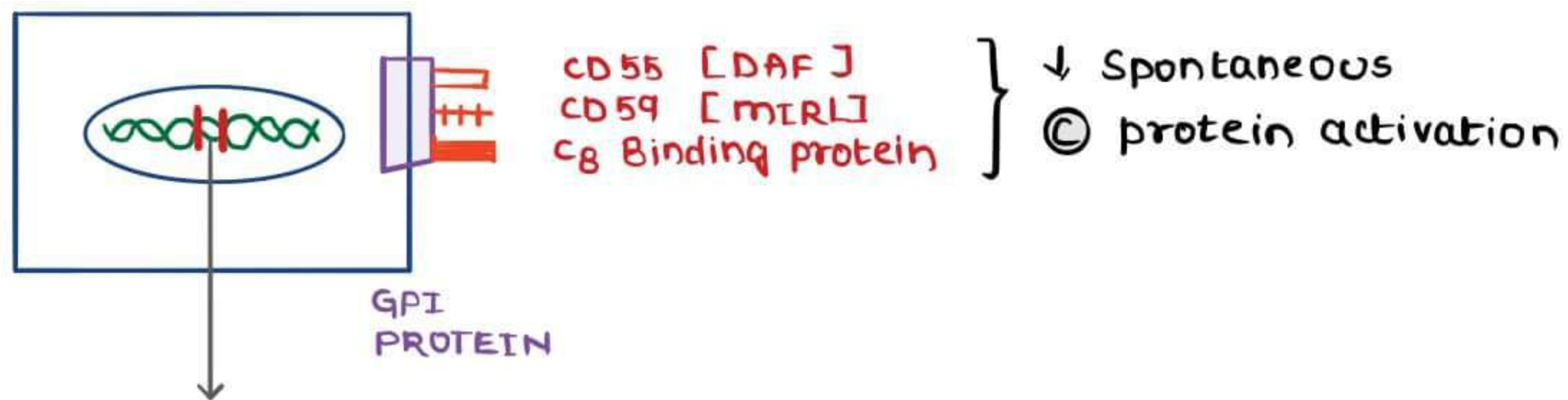
→ chr 16 → 4 α genes → 2 α chains

1. $\alpha\alpha / \alpha\alpha$ → Normal [100% α chains]
1. $\alpha\alpha / \alpha-$ → Asymptomatic [75% α chains]
2. $\alpha- / \alpha-$ → Asymptomatic [50% α chains]
- $\alpha\alpha / --$ → Asymptomatic [Asians] [50% α chains] [cis α Thalassemia] [marriage not advised]
3. $\alpha- / --$ → [25% α chains]

↓
 β_4 TETRAMER [Hb H]
 ↳ high precipitability → EVHA
 ↳ high O₂ affinity → Tissue hypoxia

4. $-- / --$ → Fetal life
 ↓
 γ_4 TETRAMER [BARTS Hb]
 ↳ IUD → HYDROPS FETALIS

→ ACQUIRED INCORPUSCULAR HEMOLYTIC ANEMIA [only cause]

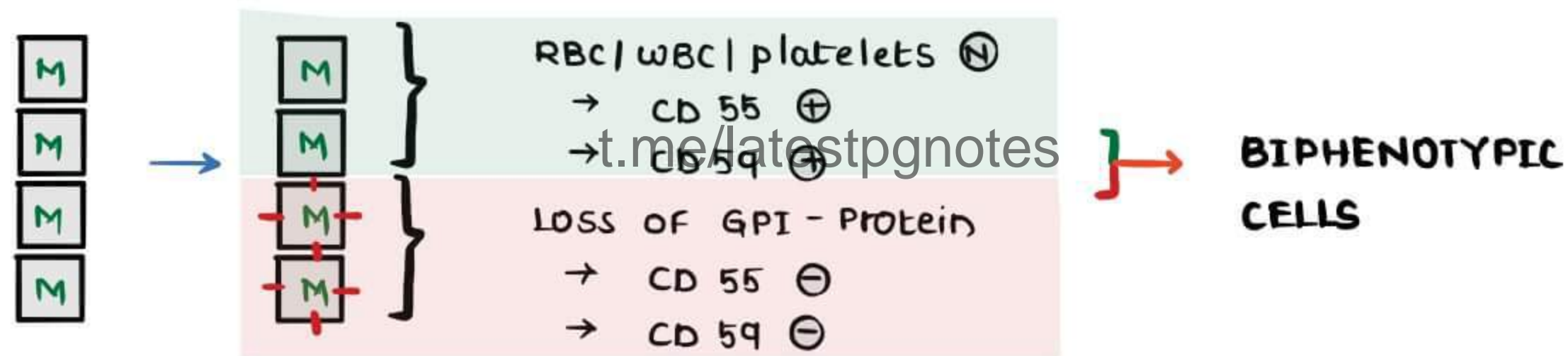


PIG-A Gene [X chr]
[Phosphatidylinositol glycan complementation A gene]

- Synthesizes GPI Link protein [Transmembrane protein]
- serves as ANCHOR

DAF - Decay Accelerating factor
MIRL - Membrane Inhibitor of Reactive Lysis

→ In PNH, PIGA gene defect ⊕



Myeloid Stem cells

→ COMPLEMENT ACTIVATION → DESTRUCTION OF RBC/WBC/PLATELETS → PANCYTOPENIA

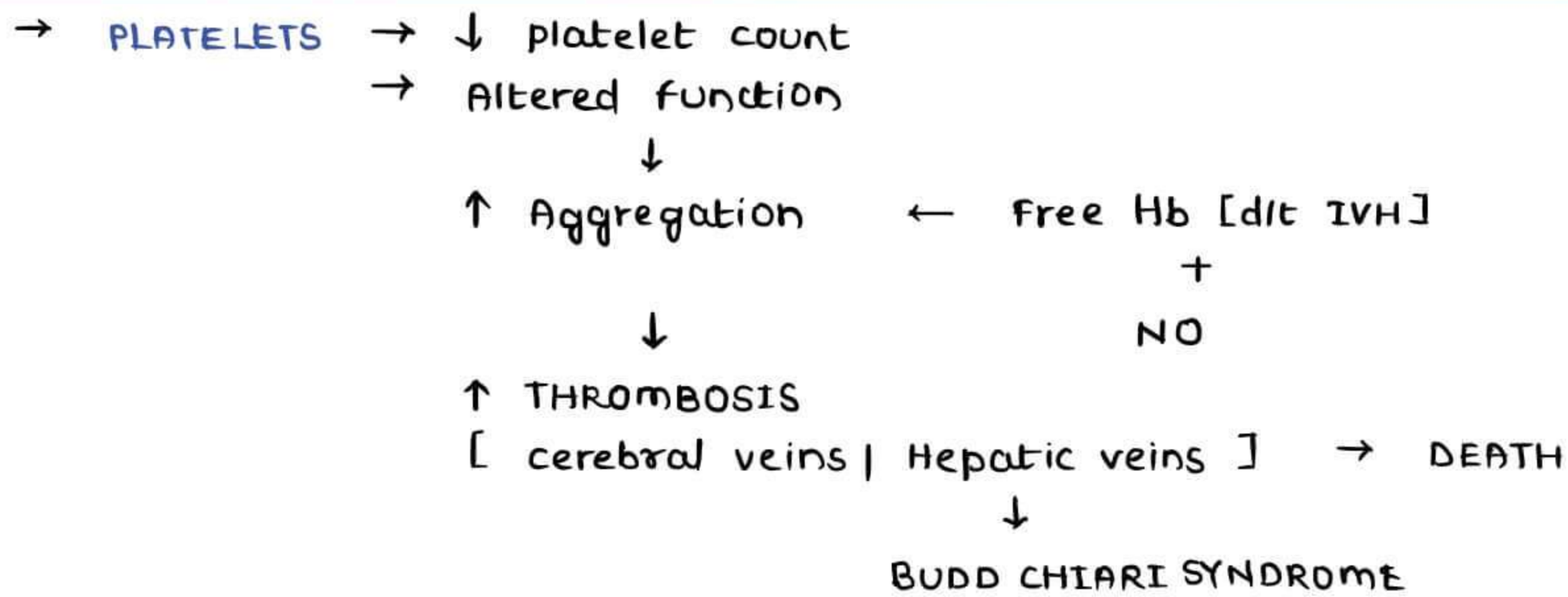
→ RBC destruction [Night]

→ ↓ RR → ↑ CO₂ → ↑ H⁺ [ACIDOSIS]



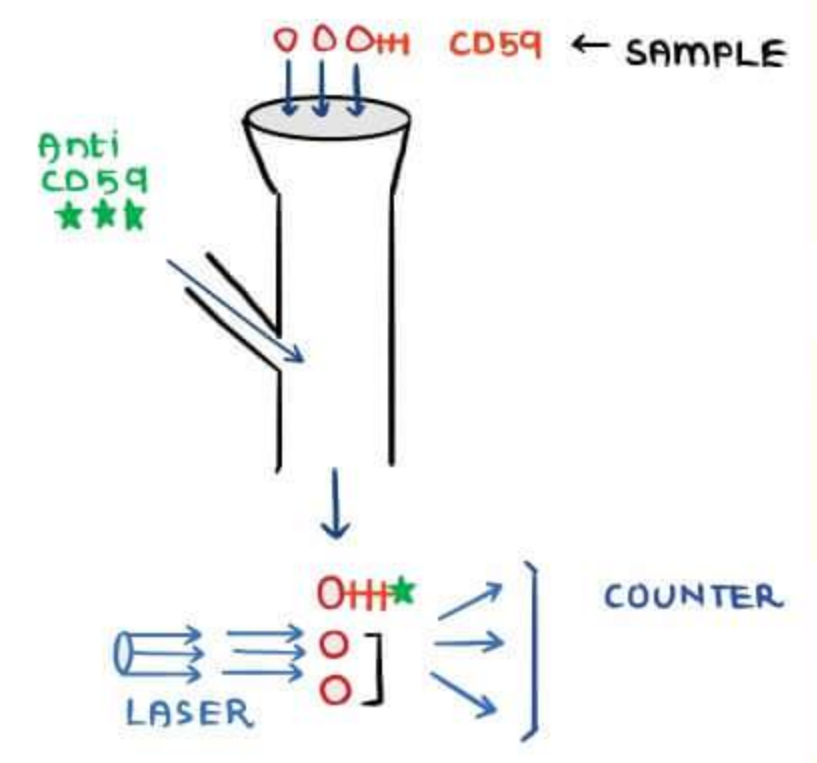
⊙ SYSTEM
↓
RBC Damage
↓
IV HEMOLYSIS
↓
HbURIA
[altered color of urine]

→ WBC → Dysfunction → ↑ INFECTIONS

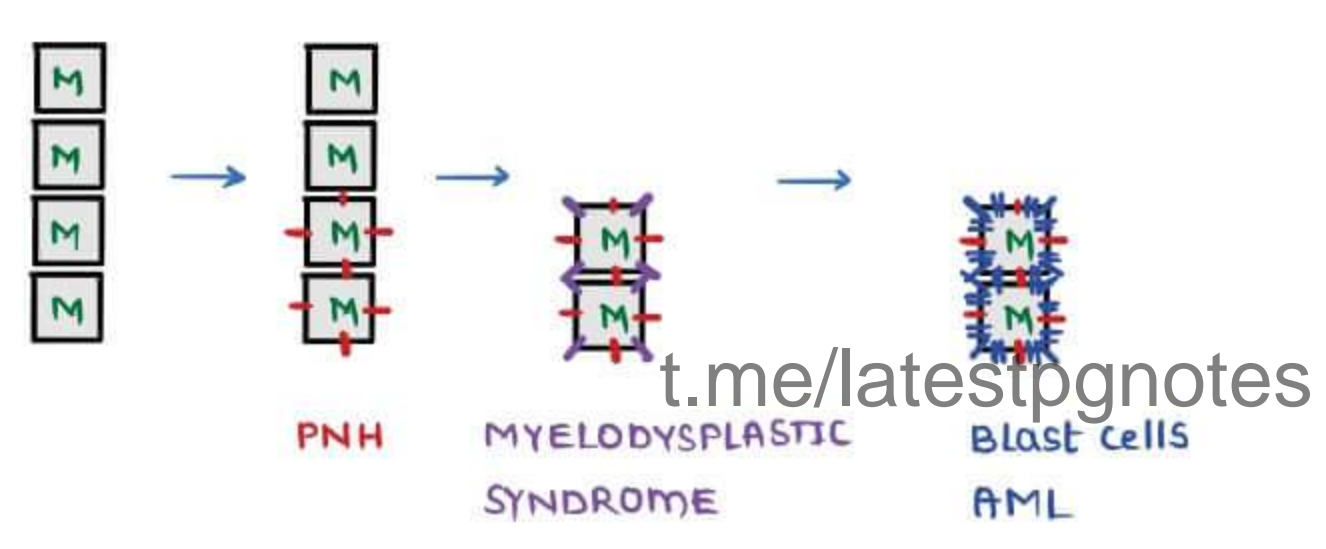


→ DIAGNOSIS

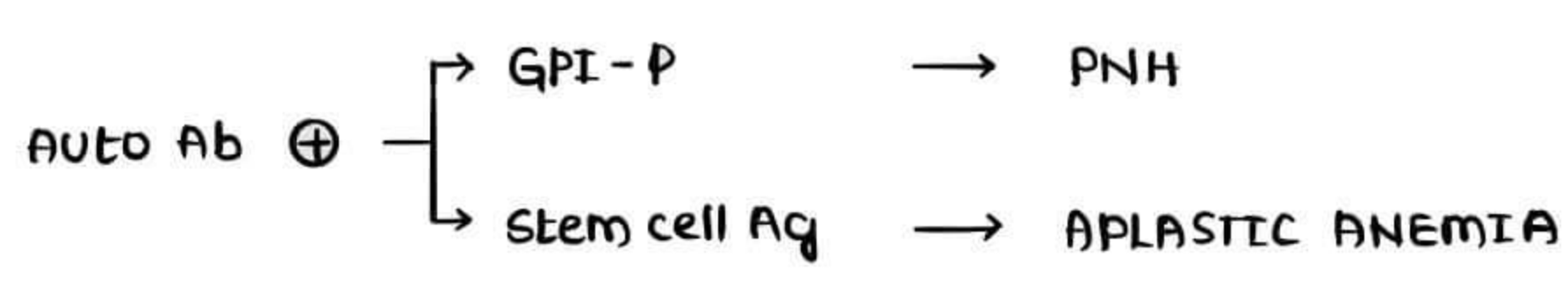
1. FLAER - FLOW CYTOMETRY [Ioc]
 → Fluorescein - Labelled Pro-Aerolysin
 → PNH → 2 DIFFERENT CELLS
 BIPHENOTYPIC APPEARANCE



- 2 ↑ © ACTIVITY → Sugar / ACID [presence]
 → HAM'S ACIDIFIED SERUM TEST
 → SUCROSE LYSIS TEST



→ PNH also a/w APLASTIC ANEMIA



→ TREATMENT

PNH → ↑↑ © Proteins Damage

C₅ CONVERTASE INHIBITOR → Eculizumab

STEM CELL TRANSPLANTATION [definitive R₁]

- EXTRA CORPUSCULAR HEMOLYTIC ANEMIA
- IMMUNE MEDIATED
 - ↳ Auto immune HA

AUTO IMMUNE HA - SUB TYPES

WARM AHA [GONA - HOT]

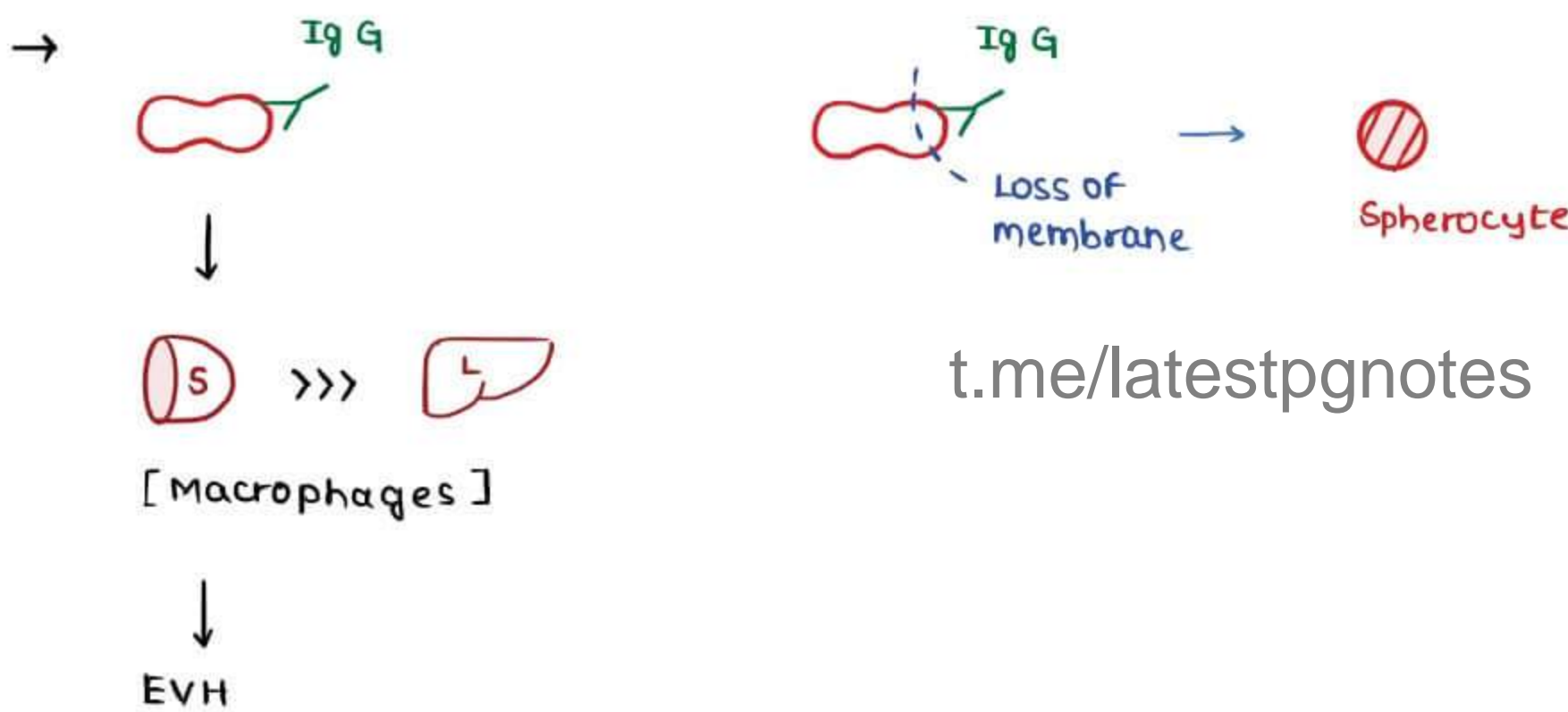
↓
Ab attach at 37°C
Ig G >>> Ig A

COLD AHA [MUSSOORIE - cold]

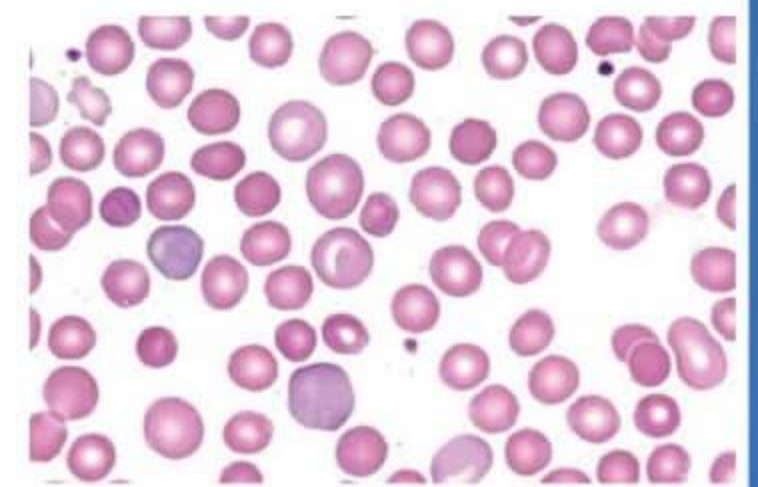
↓
Ab attach at lower temp.
Ig M >>> Ig G

WARM AHA

- Ig G / Ig A
- bind at 37°C
- Idiopathic
- alw auto immune disorders [SLE / RA]
- alw malignancies [CLL]
- alw Drugs [α methyl dopa / Penicillin / Quinidine]

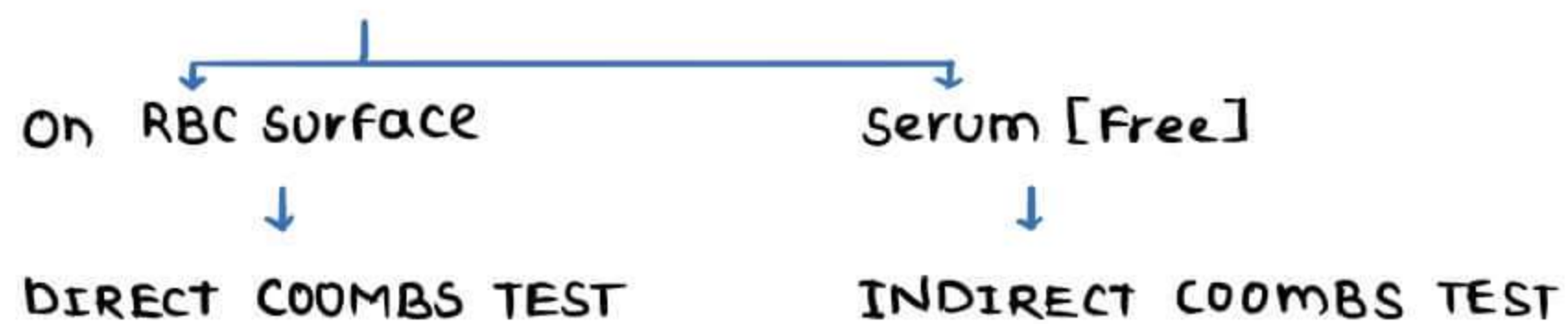

- **CIF**
 - Anemia
 - Jaundice
 - Severe splenomegaly
 - Spherocytes



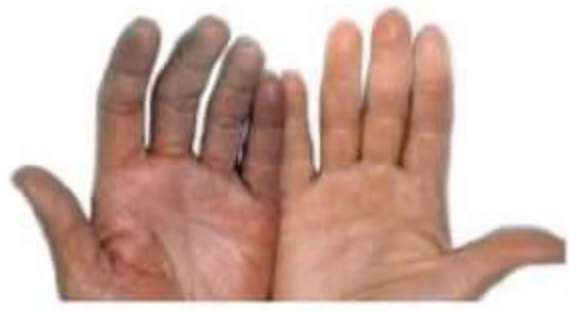→ **DIAGNOSIS**

1. ↑ LDH / ↑ UC Bilirubin / ↓ Hb
2. BLOOD → Pl smear → Spherocytes
 - AUTO - Ab ⊕



- Jaundice | Anemia | Splenomegaly | Spherocytosis seen in
 - ↳ Auto immune Hemolytic Anemia → coomb's Test → +ive
 - ↳ Hereditary Spherocytosis → coomb's Test → -ive

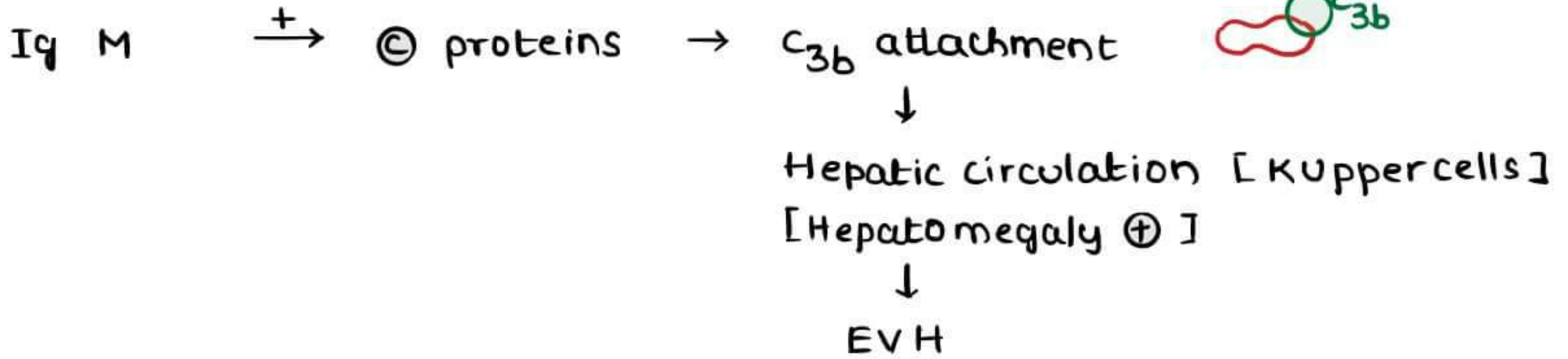
COLD AUTO IMMUNE HA - @ <37°C



1. COLD AGGLUTININ DISEASE

- Ig M against 'I' Ag of RBC
- attaches at cold temperature
- results in CLUMPING / AGGLUTINATION → ACROCYNOSIS


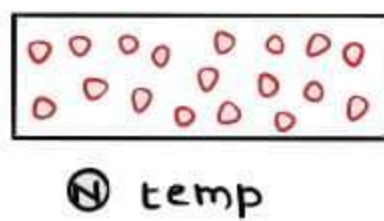
At body temp [37°C] → detachment of Ig M



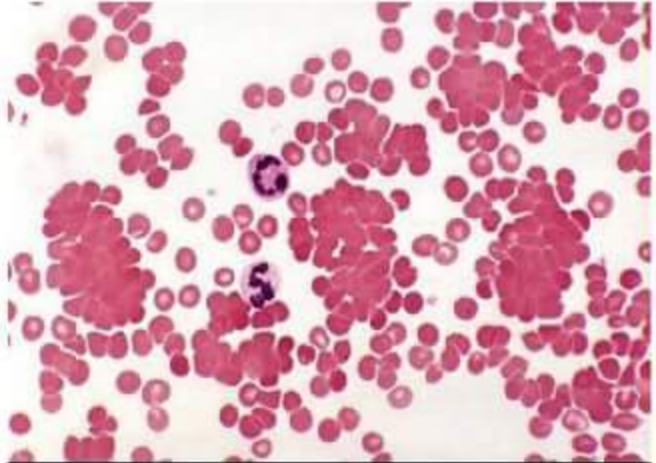
- a/w Ig M
- a/w → Mycoplasma infection
- malignancies
- infectious mononucleosis
- Waldenstrom macroglobulinemia

→ DIAGNOSIS

1. COLD SLIDE TEST

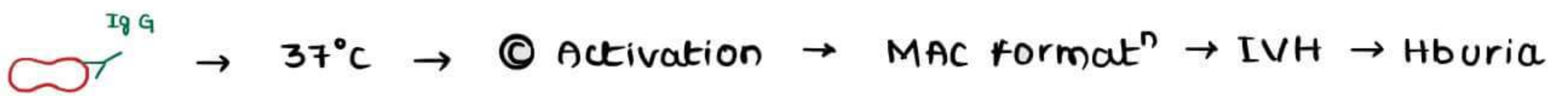


t.me/latestipnotes



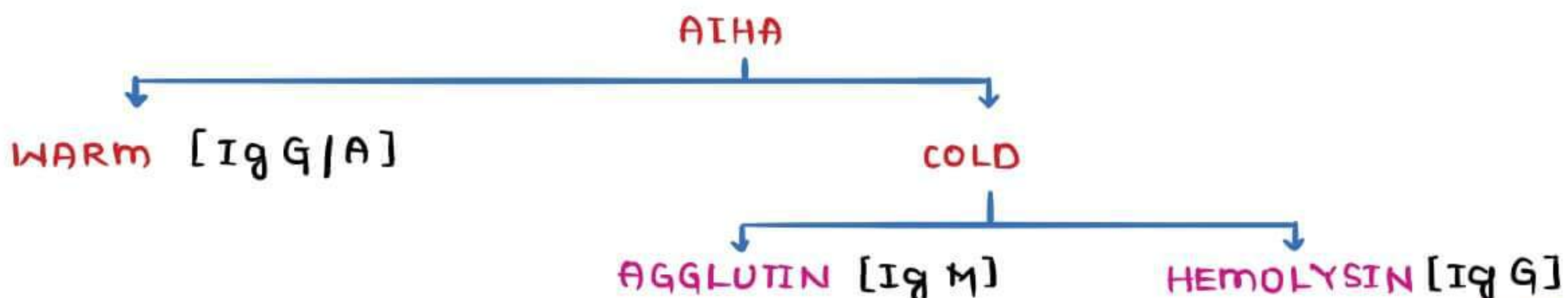
2. COLD HEMOLYSIN TYPE

- Ig G against 'P' antigen of RBC
- binds at 4°C
- \odot activation at 37°C

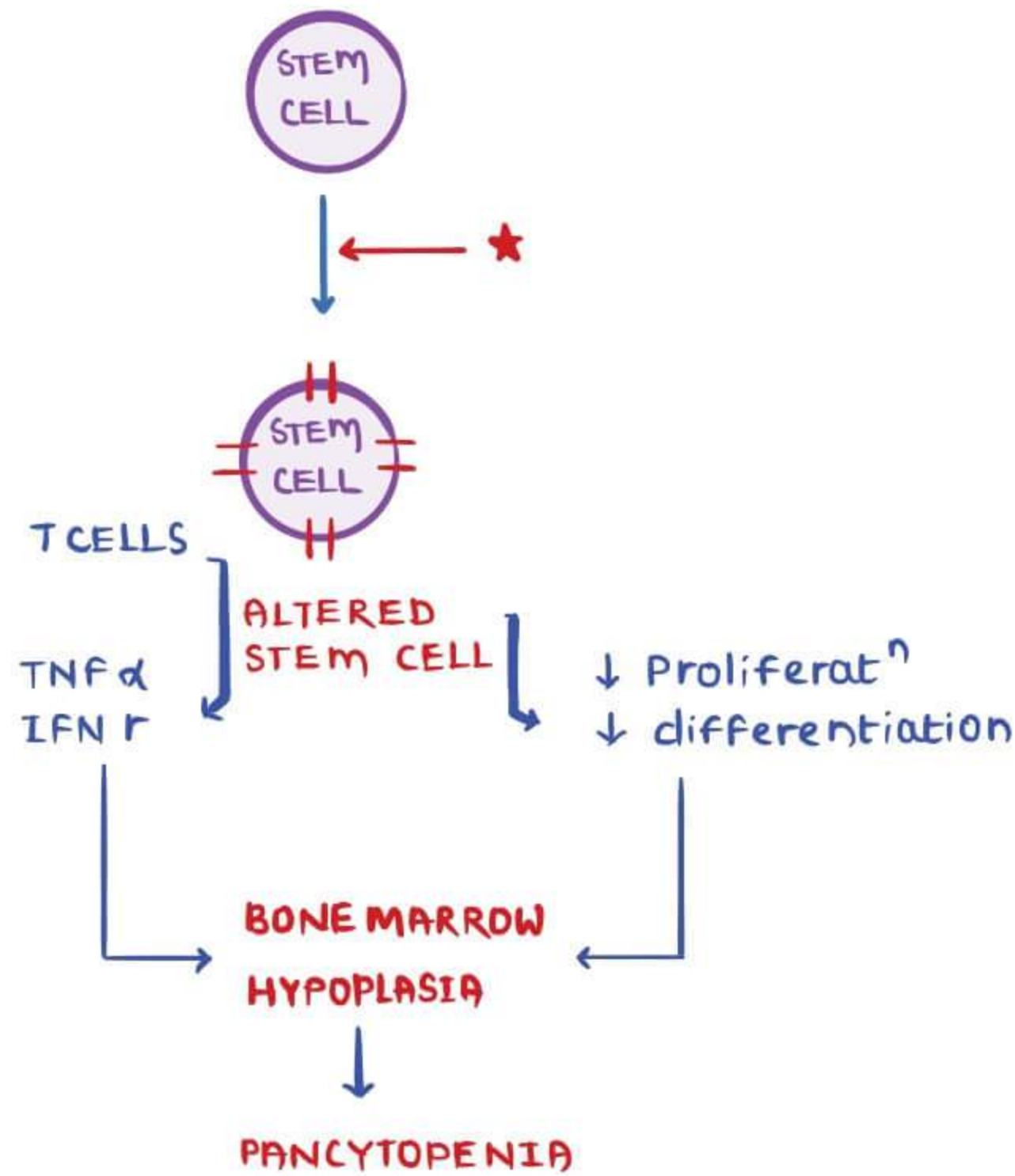


→ COLD HEMOLYSIN DISEASE [PARAOXYSMAL COLD HBURIA (PCH)]

- COLD HEMOLYSIN Ab aka → DONATH - LANDSTEINER Ab
 - ↳ seen in children i viral infection
 - ↳ a/w syphilis
 - ↳ aka BIPHASIC Ab



→ a/w Hematopoietic Stem cell defect → PANCYTOPENIA



IMPORTANT INFO

→ DRUGS

→ Anti Thymocyte Globulin [ATG] } ↓ T cell activity → useful in
 → Cyclosporine } Aplastic anemia

→ AA can progress to

- MDS
- AML

→ AA also a/w PNH [dit T cell activity against GPI-linked protein]

APLASTIC ANEMIA - CAUSES

1. INHERITED

- Telomerase defect
- Fanconi Anemia

- AR
- Defect in DNA Repair genes
- Hypoplasia [kidney | spleen]
- Bone defects [Radius | thumb]

• FANCONI SYNDROME IS A/W RENAL TUBULAR DAMAGE [different from FA]

2. ACQUIRED

- a. IMMUNE MEDIATED
- b. IDIOPATHIC [MCC]

3. CHEMICALS

- a. DOSE RELATED → Alkylating Agents / Anti metabolites / chloramphenicol
- b. DOSE UNRELATED [IDIOSYNCRATIC S/E] [even 1 single dose can cause AA]
 - Gold salts
 - chloramphenicol

4. PHYSICAL

- Radiation
- viruses [EBV, VZV, CMV]

CLINICAL FEATURES

- no age predilection
- no sex predilection
- FEATURES OF PANCYTOPENIA
 - ↳ Fatigue
 - ↳ Fever
 - ↳ Hemorrhage [bleeding manifestations]

→ SPLENOMEGALY NEVER SEEN

DIAGNOSIS

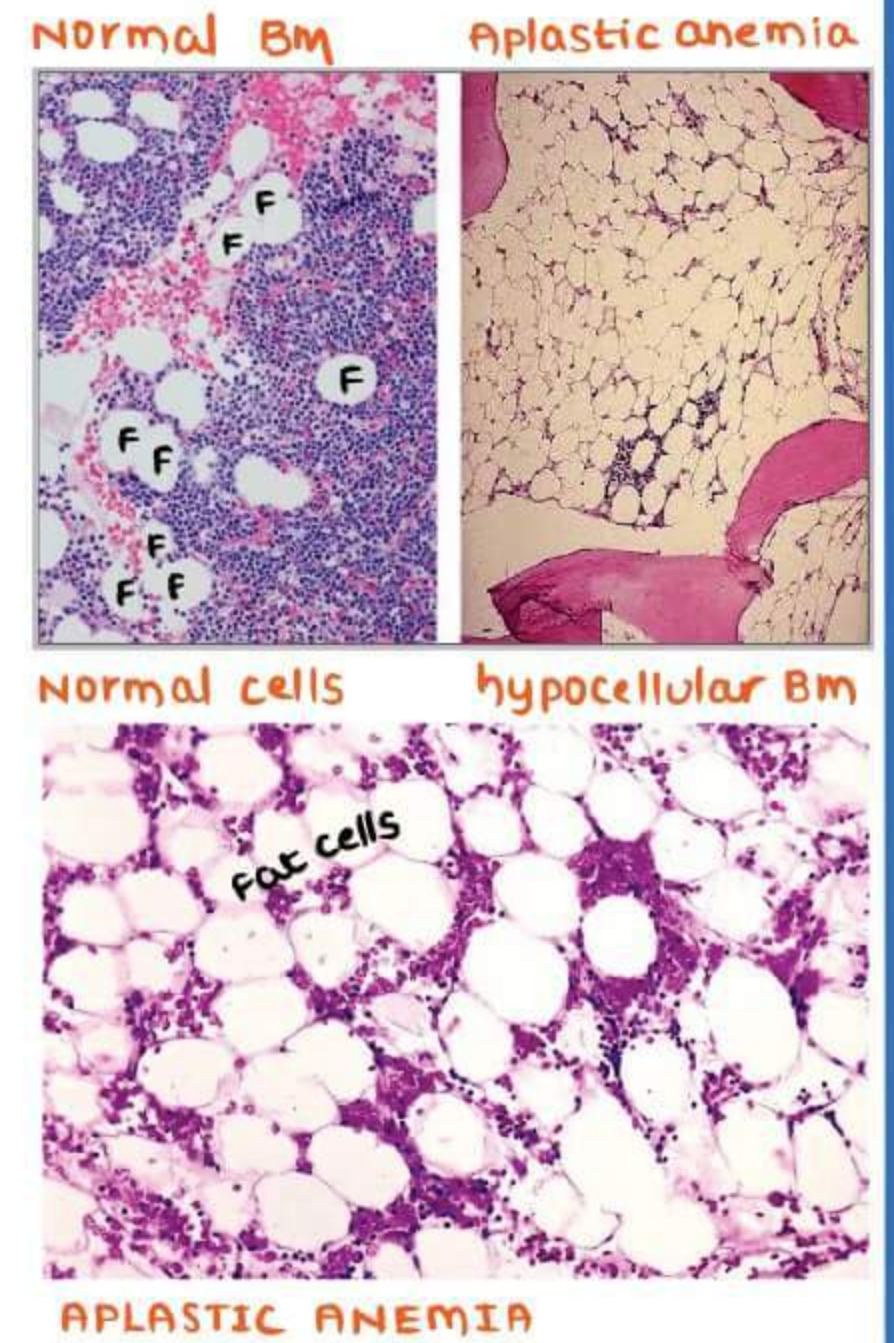
1. BLOOD

- Pancytopenia
- Reticulocytopenia
- macrocytic, normochromic RBCs

2. BM ASPIRATION → DRY TAP

3. BM BIOPSY

- ↓ cellularity
- this feature differentiates AA from
 - MDS
 - Aleukemic leukemia
 } hyper-cellular



TREATMENT

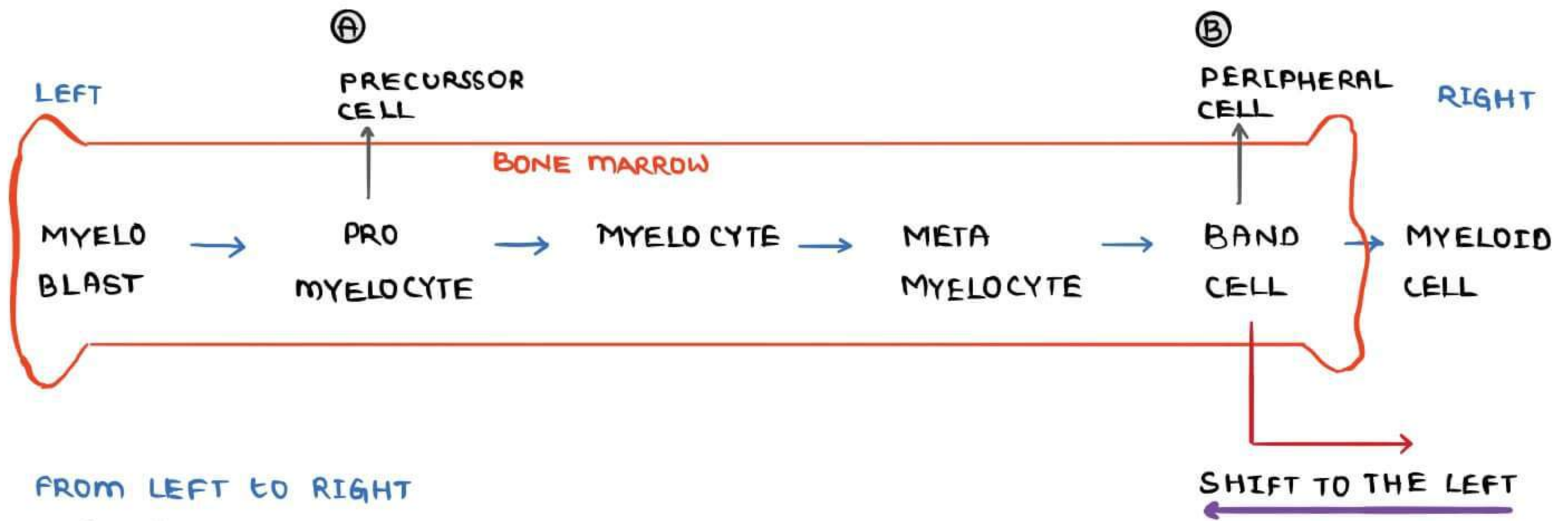
- TOC → Bone marrow Transplantation
- DRUGS → Anti Thymocyte Globulin [ATG], Cyclosporine

CLASSIFICATION OF APLASTIC ANEMIA

NON - SEVERE / MODERATE AA	Bm cellularity < 25%
SEVERE AA	Bm cellularity < 25% + Any 2 out of 3 } Absolute neutrophil count < 500/mm ³ Platelet count < 20,000/mm ³ Reticulocyte count < 60,000/mm ³
VERY SEVERE AA	SEVERE AA + Absolute neutrophil count < 200/mm ³

→ common cause of death in patients with severe & very severe AA → Septicemia

WHITE BLOOD CELLS
INTRODUCTION TO WBC DISORDERS



FROM LEFT TO RIGHT
 ↓ Size
 ↓ Rate of Replication
 ↑ maturation

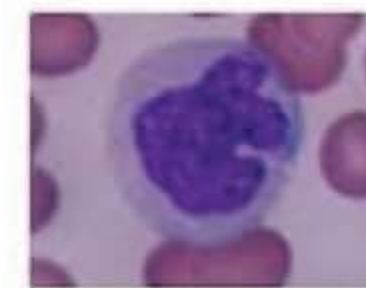
DISORDERS AFFECTING WBCs

- I ↓ WBCs → LEUCOPENIA
- II ↑ WBCs → BENIGN & NEOPLASTIC

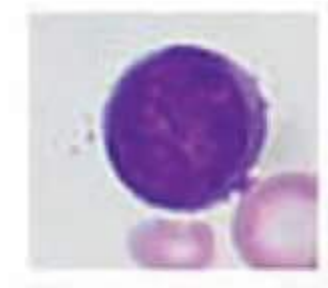
↑ WBCs - BENIGN

1. LEUCOCYTOSIS [↑↑ TLC]

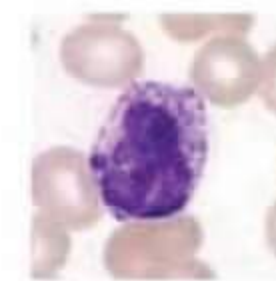
- TLC → (N) 4,000 - 11,000 /ML
- DLC [Differential Leukocyte Count]



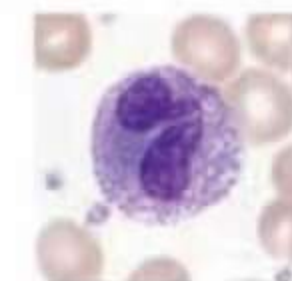
Monocyte



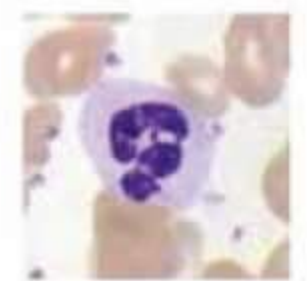Lymphocyte



Basophil



Eosinophil



Neutrophil

- Never → Neutrophils [50-70%]
- Let → Lymphocytes [20-40%]
- Monkeys → Monocytes [8-10%]
- Eat → Eosinophils [0-5%]
- Bananas → Basophils [0-2%]

→ **NEUTROPHILIA**

- Bacterial infections
- necrosis
- Acute inflammation
- DRUGS
 - ↳ Steroids
 - ↳ Lithium

→ **monocytosis**

- chronic inflammation
- cancers

→ **EOSINOPHILIA**

- Allergy
- parasitic infections
- Hodgkin Lymphoma

→ **Lymphocytosis**

- viral infections
- chronic inflammation

→ **Basophilia**

- allergy
- cML

2. LEUKEMOID REACTION

→ TLC → 40,000/ μ l

→ Seen in

- ↳ Pneumonia
- ↳ Infective Endocarditis
- ↳ Sepsis
- ↳ Kawasaki Disease

} ↑ Mature
white Blood cells

→ D/D → CML

→ differentiated by LAP SCORE

→ LAP SCORE

→ ↑ed in Leukemoid reaction

↓ed in CML

→ Dohle Bodies & toxic granules are a/w Leukemoid reactions
Dohle Bodies → Dilated Endoplasmic reticular structures

↑ WBC - NEOPLASTIC WBC PROLIFERATION

LEUKEMIA

SEQUENCE OF INVOLVEMENT

Extensive Bm involvement



SYSTEMIC circulation



Liver / LN / Spleen / Brain
[organs]

LYMPHOMA

SEQUENCE OF INVOLVEMENT

LN / Liver / Spleen [Organs]



SYSTEMIC CIRCULATION

LEUKEMIA



LYMPHOMA

CLINICAL FEATURES - LEUKEMIA

→ ↓ RBC / WBC / platelets → PANCYTOPENIA

- ↳ Fatigue / pallor
- ↳ recurrent fever
- ↳ petechiae / purpura

→ HYPERVISCOSITY OF BLOOD

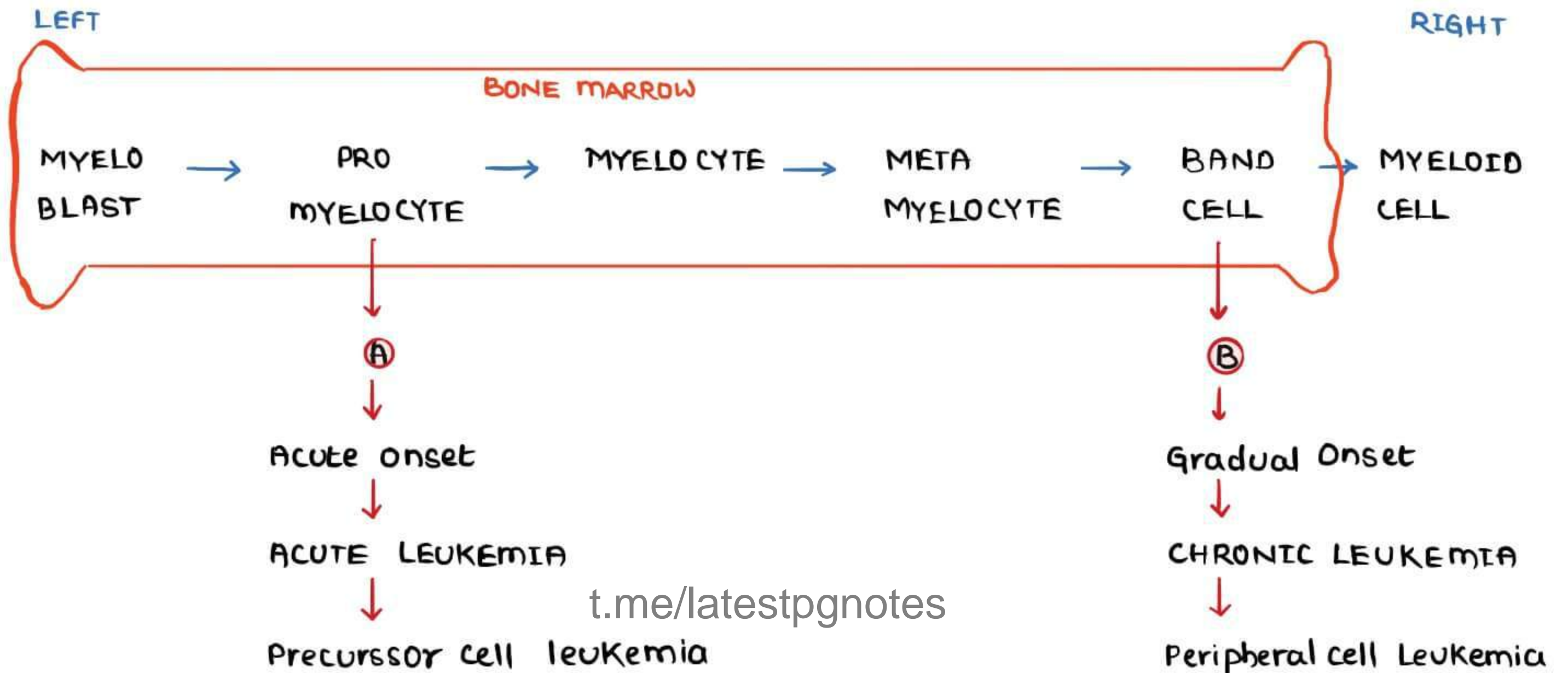
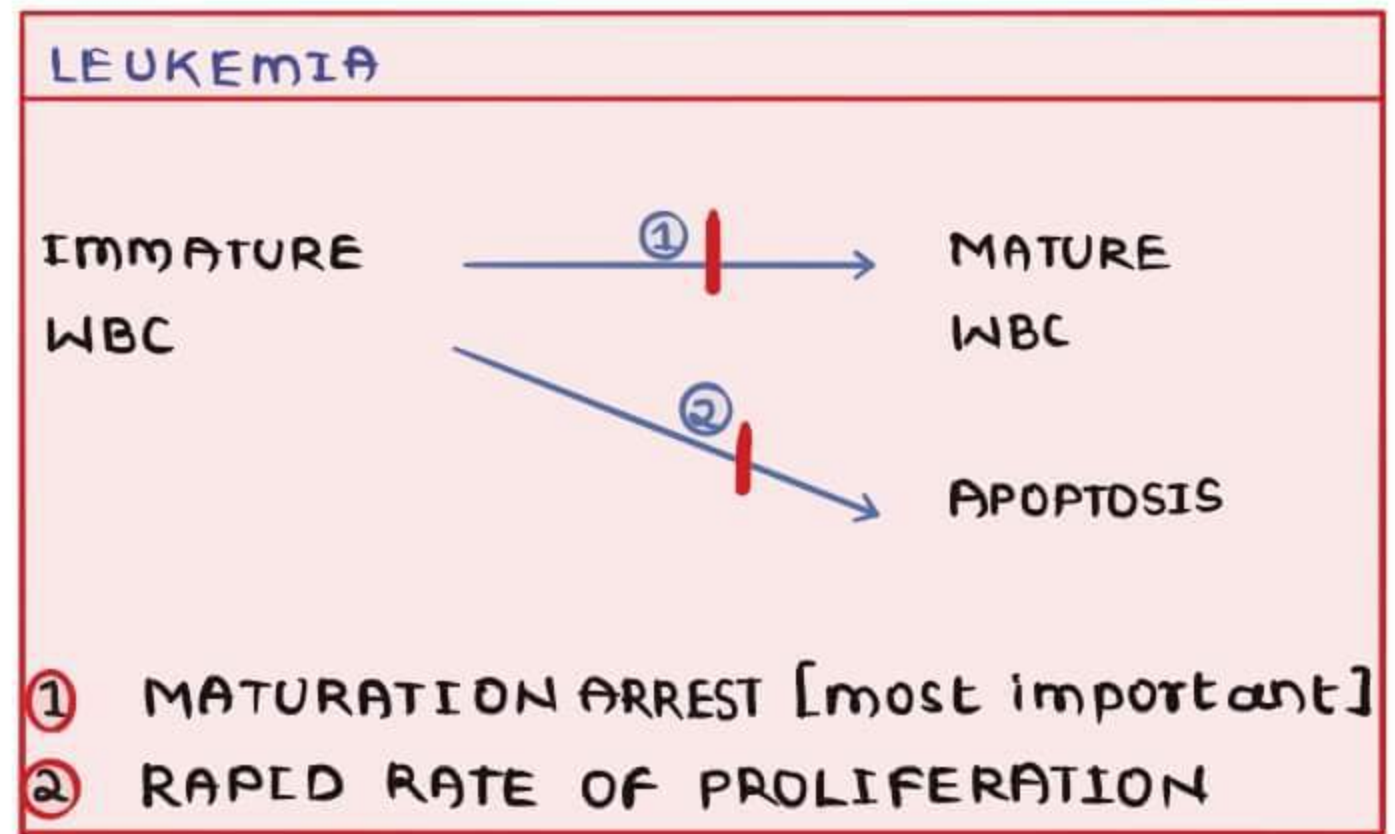
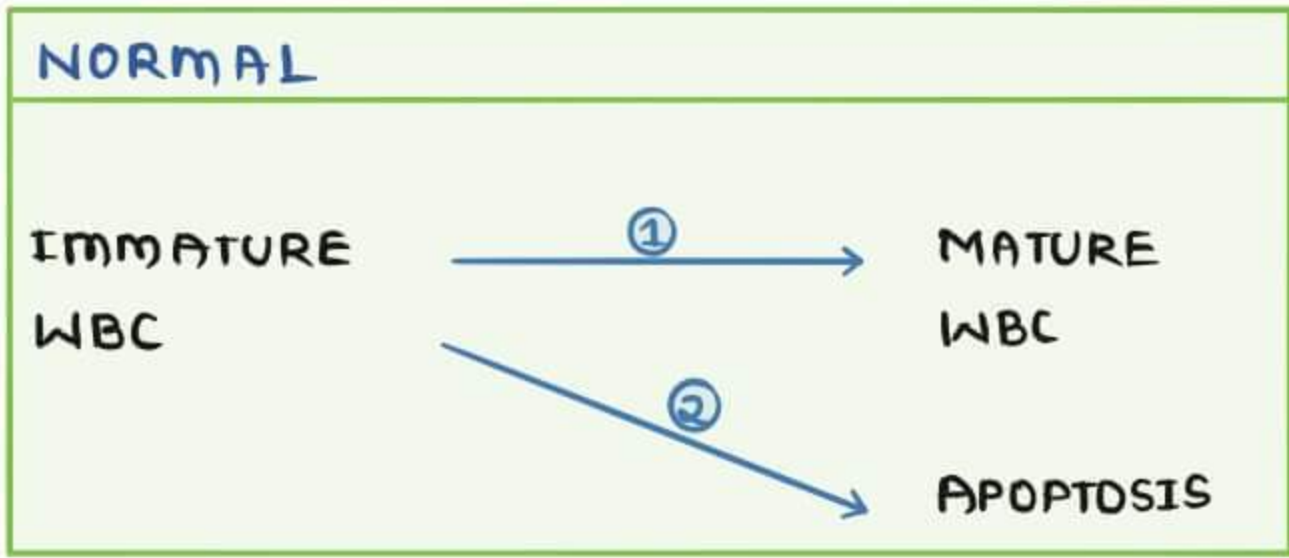
→ LYMPHADENOPATHY | HEPATO SPLENO MEGALY

→ HEADACHE | CRANIAL NERVE PALSY

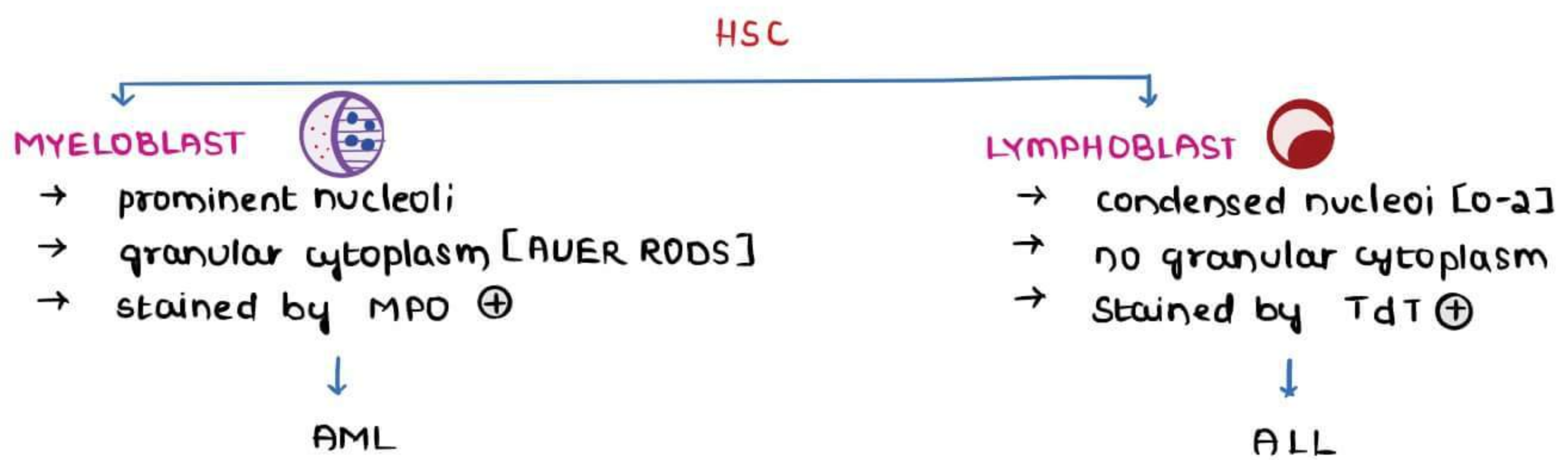
CLINICAL FEATURES - LYMPHOMA

→ LYMPHADENOPATHY | HEPATO SPLENO MEGALY

→ BLOOD & Bm INVOLVEMENT



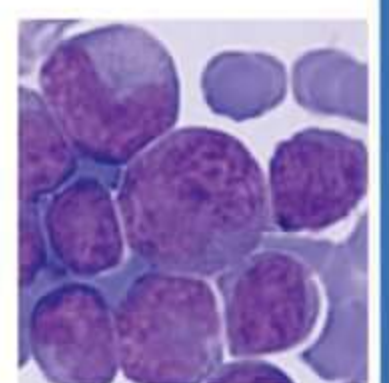
ACUTE LYMPHOBLASTIC LEUKEMIA



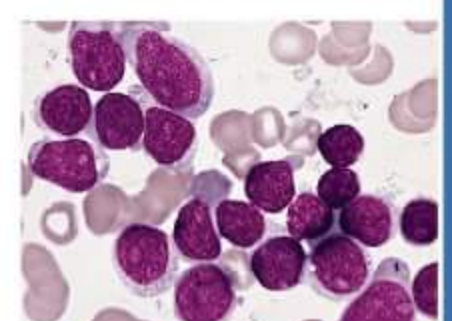
MPO → myeloperoxidase
 TdT → Terminal deoxynucleotidyl transferase

BLAST CELLS IN BM

- (N) → 1-2%
- Acute leukemias → > 20% [WHO]
- IOC → BM Examination



myeloblast



LYMPHOBLAST

GENETIC	ACQUIRED
↳ Fanconi anemia	↳ Radiation exposure
↳ Bloom Syndrome	↳ chemicals [Benzene Smoking [PHC]]
↳ Ataxia telangiectasia	↳ Infections [EBV HTLV 1]
↳ Down Syndrome	↳ Drugs [Anti cancer drugs]
↳ ALL [overall]	
↳ AML [< 3yrs]	

ACUTE LYMPHOBLASTIC LEUKEMIA [ALL]

- mc leukemia in children
- **C/F** → sudden onset of clinical symptoms
 - ↳ fatigue / fever / petechiae
 - ↳ hepatosplenomegaly / Lymphadenopathy
 - ↳ sternal tenderness ⊕
- **GENETIC DEFECT** → Hyperploidy / hypoploidy
 - Trisomy 4/7/10
 - t [12;21] , t [4;11] , t [9;22]

→ **DIAGNOSIS**

1. BONE MARROW EXAMINATION [IQC]


- Hypercellular t.me/latestpgnotes
- Blasts
 - ↳ > 20%
 - ↳ Lymphoblasts → TdT ⊕ , PAS ⊕

2. BLOOD

- ↑↑↑ TLC
- ↓ Hb
- ↓ platelets
- Lymphoblasts ⊕
- ALEUKEMIC LEUKEMIA → absence of WBC in Blood

3. IMMUNOPHENOTYPING

→ **WHO CLASSIFICATION**



PRE - ● ALL	PRE - ● ALL
→ more common	→ Less common
→ Bm ⊕ ⊕ ⊕	→ Thymus ⊕ ⊕ ⊕
→ Peak @ 3 yrs	→ Peak @ Puberty
→ Pancytopenia ⊕	→ Retrosternal mass ⊕
→ EBF / PAX-5 mutation	→ NOTCH gene mutation
→ [Loss of function]	→ [Gain of function]
→ Good prognosis	→ Poor prognosis
→ CD 19 / 20 ⊕	→ CD 112 / 5 / 7 ⊕

PROGNOSTIC FACTORS FOR ALL

	GOOD PROGNOSIS	POOR PROGNOSIS
● PLOIDY	→ Hyperploidy t [12;21]	→ t [9;22]
● RACE	→ White	→ Black
● OLD	→ 1 - 10 years	→ < 1 year or > 10 years
● GENDER	→ Girl	→ Boy
● No. OF cells	→ Less Blasts	→ more Blasts
● ORGANS	→ Less involvement	→ more involvement ↳ Thymus ↳ Testis
● SUB TYPE	→ Pre-B ALL	→ Pre T - ALL
● INFILTRAT ⁿ	→ Lesser	→ Higher
● STEROIDS / DRUG RESPONSE	} ⊕	} ⊖

TREATMENT

ANTI CANCER DRUGS

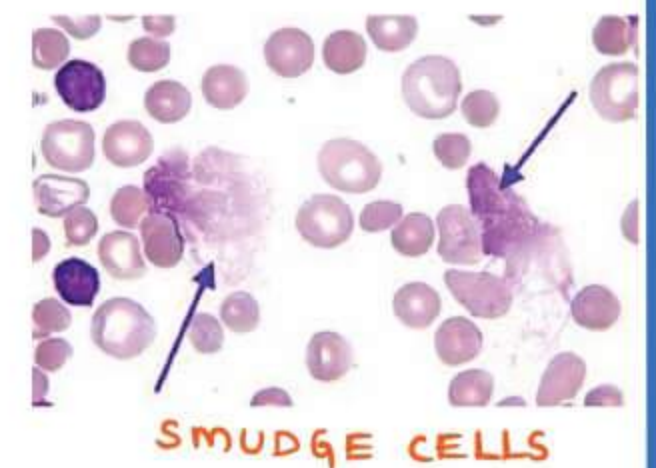
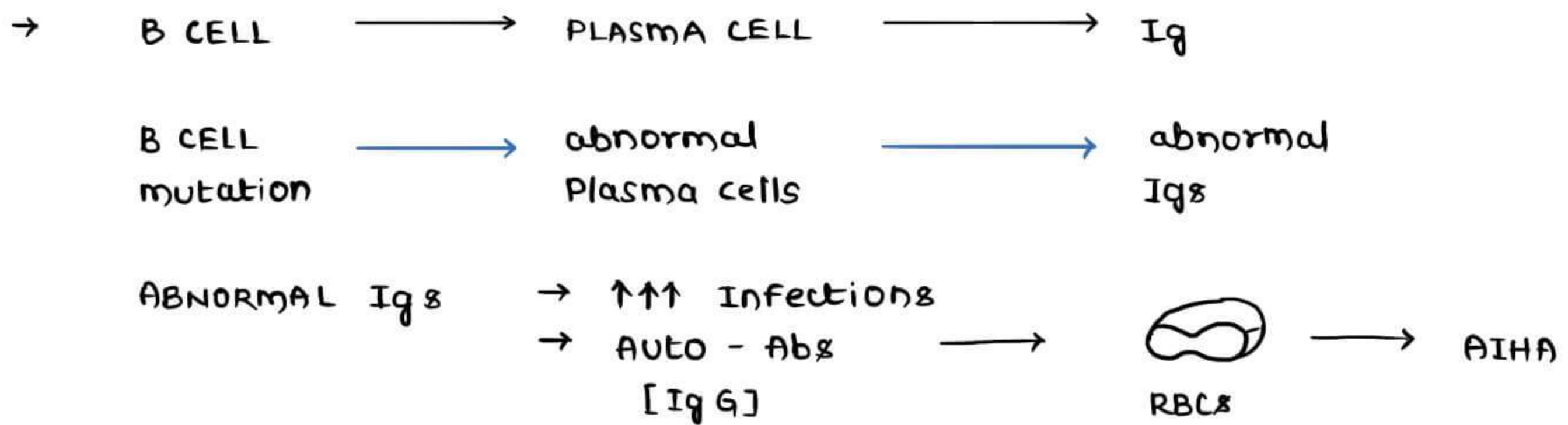
- V → VINCRISTINE
A → ASPARAGINASE
P → PREDNISOLONE
D → DAUNORUBICIN
MEX → METHOTREXATE
↳ intra thecally
↳ for brain metastasis

ALLOGENIC BONE MARROW TRANSPLANTATION [Definitive R_p]

- mc leukemia in adults
- ETIOLOGY UNKNOWN
- Radiation not associated τ CLL

→ GENETIC DEFECTS

- ↳ 11q deletion
- ↳ 17p deletion
- ↳ 13q deletion
- ↳ Trisomy 12q
- ↳ NOTCH - \otimes gain function



→ C/P

- Elderly [age group]
- Gradual onset
- Asymptomatic mostly
- fatigue | cervical Lymphadenopathy | fever | hepatosplenomegaly

→ DIAGNOSIS

1. BLOOD EXAMINATION

- Absolute lymphocyte count [ALC] → > 5000 cells/ μ l
- \downarrow Hb / \uparrow TLC
- Peripheral smear shows SMUDGE CELLS
- AUTO Abs \oplus detected by coomb's Test

2. BM EXAMINATION

→ Hypercellular [\uparrow Lymphoid cells]

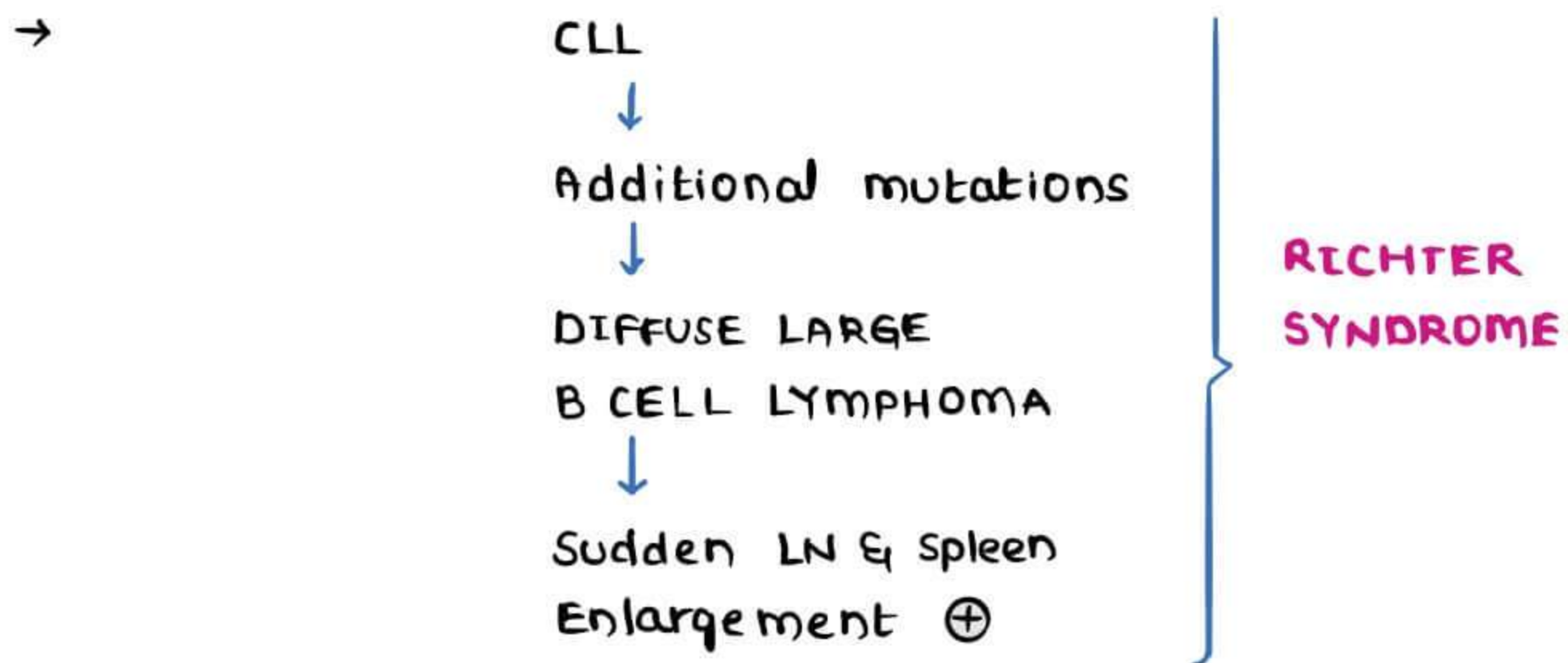
3. LN EXAMINATION

- GROSS → Effaced
- MICROSCOPIC → Proliferation centres



4. IMMUNO PHENOTYPING

B CELL CANCER → CD19 \oplus , CD23 \oplus
 → CD20 \oplus , CD5 \oplus



→ PROGNOSTIC FACTORS

POOR PROGNOSIS

1. 11q ⊖ / 17p ⊖
2. ZAP 70 ⊕
3. NOTCH - ⊕ mutation
4. Somatic hypermutation ⊖

→ TREATMENT

1. FLUDARABINE [DOC] → anti metabolite
2. IBRUTINIB → B cell tyrosine kinase ⊖

t.me/latestpgnotes

RISK FACTORS

- ANTI - CANCER DRUGS
- poor a/w viruses
- t [8;21] , t [15;17] , inv 16 [t [16;16]]
- 50-60 yrs age
- MYELOBLAST ⊕

AML - CLASSIFICATION

FAB CLASSIFICATION [BLASTS → > 30%]

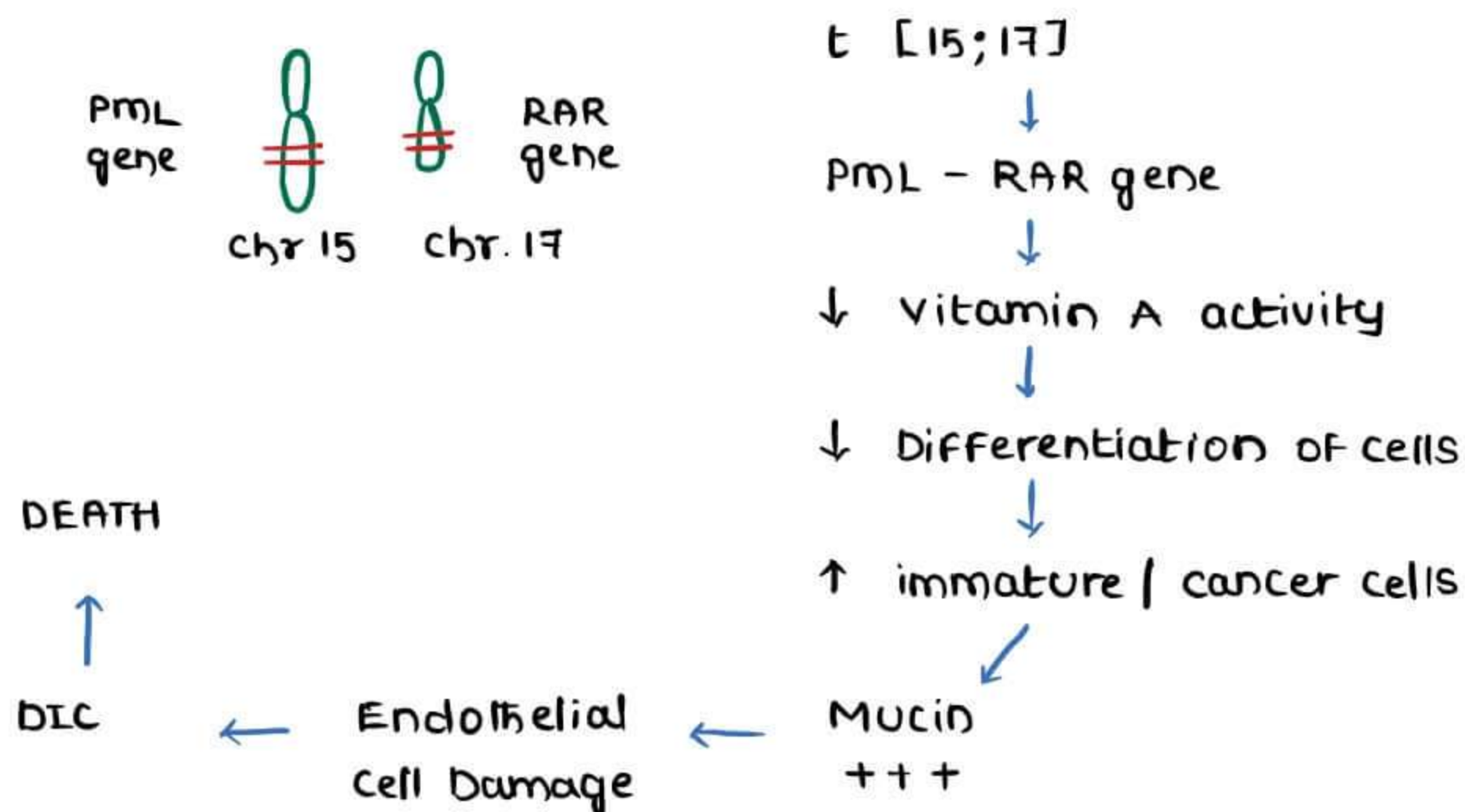
- M₀ → Minimally Differentiated AML
- M₁ → AML without maturation
- M₂ → AML with maturation
- M₃ → Acute Promyelocytic leukemia
- M₄ → Acute myelomonocytic leukemia
- M₅ → Acute monocytic leukemia
- M₆ → Acute Erythroleukemia
- M₇ → Acute megakaryocytic leukemia

- M₁ , M₂ , M₃ , M₄ → mPO ⊕
- M₅ → Non Specific Esterase ⊕
- M₆ → PAS ⊕
- M₇ → CD₄₁ / CD₆₁ ⊕

t.me/latestpnotes

ASSOCIATIONS

- AML - M₂ → t [8;21] → CHLOROMA
- AML - M₃ → t [15;17] → AUER RODS +++



- Rx by → 1. Vitamin A [All Trans Retinoic Acid]
 - ↳ induce differentiatⁿ of cells
 - ↳ useful in AML - m₃ [APL]
- 2. ARSENIC TRIOXIDE → for AML - m₃

- M₇ - AML
 - ↳ mc AML seen in Down Syndrome
 - ↳ tumor cell secretes PDGF → responsible for MYELOFIBROSIS
- mc AML seen in clinical practice → M₂ - AML
- mc AML seen in infants → M₅ - AML
- mc AML in children → M₇ - AML

WHO CLASSIFICATION [>20% BLASTS]

I AML with Specific Genetic Defects

- t [8;21]
- t [15;17]
- t [16;16]

II AML [Therapy related]

III AML with multilineage dysplasia → with or without MDS

IV AML [NOS - Not otherwise specified]

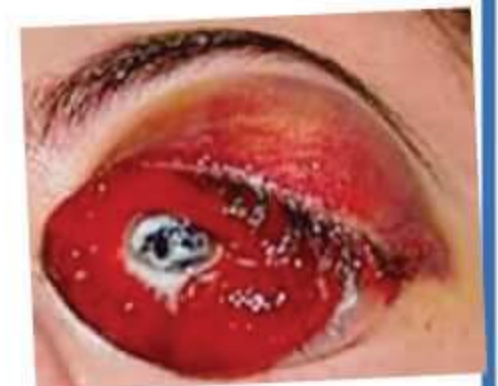- AML with specific gene defects can be diagnosed as AML even if there are < 20% of blasts

PROGNOSIS

- I. AML with specific genetic defects → Good
- IV. AML [NOS] → Intermediate
- III. AML with multilineage dysplasia → poor
- II. AML [Therapy related] → worst prognosis

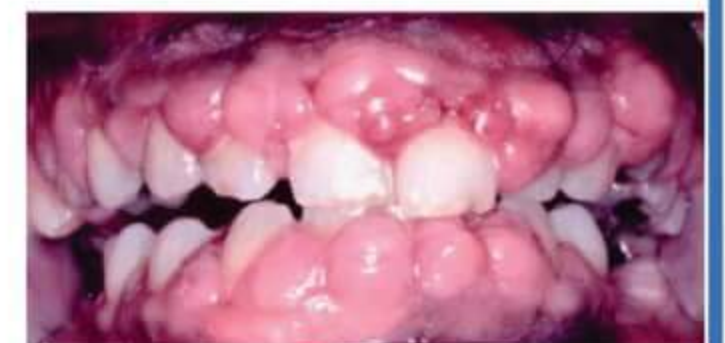CLF

- Acute onset of clinical symptoms
- t [8;21] → chloroma [green]
 - mc site → Retro orbital tissue
 - Proptosis ⊕
 - CD 45, CD 43, Lysozyme ⊕
 - aka GRANULOCYTIC SARCOMA



Proptosis

- M₄ } GUM HYPERTROPHY
- M₅ } LEUKEMIA CUTIS



Gum Hypertrophy

- t [15;17] → ↑ DIC → Death

DIAGNOSIS

1. Bm EXAMINATION [IOC]

- myeloblasts ⊕ → MPO ⊕ /NSE ⊕ /Sudan Black B ⊕

2. IMMUNOPHENOTYPING

- CD 41 / CD 61 → AML - M₇
- CD 45 → AML - M₂

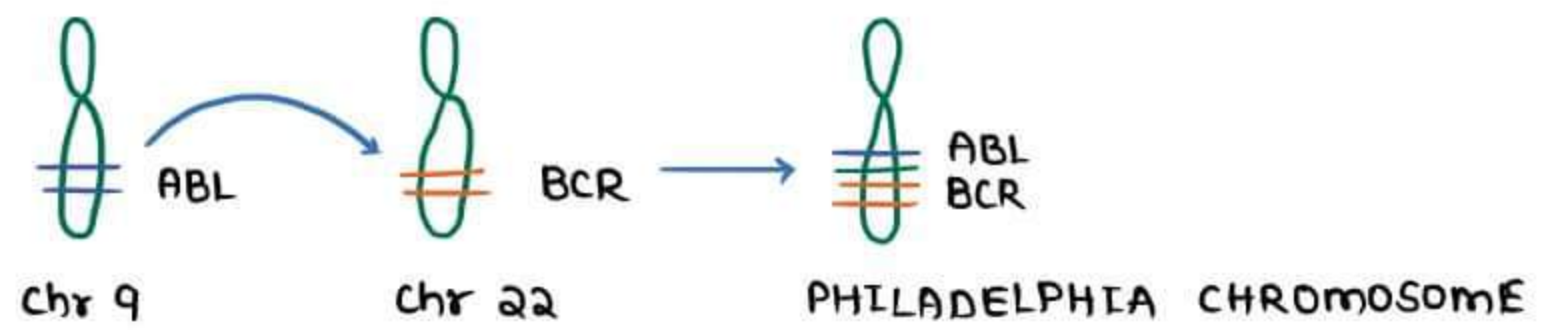
3. CYTOGENETICS

→ Myeloproliferative disorder

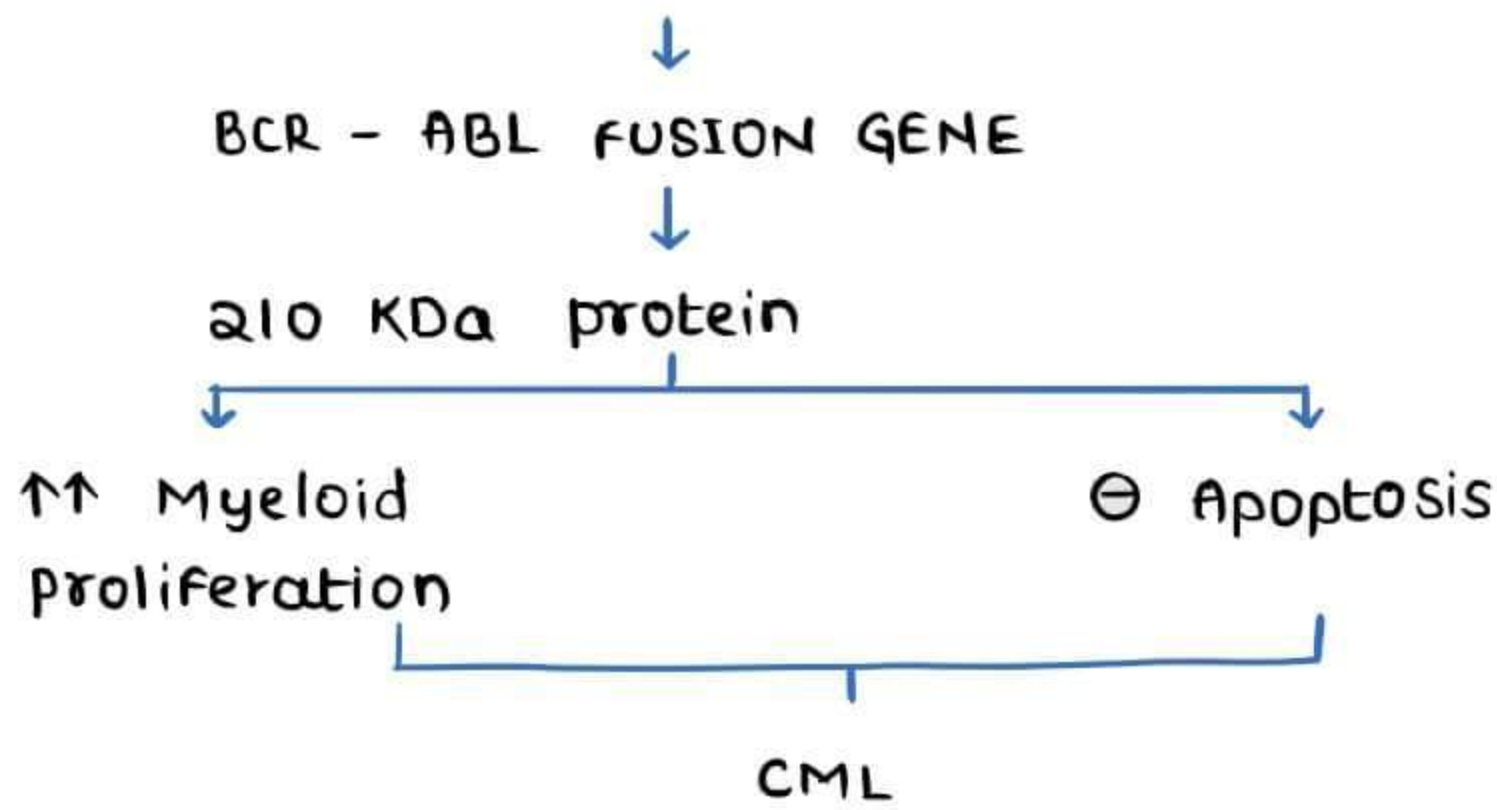
→ **RISK FACTORS**

- 1. Radiation
- 2. Benzene

→ **t [9;22]**



PHILADELPHIA CHROMOSOME



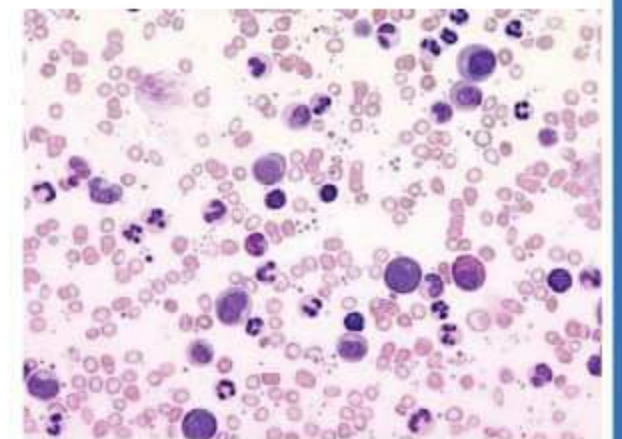
→ **CIF**

- middle age [40-60 yrs]
- mostly asymptomatic [incidental finding]
- massive splenomegaly > hepatomegaly > Lymphadenopathy [rare]

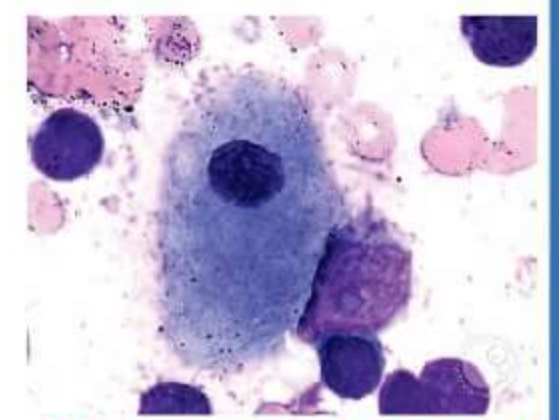
→ **DIAGNOSIS**

1. **BLOOD EXAMINATION**

- ↑↑ TLC / ↑ Platelets
- ↑ DLC → ↑ Eosinophils
- ↑ Basophils



- DJD → LEUKEMOID REACTION → ↑ LAP SCORE
- CML → ↓ LAP SCORE



PSEUDO - GAUCHER CELL

2. **BM EXAMINATION**

- Hypercellular
- WBC at different stages
- ↑ Reticulin
- PSEUDO - GAUCHER CELLS [Histiocytes with sea blue granules in cytoplasm]

3. **CML** → Serum B₁₂ ↑

4. **CYTOCHEMISTRY** → ↓↓ LAP SCORE

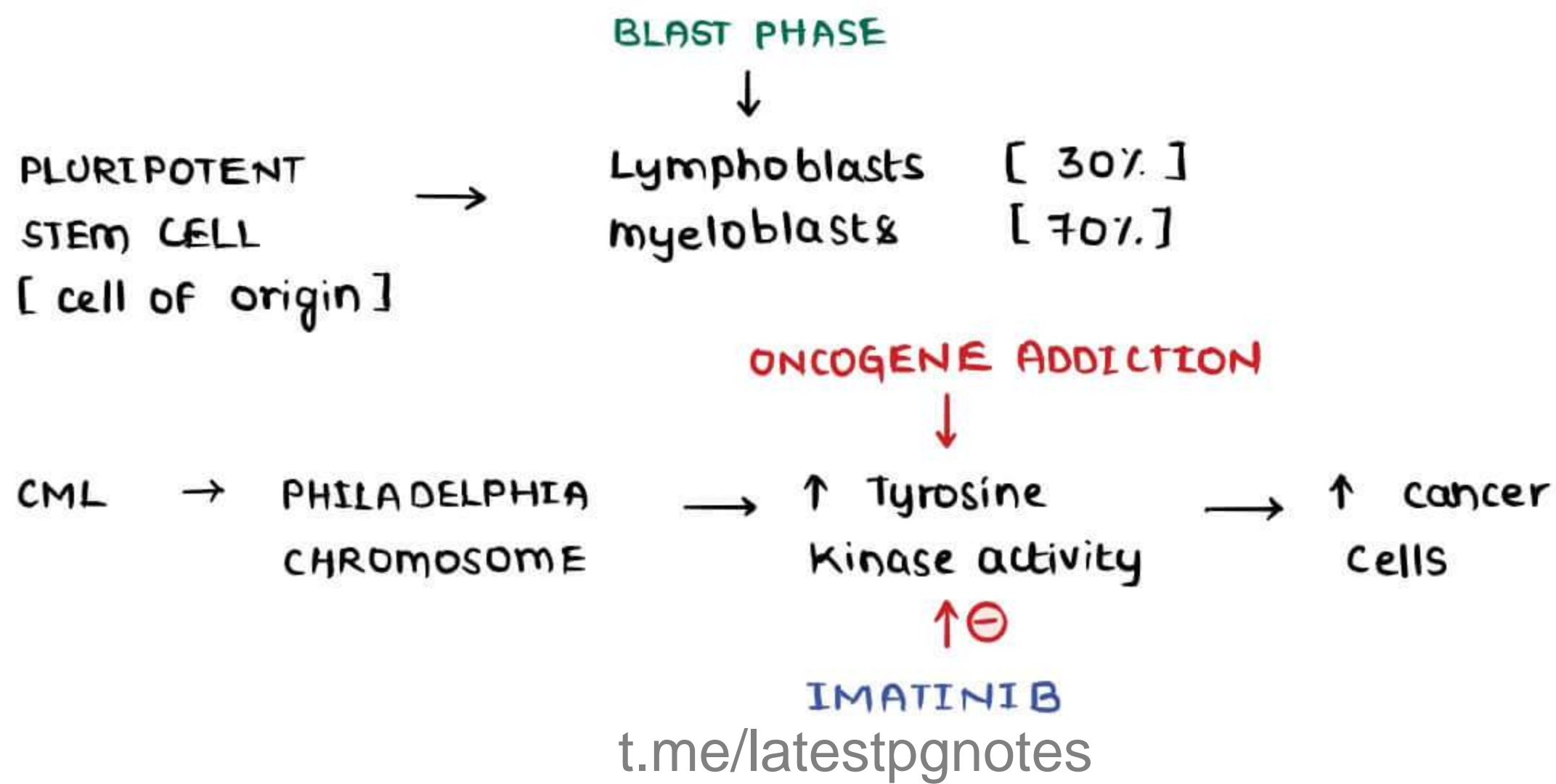
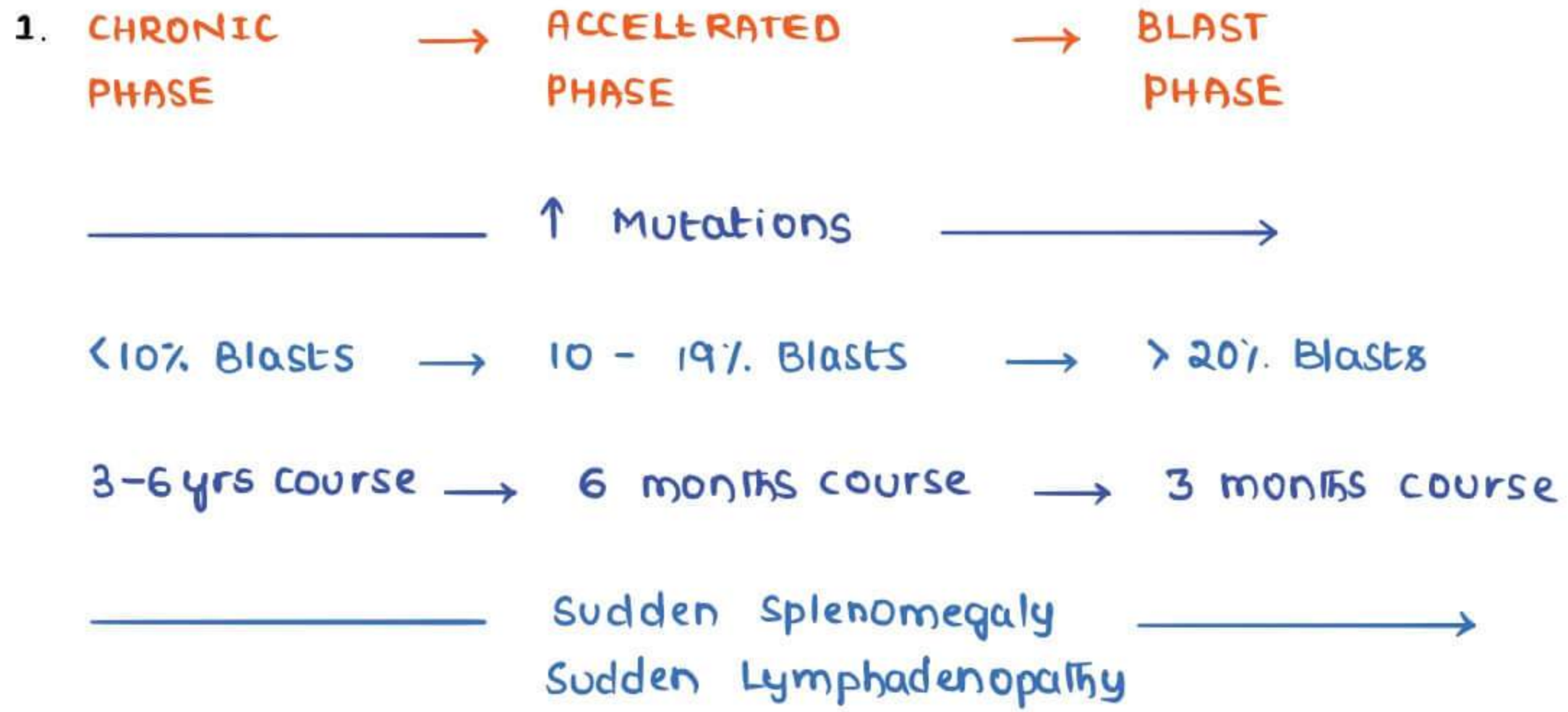
5. **DETECTION OF PHILADELPHIA CHROMOSOME**

- confirmatory
- done by FISH [FLUORESCENT IN SITU HYBRIDIZATION] → IOC



→ BCR ABL fusion DNA also detected by SOUTHERN BLOT

→ STAGES

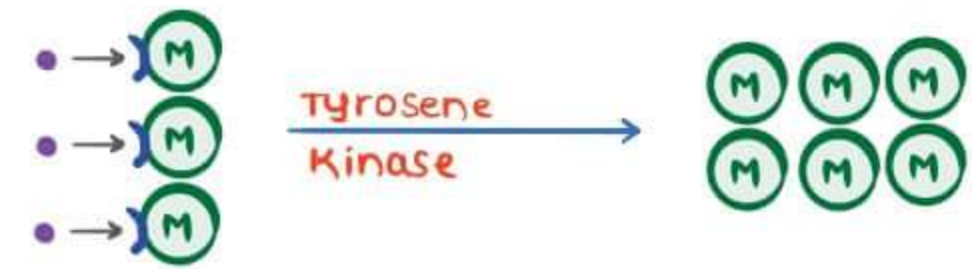


MYELOPROLIFERATIVE DISORDERS

123

→ ↑↑↑ TYROSINE KINASE ACTIVITY → ↑ cell numbers [usually one type]
[RBC | WBC | platelets]

→ MYELOFIBROSIS [SPENT PHASE] OF BM
↓
Extra medullary hematopoiesis



→ ADDITIONAL MUTATIONS → ACUTE LEUKEMIA

EXAMPLES

1. CML → ↑ WBC [predominant]
2. POLYCYTHEMIA VERA → ↑↑ RBCs
3. ESSENTIAL THROMBOCYTHEMIA } ↑ Platelets
4. 1° MYELOFIBROSIS }

POLYCYTHEMIA VERA

- JAK2 Tyrosine Kinase ⊕
- valine substituted by PHENYL ALANINE [at 617 position]
- ↑↑↑ RBCs
- ↑ WBCs
- ↑ platelets

- **CIF** → Hyper viscosity OF Blood
↓ t.me/latestpnotes
Neurological manifestations
 - ↳ headache
 - ↳ dizziness
 - ↳ visual disturbance

- Peripheral circulation
 - ↳ ischemia
 - ↳ cyanosis

- ↑ venous thrombosis → Hepatic vein thrombosis & DVT
- ↑ Arterial thrombosis

- ↑ PLATELETS [dysfunctional] → ↑ Bleeding

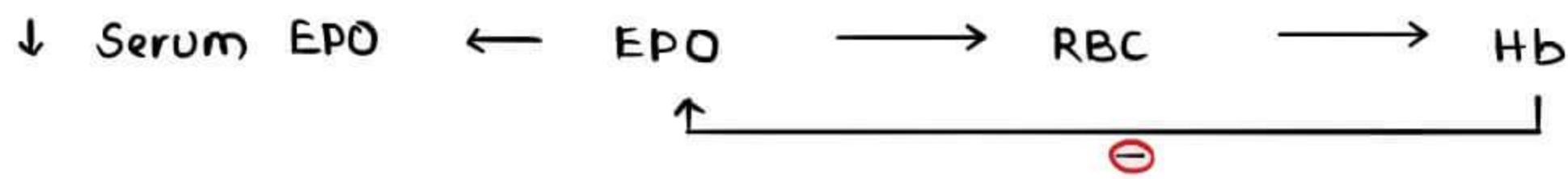
- ↑ WBCs [nearly mature] → no risk of Infections
 - ↳ ↑ Neutrophils → ↑ LAP SCORE
 - ↳ ↑ Basophils

ALL MYELOPROLIFERATIVE DISORDERS EXCEPT CML → ↑ LAP SCORE

- ↑ BASOPHILS → HISTAMINE
 - ↳ pruritus [after hot water bath]
 - ↳ Flushing
 - ↳ Peptic ulcer disease

→ **DIAGNOSIS**

1. DEMONSTRATION OF JAK 2 MUTATION
2. ↑↑ Hb



	RBC MASS	EPO	SaO ₂
Dehydration	Normal	Normal	Normal
Polycythemia vera	↑↑	↓	Normal
COPD / High altitude	↑	↑	↓
Ectopic EPO [tumors]	↑	↑↑	Normal

→ relative polycythemia

→ POLYCYTHEMIA VERA → ACUTE LEUKEMIA

→ **R_y**

1. PHLEBOTOMY
2. DRUGS
 - ↳ Hydroxyuria
 - ↳ Anagrelide

ESSENTIAL THROMBOCYTHEMIA

ETIOLOGY

t.me/latestpnotes

1. JAK 2 mutation [mc]
2. MPL mutation
3. calreticulin mutation

ET → ↑↑↑ PLATELETS

CF

- ↑ venous Thrombosis
- ↑ Bleeding
- ERYTHROMELALGIA → Small vessel occlusion
→ Throbbing & burning pain of hands & feet
- Less chance of going into spent phase
- Lesser chances of myelofibrosis transformation
- mild splenomegaly

PRIMARY MYELOFIBROSIS

JAK2 mutation > MPL mutation

↓
↑↑ No. of Neoplastic megakaryocytes

↓
BM Fibrosis / ↑↑ collagen

↓
Ineffective EPO

↓
Anemia

↓
Extra medullary hematopoiesis

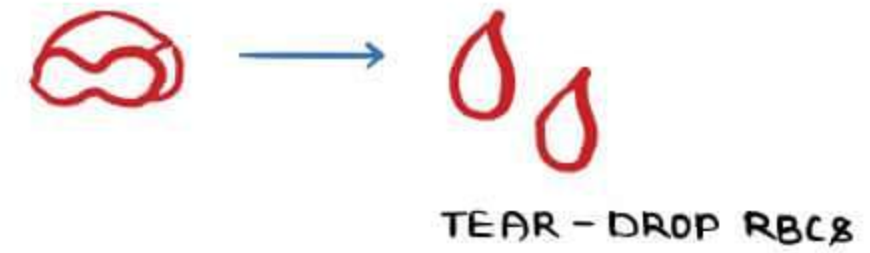↓
massive splenomegaly

↓
LEUCO ERYTHROBLASTS [Immature WBC & RBCs]

→ **CIF**

→ **CLASSICAL TRIAD**

- ↳ TEAR DROP RBCs
- ↳ LEUCO ERYTHROBLAST
- ↳ AB NORMAL PLATELETS



→ Elderly / Anemia / Splenomegaly

→ **DIAGNOSIS**

Bm EXAMINATION

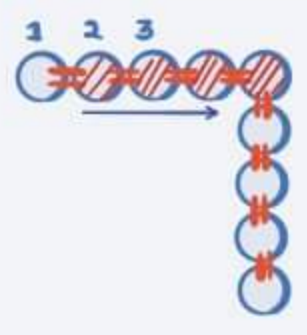
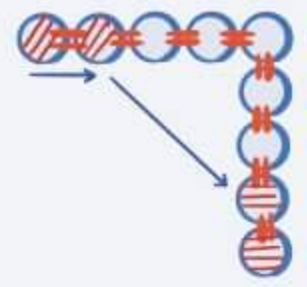
- BM ASPIRATION → DRY TAP
- BM BIOPSY [IOC]

→ 1° MYELOFIBROSIS → ACUTE LEUKEMIA

→ Least Risk of progression to Acute leukemia among myeloproliferative disorders } ESSENTIAL THROMBOCYTOSIS
 → Least Risk of complications } → ET

HODGKIN'S LYMPHOMA

LYMPHOMAS

HODGKIN'S LYMPHOMA	NON HODGKIN'S LYMPHOMA
→ LN involvement ⊕	→ LN involvement ⊕
→ Extra nodal Involvement ⊖	→ Extra nodal Involvement ⊕
→ cervical / mediastinal LN ⊕	→ Waldeyer Ring ⊕ Mesenteric LN ⊕
	
→ contiguous spread ⊕	→ Non - contiguous spread
→ Staging predictable	→ Staging unpredictable
→ response to R ₁ ⊕	→ response to R ₁ ⊖
→ Good prognosis	→ Poor Prognosis

HODGKIN'S LYMPHOMA

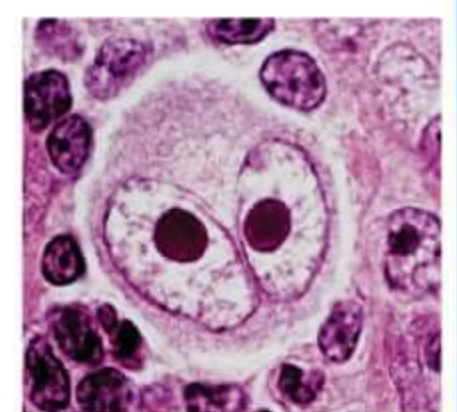
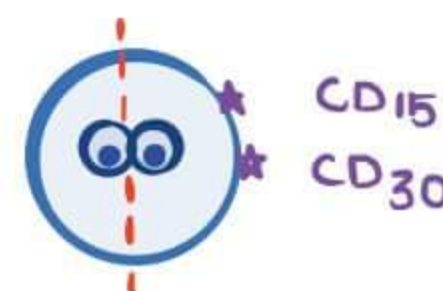
ETIOLOGY

- EBV [mc association]
- OTHER FACTORS
 - ↳ B CELL → ↑↑ NF - K β → ↑↑ cancer cells
 - ↳ Germinal / Post Germinal → ↓↓ I - K β [Inhibitor - K β]

REED STERNBERG CELL

CLASSICAL RS CELL

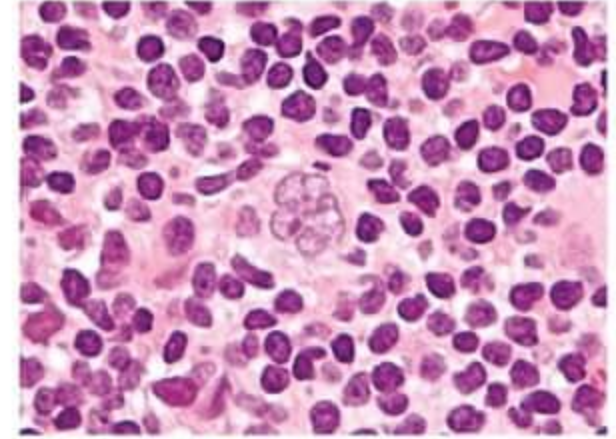
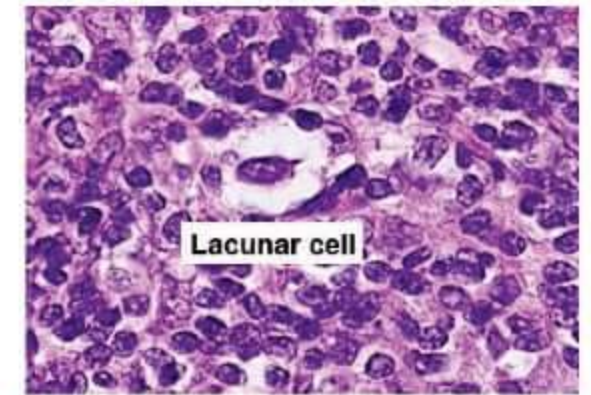
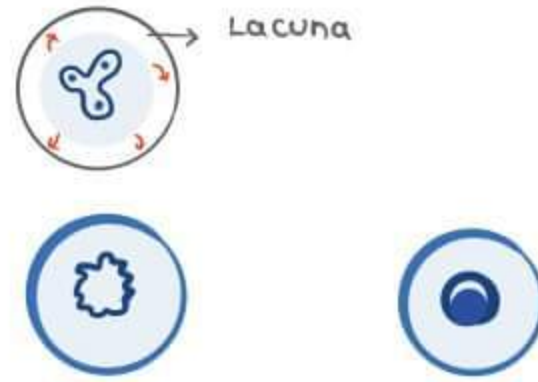
- 15 - 45 μ
- OWL - EYE APPEARANCE
- Aneuploidy ⊕ → ↑↑↑ chr. 2p
- CD15 ⊕
- CD30 ⊕ - marker of Lymphocyte activation



RS CELL

VARIANTS OF RS CELL

- 1. LACUNAR CELL → alw TGF-β release → Fibrosis
- 2. MONONUCLEAR CELL → prominent nucleus
- 3. LYMPHO HISTIOCYTIC / POP CORN CELL
 - irregular indentation of nucleus
 - CD 15 & CD 30 ⊖
 - CD 20 ⊕
 - BCL-6 ⊕



POPCORN CELL

RS CELLS & CYTOKINES

- IL-13 → ↑ Reed Sternberg cells
- IL-5 → ↑ Eosinophils
- TGF-β → Bands [nodules]
- M-CSF → ↑ monocytes

HL [Hodgkin Lymphoma] → RS cell + Inflammatory cells

RS-LIKE CELLS SEEN IN

- Infectious mononucleosis
- Solid tissue cancer
- Immunoblastic lymphoma

CIF

- PAINLESS RUBBERY LYMPHADENOPATHY [cervical LN mostly]
- CONSTITUTIONAL [B] SYMPTOMS
 - ↳ Fever
 - ↳ Night sweats
 - ↳ wt loss

→ FEVER  PEL - EBSTEIN FEVER

- PARA NEOPLASTIC SYNDROME
 1. Alcohol consumptⁿ causes PAIN
 2. 2^o Amyloidosis

DIAGNOSIS

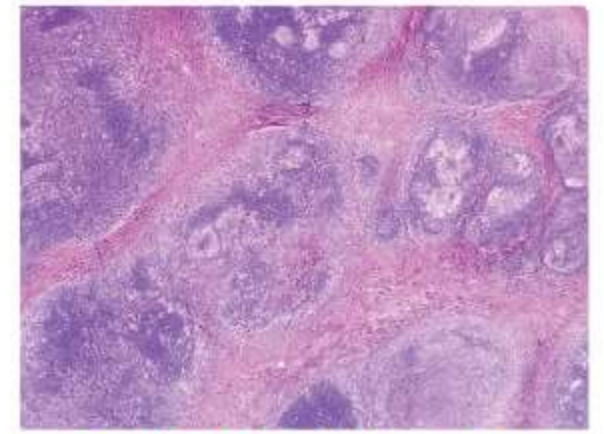
1. CUTANEOUS ANERGY
2. EXCISIONAL LN BIOPSY
 - IOC
 - diagnostic & therapeutic
 - On m/E



SUBTYPES

1. NODULAR SCLEROSIS

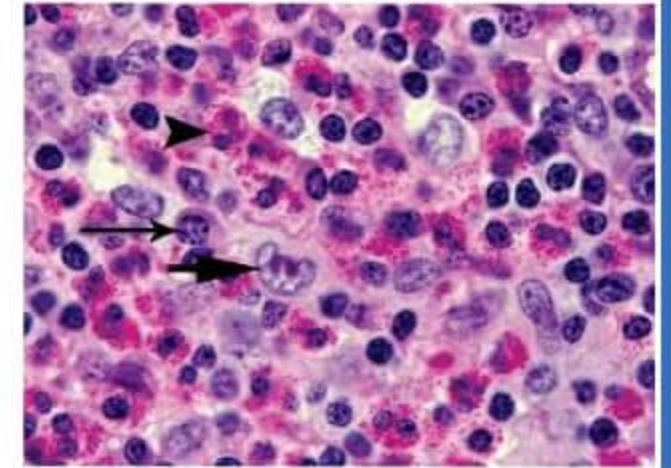
- MC HL in the world
- M = F
- Nodules ⊕
- young adults ⊕
- Lacunar RS cells ⊕



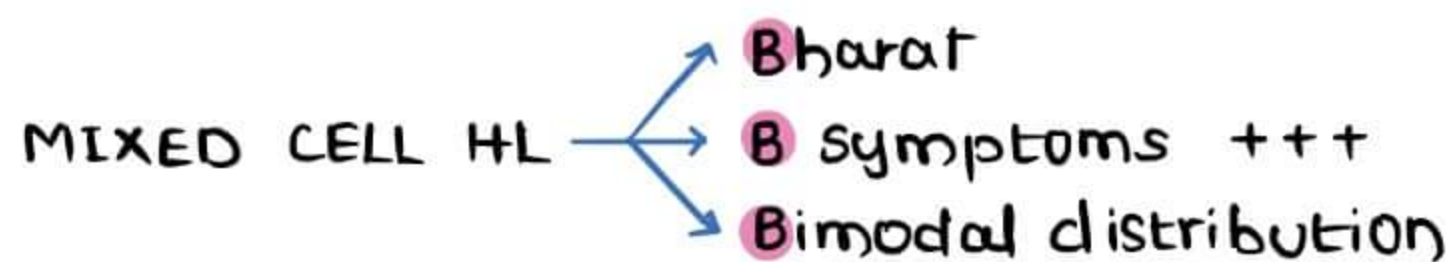
NODULAR SCLEROSIS

2. MIXED CELLULARITY

- mc HL in India
- RS cells / plasma cells / Eosinophils / Lymphocytes ⊕
- mono nuclear RS cells ⊕
- BIMODAL DISTRIBUTION → young & > 55 yrs
- maximum incidence of 'B' symptoms

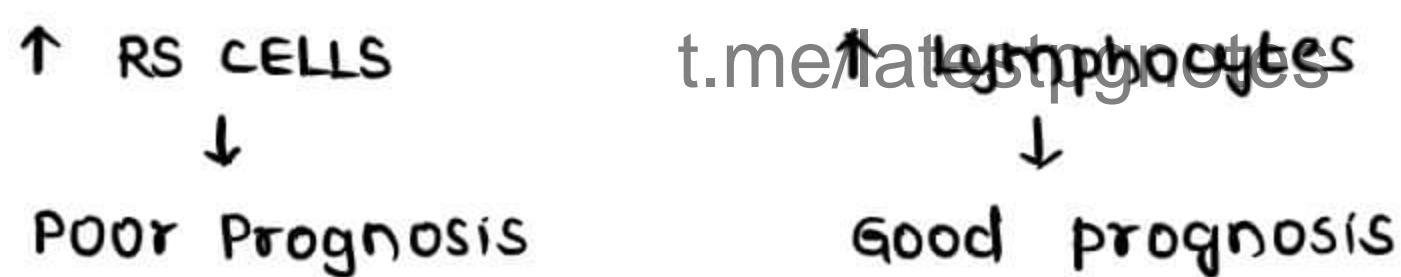


mixed cellularity



3. LYMPHOCYTE RICH HL

- Elderly age group
- classical RS cells < mono nuclear RS cells ⊕
- Better prognosis



4. LYMPHOCYTE DEPLETED HL

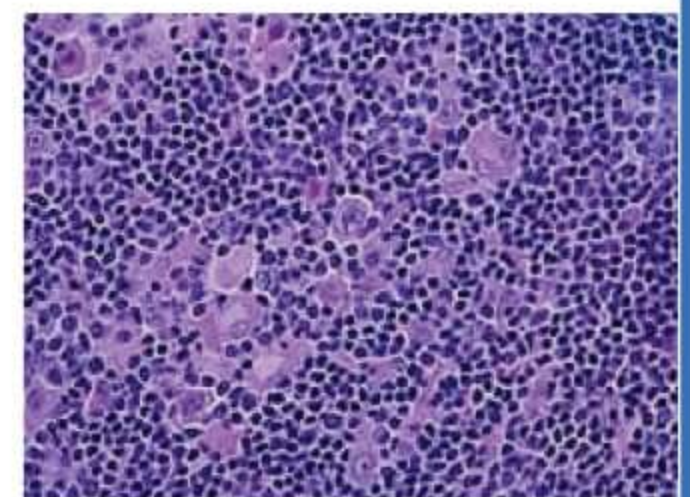
- Elderly age group
- a/w HIV ⊕
- HODGKIN CELLS ⊕ [Atypical Histiocytes]
- worst prognosis

NON CLASSICAL HL

LYMPHOCYTE PREDOMINANT HL

- RS cells → CD15 ⊖
- CD30 ⊖
- CD20 ⊕

- Best prognosis overall
- Popcorn / Lympho-histiocytic cells ⊕

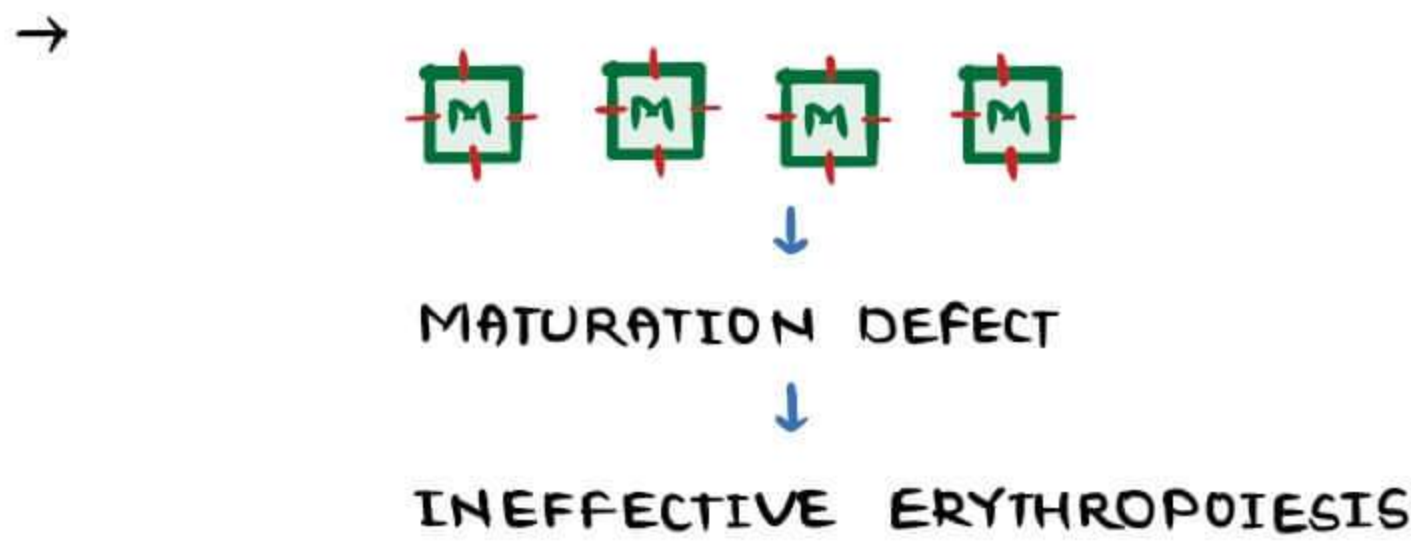
LYMPHOCYTE PREDOMINANT
HODGKIN LYMPHOMA

METASTASIS → Nodal disease >> Spleen >> Liver >> Bm

TREATMENT → ANTI - CANCER DRUGS

- | | |
|-----|---------------|
| ↳ A | → Adriamycin |
| ↳ B | → Bleomycin |
| ↳ V | → Vinblastine |
| ↳ D | → Dacarbazine |

→ Hypercellular Bone marrow + CYTOPENIA [BLASTS → < 10%.]



SUB TYPES

1. 1° MDS → Elderly [mean age 70 yrs]

2. 2° MDS

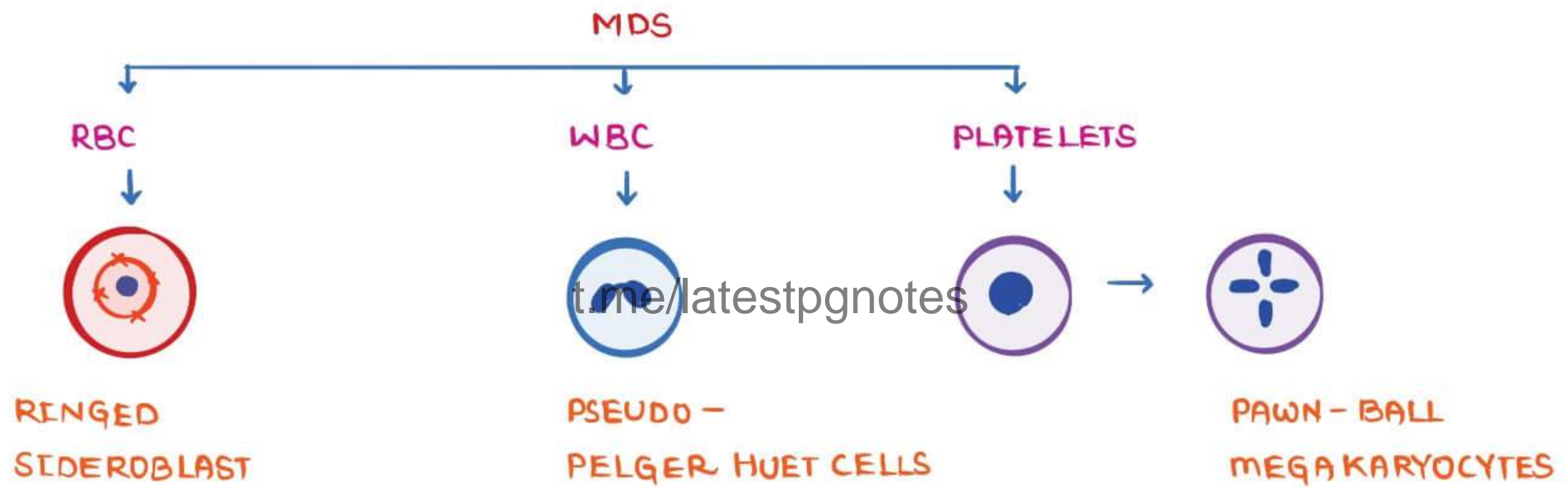
a. H/O exposure to Drugs / Radiations $\xrightarrow{2-8\text{yrs}}$ MDS

b. GENETIC DEFECTS

→ chr 5q deletion → Seen in Adults [mc overall]

→ monosomy 7 → Seen in children

→ Trisomy 8 [MYC]



→ Clf → Fatigue / petechiae / fever

→ DIAGNOSIS

1. BM EXAMINATION

2. PERIPHERAL SMEAR

→ hypercellularity

→ Pancytopenia

Ringed sideroblasts

Pseudo pelger huet cells

Pawn - ball megakaryocytes

→ TREATMENT

1. ALLOGENEIC BM TRANSPLANTATION

→ for young patients

2. AZACITIDINE

DECITABINE

} ⊖ DNA

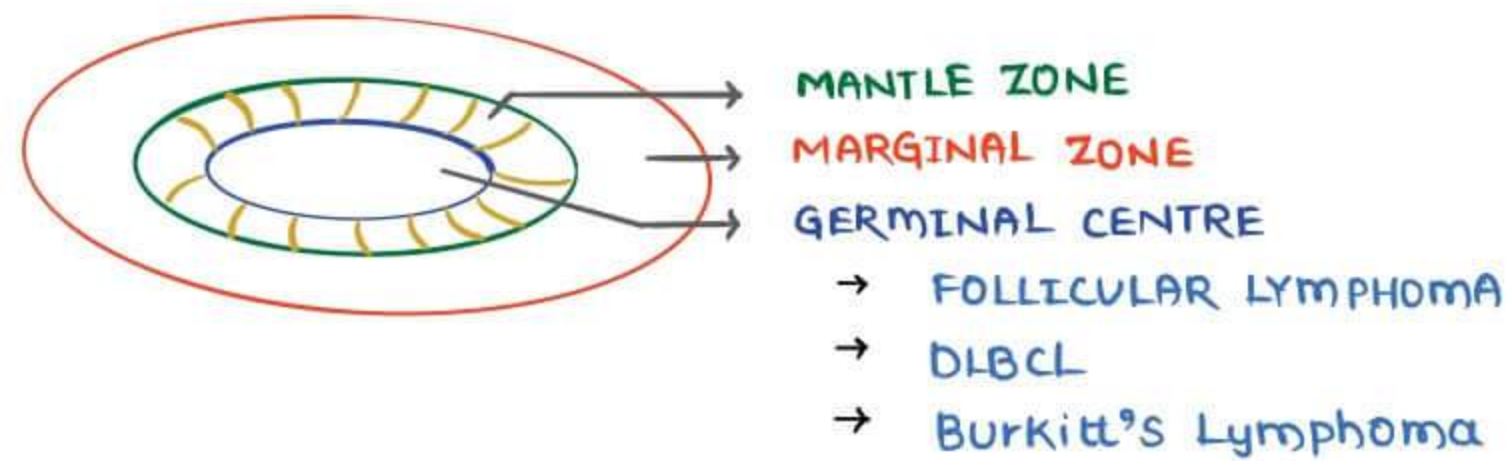
Methylation

3. LENALIDOMIDE

→ for 5q deletion

4. ANTIBIOTICS

5. REPEATED BLOOD TRANSFUSIONS



MANTLE ZONE LYMPHOMA

- arises from NAIVE ^eB⁹ CELLS
- t [11;14] → Chr 14 → has locus for Ig gene
- Chr 11 → has locus for Cyclin D1
- t [11;14] → ↑↑↑ cyclin D1 → ↑ cells

- C/P → diffuse lymphadenopathy
- LN B_x → CD 5 ⊕
 CD 23 ⊖
 cyclin D₁ ⊕
 → so the absence of cyclin D₁, SOX-11 acts as marker

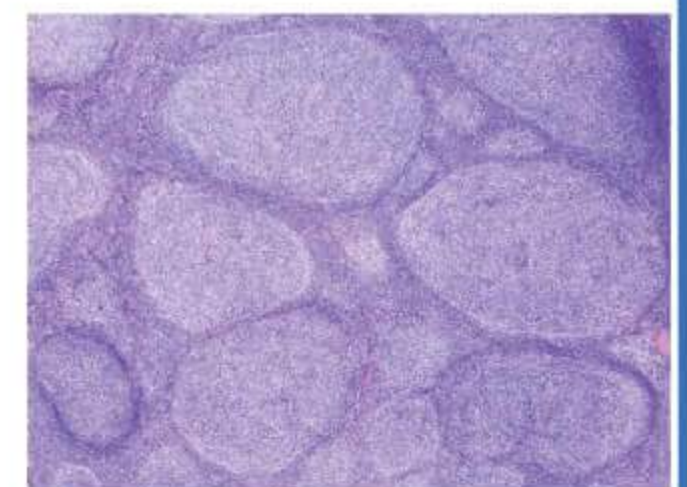
MARGINAL ZONE LYMPHOMA

- site of origin
 - ↳ MALT → GIT, Lungs
 - ↳ Extra nodal → orbit, stomach
- INDOLENT TUMOR
- chronic B cell stimulation dlt
 - ↳ H. pylori
 - ↳ Auto Immune Disorders [RA / Sjogren syn / Hashimoto's thyroiditis]
- t [11;18]
- INITIALLY → good response to Antibiotics
- LATER → poor response to Antibiotics
- mc site for
 - MALT → Ileum
 - MALTOMA → stomach

GERMINAL CENTRE LYMPHOMAS

1. FOLLICULAR LYMPHOMA

- t [14;18] → ↑↑ bcl-2
- MLL-2 gene mutation ↓
- ↑ cells [Follicles]
- ↓
- Painless LN ⊕
- Indolent

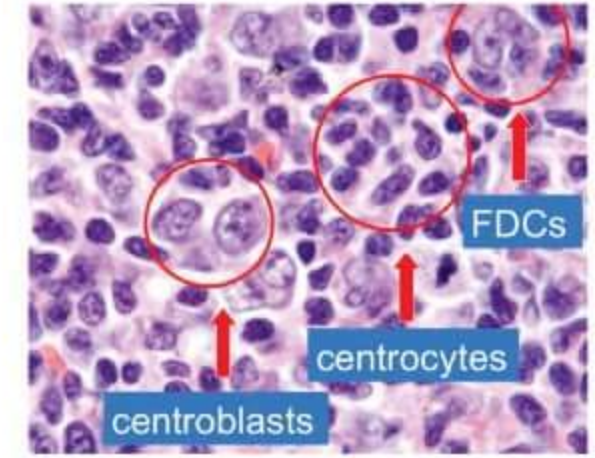


FOLLICULAR LYMPHOMA

→ DIAGNOSIS

1. IMMUNO PHENOTYPING

→ CD 15 / 20 → ⊕
 bcl - 2 → ⊕
 CD 5 → ⊖



2. Tumor cells shows

→ CENTROBLASTS & CENTROCYTES → aka BUTTOCK CELLS

→ FL → → → → DLBCL

2. DIFFUSE LARGE B CELL LYMPHOMA

→ ETIOLOGY

↳ Idiopathic [50%]
 ↳ Over expression of BCL - 6 [30%]
 ↳ a/w follicular lymphoma [20%]

→ MC NHL

→ seen in immunosuppression [HIV/transplant] ← EBV
 HHV - 8 [AIDS] → 1° EFFUSION LYMPHOMA



3. BURKITT'S LYMPHOMA

→ t [8;14] → ↑↑ c-MYC [transcription factor]
 t [2;8] ↓
 t [8;22] ↑↑↑ MITOSIS

→ most aggressive NHL

→ mc a/w Tumor Lysis Syndrome

→ DIAGNOSIS

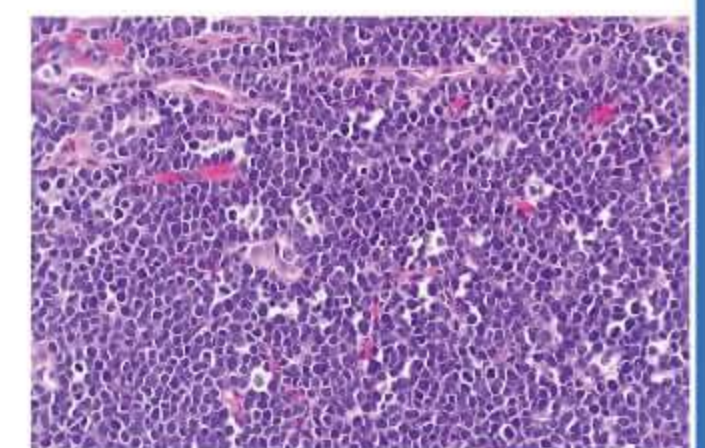
LN BIOPSY



Macrophages
 chromatin of
 tumor cells

STARRY SKY APPEARANCE

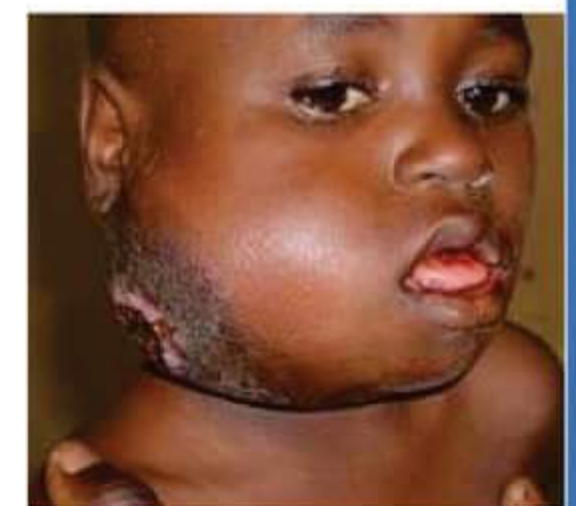↓ ↓
 macro- Tumor cells
 phages [chromatin]



STARRY SKY APPEARANCE

→ SUB TYPES

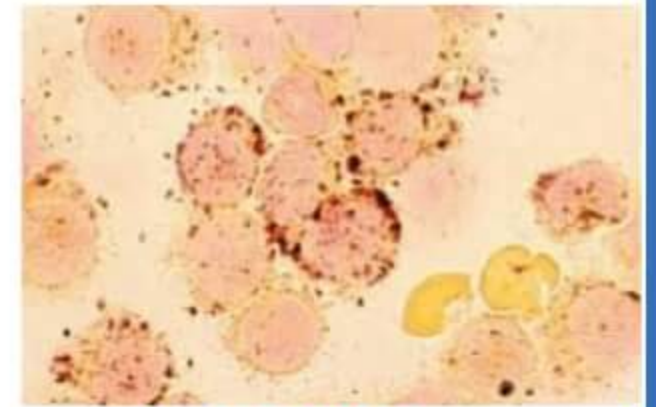
1. ENDEMIC → 100% a/w EBV
 → affects jaw bones & maxilla
 → seen in AFRICANS
2. SPORADIC → seen in developed countries
 → Abdominal mass ⊕
3. A/w HIV → dit immunosuppression



→ worst prognosis

HAIRY CELL LEUKEMIA

- B - cell tumor
- involves BM ; Spleen ; Liver
- M >> F
- **CIF**
 - massive splenomegaly [RED PULP INVOLVED]
 - ↑ Infections [by MAC - mycobacterium avium complex]
- **RED PULP OF SPLEEN INVOLVED IN**
 1. Hairy cell Leukemia
 2. Hepato splenic Lymphoma



TRAP STAIN

→ **DIAGNOSIS**

1. BLOOD

- pancytopenia
- Phase contrast microscopy → HAIRY - PROJECTIONS ⊕
- Staining → Tartrate Resistant Acid Phosphatase [TRAP] ⊕

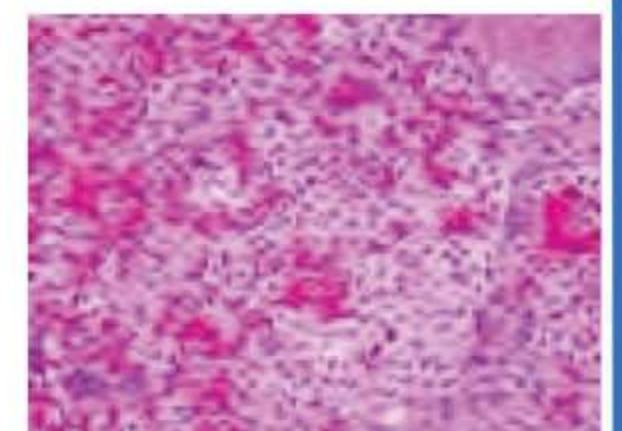
2. IMMUNO PHENOTYPING

- CD 11 ⊕
- CD 25 ⊕
- CD 103 ⊕
- ANNEXIN A1 ⊕ [Best marker]

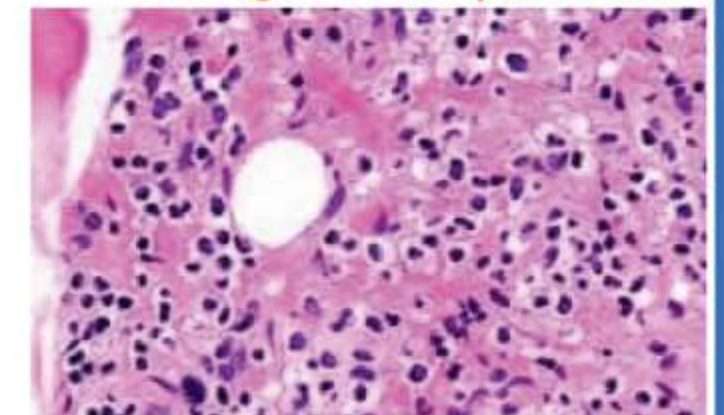
t.me/latestpgnotes

3. BM EXAMINATION

- a. BM ASPIRATION → Dry Tap
- b. BM BIOPSY
 - ↳ HONEY COMB APPEARANCE
 - ↳ FRIED EGG APPEARANCE



Honeycomb appearance

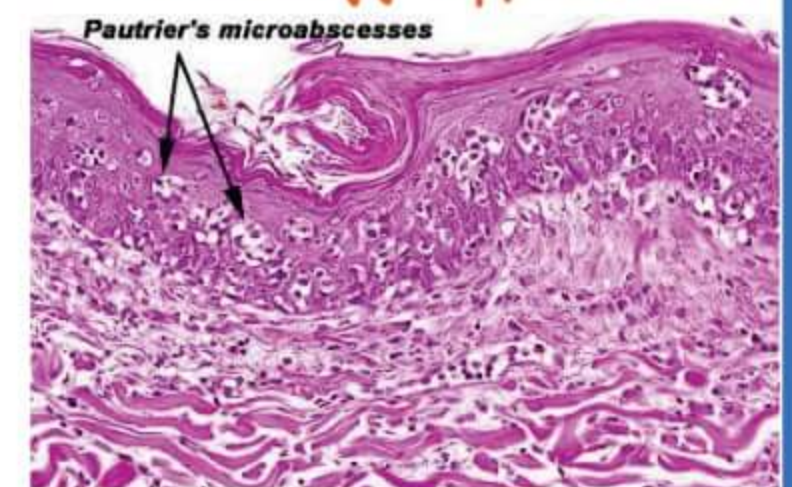

Fried egg appearance

→ **R₁** → CLADRIBINE [DOC]

CUTANEOUS T-CELL LYMPHOMA

- CD₄ T CELL TUMOR
- Involves
 - Blood → SEZARY SYNDROME
 - Skin → Epidermotropism




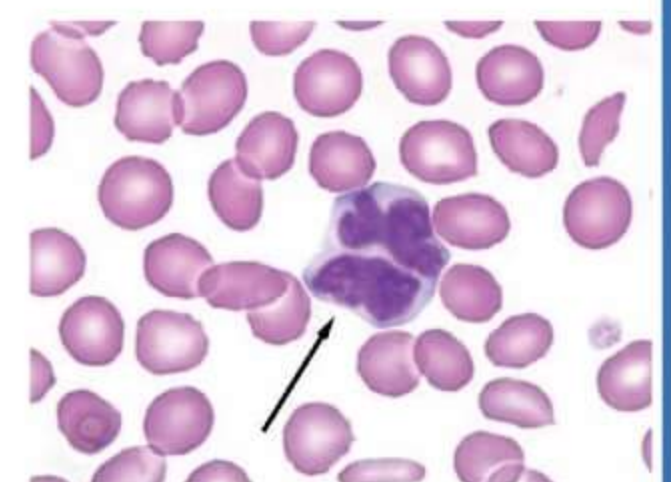
Pautrier's microabscesses

→ PAUTRIER'S MICROABSCCESS



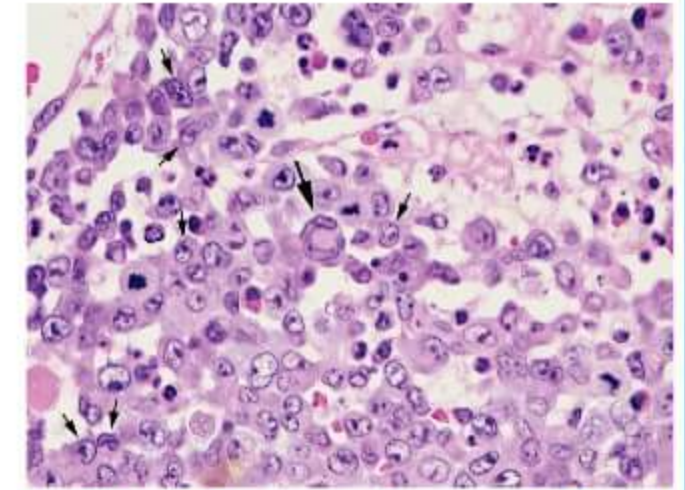
MYCOSIS FUNGOIDES
[Skin → LN / BM]

- CEREBRIFORM NUCLEI ⊕⊕ 
- CLA ⊕ / CCR₄ ⊕ / CCR 10 ⊕
- OLW GENERALISED EXFOLIATIVE ERYTHRODERMA



Cerebriform nucleus

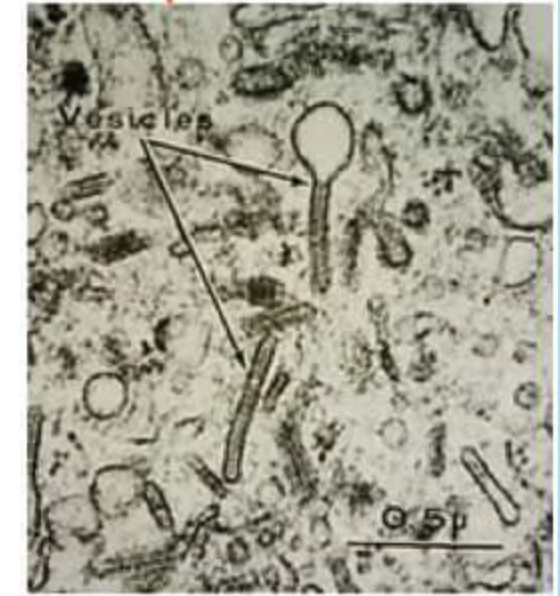
- children & young adults
- HALL MARK CELLS → Horse shaped nucleus \bar{c} abundant cytoplasm
- ALK gene [chr 2p] expressed
- CD 30 \oplus [R_y by Anti - CD 30]
- Good prognosis



horse-shaped nucleus

LANGERHANS CELL HISTIOCYTOSIS

- BRAF mutation \oplus
- arises from Langerhans cells
 - contains BIRBECK GRANULES
 - ↳ TENNIS - RACKET APPEARANCE ON EIM
- **MARKERS** → CD 1a / S-100 / HLA - DR \oplus

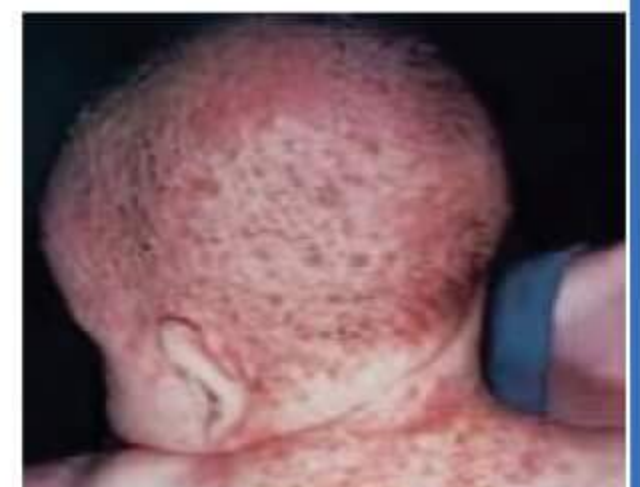

Birbeck granules

DISORDERS

1. LETTERER - SIWE DISEASE

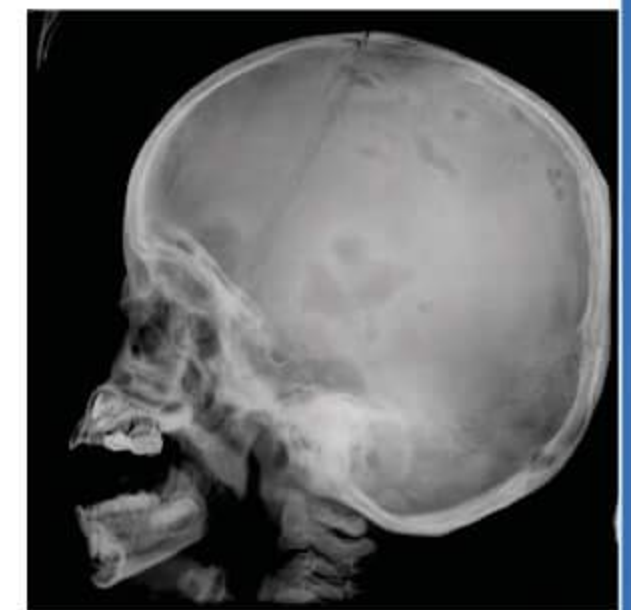- < 2yrs age
- multifocal & multi system
- **Lytic lesions** [multiple bones involved]
- **SKIN lesions** [seborrheic dermatitis]



Letterer - Siwe disease

2. EOSINOPHILIC GRANULOMA

- Unisystem
- TRIAD [HAND SCHULLER CHRISTIAN TRIAD]
 - ↳ Exophthalmos
 - ↳ calvarial Defects
 - ↳ Diabetes Insipidus



calvarial defects

3. PULMONARY LANGERHANS CELL HISTIOCYTOSIS

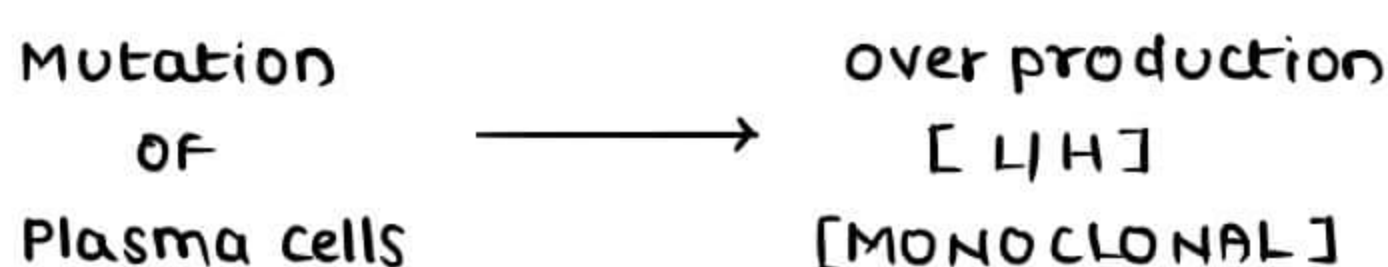
- seen in Adult smokers
- Cessation of smoking → Regression of disease

PLASMA CELL DYSCRASIAS

→ NORMAL PLASMA CELLS




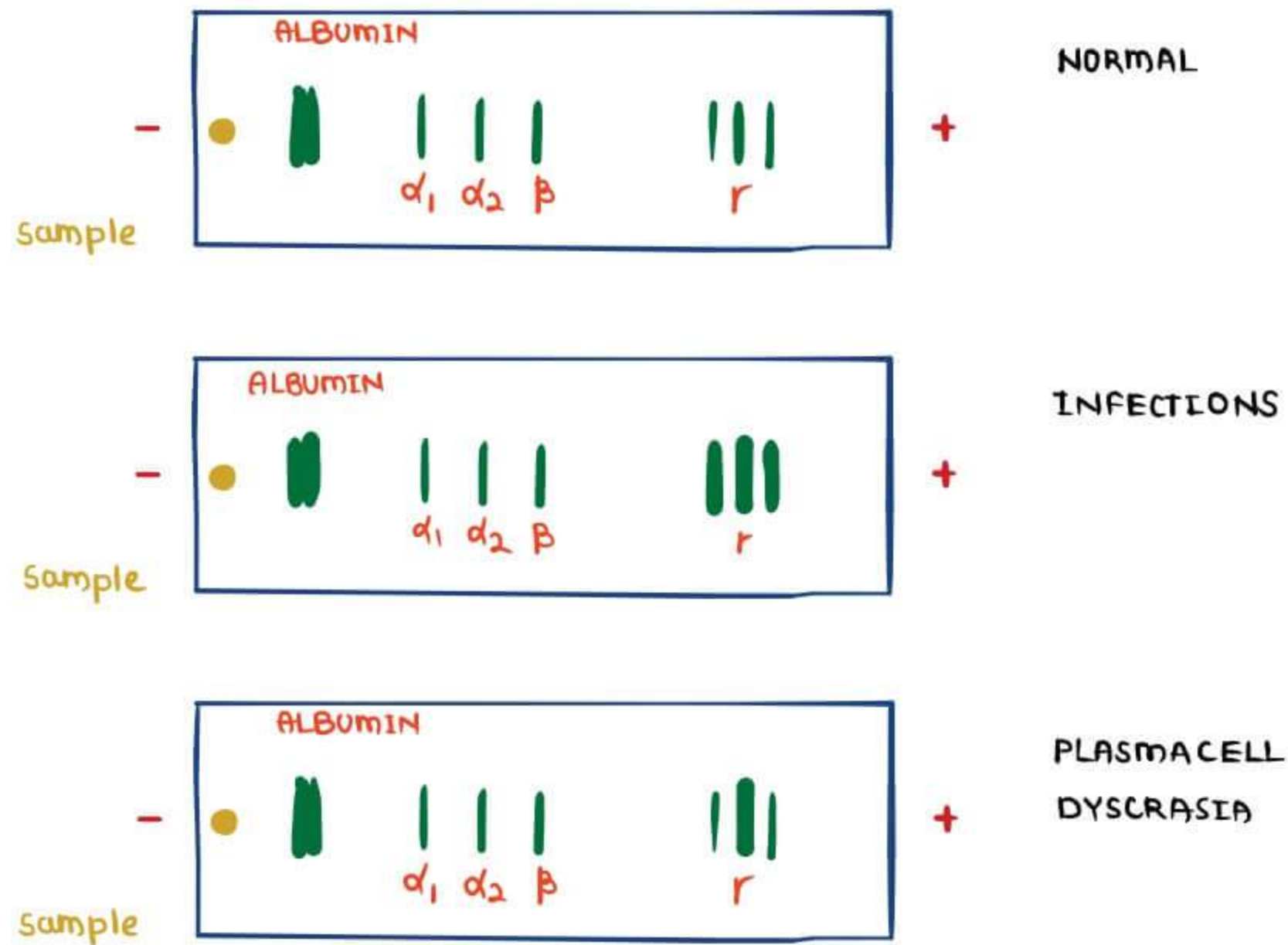
→ PLASMA CELL DYSCRASIAS [MONOCLONAL GAMMOPATHY / PARA PROTEINEMIA]



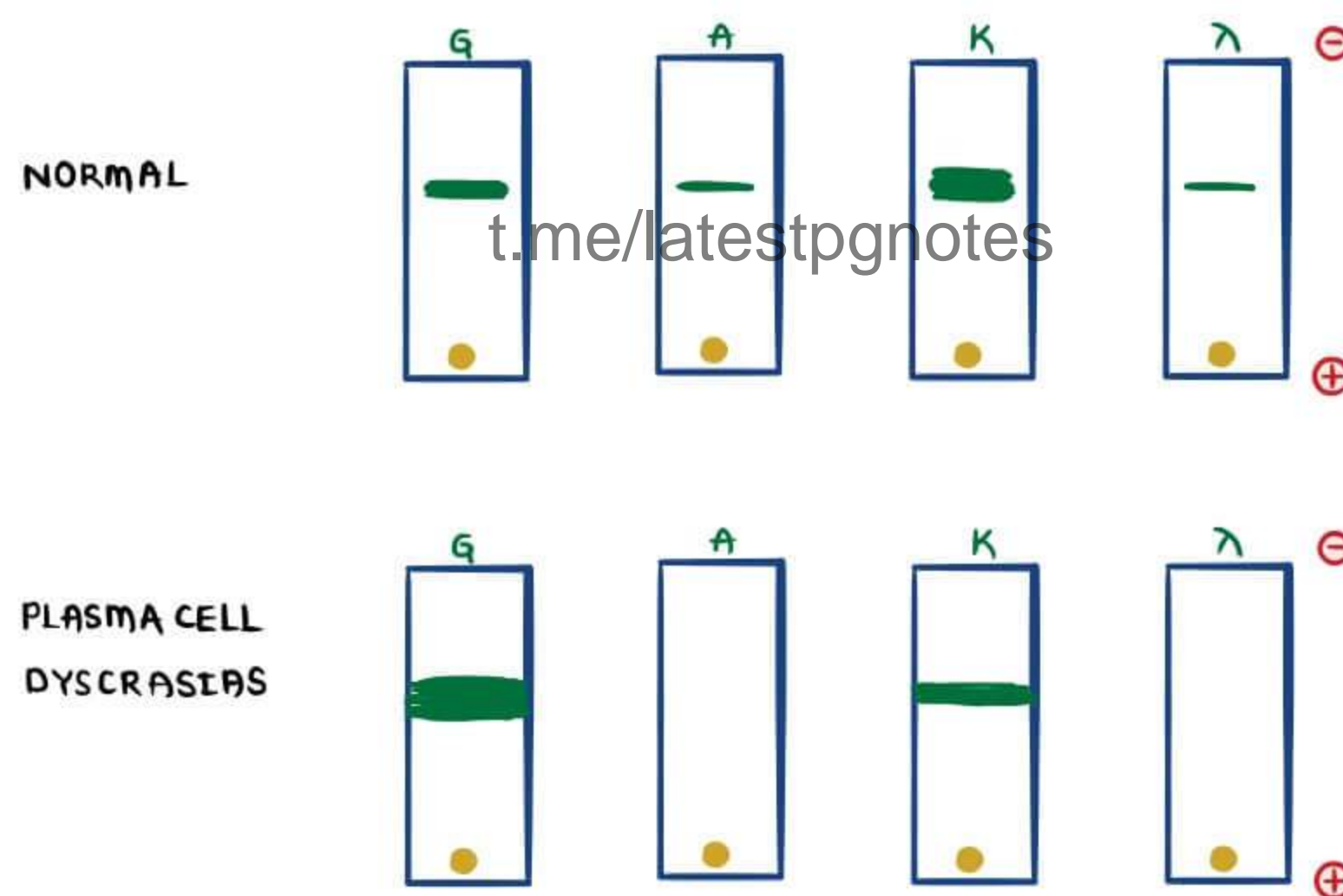
→ DIAGNOSIS

1. PROTEIN ELECTROPHORESIS → Quantity estimated
2. IMMUNO FIXATION ELECTROPHORESIS → Quality estimated

PROTEIN ELECTROPHORESIS



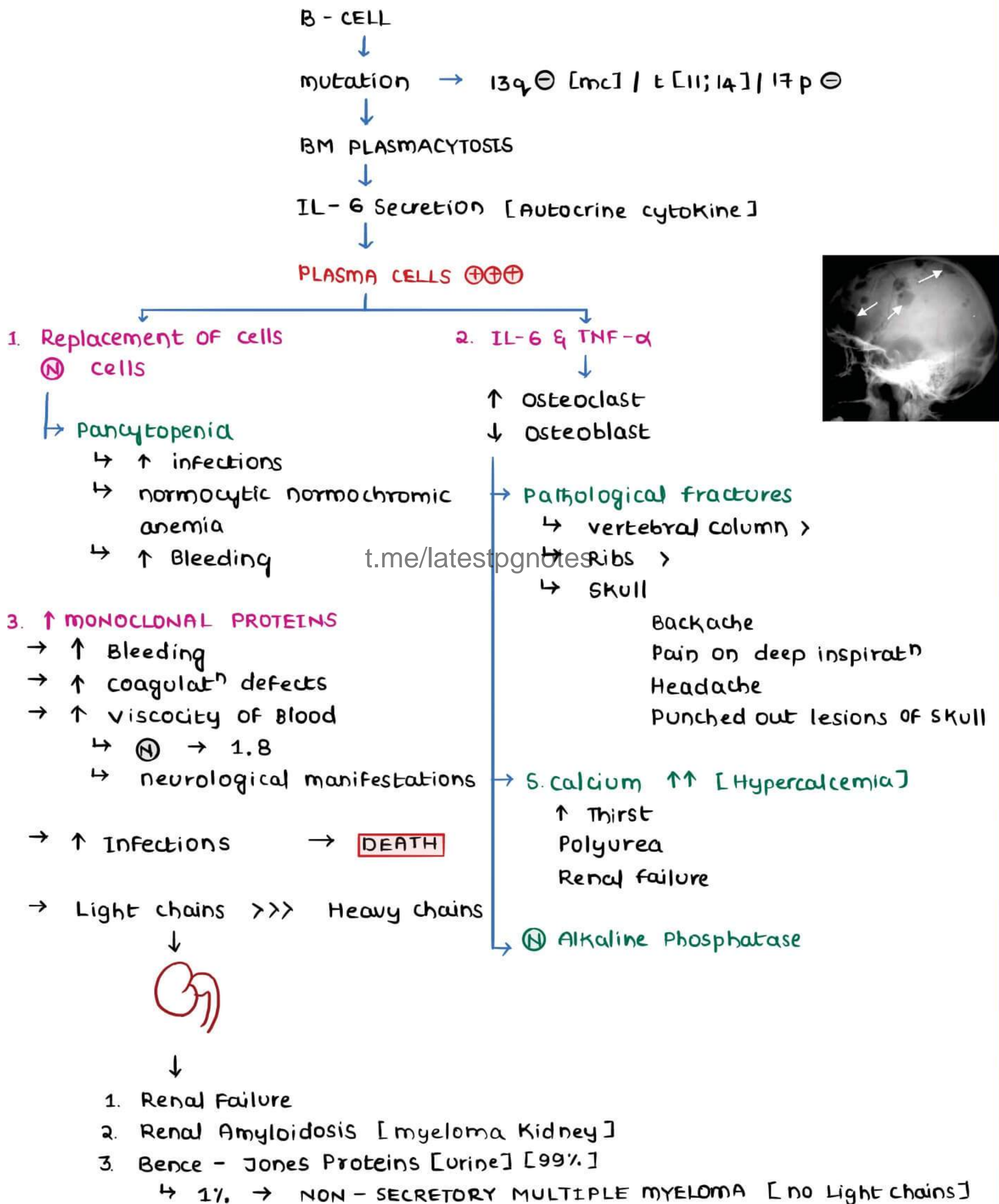
IMMUNO FIXATION ELECTROPHORESIS



MONOCLONAL GAMMOPATHY [MG] CLASSIFICATION

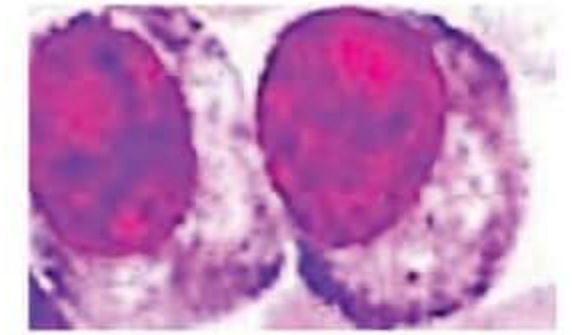
1. MGUS [MG OF UNKNOWN SIGNIFICANCE] [most common]
2. MULTIPLE MYELOMA [light chains > Heavy chains]
3. LYMPHOPLASMOCYTIC LYMPHOMA [\uparrow plasma cells & lymphocytes ; LC = HC]
4. HEAVY CHAIN DISEASE [\uparrow Heavy chains]

- Multi Focal in Bones
- γ chain $>$ α chain
- **PATHOGENESIS**





NORMAL PLASMA CELL → CART WHEEL NUCLEUS [Eccentric]

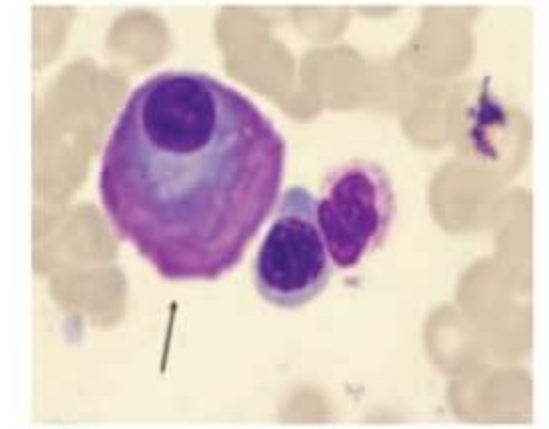


Cart wheel nucleus

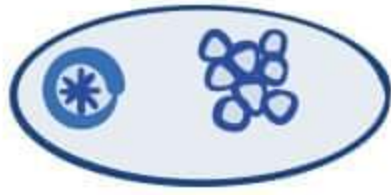MULTIPLE MYELOMA [PCD]



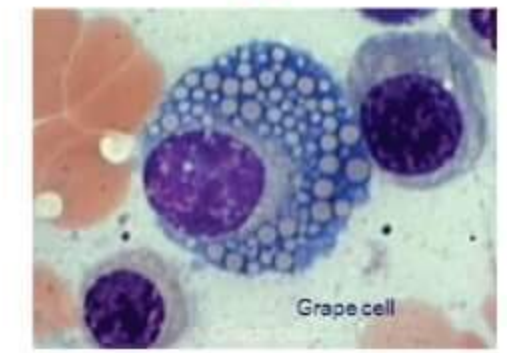
→ **FLAME CELL**
[Ig depositⁿ in cytoplasm]



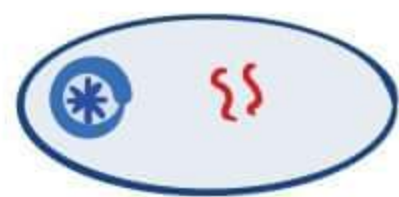Flame cell



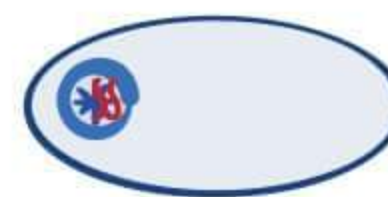
→ **MOTT CELL**
[Fibrils / globules in cytoplasm]



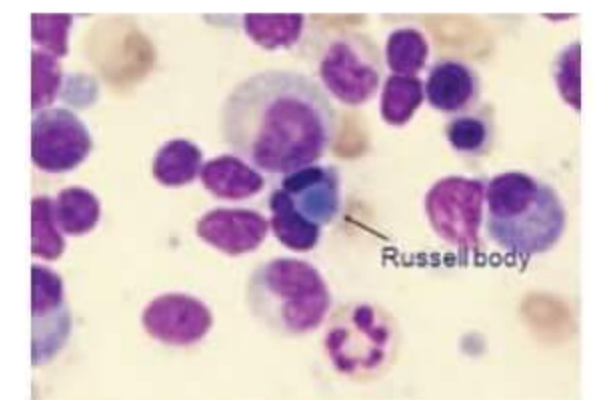
Mott cell



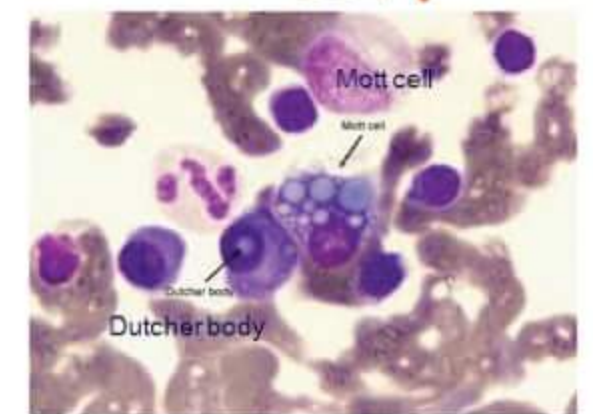RUSSEL BODY
[Intra cytoplasmic inclusion]



DUTCHER BODY
[intra nuclear inclusion]



Russell body



Mott cell
Dutcher body

DIAGNOSIS

1. Bm BIOPSY

→ IOC

→ International Myeloma Working group CRITERIA

→ Bm Plasma cells → $\geq 10\%$

⊕

Any one of myeloma defining events

→ Ⓐ → Evidence of Tissue impairment

C → $\uparrow\uparrow$ Ca^{2+} [> 11 mg/dl]

R → Renal Insufficiency

A → Anemia [< 10 gm/dl]

B → Bony lesions [≥ 1 lesion]

→ Ⓑ → ≥ 1 out of the following

→ $\geq 60\%$ clonal plasma cells

→ > 1 focal lesion [on MRI, > 5 mm]

→ Serum involved : uninvolved

Free light chain ratio

→ > 100

2. BLOOD

→ \uparrow ESR

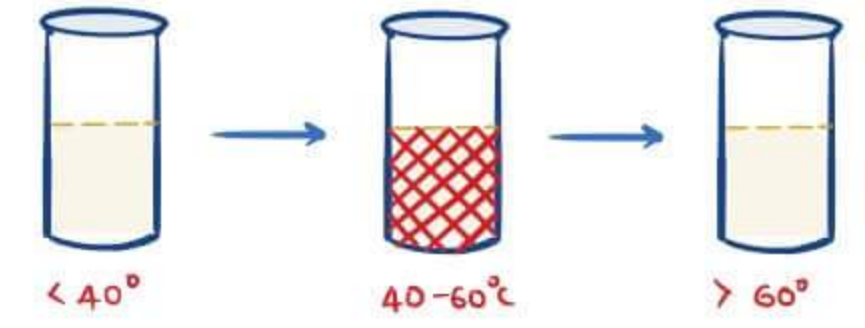
→ Normocytic Normochromic Anemia

→ $\uparrow\uparrow$ s. Ca^{2+}

→ Ⓐ s. Alkaline phosphatase level

3. SERUM } Protein Electrophoresis &
URINE } Immuno fixation Electrophoresis

4. URINE → Bence - Jones proteins
 → Less Soluble at 40-60°C



HEAT COAGULABILITY / HEAT SOLUBILITY TEST

5. X-RAY

Skull }
 spine } OSTEOLYTIC
 Pelvis } LESIONS ⊕

5. IMMUNO PHENOTYPING

Ⓝ → CD 19 / 38 / 45 ⊕

Plasma cells → CD 138 ⊕
 [mm] CD 45 ⊖
 ↙ ↘
 CD 19 ⊕ CD 19 ⊖
 CD 56 ⊖ CD 56 ⊕

MONOCLONAL PROTEINS → on Electrophoresis
 t.me/atestpnotes
 ↓
 'M' spike [m-monoclonal protein]

→ MC antibody seen in mm → Ig G > Ig A

TREATMENT → LENALIDOMIDE + BORTEZOMIB + STEROIDS
 DID

1. MGUS

- Asymptomatic
- Bm plasma cells → < 10%
- S. para proteins → < 3g/dl
- 3% OF MGUS [aged > 50yrs] can develop multiple myeloma
- 5% OF MGUS [aged > 70yrs] can develop multiple myeloma

2. SMOLDERING MYELOMA

- Bm plasma cells → 10 - 60%
- S. para proteins → > 3g/dl
- no myeloma defining event

MGUS	SMOLDERING MYELOMA	MULTIPLE MYELOMA
→ < 10%	→ 10 - 60%	→ > 60%
→ < 3g/dl	→ > 3g/dl	
	→ mde ⊗	→ mde ⊕

LYMPHOPLASMACYTIC LYMPHOMA / WALDENSTROM'S MACROGLOBULINEMIA

- a/w MYD 88 mutation
- a/w 'M' Spike → Ig M

MULTIPLE MYELOMA	LYMPHOPLASMACYTIC LYMPHOMA
<ul style="list-style-type: none"> → Ig G >> Ig A → Plasma cells ⊕ 	<ul style="list-style-type: none"> → Ig M → Plasma cells ⊕ Lymphocytes ⊕ mast cells ⊕
<ul style="list-style-type: none"> → C → ↑↑ Ca²⁺ R → ⊕⊕ A → ⊕⊕ B → ⊕⊕ 	<ul style="list-style-type: none"> → N ⊖ ⊖ ⊖
<ul style="list-style-type: none"> → INFILTRATION OF Liver / LN / Spleen ⊖ 	<ul style="list-style-type: none"> ⊕

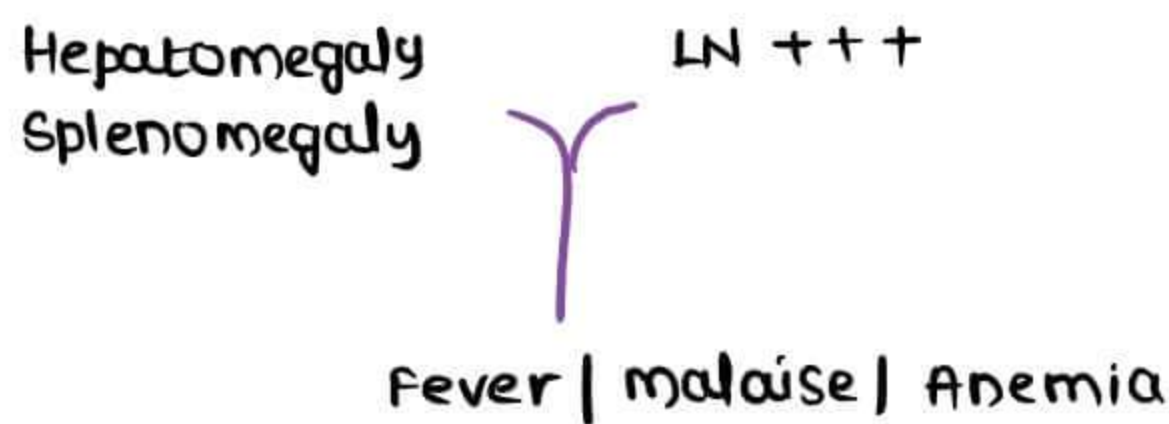
→ TREATMENT → Ig M can be removed by PLASMAPHARESIS

HEAVY CHAIN DISEASE

1. α HCD | SELIGMANN DISEASE [mc HCD]

α MEDITERRANEAN LYMPHOMA t.me/latestpgnotes
 GIT ⊕ >>> Respiratory tract ⊕

2. γ HCD | FRANKLIN'S DISEASE



- affects waldeyer Ring → Palatal edema ⊕
- a/w Rheumatoid Arthritis

3. μ HCD → a/w CLL

HEMOSTASIS

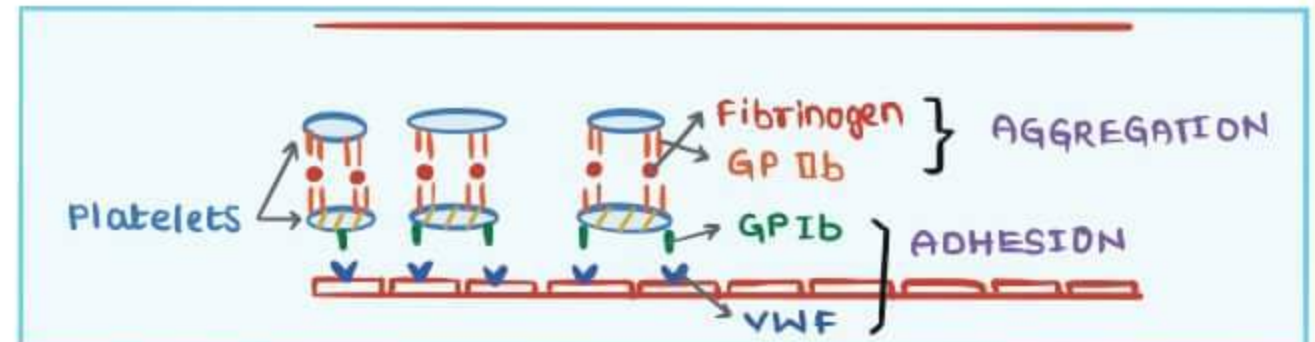
Contributed by

- 1. Blood vessels → vaso constriction
- 2. Platelets → Temporary plug
- 3. coagulatⁿ cascades → Permanent plug

TEMPORARY HEMOSTATIC PLUG

Temporary plug formatⁿ requires

- 1. ADHESION → Gp Ib, vWF
- 2. ACTIVATION → TXA₂, ADP
- 3. AGGREGATION → Gp IIb, fibrinogen



FUNCTIONAL PLATELET DISORDERS [↑ Bleeding ; N platelet count]

1. ADHESION DEFECTS

- a. Gp Ib defect → **BERNARD SOULIER DISEASE** [BS Disease]
- b. vWF defect → **VWD**

2. DRUGS

- ⊖ TXA₂ → Aspirin
- ⊖ ADP → Clopidogrel

3. Gp IIb defect

→ **GLANZMANN'S DISEASE**

Fibrinogen defect

→ **HYPOFIBRINOGENEMIA**

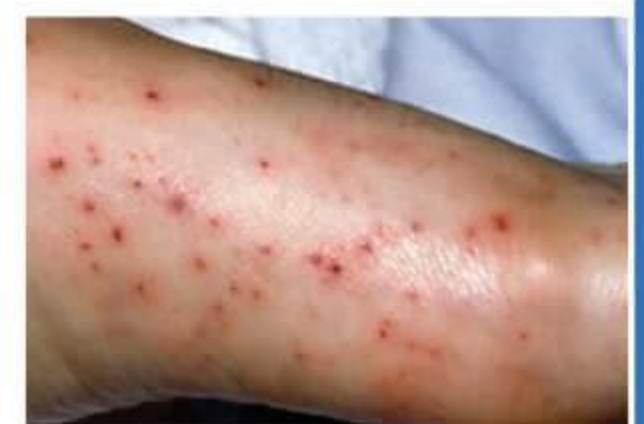adhesion	→	Gp Ib defect	→	BERNARD SOULIER DISEASE
aggregation	→	Gp IIb defect	→	GLANZMANN'S DISEASE
BERNARD SOULIER DISEASE	→	Big size platelets ⊕ in peripheral circulat ⁿ		

PLATELET DEFECTS	→	↑ BLEEDING TIME
COAGULATION DEFECT	→	↑ PT [Extrinsic pathway indicator]
		↑ aPTT [Intrinsic pathway indicator]

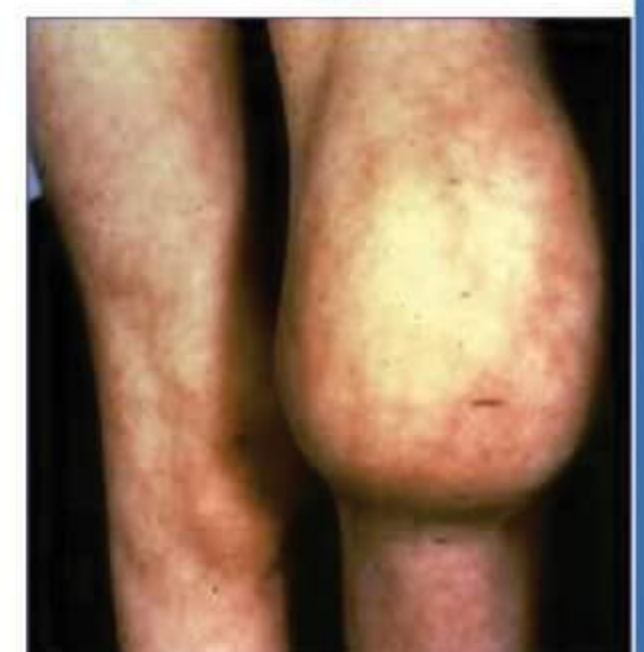BLEEDING DISORDERS - SUB TYPES

● PLATELET DEFECTS [spontaneous bleeding ⊕]

- **SUPERFICIAL [SKIN | MUCOSA] BLEEDING ⊕**
 - ↳ petechiae [< 1mm] / purpura [1-2mm]
 - ↳ Hematuria
 - ↳ ↑ menstrual loss
 - ↳ gum bleeding
 - ↳ melena



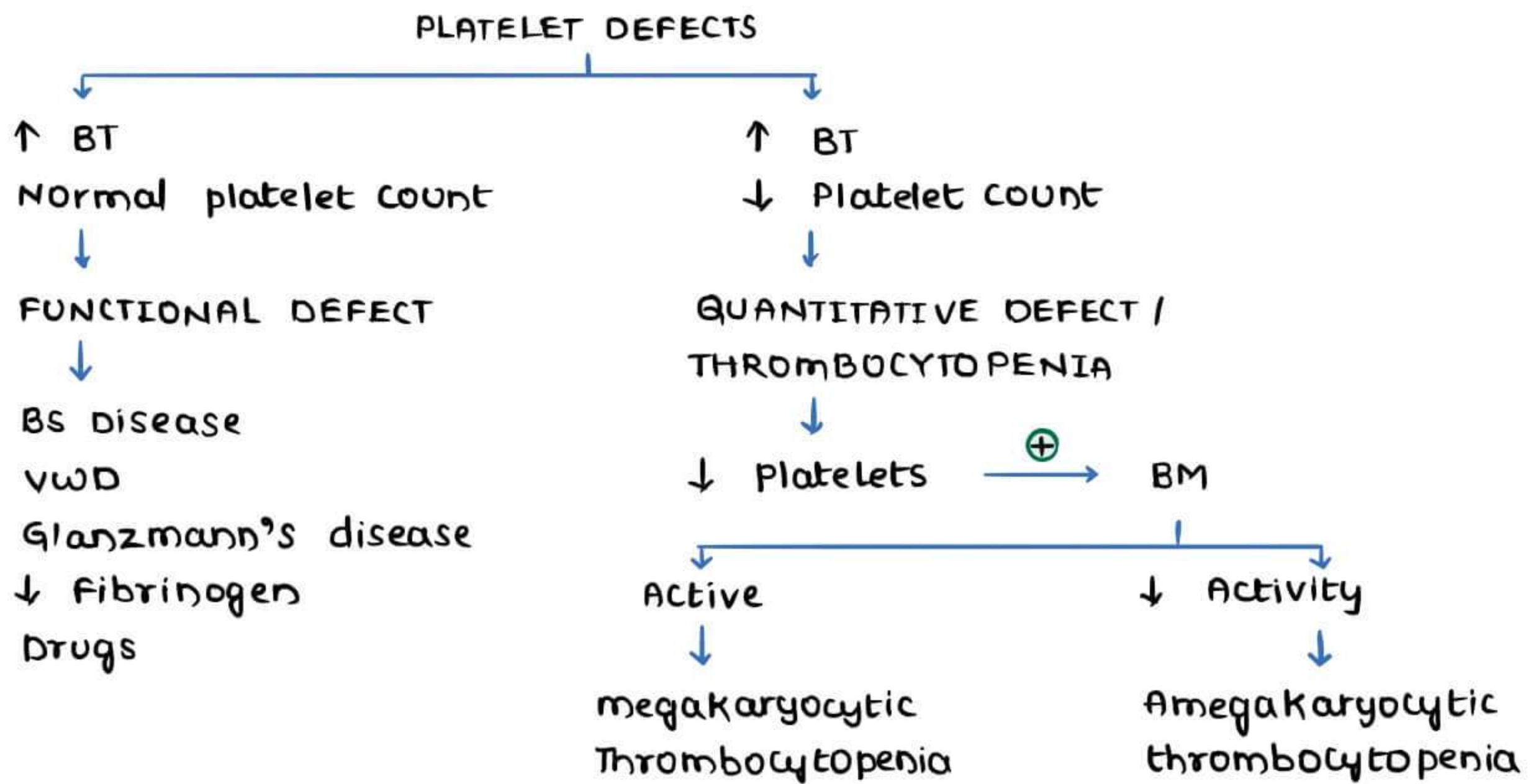
petechiae



Hemarthrosis

COAGULATION DEFECTS [H/O trauma ⊕]

- **DEEP TISSUE BLEEDING ⊕**
 - ↳ Joints → Hemarthrosis
 - ↳ Muscles → Hematoma



Ⓝ Platelets → 1.5 Lakh - 4.5 Lakh / mm³
 Thrombocytopenia → < 1 Lakh / mm³

MEGAKARYOCYTIC THROMBOCYTOPENIA

1. IMMUNE DISORDERS [Coombs TEST ⊕]
 - a. ITP
 - b. Dengue
 - c. SLE
 - d. B cell cancers
 - e. Drugs [Quinidine]

2. NON IMMUNE DISORDERS [Coombs TEST ⊖]
 - a. DIC
 - b. HUS
 - c. TTP

AMEGAKARYOCYTIC THROMBOCYTOPENIA

1. BM FAILURE [Fibrosis | Radiation]
2. B₁₂ / FA Deficiency
3. Leukemia
4. Drugs [Anti cancer Drugs]

ITP [IMMUNE THROMBOCYTOPENIC PURPURA]

SUB TYPES

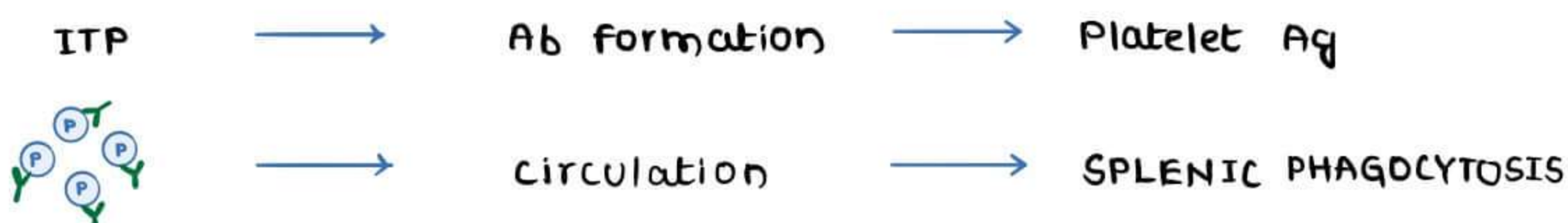
1. ACUTE ITP

- Short duration history
- Severe
- Sudden onset
- seen in children
- HIV viral infection ⊕

2. CHRONIC ITP

- longer duration History
- less severe
- seen in adults
- sub types
 - 1° | Idiopathic
 - 2° [SLE / HIV / CLL]

PATHOGENESIS



C/F

- Petechia
- Purpura
- Hemorrhagic Bullae [more in Acute ITP]
- Gum bleeding
- Hematuria
- melena

- NORMAL SIZED SPLEEN

DIAGNOSIS → ITP IS DIAGNOSIS OF EXCLUSION

- BT ↑ / PIC ↓
- PT } Normal
- aPTT }
- Coombs Test ⊕
- Bm EXAMINATⁿ → Active → MEGAKARYOCYTIC THROMBOCYTOPENIA

TREATMENT

1. SYMPTOMATIC m_x for Acute ITP
2. CHRONIC ITP
 - steroids
 - IV Igs
 - Splenectomy

HEMOLYTIC UREMIC SYNDROME [HUS]**SUB TYPES**

1. TYPICAL HUS → Acute Gastro-enteritis

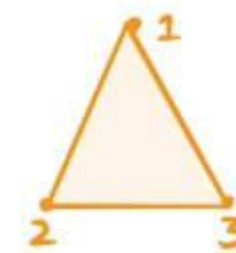
1. E.coli O157/H7 }
2. Shigella dysenteriae } → Release TOXIN → $\xrightarrow{\text{EC damage}}$ PLATELET-THROMBI

2. ATYPICAL HUS

1. mutation of © Proteins [CD 46 / factor H] }
2. Drugs [Mitomycin / Ticlopidine] } → $\xrightarrow{\text{EC damage}}$ PLATELET-THROMBI

CLINICAL FEATURES

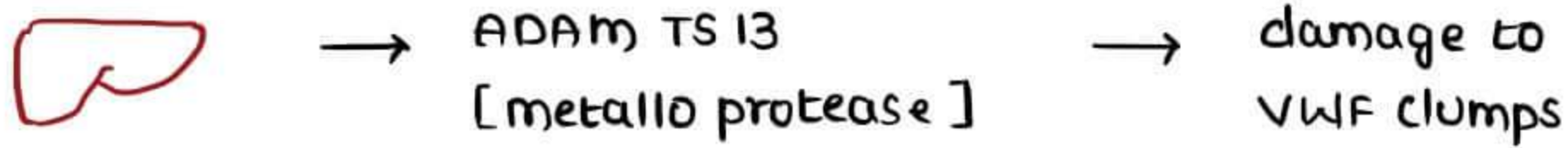
- CLASSICAL Triad
- 1. Renal failure [K/AIT or R/AIT syndrome]
- 2. microangiopathic HA
- 3. Thrombocytopenia



- child ⚭ H/O Bloody Diarrhea → Renal Dysfunction + Purpura

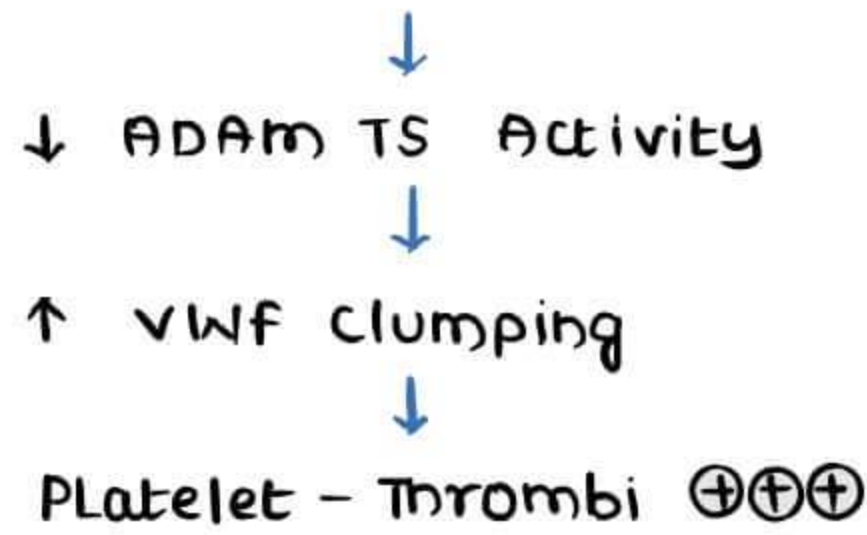DIAGNOSIS → ↑ BT
→ PT } Normal
→ aPTT }

→ NORMAL

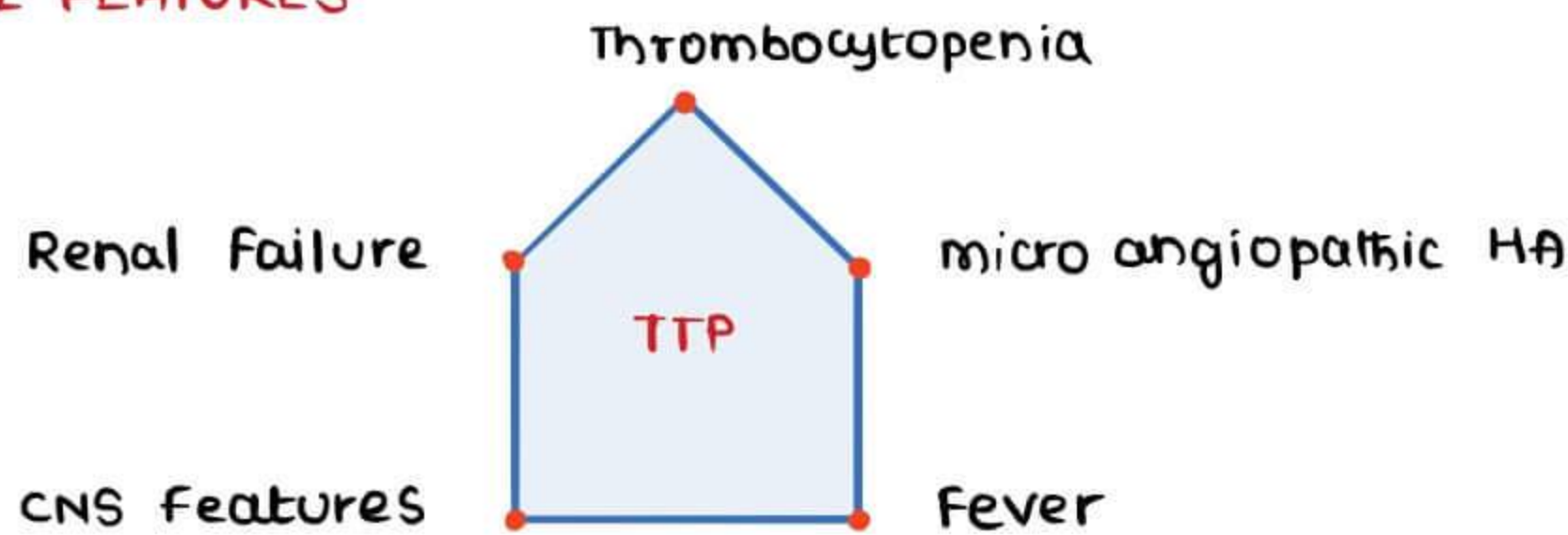


→ TTP

1. DEFICIENCY OF ADAMTS13 [LUPSHAW - SCHULMAN SYNDROME]
2. Ab Formatⁿ against ADAMTS13
→ seen i Auto immune disorders & certain Drugs



→ CLINICAL FEATURES



→ TREATED BY PLASMAPHERESIS <https://www.youtube.com/watch?v=me/latestspgnotes>

DISSEMINATED INTRA VASCULAR COAGULATION [DIC]

- Thrombo - Hemorrhagic disorder
- Acute | Sub acute | Chronic disorder

→ RISK FACTORS

1. OBSTETRIC CAUSES [mc]

- Retained placenta
- Dead fetus
- Amniotic fluid embolism

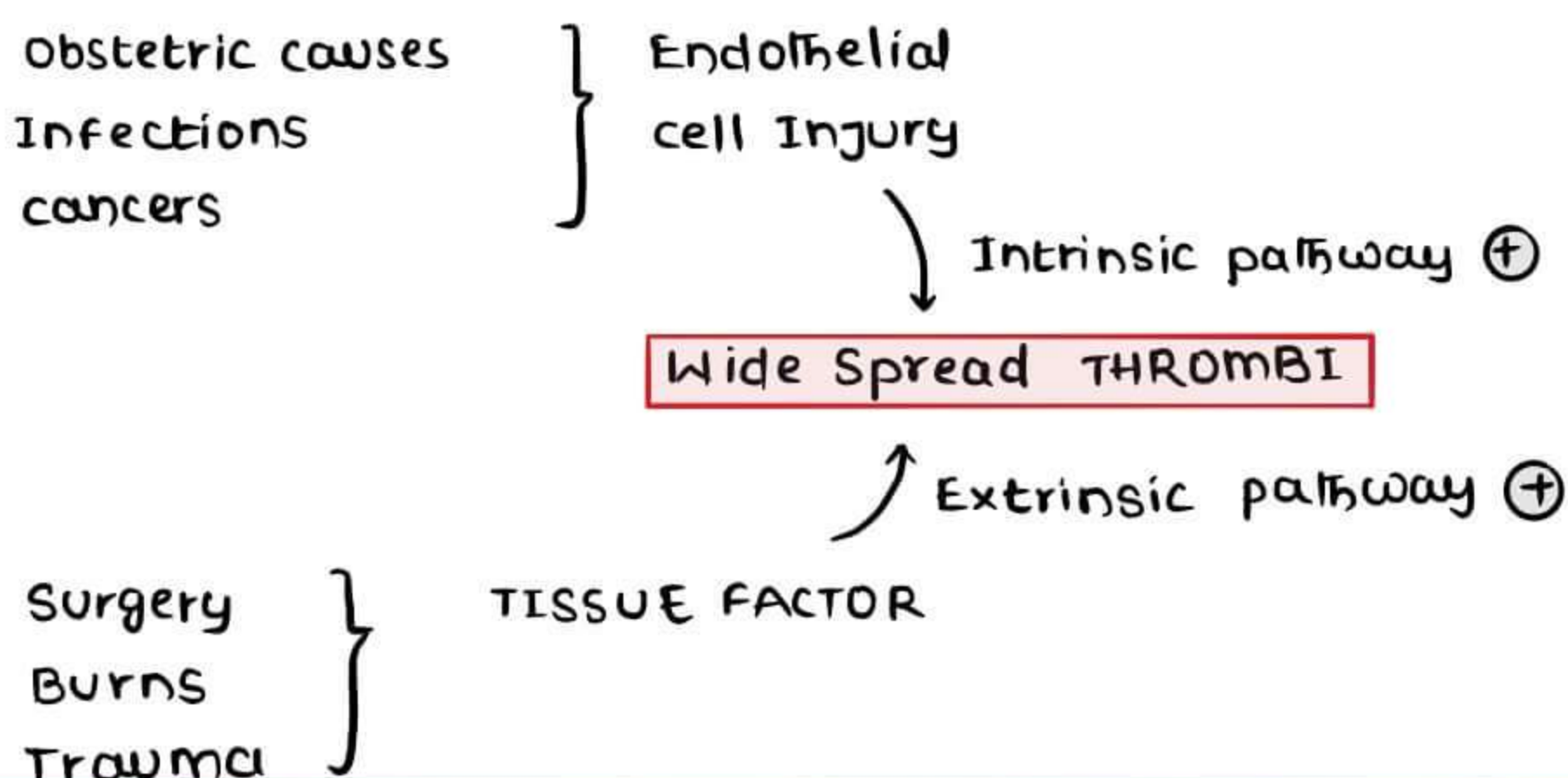
2. INFECTIONS

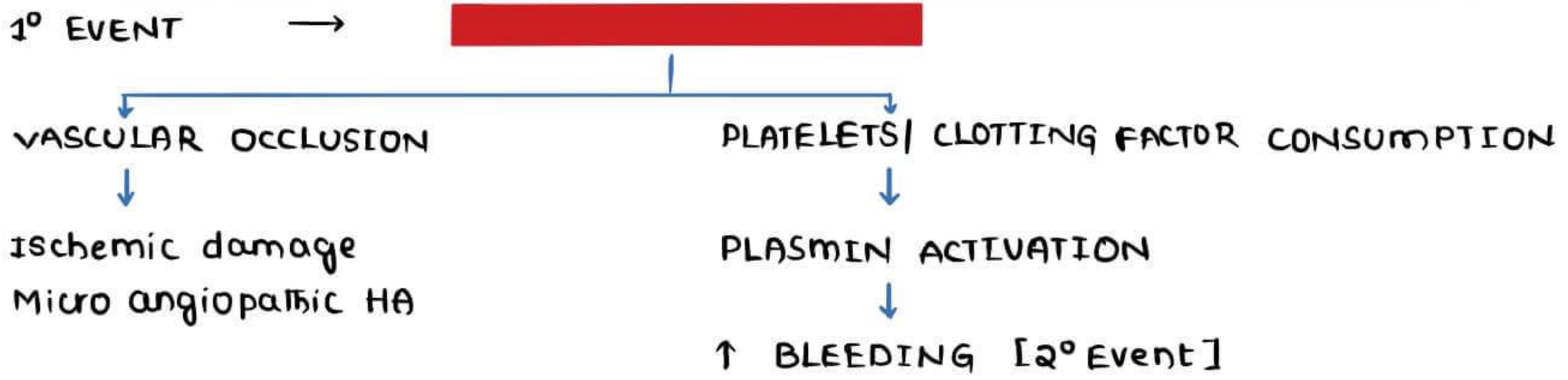
CANCERS

- stomach
- colon
- Pancreas
- AML - M3

3. BURNS | SURGERY | TRAUMA

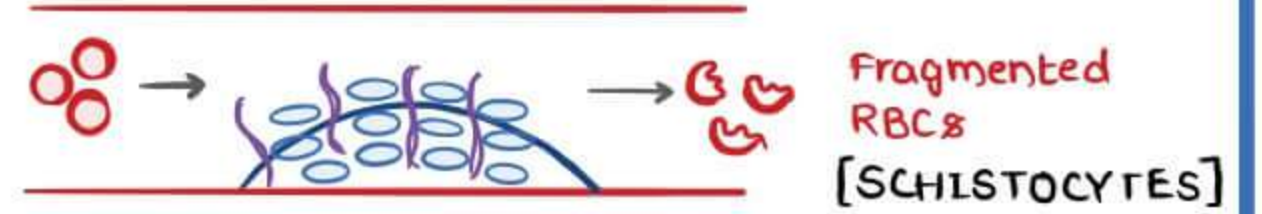
PATHOGENESIS





DIAGNOSIS

- 1. ↓ Hb ↑ LDH
- ↓ PC ↑ UC Bilirubin



- 2. PERIPHERAL SMEAR Shows SCHISTOCYTES [MAHA]
- 3. ↑ BT ↑ PT ↑ aPTT
- 4. D-DIMER ASSAY [Specific]

D - E - D [Fibrinogen]



↓ Plasmin ⊕



D - Dimers suggests
→ ↑ Plasmin
→ Fibrin

CIF

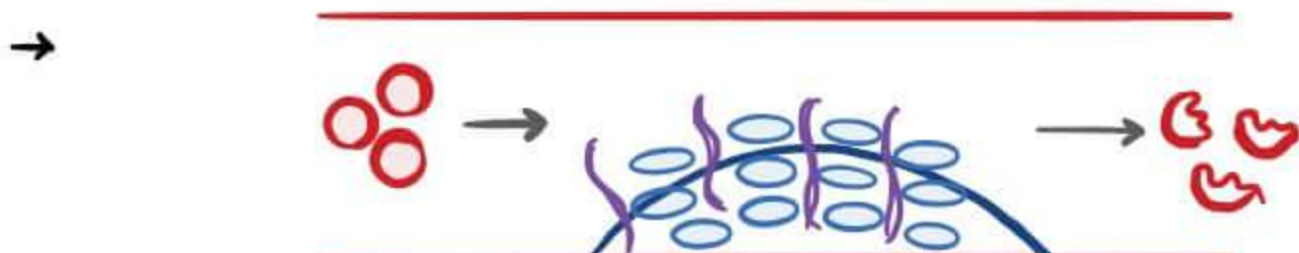
- 1. BRAIN → mc affected → Confusion, altered sensorium, Dizziness, Coma
 - 2. HEART → ↓ CO / Dyspnea
 - 3. KIDNEY → Acute tubular necrosis
 - 4. LUNGS → difficulty in breathing, hypoxemia
 - 5. ADRENAL GLAND → Hemorrhage [Meningococemia]
- ↓
- WATERHOUSE - FRIDERICHSEN SYNDROME

TREATMENT

- 1. TREAT PRIMARY CAUSE
- 2. FRESH FROZEN PLASMA
- 3. ANTI COAGULANTS

INSPIRE OF BEST EFFORTS, DIC a/w HIGH MORTALITY

ANGIOPATHIC HEMOLYTIC ANEMIA : BASIC CONCEPTS



SUB TYPES**1. MACRO ANGIOPATHIC HA**

- a/w Prosthetic cardiac valves [Aortic valve >>> mitral valve]
- a/w Severe Aortic Stenosis
- a/w Synthetic vascular grafts
- a/w Cavernous Hemangioma

2. MICRO ANGIOPATHIC HEMOLYTIC ANEMIA

- a/w HUS / TTP / DIC
- a/w Eclampsia
- a/w Scleroderma
- a/w malignant HTN
- a/w march hemoglobinuria [Soldiers]

CLOTTING FACTOR DISORDERS [HEMOPHILIAS] & CONCEPT OF FACTOR INHIBITORS**HEMOPHILIA SUB TYPES**

- | | |
|----------|-------------------------------|
| A | → Factor 8 defect [mc] |
| B | Factor 9 defect |
| C | factor 11 defect |

FACTOR 8**SOURCE**

- | | |
|--------------------------------|----------------------------|
| → LIVER | → KIDNEY |
| ↳ Sinusoidal Endothelial cells | ↳ Tubular Epithelial cells |
| ↳ Kupffer cells | |

HEMOPHILIA - A

- x Linked disorder
- 90% → ↓↓↓ Factor 8
- 10% → functional defect of Factor 8
- Intrinsic pathway affected

VARIANTS

1. MILD → 6-50% factor 8 ⊕
2. MODERATE → 2-5% factor 8 ⊕
3. SEVERE → < 1% factor 8 ⊕

C/F

- children [♂ >>> ♀]
- H/O trauma
- HEMARTHROSIS
- HEMATOMA
- H/O Excessive Bleeding
 - ↳ Circumcision
 - ↳ TOOTH Extraction

DIAGNOSIS

- 1. P/C → Normal PT → Normal
- BT → Normal aPTT → Elevated

- 2. Factor 8 level → ↓↓↓ [confirmatory]

TREATMENT

- 1. MILD → Desmopressin
- 2. Severe → r factor 8 [HUMATE]
- 3. CRYOPRECIPITATE

HEMOPHILIA B [CHRISTMAS DISEASE]

- ↓↓ Factor 9
- X Linked Recessive
- Similar c/f as Hemophilia A

DIAGNOSIS

- 1. BT → N PT → N
- P/C → N aPTT → ↑

- **R_y** 1. r factor 9
- 2. FRESH FROZEN PLASMA

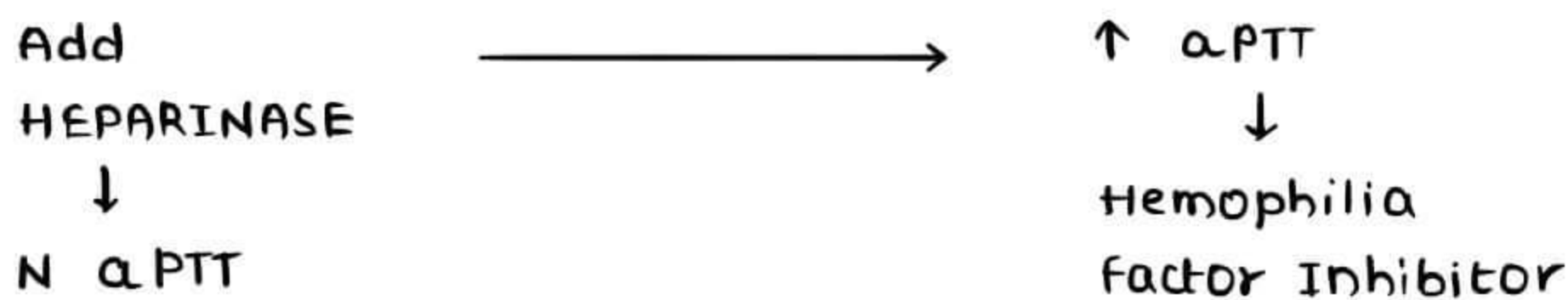
FACTOR INHIBITORS

- Abs → ↓ clotting factor activity
- **CAUSES** t.me/latestpnotes

- 1. RECIPIENTS OF CLOTTING FACTORS
- 2. PREGNANCY
- 3. AUTO IMMUNE DISORDERS
- 4. B CELL CANCERS

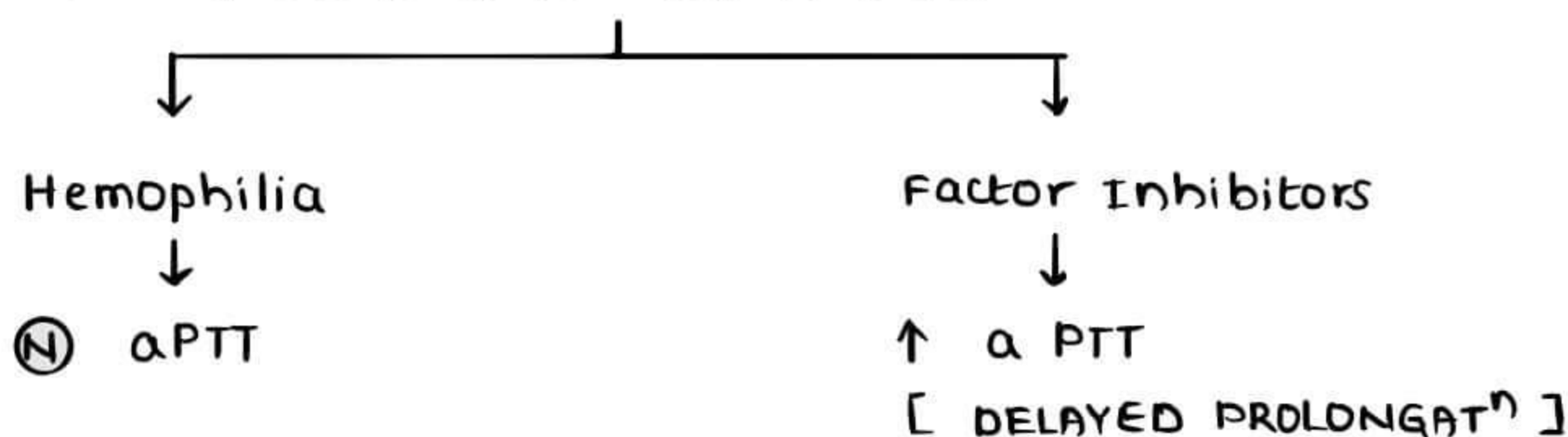
- c/f** → Similar to Hemophilia
- ↑ aPTT

ISOLATED ↑ aPTT



MIXING STUDY [distinguishes Hemophilia & factor inhibitor]

- 1:1 Patient & normal Plasma



VON WILLEBRAND FACTOR

SOURCE

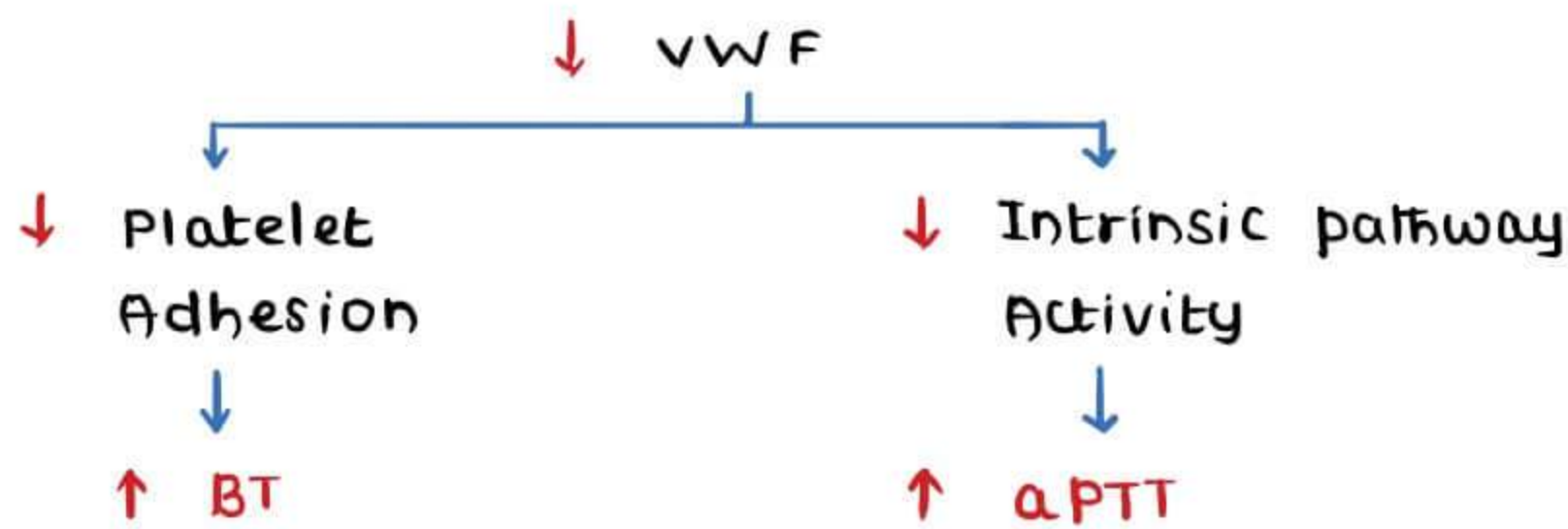
- Endothelial cells
- megakaryocytes
- Hepatocytes [small quantity]

- Gene Located on Chr. 12

FUNCTIONS

1. Transport of Factor 8
 - ↳ $t_{1/2}$ → 2.4 hrs
 - ↳ $t_{1/2}$ \bar{v} Wf → 12 hrs

2. PLATELET ADHESION



SUBTYPES OF VON WILLEBRAND DISEASE

1. TYPE I VWD → ↓ vWf [mc] → Autosomal Dominant
2. TYPE II VWD → ⊕ vWf → Qualitative Defect
3. TYPE III VWD → ↓↓↓ vWf [most severe] → Aut. Recessive

TYPE 2

SUB TYPES

- | | |
|--------------|---------|
| Type 2A [mc] | Type 2C |
| Type 2B | Type 2D |

→ Autosomal Dominant

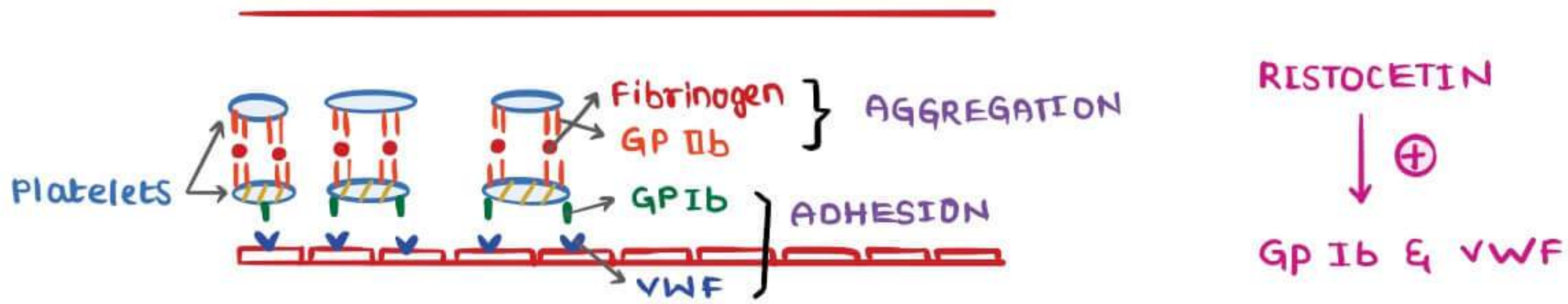
CIF

→ MUCOSAL BLEEDING → Petechiae | purpura
Epistaxis | melena

→ TISSUE BLEEDING [rare]

DIAGNOSIS

- | | | | |
|--------|-----|------|-----|
| 1. P/C | → N | PT | → N |
| BT | → ↑ | aPTT | → ↑ |



RISTOCETIN TEST

Formalin - fixed Platelets + Plasma [person]
 Ristocetin

Normal → RAT ⊕ [elicited by AGGREGOMETER]
 VWD → RAT ⊖

VWD

→ ↑ BT & ↑ aPTT → RAT ⊖
 ⊕ PT & ⊕ PIC → VWF ASSAY

R₁ → 1. DESMOPRESSIN for mild form
 2. CRYOPRECIPITATE for Severe form

BLOOD TRANSFUSION

t.me/latestpnotes

HEALTHY VOLUNTARY → 350 ml in CHITRA BAG + Anticoagulant solution [49 ml]

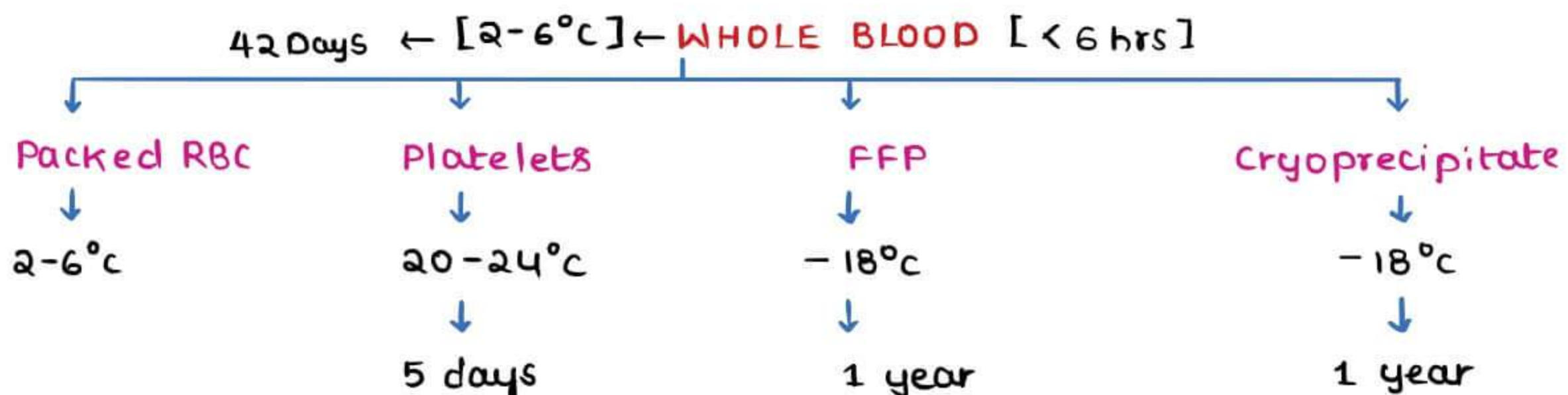
450 ml Blood → 63 ml anticoagulants

ANTI COAGULANTS

SHELF LIFE

- | | | |
|----------|---------------------------------------------------------|---------|
| 1. ACD | → Acid Citrate Dextrose | 21 Days |
| 2. CPD | → Citrate Phosphate Dextrose | 21 Days |
| 3. CPD-A | → Citrate Phosphate Dextrose - Adenine | 35 Days |
| 4. SAGM | → Saline Adenine Glucose mannitol & Citrate & Phosphate | 42 Days |

- Saline → Isotonic
- Adenine → ATP generation
- Glucose → RBC nutrition
- Mannitol → ↓ Lysis
- CITRATE → ↓ Ca²⁺ → ↓ clot formation
- Phosphate → BUFFER [maintains PH]



CRYOPRECIPITATE RICH IN

1. VWF
2. Factor 8
3. Factor 13
4. Fibrinogen

FFP RICH IN

→ Other clotting factors

WHOLE BLOOD TRANSFUSION - INDICATIONS

1. Massive Blood transfusion
2. Exchange transfusion

1 unit transfusion → ↑ 1 gm/dl Hb & 3% ↑ HCT

PACKED RBC INDICATION

→ Anemia

FROZEN RBCs + Glycerol (↓ lysis) indicated for Autologous transfusion

PLATELETS INDICATION

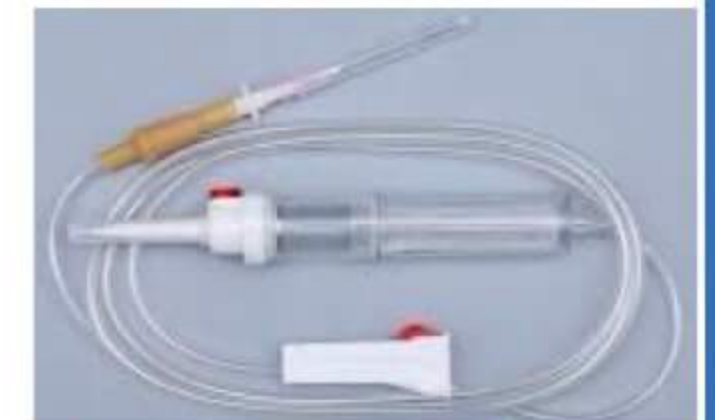→ ↓ Platelet count

FFP INDICATIONS

- Burns
- clotting factor deficiencies

CRYOPRECIPITATE INDICATIONS

→ clotting factor deficiencies



BLOOD TRANSFUSION SET

BLOOD TRANSFUSION SET

- Transfusion needle → 18-19 gauge
- Filter → 170-200 μ
- microaggregates can enter

t.me/latestpgnotes

	START	FINISH
WHOLE BLOOD	in 30 min	4 hrs
FFP	ASAP	in 20 min
CRYOPRECIPITATE	ASAP	in 20 min

PLATELETS

- Random Donor Platelets → ↑↑ 5000 - 10000 ~ 1 unit
- Alloimmunization
- Single Donor Platelets → Plateletpheresis
 - ↳ 6 units can obtained
 - ↳ ↓ Immune Reactions
 - ↳ transient hypocalcemia can occur
 - ↳ peri oral numbness/tingling ⊕

COMPLICATIONS

DONOR

1. pain, bruise, hematoma
2. vasovagal Syncope
 - countered by
 1. raising the foot end of donor
 2. Supplementing + fluids

3. Apheresis → Citrate
 - Transient hypocalcemia
 - prevented by slow infusion
 - Rx by Oral Ca²⁺ Supplementation

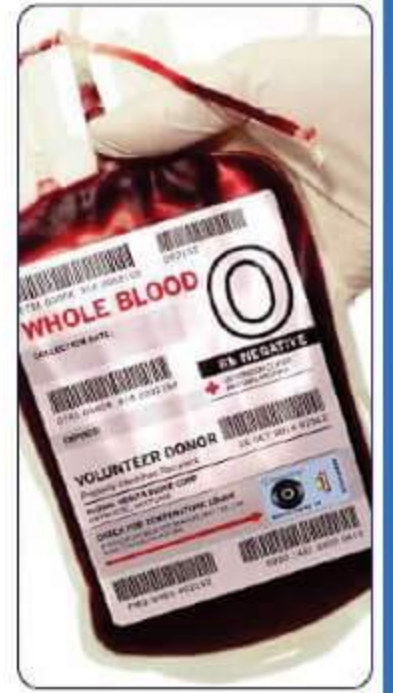RECIPIENTS

1. Fever
 - $> 1^{\circ}\text{C}$ than N
 - aka febrile Non Hemolytic Transfusion Reaction [FNHTR]
 - mc blood transfusion Reaction

2. HEMOLYTIC TRANSFUSION REACTION

- dit mismatching [mostly dit clerical error]
- Acute Reaction
- takes place in

whole blood	}	should be ABO compatible
Platelets		
FFP		
- CIF
 - High grade fever in chills & rigors
 - Flank pain [Hemoglobinemia & Hemoglobinuria \oplus]
 - oozing of blood from veni puncture [in comatose patient]
- MANAGEMENT
 1. stop BT
 2. maintain IV Line in N Saline
 3. Blood Bank → sampling for mismatch



3. ANAPHYLACTIC REACTION

- Recipient may be in Ig A deficiency

4. TRALI [Transfusion Related Acute Lung Injury]

- seen in 6 hrs of FFP infusion
- dit antibodies against WBCs
- Non - cardiogenic pulmonary edema \oplus

5. POST TRANSFUSION PURPURA

- seen in platelet transfusion after 7-10 days

6. GRAFT VS HOST DISEASE

- dit donor T cells
- seen after 8-10 days


7. INFECTIONS

- maximum in Platelets
- malarial trophozoites transmits through all components
- seen in
 - Bacteria
 - ↳ Yersinia enterocolitica
 - ↳ Pseudomonas
 - ↳ coagulase negative Staphylococcus
- Prevented by Screening

MASSIVE BLOOD TRANSFUSION

- > 1 Blood volume in 24 hrs
- > 50% Blood volume in 3 hrs

COMPLICATIONS

1. HYPOTHERMIA [prevented by inline warmers]
2. ELECTROLYTE DISTURBANCES
 - ↳ ↑↑ K⁺
 - ↳ citrate → ↓↓ Ca²⁺ →  → HCO₃⁻ → metabolic alkalosis
3. DILUTIONAL COAGULOPATHY → DIC → Death
 - 1:1:1 PROTOCOL → Protective against dilutional coagulopathy related mortality
 - RBC Plasma Platelets

ALTERNATIVES

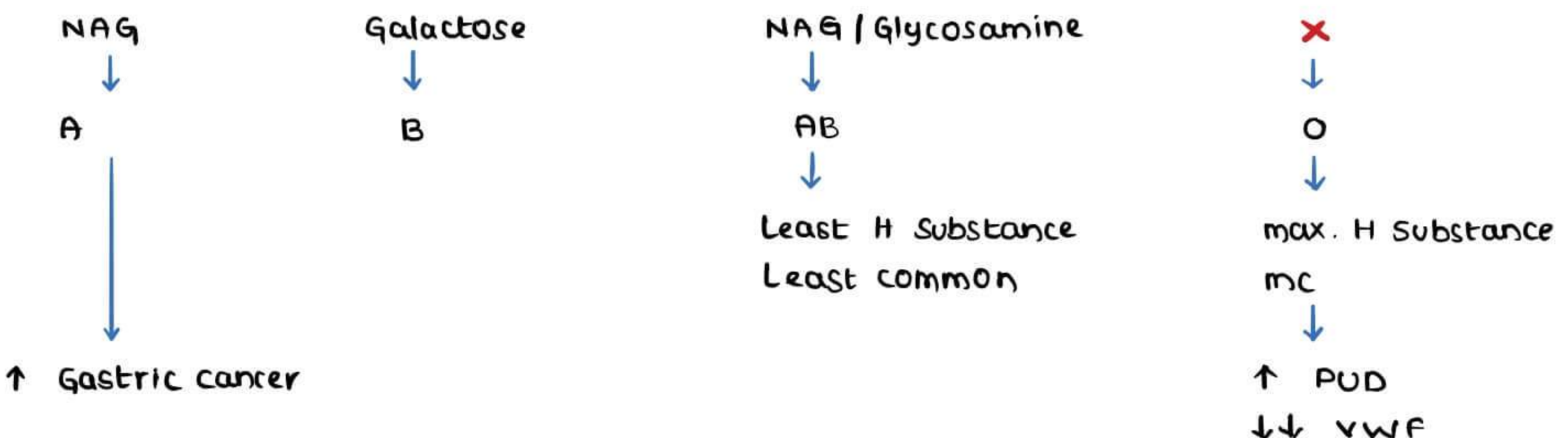
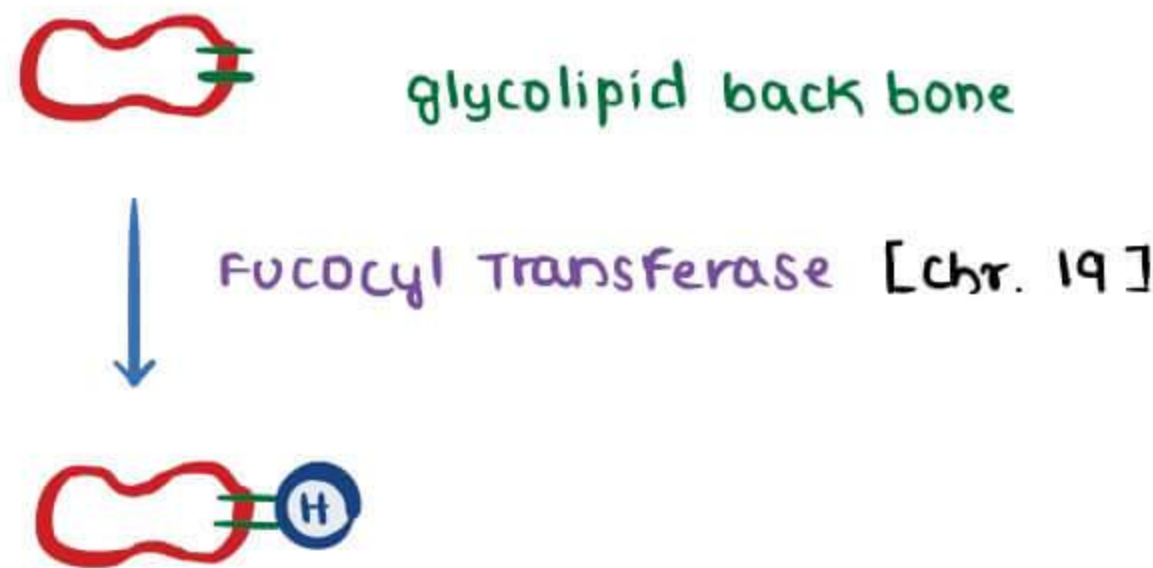
1. Hb solutions
 2. perfluoro carbons
- } ↓ t_{1/2}
- used at Balloon angioplasty

BLOOD GROUPING

t.me/latestpgnotes

ABO BLOOD GROUPING

- mc Blood grouping system
- A/B antigen genes located on → chr 9
- H antigen genes located on → chr 19
- Full expression of these genes occur at → 1 yr of age
- ABO antigens are → Glycoproteins
- ABO Antigens expressed on the surface of → RBCs & platelets



SECRETORS [80%]

→ Saliva | sweat | Plasma | semen

→ Except CSF

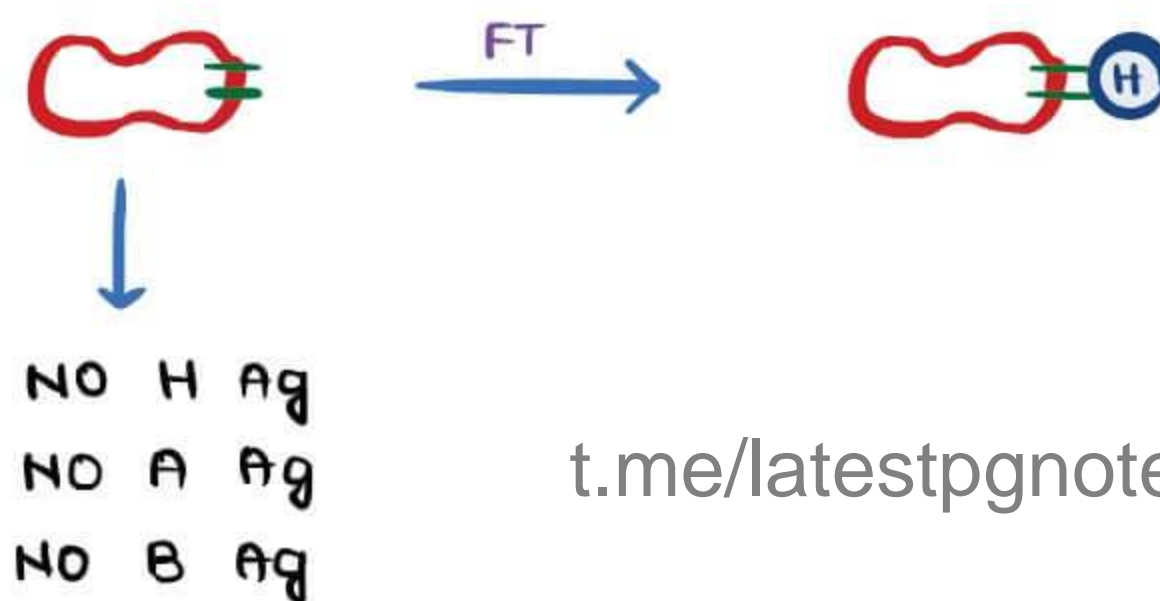NON-SECRETORS

→ mc specimen used to check secretors & non-secretors → Saliva

BLOOD GROUP	Ag ON RBC	Ab in plasma
A	A, H	anti - B Ab
B	B, H	anti - A Ab
AB	A, B, H	NO Ab
O	H	anti - A & anti B Ab

AB → universal recipient

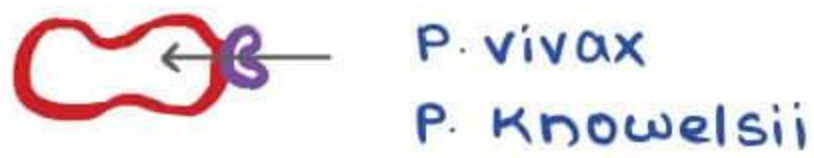O → universal donor

safest blood group for transfusⁿ in emergency → O -safest plasma for transfusⁿ in emergency → AB +**BOMBAY BLOOD GROUP**

- discovered by BHENDE
- rare blood group
- anti A/B/H Ab in plasma
- Even "O" can't be given to these patients
- safest for transfusⁿ for these patient → Bombay
- detected by REVERSE GROUPING [detectⁿ of Ab in plasma]

OTHER BLOOD GROUPS**1. RHESUS | Rh**

- antigens expressed since birth
 - C/D/E Antigens
 - D → most important
 - genes located on Chr. 1
 - 85% → Rh ⊕
 - 15% → Rh ⊖
- HEMOLYTIC DISEASE OF NEW BORN
- ↳ Ig G Antibodies
 - ↳ dit mismatch b/w Rh group of mother & fetus
 - mother → Rh ⊖
 - fetus → Rh ⊕



→ Duffy \ominus RBCs have resistance to P. vivax / P. Knowelsii infection

3. P ANTIGEN

→ a/w Parvovirus B19 infection

→ P \ominus → resistant to Parvovirus B19 Infection

Auto - Ab → P → DONATH LANDSTEINER Ab
[Biphasic Ab]
- attaches at 4°C
- hemolysis at body temp.

↓
PAROXYSMAL COLD HEMOGLOBINURIA

4 I ANTIGEN

Ab formation → COLD AGGLUTININ DISEASE

5 LEWIS ANTIGEN

t.me/latestpgnotes

→ gene located on chr 19

→ Ab → Ig M

→ do not cross placental barrier

→ do not cause hemolytic disease of new born

Ab formation → mc cause of incompatibility during
Pretransfusion testing

KELL ANTIGEN

→ KELL Ag + Kx Ag → McLeod Phenotype

→ ↓ RBC life span

→ cardiac defects \oplus

→ muscular dystrophy \oplus

→ Acanthocytes \oplus

GASTROINTESTINAL TRACT

HISTOLOGY - LAYERS OF GIT

1. MUCOSA [EPITHELIUM]

Oesophagus	→	Stratified Squamous non Keratinized
Stomach	→	columnar
Small Intestine	}	columnar
Large Intestine [upto colon]		
Anal canal	→	Squamous

2. SUB MUCOSA

→ contains **MEISSNER'S PLEXUS** [secretory & absorptive in functⁿ]

3. MUSCULARIS PROPRIA

→ Inner → circular

→ In b/w → **AUERBACH'S | MYENTERIC PLEXUS** [motor in functⁿ]

→ OUTER → Longitudinal

4. SEROSA

→ absent in OESOPHAGUS

GALL BLADDER DO NOT HAVE MUSCULARIS MUCOSAE [not mus. propria]

t.me/latestpgnotes

INFANTILE HYPERTROPHIC PYLORIC STENOSIS

→ EARLIER NAME → CONGENITAL HYPERTROPHIC PYLORIC STENOSIS

→ But this condition, NOT PRESENT AT THE TIME OF BIRTH

→ more common in Male babies

→ Associated \bar{i}

- Trisomy 18 [Edward Syndrome]

- Trisomy 21 [Down Syndrome]

- Exposure to **ERYTHROMYCIN** [motilin receptor agonist] in 1st two wks of life

→ CLINICAL FEATURES

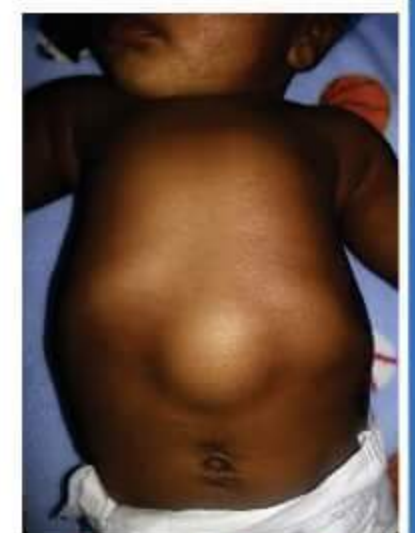- present at 3-6 wks after birth

- New onset regurgitation

- Non-bilious, projectile vomiting after feeding

- Demands refeeding

- **OLIVE LUMP** [1-2 cm firm, ovoid, abdominal mass]



OLIVE LUMP

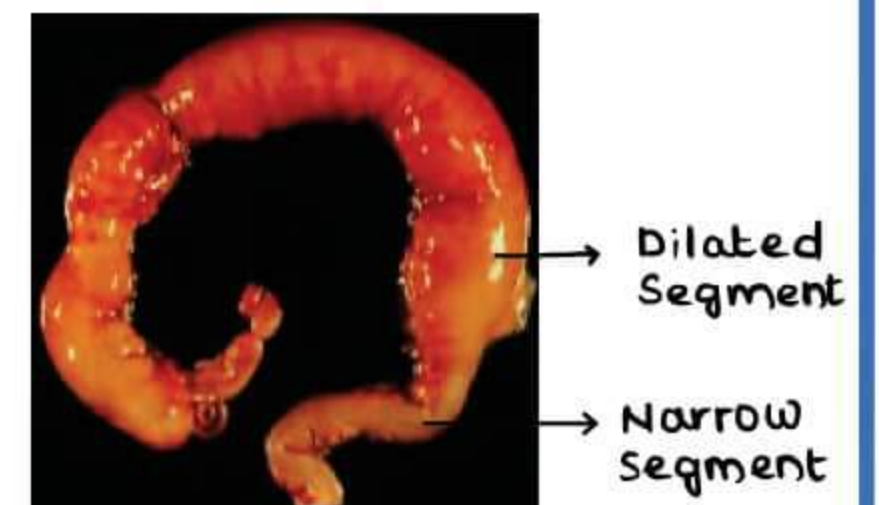
→ DIAGNOSIS by USG

→ TREATMENT by PYLOROMYOTOMY

- AKA CONGENITAL AGANGLIONIC MEGACOLON
- Prevalence → 1 : 5000 live births
- due failure of migration of neural crest cells into the bowel
 - ↓
 - Absence of ganglionic cells [particularly Nitric oxide releasing cells] in bowel
 - ↓
 - Affected part of bowel not able to relax
 - ↓
 - Proximal part of affected bowel will be dilated

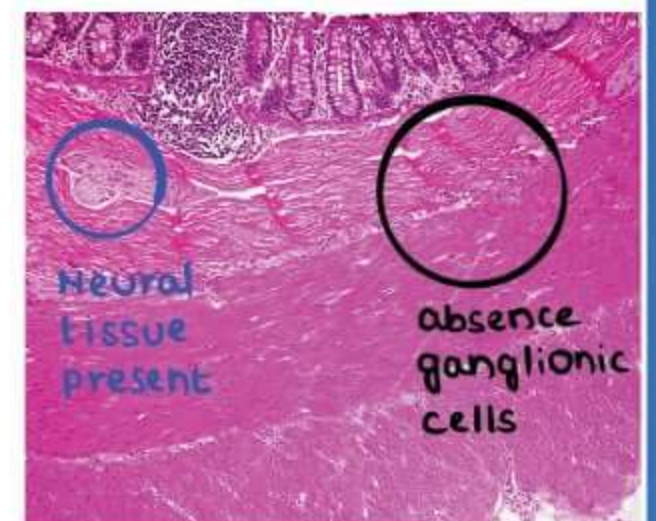
- SHORT SEGMENT HIRSHPRUNG DISEASE → if it involves part of large intestine
- LONG SEGMENT HIRSHPRUNG DISEASE → if it involves entire colon
- MC SITE INVOLVED → RECTUM

- more common in male babies
- GENETICS
 - Loss / under activity of RET gene
 - in 10% , also Down Syndrome



- CLINICAL FEATURES
 - Failure of passage of meconium / abdominal distension
 - constipation
 - Dilatation of segment leads to thinning of bowel wall
 - cecum is prone for rupture

- DIAGNOSIS confirmed by RECTAL SUCTION BIOPSY
 - Absence of ganglionic cells
 - Nerve fibres are hypertrophied



• SPECIAL STAINS

	NORMAL	HIRSHPRUNG
AChE	-	+ + +
CALRETININ	+	-

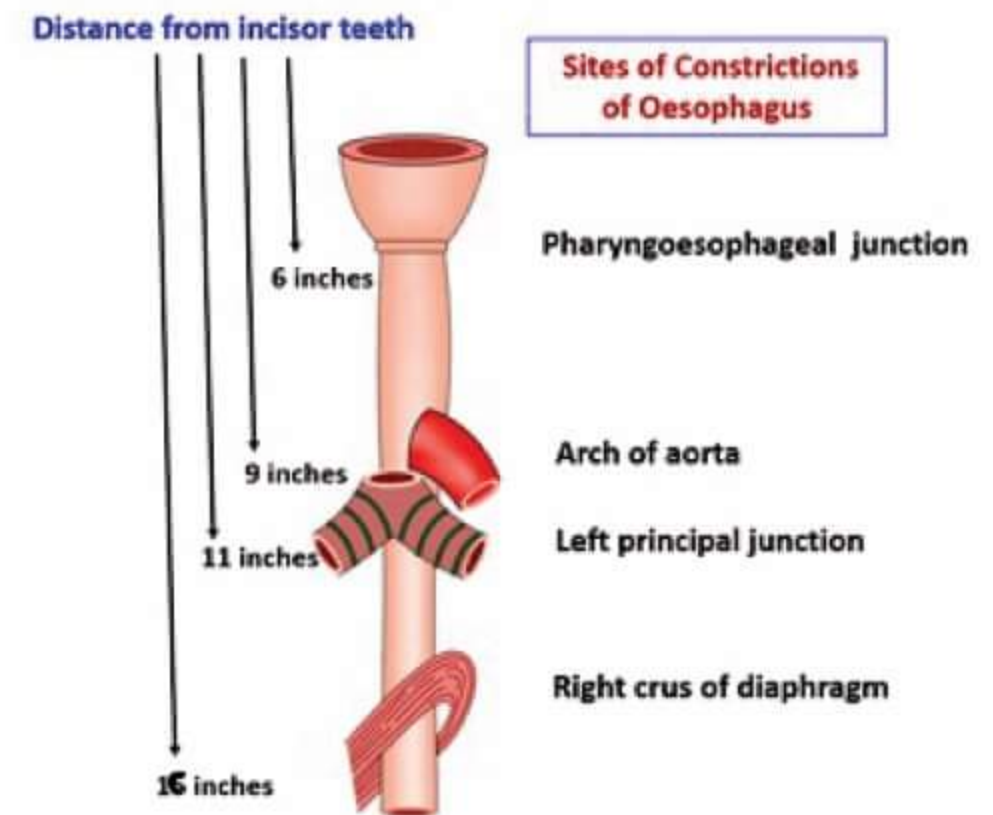
- 25 cm → in adult
- 10 cm → in New born

→ 4 CONSTRICTIONS

- ↳ at Upper esophageal sphincter [by Cricopharyngeus]
- ↳ dit Aortic Arch cross over
- ↳ dit Left Bronchus cross over
- ↳ at Lower esophageal sphincter

→ Distance from Incisor teeth

1. 6" [15 cm]
2. 9" [22.5 cm]
3. 11" [27.5 cm]
4. 16" [40 cm]



- maximum narrowing at → Upper esophageal sphincter
- mc site for perforation → Upper esophageal sphincter
- common causes of perforatⁿ → Iatrogenic / Instrumentatⁿ

→ stratified squamous non-keratinized epithelium [acid sensitive]

→ LES

- a/w HIGH TONE → helps in unidirectional movement of food
- LES DYSFUNCTⁿ → REFLUX ESOPHAGITIS

GERD

REFLUX ESOPHAGITIS

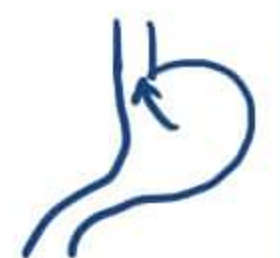RISK FACTORS

- Transient Lower Esophageal Sphincter Relaxatⁿ [TLESR] [most important]
- Smoking
- Alcohol
- obesity
- over eating
- Pregnancy
- Hiatal Hernia

CLINICAL FEATURES

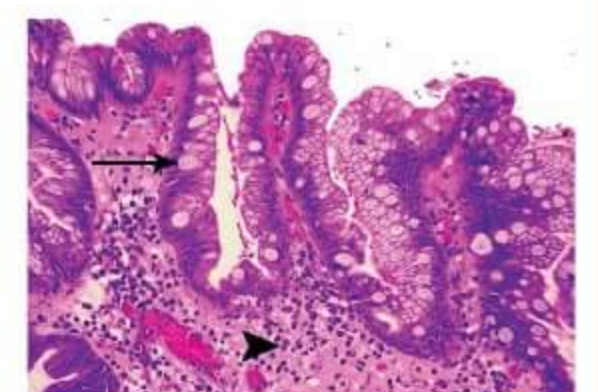
- Retro sternal pain [Burning]
- Sour brash
- teeth discoloration

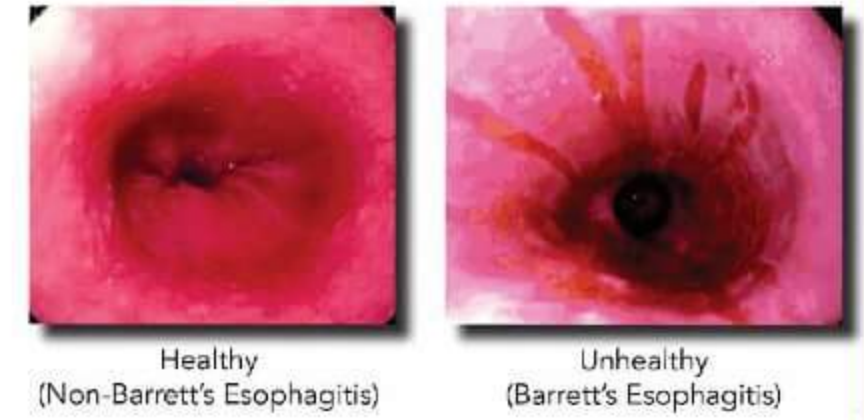
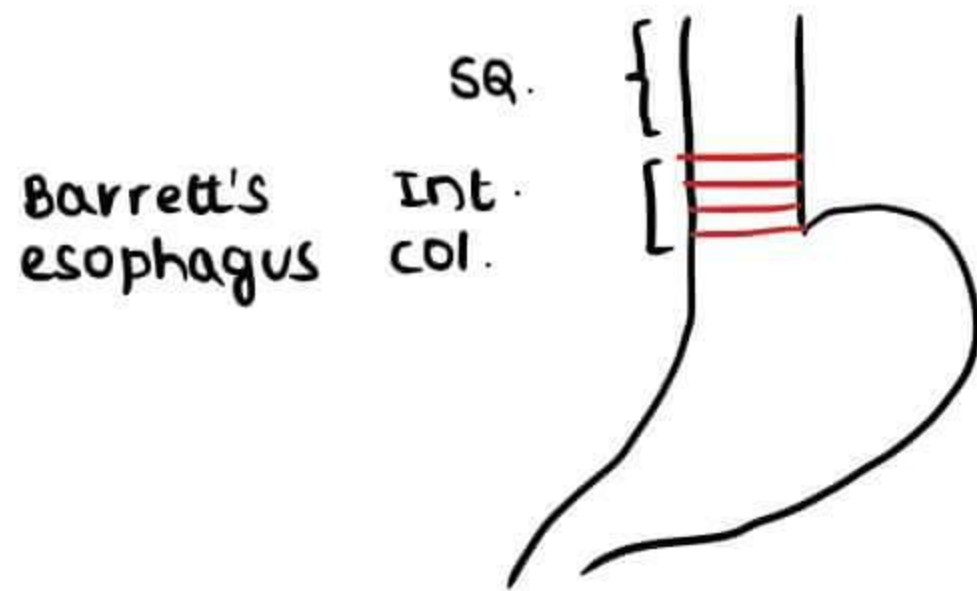
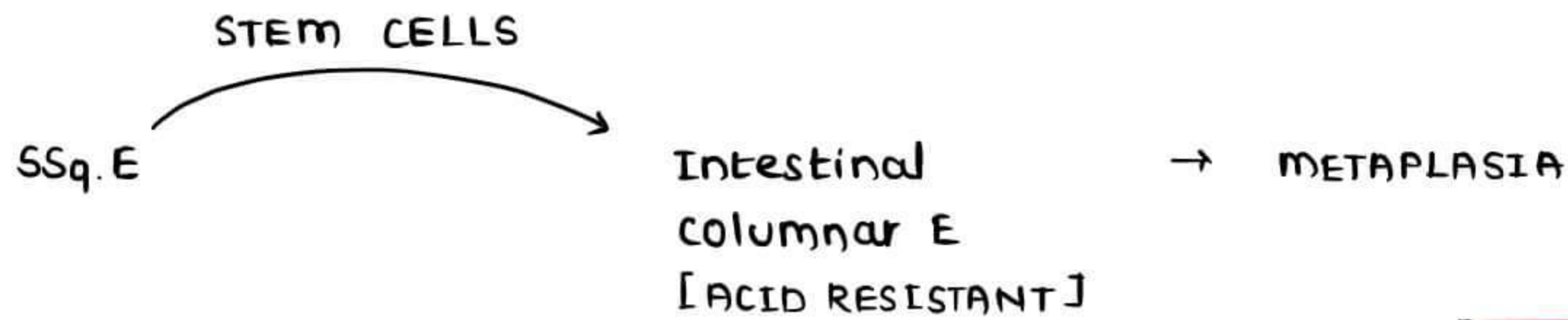
RE ≈ GERD



DIAGNOSIS

1. 24 HOUR pH STUDY
2. MANOMETRY → ↓ LES pressure
3. ENDOSCOPY + BIOPSY → confirmed Dx





BARRETT'S ESOPHAGUS

[Intestinal Metaplasia]

- ↳ Dysphagia
- ↳ Cancer → Adeno carcinoma of Lower part of oesophagus

MANAGEMENT

1. ↓ HCL → PPIs [DOC]
2. PROKINETIC DRUGS
3. SURGERY → FUNDOPLICATION

t.me/latestpnotes

ICE → Goblet cells ⊕

TRACHEO - ESOPHAGEAL FISTULA

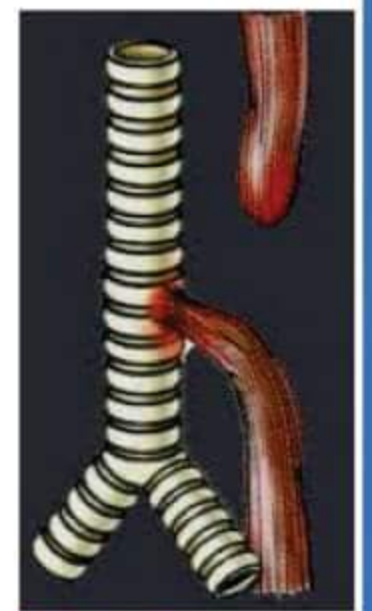→ FISTULA

- abnormal connection blw 2 epithelial surfaces
- can be blw 2 tubings or blw 1 tubing & skin

→ congenital defect

→ MOST COMMON VARIANT

- upper end of esophagus end in a blind pouch
- Lower end of esophagus communicates i part of trachea just above the bifurcation



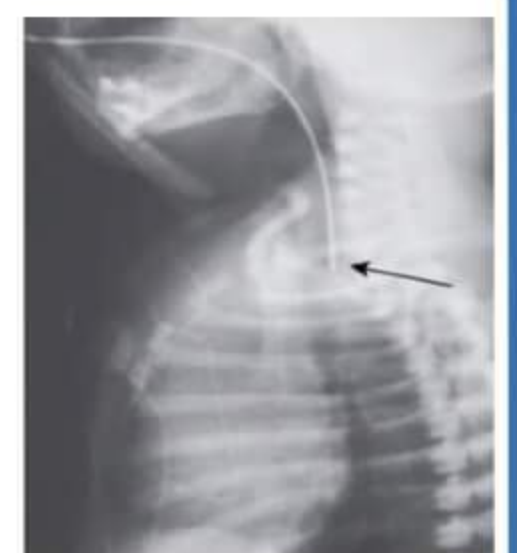MC VARIANT

→ CLINICAL FEATURES

- Polyhydramnios
- Abdominal distension
- Aspiration [pneumonia]

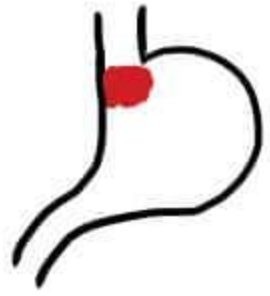→ SUSPECTED WHEN

- When newborn baby not able to swallow milk
- when not able to pass NG tube in newborn baby



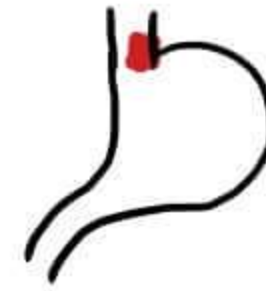ALCOHOLICS

MALLORY-WEISS TEAR



- Superficial [involves only mucosa]
- Located below the GEJ [90%]

BOERHAAVE SYNDROME

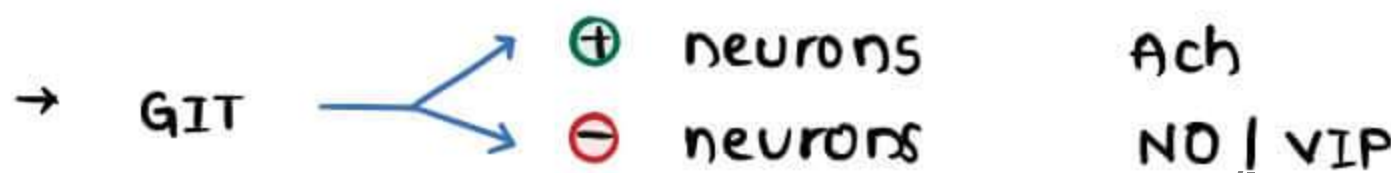

- Muscles rupture on postero-lateral part on left side
- Located above the GEJ [3-5cm above]

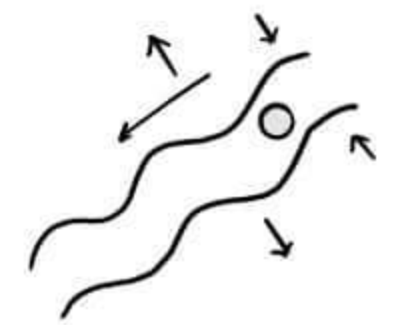
CIF

- Chest pain
- Hematemesis [painful]
- Subcutaneous emphysema [esply in Boerhaave syndrome]
- PAINLESS HEMATEMESIS seen in Esophageal varices [Portal HTN Liver Cirrhosis]

ACHALASIA CARDIA



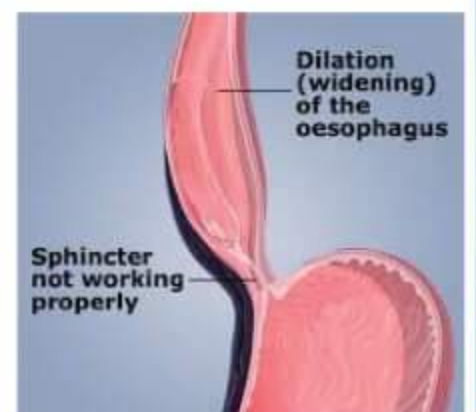
t.me/latestnnotes



- Selective loss of ⊖ neurons → ↑ Muscle tone → Abnormal motility

ETIOLOGY

- 1. PRIMARY
- 2. SECONDARY
 - ↳ Chagas disease
 - ↳ Varicella Zoster virus



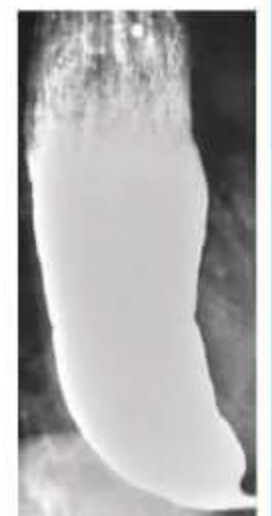CIF

- dysphagia [Liquids >>> solids]
- wt loss

Pre malignant condition

DIAGNOSIS

- 1. MANOMETRY → IOC ; ↑ LES tone
- 2. BARIUM SWALLOW → BIRD BEAK APPEARANCE



MANAGEMENT

- 1. DRUGS
 - Botulinum toxin
 - Ca²⁺ channel blocker
- 2. HELLER'S MYOTOMY [definitive Rx]

COMPLICATIONS

- 1. Aspiratⁿ pneumonia
- 2. chronic Achalasia cardia → Squamous cell carcinoma [in lower part]

ADENOCARCINOMA

- lower 1/3 rd
- mc in USA

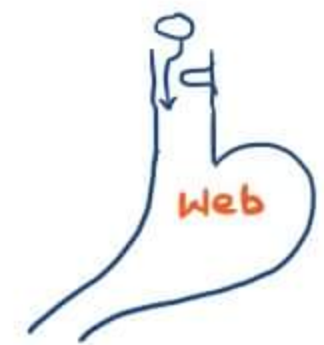SQUAMOUS CELL CARCINOMA

- upper & middle 1/3 rd
- mc in India

RISK FACTORS

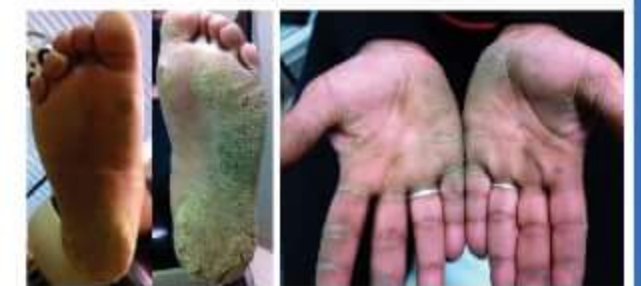SQUAMOUS CELL CARCINOMA

- smoking / Alcohol
- intake of Nitrosamines [Grilled / smoked Foods]
- intake of Hot drinks
- chronic achalasia cardia
- Plummer Vinson syndrome [Patterson Kelly Brown Syndrome]
 - ↳ IDA
 - ↳ Atrophic glossitis
 - ↳ esophageal webs
 - ↳ seen in middle aged female
 - ↳ web located in upper 1/3 rd



TYLOSIS et PALMARIS

- ↳ congenital
- ↳ thickened palms & soles



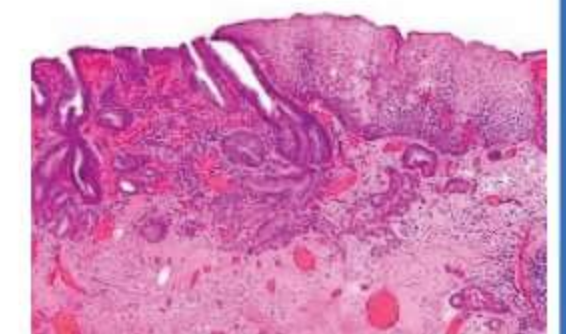
Deficiency of Zn / Mo / vit A / vit C

t.me/latestpgnotes

ADENOCARCINOMA → Barrett's esophagus

CLINICAL FEATURES

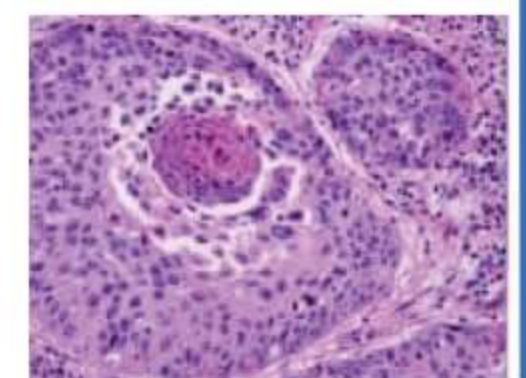
- Progressive dysphagia [Solids >>> Liquids]
- weight loss
- chest pain
- hoarseness of voice [d/t recurrent laryngeal nerve involvement]
- cough [d/t tracheal involvement]



DIAGNOSIS

1. ENDOSCOPY + BIOPSY

- | | |
|--------------------|---------------------------|
| → Goblet cells ⊕ | → Adenocarcinoma |
| → Squamous cells ⊕ | → Squamous cell carcinoma |



2. BARIUM SWALLOW → RAT - TAIL APPEARANCE

SPREAD OF ESOPHAGEAL CANCERS

- mc site → Liver
- LN
 - ↳ upper 1/3 rd → cervical LN
 - ↳ middle 1/3 rd → Mediastinal LN / Tracheobroncheal LN
 - ↳ lower 1/3 rd → cardiac / gastric / celiac LN

MANAGEMENT

- Partial / total esophagectomy

CELLS

1. PARIETAL CELLS

- Secretes Intrinsic factor
- secretes HCl [secretⁿ a/w Ach / Histamine / Gastrin → ⊕]

2. CHIEF CELLS

→ secretes pepsinogen

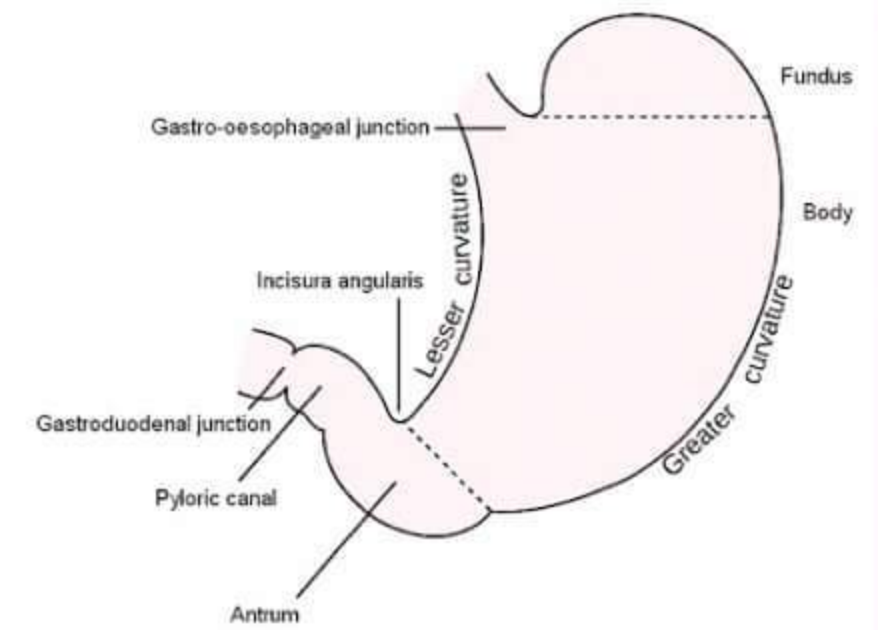
3. FOVEOLAR CELLS

→ secretes mucin [protective]

4. G - CELLS

located in antrum

Secretes GASTRIN → ⊕ → HCl



FACTORS

DAMAGING FACTORS

- HCl
- COX ⊖ [NSAIDs] → Gastric mucosal damage

PROTECTIVE FACTORS

- Epithelial regenerative capacity
- MUCUS
- HCO₃⁻
- PG₂
 - ↳ ↑ mucus
 - ↳ ↑ HCO₃⁻
 - ↳ ↑ ERG
 - ↳ ↓ HCl secretion

ACUTE & CHRONIC GASTRITIS

ACUTE GASTRITIS [imbalance blw Protective & damaging factors]

RISK FACTORS

- Alcohol
- Drugs → NSAIDs & ANTI CANCER DRUGS
- uremia
- Stress → ICU
- Burns → CURLING ULCER
- ↑ ICT → CUSHING ULCER

C/F → Epigastric pain, Nausea & vomiting

CHRONIC GASTRITIS

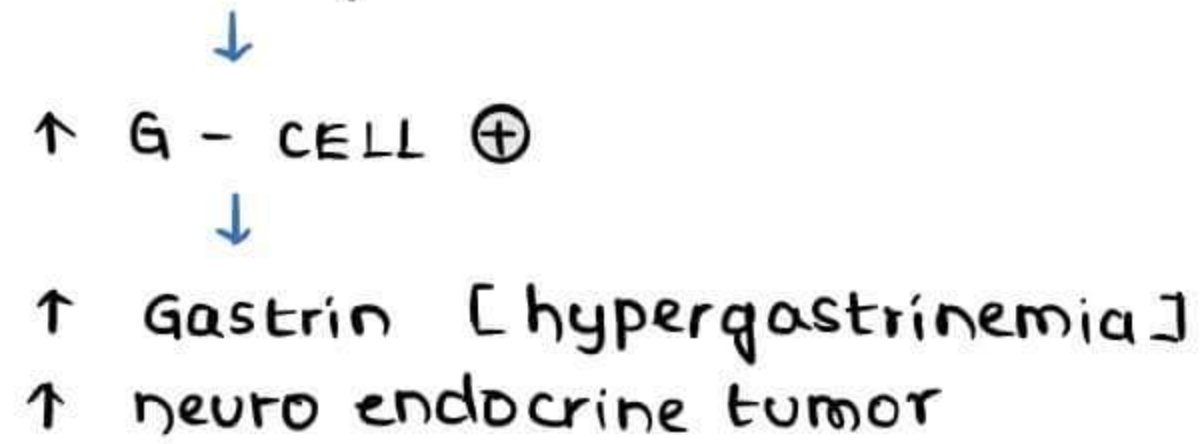
RISK FACTORS

- H. pylori
- Autoimmune gastritis
- uremia
- Radiation
- GVHD

TYPE A GASTRITIS

- Auto immune
- self reactive CD₄ T cell
- a/w Type I Dm
- Addison's Disease
- Hashimoto's thyroiditis

→ parietal cells are damaged → Achlorhydria

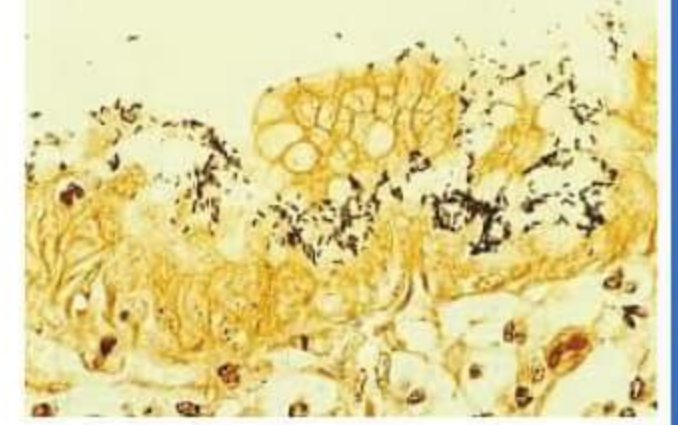

→ mc ly involves fundus & Body

TYPE ● GASTRITIS [90%]

- dit H. pylori
- mc ly involves Antrum
- H. pylori secretes

↳ Urease }
 CAG - A } Gastric mucosal inflammatⁿ
 VAC - A }



→ CLINICAL MANIFESTATIONS OF H. pylori associated inflammatⁿ

1. DUODENAL ULCER [dit hypersecretⁿ of acid → Gastric metaplasia]
2. STOMACH CANCER
3. REACTIVE T-CELLS → FACTORS → Polyclonal B-cell proliferatⁿ
 ↓
 MALTOMA

PEPTIC ULCER DISEASE

- damage to mucosal lining
- complicatⁿ of chronic gastritis
- COMMON SITES
 1. Duodenum [1st part]
 2. Antrum [Lesser curvature]
 3. GEJ

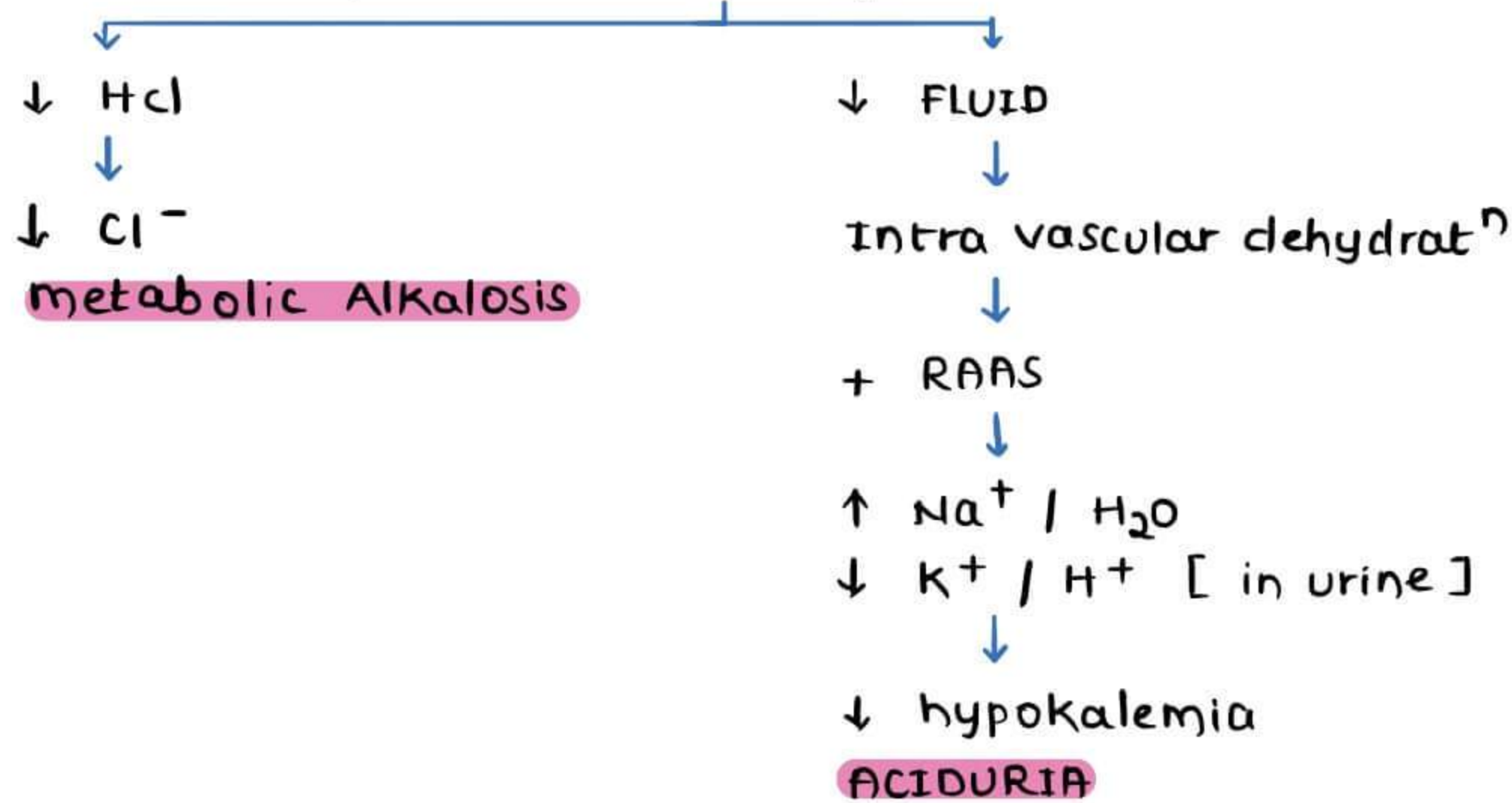
DUODENAL ULCER	GASTRIC ULCER
→ Located in anterior wall of D ₁	→ at Lesser curvature [B-A junct ⁿ]
→ H. pylori ⁺ +++	→ H. pylori ⊕ / NSAIDs ⊕ / Smoking ⊕
→ ↑ Acid	→ ⊖ Acid & ab ⊖ mucosal sensitivity
→ Epigastric pain ↳ ↓ ē food ↳ wt. gain	→ Epigastric pain ↳ ↑ ē food ↳ wt. loss
→ Brunner gland hypertrophy ⊕	→ Brunner gland hypertrophy ⊖
→ not premalignant	→ Pre malignant
COMPLICATIONS	COMPLICATIONS
1. Bleeding ↳ melena ↳ from gastroduodenal artery	1. Bleeding ↳ Hematemesis ↳ source - Left gastric artery
2. MALIGNANCY ↳ benign always	2. Malignancy ↳ can be malignant

3. PERFORATION

- maly involves anterior wall
- can lead to pancreatitis } poor prognosis
- peritonitis } mortality

4. GASTRIC OUTLET OBSTRUCTION

- occurs at D₁
- a/w repeated episodes of vomiting



- © HYPOCHLOREMIC
HYPOKALEMIC
METABOLIC ALKALOSIS ±
PARADOXICAL ACIDURIA

t.me/latestpnotes

- common SITE → D₁
- mc cause in adults → stomach cancer

PUD

1. Bleeding [mc]
2. Perforatⁿ [mc a/w mortality]
3. GOO [hypochloremic hypokalemic metabolic alkalosis ± ACIDURIA]
4. Malignancy [± gastric ulcer]

DIAGNOSIS

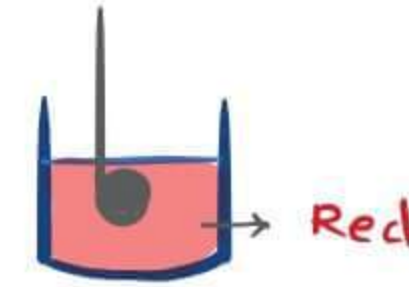
1. UREA BREATH TEST

Urea ¹⁴ } Breath Analyzer → detects CO₂ ¹⁴
Water }

H. pylori → Urease → Urea ¹⁴
CO₂ ¹⁴

BENIGN ULCER	MALIGNANT
→ small [$<4\text{cm}$]	→ big
→ flat	→ irregular
→ regular folds	→ Heaping margins
→ clean base	
→ at LC commonly	→ at GC commonly

3. CLO TEST [campylobacter like organisms]
- indicator → Phenyl Red
 - discoloratⁿ → positive



TREATMENT

- 1 PPI
 - 2 ANTI BIOTICS
- } TRIPLE DRUG THERAPY

GASTRIC TUMORS

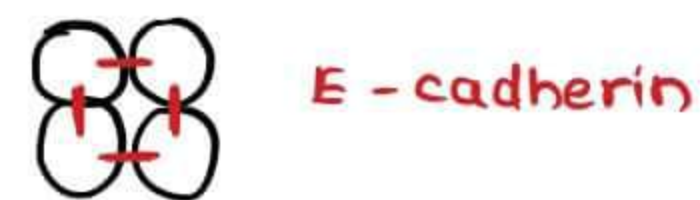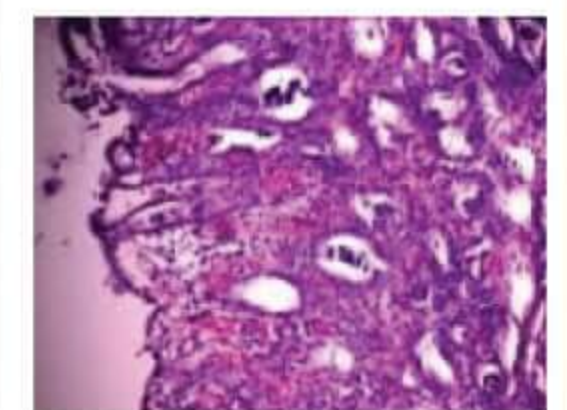
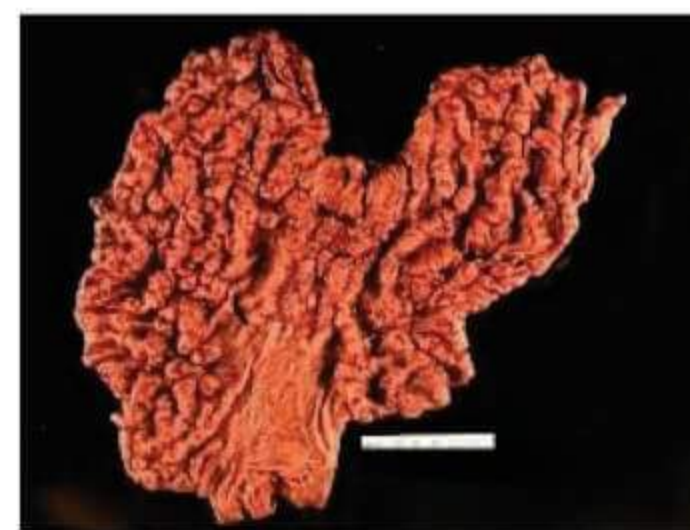
- MC Benign tumor
- MC malignant tumor
- MC malignant tumor which bleeds
- MC mesenchymal tumor
- LEIOMYOMA
- ADENOCARCINOMA
- LEIOMYOSARCOMA
- GIST

t.me/latestpgnotes

ADENOCARCINOMA

RISK FACTORS

- TOBACCO / ALCOHOL
- Nitrosamines
- H. pylori
- Autoimmune gastritis [A & B]
- Blood group A
- H/o previous gastric Sx
- Nutritional Deficiency
- Menetrier's disease
 - ↳ Foveolar hypertrophy
 - ↳ ↑ TNF α
 - ↳ Prominent gastric rugal folds



- CDH₁ mutation → E-cadherin
- APC mutation → ↑ adenomatous polyps
- LOCATION → ANTRUM

CF

- Early satiety [Post prandial heaviness] [earliest]
- wt loss [mc]
- abdominal pain

DIAGNOSIS

1. ENDOSCOPY + BIOPSY [IOC]

↓
Ulcer

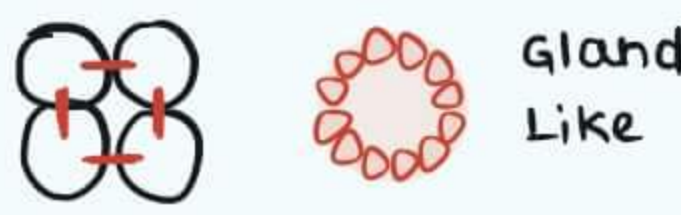

- ↓
1. Early
2. Late

→ mucosa & sub mucosa involved
→ muscle & Serosa also involved

Early → better prognosis
Late → poor prognosis



LAUREN'S CLASSIFICATION

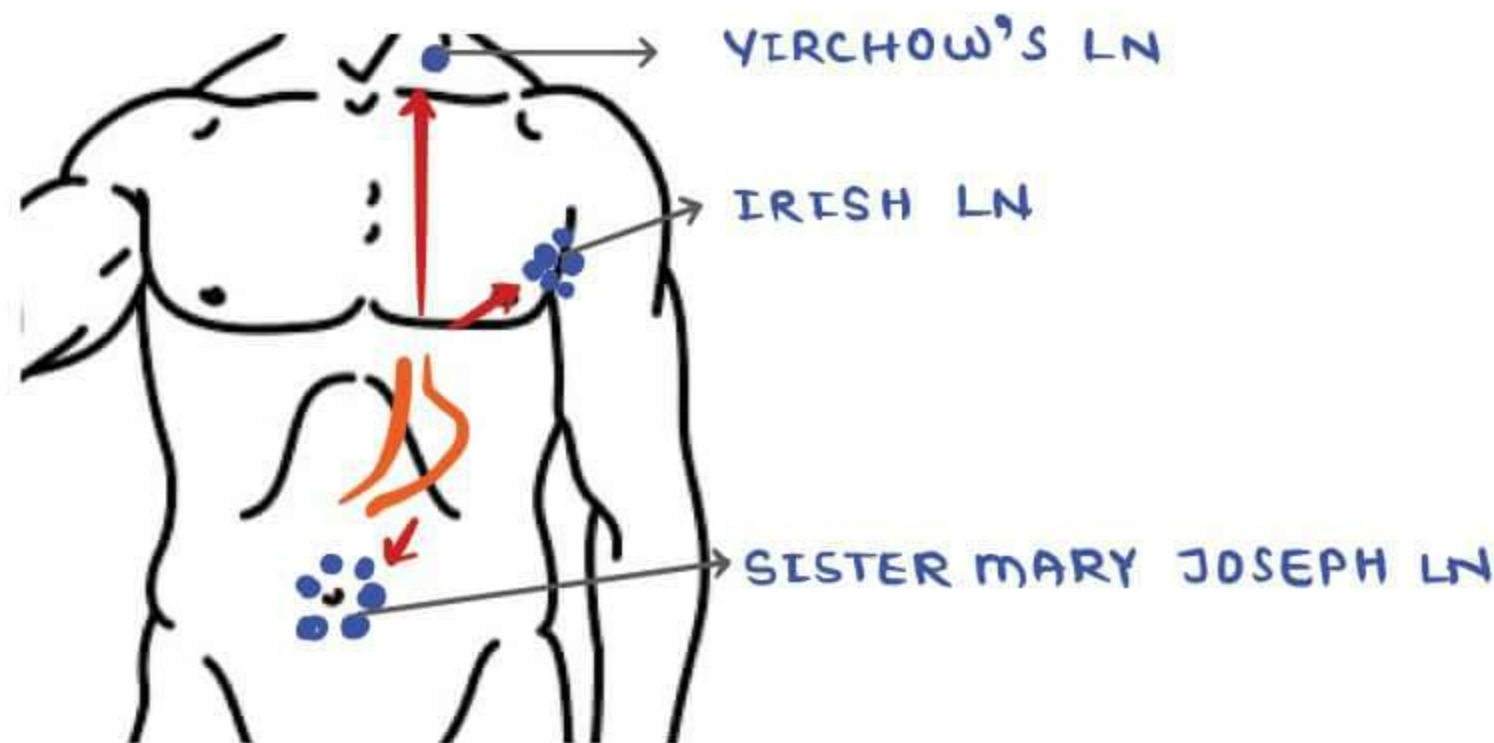
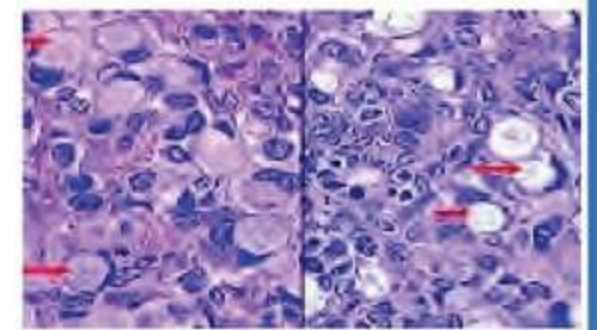
INTESTINAL TYPE	DIFFUSE TYPE
→ Localised cancer 	→ diffuse infiltration 
→ APC mutation ⊕	→ CDH1 mutation ⊕ → mucinous vacuole ⊕ → SIGNET-RING APPEARANCE → a/w DESMOPLASIA → LINITIS PLASTICA [Leather bottle appearance]
→ Better prognosis	→ Poor prognosis

BEST PROGNOSIS → SUPERFICIAL SPREADING VARIANT
t.me/latestpnotes

SPREAD

common organs involved

- ↳ Liver → mc
- ↳ Lungs
- ↳ ovaries → B/L ;  KRUKENBERG TUMOR
- ↳ LN → mī reason → 1° Gastric cancer



→ POD Involvement → BLUMER'S SHELF

GASTRO INTESTINAL STROMAL TUMOR

CELLS OF CAJAL

- component of MYENTERIC PLEXUS
- Pacemaker cells of GIT
- mutation of cells → ↑↑↑ Proliferatⁿ [dit Tyrosine kinase]

- Definitive markers
 CD 117 / C-KIT [more specific]
 CD - 34 [non-specific]

- other markers → DOG - 1 [detected on GIST 1]
- Rx by IMATINIB [Tyrosine kinase ⊖]
- mc mesenchymal tumor of stomach

NHL → mc Extranodal site → stomach (immunocompetent)
 → CNS [immunocompromised / AIDS]

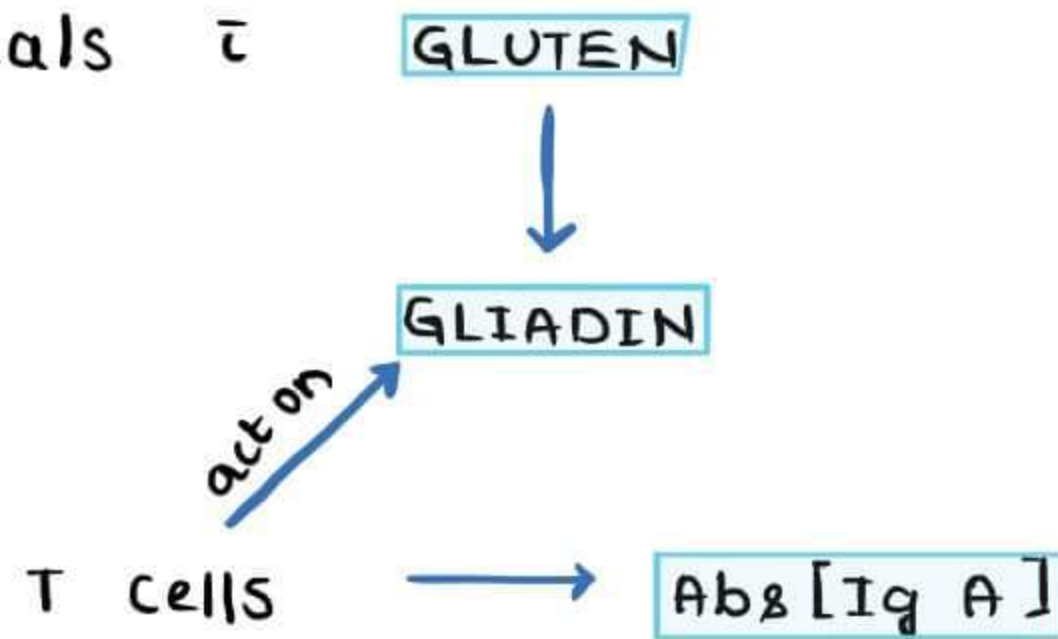
SMALL INTESTINE MALABSORPTION DISORDERS DIARRHEA ⊕

CELIAC SPRUE

→ a/w HLA - DQ₂ / DQ₈

→ **PATHOGENESIS**

1. cereals ⊖



GLUTEN CONTAINING CEREALS	
↳	wheat
↳	oat
↳	Barley
↳	Rye

- ↳ t. membrane gliadin Ab ⊕
- ↳ Anti - tissue transglutaminase Ab
- ↳ Anti - endomysial Ab ⊕

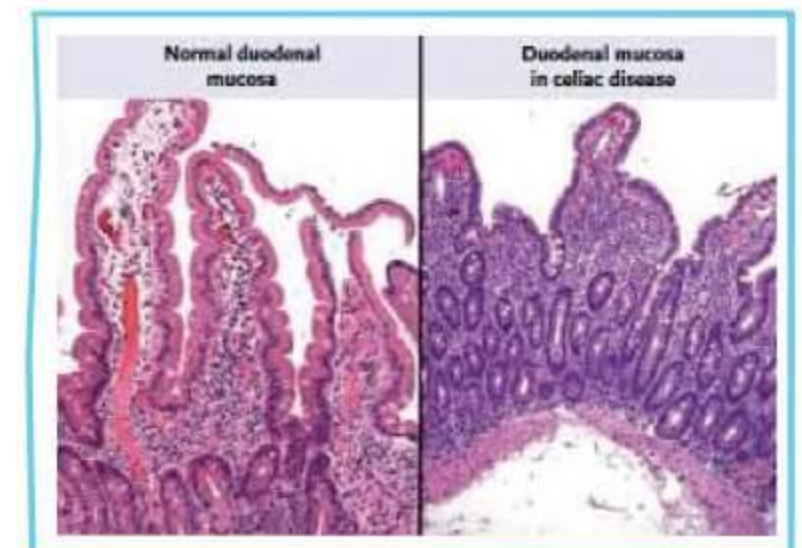
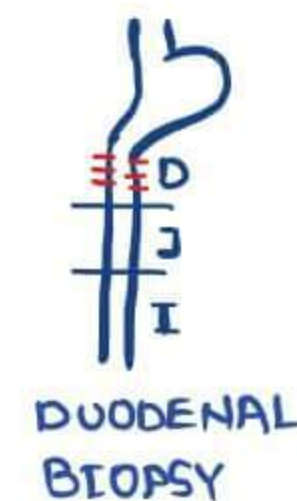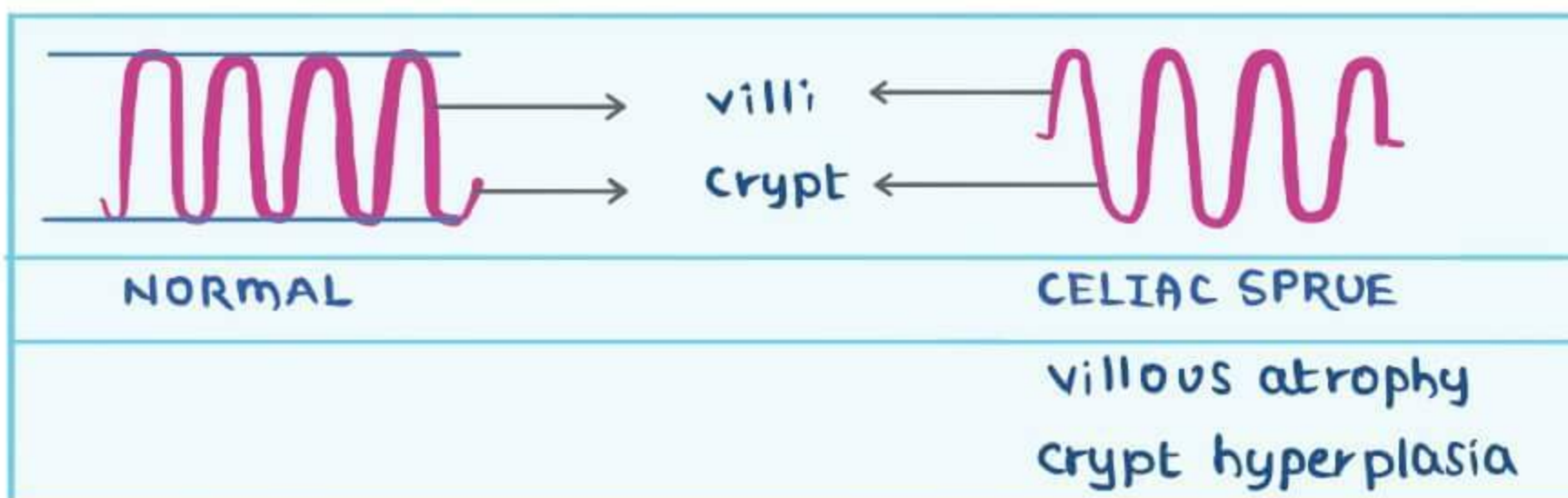
2. Ig A → DERMAL PAPILLAE ⊕ → DERMATITIS HERPETIFORMIS

→ **CLINICAL FEATURES**

- ↳ Diarrhea
- ↳ Abdominal pain
- ↳ Dermatitis herpetiformis

→ **DIAGNOSIS**

1. **INTESTINAL BIOPSY** [duodenal Bx]



THICKNESS MUCOSA NOT ALTERED
 Lymphocytic infiltration ⊕

→ repeated duodenal biopsies are indicated [at least 2]

→ COMPLICATIONS OF CELIAC SPRUE

- Malabsorptⁿ & SKIN manifestations
- DUODENAL COMPLICATION → IDA
- ↑ Enteropathic T-cell lymphoma

2. ANTI ANTIBODIES

- Anti TTG Ab + + + [preferred]
- Anti endomysial Ab

3. SKIN Bx

→ MANAGEMENT

1. CEREAL SUBSTITUTION → maize & Rice
2. DAPSONE for Dermatitis Herpetiformis
3. STEROIDS

- clinical manifestations instead of good dietary control indicates → ↑ Enteropathic T cell lymphoma

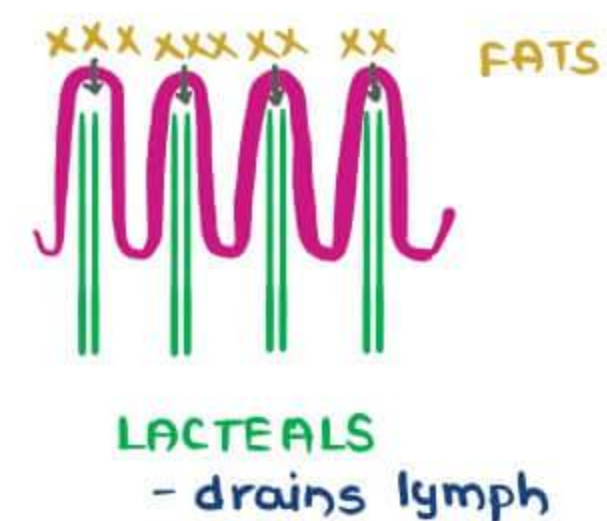
TROPICAL SPRUE

- Infectious disease [E. coli]
- Tropical distribution
- Total Intestinal involvement ⊕
 - ↳ deficiency of Fe / FA / B₁₂
- Benign condition
- good response to antibiotics

t.me/latestpgnotes

WHIPPLE DISEASE

- Causative Agent → TROPHYREMA WHIPPELLII
- MULTI SYSTEM INVOLVEMENT
 - ↳ Intestine
 - ↳ CNS [late involvement]
 - ↳ JOINTS [early involvement]
 - ↳ LN



- TROPHYREMA WHIPPELLI INFECTION → Macrophage infiltratⁿ in Lamina propria
- ↓
- ROD SHAPED BACILLI ⊕ Inside macrophages
- ← LACTEAL COMPRESSION & OBSTRUCTⁿ OF LYMPHATIC DRAINAGE →
- DIARRHEA

→ DIAGNOSIS

1. BIOPSY
 - a. PAS ⊕ , Diastase resistant granules inside macrophages
 - b. Rod shaped bacilli ⊕


- R_y by ANTIBIOTICS

- arises from NEURO ENDOCRINE CELLS
 - ↳ Chromogranin ⊕
 - ↳ NSE ⊕
- mc site involved → GIT > Bronchus

CASE I

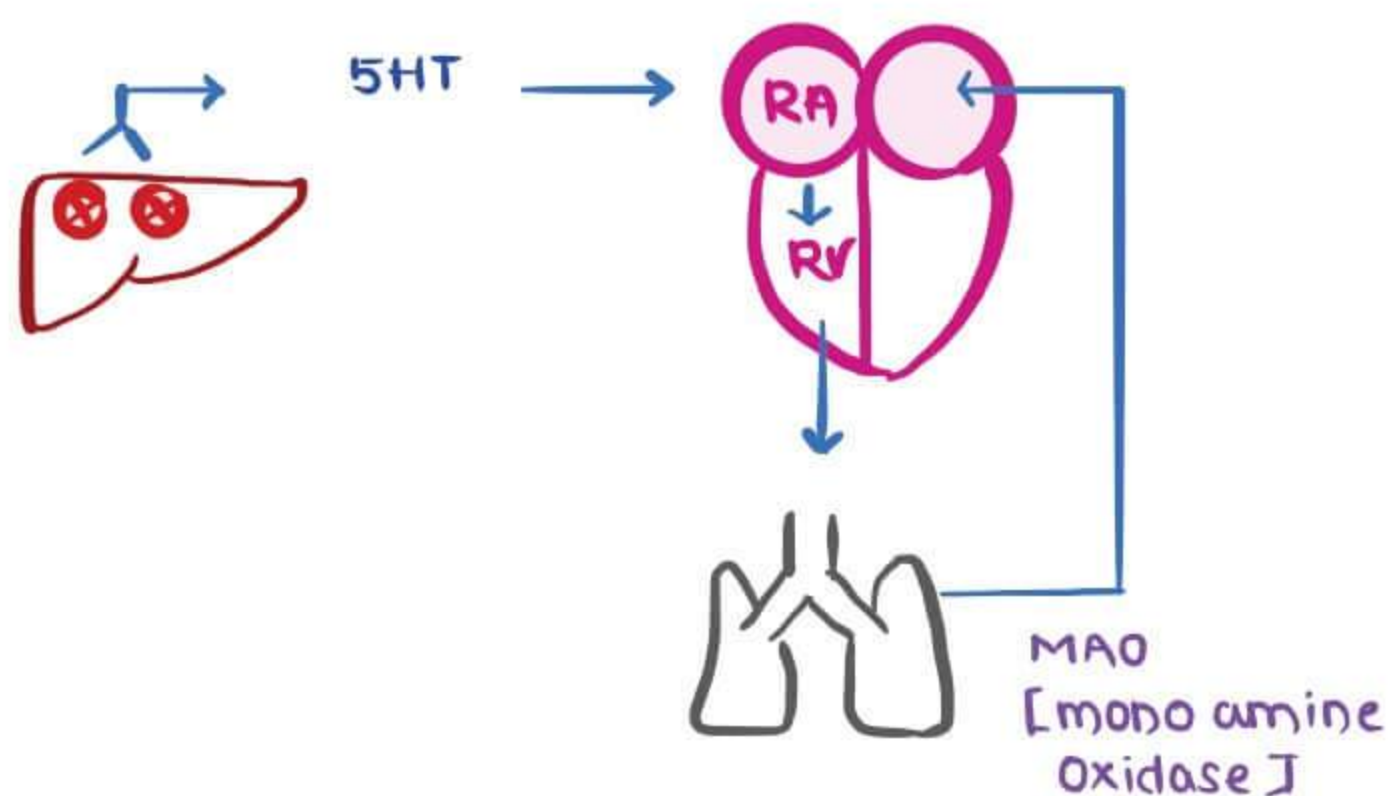


CASE II



CARCINOID SYNDROME

- ↑ 5HT in circulatⁿ by cancer cells
- CLINICAL FEATURES
 - Flushing
 - Diarrhea
 - Asthma like symptoms
 - Systemic fibrosis t.me/istatpnotes
 - ↳ isolated Rt heart involvement
 - ↳ Tricuspid valve → Regurgitatⁿ / Insufficiency
 - ↳ pulmonary valve → Stenosis



T	}	Tricuspid valve
I		Insufficiency
P	}	Pulmonary valve
S		Stenosis

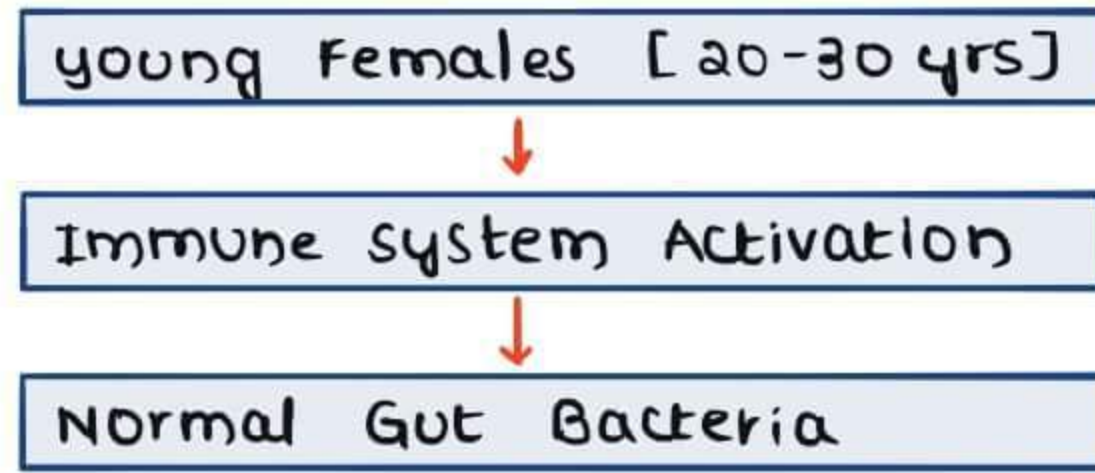
S	→ Systemic fibrosis [Rt ♡]
H	→ hepatomegaly
I	→ Intestine [Diarrhea]
V	→ vasomotor [Flushing]
A	→ Asthma like symptoms

DIAGNOSIS

1. SCREENING TEST → 24hr HIAA Levels in urine
2. PLASMA CHROMOGRAMIN - A Levels → ↑↑↑
3. BIOPSY & ELECTRON MICROSCOPY
 - Granules
 - ↳ chromogranin A ⊕
 - ↳ NSE ⊕

TREATMENT

1. Drugs for small tumors
2. Surgery for big tumors



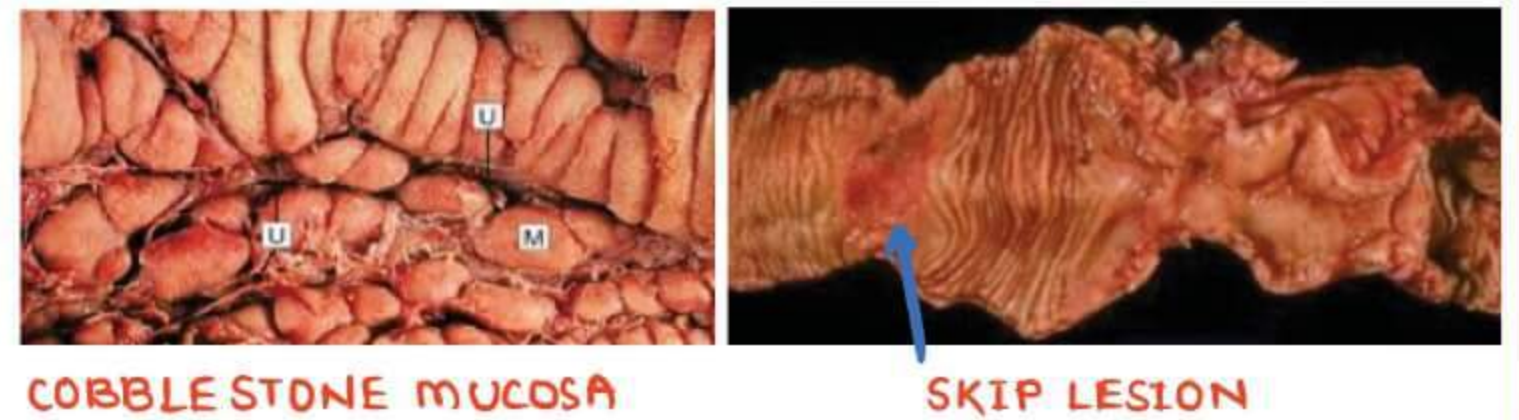AFFECTS

- GIT → Abdominal pain [colicky], diarrhea [bloody]
- Eyes → Uveitis
- Bile ducts → Obstructive jaundice
- Joints → migratory arthritis
- Skin → Erythema nodosum, pyoderma gangrenosum

CROHN'S DISEASE

- Involves ANY PART OF GIT
 - ↳ mclly → ILEUM
 - ↳ lclly → RECTUM

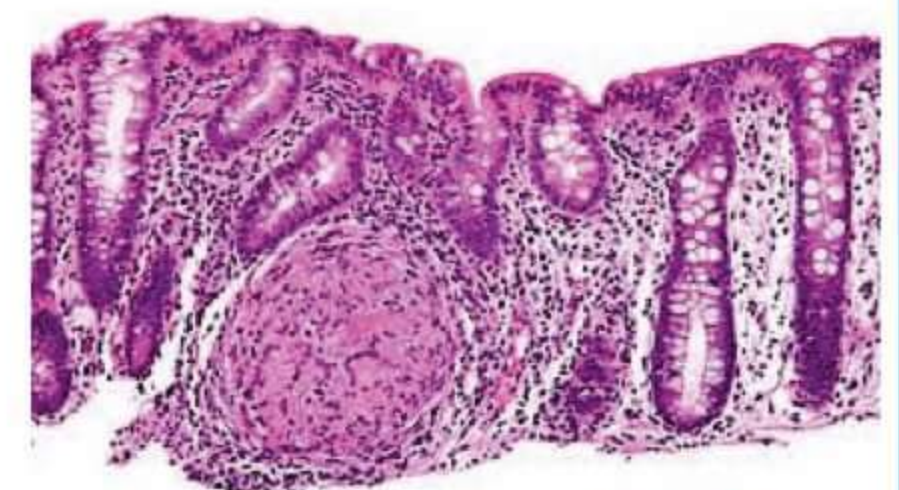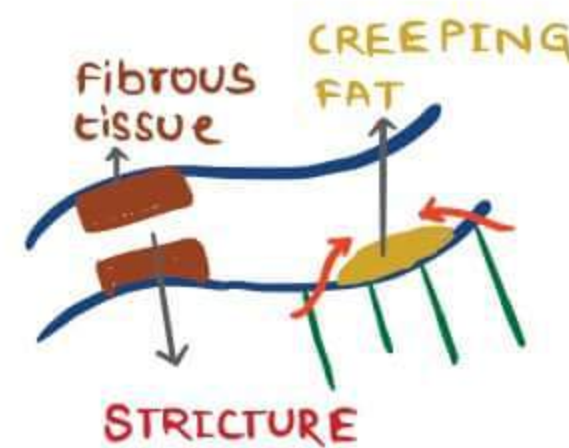
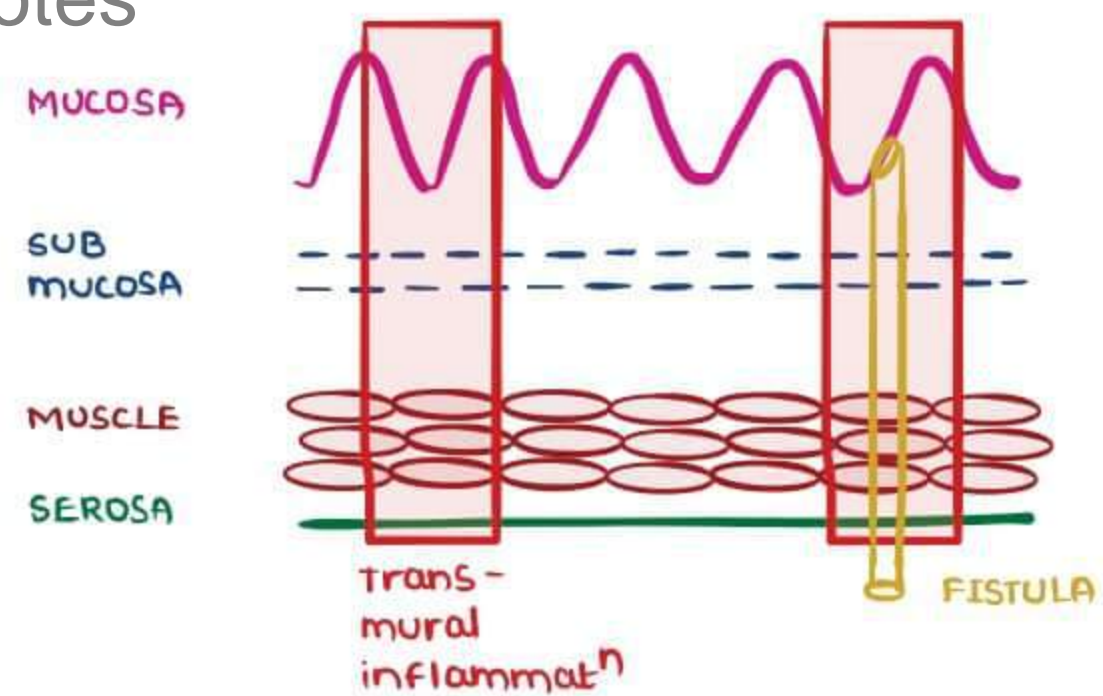
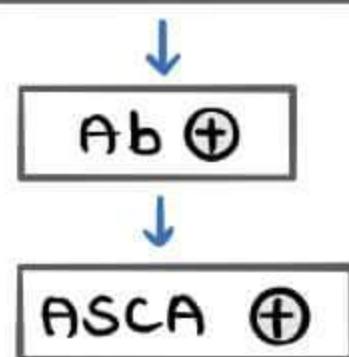
- SKIP LESIONS ⊕
- COBBLE - STONE MUCOSA ⊕



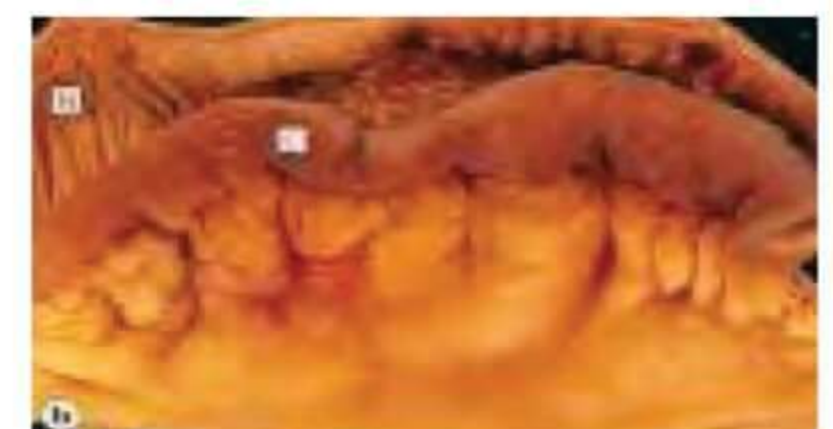- TRANSMURAL INFLAMMATION t.me/latestpnotes

- ↳ alw granuloma formatⁿ
- ↳ alw fistula formatⁿ
- ↳ alw Stricture formatⁿ
- ↳ CREEPING FAT ⊕

- SACCHAROMYCES CEREVISIAE



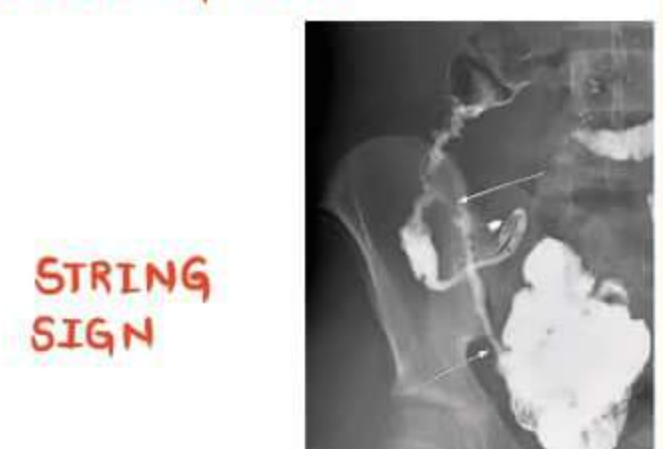TRANSMURAL INFLAMMATION



CREEPING FAT

CROHN'S DISEASE	
S	→ Skip lesions
I	→ Ileum [mc]
S	→ S.c. → ASCA ⊕
T	→ Transmural Inflammation [granuloma ⊕]
E	→ Extra Fibrosis → Stricture creeping fat
R	→ Rectum spared

- STRICTURE → STRING SIGN on Barium investigation



STRING SIGN

→ **CLINICAL FEATURES**

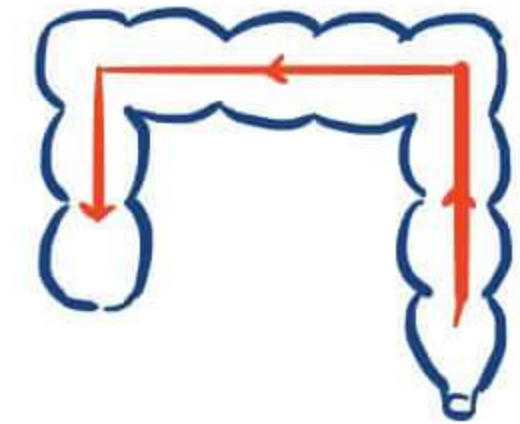
- Abdominal pain [Rt lower quadrant]
- Diarrhea
- Eyes ⊕
- SKIN ⊕

→ ↑ oxalate absorptⁿ in ileum → Systemic circulation → Kidney → RENAL STONES

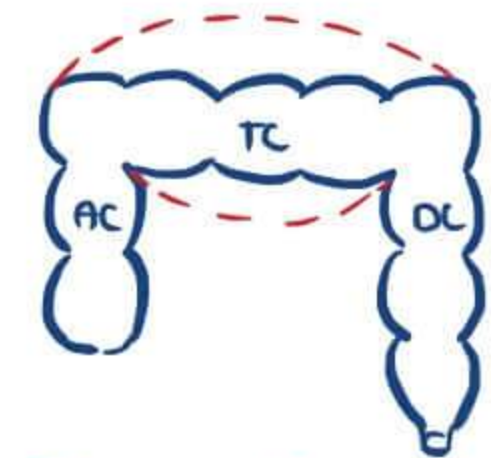
→ ↑ colon cancer

ULCERATIVE COLITIS

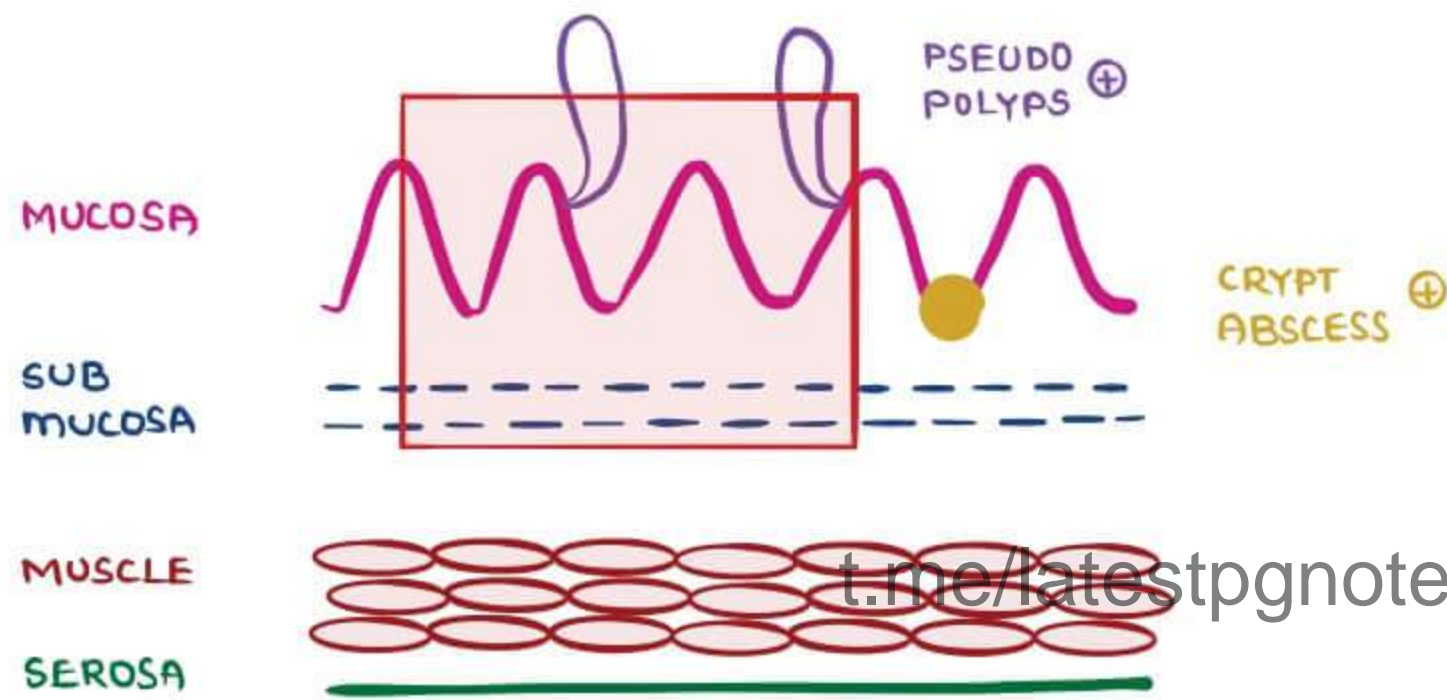
- involves COLON → Rectum [Retrograde spread]
- ↓
- PAN COLITIS [severe form]



RETROGRADE SPREAD

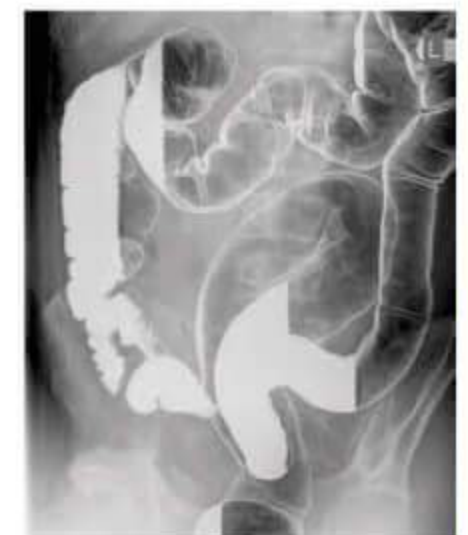

TOXIC MEGACOLON



t.me/latestpnotes

- SUPERFICIAL INVOLVEMENT [mucosa & sub mucosa]
- CRYPT Abscess ⊕
- PSEDO POLYPS ⊕
- TOXIC MEGACOLON [may rupture]
- LOSS OF HAUSTRATIONS ⊕ → LEAD - PIPE APPEARANCE
- p - ANCA ⊕ [also seen in vasculitis]



LEAD-PIPE APPEARANCE

→ **CLINICAL FEATURES**

- ↳ Abdominal pain [Lt. lower quadrant]
- ↳ Diarrhea
- ↳ Jaundice
- ↳ Joint involvement
- ↳ ↑ colon cancer [UC > CD]

U	→ ulcers [mucosa & sub mucosa]
C	→ continuous involvement
O	→ origin
L	→ Lead pipe appearance
I	→ ↑ growth [pseudopolyps]
T	→ Toxic mega colon
I	} ↑ severity / ↑ colon cancer
S	

p ANCA ⊕
Granuloma ⊖

POLYPS

NON-NEOPLASTIC POLYPS

- 1. Inflammatory polyps
- 2. Hyperplastic polyps → mc, Recto Sigmoid locatⁿ
- 3. Hamartomatous polyps
 - a. PEUTZ-JEGHERS POLYP → origin → Jejunum
 - b. JUVENILE → origin → Rectum
 - < 5 yrs age group
 - Solitary

JUVENILE POLYPOSIS SYNDROME

- ↑ Stomach | colon cancer
- multiple polyps

PJ SYNDROME

NEOPLASTIC POLYPS → Adenomatous Polyps

COLON CANCER

- Elderly
- Rectum >> Sigmoid colon
- Adeno carcinoma

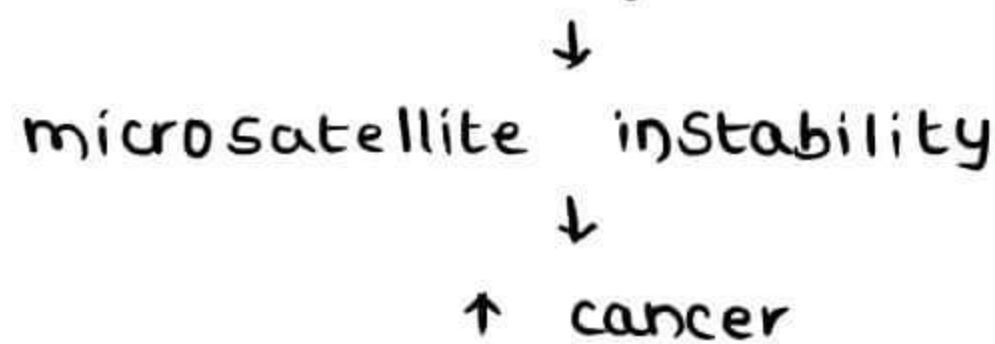
t.me/latestpgnotes

RISK FACTORS

A. GENETIC

1. HNPCC / LYNCH SYNDROME

→ a/w DNA Repair genes defect [MSH | MLH]



→ LYNCH SYNDROME | C/E/O SYNDROME

- C → Colon cancer [Rt]
- E → Endometrial cancer
- O → Ovarian cancer

→ < 50 yrs age group

2. FAMILIAL ADENOMATOUS POLYPOSIS [FAP]

APC gene → Chr 5q → ↓ Adenoma

mutation → ↑↑ Adenomatous Polyps → ↑ colon ca

SUB TYPES

1. CLASSICAL

→ \gg 100 Adenomas + Retinal Pigment Epithelium hypertrophy

2. TURCOT SYNDROME

→ classical FAP + CNS tumors [medulloblastoma | glioma]

3. GARDNER SYNDROME

- FAP
- Osteoma
- Fibromatosis
- epidermal cysts

B. ENVIRONMENTAL RF

↑ RISK

Dietary lipids
Pelvic irradiation
Streptococcus bovis endocarditis
Ureterosigmoidostomy

↓ RISK

Dietary fibers
NSAIDs
HRT

C. IBD

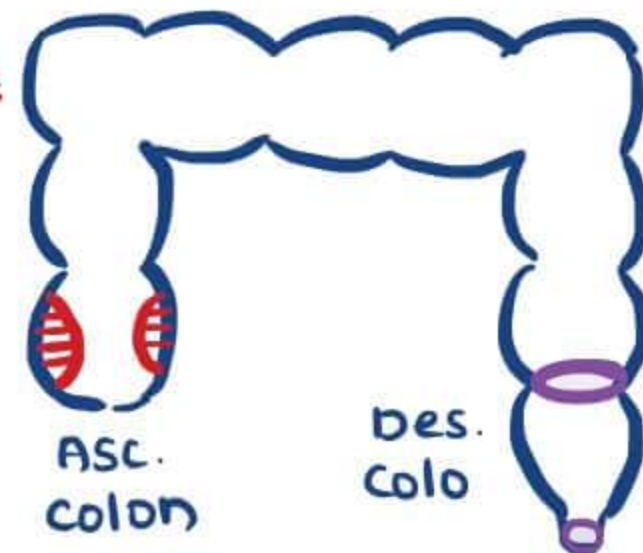
- CD → ↑↑
- UC → ↑↑↑

CLINICAL FEATURES

t.me/latestpgnotes

ULCERATIVE | FUNGATIVE

↳ SIS of Anemia



CIRCUMFERENTIAL | NAPKIN RING APPEARANCE

- Alteration of bowel habits
- Bleeding per rectum [Rectal cancer]
 - ↳ Tenesmus
 - ↳ Spurious diarrhea

DIAGNOSIS

1. COLONOSCOPY + BIOPSY [IOC]
2. FECAL OCCULT BLOOD TEST
 - detected by
 - a. Microscopic Examination of Stool sample
 - b. GUAIC TEST

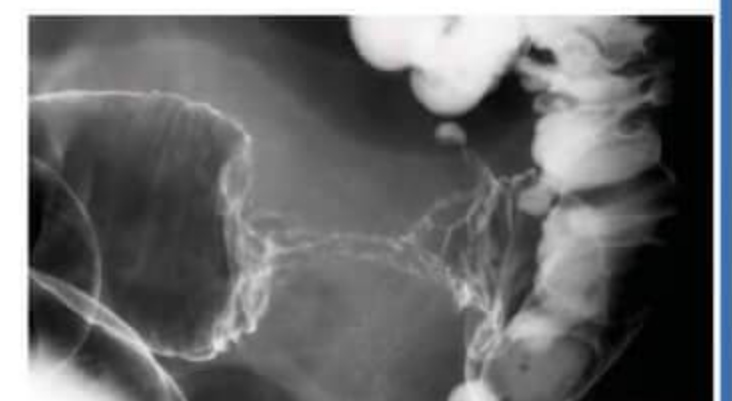
3. TUMOR MARKERS

→ ↑↑ S. CEA [carcino Embryonic Antigen] → useful to check recurrence

4. APPLE CORE APPEARANCE ON Barium enema

SCREENING TEST

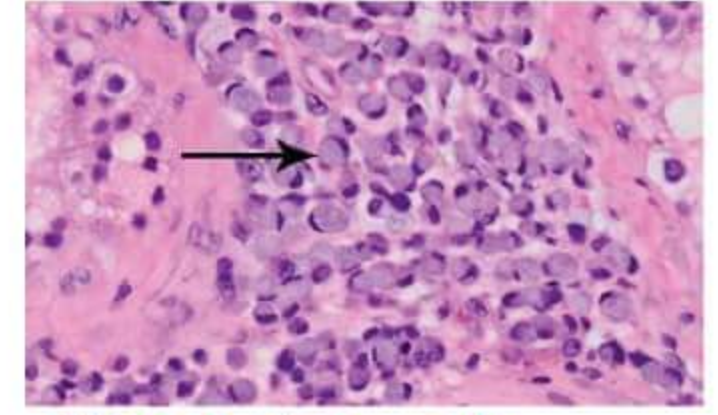
1. colonoscopy
2. fecal occult Blood Test



Apple core lesion

METASTASIS

1. Liver
2. Lymph nodes
3. Ovaries [Krukenberg tumor - signet-ring appearance]



Signet ring cell

Rx**1. SURGERY****2. ANTI CANCER DRUGS****a. FOLFOX REGIME**

- Folinic Acid
- 5-FU
- Oxaliplatin

b. FOLFIRI REGIME

- Folinic Acid
- 5-FU
- Irinotecan

ANAL CARCINOMA

- Squamous cell carcinoma
- Rx by CHEMO - RADIATION → NIGRO'S REGIME

t.me/latestpgnotes

RESPIRATORY SYSTEM

INTRODUCTION

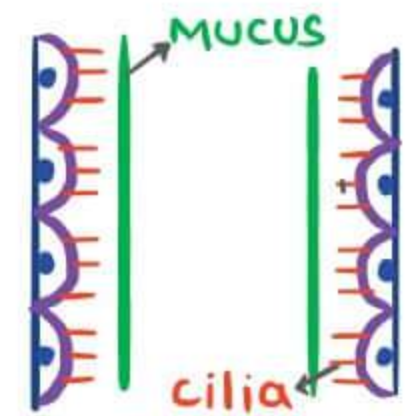
171

BASIC CONCEPTS

- RIGHT BRONCHUS IS MORE ALIGNED WITH TRACHEA THAN LEFT → FB impactⁿ is more
- Airway is lined by PSEUDO STRATIFIED CILIATED COLUMNAR EPITHELIUM
- DEFENCE MECHANISMS WHICH HELPS IN REMOVAL OF DUST/BACTERIA/Ag
 1. upward movement of MUCUS d/t CILIARY movement
 2. ALVEOLAR MACROPHAGES → helps in phagocytosis

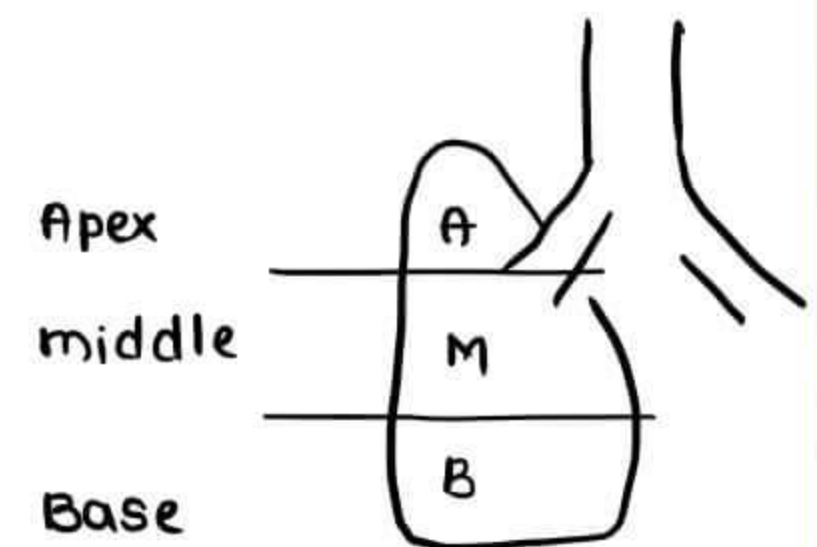
→ ↓ CILIARY ACTIVITY SEEN IN

1. SMOKING
2. KARTAGENER SYNDROME [d/t DYNEIN defect]
 - TRIAD OF
 - ↳ Bronchiectasis
 - ↳ Situs inversus [dextro cardia]
 - ↳ sinusitis



→ ↓ fertility

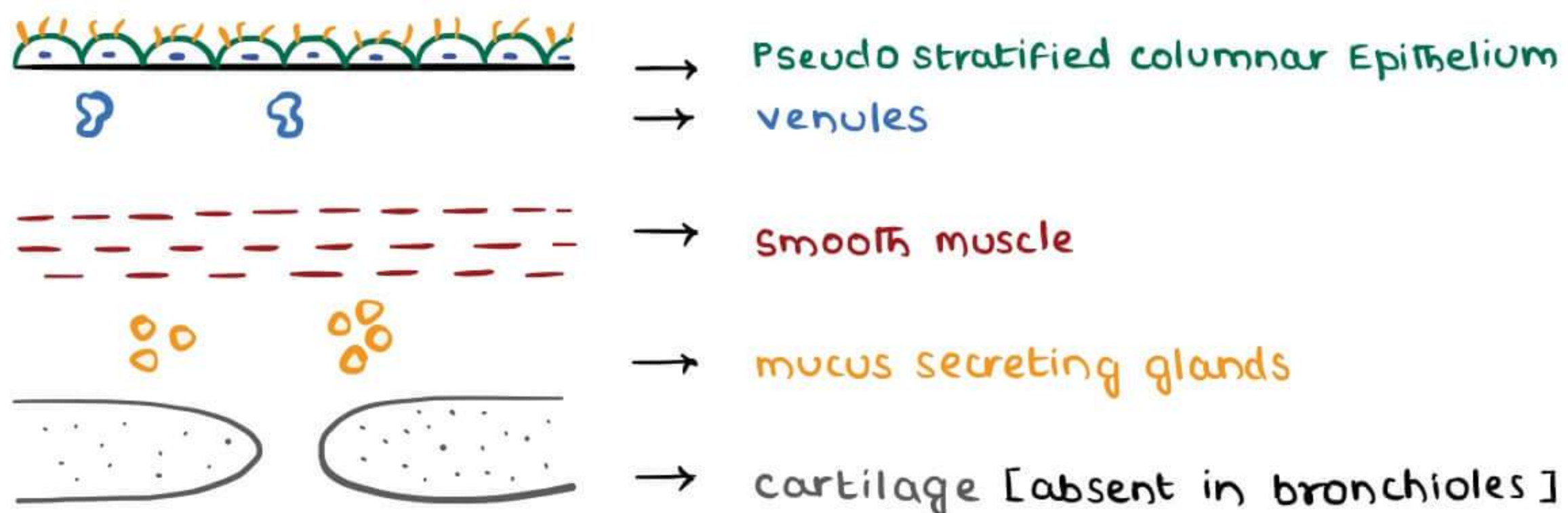
- ventilation is maximum at BASE
- Perfusion is maximum at BASE
- V/P Ratio is maximum at APEX



→ PNEUMOCYTES

1. TYPE I → Lining of alveoli
2. TYPE II → Secretes surfactant [↓ ST] & has repair function

→ HISTOLOGY



REID'S INDEX

$\frac{A}{B}$ [Thickness of mucus gland layer]
B [distance b/w epithelial cell & cartilage]

→ N → < 0.4

→ Increased in PULMONARY BRONCHITIS

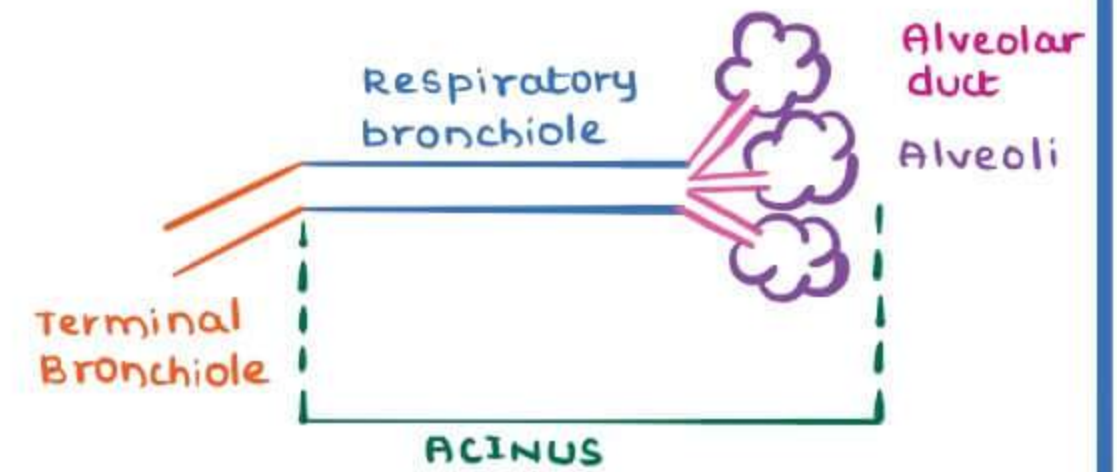
SPIROMETRY

- FEV₁ ↓↓↓ & FVC ↓
- $\frac{FEV_1}{FVC}$ ↓
- RV ↑↑ → ↑ TLC

EMPHYSEMA

ACINUS

- functional unit of lung
- DAMAGING FACTORS
 - ↳ Elastase [N/m] → Elastin damage
- PROTECTIVE FACTORS
 - ↳ Anti Elastase activity
 - α₁ anti trypsin
 - α₁ macroglobulin



EMPHYSEMA → Permanent abnormal dilatation of Acinus

ETIOLOGY

- Smoking
- α₁ - anti trypsin deficiency / late stage notes
 - ↳ PiMM gene
 - ↳ α₁ - anti trypsin misfolded
 - ↳ causes micro nodular cirrhosis + Emphysema
 - PiMZ gene defect → heterozygous
 - PiZZ gene defect → homozygous → total absence of enzyme

SUB TYPES

1. CENTRI ACINAR EMPHYSEMA

- dlt smoking
- Upper lobes of Lungs are affected
- mc clinically seen emphysema

2. PAN ACINAR EMPHYSEMA

- whole acinus involved
- dlt α₁ - anti trypsin deficiency
- base of lung involved
- alw micro nodular cirrhosis
- autosomal recessive

3. DISTAL ACINAR EMPHYSEMA

- seen in smokers
- alw Spontaneous pneumothorax
- Upper lobe involved

A. IRREGULAR EMPHYSEMA

- patchy involvement
- mc microscopic emphysema

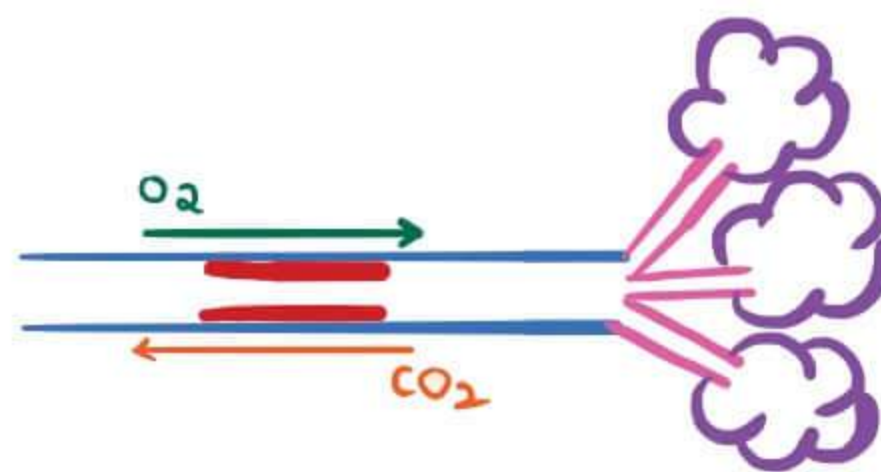
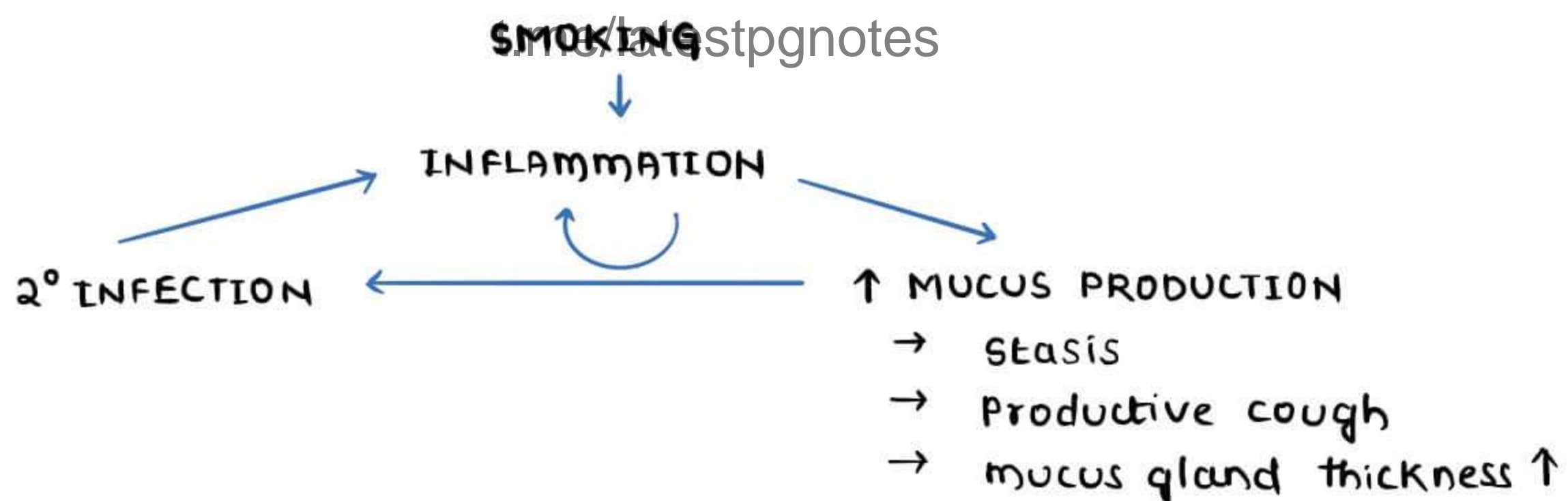
CLINICAL FEATURES

- ELASTIN FIBRES
 - ↳ Alveolar recoil maintained
 - ↳ maintain patency
- Dyspnea
- weight loss
- HD SMOKING
- PURSED LIP BREATHING
- AIR TRAPPING Leads to
 - ↳ Flat diaphragm
 - ↳ Barrel chest
- $pO_2 \rightarrow \uparrow$ → PINK PUFFERS
- Later → $pO_2 \downarrow$ → RT. ventricular failure

} dilatation of Alveoli
airway collapse

CHRONIC BRONCHITIS

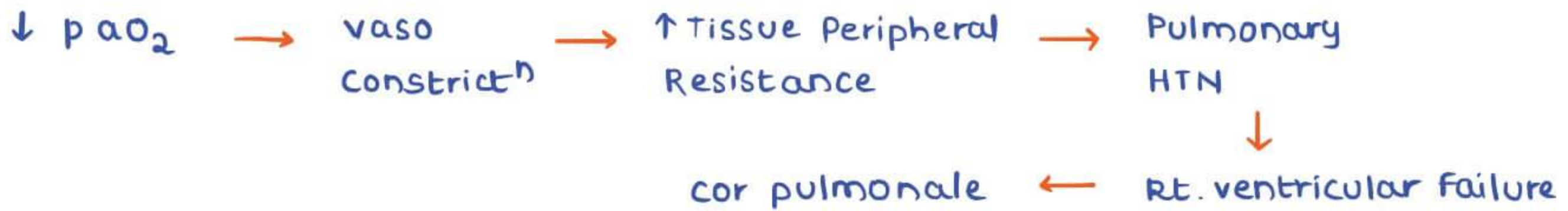
- productive cough ± sputum for at least 3 months in 2 consecutive years
- seen in SMOKERS



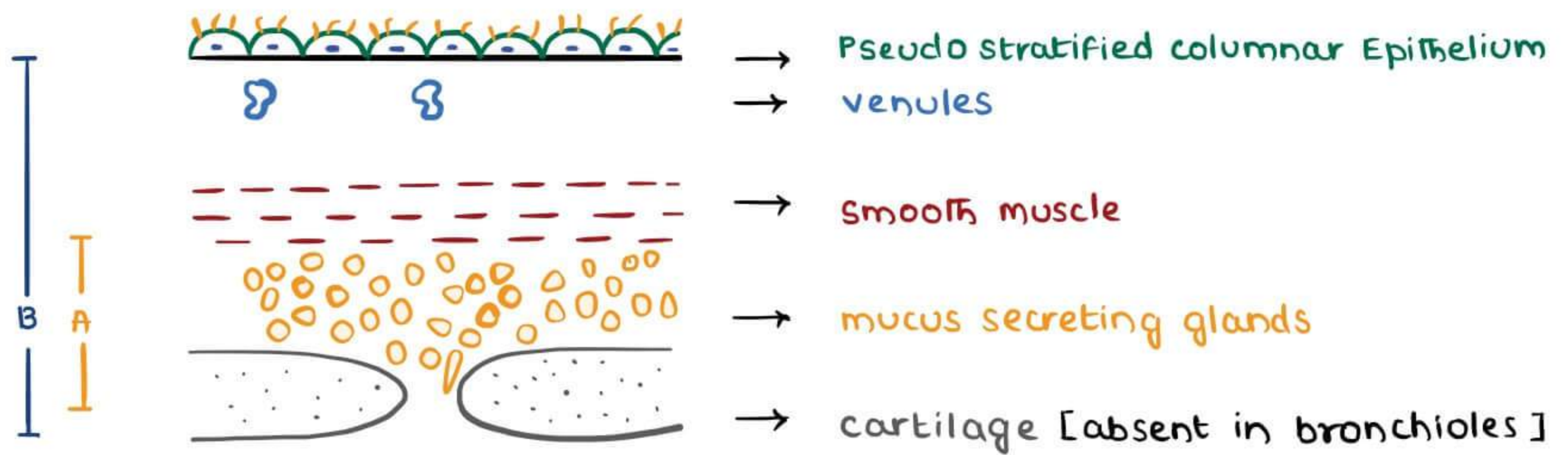
↑↑ $pA CO_2$
↓ $pA O_2$ → $pa O_2 \downarrow \downarrow$ → cyanosis

CLINICAL FEATURES

- Productive cough
 - Fever
 - Cyanosis
- } BLUE BLOATERS

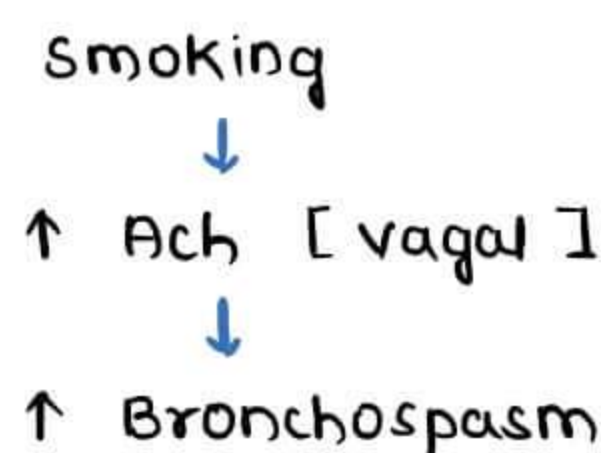


REID'S INDEX = $\frac{A}{B} \rightarrow \uparrow\uparrow$



- \rightarrow Squamous metaplasia \rightarrow Dysplasia \rightarrow \uparrow Bronchogenic cancer
- \rightarrow NO amyloid deposition \rightarrow NO AMYLOIDOSIS
- \rightarrow CHEST X-RAY \rightarrow Prominent markings [dit Pulm. HTN]

COPD \rightarrow Emphysema + me/chronic Bronchitis



R₁

1. Quit smoking
 2. O₂ Supplementatⁿ
 3. Ipratropium
 4. Antibiotics
 5. mucolytics
- } \uparrow Longevity

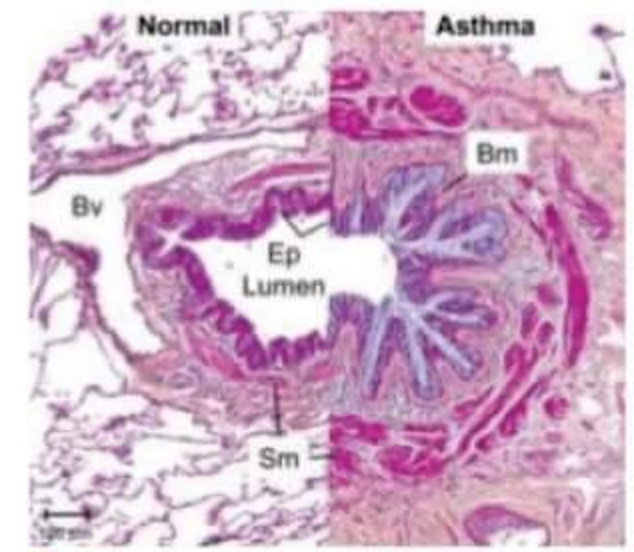
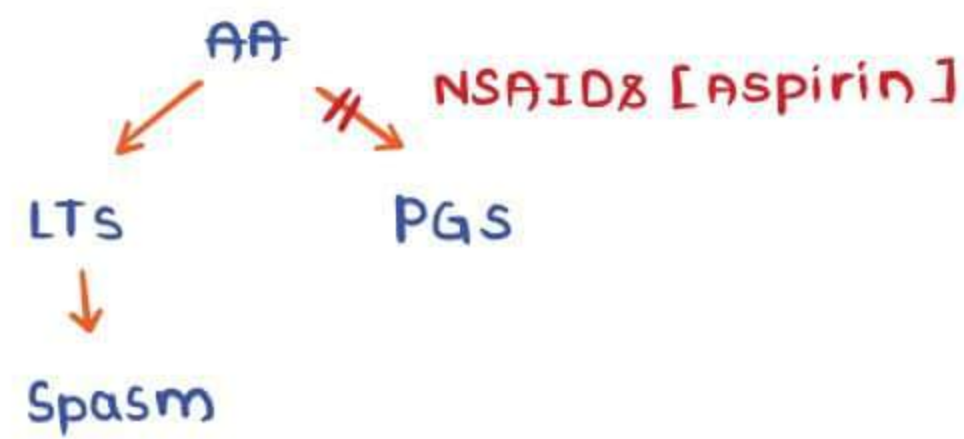
BRONCHIAL ASTHMA [Reversible]

EXTRINSIC

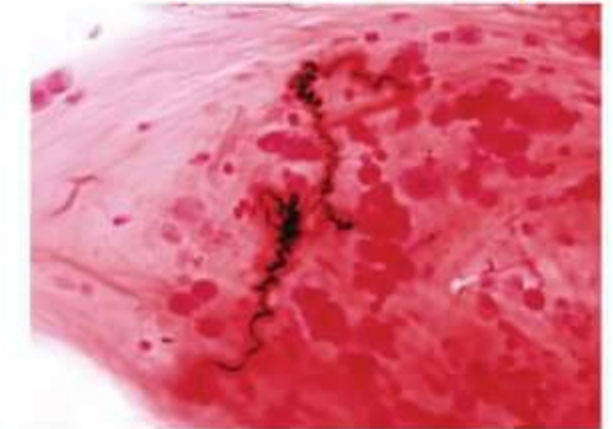
- \rightarrow dit Ext. antigen [dust / pollen]
- \rightarrow Type 1 HR
- \rightarrow \uparrow Ig E
- \rightarrow seen in children
- \rightarrow H10 Eczema ; atopy

INTRINSIC

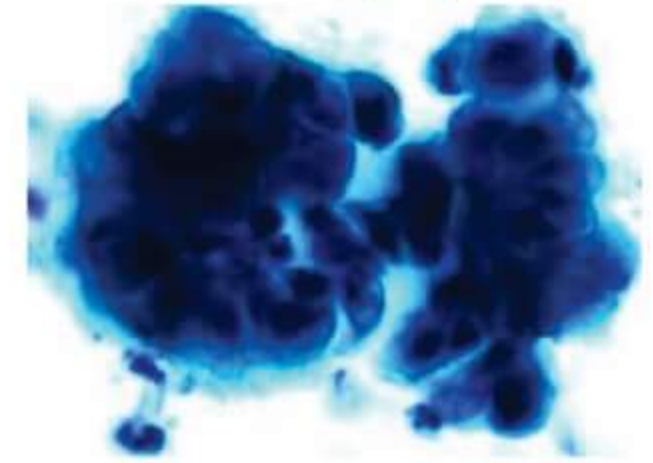- \rightarrow dit viruses [\downarrow Spasm threshold]
- Occupational disorders
- Exercise
- Drugs [NSAIDs]



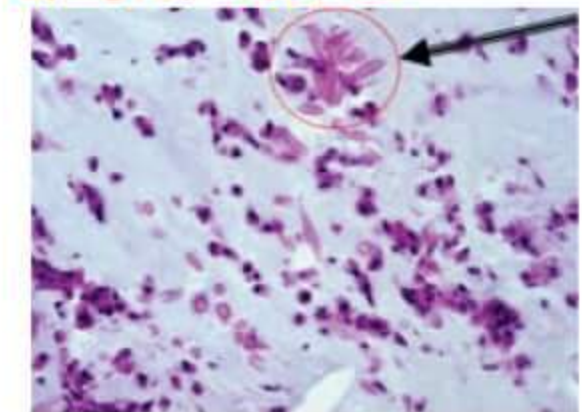
Airway remodelling



Curschmann spirals



Creola bodies



Charcot-Leyden crystals

→ SAMTER'S TRIAD

- ↳ ASA intolerance [Aspirin]
- ↳ Asthma
- ↳ Adult Nasal polyps

↳ Child Nasal polyps → CYSTIC FIBROSIS

→ CF

- Wheezing
- dyspnea
- nocturnal cough
- respiratory alkalosis

MICROSCOPIC EXAMINATION

- Airway remodelling

SPUTUM FINDINGS [3 'c's]

- CURSCHMANN SPIRALS
- CREOLA BODIES t.me/latestpgnotes
- CHARCOT - LEYDEN CRYSTALS

→ ADAM 33 gene alw ↑ fibrosis & ↑ smooth muscles

→ YKL - 40 PROTEIN → directly related to severity of Asthma

BRONCHIECTASIS

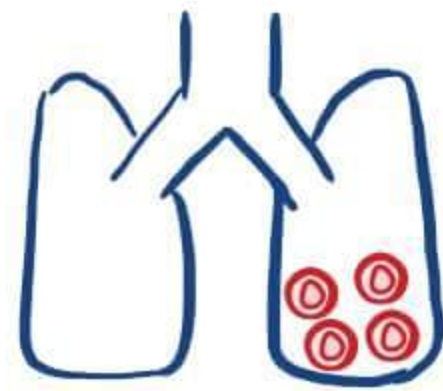
- chronic necrotising infection → Abnormal permanent dilatation of airways

ETIOLOGY

- Kartagener Syndrome
- cystic Fibrosis
- obstruction → FB or tumor
- Necrotising infection [TB [mc] | stap. aureus | Adenovirus]
- Allergic Broncho pulmonary Aspergillosis

CF

- Productive cough → clubbing
- dyspnea → ↓ pO₂ → cor pulmonale



Dilated Airways
upto pleura

- AFFECTS Left lower lobe commonly [Others involves Right lung]
- **GROSS** → Dilated airways upto pleura
- **HRCT SCAN** → HONEY COMB | TRAM TRACK APPEARANCE
- BRONCHIECTASIS → Benign & ↑↑ 2° Amyloidosis
- CHRONIC BRONCHITIS → ↑ cancer & no amyloidosis

RESTRICTIVE LUNG DISEASE

SPIROMETRY

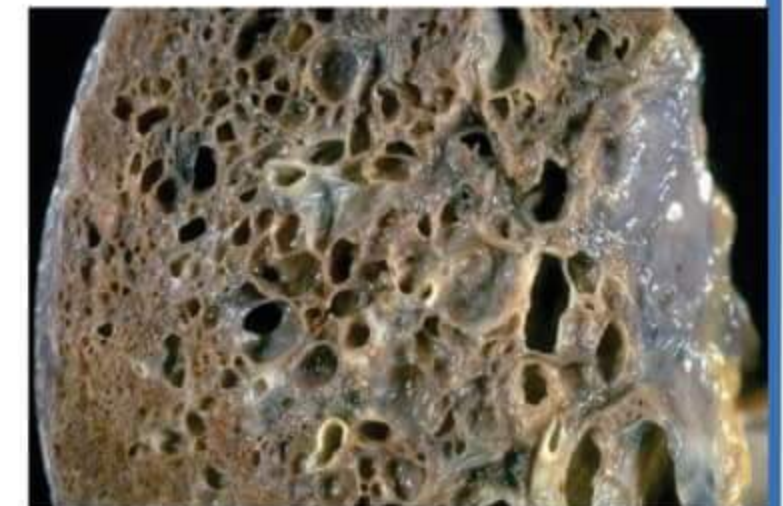- FVC ↓↓
- TLC ↓
- FEV₁ ↓

$$\rightarrow \frac{FEV_1}{FVC} \uparrow$$

- ↓ compliance
 - ↓ Diffusion capacity
- t.me/latestpnotes

- CIF**
- Cough
 - Dyspnea

- ↑ RR
- HONEY COMBING OF LUNGS [later stages]



Honey combing of lungs

ETIOLOGY

1. CHEST WALL DISORDERS

- a. NEURO MUSCULAR
 - Polio
 - muscular dystrophies
- b. OBESITY
- c. KYPHOSCOLIOSIS

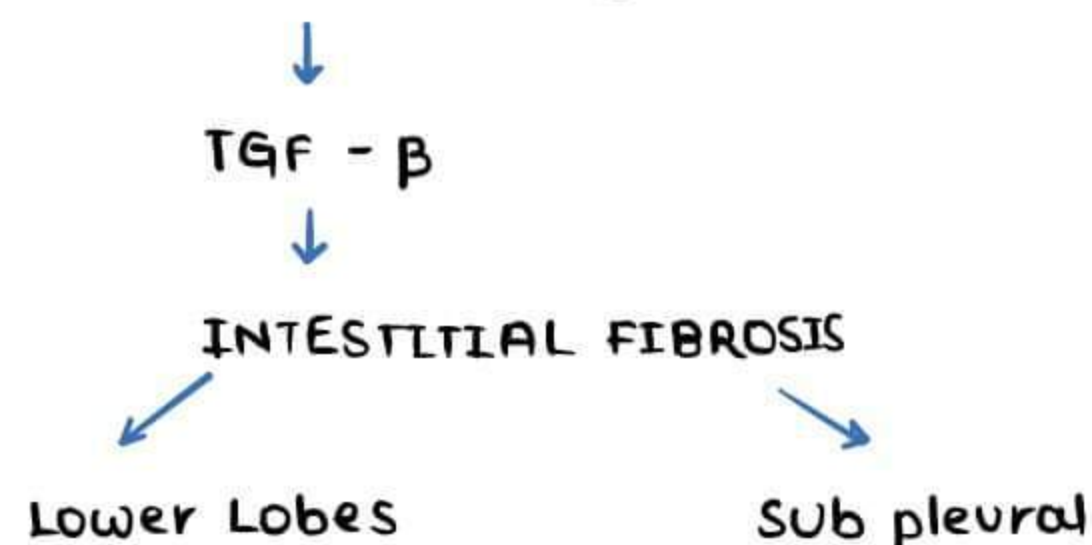
2. INTERSTITIAL DISORDERS

- a. Interstitial fibrosis
- b. Pneumoconiosis
- c. Hypersensitivity Pneumonitis
- d. Sarcoidosis

1. IDIOPATHIC PULMONARY FIBROSIS / CRYPTOGENIC FIBROSING ALVEOLITIS

ETIOLOGY

- cause unknown
- Alveolar Epithelial Injury → ALVEOLITIS ⊕



RISK FACTORS

- Age → Elderly
- GENETIC FACTORS → Telomerase / mucin / Surfactant
- ENVIRONMENTAL FACTORS → Smoking

- CIF**
- cough
 - Dyspnea
 - ↑ RR

- MIE** → USUAL INTERSTITIAL PNEUMONIA → Hall mark

Early stages → ↑↑ Fibrosis → FIBROBLASTIC FOUL

Later stages → ↑↑ collagen
↓ cellular component

BOTH stages CO - Exist --- → HONEY COMB FIBROSIS

- PROGNOSIS** → POOR

- TOC** → PULMONARY TRANSPLANT

- RULE OUT** → Drugs Exposure → Bleomycin / Methotrexate / Amiodarone
→ Radiation

NON SPECIFIC INTERSTITIAL PNEUMONIA

- ETIOLOGY** → Idiopathic / connective Tissue Disease

t.me/latestpnotes

- CIF** → Elderly ♀ [non-smoker]
→ Dyspnea / Cough

- MIE** → Cellular pattern } Same stage lesions
→ Fibrosing pattern } co-exist

- NO Fibroblastic foci
- NO honey combing

- BIL Reticular opacities On HRCT ⊕

CRYPTOGENIC ORGANISING PNEUMONIA

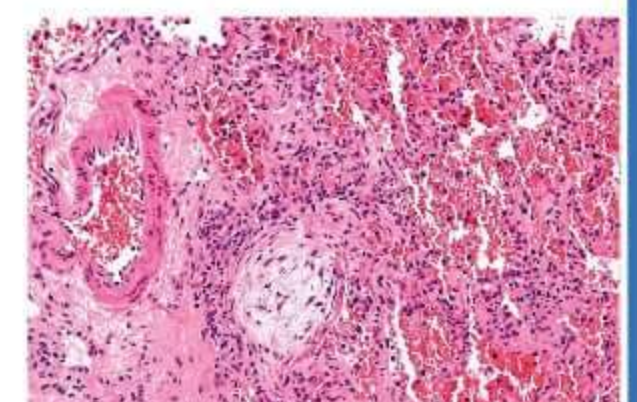
- ETIOLOGY** → unknown

- CIF** → cough & Dyspnea

- MIE** → MASSON BODY ⊕ [organised connective tissue in Alveolar ducts & bronchioles]

- NO honey combing
- NO Intstitial fibrosis

- Good response to STEROIDS



masson Body

Occupational Disorder

PATHOGENESIS → DUST PARTICLES INHALATⁿ [1-5 μ] → Alveolar macrophages ⊕ → FIBROSIS

1. SILICOSIS / GRINDER'S DISEASE / SAND BLASTING DISEASE

- mc
- dlt QUARTZ [SiO₂]
- upper lobes
- ↑↑ TB / ↑ cancer
- CXR → EGG SHELL CALCIFICATION [calcificatⁿ on Hilar LN]

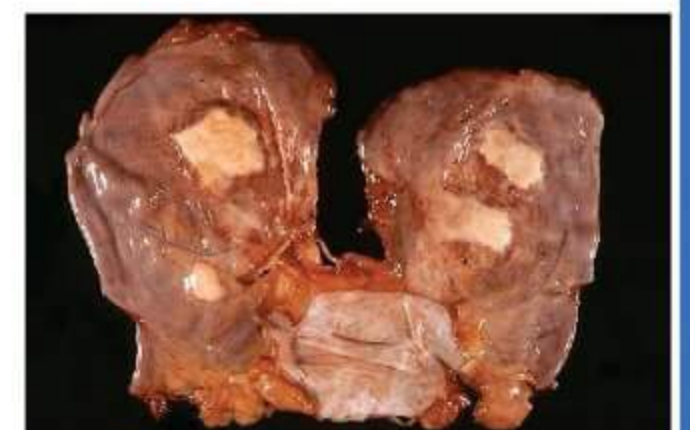

2. ASBESTOSIS

- Insulation / Plumbing
- **TYPES OF PARTICLES**
 1. Serpentine [curvy particles]
 2. Amphibole [more pathogenic] [straight particles]

→ **LESIONS**

- **PLEURAL PLAQUE**
 - ↳ mc lesion
 - ↳ seen at Basal area

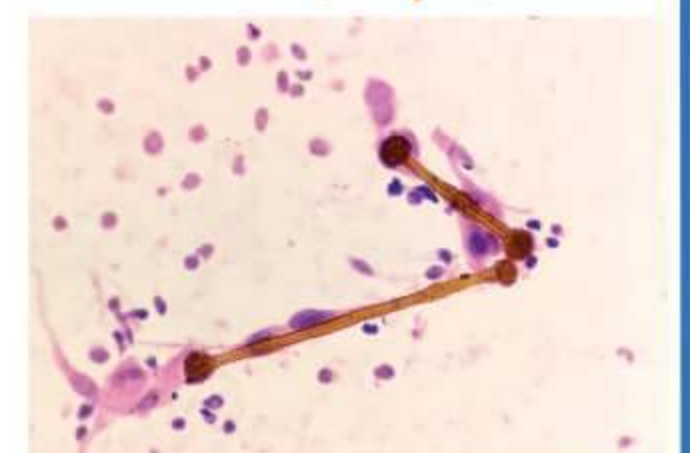

Pleural plaque

→ **INTESTITIAL FIBROSIS**



Proteaceous material = Fe
FERRUGINOUS BODY / ASBESTOS BODY



Ferruginous body

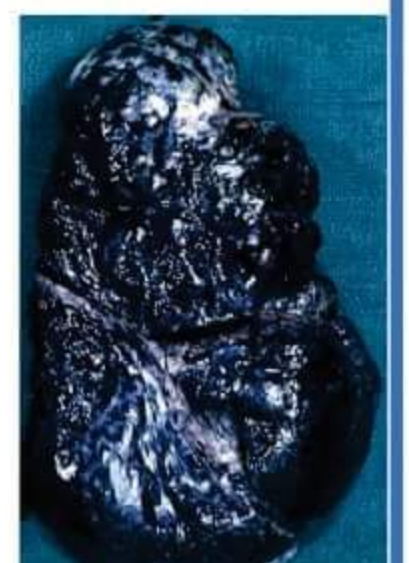- involves BASE
- ↑↑ cancers → acts as Initiator & promotor
 1. Bronchogenic carcinoma [15-20yrs exposure] → mc
 2. mesothelioma [25-35yrs exposure] → most specific

3. BERYLLIOSIS

- Nuclear Aerospace
- Intertitial fibrosis ⊕
non caseating granulomas in different organs
- ↑ cancer

4. COAL WORKER'S PNEUMOCONIOSIS

- coal dust
- **PRESENTATIONS**
 - A. PULMONARY ANTHRACOSIS
 - NO clinical symptoms
 - DUST CELLS ⊕ [macrophages ⊔ coal dust]



Black Lung

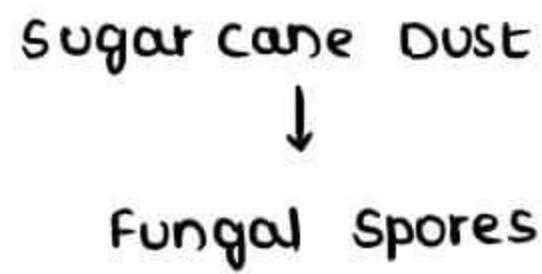
B SIMPLE COAL WORKER PNEUMOCONIOSIS

- nodules +
- Elastase → centri Acinar Emphysema

C. PROGRESSIVE MASSIVE FIBROSIS factors - Smoking & coal dust]

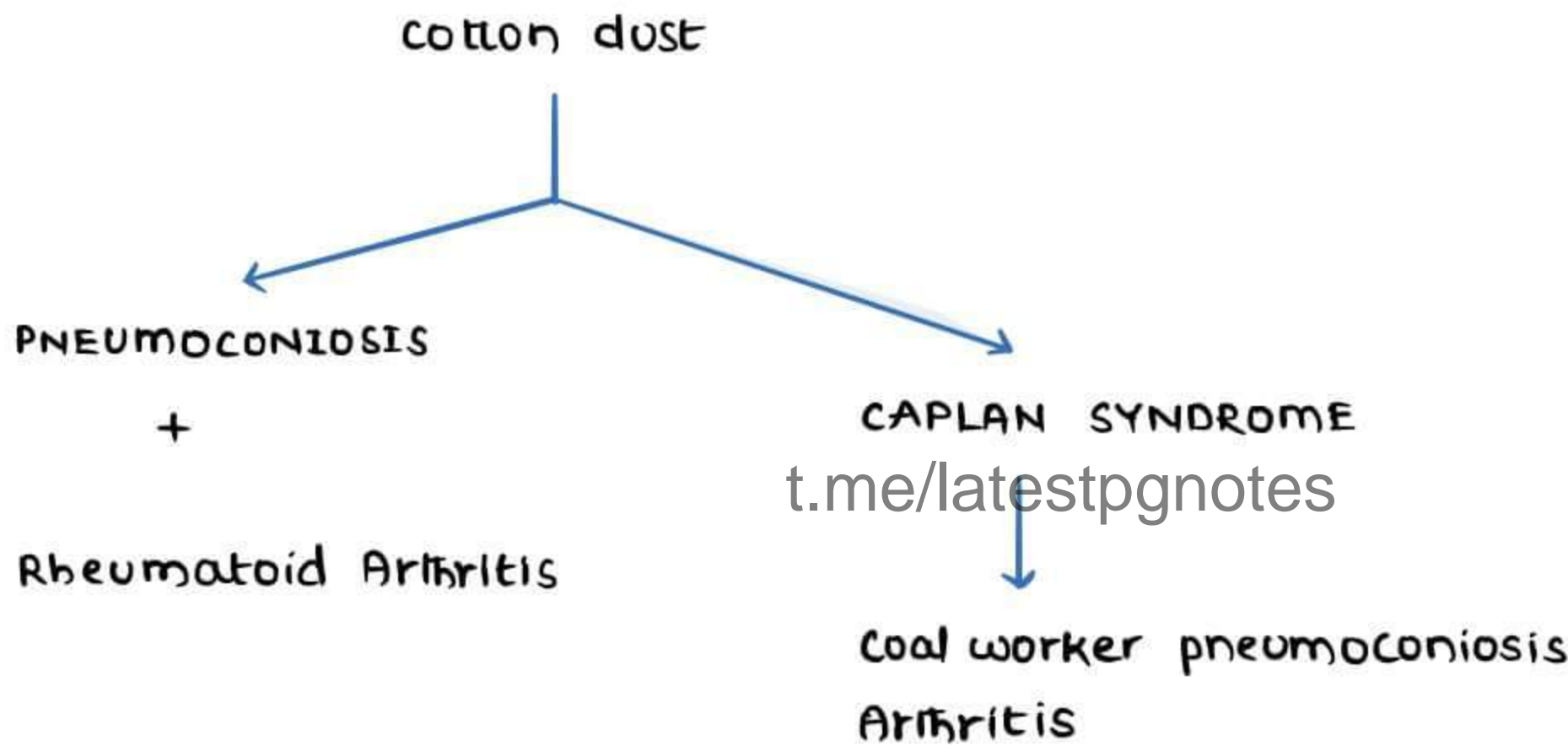
- complicated coal workers pneumoconiosis
- BLACK LUNG

5. BAGASSOSIS



2% Propionic Acid spray → Non - Pathogenic

6. BYSSINOSIS | TEXTILE WORKER DISEASE | MONDAY CHEST DISEASE



INFECTIOUS LUNG DISEASE

PNEUMONIA [Infection of Pulmonary Parenchyma]

TYPICAL | AIR- SPACE PNEUMONIA

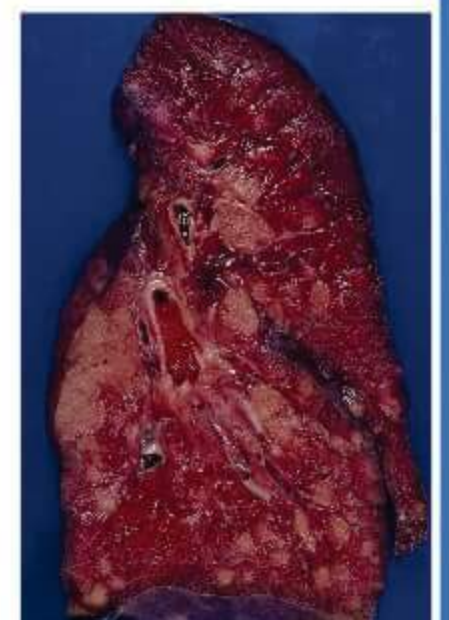
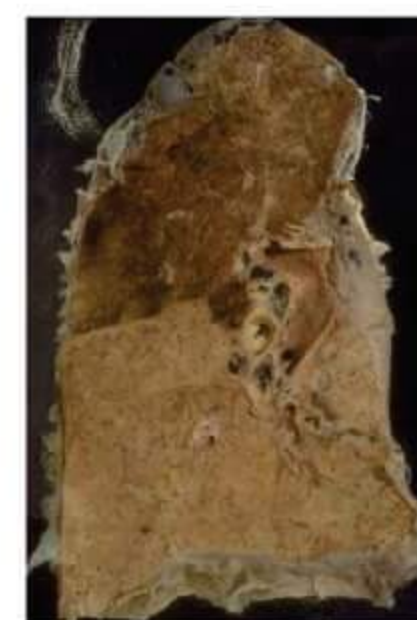- Alveolar Exudate ⊕ Neutrophilic infiltration
- **CF**
 - high grade fever
 - productive cough
 - pleuritis
 - Signs of consolidation

→ **SPUTUM** → Gram stain ⊕ & culture ⊕

→ **SUB TYPES**



- BRONCHO PNEUMONIA**
- Basal lobe +
 - **BIL**
 - 2 extremes of ages



Lobar pneumonia Bronchopneumonia



Streptococcus pneumoniae	→ CAP [Community Acquired Pneumonia] → Rusty sputum
Staphylococcus aureus	→ 2° pneumonia → abscess +
Klebsiella pneumoniae	→ Alcoholic → ↑ Aspiration → Red currant Jelly Sputum +
H. Influenzae	→ alw chronic bronchitis [Type 'b']
Pseudomonas	→ Burns → Cystic fibrosis → Immunosuppression
LEGIONELLA	→ humidified air exposure → ICU → causes pneumonia/Diarrhea/CNS ⊕ → PONTIAC FEVER [URTI] → Silver stain for identification → JG CELL damage ↳ ↓ Aldosterone ↳ ↑ K ⁺ / H ⁺ ↳ ↓ Na ⁺

STAGES OF PNEUMONIA

1. CONGESTION [1-2 days] t.me/latestpgnotes
→ Alveolar fluid ⊕ \bar{c} bacteria & neutrophils
2. RED HEPATIZATION [3-4 days]
→ RBCs ⊕ [in fluid]
→ Fibrin ⊕
3. GRAY HEPATIZATION [5-8 days]
→ Lysis of RBCs
→ Fibrin ⊕⊕⊕
4. RESOLUTION [> 8 days]
→ Neutrophils macrophages ⊕

ATYPICAL PNEUMONIA

- Non - Bacterial etiology
- Interstitial tissue Inflammation
- mono nuclear cell infiltration

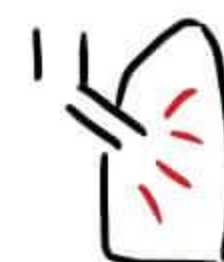

CIF

- Low grade Fever
- Dry cough
- malaise | myalgia
- no signs of consolidation

INVESTIGATION

- SPUTUM → staining ⊖
- CXR



1. MYCOPLASMA	→ mc → Ig M → AIHA (cold) → ♂ residing in closed spaces
2. CHLAMYDIA	→ 2nd MC → ↑ CAD
3. PNEUMOCYSTIS JIROVECI	→ Fungus → alw HIV → silver stain ⊕
4. COXIELLA BURNETII	→ causes Rickettsial infection i out a vector → causes 'Q' fever
5. VIRUSES	
INFLUENZA TYPE A	→ complicated by Staph. aureus → Aspirin CI (causes Reye Syndrome)
RSV	→ children → causes Bronchiolitis
CMV	→ OWL - EYE Inclusions → seen Immunosuppression [AIDS / Post transplantation]
MEASLES	→ KOPLIK SPOTS Rash → WARTHIN - FINKELDEY CELLS ⊕

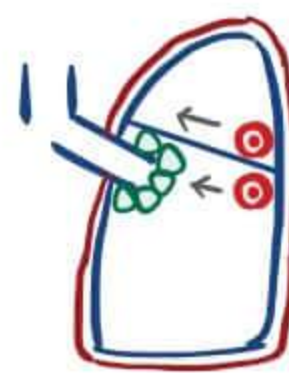PULMONARY TB & LUNG ABSCESS

PULMONARY TB timelapsestpgnotes

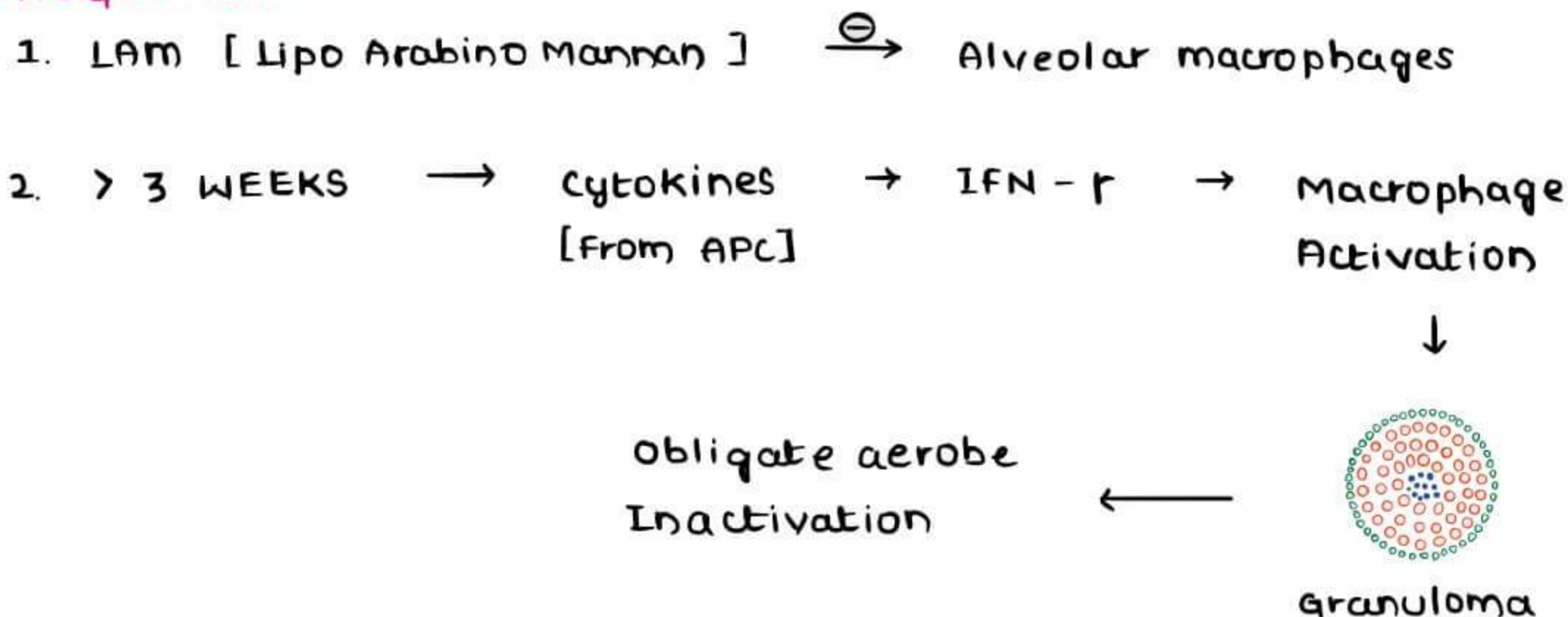
1° PULMONARY TB

- droplet infection
- GHON'S COMPLEX

SUBPLEURAL LESION
+
LYMPHATICS
+
HILAR LN



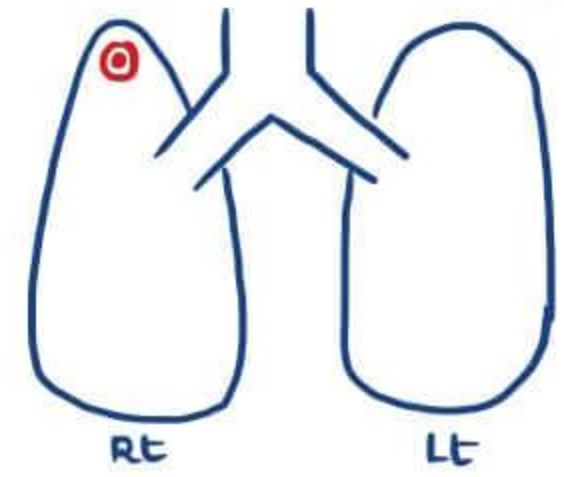
PATHOGENESIS



→ RAENKE COMPLEX \rightarrow calcified Ghon's complex

2° PULMONARY TB

- occurs due to
 - Reactivation [mc] } a/w ↑ age & AIDS
 - Fresh infection
- Apical lesion
 - Supra clavicular → PUHL'S FOCUS
 - Infra clavicular → ASSMANN'S FOCUS
- Immune activation ⊕⊕⊕ → Airway → Cavitation
- Hilar LN not affected

**ORGANS AFFECTED**

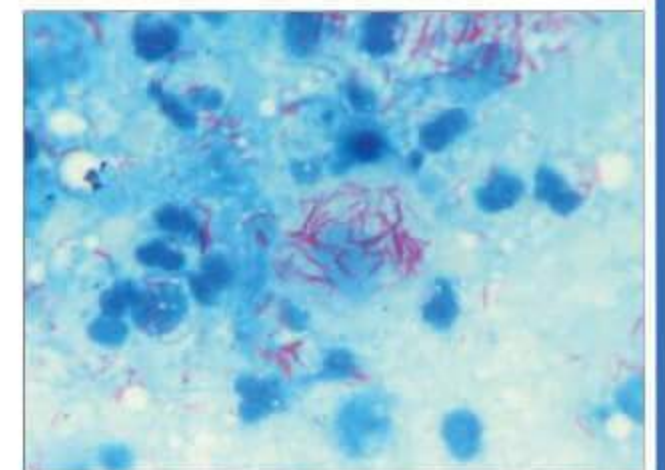
- LN → mc extrapulmonary organ affected ; cold abscess ⊕
- Kidney → Sterile pyuria
- Eyes → Phlyctenular conjunctivitis
- Ears → multiple perforations in TM
- cvs → constrictive pericarditis
- Bones → Pott's spine
- ADRENAL → adrenal insufficiency [mc cause of chronic adrenal insufficiency]
- LIVER → Simmond's focus [simon's focus found in Lungs]
- GIT → Transverse ulcers in Ileum
- Brain → RICH FOCUS
 - Basal surface involved
 - TB meningitis → COB WEB COAGULUM ⊕

CF

- cough [> 2 weeks]
- Fever [low grade evening rise]
- Hemoptysis [mclly from bronchial artery
 - rarely from pulmonary artery → RASMUSSEN'S ANEURYSM]
- Weight loss

DIAGNOSIS

1. ↑↑ ESR
2. ↑ TLC
3. SPUTUM
 - Early morning sample
 - PETROFF'S METHOD → Sputum concentration method
 - STAINING → ZN stain → Acid fast bacilli
 - CULTURE → LJ media [slow growth]
 - BACTEC MEDIA [faster growth]
 - PCR → Nucleic Acid Amplification
4. PLEURAL TAP → straw colored fluid → ↑↑ Adenosine Deaminase [ADA]



R₄ → Anti Tubercular Therapy

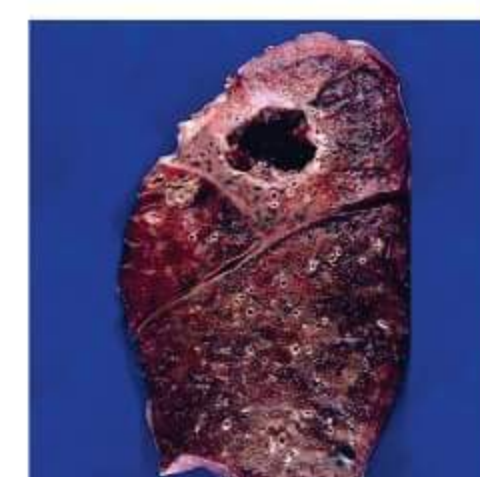CAUSES

1. ASPIRATION	→ ↓ consciousness
	→ Alcoholics
	→ hasty intake of food particles [mc]
2. SEPTIC EMBOLISM	→ Infective endocarditis
3. POST PNEUMONIA	→ Staph. aureus
	→ Klebsiella
4. OBSTRUCTIVE NEOPLASM	

CLINICAL FEATURES

- high fever
- productive cough
- foul smelling sputum

CXR → Cavitation + Air fluid level



Cavitation

PULMONARY HYPERTENSION

- Normal Pulmonary artery pressure → 10 mm Hg
- Pulmonary HTN → > 25 mm Hg

1° PULMONARY HTN

- young ♀ t.me/latestpgnotes
- BMPR 2 gene Inactivation mutation

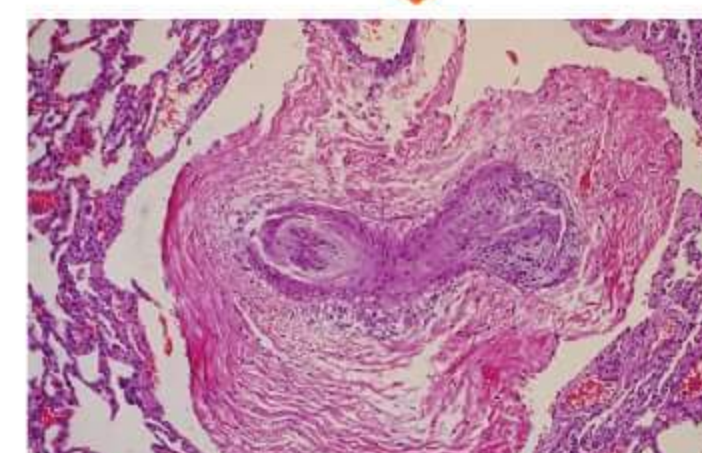
Normal gene	→ Smooth muscle cell apoptosis
mutation	→ ↑↑ Proliferation of Smooth muscle cell → Pulmonary HTN

2° PULMONARY HTN

- ETIOLOGY
- Hypoxemia → high altitude / pulmonary disease
 - Left ventricular failure / mitral stenosis
 - Recurrent Pulmonary Embolism
 - Obstructive sleep apnea

- MIE
- MEDIAL HYPERTROPHY OF Elastic & muscular arteries
 - PULMONARY ARTERIAL ATHEROSCLEROSIS
 - RIGHT VENTRICULAR HYPERTROPHY

PLEXIFORM LESION
[EUF of Capillaries]



CLINICAL FEATURES → dyspnea / Fatigue / chest pain

CXR → Tapering of pulmonary arteries

Rx

1. O₂
2. Diuretics
3. Vaso dilators → Endothelin Antagonists
→ Prostanoids
4. Lung transplantation

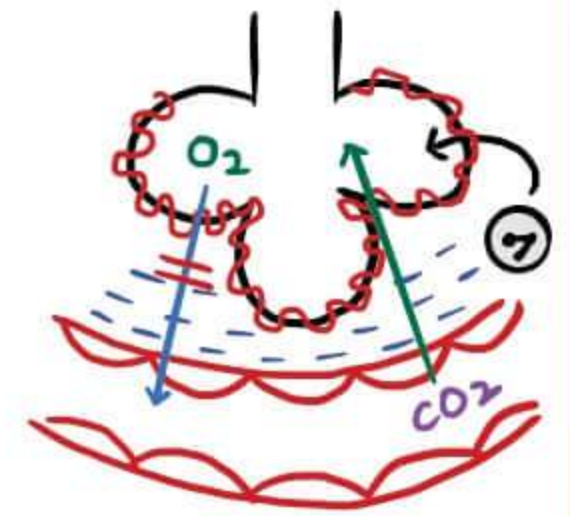
ACUTE LUNG INJURY [seen in ADULTS]

- Sudden onset of severe hypoxemia
- Bil pulmonary infiltrate
- NO H/O cardiac disease

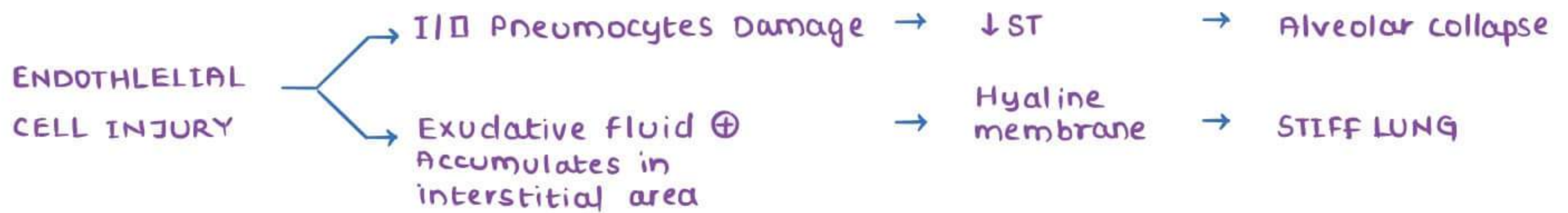ARDS / STIFF LUNG / SHOCK LUNG / HYALINE MEMBRANE DISEASE [Severe ALI]

ETIOLOGY

1. DIRECT LUNG INJURY
2. INDIRECT LUNG INJURY
 - Gram \ominus Septicemia [most important]
 - Aspiration
 - Shock
 - DIC | Heroin | pancreatitis



PATHOGENESIS



- HYPOXEMIA [↓ pao₂]
- ↓ pa CO₂

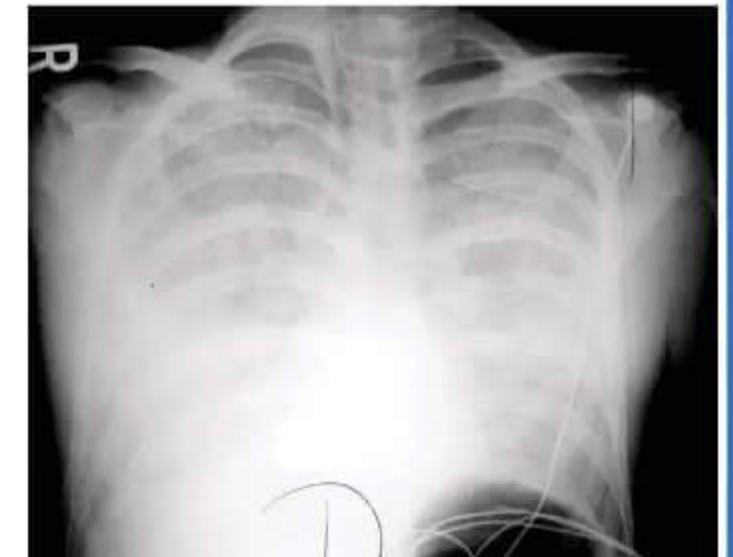
t.me/latestpgnotes

CLINICAL FEATURES

- Dyspnea
- ↑↑ RR
- Intestinal fibrosis

CXR → BIL Infiltrates \oplus [WHITE OUT LUNG]

PCWP → < 18 mm Hg [non - cardiac cause]



White out lung

- DIFFUSE ALVEOLAR DAMAGE
- REFRACTORY TO O₂ THERAPY dit
 - ↓ ST → Alveolar collapse
 - Hyaline membrane \oplus

TREATMENT

1. TOC → Rt the Primary cause
2. PEEP → ↑ O₂ diffusion & Alveolar opening
 - Positive End Expiratory pressure
3. STEROIDS

SURFACTANT

- begins at 28 weeks of gestation [in Lamellar bodies]
- max. secretion at 32 - 34 wks of gestation
- Type II Pneumocytes secrete it
- chemically it is → LECITHIN = DPPC [DiPalmitoyl Phosphatidyl choline]
- ↓ Surface tension → ↓ Alveolar collapse
- ↑ → steroids & Thyroxine
- ↓ → Insulin

RISK FACTORS

- c - section
- Prematurity
- maternal hyperglycemia [Fetal hyperglycemia]
- ↓ Surfactant → ↑ Surface Tension

CIF

- Respiratory distress [in few hours of birth]
- ↑↑ RR
- Hypoxemia

CXR

- WHITE OUT LUNG
- GROUND GLASS LUNG

Rx

- 1. STEROIDS TO MOTHER
- 2. ARTIFICIAL SURFACTANT TO BABY
- 3. CPAP [via Endotracheal tube]

COMPLICATIONS

1. ↓ O₂ → ↑↑ PDA & ↑↑ NEC
2. Supplemental O₂ → ↑ free radicals [Retinal damage & Bronchopulm dysplasia]
3. Hypoglycemia

SARCOIDOSIS

unknown Ag → CD₄ T cell ⊕ → Non-caseating granulomas

MULTISYSTEM DISORDER

LUNGS	→ mclly involved organ → Interstitial fibrosis → U/L pleural effusion → CIF → Dyspnea [mc]
LN	→ BIL hilar lymphadenopathy → POTATO NODES ⊕
SKIN	→ LUPUS PERNIO [violet colored rash on nose & cheeks] Erythema nodosum [painful, lower limbs ⊕]
EYES	→ UVEITIS → CANDLE WAX DROPPINGS
LIVER Bm SPLEEN	} mc cause of non-infectious granulomatous lesion in Liver granulomatous lesions ⊕
ENDOCRINE	→ Pituitary
MUSCLES	→ weakness fatigue

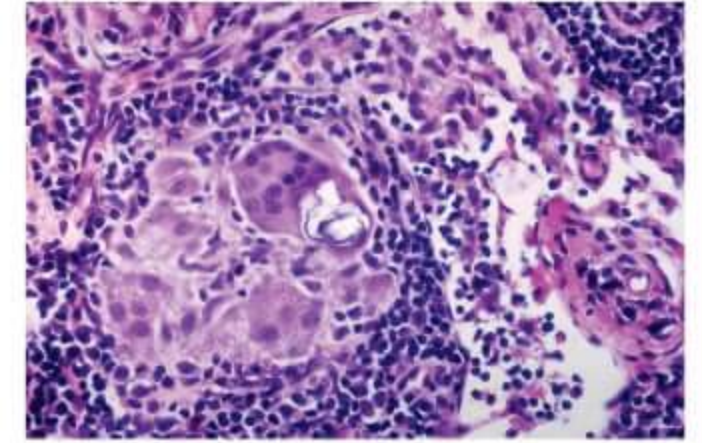
DIAGNOSTICS

1. S. ACE ↑↑↑
2. S. Ca^{2+} ↑↑↑ → ↑ 1- α OHase → vit D
3. CUTANEOUS ANERGY
4. Non-caseating granuloma ⊕ [most characteristic]

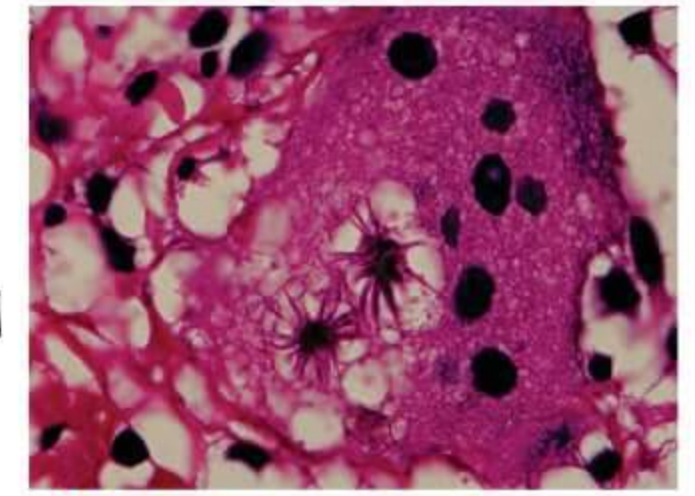
S → Schaumann Body [Ca^{2+}]
 A → Asteroid Body [stellate inclusions]
 R → Residual Body

5. BAL FLUID → ↑↑ CD_4 : CD_8 T cells [5:1 to 15:1]

- R₁ → 1. Spontaneous Recovery
 → 2. Steroids



Schaumann Body



Asteroid body

HYPERSENSITIVITY PNEUMONITIS / EXTRINSIC ALLERGIC ALVEOLITIS

→ KNOWN Ag → ALVEOLITIS & INTERSTITIAL PNEUMONITIS

PATHOGENESIS

1. ACUTE	→ 1st time → Ab formation
	→ Repeat Exposure Ag Ab → Immune complexes ⊕ [Type III HR]
2. CHRONIC	→ Non-caseating granuloma → Type IV HR [more imp]
	→ TYPE IV >>> TYPE III

SUB TYPES

1. FARMER'S LUNG → Actinomyces [Thermophilic]
2. PIGEON BREEDER'S LUNG → Proteins from bird feathers/excreta
3. HUMIDIFIER'S LUNG → Bacteria

CIF

ACUTE PHASE → Ag $\xrightarrow{4-6 \text{ hrs}}$ cough | dyspnea | Fever [few hrs - few days]

CHRONIC PHASE → Ag \longrightarrow interstitial fibrosis
 ↳ progressive dyspnea
 ↳ Respiratory failure
 ↳ cyanosis

R₁ → Avoid the allergen & Steroids

DESQUAMATIVE INTERSTITIAL PNEUMONIA

- Smokers
- macrophages in air spaces ⊕
- misnomer
- CIF → cough & dyspnea
- Interstitial fibrosis
- R₁ → steroids

BENIGN TUMORS**BRONCHIAL ADENOMA**

- type of carcinoid tumor
- well differentiated Neuro endocrine cells ⊕ → chromogranin ⊕
- Recurrent hemoptysis +
- biopsy contra indicated

HAMARTOMA

- common site → Lungs
- CXR → Popcorn calcification
- Pre neoplastic lesion

MALIGNANT TUMORS

- I 1° → BRONCHOGENIC CARCINOMA
- II 2° → METASTASES
 - ↳ Breast [mc]
 - ↳ colon
 - ↳ choriocarcinoma
 } CANNON BALL METASTASIS

BRONCHOGENIC CARCINOMA**RISK FACTORS**

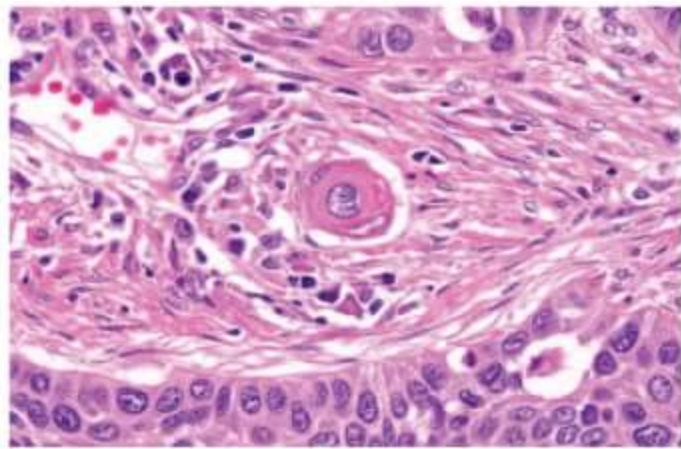
1. GENETIC
 - p53 mutation [mc]
 - L-MYC mutation
 - K-RAS mutation
 - EGFR mutation
 - ALK mutation
 - RET | MET mutation
2. NON GENETIC
 - Smoking [most dangerous] → PAH [more prone for CYP1A1 polymorphism]
 - Air pollution
 - Asbestos
 - Radiation [Radon [decay of uranium], xenon]

- CIF**
- cough [mc]
 - weight loss
 - dyspnea
 - Hemoptysis
 - RLN → Hoarsness

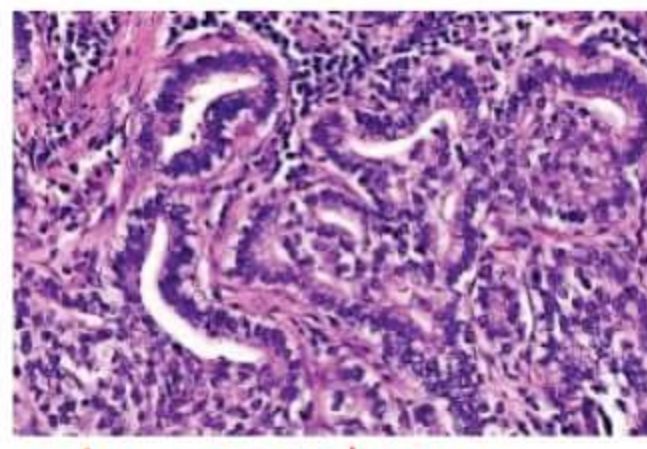
- CLINICAL FOLLOWUP**
- Radiological Exam
 - Sputum cytology
 - Bronchoscopy ± Bx [Best]

- Bx**
- 1. MIE or HPE
 - 2. Immunohistochemistry

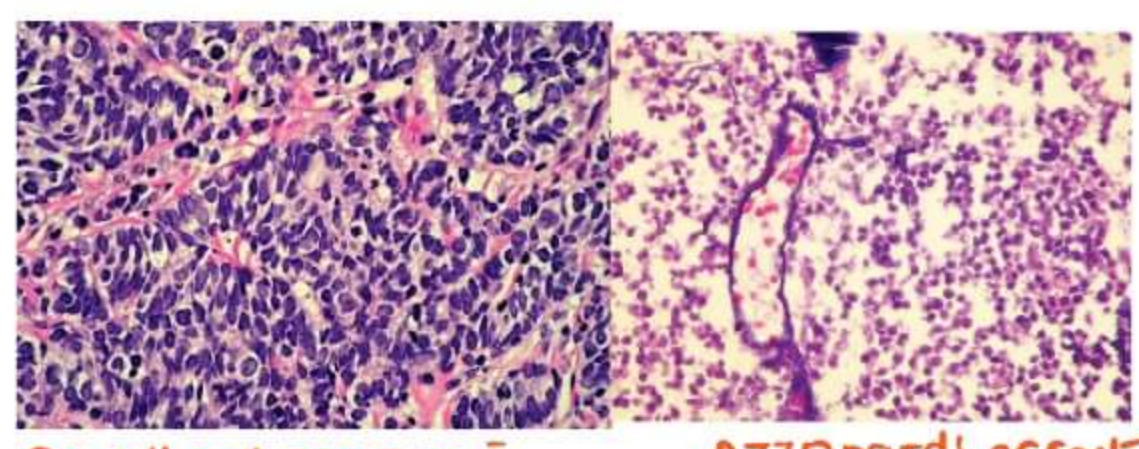
1. Keratin \oplus \rightarrow Intercellular Bridge \rightarrow Pearls } Squamous cell carcinoma } p 40 \oplus
p 63 \oplus
2. Mucin \oplus } Adeno carcinoma } TTF [Thyroid Transcription factor] \oplus
Glands \oplus } NAP-A \oplus & CK 7 \oplus
3. SMALL CELLS $\bar{}$ Neurosecretory granules \oplus } Small cell cancer }
Salt & pepper chromatin \oplus }
Basophilic staining [AZZOPARDI EFFECT] }
chromogranin \oplus
TTF \oplus
NAP-A \ominus
Low molecular wt CK 7/18/18 \oplus
4. Large cells \oplus \rightarrow Diagnosis of Exclusion \rightarrow Large cell carcinoma
 \rightarrow CD 56 \oplus
 \rightarrow Synaptophysin \oplus
 \rightarrow chromogranin \oplus



Squamous cell carcinoma
[Keratin \oplus]



Adenocarcinoma



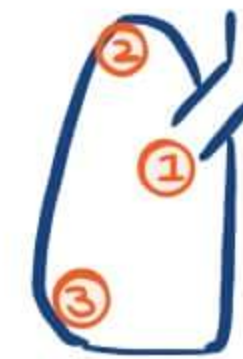Small cell cancer $\bar{}$
neuro secretory granules

AZZOPARDI effect

t.me/latestpgnotes

1. SQUAMOUS CELL CARCINOMA

- \rightarrow mc bronchogenic cancer in India
- \rightarrow mc bronchogenic cancer in males
- \rightarrow mc bronchogenic cancer in smokers
- \rightarrow CENTRAL LOCATION
- \rightarrow cavitation \oplus
- \rightarrow Late metastasis
- \rightarrow Good prognosis
- \rightarrow CELLS \rightarrow PTHrp \rightarrow Hypercalcemia



2. SMALL CELL CARCINOMA

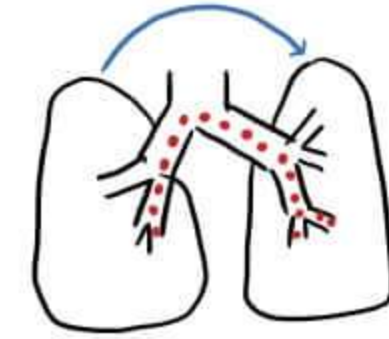
- \rightarrow σ , smokers [strongest association]
- \rightarrow central location
- \rightarrow Best response to chemotherapy & Radiotherapy
- \rightarrow WORST PROGNOSIS
- \rightarrow maximum metastasis \oplus [early metastasis]
- \rightarrow Aggressive
- \rightarrow surgery can't be performed
- \rightarrow Neuro secretory granules \oplus
 - \rightarrow ACTH \rightarrow Cushing syndrome
 - \rightarrow ADH \rightarrow SIADH [\downarrow Na $^+$]
 - \rightarrow calcitonin \rightarrow hypocalcemia

3. ADENOCARCINOMA

- overall mc Lung cancer
- ♀ >> ♂
- non-smokers
- Peripheral cancer
- Mucin ⊕ → Thrombophlebitis ⊕
- clubbing ⊕
- SCAR CANCER

ADENOCARCINOMA IN SITU

- Excellent prognosis
- suffocation ⊕ → Mortality



Aerogenous
Spread ⊕

4. LARGE CELL CARCINOMA

- non-smokers
- peripheral location
- Secretes Estrogen → Gynecomastia

METASTASIS

- Adrenal gland [mc]
- CNS [by small cell cancer]
- Bones
- Liver

COMPLICATIONS

t.me/latestpgnotes

1. PANCOAST TUMOR

- peripheral cancer
- Sympathetic plexus compression ⊕
- Adeno cancer
- Horner syndrome ⊕ [‘MAPEL’]
 - ↳ Miosis
 - ↳ Anhidrosis
 - ↳ Ptosis
 - ↳ Enophthalmos
 - ↳ Loss of ciliospinal reflex

2. SUPERIOR VENA CAVA SYNDROME

→ Bluish dusky congestⁿ of head

3. RLN Involvement

→ hoarsness of voice

4. C₈/T₁/T₂ Involvement

→ Shoulder pain

Pain on inner side of the arm

PARANEOPLASTIC SYNDROME

- | | |
|--------------------------|---------------------------|
| ↑↑ Ca ²⁺ | → Squamous cell carcinoma |
| Cushing syndrome | → Small cell carcinoma |
| SIADH | → small cell carcinoma |
| ↓↓ Ca ²⁺ | → small cell carcinoma |
| Lambert - Eaton Syndrome | → Small cell carcinoma |
| Acanthosis nigricans | → Small cell carcinoma |
| SVC syndrome | → small cell carcinoma |

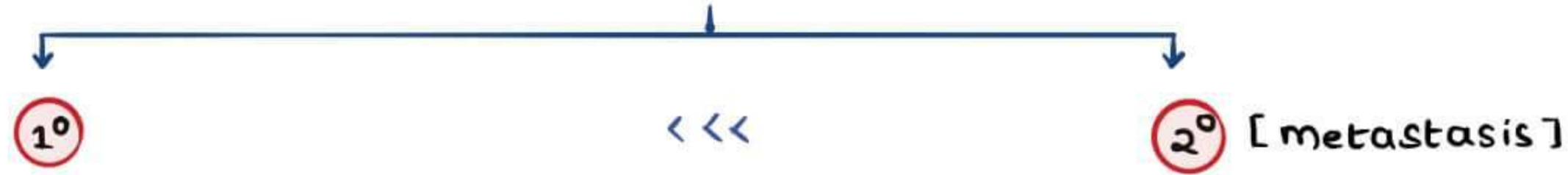
SMALL CELL CARCINOMA

→ poor prognosis

NON SMALL CELL CARCINOMA

→ good prognosis

PLEURAL TUMORS

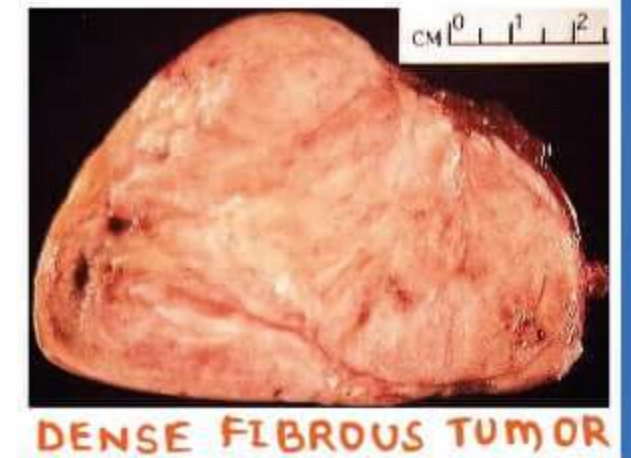


- SOLITARY FIBROUS TUMOR
- MALIGNANT MESOTHELIOMA

- mc cause → Lung cancer
- 2nd mcc → Breast cancer
- ipsilateral involvement of pleura + nt

SOLITARY FIBROUS TUMOR

- Earlier called as BENIGN MESOTHELIOMA
- Asbestos exposure is not a risk factor
- Chr. 12 inversion → NAB 2 STAT 6 FUSION GENE
- GROSS → Dense fibrous tumor
- microscopically, SPINDLE CELLS [resemble fibroblasts] + nt



DENSE FIBROUS TUMOR

	SFT	mm
CD 34	⊕	⊖
Keratin	⊖	⊕

MALIGNANT MESOTHELIOMA

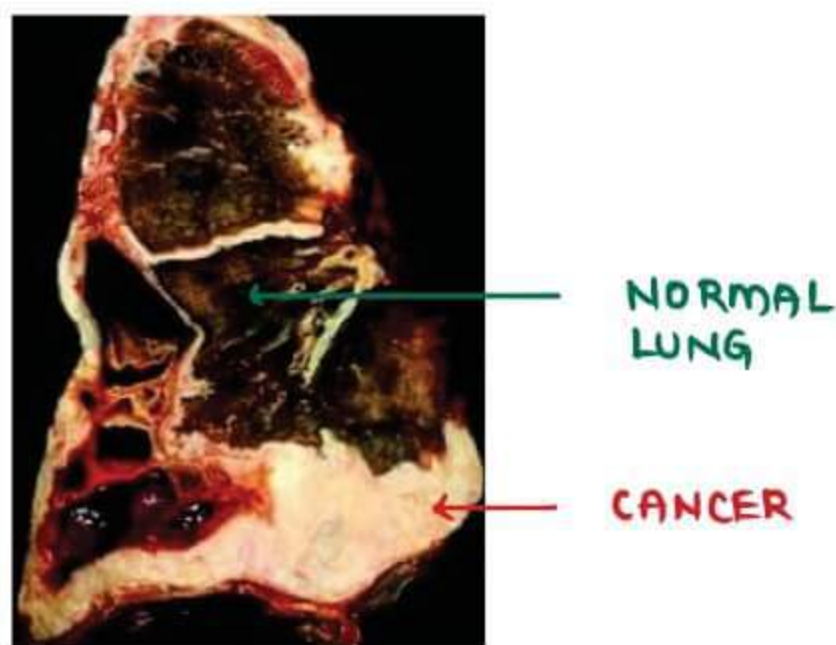
RISK FACTORS

- Asbestos exposure t.me/latestpgnotes
 - ↳ all AMPHIBOLE
 - ↳ incubation period → 25-45 yr
- Radiation exposure
- NO ALL SMOKING

CLINICAL FEATURES

- 50-60 yrs
- chest pain, difficulty in breathing, pleural effusion
- Rt Lung >>> Lt Lung
- along ± pleura, Lungs & Hilar Lymphnodes are involved

GROSS APPEARANCE



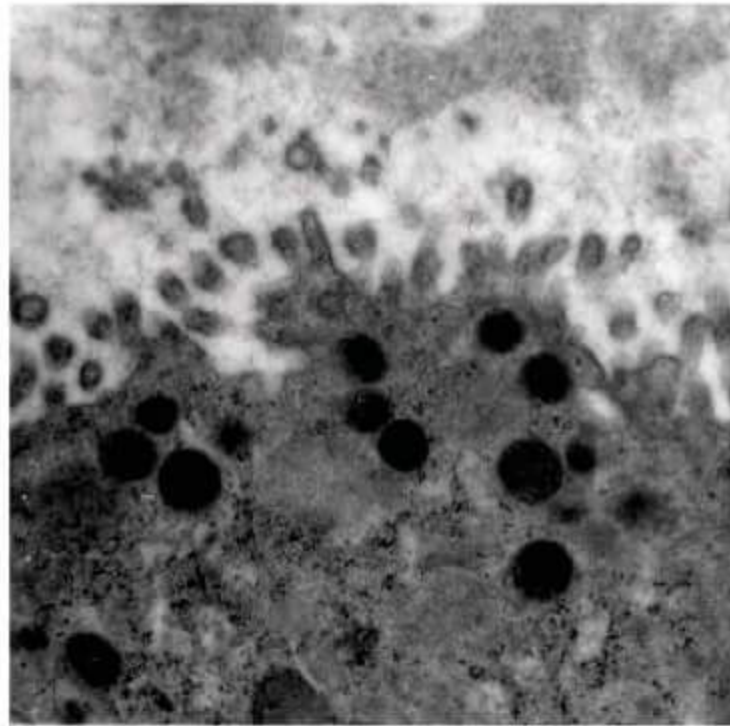
LUNG ENCASED BY CANCER

→ MJE

1. EPITHELIOID TYPE [mc type, 60%]
2. SARCOMATOID TYPE [20%]
3. MIXED / BIPHASIC TYPE [15-20%]

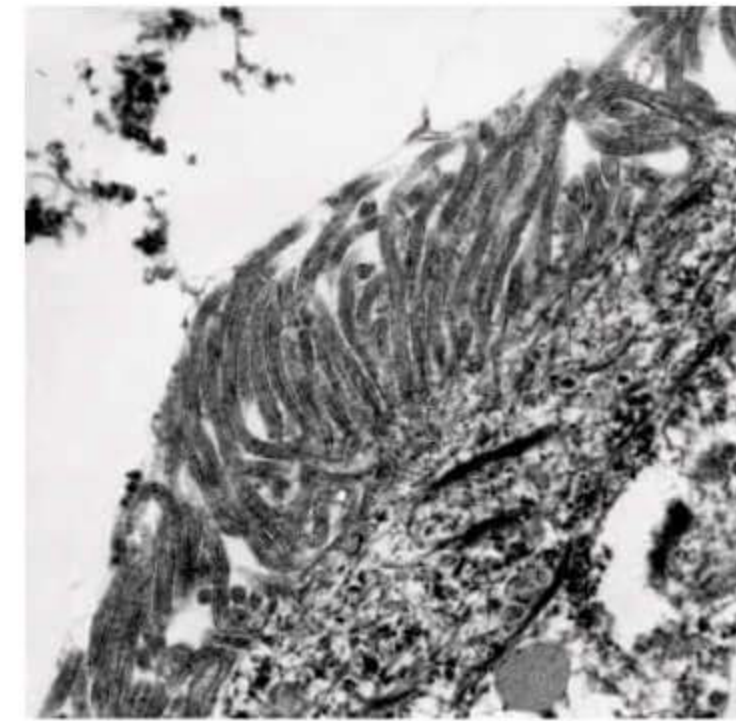
→ EPITHELIOID TYPE

- forms papillary & tubular structures
- resembles ADENOCARCINOMA OF LUNG
- distinguished from Adenocarcinoma of Lung by
 1. ELECTRON MICROSCOPY



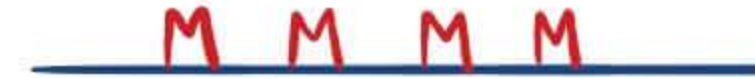ADENOCARCINOMA

- short,
- Non-branching microvilli



MESOTHELIOMA

- Long, thin,
- branching microvilli



t.me/latestpnotes

2. IMMUNO HISTOCHEMISTRY MARKERS

	ADENOCARCINOMA	MESOTHELIOMA
CALRETININ	-	+ +
WT ₁	-	+ +
CK 5/6	-	+ +
MOC 31	+ +	-

- marker of choice → calretinin
- CALRETININ POSITIVITY ASSOCIATION \bar{c} VARIOUS MESOTHELIOMA VARIANTS
 - EPITHELIOID TYPE → Extremely associated
 - SARCOMATOID TYPE → Less intensely positive
 - MIXED / BIPHASIC TYPE → Less intensely positive

BOOSTER INFO - MALIGNANT MESOTHELIOMA

- Deletion of CDKN2A / INK4a [tumor suppressor gene] on Chr 9p
- confirmed by FISH TECHNIQUE

PULMONARY HAMARTOMA

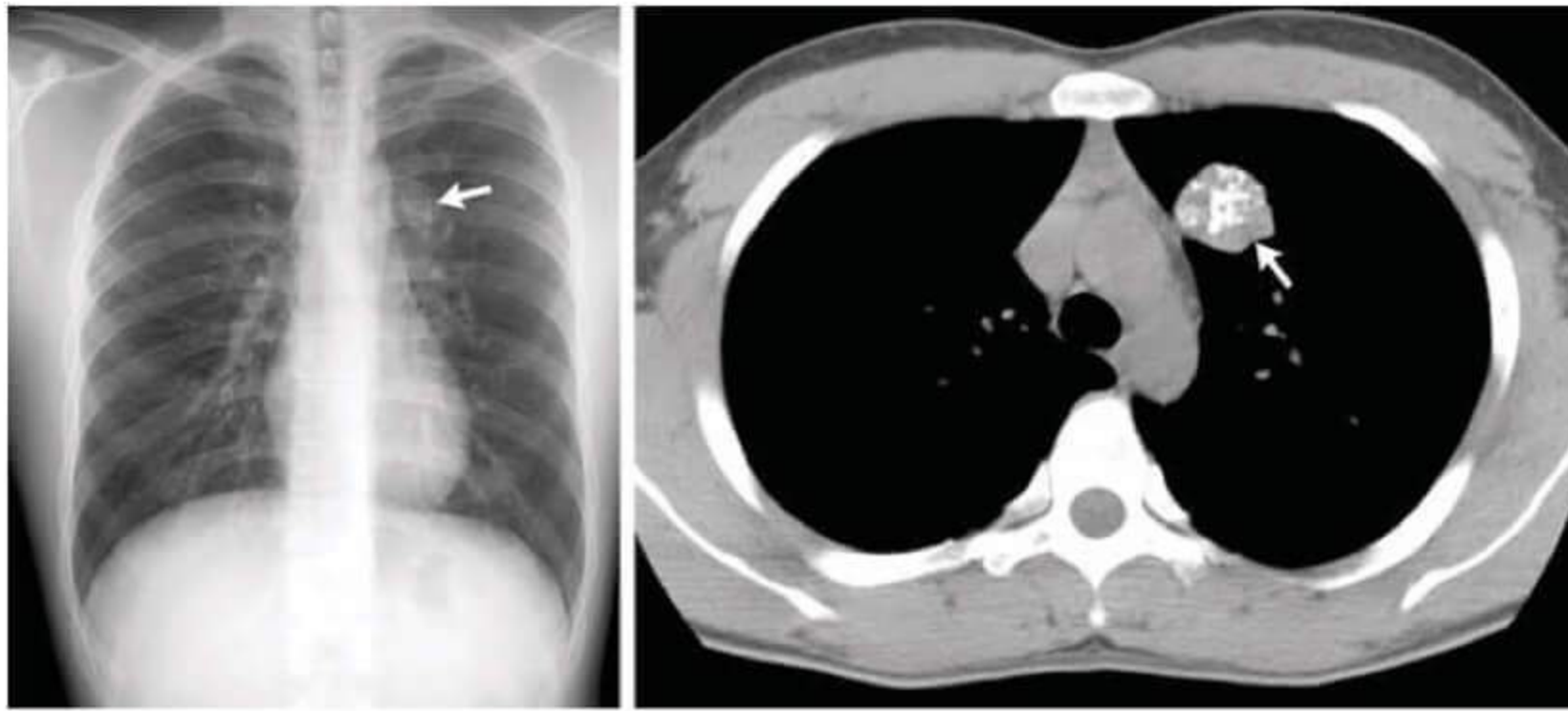
- TRUE NEOPLASM
- COMPONENTS

NODULES OF MESENCHYMAL TISSUE | ENTRAPPED RESPIRATORY EPITHELIUM

↓

connective tissue / fat /
cartilage [predominant] /
Smooth muscles

- a/w t [3;12]
- NO specific signs & symptoms → Example of INCIDENTAL FINDING
- RADIOLOGICAL FINDING



POP CORN CALCIFICATION

t.me/latestpgnotes

- TREATMENT → Surgical Excision

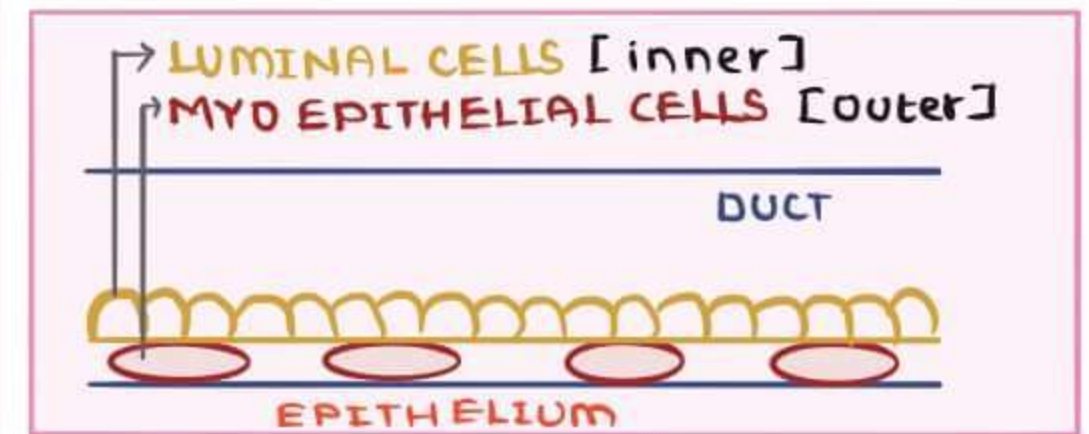
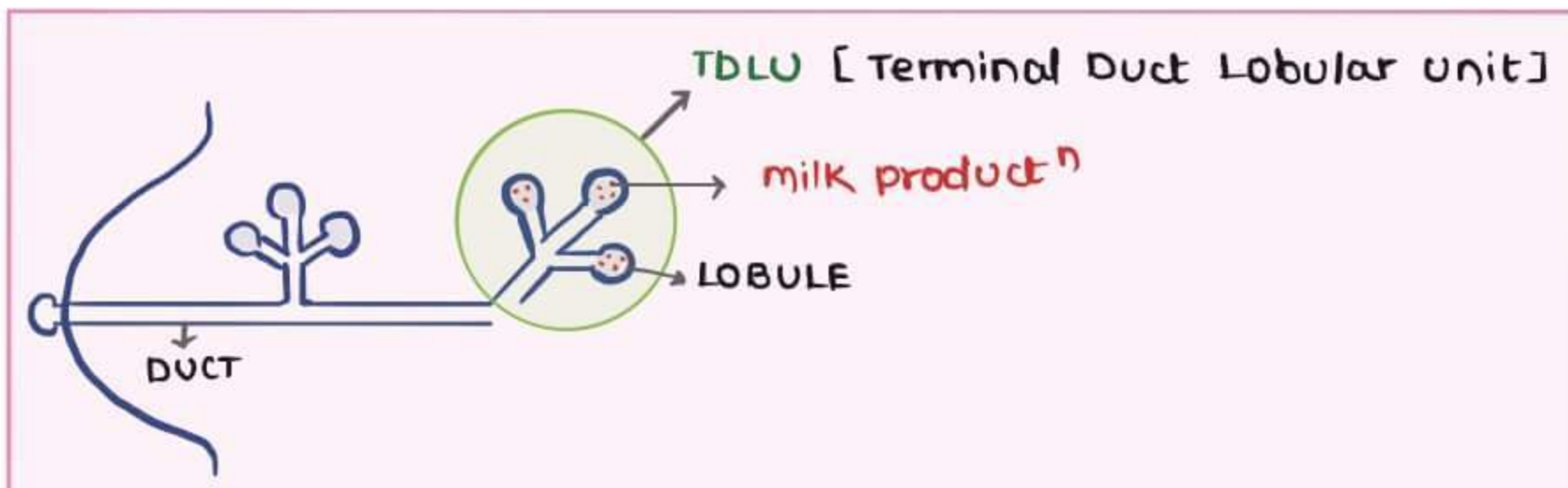
INFLAMMATORY MYOFIBROBLASTIC TUMOR

- disease of children
- NO sex predilection [m=f]
- d/t ALK Gene activation on chr 2p 23
- CIF → Fever, cough, chest pain, hemoptysis
- GROSS → Peripheral firm mass [in 25% patients, Ca^{2+} depositⁿ +nt]
- M/E
 - SPINDLE SHAPED CELLS [made up of fibroblasts & myofibroblasts]
 - Infiltration of lymphocytes & plasma cells +nt
 - Peripheral fibrosis +nt

HORMONE SENSITIVE TISSUE

- Estrogen → Alveolar & ductal growth
- Progesteron → Alveolar differentiation

- LACTATION → Oxytocin → milk ejection
- Prolactin → Lactogen



TDLU → Functional unit of Breast tissue

COMPONENTS OF BREAST TISSUE

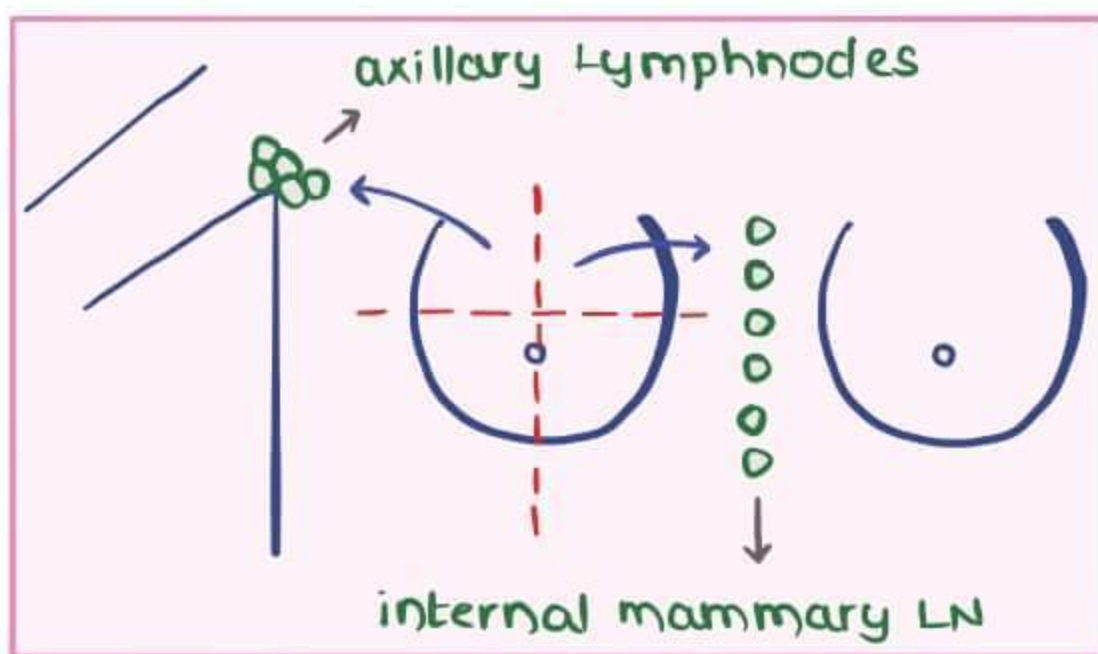
1. STROMA

2. EPITHELIUM

- Luminal cells requires vitamin A for differentiation
- Vitamin A Deficiency → Squamous metaplasia
- EPITHELIAL HYPERPLASIA → > 2 layers of cells

t.me/latestpgnotes

QUADRANTS OF BREAST



- Outer quadrant of breast tissue drains into → Axillary LN
- inner quadrant of breast tissue drains into → Internal mammary LN
- Maximum dense tissue is present in → upper outer quadrant
- most common site for malignancy → upper outer quadrant
- Least common site for malignancy → Lower inner quadrant

NIPPLE DISCHARGE - SUB TYPES

1. BLOODY

- Intra ductal Papilloma [mc cause]
- Ductal carcinoma

2. GREENISH

→ mammary duct ectasia

3. PURULENT

→ Acute mastitis

4. GALACTORRHEA

- mechanical stimulatioⁿ [mc physiological cause]
- Drugs
 - ↳ OCP
 - ↳ H₂ anti histaminic drugs
 - ↳ Antipsychotic drugs
- Endocrinological disorders
 - ↳ prolactinoma [mc pathological cause]
 - ↳ Hypothyroidism

INFLAMMATORY CONDITIONS

1. ACUTE MASTITIS

- Breast feeding young female
- dit Staphylococcus aureus → Pus ⊕
- **CF** → Pain, fever, nipple discharge [purulent]
 - Swelling
- **diagnosis** → ultrasound
- **treatment**
 1. NSAID^s
 2. ANTI BIOTICS for Staph. aureus [Penicillin group]
 - Flucloxacillin / dicloxacillin / amoxiclav
 3. ASPIRATION [guided by ultrasound]
 4. INCISION & DRAINAGE
- **BREAST FEEDING IS NOT CONTRAINDICATED**

2. ZUSKA'S DISEASE [PERIDUCTAL MASTITIS]

- smoking female

Smokers → Vit A ↓↓ → Squamous metaplasia → obstruction
 ↓
 Dilatation of duct

- **CF**
 - sub areolar mass
 - Pain & Redness
 - nipple retraction
 - Fistula formation

- may mimic MALIGNANCY

3. MAMMARY DUCT ECTASIA

- Multiparous Elderly female



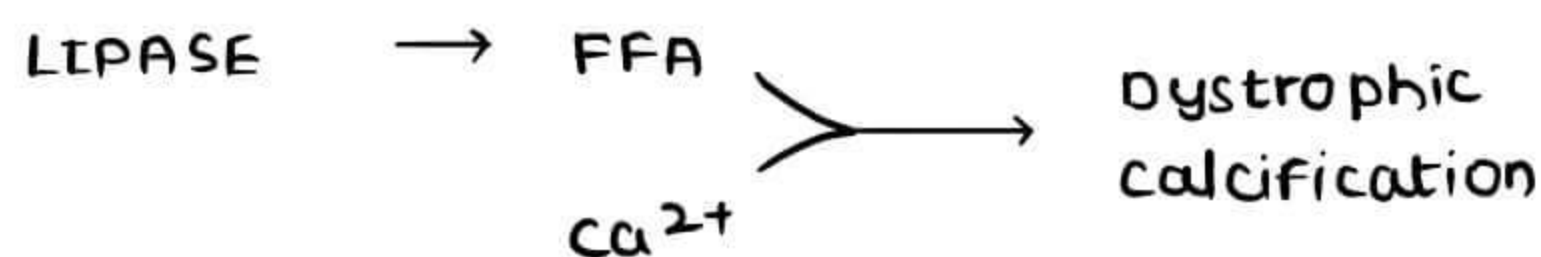
DILATATION → Accumulatⁿ of Secretions

- Nipple discharge
- Rupture → Inflammation

- not alw Smoking
- no metaplasia
- C/F
 - Green brown nipple discharge
 - Sub areolar mass
- M/E → CHRONIC GRANULOMATOUS INFLAMMATION
[Lymphocytes, macrophages & plasma cells ⊕]
- aka PLASMA CELL MASTITIS

4 FAT NECROSIS

- alw Trauma & Surgery



- mammography mimics malignancy

- M/E → FAT NECROSIS
 - FB Giant cells
 - Lipid Laden macrophages
- dystrophic calcification

5. LYMPHOCYTIC MASTOPATHY

- Autoimmune etiology
 - ♀ ↑ Type 1 DM / Auto immune thyroid disease
- C/F → ≥ 1 Hard mass in breast tissue
- BIOPSY
 1. Duct & lobular Atrophy
 2. Dense collagen
 3. Lymphocytic infiltration

BENIGN EPITHELIAL LESIONS OF BREAST TISSUE

CLASSIFIED AS

1. NON PROLIFERATIVE BREAST CHANGES / FIBROCYSTIC CHANGES [RR 1]
2. PROLIFERATIVE BREAST CHANGES
 - a. With out Atypia [Relative Risk of cancer - 1.5-2]
 - b. With Atypical hyperplasia [Relative Risk of cancer - 4-5]
3. CARCINOMA IN SITU
 - Bm not involved
 - RR - 8-10

RISK OF BREAST CANCER

	RELATIVE RISK	ABSOLUTE RISK
Fibrocystic changes of Breast	1	3%
Proliferative Breast changes [out Atypia]	1.5-2	5-7%
Proliferative Breast changes [Atypia]	4-5	15-17%
carcinoma In Situ	8-10	25-30%

1. NON PROLIFERATIVE / FIBROCYSTIC BREAST CHANGES



- a. CYSTS → BLUE - DOME CYST [fluid]
- b. FIBROSIS → Leakage of fluid from cyst → Inflammation → Fibrosis
- c. ADENOSIS → ↑ NO. of Acini per lobule

APOCRINE METAPLASIA → no progression to cancer

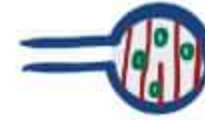
CLINICAL FEATURES → painful 'LUMPY - BUMPY BREAST' in a < 50 yr ♀

2. PROLIFERATIVE BREAST DISEASE [OUT ATYPIA]

- a. EPITHELIAL HYPERPLASIA → > 2 layers of cells
→ Incidental finding

b. SCLEROSING ADENOSIS

- ↑ collagen & fibrosis
- micro calcification ≅ malignancy



c. COMPLEX SCLEROSING LESION

- at microscopy | Radiological level → RADIAL SCAR
- mimics invasive cancer t.me/latestpgnotes



Epithelial component
stroma

d. PAPILLOMA [INTRADUCTAL]

- Incomplete compression → serous discharge
- complete compression → Bloody discharge



Fibrovascular scar
papillary growth

3. PROLIFERATIVE BREAST DISEASE [ATYPIA]

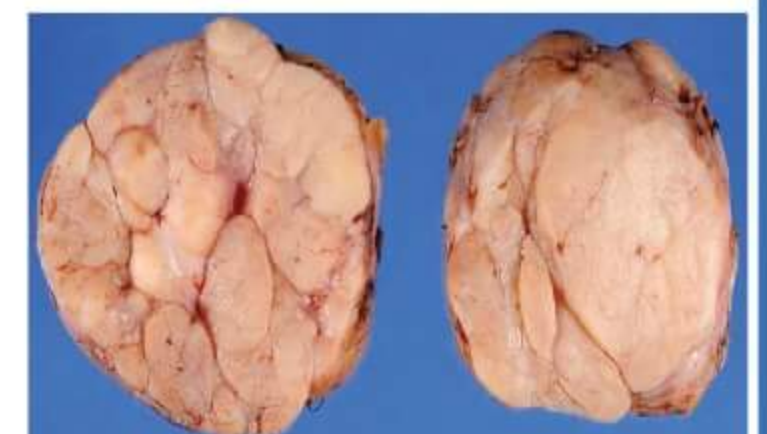- a. ATYPICAL LOBULAR HYPERPLASIA [ALH] [< 50% Acini involved per lobule]
- b. ATYPICAL DUCTAL HYPERPLASIA [ADH]
→ MONOMORPHIC CELLS → Partial Involvement of either lobes or ducts

STROMAL TUMORS

A. INTRA LOBULAR TUMORS

1. FIBROADENOMA / BREAST MOUSE

- mc benign tumor
- young ♀
- Single usually
- can be multiple & BIL
- Renal transplant → Rx by cyclosporine → BIL & multiple fibroadenomas
- cyclosporine discontinuation causes → Regression of the tumor
- well circumscribed
- freely mobile mass
- GROSS FEATURES
→ Well defined margins
→ grey white nodules
→ slit like space ⊕



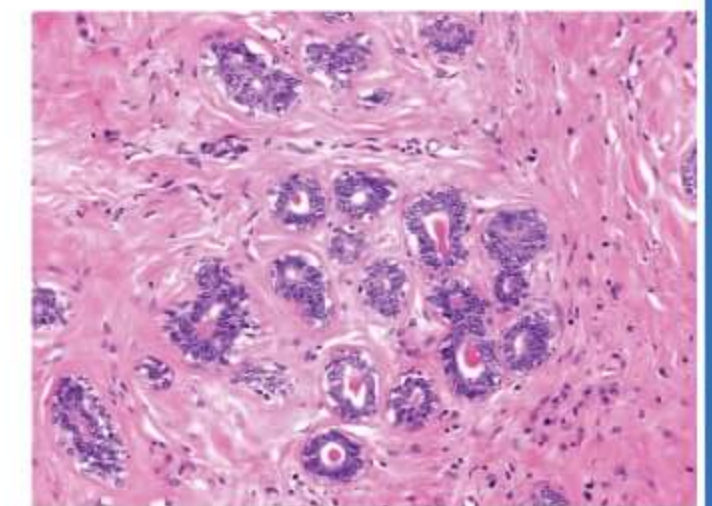
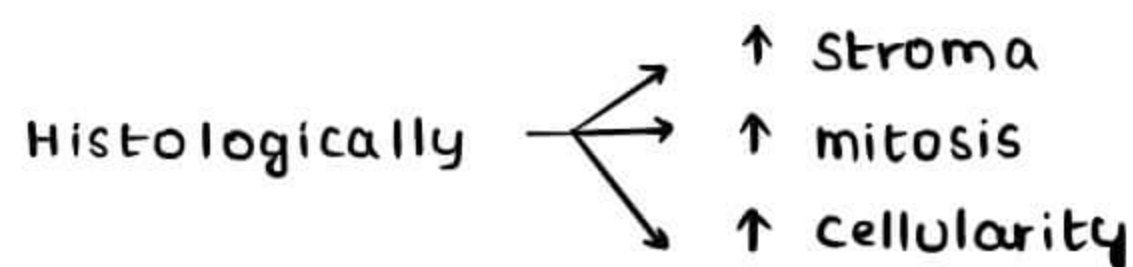
- MICROSCOPIC FEATURES → Pericanalicular Stroma
- Intracanalicular stroma

→ Rx by SIMPLE EXCISION

2. PHYLLODES TUMOR

- ↑↑ Stroma = Leaf like projections → BULKY BREAST
- Gain of Function mutation [1q]
- HOXB 13 Overexpression → Higher grade tumor
- CIF → > 60 yrs Female, palpable mass
- most are Low grade tumors → no metastasis
- High grade tumors → metastasis [hematogenous spread] ⊕
- Axillary LN Dissection is contra indicated
- Only stromal component can spread

→ DID FROM FIBROADENOMA



Pericanalicular Fibroadenoma

B. INTER LOBULAR STROMAL TUMORS

1. MYOFIBROBLASTOMA → M = F

2. ANGIOSARCOMA t.me/latestpgnotes

- mc stromal malignant tumor
- Sporadic → < 35 yrs ♀, high grade, poor prognosis
- 2° tumor → after Radiation | Edema

INTRODUCTION & IN SITU CANCER

BREAST CANCER

→ mc cancer in females in INDIA

RISK FACTORS

- ↑ Estrogen exposure [most important]
 - ↳ ♀
 - ↳ early menarche & Late menopause
 - ↳ exogenous estrogens → HRT
 - ↳ post menopausal obese ♀
 - ↳ Endometrial cancer
- AGE → Post menopausal
- Radiation exposure
- Family H/O → 1° Relatives
- Pregnancy → 1st pregnancy < 20 yrs → protective
- Lactation → protective [x ovulation & maturation of cells]
- Dietary → ↑ Lipids, Alcohol → ↑ risk

PATHOGENESIS

FAMILIAL BREAST CANCER

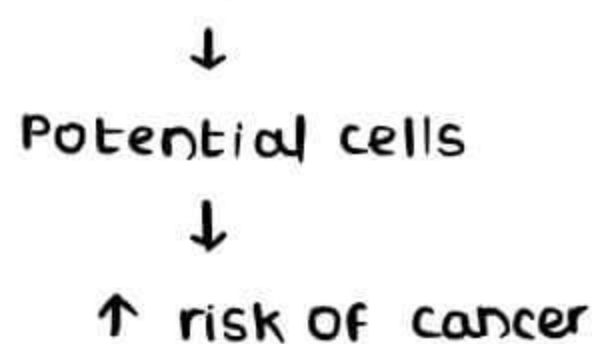
→ DNA Repair Genes

- BRCA 1 gene [17q] → ♀ >>> ♂ Breast cancer ; ↑ ovarian cancer
- BRCA 2 gene [13q] → ♂ >>> ♀ Breast cancer ; ↑ prostate cancer
- p 53 gene [17p]
- CHEK 2 gene [22q]

- BRCA 1 Gene a/w Basal like cancer & Medullary cancer
- BRCA 2 Gene a/w fanconi Anemia
- p53 gene a/w Sporadic cancer
- p53 gene is mc genetic mutation a/w breast cancer [Overall]
- p53 gene a/w Li-Fraumeni syndrome
- CHEK 2 gene a/w ↑ renal cancer | colon cancer | Thyroid cancer
- CHEK 2 gene a/w post radiation risk of cancer

SPORADIC BREAST CANCER [mc]

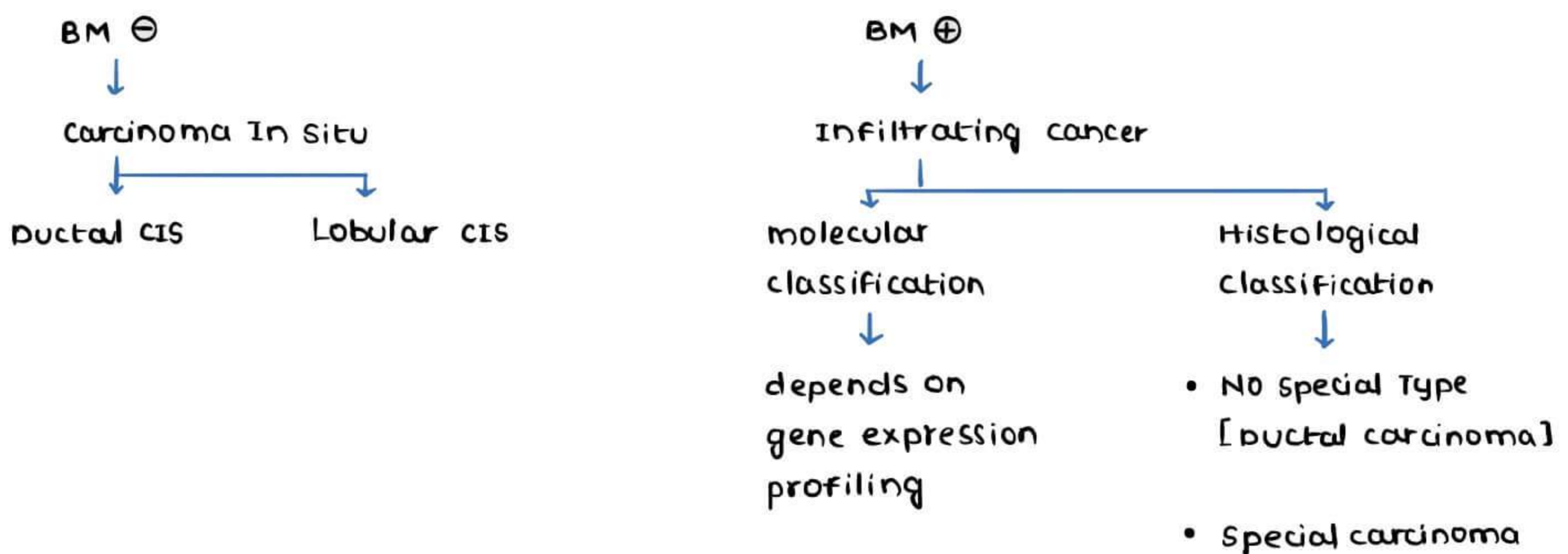
- Hormone Exposure [Estrogen]



- a/w p 53 gene mutation

TYPES OF CANCER

t.me/latestpgnotes



CARCINOMA IN SITU

- SITE → TDLU

1. DUCTAL CIS


- Bm ⊖
- cells in ducts [myoepithelial cells] preserved
- secretion } Ca²⁺ → picked up on mammography
- necrosis }
- DCIS $\xrightarrow{1\%/yr}$ Invasive cancer

- TREATMENT → MASTECTOMY
- Radiotherapy & Tamoxifen for recurrence prevention

1. COMEDO DCIS

- high grade tumor cells ⊕ ; central necrosis ⊕
- Linear / branching calcification on mammography

2. NON - COMEDO DCIS



tumor cells
calcified area

CRIBRIFORM PATTERN

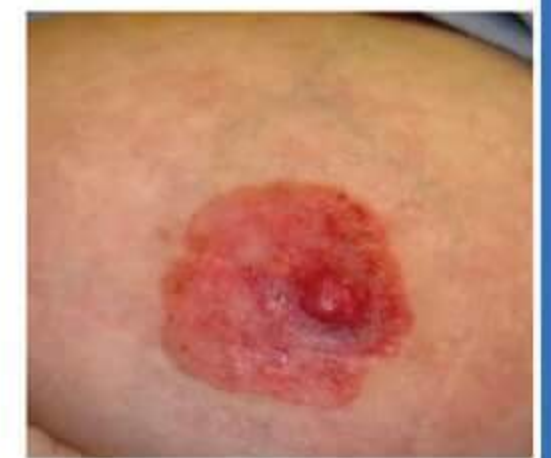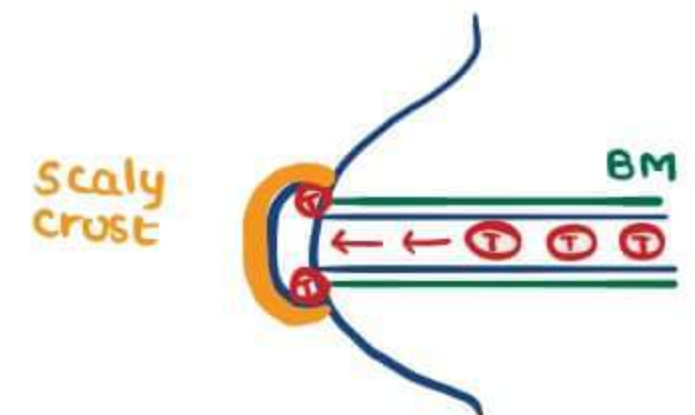


micropapillary structures

MICROPAPILLARY PATTERN

3. PAGET'S DISEASE OF NIPPLE

- type of DCIS
- U/L Lesion
- Pruritis ⊕
- ulceration of nipple ⊕
- Palpable mass [50%] ⊕ [↑ Invasive cancer]
- aka ECZEMATOID LESION
- M/E → PAGET CELLS ⊕
 - ↳ abundant cytoplasm
 - ↳ prominent nucleus & nucleoli
 - ↳ mucin ⊕
 - ↳ Her2 ⊕
 - ↳ ER / PR ⊖



Paget Disease

2. LOBULAR CARCINOMA IN SITU

t.me/latestpnotes

- malignant cells → DISCOHESIVE FASHION
- CDH1 mutation → ↓ E-cadherin → DISCOHESIVE



- no secretions } no calcification → Incidental finding
- no necrosis }

→ BIL

→ LOBULAR CIS $\xrightarrow{17.1 \text{ year}}$ INVASIVE CANCER [ipsilateral & contralateral]

- M/E → Discohesive cells
 - mucin ⊕ → Signet Ring cells
 - ER / PR ⊕
 - Her 2 ⊖

→ R₁ → BIL mastectomy

- MC SITE → Terminal duct Lobular unit [TDLU]
- mc Breast cancer → Adenocarcinoma

- 1. MOLECULAR CLASSIFICATION → Based on Gene expression profiling
- 2. HISTOLOGICAL CLASSIFICATION → special sub type
- no special sub type

MOLECULAR CLASSIFICATION

	LUMINAL A	LUMINAL B	HER 2 ENRICHED	BASAL LIKE
ER / PR	⊕	⊕	⊖	⊖
Her 2 / Neu	⊖	⊖	⊕ ⊕	⊖
Marker	Low proliferat ⁿ rate Ki67 → low	high proliferat ⁿ rate Ki67 → High		Triple ⊖ cancer [other name]

LUMINAL A BREAST CANCER

- Elderly females
- mc sub type
- Best prognosis among sub types

LUMINAL B BREAST CANCER

- BRCA 2 gene mutation ⊕
- Bad prognosis

HER 2 ENRICHED

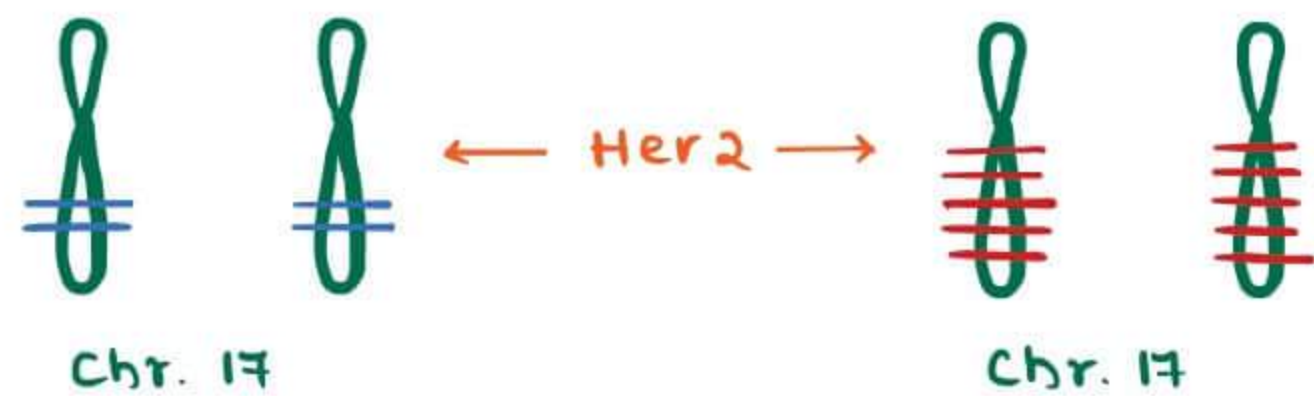
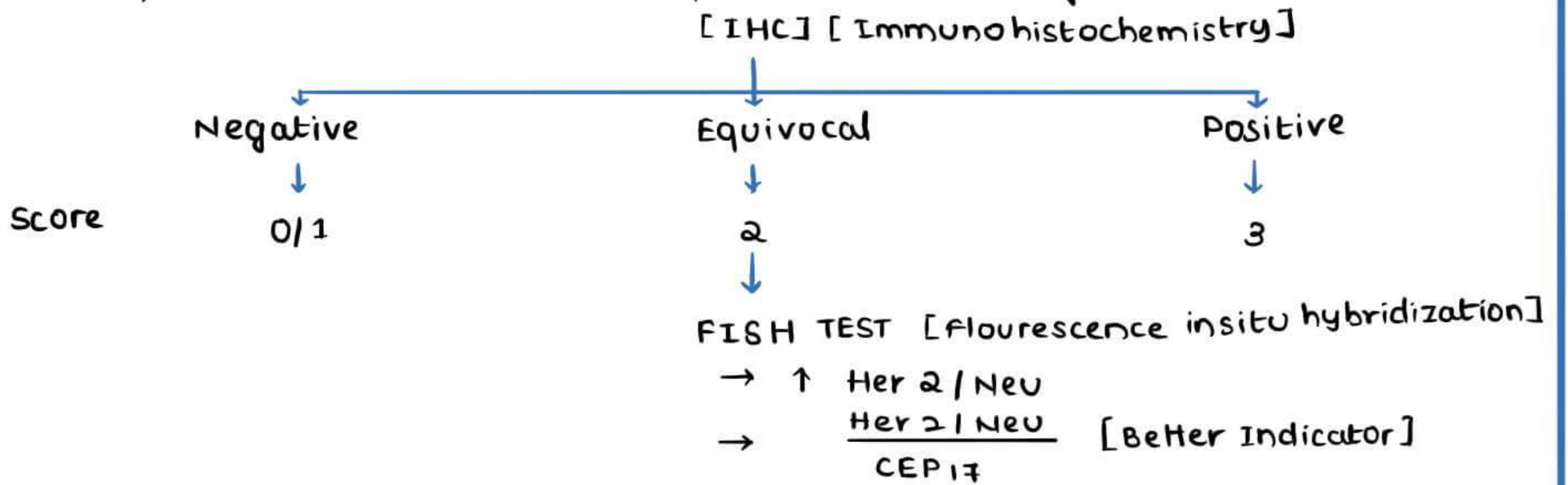
- young females
- Worst prognosis among sub types

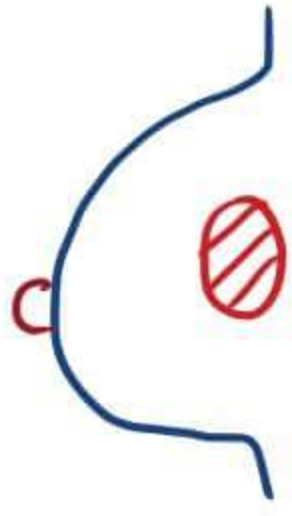
BASAL LIKE

- young female
- BRCA 1 gene mutation ⊕

ER / PR → ⊕ → Nuclear staining

Her 2 / Neu → ⊕ → Surface/membrane staining



HISTOLOGICAL CLASSIFICATION**1. NST INVASIVE CANCER [DUCTAL INVASIVE CANCER] [mc subtype]****CLINICAL PRESENTATION****BREAST LUMP [mc]**

- upper outer quadrant [mc site]
- SKIN RETRACTⁿ ⊕
- NIPPLE RETRACTⁿ ⊕
- FIXATⁿ OF CHESTWALL ⊕
- PEAU D ORANGE ⊕

SPECIAL SUBTYPES**A. INVASIVE LOBULAR CANCER**

- ↓ CDH → ↓ E-cadherin
- B/L
- multifocal
- OCCULT PRIMARY [mc cancer]

- M/E → 1. → DISCOHESIVE CELLS

→ INDIAN FILE PATTERN



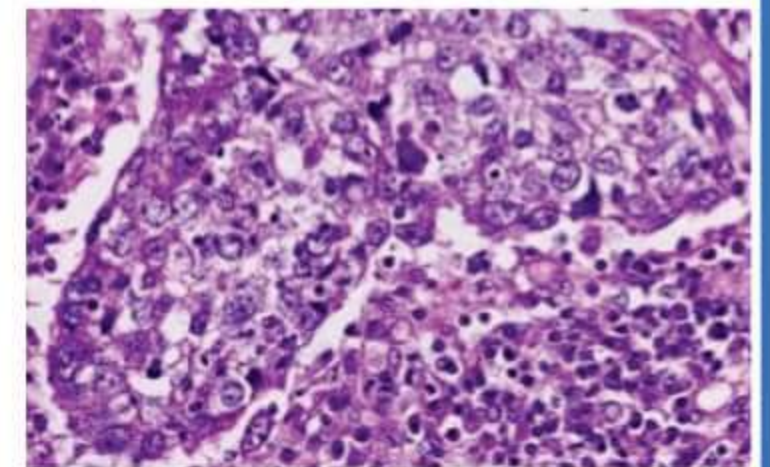
→ little stroma

- 2. ↑ SIGNET RING CELL CANCER OF STOMACH

t.me/latestpgnotes

B. MEDULLARY CANCER

- Hypermethylatⁿ OF BRCA 1 gene promoter
- M/E
 - Sheets of cancer cells
 - ↑ mitosis ⊕
 - Lymphoplasmacytic infiltration



Medullary cancer

C. MUCINOUS CANCER

- CELLS present in a pool of MUCIN
- soft, GEL like consistency
- elderly females
- Good prognosis

D. TUBULAR CANCER → Best prognosis

E. PAPPILLARY CANCER → Least common

INFLAMMATORY BREAST CANCER

- involve LYMPHATICS → Redness & swollen
- mimics MASTITIS
- no response to Antibiotics
- poor prognosis

MALE BREAST CANCER

→ 1% OF breast cancers

→ RISK FACTORS

- B → BRCA 2 gene >> 1
- R → Radiation
- E → Estrogen
- A → Age
- S → Syndrome [Klinefelter syndrome]
- T → Tumor in 1° relative

- CIF → sub areolar mass → MIE → DUCTAL CARCINOMA
- SKIN ⊕ → ♂ → ER ⊕ TUMORS
- nipple discharge ⊕

PROGNOSTIC FACTORS OF CARCINOMA BREAST

- CIS → Excellent
- Invasive Cancer → variable
- METASTASIS → most important factor
- LN STATUS → Axillary LN Status ⊕ [sentinel LN] → Poor prognosis
- SIZE OF TUMOR → ↑ size → Poor prognosis
→ Exception → HER 2 ENRICHED CANCER
- LOCALLY ADVANCED DISEASE → Poor prognosis
- INFLAMMATORY CANCER → Her 2 ⊕ → Poor prognosis
- LYMPHO VASCULAR INVASION → Poor prognosis
- MOLECULAR SUB TYPES
 - LUMINAL A → Best prognosis
 - HER 2 ENRICHED → worst prognosis
- HISTOLOGICAL SUB TYPES
 - Tubular cancer → Best prognosis

- GRADE → NOTTINGHAM SCORE

↓

Low grade

↓

Good prognosis

↓

High grade

↓

Bad prognosis

Components

 - Tubule formatⁿ
 - mitotic counts
 - Nuclear pleomorphism

→ ANEUPLOIDY → poor prognosis

→ RECEPTORS

1. ER
 - ⊕ → hormone therapy ✓
 - ⊖ → chemotherapy ✓

2. Her 2 / Neu → Poor prognosis
→ Predicts the response to TRASTUZUMAB (Herceptin)

INTRODUCTION TO BONE TUMORS

BONE TUMORS

- I. PRIMARY [1°] BONE TUMORS
- II. SECONDARY [2°] BONE TUMORS [more common]

SECONDARY [2°] BONE TUMORS | METASTASIS

- commonly occur from Prostate cancer, Breast cancer, Renal cancer, Lung cancer
- MC cancer responsible for bony metastasis → Breast cancer
- MC cancer in Females responsible for bony metastasis → Breast cancer
- MC cancer in males responsible for bony metastasis → Prostate cancer
- MC cancer in children responsible for bony metastasis → Neuroblastoma

- OSTEOLASTIC SECONDARIES → Prostate cancer, Carcinoid tumor
- OSTEOLASTIC | OSTEOLYTIC 2° → Breast cancer, Lung cancer

- In Breast & Lung cancer both Osteoclastic & Osteoblastic 2° are seen [osteoclastic 2° > osteoblastic 2°]

- MC bones involved in metastasis → vertebral column
- multifocal EXCEPT Renal & Thyroid cancers
 - Renal & Thyroid cancers are Pulsatile in nature

PRIMARY [1°] BONE TUMORS

t.me/latestpnotes

	BENIGN TUMORS	MALIGNANT TUMORS
AGE	Young	Elderly
PREVALENCE	more	Less
BONE BIOPSY	uniform	variable

Bone Biopsy [confirmatory test for diagnosis]

CLASSIFICATION

	MALIGNANT	BENIGN
HEMATOPOIETIC	Myeloma	
	Lymphoma	
CARTILAGE FORMING	chondrosarcoma	osteochondroma
		chondroma
		chondroblastoma
		Chondromyxoid fibroma
BONE FORMING	osteosarcoma	osteoid osteoma
		osteoblastoma
UNKNOWN ORIGIN	Ewing Sarcoma	Giant cell tumor
	Adamantinoma	Aneurysmal bone cyst
NOTOCHORDAL	CHORDOMA	

- CHORDOMA → NOTOCHORD ORIGIN, AGGRESSIVE BONE TUMOR
- CHONDROMA → BENIGN CARTILAGE TUMOR

- MC 1° MALIGNANT BONE TUMOR → MYELOMA > OSTEOSARCOMA

RISK FACTORS [↑ cancer]

- chronic osteomyelitis
- Bone infarct
- Radiation exposure
- Paget's disease
- metal implant / prosthesis

} a/w
chronic
inflammatⁿ → ↑ cells → ↑ cancer risk

SPECIFIC INDIVIDUAL TUMORS**OSTEOSARCOMA**

- 2nd MC 1^o malignant bone tumor
- Mineralised Bone deposition is characteristic finding

RISK FACTORS

1. Rb gene / P53 gene mutation & MDM2 / CDK4 overactivity
2. H/O previous Bone lesion [Paget's disease / Bone infarct]
3. Chemicals ; Radiation exposure

1 ^o	2 ^o
young [75%]	Elderly [25%]
more	H/O Radiation exposure / Bony lesion

- BIMODAL AGE DISTRIBUTION present

SITE

- Femur [Lower end] >> Tibia [Upper end] >> Humerus [Upper end]
- Metaphyseal region involved commonly

CLINICAL FEATURES

- Gradually growing painful MASS around the knee joint
- NIGHT PAIN
- PATHOLOGICAL FRACTURE

SUBTYPES OF OSTEOSARCOMA**A. GRADE**

- Low grade
- High grade

B. 1^o & 2^o**C. SITE**

- Intramedullary
- Intra cortical
- Surface [Better Prognosis]
 - Parosteal → Surface of cortex involved
 - Periosteal → surface of periosteum involved

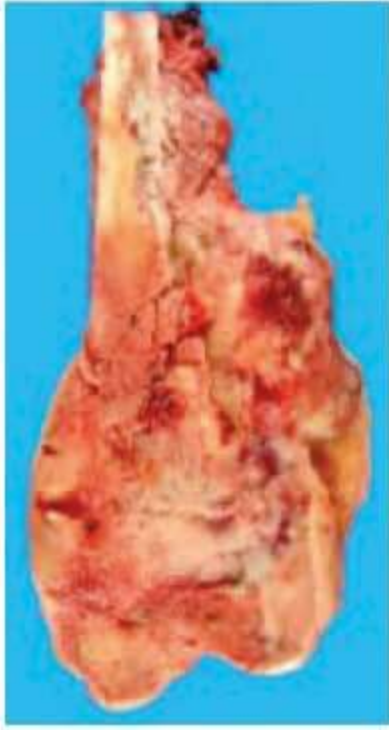D. HISTOLOGICAL SUB TYPES

- osteoblastic
- chondroblastic
- Fibroblastic
- telangiectatic
- Small cell
- Giant cell

MC OSTEOSARCOMA → HIGH GRADE / 1^o / INTRAMEDULLARY / OSTEOBLASTIC

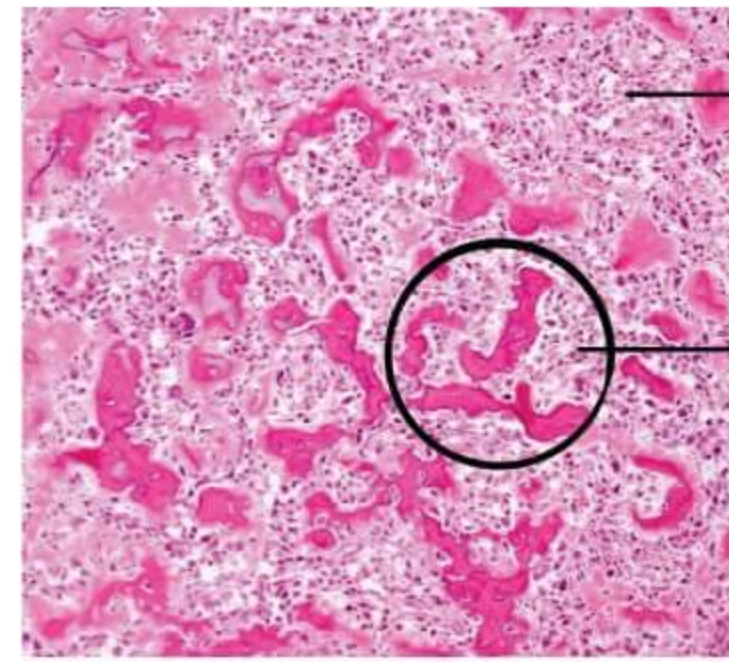
DIAGNOSIS

- BONE BIOPSY IS CONFIRMATORY
- Diagnostic finding → Bone Formation by tumor cells



GROSS

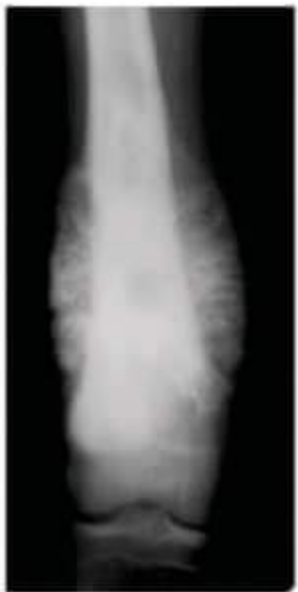- Bulky
- Gritty
- Hemorrhage/necrosis + nt



Histology

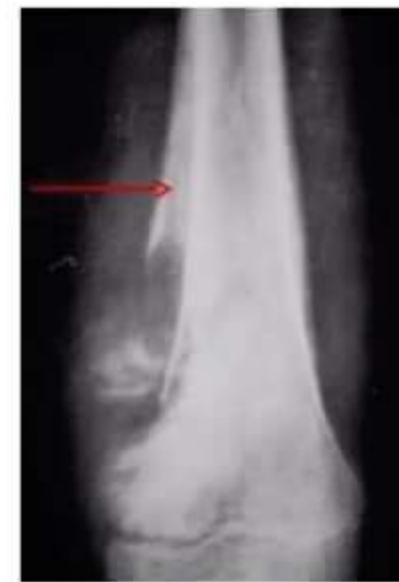Tumor cells

LACE LIKE PATTERN

→ **RADIOLOGICAL FEATURES**

SUN BURST APPEARANCE

- dit Ca^{2+} deposition



CODMAN'S TRIANGLE

- dit lifting of periosteum by tumor
- indicates the aggressive nature of tumor

t.me/latestpgnotes

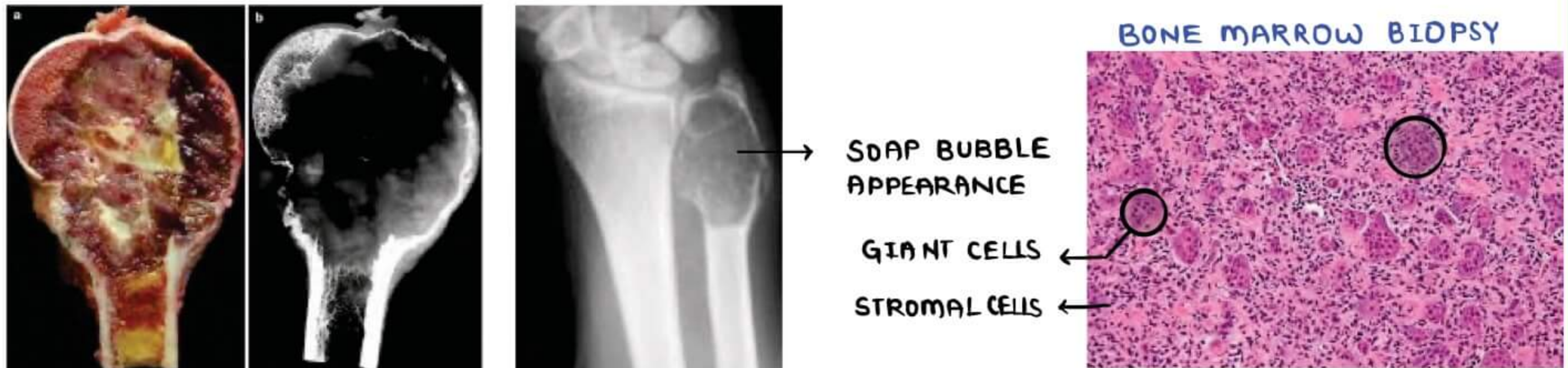- METASTASES TO Lungs >> Bones | Brain
- RADIO RESISTANT IN NATURE
- TREATMENT
 1. Surgery
 2. methotrexate

GIANT CELL TUMOR

- aka OSTEOCLASTOMA
- Benign tumor but Locally aggressive
- Tumor cells → PRIMITIVE OSTEOBLASTIC PRECURSOR CELLS
 - ↓
 - Express RANK - L
 - ↓
 - attaches to RANK on osteoclasts
 - ↓
 - EXCESS OSTEOCLAST ACTIVATION
 - ↓
 - LOCALLY DESTRUCTIVE LESIONS

CLINICAL FEATURES

- 20 - 40 yrs
- commonly affect KNEE JOINT
 - distal end of femur > Upper end of Tibia / lower end of Radius
- arises from EPIPHYSIS, but can extend into METAPHYSIS [articular cartilage involved]
- Arthritis-like manifestations + nt
- Pathological fractures occurs

DIAGNOSIS

- CLUB SHAPED TUMOR
- alw single layer of Periosteal reaction
- Red Brown mass [dit Hemorrhage & necrosis]
- Cystic degeneration + nt. + SOAP BUBBLE APPEARANCE on radiographs
- Bone marrow biopsy shows
 - ↳ GIANT CELLS SURROUNDED BY STROMAL CELLS
 - GIANT CELLS → normal cells
 - STROMAL CELLS → cancer cells
 - ↳ Hemorrhage & necrosis + nt
- In about 4% of patients, pulmonary metastasis seen
- GCT have high chances to undergo malignant transformation

TREATMENT

1. CURETTAGE [40-60% have recurrence]
2. DENOSUMAB
 - monoclonal antibody
 - inhibit osteoclast activity

CHONDROSARCOMA

- Malignant tumor → cartilage formation + nt
- GENES
 - ↳ IDH₁ / IDH₂ gene mutation
 - ↳ CDK2NA gene silencing
 - ↳ EXT mutation alw MULTIPLE OSTEochondroma SYNDROME
- arises from METAPHYSIS Except clear cell chondrosarcoma [Epiphyseal origin]

CLINICAL FEATURES

- Males >> Females
- > 40 yrs age
- Painful enlarging mass
- involves Axial skeleton
 - Pelvis [mc]
 - Shoulder
 - Ribs

CLASSIFICATION OF CHONDROSARCOMA

Based On Histology

1. CONVENTIONAL [Hyaline cartilage]
2. CLEAR CELL
3. MESENCHYMAL
4. DEDIFFERENTIATED

clearcell & mesenchymal variants are seen in relatively young patients
 mc variant → Grade 1 Intramedullary conventional / classical chondrosarcoma

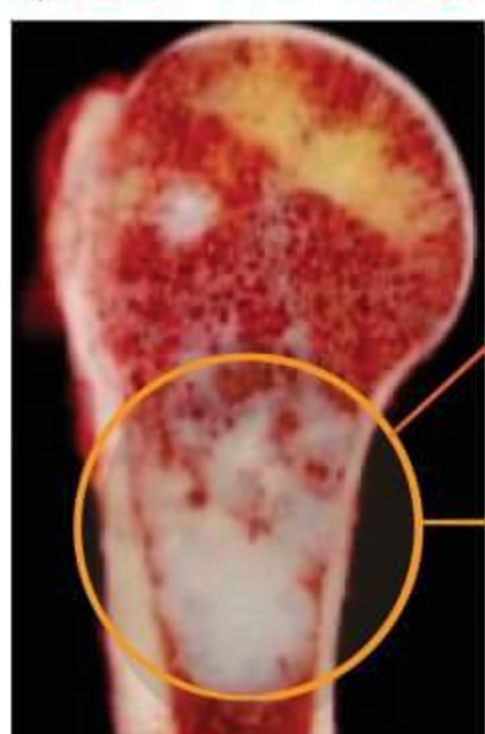CLASSICAL | CONVENTIONAL CHONDROSARCOMA



GRADING OF CHONDROSARCOMA [Based on cellularity, Atypia, mitotic activity]

- GRADE 1 → most common
- GRADE 2
- GRADE 3 → high chance of metastasis

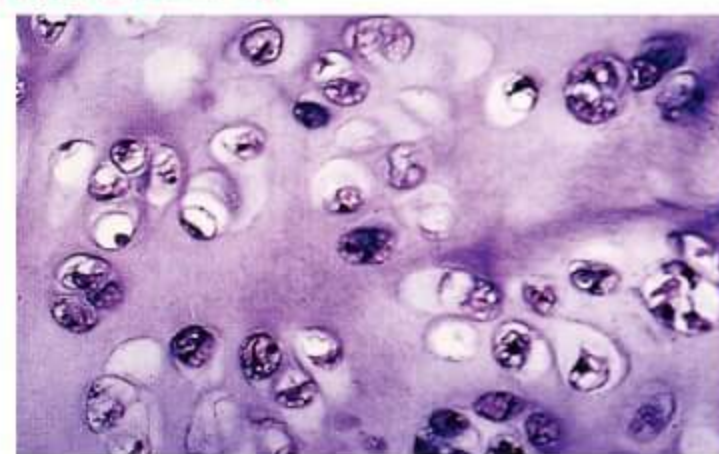
GROSS FEATURES



Firm in consistency

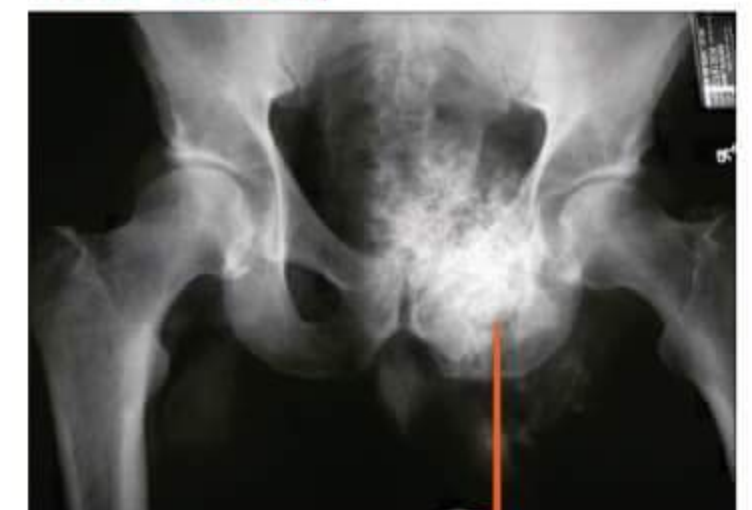NODULES OF GREY-WHITE CARTILAGE

HISTOLOGY



Malignant cartilage cells
 Permeating marrow

RADIOLOGY



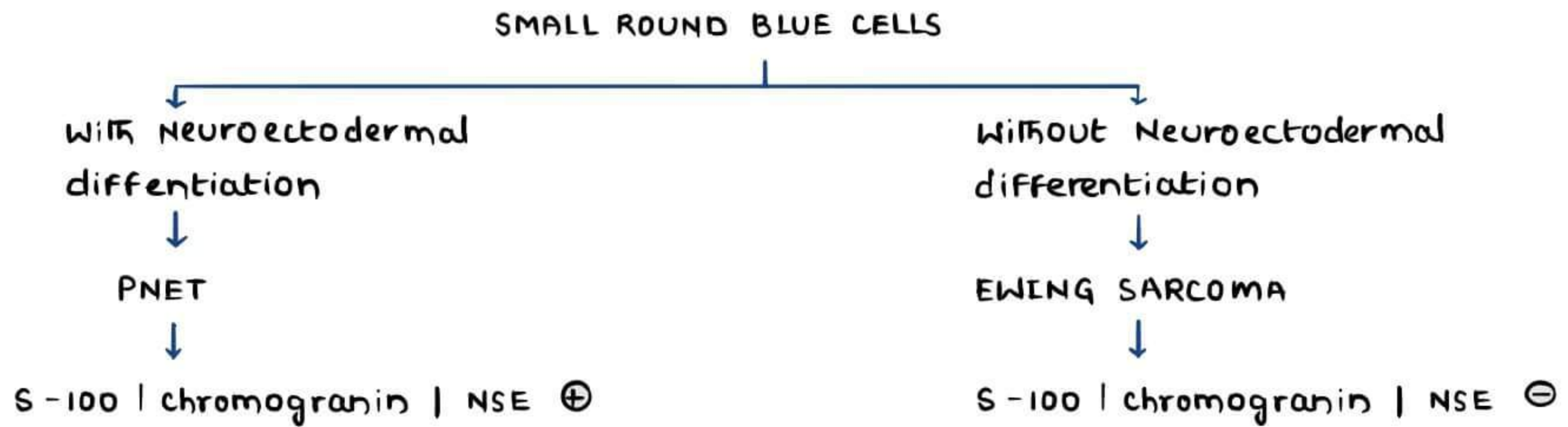
SPOTTY CALCIFICATION/
 FLOCCULENT DENSITIES

INTRAMEDULLARY TYPE

- chondrosarcoma a/w Paraneoplastic syndrome → ↑ GLUCOSE [Hyperglycemia]
- metastasis to Lungs >> Brain | Kidney
- CHEMO & RADIO RESISTANT TUMOR, Rx by Surgery
- Chondrosarcoma has the best prognosis among all other bone tumors

→ malignant tumor of Primitive Round cells without differentiation

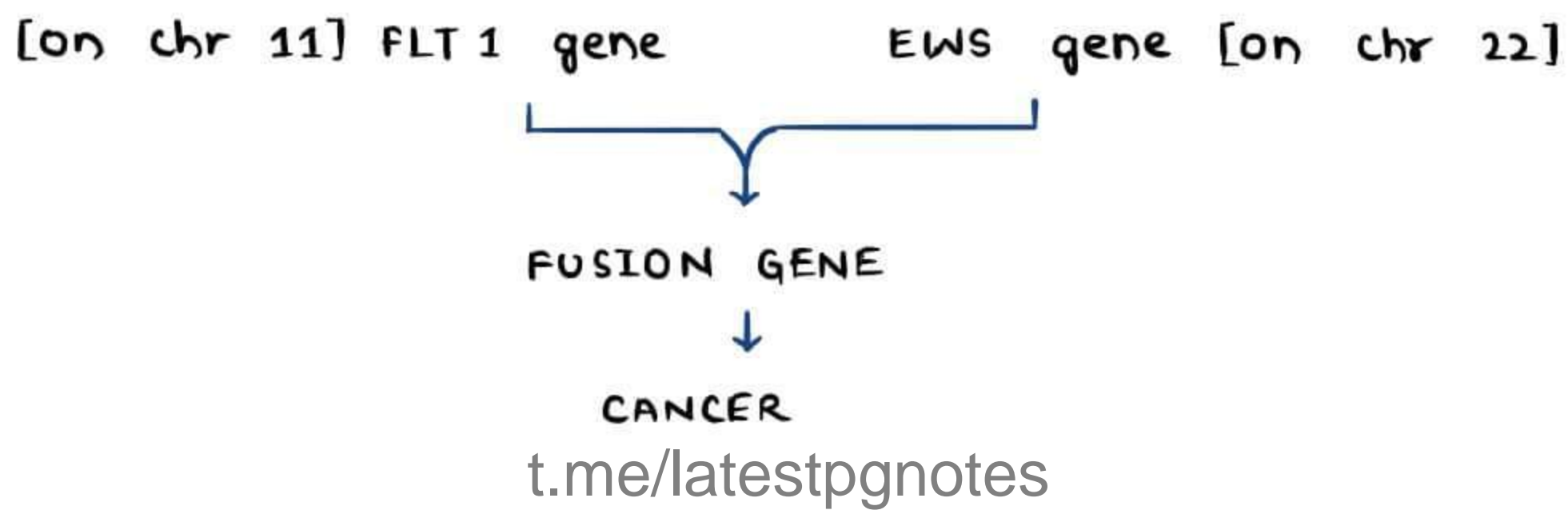
EWING SARCOMA FAMILY OF TUMORS [ESFT]



EWING SARCOMA

→ GENETICS

↳ t [11;22] [mc]



↳ t [21;22]
↳ Trisomy 8 / 12

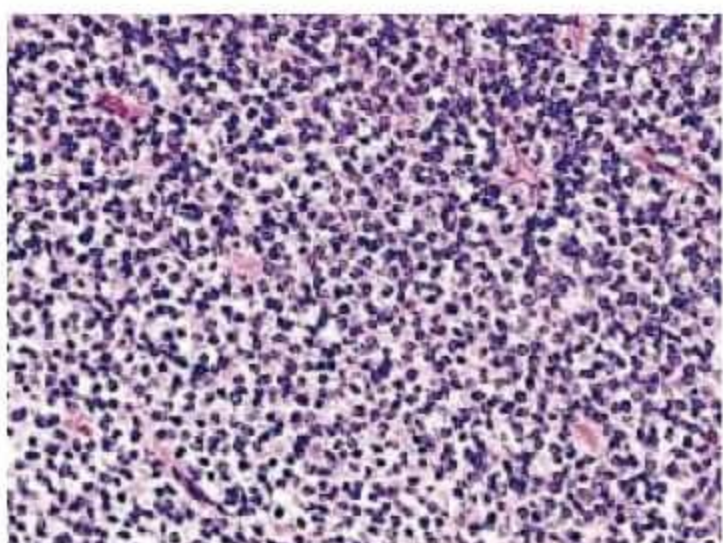
- arises from DIAPHYSIS
- mc affects Femur
- Flat bones of pelvis also involved

CLINICAL FEATURES

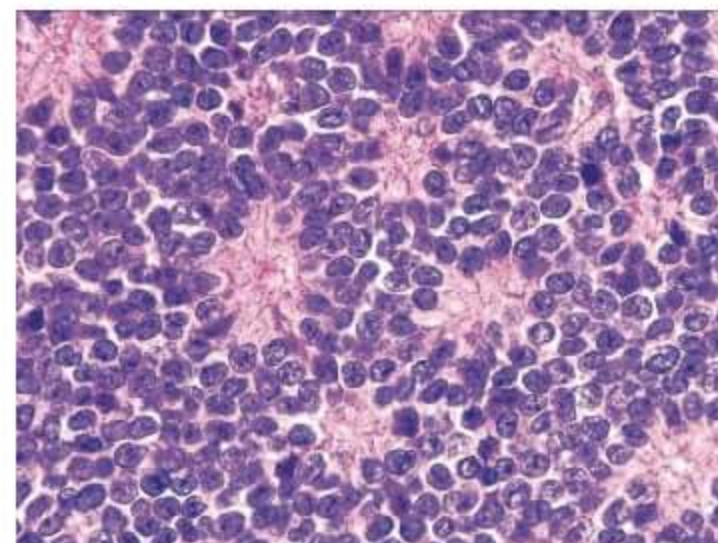
- < 20 yrs
- presents painful, tender swelling & fever
- mimics Osteomyelitis

INVESTIGATIONS


1. ↑ TLC , ↑ ESR , ↑ CRP
2. Bm BIOPSY



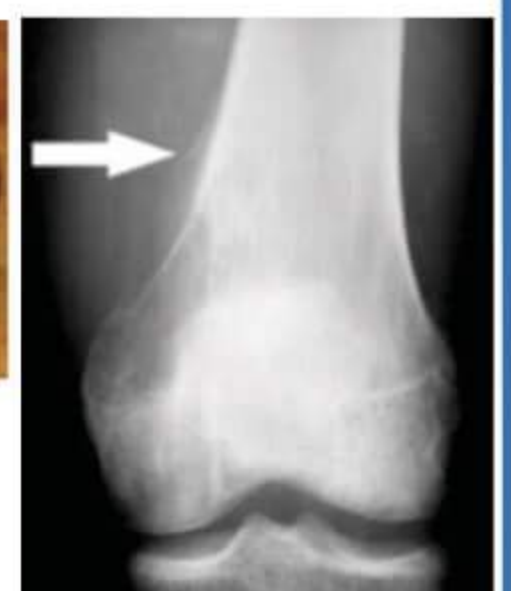- small round blue cells
- Little stroma
- clear cytoplasm



HOMER WRIGHT PSEUDO ROSETTES



ONION SKIN APPEARANCE



- Lytic lesion
- Tan grey mass involving medulla [Hemorrhage & necrosis +nt]
- Periosteal Reaction present → ONION SKIN APPEARANCE ON X RAY
- IMMUNO HISTOCHEMISTRY → mic-2 ~ CD 99 ⊕
- METASTASIS → BONE TO BONE METASTASIS SEEN
- mc tumor i Bone to Bone metastasis → EWING SARCOMA

t.me/latestpgnotes

PROPERTIES OF TUMOR CELLS

1. CONTINUE TO REPLICATE EVEN AFTER THE ABSENCE OF STIMULUS / GROWTH FACTOR

→ NORMAL CELL

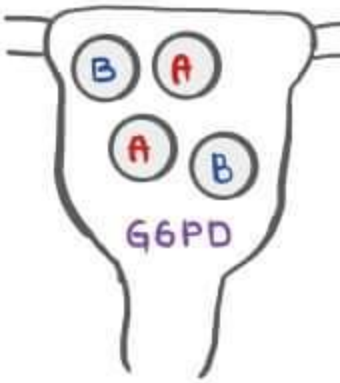
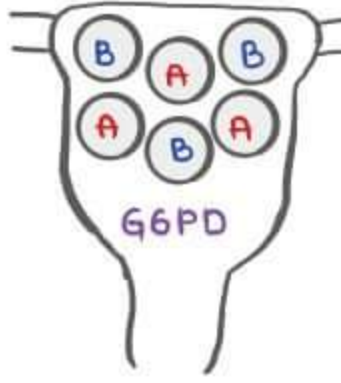
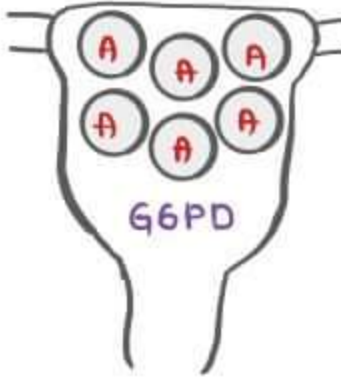


→ CANCER CELLS



GF -
Growth
factor

2. MONOCLONAL GROWTH

NORMAL	PREGNANCY	CANCER [monoclonal growth]
 <ul style="list-style-type: none"> • Normal no. of cells • isoforms of G6PD - are equally distributed 	 <ul style="list-style-type: none"> • ↑ no. of cells • isoforms of G6PD - are equally distributed 	 <ul style="list-style-type: none"> • ↑ no. of cells • isoforms of G6PD are unequally distributed

- monoclonality shown by both BENIGN & MALIGNANT TUMORS
- MC ENZYME whose isoforms are useful for detectⁿ OF MONOCLONALITY is G6PD ENZYME

3. COMPONENTS OF NEOPLASM

- PARENCHYMA [proliferating neoplastic cells]
- STROMA [connective tissue]

- MORE STROMA → FIRM appearance
- MORE PARENCHYMA → MEDULLARY appearance

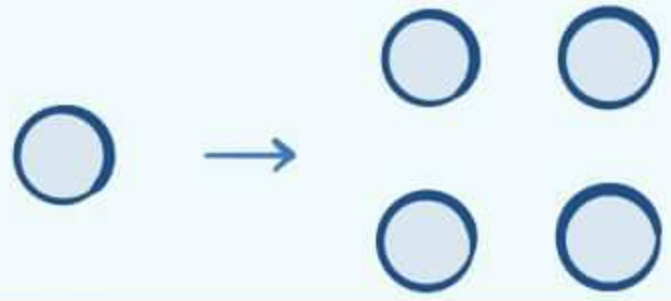

→ DESMOPLASIA

- ↳ Excessive amount of stroma
- ↳ contributed by parenchymal chemicals

- ↳ Ex: LINITIS PLASTICA
COLON CANCER
BREAST CANCER



4. TUMOR CLASSIFICATION

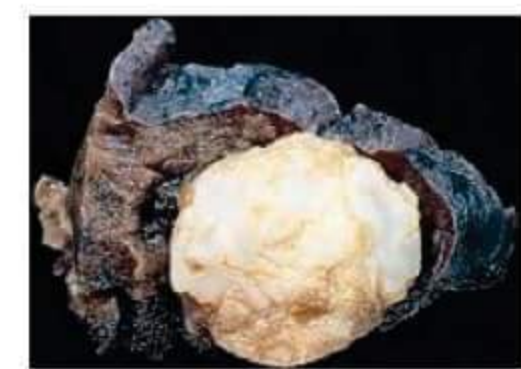BENIGN	MALIGNANT
→ slow growth	→ Rapid growth
→ capsule ⊕	→ capsule ⊖
→ well differentiated	→ poorly differentiated
	
→ Good prognosis	→ poor prognosis
→ NOMENCLATURE uses suffix 'OMA' ↳ Fibroma ↳ Osteoma ↳ Chondroma ↳ Adenoma [glandular] ↳ Papilloma [finger like]	→ NOMENCLATURE CARCINOMA [from epithelial cells] SARCOMA [from connective tissues] ↳ Adenocarcinoma [glandular] ↳ Chondrosarcoma

CHORISTOMA

- ECTOPIC REST OF NORMAL TISSUE [normal tissue at abnormal site]

HAMARTOMA

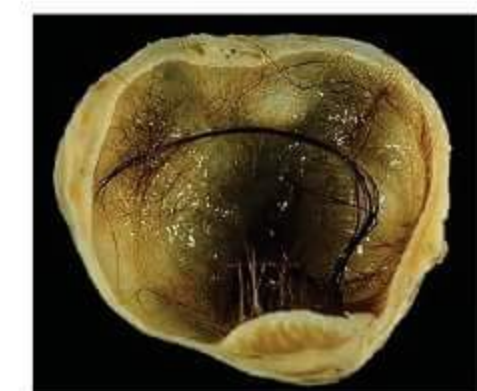- ABNORMAL TISSUE at NORMAL SITE
- commonest site [t.me/latecognotes](https://www.youtube.com/watch?v=...) Lungs
- Preneoplastic lesions [Latest Studies]



HAMARTOMA

TERATOMA

- arises from >1 GERM CELL LAYER
- usually arises from **TOTIPOTENT CELLS**
- mc site → GONADS
- mc extra gonadal site → MEDIASTINUM
- if well differentiated → BENIGN
- if poorly differentiated → MALIGNANT

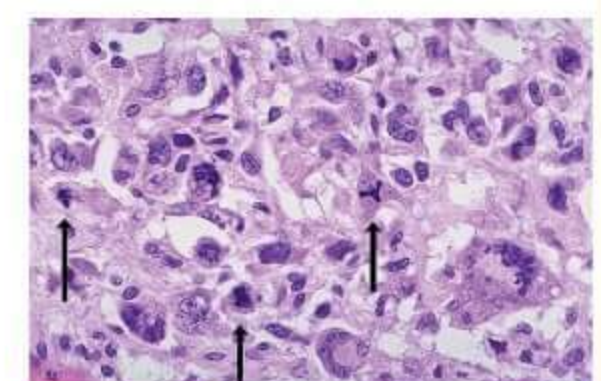


TERATOMA

FEATURES OF NEOPLASIA

1. ANAPLASIA

- TOTAL ABSENCE OF DIFFERENTIATION
- ↑↑↑ NC RATIO [NUCLEO : cytoplasmic Ratio]
 - ↳ Normal N:C Ratio → 1 : 4
 - ↳ Anaplastic N:C Ratio → 1 : 1



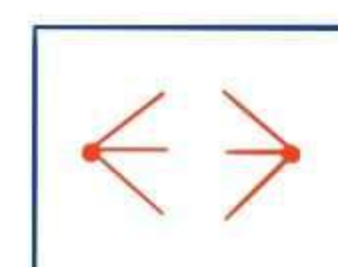
ANAPLASIA

- PLEOMORPHISM

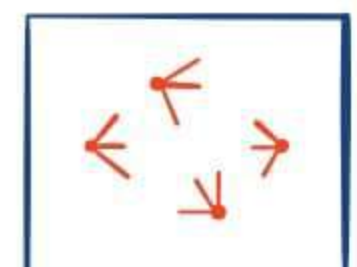
- ABNORMAL MITOSIS

- ↳ NORMAL [2 mitotic spindles]
- ↳ ABNORMAL [>2 mitotic spindles]

- 4 mitotic spindles → Quadripolar spindles
- 3 mitotic spindles → Tripolar spindle



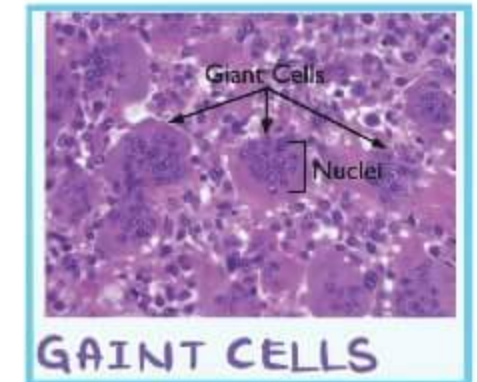
NORMAL



ABNORMAL

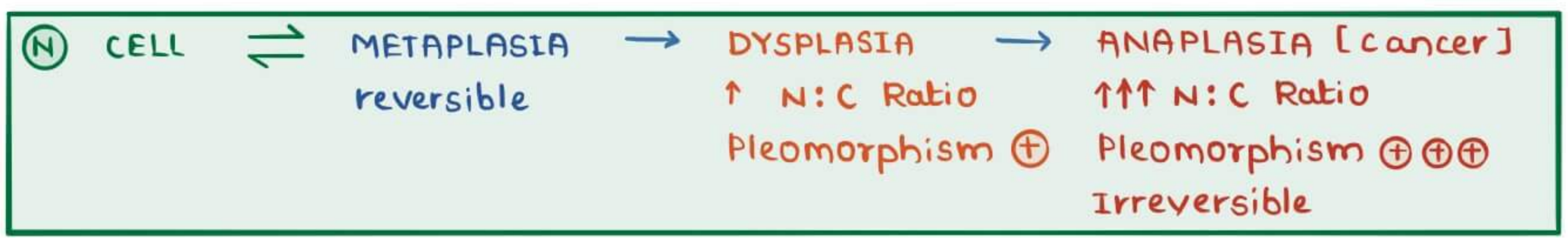


→ ABNORMAL GAIINT CELL
 ↳ REED STERNBERG CELLS [Hodgkin Lymphoma]



→ IRREVERSIBLE
 → HALLMARK OF MALIGNANT TRANSFORMATⁿ

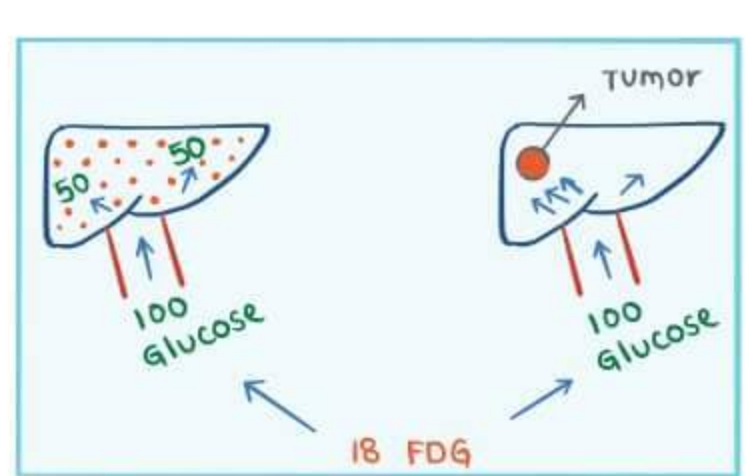
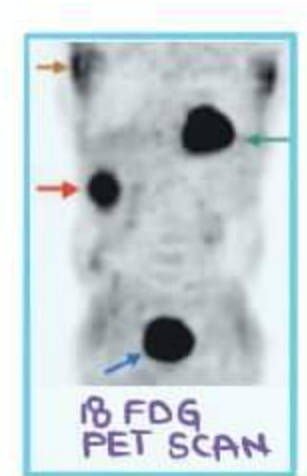
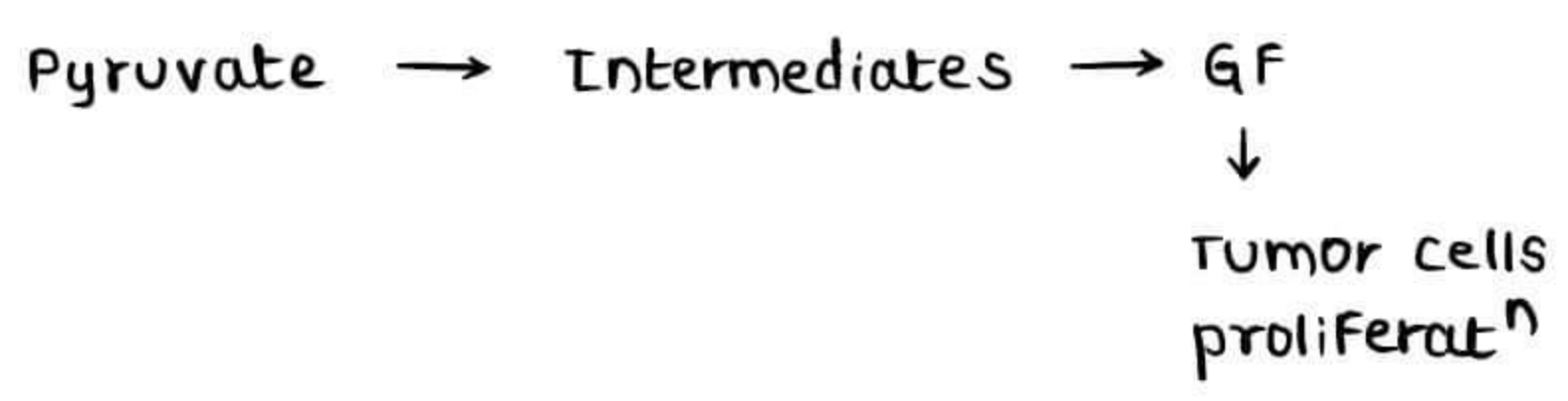
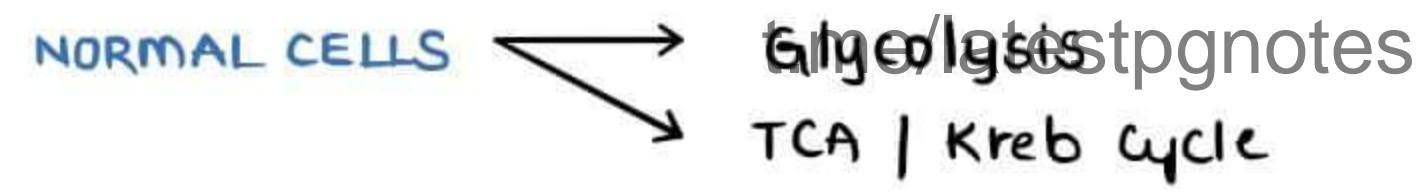
- AN → Abnormal [high] N:C Ratio
- A → Abnormal mitosis
- PL → Pleomorphism
- A → Abnormal Gaint cells
- SIA → Irreversible



2. RATE OF GROWTH ↑↑

- NO. OF divisions required for clinical manifestations → 30
- minimum mass of tumor cells to be detected clinically → 10⁹ cells (1g)
- maximum no. OF cells compatible i the life → 10¹² cells (1kg)

→ Glucose metabolism



18 FDG

- non metabolised
- sub type of glucose
- radio active
- PET scan is done to LOCALISE TUMOR CELLS

3. INVASION



VEGF - vascular Endothelial GF
 FGF - fibroblast GF

- due to VEGF, FGF → ANGIOGENESIS [r/f invasion]
- i out angiogenesis, tumor cells can grow only upto 1-2 mm

→ ANTI ANGIOGENETICS

- ↳ ANGIOSTATIN } Natural
- ↳ ENDOSTATIN }

↳ BEVACIZUMAB → Drug

- CARCINOMA IN SITU → Basement membrane not affected
- CARCINOMA → Basement membrane affected

4. METASTASIS

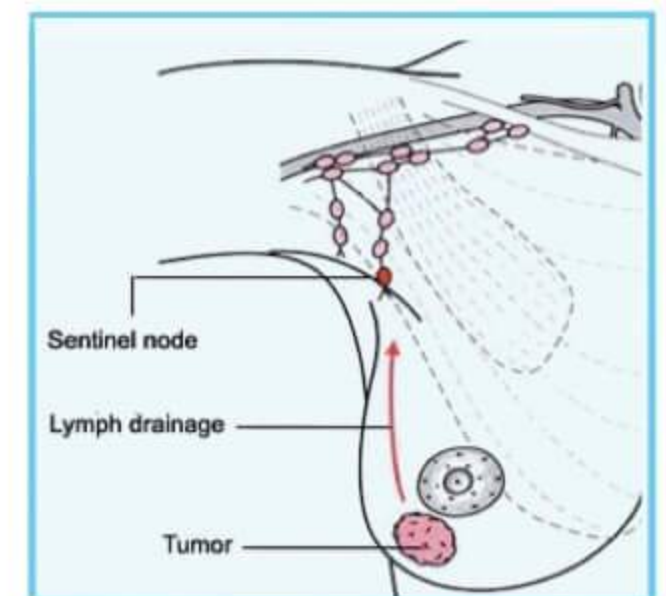
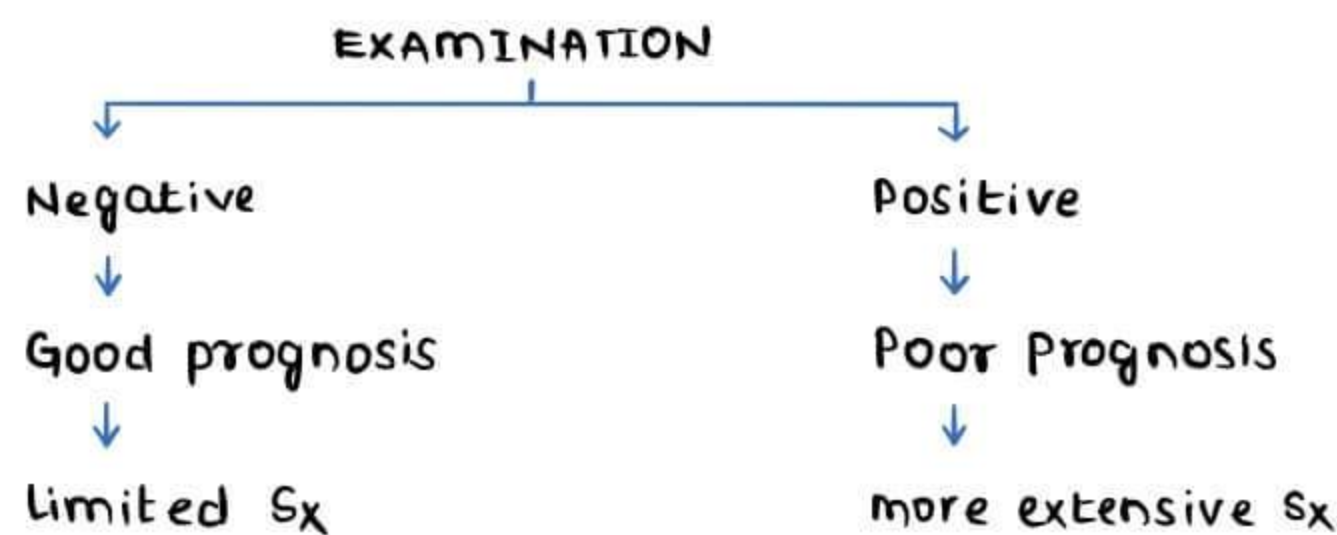
- MOST RELIABLE FEATURE OF MALIGNANCY
- Distinguishes b/w benign & malignant tumor
 - ↳ EX: • PHEOCHROMOCYTOMA
 - FOLLICULAR THYROID TUMOR

- EXCEPTIONS [malignant (out metastasis)]
 1. Basal cell carcinoma [skin]
 2. Glioma

→ Spred through

1. Lymphatic spread

- ↳ Property OF CARCINOMAS
- ↳ Except RCC, HCC, choriocarcinoma → Hematogenous
- ↳ SENTINEL [GATE KEEPER / CARE TAKER] LYMPH NODES
 - ↳ tumor cells spread first to these LN



- ↳ Tells about
 - EXTENT OF DISEASE SPREAD [prognosis]
 - EXTENT OF SURGERY

- ↳ Useful for
 - Breast cancer
 - vulval cancer
 - Melanoma

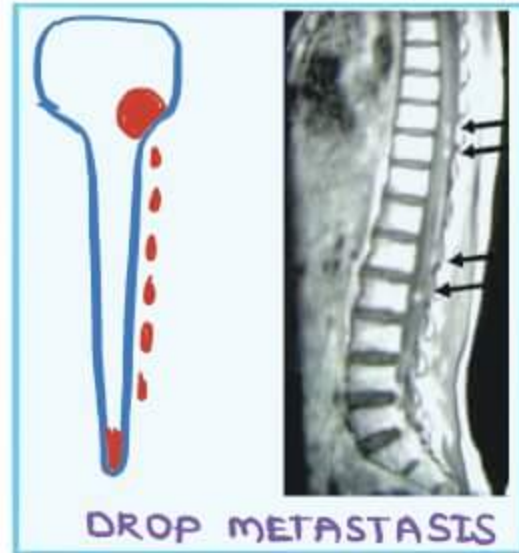2. HEMATOGENOUS SPREAD

- Feature OF SARCOMAS
- Exceptions
 - clear cell sarcoma } Lymphatic spread
 - Rhabdomyo sarcoma }

- can spread through → vein >>> Artery
- commonly affect parts recieving more blood [common sites]
 - Liver
 - Lungs

3. DIRECT SEEDING

- Body cavities are involved directly
 - ↳ pleural cavity [seen in lung cancer, mesothelioma]
 - ↳ pericardial cavity [seen in lung cancer, cardiac cavity]
 - ↳ peritoneal cavity
 - most commonly affected in direct seeding
 - responsible for



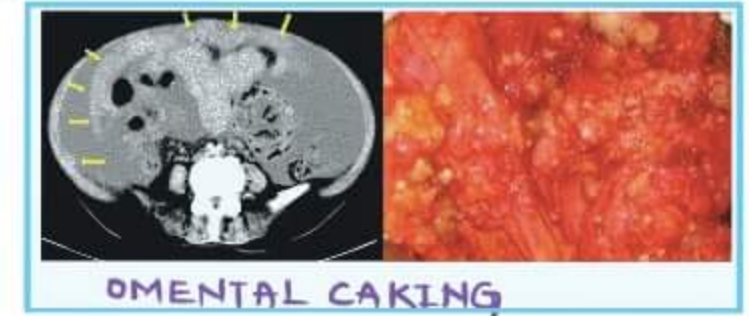
- ↳ **OMENTAL CAKING**

- ↳ **MALIGNANT ASCITIS**

- common in ovarian tumors

- Dx by ASCITIC TAP & the help of

- tumor markers
- HPE [Histo pathological Examination]



4. CSF SPREAD

- a/w 'DROP METASTASIS'
- involves lower spinal cord
- seen in MEDULLOBLASTOMA

GENETIC BASIS OF CARCINOGENESIS I

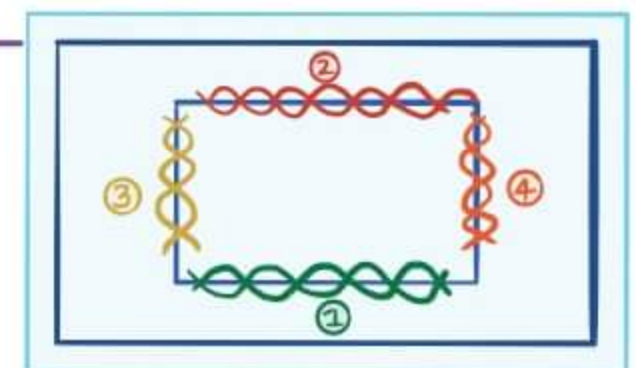
HALL MARKS OF CANCER

- Self sufficiency of Growth factors
- Insensitivity to Growth Inhibitors
- Altered metabolism t.me/latestpgnotes
- Evasion of Apoptosis
- Immortality
- Sustained Angiogenesis
- Invasion & metastasis
- Evasion of Host Immune response

GENETIC DEFECTS

1. PROTO - ONCOGENES

- causes ↑ replicatⁿ of normal cells
- mutation / overactivity → GAIN OF FUNCTION
- Single gene mutatⁿ is sufficient



2. TUMOR SUPPRESSOR GENES

- controls the replicatⁿ of normal cells
- mutation / underactivity → LOSS OF FUNCTION
- Both genes of allele should be involved

3. DNA REPAIR GENES

- defect → cancer
- Both genes of allele should be involved

4. REGULATION OF APOPTOSIS GENES

- Defect → cancer

1. SELF SUFFICIENCY IN GROWTH SIGNAL

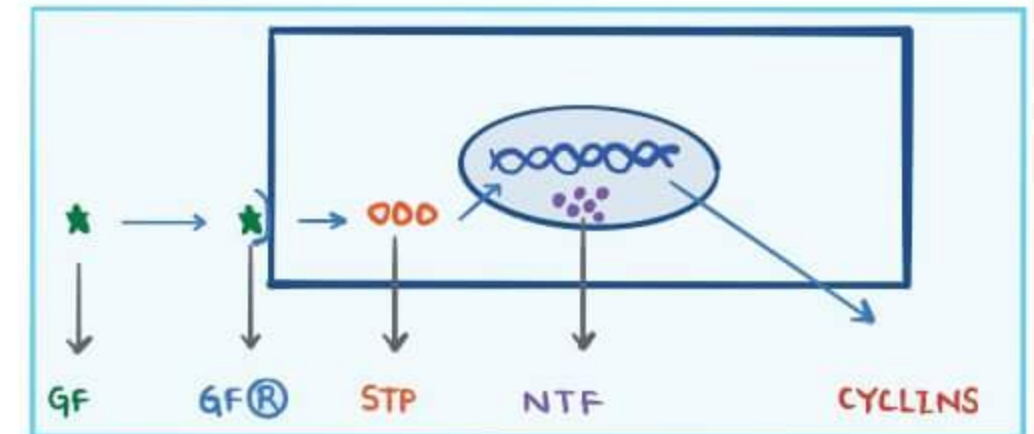
PROTO-ONCOGENES [normal] $\xrightarrow{\text{mutation}}$ ONCOGENES [↑↑↑ Gain of function]

→ due to

- Point mutation
 - Over expression
 - Translocation
- } ↑ Activity

→ NORMAL CELL GROWTH INVOLVES [ONCOGENES]

1. Growth factor [GF]
2. GF Receptors [GF[®]]
3. Signal Transduction proteins [STP]
4. Nuclear Transcription factors [NTF]
5. ↑ cyclins



ANY HYPERACTIVITY OF FIRST 4 FACTORS } ↑↑↑ CYCLINS } ↑↑↑ PROLIFERATION OF CELLS

1. GROWTH FACTORS

- PDGF → SIS gene → GLIOMA
- HGF → HGF gene → LIVER CANCER

t.me/latestpgnotes

2. GF RECEPTOR [® Associated Tyrosine Kinase]

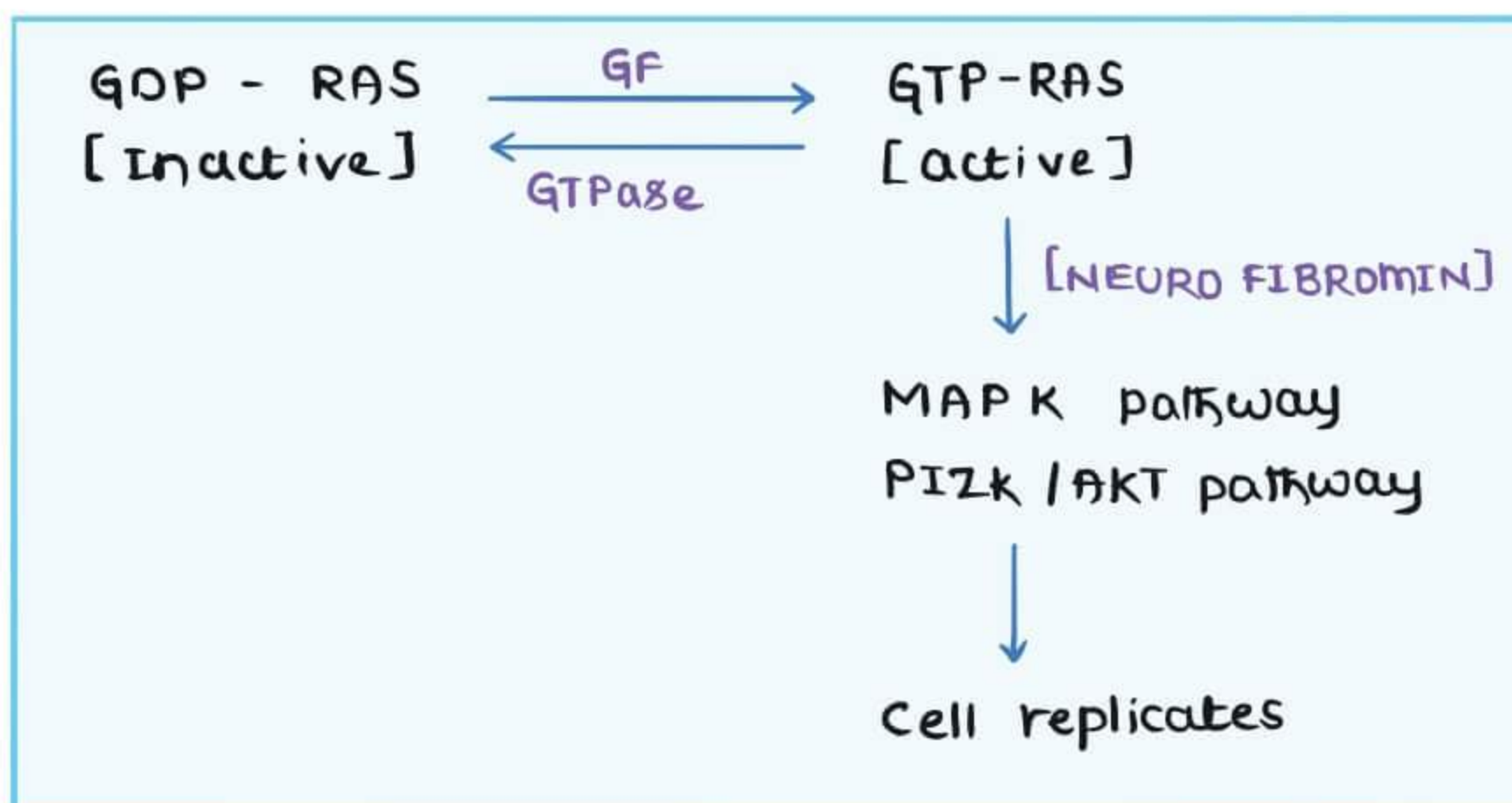
- ERB B₁ gene → Lung cancer
- ERB B₂ / HER-2 gene → Breast cancer
- RET gene → MEN II Syndrome
 - ↳ Pheochromocytoma
 - ↳ medullary carcinoma Thyroid

← GEFITINIB, ERLOTINIB
← TRASTUZUMAB

used in Rx

3. SIGNAL TRANSDUCTION PROTEINS

- RAS [most imp. STP involved in cancer]
- ABL
- β catenin
- BRAF

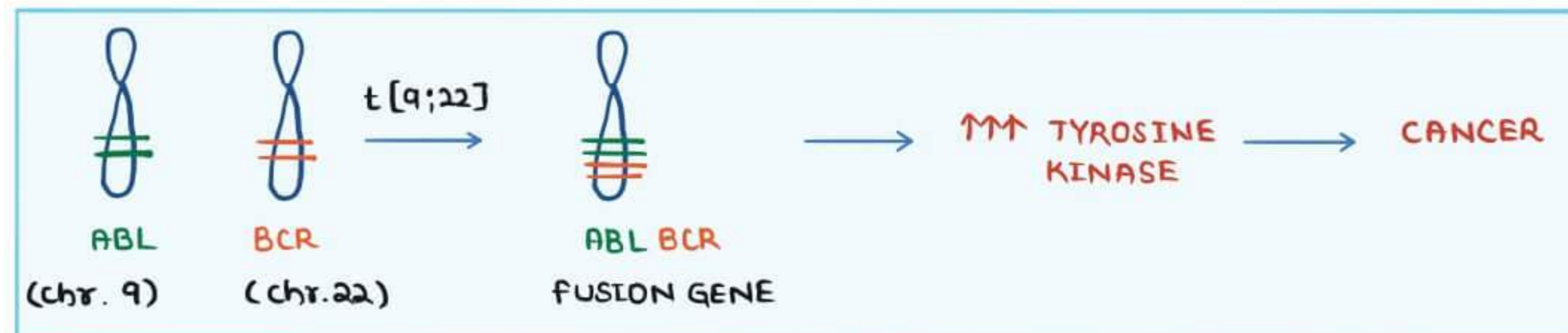


→ RAS MUTATION

- ↳ Colon cancer → K - RAS
- ↳ Kidney & bladder cancer → H - RAS
- ↳ melanoma → N - RAS

↳ MC TYPE PROTO-ONCOGENE MUTATⁿ a/w HUMAN CANCER → K - RAS

→ ABL GENE [have non-receptor tyrosine kinase activity]



↳ $t(9;22)$ → CML & ALL

↳ ONCOGENE ADDICTION [ABL] → addicted to Tyrosine Kinase for proliferatⁿ

↳ TARGETED THERAPY by IMATINIB [directs against TYROSINE KINASE]

↳ ALL [Acute] replicates faster than CML

↳ IMATINIB is more effective against CML than ALL

↳ therefore, $t(9;22)$ CML has good prognosis

$t(9;22)$ ALL has poor prognosis

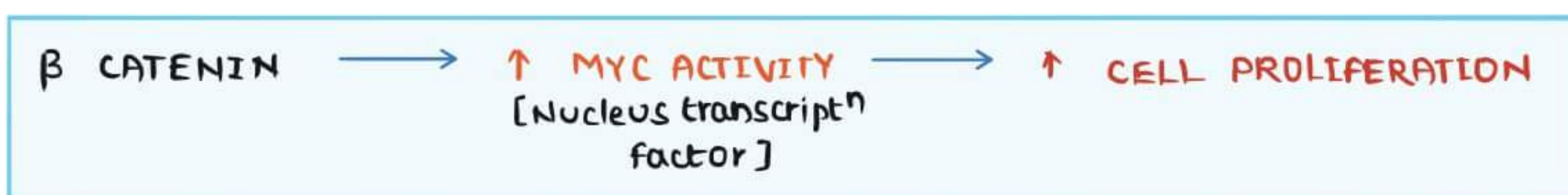t.me/latestpnotes

→ B RAF gene



↳ BRAF mutation a/w

- Hairy cell leukemia [100%]
- Benign nevi [80%]
- melanoma [60%]

→ β CATENIN

↳ APC gene } ↓ β catenin activity
 ↳ E-cadherin }

↳ β catenin mutatⁿ a/w → COLON CANCER

4. NUCLEAR TRANSCRIPTION FACTORS

1. MYC GENE

- ↑ cyclin activity
- ↑ Telomerase
- Reprogram → "STEMNESS"
- aka "MASTER REGULATOR" OF Cell

→ SUB TYPES

- C - MYC → Burkitt's lymphoma [fastest rate of replicatⁿ]
- N - MYC → Neuroblastoma
- L - MYC → Lung cancer [small cell]

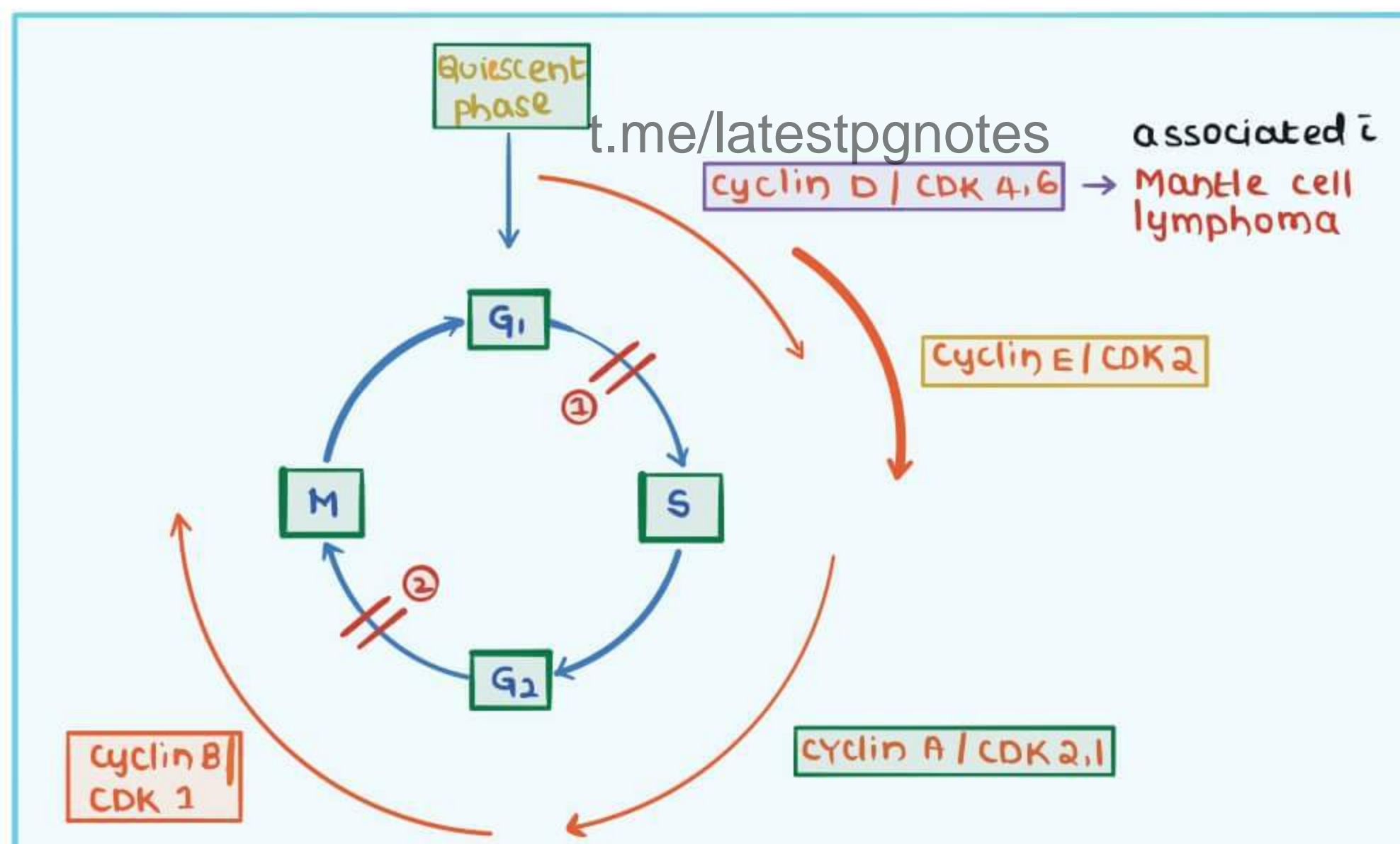
5. CYCLINS [OFF/ON] → CDKs → causes phosphorylation

→ CDKs [Cyclin Dependent Kinases]

↳ SUB TYPES & ACTIVATION SEQUENCE

- D → 4, 6
- E → 2
- A → 2
- B → 1

→ CELL CYCLE PHASES & REGULATION



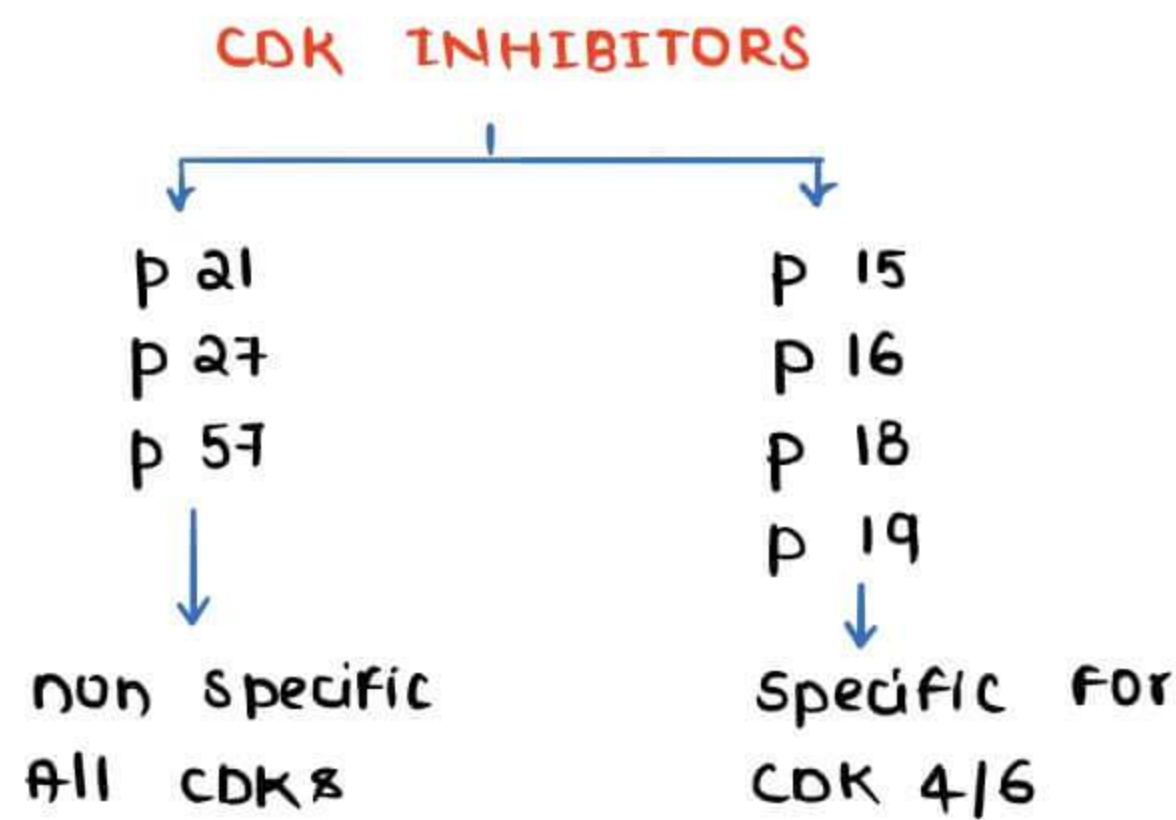
→ CELL CYCLE PHASES ARE REGULATED BY

- ↳ From Quiescent stage to just beyond check point 1 → CYCLIN D / CDK 4,6
- ↳ From just beyond check point 1 to 'S' phase → CYCLIN E / CDK 2
- ↳ From 'S' phase to 'G₂' Phase → Cyclin A / CDK 2,1
- ↳ From 'G₂' phase to 'M' phase incl. check point 2 → cyclin B / CDK 1

→ cell cycle also regulated by

- ↳ Rb gene ; p53 gene → G₁/S
- ↳ p53 gene → G₂/S

→ CDK activity → ↑ by cyclins ; ↓ by CDK inhibitors



GENETIC BASIS OF CARCINOGENESIS 2

2. INSENSITIVITY TO INHIBITORS

→ Tumor Suppressor genes → ↓ Cell Replication

→ DOUBLE - HIT HYPOTHESIS

↳ proposed by Knudson

↳ explained \bar{c} Retinoblastoma

↳ both copies of genes should be involved

→ FUNCTIONS

↳ Regulation of G₁/S Transition → RB / P53 gene

↳ DNA Repair → P53 / BRCA - 1/2 genes

↳ mitogenic pathway ⊖ → APC genes, NF1/2, PTEN genes

↳ Angiogenesis ⊖ → VHL genes

1 RB GENE

↳ located on chr 13q14

↳ proposed by Knudson in Retinoblastoma

↳ most important tumor suppressor gene in humans

↳ mc tumor suppressor gene a/w cancers

↳ Retinoblastoma

a. **Sporadic** → no alteratⁿ of genes at the time of birth

→ ① ② → **U/L** Retinoblastoma

b. **Familial** → 1 gene of allele is mutated at the time of birth

→ **B/L** Retinoblastoma

↳ RB gene is RECESSIVE in nature but

↳ FAMILIAL RB IS AUTOSOMAL DOMINANT

→ as only 1 mutatⁿ required after birth

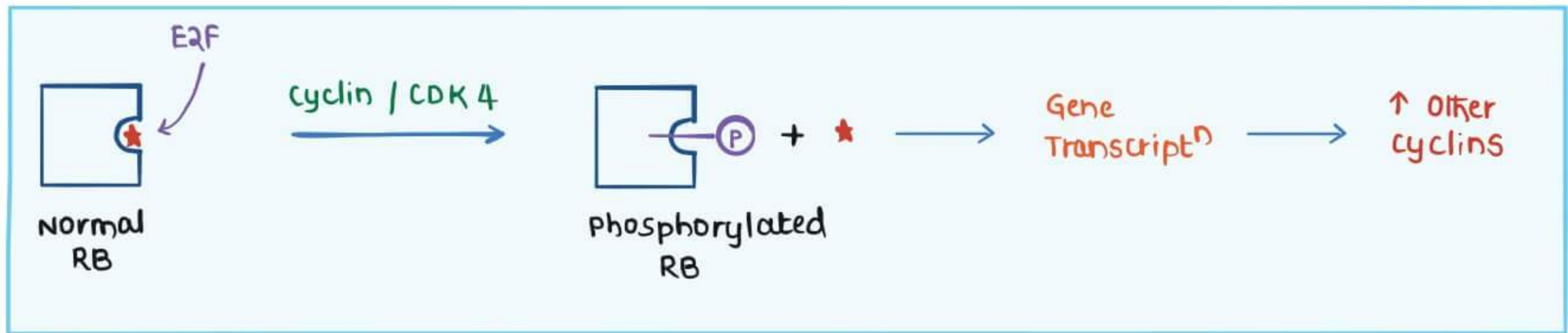
→ LOSS OF HETEROZYGOSITY occurs

↳ 1 defective & 1 normal gene → heterozygous

↳ 2 defective genes → Loss of heterozygosity

[homozygous for defective gene]

↳ sporadic RB [60%] more common than familial RB [40%]

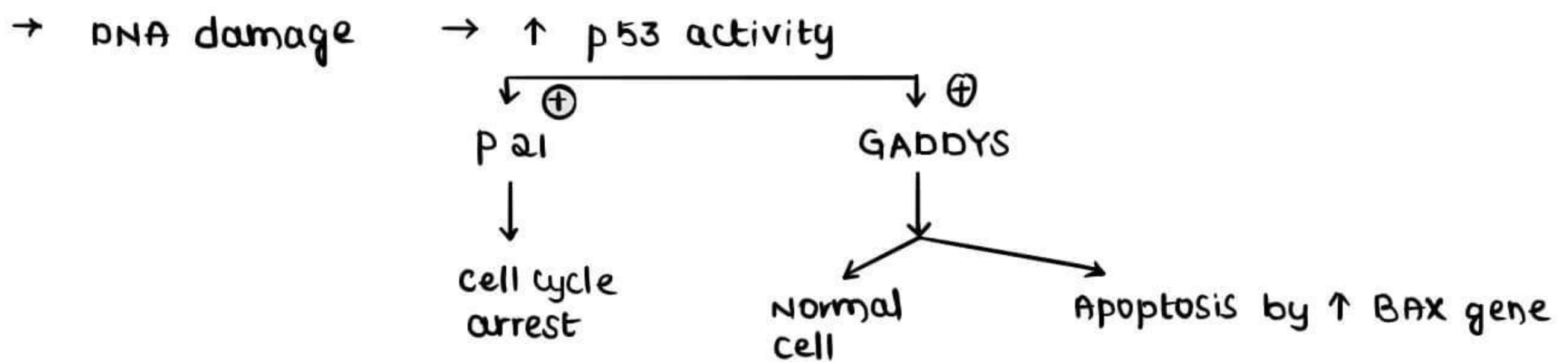


↳ AKA 'GOVERNOR OF CELL REPLICATION'

↳ EBV → E7 protein → ↓ Rb gene → ↑ Cell Replication [CA CERVIX]

2. P53 GENE / GUARDIAN OF GENOME

→ (N) cells → MDM gene destroys P53



t.me/latestpgnotes

→ FORMS OF p53 gene

a. WILD TYPE → (N) → Located on chr 17p

b. GERM LINE p53 GENE MUTATION

↳ causes LI FRAUMENI SYNDROME → ↑ cancers

c. SPORADIC p53 GENE MUTATION

↳ mc genetic mutation seen in human cancers

3. BRCA 1 → chr 17q → ♀ Breast cancer / ovarian cancer
 BRCA 2 → chr 13q → ♂ Breast cancer / prostate cancer

BRCA 1 } involved
 BRCA 2 } in DNA Repair

BRCA 1 → play a important role in familial variant of cancer
 → documented presence of BRCA 1 gene mutation → indicatⁿ for prophylactic mastectomy & oophorectomy

4. NF 1 → chr. 17q → Neurofibromatosis 1
 → cafe au lait spots

NF 2 → chr. 22q → ↑ Acoustic Neuroma
 → Leash nodules
 → cafe au lait spots
 → CNS tumors

5. WT1

- mesenchymal to epithelial transition (normal)
- mutation causes wilms tumor
- located on chr 11p

6. VHL GENE

- (N) → ↓ HIF [Hypoxia Inducible factor] → ↓ VEGF
- located on chr 3p
- aka VHL SYNDROME
 - ↳ Kidney cancers
 - ↳ Brain tumors [cerebellar hemangioblastoma]
 - ↳ Pheochromocytoma

7. APC GENE

- ↓ β catenin Activity → ↓ Adenomas (normal)
- located on chr 5q
- ↑ Adenomas → familial Adenomatous Polyposis → ↑ colon cancer
- aka GATE KEEPER OF COLONIC NEOPLASIA

III GENES REGULATING APOPTOSIS

- INTRINSIC PATHWAY AFFECTED
- BCL-2 OVERACTIVITY → ↓ APOPTOSIS → ↑ CANCER
- EX: Follicular lymphoma

t.me/latestpgnotes

IV DNA REPAIR GENE DEFECTS

- Nucleotide Excision Repair defect [NERD]
- Mismatch repair defect [MRD]
- Homologous Recombination Repair defect [HRRD]

- NERD → xeroderma pigmentosa [UV Rays] } Autosomal
 → ↑ Skin cancers } Recessive

- MRD → LYNCH Syndrome
 - ↳ Autosomal Dominant
 - ↳ dit MICRO SATELITE INSTABILITY
 - ↳ aka CEO Syndrome
 - ↑ Colon cancer
 - ↑ Endometrial cancer
 - ↑ Ovarian cancer

- HRRD → BLOOM Syndrome ← Ionising Radiation } Autosomal
 Fanconi's anemia ← Alkalisising agents } Recessive
 Ataxia-telangiectasia ← Ionising Radiation

- BRCA1/2 gene defects → involved only in FAMILIAL BREAST CANCER

OTHER HALLMARKS OF CANCER

1. ALTERED METABOLISM

→ WARBURG EFFECT → Aerobic glycolysis → GF → ↑ cell proliferatⁿ

2. IMMORTALITY

→ normally ONLY GERM CELLS have TELOMERASE

→ cancer cells have telomerase activity

3. SUSTAINED ANGIOGENESIS

→ VEGF } ↑
FGF }

→ Angiostatin } ↓
→ Endostatin }

→ BEVACIZUMAB → Anti Angiogenetic drug

4. INVASION & METASTASIS

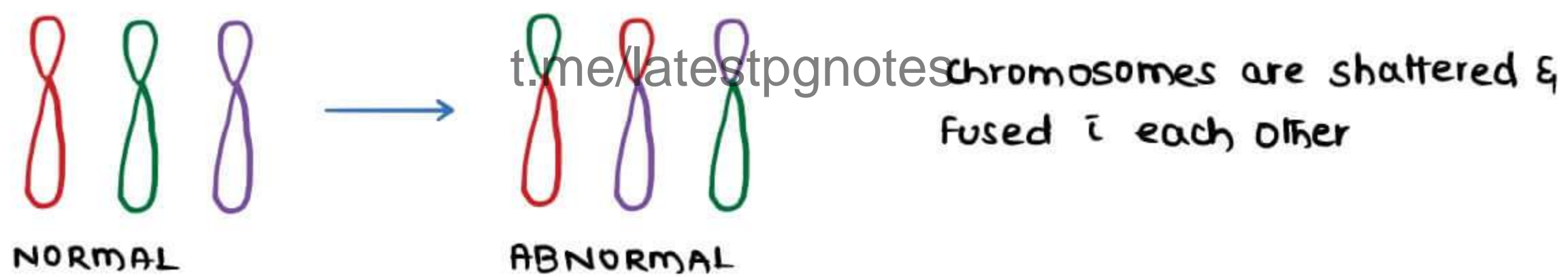
→ TWIST | SNAIL → Epithelial to Mesenchymal Transition [EMT]

5. ESCAPE IMMUNE SURVEILLANCE

→ proposed by LEWIS THOMAS & M. BURNETT

ADVANCED CONCEPTS OF GENETIC DEFECTS

CHROMOTHRYPSIS



→ AIW GLIOMA & OSTEOSARCOMA

EPIGENETIC CHANGES

→ Some genes influence the activity of other genes by

↳ DNA HYPERMETHYLATION

↳ HISTONE ACETYLATION

MICRO RNAs $\xrightarrow{\ominus}$ mRNA Translation

→ ↑ Cancer → ONCO miRNAs → miR 155 → B cell lymphoma

→ ↓ Cancer → Tumor suppressor miRNA → miR 15 defect → CLL
miR 16

→ DICER → For functional miRNA → defect → ↑ cancer

ETIOLOGICAL FACTORS OF NEOPLASIA

CHEMICALS

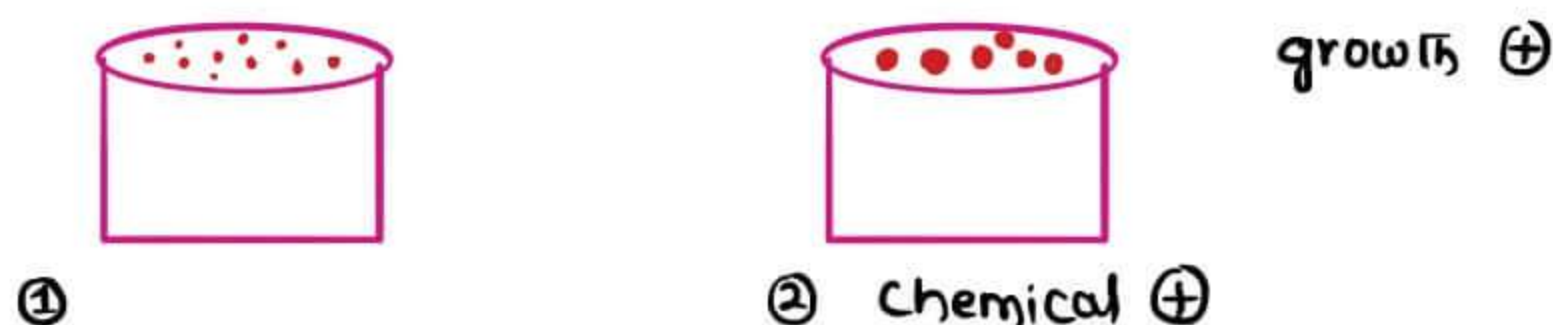
INITIATORS → ⊕ DNA → Mutated DNA
 → DIRECTLY ACTING → damage DNA & out any alterations
 → INDIRECTLY ACTING → damage DNA, forming reactive intermediates in Liver

PROMOTORS → Mutated DNA → ↑ cells

SUBTYPES OF CHEMICAL MEDIATORS

1. **SMOKERS** → PAH [Polycyclic Aromatic Hydrocarbons]
 → a/w → Squamous cell cancer of Lungs & Larynx
 → transitional cancer of Bladder [by β-Naphthylamine]
 → Adenocarcinoma of Pancreas
2. **NITROSAMINES**
 → Stomach cancer
 → Oesophageal cancer
 → more in Japan
3. **AZODYES** → GIT cancers
4. **VINYL CHLORIDE** → Angiosarcoma of Liver
 → also seen in
 ↳ Arsenic → Skin cancer
 ↳ Thorotrast
5. **ASBESTOS**
 → 'UNIQUE CARCINOGEN' → acts as both Initiator & Promotor
 → Mesothelioma [25-35 yrs exposure] [most specific]
 → Bronchogenic carcinoma [15-20 yrs exposure] [mo]
6. **DRUGS**
 → ALKYLATING AGENTS } 2° Leukemia
 → TOPOISOMERASE INHIBITORS }
 → CYCLOPHOSPHAMIDE [Alkylating agent] → urinary Bladder cancer

AMES TEST / CARCINOGENICITY / MUTAGENIC TEST



S.typhimurium [modified - can't produce histidine]
 No histidine provided in petri dishes

→ carcinogenicity / mutagenicity of a chemical can be tested

SIR PERCIVAL POTT

- chimney sweepers → scrotal skin cancer
 ↓ suggested daily bath [removes soot regularly]
 ↓ scrotal skin cancer

RADIATION EXPOSURE

1. NON IONISING → UV RAYS → A
 → B [more powerful than A]
 → C [max. chance of causing cancer]
 [filtered by ozone layer]

- ↳ causes DNA damage → PYRIMIDINE DIMERS
 ↳ dimers repaired by Nucleotide Excision Repair Genes [NER]
 ↳ defect in NER genes → ↑ cancer
 → a/w XERODERMA PIGMENTOSA
 ↳ ↑ Basal cell carcinoma
 ↳ ↑ Squamous cell carcinoma
 ↳ ↑ melanoma } Skin Cancers

2. IONISING RADIATION

- more powerful & causes DNA damage
 → includes X/Y/ β rays → OH^\bullet → DNA DAMAGE
 → Radiology / Atomic Bomb
 ↓
 Lead Aprons [protective]
- ↓
max. in G_2/M phase

- ↑ Leukemias → AML, CML, ALL [not a/w CLL]
 → ↑ Papillary Thyroid cancer
 → THOROTRAST → ↑ Angiosarcoma of Liver

- Least affected organs by Ionising radiation
 ↳ SKIN
 ↳ GIT
 ↳ BONES

INFECTIOUS MICRO ORGANISMS

1. H. PYLORI

- contains CAG^{eA} [cytotoxin] → Gastric Adeno carcinoma
 → Polyclonal B cell activatⁿ → t [11;18] → Gastric MALToma

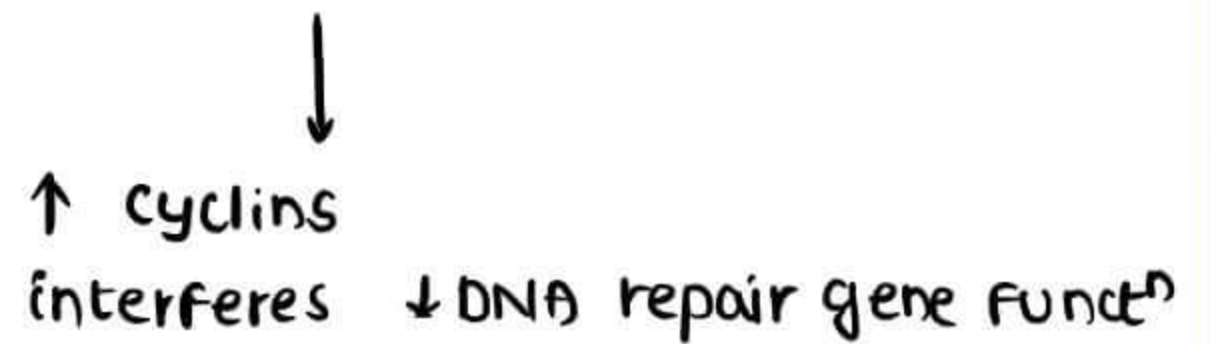2. FUNGI

- Aspergillus flavus → AFLATOXIN → Hepato cellular cancer

3. VIRUSES [most notorious

a. RNA VIRUSES

1. HTLV 1 → Adult T-cell leukemia [TAX protein]



- takes 4-6 decades to cause cancer
- involves CD₄ T cells
- transmitted by sexual, vertical & parenteral route
- more in CARIBBEAN ISLANDS

2. HEPATITIS C → Liver cancer

b. DNA VIRUSES

1. HPV [Human Papilloma Virus]

- ↳ 6, 11 → low risk → warts [condyloma acuminata] [STD]
- ↳ 16, 18 → higher risk → secretes E₆ → ⊖ p53
- E₇ → ⊖ Rb gene
- ⊖ p21 | p27
- ⊕ Cyclin A/E

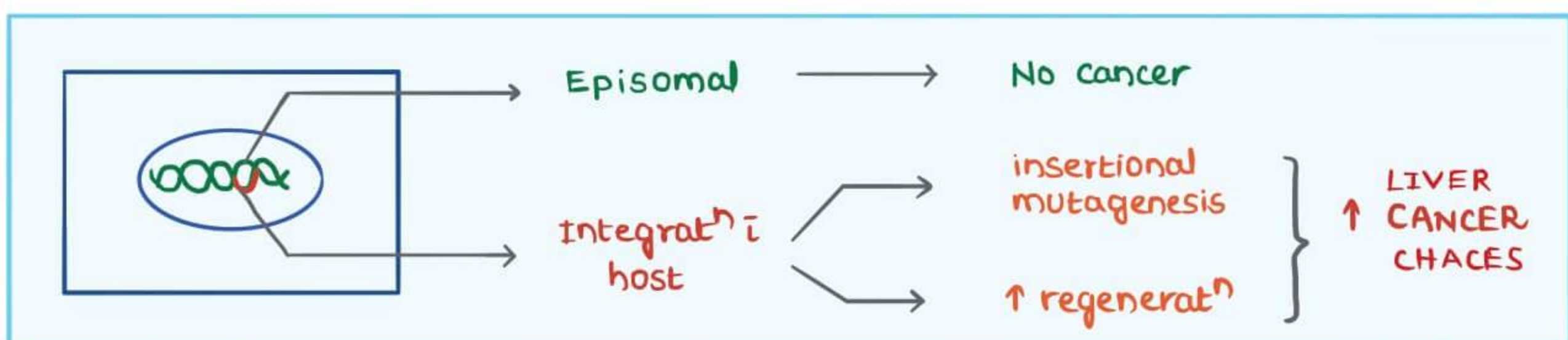
t.me/latestpnotes

- ↑ cancers
 - ↳ cervical cancer
 - ↳ Anal canal cancer
 - ↳ Oral cavity cancer

2. **K**APOSI SARCOMA HERPES VIRUS [HHV-8]

- affects immunocompromised persons
- causes
 - ↳ **K**aposi's **S**arcoma
 - ↳ 1^o Effusion Lymphoma [a/w HIV]
 - ↳ affects body cavities [a/w HIV]
 - ↳ component of DLBCL [Diffuse Large B cell Lymphoma]

3. HEPATITIS B VIRUS



4. EBV

→ dit

- ↳ LMP1 gene → ↑ NF- κ B & ↑ BCL-2
- ↳ EBNA protein → ↑ cyclin D
- ↳ VIL-10 → ↓ T cell activity

⇒ B CELL IMMORTALIZATION → ↑ cancer

- ↑ Hodgkin's Lymphoma
 - ↑ Non Hodgkin's Lymphoma
 - ↑ Burkitt's Lymphoma [African/Endemic]
- } B CELL CANCERS

↑ Nasopharyngeal carcinoma [China] → T CELL CANCER

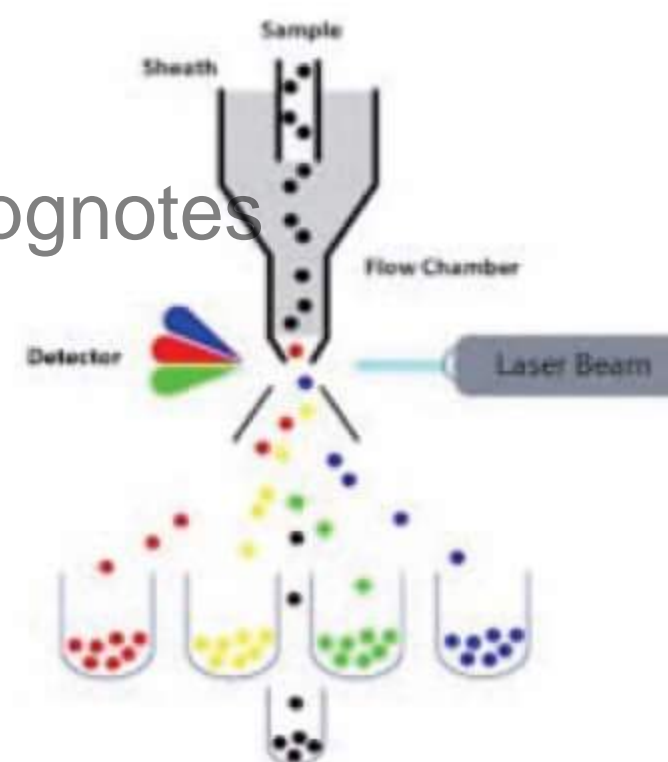
PARASITES

1. CLONORCHIS SINENSIS → cholangio carcinoma
2. SCHISTOSOMIASIS → Urinary Bladder cancer

DIAGNOSIS OF TUMORS

1. FLOW CYTOMETRY

- flowing stream of cells are used
- detects certain surface molecules on cells
- useful in detection of CD molecules
- useful in Dx of
 - ↳ haematological malignancies
 - ↳ Nucleic acid content



2. CYTOLOGICAL METHODS

a. FNAC

- 22 - 26 Gauge needle is used
 - Advantage → OPD procedure
 - Disadvantages
 - ↳ need other procedures [USG etc] for assistance at times
 - ↳ CI in bleeding disorders & vascular growths
 - ↳ can't differentiate b/w benign & malignant tumors
 - Ex: Follicular Thyroid Tumor
 - ↳ Adenoma
 - ↳ Follicular carcinoma
- } not differentiated by FNAC

b. EXFOLIATIVE CYTOLOGY

- shed cells obtained either
 - ↳ Spontaneously or by
 - ↳ Scraping



Transformation zone



AYRE'S SPATULA

→ used in

↳ bronchial washings

↳ Oral cavity

↳ cervical tissue → PAP SMEAR

↓
Squamo - columnar Junction

↓
Fixed in ETHER + 95% ETHANOL

↓
microscopy for

→ maturation index

→ Nuclear features

VIA

→ Visual Inspection after the application of acetic acid

→ BEST SCREENING METHOD FOR CERVICAL CANCER

PAP SMEAR

3. HISTOLOGICAL METHODS

→ MC METHOD used for diagnosis of cancer

→ MICROSCOPIC EXAMINATION OF FIXED TISSUE AFTER BIOPSY

→ SOLID CANCERS [Cx CANCER] } not appropriate
[High contamination] } method

→ LIGHT MICROSCOPE → formalin used

→ ELECTRON MICROSCOPE → Glutaraldehyde used

→ STAINING

a. Routine

b. Special

4. IMMUNOCYTOCHEMISTRY

→ SURFACE MARKERS are identified using FLUORESCIN ANTIBODIES

→ Useful in Δ of UNDIFFERENTIATED TUMORS

↳ EXAMPLES

→ Keratin → carcinoma

→ Desmin → myogenic tumor

→ Vimentin → sarcoma

→ GFAP → glial tumor [GFAP - Glial fibrillary associated protein]

→ Useful in IDENTIFICATION OF Δs OF PRIMARY, particularly in METASTASIS

→ Useful in PROGNOSIS/ THERAPY

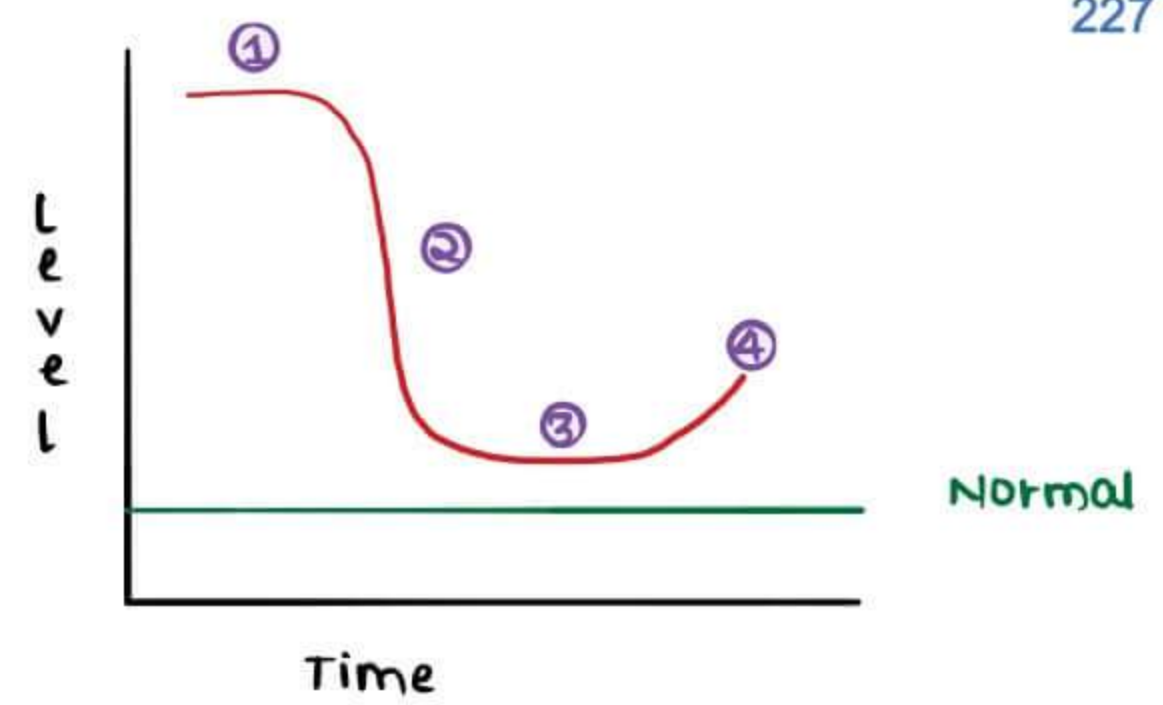
↳ EXAMPLE → Breast cancer

↳ ER ⊕ → Good prognosis / Anti Estrogenic drugs used

↳ HER2/Neu ⊕ → poor prognosis / Trastuzumab used

5. TUMOR MARKERS

- acts as SURROGATE MARKERS
- NOT FOR DEFINITIVE DIAGNOSIS
- - 1 → Suggestive of cancer
Start therapy
 - 2 → Indicates Response to therapy
 - 3 → indicates Stage of Remission
 - 4 → indicates Stage of Recurrence



→ EXAMPLES

- | | |
|------------------|----------------------------------------------|
| ↳ PSA | → Prostate cancer |
| ↳ Ig | → Multiple myeloma |
| ↳ HCG | → Chorio carcinoma |
| ↳ calcitonin | → Medullary Thyroid cancer |
| ↳ catecholamines | → Pheochromocytoma |
| ↳ CEA | → Colon cancer, pancreatic cancer |
| ↳ AFP | → Hepatocellular cancer, Non-Seminomatus GCT |
| ↳ CA 15.3 | → Breast cancer |
| ↳ CA 19-9 | → Pancreatic cancer |
| ↳ CA 125 | → ovarian cancer |
| ↳ NSE | → Neuroblastoma |

t.me/latestpgnotes

- | | | |
|-----|---|---------------------------|
| PSA | - | Prostate Specific Antigen |
| NSE | - | Neuron Specific Enolase |
| CEA | - | Carcino Embryonic Antigen |
| AFP | - | Alfa Feto Protein |

PARANEOPLASTIC SYNDROMES

- | | |
|---------------------------------|------------------------------------|
| → NOT EXPLAINED ON THE BASIS OF | SIGNIFICANCE |
| ↳ Direct spread | ↳ may be initial manifestation |
| ↳ metastasis | ↳ may mimic metastasis |
| ↳ indigenous hormones | ↳ may indicate worsening condition |

→ TYPES

I. ENDOCRINOPATHIES

1. Hypercalcemia

- ↳ mc paraneoplastic syndrome
- ↳ dit PG 8 / PTHrP [PTH related Peptide]
- ↳ seen in Lung cancer [squamous cell carcinoma]
Kidney cancer
Breast cancer

2. CUSHING SYNDROME

- ↳ seen in Lung cancer [small cell cancer]
carcinoid tumor

3. SIADH

↳ Seen in Lung cancer [small cell cancer]
CNS tumors

4. HYPOGLYCEMIA

↳ Seen in Fibrosarcoma
Hepatocellular cancer

5. POLYCYTHEMIA

↳ dit EPO [Erythropoietin like substance]
↳ seen in Hepatocellular carcinoma
Kidney cancer
Fibromyoma
cerebellar hemangioblastoma

II VASCULAR ; HEMATOLOGICAL

1. VENOUS THROMBOPHLEBITIS

→ dit MUCIN
→ causes MIGRATORY VENOUS THROMBOPLEBITIS / TROUSSEAU SIGN
→ Seen in Pancreas cancer
AML - M3
Bronchogenic cancer

2. MARANTIC ENDOCARDITIS / NON BACTERIAL THROMBOTIC ENDOCARDITIS [NBTE]

→ Seen in Pancreatic cancer
AML - M3

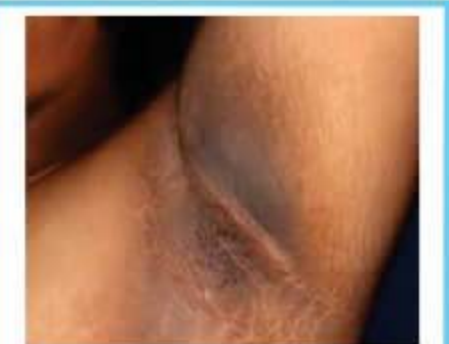→ dit mucin

3. ANEMIA → Seen in Thymoma

III DERMATOLOGICAL

1. ACANTHOSIS NIGRICANS

→ Seen in Stomach cancer
Lung cancer
uterine malignancy



ACANTHOSIS
NIGRICANS

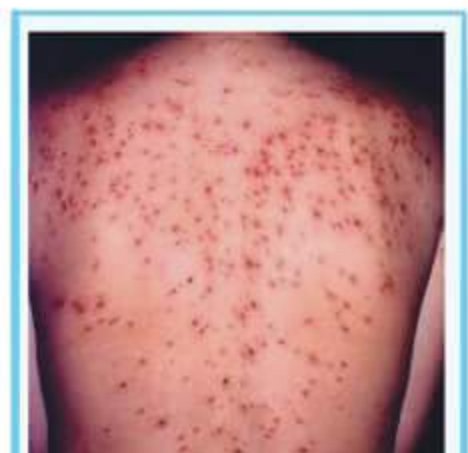2. DERMATOMYOSITIS

→ contains Anti p 140 Ab
Anti P 155 Ab (vs) Auto Immune Dermatomyositis
contains Anti - Jo 1 Ab

→ seen in Lung cancer
Breast cancer

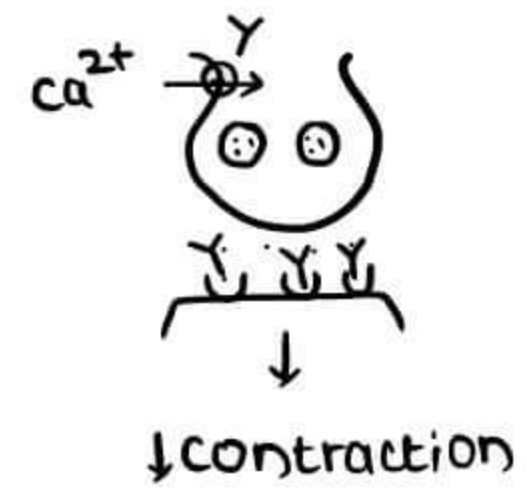
3. SEBORRHEIC KERATOSIS /

→ SIGN OF LESER TRELAT
↳ seen in stomach cancer [mc]
Colon cancer
Breast cancer



IV NEURO MUSCULAR

229



1. MYASTHENIA GRAVIS

- Ab against ACh $\text{\textcircled{R}}$ [post synaptic]
- Seen in Thymoma

2. LAMBERT - EATON SYNDROME

- Ab against Ca^{2+} channel [pre synaptic]
- Seen in Lung cancer [small cell cancer]

L → Late
E → Entry of Ca^{2+} in
S → small cell cancer

3. OPSOCLONUS [rapid eye movement] → seen in Neuroblastoma

4. LIMBIC ENCEPHALITIS

- Anti - HU Ab $\text{\textcircled{+}}$
- Seen in Lung cancer [small cell cancer]

5. SUB ACUTE CEREBELLAR DEGENERATION

- Anti - YO Antibodies $\text{\textcircled{+}}$
- Seen in Uterine cancer
Ovarian cancer
Breast cancer

V. OSSEUS ; SOFT TISSUE CHANGES

1. HYPERTROPHIC OSTEO ARTHROPATHY

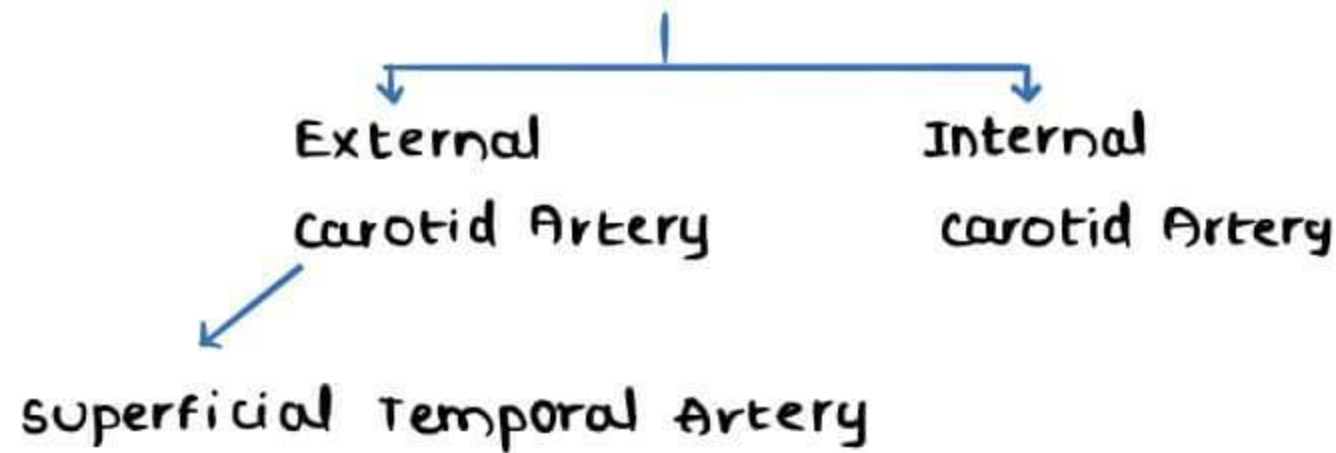- causes clubbing of fingers
- seen in Lung cancer t.me/latestpgnotes

- Non - Infectious
- Immunological
- C/F → ISCHEMIA

LARGE VESSEL VASCULITIS [Aorta & its major branches involved]

TEMPORAL ARTERITIS

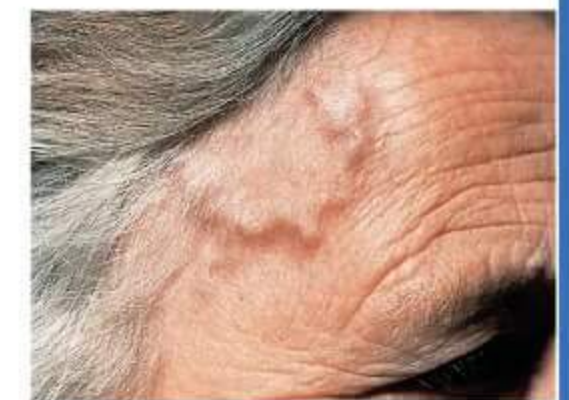- mc vasculitis in Adults
- ♀, > 50 yrs
- Aorta ⊕ carotid artery ⊕



C/F

- Headache [localized] [mc symptom]
- jaw claudication [most specific]
- fever, malaise, joint & muscle pain

↓
POLYMYALGIA RHEUMATICA
[shoulder girdle & pelvic girdle]



Temporal arteritis

DIAGNOSIS

- ↑↑ TLC
- ↑↑ ESR [> 50 mm | 1hr]
- BIOPSY

- ↳ IOC
- ↳ at least 1 cm should be taken
- ↳ Patchy involvement ⊕
- ↳ Granuloma ⊕ → Giant cells ⊕ → aka GAIANT CELL ARTERITIS
- ↳ Negative biopsy do not rule out disease



ICA → OPHTHALMIC ARTERY → ↓ Blood → BLINDNESS [sudden onset]

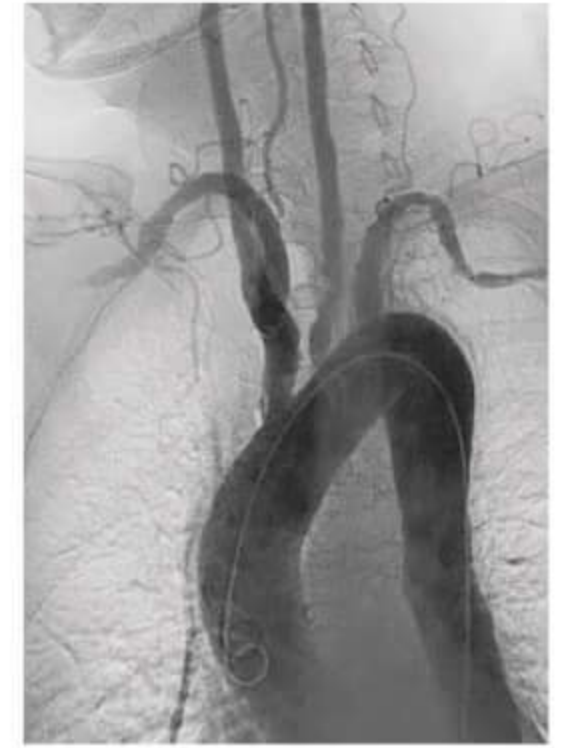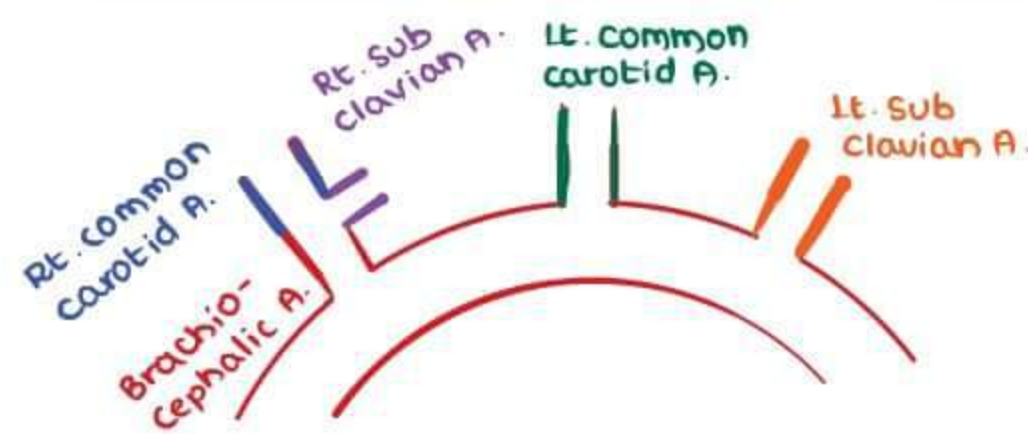
Rx

1. STEROIDS → DOC
2. Inhaling & Exhaling in plastic bag at the event of S/O Blindness

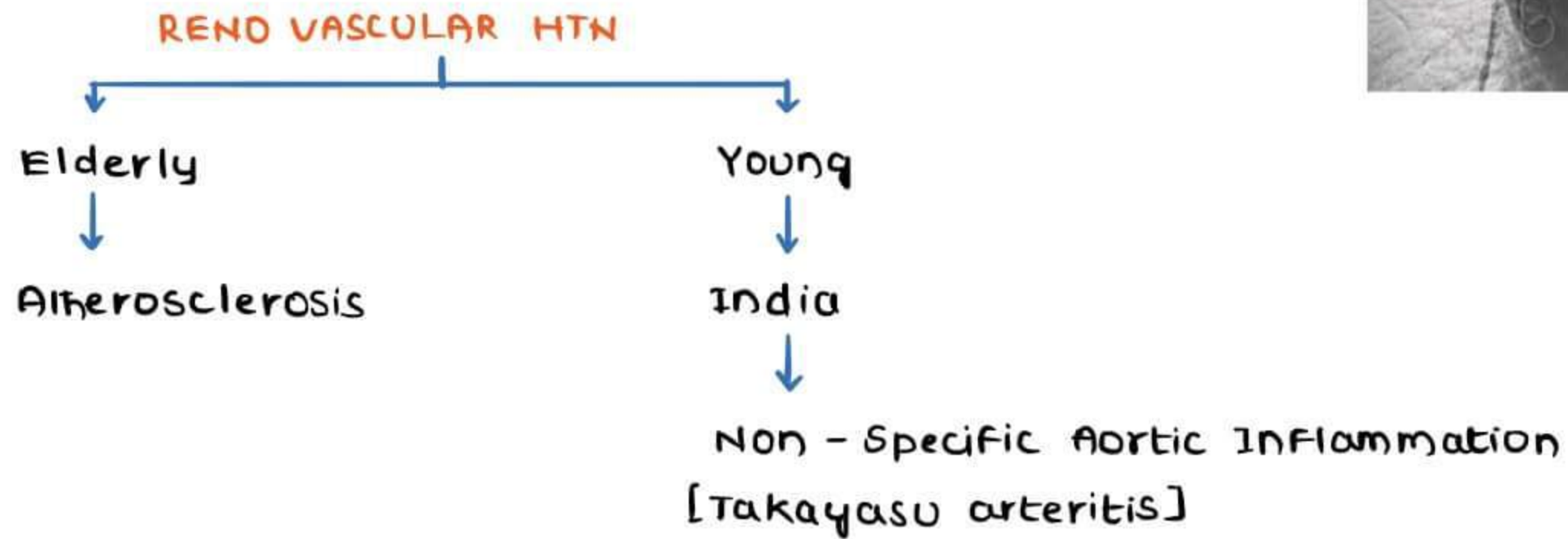
2. TAKAYASU ARTERITIS

- < 50 yrs
- discovered in Japan
- Aortic Arch involved
- AORTIC ARCH SYNDROME
- Origin point of vessels involved
 - feeble pulse → PULSELESS DISEASE

- MIE → Granuloma ⊕
- CIF → Neurological SIS
- weak pulse
- slo Blindness



- Poor prognosis
- Renal artery involvement → RAAS activation → HTN



**MEDIUM SIZED VESSEL VASCULITIS
POLYARTERITIS NODOSA**

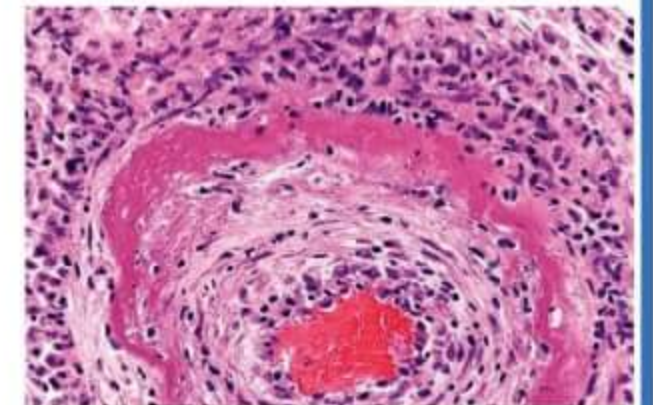
→ Renal / popliteal / coronary artery involved

- Young Adults
- Immune complexes ⊕ → Fibrinoid necrosis ⊕
- HBs Ag ⊕ anti-HBs Ag → Many organs ⊕
- small vessels are spared

→ MULTI ORGAN INVOLVEMENT [except LUNGS]

- kidney → Renal artery → RAAS ⊕ → HTN
- no glomerulonephritis [RBC casts ⊖ in urine]

- GUT → Pain / melena
- SKIN → nodules / papules / ulcers
- NERVES → mono neuritis multiplex
- JOINTS → Arthralgia
- CNS → seizures



Fibrinoid necrosis

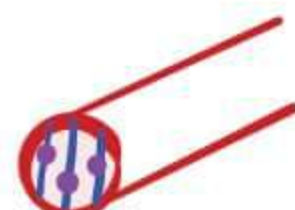
- MIE → EARLY PHASE → Fibrinoid necrosis ⊕
- Transmural Inflammation
- LATE PHASE → Fibrosis ⊕



- Rx → 1. STEROIDS
- 2. CYCLOPHOSPHAMIDE

BUERGER DISEASE

- NECROTISING INFLAMMATION → Arteries > veins > Nerves
- Lymphatics not involved



Thrombo angiitis obliterans

- Tibial artery ⊕ → ↓ Blood
 - ↳ at rest → no symptoms
 - ↳ walking → pain +
 - ↳ stopped walking → no symptoms
- } Intermittent claudication

- Young ♂ smokers
- Rx
 - 1. Quit smoking
 - 3. Surgery
 - 2. vasodilators
 - 4. Amputation

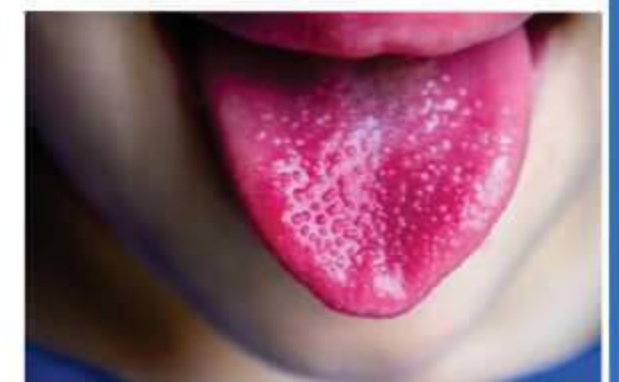KAWASAKI DISEASE

- < 4 yrs age group
 - FEVER ⊕
 - Conjunctivitis [non exudative]
 - Rash [on extensor surface]
 - Edema [hands & feet]
 - Adenopathy [cervical LN]
 - Mucosal ulcers [STRAWBERRY TONGUE]
- } at least 4

- Thrombocytosis ⊕
 - coronary vasculitis ⊕
- } mc cause of myocardial Infarctⁿ in child

- DIAGNOSIS
 - ↑↑ TLC
 - ↑ ESR
 - ↑.m.ppc/latestpgnotes

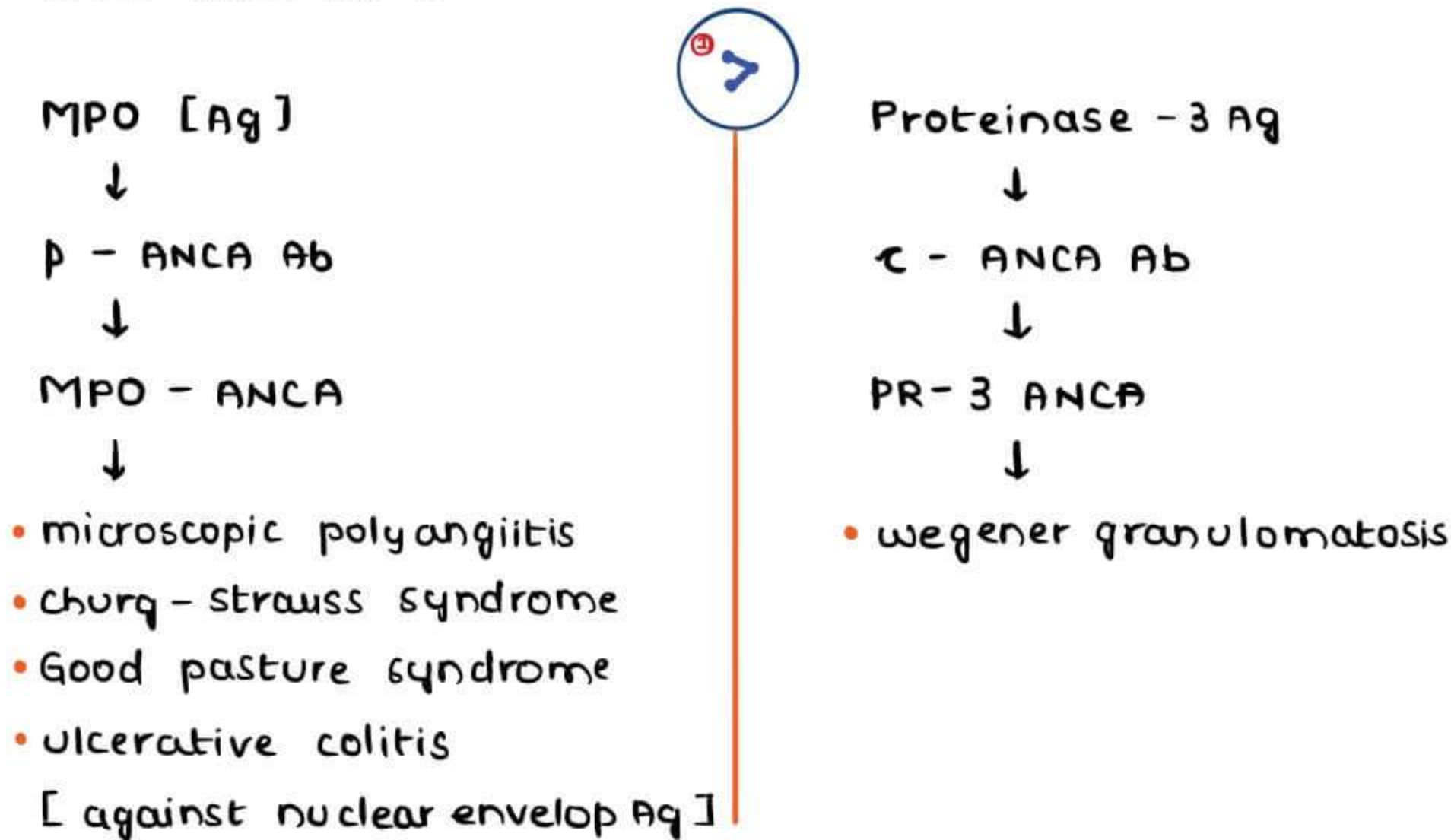
- Rx
 - IV Ig + ASPIRIN
 - steroids should be avoided



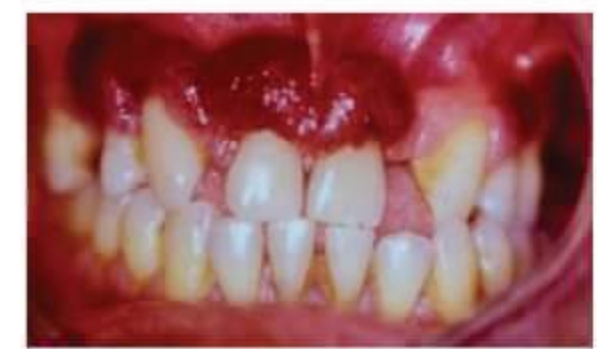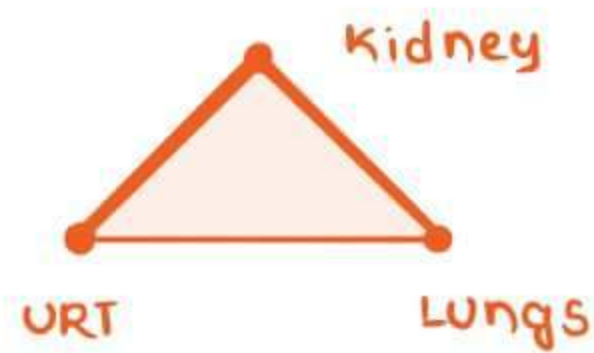
Strawberry tongue

SMALL VESSEL VASCULITIS

- ANCA auto Ab ⊕



- Necrotising granuloma \oplus
- AFFECTS



Strawberry gums

KIDNEY → crescent GN [RPGN] [RBC casts \oplus]

URT [mc] → Ear → OM
 NOSE → septal perforation, saddle nose
 Throat → strawberry gums, sub glottic stenosis

LUNGS → cough
 Hemoptysis
 cavitatory lesions \oplus

- DIAGNOSIS → 1. C-ANCA / PR-3 ANCA \oplus
 2. BIOPSY → Crescentic GN

- Rx → CYCLOPHOSPHAMIDE [DOC], STEROIDS
- Death → Renal failure

MICROSCOPIC POLYANGIITIS

t.me/latestpgnotes

- small vessels \oplus
- PAN vs MP

	PAN	MP
small vessels	\ominus	\oplus
Lungs	\ominus	\oplus
Kidneys	\oplus	\oplus
Glomerulonephritis	\ominus	\oplus
p-ANCA	\ominus	\oplus

- MP vs WEGENER GRANULOMATOSIS

MP	WEGENER
p-ANCA \oplus	C-ANCA \oplus
no nasopharyngeal involvement	Kidney \oplus
	Lungs \oplus
	URT \oplus

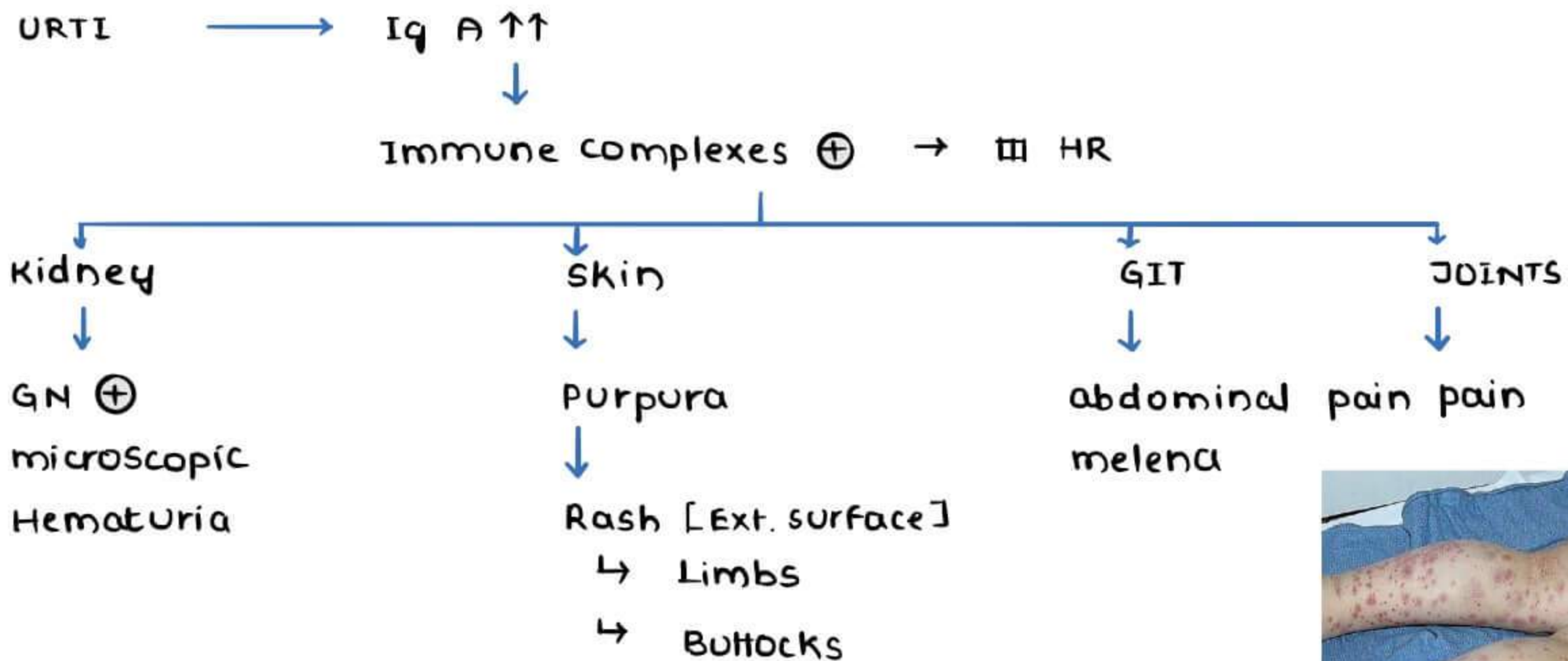
- MIE → SAME STAGE OF INFLAMMATION \oplus
 → NO GRANULOMA FORMATION

- a/w → INFECTIONS
 → PENICILLIN [DRUGS]
 → SLE

- Rx → STEROIDS

HENOCH - SCHONLEIN PURPURA

- children
- mc vasculitis in children



- Rash is dit vasculitis
- Platelet count is normal → NON THROMBOCYTOPENIC PURPURA / ANAPHYLACTOID PURPURA

CHURG STRAUSS SYNDROME

- Necrotising vasculitis
- Granuloma ⊕ → Eosinophilia ⊕ → Type I HR
- c/w Asthma & Drugs [montelukast]
- multiple organ involvement → Lungs, Skin, Heart
- p-ANCA ⊕

ANGINA

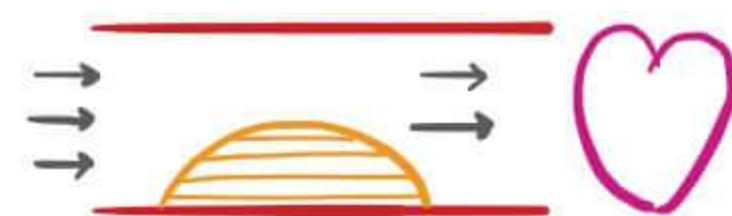
ISCHEMIC HEART DISEASE

- ANGINA
- MI
- CHRONIC IHD
- SUDDEN CARDIAC DEATH
 - < 1 hr
 - mostly dit ventricular fibrillation

ANGINA → Reversible

STABLE ANGINA → ST depression [sub endocardial ischemia]

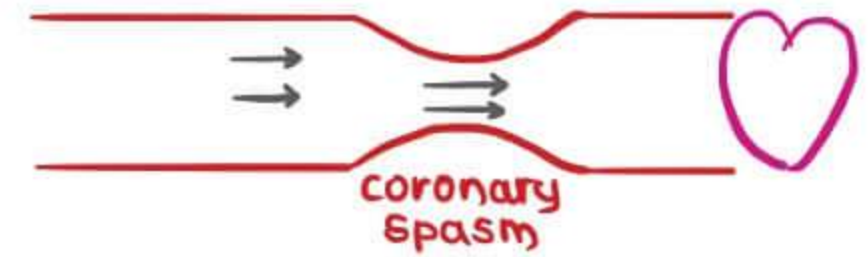
- CIS present on EXERTION
- IF coronary artery obstruction
 - > 75% → CIS appear on exertion
 - > 80% → CIS appear even at rest



- Rx by
 1. Nitrates
 2. β blockers
 3. Ca²⁺ channel Blockers

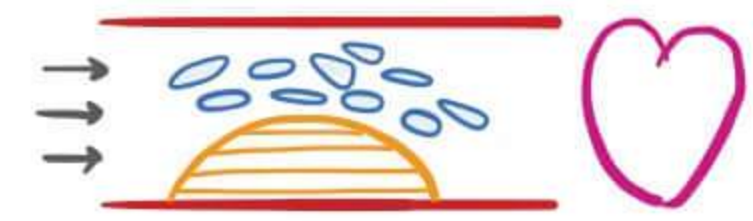
PRINZMETAL ANGINA

- d/c CORONARY ARTERY SPASM
- Coronary Spasm persists at → Rest | Exertion
- Rx by NITRATES
- β Blockers contraindicated



UNSTABLE ANGINA

- c/s → New pain
- worse pain
- Severe pain
- Aggressive in nature
- may lead to Myocardial Infarction
- Most dangerous angina
- aka PRE - INFARCTION ANGINA
- Rx by NITRATES
- ANTI PLATELET DRUGS



Ulceratⁿ of Plaque
↓
↑ platelets | fibrin | spasm

MYOCARDIAL INFARCTION

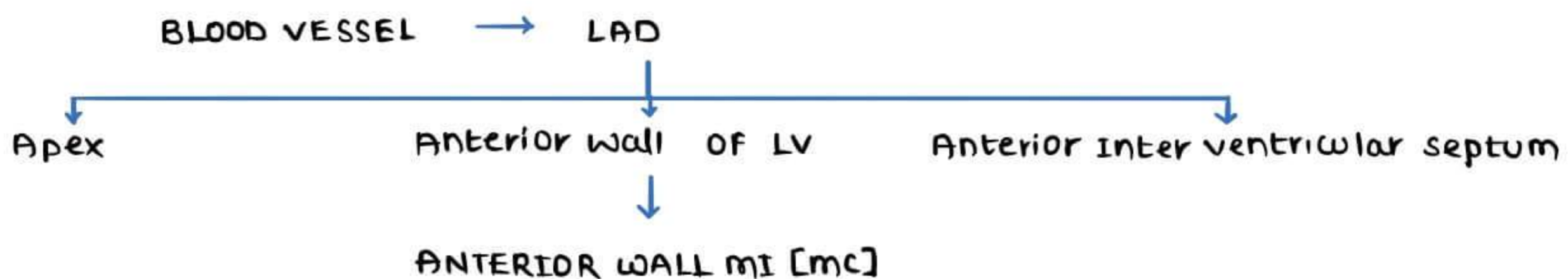
- IRREVERSIBLE
 - ULCERATION | RUPTURE | HEMORRHAGE OF PLAQUE
- ```

 graph TD
 A[ULCERATION | RUPTURE | HEMORRHAGE OF PLAQUE] --> B[THROMBUS | SPASM OF CORONARY VESSEL]
 B --> C[INFARCTION]
 C --> D[TRANSMURAL MI]
 C --> E["SUB ENDOCARDIAL MI [inner 1/3 rd]"]

```

**CHF**

- CHEST PAIN
  - radiates to inner arm / Jaw / Epigastrium
  - Squeezing pain
  - LEVINE SIGN → clenched fist on chest
- MI → NO PAIN → Elderly & DM → SILENT MI
- DIAPHORESIS
- ↑ PULSE
- DYSPNEA
- NAUSEA & VOMITING



## 1. ECG

- Hyperacute 'T' waves
- ST segment elevation
- 'Q' wave [old MI]

## 2. CARDIAC ENZYMES

## → MYOGLOBIN

- first enzyme to increase in MI
- normal  $\bar{c}$  in 24 hrs
- not specific

## → CREATINE KINASE

- CK-MM | CK-MB | CK-BB
- CK-MB → useful for MI Dx
- also increases in myocarditis

## → TROPONIN → increases in 24-48 hrs &amp; elevated for 7-10 days

c T<sub>n</sub> Tc T<sub>n</sub> I [more important]

- Best enzymes for Dx of MI → most specific & sensitive
- also useful in the Dx of RE-INFARCTION

## → LDH

t.me/latestpnotes

- in normal person, LDH<sub>2</sub> >> LDH<sub>1</sub>
- in MI, LDH<sub>1</sub> >>> LDH<sub>2</sub> [FLIPPING OF LDH RATIO]

- Last enzyme to ↑ in MI
- 

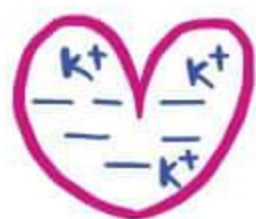
TTC [Triphenyl Tetrazolium chloride] stain + LDH

- Normal [intra cardiac LDH] → Brick Red color
- MI [leaked out LDH] → PALE or YELLOW

- useful to know cause at the time of autopsy

## 3. ECHO

- hypokinesia
- akinesia

4. THALLIUM SCAN → K<sup>+</sup>

Diffuse staining



Infarcted area is picked up against the normal background of viable area

|             |                                           |
|-------------|-------------------------------------------|
| < 4 hrs     | no change                                 |
| 4 - 24 hrs  | Inter cellular edema [WAVINESS OF FIBRES] |
|             | Pale on TTC staining                      |
| 24 - 72 hrs | COAGULATIVE NECROSIS                      |
|             | NEUTROPHILIC INFILTRATION                 |
|             | INFARCT $\bar{c}$ YELLOW BORDER           |
| 3 - 7 days  | Macrophages $\oplus\oplus\oplus$          |
|             | Neutrophils $\downarrow\downarrow$        |
|             | Hyperemic borders                         |
| 7 - 10 days | Granulation tissue                        |
|             | Red - Brown margins                       |
|             | Scar $\downarrow\downarrow$               |
| 4 - 6 WKS   | Scar                                      |
|             | white scar                                |

### REPERFUSION INJURY

- STREPTOKINASE [thrombolytics] worsens the condition in some
- also allow coronary artery stenting or other invasive procedure
- due sudden influx of WBC | free radicals |  $Ca^{2+}$
- M/E → CONTRACTION BANDS [due  $Ca^{2+}$ ]

### COMPLICATIONS

#### 1. ARRHYTHMIAS

[t.me/latestpgnotes](https://t.me/latestpgnotes)

- ↓ HR [Bradyarrhythmia]
- ventricular fibrillation
  - ↳ mostly occur  $\bar{c}$  in 1 hr
  - ↳ mortality → 25%
  - ↳ Rx by Defibrillation / cardioversion or LIGNOCAINE
  - ↳ m/c of death in the 1st hour of MI

#### 2. CARDIAC FAILURE

#### 3. CARDIAC RUPTURE SYNDROME

- seen after 3-7 days after MI
- Affects
  1. Free wall rupture [m/c]
  2. Inter ventricular septum
  3. Mitral Regurgitation



Free wall Rupture

→ CARDIAC TAMPONADE

#### 4. AUTO IMMUNE PERICARDITIS / DRESSLER SYNDROME

- NEO ANTIGENS → after 2-3 weeks usually
- Immune system activation  $\oplus$

presents  $\bar{c}$  chest pain

Symptomatic relief occur by anti inflammatory drugs

#### 5. VENTRICULAR ANEURYSM

- clot or thrombus can develop
- may rupture



**LEFT VENTRICULAR FAILURE [Ischemia]**

- 1. Renal tissue → RAAS ⊕
- 2. Brain → HIE
- 3. Pulmonary system → mc affected
  - First system to be affected
  - pulmonary edema ⊕
  - dyspnea ⊕

→ chronic failure → HEART FAILURE CELLS [macrophages  $\bar{c}$  hemosiderin]  
 ↳ seen in pulmonary tissue

**RIGHT VENTRICULAR FAILURE**

- mc cause → LVF
- Pulmonary HTN → COR PULMONALE

**CHF**

Liver → congestive hepatomegaly [Acute]  
 → NUTMEG LIVER [chronic]

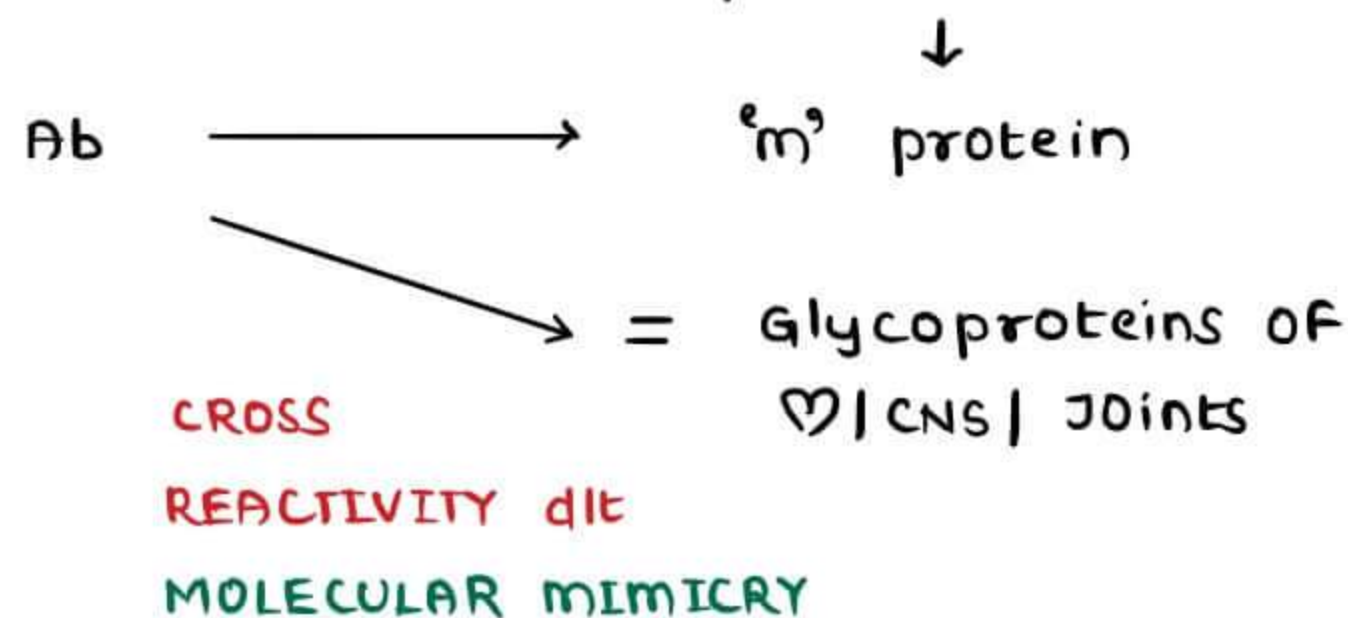
Spleen → congestive splenomegaly  
 GANDY GAMMA BODY ⊕

Pedal edema ⊕  
 Anasarca ⊕

[t.me/latestpnotes](https://t.me/latestpnotes)

**RHEUMATIC FEVER**

- children [5-15 yrs]
- Immunological disorder
- also Sore throat by Group A  $\beta$  Hemolytic Streptococcus



- Type II HR
- DIAGNOSIS

EVIDENCE OF RECENT STREPTOCOCCAL INFECTION

+

REVISED JONES CRITERIA [2 major or 1 major + 2 minor]

## REVISED JONES CRITERIA

### MINOR CRITERIA

- Fever
- Arthralgia
- ↑ ESR
- ↑ PR Interval
- ↑ C - RP

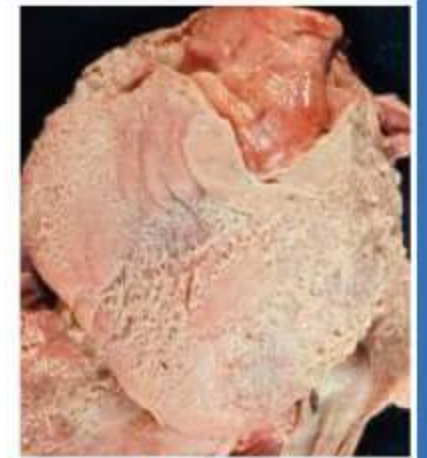### MAJOR CRITERIA

- J } JOINTS [mc] → large JOINTS → MIGRATORY POLY ARTHRITIS  
 O } → NON - EROSION ARTHRITIS → dramatic response to ASPIRIN
- N → NODULES [subcutaneous, painless, seen on extensor surface]  
 E → Erythema marginatum  
 S → Sydenham's chorea [late sign, CNS (Basal ganglia) involved]  
 C → Carditis [Pancarditis]

### PANCARDITIS

#### PERICARDITIS

- Fibrin deposition
- BREAD & BUTTER PERICARDITIS [sero fibrinous]
- pericardial rub ⊕



Bread & Butter Pericarditis

### MYOCARDIUM & MYOCARDITIS

#### ASCHOFF BODY

t.me/latestpnotes

- seen around the blood vessels
- seen in any layer of heart [mclly in myocardium]
- seen in acute phase (Acute RHD)
- Fibrinoid Necrosis surrounded by
  - ↳ plasma cells
  - ↳ T-cells
  - ↳ Plump macrophages (Anitschkow / Caterpillar cell)



- MYOCARDITIS → HEART FAILURE → MORTALITY [COD]

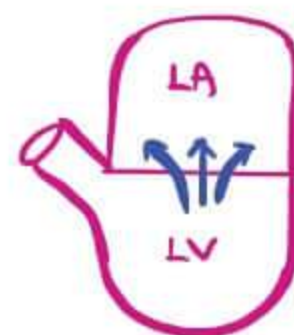### ENDOCARDITIS

- VALVES INVOLVEMENT → mitral > Aortic > Tricuspid > Pulmonary
- ACUTE RHD

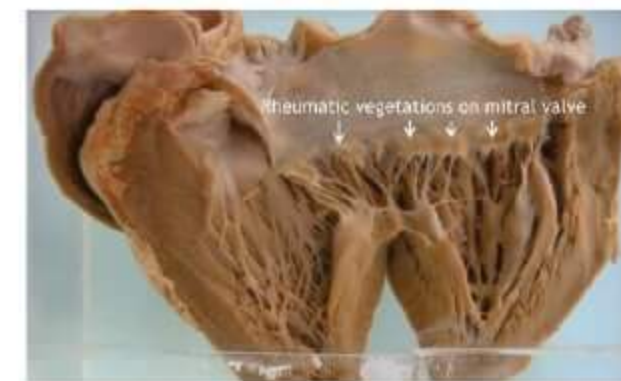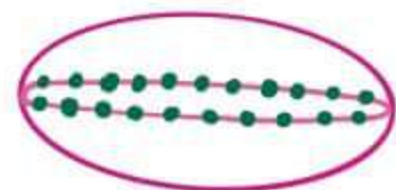
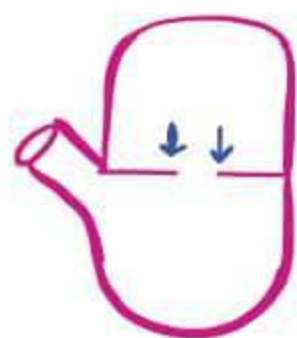
Mitral Regurgitation ⊕

↓  
Atrial wall damage

↓  
Mc CALLUM PLAQUE



→ CHRONIC RHD → Fibrosis → mitral stenosis



**VEGETATIONS IN RHD**

- small
- Sterile (Fibrin, platelets, inflammatory cells)
- present along line of closure
- no embolisation

MITRAL STENOSIS → FISH-MOUTH / BUTTON HOLE STENOSIS  
[Seen only in Chronic RHD]



**INFECTIVE ENDOCARDITIS**

**NORMAL PROTECTIVE FACTORS**

1. Normal Endothelial Lining
2. Transient Bacteremia
3. normal activity of Immune system

**RISK FACTORS**

- RHD [mc]
  - Congenital cardiac defect
  - ventricular septal defect
  - artificial cardiac valve
- } Damage to Endothelial Lining
- IV Drug abusers
  - Septisemia
- } Prolonged bacterial Presence
- Immuno suppression → abnormal immune system activity

**SUB TYPES**

**ACUTE IE**

- NO previous damage
- dlt Staph. aureus (highly virulent)

**SUB ACUTE IE**

- Previous damage ⊕ [RHD | VSD]
- dlt Streptococcus viridans

**PROSTHETIC VALVE**

→ dlt Staph. epidermidis

**IV DRUG ABUSERS**

→ dlt Staph. aureus  
→ mc valve involved → tricuspid valve

**ULCERATIVE COLITIS**

**COLON CANCER**

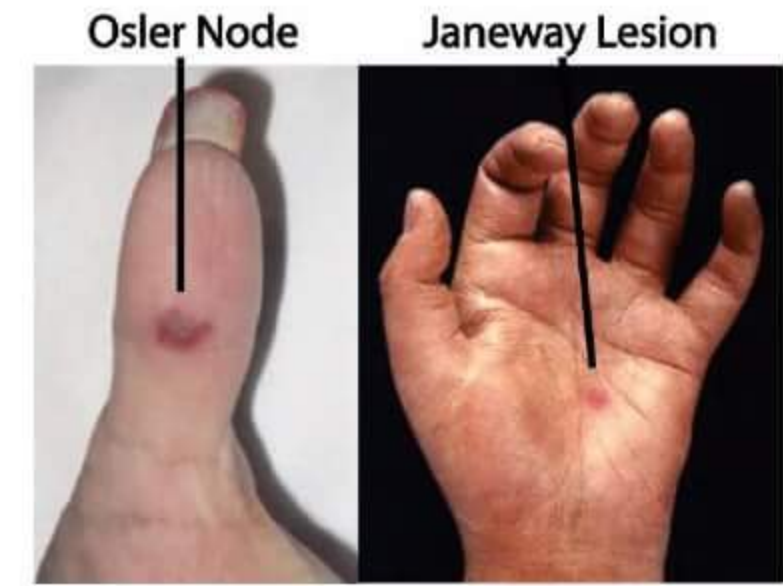
} dlt Streptococcus bovis

**HACEK BACTERIA**

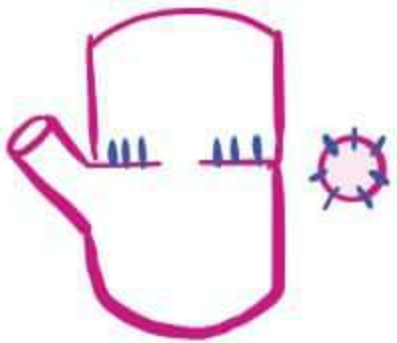
→ negative on blood culture

**CLINICAL FEATURES**

- High grade fever
- MURMURS ⊕ [ changing | dynamic nature ]
- weight loss
- ROTH SPOTS ⊕
- OSLER NODES ⊕ [ painful ]
- JANEWAY LESION ⊕ [ painless ]

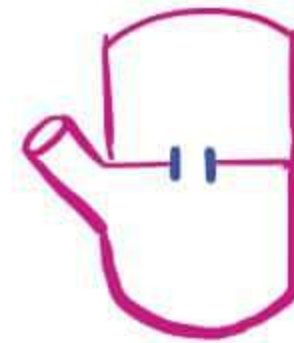**DIAGNOSIS → DUKE'S CRITERIA**

- Blood culture ⊕ [ minimum of 2 cultures, 12 hrs apart ]
- ECHOCARDIOGRAPHY FINDINGS
- Fever / ♡ predisposition / vascular & immunological features

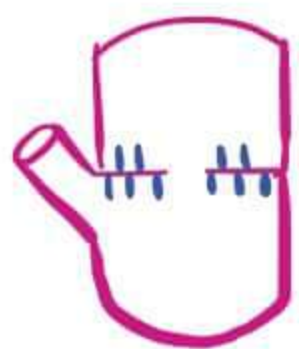
**VEGETATIONS****INFECTIVE ENDOCARDITIS**

im - 13, 14.55

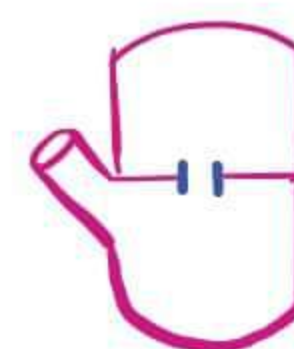
- Large
- multiple
- Friable
- Embolism ⊕
- seen on valvular cusps
- seen on peripheral aspect
- a/w RING ABSCESS

**RHEUMATIC HEART DISEASE**

- small
- sterile
- firm
- no embolism
- seen on Line of closure

**SLE [ LIBMANN SAC ENDOCARDITIS ]**

- Small
- Sterile
- Lower surface of valve affected more
- Firm
- no embolism

im - 15.50  
17.20**NON BACTERIAL THROMBOTIC ENDOCARDITIS / MARANTIC ENDOCARDITIS**

- seen on Line of closure
- small
- fibrin & platelets ⊕
- Sterile
- Embolism ⊕
- seen in Pancreatic cancer & AML - m<sub>3</sub>

I PRIMARY CARDIAC TUMORS

II SECONDARY CARDIAC TUMORS

- more common than 1° tumors
- mc 1° → Lung cancer
- pericardium affected

PRIMARY CARDIAC TUMORS

1. MALIGNANT

- Adult → ANGIO SARCOMA
- children → RHABDOMYOSARCOMA

2. BENIGN

- Adult → MYXOMA
- children → RHABDOMYOMA

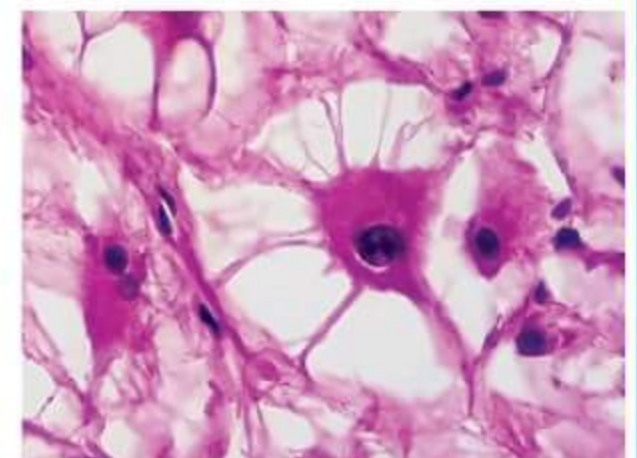
MYXOMA

Site of origin → Atrium [ LA >> RA ]

TYPES

1. SPORADIC → Single, mc
2. FAMILIAL → BIL
  - a/w CARNEY SYNDROME
    - ↳ myxoma
    - ↳ skin lesions
    - ↳ ↑ Endocrine activity

M/E → LEPIDIC CELLS in MYXOID MATRIX  
[t.me/latestpgnotes](https://t.me/latestpgnotes)



SPIDER CELLS



RHABDOMYOMA

SITE OF ORIGIN → ventricles [ RV = LV ]

HISTOLOGY → SPIDER CELLS

a/w TSC<sub>1</sub> & TSC<sub>2</sub> genes



## KIDNEY & URINARY BLADDER BASIC CONCEPTS

### KIDNEY

#### PELVIS

→ From Anterior to Posterior

Vein → Artery → Pelvis

→ determines the approach during surgery

→ Nitrogenous waste excretion

→ Acid Base Balance maintenance

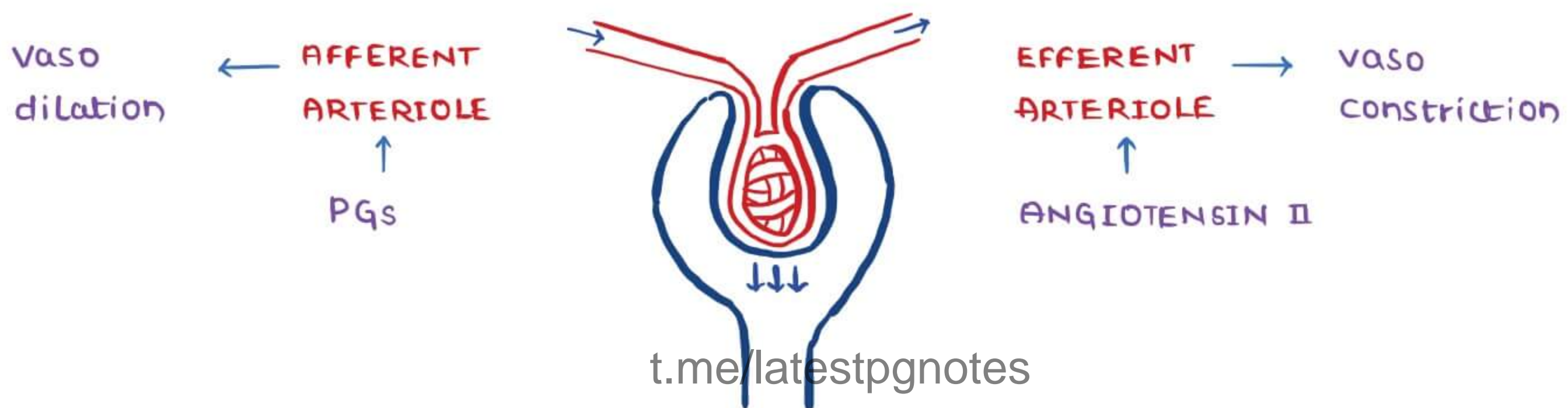
→ EPO [ from peritubular cells ]

→ Renin [ From Juxta glomerular cells ]

→ 1 $\alpha$  OHASE → aids in the format<sup>n</sup> of active form of vitamin D



### GLOMERULAR DISORDERS



→ Diameter of Afferent arteriole is under the control of → PGs

→ Diameter of Efferent arteriole is under the control of → Angiotensin II

→ GFR → 125 ml/min

### GLOMERULAR UNIT - COMPONENTS

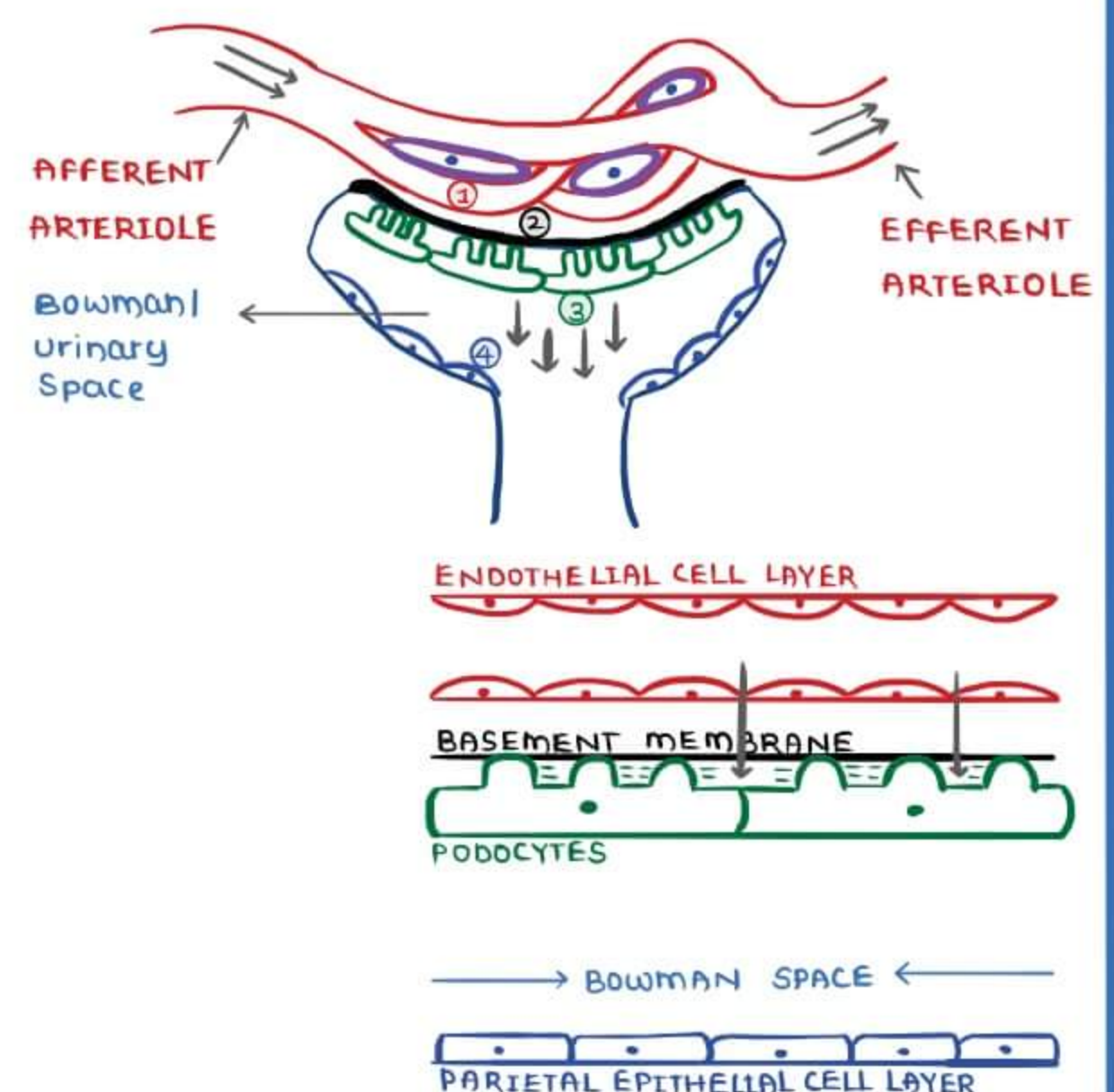
1. ENDOTHELIAL LAYER
2. BASEMENT MEMBRANE
3. VISCERAL EPITHELIAL CELLS | PODOCYTES
4. PARIETAL EPITHELIAL CELLS
5. MESANGIAL CELLS

### LAYERS OF GLOMERULAR FILTRATION BARRIER

1. ENDOTHELIAL LAYER
2. BASEMENT MEMBRANE
3. VISCERAL EPITHELIAL CELLS | PODOCYTES

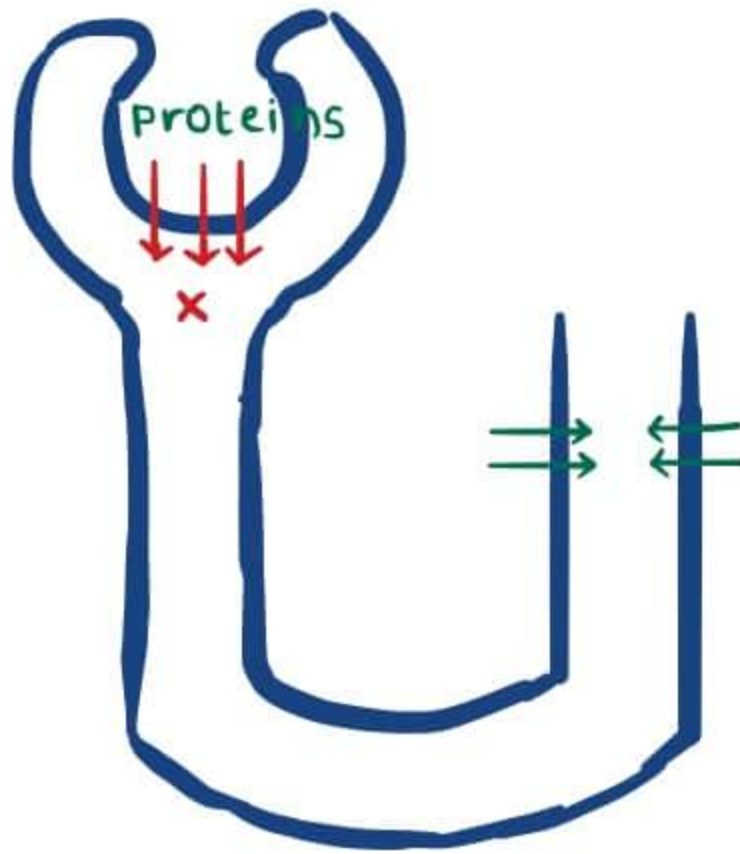
### FILTRATION AT GLOMERULUS DEPENDS ON

1. Size of molecule
2. Charge of molecule
  - Podocytes contributes
    - ↳ Anions  $\ominus$  → Negative charge
    - ↳ cations  $\oplus$  → not Filtered easily
  - Filtered easily [Glucose | AA |  $\text{Na}^+$ ]



**NON PRESENCE IN URINE DUE TO**

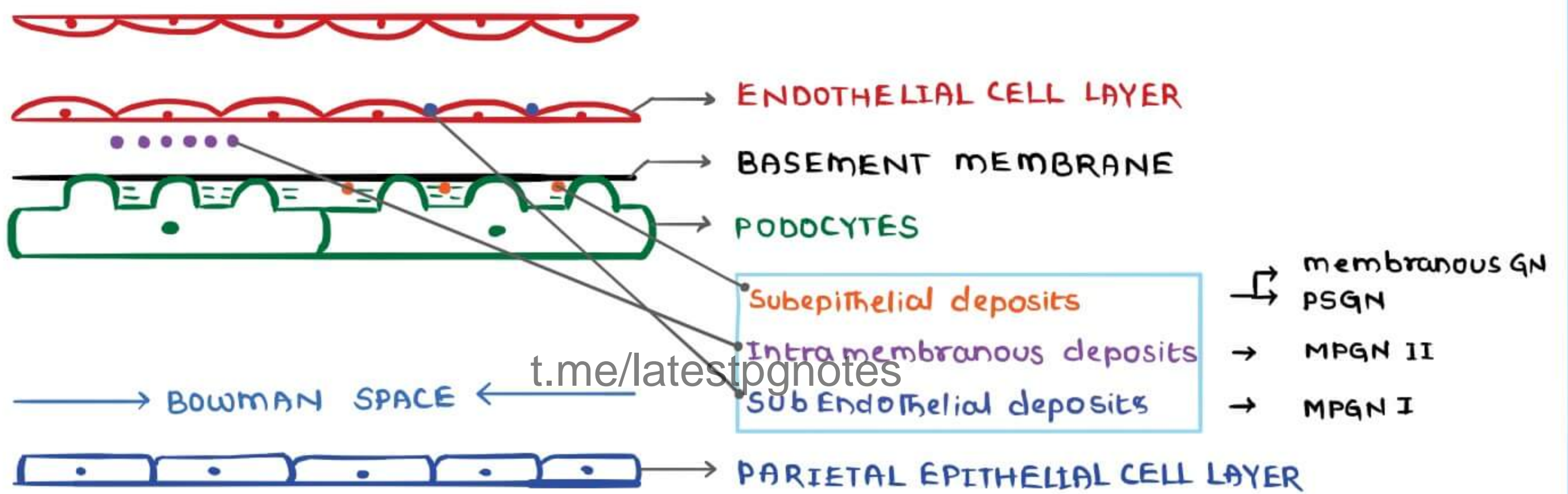
- 1. Albumin → negative charge
- 2. Globulin → Size & negative charge
- 3. Fibrinogen → Size & negative charge



**TAMM HORSFALL Protein**

- tubular protein
- Filtered from ascending Limb of LH
- < 150 mg/day urine
- Hyaline cast ⊕
- Physiological Cast
- Seen in normal persons

**IMMUNO COMPLEX DEPOSITS - LOCATION**



**ADULT POLYCYSTIC KIDNEYS**

- Autosomal Dominant
- B/L

**GENETICS**

- PKD<sub>1</sub> gene [chr. 16p] → codes for Polycystin 1 Protein
- PKD<sub>2</sub> gene [chr. 4q] → codes for Polycystin 2 Protein [BADE]

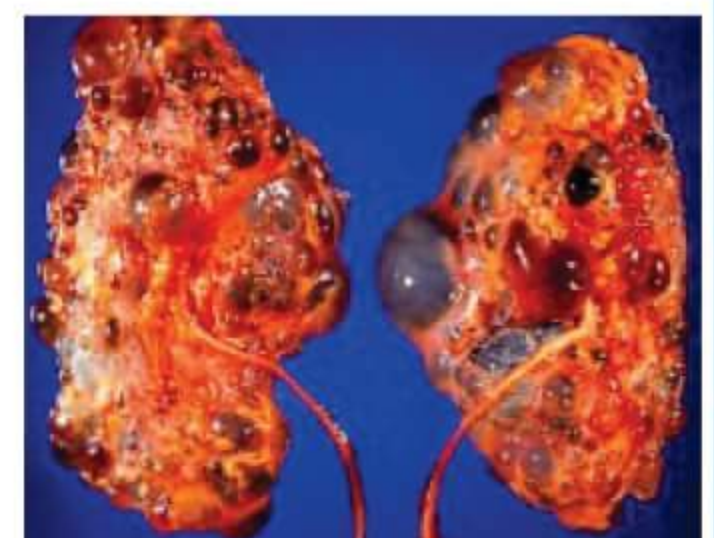
→ Polycystin 1 expresses mainly on distal tubule cells & play a role in cell-cell & cell-matrix interactions

→ Polycystin 2 expresses on all cells of nephron & play a role in Ca<sup>2+</sup> channel function

→ Mutation in above genes → ↑ cell proliferat<sup>n</sup> → ↑ secret<sup>n</sup> → CYSTS

**GROSS FEATURES**

- B/L Enlarged Kidneys
- multiple cysts + nt in cortex & medulla
- variable lining of cysts



**C/P**

- Asymptomatic till adult life
- FLANK PAIN [ mc manifestation ]
- HEMATURIA
- HTN
- PROTEINURIA

**EXTRA RENAL MANIFESTATIONS**

- cysts in other organs
  - ↳ Liver [mc]
  - ↳ Spleen
  - ↳ Pancreas
  - ↳ Ovary
  - ↳ Lungs [extremely rare]
  - ↳ NO CYSTS IN BRAIN
- BERRY ANEURYSM
- MITRAL VALVE PROLAPSE
- COLONIC DIVERTICULOSIS

**COMPLICATIONS**

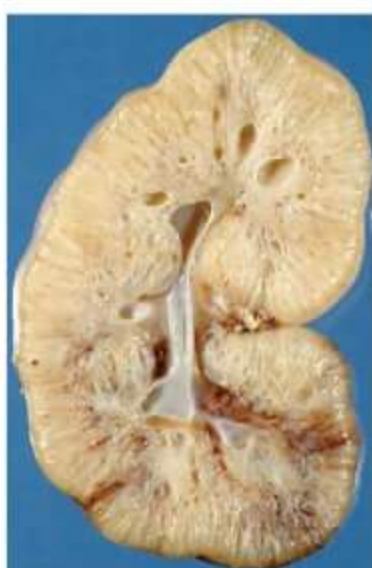- HTN | coronary Artery Disease [ commonest cause of Death ]
- ↑ Infections
- ↑ Nephrolithiasis [ also Uric acid stones ]
- ↑ Renal cancer [ BIL, multifocal & sarcomatoid type ]

**TREATMENT**

- BP control
- Renal Transplantation

**CHILDHOOD POLYCYSTIC KIDNEY**

- Autosomal Recessive
- PKHD1 gene located on chr. 6p [ **KIDDE** | **BACCHA** ]
- PKHD1 gene mutation → fibrocystin defect
- Mainly involves Kidney & Liver

**→ KIDNEY INVOLVEMENT**

- Enlarged Kidney
- multiple cysts +nt in cortex & medulla
- CYSTS PRESENT AT RIGHT ANGLE TO CORTEX → SPONGE APPEARANCE
- Epithelial lining of cysts → cuboidal Epithelium [collecting duct origin]

### → LIVER INVOLVEMENT

- cysts + nt
- congenital hepatic fibrosis
  - can develop Splenomegaly Secondary to Portal HTN
  - Bad prognosis [fatal]

### → one of the cause OF 'POTTER SEQUENCE'

- OLIGOHYDRAMNIOS → pulmonary hypoplasia, facial anomalies

### MEDULLARY CYSTIC KIDNEY

- Shrunken Kidney → End stage Renal Disease
- cortico - medullary cysts + nt

### ADULT VARIANT

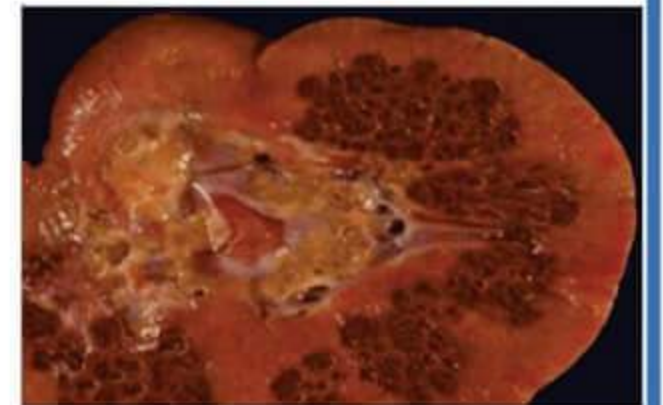
- Autosomal Dominant
- aka AUTOSOMAL DOMINANT TUBULO - INTERSTITIAL KIDNEY DISEASE
  - ↳ interstitial fibrosis
  - ↳ tubular atrophy
  - ↳ Glomeruli preserved
- MCKD 1/2 Gene mutation → Polyuria, salt wasting

### FAMILIAL JUVENILE NEPHRONOPHTHISIS

- Autosomal recessive
- ciliopathy [t.me/latestpgnotes](https://t.me/latestpgnotes)

### MEDULLARY SPONGE KIDNEY

- seen in adults
- Sporadic
- Renal medulla involved
- cystic dilatations involving collecting ducts → SPONGE APPEARANCE
- usually asymptomatic
- Some may have
  - ↑ infections
  - ↑ calcium oxalate & calcium phosphate stones → Hematuria



### → BOOSTER INFO :

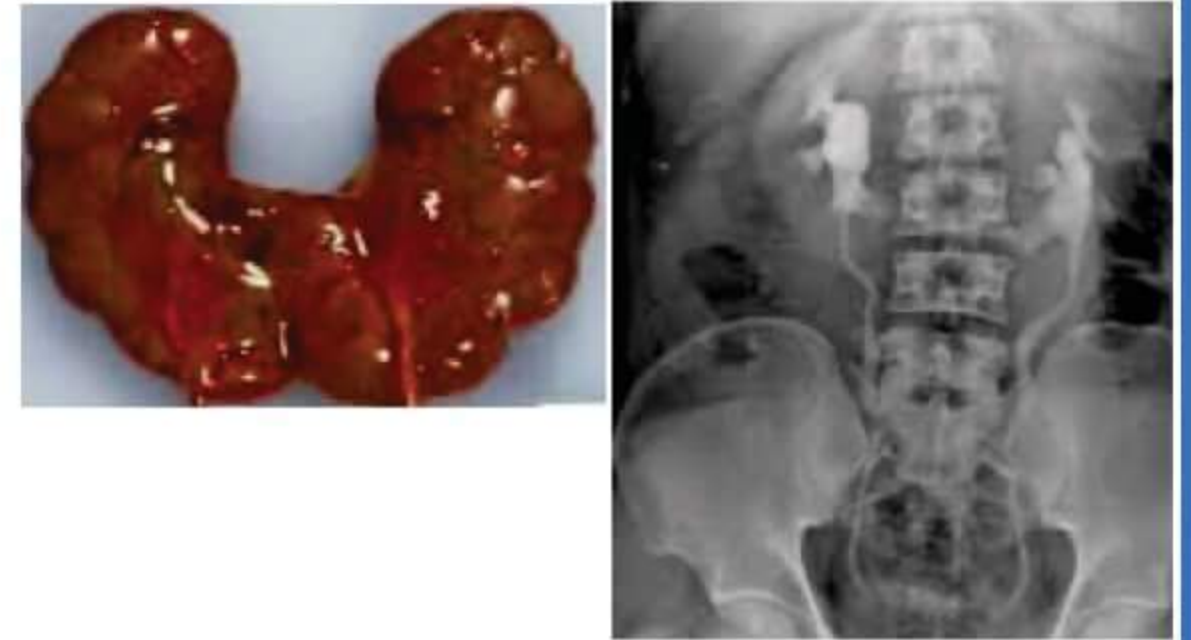
- DD → NEPHRONOPHTHISIS
- Differentiating Features OF MEDULLARY SPONGE KIDNEY
  - always involves papillary tips
  - IVP shows PAINT BRUSH APPEARANCE

### ECTOPIIC KIDNEY

- mclly involves left kidney
- mc abnormal location → PELVIC BRIM
- alw ureteric obstruction → ↑ infections

- mc congenital renal anomaly [ 1 in 500 live births]
- Fusion of kidney at the lower pole occurs during embryological development
  - 'U' shaped kidney
  - Failure of ascent of kidney
  - ectopic site of kidney
  - ureteric obstruction + nt
- Anterior to L4 | great vessels
- ↑ infections & ↑ stones


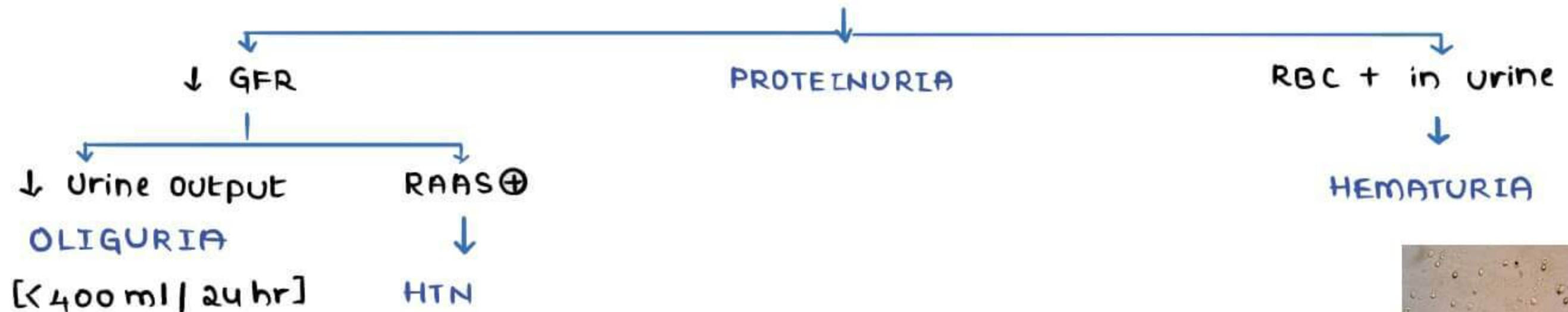

- ASSOCIATE WITH
  - Edward syndrome
  - Down's syndrome
  - Turner syndrome



FLOWER VASE APPEARANCE

- RADIOLOGICAL FEATURES
  - FLOWER VASE APPEARANCE
  - HAND JOINING SIGN

NEPHRITIC SYNDROME



dysmorphic RBC

- HEMATURIA → > 3 RBC / hpc in 3 samples, 1 week apart
- dysmorphic RBCs → glomerular hematuria
- isomorphic RBCs → non glomerular hematuria

POST STREPTOCOCCAL GLOMERULO NEPHRITIS [ PSGN ]


- pediatric age group
- H1O skin | sore throat | Group A β Hemolytic Streptococcus [ 4, 12, 1 ]
- DIFFUSE GLOMERULAR INVOLVEMENT | WBC INFILTRATION
- Type 3 HR
- time taken from H1O skin | sore throat to ClF of GN → 10 - 14 days

CLINICAL FEATURES

- HTN | Hematuria [ cola colored urine ] | oliguria | proteinuria

**DIAGNOSIS**

**1. URINE EXAM**

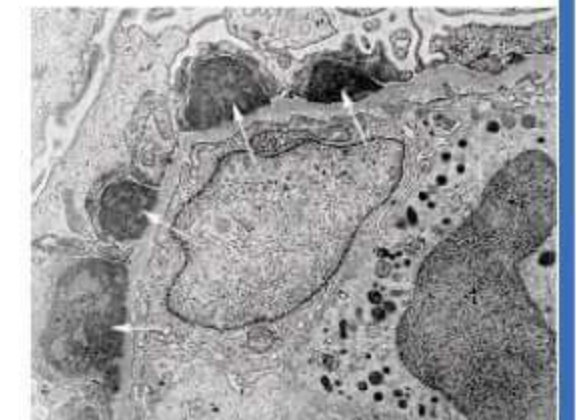- Altered color of urine
- ↓↓ urine output
- RBC cast ⊕ 

**2. BLOOD**

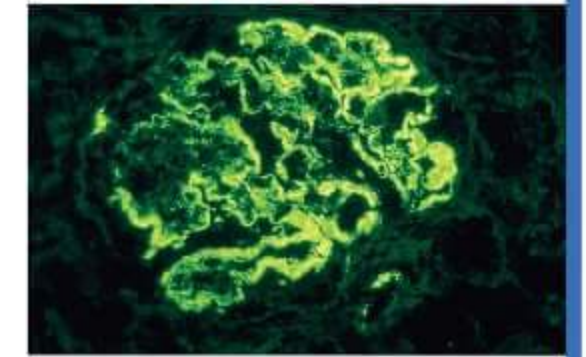
- Anti - DNase B Ab [more significant]
- Anti - Streptolysin O Ab
- ↓ C<sub>3</sub> protein at active stage → Transient hypocomplementemia

**3. RENAL BIOPSY**

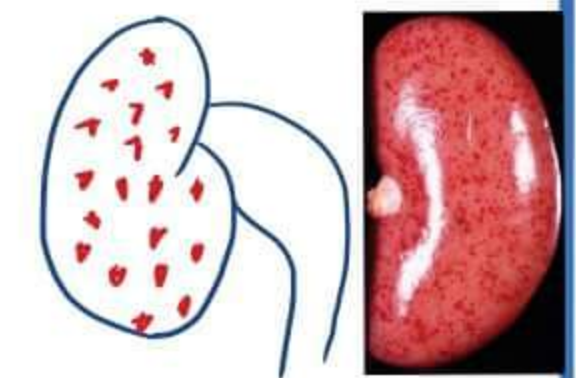
- confirmatory
- Immune complexes ⊕
  - ↳ Sub endothelial
  - ↳ Intra membranous
  - ↳ Sub epithelial HUMPS [mc]
- STARRY SKY APPEARANCE ⊕
- FLEABITTEN KIDNEY [non specific]
  - ↳ PSGN
  - ↳ vasculitis
  - ↳ IE
  - ↳ malignant HTN
  - ↳ Leukemia



SUB EPITHELIAL HUMPS



STARRY SKY APPEARANCE



FLEABITTEN KIDNEY

t.me/latestpnotes

**TREATMENT**


- mostly → complete Recovery ⊕
- Symptomatic R<sub>i</sub>

**DIFFUSE PROLIFERATIVE GN [ACUTE GN]**

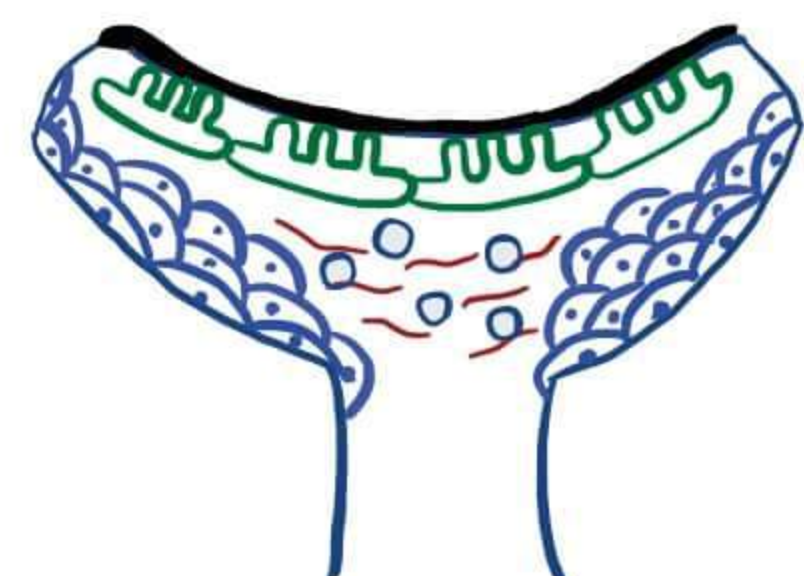
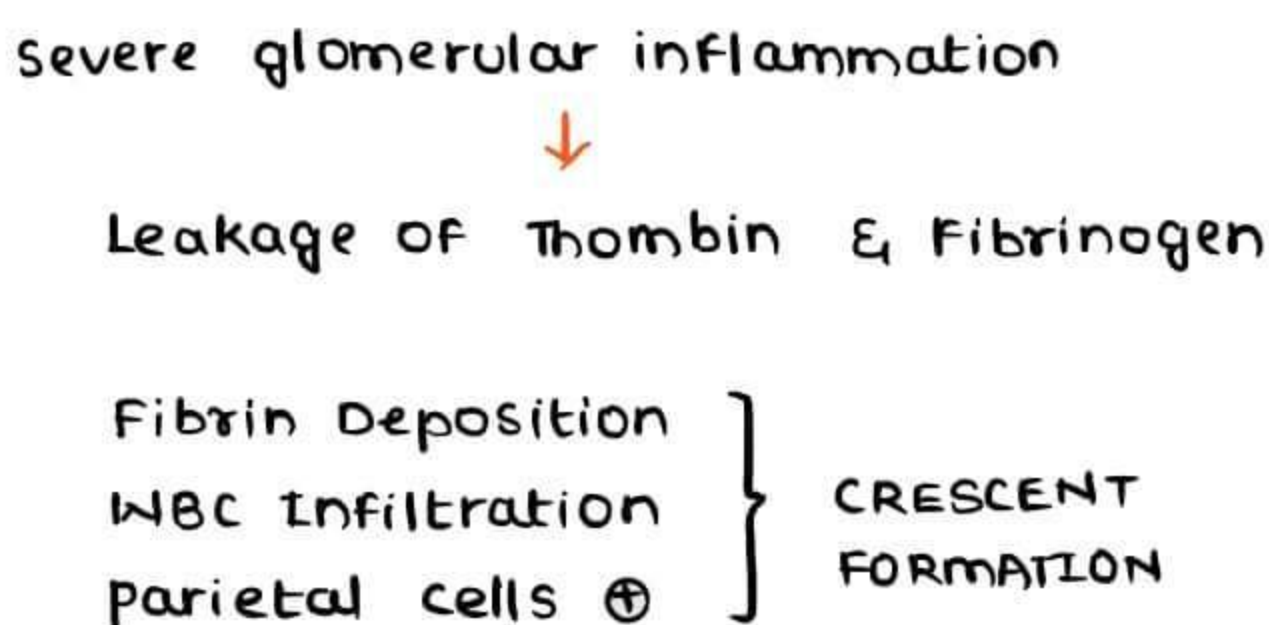
- 1. POST INFECTIOUS → PSGN
- 2. NON INFECTIOUS → SLE

**RPGN & BERGER'S DISEASE**

**RAPIDLY PROGRESSIVE GN**



**PATHOGENESIS**



↓ GFR → Renal Failure



Normal



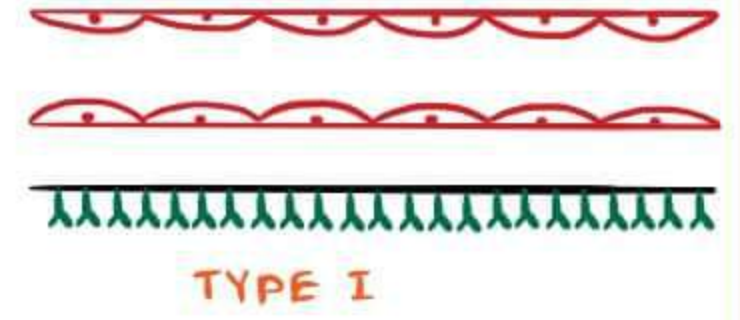
RPGN [CRESCENTIC GN]  
obliterated ⊕

**SUB TYPES**

**TYPE I → ANTI GBM DISEASE**

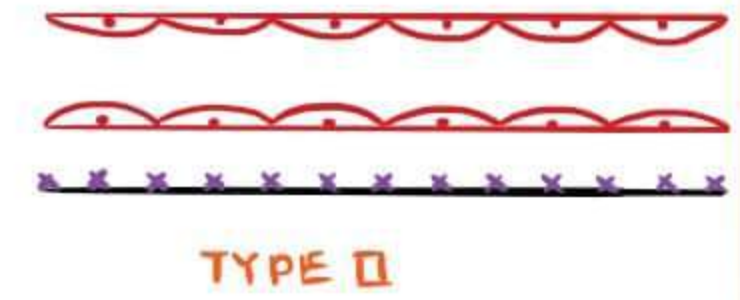
**GOOD PASTURE SYNDROME [Example]**

- IF → Linear Immuno Florescence
- R<sub>f</sub> → Plasmapheresis



**TYPE II → Immune complex deposition ⊕**

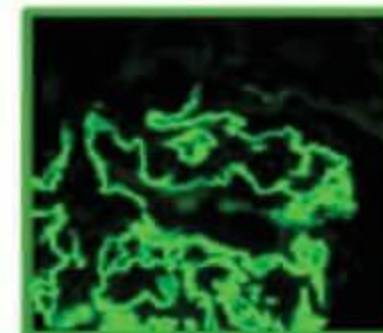
- ↳ SLE
- ↳ Ig A Nephropathy
- ↳ HSP



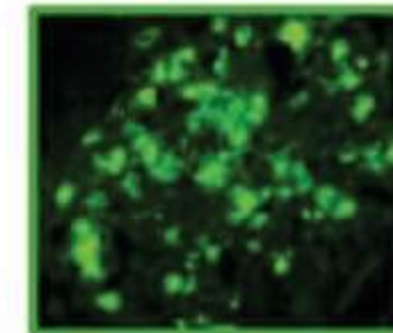
- Granular IF ⊕
- R<sub>f</sub> → R<sub>f</sub> the primary cause

**TYPE III → PAUCI IMMUNE RPGN**

- NO GBM Ab
- NO Immuno complexes
- ANCA ⊕
  - ↳ c-ANCA ⊕ → Wegener's granulomatosis
  - ↳ p-ANCA ⊕ → microscopic Polyarteritis



LINEAR



GRANULAR



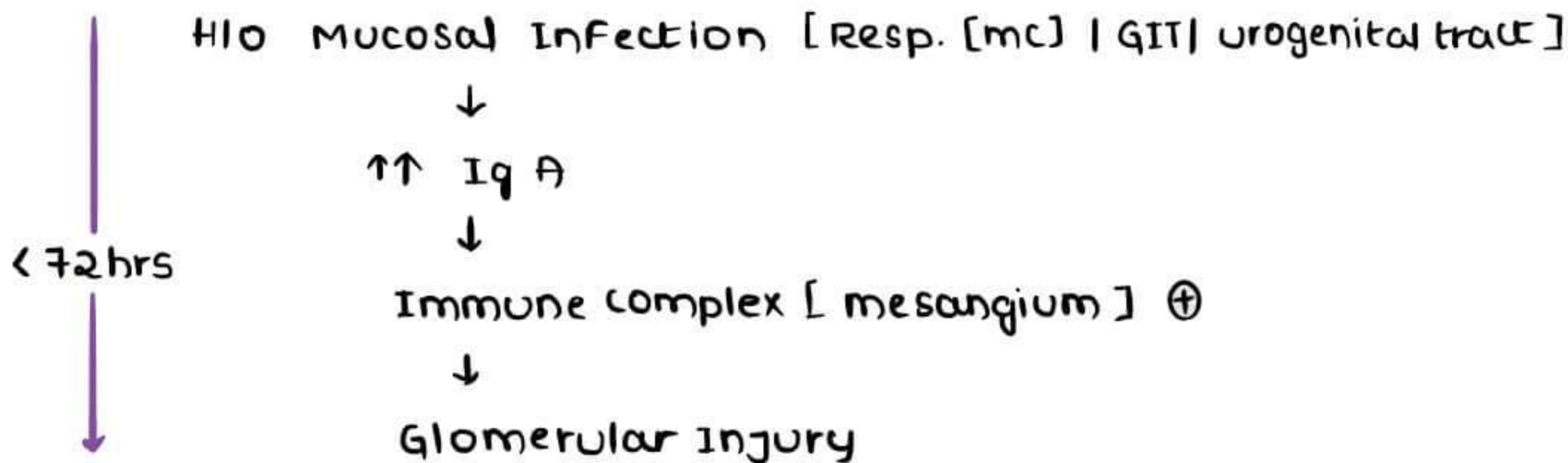
ABSENT

**CIF** → H/O disease → Rapid deteriorat<sup>n</sup> of Renal function

**DIAGNOSIS** → 1. Urine exam 2. Blood exam 3. Renal Bx

**BERGER'S DISEASE / Ig A NEPHROPATHY**

- mc cause of GN in ADULTS
- 

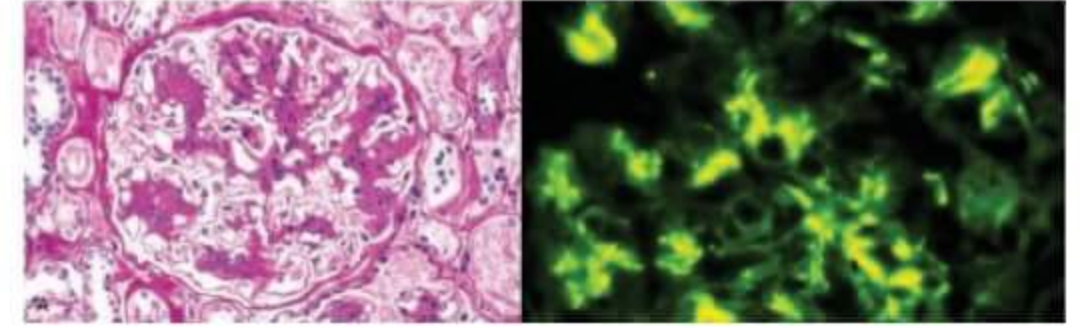


| PSGN                         | Ig A NEPHROPATHY            |
|------------------------------|-----------------------------|
| → Pediatric                  | → Adults                    |
| → 10-14 days                 | → < 72 hrs                  |
| → ↓ S. C <sub>3</sub> levels | → normal complement protein |

CIF → RECURRENT HEMATURIA [Gross > microscopic]

## DIAGNOSIS

RENAL BIOPSY → mesangium  
 ↳ hypercellularity ⊕  
 ↳ Electron dense deposits ⊕



## MEMBRANOUS GLOMERULOPATHY & MEMBRANOPROLIFERATIVE GLOMERULOPATHY

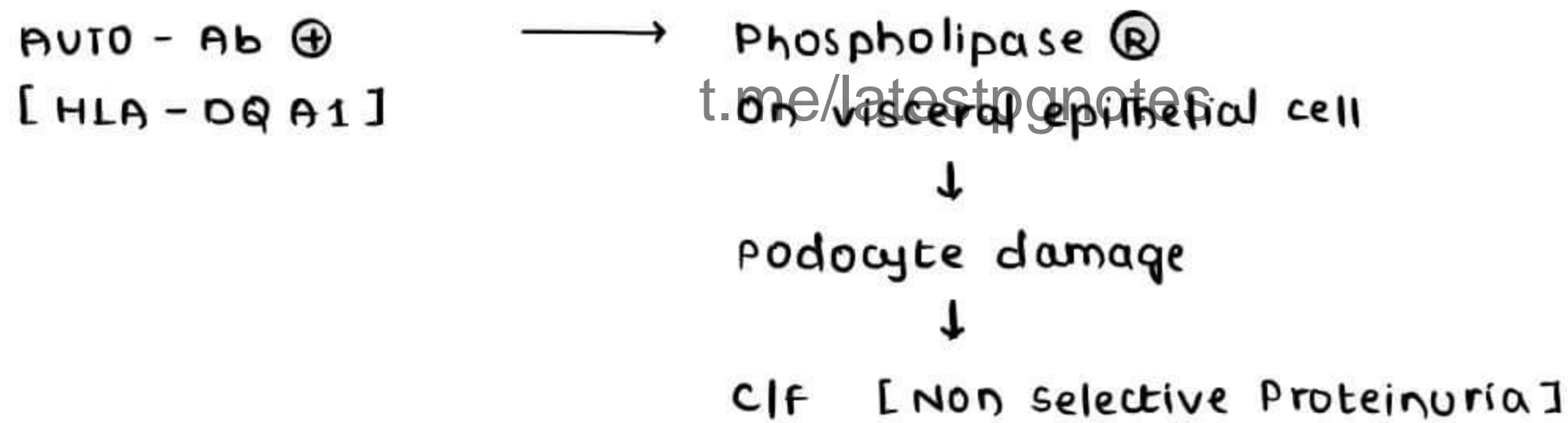
### MEMBRANOUS GLOMERULOPATHY

- mc cause of nephrotic syndrome in Elderly
- mc cause of nephrotic syndrome in SLE
- mc cause of nephrotic syndrome in Hepatitis B
- mc cause of nephrotic syndrome in Solid cancer

### ETIOLOGY

- 1° IDIOPATHIC [mc]
- 2°
  - Drugs [NSAIDs, Penicillamine]
  - Infections [Hepatitis B, malaria, toxoplasmosis]
  - SLE, Auto Immune Thyroiditis
  - Cancers [melanoma, colon cancer]

### PATHOLOGY



HEYMANN NEPHRITIS [Study model in Rat kidney]

↓  
 Ab against  
 MFGALTN

### DIAGNOSIS

1. URINE
  2. BLOOD
  3. KIDNEY BIOPSY
    - ↳ LM → Thickened glomeruli [non-specific]
    - ↳ EM → Effacement of podocytes ⊕  
 ↳ Spike & Dome appearance ⊕
    - ↳ IF → sub epithelial I/C
- POOR response to STEROIDS  
 → R<sub>1</sub> the primary cause





**MEMBRANOPROLIFERATIVE GLOMERULOPATHY /****MESANGIO - CAPILLARY GLOMERULOPATHY**

→ MIXED PICTURE [ Nephrotic Syndrome (predominant) & Nephritic syndrome]

**ETIOLOGY**

→ 1° → IDIOPATHIC [mc]

→ 2° → Hepatitis C | Leprosy | Hepatitis B

→ Partial Lipodystrophy syndrome

→ CLL

→ d, AT deficiency | SLE

**PATHOLOGY****TYPE I**

⊙ Activation by  
classical & Alternate pathways



↓ C<sub>1</sub> / C<sub>3</sub> / C<sub>4</sub>



Subendothelial IIC

**TYPE II**

C<sub>3</sub> Nephritic factor ⊕

↓ stabilizes

C<sub>3</sub> convertase

[Alternate pathway]



↓ C<sub>3</sub>



Intramembranous IIC



DENSE DEPOSIT DISEASE

[t.me/latestpgnotes](https://t.me/latestpgnotes)

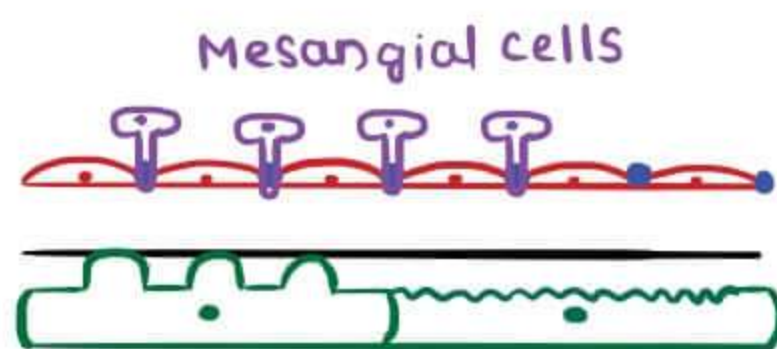

**DIAGNOSIS**

1. Blood
2. Urine
3. Renal Bx

LM → Thickened membrane

EM → EFFACEMENT OF podocytes

Intramembranous dense deposits [MPGNII]



Sub endothelial IIC


**MPGN I**

• TRAM TRACK APPEARANCE /  
SPLITTING OF BM

• MESANGIAL RINGS ⊕

R<sub>1</sub> → Poor response to STEROIDS

## ANTI-GBM DISORDERS

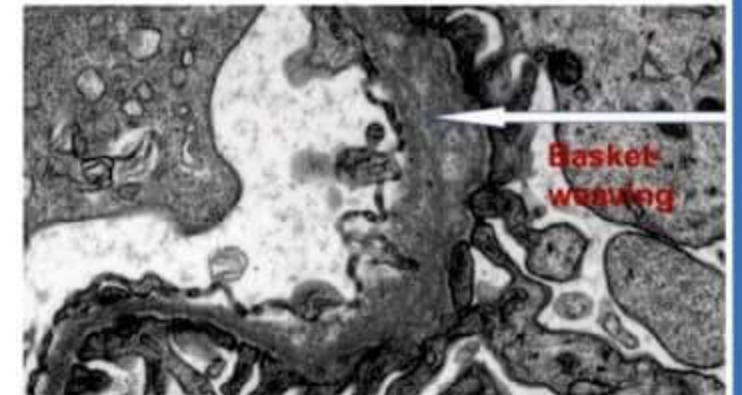
- GBM → collagen IV
- collagen I → Bone
- collagen II → cartilage [car TWO lage]
- collagen III → Blood vessels
- collagen IV → GBM [Kidneys & Lungs]
- COLLAGEN IV → 

## GOODPASTURE SYNDROME

- type II HR
- Ab against  $\alpha_3$  chain
- collagen IV involved
- causes HEMORRHAGIC INFLAMMATION
  - ↳ Kidneys → Hematuria
  - ↳ Lungs → Hemoptysis
- Renal Bx → Linear IF ⊕
- can progress to RPGN & Renal failure [cause of death]

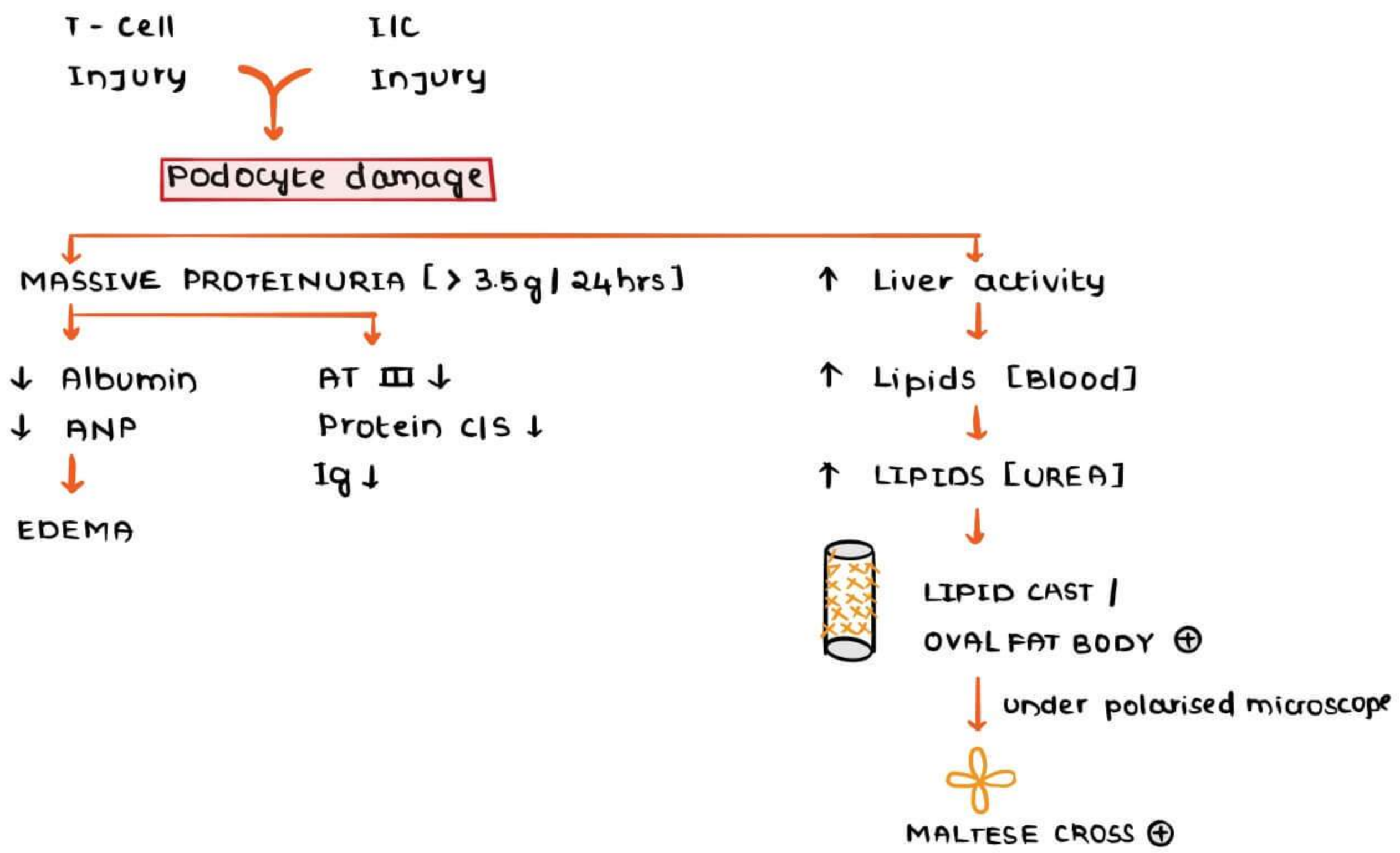
## ALPORT SYNDROME

- X Linked disorder [XLD/XLR] & Autosomal disorder [AD/AR]
- mc → XLD [t.me/latestpgnotes](https://t.me/latestpgnotes)
- $\alpha_5$  chain of collagen IV defect [XLD]

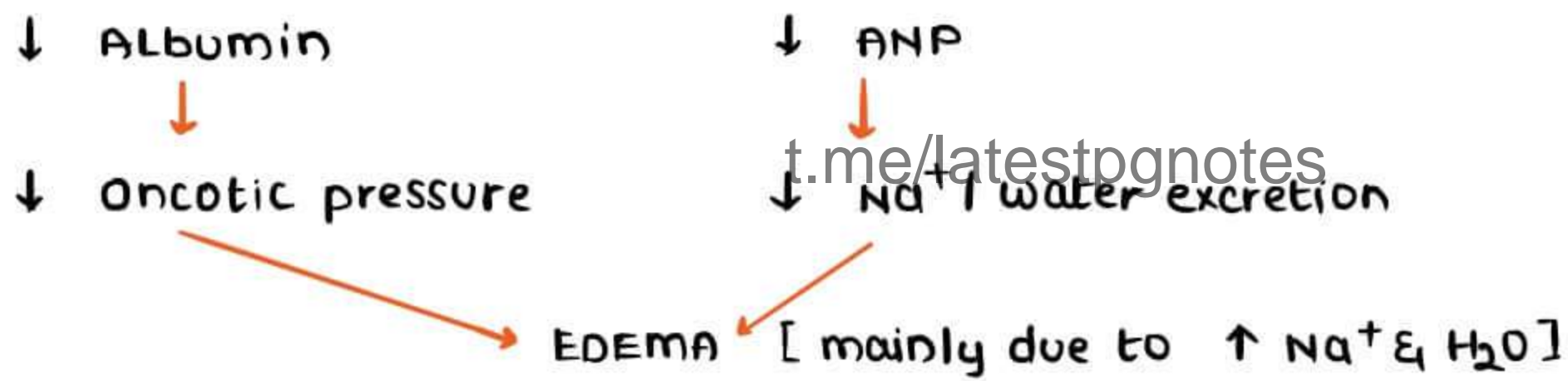


## ORGANS AFFECTED

1. KIDNEYS [mc] → Hematuria  
→ BASKET WEAVE APPEARANCE ON EM [dit splitting of BM]
2. EAR → SNHL
3. EYE → Anterior Lenticonus

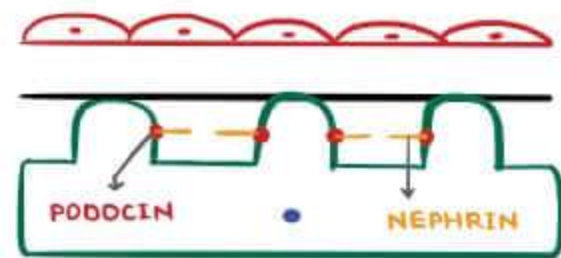


EDEMA



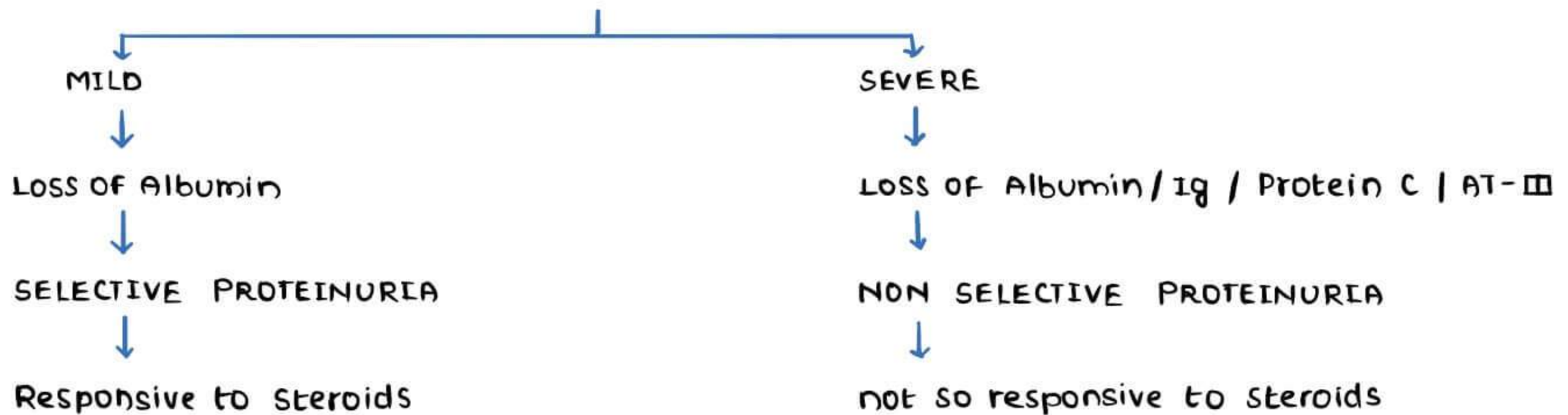
- ↓ Transferrin [ $T_f$ ]      → IDA [Iron resistant]
- ↓ TBG                      → Hypothyroidism [not responsive to  $T_3$  &  $T_4$  Supplementat<sup>n</sup>]

PODOCYTE



- Ⓝ NPSH 1 gene mutation      → Ⓝ Nephrin deficiency      → Congenital / Finnish NS
- Ⓝ NPSH 2 gene mutation      → Ⓝ Podocin deficiency      → FSGS

PODOCYTOPATHY



→ mc cause of nephrotic syndrome in children

**ETIOLOGY**

- Idiopathic
- Drugs [NSAIDS]
- Hodgkin Lymphoma
- Respiratory Infections
- Atopy

→ **PODOCYTE DAMAGE** ⊕ → **CIS** → child → Frothiness in urine ⊕⊕⊕  
Swelling

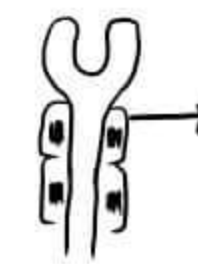
**DIAGNOSIS**

1. **BLOOD** → ↓ Albumin  
→ ↑ Lipids

2. **URINE** → 24 Hr  
→ OFB ⊕ | LC ⊕

3. **Renal BIOPSY**

- a. LM → Normal [minimal change disease]
- b. EM → EFFACEMENT OF PODOCYTES [confirmatory]
- c. IF → NO I/C [No immune deposits]



LIPID NEPHROSIS

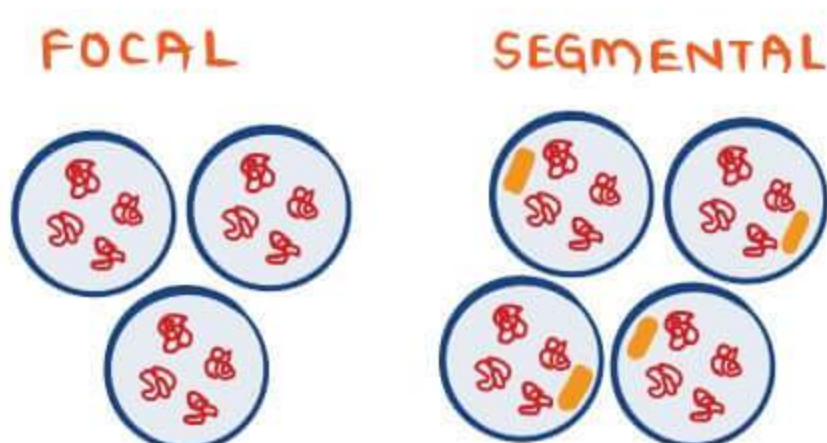
**Rx** → Selective proteinuria R<sub>x</sub> by Steroids [Excellent Response]

**FOCAL SEGMENTAL GLOMERULOSCLEROSIS**

- 1<sup>o</sup> → Idiopathic
- 2<sup>o</sup> → Reflux Nephropathy → HIV
- HTN → IV drug abusers
- Sickle cell Disease → U/L Renal agenesis

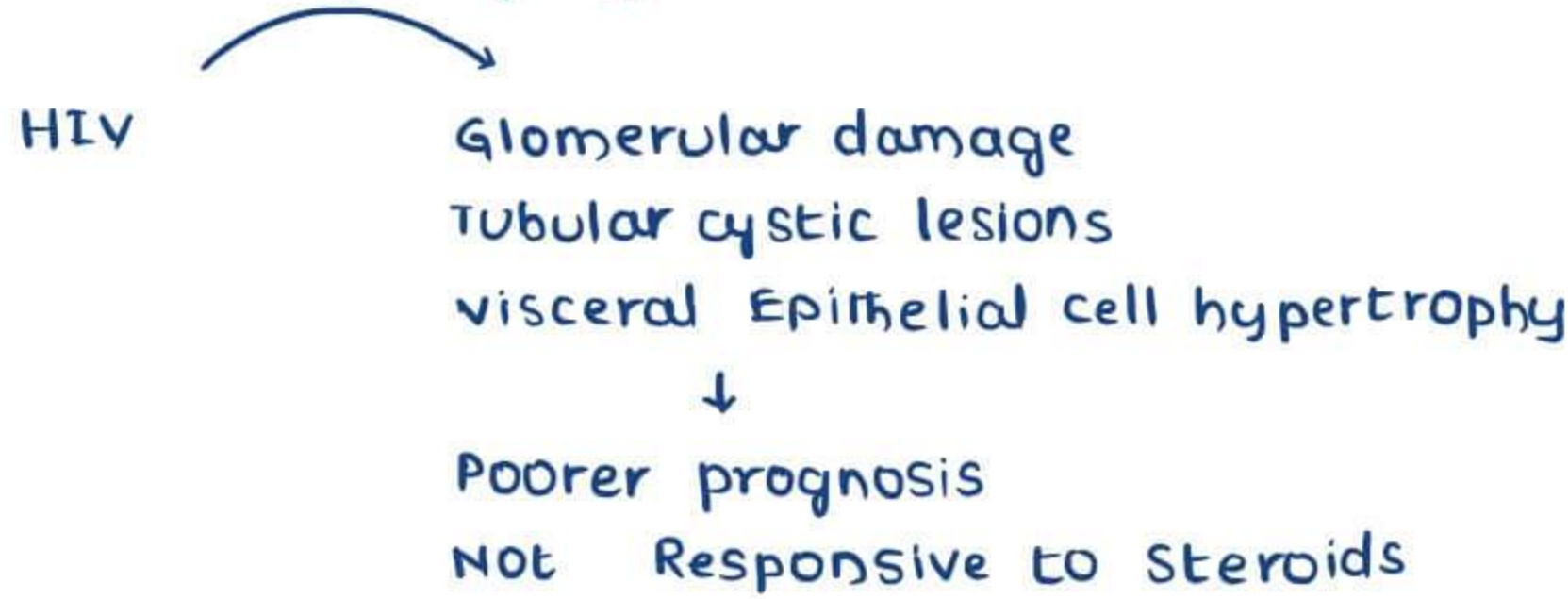
→ Adults → mc cause of Nephrotic Syndrome in adults  
→ Non-Selective proteinuria ⊕

**DIAGNOSIS**



EM → Effacement of Podocytes

FSGS → Glomerular Tip Collapsing Type → Good prognosis

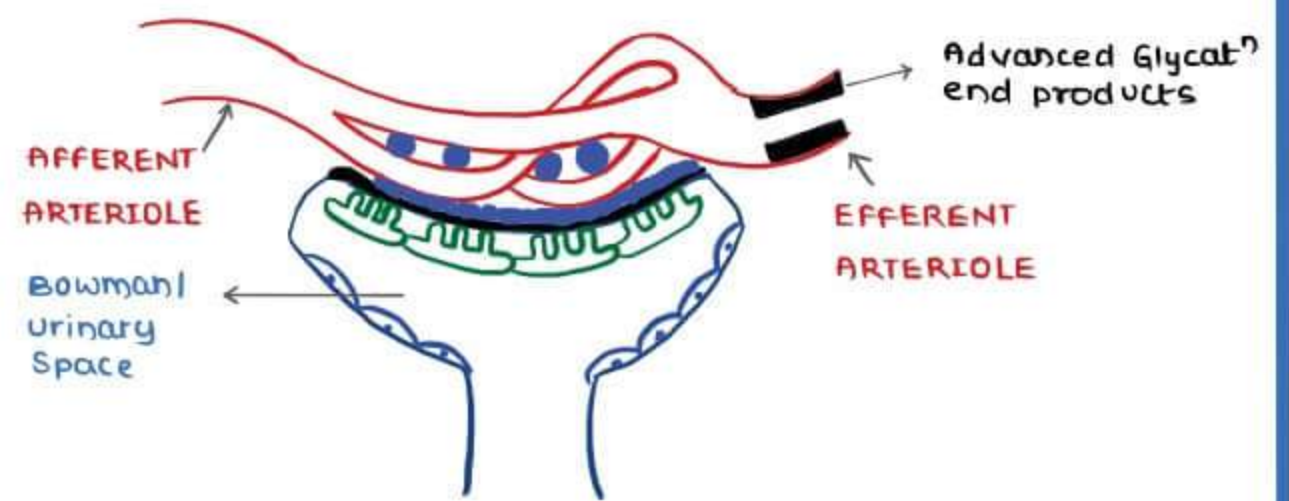
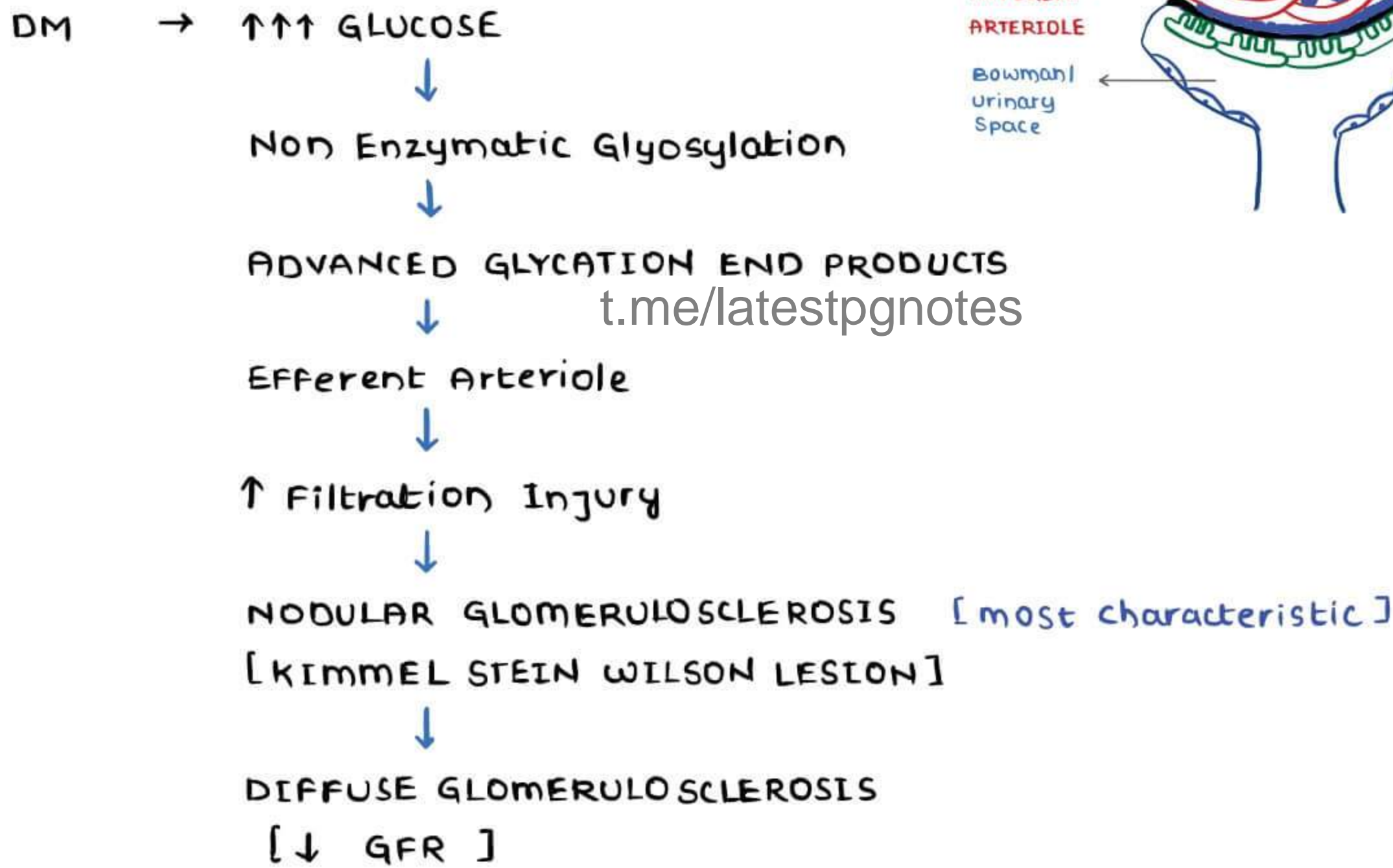


**SYSTEMIC DISORDERS AFFECTING GLOMERULUS**

**DIABETES MELLITUS [mc]**

→ MC cause of chronic kidney disease globally

**PATHOLOGY**



→ Angiotensin II → Efferent vessel constriction

→ ACE Inhibitors  
→ Angiotensin Receptor Blockers [ARB] } ↓↓ Diabetic nephropathy

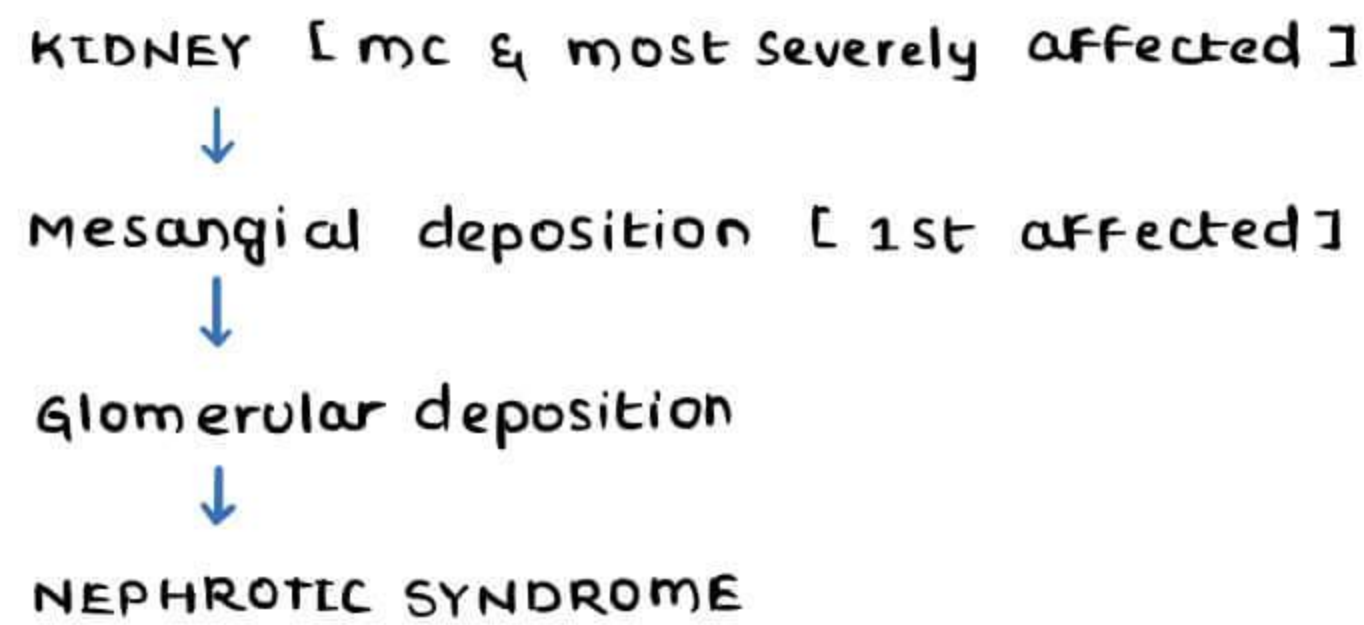
**RENAL PAPILLARY NECROSIS CAUSES**

1. DM [mc]
2. Obstruction of Urinary tract
3. Sickle cell disease
4. Analgesics [↓ PGs]

**SLE** → membranous Glomerulopathy >>>> MPGN [Nephrotic Syndrome]  
→ Diffuse Proliferative Glomerulonephritis [Nephritic Syndrome]  
↳ WIRE LOOP LESIONS ⊕

**AMYLOIDOSIS**

→ 2° Amyloidosis affects kidney

**RENAL TUMORS : RENAL CELL CARCINOMA****BENIGN TUMORS****1. ANGIOMYOLIPOMA**

- Spontaneous haemorrhage ⊕
- a/w Tuberous sclerosis
  - ↳ Epilepsy
  - ↳ Angiomyolipoma
  - ↳ Rhabdomyoma [cardiac]
  - ↳ macules

**2. ONCOCYTOMA** → Large Eosinophilic cells & prominent mitochondria

**MALIGNANT TUMORS**

[t.me/latestpgnotes](https://t.me/latestpgnotes)

**RENAL CELL CARCINOMA [RCC] | HYPERNEPHROMA | GRAVITZ TUMOR**

- 6-7<sup>th</sup> decade
- M > F
- Upper pole involved mclly

**RISK FACTORS**

1. TOBACCO [most important]
2. ASBESTOS
3. HTN / obesity
4. Estrogen
5. Sickle cell trait
6. ESRD → dialysis [dysplasia in cystic lesion]

**FAMILIAL VARIANTS****1. VHL SYNDROME**

- VHL gene on chr. 3p
- VHL gene mutation
- TRIAD
  - ↳ Renal cancer
  - ↳ Pheochromocytoma
  - ↳ cerebellar hemangioblastoma
- ↓ HIF [Hypoxia Inducible factor]
- ↑ HIF → ↑ VEGF → ↑ cancer

2. HEREDITARY LEIOMYOMATOSIS + RCC → FH gene mutation

### 3. BIRT - HOGG DUBE SYNDROME

#### TRIAD

- S → Skin cancer
- R → Renal cancer
- P → Pulmonary Cysts

4. HEREDITARY PAPILLARY CANCER → MET gene [protooncogene] mutation

#### CF

- Hematuria [painless]
  - Palpable mass
  - costo-vertebral pain
  - fever
  - weight loss
  - malaise
- } CLASSICAL TRIAD

DIAGNOSIS → Renal Biopsy & HPE

#### SUB TYPES

##### 1. CLEAR CELL CANCER

- mc
- arises from proximal tube
- VHL gene mutation ⊕

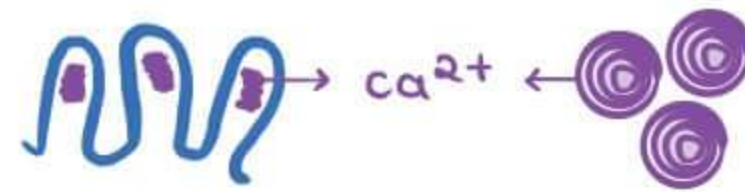


clear cytoplasm  
⊖ granules

[t.me/latestpgnotes](https://t.me/latestpgnotes)

##### 2. PAPILLARY CANCER

- arises from distal tubular cells
- multifocal & BIL
- Trisomy 7 | 16 | 17
- Trisomy 7 a/w → sporadic & familial variants
- a/w Dialysis associated cystic disease



PSAMMOMA BODIES

##### 3. CHROMOPHOBE CARCINOMA

- a/w Hypoploidy
- a/w BHD Syndrome
- Best prognosis



perinuclear halo

##### 4. BELLINI DUCT CANCER

- arises from collecting duct [medulla]
- Anaplasia ⊕⊕⊕
- worst prognosis

5. MEDULLARY CARCINOMA → a/w sickle cell trait  
→ arises from collecting duct

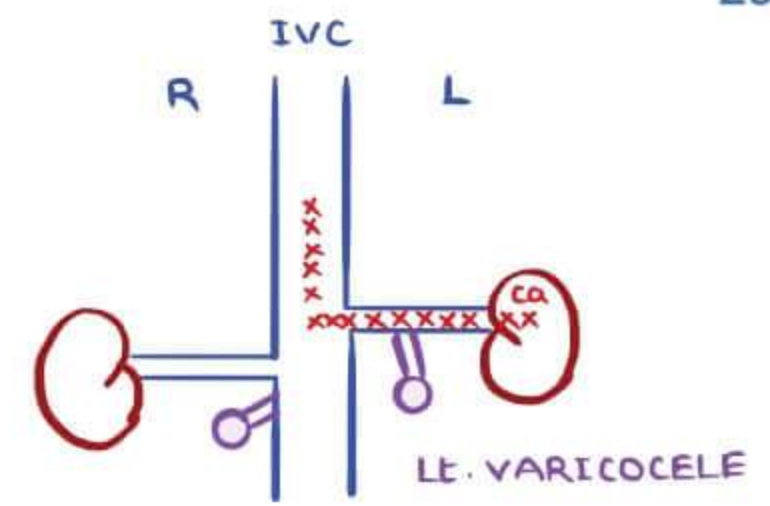
##### 6. XP 11 TRANSLOCATION CANCER

- TFE Gene involved
- young patients

**METASTASIS**

→ Lungs > Bones > Liver > Adrenal gland

→ RCC → VENOUS SPREAD

**PARANEOPLASTIC SYNDROME**

→ ↑ ESR

→ Anemia

→ Polycythemia

→ Leukemoid Reaction

→ Non metastatic Hepatic dysfunction  
[ STAUFFER SYNDROME ]

→ Amyloidosis

→ ↑  $Ca^{2+}$

→ feminization / masculinization

→ Cushing syndrome

**WILMS TUMOR**

→ children

**RISK FACTORS****1. WAGR SYNDROME**

→ Wilms tumor

→ Aniridia

→ Genital anomaly

→ Retardation [mental]

→ WT<sub>1</sub> Gene } Tumor suppressor genes  
WT<sub>2</sub> Gene }

↓ mutation

↑ WILMS TUMOR

→ located chr 11p

**2. BECKWITH - WIEDEMANN SYNDROME** → Wilms tumor + hemihypertrophy

**3. DENYS - DRASH SYNDROME** → WT + Gonadal dysgenesis

**ClF** → Abdominal mass [earliest] } TRIAD  
→ fever }  
→ Hematuria }

**DIAGNOSIS**

Renal Bx & HPE

TRIPHASIC TUMOR

- ↙ Blastemal components
- ↘ Epithelial components
- ↘ Stromal components

NEPHROGENIC REST → ↑ cancer in opposite kidney

**PROGNOSIS** → Anaplasia ⊕⊕⊕  
↳ alw p53 mutation  
↳ poorer prognosis



### ACQUIRED CYSTIC KIDNEY DISEASE

- a/w Dialysis → DIALYSIS ASSOCIATED CYSTIC DISEASE
- cortico medullary renal cysts + nt
- usually asymptomatic
- ↑ risk of kidney stones [calcium oxalate]
- ↑ risk of kidney cancer [papillary renal carcinoma]

### RENAL AGENESIS

**U/L AGENESIS** [compatible i life]

usually LEFT kidney absent  
 ↓  
 compensatory enlargement OF right kidney  
 ↓  
 Glomerulosclerosis  
 ↓  
 CHRONIC KIDNEY DISEASE

**BIL AGENESIS** [incompatible i life]

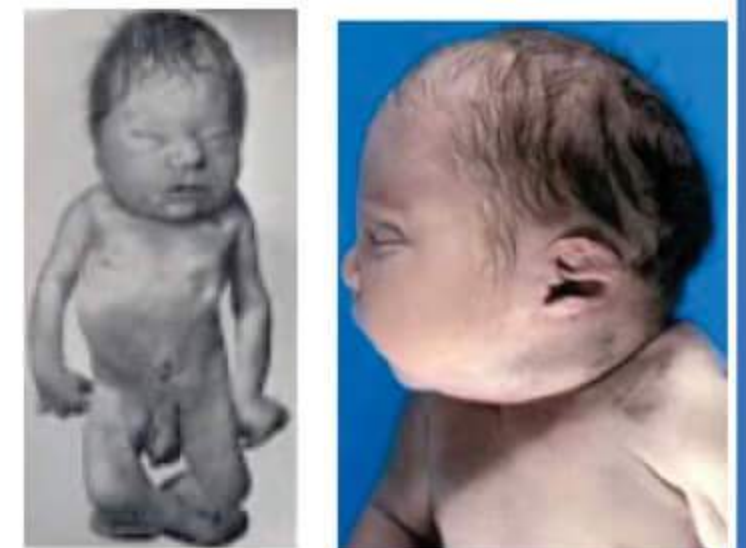↓

1. AMNION NODOSUM
2. POTTER SEQUENCE

Oligohydramnios → Pulmonary hypoplasia [mcc death]  
 → Limb defects → club feet  
 → POTTER FACIES

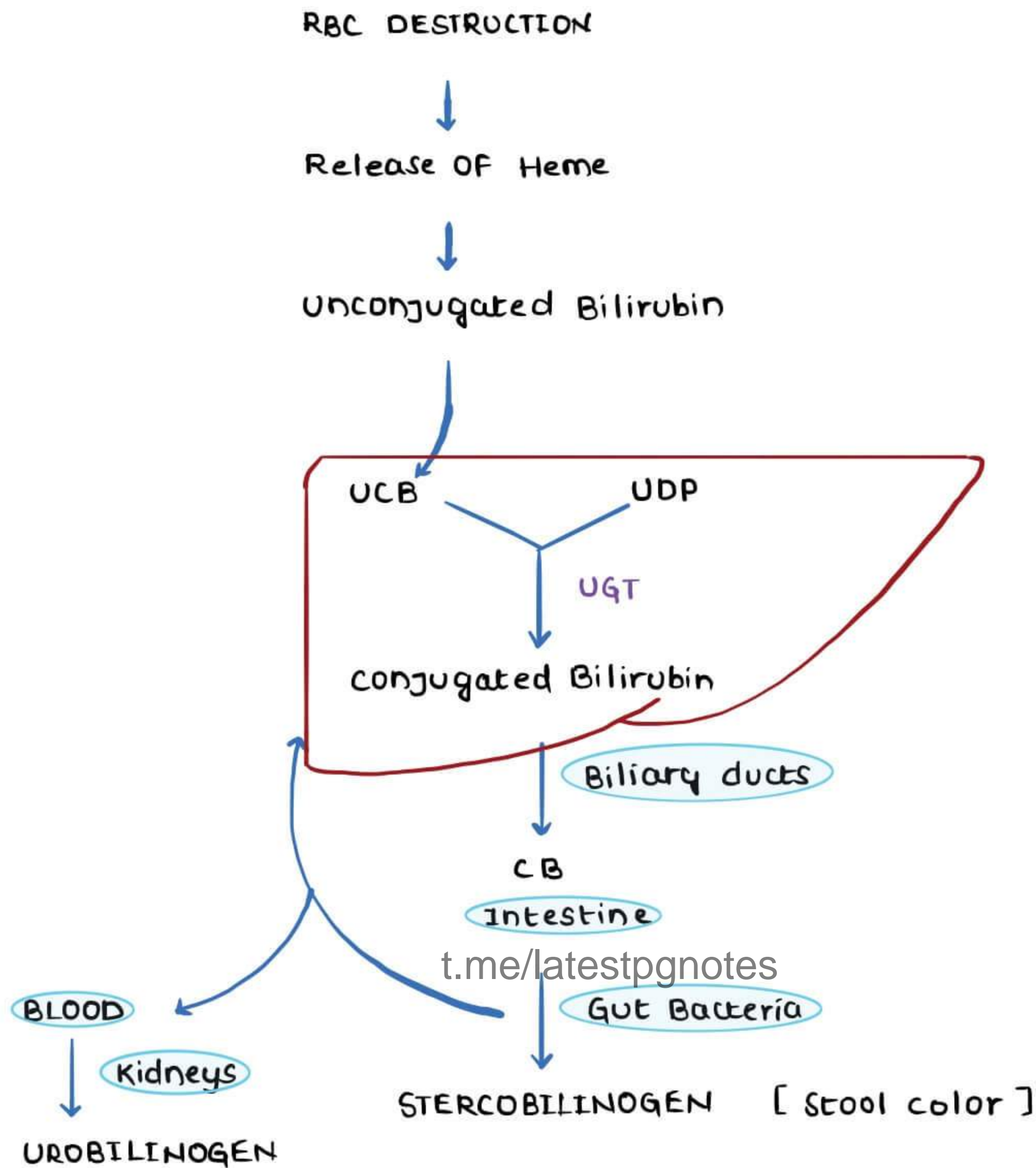
- Flat face
- Low ears
- micrognathia

**P** → Pulmonary hypoplasia  
**O** → Oligohydramnios  
**T** → Twisted Limbs / face  
**T** → Twisted skin  
**E** → Extremity defects  
**R** → Renal agenesis

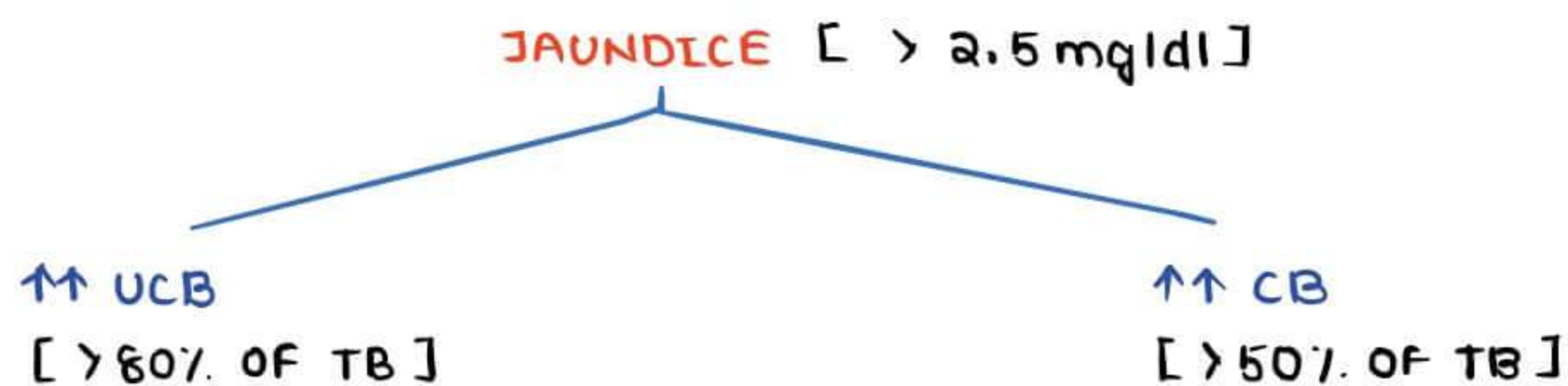


POTTER FACIES

# LIVER, BILIARY SYSTEM & PANCREAS BILLIRUBIN METABOLISM



- UGT - UDP Glucuronyl Transferase
- UCB - Lipid soluble
- CB - water soluble



Yellowish discoloration of skin & sclera is due to the affinity of Bilirubin for ELASTIN FIBERS →

- UNCONJUGATED HYPERBILIRUBINEMIA → UCB → > 80% OF TB
- CONJUGATED HYPERBILIRUBINEMIA → CB → > 50% OF TB

**UNCONJUGATED HYPERBILIRUBINEMIA**

- ↑ RBC DESTRUCTION → Hemolytic anemia
- LIVER IMMATURITY → Newborn
- UGT DEFECT [↓] → Genetic defects

**NEW BORN JAUNDICE**

1. PHYSIOLOGICAL JAUNDICE → seen from 2nd Day onwards
2. BREAST MILK JAUNDICE → d/t Glucuronidase | Pregnenediol in breast milk

**GENETIC DEFECTS [↓ ugt activity]**

1. GILBERT SYNDROME → Adult [Guy] + Stress
2. CRIGGLER NAJJAR SYNDROME
  - a. CNS I → no activity of enzyme [↑↑ mortality]
  - b. CNS II
    - ↓ activity of enzyme
    - ↑ Neurological symptoms d/t UCB deposition in Basal ganglia
    - Rx by Phenobarbitone & Phototherapy
    - seen in children | New born
    - Autosomal Recessive

**CONJUGATED HYPERBILIRUBINEMIA**

- Jaundice | Pruritis | Pale colored | clay colored stools
- Steatorrhea | dark colored urine

**CAUSES**

[t.me/latestpgnotes](https://t.me/latestpgnotes)

**1. BILE DUCT OBSTRUCTION**

- Stones
- Cancer
- Infections

**2. BILIARY TRACT DISEASE**

- Primary Biliary Cirrhosis
- Primary sclerosing cholangitis

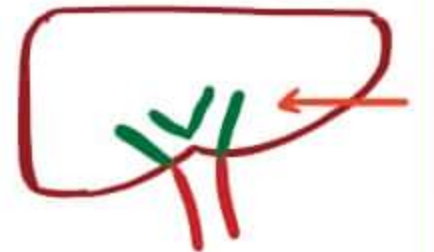
**3. GENETIC DISEASE (↓ Excret<sup>n</sup> of CB)**

- DUBIN - JOHNSON SYNDROME
  - ↳ AR
  - ↳ MRP - 2 Defect ⊕
  - ↳ Dark pigmented liver [d/t Epinephrine metabolites]
- ROTOR SYNDROME
  - ↳ Normal Liver

**VIRAL HEPATITIS** → ↑ UCB & ↑ CB

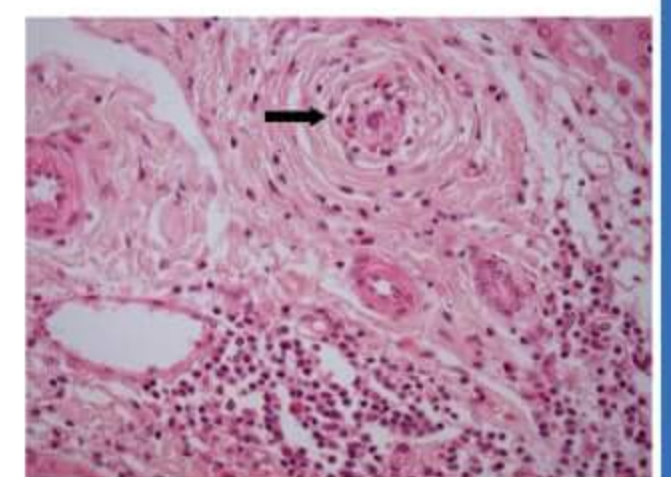
**1° BILIARY CIRRHOSIS**

- Auto Immune granulomatous destruction of INTRAHEPATIC BILE DUCT
- F >> M
- 40 - 50 yrs
- a/w SJOGREN SYNDROME
- ANTI MITOCHONDRIAL ANTIBODY [AMA] against Pyruvate Dehydrogenase
- ↑ CB → ↑ CIRRHOSIS | MALIGNANCY



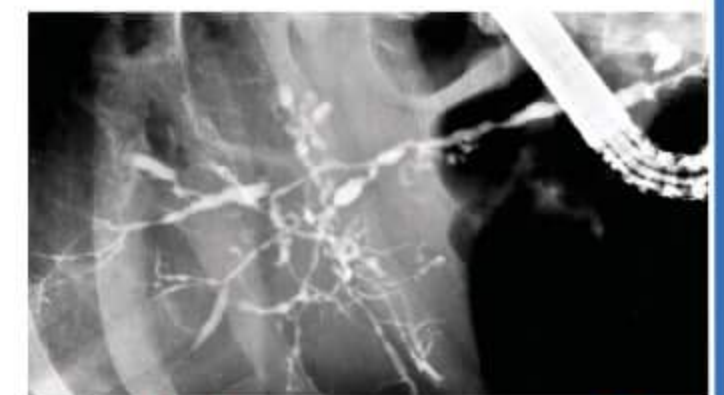**1° SCLEROSING CHOLANGITIS**

- M > F
- Damage to INTRA & EXTRA HEPATIC BILE DUCT
- Bile ducts undergo CONCENTRIC PERIDUCTAL FIBROSIS



concentric periductal fibrosis

- BEADED APPEARANCE on cholangiogram
- a/w ulcerative colitis
- p ANCA ⊕
  - ↳ p ANCA in vasculitis is against MPO
  - ↳ p ANCA in 1°SC is against Nuclear envelop protein
- obstructive jaundice ⊕
- ↑ cirrhosis | ↑ cancer



Beaded appearance on cholangiogram

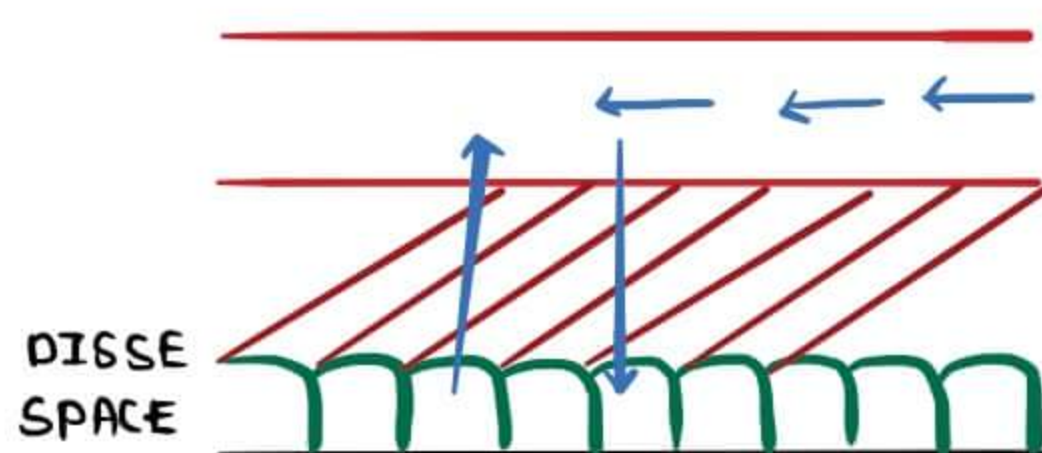
**CIRRHOSIS**

**RISK FACTORS**

- Alcohol [mc]
- NAFLD [ mc reason for cryptogenic cirrhosis]
- Viral Hepatitis
- Metabolic diseases

**PATHOLOGY**

- Damage to liver parenchyma
- Bridging fibrous Septa formation
- Regeneration of Parenchyma nodules ⊕



STELLATE ITO CELL → MYOFIBROBLAST  
TGF-β

**1. PORTAL HTN**

- ↳ congestive splenomegaly
- ↳ Ascites
- ↳ Porto systemic shunts
  - esophagus varices
  - Hemorrhoids
  - caput medusae

**2. ↓ PROTEIN SYNTHESIS**

- ↓ ALBUMIN → Ascites
- ↓ clotting factors → ↑ Bleeding, ↑ PT, ↑ aPTT
- ↑ γ globulins [Igs] [in response to ↑ed Infections]

**3. ↓ METABOLISM**

- ↑↑ ESTROGEN
  - ↳ Palmar erythema
  - ↳ Spider angioma
  - ↳ Gynecomastia
  - ↳ ↓ gonadal function
- ↑ NH<sub>3</sub> → neurotransmitter → Hepatic Encephalopathy

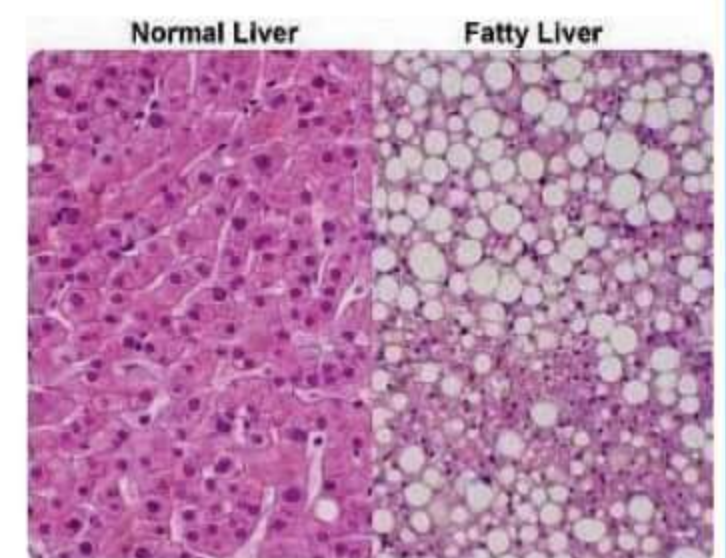
**HEPATIC ENCEPHALOPATHY**

→ precipitated by t.me/latestpgnotes

- ↳ GI Bleed
- ↳ ↓ K<sup>+</sup>
- ↳ ↓ H<sup>+</sup>
- ↳ ↓ Na<sup>+</sup>
- ↳ ↓ O<sub>2</sub>

**4. HEPATO - RENAL | HEPATO - PULMONARY SYNDROME****ALCOHOLIC LIVER DISEASE****1. ALCOHOLIC STEATOSIS / FATTY LIVER**

→ accumulation of fat droplets in hepatocytes

**FAT DROPLETS****1. MICRO VESICULAR STEATOSIS CAUSES [no displacement of nucleus]**

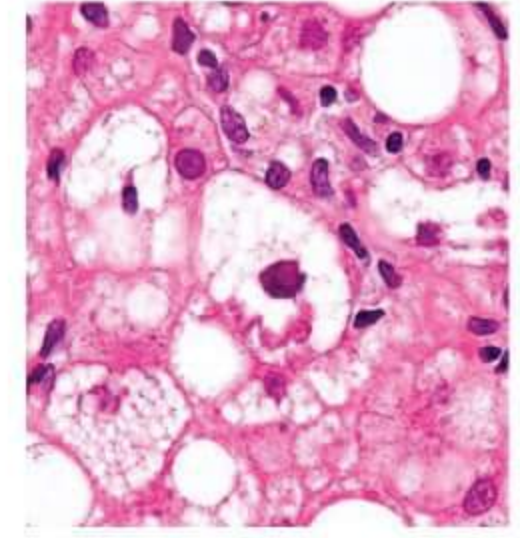
- ALD
- Reye Syndrome
- Acute fatty liver of Pregnancy
- Chronic viral hepatitis
- Tetracyclin / valproate

**2. MACRO - VESICULAR STEATOSIS CAUSES [displace nucleus]**

- ALD
- PEM
- TPN
- Jeuno - ileal bypass
- DM
- Lipodystrophy

## 2. ALCOHOLIC HEPATITIS

- Perivenular / Peri sinusoidal fibrosis ⊕
- **MALLORY DENK BODY** ⊕ → cytokeratin filaments →
- also seen in

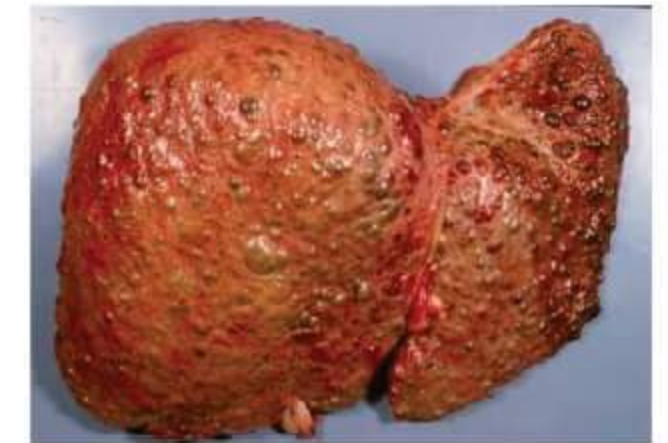

- |          |                                                          |
|----------|----------------------------------------------------------|
| <b>N</b> | → Non Alcoholic fatty Liver Disease                      |
| <b>I</b> | → Indian childhood cirrhosis [dit copper toxicity]       |
| <b>W</b> | → Wilson's Disease                                       |
| <b>A</b> | → Alcoholic Liver Disease, α <sub>1</sub> -AT Deficiency |
| <b>T</b> | → Tumor [Hepatocellular cancer]                          |
| <b>C</b> | → Chronic cholestasis [1° Biliary Cirrhosis]             |
| <b>H</b> | → Focal nodular Hyperplasia                              |

→ not seen in 2° Biliary cirrhosis & Hemochromatosis

## 3. CIRRHOSIS / LAENNEC CIRRHOSIS

- Irreversible nodular damage to Liver



cirrhosis

### NON - ALCOHOLIC FATTY LIVER DISEASE

- IDIOPATHIC / CRYPTOGENIC
- RISK FACTORS [t.me/latestpgnotes](https://t.me/latestpgnotes)
  - ↳ Obesity
  - ↳ Dyslipidemia
  - ↳ Insulin Resistance
- Asymptomatic → Diagnosis of Exclusion
- mc cause of death → cardiovascular cause
- M/E
  - Steatosis
  - Non Alcoholic steato Hepatitis [NASH]

### DD

1. HISTORY
2. TESTS

ALD →  $\frac{AST}{ALT} \rightarrow > 2$       NAFLD →  $\frac{AST}{ALT} \rightarrow < 2$

### HEPATITIS

- |           |   |                   |
|-----------|---|-------------------|
| HEPATITIS | A | → Acute Hepatitis |
| HEPATITIS | B |                   |
| HEPATITIS | C |                   |
| HEPATITIS | D |                   |
| HEPATITIS | E | → Acute Hepatitis |

**HEPATITIS A**

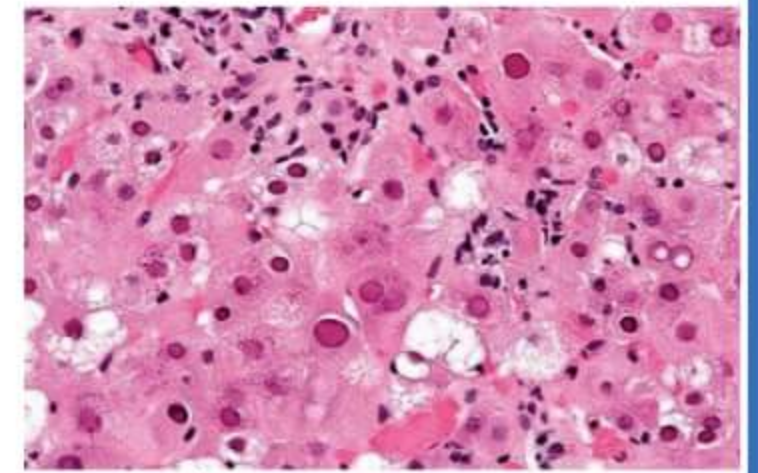
- transmitted by FECO - ORAL ROUTE
- MC cause of Hepatitis in CHILDREN

**HEPATITIS E**

- transmitted by FECO - ORAL ROUTE
- MC cause of Hepatitis in ADULTS
- a/w FULMINANT DISEASE in PREGNANCY

**HEPATITIS B**

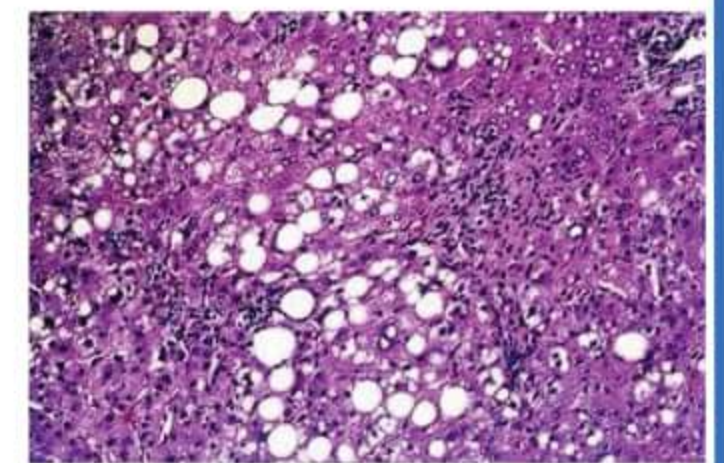
- TRANSFUSION ASSOCIATED HEPATITIS VIRUS
- CARRIER STATE ⊕
- ↑ HCC
- only DNA virus causing hepatitis
- MICROSCOPIC FEATURES
  1. GROUND GLASS APPEARANCE [ HBS Ag ]
  2. SANDED NUCLEI [ HBC Ag ]



Ground glass appearance

**HEPATITIS C**

- maximum chance of CHRONICITY
- a/w CIRRHOSIS [ RNA virus causing cirrhosis ]
- MICROSCOPIC FEATURES
  1. FOCAL FATTY CHANGE
  2. BILE DUCT DAMAGE
  3. LYMPHOCYTE AGGREGATION IN PORTAL TRACT



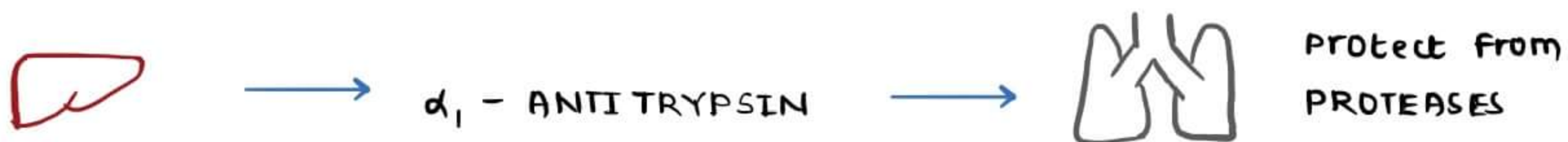Fatty change

**HEPATITIS D**

- defective virus → requires Hepatitis B for pathogenesis
- CO - INFECTION → simultaneous infect<sup>n</sup> [ Fulminant ]
- SUPER - INFECTION → Hep. B → Hep D [ ↑ chronicity ]

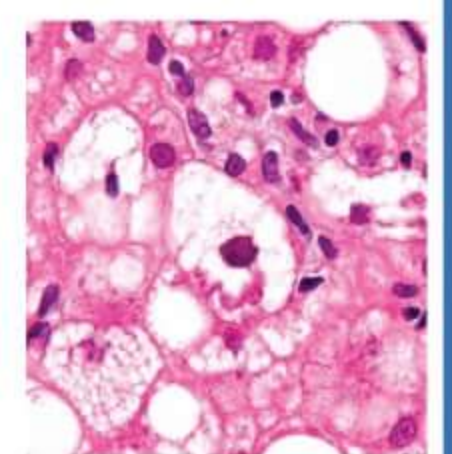
**METABOLIC DISEASES OF LIVER**

**1. α<sub>1</sub> - ANTI TRYPSIN DEFICIENCY [ α<sub>1</sub> AT Def. ]**



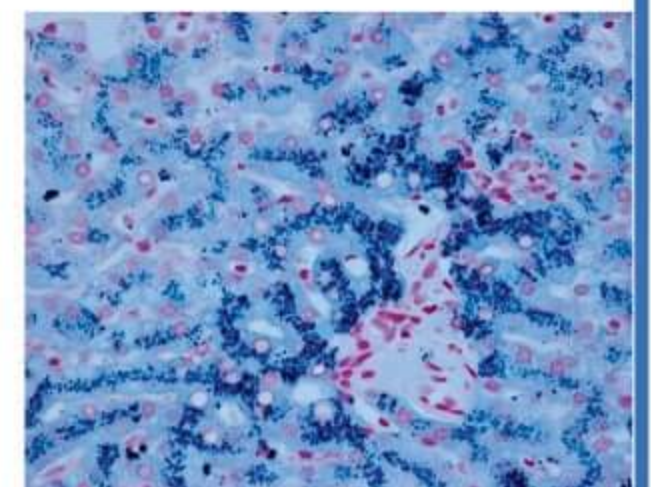
IN NORMAL PERSON → PiMM Allele  
 ABNORMAL → PiZZ Allele  
 PiMZ Allele } misfolding of Proteins } CIRRHOSIS  
 PAN ACINAR EMPHYSEMA

- AR
- DIAGNOSIS
  1. PAS ⊕ / diastase Resistant granules [pink inclusions]
  2. Mallory Denk Bodies [non-specific]



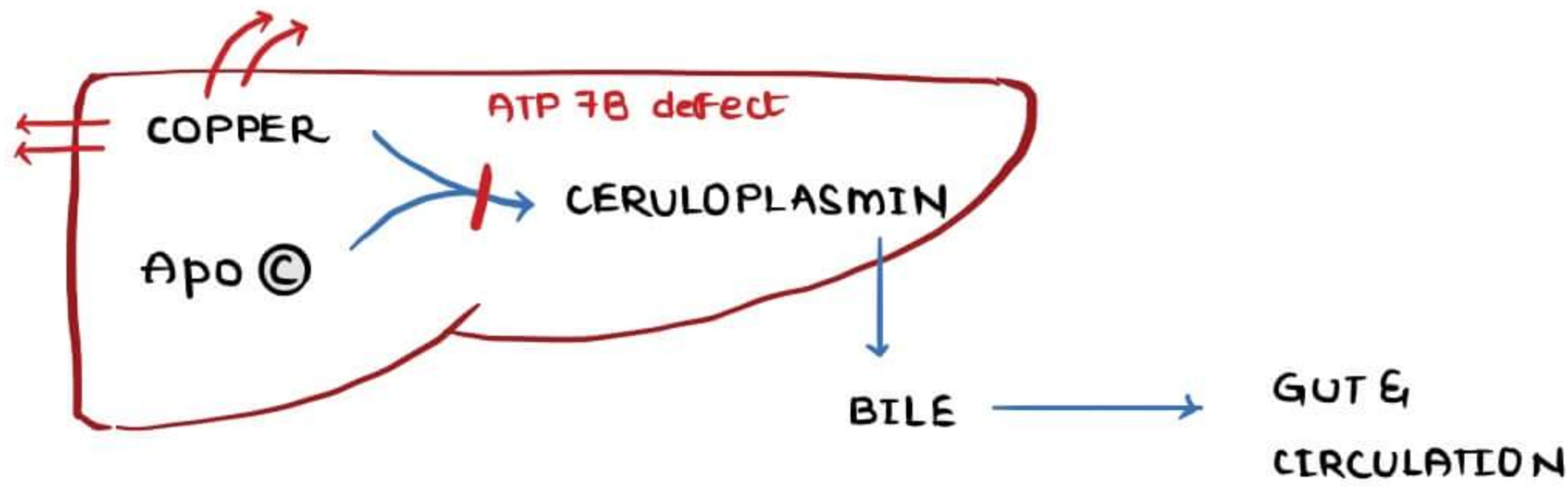
## 2. HEMOCHROMATOSIS

- Defect in regulation of Iron absorption
- **HEPCIDIN**
  - ↳ negative Iron Regulatory protein
  - ↳ ↓ Hepcidin → Iron Overload
- 1° → HFE gene defect on chr. 6p.21 [mc] } **HEMOCHROMATOSIS**  
           HJV gene defect
- 2° → multiple blood transfusions } **HEMOSIDEROSIS**  
       → Africans [dit Iron utensil usage for cooking]
- **IRON OVERLOAD CAUSES** → **FREE RADICAL INJURY**
- **CIF**
  - ↳ cirrhosis [ ↑ mortality ]
  - ↳ **SKIN**                      **PANCREAS**
  - ↓                                      ↓
  - ↑ melanin            + DM            → **BRONZE DIABETES**
- **CARDIAC** → Arrhythmia , Restrictive cardiomyopathy  
                   → ↑ mortality
- **GONADS** → ♂ → Gonadal Dysfunction  
                   ↳ Testicular atrophy  
                   → dit Iron deposition in **PITUITARY**  
                   & ↓ its function [not dit  
                   Iron deposition in testes]
- **PSEUDO - GOUT**
- ↑ **HEPATO CELLULAR CANCER** [ not common ]
- **DIAGNOSIS** → **IRON OVERLOAD**
  - ↳ ↑ s. Iron
  - ↳ ↑ % Tf [ earliest ]
  - ↳ ↑ s. Ferritin
  - ↳ ↓ Iron binding capacity
- **LIVER BIOPSY**
  - Prussian Blue stain used
  - Bluish violet granules ⊕
- **Rx**
  - 1. **IRON CHELATOR**
  - 2. **PHLEBOTOMY**



Prussian Blue Stain



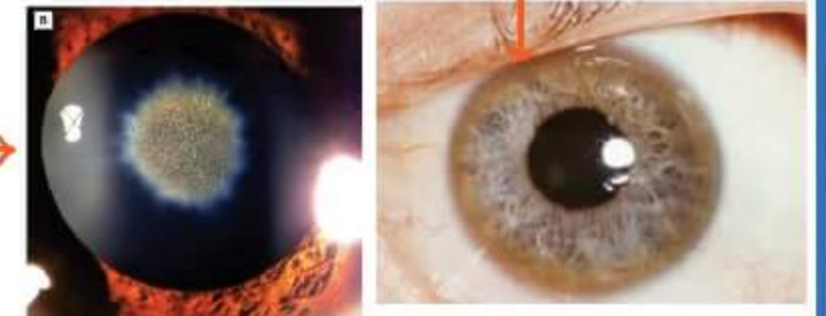


- Autosomal recessive disorder
- ATP 7B gene defect [located on chr. 13]

↓

Hepatic Damage → Cirrhosis / ↑ cancer  
 CNS damage → Basal ganglia damage → Parkinsonism  
 → Astrocyte damage [ALZHEIMER II CELLS]

EYES → cornea → decemet membrane → KF RING  
 → sunflower cataract



**DIAGNOSIS**

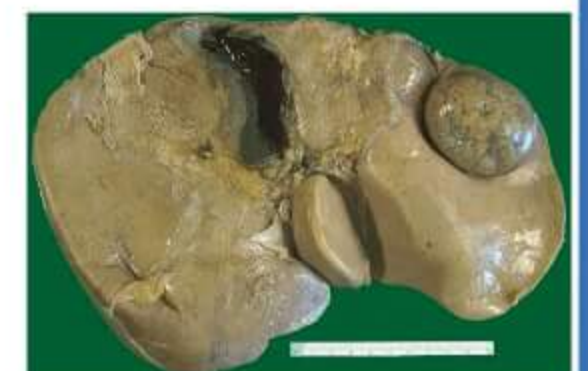1. ↑ urinary copper [most specific]
2. Copper level in 1gm of dried liver → > 250 µg Cu [confirmatory]
3. S. copper → ↓ / N / ↑ / latest pgnotes

Rx → DMT<sub>1</sub> → ZINC [competitive inhibitor]  
 [competes w/ Cu for DMT<sub>1</sub>]

**TUMORS**

**BENIGN TUMORS**

**CAVERNOUS HEMANGIOMA** → mc benign tumor of liver  
**HEPATIC ADENOMA**



Hepatic Adenoma

- young female w/ OCP intake
- sub capsular
- During pregnancy, may rupture → ↑ Hemorrhage
- β CATENIN MUTATION ⊕ → HCC [in 10%]

**MALIGNANT LIVER TUMORS**

**SECONDARY MALIGNANT TUMORS**

- Metastasis [mc malignant tumors of Liver]
- CAN BE FROM
  - ↳ Pancreas
  - ↳ colon [mc 1° causing 2° tumor in Liver]
  - ↳ Breast

→ HEPATOMEGALY w/ NODULAR EDGES



**PRIMARY MALIGNANT TUMORS**

1. **HEPATOBLASTOMA** → mc malignant liver tumor in children

**2. ANGIOSARCOMA****RISK FACTORS**

- Arsenic
- Thorotrast
- Poly vinyl chloride

**3. HEPATOCELLULAR CARCINOMA**

→ mc malignant liver tumor in adults

**RISK FACTORS**

1. Chronic hepatitis [ Hep B > C ]
2. Alcohol intake
3. Aflatoxins [ Peanut ingestion  $\bar{c}$  Aspergillus flavus ]
4. Hemochromatosis
5. Wilson's Disease
6. Hereditary tyrosinemia

**PATHOLOGY**

1.  $\beta$  CATENIN ACTIVATION
2.  $\downarrow$  p53 ACTIVITY
3.  $\uparrow$  IL-6 →  $\uparrow$  multiplication,  $\downarrow$  Differentiation

4. **DYSPLASTIC MODULE** [t.me/latestpgnotes](https://t.me/latestpgnotes)

- a. Low Grade → + cancer
- b. High Grade → +++ cancer

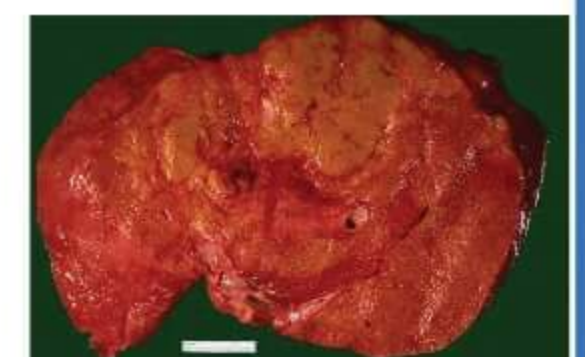5. **CHRONIC LIVER DISEASE  $\bar{c}$  CELLULAR CHANGE**

- |                                                                                                                                                 |                                                                                                                                       |
|-------------------------------------------------------------------------------------------------------------------------------------------------|---------------------------------------------------------------------------------------------------------------------------------------|
| <ol style="list-style-type: none"> <li>a. Small cell change</li> <li>→ N:C Ratio <math>\uparrow\uparrow</math></li> <li>→ +++ cancer</li> </ol> | <ol style="list-style-type: none"> <li>b. Large cell change</li> <li>→ N:C Ratio <math>\uparrow</math></li> <li>→ + cancer</li> </ol> |
|-------------------------------------------------------------------------------------------------------------------------------------------------|---------------------------------------------------------------------------------------------------------------------------------------|

→ HBV → HBX PROTEIN → ONCOGENIC

**C/F**

- |           |                               |
|-----------|-------------------------------|
| → M > F   | → Abdominal pain [mc symptom] |
| → Elderly | → weight loss                 |
| → malaise | → hepatomegaly [mc sign]      |



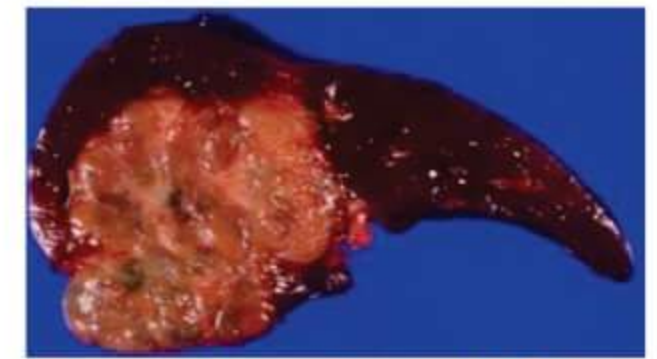
Hepatomegaly

**DIAGNOSIS**

1.  $\alpha$  - FETO PROTEIN  $\uparrow\uparrow\uparrow$
2. ARGINASE - 3 [ most sensitive & specific ]
3. HEP - PAR - 1
4. GLYPICAN - 3

## FIBROLAMELLAR VARIANT OF HCC

- Young adults
- m = f [ India → F >> m ]
- not a/w Hepatitis B or cirrhosis
- Left lobe predilection
- slow growth ⊕
- Good prognosis
- Normal AFP levels
- NEUROTENSIN is the marker
- M/E → ONCOCYTES ⊕  $\bar{c}$  collagen



Fibrolamellar HCC

## METASTASIS OF HCC



- SATELLITE NODULES ⊕  $\bar{c}$  central umbilication [depression]
- also spreads to LUNGS
- PERI HILAR LN
- PERI PANCREATIC LN
- PERI AORTIC LN

## TREATMENT

1. SORAFENIB
2. TRANSPLANTATION

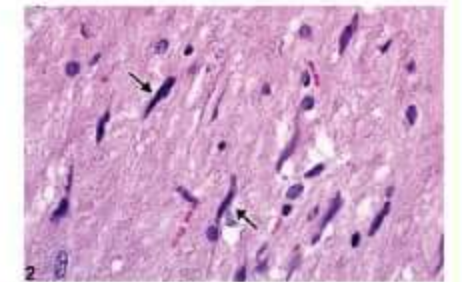
[t.me/latestpgnotes](https://t.me/latestpgnotes)

## CENTRAL NERVOUS SYSTEM GENERAL INTRODUCTION

270

### CELLS → NEURONS + GLIAL CELLS

1. OLIGODENDROCYTES → form & myelin in CNS
2. ASTROCYTES → forms blood brain barrier  
→ post injury cells responsible for gliotic React<sup>n</sup>
3. EPENDYMAL CELLS → ventricular lining
4. MENINGOTHELIAL CELLS → cover brain [protective]
5. MICROGLIA → Phagocytosis  
→ aka GITTER CELLS  
→ aka ROD CELLS [Neuro syphilis]



ROD CELLS

### MENINGITIS

#### CSF FINDINGS

|           | GROSS               | CELLS / ML  | PROTEIN [mg/dL] | GLUCOSE [mg/dL] | Cl <sup>-</sup> [mEq/L] |
|-----------|---------------------|-------------|-----------------|-----------------|-------------------------|
| NORMAL    | Clear               | 0-5         | 15-40           | 40-70           | 115-120                 |
| BACTERIAL | Turbid              | ↑↑↑ [Neut]  | ↑↑↑             | ↓↓↓             | ↓                       |
| TB        | COB WEB<br>COAGULUM | ↑↑<br>[N+M] | ↑↑              | ↓               | ↓↓↓                     |
| VIRAL     | clear               | ↑ [L]       | ↑↑              | Normal          | ↓                       |
| FUNGAL    | clear               | ↑ [m]       | ↑↑              | ↓               | ↓                       |

TB → CSF PLEOCYTOSIS

VIRAL → Glucose levels are normal  
Except for mumps & Herpes virus [↓]



COB WEB  
COAGULUM

#### BACTERIAL CAUSES OF MENINGITIS

- Streptococcus pneumoniae → E. coli
- Streptococcus agalactiae → Neisseria meningitidis

#### VIRAL MENINGITIS

- commonly caused by Enterovirus
- Spreads by feco oral route

### NEURODEGENERATIVE DISORDERS

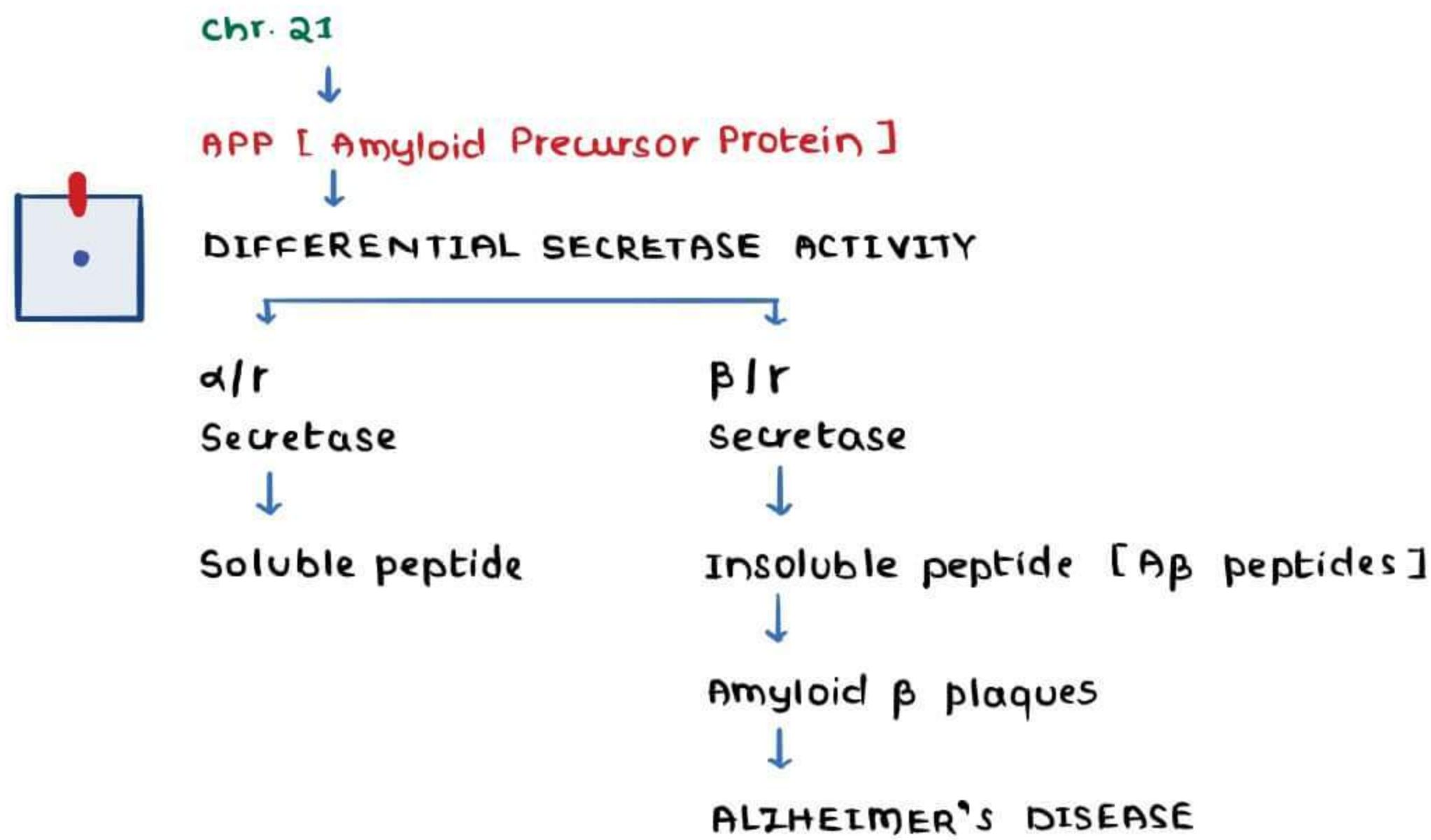
- Neuronal loss + Intra cellular Protein aggregates

### ALZHEIMER'S DISEASE

- mc cause of memory loss

- SPORADIC → a/w ↑ Age, ↑ Apo E<sub>4</sub> [Apo E<sub>2</sub> ↓ → Protective]
- FAMILIAL → a/w Down Syndrome [Trisomy 21]  
Presenilin 1 gene on chr 14  
Presenilin 2 gene on chr 1

1.



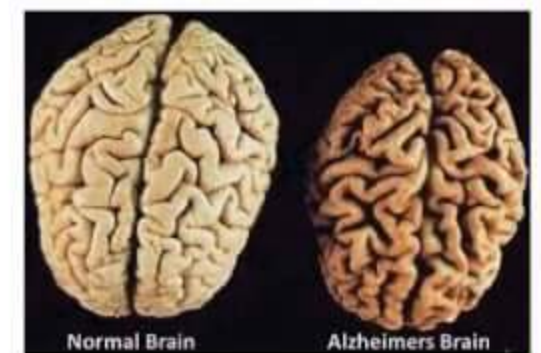
2. **TAU PROTEIN** → attaches to microtubules & stabilizes them

Tau Phosphorylat<sup>n</sup> → do not attaches to MT → TANGLES

**FINDINGS**

1. **DIFFUSE CEREBRAL ATROPHY**

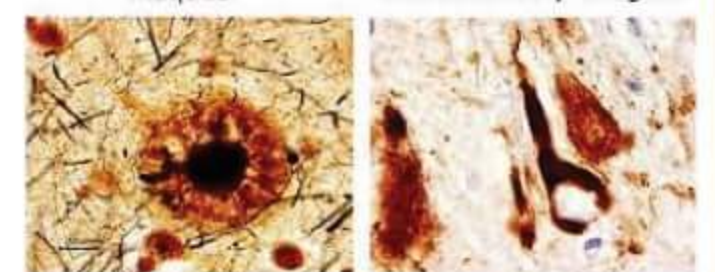
- Affects frontal lobe, parietal lobe, Temporal lobe
- Occipital lobe is spared



[t.me/latestpgnotes](https://t.me/latestpgnotes)

2. **NEUROFIBRILLARY TANGLES**

- hyperphosphorylated Tau protein
- Number correlates with severity of dementia
- best visualized by silver stain



3. **NEURITIC PLAQUES [Aβ peptides]**

- central core of amyloid ⊕ → stained by CONGO RED
- DIFFUSE PLAQUE → only amyloid ⊖ out neuritic process around it

4. **CEREBRAL AMYLOID ANGIOPATHY**

- Aβ plaques around blood vessels → fragile BV → ↑ Hemorrhage

**CIF**

- Short term MEMORY LOSS
  - LOSS OF SMELL
  - Language & Behavioral defect
- } Early stage
- Advance stage

**DEATH** → dlt Pneumonia

**R<sub>4</sub>** → AChE inhibitors  
MEMANTINE

## FRONTO TEMPORAL LOBE DEGENERATION

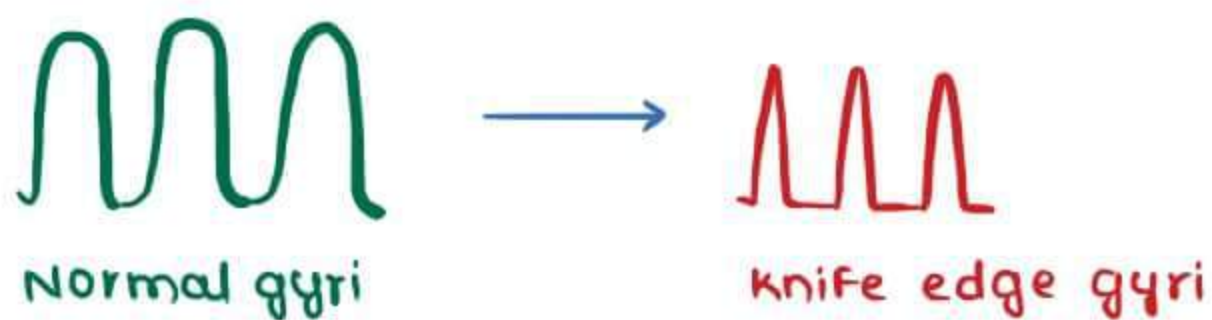
- Frontal involvement      → Behavioral defects
  - Temporal involvement    → Language defects
- } Early features
- LATE DEMENTIA

### SUB TYPES

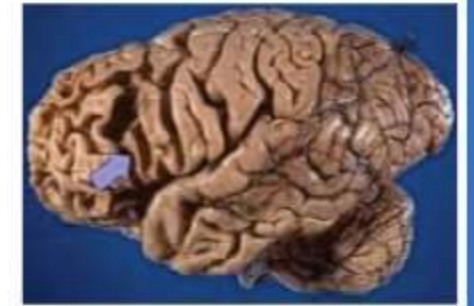1. FTLD - Tau / PICK'S DISEASE
2. FTLD - TDP

#### 1. FTLD - Tau / PICK'S DISEASE

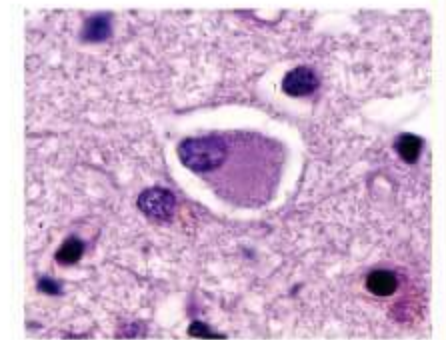
- Atrophy      → Frontal & Temporal lobe
- Parietal / Occipital lobes are spared
- KNIFE - EDGE GYRI / WAFER - THIN GYRI



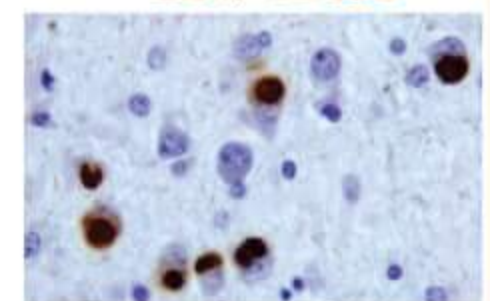
- PICK CELLS      → swollen up neurons
- PICK BODY      → Intracellular 3 R Tau protein



Knife Edge gyri



PICK CELLS



PICK BODY

## PARKINSONISM

[t.me/latestpnotes](https://t.me/latestpnotes)

- Loss of Dopaminergic neurons in Substantia nigra

### FACTORS

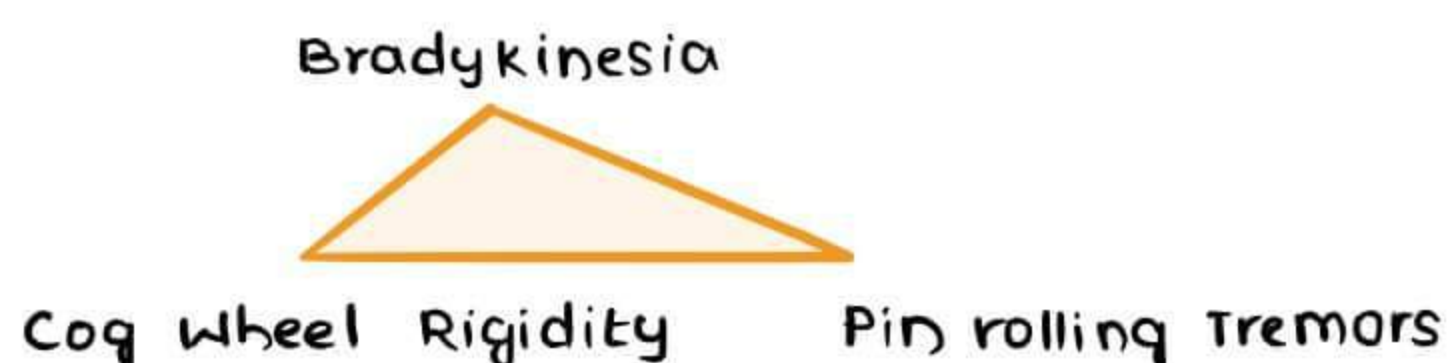
#### Risk factors

- Age                      → Idiopathic      → PARKINSON'S DISEASE
- MPTP                    → contaminant OF MEPERIDINE
- Wilson disease
- CO poisoning
- Drugs                    → Anti psychotic Drugs

Protective factors      → Caffeine & Nicotine

PATHOLOGY              → NIGRO - STRIATAL PATHWAY AFFECTED

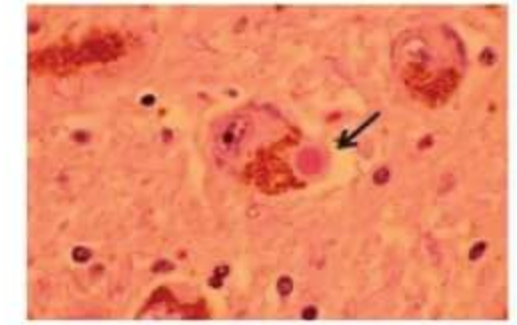
#### CLINICAL FEATURES



- mask like faces
- Stooping posture
- ↑ Seborrheic dermatitis
- Dementia [Late feature]

**FINDINGS**

- Pallor of substantia nigra
- LEWY BODY
  - ↳ made up of  $\alpha$  - SYNUCLEIN
  - ↳ Located in substantia nigra



LEWY BODY

**HUNTINGTON'S DISEASE****GENETICS**

- Autosomal dominant
- **CAG** Repeats

↑↑↑ [Spermatogenesis]



ANTICIPATION [early onset in next generat<sup>n</sup>]

- Chr. 4
- 4<sup>th</sup> - 5<sup>th</sup> decade
- CAUDATE NUCLEUS ATROPHY

**CIF**

- chorea - Athetosis [involuntary purposeless movements  $\bar{c}$  writhing property]
- **O**cculomotor abnormality
- **D**epression [t.me/latestpgnotes](https://t.me/latestpgnotes)

**DEATH** → Recurrent Infections

- 2° → MESTASTASIS [mc]
- small cell Lung cancer [mc]
  - Breast cancer
  - malignant melanoma
  - Renal cancer

1° TUMORS

RISK FACTORS

I. Smoking | Radiation

II FAMILIAL SYNDROMES

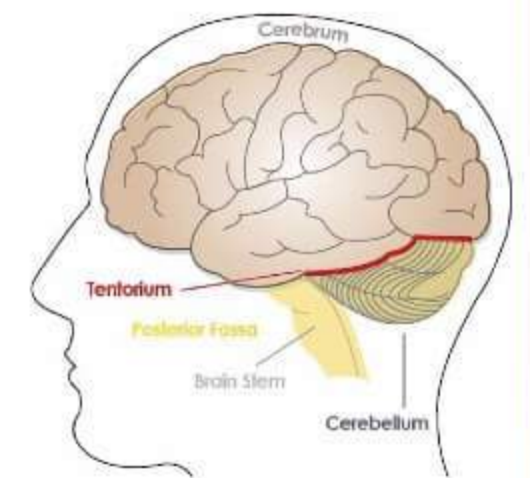
1. TURCOT SYNDROME → APC mutation [↑ colorectal carcinoma]
2. LI-FRAUMENI SYNDROME → P53 mutation
3. GORLIN SYNDROME → PTCH mutation
4. COWDEN SYNDROME → PTEN mutation

CLINICAL FEATURES

- Headache
- vomiting
- seizures
- ↑ ICT

GENERAL PRINCIPLES

- mostly SUPRATENTORIAL in location in ADULTS
- mostly INFRA TENTORIAL in location in CHILDREN



→ WHO CLASSIFICATION

- ↳ Based on → Histology + molecular parameters
  - ↳ Atypical cells
  - ↳ mitotic activity
  - ↳ necrosis
  - ↳ microvascular invasion

↳ GRADE I [slow growth] → GRADE IV [Aggressive]

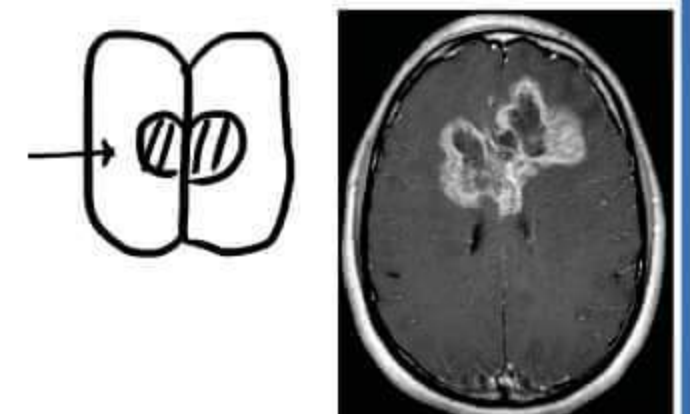
ADULT CNS TUMORS → supra tentorial [cerebral Hemispheres] involvement

INFILTRATING ASTROCYTOMA

- LOW GRADE → p53 mutation | PDGF-α overactivity
- HIGH GRADE → Rb mutation | CDK2NA overactivity

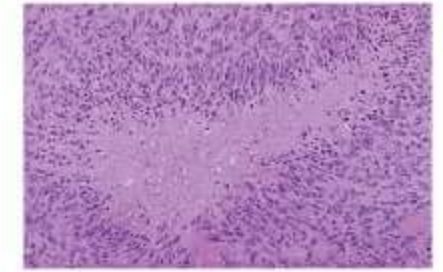
GLIOBLASTOMA

- high grade tumor → WHO GRADE IV
- mc 1° malignant tumor in adults
- BUTTERFLY GLIOMA or BLOOD BUTTERFLY TUMOR
- 1° → denovo
  - wild IDH1 mutation
  - mc [90%], Elderly age



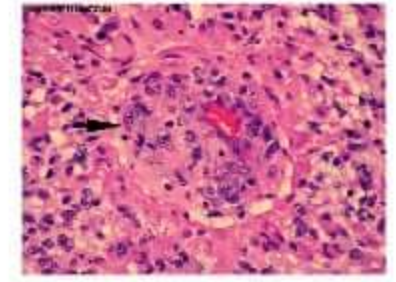


- 2° → Low grade astrocytoma dedifferentiation
- IDH<sub>1</sub> mutation
- 10% , young age



**MIE**

- PSEUDOPALISADING → NECROSIS surrounded by tumor cells
- GLOMERULOID BODY → Endothelial cell proliferation ⊕⊕⊕



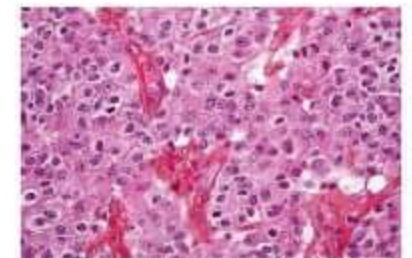
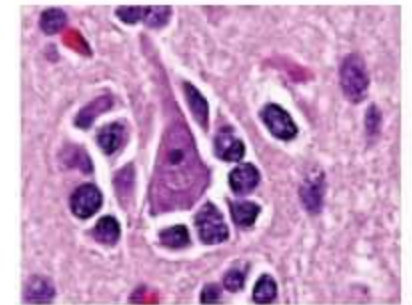
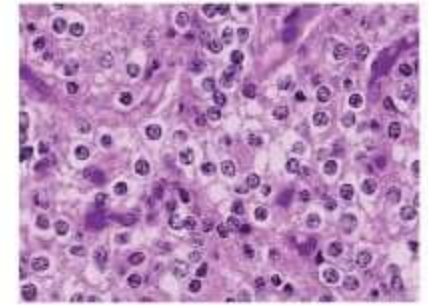
TREATMENT → TEMOZOLOMIDE

**OLIGODENDROGLIOMA**

- arises from FRONTAL LOBE
- 4th - 5th decade
- CALCIFICATION +

**MIE**

- FRIED EGG APPEARANCE
- PERINEURONAL SATELLITOSIS
- CHICKEN WIRE CAPILLARIES [thin capillaries ⊕⊕⊕ ]



**GENETICS**

- IDH<sub>1</sub> | IDH<sub>2</sub> mutation [mc]
- 1p deletion } CO-deletion → ↑↑ Response Rate to Rx
- 19q deletion } → Better prognosis

[t.me/latestpnotes](https://t.me/latestpnotes)

**MENINGIOMA**

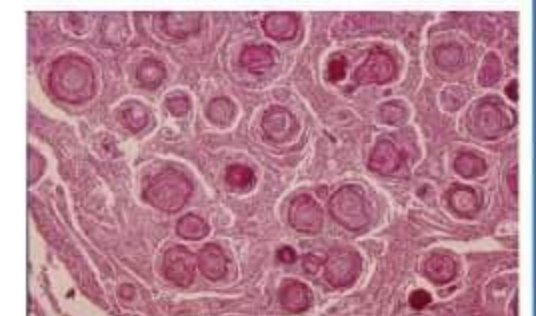
- arises from ARACHNOID MENINGOTHELIAL CELLS
- m/c 1° brain tumor of adults
- Benign
- F >> M
- Progesterone ⊕ on tumor cells ⊕ → ↑ in size during pregnancy

**RISK FACTORS**

- Radiation
- Gene mutation
  1. NF2 gene [mc]
  2. TRAF-7 gene

→ U/L → BIL } Neurofibromatosis 2 [NF2 gene mutation]

Acoustic neuroma



MIE → PSAMMOMA BODY ⊕

**VARIANTS**

**I. LOW GRADE**

1. Fibroblastic
2. Syncytial
3. Secretory
4. Transitional

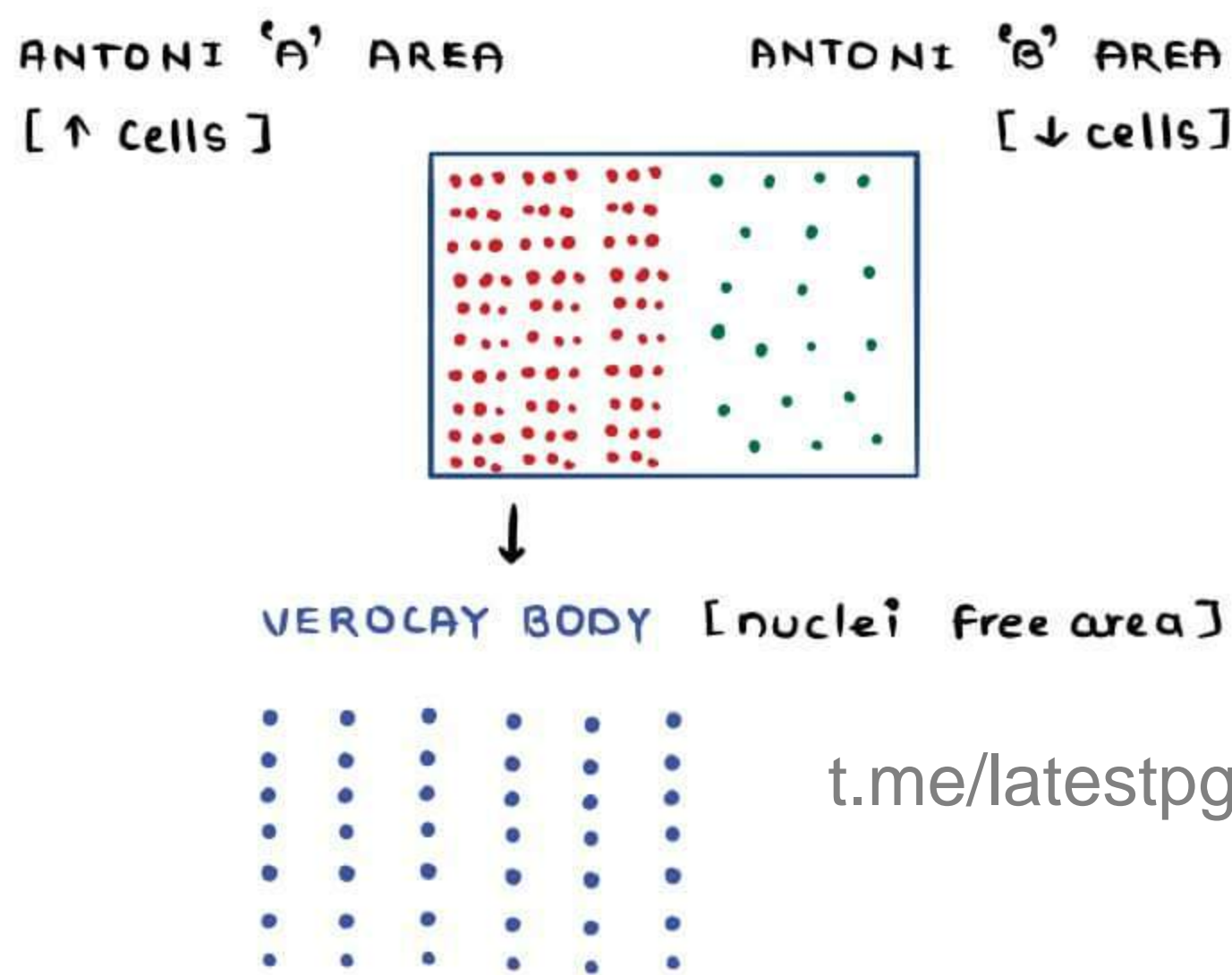
**II. HIGH GRADE**

1. Atypical
2. Anaplastic [most aggressive]

**SCHWANNOMA**

- Benign
- arises from Schwann cells of
  - ↳ Peripheral Nerves
  - ↳ Cranial nerves
    - ↳ V, VI
    - ↳ VIII, IX [vestibular part] → ACOUSTIC NEUROMA
      - Tinnitus
      - SNHL
      - sensory findings
      - SITE - cerebello - pontine angle
      - U/L [B/L Acoustic neuroma also NF2]

→ MIE



→ 5 100 ⊕

**PEDIATRIC CNS TUMORS****1. PILOCYTIC ASTROCYTOMA**

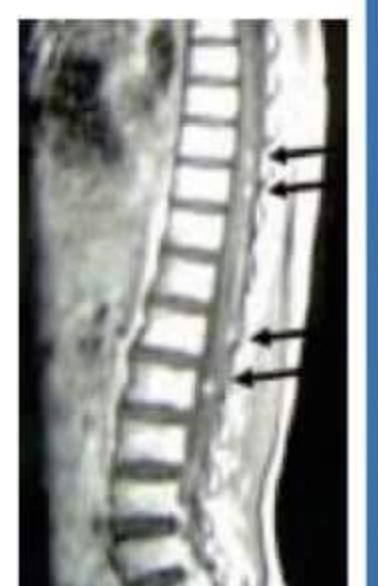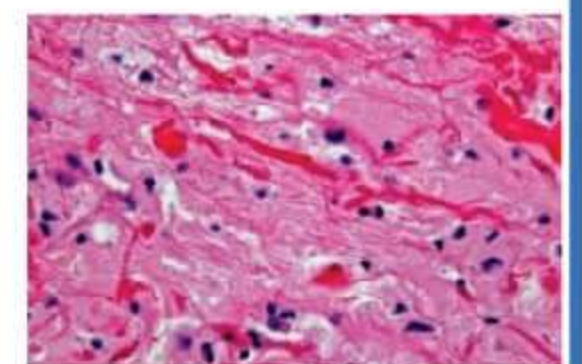
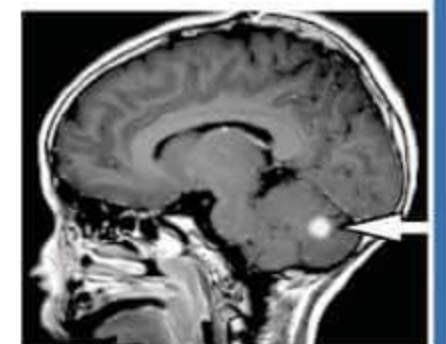
- children [mc 1° benign brain tumor of children]
- "C" ↔ cerebellar location  
cystic mass  
p53 mutation is rare

MIE → ROSENTHAL FIBERS  
[intra cytoplasmic red - pink fibers]

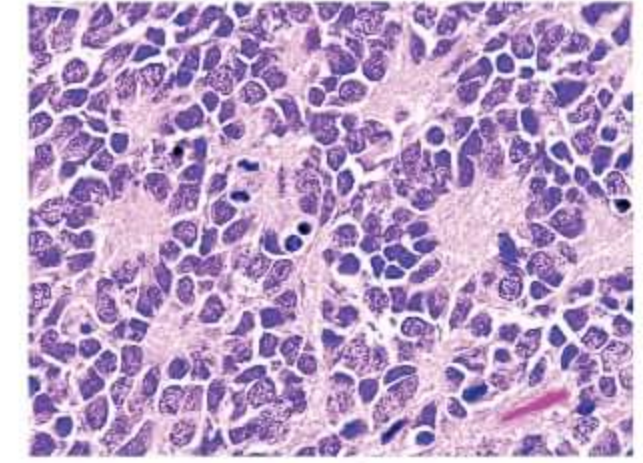
→ good prognosis

**2. MEDULLOBLASTOMA**

- malignant
- mc 1° malignant brain tumor in children
- arises in cerebellum
- arises from neuro ectodermal cells [poor differentiat<sup>n</sup>]
- metastasis occurs through CSF → DROP METASTASIS



- MIF
  - ↳ Atypical cells ⊕
  - ↳ ↑ mitosis ⊕ → Ki-67 ⊕
  - ↳ HOMER WRIGHT ROSETTES [ fibrillary structure surrounded by tumor cells



Homer wright rosettes

### → WHO CLASSIFICATION

#### 1. WNT TYPE

- have monosomy 6 & β catenin overactivity
- alw Best prognosis

#### 2. SHH TYPE

#### 3. GROUP 3 MEDULLOBLASTOMA

→ alw Worst Prognosis

- alw MYC gene mutation | Isochromosome 17q presence → WORST PROGNOSIS

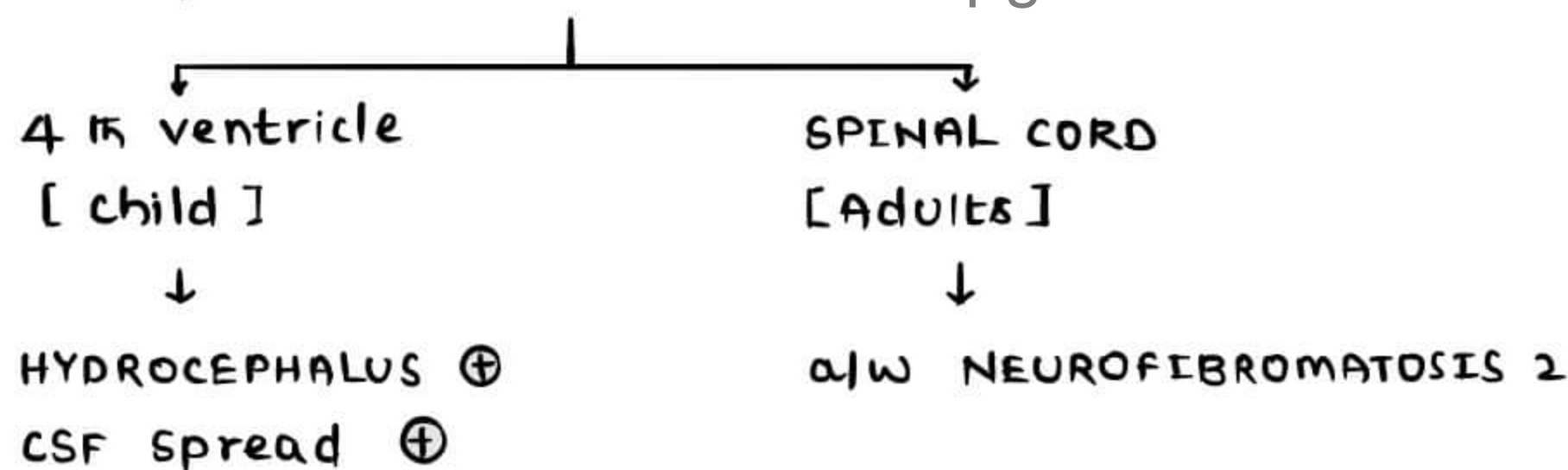
#### 4. GROUP 4 MEDULLOBLASTOMA

### → TREATMENT

- ↳ Radiosensitive tumor
- ↳ Surgery + Radiotherapy

### 3. EPENDYMOMA

- malignant tumor
- arises from EPENDYMAL CELLS / late stem cells



### → M/E

- Perivascular pseudorosettes ⊕ [tumor cells surrounding a blood vessel]
- GFAP [glial fibrillary acidic protein] ⊕

- alw POOR PROGNOSIS

### 4. 1° CNS LYMPHOMA

- alw Immunosuppression
  - ↳ AIDS
  - ↳ Post-transplant patient

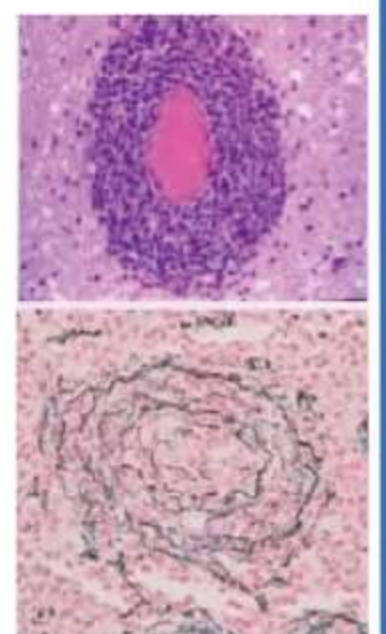
### → B-cell tumor [DLBCL]

### → alw EBV infection

### → multifocal tumor

### → M/E → "HOOPING"

- characteristic finding [distinguishes it from 2° CNS lymphoma]
- blood vessel surrounded by tumor cells, tumor cells are separated by silver staining material



HOOPING

**TESTIS**

**CRYPTORCHIDISM**

- MC genito urinary disorder in male child
- Failure of testicular descent
- LEYDIG CELLS are SPARED

**COMPLICATIONS** [dit ↑ temp]

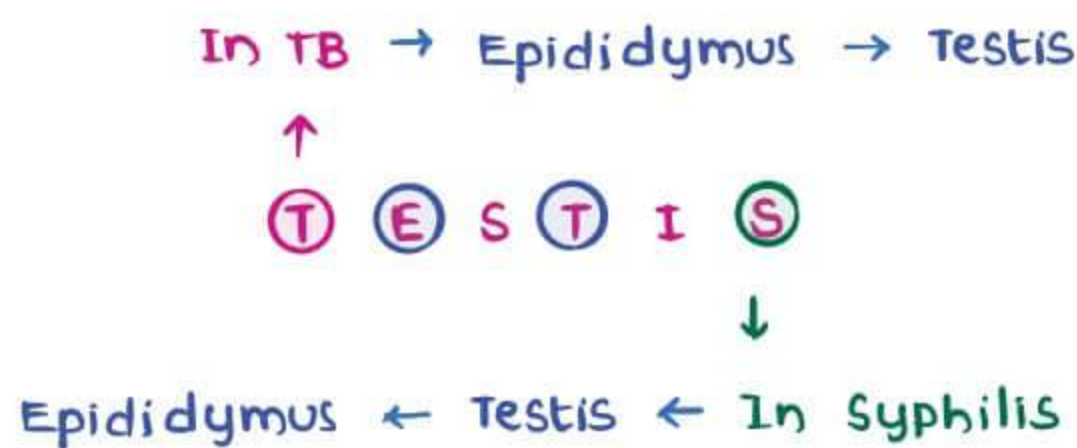
- Atrophy → ↓ fertility
- Tumor → ↑ Seminoma
- Torsion

**TREATMENT**

- orchidoplexy
  - age recommended → 6 m - 2 years
  - risk of development of tumor → not decreased

**ORCHITIS**

- Inflammation of testis & Epididymus
- **CAUSES**
  - E. coli
  - Chlamydia
  - mumps → involves testis, parotid gland & pancreas
  - TB → granulomatous orchitis
  - Syphilis



|                    | ORCHITIS | TORSION              |
|--------------------|----------|----------------------|
| Scrotum elevation  | ↓↓ Pain  | ↑↑ Pain [PREHN SIGN] |
| cremasteric reflex | +        | -                    |

**TESTICULAR TUMORS**

- Adult age group
- CIF → Painless enlargement of testes
- SPREAD → Lymphatic → Para aortic LN
  - Hematogenous → Lungs [mc] / CNS / Liver / Bones
- BIOPSY IS CONTRA INDICATED [dit disseminat<sup>n</sup>]

**RISK FACTORS**

- Gonadal dysgenesis & Genetic defects **G**
- Opposite Testis **O**
- Temp. [Cryptorchidism] **T**
- Intra Tubular germ cell Neoplasia [ITGCN] **I**

**GONADAL DYSGENESIS****CAUSES**

- Klinefelter syndrome
- Testicular feminization
- isochromosome 12 p
- overexpression of NANOG & OCT 3/4
- cryptorchidism [Abdominal >> Inguinal]

Pre cancerous condition

not a/w Teratoma & Spermatoctytic seminoma

**CLASSIFICATION** [Based on cell of origin]**GERM CELL TUMOR**

- common site → gonads
- mc extragonadal site → mediastinum

**SEMINOMATOUS GERM CELL TUMORS**

- slow growth
- sparing of Tunica albuginea
- Radio sensitive
- Lymphatic spread
- Good prognosis

**NON SEMINOMA GERM CELL TUMORS**

→ Examples

Chorio carcinom  
Embryonal carcinoma  
Teratoma  
yolk sac tumors

- Poor Prognosis
- Hemorrhage & necrosis ⊕
- Hematogenous spread

**NON GERM CELL TUMORS****STROMAL TUMORS**

- Leydig cell tumor
- sertoli cell tumor

**LYMPHOMA****SEMINOMA****VARIANTS**

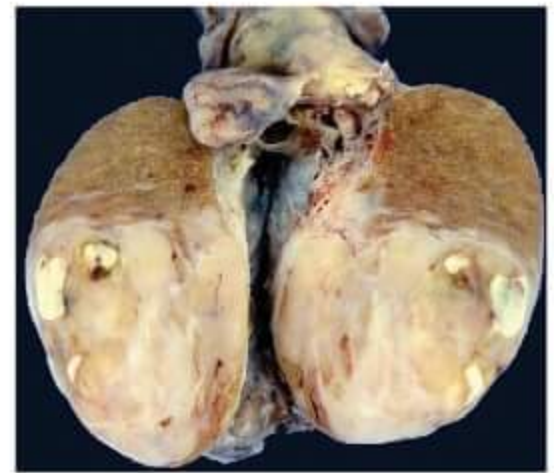1. CLASSICAL
2. ANAPLASTIC
3. SPERMATOCYTIC

**CLASSICAL SEMINOMA**

- mc testicular tumor in adults
- malignant tumor
- OVER EXPRESSION OF GENES → OCT 3/4 / NANOG / C - KIT

**GROSS FEATURES**

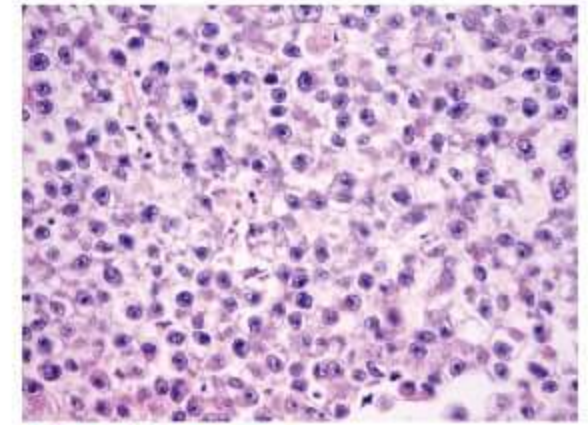
- Grey tumor
- no hemorrhage or necrosis



Seminoma - Gross

**MICROSCOPIC FEATURES**

- Sheets of cells [ clear cytoplasm [dit glycogen] ]  
[ prominent nucleoli ]
- Lymphocytic infiltration in stroma



Seminoma

**ANAPLASTIC SEMINOMA**

- Anaplasia ⊕
- mitosis ⊕

**SPERMATOCYTIC SEMINOMA**

- Elderly
- Excellent prognosis
- no LN metastasis
- MIE → Similar to 2° Spermatoocytes  
no Lymphocytic infiltration

**NSGCT****EMBRYONAL CANCER**

[t.me/latestpnotes](https://t.me/latestpnotes)

- 20-30yrs age
- Primitive cells ⊕
- ↑ β HCG
- ↑ AFP
- Hemorrhage & necrosis ⊕

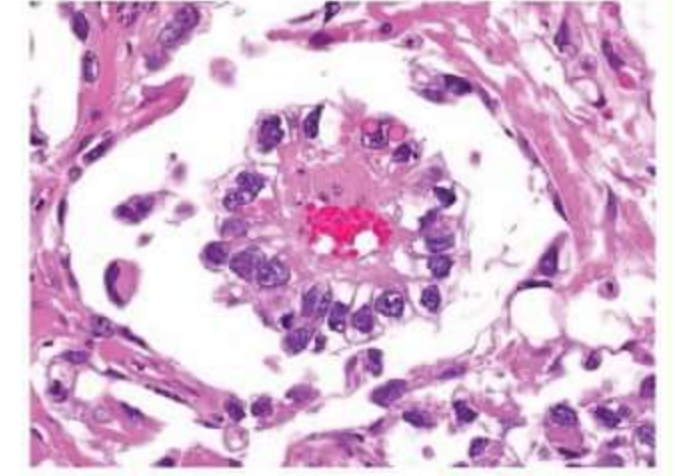

**TERATOMA**

- arises from > 1 germ cell layer
- Origin from Totipotent Cells
- Pediatric → Pure [rare]  
→ mixed → alw Embryonal cancer
- Adult → malignant [ unless proved otherwise ]
- M/E → Ectoderm derivatives [mc] → ↑ Squamous cell cancer  
→ mesoderm derivatives  
→ Endoderm derivatives
- MARKERS → ↑ AFP , ↑ β HCG

**YOLKSAC TUMOR / ENDODERMAL SINUS TUMOR**

- mc testicular tumor in a < 4yr child
- ↑ AFP
- ↑ α<sub>1</sub> - Anti trypsin

→ MIE → SCHILLER - DUVAL BODY ⊕ / GLOMERULOID BODY ⊕



GLOMERULOID BODY

### CHORIO CARCINOMA

→ derived from TROPHOBLAST

↳ CytoTrophoblast

↳ Syncytio Trophoblast → ↑↑↑ β - HCG

↳ Hyperthyroidism  
↳ Gynecomastia

→ Small palpable mass ⊕

→ Early spread ⊕ ⊕ ⊕

→ Poor prognosis

### NON - GERM CELL TUMORS

#### STROMAL TUMORS

#### LEYDIG CELL TUMOR

→ Hormone secretion ⊕

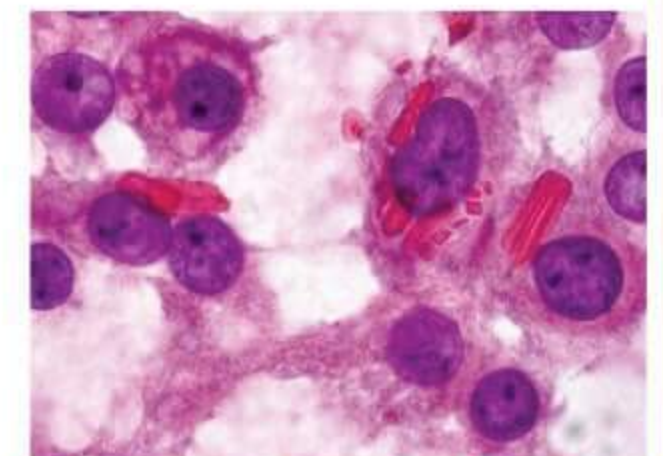
↳ Androgen → Precocious Puberty

↳ Estrogen → Gynecomastia

→ MIE → Lipid droplets ⊕

→ REINKE CRYSTALS ⊕

↳ rod shaped eosinophilic inclusions



REINKE CRYSTALS

#### SERTOLI CELL TUMOR

→ SILENT TUMOR

→ a/w ↑ Estrogen → Gynecomastia

#### LYMPHOMA

→ MC testicular tumor seen in Elderly

→ BIL

→ MIE → DIFFUSE LARGE B CELL LYMPHOMA

→ malignant tumor

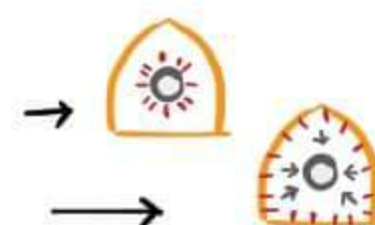→ poor prognosis

### PROSTATE

#### PROSTATE GLAND

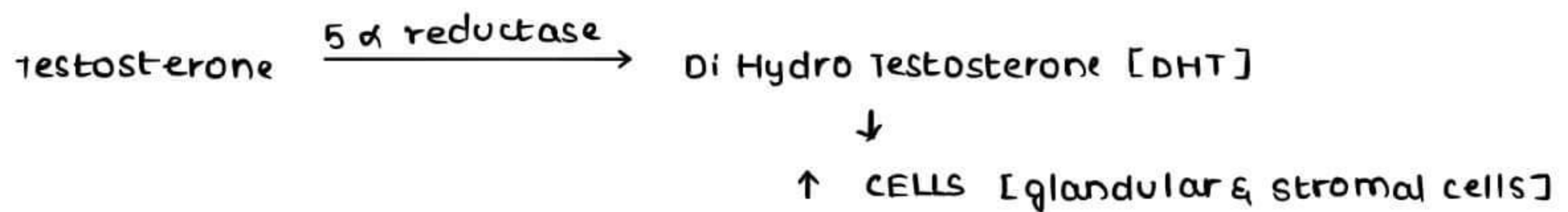
→ Peri Urethral zone → BHP → Early presentat<sup>n</sup>

→ Peripheral zone → CANCER → Late presentat<sup>n</sup>



**BENIGN HYPERPLASIA OF PROSTATE**

- mc cause of enlarged prostate in > 50 yrs
- **HORMONE DEPENDENT**
  - Androgen



- Estrogen → ↑ no. & sensitivity of DHT Receptors
- GROSS → Nodularity ⊕
- MIE → Hyperplasia of stromal cells & glands
- GLANDS → Basal layer i cuboidal cells
- columnar cells

- CLINICAL FEATURES** → **URETHRAL COMPRESSION**
- urine Retention
  - ↑ frequency
  - Difficulty in starting & stopping the Stream

- MC complication** → **OBSTRUCTIVE UROPATHY**
- medial lobe hypertrophy
  - Bladder diverticula
  - hydronephrosis
  - hydroureter

- RISK OF CANCER** → NO association

- R<sub>x</sub>**
- 1. FENASTERIDE / DUTASTERIDE [ 5- $\alpha$  Reductase inhibitors]
  - 2. TAMSULOSIN [ selective  $\alpha_1$  blockers ]
  - 3. TURP [ Transurethral Resection of Prostate ] [ definitive R<sub>x</sub> ]

**PROSTATE CANCER****RISK FACTORS**

- Age → Advancing age [ most important ]
- Diet → ↑↑ Lipids
- ↓↓ vitamin A, vitamin c, soya foods ]
- Androgens
- Genes
  - BRCA - 2 gene mutation
  - 1<sup>o</sup> relatives
  - Hypermethylation of GLUTATHION - S - TRANSFERASE
  - ↓↓ E - CADHERIN
  - TMPRSS2 - ERG FUSION

**CLINICAL FEATURES**

- Asymptomatic
- Pain → Back / pelvis



**METASTASIS**

- LN
- HEMATOGENOUS
- Obturator LN
- Bones
  - Lumbar Spine [mc]
  - Pelvis
  - Proximal femur
- Lungs & Liver

→ OSTEOLASTIC METASTASIS

**CORE BIOPSY**

- MIE → Adenocarcinoma
  - single layer of cells ⊕
  - no basal cells
- GRADING
- GLEASON SCORING

**SERUM PSA PARAMETERS [sensitive but not specific]**

1. S. PSA Levels →  $> 10 \text{ ng/ml}$  [⊕] →  $< 4 \text{ ng/ml}$
  2. PSA DENSITY →  $\frac{\text{S. PSA}}{\text{volume}}$
  3. PSA VELOCITY →  $> 0.75 \text{ ng/ml}$
- [t.me/latestpnotes](https://t.me/latestpnotes)

**SUB TYPE**

- Free form → BHP
- Bound form → cancer

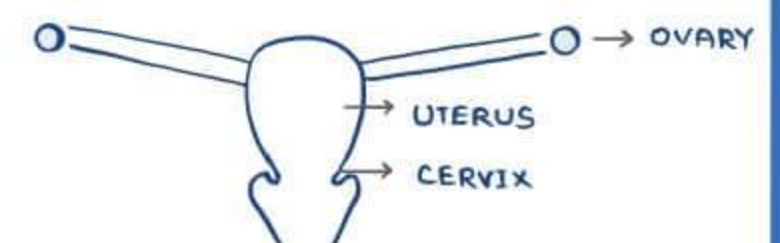
**NEW BIOMARKERS**

1. Urinary PCA-3 ↑
2. TMPRSS2 - ERG FUSION DNA ⊕

**FEMALE GENITAL TRACT : CERVIX****FEMALE GENITAL TRACT****CERVIX**

- Endocervix → columnar cells
  - Exocervix
  - [cervical os]
- } Squamous cells

→ Transform<sup>n</sup> zone → Squamous dysplasia [Pap smear taken from here]

**CERVICAL INTRA EPITHELIAL NEOPLASIA [CIN]****Dysplastic changes**

- ↑↑ N:C Ratio
- ↑ mitosis

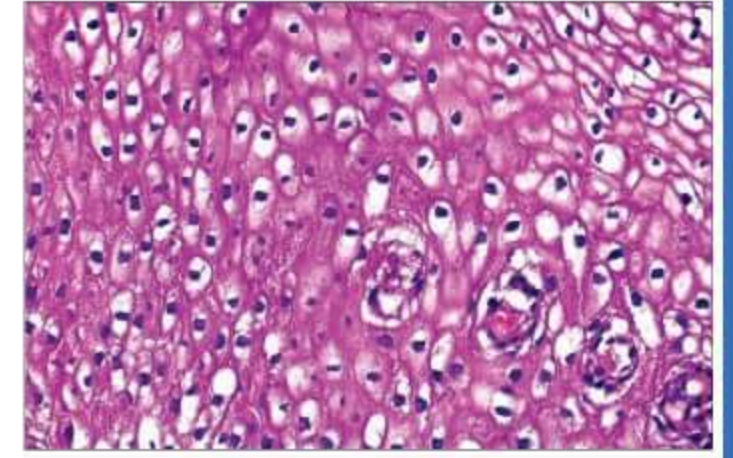
**RISK FACTOR**

**HPV INFECTION**

- most important
- Low risk sub types → 6, 11 → condyloma acuminata
- High risk sub types → 16, 18, 31, 33 → cancer

**HISTOLOGY** → **KOILOCYTOSIS**

- Shrunken / pyknotic nucleus
- perinuclear halo



koilocytosis

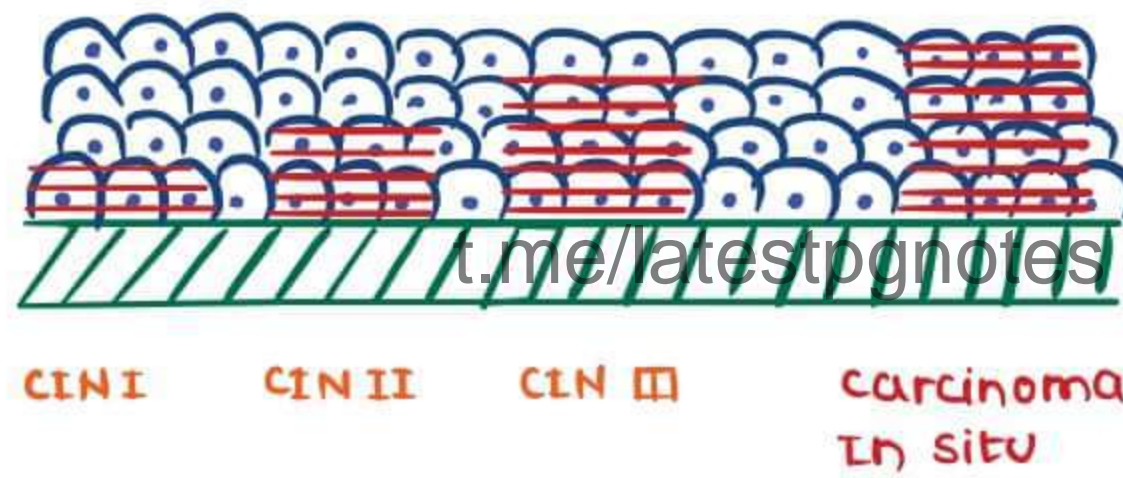
→ Ki-67 / p16 ⊕

→ E6 protein → ↓ p53 / ↑ Telomerase  
 E7 protein → ↓ Rb } ↑ cancer

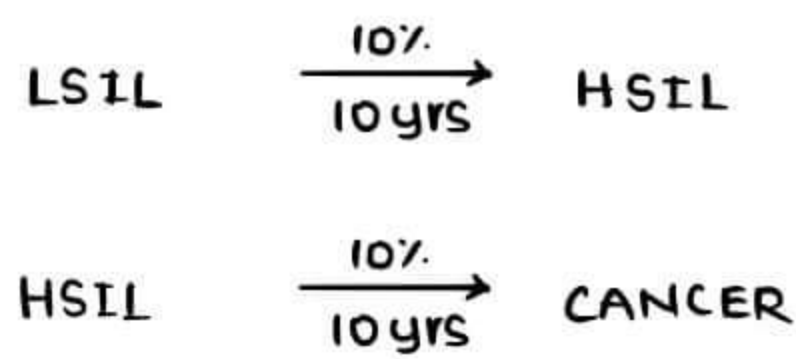
↑ HPV Infection

- Early age of Intercourse
- multiple partners
- High risk partner
- multiparity

**CIN**



- LOW GRADE SIL [Squamous Intraepithelial lesion] → mild dysplasia
- HIGH GRADE SIL → moderate / severe dysplasia



- COLPOSCOPY [VIA] → Acetic Acid → mosaic pattern ⊕ } dysplasia
- Abnormal vascularity ⊕

**CERVICAL CANCER**

**RISK FACTORS**

1. HPV Infection [most important]
2. Smoking [Polycyclic aromatic hydrocarbons]
3. Immuno deficiency
4. OCPs

→ 2nd mc cancer of Females

- CIF → Post-coital Bleeding [mc]
- Foul smelling discharge

**EXTENSION** → 1. vagina → Ureteric obstruct<sup>n</sup> → Post renal azotemia → Renal failure → Death  
 → 2. Bladder  
 → 3. Lungs

**MIE** → Squamous cell cancer [mc]  
 → Adenocarcinoma  
 → mixed carcinoma




Ayre spatula

**SCREENING** [For squamous dysplasia]

1. **VIA** [visual inspection after Acetic Acid] & colposcopy [Best]

2. **PAP SMEAR**

→  → Transforma<sup>n</sup> zone

→ ♀ → H10 HPV vaccination → screening still advised

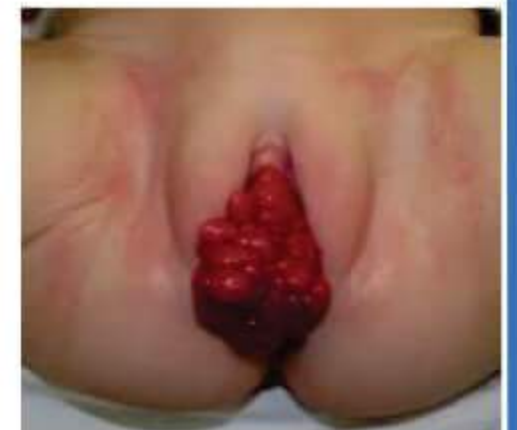→ screening do not pick up Adenocarcinoma

### VAGINA

**EMBRYONAL RHABDOMYOSARCOMA / SARCOMA BOTRYOIDES**

→ children (<5 yrs) ♂ H10 grape like mass from vagina

→ **MIE** → TENNIS - RACKET CELLS ⊕  
 → Myoglobin ⊕ [t.me/latestpgnotes](https://t.me/latestpgnotes)  
 Desmin ⊕



Sarcoma botryoides

**CLEAR CELL ADENOCARCINOMA**

→ Precursor lesion → VAGINAL ADENOSIS

♀ → Intra uterine exposure of  
 DES [diethylstilbestrol]

↓  
 Incompetent cervix      Mullarian duct differentiat<sup>n</sup> ⊖      Abnormal uterine shape

**SQUAMOUS CELL CANCER**

→ alw HPV 16 infection  
 → extension of carcinoma cervix

### UTERUS

**COMPONENTS**

1. **MYOMETRIUM**

2. **ENDOMETRIUM**

↳ Estrogen → ↑ growth  
 ↳ Progesteron → Implantation

**ENDOMETRIOSIS**

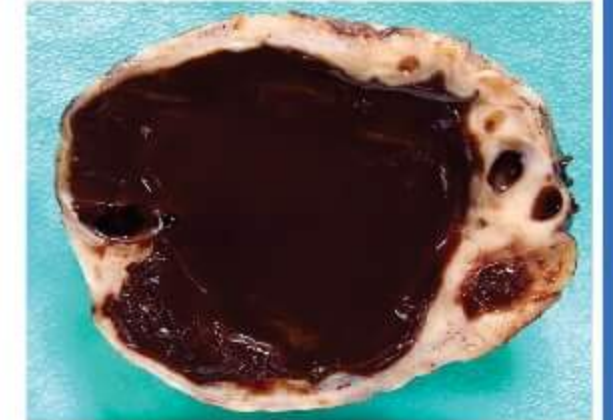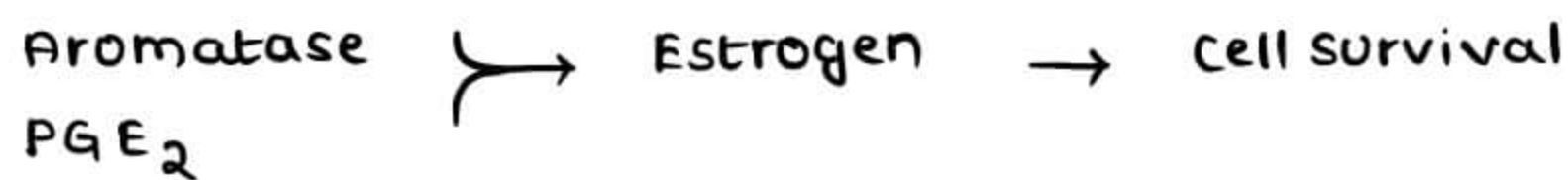
→ ECTOPIC ENDOMETRIAL TISSUE

→ **SITES**

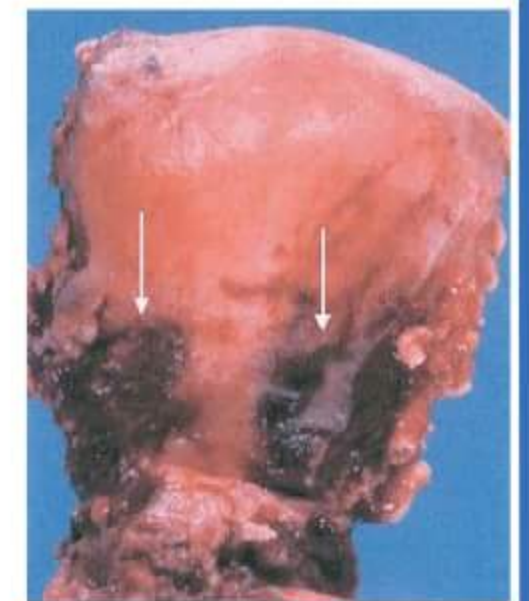- ↳ Ovary [mc] → CHOCOLATE CYST → ↓ fertility
- ↳ uterine ligament → Pelvic pain & dysmenorrhea
- ↳ Recto-uterine pouch → pain on defecation
- ↳ Bladder / Bowel → pain on urination / defecation / abdominal pain
- ↳ mucosa of fallopian tube → ↓ fertility

→ **PATHOGENESIS**

1. REGURGITATION THEORY [mc accepted] [during menstruat<sup>n</sup>]
2. METAPLASTIC THEORY
3. LYMPHATIC DISSEMINATION
4. STEM CELL THEORY



CHOCOLATE CYST OF OVARY



Burn powder appearance

→ **COMPLICATIONS**

- ↑↑ ovarian cancer
- chocolate cyst ⊕ / BURN POWDER APPEARANCE

**ADENOMYOSIS**

- Endometrial tissue in myometrium
- > 2.5 mm below Endo myometrial Junction

**ENDOMETRIAL HYPERPLASIA**

- ↑↑ Estrogen → ↑↑ Endometrial glands → Heavy Bleeding
- PTEN GENE MUTATION ⊕

→ **WHO CLASSIFICATION**

1. NON - ATYPICAL EH → 1-3% risk of cancer
2. ATYPICAL EH → 23-48% risk of cancer

→ Atypical EH aka → ENDOMETRIAL INTRA EPITHELIAL NEOPLASIA [EIN]

**ENDOMETRIAL CARCINOMA**

- MC invasive cancer of female genital tract
- CIF → Post menopausal bleeding [mc]
- METASTASIS → Lungs [mc]

→ **WHO CLASSIFICATION**

1. TYPE I ENDOMETRIAL CARCINOMA
2. TYPE II ENDOMETRIAL CARCINOMA

|                  | TYPE I                                                      | TYPE II                      |
|------------------|-------------------------------------------------------------|------------------------------|
| AGE              | → 55 - 65 yrs                                               | → 65 - 75 yrs                |
| CLINICAL SETTING | → unopposed estrogen exposure<br>→ Obesity<br>→ HTN<br>→ DM | → Atrophy<br>→ Thin physique |
| GENETICS         | → PTEN mutation                                             | → p 53 mutation              |
|                  | → Indolent in nature                                        | → Aggressive nature          |
|                  | → LN spread ⊕                                               | → Intra peritoneal spread    |
|                  | → Better prognosis                                          | → poor prognosis             |
|                  | → ENDOMETROID CANCER                                        | → PAPILLARY SEROUS CANCER    |

## MYOMETRIAL DISORDERS

### LEIOMYOMA / FIBROID

- smooth muscle mass
- Benign
- Reproductive age group

#### SUB TYPES

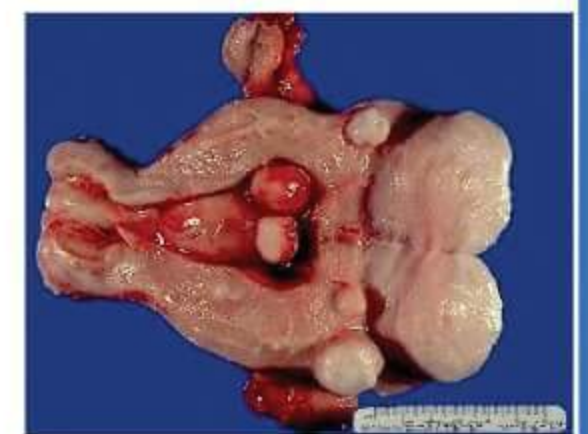
- SUB MUCOSAL
- INTRA MURAL
- SUB SEROSAL

#### CLINICAL FEATURES

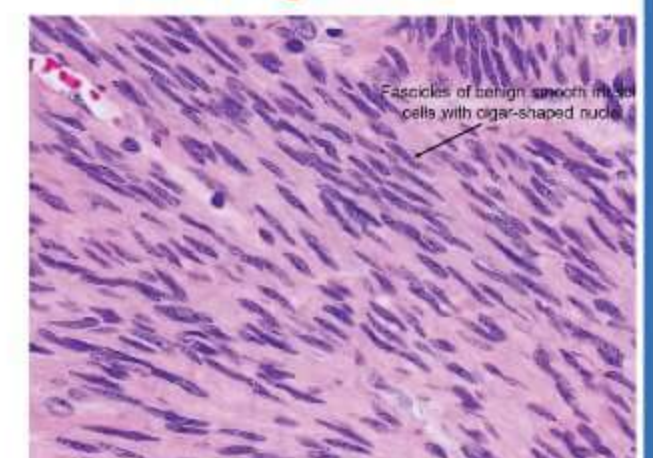
- Asymptomatic usually
- menorrhagia
- ↓ fertility

t.me/latestpnotes → Pressure symptoms

- **GROSS FEATURES**
  - well circumscribed ; multiple
  - whorled mass ⊕ → Grey white
- **MIE** → Smooth muscle cells ⊕ whorled ⊕
- **Advanced Info** → MED 12 mutation ⊕



Leiomyoma



Leiomyoma

### LEIOMYOSARCOMA

- DE-NOVO origin
- mc sarcoma of uterus
- **GROSS** → single ; Brown
- **MIE** → Hemorrhage & necrosis
- Atypical mitosis → ≥ 10 mitosis / hpf

## OVARIES

### OVARIAN TUMORS

- 1° OVARIAN TUMORS
- 2° OVARIAN TUMORS

Surface Epithelium  
Germ cell  
Sex cord stromal cell



### OVARY

#### COMPONENTS

- Surface Epithelial cells
- Germ cells
- Sex - cord Stromal cells  
[Theca | granulosa | fibrosa cells]

#### 1° TUMORS

- Surface Epithelial tumors [mc]
- Germ cell tumors
- sex cord stromal tumors

**RISK FACTORS**

|             |                                                                                             |
|-------------|---------------------------------------------------------------------------------------------|
| NON GENETIC | → Nulliparity<br>→ Asbestos                                                                 |
| GENETIC     | → BRCA 1/2 mutat <sup>n</sup> ; K-RAS mutat <sup>n</sup><br>→ LYNCH   TURNER   PJ SYNDROMES |

|                 |                                   |
|-----------------|-----------------------------------|
| BRCA 1          | → serous surface epithelial tumor |
| Turner Syndrome | → dysgerminoma                    |
| PJ syndrome     | → Sex cord stromal tumors         |

**PROTECTIVE FACTORS** → pregnancy & OCPs

**SURFACE EPITHELIAL TUMORS**

- mc 1<sup>o</sup> ovarian tumors
- may be Benign | Borderline | malignant
- usually cystic

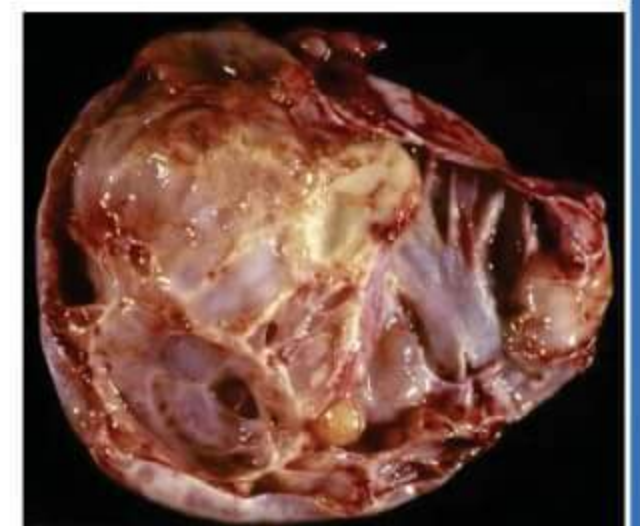- Benign c/w → young female
- malignant c/w → Elderly female & Atypia, Hemorrhage & necrosis ⊕

→ **SUB TYPES**

- |              |                      |
|--------------|----------------------|
| My           | → Mucinous Tumor     |
| servant      | → Serous tumor       |
| Began        | → Brenner tumor      |
| Experiencing | → Endometrioid tumor |
| Cancer       | → Clear cell tumor   |

**1. MUCINOUS TUMOR**

- cystic tumor i columnar non-ciliated epithelium [secretes mucus]
- Benign → mucinous cystadenoma
- malignant → mucinous cystadenocarcinoma



mucinous tumor

**FEATURES**

- U/L
- ↑↑↑ Size
- multiple cysts ⊕
- PSEUDO MYXOMA PERITONEI [mucin in peritoneal cavity]

**RISK FACTORS**

- Smoking
- K-RAS mutation

**2. SEROUS TUMOR**

- cyst mass  $\bar{c}$  ciliated epithelium [ $\cong$  fallopian tube]
- BENIGN → mc benign ovarian tumor
- MALIGNANT → mc BIL malignant ovarian tumor
- SEROUS CYSTADENOCARCINOMA [malignant]
  - BRCA 1 gene mutation
  - PSAMMOMA BODIES  $\oplus$

**3. BRENNER TUMOR**

- UIL
- WALTHARD NESTS  $\oplus$  → Transitional Epithelium [ $\cong$  Bladder]

**4. ENDOMETROID CANCER**

- PTEN gene mutation
- $\cong$  Endometrial adenocarcinoma
- alw Endometriosis

**5. CLEAR CELL CANCER** → clear dlt glycogen**CLINICAL FEATURES OF SURFACE EPITHELIAL TUMORS**

- Abdominal Enlargement [ $\uparrow$  ovarian size / Ascites]
- Abdominal pain
- Palpable ovaries [in post menopausal  $q$ ]
- malignant pleural effusion
- hepatic metastasis [t.me/latestpgnotes](https://t.me/latestpgnotes)

**MARKERS**

- CA 125 → indicates the progression of disease
- OSTEOPONTIN

**GERM CELL TUMORS**

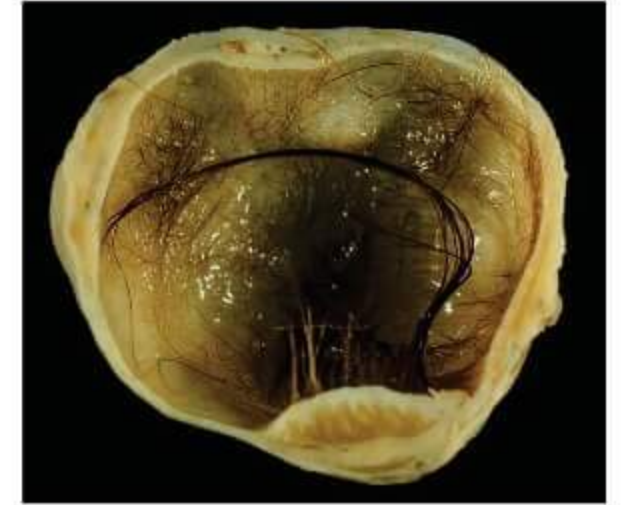1. **DYSGERMINOMA**
2. **ENDODERMAL SINUS TUMOR**
3. **TERATOMA**
4. **OVARIAN CHORIOCARCINOMA**

**1. DYSGERMINOMA**

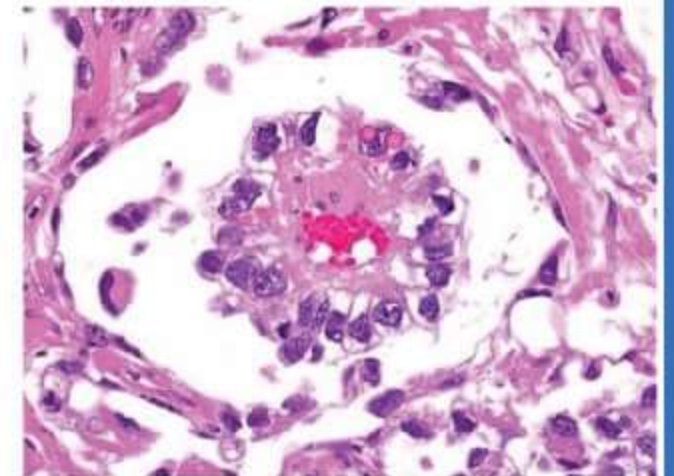
- $q$  counterpart OF SEMINOMA
- mc malignant GCT
- Radiosensitive
- UIL
- alw Turner Syndrome
- marker →  $\uparrow$  S. LDH
- Good prognosis

## 2. TERATOMA

- arise from totipotent cells
- arise from > 1 germ cell layer
- **MATURE TERATOMA** → **DERMOID CYST**
  - ↳ skin/hair/cartilage/sebaceous gland ⊕
  - ↳ Reproductive age group
  - ↳ 46 XX
  - ↳ Skin  $\xrightarrow{1\%}$  Squamous cell carcinoma
- **IMMATURE TERATOMA**
  - ↳ Adolescent females
  - ↳ malignant
- **SPECIALISED TERATOMA**
  - ↳ STRUMA OVARII [contains functional thyroid tissue/hyperthyroidism ⊕]
  - ↳ ↑ 5 HT → CARCINOID [LUI]



Teratoma



SCHILLER DUAL BODY

## ENDODERMAL SINUS / YOLK SAC TUMOR

- mc malignant ovarian tumor of children [ $< 4$  yr]
- 2nd mc malignant GCT
- MIE → SCHILLER DUVAL BODY
- TUMOR MARKERS → AFP ⊕ /  $\alpha_1$ -AT ⊕

## OVARIAN CHORIOCARCINOMA [t.me/latestpgnotes](https://t.me/latestpgnotes)

- co-exist w/ other GCT
- Placental Origin
- Marker →  $\beta$  HCG ↑↑↑
- non responsive to chemotherapy
- poor prognosis

## III SEX CORD STROMAL TUMORS [FUNCTIONAL TUMORS]

### 1. THECOMA - FIBROMA

- SPINDLE CELLS ⊕
- Theca cells → OIL RED 'o' +
- Fibroma → OIL RED 'o'

- FIBROMA a/w

#### 1. MEIG SYNDROME

- Fibroma
- Ascites
- Rt sided pleural effusion

#### 2. BASAL CELL NEVUS SYNDROME

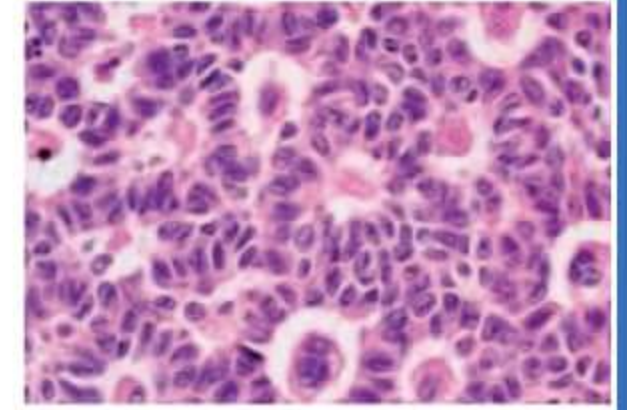
- > 6 cm fibroma



## 2. GRANULOSA - THECA CELL TUMORS

- FOX L2 mutation
- Hormone Secretion
  - Estrogen
    - precocious puberty
    - Endometrial hyperplasia
    - Endometrial malignancy

- MIE
  1. CALL EXNER BODY
    - acidophilic inclusion centre
    - surrounded by tumor cells



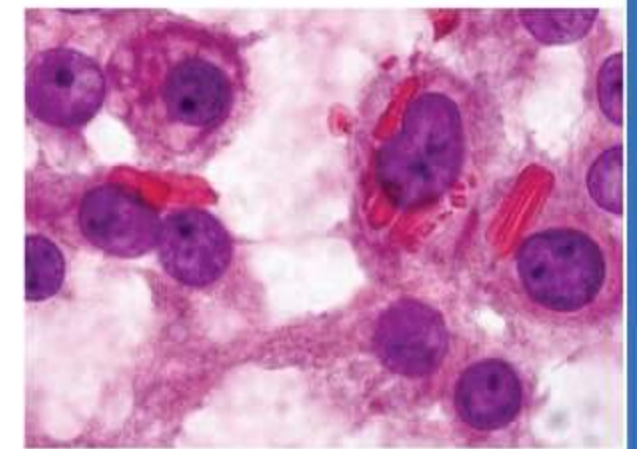
Call Exner Bodies

### 2. COFFEE BEAN NUCLEUS

- STAIN → Inhibin ⊕

## 3. SERTOLI - LEYDIG CELL TUMOR

- Functional tumors [Androgen → masculinization]
- PURE LEYDIG CELL TUMOR → MIE → REINKE CRYSTALS ⊕



Reinke crystals

## 4. GONADOBLASTOMA

- Mixed tumor [stroma + Germ cell]
- Abnormal sexual development [♀ (80%); ♂ (20%)]
- Rx by surgical excision
- Good Prognosis

t.me/latestpgnotes

## 2° OVARIAN TUMORS

- mc metastasis → mullerian Origin tumor
  - ↳ uterus
  - ↳ fallopian tube
  - ↳ Opposite ovary
  - ↳ pelvic peritoneum

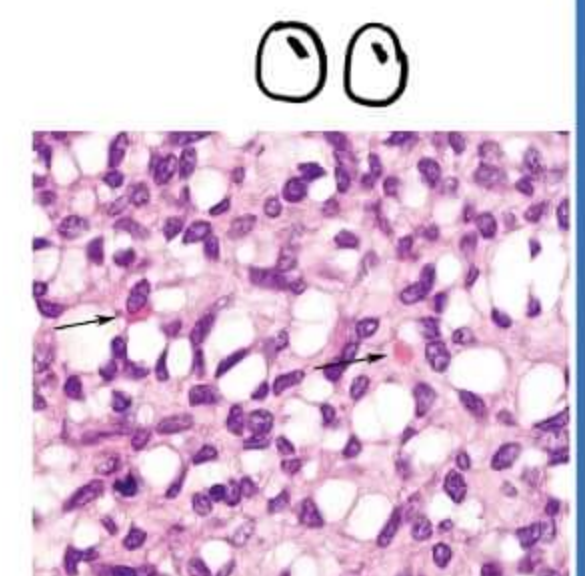
### → EXTRA - MULLERIAN ORIGIN

- ↳ stomach cancer
- ↳ colon cancer
- ↳ Breast cancer

## 1 KRUKENBERG TUMOR

- B/L [dit lymphatic spread]
- ORIGIN
  - ↳ stomach [mc] → Diffuse variant
  - ↳ Breast → infiltrating lobular carcinoma
  - ↳ colon
  - ↳ pancreas

- MIE → SIGNET-RING APPEARANCE [dit mucinous vacuole]

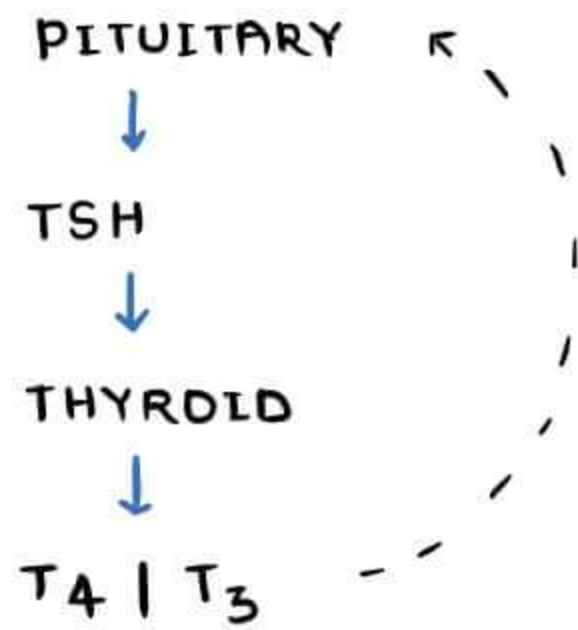


Signet-ring cells

## 2. PSEUDO - MYXOMA PERITONEI [mucus in peritoneum]

- can be Appendiceal tumor → mc mucinous ovarian tumor

THYROID



THYROID HORMONES

- more produced form → T<sub>4</sub>
- more active form → T<sub>3</sub>
  
- FUNCTIONS
  - ↑ BMR
  - proper bone growth
  - ↑ β adrenergic receptors on CVS
  - proper Brain growth

THYROID FUNCTION TESTS

1. S.TSH
  - ↑ [ seen in hypothyroidism ]
  - ↓ [ seen in hyperthyroidism ]
  - preferred parameter in thyroid disorders

SUB CLINICAL DISEASE

- sub clinical hypothyroidism → ↑ TSH & ⊕ T<sub>3</sub>/T<sub>4</sub>
- sub clinical hyperthyroidism → ↓ TSH & ⊕ T<sub>3</sub>/T<sub>4</sub>

2. S.T<sub>4</sub> LEVELS

a. FREE FORM

→ Symptoms depends on free form

b. PROTEIN [TBG] FORM

Increased in

- OCPs
- Pregnancy
- HRT

↓  
↑ S.T<sub>4</sub> levels

decreased in

- Nephrotic Syndrome
- anabolic steroids

↓  
↓ S.T<sub>4</sub> levels

3. I<sup>131</sup> UPTAKE

↑ Synthetic capacity

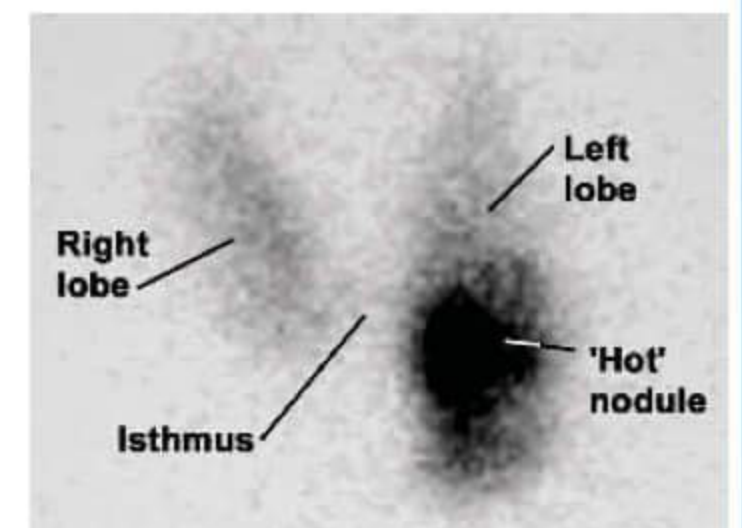
↓  
HOT NODULE

- Graves Disease
- Toxic Nodular goitre

↓ Synthetic capacity

↓  
COLD NODULE

- Thyroiditis
- Excess intake of Thyroid hormones
- Malignancy



4. S. THYROGLOBULIN

→ marker for Thyroid cancer

1. ACUTE THYROIDITIS

- dit Bacterial infection
- C/F → fever / tender thyroid / cervical Lymphadenopathy
- INVESTIGATIONS
  - ↳ S. TA ↑
  - ↳ S. TSH ↓
  - ↳ I<sup>131</sup> ↓
- Rx → Antibiotics

2. HASHIMOTO'S / CHRONIC LYMPHOCYTIC THYROIDITIS

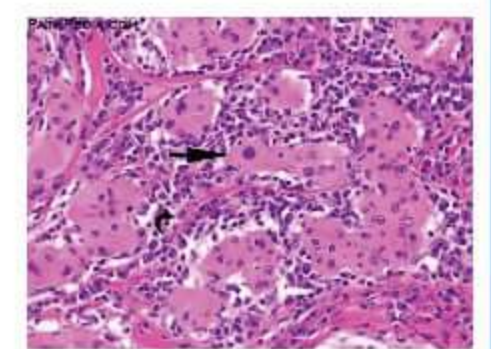
- Auto Immune Disorder → PTPN-22 / CTLA-4 gene mutation
  - ↓
  - CD<sub>4</sub> T cells / CD<sub>8</sub> T cells [main reason for pathogenesis]
  - Auto Ab ⊕ [useful for Dx]
- ♀
- HLA DR3 / DR5 ⊕
- αW
  - ↳ Klinefelter syndrome → Pernicious anemia
  - ↳ Down syndrome → SLE
  - ↳ Turner syndrome → Type 1 DM
  - myasthenia gravis
  - Rheumatoid Arthritis

- C/F → middle aged ♀ → HASHITOXICOSIS → → HYPOTHYROIDISM
- Painless enlargement of thyroid
- mc cause of hypothyroidism in iodine - sufficient areas

→ DIAGNOSIS

1. FOLLICULAR DAMAGE ⊕
2. LYMPHOCYTIC INFILTRATION ⊕
3. Well formed GERMINAL CENTERS ⊕
4. HURTHLE CELLS / ASKANAZY CELLS ⊕
  - pink granular eosinophilic cytoplasm ⊕
  - ONCOCYTIC METAPLASIA


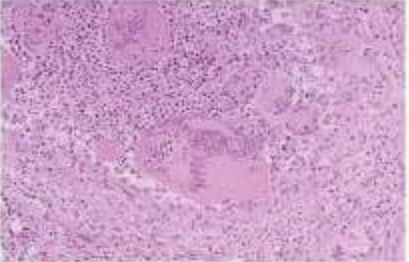
- ↑ Risk for B-CELL CANCER → MARGINAL ZONE LYMPHOMA



3. REIDEL'S THYROIDITIS

- Ig G<sub>4</sub> related disease → young ♀ → Fibrosis of Thyroid & Extra thyroid structures [Trachea & esophagus]
- FEATURES → HARD - ROCK LIKE THYROID → Hypothyroidism
  - Dysphagia
  - Stridor / Dyspnea
- mimics THYROID CANCER [DD → young ♀ → RT]
- Rx → RITUXIMAB / TAMOXIFEN / STEROIDS

#### 4. DEQUERVAIN'S / GRANULOMATOUS

- ♀ & H10 viral infection [fever, malaise, pain in neck]
- mc cause of tender thyroid
- **CIF**
  - Tender Thyroid
  - Transient Hyperthyroidism
  - Cervical Lymphadenopathy ±
- **MIE** → Granuloma → Giant cells + around colloid  
- S. T<sub>4</sub> ↑  
S. TSH ↓  
I<sup>131</sup> ↓
- **R<sub>1</sub>** → NSAIDs  
→ SELF limiting → do not cause permanent hypothyroidism

#### 5. SUB - ACUTE LYMPHOCYTIC THYROIDITIS

- Autoimmune Disease
  - ↳ painless
  - ↳ post-partum ♀
- Painless thyroiditis  
Transient hyperthyroidism → hypothyroidism
- NO fibrosis  
NO Hurthle cells

#### HYPERTHYROIDISM & GOITRE

##### THYROTOXICOSIS [↑ Thyroid hormones by any cause]

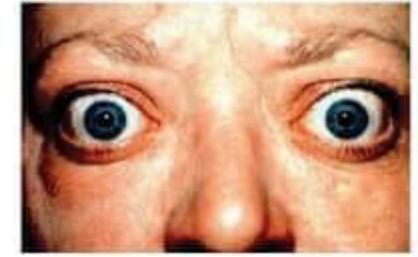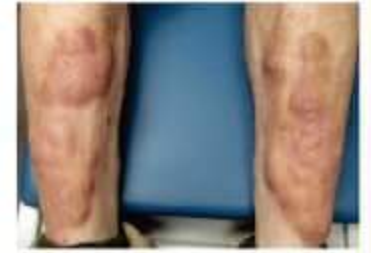- ↑ gland activity → Graves disease  
[Hyperthyroidism] → Toxic multinodular goitre
- Normal activity → External supplementation [Iatrogenic]
  - Stress
  - Struma ovarii

#### GRAVE'S DISEASE

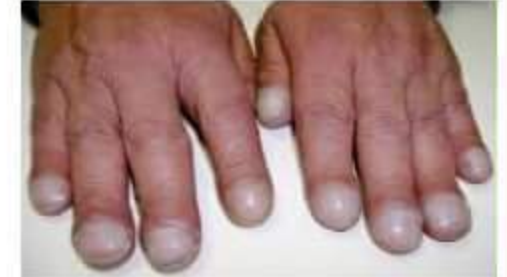- mc cause of Thyrotoxicosis & Hyperthyroidism → GRAVE'S DISEASE
- Auto Immune disease
- ♀ >>> ♂
- 20 - 40 yrs
- HLA DR3 | B-8
- ↑ SLE | Type 1 DM | pernicious anemia | Addison disease  
AUTO - Ab ⊕ → TG Ig → ⊕⊕⊕ TSH R → Hyperthyroidism

**TRIAD**

- THYROID** → Hyperthyroidism
- SKIN** → PRE TIBIAL myxedema  
↳ Shin involved  
↳ non-pitting edema
- EYE** → PROPTOSIS  
→ Extra ocular muscle weakness

**CIF**

- weight loss alw good appetite
  - Heat Intolerance
  - Diarrhea
  - oligomenorrhea
  - Osteoporosis
  - Systolic HTN
  - Sinus tachycardia
  - AF ↑
- THYROID ACROPACHY → Swelling of digits & clubbing
- APATHETIC HYPERTHYROIDISM  
↳ Elderly  
↳ ↑ skeletal & CVS manifestation



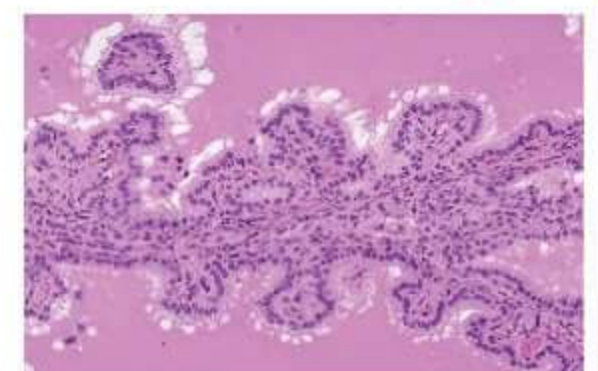
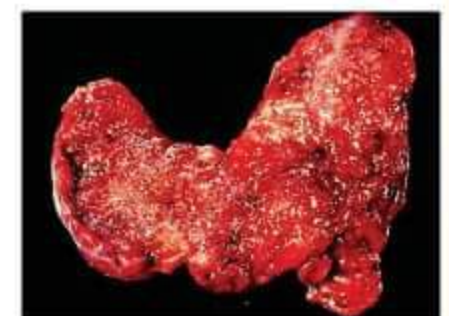[t.me/latestpgnotes](https://t.me/latestpgnotes)

**DIAGNOSIS**

1. S.  $T_4$  → ↑ } Thyroiditis
- S. TSH → ↓ } External hormone intake
- I<sup>131</sup> uptake → ↑↑

2. MIE → Diffuse increase in the size of the gland  
→ Follicular hypertrophy & hyperplasia

↓  
PAPILLAE FORMATION  
[ no fibrovascular core ]  
↓  
SCALLOPING OF COLLOID



- Rx** THIOAMIDES  
Non selective  $\beta$  blockers

**GOITRE**

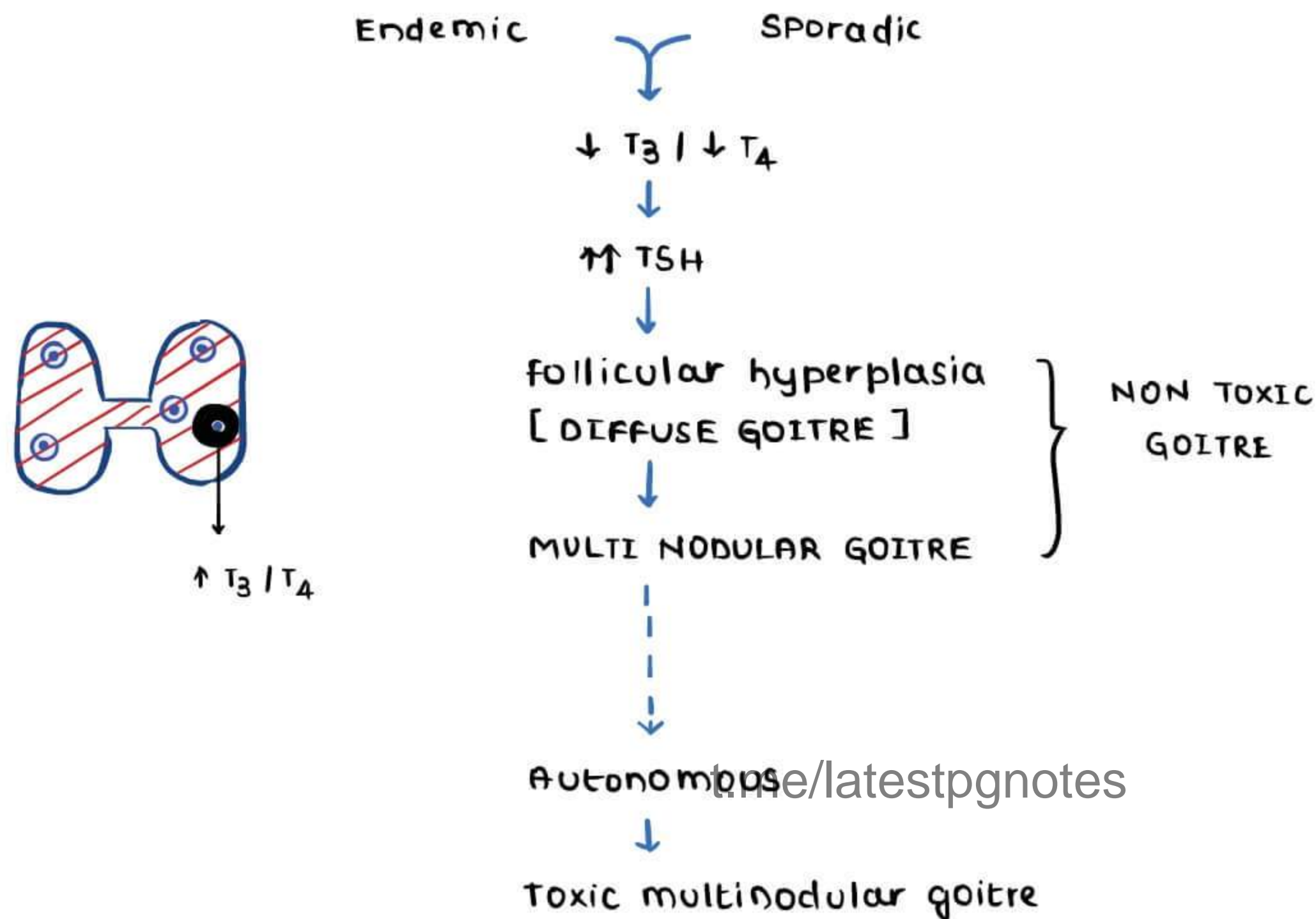
- Enlargement of thyroid gland
- ↓ Hormones → ↑ Size

1. ENDEMIC → > 10% are affected  
→ Himalayan, Andes

## 2. SPORADIC

- ♀
- puberty, pregnancy
- goitrogens
- drugs [Lithium, Amiodarone, PAS]
- **PENDRED SYNDROME**
  - ↳ Pendrin defect
  - ↳ SNHL + ↓ function of thyroid

## PATHOGENESIS



- CIF**
- mostly hypo | Euthyroid
  - Hyperthyroid in toxic multinodular goitre

## COMPLICATIONS

1. Cyst formation
2. Hemorrhage
3. Jugular venous compression → **PEMBERTON SIGN**
4. Hoarseness [RLN⊕]
5. Dyspnea [trachea compression]
6. **TOXIC MNG** → **PLUMMER SYNDROME**

↓  
 hyperthyroidism  
 NO SKIN involvement  
 NO Eye involvement

## PLUMMER VINSON SYNDROME

- ♀
- IDA
- esophageal webs
- atrophic glossitis

## MIE

1. Hyperplastic Stage
2. Involution

**BENIGN**

**FOLLICULAR ADENOMA**

- mc benign thyroid tumor
- G protein couple receptor mutation ⊕

**MALIGNANT**

**RISK FACTORS**

**1. GENETIC**

- |                           |                             |
|---------------------------|-----------------------------|
| → RET gene mutation       | → Medullary Thyroid cancer  |
| → RAS gene mutation       | → Follicular Thyroid cancer |
| → RET / PTC gene mutation | → Papillary Thyroid cancer  |
| → p 53 gene mutation      | → Anaplastic Thyroid cancer |

**2. ENVIRONMENTAL**

- |             |                             |
|-------------|-----------------------------|
| → Radiation | → Papillary Thyroid cancer  |
| → TSH ⊕⊕⊕   | → Follicular Thyroid cancer |

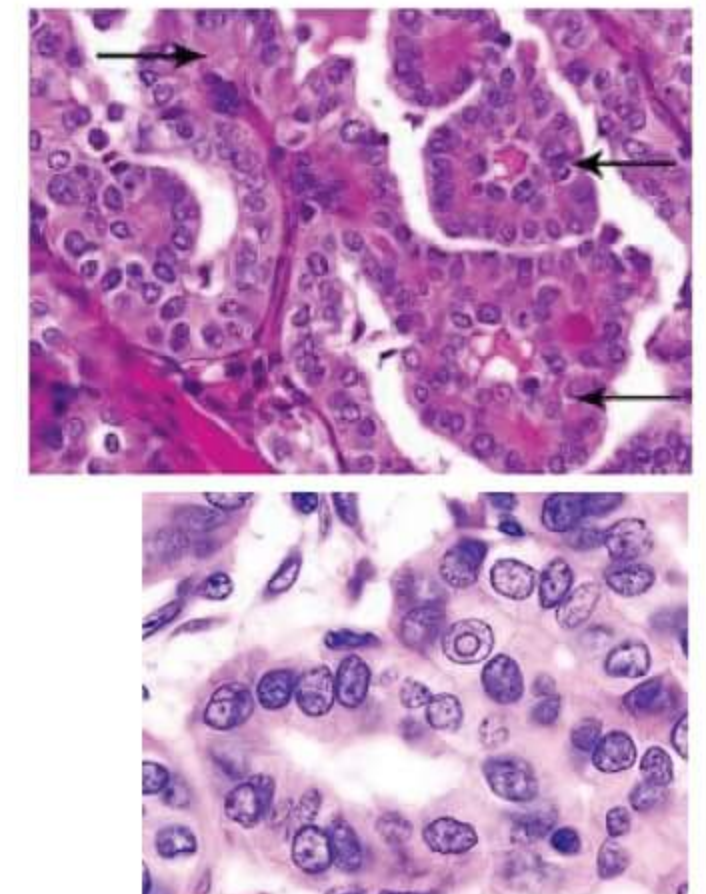
**PAPILLARY THYROID CANCER**

- mc thyroid cancer
- alw Post Radiation
- RET - PTC gene mutation
- young patients [20-30 years]
- Lymphatic Spread → Palpable LN ⊕ [cervical LN]

**DIAGNOSIS**

**MIE**

1. PAPILLE FORMATION ⊕ [fibro vascular core ⊕]
2. PSAMMOMA BODIES ⊕
3. NUCLER FINDINGS ⊕ [Hall mark]
  - orphan - Annie Eye nuclei
  - Pseudo inclusions
  - Nuclear grooving



**SUB TYPES**

1. Follicular variant [mc]
2. Diffuse sclerosing variant
3. Tall cell variant → BRAF mutation ⊕ , more aggressive , ↑ metastasis
4. Papillary micro carcinoma → < 1 cm

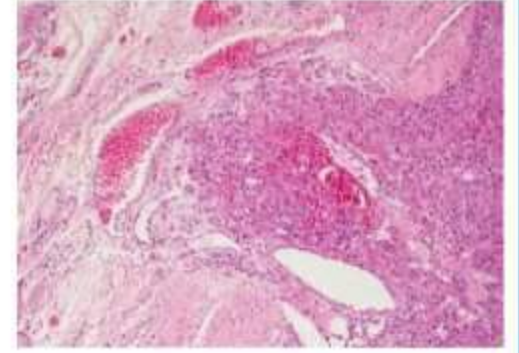
**2. FOLLICULAR THYROID CANCER**

**RISK FACTORS**

- RAS mutation
- Endemic goitre
- 40-50 yr ♀
- Hematogenous spread ⊕ → Bones, Lungs, Liver
- FNAC NOT USEFUL → can't differentiate b/w Adenoma & carcinoma

**DIAGNOSIS**

1. BIOPSY → metastasis ⊕
- Follicular carcinoma
Capsular invasion ⊕  
Vascular invasion ⊕



2. S. Thyroglobulin ↑ → marker of Recurrence

**HURTHLE CELLS ⊕**

- Seen in Follicular adenoma  
Follicular carcinoma  
Hashimoto's Thyroiditis
- if > 50% → HURTHLE CELL TUMOR → poorer prognosis

**3. MEDULLARY THYROID CANCER**

- arises from Para-follicular cells / C cells
- C cells secretes → calcitonin [best tumor marker]  
→ ACTH / 5-HT / VIP [aw Cushing syndrome, Diarrhea]
- Only thyroid cancer aw Amyloid deposition  
→ RET mutation ⊕

**SUB TYPES**

[t.me/latestpnotes](https://t.me/latestpnotes)

**1. SPORADIC**

- U/L, Unicentric  
→ 60-70yrs

**2. FAMILIAL**

- B/L, multicentric  
→ Indolent  
→ Better prognosis

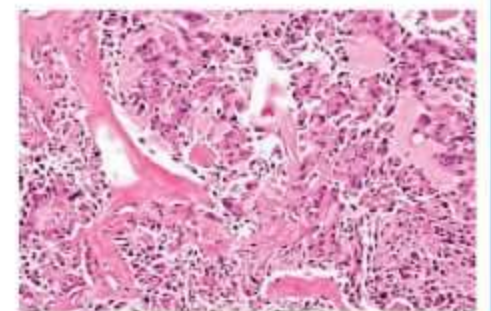
**MEN SYNDROME - MEN 2A & 2B [more aggressive]**

- more aggressive  
→ younger age group affected  
→ poor prognosis

- Prophylactic Thyroidectomy indicated in a patient w family H/O RET mutation

**DIAGNOSIS**

1. FNAC → MIE → POLYGONAL CELLS + in AMYLOID STROMA
2. CALCITONIN
3. CEA → used in calcitonin negative medullary cancer  
→ Tumor Burden can be known

**4. ANAPLASTIC THYROID CANCER**

- p 53 mutation  
→ highly aggressive → metastasis +++  
→ Elderly  
→ Firm Non-tender gland  
→ THYROGLOBULIN ⊖ CYTOKERATIN ⊕



- Extra thyroidal structures also involved
  - ↳ Esophagus [dysphagia]
  - ↳ Trachea [stridor]
  - ↳ Laryngeal Nerve [Hoarsness]

- 1° B CELL LYMPHOMA** → Marginal zone Lymphoma
- alw Hashimoto's Thyroiditis

### PARATHYROID

#### PARATHYROID GLAND

- ④ → Superior [4th pharyngeal pouch]
- Inferior [3rd pharyngeal pouch]
- PTH → Distal tubules of kidney →  $\text{Ca}^{2+}$  reabsorption [ $\uparrow \text{Ca}^{2+}$ ]
- 1- $\alpha$  OHase ⊕ → calcitriol [vit D]
- BONES → Osteoblasts → osteoclast →  $\uparrow \text{Ca}^{2+}$
- NET EFFECT →  $\uparrow \text{s. Ca}^{2+}$ ,  $\downarrow \text{s. PO}_4^{3-}$
- $\downarrow \text{Ca}^{2+}$  →  $\text{Ca}^{2+}$  Sensing ⊕ [parathyroid gland] →  $\uparrow$  PTH →  $\uparrow \text{s. Ca}^{2+}$

### HYPERPARATHYROIDISM

#### 1° HYPERPARATHYROIDISM

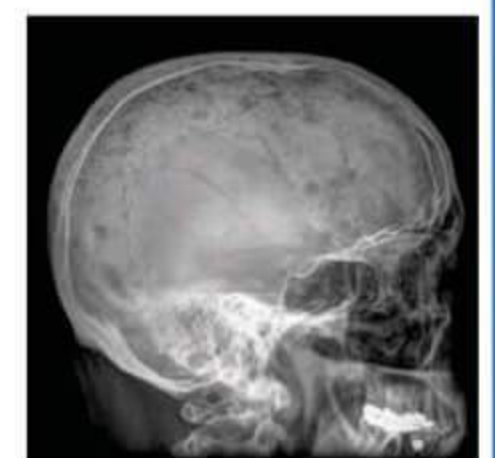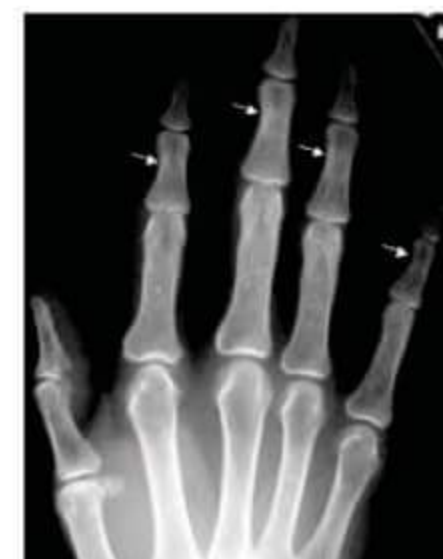- PTH  $\uparrow\uparrow$  →  $\uparrow \text{s. Ca}^{2+}$  →  $\downarrow \text{s. PO}_4^{3-}$  →  $\uparrow$  hypercalcemia [Incidental]
- post menopausal females

#### ETIOLOGY

1. Parathyroid adenoma [mc]
2. Parathyroid hyperplasia
3. Parathyroid Carcinoma

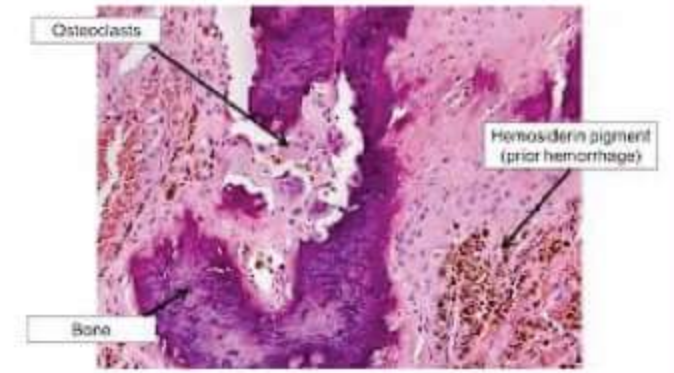
#### PARATHYROID ADENOMA

- mcc 1° Hyper PTH
- mc site → Rt. Inferior gland
- Remaining glands undergo atrophy
- MIE → sheets of cells ⊕  $\bar{}$  no adipose tissue in blw
- GENETICS
  1. cyclin D<sub>1</sub> overactivity
  2. MEN 1 gene under activity
- sporadic also



**CIF**

- Kidneys → ↑ Stones, polyuria
- GIT → nausea, Constipation, ↑ PUD, ↑ Pancreatitis
- CNS → confusion, anxiety
- BONES → Osteoporosis
  - ↳ concavity on radial side of phalanges
  - ↳ X Ray skull → salt & pepper appearance



→ CYST + HEMORRHAGE → OSTEITIS FIBROSA CYSTICA / BROWN TUMOR

→ JOINTS → PSEUDO GOUT

**DIAGNOSIS**

1. S. PTH → ↑↑↑
- S.  $Ca^{2+}$  → ↑↑
- S.  $PO_4^{3-}$  → ↓↓

**GLANDS**

| Adenoma     | Hyperplasia                  |
|-------------|------------------------------|
| One → ↑↑↑   | 4 → ↑↑↑                      |
| Others → ↓↓ | WASSERHELLE CELL HYPERPLASIA |

→ ↑↑  $Ca^{2+}$  seen in

- D** → Drugs [Thiazides] / Vit D intoxication
- I** → Immobilization [t.me/latestpgnotes](https://t.me/latestpgnotes)
- S** → Sarcoidosis [↑  $1\alpha$  OHase]
- C** → Cancers [Symptomatic hypercalcemia]
  - multiple myeloma
  - metastasis
    - ↳ Squamous cell Lung cancer
    - ↳ Renal cancer
    - ↳ Breast cancer

**2° HYPER PARATHYROIDISM** [↓↓  $Ca^{2+}$  → → → ↑ PTH]

**ETIOLOGY**

1. Renal failure [mc]
2. Vit D deficiency
3. GIT [steatorrhea]

**HYPO PARATHYROIDISM****ETIOLOGY**

- Surgical Removal [Thyroid Sx] [mc]
- Auto immune Disease [Autoimmune Polyendocrinopathy Syndrome I (APS I)]
- hypomagnesemia
- Di - GEORGE Syndrome

**APS I**

- dlt AIRE gene defect
- adrenal insufficiency ⊕  
muco cutaneous candidiasis ⊕

**Hypomagnesemia**

- alw Diuretics  
Alcohol  
aminoglycoside  
diarrhea

**CIF** → ↓  $Ca^{2+}$  ; ↑  $PO_4^{3-}$  ; s. PTH ↓

- TETANY → Carpo pedal spasm  
↳ chvostek sign  
↳ Trousseau sign

→ CVS → ↑ QT interval

→ calcification [Basal ganglia]

→ Dental caries

→ Cataract



[t.me/latestpgnotes](https://t.me/latestpgnotes)

**PSEUDO - HYPOPARATHYROIDISM**

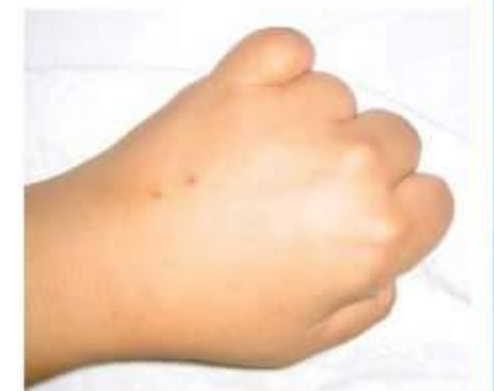- S.  $Ca^{2+}$  ↓
- S.  $PO_4^{3-}$  ↑
- S. PTH ↑↑

→ End organ resistance +

- CIF → mental Retardation  
calcification  
short stature

Small 4th/5th metacarpals → KNUCKLE KNUCKLE DIMPLE DIMPLE SIGN / ARCHIBALD SIGN

→ alw Maternal Imprinting

**●SEUDO - ●SEUDO HYPO PARATHYROIDISM**

- S.  $Ca^{2+}$  } normal
- S.  $PO_4^{3-}$  }
- S. PTH }

→ CIF → MR, Obesity, skeletal defects

→ alw Paternal Imprinting

ADRENAL CORTEX

- 1. Zona glomerulosa → Aldosterone
- 2. Zona fasciculata → Cortisol
- 3. Zona Reticulosa → Sex - Steroids

CUSHING SYNDROME

→ ↑ Cortisol

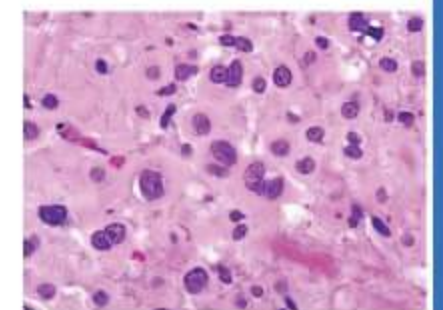
CIF

- central obesity
- moon faces
- HTN
- muscle wasting
- Skin atrophy
- Osteoporosis

ETIOLOGY

1. EXTERNAL [ IATROGENIC ] SUPPLEMENTATION [mc]

⊖ ACTH secretion → BIL adrenal atrophy



2. ENDOGENOUS CAUSES

i. Pituitary adenoma

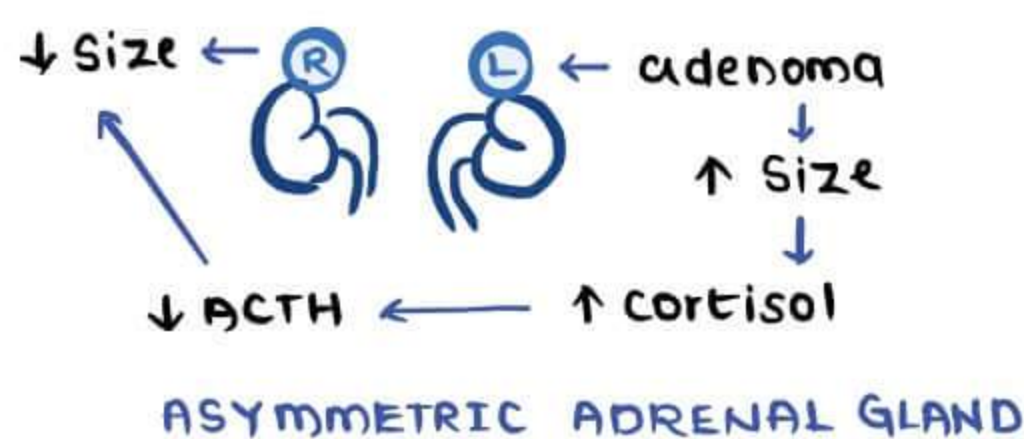
- ↑↑ ACTH → BIL adrenal hyperplasia → CUSHING DISEASE
- MIE → N → Basophilic granular cytoplasm
- CD → Intermediate filaments → CROOKS HYALINE CHANGE

ii ECTOPIC ACTH SECRETION

- alw small cell cancer of lung
- medullary thyroid cancer
- ↑ ACTH by tumor cells → BIL Adrenal hyperplasia
- DEXA METHASONE SUPPRESSION TEST
  - ↳ high dose → ⊖ pituitary
  - ⊗ Ectopic ACTH

iii ADRENAL CAUSE

→ dit hyperplasia | adenoma [mc] | cancer



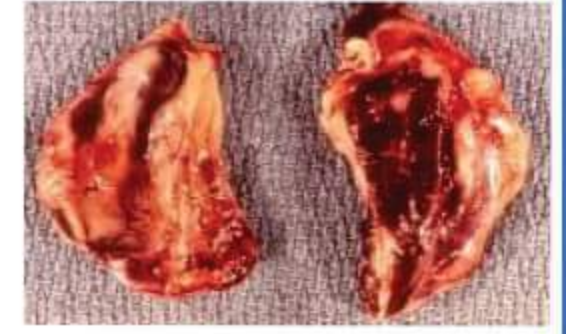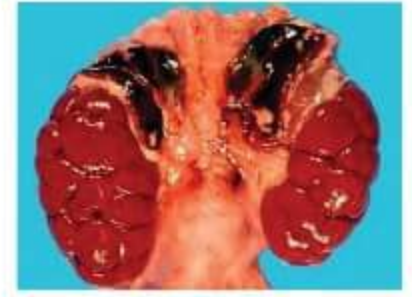## ADRENO - CORTICAL DISORDERS

### 1° DISEASE

#### 1. ACUTE DISEASE [ADRENAL CRISIS]

##### ETIOLOGY

1. abrupt withdrawal of steroids [mc]
2. Stress (chronic adrenal insufficiency)
3. Adrenal hemorrhage
  - ↳ Anti coagulant therapy
  - ↳ DIC
  - ↳ meningococcus infection [WATERHOUSE - FREDRICKSON SYNDROME]
  - ↳ difficult delivery



#### 2. CHRONIC ADRENO CORTICAL INSUFFICIENCY [ADDISON'S DISEASE]

##### ETIOLOGY

##### 1. AUTO IMMUNE DISORDERS

→ mc cause of addison's disease in developed countries

##### → APS 1

- Auto Ab against IL-17
- hypoparathyroidism ⊕
- addison's disease ⊕
- mucocutaneous candidiasis ⊕

##### → APS 2 = SCHIMDT SYNDROME

- addison's ⊕
  - Thyroiditis ⊕
  - Type 1 DM ⊕
- [t.me/latestpgnotes](https://t.me/latestpgnotes)

##### 2. INFECTIONS

- TB [mc cause of addison's disease in developing countries]
- Histoplasmosis
- AIDS

##### 3. METASTASIS

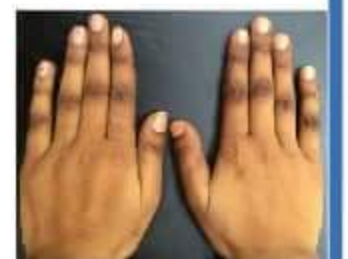- Lung cancer [mc]
- Breast cancer

##### 4. GENETIC → ADRENO GENITAL SYNDROME

→ mcc of addison's disease in a child

##### CIF

- Progressive Weakness → HTN
- ↑ Fatigue → ↓ Na<sup>+</sup> / ↑ K<sup>+</sup>



##### POMC [Proopiomelanocortin]

- ↑ ACTH
- ↑ MSH [melanocyte stimulating Hormone]
- ↳ Hyperpigmentation ⊕
  - sun exposed areas [neck]
  - Knuckles | Elbows | Knees

## 2° ADRENAL INSUFFICIENCY

→ due Hypothalamus or Pituitary defects

**ETIOLOGY** → metastasis → Infarction  
→ Infection → Post - Radiation

### CIF

→ ↓ ACTH → NO pigmentation  
→ ↓ cortisol / ↓ Androgens  
→ Nearly Normal Aldosterone → no hyponatremia or hyperkalemia

## ADRENAL MEDULLA

- composed OF CHROMAFFIN CELLS [derived from Neural crest]
- NEURAL CREST CELLS
  - Secretes Adrenaline & Nor adrenaline
  - Located at
    - ↳ Adrenal gland
    - ↳ mediastinum
    - ↳ Bladder
    - ↳ ORGAN OF ZUCKERKANDL [Aortic bifurcation]
- at Adrenal medulla & Organ of zuckerkandl

Adrenaline  $\xrightarrow{\text{N-methyl Transferase}}$  Nor Adrenaline

## PHEOCHROMOCYTOMA

- Adrenal medullary tumor
- Adult
- **aiw** VHL syndrome
  - NF-1 gene mutation
  - MEN 2A & 2B
  - Sturge Weber syndrome
  - Succinyl dehydrogenase mutations
- aka **RULE OF TEN TUMOR**
  - ↳ 10% → BIL
  - ↳ 10% → Extra adrenal location [PARAGANGLIOMA]
  - ↳ 10% → children
  - ↳ 10% → NO HTN
  - ↳ 10% → malignant [metastasis is the differentiating feature [vs Benign]]
  - ↳ 25% → Familial [previously it was 10%.]