Content

1) ENDOCRINE SURGERY		1 - 62
	Breast – 1	1
	Breast – 2	17
	Thyroid – 1	30
	Thyroid – 2	43
	Parathyroid and Adrenal glands	51
2) HEPATOBILIARY PANCREATIC SURGERY		63 - 136
	Liver – 1	63
	Liver – 2	73
	Portal hypertension	83
	Gall bladder	93
	Bile duct – 1	104
	Bile duct – 2	111
	Pancreas – 1	117
	Pancreas – 2	129
3) GASTROINTESTINAL SURGERY		137 - 270
	Esophagus – 1	137
	Esophagus – 2	150
	Stomach – 1	158
	Stomach – 2	166
	Peritoneum	178
	Intestinal obstruction	184
	Small intestine	194
	Large intestine	202
	Ileostomy and Colostomy	210
	Inflammatory Bowel disease – 1	213
	Inflammatory Bowel disease – 2	222
	Vermiform Appendix	235
	Rectum and Anal canal	240
	Hernia and Abdominal wall - 1	251
	Hernia and Abdominal wall – 2	259
	Spleen	267
4) UROLOGY		271 - 252
	Kidney and Ureter – 1	271
	Kidney and Ureter – 2	287
	Kidney and Ureter – 3	295
	Urinary bladder	305
	Prostate and Seminal vesicles	316
	Urethra and Penis	326

t.me/latestpgnotes



This PDF was created and uploaded by www.medicalstudyzone.com which is one the biggest free resources platform for medical students and healthcare professionals. You can access all medical Video Lectures, Books in PDF Format or kindle Edition, Paid Medical Apps and Softwares, Qbanks, Audio Lectures And Much More Absolutely for Free By visiting our Website https://medicalstudyzone.com all stuff are free with no cost at all.

Furthermore You can also request a specific Book In PDF Format OR Medical Video Lectures.

	Testis and Scrotum – 1	337
	Testis and Scrotum – 2	344
5) CARDIOTHORACIC VASCULAR SURGERY		253 - 409
	Arterial disorders – 1	253
	Arterial disorders – 2	261
	Venous disorders	373
	Lymphatic system	383
	Thorax and Mediastinum – 1	388
	Thorax and Mediastinum – 2	397
6) Plastic surgery		410 - 440
	Burns	410
	Plastic surgery and Skin lesions	418
	Wound healing, Tissue repair and Scar	430
7) Neurosurgery		441 - 460
	Cerebrovascular surgery	441
	CNS Tumors	449
8) Head and Neck		461 - 492
	Oral cavity	461
	Salivary glands	472
	Neck	481
	Facial injuries and Abnormalities	487
9) Oncology		493 - 499
10) Others		500 - 651
	Pediatric surgery – 1	500
	Pediatric surgery – 2	510
	Trauma	522
	Head injury	529
	Neck and Thoracic injuries	537
	Abdominal Trauma	545
	Transplantation – 1	556
	Transplantation – 2	563
	Robotics, Laparoscopy and Bariatric surgery	577
	Sutures and Anastomosis	585
	Nutrition	593
	Shock	598
	General surgery	606
	Instruments – 1	617
	Instruments – 2	627
	Instruments – 3	639

t.me/latestpgnotes

- Cyst in lungs & brain (does not have pericyst)
- Calcified cyst (dead cyst)

2) **Cyst Evacuation + Omentopexy**

3) **Peri-cystectomy** (Most effective treatment)
   → Excision of cyst outside of Pericyst

4) **Hepatic Resection** (Most Radical Treatment)

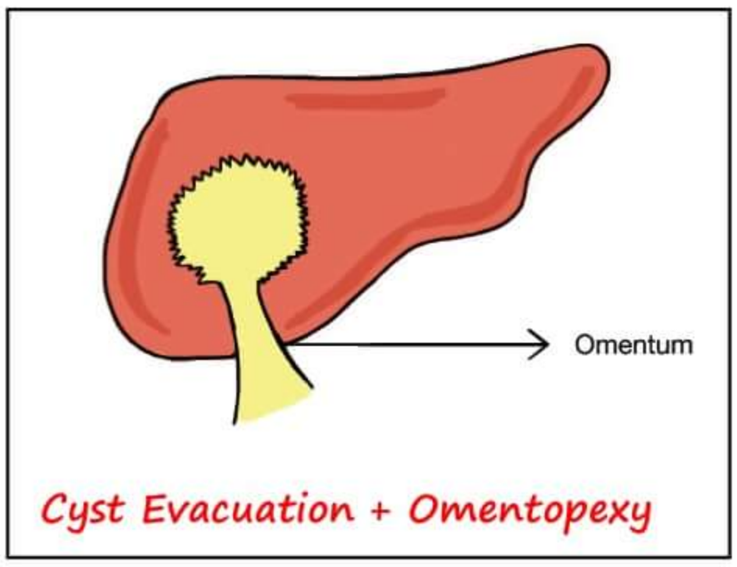

Cyst Evacuation + Omentopexy

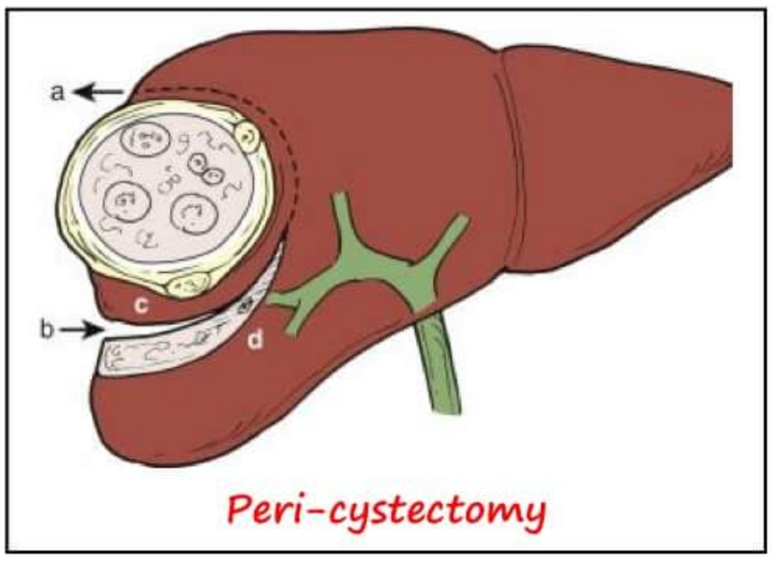

Peri-cystectomy

Gharbi's Classification for Hydatid Cyst Based On USG

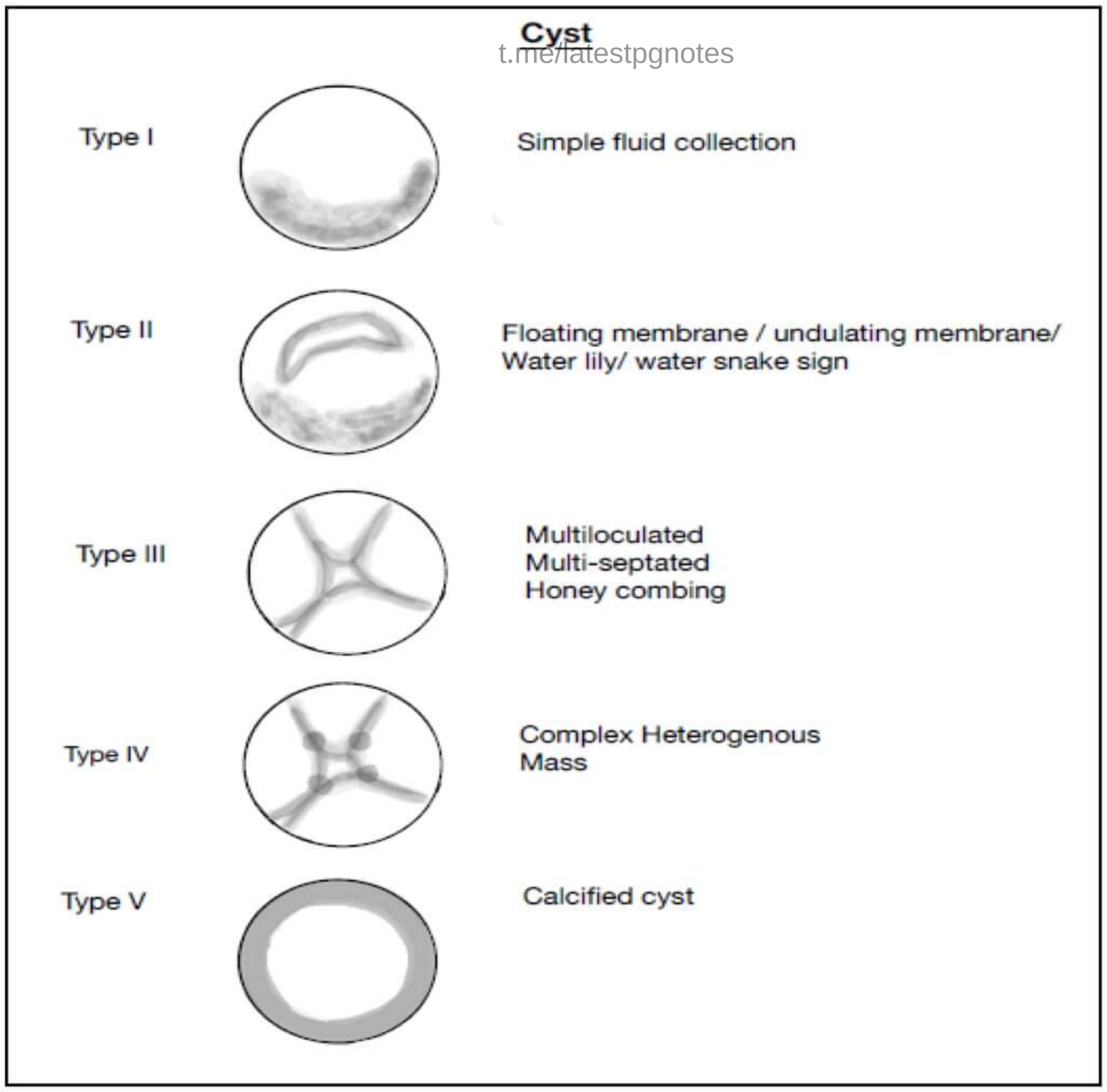

PrepLadder

Bloody discharge Differential Diagnosis

Findings	Probable diagnosis	Treatment
→ Single, smooth intraluminal Filling defect.	Duct papilloma (Benign)	Microdochectomy (excision of involved duct)
→ Multiple, irregular intraluminal Filling defects	Breast Carcinoma	
→ Dilated duct	Duct ectasia	HADFIELD'S operation (conical excision of involved duct)

Risk Factors (based on high socio-economic status)

→ Advancing Age
→ Western countries
→ High socio-economic status
→ Alcohol intake
→ High Fat diet, obesity
→ State of hyperestrogenemia (early menarche, late menopause, nulliparity, late first full-term pregnancy)
→ Positive family history
→ Personal H/O malignancy
  - Ovarian cancer
  - Endometrial cancer
→ Genetic mutations
→ BRCA mutations
  - Both BRCA 1 and BRCA 2 are responsible for breast cancer in both males and females.
  - But BRCA 1 is mainly responsible for breast cancer in females
  - And BRCA 2 is mainly responsible for breast cancer in males.
    (Mnemonic- LADIES FIRST)
→ Hormone replacement therapy
→ History of therapeutic radiation exposure
  - Total therapeutic radiation- **40- 50 gray**
  - **1.8- 2 gray/ day**
  - **5 days a week for 4-6 weeks**
  - **If total radiation exposure > 60 gray** → increased risk of malignancy.
→ OCPs & smoking – **not** the significant risk factor for breast cancer.
→ Long duration of breast feeding is protective for breast cancer

t.me/latestpgnotes

PrepLadder

Risk assessment models of CA Breast

CLAUS model	GAIL model
→ MC used	→ More information about family history
→ Includes • No. of breast biopsy • Age at menarche • No. of first degree relative with CA breast • Age at first live birth	→ Based on • Decades of life • Based on first and second degree relative with CA breast • Their age at diagnosis

WHO classification of Breast cancer

→ **In situ carcinoma**
- DCIS
- LCIS

→ **Invasive carcinoma**
- Ductal carcinoma
- Lobular carcinoma
- Tubular (cribriform carcinoma)
- Mucinous (colloid) carcinoma
- Medullary carcinoma
- Papillary carcinoma
- Metaplastic carcinoma
- Inflammatory breast cancer

→ **Paget's disease of nipple**

t.me/latestpgnotes

Most Frequently asked Questions

→ Least common type - Papillary carcinoma of breast
→ Most malignant and Worst prognosis - Inflammatory breast cancer
→ Least malignant and best prognosis - Tubular carcinoma of breast

DCIS (Ductal carcinoma insitu)

→ **DCIS** - high risk for progression to invasive ductal cancer
→ Ducts are present in breast of males and females - hence Ductal carcinoma is common in both males and females
→ Lobules are seen in females only- hence lobular carcinoma is common in females exclusively.
→ **Classification of DCIS is based on**
- Nuclear grade
- Necrosis

PrepLadder

Types of DCIS

→ **Low grade DCIS**
- Cribriform
- Papillary
- Micropapillary

→ **High grade DCIS**
- Solid
- Comedocarcinoma

Investigations

→ **On mammography** - presence of Microcalcifications due to necrosis

→ Most sensitive investigation for diagnosis of DCIS - MRI

→ Most sensitive investigation for diagnosis of microcalcification in DCIS – Mammography

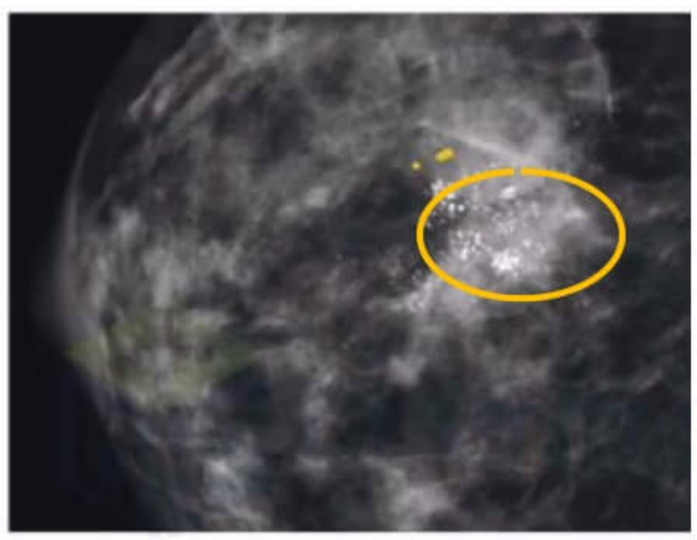

Microcalcification in DCIS

Treatment

→ Non palpable DCIS - Excision by needle localization with specimen mammography

→ For Low grade DCIS - Lumpectomy

→ For DCIS with limited disease - Lumpectomy + RT

t.me/latestpgnotes

LCIS (Lobular carcinoma insitu)

→ Originates from terminal duct lobular units

→ Only seen in females

→ Multicentric and bilateral- Increased risk of bilateral breast cancer

→ It is a marker for increased risk of bilateral breast cancer

Pathology

→ Cytoplasmic mucoid globules

→ Histologic hallmark

→ Indian file pattern (tendency of tumor cells to invade in linear strands)

Clinical features

→ Mc presentation - lump with ill-defined margins

Diagnosis

→ Characteristic feature of LCIS - Neighbourhood calcification

PrepLadder

Treatment

→ Observation/chemoprevention by tamoxifen / Raloxifene

→ Prophylactic bilateral mastectomy

Breast cancer

→ MC type histological type – Adenocarcinoma

→ MC histological subtype - Invasive Ductal cancer

→ Least common type - Papillary carcinoma of breast

→ Most malignant and Worst prognosis - Inflammatory breast cancer

→ Least malignant and best prognosis - Tubular carcinoma of breast

Site of Breast Cancer

→ Breast cancer is more common in left breast compared to right breast.

→ MC Site - Upper outer quadrant (due to maximum amount of breast tissue at this quadrant)

→ LC Site – Lower inner quadrant

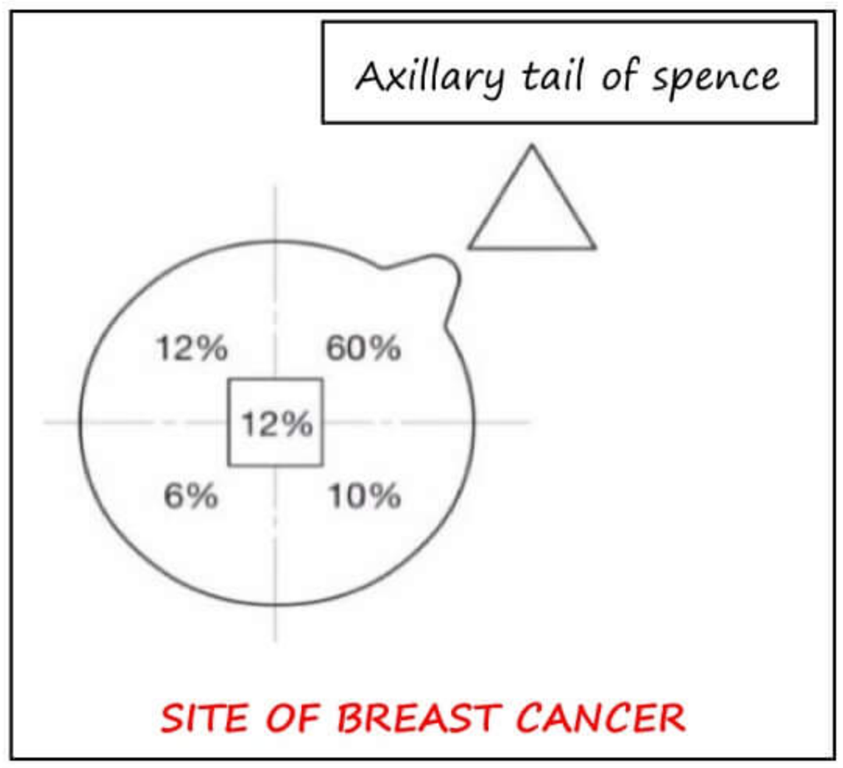

SITE OF BREAST CANCER

Route of spread

→ MC route of spread in CA Breast – Hematogenous

→ MC site of metastasis – Bones (Lumber vertebra > Femur > thoracic vertebra)

t.me/latestpgnotes

→ Both Osteolytic & osteoblastic secondaries

→ MC secondaries - Osteolytic > Osteoblastic

→ MC primary for both osteolytic & osteogenic secondaries in females - CA breast

→ MC cause of death - Malignant pleural effusion

Pathway of spread in breast cancer

Breast cancer cells

↓

Invade Posterior intercostal vein

↓

Invade BATSON PLEXUS

↓

Invade Lumbar Vertebra

Dural venous Sinuses

↓

Leptomeninges

↓

Brain

→ MC Primary cancer responsible for leptomeningeal metastasis – CA Breast

→ MC Primary cancer responsible for brain metastasis – CA Lung > CA breast.

PrepLadder

Clinical Features

→ MC presentation – **Breast lump**

→ **In advanced cases**

- Architectural distortion of breast
- Asymmetry
- Skin fixity
- Fixity to chest wall
- Involvement of nipple Leading to nipple retraction, nipple deviation, nipple ulceration

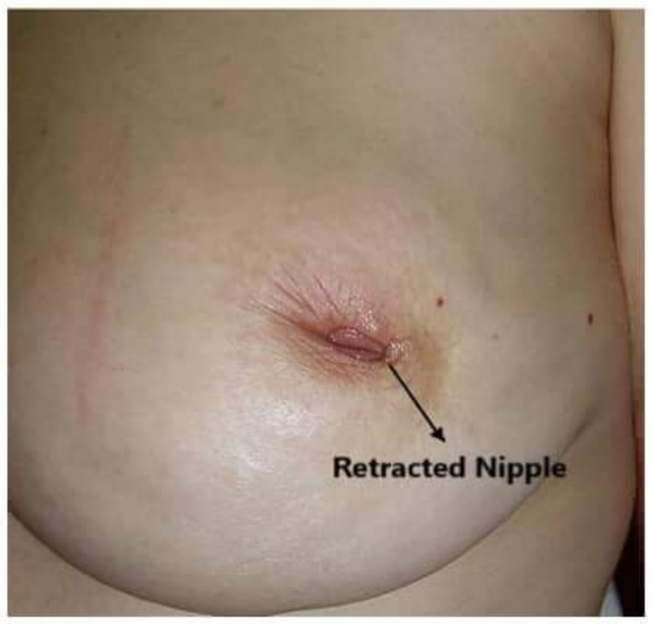

NIPPLE RETRACTION

Signs and symptoms of metastasis

→ Backache/ bony pains

→ Headache

→ Jaundice

→ Anorexia

→ Weight loss

PEAU-D-ORANGE → Most conspicuous sign of breast cancer Tumor cells enter lymphatics ↓ Lymphatic obstruction/Lymphatic permeation by tumor cells ↓ Cutaneous edema (PEAU – D – ORANGE)	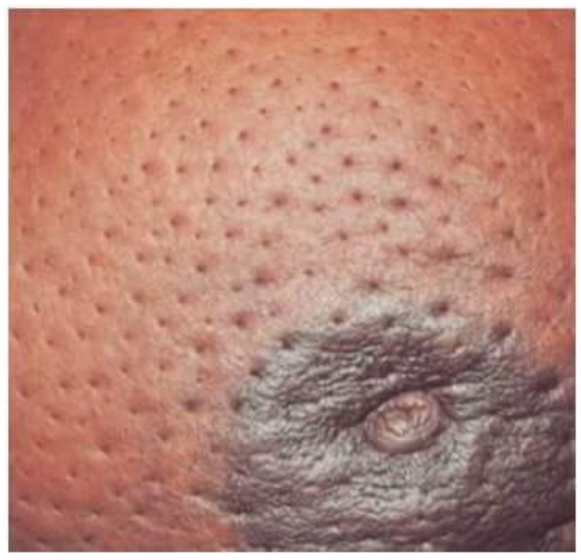
Dimpling → skin depression due to involvement of ligament of cooper	
Puckering → wrinkling/skin fold due to involvement of ligament of cooper.	

t.me/latestpgnotes

PrepLadder

Cancer en-cuirasse → Multiple nodules and ulceration in breast skin due to involvement of breast skin and chest wall	

Triple Assessment

- → **Clinical** – signs and symptoms
- → **Imaging** – ultrasound or mammography
- → **Tissue sampling** – FNAC or biopsy
- → Positive predictive value /accuracy of triple assessment – 99.9%

Investigations

- → First investigation done in suspected case of breast cancer – Mammography
- → IOC for diagnosis of breast cancer – Biopsy/ True cut biopsy/ Core cut biopsy/ Needle biopsy

t.me/latestpgnotes

FNAC	BIOPSY
→ Size of needle- 22- 26 gauge	→ Size of needle- 14- 16 gauge
→ Experienced cytopathologist is required	→ Diagnosis is made easily
→ High risk of false positive or false negative results (Difficult to differentiate DCIS from Invasive ductal cancer)	→ Easy to differentiate DCIS from invasive ductal cancer
→ Difficult to assess hormone receptor status	→ Hormone receptor status level can be assessed easily
	→ More painful

Mammography

- → IOC for screening of breast cancer
- → Screening mammography should be started at 45 years of age
- → Annual mammography is recommended
- → BREMSSTAHLUNG X RAY is used in mammography
- → Radiation exposure in Mammography - 0.1 centi-gray per study
- → **One mammography = 4 chest X ray**

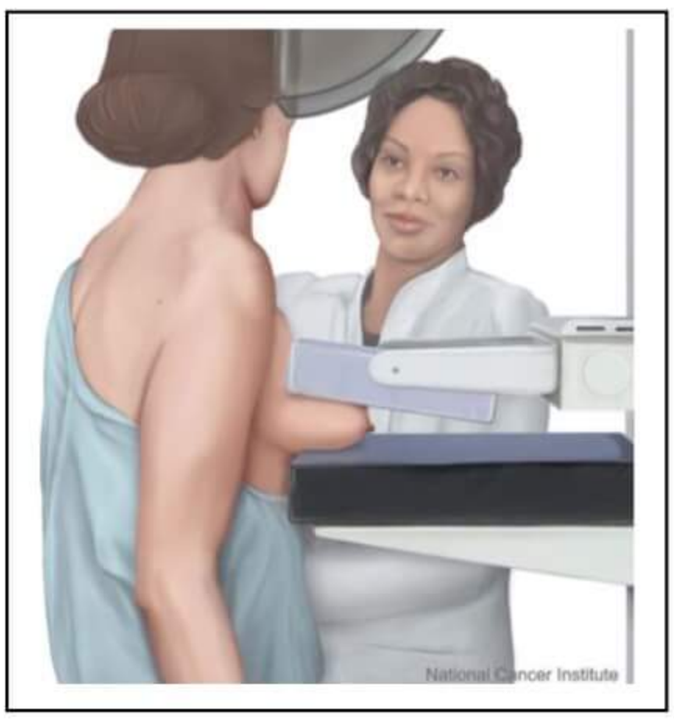

PrepLadder

→ Compression paddle moves up and down and compresses the breast to better delineate the lesions that cannot be appreciated by flabby breast.

→ **Mammography has two views.**

Craniocaudal view	Mediolateral oblique / MLO view
• Medial aspect of breast is best assessed	• Maximum amount of breast tissues is assessed
• Breast compression is assessed	• Axillary tail of spence is assessed

Advantage of Mammography

→ Diagnosis of non- palpable cancer
→ Diagnosis of malignancy at early stage
→ Better prognosis
→ By early detection, mammography decreases mortality and increases survival by > 33% due to early detection of breast cancer.

In mammography film, the following are assessed

→ Nipple retraction/ deviation
→ Skin thickening
→ Obliteration of retro mammary space
→ Microcalcification
→ Opacity

t.me/latestpgnotes

Features	Benign	Malignant
Opacity	→ Regular smooth margin → Homogenous → Low density → Thin Halo	→ Irregular margins • Stellate • Spiculate • Comet tail → Heterogenous → High density → Wide halo
Calcifications	→ Macro calcification > 0.5mm	→ Micro calcification < 0.5 mm
Associated changes in breast	→ Absent	→ Present → Nipple retraction → Skin thickening → Obliteration of retromammary space

PrepLadder

BIRADS/ Breast imaging Reporting and data system

Category	Description	Risk of malignancy
0	→ Incomplete assessment → Additional imaging is required	N/A
1	→ Mammography is -ve → Annual mammography is recommended	0 %
2	→ Benign → Annual mammography is recommended	0 %
3	→ Probably benign → short term follow up is recommended.	> 0 -2 %
4	→ Suspicious → Biopsy is recommended	
4A	→ Low suspicion → Biopsy is recommended	> 2 – 10 %
4B	→ Moderate suspicion → Biopsy is recommended	> 10 – 50 %
4C	→ High suspicion → Biopsy is recommended	> 50 – 95 %
5	→ Highly suggestive of malignancy → Intervention is recommended	> 95 %
6	→ Biopsy proven malignancy	

NOTE

→ **For Breast** - BIRADS (based on Mammography)

→ **For thyroid** - TIRADS (based on Sonography)

→ **For prostate** - PIRADS (based on MRI)

t.me/latestpgnotes

Role of MRI in Breast cancer

→ IOC for **screening** of breast CA in **high risk female** – MRI.
(High risk females- females having positive history or BRCA mutation)
E.g. – Angelina Jolie (high risk female)

→ IOC for **implant related complication** – MRI

→ IOC used to differentiate scar from benign lesions- MRI

Role of Ultrasound

→ First Investigation done in young females of age < 35 years with breast lump because these patients have dense and glandular breast for which sensitivity of mammography is low.

→ First investigation done in females <35 years of age with breast lump - ultrasound

PrepLadder

Role of PET- Scan in Breast cancer

→ IOC for diagnosis of distant metastasis

→ Differentiates recurrence of Breast CA from scarring, fibrosis and necrosis.

Role of BONE- Scan in breast cancer

→ IOC for diagnosis of **bone** metastasis

→ Samarium-153 is useful for painful bony metastasis

Role of Biopsy in breast cancer

→ IOC for Breast Cancer – BIOPSY

Staging of breast cancer

→ **cTNM**- Clinical

→ **pTNM**- Pathological

→ **rTNM**- Recurrent

→ **mTNM**- Multiple

→ **yTNM**- Staging done when patient has received NACT

8th AJCC TNM CLASSIFICATION FOR BREAST CANCER

Stage	Size of tumor and other characteristics of tumor
T_1	→ up to 2 cm
T_2	→ > 2 - 5cm
T_3	→ >5cm
T_{4a}	→ Extension to chest wall (chest wall is formed by Ribs, Intercostal muscles, Serratus Anterior)
T_{4b}	→ Ulceration → edema including Peau-D-Orange → Satellite nodules → These changes are confined to the same breast.
T_{4c}	→ T4a + T4b
T_{4d}	→ Inflammatory breast cancer

t.me/latestpgnotes

Not included in T4

→ Involvement of dermis alone

→ Nipple retraction/ deviation

→ Involvement of Pectoralis major/ Pectoralis minor

PrepLadder

Lymph node (N)	Staging
N_1	→ Metastasis to ipsilateral axillary lymph node level I and II → Mobile
N_{2a}	→ Metastasis to ipsilateral axillary LN – I and II → Fixed / matted lymph nodes
N_{2b}	→ Clinically apparent internal mammary nodes → detected on clinical examination /grossly visible pathologically/detected on radiological examination except lymphoscintigraphy
N_{3a}	→ Metastasis to ipsilateral infraclavicular LN
N_{3b}	→ Metastasis to ipsilateral axillary + internal mammary LN
N_{3c}	→ Metastasis to ipsilateral supraclavicular LN

Metastasis

M_0	→ No metastasis
M_1	→ Distant Metastasis

t.me/latestpgnotes

Staging of Ca Breast

Stage I	→ T_1
Stage II_A	→ $T_{0-1}\ N_1$ → T_2
Stage II_B	→ $T_2\ N_1$ → T_3
Stage III_A	→ $T_{0-2}\ N_2$ → $T_3\ N_{1-2}$
Stage III_B	→ $T_4\ N_{0-2}$
Stage III_c	→ T any N_3
Stage IV	→ T any N any M_1

NOTE

→ **Two lumps in same breast** – Staging is based on size of bigger lump

→ **Lump in each breast** – each breast lump is staged separately

→ Breast lump with involvement of contralateral lymph nodes – metastasis

PrepLadder

Management of breast cancer

→ Early invasive breast cancer (Stage I, IIA, IIB) – **Breast conservation surgery +Sentinel LN biopsy + Radiotherapy.**

→ If breast conservation surgery is contraindicated – **Simple I total mastectomy +Sentinel LN biopsy (Axillary Lymph node sampling)**

Indications of adjuvant chemotherapy

→ Size >1cm

→ Lymph node +ve

→ Size >0.5 cm & lymph node -ve with adverse prognostic factors.

→ **The following are the adverse prognostic factors**

- High histological grade
- Lymphovascular invasion
- Hormone receptor – ve (Estrogen receptor / Progesterone receptor-ve)
- Her-2-neu +ve

Treatment for locally advanced breast cancer (LABC)

→ Stage III_A
→ Stage III_B
→ Stage III_C

Neo-adjuvant Chemotherapy (NACT) + Modified Radical Mastectomy (MRM) + Radiotherapy (RT)

Treatment for metastatic breast cancer

t.me/latestpgnotes

→ **Stage IV**

- Prolong the survival of patient
- Improve the quality of life
- **Hormone therapy is preferred over chemotherapy** (due to lesser side effects)

Indications

Hormone Therapy	Chemotherapy
→ ER/PR +ve	→ ER/PR- ve
→ Asymptomatic visceral metastasis	→ Symptomatic visceral metastasis
→ Bony or soft tissue metastasis	→ Hormone refractory (patient not responding for hormone therapy)

Indications of radiotherapy in CA Breast

→ Breast conservation surgery

→ Locally advanced breast cancer

→ **4 or more +ve LN**

→ Positive margins

PrepLadder

Chemotherapy regimen in CA Breast

Mnemonic- CMF

→ **C**- cyclophosphamide

→ **M**- methotrexate

→ **F** -5- FU

Mnemonic-CAF

→ **C**- cyclophosphamide

→ **A**- Adriamycin (doxorubicin)
(anthracycline derivative)

→ **F** – 5 – FU

→ The preferred form of chemotherapy for CA breast – **CAF or Adriamycin or Anthracycline based Chemotherapy.**

→ Usually 6 cycles are given

→ For Adriamycin resistant breast cancer - **Taxanes** are given (**Docetaxel, Paclitaxel**)

→ Chemotherapy agent given in Adriamycin & Taxane resistant breast cancer - **IXABEPILONE**

→ **LAPATINIB** - 2nd line agent for HER-2-NEU + ve breast cancer

→ **HERCEPTIN /TRASTUZUMAB** – 1st line agent for HER-2-neu +ve breast cancer

t.me/latestpgnotes

→ Drug given in metastatic and refractory breast cancer - **SUNITINIB**

EXTRA LINK

- 1st line agent for advanced and metastatic RCC → **SUNITINIB**
- Drug of choice for **Imatinib resistant GIST** → **SUNITINIB**

Hormone therapy

→ Estrogen has positive effect on breast cancer cells

→ In hormone therapy either source of production of estrogen (ovary) is **cut surgically or medically.**

→ Surgical method of stopping estrogen production - **Bilateral oophorectomy**

→ Medical method of stopping estrogen production - **Medical oophorectomy** (block receptor of estrogen)

→ In premenopausal females, ovary is the main site of estrogen production

→ In postmenopausal females, estrogen is produced by peripheral aromatization from adipose tissues. (so, aromatase inhibitors are used in post-menopausal females).

Treatment

→ **Ovarian ablation**

- Bilateral oophorectomy
- LH/ RH agonist (Goserelin, Leuprolide)

PrepLadder

→ **SERM** (Selective estrogen receptor modulator)
- Tamoxifen
- Raloxifene

→ **Aromatase Inhibitors** (useful only in post-menopausal females)
- Non- steroidal (Letrozole, Anastrozole)
- Steroidal (Exemestane)

→ **Anti- estrogens**
- Fulvestrant

→ **Progestins**
- Megestrol
- Medroxy progesterone acetate

→ Drug of choice for hormone therapy in pre- menopausal patients - Tamoxifen

→ Drug of choice for Hormone therapy in post-menopausal patients - Aromatase inhibitors

Tamoxifen

→ Dose – 10 mg BD x 5 years

→ **Potent antagonistic activity against (BB)**
- Breast cancer cells
- Blood vessels

t.me/latestpgnotes

→ **Partial agonist on**
(Mnemonic – PITBUL)
- **PIT** - Pituitary
- **B** - Bone
- **U** - Uterus (Tamoxifen ↑se risk of endometrial cancer in postmenopausal pts.)
- **L** - Liver

LN levels in relation to pectoralis minor

→ **Level I**- below and lateral to pectoralis minor
- **A** -anterior
- **P** – Posterior
- **L** – Lateral

→ **Level II** -behind pectoralis minor
- Central LN
- Interpectoral LN (Rotter's Nodes)

→ **Level III** – Medial and above pectoralis minor
- Apical group of lymph nodes.

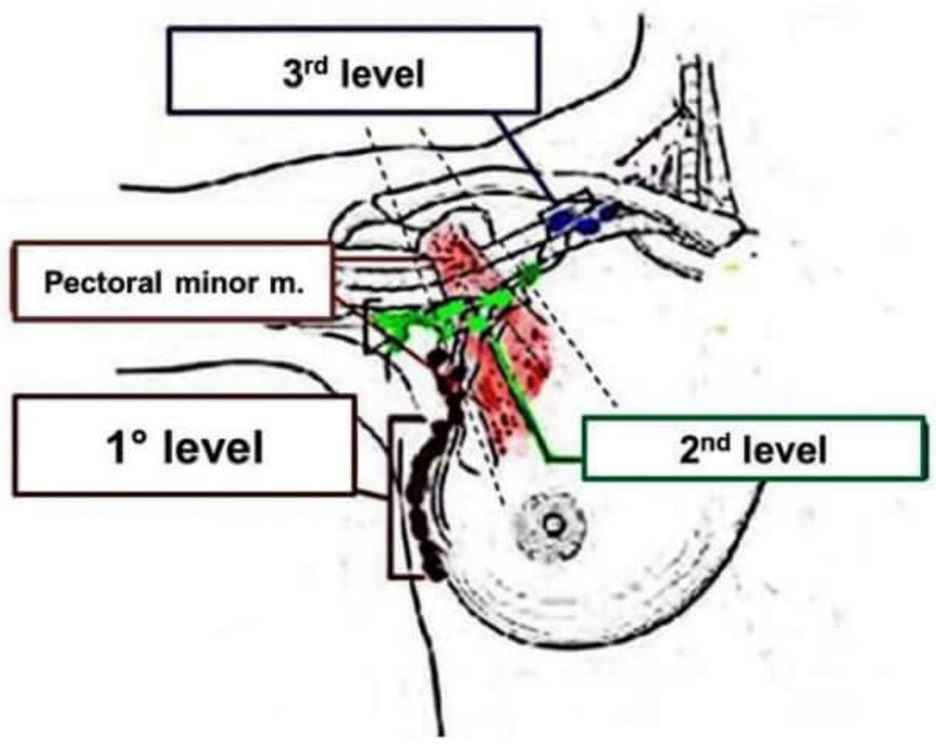

PrepLadder

Mastectomy

Types of Mastectomy
→ **Simple / Total mastectomy** • Elliptical Incision (skin overlying the lump included in incision) • En-bloc removal of nipple, areola, skin, breast tissue, breast mass.
→ **Extended mastectomy** • Simple Mastectomy + Removal of level 1 LN
→ **Modified Radical Mastectomy (MRM)** • En-bloc removal of nipple, areola, skin, breast tissue, breast mass + level I and II LN
→ **Halsted Radical Mastectomy** • En-bloc removal of nipple, areola, skin, breast tissue, breast mass + level I, II and III LN + Excision of pectoralis major and minor muscle. • **Structures spared in Halsted radical mastectomy** **(Mnemonic- ABC)** ➢ **A** - Axillary vein ➢ **B** - Bell's nerve (long thoracic nerve) ➢ **C** - Cephalic vein
→ **Extended radical mastectomy** • Radical mastectomy + Removal of **I**nternal mammary nodes **(RIM)**
→ **Super radical mastectomy** • Radical mastectomy + Removal of **S**upraclavicular lymph node + **I**nternal mammary lymph node + **M**ediastinal lymph node **(SIM)**

t.me/latestpgnotes

Modifications of modified radical mastectomy / variant of MRM
→ **AUSCHINCLOSS** • similar as MRM
→ **PATEY'S modification** • En bloc removal of nipple, areola, skin, breast tissue, breast mass + level, I, II, III LN + Excision of pectoralis minor.
→ **SCANLON'S modification** • En block removal of nipple, areola, skin breast tissue, breast mass + level, I II, III + division of pectoralis minor (not excision of pectoralis minor)

PrepLadder

Complications of mastectomy

- → **Seroma** – seen in 30% of patients (MC complication)
- → Wound infection / flap necrosis
- → Injury of **long thoracic nerve**
- → Injury of **thoracodorsal nerve**
- → Persistent axillary fat pad
- → Lymphedema
- → Patients with lymphedema, approximately after 10.5 years it may progress to Angiosarcoma. These patients of breast cancer with MRM and RT done and diagnosed to have angiosarcoma is known as **Stewart Treves Syndrome**.

t.me/latestpgnotes

PrepLadder

BREAST PART-2

Breast Conservation Surgery (BCS)

→ Performed for early invasive breast cancer (**Stage I, IIA, IIB**)

Treatment options

→ Excision of lump – **Lumpectomy**

→ **Wide local excision with 1 cm margin**

→ Whole quadrant excision (**Quadrantectomy**)

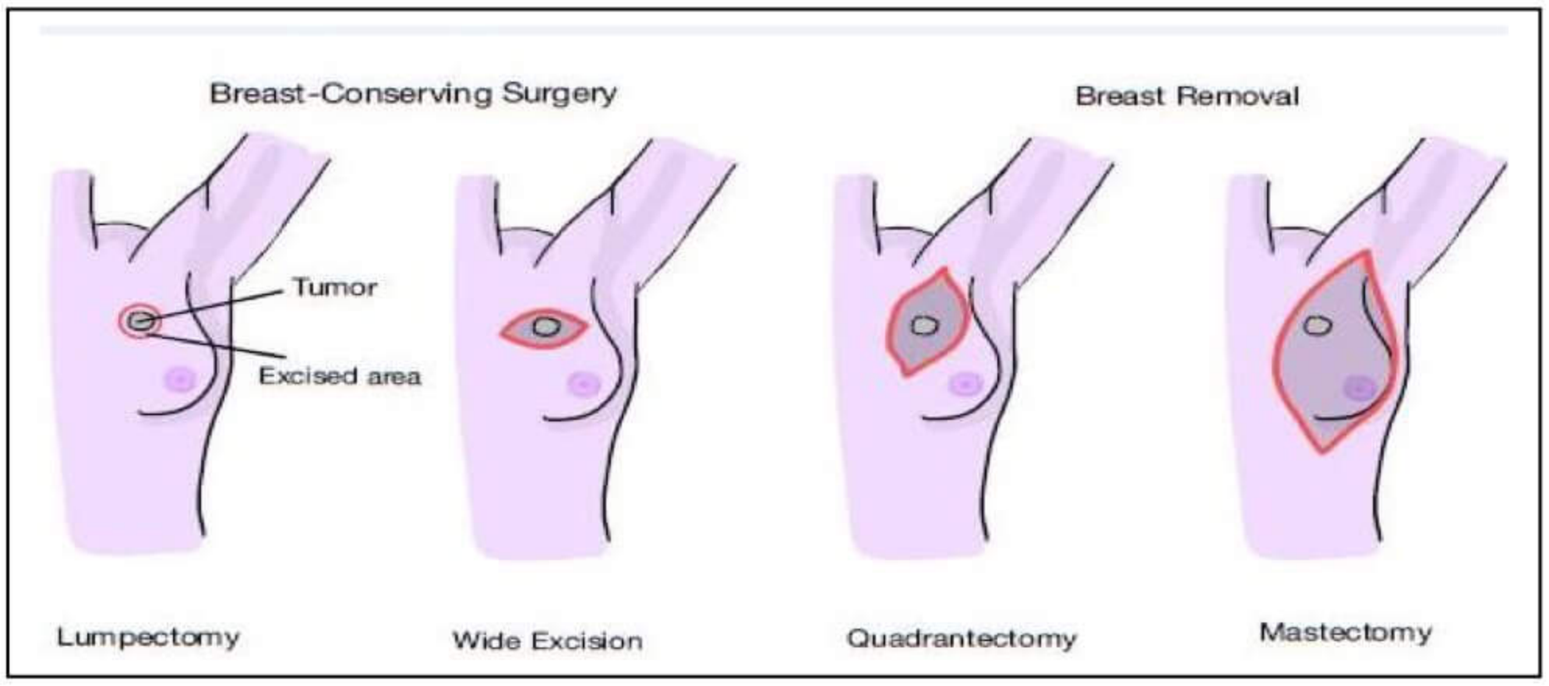

t.me/latestpgnotes

Contraindications of Breast conservation surgery

Absolute contraindications	Relative contraindications
→ Pregnancy	→ H/ O Collagen vascular disease (Scleroderma, Active lupus erythematosus)
→ 2 or >2 tumors in different quadrants or diffuse malignant appearing diffuse micro-calcification.	→ Multiple tumors in same quadrant
→ Persistently +ve margins	→ Large tumor in small breast
→ History of exposure of therapeutic radiation	→ Large pendulous breast (difficult to give uniform dose of radiotherapy)
	→ Centrally located tumor (excision of nipple and areola should also be done for centrally located tumor but reconstruction of nipple of areola is difficult

→ If there is contraindication for Breast conservation surgery, Simple/Oblique/Total Mastectomy is preferred

PrepLadder

Breast Reconstruction

Methods of Breast Reconstruction

→ **Autogenous methods** (reconstruction of breast using own tissues)

→ **Alloplastic methods** (reconstruction of breast using silicone implants)

→ **Combined methods** (reconstruction of breast using both Autogenous and Alloplastic methods)

Autogenous methods

→ **TRAM Flap** - Transverse Rectus Abdominis muscle flap

→ **LD Flap** - Latissimus dorsi flap

→ **Thoraco epigastric flap**

→ **Lateral thigh flap**

→ **Gluteal flap**

→ **Ruben's flap** - based on **deep circumflex iliac artery**

Alloplastic methods

→ **Silicone gel implants**

→ **Silicone implants with saline refill**

→ Most commonly used method for breast augmentation and breast reconstruction

Combined methods

→ For females with large breast– after mastectomy, symmetry cannot be restored with flap. so, flap + silicone implants used.

t.me/latestpgnotes

→ To restore symmetry - **TRAM FLAP + IMPLANT, LD FLAP + IMPLANT**

→ Most commonly used flap for Breast Reconstruction - **TRAM Flap**.

→ Best flap used for breast reconstruction -**DIEP Flap (Deep Inferior epigastric artery perforator Flap)**

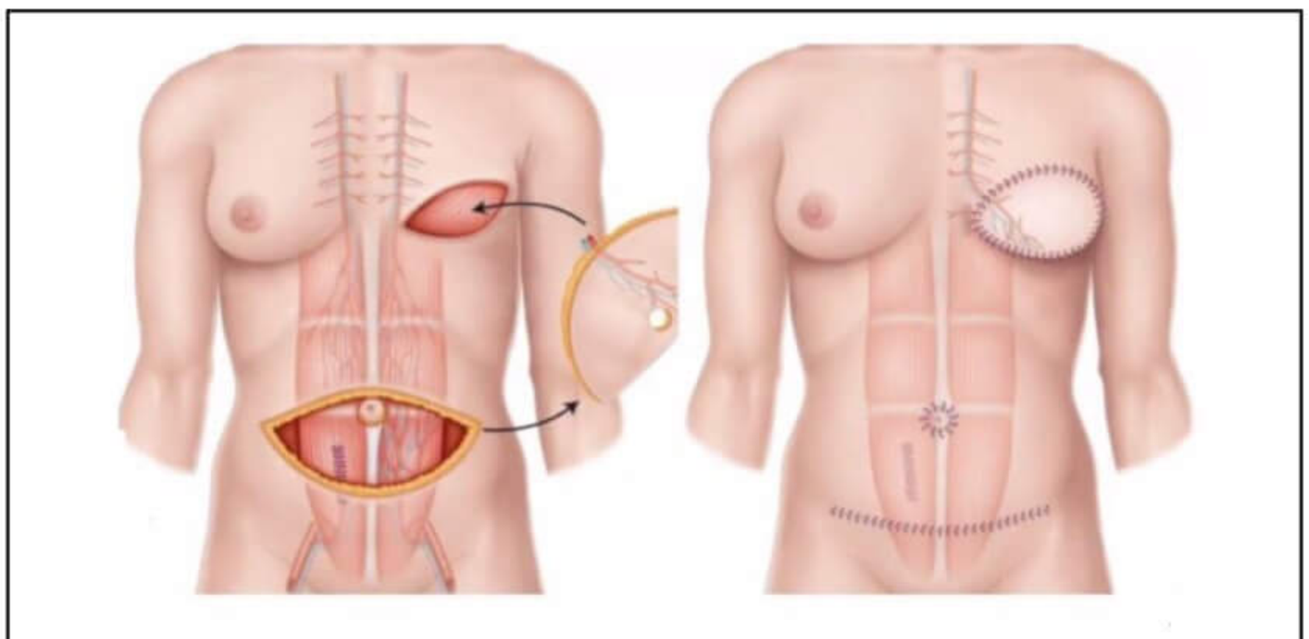

TRAM FLAP

TRAM flap

→ Internal mammary artery and vein are anastomosed with Inferior Epigastric artery and vein respectively.

→ It is a free flap.

PrepLadder

→ **Disadvantage of TRAM flap** - Transverse rectus abdominis muscle is excised from lower abdominal area and so there will be a weakness which can further lead to Hernia

DIEP flap

→ Only abdominal skin and fat along with **deep inferior epigastric artery and vein** are used
→ Abdominal muscle is spared
→ So, there will be no weakness or hernia **and so it becomes the best method.**

LD flap

→ Latissimus dorsi muscle is excised and subcutaneous tract is created.
→ It is subcutaneous flap for reconstruction of breast.

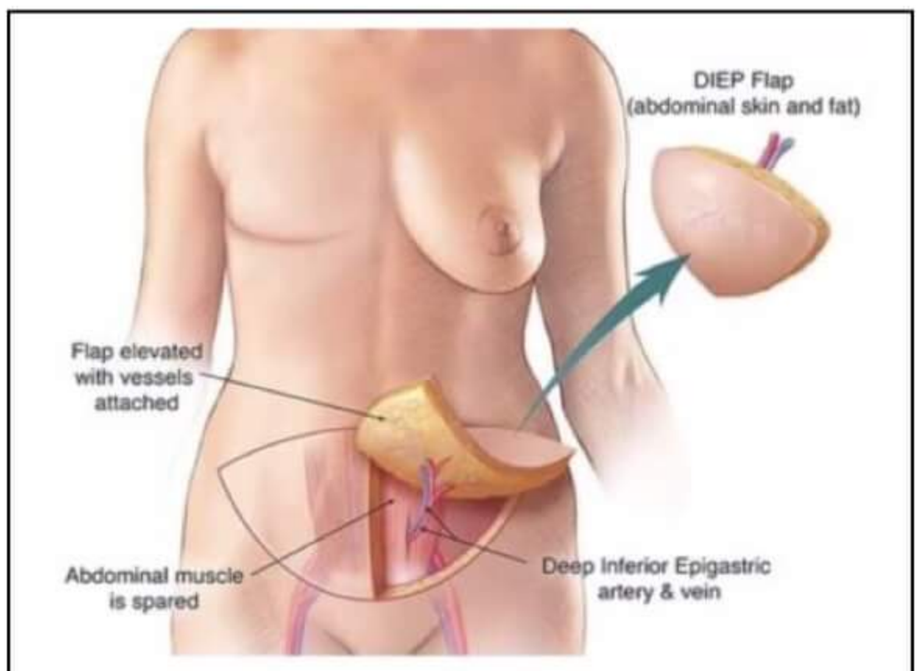

DIEP FLAP

t.me/latestpgnotes

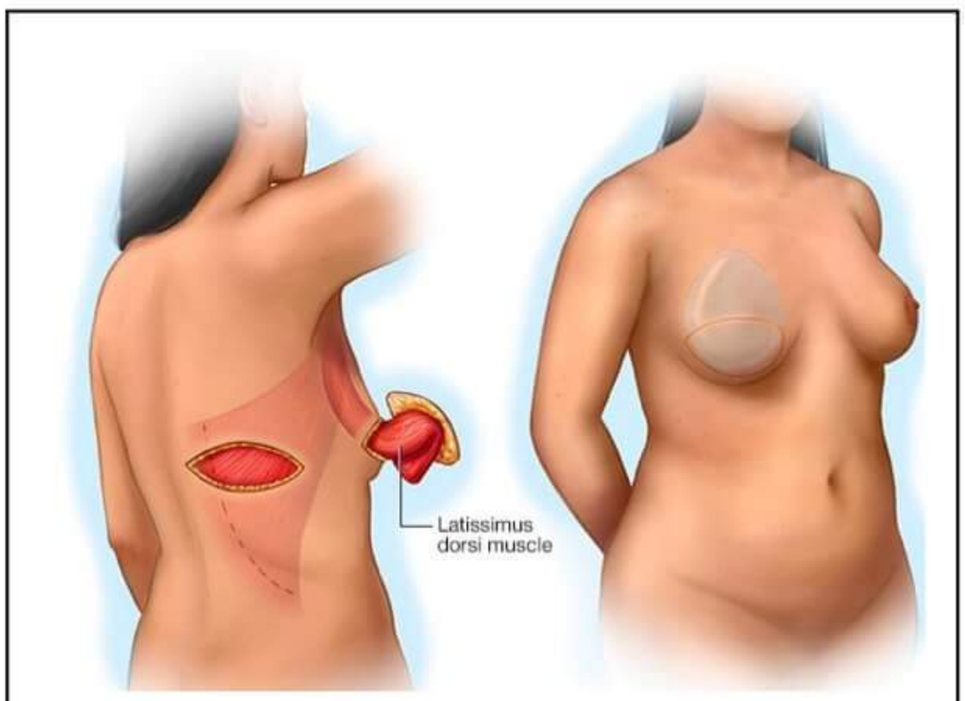

LD FLAP

Silicone implants

→ Most commonly used method for breast augmentation and breast reconstruction is silicone Implants.

Placement of implant

→ For **breast augmentation**, silicone implants are placed in front of muscle.
→ For **breast reconstruction**, behind the muscle is most preferred
→ IOC for implant related complications– MRI

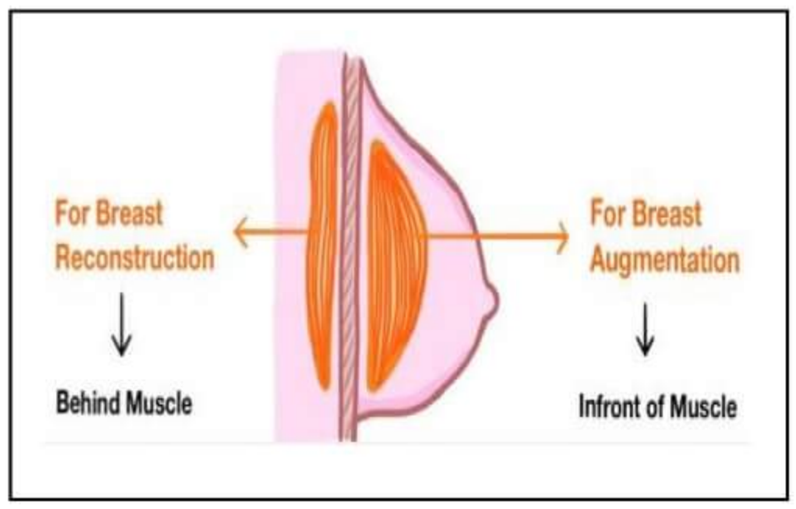

Breast cancer follow up

→ **History + physical examination**
- Every 3 to 6 months for first 3 years
- Every 6 to 12 months for 4th and 5th year
- Annually thereafter

→ **Mammography**
- Annually
- **Beginning no earlier than 6 months of Radiotherapy**

PrepLadder

→ Breast self-examination - **Monthly**

→ Pelvic examination - **Annually**

→ Co-ordination of care in various health care providers

Investigations that are not recommended for routine surveillance of breast cancer patients

→ **Blood investigations**

- CBC
- LFT

→ **Imaging**

- CXR
- USG- Liver
- Bone scan
- PET scan
- CT scan
- MRI breast

→ **Tumor markers**

- CA antigens
- CEA

Prognostic factors in CA breast

→ Most important prognostic factor in most of the malignancies- **Stage (TNM Staging)**

→ **Exceptions for staging as prognostic factor**

- For Wilms tumor - **histology > staging**
- For Soft tissue sarcoma - **tumor grade**

→ Most important prognostic factor in breast cancer - **Stage (TNM Staging)**

→ Single most important prognostic factor in breast cancer - **Axillary Lymph node status**

→ Most important prognostic factor in metastatic breast cancer - **ER/PR status**

t.me/latestpgnotes

NOTTINGHAM PROGNOSTIC INDEX

→ **NPI** - (0.2 * Tumor size) + LN stage + Tumor grade

→ To select patients for adjuvant treatment

BLOOM RICHARDSON GRADING

→ **T** - Tubule formation

→ **N** - Nuclear pleomorphism

→ **M** - Mitosis

VAN- NUYS PROGNOSTIC INDEX(VNPI)

→ For Patients of DCIS who do not require radiotherapy

→ It is based on

(Mnemonic- Micro SWAG)

- **Micro** - Microcalcification

PrepLadder

- **S** – Size of tumor
- **W** – Width of margin
- **A** –Age of patient
- **G** – Grade of tumor

Sentinel lymph node biopsy

→ SLN is first LN which receives lymph directly from tumor

→ First described by – Cabana in Carcinoma penis

→ SLN Biopsy in Carcinoma Penis – Cabana procedure

→ **Established role of SLN Biopsy in**

- Carcinoma Breast
- Carcinoma Penis
- Malignant melanoma
- Head and neck malignancies
- Vulvar carcinoma

→ Indication of SLN biopsy – clinically non-palpable axillary lymph nodes

→ There are two techniques followed for sentinel lymph node biopsy.

- **Blue dye technique** – Using 1% LYMPHAZURIN (aka Isosulphan blue, Paten V blue, Methylene blue)
- **Radioactive colloid technique** – Using Tc-99 labelled Sulphur

→ Maximum accuracy of detection in sentinel lymph node biopsy – when both techniques are combined together.

t.me/latestpgnotes

SLN biopsy in breast cancer

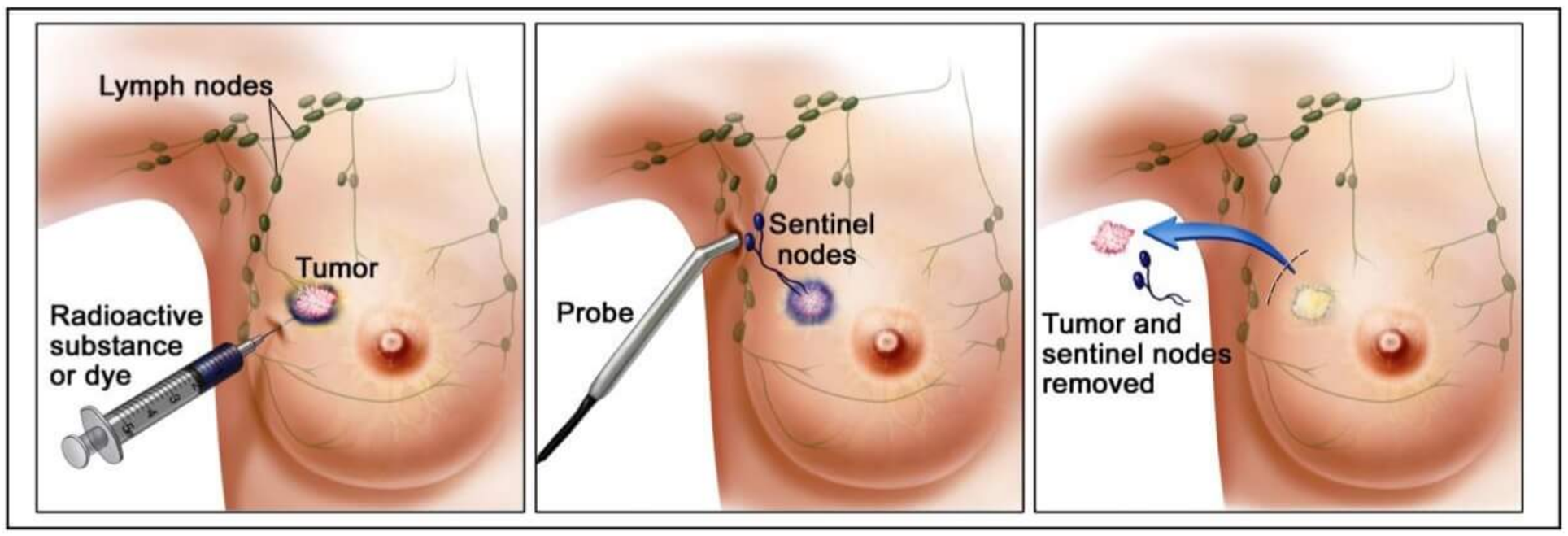

Procedure of technique

→ A dye and radioactive substance are injected around the tumor or subcutaneously around areola.

→ The lymph nodes that is immediately linked to the tumor becomes blue.

→ Generally, in CA Breast, there are >1 sentinel lymph node.

→ Simultaneously gamma probe is also inserted for detecting the radioactivity.

→ The lymph node with maximum radioactivity will have maximum uptake of radioactive substance and hence this lymph node is the sentinel lymph node.

→ Bluish sentinel lymph node will be removed and sent for pathological examination.

PrepLadder

BLUE DYE TECHNIQUE

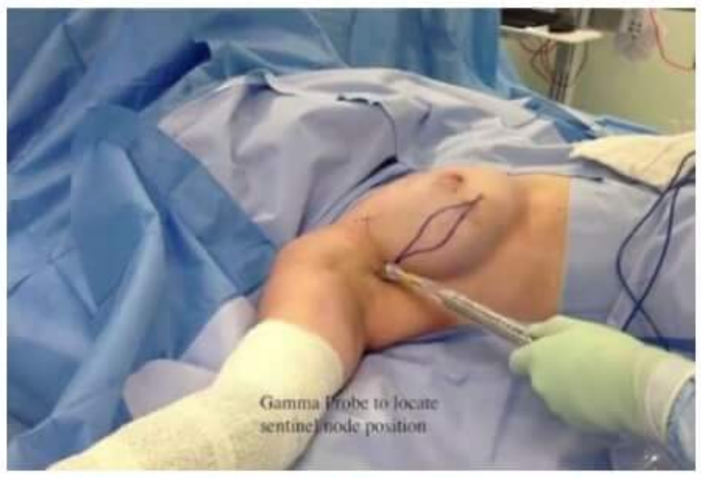

GAMMA PROBE TECHNQIUE

Complications of SLN biopsy in CA Breast

→ Most common complication – **skin tattooing**

→ Most common injured nerve in SLN biopsy – **Intercostobrachial nerve**

Contraindications of SLN biopsy in CA breast

→ Palpable lymphadenopathy

→ Prior axillary surgery, Chemotherapy, Radiotherapy

→ Multi focal breast cancer

Complications of sentinel lymph node biopsy

→ MC – **Skin tattooing**

→ Necrosis

→ Urine discoloration

t.me/latestpgnotes

→ Anaphylaxis

→ MC injured nerve – **Intercostobrachial nerve injury**

Inflammatory breast cancer

→ Aka **Mastitis Carcinomatosa**

→ Corresponds to **Stage T_{4D} = Stage III_B**

→ Behaves like **LABC (locally advanced breast cancer)**

→ Involvement of **> 33%** of breast skin by inflammatory changes

- Erythema
- Brawny induration
- Early onset of **Peau D Orange**

↓due to

Early lymphatic permeation by tumor cells – Cutaneous Lymphedema

↓

Early lymph node metastasis

↓

Early distant metastasis

→ Presence of lump is not mandatory for diagnosis of Inflammatory Breast cancer and Paget's diseases of nipple

PrepLadder

Clinical features

→ Presence of inflammatory changes in breast skin
→ 75% patients present with axillary LN metastasis
→ 25% patients present with distant metastasis

Investigations

→ IOC - **Skin Biopsy** (Lump not present)
→ **On skin biopsy** – presence of tumor cells in the lymphatics
→ Inflammatory breast cancer is the only cancer of breast where skin biopsy is the IOC

Treatment

→ NACT + MRM + RT
→ It is the **most malignant type of breast cancer & worst prognosis**

Breast cancer in pregnancy

→ Incidence of breast cancer in pregnancy - **1: 3000 pregnancies**
→ Most common type of non-gynecological malignancy of pregnancy
→ Most common type - **invasive ductal cancer.**

Clinical features

→ Mc presentation during pregnancy - **Breast Lump**
→ Breast changes during pregnancy mask the sign and symptoms of Breast cancer. so patient is in the **advanced stage at the time of presentation**
→ **75% patient** – axillary LN metastasis at the time of presentation

t.me/latestpgnotes

Investigations

→ first investigation done – **Ultrasound**
→ Mammography is not preferred as first investigation (due to radiation exposure)
→ IOC for diagnosis – **biopsy**

Treatment

→ Early invasive breast cancer – **Simple mastectomy**
→ Locally advanced Breast cancer – **Neoadjuvant chemotherapy (NACT) + MRM + Radiotherapy**
→ **General Anesthesia** – Increased risk of abortion in 1st trimester – so MRM done in 2nd trimester.
→ Maximum Organogenesis occurs in 1st trimester – No chemotherapy can be given → Congenital malformations can occur
→ Radiotherapy is contraindicated in pregnancy
→ NACT is given **after completion of 1st trimester**
→ MRM – **2nd trimester**
→ RT - **After delivery**

PrepLadder

Male Breast Cancer

→ Responsible for 1% of breast cancer
→ Mc type – Invasive ductal cancer
→ **In male breast** - only ducts are present; only invasive ductal cancer can occur in males
→ **In female breast** - both ducts and lobules are present, so invasive ductal cancer and lobular cancer can occur.
→ Lobular carcinoma of breast - exclusively seen in females
→ Generally seen in 6th decade
→ **ER/PR +ve** in 80% cases
→ **HER-2-NEU + ve** in 35% cases
→ Endogenous / exogenous estrogen – Increases risk

Risk factors for male breast cancer

(State of Hyperestrogenemia)

→ Cirrhosis of liver
→ Infertility
→ Bilateral undescended testis
→ Androgen insensitivity syndrome/testicular feminization syndrome
→ BRCA 2 mutation.

Catabolism of estrogen occurs in liver
↓
If liver disease
t.me/latestpgnotes
↓
Catabolism is affected
↓
Relative dominance of Estrogen in males
↓
State of Hyperestrogenemia

(cirrhosis of liver, chronic liver disease, infertility, bilateral undescended testis, AIS/TFS, Klinefelter's syndrome, BRCA2 mutation are all examples of state of Hyperestrogenemia)

→ In 20% cases gynecomastia precedes breast cancer but gynecomastia is not risk factor for male breast cancer

Clinical features

→ MC Presentation – **Lump**
→ Early involvement of nipple, breast skin, chest wall due to scanty breast tissue in males

Investigations

→ IOC – Biopsy

Treatment

→ Stage by stage treatment and prognosis is similar to female Breast cancer.

PrepLadder

Paget's Diseases of Nipple

→ Chronic eczematous lesion or eruption of nipple

→ Associated with underlying malignancies are **Ductal carcinoma in-situ** and **Invasive ductal cancer**

→ CEA positivity differentiates Paget's disease of nipple from superficial spreading of melanoma whereas melanoma is positive for S-100

Clinical features

→ Eczematous eruption of nipple

→ **Presence of lump not mandatory** for diagnosis

Investigations

→ For diagnosis – **Complete mammography + Biopsy** (to rule out occult multicentric disease and presence of Paget cells are diagnostic)

Treatment

→ Simple mastectomy

Phyllodes Tumor

→ **Aka**

- Cystosarcoma phyllodes
- Serocystic disease of Brodie (Phyllodes – leaf like appearance on cut section)

→ **Dual origin**

- Mammary epithelium and
- Connective tissue (stroma)

→ Can be Benign, borderline or malignant

→ **On cut section**

- Leaf like appearance
- Monoclonal stroma

→ **Cystic areas** – because of hemorrhage + necrosis

→ **Unique feature of Cystosarcoma phyllodes** – 3 Structures not involved

- Nipple
- chest wall
- Breast skin

PHYLLODES TUMOR

t.me/latestpgnotes

Clinical features

→ Affected breast is massively enlarged

→ Bosselated appearance (like in lipoma)

→ Pressure atrophy /Necrosis of skin

→ No Skin fixity (because breast skin is not involved)

→ No Fixation of tumor to the chest wall as chest wall is not involved. (tumor is mobile over the chest wall).

PrepLadder

→ No nipple retraction/ulceration/deviation (because nipple is also not involved)

Route of spread

→ Most common route of spread – **Hematogenous spread** **(Lymphatic route of spread is not seen)**

→ Most common site of metastasis – **Lungs**

Investigations

→ **IOC**- Biopsy

Treatment

→ Benign appearing Cystosarcoma phyllodes –**WLE** (wide local excision with 2cm margin)

→ Malignant appearing Cystosarcoma phyllodes – **Simple mastectomy**

→ **MRM not performed because it is not associated with LN metastasis**

→ Usually sarcomas are not spread via lymphatics.

→ Few Sarcomas with lymphatic spread are

(Mnemonic- MARCES)

- **M**- Malignant fibrous histiocytoma
- **A**-Angiosarcoma
- **R**- Rhabdomyosarcoma
- **C**- Clear cell sarcoma
- **E**- Epithelial Sarcoma
- **S**- Synovial Sarcoma

t.me/latestpgnotes

Benign conditions of breast

Cancer risk associated with Benign breast disease and carcinoma in situ

Abnormality	Relative risk
→ Non proliferative lesions	• No increased risk
→ Sclerosing adenosis	• No increased risk
→ Duct papilloma	• No increased risk
→ Florid hyperplasia	• 1.5-2-fold increased risk
→ Atypical ductal hyperplasia	• 4-fold increased risk
→ Atypical lobular hyperplasia	• 4-fold increased risk
→ **Ductal involvement** by cells of Atypical ductal hyperplasia	• 7-fold increased risk
→ LCIS	• 10-fold increased risk
→ DCIS	• 10-fold increased risk

ANDI (Aberrations in normal development & Involution)

→ 15 - 25 years - **Fibroadenoma**

→ 25 - 40 years – **Fibro adenosis**

→ > 40 years - **Fibro adenosis > Duct ectasia**

PrepLadder

Fibroadenoma

→ Benign tumor

→ Seen in young patients of age 15-30 years

→ Aka – breast mouse (tumor is highly mobile)

Clinical features

→ **Lump** - highly mobile, firm

→ Most common presentation - lump

Investigations

→ IOC - FNAC

→ On mammography – Popcorn calcification

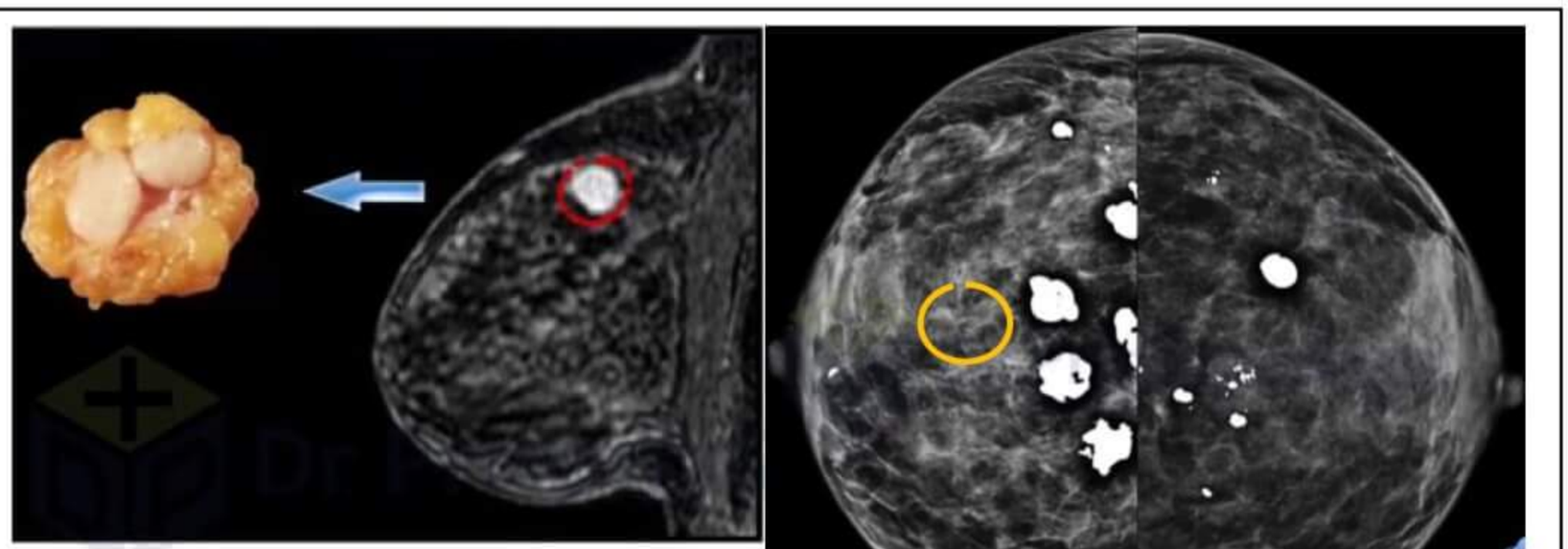

FIBROADENOMA POP CORN CALCIFICATION

t.me/latestpgnotes

Treatment

→ Observation (benign tumor)

→ **Alternative treatment** - Surgical excision is done for suspicious lesions or for cosmetic reasons

Mastalgia

Non- Cyclical mastalgia

→ Due to musculoskeletal causes

→ TIETZ syndrome

- **Aka Costochondritis** - inflammation of one or more costal cartilages
- **Treatment** - intralesional injection of Triamcinolone

→ Mondor's disease

- Aka **String phlebitis**
- Characterized by superficial thrombophlebitis of inframammary veins
- Veins involved - lateral thoracic > thoraco epigastric veins.
- **Treatment**
  - NSAIDS
  - For non-responding patients, Excision of thrombosed vein is done

MONDOR'S DISEASE

PrepLadder

Cyclical mastalgia

→ **Fibroadenosis / Fibrocystic disease**

- Pain follows the cyclical pattern of menses
- Maximum pain before menses
- 25 - 40 years
- Bilateral serous nipple discharge arising from multiple ducts.
- Diagnosed on Ultrasound
- Lumpy breast on examination/ palpation
- **Treatment**
  - Weight reduction & regular exercise
  - Decrease caffeine intake
  - Vitamin E and Primrose oil capsule (for a maximum of **3 months**).
  - If no improvement - Low dose Tamoxifen is given

Breast cyst

→ Seen in last decade of reproductive life

→ Due to nonintegrated involution of stroma and epithelium

Clinical features

→ Multiple

→ Can be bilateral

→ Can mimic malignancy- Sudden presentation can be used to differentiate from malignancy

t.me/latestpgnotes

Investigation

→ Aspiration ± Ultrasound

Treatment

→ Aspiration

→ **For recurrence** - Reaspiration

Breast Abscess

→ MC in lactating females

→ MC in Primi females - because of **faulty technique of breast feeding**, injury to nipple by which the staph aureus from the overlying skin penetrates to produce breast abscess.

→ MC organism responsible is Staph Aureus

BREAST ABSCESS

Clinical features

→ pain & tenderness over the affected breast

→ Fever with chills and rigor

→ Breast is engorged

PrepLadder

Treatment

→ Incision and drainage + Antibiotics

→ 1st line agent - Cloxacillin / Dicloxacillin for 10 -14 days

ZUSKA'S disease

→ Aka **Recurrent periductal mastitis**

→ More common in **female smokers**

Clinical features

→ Recurrent breast abscess

Treatment

→ Incision and drainage + Antibiotics

t.me/latestpgnotes

PrepLadder

THYROID Part-1

→ Normal weight of Thyroid – 20-25 grams
→ Storage site of iodine - Thyroid (90% of body's iodine is stored in thyroid)
→ Normal daily iodine requirement - 100 -150 microgram/day
→ Weight of thyroid is inversely proportional to iodide intake
→ Father of Thyroid Surgery – Theodor Kocher
→ Isthmus in relation to 2nd, 3rd and 4th tracheal rings (mainly 3rd)

Wolf Chaikoff effect	→ Iodine induced Hypothyroidism
Jod Basedow's effect	→ Iodine induced Hyperthyroidism
Pendred syndrome	→ **Congenital sensorineural hearing loss + Goiter** → Gene is located on chromosome no.7q (long arm)
Refetoff syndrome	→ End organ resistance to T4

Congenital disorders of thyroid

Thyroglossal Cyst

→ Congenital
→ Age of presentation – 15-30 years
→ There is cyst in connection to thyroid and tongue. So, on protrusion of tongue, the cyst moves up
→ MC location – Subhyoid
→ **Other common locations**
  - Suprahyoid
  - Near thyroid cartilage
  - Near Foramen cecum
  - In floor of mouth

t.me/latestngnotes

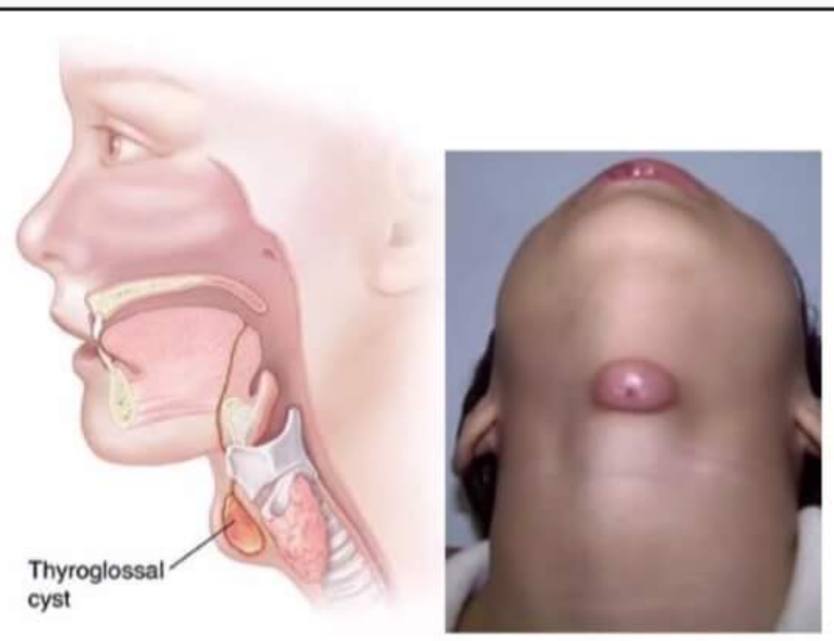

THYROGLOSSAL CYST

Clinical features

→ Midline swelling in anterior part of neck
→ Thyroglossal cyst moves with deglutination
→ Moves up on protrusion of tongue

Complications of Thyroglossal cyst

→ Infection → Abscess → if Incision and Drainage
↓
Thyroglossal fistula (acquired condition due to I & D of abscess of thyroglossal cyst)
→ Increased risk of papillary carcinoma of thyroid

Treatment

→ TOC – Sistrunk operation.

PrepLadder

→ The cyst passes via body of hyoid bone – so excision is made

→ Enbloc removal of central part of body of hyoid bone + cyst

Goiter

→ **Endemic Goiter**

- If >5% people in population have goiter

→ **Retrosternal goiter / substernal goiter / Mediastinal goiter**

- If > 50% of thyroid tissue is located below the opening of thoracic cage.
- Most patients are asymptomatic
- Diagnosed incidentally on radiological investigations

Signs & Symptoms

→ MC symptom – Dyspnea (due to compression of trachea), in night

→ Dysphagia (due to compression of esophagus)

→ Hoarseness of voice (due to compression of Recurrent laryngeal nerve)

→ Dilated veins over Anterior chest wall.

→ PEMBERTON sign- positive

- If bilateral upper limb elevated above forehead, facial puffiness and facial congestion seen

Treatment

t.me/latestpgnotes

→ Thyroidectomy by cervical incision [Vessels supplying the thyroid are loaded in the neck & easy for ligating those vessels if cervical incision is made]

→ **Radioisotopes used**

- $T_{1/2}$ of I^{123} → 13 hours (shorter fall life) - so used for **diagnostic purposes (RAI SCAN)**
- $T_{1/2}$ of I^{131} → 8 days (Longer half-life) - so used for **therapeutic purposes (RAI ABLATION)**

Radio Active Iodine Ablation

→ I^{131} emits beta- rays (90%) and gamma- rays (10%)

→ Beta rays are responsible for Therapeutic effects (ablation)

→ Depth of penetration of beta rays - 0.5 mm (Ablates only thyroid, even parathyroid are safe)

→ Gamma rays are responsible for side effects

→ Gamma rays are used in Tracer studies – Gamma probe can be used for identifying the area that emits gamma rays. So, useful in **Radioactive Iodine scan**

→ **Absolute contraindication of RAI Ablation** (because gamma rays are emitted)

- Pregnancy
- Lactation

PrepLadder

Radioactive Iodine uptake

→ Amount of Radioactive iodine taken by thyroid gland within stipulated period of time (6 - 24 hours)

RAI scan

→ Aka **Thyroid scan**

→ Scanning of cervical region with gamma probe

Hot Nodule

→ Nodule with relatively increased uptake as compared to surrounding tissue

→ Risk of malignancy in hot nodule – **1 to 3 %**

Cold Nodule

→ Nodule with relatively decreased uptake as compared to surrounding tissue

→ Risk of malignancy for cold nodule – **17 to 20%**

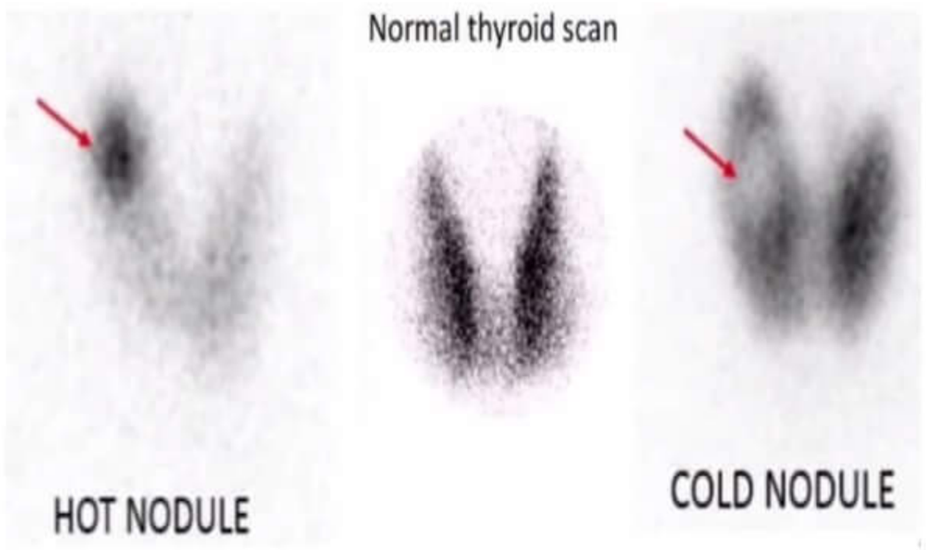

Grave disease (Diffuse toxic goiter)

→ Increased uptake of RAI on all Thyroid tissues

Toxic multinodular goiter

→ Increased uptake & Decreased uptake at certain areas

Autonomous Nodule

→ Increased uptake in one nodule with suppression of remainder of gland.

Thyroiditis

→ Damaged thyroid gland

→ Decreased RAI uptake (RAI < 5%)

t.me/latestpgnotes

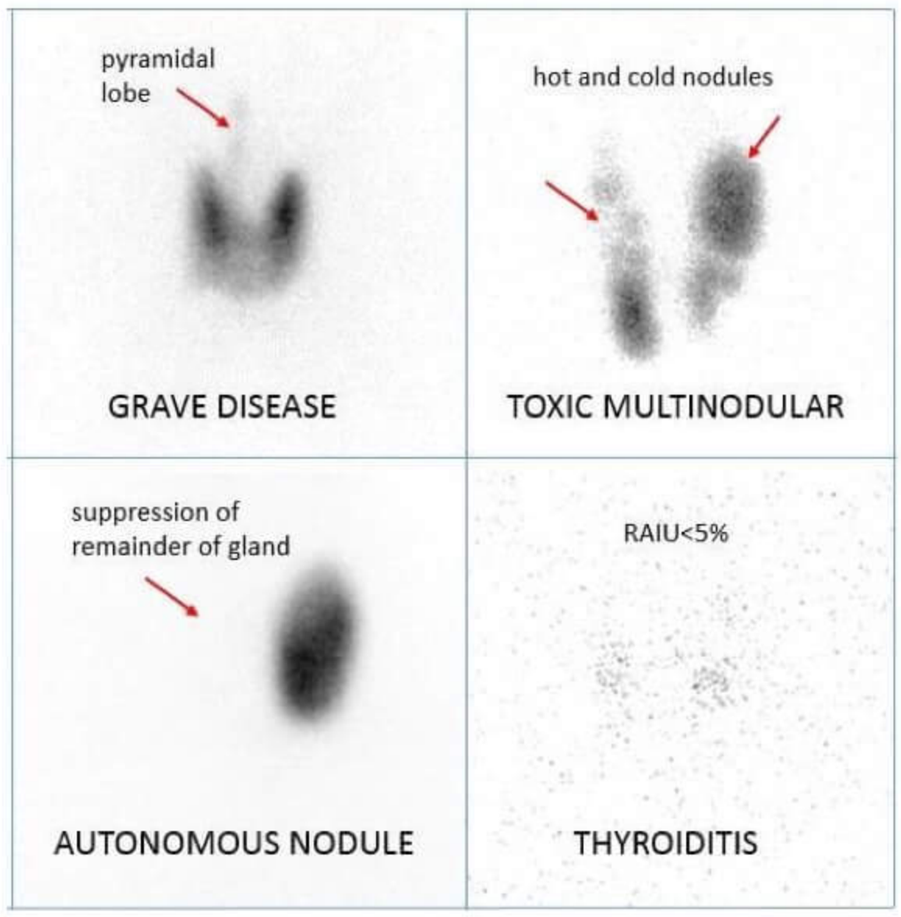

PrepLadder

Thyroidectomy

Total Thyroidectomy → Removal of all visible Thyroid tissue	Total thyroidectomy
Hemi Thyroidectomy → Removal of one lobe with isthmus	Hemi- Thyroidectomy (Removal of 1 lobe with Isthmus)
Subtotal Thyroidectomy → Leaving **3-4 grams** of thyroid tissue in each lobe superiorly with removal of rest of thyroid gland.	Sub- Total Thyroidectomy (Leaving 3-4gm of tissue)
Hartley Dunhill Procedure → Leaving **4-6 grams** of thyroid in one lobe with removal of rest of thyroid gland.	Hartley Dunhill Procedure (Leaving 4-6gms of tissue)
Near total Thyroidectomy → Leaving **< 1 gram** of thyroid tissue adjacent to recurrent laryngeal nerve near ligament of berry.	Near Thyroidectomy (Leaving <1gm of tissue adjacent to Recurrent Laryngeal Nerve, near ligament of Berry).

t.me/latestpgnotes

PrepLadder

→ **Hemi Thyroidectomy** – Benign disorder involving one lobe.
→ **Total Thyroidectomy** - Preferred for Thyroid malignancy and Benign disorders involving both lobes
→ For **Multinodular goiter** earlier subtotal thyroidotomy was performed. But after prolonged follow up (20- 30 years) recurrence was noted from thyroid remnant. So, now a days even for multi modular goiter – **Total thyroidectomy preferred** (easy to manage patients lifelong on Levothyroxine than getting recurrence which is more dangerous)
→ However, **subtotal thyroidectomy is performed for patients with multinodular goiter only in elderly** (as recurrence at long term is not expected in elderly due to short life expectancy)
→ Therefore, **only indication for subtotal thyroidectomy is MNG is in elderly population.**

Solitary Thyroid Nodule (STN)

→ MC Solitary Thyroid Nodule - **Colloid goiter > Follicular adenoma**
→ 1st investigation for STN - **Thyroid Function Test (T3, T4, TSH)**
→ **TSH**
- Most informative among thyroid function test parameters because of **ultra-sensitivity**
- Can detect **subclinical hypothyroidism & subclinical hyperthyroidism**
- Hypothyroidism – TSH ↑
- Hyperthyroidism – TSH ↓

t.me/latestpgnotes

Investigations

→ IOC for Diagnosis of STN- **FNAC** (Fine needle Aspiration cytology)

Limitation of FNAC

→ **Cannot differentiate follicular adenoma from follicular carcinoma**
- Diagnosis of follicular carcinoma is based on vascular invasion/ capsular invasion that can be seen on biopsy only and not on FNAC

→ **REIDEL'S Thyroiditis**
- All Thyroid tissue is replaced by fibrosis even if FNAC is performed there is no yield

→ **Thyroid lymphoma.**
- For lymphoma anywhere in the body, **IOC- Biopsy** (because markers are put over tissue specimen to confirm the diagnosis of lymphoma)

→ Most of cases of thyroid problem – FNAC is preferred except the 3 limitations mentioned above.
→ All thyroid gland related problems (benign / malignant) – more common in females.

PrepLadder

Management

→ For Solitary thyroid nodule, using FNAC, it can be either

- Inconclusive
- Benign
- Suspicious
- Malignant

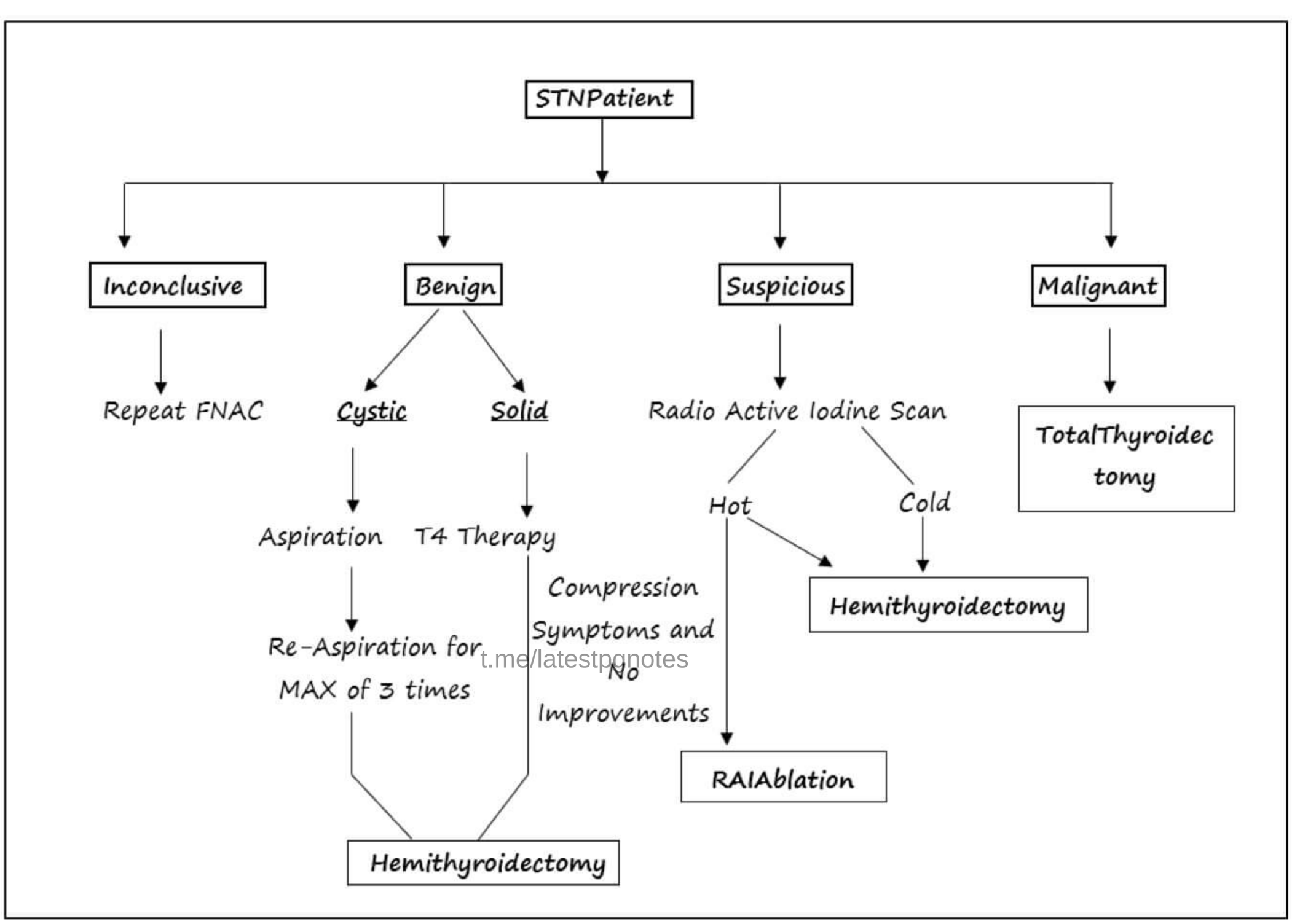

t.me/latestpgnotes

BETHESDA SYSTEM REPORTING THYROID CYTOPATHOLOGY (TBSRTC)

- THY 1 – Non diagnostic
- THY 1C – Non diagnostic- cystic
- THY 2 - Non neoplastic
- THY 3 – Follicular
- THY 4 – Suspicious malignancy
- THY 5 – Malignant

Function of Thyroid hormones

→ Conversion of mass into energy.

→ Thyroid Hormone controls basal Metabolic rate

→ **Hyperthyroidism** - Too much of energy, very low mass (weight loss)

→ **Hypothyroidism** - Too much of mass, but very low energy (weight gain)

PrepLadder

HYPOTHYROIDISM	HYPERTHYROIDISM
• Weight gain • Decreased appetite • Confusion • Middle ear effusion • Bradycardia • Diastolic hypertension • Constipation • Menorrhagia • Loss of hair	• Weight loss • Increased appetite • Tachycardia • Increased sweating • Heat intolerance • Diarrhea • Amenorrhea • Increased risk of abortions • Infertility

→ MC cause of hypothyroidism worldwide - Hashimoto's thyroiditis

→ MC cause of hyperthyroidism worldwide – Graves' disease

Graves' disease

→ Aka **Diffuse toxic goiter**

→ Associated with HLA B-8, DR- 3

→ Auto immune disorder

→ Thyroid stimulating auto antibody **against TSH -receptor**

Characteristic features

→ Thyrotoxicosis

t.me/latestpgnotes

→ **Ophthalmopathy**
- Exophthalmos - collection of loose areolar area tissue behind the eyeball

→ **Dermopathy**
- Aka Pretibial myxedema
- deposition of glycosaminoglycan
- also found in Hypothyroidism

→ **Acropachy**
- Subperiosteal new bone formation in metacarpals

→ Gynecomastia

In Graves' disease,

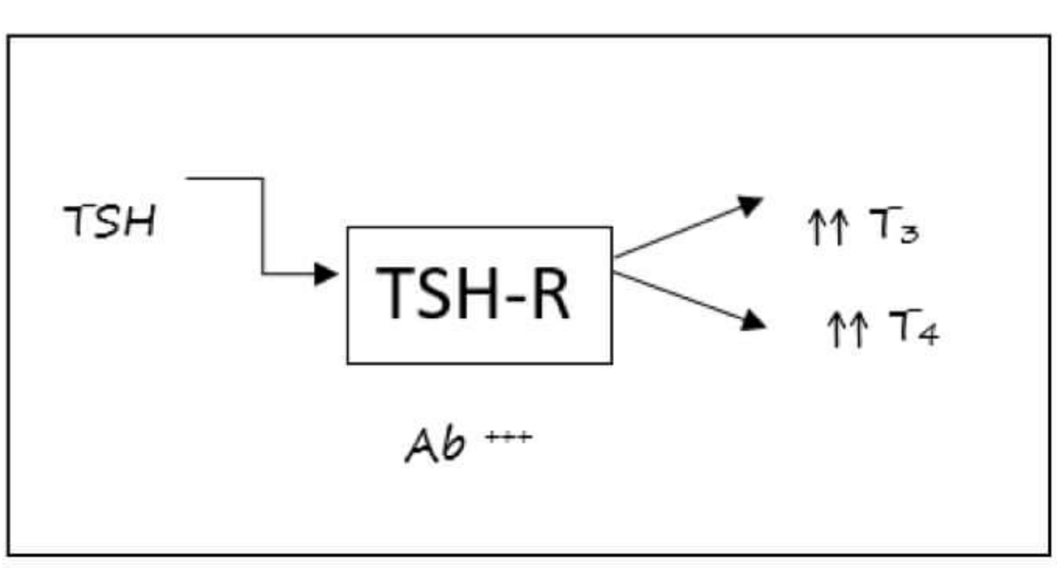

PrepLadder

→ Excessive stimulation of autoantibody on TSH receptor increase release of T_3 & T_4.

→ Excessive release of T_3 & T_4 causes feedback inhibition of TSH.

So,

↑T3
↑T4
↓TSH
} in Graves' disease

→ These patients have **increased expression of β -receptor** - Signs & symptoms of sympathetic stimulation

→ So, Treatment - **Non selective β- blockers** (to block sympathetic stimulation) + **Antithyroid hormone medication**

Clinical features

→ **Signs and symptoms of sympathetic stimulation**

- Tachycardia
- Palpitation
- Excessive sweating
- Tremors - **Fine tremors in fingers & tongue**

→ **Signs & symptom of thyroid stimulation**

- Increased BMR – Increased Appetite and Weight loss
- Excessive sweating
- Heat intolerance
- **Diarrhea** (MC GI symptom In Hyperthyroidism)

t.me/latestpgnotes

→ **In females**

- Amenorrhea
- ↑ risk of abortion
- Infertility

→ **In children** - Early growth and Maturation

→ **In young patients** - CNS symptoms are predominant

→ **In elderly** - CVS symptoms (AF & CHF) are predominant

Findings in thyroid gland in Graves' disease

→ **Hyperactive** - Increased Radio Active uptake

→ **Hypervascularity** - Most prominent at upper pole

→ Palpable thrill

→ Audible bruit

→ Audible venous hum

Investigations for diagnosis

→ **Presence of eye signs** in patients of hyperthyroidism is **diagnostic**

PrepLadder

→ Single investigation used to confirm the diagnosis (confirmation) – presence of autoantibodies

Management

→ For sympathetic stimulation, first drug given is Propranolol
→ **Antithyroid drugs** - symptomatic improvement within 2 weeks
→ Patient becomes euthyroid within 6 weeks

→ **Antithyroid drugs**
- Methimazole
- Carbimazole
- Propylthiouracil

→ **Side effect of Methimazole**
- Increased risk of Choanal Atresia
- Increased risk of Aplasia cutis
- So, not used in pregnancy
- Agranulocytosis

→ **Side effect of Propylthiouracil**
- Increased risk of hepatic failure in females and children. (Not to be used in females & children until and unless there is life threatening situation like thyrotoxic crisis)
- In Thyrotoxic crisis, Propylthiouracil is used because it blocks the peripheral conversion of T_4 to T_3

t.me/latestpgnotes

→ **Anti-thyroid DOC**
- In Graves' disease – Methimazole
- In Pregnancy – Carbimazole
- In Thyrotoxic crisis – Propylthiouracil

→ **TOC** - Total Thyroidectomy
→ **Alternative treatment** – Radioactive Iodine Ablation

→ **Indications of RAI Ablation**
- Elderly Patients
- Patient with surgical co-morbidities
- Recurrence after surgery

Contraindications of RAI ablation

Absolute contraindications	Relative contraindications
→ Pregnancy	→ Young patient (to decrease exposure of gamma rays to young patients)
→ Lactation	→ Smokers
	→ Ophthalmopathy (RAI ablation leads to worsening of ophthalmopathy)

Hashimoto's Thyroiditis

→ Aka **Struma Lymphomatosa** (conversion of thyroid tissue into lymphoid tissue)

→ Auto immune disorder

→ Anti- TPO (anti thyroid peroxidase) autoantibody

→ Associated with HLA B- 8, DR-3, DR-5

Etiopathogenesis

CD_4 mediated CD8 cytotoxicity

↓

Permanent destruction of

Thyroid follicles

t.me/latestpgnotes

↓

Permanent hypothyroidism

→ Lifelong Levothyroxine should be given for these patients.

→ Associated with increased risk of Thyroid Lymphoma & Papillary carcinoma

Clinical features

→ Signs & symptoms of Hypothyroidism

→ Mild enlargement of thyroid gland

↓ so

Increased circumference of neck

Investigations

→ Diagnosis is done by detection of anti TPO antibodies

→ FNAC

- Increased lymphocytic infiltration
- Presence of Hurthle cells/ Askanazy cells.

Treatment

→ Lifelong levothyroxine

→ If Suspicion of malignancy – Total thyroidectomy

PrepLadder

Acute suppurative thyroiditis

→ Suppurative infection of thyroid
→ MC organism – staph aureus > streptococci
→ MC in children because of persistent Pyriform sinus (connection between oropharynx and thyroid)
→ Preceded by otitis media and URTI
→ Thyroid is resistant to infection – Because of
  - Rich vascular and lymphatic supply
  - High iodide content
  - Fibrous capsule

Routes of infection

→ Hematogenous or lymphatic route
→ Direct spread from pyriform sinus fistula or from thyroglossal duct cyst
→ Penetrating trauma
→ Immunocompromised

Clinical features

→ Pain and tenderness over thyroid
→ Fever, chills and rigor

Lab investigation

t.me/latestpgnotes

→ ↑ ESR
→ ↑ WBC count

Diagnosis

→ **FNAC** - Presence of neutrophils
→ **Culture and sensitivity** - Organism and antibiotic sensitivity

Treatment

→ Incision and drainage + antibiotics
→ **Recurrence** – rule out pyriform sinus by barium swallow **(if present, then excision should be done)**

Subacute Thyroiditis

→ **Aka**
  - DEQUERVAINS thyroiditis
  - Viral thyroiditis
  - Granulomatous thyroiditis
  - Giant cell thyroiditis

PrepLadder

→ **Characterized by**

Upper respiratory tract infection caused by virus

↓ leading to

Granulomatous inflammation

↓ leading to

Follicular destruction & giant cell formation

→ Associated with HLA B-35

Stages

→ **Initially** - Hyperthyroid (due to follicle destruction → T_3 & T_4 released)

→ **After** - Euthyroid (Released T_3 & T_4 used up)

→ **Later** - Hypothyroid (follicular destruction → No further T_3 & T_4)

→ **Again**- Euthyroid (due to spontaneous resolution – 90%)

Clinical features

→ Pain & Tenderness - over thyroid region

→ Associated with signs and symptoms of hyperthyroidism and hypothyroidism (depending upon the stage of presentation)

Lab investigations

→ ↑ ESR (Inflammation)

t.me/latestpgnotes

→ ↓ RAI uptake (because follicles are destroyed)

Diagnosis

→ IOC for diagnosis – **FNAC**

→ Presence of Multinucleated giant cells

Treatment

→ NSAIDS to control inflammation

→ Steroids for non-responding patients

→ In 90% of patients - spontaneous resolution occurs

Riedel's Thyroiditis

→ Aka **Invasive Fibrous thyroiditis**

→ Characterized by complete replacement of thyroid and parathyroid glands by fibrous tissue

→ **Associated with**

- Retro orbital fibrosis
- Periorbital fibrosis
- Retroperitoneal fibrosis
- Sclerosing cholangitis

PrepLadder

Clinical features

→ Signs & symptoms of Hypothyroidism and Hypoparathyroidism (permanent)

→ **On examination** – Thyroid becomes hard & woody.

→ Signs & symptoms of compression like dyspnea (tracheal compression), dysphagia (esophageal compression), hoarseness of voice

Investigations

→ FNAC is not sufficient for diagnosis (Riedel's thyroiditis is a limitation)

→ IOC for Diagnosis – **Wedge shaped excision biopsy**

Management

→ **Toc** – Wedge shaped excision biopsy (it can also relieve the compression symptoms)

→ **Lifelong levothyroxine** (due to permanent hypothyroidism)

→ **Lifelong calcium and Vitamin D supplementation** (due to permanent hypoparathyroidism)

t.me/latestpgnotes

THYROID PART - 2

→ Most common thyroid malignancy - **Papillary > Follicular > Medullary > Anaplastic**

Papillary carcinoma of thyroid

→ MC among thyroid malignancy
→ Commonly seen in iodine sufficient areas
→ Low dose radiation exposure during childhood increases the risk
→ **Thyroglossal cyst & Hashimoto's thyroiditis** also Increases the risk

Pathology

→ Papillary projections
→ Optically clear nuclei – aka **ORPHAN ANNIE EYE NUCLEI**
→ Pseudo inclusion bodies
→ Dystrophic calcification – **PSAMMOMA BODIES**
→ **Other conditions for psammoma bodies**
(Mnemonic - PSM)
- P- Papillary carcinoma of thyroid, Papillary variant of RCC
- S- Serous cystadenoma ovary
- M- Meningioma

Clinical Features

t.me/latestpgnotes

→ Midline swelling in anterior part of neck
→ **Lateral aberrant thyroid** (palpable lateral cervical lymph node with metastatic deposit from papillary carcinoma of thyroid)

Route of spread

→ Most common route of spread – **lymphatic**
→ Most common site of metastasis – **lungs**

Investigations

→ IOC for Diagnosis- **FNAC**

Treatment

→ Total thyroidectomy + removal of enlarged central group of lymph node ± Ipsilateral modified radical neck dissection MRND (if any LN is positive)
→ **Lymph nodes**
- IA - submental nodes
- IB - Submandibular node
- II - upper jugular node
- III - Middle jugular nodes
- IV - Lower jugular node
- V - Posterior triangular nodes

PrepLadder

- VI – Central /Anterior compartmental nodes
- VII – Superior mediastinal nodes

Follicular Carcinoma of thyroid

→ Seen in **Iodine deficient areas**

→ MC malignancy in **long standing goiter**

→ Common among 5th – 6th decade

→ **Mutation of**

- PAX – 8/ PPAR -1
- PTEN
- P-53
- RAS

Clinical presentations

→ Sudden increase in size of swelling

→ Minimal /no pain over the swelling

→ **No evidence of compression of trachea, esophagus or RLN**

→ **Lymphatic spread is not seen** (So lymph node need not be removed during surgery)

→ MC route of spread – Hematogenous

→ MC site of metastasis – Bones (Thoracic vertebra > Ribs > Pelvis > skull)

→ Follicular carcinoma thyroid & Renal cell carcinoma — leads to pulsatile secondaries (osteolytic & hyper vascular)

t.me/latestpgnotes

Investigations

→ **FNAC** cannot differentiate follicular adenoma from follicular carcinoma.

→ So, IOC – Biopsy (Diagnosis of follicular carcinoma thyroid is based on **vascular invasion / capsular invasion**)

Treatment

→ TOC – **Total thyroidectomy** (LN dissection not needed as there is no lymphatic spread)

Well differentiated thyroid cancer

- Papillary carcinoma thyroid
- Follicular carcinoma thyroid

Postoperative management of well differentiate thyroid cancer

→ **Thyroxine suppression**

- High dose thyroxine for 6 weeks → to suppress TSH
- TSH is suppressed to prevent proliferation of thyroid remnant preoperatively (TSH will be elevated after thyroidectomy)

→ **Whole body scan** – I^{131} is used

- Stop thyroxine at least for 6 weeks
- Switch T_4 to T_3 and then stop T_3 for 2 weeks

PrepLadder

- **Recombinant TSH is given 48 hours before whole body scan** (because Na^+/I^- Symporter is required for radioiodine uptake & for expression of this symporter, TSH must be raised)
- **Advantage of I^{131}**
  - ➢ It diagnoses and ablates the thyroid remnant
  - ➢ It makes thyroglobulin a better marker for postoperative follow up

Investigations useful for follow up

→ **Thyroglobulin** should be < 2ng/ ml (after thyroidectomy)
→ USG-Neck
→ CXR

Indication of PET scan

→ Rising thyroglobulin with normal USG-Neck and CXR

Management for recurrence

→ Radio-active Iodine Ablation

Prognostic indicators of well-defined thyroid cancer

AGES	AMES	MACIS
• A - Age • G - Grade • E - Extra thyroid invasion • S - Size	• A - Age • M - Metastasis • E - Extra thyroid invasion • S - Size	• M - Metastasis • A - Age • C - Completeness of original surgical resection • I - Invasion (extra thyroid) • S - Size

t.me/latestpgnotes

Bad prognosis

→ Size > 4 cm
→ Extra capsular spread

Good prognosis

→ Size < 1 cm
→ Age < 40 years

Medullary Carcinoma of thyroid (MCT)

→ Arise form para follicular 'C' Cells
→ **Parafollicular 'C 'Cells**
  - Derived from - Ultimobranchial bodies
  - Secretes - calcitonin
→ In medullary carcinoma of thyroid, level of calcitonin is raised
→ Despite of raised calcitonin, the level of calcium is normal in these patients (Normocalcemia)

PrepLadder

Types of Medullary carcinoma

Sporadic	Familial
• 80% of cases	• 20% of cases
	• Associated with MEN/ Non-MEN • If ass. with MEN, it is MEN 2A/2B
• Seen in 6th decade	• Young patients
• Single	• Multiple
• Unilateral	• Bilateral
→ **Similarity between sporadic and familial MCT** – Both have RET Proto oncogene mutation	

Clinical Features

→ Midline swelling in anterior part of neck

→ **Characteristic features**

- Raised calcitonin
- History of diarrhea
- Presence of amyloid stroma
- Positive family history of Pheochromocytoma & Hyperparathyroidism (due to association with MEN 2A & MEN 2B)

t.me/latestnotes

Route of spread

→ Both hematogenous & lymphatic spread are seen

→ MC site of metastasis – Liver

→ **MCT is TSH independent** – So, doesn't take RAI (hence, Radioactive Iodine Ablation is not effective for MCT)

→ **Chemotherapy has limited role in**

- Thyroid malignancies
- Salivary gland tumors

Investigation

→ IOC – FNAC

Management

→ **Total thyroidectomy + Routine central LN dissection + Ipsilateral MRND (Tumor > 1cm) ± Bilateral MRND** (if any lymph node is positive)

→ Has Poor prognosis (because it does not respond to radioactive iodine ablation)

PrepLadder

Anaplastic carcinoma

→ Rare

→ Seen in 7th–8th decade

→ There are two malignancies that appear during 7th–8th decade

- Anaplastic carcinoma of thyroid
- Carcinoma prostate

Clinical features

→ Sudden increase in the size of swelling

→ Severe pain over the swelling

→ Most common route of spread – Direct invasion

→ **Evidence of compression of**

- Trachea – Dyspnea
- Esophagus – Dysphagia
- Recurrent laryngeal nerve – Hoarseness of voice

→ Most common site of metastasis – Lungs

Investigations

→ IOC for Diagnosis – FNAC

Treatment

→ **For resectable tumor** – Total thyroidectomy

→ **For unresectable tumor** – Tracheostomy (lifesaving procedure when tumor is obstructing trachea)

→ Poor prognosis.

t.me/latestpgnotes

Thyroid lymphoma

→ MC type – Non-Hodgkin lymphoma (diffuse large B cell lymphoma)

→ **Risk factor**

- Hashimoto's thyroiditis
- Chronic lymphocytic thyroiditis

Clinical features

→ Rapid growing tumors

→ Painless & Fever (Characteristic features)

→ Associated with **cervical lymphadenopathy**

↓ leads to

Compression – Dyspnea

– Dysphagia

→ Invasion of recurrent laryngeal nerve leads to hoarseness of voice

→ Some patients develop hypothyroidism (associated with Hashimoto)

Investigation

→ IOC for diagnosis – Biopsy

PrepLadder

Treatment

→ External beam radiotherapy (EBRT) + Chemotherapy

→ Chemotherapy Regimen (CHOP)

- C – cyclophosphamide
- H – Hydroxydaunorubicin (doxorubicin)
- O – Oncovin (vincristine)
- P – Prednisone

→ In cases of compression symptoms – Thyroidectomy + LN dissection

Thyroidectomy

→ Position – Rose position / Barking dog position

- Head is extended
- 30° head-up
- Towels below shoulder blade
- **Advantage** – Bloodless field
- **Disadvantage** – increased risk of embolism

Rose position/Barking dog position

→ Incision

- Kocher's transverse cervical collar incision
- 1cm below cricoid cartilage

t.me/laterstnpnotes

→ Subcutaneous tissue and platysma incised sharply

→ **Sub platysma flaps are raised**

- Superiorly till thyroid cartilage
- Inferiorly till suprasternal notch

→ Incise strap muscles in midline and retract them laterally – **Thyroid gland is exposed**

→ Middle thyroid vein

- **First structure ligated** and divided to prevent avulsion
- Avulsion of middle thyroid vein leads to **air embolism**

→ Superior thyroid vessels

- Artery and vein ligated **separately & close** to thyroid
- To prevent injury of external branch of superior laryngeal nerve

→ Inferior thyroid vessels

- Ligated **close** to thyroid
- To prevent vascular infarction of **parathyroid gland** (because PG is supplied by Parathyroid artery which is an end artery & br. of inferior thyroid artery)

→ Recurrent laryngeal nerve

- Most vulnerable to injury in vicinity of **ligament of berry**
- Bleeding in this region is controlled with gentle pressure (use of electrocautery should be avoided)

→ After division of ligament, thyroid is separated from trachea by sharp dissection

PrepLadder

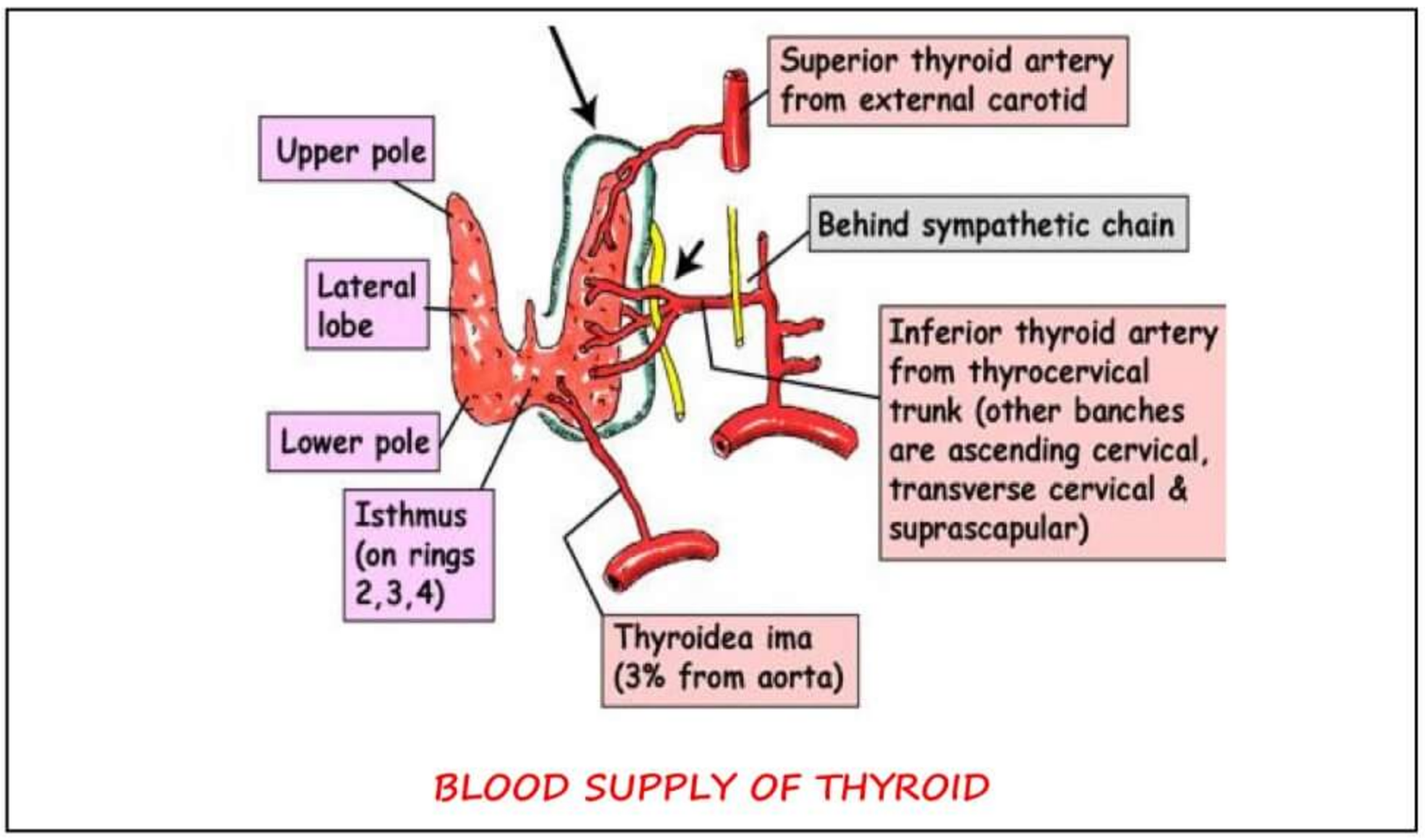

BLOOD SUPPLY OF THYROID

\

Parathyroid glands

→ Color of parathyroid glad – golden brown / canary yellow

→ **Accidental removal of Parathyroid gland**

- They are divided into 1 mm pieces and auto transplanted in belly of sternocleidomastoid muscle.
- Site of auto transplantation should be marked with silk suture (non-absorbed) or with a clip.

→ **Hyperparathyroidism caused by parathyroid hyperplasia**

- 3 ½ glands are removed and
- Remaining ½ gland is auto transplanted in brachioradialis of non-dominant arm

t.me/latestpgnotes

Complications of thyroidectomy

1) Hemorrhage

→ Caused by

- Bleeding from muscular artery
- Slippage of ligature from superior thyroid vessels

→ Massive bleeding – leads to Tension hematoma (Patient may experience respiratory distress after surgery)

→ **Management in case of tension hematoma**

- Shift the patient to OT
- Open the sutures
- Control bleeding by Ligating the bleeding vessel
- Drain the hematoma
- Close wound after drain insertion

2) Respiratory obstruction

→ MC cause – Laryngeal edema (due to Extubation injury)

→ **Other causes** - RLN Palsy / Tension hematoma

PrepLadder

3) Nerve injuries

→ MC injured nerve – External branch of superior laryngeal nerve (aka **External laryngeal nerve**)

→ Other nerves injured are

- Recurrent laryngeal nerve
- Cervical sympathetic trunk

4) Parathyroid insufficiency

→ Most commonly occur on 2nd – 5th day of surgery

→ MC cause – Vascular infarction of parathyroid gland

→ **Manifestations**

- Carpopedal spasm
- Tingling / numbness over perioral region

→ **Treatment**

- Mild to moderate symptoms (**calcium level >8gm/dl**) - Oral calcium supplementation
- Severe symptoms (**<8gm /dl**) - IV calcium gluconate

5) Thyroid insufficiency

6) Thyrotoxic crisis

→ MC cause- Inadequate preoperative preparation

t.me/latestpgnotes

MIVAT (Minimally Invasive Video Assisted Thyroidectomy)

→ Length of cervical incision - 1.5 to 2 cm for placement of

- Endoscopic camera
- Instruments for retraction and dissection

→ Performed for

- **Benign** – lobectomy
- **Malignant** – Total thyroidectomy (generally performed for papillary carcinoma thyroid)

Indications of MIVAT

→ Benign thyroid nodules < 3 cm

→ Papillary carcinoma < 2 cm

Contraindication of MIVAT

→ Thyroiditis

PrepLadder

PARATHYROID & ADRENAL GLANDS

MEN-1

→ **AKA Wermer syndrome**

→ Autosomal dominant

→ **Characterized by triad of tumors** involving

1. Parathyroid tumors
2. Pituitary tumors
3. Pancreatic neuroendocrine tumors

→ **Gene responsible**

- Mutation of **MEN-1 gene** located on **chromosome no. 11**
- Encodes tumors suppressor protein "**MENIN**"

Characteristic features

Common Manifestations	Less Common Manifestations
• Parathyroid hyperplasia or adenoma • Pancreatic Neuroendocrine tumors • Pituitary Adenoma	• Adrenocortical tumors • Bronchial of thymic carcinoids • Collagenomas • Facial cutaneous angiofibroma • Subcutaneous / Visceral lipomas

t.me/latestpgnotes

Parathyroid Gland

→ MC endocrine abnormality in MEN 1 - **Multiglandular parathyroid tumor**

→ Cardinal sign of MEN 1 - **Parathyroid adenoma of multicentricity**

→ MC manifestation of MEN 1 - **Hyperparathyroidism**

→ MC cause of hyperparathyroidism – **Parathyroid hyperplasia**

→ 1st biochemical abnormality detected in MEN 1 - **Hypercalcemia**

Pancreatic Neuroendocrine Tumors

→ It is the 2nd most common manifestation of MEN 1

→ MC Enteropancreatic NET seen in MEN 1 - **Nonfunctioning PPoma (pancreatic polypeptide secreting tumor)**

→ MC Functional Enteropancreatic NET in MEN 1 - **Gastrinoma > Insulinoma**

→ MC increased hormone in MEN 1 – **Pancreatic polypeptide > Gastrin > insulin**

Pituitary Adenoma

→ MC pituitary tumor in MEN 1 – **Prolactinoma > Somatotrophinoma >Corticotrophinoma**

PrepLadder

MEN-2

→ **Aka MEN 2A / Sipple syndrome**

→ Autosomal dominant

→ **Characterized by**

- Medullary carcinoma thyroid
- Pheochromocytoma
- Parathyroid hyperplasia / Adenoma
- Hirschsprung disease
- Cutaneous lichen amyloidosis

→ **Gene responsible**

- Mutation of RET oncogene located on chromosome 10
- Mutated codon - Cysteine codon

MEN-3 / MEN -2B

→ Autosomal dominant

→ **Characterized by**

- Medullary carcinoma thyroid
- Pheochromocytoma
- Mucosal neuroma
- Megacolon
- Marfanoid features
- Intestinal ganglioneuromas

t.me/latestpgnotes

→ **Gene responsible**

- Mutation of RET oncogene located on chromosome 10
- Mutated codon - Tyrosine kinase codon

→ **Age of prophylactic Thyroidectomy in RET mutation carriers**

- In MEN 2A – Before 5 years
- In MEN 2B – Before 1 year

MEN-4 (MEN X)

→ Autosomal dominant

→ It is MEN-1 associated tumors with CDNKIB mutation (Cyclin dependent kinase inhibitor gene)

→ CDNKIB gene is located on chromosome 12

→ **Characterized by**

- Hyperparathyroidism
- Pancreatic NET
- Target tumors (Thyroid tumor; Adrenal tumor; Renal tumor; Gonadal tumor)

PrepLadder

DISORDERS OF PARATHYROID GLANDS

Primary Hyperparathyroidism (PHPT)

→ Caused by increased secretion of Parathyroid hormone (PTH) from abnormal parathyroid gland

→ More common in females

→ MC cause of PHPT – Solitary Adenoma (80% of cases)

↓

MC location – Inferior parathyroid

→ ↑sed PTH leads to hypercalcemia

→ **Mechanism that can leads to hypercalcemia**

- Increased GI absorption of calcium
- Decreased renal calcium clearance
- Increased production of vitamin D_3

→ **Etiology**

- Familial predisposition
- Exposure of low therapeutic ionizing radiation
- Declining renal function with age
- Alteration in the sensitivity of parathyroid gland to suppression by calcium
- Lithium therapy

→ Most cases of PHPT are Sporadic

→ It is associated with – MEN-1, MEN 2A, Isolated familial HPT, Familial HPT with jaw tumor syndrome

t.me/latestnpgnotes

Clinical features

→ **Classical pentad**

- Kidney stone
- Painful bones
- Abdominal groans
- Psychic moans
- Fatigue over tones

→ Due to **Automated blood analyzer** availability – patients are asymptomatic or minimally symptomatic due to early diagnosis

→ **Signs and symptoms of hypercalcemia**

- Weakness & Fatigue
- Polydipsia & Polyuria
- Nocturia
- Bone & joint pain
- Constipation
- Decreased appetite, Heart burn & Pruritis

→ **Kidney stone composition** – Calcium phosphate / Calcium oxalate in PHTP patients.

PrepLadder

Osteitis fibrosa Cystica

→ Seen in **Advanced Primary Hyperparathyroidism**

→ **X-ray findings of hands**

- Subperiosteal resorption – Most apparent on radial aspect of middle phalanx of 2nd & 3rd finger
- Bone cyst
- Tufting of distal phalanges

Diagnosis

→ Increased concentration of PTH - Elevated immunoreactive PTH in asymptomatic hypercalcemia

→ Decreased serum phosphate & increased 24 hours urinary calcium

→ Most widely used and accurate investigation for localization of hyperparathyroidism – T_c labelled Sestamibi scan

Management

→ **Basic principles of management**

1) SERM (Selective estrogen receptor modulator) or Bisphosphonates
   - To decrease Ca^{2+} level
   - To increase bone mineral density
2) Parathyroidectomy – if patient has
   - Classical pentad (or)
   - Age < 50 years

t.me/laterstpgnotes

Steps in management of PHTP

1. **Correction of Hypercalcemia** - by IV normal saline followed by Forced diuresis with furosemide
2. **Neck exploration**
   - Single adenoma (80-85% cases) - Resection
   - Two adenomas (5% cases) – Resection
   - Hyperplasia of all 4 glands (10-15% cases)
     - Excision of 3 and half gland or
     - Excision of all 4 glands

     } With Parathyroid auto transplantation - into Brachioradialis of non-dominant arm

Note

→ Accidentally removed parathyroid gland during thyroidectomy - should be auto transplanted into belly of sternocleidomastoid muscle. (PTG are broken into 1 mm pieces for placing into SCM)

→ Site of transplantation is marked with suture / Clip.

PrepLadder

Secondary Hyperparathyroidism

→ Usually occurs in association with Chronic renal failure (CRF)

→ May occur in Hypocalcemia secondary to inadequate calcium or vitamin D intake or in patients of malabsorption

Pathophysiology of 2° HPT in patients of CRF

→ Hyperphosphatemia & Resultant hypocalcemia
→ Deficiency of 1,25 – Dihydroxy vitamin D
→ Low calcium intake & Low calcium absorption

} Hypocalcemia → ↑sed PTH

Clinical features

→ Signs & symptoms of Hypocalcemia

→ In some patients – Normocalcemia

Management

→ Low phosphate diet advised

→ Phosphate binders

→ Adequate intake of calcium & vitamin D

→ High calcium, low Aluminum dialysis bath

→ Parathyroidectomy – If PTH remains high despite of above management

t.me/latestpgnotes

Tertiary Hyperparathyroidism

→ Due to development of autonomous parathyroid gland function - After long standing secondary hyperparathyroidism, most often in renal disease

Clinical features

→ Signs and symptoms similar to PHPT

→ Pathologic fracture

→ Bone pain

→ Renal stone

→ Constipation

→ Peptic ulcer

Management

→ Subtotal parathyroidectomy / Total parathyroidectomy with auto transplantation

PrepLadder

Parathyroid carcinoma

→ Responsible for 1% of Primary hyperparathyroidism

Clinical features

→ Parathyroid carcinoma can be suspected pre-operatively by presence of

- Severe symptoms
- Serum calcium levels > 14 mg / dl
- ↑ PTH (> 5 times of normal levels)
- Palpable parathyroid gland

Route of spread

→ MC route of spread – **Local invasion**

→ Lymph node metastasis in 50% cases

→ Distant metastasis in 33% cases

Treatment

→ Bilateral neck exploration + Enbloc resection of tumor with ipsilateral thyroid lobe ± Modified radical neck dissection (MRND) if LN is positive

→ **Reoperation** – should be done for

- Local recurrence
- Metastatic disease

} as these cases are **associated with Hypercalcemia**

t.me/latestpgnotes

→ **Cinacalcet**

- Controls hypercalcemia in refractory parathyroid carcinoma
- Decrease PTH by directly acting on CASR (Calcium sensing receptors) of parathyroid

ADRENAL GLANDS

Adrenal Incidentaloma

→ These are **incidentally detected adrenal masses** through imaging performed for unrelated disease

- Non-functioning adenoma (MC) – 82% of incidentaloma
- Preclinical Cushing's – 5%
- Pheochromocytoma – 5%
- Adreno cortical carcinoma – 5%
- Metastatic carcinoma – 2%
- Aldosterone producing adenoma – 1%

Diagnostic work up for incidentaloma

→ To identity patient who would benefit from adrenalectomy

→ **Work up includes**

1. Hormonal evaluation

PrepLadder

2. Size of tumor
3. History of previous malignancy
4. Hypertension (MC manifestation of pheochromocytoma)
5. Symptoms of Glucocorticoid or sex-corticoid excess

→ **CT guided FNAC**

- Rarely performed
- Performed for patients with history of extra-adrenal malignancy - to rule out metastatic disease
- Pheochromocytoma should always be ruled out before performing FNAC

Treatment

→ **Surgery** is done for

- Hormonally active tumor
- Masses carrying significant risk of malignancy

→ Most incidentalomas – can be removed **Laparoscopically** (Avoided if masses are suspected for malignancy in imaging)

→ **Management based on size of masses**

- Size > 5 cm – Surgical removal
- Size 3-5 cm – Strongly consider patients for surgery
- Size < 3 cm – Follow up with CT every 6 months

t.me/latestpgnotes

→ **Indications for surgery in incidentaloma of size 3-5 cm**

- Suspicious lesion on imaging
- Young patients
- Few surgical risks
- Interval tumor growth
- Patient preference for surgery

Adrenocortical carcinoma

→ Rare tumor

→ > 50% of tumors are functional

→ Leads to **Cushing syndrome > Virilization**

Clinical features

→ Seen in 4th to 5th decade

→ Size of tumor at the time of presentation - **9 to 12 cm**

Investigations

→ IOC for diagnosis – **CECT**

→ Single most important criteria for malignancy – **size of tumor**

PrepLadder

Treatment

→ **Radical open surgery** – Enbloc removal of tumor + Adjacent organs or Regional lymphadenectomy or Both

→ **Drugs given to control steroid hypersecretion**

- Ketoconazole
- Aminoglutethimide
- Metyrapone

→ **Mitotane**

- Used as adjuvant to surgery
- Primary therapy in unresectable or metastatic disease

→ Most important predictor of survival – **Adequacy of resection**

→ Most important prognostic factor – **Adequacy of resection**

Pheochromocytoma

→ Arises from chromaffin cells in adrenal medulla

→ Usually seen in 4th to 5th decade

→ Equally common in males & females

→ **Paraganglioma**

- Aka Extra adrenal pheochromocytoma
- MC site of extra adrenal pheochromocytoma – **Organ of Zuckerkandl**

→ **AKA 10% tumor**

t.me/latestpgnotes

- 10% malignant
- 10% Bilateral
- 10% seen in pediatric population
- 10% familial
- 10% extra-adrenal

Risk factors

→ Sporadic / familial

→ Syndromic / Non-syndromic

→ **Syndromes associated with Pheochromocytoma**

- MEN 2A / 2B
- VHL syndrome
- **Von-Recklinghausen syndrome (Aka NF-1)** – MC associated with pheochromocytoma
- Sturge– Weber syndrome

→ **Non-syndromic familial association of Pheochromocytoma**

- MC associated with – **Succinyl dehydrogenase D & B mutation**

Pathology

→ Most of Pheochromocytoma's are **unilateral and solitary**

PrepLadder

→ Pheochromocytoma in multiple endocrine neoplasia (MEN) – rarely malignant

→ In succinyl dehydrogenases D & B mutation – High propensity for Extra adrenal & Malignant pheochromocytoma

→ **Pheochromocytoma** – secrete both Nor-Adrenaline and Adrenaline (NA > A)

→ **Extra adrenal Pheochromocytoma** – Secrete Nor-Adrenaline and exclusively due to deficiency of PNMT (Phenyl ethanolamine N-methyl transferase)

→ **Pheochromocytoma associated with MEN** – Secrete Adrenaline only

→ **Malignant pheochromocytoma** – secrete

- Dopamine
- HVA (Homovanillic acid)

Note:

→ Criteria of malignancy is based on – Metastasis

→ Because vascular invasion & capsular invasion is also seen in benign tumors of pheochromocytoma

Clinical features

→ **Classical triad**

- Headache
- Diaphoresis
- Palpitation

→ MC symptom of pheochromocytoma – Headache

→ MC manifestation of pheochromocytoma – HTN

t.me/latestpgnotes

Pathophysiology

Blood pressure = Cardiac output x Total peripheral resistance

Cardiac output = Stroke volume x Heart Rate

→ In Pheochromocytoma – Release of NA & Adrenaline

↓

Sympathetic stimulation →

- ↑ HR leads to ↑CO
- ↑ TPR
- ↑ BP

→ **Body tries to normalize blood pressure** – Decreases stroke volume by decreasing fluid in vascular compartment

→ Hence, Pheochromocytoma is a state of volume depletion

- ↓sed Blood volume
- ↓sed Plasma volume

Note:

→ In patients of Pheochromocytoma

- High chances of Orthostatic hypotension (First dose effect) when **α blockers** are given
- Hence, **before giving α blockers** – Crystalloids & Colloids should be given to restore the normal volume status

PrepLadder

Clinical features

→ **Due to sympathetic stimulation**
- Carbohydrate intolerance
- Weight loss - Due to increased energy expenditure

→ **Cardiac manifestations**
- Sinus tachycardia
- Supraventricular arrythmia
- Ventricular premature contractions

Investigations

→ Most sensitive Screening test – **Urinary catecholamines & VMA level**

→ Best test for diagnosis – **Fractionated plasma metanephrines**

→ Radiological IOC for Adrenal pheochromocytoma

→ Radiological IOC for Extra adrenal pheochromocytoma } **MRI**

→ Radiological IOC for pheochromocytoma in pregnancy

→ **MIBG scan** - useful for diagnosis of extra adrenal pheochromocytoma

→ **FNAC and biopsy** - contraindicated in pheochromocytoma as they can lead to hypertensive crisis

Treatment

→ **Pre-operatively non-selective alpha blockers**
- To control blood pressure
- DOC – **Phenoxybenzamine**

→ **Beta blockers**
- Indicated only if tachycardia develops
- β-blockers should not be given until patient is fully alpha blocked - to avoid hypertensive crisis that may develop due to unopposed α-stimulation

→ TOC for Pheochromocytoma – **Adrenalectomy**

→ Laparoscopic adrenalectomy can be performed for **Tumor size < 5 cm**

Malignant pheochromocytoma

→ Risk of malignancy increases with size

→ Malignant tumor express p53, BCL-2 & have activated Telomerase

→ Diagnosis of malignancy is based on - **Metastasis**

→ MC site of metastasis – **Bone > Liver > Lymph node**

→ Malignant pheochromocytoma secretes - **Dopamine & Homovanillic acid**

Treatment

→ **Resection followed by chemotherapy**

PrepLadder

→ **Chemotherapy agents used are**

- V – Vincristine
- C – Cyclophosphamide
- D – Dacarbazine

Neuroblastoma

→ Arises from neural crest

→ It can originate anywhere along the sympathetic chain

→ MC site of Neuroblastoma – Adrenal > Paravertebral > Retroperitoneal > Posterior Mediastinum > Pelvis > Cervical area

→ It is the MC tumor diagnosed in infants < 1 year of age

→ It is the MC intraabdominal malignancy of children

→ Unique feature of neuroblastoma – Spontaneous regression **(Especially, Stage 4s)**

→ **Malignancies with spontaneous regression**

- Neuroblastoma
- Choriocarcinoma
- Retinoblastoma
- Malignant melanoma
- Renal cell carcinoma

t.me/latestpgnotes

Clinical features

→ MC presentation – Fixed, lobular mass extending from the flank towards midline of abdomen

→ **Peak incidence** – 2 years of age

→ Most patients present – before 4 years

→ 60-70% of patients have metastasis at the time of diagnosis

→ **Orbital metastasis** – present as Periorbital ecchymosis + Proptosis (Racoon eyes)

→ **Infants with stage 4s** – may develop Cutaneous metastasis known as Blue berry muffin lesions

→ **Unusual paraneoplastic manifestations**

- Chronic watery diarrhea (Increased secretion of VIP)
- Opsoclonus – Myoclonus (Dancing eye, Dancing feet)

→ MC site of metastasis in neuroblastoma in older children – Long bones

→ In skull – Sphenoid bone is involved

→ **In Infants** – metastasis is confined to liver / Subcutaneous tissue

→ Lung metastasis is rare in neuroblastoma

Laboratory investigation

→ **Lab. findings**

- Anemia
- Thrombocytosis

PrepLadder

- ↑ LDH
- ↑ Ferritin
- ↑ Urinary catecholamines
- ↑ Neuron specific enolase

→ **On X-ray / CT** – Stippled calcification

→ **On IVP** - Drooping Lilly sign (Neuroblastoma displaces kidney inferolaterally)

→ **In assessment of the following** - MRI > CT

- Vascular invasion / encasement
- Patency
- Spinal cord compression
- Bone marrow involvement

→ MIBG scan – Single best study to document presence of metastasis

Treatment

→ Localized neuroblastoma – Excision

→ Unresectable neuroblastoma – Do biopsy and then downstage the tumor by chemotherapy & Radiotherapy of followed by surgical resection.

→ In cases of disseminated disease – Chemotherapy

Esthesioneuroblastoma (olfactory neuroblastoma)

t.me/latestpgnotes

→ It's a rare tumor with neural crest origin

→ Arises from Basal neural cells of - **olfactory mucosa of**

- Cribriform plate
- Upper nasal wall
- Superior turbinate

Clinical features

→ Unilateral polypoidal mass located on upper third of nose

→ Associated with symptoms of

- Nasal obstruction
- Anosmia
- Epistasis (Vascular tumor that bleeds profusely on biopsy)

Treatment

→ Surgical excision followed by radiotherapy

PrepLadder

Liver Part - 1

NORMAL ANATOMY:

→ **Normal weight**
- Male - 1800 gms
- Female - 1400 gms

→ Glycogen storage capacity is 65 gms/kg of liver tissue

→ **Liver has**
- Dual blood supply (also in lungs)
- unique property of regeneration

→ **Blood supply of liver**
- 75% from Portal vein
- 25% from Hepatic artery

→ Portal venous blood is mainly deoxygenated therefore despite of 75% blood supply, O_2 supply is only 50%-70% while hepatic artery gives 30%-50% O_2.

→ If branch of PV is ligated, hepatic artery increases blood supply to the liver but not vice versa

→ HCC are exclusively supplied by branches of hepatic artery

→ Hence on TRIPLE-PHASE CT (IOC for HCC)
- Non-contrast phase
- Arterial phase
- Venous phase

} **Shows Dx. Feature of HCC**

Arterial hypervascularization with venous washout

t.me/latestpgnotes

→ Portal triad on USG appears like Mickey mouse - known as Mickey mouse view

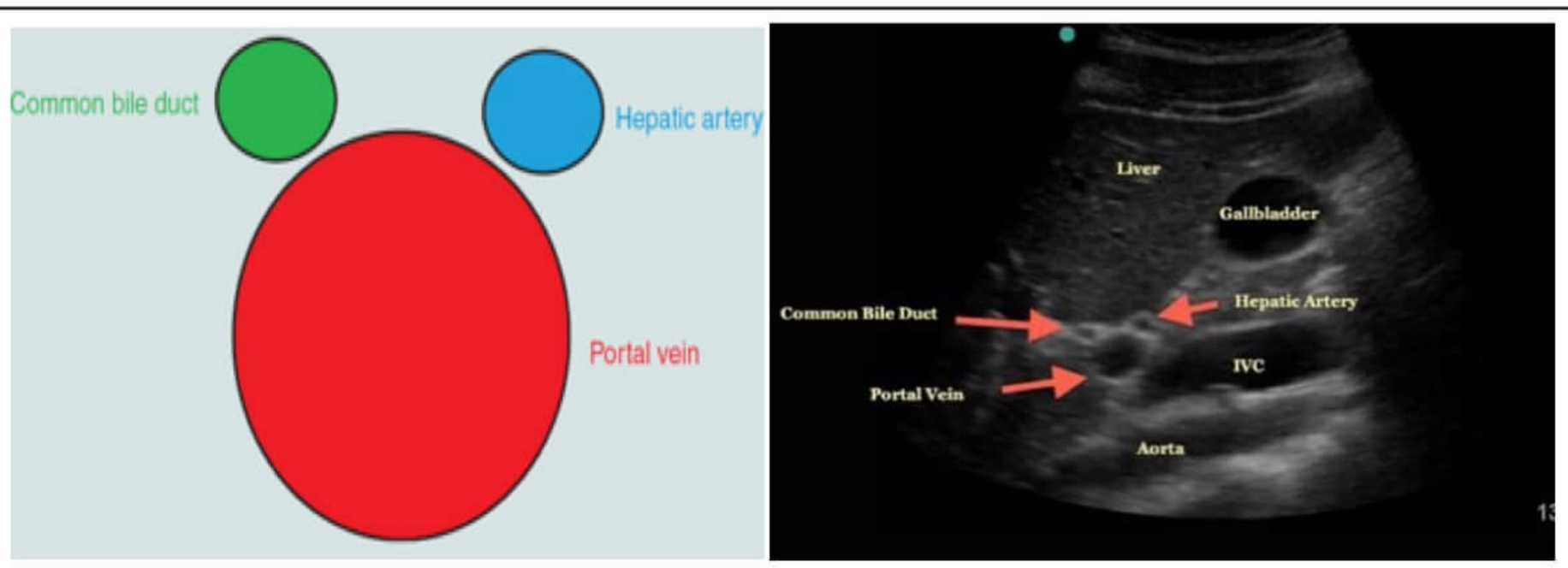

Mickey mouse view

PrepLadder

COUINAUD Segments

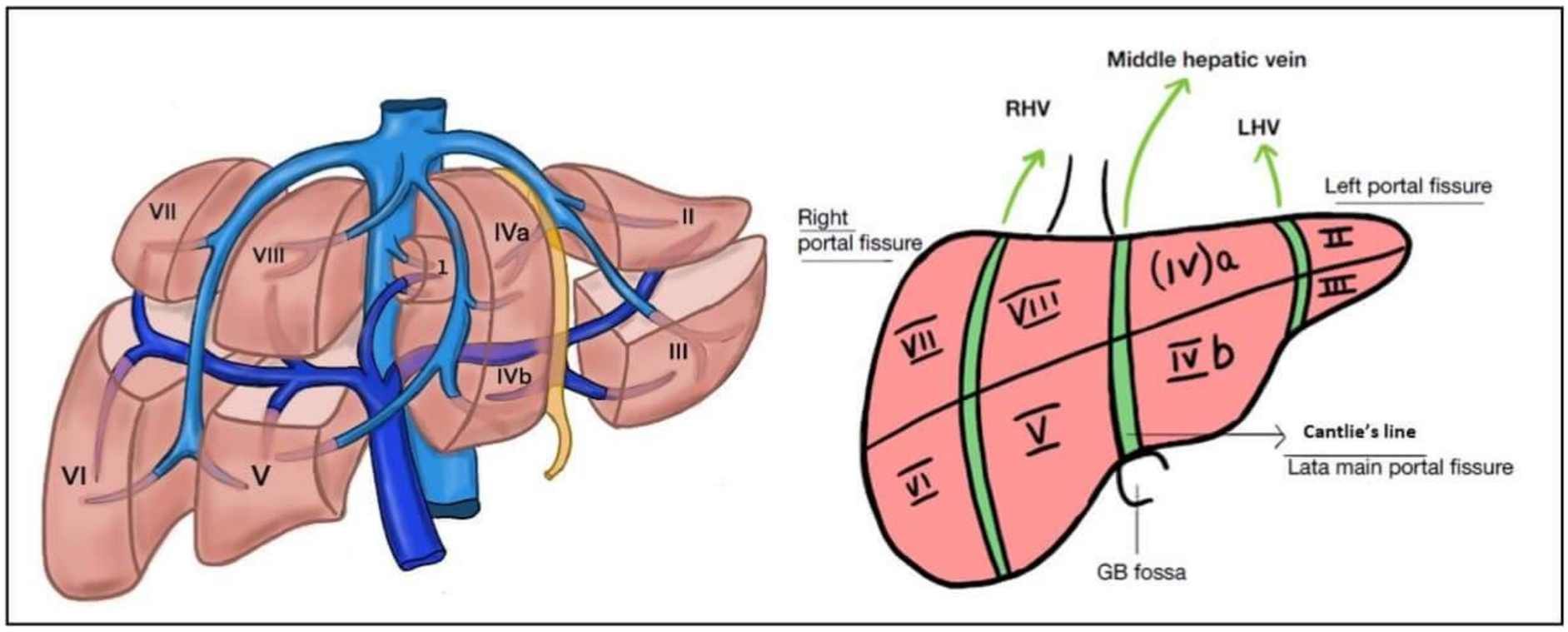

→ COUINAUD divides liver into 8 Segments on basis of Portal vein and Hepatic Vein

→ Gall bladder is in relation with 2 segments (IVb & V)

→ Hence in **Ca Gall bladder**, Segments IVb and V are involved early and in the extended cholecystectomy they are removed.

→ **Right lobe of liver contains segments V, VI, VII, VIII**

- Right Anterior Sector → V, VIII
- Right posterior Sector → VI, VII

→ **Left lobe of liver contains segments II, III, IV**

- Left Anterior Sector → III, IVa, IVb
- Left posterior Sector → II

t.me/latestpgnotes

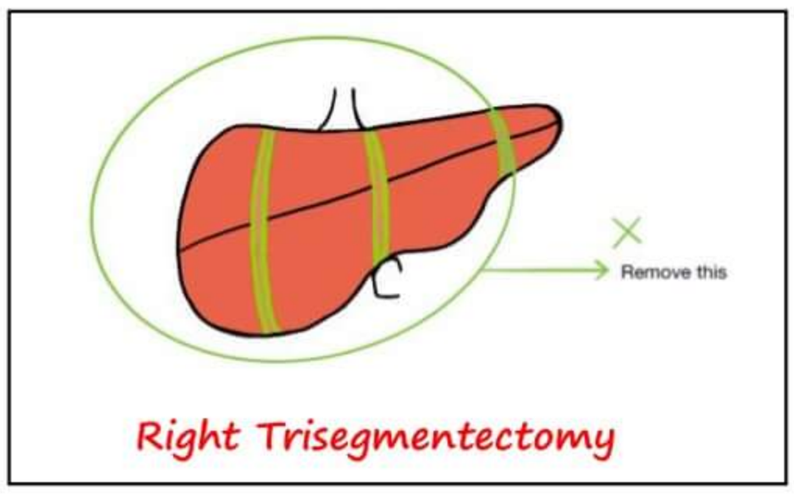

Right Trisegmentectomy

Hemi Hepatectomy

→ In Right Hemi Hepatectomy - V, VI, VII, VIII removed

→ In Left Hemi Hepatectomy - II, III, IVa, IVb removed

Trisegmentectomy (Extended Hepatectomy)

→ Right Trisegmentectomy aka Extended Right Hepatectomy we remove => V, VI, VII, VIII and IVa, IVb

→ Left Trisegmentectomy aka Extended Left Hepatectomy we remove => II, III, IVa, IVb and V, VIII

→ **Extra**

- Segment I → Caudate lobe
- Segment IV → Quadrate lobe

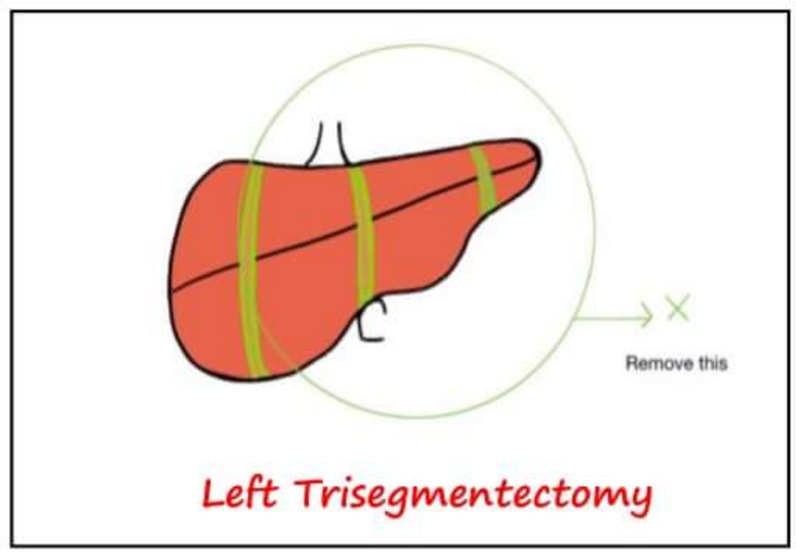

Left Trisegmentectomy

PrepLadder

Caudate Lobe

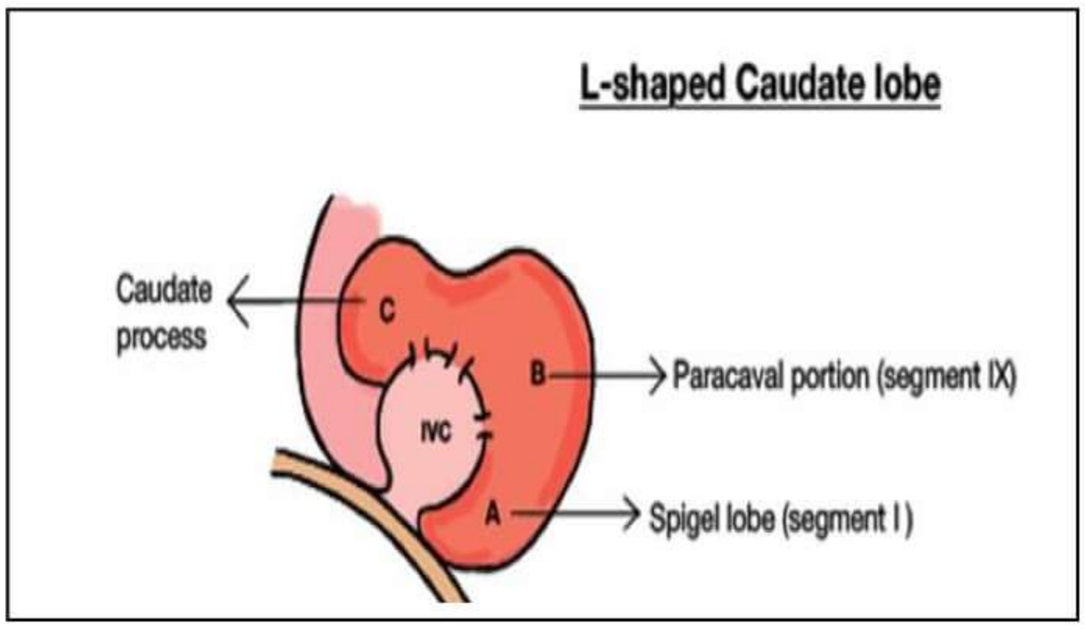

→ According to latest study total 9 segments are there - Segment IX is Paracaval portion of caudate lobe.

Properties of caudate lobe:

→ **Parts of caudate lobe**
- Spiegel lobe (segment I)
- Paracaval portion (segment IX)
- Caudate process

→ Receives blood supply from - both left and Right branch of portal Vein (Mainly Left branch)

→ It gives biliary drainage to - both Left and Right Hepatic duct (Mainly Left Hepatic duct)

→ Venous drainage directly into IVC

t.me/latestpgnotes

Advantage of caudate lobe

→ In BUDD-CHIARI Syndrome caused by Hepatic vein Thrombosis whole liver is affected except caudate lobe (In chronic cases, whole liver – atrophied; Caudate lobe – Hypertrophied)

Disadvantage of caudate lobe

→ Routine Caudate lobectomy is done in "Hilar Cholangiocarcinoma" (due to Early Involvement of the lobe in this carcinoma)

Fascial plate around Liver Hilus

→ It is condensation of endo-abdominal fascia around portal structures

→ Hepatic vein lacks this condensation of endo-abdominal fascia

→ **Fascial plate**
- Around GB – Cystic plate
- Around hilum of liver – Hilar plate
- Near umbilical fissure – Umbilical plate

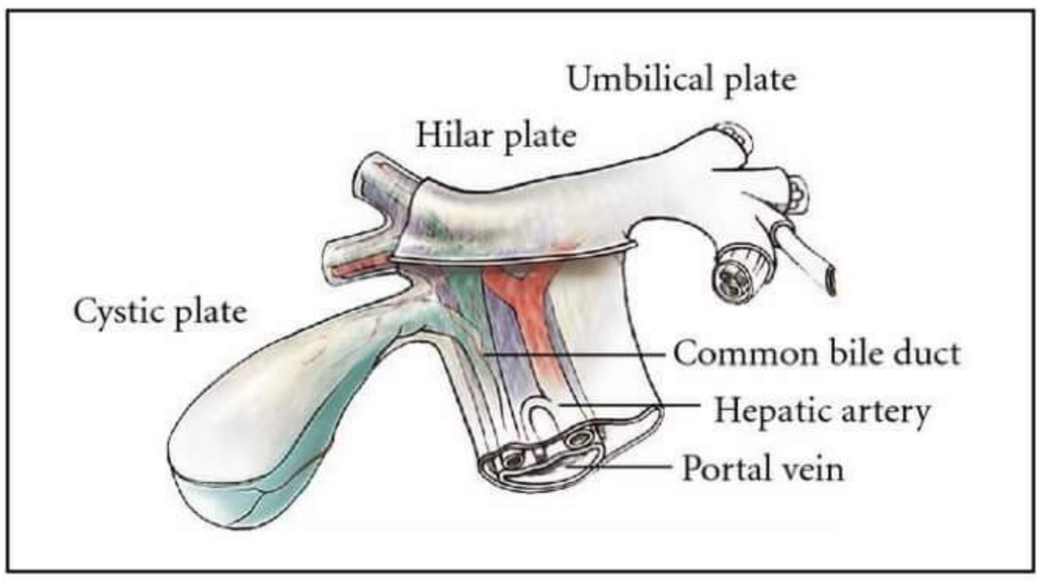

PrepLadder

PRINGLE's Maneuver

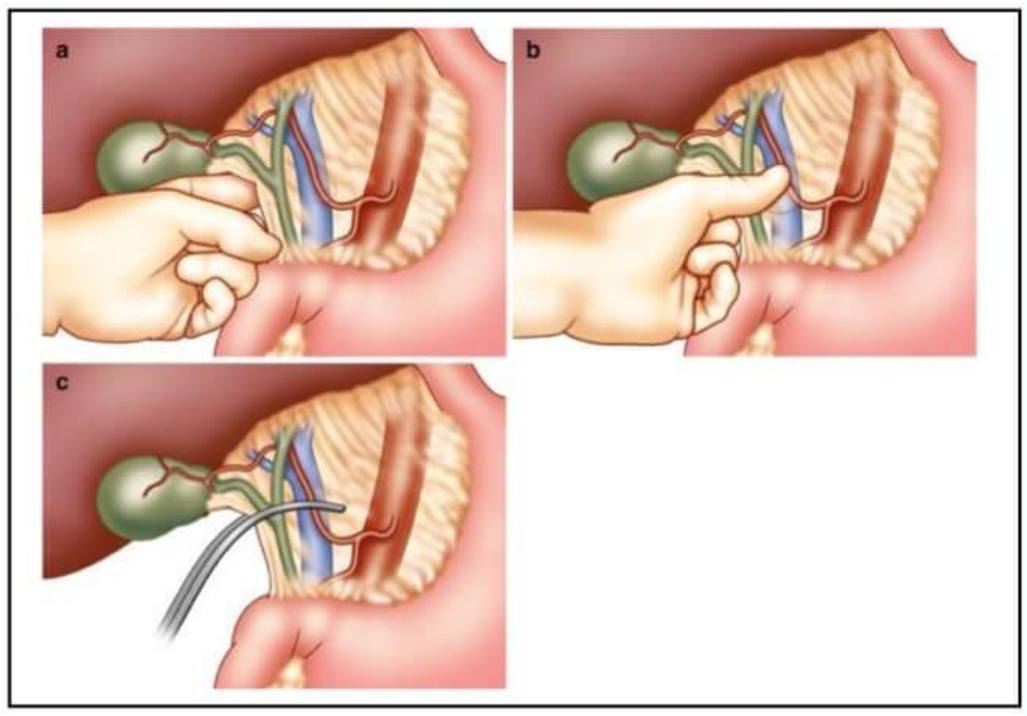

→ aka Total Inflow Occlusion
→ Clamping in foramen of Winslow and we occlude the Portal triad.
→ It controls bleeding from Portal Vein and Hepatic Artery.
→ Bleeding is effectively controlled from Portal Vein as compared to Hepatic Artery.
→ It doesn't control bleeding from IVC and Hepatic Vein

Liver Abscess

Pyogenic Liver Abscess

→ M/C type of liver Abscess
→ Present in 5th/6th Decade and commonly in Alcoholic Males.
→ M/C organism
- Worldwide → E. Coli
- Asia → Klebsiella
- Children (Suffering from Chronic granulomatous disease) →Staph Aureus

Routes of infection

1) **Bile duct/Biliary tract (MC)**

t.me/latestpgnotes

→ CBD stones
→ Hilar cholangiocarcinoma
→ CBD strictures

} leads to Cholangitis ↓ Pyogenic liver abscess

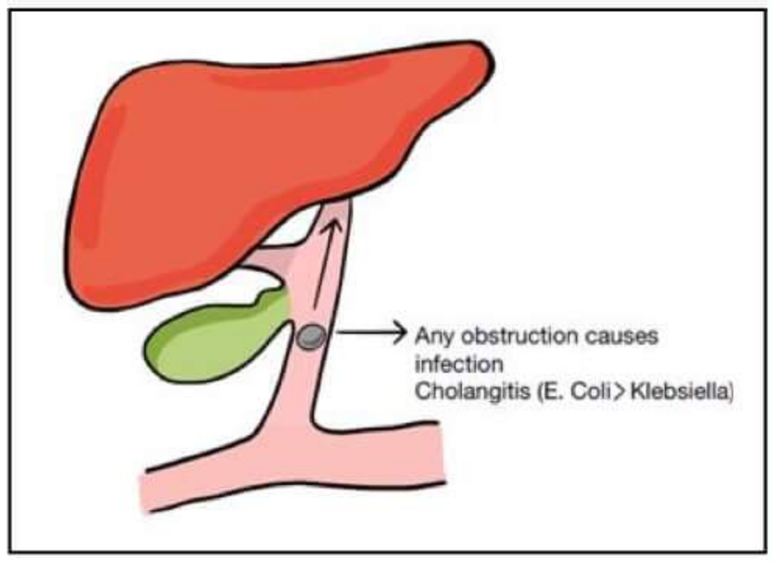

→ In PLA – obst. Jaundice is common (seen in 25% cases)
→ M/C LFT Abnormality - ↑↑ ALP

2) **Portal vein (2nd MC)**

→ Appendicular perforation or Diverticulitis can increase the risk of Pyogenic liver abscess

3) **Hepatic artery**

→ Children suffering from Chronic granulomatous disease
↓
Defective Neutrophil function
↓
↑sed risk of SABE
↓
Infection reaches liver via Hepatic artery → Pyogenic liver abscess

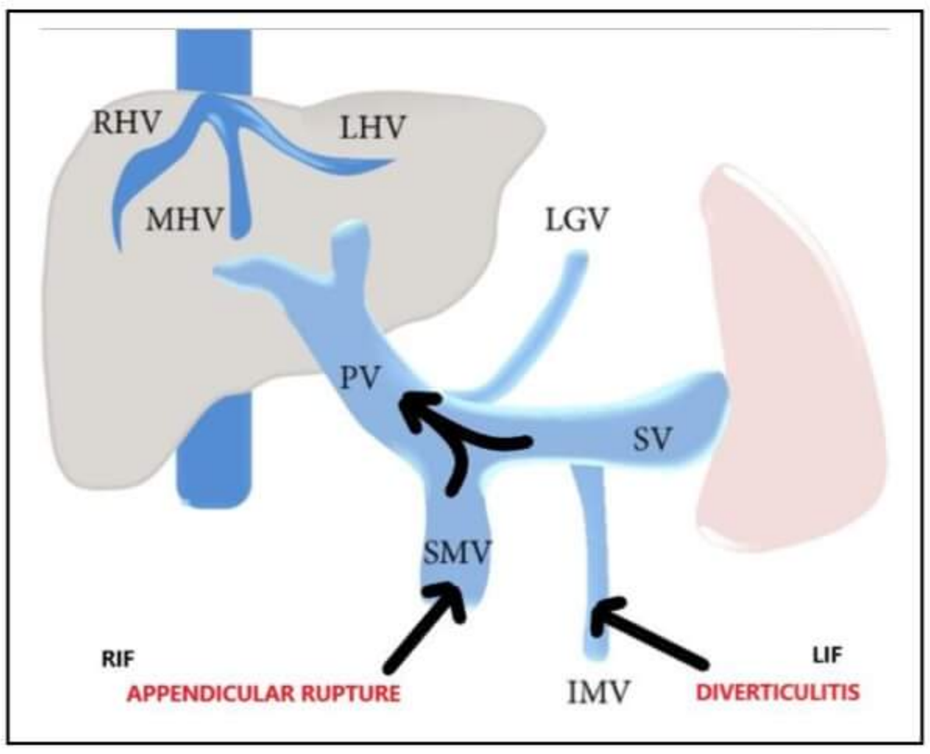

PrepLadder

4) **Direct extension of infection from**
   - → Pyothorax
   - → Sub-diaphragmatic abscess
   - → Acute suppurative cholecystitis
   - → Perinephric abscess

Clinical features

- → M/C Symptom - fever with Chills and Rigor
- → Abdominal pain
- → Anorexia
- → Fatigue (most characteristic symptom)
- → 20%-25% cases present with Jaundice

Lab parameters

- → **In any kind of CBD obstruction** - 3 parameters are raised
  - ALP (M/C LFT Abnormality)
  - GGT
  - 5' Nucleotidase

Diagnosis:

- → First investigation done - **USG**
- → Dx. Is highly suggested by **USG or CT**
- → IOC is **Aspiration and culture**

t.me/latestpgnotes

Rx

- → Percutaneous Catheter drainage + Systemic Antibiotics

Amoebic Liver Abscess

- → Caused by **Entamoeba Histolytica**
- → M/C in developing Countries
- → M/C route - **Feco-oral**
- → Common in young patients
- → Infective stage – **Quadrinucleate Cyst**

↓

Octanucleate cyst

↓

8 Trophozoites released

↓

Cause **Flask Shaped Ulcers**

Aspirating "anchovy paste" pus from amebic liver abscess

- → **M/C location of**
  - Flask Shaped Ulcer
  - Amoebic Colitis
  - Ameboma

  } **Caecum and Ascending Colon**

PrepLadder

→ E. Histolytica reaches liver via Superior Mesenteric Vein or Portal Vein – it causes, Histolysis of Hepatocytes and necrosis by WBC – "Anchovy Sauce pus" is accumulated

Clinical features

→ M/C Symptom – Abdominal pain
→ Fever
→ Anorexia
→ Fatigue
→ Jaundice is rare
→ M/C LFT Abnormality – ↑↑ PT

Diagnosis:

→ First investigation done – USG
→ Dx. Is suggested by – USG or CT
→ Dx. Is confirmed by – Amoebic Serology (ELISA)

Rx

→ High dose Oral Metronidazole 750mg TDS for 10-14 days

Indications of Aspiration in Amoebic Liver Abscess

→ No Improvement after Medical Mx within 3-5 days
→ High Risk Abscess I.e. Left Lobe Abscess and size > 5cm
→ Diagnostic Uncertainty
→ Bacterial Super infection
→ Pregnancy (high dose metronidazole is not safe)

t.me/latestpgnotes

Treatment for Carriers

→ **Carriers** – asymptomatic cyst passers
→ **Intraluminal agents** are used for cyst passers. They are
- Paromomycin
- Iodoquinol
- Diloxanide furoate

Complications

→ Rupture into Peritoneal Cavity (M/C site of rupture)
– **Rx**: Exp. Laparotomy + Peritoneal Lavage + Drain insertion

→ Rupture into pleural cavity (2nd M/C)
– **Rx**: ICD insertion

→ Rupture into pericardial cavity (3rd M/C)
– **Rx**: Needle pericardiocentesis F/B Pericardiotomy

PrepLadder

Hydatid Cyst

→ Hydatid disease is a zoonosis, occurs primarily in sheep rearing areas of the world

→ Endemic in Mediterranean countries, Middle east, Far east, South America, Australia, New Zealand & east Africa

→ **Caused by**

- E. Granulosus (M/C)
- E. Multilocularis → Responsible for "Malignant Hydatidosis"
- E. Vogeli
- E. Oligarthus

→ **Host**

- Definitive Host (sexual phase occurs inside the host) – DOG
- Intermediate Host - Sheep
- Accidental Host
- Dead-End Host
- Intermediate Host

  } Man

- Without Human to Human transmission

→ Route of infection is Feco-oral

→ Infective Stage is Eggs of Echinococcus

↓

Hexacanth Larva

↓

t.me/latestpgnotes

Penetrate duodenal capillaries

Portal vein — IVC

↓ — ↓

Liver — **Lungs & other solid organs**

→ Involves -Liver > Lungs > Spleen > Kidney > Brain > Bone

Clinical features

→ Equal distribution (Male = Female)

→ Most patients – Asymptomatic

→ M/C presentation is Asymptomatic palpable Intra- Abdominal mass (Hepatomegaly).

→ **In symptomatic patients**

- Abdominal pain
- Abdominal discomfort
- Dyspepsia

→ **M/C Complication** - Intra-biliary Rupture

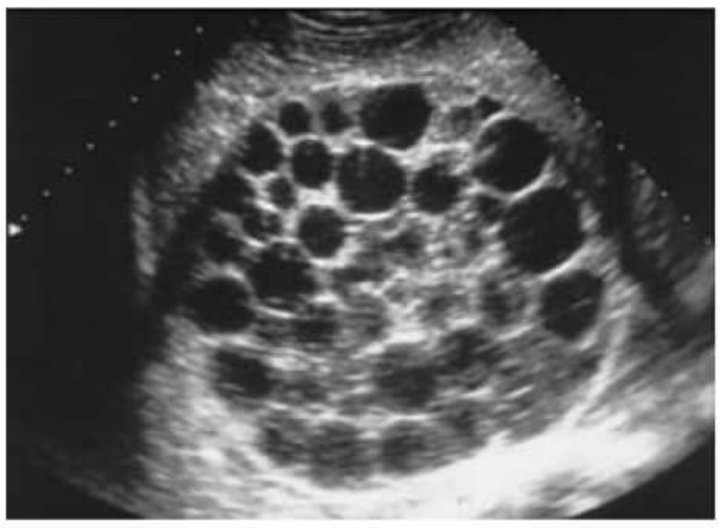

Rosette appearance (USG)

PrepLadder

Diagnosis

→ First investigation done: **USG**

→ Dx. is Highly suggested by

- USG – Rosette appearance
- CT – Ring like calcification

→ IOC is **Hydatid Serology**

- ELISA
- ARC – 5
- Immunoblot

} >95% Sensitivity & Specificity

→ **Casoni's Test** – Obsolete because of

- Low sensitivity (55-60%)
- Risk of Anaphylaxis

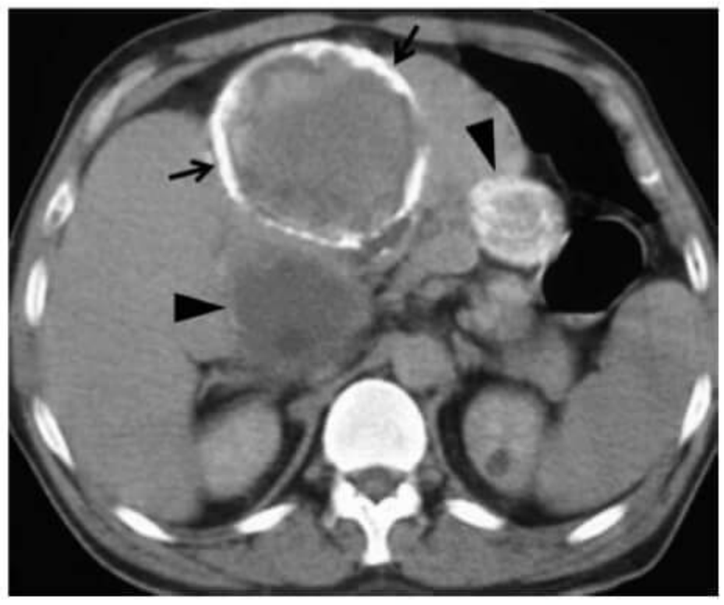

Ring like calcification (CT)

Rx

→ DOC for perioperative chemoprophylaxis – Albendazole > Mebendazole

↓

- Scolicidal
- Shrinks the size of cyst

Sx Intervention

1) **Pair** (Most preferred technique for Anatomically & Surgically appropriate lesions)

t.me/latestpgnotes

- Puncture
- Aspiration of Content
- Instillation of Scolicidal Agents
- Reaspiration

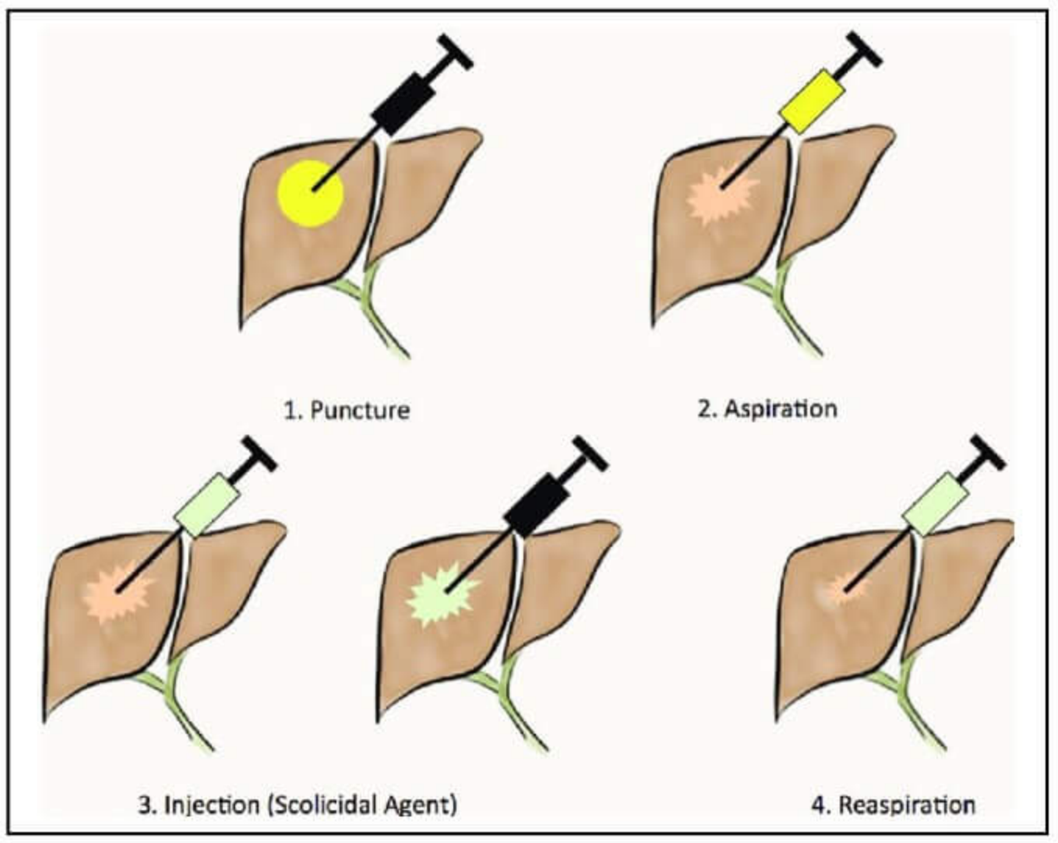

Scolicidal Agent used:

- Hypertonic Saline (20%) is M/C used
- 0.5% cetrimide with 0.05% chlorhexidine
- 10% povidone iodine
- Absolute alcohol

Note:

- Formalin
- Silver Nitrate

} Not used because of Toxicity

Contraindications for PAIR:

- Inaccessible cyst
- Peripherally located cyst
- Multiloculated cyst
- Cysto-biliary communication

PrepLadder

- Cyst in lungs & brain (does not have pericyst)
- Calcified cyst (dead cyst)

2) **Cyst Evacuation + Omentopexy**

3) **Peri-cystectomy** (Most effective treatment)
   → Excision of cyst outside of Pericyst

4) **Hepatic Resection** (Most Radical Treatment)

Cyst Evacuation + Omentopexy

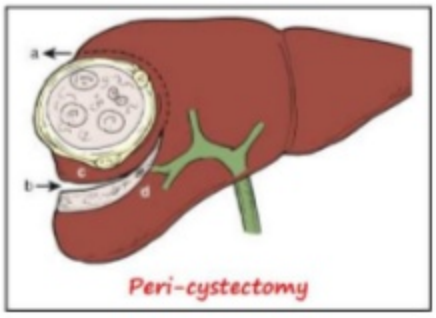

Peri-cystectomy

Gharbi's Classification for Hydatid Cyst Based On USG

t.me/latestpgnotes

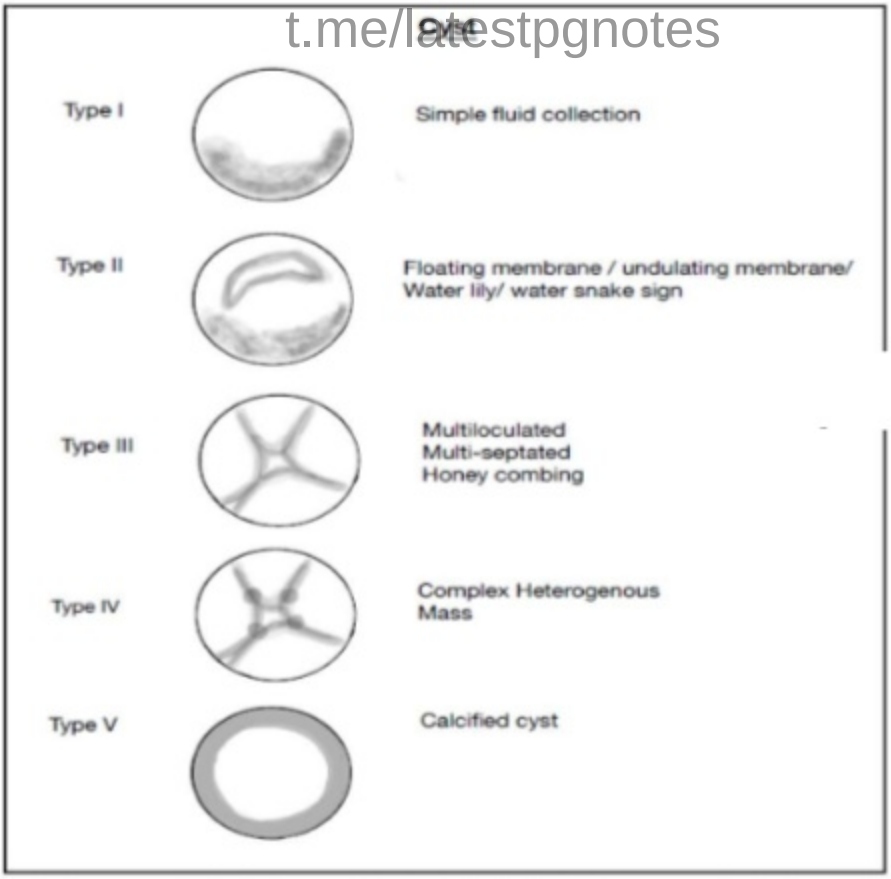

PrepLadder

Similarities among Pyogenic liver abscess, Amoebic liver abscess & hydatid cyst

→ In all these conditions Cyst is usually single and involves Right lobe of liver

→ **Chest X-ray changes are similar**

- Raised right dome of Diaphragm
- Collapse of right lung (Atelectasis)
- Reactive pleural effusion

t.me/latestpgnotes

PrepLadder

LIVER PART – II

Liver Tumors

→ M/C Malignancy of Liver - Metastasis
→ M/C primary Malignancy of Liver - HCC
→ M/C primary Malignancy of Liver in Children - Hepatoblastoma
→ M/C Benign tumour of liver - Hemangioma

Liver metastasis

→ GIT develops from foregut, midgut & hind gut
- **Foregut extends** – from cricopharynx to 2nd part of duodenum
- **Midgut extends** – from 2nd part of duodenum to 2/3rd of transverse colon
- **Hindgut** - from 2/3rd of transverse colon to Anorectal junction

→ **Blood supply of foregut**
- Celiac trunk has 3 branches
  - Left gastric artery
  - Splenic artery
  - Common hepatic artery
- All these branches have their corresponding veins which drains into portal vein directly or indirectly

t.me/latestpgnotes

→ **Blood supply of Midgut** - Superior mesenteric artery (Superior mesenteric vein → Portal vein)
→ **Blood supply of Hindgut** - Inferior mesenteric artery (Inferior mesenteric vein → Portal vein)

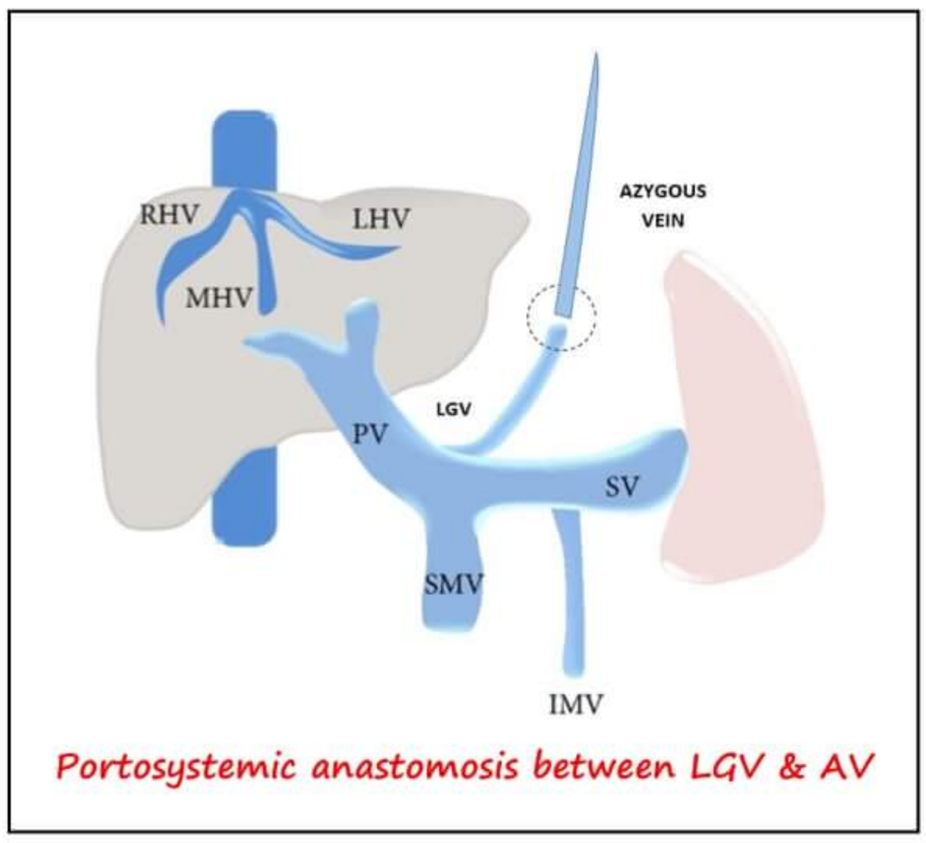

Portosystemic anastomosis between LGV & AV

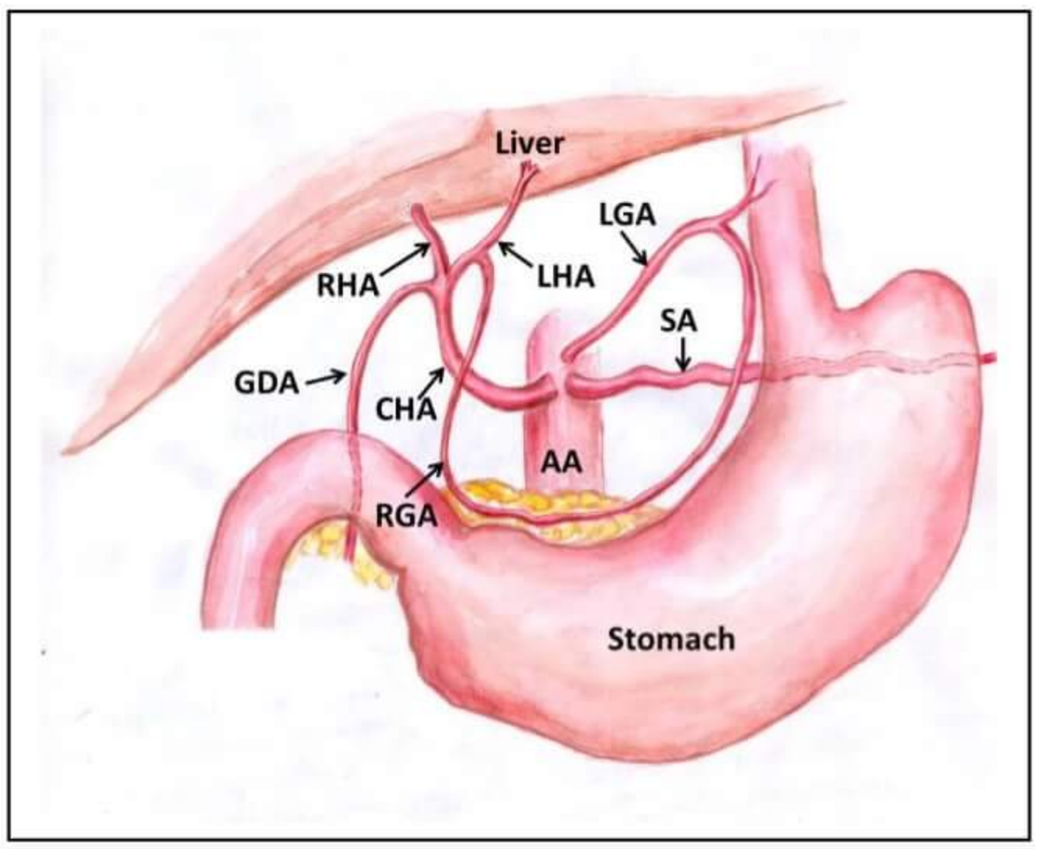

→ Liver acts as a filter organ for most of GI venous drainage. So, if the blood has any malignant cells it gets filtered in liver.

PrepLadder

→ Therefore,

- For malignancies of GIT from esophagus to rectum having hematogenous spread, the MC site of metastasis is **liver.**
- For non-GI malignancies having hematogenous spread, the MC site of metastasis is **lung.**

  Examples:

  1. CA anal canal
  2. RCC
  3. CA penis
  4. Testicular tumor
  5. Soft tissue sarcoma
  6. HCC
  7. Hepatoblastoma
  8. Wilm's tumor
  9. CA oral cavity

→ MC primary for liver metastasis – **Colorectal cancer followed by CA lung**

→ **CA lung is the MC primary for metastasis to 6 organs**

- Kidney
- Esophagus
- Pancreas
- Adrenal
- Brain (MC site of metastasis in **CA lung**)
- Skin

t.me/latestpgnotes

→ **CA Breast is the MC primary for metastasis to**

- Thyroid
- Lungs, Lumbar vertebra
- Leptomeninges

→ **Metastasis to heart**

- MC primary in male – **CA lung**
- MC primary in female – **CA breast**

→ MC primary for metastasis to Spleen – **Malignant melanoma**

→ MC primary for isolated secondaries to Spleen – **CA ovary**

→ MC primary for metastasis to Testes – **CA prostate**

→ MC primary for metastasis to penis – **CA bladder**

Bone metastasis

→ MC primary for bone metastasis

- Male – CA prostate
- Female – CA breast

→ Overall MC primary for bone metastasis **CA breast > CA prostate**

PrepLadder

→ MC primary for both Osteolytic & Osteoblastic secondaries in female - **CA breast**
→ MC primary for Osteoblastic secondaries in male - **CA prostate**
→ MC primary for Osteolytic secondaries in male – **RCC** (Has Pulsatile secondaries – Osteolytic & hypervascular)
→ Pulsatile secondaries are also seen in follicular carcinoma of thyroid
→ Overall MC site of bone metastasis – **Thoracic vertebra** (Dorsal spine)
→ IOC for bone metastasis – **Bone scan** (radioisotope SAMARIUM 153 → used for painful bone metastasis)

Hemangioma

→ MC benign tumor of liver
→ More common in Females and associated with OCP use
→ **It is of two types**
  - Capillary
  - Cavernous
→ Usually they are small (< 5cm)
→ If size of Hemangioma is > 5cm – **Giant Hemangioma**
→ Hemangioma increases its size by **Ectasia** and not by neoplasia like other tumors

Clinical features

→ Usually Asymptomatic – incidentally diagnosed by radiological investigations
→ In symptomatic patients – Abdominal discomfort & abdominal pain
→ It is rarely associated with **Kasabach – Meritt syndrome**

↓

Manifestations:

- Microangiopathic Hemolytic anemia
- Platelet trapping anemia
- Consumptive coagulopathy
- Thrombocytopenia

t.me/latestpgnotes

Diagnosis:

→ Hemangioma is a vascular tumor – so, **FNAC/Biopsy are contraindicated**
→ IOC for diagnosis is **MRI** – Shows peripheral nodular enhancement

Treatment:

→ TOC for Hemangioma is **Enucleation**

NOTE:

→ Enucleation is the Treatment of choice for
  - Hemangioma liver
  - Leiomyoma esophagus (MC benign tumor of Esophagus)
  - Chylolymphatic cyst
  - Insulinoma head of pancreas

PrepLadder

FNH-Focal Nodular Hyperplasia

→ 2nd M/C Benign tumour of liver

→ More common in Females and associated with OCP use

→ Hepatic architecture is maintained in FNH

Clinical features

→ Usually Asymptomatic – incidentally diagnosed

Diagnosis:

→ IOC is **CECT**

→ **On CECT**, gives **Central Stellate Scar** because of central feeding arteriole with multiple peripheral branches

→ **On Angiography** due to Abnormal Vascularity, there is **Spoke Wheel/Cart Wheel Pattern**

Treatment:

→ Observation

→ Excision in case of diagnostic uncertainty

NOTE:

→ **Central stellate scar is also seen in:**

- FNH
- Fibrolamellar variant of HCC
- Serous cystadenoma of pancreas
- Renal oncocytoma

t.me/latestpgnotes

Hepatic Adenoma:

→ Benign proliferative disorder of hepatocyte

→ Has Low risk of malignant transformation to HCC

→ More common in Females and associated with OCP use

→ Hepatic architecture is not maintained

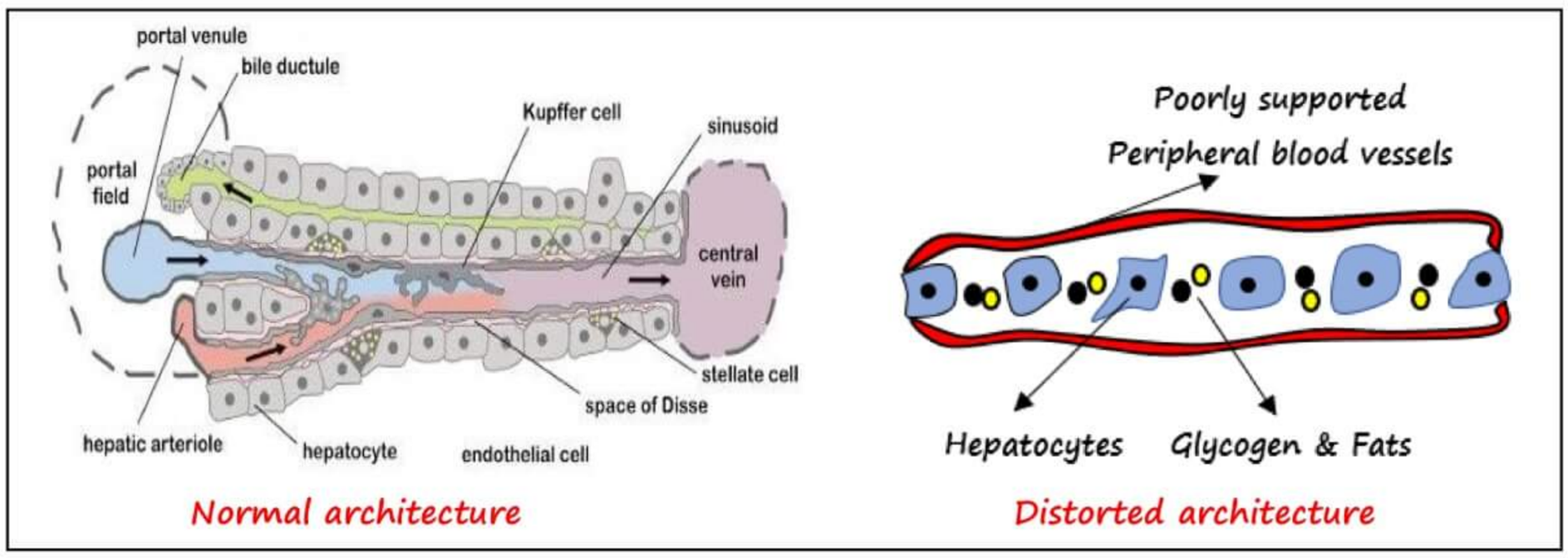

→ Poorly supported peripheral Blood vessel - ↑sed risk of Hemorrhage & Necrosis

↓

- Causes symptoms – Abdominal pain
- High risk of **tumor Rupture** (30-50%)

→ Risk of Tumor rupture increases in pregnancy

PrepLadder

Clinical features

→ Most patients are symptomatic
→ MC symptom – Abdominal pain
→ Tumor Rupture leads to Hemoperitoneum → shock

Diagnosis:

→ IOC is **CECT** – Shows Peripheral hypervascularization

Treatment:

→ Excision

Hepatocellular carcinoma

Risk Factors

Cirrhosis	Metabolic Disorders	Environmental Factors
→ HBV → HCV → Alcohol → NAFLD → PBC → Chronic active hepatitis	→ Hemochromatosis → Wilson's Disease → Glycogen Storage Disorder → α_1 AT deficiency → Porphyria cutanea tarda → Citrullinemia → Orotic aciduria → Alagille's syndrome	→ Cigarette Smoking → Anabolic steroids → Aflatoxin → **Thorotrast** – also ↑se risk of • Cholangiocarcinoma • HCC • Angiosarcoma • Hepatic Fibrosis

t.me/latestpgnotes

→ MC 1° Malignancy of liver
→ Common in Male, 5th – 6th decade
→ Max. incidence in Asia & Sub-Saharan Africa
→ MCC of HCC – **HBV**
→ HBV induced HCC is decreasing because of Vaccination
→ HCV induced HCC – increasing in western countries because of
- Blood transfusion
- Sexual transmission
- Associated with HIV

Pathological types of HCC

- Hanging (best prognosis)
- Pushing
- Infiltrative (MC, Worst prognosis)

HCC has propensity for Vascular Invasion (also in RCC)

↓

Tumor invades from one branch of portal vein to other

↓

causing "**Multicentric & Bi-lobar**" spread (in 75%-80%)

PrepLadder

NOTE: This happens because PORTAL VEINS are valveless

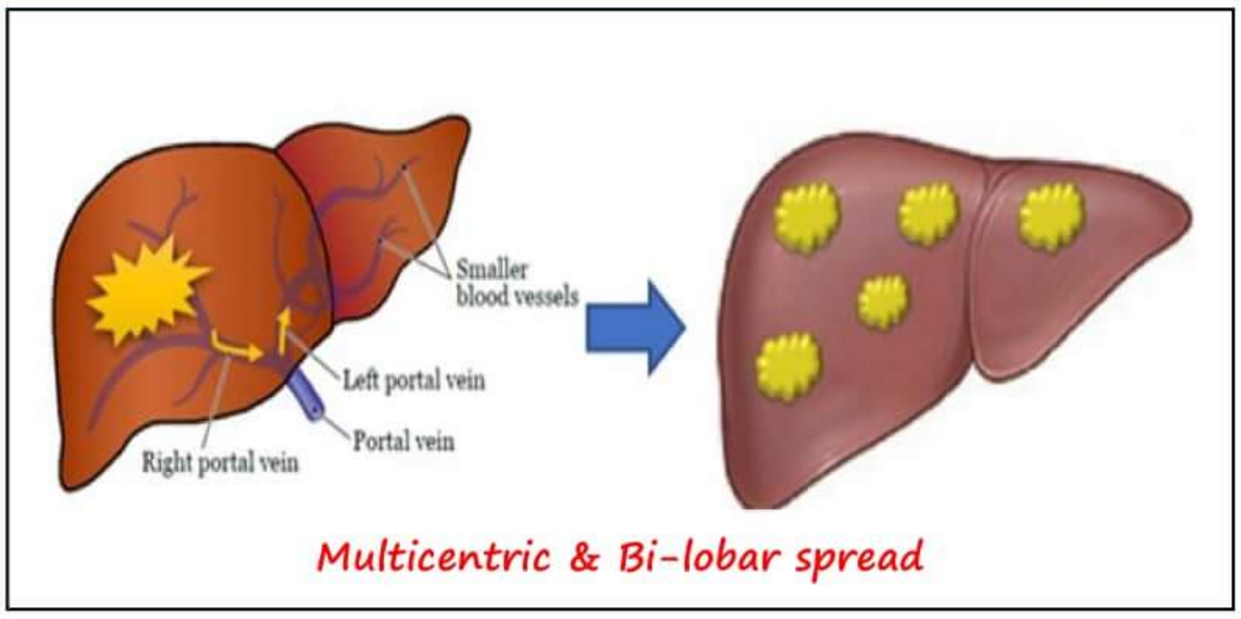

Multicentric & Bi-lobar spread

Valveless veins are

→ IVC
→ PV
→ SVC
→ Batson plexus
→ Dural venous sinuses

Clinical features

→ M/C Symptom - Abdominal pain > Weight loss
→ **Significant weight loss definition:**
  - > 5% → 1 months
  - > 10% → 6 months
  - > 20% → 1 year
→ **Other symptoms**
  - Anorexia, fatigue
  - Jaundice (10%)
  - Tumour Rupture (3-5%)
  - Audible BRUIT (20-25%)
  - Paraneoplastic Manifestation
    - Hypercholesterolemia (M/C)
    - Hypoglycemia (2nd M/C)
    - Erythrocytosis
    - Hypercalcemia

t.me/latestpgnotes

Tumour Markers

→ AFP > 20 mg/ml (seen in 70% of HCC)
→ ↑se in PIVKA-2 (Protein induced by Vitamin-K Absence-2)

Diagnosis:

→ First investigation done in a suspected case of HCC – USG
→ IOC – Triple Phase CT (Arterial Hypervascularization with Venous Washout)

PrepLadder

Staging For HCC

→ **TNM** not used commonly

→ **OKUDA Classification (MC used)**

- **B** – Bilirubin
- **A** – Albumin
- **T** – Tumour size
- **A** – Ascites

→ **CLIP (Cancer Liver Italian Program)**

- **P** – Portal Vein Thrombosis
- **A** – AFP
- **C** – Child Turcotte Pugh Score (CTP Score)
- **T** – Tumour Extension

→ **CUPI (Chinese University Prognostic Index)**

- **B** – Bilirubin
- **A_3** – AFP, Ascites, ALP
- **T** – TNM Staging
- **S** – Symptoms

Management

→ **BCLC** (Barcelona clinic for Liver Cancer) – This Criteria is based on OKUDA Staging & patients performance status.

t.me/latestpgnotes

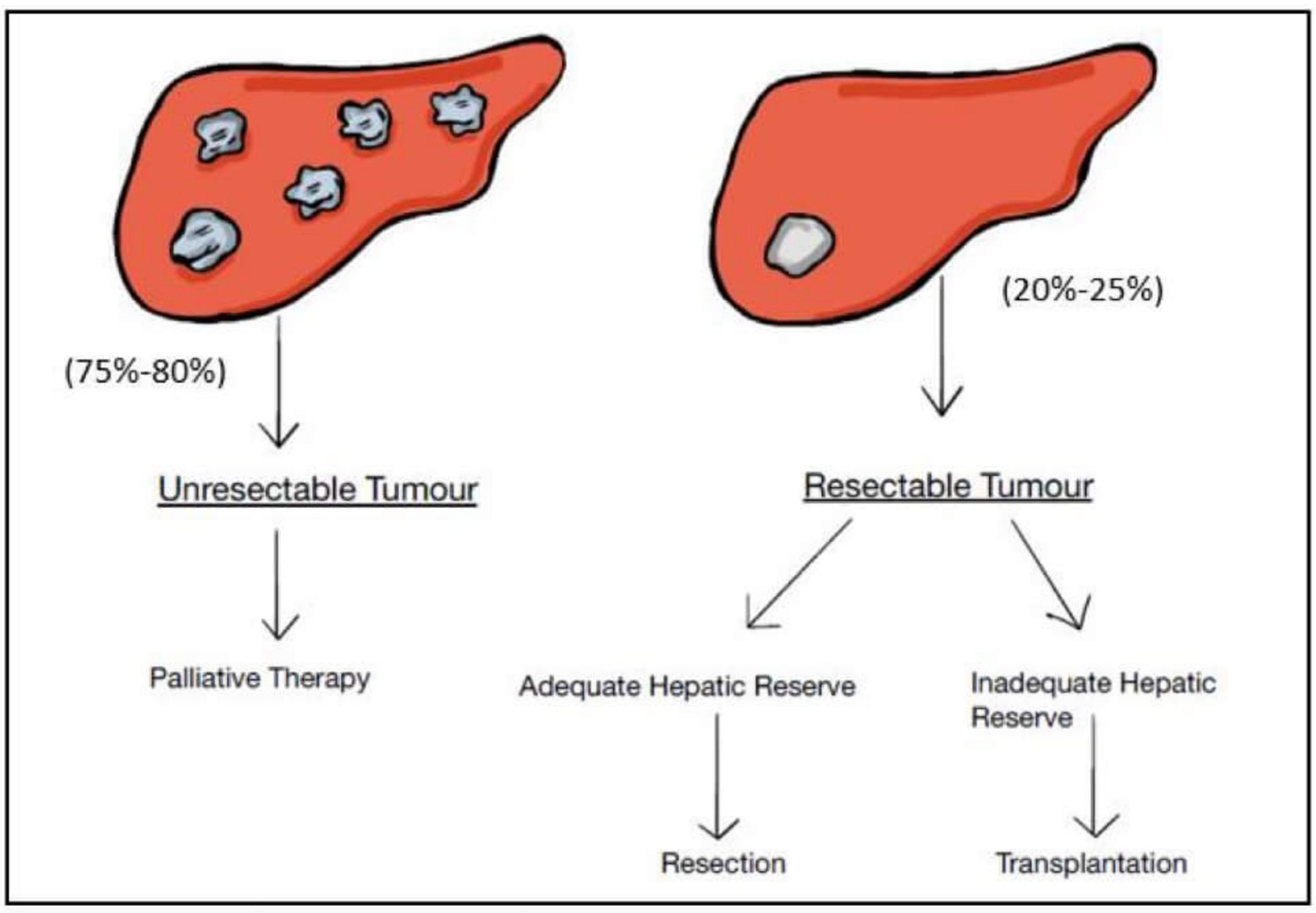

→ **Milan's criteria for Liver transplantation in HCC**

1) Single tumor <5cm in size
2) Multiple tumors (NO. 2-3) & size <3cm
3) No Extrahepatic/ Vascular spread

- After LT – has 5-year survival in 70%

PrepLadder

→ For unresectable tumor – **Palliation**

↓

- Percutaneous ethanol injection
- Percutaneous acetic acid injection
- Radiofrequency ablation
- Microwave ablation
- Cryoablation (liquid nitrogen used)
- TACE (Trans Arterial Chemo Embolization)

→ **TACE (Trans Arterial Chemo Embolization)**

- Only palliative method that has Survival advantage
- With local delivery of chemotherapy agent – it obstructs the hepatic artery giving Survival advantage (HCC is exclusively supplied by hepatic artery)
- Chemotherapy agents used
  - Cisplatin
  - Doxorubicin

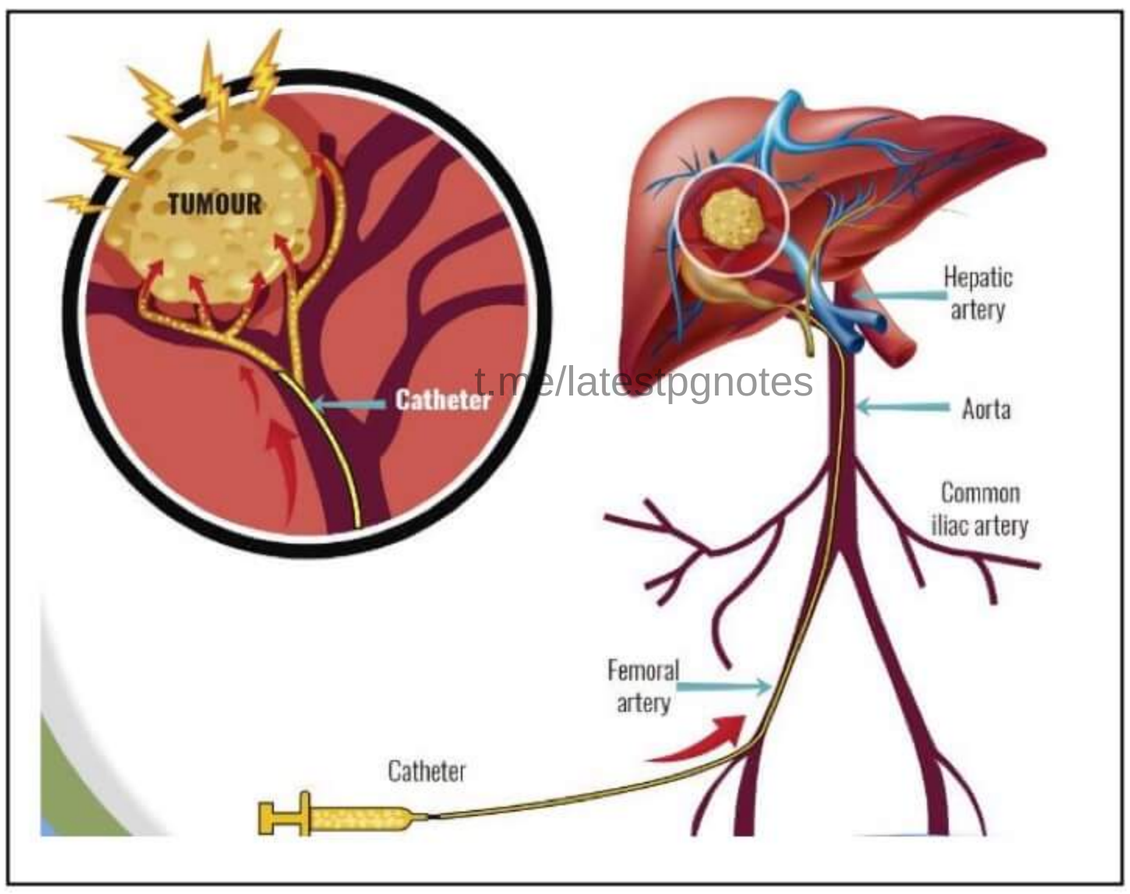

t.me/latestpgnotes

→ For Advanced & metastatic HCC – **SORAFENIB**

→ **Drugs with Similar Action**

1) **Imatinib**
   - DOC for GIST & CML

2) **Sunitinib**
   - DOC for Imatinib resistant GIST
   - 1st line – for Advanced/Metastatic RCC
   - Refractory and Metastatic Breast Ca

3) **Regorafenib**
   - Third line Agent for GIST

4) **Vandetanib**
   - Only drug (US-FDA approved) for Advanced and progressive Medullary Thyroid Ca

PrepLadder

5) Lapatinib

- 2nd Line Agent for HER – 2 neu positive Breast Cancer.

6) Gefitinib

- Used for "Adenocarcinoma Lung" in female who are non-smokers

Fibrolamellar Variant of HCC

→ Well Circumscribed and Non – Encapsulated Tumour
→ Has fibrous stroma with lamellar structures
→ Has slow growth and present in Young Patient.
→ **Not Associated With**
- HBV Infection
- HCV Infection
- Cirrhosis

Pathology

→ Has fibrous stroma with Lamellar structure
→ AFP is normal, but raised **Neurotensin and B_{12} binding globulin**

Diagnosis:

→ IOC is **CECT** – shows Central stellate scar

Rx:

t.me/latestpgnotes

→ In Majority of Cases it has good prognosis and tumour is Resectable.

Hepatoblastoma

→ M/C 1° Malignancy of Liver in children
→ LBW (Low Birth rate) increases the risk.
→ Associated with
- **FAP** – Familial Adenomatous Polyposis
- **BWS** – Beckwith Wiedemann Syndrome

→ Not associated with
- HBV
- HCV
- Metabolic disorders
- Cirrhosis

→ AFP raised in 90% patients

C/F

→ Most patients are <18 months and all patients are <3yrs of Age.
→ M/C presentation – Asymptomatic palpable I/A Mass
→ Characteristic Laboratory Abnormality – Thrombocytosis
→ M/C route of spread – Hematogenous
→ M/C Site of Mets – Lungs

PrepLadder

Diagnosis:

→ IOC for diagnosis - **Biopsy**

→ Radiology IOC – **CECT**

Management

→ Resection

→ **But in cases of Metastatic** Disease

- Neo Adjuvant Chemotherapy (NACT) + Surgery is done
- Chemotherapy agent used
  - Vincristine
  - Cisplatin
  - 5-FU
- >50% of pts. – Pulmonary metastasis disappears after chemotherapy

t.me/latestpgnotes

PrepLadder

Portal hypertension

→ **Normal portal pressure**
- 5 – 10 mmHg (or)
- 10 – 15 cm of saline

→ **Definition of portal HTN**
- Pressure more than 10 mmHg

→ **Universal manifestations of portal HTN**
1. Esophageal Varices
2. Splenomegaly

Note: Esophagus variceal bleeding occurs when pressure is > 12 mmHg

→ Most common cause of portal HTN worldwide – Cirrhosis

→ M/C/C of portal HTN in children – Extra hepatic portal venous obstruction (EHPVO)

→ **Causes of increased pressures**
1. Increased resistance
2. Increased flow

Anatomy of liver

→ The region where blood from portal vein & hepatic artery mixes is known as Sinusoid

→ Sinusoid is surrounded by hepatocytes, Kupffer cells & bile canaliculi

t.me/latestpgnotes

→ **Anything that causes portal HTN**
- Before sinusoid → pre-sinusoidal
- After sinusoid → post – sinusoidal
- In sinusoid → Sinusoidal
- Outside liver → Extra hepatic
- Inside liver → intra hepatic

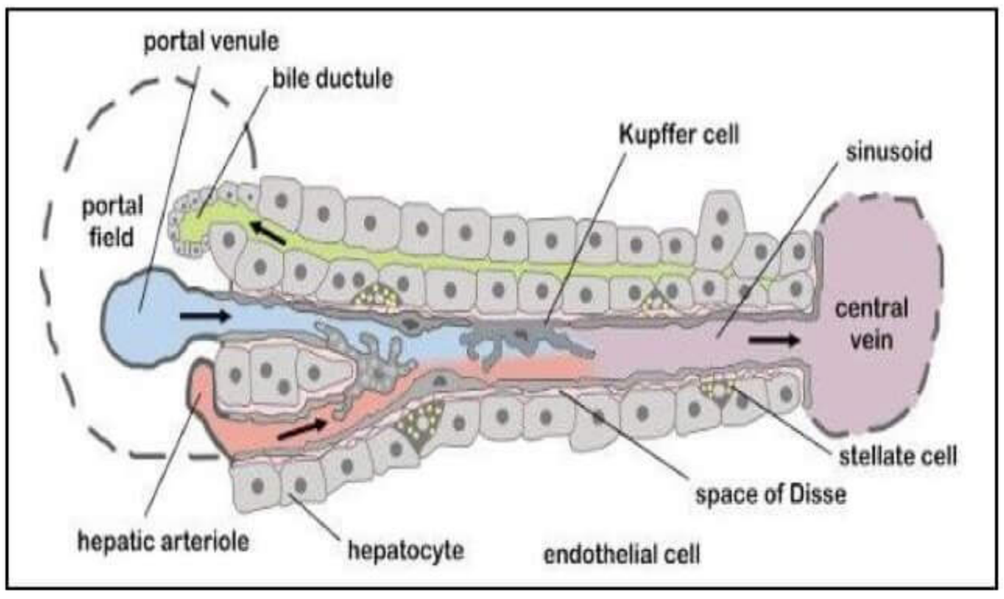

Causes of portal HTN:

→ **Pre sinusoidal extrahepatic**
- Splenic vein thrombosis
- Splenic AV fistula
- Splenomegaly

→ **Pre sinusoidal intrahepatic**
- Schistosomiasis (MC)
- Sarcoidosis
- Nodular regenerative hyperplasia
- Graft vs. host disease

PrepLadder

→ **Sinusoidal**

Cirrhosis caused by

- HBV, HCV infection
- Alcohol
- PBC (1° biliary cirrhosis)
- PSC (1° Sclerosing cholangitis)

→ **Post sinusoidal intrahepatic**

- VOD (Veno-occlusive disease)

→ **Post sinusoidal extrahepatic**

- Budd Chiari syndrome
- IVC obstruction
- Right hepatic failure
- Constrictive pericarditis

Diagnosis

→ **Investigation of choice – Doppler** done in

1. Portal HTN
2. Varicose vein
3. DVT
4. Testicular torsion
5. Varicocele

t.me/latestpgnotes

Portal systemic Anastomotic sites:

→ Between LGV (coronary vein) & Azygous vein – Esophageal varices

→ Between superior epigastric vein, inferior epigastric vein & paraumbilical vein – Caput medusae

→ Between superior, medial & inferior rectal vein – Rectal varices

→ Audible venous hum at caput medusae is known as Cruvelhier Baumgarten murmur

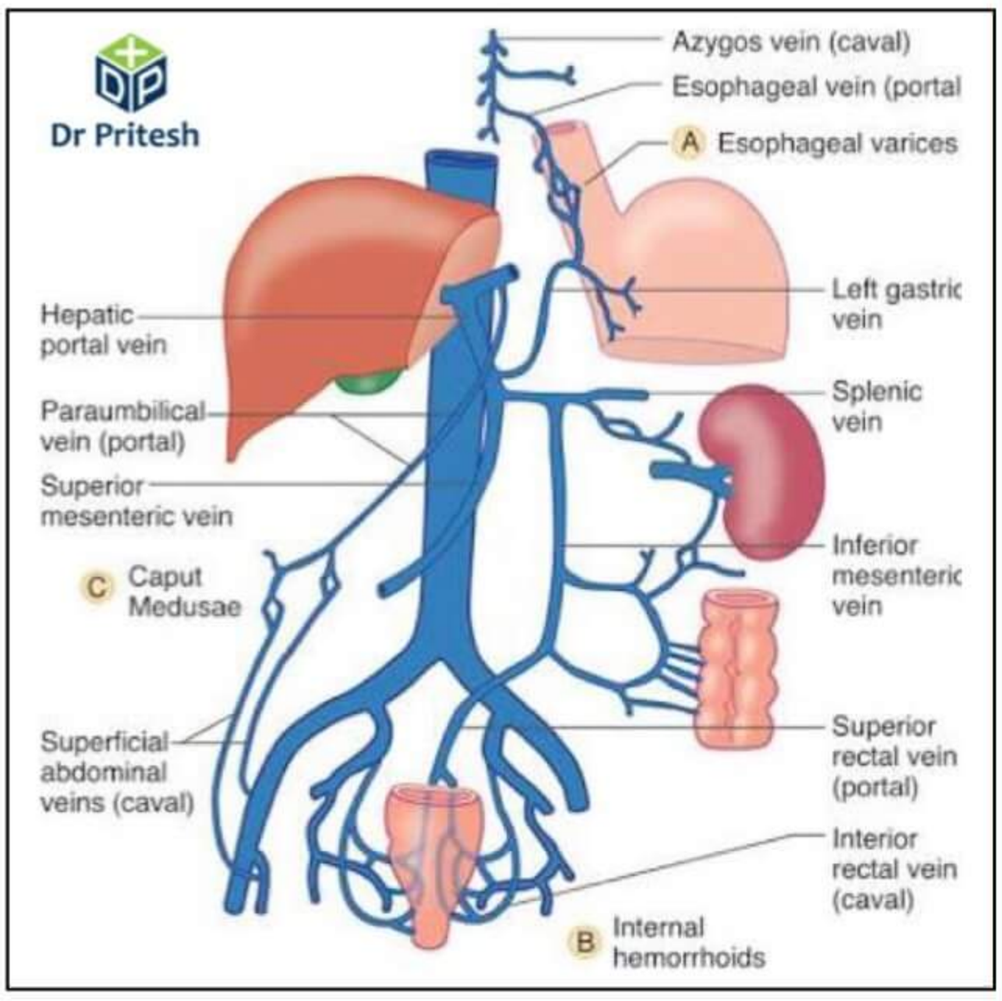

Most common cause of death in cirrhosis

→ Hepatic failure > variceal bleeding

PrepLadder

Variceal bleeding

→ M/C site – lower 3cm of esophagus

→ Coffee colored bleeding (as venous blood is mixed with acid in stomach)

Management

→ As patient goes to shock after 2 – 3 episodes of variceal bleed

- Put two large bore IV cannulas
- Start IV fluid
- Fluid of choice – RL
- Cut off BP – 100 mmHg
- Cut off Hb – 8 gm%

→ Indication of blood transfusion - Hb <8gm%

Pharmacotherapy:

→ **Drug of choice for controlling bleeding** - Octreotide > Terlipressin + nitrates

→ **Gastric lavage** – room temperature saline

Note: cold saline (not to be used)

↓

Cause hypothermia

↓

Cause (platelet dysfunction) reversible coagulopathy

t.me/latestpgnotes

→ **Endoscopy** - EVL (Endoscopic variceal ligation) > Endoscopic sclerotherapy

↓

Easy to perform but increased risk of esophageal perforation

→ **IV antibiotics**

Given for 7 days

- ↓ risk of infections
- ↓ duration of hospitalization
- ↓ risk of rebleeding

If bleeding not controlled, next what?

→ Repeat endoscopy

→ Surgical intervention – TIPPS / shunt

2 attempts of endoscopy failed (failed endoscopy)

→ TIIPS / shunt

For transportation of pts, from rural areas

→ **Sengstaken Blakemore tube used: -**

- It is a triple lumen double balloon tube

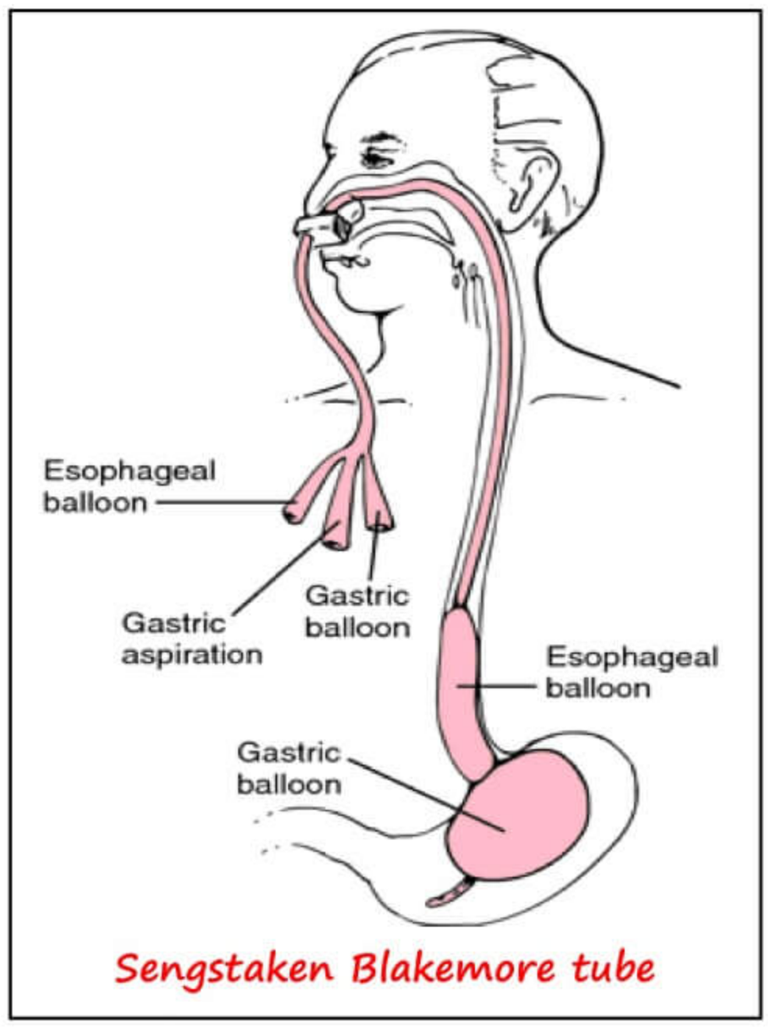

Sengstaken Blakemore tube

PrepLadder

- Control variceal bleeding during transportation
- First gastric balloon is inflated with 50 ml of air then esophageal balloon is filled with 250 ml of air.
- **Only air is used to inflate balloon**

  Water
  Saline } contraindicated
  Contrast

- MC complication – Aspiration
- Max pressure used → 35 – 40 mmHg
- Every 12 hourly used esophageal balloon should be deflated to prevent esophageal ischemia

→ **Linton's Nachalas tube**

- It is a single balloon tube
- Linton's tube capacity → 400 – 700ml
- **Use:** – isolated gastric varices

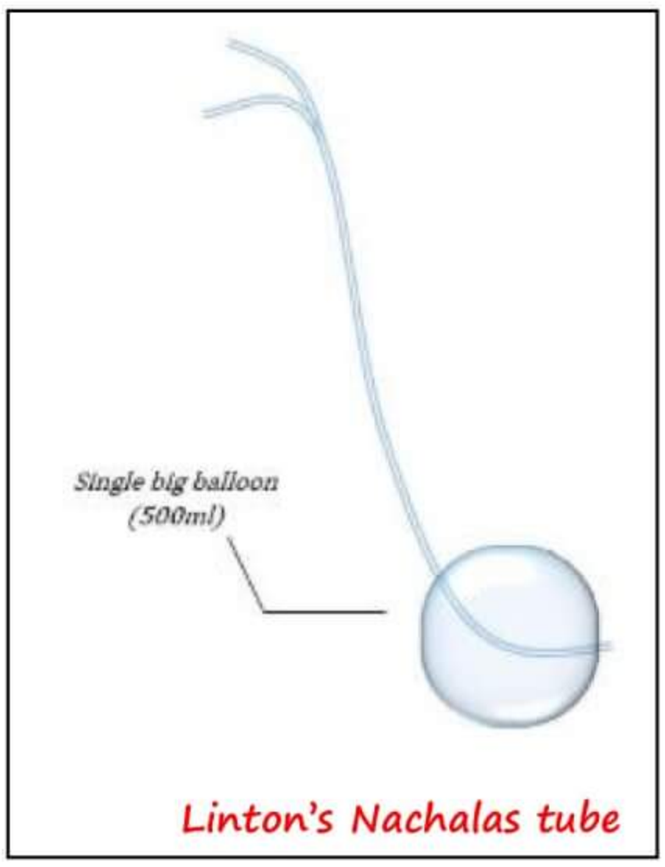

Linton's Nachalas tube

TIPSS (Trans jugular intrahepatic Porto systemic shunt)

→ Non selective shunt

→ Stent is inserted between right hepatic vein & right branch of portal vein

→ For cannulation right **internal JV** is preferred

→ For cannulation of portal vein, **Rosch needle** is used

→ Stent name – VIATORR

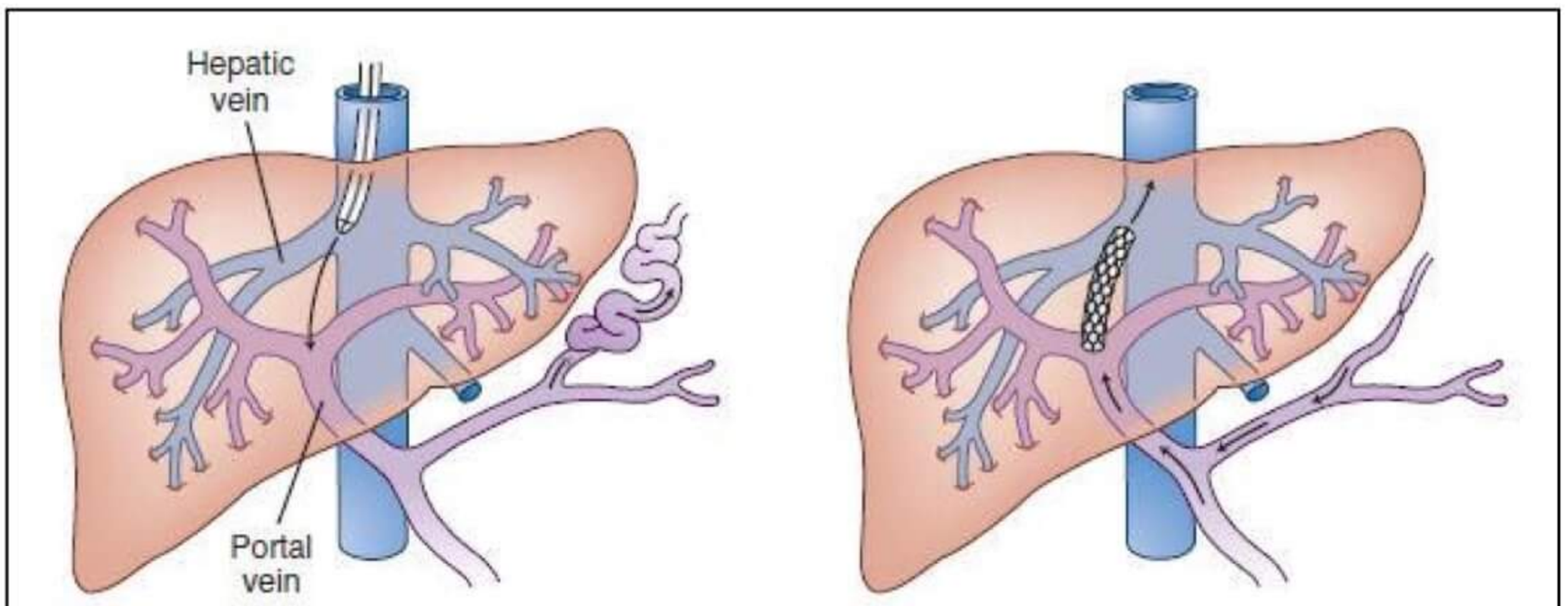

TIPSS (Trans jugular intrahepatic Porto systemic shunt)

Complications of TIPS

1. Encephalopathy (due to NH_3) (M/C)
2. Stent stenosis
3. Stent thrombosis

PrepLadder

Contraindications of TIPSS

Absolute	Relative
• Right heart failure • Pulmonary HTN • Hepato pulmonary syndrome • Polycystic liver disease	• Portal vein thrombosis • Hypervascular liver tumor • Encephalopathy

Indications of TIPSS

1. Prevention of acute variceal bleeding (MC)
2. **Refractory variceal bleeding**
3. **Refractory ascites**
4. **Refractory hepatic hydrothorax**
5. **Hepatorenal syndrome**
6. Budd Chiari syndrome
7. Veno-occlusive disease
8. Portal hypertensive gastropathy

Shunts:

Types of shunts

1. Non selective
2. Selective
3. Partial

t.me/latestpgnotes

Non-selective shunts

1. Eck fistula
2. Side to side porta-caval shunt (SSPCS)
3. Inter position graft
    a) Porto caval
    b) Mesocaval
    c) Mesorenal
4. Proximal splenorenal shunt (PSRS)/Linton's shunt

Selective shunt

1. DSRS (Warren shunt) – distal splenorenal shunt
2. INOKUCHI shunt

Partial shunt

→ any shunt with diameter < 10 mm

PrepLadder

Non-selective shunts

EcK fistula

→ End to side portocaval shunt

Portal vein is divided

- Proximal part is ligated
- Distal part is anastomosed with IVC.

→ No blood flow from PV – liver

→ Increased risk of hepatic ischemia

→ Historical importance only

→ Obsolete shunt

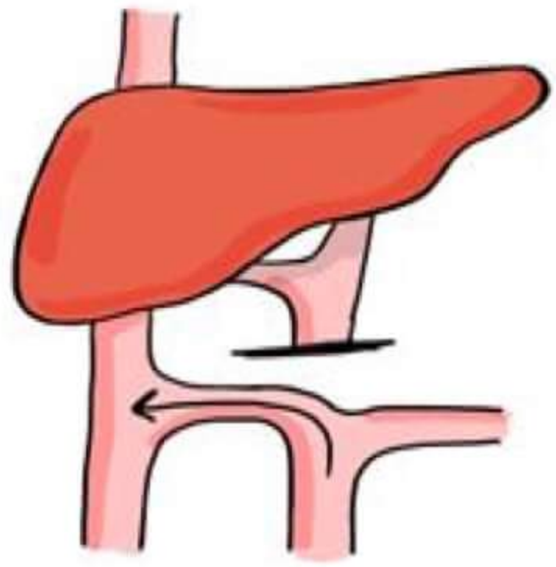

EcK fistula

Side to side portocaval shunt (SSPCS)

→ Portal vein is divided

- Proximal & distal part – both are anastomosed with IVC

→ MC performed shunt

→ **Shunt of choice for**

a) Refractory ascites
b) Budd Chiari syndrome
c) Veno-occlusive disease

t.me/latestpgnotes

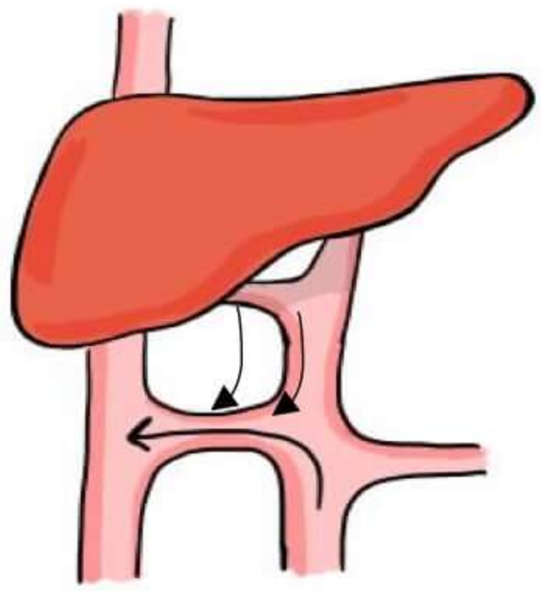

SSPCS

Interposition graft

Types:

→ **Porto canal** – between portal vein & vena cava

→ **Mesocaval** – between portal SMV & vena cava

→ **Mesorenal** – between SMV & splenic vein

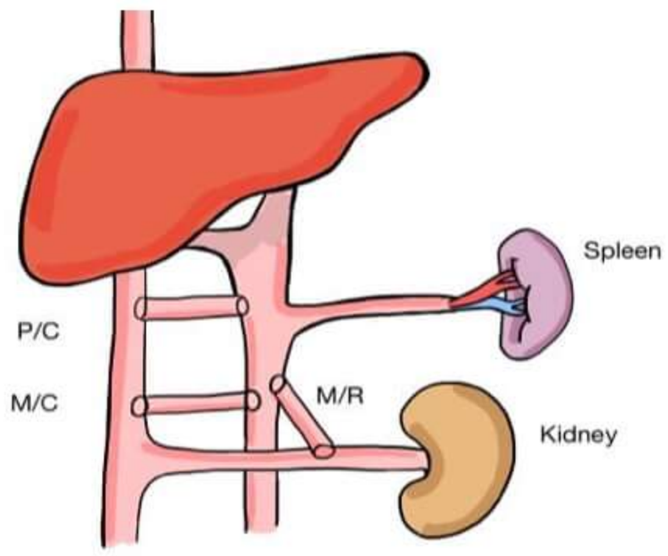

Interposition graft

PSRS

→ Performed after splenectomy

→ Suture proximal part of splenic vein into renal vein

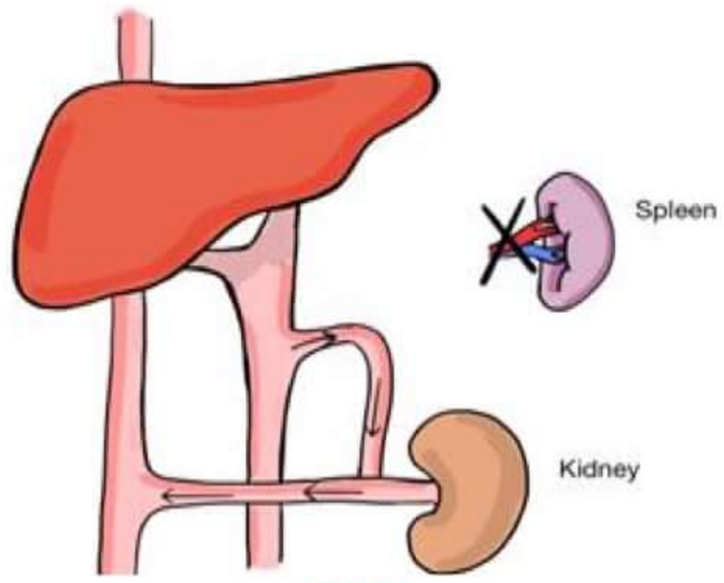

PSRS

PrepLadder

Selective shunt

Distal SRS

→ Distal Spleno renal shunt (warren shunt)

→ Type of selective shunt

→ Distal part of splenic vein is divided & sutured with renal vein

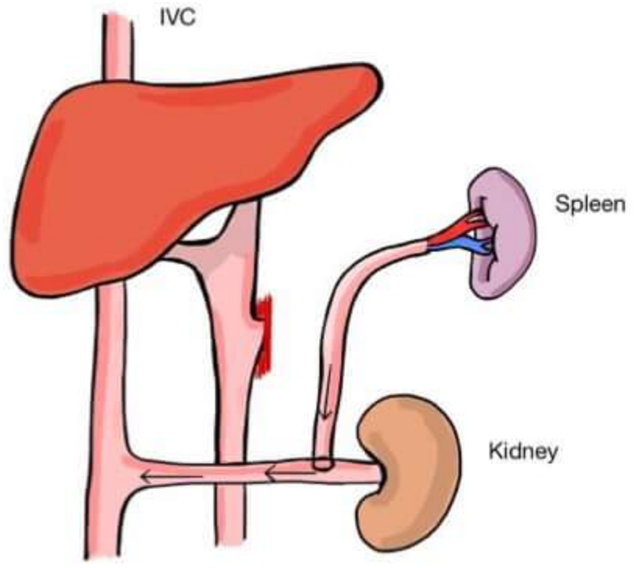

Distal SRS

Inokuchi shunt

→ IP graft between left gastric vein (coronary vein) & IVC is done.

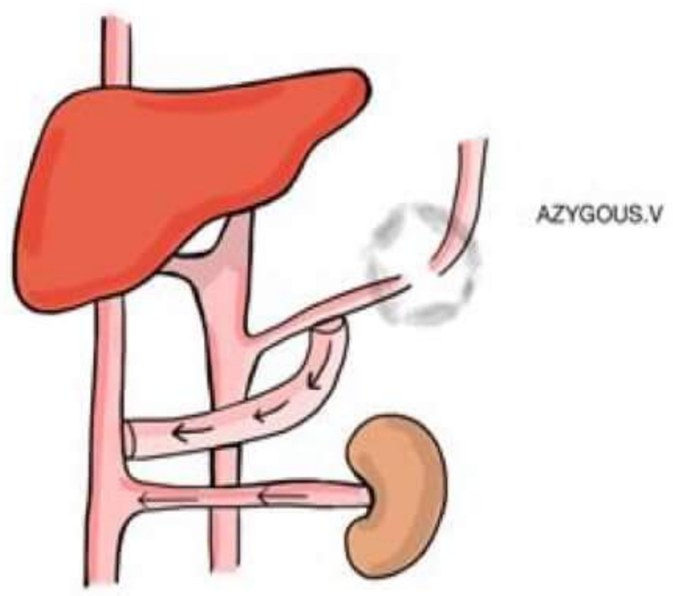

Inokuchi shunt

t.me/latestpgnotes

Peritoneo-venous Shunt

→ **Shunts used**

- Denver
- LE-VEEN
- Minnesota

→ Used in patients having refractory ascites

→ Valves are present in this shunt so that only unidirectional flow should be there

→ Preferred vein – **Right Internal Jugular Vein > Superior vena cava**

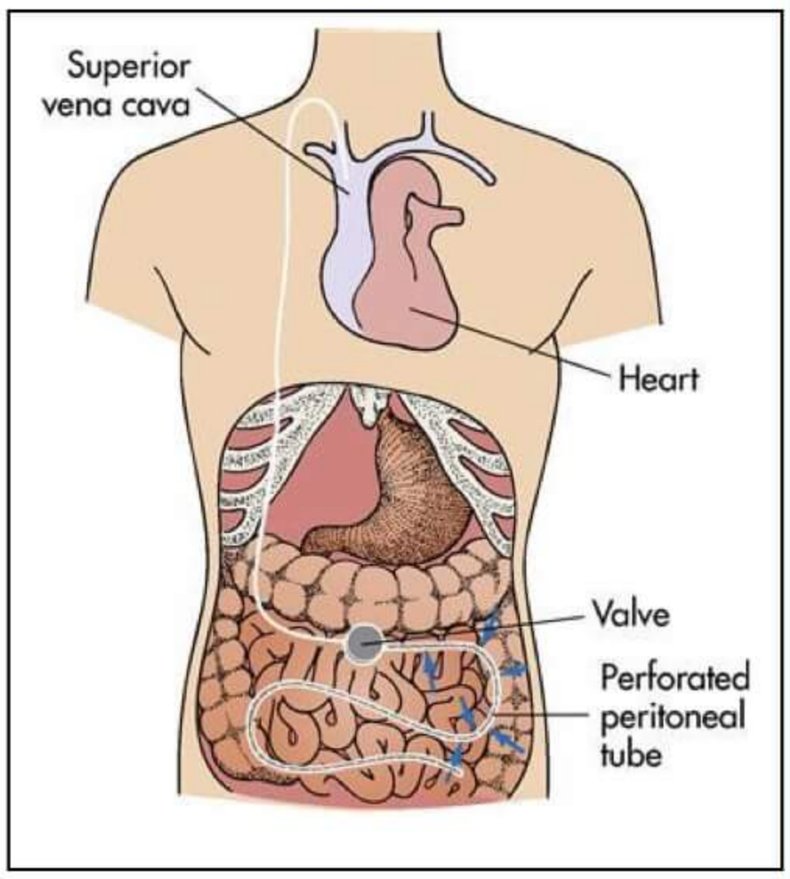

Non-Cirrhotic Portal HTN

→ **Types**

- EHPVO (Extra Hepatic Portal Venous Obstruction)
- NCPF (Non-Cirrhotic Portal Fibrosis)

Similarities Between EHPVO and NCPF

→ No ascites

→ No jaundice

→ No encephalopathy

→ No hepatic failure

PrepLadder

→ Varices present

→ Splenomegaly

Difference Between EHPVO and NCPF

EHPVO	NCPF
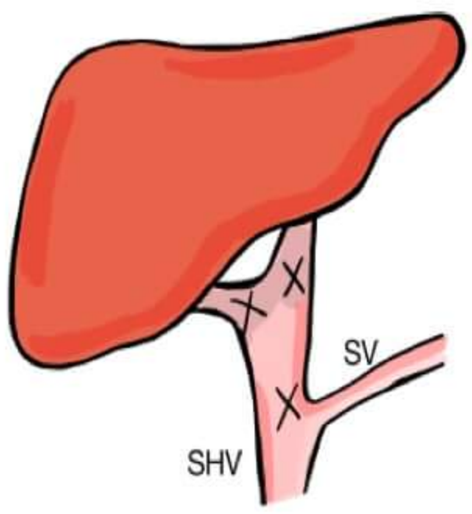	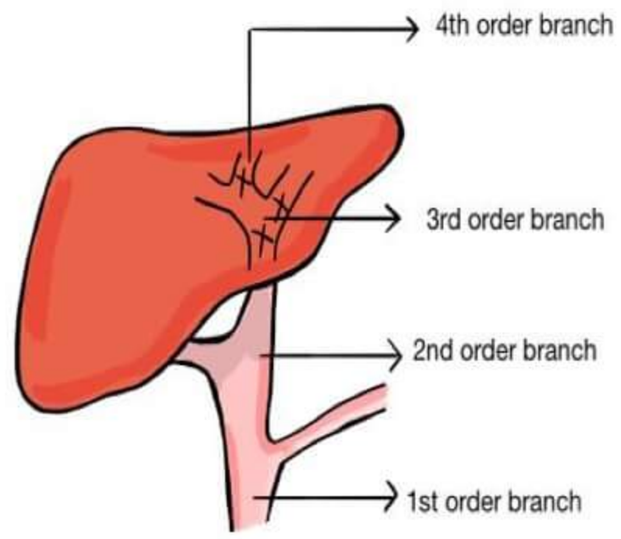
→ 1st and 2nd order branches are involved → M/C site of obstruction - Confluence of splenic vein and Superior mesenteric vein → Seen in 1-2nd decade → Splenomegaly is less common (Mild to Moderate)	→ Involvement of 3rd and 4th outer branches. → Seen in 2nd-4th decade → **Substances that increases the risk of NCPF** • V - Vinyl chloride • A - Arsenic • C - Copper → Splenomegaly is more common (Moderate to Massive)

t.me/latestpgnotes

Budd Chiari syndrome

→ Hepatic venous outflow obstruction

→ **Cause**: HVT or IVC obstructions

→ **Etiology**: Polycythemia Vera (has hypercoagulability – cause Hepatic venous thrombosis (HVT)

→ M/C/C is western countries – HVT

→ In India, china, japan, south Africa – IVC obstruction

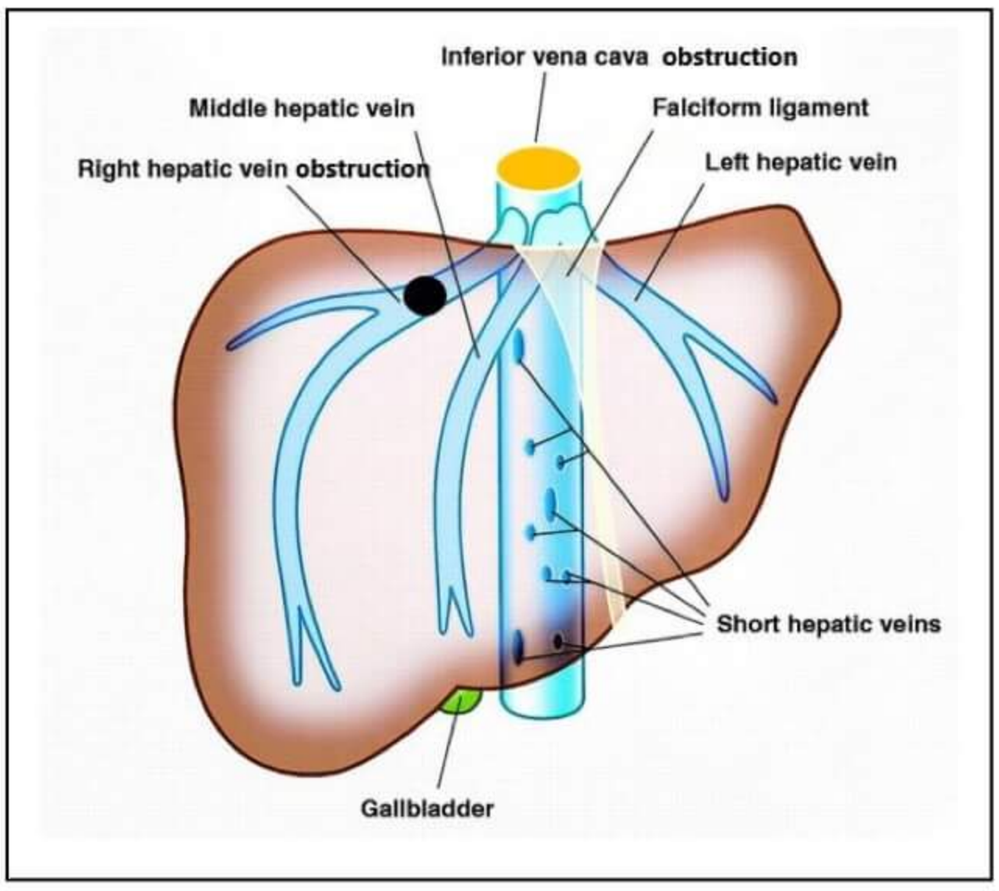

Clinical features

→ **Characteristic triad**

- Ascites
- Hepatomegaly
- Abdominal pain

→ In BCS caused by HVT, caudate lobe is spared (as it has to own venous drainage).

→ In chronic case, liver is atrophied & caudate lobe is hypertrophied giving Central hot spot sign on scintigraphy

PrepLadder

Diagnosis

→ **IOC** - Venography (if problem in hepatic vein) – shows spider web collaterals (in BCS)
- Venocavagraphy (if problem in IVC)

Note:

- In Buerger's disease /Thromboangiitis obliterans investigation of choice is **Angiography → shows** cork screw collaterals

Treatment

→ Thrombolysis (window period 2 – 3 weeks)

→ Anticoagulants

→ Most pts. present to hospital only after 2 – 3 weeks. Hence thrombolysis is not useful

→ **In HVT**
- SSPCS can be performed

→ **In IVC obstruction**
- Trans cardiac membranotomy (or)
- Excision with grafting (in stenosis)

→ **In IVC obstruction with HVT**
- SSPCS + Cavo-atrial graft

t.me/latestpgnotes

→ **In hepatic failure**
- liver transplantation (TOC)

Veno-Occlusive Disease

→ Hepatic venous outflow obstruction

→ Caused by endothelial sclerosis of sub lobular hepatic vein or venules.

→ M/C/C in western countries – BM transplantation

→ **Other causes include**
- Chemotherapy agents
  - Cytarabine
  - Thioguanine
  - Gemtuzumab
  - Ozogamucin
- Immunosuppressive agents
  - Azathioprine
- Consumption of Bush Teas (Crotalaria scenacio) – Contains Pyrrolizidine Alkaloid also ↑↑ risk

PrepLadder

Clinical features

→ **T** – Tender hepatomegaly

→ **H** – Hyperbilirubinemia

→ **R** – Retention of fluids

→ **According to Modified Seattle criteria**

- Tender hepatomegaly
- Hyperbilirubinemia > 2
- Retention of fluids or weight gain > 2%
  - If 2 of the above 3 is present within 20 days of stem cell transplantation, then it is **Veno-Occlusive Disease**

Diagnosis

→ IOC – **Biopsy**

Management

→ Only hepatic venous outflow obstruction – **SSPCS**

→ If patient has hepatic failure – **Liver transplantation**

→ **Defibrotide** – improve survival

t.me/latestpgnotes

PrepLadder

Gallbladder

Basic anatomy of GIT

→ **4 layers of GIT**

- Mucosa → 1. Epithelium → 2. Lamina propria → 3. Muscularis mucosa
- Submucosa
- Muscularis propria → 1. Inner circular → 2. Outer longitudinal
- Serosa

→ There are two kinds of plexus in **GIT**

Auerbach plexus	Meissner's plexus
• Peristaltic function • Location between inner circular & outer longitudinal layer	• Villous motility & intestinal secretion • Location between inner circular layer & muscular mucosa

NOTE:

- In Esophagus there is no serosa, No villi, no secretions, no Meissner's plexus
- Unique feature of Esophagus – Lymphatics in Lamina propria
- Strongest layer of GIT – Submucosa (Catgut – prepared from submucosa of sheep's ileum)

t.me/latestpgnotes

→ Muscularis mucosa & submucosa are missing in gall bladder

→ Maximum absorptive capacity - **jejunum**

→ Maximum absorptive capacity per unit surface area - **gall bladder**

Gall bladder

→ Pyriform in shape

→ Sea green in color

→ 30 – 50 ml capacity lined by tall columnar epithelium

→ **Functions of GB**

- Storage
- Concentration (5 – 10 ml)
- Acidification of bile

→ **Composition of bile**

- 85% – 95 % water
- 5% – 10 % of
  a) Cholesterol
  b) Bile duct } Micelle
  c) Lecithin }

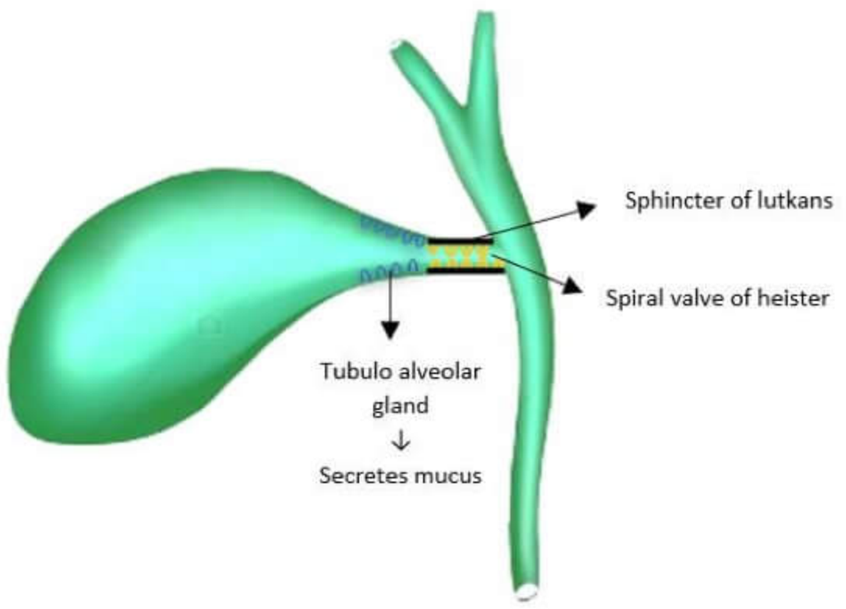

If large stone is impacted in the cystic duct and CBD junction – causes distention of GB with mucus known as **mucocele**

PrepLadder

Gall stones

→ Most common type of gall stone – **cholesterol gall stone**

Cholesterol gall stone

→ Cholesterol gall stone formation requires 3 mandatory factors

- Lithogenic bile
- Nucleation
- Stasis

Cholesterol gall stone

→ **Lithogenic bile** – caused by

- **Supersaturation of cholesterol**
  - Obesity
  - High cholesterol intake
  - Clofibrate therapy
- **Bile acid deficiency**
  - Ileal resection (as terminal ileum is involved in B_{12} reabsorption & Enterohepatic circulation of bile salt)
  - ileal disease
  - Bile acid sequestrants → cholestyramine & Colestipol
  - CYP7A – 1 gene mutation
- **Lecithin deficiency**
  - MDR – 3 gene mutation

t.me/latestpgnotes

→ **Nucleation**

- **Promoting factors are**
  - Infection
  - Mucin glycoproteins

→ **Stasis**

- **Promoting factors are**
  - Prolonged fasting
  - Prolonged TPN required
  - Pregnancy
  - Octreotide intake
  - OCP's
  - Massive burns

Pigmented gall stones

→ **Black**

- **Insoluble bilirubin pigment** – polymer of calcium phosphate & calcium bicarbonate
- **Properties:**
  - Hard

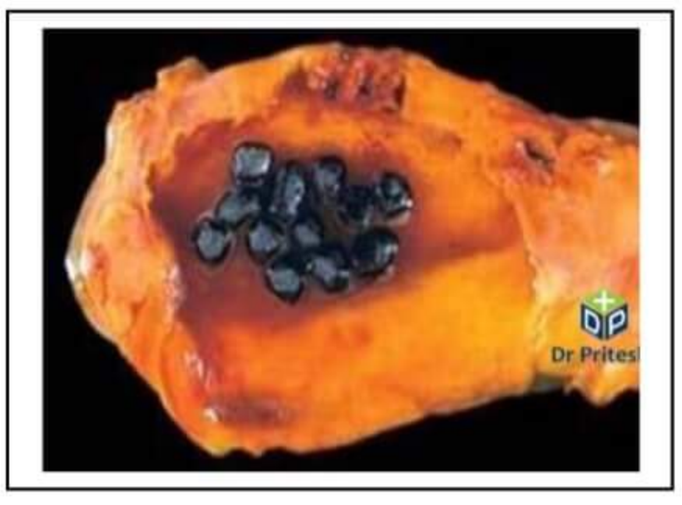

PrepLadder

- Radiopaque

- **Risk factors:**
  - Chronic hemolytic conditions
  - Hereditary spherocytosis
  - Prosthetic heart valves
  - Gilbert syndrome

→ **Brown**

- **Composed of**
  - Calcium bilirubinate
  - Calcium palmitate
  - Calcium stearate

- MC in CBD
- Rare in gall bladder
- MC in developing countries because of increased risk of worm infestation like ascaris, Clonorchis sinensis
- **Pathophysiology**

Dead product in CBD (dead worms trapped in CBD).

↓

Infection by E. coli & klebsiella

↓

β-glucuronidase is produced

t.me/latestpgnotes

↓

Converts conjugated → unconjugated bilirubin

↓

Brown stone

Commonly asked questions

→ MC type of gall stone worldwide – **Cholesterol stones** (**mixed stone is the answer – if given in option**)

→ MC type of gall stone in Asia – **Pigmented stones** (**combined incidence of black & brown**)

→ Gall stones having triradiate fissure known as **Mercedes Benz sign**

→ Gall stones having Biradiate fissure known as **Sea gull sign**

Investigation

→ Investigation of choice for

- Gall stone
- Acute cholecystitis
- Acute acalculus cholecystitis
- Chronic cholecystitis

} **Ultrasound**

→ Gold standard investigation for diagnosis of acute cholecystitis – **HIDA SCAN**

→ Dx. criteria for acute cholecystitis in HIDA scan → **Non – visualization of GB**

PrepLadder

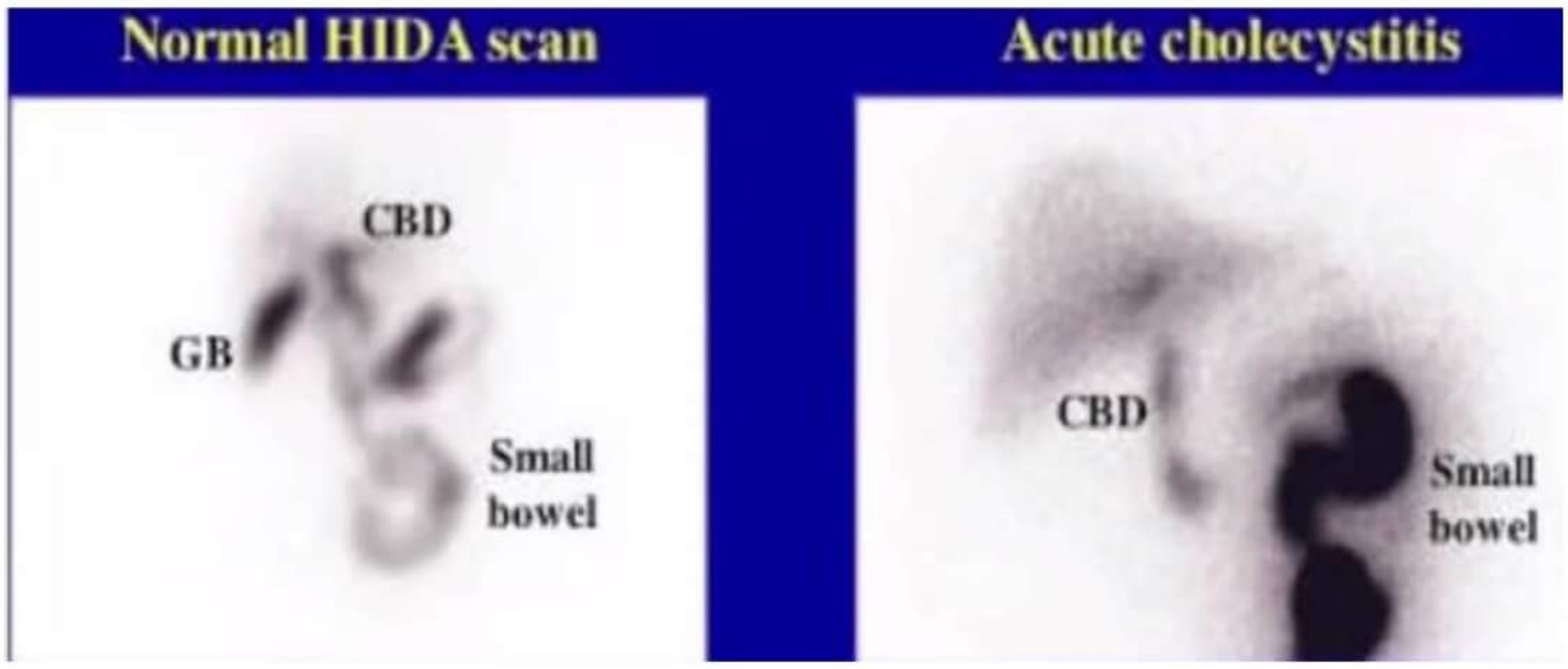

Note:

→ A fat fertile flatulent female of forty, complaining of pain in right upper quadrant or epigastrium after taking fatty food is **biliary colic**. It is of

- Short duration (4-6 hours)
- Not associated with fever
- Usually relieved on its own

Acute cholecystitis

→ **Characterized by**

- Right upper quadrant pain
- Fever
- Leukocytosis

→ Minimum duration 24 hour

→ Not relieved on its own

→ When right 9th costal cartilage is pressed there is catch in inspiration & this is known as **Murphy's sign / Naunyn's sign**

→ Hyperesthesia at inferior angle of right scapula is **BOA's sign**

t.me/latestpgnotes

Tokyo guidelines used for

→ Assessment of diagnosis

→ Severity

→ Management of acute cholecystitis and cholangitis

Diagnosis

→ Investigation of choice is **Ultrasound** (> 4mm thickness of GB wall)

→ Gold standard investigation – **HIDA scan**

Treatment

→ **Patient presents within 72 hours of attack** - Conservative management followed by in hospital or same siting cholecystectomy

→ **After 72 hours of patient presenting, then** - Conservative management followed by interval lap cholecystectomy (after 4 – 6 weeks)

PrepLadder

Medical management of gall stone

→ **UDCA** – Urso Deoxycholic acid

→ **CDCA** – Cheno Deoxy cholic acid

Mechanism of action

They inhibit HMG–Co–A reductase (rate limiting enzyme)

↓

Decrease cholesterol synthesis

↓

Dispersion of cholesterol occurs by physio-chemical means

Indications for medical management

- For cholesterol stones
- Size < 10mm
- Non- Acute symptoms
- Functioning GB

Prophylactic cholecystectomy

Indications

→ Heart transplant recipient
→ Lung transplant recipient

} **Cyclosporine** is given that increases the risk of gall stone

→ Prolonged TPN requirement

→ Bilio pancreatic diversion

t.me/latestpgnotes

→ Non-functioning Gall bladder

→ Trauma to gall bladder

→ Chronic typhoid carrier

→ Gall Stone ≥ 3.0cm (>2.5cm)

→ Adenomatous polyp with stone

→ Chronic haemolytic condition

→ Incidentally detected gall stone during elective surgery

→ Porcelain gall bladder

→ Gall stone inn the relative of carcinoma gall bladder patient

Note:

Q.1) what's the most common organism for emphysematous cholecystitis

Ans. Clostridium perfringens (Welchii) anaerobe

Q.2) 2nd most common organism for emphysematous cholecystitis

Ans. E. Coli (Aerobe)

Q3) What is the most common organism for emphysematous pyelonephritis

Ans. E. coli (aerobe)

Q.4) Most common organism for Xanthogranulomatous pyelonephritis

Ans. Proteus associated with staghorn calculi

Q.5) Xanthogranulomatous cholecystitis is caused by

Ans. Rupture of Rokitansky Aschoff sinuses → cause bile leak → Xanthogranulomatous cholecystitis

PrepLadder

Effects of gall stones on various organs

Gall bladder	CBD & Pancreas	Small intestine
• Asymptomatic • Acute cholecystitis • Chronic cholecystitis • Mucocele • Empyema • Necrosis • Perforation • Carcinoma GB	• Jaundice • Acute pancreatitis	• Gall stone ileus

Gall stone ileus

→ More common in elderly (> 70 years)

→ Have single large stone

→ Asymptomatic

→ Most common site of fistula - **Cholecysto duodenal**

→ 2nd most common site of fistula - **Cholecystocholic**

Pathophysiology

→ Large stone in GB

↓

Causes inflammation and then erosion of GB wall

↓

Leads to fistula formation between GB & Duodenum

↓

Stone moves to GIT & cause obstruction in its narrowest part (terminal ileum)

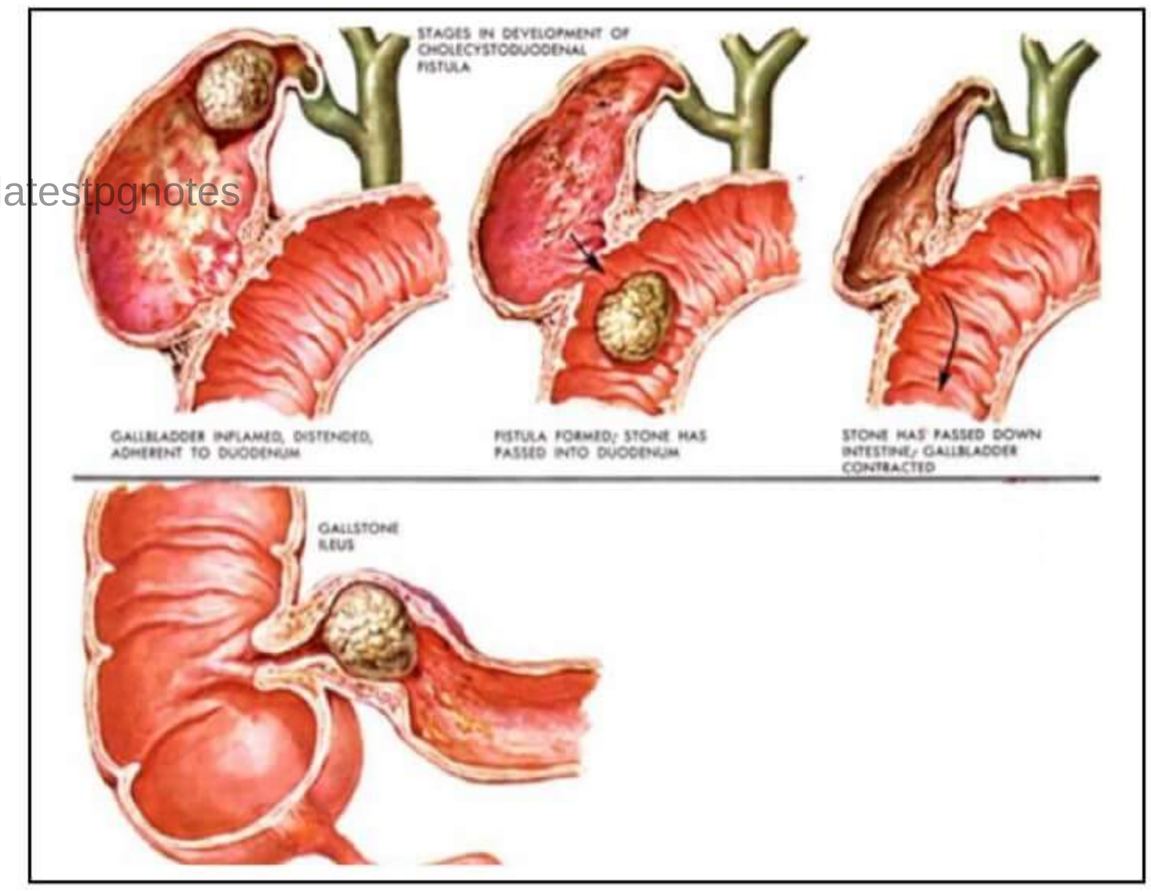

t.me/latestpgnotes

→ Small bowel obstruction
+
Ectopic gall stone
+
Pneumobilia

} **Rigler's triad**

Sign & symptoms of small bowel obstructions

→ Colicky pain

→ multiple episodes if bilious vomiting &

→ Non passage of feces

PrepLadder

Diagnosis

→ **X-Ray** – dilated bowel loops with multiple air fluid levels

→ **Ultrasound** – gall bladder empty detects presence of air

Treatment

→ Enterotomy & removal of obstruction

→ Cholecystectomy is performed only in young & stable pts.

Acalculous cholecystitis

→ Inflammation of GB in absence of gall stone

→ 2 factors are responsible - GB stasis; GB ischemia

Predisposing factors

→ Prolonged fasting

→ Prolonged TPN requirement

→ Prolonged hospitalization

→ Prolonged ICU stays

→ Long duration surgeries - CABG, THR (Total Hip Replacement)

→ Massive burns

Investigation

→ Investigation of choice – Ultrasound

→ Gold standard investigation – HIDA scan

t.me/latestpgnotes

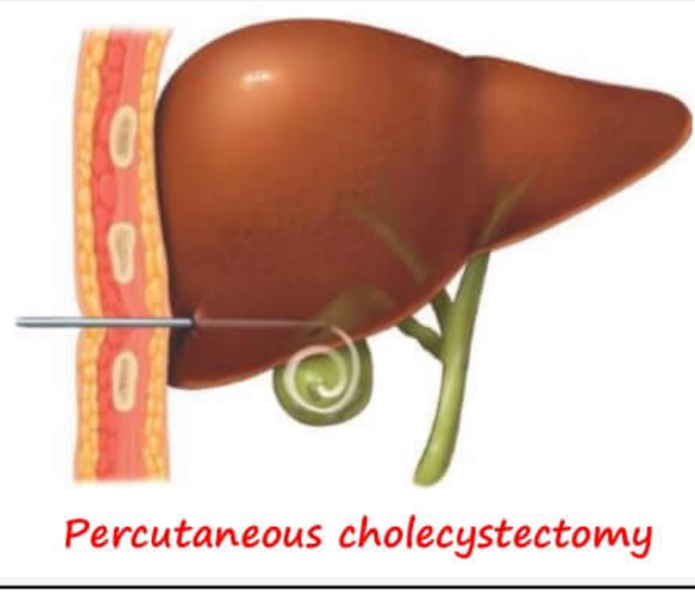

Percutaneous cholecystectomy

Treatment

→ Lap cholecystectomy (TOC)

→ But for unstable patient treatment of choice is Percutaneous cholecystectomy

GB polyp

Cholesterol polyp	Adenomatous polyp
• More common • Small <10 mm • Multiple • Benign • Pedunculated	• Less common • Large • Single • Premalignant • Sessile

Factors which increases risk of invasive cancer in adenomatous polyp

→ Age > 60 years

→ Presence of gall stone

→ Size of polyp > 1cm

→ Documented increase in size on repeated scan

PrepLadder

Strawberry gall bladder

→ **Aka Cholesterolosis**

→ Caused by – deposition of cholesterol ester & triglyceride in epithelial macrophages of gall bladder

→ Acquired condition

→ Hyper cholesterolemia

→ Presence of cholesterol stones

→ Presence of cholesterol polyp

Management

→ Lap cholecystectomy in symptomatic patient & patients having gall stones

Adeno myomatosis

→ **Characterized by**

- Hyperplastic changes in GB wall
- Mucosal hyperproliferation

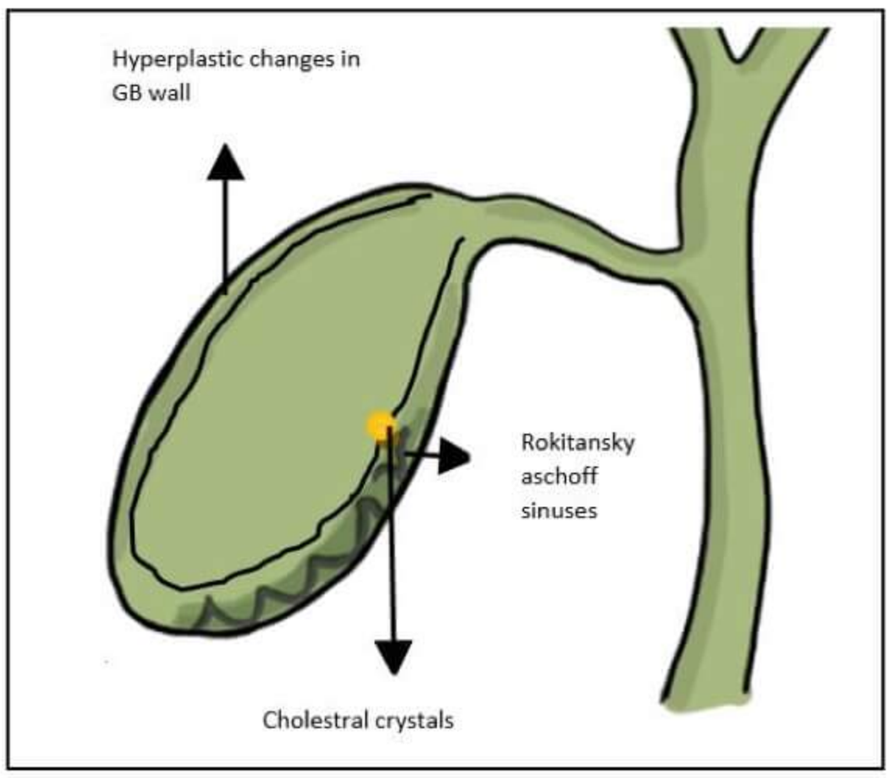

Diagnosis

→ On ultrasound there is diamond ring sign also K/as **'comet tail artefacts' or V shaped artefact.**

Treatment

→ Lap cholecystectomy in symptomatic patients

t.me/latestpgnotes

Porcelain gall bladder

→ **Aka Calcified gall bladder**

→ Characterized by extensive calcium encrustation in the gall bladder wall

→ **On surgery** – **bluish appearance of GB & Brittle in consistency** is noted

→ Most patient are asymptomatic

→ Seen in 5th – 6th decade

→ > 90 % patients have gall stone

→ Generally diagnosed incidentally on X-Ray or CT

→ It increases the risk of malignancy by 10%

→ **Treatment** – Early cholecystectomy

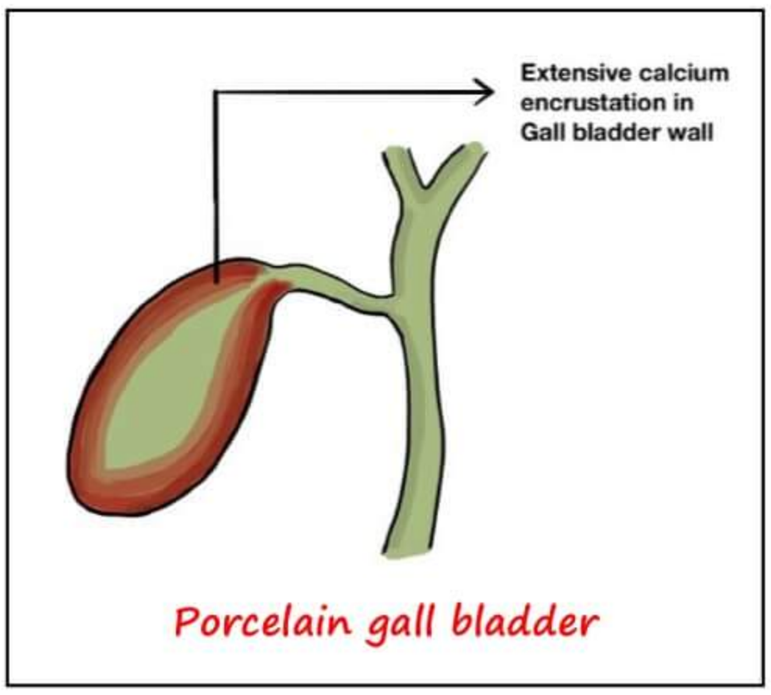

Porcelain gall bladder

Carcinoma gall bladder

→ Smoking is not a risk factor for carcinoma gall bladder

→ **Risk factors are**

- Choledochal cyst
- Obesity

PrepLadder

- Gall stone > 3cm
- Primary sclerosing cholangitis
- Adenomatous polyp
- Chronic typhoid carrier
- Porcelain gall bladder

→ Maximum incidence of C.A gall bladder is seen in India > Pakistan
→ In India, max incidence is in UP > Bihar
→ More common in females (6th – 7th decode)
→ M/C site – fundus (60%) > Body (30%) > Neck (10%)

Carcinoma gall bladder & Cholangioma have following similarities

→ Both are adenocarcinoma
→ CEA (non-specific marker)
→ CA-19-9 (specific marker)
→ Chemotherapy regimen - gemcitabine + cisplatin
→ **Histological types are also same**
- Diffuse infiltrative / sclerosing (most common type, worst prognosis)
- Nodular
- Papillary – best prognosis

Important points

→ Most common route of spread is direct hepatic invasion (hepatic > lymphatic > perineural)
t.me/latestpgnotes
→ CA gallbladder patient have gall stone in 75 – 98% cases
→ Gall stone patient develop CA gallbladder in 0.3 – 3 % cases (large gall stones are risk factor for C.A gall bladder i.e. > 3 cm)

Clinical features

→ Long history of repeated attacks of biliary colic
→ **Associated with**
- ↑ frequency of attack
- ↑ severity of pain
- Sudden change in character of pain i.e. persistent dull aching pain
- Anorexia & weight loss

Investigation

→ First investigation – ultrasound
→ Investigation of choice for Ca gall bladder - CECT
→ **Findings on CECT:**
- GB wall thickened associated with gall stones
- GB replaced by a mass (growth arising from fundus – protruding into lumen)
- LN @ Porta hepatis
- ± Ascites

PrepLadder

Staging of Ca gall bladder

8TH AJCC (2017) TNM classification	
T_{1A}	→ Involvement of lamina propria
T_{1B}	→ Involvement of muscularis propria
T_{2A}	→ Invasion of perimuscular connective tissue towards peritoneal side without extension to serosa
T_{2B}	→ Invasion of perimuscular connective tissue towards hepatic side without direct hepatic invasion
T_3	→ Serosal perforation or direct hepatic invasion or involvement of single extrahepatic organ
T_4	→ Involvement of portal vein or hepatic artery or two or more extrahepatic organ
N_1	→ Metastasis to 1 – 3 lymph nodes
N_2	→ Metastasis to 4 or more lymph nodes
M_0	→ No distant metastasis
M_1	→ Distant metastasis

Staging	Treatment
I_A – T_{1a}	Lap cholecystectomy
I_B – T_{1b} II_A – T_{2a} II_B – T_{2b} III_A – T_3 III_B – T_{1-3} N_1	Extended cholecystectomy
IV_A – T_4 N_{0-1}	Extended cholecystectomy + Extended R hepatectomy
IV_B – T any N_2 – T any N any M_1	Palliation (we give chemotherapy)

t.me/latestpgnotes

Extended cholecystectomy

→ Enbloc removal of segment IV b & V of liver + gall bladder + lymph node along

- Cystic duct
- CBD (peri-choledochal lymph node)
- Periportal
- Retro-pancreatic

PrepLadder

Note:

In a patient with gall stone disease, lap cholecystectomy is performed & specimen taken is send to the pathology lab.

(i) Report came back positive for Adenocarcinoma (stage 1_A / T_{1a})

Ans. Tx: observation & follow up (as lap cholecystectomy is already performed)

(ii) if stage II_A / T_{2A}

Ans. - Completion extended cholecystectomy
- Port site excision is also performed
  → No survival advantages
  → Only prognostic importance

→ 1st lap cholecystectomy was performed by **ERIC MUHE**
→ 1st video assisted lap cholecystectomy was performed by **Philip Mouret**
→ 1st lap appendectomy – **KURT SEMM** also known as father of pelviscopy (modern laparoscopy)

t.me/latestpgnotes

PrepLadder

Bile duct Part - 1

Anatomy

Common hepatic duct:

→ Length → 1 – 4 cm

→ Diameter → 4 mm

Common bile duct:

→ Length → 7 - 11cm

→ Diameter → 5 – 10mm

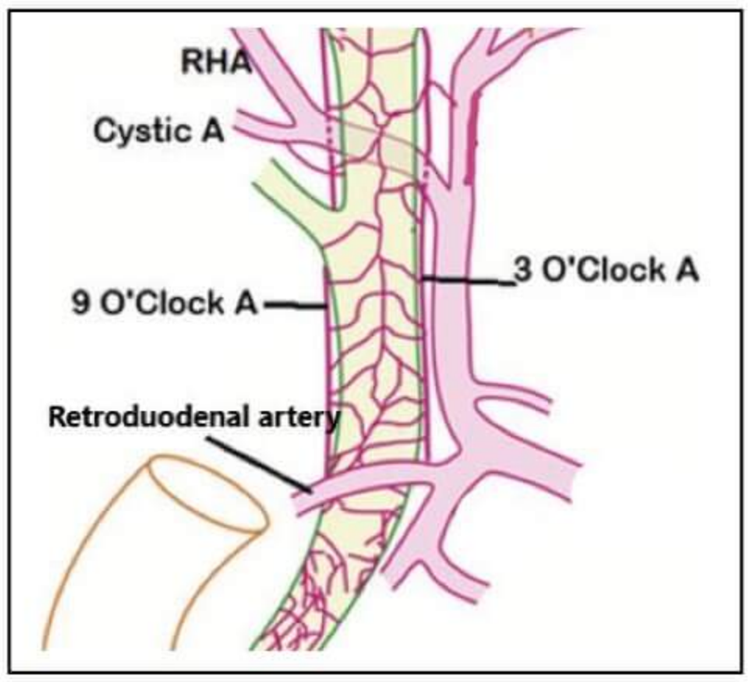

Blood supply

→ Supra duodenal bile duct gets blood supply

Inferior (60%) from	Superiorly (38%) from
• Pancreatic duodenal artery • Retro duodenal artery	• Right hepatic artery • Cystic duct artery

→ **Has Co-axial blood supply**

- Blood supply is present at 3 O'clock & 9 O'clock position
- Hence, longitudinal incision is given in bile duct

t.me/laterstudynotes

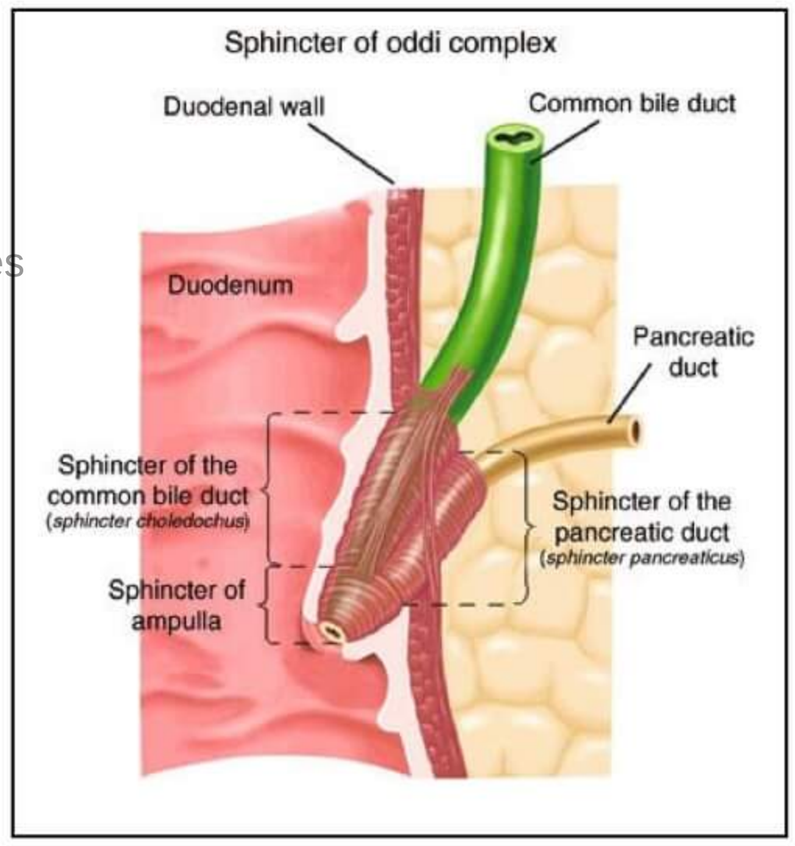

Sphincter of oddi complex:

1. Sphincter ampullae
2. Sphincter pancreaticus
3. Superior choledochal sphincter
4. Inferior choledochal sphincter

Choledochal cyst

→ Dilatation of bile duct

→ Congenital

→ M/C in children (female)

Pathophysiology:

→ Most accepted hypothesis: - **APBDJ**

(abnormal Pancreatico biliary duct junction)

Has long common channel

↓

Reflux of pancreatic enzyme

↓

Digestion of bile duct wall

↓

Dilatation

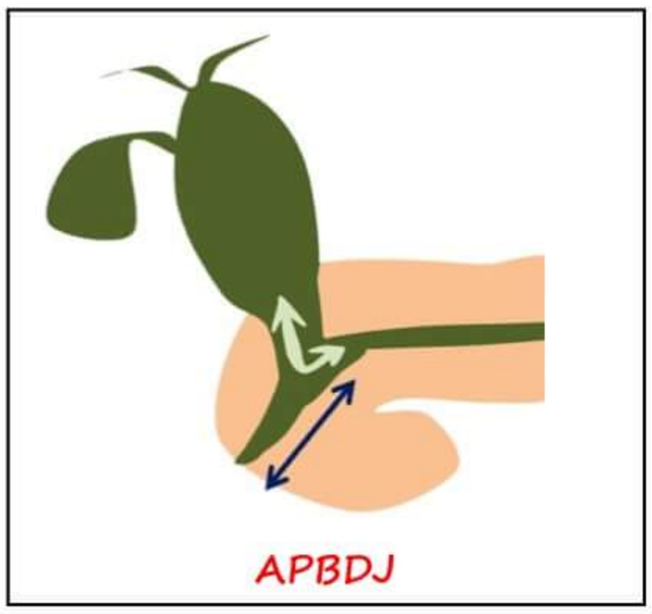

PrepLadder

Classification

TODANI MODIFICATION OF ALONSO-LEJ CLASSIFICATION		
Type I	I_a	→ Cystic dilatation of extra hepatic bile duct
	I_b	→ Focal segmental dilatation of extra hepatic bile duct
	I_c	→ Fusiform dilatation of extra hepatic bile duct
Type II		→ Diverticular dilatation of extra hepatic bile duct
Type III		→ Dilatation of intraduodenal part of bile duct (choledochocele
Type IV	IV_a	→ Dilatation of both intra and extra hepatic bile duct
	IV_b	→ Multiple cyst involving only extra hepatic bile duct
Type V		→ Multiple cyst involving only intra hepatic bile duct (Caroli's disease)

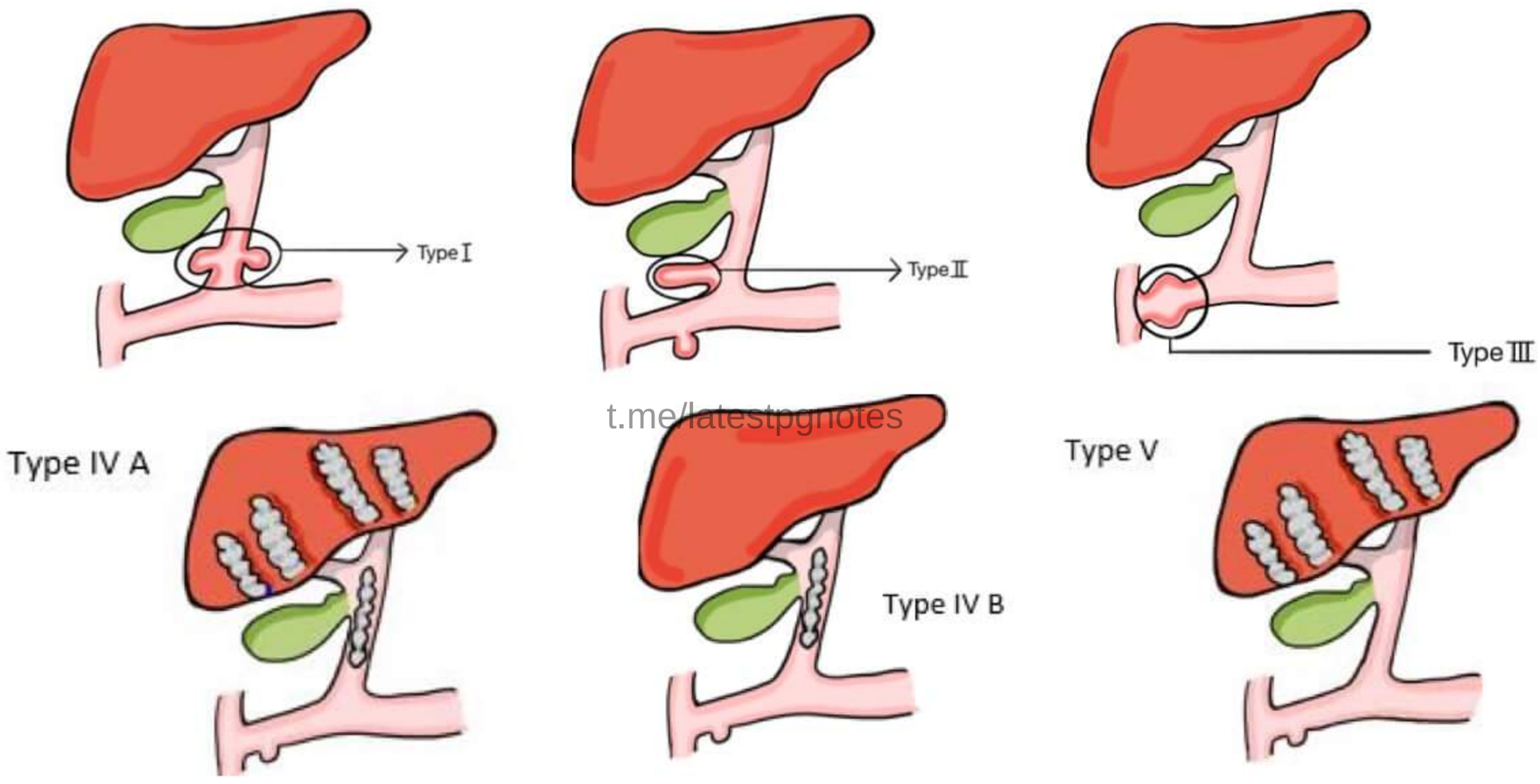

t.me/latestpgnotes

Treatment	
Type IVA and V	→ Liver transplantation
Type I, II, IVB	→ Roux-en-Y Hepatico- jejunostomy
Type III	→ Endoscopic sphincterotomy with cyst unroofing

Note:

→ Most common type of choledochal cyst - Type I > Type 4 > Type 3

→ Type VI - cystic dilatation of cystic duct (not a part of Todani's classification)

Clinical features

→ Mass + pain + jaundice (intermittent jaundice)

→ Most common symptom in < 2 years of age - Jaundice

→ Most common symptom in ≥ 2 years of age - Abdominal pain

→ Most common site of cholangiocarcinoma - Posterior wall of cyst

PrepLadder

Note:

→ Stones in gall bladder – cholelithiasis

→ Stones in bile duct – choledocholithiasis

→ Stones in cyst – cystolithiasis

Choledochal cyst increases the risk of following organ malignancies

1. Liver
2. Gall bladder
3. Bile duct (has max. risk of malignancy)
4. Pancreas
5. Duodenum

Roux-en-Y Hepatico – jejunostomy procedure

→ MC performed gastro-intestinal reconstruction

→ Jejunum is divided into proximal (afferent limb) & distal (efferent limb or Roux-en-y limb)

→ Length of Roux Limb – 40 – 50 cm

→ Proximal part is anastamosed with the lower part of Roux-en-y limb

→ Roux-en-y limb is pulled up and anastomosed with hepatic duct

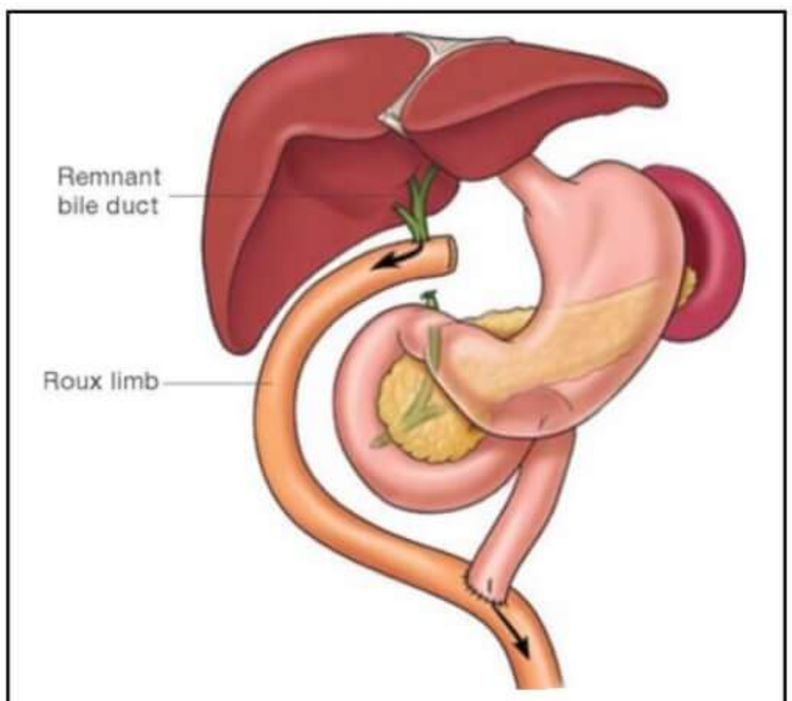

Roux-en-Y Hepatico – jejunostomy

t.me/latestpgnotes

Investigation

→ Investigation of choice – MRCP

1. **MRCP:** Magnetic Resonance Cholangiopancreatography (purely diagnostic)

T2 phase of MRI

Fast moving fluids, tissues, fat	Slow moving fluids like bile, pancreatic juice
↓	↓
Gives no signal	high signal intensity
↓	↓
Appears black	Appears white

→ **MRCP is IOC for**

- CBD stone
- Choledochal cyst
- Biliary stricture

→ **MRI + MRCP is IOC for**

- Cholangiocarcinoma

2. **ERCP:** Endoscopic Retrograde Cholangiopancreatography

→ Diagnostic + Therapeutic

→ Side viewing endoscope is used

PrepLadder

→ After reaching the ampullae using the endoscope, both bile duct & pancreatic ducts are cannulated & dye is injected to detect stone or stenosis

→ **ERCP is used to:**

- Removed stone from distal part of bile duct
- Put stent mainly for distal biliary stricture

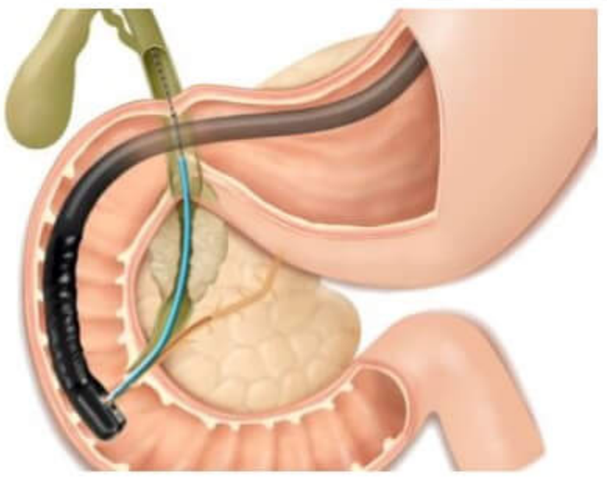

ERCP

3. **PTC:** Percutaneous Transhepatic Cholangiography

→ Diagnostic + therapeutic

→ **Used to:**

- Remove stone from proximal part of bile duct, intrahepatic bile duct.
- Locate stent for proximal biliary strictures

CBD stone (aka choledocholithiasis)

→ Present in 6 – 12% patients of gall stones

2 types

Retained CBD stones
Detected within 2 Years of cholecystectomy

Recurrent CBD stones
Detected after 2 years of cholecystectomy

Primary stones	Secondary stones
• Formed inside CBD • Most common stone – brown • More common in developing countries	• Formed in gall bladder ↓ Slips into CBD • Most common type: - cholesterol stone • More common in western countries

t.me/latestpgnotes

Lab parameters

→ ↑ ALP

→ ↑ GGT

→ ↑ 5' Nucleotidase

Clinical features

→ 2 types of presentation

1. Asymptomatic - Asymptomatic elevation of ALP, GGT, 5' nucleosidase
2. Jaundice with or without complication

Complications

→ Increased risk of infection (cholangitis)

→ Increased risk of pancreatitis

→ Increased risk of cholangiocarcinoma

PrepLadder

Investigation

→ Gold standard investigation - ERCP

→ IOC – MRCP

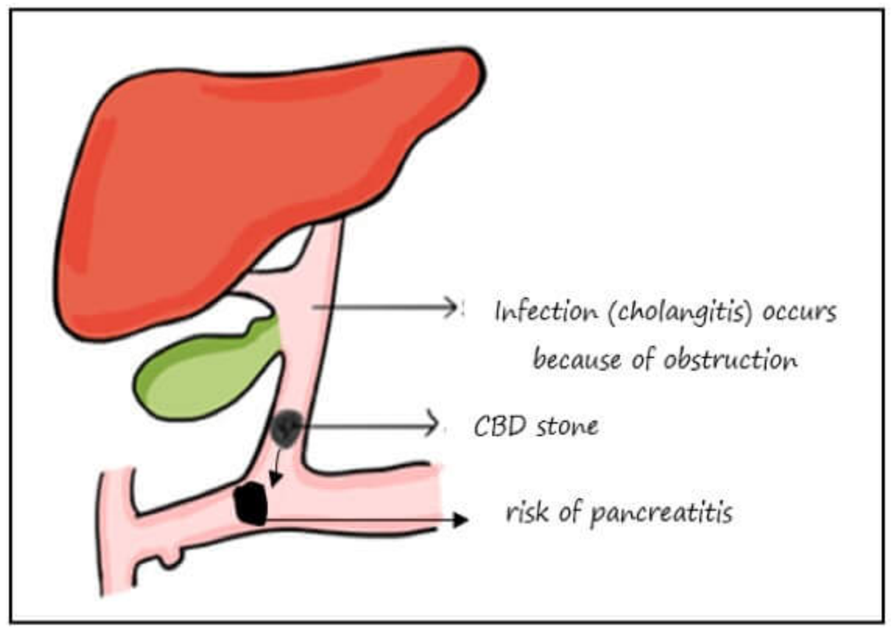

Treatment

→ **ERCP + stone removal**

- Maximum size of stone removed by ERCP - 1.5 cm

→ Stones > 1.5cm - **Choledochotomy**

→ When distal obstruction is suspected - Choledocho-duodenostomy

Cholangitis

Mandatory principles

→ Obstruction

→ Infection

Predisposing factors

→ Choledocholithiasis (most common)

→ Biliary stricture

→ Choledochal cyst

→ Cholangio carcinoma

→ Worms

t.me/latestpgnotes

Pathophysiology

→ Most common organism: E. Coli > KLEBSIELLA

→ **Infection reaches systemic circulation by**

1. Cholangiovenous reflux
2. Cholangiolymphatic reflux

→ Normal CBD pressure: 10 – 12 cm of H2O

→ When obstruction occurs

↓

CBD pressure: > 25cm of H2O

↓

Cause reflux - Cholangiovenous

- Cholangio lymphatic

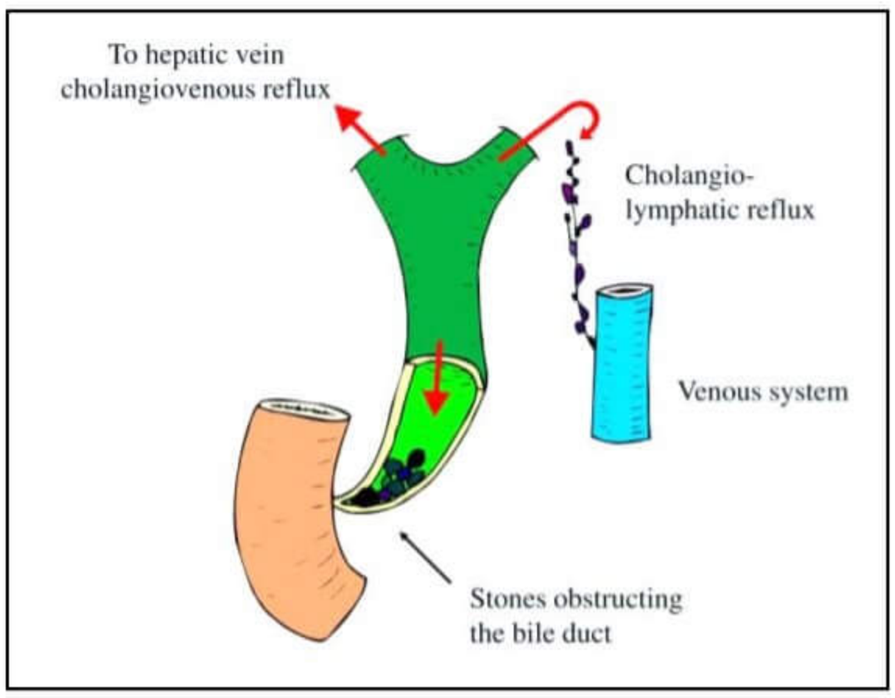

Clinical features

→ **Charcot's Triad:**

- Pain + Jaundice + fever

→ **Reynold's Pentad** (if delayed t/t)

- Charcot's triad + Shock + Mental status changes

→ > 50% of pts have positive blood culture

PrepLadder

Management

→ Put 2 large IV cannula

→ Start IV fluids + IV antibiotics

↓ no improvement

ERCP with stone extraction / stenting

↓ not available / failed

PTC with stone extraction / stenting

↓ not available / failed

Open biliary decompression

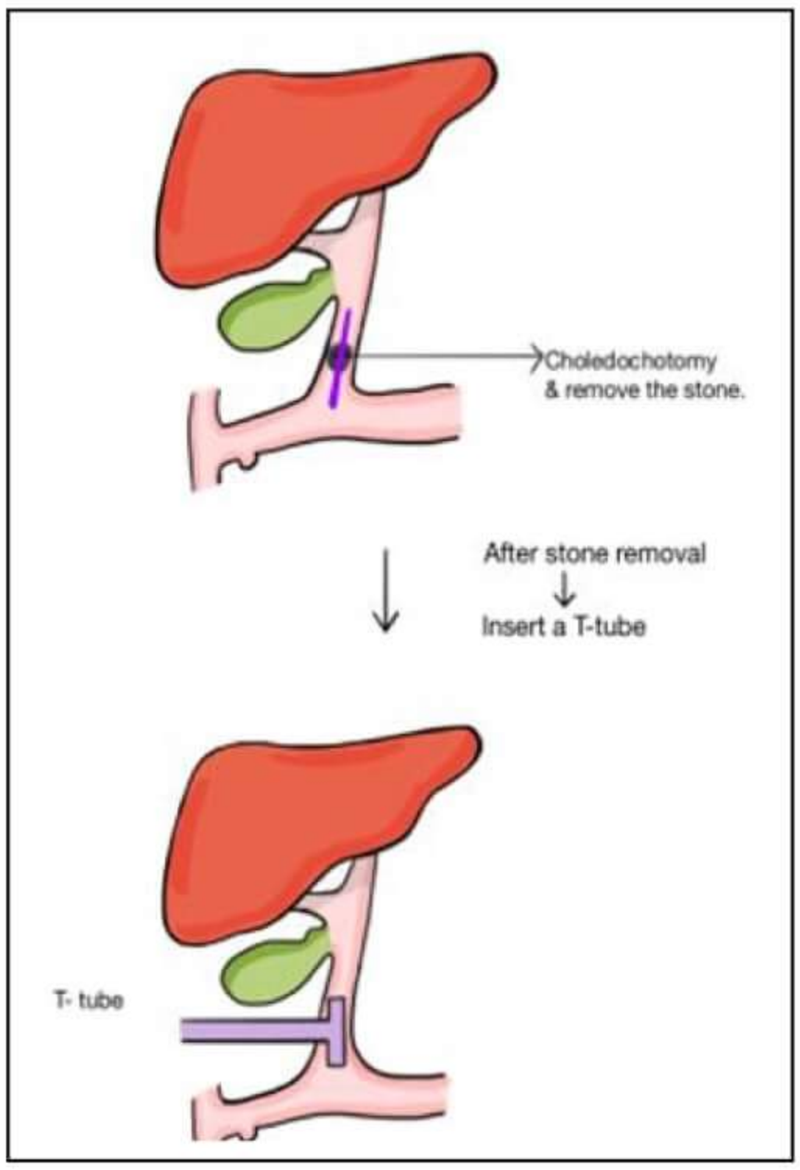

Open biliary decompression

Longitudinal incision on bile duct

↓

Stone removed

↓

T- Tube inserted

↓

T-tube cholangiogram (after 7th to 10th day)

↓

Retain T-tube (if presence of distal filling defects) for 4 – 6 weeks

↓

Percutaneous stone extraction is performed via BURHENNEL'S TECHNIQUE

t.me/latestpgnotes

Note:

- Primary sclerosing cholangitis - more common in males
- Primary biliary cirrhosis (Autoimmune disorder) - more common in females

Autoimmune disorders

Primary biliary cirrhosis	→ Anti – mitochondrial (auto antibody)
Grave's disease	→ Thyroid stimulation Ab against TSH – R
Hashimoto's thyroiditis	→ Anti – TPO
Pernicious anemia	→ Ab against parietal cells

PCB- primary biliary cirrhosis

→ Autoimmune disorder

→ M/C in females

→ Anti- mitochondrial antibody is the autoantibody

Pathology

→ Progressive destruction of intrahepatic bile ducts only

→ **Diagnostic appearance** – florid duct lesion with lymphocytic infiltration and granulomatous inflammation

Clinical features

→ Pruritis precedes jaundice
→ **Pruritis and fatigue** – characteristic symptoms
→ **Pruritis** – most bothersome in evening
→ **Associated with:**
- Hyper lipidemia
- Xanthoma, Xanthelasma
- Melanosis

Diagnosis

→ Anti-mitochondrial Ab - Can confirm diagnosis
→ Investigation of choice – **Biopsy**

Treatment

→ Liver transplantation (severe pruritus & fatigue are indications for LT)

t.me/latestpgnotes

PrepLadder

Bile duct Part – 2

Primary sclerosing cholangitis

→ More common in males

→ Characterized by multiple strictures in both Intra hepatic & Extra hepatic

→ **Associated with**

- HLA B – 8 / DR – 3
- Ulcerative colitis (UC)

→ **Ulcerative colitis**

- PSC seen in 5 – 6 % cases of UC
- UC seen in 70 – 80% cases of PSC

→ **Smoking is protective in**

- UC
- PSC
- Parkinson's
- Alzheimer's ds.

Pathophysiology

Target cell of injury in PSC is

Cholangiocytes (cells living bile duct)

↓

Stricture formation in both intrahepatic & extrahepatic bile duct

t.me/latestpgnotes

↓

Gives onion skin appearance with cut section

↓

Destruction of terminal intra-hepatic branches

↓

Gives Pruned tree appearance (selective destruction of terminal intra-hepatic branches)

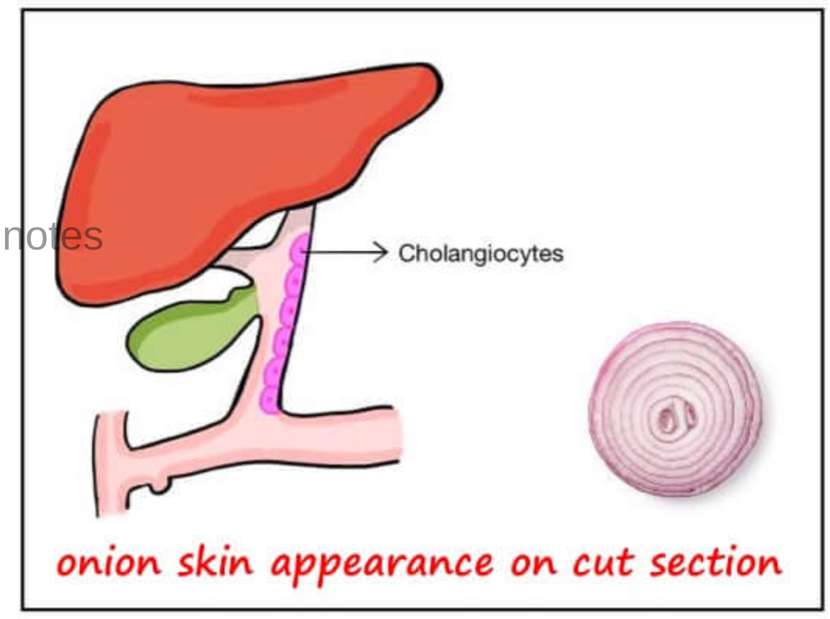

onion skin appearance on cut section

Clinical features

→ Asymptomatic elevation of gamma – Glutamyl transpeptidase (GGT) initially

→ **Formation of multiple strictures leads to**

1. ↑↑ risk of cholangitis
2. CBD stones
3. Acute pancreatitis
4. Cholangio carcinoma

PrepLadder

Investigation

- → IOC - MRCP
- → Gold standard investigation – ERCP
- → **Characteristic appearance in ERCP**
  - Beaded appearance or
  - Pseudo-diverticula appearance

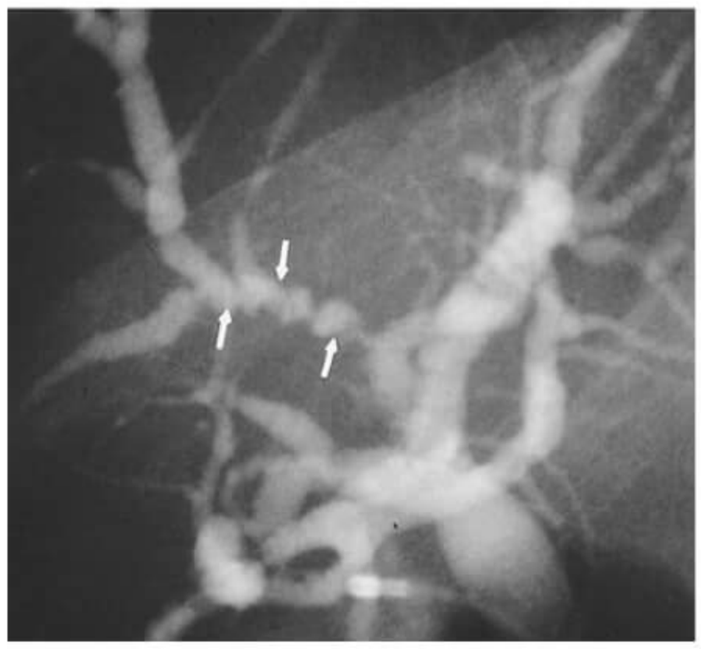

Beaded appearance /Pseudo-diverticula appearance

Treatment

- → Rx of choice is Liver Transplantation
- → Control of inflammation - High dose UDCA (URSO-DEOXY CHOLIC ACID) used
- → Tx of PSC does not affect the course and prognosis of UC

Bile duct injury

- → Incidence of BDI in lap cholecystectomy (0.3 – 0.85%)
- → Incidence of BDI in open cholecystectomy (0.1 – 0.2%)
- → Most commonly injured part of bile duct in lap cholecystectomy
  - Proximal part of bile duct
  - lateral wall of common hepatic duct (specifically)

Classification of bile duct injuries

1. BISMUTH Classification for Biliary strictures:

t.me/latestpgnotes

Type I	→ CHD stump > 2cm → Stricture is low
Type II	→ CHD stump < 2cm → Stricture is mid
Type III	→ Hilar stricture with intact confluence → Stricture is high
Type III	→ Hilar stricture with intact confluence → Stricture is high
Type IV	→ Hilar stricture with destroyed confluence
Type V	→ Stricture involving aberrant right sectoral duct with or without involvement of common hepatic duct.

Drawback of BISMUTH Classification:

- → No idea about intraoperative bile leak

PrepLadder

2. Strasberg classification for laparoscopic bile duct injuries	
Type A	→ Cystic duct stump leak or leak from sub-vesical duct of Luschka
Type B	→ Ligation or occlusion of aberrant right sectoral duct
Type C	→ Transection without occlusion of aberrant right sectoral duct
Type D	→ Injury to lateral wall of CHD
Type E	→ E1 to E5 Bismuth classification

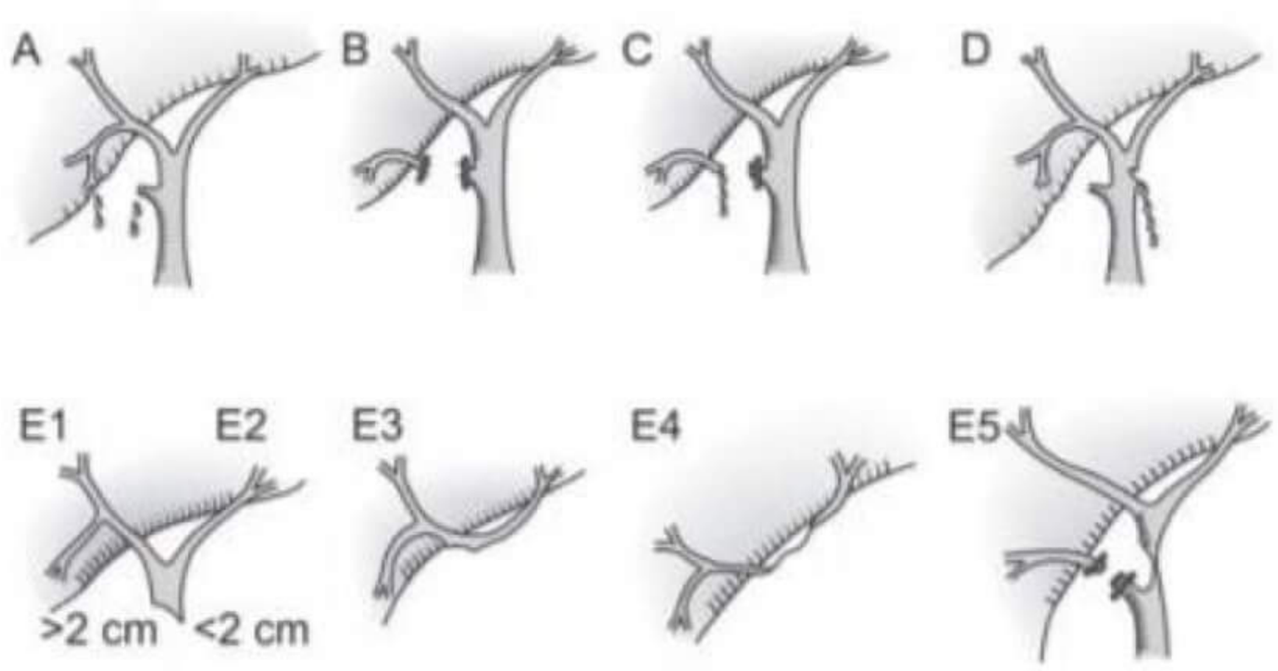

Management of Post-op diagnosed Bile duct injury:

t.me/latestpgnotes

→ **Step 1** – Control the infections → IV antibiotics

→ **Step 2** – **Drain the biloma**

- USG / CT guided Percutaneous aspiration
- Drain insertion / digital catheter insertion

→ **Step 3** – complete cholangiography - MRCP

→ **Step 4** – **Definitive treatment**

- ERCP with stenting
- Hepatico-jejunostomy

Note:

(i). if drain output ↓↓ sing - Observation

(ii). If drain output ↑↑ sing or constant - ERCP with stenting

Cholangiocarcinoma

Risk factors:

- Choledochal cyst
- Choledocholithiasis
- PSC
- UC

PrepLadder

- Cirrhosis
- Clonorchis sinensis and Opisthorchis viverrini
- HBV
- HIV
- HCV
- Asbestos
- Nitrosamines
- Dioxin
- DM / obesity / OCPs / Smoking
- Thorotrast
- Isoniazid

→ Most common site of cholangiocarcinoma is hilum – **Hilar cholangiocarcinoma**

→ It is also known as **Klatskin tumor**

Similarities between Cholangiocarcinoma and GB carcinoma

→ Both are adenocarcinoma

→ CEA increased (non-specific marks)

→ CA 19 – 9 (specific marker)

→ Chemotherapy regimen – gemcitabine + cisplatin

→ Histological types are also same

t.me/latestpgnotes

- **Diffuse infiltrative / sclerosing** (most common, wort prognosis)
- **Nodular/ mass forming**
- **Papillary** (best prognosis)

Clinical features

→ Most common presentation / symptom is **Painless progressive jaundice > weight loss**

→ Symptoms of painless progressive jaundice

- **Anorexia**
- **Fatigue**
- **Pruritis**
- **Passage of clay colored stools**

Courvoisier's law

→ In a case of obstructive jaundice **due to stone disease**

↓

Gall bladder is not palpable

↓

Because GB is shriveled / fibrosed due to chronic inflammation

→ In a case of obstructive jaundice, if **GB is palpable** **it is due to Peri–ampullary carcinoma**

→ **Exceptions of CURVOISIER'S LAW**

- Double impaction of stone
  - One stone in cystic duct
  - One stone is CBD
- Mucocele

PrepLadder

- Oriented cholangiohepatitis (hepatoliathiasis)
- Stone impacted at ampulla of Vater

Ampullary and Peri ampullary carcinoma

→ Ampullary – malignancy arising from ampulla itself

→ Periampullary – malignancy arising within 2cm of ampulla

Malignancies in Peri-ampullary area

→ Ampullary carcinoma

→ CA head of pancreas (Worst prognosis)

→ Distal cholangiocarcinoma (GB palpable)

→ Duodenal cholangiocarcinoma (Best prognosis)

Diagnosis

→ IOC – MRI + MRCP > CECT

→ **Complication of CECT** – Increased risk of hepatorenal syndrome

Management

→ **For hilar cholangiocarcinoma**

- CBD resection + routine caudate lobectomy + lymphadenectomy

→ **For distal cholangiocarcinoma**

t.me/latestpgnotes

- Pylorus preserving whipples procedure

→ **For advanced and metastatic stage**

- Palliation by chemotherapy – gemcitabine + cisplatin

Hemobilia

→ Blood in bile duct

Causes

→ MC cause – Iatrogenic trauma (PTC)

→ Trauma (Blunt)

→ Gall stones

→ Vascular pathologies

- AV malformations,
- Angiodysplasia

→ Most common source of Hemobilia is arterial source

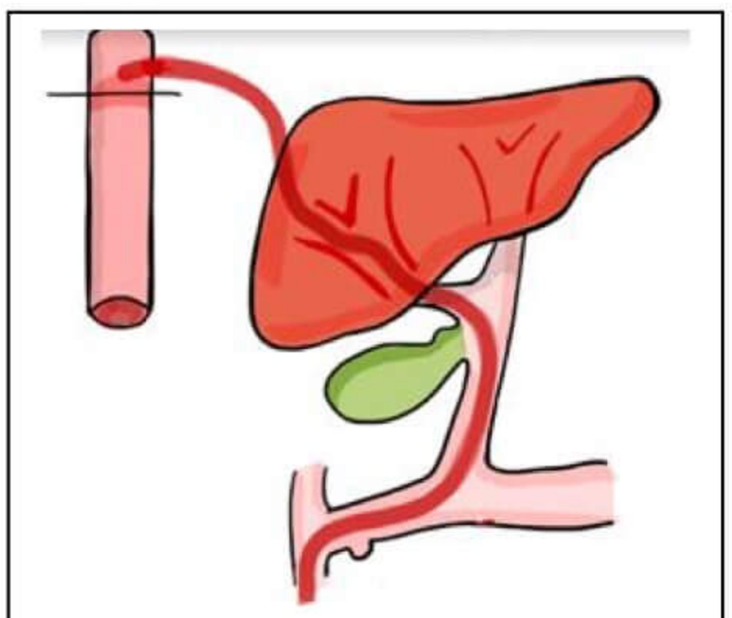

Hemobilia

Clinical features

→ QUINCKE'S TRIAD / SANDBLOM'S TRIAD

- GI hemorrhage (upper / lower)
- Clot colic
- Jaundice

PrepLadder

→ Melena (MC symptom)

- Seen in 90 % cases
- Minimal bleeding to cause melena is 40 – 60ml

Investigation

→ **Upper GI endoscopy** – 1st investigation done for diagnosis of melena

→ Investigation of choice for Hemobilia - **Angiography** (diagnostic & Therapeutic)

Treatment of Hemobilia

→ **Conservative management** - in most patients

→ **Angiography + embolization** - for rest of the pts.

↓ not available/ failed

Open surgical ligation of bleeding vessel

t.me/latestpgnotes

PrepLadder

Pancreas part -1

Sphincter of oddi complex:

1) Superior choledochal sphincter
2) Inferior choledochal sphincter
3) Sphincter ampullae
4) Sphincter pancreaticus

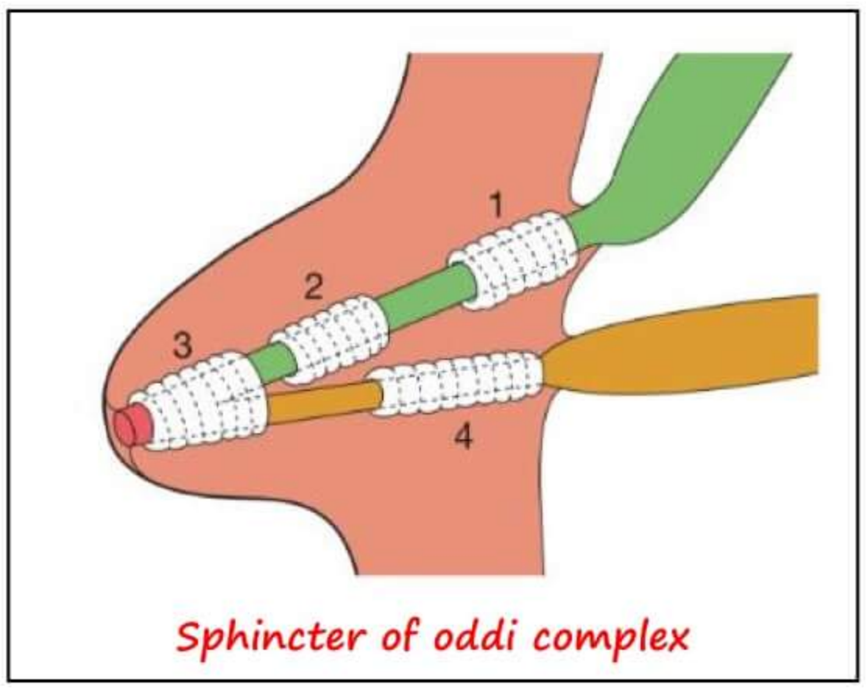

Sphincter of oddi complex

Pancreas Divisum

→ MC congenital anomaly of pancreas
→ Characterized by divided drainage
→ **From Dorsal bud**
  - Part of head
  - Body & Tail

→ **From ventral bud**
  - Part of head
  - Uncinate process

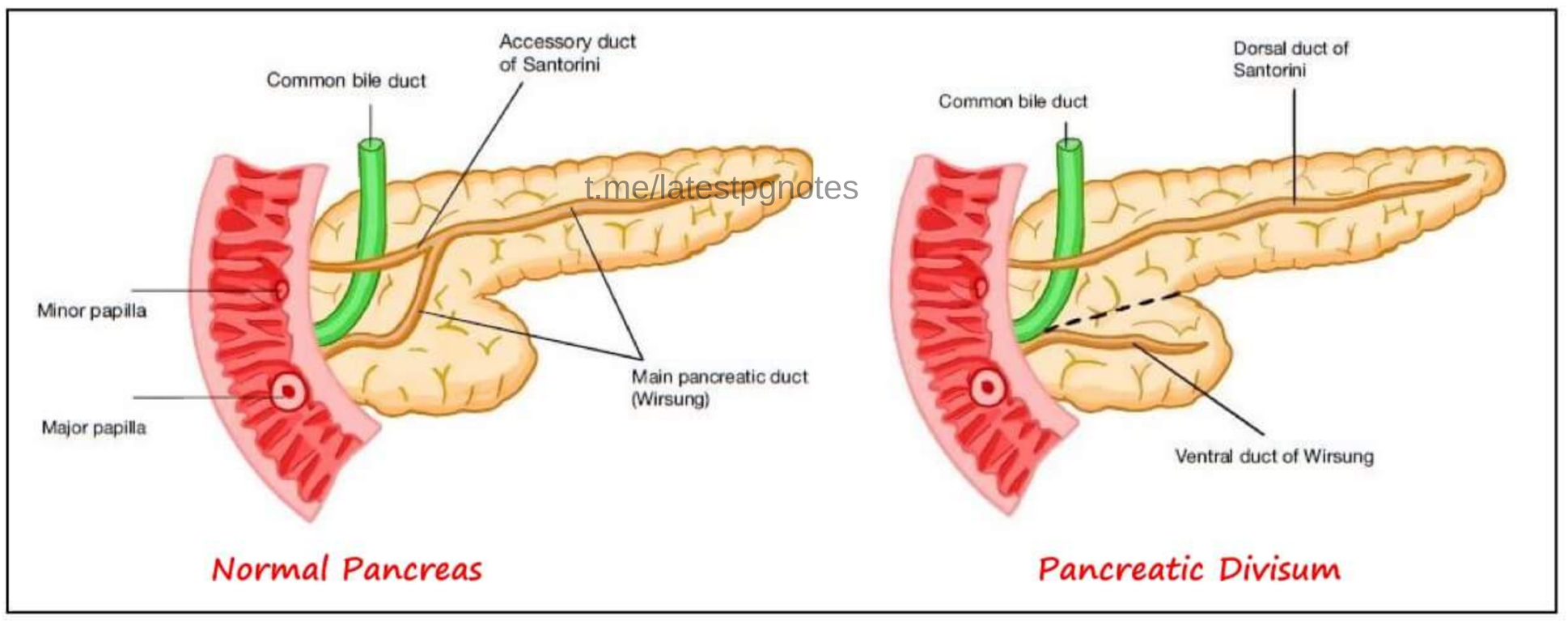

t.me/latestpgnotes

→ Major part of pancreas (part of head, body & tail) is drained by Accessory duct of Santorini via Minor papillae
→ Small part of pancreas (part of head & uncinate process) is drained by major duct of Wirsung via Major papilla

Clinical features

→ Recurrent attacks of Acute pancreatitis (because of relative obstruction)

Investigation:

→ IOC for diagnosis – MRCP
→ Gold std. investigation – ERCP

Treatment

→ Endoscopic Sphincterotomy
  - Dorsal duct Sphincterotomy or
  - Dorsal duct Sphincteroplasty

PrepLadder

Annular Pancreas

→ Ring of ventral pancreas present around 2nd part of Duodenum
→ Located proximal to ampulla
→ Associated with Down Syndrome and Duodenal Atresia

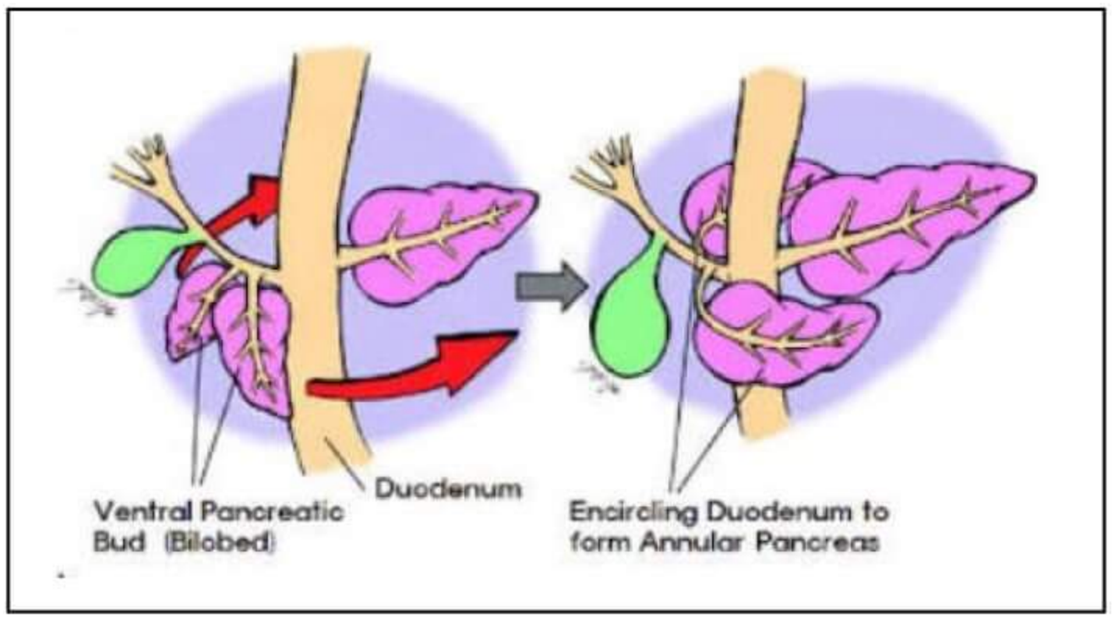

Clinical features

→ Non – Bilious Vomiting (as obstruction is proximal to ampulla)

Investigation

→ IOC for Dx – ERCP

Management

→ TOC – Duodeno-duodenostomy > Duodenojejunostomy

Duodenal Atresia:

→ MCC of neonatal intestinal obstruction
→ Located distal to ampulla
→ Have bilious vomiting

Management:

t.me/latestpgnotes

→ TOC – Duodeno-duodenostomy > Duodenojejunostomy

Note:

In abdominal X-ray

- Single bubble appearance = CHPS
- Double bubble appearance = Duodenal atresia & Annular pancreas
- Triple bubble appearance = Jejunal atresia
- Multiple air fluid levels = Ileal atresia

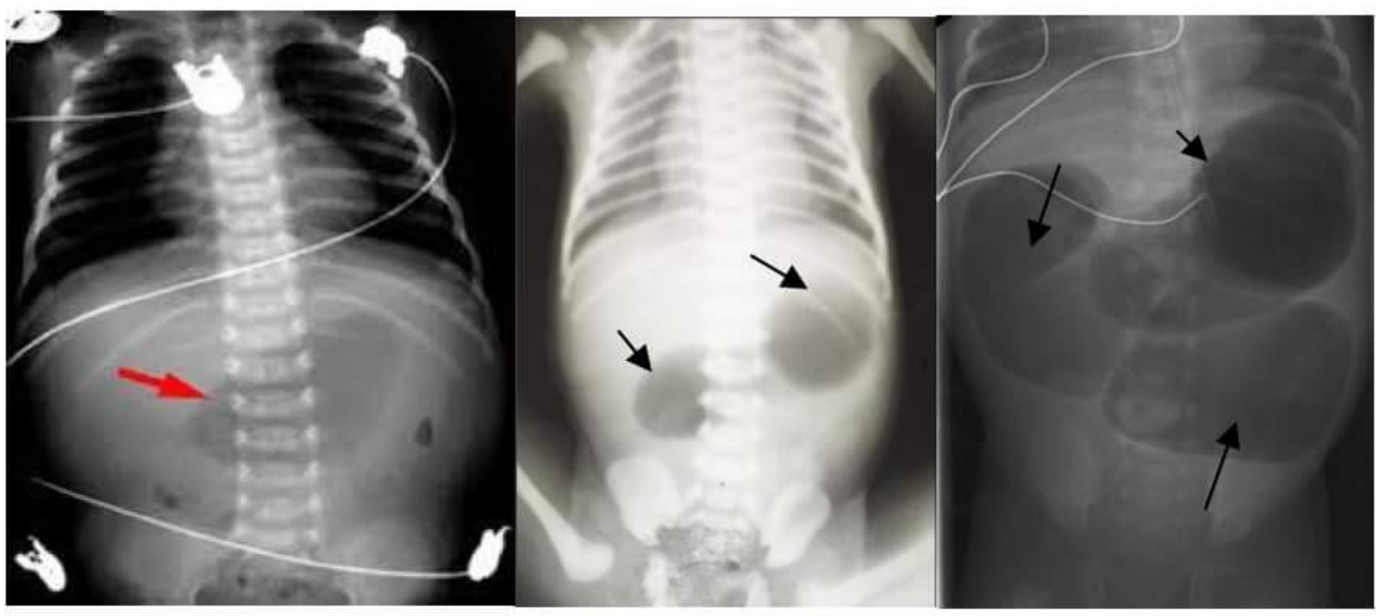

CHPS | Duodenal atresia | Jejunal atresia

PrepLadder

Acute Pancreatitis

→ M/C/C - Gall stones > Alcohol

Other Causes	Viral Infections	Drugs Having Definite Association with Acute Pancreatitis
• Blunt trauma • ERCP • Hypertriglyceridemia • Hyperparathyroidism • Hypercalcemia • Ca pancreas • Cystic fibrosis	• Cytomegalovirus • Mumps • Echo Virus	• 6 – Mercaptopurine • Azathioprine • Deoxy inosine • Cytarabine • Amino salicylic Acid • Tetracycline • Pentamidine • Estrogen • Trimethoprim – Sulfamethoxazole • Thiazide • Valproate • Furosemide • Metronidazole
Drugs Having Possible Association with Acute Pancreatitis • L-Asparaginase and Acetaminophen		

t.me/latestpgnotes

Pathophysiology

- Abnormal intra-pancreatic activation of Pancreatic enzymes

↓

Injury to duct acini

- It is mild & self-limited in majority of cases
- Mild AP: <1% mortality
- Severe AP: 10-30% mortality
- Gallstones induced pancreatitis – has Best prognosis.
- These pancreatic enzymes have lipase which digest the fat of greater omentum

↓

Fat is converted to fatty acid and glycerol

↓

Fatty acids combine with calcium & forms chalky white deposits-Saponification

↓

Hypocalcemia

PrepLadder

M/C/C of Death in Acute Pancreatitis

→ Within 2 weeks of Hospitalization – **MODS (Multi Organ Dysfunction Syndrome)**

→ After 2 weeks of Hospitalization - **Sepsis**

Initial Sign of MODS

→ Impaired lung function (ARDS)

Clinical features

→ Pain in Epigastrium, radiating to Left side of back and partially relieved by sitting or bending forward.

→ Due to Paralytic Ileus - there is Nausea, Vomiting and Abdominal distention

→ **Signs of Paralytic Ileus in X-ray abdomen**

- Gasless abdomen
- Ground glass appearance
- Sentinel loop sign
- Colon cut off sign

→ It is associated with left sided pleural effusion

→ **Hemorrhage (rare)**

- **Cullen sign** - ecchymosis around umbilicus
- **Grey turner sign** - ecchymosis around flank
- **Fox sign** - ecchymosis around inguinal region

Colon cut off sign

t.me/latestpgnotes

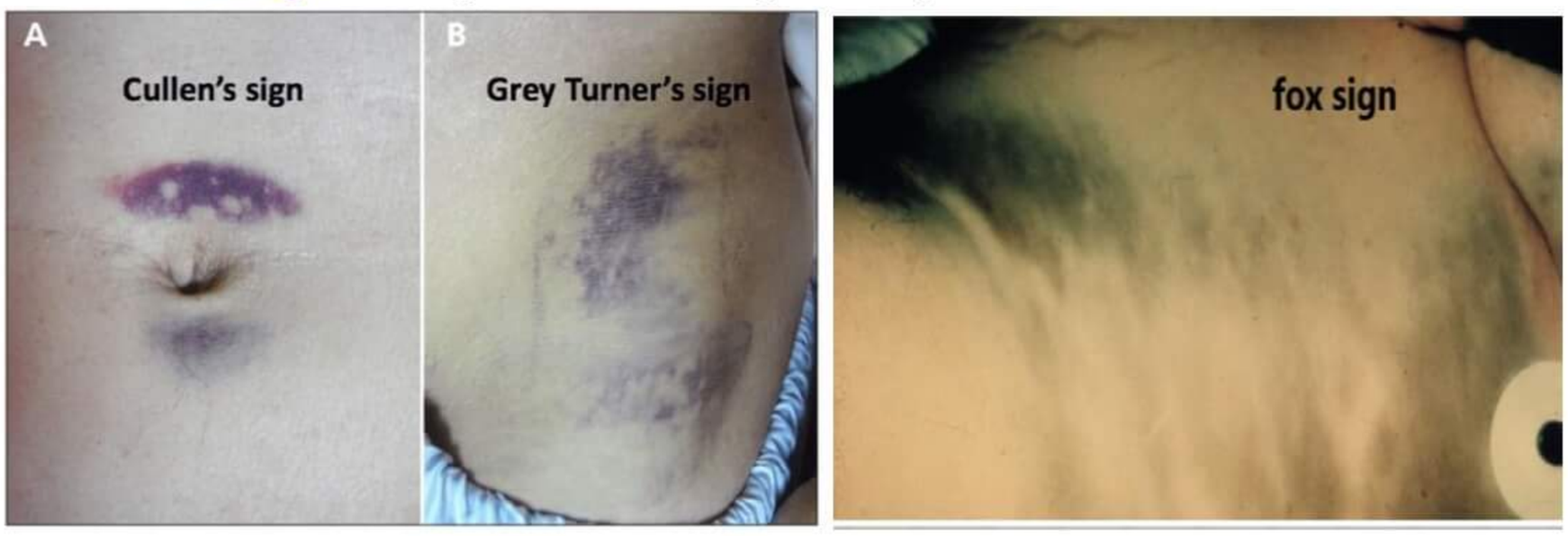

Diagnosis

→ IOC - **CECT** (Reserved for complication; Best time – After 72 hrs.)

→ Diagnosis is usually made by clinical findings and laboratory Investigation

- Amylase (not very specific)
  - ➢ Raised in non-pancreatic causes
  - ➢ No correlation between level of amylase & severity of AP
- Lipase (More specific)

→ CECT is the IOC for diagnosis of most of retroperitoneal organs

1. **Pancreas related:**

   CECT is the IOC for

   - Acute pancreatitis

PrepLadder

- Pancreatic pseudocyst
- Pancreatic abscess
- Pancreatic necrosis
- CA pancreas

2. **Kidney related:**

   CECT is the IOC for

   - Autosomal dominant Polycystic kidney disease
   - Renal TB
   - RCC
   - Angiomyolipoma
   - Renal oncocytoma

3. **CECT is the IOC for**

   - Retroperitoneal fibrosis
   - Retroperitoneal sarcomas

Management:

→ Fluid resuscitation – Fluid of choice is Ringer lactate

→ O_2 supplementation

→ **Analgesics**

- NSAIDS → Metamizole
- OPOIDS → Buprenorphine

→ **Enteral Nutrition > TPN**

t.me/latestpgnotes

Indication for TPN

- Shock
- Severe Acute Pancreatitis

Prognostic scoring system in A. Pancreatitis

1. RANSON'S score
2. Modified Glasgow score
3. BISAP Score

   } Score ≥ 3 in **severe Acute Pancreatitis**

4. Q-SOFA
5. APACE – II → Score ≥ 8 in **severe acute pancreatitis**
6. CT Severity index → Components are – Balthazar CT grading + Necrosis Score.
7. CRP ≥ 130 mg/ml

1) RANSONS'S Prognostic Criteria (for Non-Gall Stone Induced Pancreatitis)

At the Time of Admission	After 48 Hours
• Age > 55 years	• Fall in Hematocrit > 10 points
• WBC count > 16,000/mm^3	• BUN Elevation > 5mg/dL
• RBS > 200 mg/dl	• S. Ca^{2+} < 8 mg/dL
• LBH > 350 IU/L	• Base deficit > 4 mEq/L
• AST > 250 U/L	• Arterial PO_2< 60 mm Hg
	• Fluid Sequestration > 6 L.

PrepLadder

→ Out of 11 if ≥ 3 present – "Severe Acute Pancreatitis"

→ Minimum time for complete Evaluation – 48 hrs.

2) BISAP Score (Bed site Index for Severity of Acute Pancreatitis)

- B → BUN > 25 mg/dL
- I → Impaired Mental Status
- S → SIRS (≥ 2 of 4)
    1. Temperature (core) >38°C or <36°C
    2. Heart rate >90 beats/min
    3. Respiratory rate >20 breaths/min
    4. WBC count >12,000 cells/mm^3 or <4000 cells/mm^3 or >10% immature (band) cells in the peripheral blood smear
- A → Age > 60 years
- P → Pleural Effusion

- If Score ≥ 3 → **Severe Acute pancreatitis**
- If Score is 0-2 → <2% mortality
- If Score is 3-5 → >15% mortality

3) Q – SOFA (Quick Sequential Organ Failure Assessment)

- Respiratory Rate ≥ 22/min
- Systolic BP ≤ 100 mmHg
- Alteration in Mental Status

t.me/latestpgnotes

SCORE	MORTALITY
0	< 1%
1	2-3%
≥ 2	≥ 10%

4. APACHE II → Acute Physiology and Chronic Health Evaluation – II

1) BP	5) S. Creatinine	10) Oxygenation
2) Temp	6) WBC count	11) PH
3) HR	7) Glasgow Coma scale	12) Potassium
4) RR	8) Sodium	
	9) Hematocrit	

→ Score ≥ 8 is suggestive of Severe Acute pancreatitis

PrepLadder

Local complications of AP

Acute (< 4weeks, no defined wall)	Chronic (>4weeks, defined wall)
• Acute pancreatic fluid collection (APFC) • Acute necrotic collection (ANC)	• Pseudocyst • Walled off necrosis

Acute pancreatic fluid collection (APFC)

→ Resolve spontaneously

→ Some cases, after 4 weeks develops into Pancreatic pseudocyst

Pancreatic abscess

→ Pus collection in peripancreatic region

→ **Rx:** USG/CT guided Percutaneous aspiration + Antibiotics

Pancreatic necrosis

→ Non-viable pancreatic tissue or peripancreatic fat

→ It is a sterile condition

→ MC complication is infection

→ MC organism responsible is E. coli

→ Drugs with good pancreatic penetration power is Carbapenems

- Imipenem
- Meropenem

t.me/latestpgnotes

→ **Management** – Repeated Necrosectomy / Surgical debridement with ongoing lavage

Pancreatic Pseudocyst

→ MC cystic lesion of pancreas (75%)

→ It is a false cyst (Not lined by Epithelium, but with granulation tissue)

→ MCC of pseudocyst – Alcohol

→ MC site – Lesser sac

→ Pseudocyst can be seen in both Acute pancreatitis and Chronic pancreatitis but the difference is

In Acute pancreatitis	In Chronic pancreatitis
→ Single/ Large → Extra pancreatic	→ Multiple/Small → Intra pancreatic
Incidence	
10 – 12 %	20 – 40%

PrepLadder

Clinical features

→ In most patients, pseudocyst is small, so it is Asymptomatic

→ **In symptomatic patients**

- M/C symptom - Abdominal pain
- Vomiting (Non-Bilious) containing undigested food particles

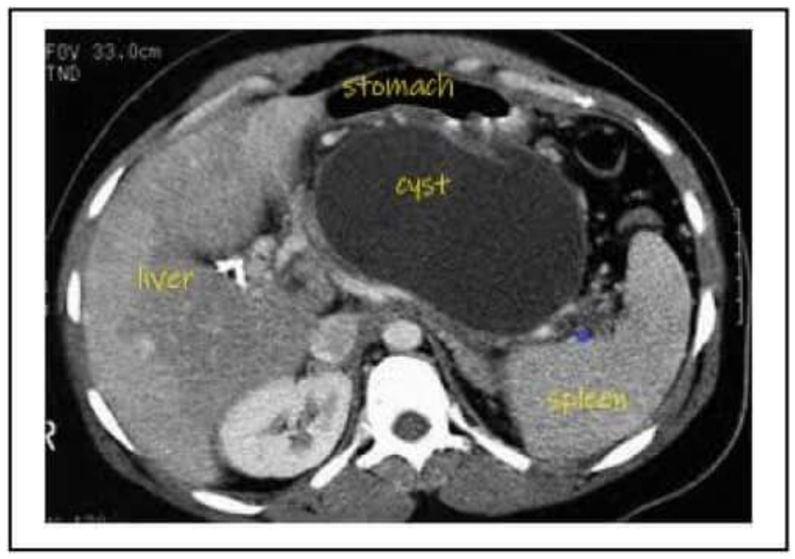

Complication

→ MC complication is Infection (14%) > Hemorrhage (10%)

Diagnosis

→ IOC – CECT

Treatment

→ Conservative management - most of pseudocyst resolve spontaneously

→ **Indications of surgery**

- Duration > 6 weeks
- Size ≥ 6 cm

Surgery

t.me/latestpgnotes

→ Cysto jejunostomy – TOC (Gives best results)

→ Cysto gastrostomy - M/C performed procedure

→ Cysto duodenostomy

Cysto gastrostomy

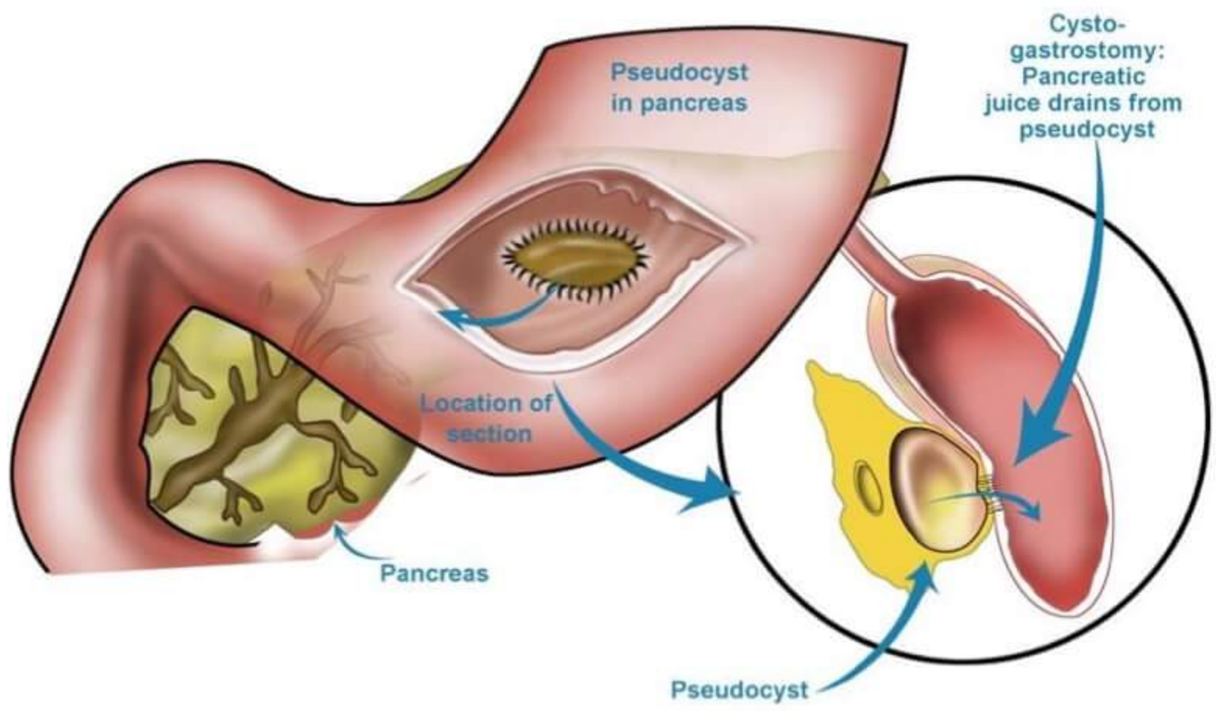

Disadvantages:

→ Drainage against gravity

→ Since the drainage is against gravity, food particles may enter pseudocyst and cause infection (bacterial overgrowth) leading to SUMP Syndrome

PrepLadder

Cysto jejunostomy/ Roux-en-Y- Cysto jejunostomy

a) Jejunum is divided into proximal (afferent limb) & distal (efferent limb or Roux-en-y limb)

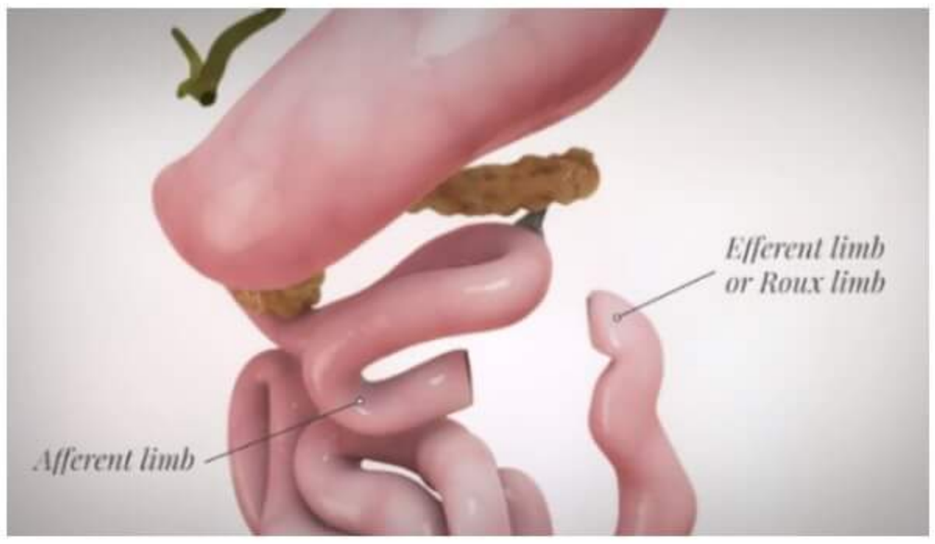

b) Proximal part is anastamosed with the lower part of Roux-en-y limb

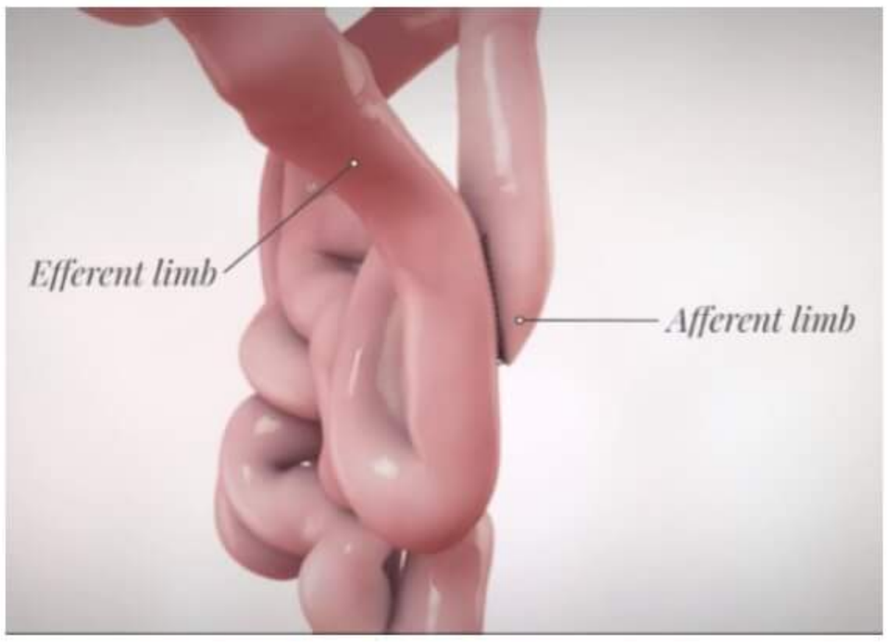

c) Roux-en-y limb is pulled up and anastomosed with cyst

t.me/latestpgnotes

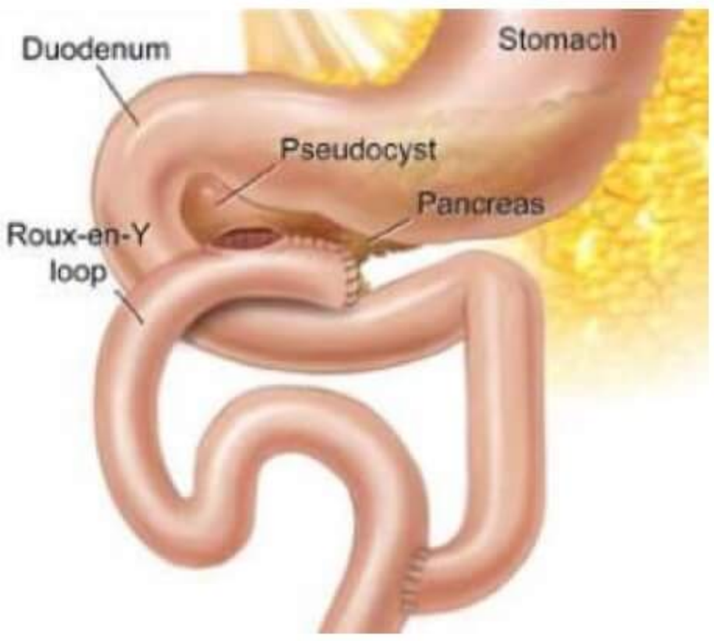

Advantages:

- Drainage along gravity
- No formation of SUMP syndrome

Disadvantages:

- Long duration of surgery
- Increased blood loss

PrepLadder

Mutations associated with Clinical pancreatic syndrome

→ **Hereditary pancreatitis** – PRSS1 gene (cationic trypsinogen gene)

→ **Idiopathic chronic pancreatitis** – CFTR gene

→ **Tropical calcific pancreatitis** – SPINK1 (PTSI)

Chronic Pancreatitis

Characterized by irreversible fibrosis of pancreatic parenchyma with ongoing inflammation

Exocrine insufficiency	Endocrine insufficiency	Chronic pain
• It precedes Endocrine insufficiency • >90% acini permanently destroyed • Leads to – Indigestion – Malabsorption – Steatorrhea (fecal fat >7gms/day)	• >90% of islet cells permanently destroyed • Leads to Diabetes mellitus	

Causes:

→ M/C/C – Heavy alcohol consumption (Smoking have Synergistic Effect)

→ **TIGARO Classification of Etiology of Chronic Pancreatitis**

- T → Toxic – Metabolic
- I → Idiopathic
- G → Genetic
- A → Auto Immune
- R → Recurrent sever
- O → Obstructive

t.me/latestpgnotes

Clinical features

→ **Characterized by**

- Diabetes Mellitus
- Pancreatic Calcification (calcifications present in 30-40% cases)
- Steatorrhea

→ MC symptom is Abdominal pain

Diagnosis

→ IOC - MRCP

→ Gold Standard investigation - ERCP (Both Diagnostic/ Therapeutic)

→ **On ERCP**

- Shows alternate stricture & dilatation of pancreatic duct with pancreatic stones enclosed giving String of pearls/ Chains of lakes Appearance (Beaded Appearance)
- **Composition of stone** - Calcium carbonate

PrepLadder

→ **Endoscopic ultrasound** – most accurate investigation for diagnosis of minimal change in chronic pancreatitis

→ **ROSEMONT criteria** is based on Endoscopic ultrasound findings for diagnosis of chronic pancreatitis

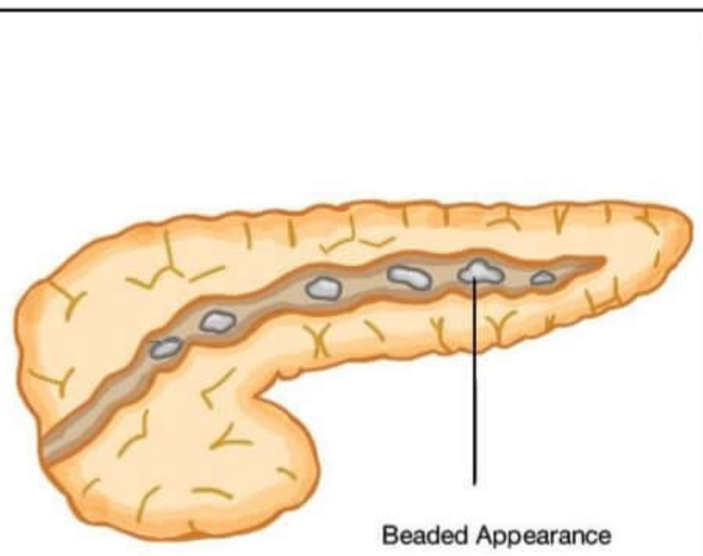

Pancreatic Calcifications

CT

X-ray

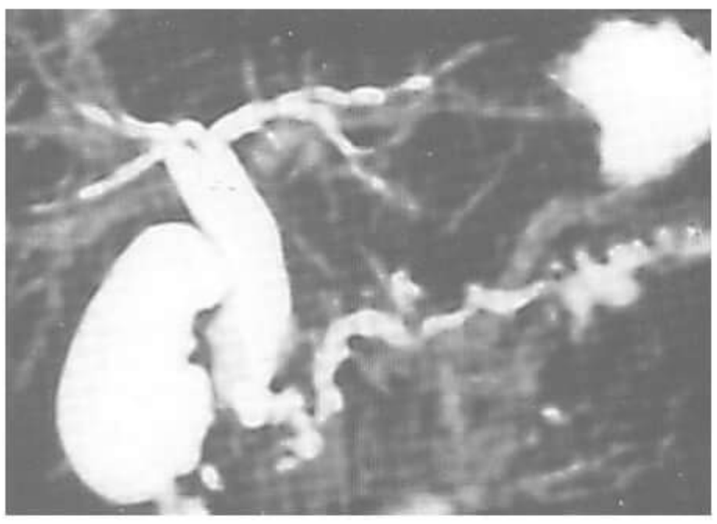

Chains of lakes Appearance

t.me/Prepladdergroup

Management

→ **Exocrine Insufficiency** – Enteric coated Pancreatic Enzyme Supplementation

→ **Endocrine Insufficiency** – Insulin

→ **Pain** – Analgesics

- NSAIDS – Metamizole
- Opioids – Buprenorphine

↓ **Pain not relived**

ERCP stenting/ oblique stone removal

↓ **Pain not relieved**

Celiac Ganglion Blockade

↓ **Pain not relived**

Surgery

PrepLadder

SURGERY

Drainage Procedure	Resection Procedure
Puestow's procedure • AKa LPJ (Longitudinal Pancreatico jejunostomy) • Opening pancreatic duct and suture with jejunum. 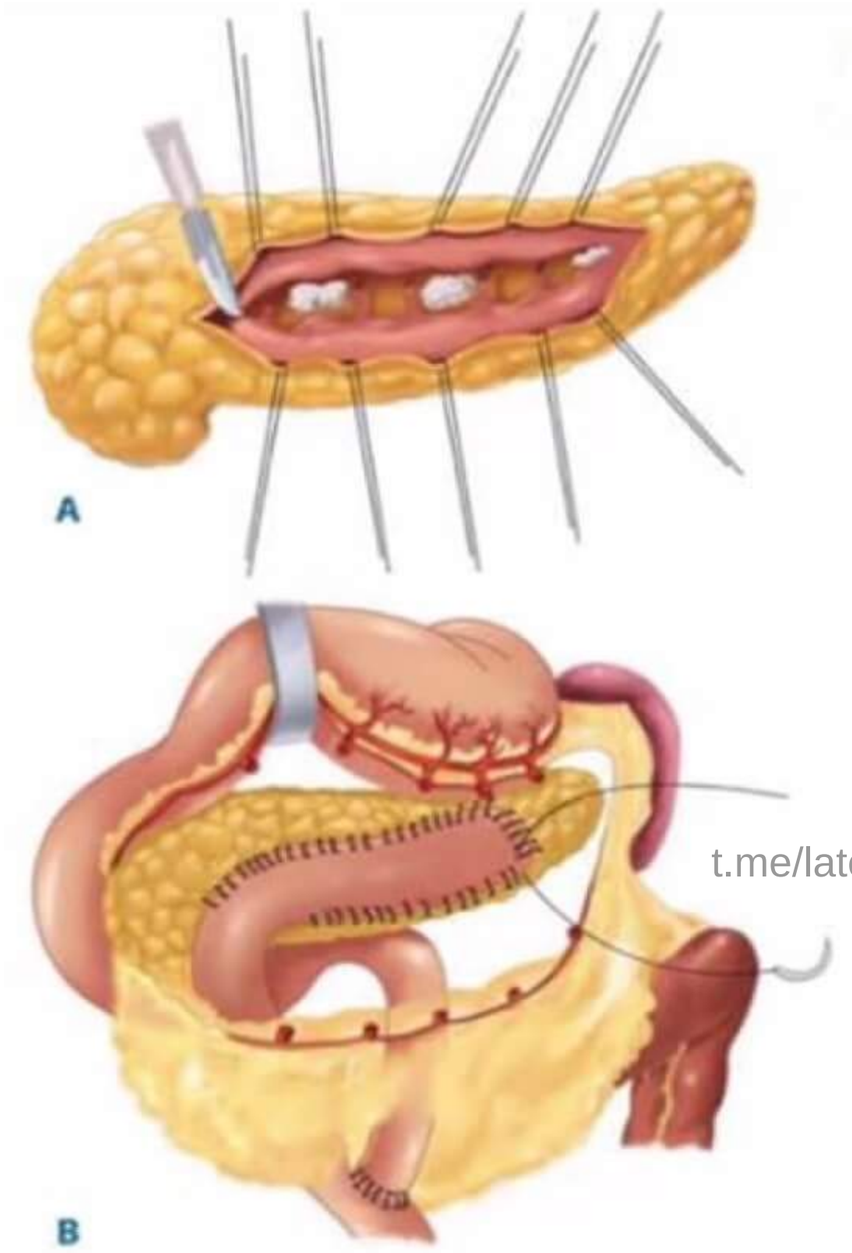 	→ BEGER's procedure → FREY'S procedure **BEGER'S Procedure** • Aka DPPHR - Duodenal preserving pancreatic head resection. • After shaving the pancreatic Head suture the body with jejunum. • Has maximum Pain Relief 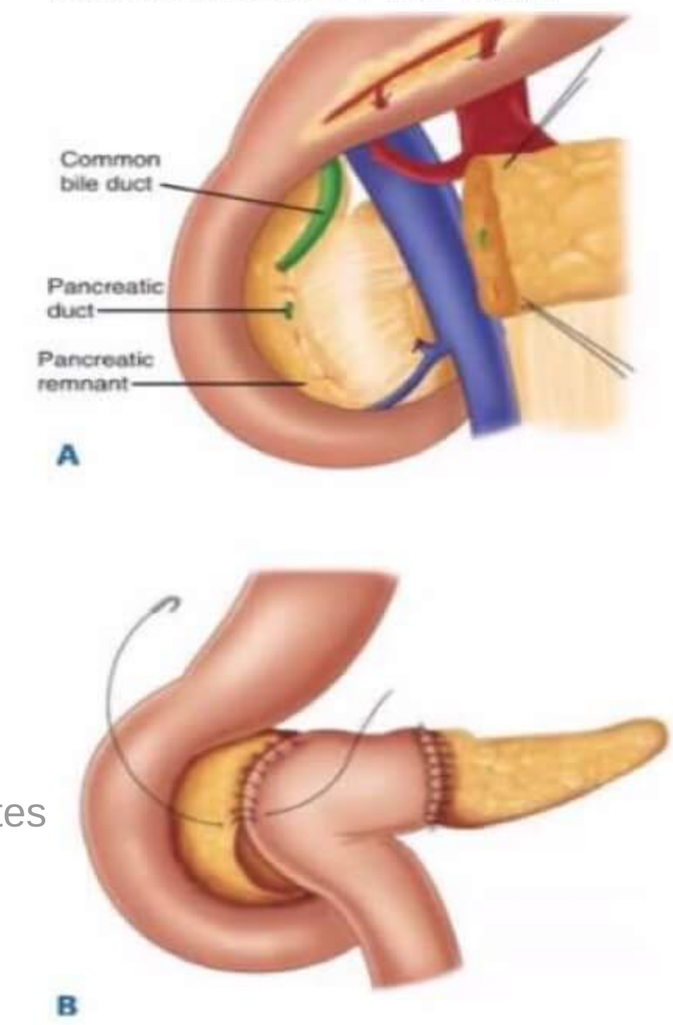 **FREY'S Procedure** • AKa LRLPJ → Local resection of Pancreatic head with Longitudinal Pancreatic – jejunostomy. 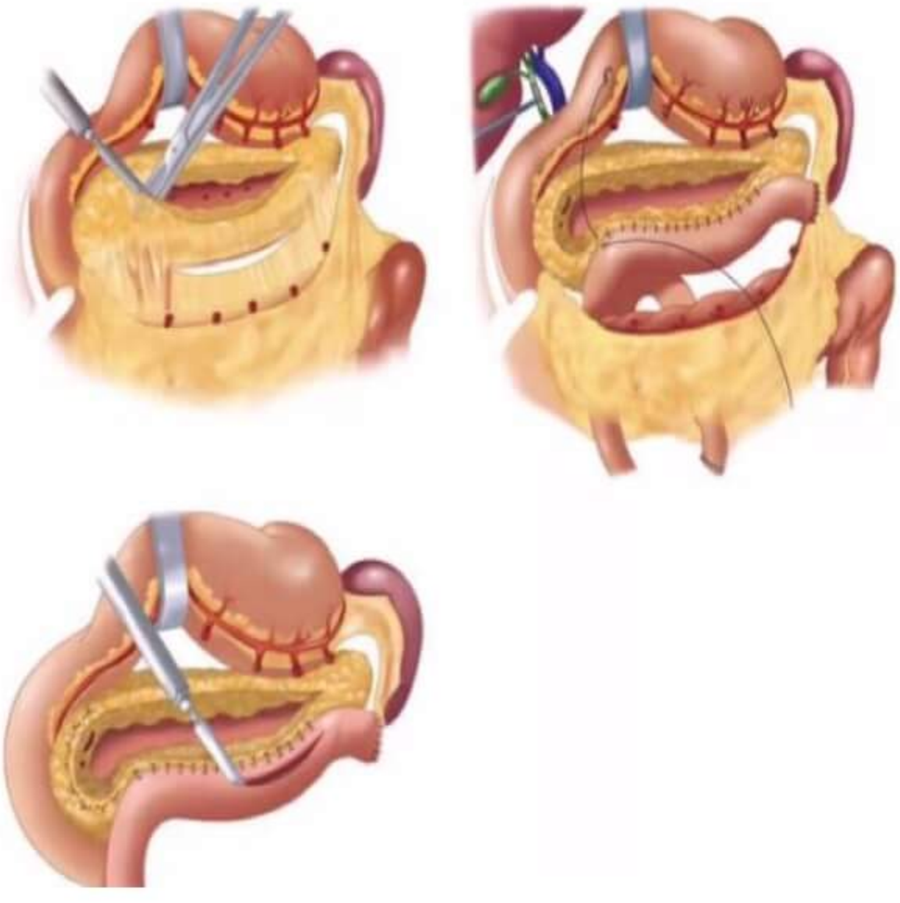

t.me/latestpgnotes

Pancreas part -2

Ca-Pancreas

→ MC genetic mutation in Ca pancreas/ Cholangiocarcinoma → K-RAS > p-16

→ MC genetic mutation in Ca- GB → P53 > K-RAS

→ MC genetic mutation in Ca stomach → P53 > COX – II

Risk Factors	
Established	**Associations**
• Smoking/tobacco • Hereditary Factors /genetic susceptibility ✓ Hereditary pancreatitis – AD ✓ HNPCC- AD ✓ Hereditary Breast and Ovarian Ca (BRCA – 2) – AD ✓ Ataxia Telangiectasia – AR ✓ Familial atypical multiple mole melanoma (FAMMM) syndrome – AD ✓ Peutz Jeghers Syndrome – AD	• DM • Obesity • Chronic pancreatitis

Note → Peutz Jeghers Syndrome → Max Risk for Ca – pancreas

→ M/C type – Adenocarcinoma

t.me/latestpgnotes

→ Non-specific Tumour Marker – CEA

→ Specific Tumour Marker – CA 19.9

→ Chemotherapy Regimen – Gemcitabine

→ MC site of metastasis – Liver

→ M/C site for CA pancreas – Head > Body > Tail

→ **Pathology**: it is associated with intense Desmoplastic reaction

↓

Increased fibrosis around the tumor

Clinical features

→ MC symptom – Jaundice > weight loss

→ **Ca head of pancreas** – Jaundice > weight loss

→ **Ca Body and Tail Pancreas** – Weight loss

→ **Ampullary Carcinoma**

- MC symptom is Jaundice
- Waxing and waning of jaundice with melena (seen every 2-3 months in 1/3rd cases)

→ TROUSSEAU Syndrome – Migratory Superficial Thrombophlebitis seen in Malignancy

→ TROUSSEAU Sign – Carpopedal Spasm in Hypocalcemia

→ TROISIER'S sign – Left Supraclavicular LN (Virchow's Node/signal node) involvement in Malignancy (Ca pancreas)

PrepLadder

Diagnosis:

→ IOC for Ca pancreas – CECT

Radiological Signs seen in

→ **Ca head of pancreas**

1) Antral pad sign
2) Widening of C loop
3) Reverse 3 Sign of Frost Berg
4) Double Duct Sign

→ **Other signs in Ca pancreas**

1) Rose-thorn Appearance
2) Mucosal Irregularity
3) Scrambled Egg Appearance

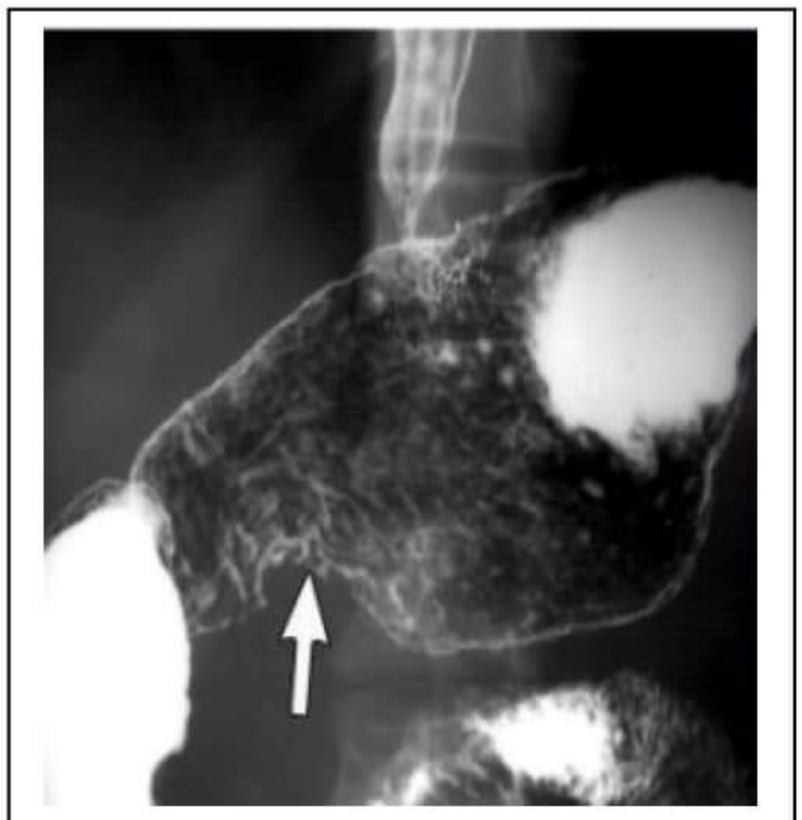

Antral pad sign

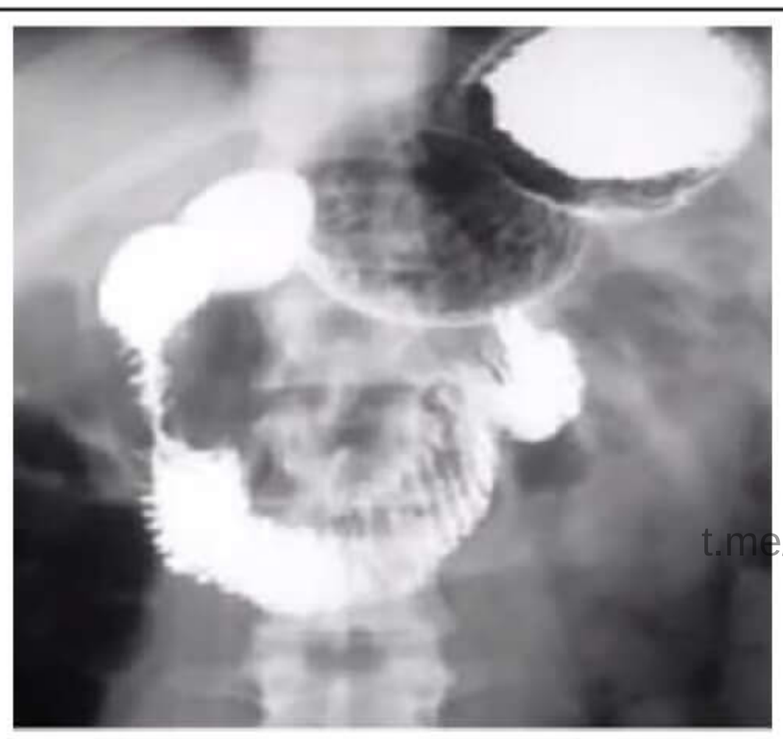

Reverse 3 Sign of Frost Berg

Double Duct Sign

t.me/latestpgnotes

Management

Depends on location

→ Ca Body and Tail Pancreas – Distal pancreatectomy

→ Benign tumor in head of Pancreas – Enucleation

→ Ca head of Pancreas

- Whipple's procedure - Pancreatico duodenectomy (PD)
- Long wire traverso procedure - Pylorus preserving Pancreatico duodenectomy (PPPD) → **Preferred**

→ For advanced /metastatic stage - Gemcitabine

PrepLadder

Anastomosis performed in

Whipple's procedure	Long wire traverso procedure (pylorus preserved)
• 1st – Pancreatico – jejunostomy • 2nd –Hepatico – jejunostomy • 3rd –Gastro – jejunostomy	• 1st –Pancreatico – jejunostomy • 2nd –Hepatico – jejunostomy • 3rd –Duodeno – jejunostomy
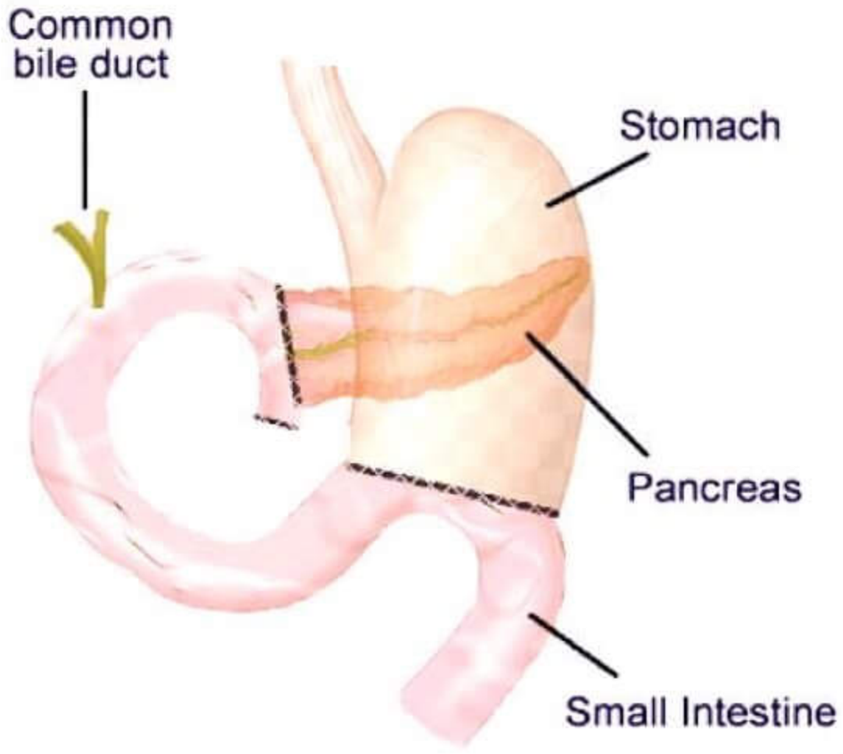	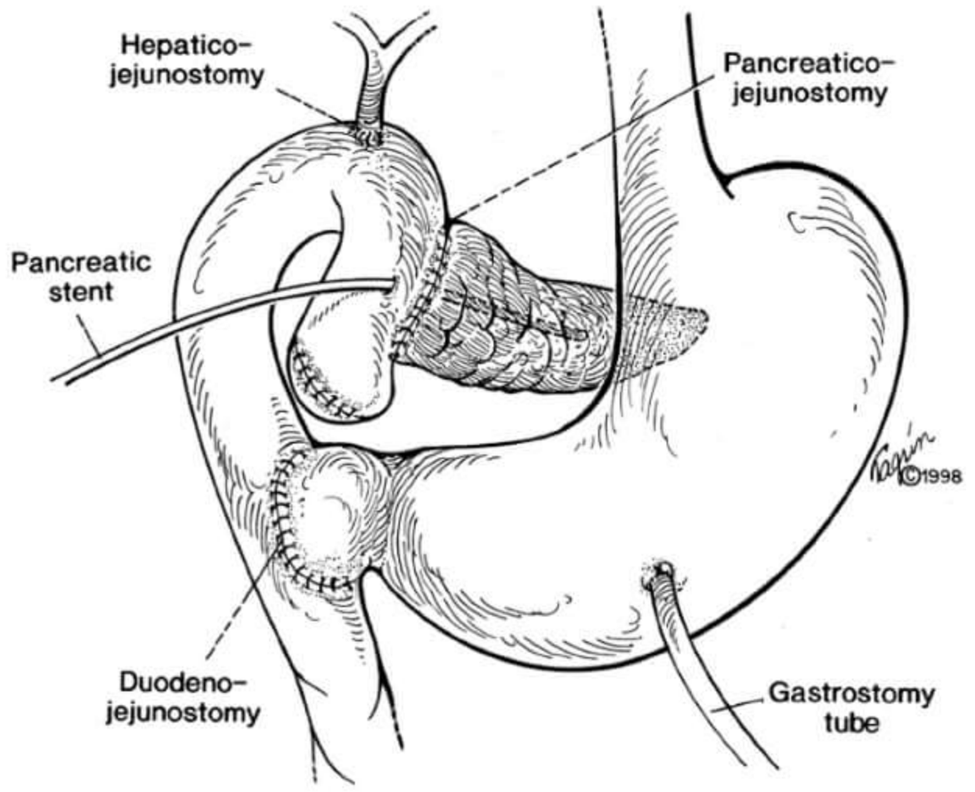

→ MC site of anastomotic leak – PJ > GJ > HJ

→ MC complication of Pancreatico duodenectomy – Delayed gastric emptying

t.me/latestnpnotes

→ MC cause of death after Pancreatico duodenectomy – Cardio-pulmonary complications

→ Most important predictor of survival – R_0 resection

→ **Types of resection:**

- R_0 resection – negative margin
- R_1 resection – microscopic positive margin
- R_2 resection – macroscopic positive margin

→ Most important margin in Pancreatico duodenectomy – Uncinate margin/retroperitoneal margin/ SMV margin

→ **Survival in Ca Pancreas**

- Stage I and II→ 16-20 months
- Stage III→ 6-10 months
- Stage IV→ 3-6 months

Neuroendocrine Tumors (NET) of Pancreas

→ M/C NET of Pancreases - Non-Functional (PP_{OMA})

→ M/C functional NET of Pancreas – Insulinoma

→ M/C functional & Malignant NET of Pancreas – Gastrinoma

→ Neuroendocrine Tumors are symptomatic because of production of active substances. So, patients are

- Symptomatic at early stage
- Diagnosed at early stage

PrepLadder

- Treated at early stage

→ **Better prognosis** - NET > Adenocarcinoma

→ **Diagnosis**

- Diagnosed in Lab by measuring active substance or its by product
- IOC for localization of NET – SRS (Somatostatin receptor Scintigraphy) (as all NET express Somatostatin receptors except Insulinoma)

Insulinoma

→ M/C functional NET of pancreas

→ Mostly Benign

→ M/C site - Head = Body = Tail = equally distributed

Clinical features

→ **Characterized by Whipple's Triad**

✓ Symptoms of Hypoglycemia

✓ Blood glucose (45 – 50 mg/dl)

✓ Improvement in symptoms after taking oral glucose

→ **Neuroglycopenic symptoms**

✓ Dizziness

✓ Headache

✓ Confusion

✓ Coma

t.me/latestpgnotes

→ **Sympathetic overactivity leading to**

✓ Tachycardia

✓ Palpitation

✓ Excessive sweating

→ Painless condition associated with weight gain

Diagnosis

→ Gold Standard Investigation – 72 hours fasting

- **Insulin/ Glucose (ratio) > 0.4 is diagnostic**

→ Best pre-op Test for localization- Intra Arterial Ca^{+} injection with portal venous blood sampling

→ Overall best Investigation for localization - EUS along with "Intra-Op Palpation"

Management

→ **For preoperative preparation**

- Diazoxide
- Octreotide

} To Control Hypo-glycemia

→ **For Body and Tail Tumour** - Distal Pancreatectomy

→ **For head Tumor** – Enucleation (since it's benign)

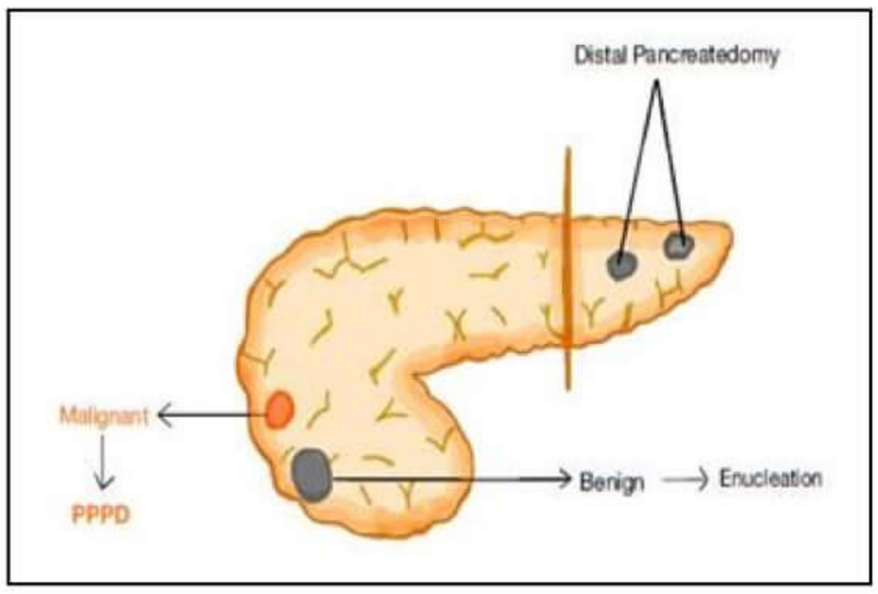

PrepLadder

Gastrinoma / Zollinger Ellison Syndrome

- M/C functional & Malignant NET of Pancreas
- M/C site - **Duodenum** > Pancreas

↓

1st part > 2nd part > 3rd part (4th not Involved)

- 75% sporadic and 25% associated with MEN 1
- 90% of gastrinoma are present in Triangle of Passaro/Gastrinoma triangle
- Has ↑↑Gastrin production → ↑ Acid → Peptic Ulcer Disease

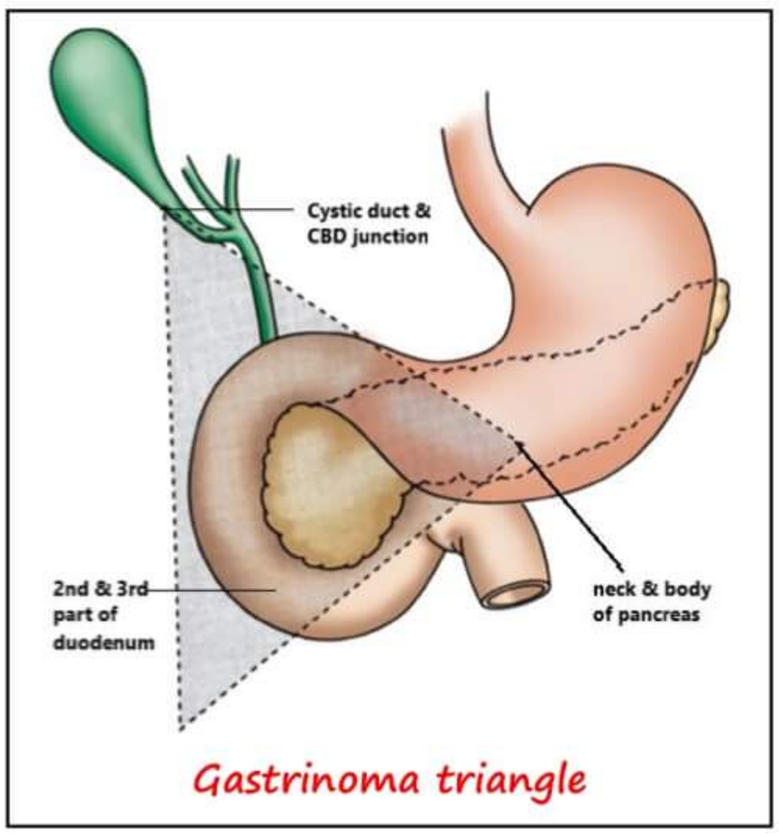

Gastrinoma triangle

Clinical features

→ M/C symptom - Abdominal pain

→ **Other symptoms include**

- ✓ Retrosternal heart burn
- ✓ Dyspepsia
- ✓ Diarrhea (acid induced) → Nasogastric aspiration halts Acid induced Diarrhea
- ✓ Has large ulcers / multiple ulcers / Jejunal ulcers / Refractory ulcers

Diagnosis

→ Gastrin > 1000 Pg/ml is diagnostic

t.me/latestpgnotes

→ Basal Acid Output (BAO) > 15 mEq/hr. is also diagnostic

→ Best Provocative Test- Secretin Stimulation Test (release of gastrin >200 Pg/ml)

→ IOC for localization – Somatostatin receptor scintigraphy (SRS)

Treatment

→ DOC - **Proton pump inhibitors**

→ TOC – **Pylorus preserving whipples procedure**

Glucagonoma/ Hyperglycemic Cutaneous Syndrome

→ **Aka "4" D Syndrome**

- Diabetes Mellitus
- Dermatitis - Necrolytic Erythema Migrans (M/C symptom)
- DVT
- Depression

→ M/C site of Tumour - Body and Tail of Pancreas

Diagnosis

→ IOC - ↑↑ Glucagon levels

→ IOC for localization - SRS (Somatostatin Receptor Scintigraphy)

PrepLadder

Treatment

→ Distal Pancreatectomy

VIPOMA

→ **aKa Verner Morrison Syndrome / Pancreatic Cholera / WDHA Syndrome**

→ Watery Diarrhea (4 – 6 Liters) – cause

- ↓ Na, ↓ Cl^-, ↓ K^+, ↓ HCO_3^-
- ↑ RBS, ↑ Ca^{2+} (Hyperglycemia/ Hypercalcemia)

→ Hyperkalemia

→ Achlorhydria

→ M/C site – Tail

→ It is a medical emergency

Diagnosis

→ Dx. is based on VIP (Vasoactive Intestinal Peptides) levels

→ IOC for localization - SRS (Somatostatin Receptor Scintigraphy)

Management

→ Fluid resuscitation + Correction of Dyselectrolytemia

→ **Octreotide** – control preoperative diarrhea

→ TOC - Distal Pancreatectomy

t.me/latestpgnotes

Cystic Neoplasm of Pancreas

- M/C Cystic lesion of Pancreas - Pseudocyst **(75%)**
- M/C Cystic Neoplasm of Pancreas - Mucinous Cystic Neoplasm

Serous Cyst Neoplasm/Adenoma (SCN)

→ Benign

→ M/C site - Head of Pancreas

→ M/C seen in females (5th -6th decade)

Pathological features

→ **Individual cyst in SCN is**

- Microcystic
- Sponge-like/ honeycomb appearance

Clinical features

→ Most patients are asymptomatic

→ In symptomatic patients – Vague abdominal pain

Diagnosis

→ IOC - CECT

PrepLadder

→ On CECT

- Central Stellate scar
- Central Sunburst Calcification

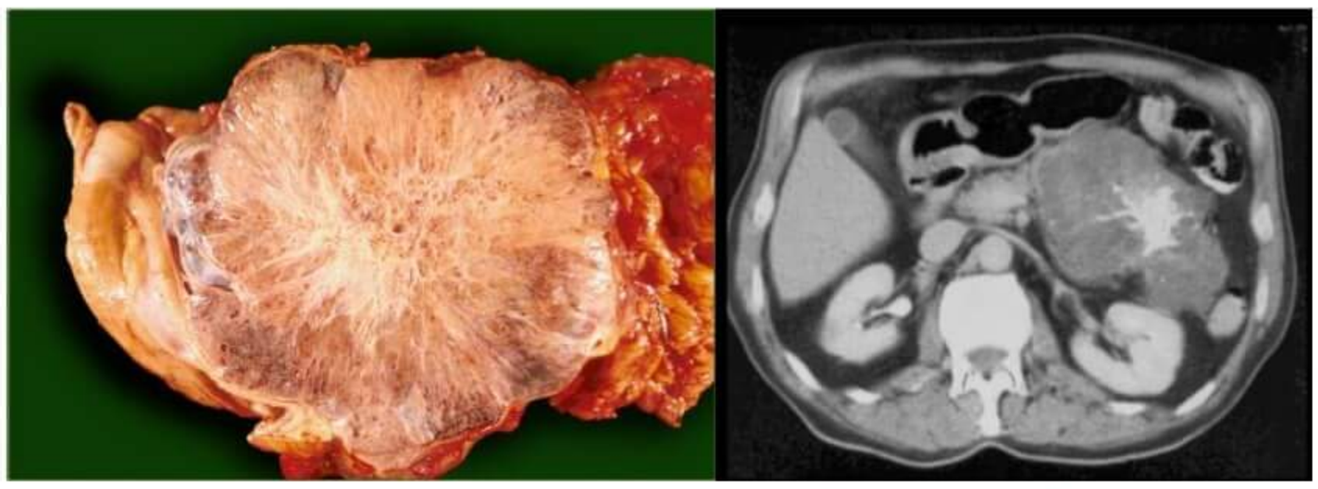

Central Stellate scar / Central Sunburst Calcification

On aspiration of Cyst content

→ Content – Serous

→ CEA – decreased

→ Amylase – decreased

Treatment

→ Observation

→ **Resection is indicated if**

- Diagnostic uncertainty
- Symptomatic
- Size > 4cm

t.me/latestpgnotes

Mucinous Cyst Neoplasm/Adenoma

→ M/C cystic Neoplasm of pancreas

→ It is a pre-malignant condition

→ M/C in females (5th -6th decade)

→ M/C site - Body and Tail of Pancreas

Pathological feature

→ Macrocystic

Clinical features

→ Most patients are symptomatic – Vague abdominal pain

Diagnosis

→ IOC - CECT (shows Peripheral Egg Shell Calcification)

On aspiration of Cyst content

→ **Content** – mucin

→ CEA – increased

→ Amylase – decreased

PrepLadder

Treatment

→ Surgical Resection of Tumour in all the cases

IPMN – Intraductal Papillary Mucinous Neoplasm

→ Pre-malignant

→ Common in both male and Female (6th/7th decade)

→ MC site – Head & Uncinate process

→ **3 Types:**

- Main duct variety
- Side branch variety
- Mixed variety

Clinical features

→ Recurrent attack of acute pancreatitis

→ Abdominal pain

Diagnosis

→ IOC – Endoscopy

→ **On Endoscopy** – Mucin extruding through large Fish-Mouth Opening (ampulla)

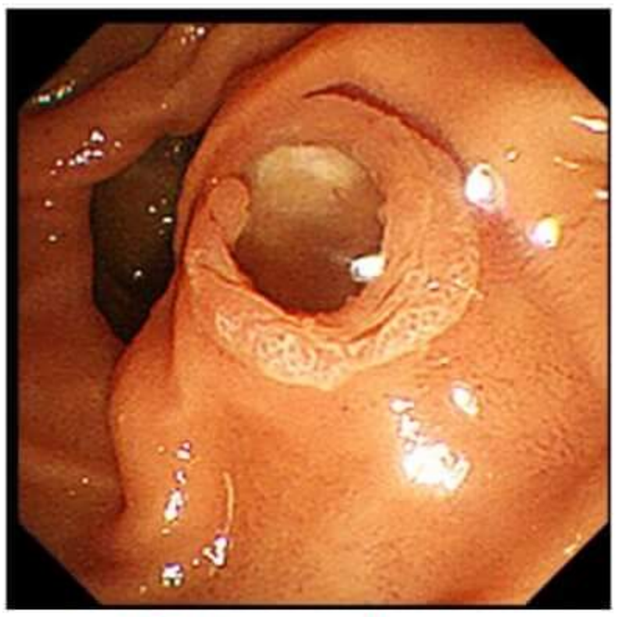

IPMN on endoscopy

t.me/latestpgnotes

On aspiration of Cyst content

→ **Content** – mucinous

→ CEA – increased

→ Amylase – increased

Treatment

→ Partial pancreatectomy

ESOPHAGUS PART - 1

Anatomy of Esophagus

→ Length of esophagus – 25cm

→ Extent of esophagus - C_6 - T_{11}

→ On endoscopy, 3 narrowing's are seen from upper incisors

1) At beginning/cricopharynx	→ 15 cm from upper incisors
2) At Arch of aorta	→ 25 cm from upper incisors
3) At Left Bronchus	→ 25 cm from upper incisors
4) At Diaphragm	→ 40 cm from upper incision

→ **Lining epithelium of esophagus** - Stratified squamous nonkeratinized epithelium.

- Upper $^1/_{3^{rd}}$ – stratified muscle fibers
- Lower $1/_{3^{rd}}$ – smooth muscle fibers
- Middle $^1/_{3^{rd}}$ – slow transition from stratified muscle fibers to smooth muscle fibres

→ **Characteristic features of esophagus**

- Lacks serosa
- No villi
- No secretions
- No Meissner's plexus.
- Has single plexus only – Auerbach's plexus.

t.me/latestpgnotes

→ **Unique feature of esophagus** - Presence of **Lymphatics in Lamina propria**

→ **Other Features**

- Narrowest tube of GIT
- Narrowest part of esophagus- **Cricopharynx** (Diameter – 1.5 cm/15mm)
  (Any foreign body that can cross cricopharynx, can cross other GIT parts and is excreted in stool)
- In case of sharp foreign bodies and button batteries, intervention has to be performed to remove them and others can be absorbed into GI tract.

Congenital Diaphragmatic Hernia (CDH)

→ Protrusion of viscous / part of viscous through the wall of its containing cavity.

Bochdalek Hernia

→ Most common type of CDH

→ **Aka left sided posterolateral Hernia**

PrepLadder

→ **Incidence** – 1 in 2000-5000 live birth
→ **Cause** - Failure of fusion of pleuro peritoneal canal at left side
→ Bag and mask ventilation are contraindicated.
→ Because there is failure of fusion of pleuro peritoneal canal at left side, left sided structures like spleen, stomach and transverse colon herniate above causing ipsilateral collapse of lung and shifting of heart to right side (dextrocardia)
→ The left-out space at the abdomen due to herniation, causes the scaphoid abdomen.

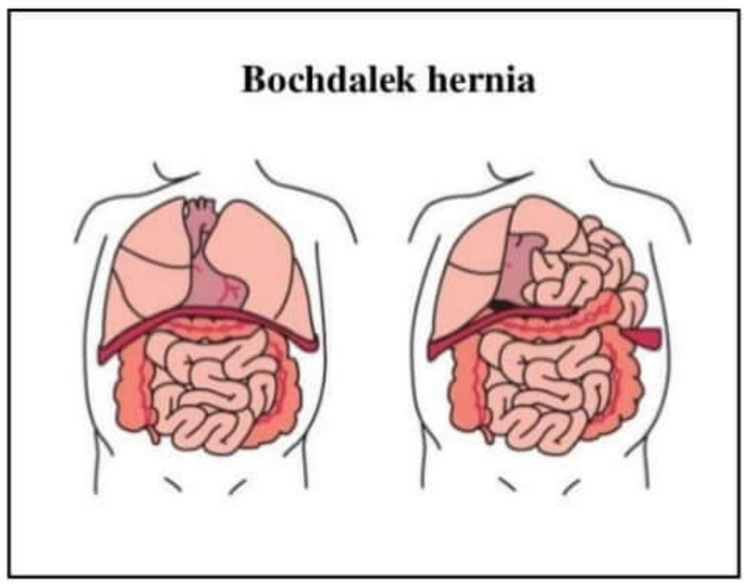

Triad of CDH

Mnemonic – **RDS**

- Respiratory distress
- Dextrocardia
- Scaphoid Abdomen

→ Most important prognostic factor } Pulmonary Hypoplasia > Pulmonary hypertension.
→ Most common cause of death

→ In Bag & Mask ventilation, there will be massive amount of air collected in stomach.
→ In CDH, stomach distention will further deteriorate the collapse of lung and so, bag & mask ventilation is contraindicated.

t.me/latestpgnotes

Diagnosis

→ **During pregnancy** - mother will experience Polyhydramnios.
→ **After delivery** - On Chest X-ray
- Presence of gastric bubble in thorax
- Presence of bowel loops in thorax
- Coiling of Ryle's Tube in thorax (as stomach is present in thorax region)

Management

→ **Principle of Treatment** - Reduce the herniated organs back in the abdominal cavity and close the defect
→ **For large defects** - use the prosthetic patch for closure of defect.
→ If sac is present - Excision is done.
→ Mesh should not be used in children as children will grow.

Morgagni Hernia

→ Aka **Larrey's Hernia**
→ Aka **Right sided/ retrosternal Hernia**
→ In between the right side of xiphoid process and central tendon of diaphragm, there is a shape known as space of Larrey
→ Superior epigastric vessels are passing via the space of Larrey

PrepLadder

→ If there is defective development of central tendon of diaphragm, the space of Larrey / Morgagni is enlarged leading to high chances of herniation of transverse colon.
→ MC in right side
→ MC organ herniated - Transverse colon

Management

→ Principle of treatment- Reduce the herniated organ and close the defect

Hiatus Hernia

→ Acquired hernia
→ Common in adults

Types of Hiatal Hernia

Type I	→ Aka Sliding Hernia (most common type) → Herniation of GE junction
Type II	→ Aka True Paraesophageal hernia (Rolling Hernia) → Herniation of fundus of stomach → GE junction located below diaphragm
Type III	→ Aka Mixed Paraesophageal hernia (sliding + rolling hernia) → Herniation of both GE junction of fundus of stomach
Type IV	• Paraesophageal hernia with herniation of content other than stomach

t.me/latestpgnotes

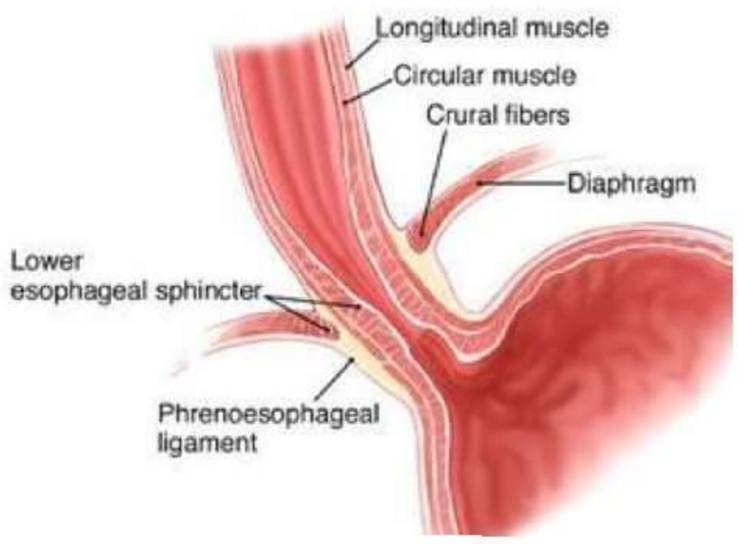

→ Most common type of Hiatus hernia - Siding Hernia (Type I)
→ Most common type of Paraesophageal hernia - Type III (Mixed Paraesophageal hernia)

PrepLadder

Signs & Symptoms

- **Type I** – Reflux
- **Type II** – Herniation of fundus leading to ischemia which can cause abdominal pain
- **Type III** – Reflux and Abdominal pain
- **Type IV** – High risk of ischemia and strangulation (Abdominal pain + increased risk of complications)

Investigation

→ IOC for diagnosis – **Barium swallow**

Treatment

→ Laparoscopic Hiatal Hernia repair via abdominal route

Sliding Hernia

→ Due to sliding of GE junction up and down there will be formation of ulcer at the lesser curvature known as **Riding ulcer / Cameron's ulcer**

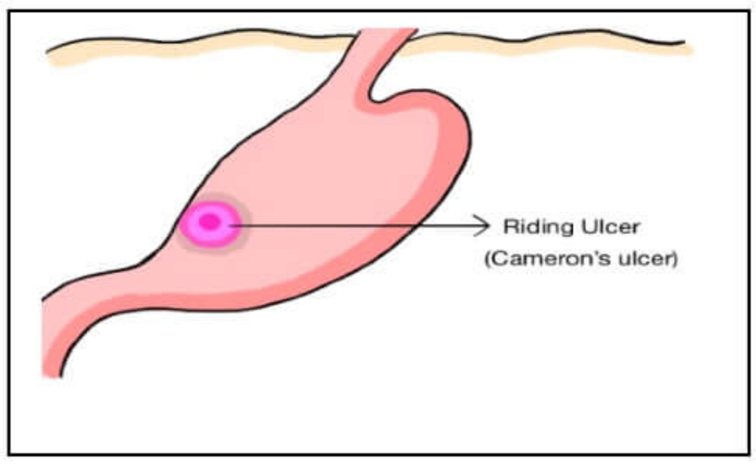

Stress ulcers

→ **Aka Stress gastritis /Hemorrhagic gastritis**

→ **Cushing ulcer** – due to **Head injury**

→ **Curling ulcer** – due to **Burns** (Develops when > 1/3rd of body surface area involved)

t.me/latestpgnotes

→ MC site of stress ulcer – **Stomach** (Fundus > Body > Antrum > Pylorus)

→ MC site of stress ulcer **in Duodenum** – 1st part > 2nd part > 3rd part > 4th part of duodenum

Normal anatomy

	Upper esophageal Sphincter	Lower esophageal Sphincter
Normal Length	• 4 – 5 cm	• 5 cm • Intrabdominal length of LES – 2 cm
Normal pressure	• 60 mmHg	• 6-26 mmHg
Muscles	• Has 3 muscles – Distal portion of inferior pharyngeal constrictor – Cricopharyngeus – Circular muscles of Proximal esophagus	

PrepLadder

Lower Esophageal Sphincter (LES)

Factors that decreases LES pressure	
Drugs	**Foods**
(Mnemonic – PMT BD CAN) • P – Prostaglandin E1, E2, Progesterone • M – Morphine, Meperidine • T – Theophylline • B – Barbiturates • D – Diazepam, Dopamine • C – Calcium channel blockers • A – Atropine • N – Nitrates	(Mnemonic – CAPS FAT) • C – Chocolate, Coffee • A – Alcohol • P – Peppermint • S – Smoking • F – Fat

Incompetent LES

→ **Characterised by**

- Total length of LES < 2cm
- Intra-abdominal length of LES < 1 cm
- LES pressure < 6mm Hg

GERD

→ Incompetent LES leads to GERD

t.me/latestpgnotes

Sequence of events

→ Incompetent LES – **Reflux of Gastric content**

↓

Esophagitis

↓

Ulceration

↓

Fibrosis

↓

Stricture formation

↓

Columnar Metaplasia (On long term exposure)

(BARRET'S Esophagus)

↓

↑sed risk of Adenocarcinoma

Clinical features

→ **Classical triad of**

- Retrosternal Heart burn
- Epigastric pain
- Regurgitation

PrepLadder

→ MC Presentation - H/o long standing heartburn with shorter h/o regurgitation

Diagnosis

→ IOC for Dx - 24 hours ambulatory PH monitoring

↓

DE-MEESTER's score calculated

- Normal - < 14.7
- GERD - > 14.7

Management:

→ **Lifestyle modifications:**
- Cessation of smoking
- Decrease caffeine intake
- Avoid large meals just before lying down

→ **For symptomatic improvement**
- Double dose of PPI

→ **Before performing surgery, following investigations are mandatory.**

1) 24 hours Ambulatory PH monitoring
2) Barium swallow (to rule out sliding Hernia)
3) Endoscopy with biopsy (to rule out Barret's esophagus)

→ **Gold standard treatment of GERD**
- Laparoscopic Nissen fundoplication (360°)

t.me/latestpgnotes

Fundoplication

Types of fundoplication

a) **Watson fundoplication**

→ Fundus of stomach is taken to cover only 90° /one fourth of esophagus anteriorly.

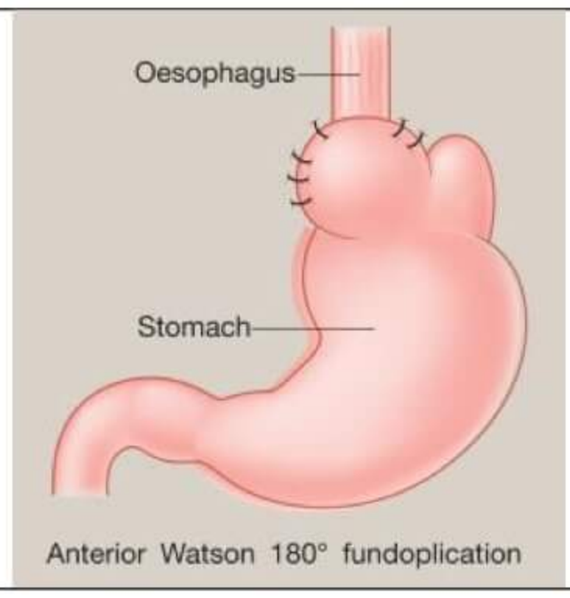

Anterior Watson 180° fundoplication

b) **DOR fundoplication**

→ Fundus of stomach is taken to cover 180° of esophagus anteriorly

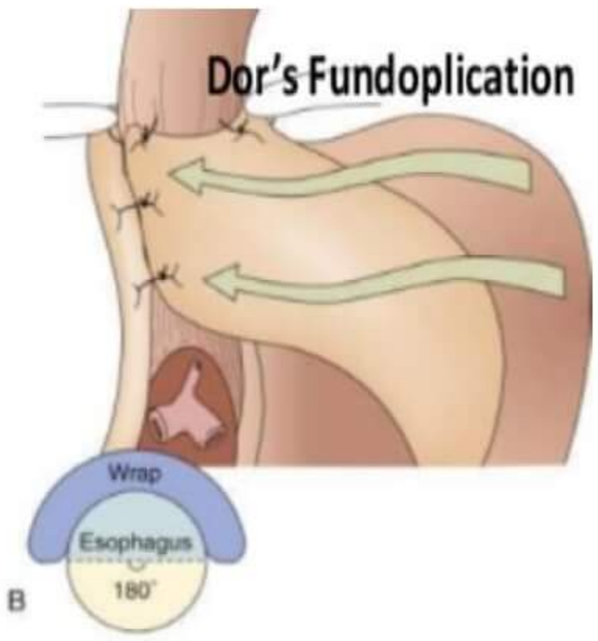

PrepLadder

c) **Toupet fundoplication**

→ Fundus of stomach is taken to 270° of esophagus posteriorly

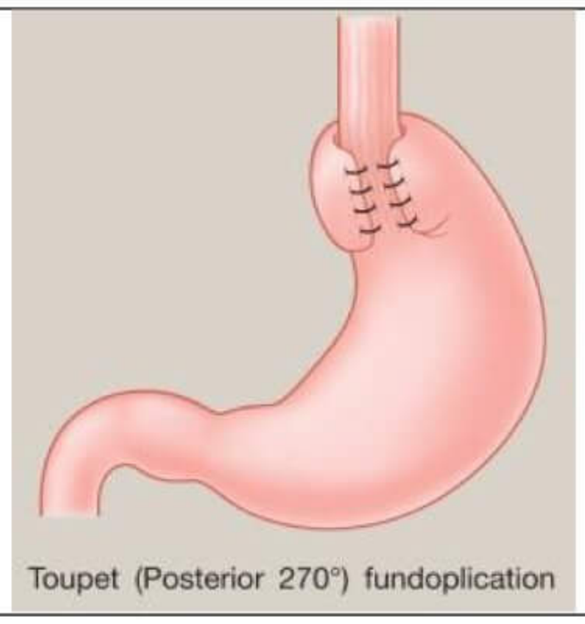
Toupet (Posterior 270°) fundoplication

d) **Belsey Mark IV**

→ Fundus of stomach is taken to cover 270° of esophagus anteriorly.

e) **Nissen's fundoplication for 360°**

→ One part of fundus is taken behind the esophagus of other part of fundus is taken in front of esophagus

→ Both of them are plicated in front of esophagus.

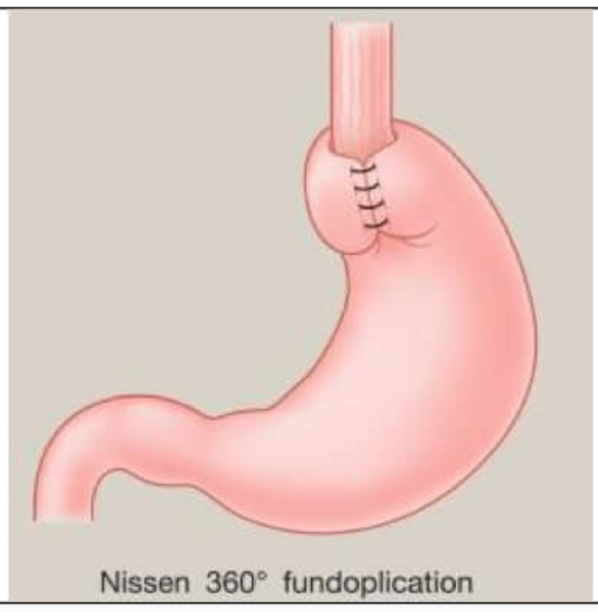
Nissen 360° fundoplication

→ Most commonly performed fundoplication – **Nissen's fundoplication**

→ **Rarely performed fundoplication**
- Watson fundoplication
- Belsey Mark IV fundoplication

→ **MC performed Partial fundoplication**
- DOR fundoplication
- Toupet fundoplication

t.me/latestpgnotes

Upper Esophageal Sphincter

→ It is composed of oblique fibers of thyropharyngeal and transverse fibers of cricopharyngeal muscle

→ Dehiscence between the fibers of thyropharyngeal and cricopharyngeal muscle - **Killian's dehiscence**

→ Dehiscence below cricopharyngeal muscle – **Laimer's dehiscence**

→ Area below and laterally to cricopharyngeal muscle - **Killian-Jamieson's area**

→ **Esophageal diverticula**
- Herniation in Killian's dehiscence is called **Zenker's diverticulum**
- Herniation in Killian-Jamieson's area is called **Killian-Jamieson's diverticulum**

→ **Other esophageal diverticula are**
- **Mid esophageal / Traction diverticulum**
- **Epiphrenic diverticulum** (located above diaphragm)

PrepLadder

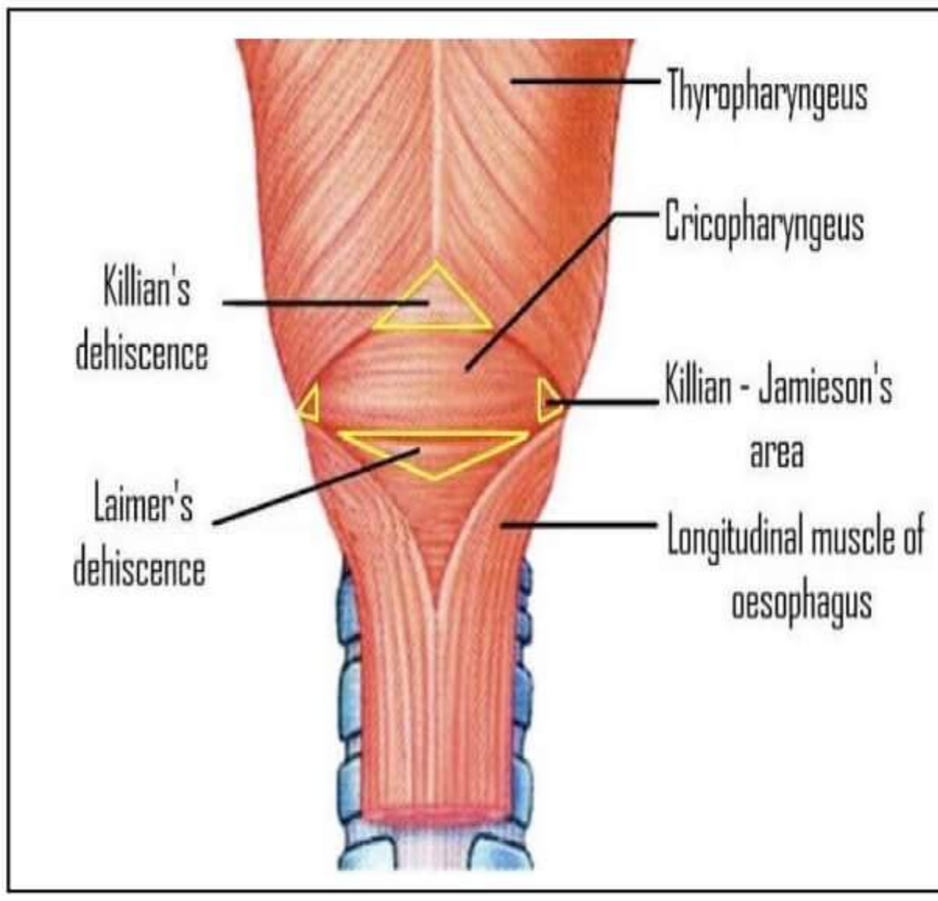

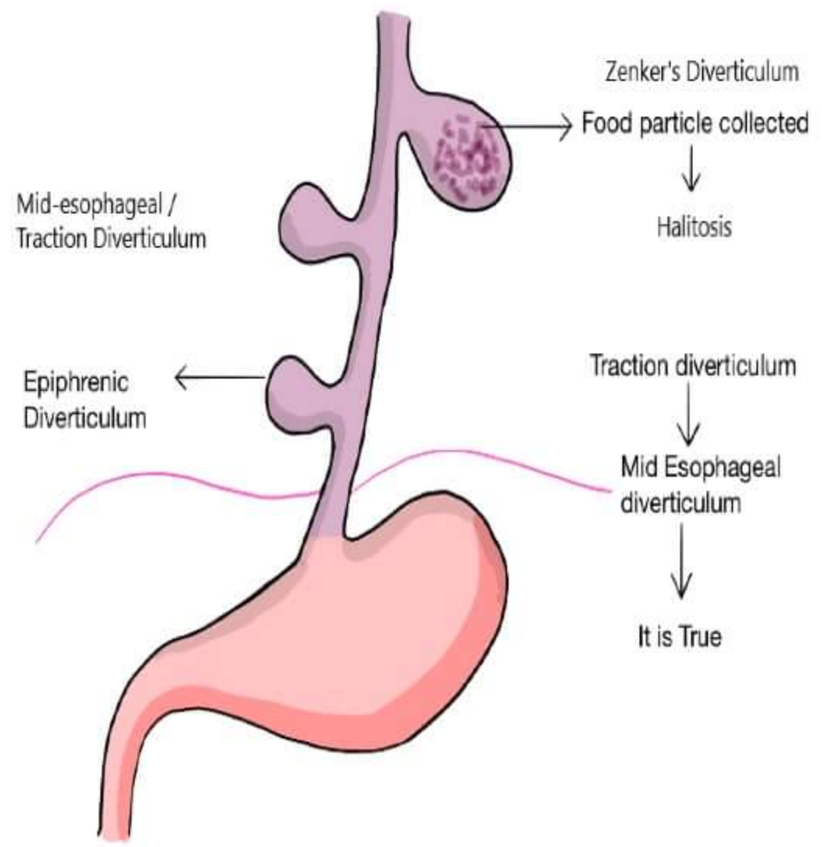

True diverticulum	False diverticulum
• Has herniation of all the layers of wall **(Mucosa + Submucosa + Muscularis)**	• Has herniation of only Mucosa & Submucosa
• Only one true diverticulum in esophagus – Mid esophageal / Traction diverticulum	• Zenker's diverticulum • Epiphrenic diverticulum

Zenker's diverticulum

t.me/latestpgnotes

→ MC type of esophageal diverticulum
→ It is a false diverticulum (mucosa & submucosa)
→ MC in Elderly / Diabetic / Males
→ **Inferior constrictor muscle has Dual nerve supply**
  - Thyropharyngeus – supplied by Pharyngeal Plexus
  - Cricopharyngeus – supplied by RLN
→ **Due to this dual nerve supply** – Neuromuscular incoordination during swallowing leads to herniation through killian's dehiscence due to increased pressure

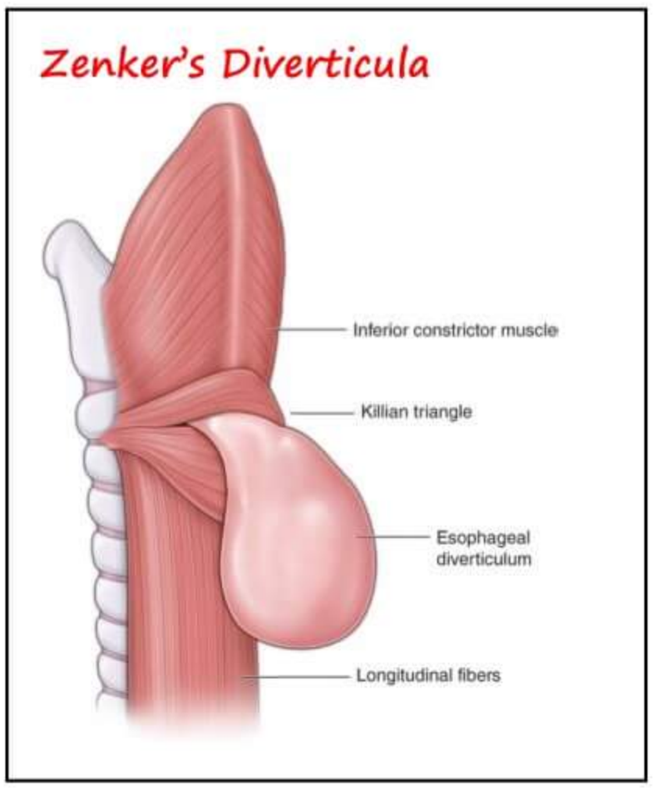

Symptoms

→ MC symptom – Dysphagia
→ > 50% of cases– Zenker's diverticula is associated with cervical web.
→ Halitosis
→ Regurgitation

Complications

→ Increased risk of aspiration (due to regurgitation)
↓
Increased risk of pneumonitis
↓
Increased risk of lung abscess (**MC complication → Lung abscess**)

PrepLadder

→ Increased risk of SCC (due to chronic inflammation at Zenker's diverticula)

Investigation

→ IOC for Dx – **Barium swallow**

Treatment

→ **Treatment of choice** – Cricopharyngeal Myotomy + Diverticuloplexy

→ **Other alternative procedures:**

- Diverticulectomy (for larger diverticula's > 4cm)
- Dohlman procedure

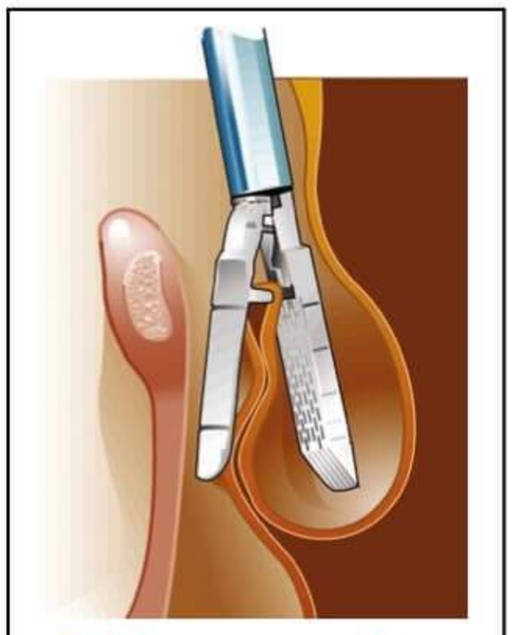

Dohlman procedure

Dohlman's procedure

→ **Aka Diverticulo-esophagostomy**

→ It is Endoscopic stapling of septum located between Esophagus & Diverticula

MOTILITY DISORDERS OF ESOPHAGUS

- Achalasia cardia
- Diffuse esophageal spasm
- Nut cracker esophagus
- Hypertensive LES

t.me/latestpgnotes

→ MC motility disorder of esophagus – **Achalasia cardia**

→ MC hypomotility disorder of esophagus – **Achalasia cardia**

→ MC hypermotility disorder of esophagus – **Nut cracker esophagus**

→ Most painful motility disorder of esophagus – **Nut cracker esophagus**

→ Investigation of choice for motility disorders – **Manometry**

ACHALASIA CARDIA

→ Characterized by absence of LES relaxation

→ Equal distribution (M = F)

Pathophysiology

→ Only Auerbach's plexus is present in esophagus

→ It has 2 types of neurons

- Stimulatory – Responsible for contraction
- Inhibitory – Responsible for relaxation

→ In Achalasia cardia – **Selective loss of inhibitory neurons**

↓

Absence of LES relaxation

PrepLadder

Clinical features

→ MC symptom – Dysphagia > weight loss

↓

(Liquid > Solid)

→ **Triad**

- Dysphagia
- Regurgitation
- Weight loss

Complication

→ Increased risk of aspiration (due to regurgitation)

↓

Increased risk of pneumonitis

↓

Increased risk of lung abscess (**MC complication** → Lung abscess)

→ Increased risk of SCC

TRIPLE "A" SYNDROME (ALGROOVES DISEASE)

- Achalasia
- Alacrimia
- ACTH Resistant Adrenal Insufficiency

t.me/latestpgnotes

Investigation

→ IOC – Manometry

→ **Findings of Manometry**

LES Related	Esophageal body Related
→ Absence of LES relaxation	→ Absence of Peristalsis → Ineffective contraction
→ Increased LES pressure	→ Increased Esophageal pressure

→ **On Barium Swallow**

- Bird beak appearance
- Pencil tip appearance
- Rat tail appearance

→ Rat tail filling defects – seen in CA esophagus



PrepLadder

Types of Achalasia:

1) **Primary**
2) **Secondary** (Pseudo-Achalasia) - Secondary to known causes:
    - Malignancy
    - Chagas Disease

Management

→ **Drugs**
- Calcium channel blockers
- Nitrates

→ Botox injections (Botulinum toxin)

→ Bougie dilatation or Balloon dilatation (insert bougie and rupture circular muscle fibres to relax LES)

→ **Treatment of choice** - **Laparoscopic Heller's cardio myotomy** (Myotomy extended till cardia or 1 cm of stomach)

→ **After Heller's cardio myotomy** - Partial fundoplication needs to be performed
- DOR Fundoplication
- Toupet Fundoplication

→ **POEM (Per- Oral Endoscopic Myotomy)** – New treatment of Achalasia cardia

t.me/latestpgnotes

→ **In Chronic cases** - Massive dilated esophagus

↓

- Mega-esophagus (or)
- Sigmoid Esophagus

↓

Tx: ESOPHAGECTOMY

Sigmoid Esophagus

Types of Esophageal contraction

Primary	Secondary	Tertiary
• Progressive contraction • Triggered by voluntary swallowing	• Progressive contraction • Triggered by irritation or distention caused by food bolus	• Non-progressive • Non-peristaltic spasmodic contraction

PrepLadder

Blood supply of esophagus

→ **Esophagus does not have own blood supply**

- In lower neck - Inferior thyroid Artery
- In thorax, behind trachea - Bronchial artery
- Below T_4, anterior to aorta - Direct branches from Aorta
- Near diaphragm - Inferior phrenic artery
- Near JE Junction - Left gastric artery

→ Arteries penetrate the muscularis at right angle

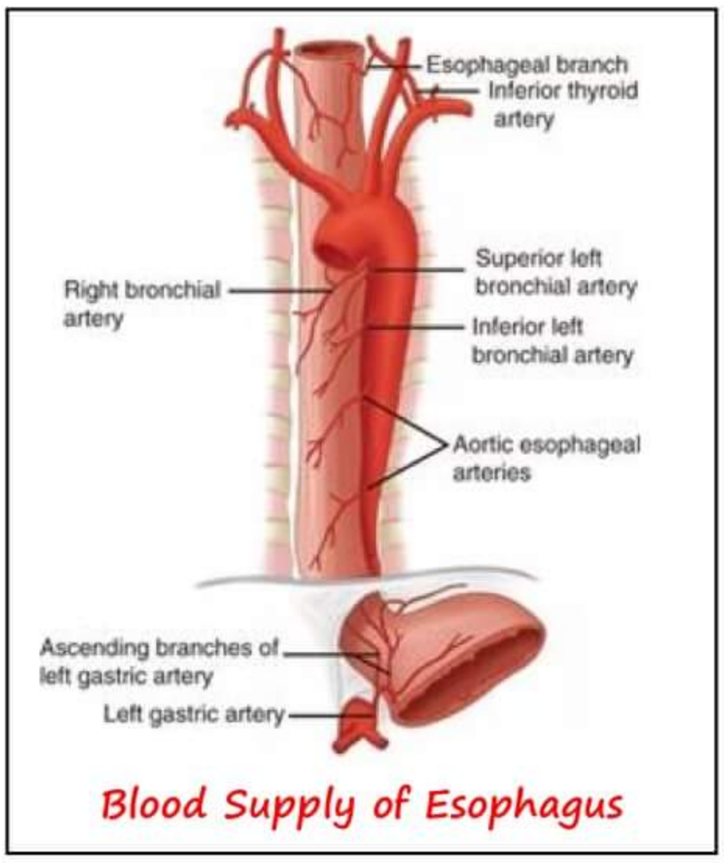

Blood Supply of Esophagus

Diffuse Esophageal Spasm

→ Caused by **Tertiary contraction / spasmodic contraction**

↓

Spasm

↓

Esophageal blood supply cut off - Ischemia

↓

Left sided chest pain/ pain in lower part of neck (mistaken as angina)

Clinical features

→ Chest pain

→ Dysphagia

t.me/latestpgnotes

Investigation

→ IOC - Manometry

→ **Diagnostic criteria**

- Amplitude of contraction > 120 mm Hg
- Duration of contraction > 2.5 sec

→ **On Barium Swallow**

- Cork screw appearance
- Pseudo diverticula appearance
- Rosary bead appearance

Treatment

→ Antispasmodics

- calcium channel blockers (CCB)
- Nitrates

→ If no improvements - Esophagomyotomy

PrepLadder

NUT CRACKER'S ESOPHAGUS

→ MC Hypermotility disorder

→ Most painful motility disorders

Clinical features

→ Chest pain

→ Dysphagia

Investigations

→ IOC - Manometry

→ **Diagnostic criteria**

- Amplitude of contraction > 180 mm Hg
- Duration of contraction > 6 sec

Treatment

→ Antispasmodics

- calcium channel blockers (CCB)
- Nitrates

→ If no improvements - **Esophagomyotomy**

t.me/latestpgnotes

PrepLadder

ESOPHAGUS PART - 2

Barrett's Esophagus

→ Characterized by Columnar metaplasia
→ In lower part /distal esophagus – Squamous mucosa is replaced by columnar mucosa
→ MC Columnar epithelium - **Intestinal Epithelium** (hence, aka Intestinal metaplasia)

Etiology

→ Chronic GERD
→ Ass. With Sliding Hernia

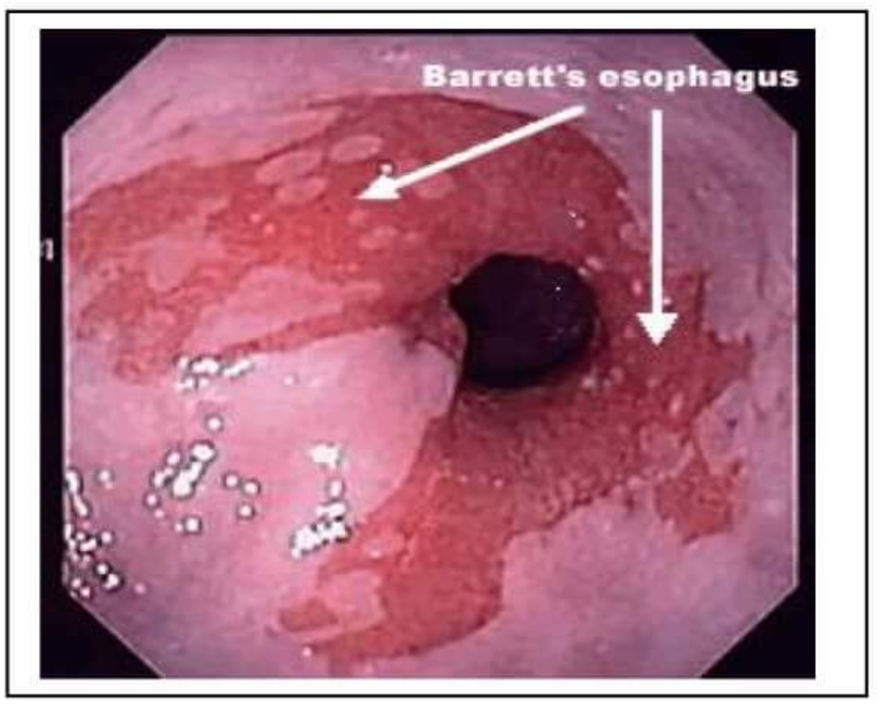

Clinical Features

→ Long history Heart Burn

Investigation of choice for Dx

→ **Endoscopy** (red velvety GI mucosa)
+
→ **Biopsy** (intestinal metaplasia + Goblet Cells)

Treatment

→ Anti- reflux treatment
→ 1-2 year - Endoscopy + Biopsy (to rule out Dysplasia and Adenocarcinoma)

t.me/latestngnotes

CA Esophagus

→ MC type of CA Esophagus World Wide - **Squamous cell carcinoma**
→ MC type of CA in western countries - **Adenocarcinoma**
→ MC site of Squamous cell carcinoma - **Middle 1/3rd**
→ MC site of Adenocarcinoma - **Lower 1/3rd**
→ MC site of CA Esophagus overall - **Middle 1/3rd**
→ **SCC** - more common in low socio-economic status
→ **Adenocarcinoma** - more common in high socio-economic status

Risk Factors for SCC And Adenocarcinoma

SCC	ADENOCARCINOMA
→ Alcohol → Smoking → Zenker's diverticula → Achalasia cardia → Intake of • Nitrites • Nitrates • Nitrosamine → Fungal toxins	→ GERD → High fat diet → Scleroderma - Esophageal dysmotility & smooth muscle atrophy ↓ GERD → Barret's esophagus

PrepLadder

→ HPV infections (16, 18, 31, 33) → Plummer- Vinson syndrome → Hot liquid ingestion → Tylosis Palmaris & Plantaris → **Deficiency of** • MO - Molybdenum • Z - Zinc • A -VITAMIN A → Bulimia nervosa	

→ Seen in 6th Decade

→ Mc site of metastasis – Liver

→ **Chemotherapy regimen** (Same for CA Esophagus and CA stomach)

- E - Epirubicin
- C - Cisplatin
- F - 5-Fluorouracil

Clinical Features

→ MC symptom – Dysphagia > weight loss

→ Progressive dysphagia (Initially Solid → semisolid → liquid)

→ **In pts. with Malignant Tracheo esophageal fistula**

- Choking
- Coughing
- Cyanosis
- Dyspnea

t.me/latestpgnotes

→ Invasion of RLN - Hoarseness of voice

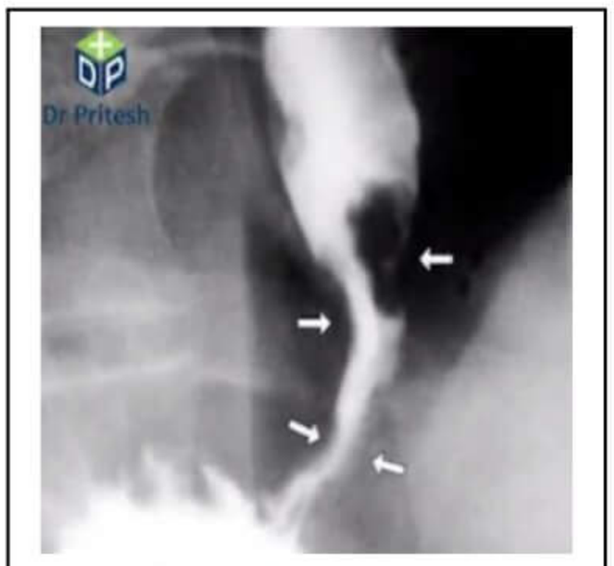

Apple Core Appearance

Investigations

→ First Ix done in a suspected case of CA esophagus - Barium Swallow

→ **On Barium swallow** - Apple core appearance

→ IOC for **diagnosis** of CA Esophagus - Endoscopy + Biopsy

→ IOC for **staging** of CA Esophagus & CA stomach - Endoscopic ultrasound

→ In case of Advanced malignancy or luminal obstruction - CECT

→ IOC for distant metastasis - PET Scan

8th AJCC TNM classification for carcinoma esophagus

T_{is}	→ Carcinoma insitu / High – grade dysplasia
T_{1a}	→ Tumor invades lamina propria or muscularis mucosa
T_{1b}	→ Tumor invades Submucosa

PrepLadder

T_2	→ Tumor invades Muscularis propria
T_3	→ Tumor invades Adventitia
T_{4a}	→ Tumor invades **P** – Pleura, Pericardium, Peritoneum **A** – Azygous vein **D** – Diaphragm
T_{4b}	→ Tumor invades **V** – Vertebral body **A** – Aorta **T** – Trachea
N_1	→ Metastasis to 1-2 regional LN
N_2	→ Metastasis to 3-6 regional LN
N_3	→ Metastasis to 7 or more regional LN
M_0	→ No Metastasis
M_1	→ Distant Metastasis

t.me/latestpgnotes

Treatment

→ Esophagectomy – 10cm margin

→ **Definitive Chemoradiation:**

- SCC of cervical Esophagus
- CA esophagus not amenable to resection

Margin taken during surgery

→ In GI malignancies, for Resection & Anastomosis – **5 cm margin** is taken

→ **Exceptions**

- Esophagus – 10 cm margin
- Distal rectum – 2cm margin

→ **During wide local excision of**

- Squamous cell Ca
- Barret cell Ca
- Malignant melanoma
- Soft tissue sarcoma

} **2 cm margin** is taken

→ During wide local excision in breast conservation surgery – **1 cm margin** is taken

PrepLadder

Types of Esophagectomy

→ Ivor-Lewis operation
→ Orringer trans hiatal esophagectomy
→ McKeon En-bloc esophagectomy

Ivor- Lewis Operation

→ **Step 1** – Laparotomy followed by Thoracotomy is performed
→ **Step 2** - Intrathoracic esophago- gastric anastomosis is performed

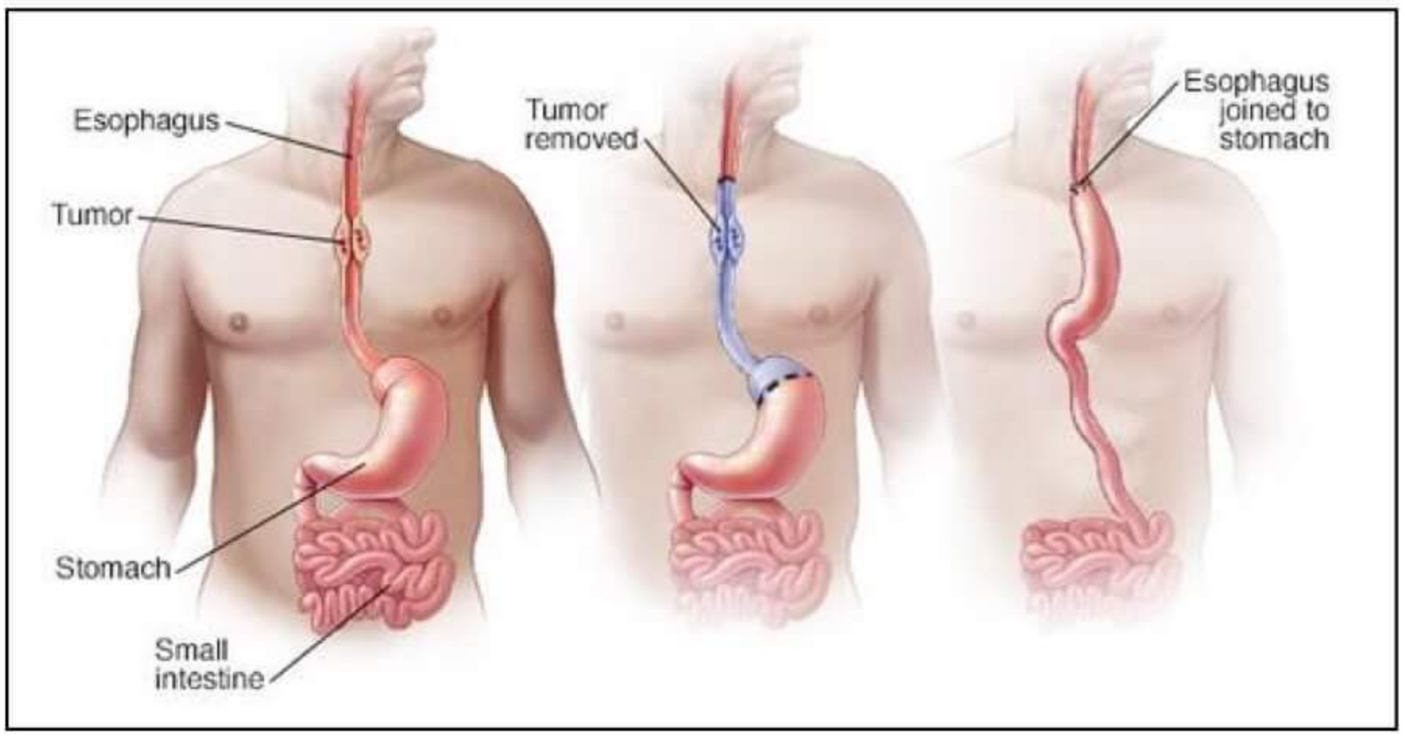

→ **Low risk of anastomotic leak** – Due to increased Vascularity at anastomosis site
→ If anastomotic leak occurs - Severe mediastinitis (has high Morbidity and mortality associated)
→ MC cause of death - anastomotic leak

t.me/latestpgnotes

Orringer Trans-Hiatal Esophagectomy

Laparotomy F/b Dissection around hiatus
↓ enter thorax
Dissection around Esophagus & Thorax (blindly)
↓
Incision in Neck – Dissection around cervical part of Esophagus
↓
Ryle's tube inserted & Esophagus excised
↓
Pull the stomach & the Esophagus delivered to abdomen is excised
↓
Stomach is pulled up to cervical region
↓
Cervical esophago- gastric anastomosis

→ Has high risk of anastomotic leak – but morbidity and mortality associated with leak is low
→ It is the most popular/ most commonly performed procedure

PrepLadder

Mc- Keon Enbloc esophagectomy

Thoracotomy
↓
Direct dissection of Esophagus (max. no. of LN removed)
↓
Laparotomy
↓
Incision in cervical region
(Followed by similar steps as Orringer esophagectomy)

→ **Advantage** - Associated with low recurrence rate
→ **Disadvantage**
- Increased risk of pulmonary complication due to thoracotomy
- MC cause of death - Pneumonia

Replacement Conduits after esophagectomy

→ **Best conduit** - Stomach > left colon > jejunum
- Stomach is based on Right gastric + Right gastroepiploic artery
- Left Colon is based on Left colic artery (IMA)
- Jejunum is based on Jejunal Arteries (SMA)

→ **Conduit of choice after esophagectomy for benign disorders like**
- Corrosive Injury
- Acid-Peptic Disease

} Colon (left)

t.me/latestpgnotes

→ Route of replacement for Esophagus - Posterior Mediastinal Route **(Shortest route and most preferred route)**

→ Preferred treatment for **Malignant Tracheo-esophageal fistula** - Self expanding metallic stent (SEMS)

Prognostic Factors for Ca Esophagus

a) Depth of invasion (Most Important)
b) No. of involved LN
c) Location of Tumor
- Cervical
- GE Junction

} has Better Prognosis

Leiomyoma

→ Mc Benign tumor of esophagus
→ **Location** - > 90% in lower 2/3rd of esophagus
→ MC in males
→ MC in 4-5th decade

PrepLadder

Clinical features

→ Most pts - Asymptomatic

→ MC Symptom – Dysphagia & Chest pain

Investigation

→ IOC for Dx - Barium swallow

→ **On Barium swallow** - Smooth punched out filling defect

Treatment

→ **TOC** - Enucleation

Plummer-Vinson Syndrome

→ Aka **Paterson Brown Kelly Syndrome / Sideropenic Dysphagia**

→ It is a Premalignant Condition - ↑ses risk of SCC of Oral Cavity / Hypopharynx / Esophagus

→ **Characterised by:**

- Dysphagia - Upper Esophageal web
- Chronic Iron deficiency Anemia
- Atrophic Oral mucosa/Glossitis
- Koilonychia
- Splenomegaly
- Achlorhydria

t.me/latestpgnotes

Dysphagia Lusoria

→ Characterised by disorder of swallowing - Congenital Vascular anomalies

→ MC Anomaly – Aberrant Right Subclavian Artery (Arises from descending aorta)

↓

Travels behind esophagus to supply right upper extremity

↓

Posterior compression of esophagus

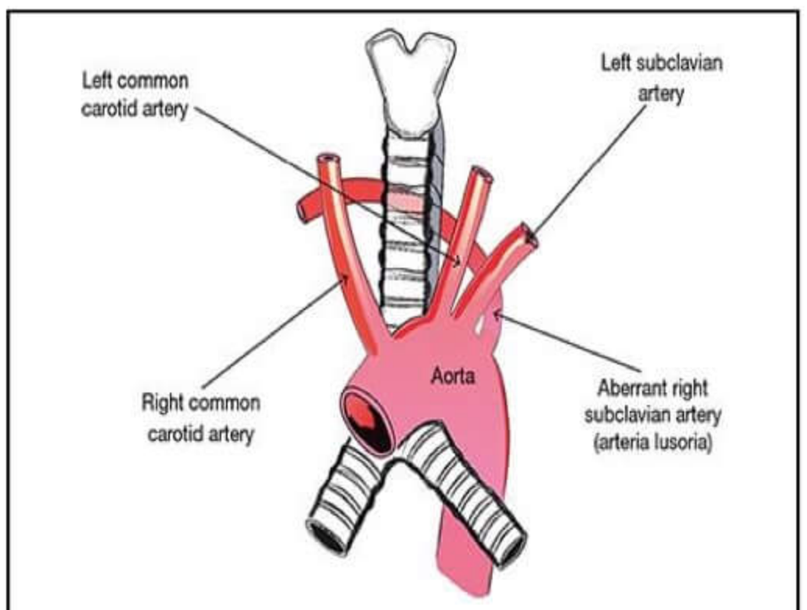

Dysphagia Lusoria

Other Anomalies

→ Anomalous Right aortic arch with left Ligamentum Arteriosum

→ Pulmonary artery sling

Clinical Features:

→ Pulmonary A. slings } **Dysphagia**

→ Vascular rings

→ Compression of trachea - **recurrent respiratory infections & Dyspnea**

PrepLadder

Diagnosis

→ **Barium Swallow** – Evaluate compression of esophagus

→ **Angiography** - Diagnosis of vascular anomaly

Treatment

→ Both vascular rings } **Repaired**

→ Pulmonary artery slings }

Schatzki's Ring

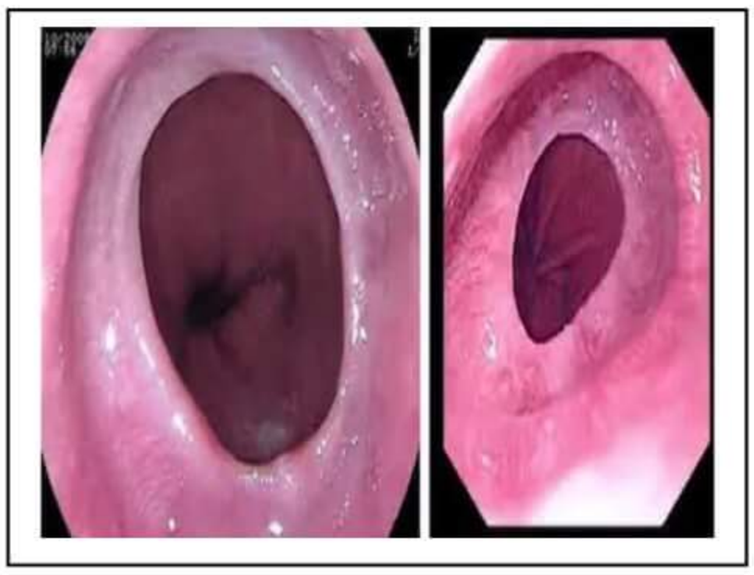

→ Characterised by Concentric symmetric narrowing

↓

Restricted distensibility of lower esophagus

→ It is composed of mucosa and submucosa

→ Located at Squamo-columnar mucosal GE junction

Clinical Features

→ MC symptom - Dysphagia (**for solid food only**)

→ Episodic aphagia (because of intermittent obstruction by large piece of Food)

Investigation

→ IOC for Dx - Barium swallow

→ **On Barium Swallow** – 3 types of ring seen

t.me/latestpgnotes

- **Type A**
  - Located few cm above GE junction
- **Type B**
  - Known as Schatzki's ring
  - Located at GE junction
- **Type C**
  - Located Distal to GE junction

Schatzki's Ring

Treatment

→ Incidentally detected Asymptomatic patients - No treatment

→ **For Symptomatic pts.** - Esophageal dilatation

→ **Surgical excisions** – Not Recommended (lead to stricture formation)

Esophageal Perforation

→ MC cause - Iatrogenic (during endoscopy)

→ MC site of perforation - Posterior wall of Cricopharynx

Note

→ Longitudinal tear in stomach – Mallory Weiss syndrome

→ Longitudinal tear in Esophagus – Boerhaave syndrome

PrepLadder

BOERHAAVE Syndrome

→ **Aka Spontaneous esophageal perforation**

→ **Caused by**

- Forceful vomiting
- Repeated vomiting

→ MC site of perforation - Lower 1/3rd of esophagus along Left posterolateral direction

→ More common in males

Clinical features

→ Characterized by **Mackler's triad**

- Thoracic Pain
- Vomiting
- Cervical subcutaneous emphysema

→ **In case of massive contamination / inflammation**

- Fever
- Sepsis

Investigation

→ **On CXR – Hydropneumothorax**

→ **IOC for Dx - Water soluble contrast esophagogram (Gastrograffin > Hypaque)**

Management

t.me/latestpgnotes

→ Depends on Time of Presentation

Within 24 hours	After 24 hours
• Golden period of repair • Repair of Perforation + ICD insertion + Feeding jejunostomy	• Esophagostomy + ICD insertion + feeding jejunostomy
• Mortality rate upto 20%	• Mortality rate > 50%

PrepLadder

STOMACH Part - 1

Anatomy of stomach

Parts of stomach

→ **Cardia** - the MC site of
- Mallory-Weiss syndrome
- Burkitt's lymphoma

→ **Fundus**
- MC site of stress ulcers/stress gastritis
- MC site of Ca stomach in pernicious Anemia
- MC site of diffuse variety of Ca stomach

→ **Body**
- MC site of Gastric pacemaker cells K/A INTERSTITIAL CELLS of CAJAL
- Gastric pacemaker cells located in midbody along greater curvature

→ **Antrum**
- MC site of Ca stomach (overall)
- MC site of gastric Lymphoma

→ **Incisura Angularis (notch near longer curvature)**
- ➢ MC Site of gastric ulcer

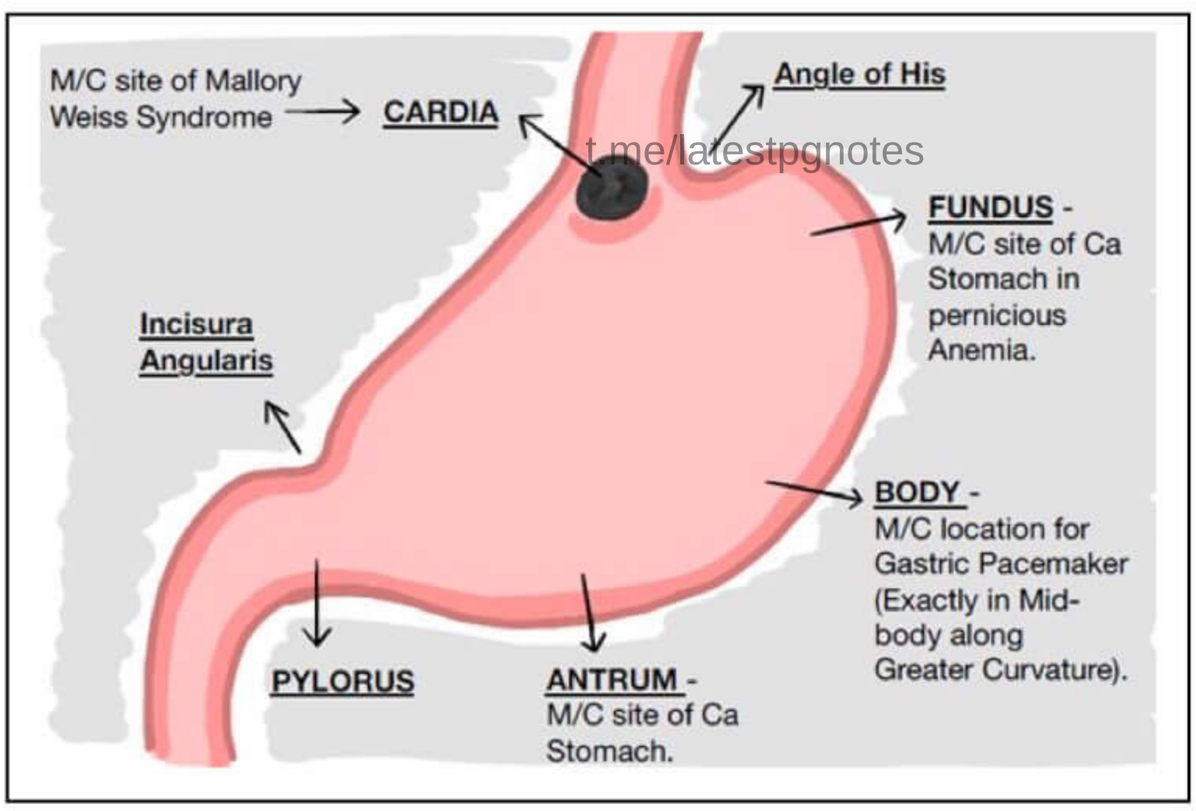

Nerve Relation

→ **Left vagus (anterior)**
- Hepatic branch - 1st branch
- seromuscular branches

→ **Right vagus (posterior)**
- Criminal Nerve of Grassi (CNG) - 1st branch
- Celiac branch
- Seromuscular branches

PrepLadder

→ Terminal branches supplying pylorus known as **Nerve of Latarjet**

- **Anterior** → **Branch of Lt. Vagus**
- **Posterior** → **Branch of Rt. Vagus**

→ Nerve of Latarjet has nerve endings knows as crows' foot.

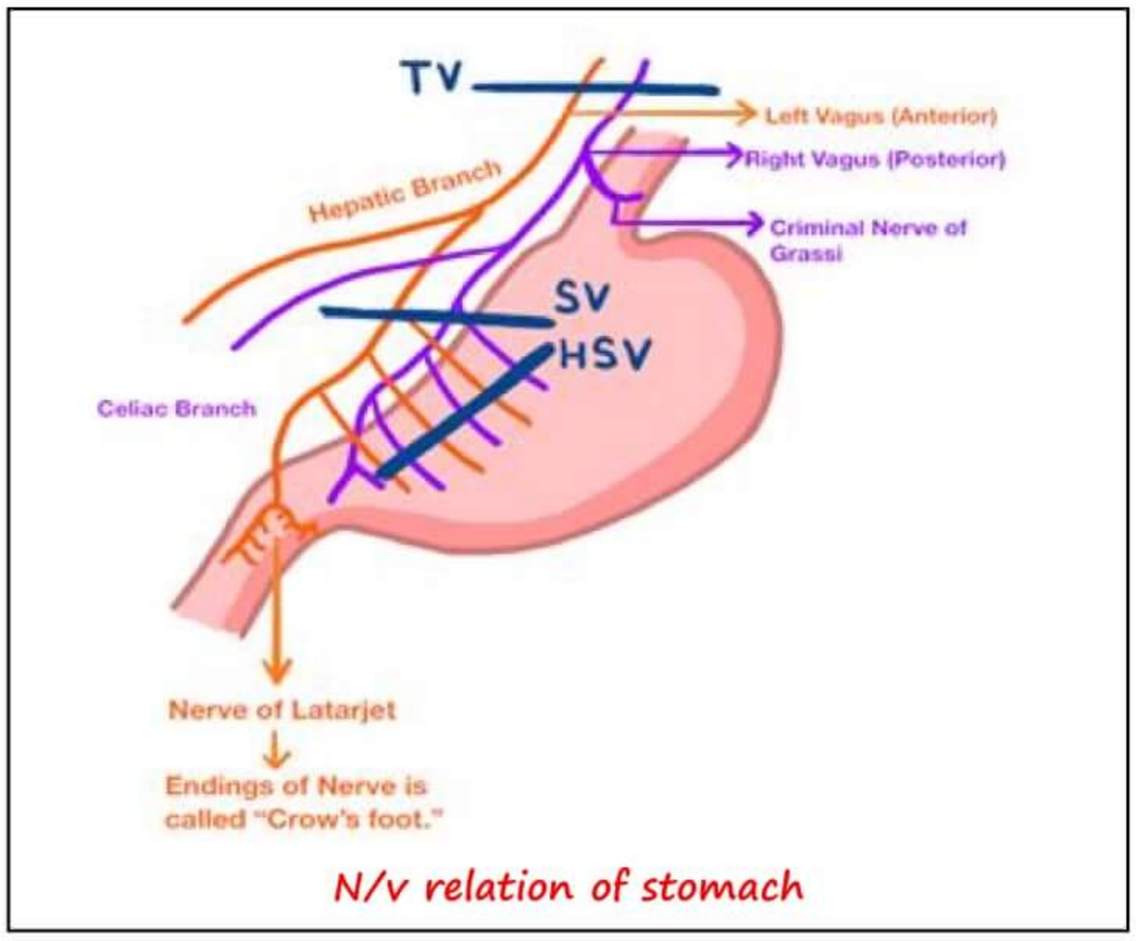

N/v relation of stomach

t.me/latestpgnotes

Vagotomy

Types of vagotomy

Highly selective vagotomy (HSV)

→ Division of seromuscular branches with preserved supply of pylorus
→ Nerve of Latarjet is intact
→ Associated with maximum risk of recurrence
→ Minimum morbidity

Selective vagotomy

→ Division of vagus after celiac and Hepatic branch

Truncal vagotomy

→ Division of main trunk of vagus
→ Minimum risk of recurrence
→ Maximum morbidity

Gastric and Duodenal Ulcer

→ Increased acid production
→ For healing to occur vagotomy has to be performed
- For intractable duodenal ulcer – **TOC** – HSV (Highly selective vagotomy)
- Recurrent duodenal ulcer – **TOC**– TV (Truncal vagotomy)

PrepLadder

PEPTIC ULCER

→ Peptic ulcer is of 2 Types
- Duodenal ulcer
- Gastric ulcer

→ H pylori is responsible for
- 90% cases of duodenal ulcer
- 75% of cases of gastric ulcer

→ MC type of peptic ulcer – Duodenal ulcer

→ MC Site of peptic ulcers – 1st part of duodenum

→ Treatment for Gastric ulcer - depends on location/type

→ Treatment for Duodenal ulcer - depends on complications

Classification of Gastric Ulcers

Modified Johnson's classification	
Type I	→ Ulcer located at incisura Angularis → Most common
Type II	→ Two ulcers: • One in t body of stomach • One at 1st part of duodenum.
Type III	→ AKA Prepyloric ulcer → Ulcer located just before pylorus
Type IV	→ Ulcer located higher on lesser curvature
Type V	→ NSAIDS induced ulcers

t.me/latestpgnotes

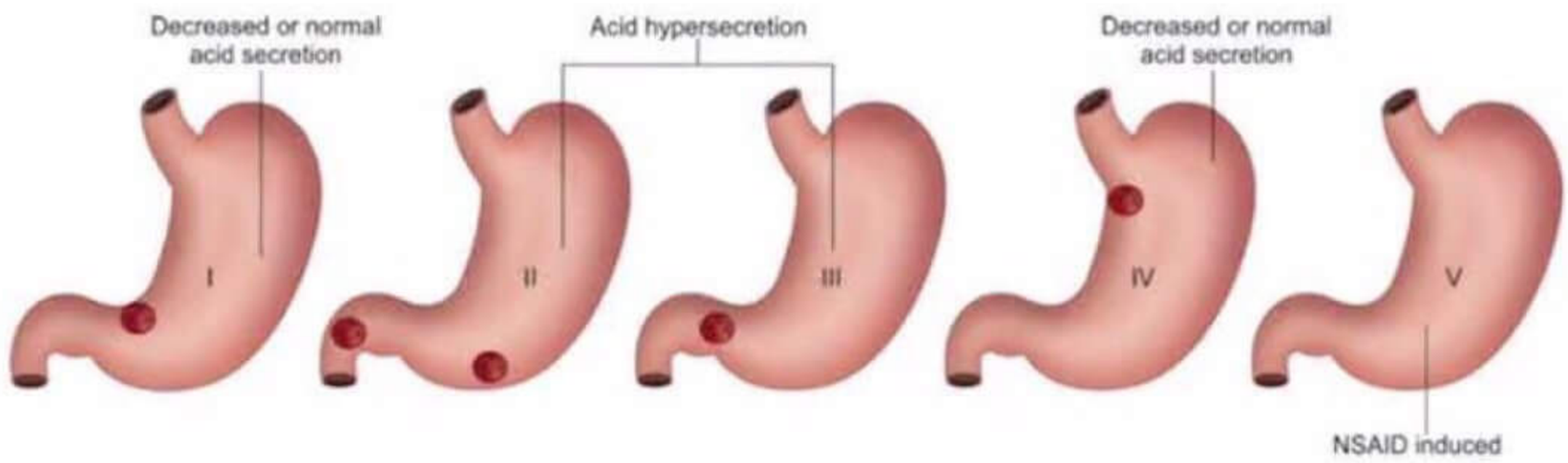

→ Type I - associated with blood group 'A'

→ Type II to Type IV - associated with blood group 'O'

→ In Type I, IV, V
- Acid production is either normal or low
- So, Vagotomy not performed

→ In Type II, III
- Increased acid production
- Truncal vagotomy routinely

PrepLadder

Management of Gastric Ulcer

→ **Type I** - Distal Gastrectomy

→ **Type II & III** - Truncal vagotomy + antrectomy

→ **Type IV** (special surgeries)

- CSENDES
- POUCHET
- KELLING – MADLENER
- SHOE – MAKER

→ **Type V** - Stop NSAIDS

Complications of peptic ulcers

1. **Intractability** – not healing after medical management
2. **Bleeding** – MC complication of peptic ulcer
3. **Perforation** – MC complication of gastric ulcer
4. **Gastric outlet obstruction**

Treatment

→ HSV (Highly Selective Vagotomy) – Performed for

- Intractable Duodenal ulcer
- Chronic duodenal ulcer

→ Ulcers located on anterior wall of duodenum - Perforate

→ Ulcers located on posterior wall of duodenum – Bleed

→ MC involved artery in Bleeding duodenum ulcer - Gastro duodenal artery

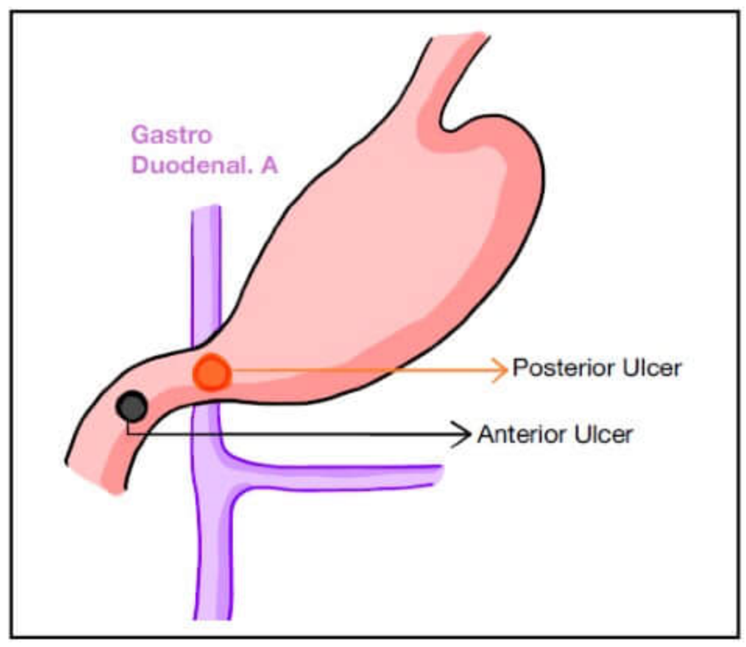

t.me/latestpgnotes

1) For Bleeding Duodenal ulcer

- Duodenotomy + Ligation of bleeding vessel + Truncal vagotomy (to prevent re-bleeding & recurrence due to high acid production)

(+)

- Pyloroplasty (to prevent stricture formation)

2) For duodenal perforation

- Modified GRAHAM'S REPAIR
  - Aka OMENTAL PATCH REPAIR
  - Vascularized pedicle of Omentum is patched over the defect

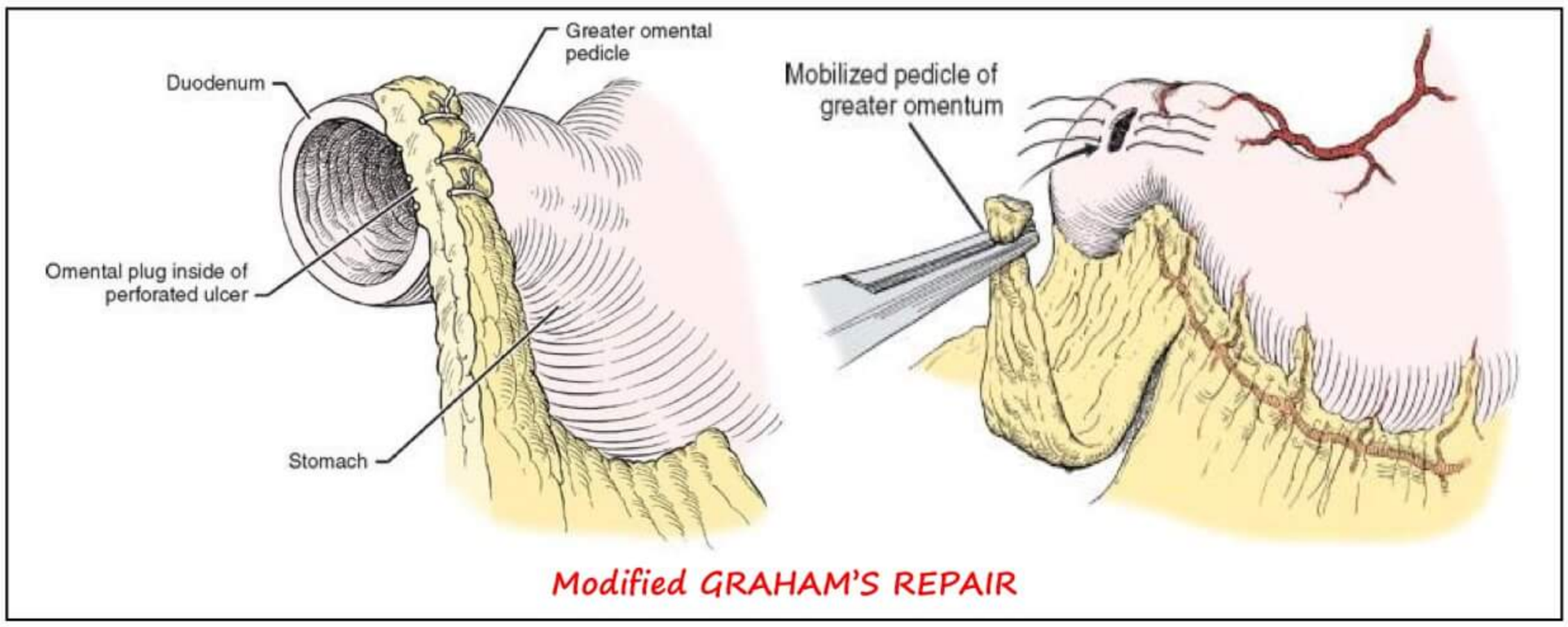

Modified GRAHAM'S REPAIR

3) **For Gastric Outlet Obstruction** (GOO)

- Rare complication of peptic ulcer
- MC cause GOO world wide - CA stomach
- MC site of obstruction in GOO - 1st part of duodenum

Diagnosis

→ Saline load test

- **Empty the stomach** - Insert Ryle's tube

↓

Instill 750 ml of saline & place patient in sitting position

↓ after 30 min

Nasogastric aspiration

↓

If residual saline

< 400 ml → Normal

> 400 ml → Gastric outlet obstruction

Management

Initial management

→ NPO for 48hrs

→ IV fluids (Fluid of choice - Normal Saline)

→ Most patients improve

For non-responding pts

→ TOC – Truncal vagotomy + antrectomy

→ If antrectomy becomes difficult (due to extensive fibrosis and scarring)

↓

Alternative Treatment - Truncal vagotomy + Gastrojejunostomy

PrepLadder

GASTRECTOMY

→ 1st performed by **THEODOR BILLROTH in 1881**

→ Types of Gastrectomy based on method of reconstruction

a) Billroth- I
b) Billroth- 2
c) Roux-en-Y gastrojejunostomy

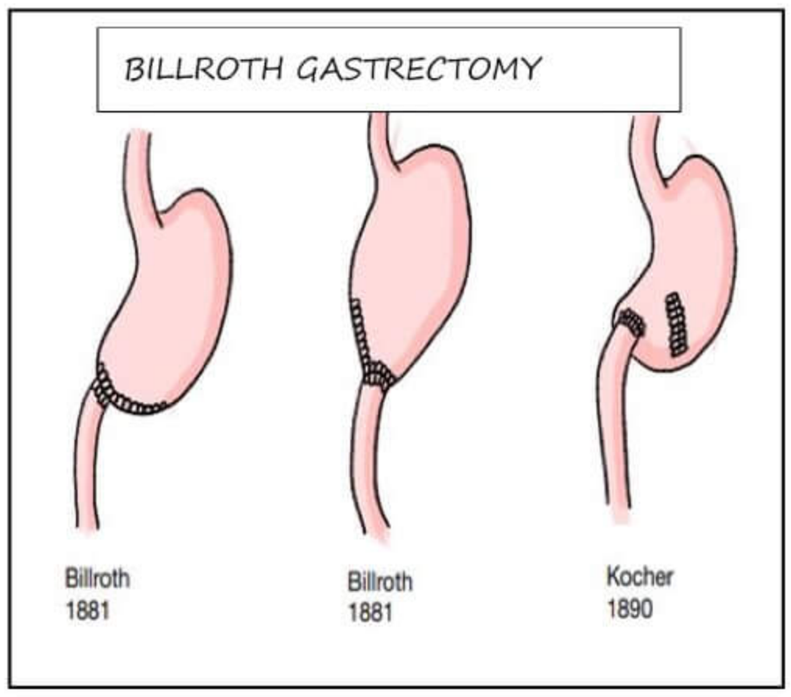

Billroth- I Gastrectomy

→ Aka Gastro – duodenostomy

→ Physiological (so, minimal risk of complications)

Billroth- II Gastrectomy

→ Aka Loop gastrojejunostomy

→ Maximum risk of complications

Types of Gastrectomy based on amount of Stomach removed

TYPE	Amount of Stomach removed
1. Total Gastrectomy	→ Entire Stomach
2. Near Total Gastrectomy	→ >90%
3. Sub-total gastrectomy	→ 80-90%
4. Partial gastrectomy	→ 65-75%
5. Hemi gastrectomy	→ 50%
6. Antrectomy (distal gastrectomy)	→ 35-50%

t.me/latestpgnotes

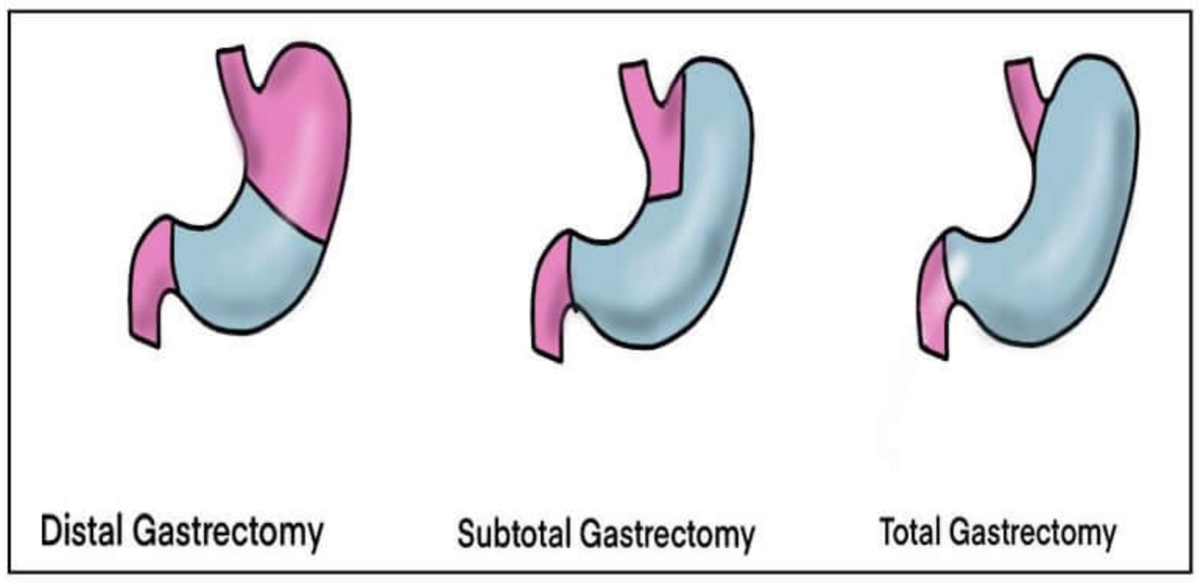

Complications of gastrectomy

1) **Secondary to Gastric Resection**
   - Dumping Syndrome
   - Metabolic disturbances

2) **Secondary to Gastric Reconstruction**
   - Afferent Loop syndrome
   - Efferent Loop obstruction
   - Alkaline reflux gastritis
   - Retained antrum syndrome

PrepLadder

3) **Post-Vagotomy Syndrome**
   - Post vagotomy diarrhea
   - Post vagotomy gastric atony
   - Incomplete vagal transection

Function of stomach

→ Temporary storage of food stuff

→ Converting of Hyperosmolar content into Iso-osmolar content

DUMPING SYNDROME

→ Constellation of symptoms due to accelerated emptying / dumping of hyperosmolar content into proximal part of small intestine.

→ **More common in - Billroth –II > Billroth-I**

EARLY DUMPING	LATE DUMPING
• Seen within 15-30 min of meals • Hyperosmolar content in jejunum ↓ ↑se secretion in jejunum ↓ Third-space loss ↓ Hypovolemia • **Treatment** – IV fluids	• Seen after 2-3 hours of meals • Hyperosmotic/ Hyperglycemic content in jejunum ↓ Increased release of insulin ↓ Leading to **Reactive Hypoglycemia** ↓ Late dumping • **Treatment** – Oral glucose

t.me/latestpgnotes

"PREVENTION IS BETTER THAN CURE"

Prevention of dumping syndrome

→ **Dietary modification**
   - Small frequent meals
   - Low carbohydrate, high fat, high protein diet
   - Avoid high calorie drink
   - Avoid liquids during meals

→ **If patient is not improving after dietary modification**
   - Octreotide intake (Somatostatin analogue) - To decrease secretions of GIT and to decrease insulin release

→ **If patient not improving even after Octreotide intake**
   - Surgery
     1) Convert BILLROTH II to BILLROTH I
     2) Interposition of anti-peristaltic segment of jejunum

PrepLadder

Metabolic complications of Gastrectomy

→ MC Metabolic complication – **Iron Deficiency Anemia**

Fe^{3+} —acid→ Fe^{2+}

(ORAL) (ABSORBABLE)

Rx: ↑ oral supplementation

→ **Megaloblastic anemia**

- >50% of stomach removed (deficiency of intrinsic factor- ↓secretion of Vit B_{12})
- **Mx:** Life-long parenteral supplementation of Vit B_{12}

t.me/latestpgnotes

PrepLadder

STOMACH Part - 2

Upper GI Bleeding

→ MC cause of UGI bleeding – **Peptic Ulcer**

→ 1st Investigation done in UGI bleeding – **Endoscopy**

Risk Stratification System

→ Used to identify the patient at risk of → **Major Bleeding**, **Death**

→ **MC used scoring systems**

a) **Rockall-Baylor Score:** Most useful as it is based on Endoscopic findings

b) **Blatchford score:** Used during Initial assessment, Endoscopic data is not included

Commonly Used Risk Stratification Systems for Upper GI Bleeds	
Blatchford Score (PUSH + Melena/Syncope +Cardiac/Hepatic Dysfunction)	**Rockall & Baylor Score (CASDE)**
• Pulse • Blood Urea nitrogen • Systolic BP • Haemoglobin • Presence of Melena, Syncope, Hepatic or Cardiac dysfunction	• Comorbid disease (cardia, hepatic, renal, or disseminated) • Age (<60 years, 60-79 years >80 years) • Shock (systolic BP <100 mm Hg. HR >100 beats/min) • Diagnosis at the time of endoscopy (Mallory-Weiss non-malignant lesions, or malignant lesions) • Endoscopic Stigmata of recent bleed

t.me/latestpgnotes

BLEED risk Classification

→ Used to predict the risk of rebleeding & Mortality in patients of UGI bleeding

→ **Based on the following criteria**

1) Ongoing Bleeding
2) Low SBP
3) Elevated PT (>1.2 times)
4) Erratic mental status
5) Unstable comorbid Disease

FORREST CLASSIFICATION

→ For estimation of risk or re-bleeding based on endoscopic findings

→ I_A: Active pulsatile bleeding

→ I_B: Oozing

→ II_A: Non – bleeding visible vessel

→ **High risk** of rebleeding

→ II_B: Adherent clot - **Intermediate risk** of rebleeding

PrepLadder

→ IIc: Black Dot
→ III: Clean base

} **Low risk** of rebleeding

BLEEDING DISORDERS OF STOMATCH

Mallory – Weiss Syndrome

→ Characterized by longitudinal partial tear (only mucosa + sub mucosa involved)
→ MC site is cardia (just below GE junction.)
→ MC in Alcoholic males

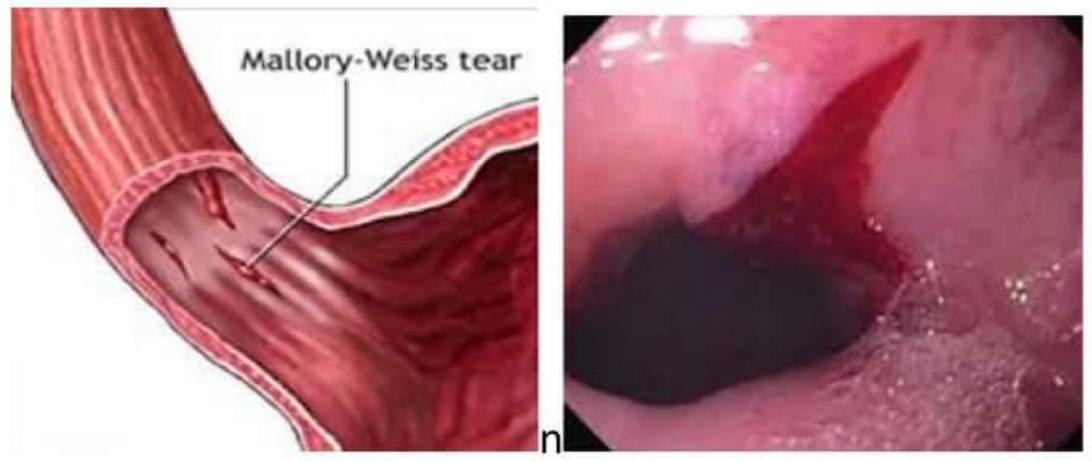

Mallory Weiss Syndrome

Risk Factors

→ Repeated vomiting
→ Forceful vomiting
→ Retching

Clinical features

→ Minor bleeding in Majority
→ Massive bleeding in only 10-20% cases.
→ Painless condition
→ MC vessel responsible for bleeding – Left gastric artery
→ Largest vessel supplying stomach – Left gastric artery

t.me/latestpgnotes

Diagnosis

→ IOC for Dx – Endoscopy

Management

→ Conservative management (because of minor bleeding)
↓ If not controlled then
Endoscopy + Electro coagulation
↓ If not available / failed
Angiography + embolization
↓ If not available/ failed
Open surgical ligation of bleeding vessel.

Sengstaken-Blakemore tube

→ Use is **indicated** in variceal bleeding (bleeding in veins)
→ Use is **contraindicated in** Mallory Weiss syndrome (bleeding is from artery)

PrepLadder

DIEULAFOY'S LESION

Characterized by

→ Presence of large arteriole below mucosa with diameter of 1-3 mm within 6cm – 10cm of GE junction near lesser curvature

→ Placed just below mucosa

→ Necrosis of overlying mucosa

→ Arteriole is exposed to acidic environment of stomach

↓

Injury to wall of arteriole

↓

Massive bleeding (active pulsatile bleeding) - increased risk of rebleeding

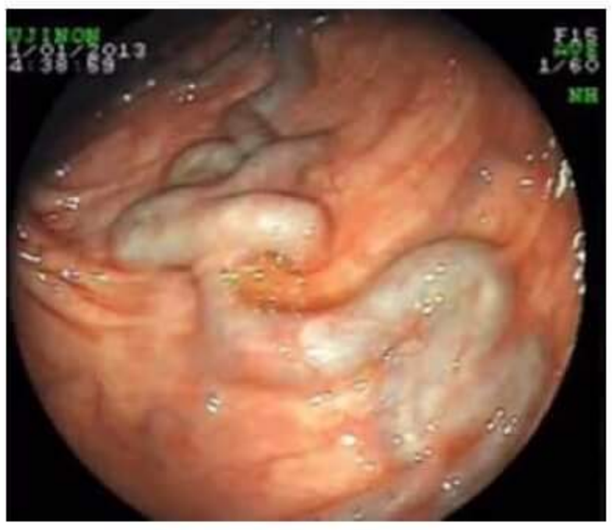

Large pulsatile arteriole

Clinical features

→ Massive bleeding

- Hematemesis
- Recurrent Hypotension

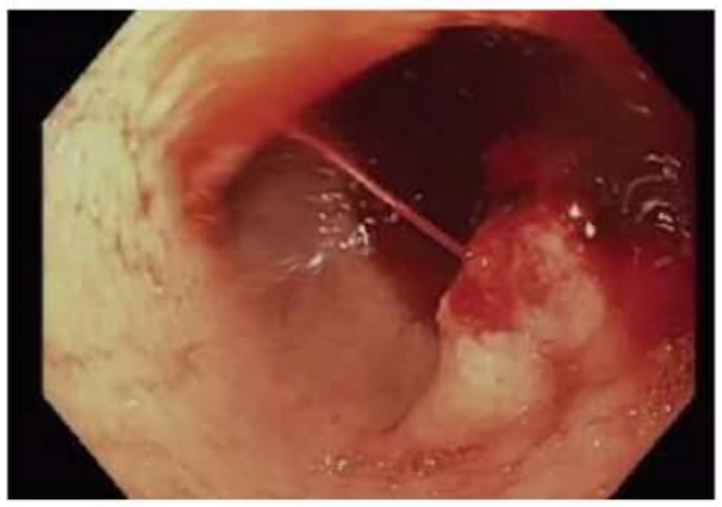

Dieulfoy's lesion

Diagnosis

→ IOC- Endoscopy

Management

→ Endoscopic electrocoagulation

↓ if not available / failed

Angiography + embolization

↓ if not available/failed

Surgical ligation of bleeding vessels or wedge resection of stomach containing the arteriole

t.me/latestpgnotes

WATER MELON STOMACH

→ **Aka GAVE (Gastric Antral Vascular Ectasia)**

→ MC site - Gastric antrum

→ Pathology is vascular ectasia

Watermelon Stomach

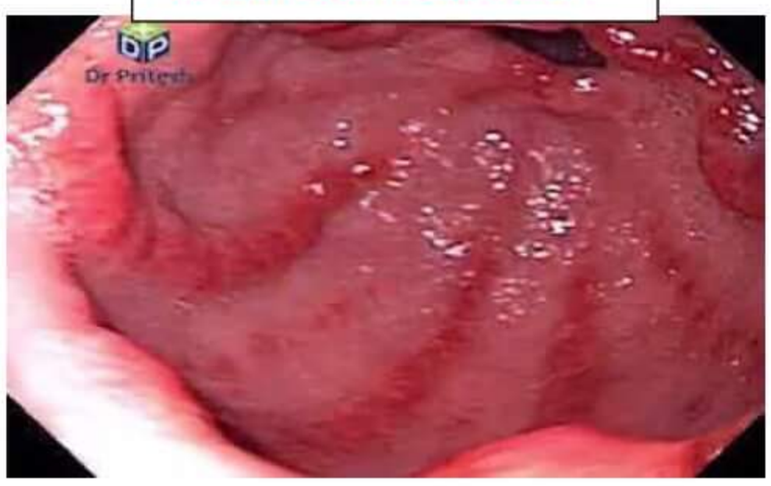

Clinical features

→ more common in elderly females

→ Chronic Occult bleeding

↓

Anemia

↓

Fatigue associated with Chronic liver disease in 25% of females

PrepLadder

Diagnosis

→ IOC - **Endoscopy + Biopsy**

→ **On endoscopy** - Parallel stripes of dilated blood vessels near antrum

(like covering of watermelon)

↓

Watermelon stomach

Treatment

→ Endoscopic electrocoagulation

CA Stomach

→ MC histological type - **Adenocarcinoma**

→ MC in Low Socio-economic status

Risk factors

1. **Nutritional** • Low fat/ Low protein intake • High complex carbohydrate Intake • ↑sed nitrate intake • Consumption of salted meat	2. **Social** • Low socio- economic status
3. **Environmental** • Smoking • Lack of refrigeration • Use of well water • Poor food preservation technique	4. **Medical** • H/O partial Gastrectomy • H. pylori infection • EBV infection • Adenomatous polyp • Chronic atrophic gastritis • Menetrier's disease
5. **Occupational** • Rubber and coal workers	6. **Genetic factors** • Male gender • Blood group 'A' • HNPCC • Li- Fraumeni syndrome • Pernicious Anemia
→ **Alcohol is not a risk factor for carcinoma stomach**	

t.me/latestpgnotes

Protective Factors

→ **S**- Selenium

→ **I** – Iron

→ **Z**- Zinc

→ **A**- Aspirin, Vitamin A

→ **C**- Calcium, Vitamin C

PrepLadder

Classification

BORRMAN'S Classification

→ A Pathologic classification based on macroscopic appearance

- **Type I** – Diffuse polypoidal growth
- **Type II**- Ulcerated Lesions with raised/ elevated borders
- **Type III**- Ulcerated Lesions infiltrating the gastric wall
- **Type IV**- Linitis Plastica
- **Type V** – Non – classifiable

LAUREN'S Classification

Intestinal variety (Classical)	Diffuse variety (Atypical)
→ MC in males, elderly (5th – 6th decade)	→ MC in females, young age
→ MC site is distal part	→ MC site is fundus / proximal part
→ Environmental risk factors	→ Familial risk factors
→ Well defined gland formation	→ Poor gland formation - Signet ring variety
→ Hematogenous spread	→ Lymphatic or transmural spread
→ Associated with APC Gene mutation	→ Decreased E- CADHERIN
→ Epidemic	→ Endemic
Both are associated with P16 & P53 inactivation	

t.me/latestpgnotes

CA Stomach

→ Maximum incidence of CA stomach - JAPAN
→ More common in males, 6th decade
→ MC site of CA stomach – Antrum
→ MC site of CA stomach in Pernicious Anemia – Fundus
→ MC site of metastasis - Liver
→ **Chemotherapy regimen** (same as Ca esophagus)

- E – Epirubicin
- C – Cisplatin
- F – 5-FU

Clinical features

→ MC symptom - Abdominal pain > weight loss
→ **For GE junction tumors** - MC symptom – Dysphagia

PrepLadder

Siewert Classification

→ For GE junction tumors

Type	Adenocarcinoma of	Location
• Type I	• Distal esophagus	• 1-5 cm above cardia
• Type II	• Real Cardia	• 1 cm above and 2 cm below cardia
• Type III	• Sub-Cardial Stomach	• 2-5 cm below cardia

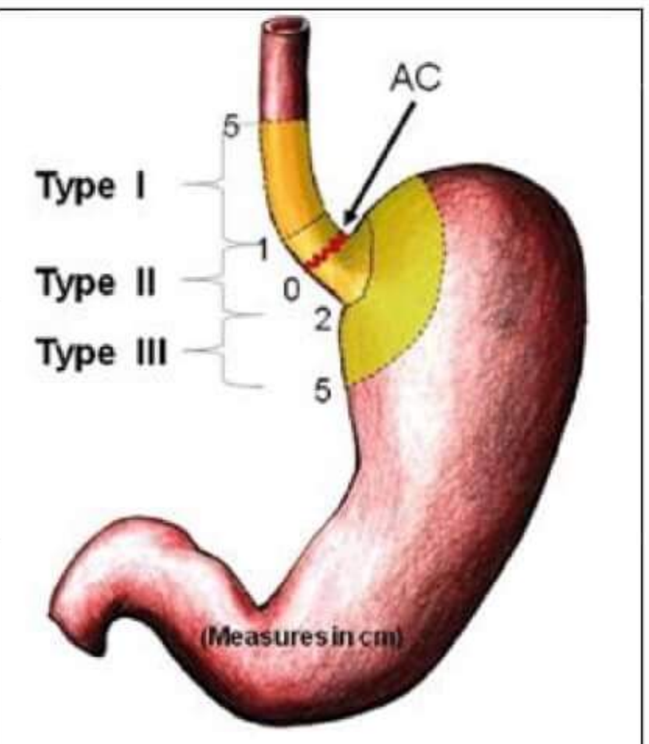

LINITIS PLASTICA

→ **Aka Leather bottle stomach**

→ Characterised by Diffuse proliferation of fibrous tissue

→ MC Symptom - Early satiety

t.me/latestpgnotes

LEATHER BOTTLE STOMACH

Lymph Node involvement in Ca stomach

→ Involvement of Axillary LN - Irish nodes

→ Involvement of left supraclavicular LN - Virchow's Node (Aka Troisier's Sign)

→ Cutaneous metastatic deposit around umbilicus called as Sister Mary Joseph nodes (Not Lymph node)

→ Palpable intraperitoneal metastasis on digital rectal examination - Blummer's shelf

→ Krukenberg tumor – it is the involvement of bilateral ovary in CA stomach via

- Retrograde Lymphatic route (MC)
- Hematogenous route
- Trans – coelomic / Transperitoneal route

Diagnosis

→ IOC - Endoscopy + Biopsy

→ IOC for staging – Endoscopic ultrasound

→ Best investigation for pre-operative staging – CECT

PrepLadder

8th AJCC TNM classification For CA Stomach

T_{is}	→ Carcinoma in-situ / High grade dysplasia (HGS)
T_{1a}	→ Tumor invades lamina propria or muscularis mucosa
T_{1b}	→ Tumor invades Submucosa
T_2	→ Tumor invades Muscularis propria
T_3	→ Tumor Penetrates sub serosal connective tissue without invasion of visceral peritoneum or adjacent structures.
T_{4a}	→ Involvement of visceral peritoneum/serosa
T_{4b}	→ Involvement of adjacent structures
N_1	→ Metastasis to 1-2 regional LN
N_2	→ Metastasis to 3-6 regional LN
N_{3a}	→ Metastasis to 7-15 regional LN
N_{3b}	→ Metastasis to 16 or more regional LN
M_0	→ No Metastasis
M_1	→ Distant Metastasis

t.me/latestpgnotes

Treatment

→ Depends on the location of malignancy

- **Proximal 1/3rd**
  Extended gastrectomy + D_2 Lymphadenectomy
- **Middle 1/3rd**
  Total gastrectomy + D_2 Lymphadenectomy
- **Distal 1/3rd**
  Subtotal gastrectomy + D_2 Lymphadenectomy

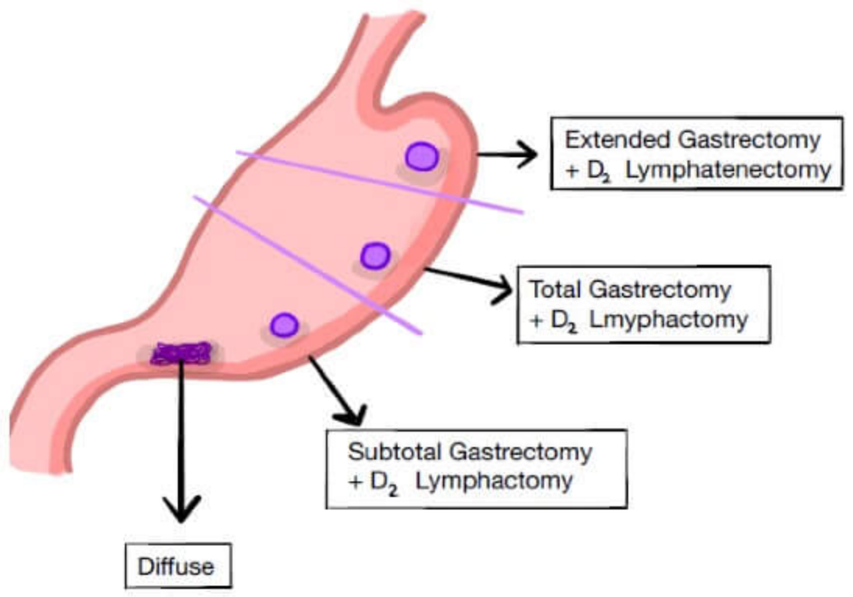

→ This treatment is same for both Intestinal & Diffuse variety of CA Stomach

→ **Exception** - Diffuse variety involving distal 1/3rd malignancy

↓

Total gastrectomy + D_2 Lymphadenectomy.

→ **Indication of distal Pancreatectomy**

- Involvement of body / tail of pancreas by the tumor

PrepLadder

→ **Indications of Splenectomy**

- Direct involvement of spleen by CA Stomach
- CA Stomach in the **proximal part** along posterior wall or greater curvature.

Prognostic factors

1. Depth of invasion
2. **LN status** – Single most important prognostic factor

GIST (Gastro intestinal stromal tumor)

→ MC site - **Stomach > SI > colon-rectum > esophagus**

→ Arises from gastric pacemaker cells knows as **Interstitial cells of CAJAL**

→ GIST expresses Tyrosine kinase receptor known as **C-KIT**

→ **C-KIT**- express marker called **CD – 117**

→ **Other markers**

- **BCL -2**
- **CD-34**
- **PDGFR – α** (Platelet derived growth factor receptor – Alpha)

→ **New markers**

- **DOG-1** - Detected on GIST- 1
- **Protein kinase "C" theta**

Types

t.me/latestpgnotes

→ Spindle cell variety– 70% (MC type)

→ Epithelioid variety – 30%

Difference between Adenocarcinoma & GIST

Adenocarcinoma	GIST
→ Intraluminal growth	→ Extramural / extraluminal growth → Highly vascular tumor (Bleeding - MC presentation) → Abdominal pain (sometimes) → Patient symptomatic at advanced stage

Clinical Features

→ MC symptom – **Bleeding and abdominal pain**

→ MC route of spread - **Hematogenous spread**

→ Not associated with lymphatic spread

→ MC site of metastasis – **LIVER**

Diagnosis

→ IOC for Dx – **CECT**

→ **Endoscopic Bx** – Contraindicated (Risk of tumor rupture)

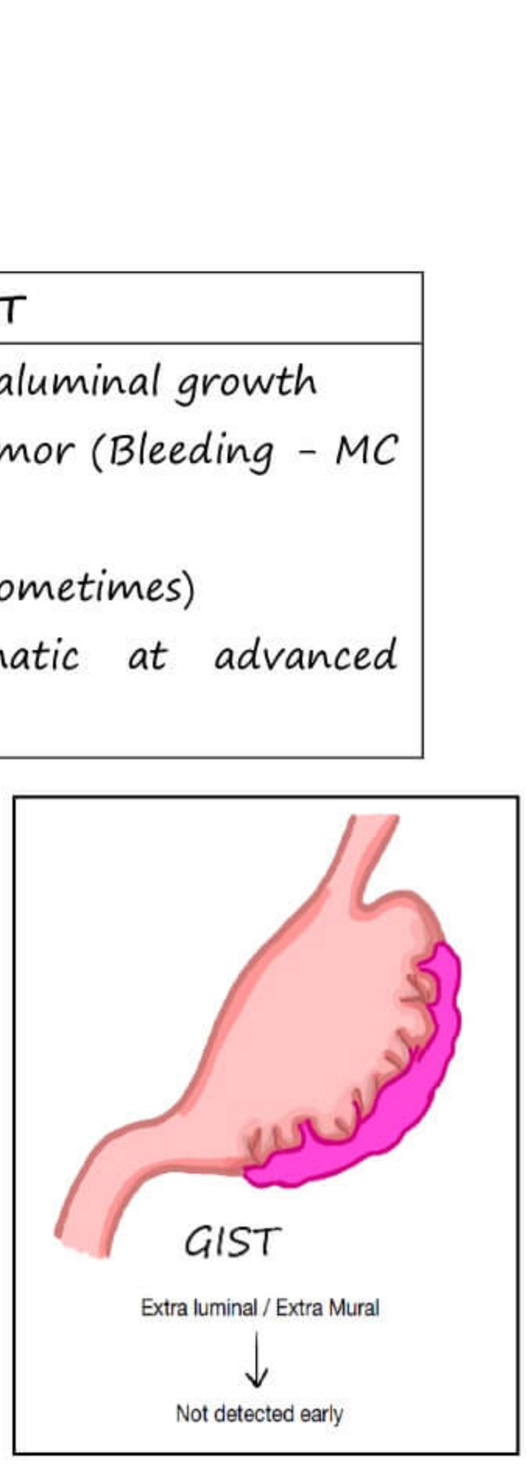

PrepLadder

Treatment

→ Resectable GIST - Segmental resection / wedge shaped excision with 2cm margin

→ Drug of choice for unresectable GIST - Imatinib Mesylate

- 2nd line agent– SUNITINIB
- 3rd line agent - REGORAFINIB

→ IOC for assessment of Response of Imatinib – PET scan

→ Gold standard investigation for diagnosis of recurrent GIST – PET CT

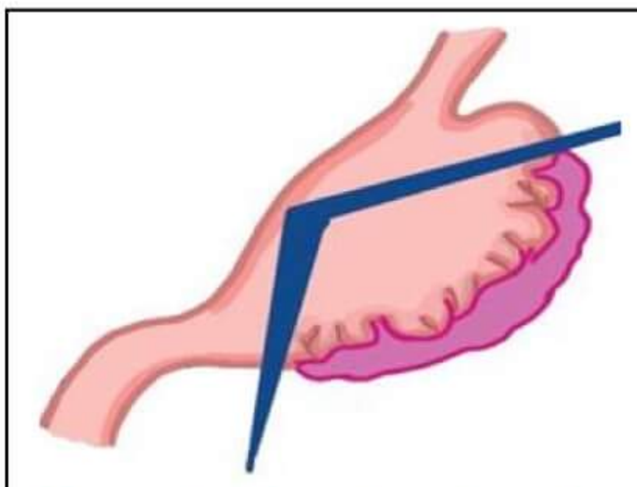

Segmental / wedge shaped excision with 2cm margin

CARNEY's TRIAD

→ **Components**

- Multifocal GIST
- Pulmonary chondroma
- Extra- adrenal paraganglioma

Congenital hypertrophic pyloric stenosis (CHPS)

→ Now name has changed as **Infantile hypertrophic pyloric stenosis** (IHPS) because it is an acquired disease

Infantile hypertrophic pyloric stenosis

→ Characterized by hypertrophy of circular muscle fibers at pylorus

→ Acquired condition

t.me/latestpgnotes

→ Incidence – 1: 3000-4000 live birth

→ MC in first born male

→ Child is normal at birth – Age of presentation is at 4-6th week after birth

Clinical features

→ Multiple episodes of non-bilious vomiting which can be projectile/non-projectile.

→ **On examination**

- Palpable mass or olive in the epigastrium > Right hypochondrium
- Direction of peristalsis from left to right

Diagnosis

→ IOC for diagnosis - Ultrasound

→ **Diagnostic criteria**

- Pyloric muscle thickness >4mm
- Channel length >16mm
- Transverse diameter >13mm

→ **On plain X-ray** - Single bubble appearance

→ **On Barium meal**

- String sign
- Shoulder sign
- Double - track sign

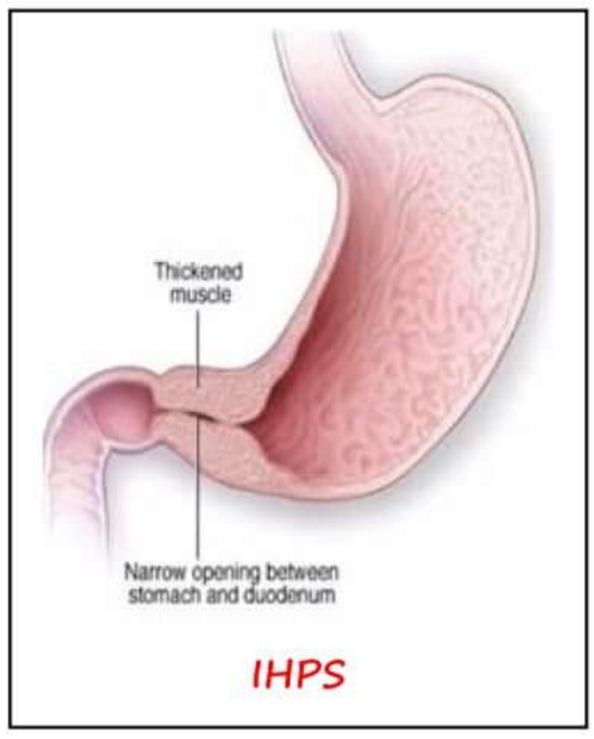

IHPS

PrepLadder

Dyselectrolytemia in IHPS

→ Hypokalemia (Loss of K^+ due to repeated vomiting of mucous)
→ Hypochloremia (loss of Cl^- due to repeated vomiting)
→ Metabolic alkalosis (due to loss of H^+)
→ Paradoxical Aciduria (only in severe cases)
→ **IHPS is Medical emergency.**

Management

→ Resuscitation by IV fluids + correction of Dyselectrolytemia
→ Fluid of choice - Normal Saline
→ **Treatment of choice** – Ramstedt-Fredet Pyloromyotomy

Bezoars

→ Collection of non-digestible material in stomach

Types

→ **Phytobezoar**
  - Collection of Vegetable
  - MC type
→ **Trichobezoar**
  - Collection of Hair
  - MC in children
→ **Pharmacobezoar**
  - Collection of Drugs
→ **Lactobezoar**
  - Collection of undigested Milk concretions

t.me/latestpgnotes

Trichobezoar

→ Concretion of hair
→ Common in Long haired girls or women
→ Seen in Trichophagia (habit of eating their own hair)
→ Formation of hair ball in stomach

Rapunzel Syndrome

Rapunzel Syndrome

→ Gastric trichobezoar with extension into duodenum

Clinical features

→ Abdominal pain (Due to ulceration)
→ Gastric outlet obstruction

Management

→ Surgical removal of hair ball after gastrectomy
→ After surgery - Psychiatric referral

PrepLadder

GASTRIC VOLVULUS

→ Torsion of stomach

→ **2 types**

a) Organoaxial

b) Mesenteroaxial

Organoaxial	Mesenteroaxial
→ MC type → Responsible for 2/3rd of cases → Torsion along longitudinal axis of stomach 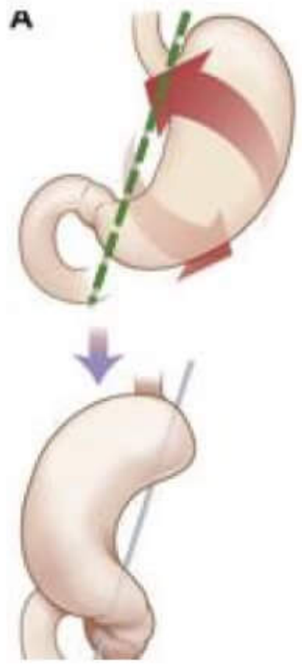	→ Less common → Responsible for less than 1/3rd of cases → Torsion along vertical axis of stomach 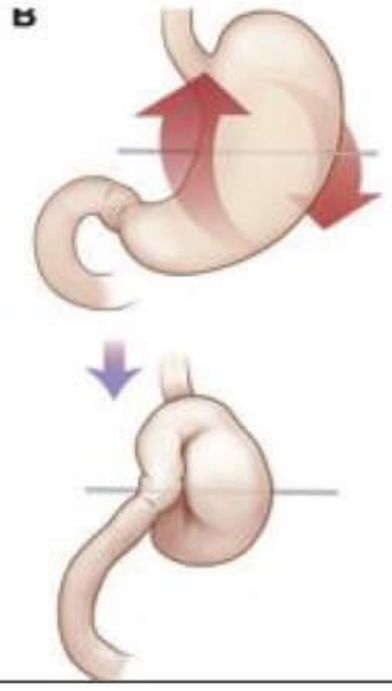

Primary Gastric Volvulus	Secondary Gastric Volvulus
→ Associated with a) Cong. Asplenia b) Wandering spleen → Mesenteroaxial volvulus is seen • Partial (<180°) • Recurrent → Not a/w diaphragmatic defect	→ 2° to anatomical defect - Diaphragmatic hernia → Organoaxial volvulus is seen → **MC cause** a) Children – CDH b) Adults – Paraesophageal hernia

t.me/latestpgnotes

Clinical features

→ **In Organoaxial**

- Acute presentation
- A/w diaphragmatic defect

→ **In Mesenteroaxial**

- Partial
- Recurrent
- Not a/w diaphragmatic defect

→ **Borchardt's triad**

- Epigastric pain
- Inability to vomit
- Inability to Ryle's tube/NG tube

PrepLadder

Diagnosis

→ Barium studies (or)

→ Endoscopy

Treatment

→ **Acute volvulus** – Stomach reduced & uncoiled followed by repair of diaphragmatic defect

→ **Spontaneous volvulus** – Detorsion followed by fixation of stomach (gastropexy)

Tea-pot stomach

→ **AKA Hand-bag stomach**

→ Characterised by Longitudinal shortening of lesser curvature due to healing of gastric ulcer

Hour-glass stomach

→ D/t cicatricial contraction of a saddle shaped ulcer at lesser curvature

Tea-Pot Stomach

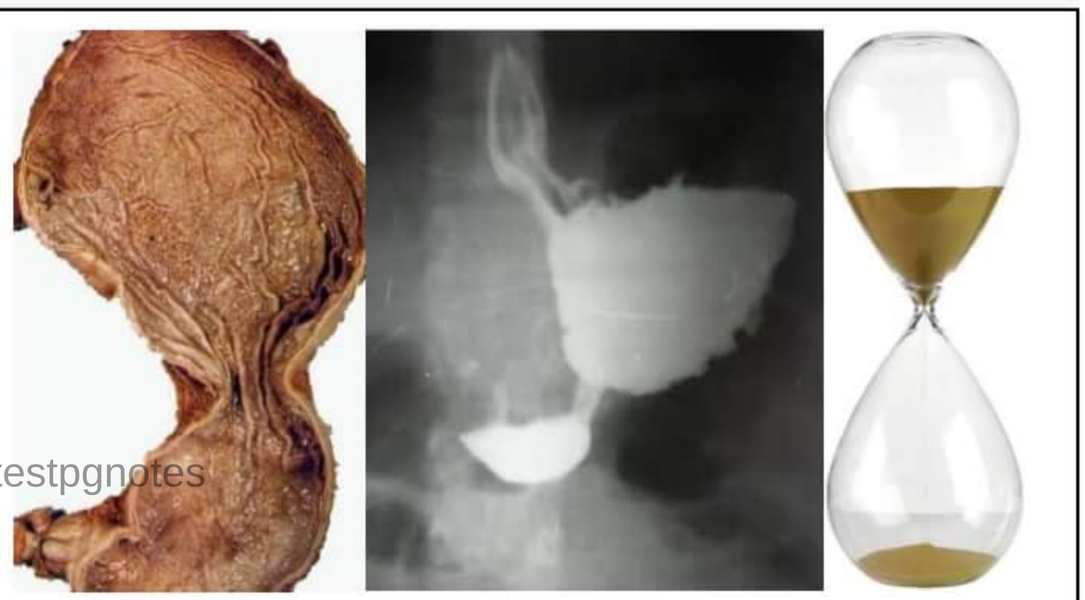

Hour-glass stomach

t.me/latestpgnotes

PERITONEUM

Peritonitis

Types of peritonitis

a) Spontaneous bacterial peritonitis (SBP)
b) Secondary bacterial peritonitis
c) Peritonitis in chronic ambulatory peritoneal dialysis (CAPD)

Spontaneous bacterial peritonitis

→ Spontaneous infection of ascitic fluid
→ **Pre-requisite** – Ascites
→ MC cause of ascites in adults – Cirrhosis or chronic liver disease
→ MC cause of ascites in children – Nephrotic syndrome

Pathophysiology

→ Bacterial translocation from GUT to mesenteric LN and then to Ascitic fluid
→ MC organism responsible for SBP
  - In adults - E coli > Klebsiella
  - In children – Group A streptococci

Clinical Features

→ Abdominal pain and tenderness t.me/latestpgnotes
→ Fever
→ Tachycardia

Investigations

→ Lab findings
  - ↑sed ESR
  - ↑TLC count
→ IOC - Paracentesis (aspiration of ascitic fluid)
→ **Diagnostic criteria for SBP**
  - Monomicrobial growth
  - Neutrophils > 250/mm^3

Treatment

→ IV Cefotaxime + Albumin

Secondary bacterial peritonitis

→ Caused by visceral perforation
→ **Poly microbial**
  - E. coli (aerobe)
  - Bacteroides fragilis (anaerobe)

PrepLadder

Treatment

→ Exploratory laparotomy + peritoneal lavage + repair of perforation / stoma formation

Peritonitis in CAPD

→ For Chronic renal failure patients who cannot afford dialysis or renal transplantation

↓

Insert Peritoneal catheter & attach to dialyzing fluid

↓

Fluid will enter peritoneal cavity

(Peritoneum is a semi permeable via which toxins can be exchanged)

↓

After 4-6 hours collected peritoneal fluid goes out

↓

Done in daily basis → so it is called **Chronic ambulatory peritoneal dialysis**

→ MC organism causing peritonitis in CAPD - Staph epidermidis (Slime producing organism that colonizes the catheter)

Treatment

→ Intra peritoneal instillation of 1st generation cephalosporin via catheter

→ **In cases of Recurrent attacks** - Change catheter

→ Most dependent cavity in peritoneum in **recumbent position or lying down position** - Hepato Morrison pouch or right subhepatic space

→ Most dependent cavity in peritoneum in **up right posture** - Pelvis

→ MC site of **intra-peritoneal abscess in recumbent or lying down position** - Hepato-Morison pouch or right sub hepatic space

→ MC site of **intra- peritoneal abscess in upright posture** - Pelvis

→ **Overall** MC site of intra-peritoneal abscess - Pelvis

Pelvic Abscess

→ MC site of intra peritoneal abscess

Clinical features

→ Pain in lower abdomen

→ Chills and rigor, fever

→ Irritates the rectum - Multiple episodes of loose stool with mucous

→ On digital Rectal exam - Bulge on anterior wall of rectum

Investigation

→ 1st investigation done - Ultrasound

→ IOC - CECT

t.me/latestpgnotes

PrepLadder

Management

→ Ultrasound /CT guided per cutaneous aspiration

→ If bowel adhered over abscess cavity, percutaneous drainage not possible.

- In females → posterior colpotomy (via posterior wall of vagina)
- In males → anterior rectal drainage

Mesenteric Cyst

→ MC in females

→ Usually seen in 2nd decade.

Types

1) Chylolymphatic (MC)
2) Enterogenous (2nd MC)
3) Simple/ mesothelial
4) Uro-genital remnant
5) Dermoid

Chylolymphatic mesenteric cyst	Enterogenous mesenteric cyst
→ Congenitally misplaced lymphatics in ileum with Afferent lymphatics only. → Absence of efferent lymphatics ↓ Collection of Chyle ↓ Progressive increase in size of cyst → Cyst has independent vascular supply **Treatment** – Enucleation	→ Duplications cysts (walled off diverticula) → Origin is from diverticula / duplication cyst → SI lined by columnar epithelium (has goblet cells that produce mucin) → Mucin collection leads to cyst ↓ Enterogenous cysts → Content is mucinous (has shared wall & shared vascular supply) **Treatment** – Resection + anastomosis

t.me/latestpgnotes

Extent of mesentery

→ Starts from L2 on left to right Sacro Iliac joint

→ Mesentery is a fan shaped structure via which the bowel is hanged from posterior abdominal wall.

PrepLadder

→ Patient has a large swelling moving perpendicular to the attachment of mesentery characterized by a triad known as Tillaux Triad

TILLAUX TRIAD

→ Soft fluctuant swelling in periumbilical region
→ Zone of hyper resonance around the swelling
→ Swelling moving perpendicular to the attachment of mesentery

Presentation

→ Asymptomatic
→ Large palpable mass
→ 20 years old female

IOC- CECT

Pseudomyxoma Peritonei

→ Mucinous ascites
→ Caused by ruptured Appendiceal or Ovarian Adenocarcinoma
→ MC primary cause - Appendix > ovary
→ Incidence - male = female
→ Usually seen in 4th – 5th decade
→ Peritoneal cavity is filled with mucinous substances (JELLY like) creates pressure in abdomen compressing the bowel & simultaneously in **Upright posture** - Abdominal distension

t.me/latestpgnotes

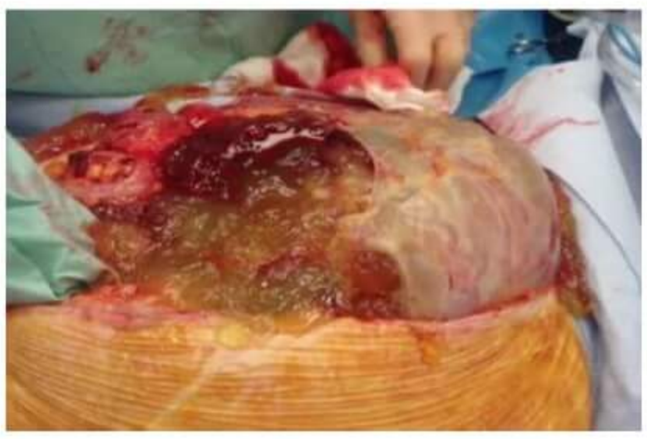

Pseudomyxoma Peritonei

Clinical Features

→ Most patients are asymptomatic initially
→ Later generalized/ global deterioration of health (amino acid is used up in the production of jelly like substance).
→ Progressive abdominal distension
→ **On examination**
  - Multiple hernias (due to increased intrabdominal pressure)
  - Ascites
  - Non- shifting dullness (due to semisolid substance)

IOC – CECT

Treatment

→ Cytoreduction (to remove maximum amount of tumor) + intra- peritoneal hyper thermic chemotherapy

PrepLadder

Cytoreduction

→ Omentectomy + stripping of peritoneum (peritonectomy) + Right hemicolectomy

→ **In females** - Omentectomy + stripping of peritoneum (peritonectomy) + right hemicolectomy + Bilateral Salpingo–oophorectomy

Retroperitoneal Fibrosis

→ Characterized by fibrotic proliferation in retroperitoneum

Boundaries of retro peritoneum

→ Superiorly – dome of diaphragm

→ Inferiorly – Levator ani

→ Posteriorly – psoas muscle

→ Anteriorly – peritoneum

→ **Organs involved** - Kidney, ureter, adrenal, inferior vena cava, aorta.

→ Fibrotic proliferation that starts from aortic bifurcation and moves cranially upwards

→ Most commonly involved - Ureter > IVC > aorta

Types of Retroperitoneal Fibrosis

Primary / idiopathic RPF

→ Aka Ormond's disease responsible for 70% of cases

t.me/latestpgnotes

Secondary RPF

→ Secondary to causes

→ **Chronic inflammation**

- Chronic pancreatitis
- Actinomycosis
- TB
- Histoplasmosis

→ **Drugs**

- Methesergide
- Amphetamines
- Hydralazine
- Entacapone
- β- blockers, Bromocriptine
- Phenacetin

→ **Malignancies**

- Non-Hodgkin lymphoma
- Ca stomach
- Carcinoid tumor

→ **Autoimmune disorders**

→ **Radiation exposure**

PrepLadder

Clinical features

→ Initially dull aching, non- specific pain
→ MC specific earliest symptoms →signs and symptoms of obstructive uropathy
→ Increased frequency
→ Dysuria
→ Fever (due to infected hydronephrosis)

Diagnosis

→ IOC - CECT (for most of retroperitoneal pathologies)
→ **On IVP** - due to fibrosis & inflammation, there is **medialization/ medial pulling of ureter** known as PIPESTEM URETER.
→ In retroperitoneal sarcoma - lateralization of ureter/lateral pulling of ureter

Treatment

In primary RPF / Idiopathic RPF

→ Ureteric stenting (to relieve extrinsic compression) + immune suppression
→ Drugs for immunosuppression
- **T**- Tamoxifen
- **A**- Azathioprine
- **P**- Penicillamine
- **S**- Steroids

t.me/latestpgnotes

In secondary RPF

→ Transperitoneal ureterolysis with omental wrapping

PrepLadder

INTESTINAL OBSTRUCTION

→ Most common cause of **large bowel obstruction** – Malignancy
→ Most common cause of **small bowel obstruction** – Adhesions

Small bowel obstruction

Causes

→ Adhesions (MC)
→ Malignancy – metastasis or peritoneal carcinomatosis
→ Hernia
→ Crohn's disease

Risk of Adhesive intestinal obstruction

- Pelvic surgeries > lower abdominal > upper abdominal surgeries

Clinical features

→ Intestinal obstruction - Hyperperistalsis
↓
Colicky abdominal pain (1st symptom of small bowel obstruction)
→ Bilious vomiting (multiple episodes)
→ Obstipation (absolute constipation)
→ **Symptoms of Proximal obstruction**
me/latestpgnotes
- Vomiting
- Dyselectrolytemia

→ **Symptoms of Distal obstruction**
- Distension

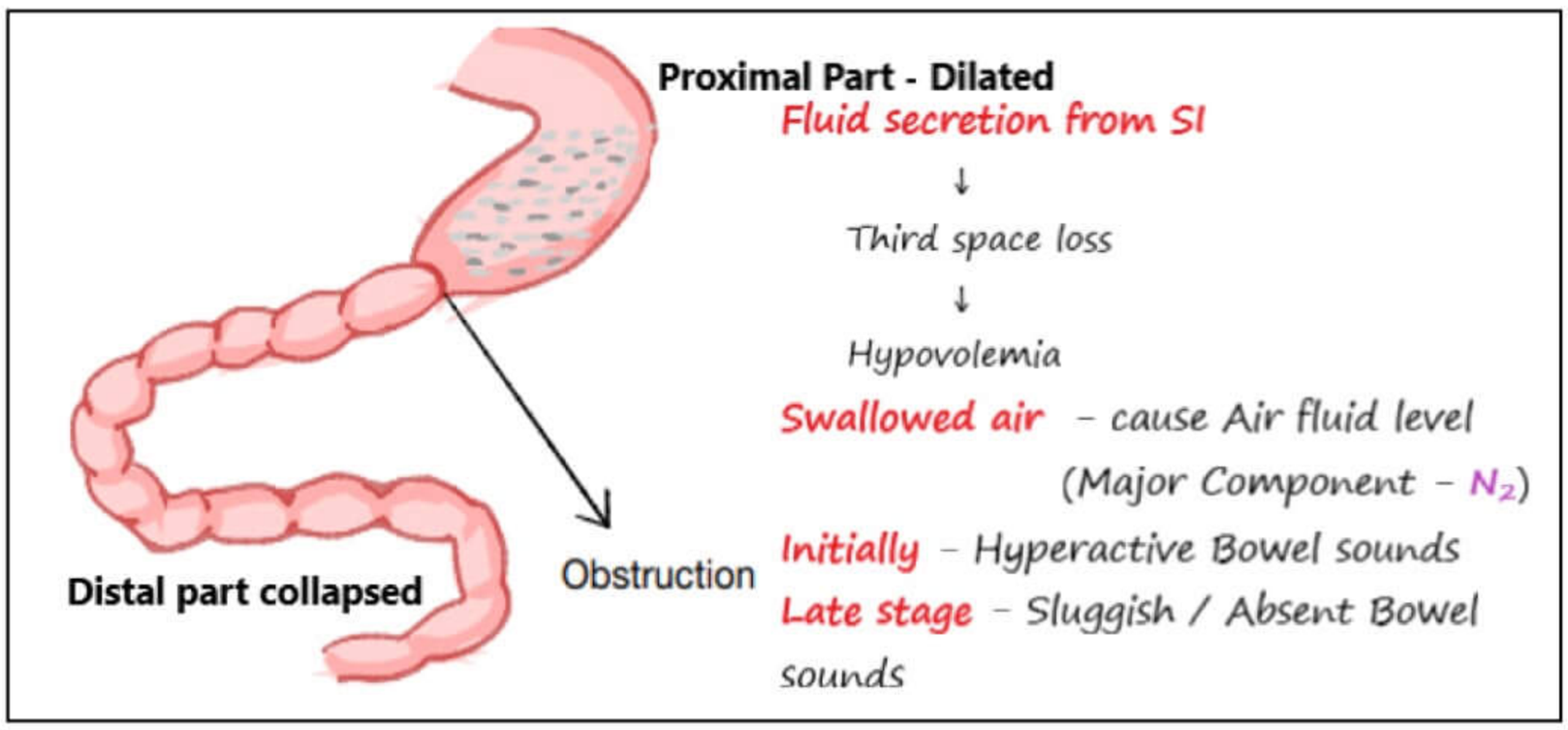

Management

→ Put 2 large bore IV cannula
→ Start IV fluids
→ Fluids of choice is Ringer's Lactate
→ Ryle's tube insertion for proximal decompression

PrepLadder

→ Foley's catheterization for monitoring of urine output

→ Best clinical indicator of tissue perfusion is urine output

→ **After adequate tissue perfusion, urine output should be**

- In adults - 1 ml/min
- In children – 0.5-1 ml/min

Investigations

→ IOC for diagnosis of small bowl obstruction – Abdominal X-ray (Supine > Erect)

Erect view	Supine view
↓	↓
for Air fluid levels	for site of obstruction

→ Normal air fluid levels in adults - 3 to 5 air fluid levels

→ **CECT** – Used for

- High grade obstruction
- Extraluminal Causes
- Strangulation

→ IOC for Low Grade Intermittent SBO – Enteroclysis

→ **Features of bowel in X-ray**

Jejunum

- Dilated bowel loops placed centrally
- Valvulae Conniventes - circumferential ring like pattern

t.me/latestpgnotes

Ileum

- Dilated bowel loops placed centrally
- Featureless / characteristically characterless

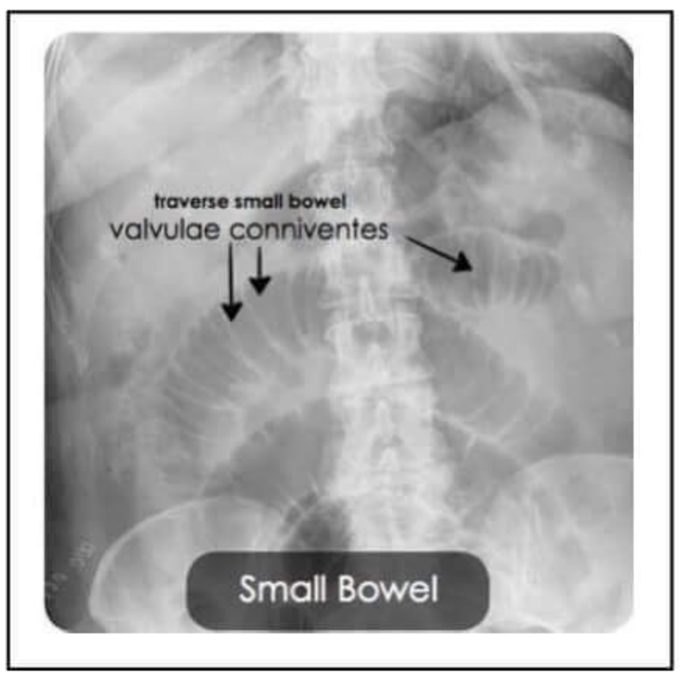

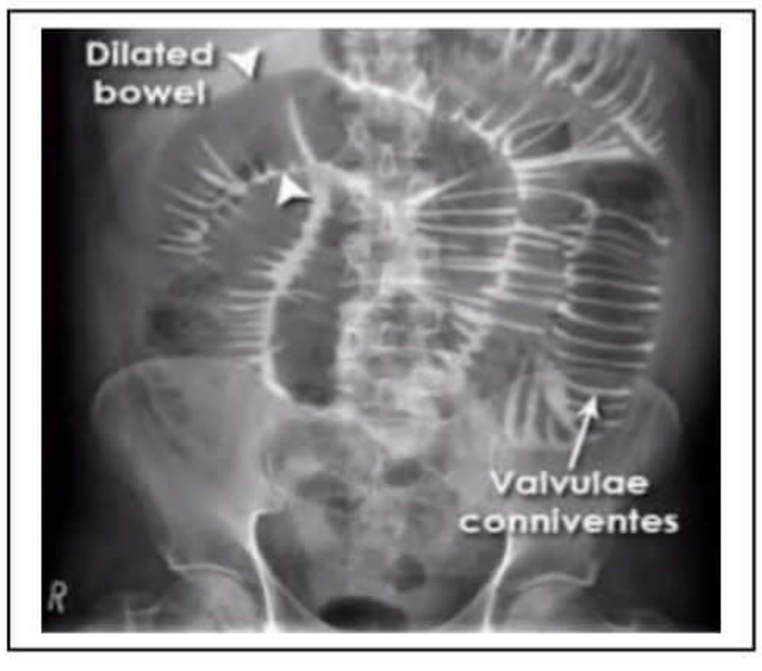

Large bowel

- Wider in caliber
- Bowel loops are placed peripherally
- Presence of haustrations
- Few bowel loops

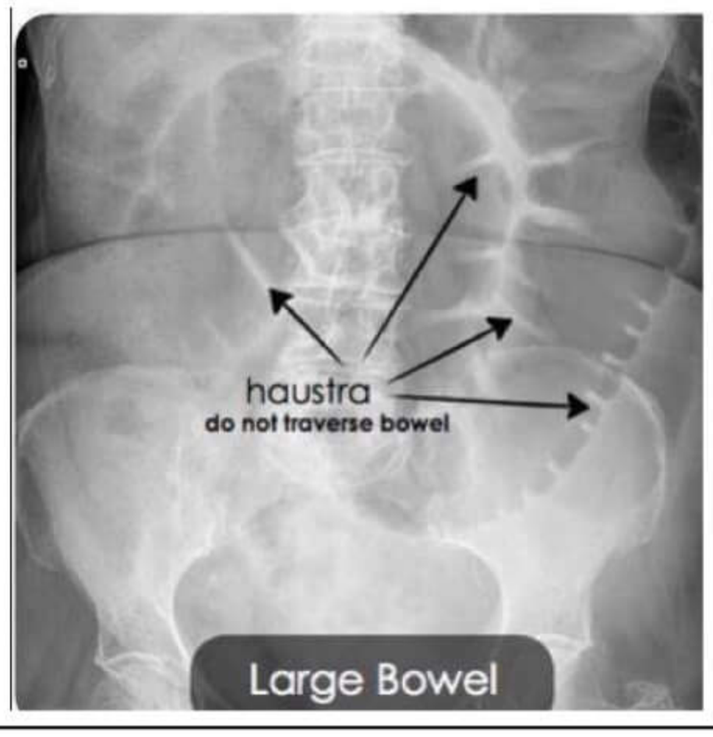

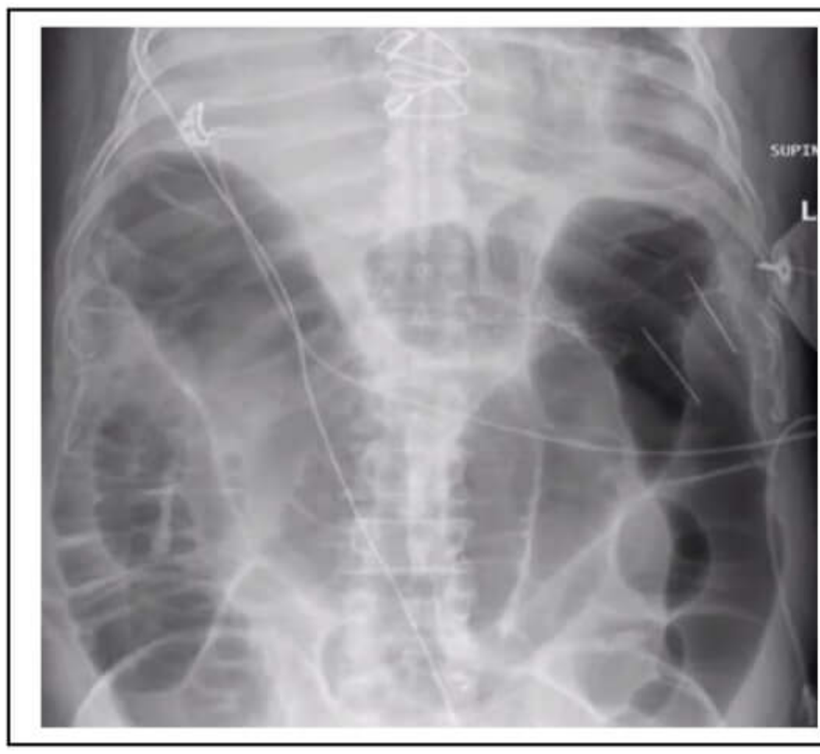

Treatment

→ **Depends on cause**

- For Adhesion – Adhesiolysis
- For Malignancy – Resection + anastomosis (Peritoneal carcinomatosis)
- For Hernia – Reduction
- For Crohn's disease – Resection + anastomosis

Simple obstruction	Strangulating obstruction
→ Mechanical obstruction in the lumen with preserved blood supply. → Has Colicky pain → Diagnosed by Abdominal X-ray	→ Closed loop of obstruction + compromised vascular supply → **Signs and symptoms of strangulation** • Fever, • Tachycardia • Leucocytosis → Steady non-crampy abdominal pain → Diagnosed by CECT

t.me/latestpgnotes

Paralytic Ileus

→ Characterised by Impaired intestinal motility due to failure of transmission of peristaltic waves – leads to collection of fluid & gas in bowel

↓

Abdominal distension

→ **Caused by** – Neuromuscular failure

→ It is a type of adynamic obstruction

Etiology

→ Abdominal surgery

→ Uremia

→ Mesenteric ischemia

→ Retro peritoneal hematoma

→ Intra-abdominal sepsis

PrepLadder

→ Dyselectrolytemia
→ **Drugs**
- Opiates
- Antipsychotics

Clinical features

→ Abdominal distension (due to collection of blood & fluid in small bowel)
→ Steady abdominal discomfort / pain (non-colicky)
→ Vomiting
→ Absent Bowel sounds
→ Non passage or feces and flatus

Investigations

→ IOC for Dx - Abdominal X-ray
→ **Findings**
- Dilated bowel loops
- Presence of multiple air fluid levels
- Air in rectum and colon

Management

→ Nasogastric obstruction
→ **Restriction of oral fluid intake**
- Until return of bowel sounds
- Until pt. starts passing flatus

→ Treatment of Underlying cause

t.me/latestpgnotes

Postoperative ileus

→ It is a kind of paralytic ileus in which because of surgery there is failure of neuromuscular transmission
→ **Earliest activity after surgery is seen**
- In small intestine - within 24 hours (In jejunum within 8 hours)
- In Stomach - within 48 hours
- In colon - 3 to 5 days

→ Colon is mainly responsible for post- operative ileus
→ Earliest activity is seen in Jejunum – Within 8 hours

.

Paralytic ileus	Mechanical obstruction
→ Absence of Peristalsis • No colicky pain • Absent bowel sounds → Presence of gas in Rectum	→ Associated with Hyperperistalsis • Colicky pain • Hyper active bowel sounds → Complete obstruction - Absence of air in rectum

PrepLadder

Intussusception

→ Telescoping of one segment of bowel into another
→ More common in children of age 4-10 months
→ MC type – ILEOCOLIC > ILEO-ILEOCOLIC > ILEO-ILEAL > COLO-COLIC
→ MC type in adults – COLOCOLIC

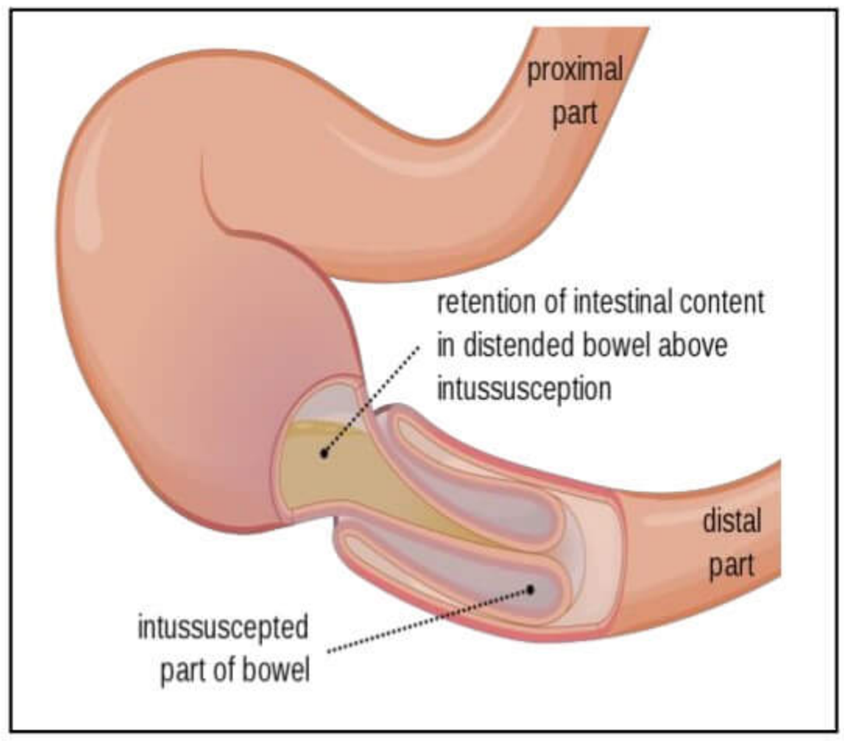

Parts of intussusception

→ **Intussusceptum**- incoming segment
→ **Intussuscepiens**- receiving segment
→ **Neck**- narrowest part of intussusception
→ **Apex** - most prone to gangrene
→ **Middle layer** is most prone to gangrene because it is sandwiched between outer and inner layer and has two acute bends

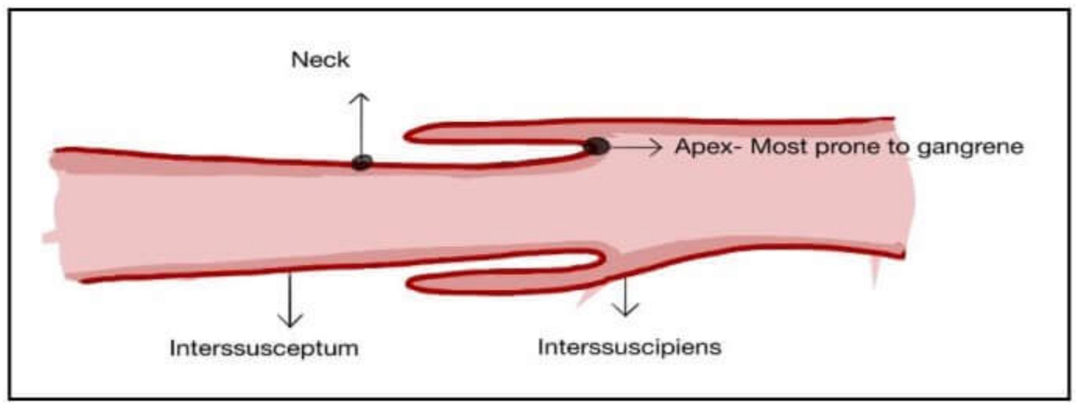

t.me/latestpgnotes

Predisposing factors

→ Weaning child (4-10 months) prone to Infections (Rota Virus Diarrhea)
↓
Peyer's patches hypertrophy
↓
Increased risk of Intussusception
→ MC type in children is Ileocolic
→ **Lead point** - point which initiate or lead the intussusception
→ MC lead point is Meckel's diverticulum > Polyps
→ **Other lead points for intussusception**
- Lipoma
- Lymphoma
- Villous adenoma
- Hematoma in Henoch Schoenlein purpura (HSP)
- Cystic fibrosis

→ MC tumor responsible for intussusception in children - Lymphoma
→ MC tumor responsible for intussusception in adults - Villous Adenoma

Clinical features

→ **At time of attack**
- Child cries a lot, pulls legs towards abdomen
- Colicky pain

PrepLadder

- Bilious vomiting (Multiple episodes)

→ In between attacks, patient is normal

→ **After many attacks**

- Passage of small amount of stools mixed with blood (Red current jelly appearance)

On examination

→ Sausage shaped mass in right lumbar region

→ Empty right iliac fossa known as Sign of dance

Investigation

→ Diagnostic + therapeutic – Enema (air > barium)

Treatment

→ Air enema (Enema creates pressure by which there will be reduction of bowel back to normal)

→ **For Recurrence** – Air enema is repeated.

→ **If recurrence occurs for the third time** – indication for surgery i.e. Ileocolectomy + Ileo-transverse anastomosis

Radiological signs

Plain x- ray	Barium enema	Ultrasound
• Meniscus sign • Target sign	• Claw sign • Coiled spring sign	• Target sign (transverse scan) • Pseudo kidney sign (longitudinal scan)

t.me/latestpgnotes

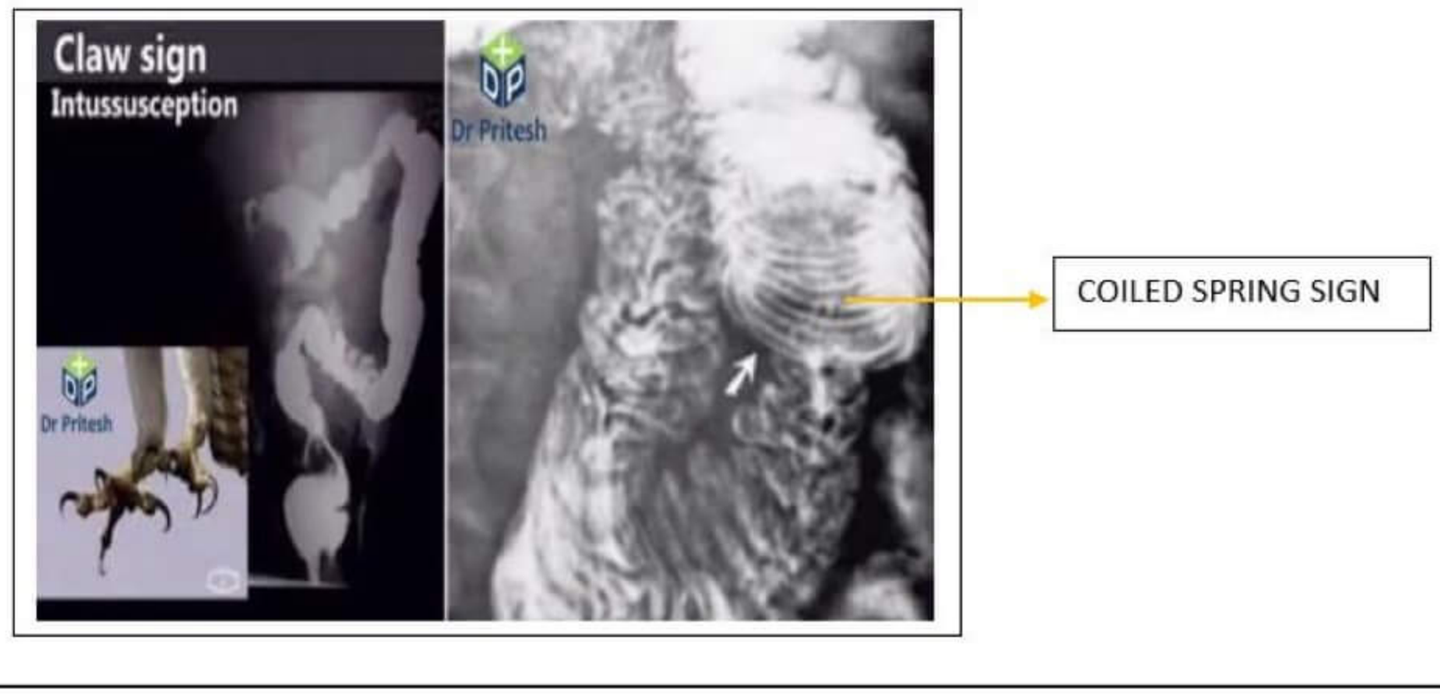

Colonic Pseudo Obstruction

→ Characterized by signs & symptoms of colonic obstruction in absence of mechanical cause of obstruction

PrepLadder

Types

1) **Idiopathic colonic pseudo obstruction** - known as **Ogilvie's syndrome**
2) **Secondary pseudo obstruction** – Factors responsible are
    - Retroperitoneal hematoma
    - Uremia
    - Hypothyroidism
    - Dyselectrolytemia
    - Drugs
        - Opiates
        - Anti- psychotics
    - Parkinson's disease
    - Chronic visceral myopathy

Etiopathology

→ **Sympathetic overactivity**

↓

Impaired peristalsis (Bowel sounds are present but sluggish)

↓

Colonic distension (with air)

Clinical features

→ Abdominal distension + abdominal discomfort

t.me/latestpgnotes

→ Sluggish bowel sounds are present

Investigations

→ Diagnosed by giving **Enema** – shows **Massive distention of colon**

Treatment

→ Drug of choice – **Neostigmine (IV)**

- It is **Parasympathomimetic**
- Most of the patients are relieved within 3-10 mins after passing massive amount of flatus.
- **Precautions**
    - ➢ R/O Cardiovascular contraindications
    - ➢ R/O Acute obstruction
- If contraindications cannot be ruled out for neostigmine → **Flatus tube insertion**

Large Bowel Obstruction

→ MC cause of LBO – **Malignancy**

→ MC site of LBO – **Rectum > Sigmoid**

→ Adhesions are rarely responsible for LBO

PrepLadder

Clinical Features

→ Colicky pain in lower abdomen in hypogastric region
→ Abdominal distension (not vomiting)
→ Absolute constipation /obstipation
→ LBO is a type of Closed loop obstruction (Real emergency - Surgery ASAP)

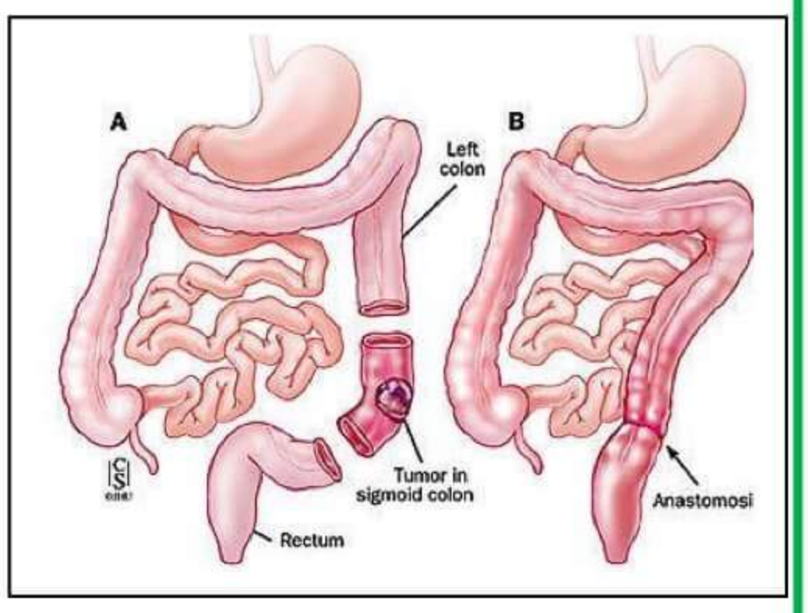

Treatment

→ **For Right colonic malignancies**
  • Resection + Ileo-Transverse Anastomosis

→ **For Sigmoid malignancy**
  • Sigmoidectomy + Colorectal anastomosis
  • Total Colectomy + Ileorectal anastomosis
    ➢ Performed under delayed presentation, if **whole colon is ischemic**
  • Hartman's procedure

→ **Hartman's procedure**
  • Components
    ➢ Sigmoidectomy
    ➢ Descending colostomy
    ➢ Closure of rectal stump
  • Performed for Sigmoid malignancy in elderly

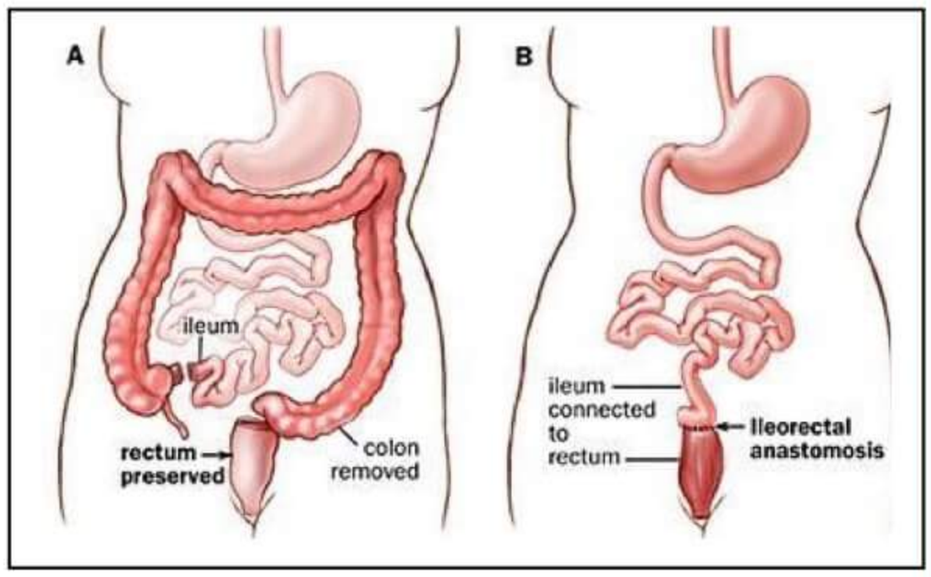

t.me/neetpgnotes

→ **Malignancy in Mid / lower Rectum**
  • Defunctioning colostomy
    ↓ f/b
    Chemoradiation
    ↓ f/b
    Tumor resection & Colostomy closure

Hartman's Procedure

Sigmoid Volvulus

→ MC Site of volvulus
→ **Volvulus can be both**
  • Anti- clockwise (MC)
  • Clockwise
→ **Mandatory factors for volvulus**
  • Constipation
  • Long narrow mesentery

Predisposing factors

→ Old Age
→ Hospitalized patients

PrepLadder

→ Mentally impaired patients

→ Intake of opioids/ antipsychotics

Clinical features

→ It is a type of **Closed loop obstruction** - Has signs & symptoms of LBO

- Colicky pain in lower abdomen
- Abdominal Distention
- Absolute constipation / obstipation

Investigations

→ On X-ray

- Coffee Bean sign
- Bent Inner Tube sign
- OMEGA sign

→ On Barium enema

- Bird beak sign
- Ace of spade sign
- Bird of prey sign

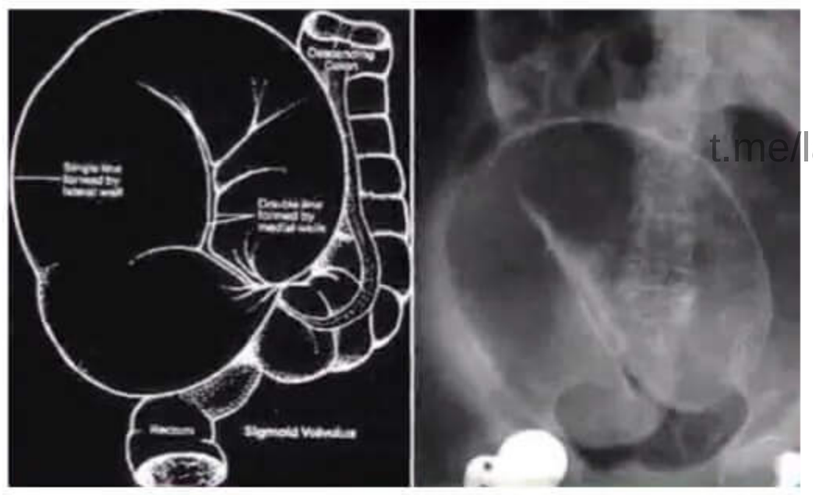

Coffee Bean sign (X -ray)

Bird beak sign

t.me/latestpgnotes

Treatment

→ TOC- Colonoscopic Detorsion

↓ followed by

Elective sigmoid colectomy (After 72 hrs)

CECAL VOLVULUS

→ Misnomer - should have been **Cecocolic volvulus**

→ Has involvement of part of ileum, cecum & Ascending colon

→ Volvulus is Mainly clockwise

→ Caecum is relatively fixed - If free or mobile

↓

Increased chances of torsion

PrepLadder

Predisposing factors

→ Multipara patients (due to release of relaxin)
→ H/O previous surgery (ligaments are divided)
→ Malrotation (abnormal location of cecum which is free)
→ Distal obstructing lesion (proximal part of colon distention loading to torsion)

Clinical features

→ **Has signs and symptoms of SBO** (Because Twisting is at the level of ileum)
- Colicky pain
- Bilious vomiting
- Absolute constipation

Investigations

→ IOC – Abdominal X-ray
→ **Findings**
- Kidney bean sign
- Comma shaped cecum

Kidney Bean Sign

Treatment

→ Ileocolectomy + Ileo-transverse anastomosis

Cecal Bascule

t.me/latestpgnotes

→ **Cecum Folds in a cephalad direction** anteriorly over fixed Ascending colon
→ **Clinical Features** - Intermittent episodes of abdominal pain

↓ because of

Intermittent isolated cecal obstruction

→ Resolves spontaneously

SMALL INTESTINE

BOWEL DIVERTICULA

Pathophysiology of Bowel Diverticula

→ Mesentery (Lymphovascular supply)
→ Nutrient artery (penetrates the muscularis propria of bowel)
→ Increased intraluminal pressure (due to constipation)

↓

Herniation of Mucosa & Submucosa

Bowel Diverticula

Bowel Diverticula

→ Acquired
→ Multiple
→ False
→ Located along mesenteric aspect

Meckel's Diverticulum

→ Single / True / Congenital
→ Located along Anti- mesenteric border
→ MC congenital anomaly of midgut
→ Caused by Persistent Omphalomesenteric duct/ vitello- intestinal duct
→ Characterized by Rule of '2'
  1. Seen in 2% population
  2. 2 inches in length.
  3. 2 feet proximal to ileocecal junction
  4. Symptomatic patients are < 2 years of age
→ MC ectopic mucosa - Gastric > pancreatic > colonic

t.me/latestpgnotes

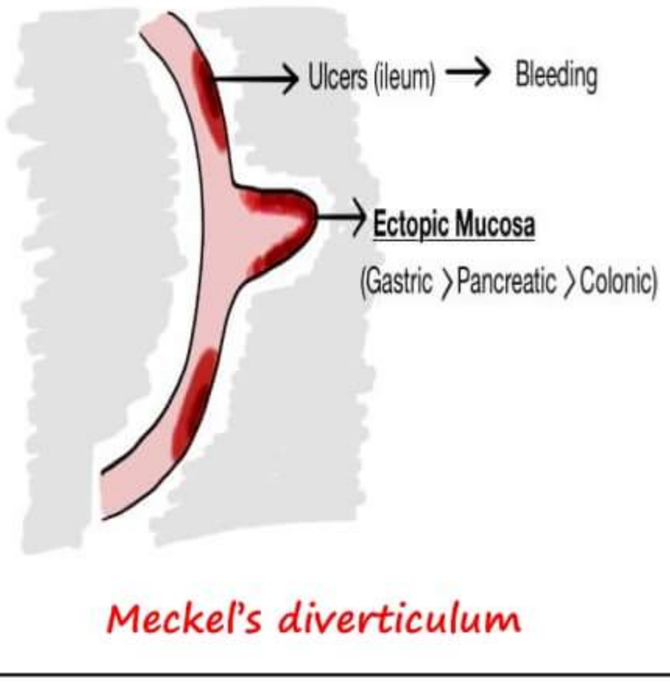

Meckel's diverticulum

Clinical Features

→ If Ectopic mucosa contains gastric substance → produces acid → ulcer formed → bleeding
→ Most common presentation - Bleeding
→ MC presentation / symptom in adults - Abdominal pain
(No symptoms during childhood – don't have ectopic mucosa in the diverticulum)

Causes of Abdominal pain in Meckel's diverticula

→ Midgut volvulus (due to TORSION)
→ Intussusceptions
→ Diverticulitis

Meckel's Diverticulitis mimics acute appendicitis. (On exploration, if appendix was found to be normal, at least 2 feet of ileum should be screened for presence of Meckel's diverticulum)

PrepLadder

Investigation

→ IOC for Dx - **Tc Pertechnate scan** (to detect ectopic mucosa)

→ In absence of ectopic mucosa in T_c Pertechnate scan, IOC is - **Enteroclysis**

Treatment

→ **MD with Healthy base** - Diverticulectomy + Anastomosis

→ **MD with unhealthy base** - Resection + Anastomosis

→ **Incidentally detected Meckel's diverticulum during elective surgery** - should be removed in all the patients up to 80 years of age. (No added morbidity in performing diverticulectomy)

→ **If left untreated** - Increased Risk of complication in 12% of patients.

Conditions in which there is increased risk complications in Meckel's diverticulum

- Narrow mouthed
- Unhealthy base
- Presence of Ectopic gastric mucosa

Superior Mesenteric Artery Syndrome (SMA syndrome)

→ **Aka Wilkie's Syndrome / Cast Syndrome**

→ Characterised by Compression / obstruction of **3rd part of duodenum** by SMA

→ Caused by loss of Fat that acts as cushion for 3rd part of duodenum between aorta & SMA

t.me/latestpgnotes

→ If Angle between aorta & SMA is < 20° – presents with symptoms (**Normally angle 50-60°**)

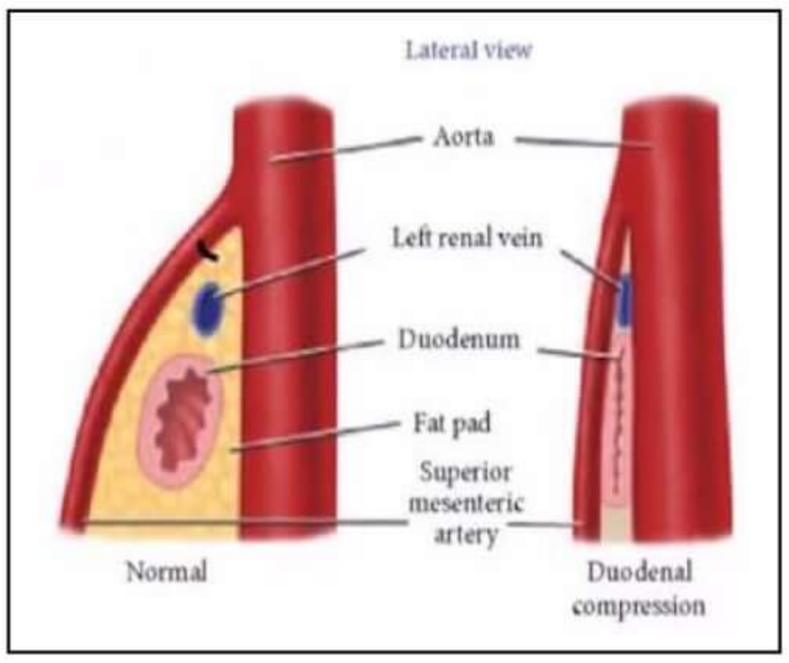

Predisposing factors

1) Rapid weight loss
2) Rapid gain of height
3) Prolonged immobilization
4) Body cast application

Clinical features

→ Colicky pain after meals

→ Feces & Flatus passed by patient (due to partial obstruction)

Investigation

→ Diagnose is made by - **Hypotonic duodenography or CECT**

Management

→ Conservative management

→ TOC for SMA syndrome - **Duodenojejunostomy**

PrepLadder

→ TOC for Annular Pancreas and Duodenal Atresia - **Duodeno-duodenostomy f/b Duodenojejunostomy**

GI Tuberculosis

→ **Caused by:**
- M. Tuberculosis
- M. Bovis (eliminated by Public health measures)

→ In India, majority of people are infected with M. tuberculosis
- If good immunity → infection cleared.
- Still in few cases → infection is in dormant state
- If immunity is low → Reactivation of infection takes place

Pathway of Spread of GI TB

→ 1st organ involved - **Lung**

→ GIT is involved by - Swallowing of infected sputum

↓ Reaches terminal ileum

Recruitment of lymphocytes in submucosa

↓

Oxidative stress and loss of epithelium

↓

Formation of **Transverse ulcer**

t.me/latestpgnotes

→ Earliest activity of GI TB is seen in - **Submucosal layer of GIT**

→ MC site of GI Tuberculosis - **Ileocecal junction**

Pathological types of TB

Ulcerative (60% cases)	Hyperplastic (10% cases)	Sclerotic/ fibrotic (30% cases)
↓ Immunity & ↑ Virulence ↓Formation of **Transverse ulcer in ileum**	↑ Immunity & ↓ Virulence ↓ Strong inflammatory response ↓ Mesenteric lymphadenopathy ↓ **Caseous necrosis** ↓ Formation of Matted bowel loops (**Bowel wall – Thickened**)	Formation of Strictures

Clinical features

→ **Initially** - Nonspecific signs and symptoms of TB
- Evening rise of temperature
- Low grade fever

PrepLadder

- Night sweats
- Anorexia
- weight loss

→ **Specific symptoms**

- Formation of transverse ulcers

↓

Ileum gets hyperirritable

↓

Contents are going to colon at a faster rate

↓

Diarrhea

- Later, at the site of transverse ulcer

↓

Formation of stricture (Passable stricture)

↓

Sub-Acute Intestinal obstruction (SAIO)

- So, MC presentation - Abdominal pain **(due to SAIO)**

Complications of TB

1) Acute obstruction
2) Perforation
3) Fistula formation
4) Abscess

t.me/latestpgnotes

Investigations

→ MC Lab abnormality - ↑ ESR (> 90% of cases)

→ **On Ultrasound** - Club Sandwich Appearance (due to formation of matted bowel loops with collection of fluid in between the bowel)

→ **Paracentesis**

- Lymphocytes > 500 / mm^3
- Protein > 2.5 gm/dl (Exudate)
- SAAG < 1.1
- ADA ↑↑

→ IOC for GI tuberculosis – CECT

PrepLadder

→ **On Barium meal follow through**

- Pulled – up cecum (due to contraction of mesocolon)

  ↓

  Obtuse I/C Angle (Goose Neck Deformity)

- Narrowed appearance of ileum (Due to Hyperirritability)

  ↓

  "STERLEIN SIGN"

- Persistent narrowing due to strictures – String of KANTOR sign

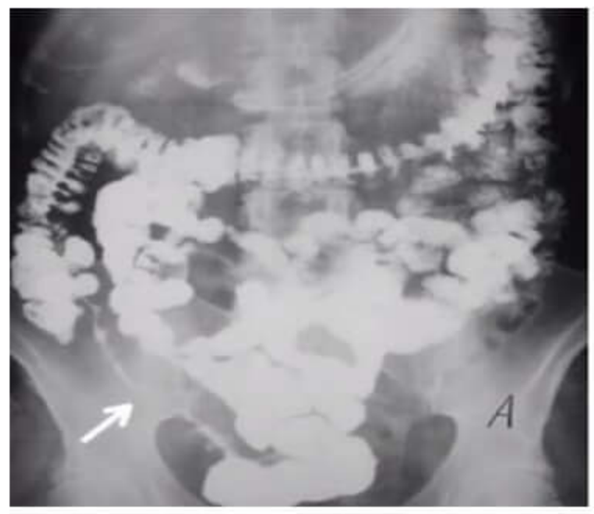

String of KANTOR sign

- **In chronic cases** – Thickened IC value, rigid cecum, narrowed ileum

  ↓

  UMBRELLA SIGN/ FLEISCHNER'S SIGN

Note

→ Sterling sign & String sign of Kantor – are seen in GI TB, as well as Crohn's disease.

Treatment

→ ATT with Management of complications

t.me/latestpgnotes

→ **Indications of Surgery**

- Acute obstruction
- Perforation
- Bleeding
- Abscess
- Fistula formation

Small Bowel Tumor

→ MC SBT – Stromal tumor > Adenoma

→ MC SBT in children – Lymphoma

→ MC malignant SBT – Adenocarcinoma > Carcinoid

Carcinoid Tumor

→ Neuroendocrine Tumors

→ **Arises from**

- ECL cells (enterochromaffin like cells)
- Argentaffin cells
- APUD cells
- Kulchitsky cells

→ MC site of carcinoid tumors – Bronchus > Ileum> Rectum > Appendix > colon> Stomach

→ Combined Incidence of carcinoid tumor – Duodenum + Jejunum + Ileum > Bronchus

PrepLadder

→ Overall most common site - **Small intestine > Bronchus** > I > R> A> C> S

Types of carcinoid (based on location of tumor)

1) **Localized carcinoid**
   - Larynx > ovary, Appendix > Rectum
   - GI carcinoid with best prognosis – carcinoid of Appendix

2) **Non localized carcinoid**
   - Pancreas > Colon > Small intestine
   - Carcinoid with worst prognosis - carcinoid of pancreas

→ MC site of carcinoid tumor in GIT – **Ileum**
→ MC site of carcinoid tumor in Hindgut – **Rectum**
→ MC site of carcinoid tumor in foregut in GIT – **Stomach**

Types of carcinoid (based on Argentaffinic /argyrophilic)

Foregut carcinoids	Argyrophilic	→ Produces Low levels of 5-HT
Midgut carcinoids	Argentaffinic	→ Produces 5- HT
Hindgut carcinoids	Mixed (Mainly Argentaffinic & some Argyrophilic)	→ Rarely produces 5- HT

t.me/latestpgnotes

→ Foregut and Hindgut carcinoids are rarely associated with carcinoid syndrome.
→ Midgut carcinoids are associated with
   - Carcinoid syndrome
   - MEN- I (10% of cases)

Risk of malignancy dependent on

→ **L** - Location
→ **S** - Size
→ **D** - Depth of invasion
→ **Growth** - Growth pattern

Manifestations of CARCINOID SYNDROME

→ MC manifestation - **Flushing**
→ Wheezing, Bronchospasm & Diarrhea
→ Intense desmoplastic reaction around the tumor – leads to excessive fibrosis causing compression of lumen

↓

Intestinal obstruction

↓

Abdominal pain

PrepLadder

Clinical features

→ MC symptom - **Abdominal pain**

→ MC site of metastasis in GI carcinoid - **Liver**

→ Catabolism of serotonin occurs in pulmonary capillaries

↓

So, right side of heart is mainly affected

↓

Tricuspid valve involved > pulmonary valve

→ MC valvular abnormality - **Tricuspid regurgitation > Pulmonary regurgitation > Tricuspid stenosis > Pulmonary Stenosis**

→ Peculiar symptom of Gastric carcinoid - **Bright red patchy flushing**

Investigations

→ IOC for Dx - estimation of **5- HIAA** in urine

→ In neuroendocrinal tumors, initial investigation for localization & staging - **SRS** (Somatostatin receptor Scintigraphy)

→ Best investigation - **DOPA – PET**

Treatment

→ **Segmental resection + En-bloc lymphadenectomy**

t.me/latestpgnotes

→ **In advanced cases** - Chemotherapy regimen

- **D** - Dacarbazine
- **E** - Epirubicin
- **F** - 5- Fluorouracil

→ **Targeted Radiotherapy**

- **Smart BOMBS** - Somatostatin analogue that delivers radiation specifically to the carcinoid Tumors
  (Indium labelled PENTREOTIDE)

  ↓

  Selectively taken by carcinoid tumors

  ↓

  Localized delivery of radiation to the tumor

→ Most important prognostic marker in carcinoid syndrome - **Chromogranin A**

→ Main treatment of small bowel carcinoid - Resection and anastomosis

→ After so many resection anastomoses as treatment patient may develop **Short bowel syndrome.**

PrepLadder

Short Bowel Syndrome

→ Caused by Massive resection of small bowel

→ Normal length of small bowel - 600 cm

→ In Short bowel syndrome - Length of bowel <200 cm.

Conditions that leads to Short bowel syndrome due to massive resection

a) Mesenteric ischemia

b) Mesenteric trauma

c) Midgut volvulus

d) Crohn's disease

→ Ileum has better adaptability, so jejunal resections are better tolerated

→ Function of terminal ileum - B_{12} absorption and enterohepatic circulation of bile salts

After effects

1) Megaloblastic anemia - impaired absorption of B_{12}
2) Cholesterol gall stone - impaired enterohepatic circulation of bile salts
3) Malabsorption - Free fatty acids binds with calcium
4) Oxalate stone formation - free oxalates is absorbed from colon
5) Choleretic diarrhea - watery diarrhea due to irritation of colon by bile salts
6) If Ileocolic valve is removed - reflex of fecal matter leading to Bacterial overgrowth + Diarrhea

t.me/latestpgnotes

Treatment

→ Immediate post-operative treatment is Conservative management (Total parenteral Nutrition)

→ **TOC** for short bowel syndrome – Small bowel transplantation

Intestinal lengthening procedures

a) **BIANCHI procedure**

- Aka LILT (Longitudinal Intestinal Lengthening & Tailoring)

b) **STEP (Serial Transverse Enteroplasty Procedure)**

→ Catabolism of gastrin occurs in small bowel mucosa.

So, In cases of short bowel syndrome – Hypergastrinemia

PrepLadder

LARGE INTESTINE

Hirschsprung's disease

→ Incidence = 1:5000 live birth
→ Characterised by Absence of ganglion cells in both Auerbach plexus & Meissner's plexus
→ MC site - Rectum > sigmoid
→ It is a **type of Neurocristopathy** - characterized by failure of migration of neural crest cells to colonic mucosa
→ **Severity of symptoms and age of presentation** - depends upon length of segment involved and severity of obstruction.

Clinical presentation

Just after birth	After first few weeks of life	Older children & adults
→ Delay of passage of Meconium (longer the involved segment severe the obstruction) → MC symptom - Abdominal distention	→ Chronic constipation → Abdominal distention → Failure to thrive	→ Chronic constipation

Investigations

→ IOC for Dx – Rectal Biopsy (Suction Biopsy> full Thickness Biopsy)
→ **Biopsy findings**
- Aganglionosis (Absence of ganglion cells)
- Hypertrophied nerve trunks
- (+) Acetylcholine esterase staining

t.me/latestpgnotes

Management

→ **For Short segment disease** - Extended myectomy
→ **For Long segment disease** - Temporary colostomy followed by definitive operation
→ **Definitive procedures are**
- Swenson
- Duhamel
- Soave

Colorectal polyps

Neoplastic (adenomatous) polyp	Non-neoplastic polyp
1) Tubular (most common benign) 2) Villous (most malignant) 3) Tubulovillous	1) MC Overall - Hyperplastic 2) Hamartomatous • Juvenile polyps • Peutz Jeghers polyp 3) Inflammatory polyp

PrepLadder

Note

→ Overall most common type of colorectal polyps- Hyperplastic polyps
→ Overall most common Neoplastic polyp –Tubular polyps
→ Overall most malignant colorectal polyp –Villous polyps

Similarly

→ Overall most common type of gastric polyp- Hyperplastic polyps
→ Most common neoplastic gastric polyp– Tubular polyps
→ Most common malignant gastric polyp –Villous polyps

Juvenile polyp

→ Usually Single, seen in children < 5 years of age
→ MC site - Rectum

Clinical presentation

→ Bleeding Per rectum associated with mucus discharge

Management

→ Polypectomy

Note

→ Juvenile polyposis syndrome
- Has multiple juvenile polyps
- Both juvenile polyp and juvenile polyposis syndrome have lower risk of malignancy (But on comparison, Risk of malignancy= **Juvenile polyposis syndrome > Juvenile polyp**

t.me/latestpgnotes

Peutz –Jegher's syndrome (P-JS)

→ Has multiple hamartomatous polyps
→ MC site - Small intestine (jejunum) > Colon > Stomach
→ Mutated Gene - LKB1 / STK11 **(located on chromosome 19)**
→ Characterized by Hyper melanotic macules (No risk of malignancy) over lips & buccal mucosa.
→ **Pathology** – shows Arborization &Pseudo invasion

Clinical Features

→ Recurrent intussusception – leads to Recurrent abdominal pain (Polyps act as lead point)
→ Doesn't increase the risk of colorectal cancer. But
- ↑ses the risk of **SI malignancy**
- ↑ses the risk of **Pancreatic malignancy** (maximum)
- ↑ses the risk of **Breast cancer**
- ↑ses the risk of **Thyroid cancer**
- ↑ses the risk of **Endometrial cancer**
- ↑ses the risk of **Sertoli cell tumor**

PrepLadder

Inflammatory polyps

→ **Aka Pseudo polyp**

→ Seen in Inflammatory bowel diseases (Ulcerative colitis >Crohn's disease)

→ It is Non-malignant (But IBD like UC & CD are pre-malignant condition for CRC)

Adenomatous polyp

→ Premalignant polyp

→ **Conditions that increases the risk of adenomatous polyp**

- U - Ureterosigmoidostomy
- S - Streptococcus bovis Bacteremia
- A - Acromegaly

→ **Factors which increases risk of malignancy in adenomatous polyp**

- Villous polyp (Max. risk)
- Sessile polyp
- Size > 2cm

→ **Syndromes related to Adenomatous polyp**

- Familial Adenomatous Polyposis (FAP)
- HNPCC

Note:

→ **FAP**– Responsible for 1% of CRC in population, having 100% risk of malignancy (Prophylactic Treatment Recommended)

t.me/latestpgnotes

→ **HNPCC** - Responsible for 5% CRC in population, having upto 80% risk of malignancy (Prophylactic not Treatment Recommended)

Familial Adenomatous Polyposis (FAP)

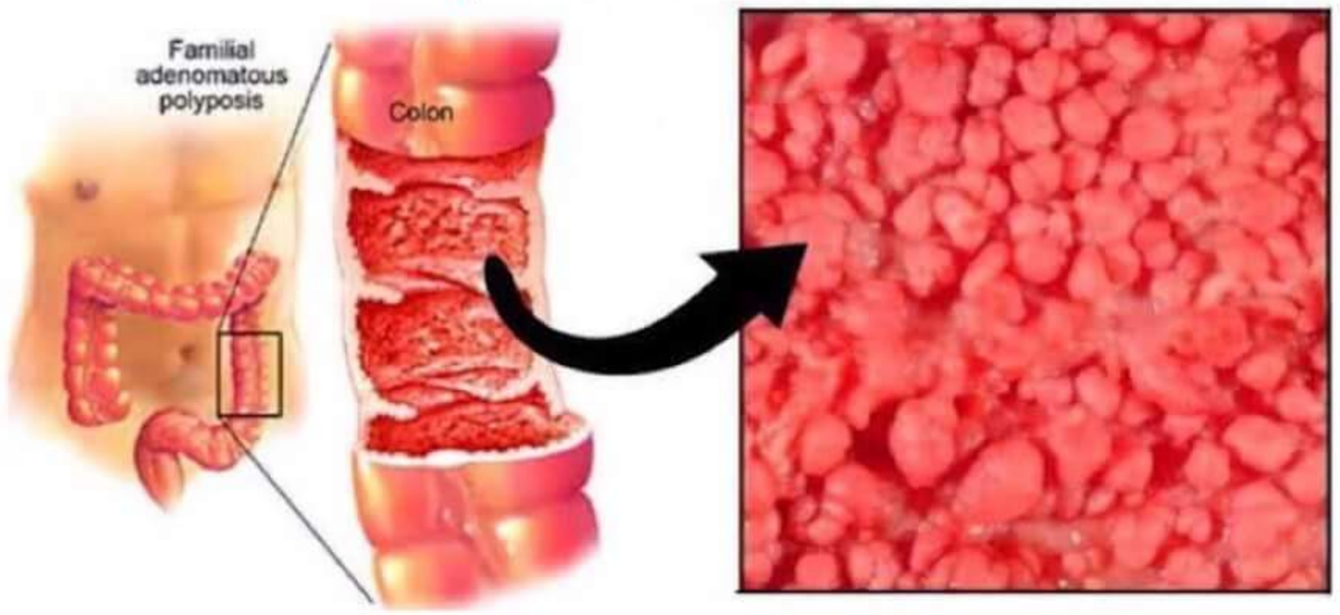

→ **Autosomal dominant**

→ Mutated gene - APC gene (Adenomatous Polyposis Coli)

→ Gene is located in - Chromosome 5q 21 (long-arm)

→ It is Characterised by > 100 adenomatous polyps

→ Associated with 100% risk of malignancy

→ Polyp formation begins at the age of 15 years

→ **100% patients** – develop malignancy by 40 years

PrepLadder

Clinical presentation

→ Bleeding per rectum

Investigations

→ **On DRE/ proctoscopy** - Polyps can be identified

→ IOC for FAP - Colonoscopy (> 100 polyps) + On histology (Adenomatous variety of polyp)

Treatment

→ **TOC** - Total proctocolectomy + Ileal pouch anal anastomosis

→ MC cause of death after proctocolectomy in FAP patients - Periampullary Carcinoma

Complication of surgery (TPC + IPAA)

→ MC complication - Small bowel obstruction (25% of cases)

→ **Pouchitis**- not seen in FAP but is seen in IBD **(UC - Pouchitis [33%]>SBO [25%])**

Screening

→ **FAP is Autosomal dominant** - 50%of patient's family members can have FAP. So, screening should be done

→ IOC for screening of family members of FAP - APC gene testing

→ If mutation is positive - Surveillance is done by colonoscopy

→ If Polyp is detected - Total proctocolectomy is recommended

t.me/latestpgnotes

Variants of FAP

Gardner's syndrome

→ Autosomal dominant condition

→ **Associated with**

- Osteoma (MC bone involved - Mandible)
- Congenital Hypertrophied Retinal Pigmented Epithelium (CHRPE)
- Desmoid tumors
- Sebaceous cyst
- Benign lymphoid polyposis of ileum
- Supernumerary teeth (extra teeth)

Turcot's syndrome

→ Autosomal recessive

→ Associated with - Brain tumors

→ It is associated with both

- **FAP** → MC brain tumor - Medulloblastoma
- **HNPCC** → MC brain tumor - Glioblastoma multiforme

PrepLadder

HNPCC (Hereditary Non-Polyposis Colorectal Cancer)

→ Autosomal dominant

→ Caused by Mismatch repair gene abnormality

- 3 Chromosomes involved - Chromosome2, 3, 7
- 7 genes are involved – in > 90% of cases → h MLH1, h MSH2is responsible

→ **Modified Amsterdam criteria** - used for diagnosis of HNPCC

→ **Revised Bethesda criteria** - used for detecting micro satellite instability in HNPCC

→ Responsible for 5% of Colorectal cancer in the population – **upto 80% risk of malignancy.** So, prophylactic treatment is not recommended.

→ HNPCC is Aka Lynch syndrome

Types

→ **Lynch I** - Colorectal cancer

→ **Lynch II** - Colorectal cancer + Extraintestinal malignancy

↓

(MC– Endometrium > Gastric >Ovarian)

Muir- Torre syndrome

→ Variant of a HNPCC – Characterised by Benign & Malignant tumor of sebaceous gland + keratoacanthoma

t.me/latestpgnotes

Management

→ **Surveillance colonoscopy** should be started at 20 years

→ **If Patient develop CA Colon** - Total colectomy + IRA (Ileorectal anastomosis)

→ But Rectum also has high risk of malignancy - Annual proctoscopy has to be done to detect malignancy

→ For females who have completed their family, **Prophylactic treatment** is - Trans-abdominal hysterectomy + Bilateral salpingo oophorectomy

Screening of Colorectal cancer

→ Starts at 50 years of age

Investigations used

1. FOBT	Should be performed annually after 40yrs of Age
2. Flexible sigmoidoscopy	Should be performed every 5 years
3. Double contrast barium enema	Should be performed every 10 years
4. Colonoscopy	Should be performed every 10 years

→ Colonoscopy is the most preferred investigation

→ If colonoscopy is contraindicated - Double Contrast barium enema is preferred

PrepLadder

Risk factor for colorectal cancers

→ Smoking → Alcohol → High fat diet → FAP → HNPCC	→ Adenomatous polyp → Ureterosigmoidostomy → Streptococcus bovis bacteremia → Acromegaly → IBD (UC & CD) → Pelvic irradiation
→ Risk factors for CA colon & CA rectum are similar	

CA Colon

→ Mc site of CA colon – **Sigmoid** (MC site of large bowel malignancy- Rectum > colon)

→ Least common site of CA colon - **Hepatic flexure**

→ Most common site of metastasis -**Liver > lungs**

Chemotherapy regimen for CA colon

→ **FOLFOX-IV** • **FOL** – Folinic acid (Leucovorin) • **F** - 5 Fluorouracil • **OX** – Oxaliplatin	→ **FOLFIRI** • **FOL** - Folinic acid (Leucovorin) • **F** - 5 fluorouracil • **IRI** - Irinotecan
→ **FOLFIRI** – Not preferred → **FOLFOX IV** – **preferred for CA colon & CA rectum**	

t.me/latestpgnotes

Clinical features

→ MC symptom - **Abdominal pain**

→ RIF mass & Alteration in bowel habit

→ Hematochezia & Melena

→ Anemia (which can lead to fatigue)

→ In CRC, Symptoms differ depending on the location

Right colonic malignancy	Left colonic malignancy
→ Fungating /cauliflower like growth → Liquid fecal matter → Mc symptom • Bleeding + Melena→ Anemia (fatigue) → Right iliac fossa mass in advances cases	→ Annular/stenosing growth → Solid fecal matter → Narrow caliber → MC symptom-Abdominal pain (due to Obstruction)
MC symptom of **CA Transverse Colon** → **Bleeding + Obstruction**	

Investigations

→ IOC for diagnosis of CA colon-**Colonoscopy + Biopsy**

→ IOC for staging of CA colon - **CECT**

PrepLadder

Modified Dukes/ Modified Astler Collar classification

→ **A** – Tumor confined to mucosa

→ **B_1** – Partial penetration of muscularis propria

→ **B_2** – Full penetration of muscularis propria

→ **C_1** – Partial penetration of muscularis propria + LN involvement

→ **C_2** – Full penetration of muscularis propria + LN involvement

→ **D** – Distant metastasis

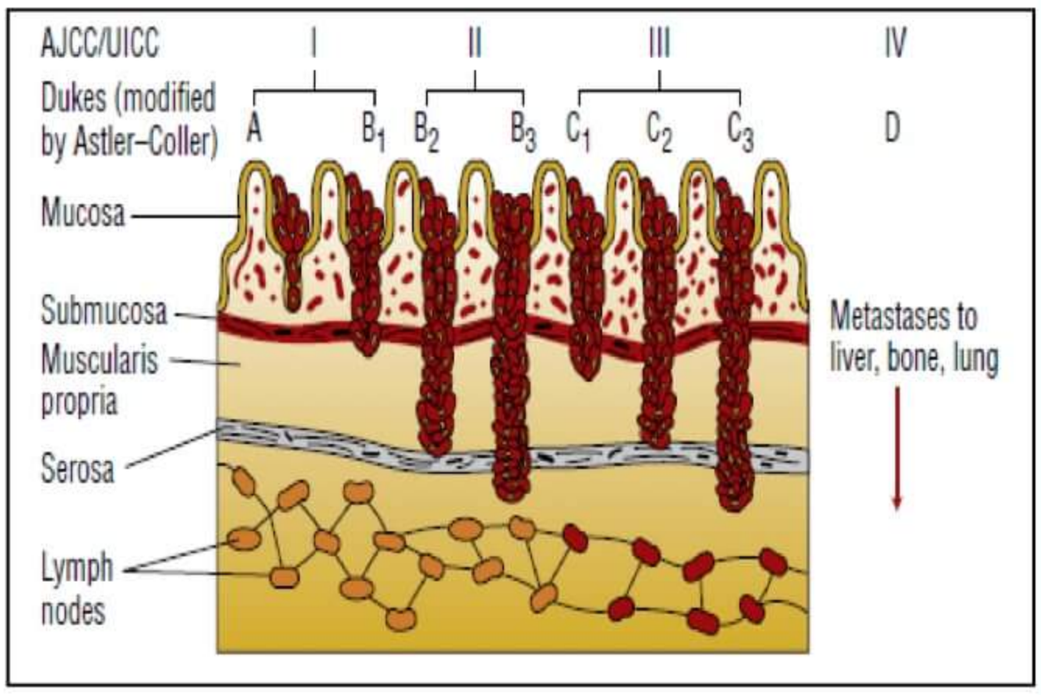

8th AJCC TNM classification for CRC

Tumor	
T_{IS}	→ **Carcinoma insitu** /Intraepithelial tumor/ **invasion of** Lamina propria
T_1	→ Tumor invades submucosa
T_2	→ Tumor invades muscularis propria
T_3	→ Tumor invades Subserosa or into Non- Peritonealized pericolic or perirectal tissues
T_{4a}	→ Tumor penetrates surface of visceral peritoneum
T_{4b}	→ Tumor directly invades or is adherent to other organs or structures.
Lymph Node	
N_1	→ Metastasis to 1-3 regional LN
N_{1a}	→ Metastasis to 1 regional LN
N_{1b}	→ Metastasis to 2-3 regional LN
N_{1C}	→ Tumor deposits in the Subserosa, Mesentery or Non- Peritonealized pericolic or perirectal tissues without regional lymph node metastasis
N_{2a}	→ Metastasis to 4-6 regional LN
N_{2b}	→ Metastasis to 7 or more regional LN
Metastasis	
M_{1a}	→ Metastasis confined to one organ or site without peritoneal metastasis
M_{1b}	→ Metastasis to more than one organ
M_{1C}	→ Metastasis to peritoneum with or without other organ involvement

t.me/latestpgnotes

PrepLadder

Management

T_{IS}	→ Polypectomy
Stage I & II	→ Segmental resection
Stage III	→ Segmental resection + chemotherapy (**FOLFOX IV**)
Stage IV	→ Metastasectomy + palliation by chemotherapy
	Note → Most common site of metastasis Liver > Lung → Isolated 3 metastasis to Liver, Lung & Brain are resectable
→ **Chemotherapeutic agents used only in Metastasis** • Irinotecan • Cetuximab – acts against EGFR • Bevacizumab – acts against VGEF	
→ Most important prognostic factor in CA colon – Staging (TNM) → Single independent most important prognostic factor – Lymph node status	

t.me/latestpgnotes

PrepLadder

ILEOSTOMY & COLOSTOMY

Colostomy

→ Connection of colon to abdominal skin

Ileostomy

→ Exteriorization of ileum to the abdominal skin

Most common Indications for Stoma Formation

→ Colorectal cancer
→ Chronic ulcerative colitis
→ Crohn's disease

Types of stoma

→ Stoma is of two types- Temporary stoma and Permanent stoma
→ **Temporary stoma**
- To divert fecal matter
- Are usually Loop stoma

→ **Permanent stoma**
- Are usually End stomas

Location of ileostomy

→ Right iliac fossa

Location of transverse colostomy

→ Temporary colostomy
→ Right upper quadrant

Location of Sigmoid colostomy

→ Permanent colostomy
→ Left iliac fossa

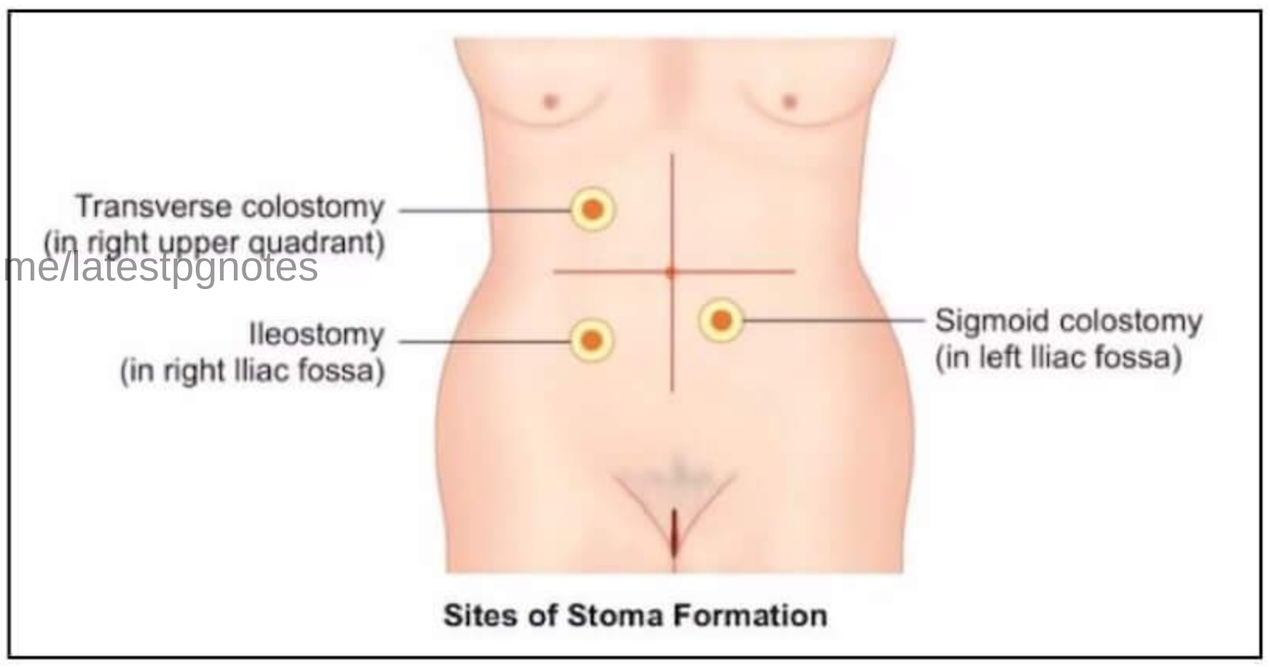

Sites of Stoma Formation

t.me/latestpgnotes

Ileostomy	Colostomy
• Spouted • Effluent is liquid and so it is made spouted. • Maximum risk of Dyselectrolytemia (because effluent is Liquid)	• Flush • Effluent is Solid and so it is made flush

PrepLadder

Types of Ileostomy

a) End
b) Loop
c) Double Barrel

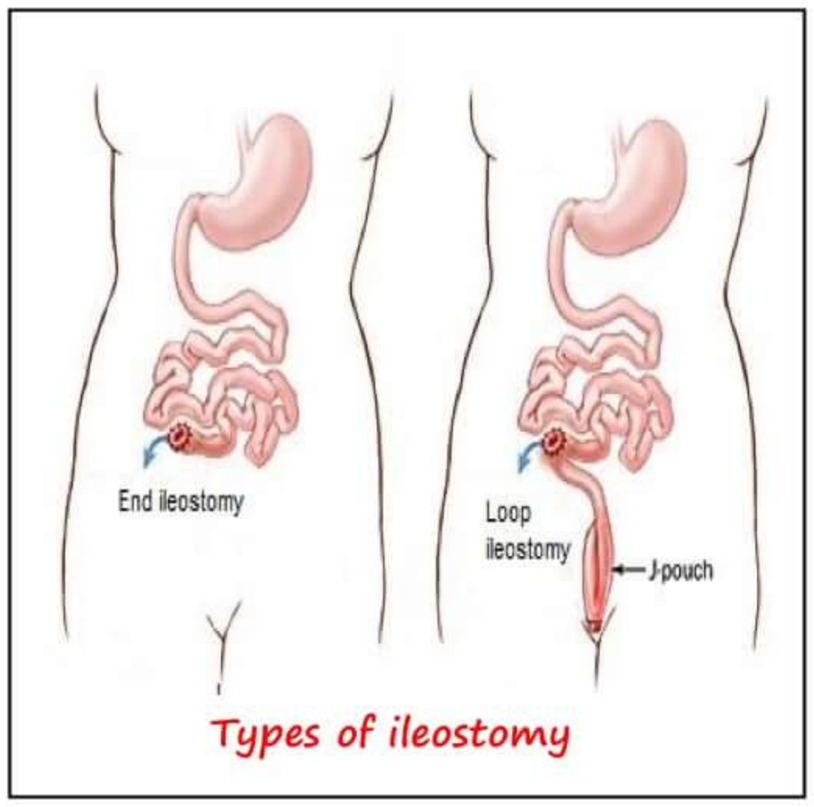

Types of ileostomy

End ileostomy

→ Only one end is taken out and the Other end is closed and placed inside the abdomen
→ Usually Permanent stomas

Loop Ileostomy

→ Loop of small intestine is brought through the abdomen and cut before suturing.
→ Has 2 stomas joined together
→ Usually Temporary stomas (for fecal diversion)

Double barrel ileostomy

→ 2 separate openings with skin bridge in between

Stomal Complications

Early complications	Late complications
→ Retraction	→ Stenosis
→ Abscess	→ Prolapse
→ Poor location	→ Parastomal hernia
→ Ischemia/ necrosis	→ Gas
→ Detachment dermatitis	→ Odor
→ Opening wrong end	→ Obstruction
→ Output is high	
Mnemonic→ RAPID- O	Mnemonic → SPF - GO

t.me/latestpgnotes

→ MC early complication of ileostomy – Ischemia / necrosis
→ Overall M/c complication of ileostomy -Skin excoriation / dermatitis

Ischemia / necrosis

Skin excoriation / dermatitis

→ MC complication of both end colostomy and loop colostomy – Parastomal hernia
→ Prolapse is more common in LOOP colostomy (due to larger opening)

PrepLadder

→ *Parastomal hernia* is more common in END colostomy (due to extensive dissection)

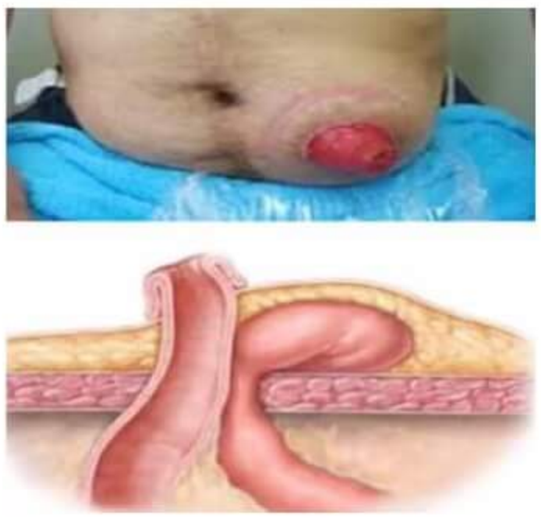

Parastomal hernia

Prolapse

t.me/latestpgnotes

PrepLadder

INFLAMMATORY BOWEL DISEASE – 1

Inflammatory Bowel disease (IBD)

→ It's an **Idiopathic chronic inflammatory disease**

→ Characterized by Chronic relapsing course

→ MC in developed countries

→ MC in Females (OCP use)

→ Has **Bimodal distribution**

- $2^{nd}/3^{rd}$ Decade
- $6^{th}/7^{th}$ Decade

→ **Crohns disease** is **more common in Smokers** whereas **Smoking is protective** in **Ulcerative colitis**

→ **Etiology** – Unknown

Risk factors

→ **Positive family history** (Greatest Risk factor)

→ **Genetic susceptibility – 3 Genes implicated are**

1) NOD – 2 (Nucleotide Oligomerization Domain – 2)
2) ATG -16 L-1 (Autophagy related 16 Like 1)
3) IRGM (Immunity related GTPase M)

t.me/latestpgnotes

→ **Other factors responsible are**

- Alteration in host interaction with intestinal micro-organisms
- Altered Gut Micro-Biota
- Intestinal epithelial dysfunction
- Aberrant Mucosal immune response

Crohn's disease (CD)

→ Chronic Transmural inflammatory disorder of GIT with unknown etiology

→ **Can involve any part** – From mouth to Anus

→ **MC sites involved**

- Ileum
- Ileocecal valve
- Cecum

→ Upper GI Crohn's disease has involvement of – **Gastric antrum & Duodenum**

→ **In patients of Colonic disease – Rectal sparing is characteristic** in Crohn's

→ **In Crohn's disease, involvement of**

- Small intestine + Large intestine – seen in 55% cases
- Only small intestine – 30% cases
- Only Large intestine – 15% cases

PrepLadder

→ Attacks young adults – 2nd/3rd decade

→ MC in Females (OCP use), Smokers & Urban dwellers

Etiology

→ Unknown

→ **Infectious agents that are proposed to be causative agents are**

- Mycobacterium Paratuberculosis
- Measles

→ **CARD-15/NOD-2 mutation** (Located on chromosome 16q)

- Aka IBD-1 Locus
- Relatively specific for Crohn's disease

Note

→ **IBD-2 Locus** (Located on chromosome 12q) – MC in Ulcerative colitis

Pathology

→ Earliest Gross pathologic lesion – Superficial aphthous ulcer in Mucosa

→ Diseased bowel is separated by areas of grossly normal bowel - known as Skip lesions

→ Extensive fat wrapping caused by circumferential growth of mesenteric fat around the bowel wall – known as Creeping fat

→ Has Thick, Firm, Rubbery & almost incompressible Bowel wall

t.me/latestpgnotes

→ One part of bowel gets attached with the other part of bowel & form fistula – known as Internal fistula

→ Mesentery of involved bowel gets thickened

→ Linear ulcers collides & forms Transverse ulcers with islands of normal mucosa in between – Cobblestone appearance

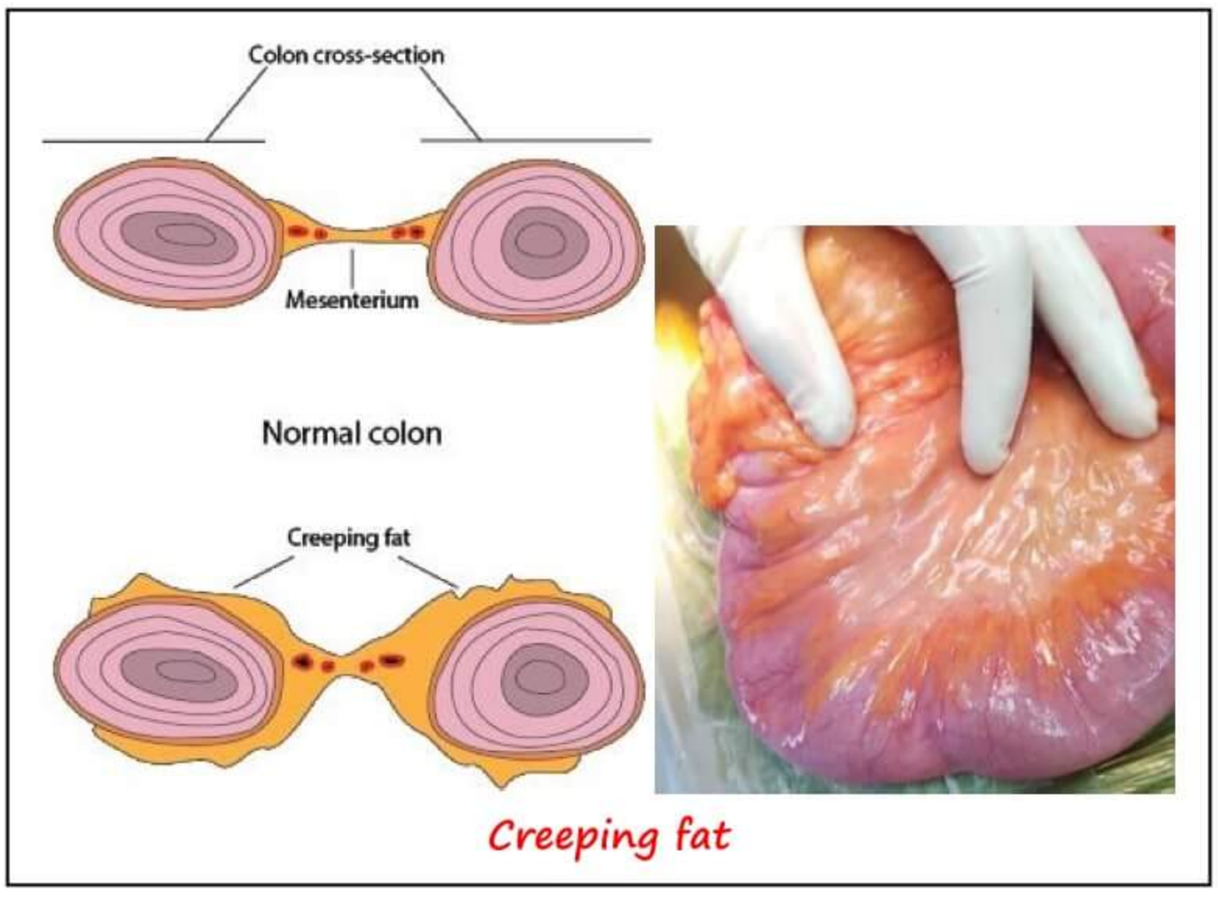

Creeping fat

Aphthous ulcer

Cobblestone appearance

PrepLadder

On Microscopic examination

→ **Inflammatory reactions**
- Extensive edema
- Hyperemia
- Lymphangiectasia
- Distortion of mucosal architecture
- Paneth cell hyperplasia

→ Characteristic histologic lesion in Crohn's – **Non Caseating granuloma with Langerhans giant cells**

→ These Non-Caseating granulomas are located – both in **Bowel wall & Regional Lymph nodes**

Clinical features

→ MC symptom – **Intermittent colicky lower abdominal pain > Diarrhea (Intermittent)**

→ **In CD (As compared to UC)**
- Fewer bowel movements
- Stool rarely contains mucus, pus, & Blood

→ **Main intestinal complication of Crohn's disease**
- **Obstruction**
- **Perforation** – Leads to formation of Internal fistula

t.me/latestpgnotes

→ **Fistula occurs in**
- Sites of Perforation & Adjacent organs
- Sites of Previous Laparotomy

→ **In Long standing CD**
- Increased risk of malignancy in – Small intestine & Large intestine (Colon)

→ **In Anus & Perianal involvement**
- Fissures
- Fistula
- Strictures
- Perianal abscess

→ **In CD – MC site of**
- E/c fistula & E/v fistula
- Ulcers / Strictures
- Carcinoma

} **Ileum**

Investigations

→ IOC for Dx of CD – **CT Enteroclysis**

→ Earliest Radiographic finding in CD – **Aphthous ulceration**

→ **Other Radiologic findings**
- **Deep ulcers**

PrepLadder

- **Hose-pipe Appearance** (Long stricture extending into I/C valve with Thickened wall) – Corresponds to String sign of Kantor
- Fat Halo sign
- Raspberry Thorn / Rose Thorn appearance – Linear Transmural fissure / ulcer
- Creeping fat sign
- Comb sign
- Cobble stone appearance – Deep fissuring ulcers around inflamed mucosa

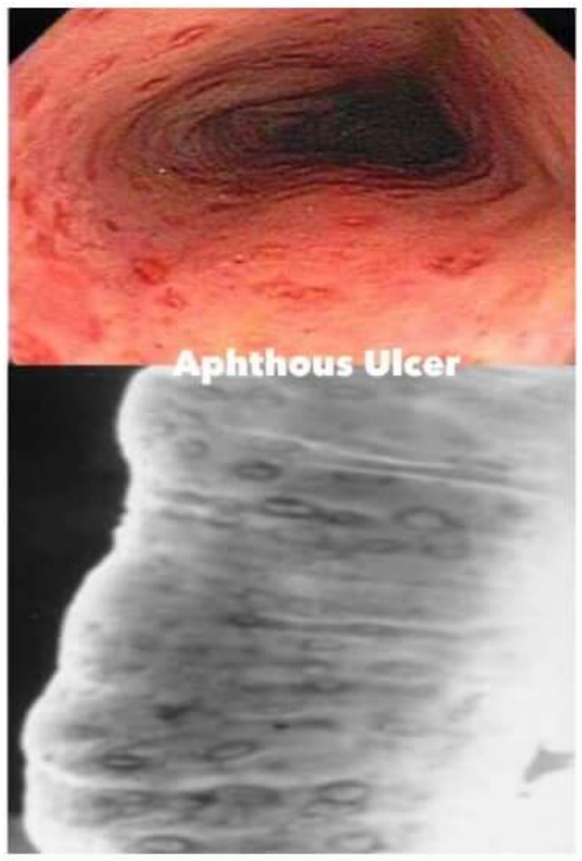

t.me/latestpgnotes

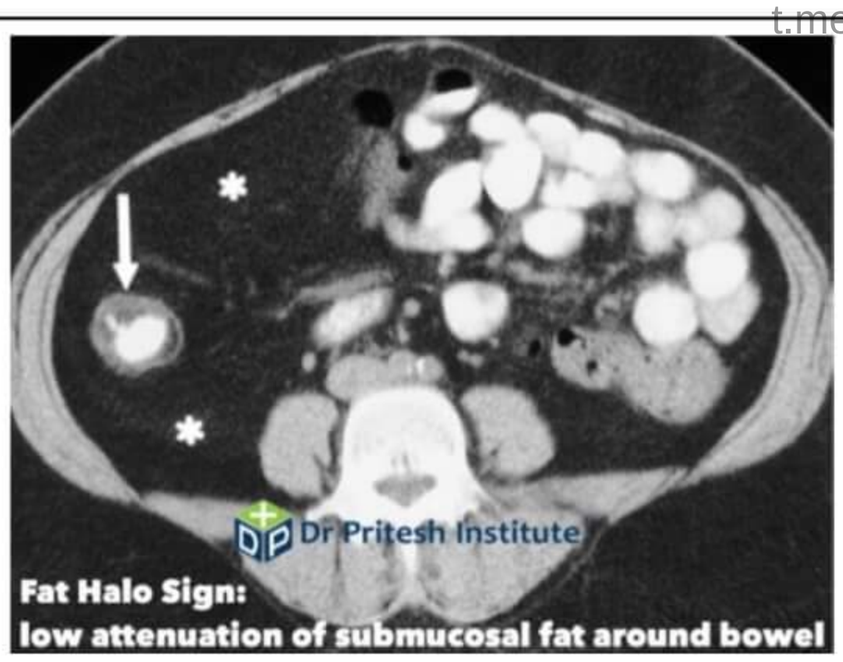

PrepLadder

→ **Serology**

- **ASCA** (Anti-Saccharomyces Cerevisiae Antibody) – **Relatively Specific for CD**
- **P-ANCA** (Perinuclear Anti - Neutrophil Cytoplasmic Antibodies) - **Relatively Specific for UC**

Extra Intestinal manifestations of CD

<table>
<tr><td>

1) Skin

- Erythema nodosum
- Erythema multiforme
- Pyoderma gangrenosum

</td><td>

2) Eyes

- Iritis
- Uveitis
- Conjunctivitis

</td></tr>
<tr><td>

3) Blood

- Anemia
- Thrombocytosis
- Phlebothrombosis
- Arterial thrombosis

</td><td>

4) Joints

- Peripheral Arthritis
- Ankylosing spondylitis

</td></tr>
<tr><td>

5) Liver

- Non – specific Triaditis
- Primary sclerosing cholangitis
- Cholesterol gall stones

</td><td>

6) Kidney

- Nephrotic syndrome

</td></tr>
<tr><td>

7) Urological

- Stones (MC type – Oxalate stones)
- Ureteral obstruction
- Entero-vesical fistula

</td><td>

8) Pancreas

- Pancreatitis

</td></tr>
<tr><td colspan="2">

9) Amyloidosis

</td></tr>
<tr><td colspan="2">

→ MC cutaneous manifestations of IBD – **Erythema Nodosum**

→ **Erythema Nodosum**

- Most Responsive for Rx of Bowel disease
- Persistence of Erythema Nodosum – Indicates inadequate control of IBD

</td></tr>
<tr><td>

→ **Manifestations MC in Crohn's disease**

- Erythema Nodosum
- Peripheral arthritis
- Ankylosing spondylitis
- Stones (Cholesterol gall stones/Oxalate stones)
- Ureteral obstruction

</td><td>

→ **Manifestations MC in Ulcerative Colitis**

- Primary sclerosing cholangitis
- Pyoderma gangrenosum

</td></tr>
</table>

t.me/latestpgnotes

PrepLadder

Ulcerative colitis

→ MC in developed countries

→ Usually occur in Age < 30 years (Young adults)

→ MC in Females (OCP's use)

→ Smoking is protective

→ MC in Whites, Jews & Persons of Northern European Ancestry

Etiology

→ Unknown

→ **Infectious agents Implicated are**

- Clostridium Difficile
- Campylobacter Jejuni

→ **Risk factors**

- Family history – Significant risk
- Smoking – Protective
- Appendectomy - ↓ses risk of UC

Pathology

→ **In UC**

- Mucosa + Submucosa only involved
- Muscularis Propria – spared

t.me/latestpgnotes

→ Typical Gross appearance in UC – Hyperemic mucosa

↓

Responsible for **fine mucosal granularity**

(Earliest Radiographic finding)

Hyperemic mucosa

→ Rectal involvement / Proctitis – Hall mark of UC **(+ in 100% pts.)**

→ Disease starts from Rectum – Extends Proximally **(It is continuous)**

→ Pseudo polyps are MC in UC **(UC > CD)**

→ Most characteristic lesion of UC – Crypt Abscess

↓

- Not specific for UC
- Also seen in CD & Infectious colitis

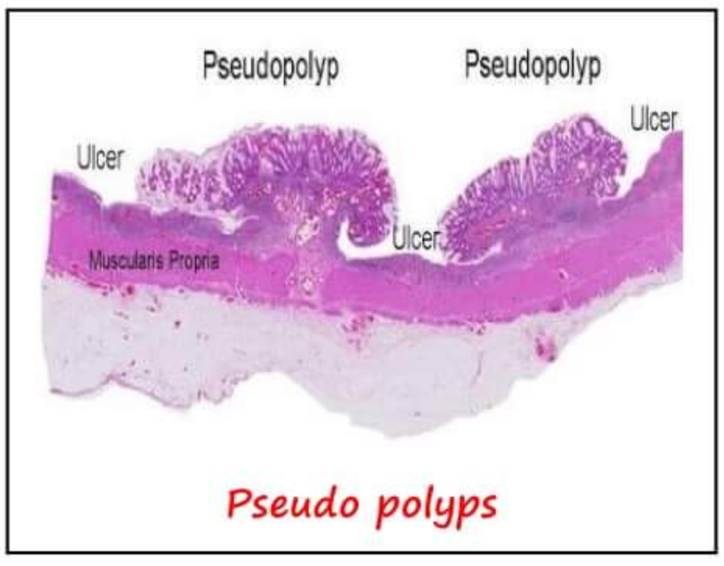

Pseudo polyps

→ Important Characteristic feature of Chronic UC – Crypt Branching

→ **Patients of UC has**

- ↓sed No. of Goblet cells
- ↓sed Mucus production

PrepLadder

Clinical features

- Diarrhea
- Rectal bleeding
- Tenesmus
- Passage of mucus
- Crampy abdominal pain

→ **Diarrhea & Bleeding** - intermittent

→ **Rectal involvement** – 100% cases

→ **Anal involvement** - Rare

Investigations

→ **Lab findings**

- ↑ CRP, ↑ ESR, ↑Platelet count
- ↓ Hb
- **Fecal lactoferrin** – highly Sensitive & Specific marker for Intestinal inflammation
- **Fecal calprotectin**
  - Levels correlate well with histologic inflammation
  - Predict relapses
  - Detect Pouchitis
- **Fecal lactoferrin & Fecal calprotectin** – Helps to rule out **Active inflammation Vs Irritable bowel or Bacterial overgrowth**

t.me/latestpgnotes

→ **Serology**

- **P – ANCA** → Specific for UC

→ **Colonoscopy**

- Done to pts. Not having Acute flare
- Used to assess the disease extent & activity
- **Earliest finding** - ↓sed vascularity with Erythematous & Edematous mucosa

→ **Radiological findings**

- Earliest change – **Fine mucosal granularity**
- **Collar button ulcers** – Deep ulcers (ulcer has penetrated the mucosa)

→ **Radiological findings in End stage / Burnt out UC**

- Shortening of colon
- Loss of normal Redundancy - in Sigmoid region, Splenic & Hepatic flexure
- **Ahaustral colon** – also known as
  - Pipe stem colon
  - Lead pipe sign

PrepLadder

- Garden hose appearance
- Stove pipe sign

- Featureless mucosa
- Narrow caliber of bowel

→ Backwash ileitis – seen in 15 – 20% cases of UC

- **On Barium enema**
  - Fixed Patulous I/C Valve
  - Dilated granular Terminal ileum

Collar button ulcers

Lead Pipe Sign/ Pipestem Colon/ Ahaustral colon /Gardenhose app/ Stove pipe appearance

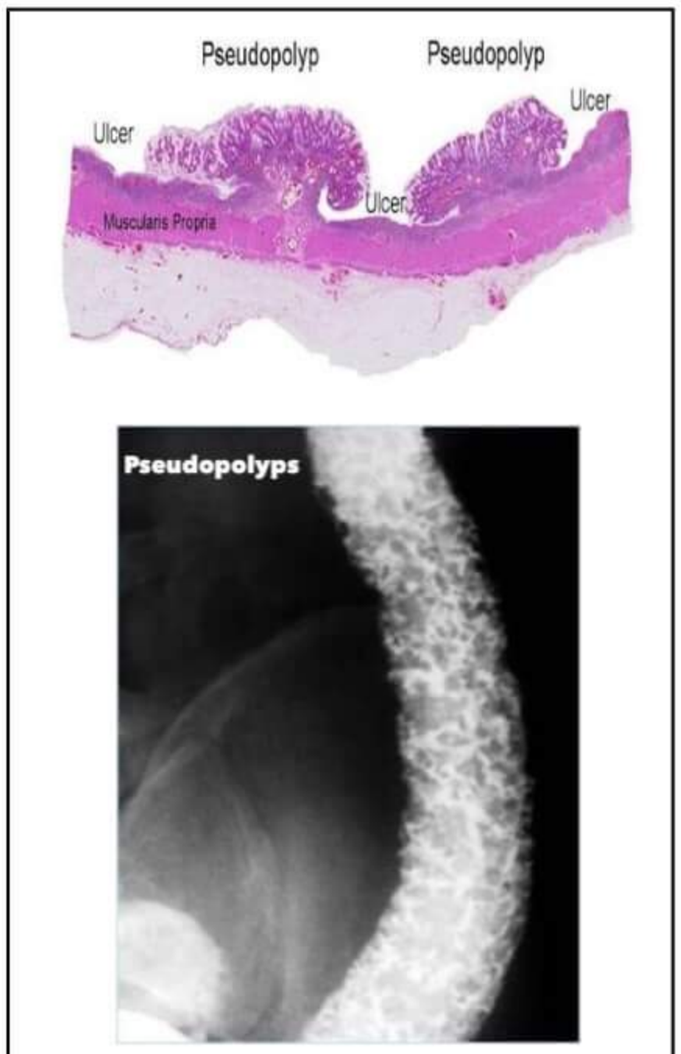

t.me/latestpgnotes

PrepLadder

Modified Truelove and Witts severity index

→ Done for **Disease severity grading** of UC

Extra intestinal manifestations of UC

1. Arthritis
2. Ankylosing spondylitis
3. Erythema nodosum
4. Pyoderma gangrenosum
5. Primary sclerosing cholangitis

t.me/latestpgnotes

PrepLadder

Inflammatory bowel disease – 2

Management of IBD

1) 5 – ASA Agents

→ Mainstay of therapy in UC & CD

→ **MOA**

- Inhibition of NF-KB Activation
- Inhibition of PG synthesis
- Scavenging of Free radicals

→ Upto 80% of unformulated acquired **5 – ASA is absorbed at Proximal SI** (Does not reach distal SI & Colon)

→ To overcome the Rapid absorption in SI, **5-ASA is attached with Carriers**

- **Sulfasalazine (5-ASA + Sulfapyridine)**

> **5-ASA** → Anti-inflammatory activity
>
> **Sulfapyridine** → Carrier
>
> → Linked by Azo bond
>
> → Responsible for most of the Side effects
>
> → Deliver 5-ASA moiety to the colon

- **Olsalazine (5-ASA + 5-ASA)**
- **Balsalazide (5-ASA + 4 – Amino benzoyl Beta-Alanine)**

t.me/latestpgnotes

2) Antibiotics

→ **Metronidazole**

- Mainly used in
  - Active inflammatory
  - Fistulous
  - Perianal

  } Crohn's disease
- No role in Rx of Active or Quiescent Ulcerative Colitis
- Used in pts. of Pouchitis (Total Proctocolectomy + Ileal Pouch-Anal Anastomosis)

→ **Ciprofloxacin**

- Used in
  - Active inflammatory
  - Fistulous
  - Perianal

  } Crohn's disease
- Used in pts. of Pouchitis

PrepLadder

→ **Glucocorticoids**

- Used in inducing remission of both UC & CD
- No role in Maintenance therapy

3) Agents used for inducing Remission

→ **Prednisone**

→ **Parenteral agents**

- Hydrocortisone
- Methyl Prednisolone

→ **Budesonide**

- It is released entirely in Colon
- Has minimal or no steroid related side effects

4) Azathioprine & 6-Mercaptopurine

→ Used in management of Steroid dependent IBD

→ Used as Maintenance therapy in both UC & CD

→ Used in treating Active perianal disease & Fistula in CD

5) Methotrexate

→ Effective in inducing Remission & reducing steroid doses

t.me/latestpgnotes

→ Effective in maintaining remission in Active CD

→ Promising role in Maintenance therapy

6) Cyclosporine

→ Used in Severe UC, refractory to IV Glucocorticoids

7) Tacrolimus

→ **Good efficacy in**

- Children with IBD
- Adults with extensive involvement of Small intestine

→ **Effective in adults with**

- Steroid dependent or Refractory UC & CD
- Refractory fistulizing Crohn's disease

8) Anti – TNF Therapies

→ **Infliximab**

- It is a chimeric IgG_1 antibody against TNF-1
- Used for
  - Active CD refractory to Steroids & 6-MP OR ASA
  - Crohn's disease with refractory perianal or E/C Fistula
  - Approved for Rx of Moderate to Severely Active UC

PrepLadder

→ **Adalimumab**

- It is a **Humanized Recombinant IgG_1 Monoclonal antibody against TNF-α**
- Approved for Rx of
  - Moderate to Severe CD
  - Moderate to Severely active UC

→ **Certolizumab Pegol**

- It is a **Recombinant FAB antibody fragment against TNF-α**
- Effective for induction of clinical response in patients with Active inflammatory Crohn's disease

→ **Golimumab**

- It is a **Human IgG_1 antibody against TNF-α**
- Approved for Rx of - Moderate to Severely active UC

9) Anti-Integrins

→ **Natalizumab**

- It is a **Recombinant Humanized IgG_4 antibody against α_4-Integrins**
- Used for
  - Induction & Maintenance of therapy in CD
  - Rx of refractory or intolerant to Anti-TNF therapies

t.me/latestpgnotes

→ **Vedolizumab**

- It is a **Monoclonal antibody against $\alpha_4\beta_7$ Integrins**
- Indicated for pts. with inadequate response to Glucocorticoids or Anti-TNF therapies or Immunomodulators

PrepLadder

Management of Mild to Moderate Crohn's disease

For inducing Remission

Budesonide (for ileal & Right Colon CD)

↓

For Maintenance therapy

Sulfasalazine

↓ No improvement

For inducing Remission

Prednisone

↓

Azathioprine /6-MP → For Steroid dependent CD

(OR)

Methotrexate → Maintenance of remission in Active CD

↓ Refractory to Azathioprine /6-MP

Anti-TNF Therapy

- Infliximab
- Adalimumab
- Certolizumab

t.me/latestpgnotes

Management of Moderate to Severe Crohn's disease

Azathioprine / 6-MP / Methotrexate

(+)

Infliximab / Adalimumab / Certolizumab Pegol

↓ Refractory / intolerant to Anti-TNF Therapy

Natalizumab / Vedolizumab

↓

For inducing Remission

Glucocorticoids (IV)

↓

Start TPN

PrepLadder

Management of Fistulizing Crohn's disease

I/D of Abscess + Antibiotics

↓

Infliximab / Adalimumab / Certolizumab Pegol – For CD with Perianal & E/C Fistula

(+/–)

Azathioprine /6-MP – for Active Perianal disease & Fistula in CD

↓ Pt. is intolerant to Anti-TNF therapy

Natalizumab / Vedolizumab

↓ No improvement

Start TPN

Management of Mild to Moderate Ulcerative colitis

Mainstay of therapy

5-ASA (Oral &/or Rectal)

t.me/latestpgnotes

↓ No improvement

For Maintenance of Remission

Glucocorticoids (Rectal)

↓ No improvement

Glucocorticoids (Oral)

↓

Maintenance therapy in steroid dependent UC

Azathioprine /6-MP

↓ Refractory to Azathioprine /6-MP

Anti-TNF therapy

- Infliximab
- Adalimumab
- Golimumab

PrepLadder

Management of Moderate to Severe Crohn's disease

For inducing Remission

Glucocorticoids (Oral)

↓ No improvement

Glucocorticoids (IV)

↓

For Maintenance of therapy

Azathioprine /6-MP (+) Infliximab

↓ No improvement

Adalimumab / Golimumab

↓ No improvement

Cyclosporin (IV) – For Severe UC refractory to steroids

(OR)

Vedolizumab – For inadequate response to steroids

Indications of Surgery in Crohn's disease

Indications in Small intestine	Indications in Colon & Rectum
1) Stricture & Obstruction unresponsive to Medical therapy 2) Massive hemorrhage 3) Refractory fistula 4) Abscess	1) Intractable disease 2) Fulminant disease 3) Perianal disease unresponsive to medical management 4) Refractory fistula 5) Colonic obstruction 6) Cancer prophylaxis 7) Colonic Dysplasia or Cancer

t.me/latestpgnotes

Indications of Surgery in Ulcerative Colitis

1) Intractability
2) Dysplasia or Carcinoma
3) Massive Colonic bleeding
4) Toxic Megacolon

Surgical options in Ulcerative colitis

1) TPC + IPAA – **Definitive Rx**
2) TPC + Ileostomy
3) TPC + Continent ileal reservoir (Kock pouch)
4) TAC + End ileostomy

PrepLadder

TPC + IPAA

→ It is the Definitive treatment

→ Preferred in younger patient with no Rectal dysplasia

→ **Procedure**

- Some part of Ileum, whole Colon & Rectum are removed
- Ileal pouch created & Anastomosed with Anus

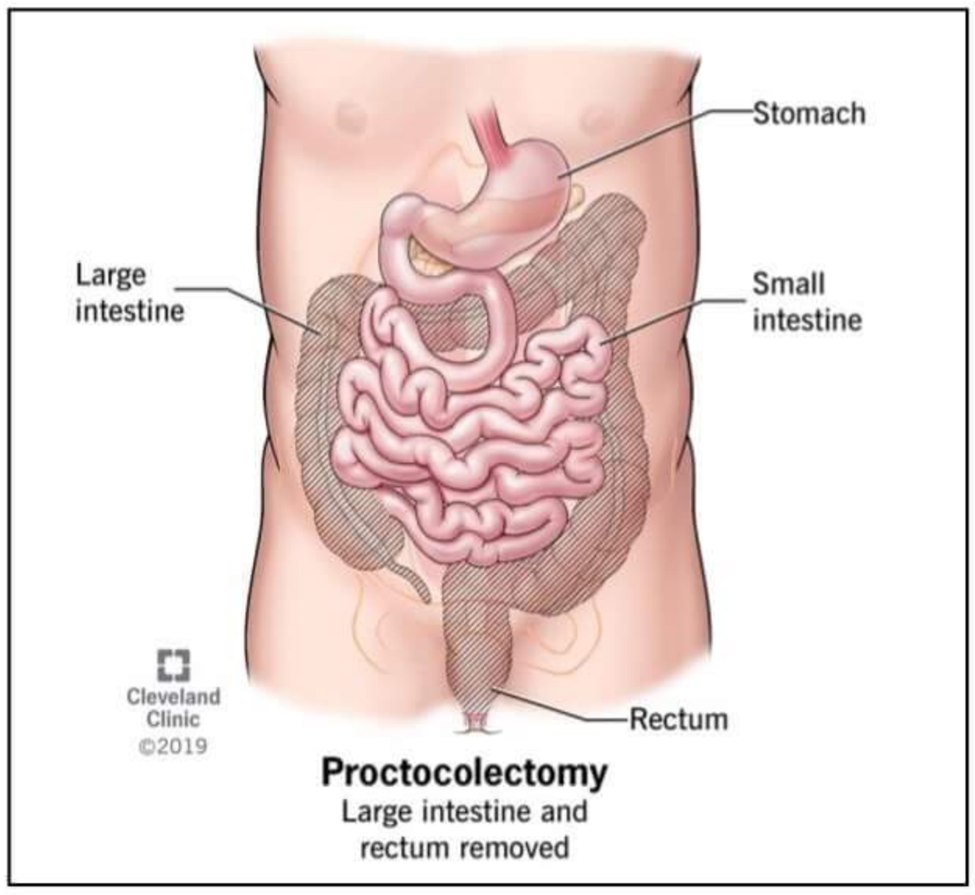

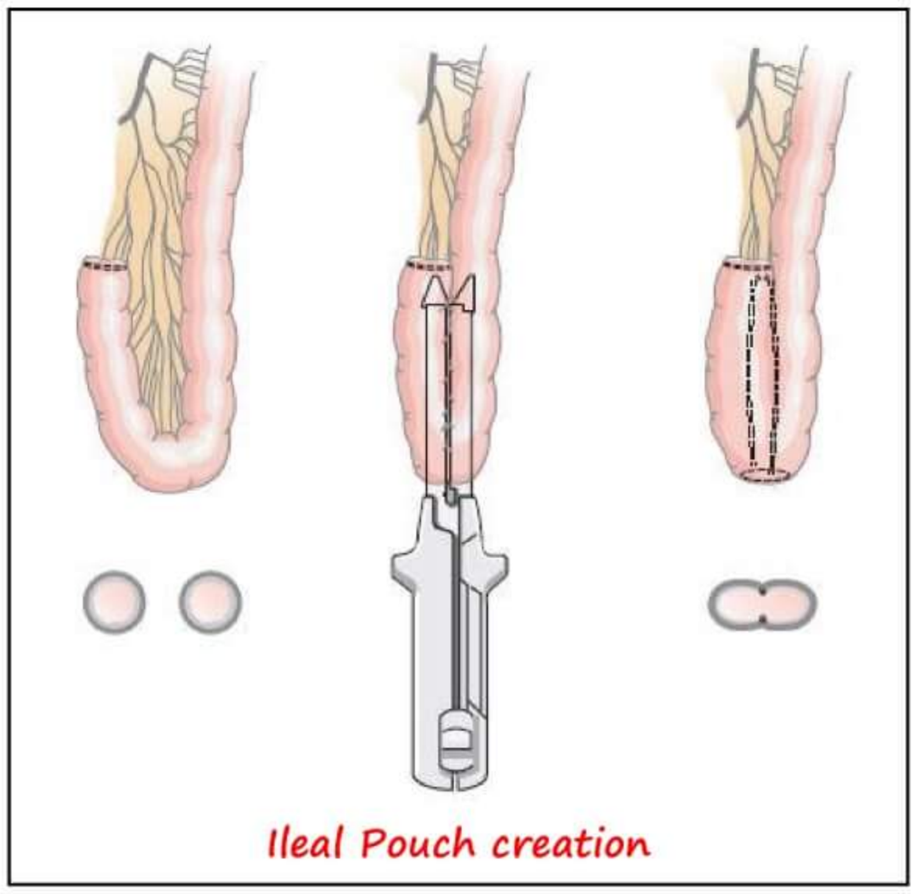

Types of Ileal pouch

t.me/latestpgnotes

- J Pouch – MC used
- S Pouch
- W Pouch

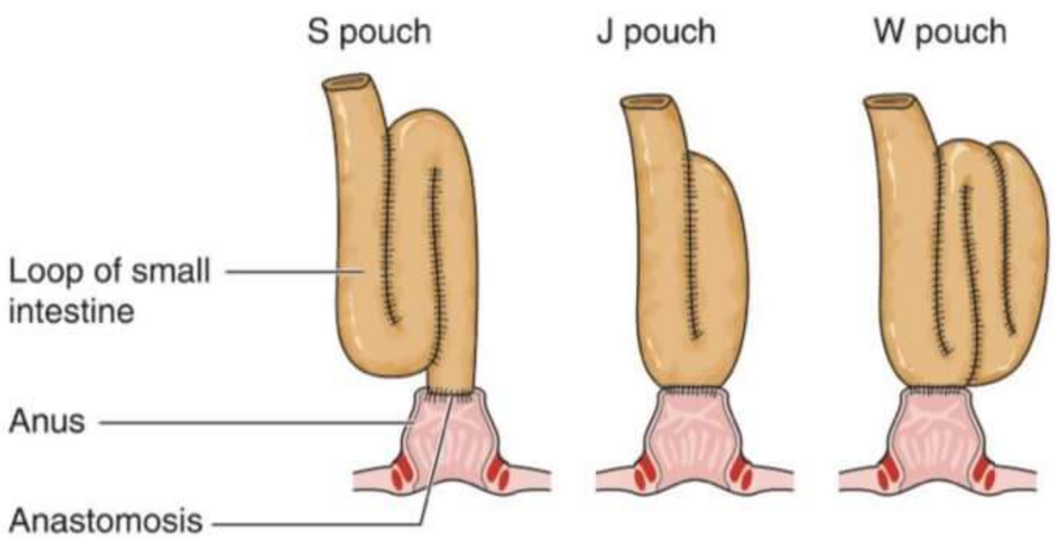

→ Complications of TPC + IPAA in Ulcerative colitis

- Pouchitis (7-33%) – MC
- Small bowel obstruction (25%)
- Pelvic sepsis
- Anastomotic & Pouch suture line leak
- Pouch vaginal fistula

Note

→ MC complication after TPC + IPAA in FAP patients – Small bowel obstruction

PrepLadder

Surgical option for UC in patients with special situation

- → Older patients
- → Pt. with Fecal incontinence

} TPC + End ileostomy

- → Pt. with confirmed Rectal dysplasia – Mucosectomy with hand sewn IPAA
- → Pt. with Significant Debility (Poor operative candidate) – TAC with very low Hartman closure with End ileostomy

Crohn's disease of Ano-Rectum

- → **Anal manifestations** – Most Devastating
  - Painful in Nature
  - Threat to Patients continence
- → Occurs in 20% of Pts. with CD
- → **Has 3 presentations**
  - Ulceration (MC)
  - Fistula
    - Cyanotic
    - Chronic
    - Indurated
    - Painless
  - Stricture

t.me/latestpgnotes

Clinical features

- → Fissure, Fistula & Abscess in Perianal region
- → Pain, Swelling & Bleeding
- → Soilage / Frank incontinence
- → Fever
- → Edematous & Purplish tags – **Characteristic feature**

Evaluation

- → Inspection
- → Digital Rectal Examination
- → Proctoscopy / Proctosigmoidoscopy

Management

- → Most pts. are managed Conservatively
- → Surgery – performed for Pain resulting from Undrained or Poorly drained abscess

PrepLadder

→ **Fissure in CD**

- Multiple
- Located off the Midline
- Avoid Fissurectomy or Lateral Sphincterotomy

→ **Infliximab**

- Very successful in the **Rx of Fistulizing CD**
- Fistula closure rate is **25 – 67%**

Staged approach for Perianal disease

→ **1st Step – Control the Local sepsis**

- I/D of Abscess + Antibiotics
- Fistula track require chronic drainage with Non-cutting Seton

→ **2nd Step – Infliximab**

- Should be given only after control of Local sepsis
- After 2-3 infusions of infliximab, Setons are removed for fistula closure

→ **3rd Step – Surgery**

- Performed if Fistula doesn't heal & Local sepsis resolved

t.me/latestpgnotes

Colitis associated Colon cancer (CAC)

Colitis associated Colon cancer	Sporadic Colon cancer
→ **Arises from** • Flat dysplasia • Dysplasia associated lesion or mass	→ **Arises from** • Adenomatous polyps
→ Has Multiple synchronous colon cancer in **12% cases**	→ Has Multiple synchronous colon cancer in **3-5% cases**
→ Mean age – **30 years**	→ Mean age – **60 years**
→ Distributed uniformly throughout the colon	→ Has left sided Predominance
→ Mucinous or Anaplastic variety is **more common**	→ Mucinous or Anaplastic variety is **less common**

→ Risk for Colonic carcinoma – **CD = UC**

→ Risk for SI Malignancy – **CD > UC**

→ Risk of Cholangiocarcinoma – **UC > CD**

PrepLadder

Risk factors for cancer in UC

1) Duration of colitis
2) Extent of colonic involvement
3) Presence of PSC & family history of CRC
4) Pancolitis & Disease diagnosed at young age

UC related CRC

→ **These cancers tend to be**

- Multicentric
- Evenly distributed throughout the colon
- Infiltrative
- Highly aggressive
- Poorly differentiated

→ Has **no significant difference between Sporadic & UC related CRC** with respect to Prognosis

→ **Cumulative risk** of cancer increases with duration of UC

- 25% Risk – at 25 years
- 35% Risk – at 30 years
- 45% Risk – at 35 years
- 65% Risk – at 40 years

t.me/latestpgnotes

Risk of malignancy in Crohn's Pancolitis

- 2% after 10 years
- 8% after 20 years
- 18% after 30 years

→ MC cause of death in Crohn's disease – GI Malignancy

→ **Other causes include**

- Sepsis
- Thromboembolic complications
- Electrolyte disorders

Toxic Megacolon

→ It is a serious Life-threatening condition

→ **Occurs in Pts. of**

- Ulcerative colitis (MC)
- Crohn's disease
- Infectious colitis (like Pseudomembranous colitis)

→ Massive dilatation of colon leads to Necrotic thin walled colon causing Perforation

PrepLadder

Investigations

→ **On Radiography** – Pneumatosis can be seen in the bowel

→ Plain X-Ray Abdomen

- Critical for diagnosis
- To follow up the course

→ **Radiological findings**

- Transverse colon diameter > 6cm
- Multiple air fluid levels
- Normal Colonic Haustrations – Absent or severely disturbed

→ **Organs & their diameter in Megacolon**

- Cecum → > 12 cm
- Ascending Colon → > 8 cm
- Transverse colon → > 6 cm
- Rectosigmoid / Descending colon → > 6.5 cm

Pneumatosis

UC – Toxic Megacolon

t.me/latestpgnotes

Management

→ **Medical management**

- Has high recurrence
- Urgent Laparotomy required

→ Pre-operatively, **Stabilization** should be done

↓

Fluids + IV Antibiotics given

→ TOC – Total Abdominal Colectomy with Ileostomy (With preservation of Rectum)

PrepLadder

Pouchitis

→ Inflammation of mucosa of Ileal pouch

→ Incidence = 7-33% cases

Etiology

→ Unknown

→ **May be due to**

- Bacterial overgrowth
- Mucosal ischemia
- Local factors

Clinical features

→ ↑sed Stool frequency – leading to Dehydration

→ Fever

→ Bleeding

→ Cramps

Definitive Treatment for UC = **TPC + IPAA**

- MC pouch used – **J shaped pouch**
- Pouch length – **15 cm**

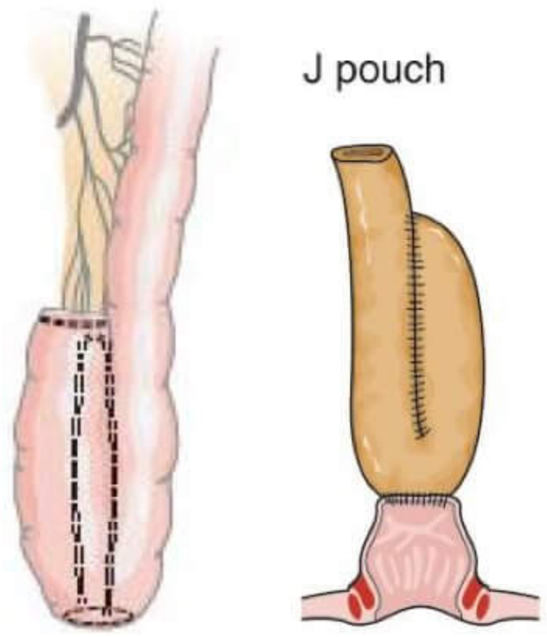

Treatment

→ Rehydration + Oral Antibiotics (**Metronidazole / Ciprofloxacin**)

→ **Probiotics** – Shows dramatic resolution in some cases resistant to Antibiotic therapy

t.me/latestpgnotes

→ For **Significant Pouchitis** not responding to Medical Rx – CD should be considered

Difference between Crohn's disease & Ulcerative colitis

Crohn's disease	Ulcerative colitis
Macroscopic features	
→ **Distribution** – Segmental with Skip areas	→ **Distribution** – Continuous without Skip areas
→ **Location** – Ileum (&/or) Cecum & Ascending colon	→ **Location** – Rectum, Sigmoid & Extending upwards cranially
→ **Extent** – Entire Thickness of Bowel wall	→ **Extent** – Superficial, confined to mucosal layer
→ **Ulcers** – Serpiginous ulcers that may develop into Deep ulcers	→ **Ulcers** – Superficial mucosal ulcers
→ **Pseudo polyps** – Rarely seen	→ **Pseudo polyps** – Commonly seen
→ **Fibrosis** - Common	→ **Fibrosis** - Rare
→ **Shortening** – Due to Fibrosis	→ **Shortening** – Due to Contraction of Muscularis

PrepLadder

Microscopic features	
→ **Depth of inflammation** - Transmural	→ **Depth of inflammation** – Mucosal + Submucosal
→ **Type of inflammation** • Non-Caseating granuloma • Infiltrate of Mononuclear cells	→ **Type of inflammation** • Non-specific Acute & Chronic inflammatory cells
→ **Mucosal changes** – Patchy Ulceration	→ **Mucosal changes** - Hemorrhagic mucosa with ulceration
→ **Submucosa** – Widened due to edema & lymphoid aggregates	→ **Submucosa** – Normal or reduced in width
→ **Muscularis** - Infiltrated by inflammatory cells	→ **Muscularis** - Spared
→ **Fibrosis** - Present	→ **Fibrosis** - Absent
Complications	
→ **Fistula formation** – Internal & External fistula in 10% cases	→ **Fistula formation** - Rare
→ **Malignant changes** • Colon cancer – UC = CD • SI Malignancy – CD > UC • Cholangiocarcinoma – UC > CD	
→ **Fibrotic strictures** - Common	→ **Fibrotic strictures** - Rare
→ **Toxic Megacolon** - Rare	→ **Toxic Megacolon** - ↑sed risk
Named features	
1) String sign of Kantor 2) Hose pipe appearance 3) Creeping fat sign 4) Comb sign 5) Raspberry Thorn / Rose Thorn appearance 6) Fat Halo sign	1) Garden hose appearance 2) Pipe stem colon 3) Lead pipe sign 4) Stove pipe appearance 5) Collar button ulcers

t.me/latestpgnotes

PrepLadder

VERMIFORM APPENDIX

Normal Anatomy

→ Normal length of appendix – 2 to 20 cm
→ Intra luminal capacity of appendix - 0.1 mL
→ Blood Supply - Appendicular artery (Branch of ileocolic artery)
→ Appendicular artery is an end artery.
→ Most common location - Retrocecal
→ Least common location - Post ileal
→ Most dangerous location – Pelvic

Acute appendicitis

→ MC general surgical emergency worldwide
→ Seen in Young patient usually of 2nd decade

Etiopathogenesis

→ **Luminal obstruction** can be due to
- Fecalith (MC cause)
- Tumors (e.g. Carcinoid tumor)
- Worm eggs (e.g. Ascaris eggs)
- Fruit seeds

→ **Luminal obstruction** - Increased Intraluminal pressure

↓

Impaired Lymphatic drainage

↓

Impaired Venous drainage & Arterial supply

↓

Ischemia

↓

Perforation

→ Mc site of perforation - Just distal to obstruction on antimesenteric border
→ Mc organism Isolated after perforated appendicitis - Bacteroides fragilis > E. coli

Clinical features

→ **Pain in peri- umbilical region** - Shifting of Pain to right lilac fossa (**Migratory Pain**)
→ Most characteristic symptom of Acute appendicitis - Migratory pain
→ Anorexia
→ Nausea, Vomiting
→ **Signs**
- Tenderness in right iliac fossa
- Rebound tenderness
- Elevated temperature

PrepLadder

Lab investigations

→ Leucocytosis

→ Shift to left

Other named signs

DUNPHYS SIGN - Pain on coughing
ARON SIGN - Pain on pressure in epigastrium
TEN-HORN SIGN - Pain on gentle traction of right testes
ROVSINGS SIGN • Pain in **right iliac fossa** on pressing **left iliac fossa** • Most characteristic sign of acute appendicitis
ROVSING'S SYNDROME - In horseshoe kidney, hyper extension of spine causes pain, nausea, Vomiting.
ROVSING'S OPERATION - Deroofing of cyst in autosomal dominant poly cystic kidney Disease (ADPKD)
OBTURATOR SIGN • Pain on internal rotation of right thigh over hip joint • Obturator sign is positive in Pelvic Appendicitis. • In Pelvic appendicitis, orientation of appendix is towards pelvis and in close relationship to rectum. So, **abdominal signs are not marked** in Pelvic appendicitis. ➢ Irritation of rectum – Diarrhea ➢ Irritation of ureter – Microscopic hematuria (> 3RBCs/ HPF)
PSOAS SIGN • Hyper extension at right hip joint causes pain in right iliac fossa • Psoas sign is Positive in Retrocecal appendicitis

t.me/latestpgnotes

Diagnosis

→ **Purely clinical** (in adults)

→ Supplemented by lab investigation and ultrasound

→ Leucocytosis is seen on laboratory investigations

→ **IOC**

- In children- ultrasound
- In Adults – Clinical diagnosis

→ **Gold standard for diagnosis of Acute appendicitis**- CECT (ever in equivocal cases, CECT can confirm the diagnosis)

Treatment

→ Emergency appendectomy

PrepLadder

Alvarado Score

Aka MANTRELS Score

MANTREL	Score
Migratory pain	1
Anorexia	1
Nausea, Vomiting	1
Tenderness	2
Rebound tenderness	1
Elevated Temperature	1
Leucocytosis	1
Shift to Left	2

→ Score of **9-10** - Certain diagnosis
→ Score of **7-8** - High likely hood of diagnosis
→ Score of **5-6** - Equivocal (most dangerous)
→ Score of 1-4 - Negative for acute appendicitis

→ **CECT** is indicated in cases of Equivocal MANTREL score findings to confirm diagnosis

Risk factors for Appendicular perforation

→ Fecalith obstruction
→ Diabetes mellitus
→ Immunocompromised state
→ Extreme of ages (<5 years, > 65 years)
→ Pelvic appendicitis
→ History of Previous surgeries
→ In patients of acute appendicitis, during emergency appendectomies → abdomen is palpated after spinal anesthesia to diagnose appendicular lump.
→ **Appendicular lump is a contraindication for surgery**. So, patients are managed conservatively by **Ochsner sherren regimen**

t.me/latestpgnotes

OCHSNER SHERREN REGIMEN

→ Conservative management of appendicular lump
→ **Components of appendicular lump**
  - Appendix
  - Ileum
  - Cecum
  - Omentum
→ Surgery done during appendicular lump formation can lead to increased risk of injury of cecum.
→ To know whether the lump is appendicular lump - **CECT** has to be done.
→ Start IV antibiotics in all the patients
→ **If abscess present** - drain the abscess.
→ Monitor pulse rate and temperature every 4 hourly

PrepLadder

→ **Within 24-28 hours** – most patients improve
→ Continue the conservative management
→ Perform **Interval appendectomy** (Not recommended in all patients)
- only for patients experiencing **Recurrent appendicitis**

Indications for surgery

→ **P** – Pulse rate rising
→ **S**- Spreading abdominal pain
→ **M** - Mass size increasing

Carcinoid Tumor of Appendix

→ MC tumor of appendix - **Carcinoid tumor**
→ **Aka Argentafinnoma**
→ Small, localized, not associated with metastasis
→ Not associated with carcinoid syndrome
→ Mc site of appendix - **tip of appendix**
→ **Treatment**
- Upto 1cm → Appendectomy
- > 2 cm → Right Hemicolectomy
- > 1cm to 2cm → Appendectomy

→ **Indications of right Hemicolectomy**
t.me/latestpgnotes
- Involvement of mesoappendix
- Involvement of cecal base
- Involvement of LN

Appendectomy

- Laparoscopic
- Open approach

→ **Mc Burney's point**
- Junction of **lateral 1/3rd from umbilicus & medial 2/3rd from ASIS.**
- Mc Burney's Point corresponds to **base of appendix**

Incisions

→ **Mc Burney's incision**
- Incision centered on Mc Burney's point & perpendicular to umbilical ASIS line.
- Aka **Grid iron incision**
- Aka **Mc Arthur incision**
- This is a **muscle splitting incision**

PrepLadder

→ **Rutherford- Morrison incision**

- In retrocecal appendicitis (appendix difficult to be visualized) extend the MC Burney incision, upward & laterally by cutting conjoint tendon.
- This incision is **Muscle Cutting incision**
- Preferred for retrocecal appendix.

→ **Lanz incision**

- This incision is a **muscle splitting incision** placed transversely 2cm below umbilicus on the line joining midpoint of clavicle to midpoint of inguinal ligament
- Aka **transverse incision**
- Aka **skin crease incision**
- Cosmetically better preferred nowadays

t.me/latestpgnotes

PrepLadder

RECTUM AND ANAL CANAL

Hemorrhoids

→ **Are Normal anatomical cushions**

→ Made of

- Venules
- Arterioles
- Smooth muscle fibers
- Elastic tissues

Location of hemorrhoids

→ 3' o clock

→ 7'O clock

→ 11'O clock

Pathophysiology

→ On constipation due to Excessive straining

↓

Abnormal descent of anatomical cushions

↓

Injury by hard fecal matter

↓

Bleeding PR

t.me/latestpgnotes

- Mc cause of bleeding PR → Hemorrhoids
- Mc cause of significant lower GI bleed → Colonic diverticula
- Mc cause of occult lower GI bleed → Angiodysplasia/ Vascular ectasia

Clinical Presentation

→ Painless bleeding

→ Amount of bleeding - 3 to 5 ml to a max of 10 ml

Diagnosis

→ They Cannot be palpated, therefore hemorrhoids **cannot be diagnosed by DRE**

→ Diagnosis of hemorrhoids - by proctoscopy

Types of Hemorrhoids

Internal hemorrhoids	External hemorrhoids
→ Location - above dentate line (Pain insensitive region)	→ Location – below dentate line (pain sensitive region)
→ Painless bleeding	→ Painful bleeding
	→ Aka **5- days painful self-curing lesion**
	→ Recurrent thrombosis in external hemorrhoids leads to semi- RIPE black currant
→ Treatment - **depends on the degree**	→ Treatment - **Excision**

PrepLadder

Internal Hemorrhoids classification

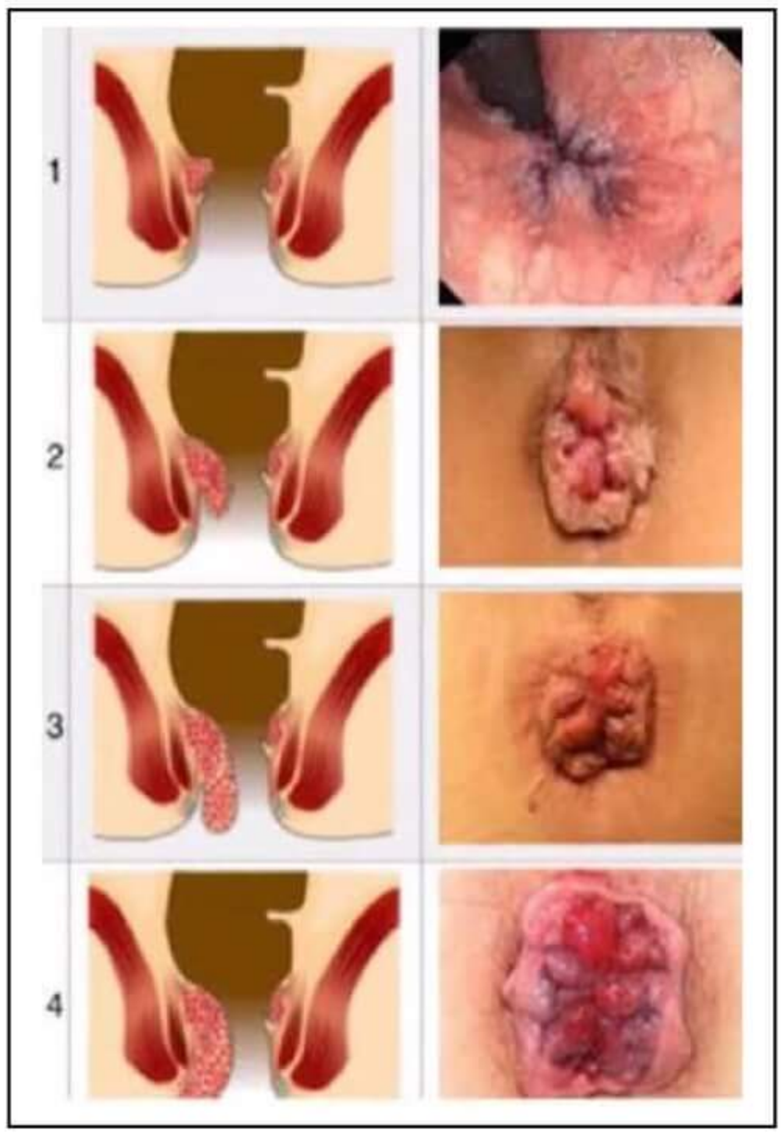

- → **First degree** – Bleeding only
- → **Second degree** – Bleeding + Prolapse during defecation (Spontaneous resolution)
- → **Third degree** – Bleeding + Prolapse with manual reposition
- → **Fourth degree** – Bleeding + Permanent prolapse

Treatment

- → **First degree hemorrhoids**
  - Dietary modification
  - Stool softener
  - High fiber diet

- → **First degree, second degree and selected patients of third degree**
  - Banding
  - Sclerotherapy (5% phenol in almond oil)
  - Both banding and sclerotherapy are very cheap and effective
  - In banding – Rubber band is applied other the hemorrhoid. After 48 hours, hemorrhoids are sloughed off because of ischemia and the lesion heals with fibrosis.

t.me/latestpgnotes

- → **Rest of third-degree patients and fourth degree patients**– Hemorrhoidectomy
  - Milligan-Morgan open Hemorrhoidectomy
  - Ferguson closed hemorrhoidectomy } **Not used**
  - Whitefield submucosal hemorrhoidectomy
  - Longo's Stapler hemorrhoidectomy
  - most preferred method- Longo's Stapler hemorrhoidectomy (Associated with Lesser post-operative pain)

Complication

- → MC complication – Pain > urinary retention

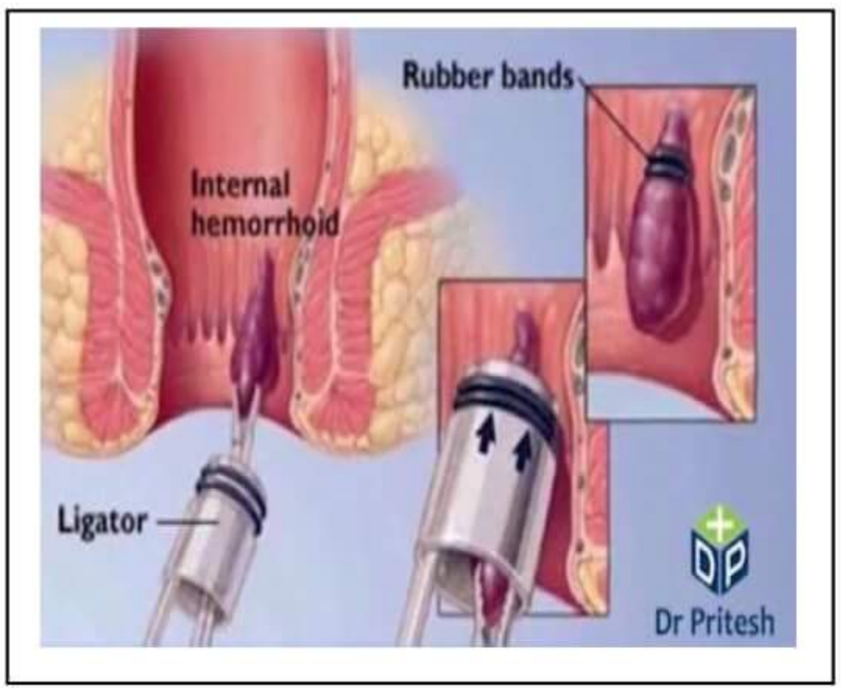

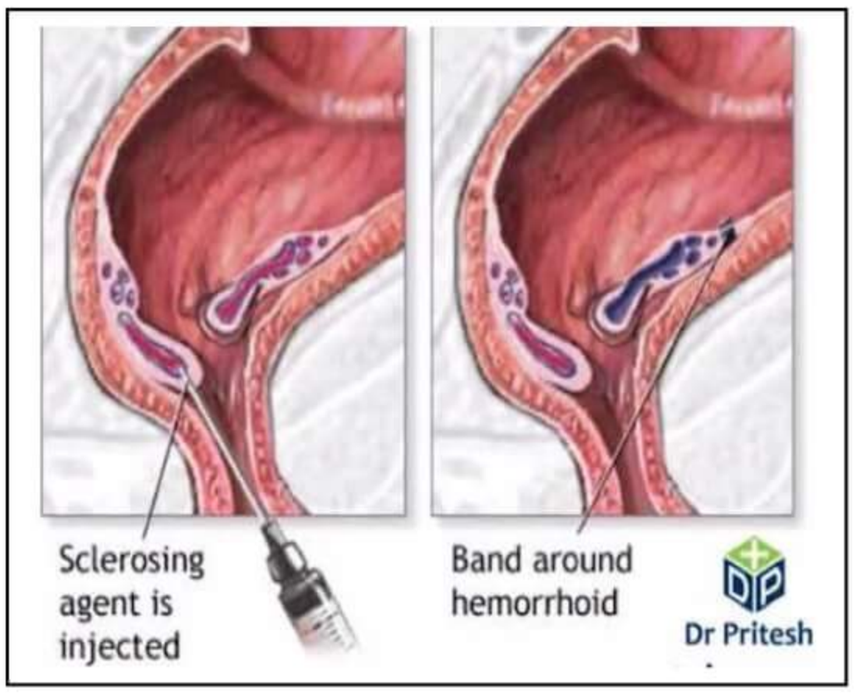

PrepLadder

Rectal prolapse

→ **Rectal Prolapse is of two types**
- Mucosal (mainly in children)
- Full thickness (mainly in adults)

Rectal prolapse

Causes of rectal prolapse

→ Protein Energy Malnutrition
→ Worm infestation
→ Diarrhea
} common causes

→ Sacral agenesis
→ Meningomyelocele
} rare causes

Management

→ Depends on cause
→ Conservative Management for common causes
→ If patient is not responding - LOKHART – MUMMARY RECTOPEXY
→ For rare causes - THIERSCH ANAL WIRING

For Adults → Rectopexy via Abdominal approach & Rectopexy via Perineal approach

Rectopexy via Abdominal Approach	Rectopexy via Perineal Approach
→ Decreased recurrence rate	→ Increased recurrence rate
→ Associated with high morbidity	→ Associated with low morbidity
→ Preferred in young patients	→ For old & frail patients
→ Types of rectopexy • W – Well's • A - Abdominal • R - Ripstein	→ Types of rectopexy • P - Perineal • A - Altmaier • D - Delorme
→ RESECTION RECTOPEXY • Goldman – Fryberg	→ THIERSCH ANAL WIRING

t.me/latestpgnotes

Anorectal Abscess

Types

a) Perianal (MC)
b) Ischiorectal (2nd MC)
c) Submucous
d) Pelvi rectal

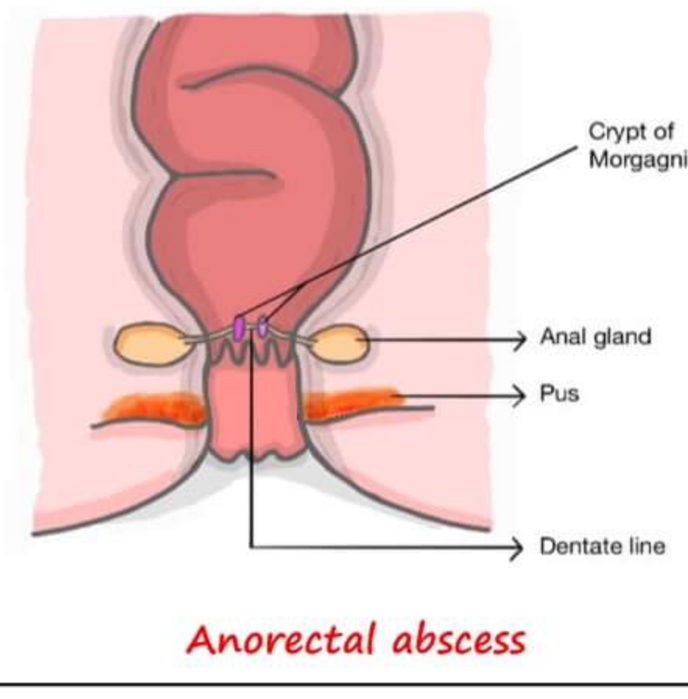

Anorectal abscess

Formation of anorectal abscess

→ Opening of anal glands at dentate line - crypt of Morgagni
→ Via the crypts, infection reaches the anal gland

PrepLadder

→ There is pus formation & it follows the path of least resistance
→ Pus is collected in the perianal area causing perianal abscess.
→ It is tract behind, **U- shaped tract** in the ischiorectal fossa forming ischiorectal abscess.
→ Theory responsible for formation of ANORECTAL ABSCESS - CRYPTOGLANDULAR THEORY

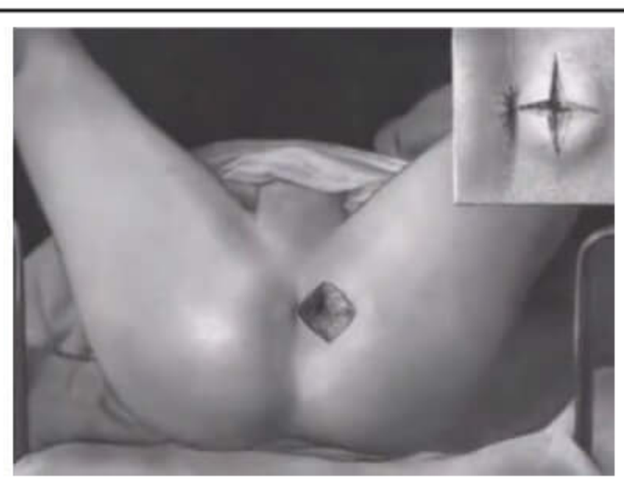

Cruciate incision

Clinical features

→ Severe pain
→ Throbbing swelling
→ Swinging pyrexia

Treatment

→ Incision (Cruciate shaped incision) and Drainage + Antibiotics

FISTULA-IN-ANO

→ Chronic abnormal communication between anorectum & perineal skin
→ History of Anorectal Abscess/ Anorectal sepsis
→ Forms a tract outside known as Fistula in Ano
→ Theory responsible for Fistula in Ano - CRYPTOGLANDULAR THEORY

t.me/latestpgnotes

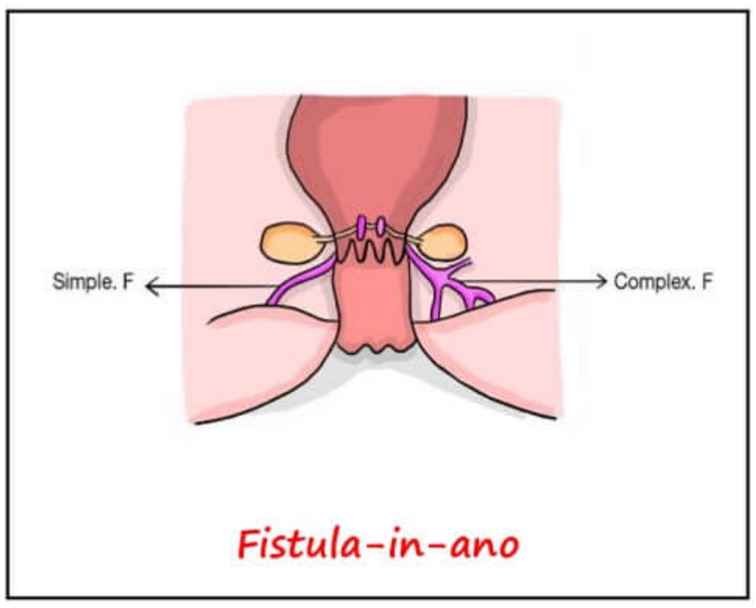

Fistula-in-ano

Components of ANORECTAL RING

→ Puborectalis (like sling around rectum junction)
→ Internal Anal Sphincter (Formed by inner circular layer)
→ External Anal Sphincter (Formed by outer longitudinal layer)

Types

→ **Low lying**
  • If internal opening of fistula is below anorectal ring
→ **High lying**
  • If internal opening of fistula is above anorectal ring
→ **Simple fistula**
  • Single straight tract
→ **Complex fistula**
  • Multiple branched tract (secondary extensions)

Causes

→ Anorectal Abscess (MC)
→ Crohn's disease
→ Lymphogranuloma venereum
→ Actinomycosis
→ Foreign body in rectum

PrepLadder

→ Malignancy
→ HIV

Clinical Features

→ More common in Males
→ Usually seen in 3rd – 5th decade
→ **Intermittent purulent discharge + Pain**
→ **If patient passes Feces & flatus from external opening** – likely position of internal opening is in **Rectum**

Key points to be assessed in fistula

→ Location of Internal opening
→ Location of External opening
→ Course of tract
→ Secondary extensions- present/not
→ Complicating disease/ condition that can affect healing of fistula

Investigations

→ First investigation – **Fistulogram**
→ IOC- **MRI**

PARK'S CLASSIFICATION

t.me/latestpgnotes

Type 1	→ Inter- sphincteric (MC)
Type 2	→ Trans- sphincteric
Type3	→ Supra- sphincteric
Type4	→ **Extra**- sphincteric

→ ON DRE, induration around internal opening can be localized.
→ On proctoscopy also, internal opening can be localized if the internal opening is within 10cm of anal verge.

GOOD SALL'S RULE

→ To indicate the likely position of internal opening on the basis of external opening
→ **Anteriorly located external openings are joined by short straight track.**
(Example - 11'o clock position of external opening is same as 11'o clock portion of internal opening)
→ **Posteriorly located external openings are joined by Long curved track & opens in posterior midline**
(in posteriorly located external openings, whatever position of external opening, internal opening is at 6'oclock position)

PrepLadder

Exception of Goodsall's rule

→ External opening > 3cm from anal verge

→ Multiple external openings

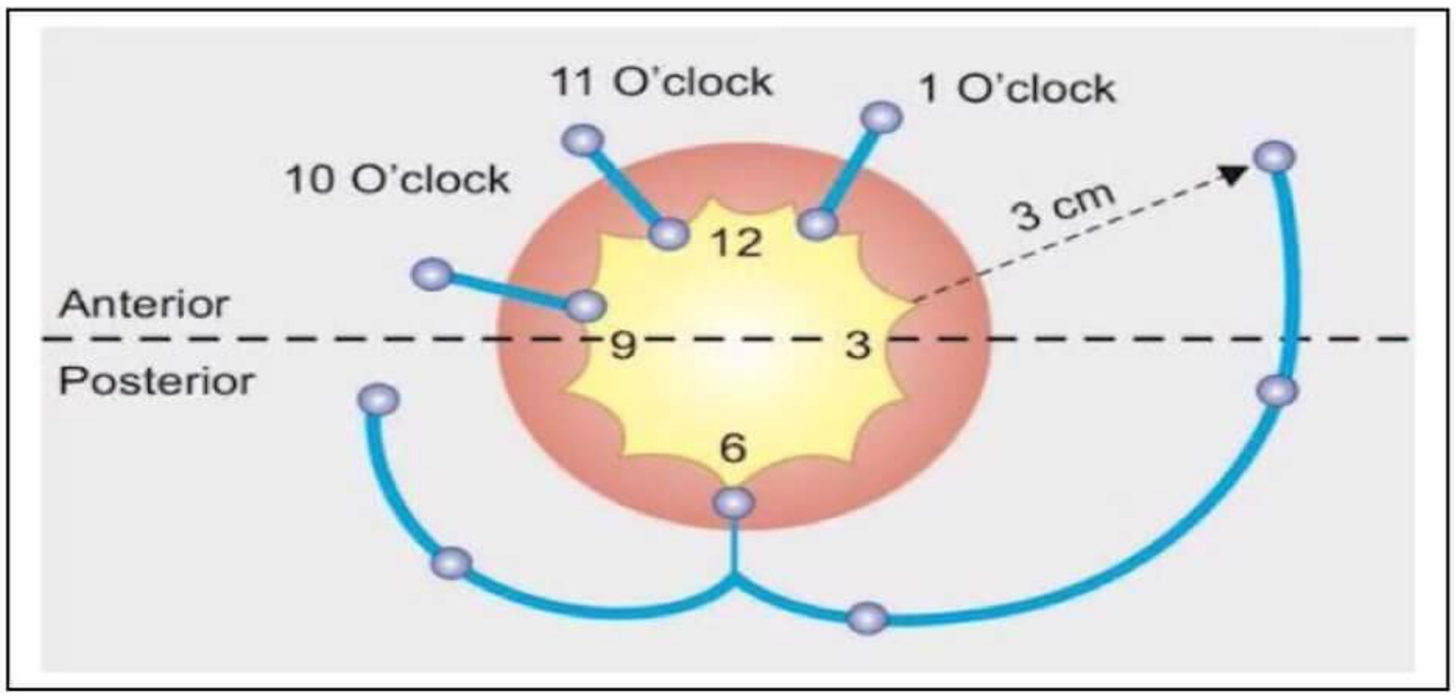

Treatment

→ Fistulotomy – Incision over fistula tract
→ Fistulectomy – Excision of fistula tract
} High morbidity

→ SETON

→ VAAFT (Video Assisted Anal Fistula Treatment)

→ Glue

SETON

t.me/latestpgnotes

→ Thread made of silk, linen, nylon, silastic

→ **Types of seton**

- Cutting seton
- Non-Cutting seton (aka Draining seton)
- Marking seton
- Staging seton

→ **Cutting seton**

- Cutting Seton is inserted over the fistula and tied and knot is applied.
- Every week, knot is made tight and hence it starts cutting the tissues.
- **Uses** – Cutting seton converts High lying fistula to Low lying fistula
  (Treatment of high lying fistula is associated with high risk of fecal incontinence)

Indications of Seton

→ Treatment of Complex Anorectal fistula

→ Treatment of fistula in Crohn's disease & HIV patients

- Draining seton is used to control infections as they have multiple, infectious fistula

→ Anterior fistulas

- More common in females

→ Fistulas associated with Chronic diarrheal state.

PrepLadder

Fissure-in-Ano

→ Location of dentate line - usually 2cm below the anal verge.

→ Longitudinal split in the anoderm from anal verge to the dentate line

→ Location – In posterior midline at 6'o clock position

→ **Fissure is of two types**

- Acute fissures
- Chronic fissures

→ **Chronic fissures** - Characterized by Triad

- CANOE- SHAPED ULCER
- SENTINEL PILE (aka skin tag)
- Hypertrophied papilla

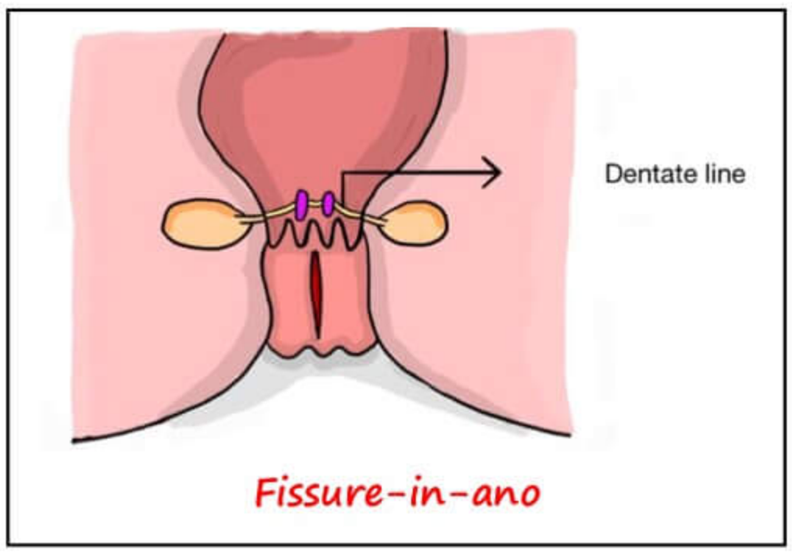

Fissure-in-ano

Pathophysiology

→ **Spasm of Internal Anal sphincter**

→ Patients have **constipation**

→ During excessive straining at the time of defecation, the fecal matter passing through internal anal sphincter injures the pain sensitive mucosa of anal canal.

Tear/ split in the anoderm

↓

Decreased vascularity

↓

Healing of Tear decreases (due to ischemia)

t.me/latestpgnotes

→ Principle of treatment is based on relaxing the spasm

→ Fissure in Ano is similar to Achalasia cardia

Clinical features

→ Serve pain during defecation

→ **Streaking of blood** over stool

→ In fissure in Ano - Digital rectal examination is contraindicated.

→ Examine the gluteal region, find the longitudinal spilt in posterior midline

Management

→ **Initially conservative management**

- Sitz bath
- Stool softener

→ **Medical Treatment**

- CCB – 2% Diltiazem Gel – (Local application)
- Nitrates - 0.2% nitroglycerine
- Botox injection into sphincters
- Lord's procedure – manual dilatation of sphincter (not performed usually).
- TOC - NOTARA'S lateral sphincterotomy (divide internal anal sphincter laterally)
- Anal advancement flap

PrepLadder

Pilonidal sinus

→ Acquired condition
→ Seen in hairy males
→ Usually among 20-29 years
→ Common in military personnel
→ Aka JEEP'S DISEASE (common in Jeep drivers of Army)
→ Collection of dead hair in the natal cleft overlying the coccyx.

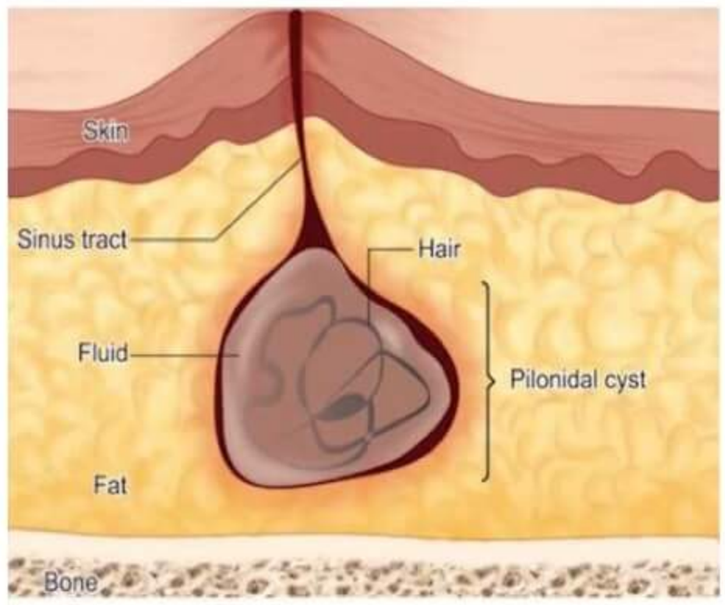

Pilonidal sinus

Clinical features

→ Discomfort in post-natal cleft region with intermittent serous discharge
→ Infection - Abscess formation
→ **Location**
  - Interdigital pilonidal sinus (common in barbers)
  - Umbilicus
  - Axilla

Management

→ **For Abscess**
  - Incision & Drainage + Antibiotics
→ **If no abscess**
  - Excision of sinus tract + Closure of defect using flap
→ **Flaps Used for closure**
  - LIMBERG'S Flap
  - KARGYDAKI'S flap
→ **Procedure performed for the treatment of Pilonidal sinus**
  - BASCOM procedure

t.me/latestpgnotes

CA rectum

→ MC site of large bowel malignancy
→ Usually seen in 5th – 6 decade
→ MC site of metastasis – Liver > lungs
→ Chemotherapy regimen- FOL FOX-IV
  - FOL – Folinic acid/ leucovorin
  - F- 5-FV (5-Flurouracil)
  - Ox- Oxaliplatin

Clinical features

→ MC symptom – Bleeding PR
→ Early morning bloody diarrhea
→ Passage of bloody slime (no fecal matter)

PrepLadder

→ Spurious diarrhea (every 2 to 3 hours, rectum is full with discharge from tumor, so patient passes like stool every 3 hours)
→ **Tenesmus** – Painful defecation with sensation of incomplete evacuation seen in lower part of CA rectum
→ Back ache/ sciatica (sacral plexus involvement posteriorly)
→ Weight loss (liver metastasis)

Investigations

→ Length of anal canal – 3cm
→ length of rectum – 14cm
→ For complete evaluation, the length of the instrument should be at least 17 cm

Investigations Options available

→ PROCTOSCOPY
→ Sigmoidoscopy

→ **Colonoscopy**
- Length of proctoscope – 10 cm
- Rigid sigmoidoscope -25 cm
- Flexible sigmoidoscope- 60cm
- Colonoscope – 160 cm

t.me/latestpgnotes

→ **Investigation of choice** – Rigid sigmoidoscopy + biopsy
→ Colonoscopy is mandatory for adequate evaluation of whole colon and to rule out any synchronous polyp or synchronous malignancy
- Synchronous- simultaneously
- Metachronous- later after surgery

→ **Virtual colonoscopy (3D reconstruction colonoscopy using CT)**
- Advantage - can visualize outside of lumen also
- Disadvantage - Biopsy of colon cannot be done

→ In head & neck malignancies & pelvic malignancies, overcrowding of nerves, blood vessels & soft tissues. So, IOC for staging of most of head and neck malignancy– MRI
→ **For T- staging,** investigation of choice- TRUS (Transrectal ultrasound)

→ Distantly lying nerve, lymph node, vessel cannot be differentiated as **Sensitivity of ultrasound decrease if distance between probe & organ increase.**
→ **For lymph node staging**, investigation of choice is – Endorectal MRI
→ Overall Best investigation for staging- MRI

PrepLadder

Treatment

→ **Principle of treatment in CA Rectum**

- Stage I – Surgical resection
- State II & III – Neoadjuvant chemoradiation followed by surgical resection (down stage the tumor & then surgery)
- Stage IV – Neoadjuvant chemoradiation followed by palliation ± surgical excision

→ **TOC- TOTAL MESORECTAL EXCISION**

- Given by **Bill Heald**
- Significant length of bowel removal around the tumor
- Removal of Surrounding tissues up to the plane between Mesorectum & Presacral Fascia **known as HEALD'S HOLYPLANE**

→ If CA rectum is located > 5 cm above Anal verge – Low Anterior Resection (LAR)

→ If CA rectum is located at or below 5 cm from anal verge – APR (Adomino Perineal resection) aka Mile's Procedure

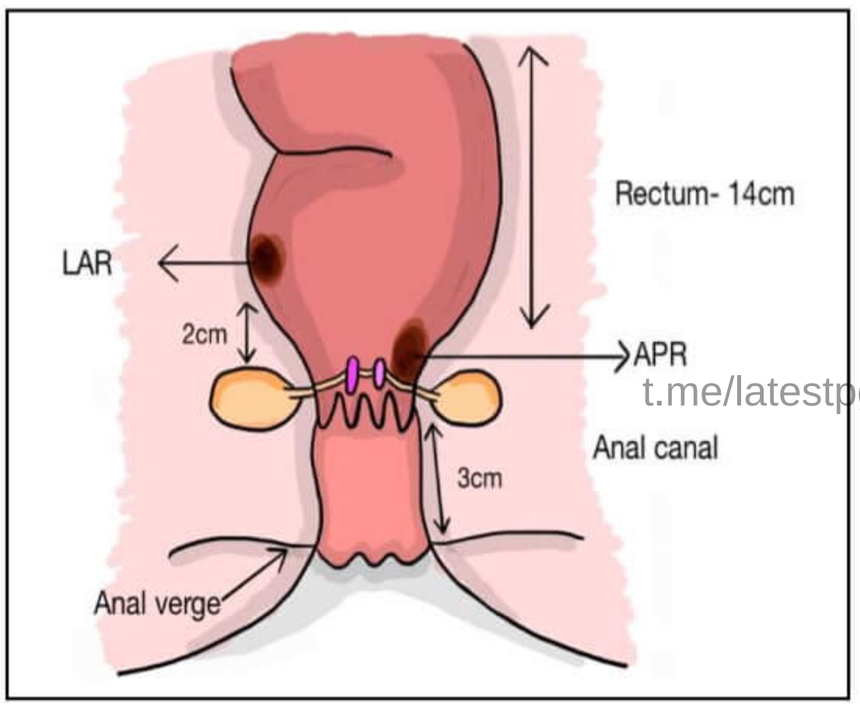

t.me/latestpgnotes

→ **LAR**- if Tumour> 5cm from Anal Verge
→ **APR**- if Tumour at or below 5cm from Anal Verge
→ **Total Mesorectum excision** is done in Ca Rectum.

Carcinoma anal canal

→ MC histological type - SCC > BCC > MM
→ MC site of metastasis – lungs
→ In perineal malignancies like CA Penis, CA Scrotum, CA Anus - **Inguinal lymph nodes are involved**

Risk Factors (based on low socio-economic status)

→ Smoking
→ HPV infection (16, 18, 31,33)
→ HIV +ve /Immunocompromised state
→ Anal receptive intercourse
→ Multiple partners
→ History of CA Cervix / Vulval cancer
→ Initially, growth in anus is inside lumen.
→ Later, growth is seen outside lumen.
→ In **advanced malignancies in anus**, they can infiltrate into bladder/ vagina leading to fistula and if sphincters are involved, incontinence can happen.

PrepLadder

Clinical features

- → MC symptom- Bleeding PR
- → Foul smelling discharge
- → Involvement of
  - Bladder
  - Vagina
  - Sphincters
- → Incontinence
- → Back ache
- → Alteration of bowel habit

} Ominous symptoms of advanced cases

- → MC site of metastasis is **Lungs**
- → MC involved group of lymph nodes - **Inguinal Lymph nodes**

Investigations

- → **IOC** - Proctoscopy with biopsy

Treatment

- → **NIGRO regimen - Chemotherapy followed by radiation**
  - 5- fluorouracil + Mitomycin-C followed by radiation

8th AJCC TNM CLASSIFICATION

T_{is}	→ Carcinoma-in-situ → Aka BOWEN'S DISEASE → Anal intraepithelial neoplasia type I – III
T_1	• Size of tumor up to 2 cm
T_2	→ Size of tumor > 2-5 cm
T_3	→ Size of tumor > 5 cm
T_4	→ Involvement of adjacent structures i.e. Vagina, Urethra, Bladder
N_{1a}	→ Metastasis to inguinal, meso rectal and/or internal iliac lymph node
N_{1b}	→ Metastasis to external iliac lymph nodes
N_{1c}	→ Metastasis to external iliac lymph nodes + inguinal lymph nodes + mesorectal and/or internal iliac lymph nodes
M_0	→ No Metastasis
M_1	→ Distant Metastasis

t.me/latestpgnotes

PrepLadder

HERNIA AND ABDOMINAL WALL - 1

Hernia

→ **Protrusion of viscus** or **part of viscus through the wall** of its containing cavity

→ Weakness of abdominal wall muscles/ Increased abdominal pressure - Herniation of abdominal contents.

NYHUS classification

Type 1	→ Indirect hernia (normal internal ring)
Type 2	→ Indirect hernia (enlarged internal ring)
Type 3A	→ Direct hernia
Type 3B	→ indirect hernial enlarge enough to encroach upon posterior inguinal wall → Indirect sliding / Scrotal hernial → Pantaloon hernia
Type 3C	→ Femoral hernia
Type 4	→ Recurrent hernia • 4A – direct hernia • 4B – indirect hernia • 4C – femoral hernia • 4D – combine hernia

t.me/latestpgnotes

GILBERT classification

→ **Type 1** – indirect, small

→ **Type 2** – indirect, medium

→ **Type 3** – indirect, large

→ **Type 4** – direct, involves entire floor

→ **Type 5** – direct, diverticular

→ **Type 6** – combined (pantaloon/saddle back/ dual hernia/ ROMBERG'S hernia)

→ **Type 7** – femoral hernia

Risk factors

→ **Factors that can cause weakness of abdominal wall muscles**

- Patent Processus vaginalis
- Patent canal of nuck
- Connective tissues disorders (Ehler's Danlos syndrome)
- Prune – Belly syndrome
- Ectopia vesicae
- Lower abdominal incision
- Defective collagen synthesis
- Smoking
- Steroid intake

PrepLadder

→ **Factors that can cause increased intrabdominal pressure**

- Chronic cough
- COPD/ Bronchitis
- Chronic constipation
- Obstructive uropathy (BPH, stricture urethra)
- Heavy weight lifting
- Ascites
- Pseudomyxoma peritonei
- Pregnancy
- Chronic ambulatory peritoneal dialysis (CAPD)

→ MC type of hernia in both male & females - **Indirect inguinal hernia**

→ **Femoral hernia** - more common in females.

→ **Deep ring** - defect in **Fascia transversalis**

→ **Superficial ring** - defect in **External oblique aponeurosis.**

Types of hernia

Indirect Inguinal Hernia

Sac enters via deep ring

↓

Traverse inguinal canal

↓

Goes out via superficial ring

t.me/latestpgnotes

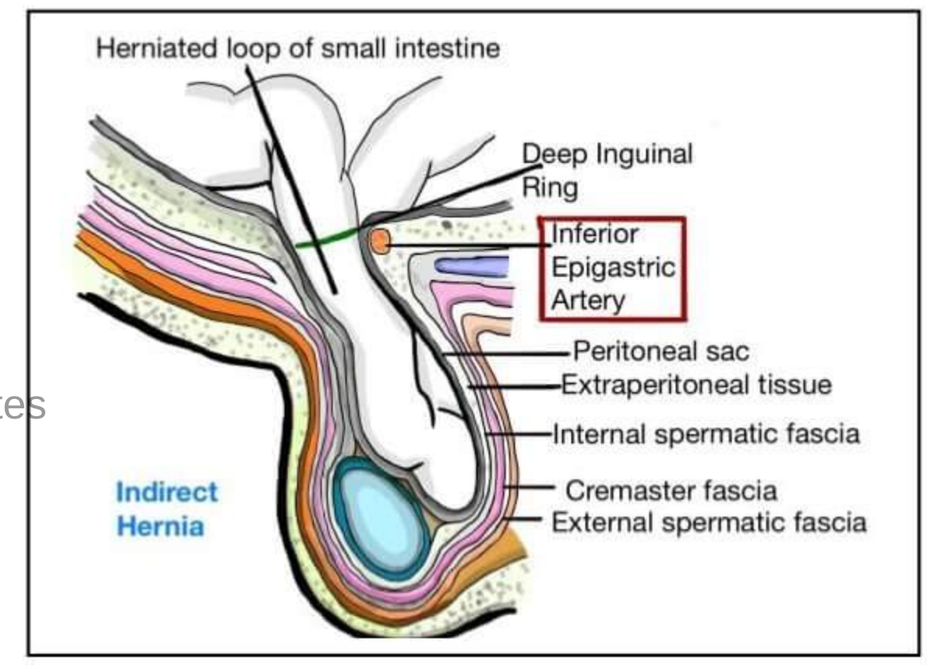

Direct Inguinal Hernia

→ Sac protruding directly from posterior abdominal wall via triangle of Hesselbach and enters into the inguinal canal

→ **Triangle of HESSELBACH**

Boundaries

- **Laterally** - Inferior epigastric artery
- **Medially** - Lateral border of Rectus abdominus
- **Inferiorly** - Inguinal ligament

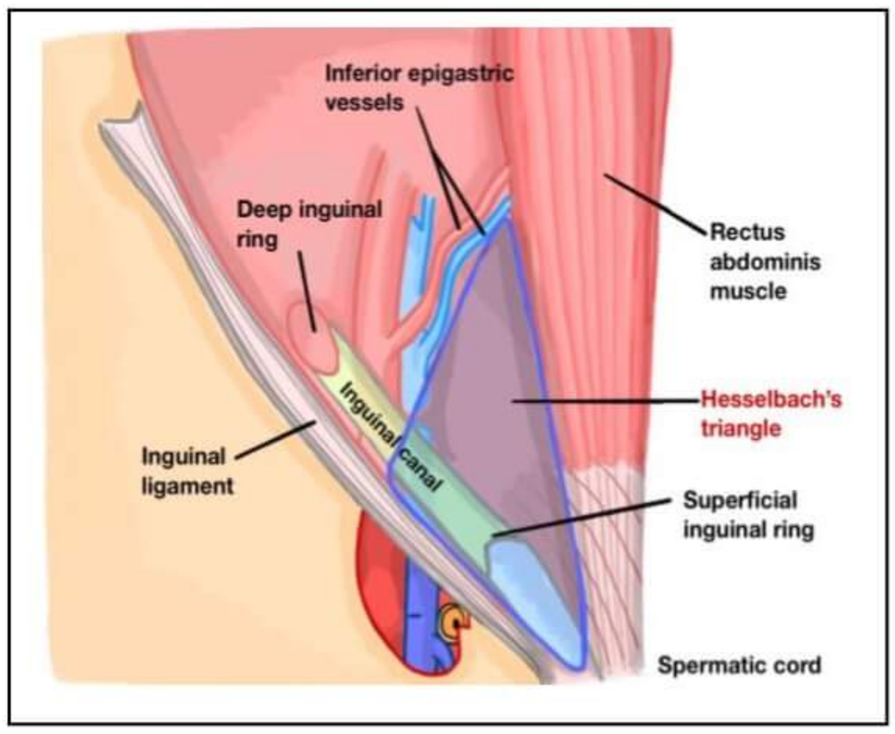

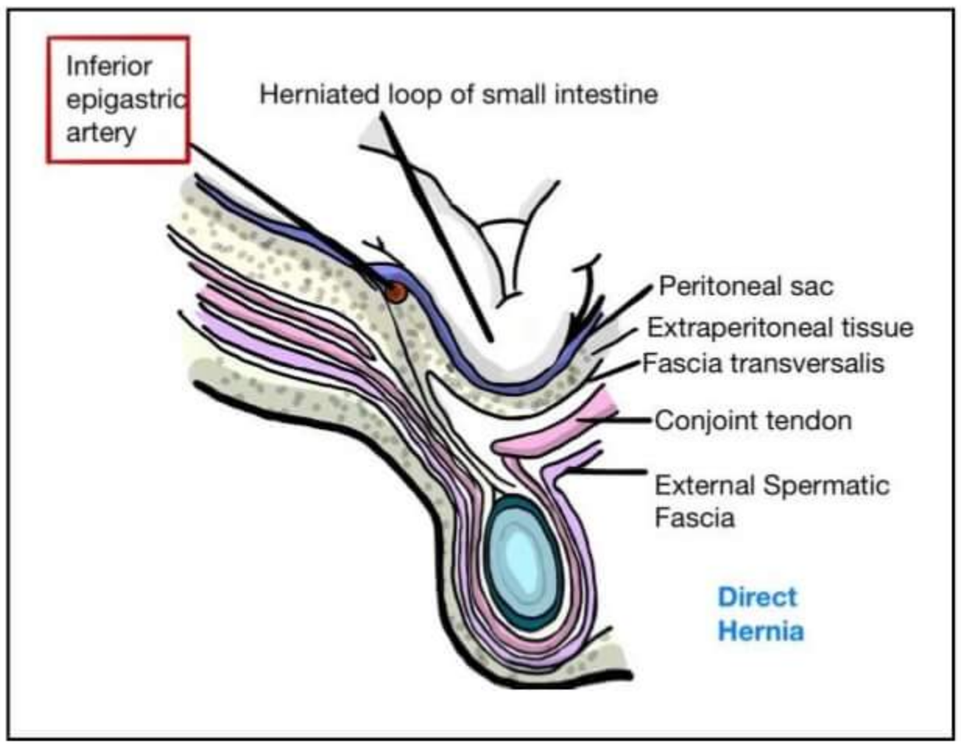

PrepLadder

Relation of sac with the spermatic cord

→ Sac is posterior to spermatic cord in Direct inguinal hernia

→ Sac is anterolateral to spermatic cord in Indirect inguinal hernia

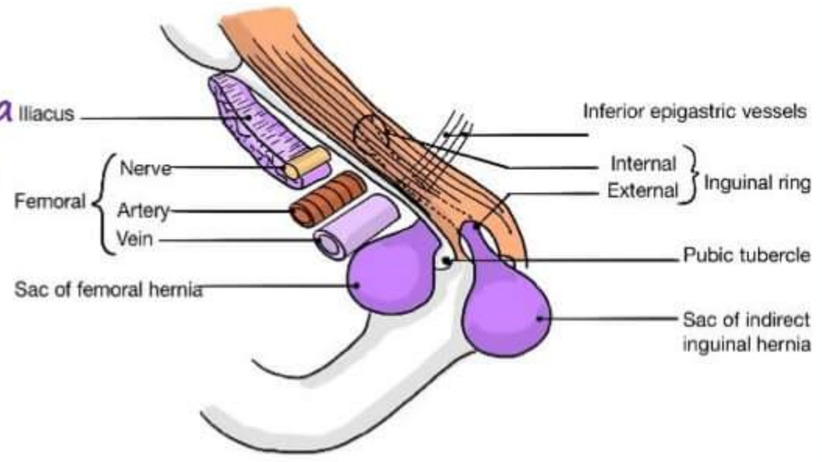

Relation of neck of sac

→ In Inguinal hernia - above and medial of pubic tubercle

→ In femoral hernia - below and lateral to pubic tubercle

Types of Indirect Inguinal hernia

→ **BUBONOCELE**

- Hernia content is limited to inguinal canal

→ **FUNICULAR**

- Processus vaginalis is closed above epididymis
- Content of hernia is felt separately from the testis.

→ **COMPLETE/ SCROTAL**

- Testes appears to lie in the lower part of hernia

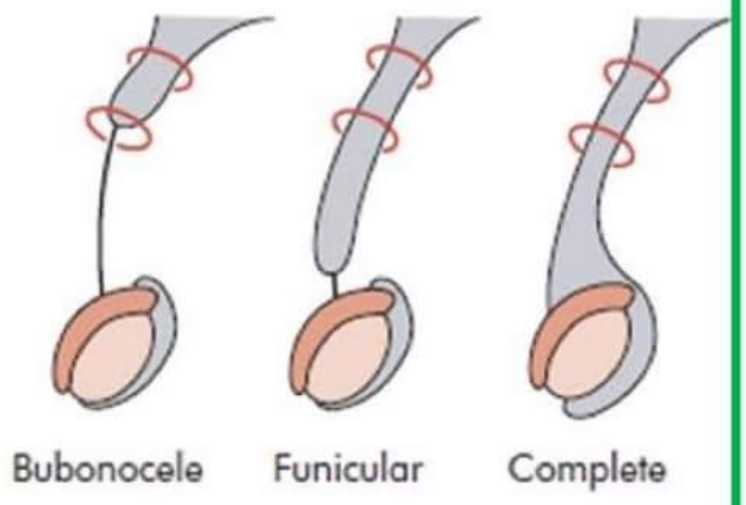

Types of Indirect (oblique) inguinal hernia

Clinical features

→ Swelling in Inguino scrotal region (more prominent on coughing/ straining)

→ Reduce spontaneously on lying position

→ Progressive increase in the size of swelling over a period of time.

t.me/latestpgnotes

Definitions

IRREDUCIBLE HERNIA → Cannot be reduced due to formation of adhesions between sac & content	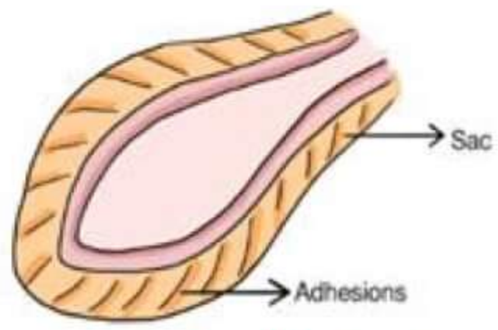 Irreducible hernia
INCARCERATED HERNIA → Contents cannot be reduced due to presence of fecal matter in the content	 incarcerated hernia
OBSTRUCTED HERNIA → Intestinal obstruction with preserved blood supply	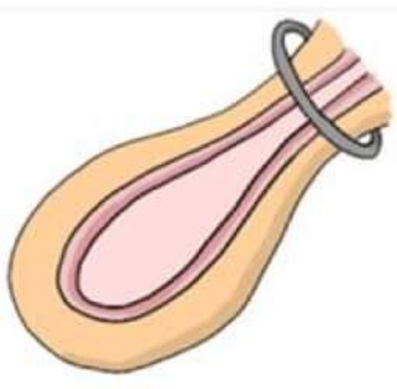 obstructed hernia

PrepLadder

STRANGULATED HERNIA

→ **Intestinal obstruction** with *impaired blood supply*

ENTEROCELE

→ Content- *Small intestine*

→ First part is difficult to reduce

→ Last part is easy to reduce (reduces with *Gurgling sound*)

OMENTOCELE

→ First part is easy to reduce

→ Last part is difficult to reduce

→ Content- *Doughy* (omentum)

LITTRE'S HERNIA

→ Content is *Meckel's diverticulum*

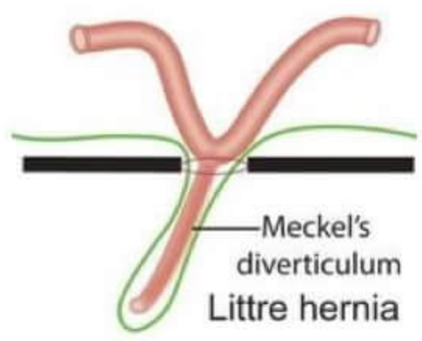

AMYAND'S HERNIA

→ Content is *Appendix*

t.me/latestpgnotes

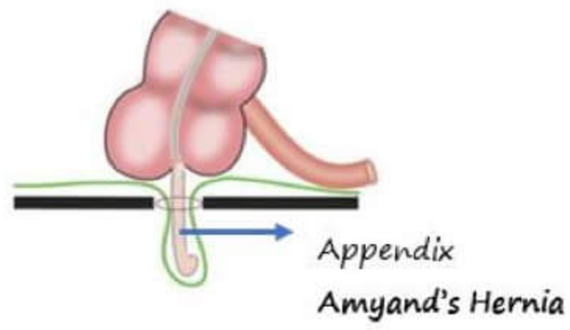

Diagnosis

→ Made by *clinical examination.*

→ Exception - Spigelian hernia/Internal hernia

- *Cannot be palpable*
- Diagnosed with help of CT/ ultrasound

Treatment

1. **Treatment of Sac**

→ **HERNIOTOMY - steps**

1) Inguinal skin crease incision
2) Division of Subcutaneous fat
3) Division of Camper's fascia, Scarpa's fascia
4) Incision along direction of fibres n external oblique aponeurosis
5) Isolate the Sac from cord
6) Open the Sac at fundus
7) Invert the contents back
8) Apply PURSE- STRING suture over the sac
9) Excise the Redundant Sac

PrepLadder

→ **Herniorrhaphy** - Herniotomy + Inguinal floor Reconstruction **with sutures**

→ **Hernioplasty** - Herniotomy + Inguinal floor Reconstruction **with MESH**

2. Inguinal floor Reconstruction

Primary tissue repair	Anterior tension free repair	Laparoscopic / Preperitoneal repair
→ BASSINI'S → SHOULDICE	→ LICHENSTEIN	→ TEP (Totally extra peritoneal) → TEP (Trans abdominal preperitoneal)

Primary tension free repair

BASSINI'S

→ Internal oblique + transverses abdominus + fascia transversalis

→ These are suture to **inferior edge / shelving edge** of inguinal ligament

→ Aka TRIPPLE LAYER REPAIR

→ Increased tension in tissues - increased recurrence rate

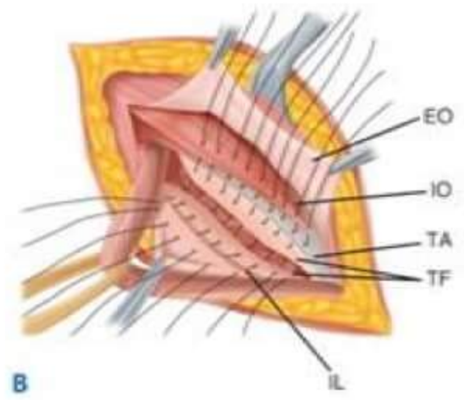

Bassini's

SHOULDICE

→ Double breasting of Fascia transversalis

→ Aka FOUR LAYERED REPAIR

→ Relatively low tension in tissues - low recurrence rate

t.me/latestpgnotes

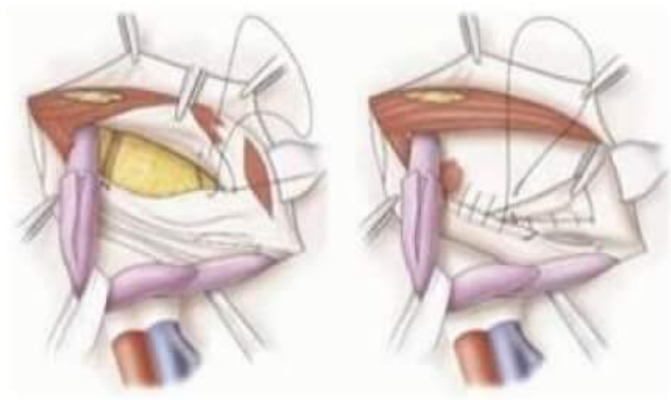

Shouldice

MODIFIED SHOULDICE

→ Double breasting of Internal oblique, Transverses Abdominis, Fascia transversalis

→ Aka SIX LAYERED REPAIR

Anterior tension free repair

→ Gold standard for Inguinal hernia repair - Lichtenstein repair

LICHTENSTEIN REPAIR

→ Fix the mesh to the anterior rectus sheath just above pubic tubercle

↓

Fix mesh (inferior aspect) to inguinal ligament

↓

Create artificial deep ring (by overlapping the cut edges of mesh)

↓

Superior aspect of mesh can be fixed to conjoint tendon

PrepLadder

Laparoscopic preperitoneal repair

→ **TEP** – Totally extra peritoneal

→ **TAPP** – Transabdominal pre peritoneal

TEP

→ Preferred by **experienced surgeon**

→ Advantage – decreased risk of bowel injury & adhesions

→ Disadvantage – small working space (surgery is difficult)

TAPP

→ Preferred by **beginners**

→ Advantage-huge working space (surgery is easy)

→ Disadvantage- increased risk of bowel injury & adhesion formation

→ Government setup – LIECHTENSTEIN REPAIR

→ Private setup – LAPROSCOPIC REPAIR

→ Early repair

→ No Scar visible

Landmarks in laparoscopic repair

TRIANGLE of DOOM

→ **Boundaries**

- **Medially** – Vas Deferens
- **Laterally** – Gonadal vessels
- **Base** – fold of peritoneum
- **Apex** – deep ring
- **Content** – Iliac vessels
- Sharp dissection in this area can lead to injury of **ILIAC vessels**
-

→ **Nerves between Iliopublic tract, gonadal vessels and fold of peritoneum**

- Femoral nerve
- Femoral branch of Genito- Femoral nerve
- Anterior cutaneous nerve of thigh
- Lateral cutaneous nerve of thigh

t.me/latestpgnotes

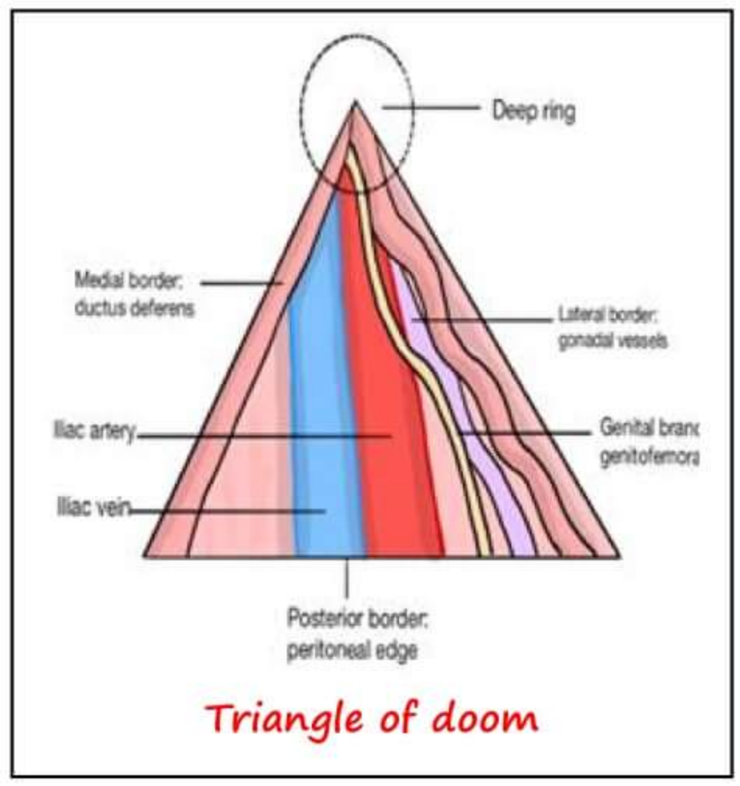

Triangle of doom

TRIANGLE OF PAIN

→ Electro cautery should not be used in this are as it is **ELECTRIC HAZARD ZONE**

→ **Boundaries**

- Laterally – fold by peritoneum
- Medially – Gonadal vessels
- Superiorly- Iliopublic tract

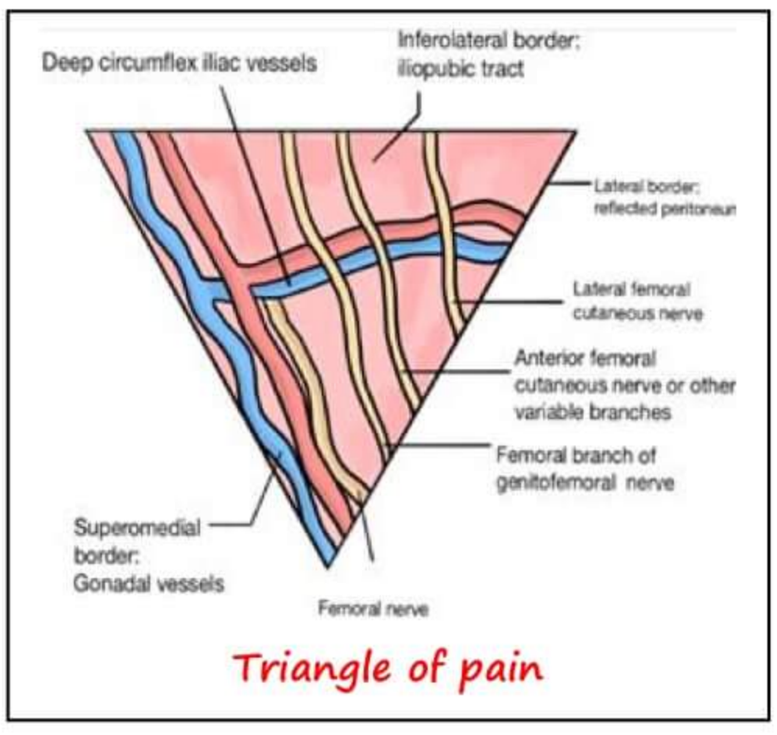

Triangle of pain

PrepLadder

- **Content**
  - Femoral Nerve
  - Femoral branch of GFM
  - Anterior Cutaneous Nerve of thigh
  - Lateral cutaneous Nerve of thigh

→ MC Nerve injured – lateral cutaneous Nerve of thigh

CROWN OF DEATH/ CORONA MORTIS

→ Inferior epigastric artery – Branch of external iliac artery

→ Obturator artery – Branch of internal iliac artery

→ Usually no communication between IEA and obturator artery.

→ Aberrant obturator artery arises from - IEA

↓

Attaches to obturator artery

↓

Forms a vascular loop

↓

Injured during dissection / mesh fixation

↓

Bleeding & death

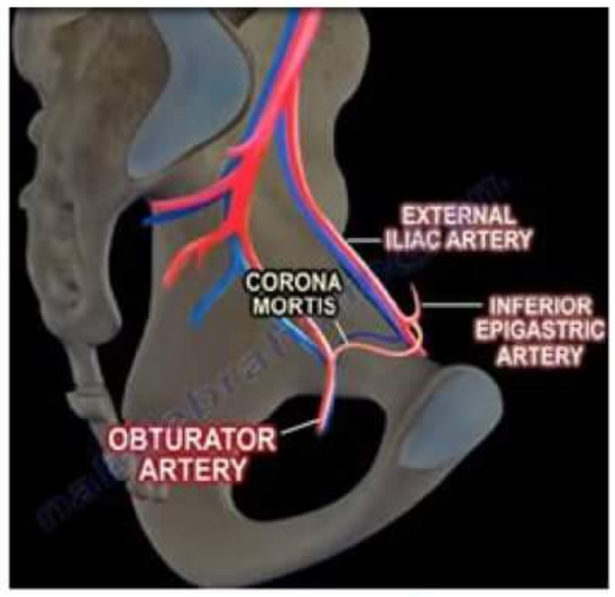

Corona mortis

t.me/latestpgnotes

SPACE OF REZIUS	SPACE OF BOGROS
→ Aka Retro pubic space → Extraperitoneal space located between pubis & urinary bladder	→ Aka Retro inguinal space → Extra-peritoneal space located deep to inguinal ligament. → Situated laterally & cranially to the space of Retzius.

Complications of Groin hernia repair

1. Recurrence
2. Hematoma formation
3. Seroma formation
4. Ischemic orchitis
5. Testicular atrophy (if testicular artery is injured)
6. Osteitis pubis (due to damage to periosteum of pubic tubercle)
7. Bladder injury
8. Wound infection
9. Mesh related complications like Contraction of mesh, Erosion due to mesh and Infection

Strangulated hernia

→ Characterised by Intestinal obstruction + impaired vascular supply of the bowl

→ MC Constricting agent - Neck of sac

PrepLadder

Clinical features

- → Irreducible hernia
- → Intestinal obstruction signs and Symptoms like colicky pain, bilious vomiting, non-passage of faeces and flatus.
- → History of sudden pain over hernia followed by Generalized pain
- → **On examination**
  - Tense and extremely tender hernia
  - Discoloration of skin (Reddish/ Bluish tinge) of skin overlying hernia.
  - No cough impulse

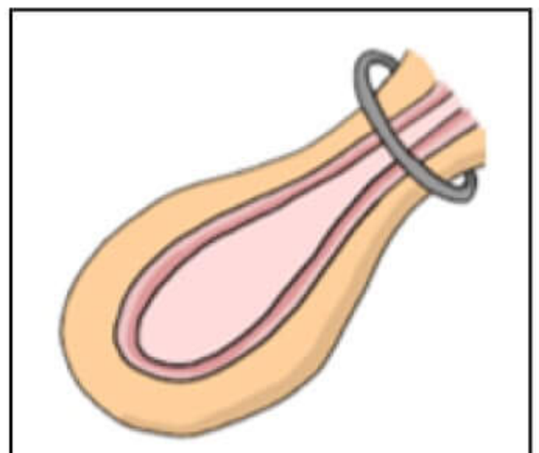

Strangulated hernia

Diagnosis of Strangulation – Based on clinical examination

Treatment

- → Resuscitation
- → Nasogastric aspiration
- → IV fluids
- → IV antibiotics
- → **Incision given on most prominent part of hernia**

↓

Dissection

↓

t.me/latestpgnotes

Reach Sac and open the sac fundus

↓

Collected fluids is aspirated

↓

Examine bowl

- Bowel viable → ↓ → Reduce bowel to Peritoneal cavity
- Gangrenous bowel → ↓ → excise gangrenous Bowel

↓

If omentum also non-viable

↓

Secure Ligature and excise the non-viable part of omentum

- → **Use of synthetic mesh is contraindicated in strangulated hernia** (because there is increased risk of infection)
- → If mesh needed → **Use bioprosthetic / absorbable mesh.**

PrepLadder

HERNIA AND ABDOMINAL WALL - 2

Femoral hernia

- → MC type of Hernia in Females - Indirect inguinal hernia
- → Femoral hernia is more common in females
- → MC in Right side
- → Bilateral in 20% cases
- → MC in Multipara females
- → TRUSS - Not to be used in femoral hernia

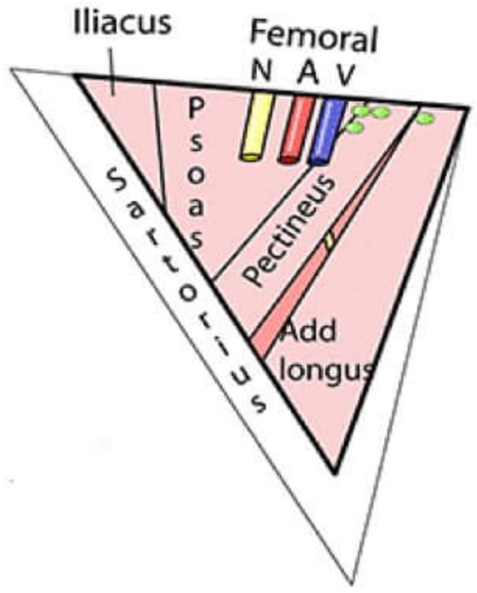

Femoral Triangle

FEMORAL CANAL AND FEMORAL RING

- → Femoral canal is rigid & narrow
  - ↓
  - Increased risk of strangulation
  - ↓
  - Surgery should be performed as early as possible to prevent strangulation

- → Diameter of femoral ring - 1.25 cm
- → Length of femoral canal - 1.25 cm
- → Cloquet group of nodes present in femoral canal

Clinical presentation

t.me/latestpgnotes

- → Swelling located below and lateral to pubic tubercle

Approaches of repair depends on incision

- → Sub inguinal incision - LOCKWOOD
- → Inguinal incision - LOTHIESSEN
- → Supra inguinal incision - Mc EVEDY

TOC

- → HENRY'S procedure
  - Midline abdominal extraperitoneal femoral hernioplasty

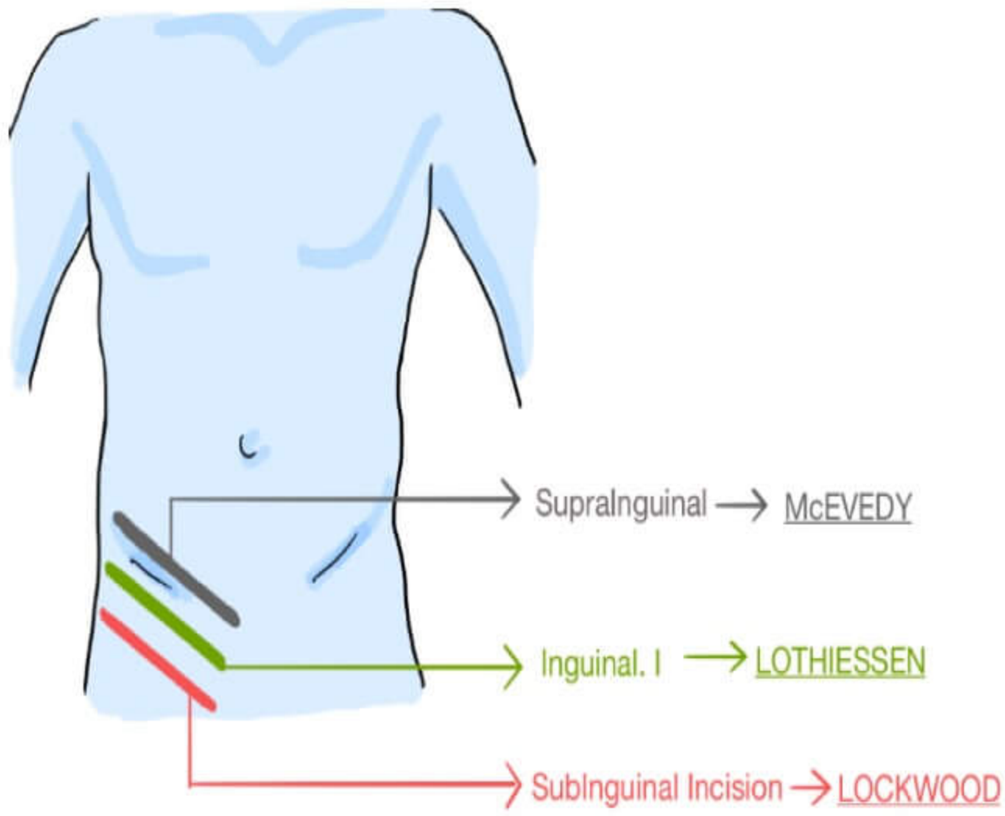

Variants of femoral hernia

- → LAUGIER'S
  - Hernia through gap in Lacunar ligament
- → CLOQUET
  - Hernia located behind pectineus fascia
- → NARATH HERNIA
  - Seen in congenital dislocation of Hip
  - Lateral displacement of Sac
  - Sac is located behind femoral vessels

PrepLadder

Spigelian hernia

→ Hernia through Spigelian fascia

→ Located at Infra umbilical region (below arcuate line)

→ Most of hernias are usually seen in **infra-umbilical region** due to **absence of posterior rectus sheath**

→ Spigelian fascia - thin aponeurosis located between **Rectus abdominus** muscle medially and **semilunar line** laterally.

→ Aka Inter parietal hernia (located between internal oblique and external oblique & penetrates spigelian fascia and internal oblique)

→ Located behind external oblique - hence not palpable/ not visible

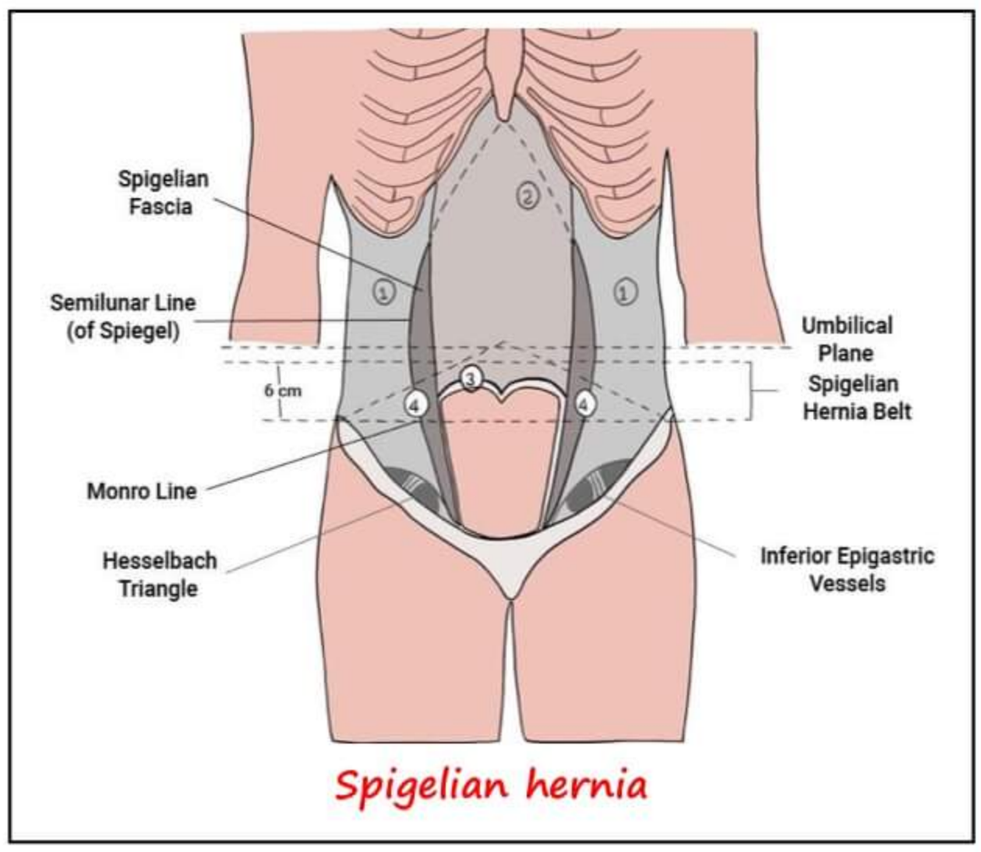

Spigelian hernia

Clinical presentation

→ Swelling is neither visible nor palpable leading to delayed presentation

→ Abdominal pain

→ Delay in presentation → Delay in diagnosis → Increased risk of strangulation

Investigations

→ USG/ CT

t.me/latestpgnotes

Management

→ Reduce the herniated content back & close the defect

Sliding hernia (Hernia -En-Glissade)

→ Posterior wall of sac is formed by viscera.

→ Increased risk of bowel surgery during ligation of Sac.

→ More common in Left side. MC content- sigmoid colon

→ More common in males

→ On Right side MC content - Cecum

Management

→ Sac along with content is reduced back

→ Close/repair the defect

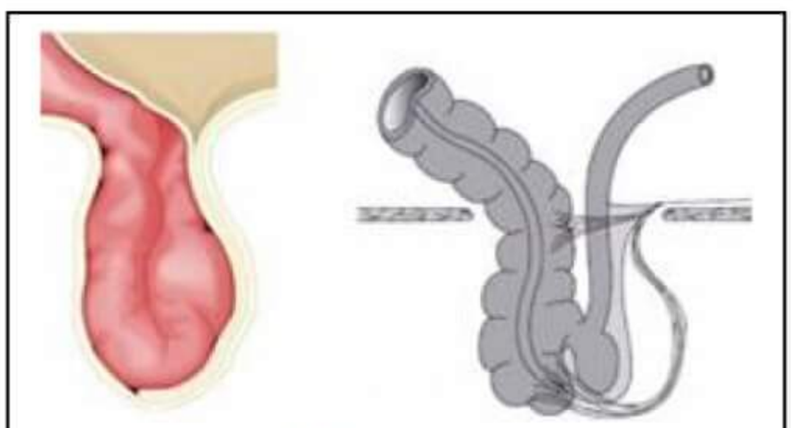
Sliding hernia

Lumbar hernia

→ Herniation in the lumbar region of posterior abdominal wall

→ MC - left side

→ Can be Congenital / acquired

→ Congenital in 20 % cases

→ Acquired in 80 % of cases

PrepLadder

→ Most of lumbar hernias are occurring through **Superior triangle of Grynfelt**

→ Some of lumbar hernias are occurring through **Inferior triangle of Petit.**

Boundaries of Superior triangle of Grynfelt

→ Posteriorly - Para spinal muscle

→ Superiorly - 12th Rib

→ Anteriorly - Internal oblique muscle

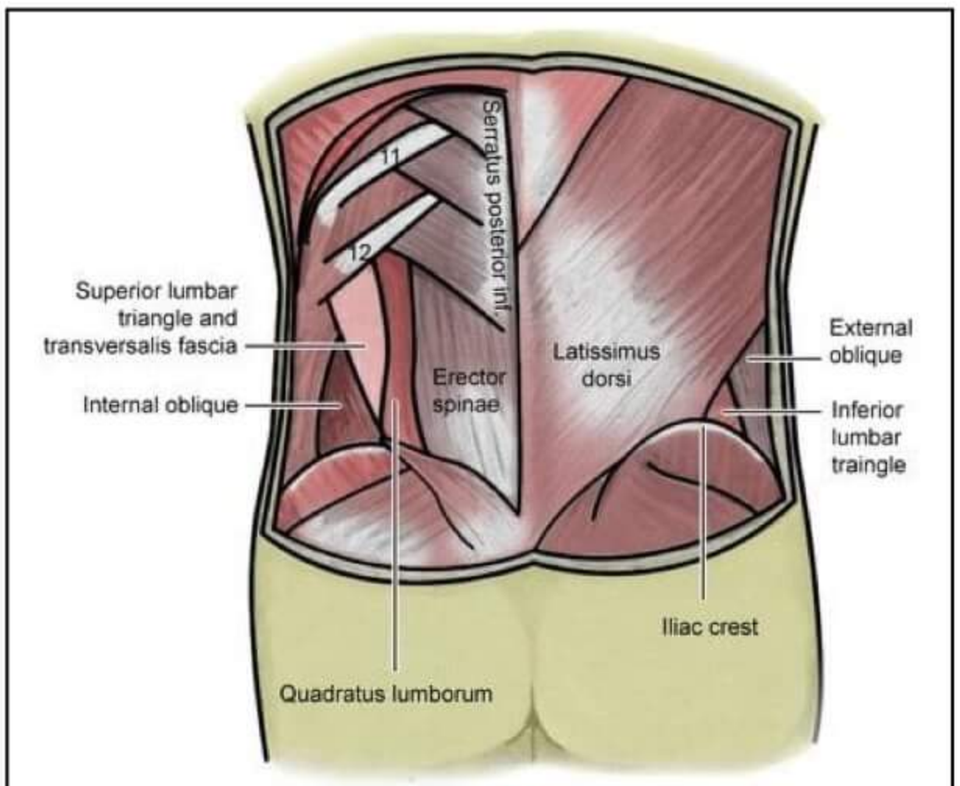

Triangle of grynfelt and petit

Boundaries of Inferior triangle of Petit

→ Posteriorly - Latissimus Dorsi

→ Anteriorly - External oblique muscle

→ Inferiorly - Iliac crest

Clinical Features

→ Defect is very large. so, patient is not aware mostly.

→ Presence of **unilateral bulge in the lumbar region**

→ **Strangulation is very rare (large defect)**

Management

→ **DOWD'S OPERATION**

t.me/latestpgnotes

Obturator hernia

→ Aka **Skinny old lady hernia**

→ Aka **French hernia**

→ Due to loss of fatty tissue in obturator canal

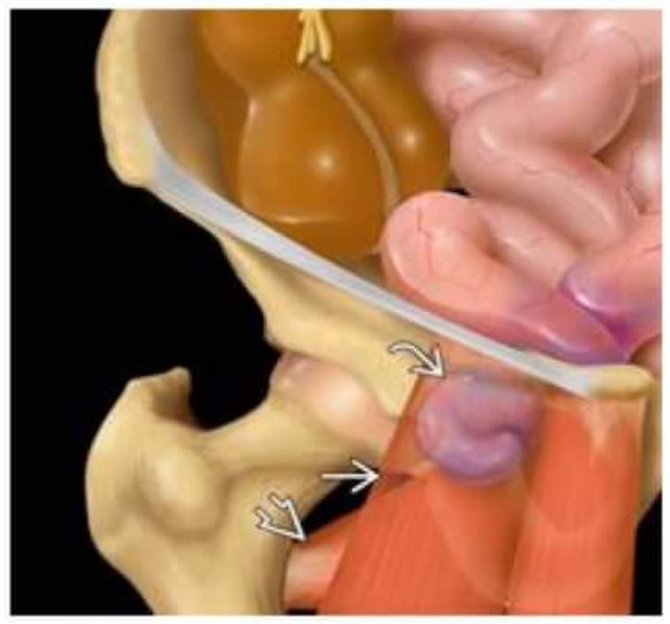

Obturator/ skinny old lady/ French hernia

Risk factors

→ Lean thin patients (chronic malnutrition)

→ Elderly females

→ Multipara patients

→ Chronic constipation

→ Other factors which increases intra-abdominal pressure

Clinical Presentations

→ **HOWSHIP – ROMBERG SIGN**

- Compression of obturator nerve → Pain along medial aspect of thigh radiating to ipsilateral knee joint

→ **HANNINGTON – KIFF- SIGN**

- Absence of obturator reflex

PrepLadder

Treatment

→ Repair by posterior approach

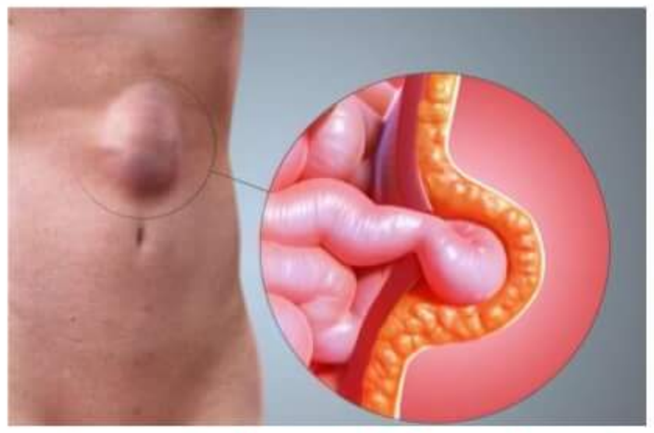

Epigastric lipoma/ fatty hernia of linea alba

Epigastric hernia

→ Any hernia from xiphoid process till 2 cm of umbilicus
→ Aka Epigastric Lipoma
→ Aka Fatty hernia of Linea Alba
→ Just off the midline in **80% cases**
→ Multiple in **20% cases**
→ Pain referred to epigastric region - It mimics peptic ulcer

Treatment

→ Excision of pre- peritoneal fat + Repair
→ If size of defect > 4cm- **MESH** is to be used

Umbilical hernia

→ Hernia occurring directly through umbilicus
→ Paraumbilical hernia- Hernia within 2cm of umbilicus **but not through umbilicus.**
→ In infants- congenital
→ More common in Africans
→ Closes spontaneously in majority of cases by 2 years.
→ Complications- rare

t.me/latestpgnotes

Treatment

→ Indications of surgery
- If it persists beyond 5yrs age
- Symptomatic patients
- Strangulation
- Size > 2 cm
- Progressive enlargement of hernia after 1-2 years
- Maximum time to wait- 5 years

→ Small defects – Closed primarily
→ Size of defect >3cm – Prosthetic mesh
→ **MAYO'S REPAIR**
- Aka vests – over- pants repair
- Not usually performed because of increased tension associated with

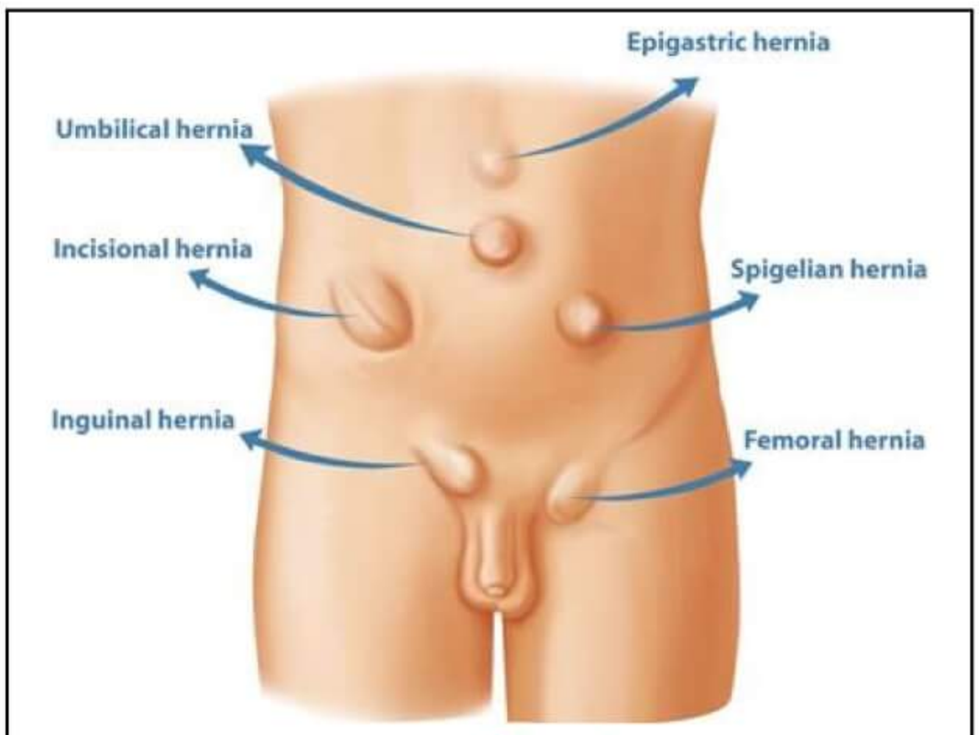

Types of hernia

PrepLadder

Abdominal wall defects

Omphalocele

→ Intestine fails return to the intra-abdominal cavity

→ Covered by 2 layers

- Amnion
- Peritoneum

→ **For Small defect** - Protrusion of small amounts of bowel

→ **For Large defect** - Protrusion of small bowel along with liver

→ Associated with **Trisomy 13, 18, 21**

→ Associated with congenital malformations - CVS > Musculoskeletal system > Gastrointestinal system > Genito urinary system

→ MC cause of death - **congenital malformations**

→ Associated with BECKWITH – WEIDMAN SYNDROME (variant of Wilms tumour)

- **Hemi hypertrophy**
- **Macroglossia**
- **Visceromegaly**
- **Omphalocele**
- **Hepatoblastoma**

→ Poor prognosis (associated with congenital malformations)

Omphalocele

t.me/latestpgnotes

Gastroschisis

→ Splitting of abdominal wall from right side with herniation of bowel.

→ Bowel is exposed, not covered **and** becomes thickened, matted and edematous

→ Associated with Intestinal atresia

Gastroschisis

Risk factors

→ If mother has history of intake of

- Alcohol
- Smoking
- Aspirin during first trimester
- Ibuprofen
- Pseudoephedrine

→ Age of mother - < 20 years age

→ **Not** associated with congenital anomalies – so good prognosis

PrepLadder

Incisional hernia

→ **Aka Post-operative ventral wall hernia**

→ Caused by failure of fusion of fascial tissues

→ **During laparotomy**

- With the help of Prolene suture (non-absorbable)
- subcutaneous fat is usually closed with Vicryl/ catgut
- skin is closed with silk (non- absorbable)
- After laparotomy, rectus sheath is closed

→ If failure of fusion of fascial tissues - Herniation of bowel

→ **Increased risk of incisional hernia**

- In Long, vertical, midline, lower abdominal incision

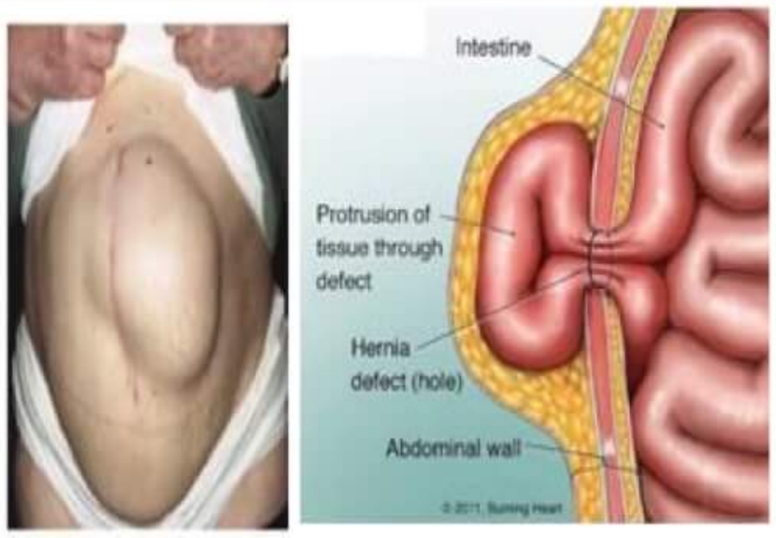

Incisional/ post-op ventral wall hernia

Risk factors

Surgery related	Surgeon related	Patient related
→ Emergency surgeries → Surgeries with Wound infections	→ Poor technique → Closure under tension → Use of absorbable sutures	→ Factors that contribute to Impaired wound healing • Diabetes mellitus • Steroid intake • HIV positive / immunocompromised • Jaundice & Cirrhosis

t.me/latestpgnotes

Treatment

→ **Gold standard Treatment- IPOM**

- IPOM- Intra peritoneal Onlay mesh repair
- Recurrence rate - > 50%
- Onlay /overlay - placing mesh above the facial sheath
- Sublay / underlay - placing mesh below the sheath & then closure
- Inlay / **Interlay** - suturing the edges of mesh through the sheath without closure & is the least commonly performed.

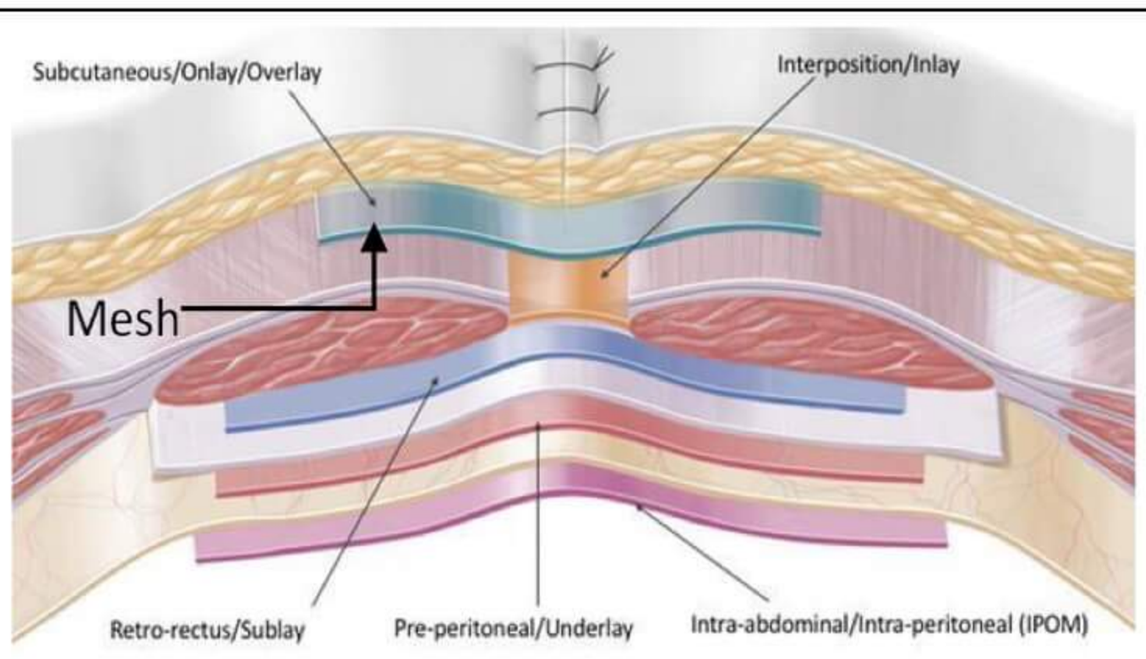

Various types of mesh for incisional hernia

PrepLadder

Desmoid tumor

→ Arises from **Musculoaponeurotic structures** in the infra-umbilical region
→ **Unencapsulated** - cracks whenever it is being cut.

Risk factors

→ History of surgical incision / Trauma
→ Estrogen stimulates growth (Mc in female)
→ Variant of FAP - Gardner's syndrome **(↑risk of desmoid tumor)**
→ No sarcomatous changes
→ No distant metastasis
→ **Increased risk of recurrence despite of excision**

Distribution of tumor

→ Extra abdominal in 60% of cases
→ Involving Abdominal wall in 25% of cases
→ Intraabdominal in 15% of cases

Clinical features

→ Lumps/ mass

Investigations

→ **Investigation of choice** - MRI (Desmoid tumor is a soft tissue tumor)

t.me/latestpgnotes

Treatment

→ Wide local excision with 2cm margin
→ For recurrent desmoids – Surgery + Radiotherapy

Other Named hernias

1. GIBBONS HERNIA - **Hernia + Hydrocele**
2. BERGER'S HERNIA - Hernia into **pouch of douglas**
3. BECLAR'S HERNIA – Hernia through **saphenous opening**
4. OGILVIE'S HERNIA – Hernia through **defect in conjoint tendon**
5. STAMMER'S HERNIA – Hernia through **transverse mesocolon after retrocolic Gastro-jejunostomy**
6. PETERSON HERNIA – Hernia **behind Roux limb** after Roux-en-Y Gastric by pass **(MC Bariatruic surgery performed worldwide)**

PrepLadder

7. VELPAEU'S HERNIA
   - Aka **pre vascular hernia**
   - **Sac is located in front of femoral vessels**

8. SERAFINI'S HERNIA
   - Aka **Retro vascular hernia**
   - Sac is located behind femoral vessels

9. HOLTHOSUE HERNIA
   - Type of inguinal hernia
   - Extension of bowel along inguinal ligament

NOTE

Ogilvie's Syndrome: Colonic pseudo obstruction

t.me/latestpgnotes

PrepLadder

SPLEEN

→ Largest lymphatic organ
→ Blood bank of body
→ Stores 2% of blood
→ Average weight 75-100 grams.
→ Usually spleen is not palpable
→ If enlarged > 2.5 times, it becomes palpable
→ Long axis of spleen is along 9th, 10th, 11th, ribs.
→ Develops from Cephalic part of Dorsal mesogastrium

Splenectomy

→ MC Indication - Trauma
→ MC indication of Elective splenectomy - ITP
→ **Splenectomy always indicated in**
  - Primary splenic tumor
  - Hereditary spherocytosis
→ **Splenectomy usually indicated in**
  - Primary hypersplenism
  - Chronic ITP
  - Splenic vein thrombosis leading to gastric varices
  - Splenic Abscess

t.me/latestpgnotes

ITP (Idiopathic thrombocytopenic purpura)

→ Aka Immune Thrombocytopenic purpura.
→ Formation of **Auto antibodies against platelets**
→ Autoantibody coated platelets are selectively destroyed in spleen

Platelet Destruction in spleen
↓
Decreased Platelet count
↓
Petechiae & purpura
↓
ITP

→ MC in children
→ Seen in both boys & girls
→ Resolve spontaneously in boys
→ **Chronic ITP** usually seen in girls
→ ITP persists in girls

Clinical features

→ Petechiae

PrepLadder

→ Purpura
→ Epistaxis
→ Gum bleeding
→ Size of spleen is characteristically normal (not enlarged)

Management

→ **Steroids** – When used in long duration causes steroid related complications (Like Hypertrichosis and Hyper pigmentation which makes patient to discontinue treatment)
→ Azathioprine
→ Cyclophosphamide
→ Gold standard treatment for ITP – **Laparoscopic Splenectomy** (open splenectomy not preferred because of normal size of spleen)
→ In **normal patient**, for elective surgery minimum platelet count – **100000**
→ In **ITP patient**, for elective surgery minimum platelet count – **50,000**
→ Best time for platelet transfusion in ITP – **after ligation of splenic artery** (So, that platelets will not reach spleen & does not gest destroyed)

Complications

→ **Lung related complications**
- MC complication responsible for fever after surgery up to 48 hours is **Atelectasis** (Noninfectious fever and is not associated with chills and rigors)
- Consolidation – (fever + chills and rigors)
- Pleural effusion

t.me/latestpgnotes

→ **Diaphragm related complications**
- Sub diaphragmatic hematoma
- Sub diaphragmatic abscess

→ **Pancreas related complications**
- Acute pancreatitis
- Injury to tail of pancreas
- Pancreatic fistula

→ **Thromboembolic complications**
- Thrombocytosis, Immobilization] Increased risk of DVT
- Immobilization] Increased risk of Pulmonary Embolism

OPSI (Overwhelming post splenectomy infection)

→ MC **late fatal complication** of splenectomy
→ Usually seen after **2-5** years of splenectomy
→ Increased risk of OPSI in **malignancy and hematological disorders**
→ Least risk in **Trauma**

PrepLadder

→ 40-50% mortality rate

→ **Normal function of Spleen** - Phagocytosis of capsulated organisms

→ In absence of spleen due to splenectomy – increased risk of capsulated organism infections

→ **Organisms responsible for OPSI**

- **MC** - Strep pneumoniae (Pneumococcus)
- Neisseria meningitidis (Meningococcus)
- H. influenza type B

→ Healthy person → strep. Pneumoniae → usually cleared by 5 to 7 days.

→ **Prevention**

By vaccination. But for splenectomy patients - if strep, pneumonia infection

↓

Initially cough

↓

High grade fever

↓

Sepsis

↓

Septicemia

↓

Shock

↓

Death (Overwhelming response after Splenectomy)

t.me/latestpgnotes

→ **Best time for vaccination**

- 2 weeks before elective splenectomy
- As early as possible after emergency splenectomy

Splenic cyst

→ MC true cyst of spleen – Hydatid cyst

→ MC non-parasitic cyst - Pseudocyst (cyst lines by granulation tissue) (70-80%)

→ MC congenital splenic cyst - Epidermoid cyst

→ Overall most common splenic cyst - Pseudocyst

→ Incidence of hydatid cyst - 10%

→ Incidence of pseudocyst - 70 to 80 %

Splenic tumors

→ MC neoplasm of spleen – NHL

→ MC primary benign tumor of spleen – Hemangioma

→ MC primary malignant tumor of spleen - Angiosarcoma

→ MC primary for splenic metastasis - Malignant melanoma

→ MC primary for isolated secondaries to spleen – CA ovary

PrepLadder

Splenic abscess

→ Rare condition
→ Healthy patient having unilocular abscess – mortality rate is 15 -20%
→ Immunocompromised, multilocular – mortality rate is 80%
→ **Predisposing factors:**
- Malignancy
- Polycythemia vera
- IV drug abuse
- HIV positive
- Hemoglobinopathy
- UTI

→ MC organism responsible – staph aureus
→ **Other organisms responsible**
- Streptococcus
- Salmonella
- Gram negative enteric bacilli

→ Fungal abscess is typically seen in **HIV positive and immunocompromised** caused by candida

Clinical features

→ Abdominal pain
→ Tenderness
→ Peritonitis
→ Pruritic chest pain

t.me/latestpgnotes

Investigation

→ Investigation of choice – CECT

Treatment

→ **Unilocular abscess** – drainage + antibiotics
→ **Multilocular abscess** – splenectomy + drainage of left upper quadrant + antibiotics

KIDNEY AND URETER - 1

Renal stones

→ **Mandatory factors for stone formation**

- Super saturation
- Crystallization

→ **RANDALL PLAQUES**

- Soft tissue calcification found in deep renal medulla
- Act as nucleating agent for renal stones

Types of Renal Stones

Ca Oxalate stones

→ Most common type of renal stones

→ Radiopaque

→ **Risk factors**

- Hypercalcemia
- Hypercalciuria
- Hyperoxaluria

Uric acid stones

t.me/latestngnotes

→ Most common type of radiolucent renal stone

→ **Risk factors**

- Gout
- Lesch- Nyhan syndrome
- Myeloproliferative disorders (due to increased breakdown of cells)
- (Hypoxanthine-> Xanthine →Uric Acid)

Management Principles

→ If acidic stone - do alkalinisation of urine

→ If basic stone - do acidification of urine.

→ Acid combines with base & forms salt which is soluble & is excreted in urine.

→ Plenty of fluids

→ Low purine diet

→ **Acetazolamide** is used for Alkalinisation of urine

→ **Allopurinol** – To block conversion of Hypoxanthine to xanthine & hence block formation of uric acid.

Struvite stones

→ **Aka staghorn calculi / Triple phosphate stone** (Ca, Mg, NH_4^+, Phosphate)

→ MC in females because of short urethra (4cm)

PrepLadder

→ Short urethra - Increased risk of UTI → Proteus → produces urease.
→ Urease converts urea into ammonia - Ammonia gets precipitated
→ 3-5 minor calyces join major calyx and later forms pelvis, pelvic ureteric junction and then ureter.
→ Struvite stone is very large & fills pelvic calyceal system and looks like staghorn (due to branching in stone)

Management

→ Sandwich Technique - **PCNL** (percutaneous nephrolithotomy) + **ESWL** (Extra corporeal shock wave lithotripsy)
→ To prevent recurrence of stone formation- Irreversible inhibitor of urease (**Acetoxy Hydroxamic acid**)



STRUVITE STONES

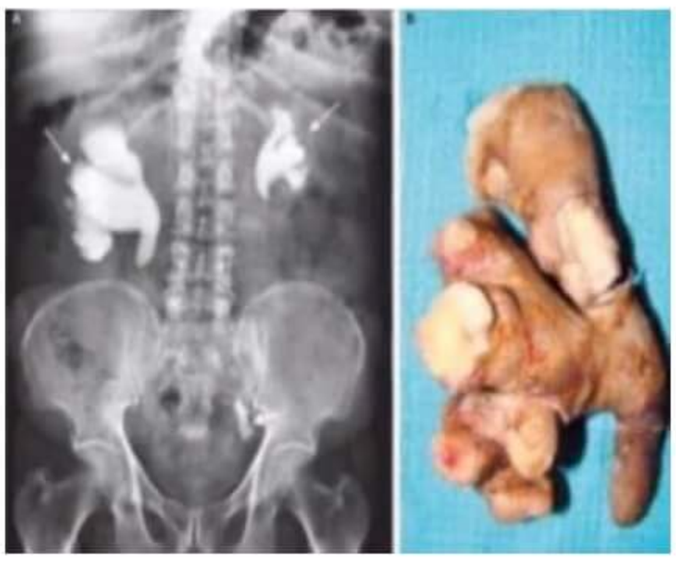
STRUVITE STONES

t.me/latestpgnotes

Cystine stones

→ Seen in cystinuria
→ Radio Opaque (double sulphide bond)
→ Very Hard (not easily broken by ESWL)
→ **Crystal** – Benzene shaped Crystal (Hexagonal Crystal
→ D- Penicillamine
→ α-MPG (Alfa- mercapto propionyl glycine) (Alfa MPG> D- penicillamine)

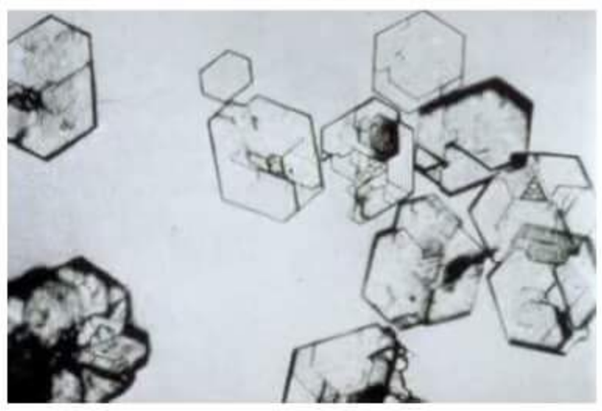
CYSTINE STONE

Xanthine stones

→ Seen in xanthinuria
→ Hypoxanthine - xanthine (Allopurinol can be used to block conversion of Hypoxanthine to xanthine)
→ Radiolucent
→ Brick- red in color
→ Lamination on cross section

XANTHINE STONE

PrepLadder

Drug induced stones

→ **Triamterene**
- excessive use of K^+ sparing diuretic leads to formation of radiolucent stone

→ **Indinavir**
- Protease inhibitor used in HIV leads to formation of radiolucent stone

→ **Silicate stone**
- Excessive consumption of antacids containing silica

→ **Radiolucent stones**
- Triamterene
- Indinavir
- Xanthine
- Uric acid

→ **Acidic stone**
- Calcium oxalate
- Cysteine
- Uric acid

→ **Renal Stones**-more common in males

→ **Infectious renal stones**-more common in females

Clinical Features

→ **Abdominal pain** - MC presentation

t.me/latestpgnotes

→ **Causes of pain in the renal stone**
- Obstruction is going to cause stretching in the renal capsule which can lead to non-colicky abdominal pain.
- Stone fragment reaches ureter, ureter starts hyperperistalsis which can lead to colicky pain.
- Radiation of pain depends on the location of stone

→ **If stone in Upper 1/3rd of ureter, pain radiates to**
- Testes (Males)
- Labia majora (Females)

→ **If stone in Middle 1/3rd of ureter, pain radiates to**
(via iliohypogastric nerve)
- Iliac fossa
- Hypogastrium
- Groin

On right side- it mimics acute appendicitis

On left side - it mimics diverticulitis

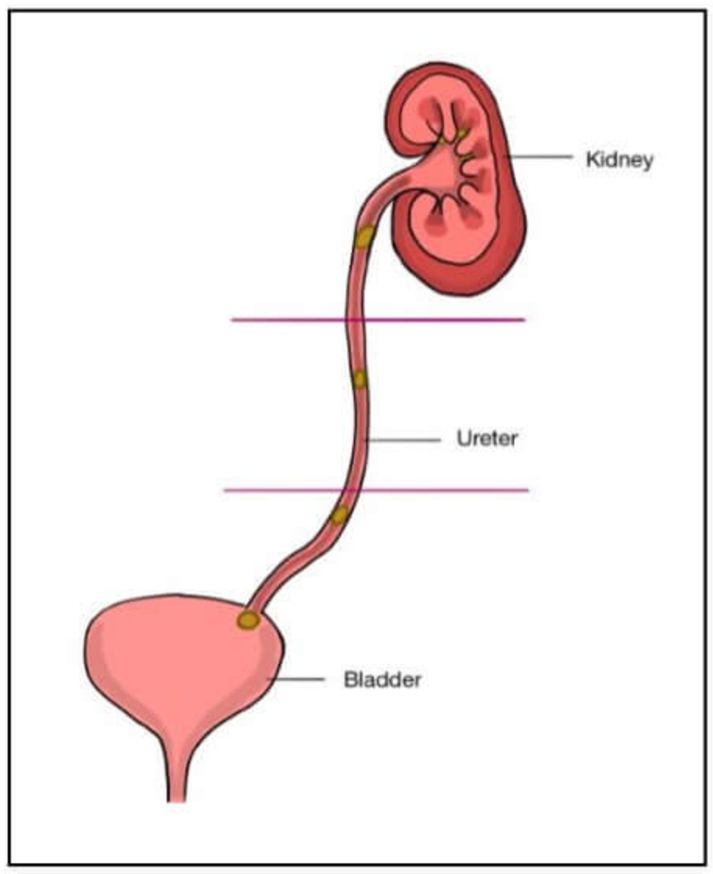

PrepLadder

→ If stone in Lower 1/3rd of ureter, pain radiates to
(Via ilioinguinal nerve)

- Scrotum
- Perineum.
- Inner aspect of thigh

→ If stone in intramural ureter - **strangury**

Investigation of choice - **Non contrast spiral CT**

Management

→ Analgesics [DOC- Diclofenac (Voveran)

Investigations Performed

→ **Urine Routine & Microscopy**

- Color
- pH
- Specific Gravity
- Presence of Sugar / Albumin
- RBCs / WBCs / Pus cells
- Cast / crystals

t.me/latestpgnotes

→ **Urine Culture & Sensitivity**

- Confirmation of infection is done
- To diagnose UTI +/-
- To identify organism
- To identify antibiotic sensitivity

→ **Calcium oxalate monohydrate stone**- Dumbbell shaped

→ **Calcium oxalate dihydrate stone**

- Envelope shaped
- Aka Bipyramidal shaped



CALCIUM OXALATE DIHYDRATE STONE

CALCIUM OXALATE MONOHYDRATE STONE

PrepLadder

→ **Uric Acid Crystals**
- Rosette shaped
- Multi-faceted

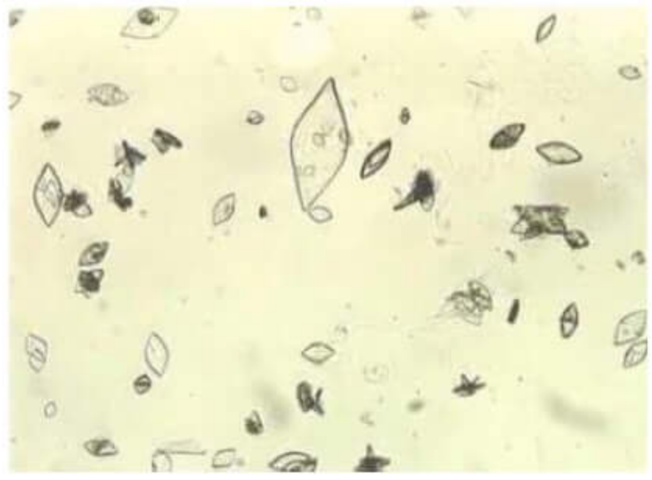

Uric Acid Crystals

→ **Calcium Phosphate**-Amorphous crystals

→ **Struvite stone** - coffin lid crystals

→ **Brushite stone**- Needle shaped



BRUSHITE

→ **Cystine**-Hexagonal or benzene shaped

→ **X- Ray KUB**
- 90% of Renal Stone- Radio opaque
- 90% of gall stones- Radiolucent

→ **Ultrasound** – Screening investigation for Hydronephrosis

→ **IVP** (access site of obstruction)- Intravenous dye injected usually antecubital fossa
Used to access
- Proximal part of obstruction
- Hydronephrosis
- Renal function

t.me/latestpgnotes

→ **RGP**
- Retrograde pyelogram
- Used to assess the distal part of obstruction

→ **DMSA**
- Dimercaprol succinic acid scan
- Used to assess M- Morphology
- S- Scar
- SA- Surface Anatomy
- Can evaluate presence of scar in kidney

→ **DTPA**
- Diethylene triamine Penta acetic acid scan
- Perfusion and Function
- **IOC**- for renal perfusion and function -DTPA

PrepLadder

→ **MAG-3**

- Mercapto Acetyl glycine
- Gold standard for Renal perfusion

Indications of Conservative management

→ Stone size up to 5mm
→ Non dilated ureter
→ Stone located in lower third of ureter
→ Progressive downward moment on repeated scan.

Principle

→ Prevent super saturation & crystallization by dilution of urine.

Management

→ Plenty amount of fluids (4-6 liters/ day)
→ **For 4mm stone -> Take 4 liters of water- > stone is excreted within 4 weeks**
→ Alkalinisation /Acidification of urine for 4 weeks

Interventions

→ ESWL (Extra corporeal shockwave lithotripsy) – 85% of cases
→ PCNL (Percutaneous nephrolithotomy) - 15% of cases
→ URS (Ureteroscopy)
→ LSS (Laparoscopic stone surgery) - Not commonly preferred
→ OSS (Open stone surgery)

t.me/latestpgnotes

OSS indications

→ Stone with non- function kidney = Nephrectomy has to be performed → open approach
→ Stone with anatomical disorder of kidney e.g. (PUJ Obstruction) - **pyelolithotomy & pyeloplasty** has to be performed → so, open approach

ESWL

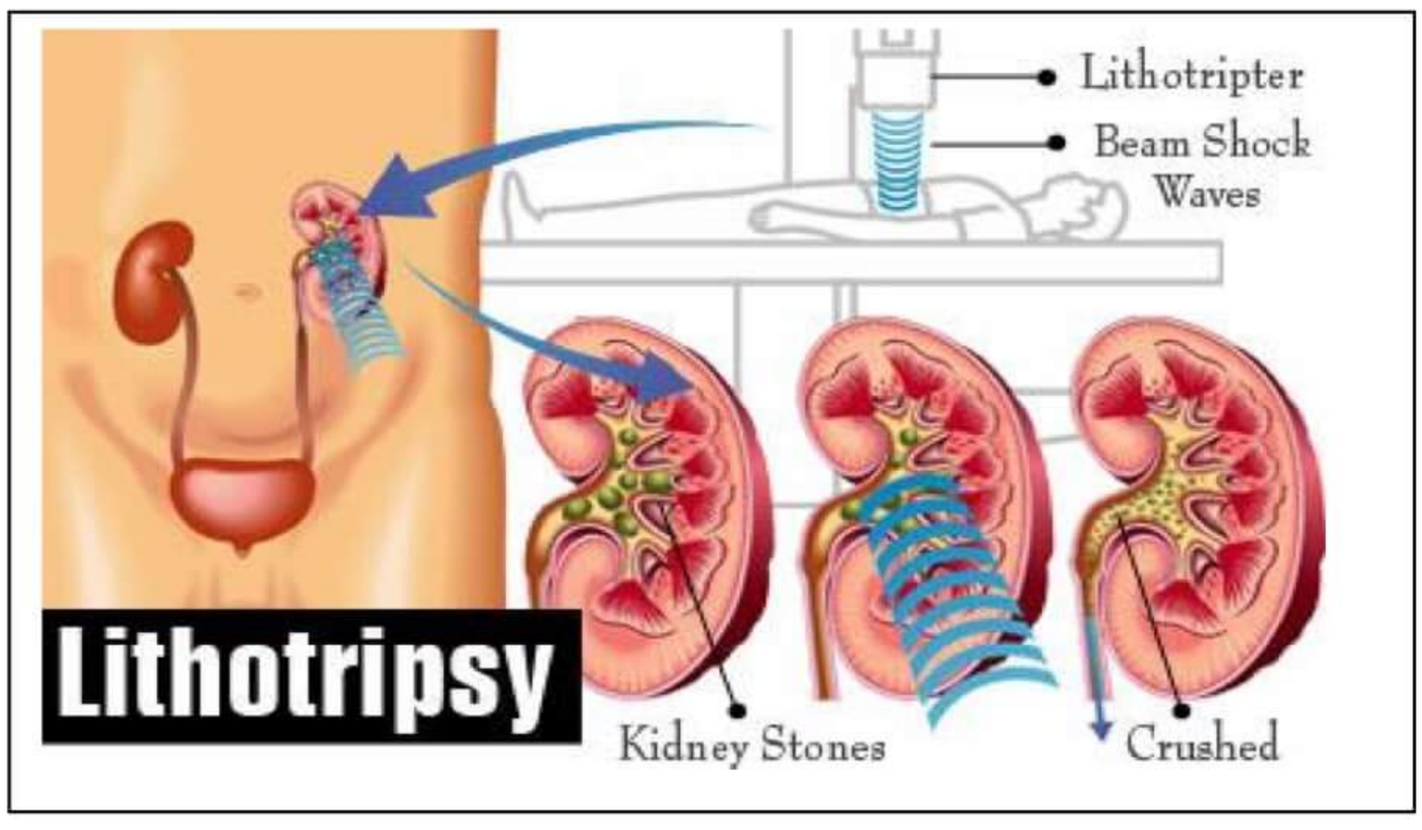

PrepLadder

→ Gold standard lithotripter used in ESWL- **Dornier unmodified HM-3**

→ Shock wave induced tensile cracking

↓

Erosion & shattering

↓

Stone fragment excreted in urine via ureter

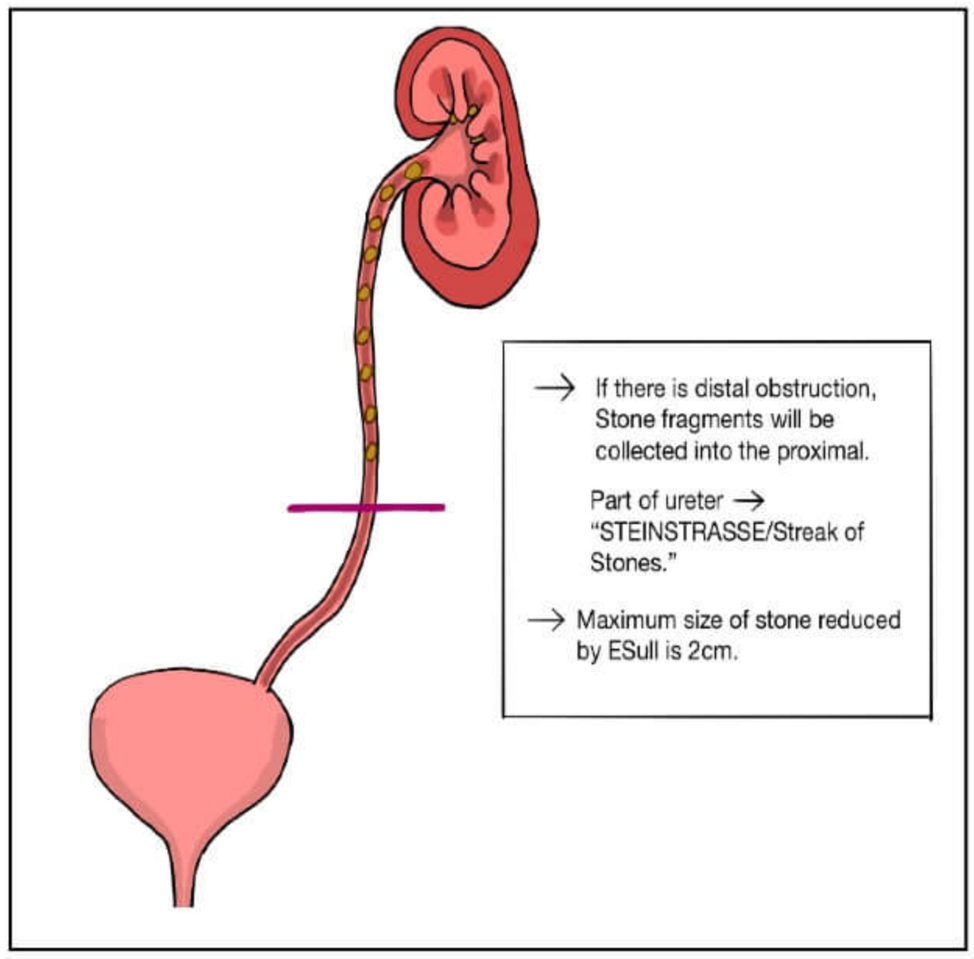

Complications

→ If there is distal obstruction of ureter, all the stone fragments are collected in the Proximal part of ureter

→ **Aka STEINSTRASSE / STREET OF STONE / COLUMMATION OF GRAVEL**

→ **Hematoma** in kidney (Bleeding due to shock waves)

→ Increase risk of UTI

→ Increased risk of Extra systoles

→ For stones of size **up to 2cm** - ESWL is used

→ **Hard stones that cannot be broken down by ESWL**

- **B**- Brushite
- **H**-Hydroxyapatite
- **C**-Cystine
- **C**-Calcium oxalate Monohydrate

t.me/latestpgnotes

Contraindications of ESWL

Absolute Contraindications	Relative Contraindications
→ Pregnancy (shock waves damage fetus) → Bleeding disorders. (Increased risk of hematoma & bleeding so not be given in patients diagnosed with bleeding disorders)	→ Pacemaker → UTI → Uncontrolled HTN → Obesity → Orthopedic abnormalities (Scoliosis/ kyphoscoliosis) → Distal Obstruction → Renal failure → Aneurysm

PrepLadder

PCNL (Percutaneous Nephrolithotomy)

→ A tract is created in kidney via abdominal skin & then nephrolithotomy is performed.

→ **Renal artery has two branches**

- Anterior branch of renal artery
- Posterior branch of renal artery

→ For PCLN - posterior approach is used. There are two posterior approaches followed.

- Posterior pelvic approach
- Posterior calyceal approach

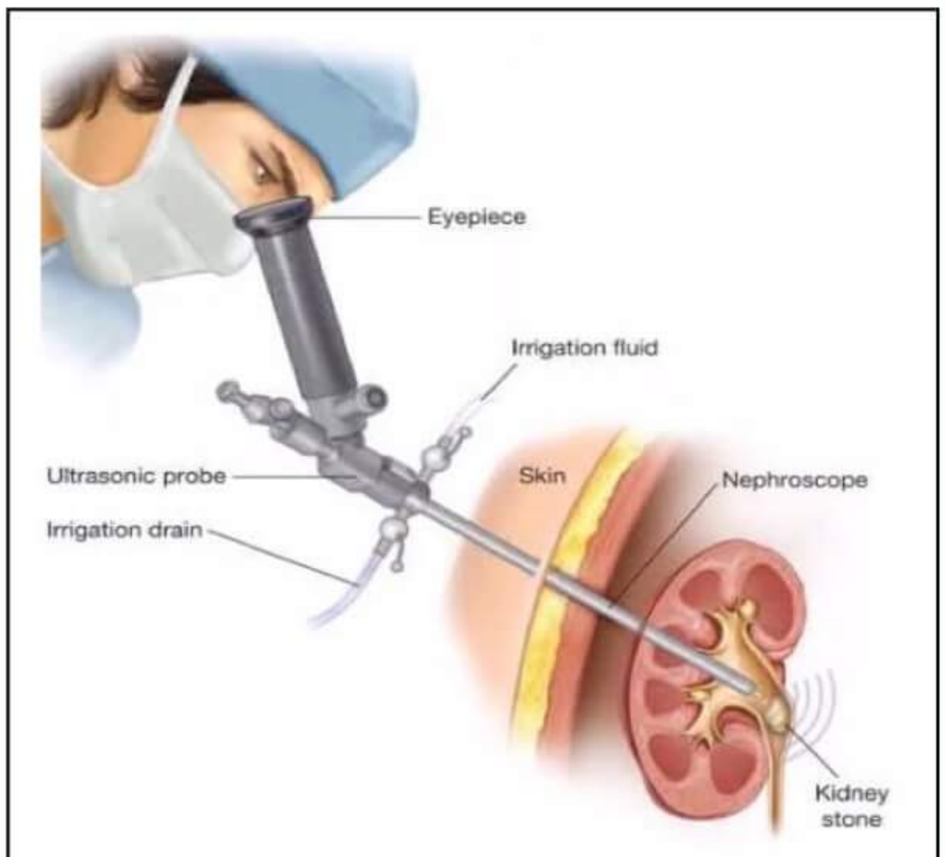

PCNL

→ In posterior pelvic approach, the **posterior branch of renal artery is injured.** So, posterior calyceal approach is preferred in percutaneous nephrolithotomy to prevent injury of posterior branch of renal artery.

→ **Indications**

- Size of stone 2cm
- Distal obstruction
- UTI
- Hard Stone (BHC-2)
- Lower calyceal stone

→ Staghorn calculi (PCNL + ESWL) - Sandwich technique

→ Most common complications of PCNL - Bleeding

→ Most commonly injured organ - Pleura > colon > Spleen

t.me/latestpgnotes

URS(Ureteroscopy)

→ Performed under spinal anesthesia

→ MC Complication of URS - Ureteric perforation of URS (Internal diameter of ureter - 4mm)

→ **Indications**

- For insertion of DJ stent
- For removal of stone
- For removal of foreign body
- Taking biopsy from urothelial tumor

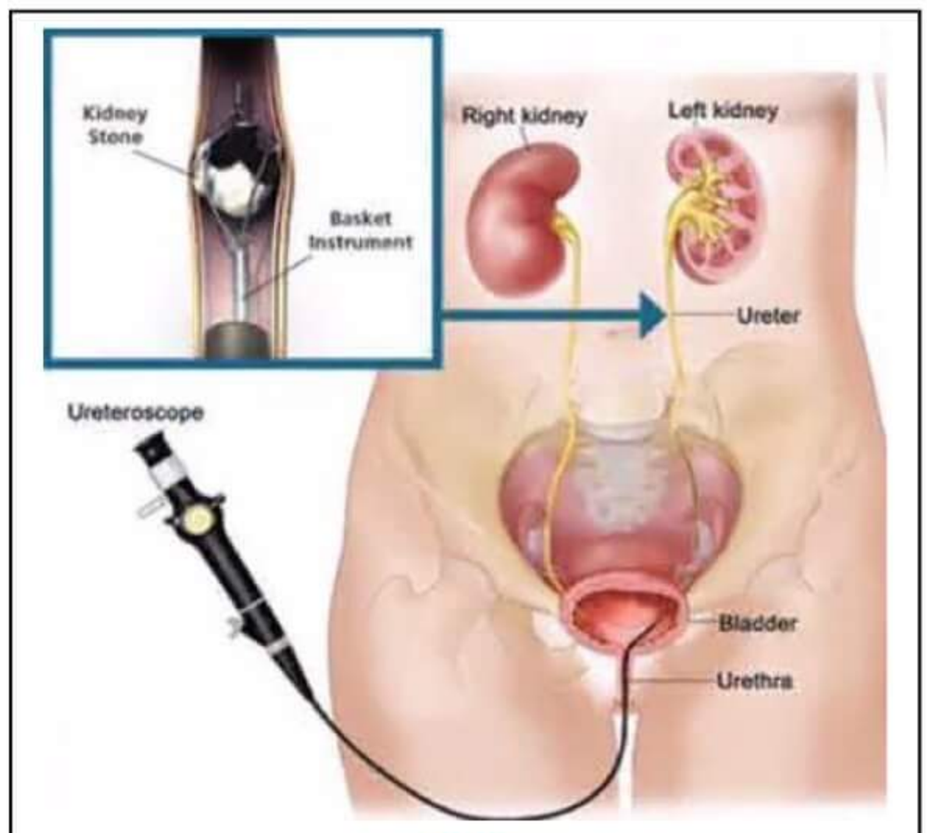

URS

PrepLadder

Intracorporeal Lithotripsy

→ 4 lithotripters are used

a) Electro – hydraulic lithotripter (mainly used)

b) Ultrasonic Lithotripter

c) Ballistic Lithotripter

d) Laser Lithotripter

EHL

→ Cheap

→ very effective

→ Narrow safety margin

→ Mainly used for bladder stone

Laser lithotripter

→ Uses "Holmium – YAG" laser

- Best source of laser for intracorporeal lithotripsy.
- MC used laser for renal stones and Benign prostatic hyperplasia.
- Causes stone vaporization by photothermal mechanism

→ If laser lithotripter used for Uric acid stones - causes production of Cyanide

t.me/latestpgnotes

→ No Significant Toxicity from the cyanide produced.

→ Hight cost, but very effective

Management of Renal Stones

→ For Stone size up to 2cm - ESWL

→ For Stone size > 2cm - PCNL

→ For Hard stone (BHC-2) - PCNL

→ For Staghorn calculi - Sandwich technique (PCNL + ESWL)

Management of Ureteric Stone

→ Depends on location of stone

- Stone in upper and middle 1/3rd of ureter
  - ➢ Size of stone up to 1cm - ESWL > URS
  - ➢ Size of stone > 1cm - URS
- Stone in lower 1/3rd of ureter - URS (No use of shockwaves in this area)

PrepLadder

Emphysematous Cholecystitis

→ MC organism involved - Cl. Perfringens (Cl. Welchii)

→ MC aerobic organism responsible - E. coli

Emphysematous pyelonephritis

→ MC organism involved - E. coli

Xanthogranulomatous Pyelonephritis

→ MC organism involved - Proteus (Staghorn calculi)

Xanthogranulomatous cholecystitis

→ Non-infectious condition

→ **Caused by** - Rupture of Rokitansky Aschoff Sinuses

↓

Bile leak

↓

Xanthogranulomatous cholecystitis

Emphysematous pyelonephritis

t.me/latestnaanotes

→ **Characterised by** - Presence of ring of air around kidney (perinephric region) or within the kidney

→ MC organism responsible - E. coli > klebsiella

→ MC in Diabetic (due to low immunity) & Females

Clinical features

→ Flank pain, Fever & Vomiting

→ Mortality rate is 19 - 43%

Investigation

→ **On X-ray** – Presence of air in relation to kidney

→ IOC - CT scan

Treatment

→ IV antibiotics

→ Resuscitation

→ Control blood glucose

→ **If pus / evidence of infection is present** - Drainage should be done

→ Nephrectomy to save the life of patient

PrepLadder

Xanthogranulomatous Pyelonephritis

→ Chronic bacterial infection

→ MC organism – **Proteus**

→ Associated with Struvite stone causing Obstructed and hydro nephrotic kidney

Pathology

→ Presence of Xanthoma cells in renal parenchyma

(Foamy lipid laden histocytes)

↓

Mimics – Clear cell variant of RCC

Clinical features

→ Flank pain

→ Fever with chills and rigor

→ Flank Mass

→ Bacteriuria

Investigation

→ IOC – **CECT**

Treatment

→ Initially, Partial Nephrectomy – if not possible

t.me/latestpgnotes

↓

Total Nephrectomy

Perinephric abscess	Pyonephrosis
• Collection of Pus around kidney	• Pus is collected inside the kidney (Bag of Pus)

Pyonephrosis

→ Kidney is a bag of Pus

→ Seen in chronic obstruction – **Hydronephrosis**

↓

Destruction of renal parenchyma

↓

Pus collection

→ MC cause of obstruction – **renal stones**

Clinical features

→ Fever

→ Anemia

→ Mass in loin

PrepLadder

Diagnosis

→ **USG**

Management

→ IV antibiotics + Drainage

→ Percutaneous nephrostomy (Older, diabetic etc)

→ **For Non-Functioning Kidney** - Nephrectomy

Perinephric abscess

→ Collection of Pus around kidney

→ **Spread by 2 routes**

- Cortical extension
- Hematogenous spread

→ Urine culture positive in 1/3rd cases

→ Blood culture positive in 50% cases

→ MC organism – E. coli > Proteus

Clinical features

→ Pain

→ Tenderness

→ Fever

t.me/latestpgnotes

Diagnosis

→ USG / CT

Management

→ IV antibiotics + percutaneous drainage

↓ not responding

Open drainage / Nephrectomy

Genitourinary TB

→ MC organism involved - Mycobacterium tuberculosis

→ MC in males, 20 to 40 years

→ MC route of spread - Hematogenous

→ Primary organ involved - Lungs

→ **Primarily involved organs by hematogenous spread**

- Kidney
- Prostate

→ **Secondarily involved organs by hematogenous spread**

- **By ascent of infection** – form Prostate to vas deferens (moving upwards)
- **By Descent of infection** – from kidney to ureter & bladder (moving down)

PrepLadder

Pathophysiology

Bacteria (From hematogenous spread)

↓

Lodged into periglomerular capillaries

↓

If good immunity - Infection cleared

If bad immunity - Activation of bacteria

↓

Formation of **cortical granuloma**

↓

Formation of **tubercular abscess**

↓

Ruptures into pelvicalyceal system

↓

Sterile Pyuria

(On urine routine & microscopy - **Pus cells**)

(On culture & sensitivity - **No growth within 48 hours**)

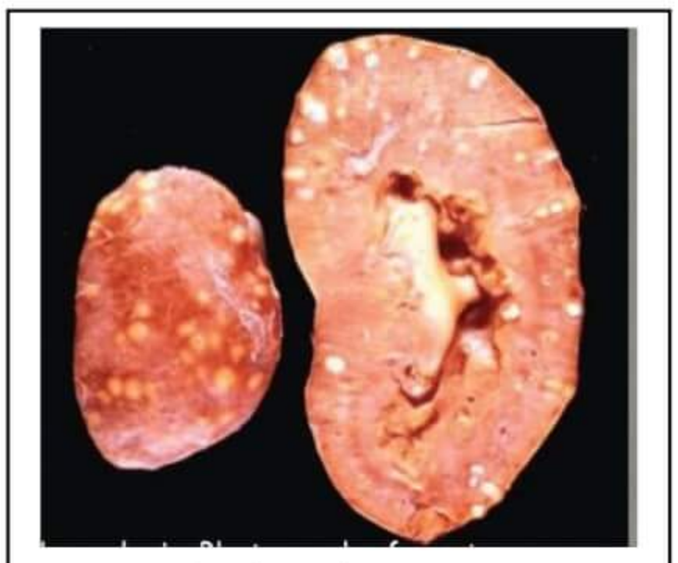

Genitourinary TB

→ MC earliest symptom of GU TB - Increased frequency of urination

In kidney and ureter

Calyceal Stenosis / stenosis at PUJ

↓

Hydronephrosis / Pyonephrosis

↓

Perinephric abscess

↓

Caseous necrosis

↓

Kidney filled with cheesy material

(Aka Putty kidney)

↓

Calcification

(Calcified kidney **Aka** cement kidney)

↓

Becomes Non-functioning calcified kidney (Auto nephrectomy)

PUTTY KIDNEY

→ Auto nephrectomy is seen in GUTB

→ Auto splenectomy is seen in sickle cell disease

t.me/latestpgnotes

PrepLadder

In Bladder

→ Infection moves from ureter into bladder - Pallor around ureteric orifice in the bladder

→ **Initial sign visualized during cystoscopy** in TB - Pallor around ureteric orifice.

→ Chronic inflammation in bladder forms tubercles

↓

Fibrosis

↓

Bladder becomes small, contracted bladder with highly reduced capacity – Thimble bladder

→ In **advanced cases** of TB, when there is contracted bladder – it gives Golf hole ureteric orifice.

Thimble bladder

In Prostate

→ Becomes Calcified - hard & nodular

→ Testis is spared in genitourinary TB

→ **Characteristic feature of TB** - Beaded appearance of vas deferens with multiple discharging sinuses via scrotum

Moth eaten Calx

Investigation

→ Urine Routine and microscopy- Pus

→ Urine culture & Sensitivity - no growth within 48 hours (sterile Pyuria)

t.me/latestpgnotes

→ Earliest sign of renal TB on IVP - Moth Eaten calyx

→ IOC for diagnosis of earliest changes of renal TB - IVP

→ **Other changes seen in IVP**

- Calectasis (calyx become swollen and dilated)
- Space occupying lesion
- Hydronephrosis

→ IOC for diagnosis of Renal TB - CECT

→ **On RGP** – Pipe- Stem Ureter (Medial deviation of ureter)

Pipe stem ureter

Treatment

→ ATT + Management of complications

Complications

1) **For Ureteric stricture** – Dilation
2) **For Small contracted bladder** - Augmentation Enterocystoplasty
3) **For non-functioning kidney** – Nephrectomy

PrepLadder

4) For Non-dilatable stricture of lower 3rd of ureter - **BOARI'S OPERATION** (Excise the Non dilatable stricture and part of ureter & then rise a flap from bladder and suture the defect)

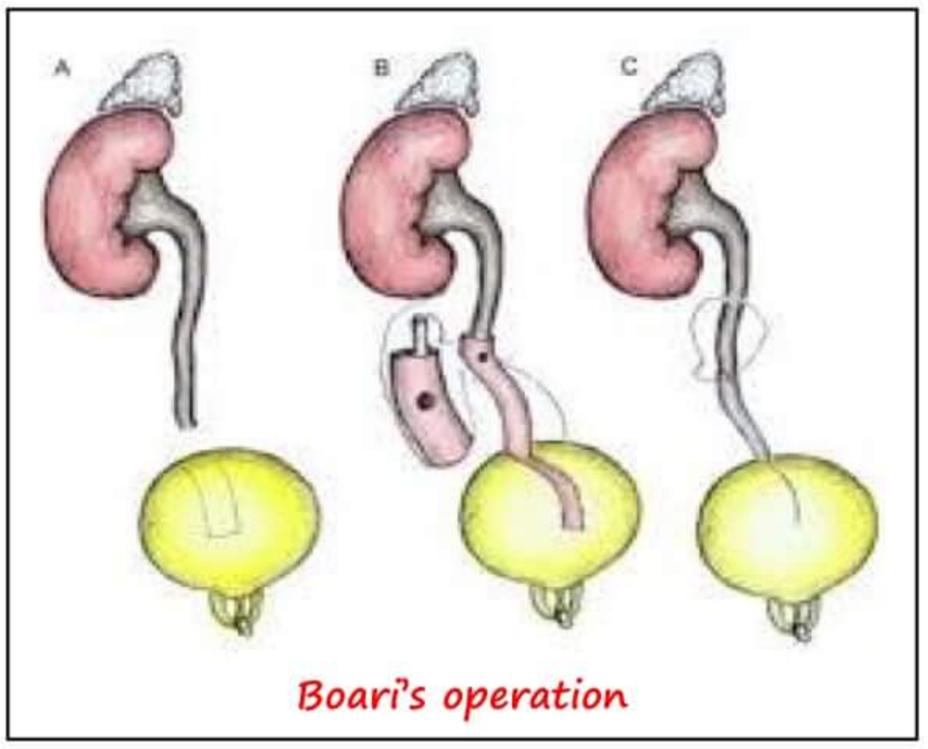

Boari's operation

Hydronephrosis

- → Aseptic dilation of kidney
- → Caused by Outflow obstruction of Urine
- → Can be Unilateral / Bilateral

- → Any kind of obstruction lead to "HIS"
  - H – Hydronephrosis
  - I – Infection
  - S – Stone

Causes of Unilateral Hydronephrosis

t.me/latestpgnotes

Extramural	Intramural	Intraluminal
→ Advanced Malignancies • Colorectal cancer • Carcinoma cervix • Carcinoma Prostate	→ PUJ Obstruction	→ Stone → DM
→ Retro peritoneal fibrosis	→ Ureterocele	→ Papillary Slough
→ Retrocaval Ureter	→ Ureteric Stricture	→ Ureteric stricture
	→ Urothelial tumor	→ Analgesic nephropathy
		→ Sickle cell anemia

Causes of Bilateral Hydronephrosis

Congenital	Acquired
→ Posterior Urethral Valve	→ Bladder neck stenosis
→ Urethral atresia	→ BPH
	→ CA Prostate
	→ Urethral strictures

PrepLadder

U/L Hydronephrosis

→ Mild pain / Dull aching pain

→ Acute Ureteric Colic

→ Intermittent hydronephrosis (DIETL'S Crisis)

↓

Patient present with severe pain in flank and palpable swelling

↓

Disappears after passage of large volume of Urine

B/L Hydronephrosis

→ Symptoms of Bladder Outlet Obstruction

→ Renal symptoms occur after renal failure

Investigation

→ Screening investigation - USG

→ IOC for Dx - DTPA

Management

→ < 10% kidney function – Indication for nephrectomy

→ Treatment of underlying cause

t.me/latestpgnotes

PrepLadder

KIDNEY AND URETER -2

Benign Renal tumors

Angiomyolipoma

→ Benign tumor

→ **Composition** - Blood vessel + Muscle + fat

→ MC in Females among 5- 6th decade

→ Associated with tuberous sclerosis (young patient with multiple & bilateral Angiolipoma)

→ **On immunohistochemistry**

- Marker - **HMB – 45** is positive in both **Angiomyolipoma & Malignant melanoma**

→ **Presence of Macro aneurysm** - Increased risk of Retroperitoneal Hemorrhage in 10% cases and is called as **WUNDERLICH Syndrome**

Clinical Features

→ Asymptomatic – so diagnosed incidentally

Investigations

→ IOC for most renal tumors - **CECT** (except Wilms tumor - MRI)

- Presence of fat
- Absence of calcification

(These features differentiate RCC from angiomyolipoma)

t.me/latestpgnotes

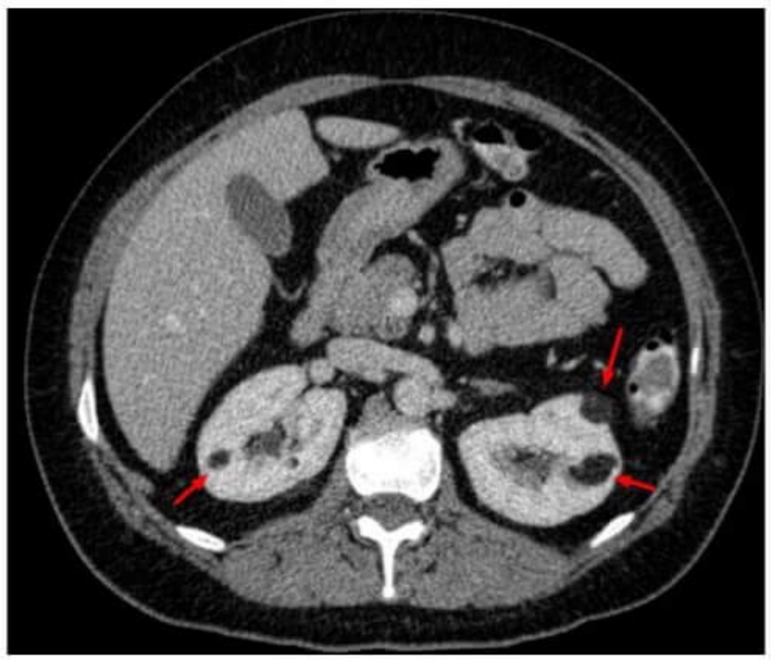

Angiolipoma (On CECT)

Treatment

→ For Asymptomatic, tumor up to 4cm - **Observation**

→ For Symptomatic, > 4cm - **Nephron sparing surgery**

→ Bleeding - **Angioembolization**

Renal oncocytoma

→ Responsible for 3-7% of solid renal tumor

→ Arise from oncocytes, having rich mitochondria

→ **Renal oncocytoma looks like eosinophilic variant of chromophobe RCC**

Investigation

→ IOC for Dx - **CECT** (shows Central stellate scar)

→ On Angiography - **spoke wheel pattern**

Treatment

→ Nephron sparing surgery

Central stellate scar

→ **Also Seen in**

- FNH (focal nodular hyperplasia)
- Fibrolamellar variant in HCC
- Serous cystadenoma pancreas
- Renal oncocytoma

PrepLadder

Renal Cell Carcinoma

Clear cell variant of RCC

→ MC variant of RCC
→ Arise from **PCT**
→ Cells contain glycogen & lipids →washed away during staining - **Cell appears clear**
→ **Mutation of VHL gene** located on chromosome 3.
- **Deletion**
- **Translocation** t (3:6, 3:8, 3:11)

Papillary cell variant of RCC

→ Papillary projection
→ MC type of RCC Seen in patients of cystic disease requiring hemodialysis
→ Mutation of MET gene located on **Chromosome 7** (trisomy)
→ In trisomy, chromosome 7, 16, 17 are also involved
→ It arises from PCT
→ This variant of RCC is Hemorrhagic + cystic Tumor
→ Associated with Dystrophic Calcification - Psammoma Bodies
→ **Psammoma bodies are seen in**
- P - Papillary variant of RCC and PCT
- S - serous cyst adenoma ovary
- M - meningioma

t.me/latestpgnotes

Chromophobe variant of RCC

→ Best prognosis
→ Arise from - Intercalated cells of collecting duct
→ **Plant cell appearance**
- Relatively clear eosinophilic cytoplasm
- Nucleus with fine chromatin
- Thickened cell membrane
- Perinuclear halo.

→ Chromosomes lost are - 1, 2, 6, 10, 13, 17, 21, Y
→ Multiple chromosome Loss - Extreme Hypodiploidy

Bellini duct Carcinoma of RCC

→ Rare
→ Arises from collecting duct
→ Has HOBNAIL Pattern
→ Associated with - Desmoplastic Reaction

Medullary variant of RCC

→ Exclusively seen in children having Sickle cell trait
→ Rare

PrepLadder

Renal Cell Carcinoma

→ **Aka Hyper nephroma / Gravitz Tumor / Radiologist tumor / Internist tumor**
→ MC malignancy of kidney
→ MC in Males among 6 - 7th decade
→ Sporadic [scattered in the population]
→ **Associated with**
- Hereditary VHL syndrome
- Hereditary clear cell carcinoma
- Hereditary papillary carcinoma Syndrome

Risk factors

→ Smoking / Tobacco
→ Analgesic Nephropathy
→ Cadmium + Asbestos exposure

Unique Features of RCC

→ Has pseudo capsule
→ Refractory to cytotoxic agents
→ Shows response to biological response modifiers (IL-2 & INF- α)
→ Prolonged period of stable disease
→ **Spontaneous Regression is seen in 5 malignancies**
- **N** – Neuroblastoma
- **C** – Choriocarcinoma
- **R** – Renal Cell Carcinoma
- **M** – Malignant Melanoma
- **R** – Retinoblastoma

t.me/latestpgnotes

Clinical Features

→ "TOO- LATE" TRAID – Mass + Pain + Hematuria
→ Triad is seen in 10% patients with advanced disease
→ MC presentation – Hematuria
→ In Advanced cases, Non-Reducing Varicocele – due to tumor thrombus in the left kidney

Route of spread

→ MC route of spread - Hematogenous
→ MC site of metastasis - lungs
→ Cannon Ball Secondaries are seen in **RCC and Choriocarcinoma** (variant of testicular tumor)

PrepLadder

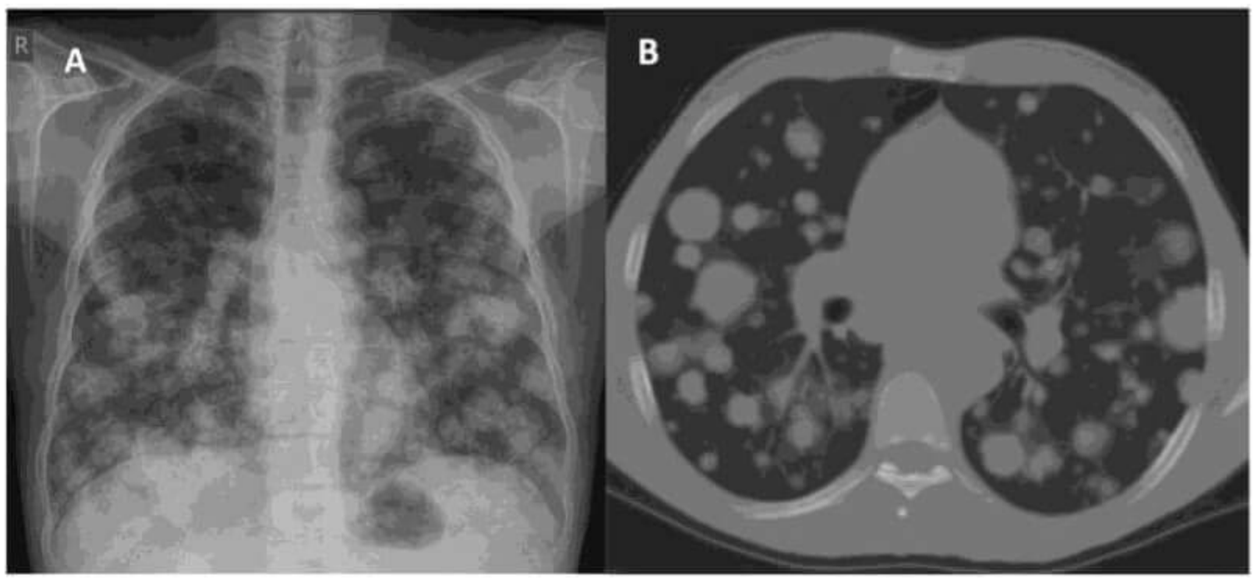

CANNON BALL SECONDARIES

→ MC malignancy responsible for **Osteoblastic secondaries** in Males - Carcinoma prostate
→ MC malignancy responsible for **Osteolytic secondaries** (Hyper vascular) in Males - RCC
→ **Pulsatile secondaries are seen in**
- RCC
- Follicular Carcinoma Thyroid

Paraneoplastic Manifestations of RCC

1) **Raised ESR** - MC (> 55% of patients)
2) **Anemia** - decreased erythropoietin due to nonfunctional mass replacing functional kidney
3) **Polycythemia** - due to functional mass which increase erythropoietin production
4) **Hypertension** - Increase Renin by production from mass / by compression of flood vessels by activation of RAAS system
5) **Hypercalcemia** - due to release of PTH- rp
6) Medically managed with Bisphosphonates
7) When consuming Bisphosphonates, plenty of water should be taken and standing erect for half an hour **to prevent esophagitis**
8) **Stauffer's Syndrome** (Non metastatic hepatic dysfunction)
9) RCC patient with jaundice - **Raised bilirubin, ALP**

→ **On USG & CT abdomen** – No evidence of metastasis. These changes are due to IL-6 and this is known as non-metastatic hepatic dysfunction and improves after tumor resection

Investigation

→ IOC - CECT
→ IOC for detecting tumor thrombus - MRI (**to differentiate tumor thrombosis from bland thrombosis**)
→ IOC for IVC invasion - Inferior vena cava gram
→ GOLD STANDARD INVESTIGATION - Inferior vena cava gram

t.me/latestpgnotes

PrepLadder

8th AJCC TNM classification of RCC

T_{1a}	→ Size up to 4cm confined to kidney
T_{1b}	→ Size > 4-7 cm confined to kidney
T_{2a}	→ Size > 7-10 cm confined to kidney
T_{2b}	→ Size > 10 cm confined to kidney
T_{3a}	→ Tumor grossly extends into renal veins or its segmental branches. → Tumor invades perirenal and/or renal sinus fat **without involvement of Gerota's fascia**
T_{3b}	→ Tumor extends grossly into IVC **below diaphragm**
T_{3C}	→ Tumor extends into IVC **above diaphragm** or tumor invades the wall of IVC.
T_4	→ Tumor invades beyond Gerota's Fascia

N Classification

N_o	→ No metastasis to regional lymph nodes
N_1	→ Metastasis to regional LN

t.me/latestpgnotes

M Classification

M_o	→ No metastasis to distant organs
M_1	→ Distant metastasis

Stages

Stage I	→ T_1
Stage II	→ T_2
Stage III	→ T_{1-3} N_1 → T_3
Stage IV	→ T_4 N_o M_o → T any N any M_1

PrepLadder

Treatment

Localized RCC	Locally advanced / Metastatic RCC
→ Radical nephrectomy → Indications of Nephron sparing surgery • RCC size up to 4cm • RCC in solitary kidney • Bilateral RCC • RCC with diseased contralateral kidney like Renal artery stenosis	→ Radical Nephrectomy → 1st line agent - SUNITINIB → 2nd line agent - IL-2 + IFN-α

Named staging & Grading

• Robson staging • Fuhrman Grading	→ RCC
• Jackson staging	→ CA Penis
• Gleason Grading	→ CA Prostate

Pediatric Tumors

→ MC malignancy of infancy – Neuroblastoma
→ MC malignancy of childhood - Leukemia
→ MC solid malignancy of childhood - Brain tumor
→ MC intra-abdominal malignancy in children - Neuroblastoma
→ MC extracranial solid malignancy - Neuroblastoma
→ 2nd MC Intra-abdominal Malignancy in children - Wilms' tumor
→ MC primary Renal Malignancy - Wilm's Tumors
→ MC Renal Tumor of infancy - Congenital Mesoblastic Nephroma
→ MC Soft tissue tumor in children - Rhabdomyosarcoma
→ MC malignancy of childhood - Leukemia (ALL)
→ MC solid malignancy of childhood - Brain tumor

t.me/laststpgnotes

Wilm's tumor

→ **Aka Nephroblastoma**
→ MC primary renal Malignancy of childhood
→ 2nd MC intraabdominal malignancy of childhood
→ Usually seen among children of 2-5 years of age
→ Usually Unilateral
→ Genes involved - WT_1 & WT_2 located on chromosome 11
→ **Components of Wilms tumor**
- B - Blastema
- E - Epithelium
- ST - Stroma

PrepLadder

Variants of Wilm's tumor

→ **WAGR Syndrome**

- Wilms Tumor
- Aniridia
- Genital anomalies
- Retardation (mental)

→ **DENYS DRASCH Syndrome**

- Gonadal Dysgenesis (associated with male pseudo hermaphroditism)
- Renal failure

→ **BECKWITH WEIDMAN Syndrome**

- Hemihypertrophy
- Visceromegaly
- Macroglossia
- Omphalocele
- Hepatoblastoma

Clinical presentation

→ **TRAID**

- Intrabdominal mass (**MC presentation**)
- Fever (**disappears after tumor resection**)
- Microscopic Hematuria

→ Pain (But pain is not part of Triad)

Route of spread

→ Route of spread - Hematogenous

→ MC site of metastasis – lungs

Investigations

→ Investigation of choice – MRI > CECT (**better soft tissue details**)

→ **In Wilm's tumor**

- CRESCENT shaped discrete and peripheral calcification
- Cannot cross midline

→ **In Neuroblastoma**

- finely stippled calcification
- Can cross midline

Treatment

→ Radical Nephrectomy

→ Most important Prognostic Factor - Histology > Stage

→ **If Adverse histological factors** - Start chemotherapy within 5 days & start Radiotherapy within 10 days

t.me/latestpgnotes

PrepLadder

→ **Chemotherapy Regimen**

- V- Vincristine
- C- Cyclophosphamide
- D- Doxorubicin/ Dactinomycin

Staging

Pre chemotherapy staging	Post chemotherapy staging
→ Preferred by NWTSG staging system → Staging & surgery is done before chemotherapy	→ Preferred by international society of Pediatric Oncology (SIOP staging system) → Staging & Surgery is done after chemotherapy

Carcinoma Renal Pelvis

→ MC histological type - Transitional Cell Carcinoma

Risk Factors

→ Smoking
→ Analgesics like phenacetin
→ Industrial Dye/ Solvent
→ Balkan's Nephropathy

Clinical Features

t.me/latestpgnotes

→ MC symptom – Painless gross hematuria
→ Flank pain
→ Irritative voiding symptoms

Investigations

→ **Ureteroscopic brush cytology** – can diagnose tumor at renal pelvis.
→ **On IVP**- Filling defect can be seen.
→ In CA of renal pelvis, due to poor cohesion between cells, these cells will pass via ureter and any obstruction in the ureter will cause dilatation of proximal as well as distal part from obstruction.
→ GOBLET sign - dilation of parts of ureter distal to obstruction seen on Retrograde pyelography.
→ Bergman sign - coiling of catheter distal to obstruction
→ IOC for Diagnosis - CT Urography

Treatment

→ Nephroureterectomy + Removal of cuff of bladder

PrepLadder

Kidney and ureter - 3

Congenital abnormalities of kidney and ureter

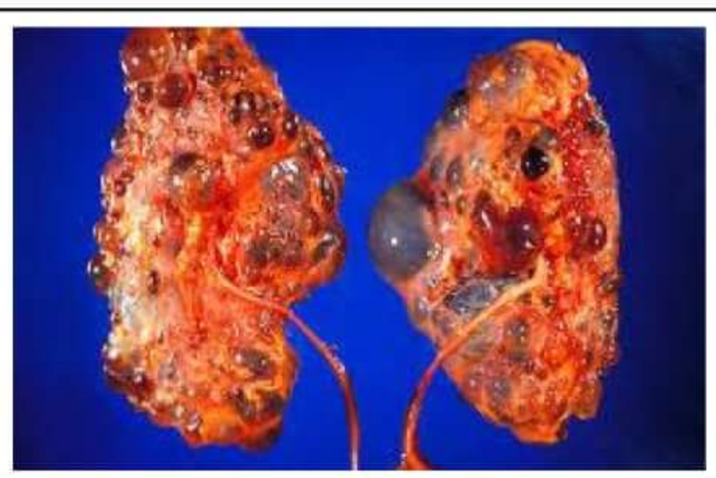

Polycystic kidney disease

Polycystic kidney disease

→ **2 Types**

- ADPKD - Autosomal Dominant
- Infantile PKD - Autosomal recessive

ADPKD [Autosomal Dominant Polycystic Kidney Disease]

→ Involvement of **chromosome 16, 4.**

→ Abnormal protein - **Polycystin**

→ **In ADPKD** - both kidneys are replaced by multiple cysts

↓

Kidney loses its function of concentration of urine

↓

Pt. passes large amount of diluted urine (polyuria)

→ **Due to cysts in kidney** - Compression of blood vessels

↓

Activation of RAAS

↓

t.me/latestpgnotes

Hypertension

→ Any compression in pelvicalyceal system will lead to **HIS** (Hydronephrosis; Infection; Stone)

Clinical Features

→ Usually presented on 3rd to 4th decade

→ MC - **Hypertension** (75% Adults & 25% Children)

→ **Other Presentations**

- Polyuria
- Nocturia
- Hematuria
- Nephrolithiasis

→ MC cause of death - **Chronic Renal Failure (CRF)**

→ **CRF**

- Usually in 5th to 6th decade
- Management - **Hemodialysis/ Renal transplantation**

Extra- renal manifestations of ADPKD

→ **Polycystic Liver Disease** (MC)

→ Cyst in Ovary, Pancreas, Spleen

→ Mitral Valve prolapses

PrepLadder

→ Berry Aneurysm
→ Colonic diverticulosis
→ Arachnoid cyst
→ Cyst in seminal vesicle
→ In ADPKD, Cyst is not seen in Lungs
→ In 8% of cases→ Arachnoid cyst is seen involving brain

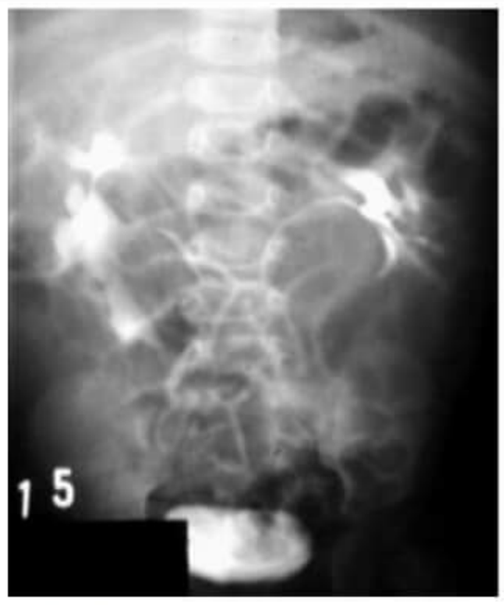

Spider leg appearance

Investigations

→ IOC – CECT
→ On IVP
- Spider leg/ Bell- Shaped appearance
- Bubble Appearance
- Swiss- Cheese Appearance

Management

→ **TOC** – Renal Transplantation
→ ROVSING'S Operation – Deroofing of Cyst in ADPKD
→ **ROVSING'S Syndrome** - Hyperextension of spine in produces Pain, Nausea, Vomiting in horse shoe kidney.
→ **ROVSING Sign** - pain in right iliac fossa on pressing left iliac fossa

Infantile polycystic kidney disease (AR)

→ Bilateral and most severe form of polycystic kidney disease
→ Most patient die within 2 months of birth because of uremia and pulmonary hypoplasia
→ Also associated with hepatic fibrosis and pulmonary fibrosis

t.me/latestpgnotes

Diagnosis

→ IVP (sunburst pattern)

Treatment

→ No cure
→ Only palliative treatment is done

Renal agenesis

→ Unilateral renal agenesis 1:1000 live birth
→ More common in males in left side
→ **Associated with:**
- Oligohydramnios
- Pulmonary hypoplasia
- Amnion nodosum
- Potter facies (usually seen in bilateral agenesis)

→ MC renal vascular abnormality – supernumerary renal artery **(supernumerary renal vein is less common)**

PrepLadder

Medullary sponge kidney (autosomal recessive)

→ Collecting duct is dilated and associated with multiple cyst
→ On cut section – sponge or honey comb appearance
→ Usually bilateral
→ Stones and infection are responsible for most of the symptoms
→ **Associated with:**
  - Hypertrophy
  - Hypercalcemia
  - Nephrolithiasis (presence of stone)
  - Nephrocalcinosis (deposition of calcium in renal parenchyma)

Clinical features

→ Renal colic>UTI>gross hematuria

Investigation

→ IOC – IVP
→ **Findings**
  - Bristles of brush appearance
  - Bouquet of flowers appearance

Treatment

→ No cure
→ Palliative treatment depends on complication

t.me/latestpgnotes

PUJ obstruction (Pelvic Ureteric Junction Obstruction)

→ Unilateral
→ Left side (MC)
→ MC in boys

Causes

Congenital causes	Acquired Causes
→ Atresia/ Stenosis of ureter at PUJ → Aberrant left renal artery	→ MC Cause- Stone → Infection → Instrumentation } can lead to Stricture and then leading to obstruction

PrepLadder

→ In PUJ obstruction, patient will be having unilateral hydronephrosis. This condition can be diagnosed even before birth by the presentation of oligohydramnios by the mother.

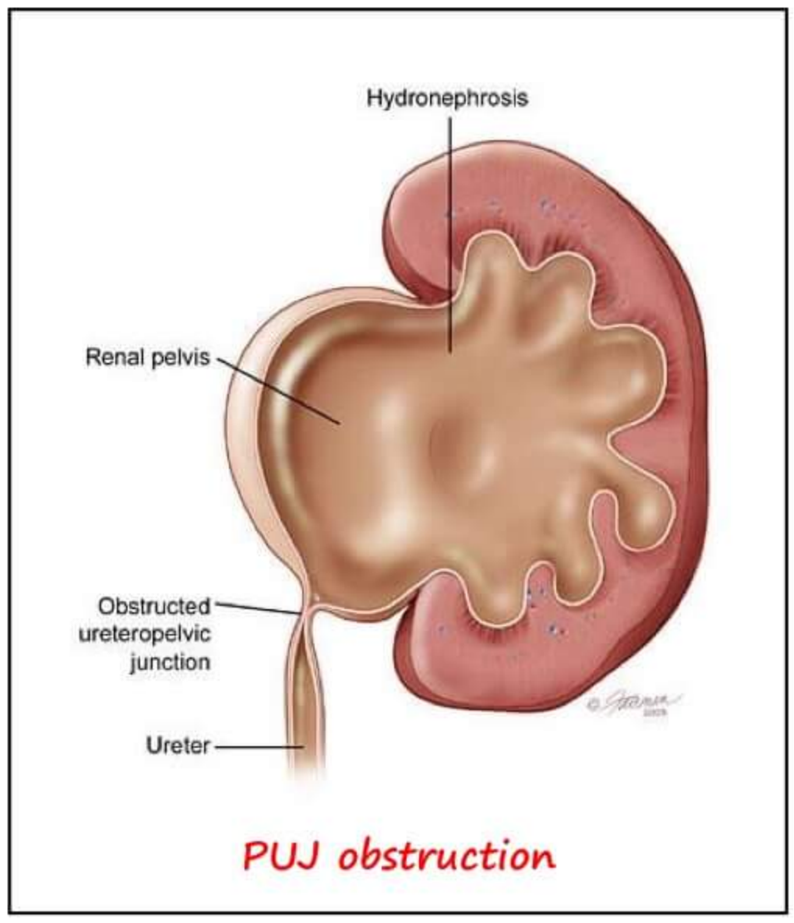

PUJ obstruction

Clinical features

→ Asymptomatic

→ Palpable intra- abdominal mass (unilateral hydronephrosis)

Investigations

→ IOC - DTPA Scan (To diagnose the obstruction & renal function of each Kidney can be identified)

↓

If equivocal

↓

Pressure – Flow study (Whittaker's test)

→ **Whittaker's test**

- Kidney is punctured percutaneously and contrast is injected into pelvis, simultaneously intrapelvic pressure is measured

→ Abnormal Rise Intrapelvic Pressure

↓ suggestive of

PUJ Obstruction

t.me/latestpgnotes

Treatment

Open Treatment	Endoscopic treatment
→ **Gold Standard** - Anderson- Hynes Dismembered Pyeloplasty → Foley V-Y Pyeloplasty → Flap (Spiral/ Vertical)	→ Done for small/ Intra- renal pelvis • Endopyelotomy • Balloon dilatation

- **In Anderson Hynes Dismembered Pyeloplasty** - Removal of obstruction site and end to end anastomosis is done.

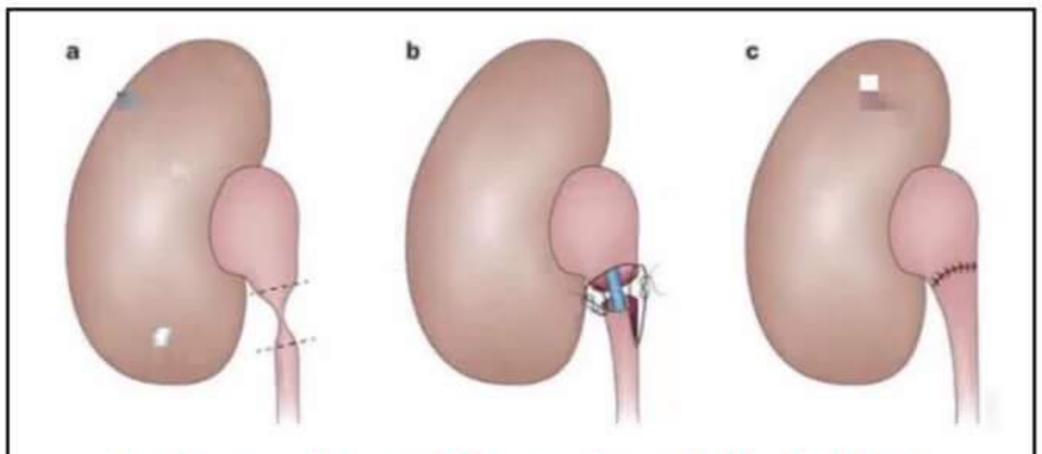

Anderson Hynes Dismembered Pyeloplasty

PrepLadder

Retrocaval ureter / Circumcaval ureter

→ Embryologically normal ureter is entrapped behind IVC
→ Caused by Abnormal persistence of right posterior subcardinal vein

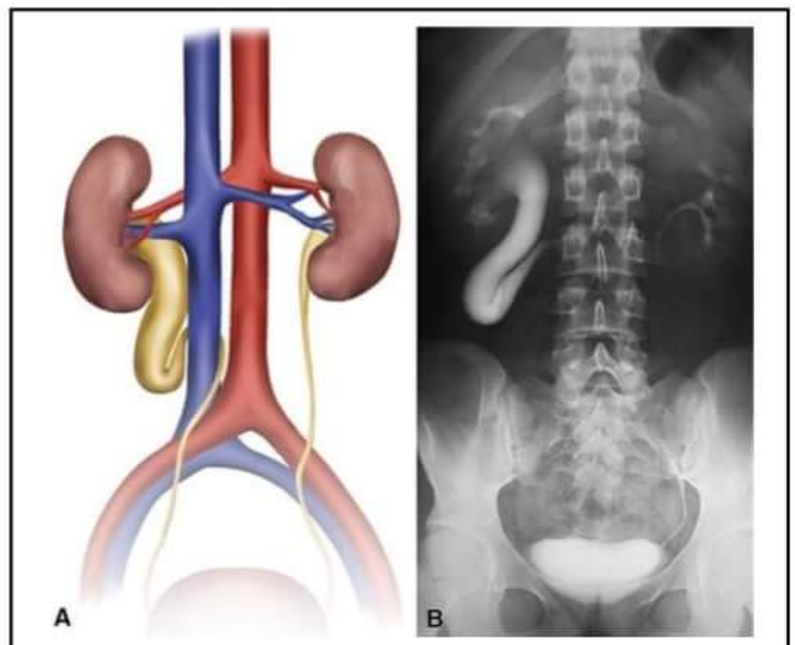

Retrocaval ureter

Clinical features

→ Signs and symptoms of Ureteric obstruction

Investigation

→ IOC for Dx - MRI
→ On IVP – Reverse J /fish hook/ shepherd crook appearance

Management

→ Treatment of choice – Relocation Uretero-ureterostomy

Horseshoe kidney

→ Fusion of kidneys at lower pole
→ Incidence - 1: 400 live births (0.25%)
→ MC in Males

Note

→ Both Testis & kidney change their permanent position after development
→ Testis
- Develops from posterior abdominal wall
- Descends to scrotum for effective spermatogenesis (has 2°C below the body temperature)

→ Kidney
- Develops in pelvis
- Ascends up and rotates from vertical axis to oblique axis

t.me/latestpgnotes

→ **If kidney fuses at lower pole - inferior Mesenteric artery (L2)** prevents the ascend of isthmus of kidney
- Level of isthmus of kidney - L3 to L4
- Kidney axis remains vertical

Clinical features

→ Asymptomatic (Diagnosed incidentally on radiologic examination)
→ MC symptom - Vague Dull Aching pain
→ **On hyperextension of spine**
- Abdominal Pain
- Nausea
- Vomiting

} ROVSING'S syndrome

PrepLadder

Investigations

→ IOC for Dx - **CECT** (to diagnose HSK & localize the position & abnormal vascularity)

→ **On IVP**

- Medial Orientation of Calyx- **Hand Joining Sign**
- High Insertion of Ureter with Anterior Transposition - **Flower vase like curve of Ureter**

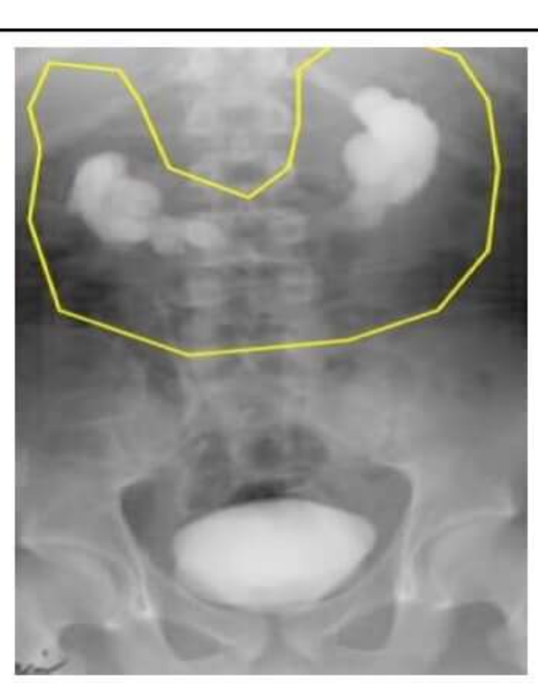

Hand Joining Sign

Flower vase like curve of Ureter

Management

→ Management of Complications

→ **Isthmus should not be divided**

→ In pregnant patients, HSK Leads to Dystocia

t.me/latestpgnotes

Ureterocele

→ Cystic dilatation of terminal ureter

→ MC in Females

→ **Types**

- Intra- Vesical **(20%)**
- Ectopic **(80%)** - A/W duplication of ureter

→ **In Intravesical ureterocele** - Terminal part of ureter is cystic & dilated and is inside the bladder

→ **In ectopic ureterocele** - Duplication of ureter and the upper pole of ureter is having ectopic ureteric orifice

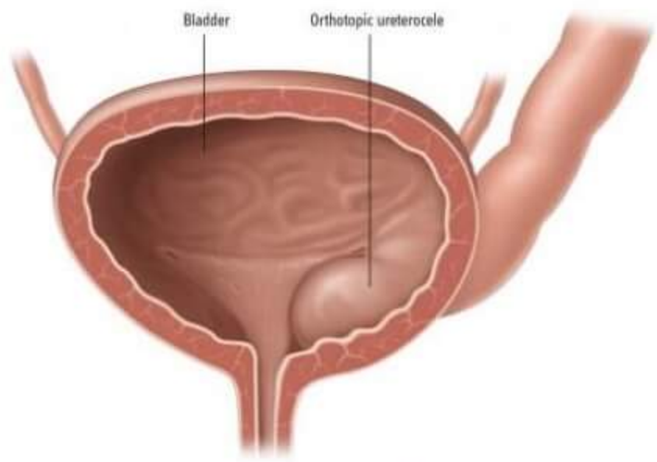

Ureterocele

Clinical presentation

→ Recurrent attacks of UTI/ Urosepsis

→ Unilateral Hydro-uretero nephrosis

→ Palpable mass

Investigations

→ On USG – **Hydroureteronephrosis with cyst in the bladder**

→ On IVP – **Adder Head/ Cobra- head appearance**

→ IOC for diagnosis - **IVP**

Adder Head appearance

PrepLadder

→ On MCU - **Filling defect in bladder**

→ On Cystoscopy - Enlarging and collapsing cyst in the bladder

Treatment

→ Depends on type of ureterocele

- **In intravesical ureterocele** - Incision over the cyst wall (Free flow of urine into bladder)
- **In ectopic ureterocele** – Excision and reimplantation into bladder

❖ MC Congenital abnormality of upper urinary tract - **Duplication of ureter** (AD)

❖ MC Congenital abnormality of urogenital tract - **VUR** (AD)

Duplication of ureter

→ Autosomal dominant

→ MC in females

→ Usually bilateral

→ **It is of two types**

- Incomplete Duplication (**bifid ureter**
- Complete Duplication **(Weigert Meyers Rule)**

→ **Weigert Meyers Rule**

- Upper pole ureter is caudal and medial compared to lower pole ureter complete duplication

t.me/latestpgnotes

→ **Yo-Yo reflux**

- Reflux of contrast in both limbs of ureter on retrograde pyelogram in incomplete duplication

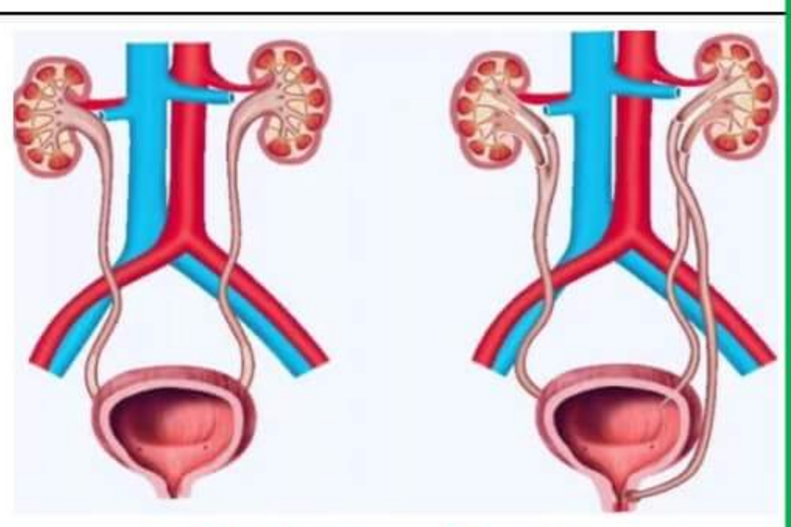

Duplication of ureter

Complete DOU

→ Upper pole ureter – Has **Ureterocele**

→ Lower pole ureter – Has **VUR** **(due to short intravesical length)**

→ **MC location of Ectopic ureteric orifice**

- **In males** - orifice is in **Prostatic urethra** & is proximal to external urinary sphincter
- **In females** - orifice of upper pole is in **Anterior urethra** & is distal to external urinary sphincter

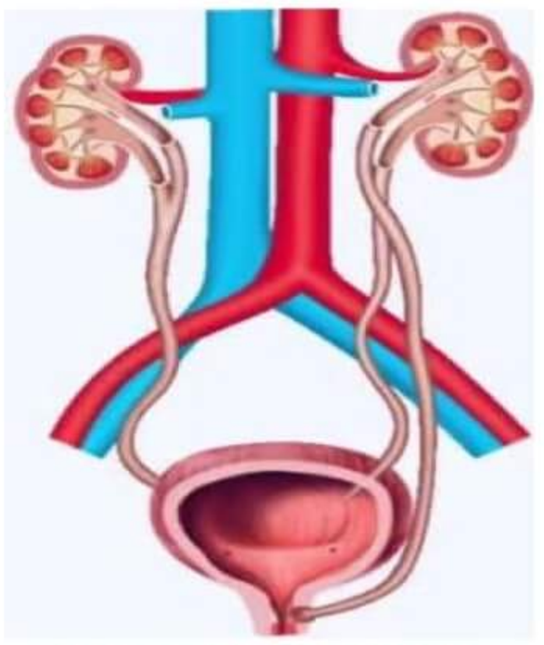

Wiegert Meyers Rule

Clinical features

→ **In Males**

- Continent
- Increased risk of UTI

→ **In Females**

- Continuous incontinence with normal voiding pattern

PrepLadder

Investigations

→ IOC for Dx is **IVP** – **Adder head/ Cobra head appearance**

→ IOC for VUR - **MCU** (micturating cysto urethrogram)

Treatment

→ **For upper pole ureter**

- Excision + Reimplantation into bladder

→ **For lower pole ureter**

- Ureterovesicoplasty (strengthening of uretero vesical junction)

→ **If there is upper pole hydronephrosis with no function**

- Upper pole nephrectomy should be performed
- On IVP – Shows Drooping Lilly sign

Drooping Lilly sign

Vesicoureteric reflux (VUR)

→ Autosomal dominant

→ MC congenital abnormality of urogenital tract

→ MC in children

→ Asymptomatic

→ **Mostly resolves Spontaneously** – because

t.me/latestpgnotes

- At the time of birth, Trigone & bladder system is not mature - High risk of VUR.
- By 5-6 years of age, maturation occurs - low grade VUR disappears

Causes

Primary causes	Secondary causes
→ Short in intravesical length of ureter → Deficiency of longitudinal muscle over the surface of ureter	→ In children - Posterior urethral valves → In adults - Neurogenic bladder

Investigations

→ IOC for Dx - **MCU**

PrepLadder

International classification of VUR (based on MCU)

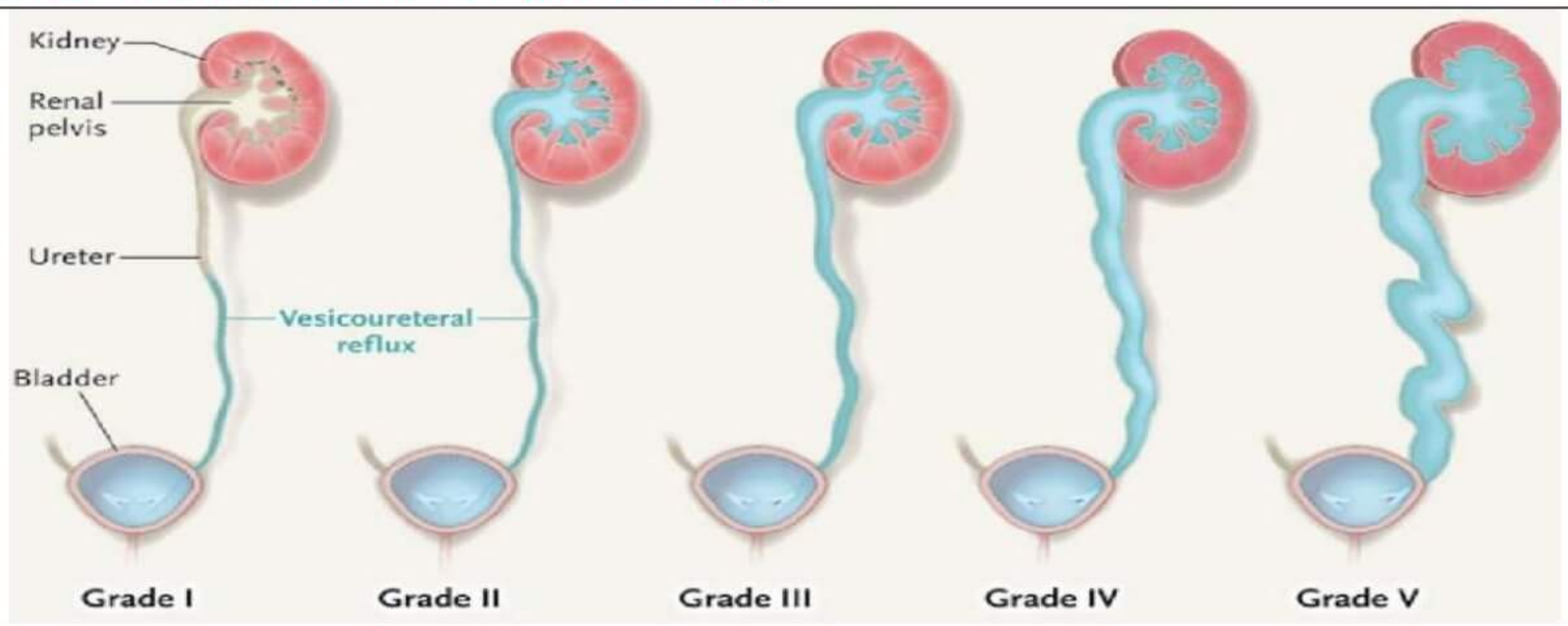

Grade I	→ Reflux into **non- dilated ureter**
Grade II	→ Reflux into **pelvicalyceal system**
Grade III	→ Mild to moderate dilatation of ureter with reflux into pelvicalyceal system
Grade IV	→ Blunting of fornix with reflux into pelvicalyceal system
Grade V	→ Dilated and tortuous ureter with reflux into pelvicalyceal system

→ **Chances of spontaneous resolution of VUR**

t.me/latestpgnotes

- Grade I & II – 80%
- Grade III – 50%
- Grade IV – 20%
- Grade V – 0-5%

Management

→ Prophylactic antibiotics to all patient irrespective of Grade of VUR – To prevent UTI

→ **For children upto 6 weeks**

- Ampicillin
- Amoxicillin

→ **Children age > 6 weeks**

- TMP- SMX

→ **Medical Management Sufficient for**

- Grade I- Grade III VUR
- Unilateral Grade IV – VUR

→ **Indications of surgical intervention**

- Bilateral Grade IV - VUR
- Grade V - VUR

PrepLadder

- Recurrent UTI despite of antibiotics
- Older Children
- Presence of Permanent scar
- Presence of Bladder Diverticula

→ **Various surgical interventions performed**

1) **Ureterovesicoplasty** - Strengthening of ureterovesical junction
2) **STING Operation** (Sub ureteric trans- urethral injection of Teflon paste)
3) **Ureteric reimplantation**
   - Lich- Gregoir technique **(preferred for ureteric reimplantation)**
   - Leadbetter Politano technique

t.me/latestpgnotes

PrepLadder

URINARY BLADDER

Ectopia vesicae

→ **Aka Exstrophy bladder**

→ Characterised by Complete ventral defect of urogenital sinus with overlying skeletal system.

→ Abnormal over maturation of urogenital sinus

↓

Ventral defect (rupture of ventral wall)

Ectopia vesicae

→ **Associated with**

- Absent anterior wall of bladder
- Absent infra-umbilical abdominal wall
- Exposed posterior wall of bladder and urine dribbling from trigone
- Widely separated public rami
- Umbilical hernia
- Rectal prolapse

→ **In Males**

- Epispadias
- Undescended testis
- Shallow scrotum

→ **In Females**

- Epispadias
- Bifid clitoris
- Widely separated labia

t.me/latestpgnotes

→ Ectopia vesicae increases the risk of - Adenocarcinoma.

Management - complex

→ Augmentation cystoplasty

→ Abdominal wall closure after posterior iliac bone osteotomy + Repair/ correction of associated abnormalities

Bladder stone

Primary bladder stone	Secondary bladder stone
→ Formed in bladder in absence of • Anatomical factors • Functional factors • Infections factors • Obstructive factors	→ Formed in bladder due to • Anatomical factors • Functional factors • Infections factors • Obstructive factors

Migrant bladder calculi

→ Stones that are formed in the kidney & retained in the bladder due to distal obstruction

PrepLadder

Primary bladder stone

→ **Aka Endemic bladder calculi**
→ Endemic in undeveloped countries (Burma, Indonesia, Thailand, Africa)
→ Usually seen in children < 10 years and commonly seen in 2-4 years and MC in males
→ In India – **Andhra Pradesh, Rajasthan** have been reported.
→ MC type of primary bladder stone - Ammonium urate
→ **Other stones** - Calcium oxalate

Causes

1) Chronic dehydration
2) Exclusive milk
3) High carbohydrate diet
4) Low phosphate intake

→ In chronic laxative abuses most common type of stone is - Ammonium urate
→ Primary bladder stones - **rarely associated** with recurrence once after treatment.

Secondary bladder stone

→ MC in elderly males due to BPH /Bladder outlet obstruction
→ MC type of secondary bladder stone - Uric acid > Struvite
→ Overall MC bladder stone – Secondary bladder stone (Uric acid)
→ Hence, most of the bladder stone are Radiolucent **(As uric acid stone is radiolucent)**

Predisposing factors

t.me/latestpgnotes

→ Bladder outlet obstruction/BPH
→ Foreign body
→ Bladder diverticula
→ Prolonged catheterization

Jack stones

→ Composition of Jack stone - **Ca Oxalate dihydrate**

Jack stones

Clinical Features (1° & 2° bladder stones)

→ Intermittent **painful voiding** with severe pain **at the end of micturition** with terminal hematuria

Investigation (1° & 2° bladder stones)

→ IOC for Dx - Ultrasound
→ **On USG** - Characteristic shadowing which changes the position with change of posture

Treatment (1° & 2° bladder stones)

→ **For small stones**
  - Cystolitholapexy

→ **For Large stones**
  - Electrohydraulic lithotripsy
  - Suprapubic cystolithotomy

PrepLadder

Schistosomiasis

→ **Aka Bilharziasis**

→ Causative agent – S. haematobium

→ Endemic in Middle east, Egypt, Africa

→ MC in Males

→ **Species of Schistosoma**

- S. Haematobium – invades bladder
- S. Japonicum – invades liver and small intestine
- S. Mansoni – invades large intestine

→ Definitive host – Man (Sexual phase occur)

→ Intermediate host – Snail (Asexual phase occur)

Life cycle

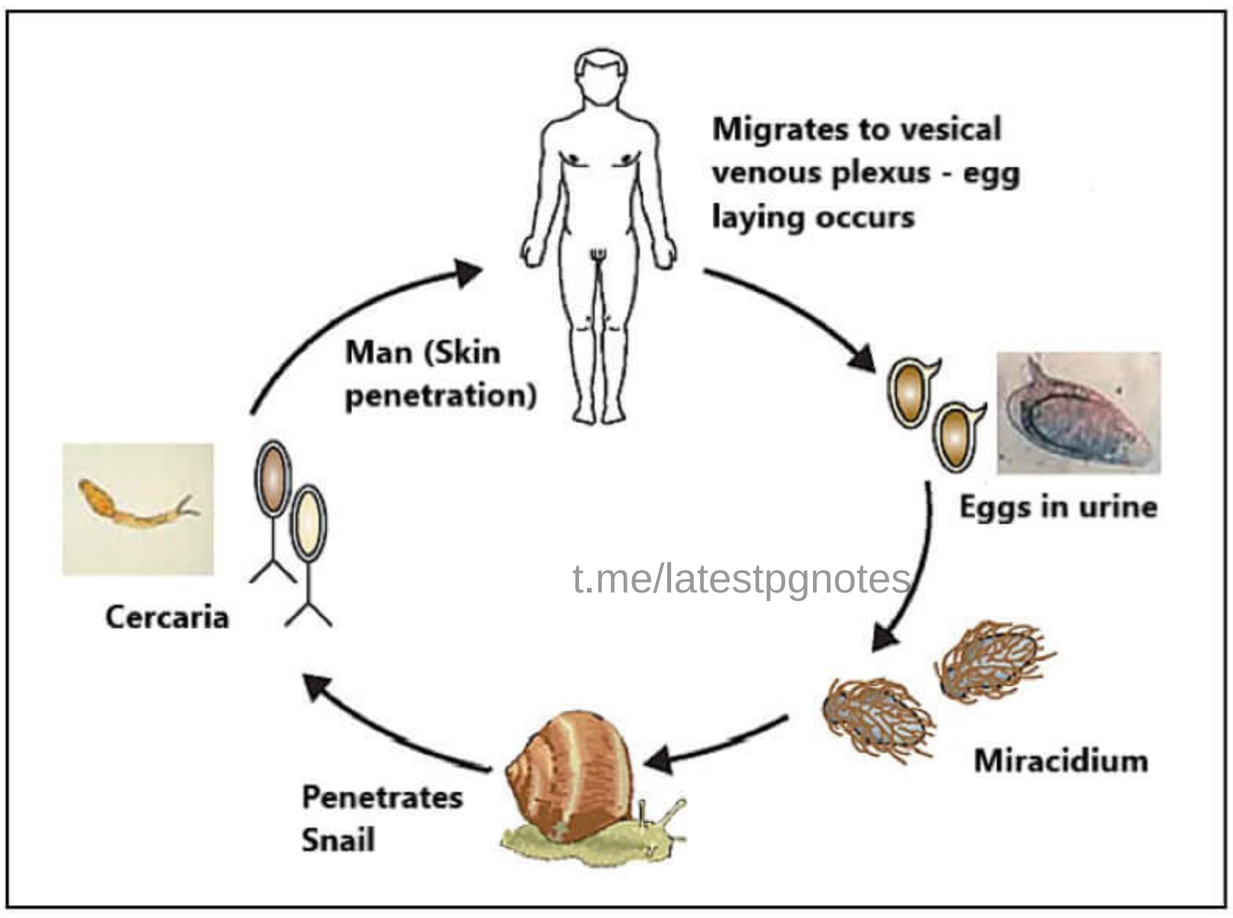

t.me/latestpgnotes

1) Swimmer's itch – occurs at the site of penetration of cercaria within < 24 hours
2) Katayama fever – Within 3 weeks- 4 months, larva converts to adult worm

↓

Egg laying occurs

(Submucosal venous plexus)

↓

Eggs are highly antigenic

↓

Forms a strong inflammatory response

- Fever
- Chills & rigor
- Hepatosplenomegaly
- Lymphadenopathy

PrepLadder

Clinical features

→ Earliest MC symptom - **increased urine frequency**

→ **Schistosomiasis** - MC cause of **bladder calcification** worldwide

→ Due to chronic inflammation - increased risk of SCC & Transitional cell Carcinoma

Investigations

→ **On cystoscopy** - **Sandy patches**

→ **On Urine examination** - presence of eggs

→ **On X-ray** - **Fetal head-in-pelvis appearance.**

Treatment

→ Drug of choice - **Praziquantel**

→ **Alternative drugs**

- Metrifonate
- Oxamniquine

Malakoplakia

→ Inflammatory disorder of bladder

→ Also involve ureter and kidney

→ Formation of nodules/plaques, composed of large histiocytes (**Von Hansemann cells**)

→ Associated with laminar inclusion bodies – **Michaelis-Guttman bodies**

t.me/latestpgnotes

Pathophysiology

→ **Defective phago-lysosomal activity** - Inadequate killing of bacteria by monocytes/macrophage

Risk factors

→ Immunosuppressed

→ Diabetes mellitus

→ Rheumatoid arthritis

→ lymphoma

clinical features

→ MC in females having UTI – Causes **Irritative symptoms**

↓

- Frequency
- Urgency

Investigation

→ **On USG/CT** - Mass in the bladder

→ **If there is involvement of ureter** - Evidence of obstruction is seen

→ **On Urine culture sensitivity** - **E. coli**

PrepLadder

Treatment

→ **Antibiotics**
- Fluoroquinolones
- TMP-SMX

→ **In case of Upper urinary tract involvement** – Antibiotics + Surgery (max. cure rate)

→ **Involvement of bilateral kidney** - Associated with poor prognosis

Interstitial cystitis (Hunner's ulcer)

→ Characterized by Chronic Pancystitis

→ Infiltration of lymphocytes and macrophages

→ MC in females

→ Etiology is unknown

→ Presence of linear bleeding ulcer in the fundus (involving mucosa)

Clinical features

→ Initial symptom - Increased frequency

→ Pain increased by distention of bladder & relieved by micturition

→ Bladder capacity is reduced to 30 – 50ml

Diagnosis

→ **On Cystoscopy** – presence of linear bleeding ulcer in fundus

→ **To rule out malignancy:**

t.me/latestpgnotes

- Urinary cytology
- Biopsy

Treatment

→ **Difficult and unsatisfactory**

→ Bladder distention under anesthesia

→ Instillation of dimethyl-sulphoxide into the bladder

Bladder rupture

→ **2 types**
- Extra- peritoneal (responsible for 80% cases)
- Intra- peritoneal (responsible for 20% cases)

Extraperitoneal bladder rupture

→ **Caused by** - Road traffic accident

→ RTA causes **Pelvic fracture**

↓ leads to

Extraperitoneal rupture of bladder and Posterior Urethral injury

PrepLadder

Clinical features

→ Suprapubic pain
→ Difficulty in passing urine
→ Hematuria

Investigations

→ IOC - CT cystography/ Cystogram
→ **Findings**
- Flame sign
- Pear sign
- Tear drop bladder

Flame sign

Management

→ Foley's catheterization
→ Spontaneous healing **within 7-10 days**

→ **Indications of surgical intervention**
- Repeated occlusion on catheter due to ongoing hematuria
- Projecting bone fragment, impinging over the bladder wall.
- Tear near neck of bladder

Intra peritoneal bladder rupture

t.me/latestpgnotes

→ External blow/ kick to full bladder may lead to intraperitoneal bladder rupture
→ MC in Males

Clinical features

→ Suprapubic pain
→ Difficulty in passing urine
→ Hematuria
→ Peritonitis

Investigation

→ IOC for Dx - Cystography
→ On Cystography - Sunburst appearance
→ On Ultrasound - Bladder in bladder appearance

Management

→ Exploratory Laparotomy + Peritoneal lavage + Repair of defect + Suprapubic catheter / Foley's catheterization

PrepLadder

CA Bladder

→ TCC > SCC > Adenocarcinoma

Risk factors

Transitional cell carcinoma	Squamous cell carcinoma
1) Smoking 2) Drugs • Phenacetin • Chlornaphazine • Cyclophosphamide 3) Exposure of • Benzidine • Hydrocarbon • Aniline • Acrolein • Beta-naphthylamine 4) Printing, Dyeing, Rubber, Leather, Automobile & Petroleum industries 5) Schistosomiasis (SSC > TCC) 6) Pelvic irradiation	1) Schistosomiasis 2) Chronic Inflammation • Bladder stone • Bladder diverticulum • Prolonged catheterization

t.me/latestpgnotes

Squamous cell carcinoma	Adenocarcinoma
→ Nodular & invasive → **Treatment** – Radical cystectomy	**Risk factors** • Ectopic vesicae • Patent urachus • Intestinal pouch/ conduit • Augmentation Enterocystoplasty **Treatment** – Radical cystectomy + Pelvic lymphadenectomy (due to involvement of pelvic group of lymph nodes)

→ MC **benign mesenchymal** tumor of bladder – Leiomyoma

→ MC **malignant mesenchymal** tumor of bladder – Leiomyosarcoma

→ MC **malignant mesenchymal** tumor of bladder **in children** – Embryonal Rhabdomyosarcoma

CA Bladder

→ MC in high socio-economic status

→ MC among whites, males and smokers

→ MC in 6th / 7th decade

→ MC type histological type – Transitional cell carcinoma

PrepLadder

→ MC site of CA bladder - Posterolateral wall of Trigone

→ **Precursor lesions of CA bladder**

- Papillary tumor
- Malignant cystitis

Papillary tumor (Benign)

→ **Aka kiss ulcer**

→ Exophytic tumor when touches(kisses) surrounding bladder mucosa, implantation of daughter tumor arises

→ Characterized by Painless, profuse paroxysmal hematuria

Carcinoma in Situ

→ **Aka Malignant cystitis**

→ High grade tumor

→ Present with Irritative symptoms

- F - frequency
- U - urgency
- D - dysuria

Investigations

→ Diagnosis is made by - Urinary cytology (Transitional epithelium has multiple layers and poor cohesion between cells - causes shedding of these cells in urine)

Treatment

→ Intravesical BCG

t.me/latestpgnotes

Clinical Features

→ MC symptom - Hematuria

- Painless
- Gross
- Intermittent hematuria

→ **Irritative symptoms**

- Frequency
- Urgency
- Dysuria

Route of spread

→ MC route of spread - Hematogenous

→ MC site of metastasis - Liver

→ **Non-GI malignancies with liver as MC site of metastasis**

- CA bladder
- Malignant melanoma
- Medullary carcinoma thyroid

→ MC group pf LN involved - Pelvic LN (obturator nodes)

PrepLadder

Investigations

→ IOC for Dx- **Cystoscopy + Biopsy**

→ **Urinary cytology**

- To confirm the diagnosis
- But location of tumor cannot be identified.

→ IOC for staging- **MRI**

→ **Urinary tumor markers**

- BTA (Bladder tumor antigen)
- NMP -22 (Nuclear Matrix Protein)
- Lewis- X- antigen
- Hyaluronidase
- Helpful in diagnosis and for follow up to assist the response of therapy and to detect recurrence

8th AJCC TNM Classification

T_a	→ Noninvasive papillary carcinoma
T_{is}	→ Carcinoma insitu
T_1	→ Tumor invades subepithelial connective tissue
T_{2a}	→ Superficial muscularis propria invasion of inner half
T_{2b}	→ Deep muscularis propria invasion of outer half
T_{3a}	→ Microscopic extension into perivesical fat
T_{3b}	→ Macroscopic extension into perivesical fat
T_{4a}	→ Cancer invading pelvic viscera • Prostatic stroma • Vaginal wall • Rectum • Uterus
T_{4b}	→ Extension to pelvic side walls, abdominal walls or bony pelvis

t.me/latestpgnotes

N_1	→ Single regional LN in true pelvis
N_2	→ Multiple regional LN in true pelvis • Hypogastric • Obturator • External iliac • Presacral
N_3	→ LN metastasis to common iliac lymph nodes

PrepLadder

M_0	No metastasis
M_1	Metastasis

Treatment

→ For T_{is} (malignant cystitis) – **Intravesical BCG**

→ For T_a (single, low to moderate grade, non-recurrent) – **Complete TUR**

→ For T_a (multiple, high grade, recurrent) – **Complete TUR + Intravesical chemotherapy**

→ For T_1 – **Complete TUR + Intravesical chemotherapy**

→ For T_2-T_4

- **Radical cystectomy**
- Neo Adjuvant chemotherapy followed by radical cystectomy
- Radical cystectomy followed by adjuvant chemotherapy ± Radiotherapy

→ **Systemic Chemotherapy agents**

- Methotrexate
- Vincristine
- Adriamycin
- Cisplatin

→ **Intravesical chemotherapy agents**

t.me/latestpgnotes

- Mitomycin-C
- Epirubicin
- Thiotepa
- BCG **(most effective)**

→ Any **T, N+, M+** → Neoadjuvant chemotherapy followed by Surgery/Palliation

→ **BCG**

- Attenuated strain, of M. bovis
- Most effective
- **MOA** – immunologically mediated (exact mechanism not known)
- MC side effects –Frequency, urgency, dysuria
- Immunocompromised patients may develop Severe BCG sepsis – treated by **ATT**

→ **Absolute Contraindications for intravesical BCG**

- Immunocompromised patients
- Gross hematuria
- Immediately after **Trans urethral resection of bladder tumor** (TURBT)
- Traumatic catheterization
- Total urinary incontinence
- History of BCG sepsis

PrepLadder

→ **Urinary diversion**

- Stricture at the site of anastomosis
- Reflux of urine
- High risk of Dyselectrolytemia
- Best or gold standard conduit for urinary diversion is ileum
  - Easy to perform
  - Minimal intraoperative and
  - Immediate postoperative complication

→ **Dyselectrolytemia in ileal/colonic conduit**

- Hyperchloremic
- Hypokalemic
- Metabolic acidosis

→ **Dyselectrolytemia in Jejunal conduit**

- Hypochloremic
- Hyponatremic
- Hyperkalemic
- Metabolic acidosis

→ **Dyselectrolytemia in Stomach conduit (same like IHPS)**

- Hypochloremic
- Hypokalemic
- Metabolic alkalosis

t.me/latestpgnotes

PrepLadder

PROSTATE AND SEMINAL VESICLE

Anatomy of prostate

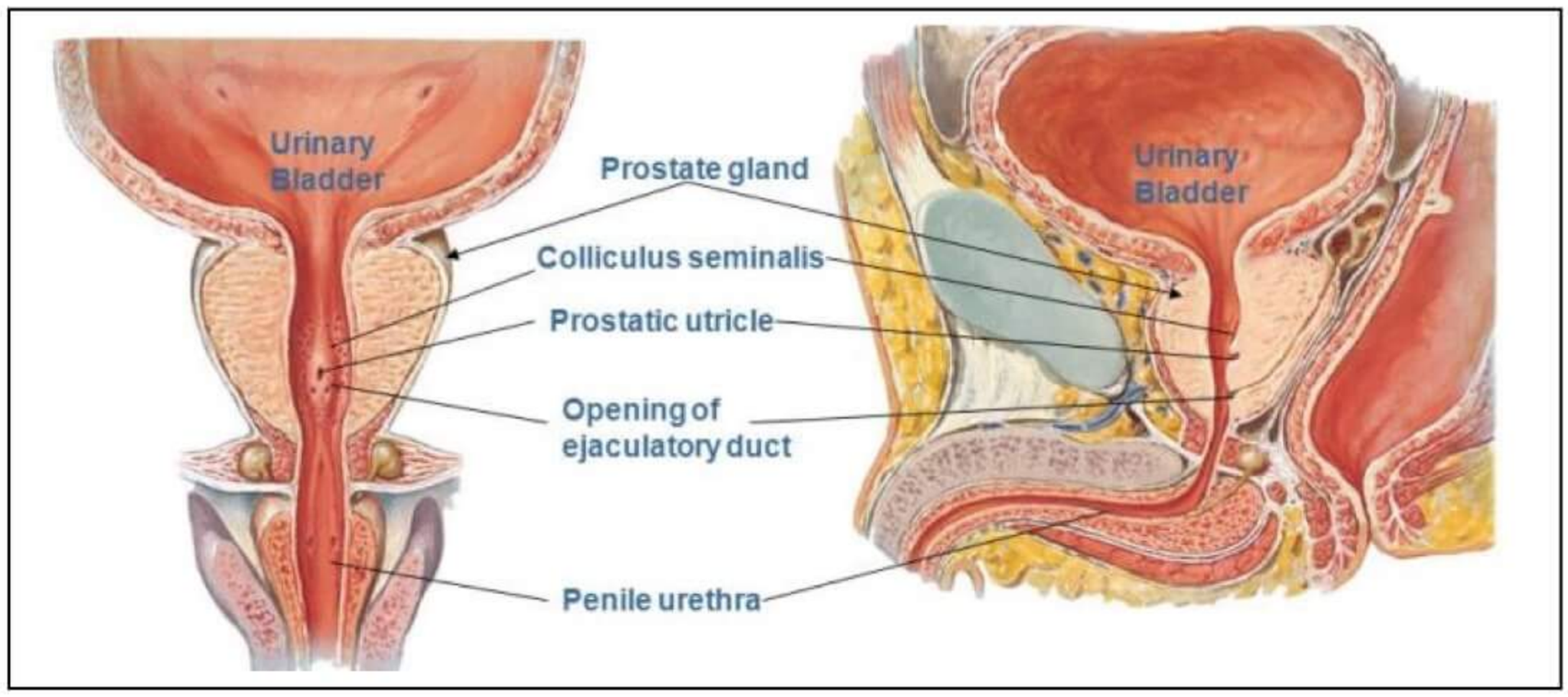

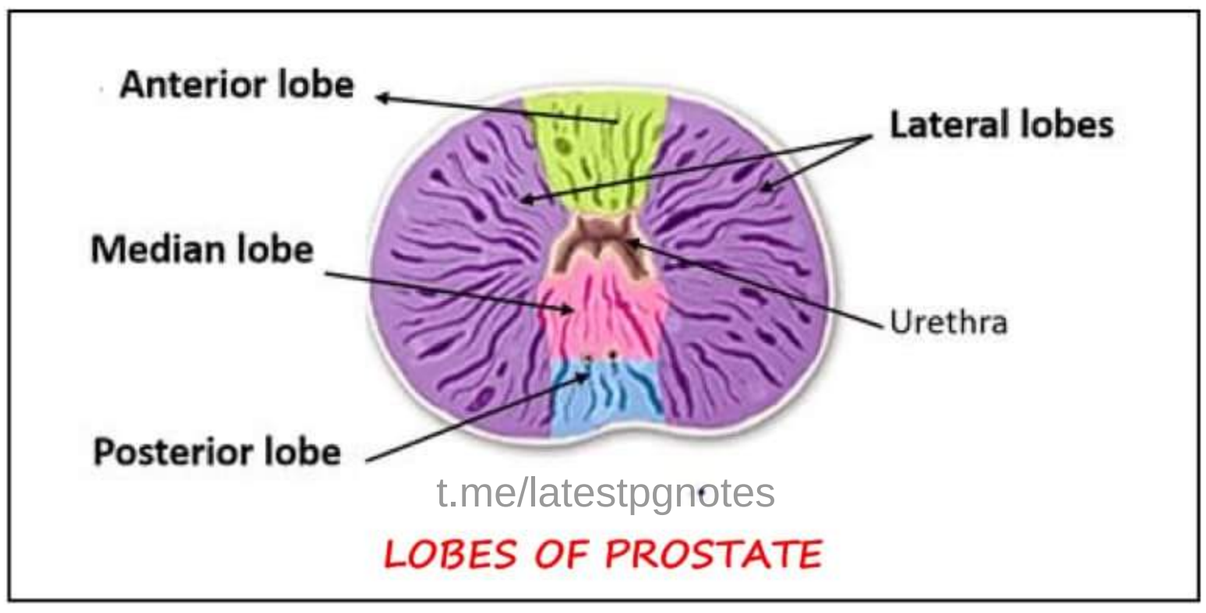

t.me/latestpgnotes

LOBES OF PROSTATE

→ MC site of BPH - **Median lobe**

→ MC site of CA Prostate - **Posterior lobe**

→ **On DRE** - Posterior lobe is felt and medial lobe is felt when enlarged.

MC Neal zones classification

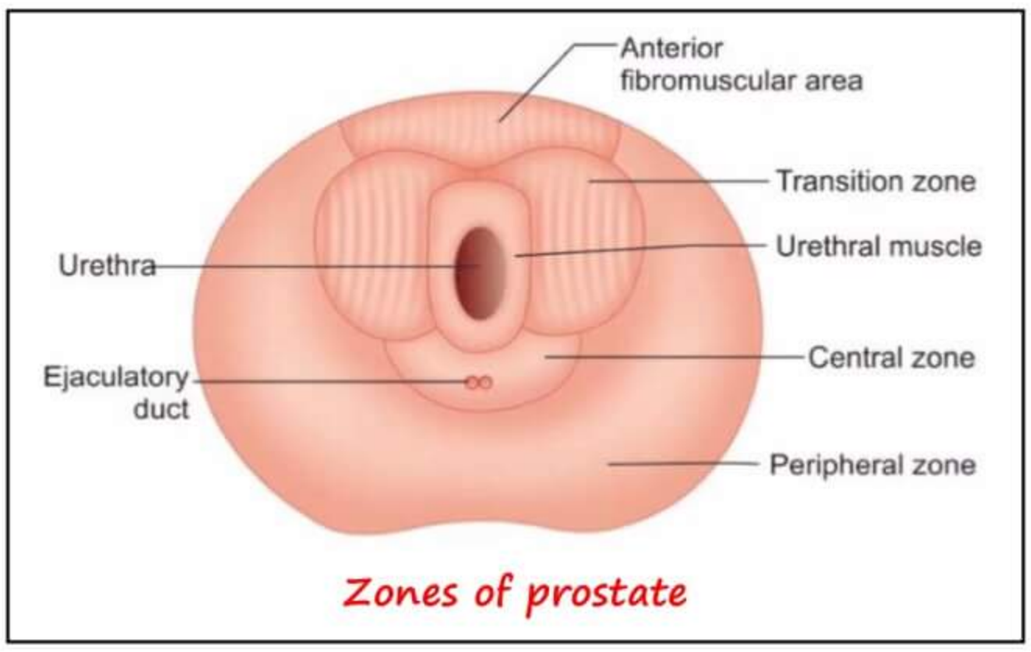

Zones of prostate

→ MC site of BPH - **Transition zone**

→ MC site of CA Prostate - **Peripheral zone**

→ Severity of symptoms depends on Nodules and its relation of being close to urethra

- Nodule close to urethra even small will be **symptomatic**

PrepLadder

- Nodule far from urethra even large will be **asymptomatic**

→ No correlation between size of prostate & severity of symptoms

→ Most patients of CA prostate - Asymptomatic (initially)

→ Screening of CA prostate – Digital rectal examination + Prostate specific antigen

→ **In patients of BPH** - TURP is done but it is not protective for CA prostate. So, DRE+ PSA is to be continued for screening of CA prostate.

Benign prostatic hyperplasia

→ Age related

→ Endocrine controlled

→ Multifactorial process

→ MC site - Transition zone

→ **Age related**

- Incidence of age 41-50 years - 20%
- Incidence of age 51-60 years - 50%
- Incidence of age >80 y - 90%

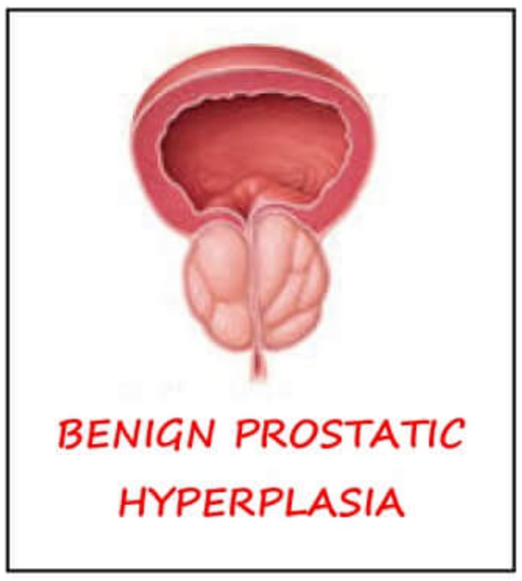

BENIGN PROSTATIC HYPERPLASIA

→ Endocrine controlled - Under control of testosterone

→ **In cut section of BPH**

- Epithelium
- Stroma – composed of collagen and smooth muscles and has rich adrenergic nerve endings.

t.me/latestpgnotes

→ Testosterone $\xrightarrow[(inhibited\ by\ 5-\alpha\ reductase\ inhibitor)]{5-\alpha\ reductase}$ 5 DHT (acts on epithelium)

→ **If smooth muscle component is predominant** - α blockers are given for relaxation of smooth muscles.

→ **If epithelial component is predominant** - 5α Reductase inhibitors are given

→ α blockers are instantaneously active.

→ Minimum time required for 5α Reductase inhibitors to act - 1 month

→ Maximum effect of 5α Reductase inhibitors is seen after 6 months

Secondary changes in bladder

→ **Due to increased force of contraction**

- Collagen deposition
- Detrusor muscle hyperplasia
- Detrusor muscle hypertrophy

→ **These changes cause irritative symptoms**

- **F**- Frequency
- **U**- Urgency
- **N**- Nocturia

PrepLadder

Clinical features

→ **Obstructive Symptoms**

- Poor flow/stream
- Hesitancy
- Intermittency
- Incomplete evacuation of bladder
- Dribbling of urine
- Post residual volume

→ **Irritative symptoms**

- Frequency
- Urgency
- Nocturia

IPSS Score- International Prostatic Symptom Score

→ Score varies from **0 to 35**

- Mild – **0 to 7**
- Moderate – **8 to 19**
- Severe – **20 to 35**

→ **On DRE**

BPH	CA Prostate
• Smooth elastic enlargement of prostate	• Enlarged & hard prostate with obliteration of median sulcus

t.me/latestpgnotes

Investigations

→ **Uroflowmetry** – to document the obstruction

- Normal – if Q_{max} **> 15 ml/s**
- Equivocal – if Q_{max} **10-15 ml/s**
- Suggestive of obstruction but not confirmatory – if Q_{max} **<10ml/s**

→ **Cystometry**- to confirm the diagnosis

- Voiding pressure > 80 cm of H_2O
- **Diagnostic criteria for BPH – Qmax < 10 ml/s & Bladder pressure > 80 cm of H_2O**

Management

→ **α blockers** (preferred)

- Prazosin
- Terazosin
- Doxazosin
- Alfuzosin
- Silodosin

PrepLadder

→ MC used - Tamsulosin (α_{1A} selective blocker)
→ 2nd line agents - **5-α Reductase inhibitors**
- Finasteride
- Dutasteride
- Triptorelin pamoate

→ Combination treatment (**α blockers + 5α RI**) preferred in patients with
- Large prostate
- High PSA level

→ **Indications of Surgical intervention**
- No improvement after medical management
- Recurrent UTI
- HDN/ Renal failure
- Bladder stone
- Gross hematuria
- Refractory urinary retention

→ **Surgical treatment**
- Gold standard - TURP (Trans Urethral Resection of Prostate)

TURP

→ **Techniques used for TURP**
- Nesbit technique (preferred)
- Mauer- Meyer technique

t.me/latestpgnotes

→ For irrigation - 1.5% Glycine is used
→ **In Monopolar** - cautery electrolyte like Normal saline should not be used (Ion dissipates current locally)
→ **In Bipolar**
- Cautery Normal saline can be used.
- This is aka TURIS (TURP in Saline)

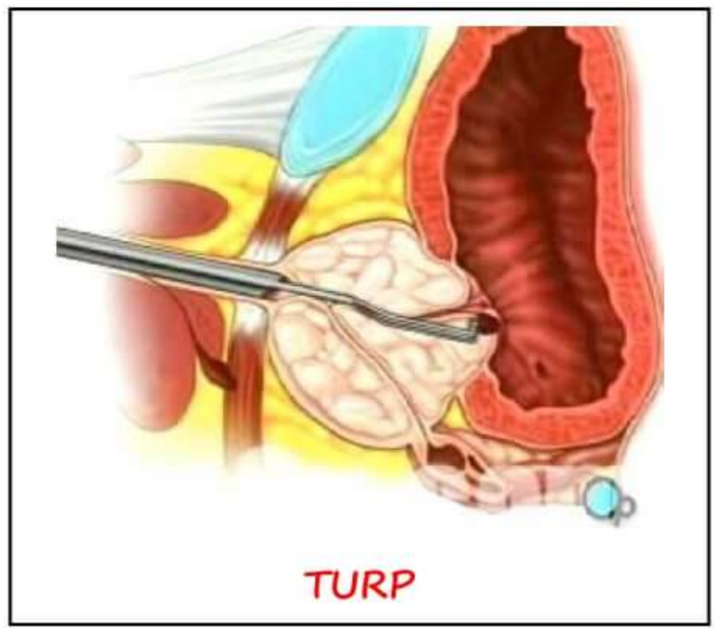

TURP

→ Most important distal landmark in TURP - Verumontanum (Located proximal to external urinary sphincter)
→ No landmark proximally - High risk of injury to internal urinary sphincter by TURP

Complications of TURP

→ MC - Retrograde ejaculation (75% of cases)
→ Impotence (10% of cases)
→ Incontinence (<1% of cases)
→ **Retrograde ejaculation**
- Erection is due to parasympathetic system and Ejaculation is due to sympathetic system.
- Internal urinary sphincter is under the control of L1 sympathetic ganglion
- Normally, at the time of ejaculation, Internal urinary sphincter is closed.

PrepLadder

- Retrograde ejaculation is seen after
  - TURP (Injury of Internal urinary sphincter)
  - Bilateral Lumbar sympathectomy
  - α Blockers (Relaxation of Smooth muscles of internal urinary sphincter)

→ **Late complications**

- MC - Bladder neck stenosis (4%) > Urethral Stricture (3.6%)

TUR syndrome

→ Aka **Water intoxication / Dilutional hyponatremia**

→ **Predisposing factors**

- Size of prostate > 75 g
- Duration of Surgery > 90 min

Clinical features

→ Dizziness

→ Confusion

→ Fluid overload

→ Visual abnormalities

→ Bradycardia

→ Hypertension

t.me/latestpgnotes

Treatment

→ Drug of choice - Furosemide

→ If no response to Furosemide - 3% saline (hypertonic saline)

Trans Urethral Incision of prostate (TUIP)

Procedure

→ Collin's Knife is used

→ Two incisions at 5'o clock & 7'o clock

Advantage

→ Prostate up to 20g can be operated without any complications as of TURP like retrograde ejaculation and Impotence.

Open prostatectomy

Indications

→ Size of prostate > 75g

→ Bladder stone

→ Bladder diverticula

PrepLadder

Named Prostatectomy

1. **Frayer's suprapubic prostectomy** – Preferred for patients having bladder stone, bladder diverticulum
2. **Millin's retropubic prostectomy**
3. **Young's Perineal Prostectomy** – obsolete

→ **Ho -YAG laser** is used for BPH, Renal Stones

Acute bacterial prostatitis

→ Acute inflammation of prostate associated with UTI

→ MC organism responsible - *E. coli*

Clinical Features

→ Fever

→ Chills and rigor

→ Irritative symptoms

→ On DRE- Prostate is enlarged, tender boggy

→ Catheterization & massage of prostate is contraindicated

Treatment

→ **Antibiotics**

- TMP-SMX
- Ciprofloxacin

} Treatment should be done 4-6 weeks to prevent Chronic bacterial Prostatitis

t.me/latestpgnotes

Chronic bacterial prostatitis

→ Persistent infection of prostate

→ Recurrent attacks of UTI

Investigations

→ Microscopic examination
→ Culture

} prostatic expresate & urine taken before & after prostatic massage

Treatment

→ Antibiotics for **3-4 months**

Prostatic abscess

→ Most cases - Complication of Acute bacterial prostatitis

→ **Fluctuation** - late sign in cases of prostatic abscess

Predisposing Factors

- DM
- Renal insufficiency
- Immunocompromised state
- Chronic catheterization

PrepLadder

Diagnosis

→ TRUS (Transrectal Ultrasound) / Pelvic CT

Treatment

→ Trans urethral drainage with antibiotics

Prostatic calculi

→ **Calcified corpora amylacea**
→ Composed of Calcium phosphate
→ Location - **Peripheral region** of transition zone
→ Occurs in clusters
→ Asymptomatic (peripheral location)
→ Doesn't predispose to infection

CA Prostate

→ MC histological type – Adenocarcinoma > TCC
→ Seen in high socio-economic status
→ MC among Afro- Americans
→ Usually seen in 7th to 8th decade
→ Other malignancies seen during 7th to 8th decade
- CA Prostate
- Anaplastic Carcinoma of thyroid

t.me/latestpgnotes

Risk factors

→ Advancing age
→ High fat diet

Protective factors

→ **L** - Lycopene
→ **E** - Vitamin E
→ **S** - Selenium
→ **A** - Vitamin A

Pathology

→ MC site of CA prostate - Peripheral zone (75%) > Transitional zone (15%) > Central zone (10 %)
→ MC genetic alteration seen in CA prostate - Hypermethylation of GSTP 1 (Glutathione Transferase promotor region 1) located on chromosome 11
→ **Histological appearance of Malignant Glands**
- Small
- Crowded
- Absence of basal layer (unlike benign)

PrepLadder

Clinical features

→ Asymptomatic in initial stages

→ **Symptoms in advanced state/ metastasis**

- Backache (MC site of metastasis is lumbar vertebrae)

Route of spread

→ MC route of spread - hematogenous

→ MC site of metastasis – lumbar vertebrae

- Osteoblastic secondaries
- Via batson plexus

→ MC malignancy responsible for **osteoblastic secondaries** in males – CA prostate

→ MC malignancy responsible for **osteolytic secondaries** in males – RCC

→ MC malignancy responsible for osteoblastic & osteolytic secondaries in females - CA Breast

→ MC site of visceral metastasis – Lungs

Investigations

→ **On DRE** - prostate is hard and nodular with obliteration of median sulcus

→ IOC for Dx - TRUS guided Biopsy

→ IOC for staging - Endo rectal MRI (TRUS can be used)

→ **Prostascint**

- Antibody imaging for CA prostate
- Radiolabeled monoclonal antibody against prostate specific membrane antigen
- **Advantage** - In Biopsy proven CA prostate → Soft tissue and lymph node metastasis can be detected

t.me/latestpgnotes

→ **Tumor markers**

- PSA
- Prostatic acid phosphatase
- ALP
- Alpha Methyl CoA racemase
- Hepsin
- DD3

PSA (Prostate Specific Antigen)

→ Can be raised in benign conditions of prostate also

→ Not cancer specific

→ Normal level - < 4ng/ml

→ diagnostic of Ca prostate – > 20ng/dl

PSA density

→ PSA / Prostate volume

→ PSA density ≥ 0.15 – Biopsy is recommended

PrepLadder

PSA velocity

→ rate of change of PSA

→ **PSA velocity ≥ 0.75ng/ml/year** is diagnostic of CA prostate

Free PSA (%)

→ If 4-10 ng/ml

Conditions that leads to increased PSA	Conditions that leads to decreased PSA
→ CA prostate	→ Castration
→ BPH	→ Radical prostatectomy
→ ABP, CBP, prostatic Abscess	→ Chemotherapy/radiotherapy
→ DRE, prostatic massage	
→ Catheterization	
→ Sexual intercourse	
→ Prostatic Biopsy	

8th AJCC TNM Classification for Ca Prostate

T_{is}	→ Carcinoma in Situ
T_{1a}	→ **up to 5%** of tissue in resection for benign disease has cancer, DRE normal
T_{1b}	→ **>5%** of tissue in resection for benign disease has cancer, DRE normal
T_{1c}	→ Tumor is identified by needle biopsy
T_{2a}	→ Tumor involves one half of lobe
T_{2b}	→ Tumor involves more than one half of lobe
T_{2c}	→ Tumor involves both lobes
T_{3a}	→ Extra capsular extension on one or both sides including bladder neck
T_{3b}	→ Seminal vesicle involvement
T_4	→ Tumor is fixed/ invades adjacent structures other than seminal vesicle like • External sphincter • Rectum • Levator muscles and or pelvic wall

t.me/latestpgnotes

N_0	→ No regional Lymph node metastasis
N_1	→ Metastasis to regional LN (obturator, internal iliac, External iliac, presacral)

PrepLadder

M_0	→ No metastasis
M_{1a}	→ Distant metastasis in non-regional LN
M_{1b}	→ Distant metastasis to bone
M_{1c}	→ Distant metastasis to other sites

Management of CA prostate

→ T_{1a} – observation + Follow up (DRE + PSA)

→ T_{1b}, T_{1c} & T_2

- > 70 years – Observation + follow up
- < 70 years – Radical prostatectomy Or Radiotherapy

→ T_3 & T_4

- Androgen ablation> Palliative radiotherapy
- Bilateral Orchidectomy + Flutamide
- LHRH Agonist (Goserelin, Leuprolide) + Flutamide

→ Goserelin – Recently FDA approved for advanced and metastatic CA prostate

→ New drugs for **castration resistant metastatic CA Prostate**

- Cabazitaxel
- Sipuleucel (vaccine)

t.me/latestpgnotes

PrepLadder

PENIS & URETHRA

Basic Anatomy

Anatomy of penis

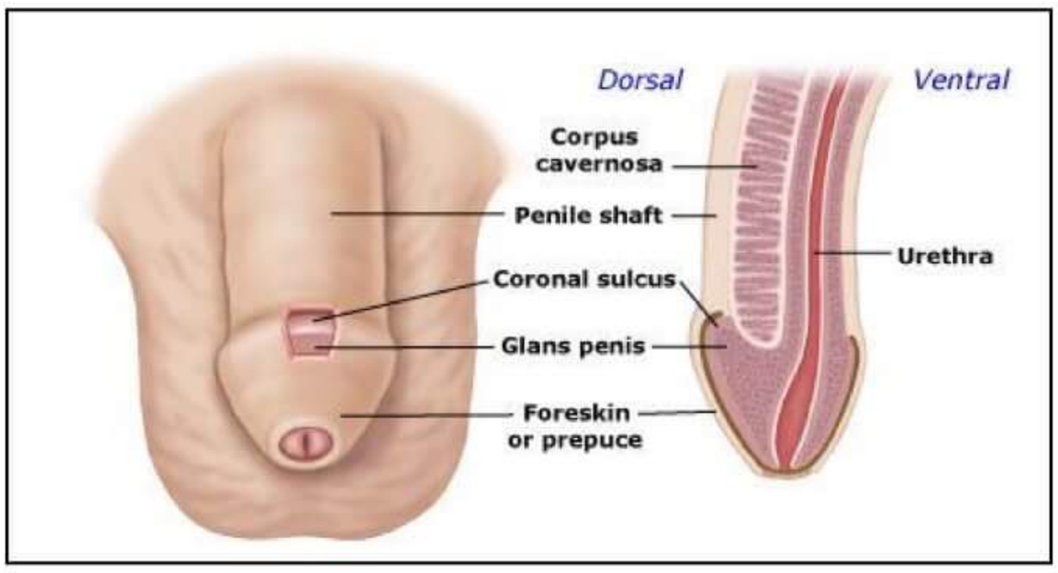

→ Length of male urethra – 20 cm

→ Length of female urethra – 4 cm

Parts of urethra

→ **Posterior urethra**
- prostatic urethra
- Membranous urethra

→ **Anterior urethra**
- Bulbar urethra
- Penile urethra
- urethra meatus

→ **Prostatic urethra** - widest & most dilatable part of urethra

→ **Membranous urethra** – shortest, narrowest & least dilatable par of urethra

→ **Penile urethra** – longest urethra

→ **Meatus > membranous urethra** - Narrowest part of urethra

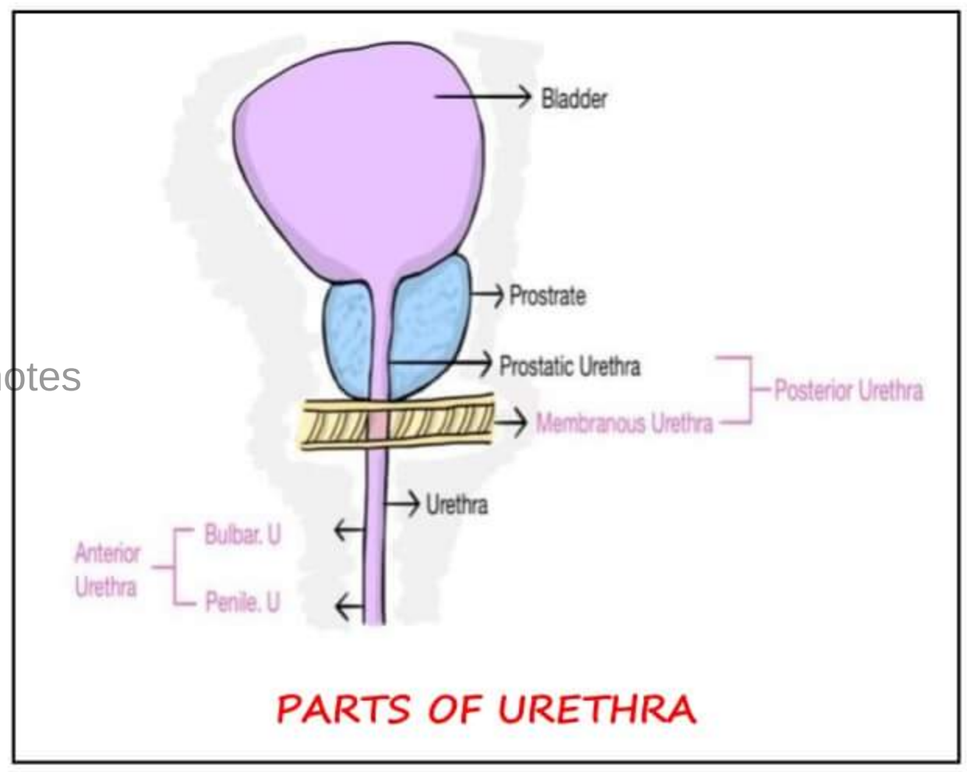

PARTS OF URETHRA

t.me/latestpgnotes

Congenital abnormality of urethra

Hypospadias

→ MC congenital abnormality of urethra

→ **Incidence**
- Hypospadias 1:250 live births.
- Horseshoe kidney 1:400 live births.
- Unilateral renal agenesis 1:1000 live births.

→ Caused by failure of fusion of urethral folds - Meatus is presents over ventral aspect.

→ Urethral fold usually closes in posterior to anterior direction.

Hypospadias

PrepLadder

Types of Hypospadias

- Glandular Hypospadias
- Coronal Hypospadias
- Distal penile hypospadias
- Mid shaft hypospadias
- Proximal penile hypospadias
- Peno scrotal hypospadias
- scrotal hypospadias
- Perineal Hypospadias

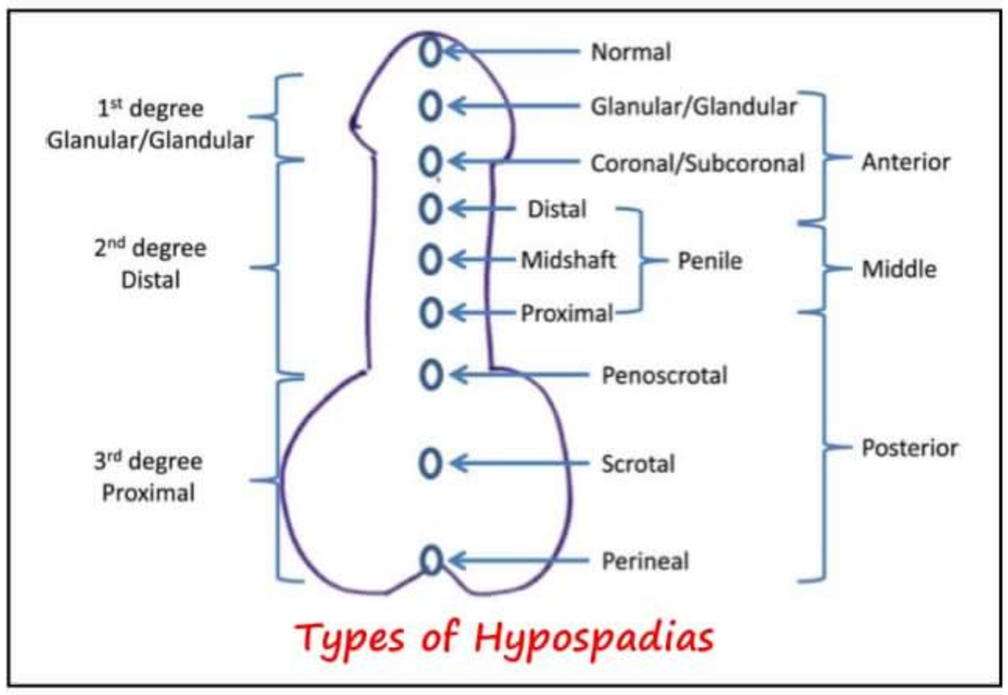

Types of Hypospadias

→ MC are Anterior types (glandular, coronal and distal penile)

→ **Coronal hypospadias and distal penile hypospadias** contribute to 70% of cases of hypospadias.

Associations

→ Hooded prepuce over dorsal aspect

→ Ventral Chordee.

→ Flattened Glans penis.

→ Microphallus [short length of penis]

→ Ectopic Meatus

→ Meatal Stenosis

→ Anterior type of hypospadias- Circumcision is contraindicated because prepuce is used for urethral reconstruction

t.me/latestpgnotes

HOODED PREPUCE OVER DORSAL ASPECT

Clinical features

Depends on type especially glandular hypospadias

→ Anterior type especially glandular hypospadias – Abnormal stream of urine

→ Posterior Type (e.g. Midshaft / proximal penile) at the time of erection, there is downward curvature of penis causing chordee and painful erection.

→ In proximal penile hypospadias, at the time of intercourse, semen is deposited outside vagina, making than infertile.

→ Abnormal Stream

→ Painful erection.

→ Infertility

Treatment

→ Best age for repair is 6 – 12 Months

→ **Principle**

- **1st Principle** – Meatal advancement
- **2nd Principle** – reconstruction of Glans Penis

→ Both Surgeries are performed together known as MAGPI

PrepLadder

Various Treatment procedures

→ MAGPI (Meatal advancement & glanuloplasty integrated)
→ DENNIS BROWN
→ THIERSCH– DUPLAY
→ BRACKA'S
→ MATHIEW'S
→ ASOPA & DUCKET

Complications

→ After reconstruction of urethra, infant feeding tube has to be inserted. If not inserted, patient may experience complication like **Urethral Fistula** in 10% of cases (most common complication of hypospadias repair)

Epispadias

→ Characterized by urethral opening over dorsal aspect of penis
→ In females - fissure or cleft in anterior wall of urethra which opens above the clitoris.
→ **Associated with**
  - Ectopia Vesicae
  - Dorsal chordee
  - VUR (40% of cases)

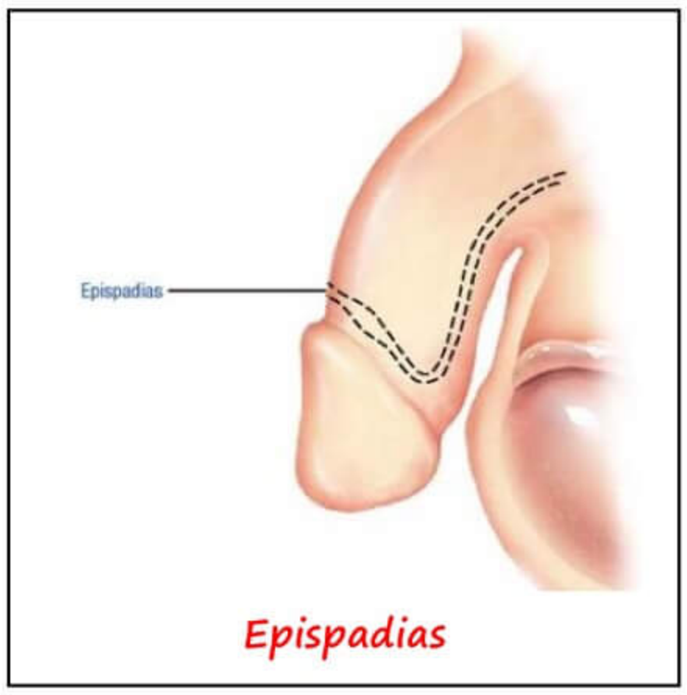

Epispadias

Clinical features

t.me/latestpgnotes

→ **In Females**
  - Maldevelopment of urinary sphincters
  - Bifid clitoris
  - Widely separated labia with incontinence
→ **In Males**
  - Undescended testis and shallow scrotum

Treatment

→ 1st – correction of incontinence
→ 2nd – Removal of Chordee
→ 3rd – Extension of urethral opening till glans

Posterior Urethral Valve

→ Symmetric folds of Urothelium that starts from prostatic urethra & extends to external urinary sphincter:
→ Male urethra is affected exclusively
→ MC type – Type 1
  - Located just distal /at verumontanum
→ **Posterior urethral value** – secondary cause of VUR

PrepLadder

Clinical features

→ Associated with Vesicoureteric reflex - 50% cases.

→ **Other associations**

- Oligohydramnios
- Pulmonary hypoplasia (most common cause of death in PUV)
- Renal parenchymal dysplasia
- Bladder dysfunction.

→ **Most patients present with**

- Symptomatic after birth
- Bilateral hydro-uretero nephrosis
- Bilateral palpable abdominal mass
- Distended bladder.
- Ascites (due to urinary problems)
- infants increased UTI/ Sepsis

Investigation

→ IOC – MCU (Micturating cysto urethrogram)

→ On Prenatal ultrasound – At 28 weeks, keyhole sign

Management

→ **1st step** – Infant feeding tube insertion

→ **2nd step** - After tube insertion

t.me/latestpgnotes

If Creatinine is normal

↓

Endoscopic Fulguration

Of valve

If Creatinine is raised

↓ (means there is no effective drainage)

Suprapubic cystostomy by Blockson Technique

↓ if creatinine Normal

Endoscopic Fulguration of valve

Phimosis

→ contracted foreskin or prepuce cannot be retracted over glans penis.

→ MC cause of phimosis chronic infection is because of poor hygiene

→ **Others causes:**

- Congenital
- Acquired
  - Trauma
  - CA Penis
  - BXO (Balanitis Xerotica Obliterans)

Clinical features

→ MC symptom – Difficulty in micturition

→ **In children** – Ballooning of Prepuce

→ **In adults** – Difficulty in intercourse

Ballooning of Prepuce

PrepLadder

Complications

→ Infection of glans/ prepuce - Increased risk of Balanoposthitis
→ Secretion become solidified - Preputial calculi
→ Chronic inflammation – CA penis

Treatment

→ **In Children** – Conservative management (Steroidal cream application for 4-6 Weeks)
→ **Circumcision**
- Not preferred for young patents because they are not co-operative for local anesthesia.
- Performed for younger age only when there is an indication for circumcision

Indications of Circumcision

→ No improvement after steroidal cream application
→ Recurrent infection
→ Age 16 – 18 years

Paraphimosis

→ Acquired condition
→ Caused by formation of ring of Prepuce around glans because once prepuce is retracted it cannot be brought to its Normal position.

Formation of ring around Glans penis

t.me/latestpgnotes

↓

Impaired Lymphatic Drainage

↓

Edema of Glans

↓

Impaired venous Drainage

↓

Further edema

↓

Impaired Arterial Supply

↓

Gangrene formation [in severe cases]

Paraphimosis

→ Urine flow not obstructed

Treatment

→ Ice bag application
→ Manual compression
→ Hyaluronidase injection
→ For non- responding patients - Circumcision

PrepLadder

Priapism

→ Persistent painful erection in absence of sexual excitement / desire or it persist after sexual excitement / desire

→ Min duration of painful erection – 24 hours

→ It is an emergency & delay in treatment leads to Cavernosal fibrosis & impotence

→ It should be treated within 6 hours to prevent other complications

→ **Priapism is of 2 types**

High Flow	Low Flow (MC)
• Non- Ischemic **Causes** • Penile Trauma • Perineal trauma • Due to formation of arterial sinusoidal shunts.	• Ischemic **Causes** • Sickle cell anemia • Leukemia • Fat emboli • Spinal cord lesion • Malignant Penile inflammation • Trazadone Injection

Clinical Presentation

→ **In children** (5 – 10 years) with sickle cell disease - Painful erection during nights

→ **In Adults** – iatrogenic

t.me/latestpgnotes

Diagnosis

→ Mainly clinical

→ Doppler is helpful in diagnosis

Treatment

→ **If patient comes within 4-6 hrs.**

- ketamine injection given (> 50% cases improve)

↓ No improvement

Aspiration & saline irrigation

↓ No improvement

Hyaluronidase injection

→ For High flow priapism – Selective internal Pudendal Angiography f/b embolization of feeding vessel.

→ **Another surgical option** - Shunts [Blood is shunted from corpora cavernosa]

- **Corporo-glanular shunt** – winter shunt
- **Corporo-spongiosal Shunt** – QUACKEL or SACHER shunt
- **Corporo–saphenous shunt** – GRAYHACK shunt
- **Corporo-dorsal vein shunt** – BARRY shunt

PrepLadder

Urethral injuries

→ **2 types**

- Posterior Urethral Injuries
- Anterior Urethral injuries

Post Urethral injuries

→ MC type

→ Caused by road traffic accident

→ Leading to pelvic fracture which further leads to

- Extra peritoneal bladder rupture
- Posterior Urethral injuries (20%)

→ MC site of injury – Membranous Urethra **(Bulbomembranous junction > Prostatomembranous junction)**

Clinical features

→ Urinary retention + Blood at meatus + pelvic hematoma

→ If injury at Prostatomembranous junction - High lying prostate

↓

On IVP – Pie in sky appearance

Instrumentation

→ **Catheterization** Shouldn't be done [if blood is found at meatus] - Partial tear may get converted to complete tear

→ **Retrograde urethrogram (RGU)** only can be performed to rule out Urethral injuries

Management

→ Gold standard Treatment – SPC (**Suprapubic cystostomy**)

→ Emergency repair should not be attempted - Can lead to increased risk of

- Impotence
- in Continence
- Stricture formation

→ Delayed repair within 3 months is preformed

Anterior Urethral Injuries

→ MC injured anterior urethral part - bulbar part of urethra

Causes

→ External blow / kick

→ Straddle / manhole injury

Clinical features

→ Urinary retention

→ Blood at meatus

t.me/latestpgnotes

PrepLadder

→ **Perineal Hematoma** – involves shaft & Bilateral scrotum (butterfly shaped)

Treatment

→ Suprapubic cystotomy performed followed by delayed repair
→ Usually Asymptomatic even after development of strictures

Investigation

→ IOC for diagnosis of post Urethral Stricture – **MCU**
→ IOC for diagnosis of ant Urethral Stricture – **RGU**
→ Perform both **RGU + MCU** in an emergency patient for adequate evaluation of stricture

Management of patients of stricture

1. Dilatation
2. Optical internal urethrotomy at 12''O clock Position – only performed for short bulbar stricture
3. **If length of stricture up to 2cm** – Excisions with end to end Anastomoses
4. **If length of stricture > 2cm** – Excision with tissue transfer for reconstruction

↓

Tissues used are

- Buccal mucosa (MC used)
- Bladder mucosa
- Penile skin

t.me/latestpgnotes

Cut Section of Penis

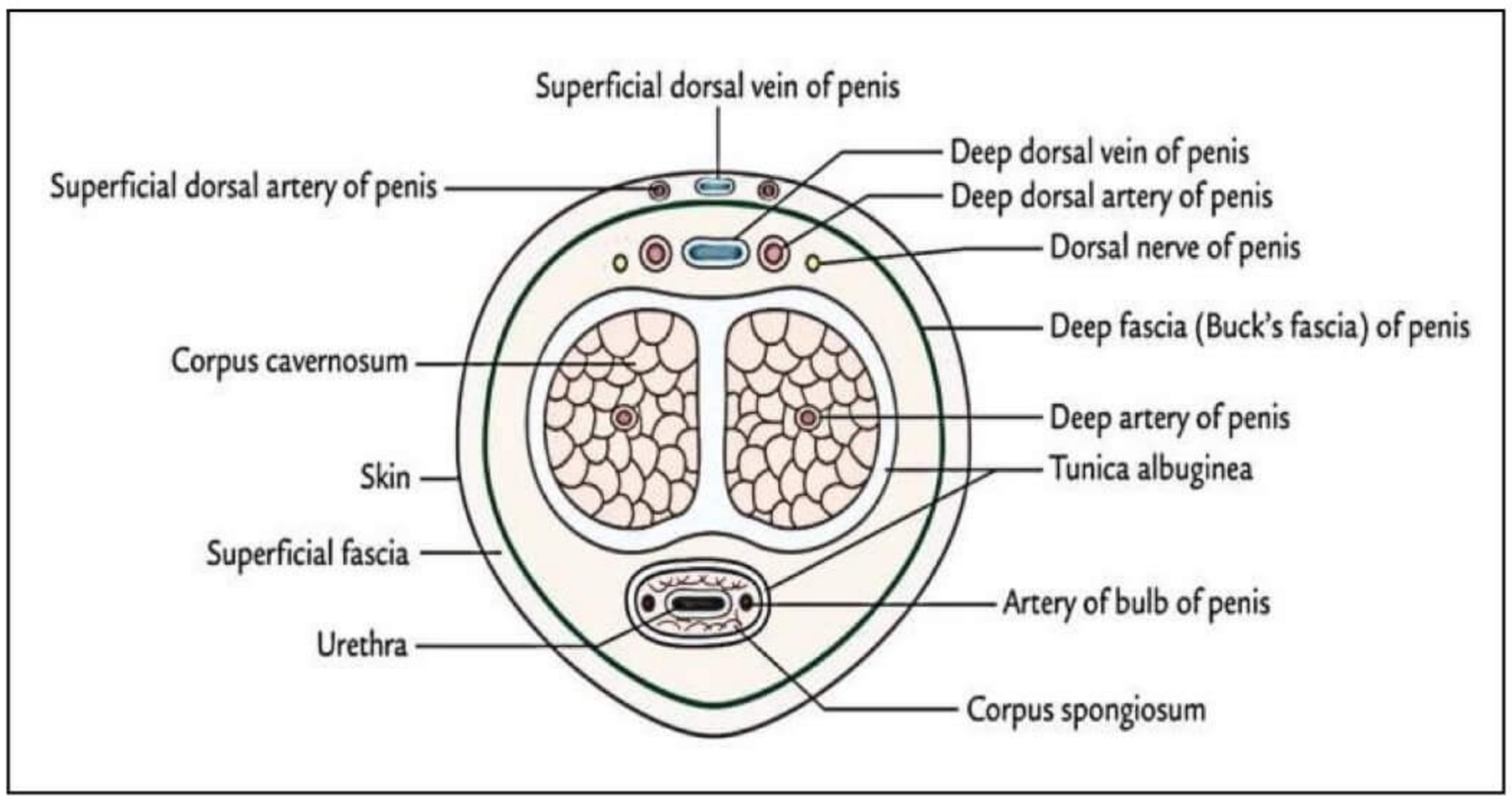

Important points about CA Penis

→ **In CA penis** – Skin and Colle's fascia is involved
→ MC route of spread in CA penis – **Hematogenous**
→ MC cause of death in CA penis – **Bleeding** caused by enlarged inguinal lymph nodes leading to erosion of Femoral blood vessels

PrepLadder

→ In Ca Penis - Incidence of **Pulmonary metastasis is rare** (even in advanced cases)

↓

Tunica Albuginea & Buck's fascia (Strong barriers)

↓

Prevents invasion vessels

PEYRONIE'S Disease

→ **Aka Penile fibromatosis**

→ Chronic vasculitis involving tunica albuginea

→ Characterised by **fibrous plaque over dorsolateral aspect of penis**

↓

Contraction causes Characteristic curvature of penis

→ Associated with **GALEZIA'S triad**

- DUPUYTREN'S contracture (+)
- PEYRONIE'S disease (+)
- RPF

Clinical features

→ Painful erection

→ Poor erection (Distal to plaque)

→ Upward curvature on erection

→ Impotency & infertility

→ Dorsolateral plaque over the penis

t.me/latestpgnotes

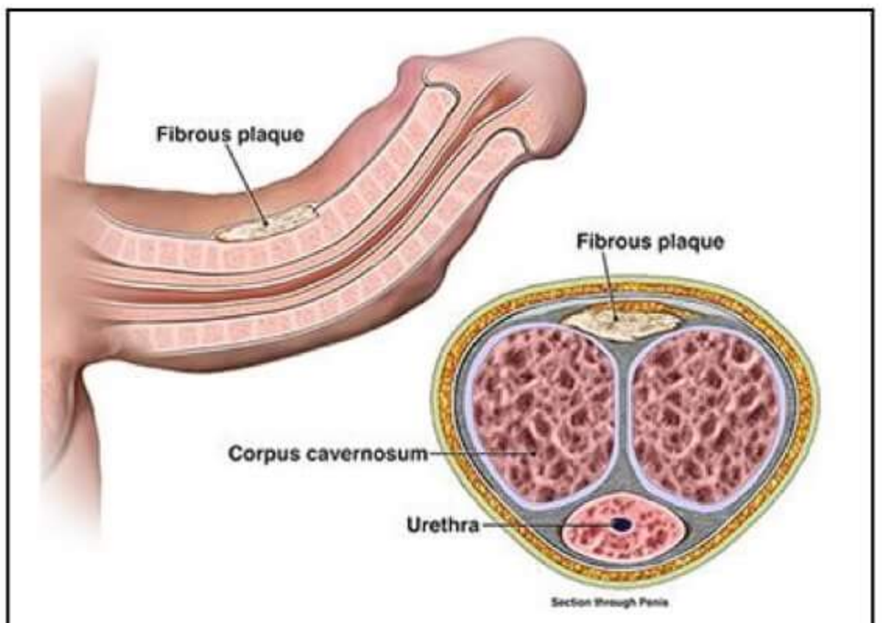

Peyronie's disease

Treatment

→ **>50% cases spontaneous resolution** - observation + emotional support

→ If doesn't reduce we go for - **NESBIT Operation** by placement of Non-absorbable suture opposite to the plaque

Carcinoma Penis

→ MC histological type - **SCC**

→ Common in Low socio-economic status

→ Poor hygiene, 6th decade

→ 40 % of patients < 40 years of age

→ > 50 % cases associated with phimosis only

- neonatal circumcision is protective for CA Penis, HIV/ STDs

→ Viral infection is cause i.e. HPV infection - (16,18,31,33)

Premalignant lesion in CA penis

→ **BUSHKEE LOWENSTEIN TUMOR - locally malignant also known as verrucous carcinoma.**

→ BXO (balanitis xerotica obliterans)

PrepLadder

→ Cutaneous Horns
→ Genital Warts
→ Leukoplakia

Erythroplasia of Queyrat

Carcinoma in situ forms in CA Penis

→ BOWEN'S disease
→ Erythroplasia of Queyrat – Glans Penis Malignancy in this Case I.e. MC site. Glans > Prepuce > Sulcus (G>P>S)

Clinical features

→ MC Presentation is lesion itself associated with foul smelling discharge & is associated with minimal or no pain
→ More than 50% cases are having enlarged inguinal lymph nodes out of which half are because of

Metastasis **Sepsis**

- And in all cases prophylactic antibiotics are again 4 -6 Weeks.
- So, MC cause of death is bleeding caused by erosion of femoral vessels.
- 2nd MC causes of death are sepsis
- Earliest & MC symptom of metastasis or CA Penis – priapism

t.me/latestpgnotes

Diagnosis

→ IOC – Biopsy
→ IOC for staging - MRI
→ **SLM Biopsy**
  - CA Breast
  - Malignant melanoma
  - CA Penis

→ 1st SLM Biopsy was performed by CABANA & Procedure was known as CABANA Procedure

8th AJCC. TNM Classification for CA Penis

T_{is}	→ Carcinoma in-situ
T_a	→ Non-invasive Verrucous Carcinoma
T_{1a}	→ Invades sub epithelial connective tissue without Lymphovascular invasion & it's not poorly differentiated.
T_{1b}	→ Invades sub epithelial connective tissue with Lymphovascular invasion or poorly differentiated
T_2	→ Invades corpus spongiosum with or without invasion of Urethra
T_3	→ Invades corpus cavernosum with or without invasion of Urethra
T_4	→ Invades other adjacent structure

PrepLadder

N_1	→ Palpable, mobile, unilateral inguinal lymph node
N_2	→ Palpable, mobile, multiple or bilateral inguinal lymph node.
N_3	→ Fixed inguinal nodal masses or pelvic lymphadenopathy which is unilateral or bilateral.
M_0	→ No metastasis
M_1	→ Distant metastasis

Other staging

Jackson staging – CA Penis

Robson Staging – RCC

Gleason Grading – CA Prostate

Treatment

→ Circumcision for CA Penis involving prepuce

→ **CA involving distal part**

- Partial penectomy with 2cm margin

→ **CA Penis involving proximal Part**

- Total penectomy + perineal urethrostomy

t.me/latestpgnotes

Chemotherapy agents

→ Bleomycin + cisplatin

CA Male Urethra

→ Chronic irritation

→ Infection (HPV – 16%)

→ Stricture (24 – 76 %)

Clinical features

→ Palpable mass + obstructive symptom

→ M.C site of CA male Urethra – Bulbomembranous > Penile urethra > Prostatic urethra

→ MC histological type – SCC > TCC > Adenocarcinoma

→ Penile Urethra – SCC > TCC

→ Prostatic – TCC > SCC

Investigations

→ MRI + Gadolinium contrast

Treatment

→ Surgery ± radiotherapy

→ If lymph node involvement, then ilioinguinal lymph node dissection

PrepLadder

TESTIS & SCROTUM Part – 1

Descent of testis

→ Lumbar Region

→ Pelvis → Scrotum (-2° C lower than body)

Factors responsible for Descent of Testis

→ **Most important**: - Disproportionate growth of upper abdominal region away from the pelvic region.

→ **Pull of Gubernaculum**

→ **Hormonal factors.**

→ **Peritoneum invaginates** along with gubernaculum and forms:

Processus vaginalis

↓obliterates

Tunica vaginalis (remnant)

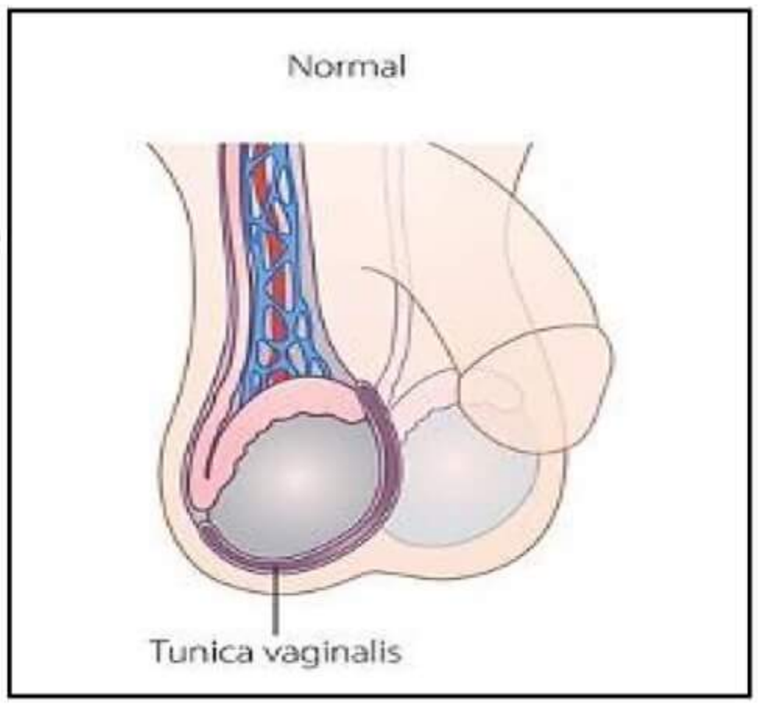

Position of testis in intrauterine life

→ **Abdomen -> 2nd Month / 7TH Week**

- Pelvis (ILIAC FOSSA) -> 3rd month (12th week)
- Deep inguinal ring-> at the end of 6th month (24th week)
- Pass inguinal canal-> During 7th Month (25th – 28th week)

→ **Superficial inguinal Ring** -> 8th month (29-32 week)

- Enters Scrotum -> Beginning of 9th Month (33 week)
- At the base of scrotum-> Before birth end of 9th Month/ 36 Week

t.me/latestpgnotes

UNDESCENDED TESTIS (UDT)

→ Incidence of UDT at Birth- 3%

→ Incidence of UDT at 1 Year of age – 1%

→ Spontaneous descent occurs in **70-77% patients by 3 months of age**

→ **Location**

- Inguinal/Palpable UDT – **80%**
- Abdominal/Non-Palpable UDT – **20%**

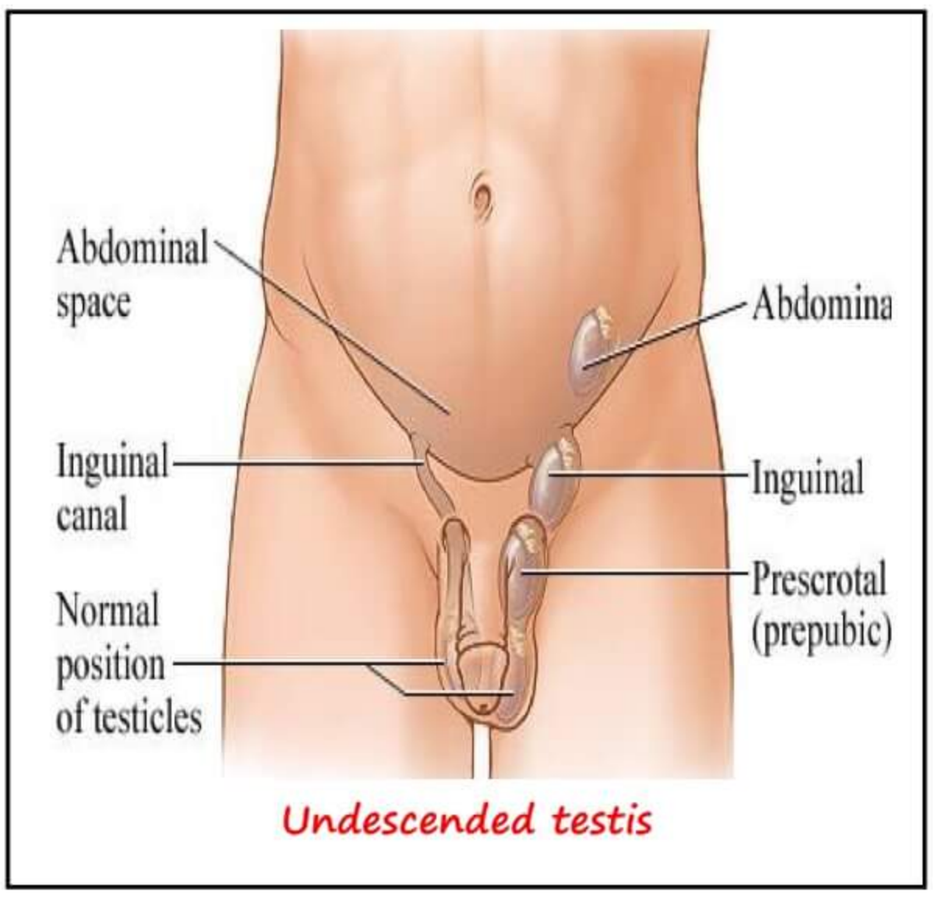

Undescended testis

Risk factors

Two independent factors

→ Prematurity

→ Low birth weight

PrepLadder

LEYDIG CELLS- are less sensitive to temperature

↓

Testosterone

↓

Secondary Sexual Characters

By 5-6 Years of age there is complete absence of spermatogenesis

Histopathology- Abnormal germ cell histology

→ 1-2 Years:

- Earliest change - Hypoplasia of Leydig cells (1 month of age)

→ Degeneration of Sertoli Cells

→ Delayed disappearance of gonocytes

→ Delayed appearance of adult dark spermatogonia

Complication

→ **S**- Sterility

→ **A**- Atrophy

→ **T**- Trauma, tumor, torsion

- Most common tumor- **Seminoma**
- Maximum risk of tumor- **Abdominal > Inguinal Testes**

→ **H**- Hernia (>90% cases PPV- **Patent Processes vaginalis**)

→ **I**- Inflammation

t.me/latestpgnotes

ORCHIDOPEXY

→ Doesn't decrease the risk of testicular tumor

→ **Only Facilitates -> Early diagnosis**

INVESTIGATION OF CHOICE FOR UDT- Inguinal exploration

INVESTIGATION OF CHOICE FOR "NON- PALPABLE" UDT - Diagnostic laparoscopy

Diagnostic Laparoscopy

→ Find the Deep Ring and trace Vas Deferens

→ If Vas Deferens -> is blind -> Testis +/- → **start tracing** Testicular artery -> if testicular artery also blind -> Testicular agenesis

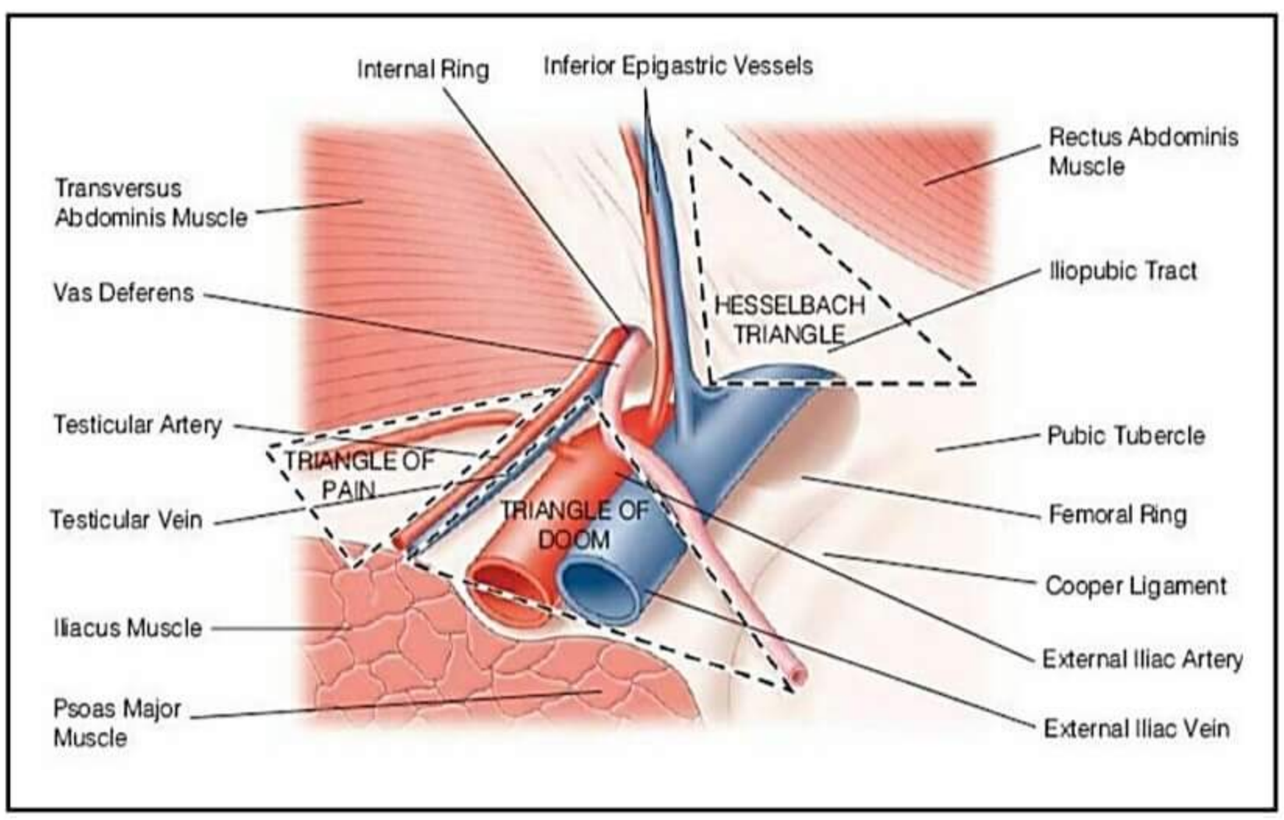

PrepLadder

→ **If testis is present need to bring it into scrotum: Orchidopexy**

→ **Best age of orchidopexy-> 6 MONTHS** Should not be delayed by **12** months (6-12 months)

→ **Main orchidopexy are**

- Ombridannes
- Keetley- Torek
- Stephen- Fowlers
- Ladd & Gross
- Placing testis in Dartos Pouch
- **Best results**- Microvascular Testicular Auto Transplantation

ECTOPIC TESTIS

→ Normal descent till inguinal canal

→ Due to abnormality of Gubernaculum

↓

→ Abnormal location in the groin

→ **MC location: Superficial Inguinal Pouch**

→ **Least Common location: Contralateral Scrotum**

→ **Normal** developed testis & palpable

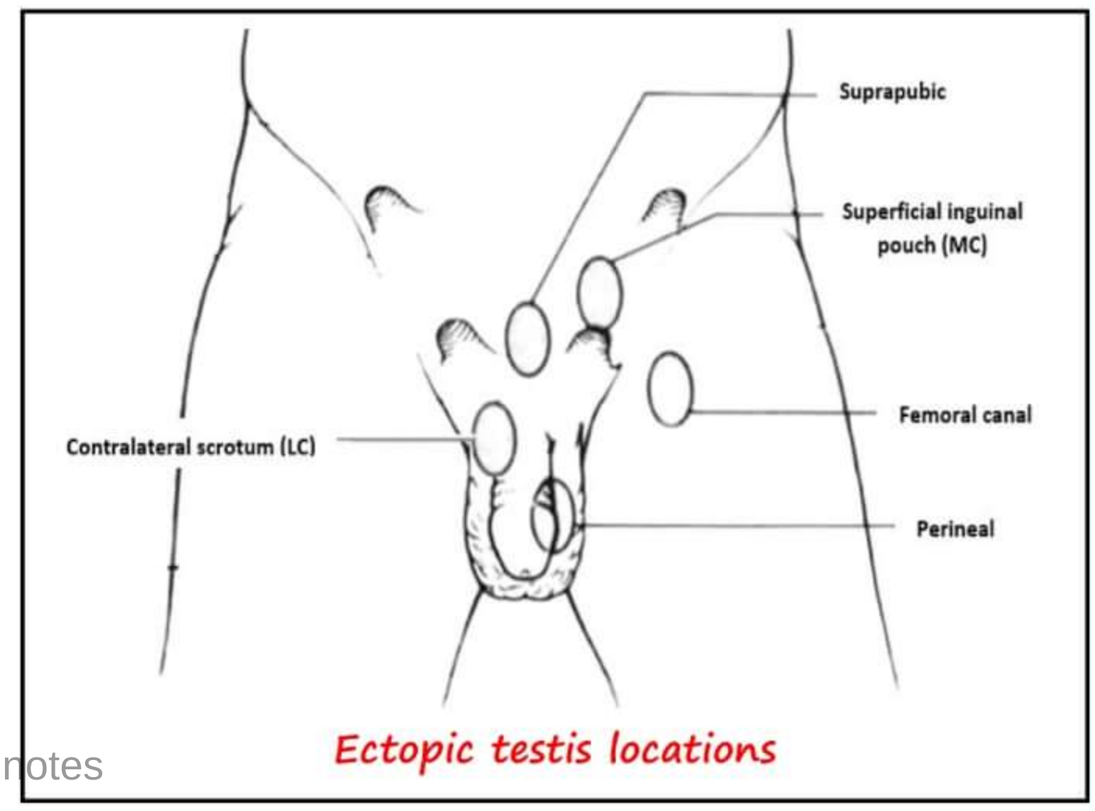

Ectopic testis locations

Rx

→ Surgical treatment: **orchidopexy – 6 months**

→ Not be delayed by 2 years

t.me/latestpgnotes

RETRACTILE TESTIS

→ Testis has completed process of normal descent but found in **Groin**

→ **Because of**

- Overactive cremasteric reflex
- Increased tone of cremasteric muscle.

→ No treatment required

ACUTE EPIDIDYMO- ORCHITIS (EDO)

→ Inflammation of testis & epididymis

→ Associated with Ascending bacterial infection from lower urinary tract (via UTI or STI)

→ Most common organism - **Acute EDO**

↓

Sexually active male (<35 years)- **Chlamydia** (Tx: DOXYCYCLINE)

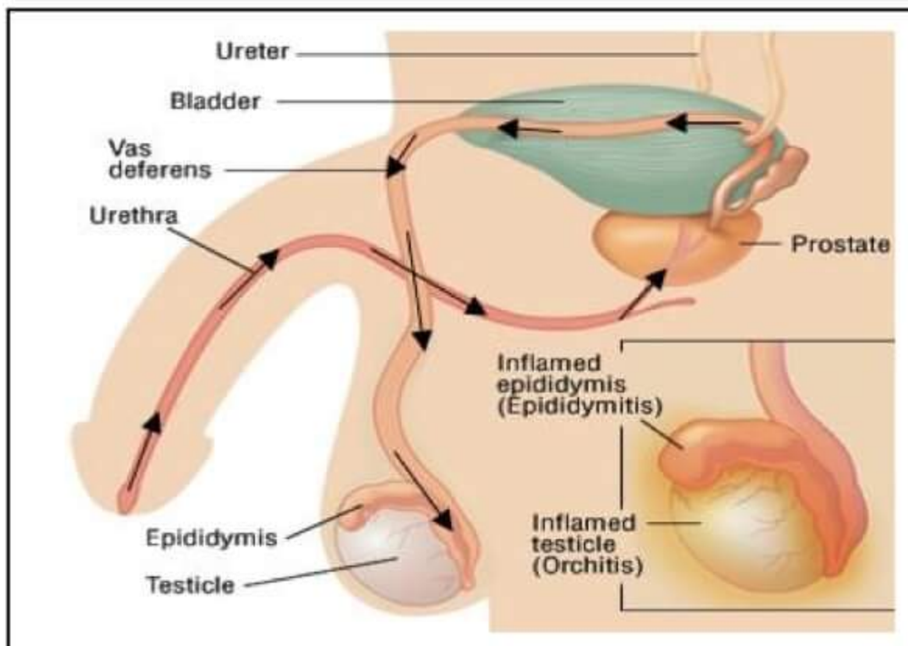

Epididymo orchitis

PrepLadder

→ Most common organism -> Acute EDO ->

- Children
- Elderly
- Homosexuals

} **E. coli**

Clinical features

→ Fever

→ Pain in scrotal region

→ Burning micturition

On Examination

→ **Prehn's Sign - +VE**

- The affected hemiscrotum is elevated. This action relieves the pain of epididymitis but exacerbates the pain of torsion (positive Prehn sign).

→ **Cremasteric reflex- +VE**

- In males is elicited when the inner part of the thigh is stroked. Stroking of the skin causes the cremaster muscle to contract and pull up the ipsilateral testicle toward the inguinal canal. (positive Cremasteric sign)

→ **Thickened Cord**

→ IOC- **Ultrasound**

- Thickened/ enlarged cord
- Secondary hydrocele-minimal amount or fluid collected

t.me/latestpgnotes

NOTE: MCC of Secondary hydrocele: Acute Epididymo-orchitis.

→ **Urine routine microscopic examination**: WBCs

→ **Urine culture and sensitivity**: UTI±

Treatment

→ Antibiotics

→ Scrotal support

→ NSAIDS

TESTICULAR TORSION (TT)

EXTRAVAGINAL	INTRA VAGINAL
→ Extra Vaginal Torsion occurs outside the tunica vaginalis	→ Torsion occurs within the tunica vaginalis → Most common

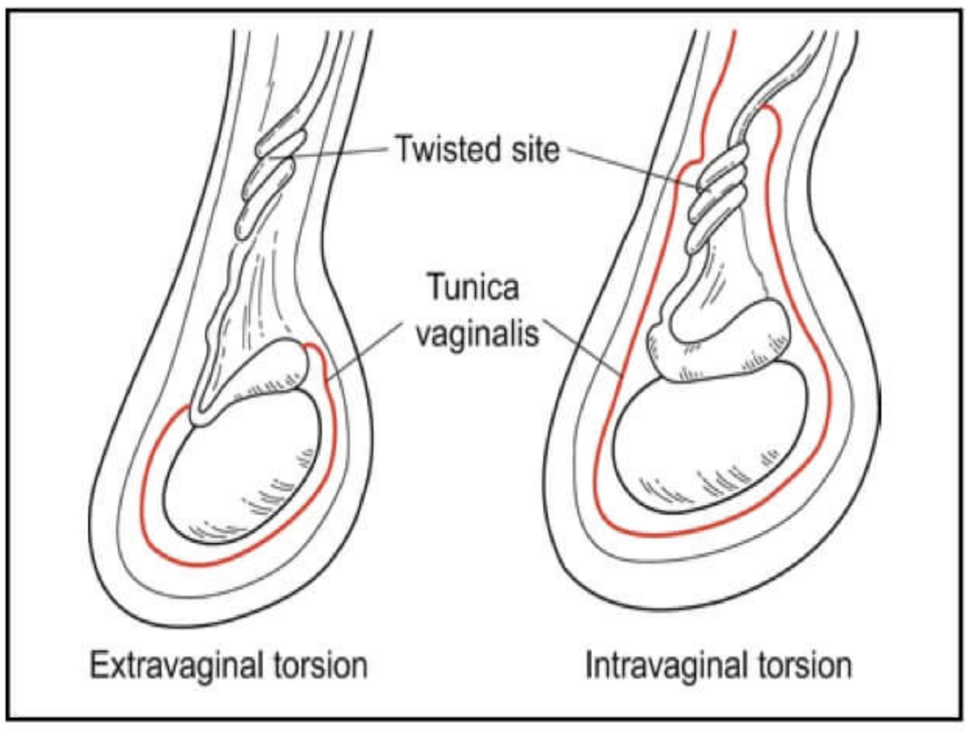

PrepLadder

INTRAVAGINAL TESTICULAR TORSION

→ 10-25 Years (Pre-Pubertal males)

→ Spiral attachment of Cremasteric fibers over the cord

↓

Brisk cremasteric reflex

↓

Testicular torsion

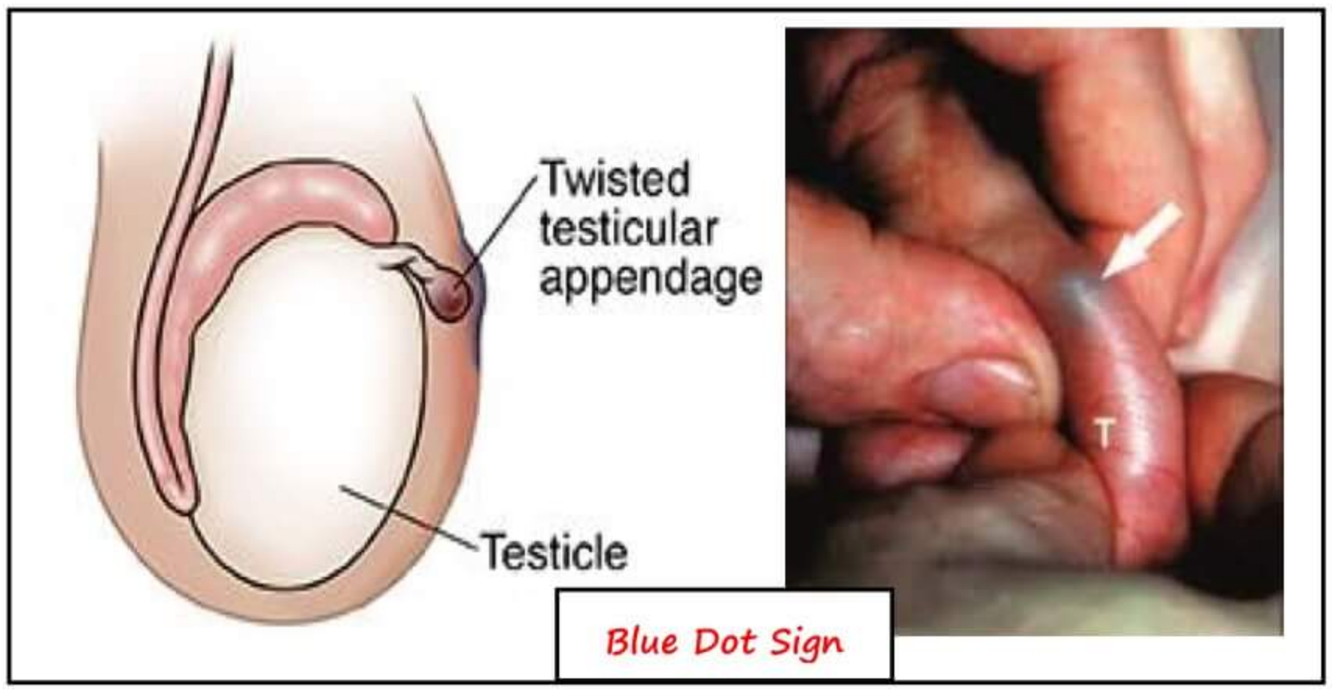

Predisposing factor

→ **MC- Inversion of Testes**

→ Bell clapper's deformity

t.me/latestpgnotes

→ Separation of testis from body of epididymis

→ Blue Dot sign: Torsion of appendage of testis

Clinical features

→ Severe agonizing pain

→ Nausea & Vomiting

→ **On examination affected testis-> High Riding in upper part of scrotum**

↓

Deming Sign

→ **Contralateral testis** is normally lying, placed transversely

↓

Due to mesorchium-> **Angel Sign**

→ PREHNS SIGN - -ve

→ Cremasteric reflex – Absent

→ **Treatment- Emergency Orchidopexy within 4 Hours**

IOC - Doppler

→ Anywhere flow needs to be assessed: Doppler is IOC like:

- Portal Hypertension
- DVT
- VV

PrepLadder

- TT
- Varicocele

→ Tc Pertechnate scan -> decrease uptake of radionuclide

Treatment - Orchidopexy

→ **Contralateral hemiscrotum should be explored.**

→ **In case of bell- clappers deformity**

↓

Bilateral Orchidopexy- Performed.

→ In case of ischemic testis -> Orchidectomy ± Prosthesis

EXTRAVAGINAL TESTICULAR TORSION

→ Perinatal Period

→ No anatomical defect

→ No testicular fixation in perinatal period is primary cause

(Spermatic cord + Tunica Vaginalis)

↓

Rotates as a single unit

PRENATAL	POSTNATAL
Testis is hard and fixed to the skin ↓ Orchidectomy	→ Tender scrotum → Testis is not fixed to skin → Treatment- Orchidopexy. → 20% - Bell- clapper's deformity

t.me/latestpgnotes

HYDROCELE

→ Collection of fluid within the layers of tunica Vaginalis

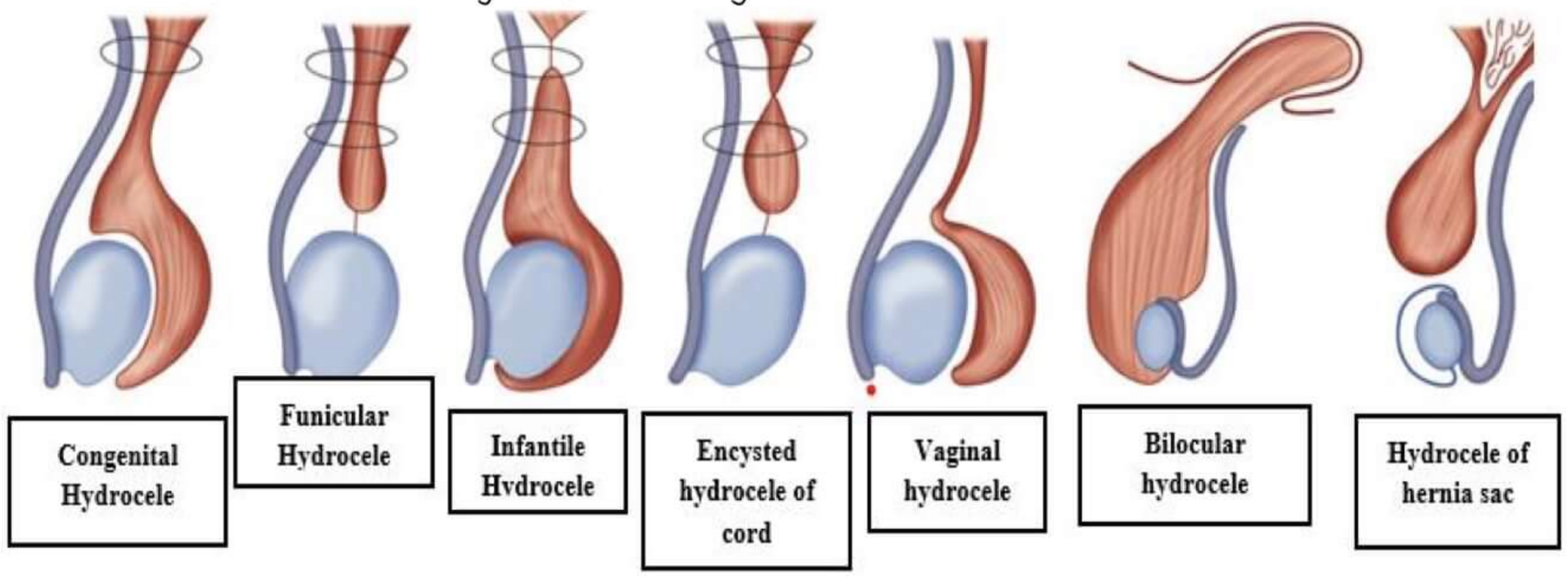

Vaginal hydrocele

→ Most common type

→ Large/ tense

→ Clear fluid

→ Trans illumination test is +ve

PrepLadder

Congenital hydrocele

→ **Patent Processus vaginalis**

→ Size varies with the activity level and posture

→ Spontaneous Obliteration - 2 Years

→ **Treatment** - Herniotomy (if spontaneous obliteration does not occur)

Funicular Hydrocele

→ Processus Vaginalis patent up to top of testis where it shuts off from tunica vaginalis

Infantile hydrocele

→ Processus vaginalis is patent up to deep ring

→ Doesn't communicate with peritoneal cavity

Hydrocele of cord/ of canal of neck

→ **Obliteration of upper & lower part of PV**

→ When testis pulled-cystic swelling goes down and when testis is released cystic swelling goes up.

Bilocular hydrocele / Hydrocele en-bisac

→ Two sacs communicating with each other near neck of scrotum

Hydrocele of Hernial sac

t.me/latestpgnotes

→ Neck of hernial Sac is closed by adhesion/ plugged by omentum

→ Retention of fluid secreted by peritoneum of hernial sac.

Vaginal Hydrocele

Primary Hydrocele	Secondary Hydrocele
→ Collection of fluid in Tunica Vaginalis → Large → Dense	→ Causes • Trauma • Tumor • Epididymo – orchitis (**MC**) → Small → Lax → **Diagnosis**- Ultrasound

Treatment

→ Small hydrocele - **LORD's PLICATION OF SAC**

→ Medium hydrocele - **Jaboulay's eversion of sac**

→ Large hydrocele - **Excision of Sac**

PrepLadder

Testis and scrotum Part - 2

Varicocele

→ Dilated } Pampiniform plexus of veins, located posterior and above testis
→ Tortuous }
→ MC surgically correctable cause of male subfertility (i.e. borderline fertility)
→ It can cause reversible atrophy of testis in adolescent males
→ 90% left **side**
→ **If left gonadal vein has incompetent or defective valves - increase transmission of pressure → varicocele**

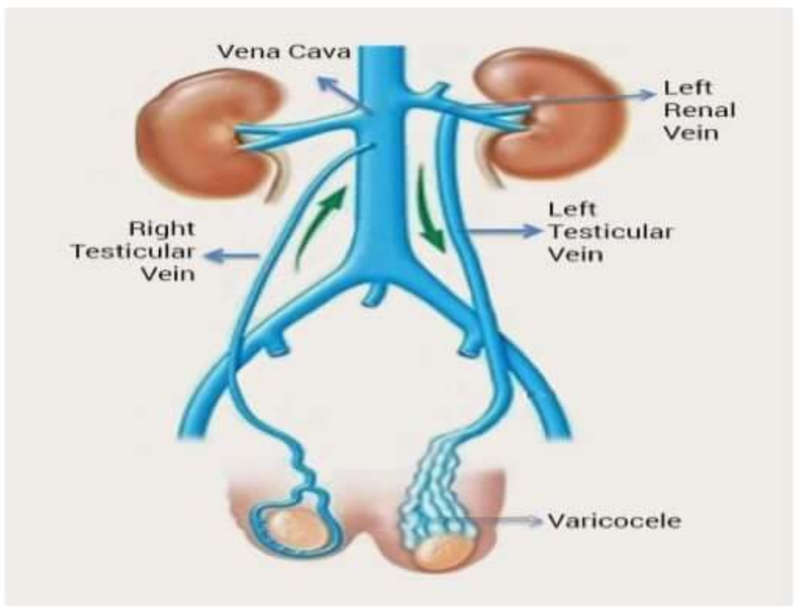

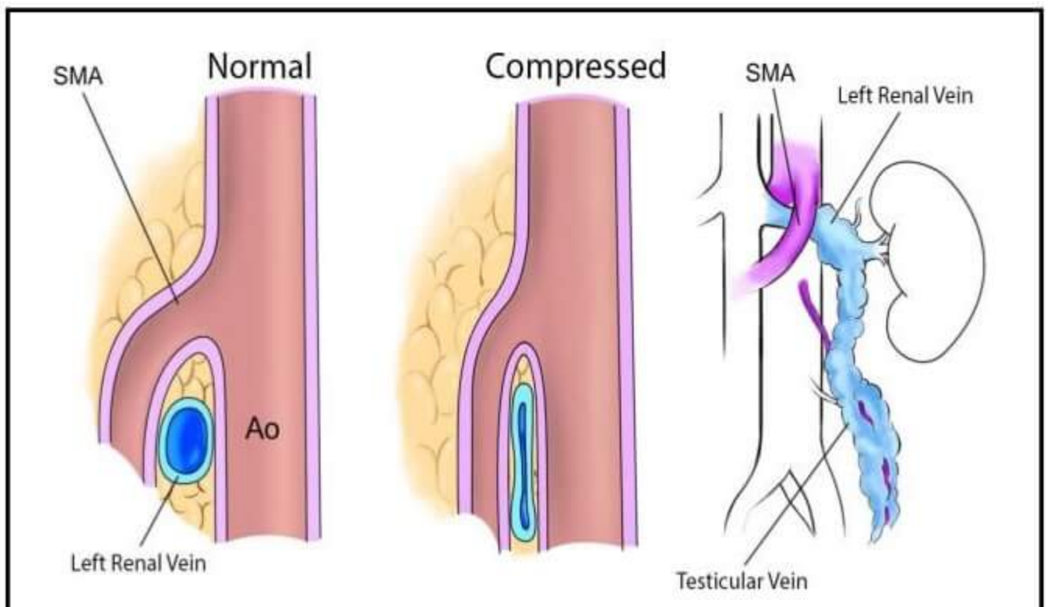

Nutcracker phenomena

Predisposing factors

t.me/latestpgnotes

- LGV drains at right angle into left RV
- **Nutcracker's phenomenon**: LRV compressed between aorta and renal vein
- Sigmoid colon – loaded fecal matter→ compresses LGV

Clinical features

→ Seen in tall, thin adults
→ Discomfort in scrotal region
→ Swelling in scrotal region-> more prominent in standing position
→ Decompress in lying down position
→ On palpation – **'Bag of worm'**
→ **Suspicious varicocele – RCC**
  - Elderly males
  - Short history
  - Does not decompress on lying down position

→ Due to large veins around scrotum → increase in temperature of testes:

↓

↓ sperm motility } Semen analysis
↓ sperm number }

PrepLadder

Investigations

→ IOC for diagnosis – **Doppler**

→ Gold standard – **Venography**

Varicocele classification

→ **Subclinical varicocele** – neither visible nor palpable at rest or during Valsalva maneuver
– Demonstrable by special test

→ **Grade 1** – palpable during Valsalva maneuver

→ **Grade 2** – palpable at rest

→ **Grade 3** – visible and palpable

Indication of treatment

→ Significant discomfort

→ Infertility

→ Poor Testicular growth in adolescents

→ ↓ motility / sperm count

→ Recruitment in army and police services

Treatment

→ High inguinal ligation (near deep ring) of pampiniform plexus of veins

→ Microvascular sub inguinal ligation of pampiniform plexus of veins (best results)

t.me/latestpgnotes

→ **Palomo's operation: ligation of Left Gonadal Vein in retroperitoneum**

→ **Alternative venous drainage via cremasteric veins**

Spermatocele

→ Unilocular retention cyst

→ Derived from some portion of sperm conducting mechanism of epididymis

→ **Location**: Epididymal head; above and behind upper pole of testis

→ Presence of spermatozoa

↓

(Barley – water appearances)

→ Softer, laxer

→ Transillumination is positive

Treatment

→ Small spermatocele – observation (ONLY)

→ Large spermatocele – aspiration or excision

→ **Chinese lantern pattern** – seen in epididymal cyst

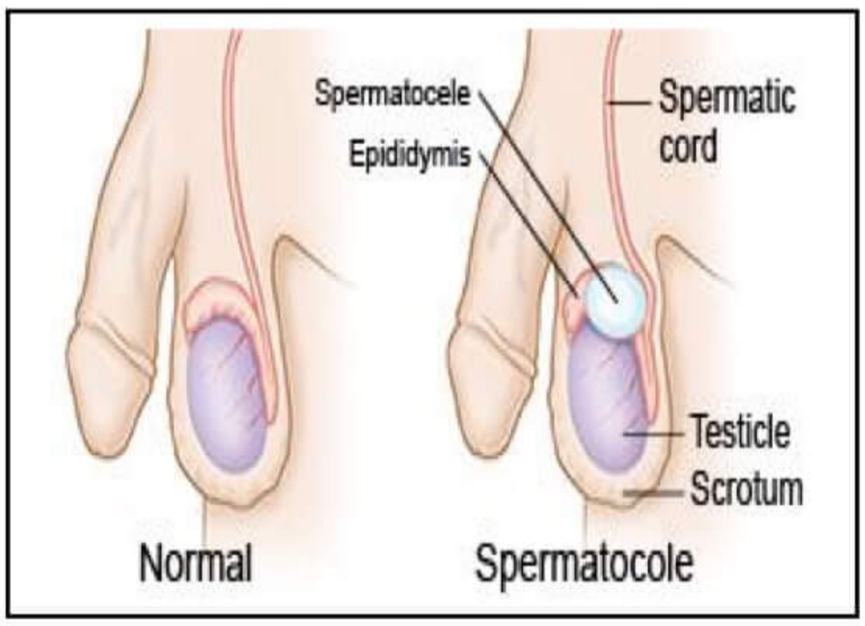

PrepLadder

Fournier's gangrene

→ **Also known as idiopathic scrotal gangrene**
→ Type of necrotizing fasciitis of scrotal region
→ Abrupt onset
→ Idiopathic

Polymicrobial infections
(aerobes + anaerobes)
↓
Obliterative end arthritis of arterioles of scrotal region
↓
Gangrene

Fournier's gangrene

→ **Involved structures**
- Skin
- Superficial Fascia
- Deep Fascia

→ **Spared structures**
- Corpora Cavernosa
- Urethra
- Testis
- Cord Structures

t.me/latestpgnotes

Predisposing factors

→ DM
→ Local Trauma
→ Para phimosis
→ Anal infections
→ Immunosuppression

Clinical features

→ H/O perineal trauma/infection/instrumentation
↓
Cellulitis
↓
Swollen, tender, erythematous skin
↓
- Blackish or purplish discoloration
- Dish water like discharge
- Fetid odour

↓
Necrosis of skin

→ Pain, fever, marked systemic toxicity

PrepLadder

Management

→ IV fluids + IV antibiotics
→ Extensive surgical debridement
→ Mortality rate – 7-75% (avg-20%)

Risk factors for testicular tumors

→ Cryptorchidism
→ Testicular feminization syndrome **(androgen insensitivity syndrome)**
→ Klinefelter's syndrome
→ H/O testicular tumor in siblings
→ Personal H/O TT- increases risk of contralateral testicular tumor
→ In-utero exposure of DES **(Diethyl stilbestrol)**

WHO classification of testicular tumor

Germ cell tumors

Seminoma

Non-Seminomatous GCT

- Yolk sac tumor
- Teratoma
- Embryonal carcinoma
- Choriocarcinoma

t.me/latestpgnotes

Sex cord / gonadal stromal tumors

→ Leydig cell tumor
→ Sertoli cell tumor
→ Granulosa cell tumor
→ Thecoma / fibroma

Mixed (germ cell & gonadal stromal tumors)

→ Gonadoblastoma

Lymphoid / hematopoietic:

→ Lymphoma
→ Leukemia
→ Plasmacytoma

Miscellaneous

→ Adenoma
→ Carcinoma
→ Carcinoid

PrepLadder

→ Tumors with increased risk of **gynecomastia – any tumor with gonadal stromal component –**

- Leydig cell tumor
- Sertoli cell tumor
- Granulosa cell tumor
- Thecoma
- Fibroma
- Gonadoblastoma

Testicular tumor (TT)

→ MC TT – seminoma (**mixed** if given in option)
→ MC primary B/L TT – Seminoma
→ MC Radiosensitive TT – Seminoma
→ MC TT in children (1-3 years) – Yolk sac tumor
→ TT with best prognosis – Yolk sac tumor
→ MC TT in pre-pubertal children (11-13 years) – Teratoma
→ MC TT in elderly
→ MC TT (B/L) — Lymphoma (diffuse large B cell lymphoma variant of NHL)
→ MC secondary TT
→ TT with early hematogenous spread
With early pulmonary metastasis — Choriocarcinoma

t.me/latestpgnotes

↓
Worst prognosis Variant (Hurricane tumor)

Non – Hodgkin lymphoma (NHL)

→ Extra nodal lymphoma
→ MC type – DLBL (Diffuse large B cell lymphoma)
→ **DLBL is MC type of lymphoma in**

- Primary CNS Lymphoma
- Orbital Lymphoma
- Thyroid Lymphoma
- Breast lymphoma
- Gastric lymphoma – DLBL (52%) case followed by MALToma (35%)
- Small intestine lymphoma
- Appendicular lymphoma
- Colonic lymphoma
- Rectal lymphoma
- Testicular Lymphoma

Intra tubular germ cell neoplasm (ITGCN)

→ A/K testicular CA-in-situ
→ Pre invasive precursor of all testicular germ cell tumor **except**

- Spermatocyte seminoma

PrepLadder

- Yolk sac tumor
- Teratoma

Risk factors

→ H/O germ cell tumor
→ Cryptorchidism
→ Infertility
→ Extra gonadal germ cell tumor
→ Atrophic – contra lateral testis
→ Somatosexual ambiguity

Clinical features

→ Affected Testis — normal / atrophic
→ No established tumor maker
→ USG testis – not reliable for diagnosis
→ **Gold standard investigation for ITGCN: testicular biopsy**

Treatment

→ Observation
→ Radiotherapy
→ Orchidectomy

t.me/latestpgnotes

Testicular tumors

→ MC TT – seminoma (3rd and 4th decades)
→ MC TT in elderly – lymphoma (6th decade)

Clinical features of Seminoma

→ **Painless swelling or mass in relation to testis**
→ **10% cases have secondary hydrocele**
→ **5% cases - Gynecomastia**
  - MC in Leydig cell tumors
  - Sertoli cell tumors
  - Granulosa cell tumor
  - Gonadoblastoma
→ Seminoma -2/3rd – localized tumor
→ NSGCT – widespread metastasis
→ MC route of spread – hematogenous
→ MC site of metastasis – lungs

→ **Choriocarcinoma**
  - Early hematogenous spread

PrepLadder

- Early metastasis to lungs
- Cannon Ball 2° (RCC> Choriocarcinoma)

Diagnosis

→ Ultrasound:

- Enlarged and hard affected testis
- Secondary hydrocele (10%)
- Hypoechoic mass in relation to testis

→ **FNAC / trans scrotal biopsy – contraindicated**

↓ (Seeding of tumor cells in tract)

lead to inguinal lymph node metastasis

Treatment

→ **High inguinal orchidectomy** (even on suspicion of TT-Because most TT are malignant)

→ **Chevassu maneuver**-Isolate testis from cord and placement of soft clamp over the cord

↓

Take frozen section biopsy

↓

If Malignant tumor

↓

High inguinal orchidectomy

t.me/latestpgnotes

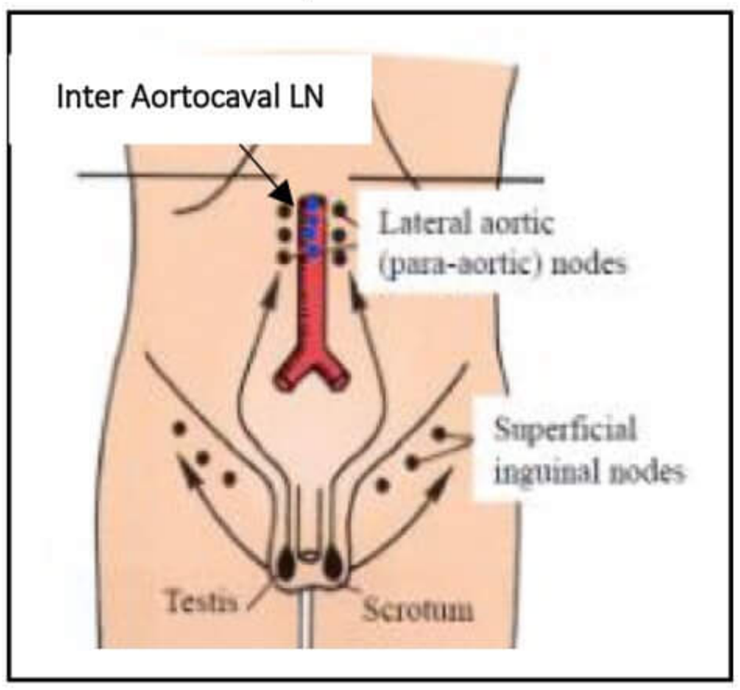

→ **CECT** – for retroperitoneal LN involvement

→ Primary landing site from **right** testicular tumor

- **inter -aortocaval LN**

→ Primary landing site from **left** testicular tumor- **Para-aortic LN**

→ Cross over metastasis from right to left but NOT left to right

→ MC group LN involved in TT- Para aortic LN

Tumor marker

→ AFP

- Y -Yolk Sac Tumor
- E-Embryonal Carcinoma
- T -Teratoma

→ B-HCG

- C – Choriocarcinoma
- E – embryonal carcinoma
- S – Seminoma (10% which have Syncytiotrophoblast)

Markers based on bulk of disease

→ LDH

→ PLAP } Seminoma

→ GGT }

PrepLadder

8th AJCC TNMS classification

↓

Serum markers

- AFB
- β – HCG
- LDH

Pathological Staging (P)

→ P Tis – ITGCN (carcinoma-in-situ)

→ P T_1 – limited to testis without Lymphovascular invasion
Tumor may invade tunica albuginea but not the tunica vaginalis

→ PT_2 – Limited to testis and epididymis with Lymphovascular invasion or extending to tunica albuginea with involvement of tunica vaginalis

→ PT_3 – invades the spermatic cord with or without Lymphovascular invasion

→ PT_4 – invades scrotum with or without Lymphovascular invasion

Lymph node staging

→ N_1 – LN mass ≤ 2cm or multiple LN mass, none ≥ 2cm

→ N_2 – LN mass > 2cm but <5cm or multiple LN mass anyone one mass is >2cm but <5cm

→ N_3 – LN mass > 5cm

Metastasis

t.me/latestpgnotes

→ M_0 – no distant metastasis

→ M_1 – metastasis to non-regional LN or pulmonary metastasis

→ M_2 – Non-pulmonary visceral metastasis

Management

	Seminoma	Non-Seminomatous GCT
I_A I_B	- Radiotherapy	- RPLND
II_A II_B		
IIc III	-Chemotherapy	- Chemotherapy± RPLND
Is		

Chemotherapy regimens

B – Bleomycin
E – Etoposide
P – cisplatin
} x 6 cycles

PrepLadder

MC group of LN involved

- → CA penis } **Inguinal LN**
- → CA scrotum }

- → CA Bladder } **Obturator LN**
- → CA prostate }

- → Primary landing site from **right** testicular tumor- inter-aortocaval LN
- → Primary landing site from **left** testicular tumor- Para-aortic LN (Overall MC)

CA scrotum

- → A/K **Chimney sweeps cancer**
- → MC histological type - **SCC**
- → 5th / 6th decades

Risk Factors

- → TAR
- → SOOT
- → Hydrocarbon

Clinical features- ulcer with everted edges and indurated base **(MC LN involved: Inguinal)**

IOC for diagnosis – Biopsy

t.me/latestpgnotes

Treatment – wide local excision with 2cm margin

Composition of stone in various organs

- → MC gall stone – cholesterol
- → MC pancreatic stone- calcium carbonate
- → MC salivary stone- calcium carbonate
- → MC renal stone – calcium oxalate
- → MC radiolucent renal stone – uric acid
- → MC 1° Bladder stone: Ammonium Urate
- → MC 2° Bladder stone: Uric Acid > Struvite
- → MC Prostatic Stone: Calcium Phosphate

ARTERIAL DISORDERS - 1

Peripheral arterial occlusion

→ **Characterized by 5Ps**

- Pain (MC)
- Pallor
- Paralysis
- Pulselessness
- Paraesthesia

Sometimes 6P – Poikilothermia

Note: it is an Emergency - requires immediate treatment

→ **Common causes**

1. **Atherosclerosis (MC)**
2. Buerger's Disease
3. Takayasu arteritis
4. SLE
5. Post-traumatic
6. Radiation injury – causes obliterative endarteritis that leads arterial occlusion

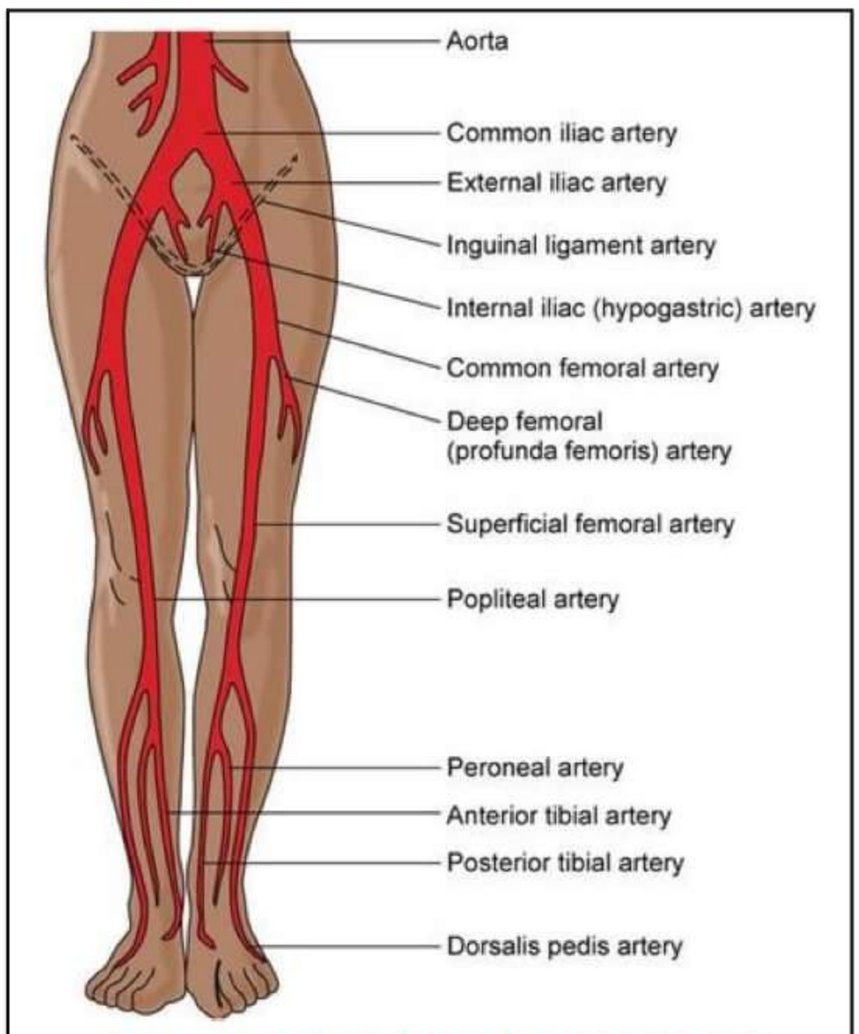

Common Sites of Peripheral Arterial Obstruction

t.me/latestpgnotes

Atherosclerosis	Buerger's disease aka Thromboangiitis obliterans
• Age group – 6th to 7th decade • Involves large & medium sized vessels like abdominal aorta, iliac, femoral, popliteal, peroneal arteries • Mainly seen in Lower limb	• Young, male, smokers, Age less than 40 years • Involve small & medium sized vessels like T-Tibial P-Plantar R-Radial • Lower limb > Upper limb

Manifestation depends on Site of obstruction

- Tissue distal to artery occlusion becomes ischemic → if this artery supplies muscles → causes Intermittent claudication

Site of obstruction	Manifestation
• Aorto-iliac disease	- Buttock, thigh, calf claudication - Leriche syndrome ↓ Erectile dysfunction → Impotence
• Common femoral disease	Thigh + Calf claudication
• Superficial femoral disease	Calf claudication
• Popliteal disease	Calf claudication
• Crural artery disease	Calf claudication

PrepLadder

Embolic Occlusion

→ **Embolus** – Detached thrombus from heart or more proximal vessels

→ MC source of embolus – **left atrium** (in pts having Atrial fibrillation)

→ Second common source of embolus – **Mural Thrombus** (in Pts of MI)

Organ involved	Symptoms caused
1. Brain	– TIA / stroke
2. Retina	– Amaurosis Fugax
3. Mesenteric vessels	– Ischemia & gangrene of small bowel
4. Spleen	– Local pain
5. Kidney	– Loin pain, haematuria

Diagnosis

→ **Made clinically (because it's an emergency) by manifestation such as**

- Have Source of emboli with no H/o claudication
- Severe pain and numbness in the limb
- Movements becomes difficult
- Distal pulses – not palpable

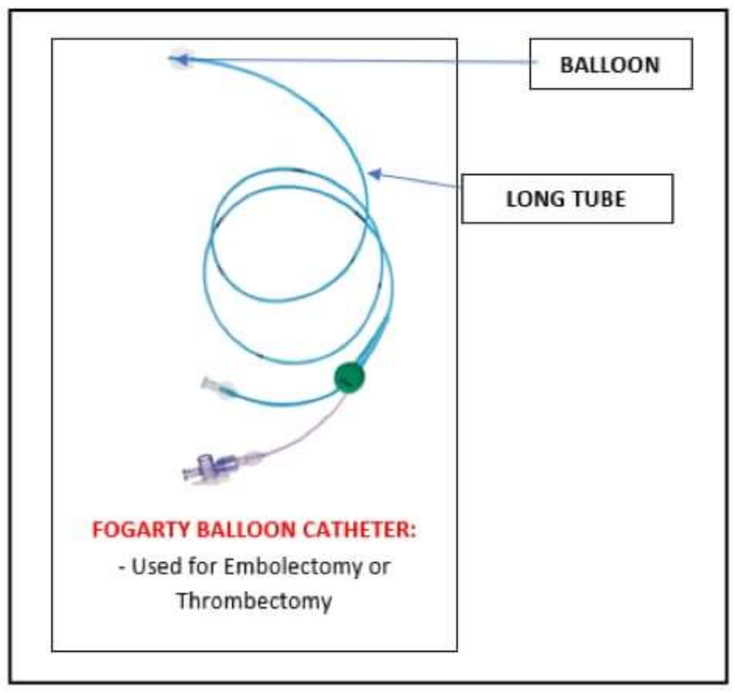

Rx

→ **Start IV heparin (5000U)** – reduce the extension and maintain the patency

t.me/latestpgnotes

→ **Perform Embolectomy and Thrombolysis**

- **Fogarty balloon catheter** is used for embolectomy, sometimes for thrombectomy also

Thrombus at aortic bifurcation

↓

Insert balloon catheter distal to catheter

↓

Inflate balloon & Withdraw catheter

↓

Thrombus will be removed

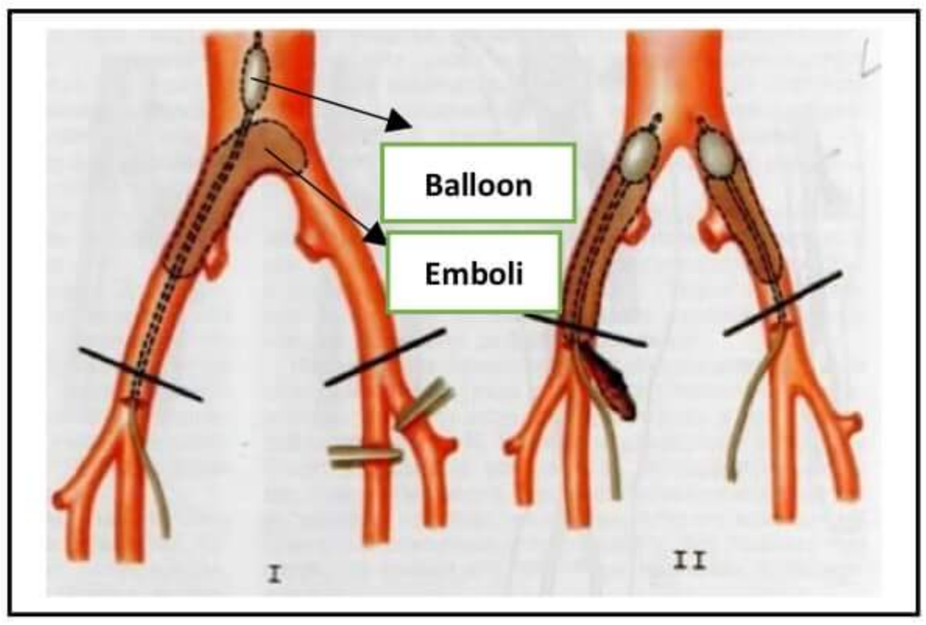

Buerger's Disease

→ **AKA Thromboangiitis Obliterans**

→ It is a segmental inflammatory disease involving **small & medium sized vessels** with skip lesions

- **T** – Tibial
- **P** – plantar
- **R** – Radial

→ Disease extends from distal to proximal

→ Exclusively seen in young, males, smokers, <40 years of age

PrepLadder

→ **Inflammatory process involves**

- Artery (mainly)
- Vein
- Nerve

C/F

→ **Characterized by a triad**

- **R** – Raynaud's Phenomenon
- **I** – Intermittent claudication (I/C)
- **M** – Migratory superficial Thrombophlebitis

Boyd's Classification (Grading of intermittent claudication)

→ **Grade I** – Pain appears at the start of walk but disappears if patient continues to walk

→ **Grade II** – Patient can walk with pain

→ **Grade III** – Pain compels the patients to take rest

→ **Grade IV** – Rest pain

Diagnosis

→ IOC – **Four limb Angiography**

↓

t.me/latestnurses

- There is characteristic collaterals present known as **corkscrew** collaterals.
- (ABPI) Ankle Brachial pressure index / Ankle brachial index (ABI) is assessed
- **ABI = systolic BP Ankle / arm**

Interpretations 0.1 to 0.4 – Critical limb ischemia

0.5 to 0.9 – Intermittent claudication

1.0 to 1.2 – Normal

> 1.2 – claudication (seen in DM, ESRD-End stage renal disease)

Fontaine's Staging for Limb Ischemia

→ **Stage I** – Asymptomatic

→ **Stage II A** – Mild I/C

→ **Stage II B** – Moderate to severe I/C

→ **Stage III** – Rest pain

→ **Stage IV** – Critical limb ischemia → leading to Ulceration + gangrene

Note:

→ Patient hangs their legs while sleeping and sitting as it relieve pain (because of pooling of blood in limb due to gravity)

PrepLadder

Treatment

1. Abstinence from smoking
2. **Vasodilators**
   a) Xanthinol nicotinate – Complamina (brand name)
   b) Pentoxifylline – Trental (brand name)
3. **Lumbar sympathectomy** – Is performed only for rest pain because rest pain is caused by cutaneous ischemia and blood supply of muscle is not under sympathetic control and is not used for intermittent claudication (I/C)
4. Omental transposition
5. For gangrene pt. – Amputation

LUMBAR SYMPATHECTOMY

→ Intermittent claudication is not an indication

→ Usually L1 to L4 ganglia removed

→ **In B/L Lumbar sympathectomy**, at least L1 on one side should be preserved to prevent retrograde ejaculation.

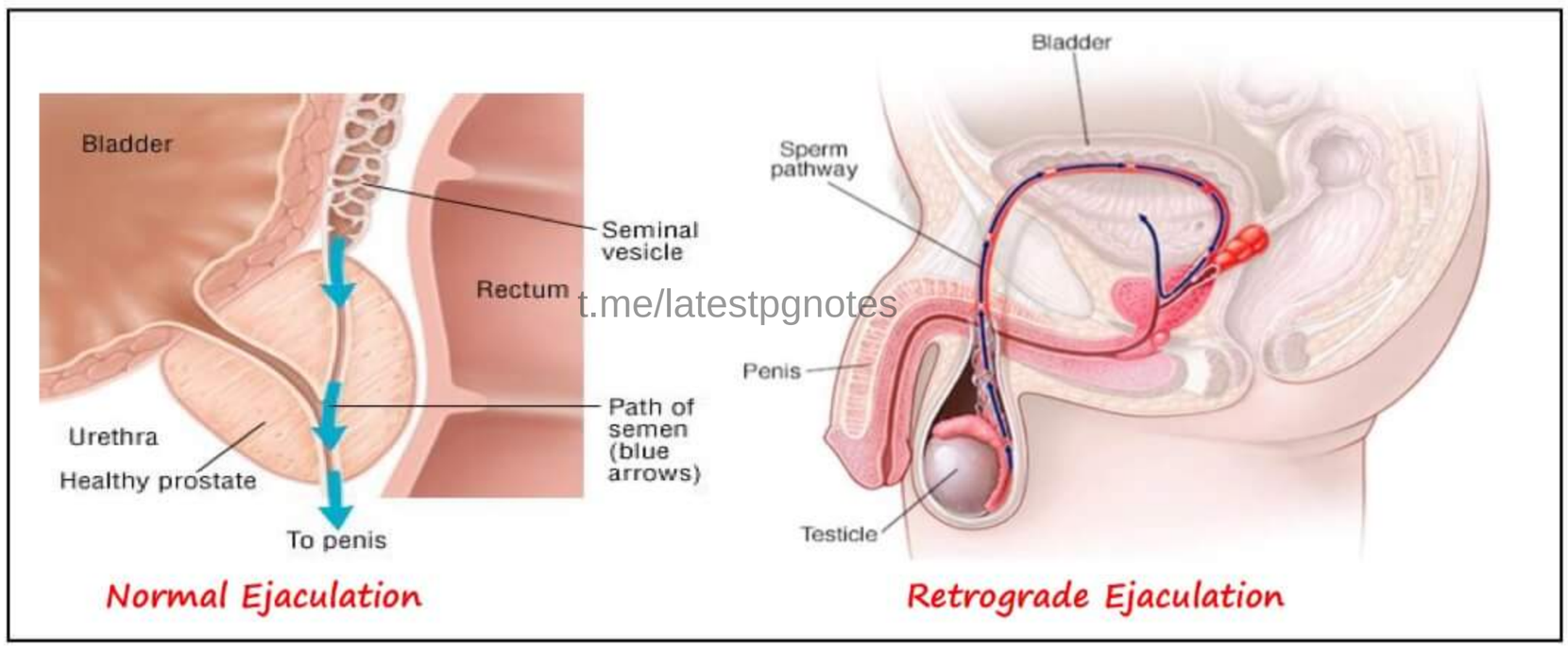

t.me/latestpgnotes

→ Structure mistaken for lumbar sympathetic ganglia and accidently removed are

- G – Genito Femoral Nerve
- P – Psoas sheath, Psoas minor
- L – Lymphatics

Indications for lumbar sympathectomy

1. Buerger's disease (Rest Pain)
2. Atherosclerosis
3. Raynaud's disease
4. Acrocyanosis
5. Causalgia
6. Hyperhidrosis
7. Erythrocyanosis
8. Frostbite

Gangrene → Amputation

PrepLadder

ARTERIAL ULCER

→ Located on the lateral surface of the ankle or distal digits

→ Distal ends of limbs (Commonly located)

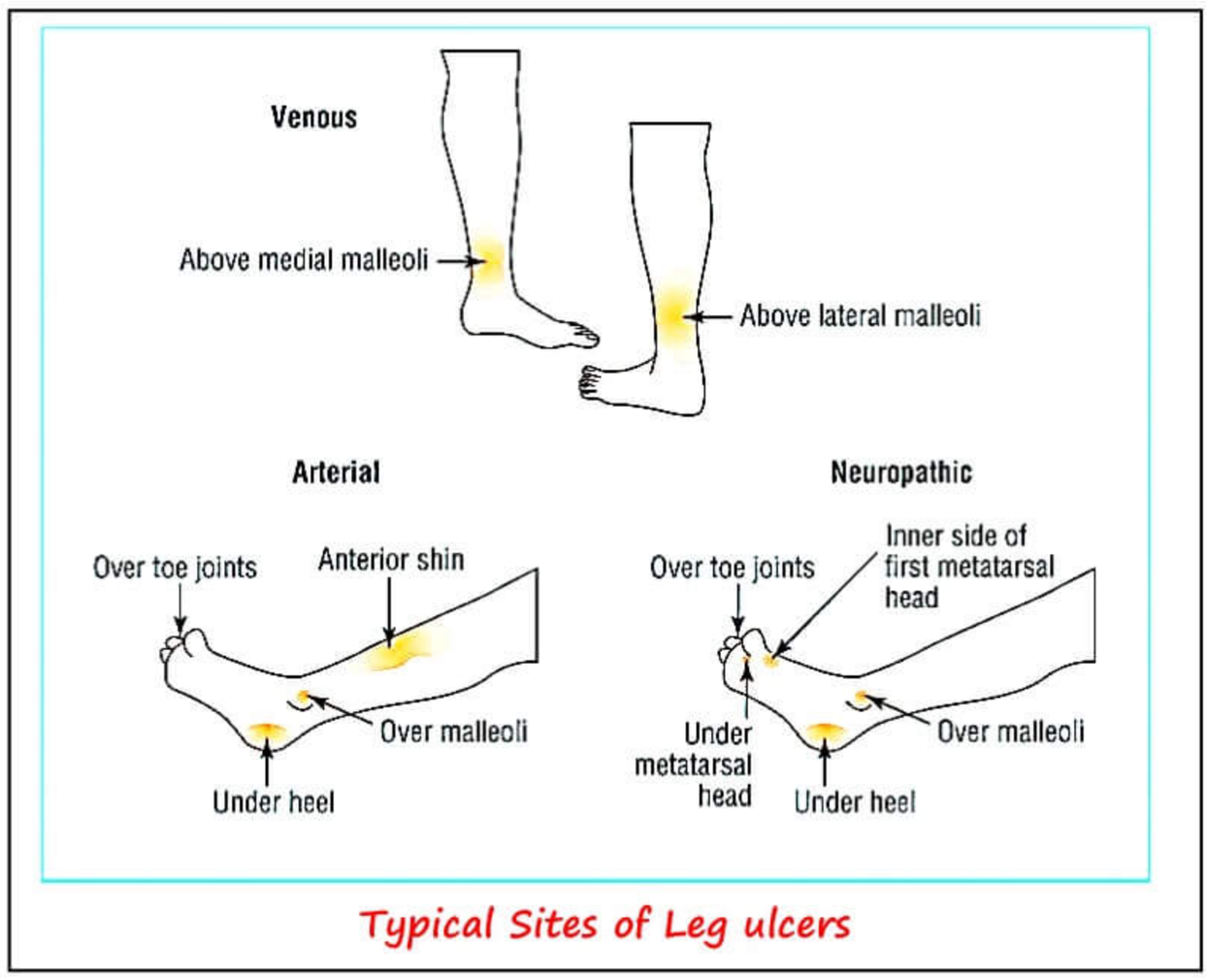

Typical Sites of Leg ulcers

Etiology

- Impaired vascular supply lack of blood flow

↓

Ischemia

↓

Tissue death

↓

Punched out ulcer

t.me/latestpgnotes

- **In Diabetes mellitus**
  - Microangiopathy
  - Macroangiopathy

} Endothelial dysfunction

Characteristic features of Arterial Ulcers

1. Punched out
2. Intensely painful
3. Distal pulses not palpable
4. Associated with changes
   - Thin shiny skin
   - Lack of hair
   - Brittle (nails)

PrepLadder

Diagnosis

→ Diagnosis is made clinically

→ Doppler is performed to assess vascular flow

Treatment

→ Revascularization procedures done

→ **For infected ulcer** – Antibiotics + Debridement

ARTERIOVENOUS FISTULA (AVF)

1. **Congenital (MC)**
2. Acquired - MC causes of acquired AVF is **Penetrating trauma > Iatrogenic**

Surgically created fistulas / Iatrogenic

1. **Brescia – Cimino fistula** – b/w Radial artery and Cephalic vein
2. **Snuff Box fistula** – b/w Posterior branch of radial artery and Cephalic vein
3. **Feinberg fistula** – b/w Radial artery and Basilic vein

Changes caused by creating AVF

→ In artery, blood flows from heart towards periphery

→ In vein, blood flows from periphery towards heart

→ On creating fistula, blood starts going from the high-pressure zone to low pressure zone i.e. going into vein **(↑ VR → ↑ CO → ↑ HR → ↑ SBP)**

→ Wide pulse pressure (because DBP does not increase as much as SBP)

→ Pulsatile mass

→ Palpable thrill

→ In chronic cases, there is arterialization of vein because vein becomes dilated, tortuous and thickened

→ **Nicoladoni's / Branham sign** – Occlusion of artery proximal to fistula leads to ↓ in size of pulsatile mass, disappearance of thrill and ↓ HR with normalization

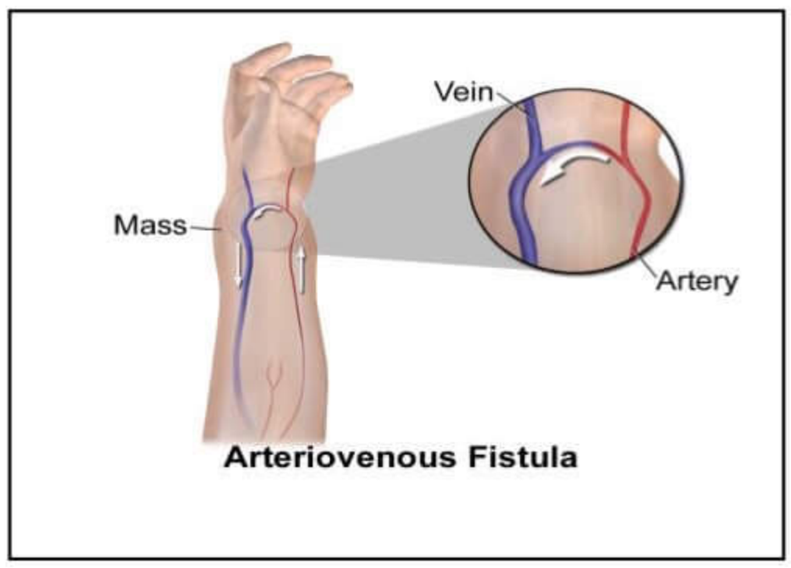

Arteriovenous Fistula

Diagnosis

→ IOC- **Angiography**

Treatment

→ Small fistula - Embolization

→ Large fistula - Surgical ligation

PrepLadder

THORACIC OUTLET COMPRESSION SYNDROME

→ Characterized by compression of subclavian vessels and nerves of brachial plexus at thoracic inlet, therefore it is a misnomer

→ MC in middle age females

→ **It is of 2 two types**

1. Neurogenic form (MC) → because of compression of brachial plexus
2. Vascular form → because of compression of subclavian vessels

→ **Compression in TOS is**

- Dynamic
- So, best diagnosed by provocative tests

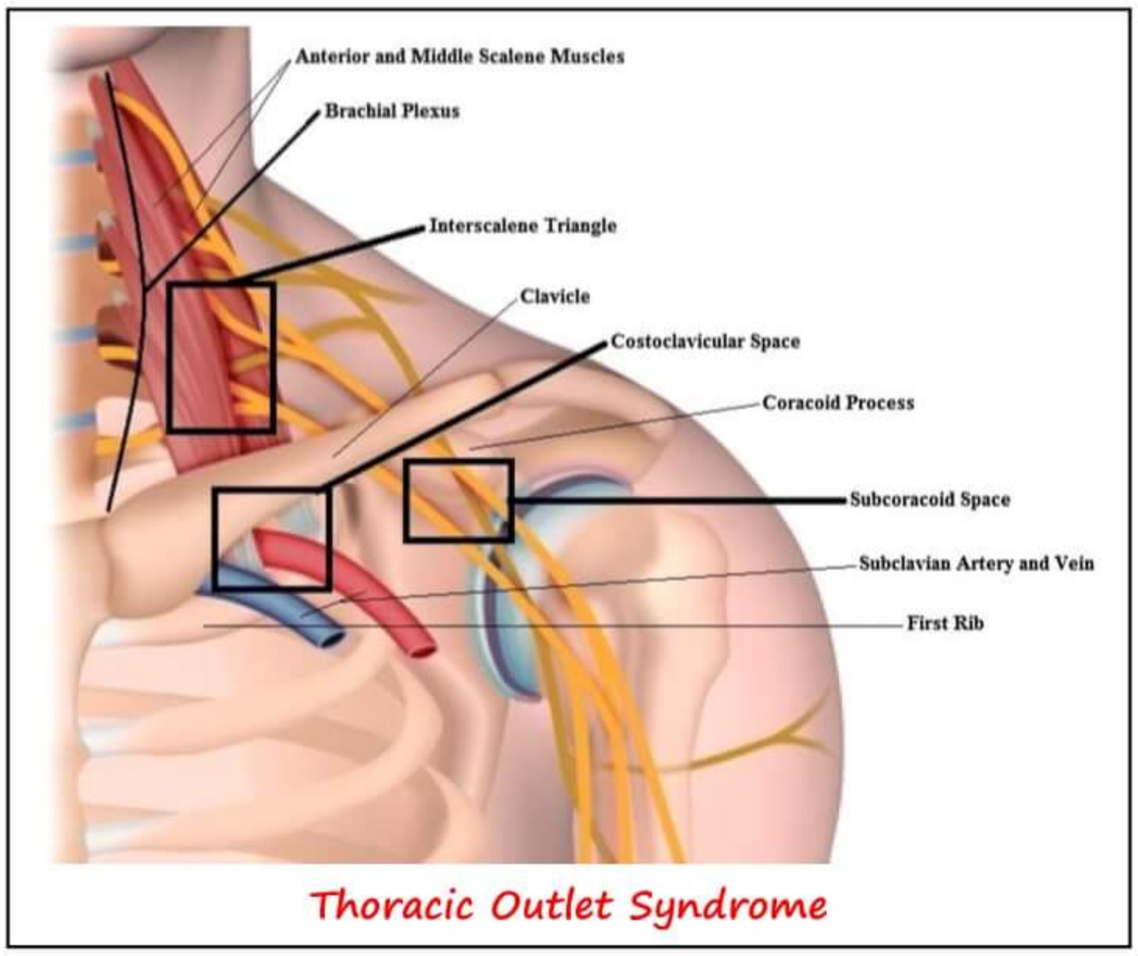

Thoracic Outlet Syndrome

Thoracic outlet space is created by

1. Clavicle
2. First rib
3. Subclavius muscle
4. Anterior scalene muscle
5. Costoclavicular ligament

t.me/latestpgnotes

Predisposing factors for TOS

1. Cervical rib / Abnormal first rib / fibrous band
2. Long transverse process of C7
3. Osteoarthritis
4. Pancoast tumor
5. Cervical haematoma

Clinical Manifestation

→ **In Neurogenic form**

- MC involved route value -C8T1; MC involved nerve-Ulnar nerve
- Patients complains of Pain, Paraesthesia along inner aspect of forearm and hand
- On examination, Atrophy of hypothenar and interossei muscles is seen
- On Arterial compression – has Pain, Pallor, Pulselessness, Paralysis, Paraesthesia
- In Venous form - has Pain, Cyanosis, Edema

Diagnosed by provocative test

1. Adson's test (Scalene test)
2. Costoclavicular Test (military position or Halsted test)
3. Hyperabduction test (Wright test)
4. Roo's test (Arm claudication test)

PrepLadder

Management

→ >90% patients are of Neurogenic form – **Treated Conservatively**

- improvement in postural sitting, standing and sleeping positions
- Advice Muscle stretching and strengthening exercise

Indications of surgical intervention are

1. Failure of conservative mx.
2. Progression of sensory or motor symptoms
3. Excessively prolonged ulnar or median nerve conduction velocity
4. Narrowing / Occlusion of subclavian artery
5. Thrombosis of axillary / subclavian vein
6. Presence of anatomical abnormality

t.me/latestpgnotes

PrepLadder

ARTERIAL DISORDERS Part – 2

RAYNAUD'S PHENOMENON

→ **It is episodic digital ischemia**

- On exposure of cold
- Emotional stress
- Use of vibrating tools

→ **Manifested by** – Sequential development of digital blanching, cyanosis and redness of fingers and toes

Sequence of Events

Blanching (Stage of local syncope)

↓

Cyanosis (Stage of local asphyxia)

↓

Redness (Stage of Recovery)

Blanching

Exposure of cold

↓

Spasm of digital arterioles

↓

Digits appear white

Cyanosis

Capillaries & Venules dilates

↓

Collection of deoxygenated blood

↓

Cyanosis

Redness

Resolution of digital spasm

↓

Increased blood flow in dilated arteries and capillaries

↓

Bright red colour of digits

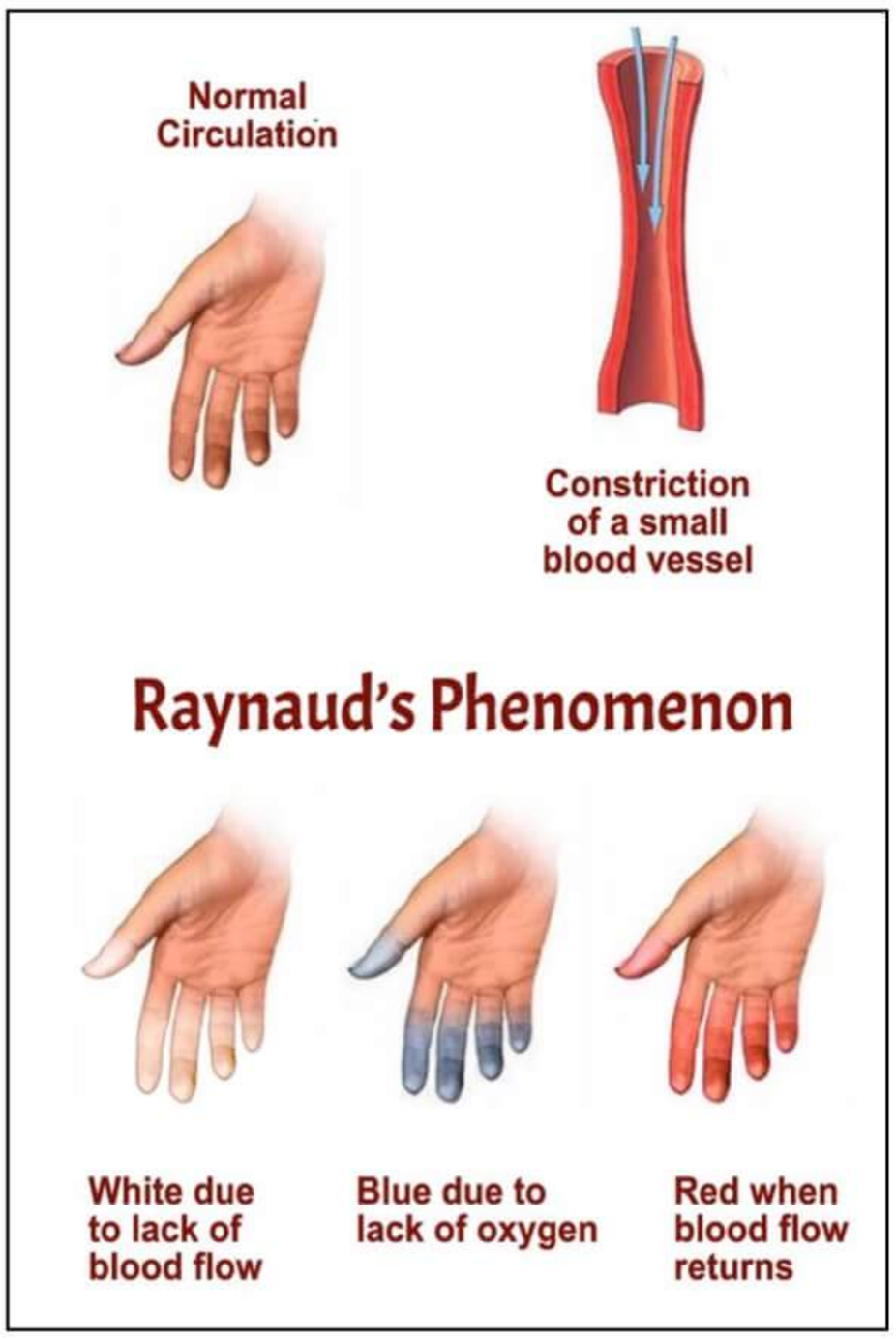

t.me/latestpgnotes

Clinical features

→ Most common in **Fingers > Toes**

→ Radial, ulnar and pedal pulses are normal

PrepLadder

Types

1. Primary (Idiopathic) / Raynaud's disease
2. Secondary

Treatment

→ To relieve spasm – **Calcium channel blockers**

- Diltiazem
- Nifedipine

ACUTE MESENTERIC ISCHEMIA

Etiology

1. **Emboli (50%)**
   - Arrythmia
   - Valvular Heart disease
   - MI
2. **Arterial thrombosis (25%)**
   - Atherosclerosis
3. **Non-Occlusive Mesenteric Ischemia (5-15%)**
   - Heart failure
   - Massive burns
   - Sepsis
   - Pancreatitis
   - Acute MI
4. **Venous thrombosis**
   - Virchow's triad (positive)
   - Hyper coagulable state (most important)

↓

Increase risk of mesenteric venous thrombosis

t.me/latestpgnotes

Note: Virchow's triad:

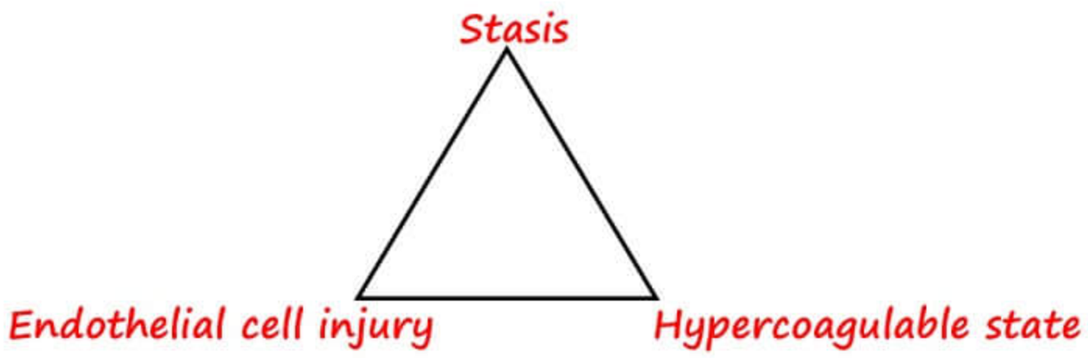

PrepLadder

Clinical features

1. Abdominal pain (MC symptom)

   ↓ Characteristic features

   - Out of proportion of physical examination findings
   - Persists for 2-3 hrs
2. Melena & Hematochezia – 15% cases

Diagnosis

→ Investigation of choice - **Mesenteric Arteriography**

→ Spasm in the vessel is k/a "STRING OF SAUSAGES" sign is seen on investigation

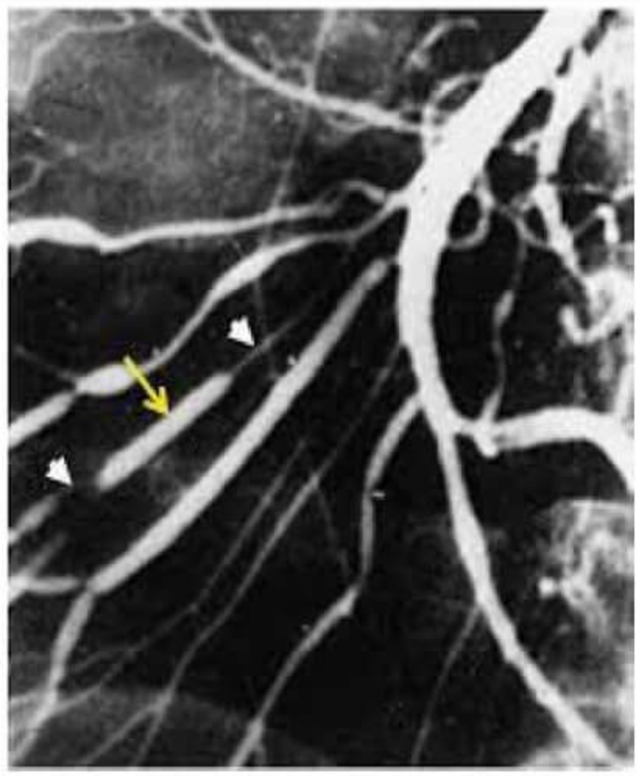

Superior Mesenteric Angiography showing the "String of Sausage Sign" in a patient of Non-Occlusive mesenteric Ischemia

Management

→ Early diagnosis

→ Aggressive Resuscitation - I/V fluids & I/V antibiotics

→ Early revascularization - Catheter directed papaverine infusion in SMA

↓

Relieves the spasm of mesenteric vessels

↓

Used in Non-Occlusive mesenteric ischemia

→ **Anticoagulants** – to prevents propagation of mesenteric thrombus

Patients with

Absence of peritonitis	Peritonitis
↓	↓
- Supportive care - Papaverine infusion - Anticoagulants	- Exploratory laparotomy with conservative resection of necrotic Bowel

MESENTERIC VEIN THROMBOSIS (MVT)

→ Responsible for 5-15% cases of mesenteric ischemia

→ Veins involved – Superior mesenteric vein (MC)

→ **Inferior mesenteric vein** is spared

Clinical features

1. Abdominal pain (most common)

   ↓ Characteristic features

   - Out of proportion of physical examination findings
   - Persists for 2-3 hrs
2. Melena & Hematochezia – 15 %

t.me/latestpgnotes

PrepLadder

Diagnosis

→ Investigation of choice – **CECT**

Management

→ **Rapid initiation of systemic anticoagulants**

- Heparin – used intra-operatively
- Anticoagulation – Should be continued post operatively (as risk of recurrence is 35-70%)

→ In case of peritonitis - **Exploratory laparotomy** (mortality rate -upto 50%)

CHRONIC MESENTERIC ISCHEMIA

→ MC cause - **Advanced atherosclerosis of multiple mesenteric vessels**

→ It is Rare - due to pressure of extensive collateral network

Risk factors

1. Positive family history
2. Hypertension
3. Smoking
4. Hypercholesterolemia

t.me/latestpgnotes

Clinical features

→ Post prandial abdominal pain (lasts for 15-45 min)

↓

Due to ischemia of mesenteric vessels as there will be increase demand for blood after meals

→ Diffuse crampy pain

→ Intestinal angina / intestinal claudication

↓

Fear / aversion for food

↓

Weight loss

Diagnosis

→ **Duplex scan** - to assess flow in Mesenteric vessels

→ Investigation of choice – **Aortography**

Management

→ Revascularization by Balloon angioplasty or stent placement in elderly

→ Definitive Rx – **Trans aortic endarterectomy or Bypass grafting**

PrepLadder

SUBCLAVIAN ARTERY STENOSIS

→ MC cause - Atherosclerosis

→ MC involved Vessel - Left SCA > Right SCA

→ MC site of stenosis - 1st part of left SCA. It occurs just distal to the origin of SCA & proximal to the origin of vertebral artery

↓ can lead to

Subclavian steal syndrome

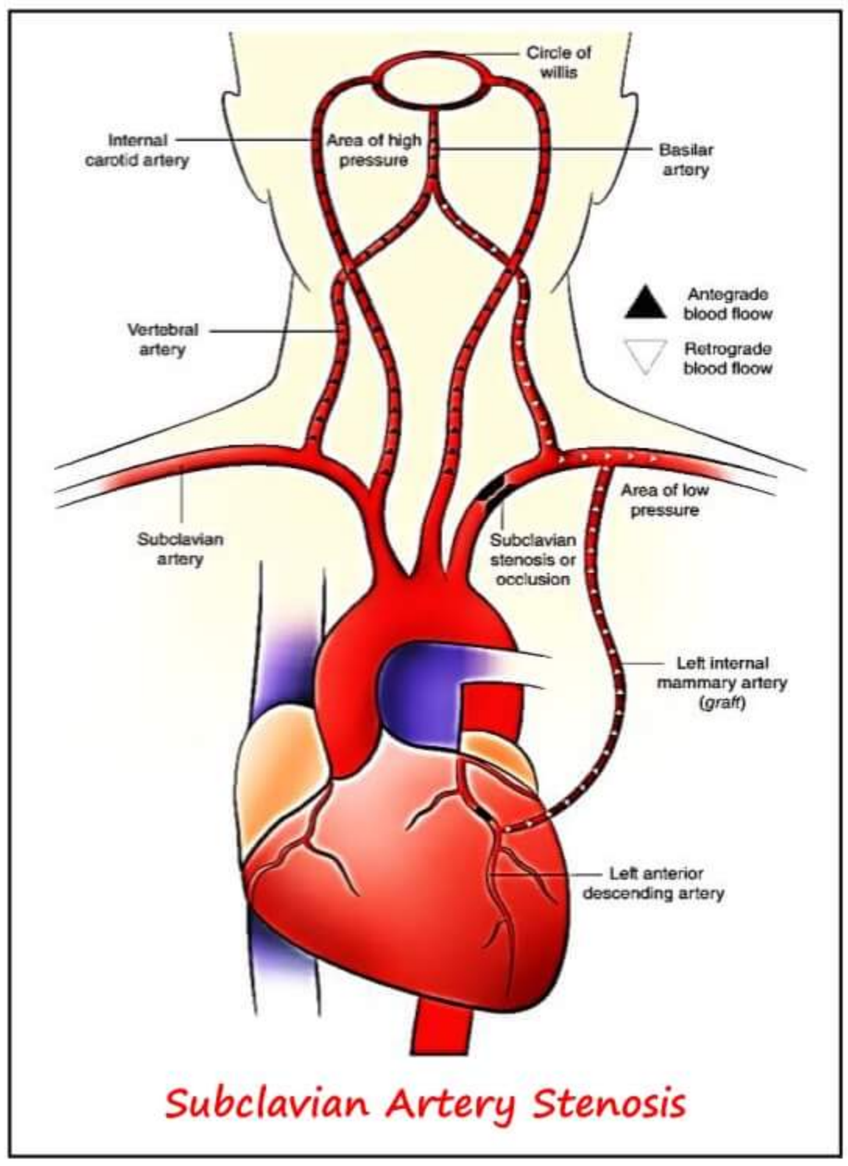

Subclavian Artery Stenosis

Subclavian steal syndrome

→ Reversal in the blood flow in the ipsilateral vertebral artery to compensate for a proximal stenosis of SCA

→ It does this by stealing the blood from brain to feed the arm

→ **Asymptomatic** (Majority of cases but if severe stenosis is there then it can lead to)

↓

Transient vertebrobasilar ischemia

- Weakness
- Syncope
- Vertigo
- Visual abnormalities

t.me/latestpgnotes

ANEURYSM

→ Permanent and irreversible localized dilatation of blood vessel with at least 50% increase in diameter

→ **ECTASIA** - Dilatation of <50% of normal diameter

→ Most common vessels of aneurysm - CIRCLE OF WILLIS

→ Most common site of extracranial aneurysm - Infrarenal aorta > iliac artery > popliteal artery > femoral artery

→ MC site of peripheral artery aneurysm- Popliteal artery

→ MC site of splanchnic arterial aneurysm - Splenic artery

→ MC site of Mycotic aneurysm - Femoral artery > Aorta

→ Most common cause of Abdominal Aortic Aneurysm - Atherosclerosis

→ Risk of rupture - determined by Width or Diameter of aneurysm

Indications of surgery

1. Descending thoracis aorta aneurysm → **Cut off diameter is ≥ 6.5 cm**
   - In case of Marfans syndrome, +ve family history, connective tissue disorders, bicuspid Aortic valve, aortic stenosis- **diameter is ≥ 6 cm**
2. Abdominal aortic & Ascending aortic aneurysm - **Cut off diameter is ≥ 5.5 cm**
3. Iliac artery aneurysm - **Cut off diameter is ≥ 3.5 cm**

PrepLadder

4. Popliteal & femoral Artery Aneurysm - **Cut off diameter is ≥ 2 cm**

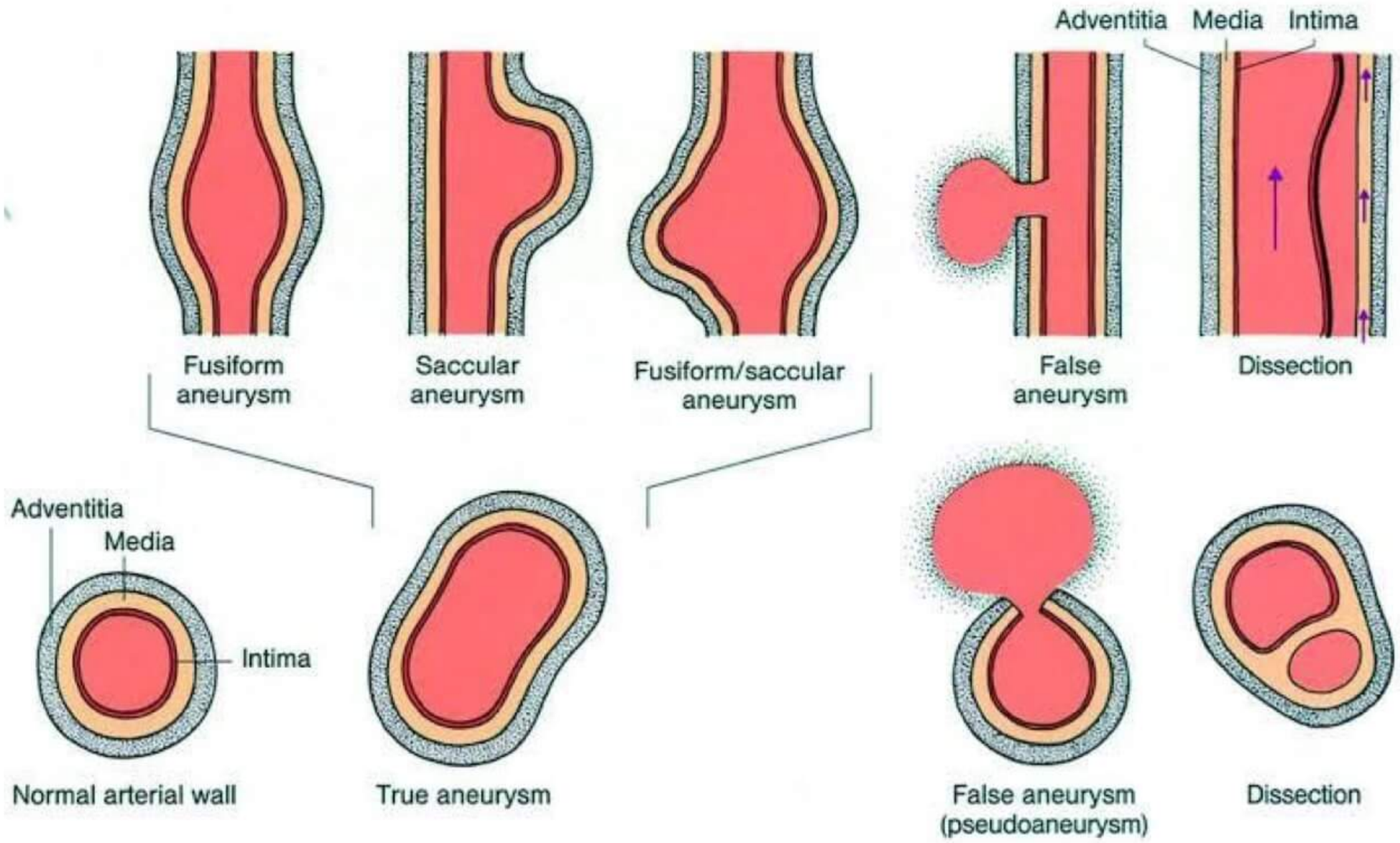

Types of Aneurysms

→ **True aneurysm** – All the three layers are involved (i.e. Intima, Media and Adventitia)

→ **Pseudo / False Aneurysm** - Doesn't contain all the 3 layers

→ **Mycotic aneurysm** - Infected aneurysm. It is a misnomer because caused by Bacteria (MC organism - Staph Aureus > Salmonella)

→ **Dissecting aneurysm** - Dissection with aneurysmal dilatation of false lumen

→ **Fusiform aneurysm** - Symmetrical enlargement involving whole circumference of artery

→ **Saccular aneurysm**

- Affect only one part of arterial circumference
- Irrespective of diameter has HIGH risk of rupture

ABDOMINAL AORTIC ANEURYSM (AAA)

→ MC Site - Infrarenal aorta

→ MC site of atherosclerosis - Infrarenal aorta

→ MC causes of AAA - Atherosclerosis

→ Most important predictor for rupture - Width / Diameter

→ MC symptom in AAA - Chronic vague abdominal pain / back pain (because location of aneurysm is retroperitoneal)

→ MC & lethal complication of aneurysm - Rupture

→ MC site of rupture - Left retroperitoneum

Triad of AAA

→ Sudden onset of midabdominal or flank pain

→ Shock

→ Pulsatile abdominal mass

} seen only in 1/3rd of cases

PrepLadder

Investigations

→ X-ray - Eggshell pattern of calcification
→ Investigation of choice for screening of abdominal aortic aneurysm - USG
→ Investigation of choice for diagnosis & planning repair of aortic aneurysm - CT
→ Investigation of choice for diagnosis & planning repair of aortic aneurysm in patients of renal failure - MRI

Indications of surgery in AAA

1) Diameter ≥ 5.5 cm / ≥ 5cm in females
2) Symptomatic aneurysm
3) Rate of expansion >1cm/year
4) Atypical aneurysm (pseudoaneurysm, dissecting aneurysm, saccular)

Management

Dacron Graft repair

- **EVAR** (Endovascular Aneurysm Repair)
- **OPEN**
  - **Transperitoneal** (Preferred)
  - **Retroperitoneal** ↓
    Indications are
    - HSK
    - H/o previous abdominal surgery

t.me/latestpgnotes

→ Mortality rate of elective AAA repair = < 5%
→ Mortality rate of ruptured AAA repair = > 50%
→ Mc cause of death after AAA repair - MI
→ MC complication - Non fatal MI > Renal failure
→ **Other complications**
  - Bleeding
  - Graft leak
  - Paraparesis – is due to injury of Arteria Radicularis magna **(artery of ADAMKIEWICZ)** → It is the main artery that supplies anterior spinal artery which supplies thoracolumbar segment of spinal cord
  - Infection
  - Colonic ischemia

PrepLadder

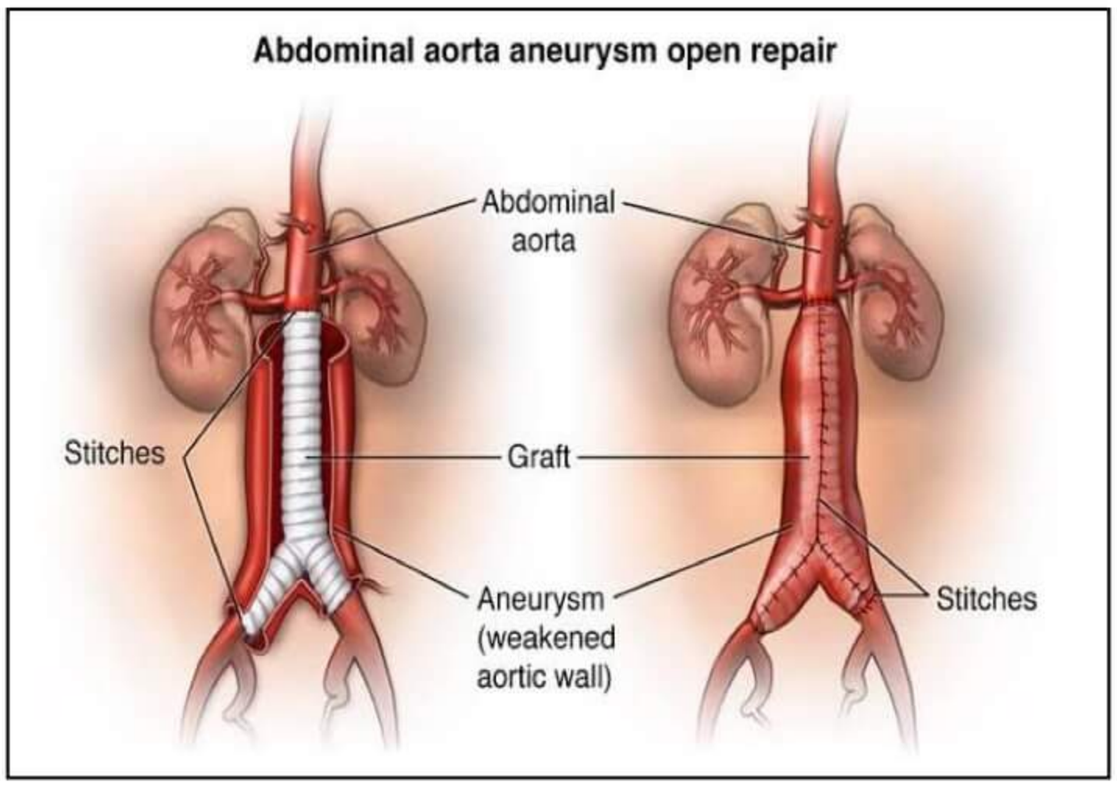

Modified Crawford classification for thoracoabdominal aortic aneurysm

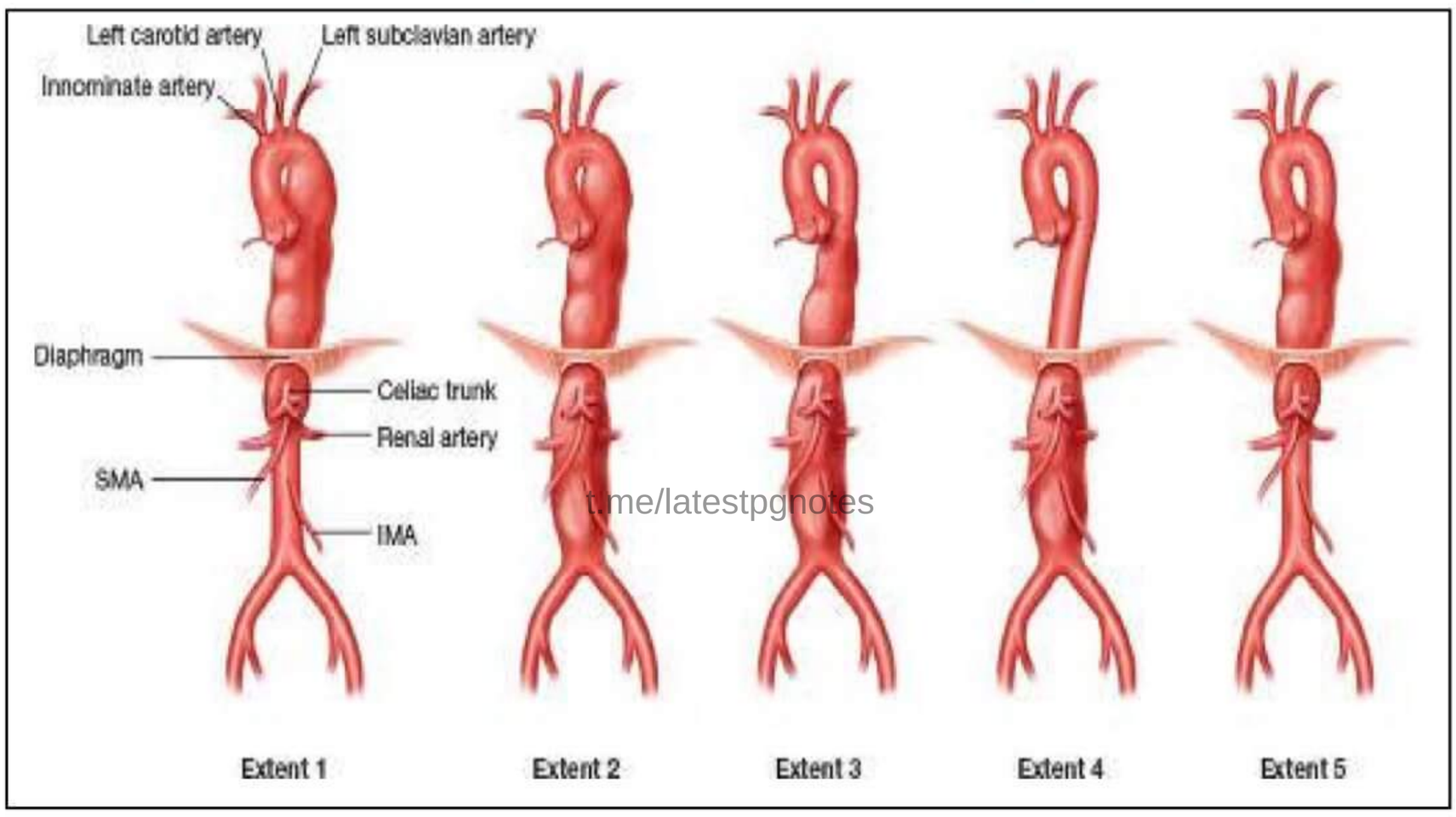

t.me/latestpgnotes

- **Type I** – Extent is from origin of Left SCA till supra renal aorta
- **Type II** – Extent is from SCA till aorto-iliac bifurcation (**most extensive**)
- **Type III** – Extent is from Distal Thoracic aorta till Aorta- iliac bifurcation
- **Type IV** – Limited to Abdominal aorta
- **Type V** – Extent is from Distal Thoracic aorta till Superior Mesenteric Artery

Mycotic aneurysm

→ Focal dilatation of arteries occurring at points in the arterial wall weakened by infection

→ MC artery involved – **Femoral > Aorta**

→ MC Organism – **Staph aureus > Salmonella**

PrepLadder

Aortic dissection

→ **Circumferential or transverse tear in the intima**

↓

Blood enters into intima-media space

↓

Separation of inner & middle layer

→ Most common site of Aortic Dissection - **Right lateral wall of ascending aorta**

→ More common in males

→ Occurs in 6th to 7th decade

Risk factors

→ Systemic hypertension **(most important)**

→ Cystic medial necrosis

→ 3rd trimester of pregnancy

Classification of aortic dissection

→ **DeBakey Classification**

- **Type I** (60%) - Intimal tear in ascending aorta involving descending aorta (most common)
- **Type II** - Dissection is just limited to ascending aorta
- **Type III** - Intimal tear in descending aorta order with distal propagation

t.me/latestpgnotes

→ **Stanford Classification**

- **Stanford A** - I & II of DeBakey
- **Stanford B** - III of DeBakey

Classification of aortic dissection

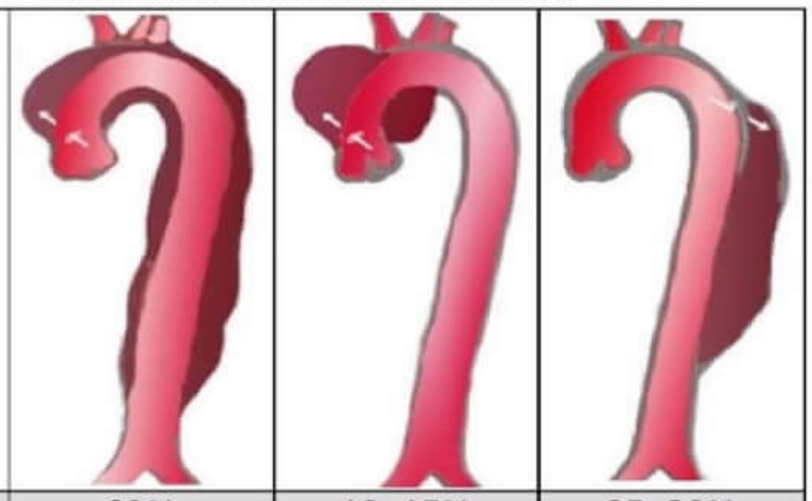

Percentage	60%	10–15%	25–30%
Type	DeBakey I	DeBakey II	DeBakey III
	Stanford A (Proximal)		Stanford B (Distal)

Clinical Features

→ Sudden onset of severe chest pain radiating to interscapular region

→ Migration of pain with propagation of dissection

→ Syncope, Dyspnea, Weakness, Hypotension /shock

PrepLadder

Investigation

→ **On CXR** – widening of superior mediastinum with left side pleural effusion

→ **IOC depends on the presentation of patient**

- If patient is Stable – CT Angio
- If patient is Unstable – Trans Esophageal Echocardiography (TEE)

Management

→ Emergency Dacron graft repair

Traumatic aortic rupture

→ It leads to sudden death of the patient after road traffic accident or fall from great height

→ Most common site of aortic rupture – Adjacent to Ligamentum Arteriosum

Clinical Features

→ Has a mortality rate of 75-90%

→ Only 15-20% arrive alive in the hospital

→ 90% of the patients who arrive alive to hospital has Aortic isthmus > ascending aorta as the site of rupture

Investigation

→ On CXR – Has widened mediastinum

t.me/latestpgnotes

→ Gold standard investigation – Aortography

→ CT / TEE – are useful for diagnosis

Management

→ Endovascular intra-aortic stenting

→ Dacron Graft Repair

MANEUVERS FOR RETROPERITONEAL EXPOSURE

1) Kocher's maneuver
2) Extended Kocher's maneuver /Right Sided medial visceral rotation
3) Mattox maneuver /Left sided medial visceral rotation
4) Cattel-Braasch maneuver

KOCHER'S MANEUVER

→ Used for mobilization / medial rotation of duodenum

→ Gives adequate visualization of head of pancreas, 2nd part of duodenum & to expose the structures located posterior to pancreas & duodenum

→ Done in Whipples procedure

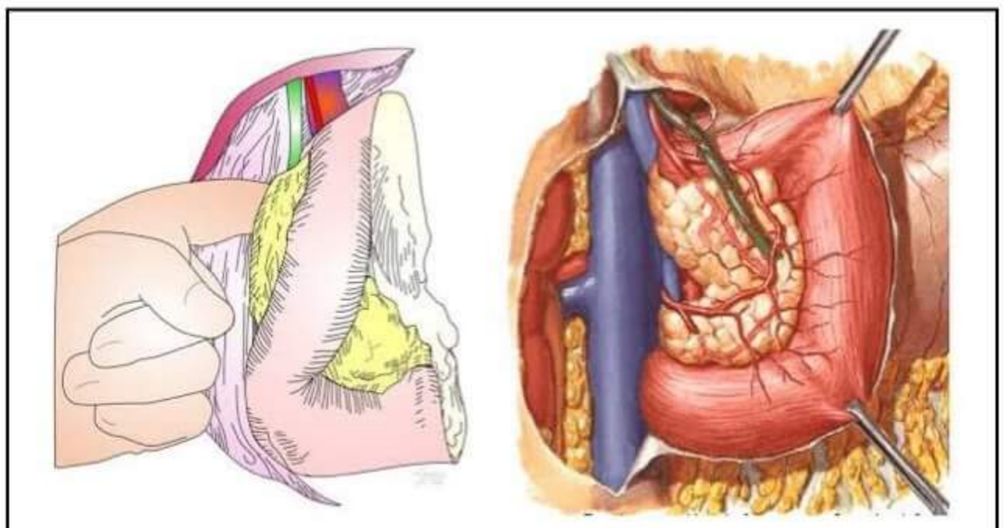

Kocher's maneuver

PrepLadder

EXTENDED KOCHER'S MANEUVER

→ AKA Right Sided medial visceral rotation

→ Right colon & duodenum are rotated medially exposing

- inferior vena cava
- Infrarenal aorta
- Rt. renal artery
- Iliac vessel

→ It is used for drainage of inframesocolic hematoma

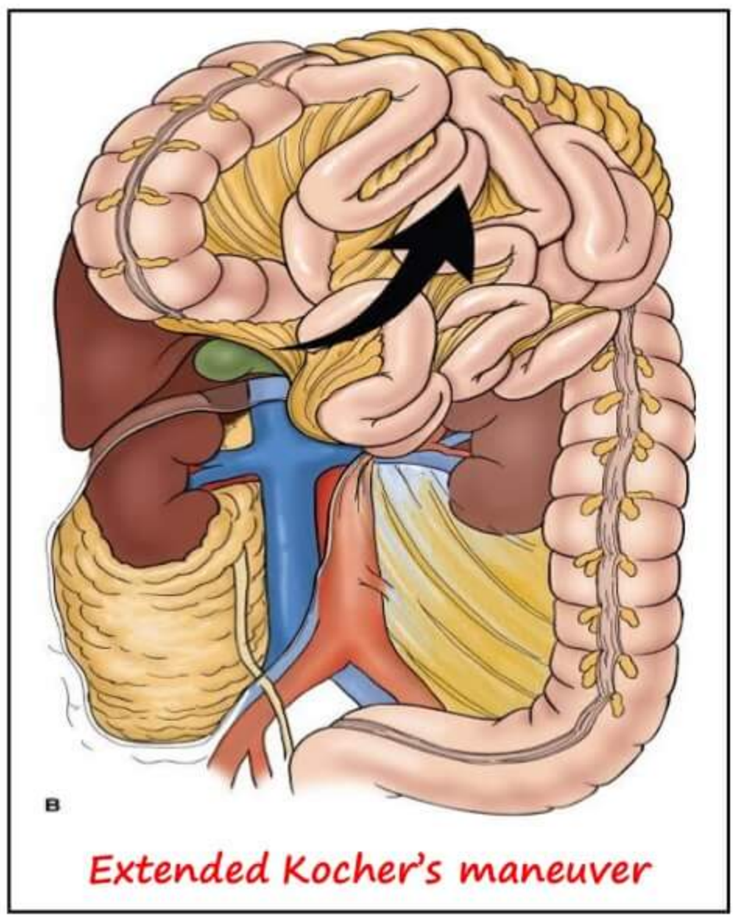

Extended Kocher's maneuver

MATTOX MANEUVER

→ AKA Left sided medial visceral rotation

→ Left kidney, left colon, spleen & pancreas are rotated medially & brought to the midline

→ This maneuver exposes

- Entire length of abdominal aorta
- Proximal part of mesenteric arteries
- Proximal left renal artery

→ It is used for drainage of central supramesocolic hematoma

CATTEL – BRAASCH MANEUVER

→ Performed for Extensive retroperitoneal exposure

→ In this maneuver, the right colon is mobilized and rotated medially exposing

- Complete length of Inferior Vena Cava
- Renal vein
- Infra- pancreatic segments

t.me/latestpgnotes

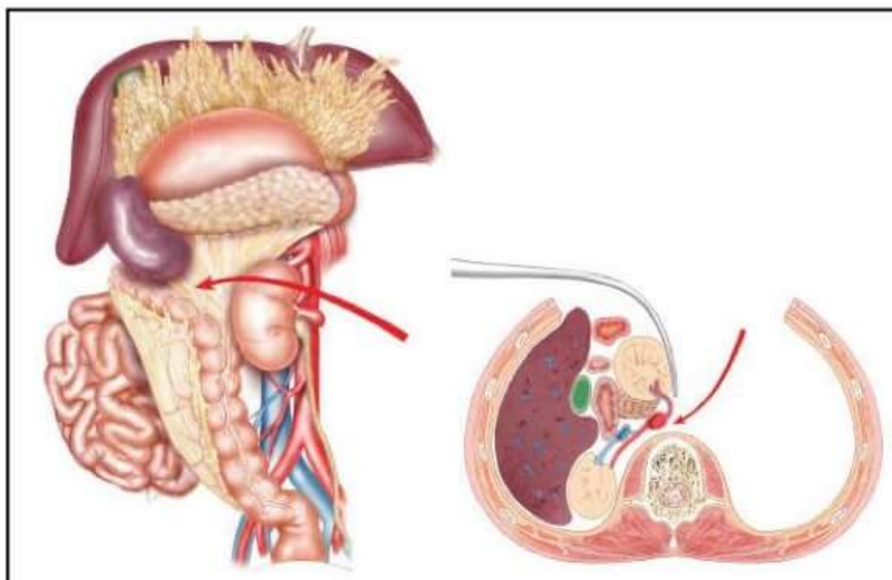
Mattox maneuver

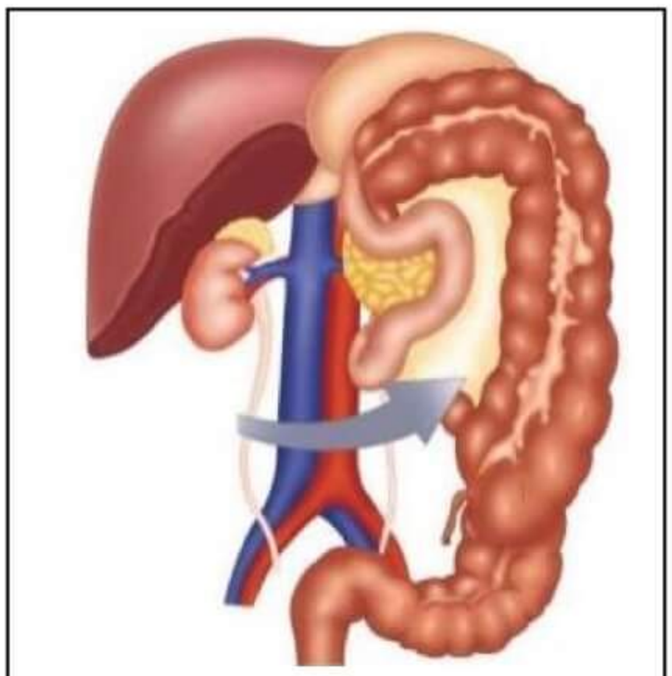
Cattel-Braasch maneuver

VASCULAR GRAFT

→ It is of 2 types

Bioprosthetic	Synthetic
• Auto graft • Homograft (Allograft) • Xenograft (Heterograft) • Tissue engineered	• Textile graft -Dacron (most common) • Non-Textile graft – ePTFE (expanded polytetrafluoroethylene) – Polyurethane

PrepLadder

→ Best natural vascular graft - **Reversed saphenous Vein**

→ Best synthetic vascular graft – **Dacron**

→ Conduit of choice / Preferred graft for infra-inguinal bypass- **Saphenous vein**

→ Conduit of choice / Preferred for supra-inguinal bypass- **Dacron**

→ Most commonly used graft for CABG (Coronary Artery Bypass graft) - **Long saphenous Vein**

→ Most preferred graft for CABG - **LIMA (left internal mammary artery)**

↓

- Has higher patency rate than long saphenous vein because
  - LSV has collapsible lumen (i.e. lumen is open during systole but collapses during diastole) whereas in LIMA lumen is open during systole and diastole
- But LSV is more commonly used because of its advantage of extra length

→ **In Bilateral iliac artery obstruction**

- Aorto-femoral bypass is done
- Dacron is the preferred graft as it is a Supra-inguinal bypass

→ **Coronary artery bypass grafting**

- **Internal mammary artery** - most preferred graft
- **Saphenous vein** - most commonly used graft
- Radial artery bypass can also be used

t.me/latestpgnotes

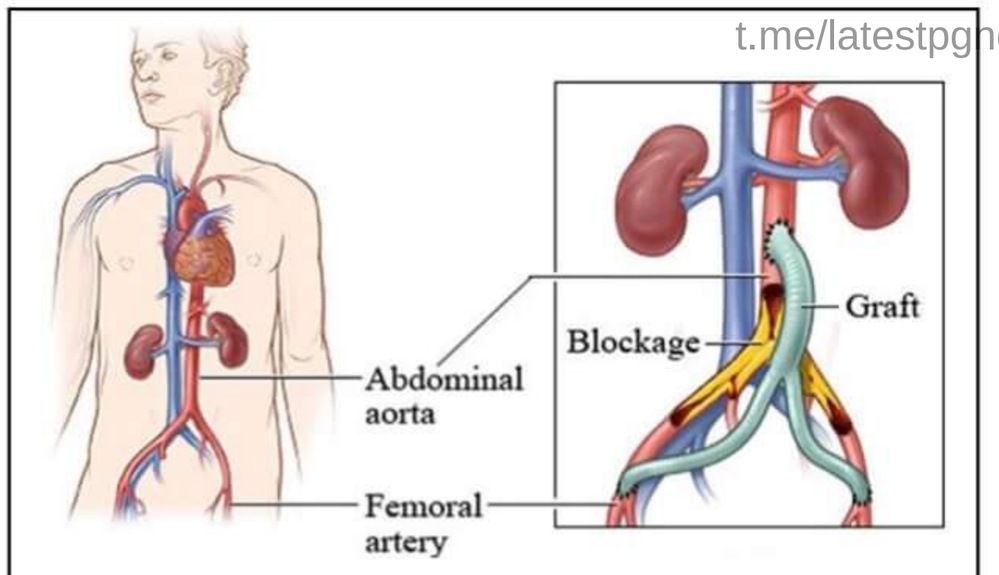

Aorto-Femoral Bypass Graft

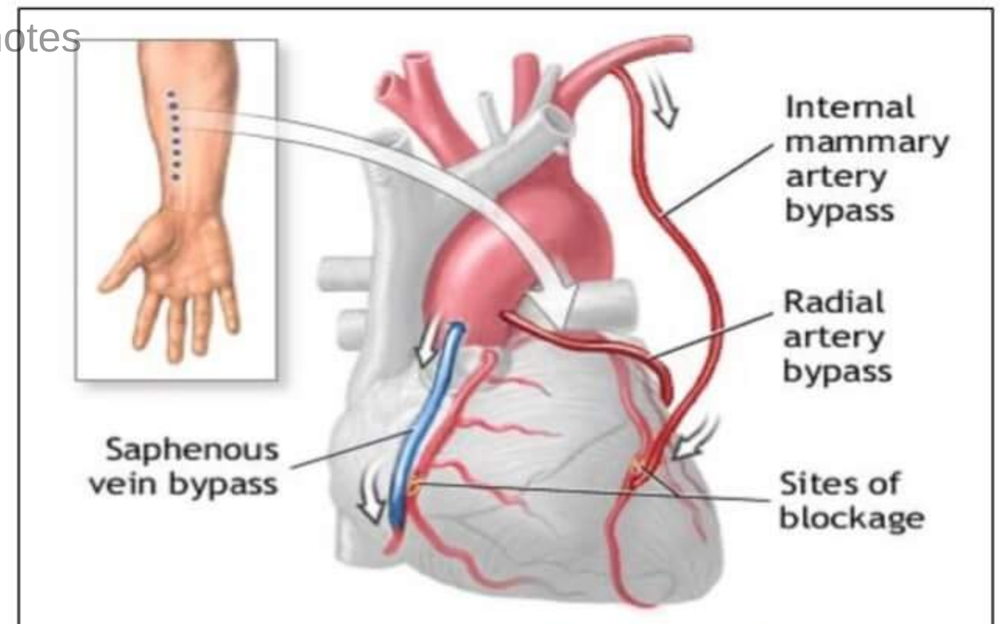

Coronary artery bypass grafting

PrepLadder

VENOUS DISORDERS

DEEP VENOUS THROMBOSIS (DVT)

→ **Virchow's Traid positive**

- Endothelial injury
- Stasis
- Hypercoagulable state

} increases the risk of DVT

RISK factors for thrombosis

INHERITED	ACQUIRED
1. **Defective inhibition of coagulation factors** • Factor V Leiden • Protein C or S deficiency • Anti-thrombin III Deficiency 2. **Impaired Clot lysis** • Dysfibrinogenemia • Plasminogen deficiency • t-PA deficiency • PAI -1 Excess 3. **Uncertain mechanism** • Homocystinuria • Hyperhomocystinemia	1. **Disease / syndrome** • Lupus Anticoagulant • Malignancy • MI • Infection • Paroxysmal Nocturnal hemoglobunuria • TTP (Thrombotic Thrombocytopenic purpura) • Nephrotic syndrome 2. **Physiological states** • Pregnancy (especially in Postpartum Period) • Obesity • Prolonged immobilization • Post-operative state

t.me/latestpgnotes

→ Most common genetic cause of Thrombophilia
→ Most common congenital cause of Venous Thrombosis
→ Most common Genetic Hereditary Blood Coagulation Disorder

} Factor V LEIDEN

→ **Surgeries Associated with High risk of DVT**

- Major abdominal/Pelvic surgery
- Major Orthopedic surgery
- Urological Surgery in patients > 40 years

} because of prolonged immobilization in these surgeries

MECHANICAL	PHARMACOLOGICAL
• Early Ambulation (simplest) • Pneumatic compression Devices (MC used method)	• Unfractionated Heparin • LMWH (Low molecule weight Heparin) ↓ Preferred (Because monitoring is not needed)

PrepLadder

DVT Prophylaxis

→ MC site of DVT – **Calf vein (Soleal vein)**

→ MC site of DVT leading to Pulmonary Embolism – **Thigh veins (Femoropopliteal veins)**

Clinical features

→ MC Presentation – **Pain & Swelling in Calf Region**

→ Bilateral DVT is seen in 30% cases (Mostly its unilateral)

→ DVT leads to Pulmonary embolism that leads to Sudden death

↓

Presentation of PE (Pulmonary embolism)

- Pleuritic chest pain
- Hemoptysis
- Dyspnea

→ Low grade Fever is typically seen in – **Recurrent Pulmonary Emboli**

→ Earliest sign of DVT

- **Calf Tenderness (MC)**
- Edema (Initially Pitting F/B Non-Pitting)
- Tenderness along the course of deep veins

Signs of DVT

t.me/latestngnotes

→ **HOMAN's SIGN** – Increased resistance to passive Dorsiflexion of Foot

→ **MOSES SIGN (BANCROFT SIGN)** – Application of Pressure over calf region causes pain

→ **PRATT'S SIGN** – Squeezing of calf leads to pain

PHLEGMASIA ALBA DOLENS (Painful white leg)	PHLEGMASIA CERULEA DOLENS (Painful Blue Leg)
• Obstructed Deep Venous channels with patent collaterals	• Obstructed Deep venous channels & Collaterals

Investigations

→ IOC for DVT – **Duplex scan**

→ **Doppler**

- Used to assess moving structures (Blood)
  - Presence / Absence of flow
  - Direction of flow
  - Velocity of flow
- Blood flow towards Probe – **Red**
- Away from Probe – **Blue**
- Turbulent Flow – **Green**
- Doppler is IOC for
  - **Portal hypertension**
  - **Testicular Torsion**

PrepLadder

→ **Duplex Scan**

- It is a combination of B-mode of Traditional Ultrasound and Doppler
  - **B-Mode of traditional ultrasound** - provides images of vessel wall + Surrounding tissue
  - **Doppler** - Blood flow
- Duplex is the investigation of choice for
  - DVT
  - Varicose vein

  } Because in both these cases we want to asses anatomy as well as the blood

Management of DVT

→ **Start Anticoagulants**

- DOC is IV Heparin x 5 days
- Also start on Warfarin – acts after 72 hrs (from 3rd Day onwards dose adjustment required)

→ **For Monitoring of**

- Heparin → aPTT (reference range is 1.5-2.5)
- WARFARIN → INR (reference range is 2.0 -3.0)

VARICOSE VEIN

→ Dilated, Elongated, Torturous vein with diameter of ≥ 3 mm

→ **If the involved vein is**

t.me/latestpgnotes

- Long saphenous vein (MC) – varicosities are present on Thigh & Anteromedial aspect of leg
- Short saphenous vein - varicosities are present on Posterolateral aspect of leg

Types of Varicose veins

PRIMARY VARIOSE VEIN	SECONDARY VARICOSE VEIN
• Has congenital predisposition with occupational Reinforcement • **Congenital predispositions are** – Decreased no. of valves – Defective Valves • **Occupational Reinforcement is** – Prolonged standing	• Causes of secondary varicose vein – DVT (MC) – Trauma – AV fistula – Compression of deep veins by Pelvic Mass / Pelvic Tumour / Pregnancy

Clinical features

→ Dull aching pain in Evening hours associated with Pedal Edema

↓

Subside completely after taking rest

PrepLadder

Pathophysiology

→ Because of decreased/defective valves, regurgitation of blood occurs

↓

Increased end diastolic volume

↓

Both superficial & deep system is massively distended

↓

Chronic Ambulatory Venous Hypertension

→ Fibrin cuff theory & WBC migratory theory are not accepted now

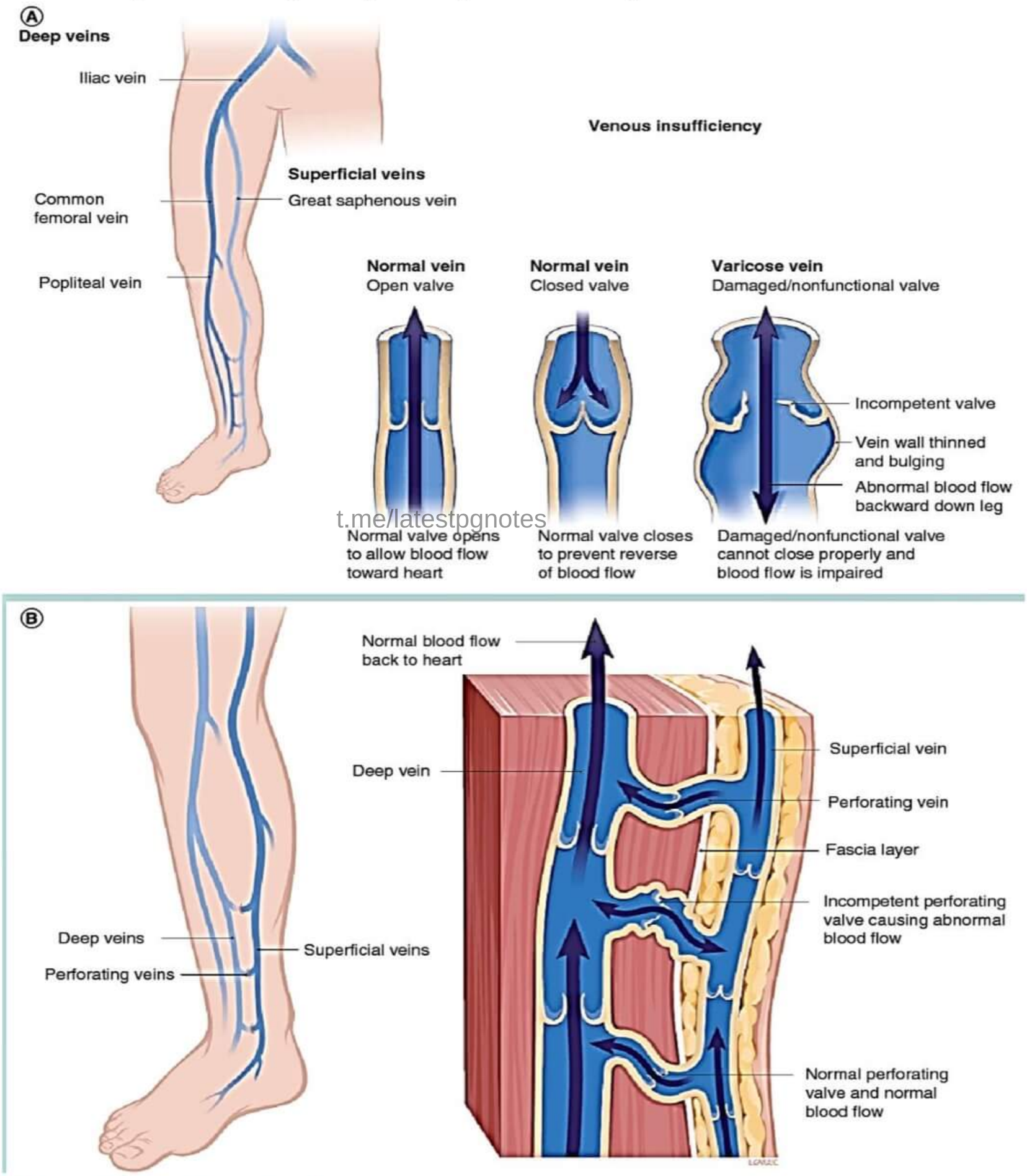

t.me/latestpgnotes

Chronic Ambulatory Venous Hypertension

→ **Responsible for complications like**

- Hyperpigmentation (hemosiderin)
- Lipodermatosclerosis
- Eczema
- Venous ulcer (Loss of Epithelium)

PrepLadder

→ To manage the patient of venous ulcer – **BISGAARD'S REGIME**

→ **Components of Bisgaard's Regime**

- Limb elevation
- Massage
- Compression stockings

Various tests performed in Varicose Vein

→ **Morrissey's Test** - Cough impulse test

→ **Schwartz Test** - Tapping the varicosity & feeling the impulse at saphenous opening (at sapheno-femoral junction)

→ **Perthes test** – Elastic bandage is applied in lower limb causing superficial vein obstruction

↓

Crampy pain after work & Exercise indicating deep vein obstruction

↓

DVT

→ **Modified Perthes Test**- Tourniquet is applied at SFJ (Sapheno-femoral junction)

↓

Crampy Pain after work or Exercise

↓

DVT

t.me/latestpgnotes

→ **Fegan's Test** – Crescentic defect in Fascia on Deep palpation at site of incompetent Perforator

→ **Brodie-Trendelenburg test** – has 2 components

Components - I	Components - II
Apply tourniquet and ask the patient to stand ↓ Remove Tourniquet in standing position ↓ Rapid filling from above ↓ Incompetent SFJ	Apply the tourniquet ↓ Ask the patient to stand ↓ Slow filling from below ↓ Incompetent perforators

Investigation

→ IOC for Dx of varicose veins - **Duplex Scan**

→ **Duplex Scan assesses**

- Status of SFJ → Competent / Incompetent
- Status & location of SPJ → Competent / Incompetent
- Perforators → Numbers & Location of Incompetent perforators

PrepLadder

- DVT (+ / -) → DVT is an absolute Contraindication for stripping

Rx For Varicose Vein

→ Surgery done for varicose veins - Trendelenburg operation

→ **Components of Trendelenburg operation**

- Individual ligation of tributaries
  - a) Superficial inferior Epigastric Vein
  - b) Superficial circumflex iliac vein
  - c) Superficial & Deep external pudendal vein
- Flush ligation at SPJ → if not performed it may lead to Saphena varix
- Stripping of LSV just below knee joint
  - During stripping of **LSV** → There is increased risk of injury of Saphenous nerve
  - During stripping of **SSV** → There is increased risk of injury of Sural nerve
  - SSV → SPL - Ligation at SPJ + Stripping till Ankle joint

→ **Other treatment options**

- Sclerotherapy - for veins < 3mm in diameter
- Sclerosing agent – Used in esophageal varices, haemorrhoids & varicose veins
  - → 5% phenol in Almond oil
  - → 5% Ethanolamine Oleate
  - → 3% Polidocanol
  - → 3% Sodium Tetradecyl sulphate (Most commonly used)

t.me/latestpgnotes

- **New technique in Varicose Vein**
  - → RFA – Radiofrequency Ablation
  - → EVLA – Endovenous laser Ablation

Complication of Varicose Vein Surgery

→ **Recurrence** - Up to 10% of cases (Most common complication)

→ **Hematoma / Ecchymosis** - Most common cause of discomfort after varicose veins surgery

→ **Sensory nerve injury**

- During stripping of **LSV** → There is increased risk of injury of Saphenous nerve
- During stripping of **SSV** → There is increased risk of injury of Sural nerve

CEAP - Classification of Lower extremity venous disease

→ **C** - Clinical sign (grade from 0-6)

- A – Asymptomatic Presentation
- S – Symptomatic Presentation

→ **E** - Etiological classification (Congenital, Primary, Secondary)

→ **A** – Anatomical Distribution (Superficial, Deep, perforators, combination)

PrepLadder

→ P – Pathophysiologic Dysfunction (Reflex or obstruction - Alone or in combination)

SEPS (Sub-facial Endoscopic Perforator Vein Surgery)

→ Used for Incompetent Perforators

→ Vascular clip is applied over incompetent perforators with the help of Endoscope below the level of deep fascia

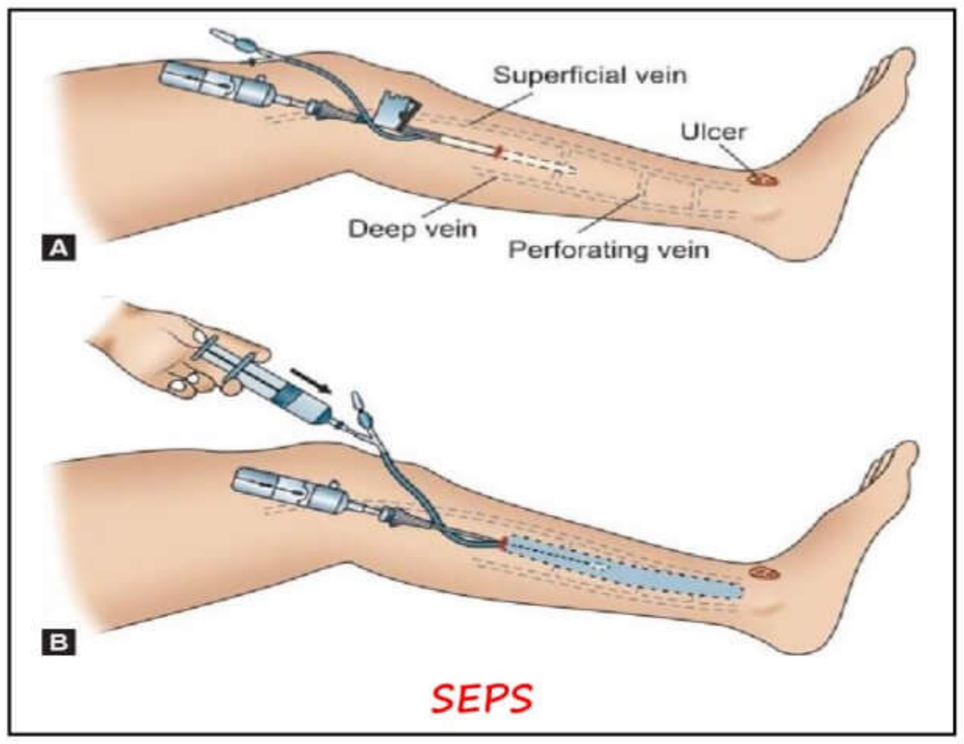

SEPS

COCKET & DODD'S OPERATION

→ It is Sub-facial ligation of incompetent perforators

→ **Various named Perforators in lower limb**

- Below the level of Medial malleolus - Inframalleolar / May or Kuster Perforator
- In the Medial Calf - Cockett Perforator
- Just below the knee - Boyd's perforator
- Just above knee – DODD'S Perforator
- At the level of Abductor Canal – Hunterian Perforator

TIPP using Trivex system

t.me/latestnaptes

→ **TIPP** – Trans illuminated powered phlebectomy

→ **Trivex system** – has two components

- Illuminator
- Vein resector

→ **Procedure**

- Irrigated transilluminator is passed deep to the varicosity making it visible
- Powered suction resector is introduced through a separate skin incision
- On activation of the system vein is sucked into the resector under direct vision. The vein is then morcellated & removed by suction

MAYTHURNER / COCKETT / ILIOCAVAL / ILIAC VEIN COMPRESSION SYNDROME

→ Characterised by left Iliac Vein Compression by over-riding Right iliac Artery

↓

Cause left Iliofemoral DVT

VENOUS ULCERS

→ Responsible for 60-70% of ulcers in lower leg

→ Varicose veins are responsible for ulcers so called Varicose ulcers

→ **Theories for formation of Ulcer**

- Fibrin-cuff Theory
- WBC Migration Theory

} Not Accepted

PrepLadder

- Chronic Ambulatory Venous Hypertension – **Most accepted theory**

→ Typical features of Varicose Vein – Inverted Champagne Bottle Appearance of leg

→ Typical feature of Varicose ulcer – ulcer in Gaiter region **(Area between Calf muscles & Malleolus)**

→ Location of ulcer – Located just above Medial Malleolus

Inverted Champagne bottle Appearance

C/F

→ **Typical features of Venous Ulcer**

- Sloping edges
- Pink granulation tissue at base
- Hyperpigmentation of skin around ulcer

→ Cause of Hyperpigmentation of skin - Hemosiderin Deposits

→ **Typical features of Arterial Ulcer**

- Punched out
- Thin shining skin
- Absence of Hair
- Brittle nails

Venous ulcer

t.me/latestpgnotes

Arterial Ulcer

Management

→ BISGARDS REGIME - Limb Elevation + Compression Stocking + Massage

Syndromes associated with AV Malformation

1) Klippel-Trenaunay syndrome

→ Characterised by

- Congenital AV Fistula
- Cutaneous Hemangioma
- Varicose veins
- Hypertrophy of involved Extremities
- Absence of Deep Venous System

→ "Stripping is contraindicated" (as deep venous system is absent)

→ **Management** - Conservatively by Compressed Stocking

PrepLadder

2) Kasabach-Merritt syndrome

→ Associated with Hemangioma /AV malformation

→ Characterised by

- Microangiopathic Hemolytic Anemia
- Consumptive coagulopathy
- Platelet trapping – leads to Thrombocytopenia

Superficial Thrombophlebitis

Causes

→ IV Infusion (MC)

→ Trauma

→ Buerger's disease

→ Malignancy

Malignancies associated migratory superficial thrombophlebitis	
• Carcinoma Pancreas (MC) • CA lung • GI malignancies	• CA prostate • Ovarian cancer • Lymphoma

Note:

→ **Trousseau's syndrome** – Migratory superficial Thrombophlebitis

→ **Trousseau's sign** – Carpopedal spasm in Hypocalcemia

→ **Troisier's sign** – Palpable left supraclavicular LN (Virchow's node)

Property of Superficial Thrombophlebitis

→ Thrombus strongly adheres to vessel wall - That's why it is not associated with Thrombo-Embolism

C/F

→ Affected veins are

- Cord like on palpation
- Tender
- Erythematous skin around the vein

Treatment

→ Majority of cases resolves spontaneously

→ For inflammation - **NSAIDS**

PrepLadder

Axillary Subclavian Vein Thrombosis (ASVT)

→ It is a type of upper extremity DVT (less common than lower Extremity DVT)

→ **Upper Extremity DVT** – Thrombus of Subclavian Vein or Axillary Vein

↓

It is associated with pulmonary embolism → Up to 1/3rd of Cases

Types of ASVT

Primary ASVT	Secondary ASVT
→ It is also known as • Venous TOS (Thoracic Outlet Syndrome) • Effort thrombosis • Paget-Shroetters syndrome → No clear cause → Less common → Repetitive motion exercise leads to damage of subclavian vein between clavicular head & first rib	→ More common → Usually associated with Hypercoagulable State / Presence of Indwelling Catheter in vein → **C/F** • Pain • Swelling/Edema of Upper Extremity • Bluish discoloration → **IOC**: Duplex SCAN

Treatment

→ Anticoagulants (initially)

→ Followed by Catheter directed Thrombolytic therapy.

t.me/latestpgnotes

PrepLadder

LYMPHATIC SYSTEM

Lymphedema

Primary lymphedema	Secondary lymphedema (MC type)

→ Caused by Congenital malformation
→ Primary lymphedema is further divided into
• Congenital lymphedema
• Lymphedema Precox
• Lymphedema Tarda
	→ Caused by Lymphatic obstruction or Lymphatic disruption
	• Lymphatic obstruction
	  • MC cause – Filariasis
	  • Overall most common cause worldwide – Filariasis
	  • MC organism responsible – Wuchereria bancrofti
	  • Other organisms responsible – Brugia malayi & Brugia timori
	• Lymphatic disruption
	  • MC cause – Lymph node dissection (Axillary LN dissection & Inguinal LN dissection)
	  • MC cause of secondary lymphedema in USA – Axillary LN dissection
	  • Other causes
	  – Trauma
	  – Malignancy
	  – Radiotherapy

t.me/latestpgnotes

Congenital lymphedema

→ Seen in < 1 year of age
→ Present at birth
→ Lower limb, genitalia and face are involved
→ Usually B/L & Multiple limbs are involved
→ Familial version of congenital lymphedema – Known as MILROY'S DISEASE

Lymphedema Precox

→ M/C type of primary lymphedema (>90% of cases)
→ M/C in females (1-35 years)
→ Usually U/L
→ Involves Calf and foot
→ Familial version of Lymphedema Precox – Known as Meig's disease

PrepLadder

Lymphedema Tarda

→ Usually seen in > 35 years age group

→ Rare disease

Brunner's clinical classification of lymphedema

Grades	Clinical features
• Subclinical / latent	• Excess interstitial fluid • Histological abnormality in lymphatic and LN • No clinically apparent lymphedema
• Grade I	• Pitting edema
• Grade II	• Non-pitting edema
• Grade III	• Edema with irreversible skin changes

Complication of chronic lymphedema

→ **Limb swelling**
- Discomfort and pain

→ **Increased risk of infection**
- Bacterial infections
- Fungal infections
- Cellulitis / Lymphangitis- Skin thickening and discoloration

→ **Increased risk of malignancy**
- Lymphangiosarcoma [especially in case of breast is known as **Stewart Treves Syndrome]**

t.me/latestpgnotes

Clinical features

→ **Buffalo hump** - Present on dorsum of foot

→ **Square toes** - Toes appear square because of confinement of foot wear

→ **Stemmer's sign** - Skin over dorsum of foot cannot be pinched

Buffalo hump

Square toes

Stemmer's sign

Diagnosis of lymphedema

→ **History + Examination (investigation not required)** in case of
- Mild swelling
- No complicating features

PrepLadder

→ **Investigation required in case of**

- Atypical presentation
- Severe lymphedema with complications
- Multifactorial swellings

→ **Investigation performed is** – Lymphangiography

Management of lymphedema

→ **Mostly conservative management**

- Use of compression stockings
- Limb elevation, regular check up
- Antibiotics in infections like cellulitis
- Complex physical therapy

→ **Surgery (not commonly used)**

- Poor efficacy
- Increased risk of complications

→ **Indications of surgery** – Despite of medical therapy if patient has

- Severe functional impairment
- Recurrent lymphangitis
- Severe pain

→ **Surgical Options are**

- Reconstructive operation
- Excisional operation (associated with High morbidity)

t.me/latestpgnotes

Reconstructive operation

Lymphedema (because of lymphangitis or some other cause)

↓

Divide lymphatic & Suture it to the vein

↓

lymph is now draining through vein, it is known as lympho-venous anastomosis

Excisional operation

Collection of unhealthy tissue, fluid, fibrosis (beneath skin & muscles)

↓

Excision on the skin

↓

Removal of unhealthy tissues

PrepLadder

Named procedures in Reconstructive operation & Excisional operation

Reconstructive operation	Excisional operation
• Neibulowitz Operation → lymphovenous anastomosis • Gilles - Skin bridge is used for reconstruction • Kinmonth - Ileal mucosa is used as bridge for reconstruction	• Sistrunk procedure • Kondoleons / Homan's procedure • Charle's procedure • Thompson procedure

Lymphangioma

→ Lymphatic analogue of Hemangioma of blood vessels

→ Represents isolated and sequestered segments of lymphatic system

↓

Retains the ability to produce lymph

↓

Size of cystic tumor increases over a period of time due to ongoing secretions of lymph.

Types

→ **Capillary lymphangioma** - Subcutaneous region in head and neck and axilla

→ **Cavernous lymphangioma** - neck and axilla (cystic hygroma is a type of Cavernous lymphangioma)

t.me/latestpgnotes

Clinical features

→ Swelling present at the time of birth

→ Usually benign

→ >90% cases - detected by the end of 1 year of age

Treatment

→ Surgical excision

ANGIOSARCOMA

→ Aka lymphangiosarcoma

→ It is a complication of long-standing lymphedema (10-11 years)

→ **Stewart - Treves syndrome**

- In patients of breast cancer after 10.5 years of MRM and radiotherapy when patient is having severe lymphedema, patient might develop malignancy known as Stewart Treves syndrome

PrepLadder

Clinical features

- → Acute worsening of lymphedema
- → Severe pain over affected limb
- → Subcutaneous nodules showing Hemorrhage and Ulceration

Treatment

- → Neoadjuvant chemoradiation followed by surgical excision
- → Radical amputation because of limbs involvement
- → Prognosis is poor

t.me/latestpgnotes

PrepLadder

THORAX & MEDIASTINUM Part 1

MEDIASTINUM

→ It is the space located between lungs in the centre of thorax

→ **Mediastinum further divided into:**

- Anterior mediastinum – Space located anterior to trachea & pericardium
- Posterior mediastinum – Space located posterior to trachea & pericardium
- Middle mediastinum – Space located within pericardial cavity including trachea

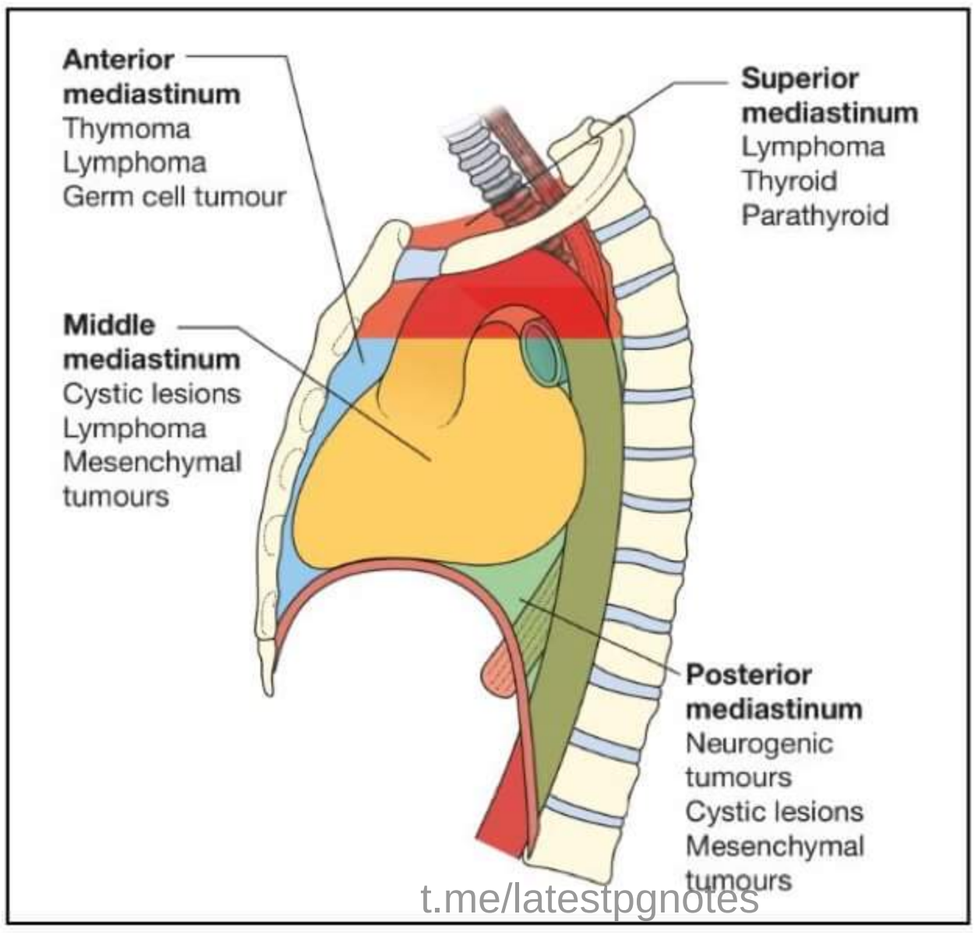

t.me/latestpgnotes

→ MC anterior mediastinal mass – Thymoma

→ MC middle mediastinal mass – Cyst (Pericardial cyst)

→ MC posterior mediastinal mass – Neurogenic tumors

→ Overall MC mediastinal mass – Neurogenic tumors

→ IOC for diagnosis of mediastinal mass – CT (Except Neurogenic tumors)

→ IOC for Neurogenic tumors – MRI

Anterior mediastinal mass	Middle mediastinal mass	Posterior mediastinal mass
• Thymoma (MC) • Lymphoma • Germ cell Tumor • Presence of thyroid & parathyroid masses • Bronchogenic cyst • Lymphoma	• Cyst (MC) – Pericardial cyst – Bronchogenic cyst – Enterogenous cyst – Neuroenteric cyst • Aneurysm • Lymphoma • Pheochromocytoma	• Neurogenic tumor (MC) • Meningocele • Mesenchymal tumors • Pheochromocytoma • Lymphoma • Bochdalek hernia • Bronchogenic cyst • Enterogenous cyst

Note:

→ Lymphoma
→ Mesenchymal tumors
→ Bronchogenic cyst

} These masses are located in all three compartments

PrepLadder

Mediastinal tumors in adults

Tumor type	Percentage	Location
• Neurogenic tumors	21 (MC)	– Posterior
• Cysts	20	– All
• Thymomas	19	– Anterior
• Lymphomas	13	– All
• Germ Cell tumors	11	– Anterior
• Mesenchymal tumors	7	– All
• Endocrine tumors	6	– Anterior / middle

Mediastinal tumors in children

Tumor type	Percentage	Location
• Neurogenic tumors	40	– Posterior
• Lymphomas	18	– All
• Cysts	18	– All
• Germ Cell tumors	11	– Anterior
• Mesenchymal tumors	9	– All
• Thymomas	Rare	– Anterior

THYMOMA

→ MC anterior Mediastinal mass

t.me/latestpgnotes

→ MC Neoplasm of thymus gland

→ 40-60 years of age

→ Thymomas are completely surrounded by fibrous capsule

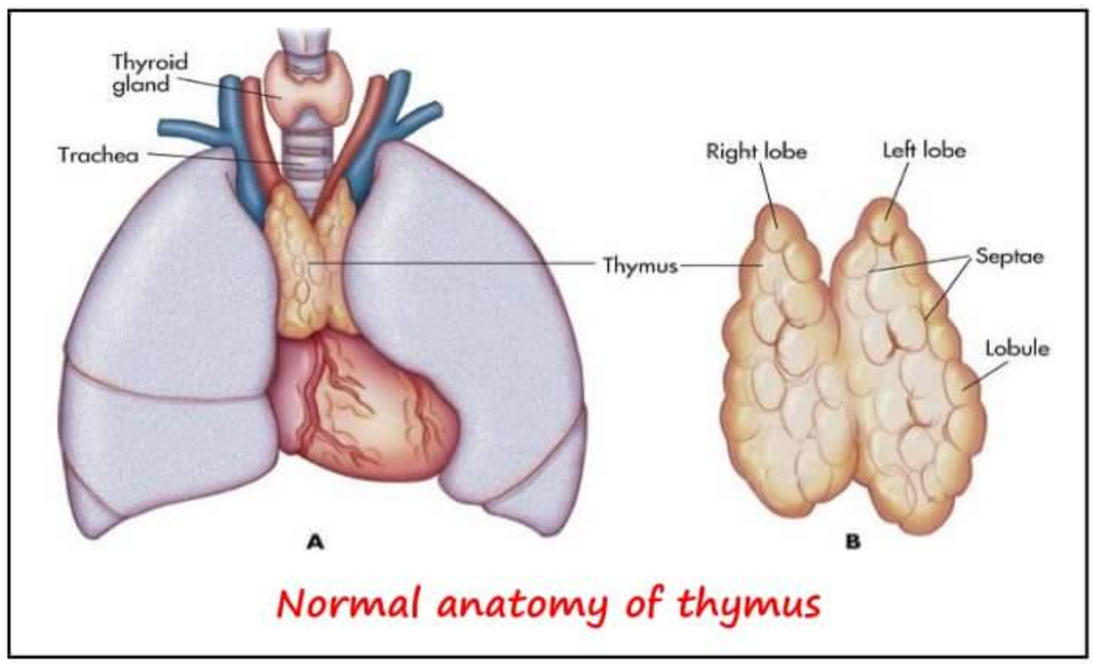

Normal anatomy of thymus

Types

1. Lymphocytic (25%)
2. Epithelial (25%)
3. Lympho-epithelial (50%) (MC)

Clinical features

→ Mostly thymomas are asymptomatic

→ Incidentally detected on CXR

→ Because of the mass

- Compression of Trachea - Dyspnea
- Compression of Esophagus - Dysphagia
- Compression of recurrent laryngeal nerve - Hoarseness of voice
- Compression of Superior vena Cava - Superior vena cava syndrome

PrepLadder

Paraneoplastic syndromes associate with Thymomas

→ **Autoimmune paraneoplastic syndrome** (Mnemonic – SLAP)

SL: SLE, Sarcoidosis

A: Arthritis (Rheumatoid)

P: Polymyositis

→ **Hematological paraneoplastic syndromes** (Mnemonic – RECH)

R: Red cell aplasia

E: Erythrocytosis

C: Cytopenias

H: Hypogammaglobulinemia

→ **Neuromuscular**

M: Myasthenia gravis

M: Myotonic dystrophy

M: Myositis

Thymoma

Investigation

→ IOC for diagnosis – CT scan

→ For Definitive diagnosis - Histology

→ Marker to distinguish Thymoma from lymphoma – Cytokeratin (Thymomas are positive for Cytokeratin)

t.me/latestpgnotes

→ Name of staging system used for Thymoma – Masaoka staging

Treatment

→ TOC for thymoma – Thymectomy (Performed through median sternotomy)

→ For Thymomas > 5 cm with evidence of invasion - Thymectomy + chemotherapy

→ For patients having Myasthenia Gravis because of Thymoma - Thymectomy + Anticholinesterase drugs

CHRONIC (FIBROSING) MEDIASTINITIS

→ Its spectrum ranges from granulomatous inflammation of LN to fibrosing mediastinitis

→ Most of the cases are because of

- Tuberculosis
- Histoplasmosis

Clinical Features:

→ Most of the cases are Asymptomatic

→ Symptoms present in fibrosing mediastinitis due to compression of mediastinal structures:

- Airways
- SVC
- RLN/Phrenic Nerve
- Pulmonary vessels

PrepLadder

IOC for DX – CT scan

Treatment

→ ATT – for Tubercular mediastinitis

→ No other medical or surgical treatment is effective for mediastinitis

DISORDERS OF PLEURA

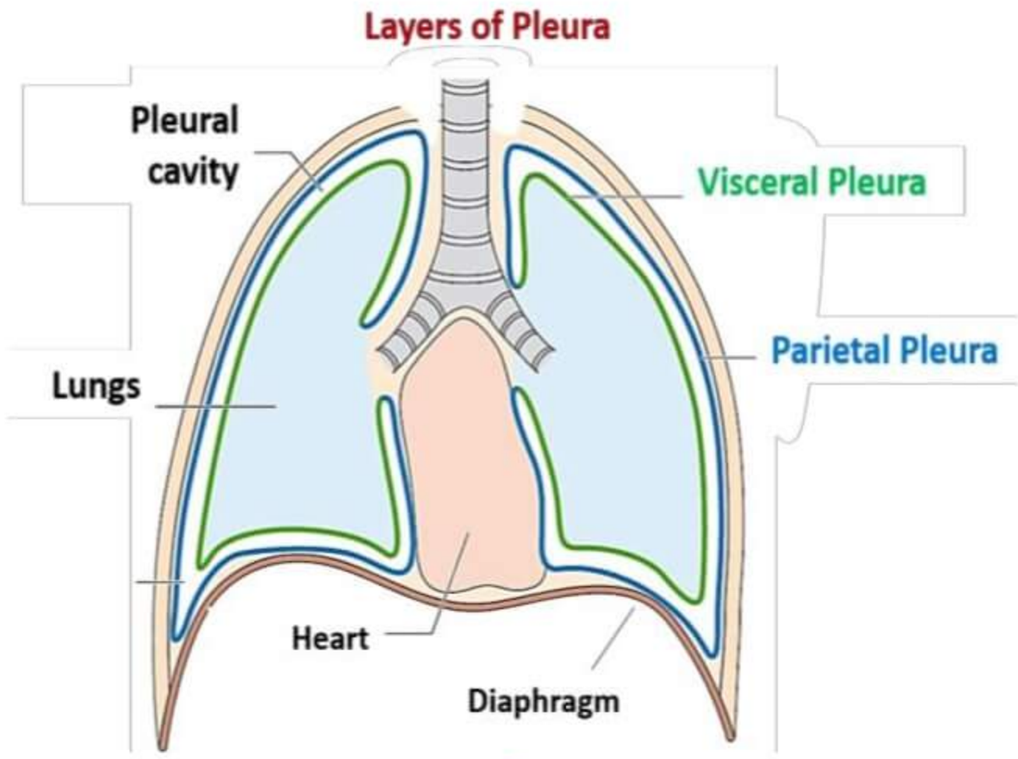

Normal

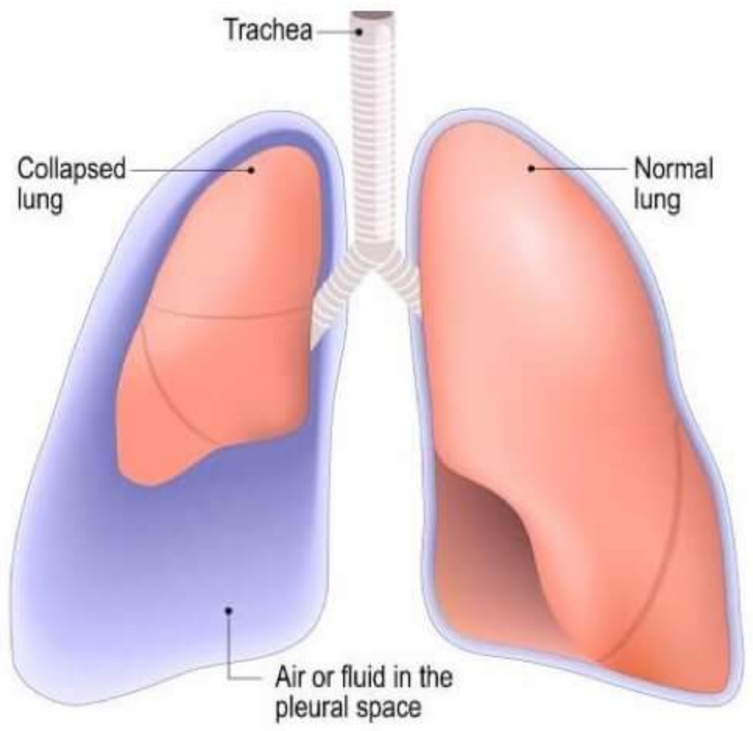

Pneumothorax vs Pleural effusion

PNEUMOTHORAX:

t.me/latestpgnotes

→ Air within pleural space – cause ipsilateral lung collapse

- Spontaneous /closed pneumothorax
- Open pneumothorax- loss of segment of chest wall
- Tension pneumothorax

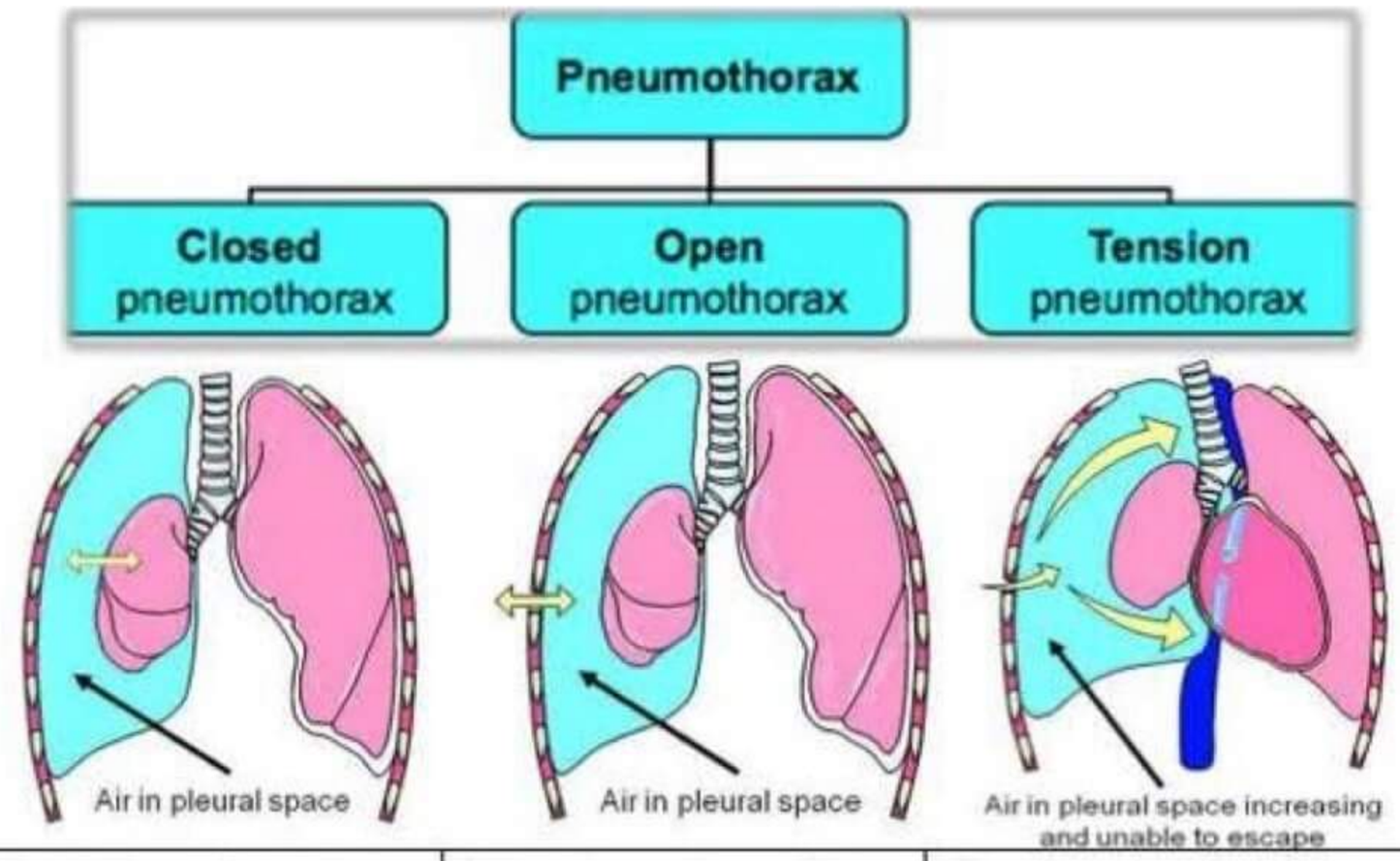

The pleural cavity pressure is < the atmospheric pressure	The pleural cavity pressure is = the atmospheric pressure	The pleural cavity pressure is > the atmospheric pressure

PrepLadder

Spontaneous Pneumothorax /Closed Pneumothorax

→ Visceral pleural ruptures without an external traumatic or iatrogenic cause
→ Pressure in pleural space < atmospheric pressure
→ It is of 2 types
- Primary spontaneous Pneumothorax
- Secondary spontaneous Pneumothorax

Primary spontaneous Pneumothorax

→ Spontaneous pneumothorax without underlying lung disease
→ Most common cause is – **Rupture of apical subpleural bleb**

Risk factors

→ Smoking
→ Family history
→ Male
→ Marfans syndrome
→ Tall Thin body habitus

C/F

→ Sudden onset
→ Mild dyspnea

t.me/latestpgnotes

Investigation

→ Best investigation for diagnosis – **NCCT**
→ Best X-Ray film for diagnosis – **CXR – PA view (Expiratory film)**

Treatment

→ Initial Rx – **Simple needle aspiration**
→ TOC – **ICD insertion in 5th Intercostal space in anterior axillary line.**
→ If Leak persists for > 3 days – **Thoracoscopic management**

Thoracoscopic management

→ Bleb resection with pleurodesis by Talc or pleural abrasion
→ Has 100% successful rate in preventing recurrence
→ **Indication**
- Recurrence
- Complete lung collapse in first episode

Secondary spontaneous pneumothorax

→ Spontaneous pneumothorax with underlying lung disease like
- COPD
- Asthma
- Cystic fibrosis

PrepLadder

C/F

→ Symptoms are more severe
→ Occurs more in Older patients
→ Has sharp pleuritic pain with breathlessness

Investigation

→ Best investigation for diagnosis – NCCT
→ Best X-Ray film for diagnosis - CXR - PA view (Expiratory film)

Treatment

→ TOC - ICD insertion

Open Pneumothorax

→ Has loss of segment of chest wall
→ Pressure in pleural space = atmospheric pressure

Pathophysiology

Loss of full thickness of chest wall
↓
Free communication b/w pleural space & atmosphere
↓
Compromised ventilation
t.me/latestpgnotes
↓
Non expansion of lung
↓
Hypoxia and hypercarbia
↓
Breathlessness

C/F

→ Signs & symptoms are proportionate to size of defect

Management

→ **Temporary management** - Cover the wound with occlusive dressing (Taped on 3 sides)
↓
Acts as Flutter valve
↓
Helps in
- Effective ventilation during inspiration
- Escape of Air during expiration

→ **Definitive management** - Closure of the Chest wall defect + ICD insertion remote from the wound

PrepLadder

HEMOTHORAX:

→ Blood accumulates in Pleural Space secondary to Trauma of chest wall/ lung laceration

→ MC cause of hemothorax – **Trauma**

→ **Other causes include**

- TB
- Tumor

→ In patients of Blunt trauma, most common cause of Massive hemothorax is **Torn intercostal vessels (due to Rib #)**

C/F

→ Hemorrhagic shock

→ Flat neck veins

→ Unilateral absence of breath sounds

→ Dullness on percussion

Investigations

→ Diagnosis is made by - **Needle aspiration of pleural fluid**

→ CXR can be performed - To assess the presence and extent of pleural cavity collections

Treatment

→ TOC – **ICD insertion + Tube Thoracostomy**

t.me/latestpgnotes

Indications of Thoracostomy

1) Initial Tube Thoracostomy Drainage of **> 1000 ml (in Penetrating trauma) or > 1500 ml (in Blunt trauma)**
2) Ongoing Tube thoracic drainage (TTD) of **> 200 ml/hr. x 3 hrs. (in non-coagulopathic patients)**
3) Caked hemothorax (despite of placement of two chest tubes)
4) Esophageal perforation
5) Tracheobronchial Injuries
6) Torn descending thoracic aorta/Great vessels injury
7) Cardiac Herniation
8) Pericardial tamponade
9) Massive air leak
10) Open Pneumothorax

PrepLadder

THORACIC DUCT

Normal anatomy of thoracic duct

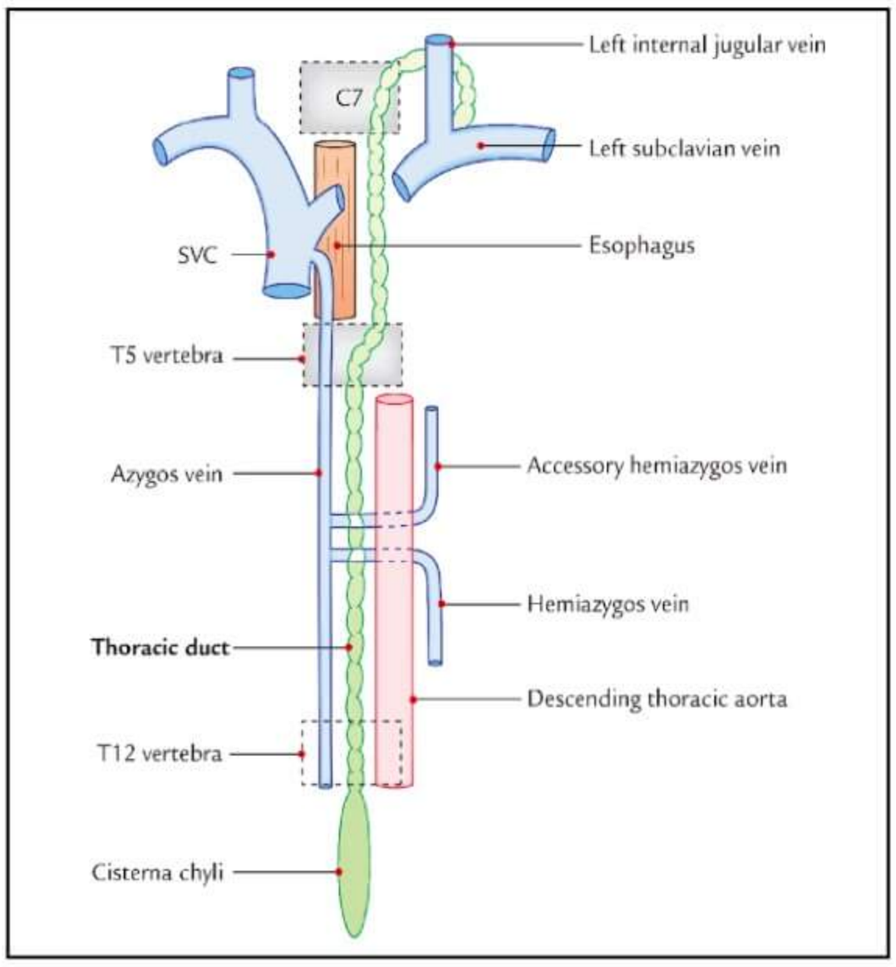

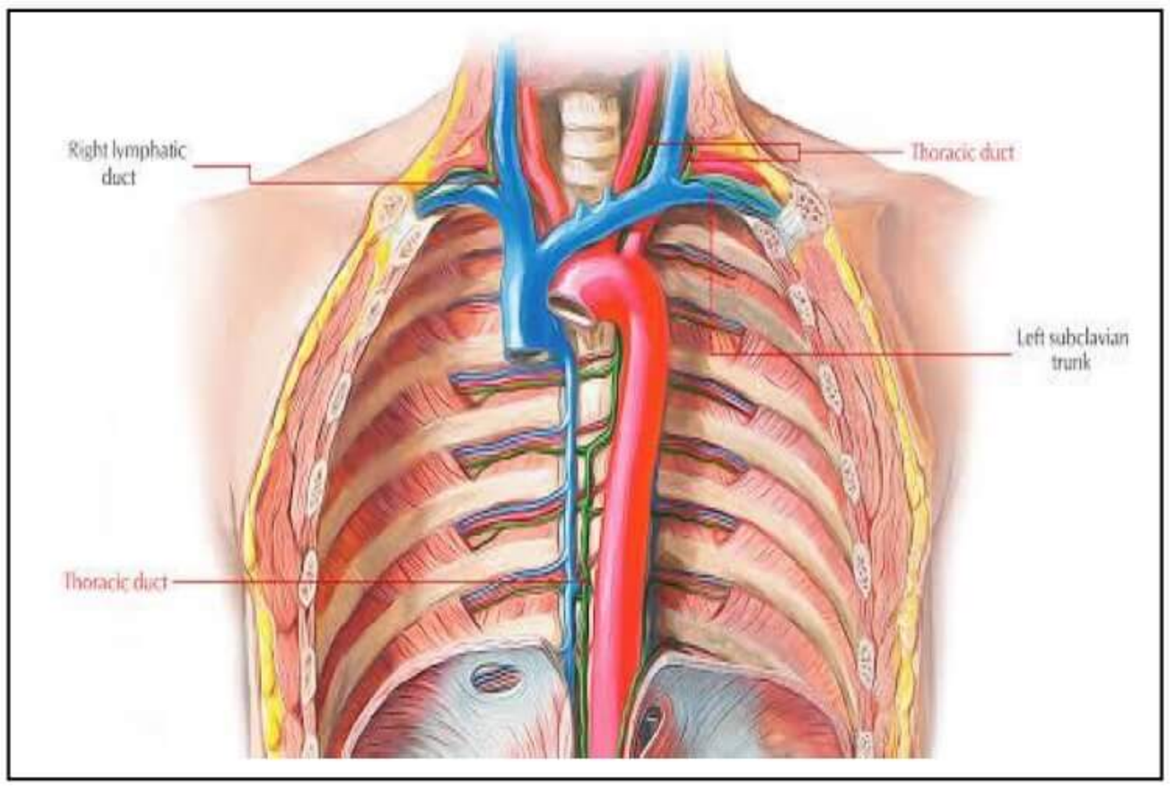

→ Thoracic duct drains into left Subclavian vein

→ By left posterolateral thoracotomy, Thoracic duct can be identified in a triangle known as **Poirier's triangle**

→ **Boundaries of Poirier's Triangle**

- Inferiorly/Base - Arch of aorta
- Posteriorly - Vertebral column
- Anteriorly - Subclavian Artery

→ Thorcic duct traverses through this triange on esophagus which forms the floor

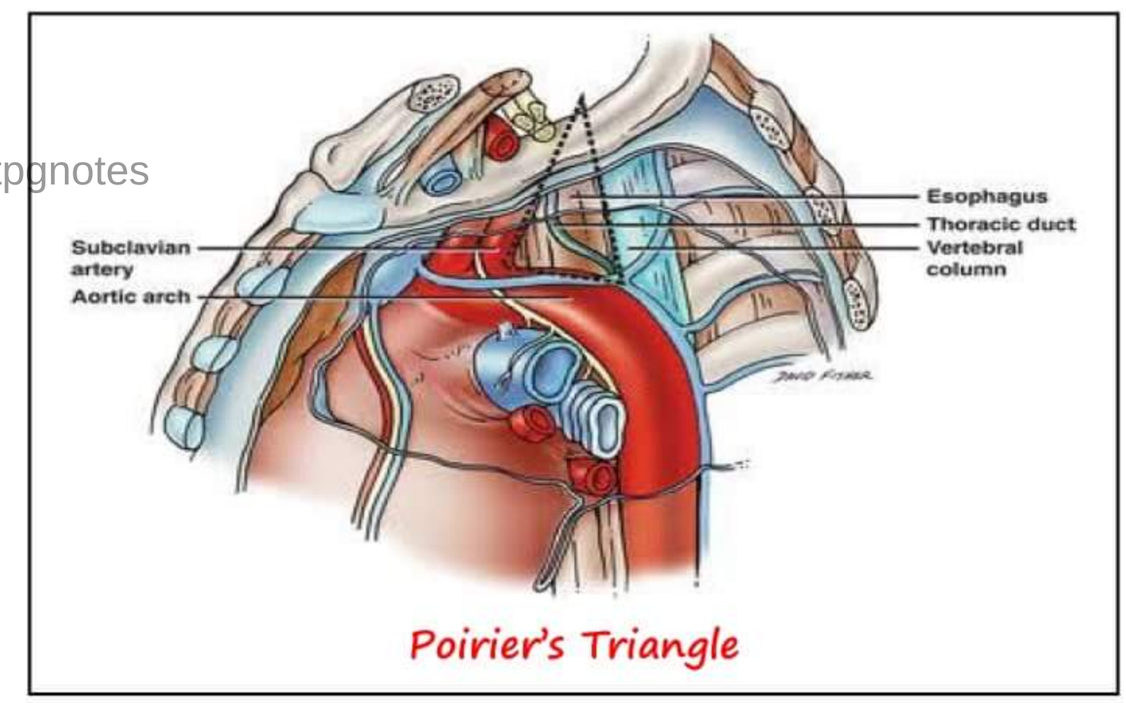

Poirier's Triangle

t.me/latestpgnotes

Thoracic duct injury

→ MC Cause - **Iatrogenic trauma** (Thoracic Surgery & Lymph node dissection in Poirier's Triangle)

→ Other cause - Blunt / penetrating trauma

C/F

→ Chylothorax

→ Chylous fluid from drainage site – **loss of Chyle leads to dehydration**

→ Composition of Chyle and effect of its loss due to duct injury

Composition	Effect of its loss
• fat & cholesterol	→ loss of fat/ fat soluble vitamins
• Proteins	→ Hypoproteinemia
• Sugar	
• Electrolytes	→ Dyselectrolytemia
• Lymphocytes	→ lymphopenia

PrepLadder

Management

→ *Conservative Management* – has Higher rate of spontaneous closure in Iatrogenic trauma

- *Low fat diet medium chain triglyceride*
- Total parenteral nutrition
- Correction of Dyselectrolytemia
- To decrease the output & to facilitate the closure 2 drugs are given
  - Octreotide
  - **Etilefrine**
    - It is an Adrenergic agent
    - Causes Smooth muscle contraction of Thoracic duct

→ Surgical TOC – *VATS (Video Assisted Thoracoscopic) Guided Thoracic duct ligation*

→ **Indications of surgery:**

1) After 5 days of conservative management - If chyle loss exceeds > 1500 ml
2) Leak persist after 2 weeks

CHYLURIA

→ Chyle in urine i.e. communication/fistula between lymphatic duct and urinary tract

→ MC cause of Chyluria – *Filariasis*

→ Other causes include

- Ascariasis
- Tumor
- Pregnancy
- Malaria
- TB
- Child birth

t.me/latestpgnotes

C/F

→ Painless passage of **milky white urine** after a fatty meal

→ If the Chyle clots in urinary tract – causes *Renal colic*

→ Loss of proteins - causes *hypoproteinemia*

Diagnosis

→ *IVU ± lymphangiography*

Management

→ Low fat & high protein diet

→ ↑ Fluid intake – to prevent clot colic

→ Laparotomy & ligation of distal lymphatics

PrepLadder

THORAX & MEDIASTINUM PART - 2

LUNG ABSCESS

→ Microbial infection of lung – causing Necrosis of pulmonary parenchyma
→ M/C cause of primary lung abscess (PLA) – **Anaerobes**
→ Etiology of Anaerobic Lung Abscess (ALA) - **Aspiration**
→ M/C site in PLA are - **Dependent segments of lung (Right >Left)**

↓

- Posterior segment of upper lobe
- Superior segment of lower lobe

Routes of infection

1) MC Route - **Aspiration of organism → Colonizing oropharynx**
2) Inhalation of infection or Aerosols
3) Hematogenous dissemination
4) Direct inoculation
5) Contiguous spread

Clinical feature

→ Cough with putrid smelling sputum production
→ Fever & fatigue

t.me/latestpgnotes

Investigation of choice for Dx

→ CT scan

Treatment

→ Depends on etiology
  - Anaerobes - **CLINDAMYCIN**
  - Staph aureus - **VANCOMYCIN**

Indications for surgery

→ Failure to respond to medical management
→ Suspected neoplasm
→ Hemorrhage

Causes of failure of Medical Management

1) Failure to drain pleural collections
2) Inappropriate anti-microbial therapy
3) Obstructed bronchus
4) Giant abscess
5) Refractory pathogen
6) Refraction lesions

PrepLadder

PLEURAL EFFUSION

→ Excess fluid in pleural space

→ **Types**

- Exudative Pleural Effusion
- Transudative Pleural Effusion

→ **Light's criteria** – to differentiate Exudate from Transudate

1. Pleural Fluid (PF) protein to serum protein: > 0.5
2. PF LDH to S. LDH: > 0.6
3. PF LDH> 2/3rd of normal upper limit for serum
   - In exudative, at least 1 is positive
   - In transudative, none is positive

→ **Causes of Exudative Pleural Effusion**

1. TB
2. Pneumonia
3. Malignancy
4. Connective tissue disorders (CTD)
5. **Drugs:**
   - D: Dantrolene, Dasatinib
   - N: Nitrofurantoin
   - B: Bromocriptine
   - M: Methyseride
   - A: Amiodarone
   - P: Procarbazine

t.me/latestpgnotes

→ **Causes of Transudative Pleural Effusion**

1. CHF
2. Cirrhosis
3. Nephrotic syndrome
4. Peritoneal dialysis
5. SVC Obstruction
6. Myxedema
7. Urinothorax

Investigation

→ IOC for detection of minimal pleural effusion – Ultrasound (1 ml fluid can be detected by USG)

→ Best X-ray view for detection of minimal pleural effusion – Lateral decubitus view (< 10 ml can be detected)

Management

→ Treatment depends on underlying cause

→ Treatment of choice in majority of cases is ICD insertion in the triangle of safety

PrepLadder

PULMONARY EMBOLISM

→ Most important risk factor - **DVT**

→ M/C site of DVT – **Calf / Soleal vein**

→ M/C site of DVT leading to pulmonary embolism - **Thigh veins / Femoropopliteal vein**

Risk factors

1. Obesity
2. Prolonged immobilization (>4 days)
3. Pregnancy and puerperium
4. Hight dose estrogen therapy
5. Surgery (involving pelvis, hip, lower limb)
6. Inherited hypercoagulable states
7. Acquired hypercoagulable states

Inherited hypercoagulable states	Acquired hypercoagulable states
• Factor V Leiden mutation • Protein C Deficiency • Protein S Deficiency • Anti-thrombin III deficiency	• Lupus anticoagulant • Malignancy • Recent MI • Myeloproliferative Disorders • Nephritic syndrome • PNH

t.me/latestpgnotes

Pathophysiology

When Embolus obstructs pulmonary artery

↓

Normal ventilation **but** No perfusion/↓ sed perfusion

↓

Ventilation perfusion mismatch

↓

↑sed anatomical dead space

↓

Arterial hypoxemia

↓

↑sed alveolar arterial O_2 tension gradient

↓

Breathlessness

Clinically features

→ 60-80% cases are clinically silent

→ M/C symptom - **Dyspnea**

→ M/C sign - **Tachypnea**

→ **Other symptoms** - Chest pain, Hemoptysis & Cough

→ **Other sign** - Fever, U/L leg swelling, wheeze & Pleural friction rub

PrepLadder

→ > 60% of obstruction in pulmonary circulation causes
- Sudden death
- Cor - pulmonale
- Cardiovascular collapse

Modified Well's criteria

→ Used for predicting Pulmonary embolism
- D- DIMER
  - Excellent screening test
  - Has high negative predictive value

Investigations

→ Investigation of choice/ Best investigation - Multi detector CT (MDCT)
→ Gold standard - Pulmonary Angiography
→ **ECG findings in Pulmonary embolism**
- M/C finding - Sinus tachycardia (non- specific)
- Most specific - $S_1Q_3T_3$ (<12% patients)

Treatment

→ For most of the pts. - Anticoagulant + Observation
→ For pts. With Severe right heart strain & shortness of breath
- Fibrinolytic treatment (or)
- Radiological guided catheter embolectomy

t.me/latestpgnotes

→ **Prophylaxis for Pulmonary embolism**
- IVC filters – for High risk patient with contraindication to anticoagulants

Tracheo-Bronchial foreign body

→ Aspiration of foreign body
- M/C in toddlers
- M/C aspirated foreign body is peanuts

→ MC anatomical location
- Right main stem bronchus or right lower lobe

Clinical features

→ Choking and coughing
→ Tracheal foreign body leads to - Total respiratory obstruction
→ U/L wheeze on auscultation

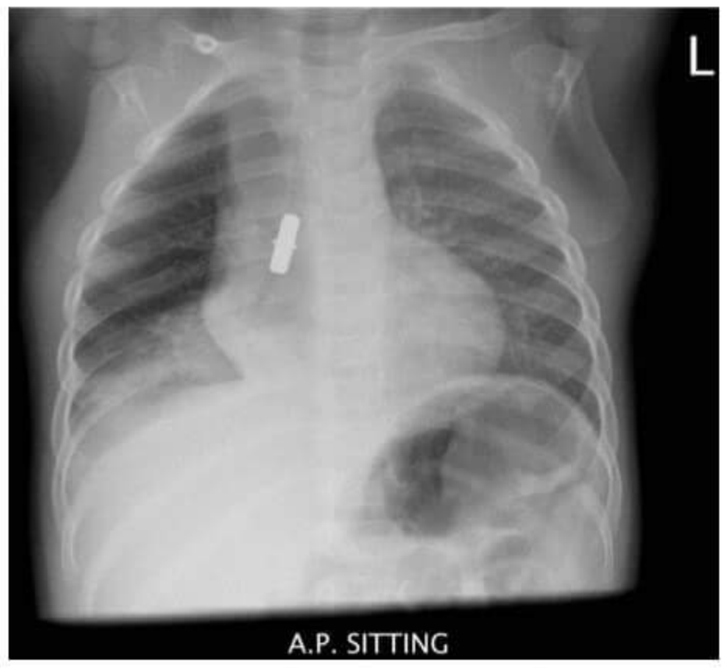

Foreign body in Trachea

Diagnosis

→ **On CXR** - Radio opaque foreign body
→ **Rigid Bronchoscopy** - Confirms the diagnosis & also removes the foreign body

PrepLadder

Complications of Tracheobronchial foreign body

→ Solid foreign body – Causes Air trapping

→ Delay in diagnosis leads to

- Atelectasis
- Infection

Pulmonary hamartoma

→ MC benign tumor of lungs

→ MC manifested as Overgrowth of cartilage

→ MC in Males

→ Age group of 40-60 years

Clinical features

→ Usually Peripheral

→ Grows slowly

Diagnosis

→ On CXR – Popcorn calcification (diagnostic)

→ On CT - Coin like lesion

Treatment

→ Excision (definitive treatment)

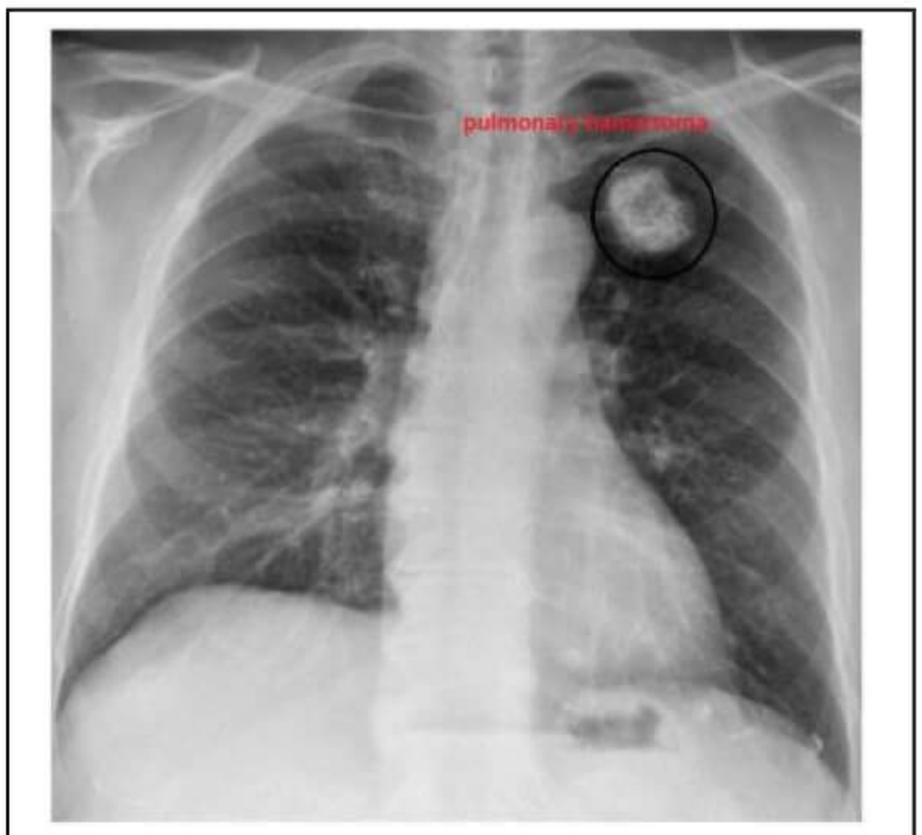

Popcorn calcification

t.me/latestpgnotes

Bronchial adenoma

→ Adenoma is a misnomer as the term **Bronchial adenoma** include all neoplasm of TBT (Tracheobronchial tree)

- Carcinoid tumors (80%-MC)
- Adenocystic tumors (10-15%)
- Muco-epidermoid tumors

→ Most of the tumors are in main bronchi (Endobronchial growth)

→ Mean age of presentation is 45 years

Clinical features of endobronchial growth

→ Recurrent Hemoptysis (m/c symptom)

→ Chronic cough

→ Intermittent Hemoptysis

→ Atelectasis

→ Pneumonia

→ Abscess formation

PrepLadder

Investigation

→ IOC for diagnosis - **Bronchoscopy + biopsy**

↓

Tumors bleed profusely while taking biopsy

Treatment

→ Surgical resection

→ After Surgical resection, 5 years survival rate is >95%

Malignant mesothelioma

→ MC tumor of pleura

→ 20% cases arise form peritoneum

→ MC in Males / 40 years of age

Risk factors

→ Asbestos exposure - **Straight amphibole fibres / Crocidolite fibre** (most dangerous type of asbestos)

→ Smoking is NOT a risk factor

Types of Malignant mesothelioma

1. Epithelioid
    - Most common type
    - Favourable prognosis
2. Sarcomatoid
3. Biphasic

t.me/latestpgnotes

Clinical features

→ Dyspnea & chest pain

→ Pleural effusion in > 90% cases

Diagnosis

→ **On chest X-ray**
    - Pleural effusion
    - Generalized pleural thickening
    - Shrunken hemithorax

→ To differentiate Malignant mesothelioma from adenocarcinoma lung
    - Thoracoscopic biopsy or open pleural biopsy with special staining
    - **Markers for MM**
        - Positive for Cytokeratin, Vimentin
        - Negative for CEA

PrepLadder

- **Markers for adenocarcinoma**
  - Negative Cytokeratin, Vimentin
  - CEA is positive
- **Pathological appearance**
  - In MM → Long sinuous villi
  - In Adenocarcinoma → Short straight villi with fuzzy glycocalyx

→ Staging for Malignant Mesothelioma - **BUTCHART STAGING**

Treatment

→ No effective treatment for MM

→ **Treatment options are**

- Supportive care
- Surgical resection
- Multi-modality treatment (Surgery + Chemotherapy + radiotherapy)

CA lung / Bronchogenic carcinoma

→ MC type of lung neoplasm

→ MC visceral malignancy worldwide

→ MC malignancy responsible for deaths

→ Arises from respiratory epithelium of

- Bronchi
- Bronchioles
- Alveoli

→ It mainly arises from **LUNG HILUM** (Except Bronchoalveolar Carcinoma & certain adenocarcinoma)

t.me/latestpgnotes

Risk factors

→ Active and passive smoking

→ Air pollution (**RADON**)

→ Exposure to Uranium, Nickel, Asbestos

→ Smoking + asbestos - Synergistic effects

→ Old infarct & lung scar - Leads to adenocarcinoma

→ Ionizing radiation exposure

Oncogenic abnormalities in CA Lung

→ **In Small cell carcinoma** – has over expression of

- Telomerase
- BCL-2
- MYC

PrepLadder

→ **In Non-small cell lung cancer** – has over Expression of
- Telomerase
- BCL-2
- RAS gene (abnormal)

→ **K-RAS mutation** - seen in 90% of adenocarcinoma

Clinical features

→ M/C symptom - **Cough > Dyspnea > chest pain > Hemoptysis** (from bronchial arteries)

→ Massive Hemoptysis – **expectoration of > 600 ml / 24 hours**

→ **Because of Endo bronchial growth**
- Cough
- Stridor
- Wheeze
- Dyspnea

→ **In Peripheral tumors**
- Pain – because of Chest & Pleural involvement

→ **Symptoms due to regional spread**
- Tracheal obstruction
- Esophageal compression
- RLN paralysis
- Pancoast syndrome – has involvement of C8 & T1 causing Pain in ipsilateral shoulder + arm
- Horner's syndrome – involvement of cervical sympathetic trunk
- SVC syndrome (compression of SVC) - MC type of lung cancer involved in SVC syndrome is Small cell carcinoma > Squamous cell carcinoma
- Malignant pleural effusion

t.me/latestpgnotes

Metastasis

→ MC site of metastasis in CA lung is brain (new updates)
- **Brain > Bone > Liver > Adrenal > lung**

→ **CA lung is most common primary for metastasis to**
- **K** – Kidney
- **E** – Esophagus
- **P** – Pancreas
- **A** – Adrenal
- **B** – Brain
- **S** – Skin

PrepLadder

Paraneoplastic syndromes associated with CA lung

→ **In CVS**
- Thrombophlebitis
- NBTE (Non-Bacterial Thrombotic Endocarditis)

→ **Metabolic Paraneoplastic syndromes**
- Inappropriate ACTH and ADH secretion (MC in small cell carcinoma)
- Hypercalcemia (MC in Squamous cell carcinoma)

→ Acanthosis nigricans (MC ass. with Adenocarcinoma)

→ Carcinoid syndrome

→ Erythrocytosis

→ **Neuromuscular paraneoplastic syndrome**
- Autonomic neuropathy } (Common in small cell carcinoma)
- Lambert eaten syndrome }
- Cerebellar degeneration

Diagnosis

→ IOC for diagnosis – **Biopsy**

↓

Bronchial / Endo-bronchial biopsy performed through fibreoptic bronchoscopy

→ Best imaging modality for diagnosis and staging – **PET-CT**

t.me/latestpgnotes

Treatment

→ **For Operable NSCLC (Non-small cell lung Ca)**
- **Stage I_A & I_B** } Surgical resection
- **Stage II_A & II_B** }
- **Stage II** – Adjuvant chemotherapy
- **Stage III_A with minimal N_2 involvement** – NACT followed by surgery with complete mediastinal LN dissection
- **Patient with N_2 Involvement** – Post OP Radiotherapy

WHO Classification of lung cancers

Adeno carcinoma lung

→ MC histological type

→ MC in young / females / non-smoker

→ Associated with slow growth

→ Propensity to metastasize to opposite lung

→ **NOGUCHI classification** is used for adenocarcinoma lung

PrepLadder

Squamous cell carcinoma lung/SCC lung

→ More common in smokers
→ MC type in India
→ MC variety associated with hypercalcemia
→ Central in distribution
→ Undergoes Central necrosis & Cavitation
→ Pancoast tumor is histologically -SCC
→ Associated with best prognosis

Small cell carcinoma lung

→ Most malignant
→ Central in distribution
→ Strongly related to smoking
→ Cells are small with little cytoplasm – so, known as **OAT CELL**
→ **Associated with**
  - Massive hilar or mediastinal lymphadenopathy
  - Mediastinal invasion
  - Peri-hilar mass
→ Most responsive to chemotherapy **(CISPLATIN + ETOPOSIDE)**
→ Shows response to radiotherapy
→ **Hormones produced by small cell CA**
  - ACTH
  - AVP (vasopressin)
  - Calcification
  - Atrial Natriuretic factor
  - Gastrin releasing peptide

t.me/latestpgnotes

Large cell carcinoma

→ Highly undifferentiated with cavitating nature
→ Metastasizes early
→ Associated with poor prognosis

Pancoast tumor

→ Aka superior sulcus tumor
→ **Pancoast syndrome** - it results from local extension of tumor growing in the apex of lung
→ Has involvement of **C_8T_{1-2} Root value (ulnar nerve)**

Clinical features

→ Insidious onset of pain – Upper arm
→ Sensory disturbances in the medial aspect of forearm and hand

PrepLadder

→ Weakness and atrophy of intrinsic muscles of hand

→ Ipsilateral Horner's syndrome

Diagnosis

→ IOC for diagnosis - **MRI**

Treatment

→ Pre-op radiotherapy followed by En-bloc resection of lung and chest wall

→ + / - Post op RT /Brachytherapy

Cardiac tumors

→ MC primary CT – **Myxoma**

→ MC malignant tumor of heart in adults – **Angiosarcoma**

→ MC benign tumor of heart in children – **Rhabdomyoma**

→ MC malignant tumor of heart in children – **Rhabdomyosarcoma**

→ MC tumor of cardiac valves – **Papillary fibroelastoma**

→ MC site of involvement in cardiac metastasis – **Pericardium**

Myxoma

→ MC primary cardiac tumor

t.me/latestpgnotes

→ Females > males

→ 3rd to 6th decade

→ Sporadic – 90%; Familial - 10% (autosomal dominant transmission)

→ Myxomas mostly are solitary

→ MC site - **left atrium** (Tumor arises from inter-atrial septum)

NAME syndrome

→ Nevi

→ Atrial myxoma

→ Myxoid neurofibroma

→ Ephelides

LAMB syndrome

→ Lentigines

→ Atrial Myxoma

→ Blue nevi

Clinical features

→ It Mimics

- Mitral stenosis
- Mitral regurgitation

PrepLadder

→ Mitral valve obstruction
→ Systemic embolization
→ Neurological deficit
→ Constitutional symptoms – Fever & weight loss

Diagnosis

→ IOC for diagnosis- **2D Transthoracic / Trans Esophageal echocardiography**

Treatment

→ Surgical excision with cardiopulmonary Bypass is curative
→ **Cause of Recurrence**
  - In Familiar cases – **Multifocal lesions**
  - In Sporadic cases – **Inadequate resection**

Pectus Excavatum

→ **Aka funnel chest**
→ MC chest wall deformity
→ Incidence is 1:400 births
→ MC in males
→ Has midline narrowing of thoracic cavity

t.me/latestpgnotes

↓

Due to Excessive growth of lower costal cartilage

↓

Leads to **Posterior sternal depression**

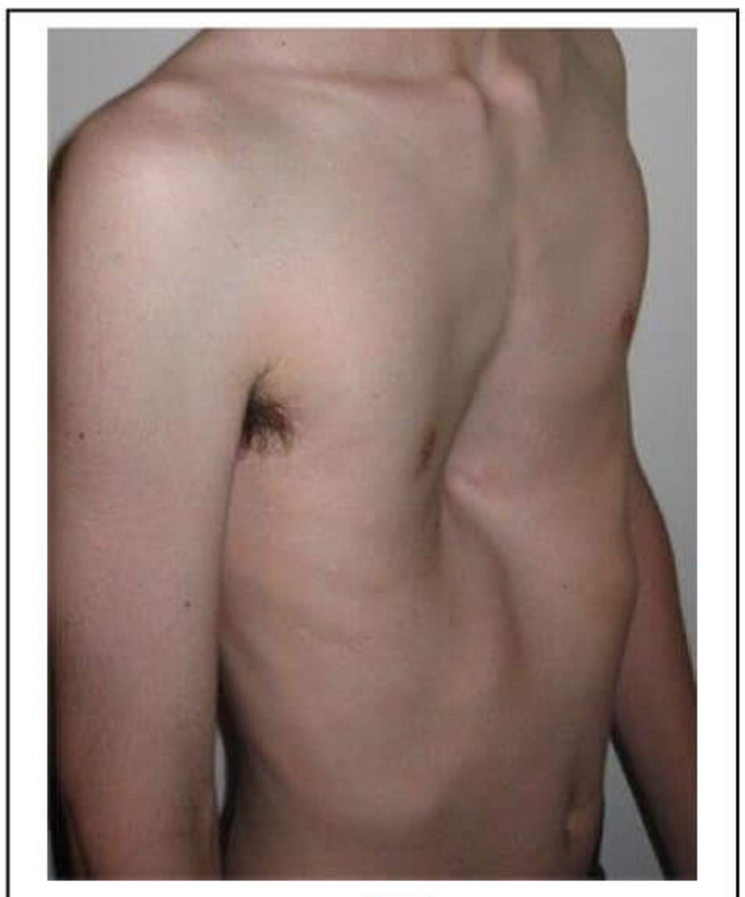

Funnel Chest

Clinical features

→ Most patients are asymptomatic
→ If symptomatic, M/C symptom is **decreased exercise tolerance**
→ In children - Psychological stress because of Cosmetic abnormality

Diagnosis

→ **Pulmonary function test** – for evaluation of base line pulmonary function
→ **2D echo** – for cardiovascular assessment
→ **Chest CT** – to calculate **Haller index**

↓

Ratio of width of chest wall to depth of sternum to vertebral body

PrepLadder

Treatment

→ Best results are expected if early surgery done (at 2-8 years)

→ **Indications of surgery:**

- Cosmesis
- Psychosocial factors
- Presence of respiratory or CVS insufficiency

→ **Surgery done**

- **Ravitch procedure** – Open procedure
- **NUSS procedure** – Minimally invasive procedure

Pectus Carinatum

→ **Aka pigeon chest**

→ Sternum is elevated above the level of ribs

→ MC type - **Anterior displacement of mid and Lower sternum with adjacent costal cartilage**

→ MC in Males

→ Associated with **Mitral valve disease + Coarctation of aorta**

Pigeon Chest

Clinical features

→ Asymptomatic

→ Only problem is Cosmetic reasons

t.me/latestpgnotes

Treatment

→ Mobilization of sternum and coastal cartilage close to its normal anatomical position

Chest wall tumor

→ MC Chest wall tumor - **Metastasis**

→ MC primary chest wall malignancy – **Chondrosarcoma**

→ MC benign primary chest wall tumor – **Osteochondroma**

PrepLadder

BURNS

Burns

Indications of Referral to dedicated burn center

1. Partial thickness burn involving > 10% of TBSA
2. Any Full thickness burns
3. Burns involving face, hands, foot, joints and genitalia
4. Electrical burn
5. Chemical burn
6. Burn with inhalational injury
7. Burn with trauma
8. Burn with comorbidity in elderly
9. Burn in children requiring special emotional care

Pathophysiology

1. ↑ **Radiant loss** – secondary to ↑ blood flow & integumentary loss
2. **Heat loss** – evaporation of water from burn wound (also cause fluid loss)
3. **Massive release of inflammatory mediators** – leads to
   - Vasodilation
   - ↑ capillary permeability – extravasation of fluid

   Edema + Third space fluid loss
   ↓
   Hypovolemia
4. Global distribution of immune function
5. ↑ release of Catecholamines, Glucagon, Corticosteroids → Hypermetabolism
   ↓
   Fever
6. **Cushing ulcers**
   - It is a stress ulcer that occurs only when 1/3rd of TBSA is burnt
   - Caused due to ↓ mucosal defenses (Acid secretion in stomach is normal)

t.me/latestpgnotes

Note:

→ In patients of head injury
- Has stress ulcers knowns as Cushing ulcers
- Occurs due to ↑ Acid secretion in stomach

PrepLadder

Areas of cutaneous injury in burn

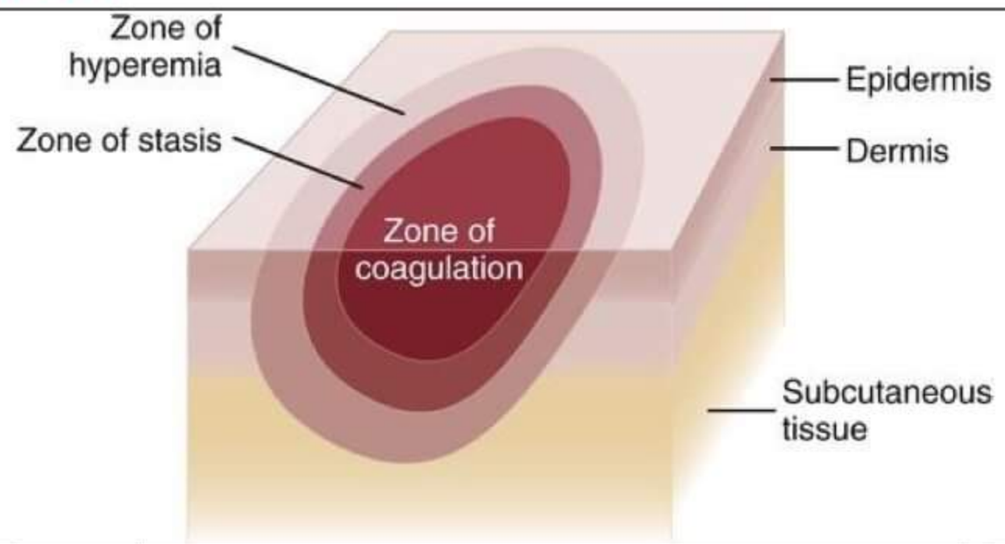

Zone of coagulation	Zone of stasis	Zone of hyperemia
• Has Coagulative necrosis • Tissue is irreversibly damaged • Disruption of cells occur	• It is area immediately surrounding the zone of coagulation • Has moderate degree of insult with ↓ tissue perfusion – Cells can survive (or) – Progress to coagulative necrosis • Has vascular damage & vessel leakage	• Vasodilation occurs • Has viable tissues – healing occurs from this zone

Note:

→ Best temperature of water used for cooling of burn wound 15° C

→ Cold water or Ice shouldn't be used as it causes vasoconstriction leading to ↓ tissue perfusion

t.me/latestpgnotes

BURN CLASSIFICATION (based on depth of burn)

First degree burns

→ Aka Epidermal burn

→ **Only epidermis** is involved

→ Painful & Erythematous

→ No blisters formation

→ Healing occurs without scarring within 5-10 days

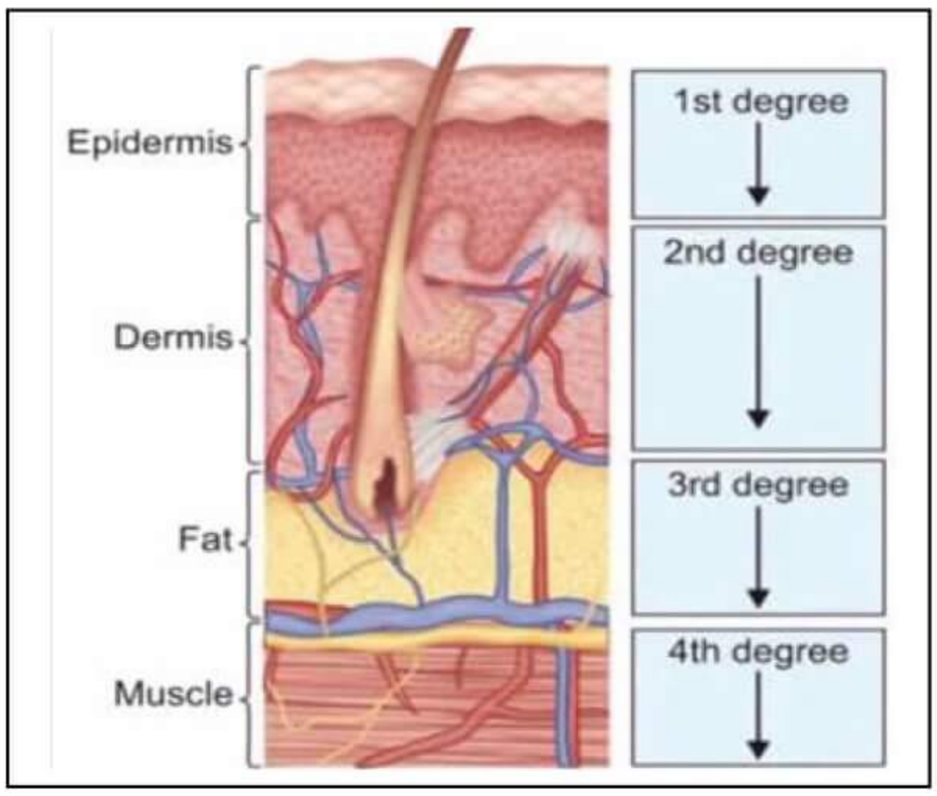

Second degree burns

→ Aka Partial thickness burn

→ It is divided into

Superficial partial thickness burn	Deep partial thickness burn
• Involvement of epidermis + Papillary dermis	• Involvement of epidermis + Reticular dermis • Burn surface area is mottled having whitish and pinkish area
• Blisters present/Painful	• No blisters / no pain
• Blanch to touch	• Pin prick sensation is preserved
• Healing occurs without scarring (within 7-14 days)	• Healing occurs with scarring (3-9 weeks)

PrepLadder

Third degree burns

→ Aka full thickness burn

→ Involvement of Epidermis + dermis + Subcutaneous fat

→ Burn Surface has **Black coloured leathery eschar** - Escharotomy is done to prevent compartment syndrome

→ **Characteristic features**

- No pain, No blister, No pin prick sensation
- Healing occurs with contracture - To prevent contracture

↓

Excision of burned skin with skin grafting

Fourth degree Burn

→ Involvement of Skin + underlying structures (Muscle, bone & brain)

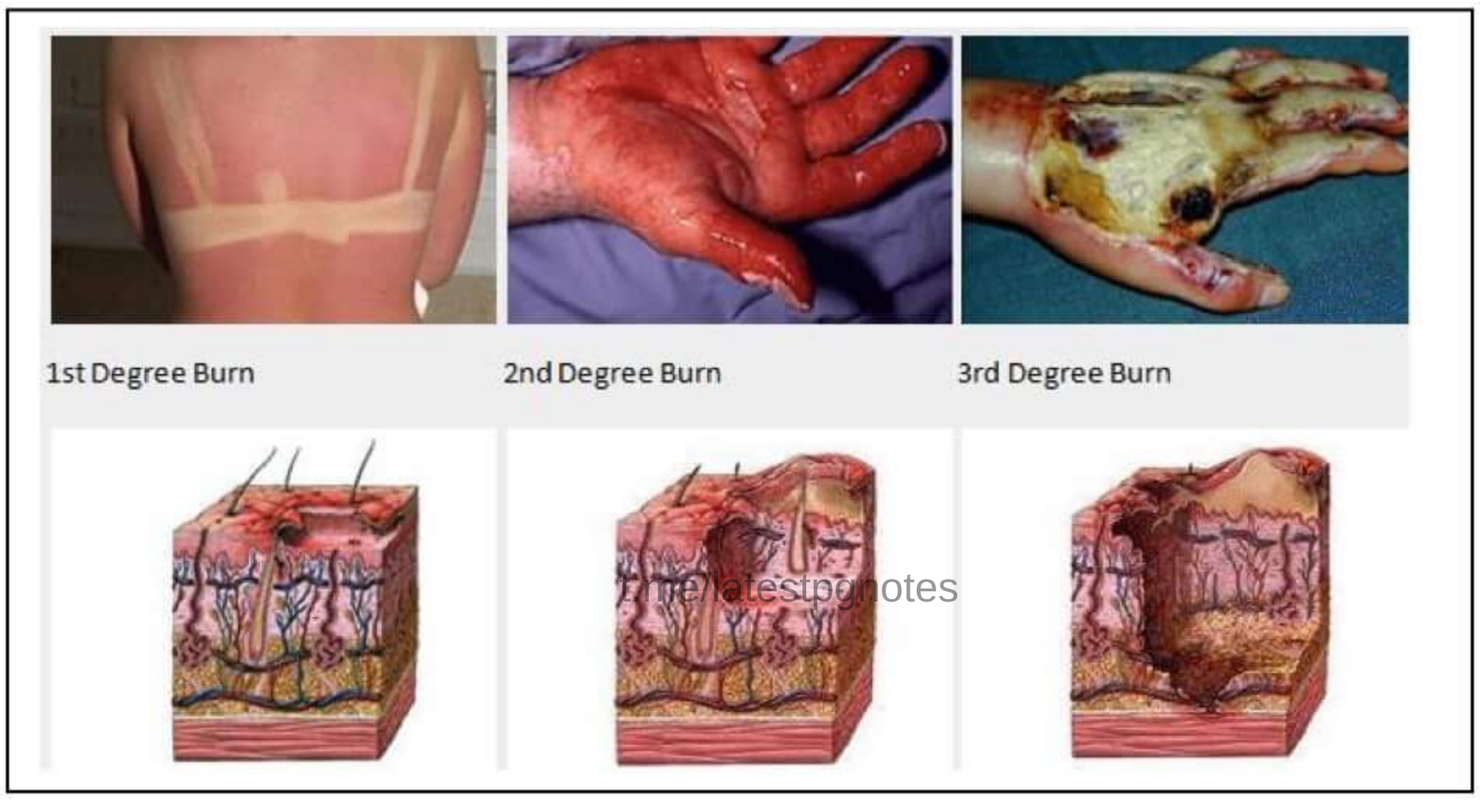

t.me/latestpgnotes

Causes of death in burns

→ MC causes of death at the site of burn - Asphyxia

→ MC causes of early death in burns - Hypovolemia /shock

→ MC cause of late death in burns - Sepsis

→ Overall MC cause of death in burns - Sepsis

→ MC organism responsible for sepsis in burns – Pseudomonas

Danger signs of Airway burns

1. Burns involving head, neck & face
2. Singed / burned nasal hair
3. Carbonaceous deposits in the sputum
4. Hoarseness of voice
5. H/o burns in a closed room

Note:

- In all this patient's Elective intubation is the safest
- **Delay in intubation** leads to Laryngeal edema → difficulty in intubation – Emergency Cricothyroidotomy should be performed

PrepLadder

Management of Burn Patients

Fluid resuscitation

→ **Venous access**

In adults

- Ideal sites – Veins of Hand, Antecubital fossa or neck
- Saphenous vein cut down
  - Performed during difficult accessibility
  - Preferred over Central line insertion
- CVP line – for CVP monitoring

↓

Helps in preventing fluid overload

→ **IV fluid Resuscitation**

- >10% TBSA in children
- >15% TBSA in adults

} Risk of Hypovolemia

↓

Requires fluid resuscitation

- Fluid of choice - **Ringers lactate**
- Maintenance fluid of choice in children - **Dextrose normal saline (DNS)**
- Other fluids used are
  - Hypertonic saline
  - Normal saline
  - Fresh frozen plasma
  - Human Albumin
- **Hypertonic saline** is used for burn shock patients

t.me/latestpgnotes

→ **Calculation for fluid requirement**

Parkland Formula

- It is **Crystalloid based**
- 24 hrs. fluid requirement = **4ml x body weight (kg) x % of burned surface area**
- Time starts when the patient gets burned
- First degree burns are not included
- Maximum fluid given should be taken for 50% TBSA - to avoid fluid overload
- Half of calculated fluid is given in first 8 hours and rest half of fluid is given in next 16 hours
- 2nd day fluid requirement should be 40- 60% of first day fluid requirement

Brooke formula

- Both **Crystalloid & Colloid based**
- Fluid requirement = **1.5 ml/kg/ %TBSA of crystalloids + 0.5 ml/kg/ %TBSA of Colloids + 2 litres of free water**

PrepLadder

Galveston

- It's a Pediatric formula
- Fluid requirement = 500 ml/m² of Total burned surface area + 1500 ml/m² of Total body surface area

→ **Monitoring of fluid resuscitation**

Best clinical indicator of tissue perfusion – Urine output.

- Minimum U.O. after adequate tissue perfusion in adults → 1ml / min
- Minimum U.O after adequate tissue perfusion in children → 0.5 – 1.0 ml/ min

In patients of Cardiac dysfunction monitoring is done by

- Trans-esophageal USG (or)
- Central line

Estimation of Burn surface area

→ **Determination of burn size** – estimates the extent of injury

Rule of "9"

→ Given by ALFRED RUSSEL WALLACE

→ Rule of 9 is followed for adults but is not very accurate for children

t.me/latestpgnotes

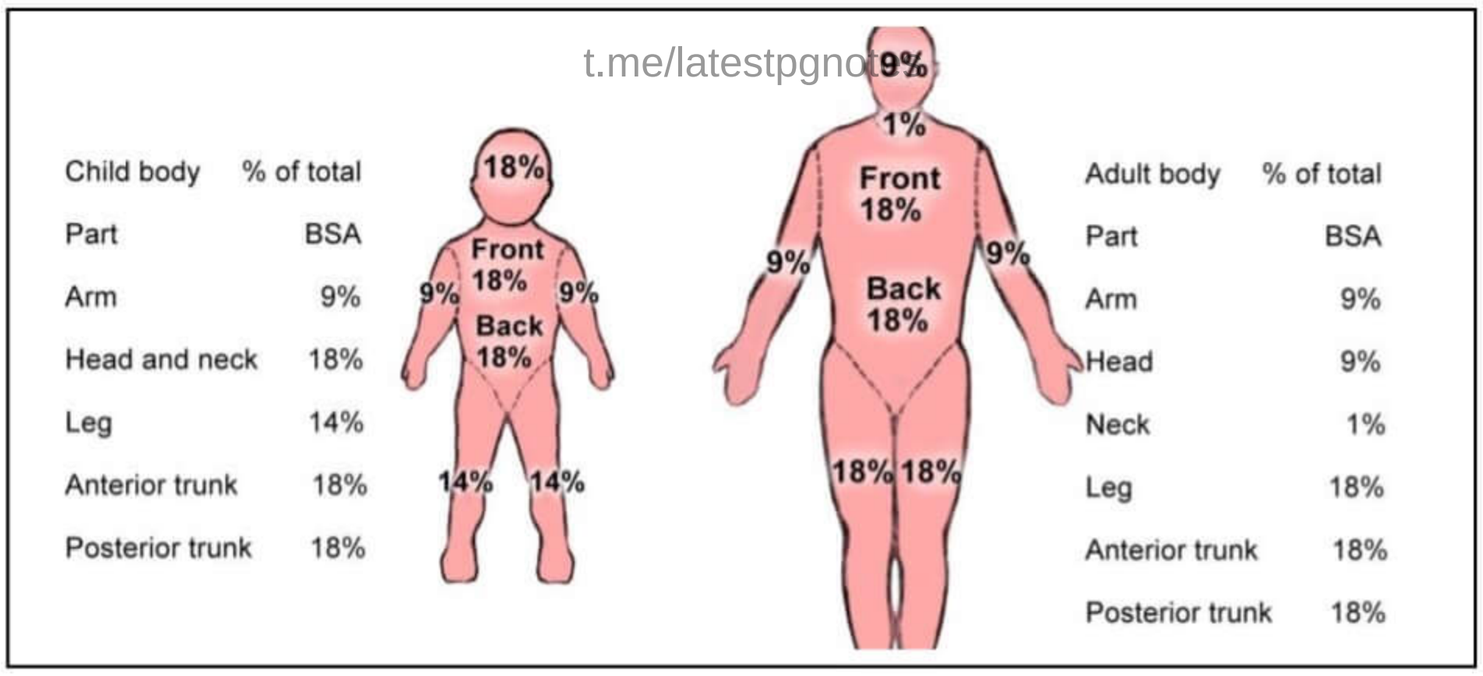

Lund & Broder chart

→ More accurate for estimation of burn surface area in Children

Berkow's formula

→ Also used for estimation of burn surface area in Children

Palmar method

→ For estimation of smaller burns – **Area of Open hand**

↓

accounts for 1%



- Used for
  1. Splash burns
  2. Mixed distribution of burns

PrepLadder

Care of Burns patient

1. Cool the burn wounds
   - → **Uses**
     - Provides analgesia
     - Slows the delayed microvascular damage
   - → Cooling should occur for a minimum of 10 mins
   - → Cooling is effective upto 1 hr. after burns
   - → Best temperature of water used for cooling of burn wound 15° C
   - → Tap water can also be used
   - → Cold water or Ice shouldn't be used because it increases the risk of
     - Hypothermia
     - Cutaneous vasoconstriction – Extend the thermal damage

2. Superficial partial thickness burns
   - → Heals without scarring within 2 weeks
   - → **Exposure method** can be used – given Antimicrobial without dressing

3. Escharotomy
   - → Performed for constricting eschar
   - → Layers incised are
     - Skin
     - Superficial fascia
     - Deep fascia

t.me/latestpgnotes

Management of burn wounds

1. Exposure method
   - → No dressing is done
   - → Antimicrobials given 2-3 times/day
   - → Used for burns in Face & Head
   - → **Disadvantages**
     - ↑sed Pain & heat loss
     - ↑sed risk of cross – contamination

2. Closed method
   - → Occlusive dressing is applied over Antimicrobial agent
   - → Changed twice daily
   - → **Advantages**
     - ↓sed Pain & heat loss
     - ↓sed risk of cross – contamination
   - → **Disadvantages**
     - ↑sed risk of Bacterial growth – if dressing is not changed twice daily

PrepLadder

3. Topical antimicrobials

→ **Silver sulphadiazine (1%)**

- Provides Broad spectrum anti-microbial prophylaxis – mainly against Pseudomonas & MRSA

→ **Silver nitrate (0.5%)**

- Highly effective against Pseudomonas colonization
- Causes "Black staining" of furniture around patients

→ **Mafenide acetate (5%)**

- Used in USA
- Painful to apply
- Usage is associated with Metabolic acidosis

→ **Silver sulphadiazine & Cerium nitrate**

- Used for full thickness burns
- Induces hard effect on burned skin
- Mainly used in elderly – ↓ses cell-mediated immuno suppression (CMI)

↓

Cerium nitrate

- Forms sterile eschar
- Boost CMI

t.me/latestpgnotes

4. Dressing materials

→ **Alginate**

- Absorptive, but non-adherent
- Used in high drainage wounds

→ **Foam**

- Can absorb moderate or heavy exudate
- Used for high-drainage wounds
- Contraindicated in non-draining wounds

→ **Hydrocolloid**

- Facilitate Autolytic debridement – used for Bedsores & stasis ulcers
- Not used in high drainage wounds

→ **Hydrogel**

- Rehydrates the wound bed
- Facilitate Autolytic debridement
- May macerate the wound by over-rehydration

PrepLadder

→ **Transparent film**

- Facilitate Autolytic debridement
- Not used in high drainage wounds

Management of chemical burn

1. Copious irrigation with water or saline
   → Performed for a minimum of 20 minutes
   → **Exceptions**
   - Elemental metals – Causes exothermic reaction with water
   - Phenol – leads to deeper infiltration of tissues

2. Treatment should continue – until skin pH is normal

3. Remove the contaminated clothing's & Jewellery

4. Do not try to neutralize the chemical burn
   → Neutralization causes Exothermic reaction – leads to further injury

Electrical injury

In direct current (DC)

→ It is low tension / Electrical appliances injury
→ It doesn't have enough energy to cause extensive tissue destruction
→ Because of **↑sed resistance** – causes small deep burn at the site of entry & exit

↓

Usual sites – fingers & toes

→ Tendon & Nerve damage can occur

In alternate current (AC)

→ **Creates tetany in the muscle** – Patient can't detach from device until main power is turned off
→ **Main danger** – AC interferes with normal cardiac pacing without causing significant Myocardial damage

t.me/latestpgnotes

PrepLadder

PLASTIC SURGERY & SKIN LESIONS

Graft take → Acceptance of graft by the vascularized recipient bed

3 Phases of graft take

Plasma Imbibition	Inosculation	Revascularization
→ Graft survives upto first 48 hours → Free absorption of nutrients into the graft	→ Donor & recipient capillaries are aligned together. → Inosculation is complete by 4-5 days	→ After 5 Days there is established arterial supply of venous drainage.

Instruments used for harvesting Skin Graft

Humby's knife

Electric dermatome

→ **Advantage** - Can be used to calibrate the thickness of skin graft.

t.me/latestpgnotes

Types of Skin Grafting

→ Split thickness skin grafting / **Thiersch**

→ Full thickness (skin grafting) / **Wolfes**

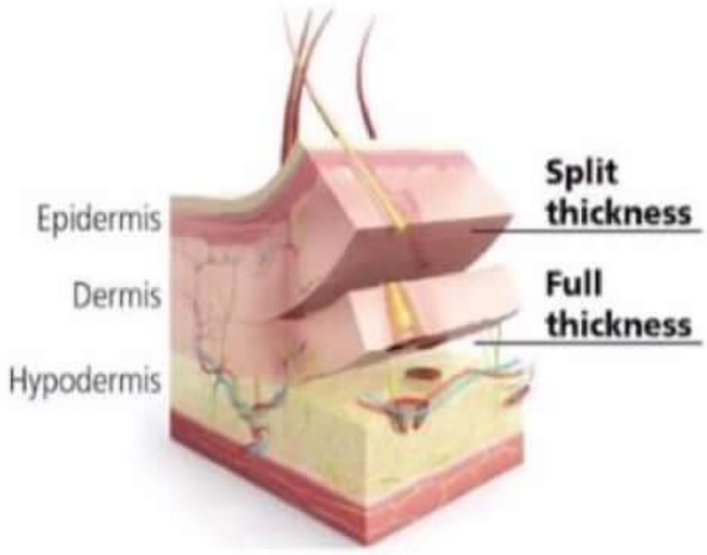

STSG (Thiersch)	FTSG (Wolfes)
→ Epidermis + part of dermis used. → Large graft can be taken → Graft survival – easy → Donor site heals spontaneously.so, repeated grafts can be taken	→ Epidermis + full thickness of dermis used. → Only small graft can be taken → Graft survival – difficult → Donor site develops permanent defect so repeated grafts cannot be taken

PrepLadder

→ Significant graft contractions ↓ Poor cosmetic appearance → **Donor sites** • MC – Inner aspect of thigh • Upper arm • Flexor aspect of forearm • Abdominal Wall	→ Lesser graft contractions ↓ Better cosmetic appearance → **Donor sites** • Upper eye lid • Retro auricular skin • Supraclavicular skin • Antecubital skin • Inframammary skin • Inguinal skin • Genital skin • Gluteal skin Axilla is not used as donor site for full thickness skin grafting.

Complications of Skin Grafting

→ Infection

→ Mechanical /Shear stress

→ Hematoma / Seroma formation

Infection	Mechanical / Shear stress	Hematoma / Seroma formation
→ **Absolute contraindication** for skin grafting- Presence of Beta haemolytic streptococci infection (Destroys STSG completely)	→ Graft immobilization is necessary → Performed by: • Bolster dressing • Light compression wraps • Vacuum assisted closure devices	→ Hematoma / seroma formation can be prevented by Pie crusting (Stab incision in graft) ↓ → Small outlets are created for the fluid to drain by which complication can be prevented.

t.me/latestpgnotes

Meshed Skin Graft

STSG

→ Meshed to expand the surface area

→ Advantage of meshed skin graft- Can resurface large area in major burns

→ Tiny splits are made in the skin graft

→ Tiny splits allow the graft to be stretched over a larger surface area.

→ The fluid egresses due to tiny splits/fenestrations and provides excellent contour matching of wound bed by graft

Meshed Skin Graft

→ Tiny splits are reepithelialised by secondary intention from underlying skin.

→ Meshing ratio → 1:1.5 to 1:6

→ **Drawbacks** - Poor cosmetic appearance due to high secondary contraction.

PrepLadder

FLAP

→ Aka Pedicled graft

→ Partially or completely isolated segment of tissues having its own blood supply.

Absolute indication for flaps

→ Exposed bone

→ Exposed brain

→ Radiated vessel (if radiotherapy given to recipient bed, it causes **obliterative end arteritis** and so recipient bed becomes relatively **hypo vascular/ avascular**). So, flap is needed.

→ Pressure sore at bony prominences

→ Open joints or non-biological implant materials.

Type of flap

Based on source of vascular supply

Random Flap	Axial Flap	Free Flap
→ Rely on low pressure found in subdermal plexus → Used to reconstruct small but full thickness defect → Not amenable to skin grafting	→ Based on named vessel → If axial flap remains attached to its proximal blood supply & transposed to a defect - known as pedicle flap.	→ **Autogenous** transplant of vascularised tissues. → There is devascularization from donor site & revascularization at recipient bed

t.me/latestpgnotes

Random Flap

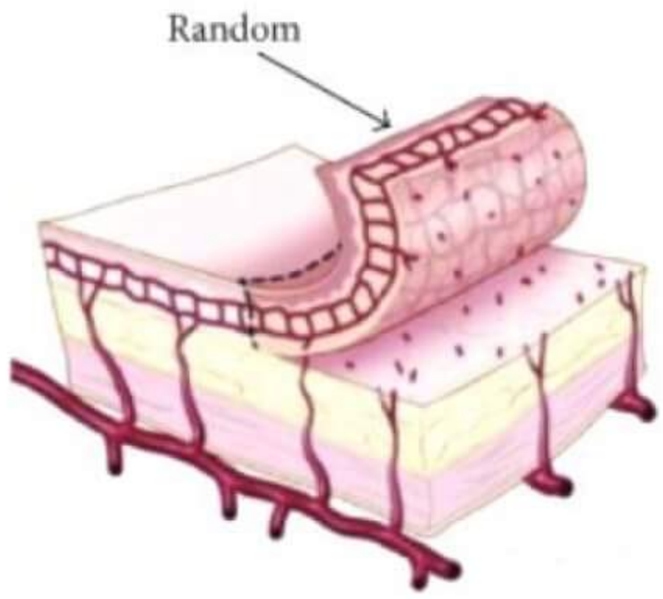

Types

VY Plasty

→ Used for fingertips & extremities

Z Plasty

→ Used for lengthening scars or tissues

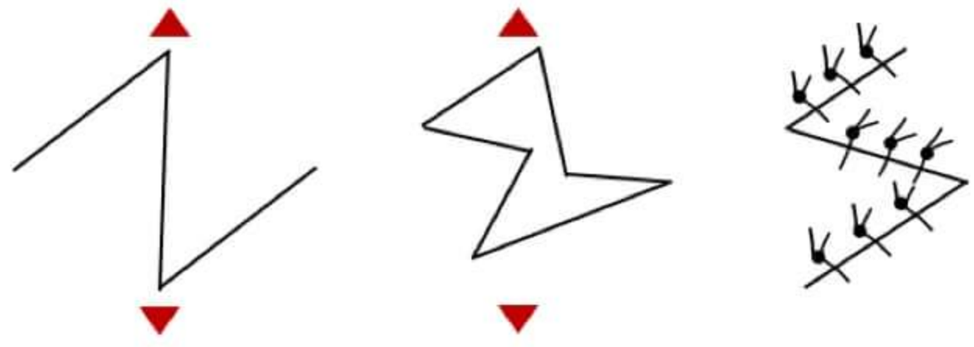

PrepLadder

Rhomboid Flap

→ Used for cheek and defects involving flat surfaces

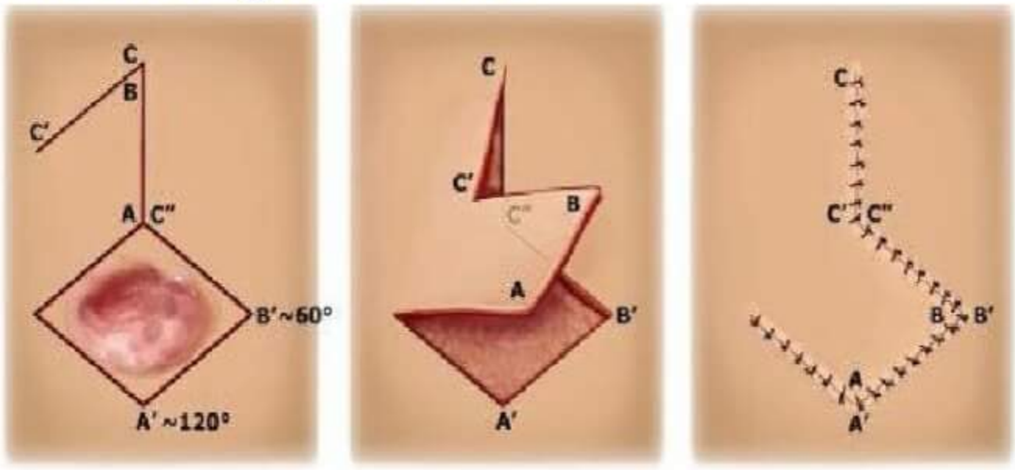

Axial Flap

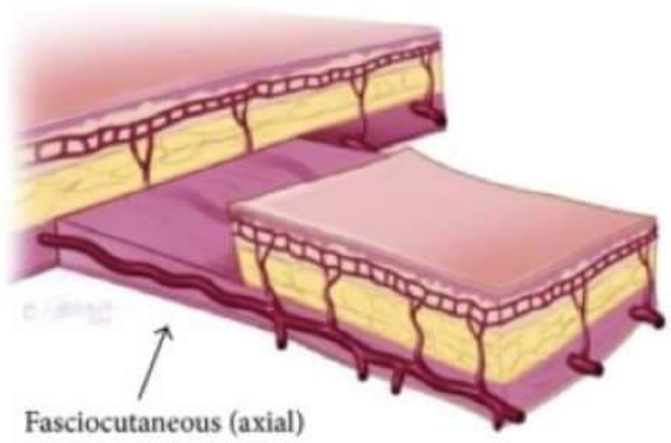

Types

L-D Flap (Latissimus Dorsi flap)

→ Based on thoracodorsal vessels

→ Used for **breast reconstruction**

→ MC used flap for breast reconstruction- **TRAM flap**

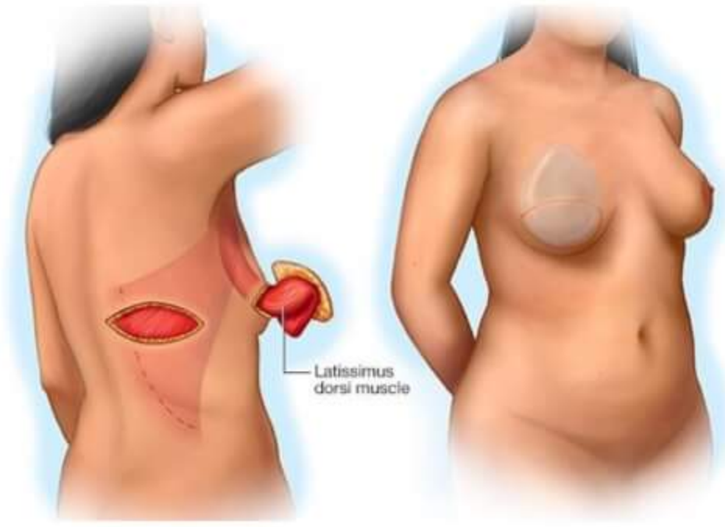

t.me/latestpgnotes

D-P Flap (Deltopectoral flap)

→ Based on perforators of Internal mammary artery

PMMC Flap (Pectoralis Major Myocutaneous Flap)

→ MC used flap for reconstruction of head and neck defects.

→ Based on pectoral branches of Thoracoacromial artery.

PrepLadder

TRAM Flap (Transverse abdominis Muscle flap)

→ Based on **Epigastric vessels** (Superior epigastric vessel/Inferior epigastric vessels)

→ Combination of both vessels - **Supercharged TRAM Flap**

→ **MC used flap for breast reconstruction**

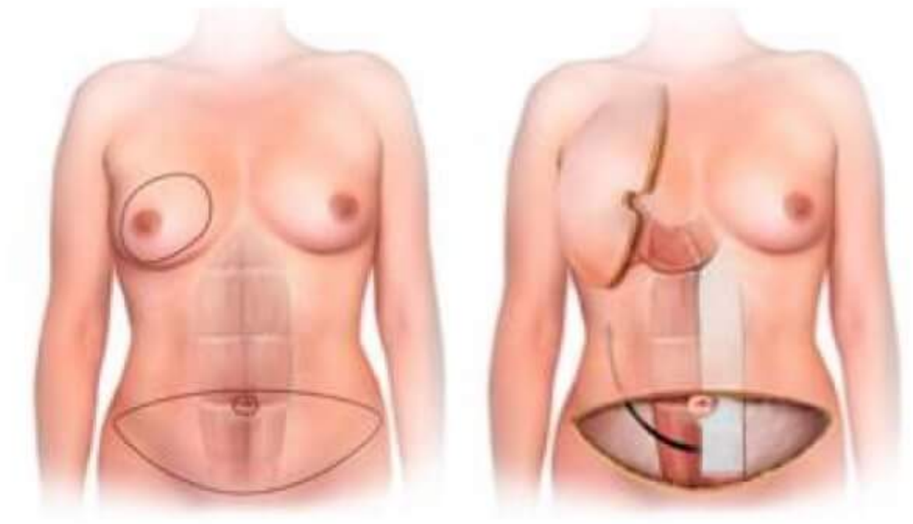

Free Flap

→ **TRAM flap** based on **inferior epigastric vessels** is usually free flap

→ **DIEP Flap (Deep inferior epigastric artery perforator flap)**

- Only Fat is taken for flap (Muscle sparing flap)
- Used for breast reconstruction
- Advantage - **No muscle weakness**

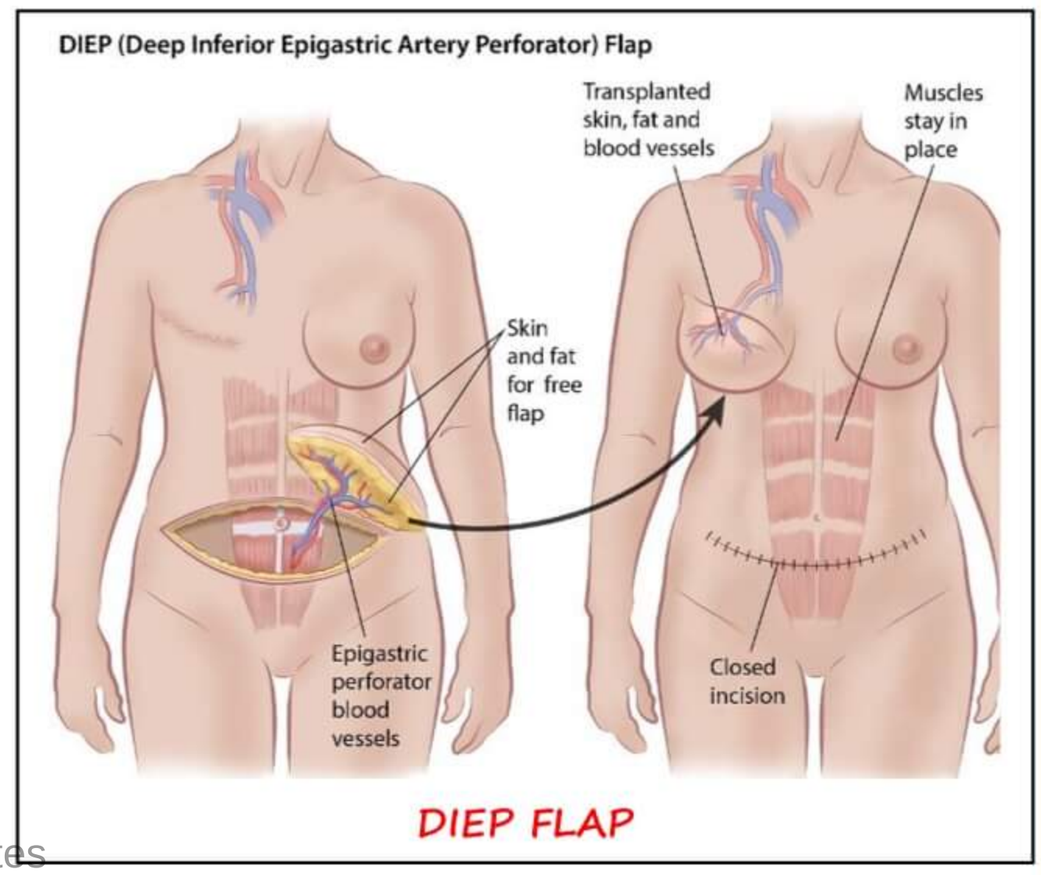

DIEP FLAP

t.me/latestpgnotes

Ulcer

→ Break in continuity of covering epithelium or mucus membrane

→ Cause of break in continuity of covering epithelium→molecular death of surface epithelium or traumatic removal

Parts of ulcer

→ **Base** - Surface on which ulcer rests (usually underlying muscles/bones)

→ **Floor** - Exposed surface of ulcer (usually seen as purulent discharge/granulation tissue)

→ **Margin** - Junction between normal epithelium & ulcer

→ **Edge** - Area between margin & floor

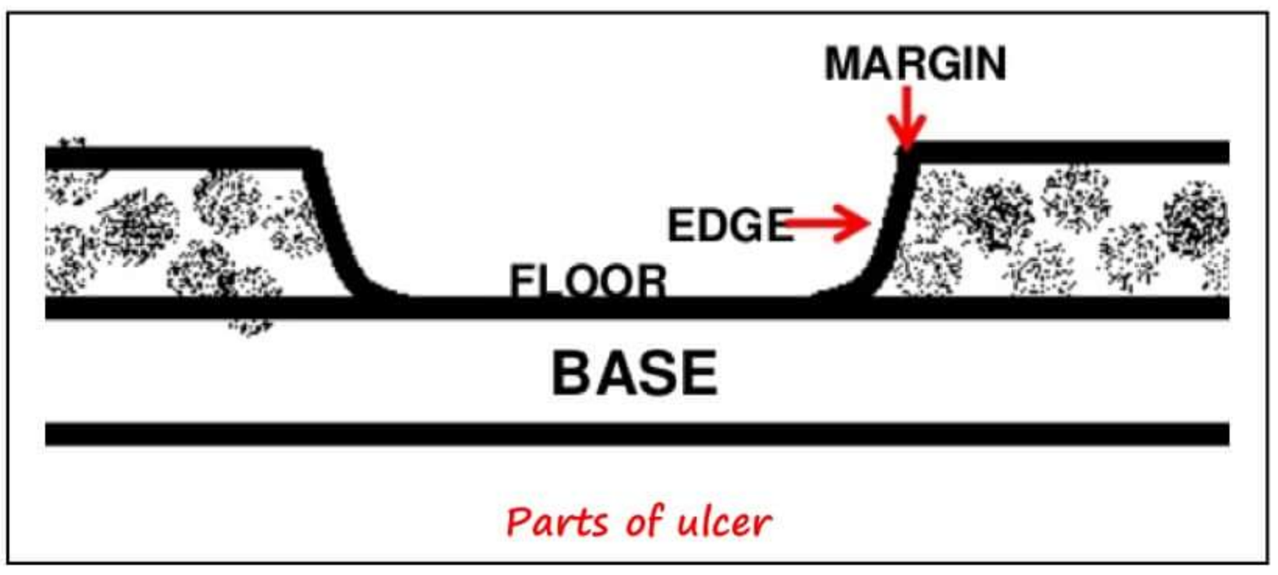

Parts of ulcer

PrepLadder

Types of ulcer margins

→ **Sloping edges** are seen in
- Healing ulcer
- Varicose ulcer

→ **Punched out edges** are seen in
- Arterial / Ischemic ulcers

→ **Undermined edges** are seen in
- Tuberculosis

→ **Rolled out/ Pearly white edges** are seen in
- Basal cell carcinoma

→ **Everted edges** are seen in
- Squamous cell carcinoma
- Classical sign of SCC - Indurated base

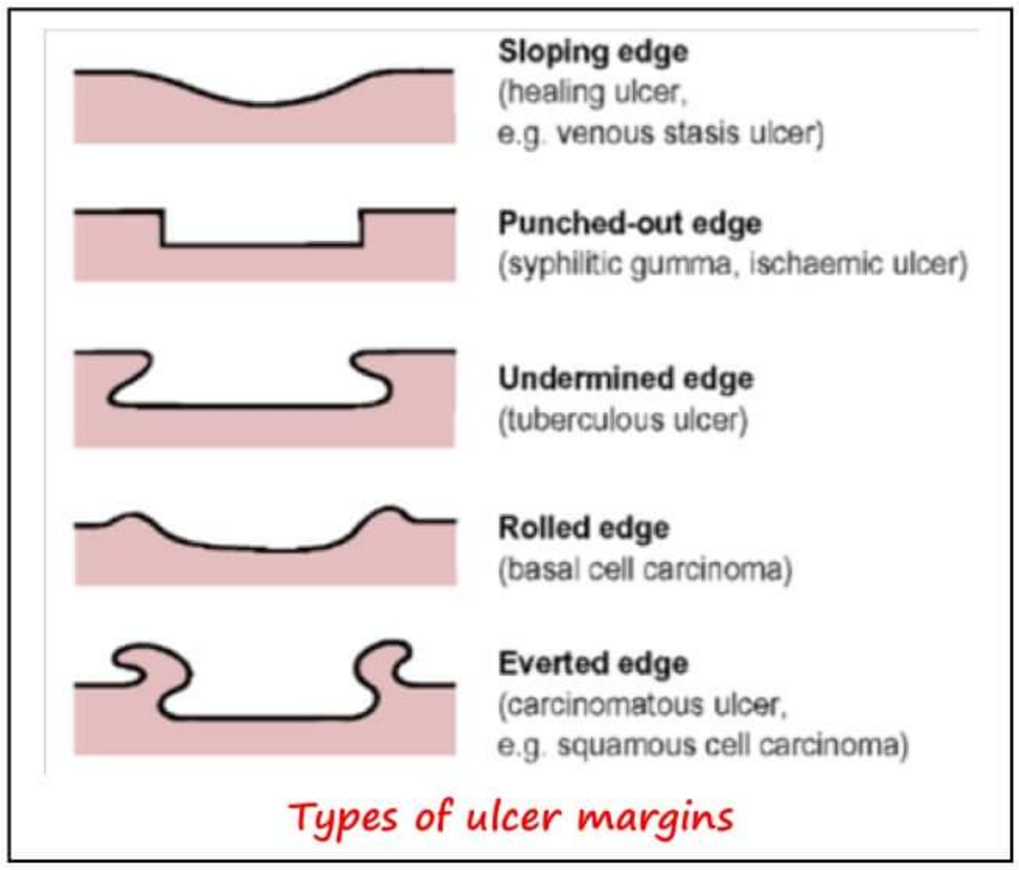

Types of ulcer margins

Marjolin's Ulcer

→ Low grade SCC

→ Arises from long standing scar tissue and from edge of ulcer

MU develops in

→ Post burn scar

→ Long standing venous ulcer

→ Chronic ulcer due to trauma

→ Chronic discharging osteomyelitis sinus

→ Post radiation ulcer

t.me/latestpgnotes

Marjolin's Ulcer

Characteristic features

→ Painless (no nerves in scar tissues)

→ Slow growing (avascular scar)

→ Radio resistant (avascular scar)

→ No regional LN metastasis (no lymphatics in scar tissue)

IOC → **Biopsy**

Management

→ **Surgery followed by flap cover**

→ **Radiotherapy should be avoided** (because this malignancy arises from scar tissues that it already avascular)

Skin Malignancies

→ MC skin malignancy – BCC > SCC > Malignant Melanoma

→ Most common skin malignancy in **darkly pigmented races** - SCC

PrepLadder

Basal cell carcinoma

→ Aka **Rodent ulcer**
- Locally invasive
- Destruction of surrounding tissues

→ Aka **Tear Cancer**
- Seen in face above the line joining **ear lobule to angle or corner of mouth**

→ Arises from Basal layer of epidermis

→ Most common site - Nose > Inner canthus

Types of BCC (based on pathology)

→ **Nodular**
- MC type
- Small, **slow growing pearly nodules**
- **Telangiectatic vessels** on the surface
- Classical sign- Central depression with umbilication

→ **Pigmented**

→ **Cystic**

→ **Superficial**

NODULAR TYPE OF BCC

Diagnosis

→ IOC for Dx - **Wedge Biopsy** (Biopsy should be taken from edges of lesion as centers are usually necrotic)

t.me/latestpgnotes

Management

→ If tumor is non-aggressive involving trunk or extremities - Wide Local Excision

→ If tumor is aggressive involving vital areas, cosmetic areas and recurrent - MOH'S micrographic surgery

Squamous cell carcinoma

→ 2nd most common type of malignancy of skin

→ MC malignancy in darkly pigmented races.

→ Arises from Cells of epidermis i.e. prickle cell layer of epidermis

→ Characteristic feature - tumor migrates outwards towards the surface

→ Most common causative factor in SCC - Sunlight

→ Most common involved areas (**parts exposed to sunlight**)
- Ears
- Cheeks
- Lower lip
- Back of hands

SQUAMOUS CELL CARCINOMA

PrepLadder

Predisposing factors

→ Senile / Actinic keratosis
→ Sunlight
→ Radiation exposure
→ HPV infection
→ Immunosuppression/ HIV
→ Arsenic exposure

Pathology

→ MC variety of SCC - Ulcerative variety
→ **On HPE** Cell nest/ epithelial pearl/ Keratin pearl

Clinical features

→ Nodule / ulcers
→ Everted edges with indurated bases

IOC

→ Wedge biopsy

Treatment

→ Small or non-invasive SCC - Wide Local excision
→ Large tumors
→ Aggressive tumors
→ Tumors involving vital areas/ cosmetic areas } MOH'S MICROGRAPHIC Surgery
→ Recurrent tumors

t.me/latestpgnotes

MOH'S MICROGRAPHIC SURGERY

→ **Serial excision** of tumor in small increments
→ Coupled with immediate microscopic analysis to ensure tumor removal
→ To limit resection of aesthetically valuable tissues

Advantages

→ All specimen margins are evaluated
→ Minimal loss of uninvolved tissues

Disadvantages

→ Long duration of surgery for adequate removal

Indications of MOH'S MICROGRAPHIC SURGERY

→ Large, aggressive tumor at vital or cosmetic areas
→ Recurrent tumors
→ For malignancies involving **eyelids, cheeks and nose**
→ If BCC involving tip of nose after excision - Bilobed flap is used for reconstruction.

PrepLadder

Malignant Melanoma

→ Caused by malignant transformation of Junctional melanocytes
→ Junctional melanocytes are located at Dermo epidermal junction.
→ Most common site of malignant melanoma
  - In males → **back & trunk**
  - In females → **lower extremity**

Malignant Melanoma

Pathology

→ **Following markers are positive for Malignant Melanoma**
  - S-100
  - HMB 45
  - Vimentin
→ **Following markers are negative for Malignant Melanoma**
  - CK-20

Risk factors

→ Xeroderma pigmentosa
→ UV radiation exposure
→ Family history of Malignant melanoma
→ Dysplastic nevus
→ Giant congenital melanocytic nevus
→ Multiple melanocytic nevi
→ History of sunburn

t.me/latestpgnotes

Types of malignant melanoma

→ **Superficial spreading**
  - MC type
  - MC site - Torso
→ **Nodular**
  - 2nd MC type
  - Most malignant
  - Only vertical growth phase
  - MC site - Head and Neck
→ **Lentigo Maligna**
  - Least malignant
  - MC site - face
→ **Acral lentiginous**
  - Least common
  - Worst prognosis
  - MC site - sole (under great toenail)

PrepLadder

Characteristic features

→ A- Asymmetry
→ B- Border irregularity
→ C- Colour variation
→ D- Change of diameter > 6mm
→ MC route of spread - lymphatic
→ MC site of metastasis - liver

Investigations

→ For small lesions - Full thickness excisional biopsy
→ For large lesions - Incisional biopsy

Treatment

→ Surgical excision with Sentinel lymph node biopsy
→ Margins to be taken depends on the tumor thickness and depth of invasion
  - < 1mm thickness → 1 cm margin
  - 1-4 mm thickness → 2cm margin
  - > 4mm thickness → 2-3 cm margin
→ Malignant Melanoma is a radio resistant tumor
  - Chemotherapy - IFN-α 2b is useful

Clark levels in Malignant melanoma

t.me/latestpgnotes

→ Based on depth of invasion
→ Types
  - TYPE I - Invasion of epidermis
  - TYPE II - Invasion of Papillary dermis
  - TYPE III - Invasion of interface of Papillary dermis & Reticular dermis
  - TYPE IV - Invasion of reticular dermis
  - TYPE V - Invasion of subcutaneous tissue

Breslow's staging

→ Preferred over Clark levels.
→ Based on actual measurement of deepest invasion from granular layer

STAGES	DEPTH OF INVASION
STAGE I	< 0.75mm
STAGE II	0.75 – 1.5mm
STAGE III	1.6 – 4.0 mm
STAGE IV	> 4.0 mm

Prognostic factors in Malignant melanoma

→ Depth of invasion
→ Ulceration
→ LN metastasis

PrepLadder

→ Satellite nodules

→ Distant metastasis

Variants of malignant melanoma

→ **Amelanotic melanoma**

- Arise from the cells which do not make melanin
- Tumor can appear pink/red/purple/normal skin colour **but not black** → leads to **delay in diagnosis and poor prognosis and high recurrence rate**
- **Characteristic features** → Asymmetrical shape, Irregular faintly pigmented border.

→ **Desmoplastic melanoma**

- Mostly seen in head & neck region
- Propensity for **perineural invasion**
- Recurs locally → Wide local excision is not performed

Vascular Anomalies of Skin

Port Wine Stain

- Present at birth
- Grows along with child and persists
- Do not regress
- Most commonly present at face in the areas supplied by CN V

t.me/latestpgnotes

Strawberry Angioma

- Type of capillary hemangioma
- Baby is normal at birth
- Appears at age 1-3 weeks
- Grows along with child by 1 year of age
- Complete involution in 90% cases by 9 years of age
- Emptying sign is positive.

Salmon Patch

- aka **Macular stain**
- aka **Stork Bite**
- Present at birth
- Site- Forehead till occiput
- Disappears by 1 year of age

PrepLadder

Cock's peculiar tumor • Infected sebaceous cyst of scalp	
Pott's puffy tumor • Osteomyelitis of skull bones • MC skull bone involved →frontal bone	
Pilomatrixoma • Aka Calcifying epithelioma of malherb • Benign hair follicle derived tumor	
Cylindroma • Aka Turban tumor (due to histological appearance) • Piling of tissues one over the other.	

t.me/latestpgnotes

PrepLadder

WOUND HEALING, TISSUE REPAIR & SCAR

Wound healing

→ Mechanism by which body attempts to restore the integrity of injured part

Phases of wound healing

1) **Inflammatory phase**
   - → Begins immediately after wounding
   - → Lasts for 2-3 days
   - → **Bleeding**

     ↓

     Vasoconstriction & Thrombus formation to limit blood loss

     ↓

     Platelets stick to damaged endothelial layer

2) **Proliferative phase**
   - → It lasts from 3rd day to 3rd week
   - → This phase has
     - Fibroblast activity
     - Production of collagen, Glycosaminoglycans & Proteoglycans
     - Angio – Neogenesis - Growth of new vessels as capillary loops
     - ↑sed Tensile strength of wounds – due to increased Type III collagen deposition in random fashion
     - Wound contraction - ↓se the surface area of wound

3) **Remodeling phase**
   - → Characterized by Maturation of collagen
   - → Type I collagen is replaced by Type III until a Ratio of 4:1 is achieved
   - → Hence, **Tissue remodeling shows**
     - Realignment of collagen fibers
     - ↓sed wound vascularity
     - Wound contraction
   - → Maturation of collagen leads to ↑sed Tensile strength of wound
   - → **Maximum wound strength** is seen at – 12th week of Post injury

     ↓

     Approximately 80% of uninjured skin strength

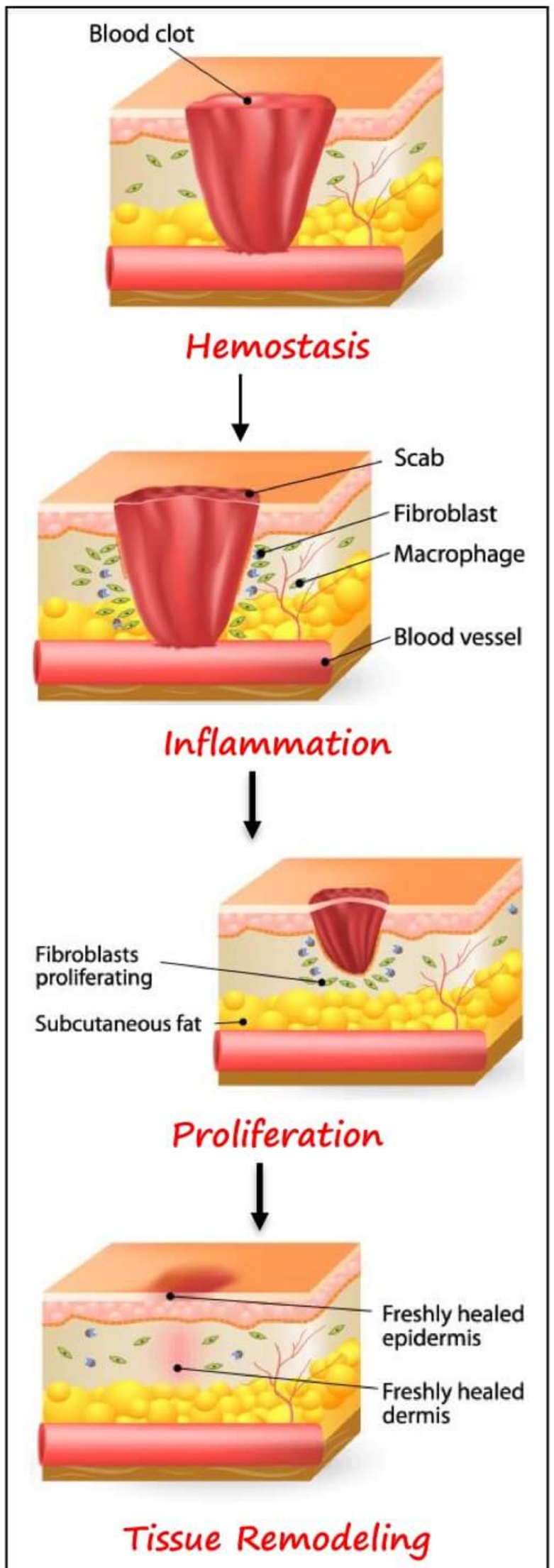

t.me/latestpgnotes

PrepLadder

Factors adversely affecting wound healing

Local factors	Systemic factors
• Infection • Ischemia • Foreign body • Hematoma • Movement • Mechanical stress • Presence of necrotic tissues	• Diabetes mellitus • Ionizing radiation (impairs wound healing by causing obliterating end arteritis & decreases vascularity) • Temperature • Advancing age • Malnutrition • Vitamin A & C deficiency • Zinc & Iron deficiency • Drugs (e.g. Steroids, Doxorubicin) • Jaundice • Uremia • Malignancy

Wound

→ Breach in continuity of skin or surface epithelium

Types of wound

Simple wound	Complex wound
Only skin + subcutaneous tissue is involved	Skin + underlying nerves, vessels, tendons with devitalized tissue are involved.

t.me/latestpgnotes

Classifications of Surgical Wounds

Class I

→ Aka **Clean wound**

→ It includes

- Uninfected Operative wounds without inflammation
- Respiratory, alimentary, genital or infected urinary tract are **not entered**

→ These wounds are closed **primarily (if necessary drained with closed drainage)**

→ **Examples**

- Inguinal hernia operation
- Mastectomy
- Thyroidectomy
- Joint replacement
- Abdominal Aortic Aneurysm repair

Class II

→ Aka **Clean contaminated wound**

→ It includes

- Operative wound in which Respiratory tract, GIT, GU tract is **entered under controlled condition without unusual contamination**

PrepLadder

→ **Examples**

- Cholecystectomy
- CBD exploration
- Elective GI surgery (Elective colonic Resection, Elective Gastrectomy)

Class III

→ Aka **Contaminated wounds**

→ It includes

- Open, fresh **Accidental wounds**
- Operations with **major break in sterile techniques** or **gross spillage from GIT**
- Incisions in which **acute non-purulent inflammation** is encountered

→ **Examples**

- Appendicular perforation
- Gastric perforation
- Enterotomy during bowel obstruction
- Human bite
- Open fracture

Class IV

→ Aka **Dirty wound**

→ It includes

t.me/latestgnotes

- **Old traumatic wound** with retained **devitalized tissue**
- Wound with **clinical infection** or perforated viscera with **high degree of contamination**
- **Organism** causing post-operative infection is **already present in the wound** before operation
- Associated with **severe inflammation**

→ **Examples**

- Perforated diverticulitis
- Fecal Peritonitis
- Presence of frank pus
- Necrotizing soft tissue infection

Risk of Infection	Antibiotic Prophylaxis
• Clean wound – **5% risk**	• Not required (usually)
• Clean contaminated wound – **10% risk**	• Usually required
• Contaminated – **20–30% risk**	• Required
• Dirty wound – **30–40% risk**	• Treatment is Required (not the prophylaxis)

How to avoid SURGICAL SITE INFECTION?

1) Staff should follow **hand washing** between patients
2) **Length of hospital stay** – should be kept **minimum** (to prevent hospital acquired infections)
3) **Preoperative sharing** – should be **avoided** if possible

PrepLadder

4) **Antibiotic skin preparation** - should be Standardized
5) **Bowel preparation** for intra – abdominal surgery – should be followed
6) Best time to give **Preoperative antibiotics** - At the time of induction via IV route
7) Attention to theatre technique & discipline
8) **Avoid hypothermia** Pre-operatively
9) **Monofilament sutures** should be preferred over polyfilament sutures (Increased risk of infection in polyfilament)
10) **Proper Apposition of wound** during suturing
11) **Prevention of** dead space & hematoma

Classification of Wound Closure & Healing

Healing by Primary intention

→ Aka **Healing by first intention**
→ Occurs when there is
- Apposition of wound edges
- Minimal surrounding tissue trauma (least inflammation)

→ Associated with Best Scar (Hair line scar)

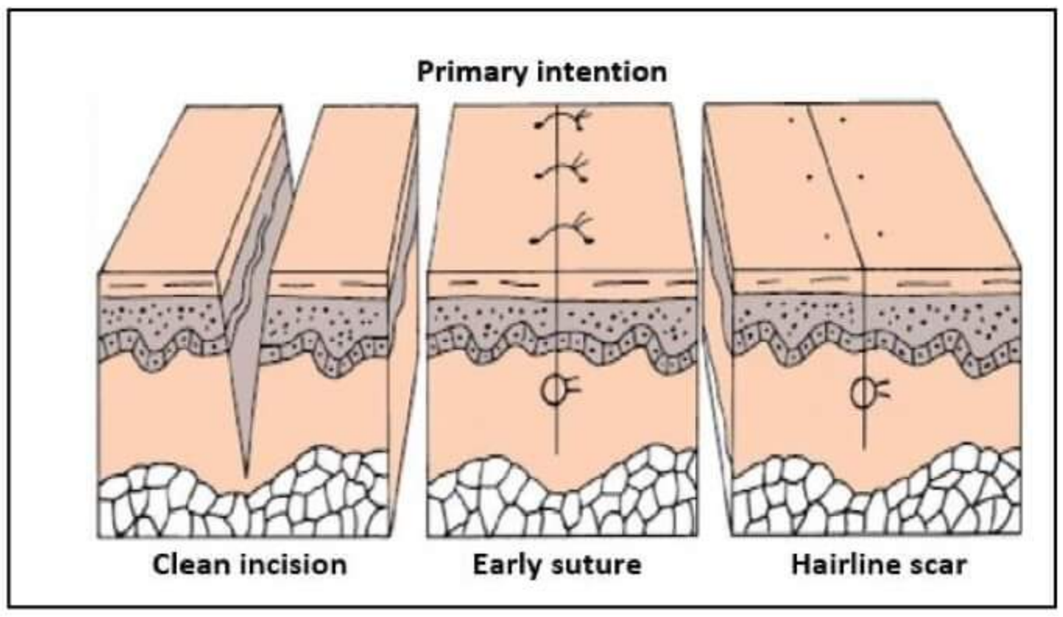

Healing by secondary intention

→ It occurs in the wound that is
- left open
- Allowed to heal by Granulation, Contraction and Epithelization

→ Associated with Large scar (cosmetically poor)

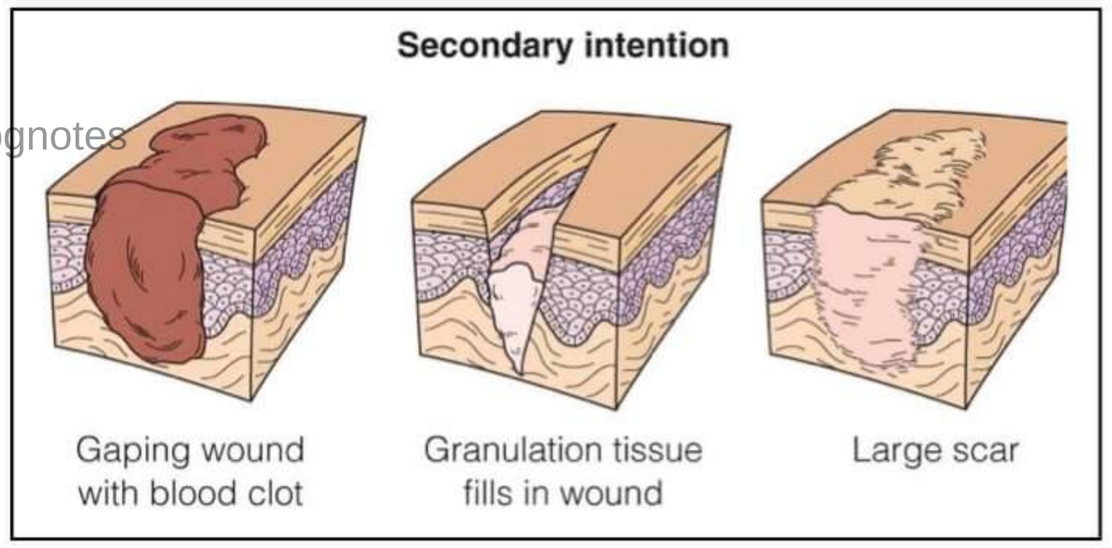

t.me/latestpgnotes

Healing by tertiary intention

→ Aka **Delayed primary intention healing**
→ It occurs when the
- Wound edges are not opposed
- Wound is contaminated

→ Delayed closure is performed when inflammation & proliferative phase is well established
→ Associated with Less satisfactory scar

Chronic wound

→ Wound, that does not heal within 3 months
→ **Delay in healing** can occur in any phase - Most frequently in Inflammatory phase
→ **Examples**- Pressure ulcers/Pressure sores

Treatment

→ **Surgical intervention is done only when**
- Non-operative treatment fails &
- when patient suffer from intractable pain

PrepLadder

Degloving injury

→ In this type of injury

- Skin & subcutaneous fat are stripped by avulsion from underlying fascia.
- Leaves neuromuscular structures, tendons & bone exposed

Degloving injury

Compartment syndrome

→ Typically occur in closed lower limb injuries

Clinical features

→ Severe pain

→ Pain on passive movement of affected compartment muscle

→ Distal sensory disturbances

→ Absences of distal pulses (late sign)

Investigation

→ For diagnosis – Compartment pressure is measured

↓

Pressure monitor & catheter inserted into muscle compartment

Treatment

t.me/latestpgnotes

→ Fasciotomy

→ Indications for fasciotomy

- If compartment pressure is > 30mmHg
- Clinical signs and symptoms of compartment syndrome

→ Procedure

- Two longitudinal incisions should be given – one on Medial and the other on lateral side
- Incised layers are
  - Skin
  - Subcutaneous fat
  - fascia
- After incision, Muscle should be bulging through fascia

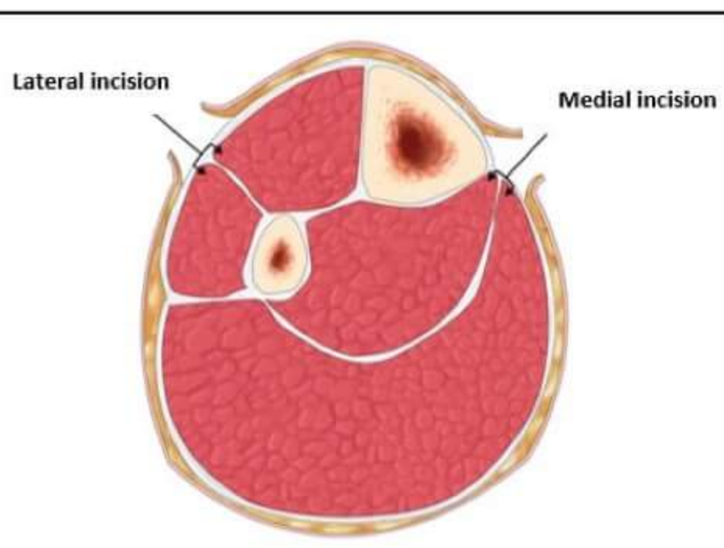

Fasciotomy

PrepLadder

Pressure sore

→ **Definition** – Tissue necrosis & ulceration due to prolonged pressure

→ **Other names**

- Bed sore
- Pressure ulcer
- Decubitus ulcer
- Trophic ulcer
- Penetrating ulcer

Mechanism

→ **External pressure exceeds capillary occlusive pressure** (> 30 mmHg)

↓

Blood flow to skin stops

↓

- Tissue Hypoxia
- Necrosis
- Ulceration

→ **Other Mechanisms responsible are**

- Impaired nutrition
- Defective blood supply
- Neurological deficit

Important points to remember regarding Pressure sores

t.me/latestpgnotes

→ Pressure sores are *preventable*

→ **Incidence** – 5% in hospitalized patients

→ **Higher incidences in**

- Paraplegic patients
- Elderly patients
- Severely ill patients

→ Most common site of pressure sores – *Ischium > Greater trochanter > Sacrum > Heel > Lateral malleolus > Medial malleolus > Occiput*

Neurological Causes of Pressure sores

• Syringomyelia • Spina bifida • Spinal injury • Peripheral neuritis • Peripheral nerve injury	• Diabetic neuropathy • Paraplegia • Tabes dorsalis • Leprosy

Clinical features

→ Painless *punched out ulcer*

→ Base is formed by bone

Pressure sore

PrepLadder

Staging of pressure sore

Stage I

→ Non blanchable erythema of skin without breach in epidermis

→ Early superficial ulcer

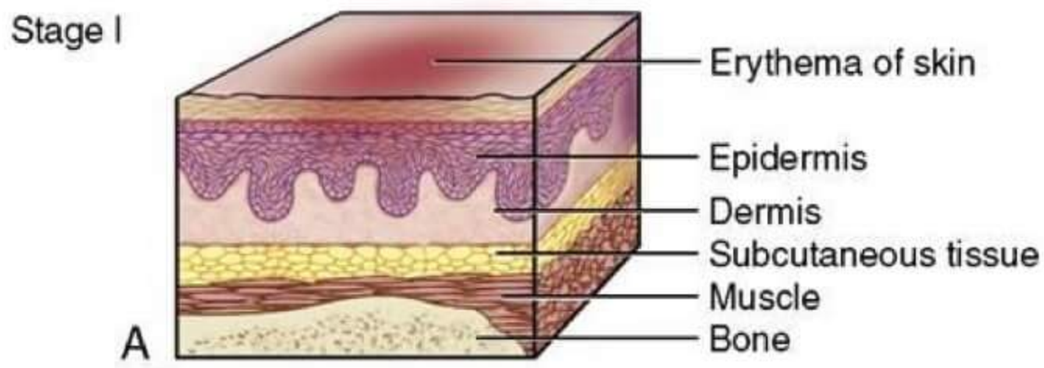

Stage II

→ Partial thickness less including epidermis + dermis.

→ Late superficial ulcer

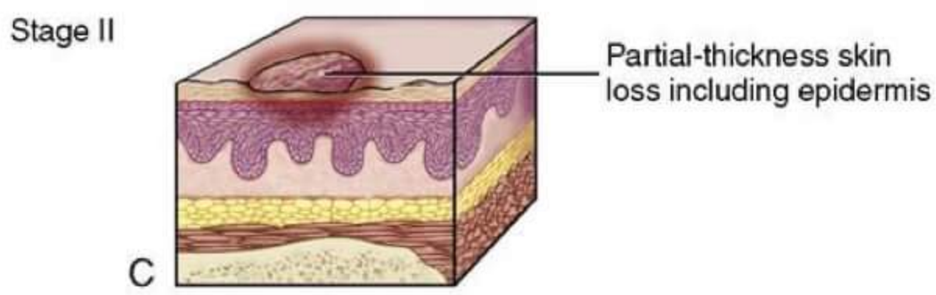

t.me/latestpgnotes

Stage III

→ Full thickness skin loss involving subcutaneous tissues but not through underlying fascia.

→ Early deep ulcer

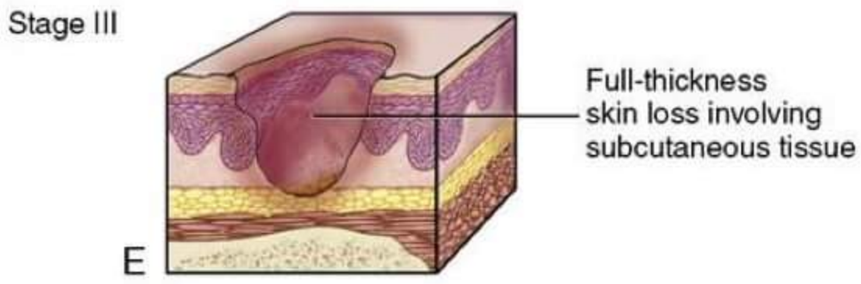

Stage IV

→ Full thickness skin loss involving subcutaneous tissue, muscle bone, joints or tendon.

→ Late deep ulcer

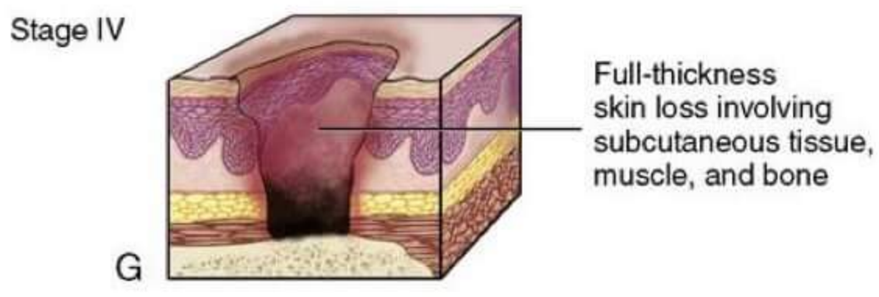

PrepLadder

Management

→ **Can be prevented by**
- Good skin care
- Use of Special pressure dispersion cushions /foams
- Use of low air loss & air fluidised beds
- Urinary and fecal diversion – if required

→ **In cases of bed bound patients** – Patient should be turned at least every 2 hourlies

→ **Wheel chair bound patients** – Patient should lift themselves off their seats for every 10 seconds every 10 minutes.

Surgical treatment

→ Reserved for patients with no improvement after conservative management

→ Surgical options are
- Adequate debridement
- Vacuum assisted closure
- Flap Closure – Large skin flap with muscle & intact sensory innervation

↓

MC used flap for pressure sores– Extensor fascia lata flap with lateral cutaneous nerve of thigh

Vacuum assisted closure

→ Aka negative Pressure wound therapy (NPWT)

t.me/latestpgnotes

→ (– 125mmHg) pressure is applied

→ Promotes wound healing by applying vacuum through a special sealed dressing.

→ Continued vacuum by NPWT
- Draws out fluid from wound
- Increases blood flow to the area.

→ Vacuum can be applied continuously or intermittently.

Vacuum assisted closure

→ **Primary effects of NPWT**
- Causes Macro deformation → draws wound edges together

↓

Contraction (helps in wound edge approximation)
- Stabilization of wound environment – by protecting the wound from outside microorganisms
- Provides warm & moist environment to wound
- Reduces edema – by removal of soft tissue exudate
- Micro deformation leading to cellular proliferation on wound surface

→ **Contraindications of NPWT**
- Malignancy in the wound
- Untreated osteomyelitis

PrepLadder

- Non enteric & undrained fistula
- Necrotic tissue with eschar

Scar formation

→ Maturation phase of wound healing leads to formation of scar

→ **Immature scar**

- Pink, hard, raised & itchy

→ **Mature scar**

- Maturation of collagen
- Denser collagen
- Scar becomes acellular (Fibroblasts and blood vessels reduce over a period of time)

→ **Changes in scar from immature state to mature state**

- Pallor
- Softer
- Flattens
- Itching diminishes

→ **Maximum tensile strength** – 12 weeks /3months post injury

↓

Approximately 80% of uninjured skin

→ **Types of scars**

1) Atrophic Scar
2) Hypertrophic Scar
3) Keloid

t.me/latestpgnotes

Atrophic scar

→ Pale, Flat and Stretched in appearance

→ Site – Back (in areas of tension)

→ Easily traumatized (due to thin epidermis and dermis)

→ Excision & Resuturing rarely improves it

ATROPHIC SCAR

Hypertrophic scar

→ Has Excessive scar tissue

→ Scar doesn't extend beyond the boundary of original wound/ incision

→ **Results from**

- Prolonged inflammatory phase
- Unfavourable scar siting (across tension lines)

→ **On Histology**

- Excess collagen
- Hypervascularity
- Well organized type III collagen

→ Improves spontaneously with time

HYPERTROPHIC SCAR

PrepLadder

→ **Management**

- For Linear hypertrophic scar – Pressure therapy/ Silicone gel sheet application
- For ongoing hypertrophy in the scar – Intralesional Steroids (Triamcinolone)
- If scar persists after 1 year – Surgical excision + Primary closure of wound

Keloid

→ Has Excessive scar tissue

→ Scar extends beyond the boundaries of original wound or incision

KELOID

→ **Etiology** – Unknown

→ **Associated with**

- Elevated levels of growth factors
- Deeply pigmented skin
- Genetic predisposition
- Areas of body where there is increased risk of keloid formation
  - Above clavicle
  - Upper extremities
  - Trunk & Face
  - Especially seen in the Triangular region with boundaries of Each shoulder tip and Xiphisternum

t.me/latestpgnotes

→ **On Histology**

- Excess collagen & Hypervascularity
- Contains disorganized Type I & III collagen
- Contains thicker collagen bundles – causes formation of acellular node like structures
- Rarely regresses with time
- Often refractory to Medical & Surgical intervention

→ **Treatment**

- First line treatment – Silicones + Pressure therapy + Intralesional injection of triamcinolone
- **In Refractory Cases** (No improvement after 12 months of treatment) – Excision + Post-operative Radiotherapy (External beam radiotherapy / Brachytherapy)

PrepLadder

Difference between Hypertrophic scar & Keloid

	HYPERTROPHIC SCAR	KELOID
Genetic	• Not familial	• May be familial
Race	• Not race related	• More common in Blacks > whites
Sex	• Females = males	• Females > males
Age	• Children	• 10 To 30 years
Border	• Remains within the wound	• Outgrows wound area
Sites	• Flexor surface	• Sternum • Shoulder • face
Etiology	• Related to tension	• unknown
Development	• Within 4 weeks	• 3 months to 1year
Clinical findings	• Raised • Some pruritis • Respects wound confines	• Pain • Pruritis • Grows beyond the wound margins
Histology	• Parallel orientation of collagen fibers	• Thick wavy collagen in random orientation

t.me/latestpgnotes

PrepLadder

CEREBROVASCULAR DISEASE

Neural tube Defects

Types

SPINA BIFIDA OCCULTA	SPINA BIFIDA APERTA
→ Also Called as Closed spina bifida → Associated with incomplete Closure of one or more vertebra without Herniation of meninges or Spinal cord	→ Divided in 3 types • MENINGOCLELE • Myelomeningocele • Myeloschisis

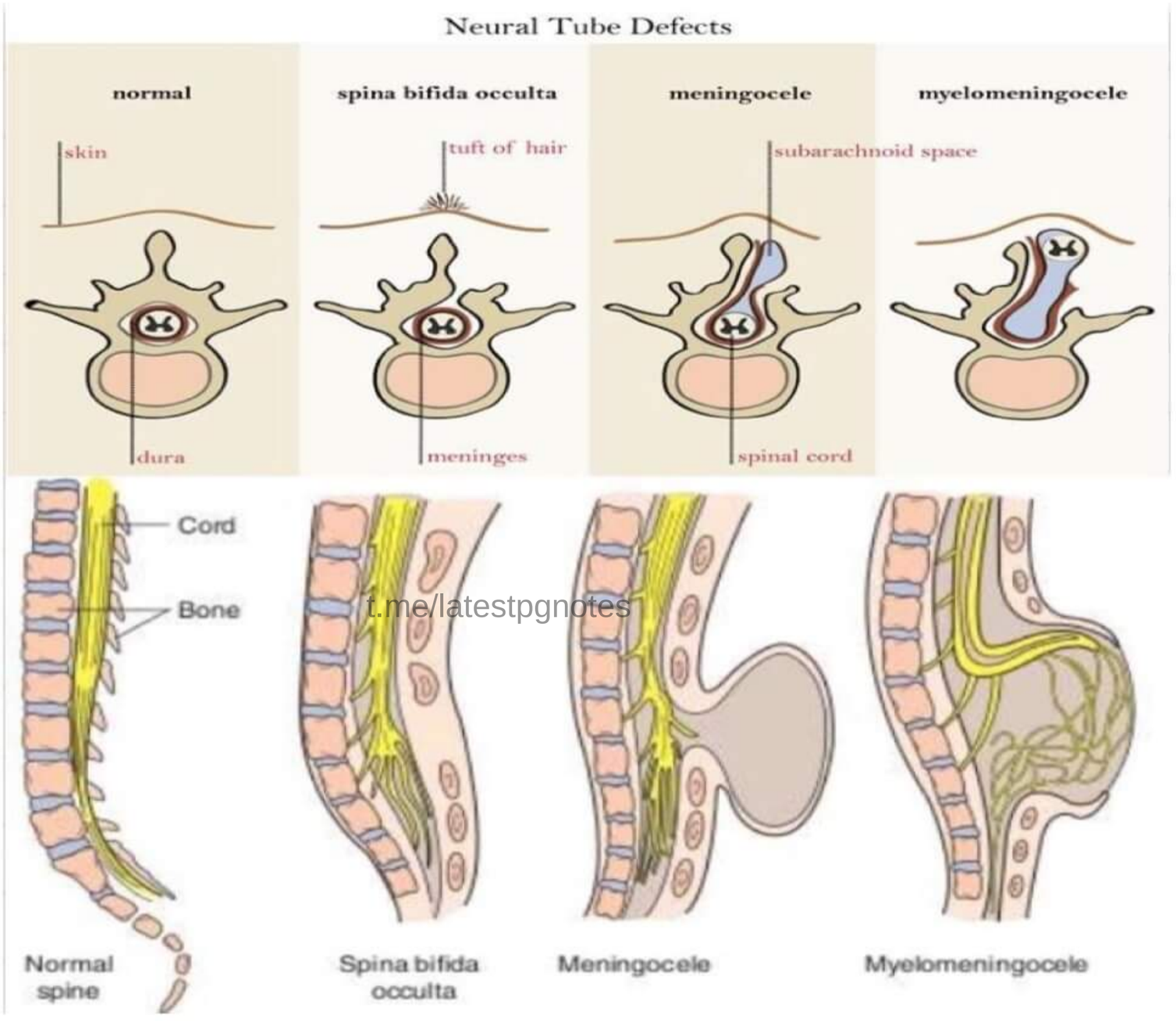

t.me/latestpgnotes

MENINGOCELE

→ Herniation of meninges through a defect in Posterior vertebral arches.

→ Spinal Cord is — Normal / Normal Position in Spinal Canal.

C/F:

→ Fluctuant midline swelling.

→ Brilliantly trans- illuminant.

→ Occurs along vertebral Column in the lower back.

→ Covered by Skin.

Dx:

→ **X-ray** - Vertebral Defect can be seen

PrepLadder

Rx:

1. **Immediate Surgery**
   - Leaking CSF
   - Thin Skin covering

   } Immediate Surgery in these conditions

2. **Delayed Surgery**
   - Asymptomatic with normal Neurological finding & full thickness skin covering.

MYELOMENINGOCELE

→ Most severe form of Dysraphism involving vertebral column
→ Characterized by Herniation of both Meninges & Spinal Cord
→ Incidence of myelomeningocele - **1:4000 Live Birth**
→ Most common Site - **LUMBOSACRAL Region**

Etiology

→ Genetic Predisposition.
→ If one child is affected, risk of occurrence – 3 to 4 %.
→ If two children are affected, risk of occurrence – 3 to 10 %.
→ Maternal Periconceptional use of folic acid supplementation decreases incidence of NTD in Pregnancies at high Risk by 50%

Drugs that Increases risk

t.me/latestpgnotes

1. Phenytoin
2. Carbamazepine
3. TMP - SMT (Trimethoprim - Sulfamethoxazole)
4. Phenobarbital
5. Primidone
6. Valproate

Note:
→ Maternal use of Anti- epileptic drugs increases risk of Neural tube defects especially **MYELOMENINGOCELE**

C/F

→ Dysfunction of skeleton, GIT, Genitourinary tract in addition to CNS & PNS
→ **Extent of Neurological Deficit depend on**
   - Site of M/M
   - Associated Lesions

Prevention

→ **0.4mg Folic Acid Supplementation / Day** - in all females of childbearing age & about to become pregnant

PrepLadder

ARNOLD CHIARI MALFORMATION

1. TYPE I CHIARI MALFORMATION
2. TYPE II CHIARI MALFORMATION

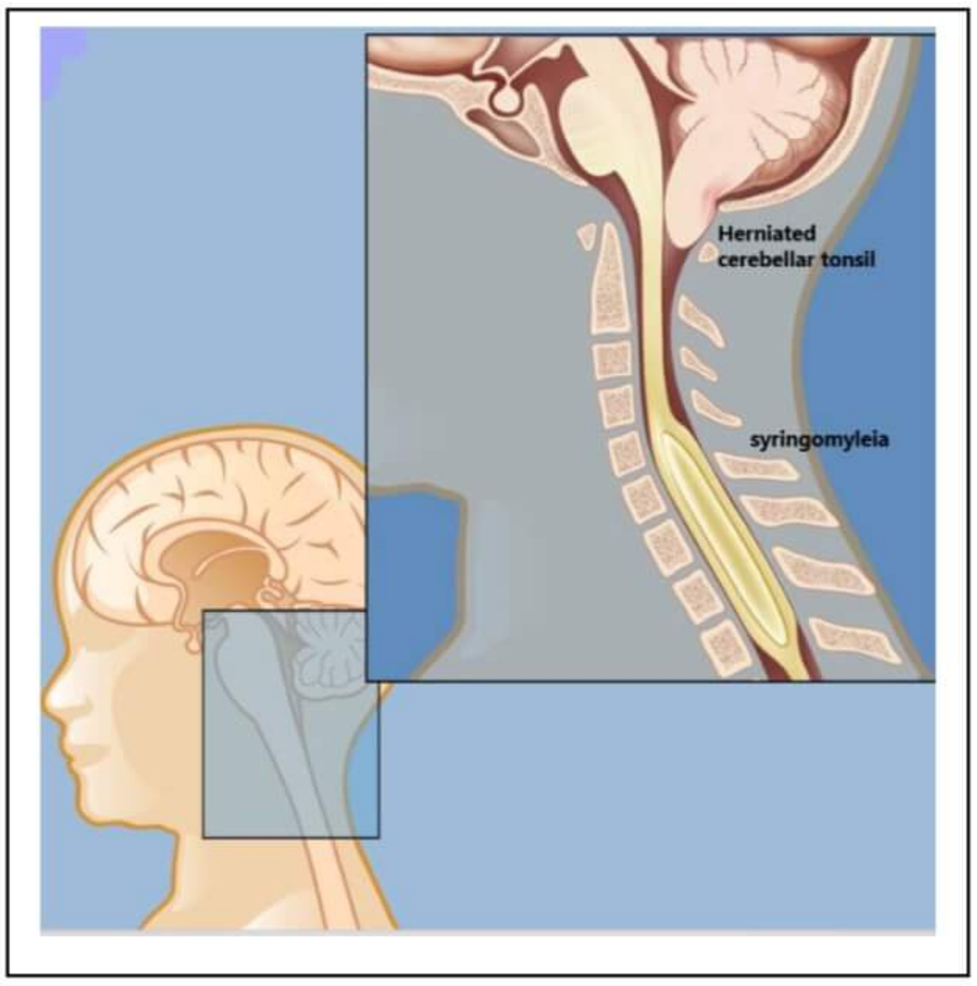

TYPE I CHIARI MALFORMATION

→ Displacement of cerebellar Tonsil into cervical canal.
→ Associated with Syringomyelia of Cervical Canal.
→ Not associated with HYDROCEPHALUS
→ Adolescence/ Adult Life

C/F

→ Recurrent Headache.
→ Neck Pain
→ Urinary Frequency
→ Progressive Lower Extremity Spasticity

TYPE II CHIARI MALFORMATION

→ It is An Anomaly of HINDBRAIN
- Elongation of 4th Ventricle
- Kinking of Brain stem
- Displacement of **(inferior vermis; Pons; Medulla)** into cervical canal

t.me/latestpgnotes

→ Associated with HYDROCEPHALUS & MYELOMENINGOCELE

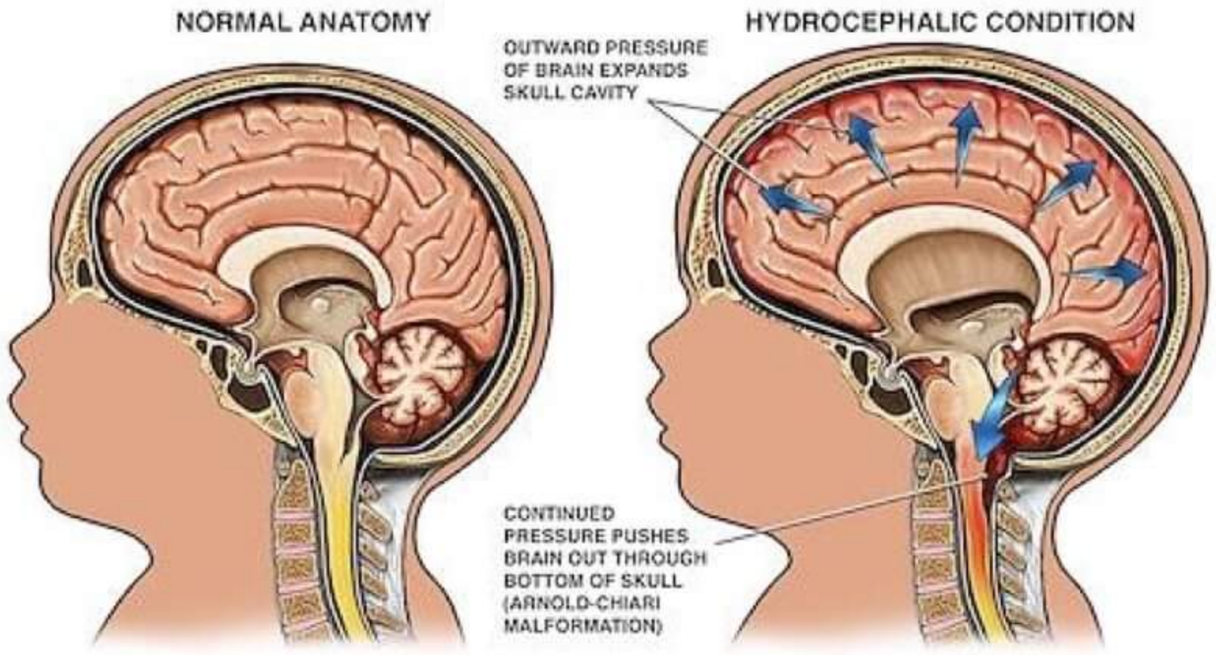

Investigation

→ X-ray - Small Posterior Fossa with WIDENED Cervical Canal.
→ MRI - Cerebellar Tonsil Protruding into Cervical Canal & Hind Brain Anomalies.

Rx

→ Surgical Decompression

PrepLadder

DANDY- WALKER MALFORMATION

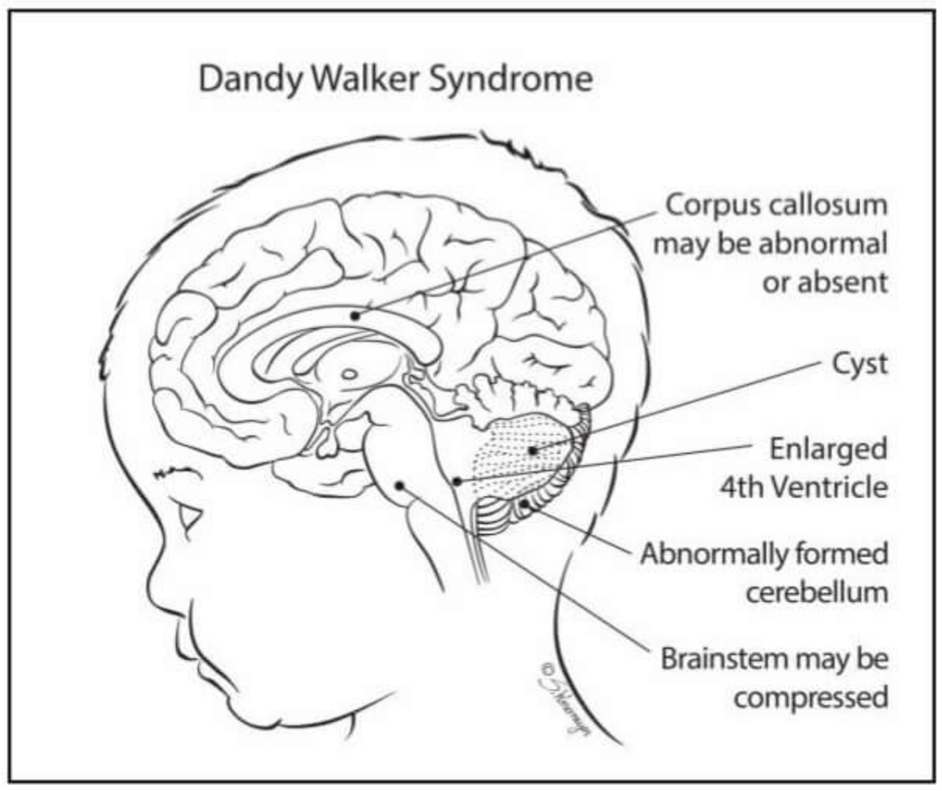

→ MC Posterior Fossa Malformation

→ **Consist of**

- Cystic Expansion of Fourth Ventricle in Posterior Fossa
- Midline Cerebellar hypoplasia

→ Result from Developmental Failure of roof of Fourth ventricle

Characteristic Triad of DWH

→ Hypoplasia of Vermis

→ Cephalad Rotation of Vermian remnant and Cystic Dilation of Fourth Ventricle - Extending posteriorly

→ Enlarged Post Fossa with Torcular Lambdoid inversion

C/F

→ MC manifestation - MACROCEPHALY

→ A/W Hydrocephalus

→ RAPID increase in Head Size with Prominent occiput

→ Evidence of long tract signs, Cerebellar ataxia

→ Delayed Motor or cognitive milestone due to associated Structural Abnormalities

t.me/latestpgnotes

Associations

→ A/W CNS Abnormalities - 70% cases

- Agenesis of Posterior cerebellar vermis & Corpus collosum
- Cortical dysplasia
- Polymicrogyria

IOC for Diagnosis – MRI

Rx

→ Shunting of Cystic cavity in pts. of Hydrocephalus

Causes of Cerebrovascular Accidents

Ischemic (85%)	Hemorrhagic (15%)
• Embolic (75%) • Thrombotic (25%)	• Parenchymal (10%) • SAH (1-2%) • EDH (<1%) • SDH (<1%)

PrepLadder

Intracerebral Hemorrhage (Parenchymal)

→ MC Type of Intracranial Hemorrhage
→ MC cause of HTN - Rupture of small Perforating arteries & arterioles
→ MC site – Basal ganglia (Putamen)

Subarachnoid Hemorrhage

→ 2nd MC causes of I/C Hemorrhage
→ MC Cause is Trauma > Rupture of Berry Aneurysm
→ MC site of Berry Aneurysm is - Anterior circulation of Circle of Willis
→ MC Site of Extra Cranial Aneurysm - Infrarenal abdominal Aorta

Berry Aneurysm

→ MC type of I/C Aneurysm
→ Saccular in appearance
→ Arise from Bifurcation of I/C arteries
→ 85% Aneurysm occur in Anterior circulation of Circle of Willis

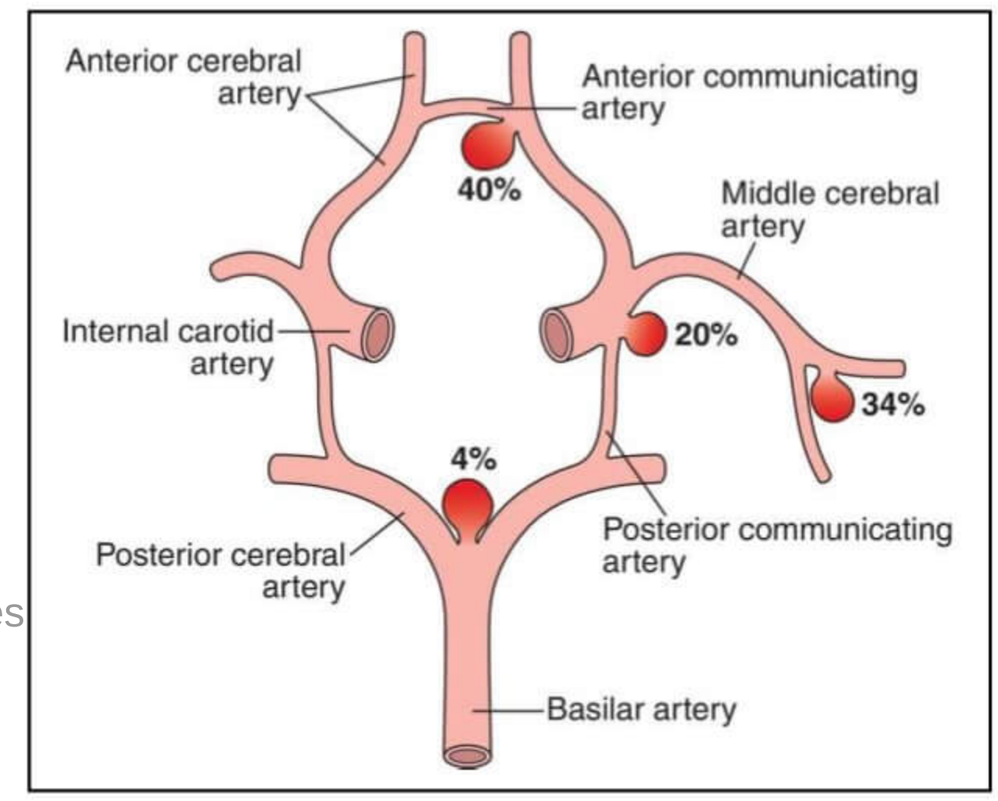

Occurrence of Berry Aneurysm

→ Anterior Communicating artery & Anterior Cerebral artery junction (M/C)
→ Posterior communicating artery & Internal carotid artery junction (2nd M/C)
→ Middle cerebral artery Bifurcation
→ Intracranial carotid bifurcation
→ Vertebrobasilar or Basilar artery Bifurcation

t.me/latestpgnotes

Risk Factors

→ Smoking
→ Hypertension.

Wall of berry Aneurysm

→ Made of thickened, hyalinized INTIMA.

Situations/ Conditions Associated with berry aneurysms

1. FMD (Fibromuscular dysplasia)
2. Marfans syndrome
3. Ehlers-Danlos syndrome
4. Coarctation of aorta
5. ADPKD (Autosomal dominant Polycystic Kidney disease)
6. NF- I

PrepLadder

Ruptured Berry Aneurysm

→ MC Site of Rupture is Dome/ Apex

→ Leads to intra cerebral haemorrhage or SAH or both

Unruptured Berry Aneurysm

→ Completely Asymptomatic

BRAIN ABSCESS

→ **Occurs as a result of**

- Direct Spread from Air sinus infection during surgery
- Hematogenous Spread- Associated with respiratory infection, endocarditis, Dental infection

↑sed Risk of Brain Abscess

→ In 2 Categories

- Cyanotic Heart Disease
- Immunocompromised

MC site of Brain Abscess based on Etiology

→ **If Etiology is**

- Otitis media
- Mastoiditis

} MC site is Temporal lobe followed by Cerebellum

t.me/latestpgnotes

- Paranasal sinusitis
- Dental infections

} MC site is Frontal lobe

- Hematogenous spread – MC site is Parietal lobe

C/F

→ FND (Focal Neurologic deficits)

→ Seizures

→ S/S of ICT

→ Fever

Diagnosis

→ MRI is the IOC

→ CT – Shows RING Enhancing Lesions

Management

→ Surgical Drainage + IV Antibiotics – 6 Weeks

→ Multiple small Abscess (+) – IV Antibiotics.

→ Steroids – Reserved for pts. with — Edema, Mass effect

→ Anti- Epileptics – Increase risk of Seizure

PrepLadder

BRAIN HERNIATION SYNDROME

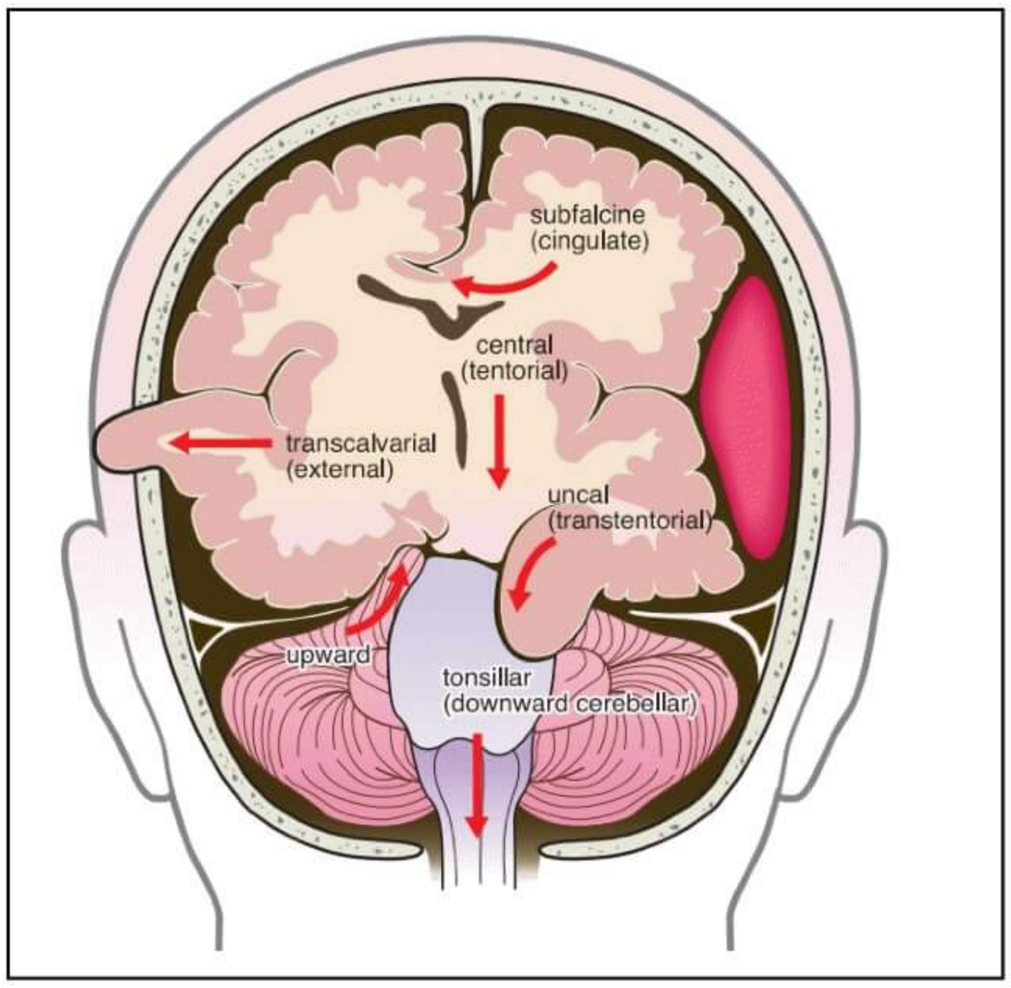

Uncal/ Transtentorial Herniation

→ Uncus & Temporal lobes are forced through Cerebellar Tentorium

→ Sequential compression of I/L 3rd nerve followed by Brainstem followed by whole Brainstem

Early Signs - I/L Dilated Pupil

Late Signs

t.me/latestpgnotes

→ I/L Hemiplegia

→ Progressive Ptosis

→ 3rd Nerve Palsy

→ Cheyne Stoke Respiration

Very Late Sign

→ Quadriparesis

→ B/L Dilated & fixed Pupil

→ Erratic Respiration & Death

KERNOHAN'S NOTCH PHENOMENON

→ It is Cerebral Peduncle indentation associated with Trans tentorial or Uncal Herniation

→ Compression of contralateral cerebral peduncle against the free edge of Tentorium (KERNOHAN'S Notch)

↓

I/L Hemiparesis & I/L 3rd Nerve Palsy

KERNOHAN WOLTMAN SIGN

→ Lateral Displacement of MIDBRAIN

↓

Compress opposite cerebral peduncle

↓

- Babinski sign
- Hemiparesis C/L to original Hemiparesis (K - WSIGN)

PrepLadder

Central Herniation

→ Diencephalon (THALAMUS & Related Structures)

↓

Forced through Tentorium.

→ Sequential Compression of upper mid Brain > Pons > Medulla

Physical Signs of central herniation

→ **Early Sign**

- Erratic Respiration
- Small Reactive Pupil
- Increased Tone of limbs
- B/L Extensor Plantar

→ **Late Sign**

- Cheyne-stokes Respiration
- Decorticate Rigidity

→ **Very late Sign**

- Fixed & Dilated Pupils
- Decerebrate Rigidity

Subfalcine Herniation

→ Displacement of Cingulate gyrus beneath free edge of falx cerebri

t.me/latestpgnotes

Signs

→ Loss of Consciousness - Leads to Coma

→ C/L weakness

→ Loss of Brainstem Reflexes

Tonsillar/ Downward Cerebellar Herniation

→ Displacement of cerebellar tonsils Via Foramen magnum

→ Leads to coma & B/L Posturing

Duret Hemorrhage

- ↑ Intracranial Tension (ICT)→ Cause Downward herniation of Brainstem

↓

Stretching of perforators of Basilar artery.

↓

Leads to Bleeding

- Small area of bleed in Ventral & Paramedian Part of upper Brainstem (Midbrain & PONS)

PrepLadder

CNS TUMORS

Brain Tumors

→ Occurs sporadically

→ **Risk factors**

- Radiation exposure
- Genetic abnormalities
  - ➢ Retinoblastoma
  - ➢ Li-Fraumeni Syndrome
  - ➢ NF-1, NF-2
  - ➢ MEN 1 Syndrome
  - ➢ Turcot's Syndrome
  - ➢ VHL Syndrome
  - ➢ Gorlin syndrome
  - ➢ Tuberous Sclerosis

Genetic abnormalities
↑ risk of B.T

WHO classification of Brain Tumor:

1) Neuroepithelia tumors
   a. **Glioma:**
      → Astrocytoma
      → Oligodendroglioma
      → Ependymoma
      → Choroid Plexus Tumor
   b. **Pineal Tumors:**
   c. **Medulloblastoma**
   d. **Neuronal Tumors:**
      → Gangliogánglioma
      → Gangliocytoma
      → Neuroblastoma
2) Nerve Sheath Tumor
   → Vestibular Schwannoma
3) Meningeal Tumor
   → Meningioma
4) Pituitary Tumors
5) Germ Cell Tumors
   → Germinoma
   → Teratoma
6) Lymphoma
7) Tumor like malformation
   → Craniopharyngioma
   → Dermoid Tumors

t.me/latestpgnotes

PrepLadder

→ Epidermoid Tumors

→ Colloid Cysts

8) Metastatic Tumors

9) Contiguous extension from regional tumor

→ Glomus Tumor

One liners of brain tumor

→ MC Brain Tumor – **Metastasis**

→ MC primary for metastasis to brain- **Ca lung > CA breast**

→ MC primary for leptomeningeal metastasis – **CA breast**

→ MC primary BT – **Meningioma (35%) > Glioma (30%)**

→ MC malignant BT in children

→ MC radio sensitive BT

Medulloblastoma

→ MC suprasellar mass in adults – **Pituitary adenoma**

→ MC Suprasellar mass in children – **Craniopharyngioma**

→ Brain Tumor A/W Calcification **Craniopharyngioma (All) > ODG (90%) > meningioma (20-25%)**

One liners of Spinal cord:

→ MC spinal tumor – **Metastasis**

t.me/latestpgnotes

→ MC primary spinal tumor – **Nerve sheath tumor**

→ MC intra – Medullary tumor – **Astrocytoma**

→ MC site of primary spinal tumor – **Intra-dural; Extra medullary**

Clinical features of Brain tumors

3 Cardinal symptoms

1. Seizure
2. ↑ ICT (Intra-Cranial tension) - **Headache**
   - Worse in Morning and on straining
   - A/W nausea and Vomiting
3. FND (Focal neurological deficit)
   - Progressive overtime
   - Characteristic of location of tumor

In Pituitary Adenoma – A/W Endocrinologic abnormalities

Investigation of choice for diagnosis of brain tumour - MRI

Management

→ Dexamethasone – reduces peritumoral edema (by stabilising cell membrane)

→ Antiepileptics – for tumors very close to Sensorimotor strip

→ Mannitol- Administered before dural opening and operative resection

PrepLadder

Surgery

→ **Primary goal**

1. Histological Dx
2. Reduction of mass effect

   (By removing max amount of tumor-with Preservation of neurological function)

→ **Post-op radiotherapy**

Used for

- Positive margins
- Tumor infiltrating the surrounding Brain Ex- Glioblastoma

→ **Craniospinal Irradiation**

Used for Tumors having CSF Spread

- CNS Lymphoma
- Pinealoblastoma
- Medulloblastoma
- Germ cell tumor
- Choroid plexus carcinoma
- Anaplastic ependymoma
- Primitive Neuroectodermal tumor

t.me/latestpgnotes

Psychiatric Symptoms in brain tumor

→ Mental Changes – More common in supra tentorial tumors

↓

1. Frontal lobe tumors
2. Temporal lobe tumors

NOTE:

Frontal lobe

→ Controls behaviour and judgement

→ Personality changes – Common in frontal lobe tumours

↓

- Display anti-social behaviour
- Socially inhibited
- Severe impairment of judgement insight and foresight.

→ Witzelsucht Syndrome – A/K **'Pathologic joking'**

↓

Seen in frontal lobe tumor

→ Psychiatric symptoms and Depression – **Frontal lobe tumors**

→ Psychosis – **Temporal lobe tumors**

→ **Delirium** – Rapidly growing large or metastatic tumors

→ Left sided FL tumor – **Akinesia & depression**

→ Right sided FL tumor - **Euphoria**

PrepLadder

Hemangioblastoma

→ MC primary intra-axial tumor in adult posterior fossa

→ Exclusively, in posterior fossa (cerebellum)

→ It can be sporadic (80%)

(or)

→ In 20% - VHL syndrome
- Pheochromocytoma
- Hemangioblastoma
- Pancreatic cyst
- Retinal angioma
- Renal cyst
- RCC

Pathology

→ Benign tumor

→ A/W erythrocytosis (↑ EPO)

→ Abundant thin walled vascular channels

C/F

→ Headache

→ Cerebellar dysfunction

→ Hydrocephalus

→ ↑ ICT

→ Polycythaemia - ↑ EPO

t.me/latestpgnotes

Diagnosis

→ IOC for Dx. - MRI

↓

Cyst tumor with enhancing tumor in the cyst wall

↓

Mural nodule

Treatment

→ **Surgical resection** is curative

↓

Enbloc resection of mural nodule

Glioma

1. Astrocytoma
2. ODG (Oligodendroglioma)
3. Ependymoma

PrepLadder

1) Astrocytoma

→ Arise from astrocytes

→ Mostly supratentorial in adults – **Cerebral cortex** (MC site)

→ Mostly infratentorial in children - **Cerebellum** (MC site)

→ MC type in children → Low grade - **Pilocytic astrocytoma**

→ MC type in adults → High grade - **GBM** (most malignant)

Pathology

→ Most of astrocytoma infiltrates surrounding brain

Except

1. Pilocytic astrocytoma
2. Pleomorphic Xantho Astrocytoma

→ **Histological features of high grade tumors**

- Hypercellularity
- Nuclear Atypia
- Endovascular Hyperplasia

→ Unique Features of GBM - **NECROSIS** (required for dx. Of GBM)

WHO classification for astrocytoma

Grade-1 (Pilocytic astrocytoma)

→ MC type of astrocytoma in children

→ Doesn't infiltrate surrounding brain

→ Often cystic with a mural nodule

Rx - Radical resection is curable

t.me/latestnotes

Grade II (Low grade astrocytoma)

→ Occurs in children and young adults

→ Seizure (MC Presentation)

Rx - Radiotherapy ± Chemotherapy ± Surgery

Grade-III (Anaplastic astrocytoma)

→ Show irregular enhancement on MRI

Rx - Cytoreductive surgery followed by EBRT (external beam radiotherapy)

Grade IV (GBM)

→ MC type in adult

→ Most Malignant

→ Worst prognosis

Features

→ Endothelial proliferation + necrosis

GBM

PrepLadder

→ Central necrosis + Ring like enhancement

→ Crosses Midline

A/K Butterfly tumor

Rx

→ Cytoreductive sx followed by EBRT

→ Two agents used in Malignant glioma

- Carmustine
- Cisplatin

→ New agents used for newly diagnosed GBM and Recurrent GBM

- Temozolomide

2) Oligodendroglioma (ODG)

→ 10% of glioma are ODG

→ Has predilection for cortex and white matter of cerebral hemisphere

→ MC site – **Frontal lobe**

→ MC genetic alteration – **Loss of Heterozygosity on chromosome**

↓ 19q > 1p

- A/W good prognosis
- Robust response to Temozolomide

Pathological Features

1. Fried egg cytoplasm
2. Chicken wire calcification
3. Microscopic calcification

t.me/latestpgnotes

Clinical features

→ MC symptom – **Seizure**

Investigation

→ IOC for diagnosis – **MRI**

→ **On CT / MRI**

- Calcification } Highly S/O for Dx
- Hemorrhage }

→ **On CT** – 90% of ODG shows calcifications

Treatment

→ Surgical excision + Chemotherapy (PCV)

P – Procarbazine

C – CCNU (Lomustine)

V – Vincristine

Loss of heterozygosity on 19q/1p – Robust response to Temozolomide

PrepLadder

3) Ependymoma

→ Arise from ependymal linings of cerebral hemisphere and remnants of central canal of spinal cord.

→ MC site in children – 4th ventricle

→ MC H/L type in adults - Myxopapillary ependymoma

↓

It arises from filum terminale in lumbosacral region

IOC - MRI

Treatment

→ Maximum possible resection followed by EBRT

→ CSI (craniospinal irradiation) – for CSF metastasis

Medulloblastoma

→ MC Malignant Brain tumor in children

→ Most radiosensitive Brain tumor

→ Associated with Turcot's syndrome

→ 3-4 years of age in children

→ MC site – Cerebellum in children (Vermis)

→ MC site in adults – Lateral cerebellar Hemisphere

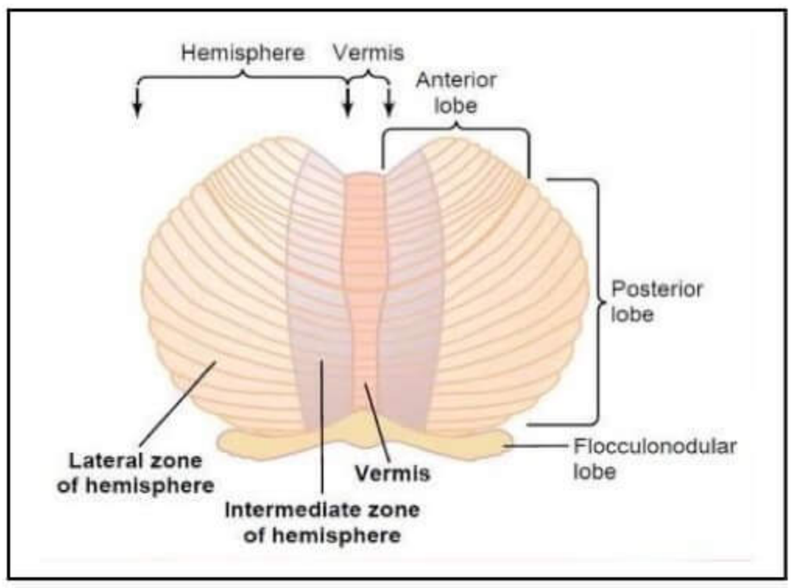

C/F

→ S/S of increased ICT in children

t.me/latestpgnotes

→ **In adults** – Ataxia & U/L dysmetria due to lateral origin of tumor

IOC

→ MRI

→ A/W CSF metastasis / Drop mets

→ Most important Prognostic factor – Tumor dissemination

Management

→ Surgical excision followed by radiotherapy + chemotherapy

→ Agents

- **Carmustine (BCNU)**, **Vincristine** – Primarily used for
  - Recurrences in Poor risk points
  - Children < 3 years to avoid Radiotherapy

MENINGIOMA

→ MC primary BT – Meningioma > glial Tumors (30%)

→ MC intracranial, extra – Axial, dural based neoplasm

→ MC in females

→ Arises from meningomesothelial cells of arachnoid

→ Along superior sagittal sinus

PrepLadder

→ Slow growing & encapsulated – Enplaque pattern of growth

Pathology

→ 20-25% - calcification

→ Presence of Psammoma bodies

Note: also seen in

P – PCT, PRCC

S – Serous cystadenoma Ovary

M – Meningioma

C/F

→ Motor deficit – 90% (spasticity and lower limb weakness)

→ Sensory deficit – 60%

→ Sphincter dysfunction of bladder

IOC for diagnosis – MRI

Radiologically

→ Dural tail sign

→ Abnormal vascular markings

→ Enlarged foramen spinosum

→ S/S raised ICT

→ Bony hyperostosis

→ Sunray spicules

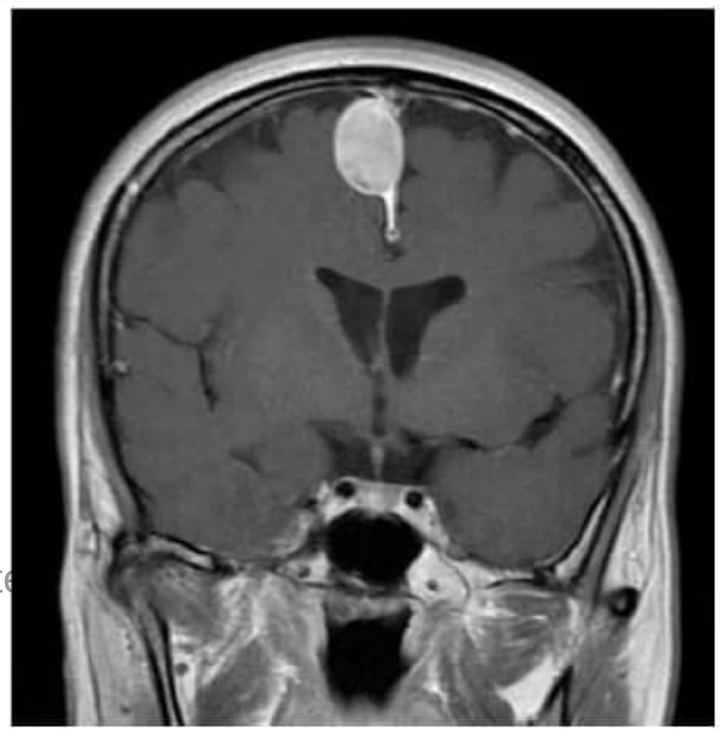

Dural tail sign

t.me/latestpgnote

Treatment

→ Surgical excision

(Simpson grading – For meningioma resection)

Note: - MC suprasellar mass in children – craniopharyngioma

- MC suprasellar mass in adults – Pituitary adenoma

Pituitary adenoma

→ Origin – anterior pituitary

→ MC cause of hyper pituitarism – Pituitary adenoma

C/F

Functional (Secreting)	Non-Functional (Non-Secreting)
Early Presentation due to physiologic effect	Delayed presentation (Big enough to cause neurological deficit) ↓ Bitemporal Hemianopia

→ Pituitary adenoma can be differentiated from pituitary hyperplasia – **Reticulin stain**

↓

(+ ve in pituitary hyperplasia)

PrepLadder

→ Seen on 3rd / 4th Decade

→ M = F

→ MC type of pituitary adenoma is

Prolactinoma

- Amenorrhea
- Galactorrhoea

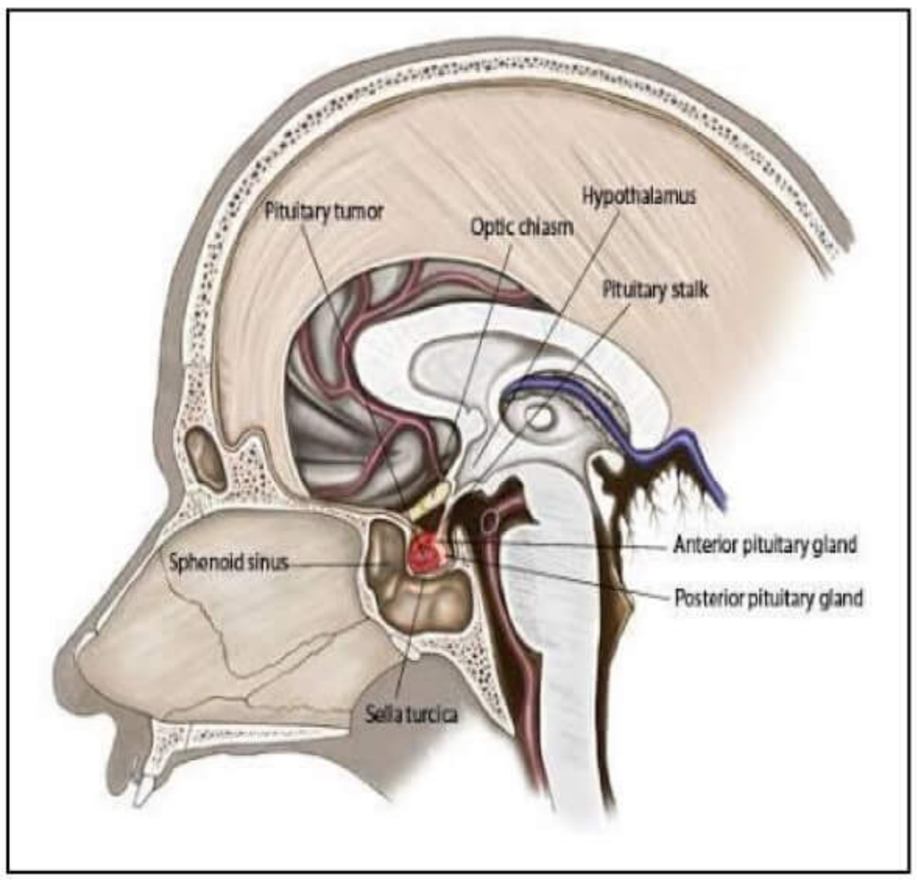

IOC for diagnosis – MRI

Other work-up done
- Full Endocrinologic Profile
- Formal visual field testing

Treatment

Bromocriptine (Dopamine agonist) – Prolactinoma

→ Shrink prolactinoma in 6 to 8 weeks

→ Growth hormone security tumors – shrinkage occur < 20% Pts

↓

Agent Octreotide
- ↓ GH level in 70% Pts
- ↓ Tumor volume in 30%

Indications of Sx in pituitary adenoma

→ GH Secreting tumors

→ Primarily Cushing Disease

t.me/latestpgnotes

→ Adenoma causing acute visual deterioration

→ Non-Prolactin secreting macroadenoma causing symptoms by mass effect

Surgical Approach

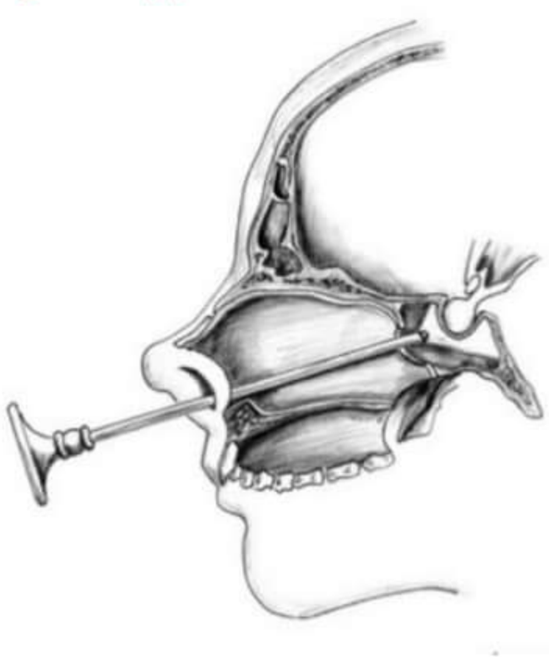

Intranasal Trans-Sphenoidal

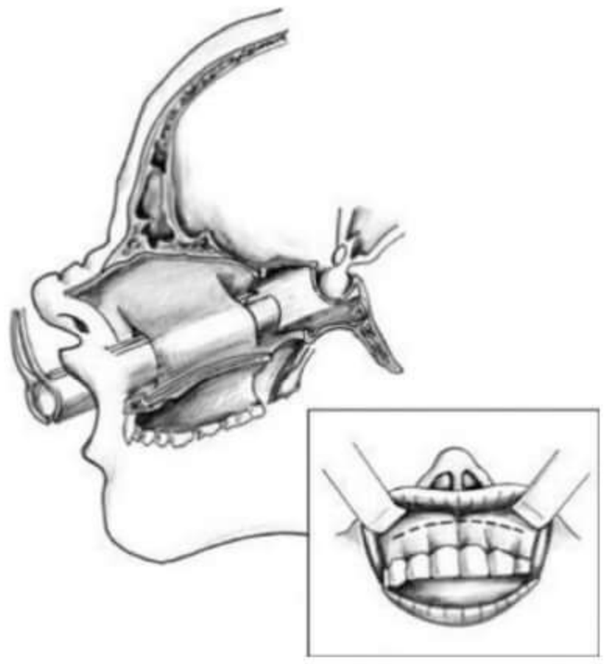

Sub labial

Indications of Radiosurgery in pituitary adenoma

→ Used as primary therapy

→ Adjuvant therapy after subtotal resection

→ Recurrent disease

PrepLadder

Craniopharyngioma

→ Benign cystic lesion

→ Children (2nd peak – 50 years)

→ Derived from Rathke's pouch[QQ]

→ Arise near pituitary stalk

↓

Extension into suprasellar cistern

→ Large, cystic, locally invasion tumor

Craniopharyngioma

C/F

1. **>50% Pts are – < 20 years**

↑ ICT symptoms are

→ Headache

→ Vomiting

→ Papilledema

→ Hydrocephalus

2. **Visual Field Abnormality**
3. **Cranial nerve damage**

→ Sleep difficulty

→ Weight gain

→ Personality changes

→ Cognitive deterioration

t.me/latestpgnotes

Characteristic Features

→ Hypopituitarism – 90%

→ Growth retardation – 50%

→ Diabetes Insipidus – 10%

IOC for diagnosis

→ MRI

→ MRI is better than CT for diagnosis of Cystic components & Tissue components

→ Use of CT – calcification evaluation

- Extent of invasion into surrounding bony structures and sinuses

Management

→ Trans-sphenoidal surgical resection followed by post-op radiotherapy

→ Surgery alone is curative in < 50% Pts (Because of reoccurrence)

Cause of reoccurrence → Due to adherence to vital structures

Small tumors deposits in hypothalamus

OR

Brain parenchyma

→ In absence of RT >75% CP – reoccur

→ Lifelong pituitary hormone replacement is needed

→ 1st Hormone replaced – Cortisol A/K Hydrocortisone

PrepLadder

Primary CNS Lymphoma- (PCNSL)

→ MC type – NHL QQ

→ Rising incidence of PCNLS — AIDS, Transplant Recipients

MC type in immunocompetent pts – DLBL (Diffused large B-Cell Lymphoma)

→ MC type of immunocompromised pts – large cell with immunoblastic and aggressive features

→ A/K Ghost cell tumor

↓

(Due to partial or complete resolution on CT after steroid administration)

C/F

→ Mass lesion A/W Neuropsychiatric symptoms

→ ↑ ICT

→ Seizure

Dx

→ MRI – Densely enhancing tumor

→ **IOC for diagnosis**

- Stereotactic guided biopsy
- Steroid should be withheld before Biopsy (has cytolytic effect on lymphoma cells)

↓

Non-diagnostic

t.me/latestpgnotes

Treatment

→ In non-AIDS Pts – Chemotherapy + EBRT

→ In AIDS Pts – WBRT + High Dose methotrexate + HAART

Prognosis

→ Very poor

→ Survival is less than 1 year

Metastatic Brain tumor

→ MC BT – Metastasis

→ MC primary for brain mets – **Ca lung > Ca breast**

→ MC primary for leptomeningeal mets – **Ca breast**

→ MC site – **Cerebral Hemisphere (Frontal Lobe) > cerebellum > Brain stem**

→ > 70% multiple Metastasis

IOC for diagnosis

→ MRI with gadolinium enhancement

- Lesion located at gray and white matter junction
- Edema
- Well circumscribed

Treatment

→ Metastasectomy – For metastasis up to 3 in No.

PrepLadder

→ 4 Or More – WBRT

→ Stereotactic Radiosurgery – Tumor < 3 cm

↓

Exception- 1) Small cell lung cancer

2) Seminoma

Stereotactic Radiosurgery

→ It is non- surgical RT- Used to treat functional abnormalities of brain

-Small brain tumor

→ It delivers precisely targeted concentrated dose of RT to a defined volume in the brain

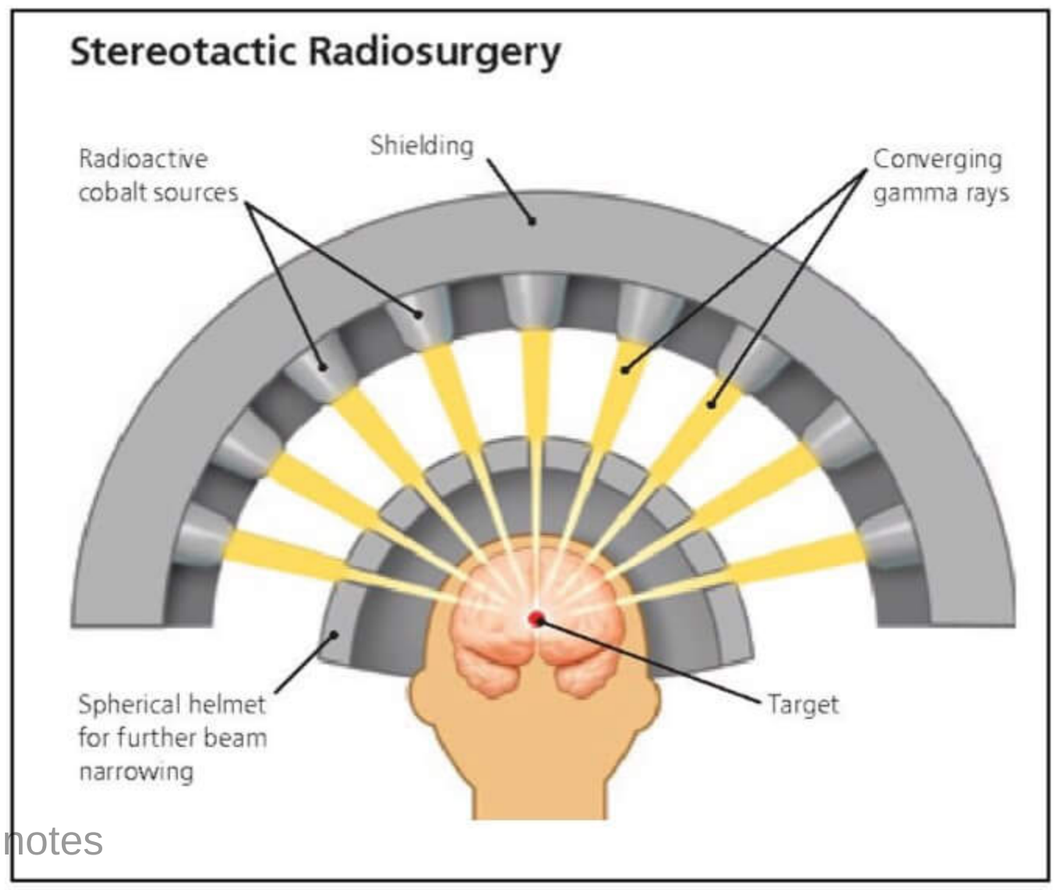

Methods of frame-Based SRS

1. Gamma knife – Co (201)
2. Modified linear accelerator – High energy X – rays

Risk associated with SRS

→ Radiation necrosis

→ Radiation injury to surrounding structure

Common uses of SRS

→ Brain tumor

→ Benign lesions of CN

→ AV malformations

→ Trigeminal neuralgia

t.me/latestpgnotes

SBRT- Stereotactic body radiotherapy

→ Used and being investigated for use in treatment of

1. Benign tumor or malignant tumors
2. Size - Middle and small
3. Location: Lung, Liver, Abdomen, Prostate, Spine head & neck

HEAD AND NECK

ORAL CAVITY

→ *Extent of oral cavity*

- **Anteriorly**: Skin and vermillion border of lips
- **Superiorly**: junction of hard palate and soft palate
- **Posteriorly**: circumvallate papillae at junction of anterior 2/3rd and posterior 1/3rd of tongue

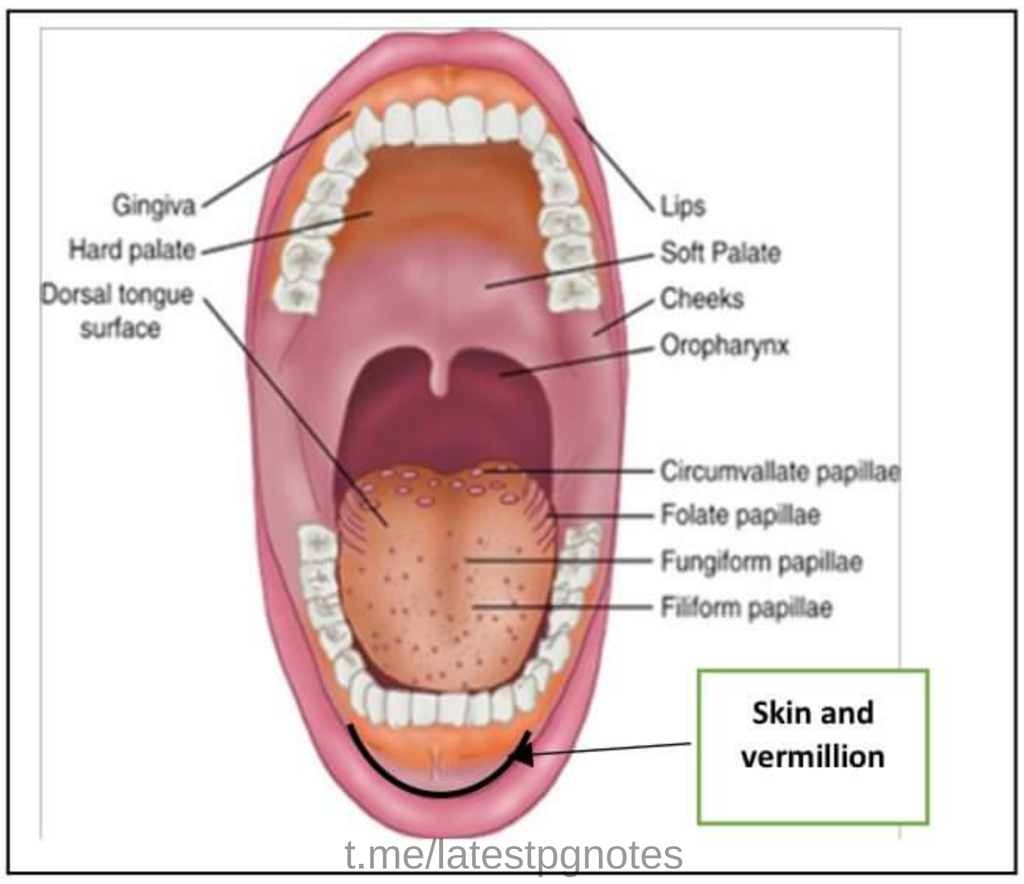

t.me/latestpgnotes

Important points of carcinoma of oral cavity:

→ MC mutation: In CA oral cavity - P53

→ MC site of CA Oral cavity – Tongue > lip

→ MC histological type – SCC

→ MC type of cancer in India - CA oral cavity (Buccal Mucosa > Anterior Tongue> Lower Alveolus)

→ MC pattern of spread - local extension and regional lymphatic spread

→ MC site of LN metastasis – lungs

→ MC lymph node metastasis – CA Tongue

→ Least common lymph node metastasis – CA lip (CA Hard Palate)

→ **B/L lymphatic spread**

- lower lip
- Supraglottis
- Soft Palate

→ IOC for **Dx** - Edge Biopsy (Not from centre to avoid taking sample from necrotic areas)

→ IOC for **staging** of Head and Neck Malignancies including CA Oral Cavity – MRI

→ MC flap used for Head & Neck reconstruction – PMMC flap (Pectoralis major myocutaneous flap) - Based on Pectoral branch of Thoraco-Acromial vessels

PrepLadder

Risk Factors for CA Oral Cavity

- → Tobacco
- → Alcohol
- → Betelnut/ Areca nut
- → Pan Masala
- → Sharp Jagged tooth
- → Plummer Vinson syndrome
- → Ill-fitting denture
- → Syphilitic glossitis
- → HPV infections
- → EBV
- → Poor nutrition

Conditions associated with malignant transformation:

High risk lesions	Medium risk lesions	Low-risk lesion
→ Erythroplakia → Speckled erythroplakia → Chronic hyperplastic candidiasis	→ Oral submucous fibrosis → Syphilitic glossitis → Plummer Vinson syndrome	→ Oral lichen planus → DLE: Discoid Lupus erythematosus → Discoid keratosis congenita

Leukoplakia

t.me/latestpgnotes

- → More common
- → whitish patch/ plaque that **cannot be rubbed off**
- → cannot be given any other diagnostic name

Leukoplakia

Risk Factors

- → Smoking
- → Alcohol
- → Ill-fitting dentures
- → Jagged tooth

Key pathological features:

- → Hyperkeratosis
- → Parakeratosis
- → Acanthosis

Diagnosis - Biopsy

Management

- → Stop alcohol and tobacco intake
- → Treat and underlying cause
- → Moderate to Severe dysplasia - Surgical excision

PrepLadder

Erythroplakia

→ Reddish mucosal patch or plaques

→ **MC location:**

- Soft palate
- Tonsillar pillar

→ High risk of malignant transformation

Erythroplakia

Key pathological features

→ Severe cellular dysplasia

Diagnosis

→ Biopsy mandatory

Management

→ Surgical ablation

Speckled Erythroplakia

Speckled erythroplakia

→ **Aka speckled leukoplakia / speckled erythroplakia / erythro-leukoplakia**

→ Leukoplakia arises on erythematous base

→ Oral erythroplakia is intermingled with white plaque

→ **Highest risk of malignancy**

t.me/latestpgnotes

Plummer Vinson Syndrome

→ Aka Paterson Brown Kelly syndrome / Sideropenic dysphagia

→ MC middle aged edentulous females

→ Risk factors for SCC of oral cavity, hypopharynx and oesophagus

Features

→ Chronic iron deficiency Anemia

→ Dysphagia-upper Esophageal web

] therefore called Sideropenic dysplasia

→ Koilonychia -Brittle spoon shaped finger nails

→ Splenomegaly

→ Achlorhydria

→ Atrophic oral mucosa, glossitis

PrepLadder

Oral submucous fibrosis:

→ Pre-malignant lesion

→ Formation of fibrous band in the oral cavity

↓

Restricted mouth opening

↓

Tongue mouth opening and tongue movement

↓

↑ risk of SCC

(Due to poor hygiene)

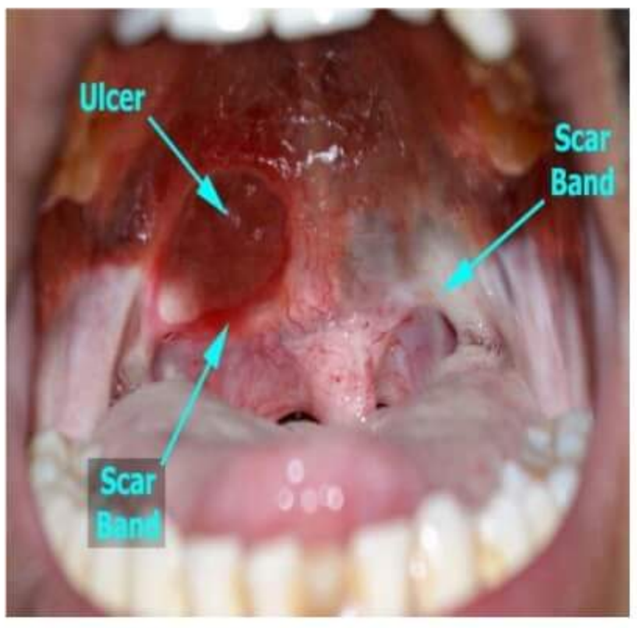

Oral Submucous Fibrosis

→ Typical seen in Asian populations

→ **Risk factors** - Areca nut

→ **Preferred form of treatment** - Intralesional injection of steroid and triamcinolone

→ **Alternative treatment** – surgical excision with grafting

Field cancerization

→ Diffuse and chronic exposure to mucosa of carcinogenic substances

↓

Wide spread adverse changes in mucosal epithelium

↓

Separate tumors at different sites

t.me/latestpgnotes

Synchronous tumors

-Detected simultaneously

Or within six months

Metachronous tumor

- Detected after six months

Examples

→ Tobacco or alcohol exposure for aero digestive tract

→ Smoking for urinary tract malignancy

CA oral cavity

Clinical features

→ Persistent swelling or ulcer > **3 weeks**

→ Sore tongue

→ Difficulty in swallowing

→ Jaw/ facial swelling

→ Painless mass in the neck

→ Trismus

Diagnosis

→ **IOC** - Edge Biopsy

→ **IOC for staging** - MRI > CT scan

PrepLadder

8TH AJCC TNM CLASSIFICATION

T_x	→ Tumor cannot be assessed
T_{is}	→ Ca – in-situ
T_1	→ Tumor upto 2cm in size; up to 5mm depth of invasion
T_2	→ Up to 2 cm in size with > 5 -10 mm depth of invasion → >2 - 4 cm, depth of invasion up to 10 mm
T_3	→ Tumor up to > 4 cm in size and >10 mm depth of invasion
T_{4a} (lip)	→ Tumor invades through cortical bone, inferior Alveolar nerve, floor of mouth, skin of chin or nose
T_{4a} (oral cavity)	→ Tumor invades the cortical bone, mandible, maxillary sinus or skin of face
T_{4b}	→ Tumor involves through masticator space, pterygoid plate Skull base and / or encases internal carotid artery
Regional lymph node	
N_x	→ Lymph node status cannot be assessed
N_1	→ Metastasis to single ipsilateral LN up to 3 cm in greatest dimension
N_{2a}	→ Metastasis to single ipsilateral LN up to > 3 -6 cm dimensions
N_{2b}	→ Metastasis to multiple ipsilateral LN none >6 cm in greatest dimension
N_{3a}	→ Metastasis to LN > 6 cm in greatest dimension
N_{3b}	→ Metastasis to single or multiple LN with clinical Extra nodal extension
Metastasis	
M_x	→ Metastasis cannot be assessed
M_0	→ No Metastasis
M_1	→ Distant Metastasis

t.me/latestpgnotes

Management

→ Surgery with reconstruction **(most important modality)**
→ Chemotherapy
→ Radiotherapy

Surgery reconstruction

→ Wide local excision with 2cm margin
→ Main modality of treatment

PrepLadder

Various flaps used are

PMMC Flap (MC)

→ Based on pectoral branch of the Thoracoacromial artery

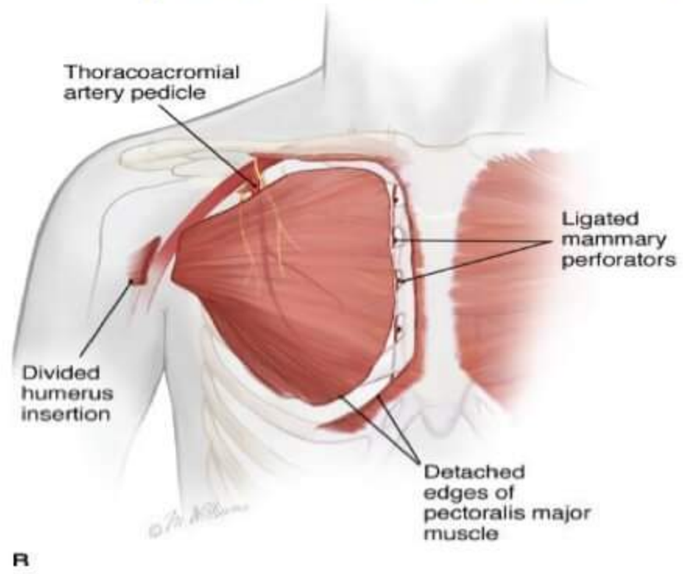

Radial forearm free flap

→ Based on radial artery

→ Used to reconstruction of

- Floor of mouth
- Lateral tongue
- Buccal mucosa
- Base of tongue
- Soft palate

t.me/latestpgnotes

Anterolateral thigh flap:

→ Based on perforator vessels of descending branch of lateral circumflex femoral artery

→ Used for reconstruction of lateral part of tongue or total tongue (glossectomy)

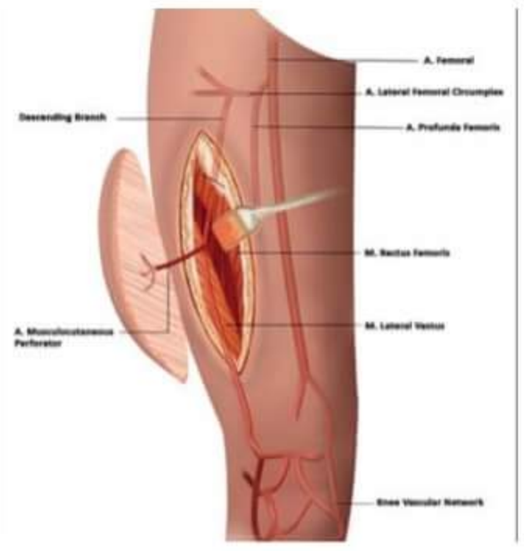

Rectus abdominis flap

→ Based on deep inferior epigastric artery

→ Used for reconstruction of total tongue after glossectomy

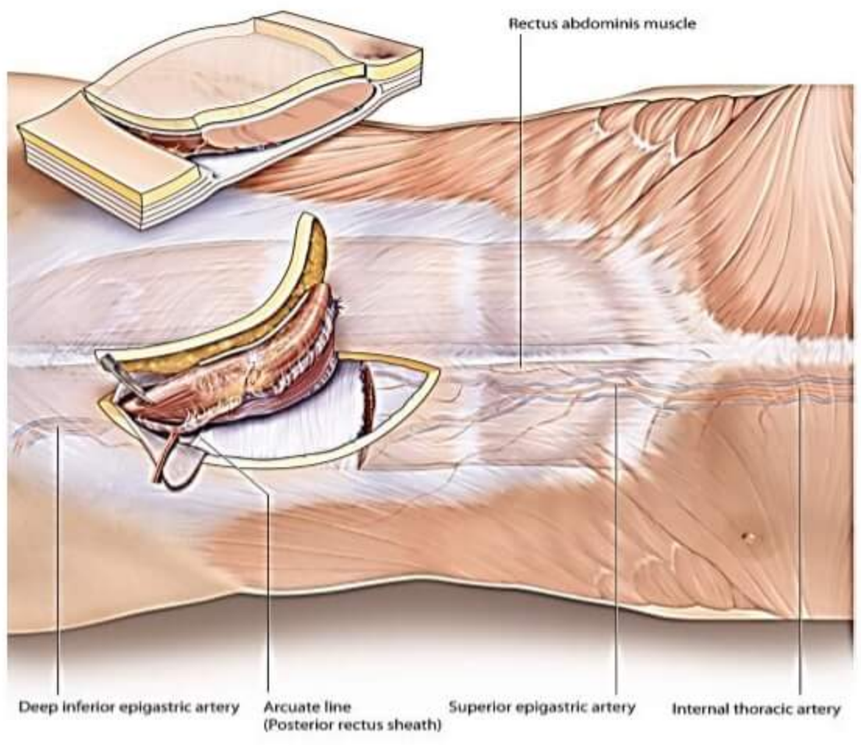

PrepLadder

Chemotherapy

→ Cisplatin + 5 fluorouracil (most preferred combination)

→ Cornerstone of most of head and neck malignancy

→ **Concurrent chemotherapy** – Cisplatin → Head & neck malignancies

→ **Concurrent chemoradiation** – Beneficial because improves survival over radiation alone

Radiotherapy

→ External beam radiation therapy is used (MC)

→ Dose- 60 gray for 6 weeks

→ **Complications of radiotherapy**

Xerostomia (MC)

- Mucositis
- Dysgeusia (Temporary / permanent)
- Osteoradionecrosis
  - Related to caries tooth in radiation field
  - ↓ production of saliva (damage to microcirculation of mandible and maxilla)

Management- Dental care, hyperbaric oxygen therapy

Carcinoma lip

→ MC site – lower lip (Vermillion border)
(due to direct exposure of UV radiation)

t.me/latestpgnotes

→ MC males (Due to more outdoor activities)

- 4th to 7th decades
- CA Lower Lip - B/L lymph metastasis
- MC lymph node involvement-late stage

IA → (Submental)

IB → (submandibular)

- Best prognosis
- IOC for diagnosis - Edge biopsy

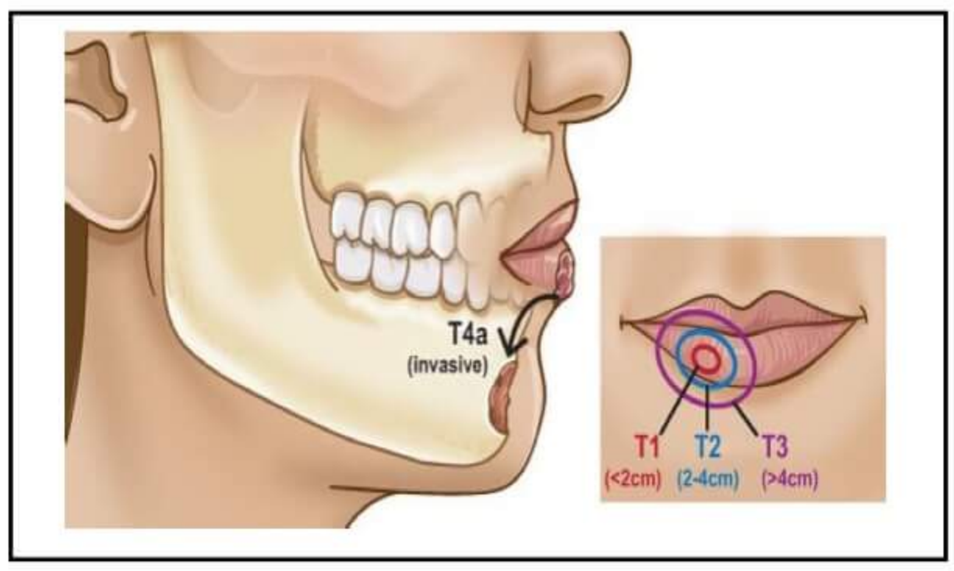

Treatment

→ **For T_1 & T_2** - Surgery

→ **For T_3 &T_4** - Surgery + Radiotherapy

→ **If 1/3rd or less than 1/3rd lip is involved** → V-shaped or W-shaped Excision +primary closure

→ **If more than 1/3rd lip is involved** - Excision with flap reconstruction
(MC flap used - Abbe- Estlander's flap)

→ **For T_3 & T_4** - Surgery + radiotherapy

PrepLadder

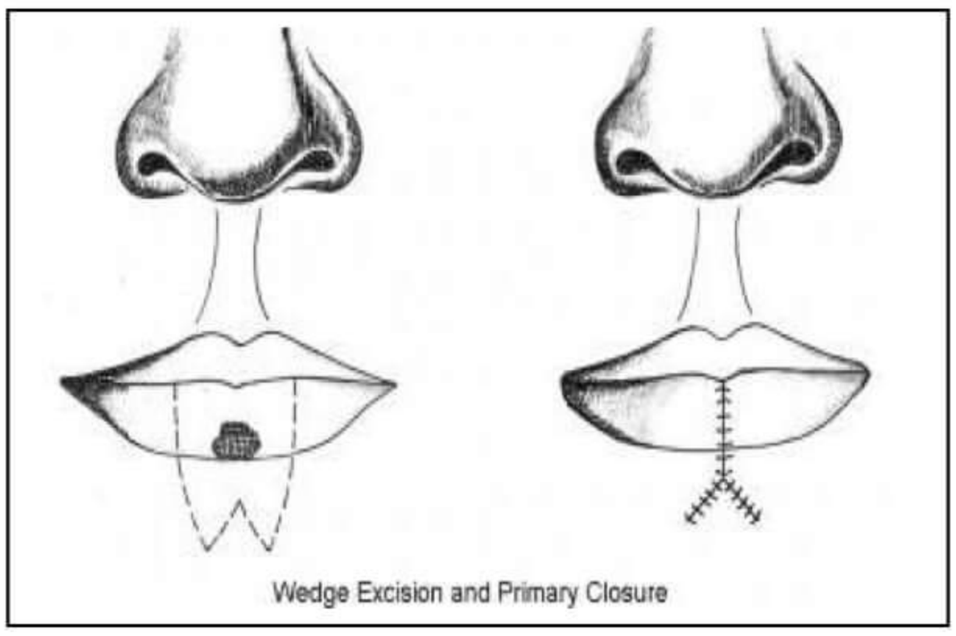

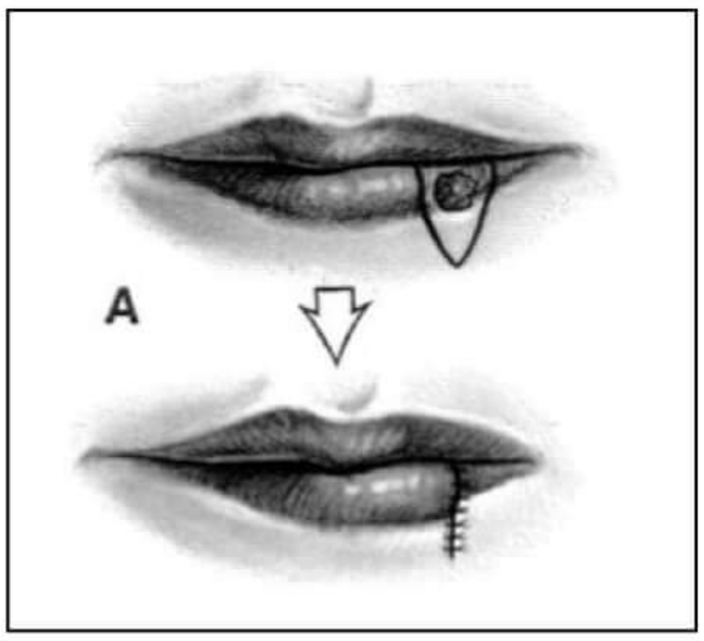

Various flaps used in Lip reconstruction

Cross lip flap	Circumoral advancement flap
Example – Abbe Estlander's flap ↓ Based on **superior** labial artery 	Example • Karapandzic flap • Webster Bernard flap

t.me/latestpgnotes

Carcinoma Tongue

→ MC type of carcinoma oral cavity

→ MC site – lateral border of tongue at junction of middle and posterior 3rd of tongue

→ MC Type – Ulcerative variety

→ MC LN involvement – Level II (upper jugular)

C/F

→ Pt. with ulcer which fail to heal & cannot tolerate hot & spicy food

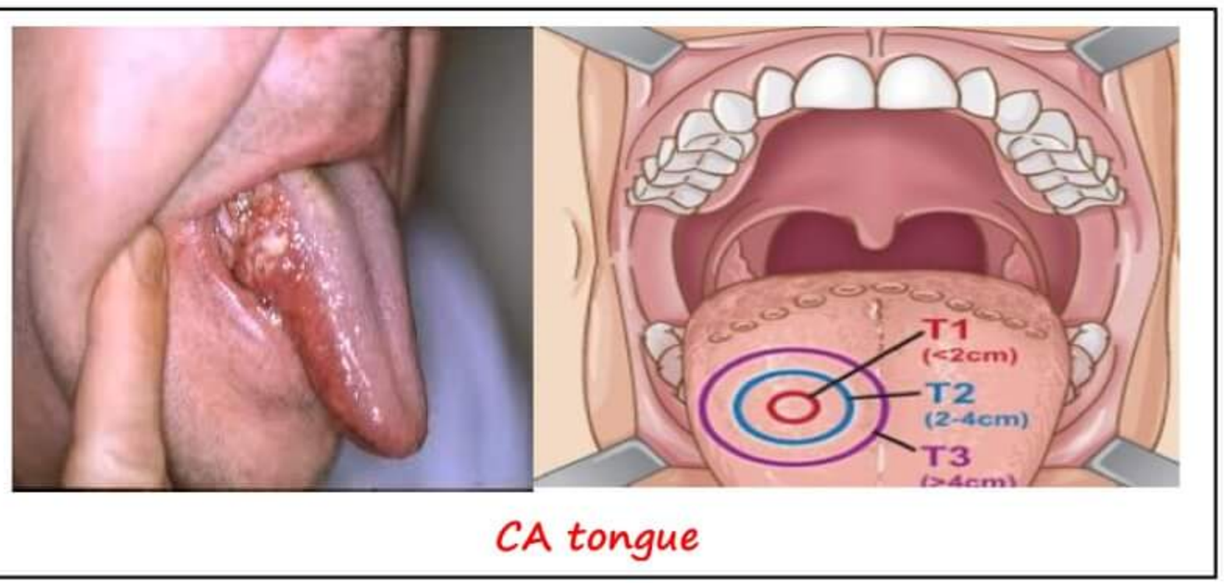

CA tongue

IOC for diagnosis

→ Edge or wedge biopsy

Treatment

→ **T1** – Partial glossectomy with primary closure

→ **T2** – Hemi glossectomy + radiotherapy

→ **T3** – Total glossectomy + mandibulectomy

→ **T4** – Total glossectomy + mandibulectomy + MRND + Laryngectomy + radiotherapy

→ **Recurrence**: within 2 years

PrepLadder

→ **Radiation fails** – Glossectomy

→ **Recurrence after surgery** – Radiotherapy

Carcinoma Buccal mucosa or cheek

→ MC site of carcinoma oral cavity in India (Due to tobacco use with betel leaf, areca nut, lime shell)

→ Involvement of level I, II LN

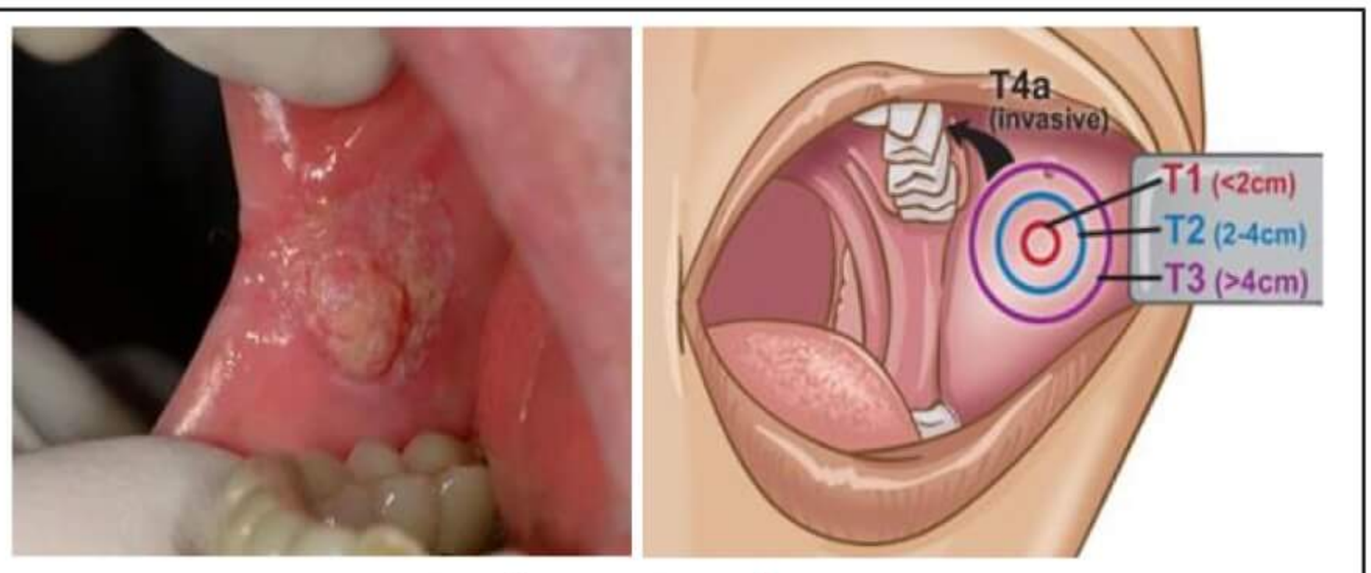

Carcinoma Buccal Mucosa

Clinical features

→ Minimal pain

→ Parotid enlargement (Due to obstruction of Stenson's duct)

Investigation of choice for diagnosis – **Edge biopsy**

t.me/latestpgnotes

Treatment

→ **T1 & T2** – surgery with wide local excision

→ **T3 & T4** – Surgery followed by radiotherapy

Cancer of Hard palate

→ SCC of hard palate is rare

→ A/W reverse smoking

→ Minor salivary glands tumor is common

Cancer of Hard palate

C/F

→ **Painless mass** on roof of mouth

→ Well differentiated tumor

→ MC ulcerative variety

→ LN metastasis – uncommon (if involved: Level I and II)

Management

→ Small tumor – Excision of tumor with underlying bone

→ Large tumor – Maxillectomy

→ **Radiotherapy in advance malignancy**

PrepLadder

Lower alveolar cancer

→ **Lateral tumor** – ipsilateral selective neck dissection

→ **Anterior tumor** – B/L selective neck dissection

→ Segmental resection of mandible, if there is bone invasion

→ Primary or immediate reconstruction > delayed reconstruction (for better functional & cosmetic outcome)

Lower alveolar cancer

Mandibulectomy

Marginal Mandibulectomy	Segmental mandibulectomy
→ Partial excision of superior portion of mandible in vertical plane → A/K conservative mandibulectomy → Inner cortical surface and part of underlying medullary cavity is excised **Indications** → Within 1 cm of mandible	→ Entire through and through segment of mandible is excised ↓ Mandible discontinuity ↓ Reconstruction of mandible **Indications** → Invasion of medullary space of mandible
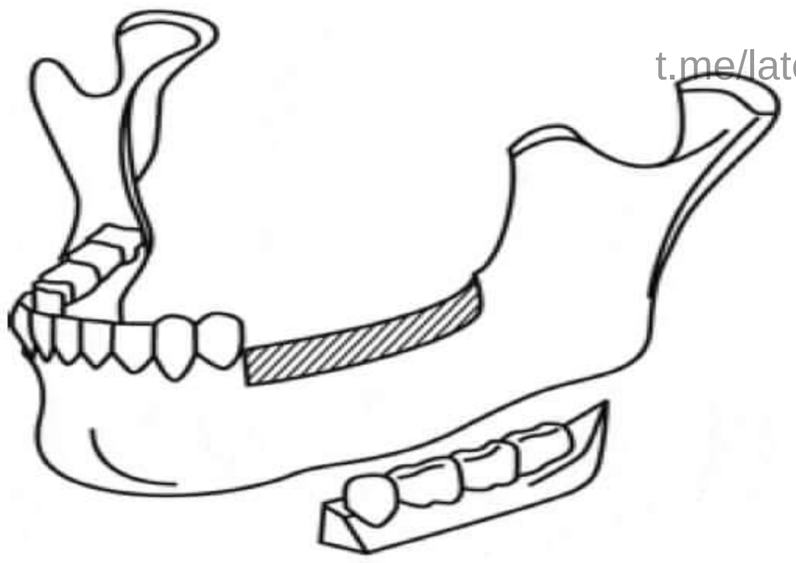 Marginal mandibulectomy	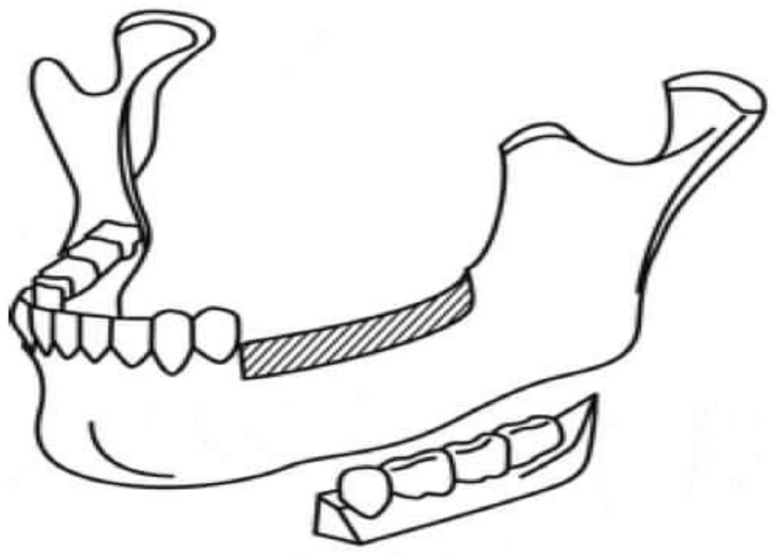 Marginal mandibulectomy
→ Tumor abuts the periosteum without direct invasion	→ Tumor fixation to occlusal surface of mandible in edentulous patients → Invasion of tumor into mandible via mental foramen / mandibular foramen

t.me/latestpgnotes

Mandibular reconstruction:

Dentate patients

→ **Iliac crest** (preferred graft) – It is based on deep circumflex iliac artery

→ **Fibula graft** – It is based on peroneal artery

→ **Scapula graft** – It is based on subcapsular artery

PrepLadder

Edentulous patients

→ Fibula graft (Preferred graft): Perineal artery

→ Scapula graft: Subscapular artery

Scapula graft also used in concomitant large soft tissue defect

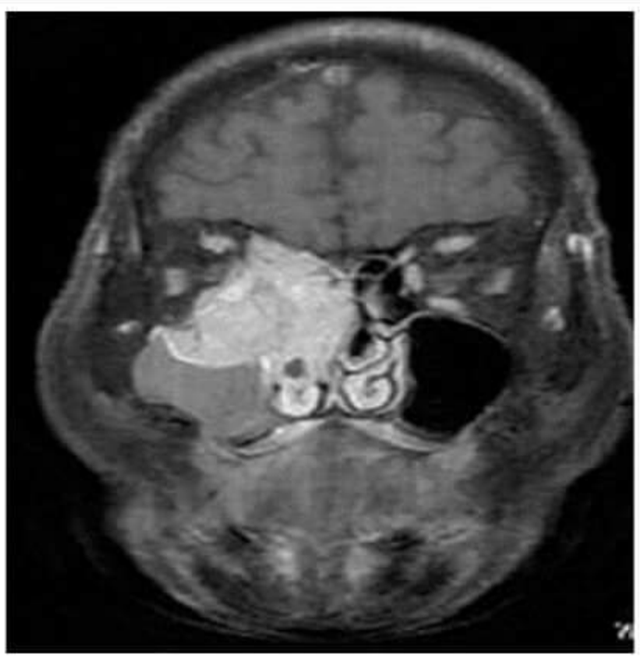

Carcinoma Maxillary Sinus

Carcinoma maxillary sinus:

→ MC site of paranasal sinus malignancy

→ 4th to 6th decades

→ MC in males

Clinical features

→ Nasal stuffiness

→ Blood stained discharge

→ Facial paresthesia / pain

→ Epiphora

→ LN metastasis – Uncommon (if occur then mandibular LN)

Diagnosis

→ CT scan – best non invasion method

Management

→ Surgery + radiotherapy – best result

t.me/latestpgnotes

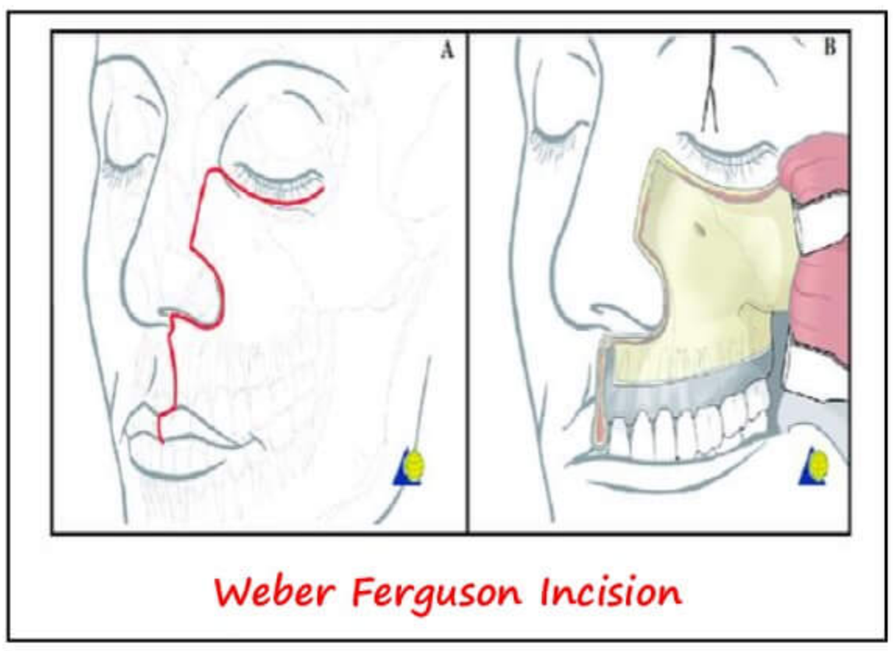

Weber Ferguson Incision

Weber Ferguson Incision

→ Involvement of infraorbital nerve

→ Involvement of floor of orbit

Commando operation

→ Combined Mandibulectomy & Neck dissection operation

→ Total glossectomy + Hemi mandibulectomy + removal of floor of mouth + Radical neck dissection

→ Carcinoma is fixed to mandible with infiltration to floor of mouth

Dental cyst	Dentigerous cyst	Ameloblastoma
→ Develops at apex of caries tooth with necrotic pulp → **MC: upper jaw** → **X-ray:** Circular radiolucent area in relation to root of normally erupted tooth → Margin: Sclerotic	→ Arises from unerupted tooth → MC in lower 3rd molar → Cyst contain unerupted tooth → **X-ray** • Unilocular cyst • Soap bubble appearance	→ Benign tumor from ameloblast → **MC odontogenic tumor** → MC location - Angle or ramus of mandible

PrepLadder

SALIVARY GLAND

Anatomy of salivary glands

→ Major salivary glands & minor salivary glands

- **Parotid glands** – contains serous acini
- **Submandibular gland** - contains serous + mucinous acini
- **Sublingual & minor salivary gland** - contains mucinous acini

→ Ducts of various glands

- **Parotid duct** - AKA Stenson's duct (Opens at upper 2nd molar)
- **Submandibular gland** – has Wharton's duct (Opens at papilla just lateral to frenulum)
- **Sublingual gland** - has Duct of Rivinus & Bartholin's duct

→ Minor salivary gland is 750(approx..) in number

Location of minor salivary gland:

→ Lip
→ Buccal Mucosa
→ Retromolar area
→ Hard Palate

t.me/latestpgnotes

Risk factors:

→ Radiotherapy of head & neck – R.F for Mucoepidermoid carcinoma
→ Epstein Barr infection - R.F for lymphoepithelial carcinoma
→ Exposure of Silica dust & Nitrosamines
→ Early menarche & Nulliparity
→ Trisomy 5 } R.F for mucoepidermoid carcinoma
→ Translocation of chromosome no.11 }
→ Polysomy 3 and 17 – R.F for Adenoid cystic carcinoma

IMPORTANT POINTS:

→ MC salivary gland tumor - Pleomorphic Adenoma
→ MC malignant tumor of salivary gland - Mucoepidermoid Carcinoma
→ MC neoplasm of salivary gland in children - Hemangioma
→ MC malignant tumor of salivary gland in children - Mucoepidermoid carcinoma
→ MC malignant tumor of minor salivary gland - Adenoid Cystic carcinoma

Note:

→ All salivary gland tumors are more common in parotid

- Pleomorphic adenoma
- Warthin's tumor } Exclusively seen in Parotid
- Mucoepidermoid Ca }

PrepLadder

- Lymphoma
- Metastasis

→ Except:

- Adenoid cystic carcinoma
- Squamous cell carcinoma – MC in submandibular gland

Diagnosis

→ Investigation of choice for Dx - **FNAC**

→ **Open incisional biopsy** - contraindicated due to

- Tumor cell seeding in tract
- Increased risk of parotid fistula

→ Best imaging investigation for salivary gland tumors - **MRI**

→ **Risk of malignancy is inversely proportional to size of gland**

Salivary gland	Benign	Malignant
• Parotid	– 75%	– 25%
• S/M & S/L	– 50%	– 50%
• Minor salivary gland	– 25%	– 75%

Management of salivary gland tumors

1) **Surgery** (principle Rx) - Surgical excision alone or in combination with radiotherapy

→ **For Parotid tumor:** depending on the involvement

- Superficial parotidectomy
- Deep lobe parotidectomy
- Total parotidectomy
- Radical parotidectomy

→ **Other salivary gland tumors** – En block excision of tumor + gland

2) **Neck dissection:** performed in

→ Clinically palpable nodes

→ High grade malignancies

3) **Radio therapy:**

→ **Indications**

- High Grade tumor
- Large primary tumor
- Perineural invasion
- Invasion of Lymph node
- Positive margins
- Cervical lymph node metastasis

PrepLadder

4) **No role of chemotherapy**

→ **In salivary gland tumors due to**

- Incomplete & short-lived response
- No survival advantages

Incisions for parotidectomy

→ Lazy 'S' incision

→ Modified Blaire's

→ Sistrunk incision

Types of Parotidectomy

1. **Superficial or lateral or classical parotidectomy:**
   - For benign and malignant tumors involving superficial lobe
   - Salivary tissue lateral to facial nerve is removed

2. **Deep lobe parotidectomy:**
   - For benign and malignant tumor involving deep lobe
   - Salivary tissue deep to facial nerve is removed

3. **Total conservative parotidectomy**
   - For benign and malignant tumor involving both superficial + deep lobe
   - All salivary tissue is removed
   - Facial nerve is preserved

t.me/latestpgnotes

4. **Radical parotidectomy**
   - For tumors invading facial nerve
   - All salivary tissue is removed + excision of facial nerve

5. **Extended radical parotidectomy**
   - Radical parotidectomy + removal of adjacent structures (mandible, temporal bone, muscles)

Surgical Landmarks for facial nerve

→ **S**: Styloid process

→ **T**: Tragal pointer, Tympanomastoid suture line (most auricular landmark)

→ **Ra**: Retromandibular vein

→ **P**: Posterior belly of diagnostic

Complications of Parotidectomy

→ Facial nerve paresis/paralysis

→ Sensory abnormalities due to sacrifice of greater auricular nerve

→ Frey's syndrome

→ Salivary fistula

PrepLadder

FREY'S SYNDROME

→ aka Auriculotemporal syndrome / Gustatory sweating

→ Injury of **Auriculotemporal nerve** - Causes aberrant cross innervation

↓

Parasympathetic secretomotor fibers & Sympathetic fibers supply sweat glands

Clinical features

→ On tasting food or Smell of food – causes Autonomic stimulation

↓

Leads to Sweating & erythema at parotid region

Diagnosis

→ Minor' starch iodine test

Management

→ Anti-perspirant application

→ Botox injection

→ Tympanic neurectomy – for non-responding cases

PAROTID FISTULA

→ **Internal fistula** – Asymptomatic (opening is inside mouth)

→ **External fistula** – 2 Types (Gland & Duct fistula)

t.me/latestpgnotes

Clinical Features

→ **Gland fistula**

- Pin point opening over gland
- Closes spontaneously

→ **Duct fistula**

- External opening over cheek
- Excoriation of surrounding skin

Risk factors

1) Rupture of parotid abscess
2) Penetrating injury
3) Incision and drainage of parotid abscess
4) After superficial parotidectomy

Diagnosis:

→ Investigation of choices for Dx - Sialogram

Treatment

→ NEWMAN & SEABROCK'S OPERATION

PrepLadder

PLEOMORPHIC ADENOMA

→ MC salivary gland tumor
→ MC site – Parotid (MC site in parotid – Superficial lobe/Tail)
→ Other sites - Submandibular, Sublingual, Minor salivary gland
→ Females, 4th decade

Pleomorphic Adenoma

Pathology

→ It is a Mixed tumor (has both epithelial & Mesenchymal component)
→ Has finger like projection (Pseudopodia) - Enucleation is contraindicated
→ Tumor is located Infront, below & behind Ear lobule - pushing it up
→ Has slow growth

Note: Pleomorphic adenoma involving deep lobe pushes faucial pillars & tonsils towards midline – hence known as Dumb bell tumor

Diagnosis

→ Investigation of choice - FNAC

Treatment

t.me/latestpgnotes

→ TOC - Superficial parotidectomy
→ Pleomorphic adenoma involving sublingual or submandibular – Excision of involved gland

Complications

1) Malignant change

→ Known as Carcinoma Ex Pleomorphic adenoma
→ AKA Malignant mixed tumor
→ Changes suggesting malignancies
  - Rapid growth
  - Pain
  - Paraesthesia
  - Facial weakness
  - Enlarged cervical lymph nodes
  - Fixation to mastoid tip

2) Recurrence: Occurs when Enucleation or Inadequate removal done

WARTHIN'S TUMOR

→ **AKA Papillary cystadenoma lymphomatosum** – because of
  - Papillary cystic pattern with marked lymphoid component

PrepLadder

→ **AKA Adenolymphoma**
  - Has both Epithelial + lymphoid component

→ 2nd MC benign tumor of parotid glands

→ Exclusively seen in parotid gland

→ It is derived from salivary tissue inclusion in lymph nodes

→ MC in Males, 5th/7th decade

→ MC in Smokers – in 10% cases it is bilateral

→ Well incapsulated, cystic, very slow growth

→ Doesn't turn malignant

→ Has characteristic Double layer of lining cells

Warthin 's Tumor

Diagnosis

→ Investigation of choice - FNAC

Treatment

→ Treatment of choice - Superficial parotidectomy

MUCOEPIDERMOID CARCINOMA

→ Most common malignant tumor of salivary gland

→ Most common radiation induced neoplasm of parotid

→ Most common malignant tumor of salivary gland in children

→ The tumor is composed of squamous cells, mucus secreting cells, clear cells / hydropic cells

t.me/latestpgnotes

→ Major component is Mucin producing cells & Epithelial cells

Low Grade	High Grade
• MC in Children • Mucin secreting cells predominate • Well differentiated • R_X: superficial / total parotidectomy	• MC in Adults • Squamous cells predominate • Poor differentiated • R_X: Total parotidectomy ± radical neck dissection

ACINIC CELL CARCINOMA

→ Rare

→ Exclusively seen in parotid

→ Tumor cells resembles normal serous acinar cells of salivary gland

→ Encapsulated

→ Tends to involve regional lymph node

Treatment

→ Radical excision

PrepLadder

ADENOID CYSTIC CARCINOMA

→ Most common malignant tumor of
- Minor salivary gland
- Sublingual gland
- Submandibular gland

→ 2nd MC malignant tumor of salivary gland

→ Most common site - Hard palate > sinonasal tract

→ Most common type - Cribriform variety (has Swiss-cheese pattern)

→ **Has Perineural invasion** – so involvement of facial nerve > trigeminal nerve

↓

Pain & facial nerve paralysis

→ Tumor grows along Haversian system of bone without causing bone destruction

→ **Also known as Tracherous tumor** because - Tumor is malignant but looks like benign

Clinical features

→ Pain

→ Facial nerve paralysis

→ High risk of distant metastasis

→ MC site of distant metastasis – Lungs

Diagnosis

→ Investigation of choice for dx - FNAC

t.me/latestpgnotes

→ Radiological IOC for detection of early perineural spread & intra cranial extension – MRI

Treatment

→ Excision with widest cuff of normal tissue around tumor – as it has Skip lesions

→ Post-operative RT – to prevent recurrence

SUBMANDIBULAR GLAND

→ **Important anatomical relationships**
- Lingual nerve
- Hypoglossal nerve
- Facial artery & anterior facial vein
- Marginal mandibular branch of facial nerve

→ Most common injured nerve- Lingual nerve > Hypoglossal nerve

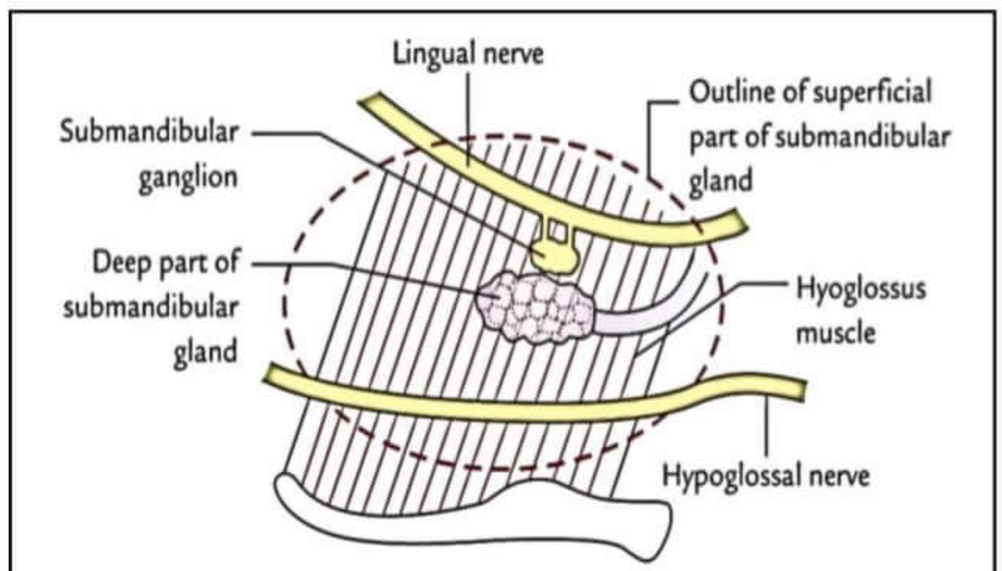

Submandibular Gland Anatomy

SIALOLITHIASIS (Salivary gland stone)

→ 80% of salivary gland stones are seen in Submandibular gland

→ 80% of salivary gland stones are - Radio-opaque

PrepLadder

→ **Composition**
- Calcium (or)
- Magnesium phosphate (or)
- Carbonate

→ **Distributions of salivary gland stones**
- Submandibular gland (80%) > Parotid (10%) > Sublingual (7%) > Minor salivary gland (3%)

Clinical Features
→ Pain & swelling in S/M region (during meals)
→ Referred pain to tongue – irritation of lingual nerve due to impacted stone

Diagnosis
→ IOC for dx - NCCT

Treatment
→ **Stone in the duct** - incision over the duct & removal of stone
→ **Stone in the gland** – excision of submandibular gland
→ Most common injured nerve during submandibular gland excision Sx - lingual nerve > Hypoglossal nerve

RANULA
t.me/latestpgnotes
→ Cystic swelling in floor of mouth - Resembles FROG'S BELLY
→ It is Mucus extravasation cyst that arises from S/L gland
→ Local trauma /duct rupture – causes Spillage of mucin in surrounding soft tissue known as Mucus Extravasation Phenomenon

↓

Mucin accumulation surrounded by Granulation tissue / fibrous tissue

Ranula

Clinical features:
→ Exclusively seen in Floor of mouth
→ Unilateral
→ Lateral to midline
→ Painless smooth dome shaped
→ fluctuating swellings
→ Bluish appearance

Diagnosis
→ Diagnosed clinically

PrepLadder

Treatment

→ **Marsupialization** – divide wall of cyst and suture edges to surrounding tissue

→ Excision of sublingual(S/L) gland

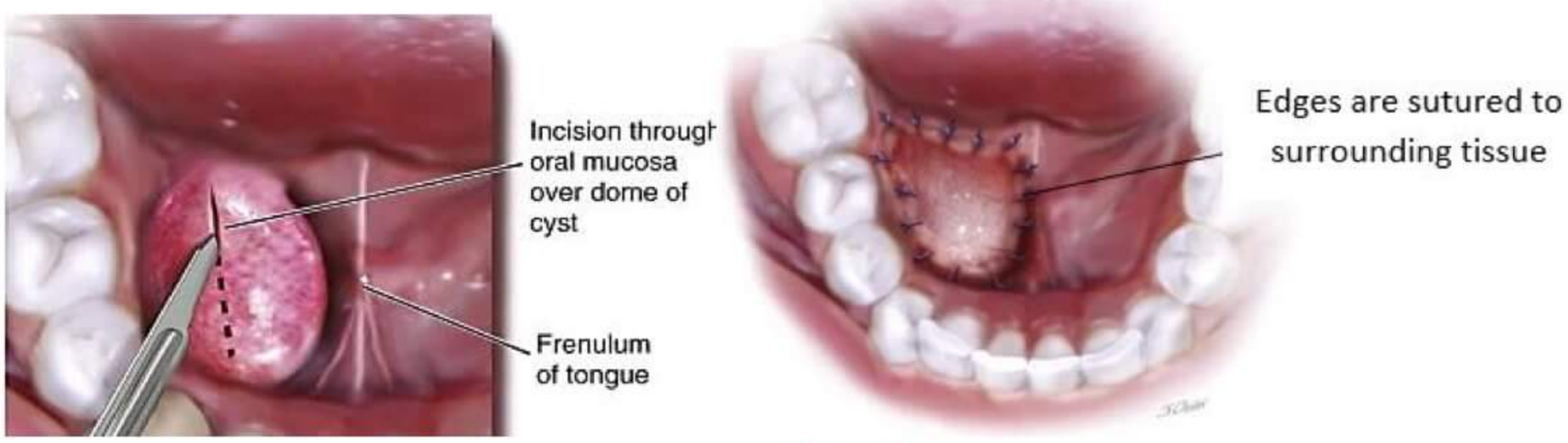

Marsupialization

PLUNGING RANULA

→ Rare mucus extravasation of cyst

→ Arises from S/L gland

→ Has 2 components - Intraoral ranula with cervical prolongations

Clinical Features:

→ Painless

→ Soft

→ Fluctuant

→ Dumb bell shaped

t.me/latestpgnotes

Diagnosis

→ Diagnosis is based on - **Ultrasound or MRI**

Treatment

→ Excision of S/L gland with aspiration of saliva out of sac

PrepLadder

NECK

CAROTID BODY TUMOR:

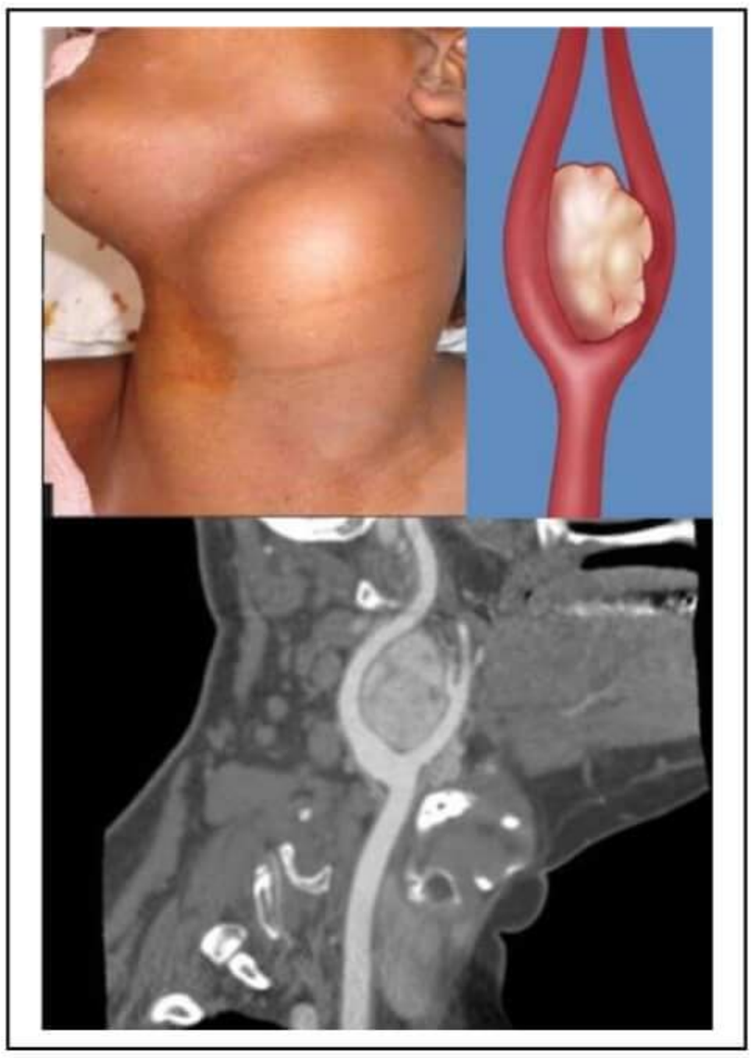

- → **AKA Chemodectoma / Non-chromaffin paraganglioma**
- → Arises from chemoreceptor cells on medical side of carotid bulb
- → It is Benign, unifocal & non-hereditary
- → Classification used for carotid body tumor - **Schamblin classification**
- → Associated with pheochromocytoma
- → Higher incidence in individual staying in high attitude (due to chronic hypoxia → carotid body hyperplasia)
- → Seen in 5th decade
- → 10% have positive family history
- → Painless swelling, slowly enlarging
- → Firm, rubbery, pulsatile, mobile from side to side
- → (+) Bruit

IOC for diagnosis

- → Carotid angiography – shows **Lyre's sign (Splaying of internal & external carotid artery)**
- → FNAC and biopsy are contraindicated (because swelling is vascular)

t.me/latestpgnotes

Treatment:

- → **In Elderly**: Only observation (surgery – **avoided**) – because tumor benign & slow growth
- → **If tumor is > 3cm** - Pre-op embolization
- → **If tumor is > 5cm** - Excision with carotid artery replacement

Complications:

- → Cranial nerve injury - **Superior laryngeal nerve (MC)**
- → **First Bite syndrome** – pain with initiation of mastication
- → Excision of B/L carotid tumor - Cause Baroreceptor failure

↓

Leads to Wide fluctuation of BP

Cystic hygroma:

- → Multi located cystic spaces
- → Lined by endothelial cells

Causes

- → Sequestration of jugular lymph sac from lymphatic system

↓

Cyst are filled with clear fluid

- → A/W – **Turner's Syndrome**

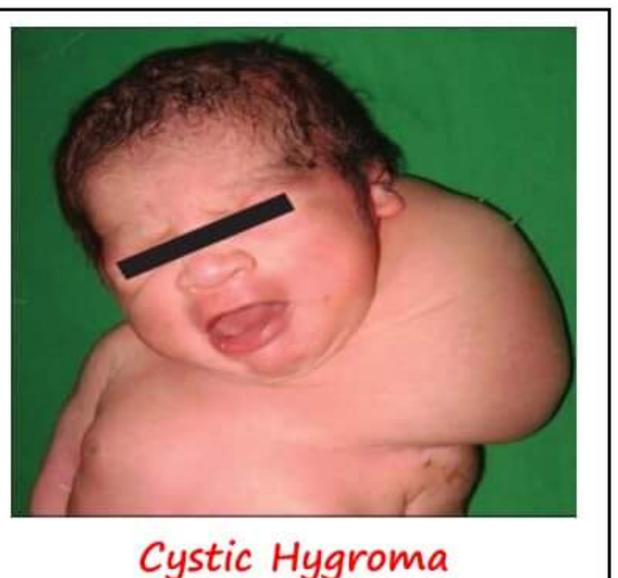

Cystic Hygroma

PrepLadder

→ MC site - Posterior triangle of neck
→ Other sites - Axilla, Mediastinum, Inguinal, Retroperitoneal region
→ In 50% cases, it is present at birth - cause difficulty in labor
→ Has spontaneous regression

Clinical features:

→ Cystic mass – cause Airway obstruction
→ Infection and Hemorrhage
→ Soft, compressible – **Size increases when child coughs or cries**
→ Brilliantly Translucent

Diagnosis

→ For Soft tissue hamartomatous malformations
- Cystic hygroma
- Lymphangioma
- Lymphovenous malformations

} IOC is MRI

Treatment:

→ Preferred Rx - Complete surgical excision
→ Injection of sclerotherapy
- Bleomycin
- OK – 432 (Picibanil) - derived from Strep. Pyogenes

t.me/latestpgnotes

Branchial Cleft Remnants

→ Typically present as lateral neck mass in toddlers
→ All branchial Cleft Remnants - Present at birth (often not recognized until later)
→ Sinus, fistula, cartilaginous rest – MC in infants
→ Cyst – MC in older children and adolescent

BRANCHIAL ABNORMALITIES

Branchial cyst

→ Vestigial remnants of 2nd branchial cleft
→ Lined by squamous epithelium
→ **Content** – Thick, turbid & full of cholesterol crystals
→ MC in early and middle adulthood
→ Located at junction of upper and middle 1/3rd of SCM.
→ Soft, fluctuant, Transillumination positive

Branchial cyst

Diagnosis

→ FNAC & Ultrasound – helps in diagnosis

Treatment

→ Complete excision of cyst

PrepLadder

Branchial fistula

→ U/L or B/L
→ Persistent 2nd branchial cleft
→ Lined by ciliated columnar epithelium
→ Mucus/mucopurulent discharge from external opening
→ **External orifice** – lower third of neck at anterior border of SCM
→ **Internal orifice** – anterior aspect of posterior faucial pillars just behind tonsil
→ If internal aspect ends blindly - Branchial sinus

Branchial Fistula

Treatment:

→ Excision by multiple transverse incisions **(Incision in Stepladder pattern)**

First branchial cleft remnants:

→ Located in front or back of ear or in upper neck near mandible
→ **Fistula** – courses through Parotid glands, Deep or through branches of facial nerve & ends in external auditory canal

Second branchial cleft remnants:

→ MC type
→ **External opening** - in lower third of neck at anterior border of neck
→ **Internal opening** – in Tonsillar fossa

t.me/latestpgnotes

Course of fistula:

→ Through carotid artery bifurcation
→ Behind posterior belly of digastric, stylohyoid muscle & ends in Tonsillar fossa

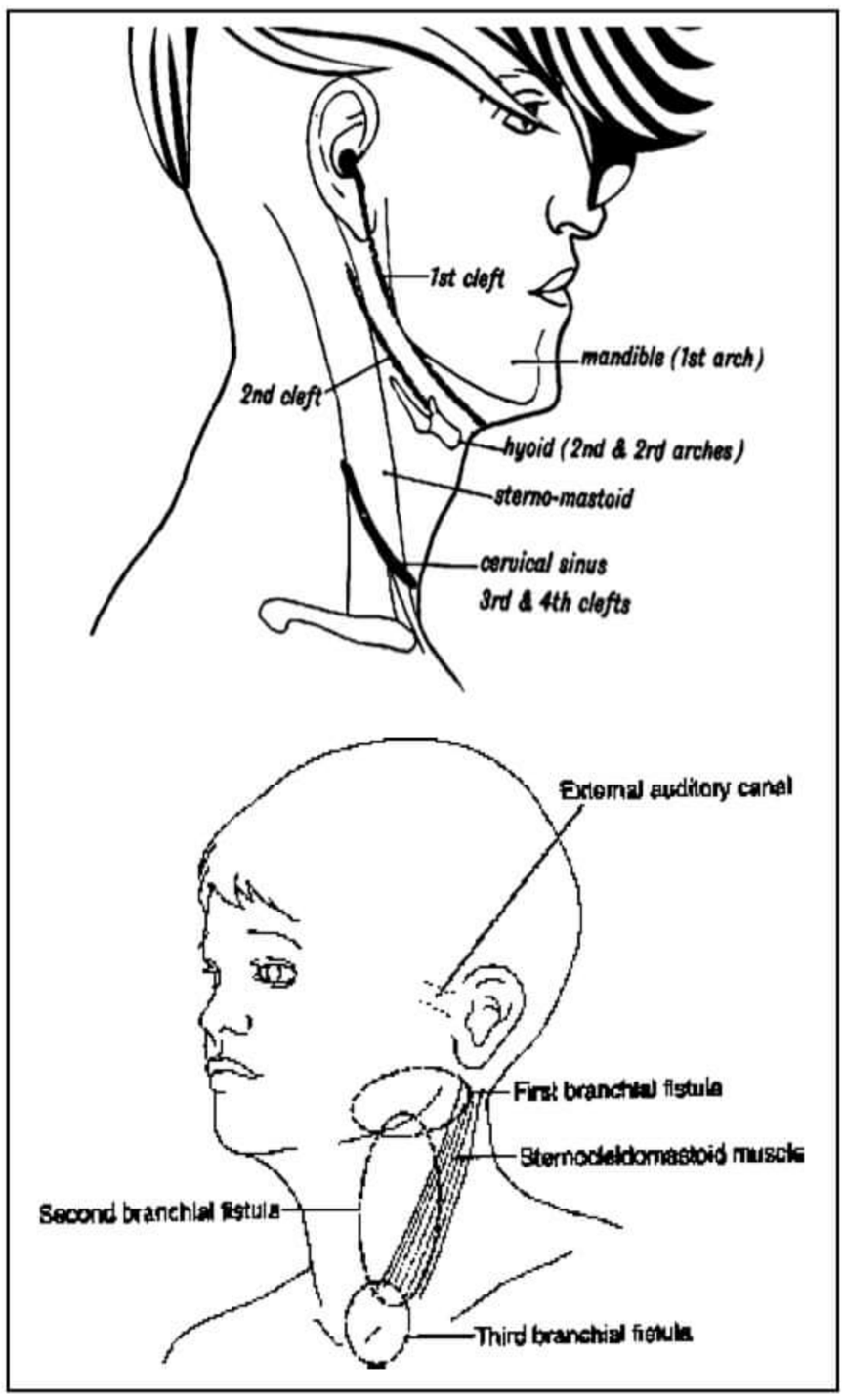

Third branchial cleft remnants:

→ Does not have associated sinus or fistula
→ Location – Suprasternal notch or clavicular region
→ Has Cartilaginous rest
→ Firm mass / subcutaneous abscess

Cervical Rib

→ Arises from 7th cervical vertebra
→ MC on Right side

PrepLadder

Types

1) **Complete cervical rib** - reaches up to 1st cervical rib
2) **Bulbous end**
3) **Tapering end**
4) **Fibrous Band** – Rib represented by fibrous band

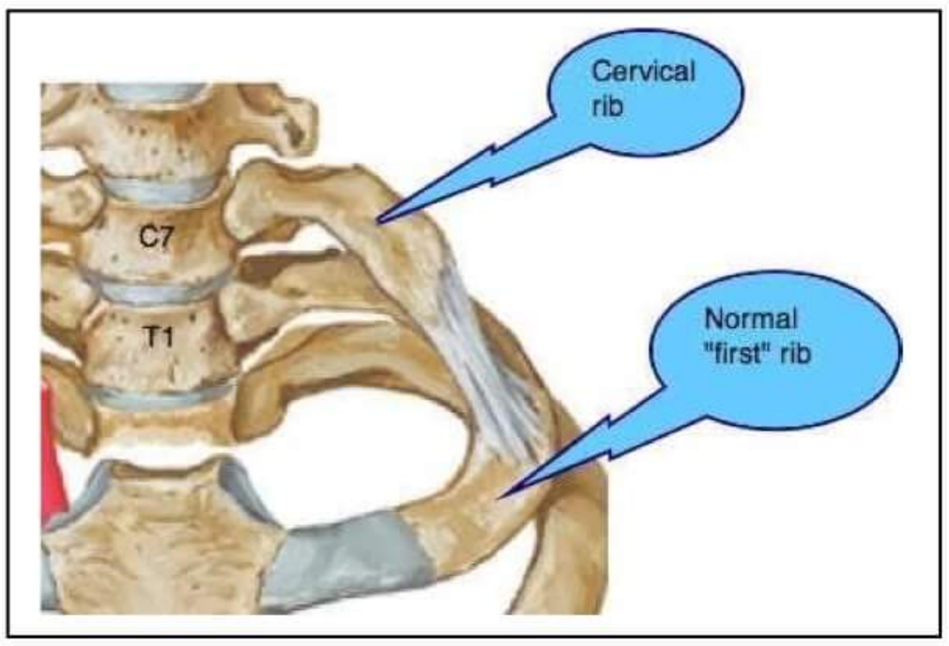

Symptoms

→ **Local symptoms**
- Lumps & tenderness in supraclavicular fossa

→ **Compression of artery**
- Pain
- Pallor
- Pulselessness
- Paresthesia

→ **Compression of branchial plexus (C_8T_1) – Ulnar**
- Pain & Paresthesia along inner aspect of forearm and hand

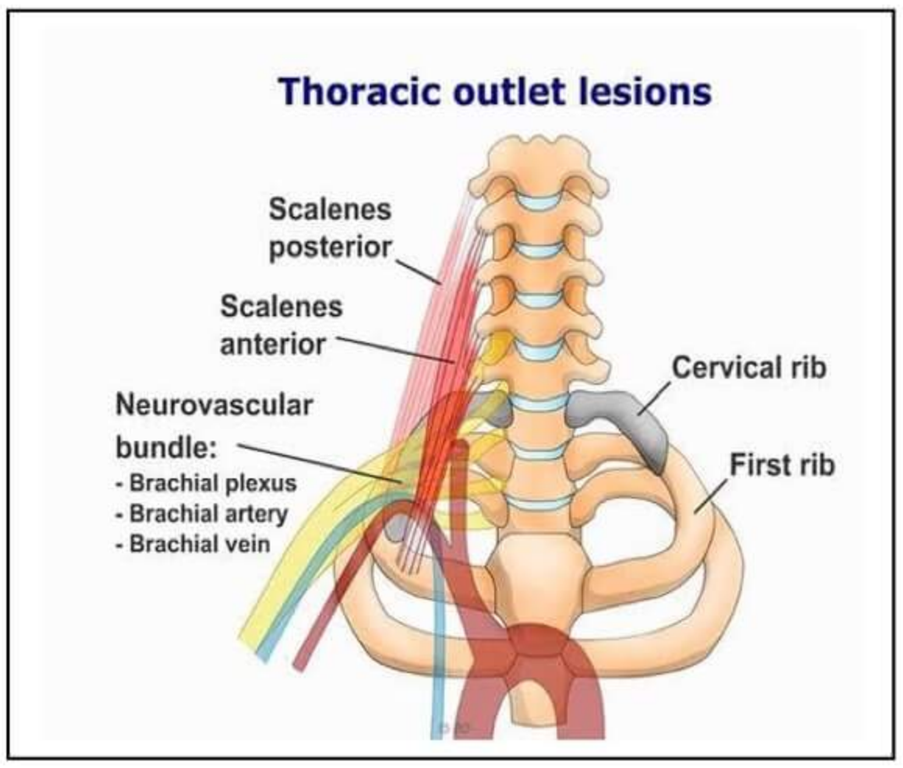

Diagnosis

→ X – Ray neck

t.me/latestpgnotes

Management

→ Mild cases - Sling exercise

→ Severe cases – Scalenotomy (Resection of scalenus anterior muscles)

→ Troublesome cases - Excision of cervical rib

Anatomy of Neck

Triangle of neck

→ **Anterior Triangle:**
- Submental triangle
- Submandibular triangle
- Carotid triangle
- Muscular triangle

→ **Posterior triangle**

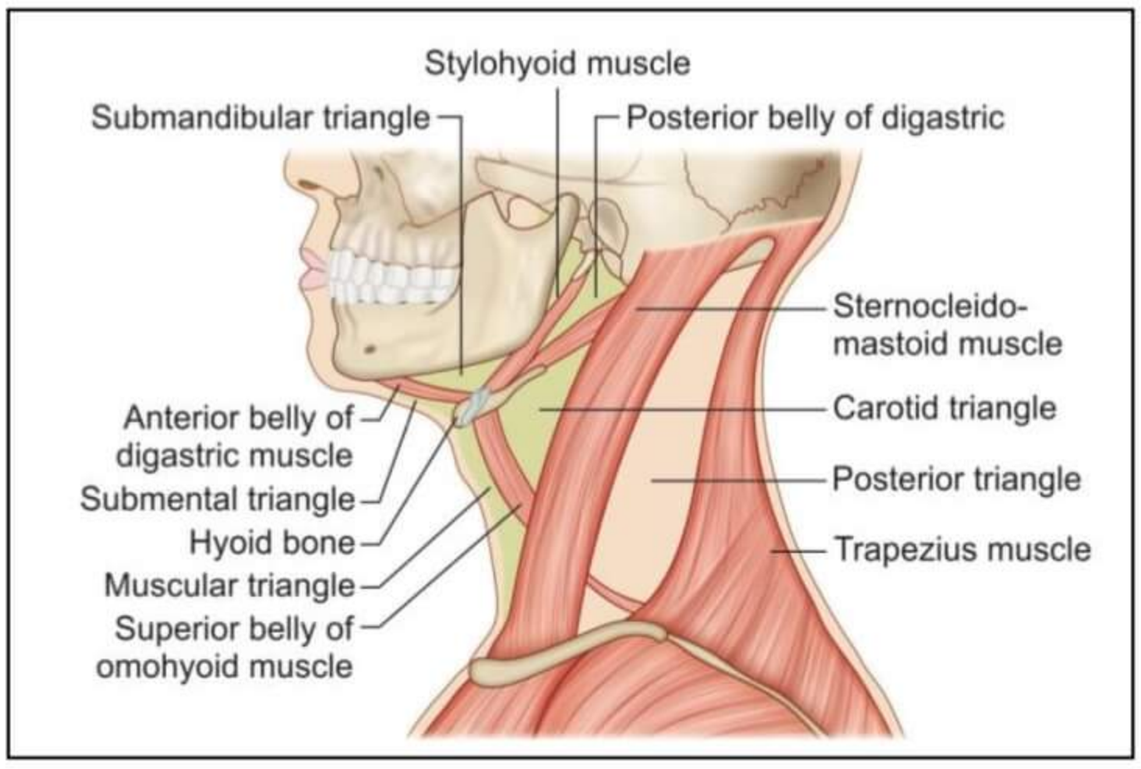

PrepLadder

Various lymph nodes levels

Level	Lymph node
IA	- Submental
IB	- Submandibular
II	- Upper jugular
III	- Middle jugular
IV	- Lower Jugular
V	- Posterior Triangular
VI	- Anterior compartmental or central
VII	- Superior mediastinal

→ **Level IV** – Includes Virchow's nodes

→ **Level VI** – Includes Delphian nodes

→ In thyroid malignancies, MC involved lymph node are central or anterior compartmental

- Papillary carcinoma thyroid – Central LN dissection
- Medullary carcinoma thyroid – Routine central LN dissection

Types of dissection in neck

Radical neck dissection	Modified Radical neck dissection
• Removal of **lymph nodes I-V** + spinal accessory nerve + Internal jugular vein + Sternocleidomastoid muscle ↓ Increased morbidity	• Removal **of level I-V nodes** with - **Type I**: preserves only spinal accessory nerve - **Type II**: Preserves both spinal accessory nerve and internal jugular vein - **Type III**: preserves spinal accessory nerve, internal jugular vein and sternocleidomastoid muscle. (Functional neck dissection)

t.me/latestpgnotes

→ Now a days, we prefer, MRND

Selective Neck Dissection

→ **Supraomohyoid neck dissection**: Removal of level I-III LNs

→ **Extended supraomohyoid neck dissection**: Removal of level I-IV LNs

→ **Posterolateral Neck Dissection**: Removal of level II-V LNs + suboccipital LNs + retro auricular LNs

→ **Lateral neck dissection**: removal of level II-V LNs + Internal jugular vein

PrepLadder

→ **Central compartment neck dissection:** Removal of level VI LNs

Complications of Neck Dissection

Intraoperative	Postoperative
→ Injury to nerves and vessels • Marginal nerve • SAN • Thoracic duct injury • Cervical plexus • Brachial plexus	→ Hemorrhage → Lymph leak → Carotid blow out • **Highest mortality rate (60%)** → **Shoulder syndrome** • Injury to SAN • Inability to abduct shoulder beyond 90° • Pain and deformity at shoulder girdle

t.me/latestpgnotes

PrepLadder

FACIAL INJURIES AND ABNORMALITIES

Development of face

→ Upper part of cheek – **Maxillary process**
→ Lower part of cheek – **Mandibular process**
→ **Frontonasal process** } Develop into nose
→ **lateral nasal process** }

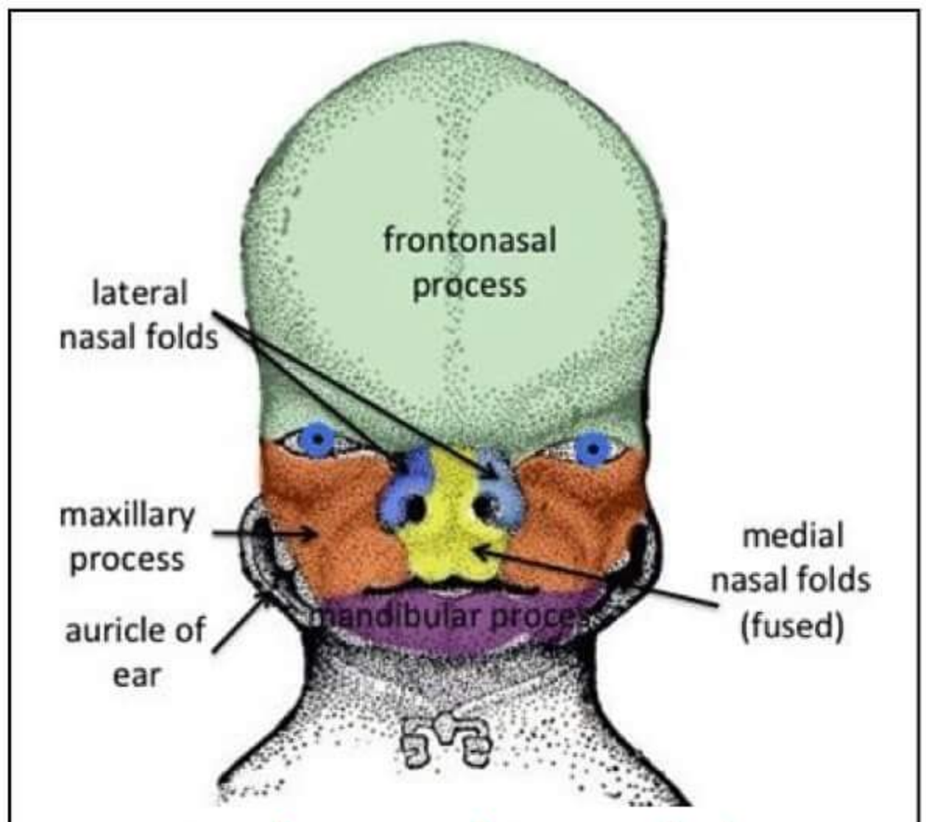

Development of Face and Lip

Development of lip

→ Philtrum – **Frontonasal process**
→ Lateral part of upper lip – **Maxillary process**
→ Lower lip – **Mandibular process**

Development of palate:

→ **Primary palate**
→ **Secondary palate** – forms from medial outgrowth of maxillary Prominence known as Palatine shelves

↓

Elevate, grow and fuse together in midline

→ Primary & secondary palate fuse together at incisive foramen - forms Definite palate
→ Bone develops in primary & anterior part of Secondary palate – forms Hard palate
→ Posterior part of secondary palate has no bone - forms Soft palate and Uvula

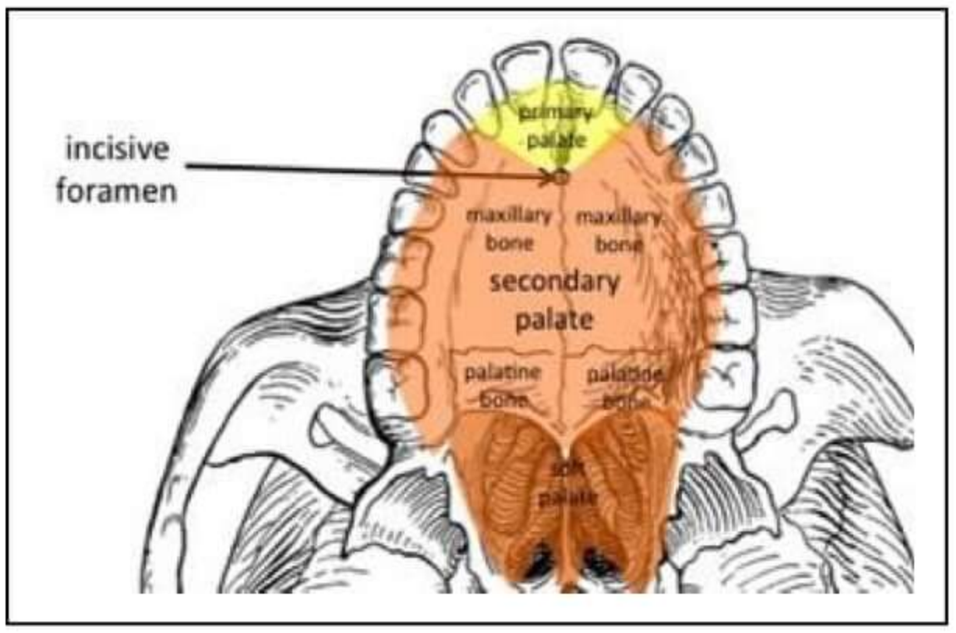

t.me/latestpgnotes

Cleft lip and cleft palate

→ MC congenital Abnormality of orofacial structures Cleft lip, Cleft of Alveolus, Soft palate & hard palate
→ It is usually isolated
→ Sometimes A/W congenital heart disease

U/L cleft lip

→ Non-Fusion of maxillary process and medial nasal process
→ Posterior displacement of alar cartilage
→ **Incidence of**
  - CL + CP → 1:600 live birth
  - Isolated CP → 1:1000 live birth
→ CL + CP – MC in males
→ CP alone – MC in females
→ CL alone - 15% patients
→ CL + CP - 45% (MC combination)

PrepLadder

→ CP alone - 40% patients

Etiology

→ Genetic predisposition

→ Environmental factors

- Maternal epilepsy
- Drugs – steroids, diazepam, Phenytoin

→ A/W syndromes

- Pierre – Robin syndrome (MC)
- Stickler syndrome, Spritzen syndrome
- Apert's syndrome
- Down's syndrome
- Treacher Collin's syndrome

→ **Problems with cleft abnormality**

- Assistance during feeding
- Breathing difficulty

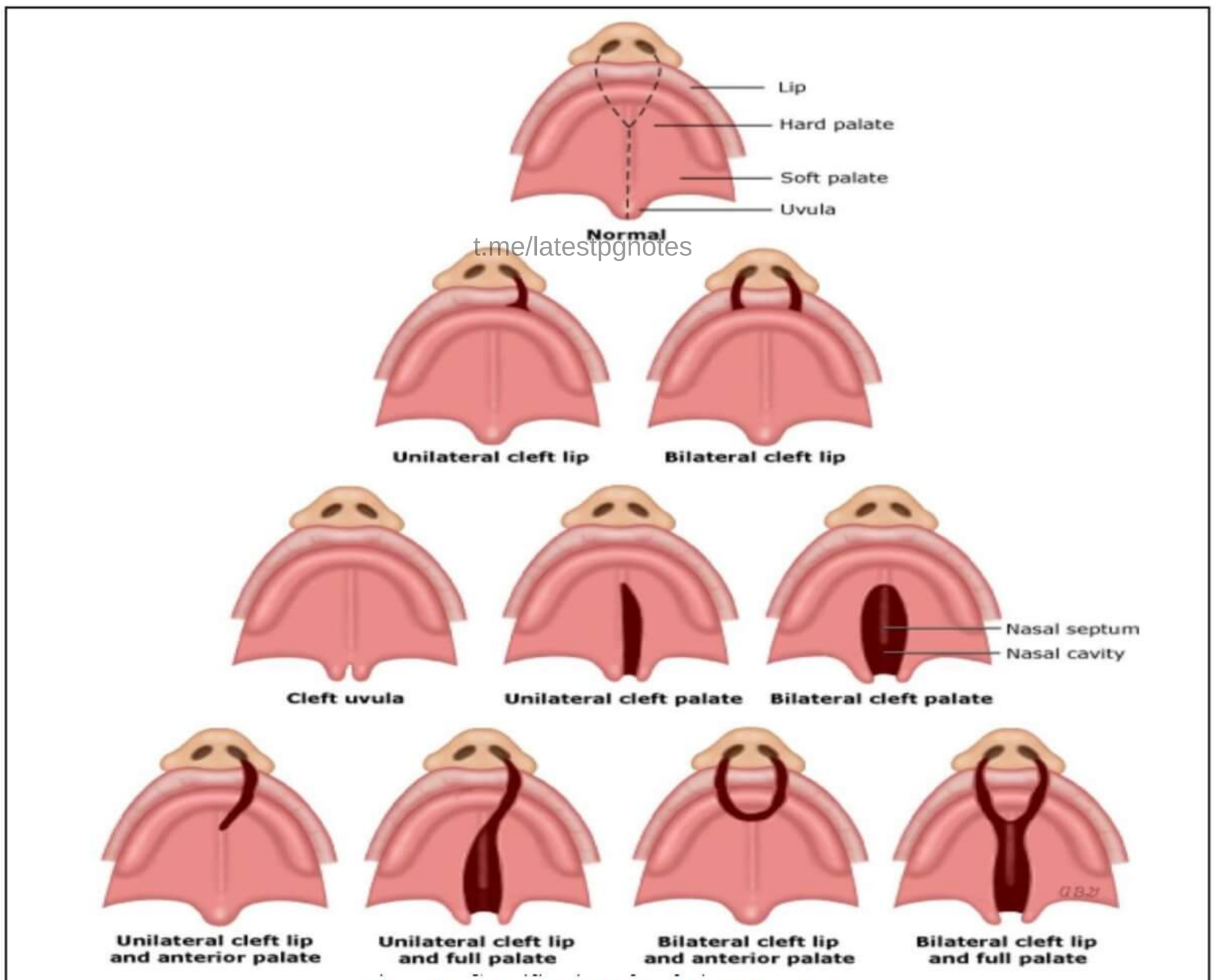

Classification of cleft lip & cleft palate

Note: Isolated CP can be diagnosed at 18 weeks of gestation

t.me/latestpgnotes

PrepLadder

Management:

→ **Surgery** – aims at restoration of normal anatomy

Principles of surgery

→ **Cleft lip repair**
- Surgery attaches and reconnects the muscles around oral sphincter

→ **Cleft palate repair**
- Produce anatomical closure of defect
- Creates apparatus for production and development speech
- To minimize maxillary growth difference and dentoalveolar deformities

→ **Two Stage procedures**
- Done to minimize dissection

Secondary management (management after surgery)

→ Regular review by multi- disciplinary team
- Hearing
- Speech
- Dental development
- Facial growth

Surgical procedures done

→ **Millard Rotation Advancement Technique (MC used)**

t.me/latestpgnotes

→ Le Muserier's

→ Tennison - Rendall

→ Thompson

Timing of repair

Cleft lip alone	Cleft palate alone	Cleft lip and palate
• **Unilateral**: One operation at 5-6 months • **Bilateral**: One operational at 4-5 months	• **Soft palate only**: One operation at 6 months • **Hard palate only**: One operation at 15-18 months • **Soft and hard palate**: Two operations - Soft palate at 6 months - Hard palate at 15-18 months	• **Unilateral**: Two operations – Cleft lip and soft palate at 5-6 months – Hard palate and gum pad with or without lip revision at 15-18 months • **Bilateral**: Two operations – Cleft lip and soft palate at 4-5 months – Hard palate and gum pad with or without lip revision at 15-18 months

PrepLadder

LAHSAL system of classification

→ Diaphragmatic classification for cleft lip & cleft palate

Right side	Left side
L – Lip A – Alveolus	A – Alveolus L – Lip
H – Hard palate S – Soft palate	

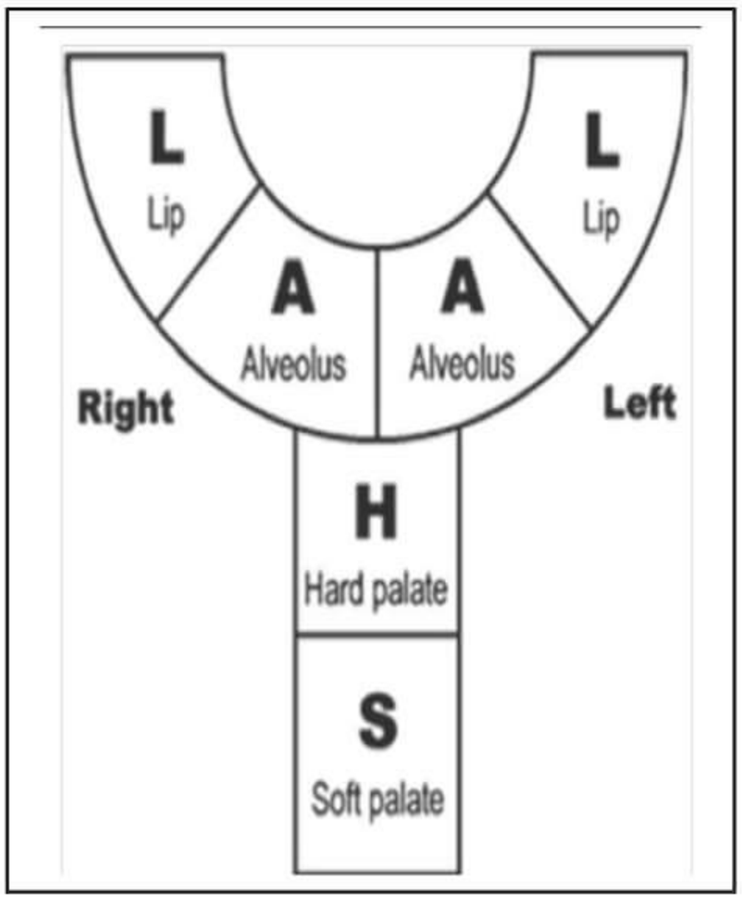

→ **Complete cleft** – designated by **Capital letter**
→ **Incomplete cleft** – designated by **Small letter**
→ **No cleft** – designated by a **dot (•)**

Example

Defect	Classification
• B/L cleft lip and cleft palate	→ L A H S A L (as it involves all parts)
• For left complete cleft lip	→ • • • • • L
• Right cleft lip + Alveolus	→ L A • • • •
• Incomplete hard palate and complete soft palate	→ • • h S • •

t.me/latestpgnotes

Mandibular fractures

→ MC site of mandibular fracture – **condylar neck (Weakest part of mandible)**
→ Fracture can occur at site of blow or
- **Guardsman fracture** – force from the site of blow is transmitted to a distant site
- **Butterfly fracture** – segment of mandible is detached from the rest of mandible in canine region

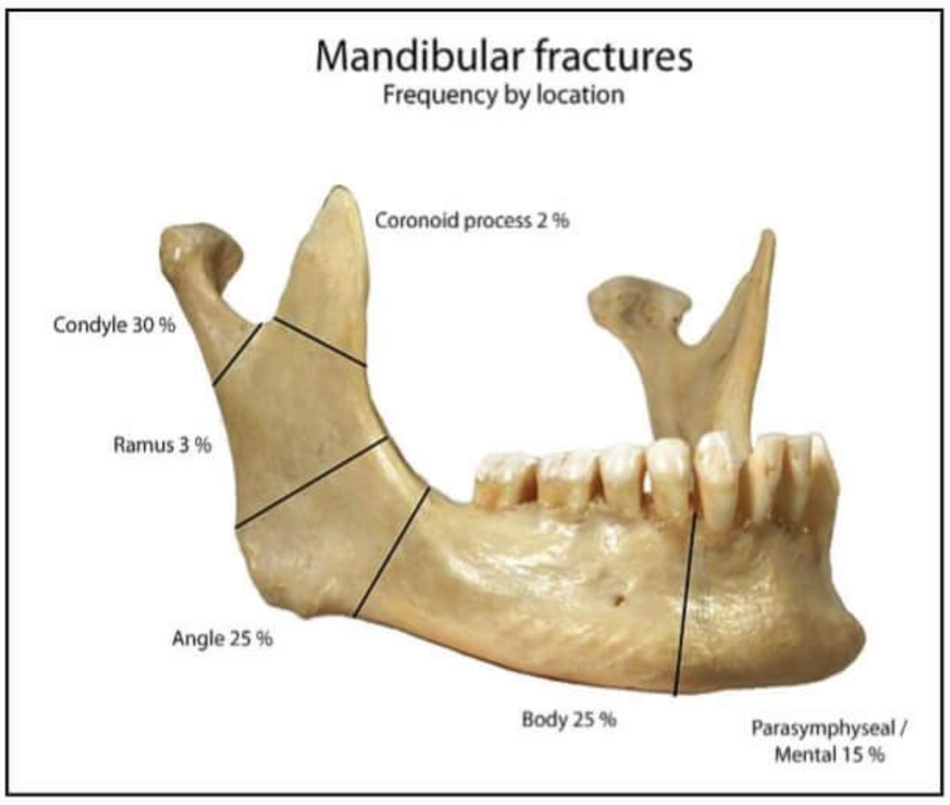

Diagnosis

→ Panoramic radiograph (Panorex) or
→ Towne's view X -ray

Management

→ Restoration of dental occlusion (it is the foundation of Mandibular # management)
- **IMF (intermaxillary fixation) before fracture exposure + Plating is done**

→ For Condylar and sub condylar fracture – **Only IMF is sufficient**

PrepLadder

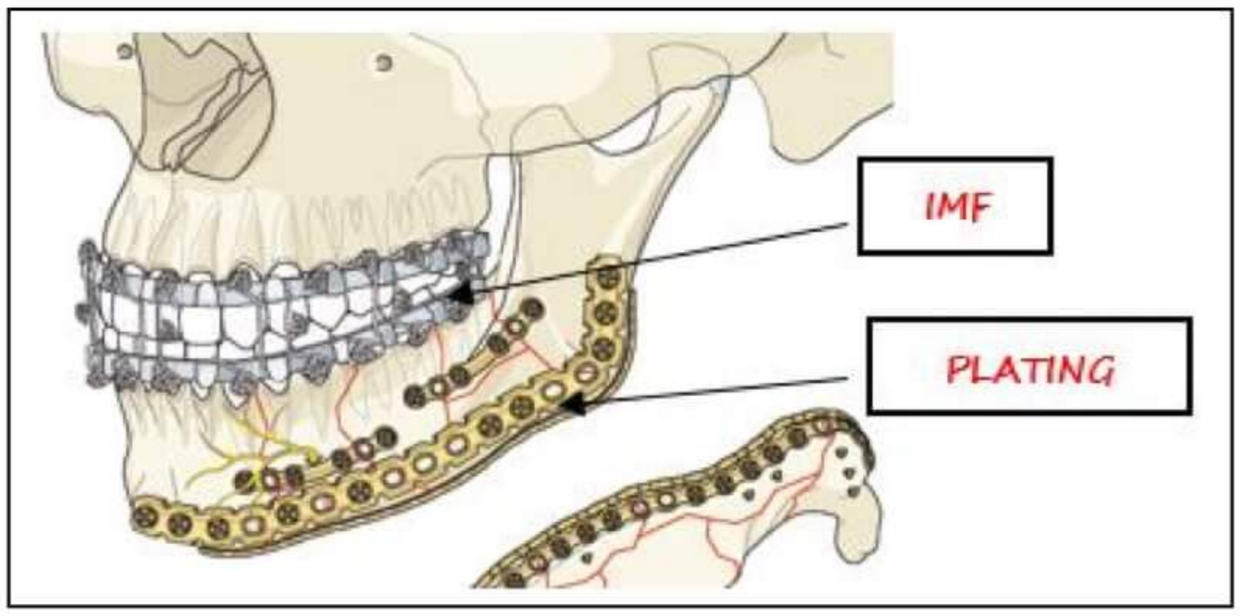

Zygomatic Bone fracture

→ MC fracture in middle third of face - Nose > Zygomatic bone

→ AKA – Tripod fracture (Fractured at 3 places)

↓

- Zygomatico - frontal fracture
- Zygomatico - temporal fracture
- Infra - orbital fracture

Clinical features

→ Flattening of malar prominence

→ Epistaxis

→ Step deformity of infra-orbital region

t.me/latestpgnotes

→ Restricted ocular movements (due to entrapment of inferior rectus)

→ Anaesthesia in intra orbital nerve distribution

→ Oblique palpebral fissure

→ Emphysema

Diagnosis

→ **X-ray** - water's view is preferred

→ Best investigation for diagnosis of zygomatic fracture - **CT scan**

Management

→ **For Undisplaced fracture** – no treatment

→ **For Displaced fracture** – Open reduction + internal fixation

Mid face fractures

→ Mid face fractures involving maxilla – Le Fort's fracture

→ **It is divided into**

PrepLadder

Le fort 1	Le fort 2	Le fort 3
• Fracture line runs above & parallel to the palate • Separates alveolus and palate from facial skeleton	• Pyramidal in shape • Fracture passes through root of nose, lacrimal bone, floor of orbital, upper part of maxillary sinus and pterygoid plate • Orbital floor always involved	• Complete disjunction of facial skeleton from skull • Fracture line through nasal bridge, septum, ethmoid and bone of orbit to frontozygomatic suture

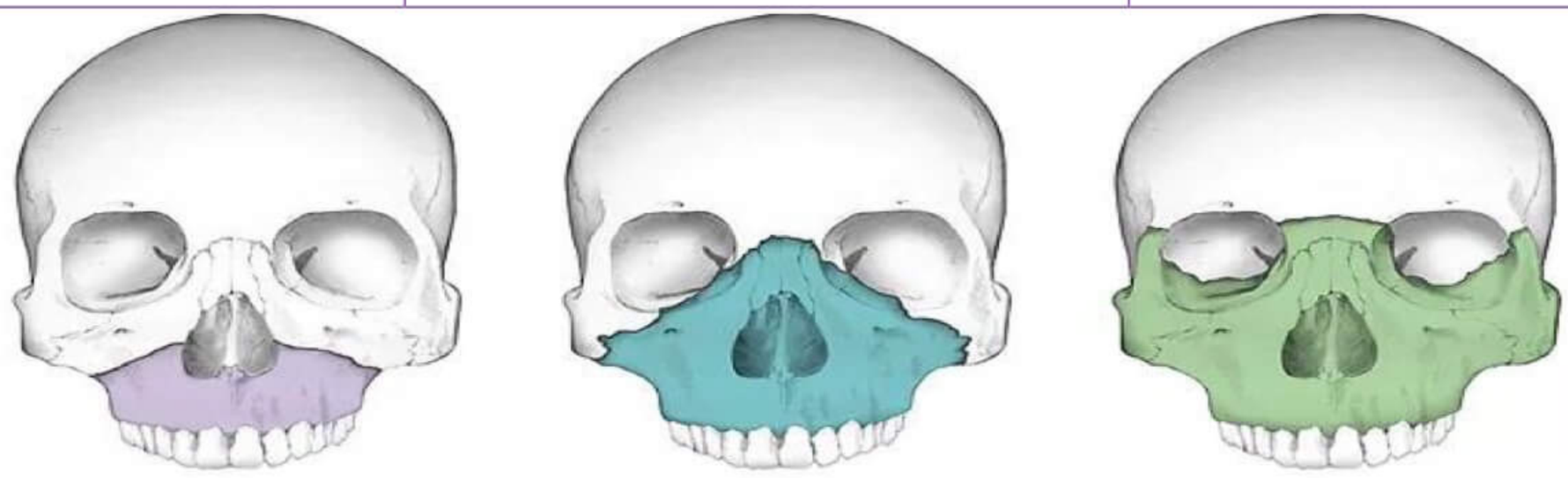

Le Fort I Le Fort II Le Fort III

Management

→ Interdental or Intermaxillary fixation is mandatory

→ It is mandatory to re-establish:

- Proper Dento – skeletal relationship
- Immobilized fracture bone
- Ensure normal postoperative occlusion

t.me/latestpgnotes

PrepLadder

ONCOLOGY

One Liners of Soft Tissue Sarcoma

→ MC type - liposarcoma > Leiomyosarcoma

→ MC site – Extremity (Lower > upper > trunk > RP > Head & Neck)

→ MC type of pediatric STS – Rhabdomyosarcoma

→ MC retroperitoneal tumor – Liposarcoma

→ MC route of spread – Hematogenous

→ MC site of metastasis in soft tissue – lungs

→ MC site of Metastasis in RPS – Liver > lungs

→ Lymph node metastasis – Rare (2-10%)

→ Lymph node dissection – Sarcoma with lymph node metastasis

Sarcomas with lymph node metastasis are

- M – MFH
- A – Angiosarcoma
- R – RMS
- C – Clear cell Sarcoma
- E – Epithelial sarcoma
- S – Synovial sarcoma

t.me/latestpgnotes

→ IOC for diagnosis for soft tissues sarcoma – True cut biopsy / Core cut biopsy

→ IOC to assess the extent of soft tissue sarcoma – MRI

→ IOC for assess the extent of RPS – CECT

→ Most important prognosis factor in STS – Grade

→ MC cause of death in STS – Metastasis

→ Most important prognosis factor in most of malignancies – Stage (TNM)

Exceptions

1. Wilms tumor – Histology > stage
2. STS – Grade

Soft Tissue Sarcoma

→ MC type of STS – Liposarcoma > Leiomyosarcoma

→ **H/P type is site dependent**

- Extremity - MFH (Malignant fibrous histiocytoma)
- Retroperitoneum – liposarcoma
- Viscera – GIST

Pathological aspect

Soft tissue sarcoma tends to grow along fascial planes

↓

Compression of soft tissue - Pseudo capsule

PrepLadder

Clinical behaviour of STS

→ Determined by

- Anatomical location / depth
- Grade
- Size of tumor

Clinical features

→ MC presentation – Painless mass

→ Size of presentation – **depends upon the location**

- Smaller - Distal extremities
- Larger
  - ➢ Proximal extremities
  - ➢ RPS (Retro-peritoneal sarcoma)

→ RPS – Larger asymptomatic mass

Diagnosis

→ IOC for diagnosis- True cut biopsy / Core cut biopsy

→ IOC for assess extent of STS – MRI

→ IOC for assess extent of RPS – CECT

Treatment

t.me/latestpgnotes

1. **Surgery**
   - Wide local excision with 2 cm margin
   - Achieve clear margins
   - Even beyond compartmental boundaries
2. **Radiotherapy**
   - EBRT
   - IMRT
3. **Chemotherapy**
   - Doxorubicin
   - Ifosfamide

   Both are most important Chemotherapeutic agents

→ R_X includes WLE + RT + Chemotherapy

Prognosis

→ Best prognosis – Extremity STS

→ Most important prognostic factor – Grade

→ Most common cause of death – Metastasis

PrepLadder

RHABDOMYOSARCOMA (RMS)

→ MC type of pediatric STS

→ MC site of RMS – Head & neck (Parameningeal > Extremity > Genitourinary tract > trunk

Pathology

→ Most common histological type of RMS – Embryonal RMS

→ Most common histological type in adults- Pleomorphic variant

→ Diagnostic cell – Rhabdomyoblast, Tadpole cells & Strap cells

→ **In Embryonal Rhabdomyosarcoma,**

Spindle cell variant

Sarcoma botryoides

(Tumor cell represent tennis racket)

Clinical features

→ MC presentation is **mass / bimodal in presentation**

- 1st peak 2-5 yrs.
- 2nd peak 15-19 yrs.

→ MC route of spread – hematogenous

→ MC site of metastasis – lungs

t.me/latestpgnotes

Diagnosis

→ IOC for diagnoses of RMS - True cut biopsy or core cut biopsy

→ IOC for assess extent of metastasis – MRI

Treatment

→ Surgery (WLE) – RMS

- For unresectable tumor – Neoadjuvant chemotherapy
- For positive margins – Post operative Radiotherapy

Prognosis

→ **Embryonal variant** – favourable prognosis

→ **Alveolar type**- Unfavourable prognosis

Favourable primary site	Unfavourable primary site
• Non parameningeal H & N • Paratestis • Orbit • Vagina	• Extremity • Parameningeal

PrepLadder

DFSP (Dermato fibrosarcoma Protuberance)

→ **Low grade sarcoma**

- Recurs locally - Radial extension of tumor through their subcutaneous tissue
- Rarely metastasis

→ Involves both dermis + subcutis

→ MC site-Trunk (50%) > extremity (30%) > H & N (20%)

Pathology

→ Tumor associate with satellite nodule

→ CD34 positive

→ >75% pt. of DFSP – Have ring chromosome

Ring chromosome
↓ Composed of
Translocation portion of 17 & 22

→ Has unpredictable radial extensions of tumor

↓

Permeate through large distances from primary nodule

↓

Increased risk of recurrence after simple excision

↓

(2-4 cm) circumferential margin is resected to prevent recurrence

t.me/latestpgnotes

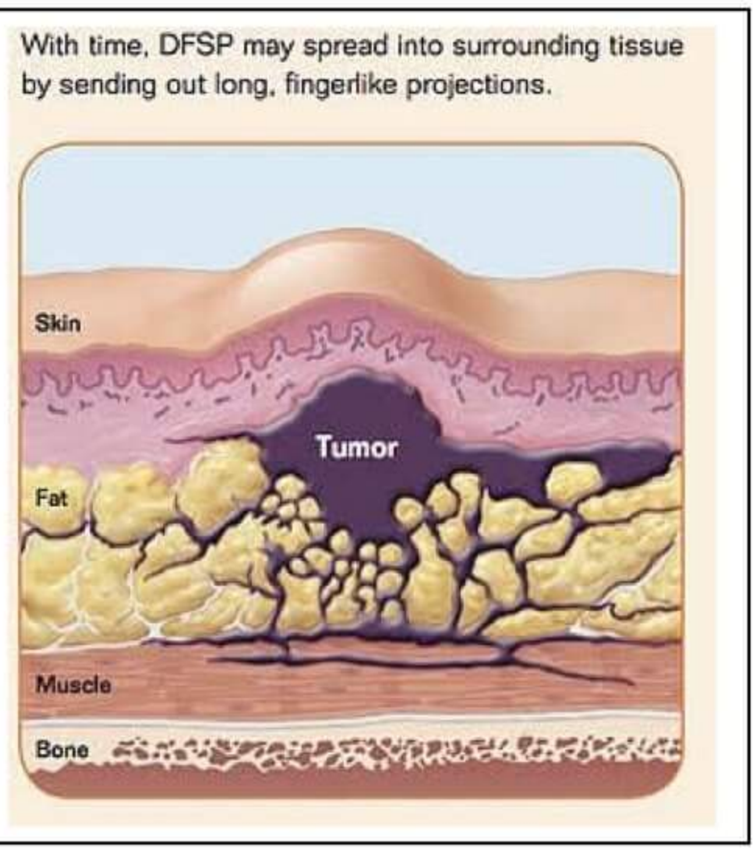

Clinical features

→ MC presentation – Nodules cutaneous mass

→ Pattern of growth – slow & persistent

→ Lesion enlarges over many years – becomes protuberant

Diagnosis

→ IOC for diagnosis – Incisional biopsy

Treatment

→ **Surgery** - WLE with 2-4 cm circumferential margin + removal of underlying fascia

→ First line treatment for advanced & unresectable tumors – Neoadjuvant imatinib

→ **3 indications of imatinib**

- DOC for GIST, CML
- DFSP

PrepLadder

TUMOR LYSIS SYNDROME

→ Syndrome caused by lysis of tumor cells

→ Caused by destruction of large number of rapidly proliferating neoplastic cells

→ **MC associated with treatment of**

1) Burkitt's Lymphoma
2) ALL
3) Chronic leukemia
4) High grade lymphoma

Pathophysiology

→ Due to destruction of malignant cells

↓

has rapid turnover of nucleic acid - **Hyperuricemia**

↑

→ Hypoxanthine → Xanthine → URIC Acid

→ Release of intracellular potassium leading to **hyperkalemia**

↓

↑ risk of Arrhythmia

→ Release of I/C phosphate – **Hyperphosphatemia**

↓

Phosphate + Ca^{2+} - **Hypocalcemia**

t.me/latestpgnotes

↓

Ca phosphate deposited in renal tubules

↓

Renal failure

→ Deranged oxidative metabolism - **lactic acidosis**

Characteristics dyselectrolytemia seen in tumor lysis syndrome

1. Aggressive hydration
2. $NaHCO_3$ – lactic acidosis
3. Allopurinol - ↑ uric acid (Hypoxanthine X Xanthine X Uric acid)
4. Rasburicase (recombinant urate oxidase) – Ex vivo enzymatic degradation of uric acid
5. Hemodialysis – Renal failure

Hypercalcemia of malignancy

→ **Main factor**

1. Increased Release of Ca^{2+} from bone
2. ↑ Ca^{2+} reabsorption from DCT

→ Most common cause is ↑ secretion of PTP-rp

PrepLadder

Management

→ Mainstay of therapy is Rehydration with normal saline and diuresis with furosemide

Drugs used to lower Ca level

→ Bisphosphonates (DOC – Zoledronic acid)
→ Calcitonin
→ Plicamycin (Mithramycin)
→ Gallium nitrate
→ Glucocorticoids (Hydrocortisone)

TYPHLITIS

→ AKA Neutropenic colitis / Necrotizing colitis / Ileocecal syndrome /cecitis
→ Classically seen in neutropenic pts after chemotherapy with cytotoxic agents
→ MC in children - AML
- ALL

Clinical features

→ Fever
→ Right lower quadrant tenderness] Immunosuppressed pt.
→ Diarrhea (bloody)

Diagnosis

t.me/latestpgnotes

→ Thickened cecal wall - USG / CT

Treatment

→ Most pt. improve after medical management i.e. antibiotics
→ **Indication of surgery**
- No improvement within 24 hrs of antibiotics
- Perforation

SUPERIOR VENA CAVA SYNDROME

→ Clinical manifestation of SVC obstruction

+

Severe reduction in venous return from head & neck & upper extremity

→ MC cause – lung cancer (small cell carcinoma) & SSC
→ MC cause of SVCS in young adults - Malignancy lymphoma

Clinical features

→ Neck & facial swelling (around eyes)
→ Dyspnea & cough
→ Dysphagia

PrepLadder

→ Hoarseness of voice
→ Tongue swelling
→ Headache
→ Nasal stuffiness – epistaxis
→ Dizziness & syncope

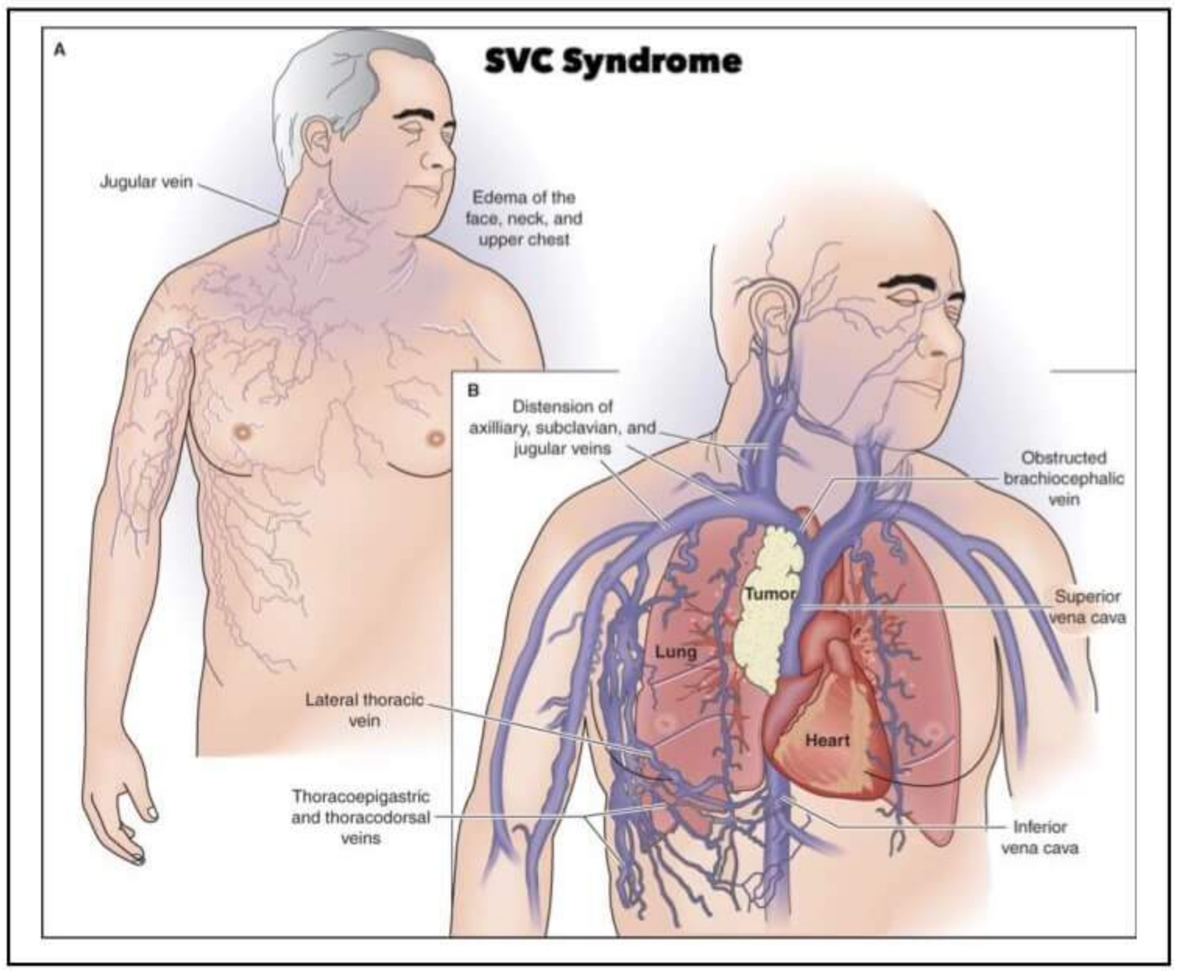

Findings

→ Dilated veins over the chest wall & neck
→ ↑ no. of collateral covering anterior chest wall
→ Cyanosis
→ (edema) – face, arm & chest

Diagnosis

→ IOC for Dx of SVC syndrome – **CECT**
→ Chest X-ray widening of superior mediastinum & more common in right side

Treatment

→ Life threatening complication - **Tracheal obstruction**

t.me/latestpgnotes

↓

- seen in superior mediastinal mass
- Emergency surgery needed

→ **Treatment depends on underlying cause**

a) We give **RT** for
   - NSCLC
   - Metastatic solid tumors

b) **Chemotherapy**
   - SCLC
   - Lymphoma

c) **Surgery** done for rest of cases

PrepLadder

PEDIATRIC SURGERY Part – I

Bronchogenic Cyst

→ Originate as sequestrations from **ventral foregut**

↓

Antecedent of tracheobronchial tree

→ It is lined by inner layer of ciliated respiratory epithelium – pathognomic of cyst

→ MC location: middle mediastinum

Types of bronchogenic cyst

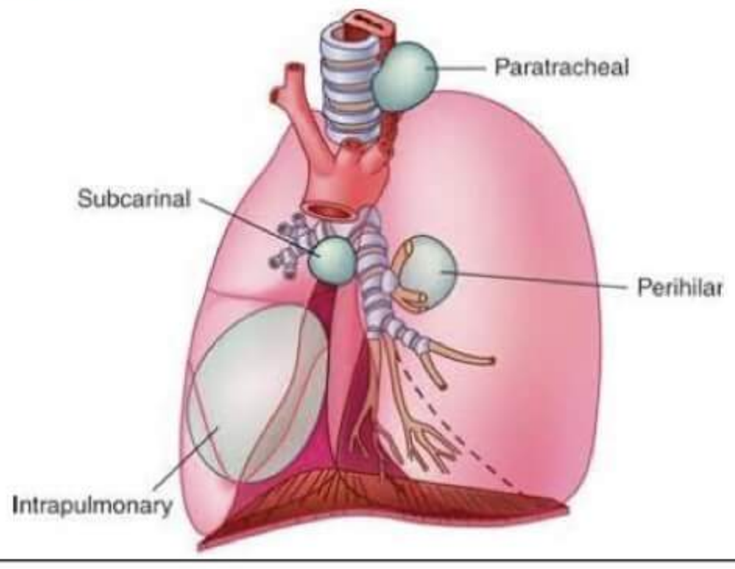

1) Mediastinal

→ Common locations are subcarinal, Right paratracheal, Hilar

→ Doesn't communicate with tracheobronchial tree

t.me/latestpgnotes

2) Parenchymal (intrapulmonary) – Typically, it is perihilar

→ MC location is middle mediastinum

→ Communicates with tracheobronchial tree.

→ Chest x-ray: dense mass

→ CT/MRI: anatomical Delineation

→ Rx: surgical excision in all the patients: – to prevent complications and for symptomatic relief & histological confirmation.

Dense mass (CXR)

PrepLadder

Pulmonary sequestration

→ It is malformation of lung
- Without bronchial communication
- With aberrant systemic blood supply

→ **MC site** - Postero basal segment of left lower lung

→ **Clinical feature** - Recurrent chest infections

→ **IOC for diagnosis** – CECT

Types of pulmonary sequestration

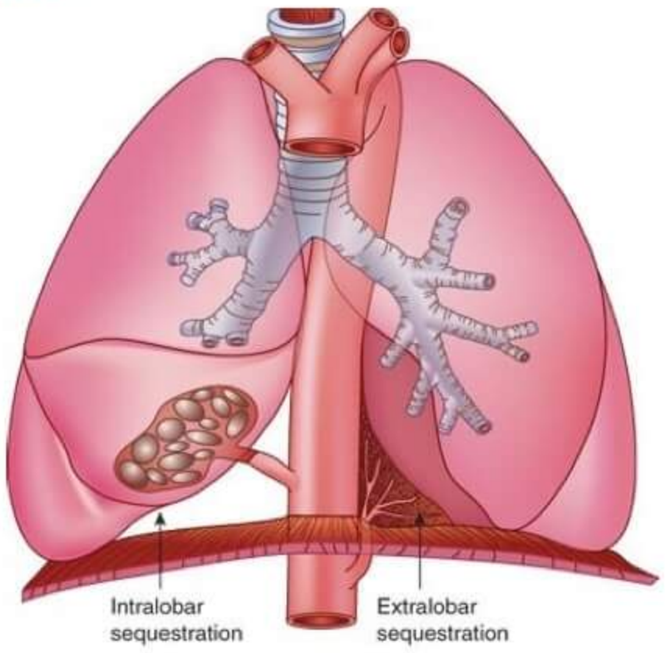

Intra lobar sequestration	Extra lobar sequestration
→ Reside within the lung parenchyma	→ Surrounded by separate pleural covering
→ 85% arterial blood supply via aberrant artery (arising from aorta)	→ Associated with multiple anomalies
→ Venous drainage - inferior pulmonary vein	→ Patient is asymptomatic
→ Rx - Segmentectomy or Lobectomy • Increased risk of infection • Increased risk of bleeding	→ Rx - Only observation

t.me/latestpgnotes

Eventration of diaphragm

→ Characterized by abnormally elevated position of diaphragm due to:
- Paralysis or
- Atrophy of muscle fibers

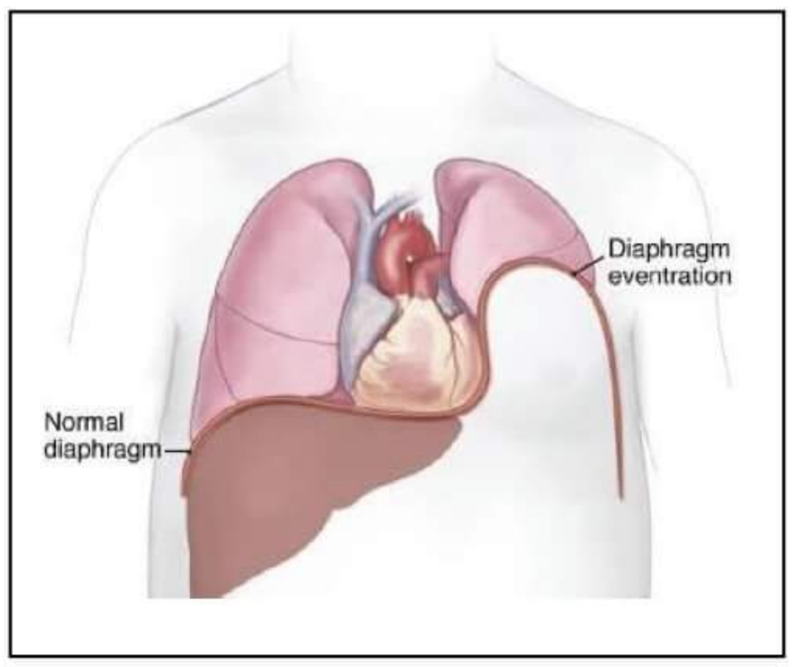

Types

1) **Congenital:**
   - Failure of muscularization of dome of diaphragm
2) **Acquired:**
   - Dysfunction of phrenic nerves due to
     - Trauma
     - Neuromuscular disorders

PrepLadder

- MCC of acquired eventration is **Birth Trauma**
  - More common in breech presentation
  - MC on left side
  - More common in males
  - Seen in pediatric age group

Treatment

→ **Plication > Resection**

- During surgery diaphragm should be fixed in inspiration
- **Advantages:** Minimises
  1. Paradoxical movement
  2. mediastinal shift

TRACHEO-ESOPHAGEAL FISTULA (TEF)

→ **Fistula** - is abnormal communication between 2 epithelialized surfaces

→ **TEF** - Abnormal communication between trachea & esophagus

→ Associated with esophageal atresia

→ MC in males

Classification of TEF

t.me/laxstpgnotes

→ **Type A** – Isolated esophageal atresia without TEF

→ **Type B** - Esophageal atresia with proximal TEF

→ **Type C** – Esophageal atresia with distal esophageal fistula **(MC type)**

→ **Type D** – Esophageal atresia with both proximal + distal esophageal fistula **(LC type)**

→ **Type E** – TEF without EA / H-shaped fistula

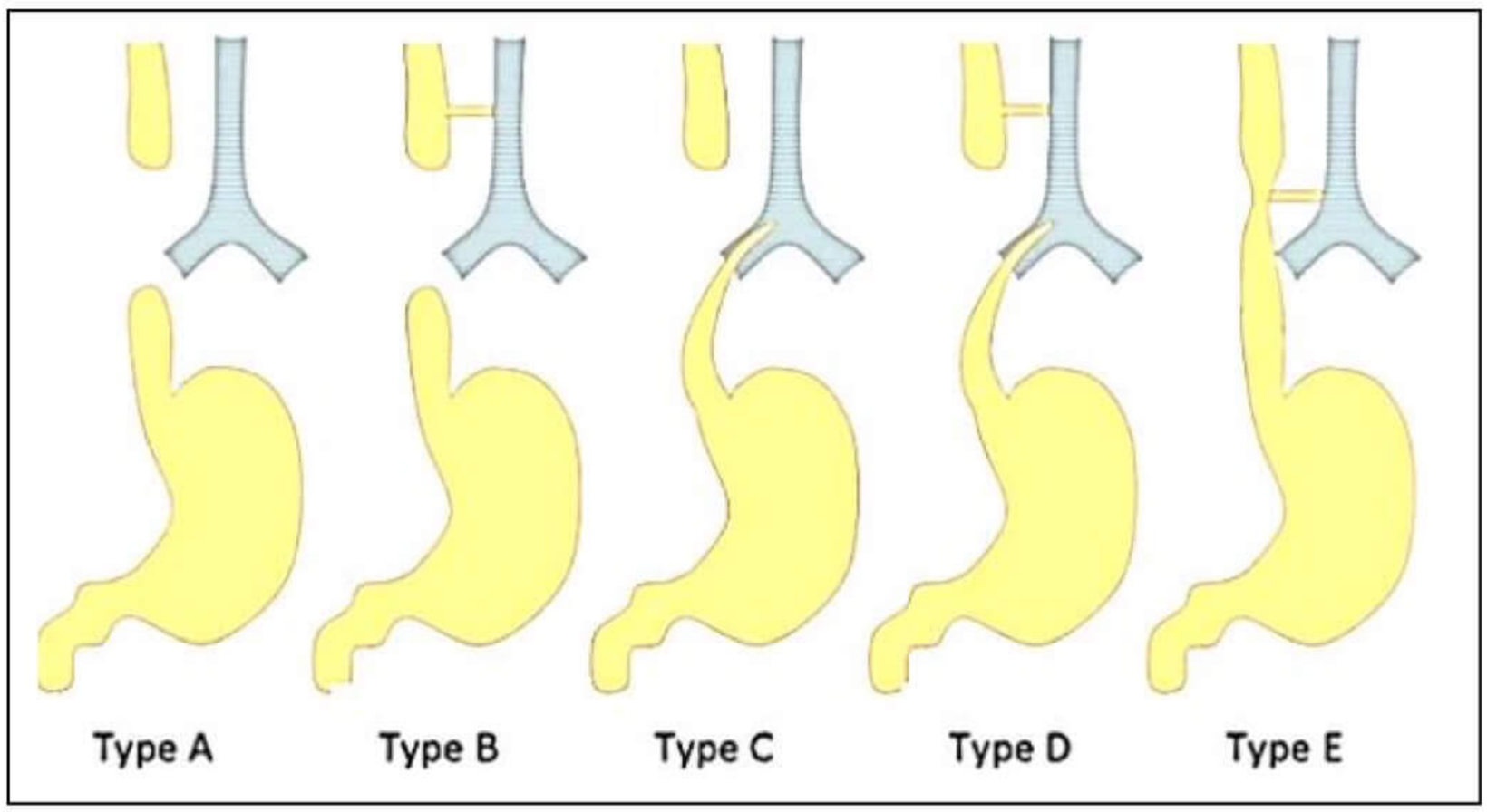

Risk factor

→ Maternal history of Polyhydramnios

PrepLadder

Clinical features

→ **Isolated EA**

a) Continuous drooling of saliva from mouth

b) Regurgitation of feeds given orally

→ **TEF** – Chocking, coughing, cyanosis, dyspnea

Diagnosis

→ Inability to pass nasogastric tube into stomach and coiling in esophagus - EA

→ Presence of gas below diaphragm - TEF

→ Inability of pass NG into stomach with absent radiographic Evidence of GI gas - EA without TEF

→ Use of isotonic contrast is highly discouraged for diagnosis of EA or TEF - Because contrast enters into trachea

↓

Aspiration

→ **For type E or H type fistula** = Dx is confirmed by Tracheo-bronchoscopy + endoscopy

Abnormalities associated with TEF

→ **VACTERL anomalies**

- V – Vertebral body segmentation defect
- A – Anal atresia
- C – CVS (**VSD**, PDA) → **MC associated**
  → **MC CVS abnormality seen**
- TE – TEF
- R – Renal (Unilateral renal agenesis)
- L – Limb anomalies (Radial ray hypoplasia)

t.me/latestpgnotes

Treatment

→ Waterston criteria was used – **not used now**

→ **For Type A** - Depends on gap

Small Gap	Large gap
↓	↓
Tension free Esophago-Esophagostomy	Feeding gastrostomy followed by Esophago-Esophagostomy (delayed)

→ **Type B, C, D** - Excision of fistula tract + Esophago-Esophagostomy

→ **Type E** - Excision of fistula tract + repair defect

PrepLadder

Prognosis

→ **Mortality of TEF depends on**
- Cardiac defects
- Chromosomal abnormalities

Biliary Atresia

→ Characterized by progressive obliteration of both intrahepatic & extrahepatic bile duct

→ Incidence of Biliary atresia is 1:12000 live birth

→ Unknown etiology

→ It is MC indication for pediatric liver transplantation

Pathology hallmark

→ Bile duct proliferation
→ Severe cholestasis with plugging
→ Inflammatory cell infiltrate

} Progress to cirrhosis

↓

- Portal hypertension
- Hepatic failure

Kasai Classification for Biliary Atresia

→ **Type I** – CBD is obliterated with patent proximal bile duct & cystic duct

t.me/latestpgnotes

→ **Type 2A** – characterized by atresia of CHD with patent cystic duct & CBD

→ **Type 2B** – characterized by obliteration of CHD, Cystic duct & CBD

→ **Type 3(MC)** – Atresia of CBD, cystic duct & hepatic duct up to Porta hepatis (>90%)

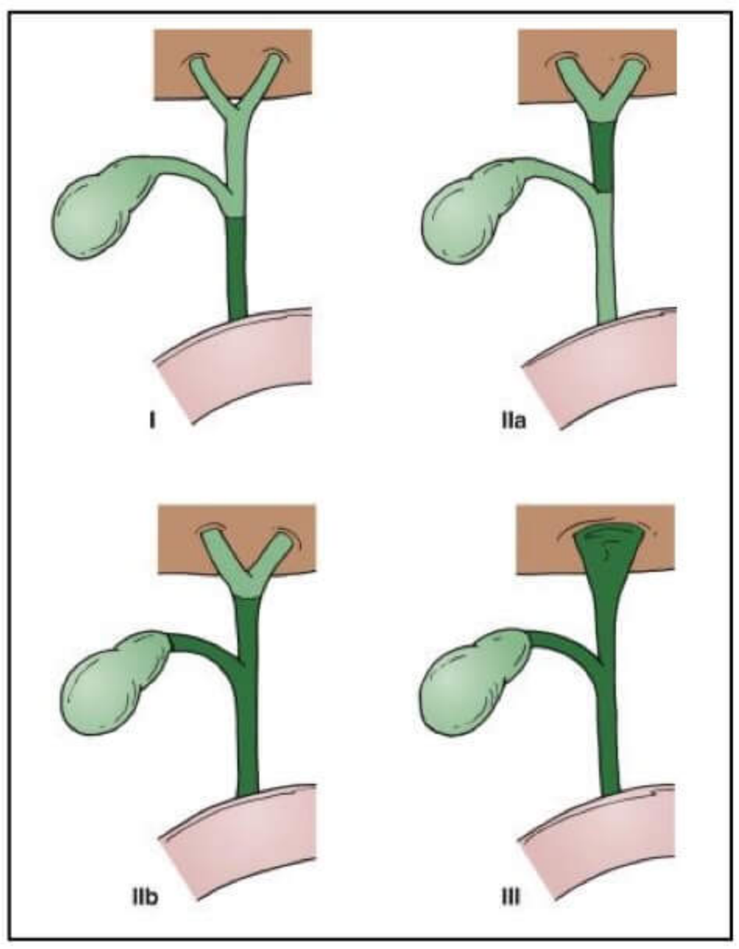

Clinical features:

→ Jaundice at birth or sometimes after birth

→ Passage of acholic pale grey stools -Due to obstructed bile flow

→ Failure to thrive

→ Signs and symptoms of – Portal hypertension & Hepatic failure

→ In 25% cases - Malformations associated
- Poly splenia
- Malrotation
- Pre duodenal Portal Vein
- Intra hepatic vena cava

PrepLadder

Diagnosis

→ Gold standard investigation for Dx of biliary atresia – **Liver Biopsy**

→ **On USG**

- Gall bladder is shrunken
- CBD – Not visible

→ **Signs seen on USG**

- GB Ghost triad
- Triangle cord sign

→ **On Hepatobiliary scintigraphy** – Uptake into liver Without any flow / excretion of radio tracer into intestine

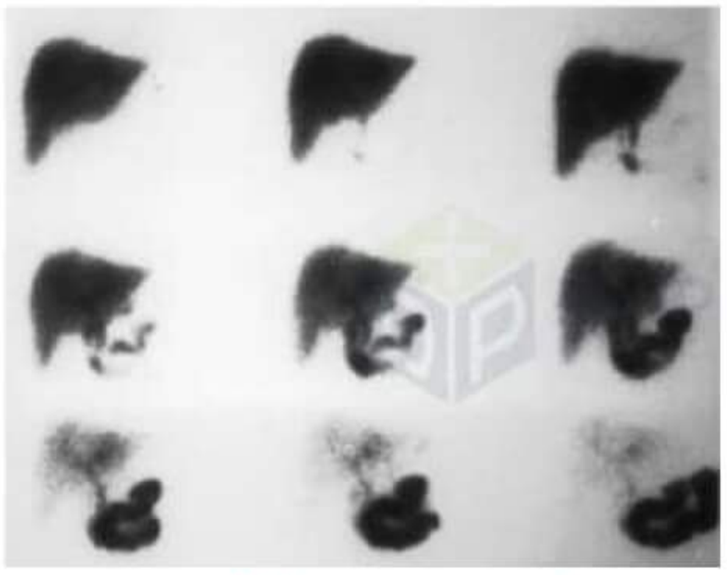

Hepatobiliary scintigraphy

Treatment

→ Exploratory laparotomy followed by **Intra-operative Cholecysto-cholangiography**

↓

- To confirm diagnosis
- Demonstration of fibrotic biliary remnant
- Definition of absent proximal & distal bile duct patency

→ **TOC** – **Kasai Portoenterostomy**

t.me/latestpgnotes

→ **Drugs given in Post-op period**

UDCA (Facilitates bile flow) +

Methylprednisolone (anti-inflammatory agent) +

TMP -SMX (For antimicrobial prophylaxis)

→ MC post-operative complication – **cholangitis**

→ No medical treatment can reverse the process & If Sx is not performed death occurs in 2 years of age

→ 30% of infants undergoing Portoenterostomy before **60 days** of age – have long term successful survival & doesn't require Liver transplantation

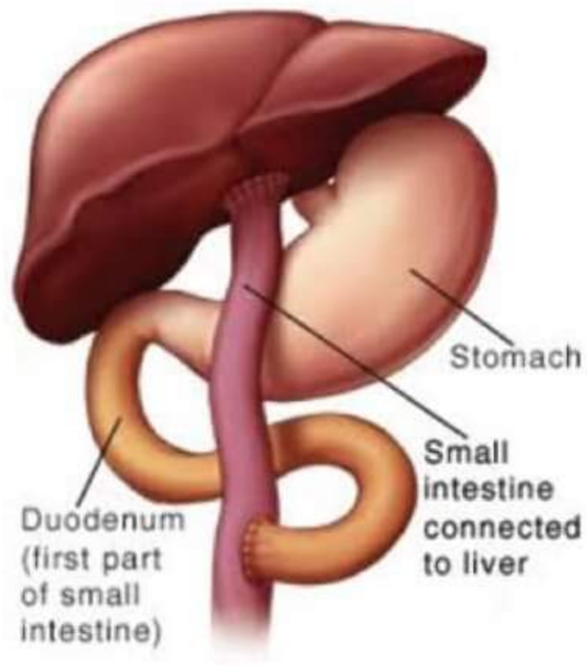

Kasai Portoenterostomy

Factors affecting the outcome of Hepato-Portoenterostomy

1. Age in days at diagnosis & Surgical intervention (**30-60 days**)
2. Length of time, jaundice was present before surgery
3. Successful & persistent bile flow post-operatively
4. Size and nature of microscopic duct (If size > **150 µm** → associated with good prognosis)
5. Degree & extent of fibrotic changes in the liver
6. Need for phototherapy as a neonate
7. Technical aspect of Portoenterostomy (P/E) & anastomosis
8. Presence of bile in hepatic lobular Zone 1

PrepLadder

Intestinal atresia

→ MC site of intestinal atresia - **Duodenum**

→ MC cause of neonatal intestinal obstruction – **Duodenal atresia**

Duodenal atresia

→ Occurs as a result of failure of vacuolization of duodenum from its solid cord stage

Types of Duodenal atresia

→ **Type 1**- Duodenal diaphragm / mucosal web (windsock deformity)

→ **Type 2** – Two end are separated by fibrous cord

→ **Type 3** – Complete separation of two ends

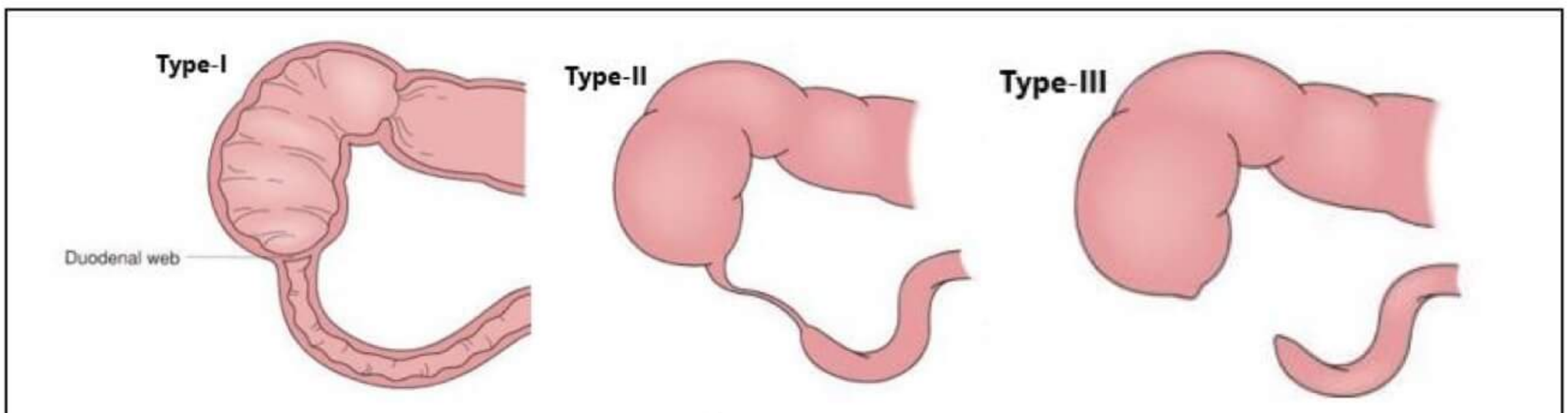

Types of Duodenal atresia

Conditions associated with DA

t.me/latestpgnotes

→ Prematurity

→ Down's syndrome

→ Poly hydramnios

→ Annular pancreas

→ Biliary atresia

→ Malrotations

Double bubble sign

C/F

→ **Bilious vomiting**

Diagnosis

→ **On X-ray** – Shows Double bubble sign

Note:

- Single bubble sign → **In hypertrophic pyloric stenosis**
- Double bubble sign → **Annular pancreas / Duodenal atresia**
- Triple bubble sign → **Jejunal atresia**

Treatment

→ TOC for Duodenal atresia - **Diamond shaped duodenostomy**

PrepLadder

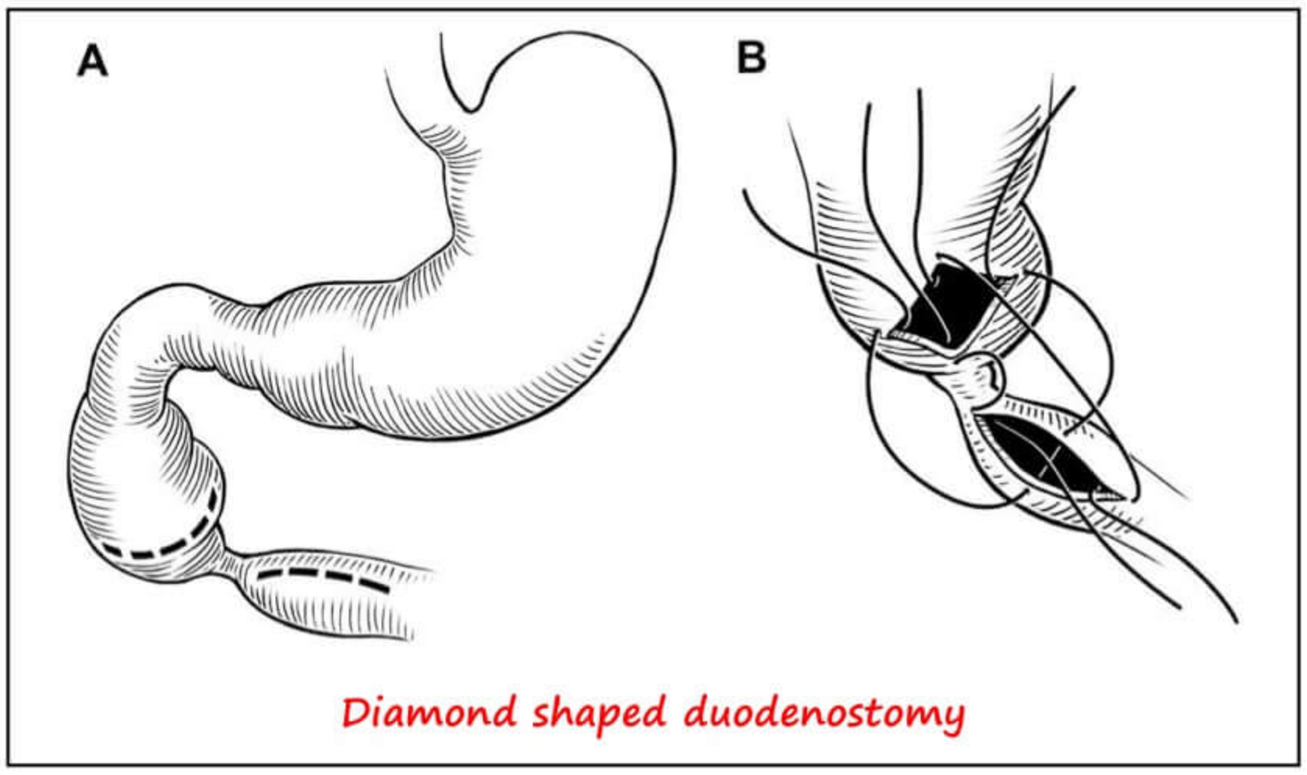

Diamond shaped duodenostomy

5 D's of duodenal atresia:

→ DA
→ Downs syndrome
→ Distal to ampulla (obstruction)
→ Double bubble sign on x-ray
→ Diamond shaped duodenostomy

Jejunoileal atresia

→ Jejunal atresia > Ileal atresia
→ Isolated atresia is seen in 80-90% cases
→ Multiple atresia is seen in 10-20% cases

t.me/latestpgnotes

Classification of Jejunoileal atresia

Type I	→ Membranous atresia with intact bowel mesentery
Type II	→ Blind ends are separated by fibrous cords
Type III A	→ Blind ends are separated by 'V' shaped defect in mesentery
Type III B	→ Apple peel atresia or Christmas tree atresia
Type IV	→ Multiple atresia (string of sausages appearance)

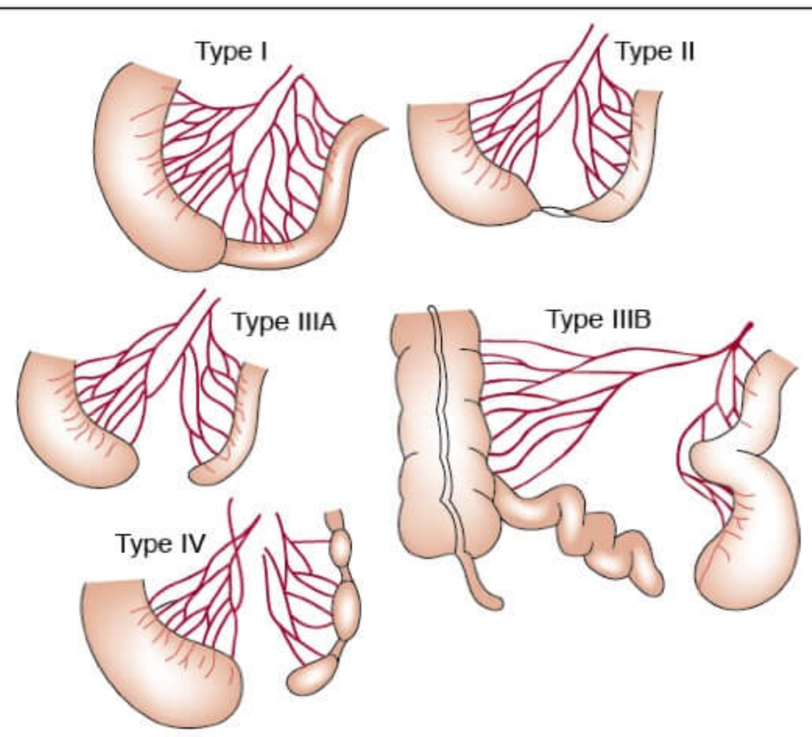

Clinical features

→ Bilious vomiting - First day
→ Vomiting – more prominent in proximal obstruction
→ Distention - More common in Distal obstruction
→ > 60% pts of Jejunal ileal Atresia - not able to pass meconium on first day

PrepLadder

Diagnosis

→ **On X-ray**: dilated bowel loops with absence of gas distally

→ Can be diagnosed by pre-natal USG

→ Maternal H/O Polyhydramnios

Management

→ IV fluids & IV antibiotics

→ Proximal gastric decompression

→ Exploratory Laparotomy -Resection of atretic segment + anastomosis

Prognosis

→ Excellent with 90% survival

Problems

1. Risk of adhesive intestinal obstruction
2. Necrotizing enterocolitis

Small Intestinal Duplication/ Duplication Cyst of Intestine

→ These are Mucosa lined structures in continuity with GI tract

→ MC site - ileum (within layers of mesentery)

→ Located along mesenteric border

→ Contains all 3 layers

t.me/latestpgnotes

→ Shares the common wall and blood supply

Types

Cystic (75% cases)	Tubular (25% cases)
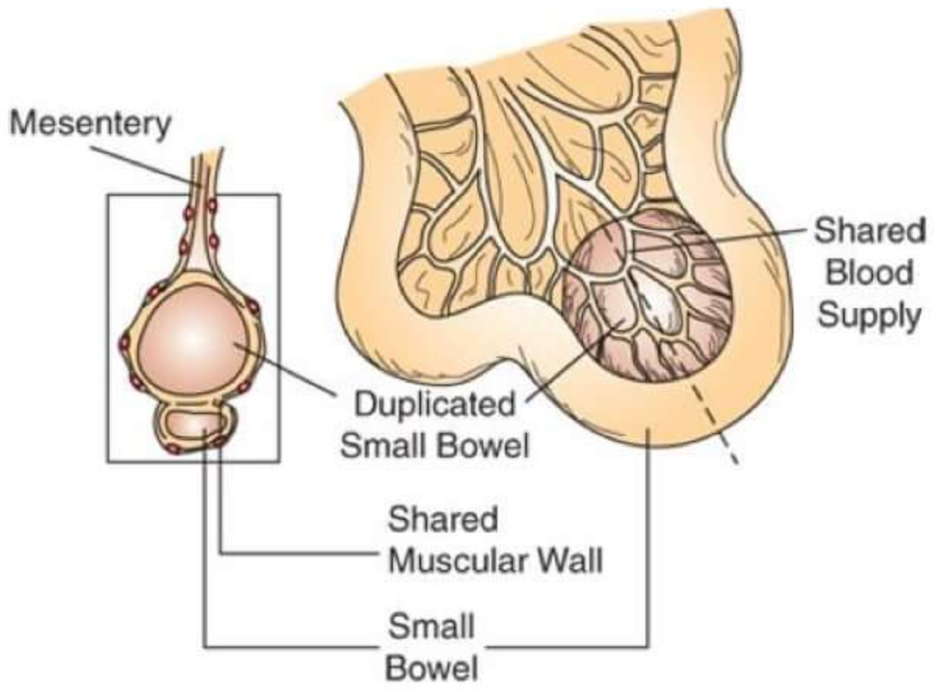 → Does not communicate with lumen of Small intestine → Partial small bowel obstruction	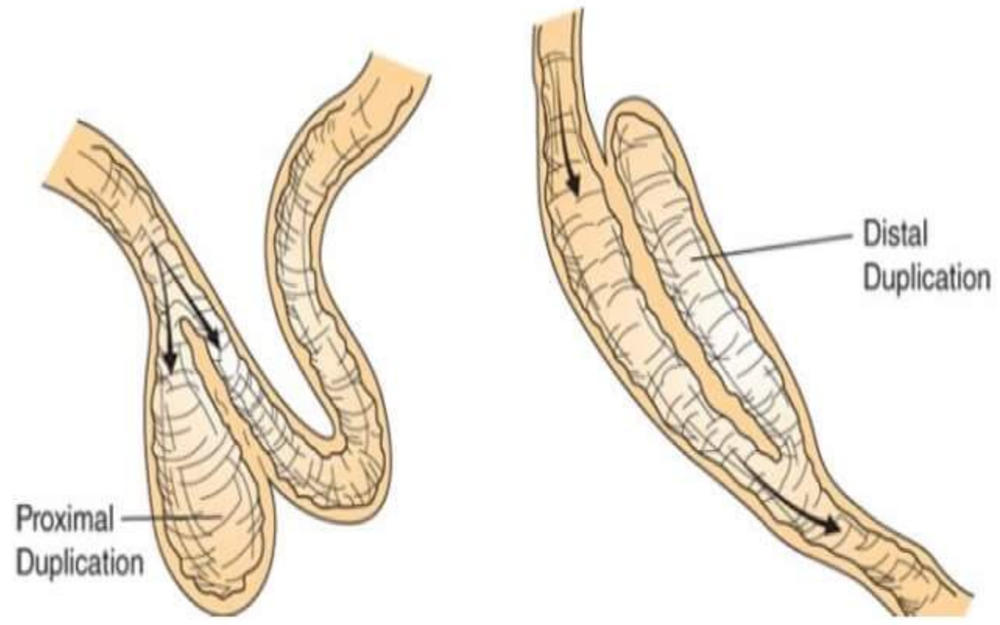 → Communicates with lumen of Small intestine → Contains ectopic gastric mucosa (-ileal ulcer) ↓ Bleeding ↓ Hematochezia

PrepLadder

C/F

→ Recurrent abdominal pain

→ Vomiting

→ Hematochezia

Diagnosis

→ On USG-Triple layer effect is seen

→ CT + Pertechnate scan can also be used

→ **IOC** - CECT

Treatment

→ For short segment duplication of – Resection and anastomosis

→ For long segment duplication

- Multiple enterotomy with stripping of mucosa or
- Division of common wall by stapler

t.me/latestpgnotes

PrepLadder

PEDIATRIC SURGERY Part – 2

Meconium syndrome

→ Group of GI conditions associated with cystic fibrosis

→ Overlap in clinical manifestation & Management

Cystic fibrosis

→ Abnormal chloride transport - Tenacious viscous secretions

→ **Organs involved in cystic fibrosis**

1. Intestine
2. Pancreas
3. Lungs
4. Salivary glands
5. Reproductive organs
6. Biliary tract

Meconium Syndrome Manifestations

→ **Meconium plug**

→ **Meconium ileus**

- Simple
- Complicated

t.me/latestpgnotes

Meconium plug

→ Frequent cause of neonatal intestinal obstruction

→ **Associated with**

- **M** - Maternal diabetes
- **H** – Hypothyroidism

– Hirschsprung's disease

- **C** – Cystic fibrosis

Clinical features

→ Preterm

→ Abdominal distention (due to Distal Bowel Obstruction)

PrepLadder

Diagnosis

→ **On abdominal X-ray** - Dilated bowel loop

→ Ix. which is both Dx. & Therapeutic – **Water soluble contrast enema (Gastrograffin)**

↓

Passage of meconium plug

↓

Relief of obstruction

Meconium Ileus

→ Unique form of neonatal intestinal obstruction in the patients of cystic fibrosis

→ it's the earliest clinical manifestation of Cystic fibrosis

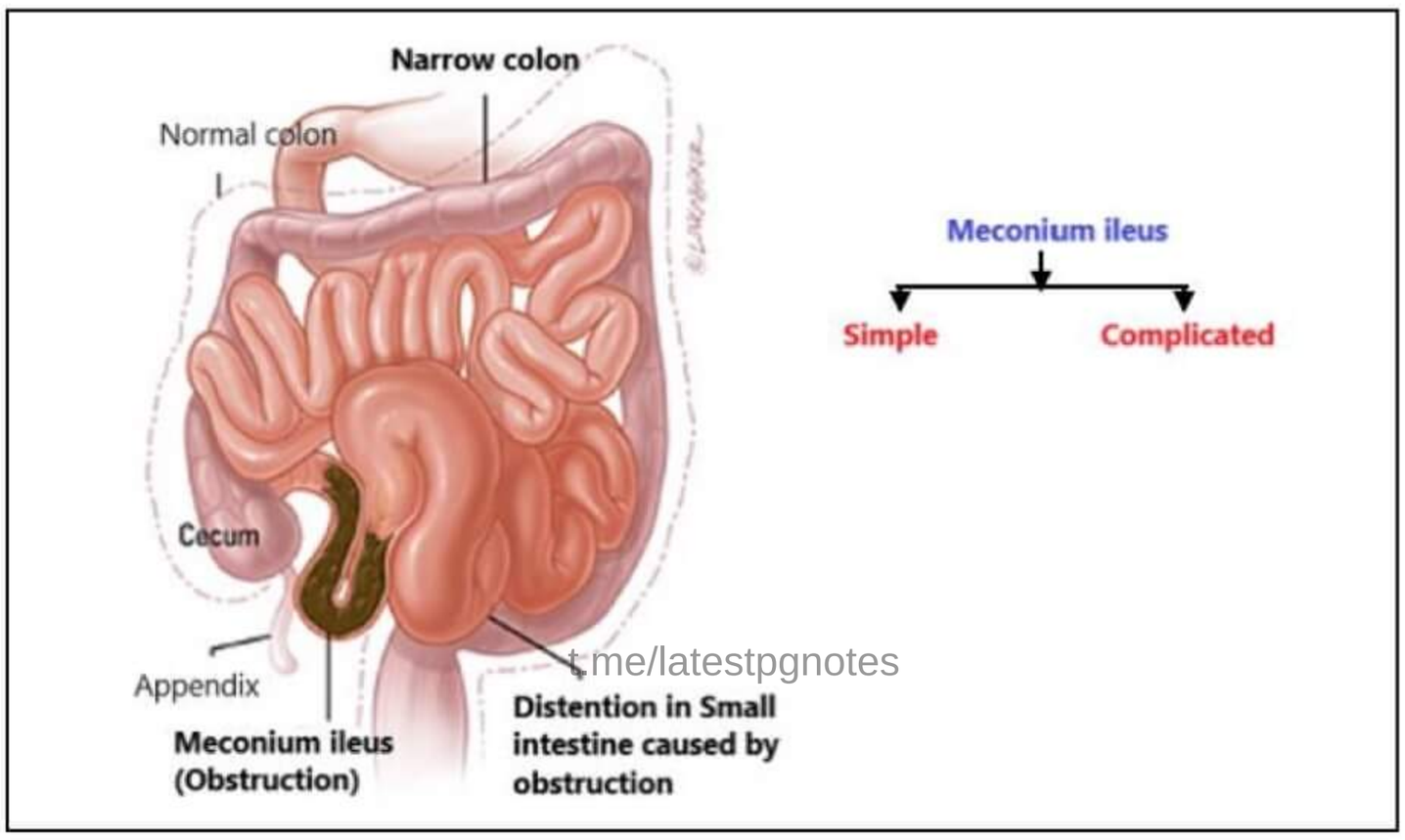

t.me/latestpgnotes

Simple meconium ileus

→ **Cardinal Features in 1st 24-48 hours**

1. Generalized abdominal distention
2. Bilious vomiting
3. Failure of passage of meconium

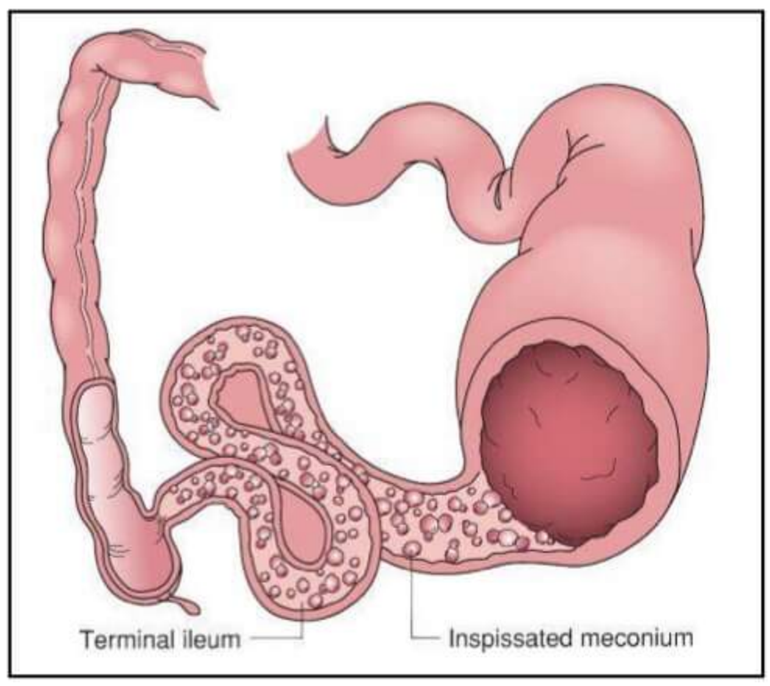

Manifestations

→ **Terminal ileum** - Dilated

→ Thick, tar like inspissated meconium

→ Smaller pellets of meconium

→ Relatively small colon in distal ileum

PrepLadder

Diagnosis

→ On X-ray

- Dilated bowel loops
- Absence of air fluid levels
- Mass of meconium in right side of abdomen is mixed with gas – Soap bubble / Ground glass appearance (Characteristic appearance)

→ IOC (Dx + Tx) – Water soluble contrast enema

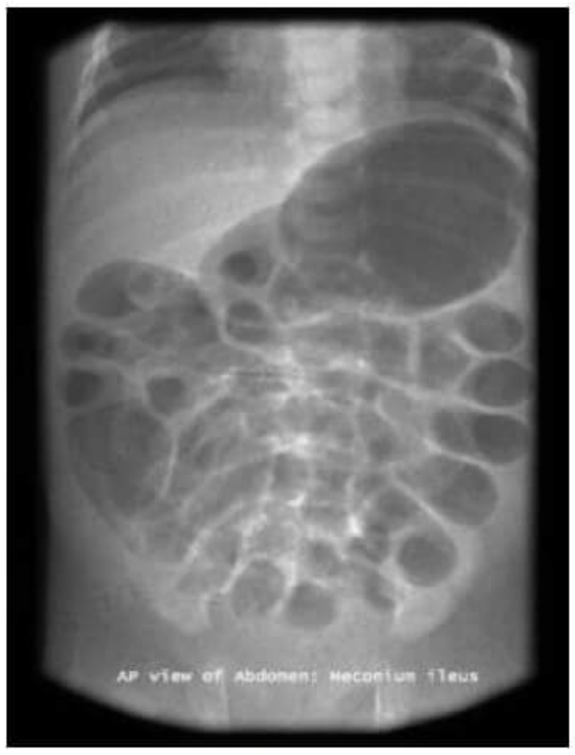

Soap bubble appearance

Management

→ Water soluble contrast enema – Relieves obstruction in >75% of patients

→ **Precaution** – Hydration of child (Hypertonic)

Operative intervention in simple meconium ileus

→ Simple evacuation of meconium with irrigation of proximal and distal bowel with Warm saline or 4% Acetyl cysteine

Named surgical interventions for simple meconium ileus

1. Paul Mikulicz Double barrel Ileostomy
2. Bishop – Koop's distal chimney Ileostomy
3. Santulli's proximal chimney ileostomy

t.me/latestpgnotes

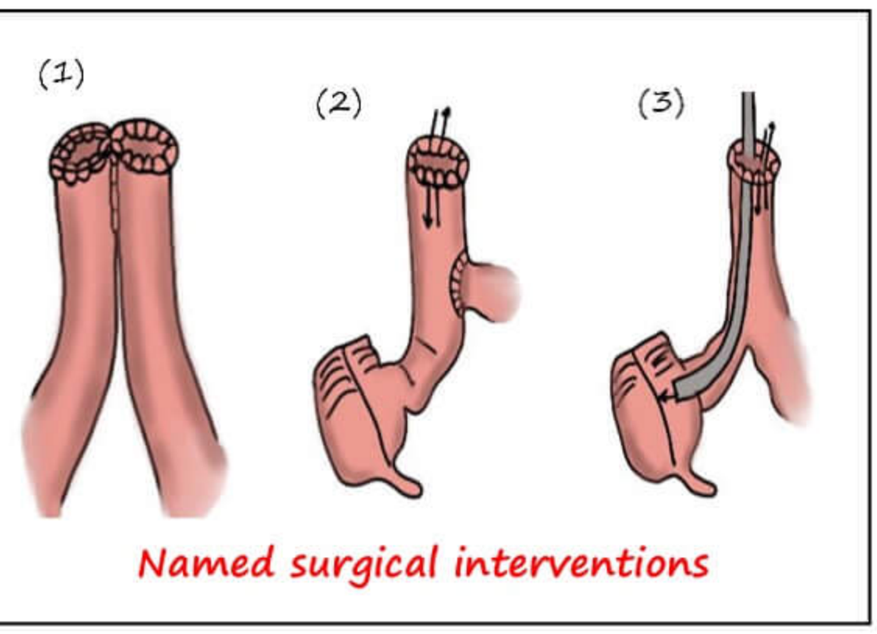

Named surgical interventions

Advantages of surgical intervention procedures

→ Lowest possible bowel resection

→ Enterostomy – Postoperative irrigation

Complicated Meconium ileus

→ **Meconium ileus** – Complicated by perforation (In Utero (or) just after birth)

↓

Peritonitis

↓

Aseptic chemical peritonitis

↓

Meconium within peritoneal cavity

- Dense inflammatory Adhesions
- Calcification
  - ↓
  - On USG – Snowstorm sign

PrepLadder

Clinical Presentation

→ Meconium pseudocyst

→ Adhesive peritonitis with or without 2° bacterial infection

→ Ascites

Diagnosis

→ **On X-ray abdomen**

- Specks of calcification
- Dilated bowel loops
- Mass effect

→ **On USG** – **Snow Storm sign** (characteristic appearance)

Management

→ **Conservative management**

- Enema
- Oral polyethylene glycol solution

Embryology of rotation

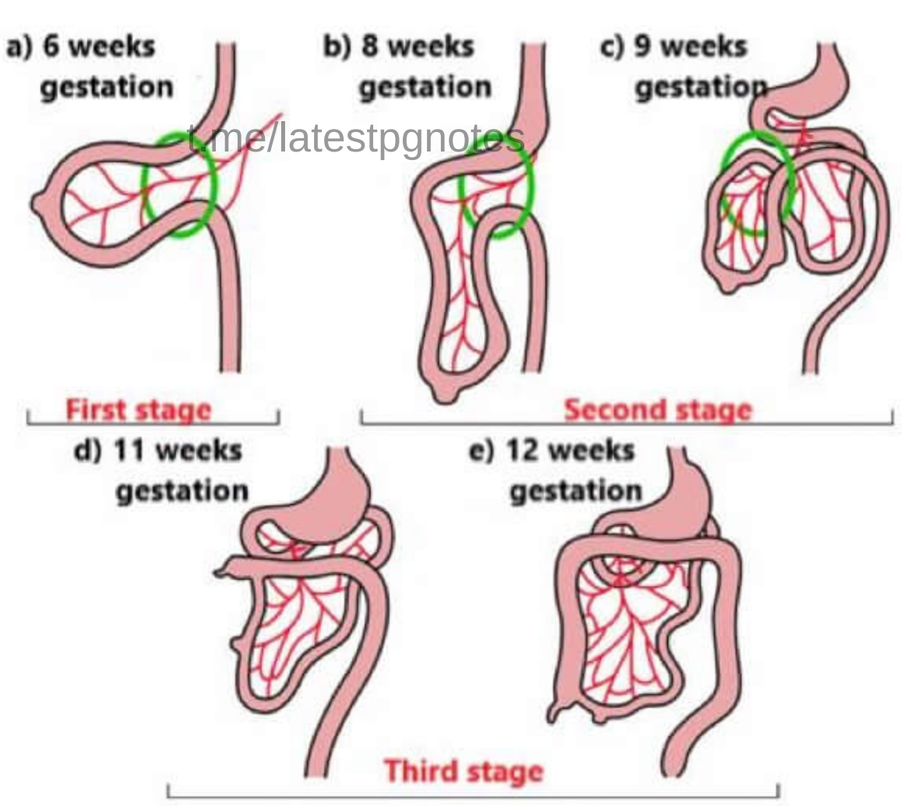

t.me/latestpgnotes

Rapid growth + Elongation of midgut starting in 5th week

↓

Herniation of midgut with superior mesenteric vessels as its stalk

↓

Midgut undergoes **270 ° Counter-clockwise rotation**

↓

- DJ flexure goes in left upper quadrant (at the level of pyloric antrum)
- DJ flexure becomes fixed to posterior abdominal wall by **ligament of Treitz**

↓

3rd part of duodenum lies posterior to Superior Mesenteric Artery

PrepLadder

↓

Herniated intestinal loop - Returns to abdominal cavity

↓

Cecocolic loops → 270 ° Counter-clockwise rotation

↓ leads to

- Normal position of cecum – Right Lower quadrant
- Ascending colon and descending colon - fixed to posterior abdominal wall

Types of Rotational abnormalities

1. Non-rotation - MC rotational abnormality
2. Incomplete rotation - MC type of malrotation
3. Reverse Rotation
4. Hyper rotation
5. Mixed rotation

1. Non-Rotation

→ MC type of rotational abnormality

→ Failure of Counter-clockwise rotation after return of midgut to abdominal cavity

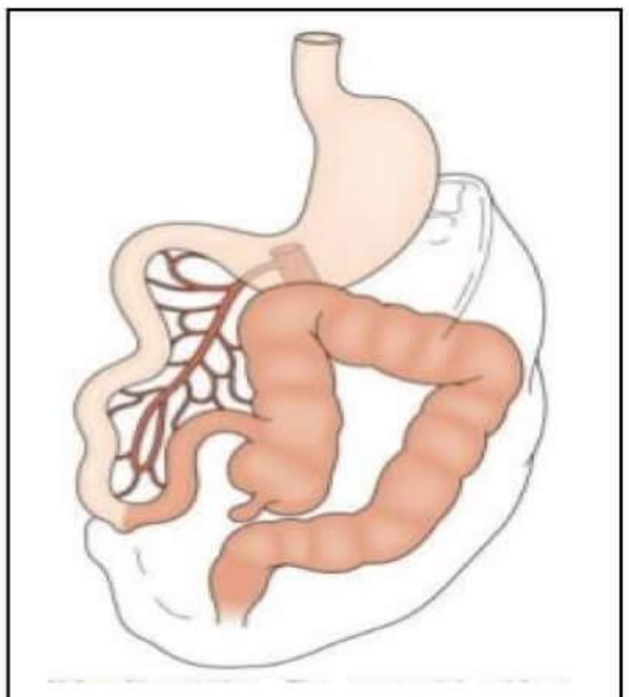

Non - Rotation

Abnormalities

t.me/latestpgnotes

→ **Duodenum (C-loop), Ligament of Treitz, Small intestine** – located on right side of abdomen

→ **Cecum** – left side of abdomen

→ **Proximal jejunum and ascending colon** are Fused as one pedicle through which blood supply of entire midgut is located via SMA

2. Incomplete Rotation

→ MC type of malrotation

→ Counter-clockwise rotation is arrested around 180°

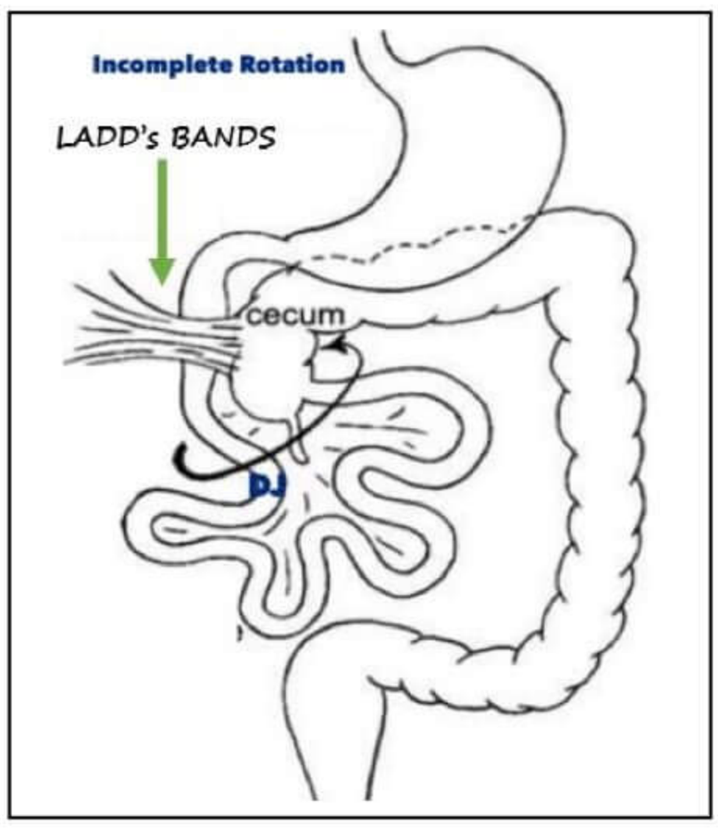

Abnormalities

→ **Small intestine** - lies on Right side

→ **With DJ flexure** - right side of vertebral column

→ **Duodenum** - has corkscrew configuration

→ **Large intestine** - lies on Left side

→ **Cecum** - Abnormal location (usually in Midline)

→ Failure of fixation of Ascending colon in Rt. hypochondrium

↓ leads to

Narrow Intestinal Mesentery and presence of LADD's BANDS (↓)

PrepLadder

LADD'S BANDS

→ Represents Retro peritoneal attachment that normally fixes the cecum and ascending colon to posterior abdominal wall

→ **Right Colon** - more medial

→ The Bands extends across the duodenum from right upper quadrant to the cecum and ascending colon

3. Reverse Rotation

→ Part of rotation occurs in clockwise direction around SMA

↓

1. **Duodenum** → Anterior to superior mesenteric artery
2. **Transverse colon** → Posterior to superior mesenteric artery

4. Hyper Rotation

→ Counter-clockwise rotation > 270°

↓

Cecum – Lies in Left hypochondrium

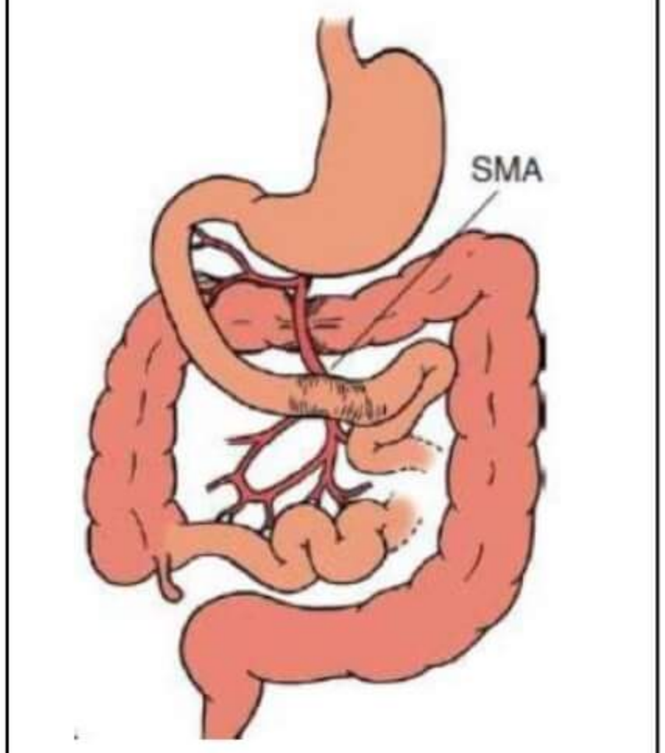

Reverse Rotation

5. Mixed Rotation

→ Intestine doesn't rotate as it re-enters the abdomen after physiological hernia

→ **Its consequences are**

- Cecum – located Inferior to pylorus
- Volvulus

t.me/latestpgnotes

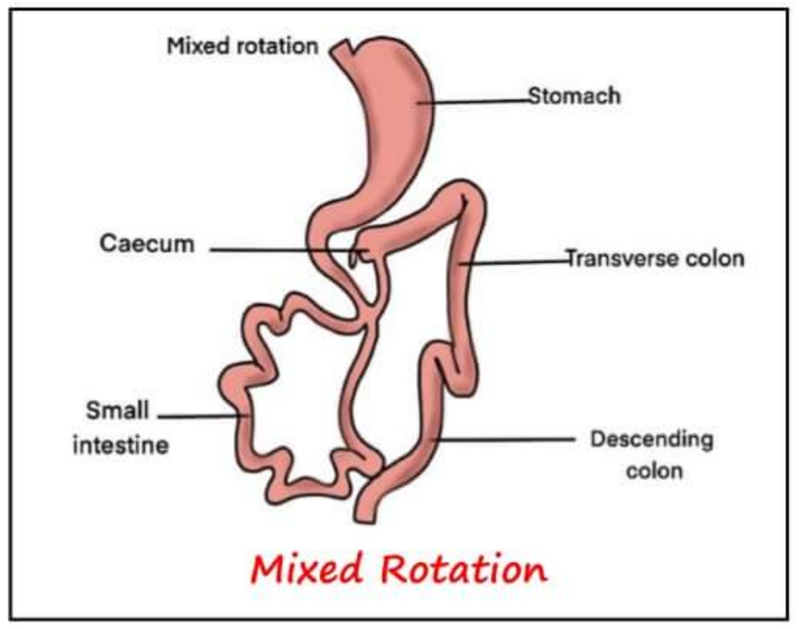

Mixed Rotation

MALROTATION

- Incidence of clinically symptomatic malrotation - 1:6000 live births
- In 30 -60% of cases → **Associated with GI Abnormalities**
- In 90% pts → **symptoms develop before 1 year of age**
- In 50 -75% pts → **Brought within first month of life**

Clinical features

→ **Asymptomatic** – Diagnosed incidentally or during Autopsy

→ **Malrotation without volvulus**

- Chronic abdominal pain ± Bilious vomiting
- Failure to thrive

→ **Malrotation with volvulus**

- Bilious vomiting, sometimes this is the only manifestation of midgut volvulus

PrepLadder

→ **Systemic Signs and symptoms in cases of delayed Dx**

- increase Lethargy because of **poor perfusion**

↓ urine output

Metabolic acidosis

↓

Cardiopulmonary compromise

Investigations

→ **Lab findings**

- Metabolic acidosis
- Thrombocytopenia
- Leucopenia

→ Acute onset of bilious vomiting in a neonate - **sign of malrotation** (until proven otherwise)

↓

Ix should be performed to confirm the Dx

→ **Gold standard investigation** for Dx of malrotation - **Upper GI contrast study** (Malrotation can be Dx by abnormal position of ligament of Treitz)

→ **Normal location of ligament of Treitz** - Left to the vertebral column located posterior to stomach

t.me/latestngnotes

→ **Barium Enema** - Not the part of diagnostic works up because normally cecum does not rule out malrotation

→ **UGI contrast study** – can diagnose Mid-Gut volvulus

→ **Findings of mid gut volvulus**

- Cork screw configuration of upper portion of Small intestine or
- Bird Beak appearance at 3rd part of duodenum

Note

→ **Bird Beak appearance on**

1. Ba. swallow- Achalasia cardia
2. Upper GI series – Mid-Gut Volvulus
3. Ba. Enema – Sigmoid volvulus

Management

1) **For Acute ill child with peritonitis** - **Exploratory Laparotomy performed (Emergency)**
2) **Symptomatic from volvulus**
   - IV fluids and IV antibiotics
   - Proximal gastric decompression
   - Emergency surgery
3) **Chronic symptoms / symptom free:**
   - Elective correction
   - Standard operative procedure → **LADD'S procedure**

PrepLadder

LADD's Operation:

→ **Components:**

a) Reduction of volvulus

b) Division of LADD'S bands

c) Appendectomy

d) Positioning of intestine with or Without fixation

→ **Steps:**

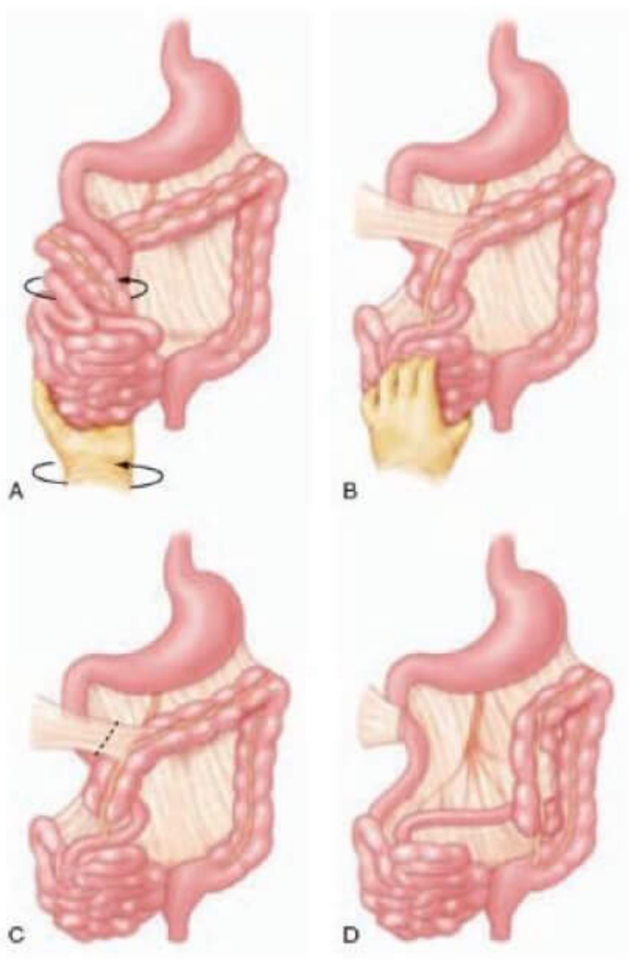

1) RUQ Transverse incision

2) Reduction of volvulus by Counter-clockwise rotation

3) **Bowel with uncertain viability** - Wrapped in warm moist sponges, minimum for 15 minutes

4) **Gangrenous bowel** - resection should be done

5) **LADD'S bands** – Divided near lateral aspect of duodenum

6) **Widening of mesenteric base** - Duodenum is mobilized and straightened by dividing abnormal ligament of Treitz and LADD'S band

t.me/latestpgnotes

7) Appendectomy to avoid diagnostic confusion

8) **Final position of bowel after LADD'S operation**
   - Duodenum and proximal jejunum - placed on right side of abdomen
   - Terminal ileum & cecum - Placed on left side of abdomen

ANORECTAL MALFORMATIONS (ARM)

→ Incidence - 1:5000 live births

→ MC in boys

→ Ranges from Anal stenosis to cloaca

→ **MC defect** - imperforate anus with fistula
   - **In boys** - Fistula between distal colon and urethra
   - **In girls** - Fistula between distal colon and vestibule of vagina

PrepLadder

Embryology

→ **By 6th week of gestation** – Urorectal septum moves caudally to divide the cloaca into 2 parts

- Anterior Urogenital sinus
- Posterior Anorectal anal

→ **Failure of this septum to form** results in

- Fistula b/w bowel and urinary tract in boys
- Fistula between bowel and vagina in girls

→ Complete or partial failure of anal membrane to resorb results in – **Anal membrane stenosis**

→ If there is **breakdown of cloacal membrane** anywhere along its course results in

↓

External anal opening anterior to external sphincter

(Anteriorly displaced anus)

Management

→ Depends upon the type of defect

- Low lesion or
- High lesion

(Depending upon site of termination of rectum in relation to pelvic floor)

→ Site of termination of Rectum is assessed by – **INVERTOGRAM**

- Usually done 6–12 hrs. after birth
- Coin is placed at expected anus and baby is turned upside down (minimum for 3 minute)
- **In high lesion** – Rectum ends above the Levator ani complex
- **In low lesion** – Rectum ends below the Levator ani complex

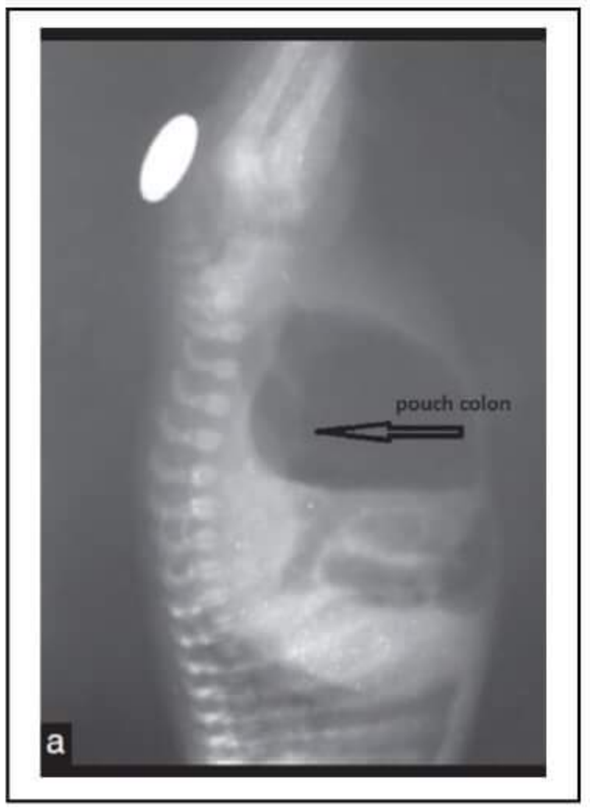

t.me/latestpgnotes

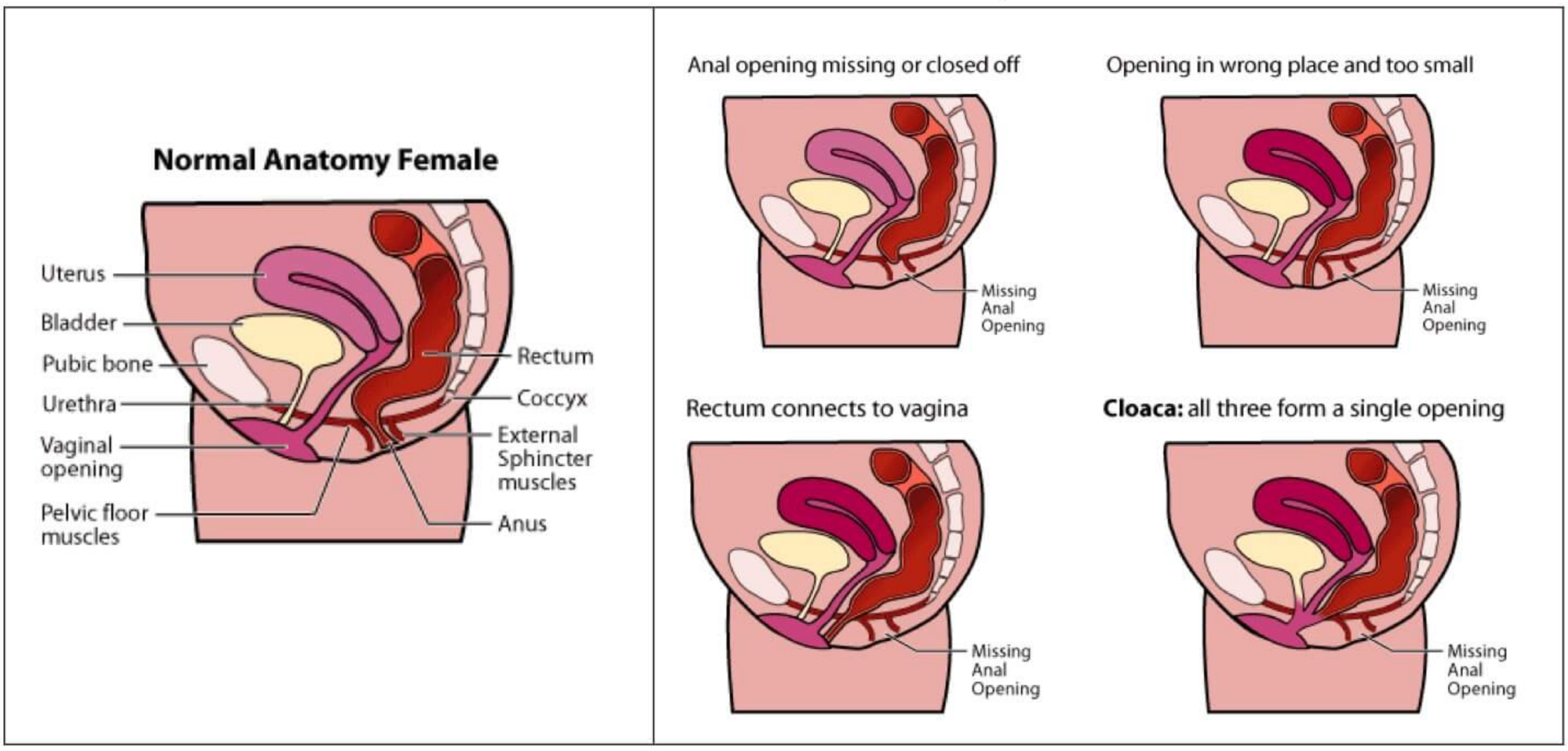

PrepLadder

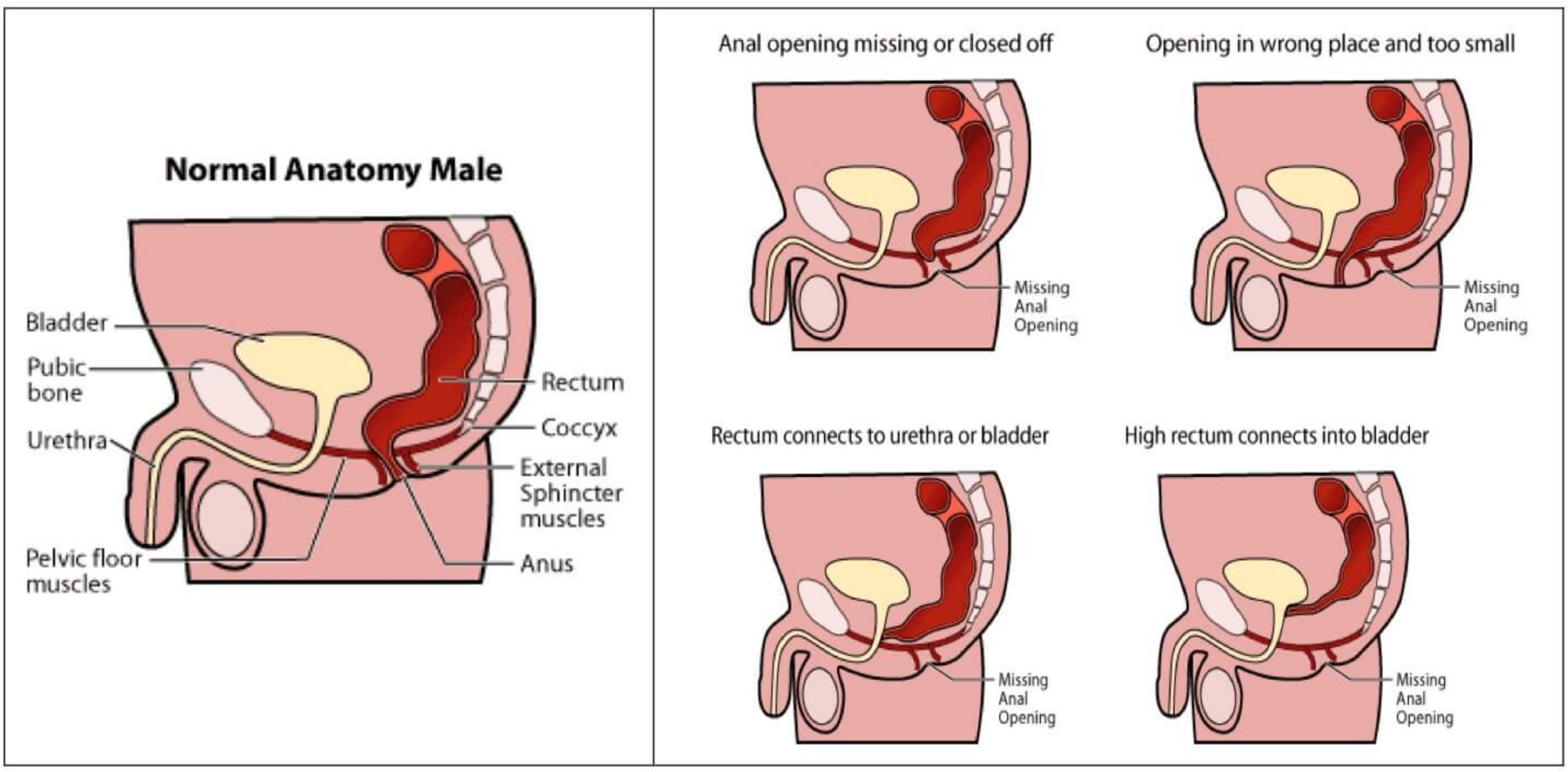

Clinical clues suggestive of high lesion

1. **Flat bottom**
    - Poor muscle structure
    - Associated with very high defects
2. **Meconuria**
    - Communication between Rectum and Urinary tract
    - Suggestive of high lesion

t.me/latestpgnotes

Clinical clues suggestive of low lesion

1. **Bucket handle deformity** – Prominent midline skin tag stem tag below which one can pass an instrument
2. **Midline Raphe fistula**
3. **Perineal fistula** – Presence of meconium coming out through a small opening anterior to anal dimple
4. **Anal stenosis** – Narrow anal canal
5. **Anal membrane** – Very thin epithelial membrane through which one can see meconium

Management

A. For high lesions

→ Protective colostomy followed by Posterior Sagittal Ano-Recto Plasty (PSARP) after 4-8 weeks

B. For low lesions

→ Only Perineal anoplasty

PrepLadder

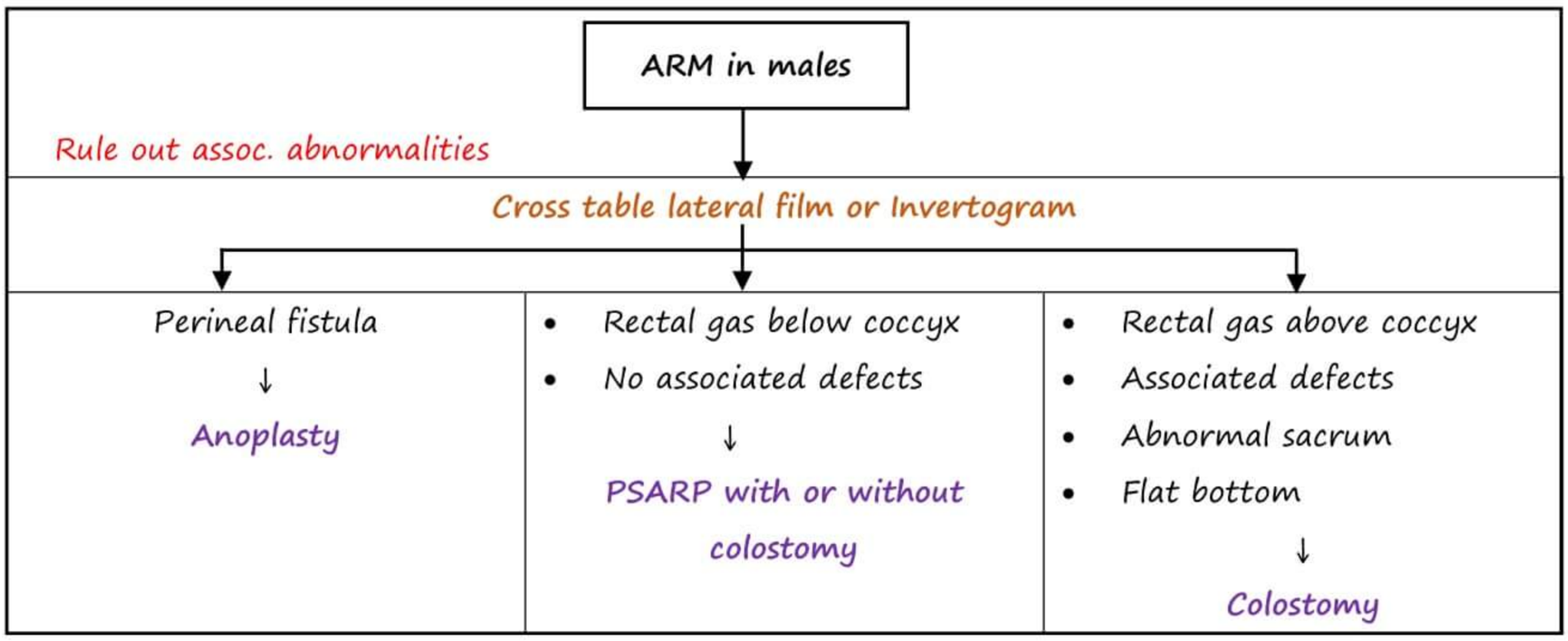

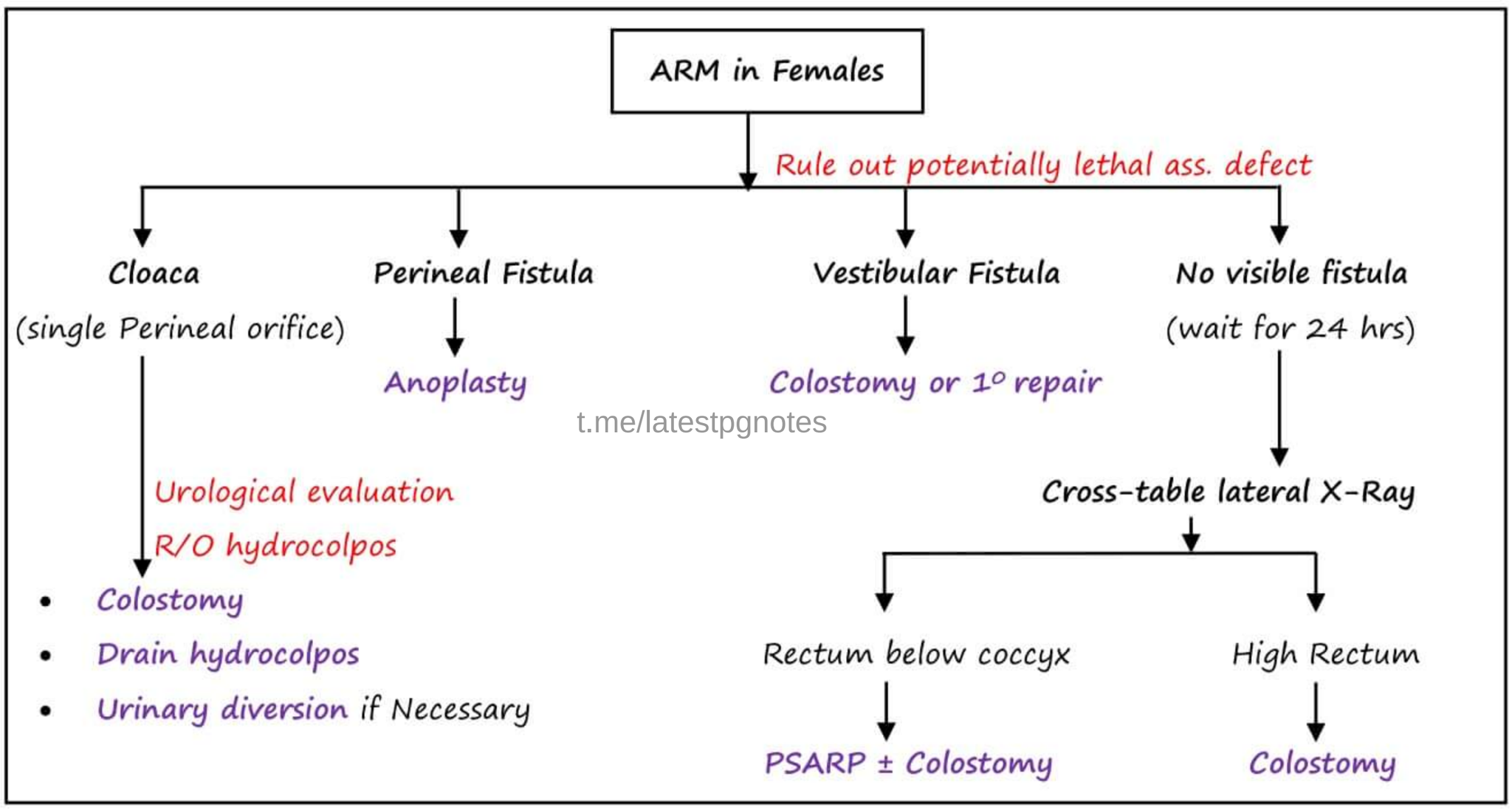

t.me/latestpgnotes

SCACROCOCCYGEAL TERATOMA (SCT)

→ Teratoma - most frequently occur during neonatal period

→ MC site – Sacrococcygeal lesion

→ More common in females

→ Most Teratoma in neonatal period - Benign

→ Risk of malignancy - increases with age

→ It is thought to be derivative of primitive streak

Clinical features

→ Presence of External presacral mass with minimal intrapelvic presacral component

PrepLadder

→ **Symptoms**

a) Weakness

b) Paralysis

c) Bladder / bowel dysfunction

Diagnosis

→ Diagnosis is done - **Clinically**

→ **CT / MRI** - to detect intra-abdominal or intra pelvic component

Treatment

→ Complete surgical excision of tumor

→ Resection of coccyx is critical – because of Local recurrence (very high rate)

Currarino Triad

→ **Components**

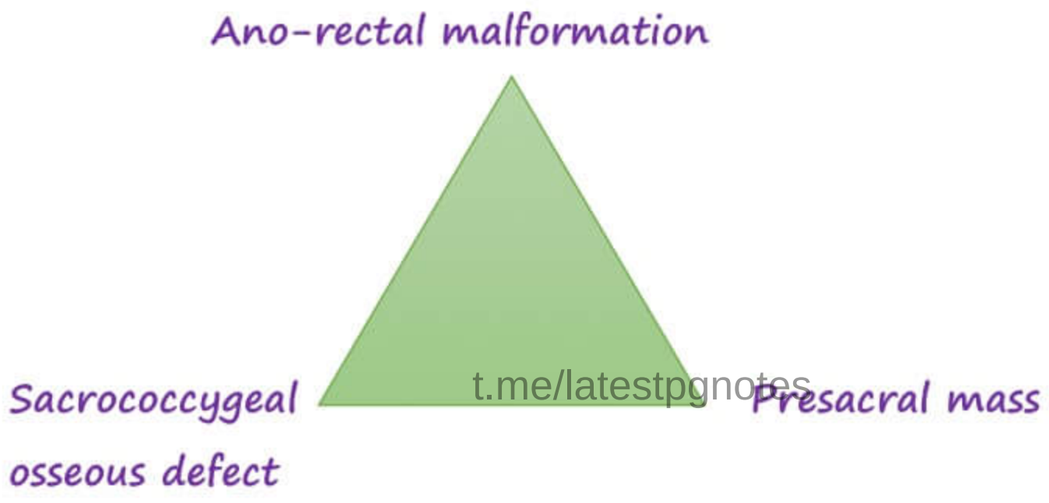

t.me/latestpgnotes

PrepLadder

TRAUMA

Trimodal mortality model for trauma

Immediate death (Occurs within minutes of injury)	Early death (Occurs within hours of arrival into hospital)	Late death (Occurs days to week after injury)
→ Declared dead at the scene → Die shortly after arrival to hospital **Causes** → Irreversible brain injury → Hemorrhage from injuries of • Heart • Aorta • Liver • Lungs • Pelvic fracture	**Causes** → Intracranial hemorrhage → Internal hemorrhage involving respiratory system & abdominal organs → Multiple injuries leading to severe blood loss → Tension pneumothorax → Cardiac tamponade	**Causes** → Sepsis (MC) → Multiple organ failure

Triage (To Sort)

→ Used during Mass casualties

t.me/latestpgnotes

→ It involves prioritizing victims into categories based on
- Severity of injury
- Likelihood of survival
- Urgency of care

Triage TAGS

→ Color codes are used to identify patient categorization

1) **Red (immediate)** – Most critically injured patients
   - Head injury
   - Injury to thorax or abdomen
   - Immediate care is required

2) **Yellow (Delayed)** - Less critically injured patients
   - Patient's require in hospital treatment

3) **Green (ambulatory patient)** – No life or limb threatening injury

4) **Black (expectant)**- dead or moribund patients



PrepLadder

Sequence followed

→ **In Trauma (According to ATLS)**

- **ABCD** (Airway → Breathing → Circulation → Disability → Exposure & environment control)

→ **In ACLS / BLS**

- **CAB** (Circulation → Airway → Breathing)

ATLS Protocol

→ **Composed of**

- Primary survey
- Secondary survey

Primary survey

→ Aimed at detecting & simultaneously treating immediately life-threatening injury

→ **Sequence followed**

- **A** – Airway maintenance with cervical spine protection
- **B** – Breathing that includes ventilation and oxygenation
- **C** – Circulation with hemorrhage control
- **D** – Disability (brief neurological examination)
- **E** – Exposure and environment control

t.me/latestpgnotes

Secondary survey

→ Consists of head to toe systematic assessment of

- Abdominal
- Pelvic and
- Thoracic areas

→ Complete inspection of body surface to find all injuries and neurological examination

Tertiary survey (not included in ATLS – Recently used)

→ It is a comprehensive patient evaluation after initial resuscitation

→ It includes

- Thorough physical examination
- Combined with targeted radiographic imaging include
  - X-ray
  - USG or CT based on examination findings

→ It decreases delays in Dx of potentially life-threatening injury (main advantage of tertiary survey)

PrepLadder

Primary survey

1) Airway maintenance with cervical spine protection

→ Cervical spine > airway

→ **In all trauma patients** – Cervical spine injury should be suspected

↓

Cervical spine immobilization should be done

→ **Assess the patency** – by eliciting verbal response

→ **Ability to speak** – suggestive of Adequate airway protection

→ **If patient not able to speak** – suspect

- Mental status depression } Indications for Airway management
- Obstruction of airway }

→ **Other indication of airway management**

- Noisy breathing
- Facial trauma
- GCS ≤ 8

→ **Stepwise progression in compromised airway**

1. Clear the airway – By suctioning of secretion of blood
2. Chin lift / Jaw thrust
3. Insertion of oropharyngeal or nasopharyngeal airway

t.me/latestpgnotes

→ Definitive airway of choice in most of trauma patient's – Oral endotracheal incubation with cuffed ET tube

Note:

→ **ATLS 10th edition recommends** – Video laryngoscope for intubation

→ **In Patients of severe maxillofacial injuries**

- Needle cricothyroidotomy
  - Emergency airway of choice
  - Performed quickly
  - High flow O2 given via 4-6 mm tube
  - **Disadvantage**
    - Co_2 retention within 20-30 mins
    - Avoided in children < 12 years due to the risk of Subglottic stenosis
- Tracheostomy – Definitive airway of choice

2) Breathing (ventilation + oxygenation)

→ **Assess breathing** – by visualizing chest moments

→ **Assess rate & depth** – by Percussion and Auscultation

→ **O_2 saturation**

→ **Limited respiratory efforts / dyspnea** – Patient requires Ventilation & further assessment

PrepLadder

→ **Causes of Ventilation problem**

1. Tension pneumothorax
    - Wide bore needle in 2nd I/C space in MCL

Note

→ **According to ATLS 10th edition** – Recent evidences support insertion of needle in 5th I/C space slightly anterior to MAL in Adults

2. Massive hemothorax
    - ICD insertion
3. Flail chest with pulmonary contusion
    - **For Severe pulmonary contusion** – Aggressive mechanical ventilation is performed

3) Circulation with hemorrhage control

→ **Assess circulation** – Primary goal is to look for shock

→ MC cause of shock in trauma – Hemorrhage

→ **Assess vitals**

- PR > 100 / min } Unstable vitals – Suggestive of Shock
- BP < 100 mmHg }

→ **Mx of shock**

- Put two Large bore IV canula
- Send blood for cross match
- 1-2 liters of warm Crystalloid solution (old edition)

t.me/latestpgnotes

Note

→ **ATLS 10th edition**

- 1 liter of warm crystalloid solution in adults
- 20 ml / kg warm crystalloid solution in children < 40 kg

→ **Rapid screening** – To identify causes of life-threatening blood loss

→ **5 major locations that cause Exsanguination leading to Shock**

1. External blood loss
2. Chest
3. Abdomen
4. Retroperitoneum (pelvic fracture)
5. Multiple long bone fracture

→ **During initial physical examination**

- Identify source of external bleeding – Direct pressure over the site of bleeding
- Identify Long bone fracture - Splinting should be done

→ **Investigations done**

- CXR – to evaluate Thoracic blood loss
- X-Ray Pelvis – to identify Pelvic fracture
- FAST – for evaluation of Abdomen

PrepLadder

- Two most important X-ray in trauma patient
  - CXR
  - X ray pelvis (AP view)

→ In non-responding pts. With ongoing signs of shock
- Manage ongoing bleeding
- Blood transfusion

→ **In Trauma transfusion,** ratio to be followed is
- Packed cell: Plasma: Platelets → 1:1:1

→ Best indicator of tissue perfusion in trauma - urine output

→ Best indicator to determine fluid requirement – CVP

→ **Acc. To ATLS manual 10th edition** - Pediatric mass transfusion Protocol
- Initial 20 ml / kg bolus of warm isotonic crystalloid
- Followed by 10-20 ml / kg of Packed cell
- 10-20 ml / kg of Plasma
- 10-20 ml / kg of Platelets

} Ratio of 1:1:1

→ **CRASH-2 TRIAL**
- Recommends use of Tranexamic acid in hypotensive trauma patients
- 1 gm I/V over 10 minutes followed by 1 gm over 8 hours
- **Advantages**
  - Reduces the risk of mortality from bleeding in both blunt & penetrating trauma
- **Indications for Tranexamic acid**
  - All trauma patients suspected to have significant hemorrhage including SBP < 110 mmHg or PR > 110/min
  - Administrated within 3 hours of injury

t.me/latestpgnotes

4) Disability (brief neurological examination)

→ Assess GCS

→ Assess pupils
- Size
- Equality
- Reaction

→ **Components of GCS**

Eye opening		Verbal response		Motor response (Best)	
E4	→ Spontaneous	V5	→ Oriented	M6	→ Patients obeys command
E3	→ To loud voice	V4	→ Disoriented/confused	M5	→ localizes pain
E2	→ To pain	V3	→ Inappropriate word	M4	→ Withdrawal to pain
E1	→ No response	V2	→ Incomprehensible sound	M3	→ Abnormal flexion posturing
		V1	→ No response	M2	→ Extension posturing
				M1	→ No response

PrepLadder

→ Maximum GCS score – 15 (E_4 V_5 M_6)

→ Minimum GCS score – 3 (E_1 V_1 M_1)

→ Best indicator of outcome - Motor response

→ **On the basis of GCS score**

- 13 -15 → Mild head injury
- 9-12 → Moderate head injury
- ≤8 → Severe head injury

→ VT is used for patients

- Incubated
- With Tracheostomy

→ Score given for VT = 1T (for example – if E_4 V_{1T} M_6, Score is **11T**)

5) **Exposure / environmental control**

→ All clothing of patients should be removed - for adequate examination

→ Core body temperature should be obtained

→ Keep the patient warm

→ **Environmental control is done by**

- Warm blankets
- ↑ room temperature
- Heated IV fluid administration
- Body warmers

t.me/latestpgnotes

1) **Acc. To ATLS 10th edition** – Life threatening injuries during primary survey are

Airway related	Breathing related	Circulation related
• Airway obstruction • Tracheobronchial injury	• Tension pneumothorax • Open pneumothorax	• Massive hemothorax • Cardiac tamponade • Traumatic circulatory arrest

Secondary survey

2) **Obtain AMPLE history from pt. / Relatives**

A – Allergies

M – Medications

P – Past illness/ pregnancy

L – last meal

E – Events related to injury

3) **Apart from ample history we must perform**

- Systemic assessment from head to toe
- Complete inspection of body surface
  - To find all injuries
  - Neurological examination

PrepLadder

Steps of secondary survey

→ Examination of

1) **Head & face** – R/O fracture & laceration
2) **Neck** – R/O neck injuries
3) **Chest**- R/O rib fracture
4) **Abdomen**
    - R/O abdominal pain, tenderness & bruising
    - NG tube insertion
    - In case of facial trauma - orogastric tube insertion
    - Check meatus - if no blood at meatus, Foley's catheterization is done
5) **Back**
    - → Aka Log roll
    - → 5 people are required for supporting
        - 1 - for Head
        - 3 - for Body
        - 1 - for Examination of back
6) **Extremities** – for Tenderness, Crepitation and Abnormal movements
7) **Neurological examination**
    - → Repeat GCS
    - → Re-Evaluate pupils
    - → Look for localizing or lateralizing signs
    - → Look for signs of cord injury

t.me/latestpgnotes

Trauma scoring systems

Revised trauma score (RTS)	Trauma & injury severity score (TRISS)	Mangled Extremity severity score (MESS)
(Mnemonic- GB Road) • **G** - GCS • **B** - Bp (systolic) • **Road** - Respiratory rate	(Mnemonic- ISS + RAM) • **ISS** - Injury severity score • **R** - Revised trauma score • **A** - Age • **M** - Mechanism(blunt/penetrating)	(Mnemonic-ELISA) • **E**- Energy • **Li**- Limb Ischemia • **S**- Shock • **A**- Age

PrepLadder

HEAD INJURY

Layers of scalp

- **S** – Skin
- **C** – Connective tissue
- **A** – Aponeurosis
- **L** – Loose areolar tissue
- **P** – Periosteum

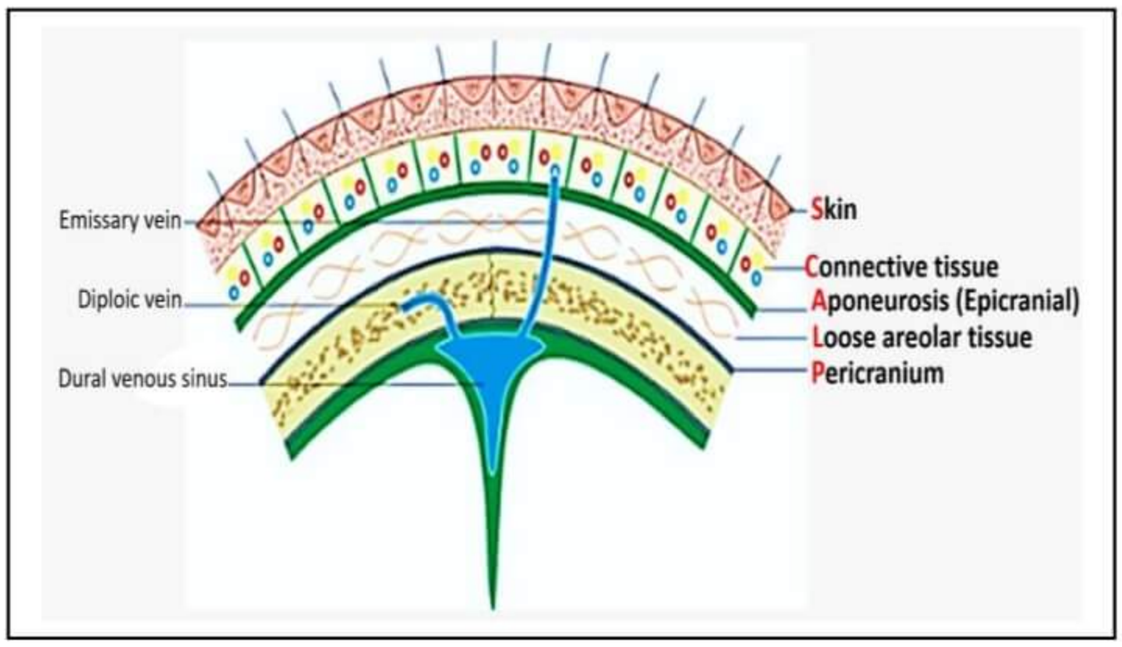

Skin

→ Has numerous Hair follicles & Sebaceous glands

→ Most common site of **sebaceous** cyst

Connective tissue (dense connective tissue)

→ Rich vascularity

→ Rich innervations

→ Blood vessels are densely adherent to Connective tissue

↓

Not able to constrict fully if lacerated

↓

Profuse bleeding – **Controlled by**

- Direct pressure
- Suturing in 2 layers
- Eversion of edges of wound

t.me/latestpgnotes

Skull fracture

→ It is of 2 two types

- Closed fracture
- Open or Compound fracture

Closed fracture

→ Covered by intact skin

→ No specific treatment required

Open or Compound fracture

→ Associated with disrupted overlying Skin

→ **Treatment** – Repair of scalp & operative debridement

→ **Indications of craniotomy**

- Depression greater than cranial thickness
- Intracranial Hematoma
- Frontal sinus involvement

PrepLadder

Depressed skull

→ Inner & outer cortex – disrupted

→ Fragment of bone is pressed towards the brain

→ Inner cortex of bone fragment can have **Multiple sharp ends** - Can lead to laceration of

- Dura
- Brain
- Vessels

Depressed skull

Treatment

→ **Craniotomy**

- To elevate fracture
- To repair dural disruption
- To obtain Hemostasis

Skull base fracture

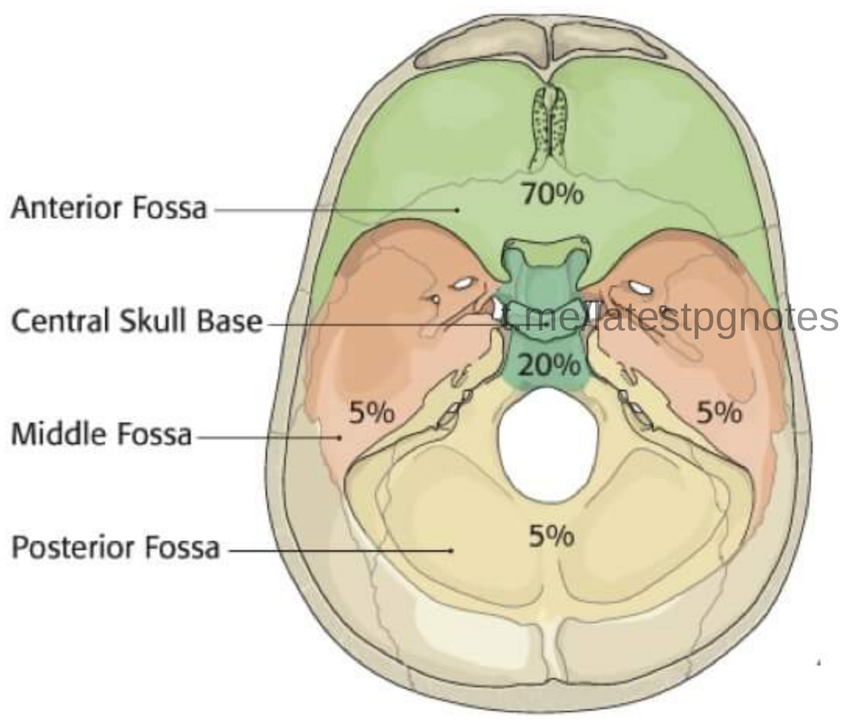

@mylatestpgnotes

Anterior cranial fossa fracture

→ Most common type of skull-based fracture

→ Site of # – Cribriform plate

↓

Sieve like structure b/w anterior cranial fossa & nasal cavity

→ **Clinical features**

- Subconjunctival Hematoma
- CSF Rhinorrhea – presence of Target sign/ Halo sign

  (Gold std. confirmatory test for detection of CSF - **β2 Transferrin assay**)
- Epistaxis
- Anosmia
- Frontal lobe contusion
- Periorbital Hematoma - Raccoon eye's or black eyes

PrepLadder

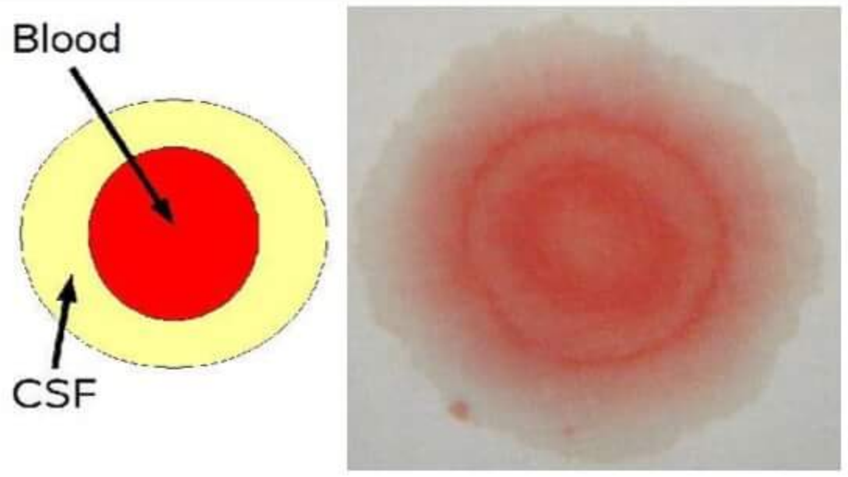

Target sign/ Halo sign

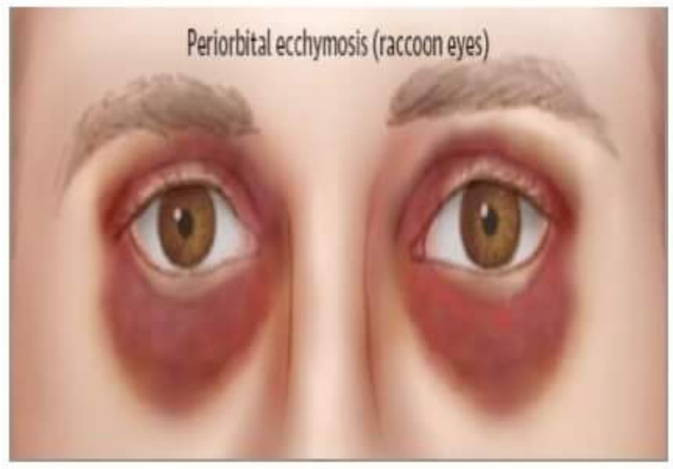

Raccoon eye's or black eyes

Middle cranial form fracture

→ Fracture of **Petrous part of temporal bone**

→ **Clinical features**

- CSF otorrhea (Occurs only if Tympanic membrane is perforated)
- **Paradoxical Rhinorrhea**
  - CSF leaks through nose (If tympanic membrane is intact)
  - Also known as otorhinorrhea
  - Collection of blood behind tympanic membrane is known as **Hemotympanum**
- **Battle sign** – Ecchymosis or bruising over mastoid process
- 7th & 8th cranial nerve injury
- Temporal lobe contusion

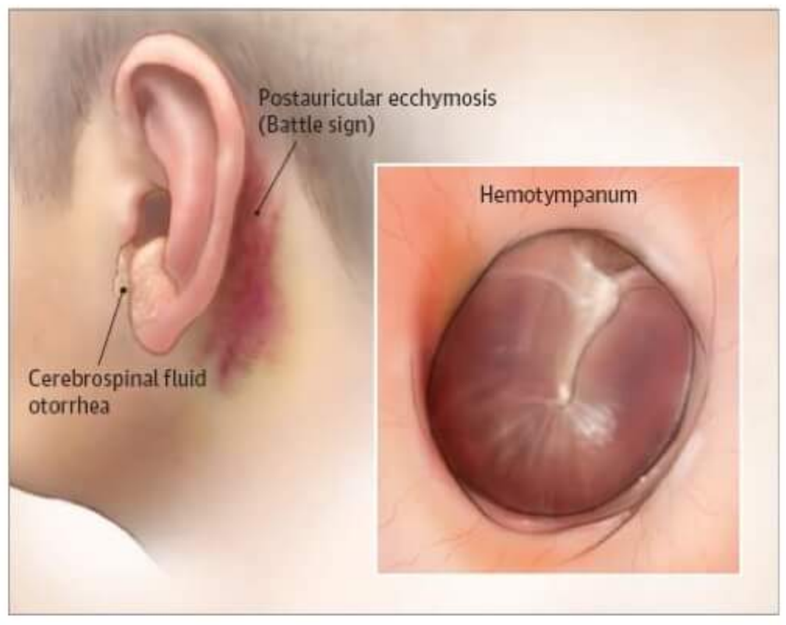

Battle sign

t.me/latestpgnotes

Posterior cranial fossa fracture

→ Fracture of **occipital bone**

→ **Clinical features**

- Visual disturbances
- Contusion of occipital bone
- VI Cranial nerve injury
- Jugular foramen syndrome / Vernet syndrome – **Paresis of 9, 10, 11 CN**
- Basilar artery injury

NICE guidelines (National institute for health & care excellence)

NICE guidelines for frequency of neurological observation in head injury patients

→ Half-hourly basis until GCS equal to 15 is achieved

→ The minimum frequency of observations for pt. with GCS equal to 15 should be

- **First 2 hours** – every half hour
- **Next 4 hours** – Every hour
- **After 6 hours**- Every 2 hours

PrepLadder

NICE guidelines for indications of CT in head injury pts

→ **Indications of CT within 1 hour**

- GCS < 13 at any point
- GCS < 15 at 2 hours
- FND (focal neurological deficit)
- Suspected Open, Depressed or Basal skull fracture
- > 1 episode of vomiting
- Post- traumatic seizure

→ **Indications of CT within 8 hours**

- Age > 65 hours
- Coagulopathy (Aspirin, Warfarin, Rivaroxaban)
- Dangerous mechanism of injury (fall from height or RTA)
- Retrograde amnesia > 30 mins

Brain injury

Primary	Secondary
• Neural damage attributed directly to traumatic insult itself • It includes – Shearing of neuronal axons – Contusion or laceration of cerebral tissues – Diffuse axonal injuries	• Occurs after some time • Preventable • Causes – Hypoxia – Hypotension – ↑ ICT – ↓CPP – Pyrexia

/latestpgnotes

Concussion

→ Temporary neuronal dysfunction following non-penetrating trauma

→ NCCT – normal

→ Deficits resolve over minutes to hours

Contusion

→ Cerebral contusion results from being damaged by

- Impacting against the skull at the point of impact (coup)
- On the other side of impact (Contrecoup)

→ Most commonly affects inferior frontal lobe & temporal lobe

→ IOC for diagnosis – NCCT head

→ **Treatment**

- Conservative management (generally)
- Surgery (Rarely required) - Delayed surgical intervention to reduce the mass effect

PrepLadder

Coverings of Brain (Meninges)

→ There are 3 layers of meninges

a) Dura mater

b) Arachnoid mater

c) Pia mater

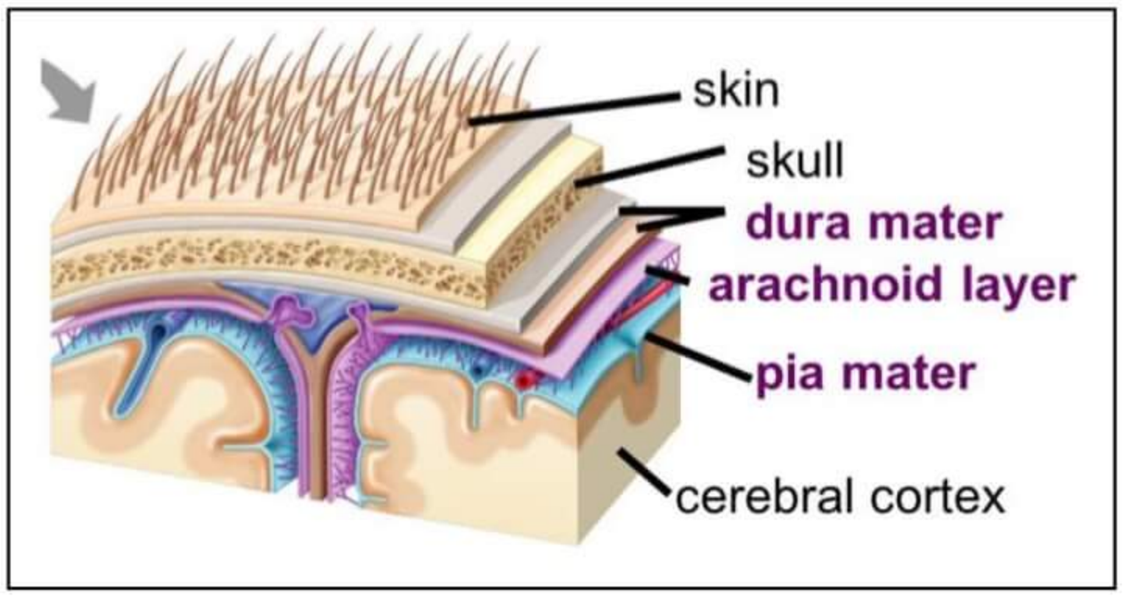

EDH (Extradural hematoma)	SDH (Subdural hematoma)
→ Blood collects between skull and dura → Caused by injury of middle meningeal artery → Most common site - Temporal bone (Pterion - thinnest part of skull) → Lucid interval is positive	**Acute SDH** → < 3 days **Subacute** → 4-21 days **Chronic** → > 21 days → Characterised by collection of blood b/w dura & arachnoid → Caused by injury of cortical veins or bridging veins → Usually caused by Significant trauma → Have impaired conscious level
Investigation • IOC for diagnosis - NCCT head • **In NCCT** – shows Biconvex or Lenticular or lens shaped hyperdense lesion 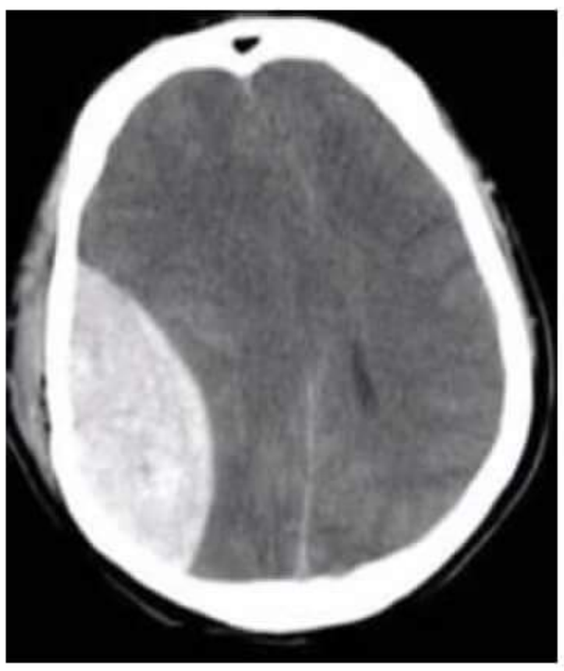	**Investigation** • IOC for Dx – NCCT head • **In NCCT** – shows Concavo- convex hyperdense lesion
Treatment – Drainage by • Burr hole • Craniotomy	**Treatment** – Drainage by • Burr hole • Craniotomy

t.me/latestpgnotes

PrepLadder

Burr hole

→ Created close to pterion, on the side of hematoma

→ At pterion - Convergence of sutures of frontal, parietal and temporal bone

→ If CT is not available, then we have to create Burr hole on the side where patient is having dilated pupil

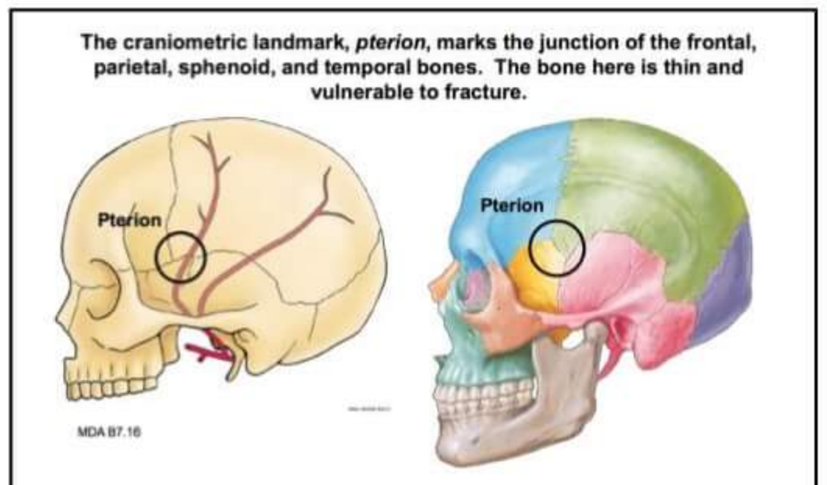

The craniometric landmark, *pterion*, marks the junction of the frontal, parietal, sphenoid, and temporal bones. The bone here is thin and vulnerable to fracture.

Fracture of pterion can be especially dangerous due to potential laceration of a branch of the middle meningeal artery

Sub-Arachnoid haemorrhage

→ MC cause – Trauma > spontaneous rupture of berry aneurysm

Clinical features

→ Sudden transient loss of consciousness

→ Excruciating severe headache (worst headache)

→ Neck stiffness & vomiting

→ FND – Uncommon

→ **Sudden Headache in absence of FND** } Hallmark of SAH caused by aneurysmal rupture

→ **Xanthochromic spinal fluid** }

Investigation

→ IOC for Diagnosis - NCCT head

t.me/latestpgnotes

Management

→ Conservative management

Diffuse axonal injury (DAI)

→ Wide spread axonal damage involving both hemispheres after severe head injury

→ It results from application of

- Acceleration / Deceleration (or) } Injury of axons by shearing force
- Angular strain to the brain }

→ MC site – Lobar white mater (at junction of grey & white matter) > Corpus callosum > Brain stem

Clinical features

→ Loss of consciousness

→ Most common cause of post-traumatic vegetative state – Diffuse axonal injury

→ ICT can be Normal or increased

Investigation

→ **NCCT head** – Normal

→ IOC for diagnosis – MRI

PrepLadder

Prognosis

→ Extremely poor

Raised ICT

Pathophysiology

→ Brain depends on continuous perfusion for O_2 & Glucose supply

→ Normal cerebral blood flow - 55 ml / min for every 100 gm of brain tissue

→ Cerebral blood flow depends on cerebral perfusion pressure

→ **Cerebral perfusion pressure** = Mean arterial pressure – intracranial pressure

CPP = MAP - IAP

- Normal **CPP** is 75 - 105 mmHg
- Normal **MAP** is 90 - 110 mmHg
- Normal **ICP** is 5 - 15 mmHg

→ If there is ↑sed ICP – CPP decreases leading to ↓se in CBF

↓

Ischemia

→ **Uncontrolled increase in ICP leads to**

- Cerebral herniation (or)
- Cerebellar tonsillar herniation through foramen magnum
  - Compresses Medullary vasomotor & respiratory centres
  - Causes **Cushing's triad**
    - Hypertension
    - Bradycardia
    - Irregular respiration

t.me/latestpgnotes

Management of ↑ ICT

→ Elevate the head end of bed to 30°

→ Goals of treatment is to bring

- ICP < 20 mmHg
- CPP ≥ 70 mmHg

→ First line of therapy for decreasing ICP - CSF drainage

CSF Drainage

External ventricular Drain | Ventriculostomy

→ Even after CSF Drainage – **if ICT is persistently raised**

↓

Pt should be sedated

↓ **still raised**

Osmotherapy (mannitol)

↓ **still raised**

Hyper ventilation

PrepLadder

→ **Second tier therapies** - For refractory elevated ICT

- High dose barbiturate therapy
- Aggressive Hyperventilation
- Hypothermia
- Hemicraniectomy

t.me/latestpgnotes

PrepLadder

NECK & THORACIC INJURIES

Neck injuries

→ Major vascular structures & Aerodigestive structures located in - Anterior triangle (Deep to Platysma)

Useful anatomical boundaries in neck injuries

Platysma	Sternocleidomastoid
1. If injuries didn't penetrate Platysma (superficial injury) - No further investigation to be done 2. If injuries penetrated Platysma -Further evaluation to be done	1. Injury anterior to SCM - high likelihood of significant injury 2. Injury posterior to SCM - Low chances of injury of major vascular & aerodigestive structures 3. Penetrating injury to posterior triangle – possible injury to • Cervical spine • Cord

Zones of neck injuries

t.me/latestpgnotes

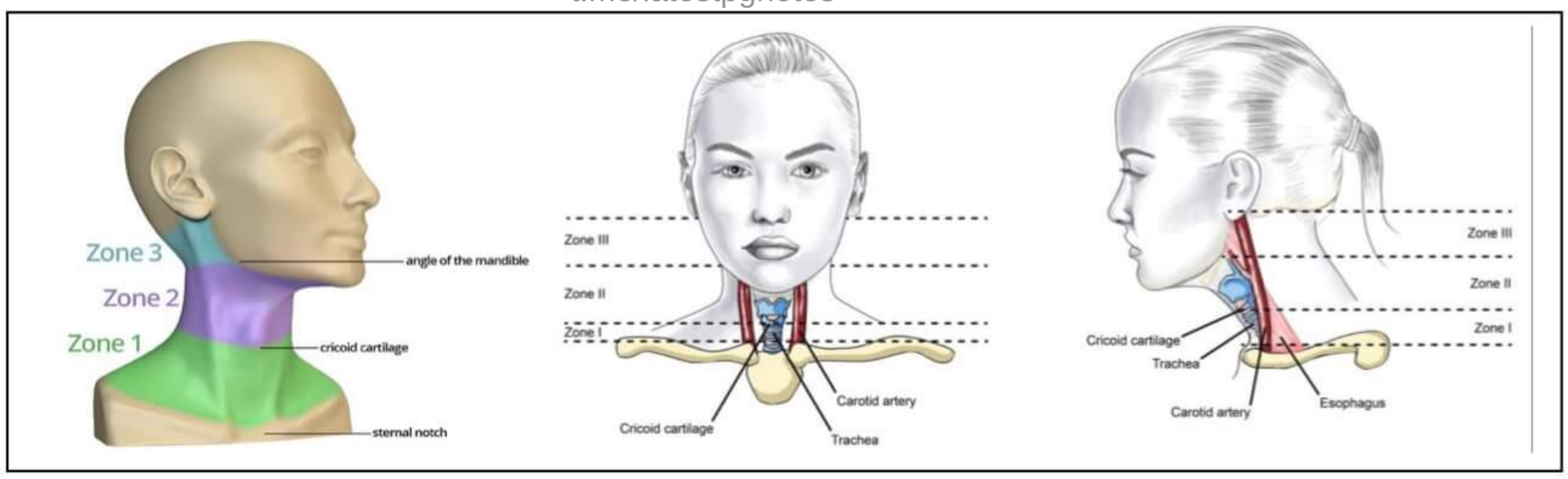

Zone I

→ B/W sternal notch to cricoid cartilage

→ Structures located

- Carotid vessels
- Aerodigestive structures (trachea & esophagus)

→ Highest mortality- due to carotid vessel injury

Zone II

→ B/W cricoid cartilage to angle of mandible

→ Most exposed & Most commonly injured zone

→ Most surgically accessible zone

Zone III

→ B/W angle of mandible to base of skull

PrepLadder

Thoracic injuries

→ Most common thoracic injuries are – chest wall injuries

→ Most common causes of mortality

- In blunt thoracic trauma - Tracheobronchial injuries
- In Penetrating trauma - Hemothorax secondary to pulmonary laceration

Rib fractures

→ Occurs secondary to compression in

- AP direction (or)
- Lateral direction

→ Most commonly fractured rib during CPR - 4th – 6th rib

→ Fracture of 1st rib and 10-12 Rib are uncommon

→ Only **High velocity impact can cause** - 1st & 10-12th Rib fracture

→ Floating ribs are 11th & 12th ribs

In 1st Rib fracture suspects injuries of

→ Subclavian vessels

→ Brachial plexus

→ Apex of lung

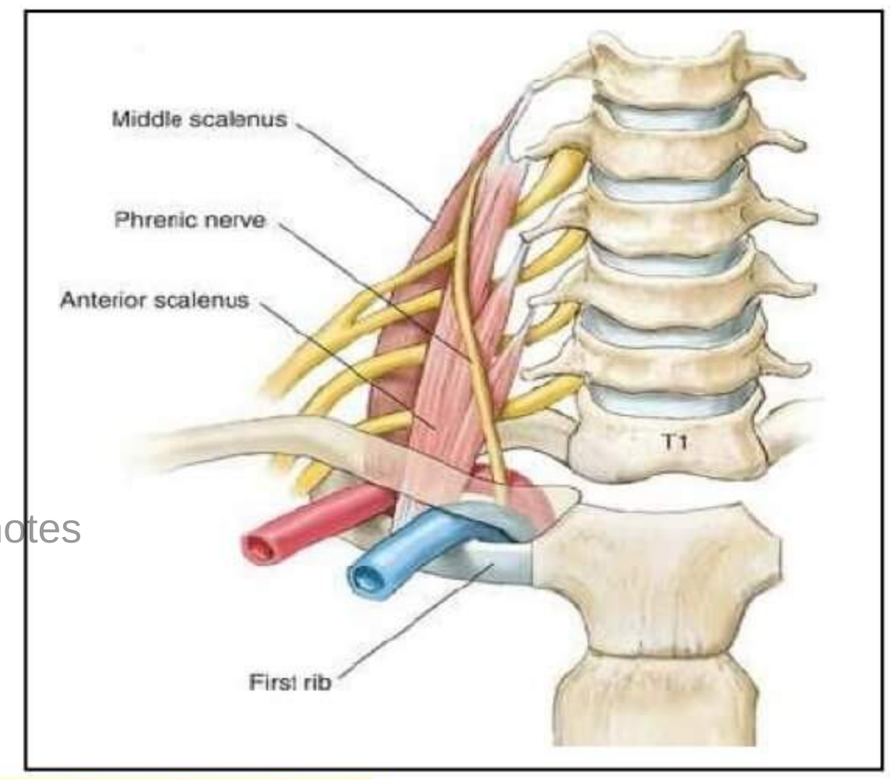

t.me/latestpgnotes

In 10th,11th and 12th fracture suspects injuries of

→ Liver (right side)

→ Spleen (left side)

Note

- Spleen is in relation with 3 ribs – 9th 10th & 11th rib
- Long axis of spleen is in relation with 10th rib

Management

→ Conservative Mx with adequate Analgesia

→ Strapping should not be done

Sternal fracture

→ Fracture is uncommon & typically transverse

→ Located in upper & midportions of body of sternum

→ **Signs of Sternal fracture**

- Tenderness
- Swelling
- Deformity

} At the site of fracture

→ It is **associated with** - Severe intrathoracic injuries

→ Has **specific injury to** – Myocardium

PrepLadder

Management

→ **Conservative management** with
- Adequate analgesia
- Good pulmonary hygiene

→ **Surgical intervention** - only for Displaced sternal fracture

Hemothorax

→ Collection of blood in pleural space

→ MC cause of Hemothorax- Trauma

→ MC cause of massive Hemothorax - Torn intercostal vessels (2 ° to Rib fracture)

Hemothorax

Clinical features

→ Dull note on percussion

→ Absent breath sounds

Diagnosis

→ Needle aspiration of pleural fluid – Shows blood

→ **CXR** – To assess the presence and extent of pleural fluid collection

t.me/latestpgnotes

Management

→ ICD (Intercostal drain) insertion in Triangle of safety in 5th I/C space in Anterior axillary line

→ **Boundaries of triangle of safety**
- **Anteriorly** - Lateral border of pectoralis major
- **Laterally** - Lateral border of latissimus dorsi
- **Inferiorly** - Line of 5th I/C space
- **Superiorly** - Base of axilla

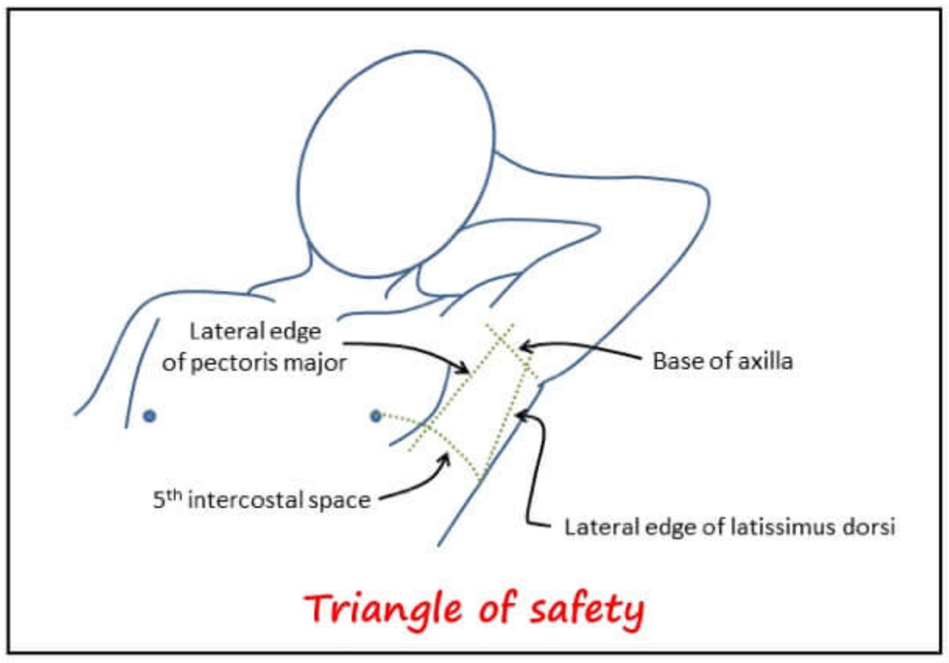

Triangle of safety

Indications of thoracotomy

→ Initial tube thoracostomy drainage
- > 1000 ml in Penetrating trauma
- > 1500 ml in Blunt trauma

→ Ongoing tube thoracostomy drainage
- > 200 ml / hour for consecutive 3 hours in non-coagulopathic patients

→ Caked Hemothorax despite of 2 chest tube placements

→ Tracheobronchial injuries (TBI)

→ Selected descending torn aorta or great vessels injuries

→ Pericardial Tamponade

→ Cardiac herniation

PrepLadder

→ Massive air leak from chest tube with inadequate ventilation

→ Open pneumothorax

→ Esophageal perforation

Tension Pneumothorax

→ Occurs when "**one-wave valve**" air leaks - either from the lung or chest wall

→ Air is forced into thoracic cavity without any means of escape which causes complete collapse of lung

→ Mediastinum

- Displaced to opposite side
- ↓ venous return & compression of opposite lung

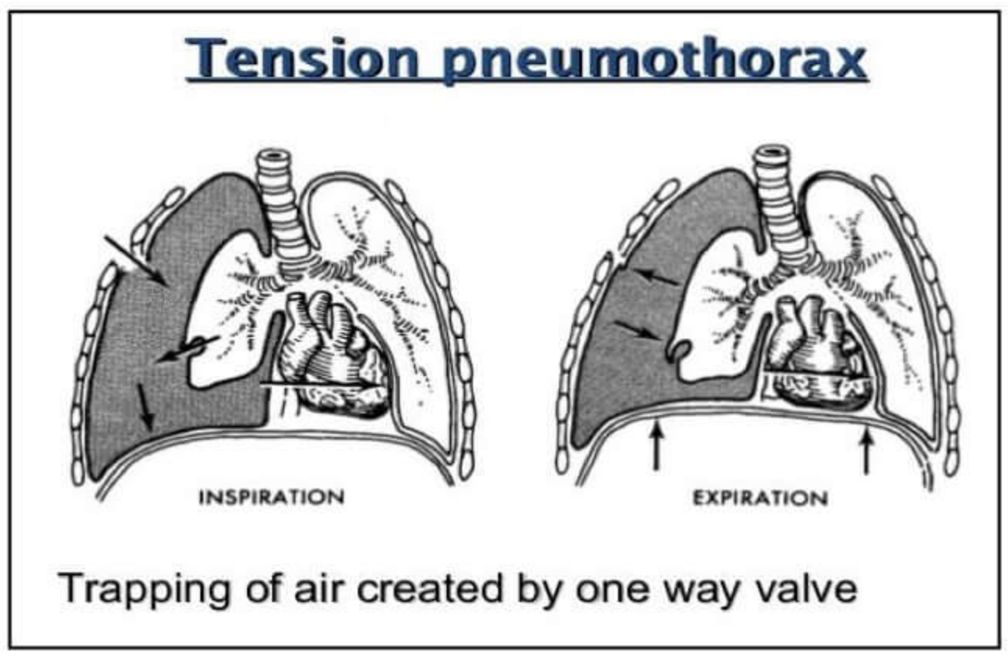

Trapping of air created by one way valve

Etiology

→ Penetrating trauma to chest

→ Blunt trauma – Tracheobronchial injury

→ Iatrogenic lung punctures - Due to subclavian central venepuncture

→ Mechanical Positive pressure ventilation

t.me/latestpgnotes

Clinical features

→ Dyspnea

→ Tachypnea

→ Distended neck veins

→ **Hyper resonance (on percussion)**

→ **Absent breath sounds (on auscultation)**

Tension Pneumothorax (CXR)

Investigation

→ **Diagnosed clinically**

Treatment

→ **Emergency treatment** - Put a large bore needle into 2nd I/C space in Midclavicular line

Note

→ **According to ATLS manual 10th edition** – Recent evidence supports placing large bore needle in **5th I/C space slightly anterior to mid-axillary line**

→ **Definitive Rx/ TOC**- ICD insertion in Triangle of safety (5th I/C space in Anterior-axillary line)

PrepLadder

Pericardial Tamponade:

→ Rapid accumulation of blood or fluid in Pericardial space

→ Quantity of even 200 ml, if collected rapidly – **leads to Pericardial Tamponade**

→ Caused by - Penetrating trauma

Clinical features

→ **Beck's Traid**

- **M:** Muffled heart sound
- **D:** Distended neck veins
- **H:** Hypotension

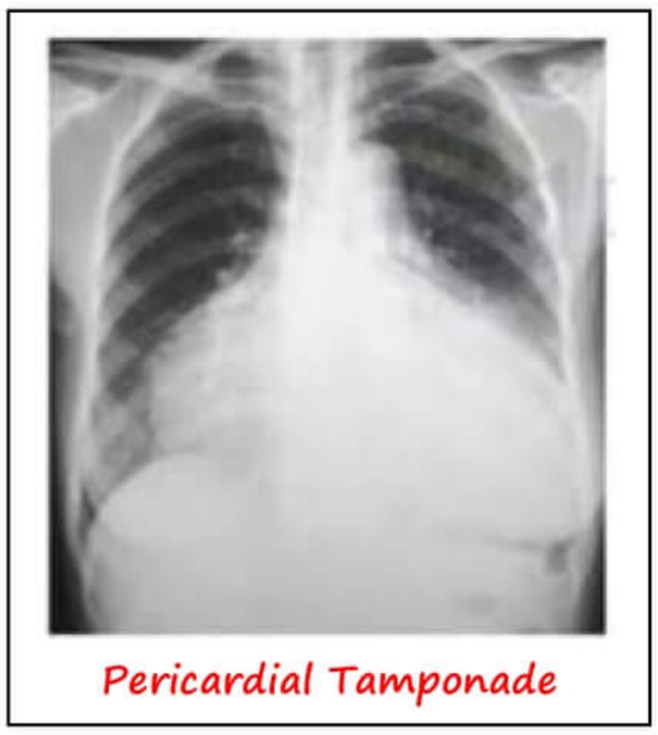

Pericardial Tamponade

Investigations

→ **Investigation of choice** – Echocardiography

→ **CXR** - shows Enlarged heart shadow

Treatment

→ **Emergency Rx** – Needle pericardiocentesis

→ **TOC** – Pericardiotomy

Flail Chest

t.me/latestpgnotes

→ Occurs when segment of chest wall doesn't have bony continuity with rest of thoracic cage

→ It is caused by – Fracture of 2 or > 2 consecutive ribs at 2 or > 2 places **(According to ATLS 10th edition)**

→ Associated with Pulmonary contusion

Clinical features

→ Paradoxical Respiration (fractured part move opposite than rest of the chest)

→ Voluntary splinting due to pain

→ Mechanically impaired chest wall movement

} ↑se risk of respiratory failure

Investigation

→ Diagnosed clinically

- Observe the patient for paradoxical motion of chest wall segment
- Ask the patient to cough – Chest cavity moves in while the flail segment moves out

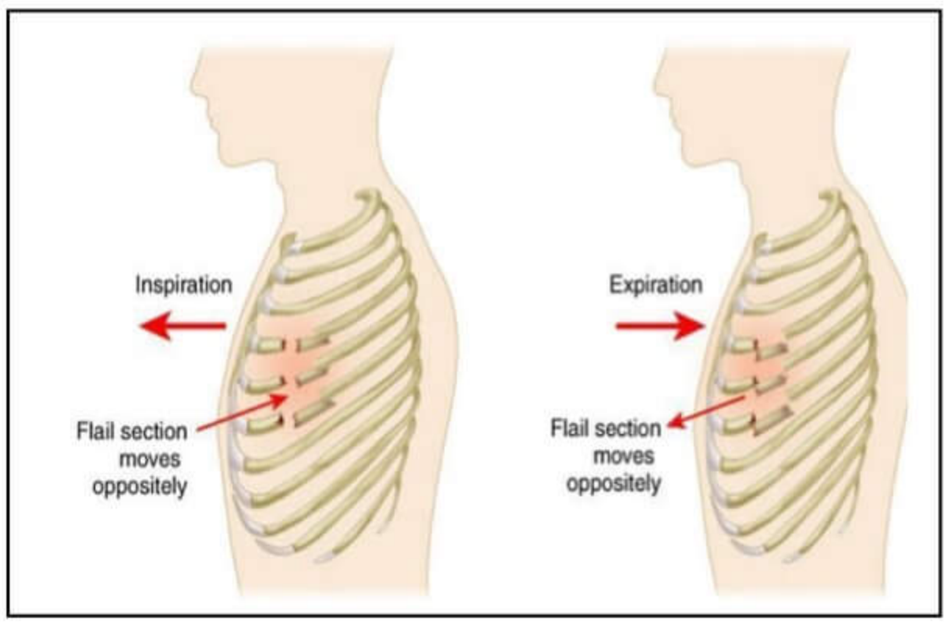

Treatment

→ O_2 administration + adequate analgesia (epidural analgesia) + Physiotherapy

→ **For Flail chest** + Respiratory failure - Intermittent positive pressure ventilation (IPPV)

PrepLadder

Diaphragmatic injury

→ Most common cause - **Penetrating injury**

→ For Penetrating injury

- Below nipple and
- Above costal margin

} **Rule out diaphragmatic injury**

Etiology

1. Penetrating trauma
2. Blunt trauma - Comprehensive force applied to pelvis or abdomen can lead to diaphragmatic injury

Clinical features

→ Most injuries are **Silent**

→ Patients presents with S/S of injury of associated organs

→ Late complication of diaphragmatic injury - **Herniation**

→ Most common organ herniated - **Stomach > colon > Small intestine**

Investigations

→ **No single standard investigation - to diagnose diaphragmatic injuries**

→ Most accurate evaluation can be done by

- **VATS (Video assisted Thoracoscopy)**
- **Laparoscopy**

} **Surgeon can also proceed for repair & evaluate the other abdominal organs**

t.me/latestpgnotes

Treatment

→ Operative repair in all cases

Note

→ Components of **Bergquist Traid**

- Rib fracture
- Spine or Pelvic fracture
- Traumatic rupture of diaphragm

Blast injuries

→ **Primary blast injury results from**

- Rapid overpressure (or)
- Shock waves by blast

→ **Dramatic changes in barometric pressure**

- Causes damage to air filled organs
  - Middle ear
  - Lungs
  - GIT

→ Most commonly injured organs - **Tympanic membrane > lungs**

PrepLadder

→ **2 types of blast**

Air Blast	Water Blast
→ MC injured - Tympanic membrane → Most severely injured - Lungs	→ **When head is submerged** • MC injured – Tympanic membrane • Most severely injured – GIT → **When head is out of water** • Most commonly & most severely injured - GIT

ICD Insertion

→ ICD insertion should be done in Triangle of safety
- 5th I/C space in Anterior axillary line

→ **Boundaries of triangle of safety**
- **Anteriorly** - Lateral border of pectoralis major
- **Laterally** - Lateral border of latissimus dorsi
- **Inferiorly** - Line of 5th I/C space
- **Superiorly** - Base of axilla

→ **ICD insertion**
- Should be done **near upper border of lower rib**
- Eyes of chest tube should be in Pleural space
- Used to provide evacuation of air or fluid from pleural space

t.me/laterstnotes

→ **Under water seal chamber**
- Acts as one-way valve for evacuation of pleural contents
- Tip of tube should be 2-3 cm below under water seal
- Fluid contents are forced out through chest tube into underwater seal

→ **Patency of chest tube** is assessed by observing oscillations of water column

→ **Position of chest tube & resolution of intrapleural air or liquid** is checked by chest X-ray

→ **If column movement stops** – indicates that the tube is Blocked or Displaced

→ **Bronchopleural fistula** leads to - Excessive bubbling of air

→ **Removal of chest tube** is considered
- When lung is expanded (or)
- Drain output < 200 ml in 24 hours

→ **ICD removal** - should be done when patients hold the breath at peak of inspiration

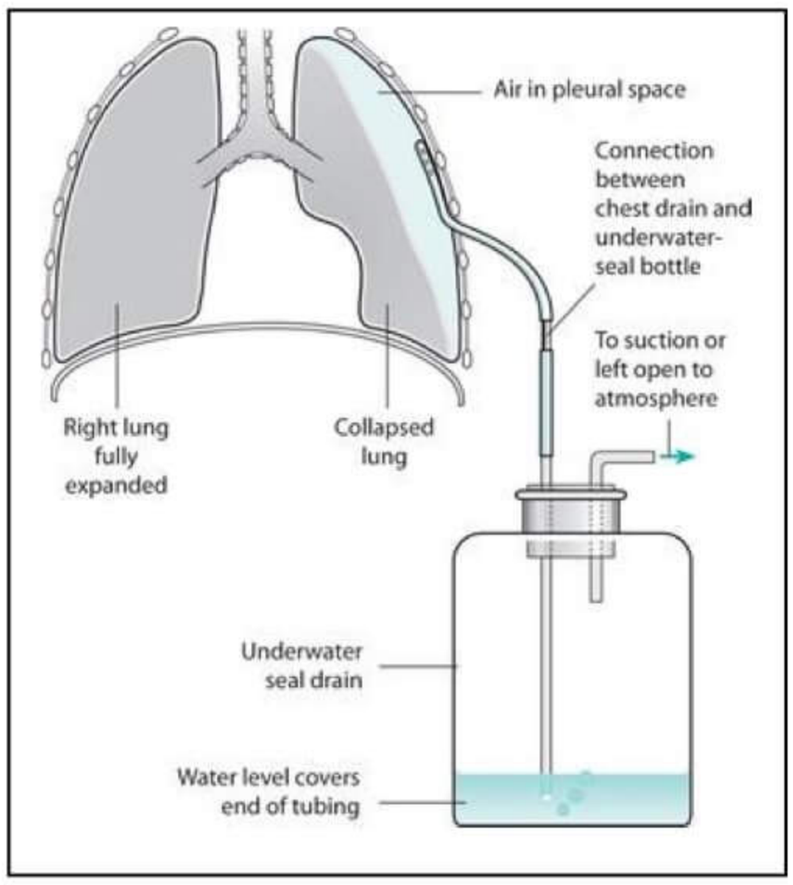

PrepLadder

→ **Ideal time of Drain removal**

1. Thyroidectomy	→ After 24 hours
2. ICD	→ When output is < 200 ml in 24 hours
3. Mastectomy	→ After 5 days
4. Colorectal anastomosis	→ After 7 days
5. T-tube	→ **After 7 - 10 days**

t.me/latestpgnotes

PrepLadder

ABDOMINAL TRAUMA

One liner on Abdominal trauma

→ Most commonly injured organ in BTA - **spleen > liver**

→ Most commonly injured organ in penetrating trauma - **liver > stomach > SI**

→ Most commonly injured part of bowel in BTA – **Jejunum**

→ Most commonly injured organ in Gunshot injury – **Small intestine**

→ Most commonly injured structure in seat belt injury - **Mesentery**

→ Most commonly site of injury in deceleration injury – **Duodenojejunal junction**

→ 1st inv. Done in patient of BTA - **FAST**

→ Gold standard investigation for stable patient of BTA - **CECT**

FAST (Focused Assessment with Sonography for Trauma)

→ It is an Emergency ultra sound i.e. performed very fast [in 2 – 4 minutes]

→ Assess Potential sites of thoracoabdominal injuries

(4P's) - Pericardial sac
- Perihepatic region
- Peri-splenic region
- Pelvis

→ **4 traditional views in FAST**

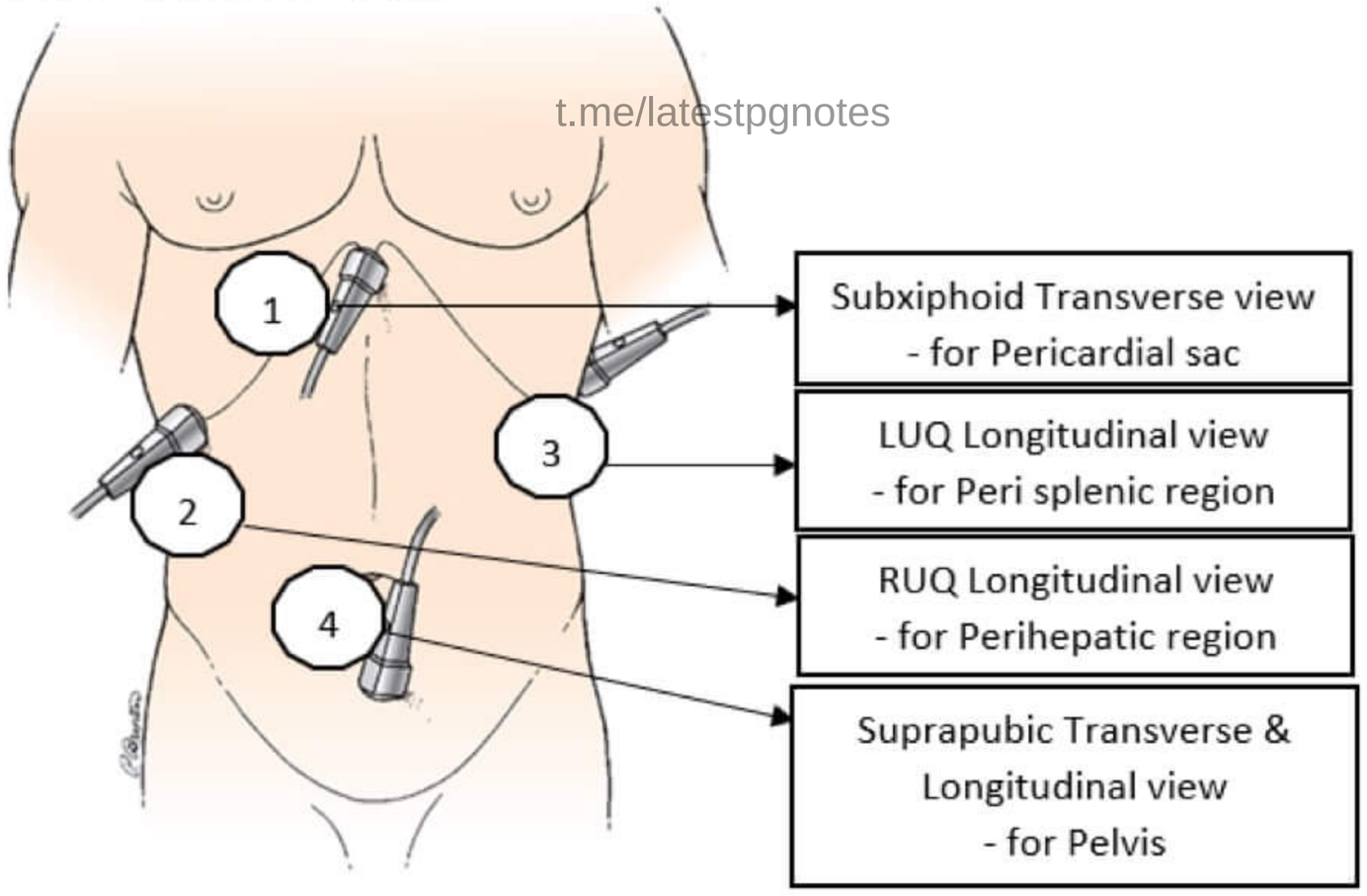

t.me/latestpgnotes

e-FAST (extended FAST)

→ Has two additional views (so, has a total of 6 views)
- Right thoracic view
- Left thoracic view

→ Pneumothorax on e-FAST shows **bar code sign / stratosphere sign**

PrepLadder

DPL (Diagnostic Peritoneal Lavage)

→ Performed for BTA patients
- Catheter is inserted after infra umbilical incision & director towards pelvis
- Aspiration is done
- Instill IL of NS / RL → for lavage
- Re-aspiration of fluid is done

↓

This fluid is sent for examination

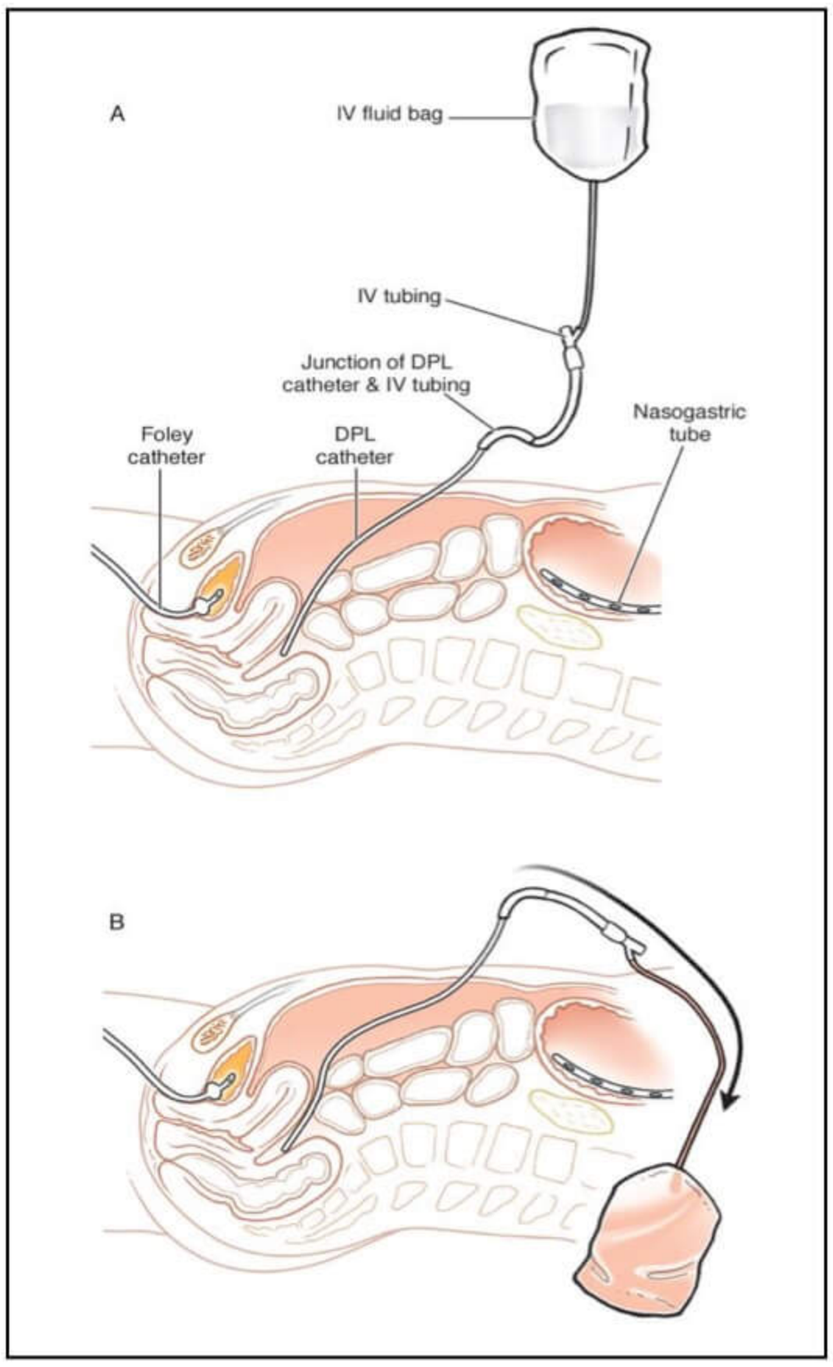

→ **DPL is considered (+) ve**
- > 10 ml of frank blood is aspirated
- Returned effluent contain:
  - RBC_s → > 1Lac/ mm^3
  - WBC_s → > 500/ mm^3
- Presence of bile, bacterial, fecal matter, vegetable matter
- Amylase > 175 IU / dl

BTA t.me/latestpgnotes

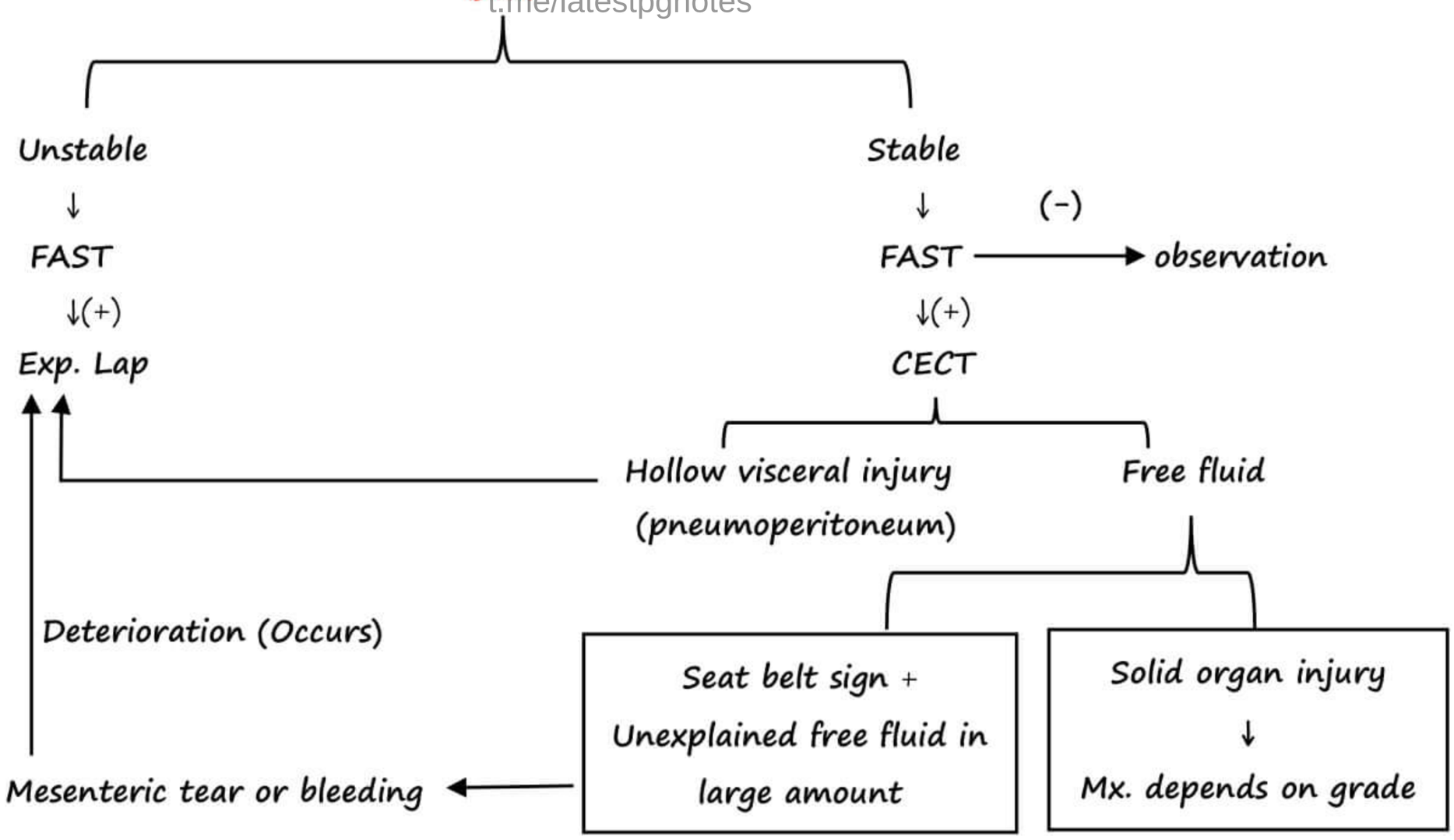

PENETRATING TRAUMA

→ MC injured organ - liver > stomach > SI

→ MC injured organ in GSW - SI

→ Exp. Lap is mandatory - GSW (Gunshot wound)

PrepLadder

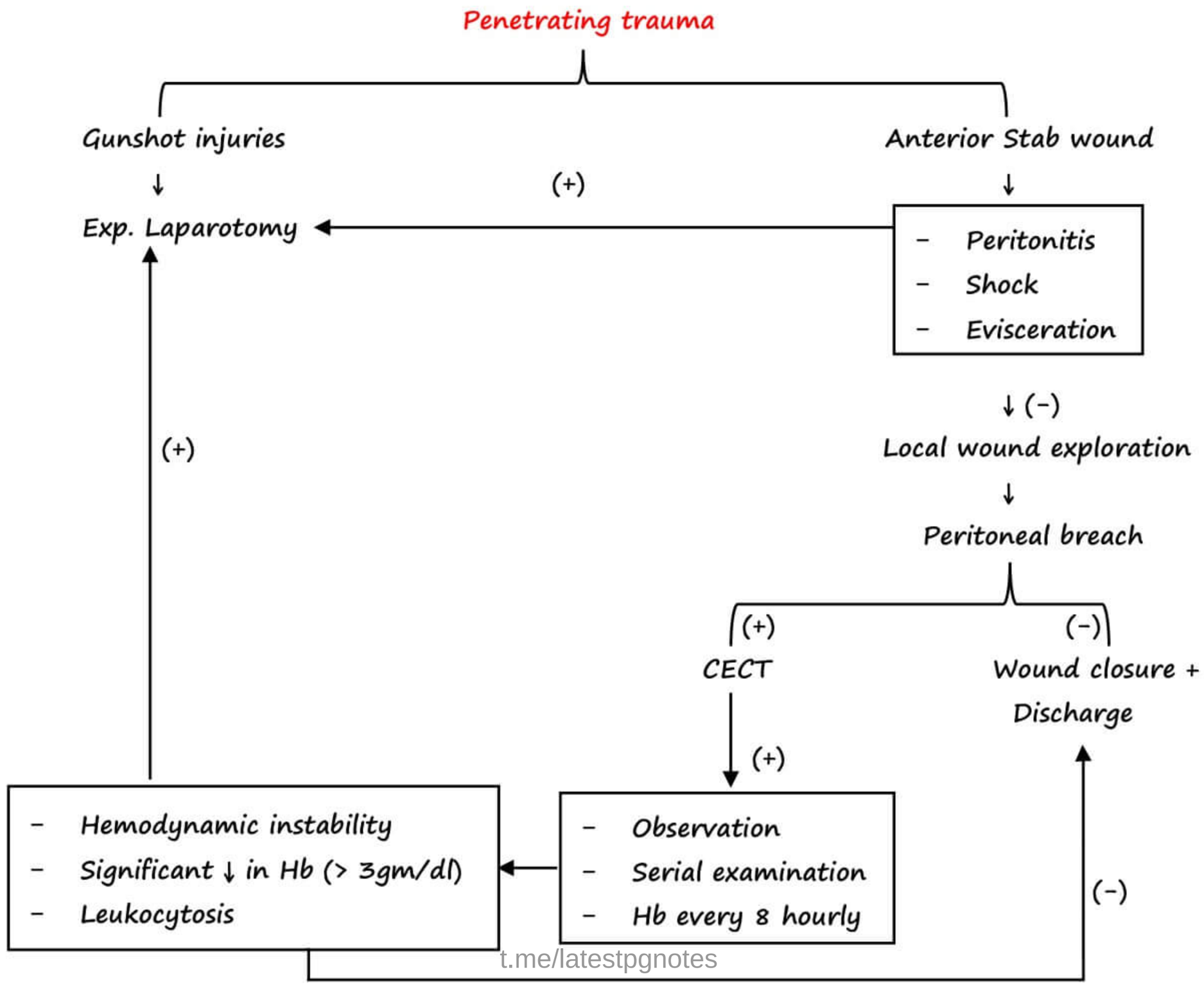

Splenic trauma

→ MC injured organ in BTA

→ **Kehr's sign**

- Pain is referred to tip of Left shoulder in splenic rupture
- Due to irritation of undersurface of diagram with blood → pain is referred to shoulder via fibers of phrenic nerve (C_4, C_5)

→ **Ballance sign**

- Fixed area of percussible dullness in LUQ due to coagulation of blood

AAST Grading for splenic trauma (American Association for Surgery of trauma)

Grade	Hematoma	Laceration
I	Subcapsular hematoma involving < 10% surface area	Capsular tear < 1cm in depth
II	S/C hematoma involving 10 – 50 % Surface area	1 – 3 depth
III	S/C hematoma involving >50 % Surface area	> 3 cm or involving Trabecular vessels
IV	> 25% devascularization	Laceration involving Hilar vessels
V	Completely shattered spleen	Complete devascularization

PrepLadder

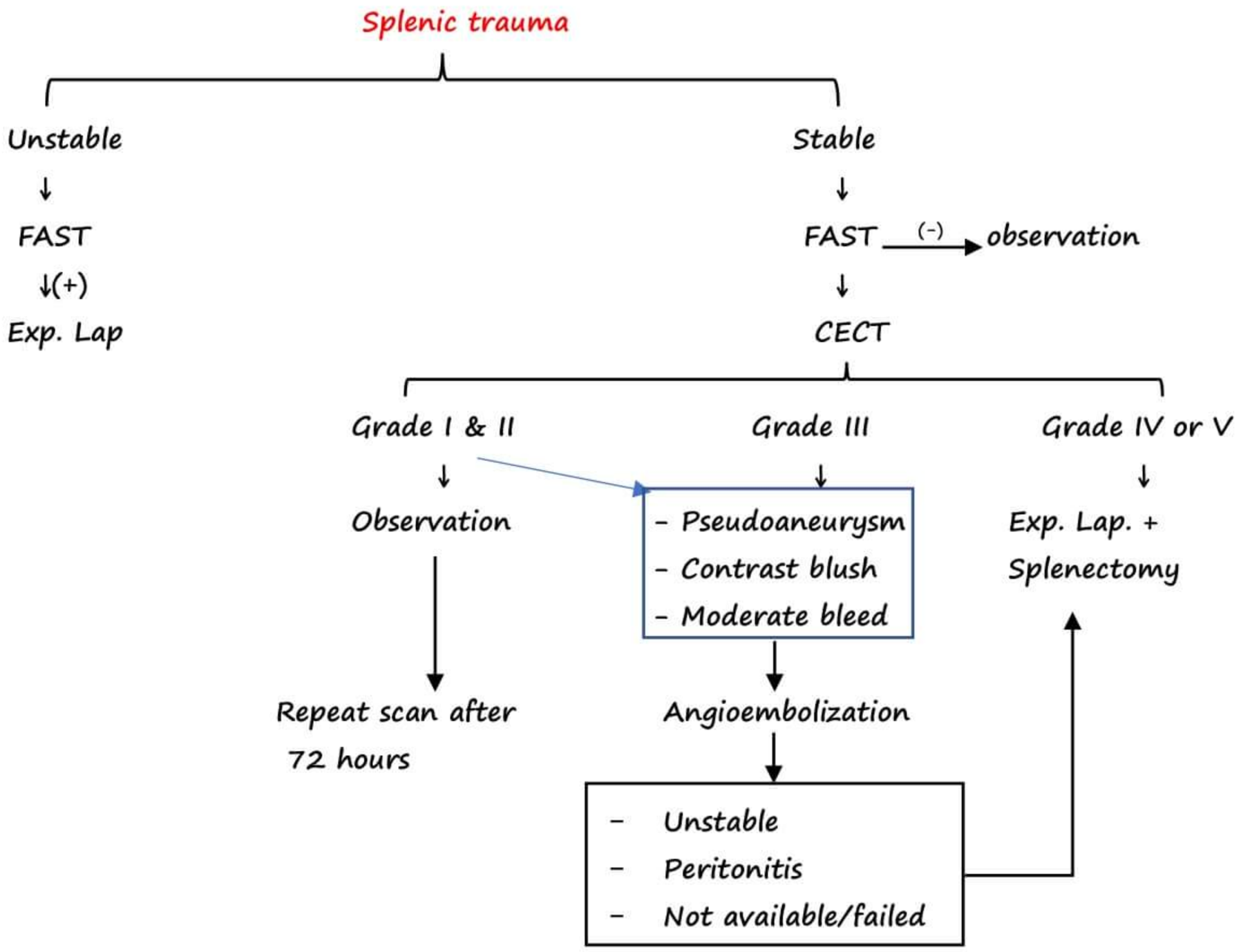

t.me/latestpgnotes

LIVER TRAUMA

→ MC injured organ in penetrating trauma
→ 2nd MC injured organ in BTA
→ Most liver injuries involve - segment 6, 7, 8
→ Bleeding - **mainly venous** → low pressure tamponade is readily performed
→ **Bear claw laceration** - multiple linear lacerations of liver on CECT
→ 4 'p's in liver injury
- Push
- Plug
- Pringle
- Pack

PRINGLE's Maneuver

→ aka Total Inflow Occlusion
→ Non-traumatic clamping in foramen of Winslow and we occlude the Portal triad.
→ It controls bleeding from Portal Vein and Hepatic Artery.
→ Bleeding is effectively controlled from Portal Vein as compared to Hepatic Artery.
→ It doesn't control bleeding from IVC and Hepatic Vein

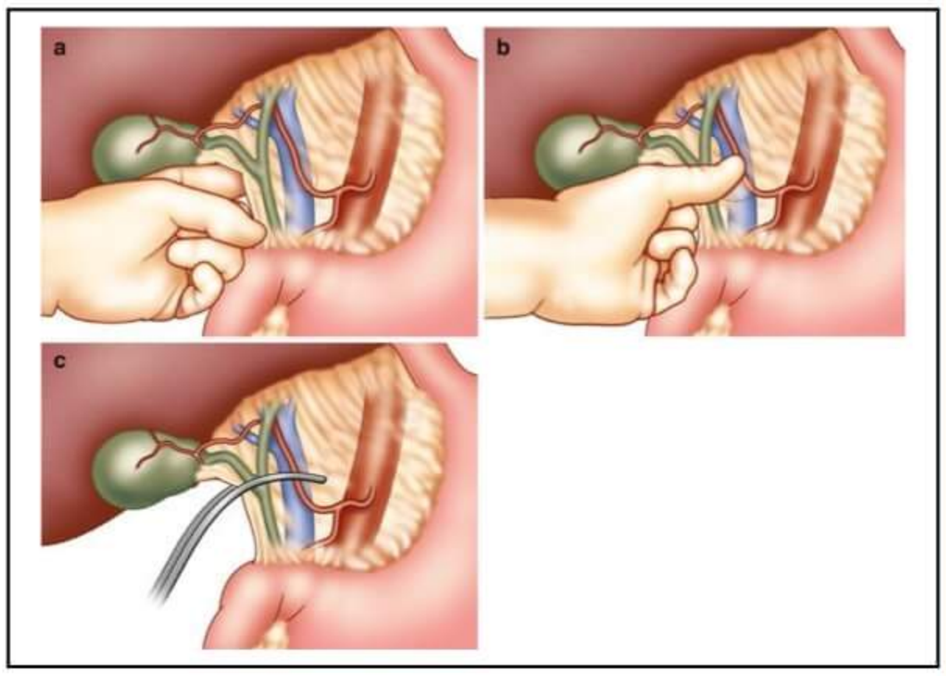

PrepLadder

AAST → Grading of liver trauma

Grade	Hematoma	Laceration
I	Subcapsular hematoma involving < 10% surface area	Capsular tear < 1cm in depth
II	S/C hematoma involving 10 – 50 % Surface area	1 – 3 cm depth
III	S/C hematoma involving >50 % Surface area	> 3cm depth
IV	-	Parenchymal disruption involving 25-75% of hepatic lobe
V	-	Parenchymal disruption involving >75% of hepatic lobe
VI	Hepatic avulsion	

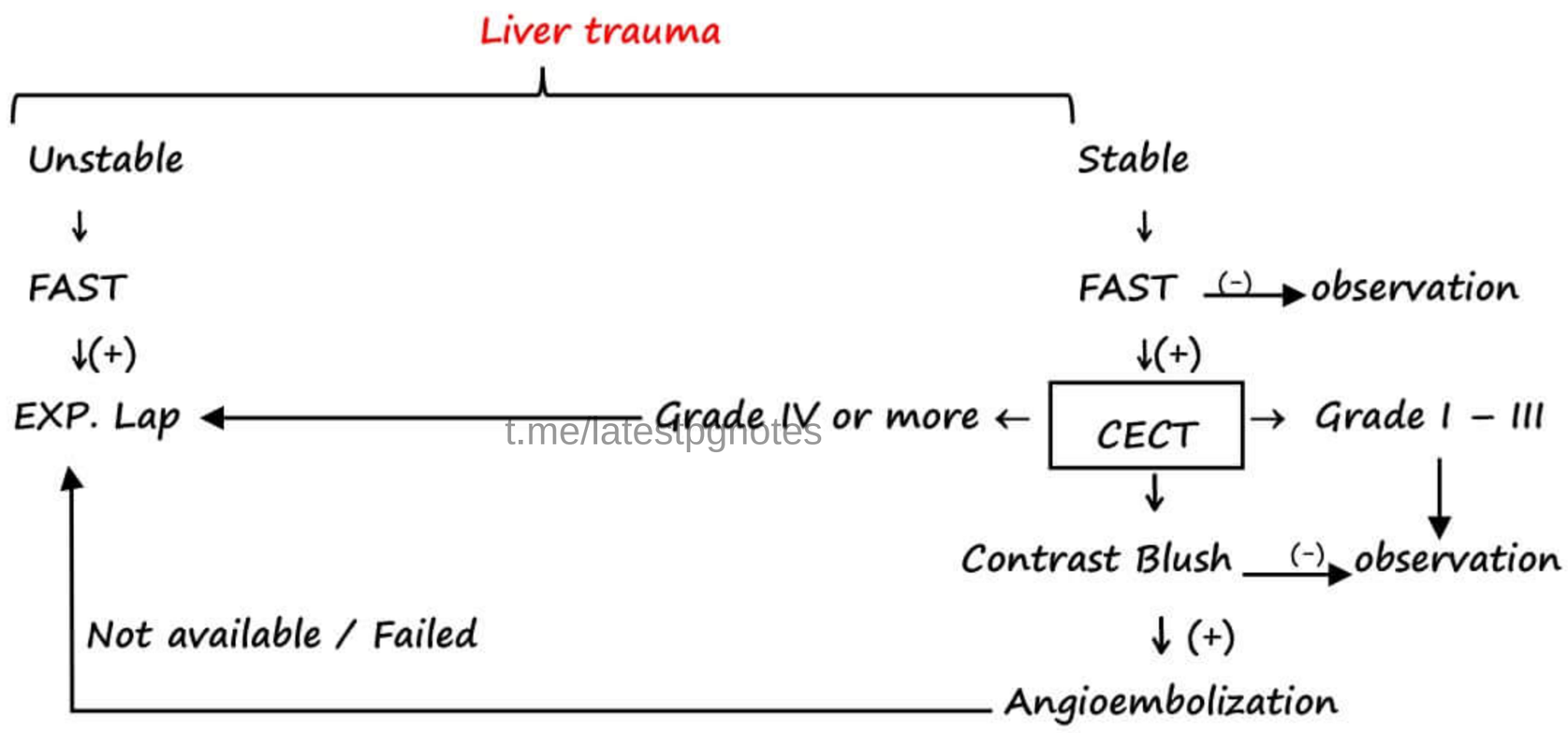

t.me/latestpgnotes

DUODENAL TRAUMA

→ A/W pancreatic injuries

→ IOC for D_x of Duodenal trauma - CECT

→ **On radiological Ix** only sign is seen - gas or fluid in R/P & leakage of oral contrast

→ Injury of 1st, 3rd or 4th part - repaired like small bowel with sutures

→ Injury of 2nd part – Damage control surgery (Triple tube ostomy)

→ **Triple tube ostomy**

- Decompressive Gastrostomy
- Decompressive Duodenostomy
- Feeding Jejunostomy

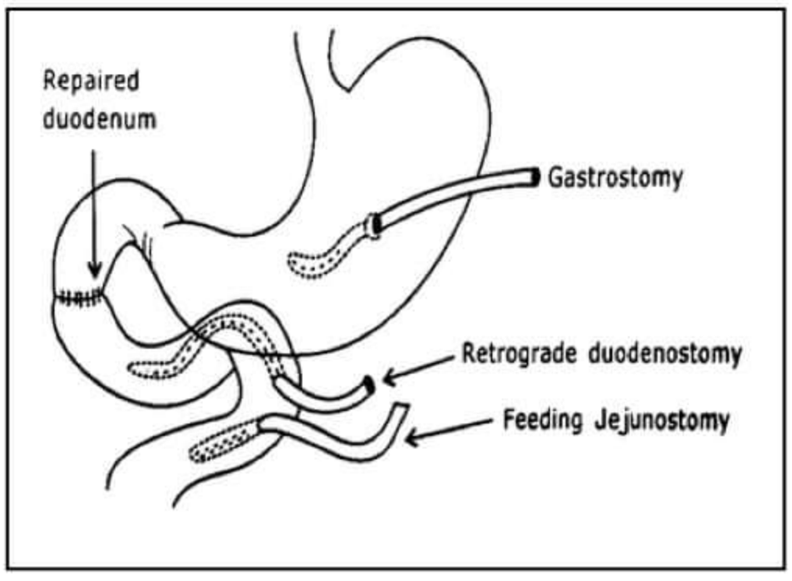

PrepLadder

PANCREATIC TRAUMA

→ In adult: MC cause - Penetrating

→ In children: MC cause - Blunt trauma

- Handlebar → bicycle
- MC affected → body of pancreas

Grade	Hematoma	Laceration
I	Minor contusion without duct injury	Superficial laceration without duct injury
II	Major contusion without duct injury	Major laceration without duct injury
III	-	Distal transection or parenchymal injury with duct injury
IV	-	Proximal transection or parenchymal injury involving Ampulla
V	-	Massive disruption of pancreatic head

Diagnosis

→ IOC for D_x - **CECT**

→ **ERCP** - Most reliable test to demonstrate pancreatic duct integrity

Management

→ I – Observation

→ II – Debridement, drainage, possible repair

→ III – Distal resection, Roux-en-Y drainage

→ IV & V - **Damage control surgery**

- Resection + Roux-en-Y drainage
- Triple tube decompression
- Pyloric exclusion
- Duodenal diverticularization
- Pancreatico Duodenectomy

→ MC complication seen after Pancreatic trauma - **Pancreatic fistula / Persistent drain output**

t.me/latestpgnotes

SEAT BELT INJURY

→ **Seat belt syndrome** - unique injury profile A/W use of seat belt

→ Most common injured structure – **Mesentery**

→ Classic seat belt sign - **Skin abrasion**

↓

- Neck
- Chest
- abdomen

Associated with

- High chances of internal organ injury
- Also associated with pancreatico-Duodenal injuries

PrepLadder

→ Longitudinal mesentery tear – **Repair**

→ Transverse mesentery tear – **Resection & anastomosis**

Trauma Traid of death

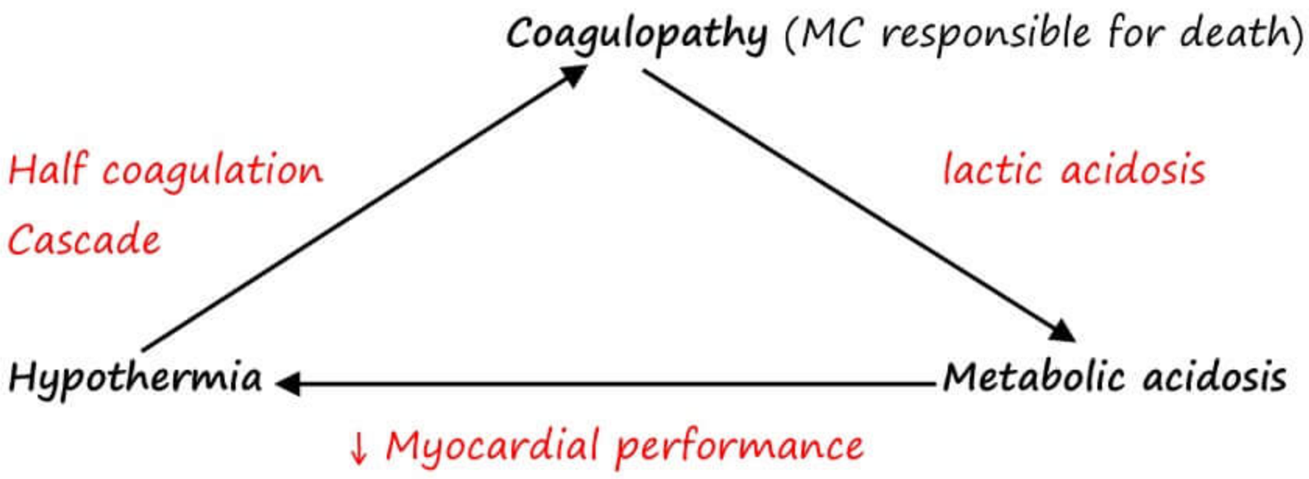

Damage control surgery (DCS)

→ Abbreviated laparotomy
→ Temporary packing
→ Closure of abdomen

} To blunt the physiological response to prolonged shock &hemorrhage

→ At limits of physiology reserve

↓

Long duration Surgery may cause

↓

Exacerbation of – Hypothermia
– Coagulopathy
– Metabolic acidosis

} leads to Death

t.me/latestpgnotes

Phase of DCS

Phase I (initial exploration)	Phase II (2° resuscitation)	Phase III (Definitive operation)
• Initial exploration ↓ • For Rapid control of hemorrhage + contamination – Packing of 4 Quadrants – For Perforation → Suture closure ↓ Segmental Stapled resection	• Shift the pt. to ICU ↓ For 2° resuscitation – 48 hours – Correct hypothermia, coagulopathy & metabolic acidosis	• Planned re-exploration • Definitive repair of injuries

Stage of DCS

- Stage I → Patient selection
- Stage II → Operative control of hemorrhage and contamination
- Stage III → ICU resuscitation
- Stage IV → Definitive surgery
- Stage V → Abdominal closure

PrepLadder

Abdominal compartment syndrome (ACS)

→ **ACS** – ↑sed IAP (>20 mmHg) – Results in compression of abdominal structures

→ Causes fatal complications

- Pulmonary failure
- Mesenteric vascular compromise

→ **Normal IAP**: 5-7 mmHg

→ Intra-abdominal HTN ≥ 12 mm Hg

Predominantly occurs in

→ Patients of profound shock

→ Patients requiring large amount of fluid or blood for resuscitation

→ Major visceral or vascular abdominal injuries

C/F

→ Sudden increase in IAP

→ ↑ peak inspiratory pressure

→ Hypoxia, hypercapnia, hypotension

→ ↓sed Venous return to heart

→ ↓sed Urine output

Physiological consequence of ACS

Decreased	Increased
• ↓ VR → ↓ **CO** → ↓ RBF → ↓ GFR → ↓ UO ↓ **↓ VBF** • ↓ venous return • ↓ Cardiac output • ↓ RBF → ↓ GFR → ↓ urine output • ↓ Visceral blood flow	• Peak inspiratory pressure • Pulmonary capillary wedge pressure • Intra-pleural pressure • Central venous pressure • Cardiac rate • Systemic vascular resistance

t.me/latestpgnotes

Diagnosis

→ Measure Bladder pressure -as it represents IAP

→ Gold standard indirect method to measure IAP -**Urinary bladder catheter**

Management (depends on grade)

Grade	Bladder pressure (mmHg)	C/F	R_x
I	12 – 15	None	Normovolemic resuscitation
II	16-20	Oliguria, Splanchnic Hypoperfusion	Hypovolemic resuscitation
III	21 – 25	Anuria, increased Ventilation pressure	Decompression
IV	> 25	Anuria, increased ventilation pressure + ↓PO_2	Emergency re exploration

PrepLadder

Pressure according to grade

- I → <10 – 15 cm H_2O
- II → < 16 – 25 cm H_2O
- III → < 26 – 35 cm H_2O
- IV → > 36 cm H_2O

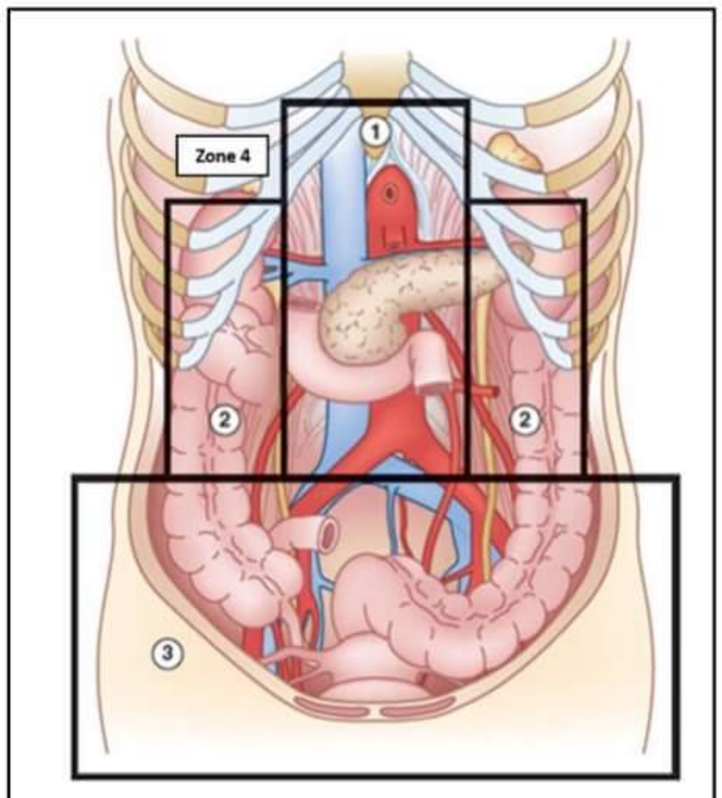

Retro peritoneal Zones

Retro peritoneal injuries

Zone I - Central

→ Extends from Esophageal hiatus to sacral promontory

→ Hemorrhage or hematoma - usually located in midline

→ A/W injuries of
  - Aorta & its proximal branches
  - IVC & its proximal tributaries

→ It is divided into

Supra mesocolic Zone 1	Infra mesocolic Zone 1
- Supra renal aorta - IVC - Superior mesenteric vessels - Proximal renal vessels	- Infra renal aorta - IVC & their bifurcation

t.me/latestpgnotes

→ **Management**
  - Central hematoma – exploration with proximal & distal vascular control

Zone 2 - lateral

→ Extends from lateral diaphragm to iliac crest

→ Structures located - Distal renal vessels

→ **Management**
  - Lateral hematoma (renal in origin) - Managed non-operatively (angio-embolization)

Zone 3- Pelvic

→ Confined to retroperitoneal Zone of pelvis

→ Structures located - Iliac vessels

→ **Management**
  - Pelvic hematoma - Exceptional difficult to control
    - Usually it should not be opened
    - Packing / Angio-embolization

Zone 4 - Portal & retro hepatic areas

PrepLadder

RENAL TRAUMA

→ MC injured part of urinary tract - kidney

→ MC cause of renal trauma - RTA

→ Best predictor of traumatic urinary system injury - hematuria

Diagnosis

→ IOC for D_x of renal injuries in stable patient - CECT

→ IOC for D_x of renal injuries in unstable patient - single shot IVP (Assess function of C/L kidney)

Grading of Renal Trauma

Grade	Description
1	- Microscopic /gross hematuria with normal urologic studies - Sub capsular, non-expanding hematoma without parenchymal laceration **(microscopic hematuria is > 3RBCs/HPF)**
2	- Non expanding peri-renal hematoma - Laceration < 1 cm in depth without urinary extravasation
3	- Laceration > 1 cm in depth of renal cortex
4	- Parenchymal laceration through collecting system - Main renal artery or vein injury with contained hematoma
5	- Completely shattered kidney - Avulsion of renal hilum → devascularization of kidney

t.me/latestngnotes

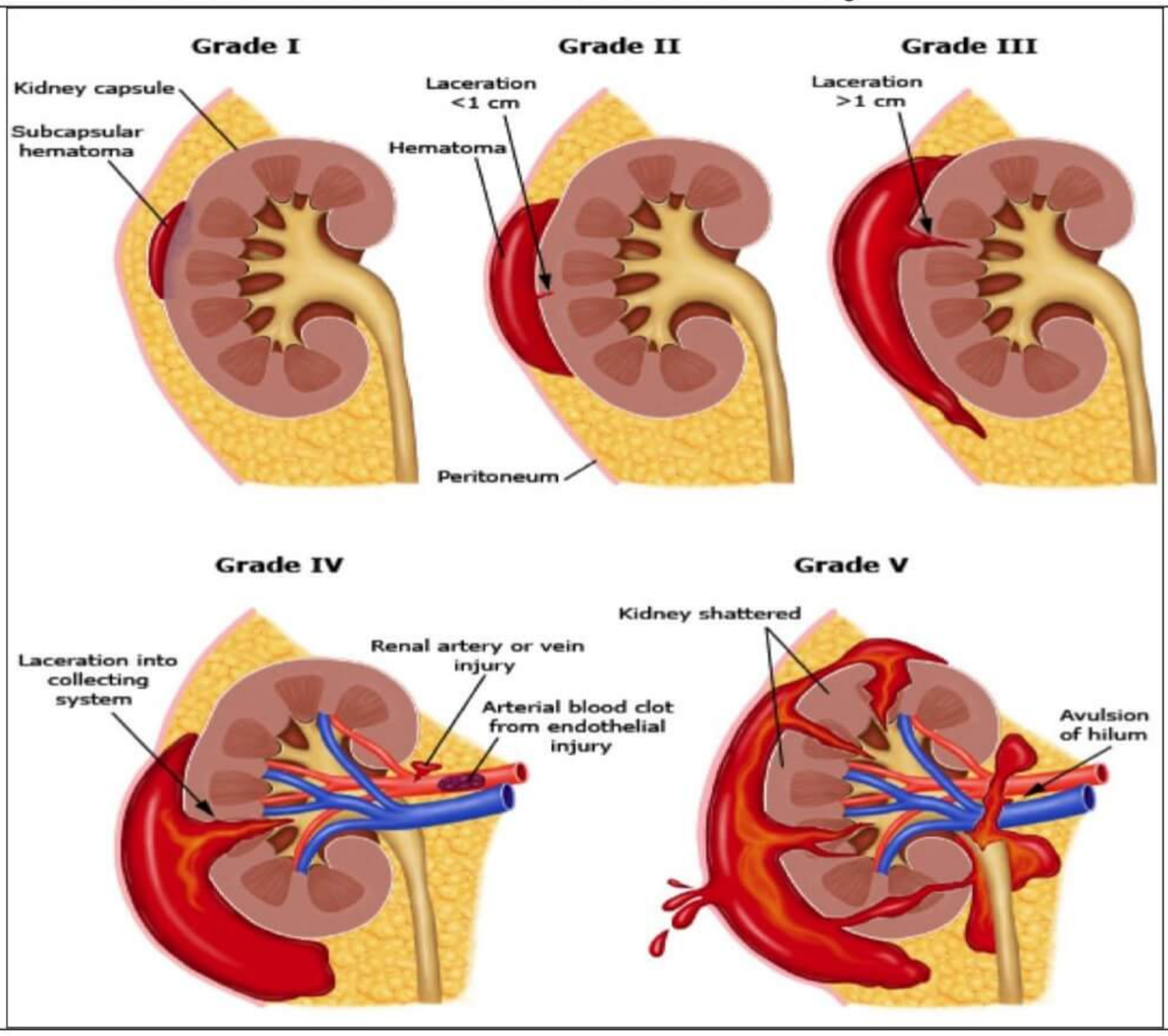

PrepLadder

Management of Renal Trauma

- >95% of cases → Conservatively (low grade injury)
- < 5% of cases → Operative intervention

Indications of Renal exploration

Absolute	Relative
• Persistent renal bleeding • Expanding or Pulsatile peri-renal hematoma	• Urinary extravasation • Non-viable tissue • Segmental arterial injuries

Indications of Nephrectomy

- Unstable pt. → hypothermia / coagulopathy with normal contralateral kidney
- Extensive renal injury
- Poor functioning hydronephrotic kidney

t.me/latestpgnotes

PrepLadder

Transplantation – 1

History of Transplantation

→ 1st renal transplantation – Murray (in 1954, on identical twins)
→ 1st liver transplantation – Starzl (in 1963)
→ 1st pancreas transplantation – Kelly and Lillhei (in 1966)
→ 1st Heart transplantation – Christian Barnard (in 1967)
→ 1st Lung transplantation – Fritz Derom (in 1968)
→ 1st Pancreatic islet cell transplantation – Sutherland (in 1974)
→ 1st heart + lung transplantation – Reitz & Shumway (in 1981)
→ 1st successful intestinal transplantation – Deltz (in 1988)
→ Human transplantation Act in India was passed in 1994

GRAFT REJECTION

Hyperacute rejection

→ Occurs within minutes to hours
→ Immediate graft destruction because of ABO / Pre-formed HLA Antibodies
→ Characterized by intravascular thrombosis
→ Kidney transplantation - vulnerable to Hyperacute rejection
→ Heart and liver transplant - relatively resistant to hyperacute rejection

t.me/latestpgnotes

Acute (cellular) rejection

→ Occurs in first 6 months
→ MC present 5 – 30 days after transplantation
→ It is T cell dependent – characterized by mononuclear cell infiltration
→ Usually reversible

Chronic rejection

→ Occurs after first 6 months
→ Most common cause of graft failure
→ Non immune factors contribute to pathogenesis
→ Characterized by **Myointimal proliferation** - in graft arteries leads to **Ischemia & fibrosis**

Manifestations of chronic graft rejection

→ **In Kidney** - Glomerular sclerosis & Tubular atrophy
→ **In Pancreas** - Acinar loss & islet cell destruction
→ **In Heart** - Accelerated coronary artery disease (cardiac allograft vasculopathy)
→ **In Liver** - Vanishing bile duct syndrome
→ **In Lungs** - Obliterative Bronchiolitis

PrepLadder

HLA matching

→ Most important antigens for matching donor & recipient to ↓ risk of rejection
- HLA-A
- HLA-B
- HLA-DR

→ Order of importance HLA-DR > HLA-B > HLA-A

→ HLA matching has relatively small but definitive beneficial effect in **Renal transplantation**

→ **HLA antigens**
- Most common cause of graft rejection
- Acts as antigen recognition units
- Highly polymorphic
- Anti – HLA antibodies - cause hyperacute rejection

→ **In Liver transplantation** - HLA matching does not confer any advantage

→ **In Heart transplantation** - HLA matching is beneficial, but not practicable, because of
- Relatively small size of recipient pool
- Short permissible cold ischemic time

Types of Graft

→ Autograft - Tissue transplanted from one side to other on same recipient

→ Isograft - Transplanted from genetically identical donor (e.g. identical twins)

t.me/latestpgnotes

→ Allograft / Homograft - Graft is taken from individual of same species

→ Heterograft / Xenograft - Transplant from different species

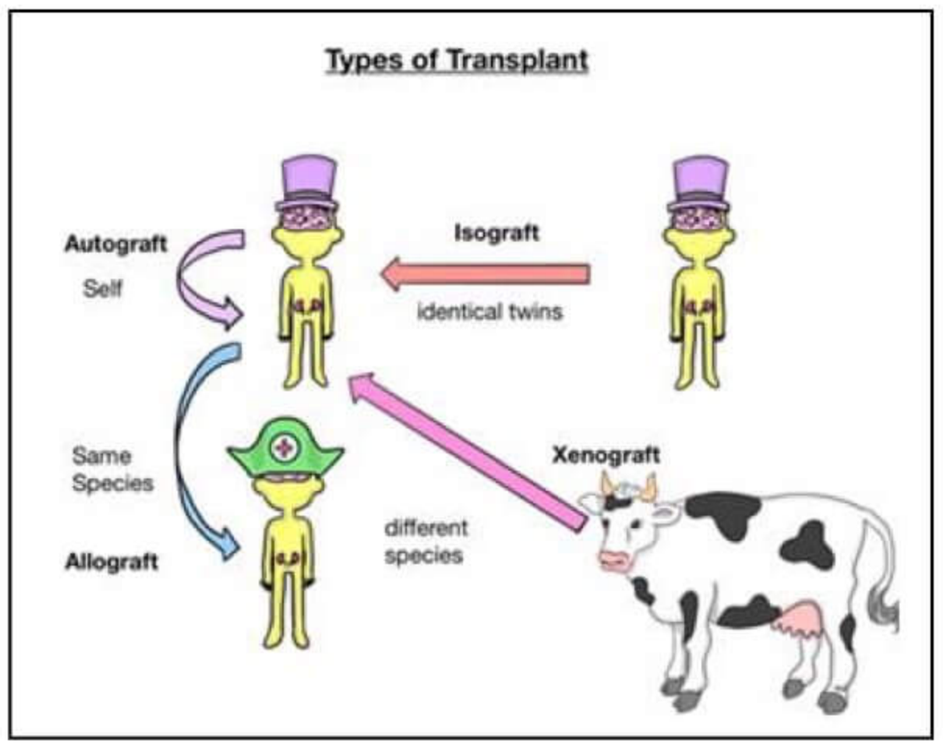

→ Concordant Xenograft
- Transplant between closely related species
- E.g. **For humans** → Old world monkey's & Apes
- **Advantage**: Hyperacute rejection → not a threat
- Mechanism of Graft rejection in Concordant Xenograft
  1. Acute cellular rejection
  2. Acute vascular rejection
  3. Chronic rejection
- **Disadvantage**: Zoonotic transfer of disease (retroviral transmission)

→ Discordant xenograft
- Transplant between distant related or divergent species
- E.g. **For humans** → New world monkey's & Other Mammals

PrepLadder

- For physiologic concern (organ size & availability) new world monkey's organs are not used – Pig is the preferred animal donor
- **Disadvantage:** High risk of hyper Acute rejection

IMMUNOSUPPRESSIVE AGENTS

Agents	Principle mode of action
1. Steroids	Wide spread Anti-inflammatory effect
2. Azathioprine	Prevents lymphocyte proliferation
3. Mycophenolic Acid	Same as Azathioprine preparation
4. Calcineurin inhibitors (**Cyclosporin, Tacrolimus**)	Block IL-2 "Gene transcription"
5. M-TOR inhibitors (**Sirolimus**)	Blocks IL – 2 "Receptor signal transductions"
6. ALG (anti lymphocyte globulin)	Depletion & blockade of lymphocytes
7. Anti-CD 25 MAB (**Basiliximab**)	Targets activated T-Cells
8. Anti-CD 52 MAB(**Alemtuzumab**)	Depletion of lymphocytes
9. Anti CD20 MAB (**Rituximab**)	Depletion of B lymphocytes
10. CTLA- 4 Ig (**Belatacept, Abatacept**)	Blocks T- Cell co-stimulation

t.me/latestpgnotes

Complications of immuno suppression

→ Infections

- High risk of opportunistic infection – by viruses
- Recipient derived infections > Donor derived infections
- **Bacterial infection** is highest – First month of Transplantation
- **Viral infection** is highest – First 6 months of Transplantation

  ↓

  - CMV infection is MC problem
  - Result from **Reactivation of latent virus / from 1°infection**
- Chemoprophylaxis needed in High risk patients
- Pre transplant vaccination should be given against community acquired infection

→ Malignancy

- MC malignancy in transplant recipient – skin cancer (**Squamous cell carcinoma**)
- Increased risk of
  - PTLD (post-transplant lymphoproliferative disorder)
  - Kaposi sarcoma

→ Non-immune side effects

- Hypertension & chronic allograft neuropathy caused by calcineurin inhibitors
- New onset DM after transplantation caused by Steroids or Tacrolimus

PrepLadder

- Increased risk of
  - Hyperlipidemia
  - Anemia
  - Accelerated CVS disease

→ Leading cause of death in transplant survivors - **CVS disease**

CMV INFECTION

→ Most important pathogen in clinical transplantation

→ Usually occurs 30-50 days after transplantation

C/F:

→ **Non-specific signs and symptoms**
- Fever
- Malaise
- Arthralgia
- Thrombocytopenia

→ Interstitial pneumonia

→ Enterocolitis

→ Disseminated disease

Diagnosis:

→ **Confirmatory test** – Invasive CMV infection with Histological evidence

Or

Positive CMV culture from deep tissue specimen

t.me/latestpgnotes

Treatment

→ **IV Ganciclovir**
- Mainstay of treatment
- Effective for both Prophylaxis and treatment

BK virus

→ It belongs to Polyoma virus family

→ A/W Nephropathy – typically occurs 1-4 months after transplantation

→ **↑ levels of BK virus replication**
- Detected by PCR in blood & urine

↓

Predictive of Pathology in Renal Transplantation

→ Urinary excretion of BK virus & BK viremia

↓

A/W development of
- Ureteric strictures
- Nephropathy
- Generalized vasculopathy

PrepLadder

→ Timely detection & Early reduction of Immunosuppression – Reduces graft loss from 90% - 10%

PTLD (Post-transplant lymphoproliferative disorder)

→ Associated with EBV in B-cells
→ Induced by enhanced immunosuppression
→ Seen in patients who have received > 1 course of
  - **Polyclonal anti lymphocyte globulin (ALG)**
  - **Monoclonal AKT -3**

Clinical features

→ Fever
→ Malaise
→ Lymphadenopathy

Diagnosis

→ Tissue Biopsy

Treatment

→ **Polyclonal PTLD**
  - Discontinue Immunosuppressive agents
  - Antiviral therapy

t.me/latestpgnotes

→ **Monoclonal PTLD**
  - Radio therapy
  - Chemotherapy
  - Surgical Resection
  - Anti-CD 20 MAB (Rituximab) is also effective

Organ donors

Dead / Deceased donors		Living donors
Brain dead / Heart beating donors / Donation after brain death (DBD)	Cardiac or circulatory dead /Non-heart beating donors / Donation after circulatory death (DCD) donors	Limited to donation of - Kidney - Liver - Lung Lobe

DBD donors

→ Most diseased donor organs are obtained from patients with brain stem death
→ Brain death occurs when brain Injury causes
  1. **Irreversible loss of capacity of consciousness combined with**
  2. **Irreversible loss of capacity for breathing**

PrepLadder

Clinical testing of brain stem death

→ **Absence of cranial nerve reflexes**

- Pupillary Reflex
- Corneal Reflex
- Pharyngeal (Gag) reflex and
- Tracheal (Cough) reflex
- Oculovestibular (caloric) reflex

→ **Absence of motor response**

- To painful stimuli applied to head and face
- Within the cranial nerve distribution to adequate stimulation

→ **Absence of spontaneous respiration**

DCD donors

→ Because of rising demand for organ transplantation – increase in use of organs from DCD donors

→ DCD donors – Grouped according to MAASTRICHT classification

MAASTRICHT classification

Category	Description
1	Dead on arrival at hospital
2	Resuscitation attempted without success
3	Awaiting cardiac arrest after withdrawal of support (Most DCD donors are cat.3)
4	Cardiac arrest while brain dead
5	Cardiac Arrest and Unsuccessful resuscitation at hospital

t.me/latestpgnotes

Uncontrolled donors[QQ]	Controlled donors
• Category 1, 2, 5 are included • Warm ischemic time is longer • Less predictable	• Category 3 & 4 are included • Death results from planned withdrawal of cardio respiratory support • Most DCD donors are Controlled donors

ECD (Extended Criteria Donors)

Kidney transplant	Liver transplant
→ Donor > 60 years → Donors with age 50 – 59 years with at least two of the following • CVA (cerebrovascular accident) as cause of death • Pre – exiting hypertension • Terminal serum creatinine > 1.5 mg/ dL	→ Mild / moderate steatosis → Hepatitis C (+) → Hepatitis B core antibody (+)

PrepLadder

Organ preservation solution

→ Liver
→ Pancreas → **Preserved up to 2 days**
→ Kidney
- By flushing the organ with University of WISCONSIN solution
- Storing at hypothermia (0 - 5°C)

University of WISCONSIN (UW) solution

→ Has cationic composition
→ ↑ K^+, ↓ Na^+ - mimics intracellular levels to minimize diffusion down Electrochemical gradient
→ **UW** → VIASPAN (brand name)
→ High K^+ & Adenosine

Composition of UW solution

- **Lactobionate & Raffinose** → Minimises cell swelling
- **HES(Hydroxy Ethyl Starch)** → Prevention of extracellular space expansion
- **Glutathione** → Anti-oxidant
- **Allopurinol** → Free Radical Scavenger
- **Adenosine** → Precursor for energy metabolism

Maximum and optimal cold storage times of various organs

Organ	Optimal storage time	Safe maximum storage time
Kidney[QQ]	< 18 hours	36 hours
Liver	< 12 Hours	18 hours
Pancreas	< 10 Hours	18 hours
Small Intestine	< 4 Hours	6 hours
Heart[QQ]	< 3 Hours	6 hours
Lungs	< 3 Hours	8 hours

t.me/latestpgnotes

PrepLadder

TRANSPLANTATION PART – 2

LIVER TRANSPLANTAITON

→ 1st liver transplant – STARZL, 1963

Indications

→ MC indication – Cirrhosis from hepatitis C virus infection
→ 2nd MC indication – Alcoholic liver disease
→ MC indication of pediatric LT – Biliary Atresia
→ MC metabolic disorder requiring LT – α_1 antitrypsin deficiency
→ MC indication for LT following acute liver failure – Acetaminophen toxicity

Contraindications

Absolute	Relative
• Advanced cardiopulmonary disease • Active untreated sepsis • Metastatic malignancy to liver • Active alcohol abuse • Severe intractable depression • Extensive venous thrombosis	• Age (>70 Years)– varies among transplant centers • Obesity (BMI > 40kg/m²) • Cholangiocarcinoma • Chronic or refractory active infection • Ongoing tobacco use or illegal drug use

t.me/latestpgnotes

Types of Liver Transplantation

→ **Orthotopic LT** – graft placed at normal anatomical position after recipient hepatectomy

→ **Heterotopic LT** – graft is placed at an alternative site rather than at normal anatomical position

→ **Auxiliary LT** – native liver remains IN-SITU and whole or partial transplant is added

→ **APOLT (Auxiliary Partial Orthotopic LT)** – Left lobe of recipient is excised & donor liver occupies the vacated space

→ **Auxiliary Heterotopic LT** – Either whole liver or lobe of liver is placed in subhepatic space

→ **Piggyback LT** – Orthotopic LT that preserves IVC

→ **Split LT** – Cadaveric liver is divided and given to 2 recipients
– Left lobe → given to child; Right lobe → given to adult

→ **Reduced LT** – graft is reduced to a functional unit of appropriate size for recipient

PrepLadder

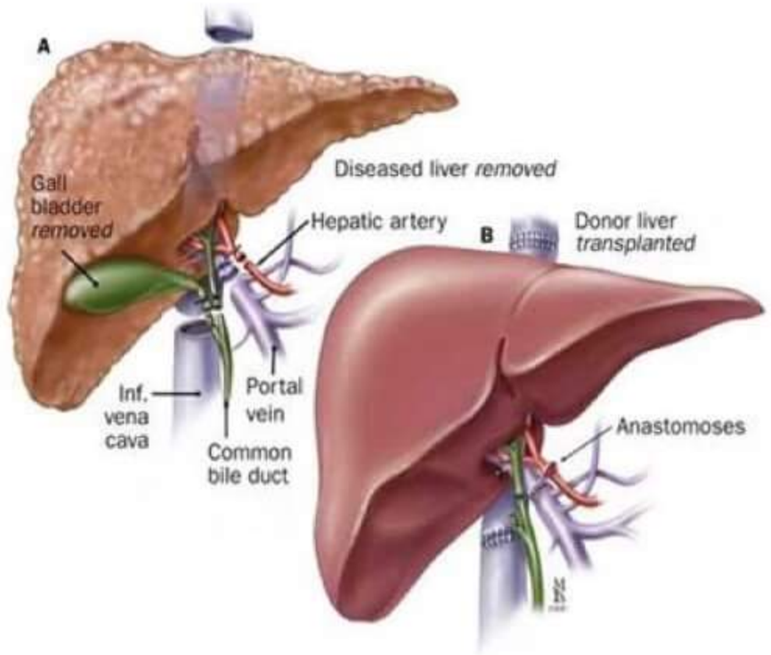

Orthotopic LT

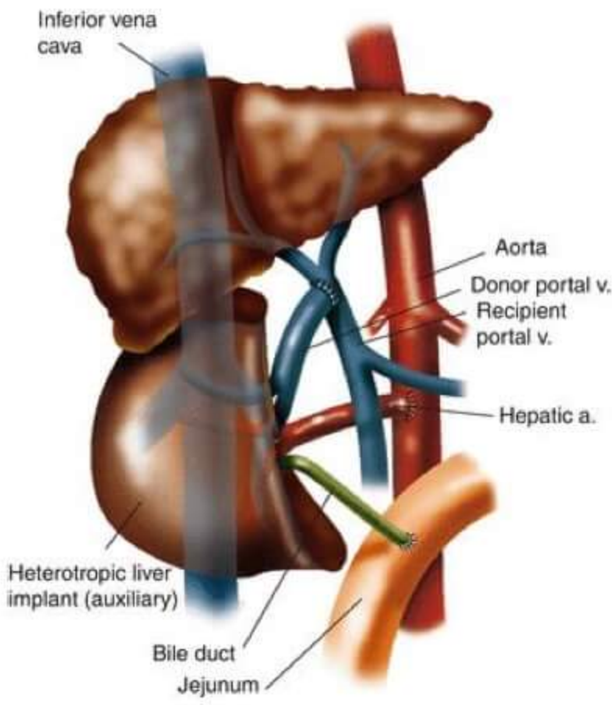

Auxiliary LT

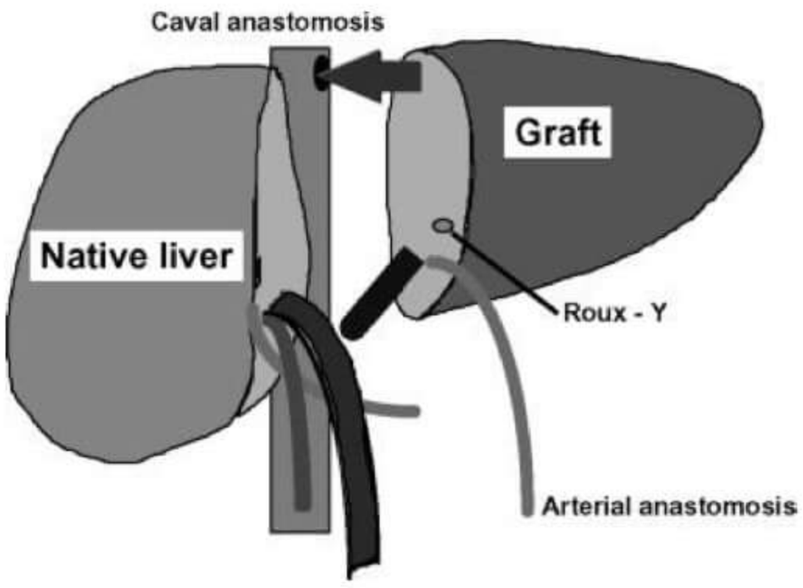

APOLT

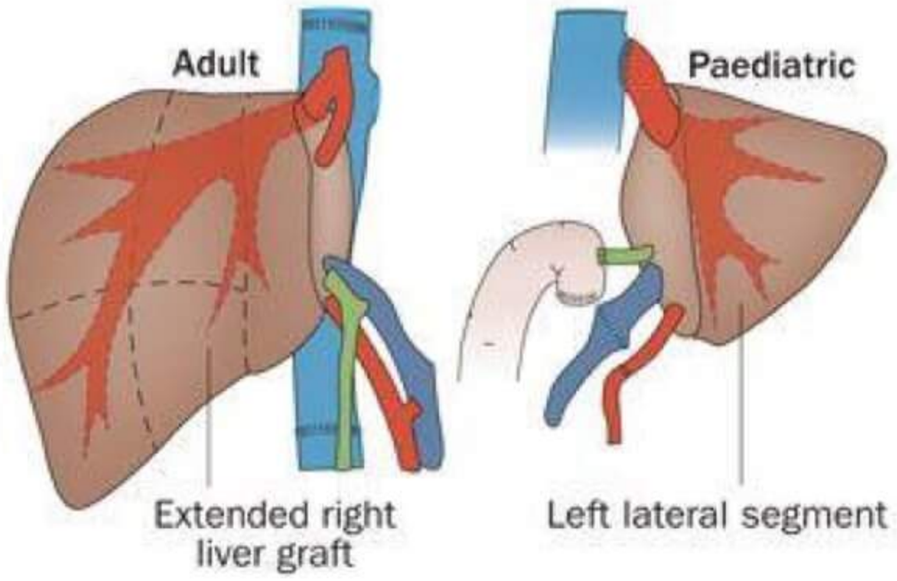

Split LT

t.me/latestpgnotes

OLT- (orthotopic liver transplantation)

Sequence of Anastomosis in OLT

- 1st → S – Suprahepatic IVC
- 2nd → I – Infrahepatic IVC
- 3rd → P – Portal vein
- 4th → H – Hepatic artery
- 5th → B – Bile duct

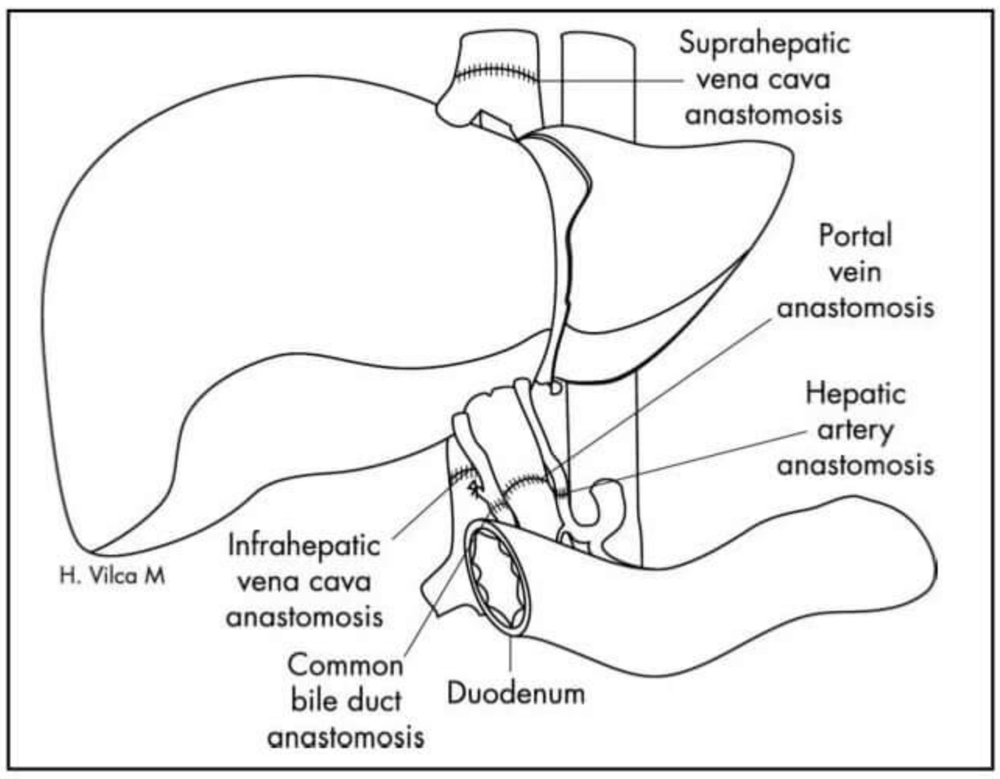

Method of Biliary Drainage

1. **Choledocho-choledochostomy** (most preferred)
   - Direct End-to-End anastomosis between bile duct of donor & bile duct of recipient is done
2. **Choledocho- Jejunostomy**
   - Bile duct of donor is sutured with Jejunum of recipient

Indications of Choledocho- Jejunostomy

1) Diseased recipient extra-hepatic bile duct
2) Significant recipient donor duct size mismatch

PrepLadder

Complications of LT

→ **Hepatic artery thrombosis**
- Occurs spontaneously or part of acute graft rejection
- Patient develops fever & bile leak
- Increased Serum Transaminase
- **Mgt**: Immediate re-transplantation

→ **Portal Vein thrombosis**
- Occurs insidiously
- Does not required Re-transplantation

→ **Chronic liver graft rejection**
- Occurs due to Vanishing bile duct syndrome
- Liver is relatively resistant to hyper acute rejection
- Chronic rejection is uncommon in LT

→ **Bile leak**

→ **Biliary strictures**

→ M/C cause of death after LT- Sepsis and Sepsis related MOF

Indications for Re-transplantation

→ MC indication for Re-transplantation - Primary Non-function > Hepatic artery thrombosis > Acute and Chronic rejection > Recurrent disease

t.me/latestpgnotes

DOMINO TRANSPLANTATION

→ Explanted liver graft from LT recipient is reused for transplantation

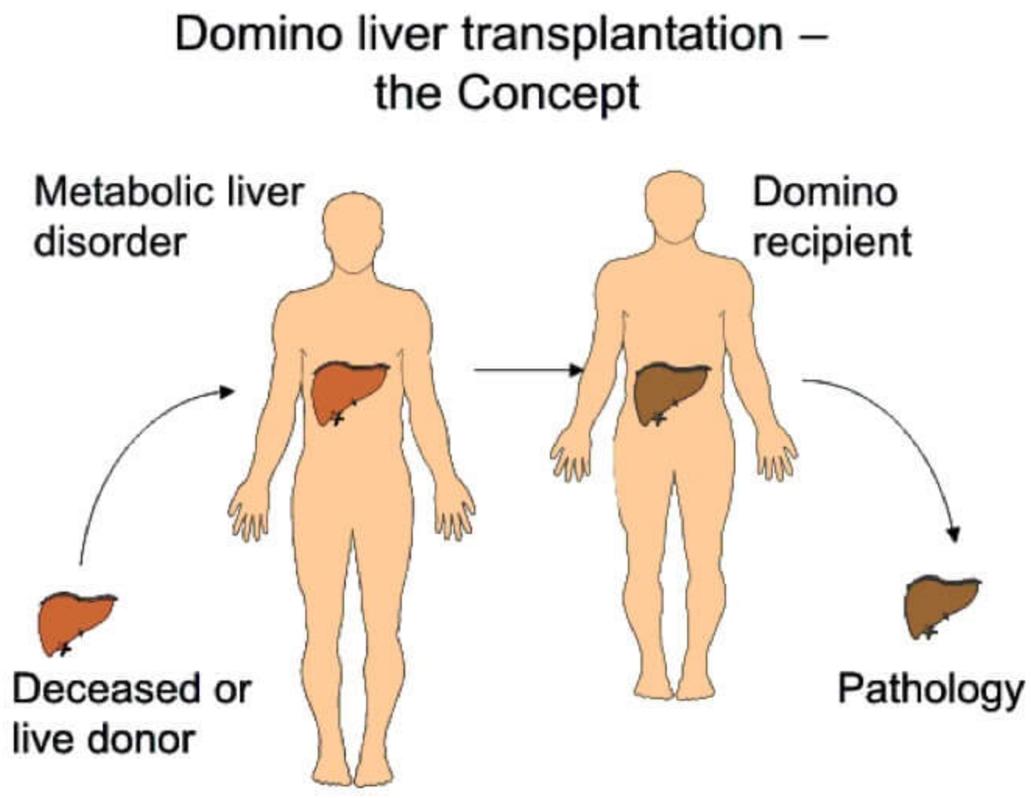

→ **Indications for DT:**
- Familial Amyloid Polyneuropathy
- MSUD (Maple Syrup Urine Disease)

PrepLadder

→ Combined Liver + Heart transplantation - done in **Amyloidosis**
→ Combined Liver + Lung transplantation - done in **Cystic fibrosis**

Model for end stage liver disease (MELD) score

→ Assess the severity of CLD
→ Predict death within 3 months of surgery in patients who underwent TIPSS (Trans jugular Intrahepatic Porto Systemic Shunt)
→ Used in UNOS (United Nations Organ Sharing Network) for prioritizing allocation of liver transplant
→ **Components of MELD Score**
- C- Creatinine
- B- Bilirubin
- I - INR

(Score 6 - 40)

PELD Score (Pediatric End Stage Liver Diseases)

→ Done for children's
→ **Components**
- Nutrition
- Age
- Bilirubin
- INR
- Albumin

t.me/latestpgnotes

RENAL TRANSPLANTATION

→ First Renal Transplantation - **Murray (in 1954)**
→ In identical twins - without immunosuppressants

Indications for Renal Transplantation

→ Glomerulonephrosis
→ Diabetic Nephropathy
→ Hypertensive nephrosclerosis
→ Renal vascular disease
→ Polycystic kidney disease /Pyelonephritis
→ Obstructive uropathy
→ SLE
→ Analgesic nephropathy
→ Metabolic disease (oxalosis, amyloid)

Procedure

→ Left kidney is preferred for Renal transplantation because of longer left renal vein.
→ Renal graft is placed in iliac fossa leaving the native kidney in-situ (in Retroperitoneal location)

PrepLadder

→ Recipient has 3 kidneys after renal transplantation

→ **Anastomosis done in RT:**

- Donor renal vein is anastomosed to External iliac vein
- Donor renal artery (on Carrel patch of donor aorta) anastomosed to External iliac artery
- In living Donor (has no carrel patch) graft renal artery is anastomosed to Internal iliac artery

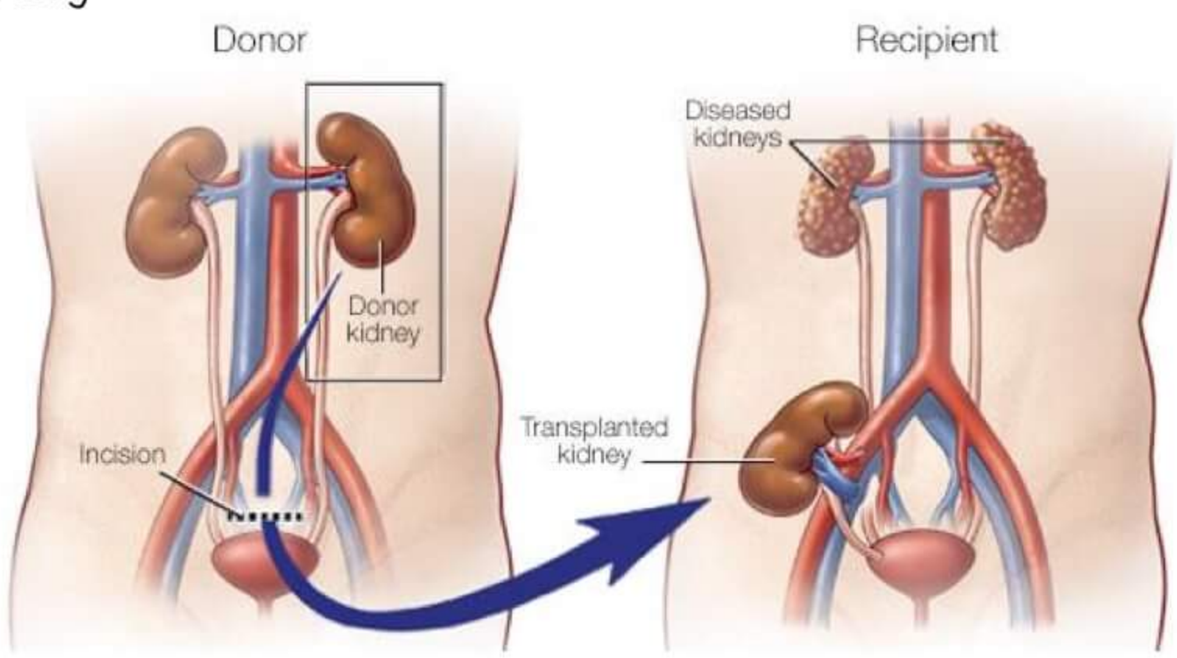

Heterotopic LT

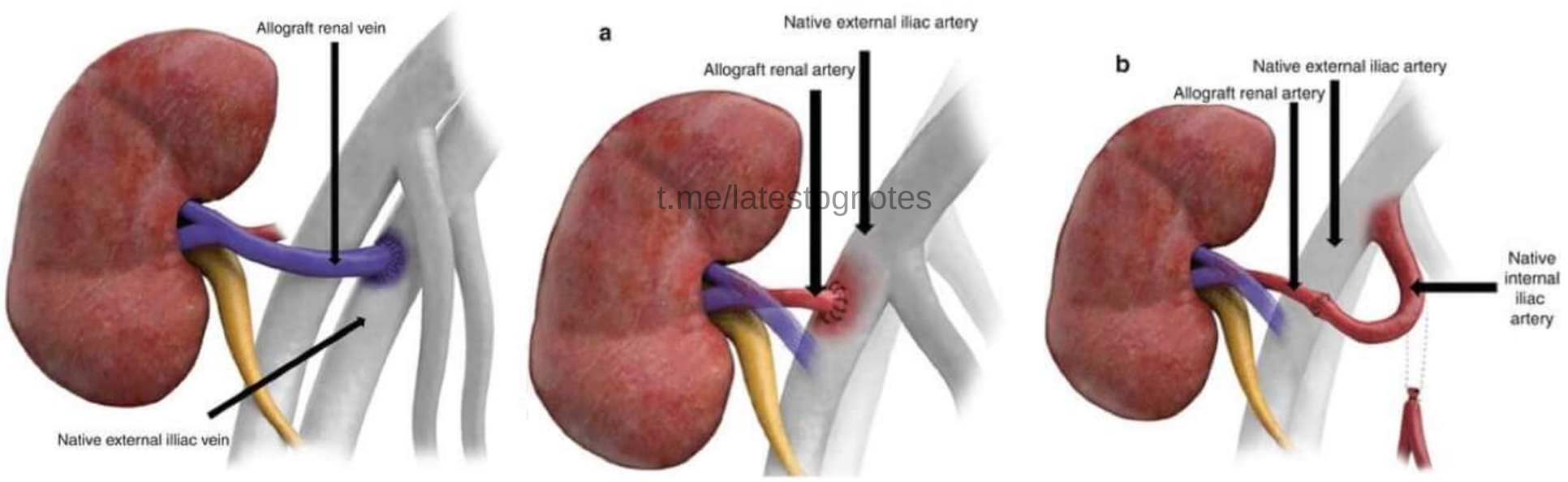

t.me/latestdgnotes

Anastomosis done in Renal Transplanation

→ **Ureter in RT**

- It is kept reasonably short to avoid distal ischemia
- Anastomosed to bladder by

a) Lich-gregoir technique (Preferred)

- Direct implantation of ureter into dome of bladder with mucosa to mucosal anastomosis followed by closure over ureter to create a short tunnel

b) Lead better politano technique

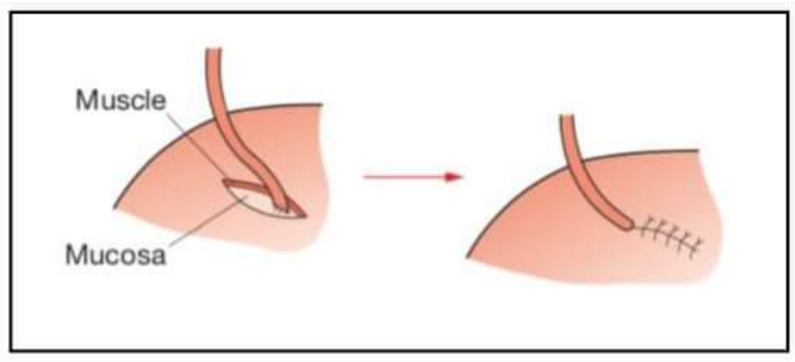

Complications of Renal transplantation

→ MC complication in donor after liver kidney donation - Urinary retention and ileus

→ **Complications in recipients**

1. Renal Vein thrombosis
   - Diagnosed by Doppler

PrepLadder

- Urgent surgical exploration is needed
- In most cases Transplant nephrectomy is required

2. **Renal artery stenosis**
   - Late presentation
   - Decrease in Renal function
   - Increase in Hypertension
   - Best treated by- Angioplasty

↓ If not possible

Open surgery & Vascular reconstruction

3. **Urinary Leak**
4. **Obstruction of transplant ureter**
   - Best treated by surgical intervention
   - Re implantation of donor ureter into bladder or
   - Anastomosed to native ureter
5. **Lymphocele**
   - Usually Asymptomatic
   - Large lymphocele
     - Ureteric obstruction
     - Edema of I/L leg
   - Management of large lymphocele
     - Ultrasound guided Percutaneous drainage or
     - Drainage into peritoneal cavity

t.me/latestpgnotes

Contraindication of renal transplantation

ABSOLUTE	RELATIVE
• Active malignant disease	• Limited Life Expectancy
• Active infection	• H/O non- adherence to medication regimen
• Unreconstructable PVD	• H/O non- compliance with dialysis
• Severe cardiac or pulmonary disease	• Financial barrier
• Active IV drug abuse	• Renal disease wit high recurrence rate
• Significant psychosocial barriers	• Morbid obesity

PANCERAS TRANSPLANTATION

→ First Pancreas transplantation – **Kelly & Lillhei (in 1966)**

→ **Types of Pancreas transplantation**

1) Simultaneous Pancreas and Kidney transplantation (SPK) – 80% cases
2) Pancreas after kidney transplantation (PAK) - 15% cases
3) Pancreas transplantation alone (PTA) - 8% cases

Indications of Pancreas transplantation

→ Type-I DM with clear c-peptide deficiency

→ **Indications of SPK**

- Insulin therapy with c-peptide level <2ng/ml
- Insulin therapy with c-peptide level >2ng/ml and BMI < 28

PrepLadder

Donor selection

→ Organ from (Younger, Leaner, hemodynamically stable) diseased donors are preferred

→ Pancreas with significant steatosis should be avoided because of

- Increased risk of Post-operative complications
- Increase risk of Peri-pancreatic fat necrosis
- Increase risk of Infection
- Increase list of Pancreatitis

Contra-indications of Procurement

→ Type – I DM

→ H/O previous pancreatic surgery

→ Chronic pancreatitis

→ H/O recent malignancy

Procurement principle, Preparation & Transplantation

→ During procurement - minimal handling of pancreas

→ En bloc removal of pancreas and liver to increase warm ischemic time

→ **Back table preparation includes:**

- Removal of spleen
- Maintaining at least 1cm of portal vein
- Trimming excess distal and proximal duodenum
- Iliac artery is used as Y graft
  - End to End anastomosis is done between
    - Internal iliac artery & splenic artery
    - External iliac artery & superior mesenteric artery

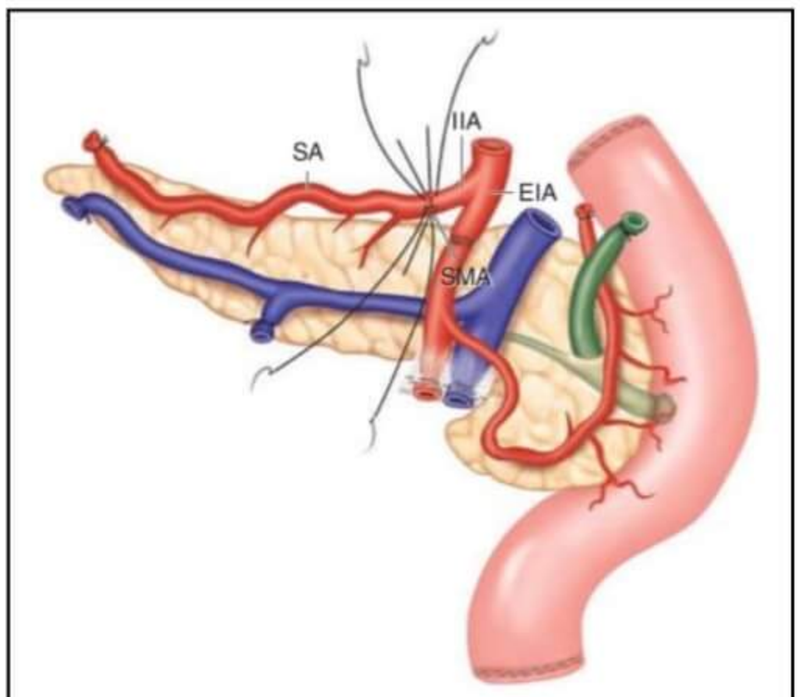

Posterior view of the Pancreas graft with Y-graft reconstruction

t.me/latestpgnotes

→ Graft is placed on right side to prevent undue stretching of venous anastomosis

→ Systemic venous drainage is preferred over Portal venous drainage in Pancreas transplantation

→ **To establish Systemic venous drainage**

- Portal vein is anastomosed to
  - External iliac vein (or)
  - Common iliac vein (or)
  - Distal part of IVC
- Iliac artery graft Anastomosed to Common iliac artery of recipient

PrepLadder

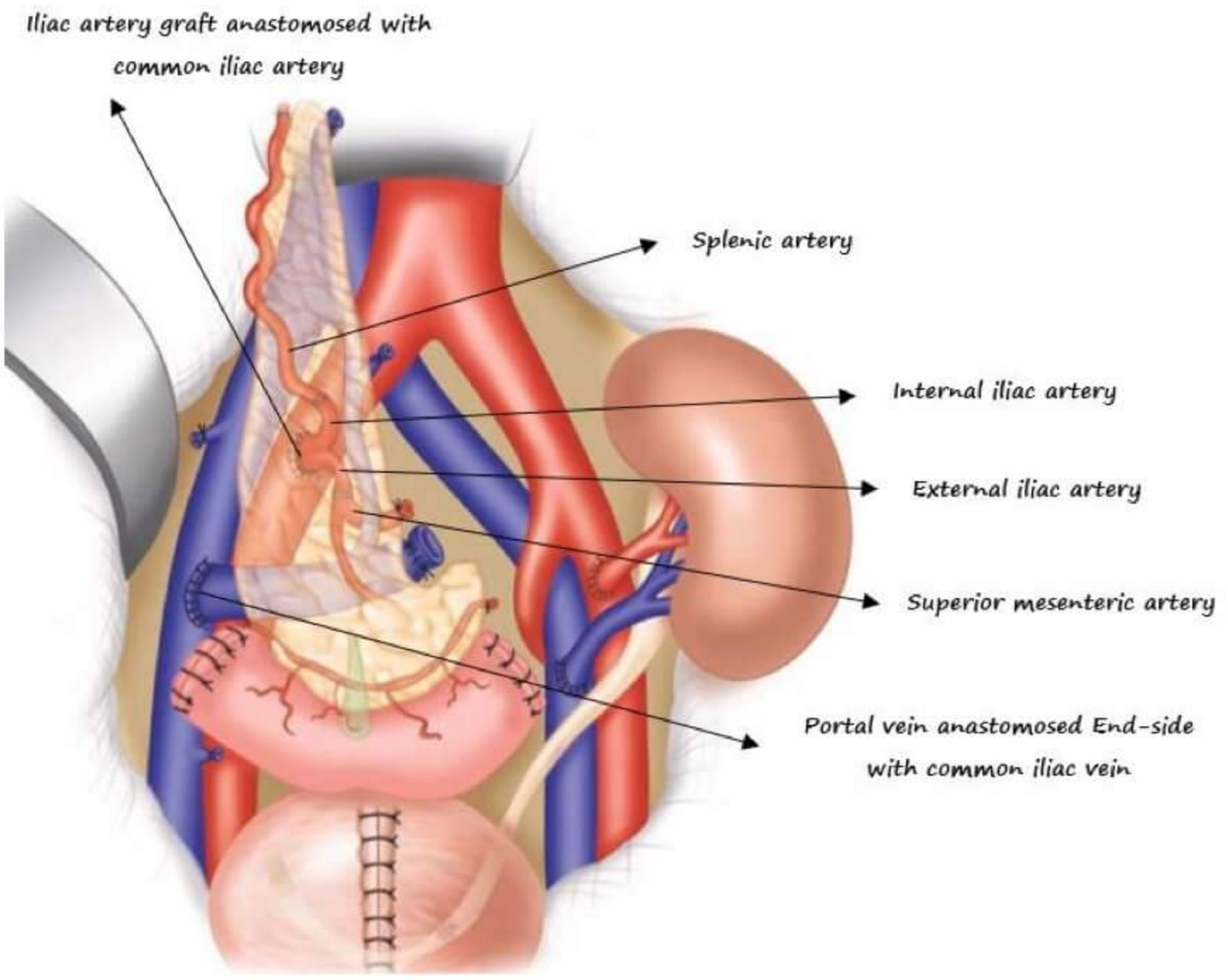

Whole organ transplant with systemic vein and bladder drainage

→ **For portal drainage**

- Donor portal vein —Anastomosed→ Recipient proximal SMV

to

→ Enteric drainage is preferred over Bladder drainage for exocrine secretions

t.me/latestpgnotes

- **Enteric drainage of exocrine secretions**
  - Duodenal stump of graft is anastomosed in side to side fashion to recipient's mid jejunum
  - Orientation of duodenum can be superior or inferior
- **Bladder drainage of exocrine secretions**
  - In this 4-5cm cystostomy is made on anterior dome of bladder
  - Orientation of duodenum is always inferior
  - Advantage of Bladder drainage → Allows monitoring of urinary amylase

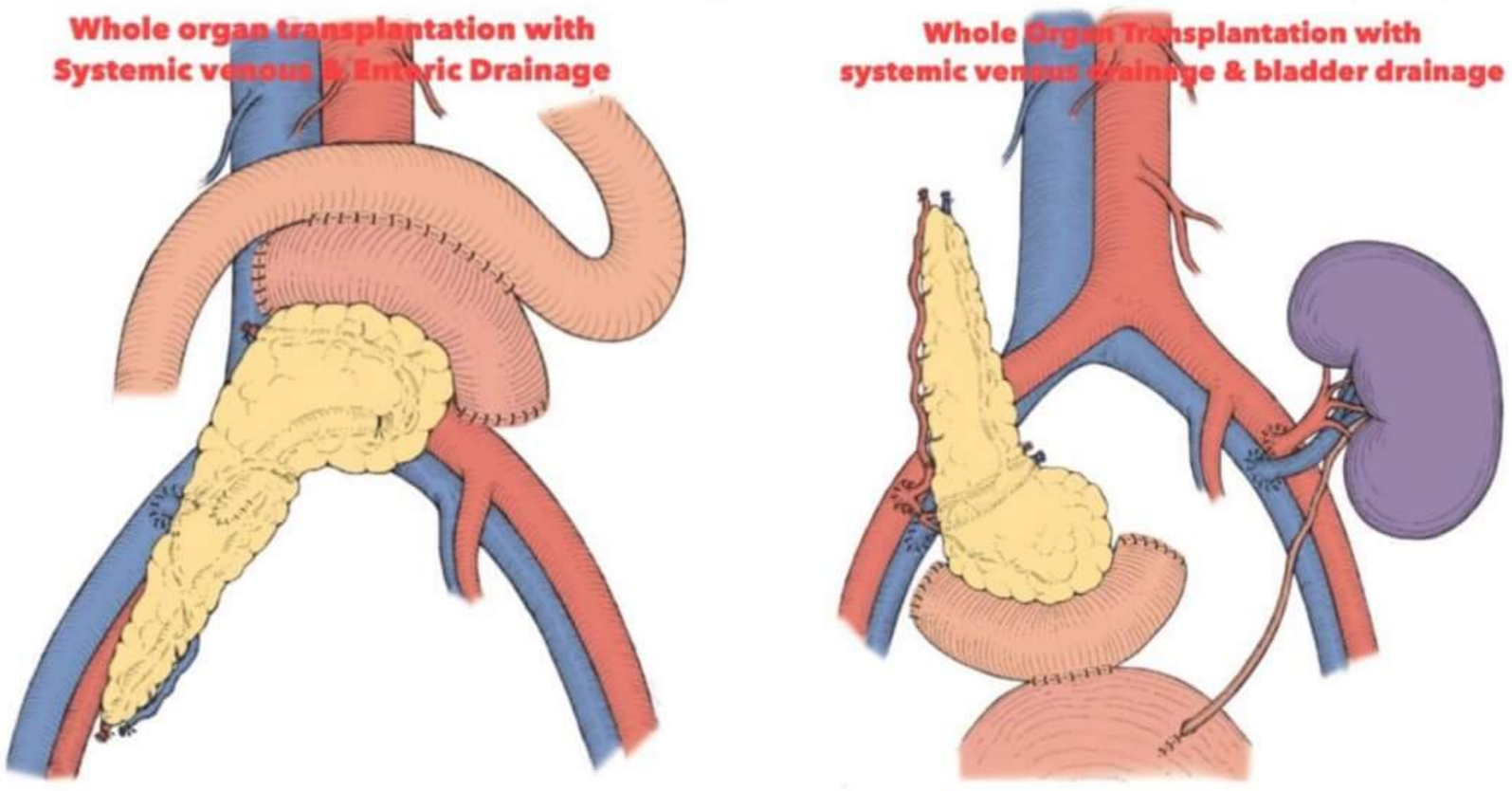

→ Enteric drainage and Systemic venous drainage is preferred for Pancreas transplantation

PrepLadder

Complications of Pancreas transplantation

1) **Pancreatic graft thrombosis**
    - More common because of Low blood flow through the organ
    - Venous thrombosis > arterial thrombosis
    - Occurs within first week of transplantation
    - Vascular thrombosis → MC non- immunologic cause of pancreatic graft failure
2) **Early pancreatitis**
3) **Leak**
    - Bladder drained transplant with small leak is managed by Foley's catheter
    - Enteric drained transplant with leak - Operative intervention is required
4) **Bleeding**
    - Immediate post- transplant bleeding occurs from Pancreatic parenchyma
    - Delayed GI bleeding occurs from Enteric anastomosis (on POD-6 to POD -10) -it is self-limited

ISLET CELL TRANSPLANTATION (ICT)

→ First human islet auto- transplantation performed by Sutherland (in University of Minnesota, 1977)

Indications of Islet cell transplantation

→ Recurrent, severe Hypoglycemia with decreased awareness to Hypoglycemia

→ Severe labile diabetes with wide swings of blood glucose throughout the day

t.me/latestpgnotes

Principles of Islet cell transplantation

→ Islet cells are infused in portal veins

→ Lifelong immune suppression is required

→ ICT is limited to most severe form of diabetes

→ **Edmonton regimen**
    - Combination of induction therapy with Daclizumab (IL-2 receptor antibody) + Maintenance therapy with Sirolimus and Tacrolimus is given
    - Steroids are avoided

→ **For Insulin independence** – 8000 to 10000 islet cells/ kg of recipient's body weight should be transferred

→ 4 donors' pancreas are required for 1 islet cell transplantation

Complications of Islet cell transplantation

→ **Bleeding**
    - Most feared
    - Occurs in 20% cases

→ **Portal vein thrombosis**
    - <1% cases (Rare)

PrepLadder

SMALL BOWEL TRANSPLANTATION

→ First successful Small bowel obstruction – Deltz (in 1988)

Indications of Small bowel obstruction

→ **Short bowel syndrome** – occurs in patients who experience

- IFALD (intestinal failure associated liver disease)
- Parenteral nutrition failure
- Recurrent catheter related infections
- Thrombosis of 2 of 6 central access veins
- Alteration in growth and development of children
- Severe dehydration with refractory electrolyte changes
- Established liver disease with cirrhosis and portal hypertension

→ **M/c indication of SBT**[QQ]

- In children's – Gastroschisis > Volvulus > Necrotising enterocolitis
- In adults – Mesenteric ischemia > Crohn's disease > Trauma

Donor selection

→ Ideal donor should have a body weight of 50-75% of recipient

→ Viral serological testing for EBV & CMV is needed

Types of intestinal Transplantation

t.me/latestpgnotes

1) Small bowel with or without a portion of colon
2) Combined liver - small bowel graft
3) Multivisceral graft (rare)

Isolated Small intestinal Transplantation

Graft

→ Isolated intestinal allograft – It includes entire jejunum and ileum with associated vasculature (SMA, SMV)

→ Donor Jejunum is just divided just distal to Ligament of Treitz

→ Ileum is transected just proximal to Ileocecal valve

→ SMA an SMV are divided at mesenteric root at inferior border of pancreas

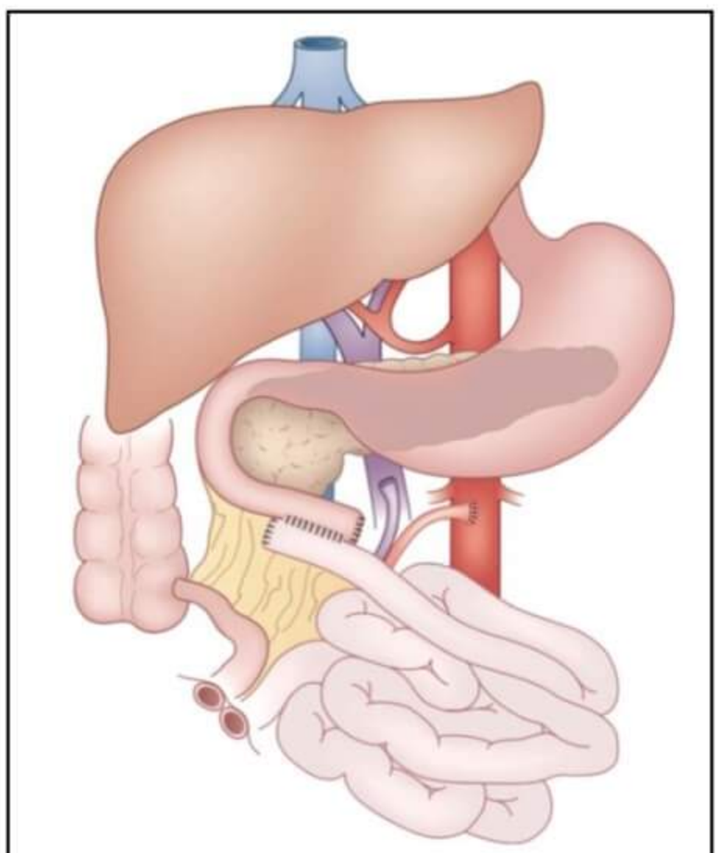

Isolated Small intestinal Transplantation

Procedure

→ In recipient's operation

- Donor SMV anastomosed to recipients PV
- Donor SMA anastomosed to recipients infra renal aorta

PrepLadder

→ **For Bowel continuity:**

- Graft jejunum anastomosed to recipient's duodenum
- Graft ileum is taken as **ileostomy**

↓

helps in routine monitoring of graft

Complications of Small bowel obstruction

→ **Technical complications**

- Anastomotic leak
- Intestinal perforation
- Wound complications

→ **M/c complication following SBT**

- Bacterial infection (E. coli > Klebsiella)
- Viral infection

→ **PTLD (Post transplantation lymphoproliferative disorder)**

- In SBT recipient → 10-20%
- In Lung-Heart recipient → 5-10%
- In liver recipient → 2-5%
- In Kidney recipient → 1-2%

t.me/latestpgnotes

→ **Graft versus host disease**

- Incidence in SBT → 0-14% because of large amount of lymphoid tissue in SI

→ M/c causes of graft loss – **Sepsis > Rejection**

→ M/c cause of death after SBT: **Sepsis**

HEART TRANSPLANTATION

→ First Heart transplantation – **Christian Bernard (in 1967)**

Indications of Heart transplantation

→ Ischemic dilated cardiomyopathy secondary to Coronary artery disease (MC)[QQ]

→ Idiopathic dilated cardiomyopathy

→ Valvular heart disease

→ Myocarditis

→ Congenital heart disease

Heart transplantation is considered

→ **In patients of End stage heart disease that**

- Failed to respond to all other conventional therapies
- Predicted survival without transplantation is only 6-12 months
- Age <65 years without irreversible damage to other organ systems

PrepLadder

Procedure

→ Median sternotomy is done

→ Systemic heparin is given

→ Patients is placed on Cardio-pulmonary bypass & cooled to 29°C

→ After cross clamping Aorta, Recipient's heart is excised at Mid-atrial level

→ **Sequence of anastomosis done**

- Left Atrial anastomosis → Right atrial anastomosis → Pulmonary artery anastomosis → Aortic anastomosis

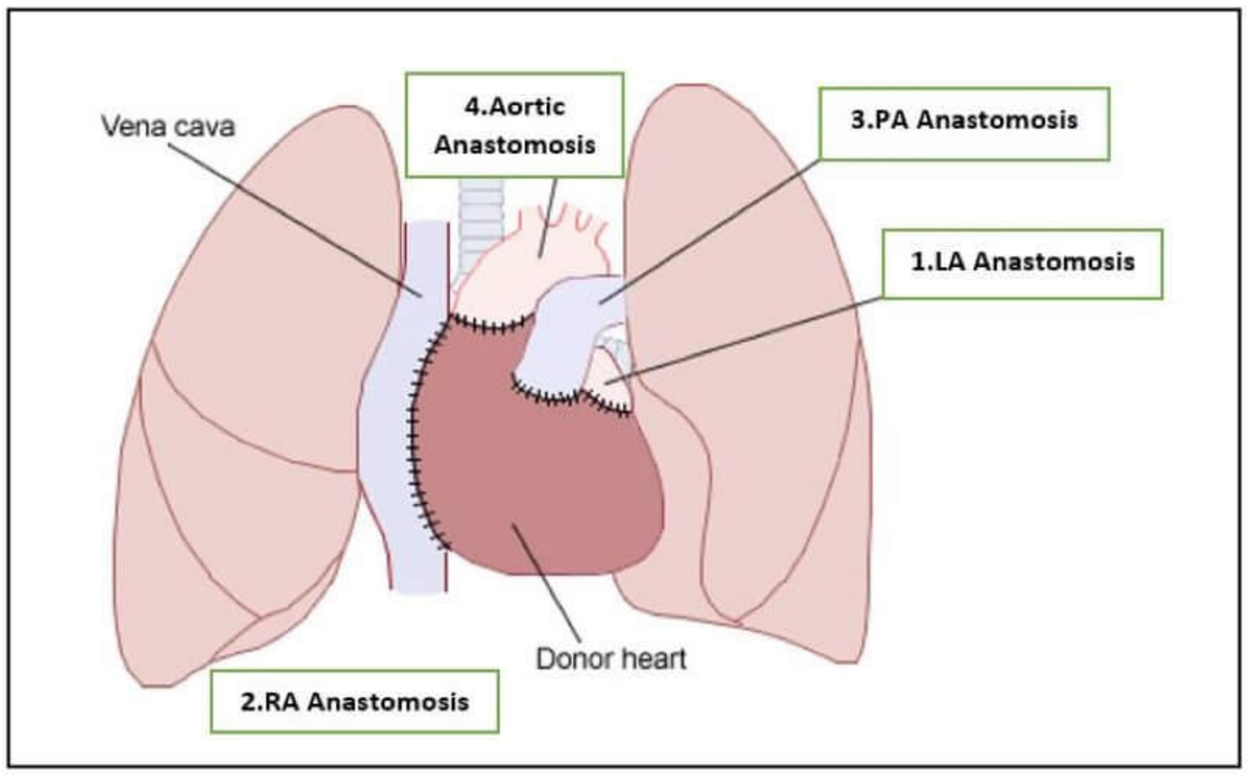

→ After these anastomoses, patient is Rewarmed and weaned from Cardiopulmonary bypass

t.me/latestpgnotes

Domino Procedure

→ If Heart-lung Transplantation is performed for Isolated Respiratory disease, the healthy native heart can be used for transplantation

→ Heart-lung transplantation is performed for

- Primary pulmonary hypertension
- Idiopathic pulmonary fibrosis

→ MC cause of death after Heart Transplantation – Infection > Acute rejection > Accelerated CAD

Contra-indications of Heart transplantation

Absolute	Relative
• Active infection or HIV positive • Irreversible pulmonary hypertension • Malignancy • Other-life threatening illness	• Age > 60 years • Significant pulmonary vascular disease • Active duodenal ulceration • Creatinine clearance <30μmol/litre • Drug or Alcohol abuse • Psychiatric illness

PrepLadder

LUNG TRANSPLANTATION

→ First lung transplantation was performed by – Fritz Derom (1968)

→ **Indications of LT:**

- Pulmonary fibrosis
- Primary pulmonary HTN
- Cystic fibrosis
- COPD
- α-1 AT deficiency
- Bronchiectasis

Types of Lung Transplantation

1) **Single lung transplantation (SLT)**
2) **Double lung transplantation (DLT)**

Single lung transplantation

→ **Advantage of SLT**

- It benefits two recipients
- Shorter Extubation time
- Less need of cardiopulmonary bypass
- Shorter hospitalisation

→ **Disadvantage of SLT**

- Quality of life } Lesser than DLT
- Success rate }

t.me/latestpgnotes

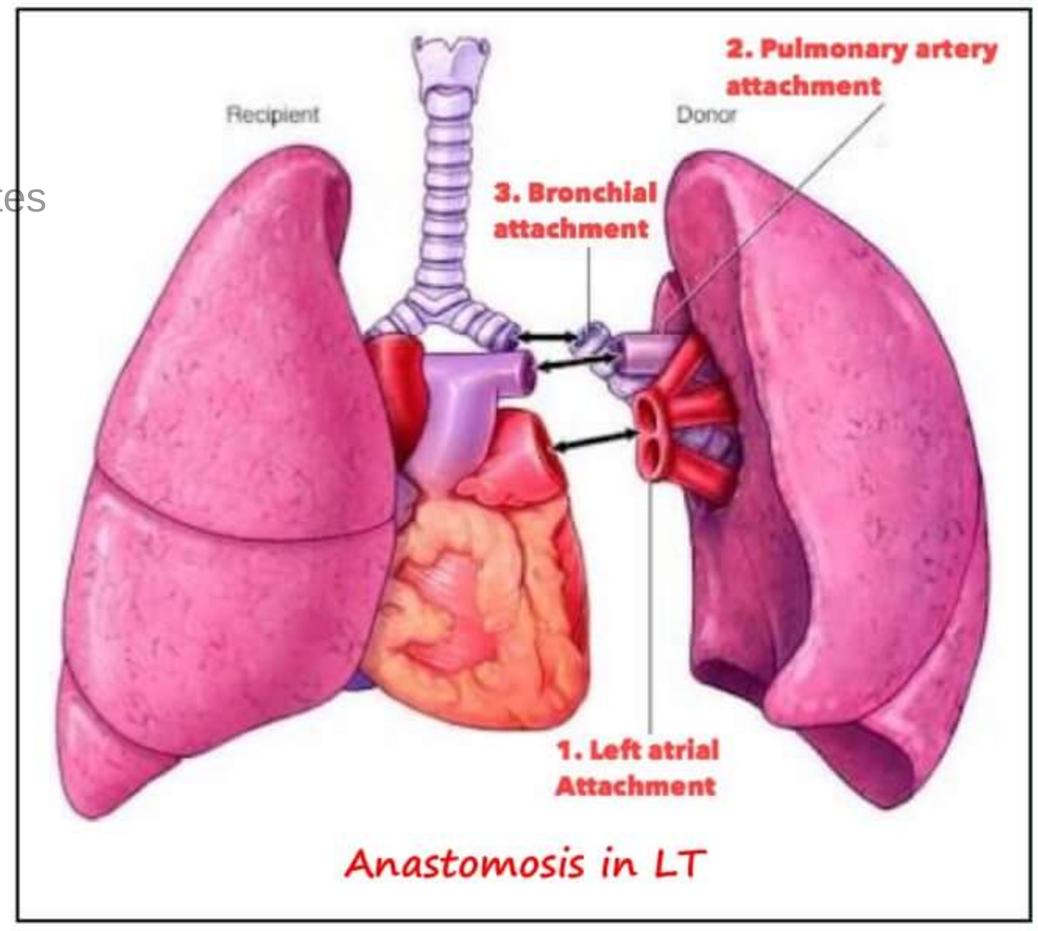

Anastomosis in LT

Procedure

→ **SLT** – Posterolateral Thoracotomy performed

→ **DLT** – Bilateral Thoracotomy or Median Sternotomy

→ **Sequence of Anastomosis in LT**

- 1st – Pulmonary vein (left atrial attachment)
- 2nd – Bronchial anastomosis
- 3rd – Pulmonary artery

→ If patient has Pulmonary HTN – Cardiopulmonary bypass is required

→ **Complications of Airway Anastomosis**

- Dehiscence of Airway anastomoses
- Late airway stenosis – at anastomosis due to ischemia (Treated by – Dilatation)
- Lung hyperinflation
  - Common complication following SLT
  - Has graft compression by hyperinflated native lung causing Mediastinal shift and Respiratory failure

PrepLadder

Double lung transplantation

→ It is the preferred surgical procedure for patients with
- Cystic fibrosis
- Bronchiectasis

→ Infection is present in both native lungs. So, both the lungs should be removed for complete cure of the infection

→ DLT is preferred over SLT for
- Better quality of life
- Higher success rate

t.me/latestpgnotes

PrepLadder

ROBOTIC, LAPAROSCOPY & BARIATRIC SURGERY

Laparoscopy

→ Needle used to create pneumoperitoneum - Veress needle

Methods of creating pneumoperitoneum

Closed methods	Open method
→ Veress needle used. → Low risk of bowel injury -due to Safety valve at the tip of this needle 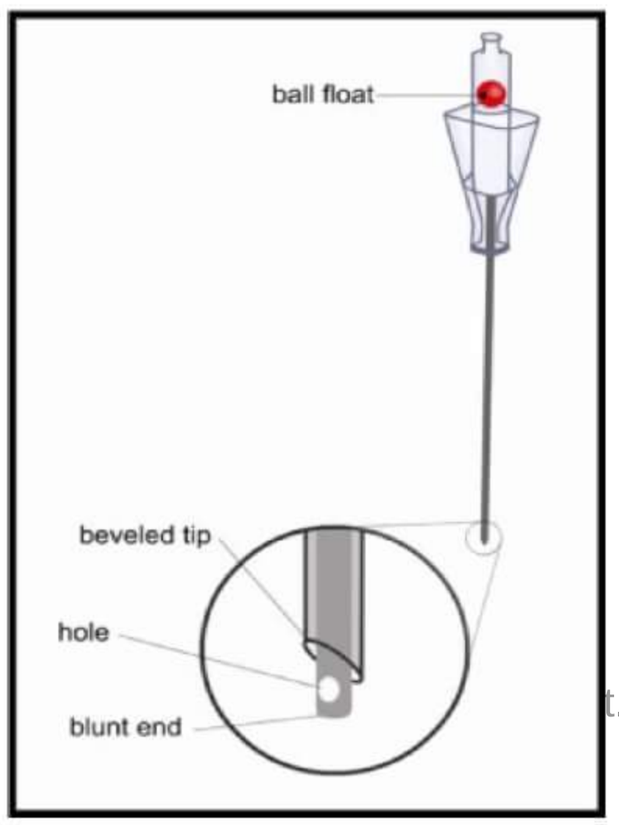	→ "HASSAN'S CANNULA" used. → ↓ Risk of vessels injury - because it is performed under direct vision

t.me/latestpgnotes

Trocar placement :

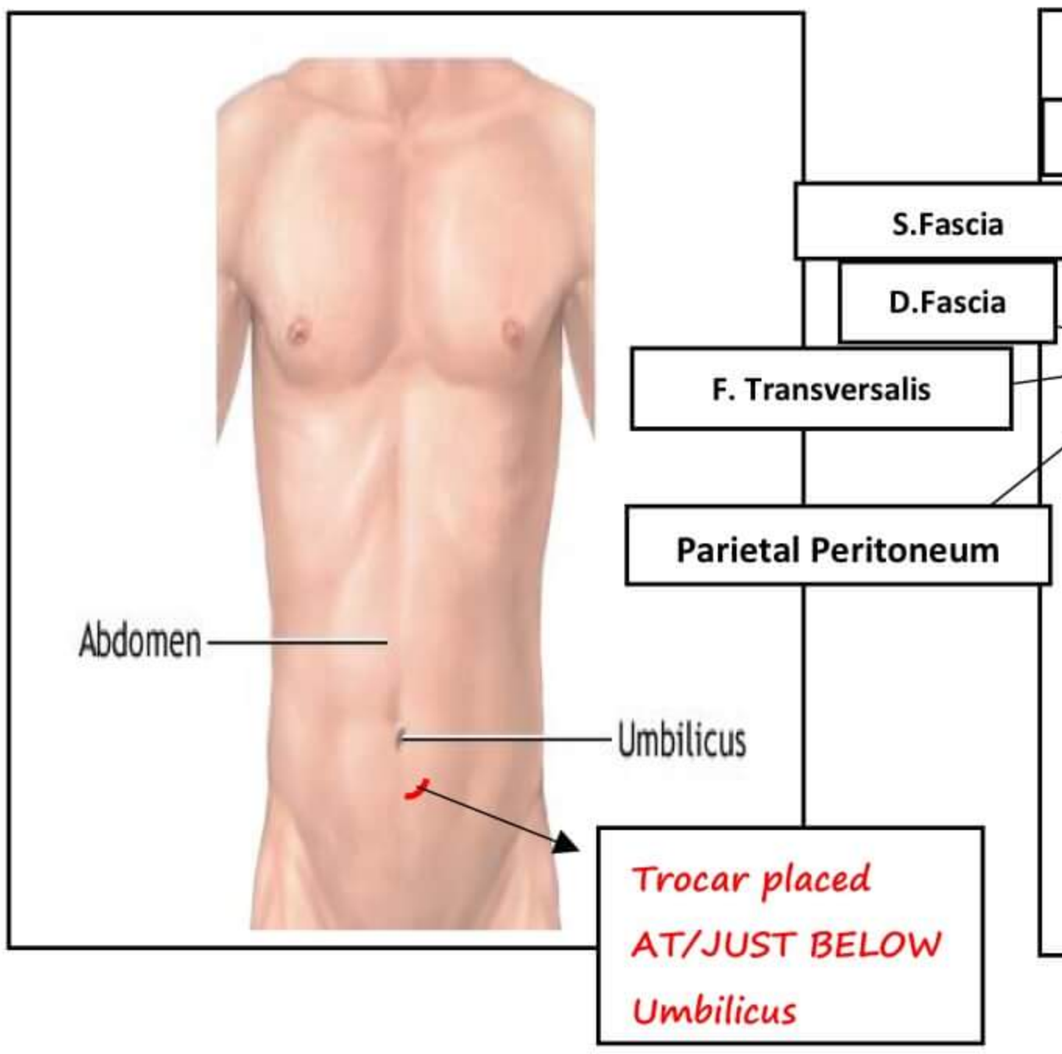

Layer's Penetrated by Trocar:

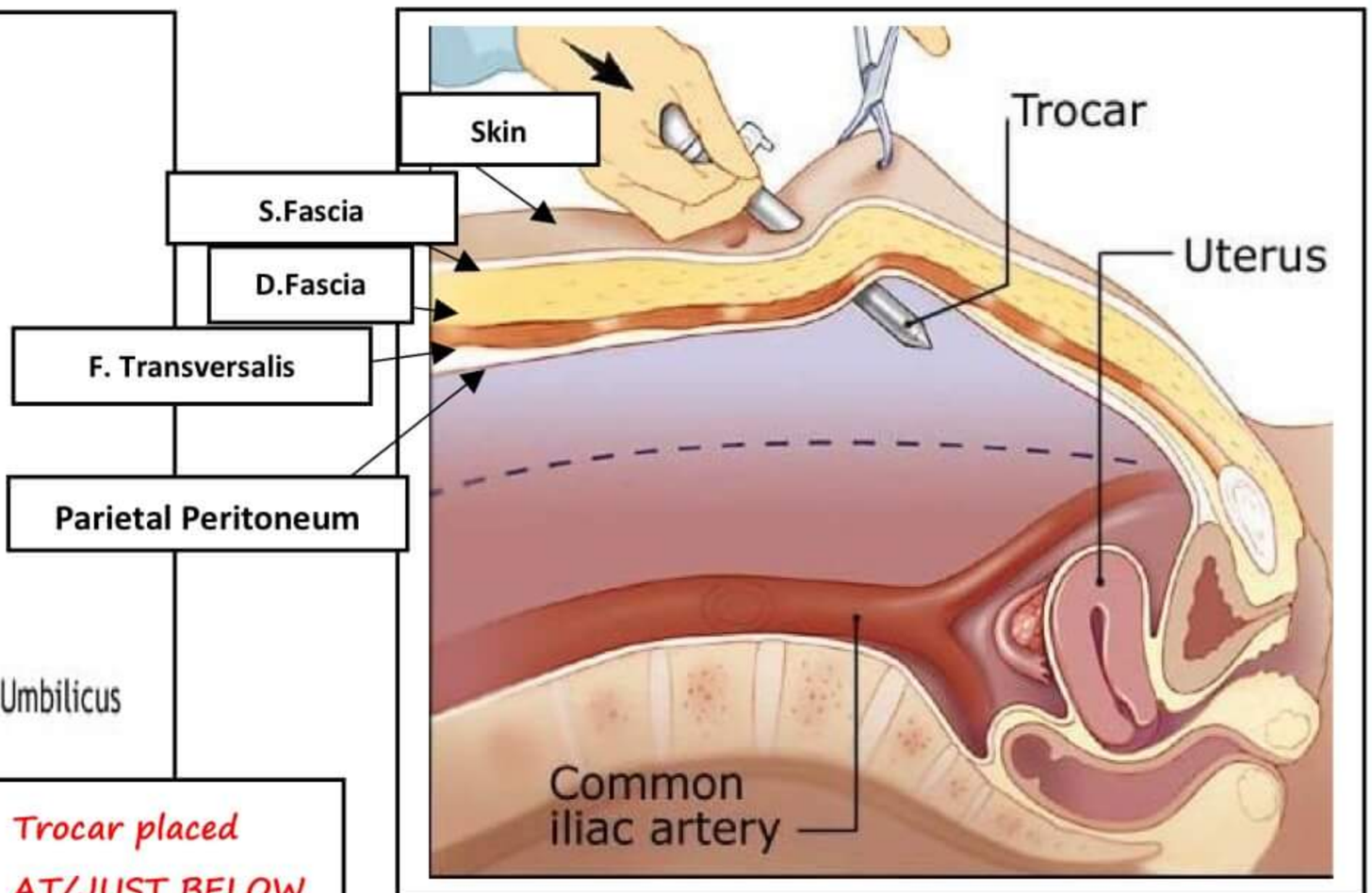

PrepLadder

→ Most commonly used/preferred gas - CO_2

→ Flow of Co_2 in creation of Pneumoperitoneum - 1 L / Min

→ Intra-Abdominal Pressure (IAP) should be maintained between 12 – 15mm/ Hg

Complications of laparoscopy

1. Shoulder pain

→ Because CO_2 Retention - Irritation of diaphragm

↓

Referred pain to shoulder via phrenic nerve

NOTE:

→ In splenic trauma - KEHR'S SIGN is seen

↓

Collection of blood below diaphragm

↓

Irritation of diaphragm

↓

Referred pain to shoulder via phrenic nerve

2. Gas embolism

- During induction of pneumoperitoneum - Insufflation of gas directly into an open vein

t.me/latestpgnotes

3. CO_2 embolism

- Has initial rise of ET CO_2 - because of Pulmonary excretion of absorbed Co_2

↓

Sudden decrease due to fall in cardiac output

Gases used in pneumoperitoneum

1. First pneumoperitoneum was created by - Filtered Room Air

↓

↑ Risk of Gas Embolism with Air

2. Preferred gas - CO_2 & N_2O

Co_2	N_2O
• Most preferred • 200 times more diffusible than air • Rapidly cleared from body and lungs • Does not support combustion	• 68% As rapidly absorbed in Blood as Co_2 • Has mild analgesic effect • Used for short operative procedure • Supports combustion. So, should not be used in long duration Sx

PrepLadder

Minimal access surgeries

1. Laparoscopy
2. Thoracoscopy
3. Endoluminal endoscopy
4. Perivisceral endoscopy
5. Arthroscopy and intra-articular joint surgeries

Advantages of minimal access surgeries

→ ↓ wound size
→ **Reduction in**
- wound infection
- Dehiscence
- Bleeding
- Herniation
- Nerve entrapment

→ ↓ in wound pain
→ Improved mobility
→ ↓ Wound trauma
→ ↓ Heat loss
→ Improved vision
→ Faster recovery & shorter hospital stay - Early return to work

t.me/latestpgnotes

Day care surgery

→ **Also called**
- Day surgery
- Same day surgery
- Day only surgery
- Ambulator surgery

→ In this surgery, patient is admitted for **12 Hours**QQ only with Same day discharge

Overnight Stay surgery

→ Patient is admitted for **23 Hours** QQ
→ Early morning discharge

Short Stay surgery

→ Patient is admitted for **72 Hours** QQ

Fasttrack surgery

→ Has Co-ordinated perioperative approach
→ Aimed at reducing surgical stress & facilitating Post-operative recovery

PrepLadder

Components

- → Pre-operative informed consent
- → Fasting — **6 hours for solids**; **2 hours for liquids**
- → Atraumatic surgical technique (Avoid placement of drains)
- → Reduction of stress
- → Elimination of pain by regional anesthesia technique (thoracic epidural anesthesia)
- → Optimized fluid & temperature management
- → Early enteral diet
- → Prevention of **GI atony & Post-Op Nausea and Vomiting**
- → Rapid Post-Operative mobilization

NOTES (Natural Orifical Transluminal Endoscopic Surgery)

- → **Peritoneal cavity is entered by a natural orifice**
  - Mouth
  - Rectum
  - Vagina
- → Successful Cholecystectomy & Appendectomy are performed via this technique (has an advantage of **No scar**)
- → **Also performed for**
  - Staging of intra- abdominal malignancy
  - Segmental colectomy
  - Gastro-jejunostomy

t.me/latestpgnotes

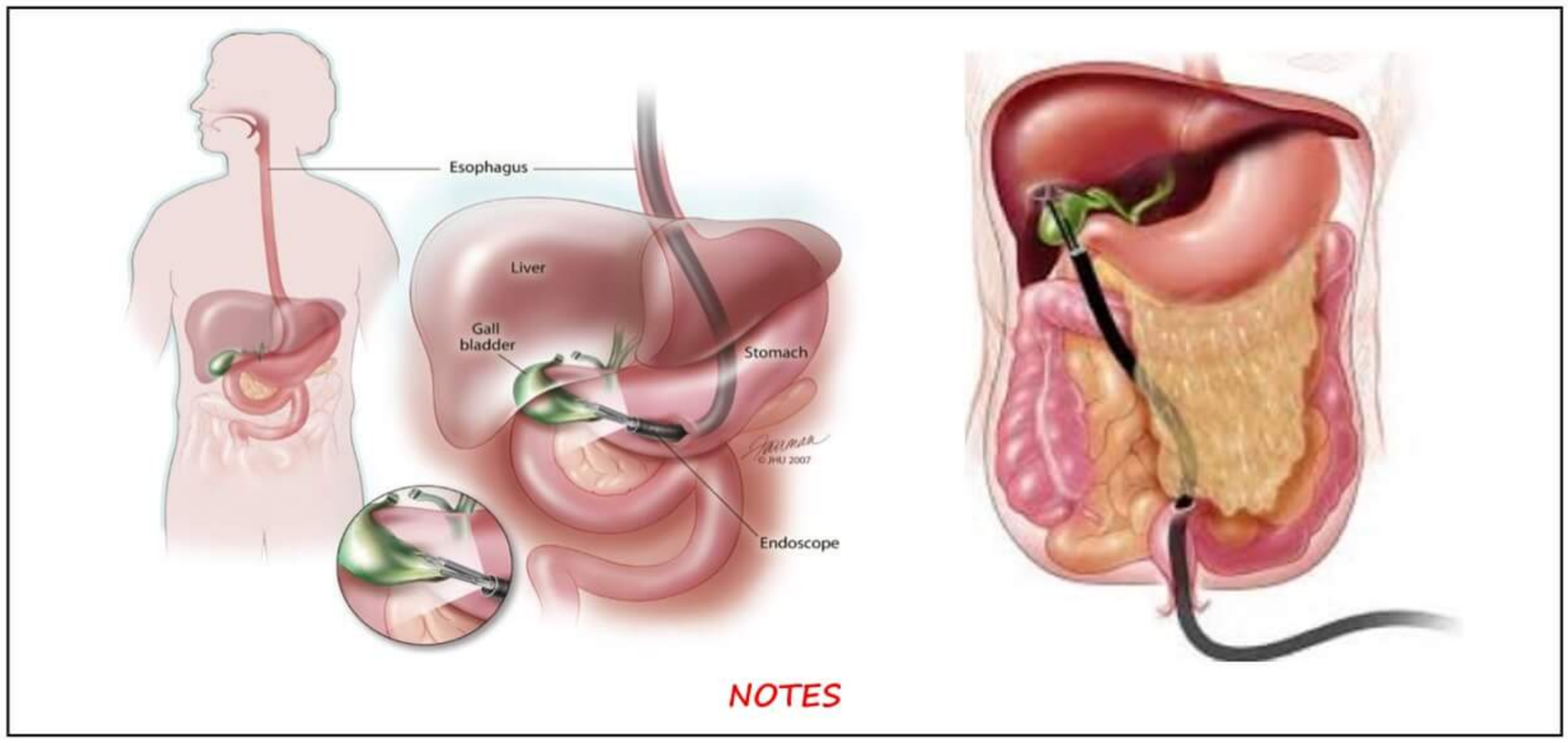

NOTES

POEM (Per-oral endoscopic myotomy)

- → Used for Achalasia Cardia
- → Creation of long Esophageal myotomy using Flexible Endoscope

PrepLadder

ROBOTIC SURGERY

- In 1985 – The PUMA560 → used to place needle in brain under CT guidance
- In 1987 – Robert was first used for Laparoscopic surgery (cholecystectomy)
- In 1988 – PROBOT → used for prostatic surgery
- In 1992 – ROBODOC → used to Millout precise fitting in femur for hip replacement.

DA-Vinci ROBOT

→ Most commonly used world-wide
→ It is based on Master Slave principle
→ Surgeon inserts hand into **Master**

↓

Translate the motion of his hands into motions of **robotic arm (Hand like instruments)**

DA-Vinci ROBOT

Indications

→ Prostatectomy
→ Cardiac valve repair
→ Gynecological operation

Bariatric surgery

→ These are surgical procedures performed for the treatment of obesity

t.me/latestpgnotes

Pathological consequences of obesity

→ ↑ Mortality
→ **Endocrine**
  - Insulin resistance
  - Type 2 DM

→ **Reproductive**
  - Male hypogonadism
  - Gynecomastia
  - PCOS

→ **CVS**
  - ↑ risk of CAD
  - ↑ risk of CHF

→ **Pulmonary**
  - Obstructive Sleep Apnea (OSA)
  - Pulmonary HTN
  - DVT
  - Pulmonary Embolism

→ **Hepatobiliary**
  - NAFLD
  - ↑ risk of Gall stones

→ **Bones & joints** – Osteoarthritis

PrepLadder

→ **Cutaneous disease** – ↑ risk of venous stasis & Ulcers

→ **Neurological complications**

- ↑ risk of Stroke
- ↑ risk of Pseudotumor cerebri
- ↑ risk of Carpal-tunnel syndrome

Increased cancer Risk due to Obesity

• Prostate	• Cervix	• kidney
• Endometrium	• Pancreas	• Breast
• Esophagus	• GB	• Bile duct
• Liver	• Ovarian	• Colon

BMI (Body Mass Index)

→ AKA Quetlet index

→ Weight in Kg/ square of height in meter

Category	BMI
• Underweight	• < 18.5 Kg/ M^2
• Normal	• 18.5 – 24.9
• Overweight	• 25 – 29.9
• Obesity (class I)	• 30 – 34.9
• Severe obesity (class II)	• 35 – 39.9
• Morbid obesity (class III)	• 40 – 49.9
• Super obesity	• >50

t.me/latestpgnotes

Indications of bariatric surgery

→ BMI ≥ 35 Kg/m^2 + comorbidity

→ BMI ≥ 40 Kg/m^2 with or without comorbidity

Indications of bariatric surgery in Asian population

→ BMI > 32.5 kg/m^2 + comorbidity

→ BMI ≥ 37.5 kg/m^2 with or without comorbidity

Various types of bariatric operations

1. Vertical banded gastroplasty (VBG)
2. Laparoscopic adjustable Gastric banding (LAGB)

} **Restrictive S_x**

3. Roux-en-Y Gastric Bypass (RYGB) – **Largely restrictive & Mildly malabsorptive**

4. Biliopancreatic Diversion
5. Duodenal Switch

} **Largely malabsorptive & Mildly restrictive**

PrepLadder

Note:

→ **RYGB** – Most commonly performed worldwide

→ **LAGB** – Safest & Reversible

1. **Vertical banded gastroplasty (VBG)**
   → Restrictive operation
   → Stomach is stapled vertically near Esophagus to create a Small pouch along the lesser curvature

2. **Laparoscopic adjustable gastric banding (LAGP)**
   → Safest, least invasive, reversible
   → Placement of silicon band around proximal part of stomach – Creates **Small proximal pouch**

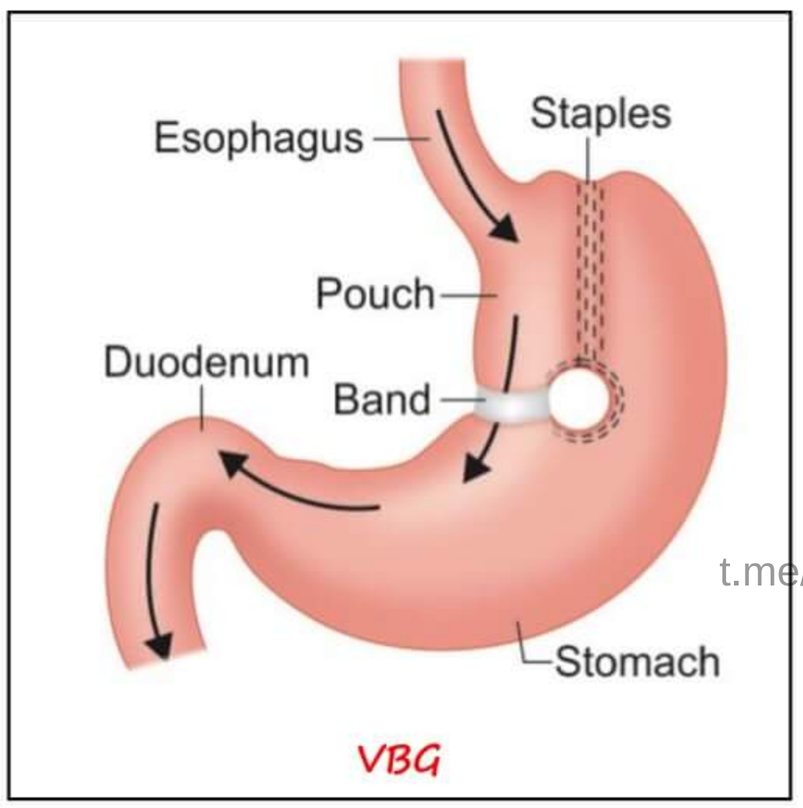

VBG

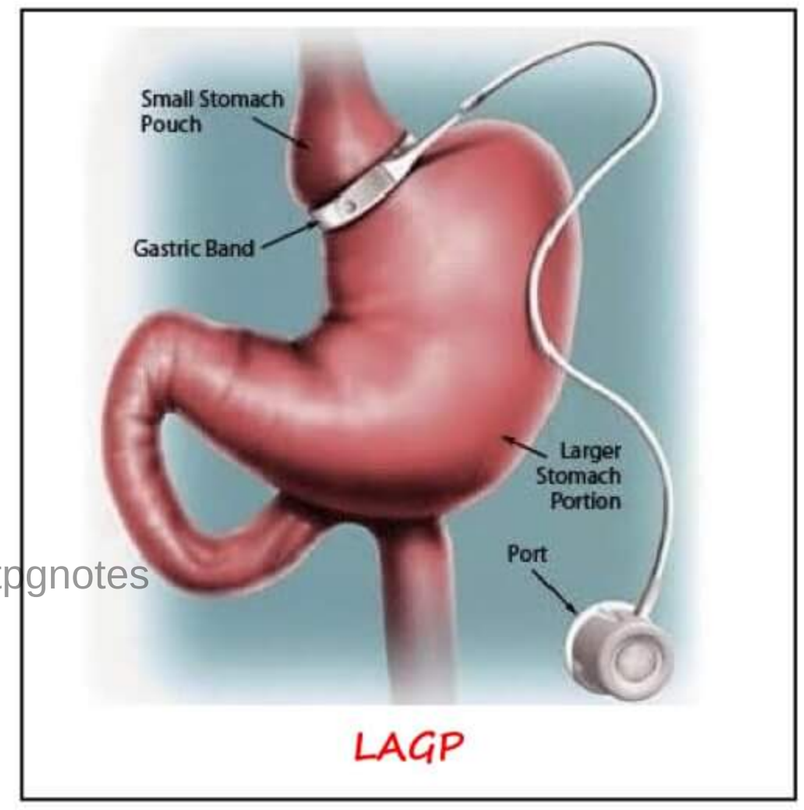

LAGP

t.me/latestpgnotes

3. **Roux-en-Y Gastric Bypass**
   → MC performed
   → Largely restrictive & Mildly malabsorptive
   → Proximal & Distal part of the stomach are divided
   → Jejunum is sutured with the proximal gastric pouch
   → Content of Proximal gastric pouch - 30-50ml
   → Roux -limb length is 70-100 cm
   → **Peterson Hernia** – Herniation bowel behind ROUX-Limb

4. **Biliopancreatic diversion**
   → Most effective Bariatric surgery
   → A/W maximum weight loss
   → Main side effect is 2- 4 bowel movements/day with Malodourous (due to fat malabsorption)
   → **Components of this procedure**
      - Distal gastrectomy
      - Gastro - ileostomy

PrepLadder

- Jejuno – ileostomy
- Cholecystectomy
- Appendectomy

→ Length of the common channel created by this procedure is 50 cm

→ By this procedure, food is allowed to mix with bile & pancreatic enzymes only in the distal 50 cm of ileum causing decreased Digestion & Fat absorption

→ Hence this procedure is Largely malabsorptive & Mildly restrictive

→ **Disadvantage** – High risk of ulcer at the site of anastomosis of Gastro - ileostomy

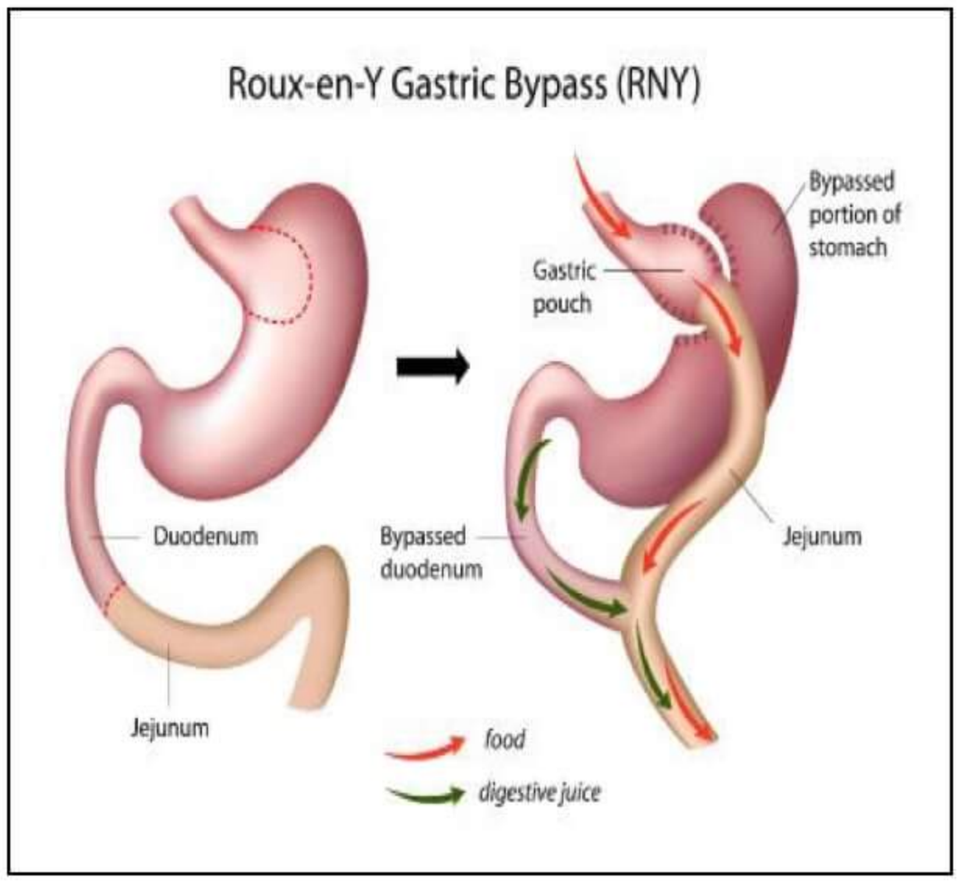

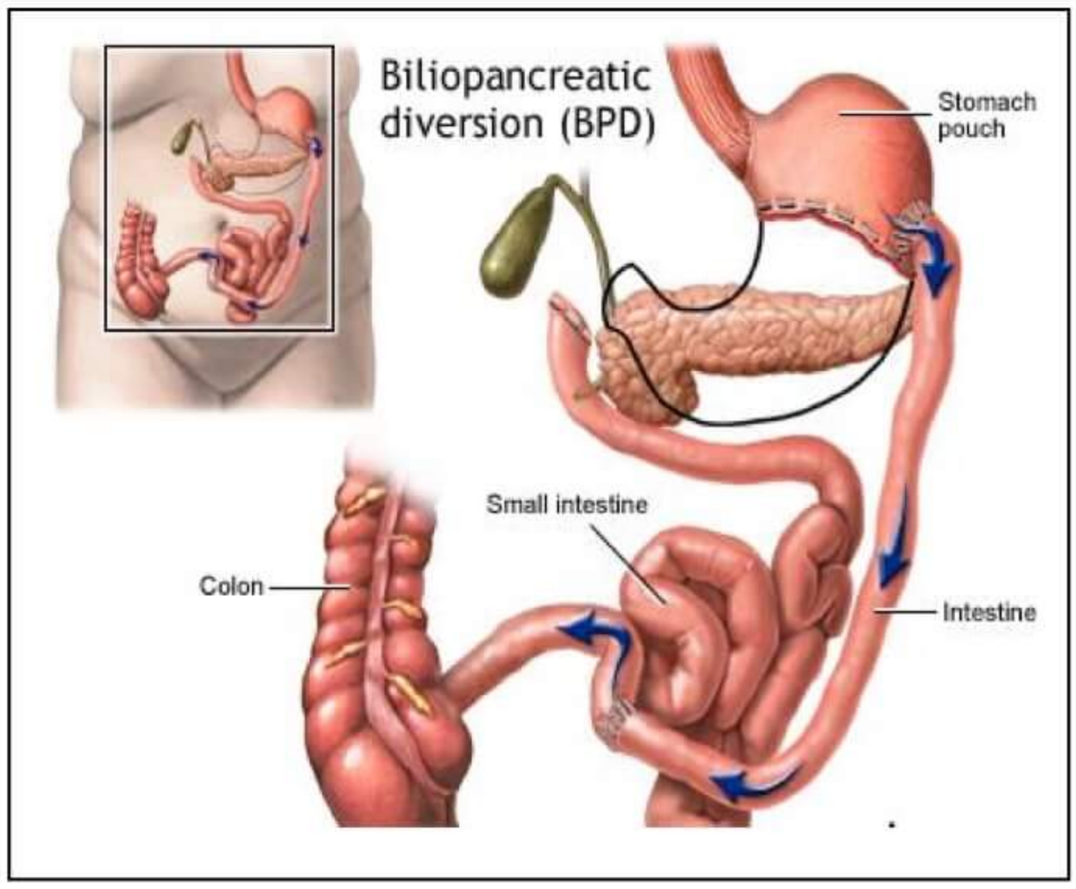

t.me/latestpgnotes

Duodenal switch

→ Prevents stromal ulcers

→ **Components**

- Sleeve Gastrectomy - 70 to 80% stomach removed
- Duodeno – Ileostomy
- Jejuno – Ileostomy
- Cholecystectomy
- Appendectomy

→ Length of common channel created by this procedure is 100 cm

→ **Advantage**

- Less risk of malabsorption
- Prevents the risk of stromal ulcers

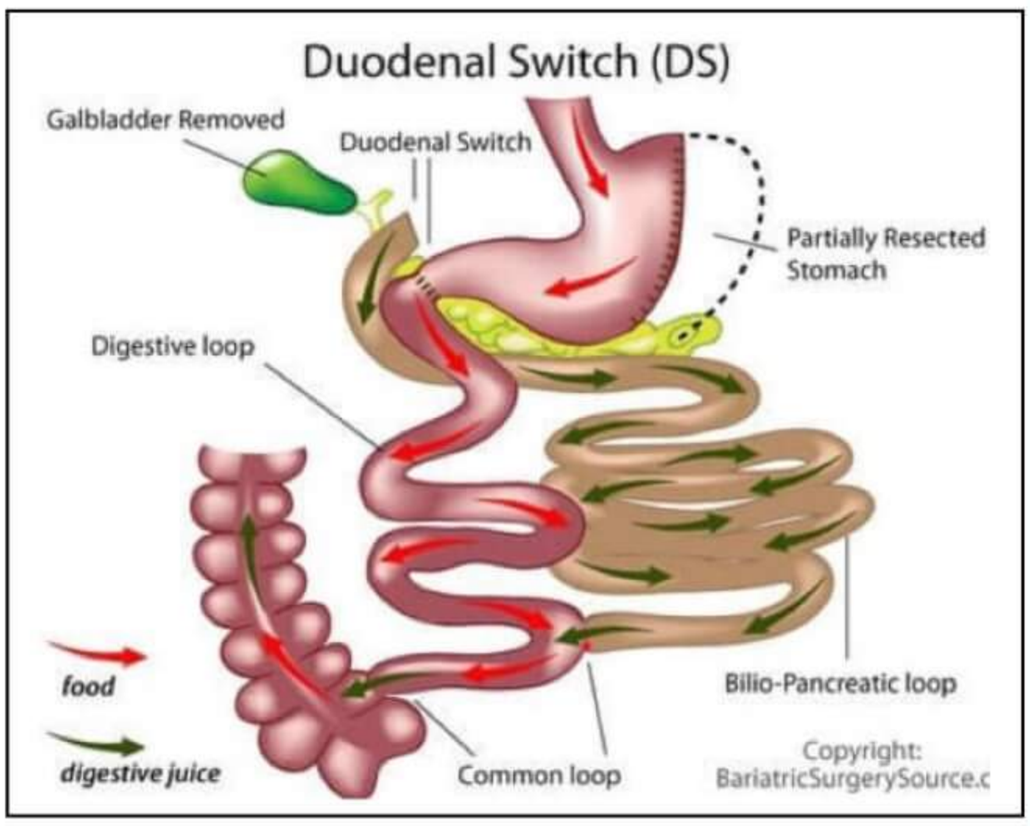

Perioperative mortality in Bariatric surgery

→ MC cause of death within 30 days of bariatric surgery - Pulmonary Embolism > Cardiac complication > Anastomotic leak

→ MC cause of death in immediate post-operative period - Anastomotic leak leading to peritonitis

→ Maximum risk of leak - Gastrojejunostomy

PrepLadder

SUTURES & ANASTOMES

TYPES OF SUTURES

ABSORBABLE	NONABSORBABLE
• Absorbed in tissues • Because of Enzymatic digestion or phagocytosis • Natural – Catgut – Chromic catgut • Synthetic **P**- Polyglycaprone / Monocryl (Polydioxanone) **V**- Vicryl (Polyglactin) **D**- Dexon (Polyglycolic acid)	• Persist in tissues for indefinite period of time • Natural – Silk – Linen • Synthetic **P**- Prolene, Polyester **E**- Ethilon **N**- Nylon

Based on number of strands

Monofilament	Polyfilament
• Single strand of fibre • Smooth & strong • ↓ chance of bacterial infection • Knots tied may become loose **E.g.** – PEN **P**rolene, **E**thilon, **N**ylon	• Multiple strands braided together • Easier to handle • Knots are stable • ↑ risk of infection → Due to lodging of bacteria in crevices **E.g.** – SLIP **S**ilk, **L**inen, **P**olyglycolic acid (Dexon)

t.me/latestpgnotes

Catgut

→ Discovered by John Hunter
→ Prepared from submucosa of sheep's ileum
→ Preservative for packing – Isopropyl alcohol
→ 50% tensile strength is lost in 3 days
→ All tensile strength lost in 15 days
→ Suture is absorbed in 60 days

Chromic catgut

→ Catgut is tanned with chromium salts
  • To improve handling of suture
  • Resist degradation in tissues
→ Tensile strength lost in 21-28 days
→ Absorbed in 60-90 days

PrepLadder

Vicryl

- → **AKA Polyglactin**
- → It is a Copolymer of Glycolide + lactide
- → Violet in Colour
- → **AKA Work- horse suture for general surgeons**
- → Tensile strength is maintained for 28-30 days
- → Absorbed in 60-90 days
- → Used in organs with ↑ risk of stone formation such as
  - CBD
  - Ureter
  - Bladder
- → **It is aka Delayed absorbable suture**



Monocryl / Polyglycaprone

- → It is a co-polymer of Glycolide + Caprolactone
- → MC used for Sub-cuticular suturing
- → Absorbed in 90-120 days[Q]

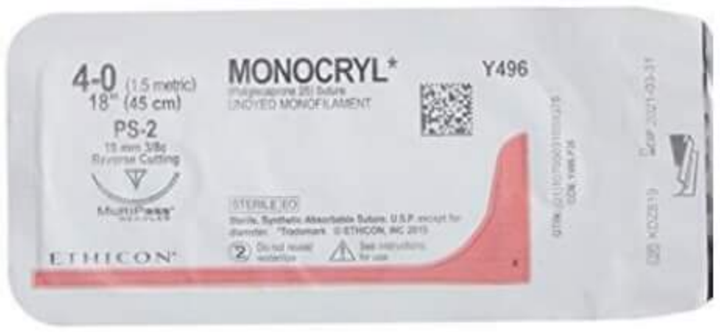

t.me/latestpgnotes

Polyglycolic acid (Dexon)

- → Polymer of polyglycolic acid
- → **Exhibits highest affinity** for adherence to E. Coli & S. Aureus
- → Absorbed in 60-90 days[Q]

Poly Dioxanone (PDS)

- → It is a Polyester polymer
- → **Has lowest affinity** for adherence to E. Coli & Staph Aureus
- → Used in Whipples procedure (Pancreatojejunostomy)
- → Absorbed in 180 days

PrepLadder

Prolene / Polypropylene

→ Monofilament

→ Non-absorbable

Use

→ Vascular anastomosis

→ Rectus sheath

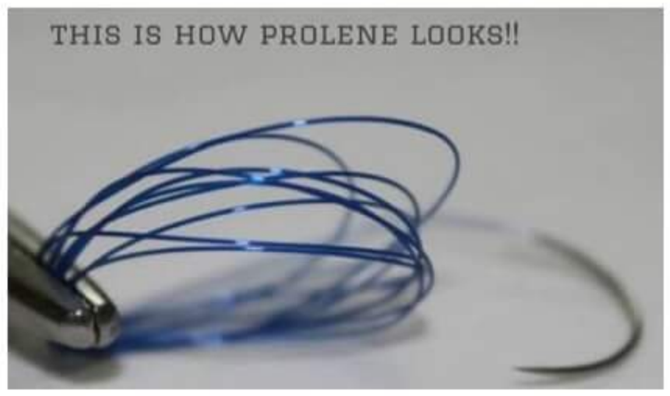

FAQ's

Time	Suture Absorbed
• 60 Days	→ Catgut
• 60-90 Days	→ Vicryl → Chromic Catgut → DEXON
• 90-120 Days	→ Monocryl (Polyglycaprone)
• 180 Days	→ Polydioxanone (PDS)

t.me/latestpgnotes

S.No.	Name of Sutures	Site
1	Silk	Skin
2	Vicryl	CBD, Ureter, Bladder
3	Prolene	Vascular anastomoses, Rectus sheath
4	Nylon	Tendons

Jenkin's Rule

1. Laparotomy Incision

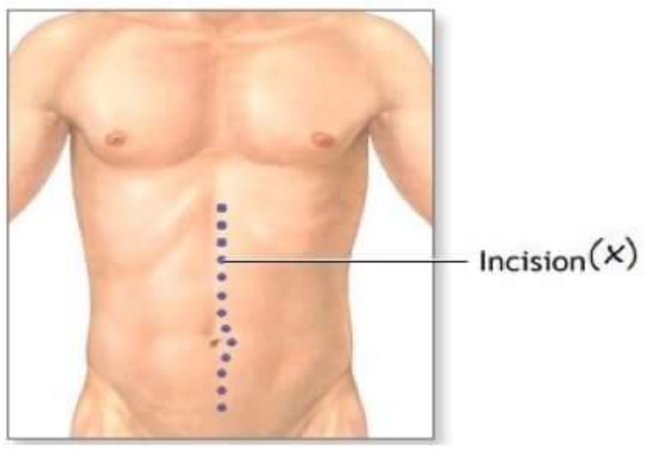

→ If Length of incision is - X

→ The required suture length should be – 4X

→ So, Ratio of suture length to wound length should be – 4:1

PrepLadder

2. Elliptical incision 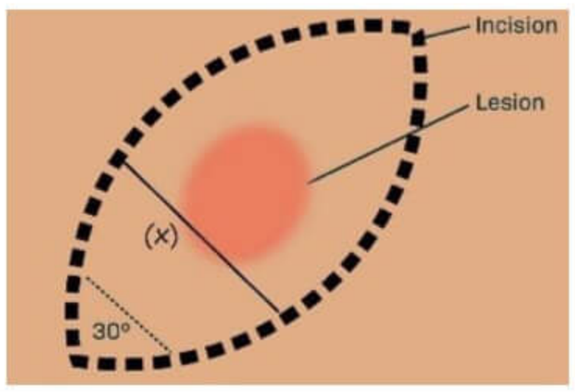 	→ To heal without tension → Length to width ratio should be – 3:1
3. Skin Suturing 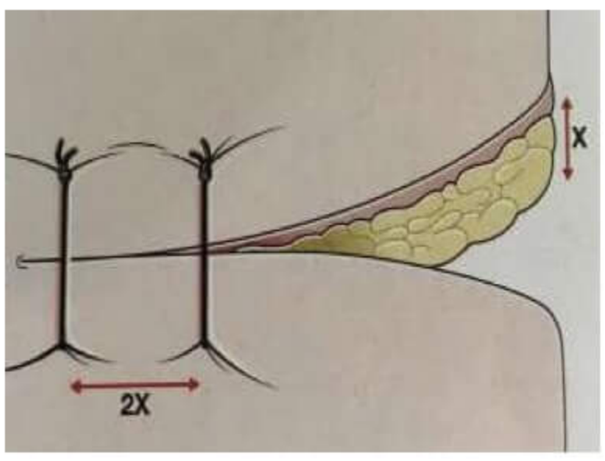 	→ If thickness of skin is – X → Then the distance between two sutures should be – 2X → So, Ratio of distance between sutures to skin thickness should be – 2:1

Types of knots–

1. Square / Reef knots

→ Consists of 2 throws

→ Crossing is done in each throw

→ It is a secured knot

t.me/latestpgnotes

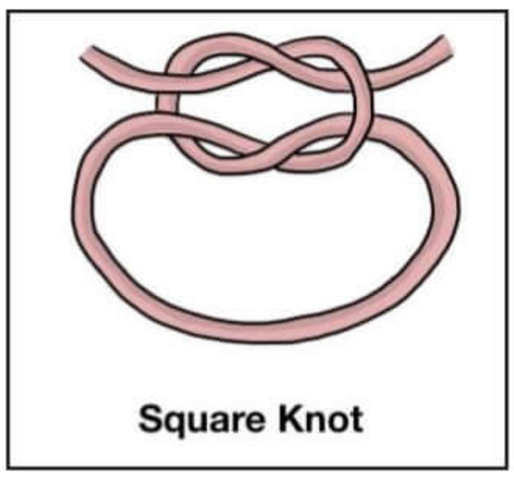
Square Knot

2. Surgeon's knot

→ Consists of 2 throws

→ Two Wraps in first throw

→ Crossing occurs in each throw

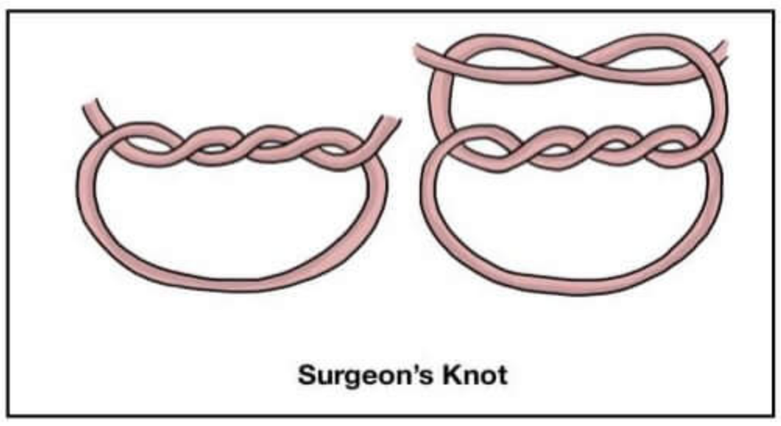
Surgeon's Knot

3. Granny knot / Pseudo square knot

→ Two throws are taken without crossing

→ More prone to slip

→ Relatively unstable

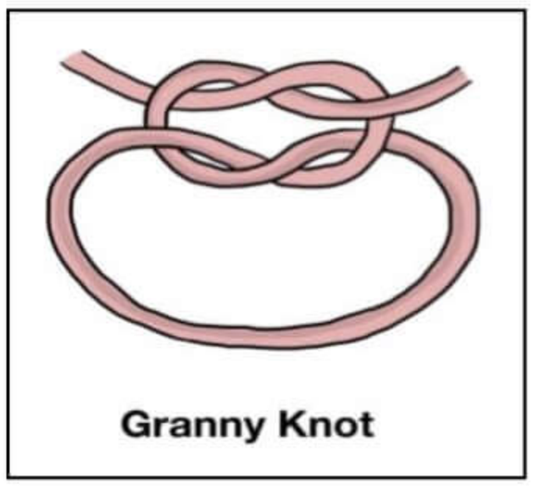
Granny Knot

Parts of needle

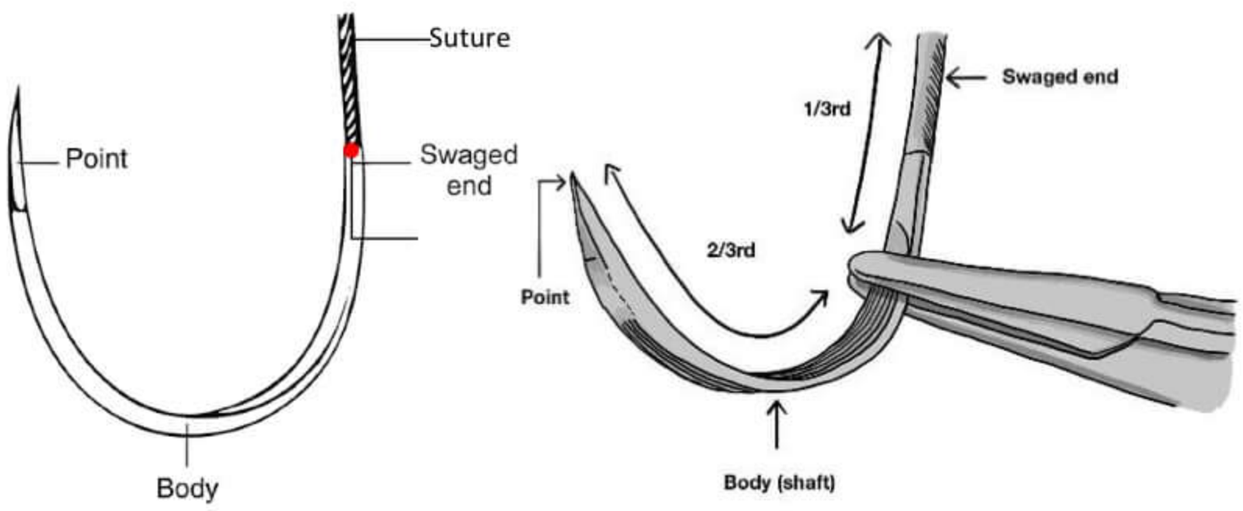

PrepLadder

→ Best site for holding the needle with needle holder- Junction of 1/3rd from swaged end & 2/3rd from pointed end

Types of needle

	Round Body Needles	Cutting Needles	
Body	Round	Cutting	Reverse Cutting 
On Cross-section	Round	• Triangular • Apex pointing inwards	• Triangular • Apex pointing outwards
Pointing	Taper Point 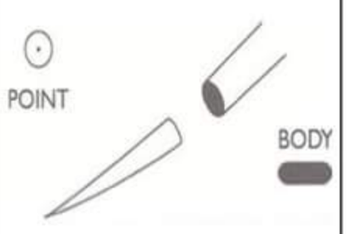	Blunt Point 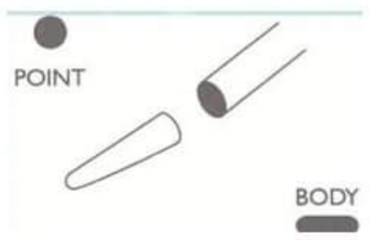	Conventional Cutting 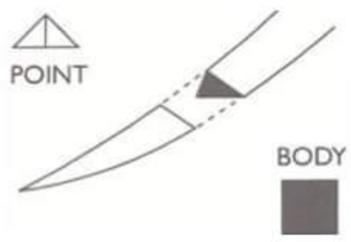	Reverse Cutting 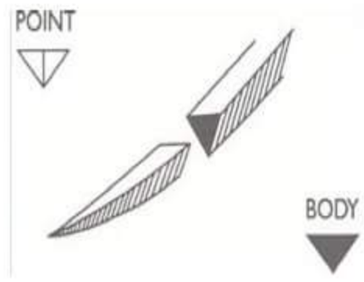
Uses	→ Non-traumatic → Used for delicate structures such as • Bladder • Bowel	→ Traumatic needles → Used for tough structures such as • Skin • Sheath • Fascia	

t.me/latestpgnotes

Suturing Techniques

1. **Simple interrupted Suture**

→ Needle inserted at right angle to the incision

→ Pass through both edges of wound and exit again at right angle

→ If the distance between suture and skin incision is x then the distance between 2 sutures should be 2x.

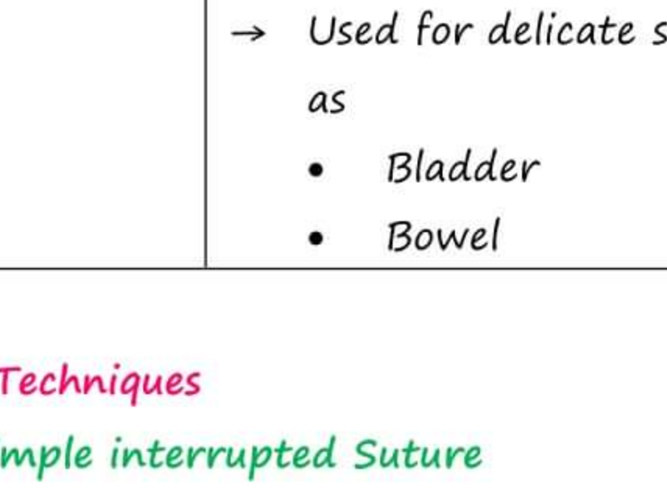

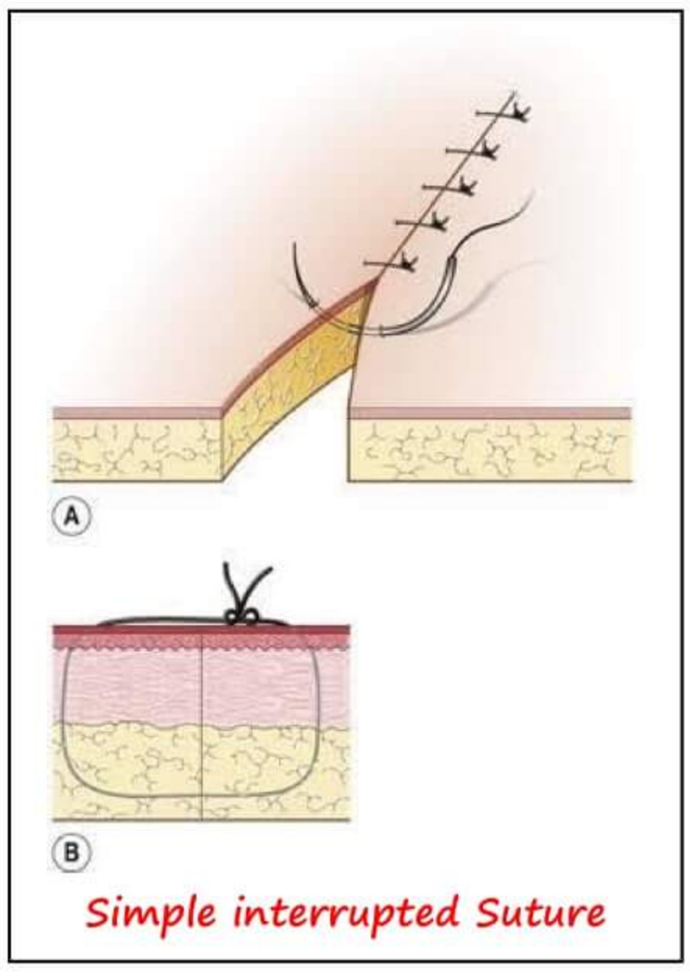

Simple interrupted Suture

PrepLadder

2. Continuous sutures

→ The first suture is inserted in an identical manner to interrupted suture

→ Rest of the sutures are inserted in continuous manner until the far end is reached

→ Far end of suture is secured with Aberdeen knot or by tying free end to the loop of last suture

→ **Aberdeen knot**

- Free end of suture is partially pulled through the final loop, several times before being pulled through a final time completely prior to cutting

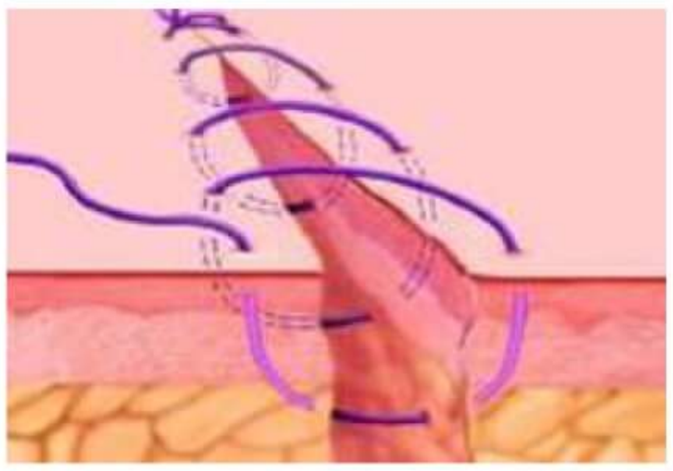

Continuous sutures

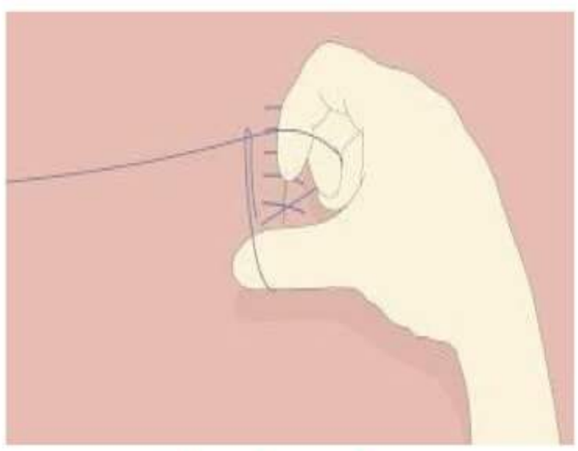

Aberdeen knot

3. Mattress sutures

→ **Used to produce**

- Eversion or inversion of wound edges
- Helps in accurate approximation of wound edges (irregular in depth or disposition)

t.me/latestpgnotes

→ **Types**

Horizontal Mattress	Vertical Mattress
 • Initial suture made is interrupted suture • Needle moves horizontally & traverses both edges of wound again.	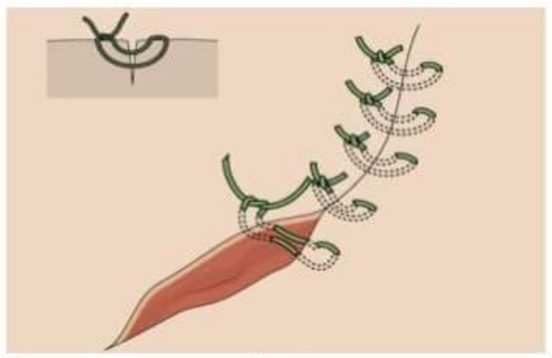 • Initial suture made is interrupted suture • Needle moves vertically and traverses both edges of wound again.

4. Subcuticular Suture

→ MC used suture – Monocryl (Polyglycaprone)

→ Specially used in skin, where cosmetic appearance is important

→ Skin edges should be approximated.

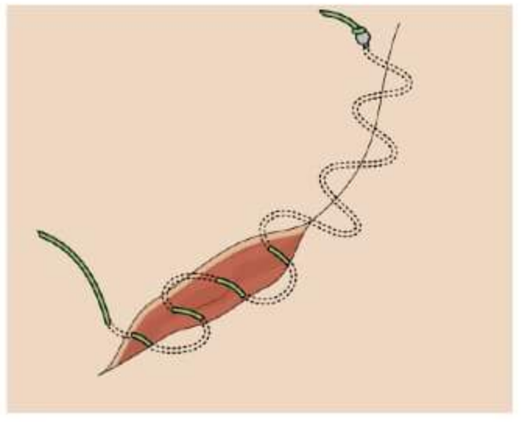

Subcuticular Suture

PrepLadder

5. Purse String Suture

→ Continuous Stitch parallel to the edges of circular wound is applied

→ **Uses**

- Hernia surgery
- Appendectomy

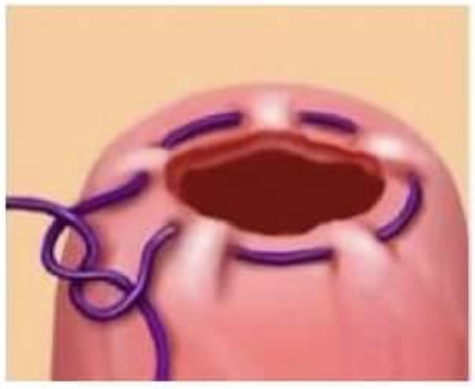

Purse String Suture

Guidelines for Day of suture removal by Area

AREA	Day of suture removal
1. Eyelid & Lip	3-4 days
2. Eyebrow & Nose	3-5 days
3. Rest of face	3-4 days
4. Scalp	6-8 days
5. Chest & abdomen	8-10 days
6. Ear & Hand	10-14 days
7. Back, Extremities, Foot & sole	12-14 days

Bowel Anastomoses

t.me/latestpgnotes

→ In Bowel Anastomoses edges should be inverted

1. Single layer extra mucosal anastomoses

- It is Halsted favoured; Matheson advocated
- Sub-mucosa must be included (high collagen content) → Most stable and strongest layer
- Most favoured technique for bowel anastomoses

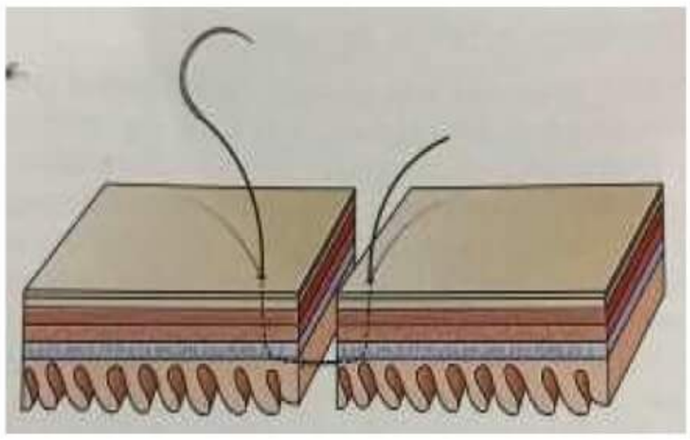

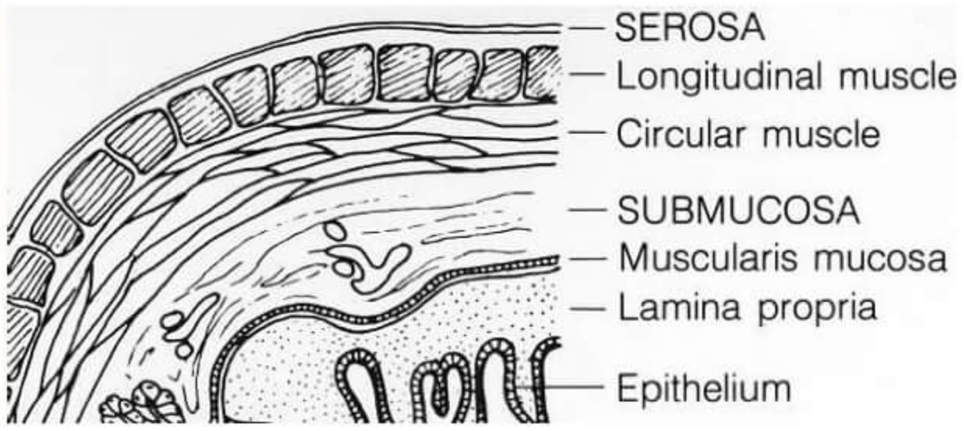

2. Kocher's Two Layer Anastomoses

- **First layer/Albert layer (→)**
  - It is continuous catgut layer
  - Nowadays, Catgut is replaced by Vicryl
- **Second layer/Lambert layer (→)**
  - it is Interrupted silk layer

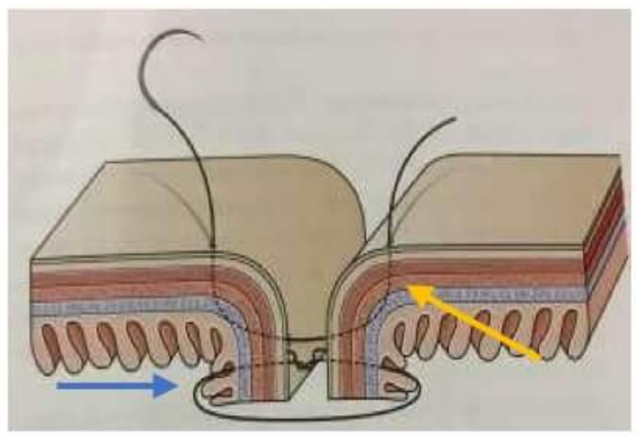

PrepLadder

3. Stapled Anastomoses

Linear Stapler	Circular Stapler
Uses • Side to side anastomoses • Ends are closed by transverse stapler	**Uses** • End to end anastomoses • Low Anterior Resection (LAR), Stapled hemorrhoidopexy
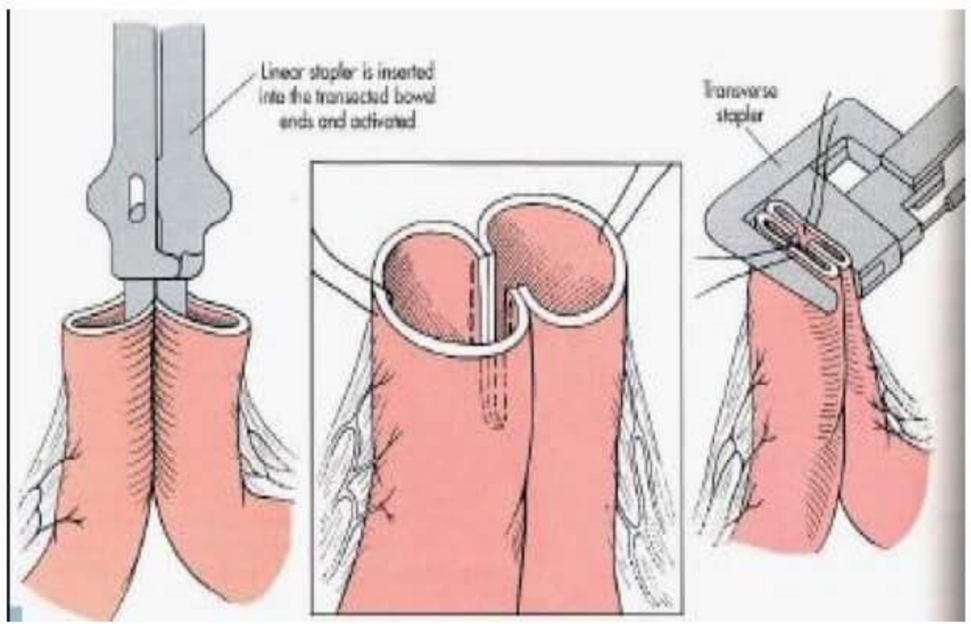	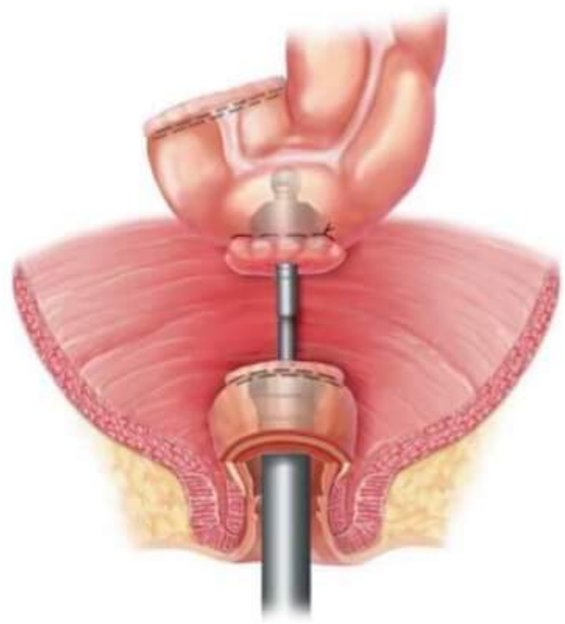

t.me/latestpgnotes

PrepLadder

NUTRITION

Adjuvant nutrition and support

→ Enteral Nutrition

→ Total Parental Nutrition (TPN)

Enteral Nutrition

→ Delivery of nutrients directly into GIT

→ In enteral nutrition, Alimentary tract is used

→ Preferred over TPN

Advantages

→ More Physiological

→ Maintains the integrity of GIT

→ Reduces translocation of bacteria from GUT

→ Reduces the levels of proinflammatory cytokines

Cytokines

↓ Released from

GUT

↓

Hypermetabolism

t.me/latestpgnotes

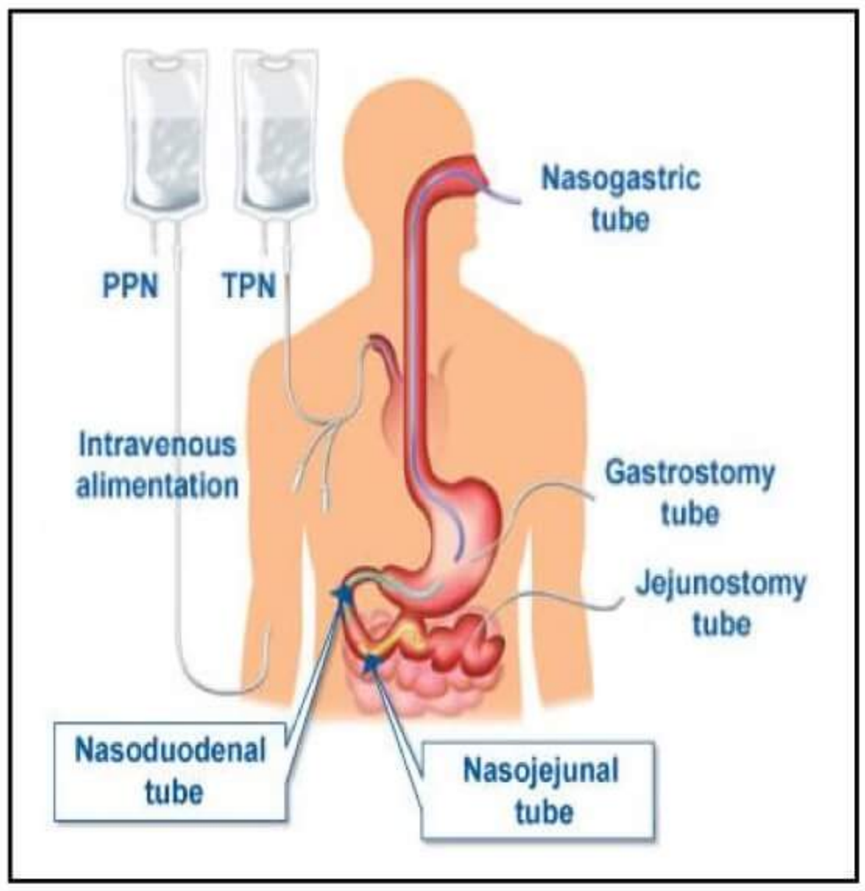

Routes of Enteral Nutrition

→ Oral supplementation by mouth

→ **Nasogastric/Nasojejunal Tube**

- **NJ** (better tolerance)> **NG** (because in
- NG stomach may be full→ increase risk of aspiration)

→ **Feeding Gastrostomy**

- In severe pancreatitis; Edematous head of pancreas →
- gastric outlet obstruction→ contraindication of gastrostomy
- and jejunostomy is preferred.

→ **Feeding Jejunostomy**

GASTROSTOMY

→ Surgical placement of a tube in stomach

→ **Methods of Gastrostomy**

a) Stamm

b) witzel

c) Janeway

→ Percutaneous insertion under endoscopic guidance is preferred

PrepLadder

PEG (PER – CUTANEOUS ENDOSCOPIC GASTROSTOMY)

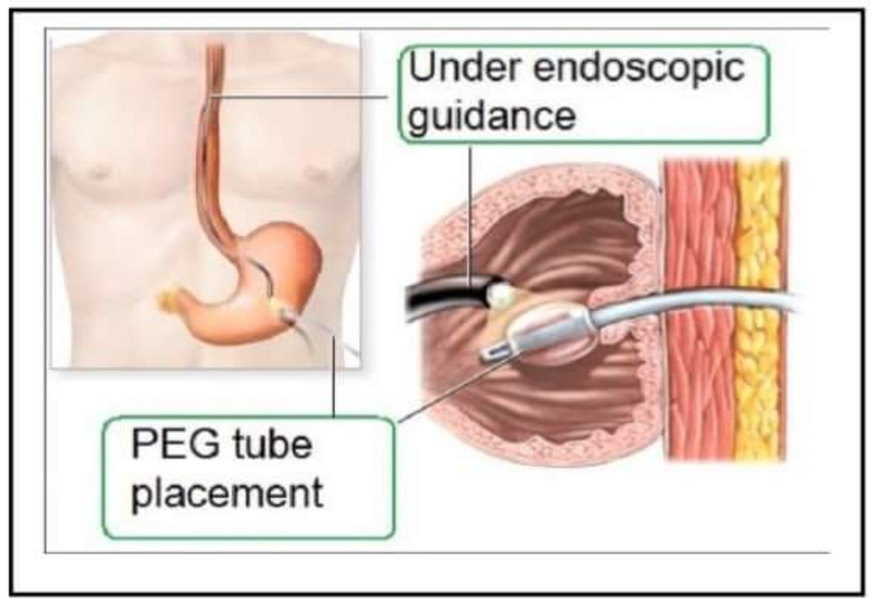

→ **Techniques of PEG**

- Push technique
- Pull technique
- Introducer technique.

FEEDING JEJUNOSTOMY

Preferred over feeding Gastrostomy because of

↓

→ Decreased Risk of aspiration
→ Better tolerance
→ Severe Pancreatitis patients

↓

Edematous head

↓

Gastric Outlet Obstruction

Indications of enteral nutrition

→ Protein energy malnutrition with inadequate oral intake
→ Dysphagia except for liquids
→ Major trauma or surgery when return to dietary intake is prolonged
→ Inflammatory bowel disease
→ Distal low output enterocutaneous fistula

t.me/latestpgnotes

Contraindications of enteral nutrition

→ Small bowel obstruction or ileus
→ Severe diarrhea
→ Proximal small intestinal fistula
→ Severe Pancreatitis

Complications of Enteral Nutrition

→ **Tube Related complications**

- Malposition
- Displacement
- Blockage
- Leakage
- Erosion of skin and mucosa

→ **Gastrointestinal complications**

- Diarrhea
- Constipation
- Abdominal cramps
- Aspirations

PrepLadder

→ **Metabolic Complications**

- Dyselectrolytemia
- Deficiency of Vitamins, minerals and Trance elements

→ **Infective complications**

- Endogenous
- Exogenous

PARENTAL NUTRITION

→ Nutrients given by IV route (without use of GIT)

Routes of delivery

→ PERIPHERAL (PPN-Peripheral Parenteral Nutrition)

→ CENTRAL (TPN-Total Parenteral Nutrition)

PPN

→ Short term nutrition up to 2 weeks

→ **Advantages** - Avoid complications of Central Venous administration

→ **Disadvantages** - Limited by development of Thrombophlebitis

TPN

→ **Central vein preferred** - **Subclavian > Internal Jugular > Femoral**

- **Infraclavicular Subclavian Approach**
- **Longer term TPN – Hickman Lines**

t.me/latestpgnotes

TPN FORMULATIONS

SOLUTIONS WITH LIPID	SOLUTIONS WITHOUT LIPIDS
(3-IN-1) → 60/20/20 → Calories from Dextrose -55-60% → Calories from amino acids-20-25% → **Calories from fat-20%** **INDICATIONS OF TPN** - Any condition where integrity of bowel is impaired and absorption is affected→ malnutrition → **Used as:** Primary Therapy • GI cutaneous Fistula • Renal failure • Short bowel syndrome • Acute burns • Hepatic Failure • Crohns disease • Anorexia Nervosa	(2-in-1) → 75 /25 → Calories from Dextrose -75-80% → Calories from Amino Acids-20-25% → NO lipids used → **Used as:** Supportive therapy • Acute radiation enteritis • Acute Chemo-toxicity • Prolonged ileus • Weight loss preliminary to surgery

PrepLadder

Complications of TPN

→ **Related to nutrient deficiency**

- Hypoglycaemia
- Hypophosphatemia
- Hypocalcemia
- Hypomagnesemia
- chronic deficiency syndrome (If patient is receiving TPN for a long time there is deficiency of Essential FA, Zinc, Trace minerals and Vitamins)

→ **Related to overfeeding**

- Hyperglycemia
- Hyperosmolar Dehydration
- Hepatic Steatosis
- Hypercapnia
- Fluid Retention
- Dyselectrolytemia

} **Excess Glucose**

→ **Excess fatty acid**

- Hyper Cholesterolemia
- Hyper triglyceridemia
- Increased risk of Hypersensitivity Reactions

t.me/latestpgnotes

→ **Excess Amino Acid**

- Hyperchloremic Metabolic acidosis
- Hypercalcemia
- Aminoacidemia
- Uremia

→ **Related to sepsis**

- Catheter related Sepsis
- Increased risk of systemic sepsis

→ **Related to line**

- Pneumothorax
- Injury to adjacent artery
- Air Embolism
- Thoracic duct injury
- Cardinal Perforation/Tamponade
- Pleural Effusion

} **Occurs at the time of insertion**

→ **Long term use**

- Occlusion
- Venous thrombosis

PrepLadder

NOTE:

→ Most dangerous complications of Central venous catheterization - **Pneumothorax**

→ MC Complications of Central venous catheterization - **Catheter Related Sepsis**

REFEEDING SYNDROME

Introduction

→ Potentially lethal complication

→ Rapid & excessive feeding of patients suffering from severe underlying malnutrition due to

- Starvation
- Alcoholism
- Anorexia Nervosa
- Delayed Nutritional support
- Massive weight loss in obese patients

Mechanism of Refeeding syndrome

Shift in metabolism of substrate from fat to Carbohydrate

↓

Increased release of Insulin

↓

Migration of electrolytes into cells/ Increased Cellular uptake of Electrolytes

Phosphate -	Hypophosphatemia	Arrhythmia
Mg^{2+} -	Hypomagnesemia	Confusion
K^{+} -	Hypokalaemia	Respiratory Failure
Ca^{2+} -	Hypocalcemia	

↓

DEATH

t.me/latestpgnotes

Refeeding syndrome MC in TPN> Enteral Nutrition

Management of refeeding syndrome

→ Matching Intake with Requirement

→ Avoid overfeeding

→ Calorie Delivery should be increased slowly

→ Vitamin administration (Thiamine) → **(Given Before feeding)**

→ Hypophosphatemia should be corrected otherwise can lead

→ Hypomagnesemia to fatal complications like arrythmia and death.

PrepLadder

SHOCK

SHOCK

→ A clinical syndrome resulting from inadequate tissue perfusion.

Classification of Shock

1) Hypovolemic shock **(MC type)**
2) Traumatic shock
3) Cardiogenic shock
4) Septic shock — **Hyperdynamic (Early phase)**, **Hypodynamic (Late phase)**
5) Neurogenic shock
6) Hypo adrenal shock

HYPOVOLEMIC SHOCK

Causes

→ **Blood loss** – Trauma, bleeding

→ **Loss of plasma** – sequestration of fluid (**3rd space loss**) (in patients of Burns)

→ **Loss of body sodium & water** - In patients with Vomiting & Diarrhea

Pathophysiology

t.me/latestpgnotes

↓ **Intravascular volume**

↓

↓ Venous Return

↓

↓ Ventricular filling

↓

↓ Stroke volume

↓

↓ **Cardiac output**

Inadequate tissue perfusion

↓

Lactic Acidosis

↓

Metabolic Acidosis

Compensatory Mechanism Activation

↓

↑Sympathetic tone

(Release of Adrenaline and Noradrenaline)

↓

↑PR & ↑ TPR

Clinical features

→ **Due to Inadequate tissue perfusion**

- Cold & Clammy skin
- Oliguria leading to Anuria
- Drowsiness & confusion

PrepLadder

→ **Due to increased sympathetic tone**

- Tachycardia
- Weak thready pulse
- Sweating
- Initially cardiac output is maintained followed by hypotension

→ **Due to metabolic acidosis**

- Tachypnoea

Classes of hypovolemic shock (Based on amount of blood loss)

→ **Class I**

- Compensatory mechanism maintains cardiac output
- AKA Compensated Hypovolemic Shock

→ **Class II**

- Hypoxemia
- Hypotension
- Generalised Vasoconstriction
- Urine output → 20-30 ml/hour

→ **Class III**

- Aka Decompensated shock (↓CO, ↓SBP)
- Hypotension
- Tachycardia [>120/mins]
- Tachypnoea
- Urine Output → 5-15ml/hour
- Confused Patient

t.me/latestpgnotes

→ **Class IV**

- aka Refractory shock
- Marked hypotension
- Tachycardia
- Tachypnoea
- No urine output
- Comatose patient

NOTE:

→ Best clinical indicator of tissue perfusion in shock patient - **Urine Output**

→ Best indicator to detect fluid required for resuscitation - **CVP (Central Venous Pressure)**

PrepLadder

Characteristics of classes of hypovolemic shock

Parameter	Class I	Class II	Class III	Class IV
Blood loss (%)	0-15°	15-30°	30-40°	>40°
CNS	Slightly anxious	Mildly anxious	Anxious or confused	Confused or lethargic
Pulse (Beats/min)	< 100	> 100	> 120	> 140
Blood pressure	Normal	Normal	Decreased	Decreased
Pulse pressure	Normal	Decreased	Decreased	Decreased
Respiratory rate	14-20/min	20-30 / min	30-40/min	> 35/ min
Urine (mL/hr)	>30	20-30	5-15	Negligible
Fluid	Crystalloid	Crystalloid	Crystalloid + Blood	Crystalloid + blood
Base deficit	0 to 2 mEq/L	2 to 6 mEq/L	6 to 10mEq/L	10mEq/L or less

CARDIOGENIC SHOCK

→ Characterised by impaired ability of heart to pump blood

Causes

t.me/latestpgnotes

→ **Systolic dysfunction**
- MI
- Myocardial depressants - CCB, B-Blockers, Anti-arrhythmics

→ **Diastolic dysfunction**
- Ventricular hypertrophy
- Restrictive cardiomyopathy
- Cardiac Tamponade

→ **Valvular Structural abnormalities**
- Papillary muscle rupture
- AR & MR

→ **Arrhythmias**
- Ventricular Tachyarrhythmias

PrepLadder

Mechanism

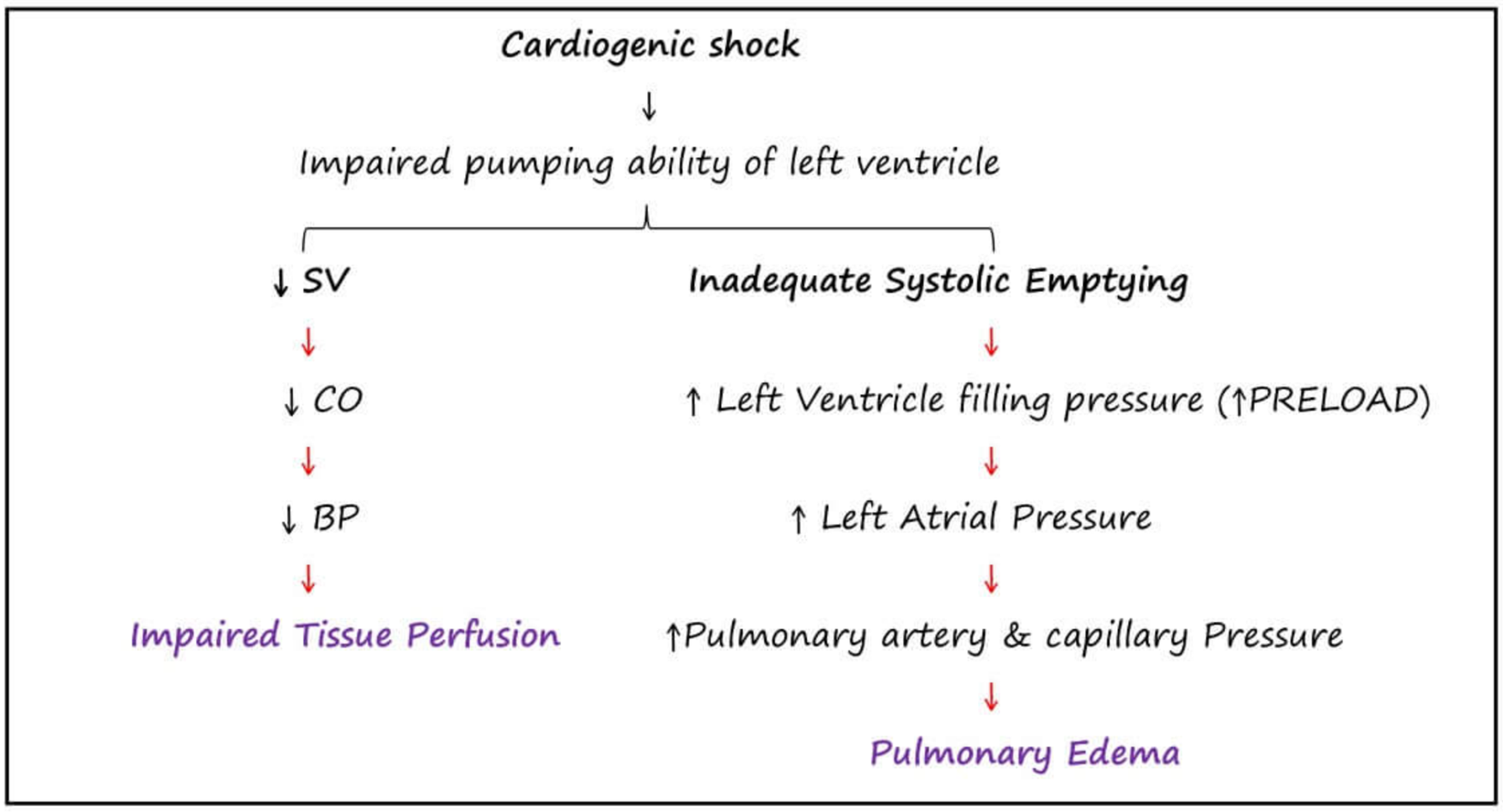

Clinical features (depends on the Etiology)

→ **Signs of Myocardial Failure**
- ↑ed JVP
- Basal Coarse Crackles
- Tachypnea
- Hypotension

→ **Obstructive**
- Cardiac Tamponade
  - **BECK'S TRIAD** (Muffled heart sound, Hypotension, Jugular venous distention)
  - Pulsus Paradoxus

→ **Pulmonary Embolism**
- Sudden onset Dyspnoea
- Tachypnoea, Tachycardia, Hypotension
- Localised Pleural Rub
- In Massive embolism → Severe Central chest pain

→ **Other signs & symptoms**
- Cold & Clammy peripheries
- Pallor
- Central & peripheral Cyanosis

t.me/latestpgnotes

SEPTIC SHOCK

→ Sepsis associated with hypotension that cannot be corrected by fluid resuscitation.

→ **Definition**
- **Sepsis + hypotension** for at least 1 hour, despite of adequate fluid Resuscitation (SBP <90mm Hg / 40mmHg less than normal BP) or
- Need for vasopressor to maintain SBP ≥90mmHg / MAP ≥70mmHg

PrepLadder

Refractory Septic Shock

→ Septic shock that last >1hour and does not respond to fluid or pressure administration

Causes

→ Septic shock is initiated by

- Bacteria → **Gram -ve** (most common)
  → **Gram +ve**
- Fungi
- Viruses

→ Cell wall of bacteria has → **Exotoxin**
→ **Endotoxin**

↓

Release of Inflammatory mediators

↓

Vasodilatation

↓

↑ Capillary permeability

↓

Altered peripheral circulation & massive dilation

↓

SHOCK

t.me/latestpgnotes

Pathophysiology of Septic shock

Infection (insult /injury)

↓

Release of inflammatory mediators

↓

Systematic Inflammatory response

↓

- **Diffuse Endothelial injury**
- **Vasodilation**
- **Increased capillary permeability**

↓

Progressive Vasodilation & mal-distribution of blood flow

↓

Organ Hypoperfusion

↓

Multiple organ dysfunction syndrome (MODS)

Clinical Features

→ Fever

→ Chills and Rigor

PrepLadder

→ Vasodilatation – leads to warm peripheries
→ Bounding pulse
→ Rapid capillary filling
→ Hypotension
→ Evidence of local infection at site

NEUROGENIC SHOCK

→ **It results from loss or separation of sympathetic tone**

↓

Massive vasodilatation
(both veins and arteries but especially venous vasculature)

↓

↓ Venous Return

↓

↓ Cardiac output

↓

Impaired tissue perfusion

↓

Shock

Causes

→ High cervical spinal cord injury
→ Inadvertent Cephalad migration of spinal anaesthesia
→ Deep general Anaesthesia (depresses Vasomotor tone)
→ Devastating head injury

t.me/latestpgnotes

Pathophysiology

Neurogenic shock

↓

Disruption of sympathetic nervous system

↓

Loss sympathetic tone

↓

Venous & Arterial Vasodilation

↓

↓ Venous return

↓

↓ Stroke volume

↓

↓ Cardiac output

↓

Impaired tissue perfusion & cellular Metabolism

PrepLadder

Clinical features

→ Paralysis below the level of lesion
→ Hypotension
→ Bradycardia – because of Loss of Sympathetic tone
→ Hypothermia
→ Warm & dry skin – because of Loss of Sympathetic tone leading to Arterial & venous vasodilatation

Note:

→ RTA patient presents with decreased HR/bradycardia and warm peripheries – *Neurogenic Shock*
→ RTA patient presents with increased HR/tachycardia and cold peripheries – *Hypovolemic Shock*

HYPOADRENAL SHOCK

→ In normal individuals – Stress / illness / Surgery / Trauma

↓

Increased amount of cortisol release (form adrenal)

→ But unrecognised adrenal insufficiency – Complicates the host response to

↓

Stress / illness / Surgery / Trauma

↓

Hypoadrenal shock

t.me/latestpgnotes

Causes

→ Chronic administration of high doses of exogenous Glucocorticoids
→ Adrenal Insufficiency due to
- Idiopathic atrophy
- Etomidate for intubation
- TB
- Metastatic disease
- Bilateral Adrenal haemorrhage
- Amyloidosis

Clinical Features

→ Loss of homeostasis
→ ↓SVR
→ Hypovolemia
→ ↓ed Cardiac output

PrepLadder

Physiological characteristics of various shock

TYPES	CVP & PCWP	CO	SVR	VENOUS O2 SATURATION
HYPOVOLEMIC	↓	↓	↑	↓
CARDIOGENIC	↑	↓	↓	↑
SEPTIC				
- Hyperdynamic	↓↑	↑	↓	↑
- Hypodynamic	↓↑	↓	↑	↓↑
NEUROGENIC	↓	↓	↓	↓
HYPOADRENAL	↓	↓	N/ ↓	↓

Parameters for shock

→ SHOCK INDEX (HR/SBP)

- Better marker for assessing severity of shock, than HR & BP alone
- also known as HEMODYNAMIC STABILITY INDICATOR

→ MODIFIED SHOCK INDEX (HR / MAP)

- **High MSI** – indicate Hypodynamic Circulation
- **Low MSI** – indicate Hyperdynamic Circulation
- MSI is a better marker than SI for mortality rate prediction

t.me/latestpgnotes

→ ROPE (Pulse rate over pressure evaluation)

- Formula is PR/PP
- PP = PR/SBP-DBP

DRUG OF CHOICE IN SHOCK

1) **Anaphylactic shock** - ADRENALINE
2) **Cardiogenic shock** - NORADRENALINE/DOPAMINE
3) **Distributive shock** - NORADRENALINE/PHENYLEPHRINE
4) **Hypovolemic shock** - CRYSTALLOIDS/FLUIDS
5) **Secondary Shock** - PRAZOSIM
6) **Shock with oliguria** - DOPAMINE
7) **Hypoadrenal shock** - CORTICOSTEROIDS
8) **Septic shock** - BROAD SPECTRUM ANTIBIOTICS

PrepLadder

GENERAL SURGERY

Hospital acquired infection

→ It is Infection that follows surgery or admission to the hospital

→ MC hospital acquired infection – UTI (30-40% of cases)

→ 2nd MC hospital acquired infection – Surgical site infection / wound infection (15-20%)

→ 3rd MC hospital acquired infection – Respiratory infection (10-15%)

→ 4th MC hospital acquired infection – Bacteremia (10-15%)

→ 5th MC hospital acquired infection in surgical patients – Surgical site infection

Note:

→ UTI
→ Acute bacterial Prostatitis
→ Chronic bacterial prostatitis
→ Prostatic abscess

} **MC organism responsible** – E. Coli

→ Acute epididimo-orchitis in
- Children
- Elderly
- Homosexuals

} **MC organ responsible** – E. Coli

t.me/latestpgnotes

→ Acute pyelonephritis
→ Chronic pyelonephritis
→ Emphysematous pyelonephritis
→ Perinephric Abscess

} **MC organism responsible** – E. Coli

→ Cholangitis
→ Pyogenic liver abscess (In Western Countries / Worldwide)
→ Spontaneous bacterial peritonitis in adults
→ Infection in Pancreatic necrosis
→ Anorectal abscess

} **MC organism responsible** – E. Coli

Surgical site infection

→ Wound that discharges significant quantity of pus spontaneously or needs secondary procedure to drain it

→ **Scoring system for severity of wound infection**
- **Southampton** wound grading system
- Asepsis wound score

PrepLadder

Southampton wound grading system

Grade	Appearance	Subtypes / appearance
0	Normal appearance	
I	Normal healing with mild Bruising / Erythema	IA – Some bruising IB – Considerable bruising IC – Mild erythema
II	Erythema plus other signs of inflammation	IIA – At one point IIB – Around sutures IIC – Along wound IID – Around wound
III	Clear or Hemoserous discharge	IIIA – At one point only (<2cm) IIIB – Along wound (> 2cm) IIIC – Large Volume IIID – Prolonged (>3 days)
IV	Pus	IVA – At one point only (<2cm) IVB – Along wound (> 2cm)

Sepsis wound score

→ **Additional Treatment**

- Antibiotic for wound infection
- Drainage of Pus under local anaesthesia
- Debridement of wound under general anaesthesia

t.me/latestpgnotes

→ **Serous discharge**

→ **Erythema**

→ **Purulent exudate**

→ **Separation of deep tissues**

→ **Isolation of bacteria from wound**

→ **Stay as inpatients** – prolonged over 14 days as a result of wound infection

Difference between Erysipelas of cellulitis

Erysipelas	Cellulitis
• Well defined margin	• Not well defined (Indistinct margins)

PrepLadder

• MC organism – Strep. pyogens	• MC organism – Strep. Pyogens (Staph. aureus -rarely)
• Associated with bulla / Vesicle formation	• Bulla formation in severe cases only
• Involvement of upper S/C tissue of lymphatics	• Involvement of deeper S/C tissue
• Common site – Face with bridge of nose & cheeks	• Common site - legs

Carbuncle

→ Abscess with one or more openings
→ Pus draining onto the skin
→ MC organism – Staph. aureus
→ MC site – Nape of Neck

carbuncle

Etiology

→ More common in Diabetics & Immunocompromised patients

Triggers

→ Folliculitis
→ Poor hygiene
→ Accidental pulling of hair during showing / Friction

t.me/latestpgnotes

C/F

→ Infected mass filled with → Pus, Dead tissue, Fluid
→ Red & white with yellow centre

Treatment

→ Incision & drainage + antibiotics
→ Cruciate incision is given

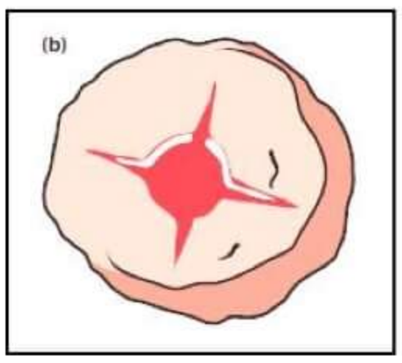

Gas Gangrene

→ MC organism responsible – Clostridium perfringen's

Risk factors

→ DM
→ Immunocompromised Pts.

PrepLadder

→ Wound containing necrotic or Foreign material

↓

Promotes Anaerobic Conditions

Gas Gangrene

C/F

→ Severe local wound pain

→ Gas in tissues – Crepitus

→ Thin, Brown, Sweet smelling exudate from wound

→ Myonecrosis

→ Characteristic features → Gas
→ Smell

Treatment

→ Large doses of IV Pencillin + Debridement of affected tissue

Prophylaxis

→ Antibiotic prophylaxis – At risk Pts.

→ Passive Anti-gas gangrene → IM (Generally)
→ IV (In emergency)

→ Closure of Traumatic wound – Delayed for 5 – 6 days

t.me/latestpgnotes

Tetanus

→ Caused by clostridium tetani

→ Exotoxin from clostridium tetani – Tetanospasmin

↓

Affects myoneural functions & motor neurons of Anterior horn of spinal cord

C/F

→ **Initial symptoms**
- Trismus (Lock-Jaw)
- Muscle pain & stiffness
- Back pain
- Difficulty in Swallowing

→ **Short prodromal period** (If present – Poor prognosis)

↓

Spasm of short motor necrosis in face

↓Followed by

Severe general motor spasm

↓

- Opisthotonos
- Respiratory arrest
- Death

PrepLadder

→ **Risus Sardonicus** (Characteristic feature of tetanus)

- AKA Sardonic grin
- Sustained spasm of fascial muscles

↓

Produce grinning

Management

→ Best preventive Rx - Prophylaxis with tetanus toxoid

→ For established infection - Wound debridement

- Benzyl Pencillin

→ Anti-toxin using Human Ig is given for → At risk pts.
→ Established infection

Necrotising Fasciitis

→ It is a rapidly progressive bacterial infection

→ Characterised by necrosis of S/C tissue + fascia and underlying muscle is spared

→ MC site – Lower limb

→ **Fournier's gangrene** – Necrotising Fasciitis involving perineum

→ It is a polymicrobial infection (I.e. Both aerobe & Anaerobes are responsible)

→ Single most common organism is Group B-Hemolytic streptococci

t.me/latestpgnotes

Risk factors

→ DH

→ Immunocompromised state

→ Penetrating trauma

→ Skin infection

→ IV drug abuse

→ Pressure sores

Necrotising Fasciitis

C/F

→ Most important presenting symptom – Pain (Very severe)

→ Sometimes without treatment pain decreases – Ominous sign

↓ Due to

- Thrombosis of small vessels
- Destruction of peripheral nerve

→ **Appearance of wound**

- Erythematous
- Edematous
- Woody hard texture of S/C tissue

PrepLadder

→ **Systemic features include**

- Fever
- Tachycardia
- Hypotension

} May progress to → Septic shock, DIC, Multiorgan failure

Management

→ Urgent surgical debridement (+) IV fluids (+) IV Antibiotics (+) Supportive care

→ Without surgical debridement – 100 % mortality

→ **Hyperbaric oxygen** – helps in wound healing

Chronic Burrowing ulcer

→ AKA Meleney's gangrene / Burrowing phagedenic ulcer/ Progressive synergistic gangrene.

→ **It is caused by Synergistic infection of**

- Microaerophilic non-haemolytic streptococci
- Aerobic Haemolytic staphylococci

→ Has formation of → Burrowing cutaneous fissures, Sinus tract } **Both opens at Distal sites**

Tuberculous Lymphadenitis

t.me/latestpgnotes

→ Occurs in children & young adults

→ MC affected lymph nodes – Deep cervical lymph nodes

→ TB bacilli gain entrance through tonsils

Pathology

→ **In 80% Cases** – TB passes is limited to affected lymph nodes

→ **In absence of Rx,**

Caseation of LN

↓

Liquidity & breakdown → Cold abscess formation

→ **Collar stud abscess**

Pus is initially confined by Deep cervical fascia

↓

Erosion at one point

↓

Pus flows through the small opening into space beneath superficial fascia

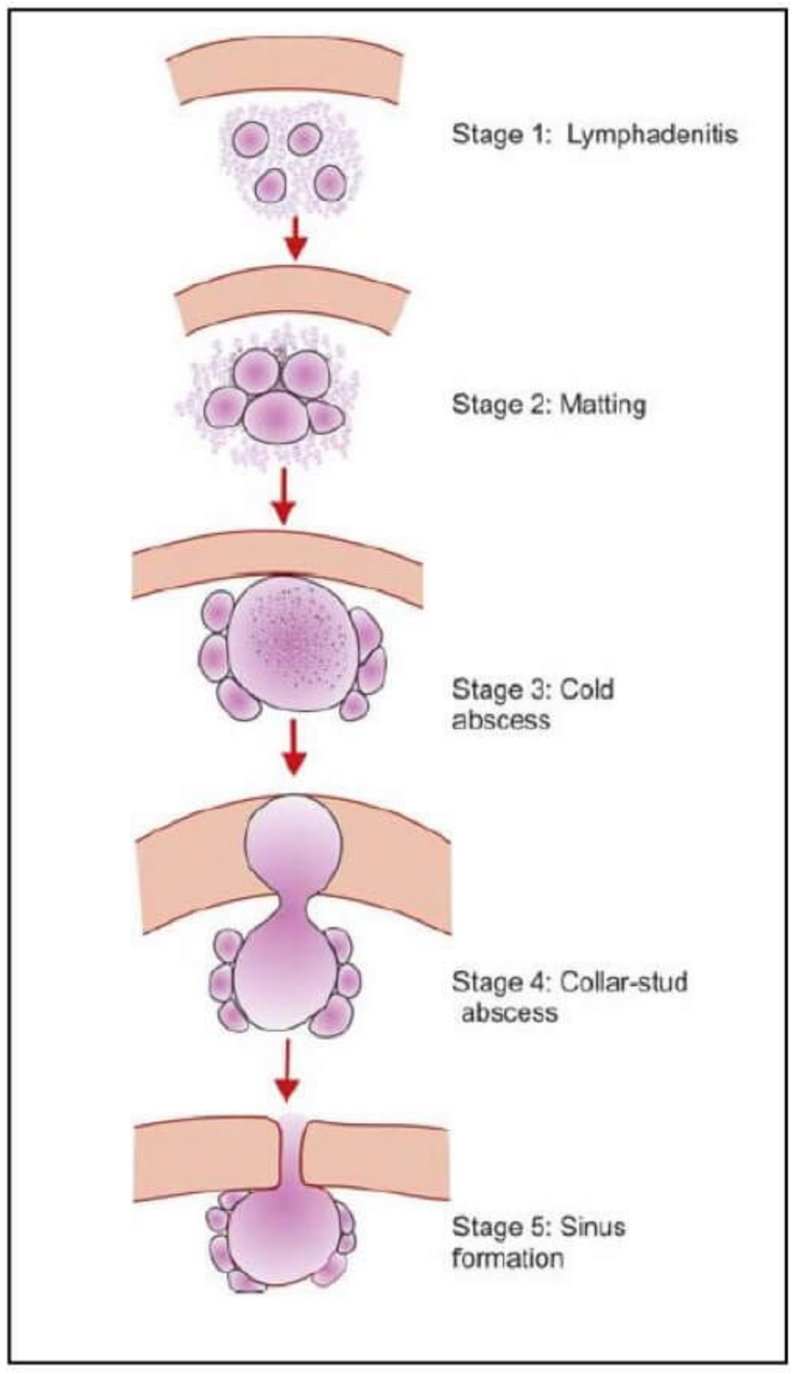

PrepLadder

Treatment

→ ATT (Anti-tuberculous drugs)

→ Abscess fails to resolve even after ATT

↓

Excision of

- Abscess
- Lymph nodes
- Fibrous capsule

Enteric Fever (Typhoid)

→ MC organism responsible – Salmonella Typhi / Para typhi

→ MC cause of Ileal perforation in tropical countries (like India)

Pathology

→ Has ulceration + Necrosis of ileo-cecal Peyer's Patches

↓

Longitudinal ulcers in Distal ileum **(Transverse ulcers – TB)**

↓

Ileal perforation (Occurs in 3rd week)

C/F

→ Hallmark symptoms – Fever & abdominal pain

→ **Non – Specific symptoms**

- Headache
- Myalgia
- Arthralgia
- Fatigue
- Cough

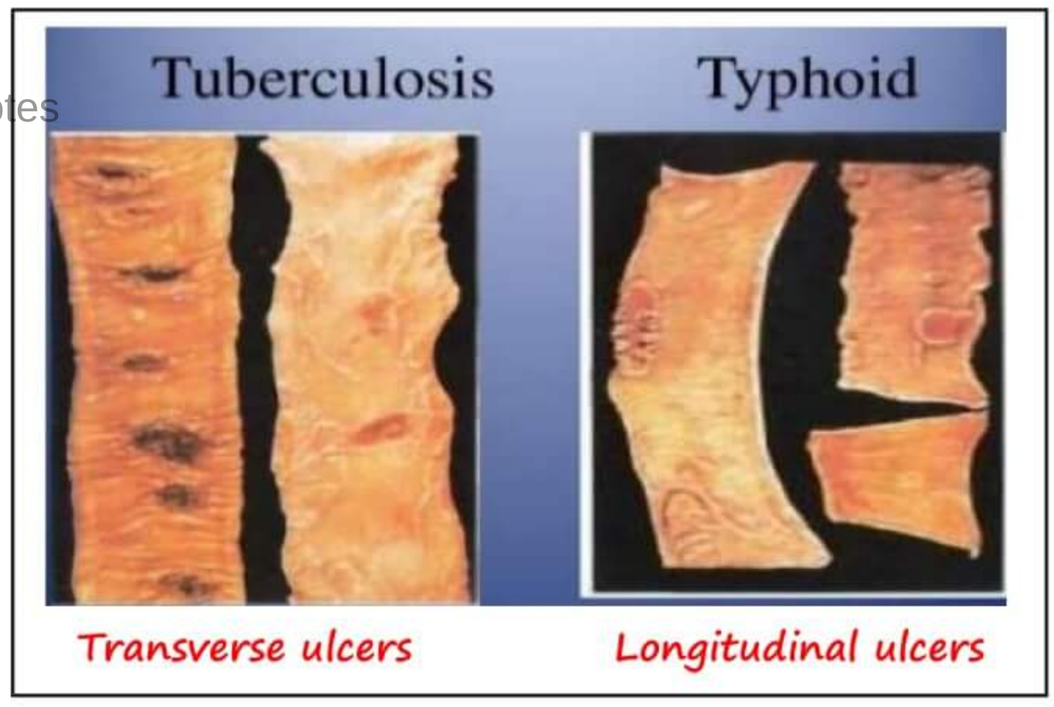

t.me/latestpgnotes

Complications

→ MC complication – Paralytic ileus > intestinal Haemorrhage

→ Perforation – at 3rd week

→ Cholecystitis

Characteristics signs

→ Rose spots

→ Splenomegaly

→ Leukopenia with shift to left

→ Relative bradycardia despite of high fever

PrepLadder

SIRS (Systemic Inflammatory Response Syndrome)

→ **Mediators of SIRS**

- IL – 1
- IL – 6
- TNF – α

→ It is body's inflammatory response to infectious or non-infectious insult

→ **Parameters of SIRS**

- Temperature (>38° C Or < 36° C)
- HR > 90 / min
- Respiratory rate > 20/min
- WBC count (> 12000/μl or < 4000/μl or >10% immature cells in the peripheral blood)

Note: > 2 of 4 should be present

Sepsis – SIRS + Established focus of infection

Severe sepsis – Sepsis with organ dysfunction of hypoperfusion

Septic shock – Sever sepsis not responding to IV Fluids

According to 2016 Criteria

t.me/latestpgnotes

→ **Sepsis** – Suspected or Documented infection & Acute increase in ≥ 2 SOFA points

→ **Septic Shock** – Suspected or documented infection + Vasopressor therapy needed to maintain MAP ≥ 65 mmHg of serum lactate > 2.0 mmol/L despite of adequate fluid resuscitation

MODS (Multi-Organ Dysfunction Syndrome)

→ Simultaneous presence of physiologic dysfunction & / or failure of 2 or more organs

Prevention of wound infection

→ Most important factor – Hand washing

→ **Hair removal prior to surgery**

- Best method – On table clipping of hair
- Maximum infection rate is with – shaving > Depilatory creams > on table clipping

→ **Use of Prophylactic antibiotics**

- Best time – at induction of anaesthesia or 30 mins to 1 hours before surgery
- In prolonged surgery – repeat dose is given after 4 hours

PrepLadder

→ **Cleaning of Part:**

- Abdominal surgery → Nipple to mid-thigh

  ↓

  Swab moves – Medial to lateral while cleaning abdomen

  – Lateral to medial while cleaning thighs

→ **Maintain ideal OT Parameters**

- Temperature → 18° - 25° C
- Relative humidity → 50 – 60%
- Positive pressure → 2 mmHg above atmospheric pressure
- Inside OT → 15 air exchanges / hour at least 4 should be fresh air
- There should be ultra clean laminar air flow inside the theatre

OT Zones

Zone I

→ Protective Zone

→ It includes

- Reception / Waiting area
- Trolley bags
- Changing rooms for staffs

t.me/latestpgnotes

Zone 2

→ Clean Zone

→ It includes

- Pre-operative Rooms
- Recovery Rooms
- Plaster / Store rooms

Zone 3

→ Sterile Zone

→ It includes

- Operating room
- Scrub room

Zone 4

→ Disposal Zone

→ It includes

- Dirty utility
- Disposal corridor

PrepLadder

OT Parameters

1) 15-25 air exchangers / Hour in PPV system (Positive pressure ventilation)
2) There should be ultra clean ventilation system
   - → Use HEPA filters (High Efficiency Particulate Air)
   - → Remove 99.9% of Particulate matter > 0.3µm in Diameter
   - → Use laminar air flow
   - → Air exchange every 2-3 minutes
3) Temperature → 18-25 ° C
4) Relative humidity → 50-80%
5) **General lighting**
   - → Ratio of intensity of general room lighting to surgical site
     - Ideally 1:3 (To Immune eye fatigue)
     - Should be second 1:5
6) **Lighting of operative area**
   - → Overhead light must be shadow less
   - → Give 25000-125000 LUX of light

Before induction of anaesthesia ▸▸▸▸▸▸▸▸▸ Before skin incision ▸▸▸▸▸▸▸▸▸▸▸▸▸ Before patient leaves operating room

SIGN IN

☐ **PATIENT HAS CONFIRMED**
- IDENTITY
- SITE
- PROCEDURE
- CONSENT

☐ **SITE MARKED/NOT APPLICABLE**

☐ **ANAESTHESIA SAFETY CHECK COMPLETED**

☐ **PULSE OXIMETER ON PATIENT AND FUNCTIONING**

DOES PATIENT HAVE A:

KNOWN ALLERGY?
☐ NO
☐ YES

DIFFICULT AIRWAY/ASPIRATION RISK?
☐ NO
☐ YES, AND EQUIPMENT/ASSISTANCE AVAILABLE

RISK OF >500ML BLOOD LOSS (7ML/KG IN CHILDREN)?
☐ NO
☐ YES, AND ADEQUATE INTRAVENOUS ACCESS AND FLUIDS PLANNED

TIME OUT

☐ **CONFIRM ALL TEAM MEMBERS HAVE INTRODUCED THEMSELVES BY NAME AND ROLE**

t.me/latestpgnotes

☐ **SURGEON, ANAESTHESIA PROFESSIONAL AND NURSE VERBALLY CONFIRM**
- PATIENT
- SITE
- PROCEDURE

ANTICIPATED CRITICAL EVENTS

☐ **SURGEON REVIEWS:** WHAT ARE THE CRITICAL OR UNEXPECTED STEPS, OPERATIVE DURATION, ANTICIPATED BLOOD LOSS?

☐ **ANAESTHESIA TEAM REVIEWS**: ARE THERE ANY PATIENT-SPECIFIC CONCERNS?

☐ **NURSING TEAM REVIEWS:** HAS STERILITY (INCLUDING INDICATOR RESULTS) BEEN CONFIRMED? ARE THERE EQUIPMENT ISSUES OR ANY CONCERNS?

HAS ANTIBIOTIC PROPHYLAXIS BEEN GIVEN WITHIN THE LAST 60 MINUTES?
☐ YES
☐ NOT APPLICABLE

IS ESSENTIAL IMAGING DISPLAYED?
☐ YES
☐ NOT APPLICABLE

SIGN OUT

NURSE VERBALLY CONFIRMS WITH THE TEAM:

☐ **THE NAME OF THE PROCEDURE RECORDED**

☐ **THAT INSTRUMENT, SPONGE AND NEEDLE COUNTS ARE CORRECT** (OR NOT APPLICABLE)

☐ **HOW THE SPECIMEN IS LABELLED** (INCLUDING PATIENT NAME)

☐ **WHETHER THERE ARE ANY EQUIPMENT PROBLEMS TO BE ADDRESSED**

☐ **SURGEON, ANAESTHESIA PROFESSIONAL AND NURSE REVIEW THE KEY CONCERNS FOR RECOVERY AND MANAGEMENT OF THIS PATIENT**

WHO Surgical safety checklist

Causes of Post-Op fever

- POD 1-2 → Atelectasis
- POD 2-3 → UTI
- POD 3-7 → Wound infection (SSI)
- POD 5-7 → DVT / Thrombophlebitis
- POD >7 → Drug fever

PrepLadder

Wound Dehiscence

→ AKA Burst abdomen

→ Occurs usually on 5th -8th post-op day

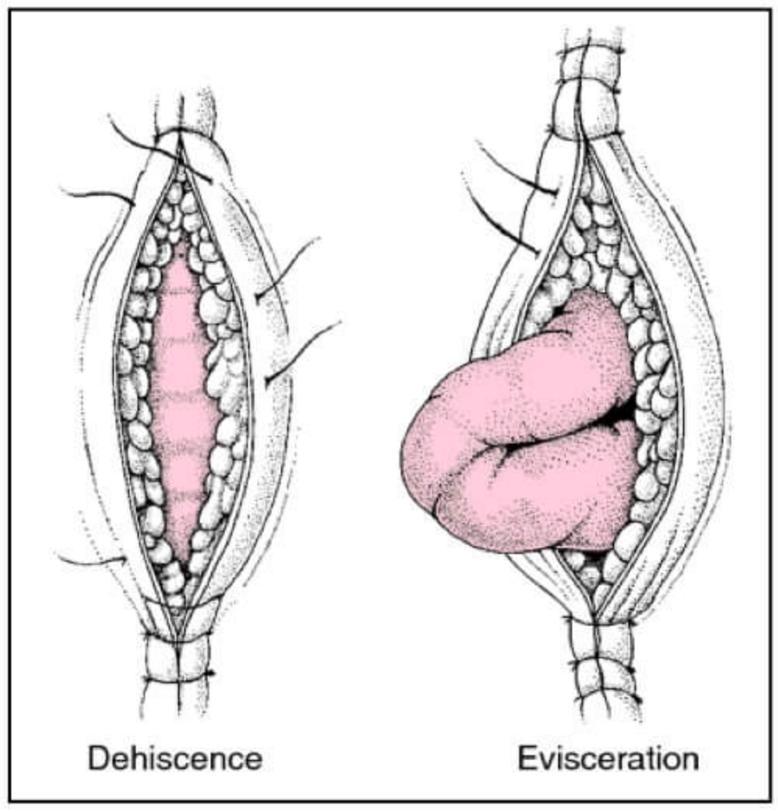

First sign of wound dehiscence

→ Serous / Serosanguinous discharge from wound – Salmon fluid sign

Types

→ Partial or

→ Total dehiscence

Evisceration

→ Extrusion of abdominal viscera after disruption of all layers

Pre disposing factors

Local	Systemic
• Inadequate closure	• DM
• Midline vertical incisions	• Immunocompromised state
• Increased IAP	• Uremia
• Deficient wound healing	• Jaundice
• Hematoma / Seroma / infection	
• Presence of drain	

t.me/latestpgnotes

Management

→ **Wound dehiscence without Evisceration** – Prompt elective closure

→ **Wound dehiscence with Evisceration**

- Wound is covered with moist towel
- Exposed Bowel is rinsed with Ringer lactate containing antibiotics & returned to abdomen
- Wound is closed by tension suturing

PrepLadder

Instruments Part - 1

Parts of Instruments

→ **Tip**

→ **Blade /Jaw** - working end of the instrument

→ **Joint/Box Lock**

→ **Teeth** – Prongs at end for firm grasping

→ **Shaft / Shank**

→ **Ratchet/Catch** – Interlocking part of instrument

→ **Finger bows** – Controls the jaw movement

→ **Teeth (Allis forceps)** - Prongs at the end of Jaw
- Helps in firm grasping of tissue

→ **Serrations** - seen at Jaw/Blade

- Transverse serrations – seen in Artery Forceps
- Longitudinal serrations – seen in Intestinal clamp
- Cross hatched serrations – seen in Needle holding forceps

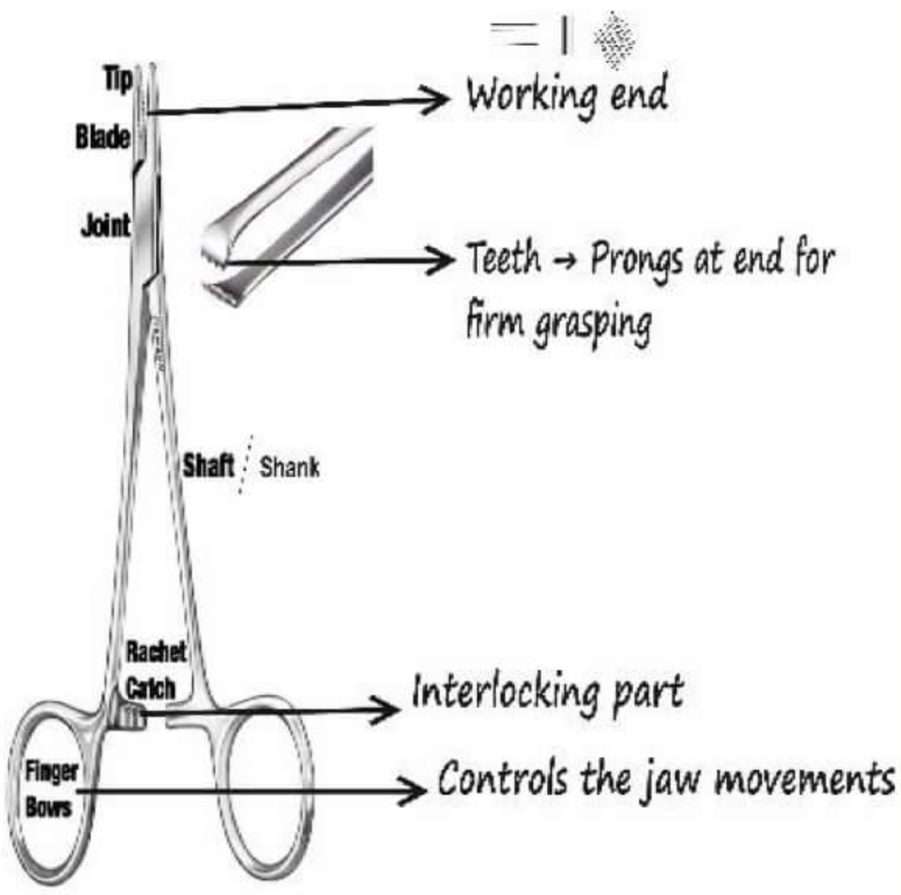

Types

Non-traumatic/Atraumatic Forceps	Traumatic Forceps
• Fine serrations • No Crushing effect on the tissue	• Toothed/deep serrations • Penetrating/Crushing effect is observed

t.me/latestpgnotes

Towel Clips

→ Curved blade, Pointed tip

→ Used to fix drapes

→ Used to fix suction, tubes, catheters, diathermy cables, Laparoscopy cables

Types of towel clip

1. Mayo's Towel Clip	2. Doyen's Towel Clip	3. Moynihan's Tetra-Towel clip
→ Has a Rachet/Catch 	→ Pinch cork mechanism 	→ Two teeth in each blade → Used to hold the cut edges of skin to the four corners of draped towels

PrepLadder

Important Instruments

1. Rampley's Sponge Holding Forceps

→ **Oval tip**

→ **Serrations** – for firm sponge grasp

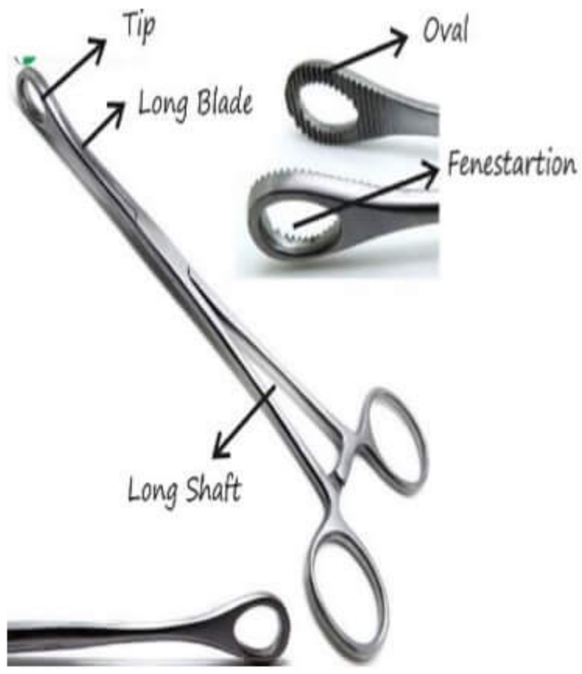

Uses

1. Cleansing
2. In Open cholecystectomy to hold
   - Fundus & Hartmann's pouch of GB
3. To swab an abscess cavity
4. Remove laminated membrane & daughter cyst

2. BP Handle (Bard Parker Handle)

→ **In Handle** – has Transverse serrations for better grip

→ **Slots** – for blade insertion

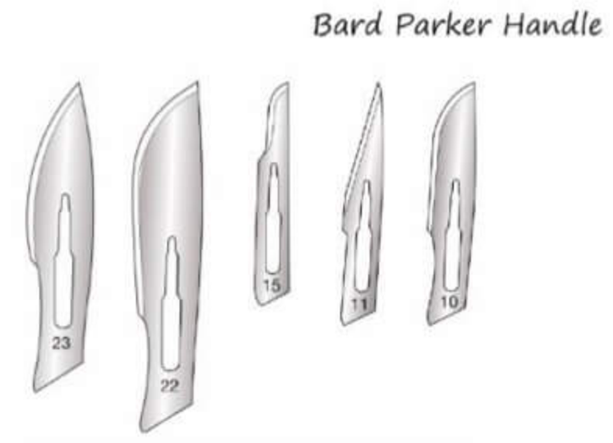

No. of blades & its uses

- **No. 10** – Open skin
- **No. 11** – Arteriotomy
- **No. 15** – Minor surgical procedure, plastic & Pediatric surgery
- **No. 22** – Abdominal incision
- **No. 23** – Very thick skin

t.me/latestpgnotes

Various Positions of Holding a BP handle

→ **Dinner knife position** – To make an incision and minimise tailing at the end

→ **Writing position** – For better handling of the knife

→ **Grasping position** – Amputation

3. Needle Holder Forceps

→ **Criss-cross serrations** – for better grip

→ **Central groove** – minimal crushing effect, and no straightening of the curved needle

→ Handle to Blade ratio = **4:1**

→ **Point of holding the needle** – At junction anterior 2/3rd & posterior 1/3rd of needle holder

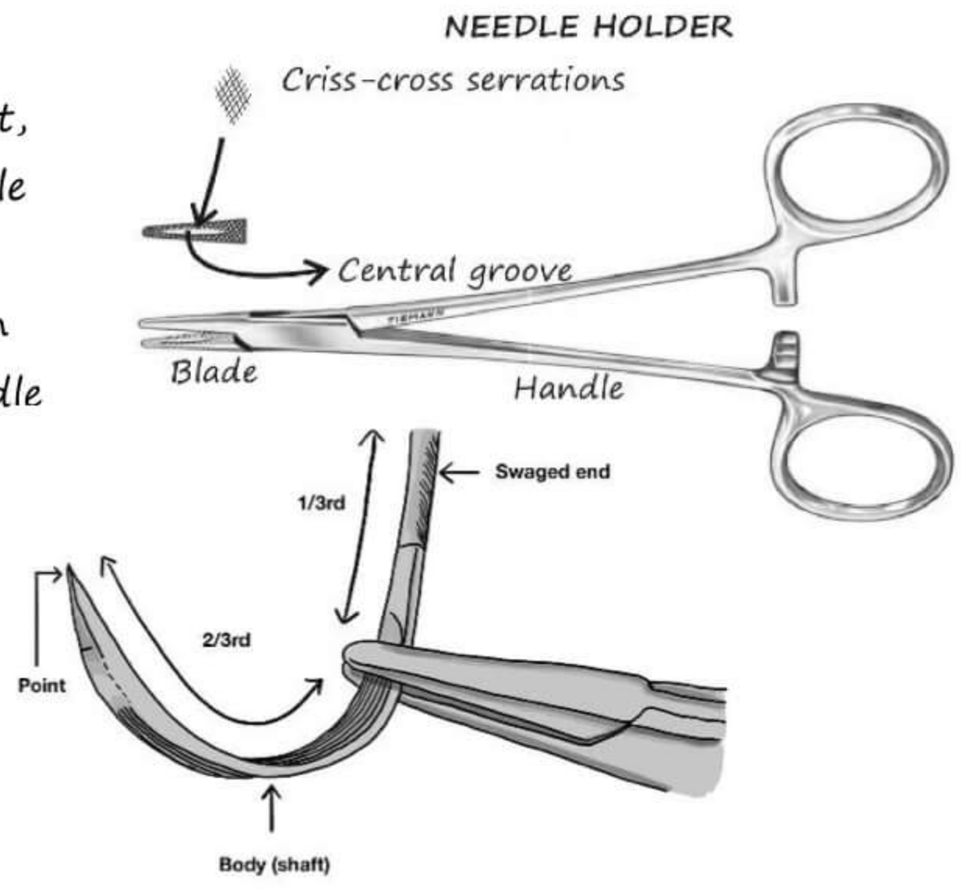

Uses

→ Suturing of tissues

→ Ligation

PrepLadder

4. Doyen's Rib Raspatory / Coastal elevator

→ Polygonal handle – for better grip

→ End in curved fashion with sharp edges – to separate periosteum from under surface of rib

→ **To determine the side**

- Handle should face laterally
- Convexity of the hook should be upwards
- Tip should face downwards

→ **Uses**

– Separate periosteum from under surface of rib

5. Kocher's Thyroid dissector

→ Used to dissect Superior thyroid pedicle during thyroid surgery

6. Aneurysm Needle

→ Used in Venesection- To pass ligature around vein

t.me/latestpgnotes

7. Humby's Knife

→ Used for harvesting split thickness skin graft & full thickness skin graft

8. Rib Shear / Rib Cutter

→ For cutting the ribs

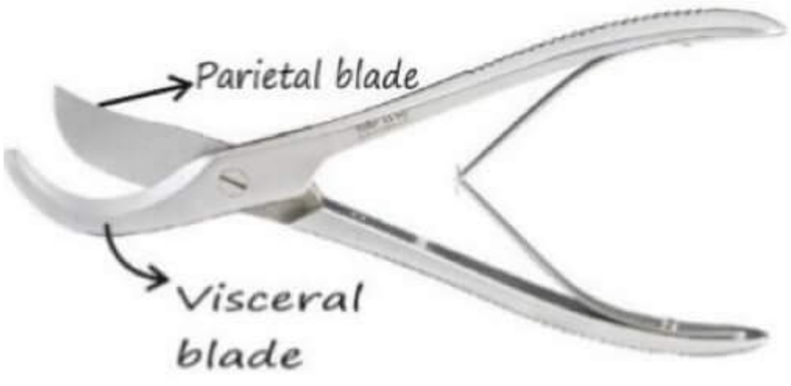

PrepLadder

→ **Difference between Rib shear & Bone cutter**

Rib Shear	Bone cutter
• Only Parietal blade is sharp • Visceral blade is blunt	• Both ends are sharp

9. Kelly's Rectal Speculum (PROTOSCOPE)

→ Length of proctoscope is – 10 cm

→ Length of Rigid sigmoidoscope - 25 cm

→ Length of Flexible sigmoidoscope - 60 cm

→ Length of Colonoscope- 160 cm

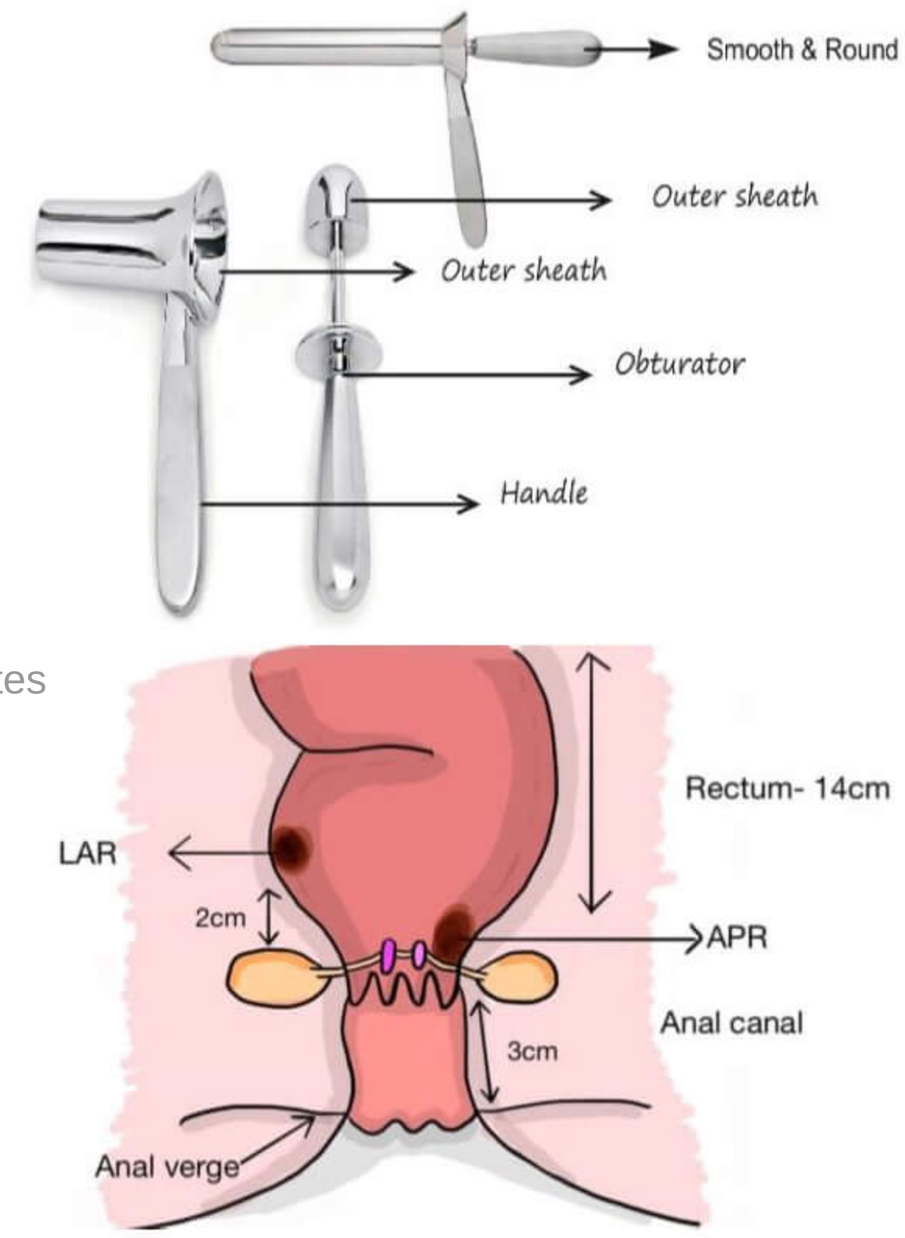

Uses

1. **Diagnostic**
   - Hemorrhoids (IOC)
   - Rectal polyp
   - Rectal Ulcer
   - Carcinoma anal canal & Lower part of rectum
   - Localising internal opening of fistula in- Ano
2. **Therapeutic**
   - Sclerotherapy & Banding of hemorrhoid
   - Polypectomy
   - Anal dilations

t.me/latestpgnotes

10. Farabeuf Periosteal elevator

→ **Parts**

- Blade
- Thumb rest
  - for better handle & control over instrument
  - Corrugated
  - Concave
  - Transversly serrated
- Handle

→ **Uses**

- Strip periosteum
- Strip muscular attachment

PrepLadder

11. Mayo's vein stripper

→ Used to strip varicose veins

→ In long saphenous vein stripping should be done just below the knee joint to avoid injury of **Saphenous nerve**

→ In stripping of short saphenous system, careful dissection should be performed to avoid injury of **Sural nerve**

→ Gold standard treatment for Varicose veins – **Endothermal abalation**

→ In endothermal abalation 2 techniques are followed

- **Endothermal laser abalation**
- **Radiofrequency abalation**

12. Gigli saw

→ Used in cutting of bones in amputation

→ The ends of the wire are anchored with hooks of handle

t.me/latestpgnotes

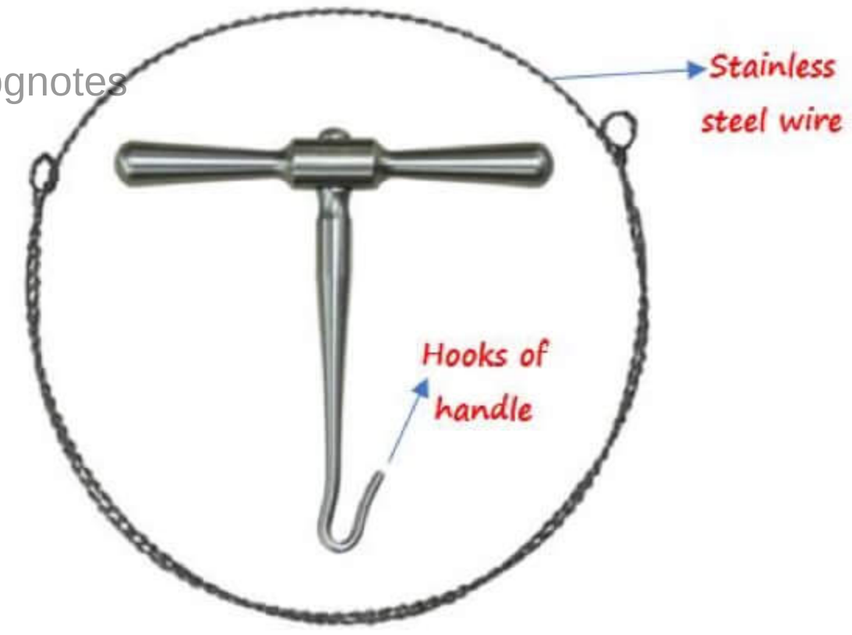

13. Fistula Probe

→ **Uses**

- Probing & treating Fistula in-ano
- Guide & protector – to release tongue tie

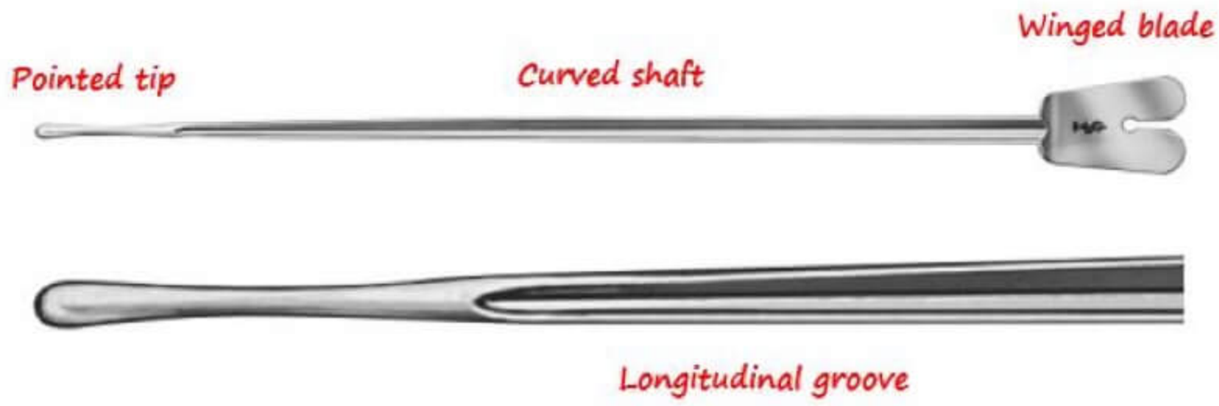

PrepLadder

14. GB Trocar

→ **Uses**

- To decompress GB (distended) during Cholecystectomy

FORCEPS

→ These are two bladed instruments

→ Used as pincher

- To hold
- To grasp
- To extract

Various types of forceps

1. Kocher's Hemostatic Forceps

→ **At Tip** – has Tooth & groove for firm grip

→ Has Transverse serrations

Uses

- To Crush the base of appendix (appendectomy)
- Hold perforating vessels in mastectomy
- Catch the bleeder in tough tissue like palm & sole
- Also used during Thyroidectomy

2. Mosquito Haemostatic forceps

→ Has fine pointed tips

Uses

- To control fine bleeding
- Puncture mesoappendix at an avascular site (during appendectomy)

3. Spencer Wells Hemostatic Forceps

→ **Tip** – Conical

→ **Blade** - Half of the length of handle

→ Has transverse serrations

Uses

- Hold the bleeding vessel
- Use to split the fibers of Internal Oblique (IO) & Transverses Abdominus (TA) during appendectomy

PrepLadder

4. Right Angle Forceps / Lahey's Forceps / Mixter Artery Forceps

→ Terminal part of blade is at right angle to rest of blade

→ Transverse serrations over the inner aspect

Uses

- To dissect pedicle of solid organs
- To pass the ligature around vessel
- To catch bleeder in depth
- To dissect & pass ligature to cystic duct & cystic artery

How to differentiate needle holder with artery forceps?

Needle holder	Artery forceps
• Criss-cross serrations • Groove- to prevent straightening & curving of needle	• Transverse serrations
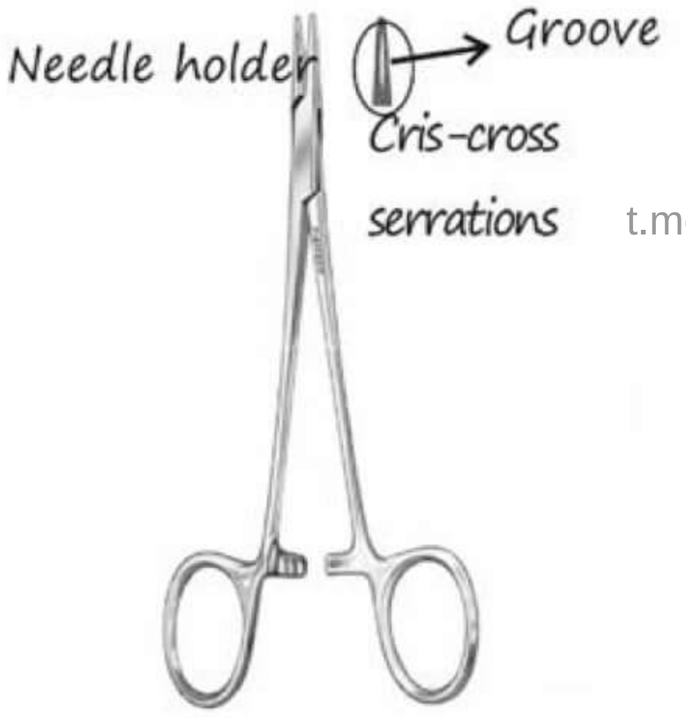	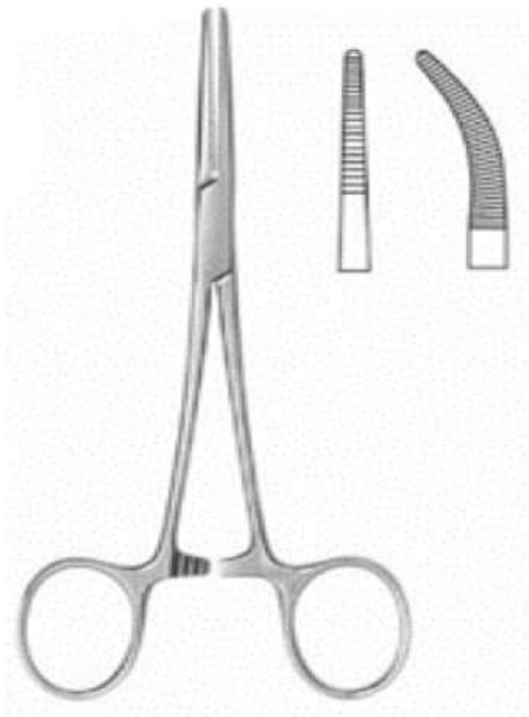

t.me/latestpgnotes

Mosquito haemostatic forceps	Kocher's haemostatic forceps
• Fine pointed tip	• Presence of tooth & groove at tip

PrepLadder

5. Allis tissue forceps

→ Long straight forceps blade - prevents crushing of the tissue

→ Tip - Curved / angulated

→ Alternate teeth / groove at the end of tip - provides firm grip and prevents slippage of the tissue

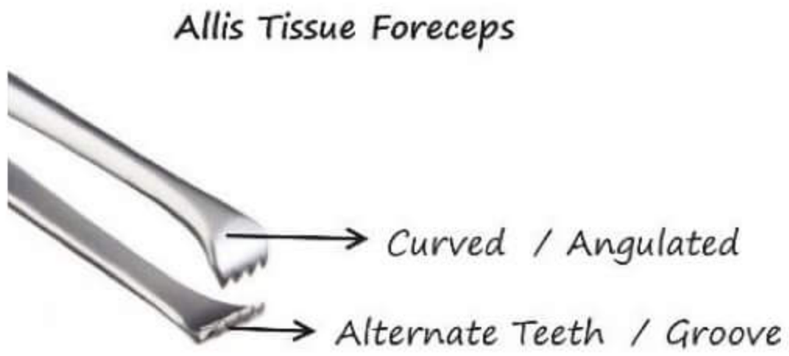

How to use this instrument?

Should be applied from the inner aspect of skin & subcutaneous tissue

Uses

- Hold skin & S/C tissue flap for retraction – (excision of LN, Sebaceous cyst, lipoma)
- Hold tough tissues - Fascia & aponeurosis approximation during suturing
- During Thyroidectomy & Neck dissection
- To hold the cut margins of skin
- In Laparotomy – retract skin margins
- In Bladder neck operations – hold the neck of bladder

6. Babcock's tissue forceps

→ Terminal part – curved

→ Fenestration to accommodate delicate structures

→ Non-traumatic instrument

t.me/latestpgnotes

Uses

- In Appendectomy - to hold the appendix
- In Gastrectomy - to hold the cut margins
- To hold Fallopian tube
- To hold Ureter - during Pyelolithotomy & Ureterolithotomy
- To hold Spermatic cord during hernia surgery
- In Resection & Anastomoses - Hold the cut edges of Small intestine & Large intestine
- In Suprapubic cystolithotomy - Used to hold cut edges of bladder

7. Lane's tissue forceps

→ Short, thick, bulkier & heavier

→ Blade - curved

→ Fenestration

→ Tooth and groove

PrepLadder

Uses

- Use to hold bulky and slippery tissue
- Hold the gland during dissection from adjacent structures in
  - Parotid gland surgery
  - Submandibular gland Sx
- Hold breast tissue structures while dissecting it from pectoral fascia in - Mastectomy

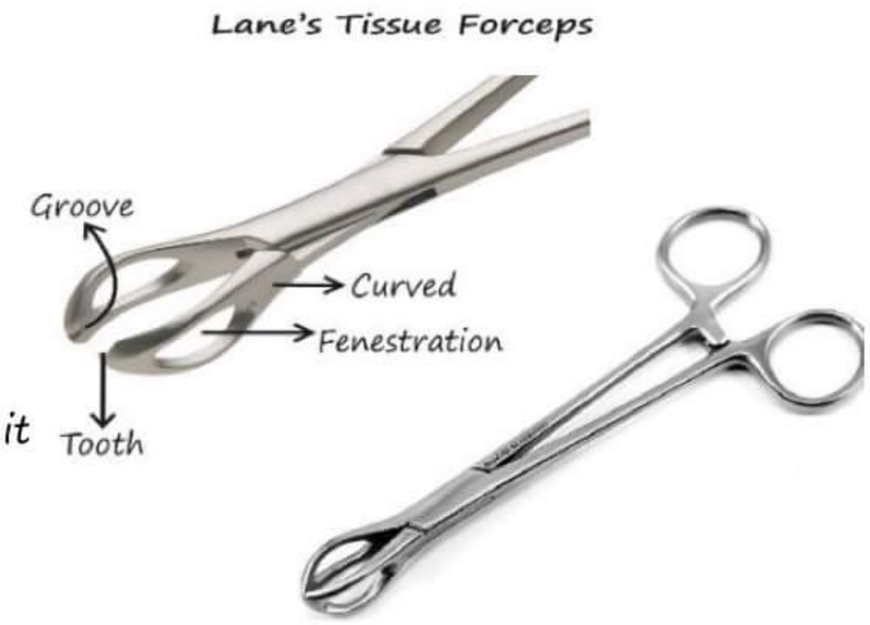

8. Plain dissecting forceps

→ Transverse serrations at tip
→ Tip is Fine / olive shaped
→ Shaft has ridges – gives better grip

Uses

→ To hold delicate structure in most of the surgeries
- Peritoneum
- Nerve
- Vessel
- Muscle & Bladder
- Bladder & bowel

t.me/latestpgnotes

9. Toothed Dissecting Forceps

→ Tooth in one blade and Groove in another
→ Has better grip - used for holding tough tissues
→ Less chance of slippage
→ Presence of Transverse serrations

Uses

→ To retract & hold
- Skin flaps during Venesection
- Excision of cyst lipoma, LM
- Tough tissue like Skin, Fascia & Aponeurosis

→ Used during Suturing of incision (main use)

Note:
- 3 Instruments required for skin suturing
  → Needle holder
  → Toothed forceps
  → Scissors

PrepLadder

10. Russian Tissue Forceps

→ Clubbed tip with serrated inner surface

Uses

→ Suturing of skin incisions



t.me/latestpgnotes

Instruments Part - 2

FORCEPS

1. Desjardin's Choledocholithotomy forceps

→ **Shaft** - curved

→ **No catch** - to prevent the crushing of stone while removing

→ **Blade** – curved to work in the minimum space required

→ Ends has fenestrations

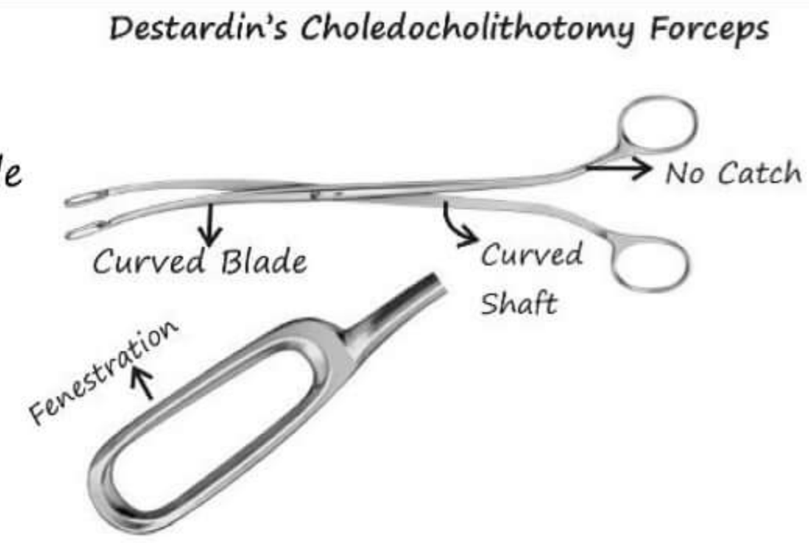

Uses

→ Stone removal during

- Choledocholithotomy
- Cholecystectomy

2. Pyelolithotomy forceps

→ **Blade** - curved/angulated

→ **Tip** – has fenestration

- inner surface has Transverse serrations

→ **No Catch** - to prevent the crushing of stone while removing

→ Different types of forceps have different angulations

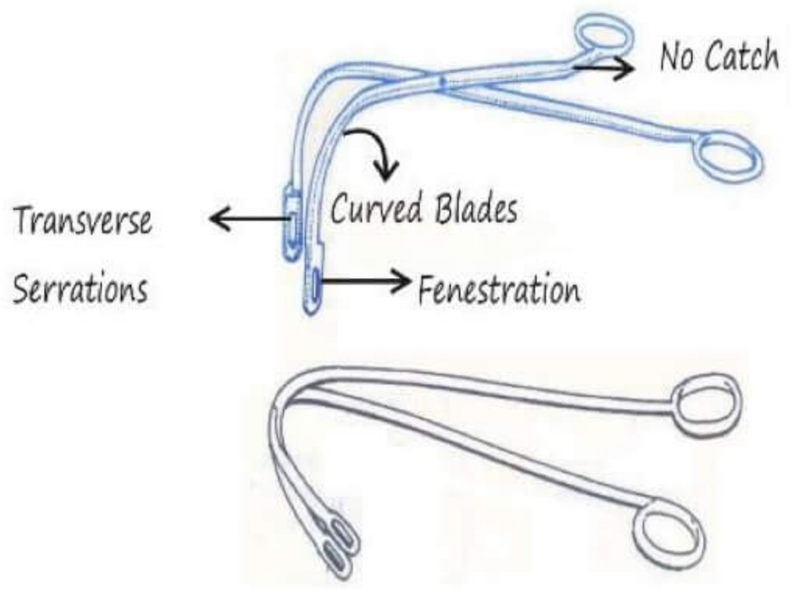

t.me/latestpgnotes

Uses

→ Removal of stones during

- Pyelolithotomy
- Nephrolithotomy
- Ureterolithotomy

3. Suprapubic Cystolithotomy forceps

→ **Blade** - curved, spoon shaped, Concave

- Spicules in the inner aspect for firm grip over the stone

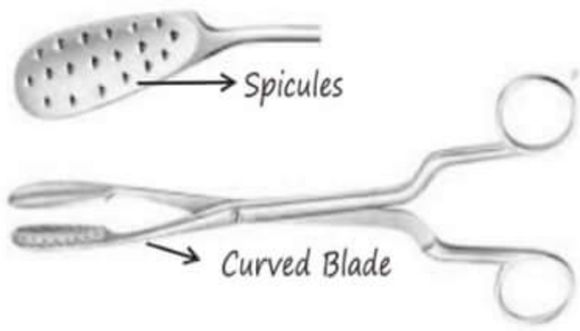

Uses

→ Removal of stones during Suprapubic cystolithotomy

4. Cheatle's forceps

→ **Blade** - Large serrations and angulation

- Curved dipping blades

→ It is kept dipped in anti-septic solution

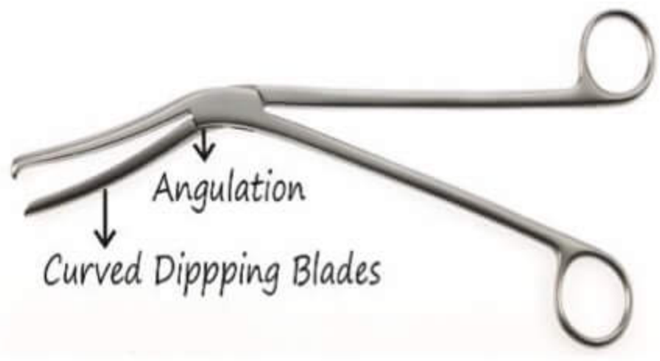

Uses

→ To pick sterile object - to avoid touching during transfer from tray to table

PrepLadder

5. Lister sinus forceps

→ Has **straight Blade**

→ **Tip**

- Blunt, rounded, olive pointed
- Non-traumatic
- Transverse serrations at the tip

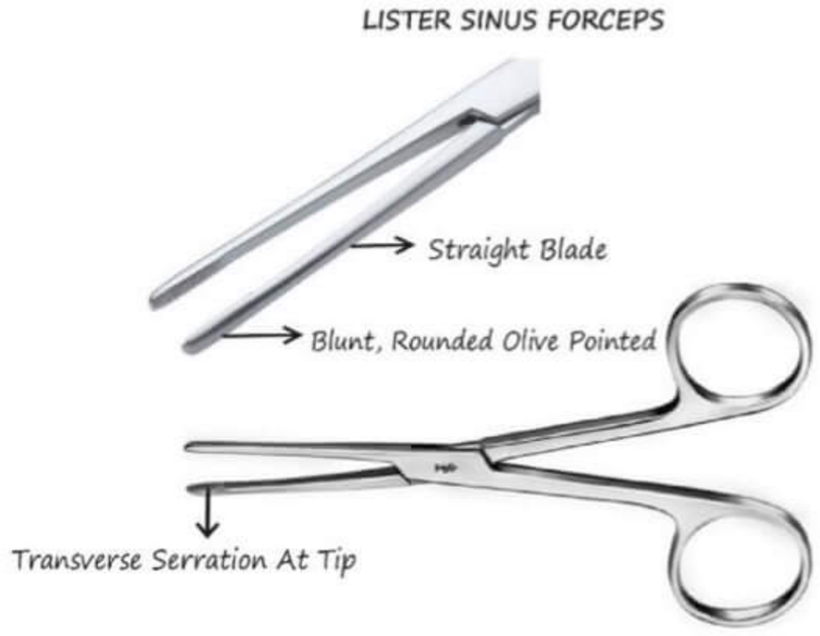

Uses

→ In incision & drainage by Hilton's method of draining abscess

→ For exploring the sinus tract

Note:

- **Hilton's method of I&D**
  - Blunt incision for drainage of the abscess near vital areas and flexor aspects
  - Applied in Neck, Groin, Axilla where Neurovascular bundle is superficial

6. Duval Lung Holding Forceps

→ **Blade** - Straight

→ **Tip** - Broad, Triangular with fenestration

- Presence of ridges & grooves

Uses

→ To Grasp lung tissue during Lobectomy & Pneumonectomy

t.me/latestpgnotes

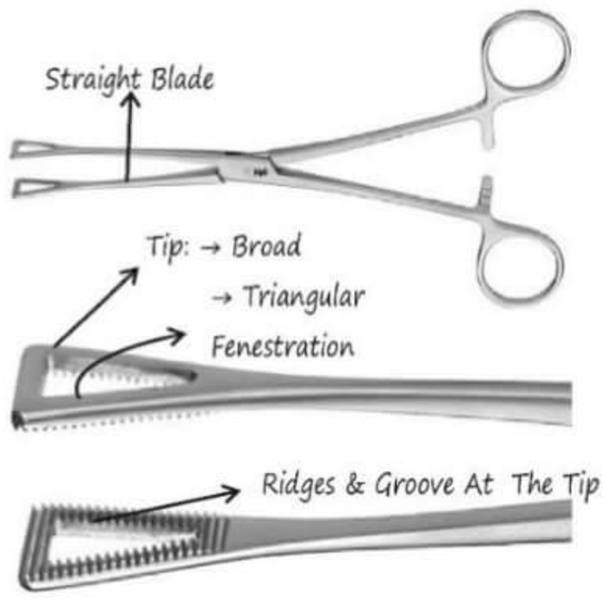

7. Pile holding forceps

→ **Blade** - Strong & curved

→ **Tip** – Has Fenestration

Uses

→ To hold piles mass during piles surgery

8. Ovum Forceps

→ Commonly used in gynaecologic surgeries

Uses

→ To remove placental fragments & Small endometrial polyps

→ For removing stones from gall bladder during extraction

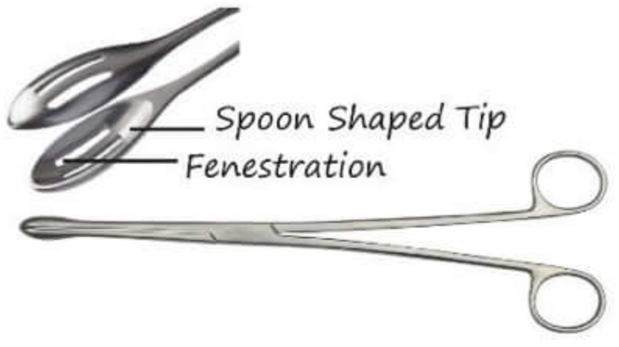

PrepLadder

9. Yeoman punch Biopsy Forceps

→ Has 2 strong stout jaws at the tip

Uses

→ For taking punch Biopsy in Rectal lesions like

- Carcinoma
- Rectal Polyp
- Rectal Ulcer

10. Cord Holding forceps / Hernia Ring

→ Has 2 semi-circular blades

Uses

→ To isolate the cord structures from operative area during sac dissection

→ To retract cord away from the site of repair

RETRACTORS

→ Used to hold open edges of wounds

→ Used to hold organs or tissues away from working area of surgery

1. Czerny's retractor

→ Has a **Solid blade** at right angle to the shaft

→ Presence of **Biflanged blade** (Blade with 2 prongs facing opposite)

→ **Tip** – curved inwards

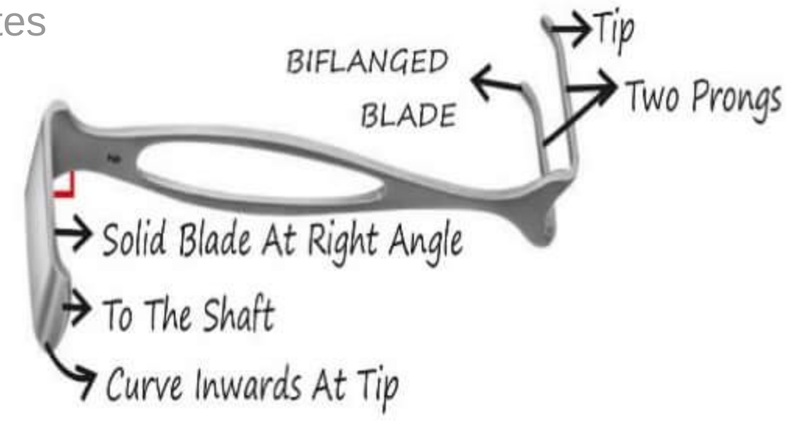

Uses of solid blade

→ Tissue retraction in

- Appendectomy
- Hernia repair
- Thyroidectomy
- Mastectomy

Use of Biflanged blade

→ Retracts the ends of incision while suturing the incision layer

PrepLadder

2. Langenbeck's Retractor

→ **Blade** – right angled to the shaft

→ **Tip** – right angled to the blade

→ **Handle** has

- Serrations – for better grip
- Fenestrations – for lighter weight

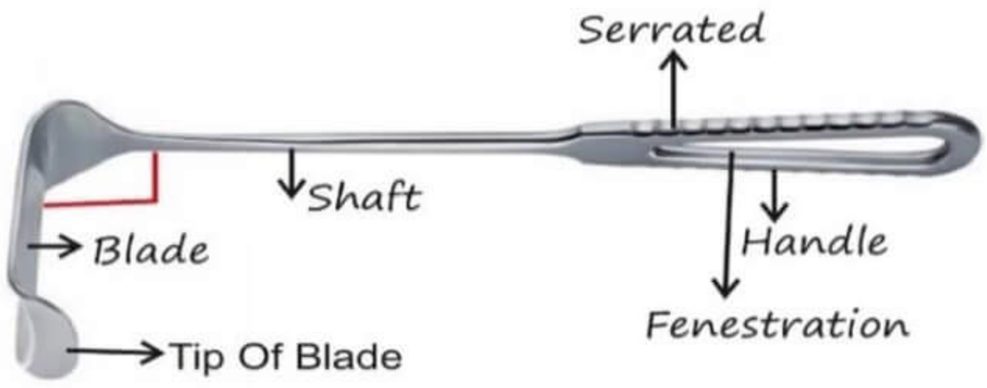

Uses

→ Used for tissue retraction in

- Appendectomy
- Thyroidectomy
- Hernia repair
- Mastectomy

3. Morris Retractor

→ **Blade**

- Wider
- Concavity in blade - provides more working space

→ **Tip** – more curved inwards

Uses

→ Tissue retraction in laparotomy

→ To retracts intra-abdominal viscus

t.me/latestpgnotes

4. Doyen's Retractor

→ **Blade** – more curved inwards than Morris Retractor

→ **Tip** – more curved inwards

Uses

→ Mainly used in pelvic surgeries (like LAR & APR – for CA Rectum) – to retract bladder & uterus

Difference between retractors

	Langenbeck's	Morris	Doyen's
Handle	Fenestrated	Fenestrated	No fenestration
Blade	Wide	Wider & more curved	More curved inside
Tip		More curved	More curved
			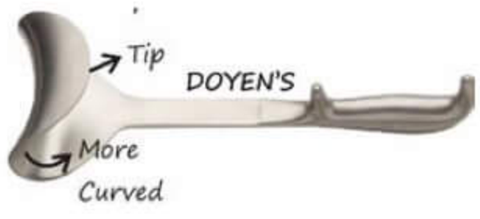

PrepLadder

5. Kelly Retractor

→ **Handle** – has standard hollow grip
→ **Blade** – right angled to shaft
→ **Tip** – slightly bent crescent shaped lip

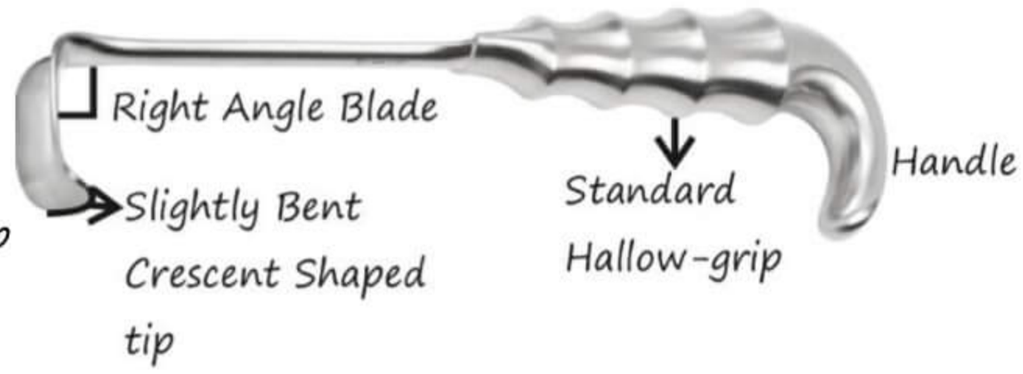

Uses

→ Mainly used in pelvic surgeries like Rectal dissection

6. Deaver's Retractor

→ Has shape like - "?"
→ Presence of flat curved blade with concavity
→ Long handle with hook at end – provides firm grip during retraction

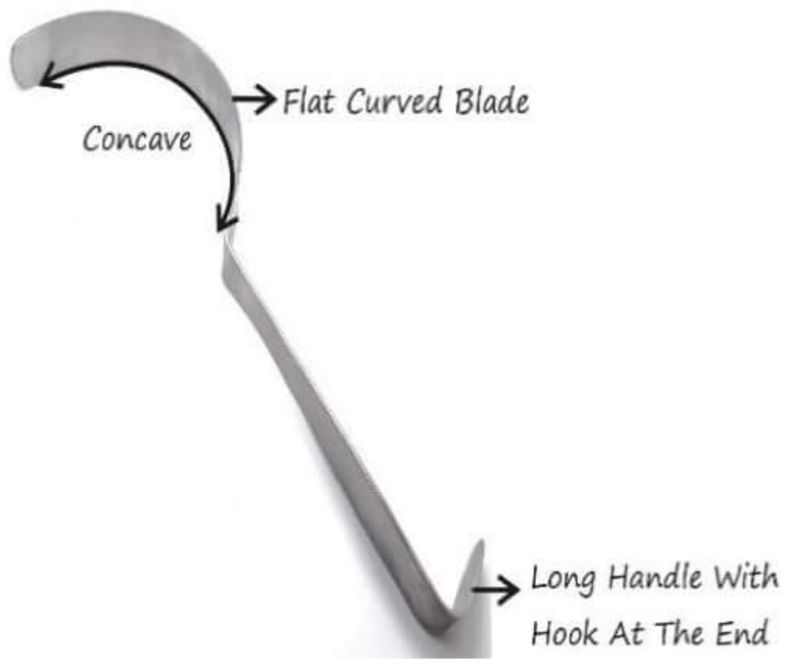

Uses

→ To retract tissues and intra-abdominal organs in
- Open cholecystectomy
- Hepatectomy
- Gastrectomy, Truncal vagotomy
- Bowel surgeries

t.me/latestpgnotes

7. Farabeuf's Double ended retractor

→ Flat solid blade at both ends
→ Curved tip



Used in

→ Dentistry
→ Wrist & Hand surgeries
→ Hernia Sx

8. Single Hook Retractor

→ Has a hook at tip in one end

Uses

1) Operations at skin surface

→ To left skin flaps/edges during
- LN excision
- Excision of Sebaceous Cyst & Lipoma

2) To Retract the edges of skin flaps in
- Mastectomy
- Thyroidectomy

PrepLadder

9. Double Hook Retractor

→ Tip of blade has 2 hooks

Uses

→ Same as single hook retractor

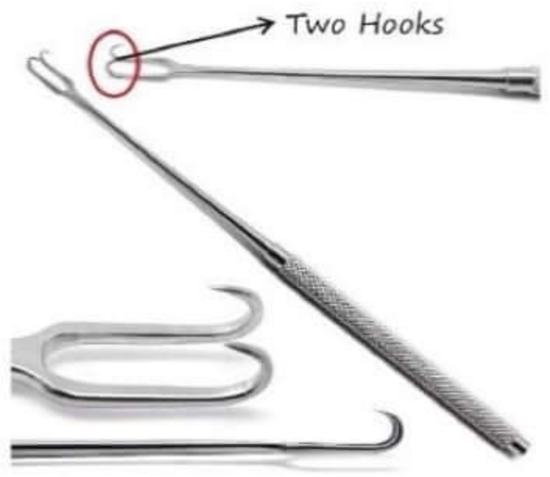

10. Volkmann Retractor / Cat's Paw Retractor

→ End of blade has multiple pointed sharp edges – for firm retraction

Uses

→ To Retract tough structure such as Fascia in

- Palm
- Sole
- Scalp

→ Retraction of skin edges during excision of

- Cyst
- Lipoma
- LN

t.me/latestpgnotes

11. Joll's Thyroid Retractor

→ Ends has – 2 towel clips like forceps

→ Screw mechanism to adjust the jaws

→ It is Self-retaining

Uses

→ To Hold and retract upper & lower skin flap during thyroid surgery

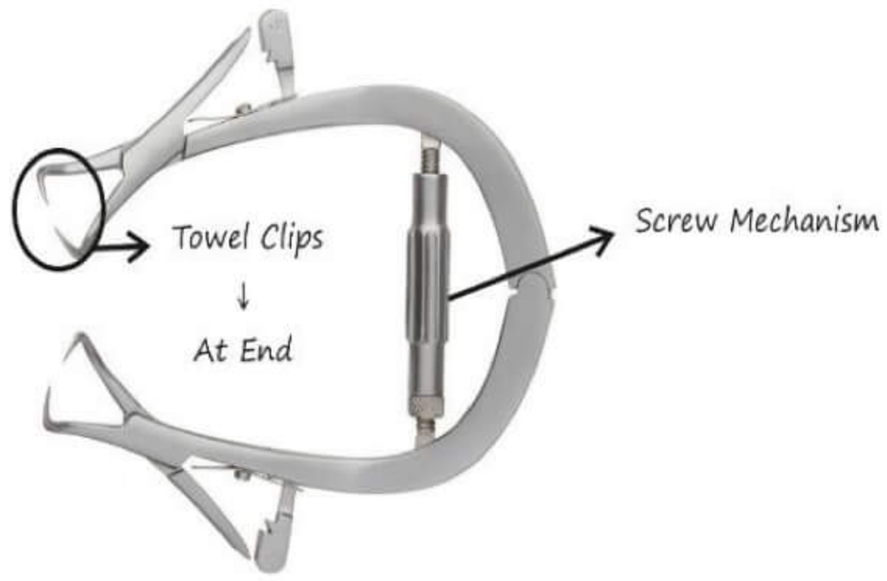

12. Doyen's Mouth Gag

→ **Blades** – Semi-circular & curved at tip

Uses

→ To Keep mouth open during intra-oral surgeries like

- Glossectomy
- Cleft palate
- Intra-oral ranula
- To acquire biopsy from suspicious lesion

PrepLadder

13. Balfour's self-retaining abdominal wall retractor

→ Has a **horizontal bar** with a fixed blade at one end & a sliding blade at the other end

→ The bar also has a screw – for fixing the third blade

→ It is self-retaining

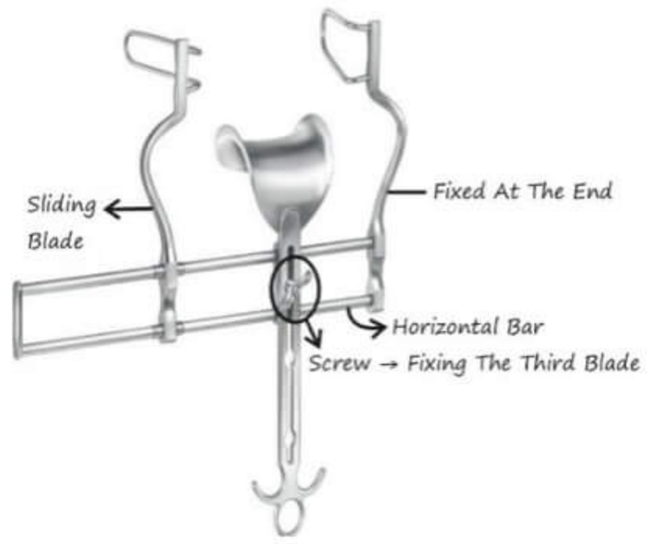

Uses

→ Retract cut edges of anterior Abdominal wall in major surgeries like

- Gastrectomy
- Hepatectomy

→ **Third blade** – Mainly used in pelvic surgeries (like LAR & APR – for CA Rectum) – to retract bladder & uterus

14. Beckman Weitlaner's retractor

→ Has 2-6 blunt/sharp outward-curving prongs

→ Prongs interdigitate on closing

Uses

→ Retract/hold back tissue or bone for exposure

www.latestpgnotes

15. Scapula Retractor

→ Has **long stout handle**

→ **Blade** – wide & right angled

Uses

→ To retract scapula during thoracotomy

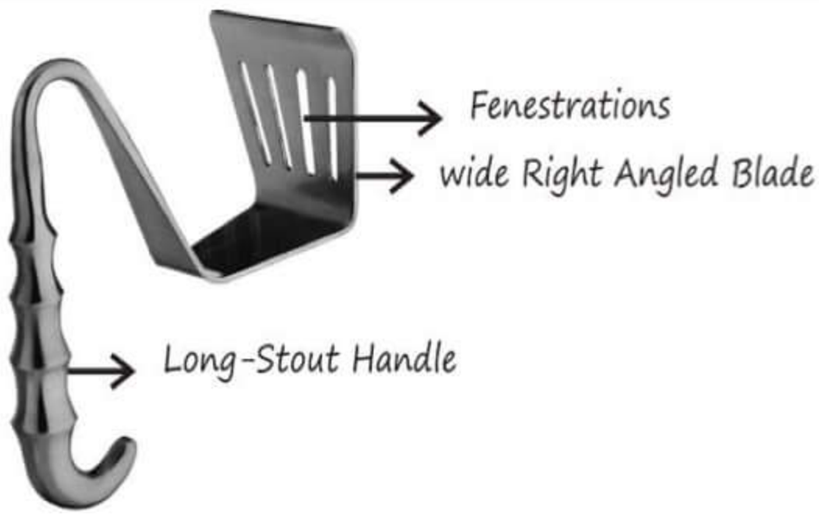

16. Allison Lung Retractor

→ **Blade** – made of wires in the form of net

→ **Handle** – long curved cylinder for firm grip

Uses

→ Prevents the damage to lung during retraction

→ Esophageal retraction in CA esophagus



PrepLadder

17. Bladder Neck Retractor

→ **Blade** – long & thin

→ Presence of hook at the end

Uses

→ Retract bladder neck during bladder surgery



CLAMPS

→ Presses 2 or more parts together to constrict or hold firmly

Types

a) Intestinal Occlusion Clamps

1. Doyen intestinal occlusion clamp (Non-crushing)

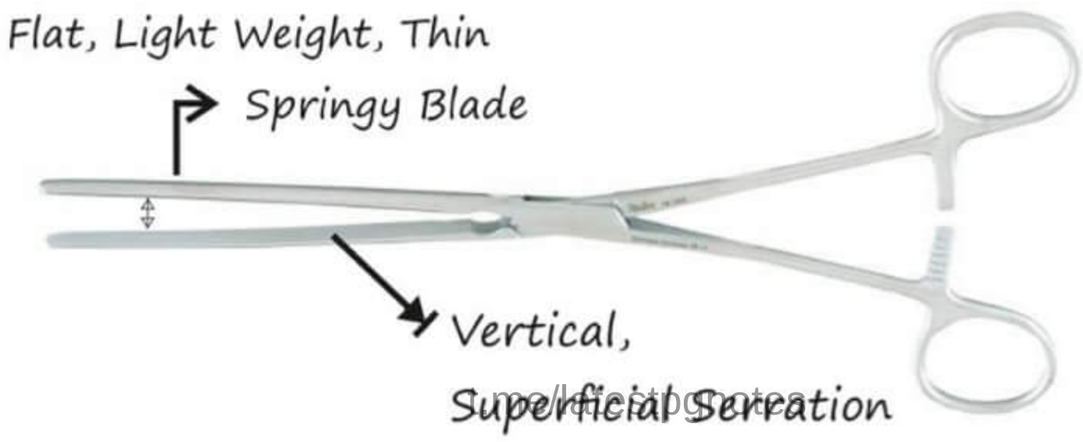

→ **Blade**

- Has vertical superficial serrations
- Has slight concavity & gap to allow bulging of bowel while clamping

→ **Uses**

- Clamp the intestine to prevent spillage of intestinal content

2. Payer's crushing clamp

→ Heavy instrument

→ Works by **double lever mechanism**

- First lever – opposes the blade firmly
- Second lever -multiplies exerted pressure & crushes the viscus

→ **Blade** – has Vertical deep serrations

→ **Uses**

- During Resection & Anastomoses of bowel
- During Gastrectomy

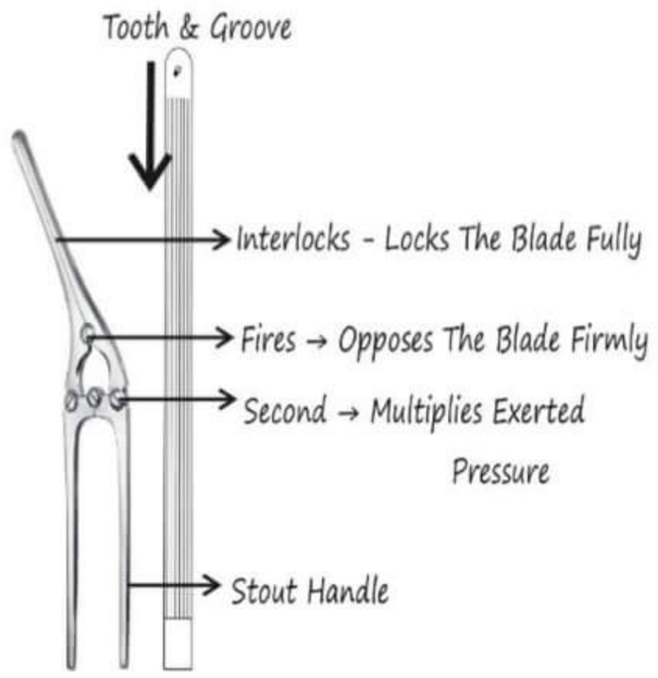

PrepLadder

b) Vascular clamps

1. Light's bull dog clamp

→ Has **Pinch-cock** like action

→ **Blade** - has fine transverse serrations

→ **Uses**

- Temporary occlusion of small blood vessel



2. Pott's bulldog clamp

→ **Paper-clip** like instrument

→ Has **spring loaded handle** – permits secure grip of vessel

→ **Uses**

- Temporary occlusion of small peripheral blood vessels

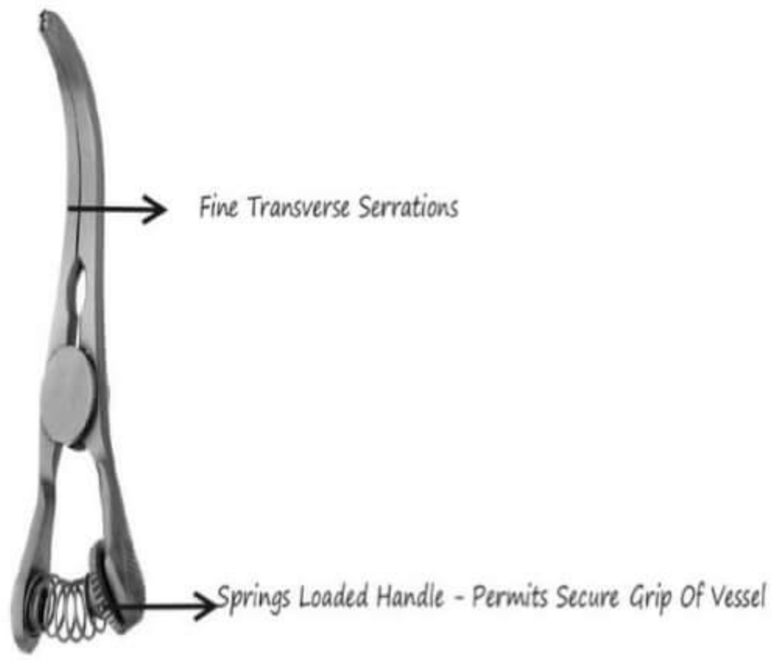

3. Satinsky Vascular clamp

t.me/latestpgnotes

→ **Shaft & blade** – both has Different degrees of angulation

→ **Advantages of angulation**

- Help to clamp the vessel in depth
- Does not obstruct the vision of surgeon

→ **Uses**

- Partial occlusion of large vessels like IVC, SVC, Aorta and its major branches – so that blood flow is maintained

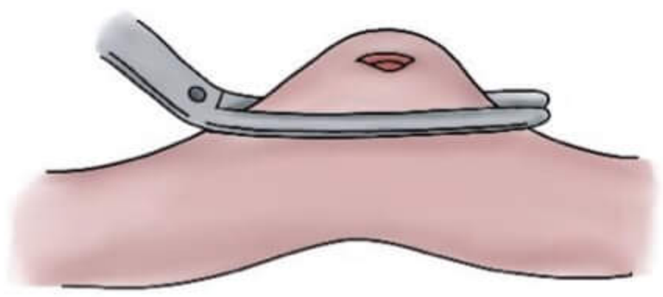

PrepLadder

SCISSORS

1. Mayo Scissor

→ Long and stout

Uses

→ To cut the sutures

→ To cut the tough structures like

- Line alba
- Aponeurosis
- Sheath & ligaments

2. Metzenbaum scissors

→ Lighter than Mayo

→ Has short blade & long shaft

Uses

→ For fine dissections

→ Cutting delicate structures

- To open Peritoneum
- To dissect the sac from cord
- To cut the intestine in resection & anastomosis

t.me/latestpgnotes

3. Lister bandage scissors

→ **Blades**

- Distal blades are bent at an angle
- Lower blade has flat, blunt atraumatic tip

Uses

→ To cut bandages

PrepLadder

Dilators

→ Enlarges any opening in a progressive manner

1) Tracheal dilator

→ **Tip of blade** – olive pointed, blunt & smooth to prevent trauma of tracheal mucosa

→ **Curvature of blade** – gently curved

Uses

→ During tracheostomy

→ Helps in reinsertion of tracheostomy tube

2) Urethral dilators

→ Used to dilate urethra in

- Strictures
- Before cystoscopy

3) Bake's bile duct dilator

→ Has a oval solid tip attached to a narrow stem

t.me/latestpgnotes



Uses

→ Used in choledacholithotomy in dilatation of bile duct after removal of CBD stone

→ Sounding of bile duct for any retained stone

→ Check the patency of Ampulla of vater

4) Volkmann Scoop

→ **Uses**

- Debriding the contents of abscess cavity, sinus or fistula
- Used for collection of cancellous bone graft

PrepLadder

5) *Gall stone Scoop*

→ **Flat instrument**

→ Both ends have **Spoon shaped tip**

Uses

→ To remove stone from Gall Bladder

t.me/latestpgnotes

PrepLadder

INSTRUMENTS PART- 3

Laparoscopic Instruments

1. Veress Needle

→ Used to create Pneumoperitoneum **(closed method)**

→ **Sharp tipped needle** – penetrates the abdominal wall

→ **Blunt tipped obturator** – Springs forward to prevent Iatrogenic injury

→ **Intraperitoneal position of Veress needle** – Checked by **Saline Drop test**

Saline Drop Test

Attach a syringe with saline to Veress needle

↓

Aspirate

↓

Remove plunger of syringe

↓

Observe for free flow of saline into peritoneal cavity

t.me/latestpgnotes

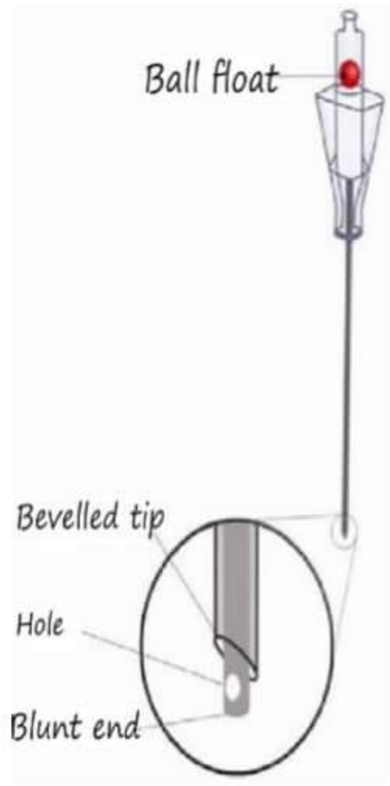

2. Hasson Cannula

→ Used for creating pneumoperitoneum **(open method)**

→ Mainly used for patients having

- Upper abdomen surgery
- Ileus

→ **Advantages** - Less chance of vascular injury

PrepLadder

3. Trocar

→ **Obturator** – has Pyramidal cutting tip

↓

Pierce muscle & rectus sheath



Uses

→ Access Peritoneal cavity

→ For maintaining Pneumoperitoneum when instruments are exchanged

4. Laparoscope

→ It is based on Hopkin's optical system

→ **Function**

- Provides Visualisation & Magnification

→ **Types**

- Oblique viewing – 30°/45°/60° (preferred because of larger field of vision)
- End viewing – 0°

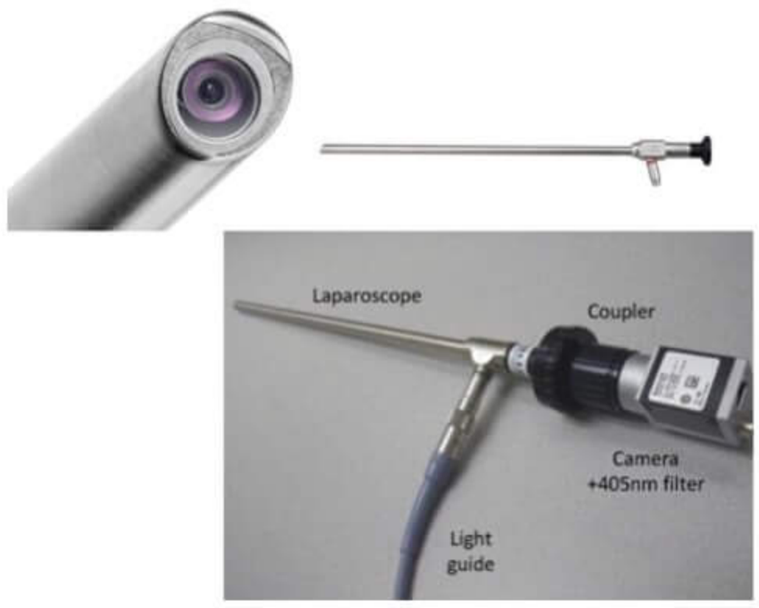

t.me/latestpgnotes

5. Other instruments used during Laparoscopy

A. Maryland

B. Blunt

C. Alligator

D. Right-angle dissector

E. Babcock

F. Fenestrated

PrepLadder

Staplers & Tubes used in Surgery

1. Linear cutter & Transverse stapler

→ **Linear cutter** divides GI organ with a knife while simultaneously firing a double row of parallel staplers at each end

→ Also used to create communication between two part of bowels and the ends are stapled with **Transverse stapler**

Linear cutter

Transverse stapler

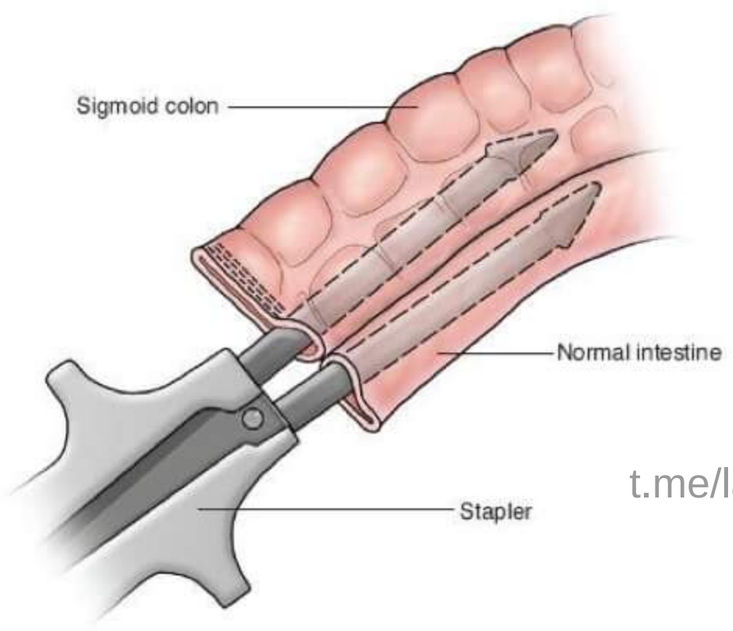

t.me/latestpgnotes

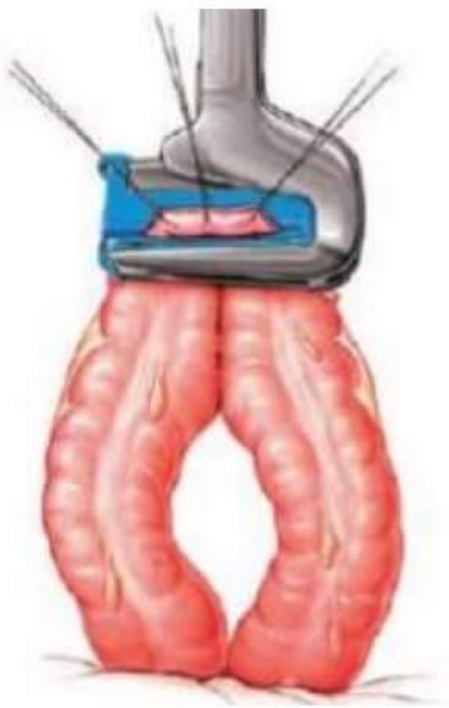

2. Intra-luminal / Circular stapler

→ Helps in anastomosis of tubular structures

Uses

→ In ileal pouch anal anastomosis for
- Ulcerative colitis
- FAP

→ In LAR – for CA Retum

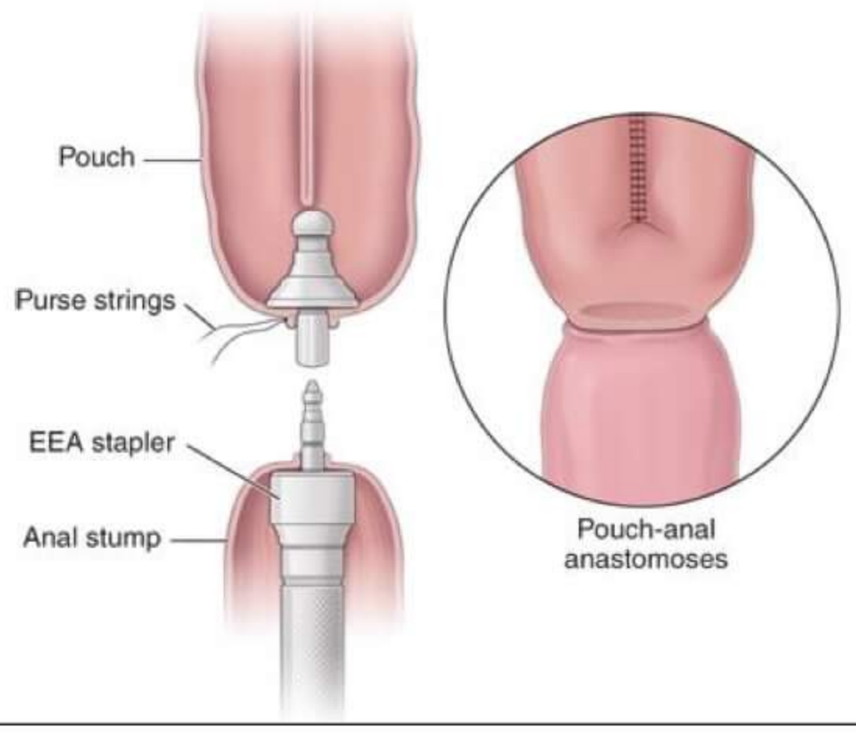

PrepLadder

3. Skin stapler

→ Has **Cartridge** – contains stapler

→ Fastest method of closure of long skin incision

4. Yankauer's suction cannula

→ **Tip**

- Blunt, smooth & rounded
- Has 2 side holes & 1 main hole

→ **Body is angulated** – doesn't obstruct the surgeon's field of vision



Uses

→ Used in surgeries where large volume of fluid should be sucked out

- Peritoneal lavage
  - Perforation peritonitis
  - Hemoperitoneum

t.me/latestpgnotes

5. Adson's suction cannula

→ Has a **Vent with thumb rest** – gives better control over suction cannula

→ Has **fine suction tip**

Uses

→ In fine & meticulus surge

- Plastic surgery
- Reconstructive surgery
- Vascular surgery

6. Romovac suction drain

→ Has **corrugation** – on compressing suction is created

Uses

→ Thyroidectomy

→ Mastectomy

→ Flap & Reconstructive surgery



PrepLadder

7. Ryle's tube Nasogastric Tube



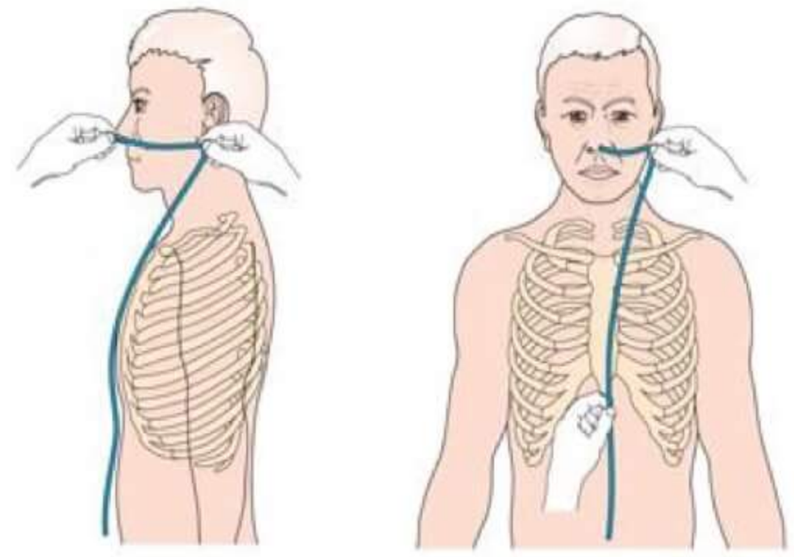

→ **Required length of Ryle's tube is measured**
- From nose to ear
- From ear to Xiphisternum

→ **Various markings in Ryle's tube**
- **40 cm** – GE junction
- **50 cm** – Body
- **60 cm** – Pylorus
- **65 cm** – Duodenum

Diagnostic Indications

→ Saline load test – for Gastric outlet obstruction

→ To asses free & total acid – In peptic Ulcer Patient

→ To diagnose TEF

→ Hollander's Test – to check Completion of Vagotomy

Therapeutic indications

→ For Decompression – Intestinal or gastric outlet obstruction
- Perforation peritonitis
- Upper GI bleed
- Upper Abdominal surgery

→ Nutrition – Enteral Nutrition

t.me/latestpgnotes

8. Infant feeding Tube

→ Has no marking / shots

Indications

→ Similar to Ryle's tube in infants + Children

9. Kehr's T-Tube

→ Used in bile duct surgeries especially Choledochotomy

→ Bile duct incision is closed over T-Tube – ↓ risk of leakage

→ T-tube acts as a stent – Kept for 4-6 weeks



PrepLadder

10. Sengstaken Blakemore Tube

→ Has Double balloon & Triple lumen

→ Most Common Complication – Aspiration

→ Airway should be protected by ET Intubation to avoid this complication

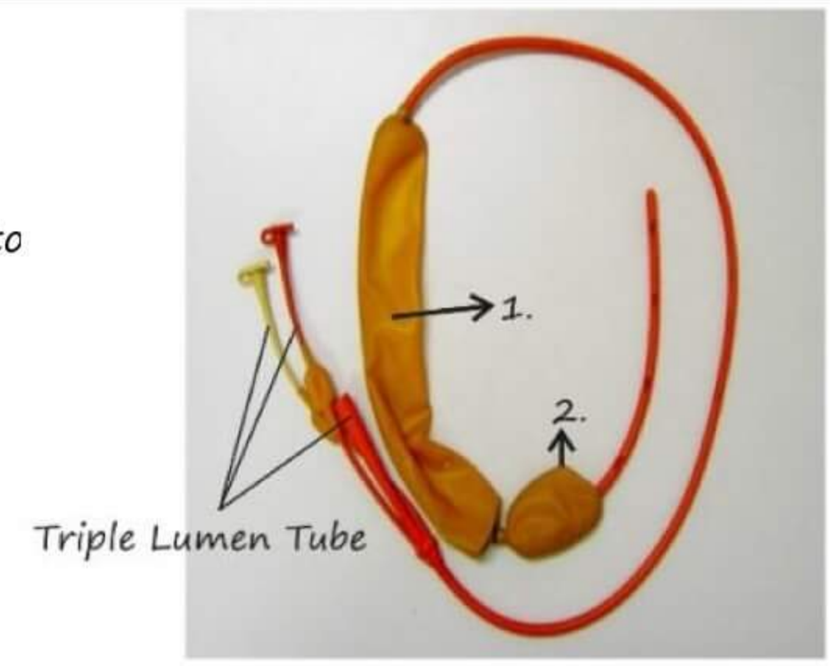

1. Esophageal baloon
2. Gastric Baloon

Uses

→ Used when bleeding is not controlled by medicines alone

→ During transportation to higher centre

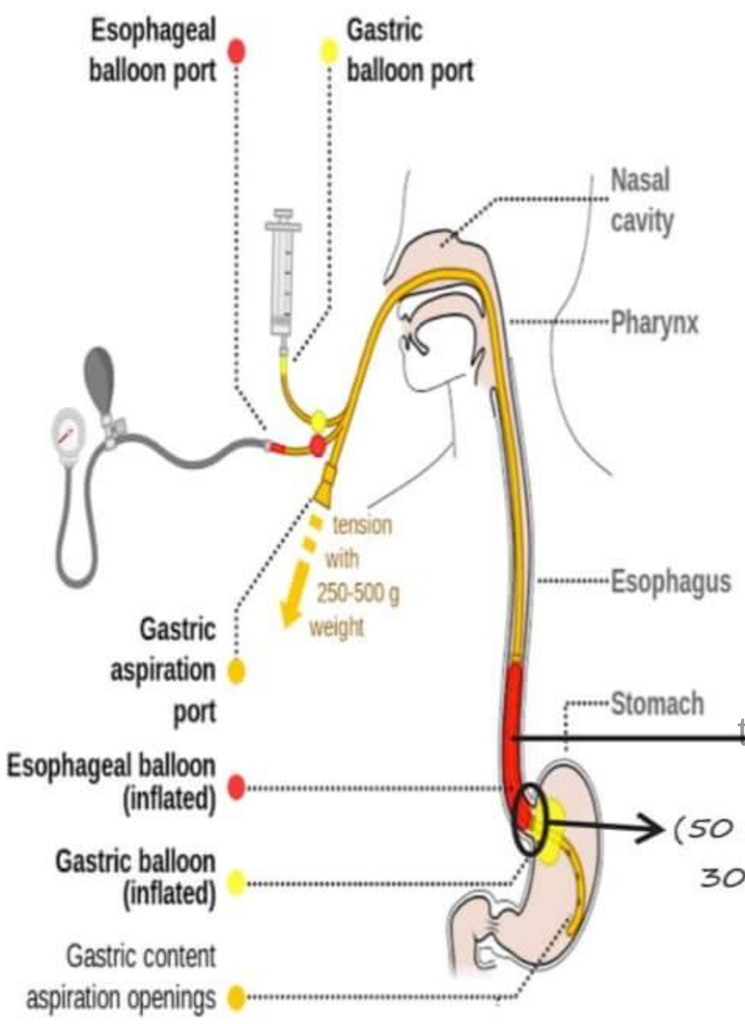

t.me/latestpgnotes

Catheters

1. Foley's Self Retaining Balloon Catheter

→ Made of **LATEX** - Less irritation & crust formation on prolonged use

→ **Types**

- 2-way foley catheter
  - **Main channel** → for drainage of urine
  - **Small channel** → for inflating balloon
- 3-way foley catheter
  - **Main channel** → for drainage of urine
  - **Small channel** → for inflating balloon
  - **Third channel** → for irrigation of bladder

PrepLadder

→ Capacity of the balloon – 5-50 ml
→ 10ml saline is inflated in the balloon – For self-retaining
→ 30-50 ml of saline is inflated in the balloon - For haemostatic compression effect
→ Diameter of catheter in mm = Fr/3 (Fr – French units)
E.g. if size of catheter is 18 French, then diameter = 18/3 = 6mm

Various sizes of catheter available are

→ In Paediatric patients = 4, 6, 8, 10
→ In Adults Patients = 12, 14, 16, 18
→ MC used size for male - 16
→ MC used size for female – 14

t.me/latestpgnotes

Uses

→ To relieve urinary retention
→ To measure urine output
→ For administration of intravesical chemotherapy
→ 3 ways catheter – for Irrigation after TURP
→ May be used for supra pubic cystostomy

2. Nelaton's catheter



→ Used for one-time emptying of bladder during or after surgery
→ Also used to determine the amount of urine in bladder

PrepLadder

3. Fogarty embolectomy catheter

→ Has a hollow tube with a balloon at the tip

→ It is inserted into blood vessel through a clot & removed by inflating the balloon

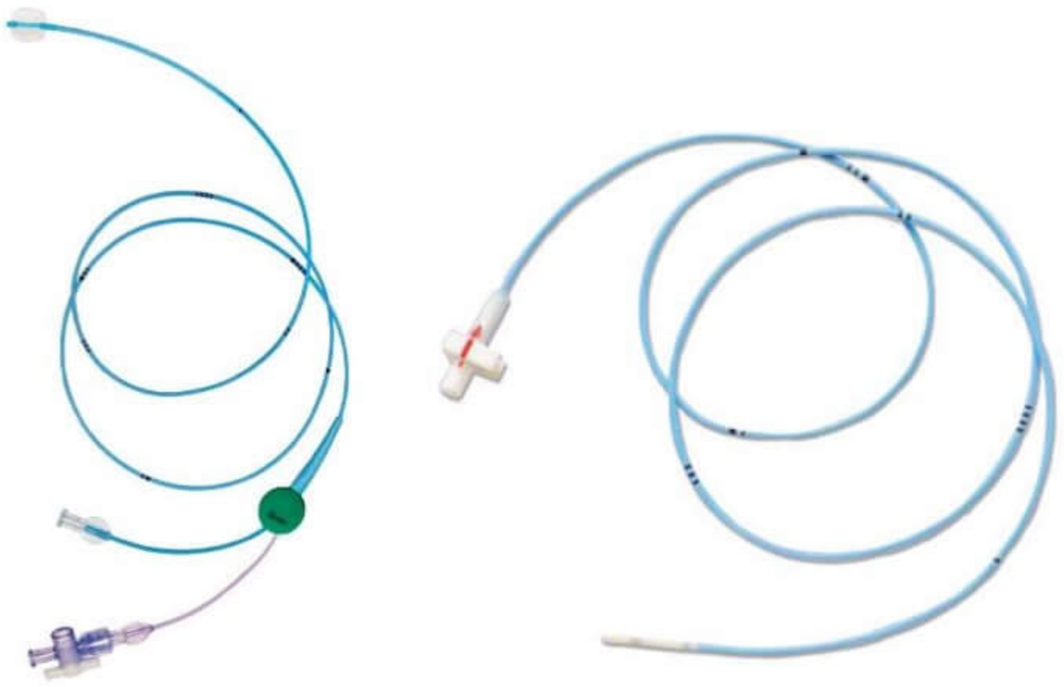

Uses

→ Remove fresh emboli from the vessel

4. Malecot's catheter

→ It is self-retaining

→ Has umbrella/flower at the tip

Uses

→ Draining of urine from bladder t.me/latestpgnotes

→ Draining of urine from kidney via P/C Nephrectomy

→ Drainage of intra-peritoneal collection

→ Also used as intercoastal drain (ICD)

5. Red rubber catheter

→ Non-self retaining

→ **Tip** – rounded & blunt

Uses

→ Temporarily used to drain urine from bladder

→ Estimate the residual urine

PrepLadder

6. Central venous Catheter

→ **Used for** – Fluid, medication, Nutrition Administration

→ **Preferred veins**

- Inside OT – Internal jugular Vein
- Outside OT – Subclavian Vein
- In acutely injured, critically ill patients – Femoral Vein

→ **Complication**

- MC complication of CVC – Catheter related sepsis
- Most dangerous complication – Pneumothorax

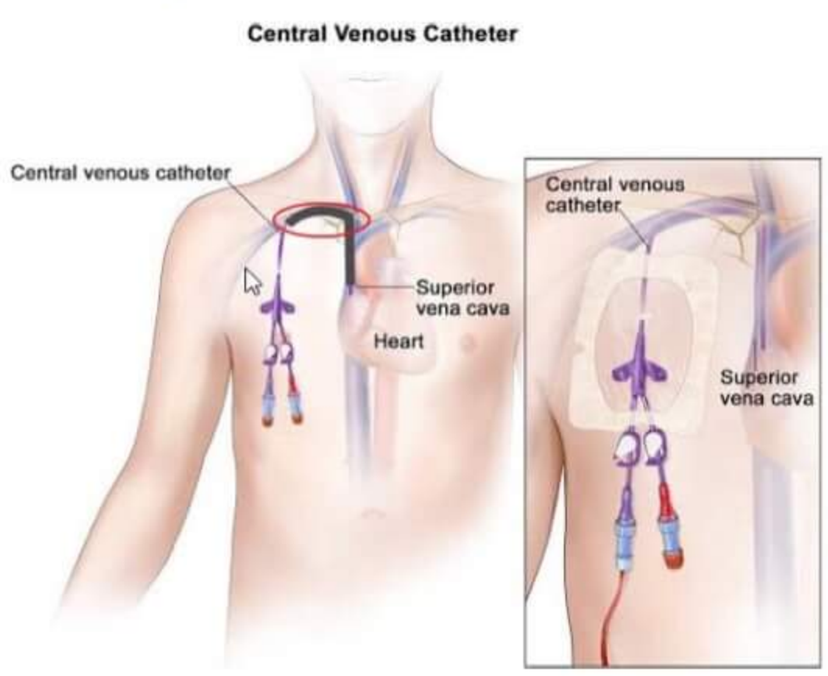

Cannulas

Colour code	Gauge	Flow rate	Indications
Orange	14	240 ml/ min	Trauma & Surgical procedures
Grey	16	180 ml/min	Trauma & Surgical procedures
Green	18	90 ml/min	Trauma & quick blood transfusion
Pink	20	60 ml/min	IV fluid / blood transfusion
Blue	22	36 ml/min	Children / Older adults
Yellow	24	20 ml/min	Neonates, children & for elderly
Violet	26	13 ml/min	Neonates

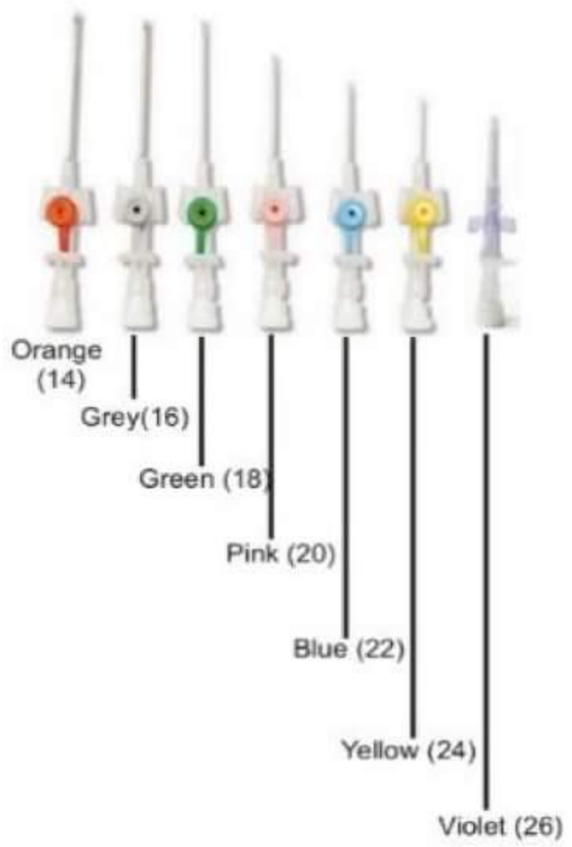

t.me/latestnotes

PrepLadder

Image based Questions related to Sutures

1. Catgut

→ Discovered by - John Hunter

→ Prepared from - Submucosa of sheep's ileum

→ Preservative used – Isopropyl alcohol

→ Absorbed in 60 days

2. Vicryl

→ AKA Polyglactin

→ It is a Co-polymer of Glycolide + Lactide

→ AKA Work horse suture of general surgeons

→ Absorbed in 60-90 days

→ Used in - CBD, Ureter, Bladder

3. Monocryl / Polyglycaprone

→ Copolymer of Glycolide + Caprolactone

→ Used for - Subcuticular suturing

→ Absorbed is 90-10 days

t.me/latestpgnotes

4. Polydioxanone

→ Has Lowest affinity for adherence to E. Coli and Staph aureus

→ Absorbed in 180 days

5. Silk

→ Non- absorbable

→ It is a Poly filament suture

→ Used for skin suturing

6. Prolene / Polypropylene

→ Non-Absorbable

→ Monofilament suture

→ Used for – Vascular anastomoses & Rectus sheath

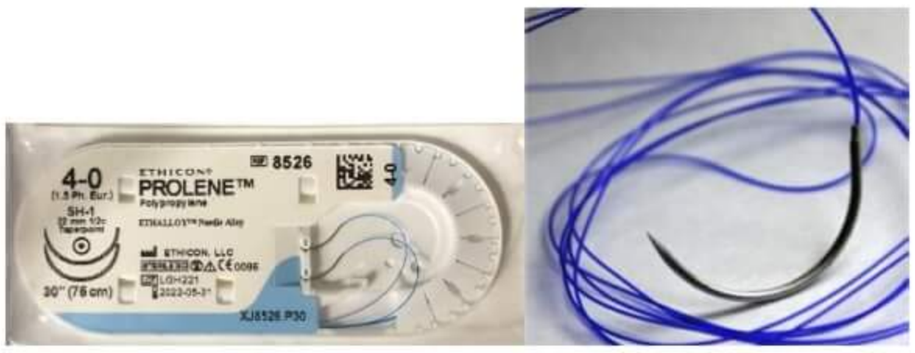

PrepLadder

Principle of Diathermy/Electro surgery

→ **Heat produced depends on**

1) Intensity of current
2) Wave form of current
3) Electrical property of tissue
4) Relative sizes of electrodes

→ **2 types of diathermy**

1) Monopolar cautery / diathermy
2) Bipolar cautery / diathermy

Monopolar diathermy

→ Most commonly used

→ Has Active electrode & Return electrode

Active electrode	Return electrode
• Small surface area	• Large surface area
• Active cable delivers AC current to the patient via Active electrode	• AC current is returned back to Return cable by Return electrode
• Heat produced by concentration current is used for **Cutting & Coagulation**	• Little heat is produced because of larger surface area

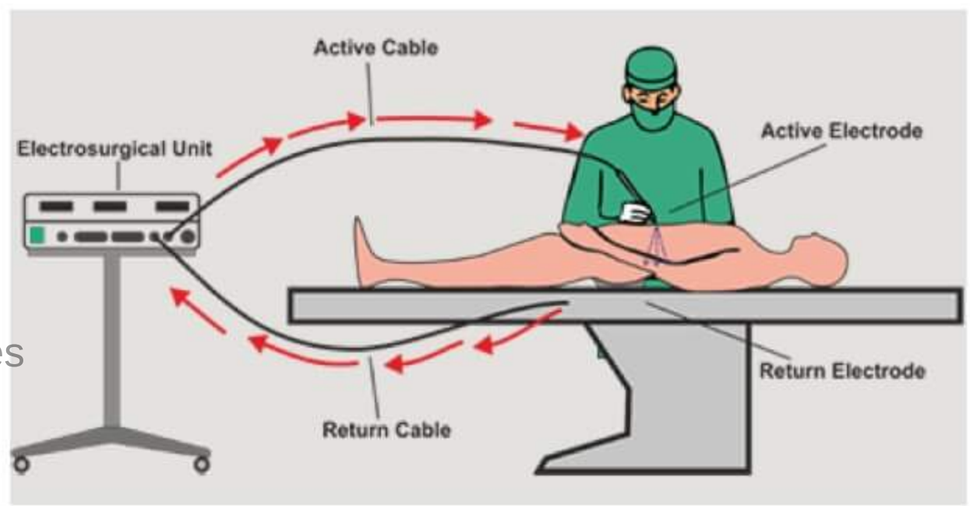

t.me/latestpgnotes

Bipolar diathermy

→ Bipolar forcep has 2 Active electrodes

→ The tissue caught between these 2 electrodes heats up & burnt while the surrounding tissues are spared from being burnt or having current passed through them

→ Used frequently in **Gynecological procedures**

PrepLadder

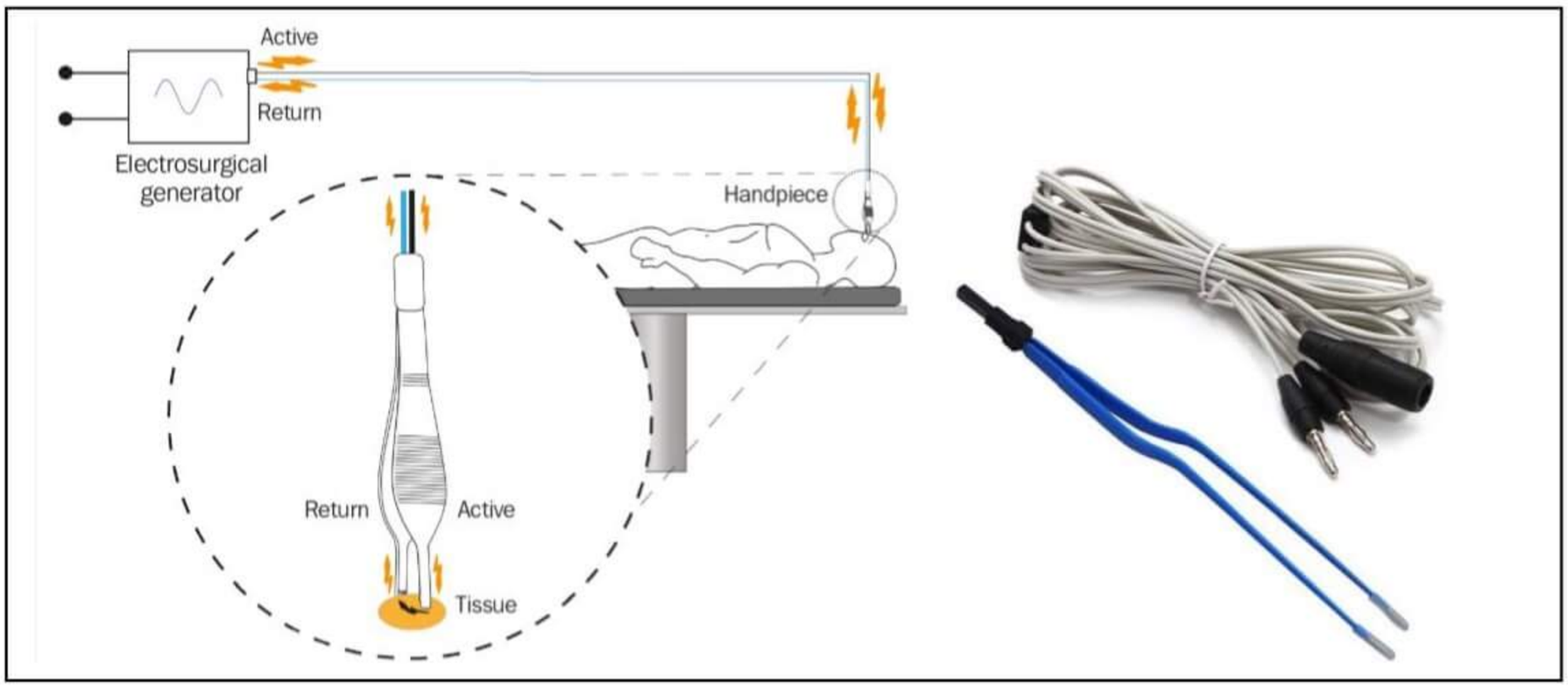

Effects of Diathermy

1) **Coagulation** – Activated by intermittent waveform
2) **Fulguration** – Destructive coagulation + Charring
3) **Cutting** – activated by constant waveform
4) **Blended waveform** – has the advantage of both Cutting & Coagulation

Capacitive coupling / Coupling capacitance

→ It is the transfer of energy from Active electrode to a nearby conductor causing **Stray current injury** to the nearby bowel or viscera

→ **2 Predisposing factors**

1) Relatively thin insulation layer
2) High frequency alternating current

→ Capacitance coupling can be avoided by using **Plastic port instead of Metallic port**

t.me/latestpgnotes

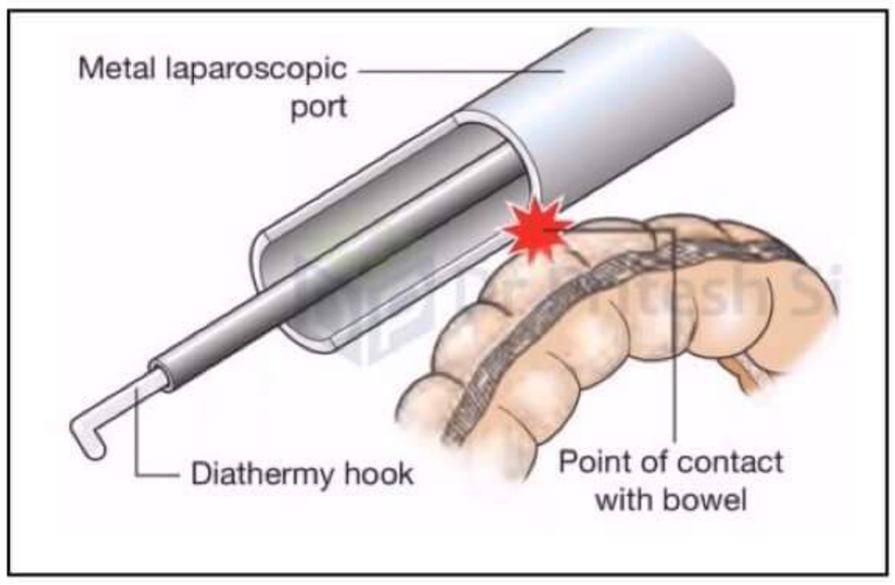

Ligasure

→ It is a new electrothermal Bipolar tissue sealing system

→ Minimum size of vessels that can be sealed by Ligasure – **upto 7mm diameter within 2-4 seconds**

→ It can also seal **Pedicle, tissue – bundles & Lymphatics**

→ Used during Laparoscopy in Abdominal & Pelvic surgeries

→ **Advantage** – improves vessel sealing with minimal lateral thermal spread

Ligasure

PrepLadder

Hormonic scalpel

→ It uses USG technology to cut tissues while simultaneously sealing them

→ The scalpel vibrates at a range of 20,000 – 50,000 Hz

→ Protein denaturation is caused by Vibration rather than heat

→ **Uses** - Divides artery & veins that are upto 7mm in diameter

→ **Advantages**

- Less thermal damage to adjacent tissue
- Less charring & less desiccation
- Reduced operative time
- Faster recover y

t.me/latestpgnotes

PrepLadder