
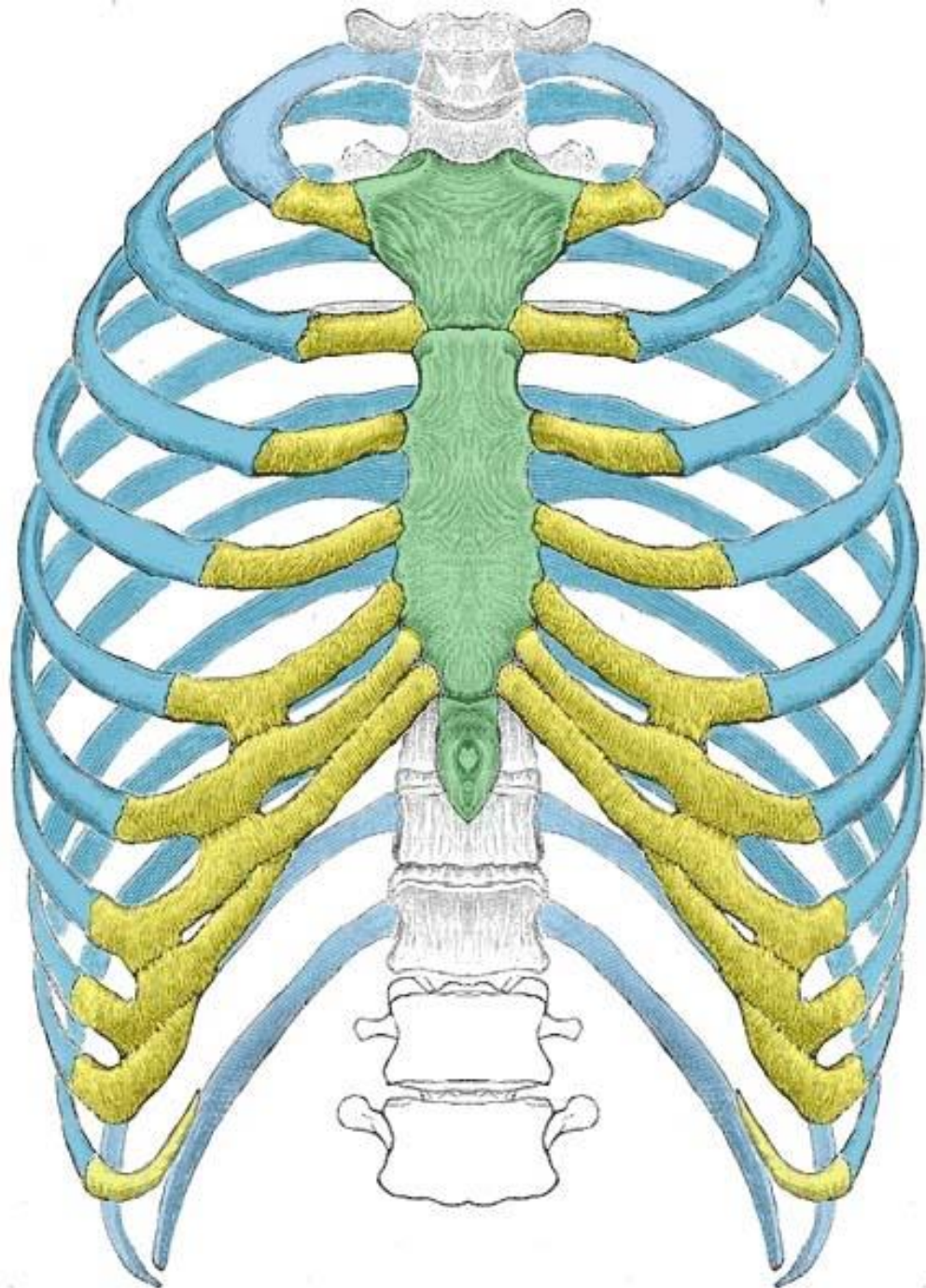



Thorax

thoracic cavity and thoracic viscera


By Dr Qaisar Afridi



Ribs



Costal Cartilage



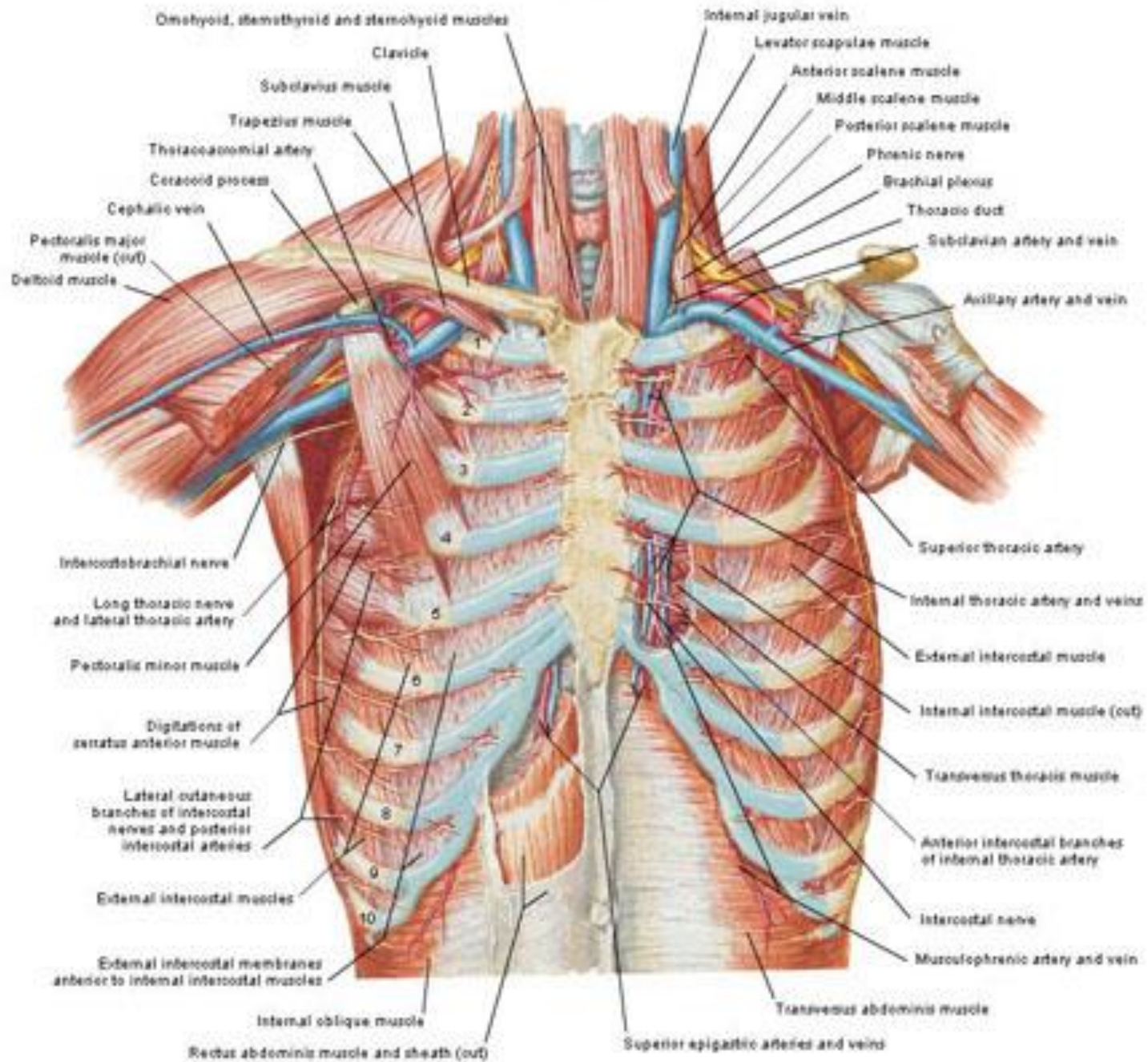
Sternum



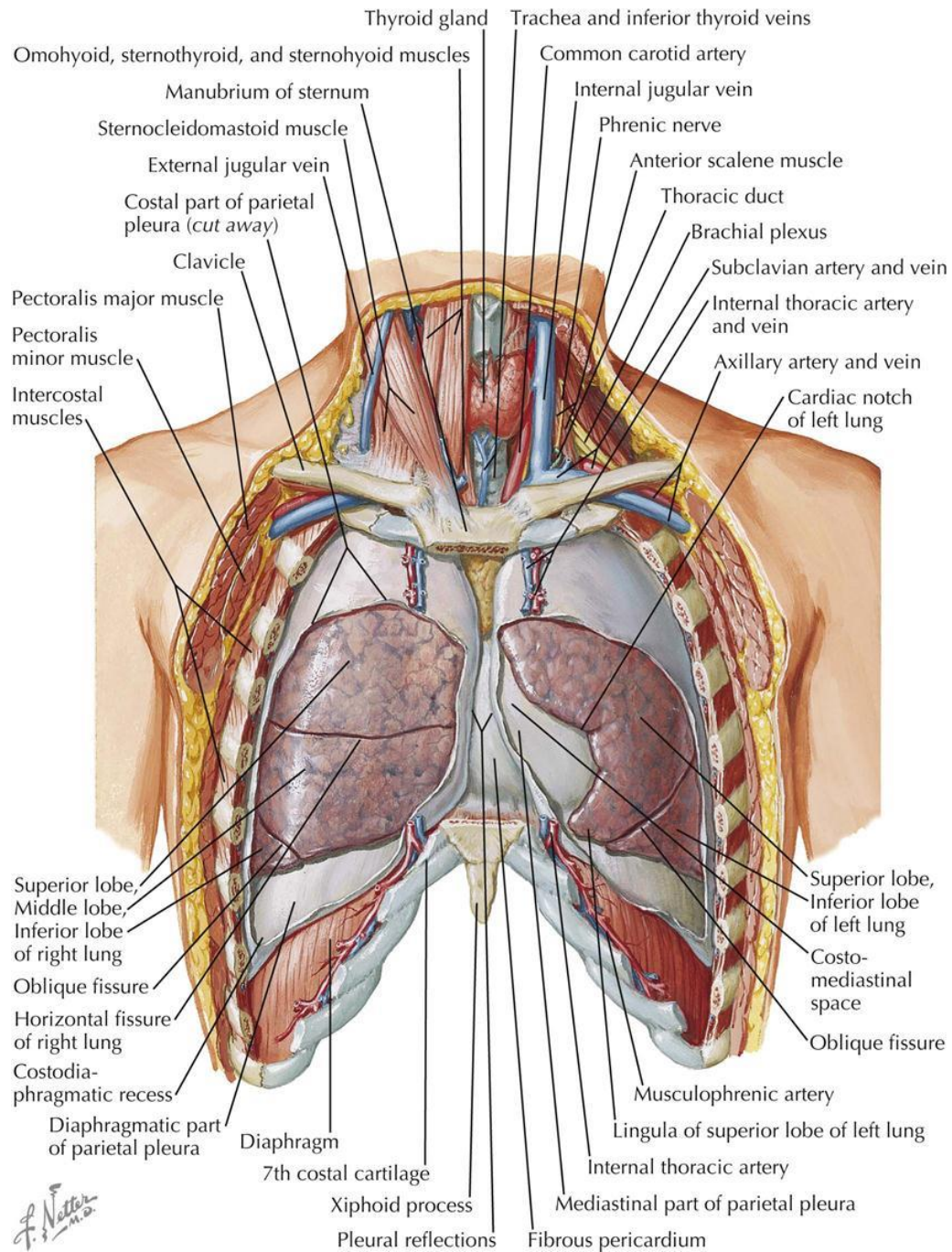
teachmeanatomy

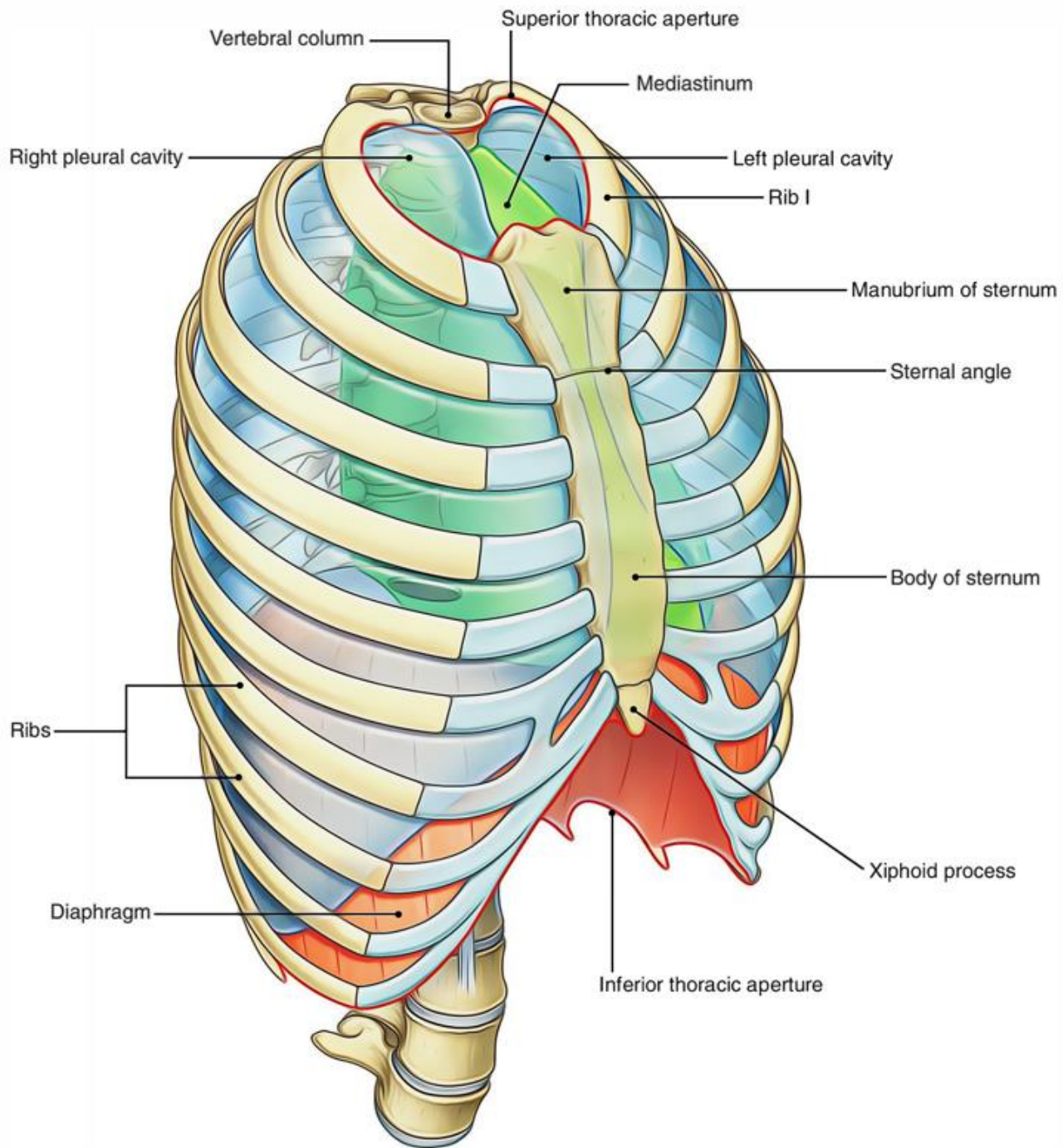
The #1 Applied Human Anatomy Site on the Web.

Anterior Thoracic Wall: Deep Dissection

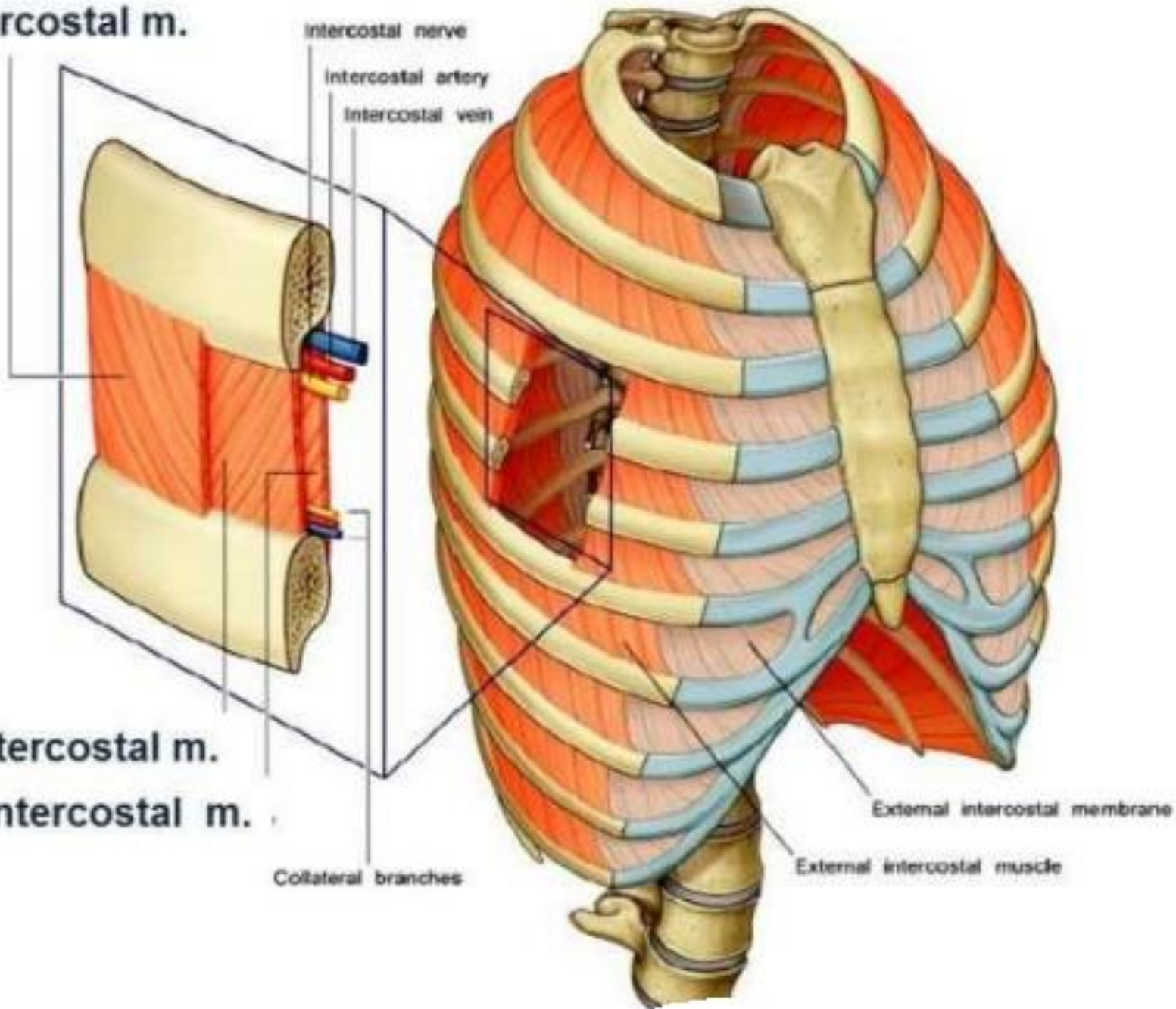


LUNGS IN SITU: ANTERIOR VIEW





External Intercostal m.



Internal Intercostal m.

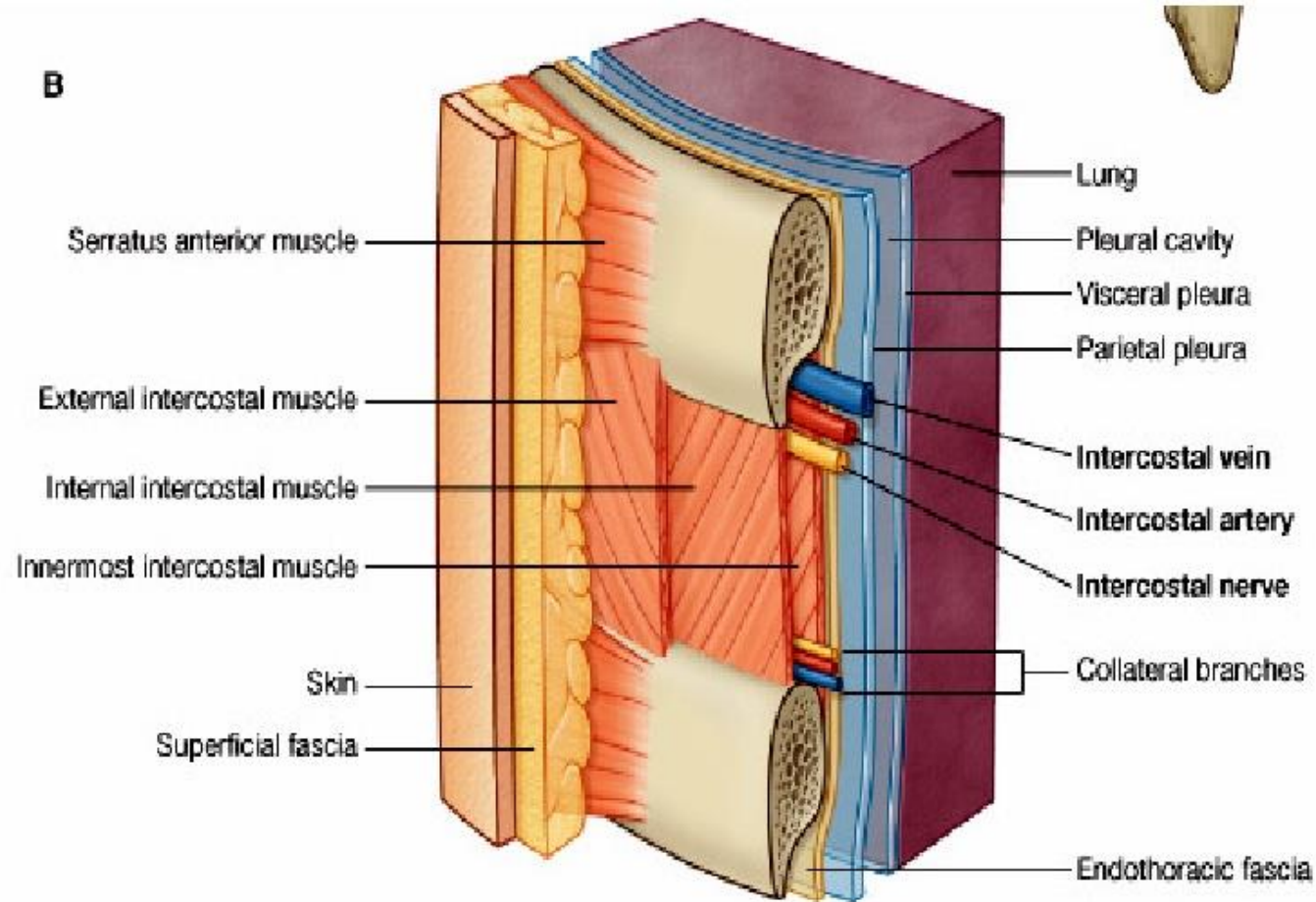
Innermost Intercostal m.

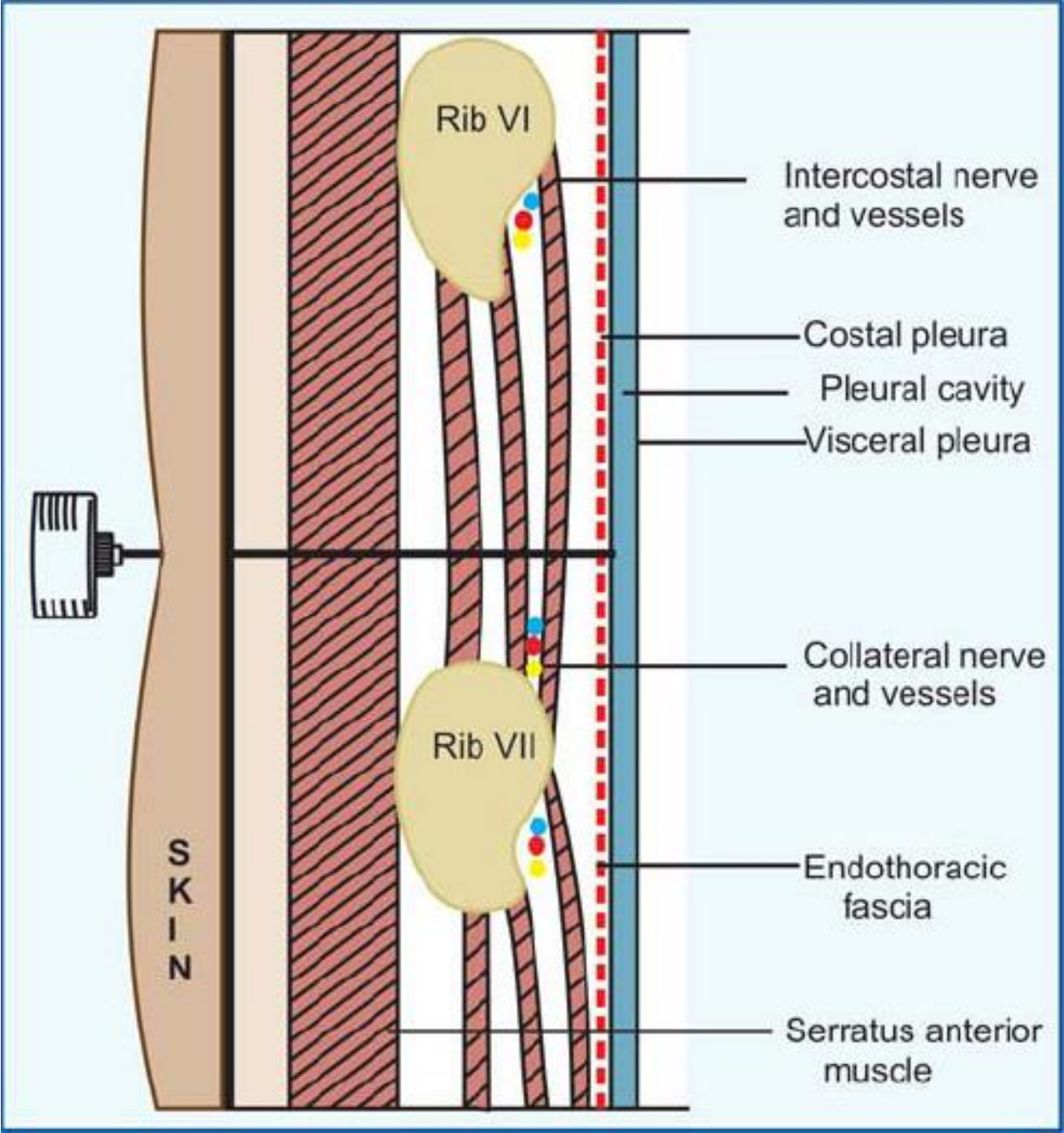
Collateral branches

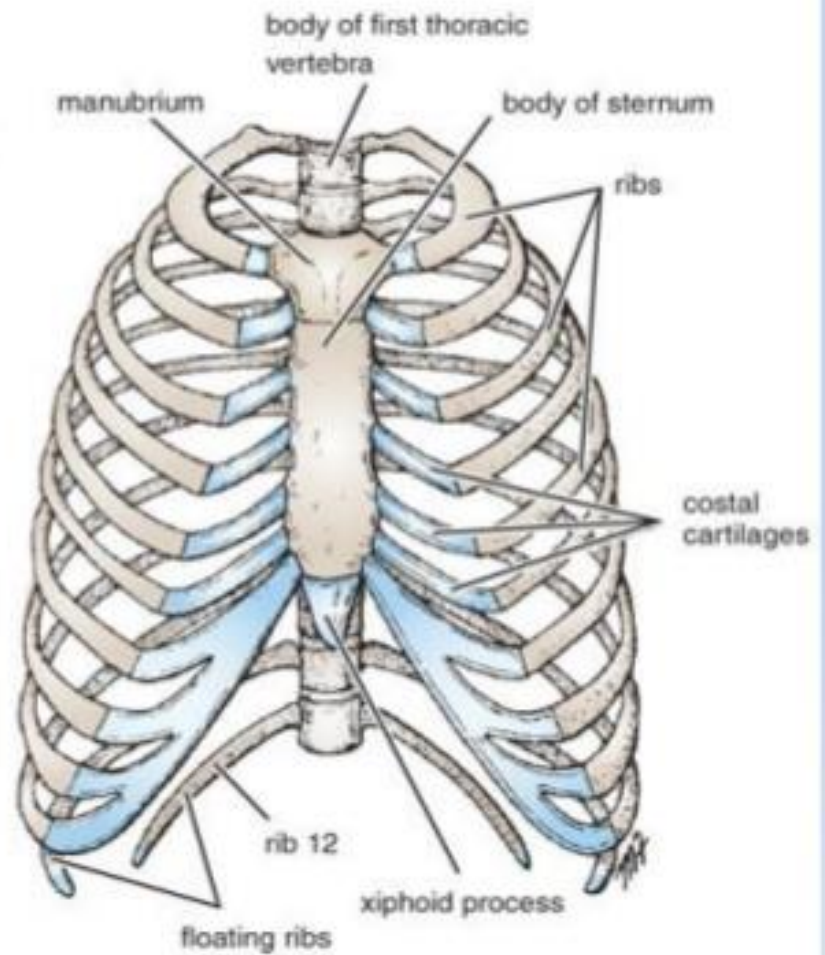
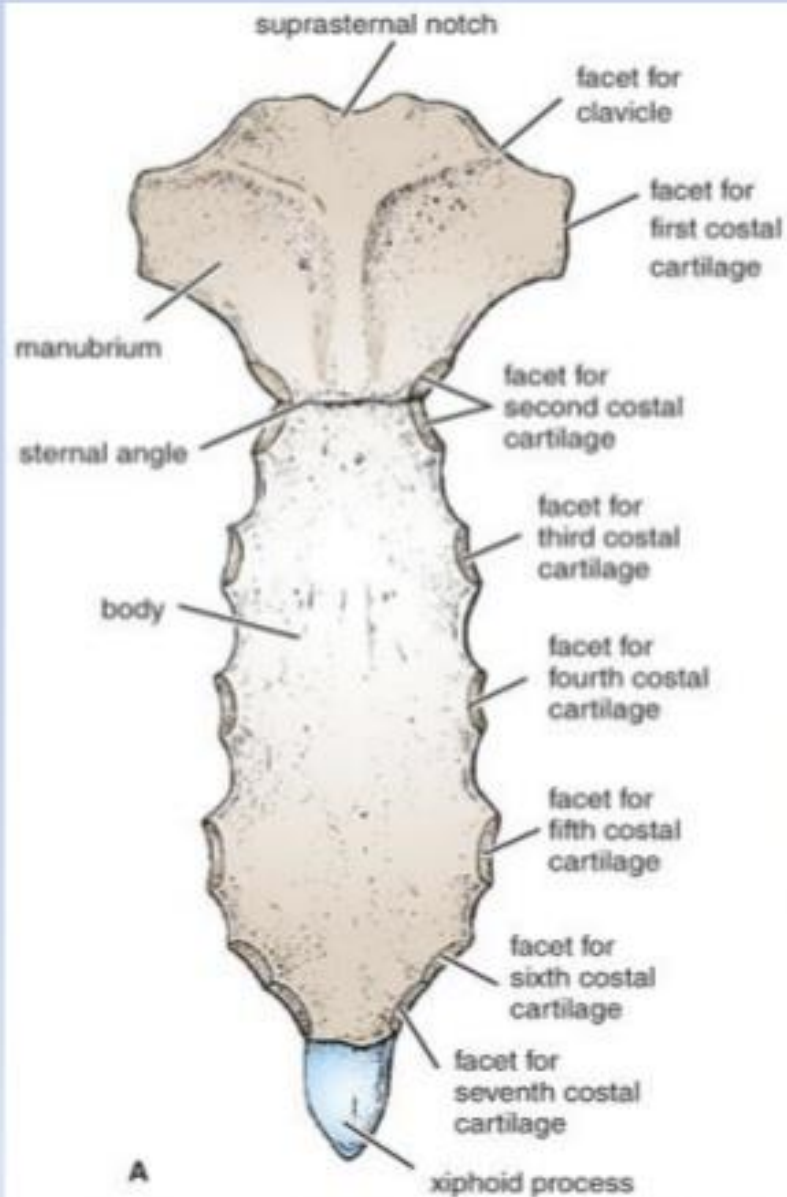
External intercostal membrane

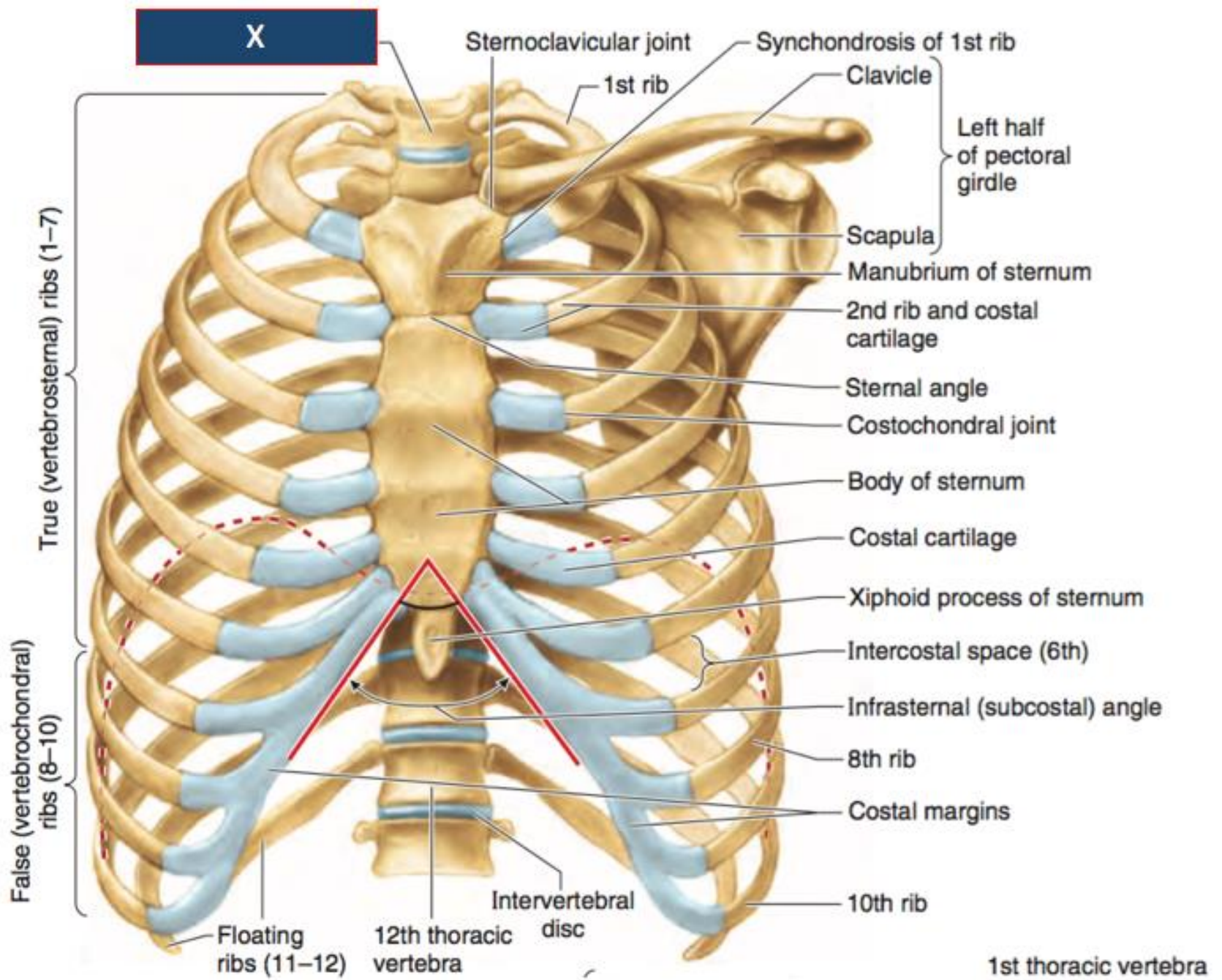
External intercostal muscle

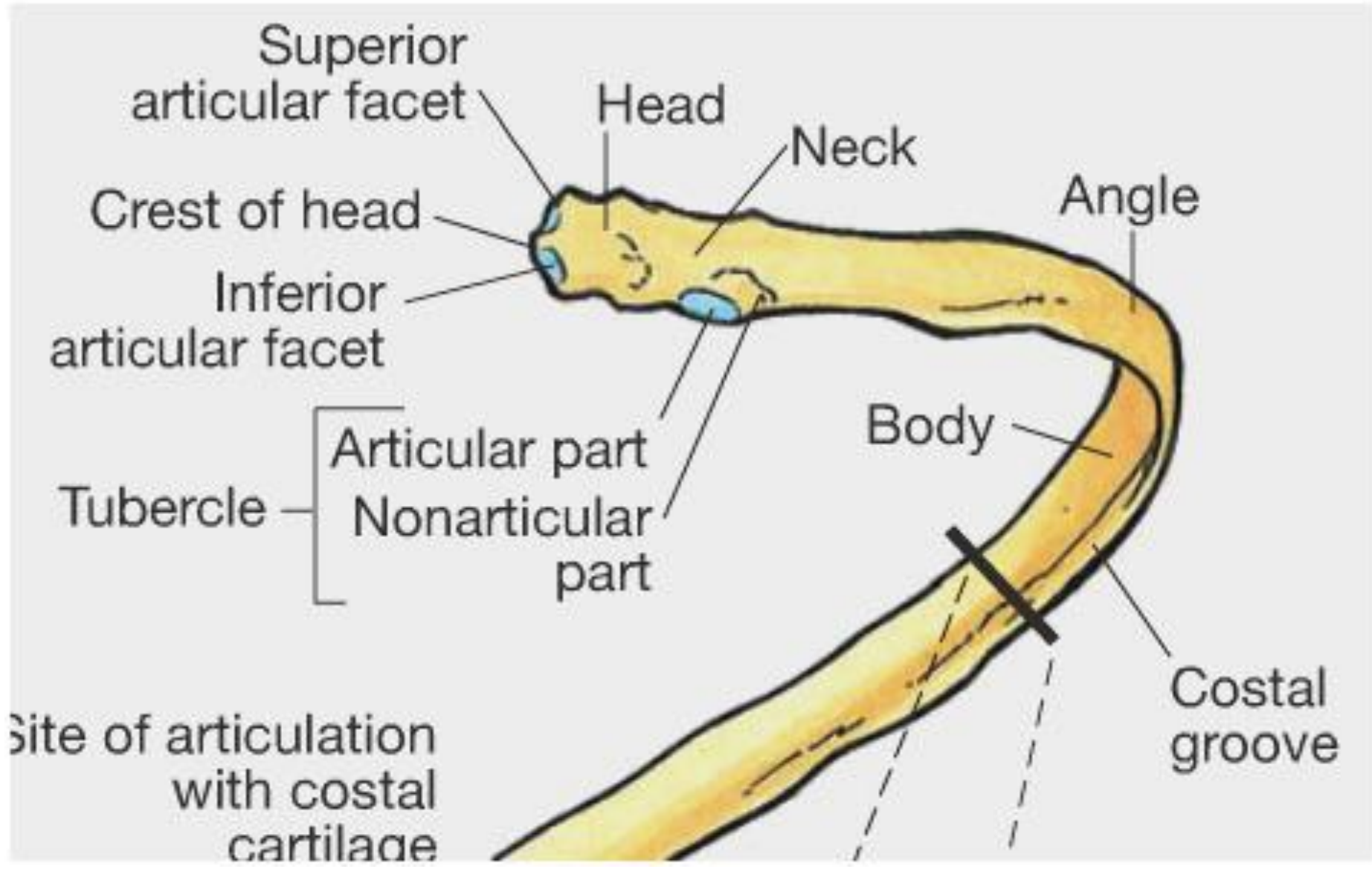
B .Details of an intercostal space and relationships











Costovertebral joints:

X

Participants in joint of head of rib

- Intervertebral disc
- Head of rib (crest)
- Body of vertebra of same number as rib

Costo-transverse joint

- Tubercle of rib
- Transverse process of vertebra of same number as rib 7
- Axis of rib rotation

Elevation

7th rib

Depression

Superior articular facets

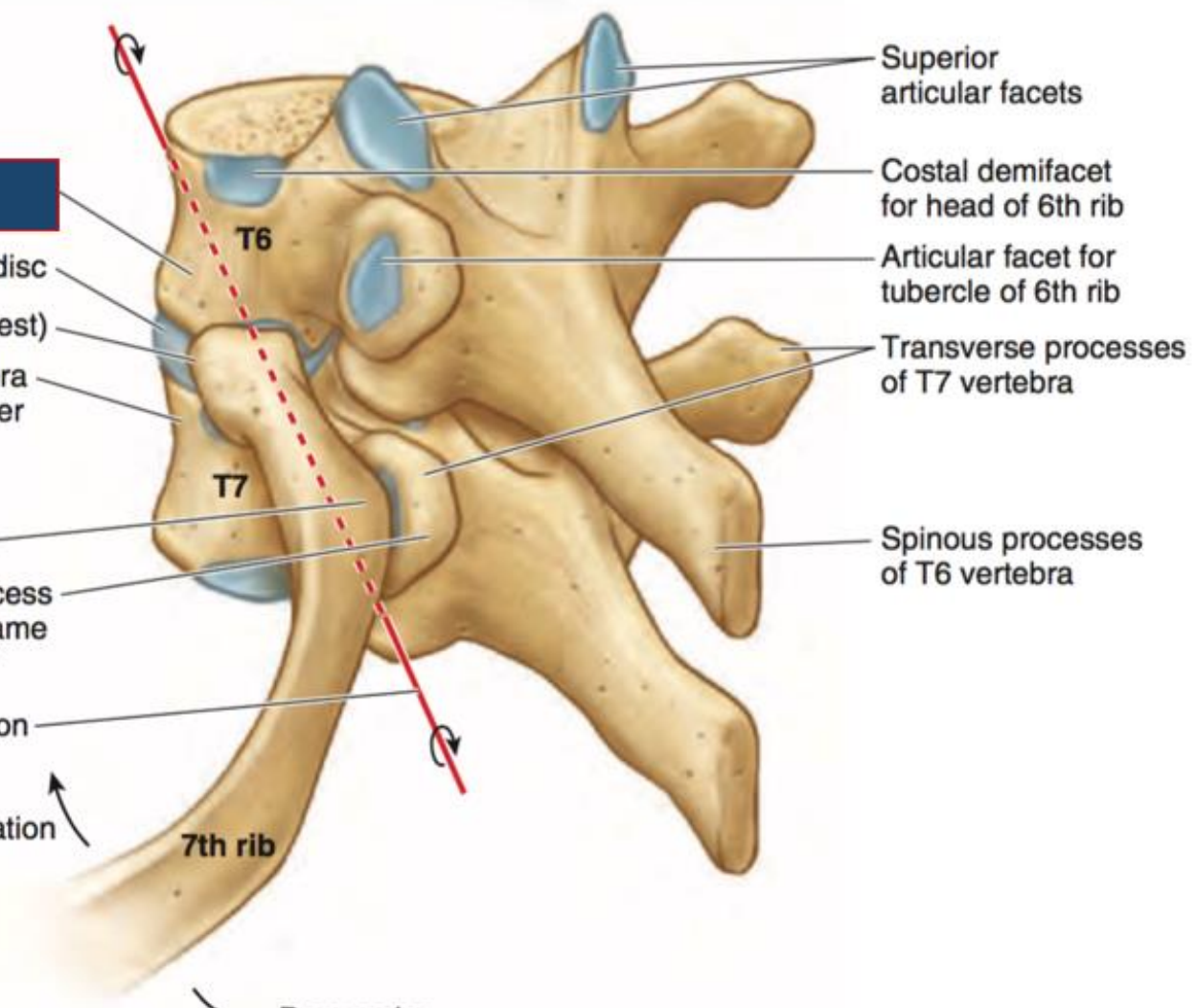
Costal demifacet for head of 6th rib

Articular facet for tubercle of 6th rib

Transverse processes of T7 vertebra

Spinous processes of T6 vertebra

Left posterolateral view



Vertebra Anatomy

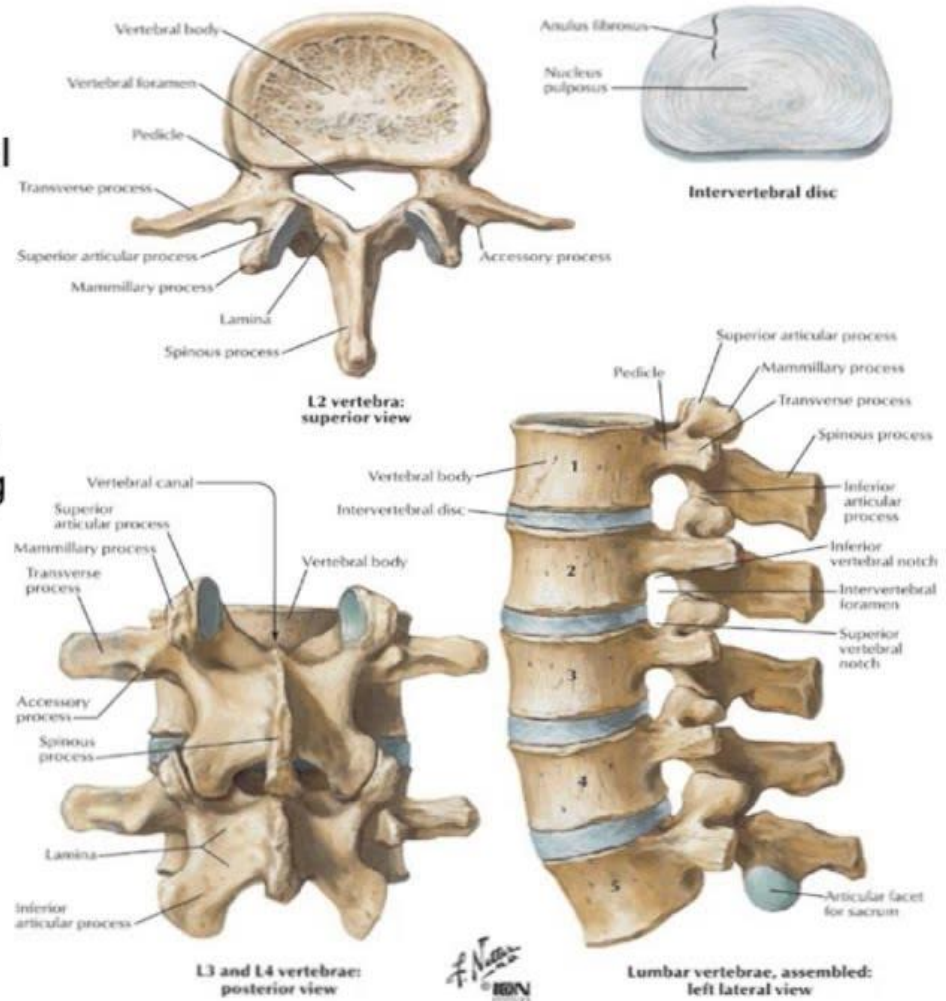
The body is made of spongy bone that contains red bone marrow, bears the weight, and is covered by compact bone

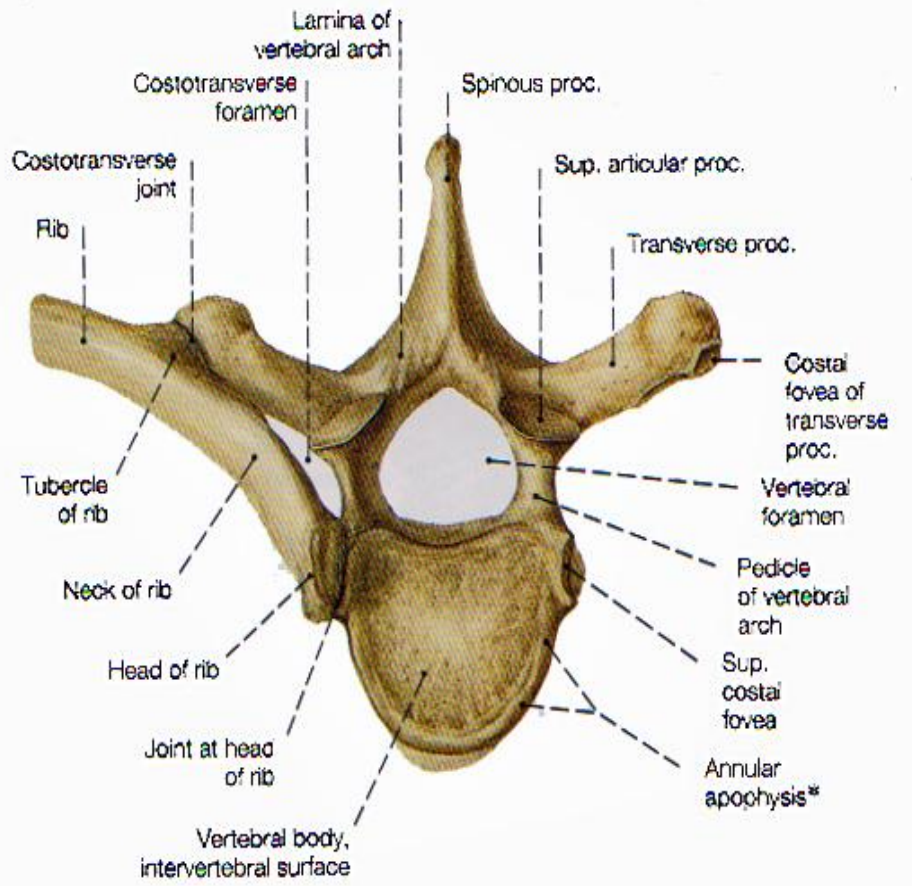
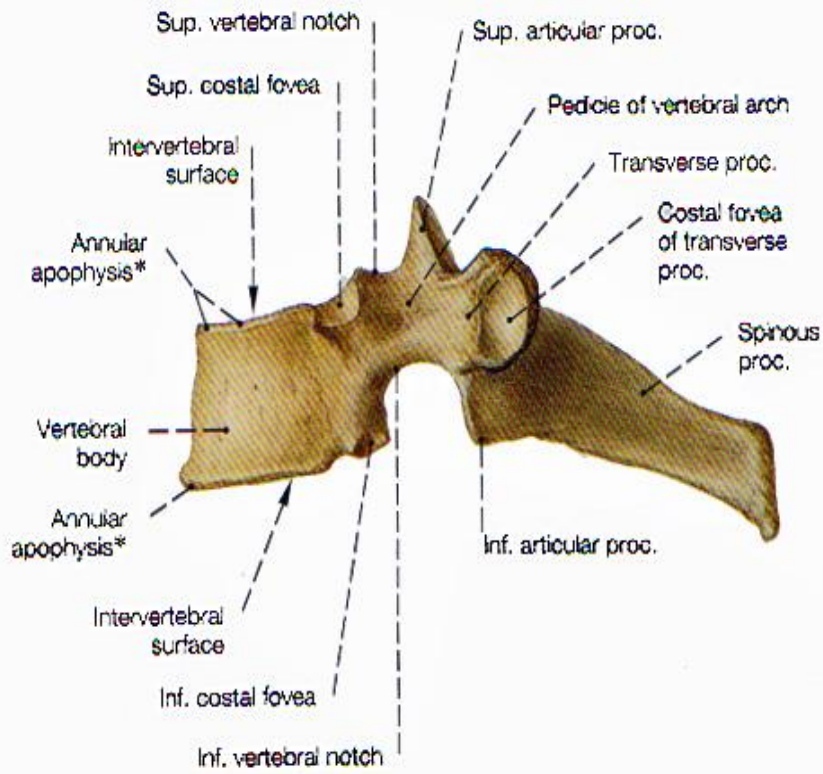
The foramina forms the vertebral canal for the spinal cord

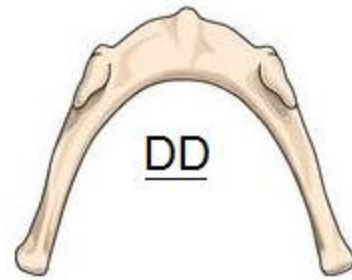
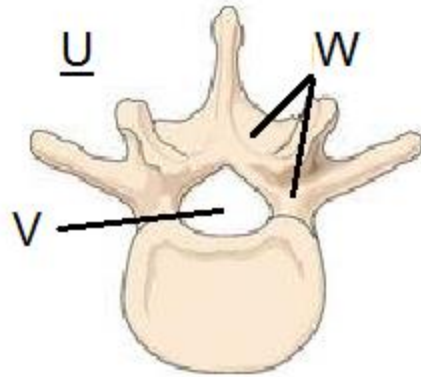
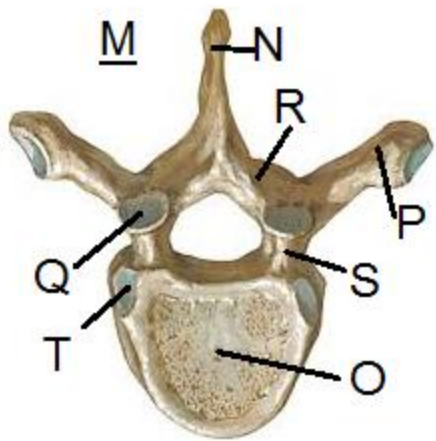
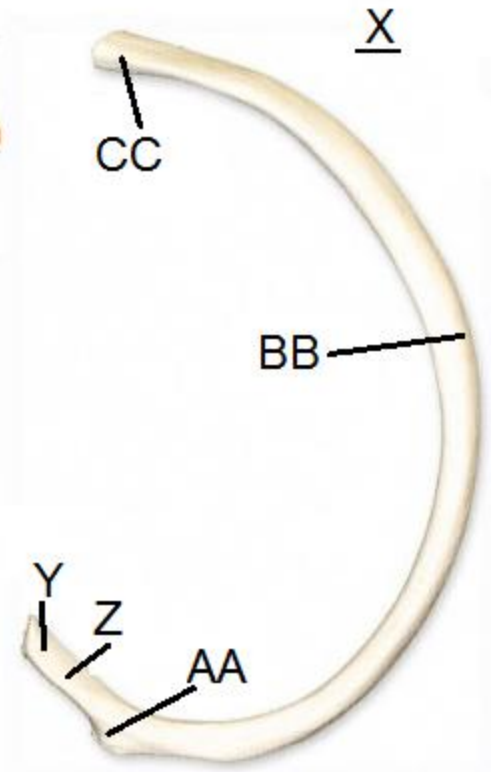
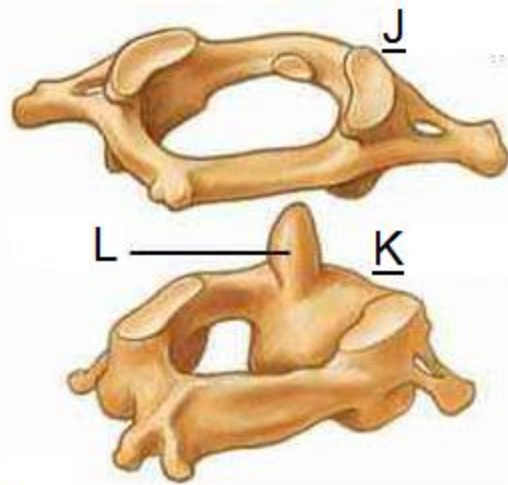
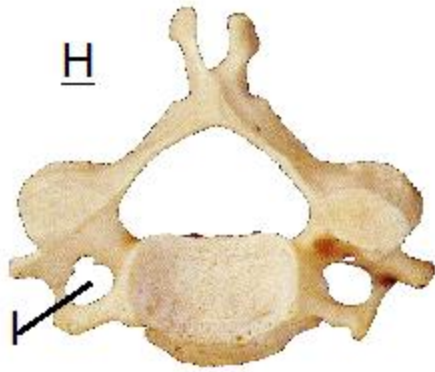
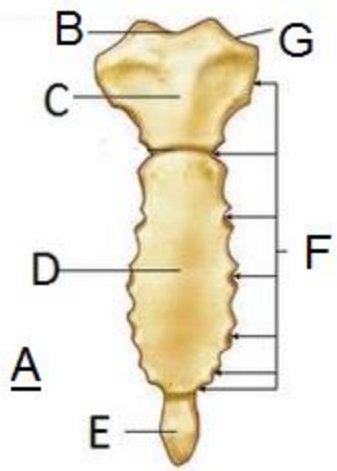
Superior articular processes project upward from one vertebra

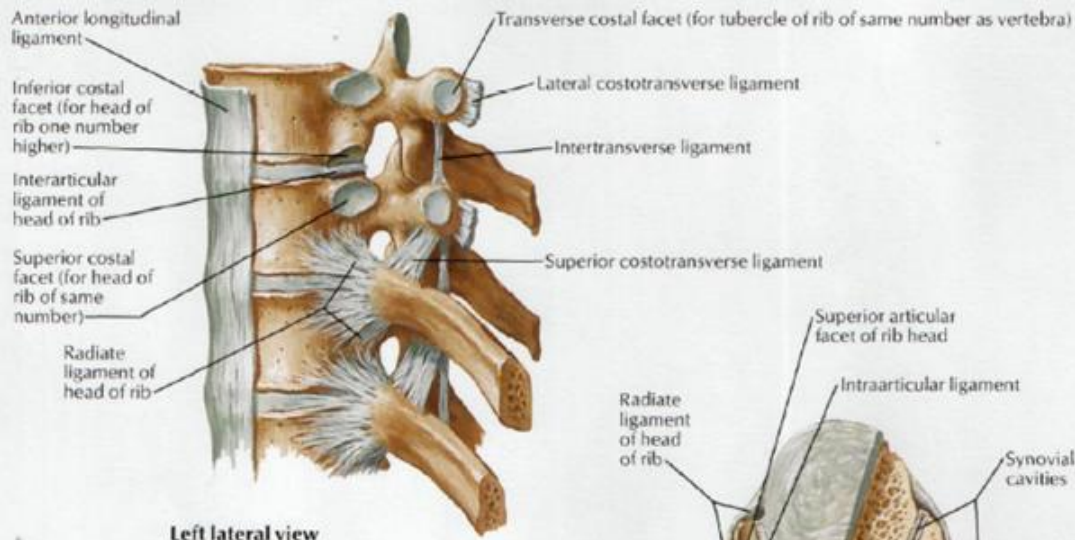
Facets are flat articular surfaces covered with hyaline cartilage

Intervertebral disks are a pad that has a gelatinous core surrounded by a ring of fibrocartilage

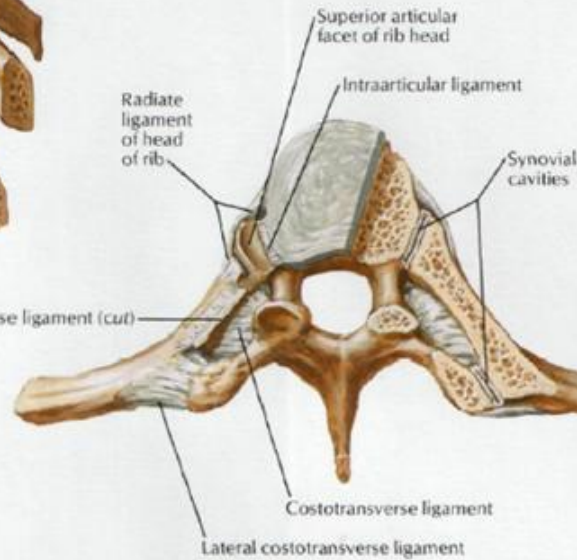




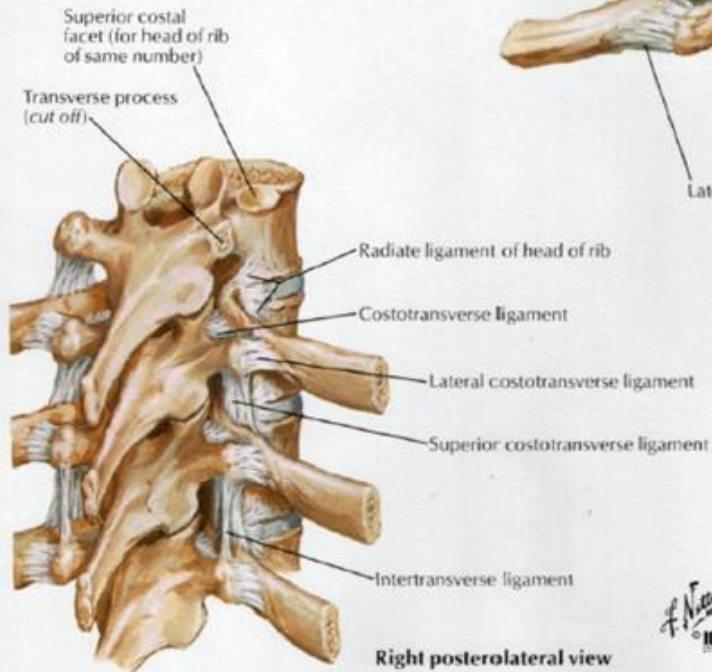




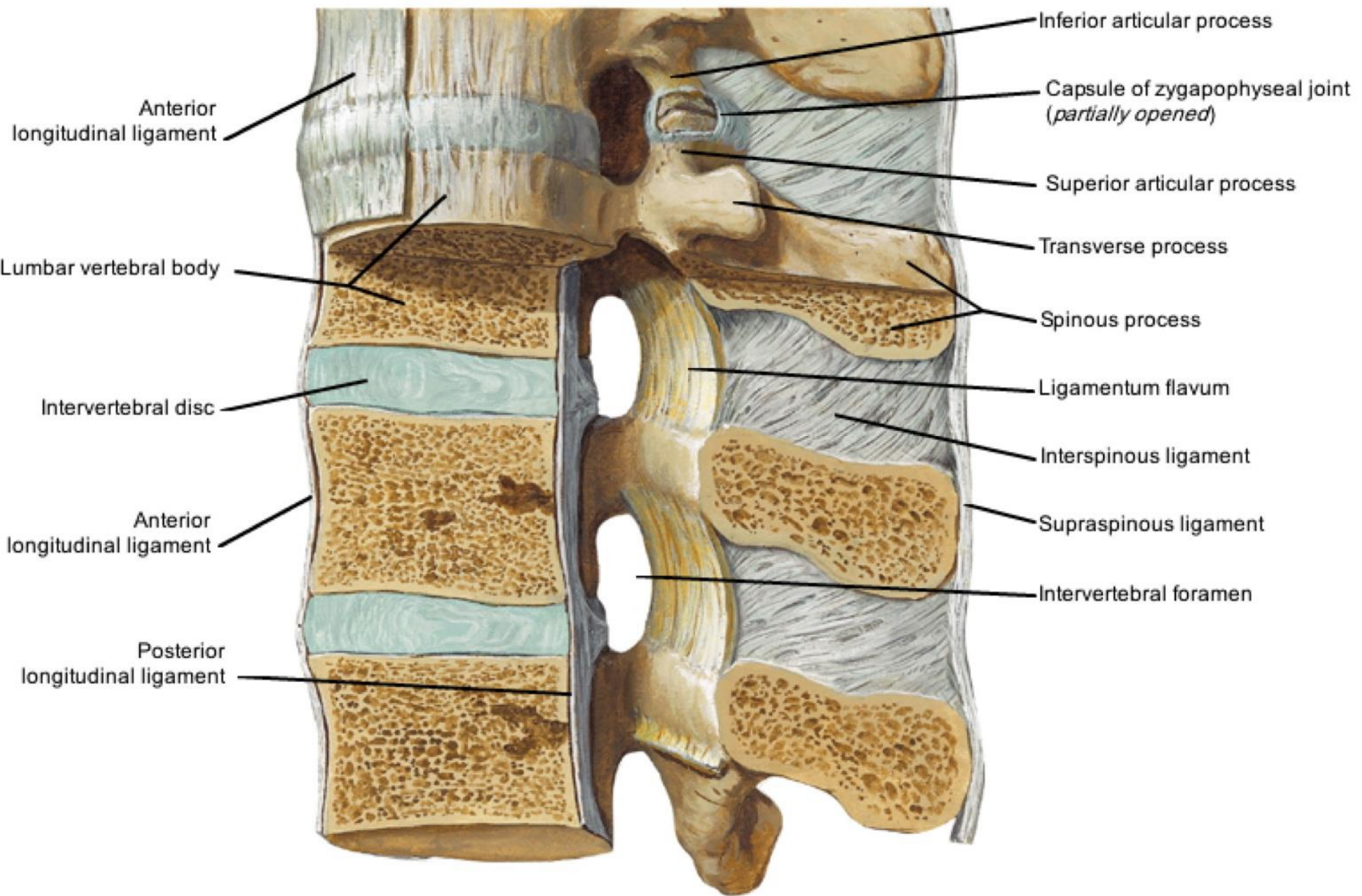
Left lateral view



Transverse section: superior view



Right posterolateral view



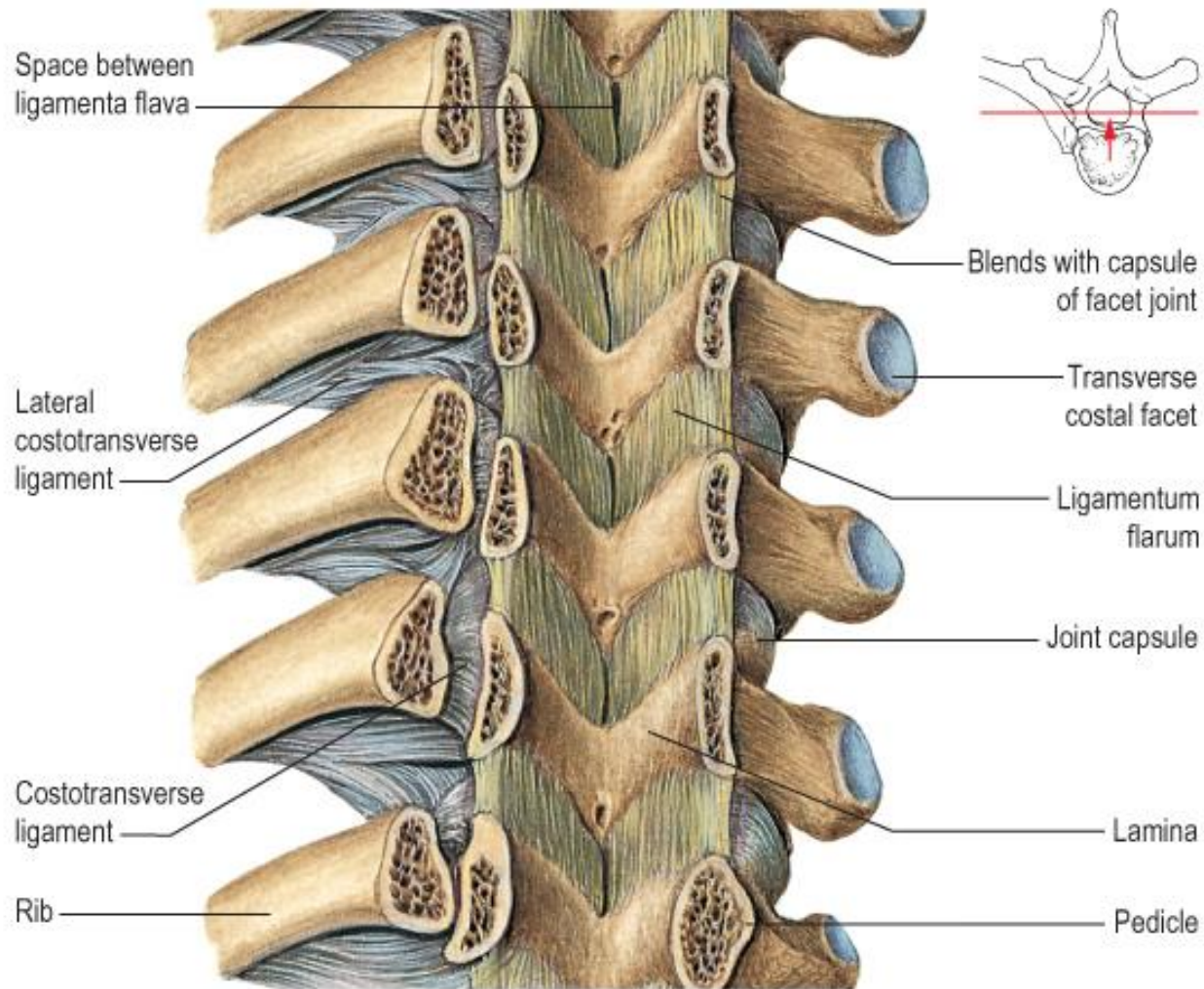
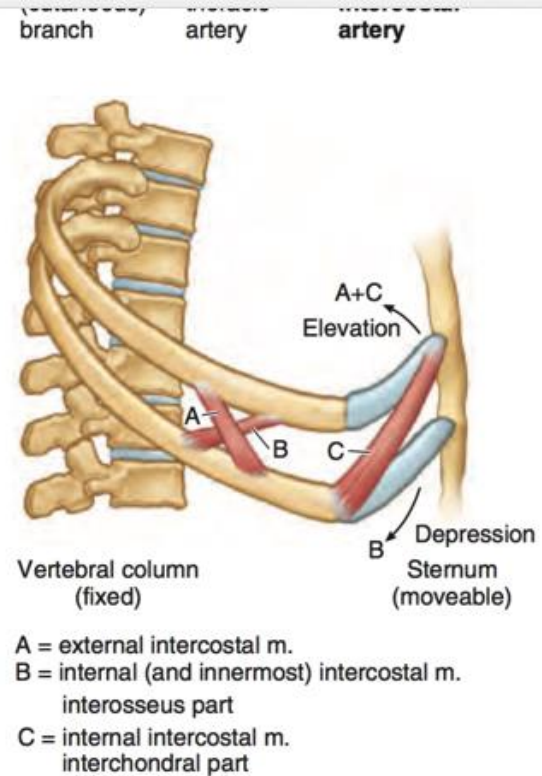
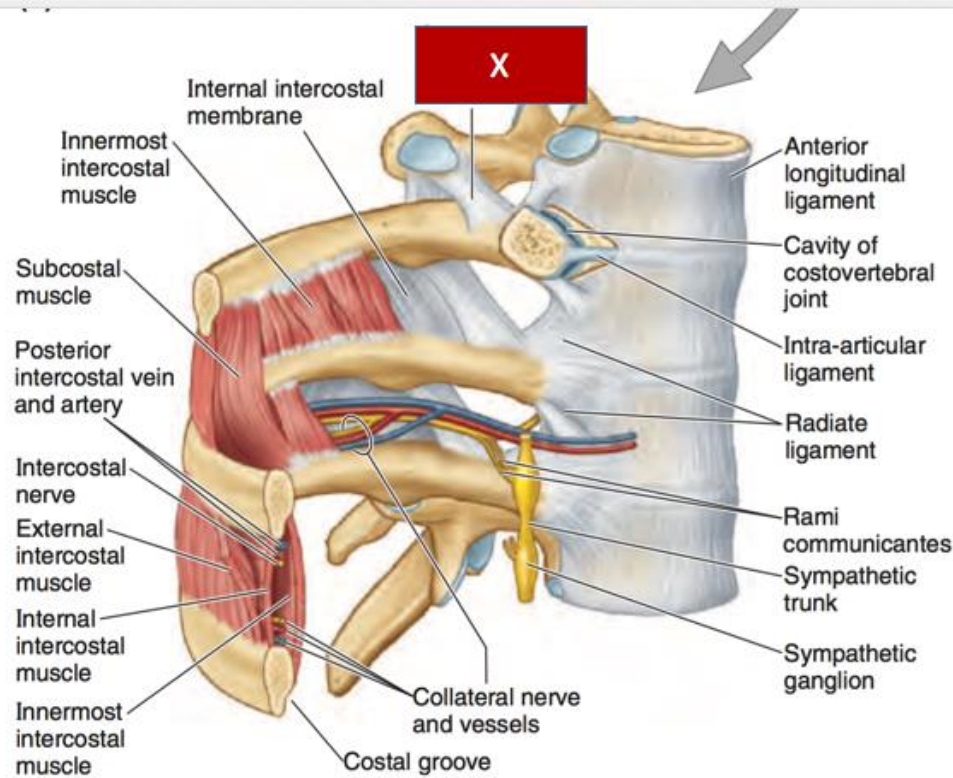


Fig. 42.42 Ligamenta flava and costotransverse ligaments (ventral aspect).

From Standing, Gray's Anatomy, 40th edn. Churchill Livingstone/Elsevier, Philadelphia, 2009 with permission.



(B) Anterolateral view

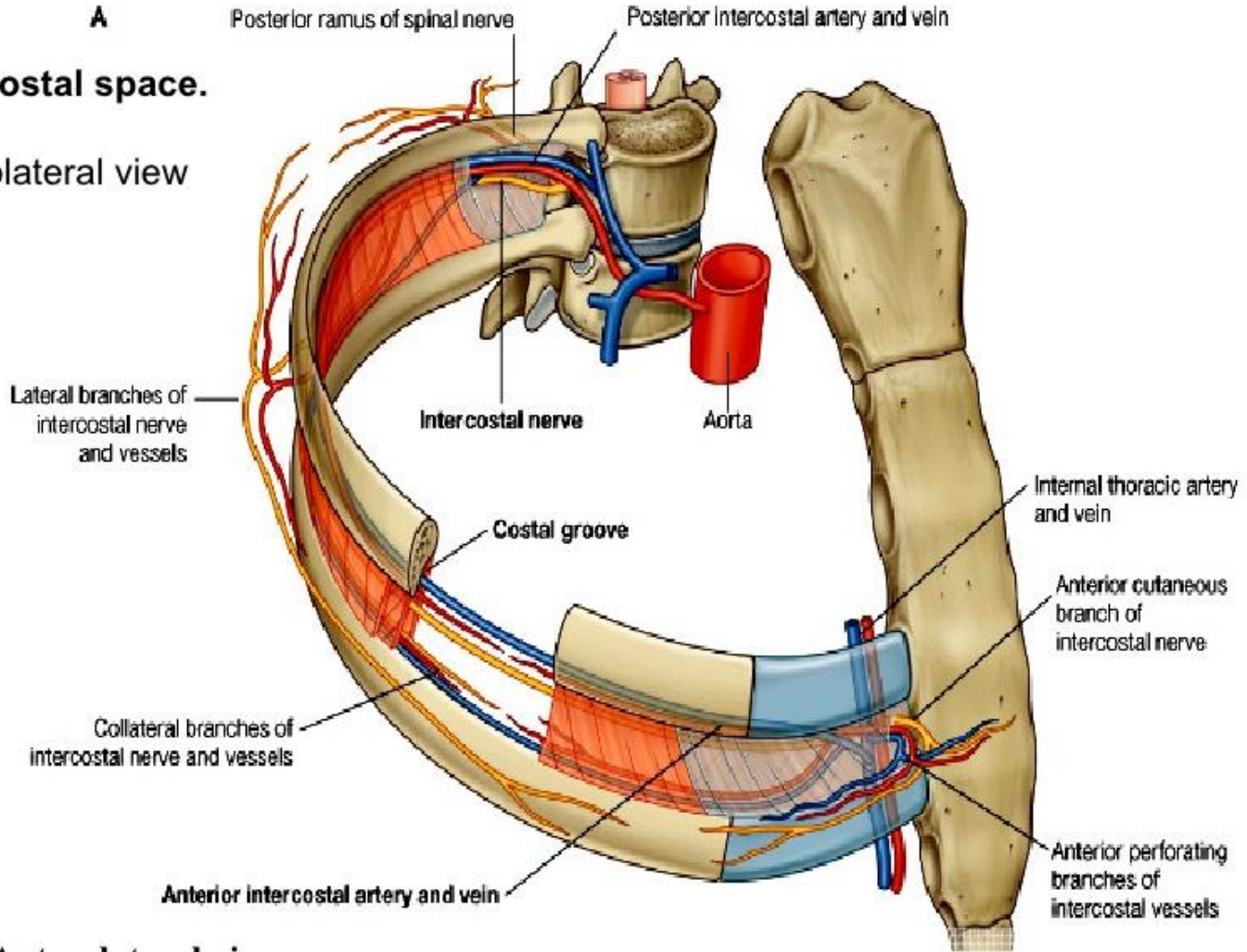
(C) Lateral view

FIGURE 1.15. Contents of an intercostal space. **A.** This transverse section shows nerves (*right side*) and arteries (*left side*) in relation to the intercostal muscles. **B.** The posterior part of an intercostal space is shown. The joint capsule (radiate ligament) of one costovertebral joint has been removed. Innermost intercostal muscles bridge one intercostal space; subcostal muscles bridge two. The mnemonic for the order of the neurovascular structures in the intercostal space from superior to inferior is VAN—vein, artery, and nerve. Communicating branches (L. *rami communicantes*) extend between the intercostal nerves and the sympathetic trunk. **C.** A simple model of the action of the intercostal muscles is shown. Contraction of the muscle fibers that most closely parallel the slope of the ribs at a given point (fibers A and C) will elevate the ribs and sternum; contraction of muscle fibers that are approximately perpendicular to the slope of the ribs (fibers B) will depress the ribs.

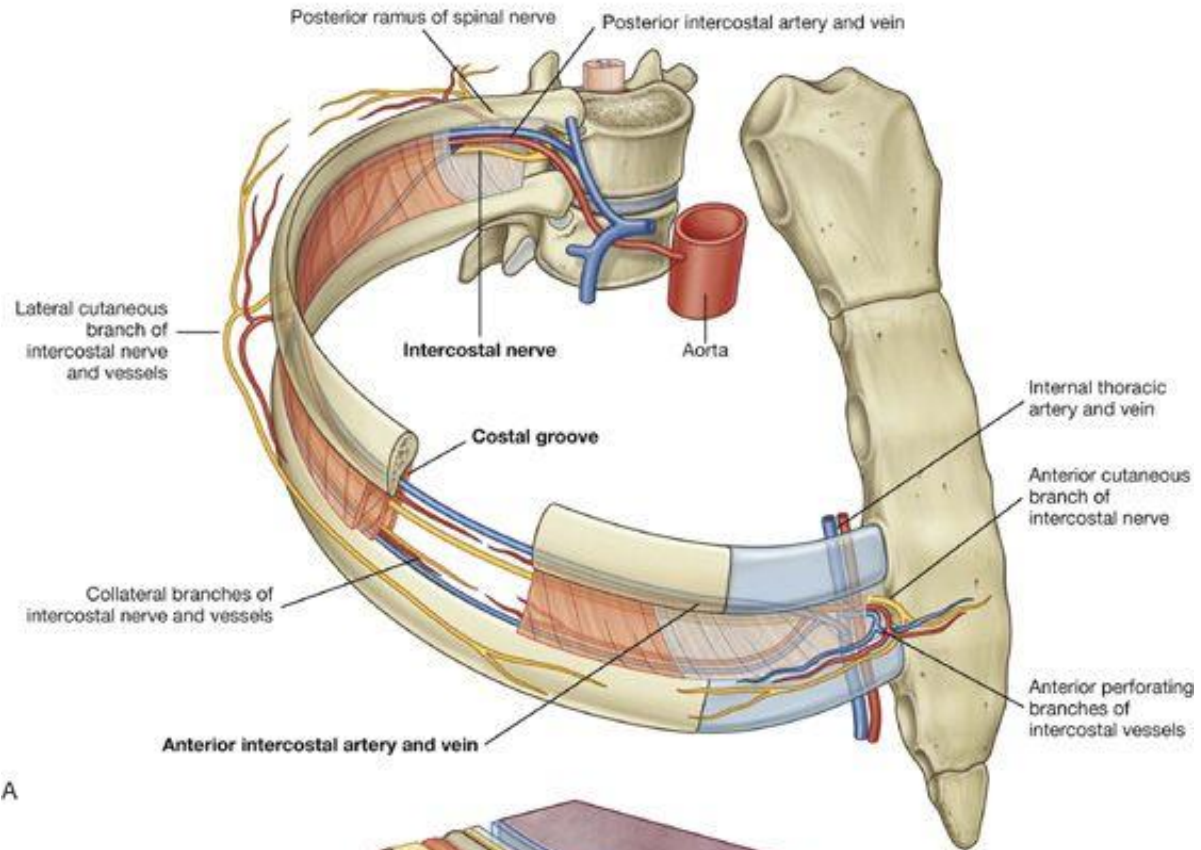
A

Intercostal space.

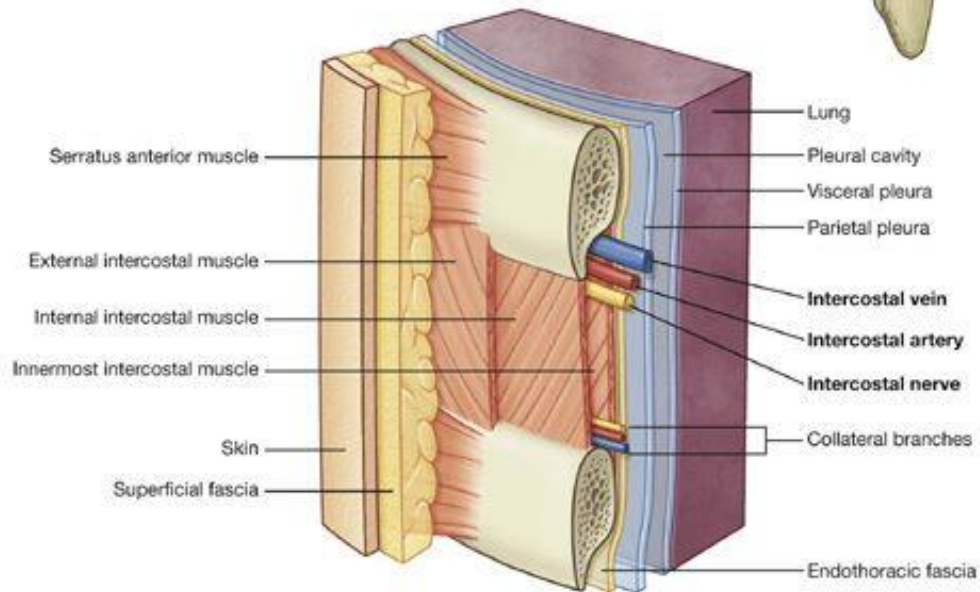
A. Anterolateral view



A. Anterolateral view.

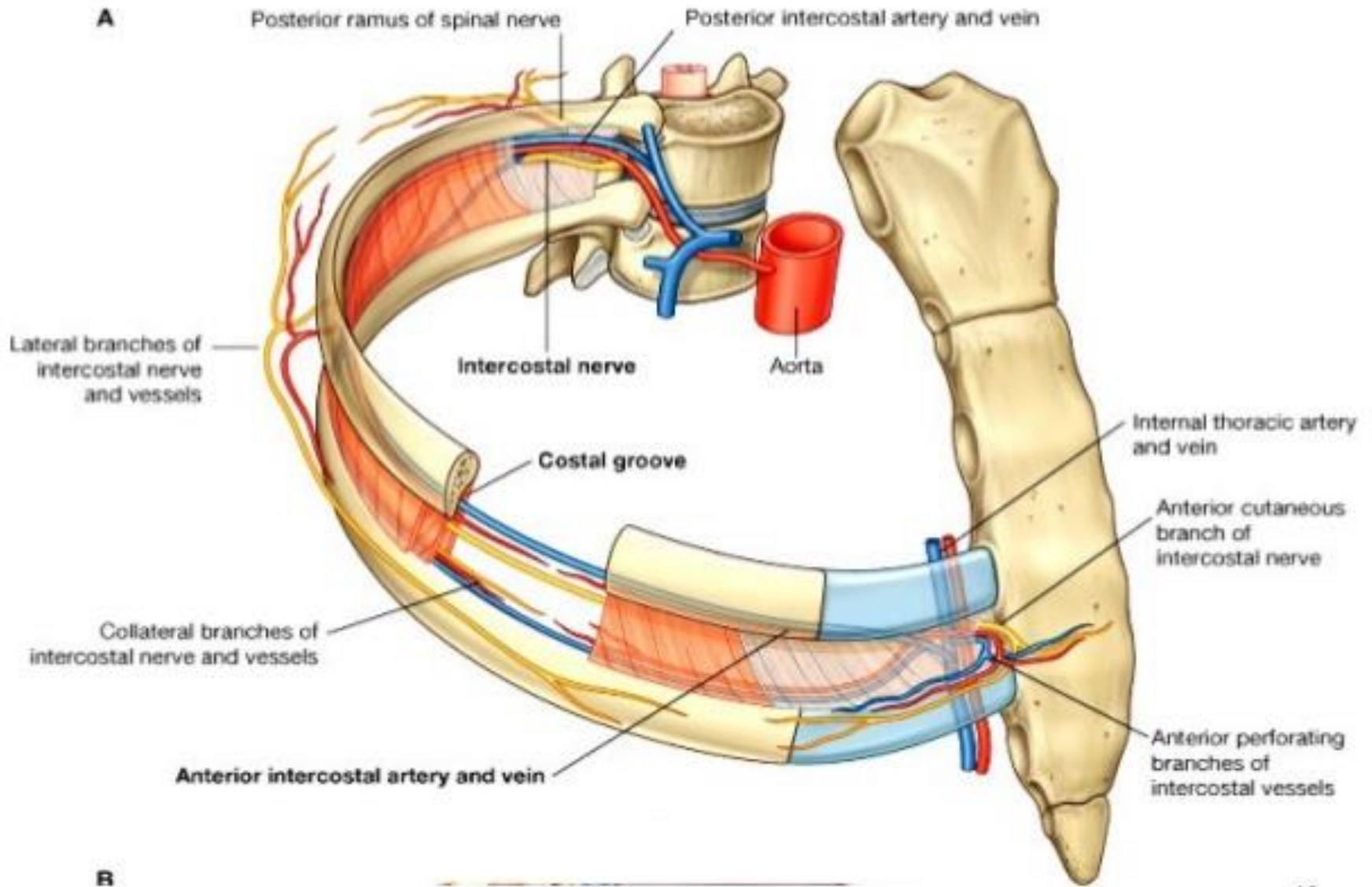


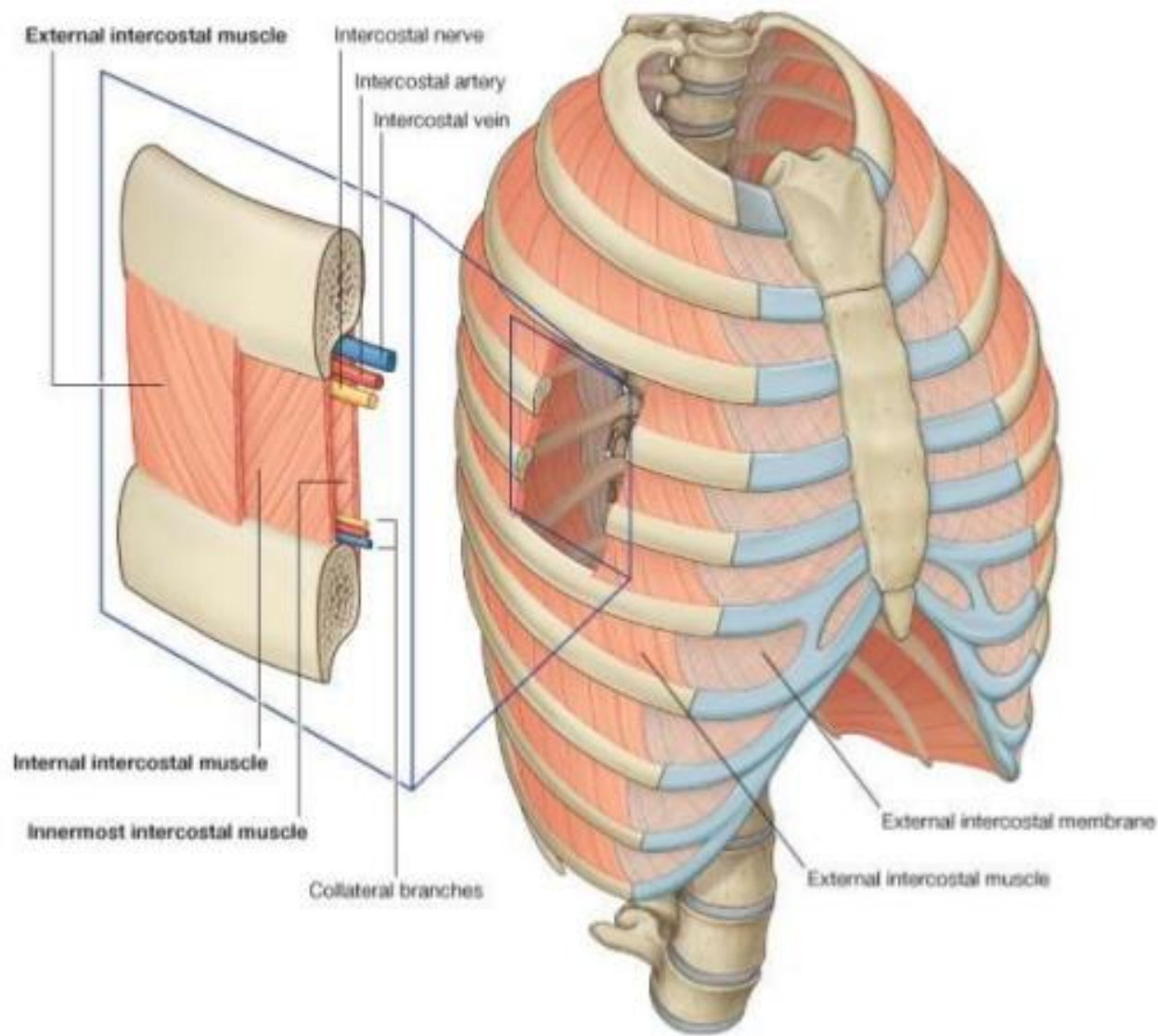
A

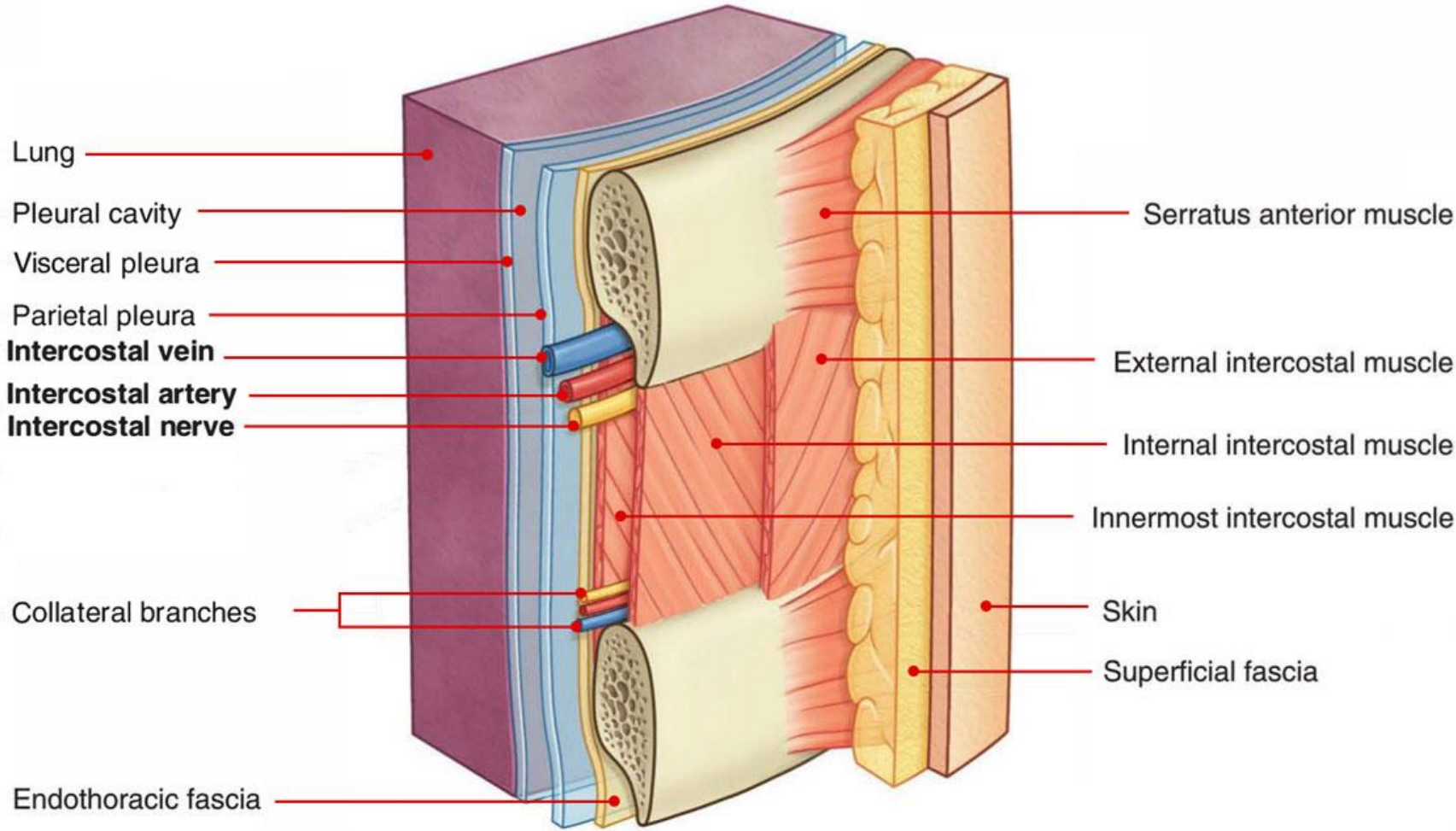


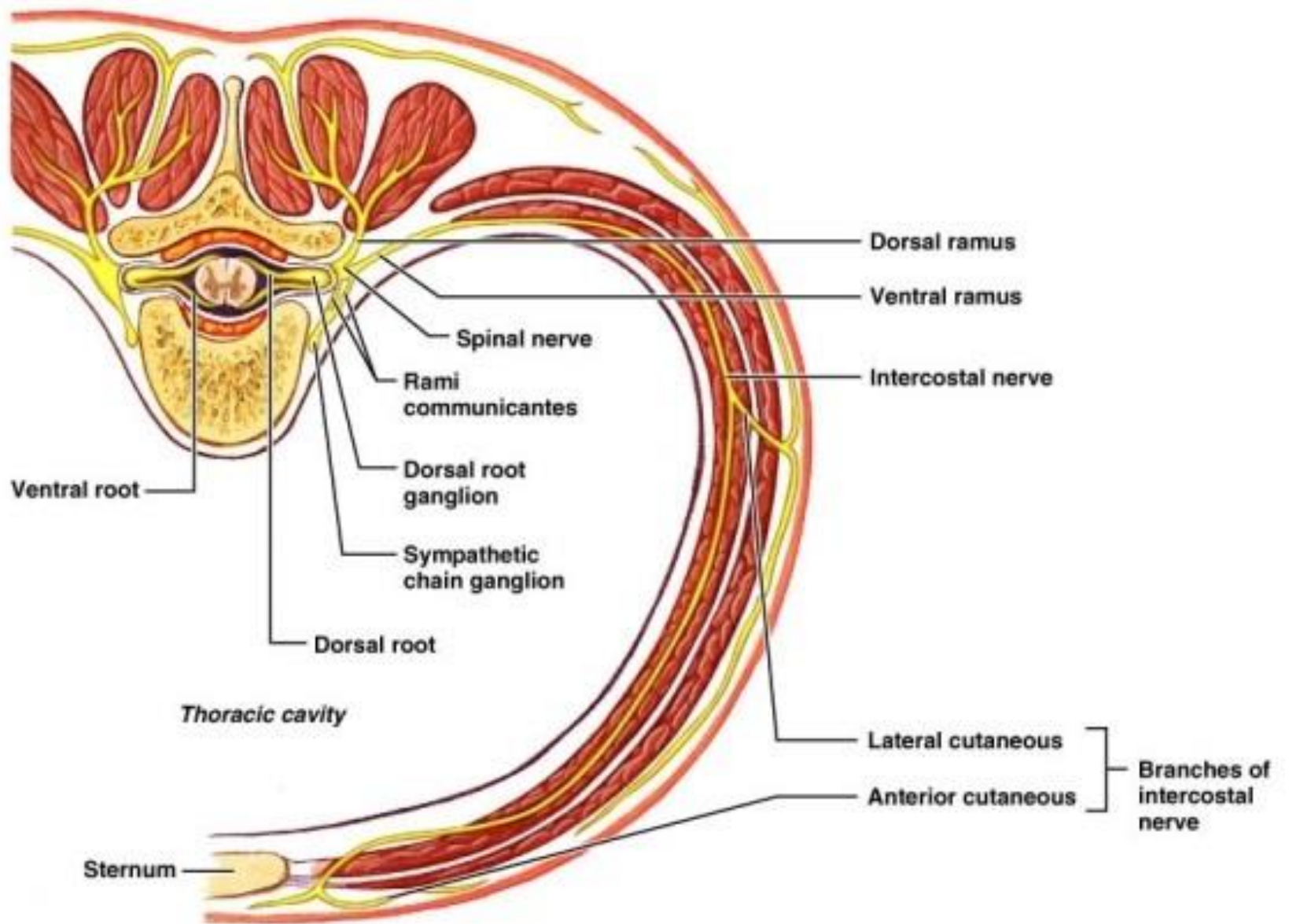
B

Intercostal arteries, nerves, and vein



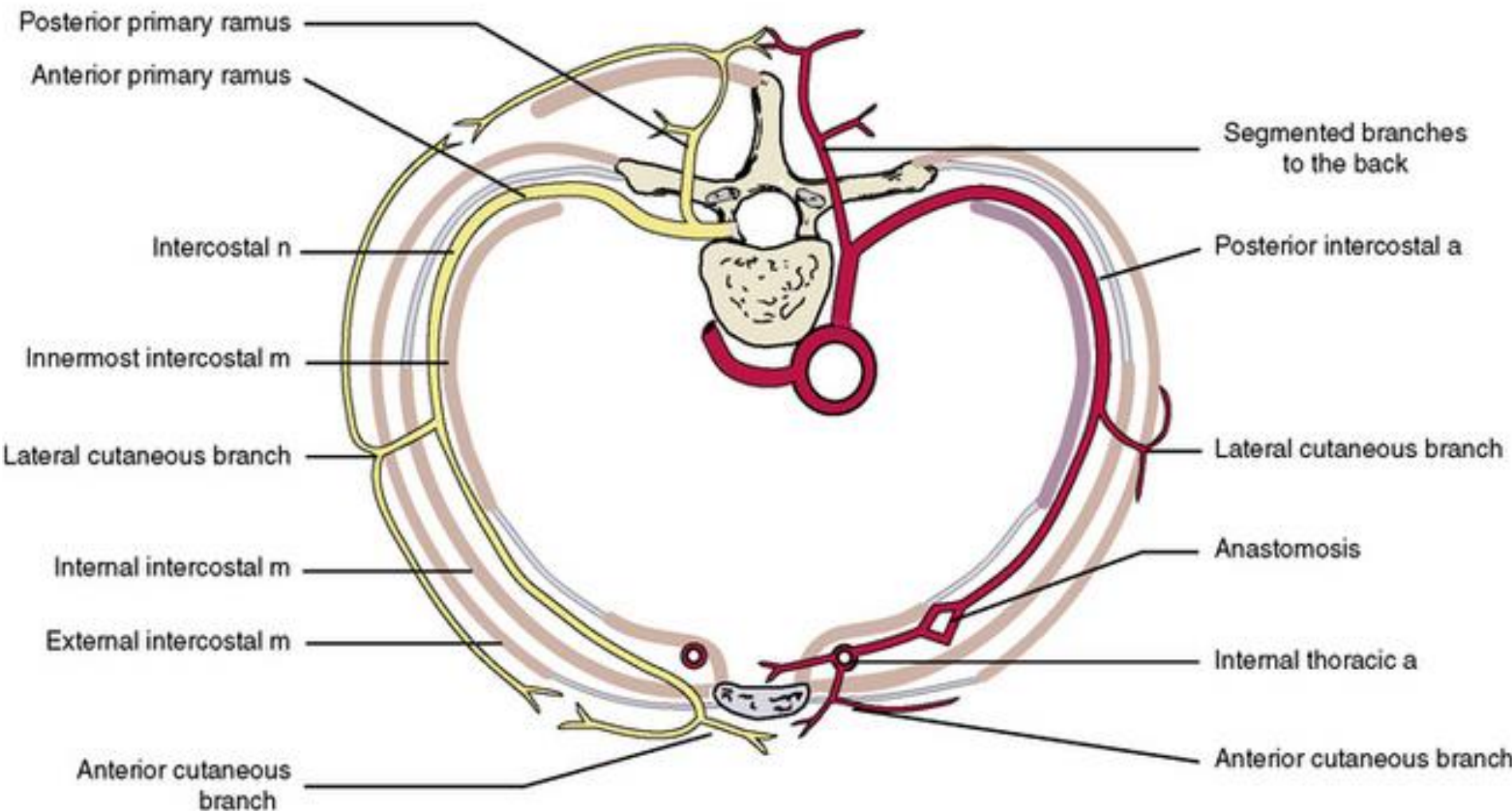


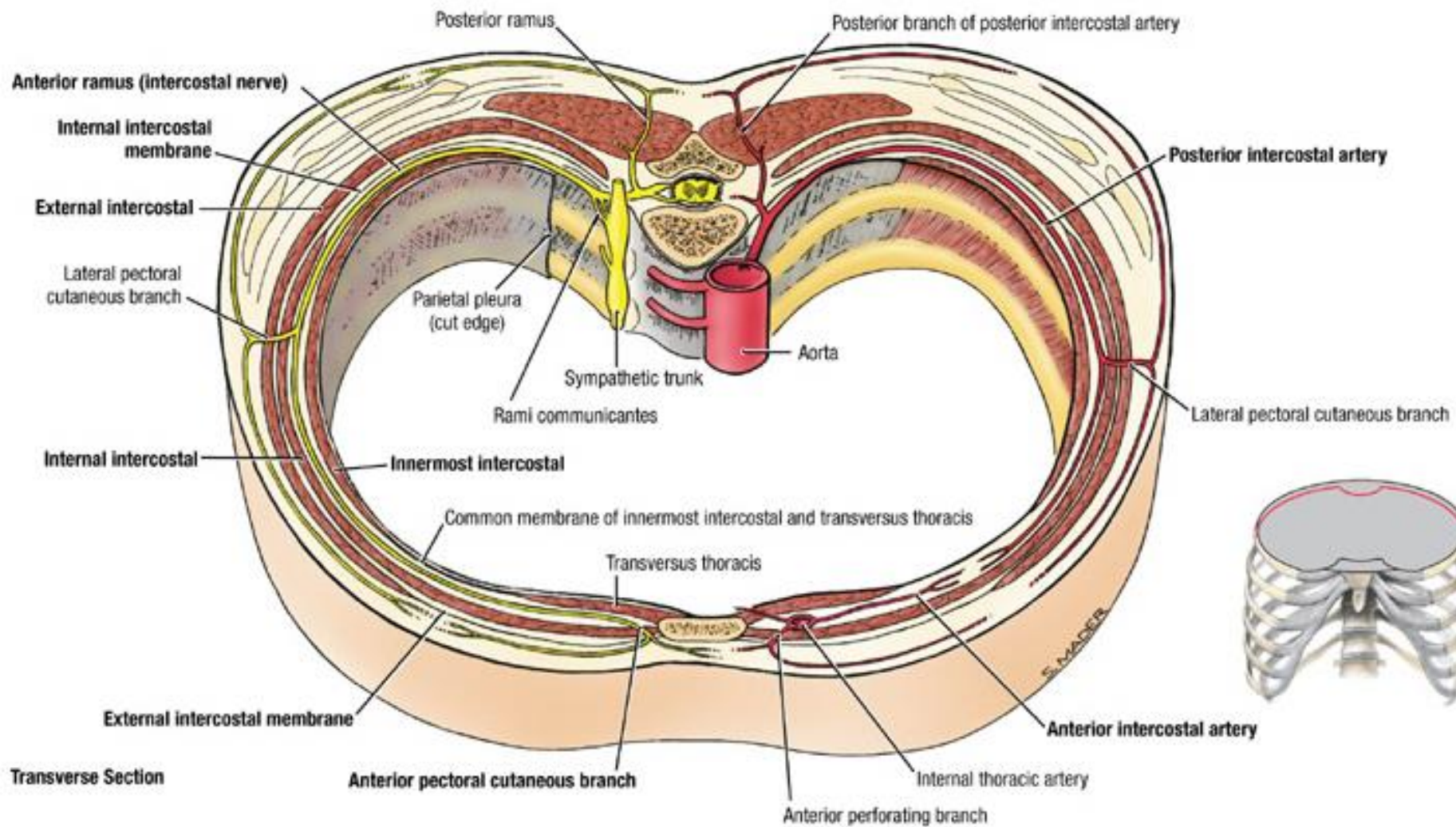




NERVES

ARTERIES





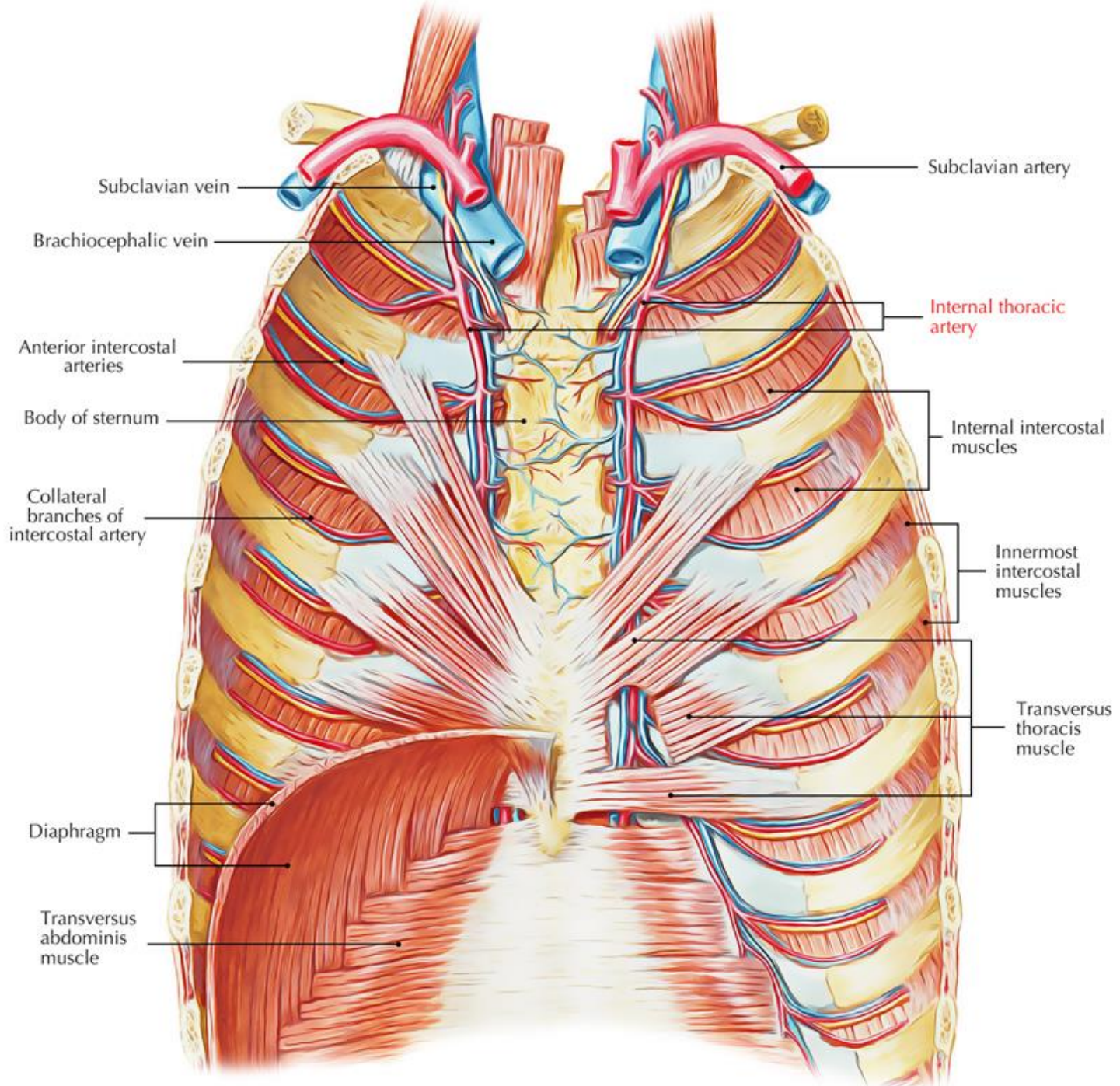
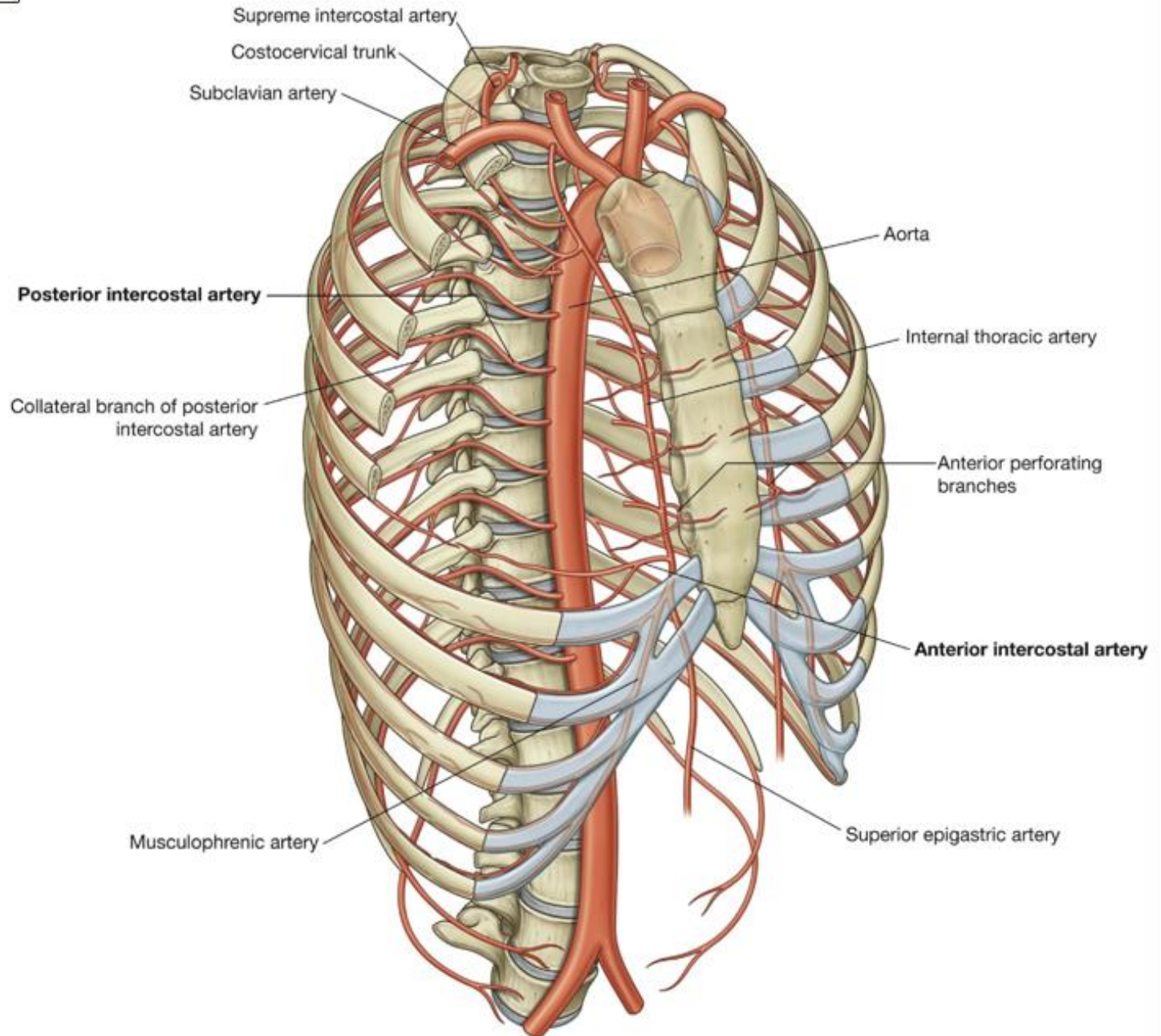
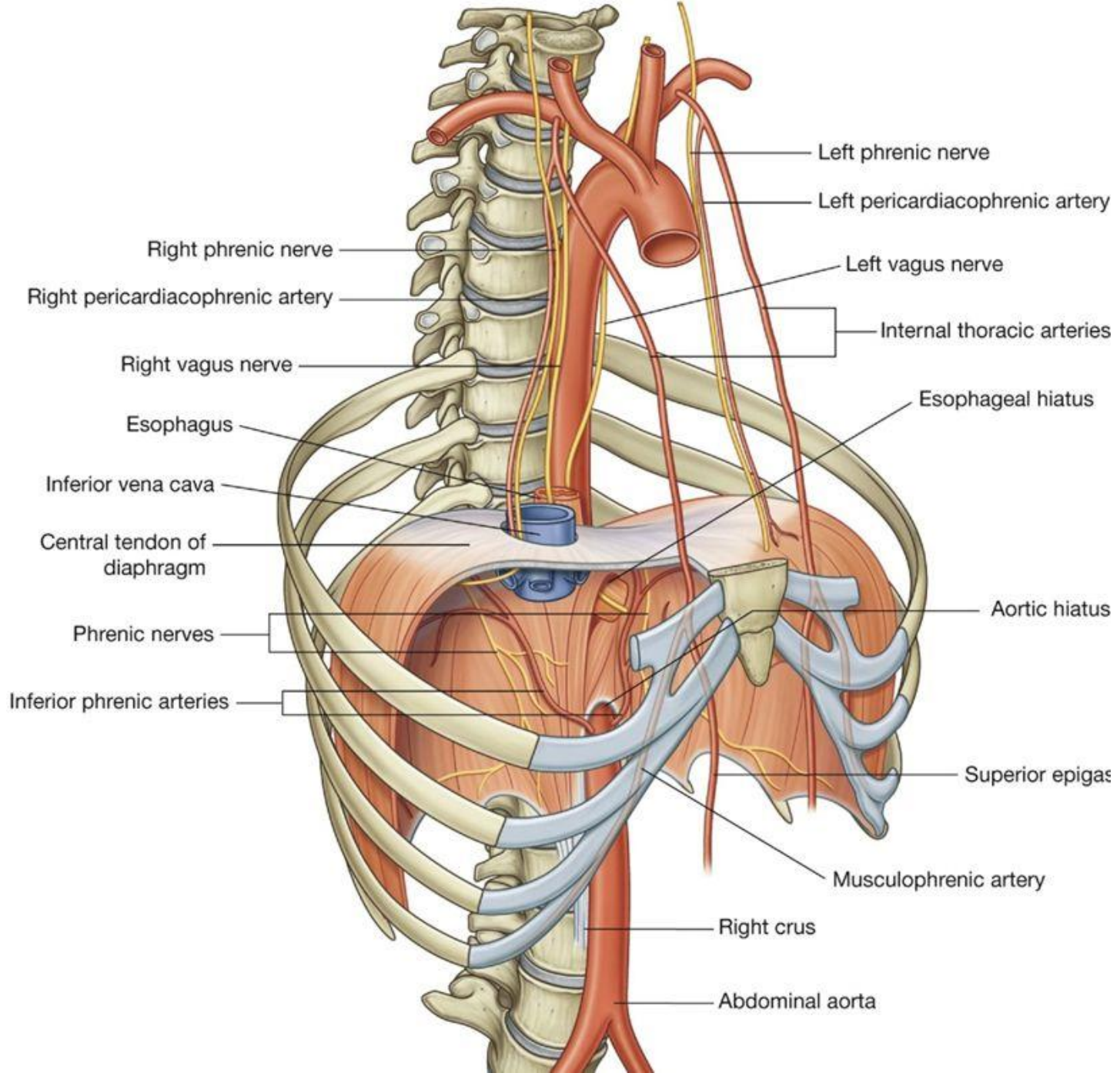
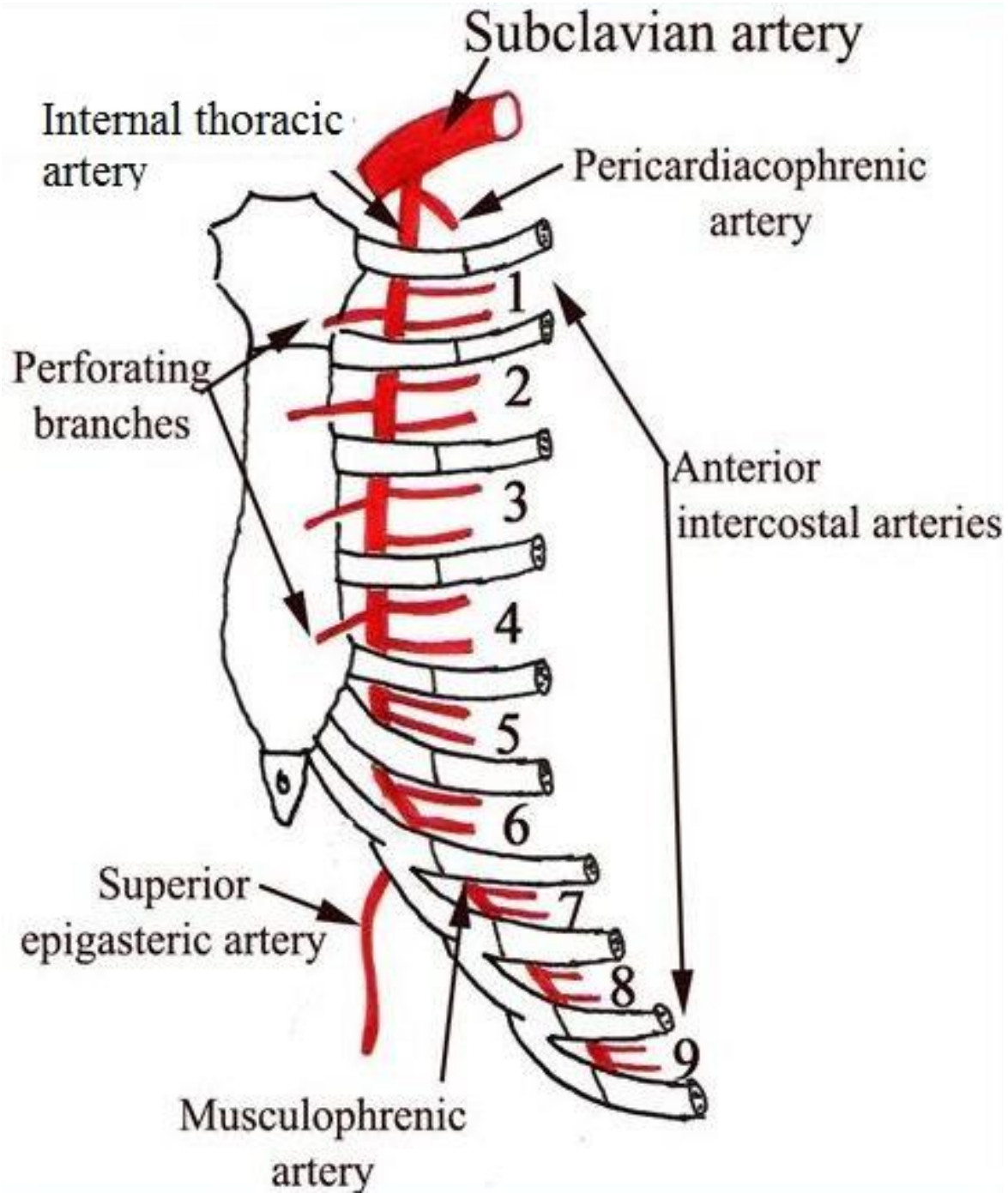
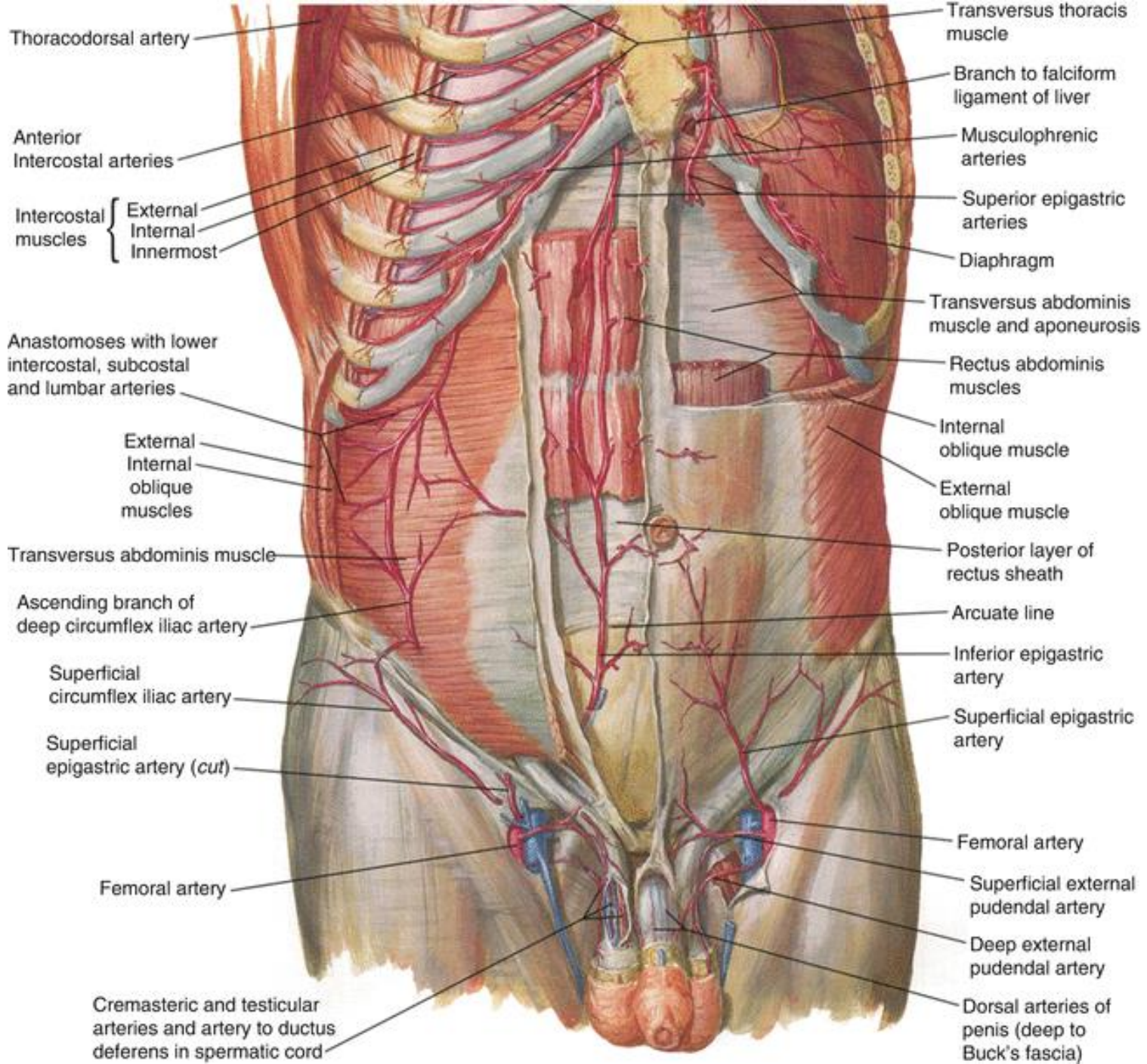


Fig. 3.29 Arteries of the thoracic wall.









Thoracodorsal artery

Anterior Intercostal arteries

Intercostal muscles { External Internal Innermost

Anastomoses with lower intercostal, subcostal and lumbar arteries

External Internal oblique muscles

Transversus abdominis muscle

Ascending branch of deep circumflex iliac artery

Superficial circumflex iliac artery

Superficial epigastric artery (cut)

Femoral artery

Cremasteric and testicular arteries and artery to ductus deferens in spermatic cord

Transversus thoracis muscle

Branch to falciform ligament of liver

Musculophrenic arteries

Superior epigastric arteries

Diaphragm

Transversus abdominis muscle and aponeurosis

Rectus abdominis muscles

Internal oblique muscle

External oblique muscle

Posterior layer of rectus sheath

Arcuate line

Inferior epigastric artery

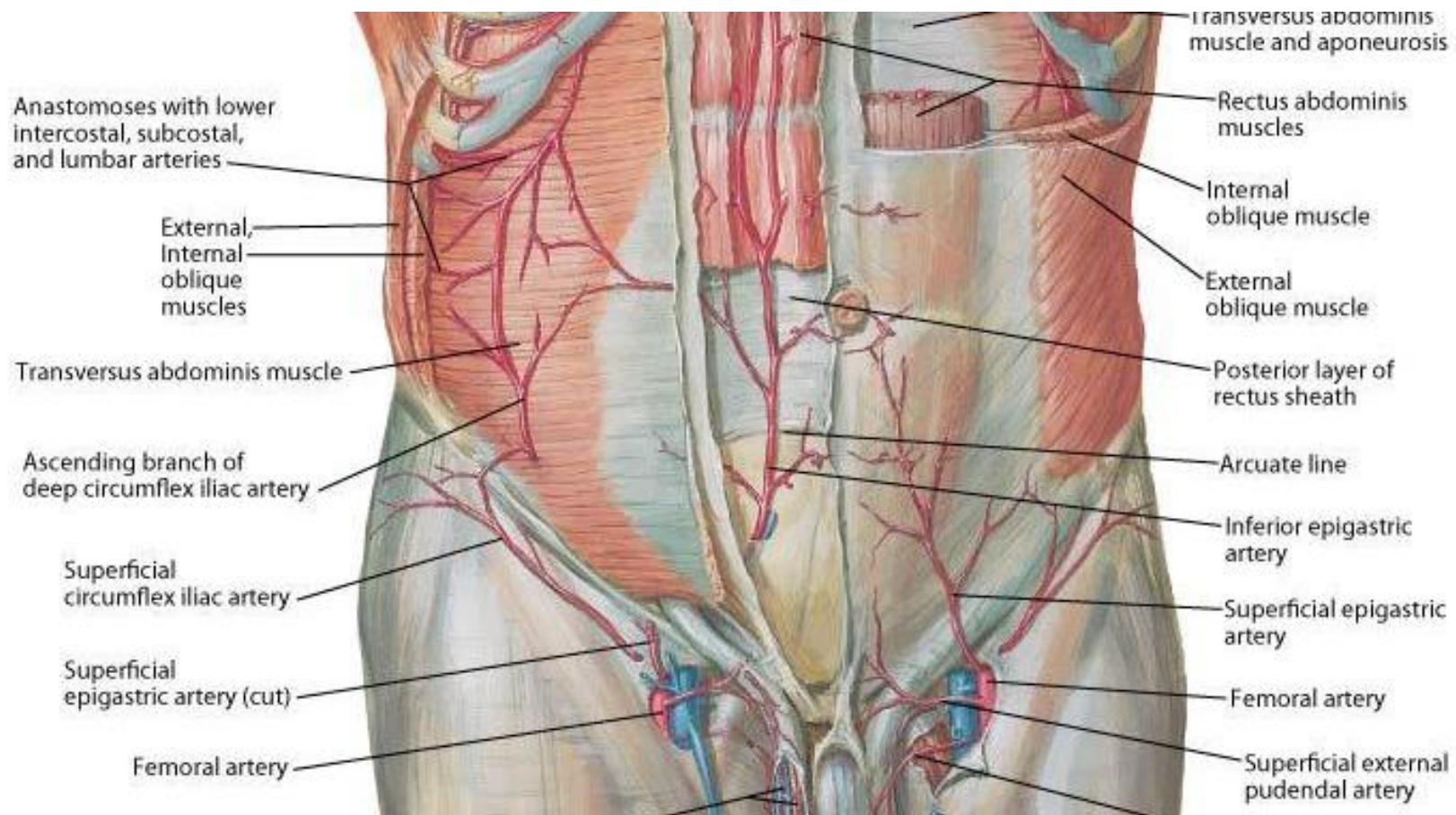
Superficial epigastric artery

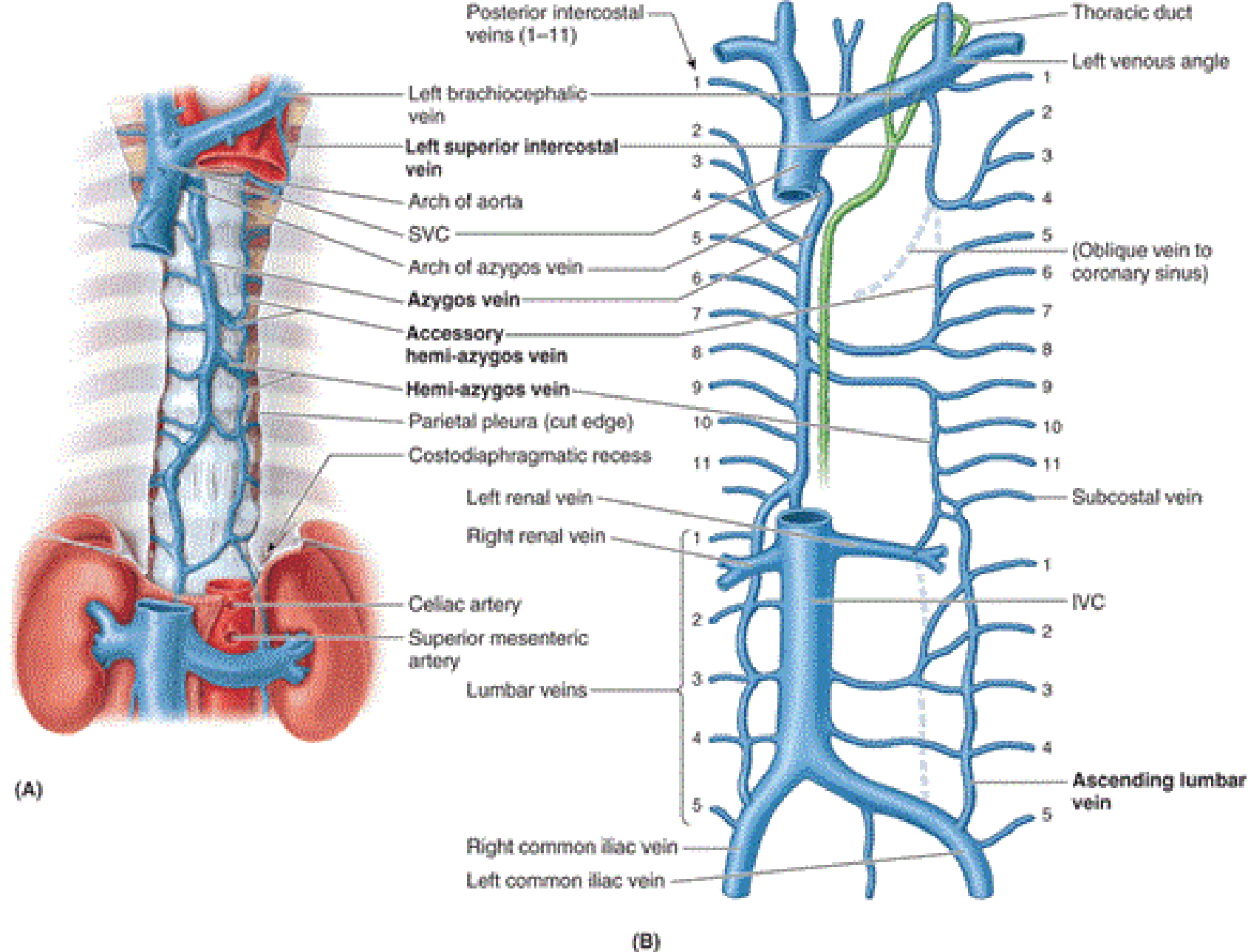
Femoral artery

Superficial external pudendal artery

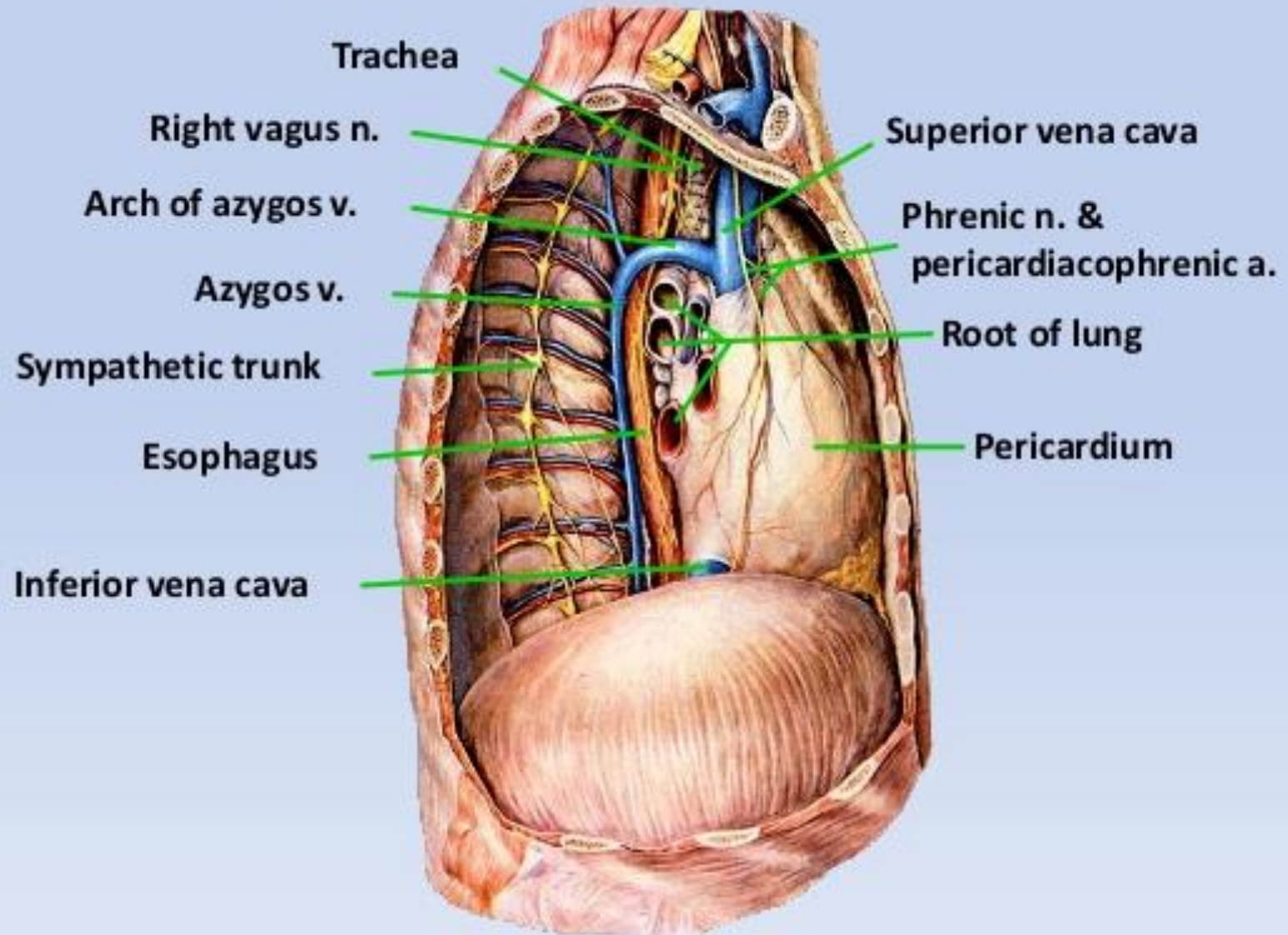
Deep external pudendal artery

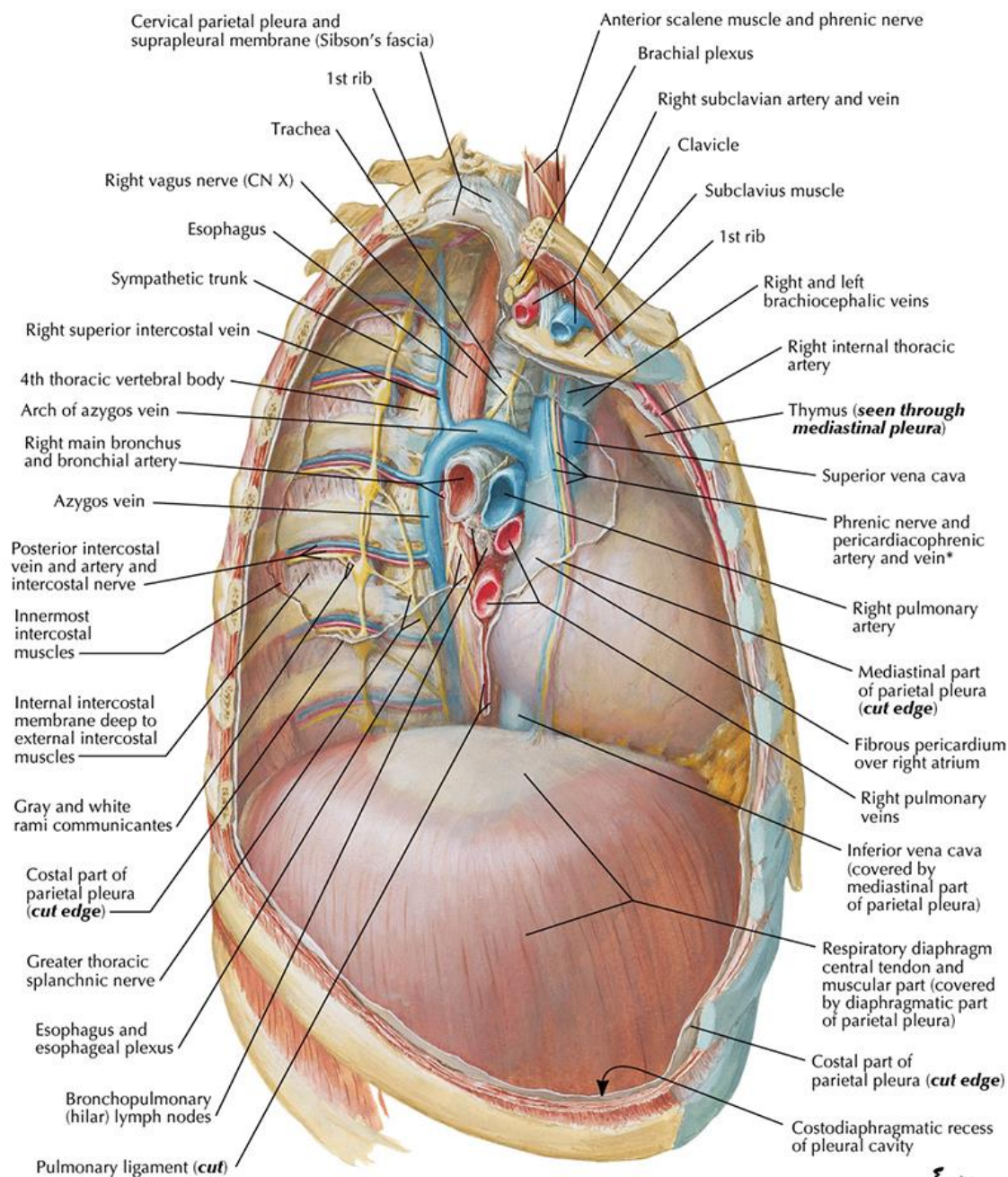
Dorsal arteries of penis (deep to Buck's fascia)



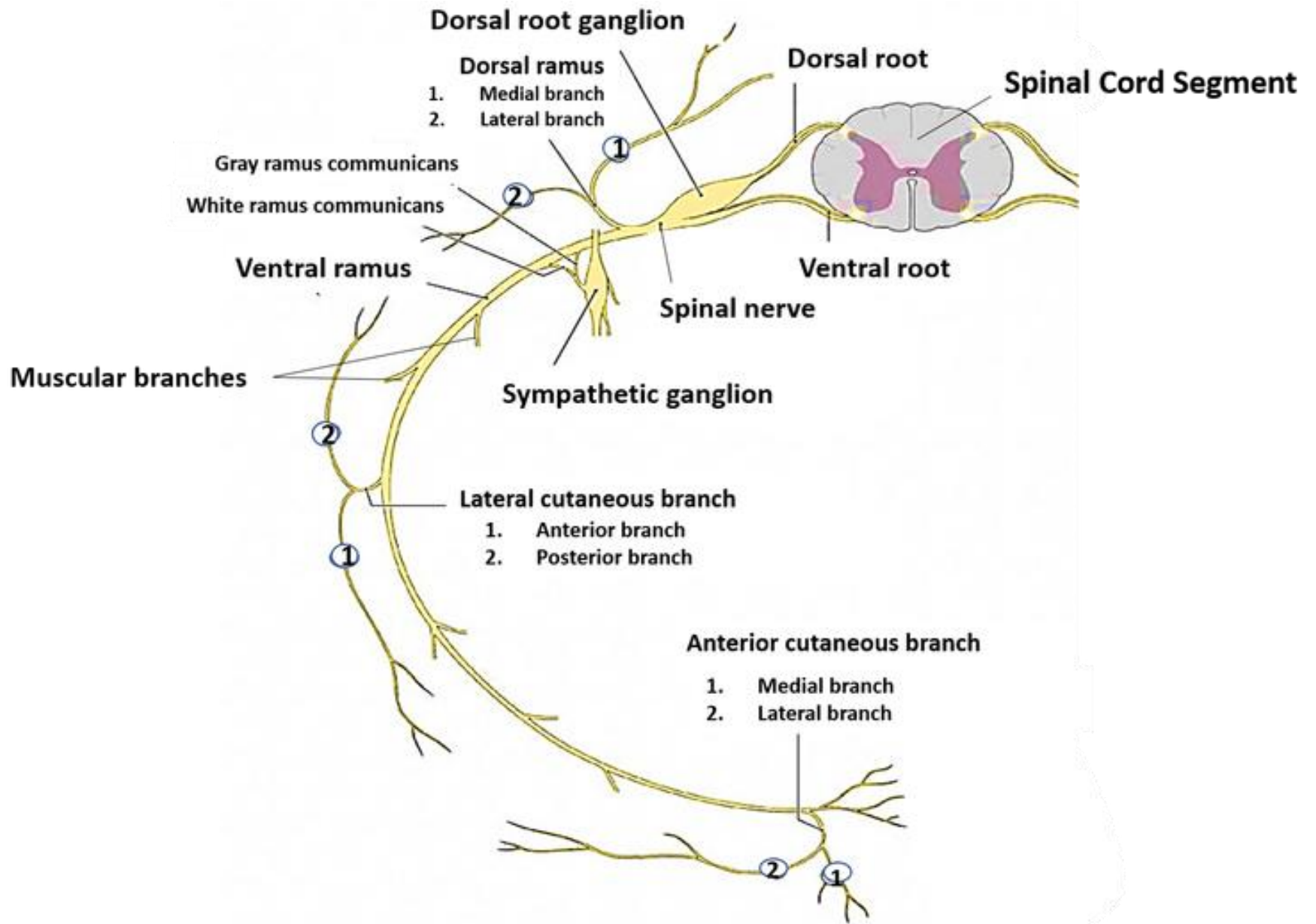


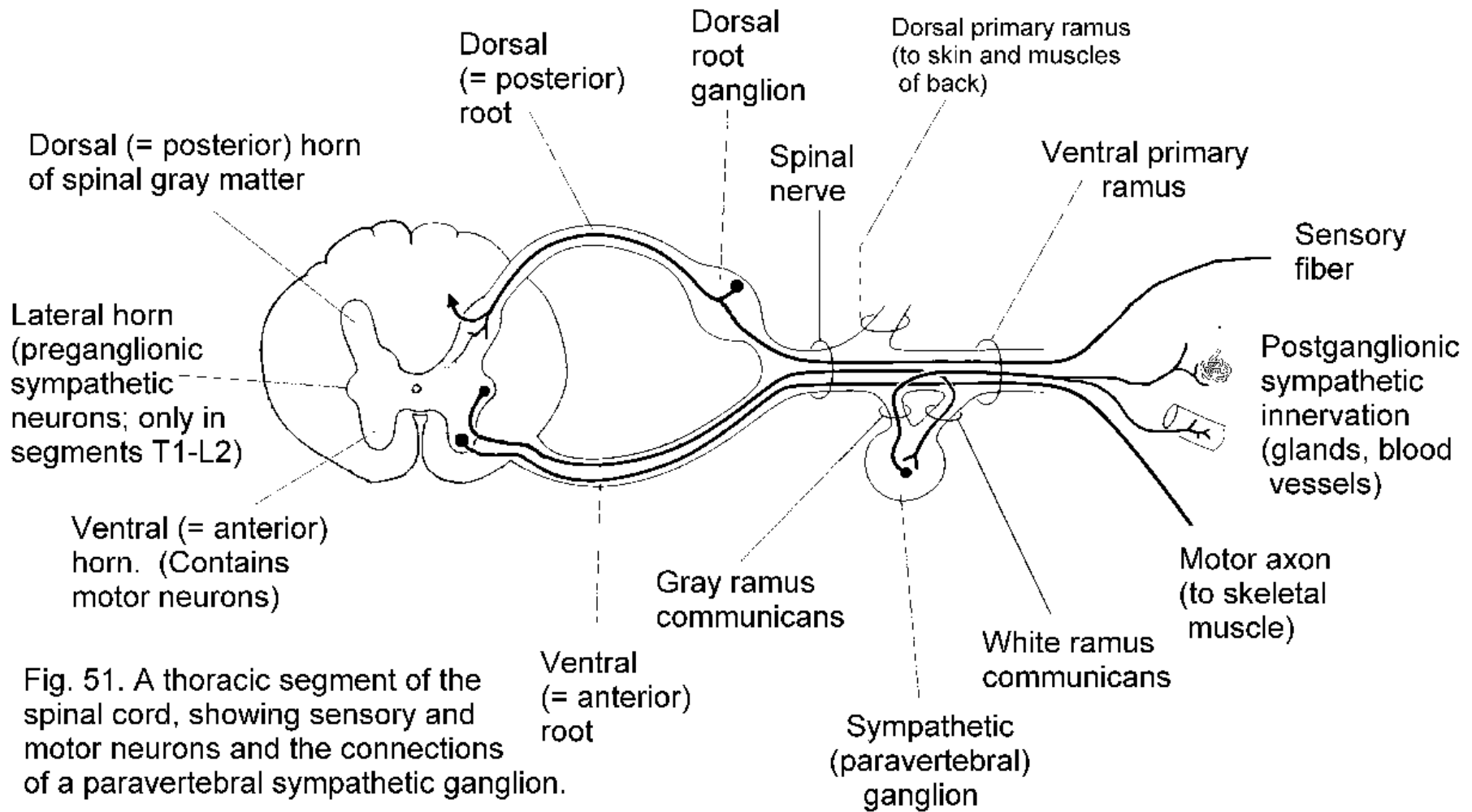
Right side of mediastinum

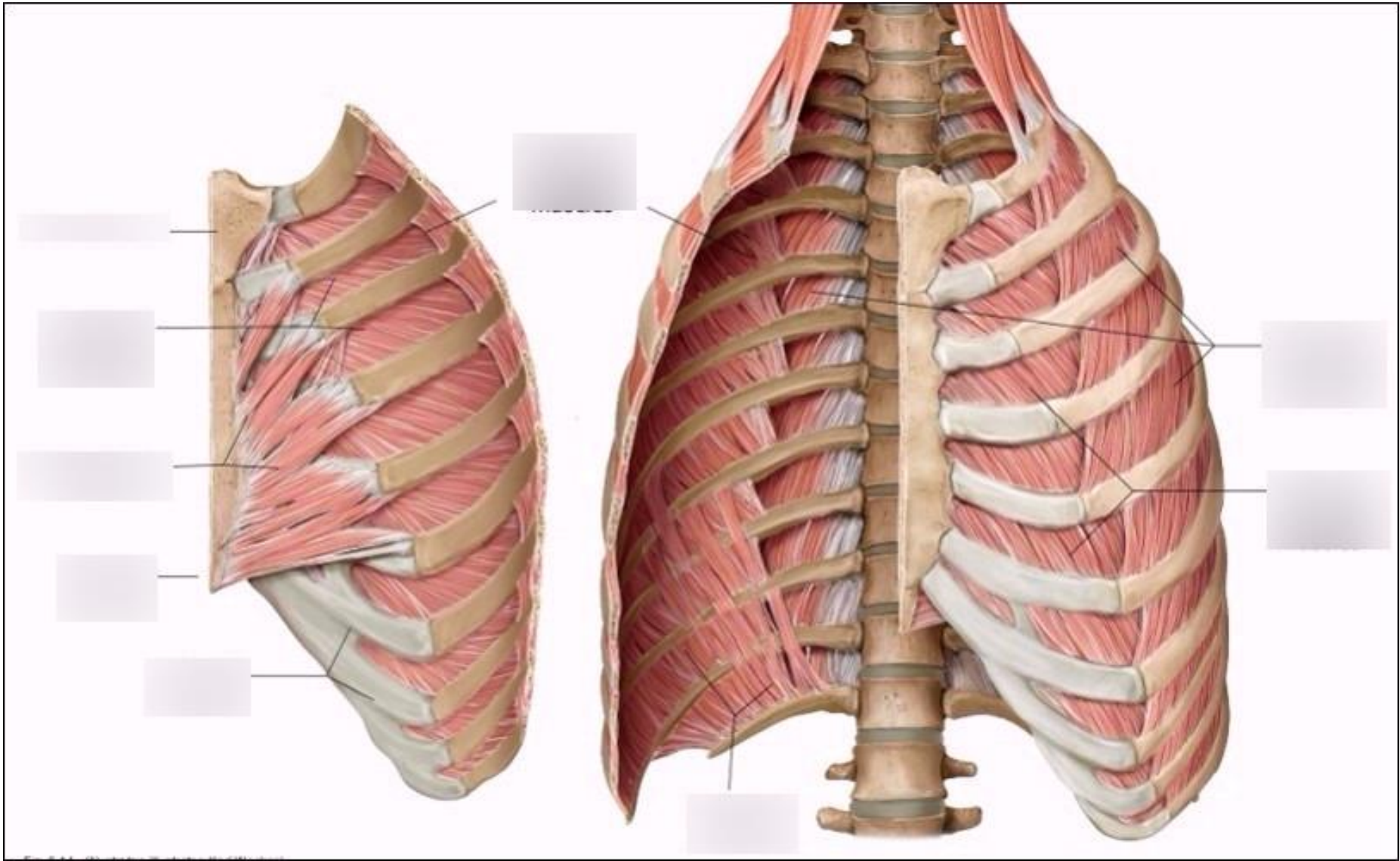


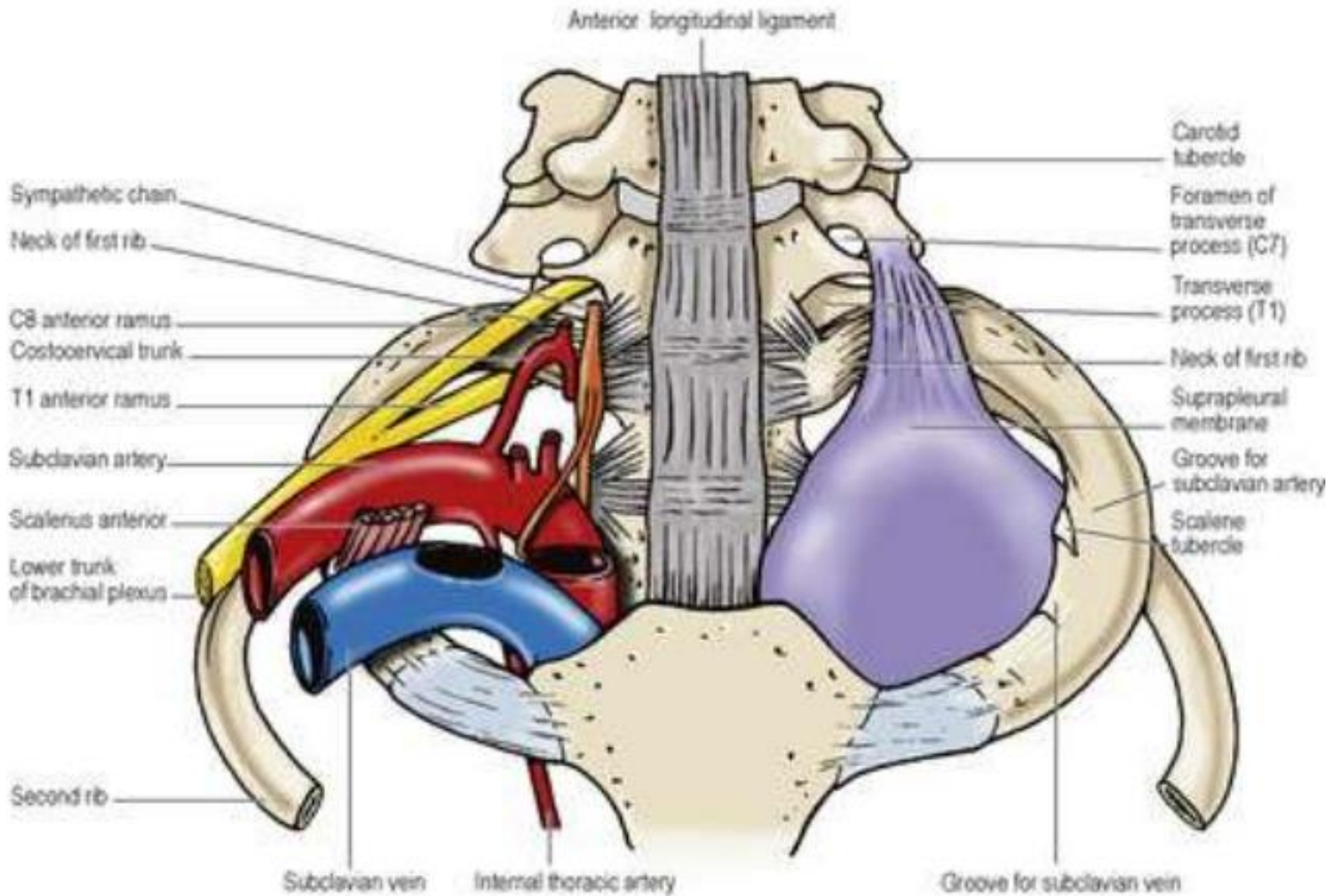


*Nerve and vessels commonly run independently.

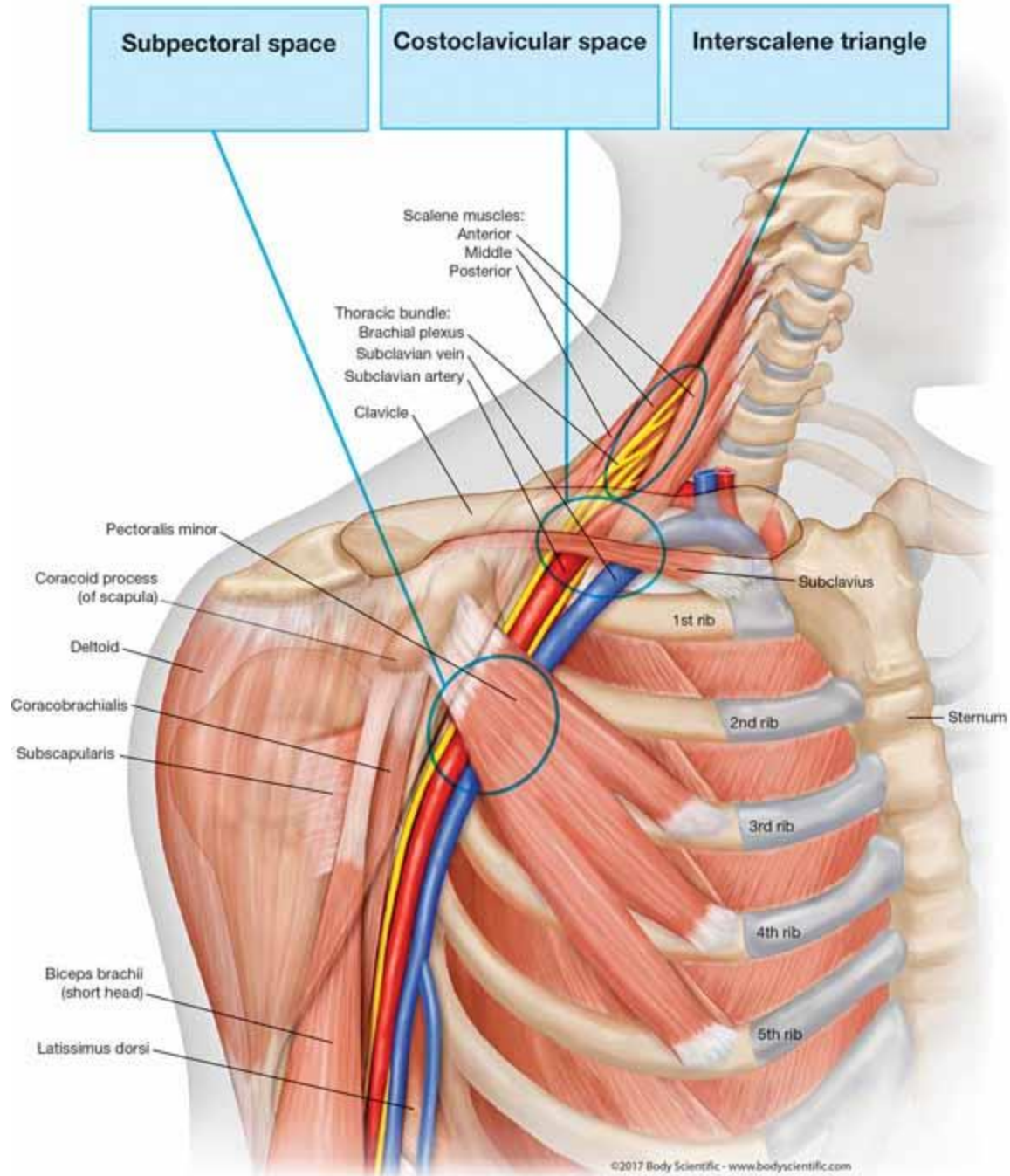


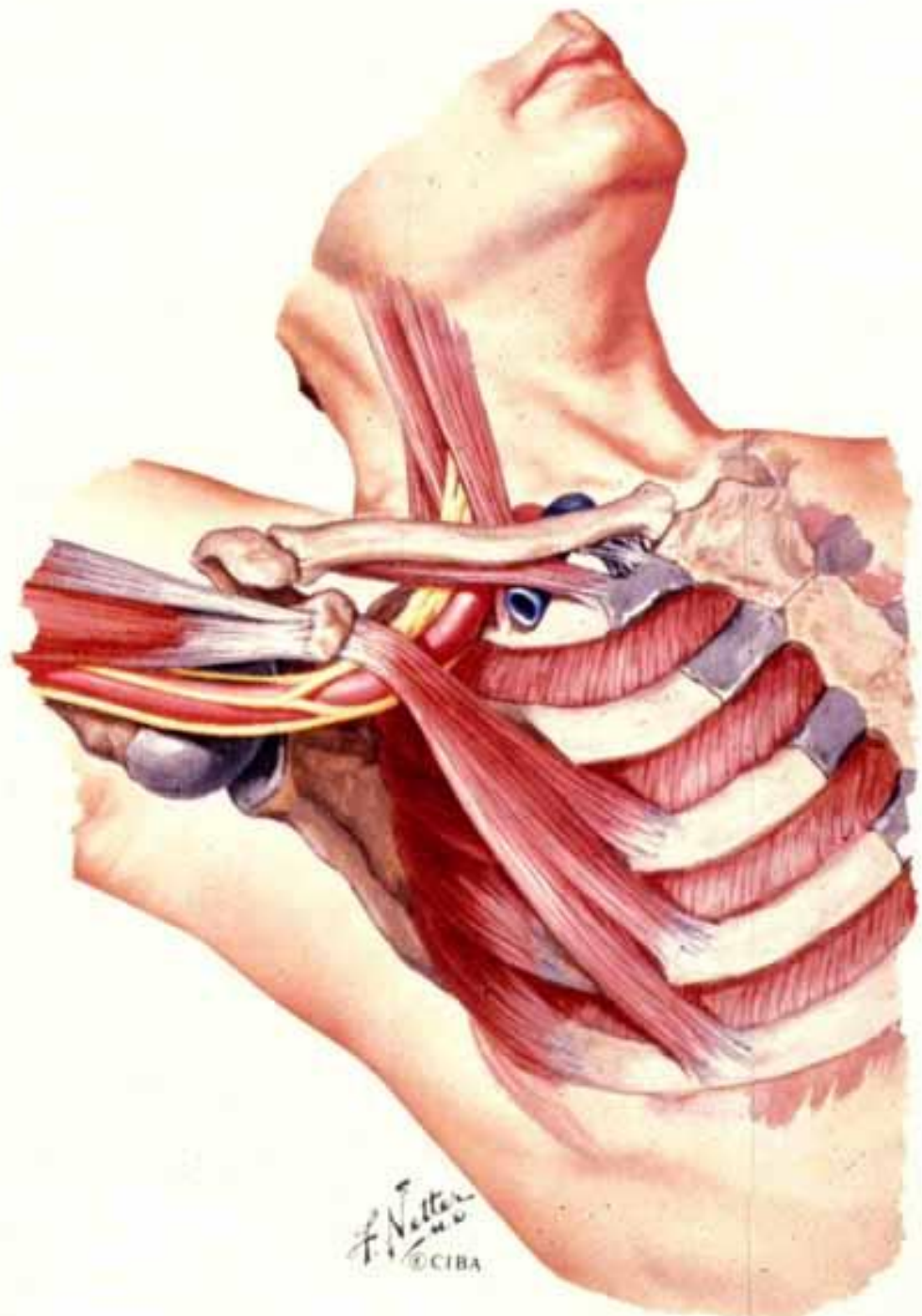






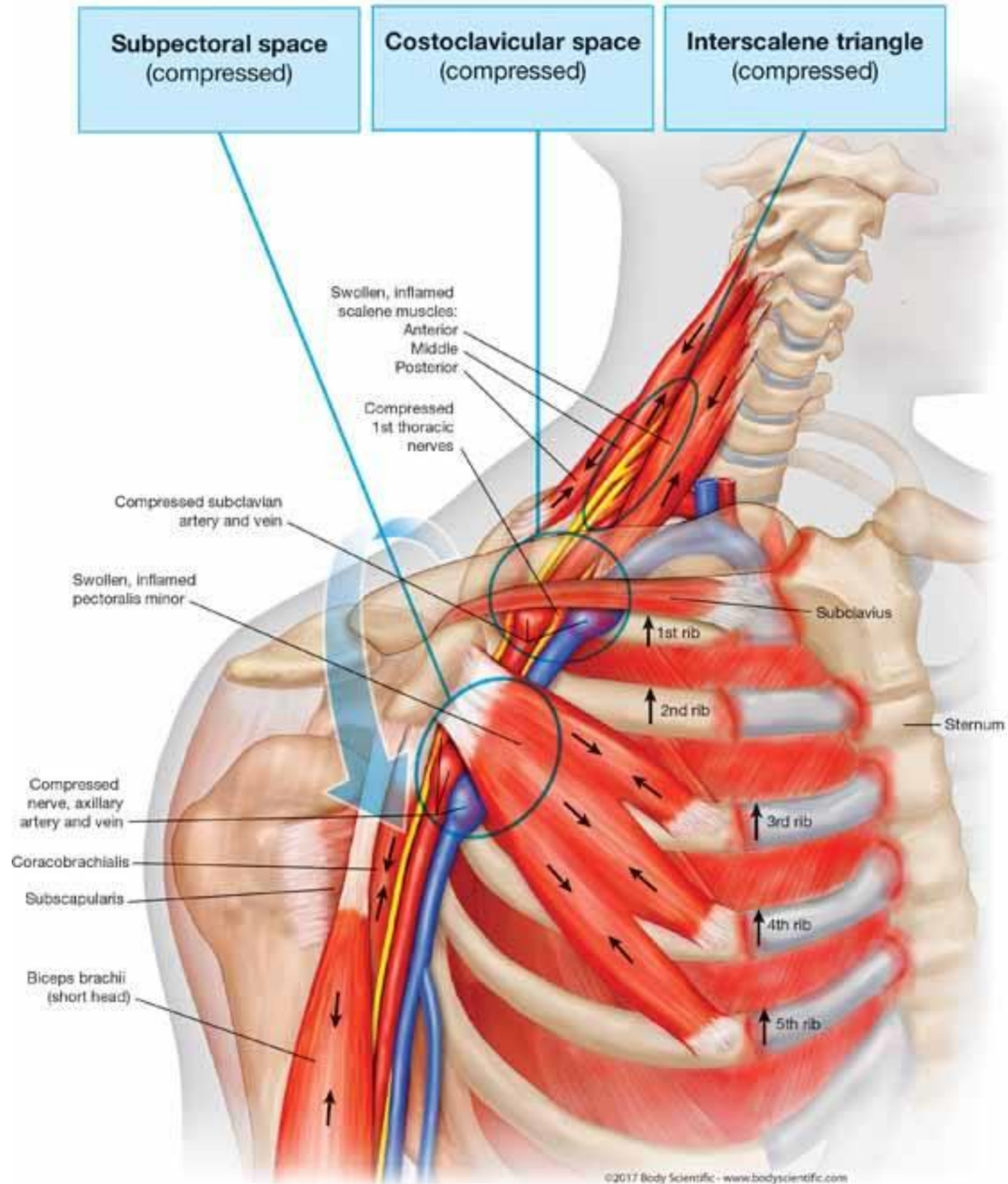
Normal Anatomy of the Thoracic Outlet Region





F. Netter
© CIBA

Causes of Rib Cage and Upper Back Pain in Patients with TOS



thoracic inlet
(or "outlet" in "thoracic outlet syndrome")
bounded by ribs 1, T1 vertebra & jugular notch

transverse thoracic plane
between sternal angle and
T4/T5 intervertebral disc

Mediastinum

- Superior
- Inferior:
 - Anterior
 - Middle
 - Posterior

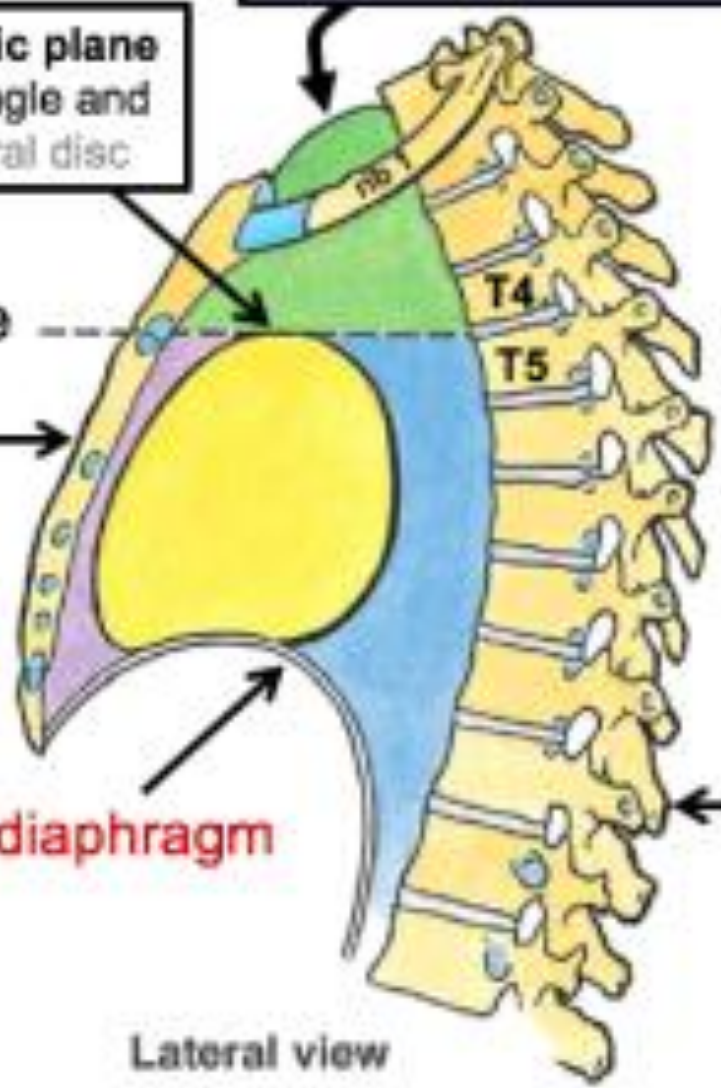
sternal angle

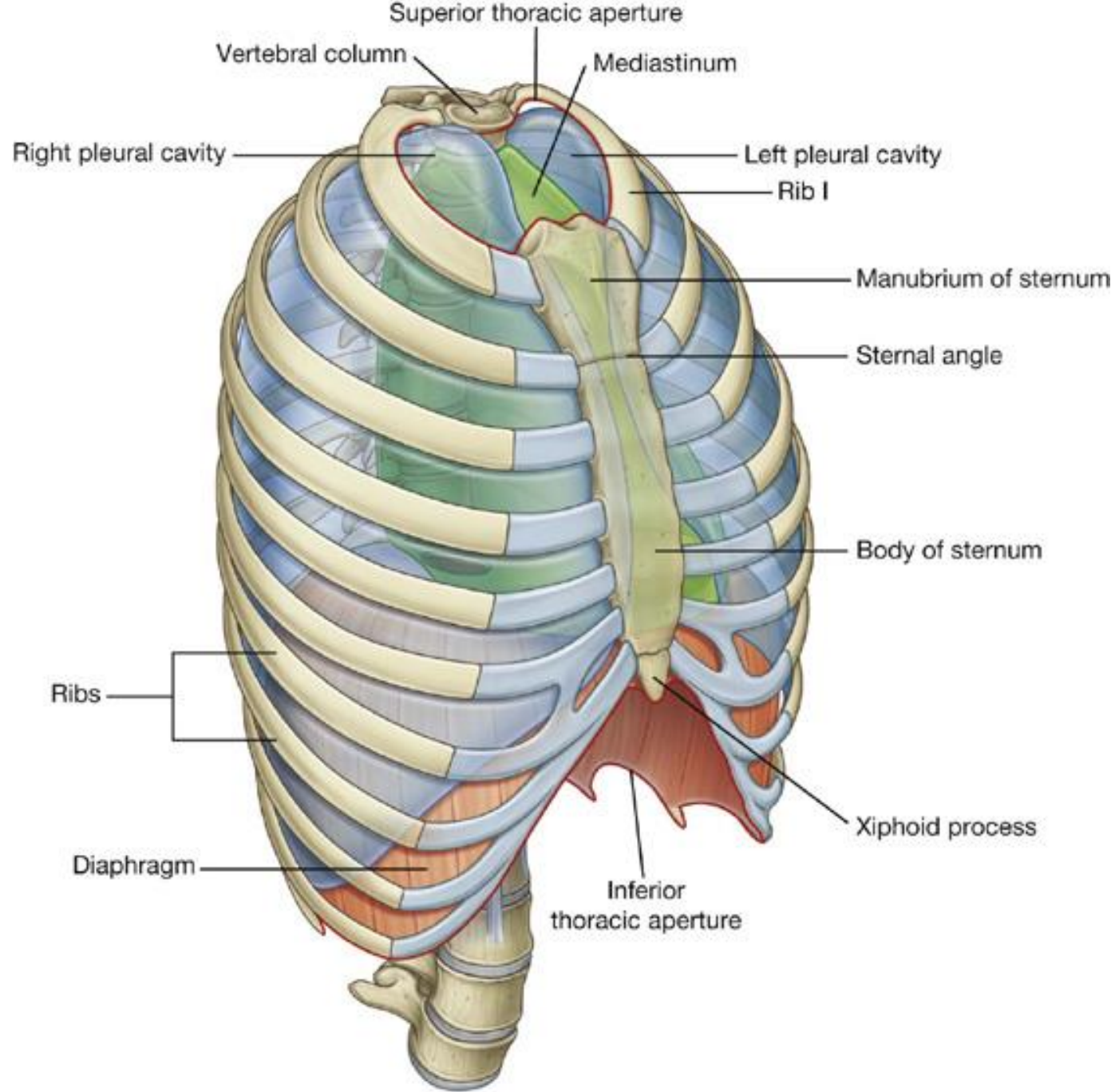
sternum

the diaphragm

vertebral column
(spine)

Lateral view





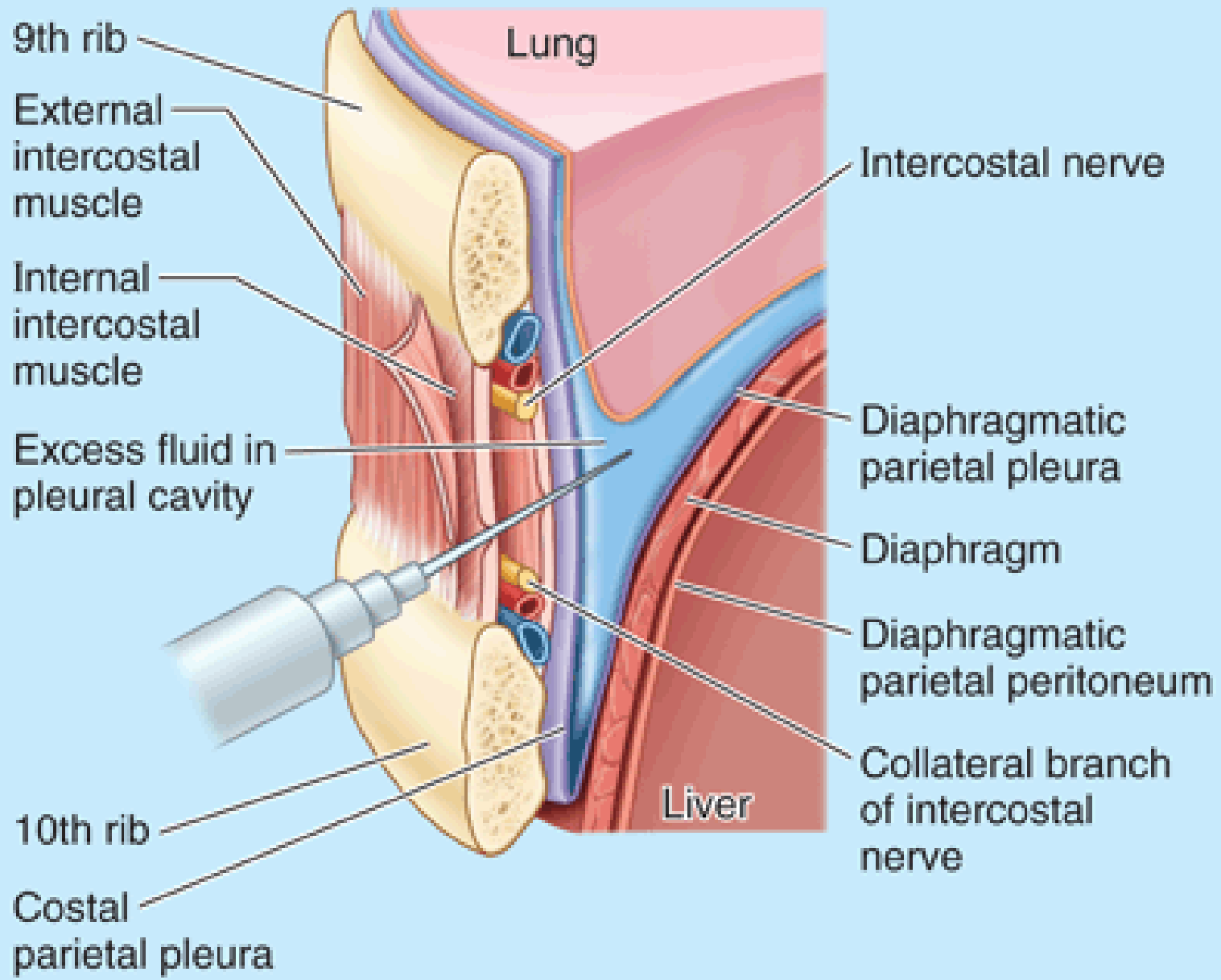
Simple

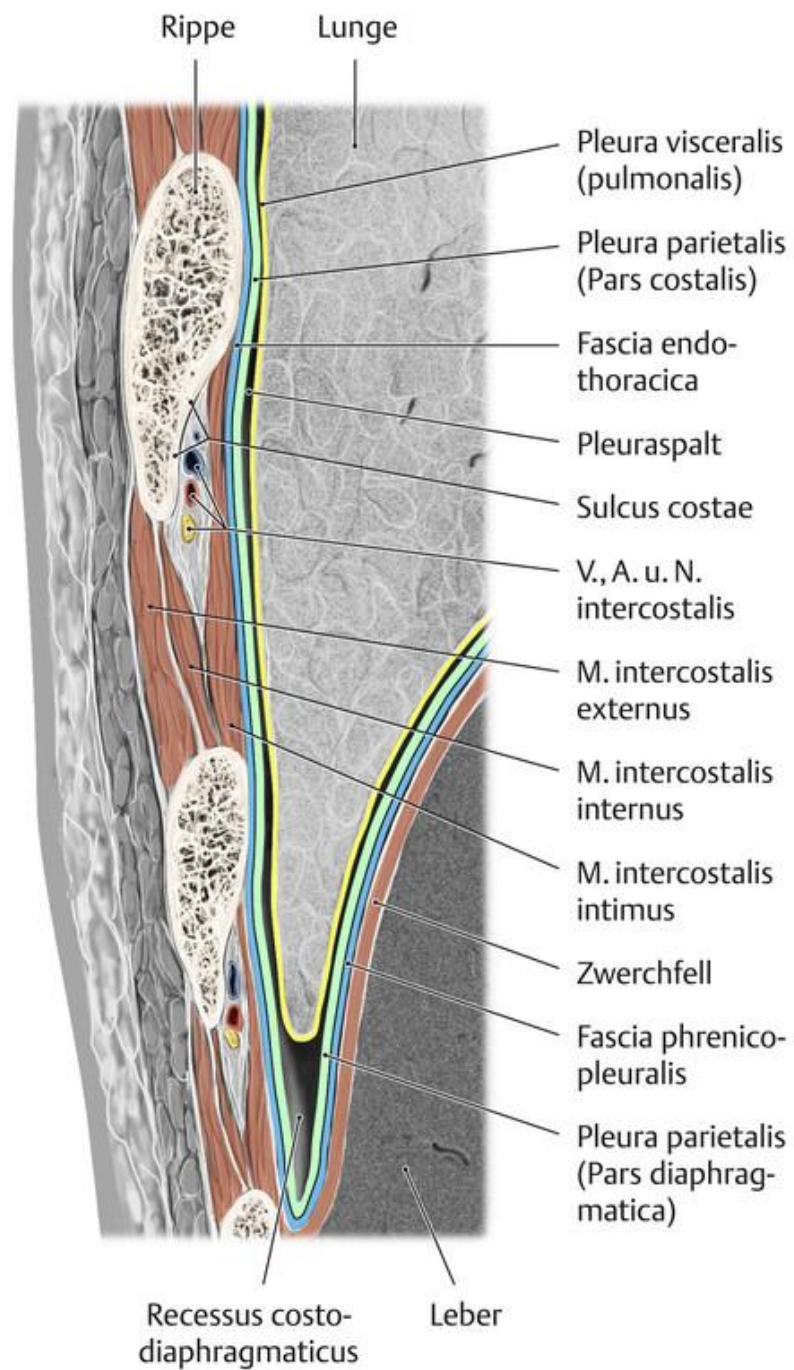
Complicated

- Costovertebral dislocation (any level)
- Transverse rib fracture
- Oblique rib fracture
- Overriding rib fracture
- Chondral fracture
- Costochondral separation
- Chondrosternal separation
- Sternal fracture

- Traumatization of pleura and of lung (pneumothorax, lung contusion, subcutaneous emphysema)
- Multiple rib fractures (stove-in or flail chest)
- Tear of blood vessels (hemothorax)
- Compound by missile (may be deflected) or by puncture wound
- Injury to heart or to great vessels

ELSEVIER

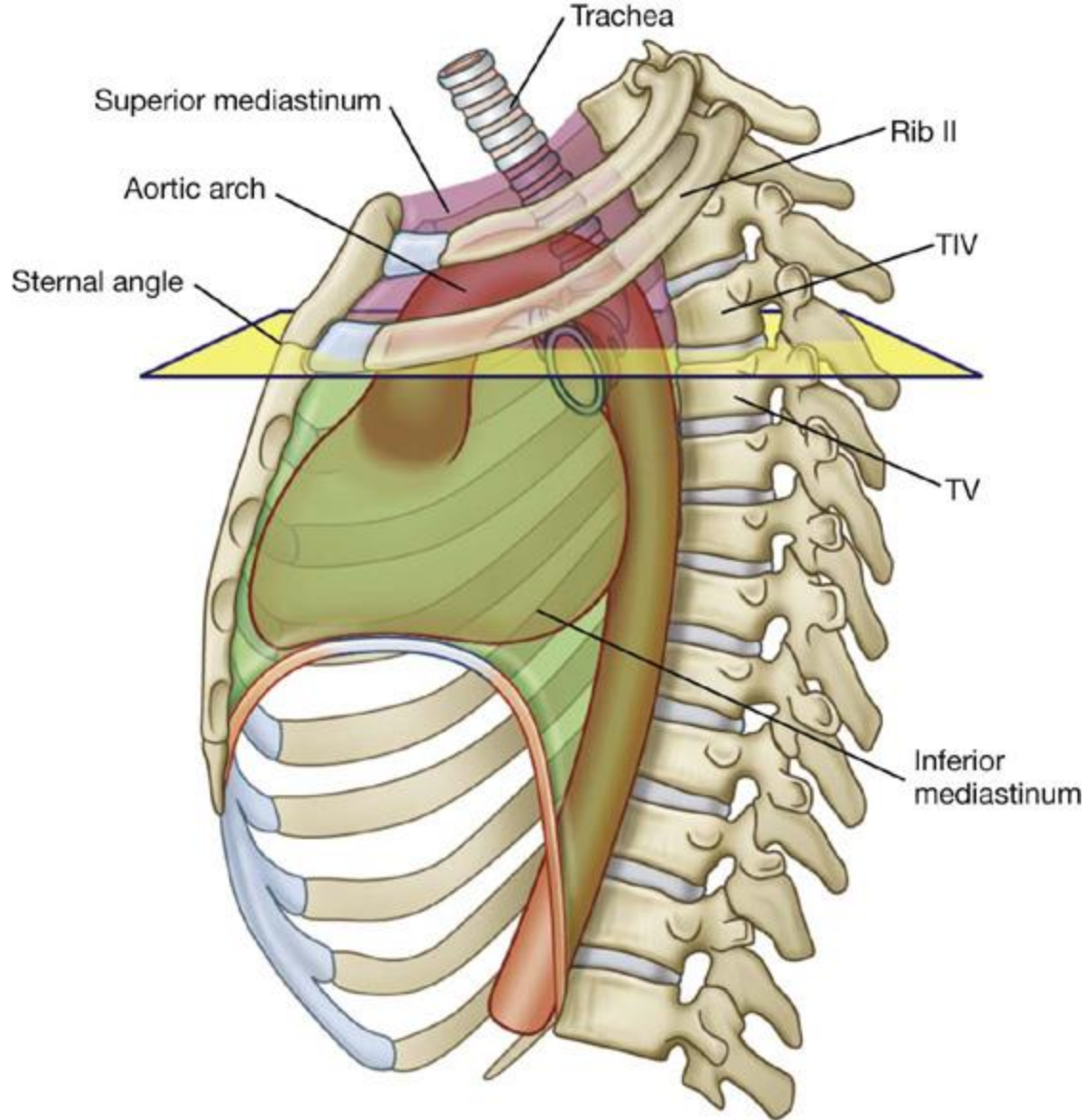




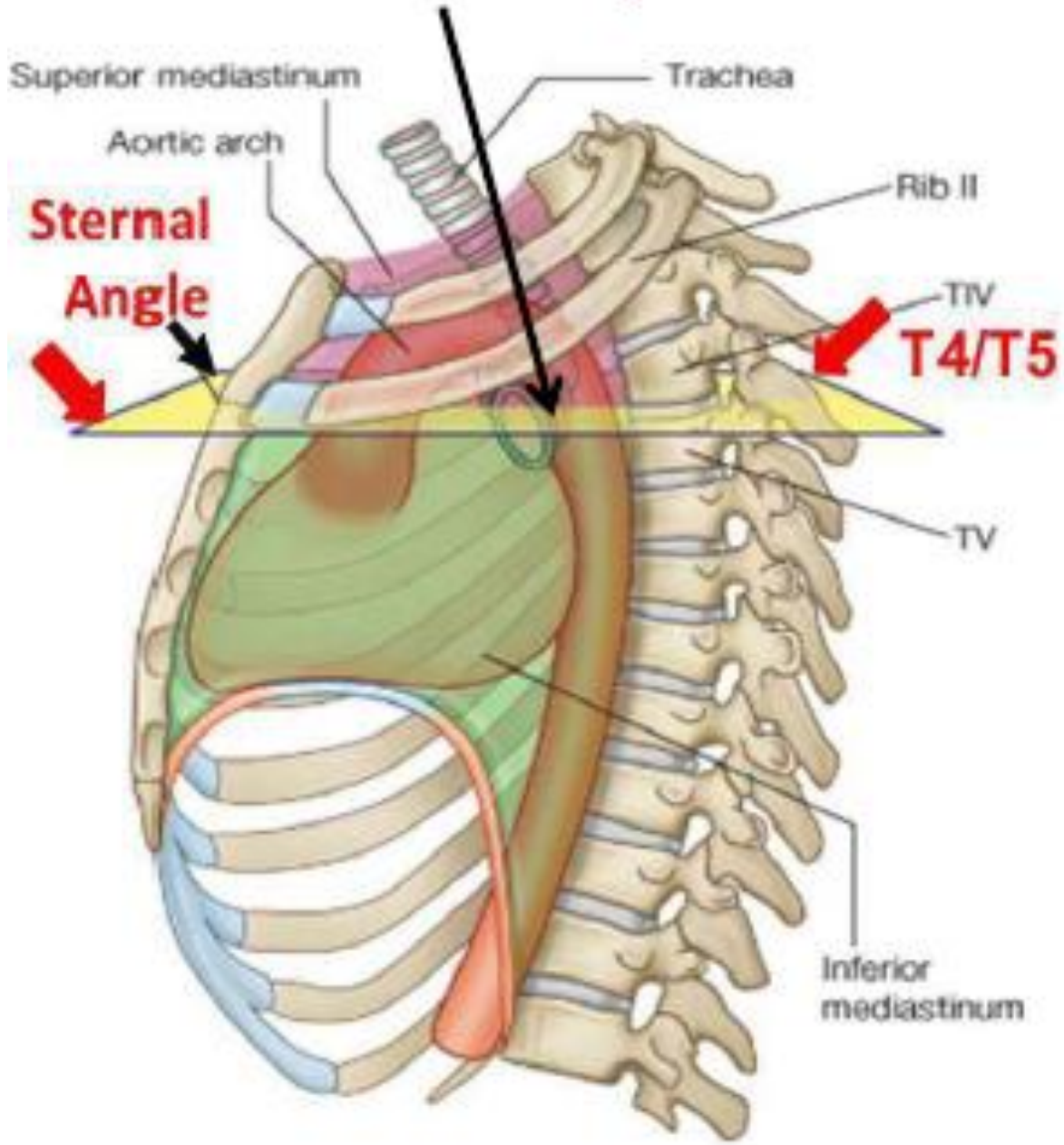
c

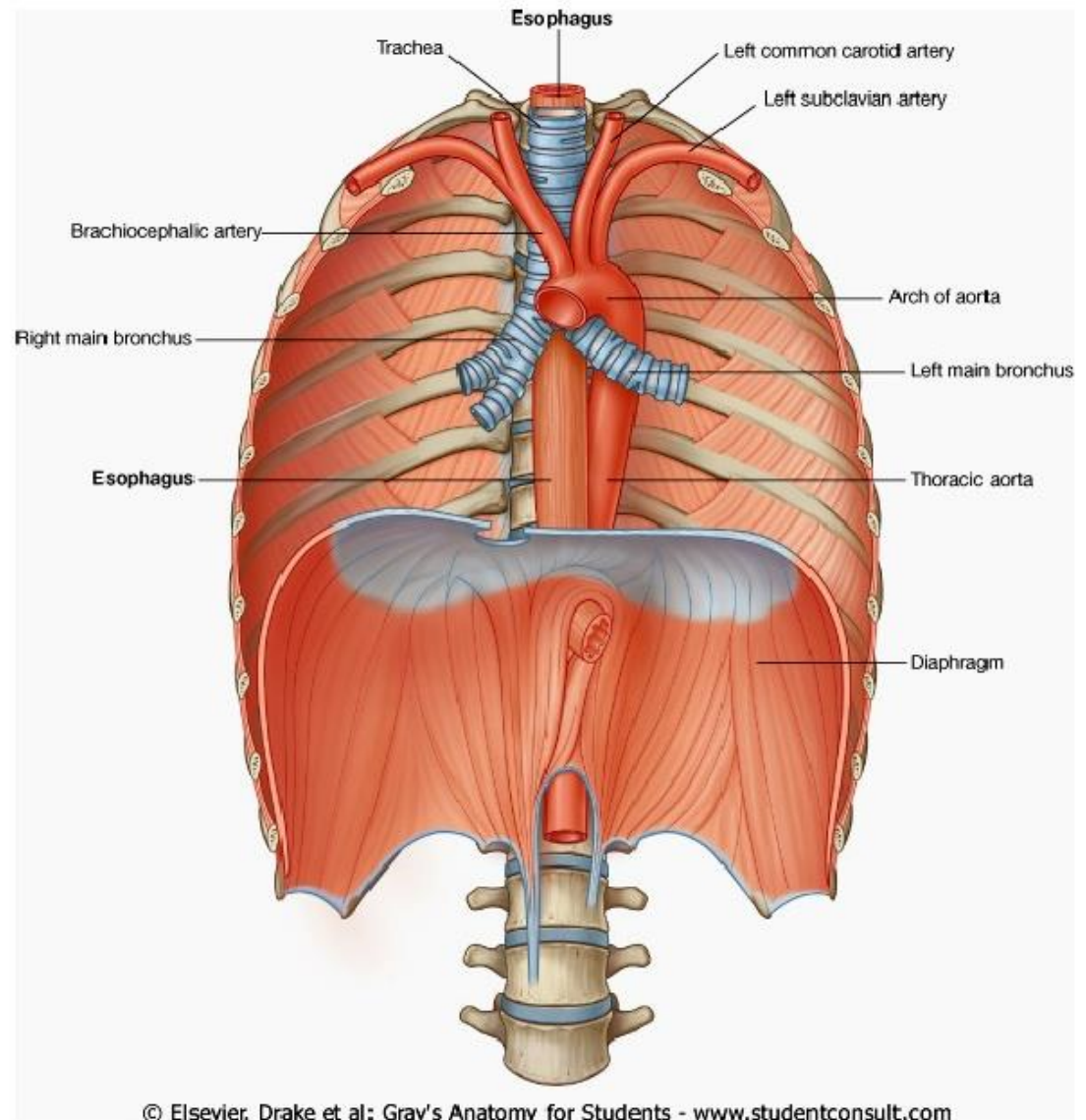
Recessus costo-
diaphragmaticus

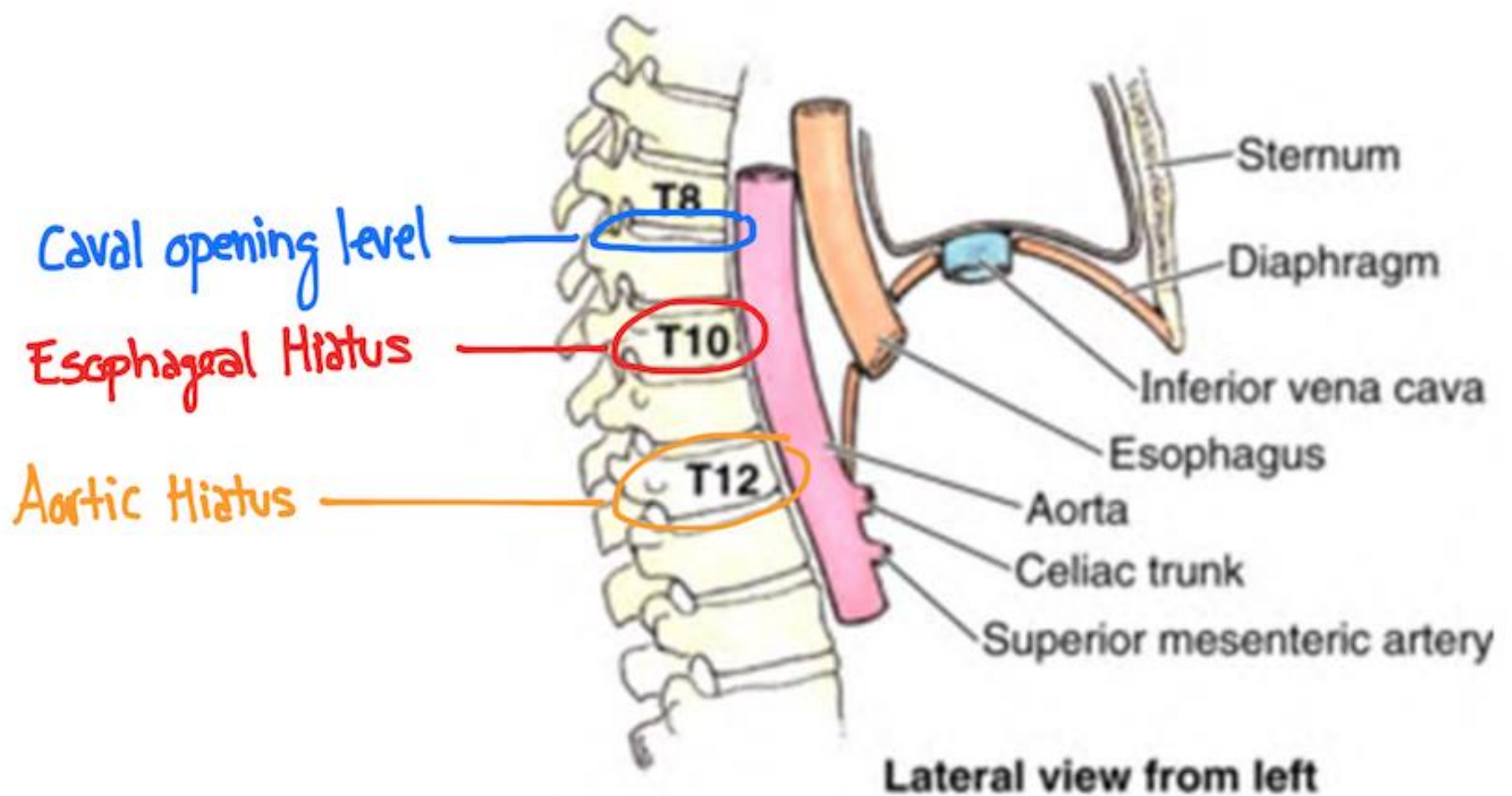
Leber

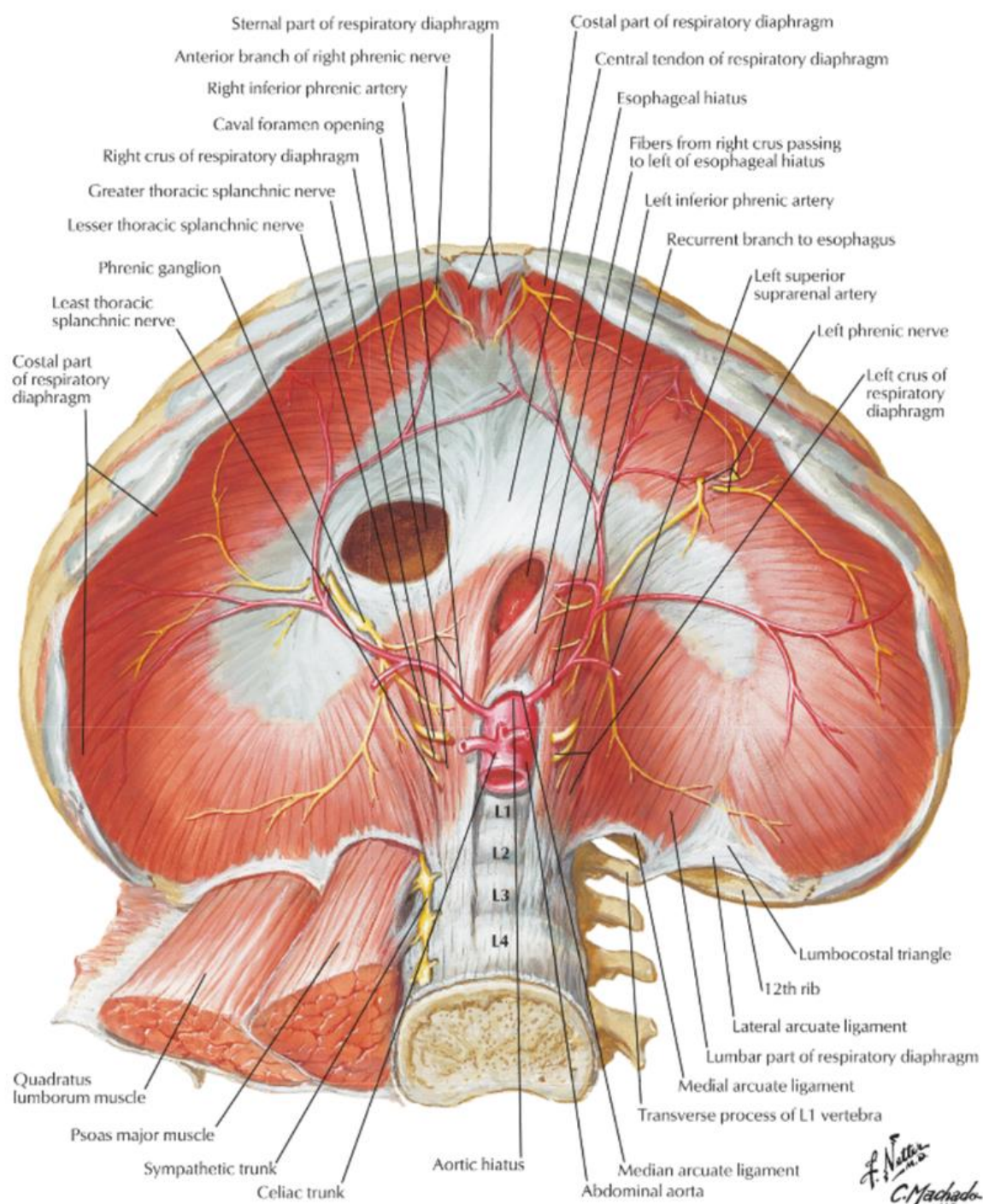


Transverse thoracic plane

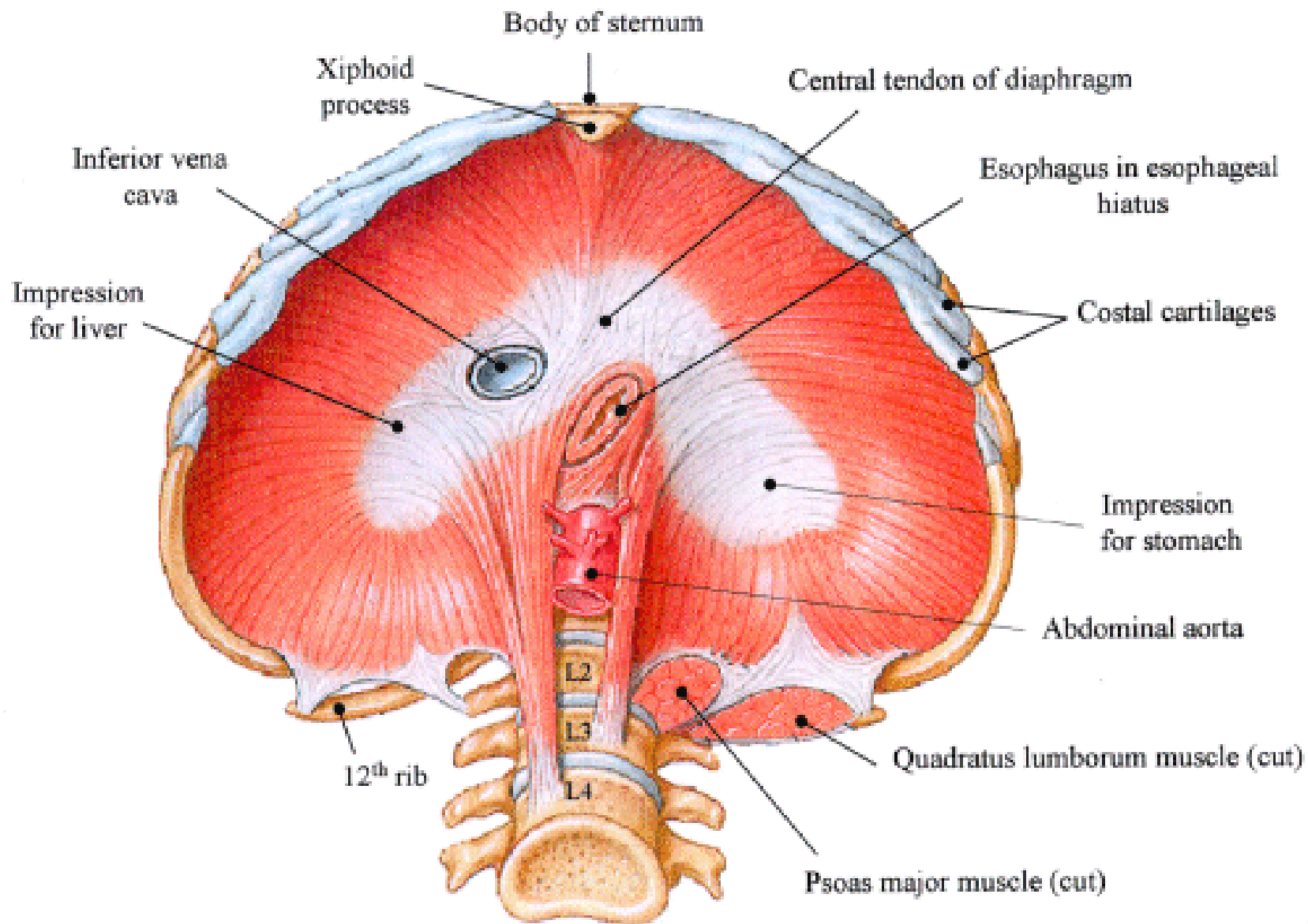


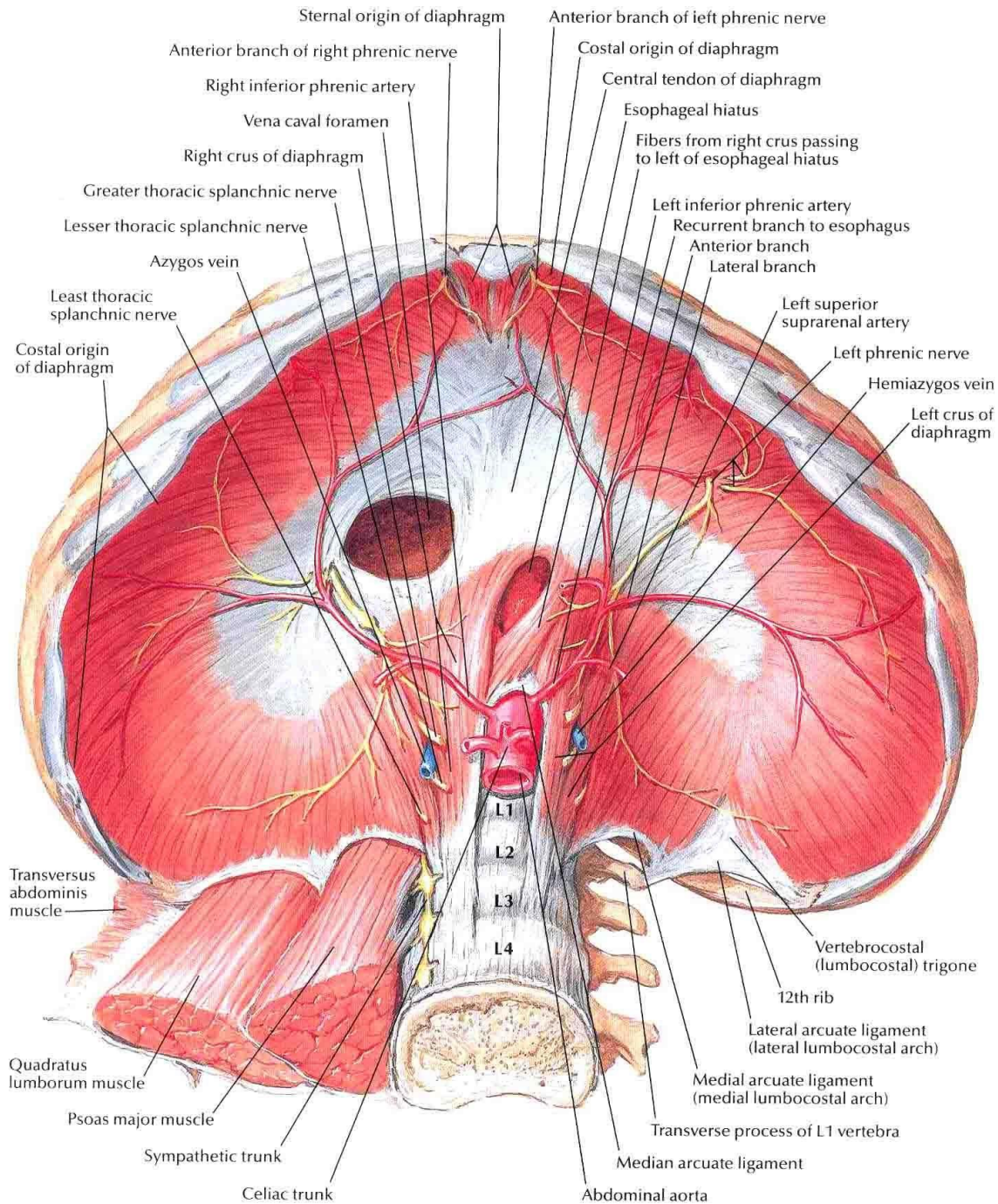


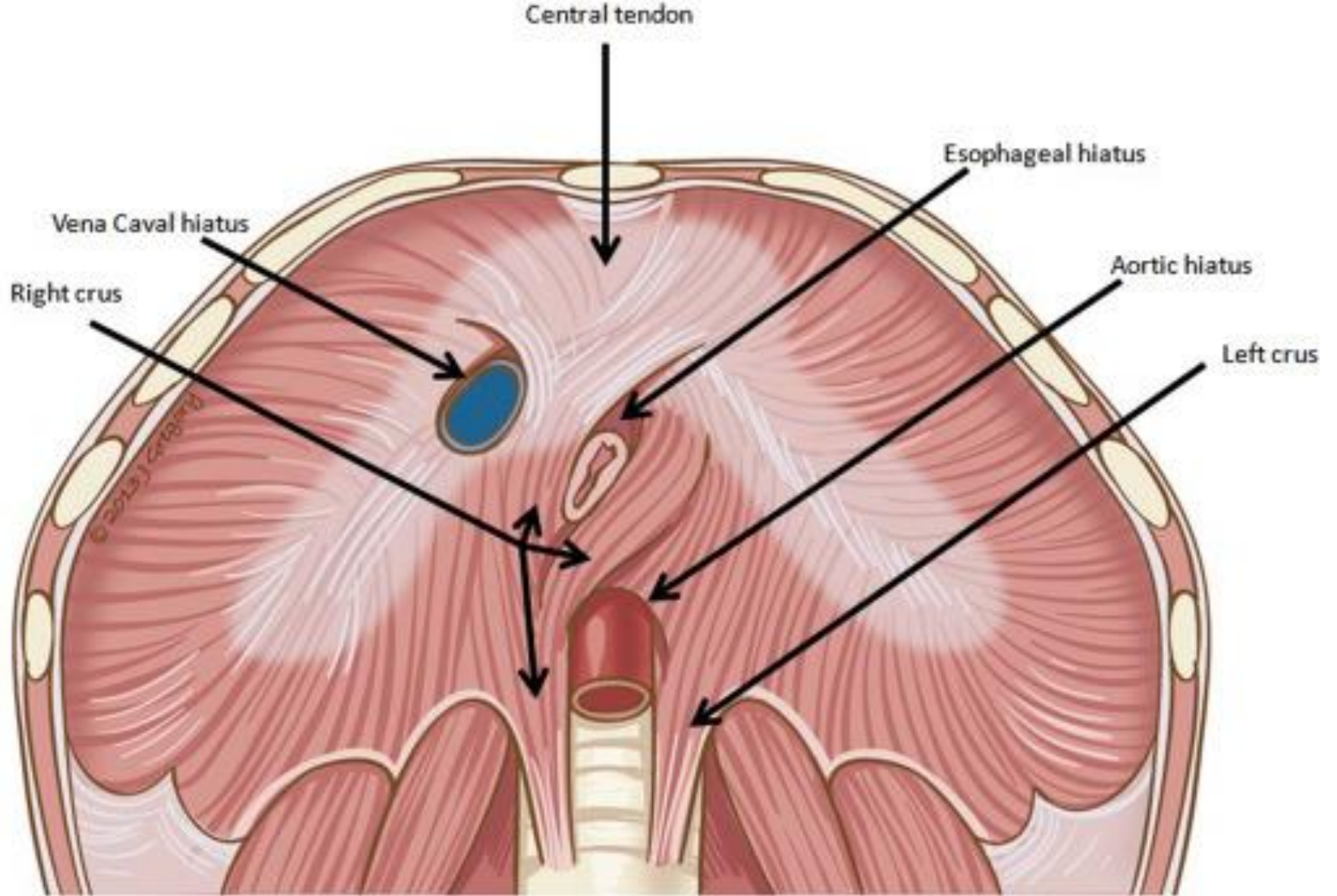


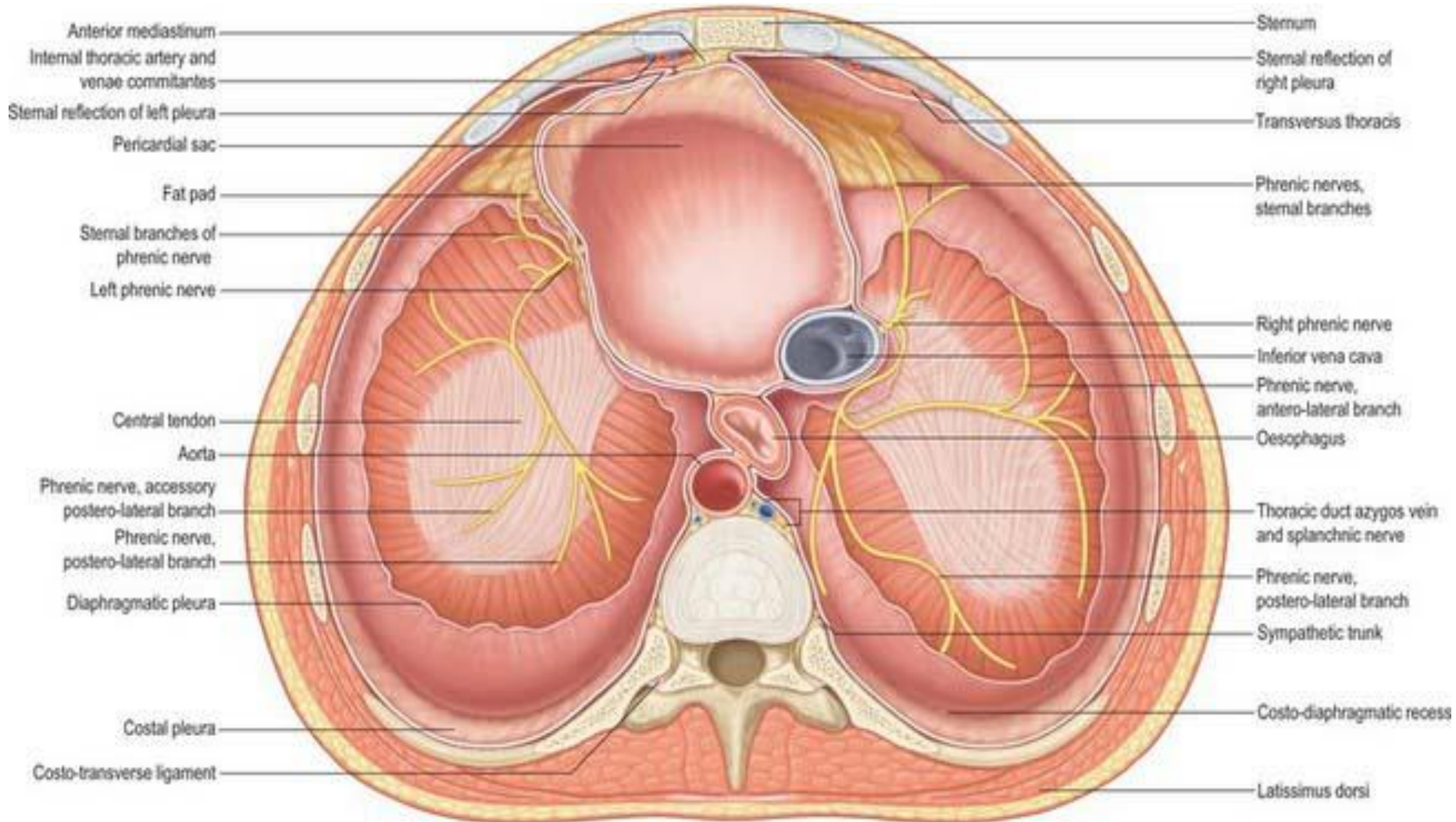


F. Netto
C. Machado
 -M.D.









Anterior mediastinum
 Internal thoracic artery and
 venae comitantes
 Sternal reflection of left pleura
 Pericardial sac
 Fat pad
 Sternal branches of
 phrenic nerve
 Left phrenic nerve
 Central tendon
 Aorta
 Phrenic nerve, accessory
 postero-lateral branch
 Phrenic nerve,
 postero-lateral branch
 Diaphragmatic pleura
 Costal pleura
 Costo-transverse ligament

Sternum
 Sternal reflection of
 right pleura
 Transversus thoracis
 Phrenic nerves,
 sternal branches
 Right phrenic nerve
 Inferior vena cava
 Phrenic nerve,
 antero-lateral branch
 Oesophagus
 Thoracic duct azygos vein
 and splanchnic nerve
 Phrenic nerve,
 postero-lateral branch
 Sympathetic trunk
 Costo-diaphragmatic recess
 Latissimus dorsi

Psoas fascia
merging with
diaphragm

Diaphragm
attac. at
12th rib

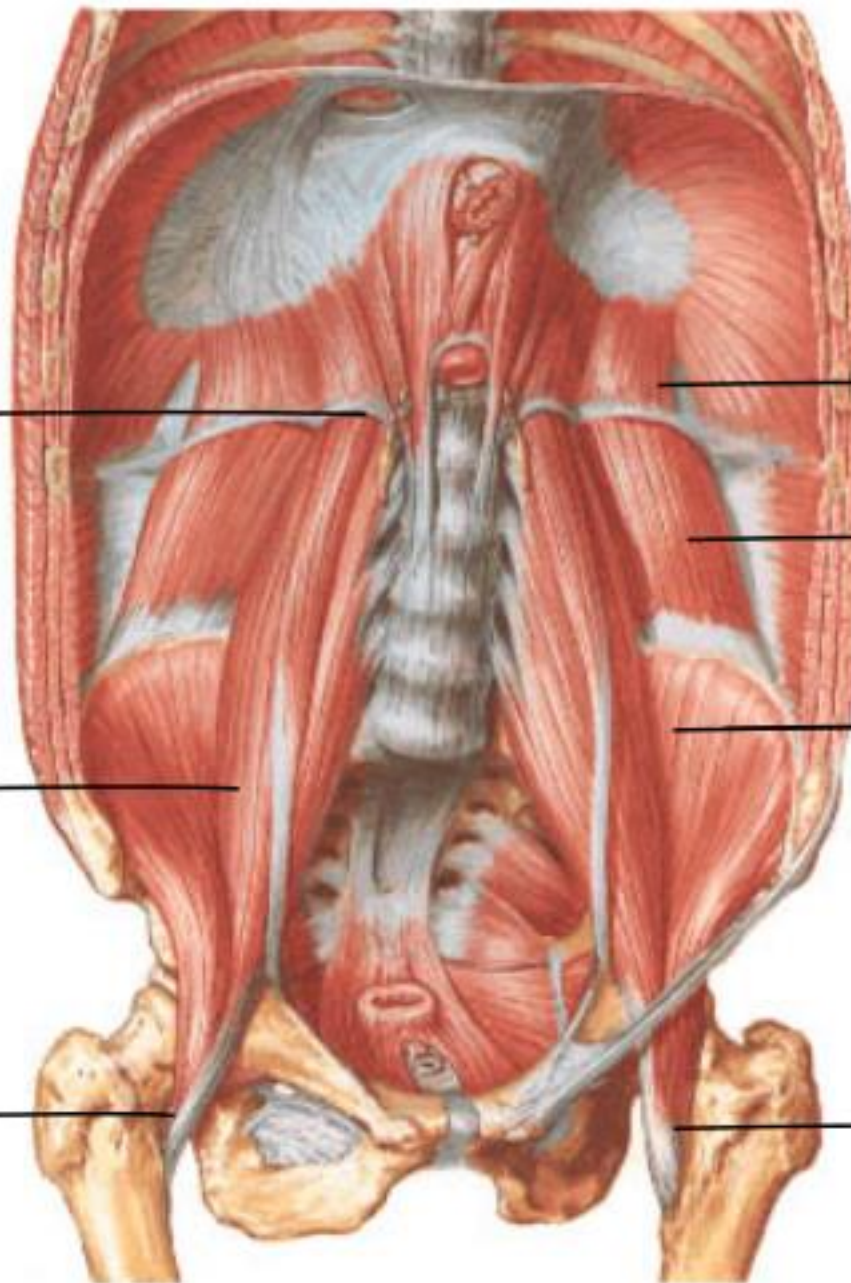
Psoas maj.

Quadratus
lumborum

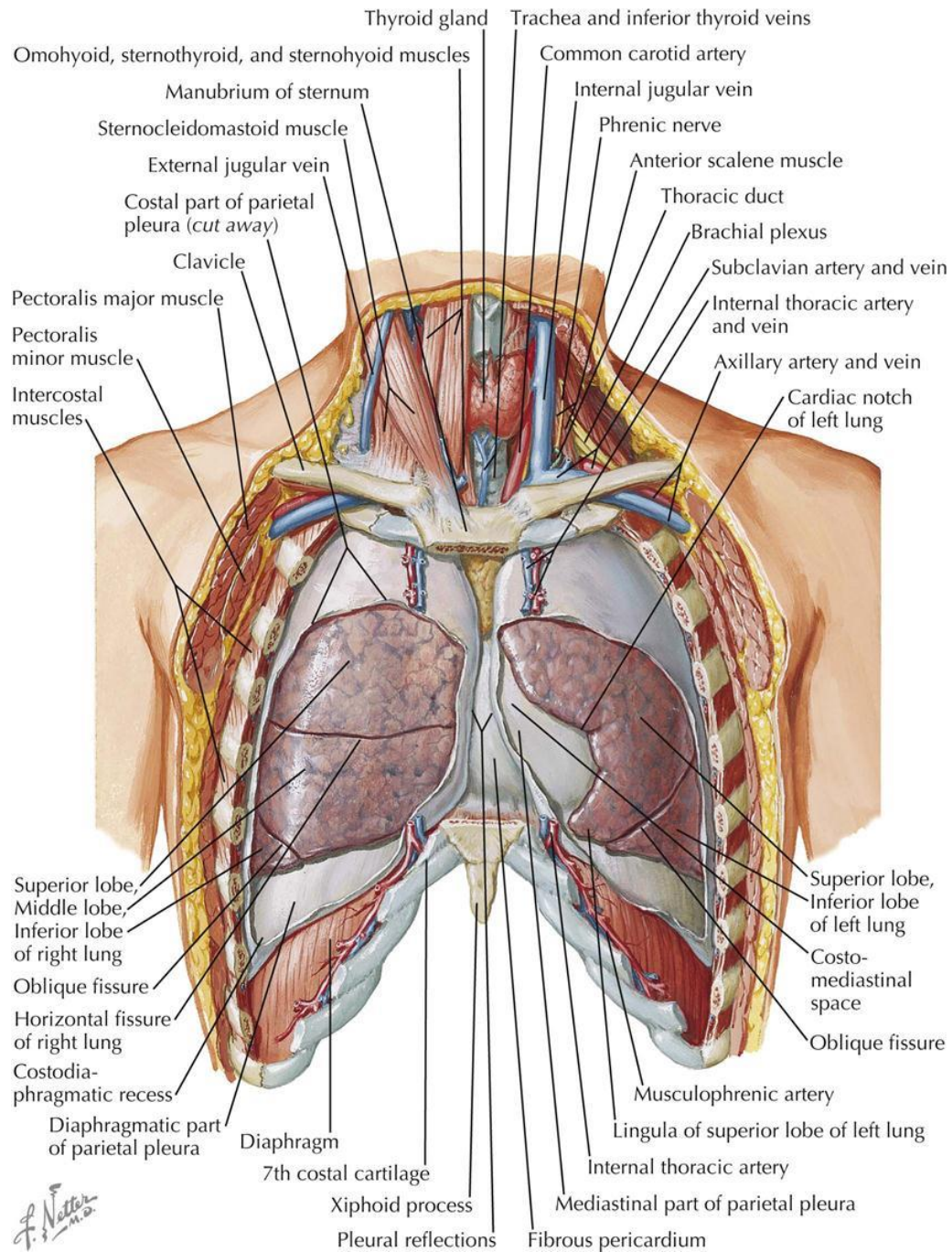
Iliacus

Iliopsoas
tendon

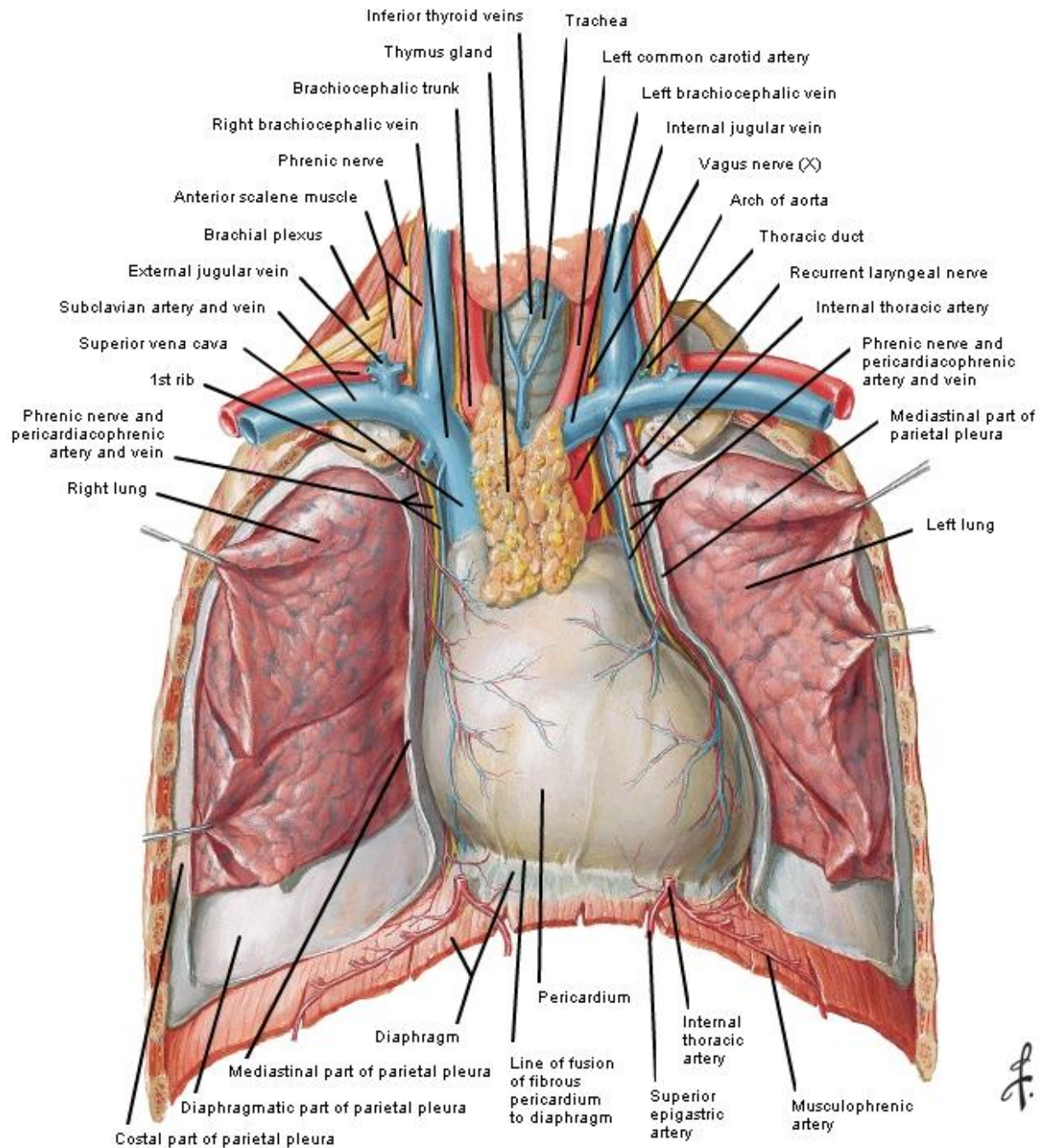
Iliopsoas
tendon



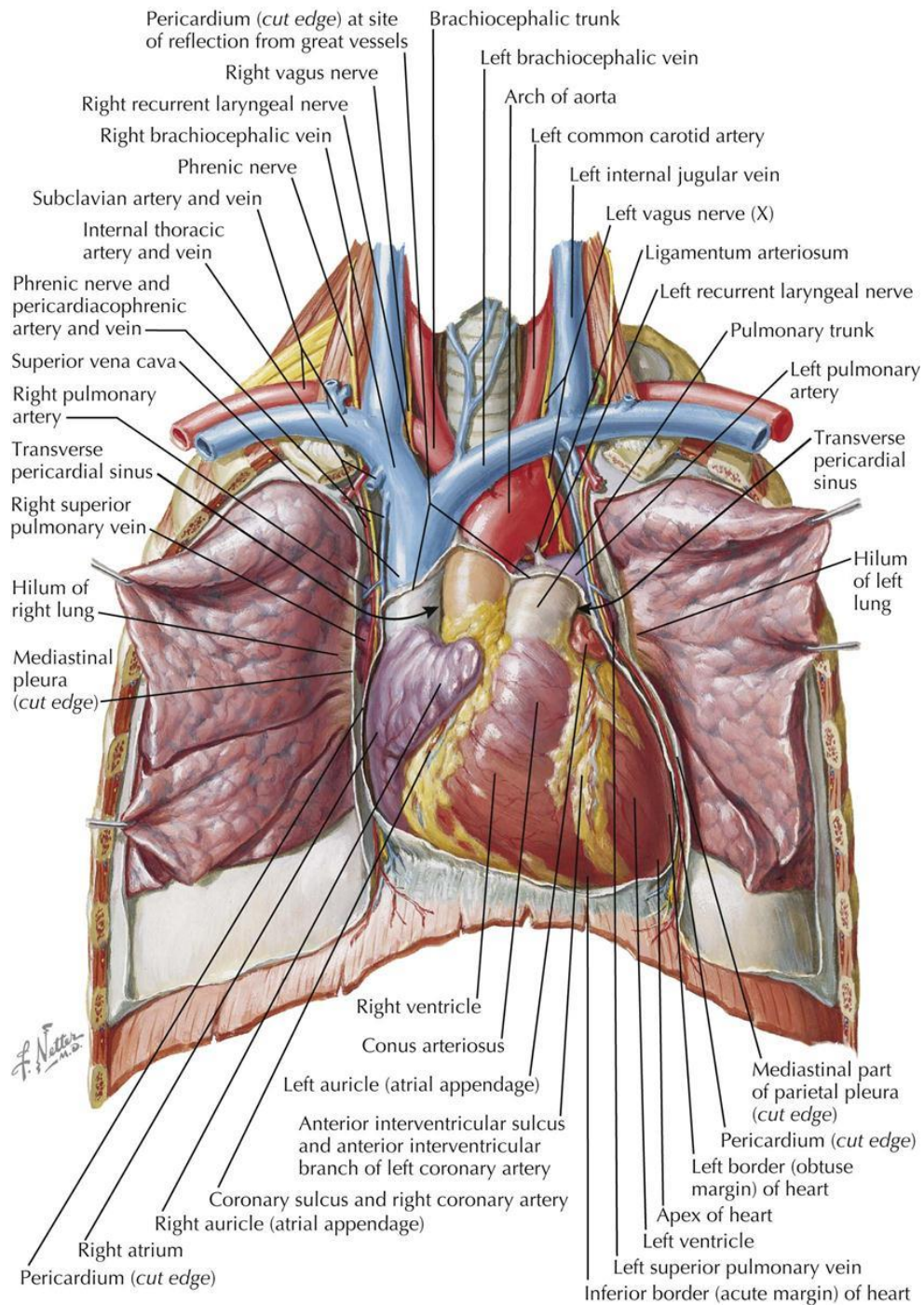
LUNGS IN SITU: ANTERIOR VIEW



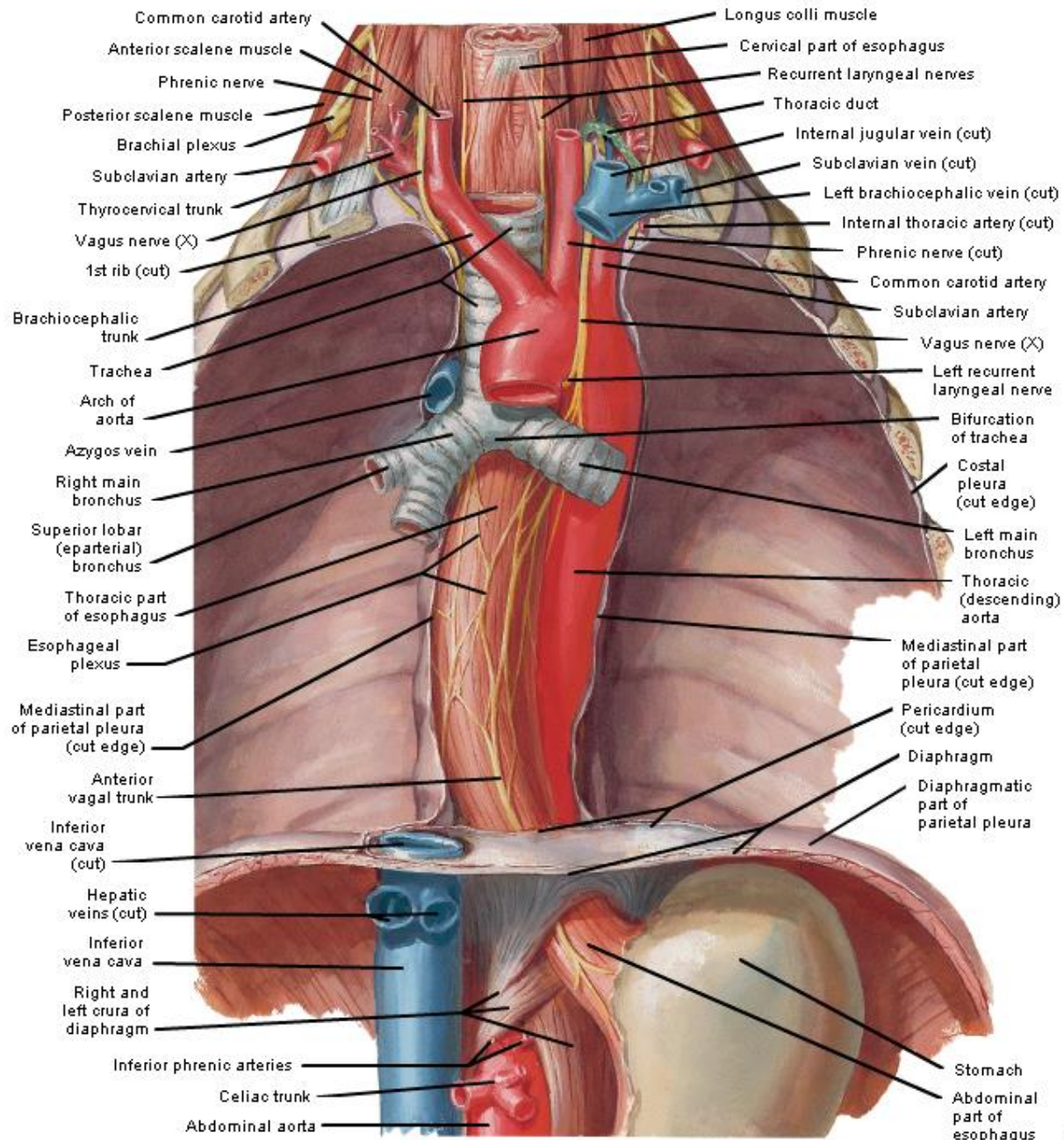
Heart In Situ



ANTERIOR EXPOSURE

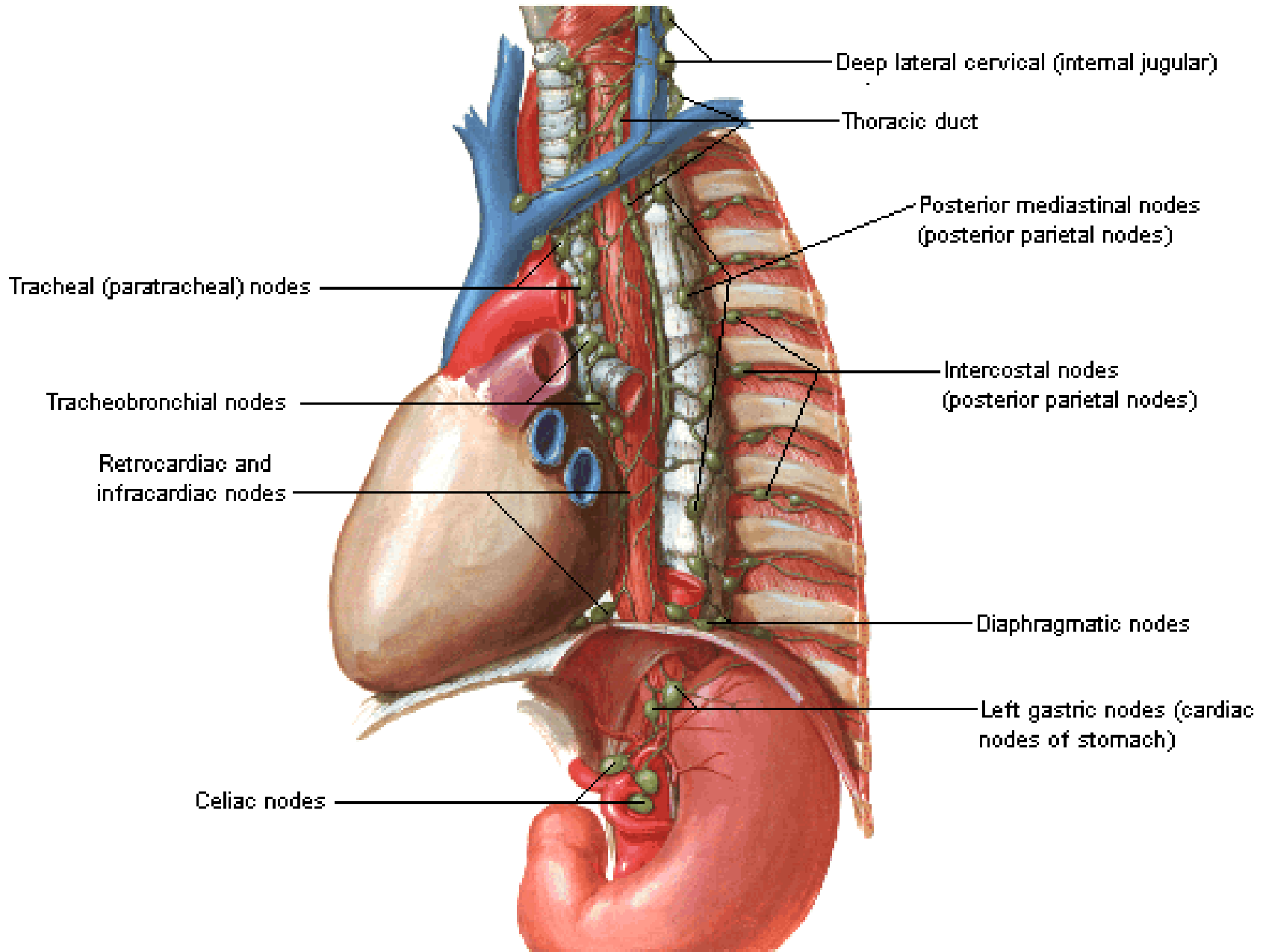


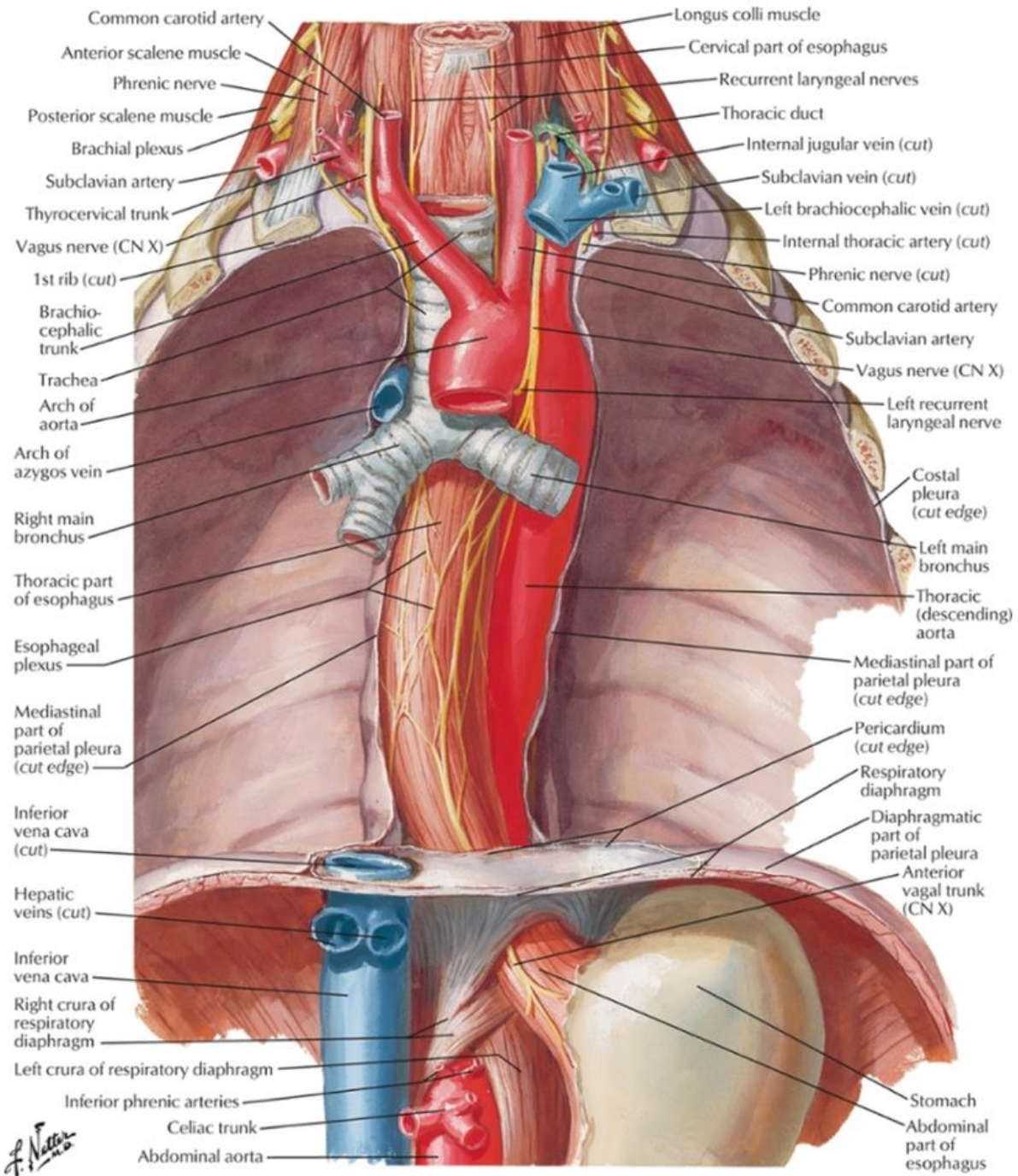
Esophagus In Situ



F. Netter M.D.
© IGV

Lymph Vessels and Nodes of Esophagus

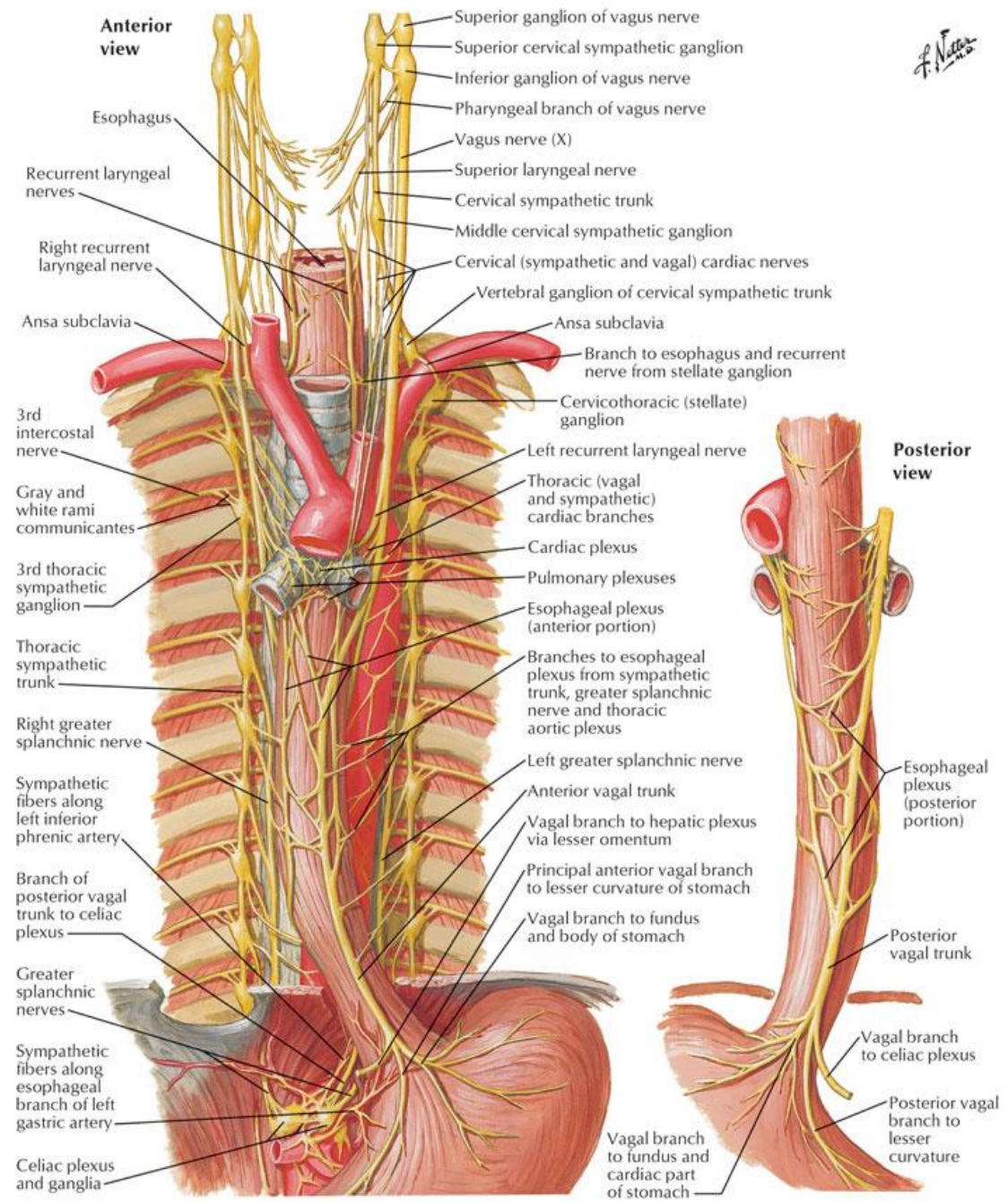




F. Netter M.D.

- Common carotid artery
- Anterior scalene muscle
- Phrenic nerve
- Posterior scalene muscle
- Brachial plexus
- Subclavian artery
- Thyrocervical trunk
- Vagus nerve (CN X)
- 1st rib (cut)
- Brachiocephalic trunk
- Trachea
- Arch of aorta
- Arch of azygos vein
- Right main bronchus
- Thoracic part of esophagus
- Esophageal plexus
- Mediastinal part of parietal pleura (cut edge)
- Inferior vena cava (cut)
- Hepatic veins (cut)
- Inferior vena cava
- Right crura of respiratory diaphragm
- Left crura of respiratory diaphragm
- Inferior phrenic arteries
- Celiac trunk
- Abdominal aorta
- Longus colli muscle
- Cervical part of esophagus
- Recurrent laryngeal nerves
- Thoracic duct
- Internal jugular vein (cut)
- Subclavian vein (cut)
- Left brachiocephalic vein (cut)
- Internal thoracic artery (cut)
- Phrenic nerve (cut)
- Common carotid artery
- Subclavian artery
- Vagus nerve (CN X)
- Left recurrent laryngeal nerve
- Costal pleura (cut edge)
- Left main bronchus
- Thoracic (descending) aorta
- Mediastinal part of parietal pleura (cut edge)
- Pericardium (cut edge)
- Respiratory diaphragm
- Diaphragmatic part of parietal pleura
- Anterior vagal trunk (CN X)
- Stomach
- Abdominal part of esophagus

Nerves of Esophagus



Sympathetic Innervation

Abdominopelvic splanchnic nn.

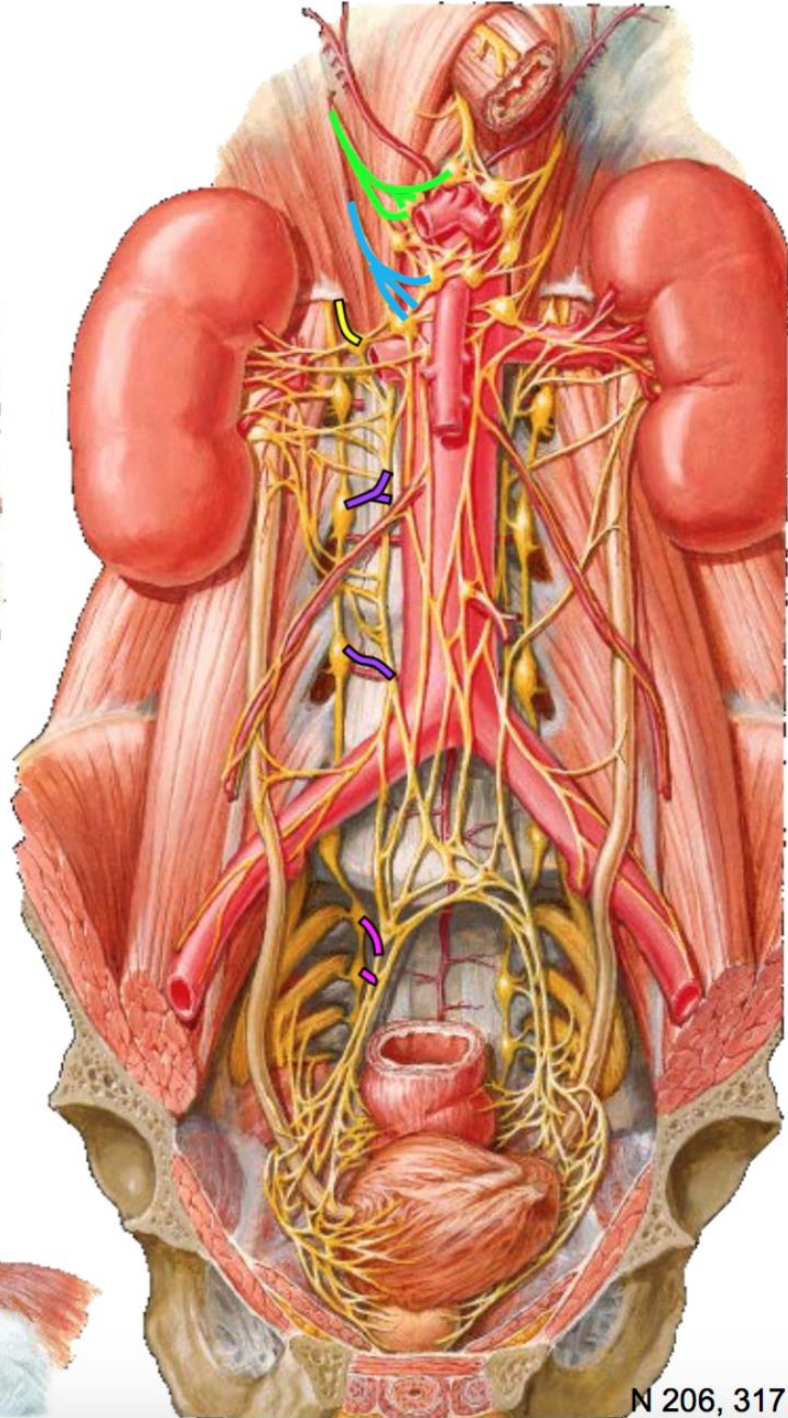
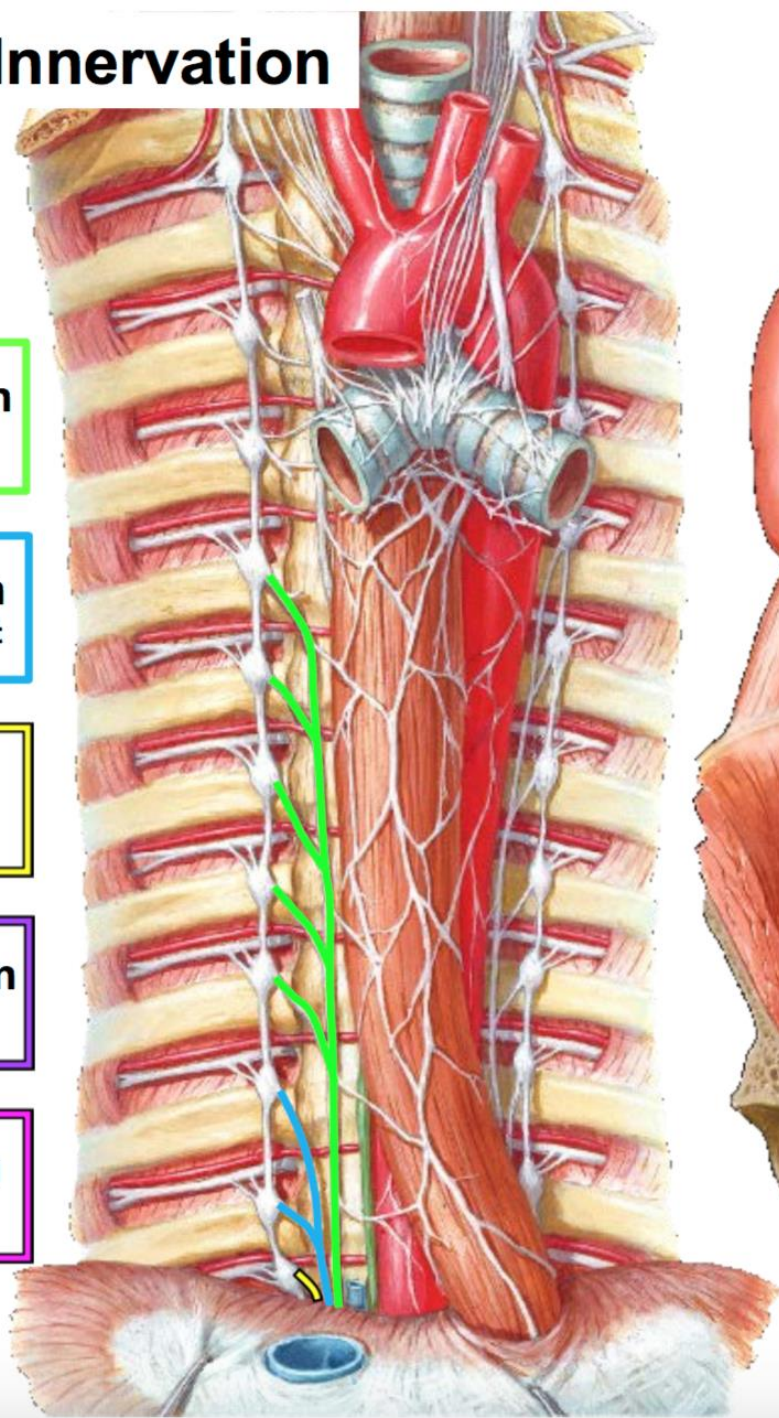
Greater splanchnic n
T5-T9 spinal cord segment

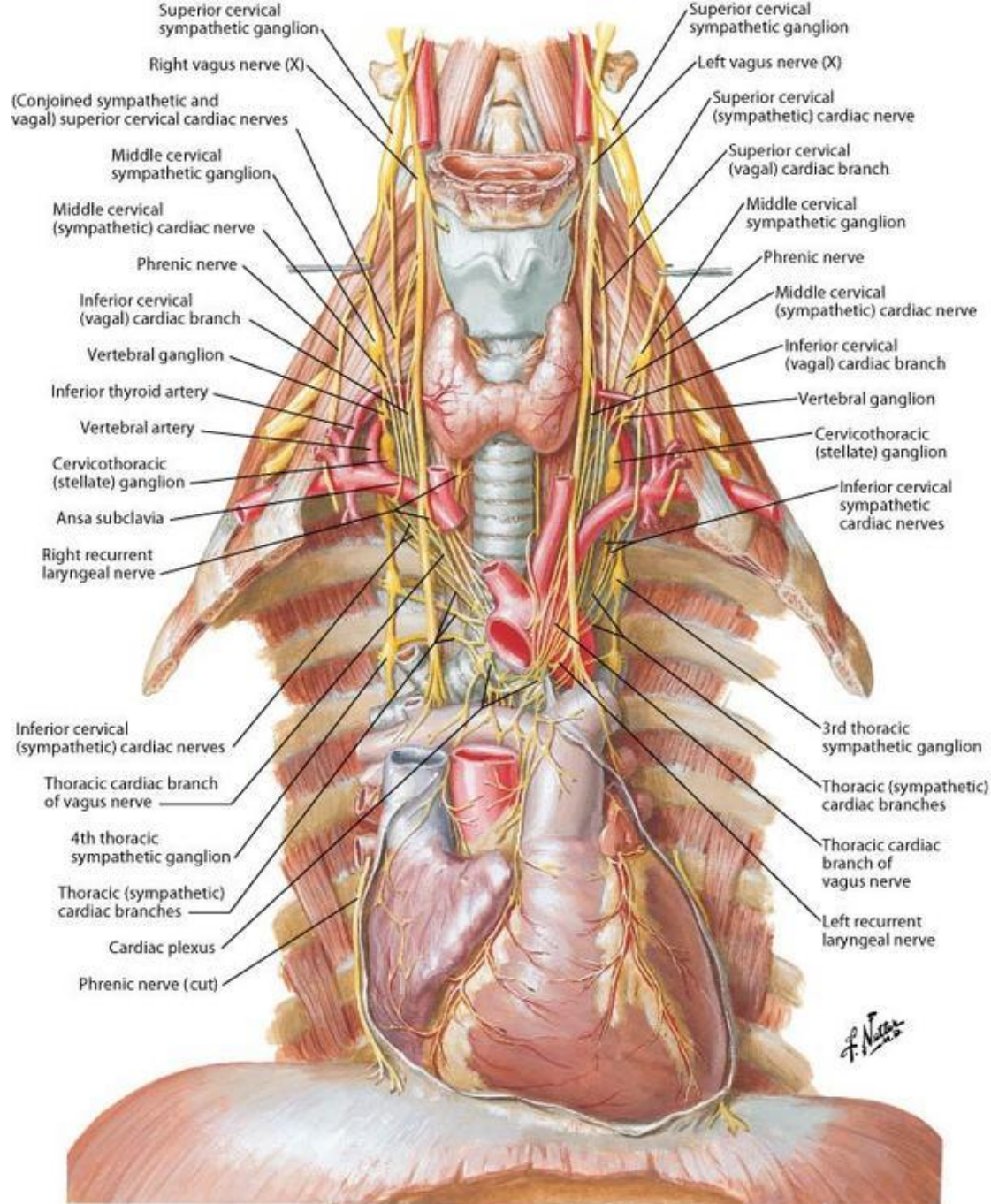
Lesser splanchnic n
T10-T11 spinal cord segment

Least splanchnic n
T12 spinal cord segment

Lumbar splanchnic n
L1-L2 spinal cord segment

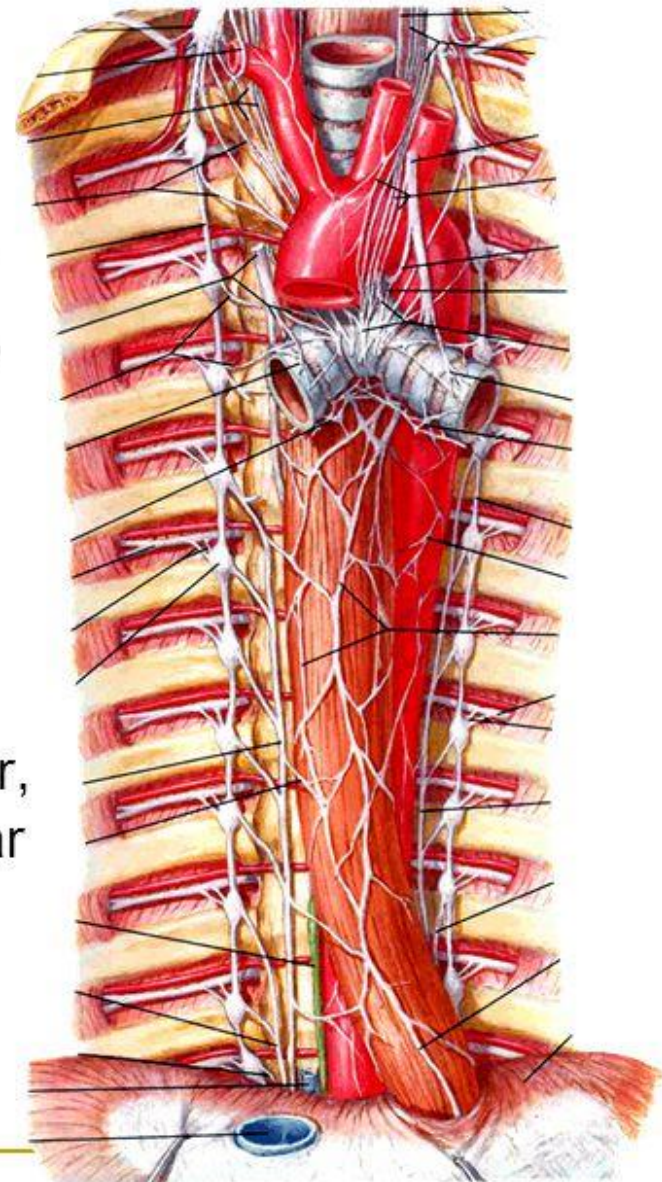
Sacral splanchnic n
L1-L2 spinal cord segment





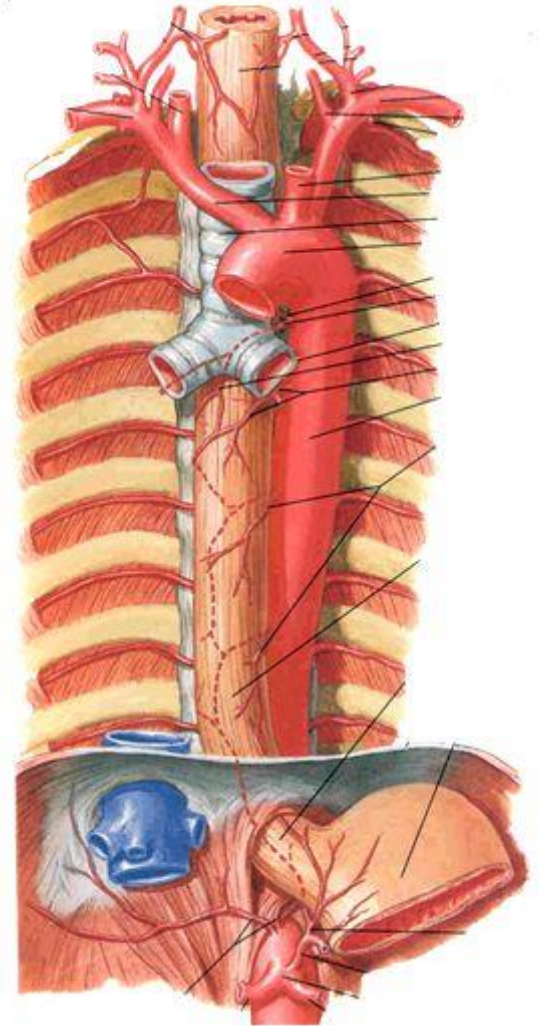
Thoracic sympathetic trunk

- Branches of sympathetic trunk to thoracic plexuses
- **Greater splanchnic nerve** - formed by preganglionic fibers from T5~T9 ganglia, and relay in celiac ganglion.
- **Lesser splanchnic nerve** - formed by preganglionic fibers from T10~T12 ganglia, and relay in aorticorenal ganglion.
- The postganglionic fibers supply the liver, spleen, kidney and alimentary tract as far as the left colic flexure.



Thoracic aorta

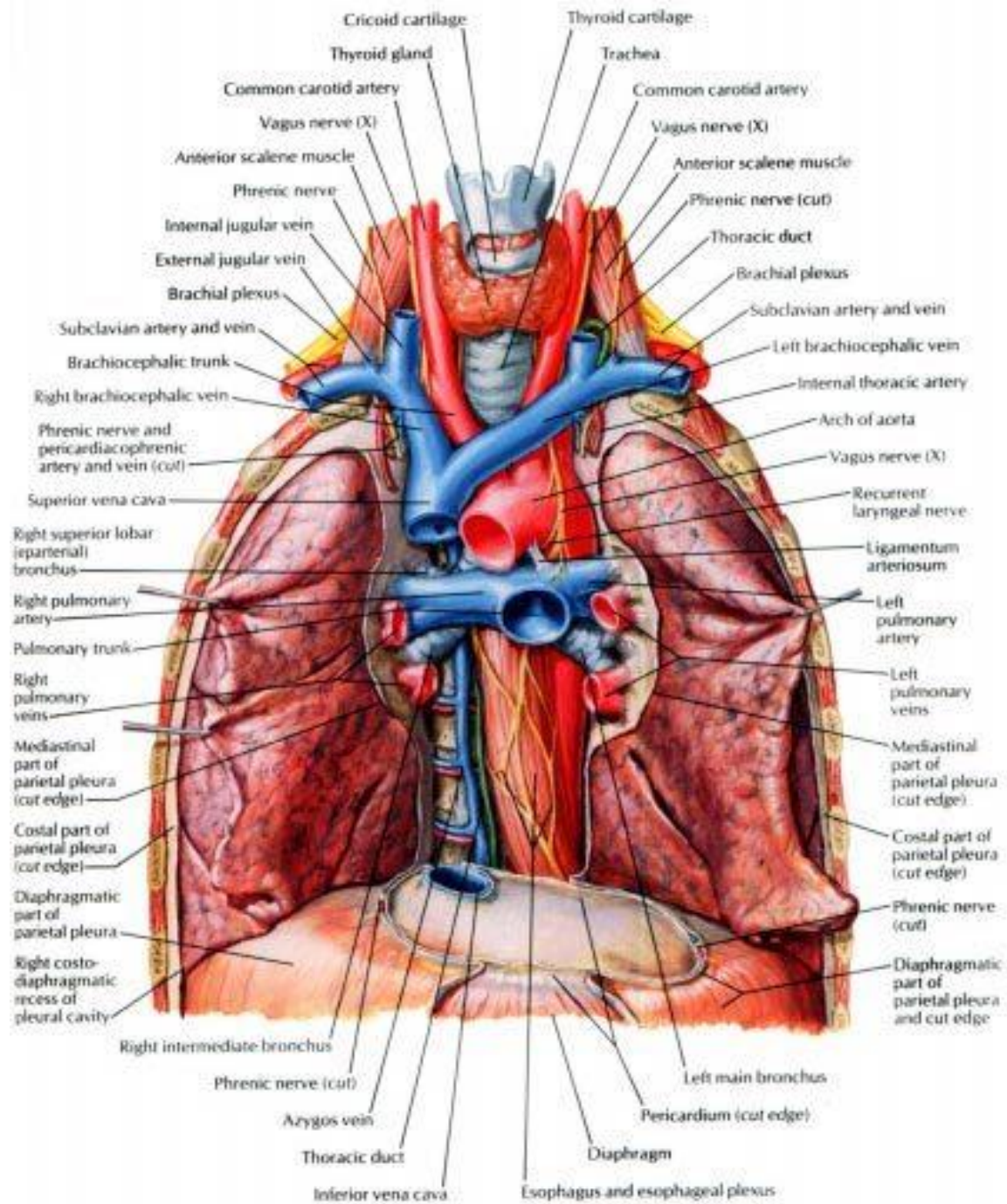
- Continuation of aortic arch at lower border of T4
- Courses downward on left side of, then in front of vertebral column
- Passes through aortic hiatus of diaphragm at level of T12 vertebra to enter abdominal cavity
- Main branches
 - Parietal branches
 - Nine pairs **posterior intercostals arteries**
 - One pair **subcostal artery**
 - For lower nine intercostals spaces and upper part of abdominal wall; superior phrenic arteries supply the superior surface of the diaphragm.
 - Visceral branches
 - Bronchial branches: one or two for each lung
 - Esophageal branches
 - Pericardial branches

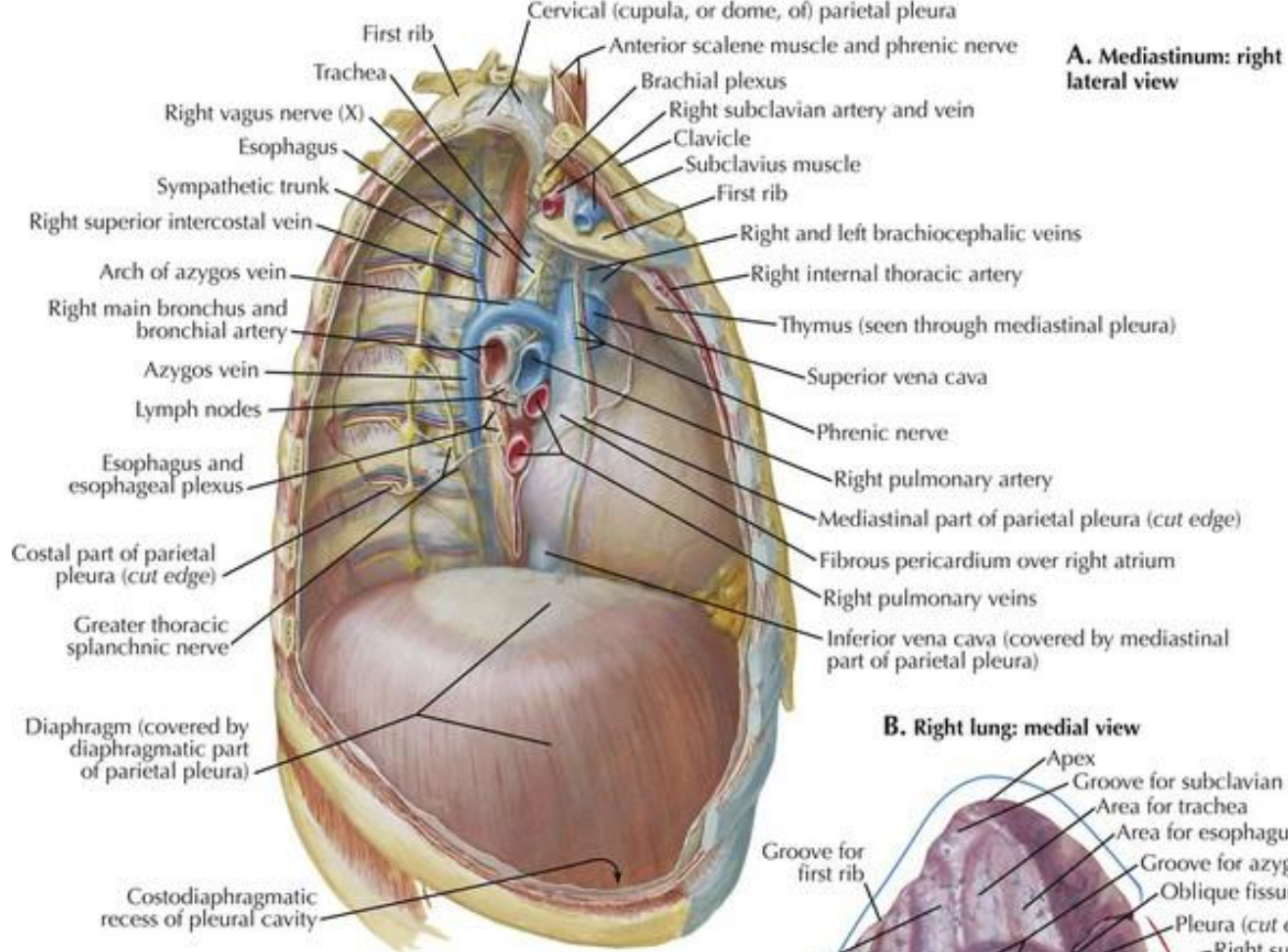


Thoracic duct

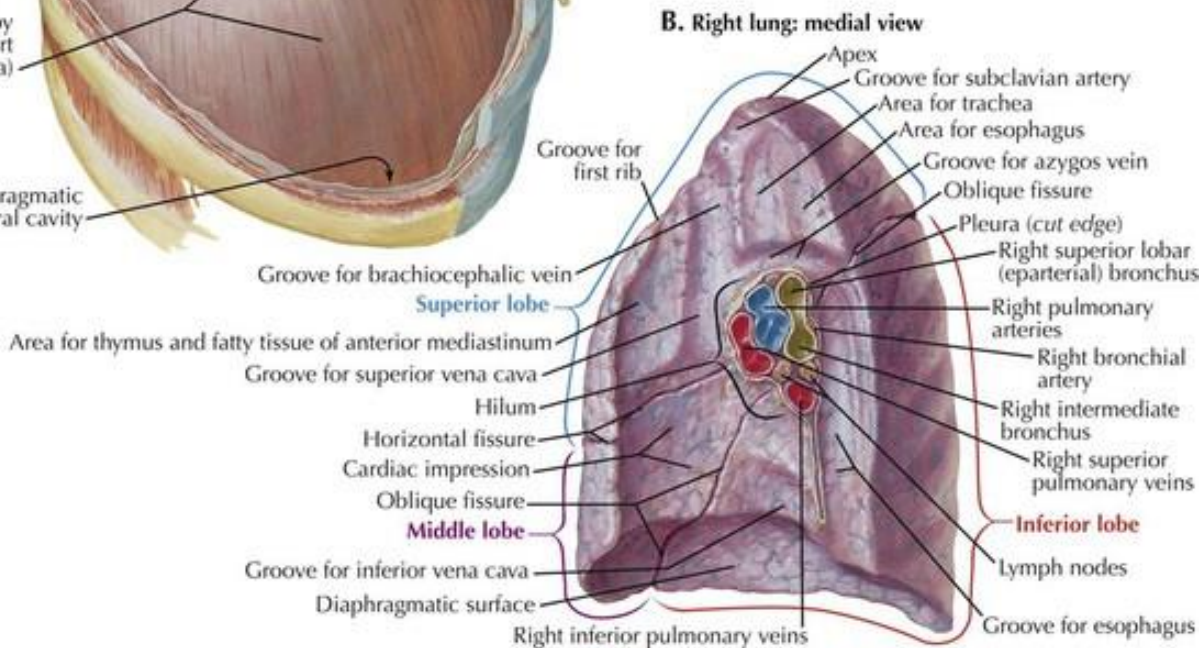
- Begins in front of L1 as a dilated sac, the cisterna chyli, which formed by joining of left and right lumbar trunks and intestinal trunk
- Enter thoracic cavity by passing through the aortic hiatus of the diaphragm and ascends along on the front of the vertebral column, between thoracic aorta and azygos vein
- Travels upward, veering to the left at the level of T5
- At the roof of the neck, it turns laterally and arches forwards and descends to enter the left venous angle



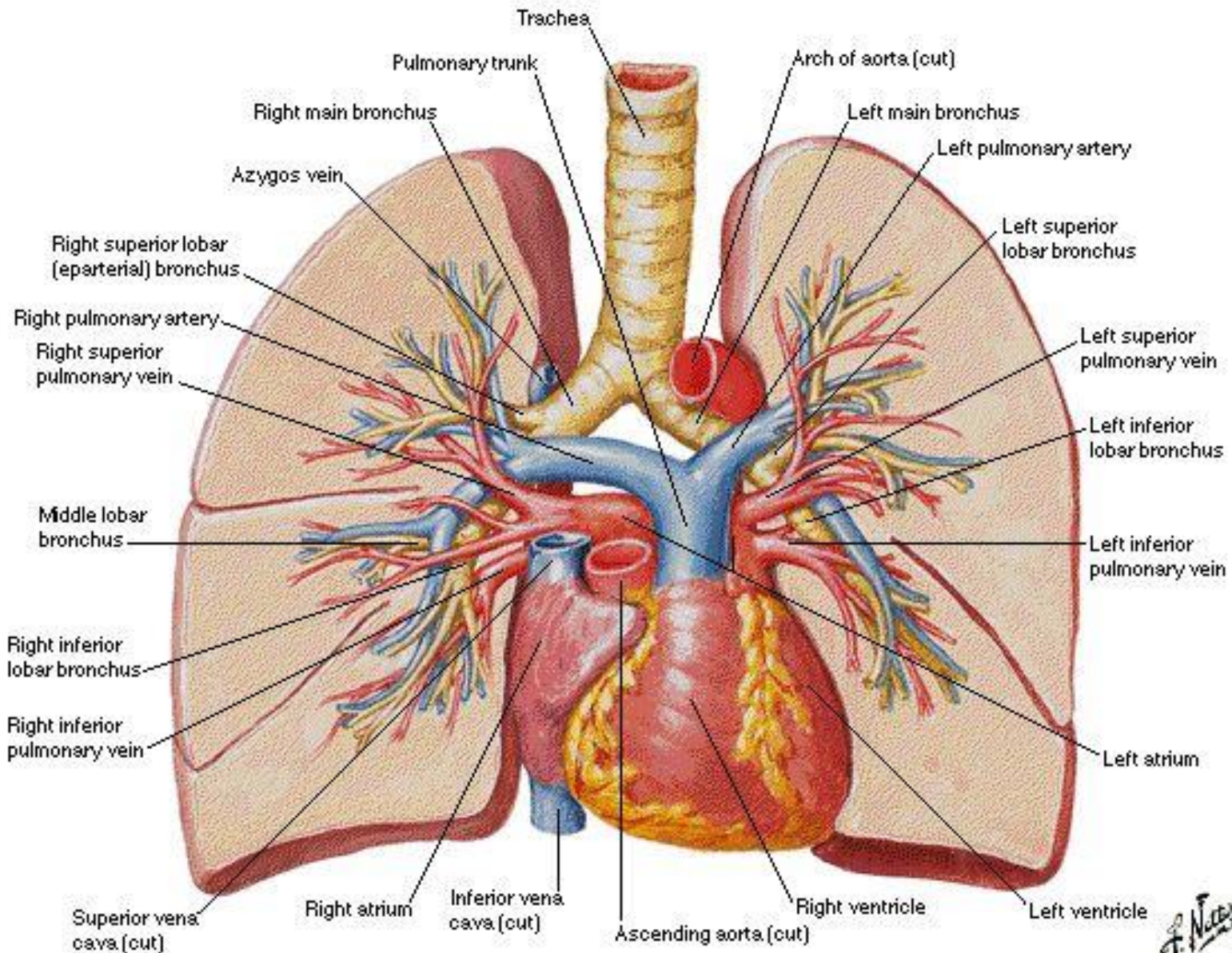


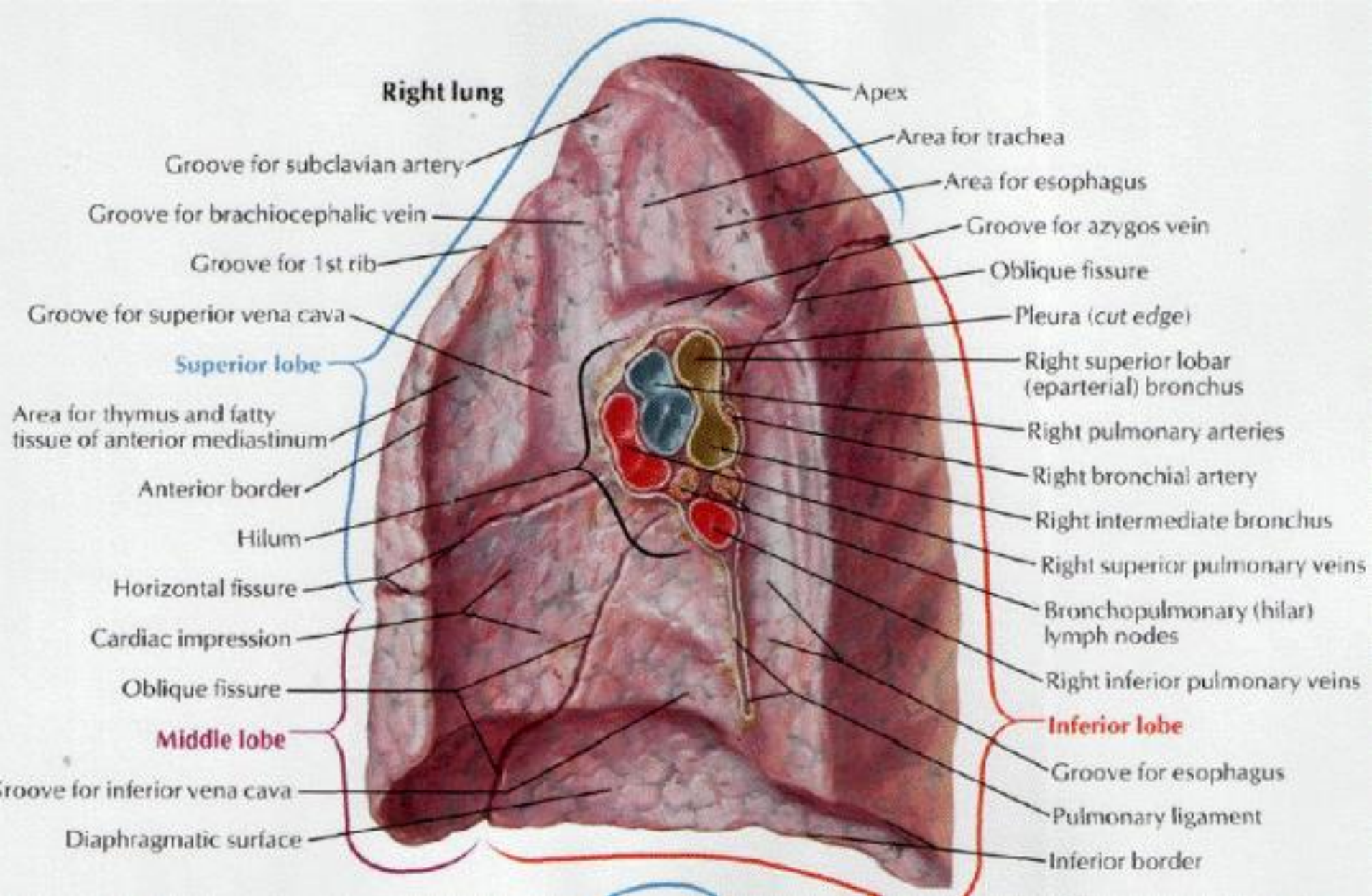


F. Netter M.D.

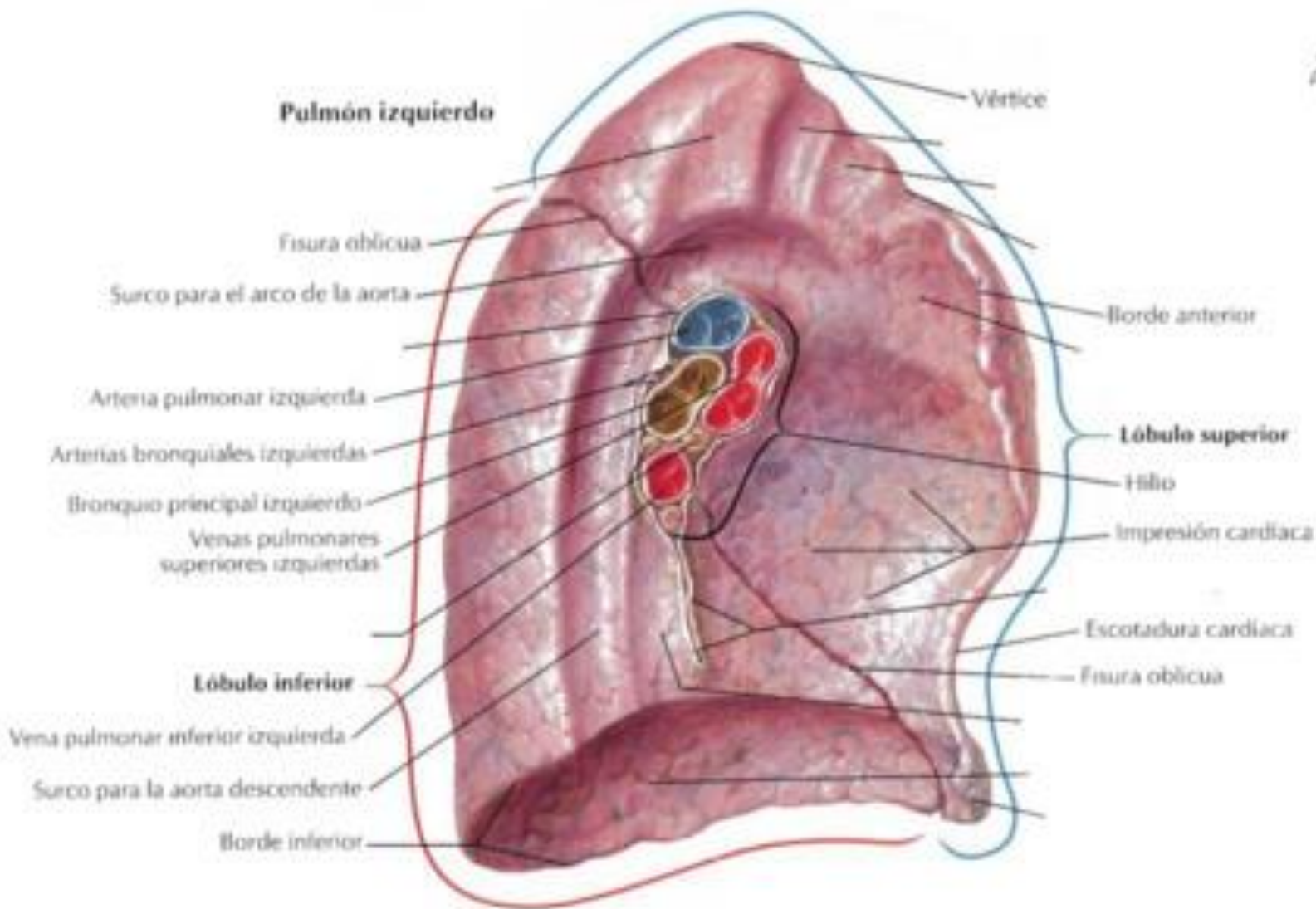


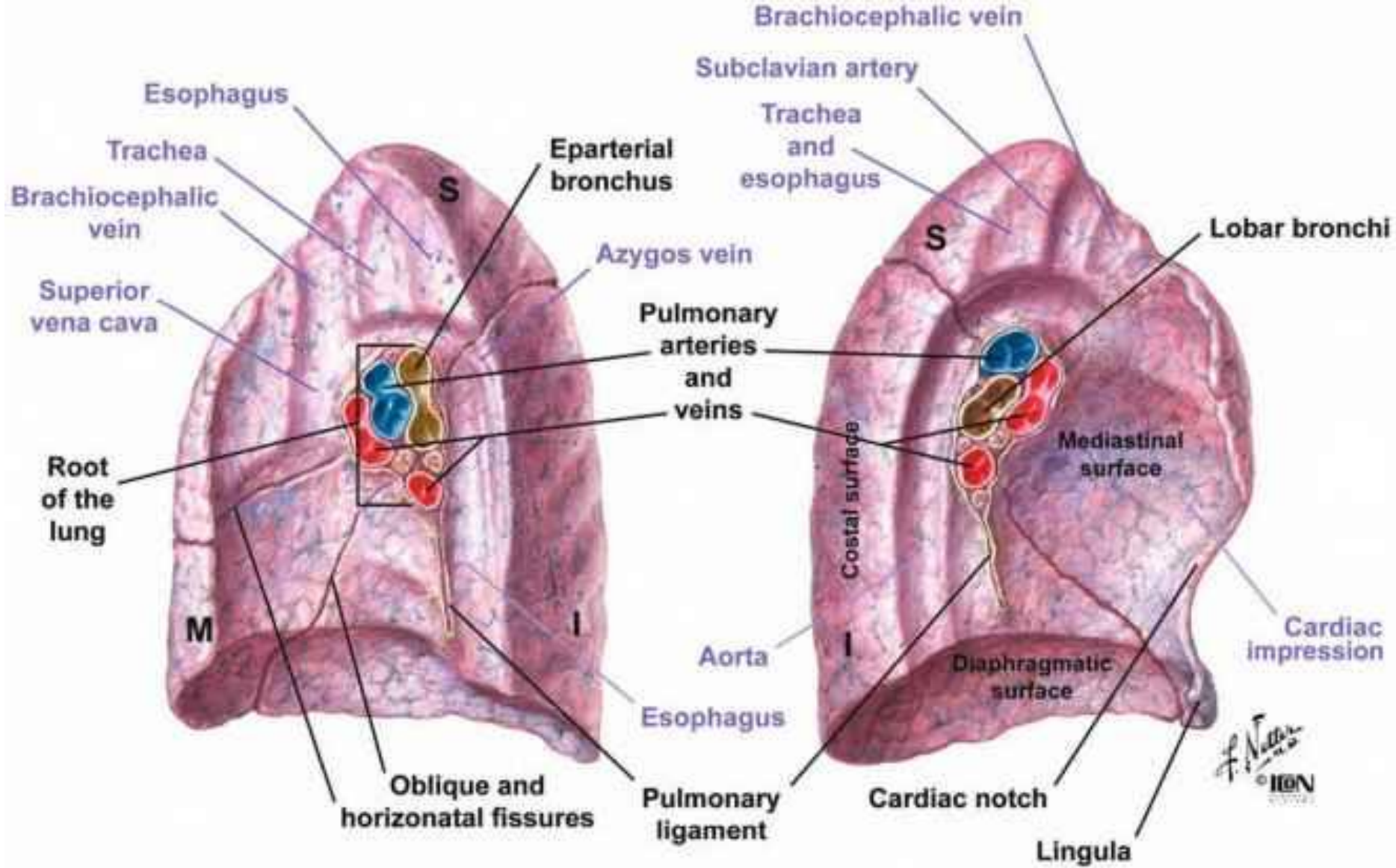
Pulmonary Arteries and Veins

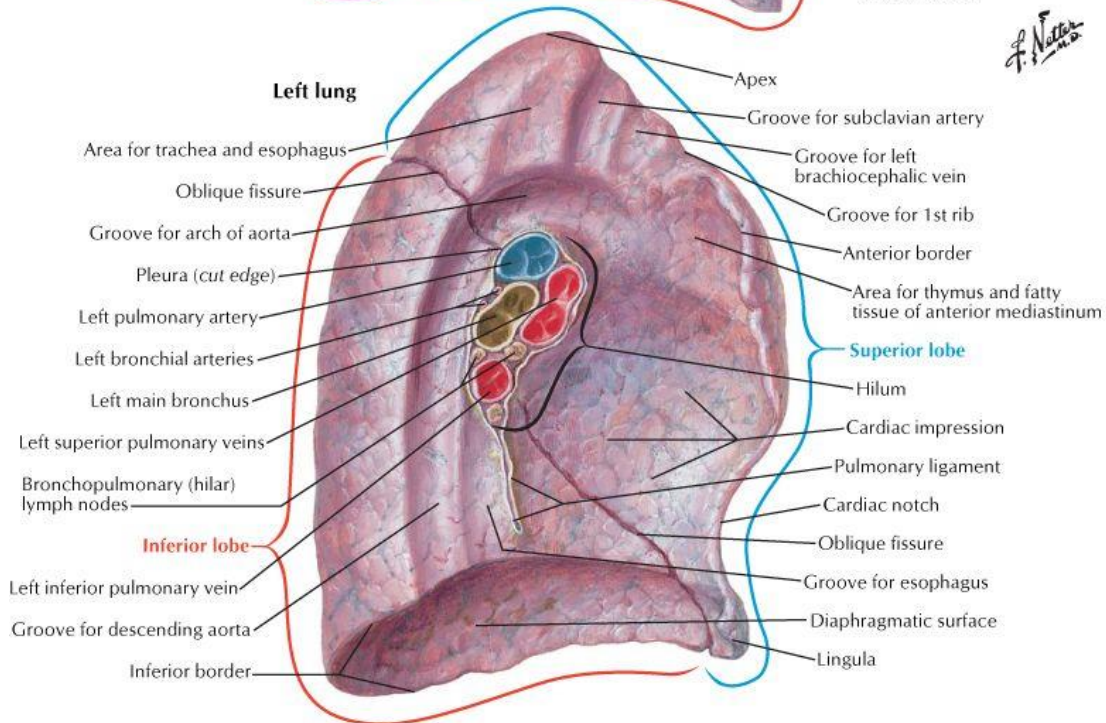
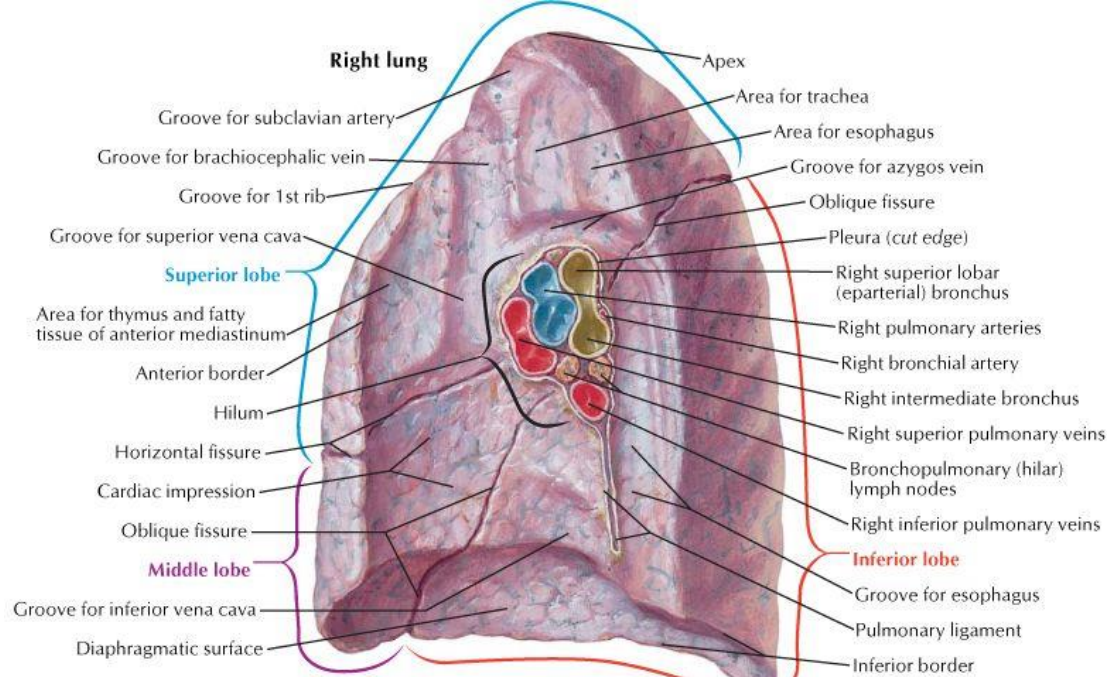


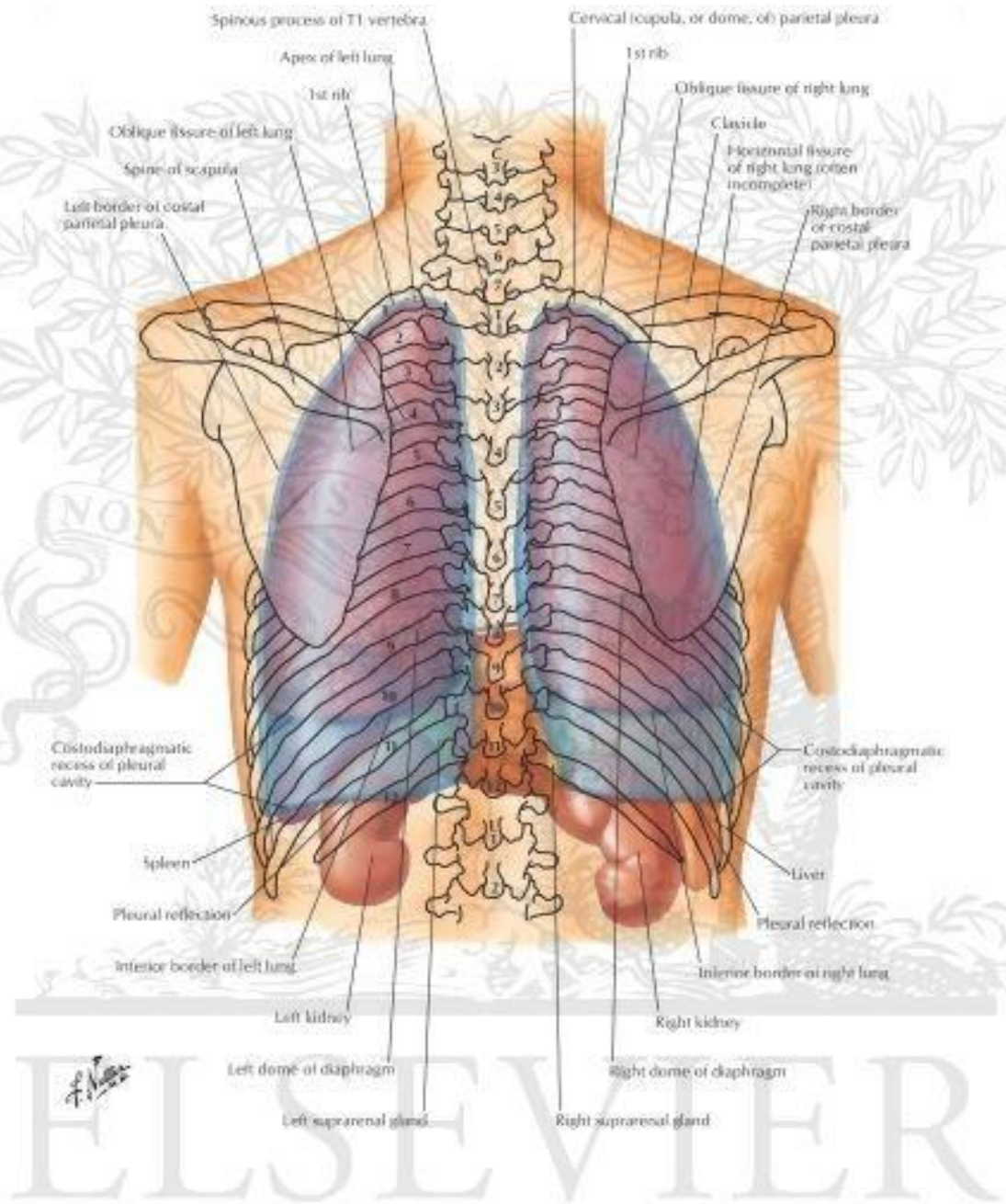


F. Negro



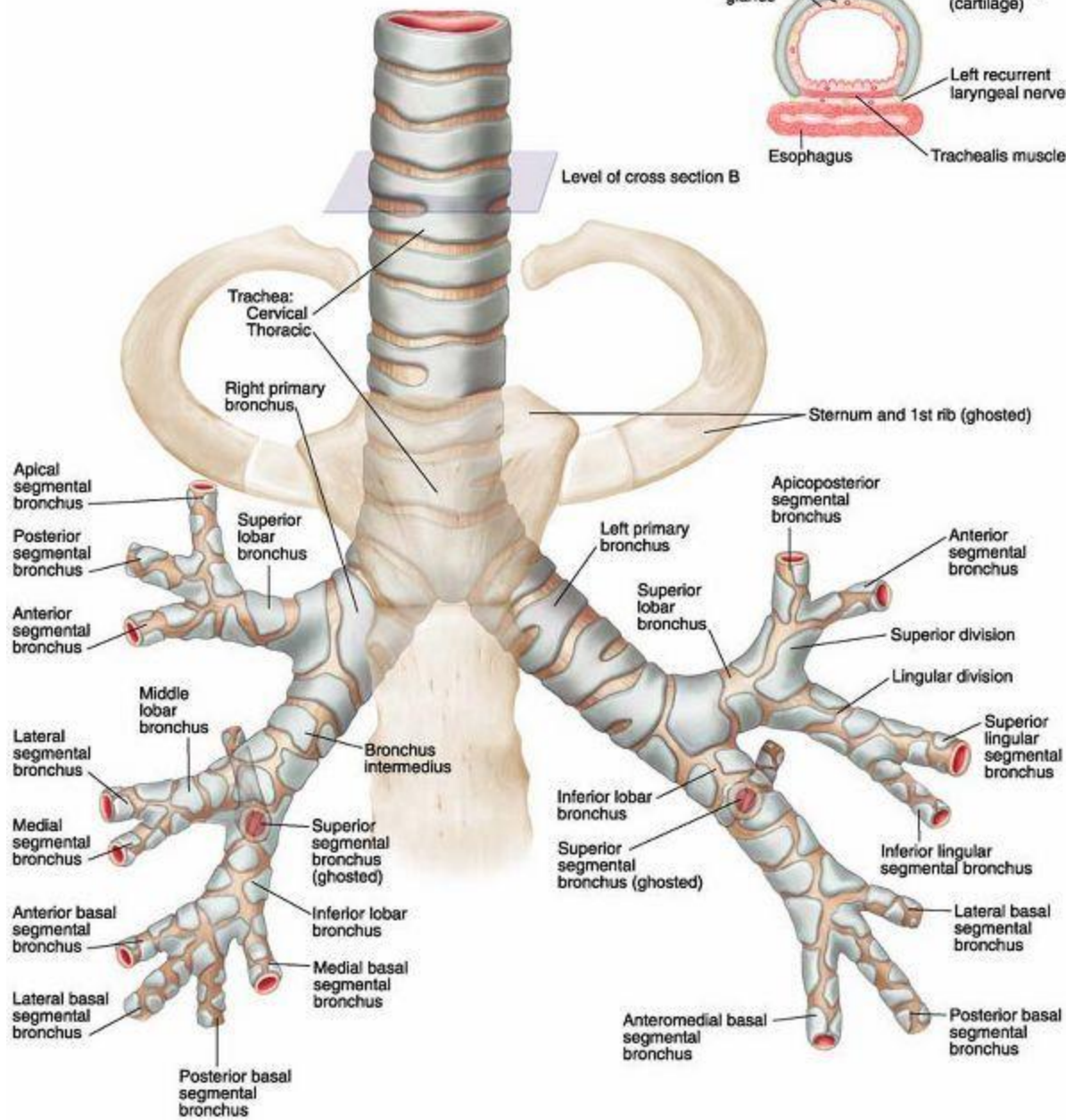




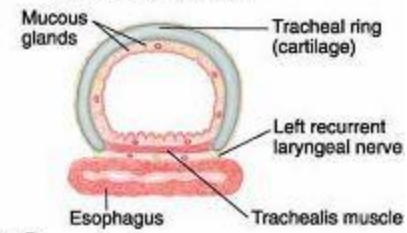


ELSEVIER

A. Anterior view

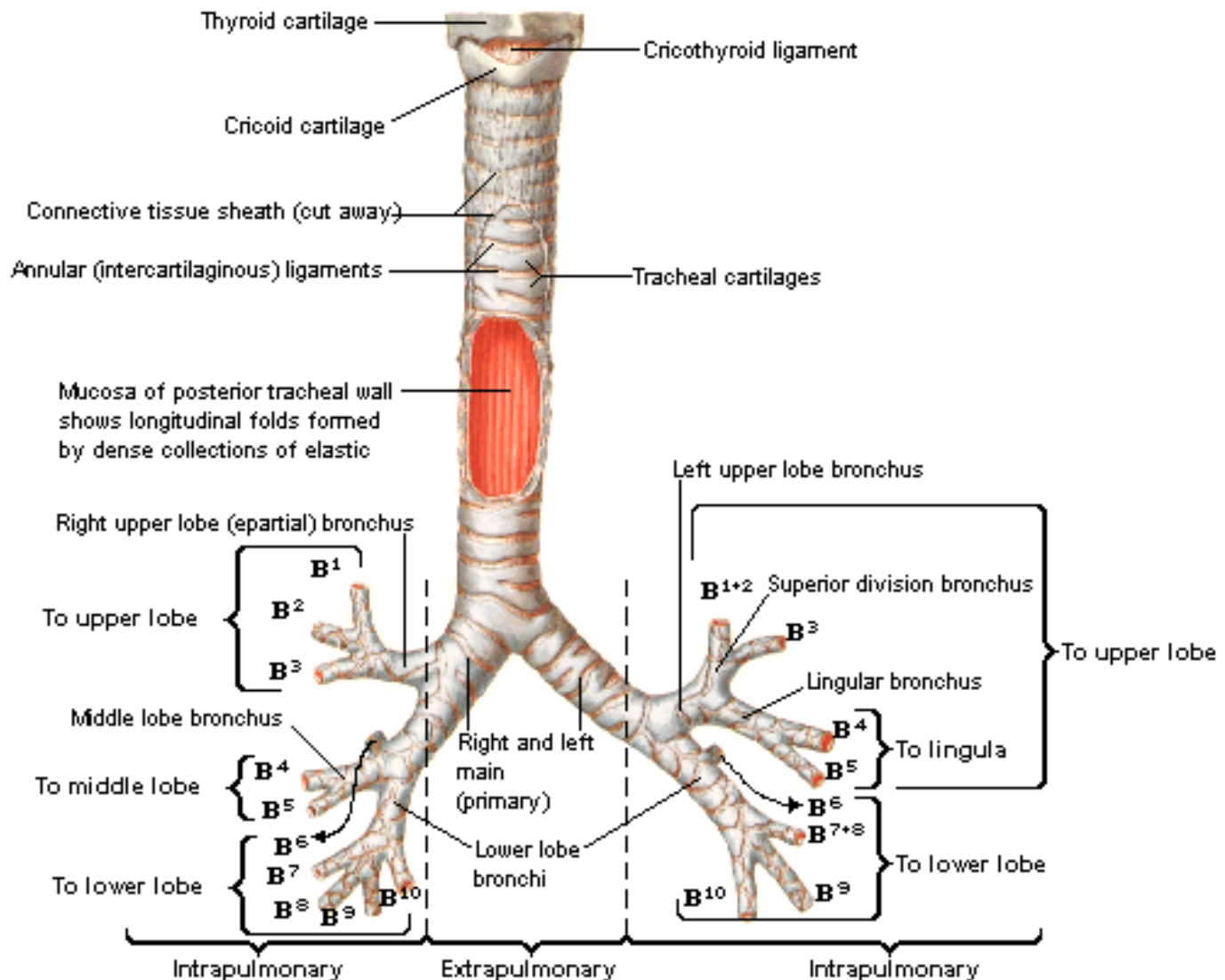


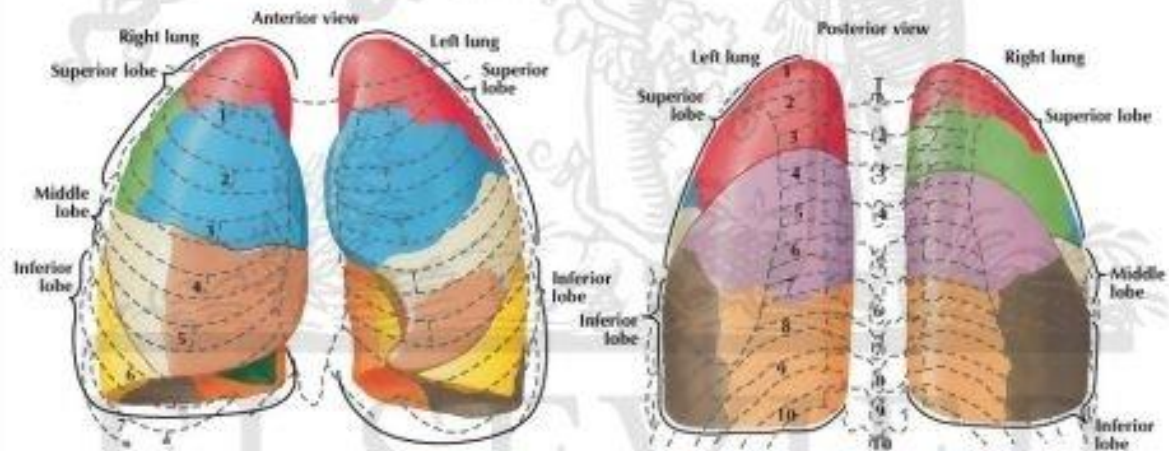
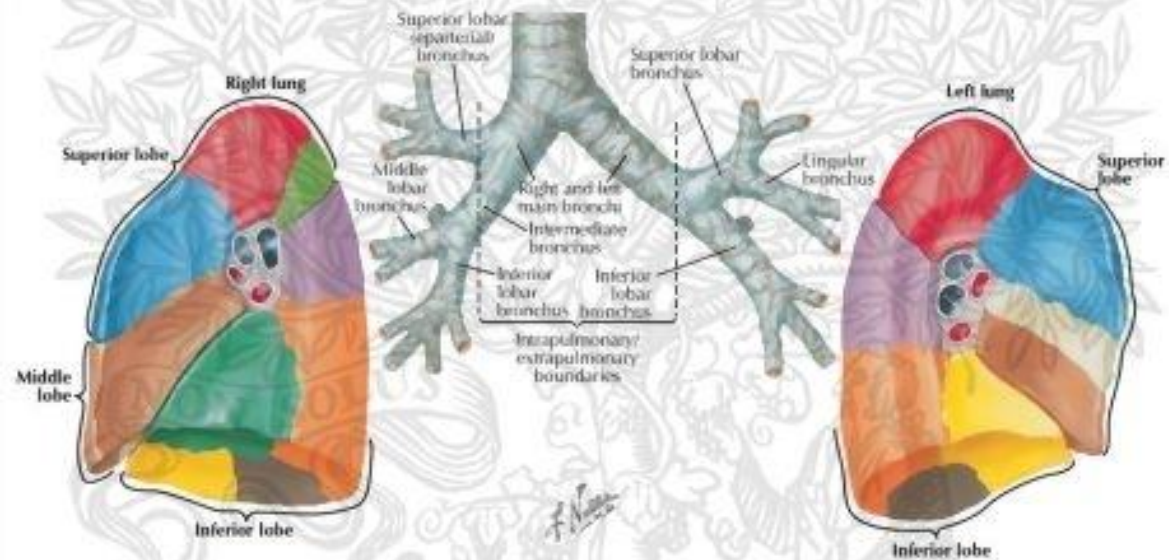
B. Cross section



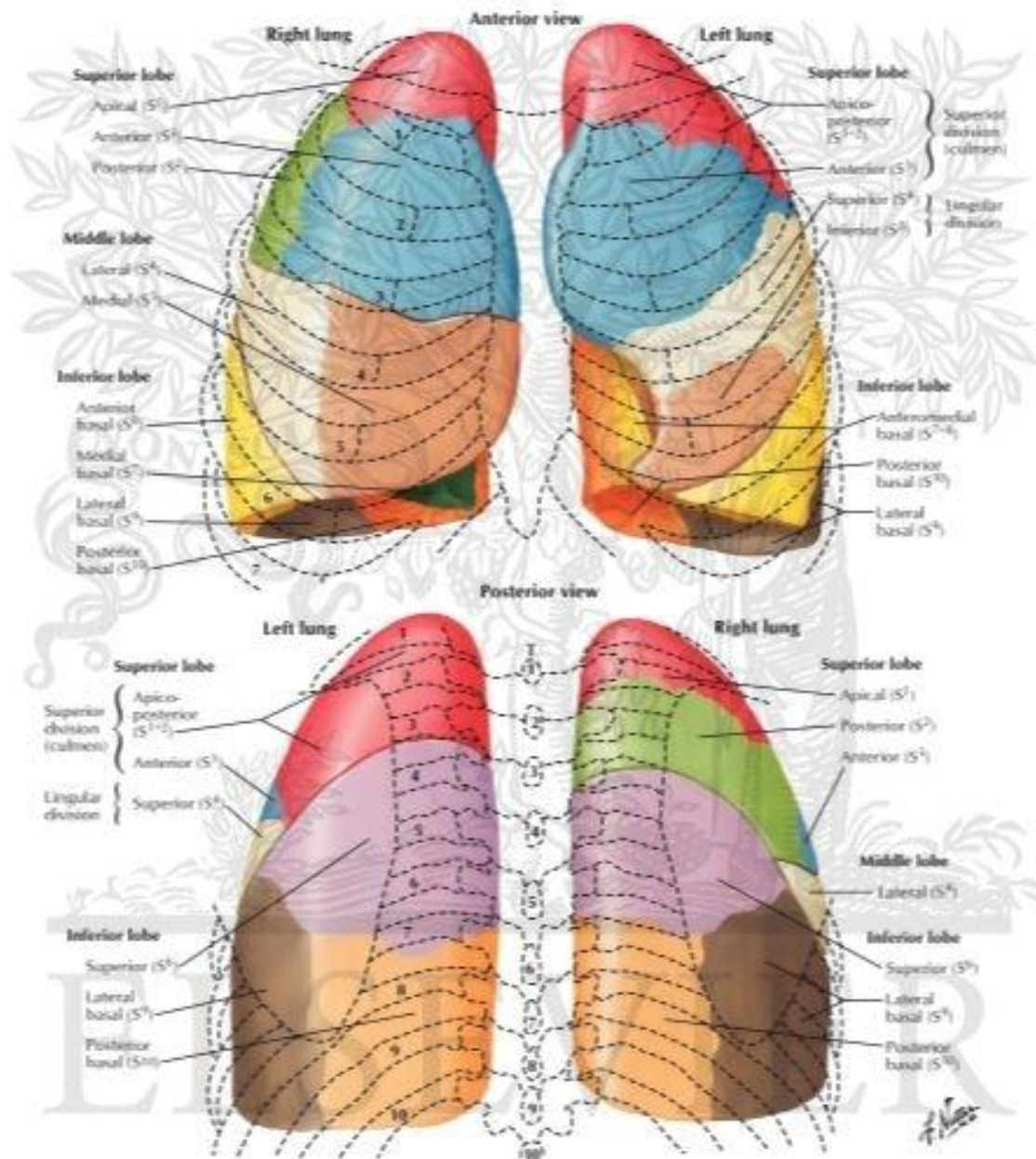
Trachea and Major Bronchi

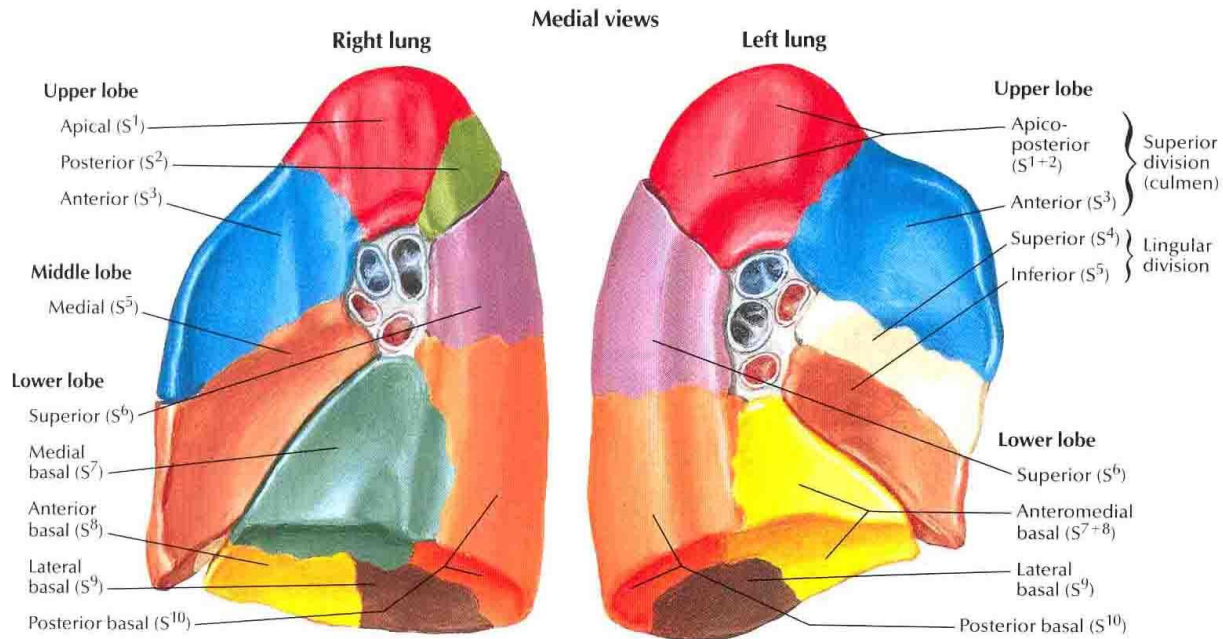
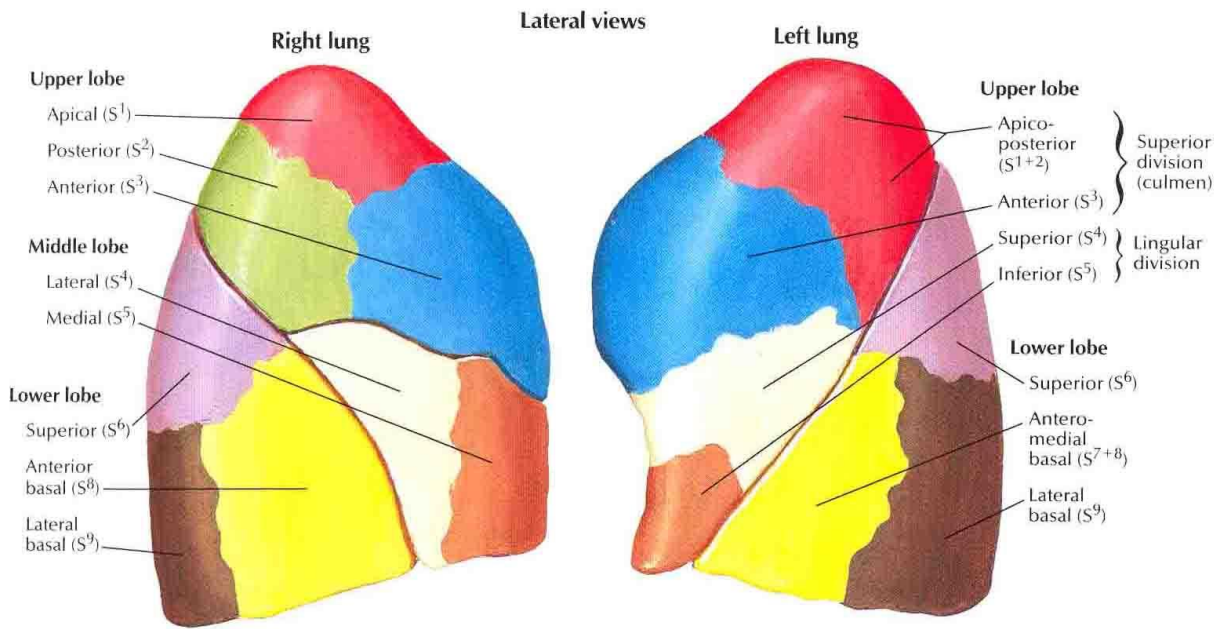
Anterior View



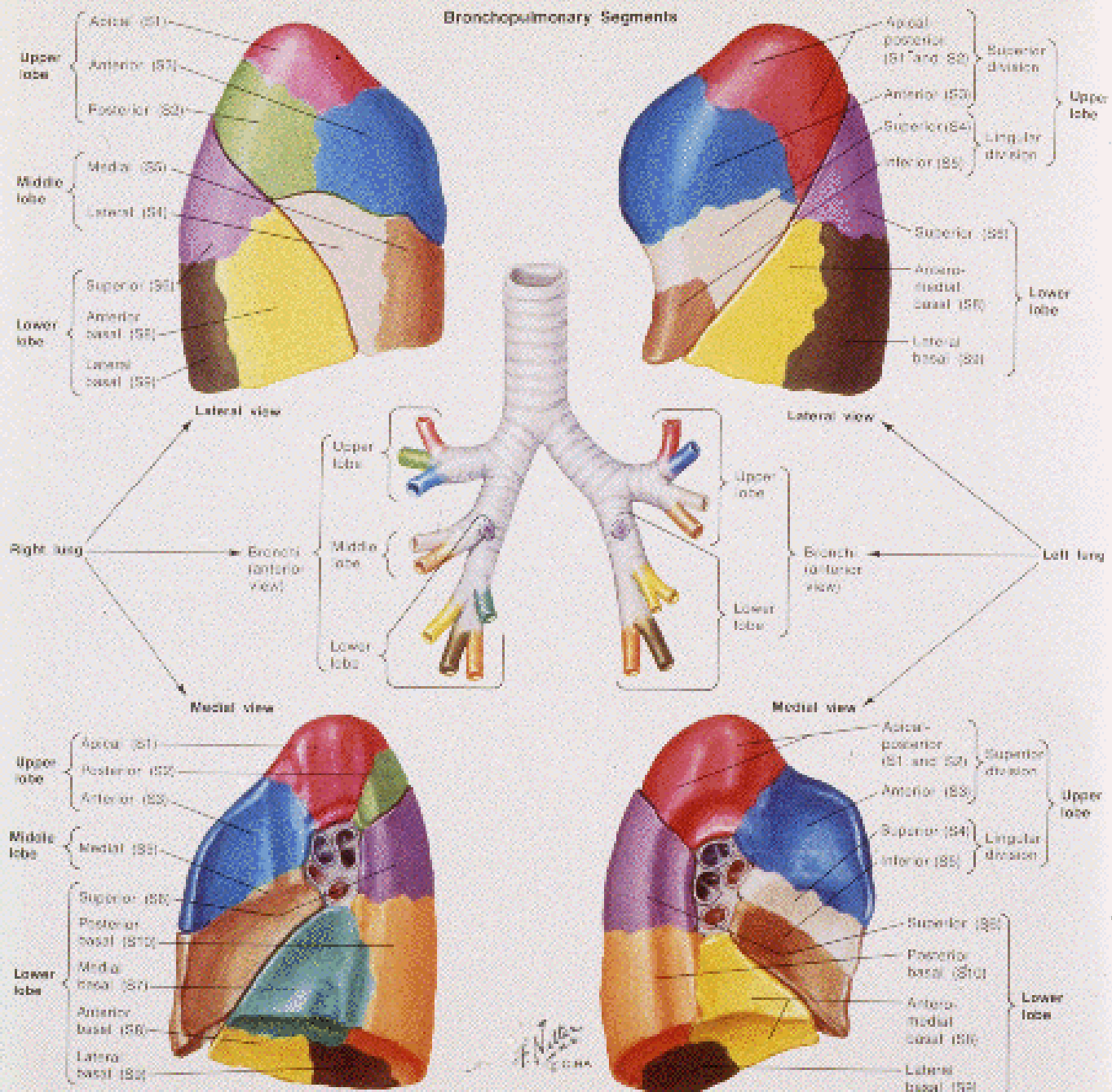


Bronchopulmonary Segments



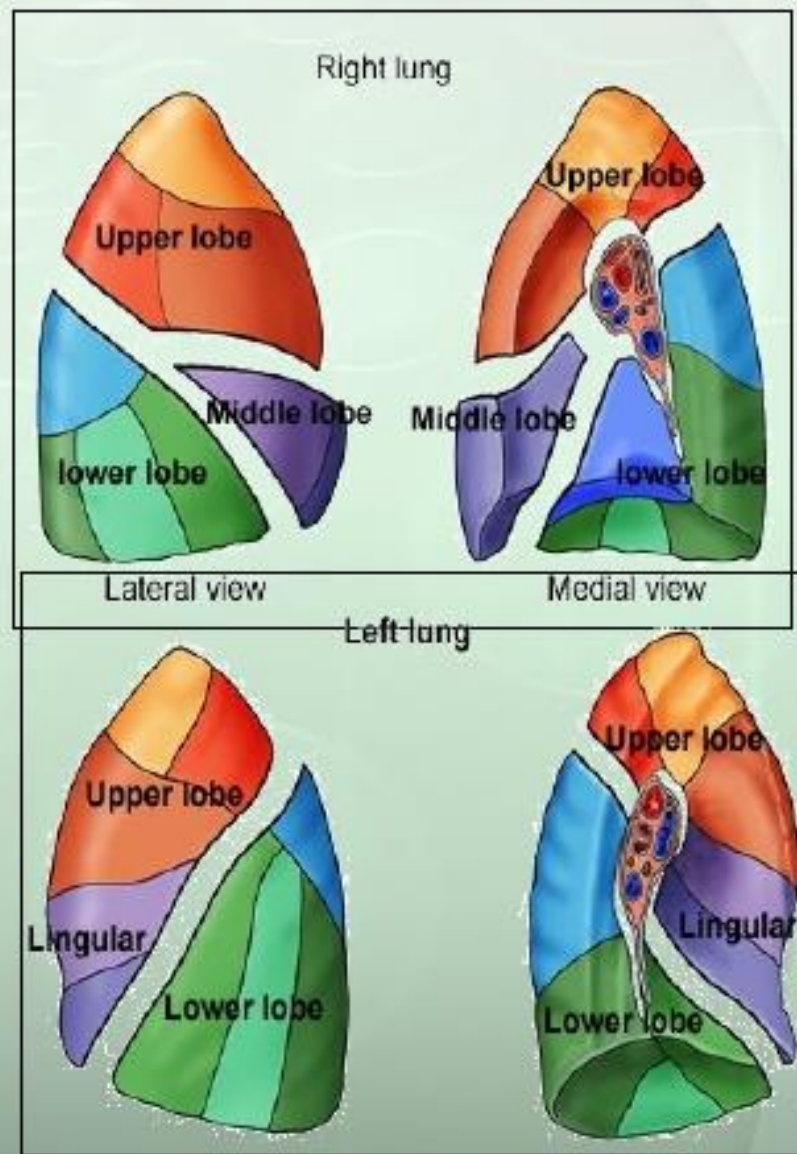


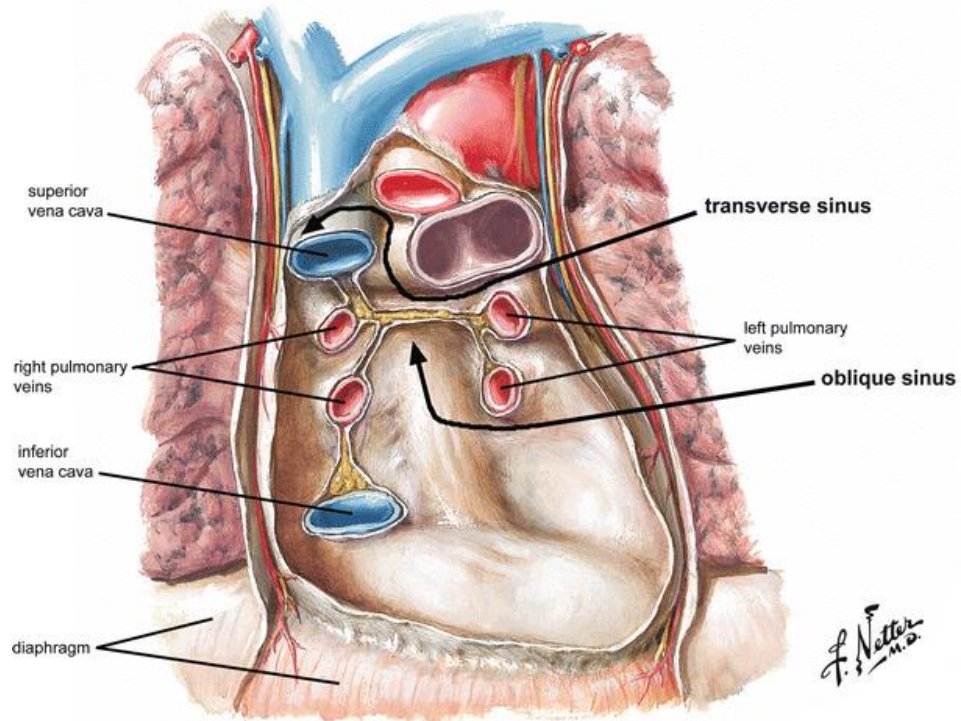
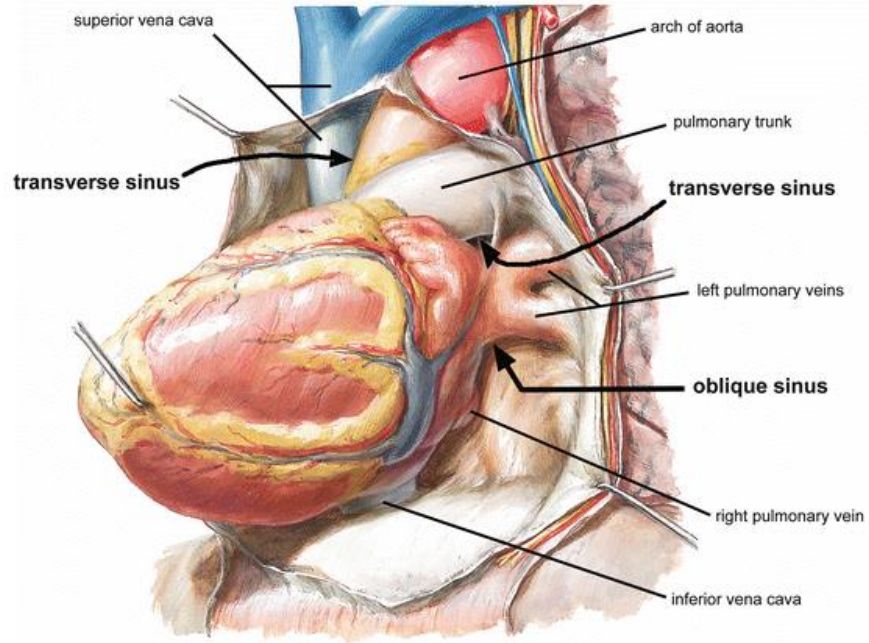
Bronchopulmonary Segments

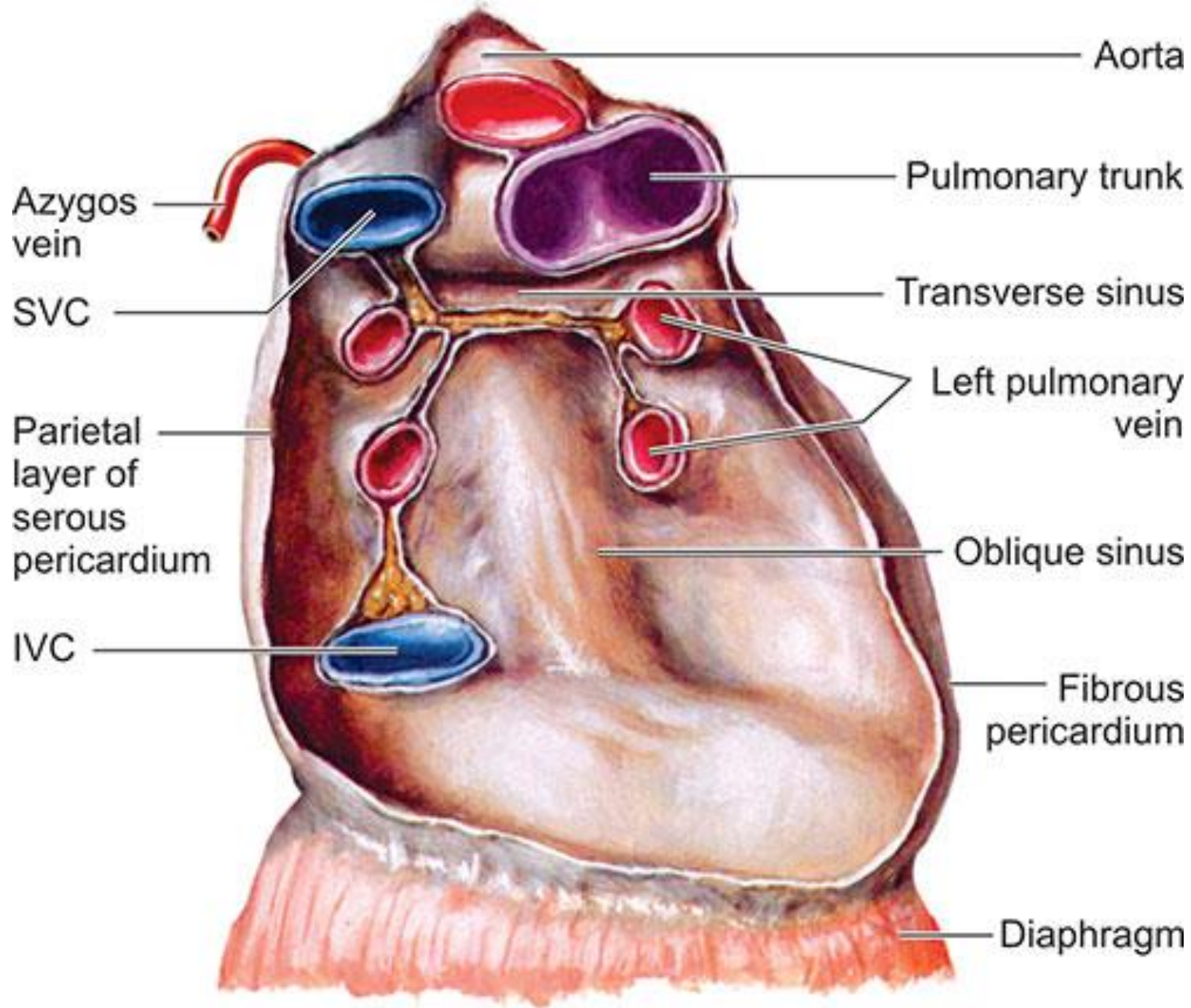


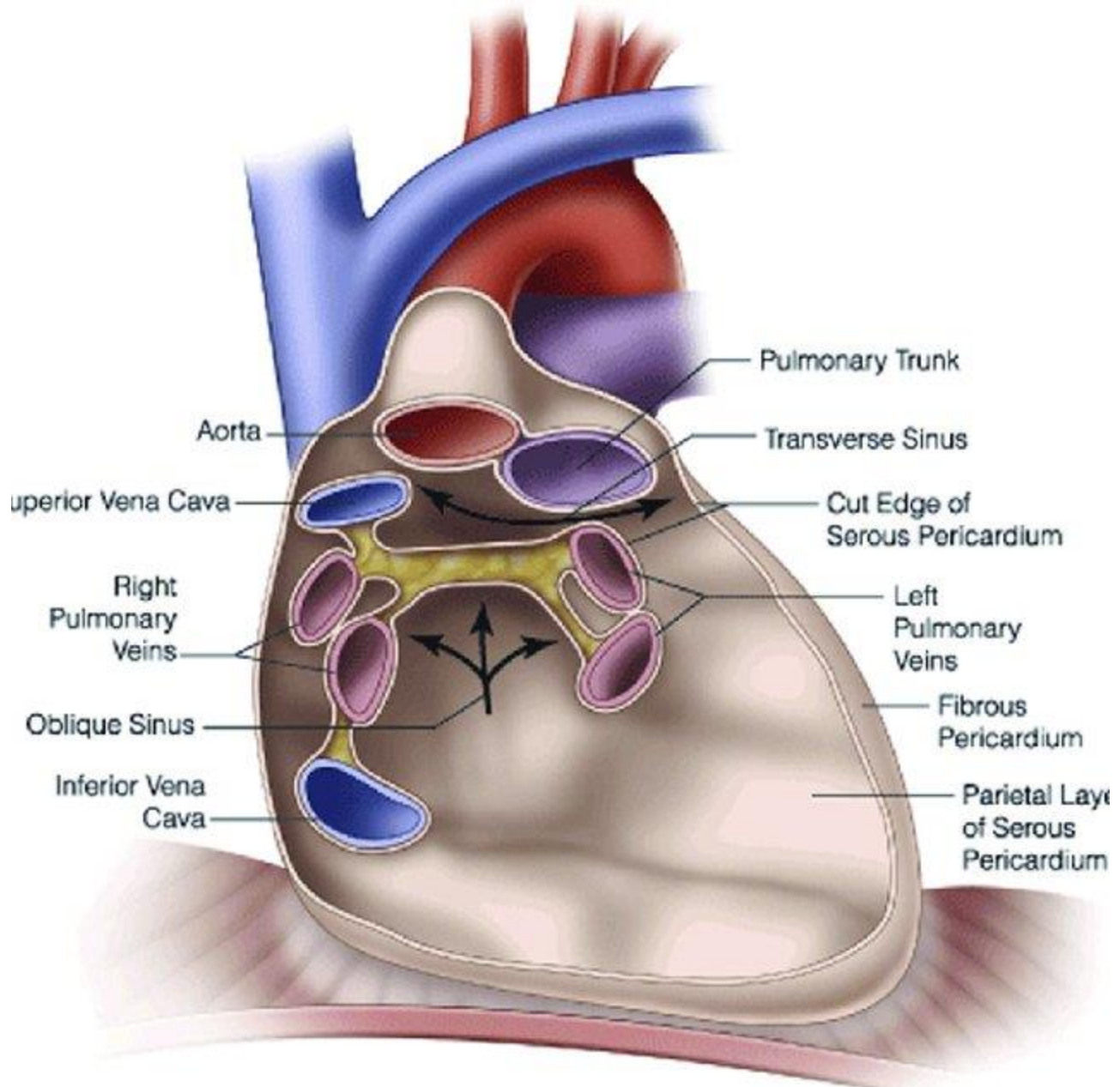
Bronchopulmonary segments

- Independent anatomical & functional subunits of lungs
- Number: 10 in each lung
- Each segment has a centrally located:
 - Segmental bronchus
 - Segmental branch of pulmonary artery
 - Segmental branch of bronchial artery
- The pulmonary veins and lymphatics are intersegmental in position.
- Early malignant pathology is usually confined to the segment from which it originates.



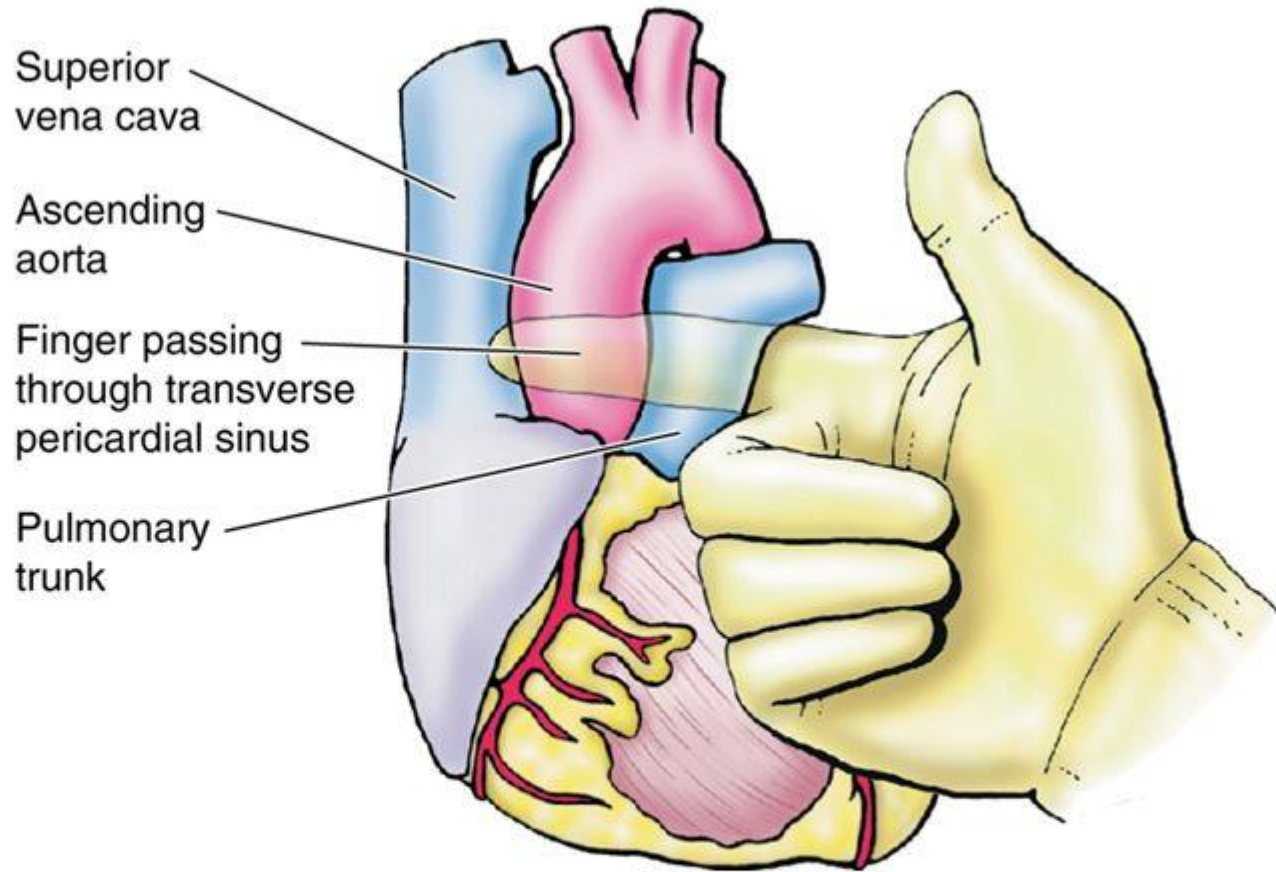




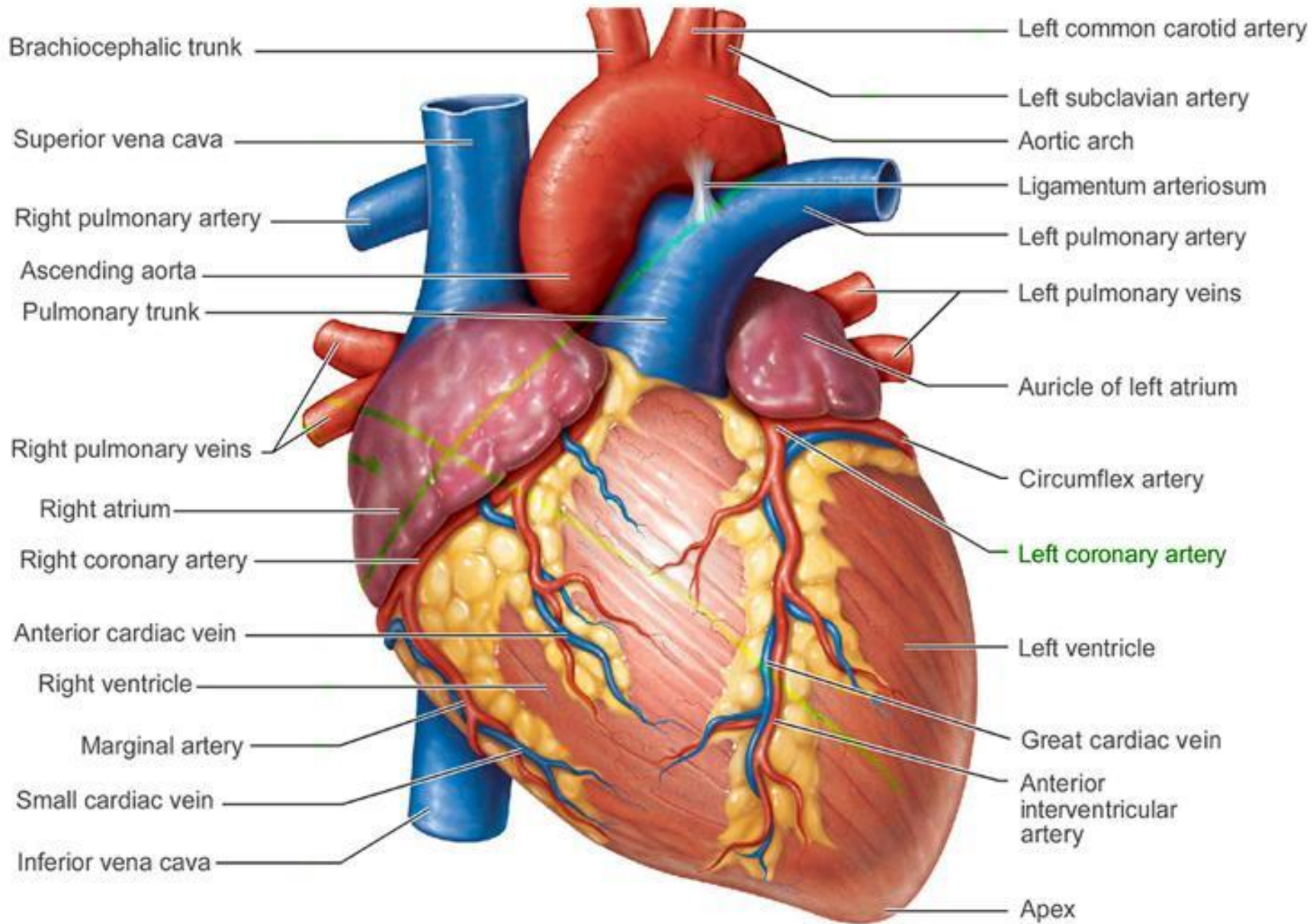


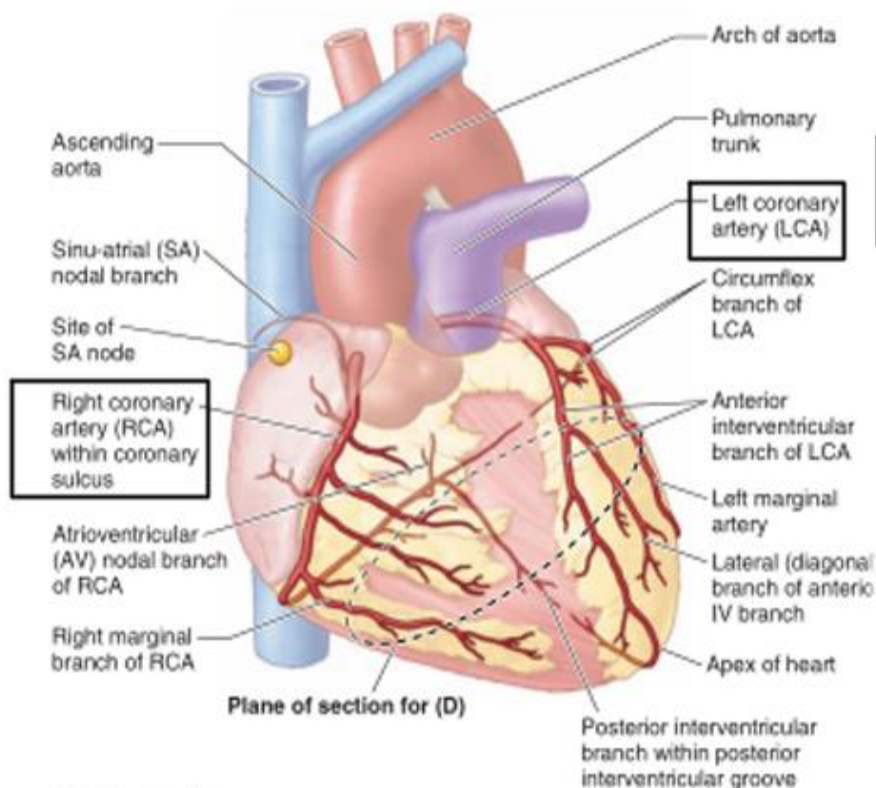
Surgical Significance of the Transverse Pericardial Sinus

- The transverse pericardial sinus is especially important to cardiac surgeons.
- After the pericardial sac is opened anteriorly, a finger can be passed through the transverse pericardial sinus posterior to the aorta and pulmonary trunk.

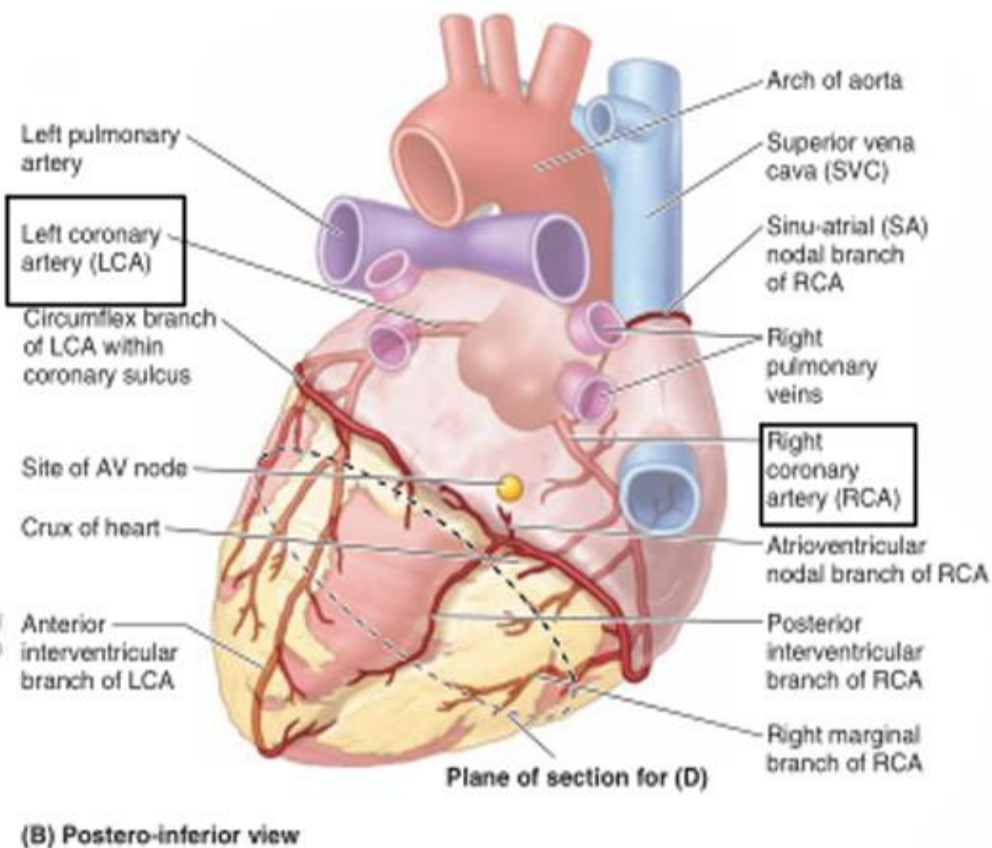


- By passing a surgical clamp or placing a ligature around these vessels, inserting the tubes of a coronary bypass machine, and then tightening the ligature, surgeons can stop or divert the circulation of blood in these large arteries while performing cardiac surgery, such as coronary artery bypass





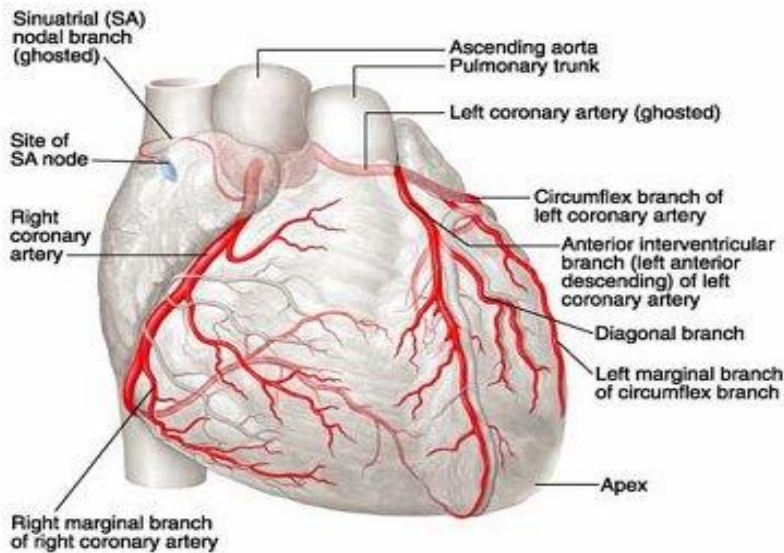
(A) Anterior view



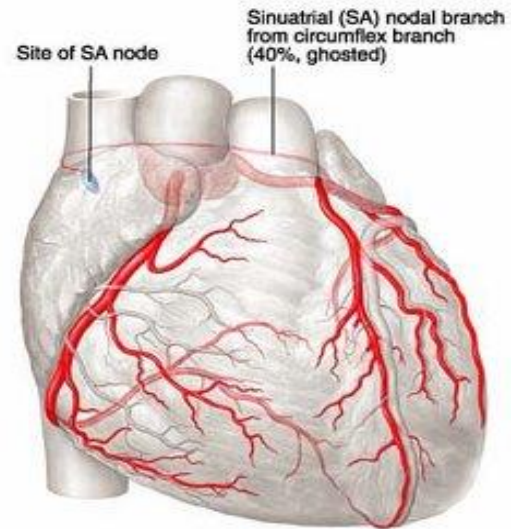
(B) Postero-inferior view

Cited from Moore's Essential Clinical Anatomy, p. 91.

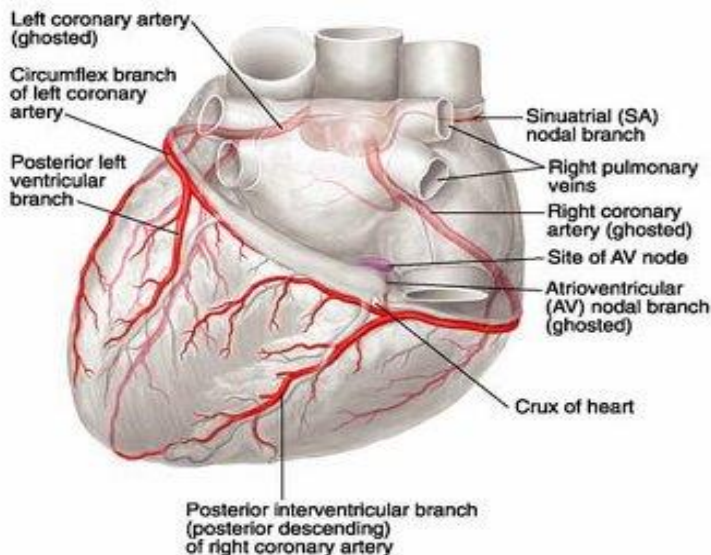
A. Normal arterial pattern, anterior view



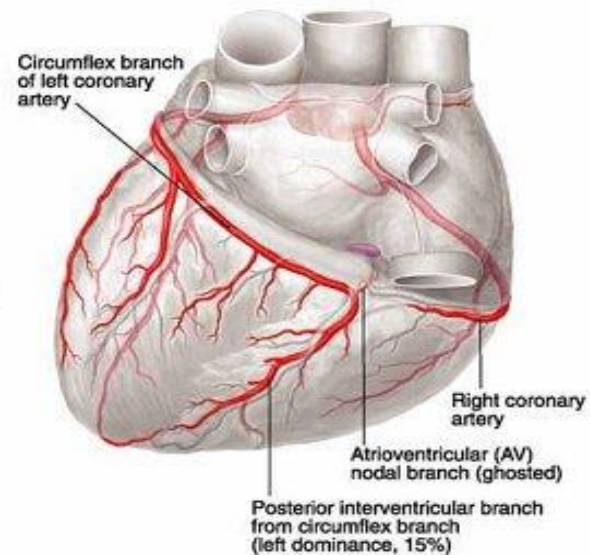
B. Variation, anterior view

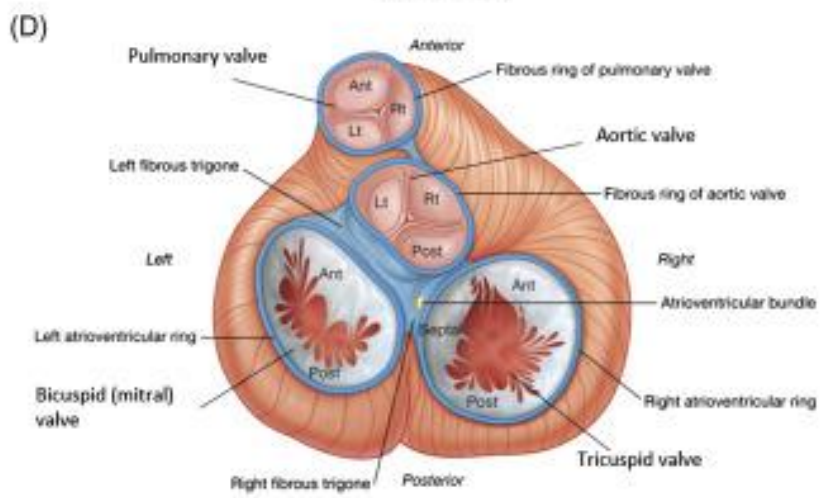
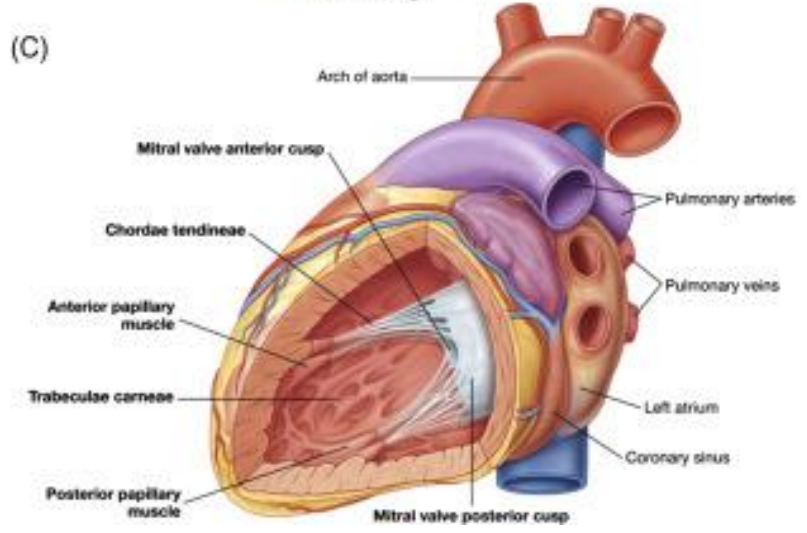
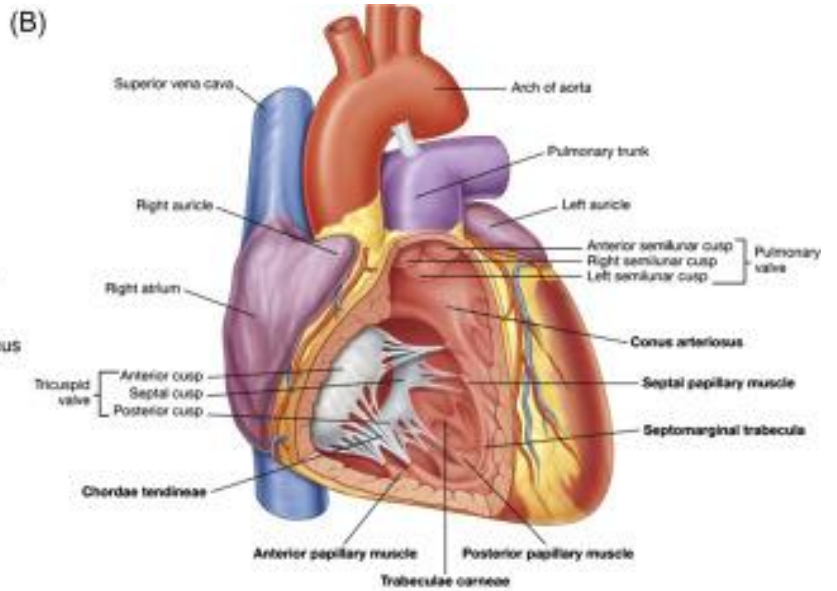
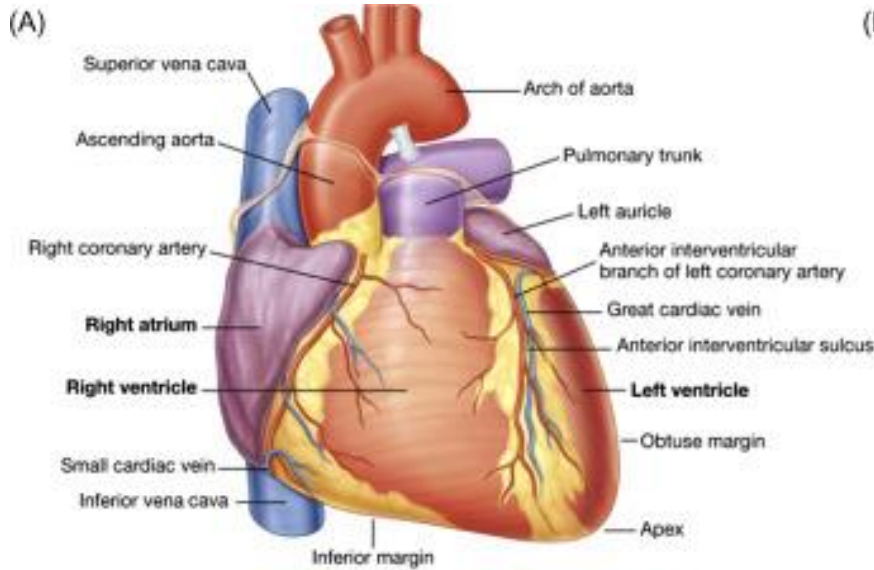


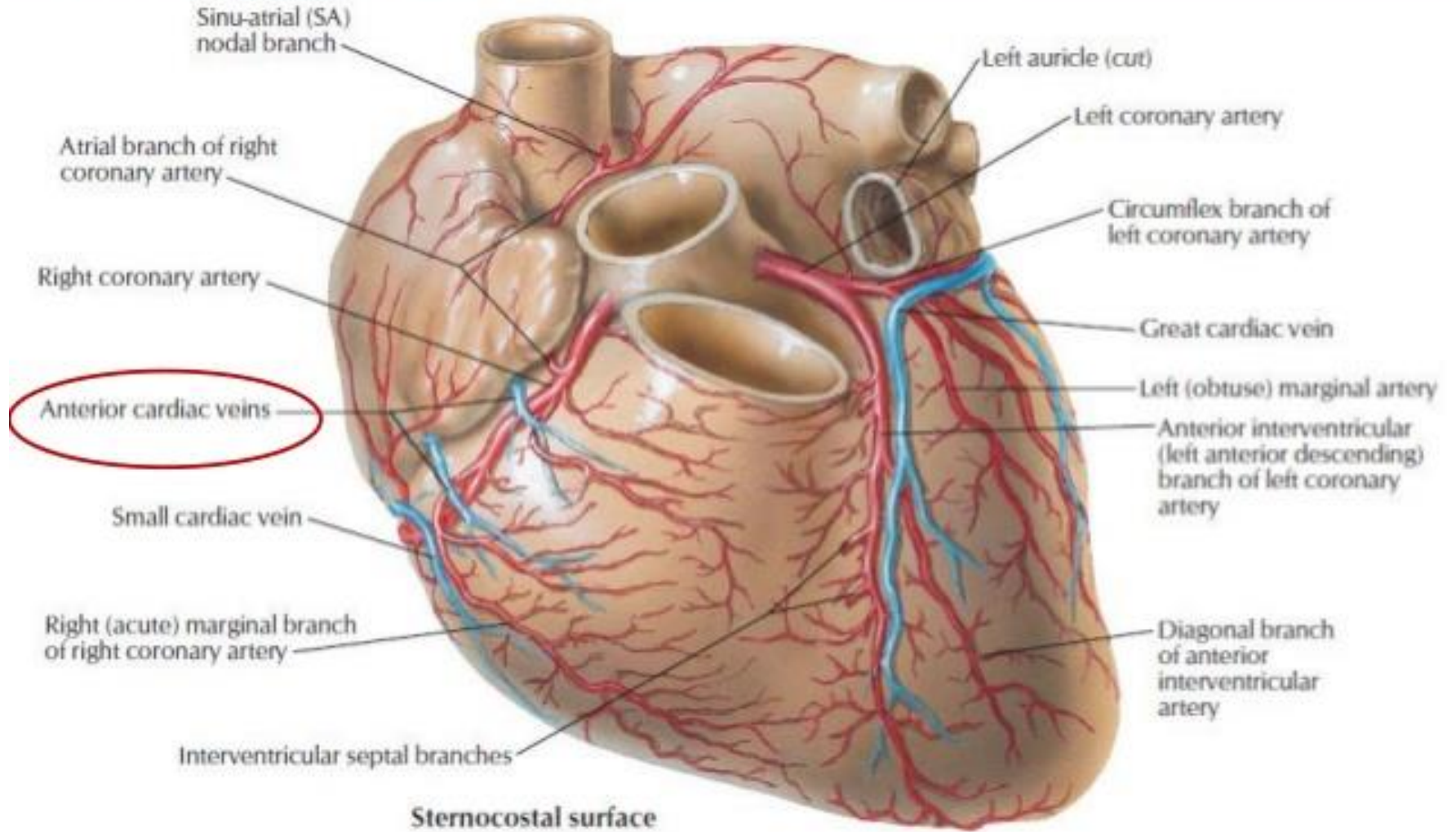
C. Normal arterial pattern, posteroinferior view

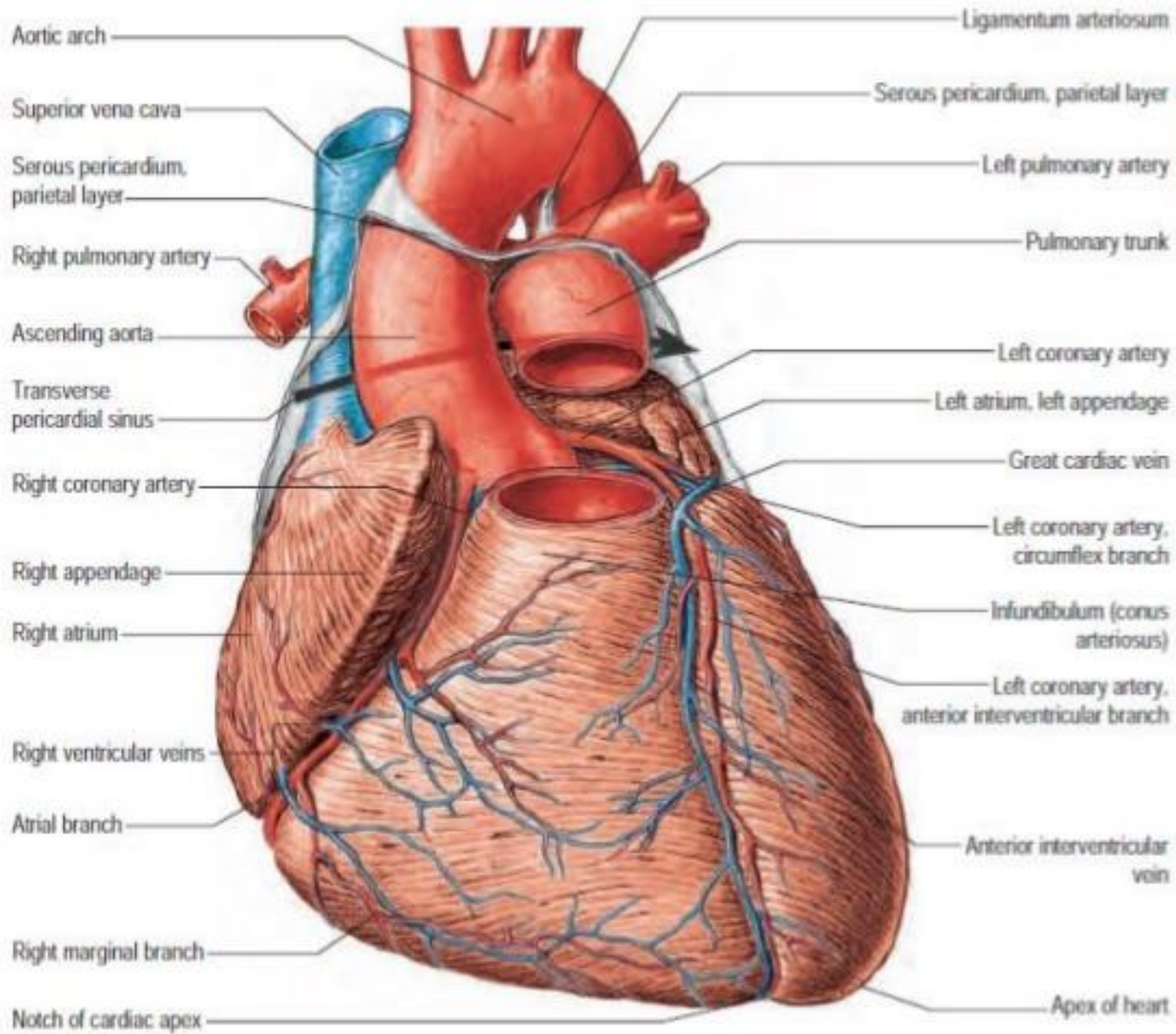


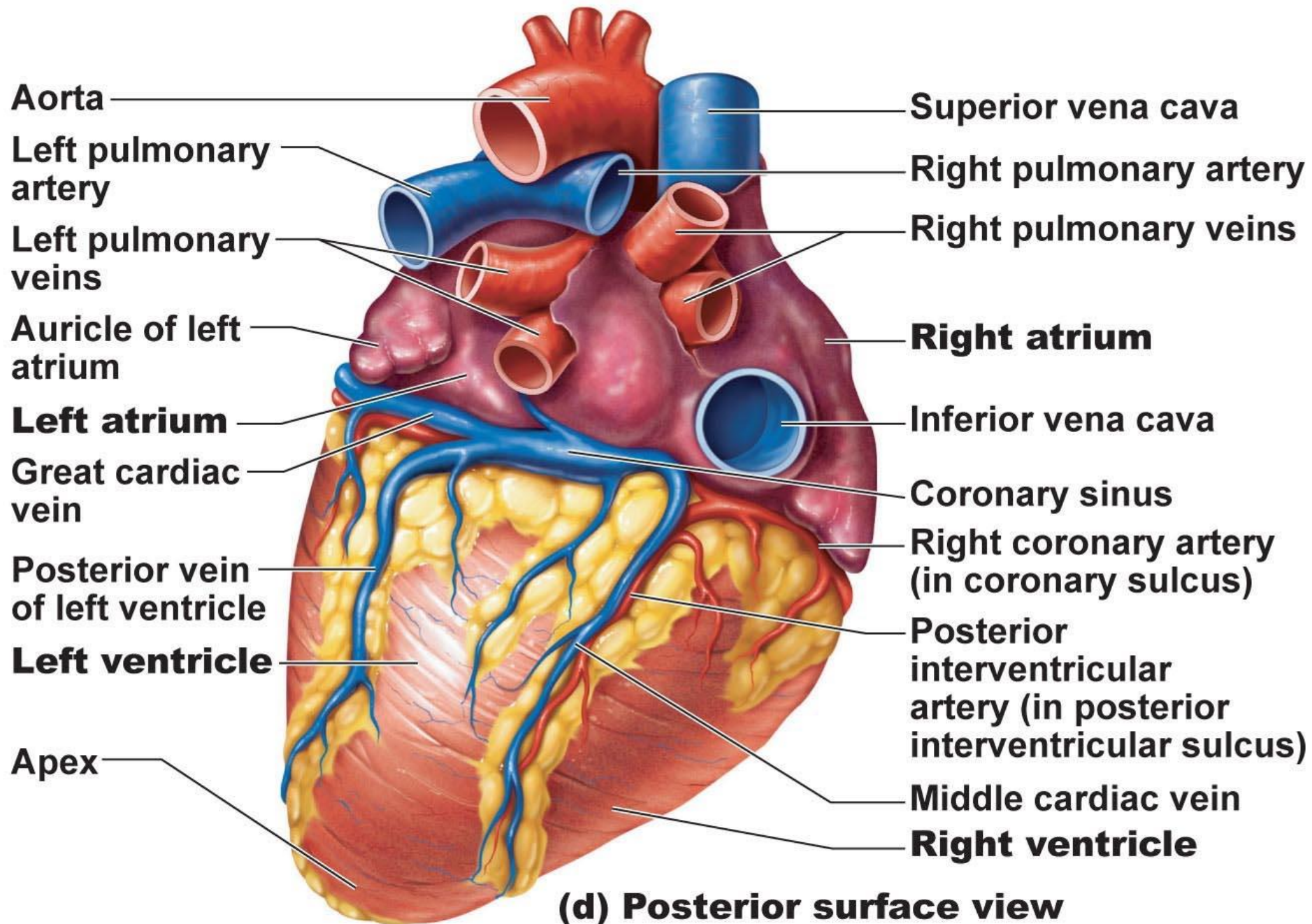
D. Variation, posteroinferior view



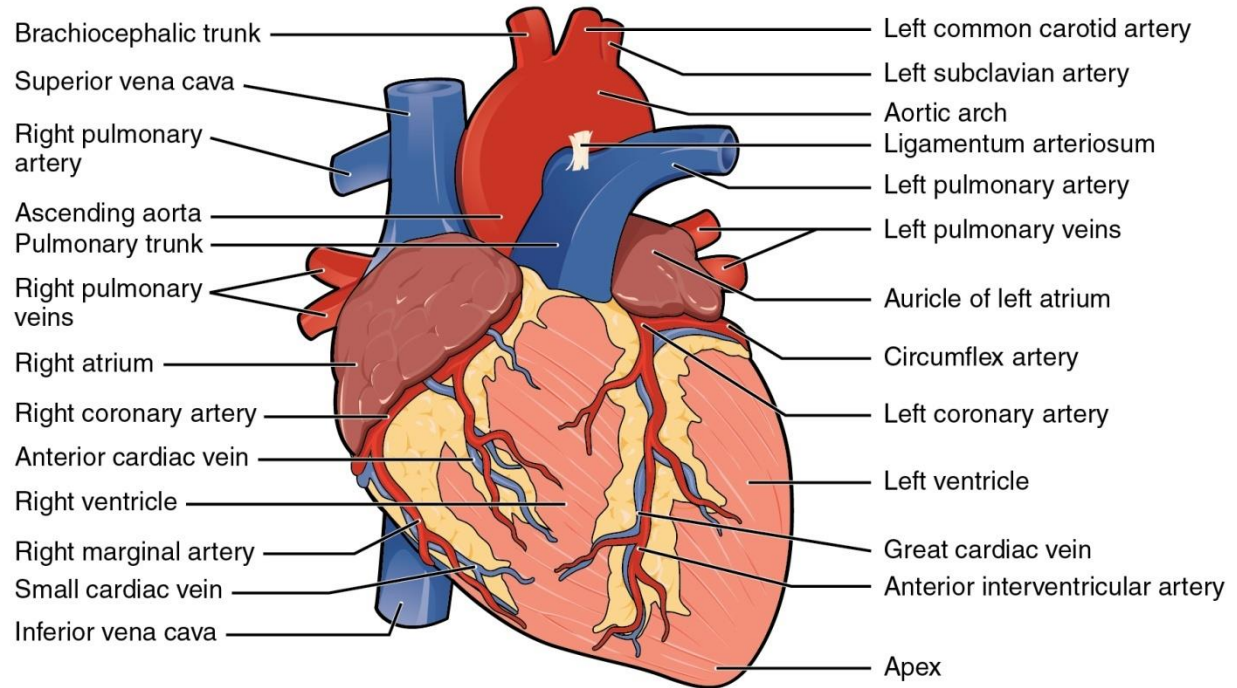




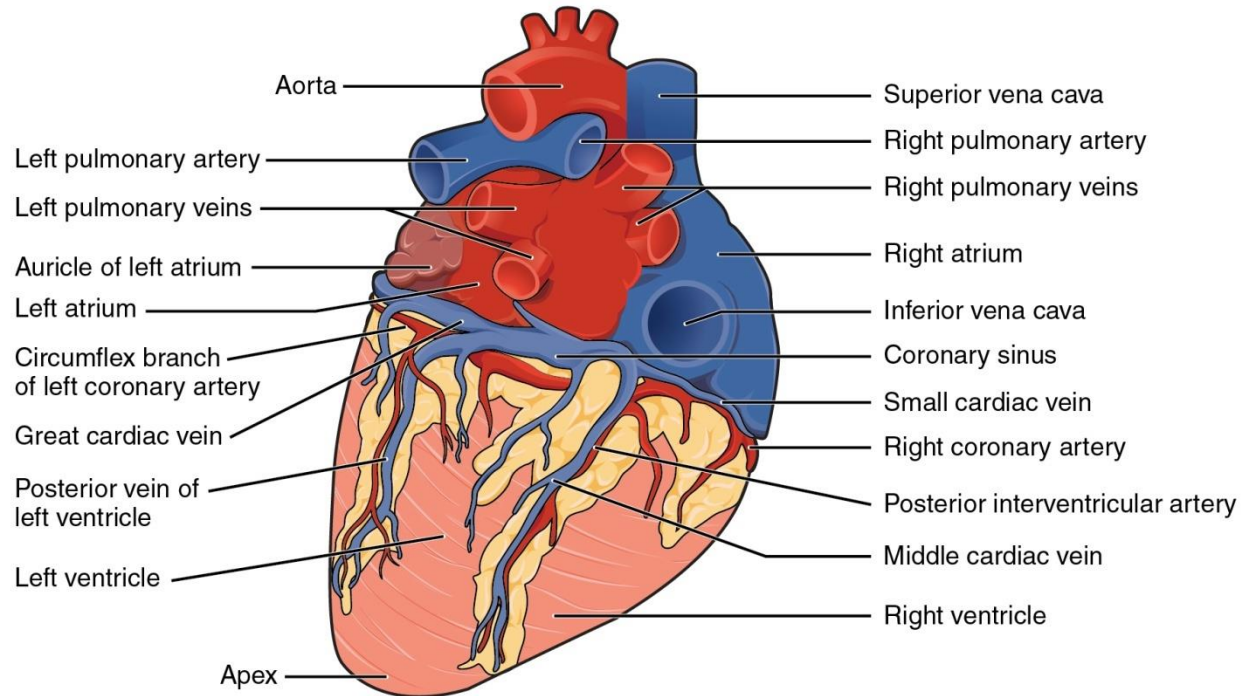


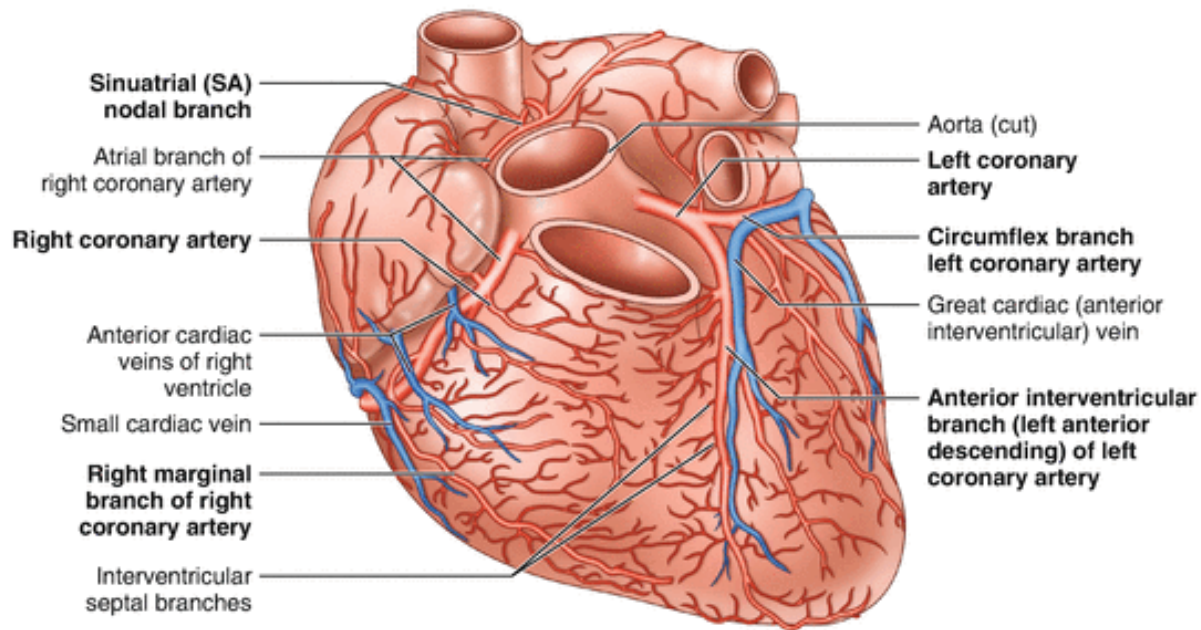


Anterior view

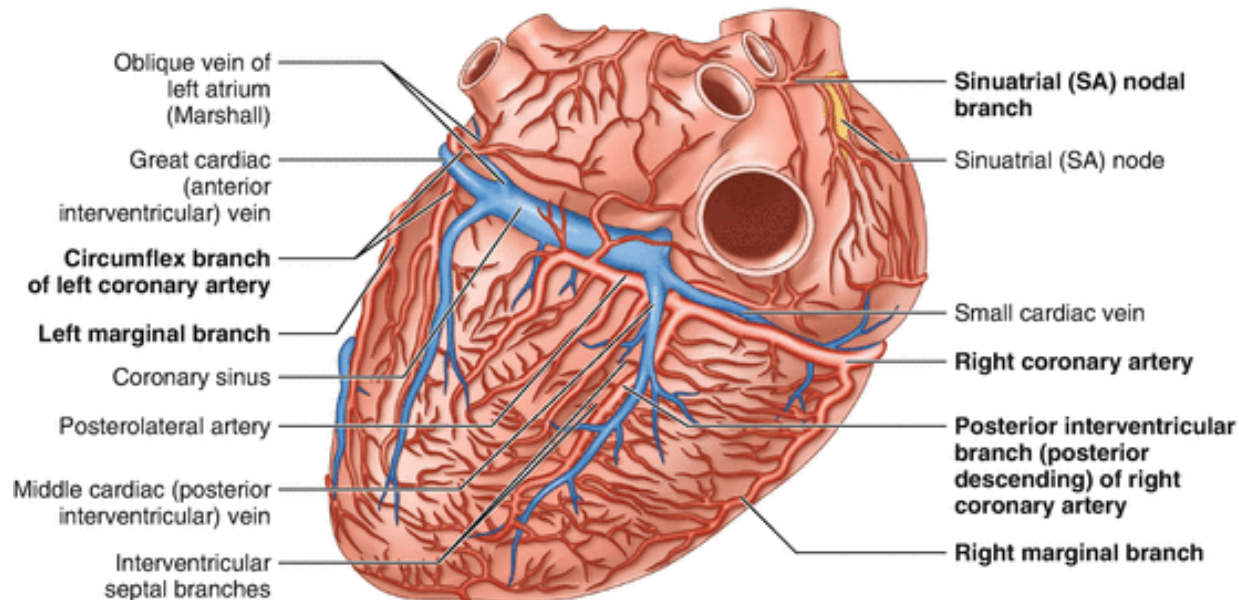


Posterior view



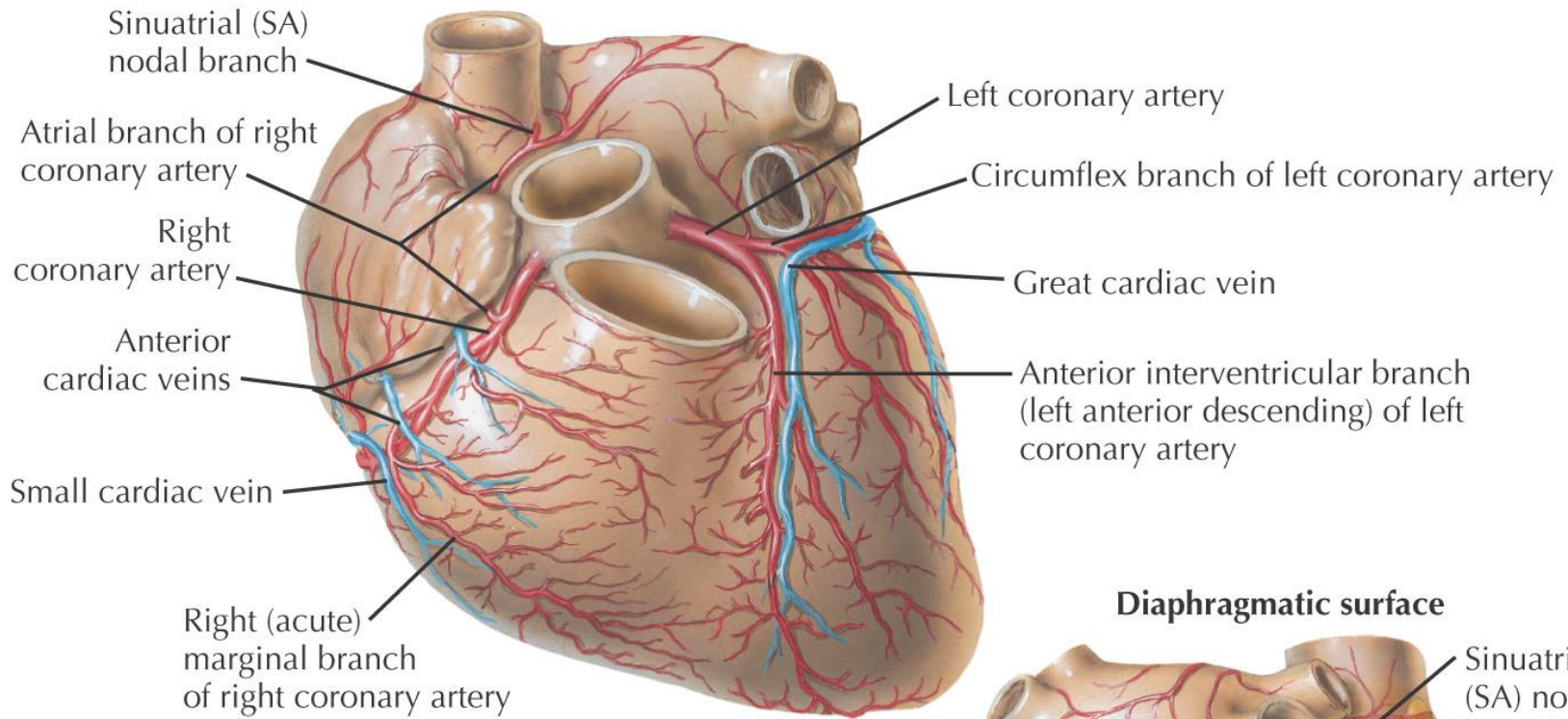


Sternocostal surface

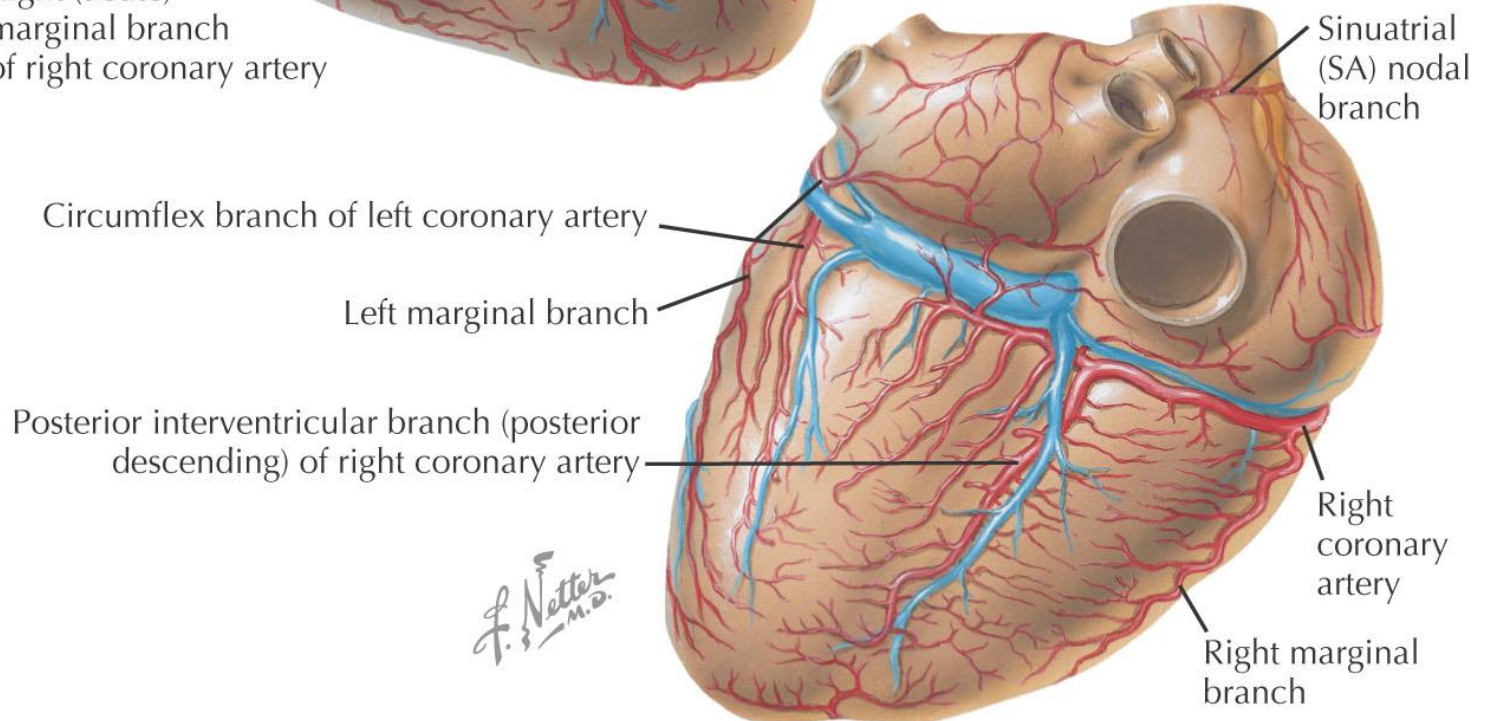


Diaphragmatic surface

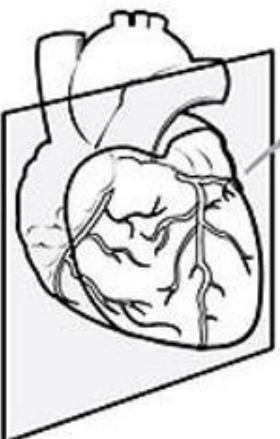Sternocostal surface



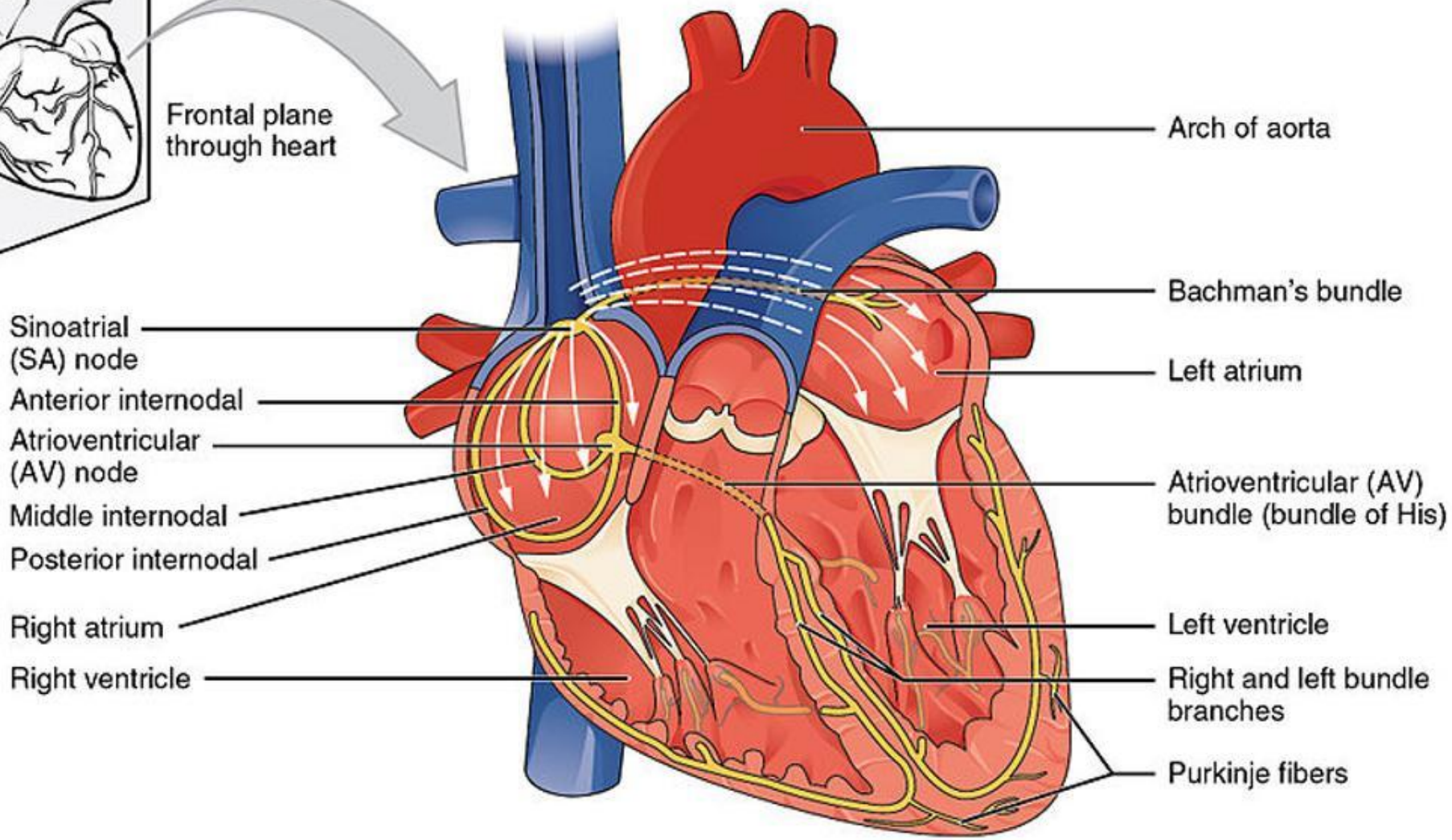
Diaphragmatic surface



F. Netter M.D.



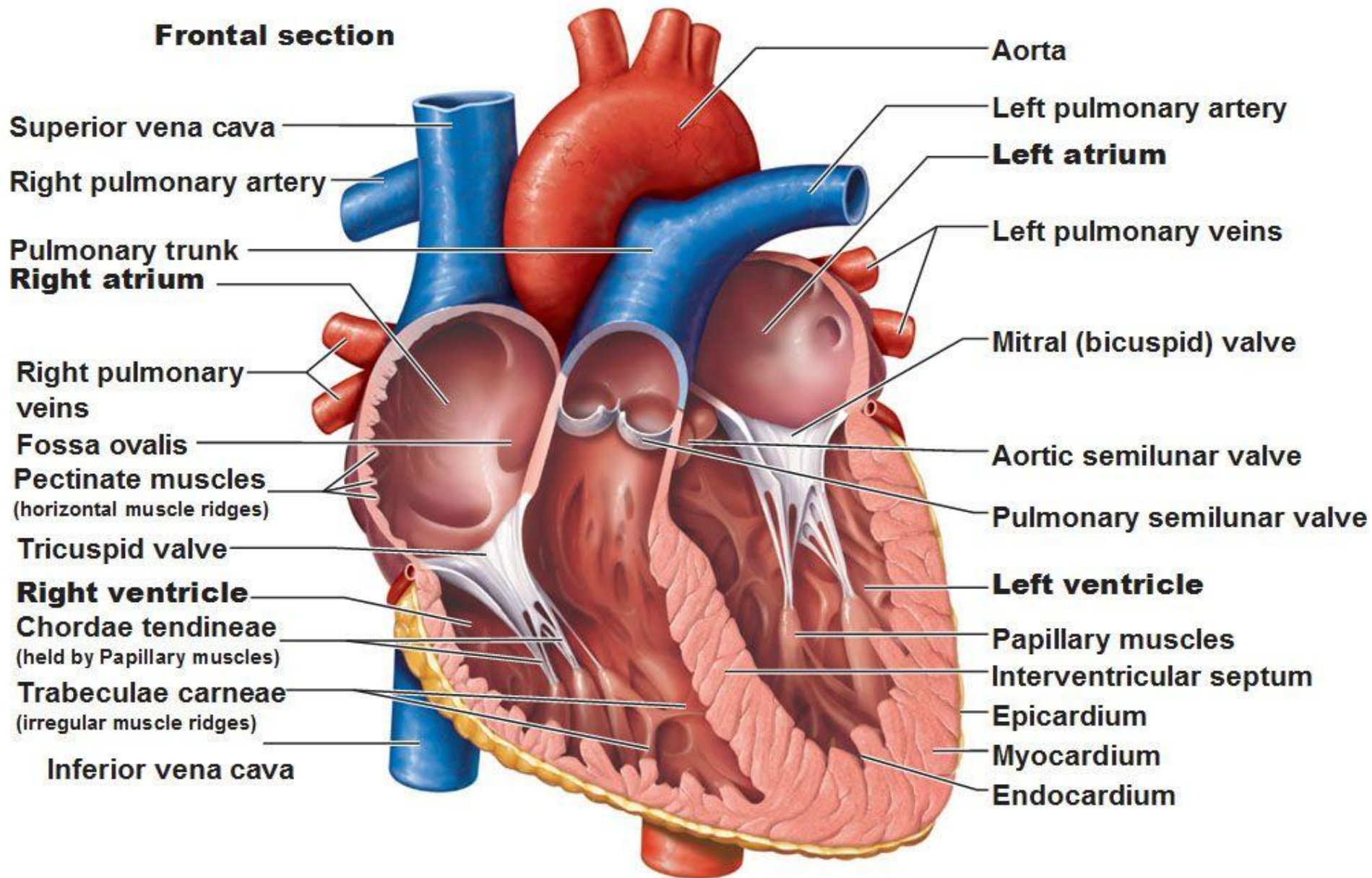
Frontal plane through heart

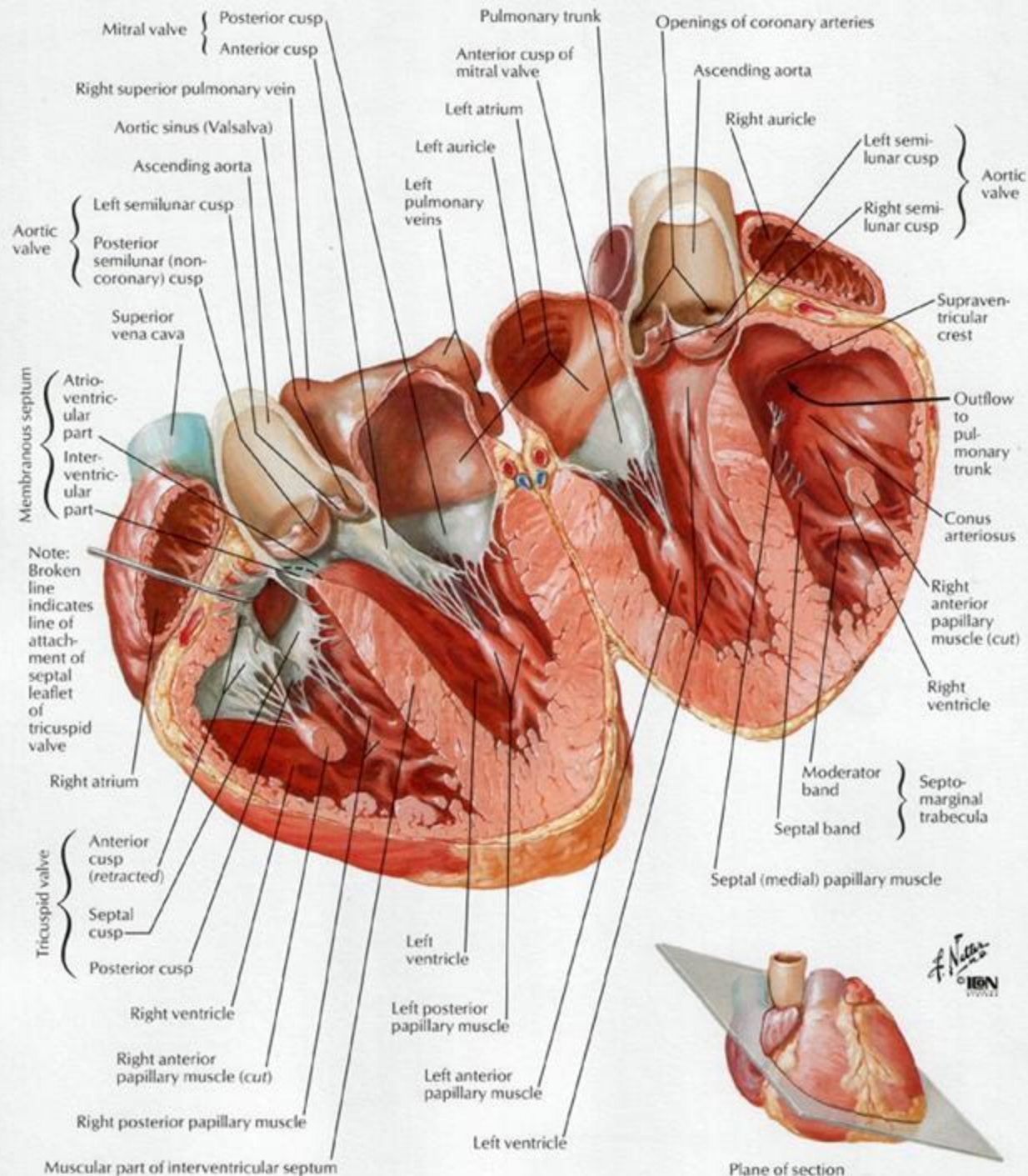


Anterior view of frontal section

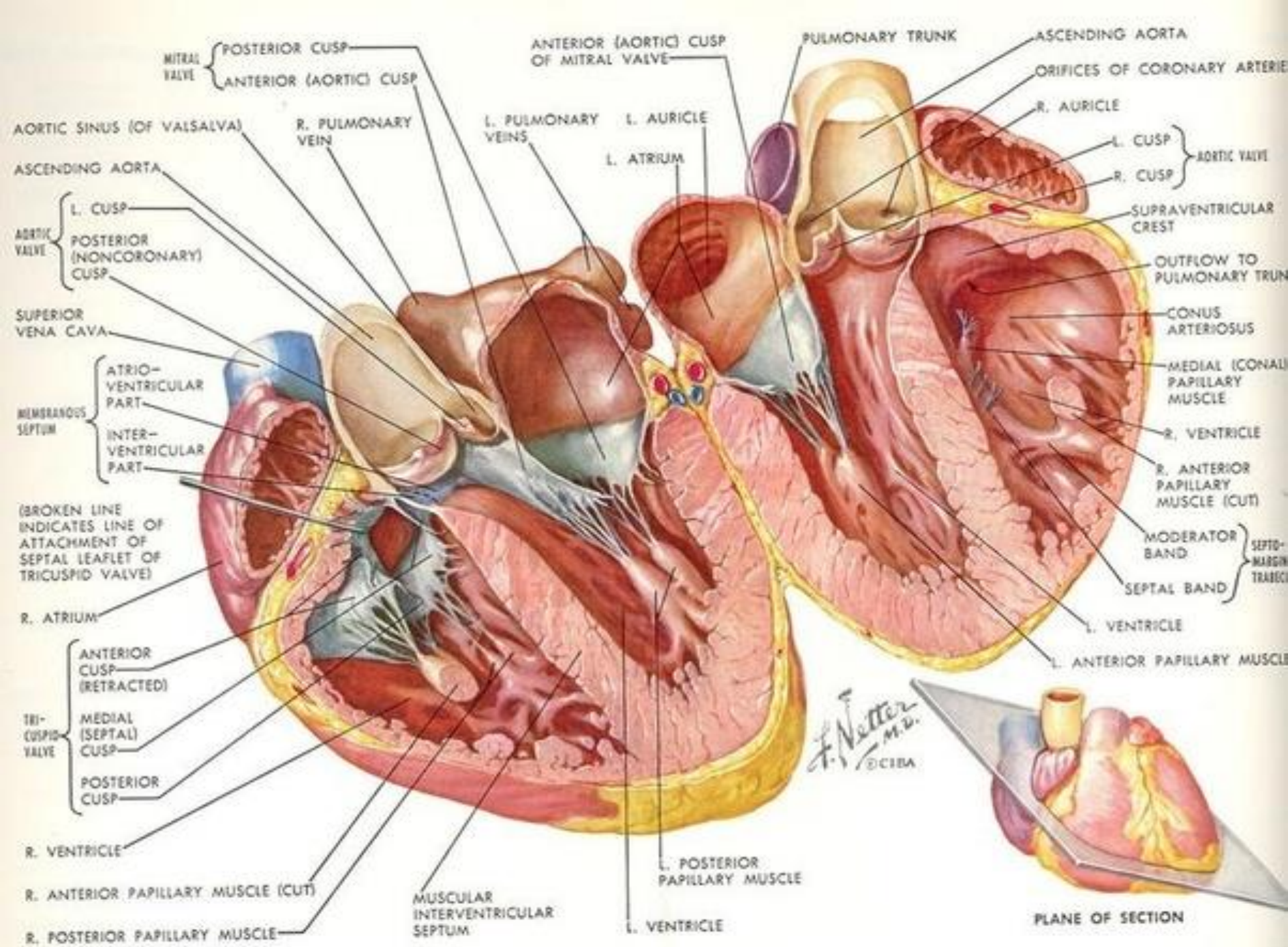
Heart Interior

Frontal section





F. Netter M.D.
© 1989



MITRAL VALVE {
 POSTERIOR CUSP
 ANTERIOR (AORTIC) CUSP

ANTERIOR (AORTIC) CUSP
 OF MITRAL VALVE

PULMONARY TRUNK

ASCENDING AORTA

ORIFICES OF CORONARY ARTERIES

R. AURICLE

AORTIC SINUS (OF VALSALVA)

R. PULMONARY VEIN

L. PULMONARY VEINS

L. AURICLE

L. ATRIUM

L. CUSP }
 AORTIC VALVE
 R. CUSP }

ASCENDING AORTA

AORTIC VALVE {
 L. CUSP
 POSTERIOR (NONCORONARY) CUSP

SUPRAVENTRICULAR CREST

OUTFLOW TO PULMONARY TRUNK

SUPERIOR VENA CAVA

MEMBRANOUS SEPTUM {
 ATRIO-VENTRICULAR PART
 INTER-VENTRICULAR PART

CONUS ARTERIOSUS

MEDIAL (CONAL) PAPILLARY MUSCLE

(BROKEN LINE INDICATES LINE OF ATTACHMENT OF SEPTAL LEAFLET OF TRICUSPID VALVE)

R. VENTRICLE

R. ANTERIOR PAPILLARY MUSCLE (CUT)

R. ATRIUM

MODERATOR BAND }
 SEPTO-MARGIN TRABECULAE
 SEPTAL BAND }

TRI-CUSPID VALVE {
 ANTERIOR CUSP (RETRACTED)
 MEDIAL (SEPTAL) CUSP
 POSTERIOR CUSP

L. VENTRICLE

L. ANTERIOR PAPILLARY MUSCLE

R. VENTRICLE

R. ANTERIOR PAPILLARY MUSCLE (CUT)

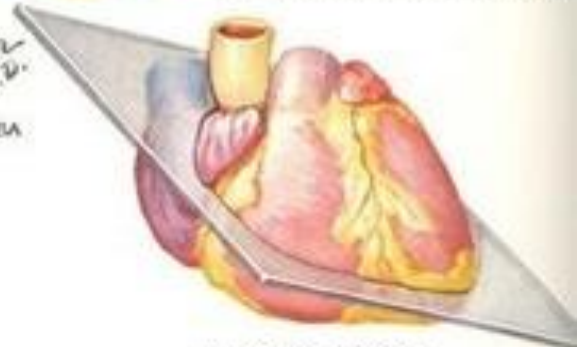R. POSTERIOR PAPILLARY MUSCLE

MUSCULAR INTERVENTRICULAR SEPTUM

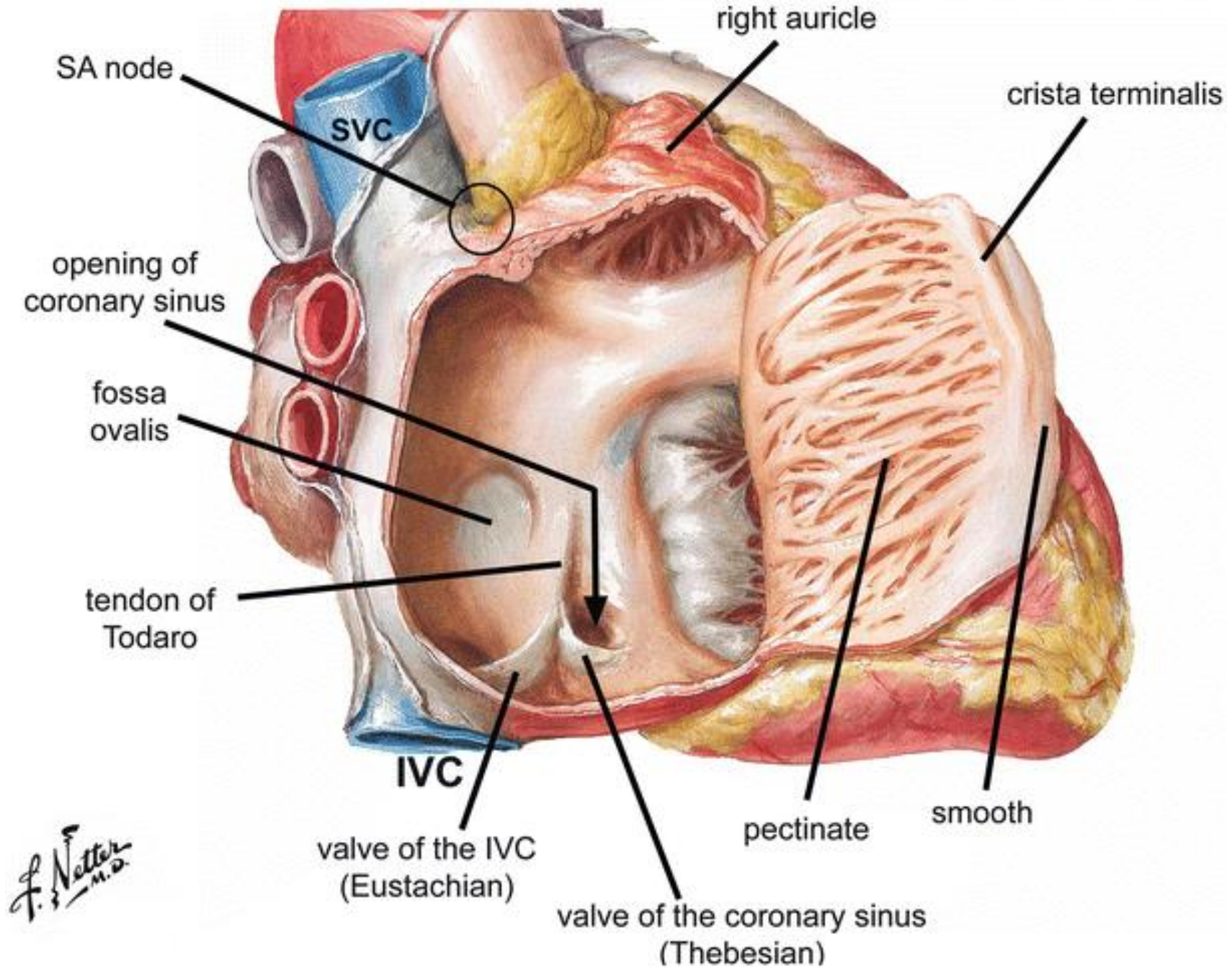
L. POSTERIOR PAPILLARY MUSCLE

L. VENTRICLE

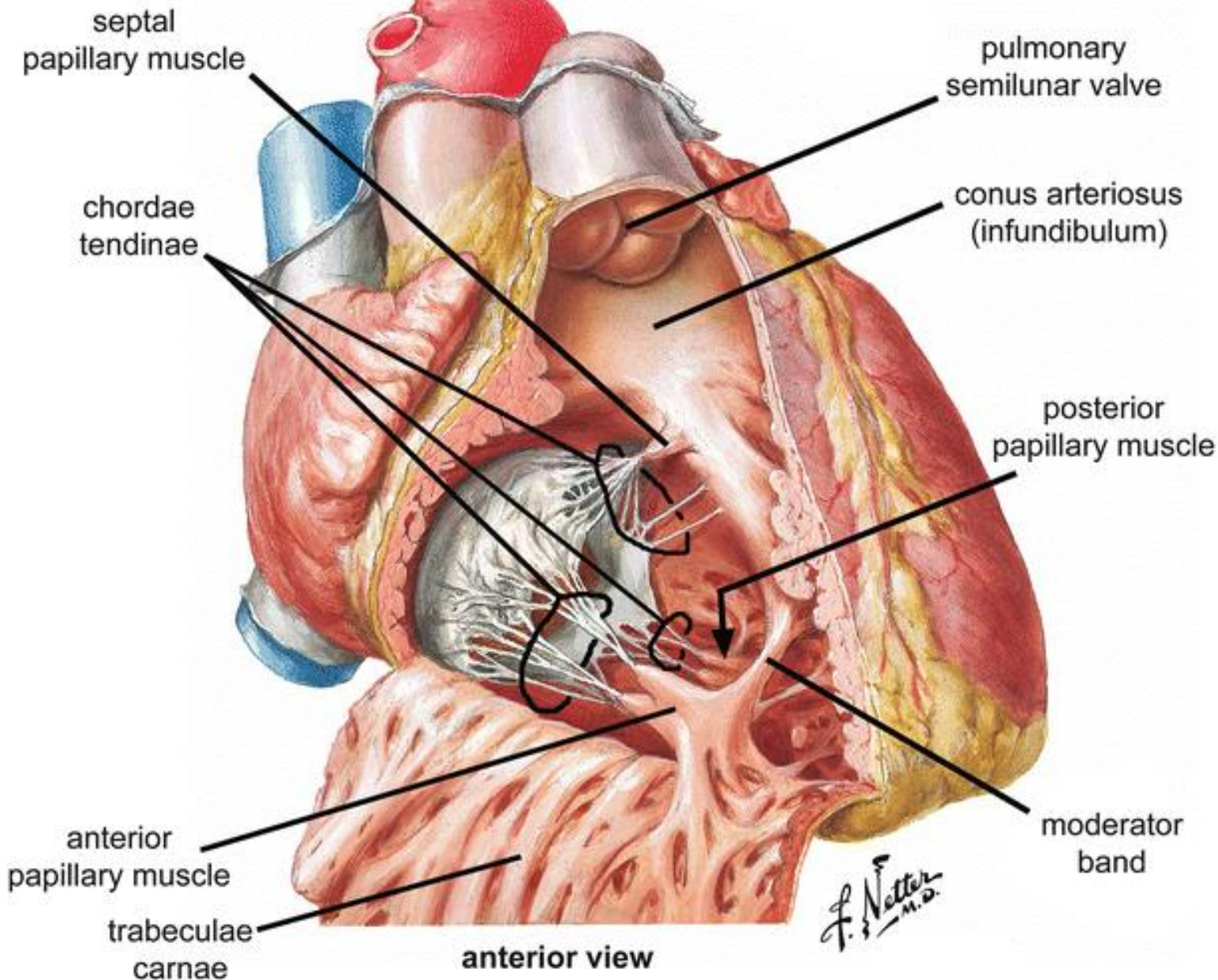
F. Netter
 M.D.
 © CIBA



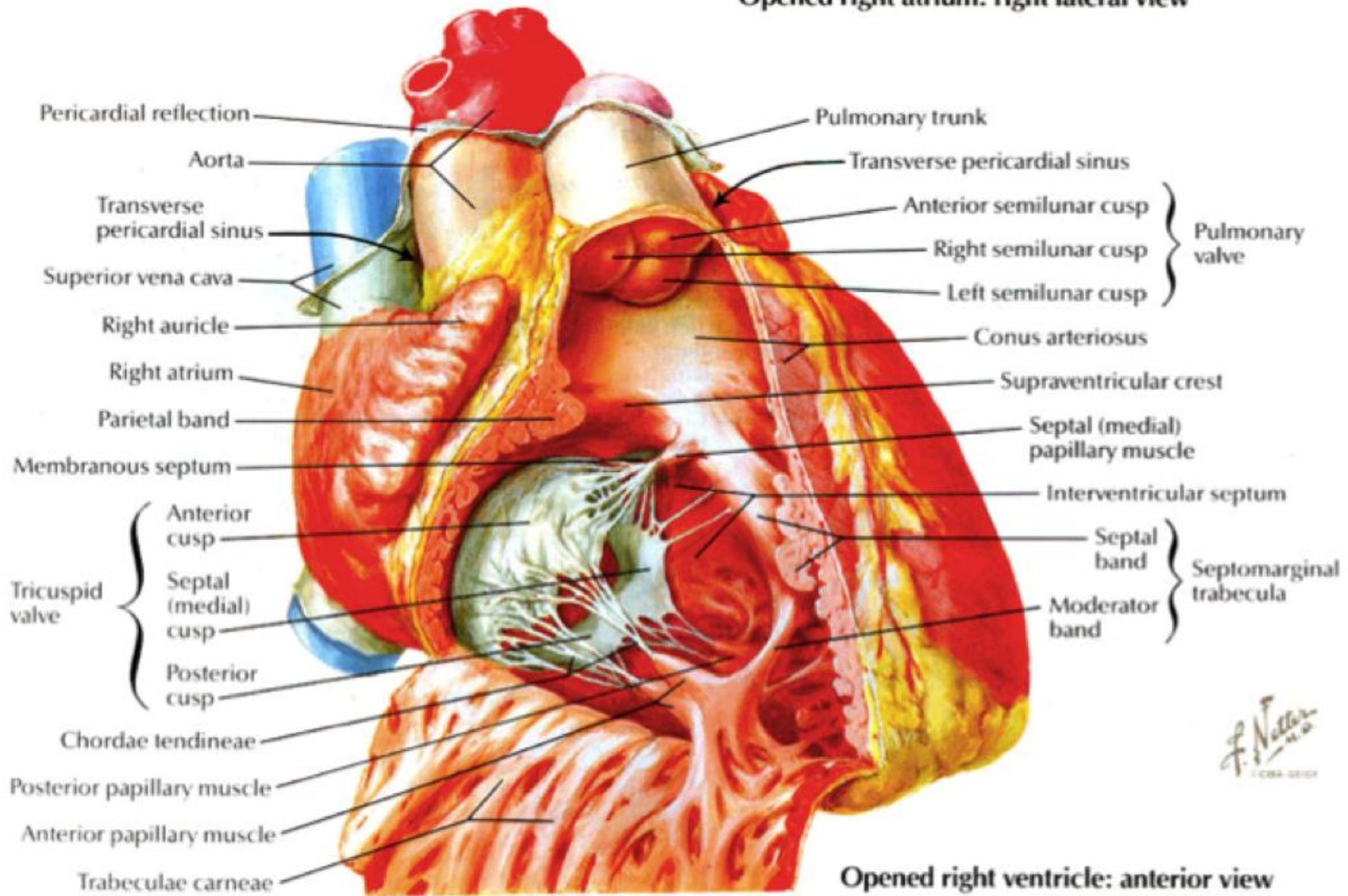
PLANE OF SECTION



F. Netter M.D.



Opened right atrium: right lateral view



Opened right ventricle: anterior view

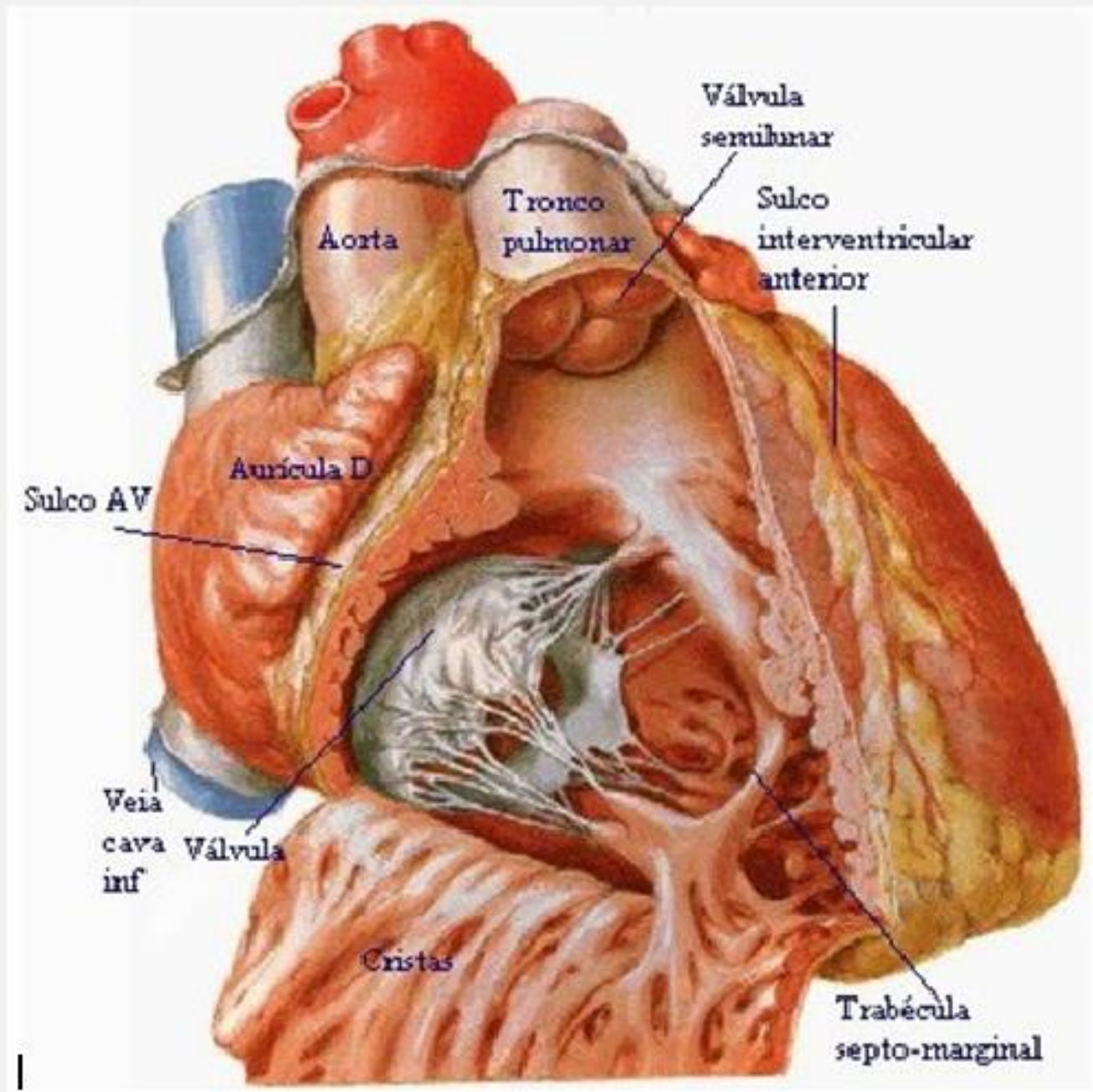
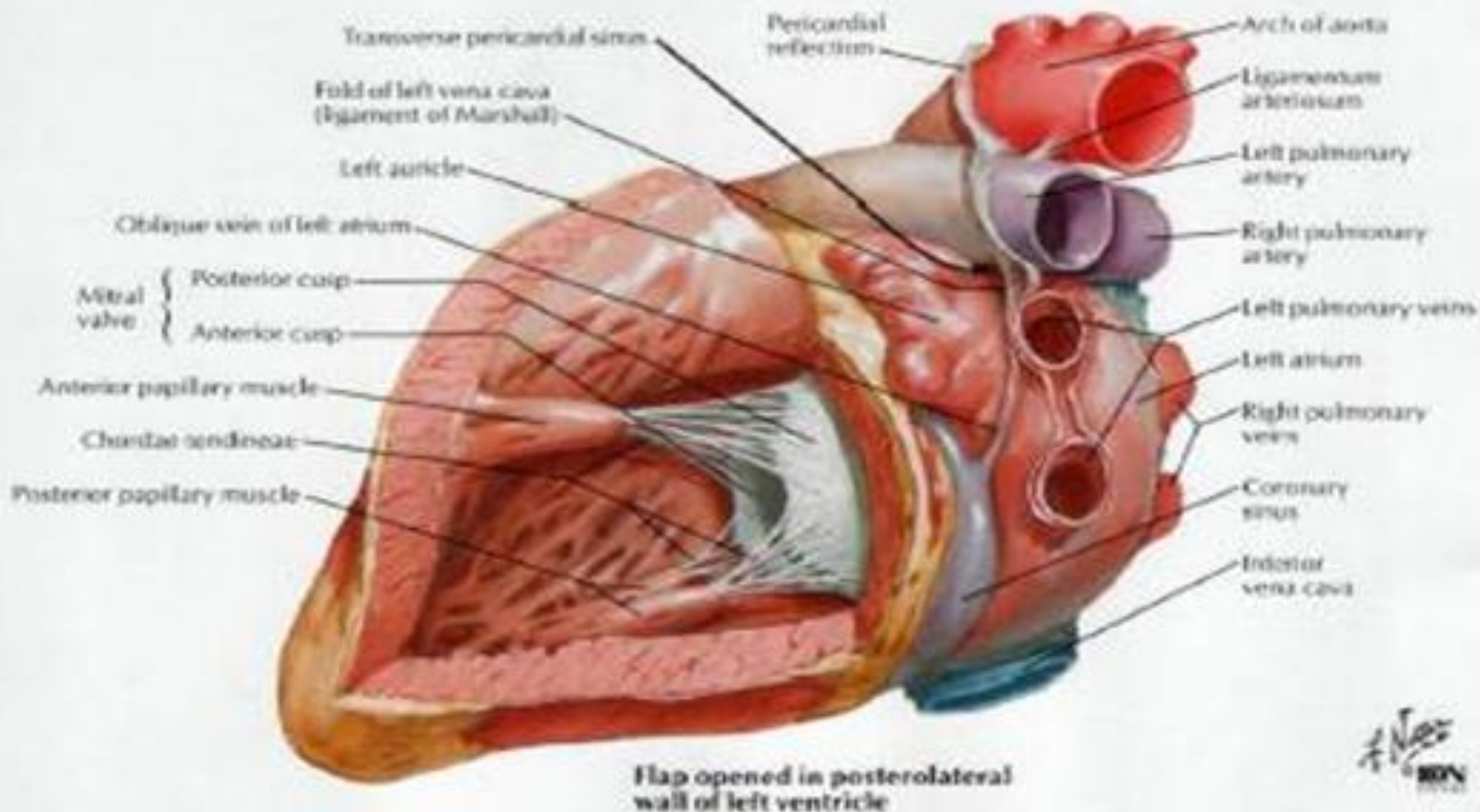
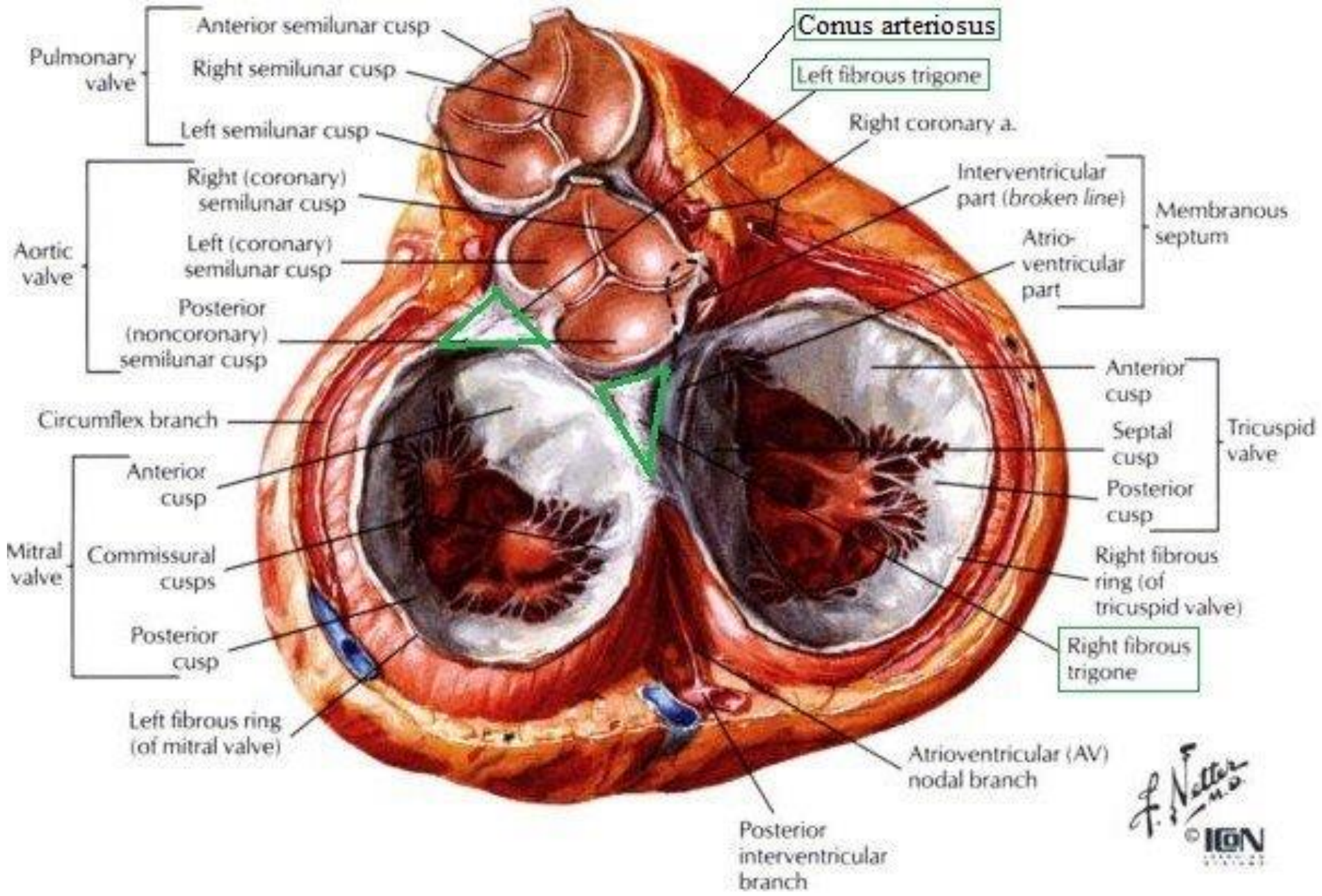
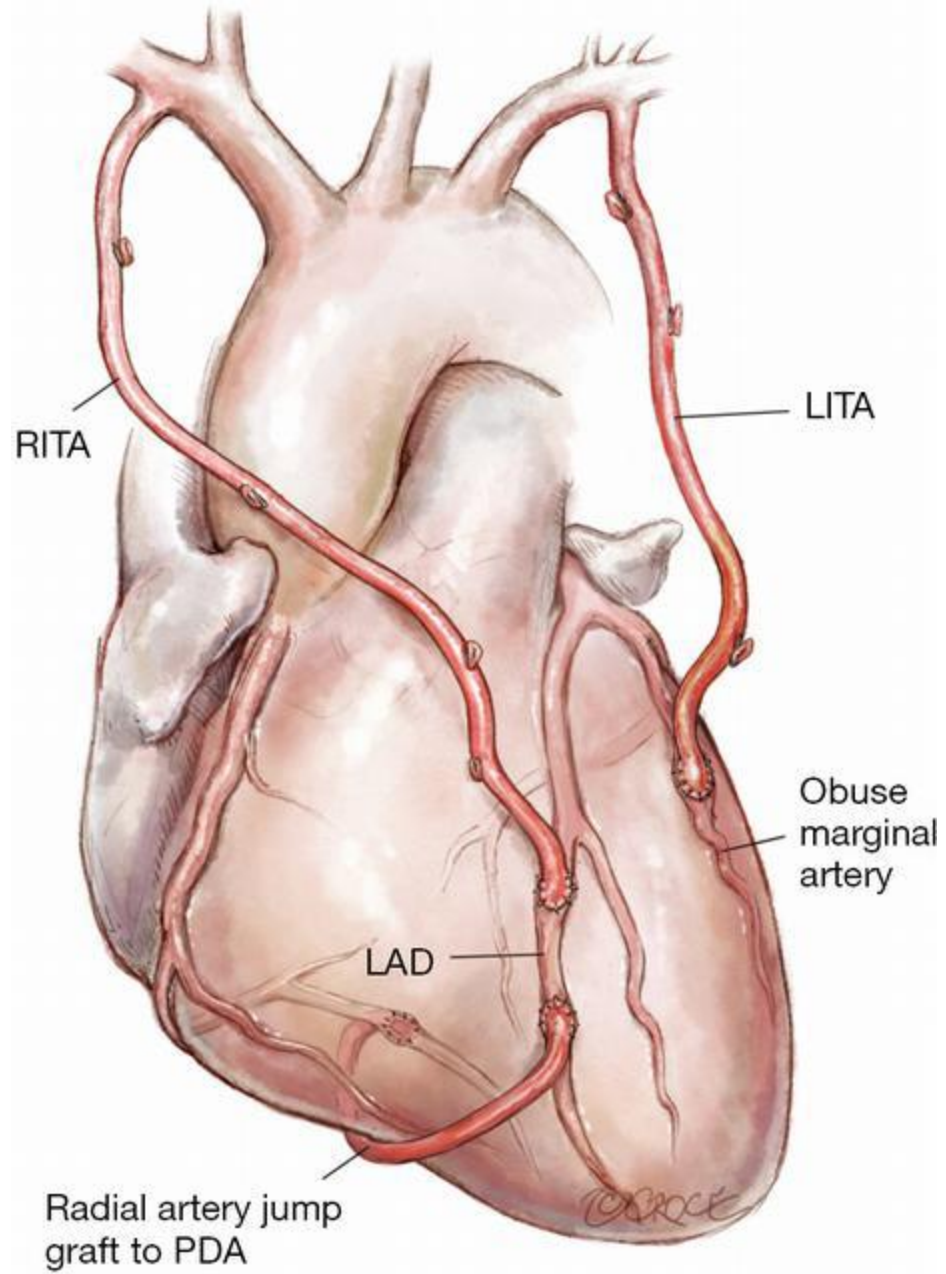


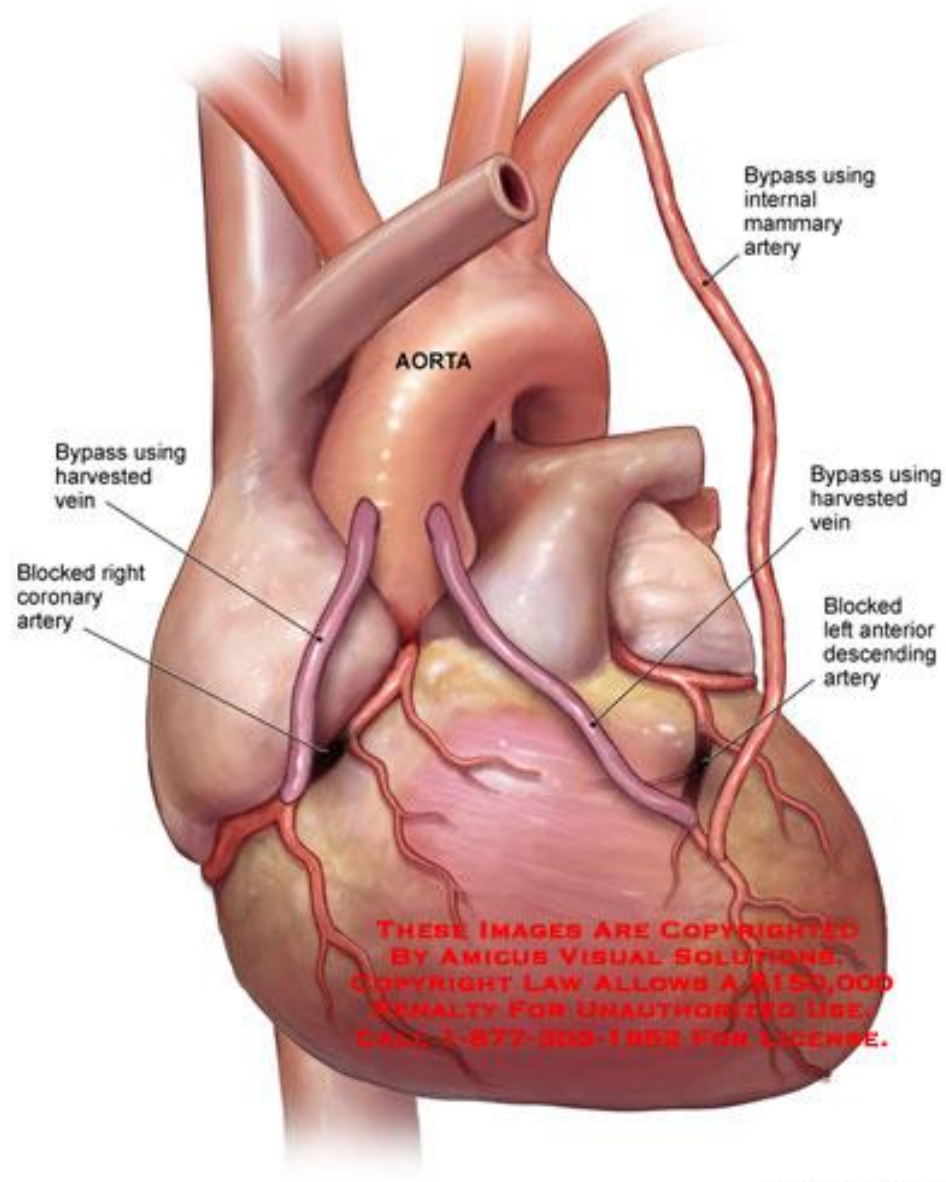
Figure 1: Interior of the right ventricle.



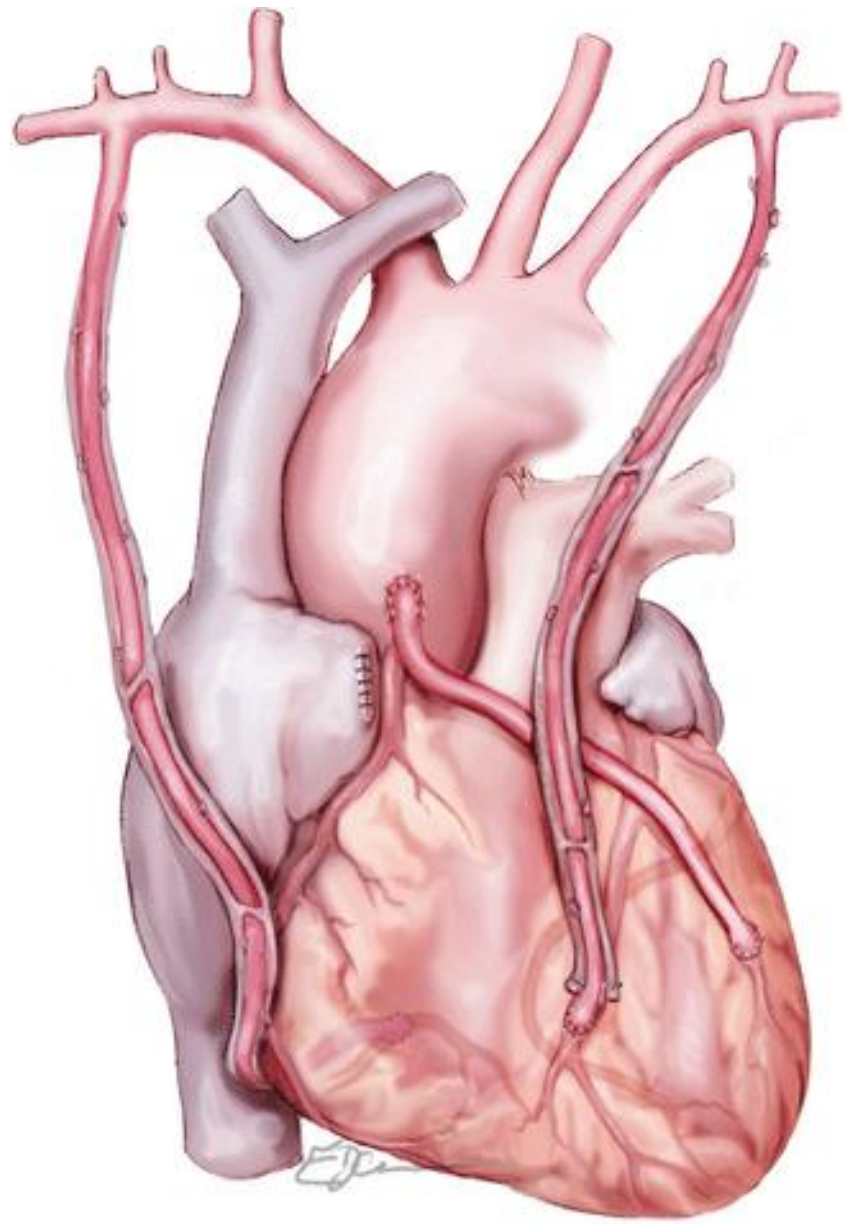




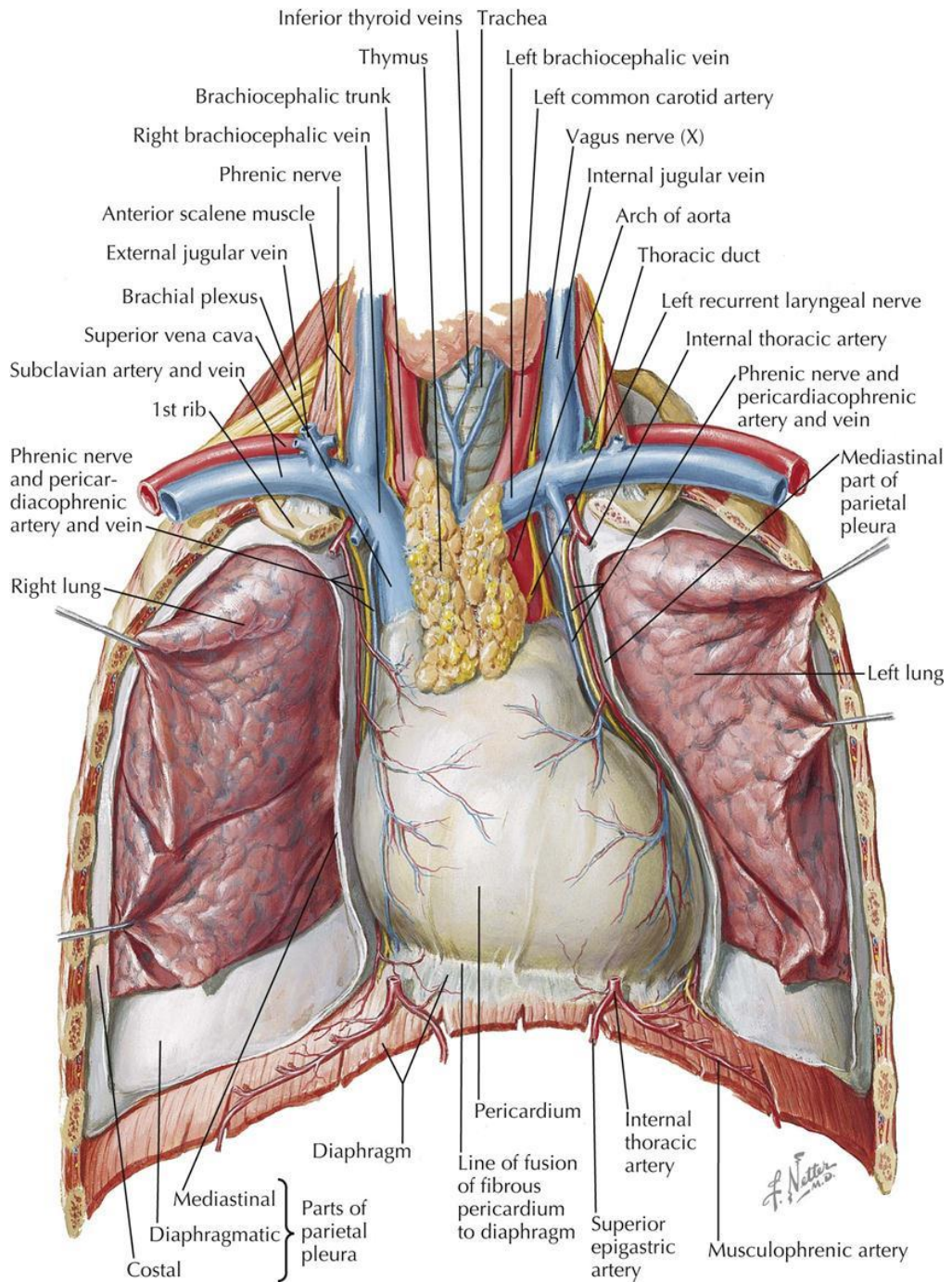
Common Coronary Bypass Grafts



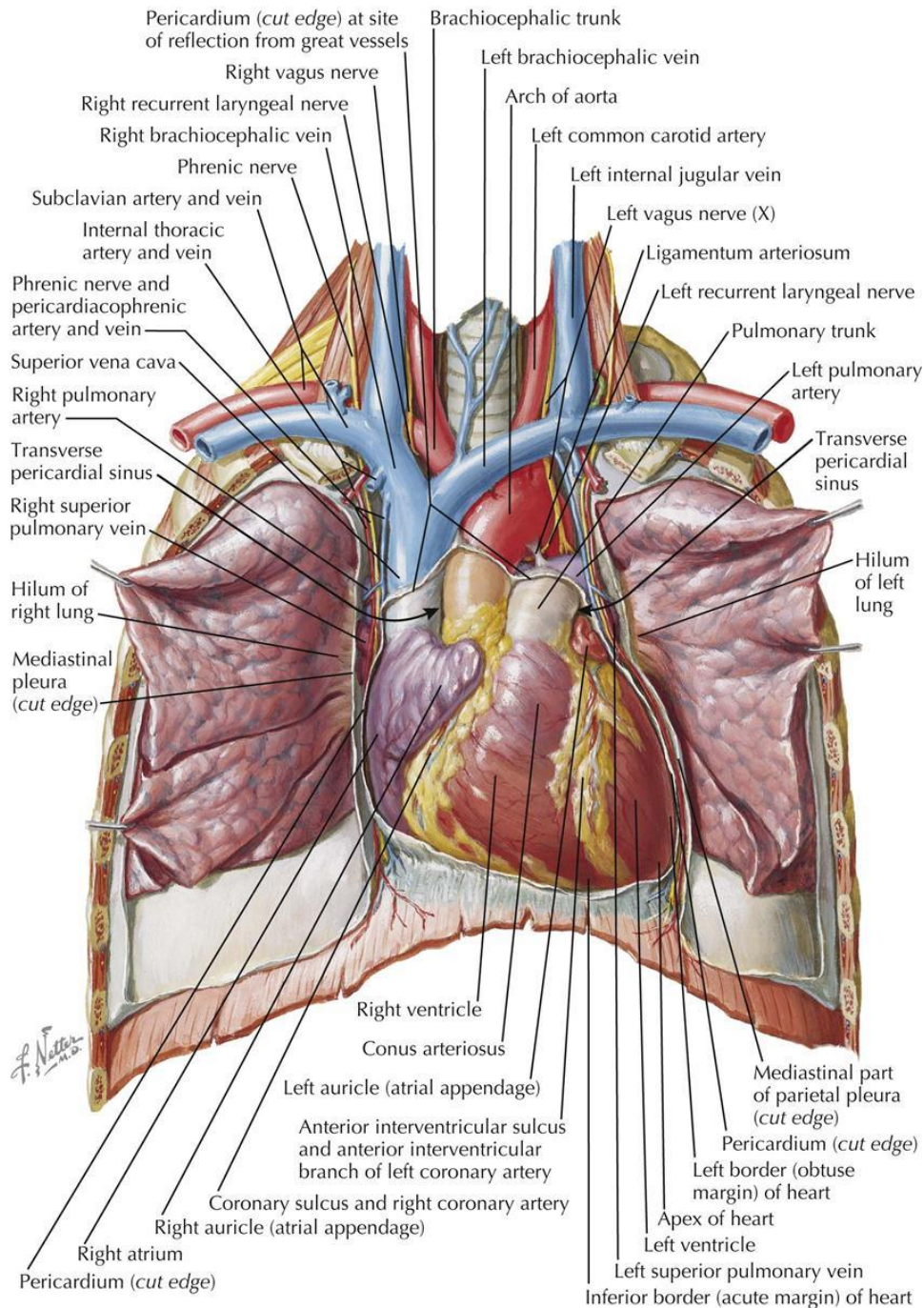
THESE IMAGES ARE COPYRIGHTED
BY AMICUS VISUAL SOLUTIONS.
COPYRIGHT LAW ALLOWS A \$100,000
PENALTY FOR UNAUTHORIZED USE.
CALL 1-877-808-1888 FOR LICENSE.

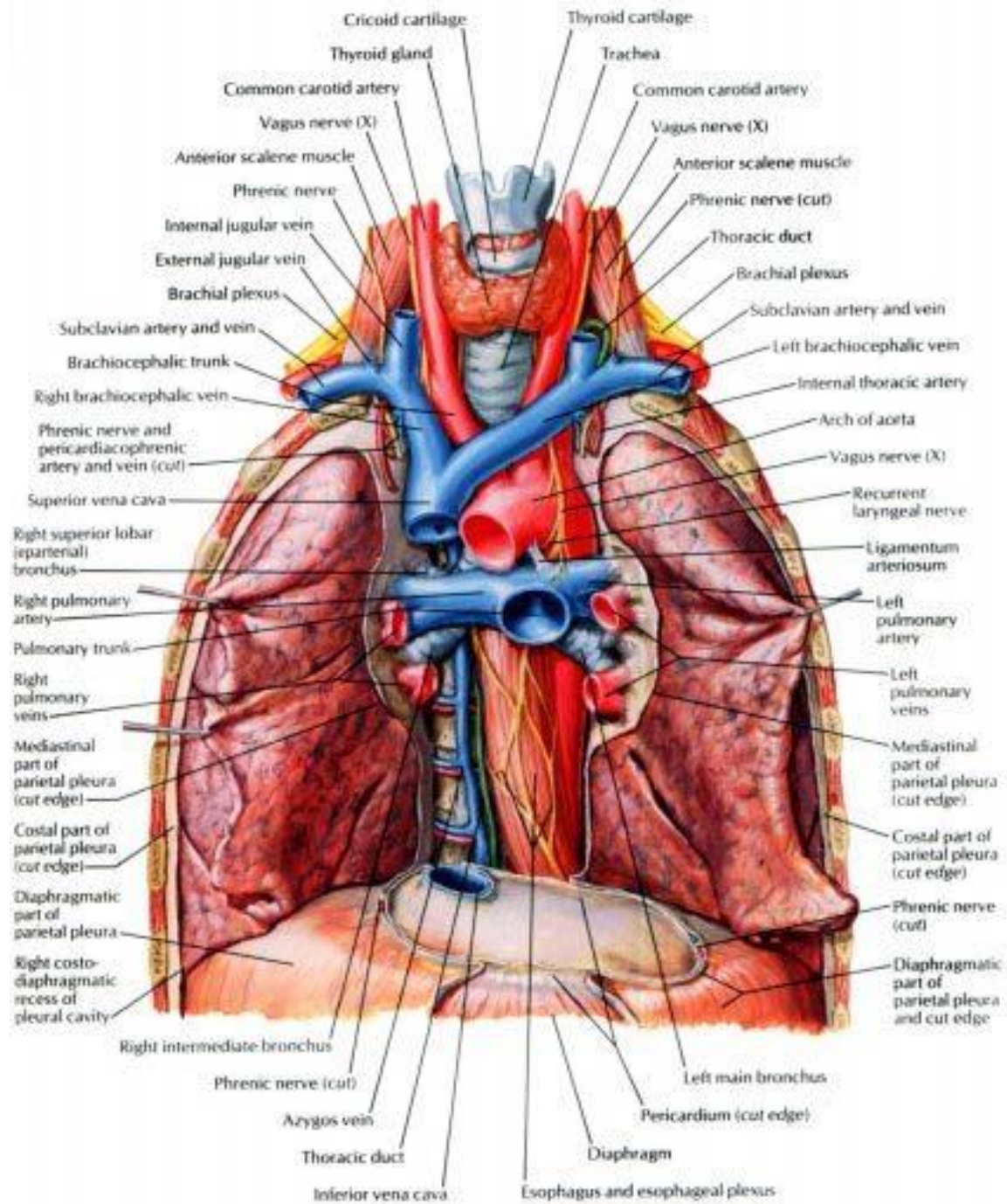


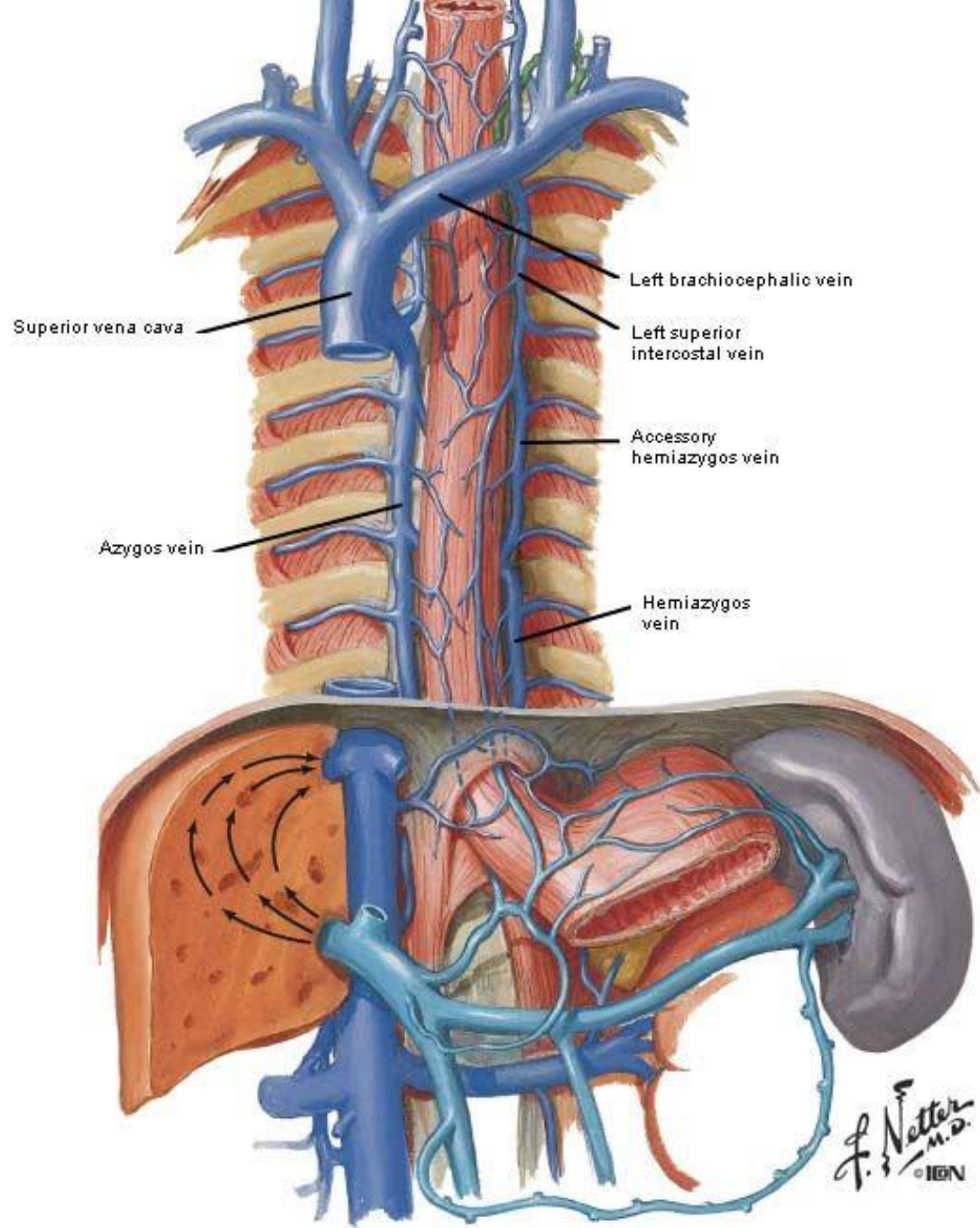
HEART IN SITU

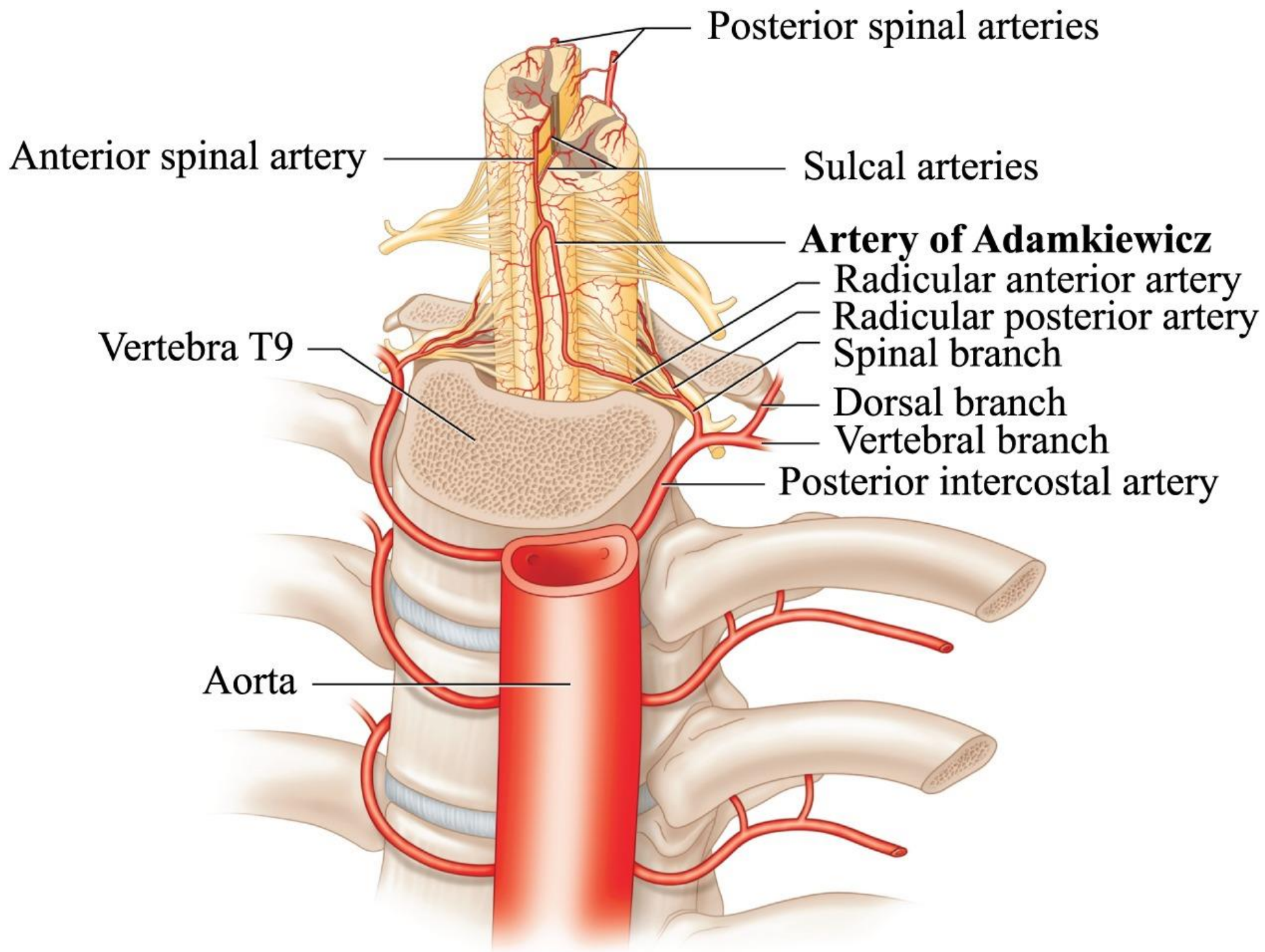


ANTERIOR EXPOSURE

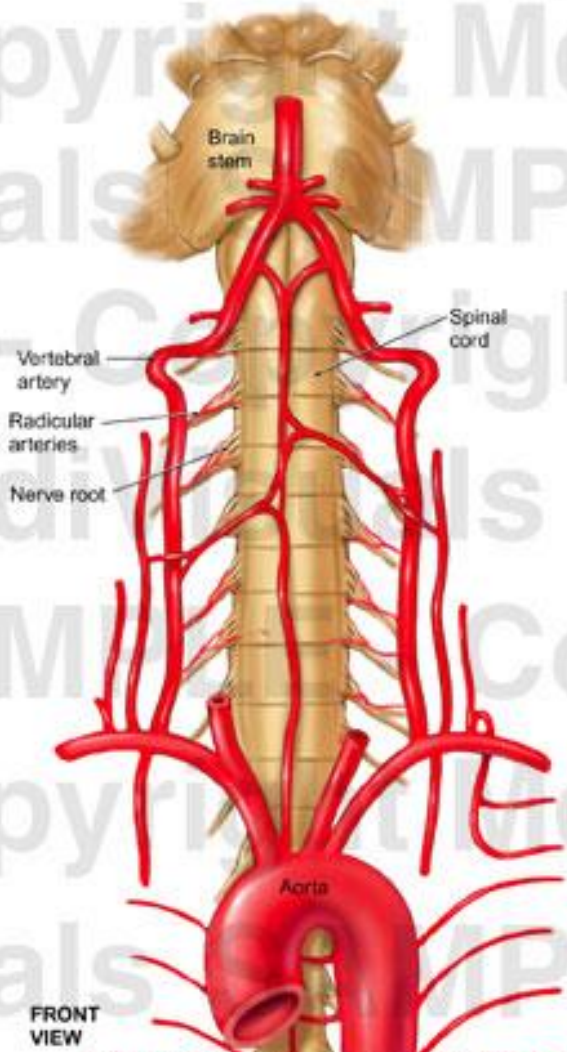








Cervical Spine and Brainstem Neural and Vascular Anatomy



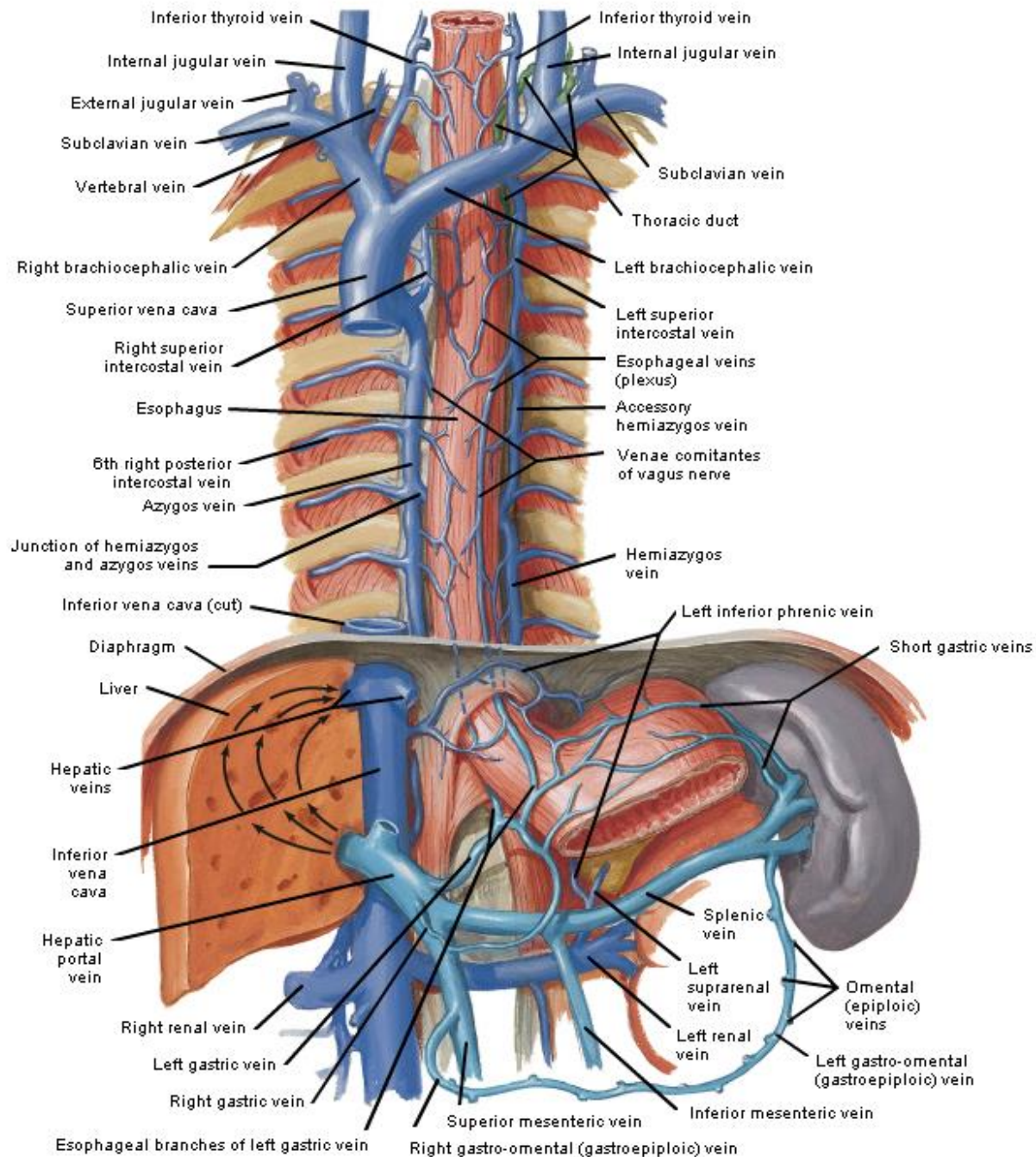
FRONT
VIEW

© MediVisuals 800-899-2154

This message indicates that this image is NOT authorized for use in settlement, deposition, mediation, trial, or any other litigation or nonlitigation use. Consistent with copyright laws, unauthorized use or reproduction of this image (or parts thereof) is subject to a maximum \$150,000 fine.

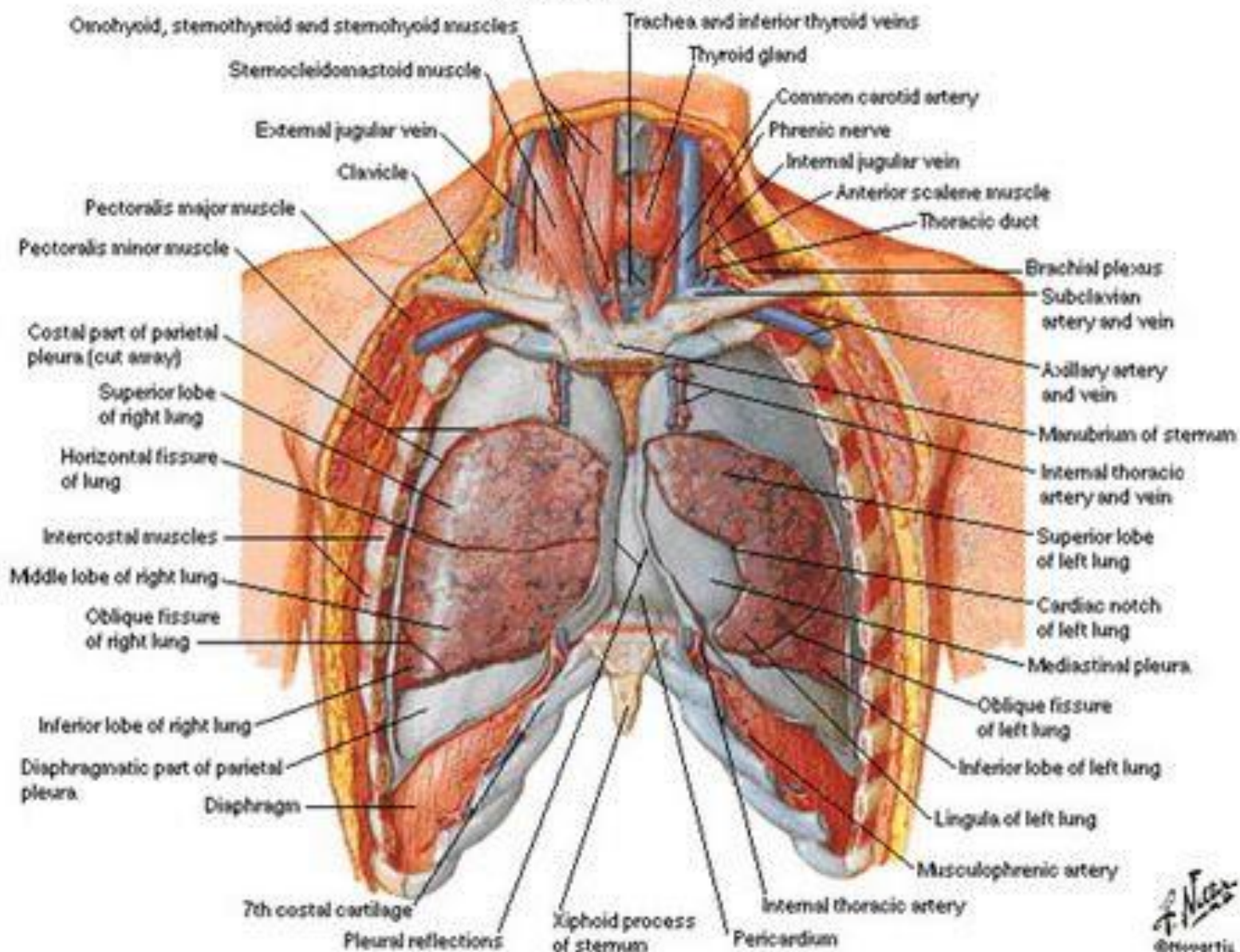
© 2006, MediVisuals Inc.

Veins of Esophagus

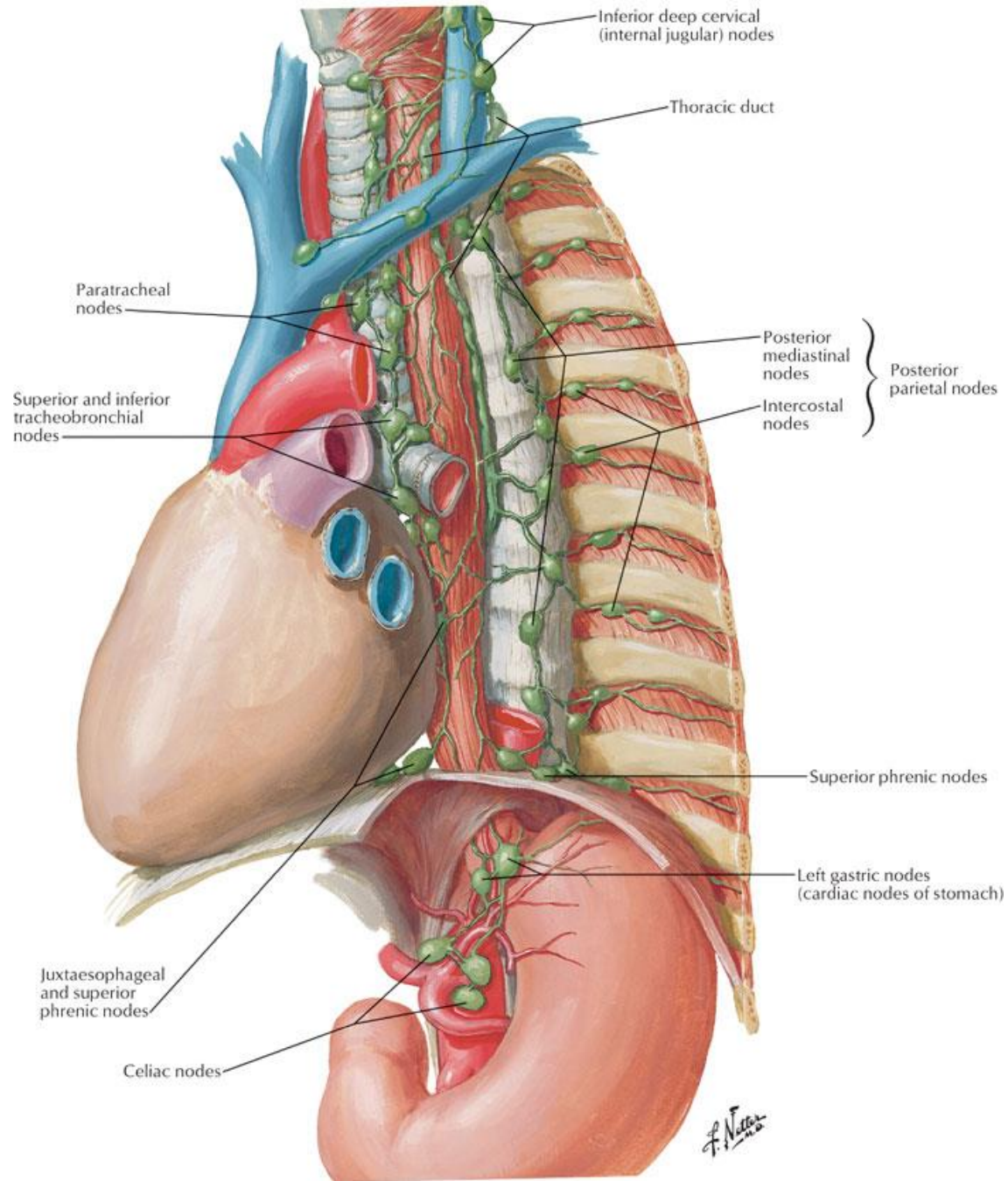


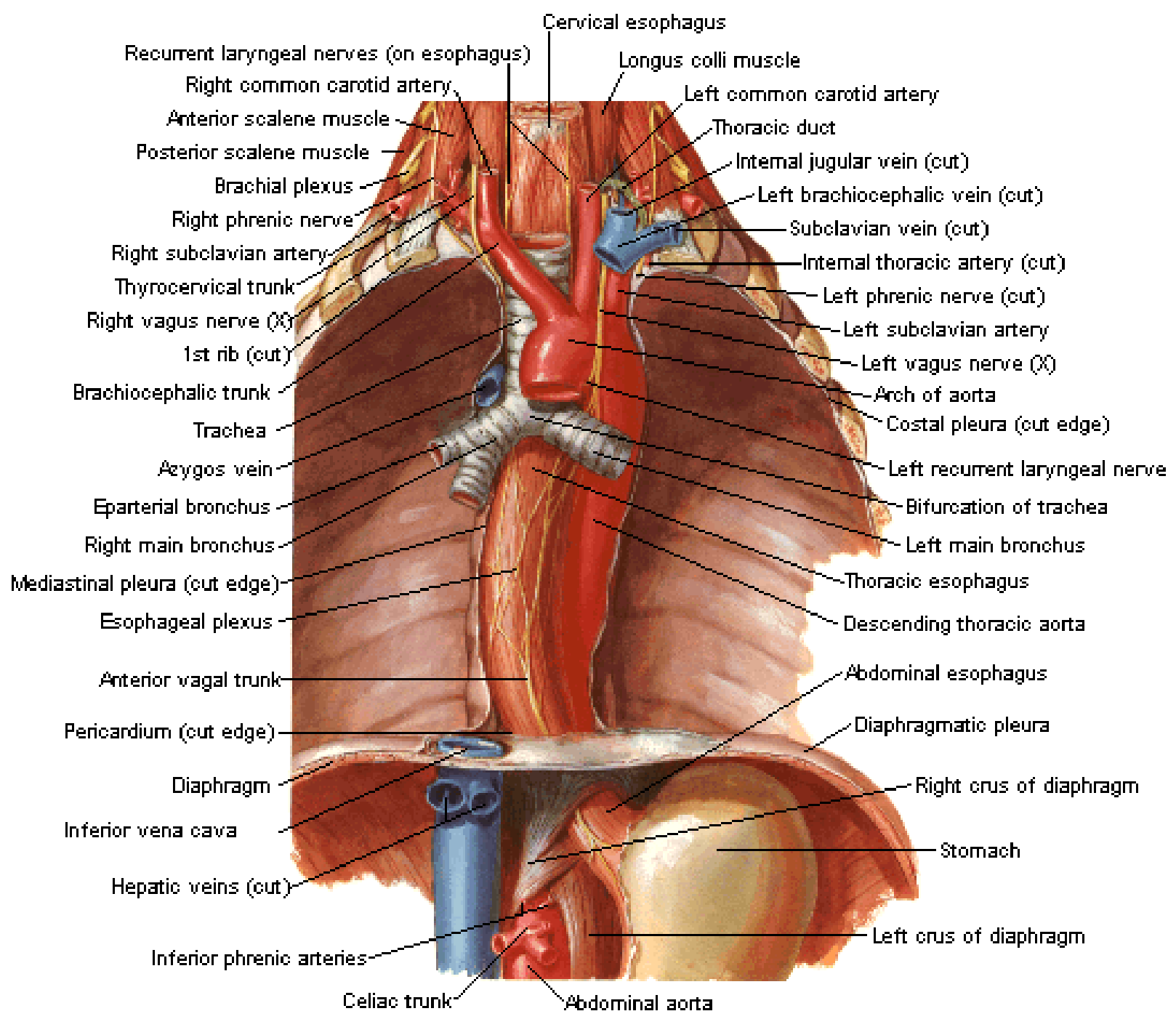
Lungs in Situ

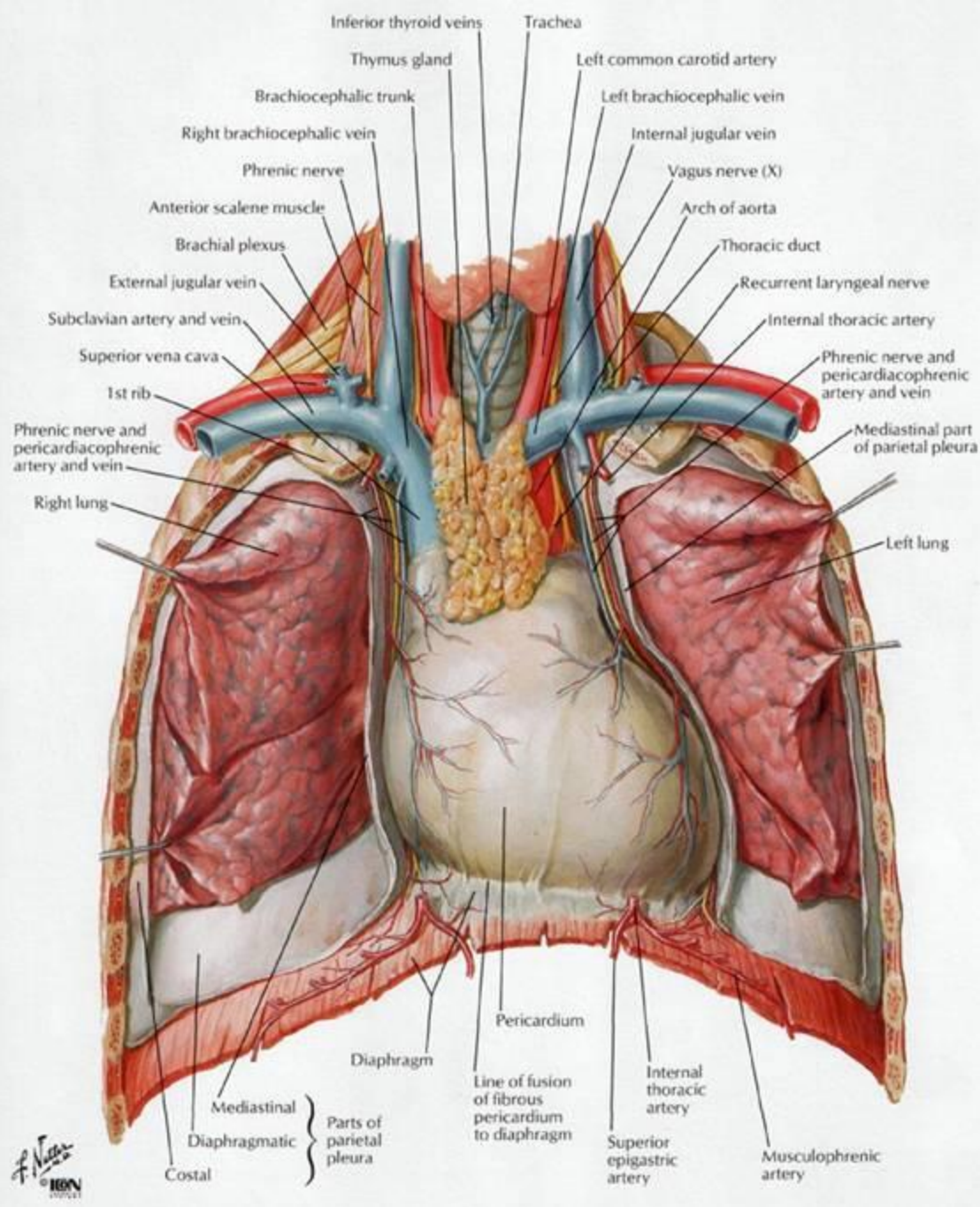
Anterior View



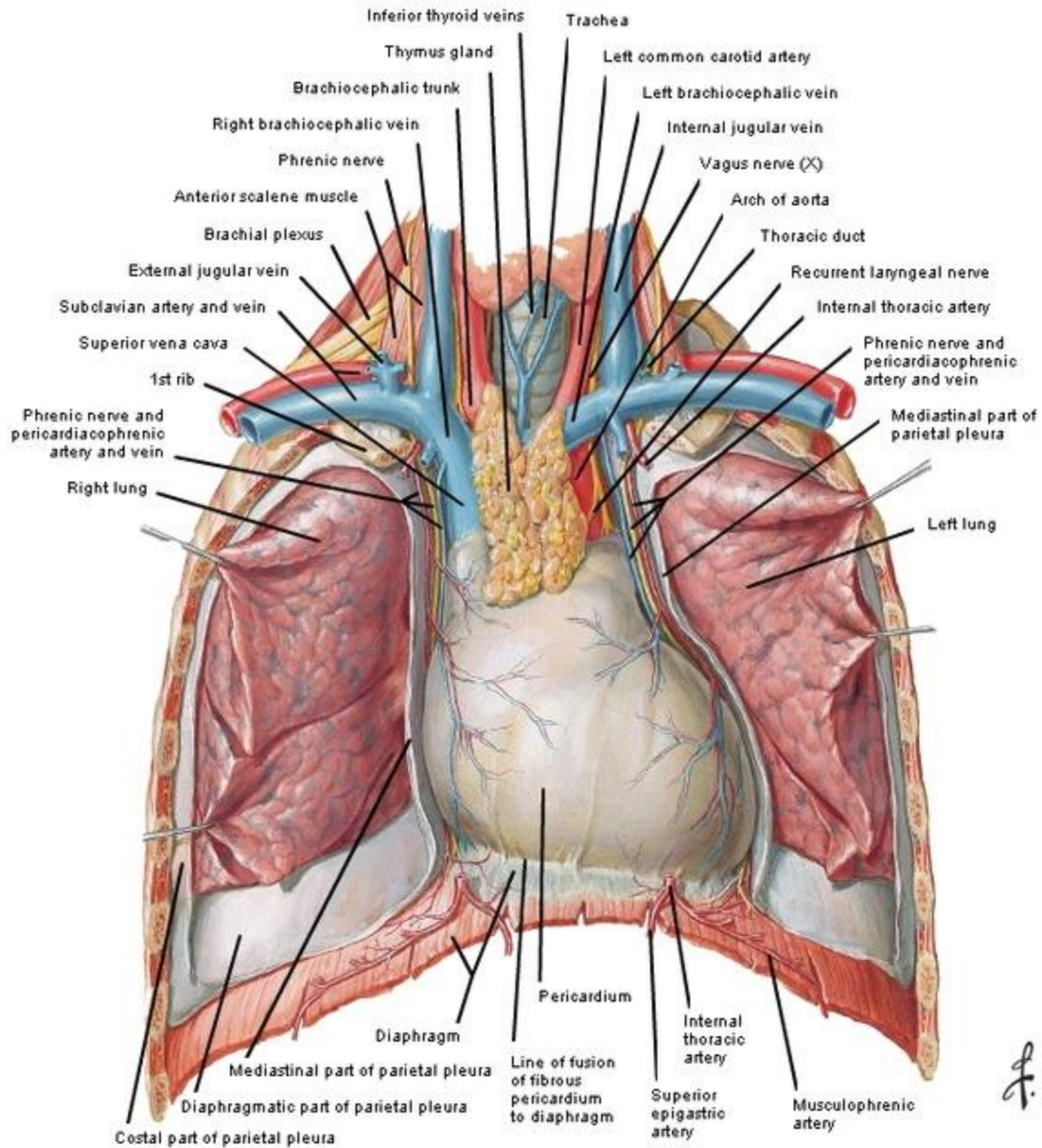
Lymph Vessels and Nodes of Esophagus





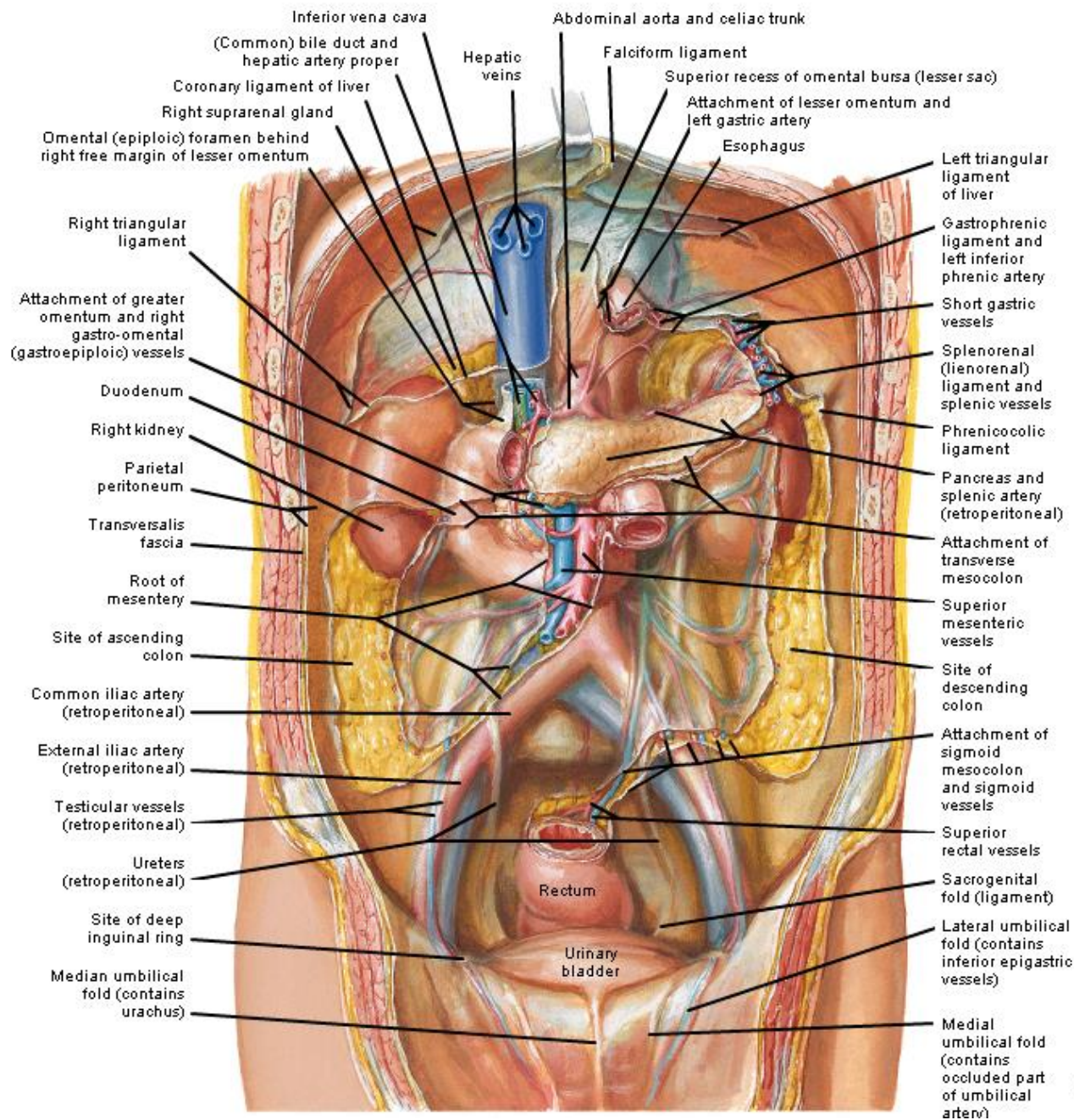


Heart In Situ



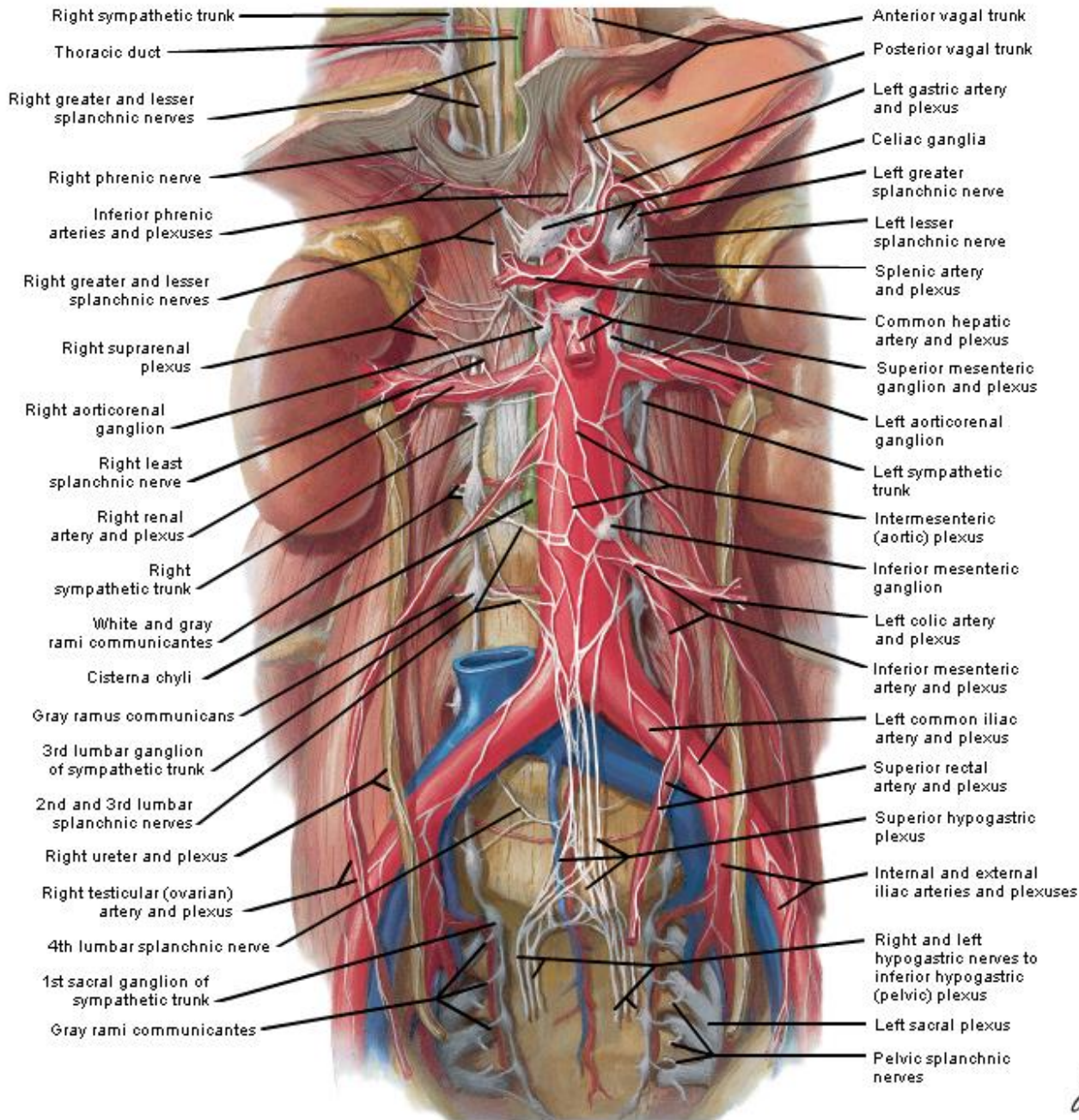
F. Netter M.D.
© IGV

Peritoneum of Posterior Abdominal Wall



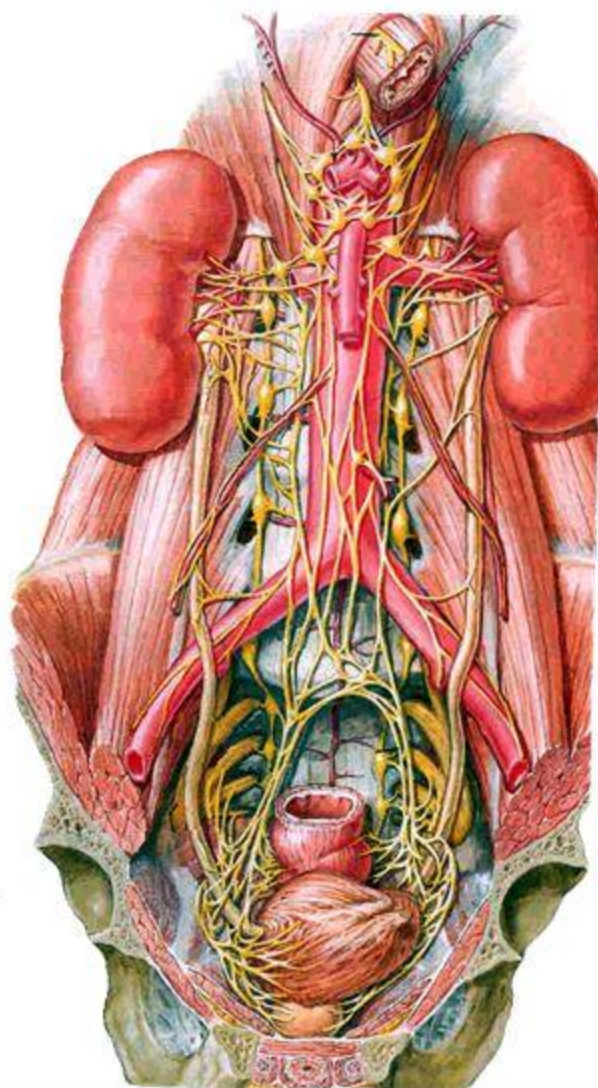
F. Netter M.D.
© H&M

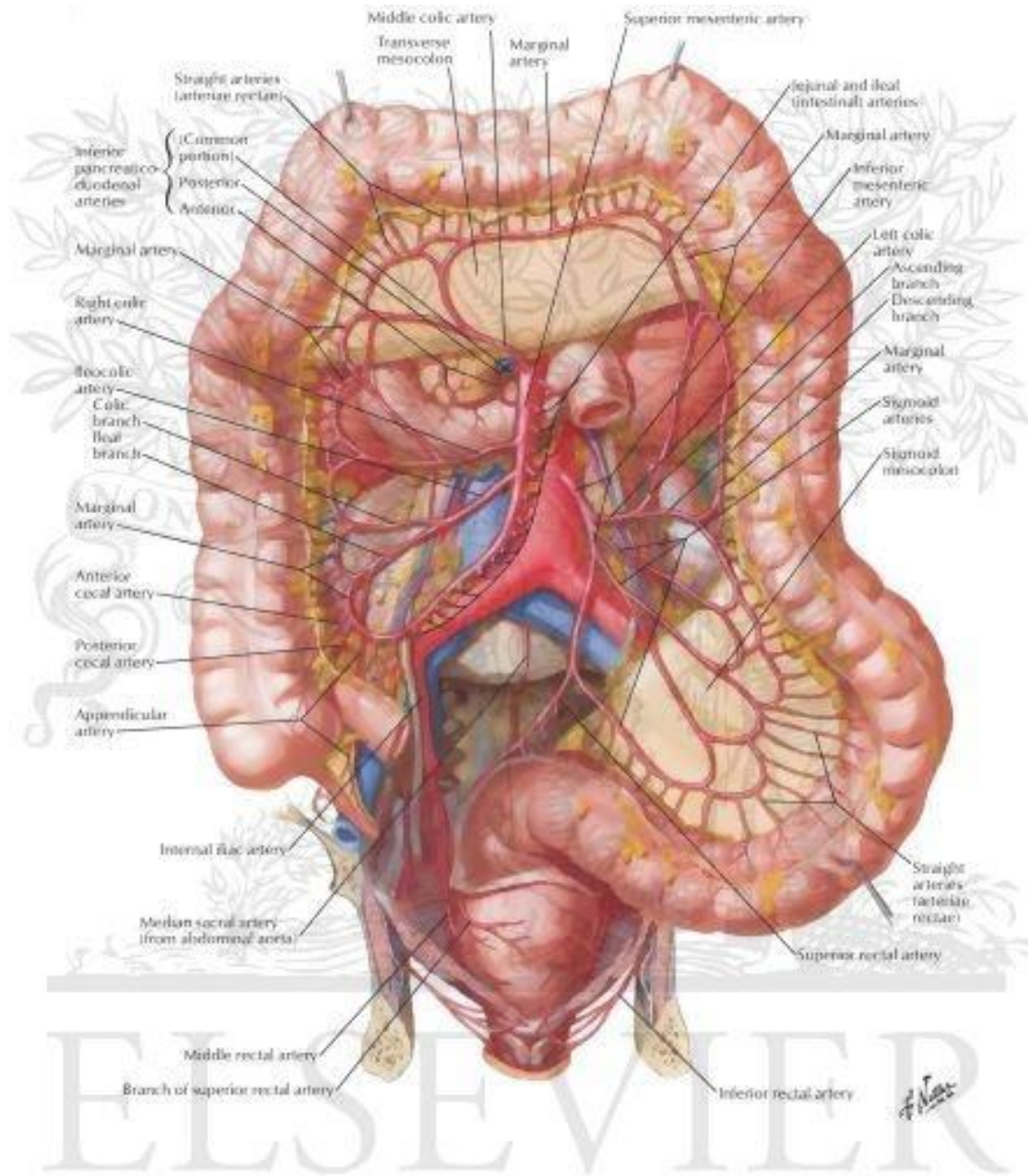
Autonomic Nerves and Ganglia of Abdomen



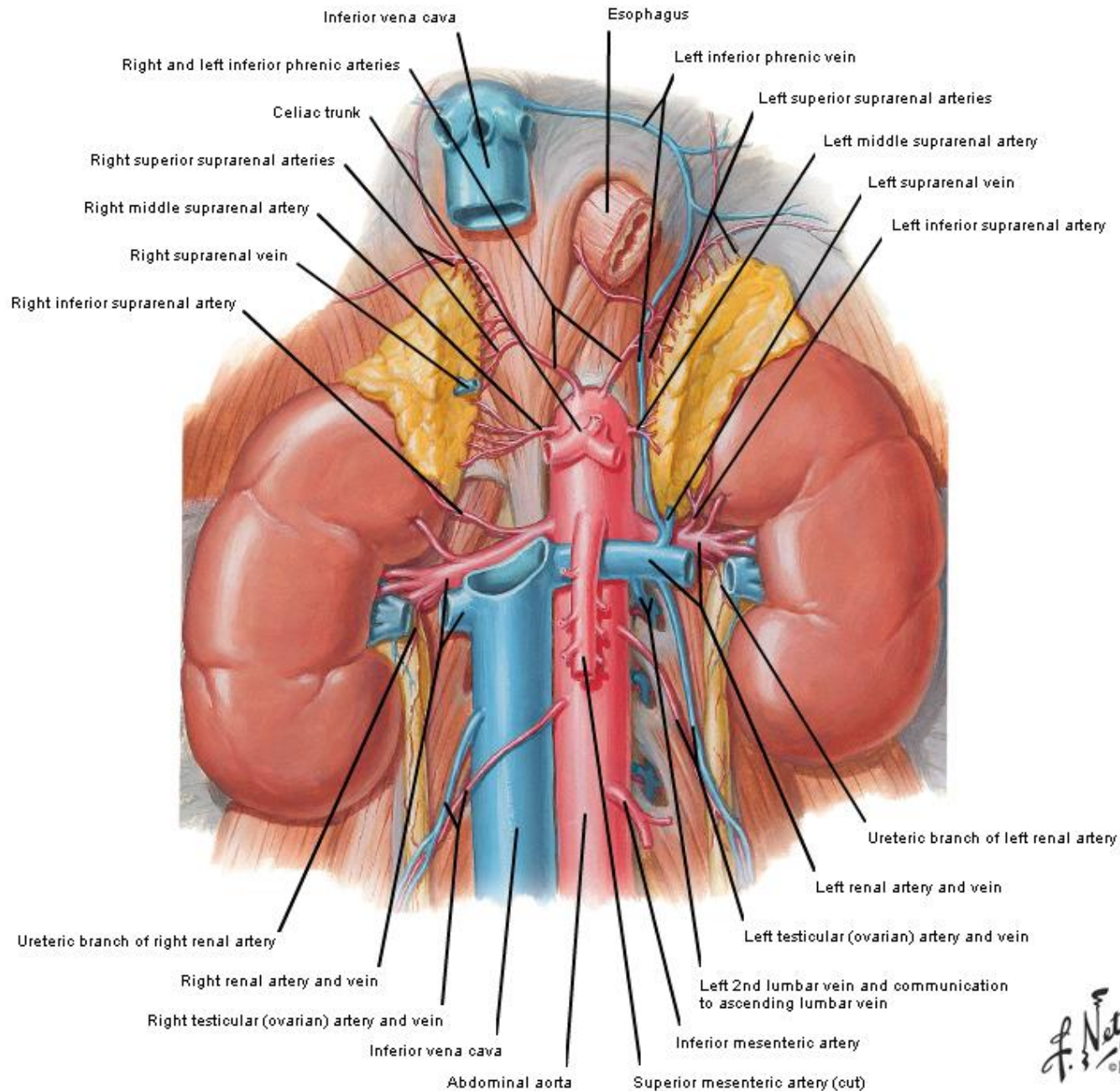
Prevertebral ganglia 椎前节

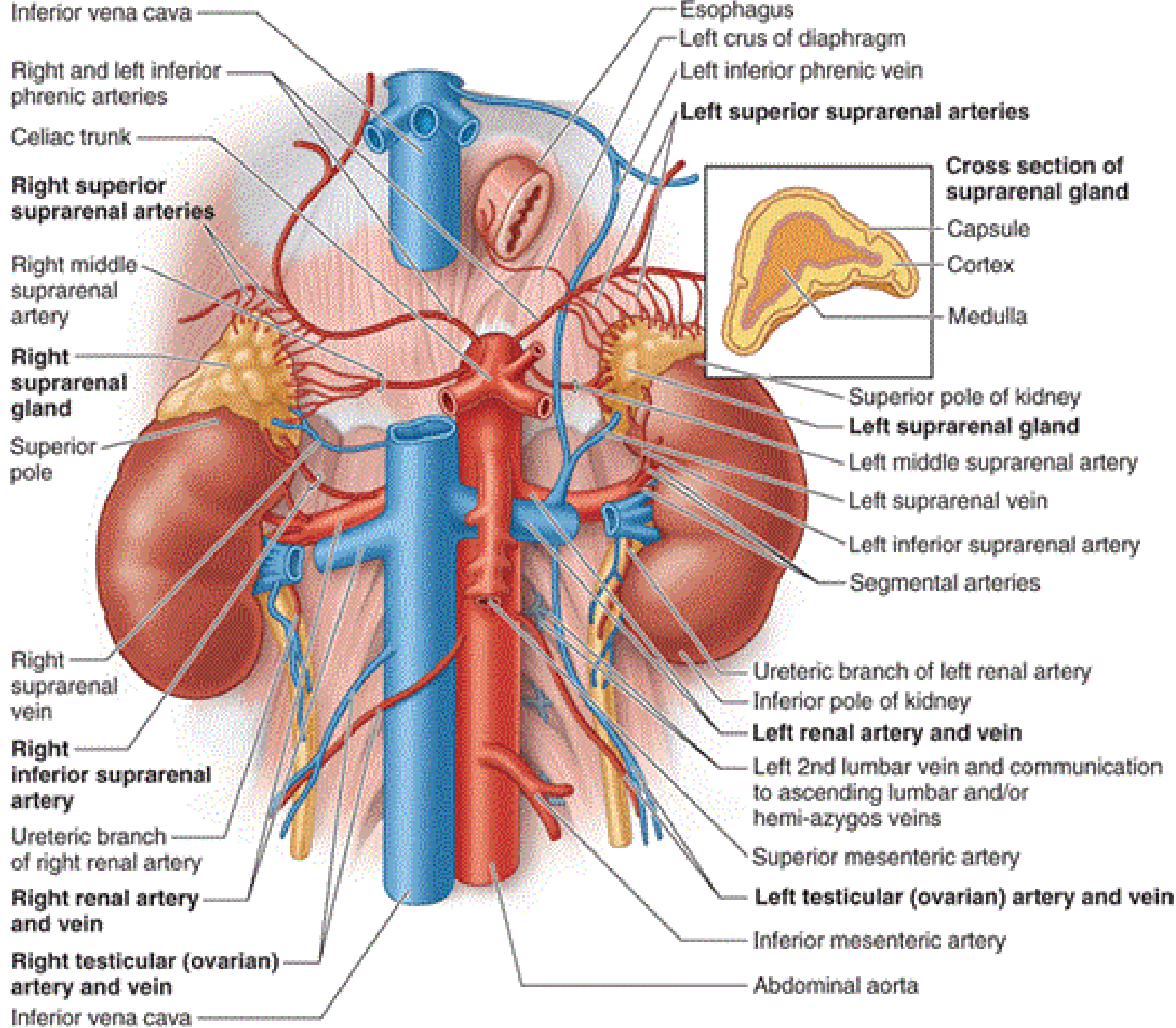
- Lie anterior to vertebral column and near the arteries for which they are named
- Celiac ganglion 腹腔神经节
- Aorticorenal ganglion 主动脉肾节
- Superior mesenteric ganglion 肠系膜上神经节
- Inferior mesenteric ganglion 肠系膜下神经节





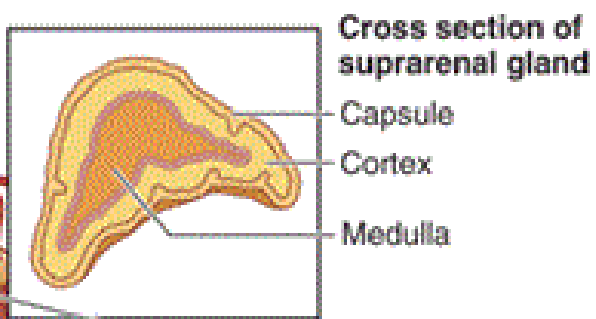
Renal Artery and Vein In Situ





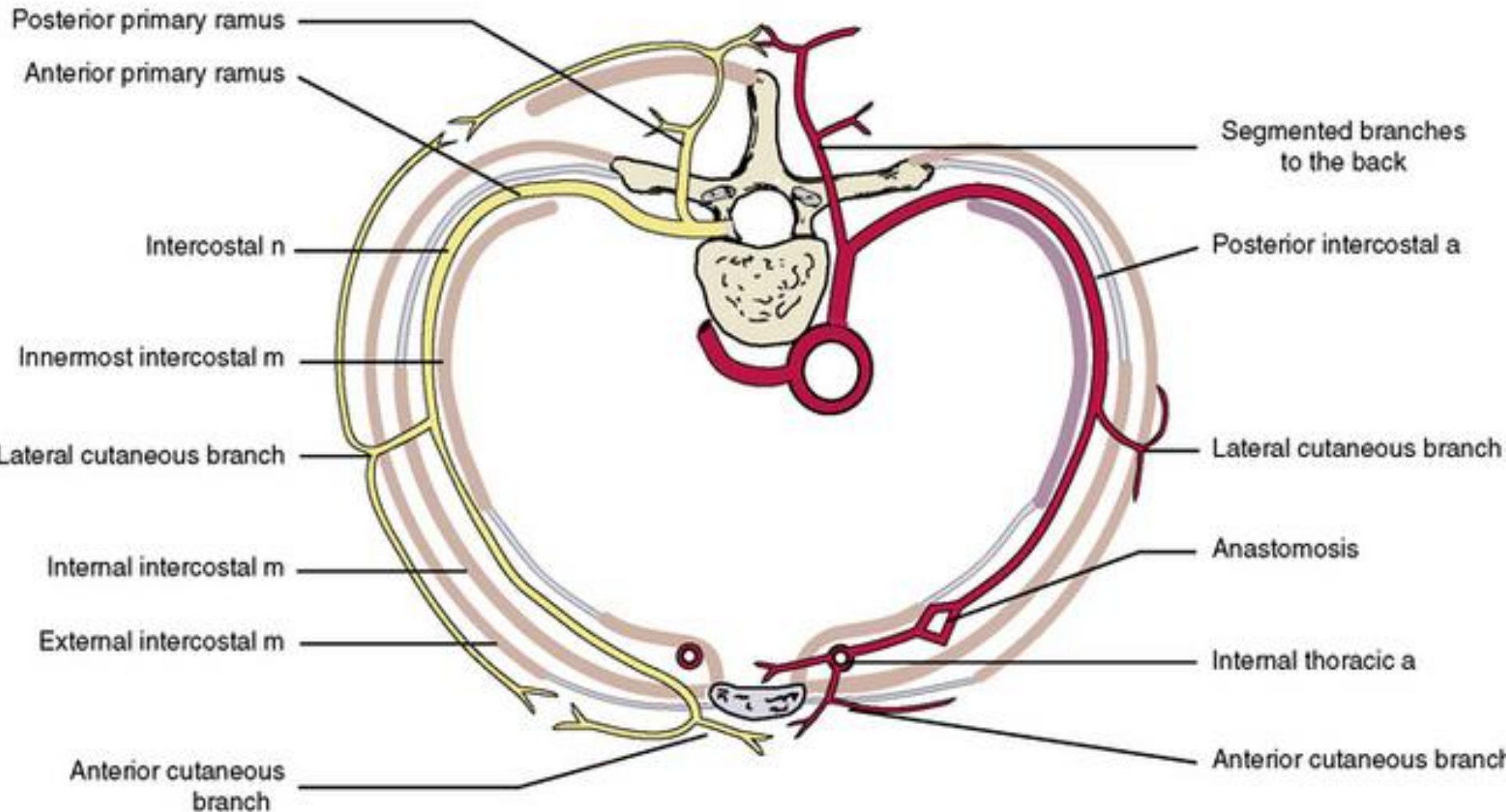
Inferior vena cava
 Right and left inferior phrenic arteries
 Celiac trunk
 Right superior suprarenal arteries
 Right middle suprarenal artery
 Right suprarenal gland
 Superior pole
 Right suprarenal vein
 Right inferior suprarenal artery
 Ureteric branch of right renal artery
 Right renal artery and vein
 Right testicular (ovarian) artery and vein
 Inferior vena cava

Esophagus
 Left crus of diaphragm
 Left inferior phrenic vein
 Left superior suprarenal arteries
 Superior pole of kidney
 Left suprarenal gland
 Left middle suprarenal artery
 Left suprarenal vein
 Left inferior suprarenal artery
 Segmental arteries
 Ureteric branch of left renal artery
 Inferior pole of kidney
 Left renal artery and vein
 Left 2nd lumbar vein and communication to ascending lumbar and/or hemi-azygos veins
 Superior mesenteric artery
 Left testicular (ovarian) artery and vein
 Inferior mesenteric artery
 Abdominal aorta

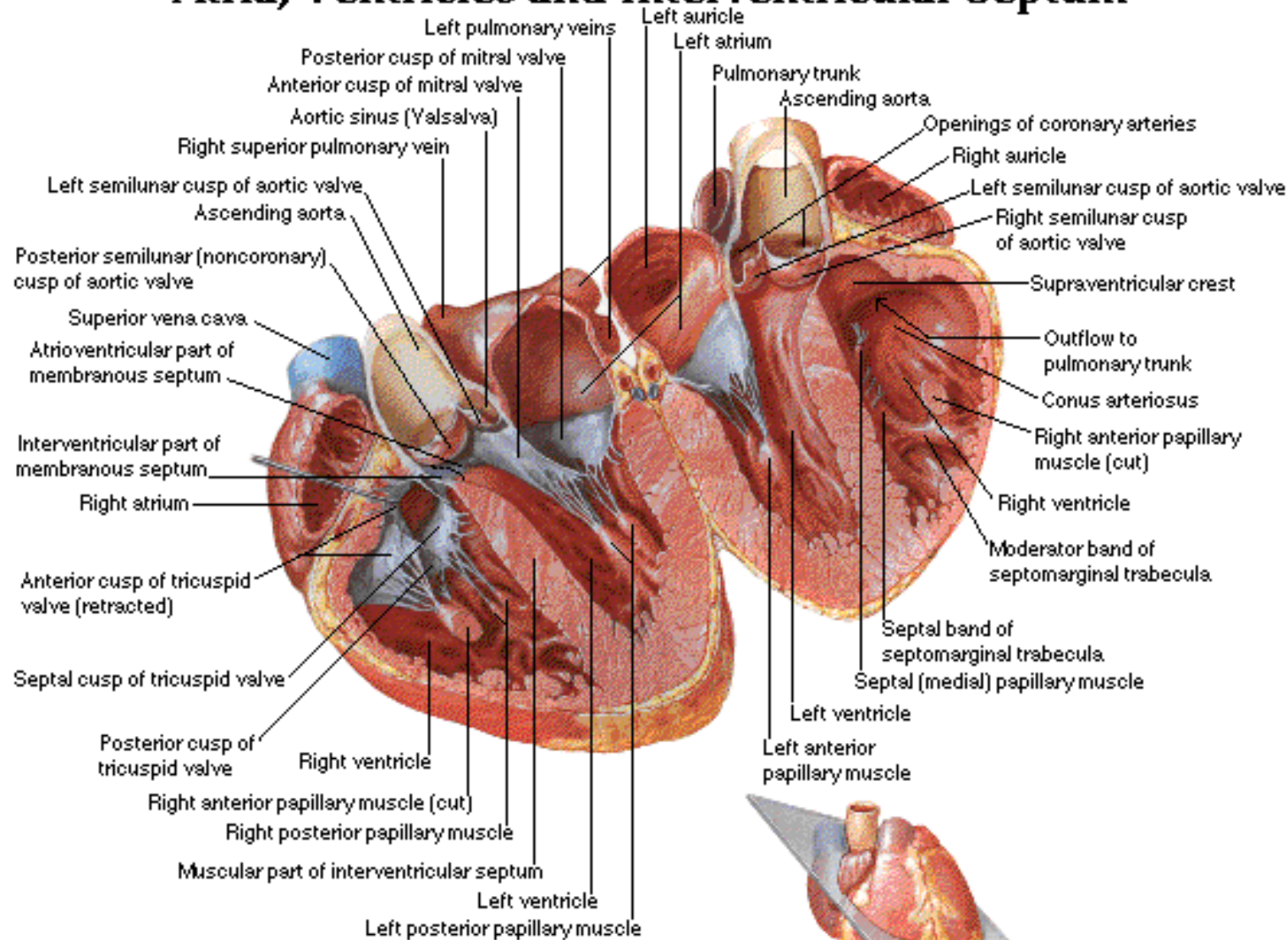


NERVES

ARTERIES



Atria, Ventricles and Interventricular Septum



Note: broken line indicates line of attachment of septal leaflet of tricuspid valve.