

# UPPER LIMB OVERVIEW

---

BY FATIMA HAIDER

KGMC

- **PALPATIONS**

1. The inferior angle of the scapula can be palpated easily in the living subject and marks the level of seventh rib and spine of seventh thoracic vertebrae
2. Acromion forms the easily palpable tip of the shoulder
3. The coracoid process can be palpated via deep pressure through the anterior part of the deltoid muscle, inferior to the lateral end of clavicle.
4. Lateral epicondyle is readily palpable.
5. Medial epicondyle is easily palpable and forms an important surface landmark in the arm
6. The ulnar nerve can be palpated and rolled against medial epicondyle
7. The olecranon is the easily palpable proximal end of the ulna that forms the “point” of the elbow
8. The posterior border of ulna is rounded and subcutaneous and easily palpable along its entire length
9. Upper Limb Arteries
  - The subclavian artery can be palpated in the root of posterior triangle of neck
  - The third part of axillary artery can be palpated in the arm as it lies on the brachialis and is overlapped from the lateral side by biceps brachii
  - The radial artery lies superficially in front of the distal end of the radius, between tendons of brachioradialis and flexor carpi radialis. This is where clinician takes the radial pulse.
  - The ulnar artery can be palpated as it crosses superficial to the flexor retinaculum in company with the ulnar nerve

- **QUADRANGULAR SPACE BOUNDARIES**

Above – Supscapularis

Teres minor

Capsule of shoulder joint

Below – Teres major

Medially – Long head of triceps brachii

Laterally – Surgical neck of humerus

- **CONTENTS OF QUADRANGULAR SPACE**

1. Axillary nerve
2. Posterior circumflex humeral artery

- **WALLS OF AXILLA**

1. Anterior Wall – Pectoralis major  
Subclavius  
Pectoralis minor
2. Posterior wall – Subscapularis  
Latissimus dorsi  
Teres major
3. Lateral wall – Coracobrachialis  
Biceps brachii
4. Medial wall – Upper four or five ribs  
Intercostal spaces covered by serratus anterior

- **CONTENTS OF AXILLA**

- Axillary artery and its branches
- Axillary vein and its tributaries
- Axillary lymph nodes
- Brachial plexus
- Short head of biceps brachii
- Coracobrachialis

- **STRUCTURES PASSING THROUGH CLAVIPECTORAL TRIANGLE**

- Cephalic vein (enters)
- Medial and lateral pectoral nerves (leaves)

- **STRUCTURES PASSING THROUGH ANTERIOR OSSEOFACIAL COMPARTMENT OF ARM**

- Musculocutaneous nerve
- Median nerve
- Ulnar nerve
- Basilica vein
- Radial nerve (in lower part of compartment)

- **STRUCTURES PASSING THROUGH POSTERIOR OSSEOFACIAL COMPARTMENT OF ARM**

- Radial nerve
- Ulnar artery
- Profunda brachii vessels

- **CUBITAL FOSSA BOUNDARIES**

Laterally – Brachioradialis

Medially – Pronator teres

Base – Imaginary line drawn between two epicondyles of humerus

Floor – Supinator muscle laterally

Brachialis muscle medially

Roof – skin and fascia, reinforced by bicipital aponeurosis

- **CONTENTS OF CUBITAL FOSSA**

From medial to lateral (Mnemonic : Really Need Beer To Be At My Nicest)

- Radial Nerve
- Biceps Tendon
- Brachial Artery (Bifurcation of brachial artery into ulnar and radial artery)
- Median Nerve

- **BOUNDARIES OF ANATOMIC SNUFFBOX**

Medially – Tendon of extensor pollicis longus

Laterally – Tendon of abductor pollicis longus

Tendon of extensor pollicis brevis

- **CONTENTS OF ANATOMIC SNUFFBOX**

- Radial artery
- Superficial branch of radial nerve
- Cephalic vein

- Two osseofacial compartments in arm i.e. anterior and posterior

- Three osseofacial compartments in forearm i.e. anterior, lateral and posterior

- **STRUCTURES PASSING SUPERFICIAL TO FLEXOR RETINACULUM:**

- Flexor carpi ulnaris tendon
- Ulnar nerve
- Ulnar artery
- Palmar cutaneous branch of ulnar nerve
- Palmaris longus tendon
- Palmar cutaneous branch of median nerve

- **STRUCTURES PASSING DEEP TO FLEXOR RETINACULUM i.e. WITHIN CARPAL TUNNEL**

(From medial to lateral)

- Flexor digitorum superficialis tendons, and deep to these the four tendons of flexor digitorum profundus
- Median nerve
- Flexor pollicis longus tendon
- Flexor carpi radialis tendon

- **STRUCTURES PASSING SUPERFICIAL TO THE EXTENSOR RETINACULUM**

(From medial to lateral)

- Dorsal (posterior) cutaneous branch of ulnar nerve
  - Basilic vein
  - Cephalic vein
  - Superficial branch of radial nerve
- **STRUCTURES PASSING DEEP TO EXTENSOR RETINACULUM WITHIN SIX EXTENSOR TENDONS**  
(From medial to lateral)
  1. Extensor carpi ulnaris tendon
  2. Extensor digiti minimi tendon
  3. Extensor digitorum and extensor indices tendons
  4. Extensor pollicis longus tendon
  5. Extensor carpi radialis longus and brevis tendons
  6. Abductor pollicis longus and extensor pollicis brevis tendons
- The **thenar space** contains the first lumbrical muscle.  
The **midpalmar space** contains the second, third and fourth lumbrical muscles.
- The lumbrical canal is a potential space surrounding the tendon of each lumbrical muscle and is normally filled with connective tissue
- **ROTATOR CUFF MUSCLES**  
Mnemonic : SITS
  - Supraspinatus
  - Infraspinatus
  - Teres minor
  - Subscapularis

Other functions of these rotator cuff muscles

- Supraspinatus – Abducts arm
  - Infraspinatus – Laterally rotates arm
  - Teres Minor – Laterally rotates arm
  - Subscapularis – Medially rotates arm
- The patient with a ruptured supraspinatus tendon is unable to initiate abduction of the arm. However, if the arm is passively assisted for the first 15° of abduction, the deltoid can take over and complete the movement to a right angle.
- The musculocutaneous nerve supplies the anterior compartment of arm, whereas the radial nerve innervates the posterior compartment of arm.
- The biceps brachii muscle is the chief supinator

- The muscles in anterior compartment of forearm produce mainly flexion or pronation. The muscles in lateral and posterior compartment of forearm produce mainly extension or supination.
- The median and ulnar nerves supply the anterior compartment of forearm. The radial nerve innervates the lateral and posterior compartments of forearm.

- **MUSCLES IN PECTORAL REGION**

- Pectoralis major
- Pectoralis minor
- Serratus anterior
- Subclavius

- **EXTRINSIC MUSCLES OF SHOULDER**

SUPERFICIAL:

- Trapezius
- Latissimus dorsi

DEEP

- Levator scapulae
- Rhomboid major
- Rhomboid minor

- **INTRINSIC MUSCLES OF SHOULDER**

- Deltoid
- Teres major
- Supraspinatus
- Infraspinatus
- Subscapularis
- Teres minor

- **MUSCLES OF ARM**

- Biceps brachii
- Brachialis
- Coracobrachialis
- Triceps brachii (Posterior)

- Muscles of **anterior compartment of forearm** are arranged in three groups:

1. Superficial Group

- Flexor carpi ulnaris

- Palmaris longus
    - Flexor carpi radialis
    - Pronator teres
  - 2. Intermediate Group
    - Flexor digitorum superficialis
  - 3. Deep Group
    - Flexor digitorum profundus
    - Flexor pollicis longus
    - Pronator quadratus
- Muscles in **lateral compartment of forearm**
    - Brachioradialis
    - Extensor carpi radialis longus
  - Muscles of **posterior compartment of forearm** are arranged in two groups:
    1. Superficial Group
      - Extensor carpi radialis brevis
      - Extensor digitorum
      - Extensor digiti minimi
      - Extensor carpi ulnaris
      - Anconeus
    2. Deep Group
      - Supinator
      - Abductor pollicis longus
      - Extensor pollicis brevis
      - Extensor pollicis longus
      - Extensor indices
  - Both extrinsic and intrinsic muscles of hand are organized in five osseofascial compartments
    1. Thenar
    2. Hypothenar
    3. Central / Midpalmar
    4. Interosseous
    5. Dorsal / Extensor

The first four compartments are located in palmar aspects. While the dorsal compartment is in the dorsum of hand
  - **THENAR COMPARTMENT** (innervated by median nerve)
    - Flexor pollicis brevis
    - Abductor pollicis brevis
    - Opponens pollicis

- **HYPOTHENAR COMPARTMENT**
  - Flexor digiti minimi
  - Abductor digiti minimi
  - Opponens digiti minimi
- **CENTRAL (MIDPALMAR) COMPARTMENT**
  - Tendons of flexor digitorum superficialis, flexor digitorum profundus and flexor pollicis longus
  - Lumbrical muscles
- **INTEROSSEOUS COMPARTMENT**
  - Adductor pollicis
  - Palmar interossei
  - Dorsal interossei
- **DORSAL (EXTENSOR) COMPARTMENT**
  - Tendons of long digital extensors
  
- Lumbricals – Four muscles  
Dorsal interossei – Four muscles  
Palmar interossei – Three muscles
  
- The brachial plexus and the axillary artery and vein are enclosed together in a connective tissue wrapping termed the **axillary sheath**.
  
- Brachial Plexus nerves arising from
  1. ROOTS
    - Dorsal scapular nerve (C<sub>5</sub>)
    - Long thoracic nerve (C<sub>5</sub>, C<sub>6</sub>, C<sub>7</sub>)
  2. UPPER TRUNK
    - Nerve to subclavius (C<sub>5</sub>, C<sub>6</sub>)
    - Suprascapular nerve (C<sub>5</sub>, C<sub>6</sub>)
  3. LATERAL CORD (Mnemonic : Lucy Loves Me)
    - Lateral pectoral nerve (C<sub>5</sub>, C<sub>6</sub>, C<sub>7</sub>)
    - Musculocutaneous nerve (C<sub>5</sub>, C<sub>6</sub>, C<sub>7</sub>)
    - Lateral root of median nerve (C<sub>5</sub>, C<sub>6</sub>, C<sub>7</sub>)
  4. MEDIAL CORD (Mnemonic : M4U)
    - Medial pectoral nerve (C<sub>8</sub>, T<sub>1</sub>)
    - Medial cutaneous nerve of arm (C<sub>8</sub>, T<sub>1</sub>, T<sub>2</sub>)
    - Medial cutaneous nerve of forearm (C<sub>8</sub>, T<sub>1</sub>)
    - Ulnar nerve (C<sub>8</sub>, T<sub>1</sub>)
    - Medial root of median nerve (C<sub>5</sub> – T<sub>1</sub>)
  5. POSTERIOR CORD (Mnemonic : STAR)
    - Upper and lower subscapular nerves (C<sub>5</sub>, C<sub>6</sub>)

- Thoracodorsal nerve (C<sub>6</sub>, C<sub>7</sub>, C<sub>8</sub>)
- Axillary nerve (C<sub>5</sub>, C<sub>6</sub>)
- Radial nerve (C<sub>5</sub> – T<sub>1</sub>)

- **Brachial plexus**

Mnemonic : Remember To Drink Cold Beer

- Roots (C<sub>5</sub> – T<sub>1</sub>)
- Trunks
  - Upper Trunk (C<sub>5</sub>, C<sub>6</sub>)
  - Middle Trunk (C<sub>7</sub>)
  - Lower Trunk (C<sub>8</sub>, T<sub>1</sub>)
- Divisions
  - Anterior and posterior divisions of each trunk
- Cords
  - Lateral Cord: Anterior divisions of upper and middle trunks
  - Medial Cord: Anterior division of lower trunk
  - Posterior Cord: Posterior divisions of all trunks
- Branches

- **AXILLARY NERVE SUPPLIES**

- Shoulder joint
- Deltoid
- Teres minor
- Upper lateral cutaneous nerve of arm

- The profunda brachii vessels accompany radial nerve in the radial groove

- **RADIAL NERVE SUPPLIES**

- Lateral and medial heads of triceps
- Anconeus
- Brachialis
- Brachioradialis
- Extensor carpi radialis longus
- Lower lateral cutaneous nerve of arm supplies skin over lateral and anterior aspects of lower part of arm
- Posterior cutaneous nerve of arm
- Posterior cutaneous nerve of forearm
- Elbow joint
- Superficial branch of radial nerve is a posterior cutaneous nerve to the wrist and hand and supplies lateral two-third of dorsum of hand and posterior surface over proximal phalanges of lateral three and a half fingers



- Deep branch supplies
      - Extensor carpi radialis brevis
      - Supinator
      - Extensor digitorum
      - Extensor digiti minimi
      - Extensor carpi ulnaris
      - Abductor pollicis longus
      - Extensor pollicis brevis
      - Extensor pollicis longus
      - Extensor indices
  
- The **median nerve** supplies all the muscles of the anterior compartment of forearm except the flexor carpi ulnaris and medial half of flexor digitorum profundus, which are supplied by ulnar nerve
 

In the palm, the median nerve supplies the muscles of the thenar compartment and the first two lumbricals and gives sensory innervation to the skin of the palmar aspect of lateral three and a half fingers, including nail beds of dorsum
  
- The **ulnar nerve** does not give off cutaneous or motor branches in the axilla or in the arm. It provides motor branches to the flexor carpi ulnaris and medial half of flexor digitorum profundus as it enters the forearm from behind the medial epicondyle.
 

Next, it gives off its palmar and posterior cutaneous branches in the distal third of the forearm. The palmar cutaneous branch supplies skin over the hypothenar eminence. The posterior cutaneous branch supplies skin over medial third of the dorsum of the hand and medial one and a half fingers. It does not supply skin over the distal part of the dorsum of these fingers.

Having entered the palm by passing superficial to the flexor retinaculum, the superficial branch of ulnar nerve supplies skin of the palmar surface of medial one half fingers, including their nail beds. It also supplies the palmaris brevis muscle.

The deep branch of the ulnar nerve supplies all the small muscles of hand except the muscles of thenar compartment and the first two lumbricals, which are supplied by median nerve
  
- **AXILLARY LYMPH NODES**
  1. **Anterior (Pectoral) Group:**

This group receives vessels from:

    - Lateral quadrants of breast
    - Superficial vessels from anterolateral abdominal wall above the level of umbilicus
  2. **Posterior (Subscapular) Group:**

This group receives lymph vessels from the back, down as far as the level of iliac crests
  3. **Lateral (Humeral) Group:**

This group receives most of the lymph vessels from most of the upper limb (except the superficial vessels draining the lateral side)

**4. Central Group:**

This group receives lymph from the above three groups

**5. Infraclavicular (Deltopectoral) Group:**

This group receives superficial lymph vessels from lateral side of hand, forearm and arm

**6. Apical Group**

Receives lymph vessels from all other axillary nodes

• **TYPES OF JOINTS**

1. Sternoclavicular Joint – Synovial double-plane joint
2. Acromioclavicular Joint – Synovial plane joint
3. Glenohumeral Joint – Synovial ball-and-socket joint
4. Elbow Joint – Synovial hinge joint
5. Proximal radioulnar Joint – Synovial pivot joint
6. Distal radioulnar Joint – Synovial pivot joint
7. Wrist Joint – Synovial ellipsoid joint
8. Intercarpal Joints – Synovial plane joint
9. Carpometacarpal Joint of thumb – Synovial saddle-shaped joint
10. Metacarpophalangeal Joint – Synovial condyloid joint
11. Interphalangeal Joint – Synovial hinge joint

• **MUSCLE INNERVATIONS**

1. Pectoralis major – medial and lateral pectoral nerves
2. Pectoralis minor – medial pectoral nerve
3. Subclavius – Nerve to subclavius
4. Serratus anterior – Long thoracic nerve
5. Trapezius – Spinal accessory nerve
6. Latissimus dorsi – Thoracodorsal nerve
7. Levator scapula – Dorsal scapular nerve
8. Rhomboid minor - Dorsal scapular nerve
9. Rhomboid major - Dorsal scapular nerve
10. Deltoid – Axillary nerve
11. Supraspinatus – Suprascapular nerve
12. Infraspinatus - Suprascapular nerve
13. Teres major – Lower subscapular nerve
14. Teres minor – Axillary nerve
15. Subscapularis – Upper and Lower subscapular nerves
16. Biceps brachii – Musculocutaneous nerve
17. Coracobrachialis - Musculocutaneous nerve
18. Brachialis - Musculocutaneous nerve
19. Triceps brachii – Radial nerve

20. Pronator teres – Median nerve
21. Flexor carpi radialis - Median nerve
22. Palmaris longus - Median nerve
23. Flexor digitorum superficialis - Median nerve
24. Flexor carpi ulnaris – Ulnar nerve
25. Flexor pollicis longus – Anterior interosseous branch of Median nerve
26. Pronator Quadratus - Anterior interosseous branch of Median nerve
27. Flexor digitorum profundus – Ulnar (medial half) and median (lateral half) nerves
28. Brachioradialis – Radial nerve
29. Extensor carpi radialis longus – Radial nerve
30. All muscles of posterior forearm – Deep branch of radial nerve
31. Thenar compartment – Median nerve (Recurrent branch)
32. Hypothenar compartment – Ulnar nerve (Deep branch)
33. Central (Midpalmar) compartment – Median nerve, deep branch of ulnar nerve
34. Interosseous compartment – Deep branch of ulnar nerve
35. Dorsal (Extensor) compartment – No intrinsic motor nerves
36. Palmaris brevis – Superficial branch of ulnar nerve
37. Lumbricals – Median nerve supplies lateral two i.e. first and second lumbrical  
Deep branch of Ulnar nerve supplies third and fourth lumbrical
38. Abductor pollicis brevis – median nerve
39. Flexor pollicis brevis – median nerve
40. Opponens pollicis – median nerve
41. Adductor pollicis – Deep branch of ulnar nerve

• **LIGAMENTS THAT STRENGTHEN DIFFERENT JOINTS:**

1. Sternoclavicular Joint  
Ligament: Sternoclavicular ligament  
Accessory ligament: Costoclavicular ligament
2. Acromioclavicular Joint  
Ligaments: Superior and inferior acromioclavicular ligaments  
Accessory ligament: Coracoclavicular Ligament
3. Glenohumeral Joint  
Ligament: Glenohumeral Ligaments  
Transverse humeral ligament  
Coracohumeral Ligament  
Accessory ligament: Coracoacromial ligament
4. Elbow Joint Ligaments
  - Lateral collateral ligament
  - Anular Ligament
  - Medial collateral Ligament
5. Proximal Radioulnar Joint Ligament
  - Anular Ligament

6. Distal Radioulnar Joint Ligaments
  - Anterior and posterior ligaments
7. Wrist Joint Ligaments
  - Anterior and posterior ligaments
  - Medial Ligament
  - Lateral Ligament
8. Intercarpal Joints Ligaments
  - Anterior, posterior, interosseous Ligaments
9. Metacarpophalangeal Joints Ligaments
  - Palmar Ligaments
  - Deep transverse metacarpal Ligaments
  - Collateral Ligaments

- **PULSE POINTS**

Peripheral pulses can be felt at six locations in the upper limb

1. Axillary pulse
2. Brachial pulse in arm
3. Brachial pulse in cubital fossa
4. Radial pulse in distal forearm
5. Ulnar pulse in distal forearm
6. Radial pulse in anatomic snuffbox

- **BRANCHES OF BRACHIAL ARTERY**

- Muscular branches to anterior compartment of arm
- Nutrient artery to humerus
- Profunda brachii artery
- Superior ulnar collateral artery
- Inferior ulnar collateral artery

- **BRANCHES OF AXILLARY ARTERY**

- Superior thoracic artery
- Thoracoacromial artery
- Lateral thoracic artery
- Subscapular artery
- Anterior circumflex humeral artery
- Posterior circumflex humeral artery

- All muscles in anterior compartment of forearm are innervated by median nerve, except for flexor carpi ulnaris and medial part of flexor digitorum profundus which are innervated by ulnar nerve.

- The superficial group of muscles of anterior compartment of forearm possess a common tendon of origin, which is attached to medial epicondyle of humerus  
(Superficial muscles include pronator teres, flexor carpi radialis, palmaris longus, flexor carpi ulnaris)
- The superficial group of posterior compartment of forearm possess a common tendon of origin, which is attached to lateral epicondyle of humerus  
(these muscles include extensor digitorum, extensor digiti minimi, extensor radialis brevis, extensor carpi ulnaris, anconeus)
- **ULNAR NERVE**  
Originates from medial cord of brachial plexus in the axilla. It runs downward on medial side of brachial artery as far as middle of arm. Here, at insertion of coracobrachialis, the nerve enters posterior compartment of arm. The nerve passes behind medial epicondyle of humerus. Ulnar nerve crosses medial border of elbow joint and enters the front of forearm by passing between two heads of flexor carpi ulnaris. Ulnar nerve enters the palm of hand by passing in front of flexor retinaculum and lateral to pisiform bone
- **RADIAL NERVE**  
On leaving the axilla, the radial nerve immediately enters the posterior compartment of arm and enters the anterior compartment just above the lateral epicondyle.  
At the level of lateral epicondyle, it divides into superficial and deep branches.  
Deep branch winds around neck of radius and enters posterior compartment  
Superficial branch is the direct continuation of the radial nerve.  
The superficial branch:
  - Supplies lateral compartment of arm
  - Reaches posterior surface of wrist
  - Supplies lateral two-thirds of posterior surface of hand
  - Posterior surface over proximal phalanges of lateral three and a half fingers
- **RADIAL ARTERY**  
Radial artery arise from bifurcation of brachial artery in the cubital fossa. It runs distally on anterior part of forearm.  
The radial artery enters the hand dorsally, crossing the floor of anatomic snuffbox.
- **BRACHIAL PLEXUS INJURIES**  
Brachial plexus can be injured in many ways – from pressure, stress or being stretched too far. The nerves may also be cut or damaged by cancer or radiation treatment. Sometimes, brachial plexus injuries happen to babies during birth.

### UPPER TRUNK PALSY

Upper-trunk palsy occurs when the angle between the shoulder and the neck forcibly widens, such as when a fall forces the shoulder down and the head to the opposite side.

Patients with upper-trunk palsies are unable to use the shoulder to raise the arm away from the body, have weakness in the arm, and may be unable to bend the arm at the elbow. There may be loss of sensation in the shoulder, outside of the arm, and the thumb. A severe upper-trunk injury may paralyze the shoulder muscles (deltoid muscle and rotator cuff), as well as the muscle in the upper arm (biceps.)

### **LOWER TRUNK PALSY**

Lower-trunk palsy occurs when the angle between the arm and the chest wall forcibly widens. This may damage the lower nerves and the lower trunks.

Patients with a lower-trunk palsy will typically maintain shoulder and elbow strength, but will lose hand function. Over time, this will cause the fingers to contract into a claw position, and the patient will not be able to perform fine motor tasks. Patients also typically have hand numbness in at least the ring finger and small finger.

- **MOVEMENTS OF WRIST JOINT**
  - Extension and abduction of wrist – Extensor carpi radialis longus and brevis
  - Flexion and adduction of wrist – Flexor carpi ulnaris
  
- PAD – Palmar interossei Adduct fingers  
DAB – Dorsal interossei Abduct fingers
  
- Ape hand seen in median nerve injury (Thenar eminence wastage)  
Claw hand seen in ulnar nerve injury  
Waiter's tip hand seen in Erb's palsy  
Wrist drop seen in radial nerve injury
  
- **Muscles with dual nerve supply:**
  1. Pectoralis major muscle – Medial pectoral nerve and lateral pectoral nerve
  2. Subscapularis muscle – Upper and lower subscapular nerve
  3. Brachialis – Musculocutaneous and radial nerve
  4. Flexor digitorum profundus – Anterior interosseous branch of median nerve and ulnar nerve

# ORIGIN AND INSERTION OF MUSCLES OF UPPER LIMB

---

BY FATIMA HAIDER

KGMC

## 1. TRAPEZIUS

ORIGIN – occipital bone

Ligamentum nuchae (C<sub>1</sub> to C<sub>7</sub>)

Spinous process (T<sub>1</sub> to T<sub>12</sub>)

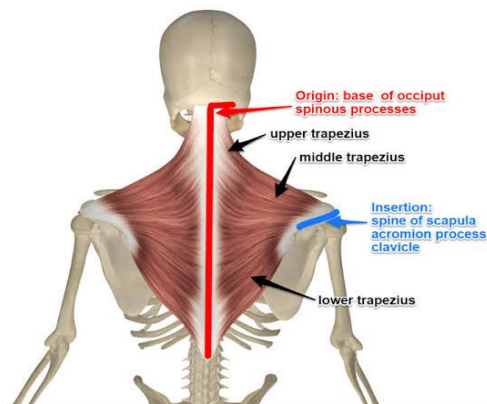
INSERTION – lateral third of clavicle

Acromion of scapula

Scapular spine of scapula

INNERVATION – motor spinal part of accessory nerve (XI)

Sensory anterior rami of C<sub>3</sub> and C<sub>4</sub>



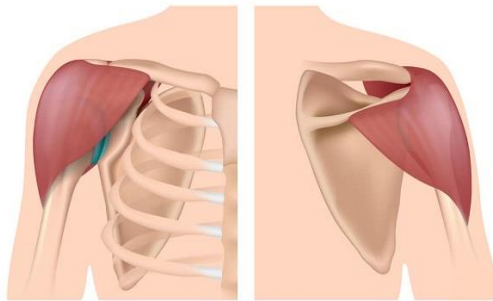
## 2. DELTOID

ORIGIN – scapula and clavicle

INSERTION – deltoid tuberosity of humerus

INNERVATION – axillary nerve

## Deltoid Muscle



Anterior view

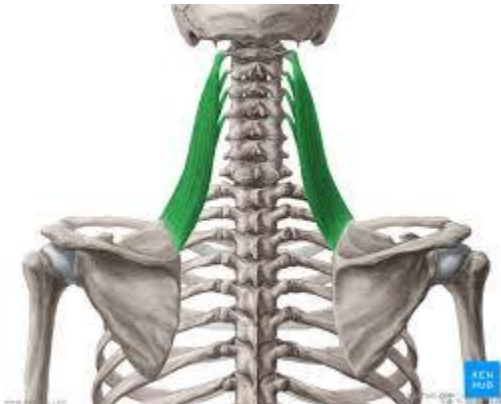Posterior view

### 3. **LEVATOR SCAPULAE**

ORIGIN – transverse process of C<sub>1</sub> to C<sub>5</sub> vertebrae

INSERTION – medial border and superior angle of scapula

INNERVATION – branches directly from anterior rami of C<sub>3</sub> and C<sub>4</sub> spinal nerves and by branches (C<sub>5</sub>) from dorsal scapular nerve



### 4. **RHOMBOID MINOR**

ORIGIN – spines of C<sub>8</sub> and T<sub>1</sub>

INSERTION – medial border of scapula

INNERVATION – dorsal scapular nerve (C<sub>4</sub>, C<sub>5</sub>)

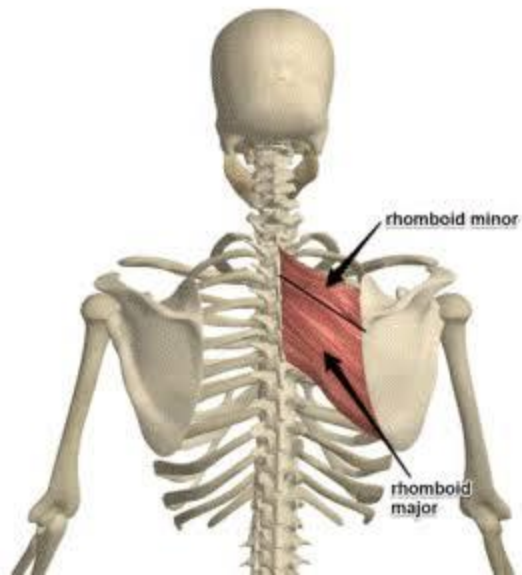
### 5. **RHOMBOID MAJOR**

ORIGIN – spinous processes T<sub>2</sub>-T<sub>5</sub>

INSERTION – medial border of scapula down towards the inferior angle

INNERVATION - dorsal scapular nerve (C<sub>4</sub>, C<sub>5</sub>)



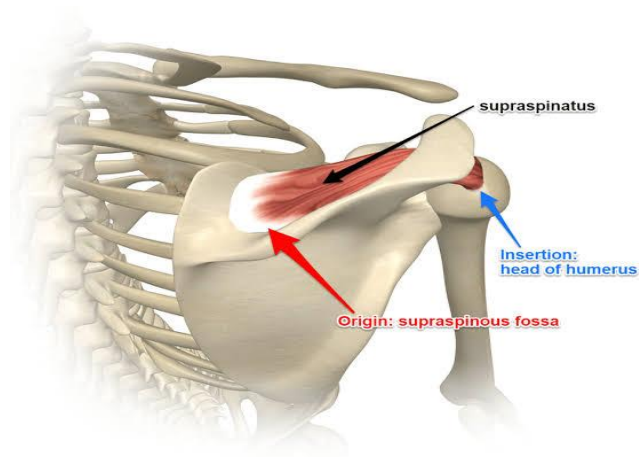


**6. SUPRASPINATUS**

ORIGIN – supraspinous fossa of scapula

INSERTION – superior facet of greater tubercle of humerus

INNERVATION – suprascapular nerve (C<sub>5</sub>, C<sub>6</sub>)

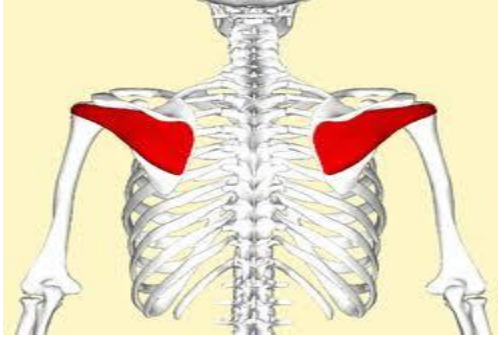


**7. INFRASPINATUS**

ORIGIN – infraspinous fossa of scapula

INSERTION - middle facet of greater tubercle of humerus

INNERVATION - suprascapular nerve (C<sub>5</sub>, C<sub>6</sub>)

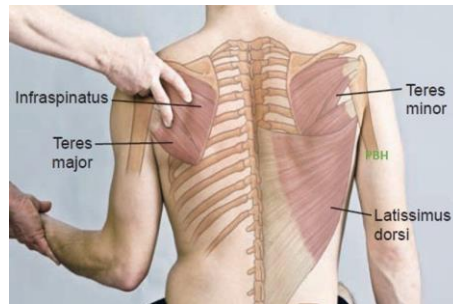
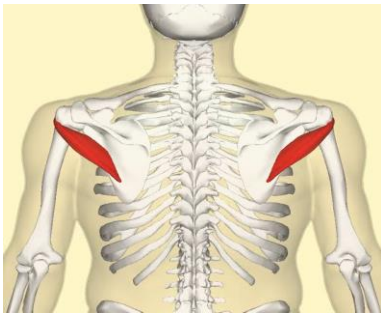


**8. TERES MINOR**

ORIGIN – lateral border of scapula

INSERTION – inferior facet of greater tubercle of humerus

INNERVATION – Axillary nerve (C<sub>5</sub>, C<sub>6</sub>)

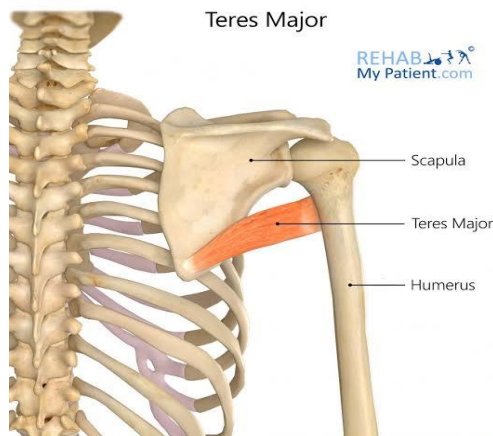


**9. TERES MAJOR**

ORIGIN – dorsal surface of inferior angle and lower part of lateral border of scapula

INSERTION – medial lip of intertubercular sulcus on anterior surface of humerus

INNERVATION – inferior subscapular nerve



**10. TRICEPS BRACHII**

**Long Head Origin** – infraglenoid tubercle of scapula

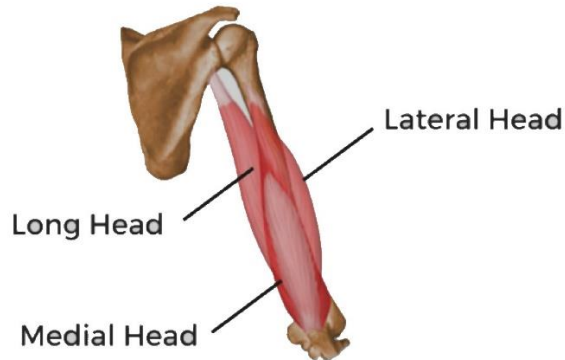
**Lateral Head Origin** – lateral and posterior surfaces of the humerus above the radial groove and lateral intermuscular septum

**Medial Head Origin** – posterior surface of humerus below the radial groove and from the medial intermuscular septum

**Insertion** – posterior surface of olecranon process of ulna, capsule of elbow joint and antebrachial fascia.

INNERVATION OF LONG HEAD– Radial nerve (C<sub>6</sub>, C<sub>7</sub>, C<sub>8</sub>)

## Triceps Brachii



### 11. PECTORALIS MAJOR (pecs)

Origin of Clavicular head – medial half of clavicle

Origin of sternocostal head – anterior surface of sternum

First seven costal cartilages

Sternal end of sixth rib

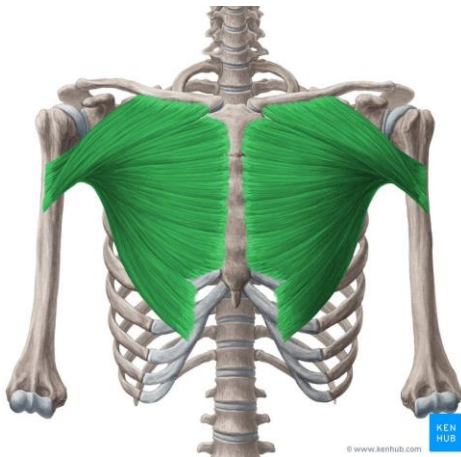
Aponeurosis of external oblique muscle

INSERTION – lateral lip of intertubercular sulcus of humerus

INNERVATION – medial and lateral pectoral nerves

Clavicular head (C<sub>5</sub>, C<sub>6</sub>)

Sternocostal head (C<sub>6</sub>, C<sub>7</sub>, C<sub>8</sub>, T<sub>1</sub>)

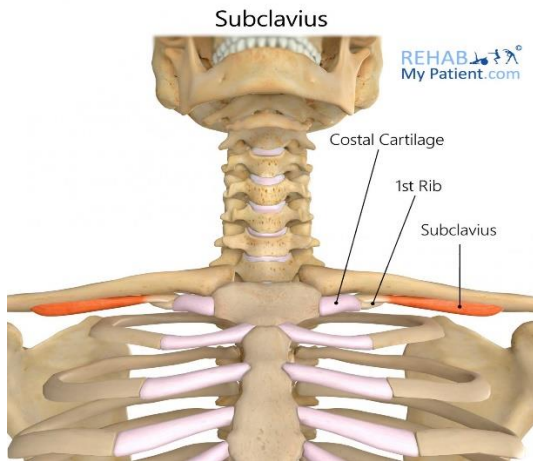


### 12. SUBCLAVIUS

ORIGIN – first rib at junction between rib and costal cartilage

INSERTION – groove on inferior surface of middle one-third of clavicle

INNERVATION – nerve to subclavius (C<sub>5</sub>, C<sub>6</sub>)

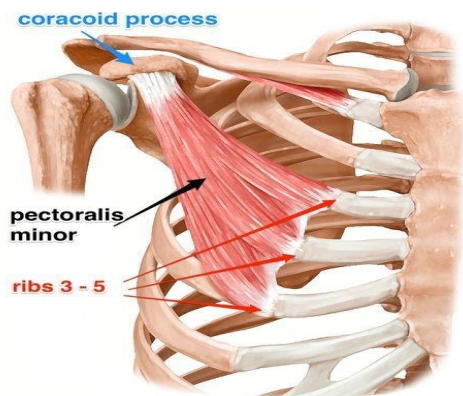


**13. PECTORALIS MINOR**

ORIGIN – 3<sup>rd</sup> to 5<sup>th</sup> rib

INSERTION – coracoid of scapula

INNERVATION – medial pectoral nerve (C<sub>5</sub>, C<sub>6</sub>, C<sub>7</sub>, C<sub>8</sub>, T<sub>1</sub>)

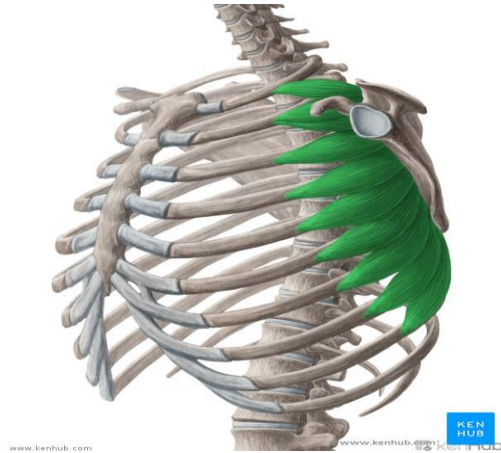
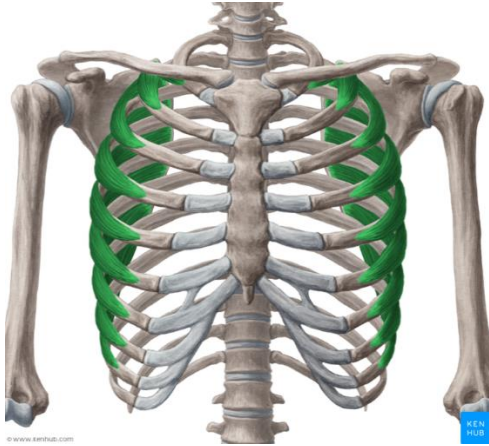


**14. SERRATUS ANTERIOR**

ORIGIN – lateral surfaces of upper 8-9 ribs and deep fascia overlying the related intercostal spaces

INSERTION – costal surface of medial border of scapula

INNERVATION – long thoracic nerve (C<sub>5</sub>, C<sub>6</sub>, C<sub>7</sub>)



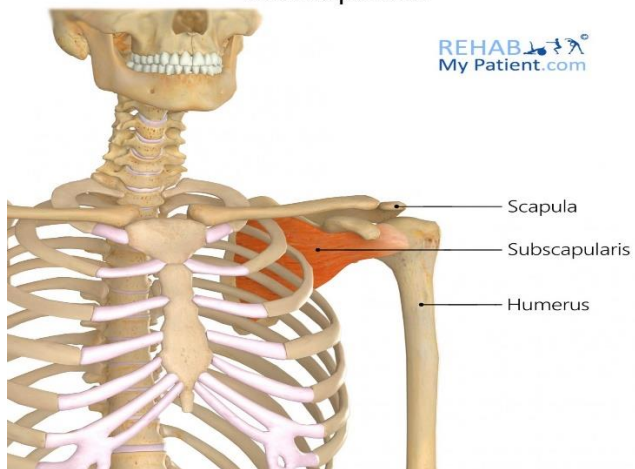
### 15. SUBSCAPULARIS

ORIGIN – subscapular fossa

INSERTION – lesser tubercle of humerus

INNERVATION – upper and lower subscapular nerves (C<sub>5</sub>, C<sub>6</sub>, C<sub>7</sub>)

Subscapularis



### 16. LATISSIMUS DORSI

ORIGIN – spinous process of thoracic T<sub>7</sub>-T<sub>12</sub>

Thoracolumbar fascia

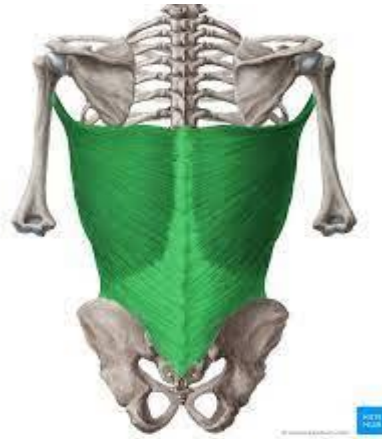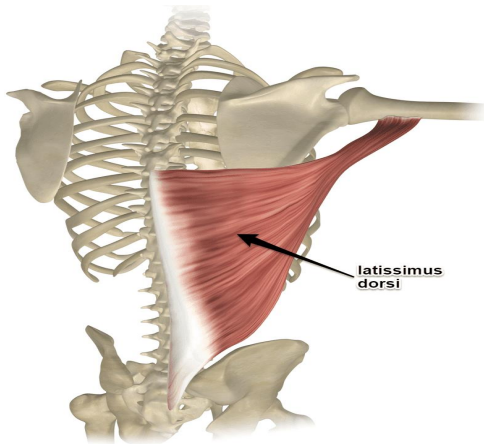
Iliac crest

Inferior 3 or 4 ribs

Inferior angle of scapula

INSERTION – floor of intertubercular sulcus of humerus

INNERVATION – thoracodorsal nerve (C<sub>6</sub>, C<sub>7</sub>, C<sub>8</sub>)



### 17. **BICEPS BRACHII**

Long Head Origin – supraglenoid tubercle of scapula

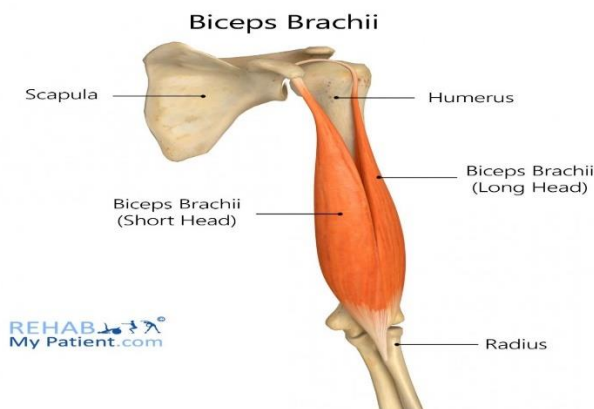
Short Head Origin – apex of coracoid process

Insertion – tuberosity of radius

INNERVATION OF LONG HEAD – radial nerve (C<sub>6</sub>, C<sub>7</sub>, C<sub>8</sub>)

Musculocutaneous nerve (C<sub>5</sub>, C<sub>6</sub>)

INNERVATION OF SHORT HEAD – musculocutaneous nerve (C<sub>5</sub>, C<sub>6</sub>)



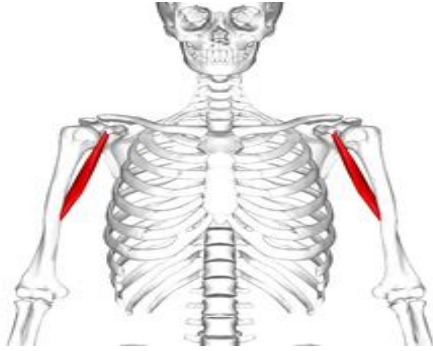### 18. **CORACOBRACHIALIS**

ORIGIN – apex of coracoid process

INSERTION – linear roughening on midshaft of humerus on medial side

INNERVATION – musculocutaneous nerve (C<sub>5</sub>, C<sub>6</sub>, C<sub>7</sub>)





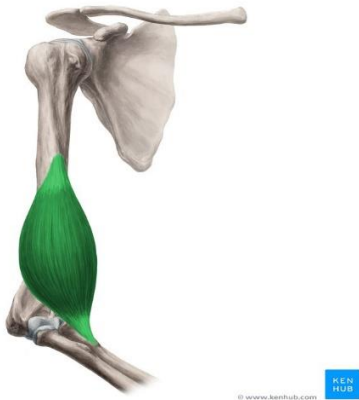### 19. **BRACHIALIS**

ORIGIN – distal half of anterior aspect of humerus (medial and lateral surfaces) and adjacent intermuscular septa

INSERTION – tuberosity of ulna

INNERVATION – musculocutaneous nerve (C<sub>5</sub>, C<sub>6</sub>)

Small contribution by the radial nerve (C<sub>7</sub>) to lateral part of muscle



### 20. **SUPINATOR**

ORIGIN – supinator crest of ulna

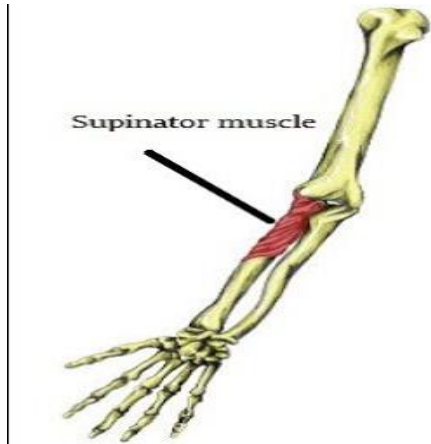
Lateral epicondyle of humerus

Radial collateral ligament

Annular radial ligament

INSERTION – lateral edge of radial tuberosity and oblique line of radius

INNERVATION – Posterior interosseous nerve (C<sub>6</sub>, C<sub>7</sub>)



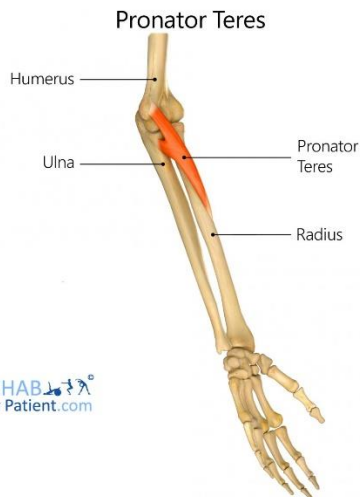
**21. PRONATOR TERES**

ORIGIN OF HUMERAL HEAD – medial epicondyle and supracondylar ridge of humerus

ORIGIN OF ULNAR HEAD – coronoid process of ulna

INSERTION – middle of lateral surface of body of radius

INNERVATION – Median nerve



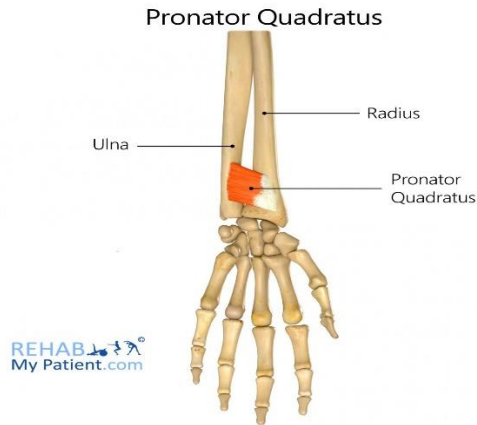
**22. PRONATOR QUADRATUS**

ORIGIN – linear ridge on anterior surface of lower end of ulna

INSERTION – lateral, anterior surface of radius

INNERVATION – median nerve (anterior interosseous nerve) [C<sub>7</sub>, C<sub>8</sub>]



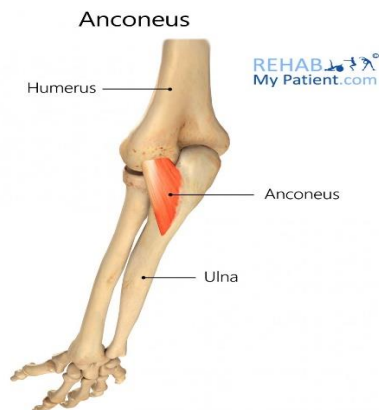

### 23. **ANCONEUS**

ORIGIN – lateral epicondyle of humerus

INSERTION – lateral surface of olecranon

INNERVATION – Radial nerve (via branch to medial head of triceps brachii)



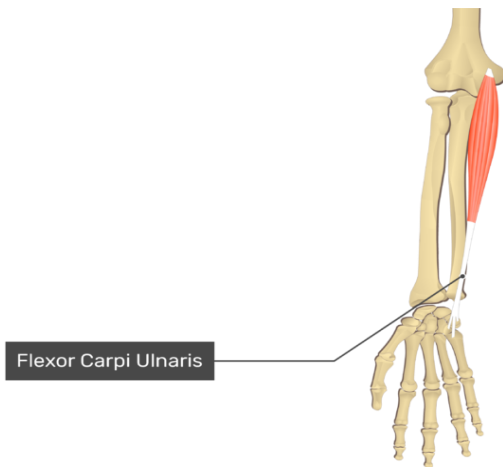
### 24. **FLEXOR CARPI ULNARIS**

ORIGIN OF HUMERAL HEAD – medial epicondyle of humerus

ORIGIN OF ULNAR HEAD – olecranon and posterior border of ulna

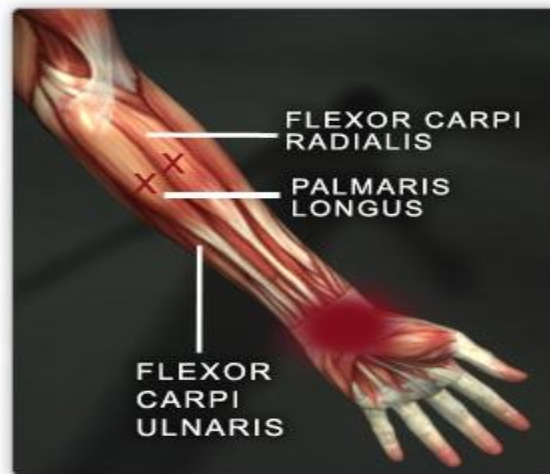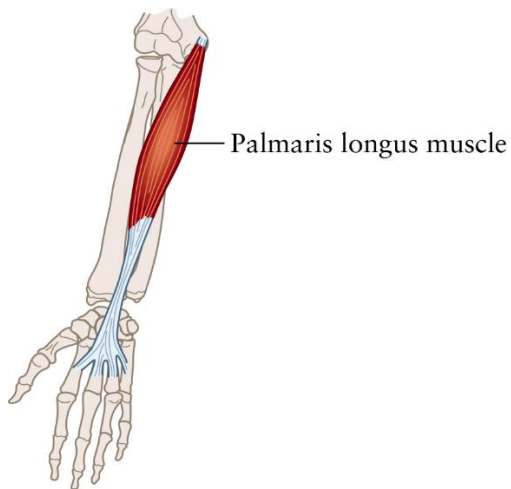
INSERTION – pisiform bone, and then via pisohamate and pisometacarpal ligaments into the hamate and base of metacarpal V.

INNERVATION – ulnar nerve (C<sub>7</sub>, C<sub>8</sub>, T<sub>1</sub>)



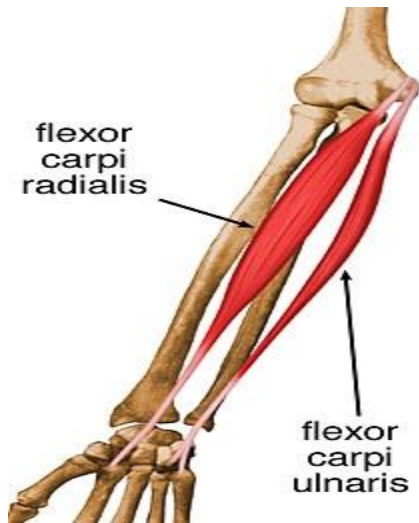**25. PALMARIS LONGUS**

ORIGIN – medial epicondyle of humerus  
 INSERTION – palmar aponeurosis of hand  
 INNERVATION – median nerve (C<sub>7</sub>, C<sub>8</sub>)



**26. FLEXOR CARPI RADIALIS**

ORIGIN – medial epicondyle of humerus  
 INSERTION – base of metacarpals II and III  
 INNERVATION – Median nerve (C<sub>6</sub>, C<sub>7</sub>)



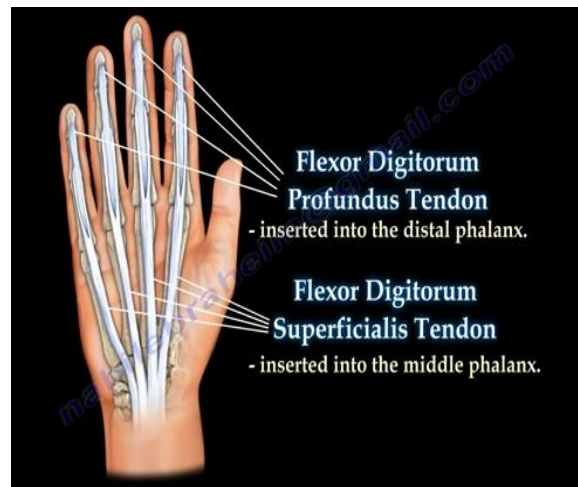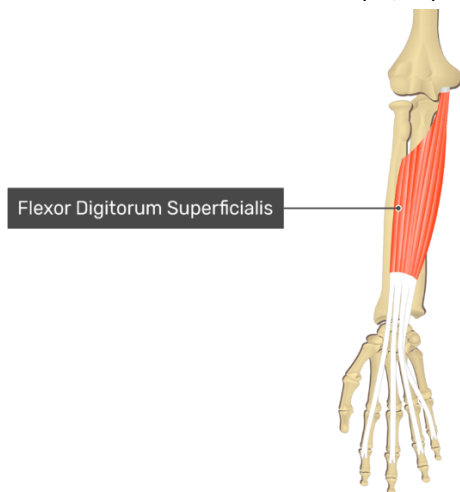
**27. FLEXOR DIGITORUM SUPERFICIALIS**

ORIGIN OF HUMERO-ULNAR HEAD – medial epicondyle of humerus and adjacent margin of coronoid process

ORIGIN OF RADIAL HEAD – oblique line of radius

INSERTION – four tendons, which attach to the palmar surfaces of the middle phalanges of the index, middle, ring, and little fingers

INNERVATION – Median nerve (C<sub>8</sub>, T<sub>1</sub>)



**28. FLEXOR DIGITORUM PROFUNDUS**

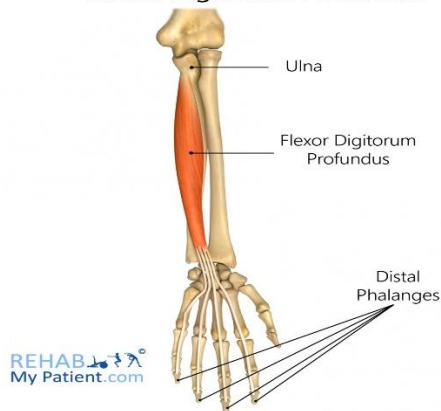
ORIGIN – anterior and medial surfaces of ulna

Anteromedial half of interosseous membrane

INSERTION – four tendons, which attach to palmar surface of distal phalanges of the index, middle, ring, and little fingers

INNERVATION – lateral half by median nerve; medial half by ulnar nerve (C<sub>8</sub>, T<sub>1</sub>)

### Flexor Digitorum Profundus



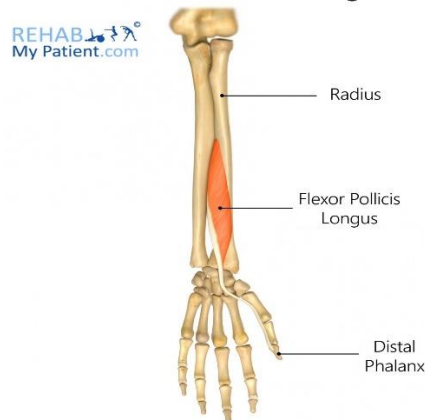
### 29. FLEXOR POLLICIS LONGUS

ORIGIN – anterior surface of radius and radial half of interosseous membrane

INSERTION – palmar surface of base of distal phalanx of thumb

INNERVATION – median nerve (anterior interosseous nerve) [C<sub>7</sub>, C<sub>8</sub>]

### Flexor Pollicis Longus

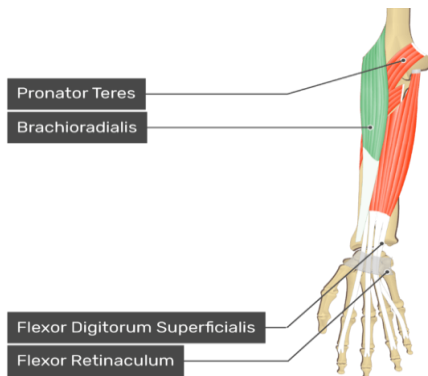


### 30. BRACHIORADIALIS

ORIGIN – Proximal part of lateral supraepicondylar ridge of humerus and adjacent intermuscular septum

INSERTION – lateral surface of distal end of radius

INNERVATION – radial nerve before division into superficial and deep branches

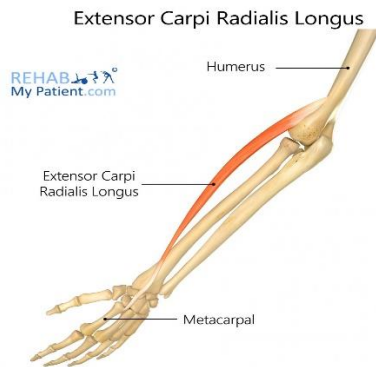


### 31. **EXTENSOR CARPI RADIALIS LONGUS**

ORIGIN – distal part of lateral supraepicondylar ridge of humerus and adjacent intermuscular septum

INSERTION – dorsal surface of base of metacarpal II

INNERVATION – radial nerve (C<sub>6</sub>, C<sub>7</sub>) before division into superficial and deep branches

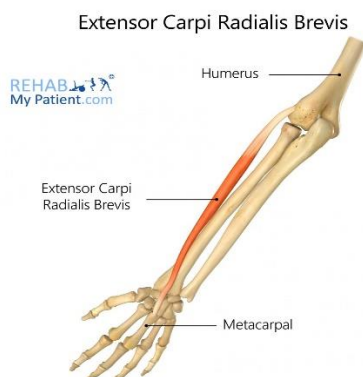


### 32. **EXTENSOR CARPI RADIALIS BREVIS**

ORIGIN – lateral epicondyle of humerus and adjacent intermuscular septum

INSERTION – dorsal surface of base of metacarpals II and III

INNERVATION - deep branch of radial nerve (C<sub>7</sub>, C<sub>8</sub>) before penetrating supinator muscle

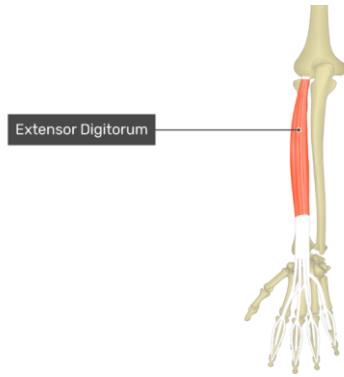


### 33. **EXTENSOR DIGITORUM**

ORIGIN – lateral epicondyle of humerus and adjacent intermuscular septum and deep fascia

INSERTION – four tendons, which insert via extensor hoods into the dorsal aspect of the bases of the middle and distal phalanges of the index, middle, ring, and little fingers

INNERVATION – posterior interosseous nerve (C<sub>7</sub>, C<sub>8</sub>)

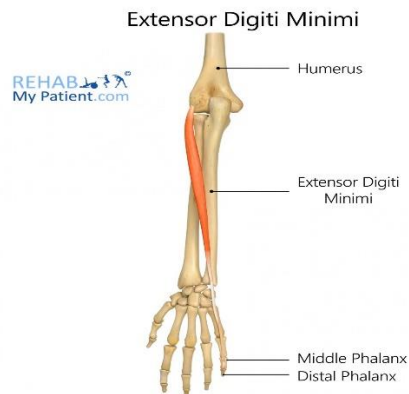

### 34. **EXTENSOR DIGITI MINIMI**

ORIGIN – lateral epicondyle of humerus and adjacent intermuscular septum together with extensor digitorum

INSERTION – extensor hood of little finger

INNERVATION – posterior interosseous nerve (C<sub>7</sub>, C<sub>8</sub>)

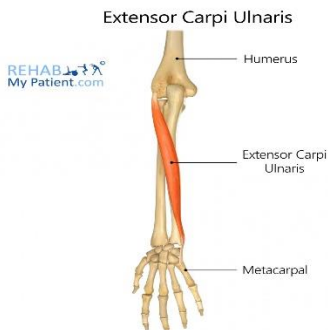


### 35. **EXTENSOR CARPI ULNARIS**

ORIGIN – lateral epicondyle of humerus and posterior border of ulna

INSERTION – tubercle on the base of the medial side of metacarpal

INNERVATION – posterior interosseous nerve (C<sub>7</sub>, C<sub>8</sub>)

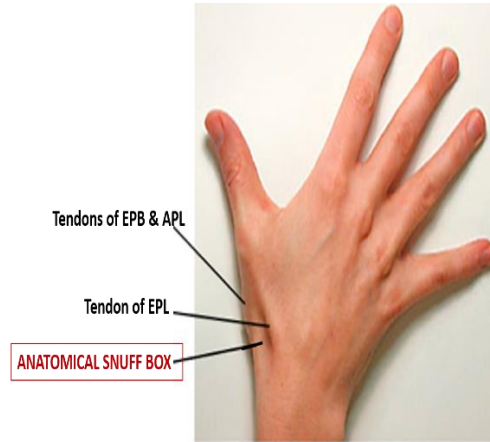
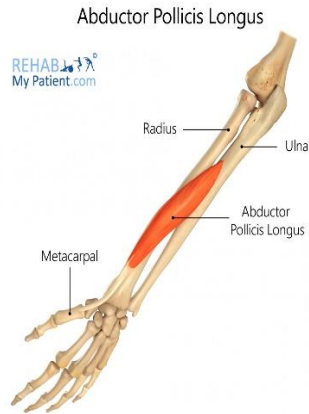

### 36. **ABDUCTOR POLLICIS LONGUS**

**ORIGIN** – Posterior surface of ulna and radius (distal to the attachments of supinator and anconeus), and intervening interosseous membrane

**INSERTION** – lateral side of base of metacarpal I

**INNERVATION** – posterior interosseous nerve (C<sub>7</sub>, C<sub>8</sub>)

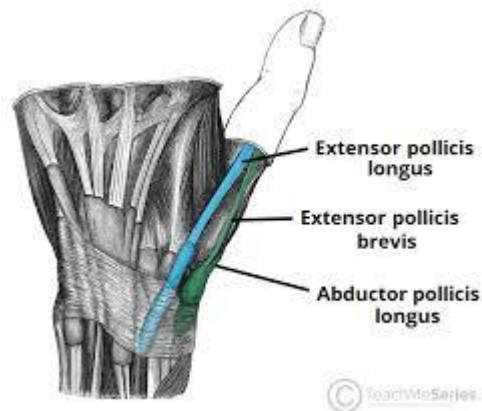
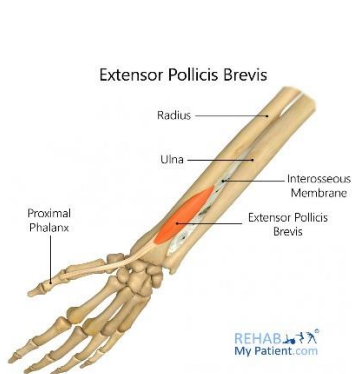


### 37. **EXTENSOR POLLICIS BREVES**

**ORIGIN** – posterior surface of radius (distal to abductor pollicis longus) and the adjacent interosseous membrane

**INSERTION** – dorsal surface of base of proximal phalanx of thumb

**INNERVATION** – posterior interosseous nerve (C<sub>7</sub>, C<sub>8</sub>)

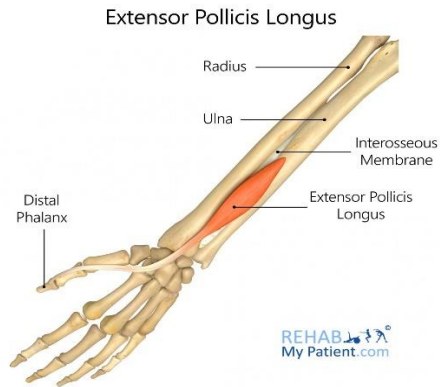


### 38. **EXTENSOR POLLICIS LONGUS**

**ORIGIN** – posterior surface of ulna (distal to the abductor pollicis longus) and the adjacent interosseous membrane

**INSERTION** – dorsal surface of base of distal phalanx of thumb

**INNERVATION** – posterior interosseous nerve (C<sub>7</sub>, C<sub>8</sub>)

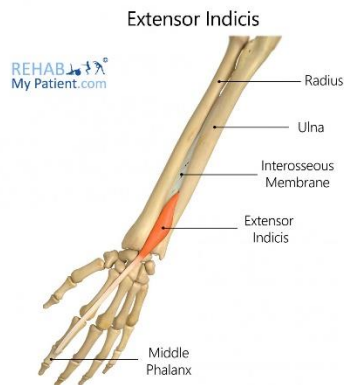


### 39. EXTENSOR INDICES

ORIGIN – posterior surface of ulna (distal to extensor pollicis longus) and the adjacent interosseous membrane

INSERTION – extensor hood of index finger

INNERVATION - posterior interosseous nerve (C<sub>7</sub>, C<sub>8</sub>)



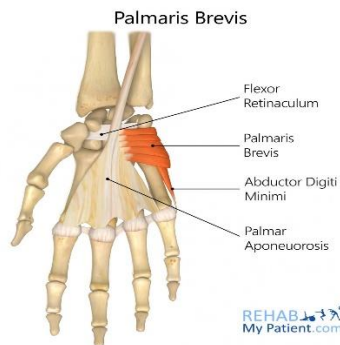
### 40. PALMARIS BREVIS

ORIGIN – Palmar aponeurosis

Flexor retinaculum

INSERTION – dermis of skin on medial margin of hand

INNERVATION – superficial branch of ulnar nerve (C<sub>8</sub>, T<sub>1</sub>)



### 41. DORSAL INTEROSSEI (FOUR MUSCLES)

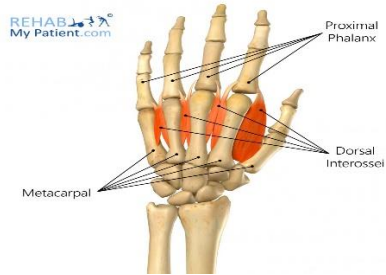


ORIGIN – adjacent sides of metacarpals

INSERTION – extensor hood and base of proximal phalanges of index, middle and ring fingers

INNERVATION – Deep branch of ulnar nerve (C8,T1)

Dorsal Interossei (Hand)



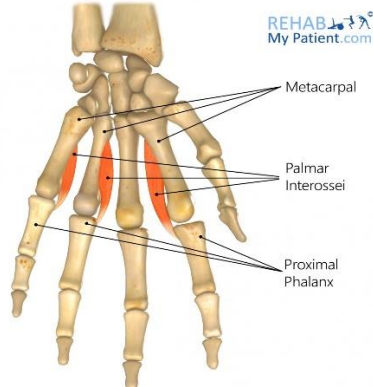
#### 42. PALMAR INTEROSSEI

ORIGIN – Sides of metacarpals

INSERTION – Extensor hoods of the thumb, index, ring, and little fingers and the proximal phalanx of thumb

INNERVATION – Deep branch of ulnar nerve (C8,T1)

Palmar Interossei



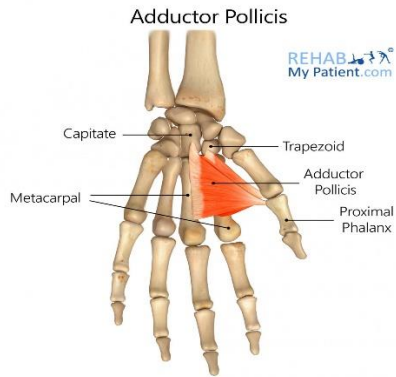
#### 43. ADDUCTOR POLLICIS

ORIGIN OF TRANSVERSE HEAD – metacarpal III

ORIGIN OF OBLIQUE HEAD – capitate and bases of metacarpal II and III

INSERTION – base of proximal phalanx extensor hood of thumb

INNERVATION – deep branch of ulnar nerve (C<sub>8</sub>, T<sub>1</sub>)

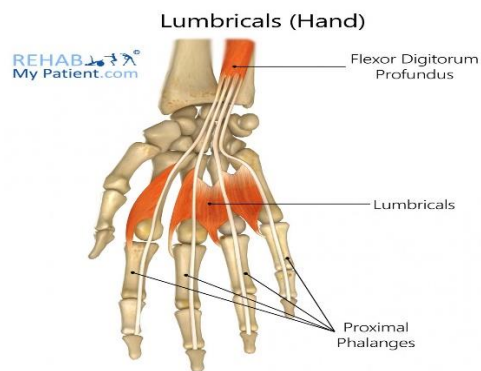


**44. LUMBRICALS (FOUR MUSCLES)**

ORIGIN – tendons of flexor digitorum profundus

INSERTION – extensor hoods of index, ring, middle and little fingers

INNERVATION – medial two by the deep branch of the ulnar nerve; lateral two by digital branches of median nerve

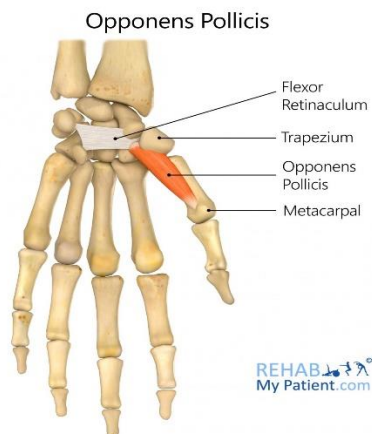


**45. OPPONENS POLLICIS**

ORIGIN – Tubercle of trapezium and flexor retinaculum

INSERTION – Lateral margin and adjacent palmar surface of metacarpal I

INNERVATION – Recurrent branch of median nerve (C<sub>8</sub>, T<sub>1</sub>)

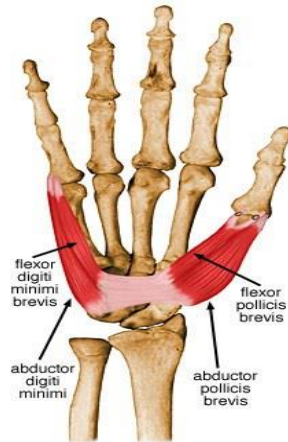

#### 46. **ABDUCTOR POLLICIS BREVIS**

ORIGIN – Tubercles of scaphoid and trapezium and adjacent flexor retinaculum

INSERION – Proximal phalanx and extensor hood of thumb

INNERVATION – Recurrent branch of median nerve (C8,T1)

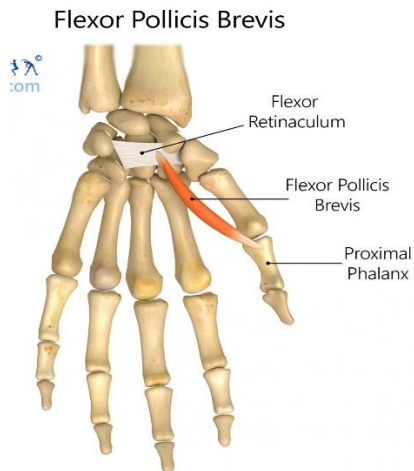


#### 47. **FLEXOR POLLICIS BREVIS**

ORIGIN – Tubercle of the trapezium and flexor retinaculum

INSERION – Proximal phalanx of the thumb

INNERVATION – Recurrent branch of median nerve (C8,T1)

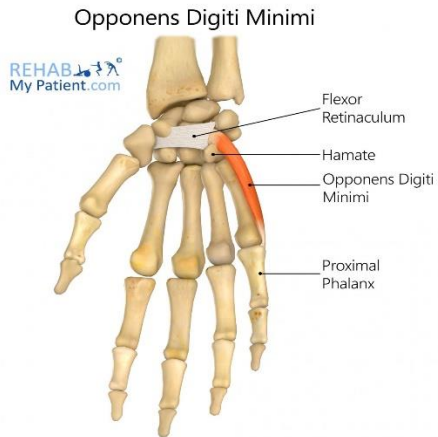

#### 48. **OPPONENS DIGITI MINIMI**

ORIGIN – Hook of hamate and flexor retinaculum

INSERION – Medial aspect of metacarpal V

INNERVATION – Deep branch of ulnar nerve (C8,T1)

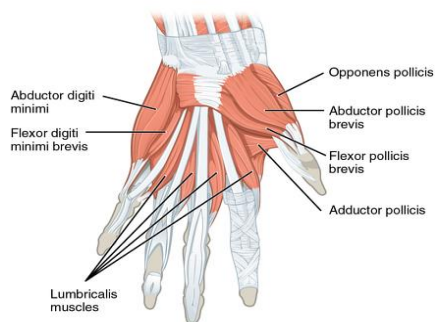


#### 49. **ABDUCTOR DIGITI MINIMI**

ORIGIN – Pisiform, the pisohamate ligament, and tendon of flexor carpi ulnaris

INSERTION – Proximal phalanx of little finger

INNERVATION – Deep branch of ulnar nerve (C8,T1)



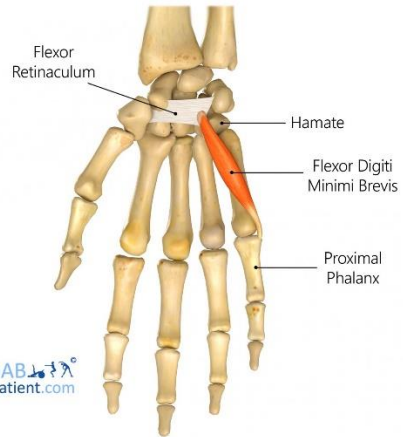
#### 50. **FLEXOR DIGITI MINIMI BREVIS**

ORIGIN – Hook of the hamate and flexor retinaculum

INSERTION – Proximal phalanx of little finger

INNERVATION – Deep branch of ulnar nerve (C8,T1)

## Flexor Digiti Minimi Brevis (Hand)



# UPPER LIMB MUSCLE FUNCTIONS

---

## 1. TRAPEZIUS

- Upper fibres elevates the scapula
- Middle fibers pull scapula medially
- Lower fibers pull medial border of scapula downward

## 2. DELTOID

- Abducts arm
- Anterior fibers flex and medially rotate arm
- Posterior fibers extend and laterally rotate arm

## 3. LEVATOR SCAPULAE

- Raises medial border of scapula

## 4. RHOMBOID MINOR

- Raises medial border of scapula upward and medially

## 5. RHOMBOID MAJOR

- Raises medial border of scapula upward and medially

## 6. SUPRASPINATUS

- Abducts arm and stabilizes shoulder joint

## 7. INFRASPINATUS

- Laterally rotates arm and stabilizes shoulder joint

## 8. TERES MINOR

- Laterally rotates arm and stabilizes shoulder joint

## 9. TERES MAJOR

- Medially rotates and adducts arm and stabilizes shoulder joint

## 10. TRICEPS BRACHII

- Extensor of elbow joint

## 11. PECTORALIS MAJOR

- Adducts arm and rotates it medially

- Clavicular fibers also flex arm

**12. PECTORALIS MINOR**

- Depresses point of shoulder (pulls tip of shoulder joint)
- If the scapula is fixed, it elevates the ribs of origin

**13. SUBCLAVIUS**

- Depresses the clavicle and steadies this bone during movements of the shoulder girdle

**14. SERRATUS ANTERIOR**

- Protraction and rotation of scapula
- Keeps medial border and inferior angle of scapula opposed to thoracic wall

**15. SUBSCAPULARIS**

- Medially rotates arm and stabilizes shoulder joint

**16. LATISSIMUS DORSI**

- Extends, adducts, and medially rotates the arm

**17. BICEPS BRACHII**

- supinator of forearm and flexor of elbow joint
- Weak flexor of shoulder joint

**18. CORACHOBRACHIALIS**

- Flexes arm and also weak adductor

**19. BRACHIALIS**

- Flexor of elbow joint

**20. SUPINATOR**

- Supination of forearm

**21. PRONATOR QUADRATUS**

- Pronates forearm

**22. ANCONEUS**

- Extends elbow joint

**23. FLEXOR CARPI ULNARIS**

- Flexes and adducts hand at wrist joint

**24. PALMARIS LONGUS**

- Flexes hand

**25. FLEXOR CARPI RADIALIS**

- Flexes and abducts hand at wrist joint

**26. FLEXOR DIGITORUM SUPERFICIALIS**

- Flexes middle phalanx of fingers and assists in flexing proximal phalanx and hand

**27. FLEXOR DIGITORUM PROFUNDUS**

- Flexes distal phalanx of fingers; then assists in flexion of middle and proximal phalanges and wrist

**28. FLEXOR POLLICIS LONGUS**

- Flexes distal phalanx of thumb

**29. EXTENSOR CARPI RADIALIS LONGUS**

- Extends and abducts hand at wrist joint

**30. EXTENSOR CARPI RADIALIS BREVIS**

- Extends and abducts hand at wrist joint

**31. EXTENSOR DIGITORUM**

- Extends fingers and hand

**32. EXTENSOR DIGITI MINIMI**

- Extends metacarpal phalangeal joint of little finger

**33. EXTENSOR CARPI ULNARIS**

- Extends and abducts hand at wrist joint

**34. ABDUCTOR POLLICIS LONGUS**

- Abducts and extends thumb

**35. EXTENSOR POLLICIS BREVIS**

- Extends metacarpophalangeal joints of thumb

**36. EXTENSOR POLLICIS LONGUS**

- Extends distal phalanx of thumb

**37. EXTENSOR INDICES**

- Extends metacarpophalangeal joint of index finger

**38. PALMARIS BREVIS**

- Corrugates skin to improve grip of palm

**39. DORSAL INTEROSSEI (FOUR MUSCLES)**

- Abducts fingers from centre of third finger



- Both palmar and dorsal interossei flex metacarpophalangeal joints and extend interphalangeal joints

**40. PALMAR INTEROSSEI**

- Adducts fingers towards center of third finger

**41. ADDUCTOR POLLICIS**

- Adduction of thumb

**42. LUMBRICALS (FOUR MUSCLES)**

- Flex metacarpophalangeal joints and extend interphalangeal joints of fingers except thumb

**43. OPPONENS POLLICIS**

- Pulls thumb medially and forward across palm

**44. ABDUCTOR POLLICIS BREVIS**

- Abduction of thumb

**45. FLEXOR POLLICIS BREVIS**

- Flexes metacarpophalangeal joint of thumb

**46. OPPONENS DIGITI MINIMI**

- Pulls fifth metacarpal forward as in cupping the palm

**47. ABDUCTOR DIGITI MINIMI**

- Abducts little finger

**48. FLEXOR DIGITI MINIMI BREVIS**

- Flexes little finger at metacarpophalangeal joints

# ARTERIAL SUPPLY TO MUSCLES OF UPPER LIMB

---

BY FATIMA HAIDER

KGMC

1. **TRAPEZIUS**

Transverse cervical artery  
Dorsal scapular artery  
Posterior intercostal arterial branches

2. **DELTOID**

Thoracoacromial artery (acromial and deltoid branches)  
the circumflex humeral arteries  
the profunda brachii artery (deltoid branch).

3. **LEVATOR SCAPULAE**

Dorsal scapular artery

4. **RHOMBOID MINOR**

Dorsal scapular artery

5. **RHOMBOID MAJOR**

Dorsal scapular artery

6. **SUPRASPINATUS**

Suprascapular artery

7. **INFRASPINATUS**

Suprascapular artery  
Circumflex scapular artery

8. **TERES MINOR**

Subscapular artery  
Circumflex scapular artery  
Posterior circumflex humeral artery

9. **TERES MAJOR**

Subscapular artery

Circumflex scapular artery

**10. TRICEPS BRACHII**

Deep brachial artery

**11. PECTORALIS MAJOR**

Pectoral branch of the thoraco-acromial artery

**12. PECTORALIS MINOR**

Thoracoacromial artery

**13. SUBCLAVIUS**

Clavicular artery

**14. SERRATUS ANTERIOR**

Lateral thoracic artery

Superior thoracic artery

Thoracodorsal artery

**15. SUBSCAPULARIS**

subscapular, suprascapular and circumflex scapular arteries

**16. LATISSIMUS DORSI**

Thoracodorsal artery

A branch of subscapular artery

**17. BICEPS BRACHII**

Brachial artery

**18. CORACHOBRACHIALIS**

Brachial artery

**19. BRACHIALIS**

Radial recurrent artery

Brachial artery

**20. SUPINATOR**

Radial recurrent artery

**21. PRONATOR TERES**

Ulnar artery

Radial artery

**22. PRONATOR QUADRATUS**

Anterior interosseous artery

**23. ANCONEUS**

Recurrent posterior interosseous artery  
Medial collateral artery  
Posterior branch of radial collateral artery

**24. FLEXOR CARPI ULNARIS**

Posterior ulnar recurrent artery  
Ulnar artery

**25. PALMARIS LONGUS**

Anterior ulnar recurrent artery  
Median artery

**26. FLEXOR CARPI RADIALIS**

Recurrent ulnar arteries  
Radial artery

**27. FLEXOR DIGITORUM SUPERFICIALIS**

Ulnar artery  
Radial artery  
Median artery

**28. FLEXOR DIGITORUM PROFUNDUS**

Ulnar artery  
common interosseous artery  
ulnar collateral artery  
ulnar recurrent  
anterior interosseous artery  
median arteries

**29. FLEXOR POLLICIS LONGUS**

Ulnar artery  
Radial artery

**30. EXTENSOR CARPI RADIALIS LONGUS**

Radial artery

**31. EXTENSOR CARPI RADIALIS BREVIS**

Radial artery

**32. EXTENSOR DIGITORUM**

Posterior interosseous artery  
radial recurrent artery  
anterior interosseous artery

**33. EXTENSOR DIGITI MINIMI**

Radial recurrent artery  
anterior interosseous artery  
posterior interosseous artery

**34. EXTENSOR CARPI ULNARIS**

Ulnar artery

**35. ABDUCTOR POLLICIS LONGUS**

Interosseous branch of ulnar artery

**36. EXTENSOR POLLICIS BREVIS**

Posterior interosseous artery  
Anterior interosseous artery

**37. EXTENSOR POLLICIS LONGUS**

Posterior interosseous artery  
Anterior interosseous artery

**38. EXTENSOR INDICES**

Posterior interosseous artery  
Anterior interosseous artery

**39. PALMARIS BREVIS**

Superficial palmar arch

**40. DORSAL INTEROSSEI (FOUR MUSCLES)**

The 1st dorsal interosseous muscle receives vascular supply from the first dorsal metacarpal branch of the radial artery.

The 2nd, 3rd, and 4th dorsal interossei receive blood supply from the second, third, and fourth dorsal metacarpal branches of the dorsal carpal anastomosis

**41. PALMAR INTEROSSEI**

Palmar metacarpal arteries derived from deep palmar arch

**42. ADDUCTOR POLLICIS**

deep palmar arterial arch, formed by the anastomosis of the radial artery and the deep palmar branch of ulnar artery.

**43. LUMBRICALS (FOUR MUSCLES)**

the superficial palmar arch (SPA), the common palmar digital artery, the deep palmar arch (DPA) and the dorsal digital artery.

**44. OPPONENS POLLICIS**

superficial palmar branch that arises from the radial artery.

**45. ABDUCTOR POLLICIS BREVIS**

Superficial palmar branch of radial artery

**46. FLEXOR POLLICIS BREVIS**

from branches of the radial artery; superficial palmar artery, branches of the princeps pollicis artery and radialis indicis artery.

**47. OPPONENS DIGITI MINIMI**

deep palmar branch of ulnar artery and the deep palmar arch, which is the terminal branch of the radial artery.

**48. ABDUCTOR DIGITI MINIMI**

palmar branch of ulnar artery, palmar digital artery, as well as branches of the ulnar side of the superficial palmar arch

**49. FLEXOR DIGITI MINIMI BREVIS**

Deep palmar branch of ulnar artery

# AXILLARY ARTERY

BY FATIMA HAIDER

KGMC

The axillary artery is separated into three parts by the pectoralis minor muscle, which crosses anteriorly to the vessel.

- The **first part** is proximal to pectoralis minor
- The **second part** is posterior to pectoralis minor
- The **third part** is distal to pectoralis minor

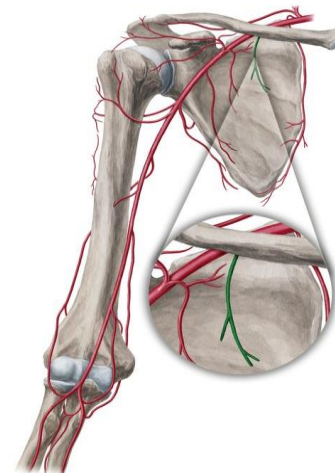
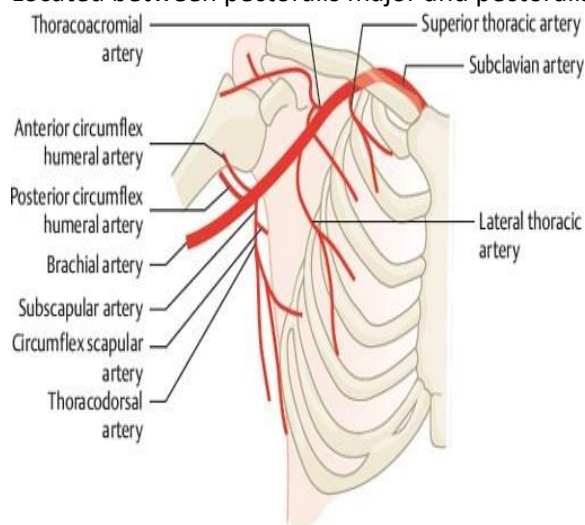
Generally, six branches arise from axillary artery:

1. Superior Thoracic artery
2. Thoraco-acromial artery
3. Lateral thoracic artery
4. Subscapular artery
5. Anterior circumflex humeral artery
6. Posterior circumflex humeral artery

## LOCATION OF ARTERIES

### 1. Superior Thoracic artery

- Originates from anterior surface of first part of axillary artery
- Located between pectoralis major and pectoralis minor

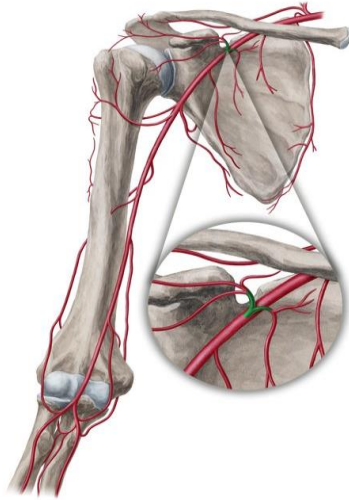


© www.kenhub.com 

### 2. Thoraco-acromial artery

- Originates from anterior surface of second part of axillary artery
- Posterior to medial (superior) margin of pectoralis minor muscle

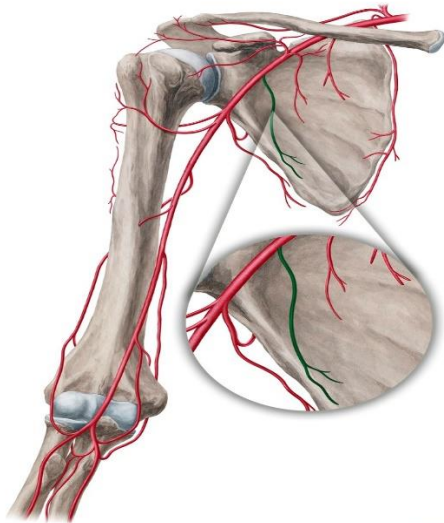
- Penetrates clavipectoral fascia  
(The green portion in diagram represent thoracoacromial artery)



© www.kenhub.com 

### 3. Lateral thoracic artery

- Originates from anterior surface of second part of axillary artery
- Posterior to lateral (inferior) margin of pectoralis minor
- Courses inferomedially along the inferior border of pectoralis minor to the anterior surface of serratus anterior

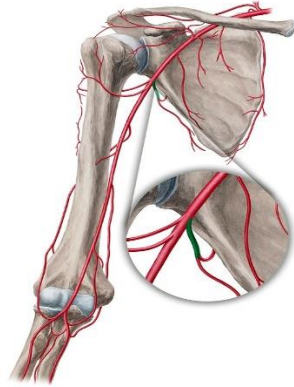


© www.kenhub.com 

### 4. Subscapular artery

- Originates from posterior surface of third part of axillary artery
- Inferior margin of subscapularis muscle



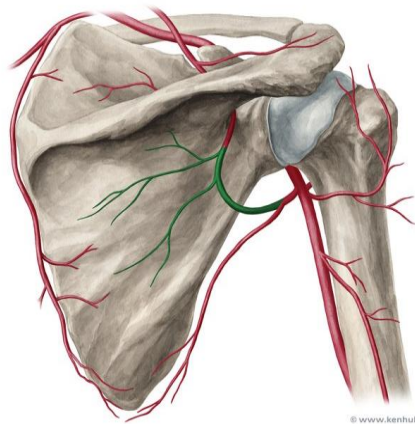


© www.kenhub.com

- Two branches:

**1. Circumflex Scapular Artery**

- Through triangular space
- Posteriorly, it passes inferior to, or pierces, the origin of the teres minor muscle to enter the infraspinatus fossa
- It anastomoses with the suprascapular artery and the dorsal scapular artery

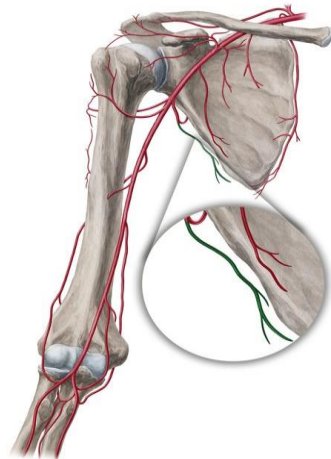


© www.kenhub.com

KEN HUB

**2. Thoracodorsal Artery**

Follows the lateral border of the scapula to the inferior angle



© www.kenhub.com

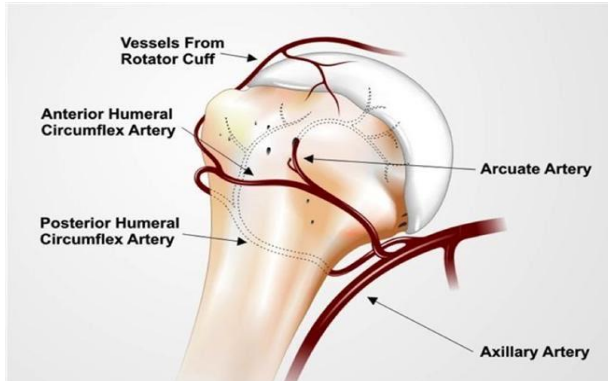
KEN HUB

**5. Anterior circumflex humeral artery**

- Originates from lateral side of third part of the axillary artery
- Passes anterior to surgical neck of humerus
- Anastomoses with posterior circumflex humeral artery

**6. Posterior circumflex humeral artery**

- Originates from lateral side of third part of the axillary artery
- Passes through quadrangular space and surgical neck of humerus



## **ARTERIAL BLOOD SUPPLY**

**1. Superior Thoracic artery**

Supplies upper regions of the medial and anterior axillary walls

**2. Thoraco-acromial artery**

Supplies the pectoralis major and minor muscles, a part of the deltoid muscle and skin overlying the clavicular fascia.

Four branches

- a. Pectoral – contributes vascular supply to breast
- b. Deltoid – supplies pectoralis major and deltoid muscle
- c. Clavicular – supplies the sternoclavicular joint and subclavius muscle
- d. Acromial – supplies the deltoid muscle

**3. Lateral thoracic artery**

- Supplies the medial and anterior walls of axilla
- Contributes to vascular supply of breasts

**4. Subscapular artery**

- Major blood supply to posterior wall of axilla
- Also contributes to blood supply of posterior scapular region

**5. Anterior circumflex humeral artery**

Supplies branches to surrounding tissues, which include the glenohumeral joint and the head of humerus.

6. **Posterior circumflex humeral artery**

Supplies the surrounding muscles and glenohumeral joint

## BRACHIAL PLEXUS

---

**By Fatima Haider**

**KGMC**

1. **ROOTS**

Anterior rami of C<sub>5</sub> – C<sub>8</sub> + T<sub>1</sub>

2. **TRUNKS**

Superior Trunk → C<sub>5</sub> + C<sub>6</sub>

Middle trunk → C<sub>7</sub>

Inferior trunk → C<sub>8</sub> + T<sub>1</sub>

3. **DIVISIONS**

Three anterior divisions by each trunk

Three posterior divisions by each trunk

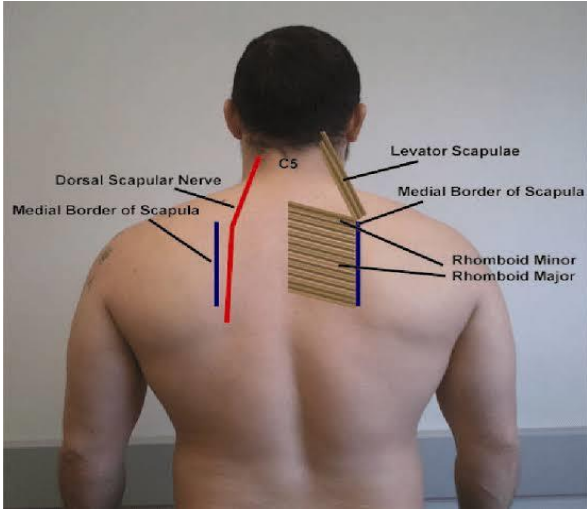
4. **CORDS**

Locations in relation to 2<sup>nd</sup> part of axillary artery

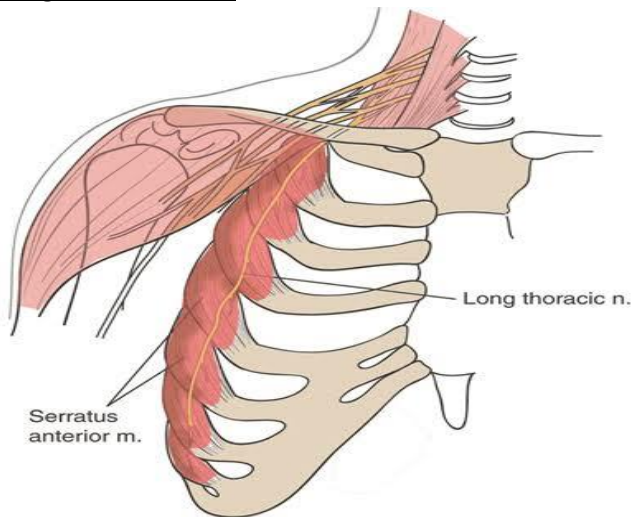
- Lateral cord → anterior divisions of superior and middle trunks (C<sub>5</sub>, C<sub>6</sub>, C<sub>7</sub>)
- Medial Cord → Anterior division of inferior trunk (C<sub>8</sub>, T<sub>1</sub>)
- Posterior cord → union of all three posterior divisions (C<sub>5</sub>-T<sub>1</sub>)

## **BRANCHES OF ROOTS**

1. **Dorsal scapular nerve**

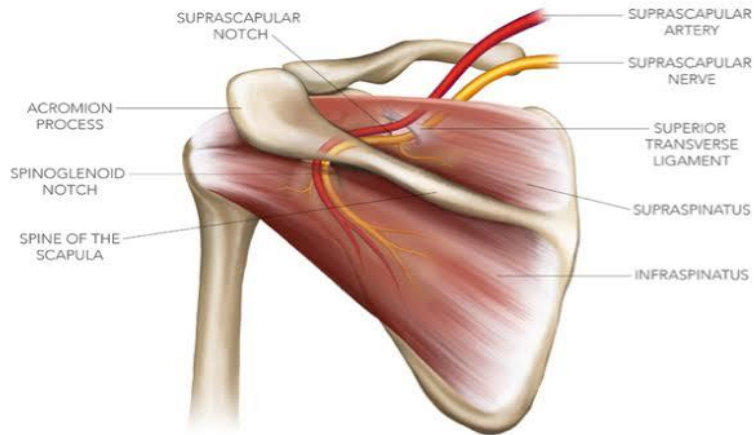


2. Long thoracic nerve



**BRANCHES FROM SUPERIOR TRUNK**

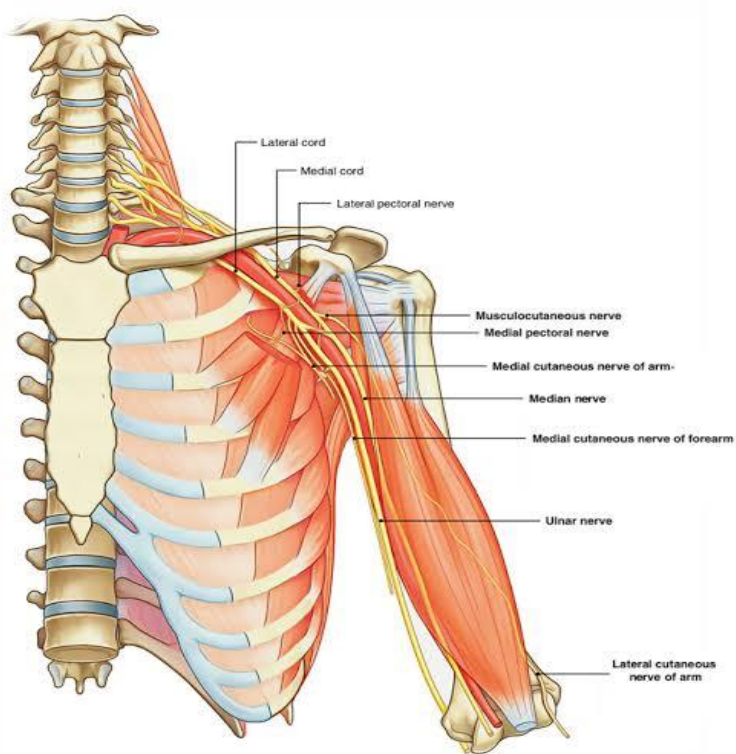
1. Suprascapular nerve



2. Nerve to subclavius muscle

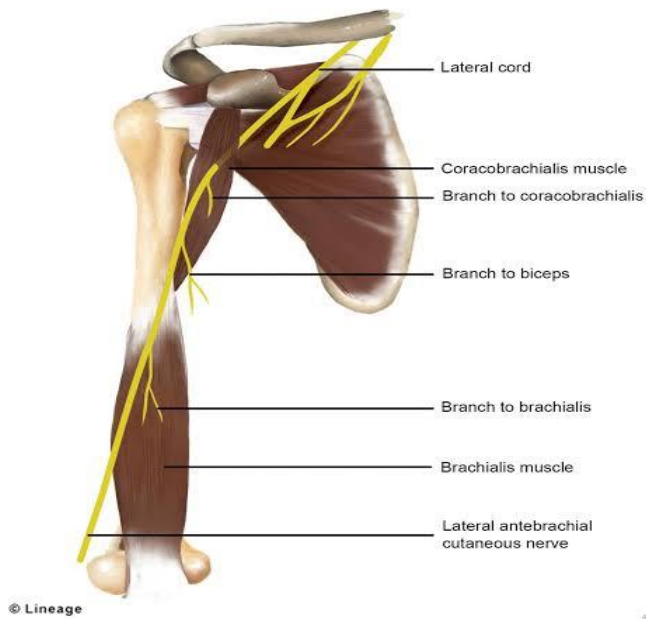
**BRANCHES OF LATERAL CORD**

1. Lateral pectoral nerve



2. Musculocutaneous nerve

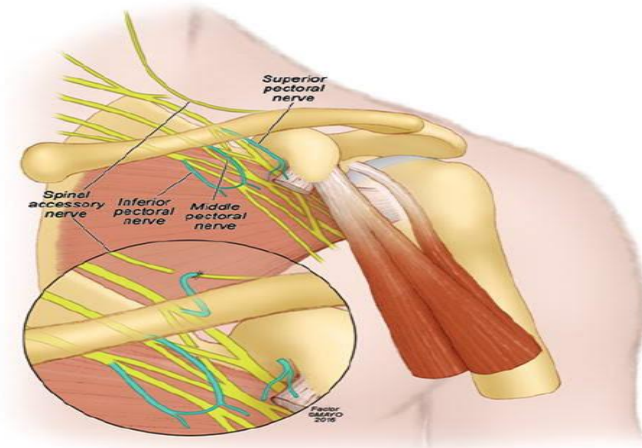
### Musculocutaneous Nerve



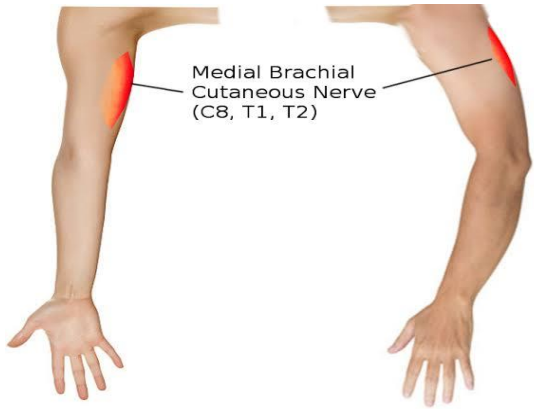
### 3. Lateral root of median nerve

## **BRANCHES OF MEDIAL CORD**

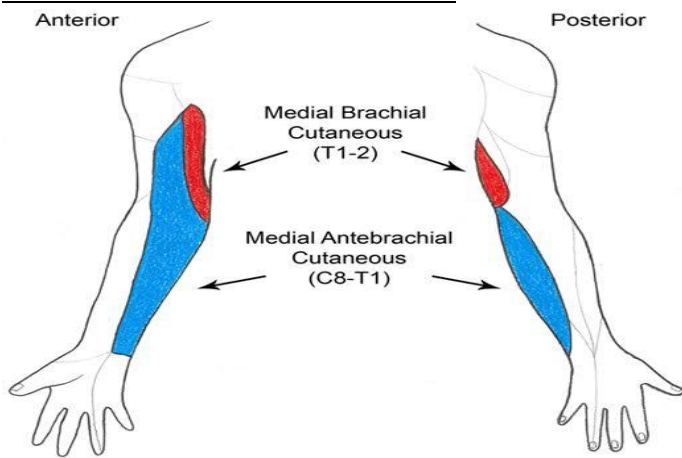
### 1. Medial pectoral nerve



### 2. Medial brachial cutaneous nerve

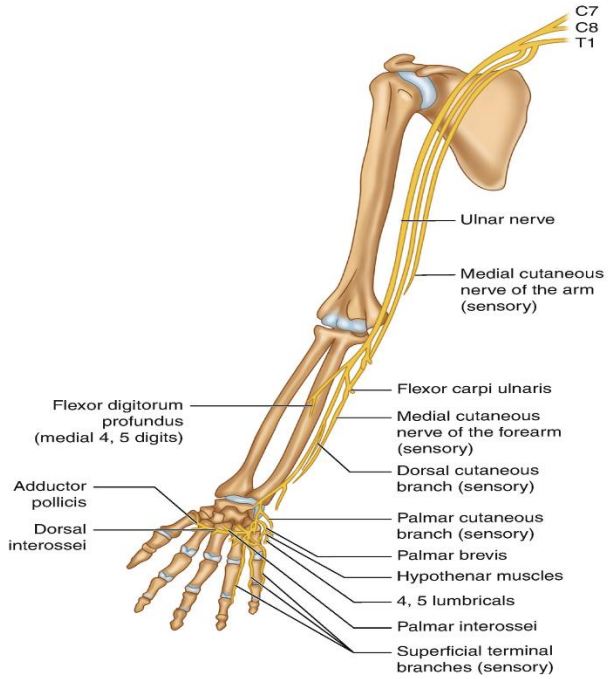


**3. Medial antebrachial cutaneous nerve**

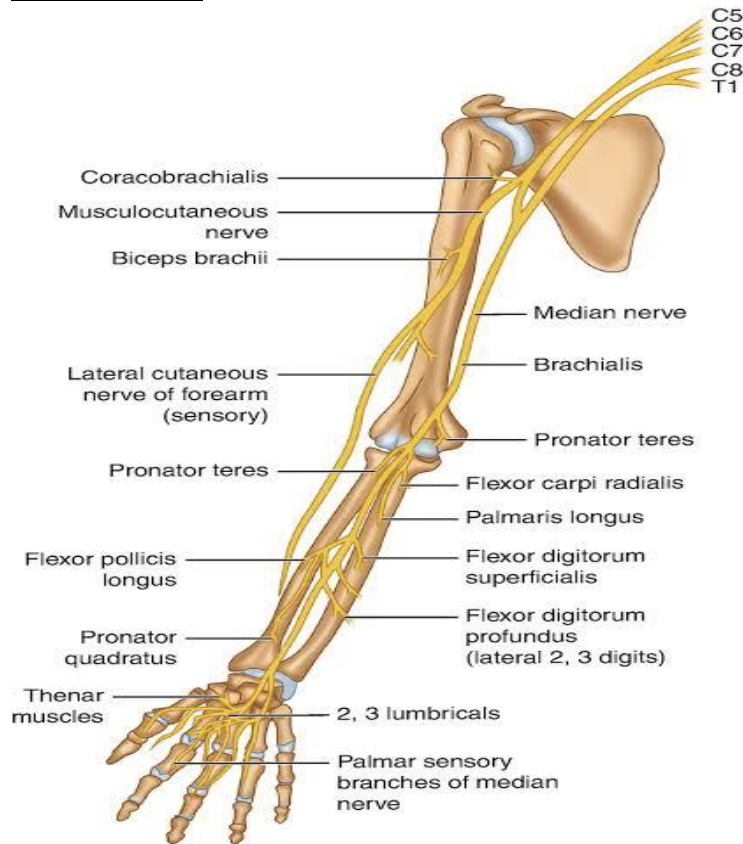


**4. Medial root of median nerve**

**5. Ulnar nerve**



- **MEDIAN NERVE**

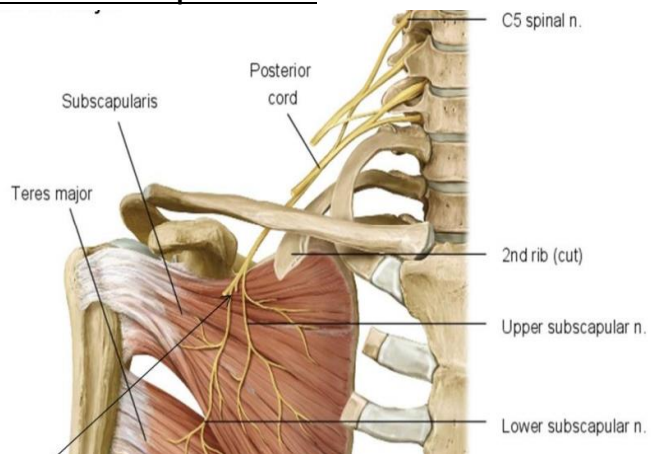




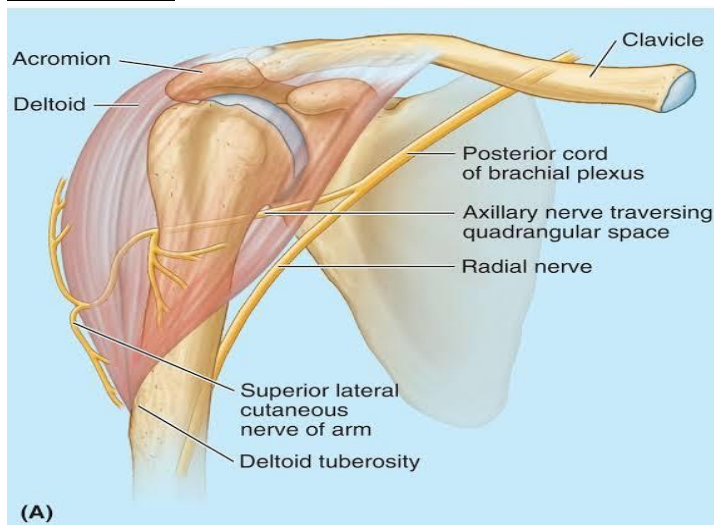
# **BRANCHES OF POSTERIOR CORD**

## **1. Superior subscapular nerve**

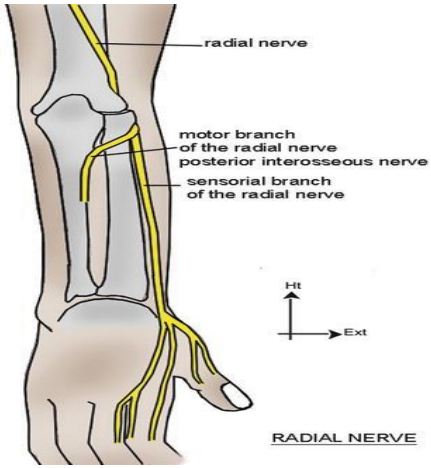
## **2. Inferior subscapular nerve**



## **3. Axillary nerve**



## **4. Radial nerve**



# PALPATIONS OF STRUCTURES OF UPPER LIMB

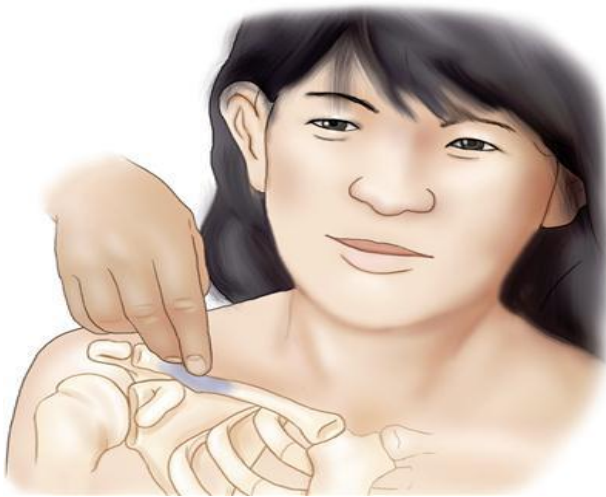---

BY FATIMA HAIDER

KGMC

## 1. CLAVICLE

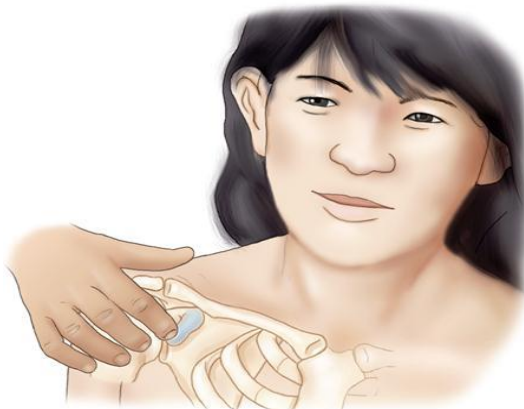ANTEROMEDIAL VIEW



Find the notch at the superior border of the sternum and palpate laterally, feeling for the sternoclavicular joint. From there, slide along the shaft of the clavicle from medial to lateral (proximal to distal) to feel its entire length. Notice that the medial end of the clavicle is convex anteriorly and the lateral end of the clavicle is concave anteriorly.

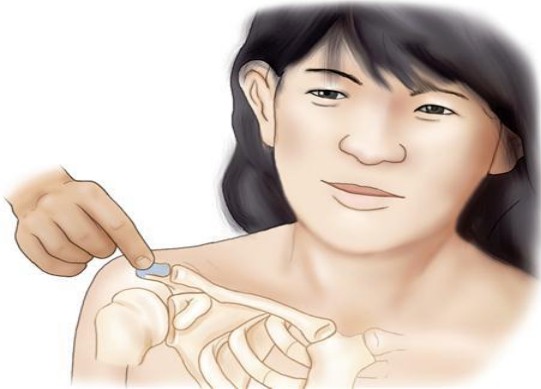## 2. CORACOID PROCESS OF SCAPULA

ANTEROMEDIAL VIEW



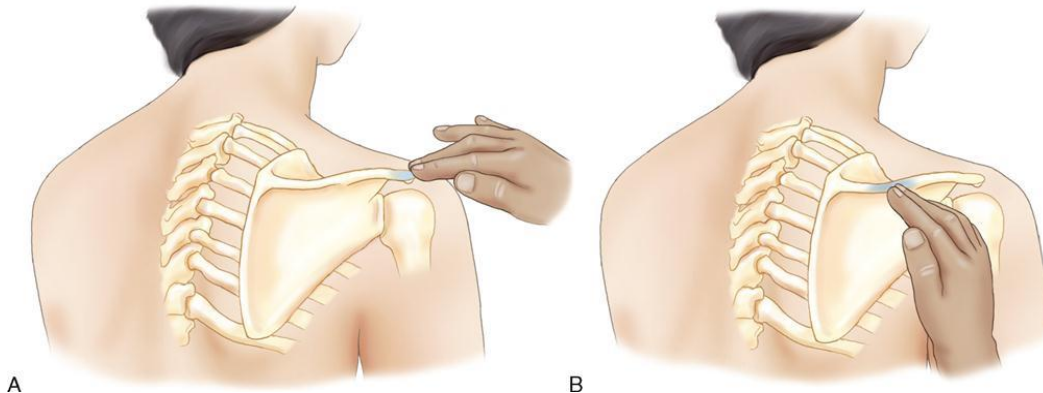
From the concavity at the lateral (distal) end of the clavicle, drop inferiorly off the clavicle to find the **coracoid process of the scapula** (located deep to the pectoralis major muscle). When palpating the coracoid process, notice that its apex (tip) points laterally

### **3. ACROMION PROCESS OF SCAPULA** ANTEROMEDIAL VIEW



After palpating the coracoid process of the scapula, move back to the clavicle and continue palpating the clavicle laterally (distally) once again until you reach the **acromion process of the scapula**. The acromion process of the scapula is at the far lateral end (i.e., the tip of the shoulder)

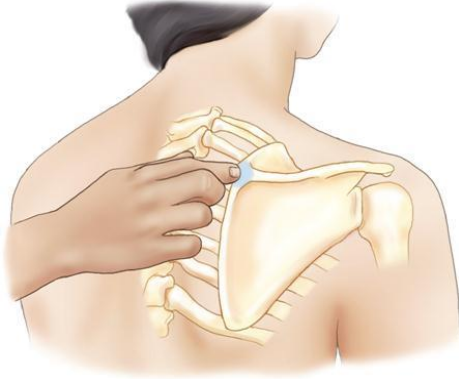### **4. ACROMION PROCESS AND SPINE OF SCAPULA** POSTEROLATERAL VIEW



The **spine of the scapula** is the posterior continuation of the acromion process. To locate the spine of the scapula, begin on the acromion process (A), and continue palpating along it posteriorly. The spine of the scapula (B) can be palpated all the way to the medial border of the scapula. The spine of the scapula can be best palpated if you strum it perpendicularly by moving your palpating fingers up and down across it as you work your way posteriorly and then medially.

## **5. MEDIAL BORDER OF SCAPULA**

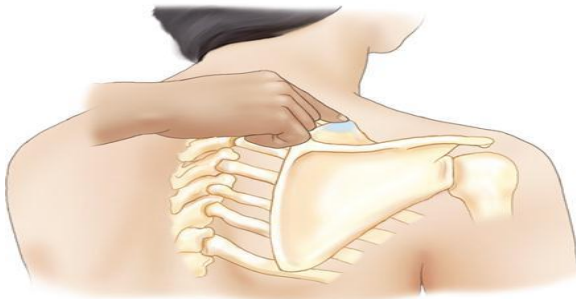
POSTEROLATERAL VIEW



Medial border of the scapula (at the root of the spine of the scapula): Continue palpating along the spine of the scapula until you reach the **medial border of the scapula**. Where the spine of the scapula ends at the medial border is called the **root of the spine of the scapula**. Passively retracting the client's scapula makes it much easier to locate the medial border

## **6. SUPERIOR ANGLE OF SCAPULA**

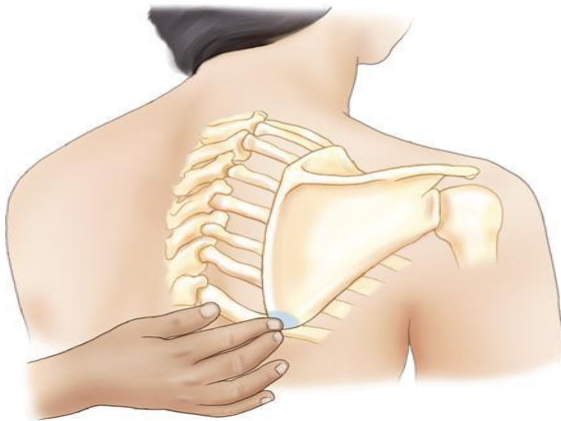POSTEROLATERAL VIEW



Once the medial border of the scapula has been located, palpate along it superiorly until you reach the **superior angle of the scapula**. Having the client elevate and depress the scapula as you palpate for its superior angle can be helpful.

## **7. INFERIOR ANGLE OF SCAPULA**

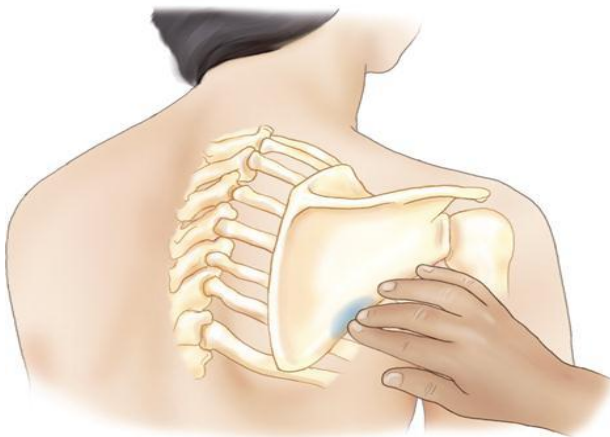
#### POSTEROLATERAL VIEW



Palpate along the medial border of the scapula from the superior angle down to the **inferior angle of the scapula**.

### 8. LATERAL BORDER OF SCAPULA

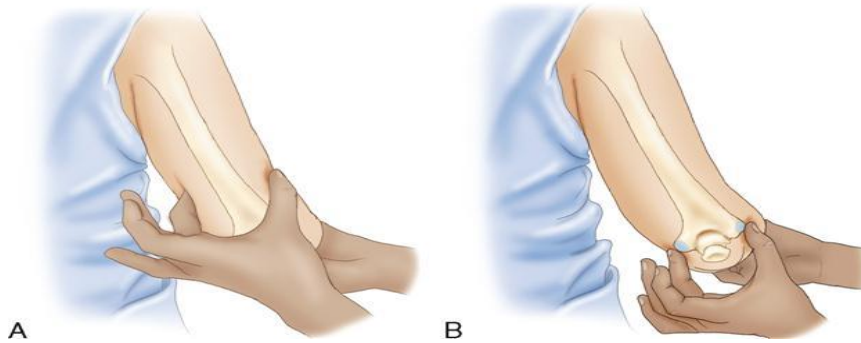
#### POSTEROLATERAL VIEW



Once you are at the inferior angle of the scapula, continue palpating superiorly along the **lateral border of the scapula**. It is easiest to feel the lateral border if your pressure is directed medially. Although challenging, the lateral border of the scapula can usually be palpated all the way to the **infraglenoid tubercle of the scapula**, just inferior to the glenoid fossa of the scapula. To confirm that you are on the infraglenoid tubercle, ask the client to extend the forearm at the elbow joint against resistance to bring out the infraglenoid attachment of the long head of the triceps brachii (you can provide the resistance or the client can provide the resistance by pressing the forearm against his or her own thigh).

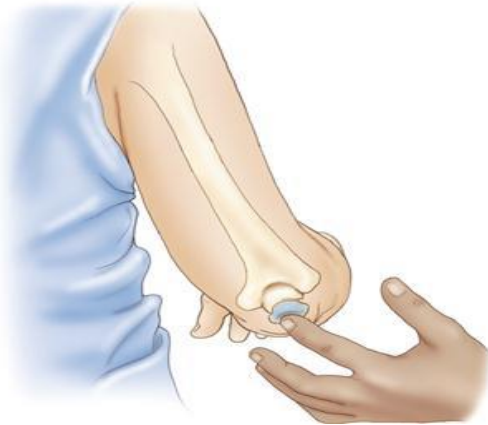### 9. MEDIAL AND LATERAL EPICONDYLES OF HUMERUS

## POSTERIOR VIEW



To locate the **medial and lateral epicondyles of the humerus**, ask the client to flex the forearm at the elbow joint to approximately 90 degrees; place your palpating fingers on the medial and lateral sides of the client's arm (A) and move distally down the client's arm. Your palpating fingers will clearly run into the medial and lateral epicondyles of the humerus; they will prominently be the widest points along the sides of the humerus near the elbow joint (B).

### 10. OLECRANON PROCESS OF ULNA POSTERIOR VIEW

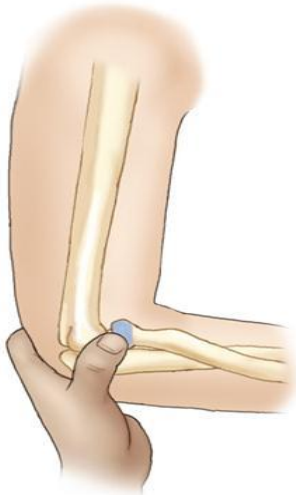


The **olecranon process of the ulna** is extremely easy to locate. With the thumb and middle finger on the medial and lateral epicondyles of the humerus, place your index finger on the olecranon process, located halfway between the two epicondyles. **NOTES:** (1) If the client's elbow joint is flexed, the olecranon process will be located farther distally than the two epicondyles of the humerus. (2) Because of the presence of the ulnar nerve, known in lay terms as the "funny bone," be careful with palpatory pressure between the medial epicondyle of the humerus and the olecranon process of the ulna.

### 11. RADIAL HEAD

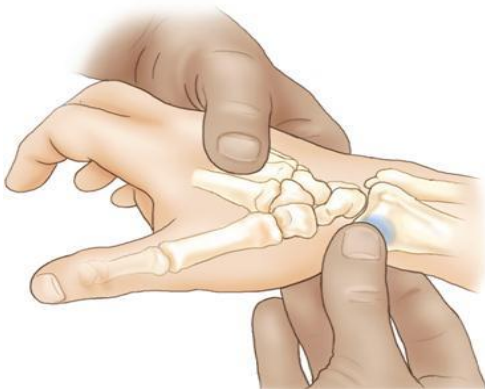

## LATERAL VIEW



The **radial head** lies at the proximal end of the radius. To palpate it, begin at the lateral epicondyle of the humerus and drop immediately distal to it. Feeling the joint space between the head of the radius and the humerus is possible. To bring out the radial head, place two fingers on either side (proximal and distal) of it and ask the client to alternately pronate and supinate the forearm at the radioulnar joints; the spinning of the head of the radius can be felt under your fingers.

## 12. STYLOID PROCESS OF RADIUS LATERAL VIEW

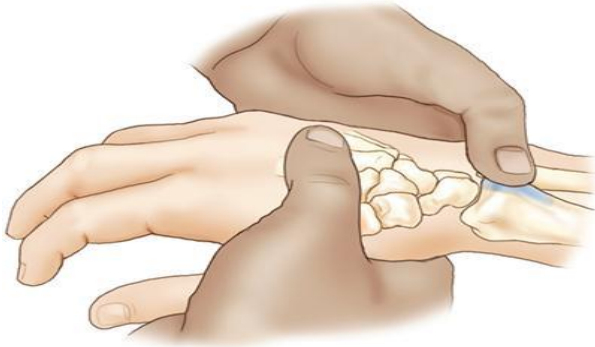

Find the lateral shaft of the radius and continue palpating it distally until you reach the **styloid process of the radius** located at the distal end. NOTE: A small portion of the distal lateral radial shaft is not directly palpable because it is deep to three deep thumb muscles of the posterior forearm.

## 13. DORSAL (LISTER'S TUBERCLE)



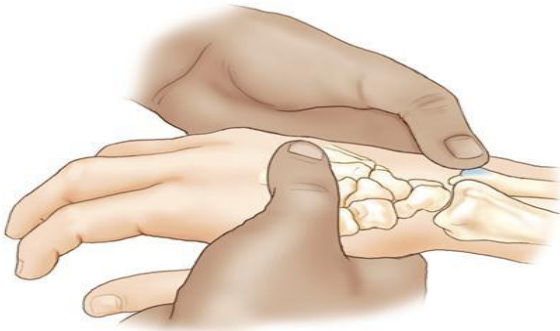
### LATERAL VIEW



The **dorsal tubercle** (also known as **Lister's tubercle**) is located on the posterior side of the distal end of the radius. From the styloid process of the radius, palpate posteriorly onto the radius; the dorsal tubercle will be a prominence located in the middle of the distal posterior radial shaft.

## 14. STYLOID PROCESS OF ULNA

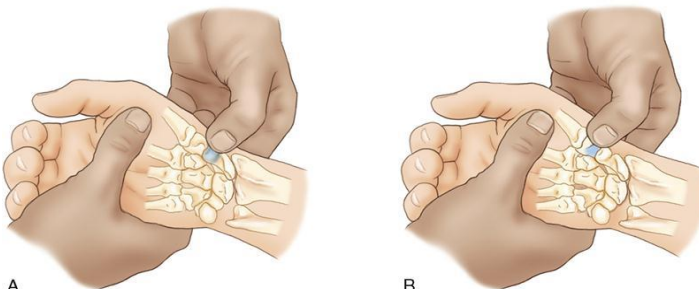
### LATERAL VIEW



The **styloid process of the ulna** is located at the distal end of the ulna on the posterior side. From the dorsal tubercle of the radius, move medially onto the posterior surface of the distal ulna and feel for the prominence of the ulnar styloid.

## 15. TUBERCLES OF SCAPHOID AND TRAPEZIUM

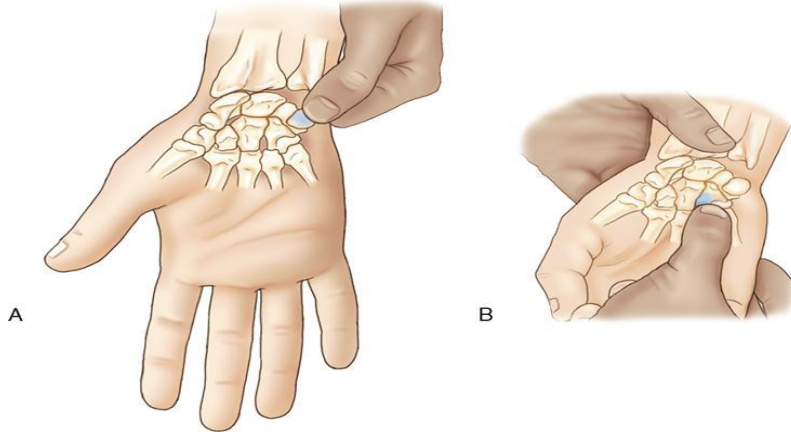
### ANTERIOR (PALMAR) VIEW



The tubercles of the scaphoid and trapezium are prominent and palpable anteriorly on the hand. To locate them, palpate the lateral (radial) surface of the anterior hand and feel for two bony prominences. *A*, The **tubercle of the scaphoid** is the smaller, more proximal one of the

two. *B*, The **tubercle of the trapezium** is the larger, more distal bony prominence. **NOTE:** The tubercle of the trapezium is located approximately  $\frac{1}{2}$  inch distal to the tubercle of the scaphoid.

## 16. PISIFORM AND HOOK OF HAMATE ANTERIOR (PALMAR) VIEW



The **pisiform** is a carpal bone located anteriorly on top of the triquetrum in the proximal row of carpals on the ulnar side. The pisiform is prominent and easily palpated on the anterior side of the wrist, just distal to the ulna (*A*). The hamate is also easily palpated anteriorly in the palm. Specifically, the **hook of the hamate** is palpable here. Begin by locating the pisiform; then palpate approximately  $\frac{1}{2}$  to  $\frac{3}{4}$  inch distal and lateral (i.e., toward the midline of the hand) from the pisiform (*B*). **NOTE:** The hook of the hamate is fairly pointy and can be somewhat tender to palpation.

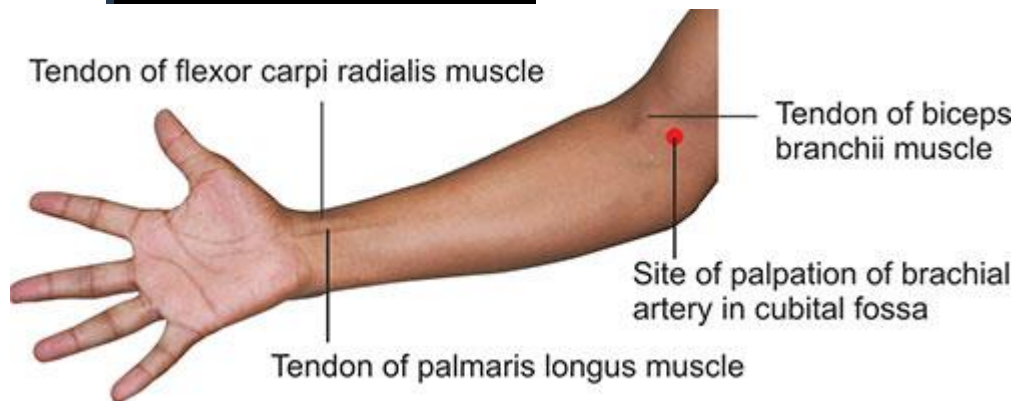
## 17. FLEXOR CARPI RADIALIS



In order to feel this muscle, bend your wrist and make a fist. Now you should be able to see and feel a couple of tendons appearing at your wrist.

Feel the outer one – that is closest to your thumb – and follow its entire length down your forearm. After a couple of centimeters, the tendon will transfer into the muscle belly. That muscle is your flexor carpi radialis. You should be able to palpate it all the way down to your medial epicondyle.

## 18. BRACHIAL ARTERY



The brachial pulse is commonly taken when you check blood pressure. It's also the easiest way to check for a pulse in infants. Taking the brachial pulse is no different from checking the pulse in your wrist or neck. It just takes some practice feeling around your inner arm for the beat of the brachial artery.

- **Extend an arm and tilt it so that your inner elbow faces upward.** Relax your arm and bend it very slightly at the elbow. It doesn't need to be rigid. You should be able to see and easily reach the crease of the elbow, also known as the cubital fossa
- **Place 2 fingers on your upper arm just above the cubital fossa.** Feel around in the area just above the crease of the elbow. You should feel a slight indent in between the bicep and your brachialis muscles, which is right above the inside of your elbow. These muscles should meet at about the midpoint of the cubital fossa

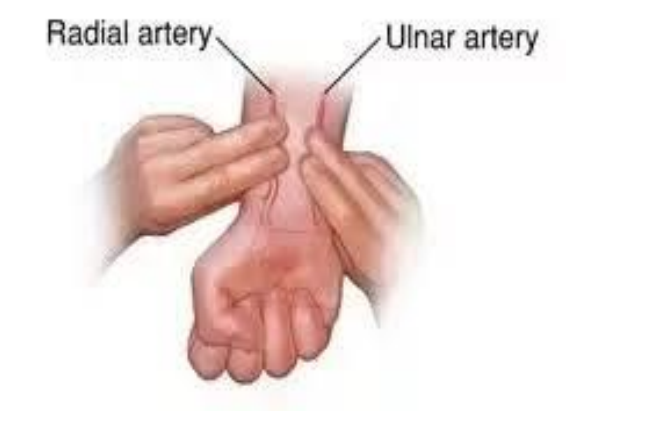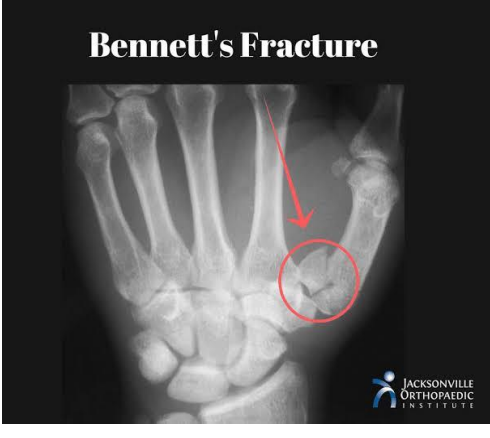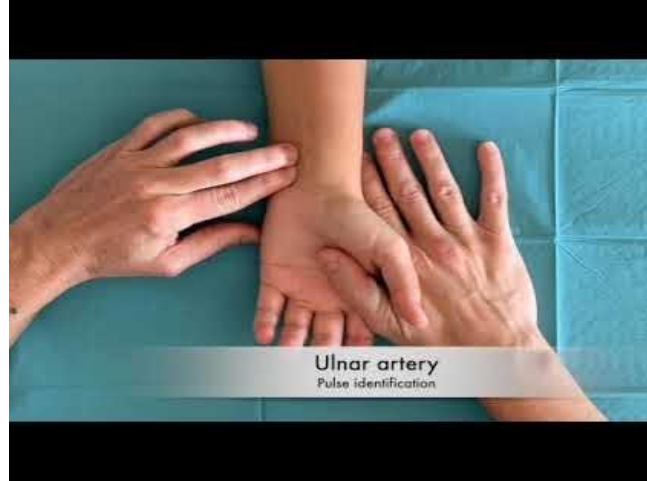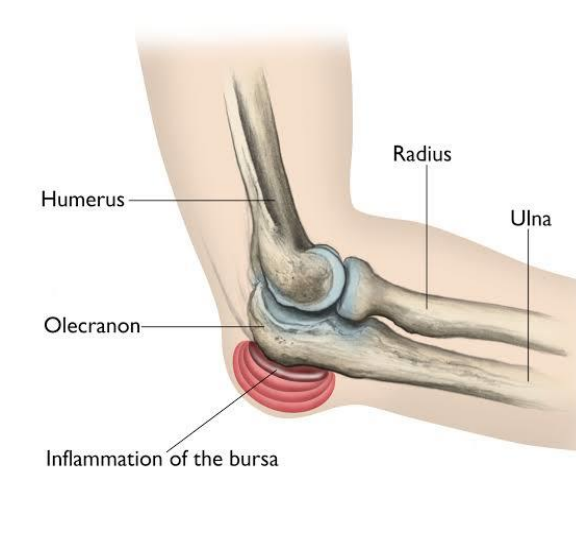
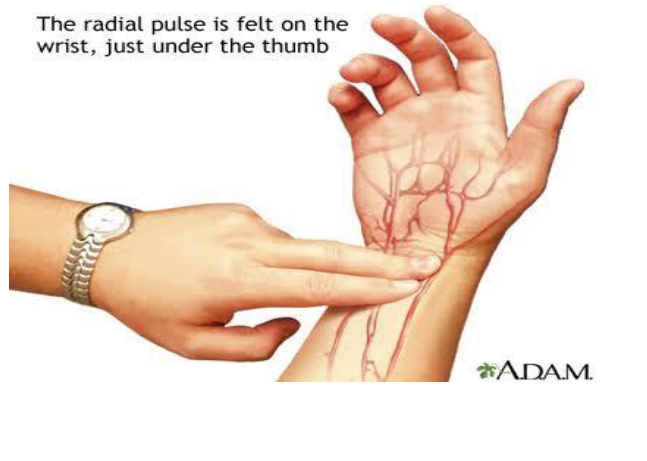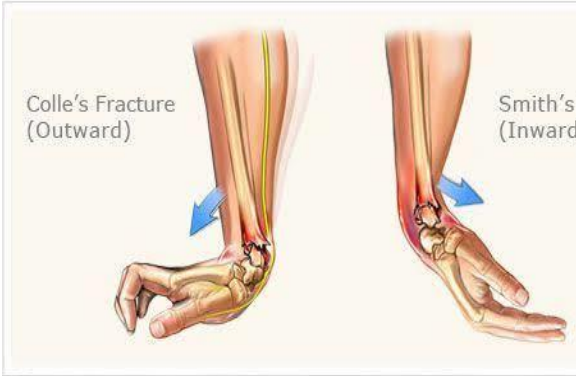
**Hold your fingers still to feel for a beat.** The pulse indicates that you've found the brachial artery. The beats will be slight, similar to the pulse on your wrist or neck.[3]

- If you've never taken a pulse before, feel for your pulse on your neck. This is where a pulse is generally easiest to feel. It should be detectable on either side of your throat. This gives you an idea of the beat you should feel in the arm

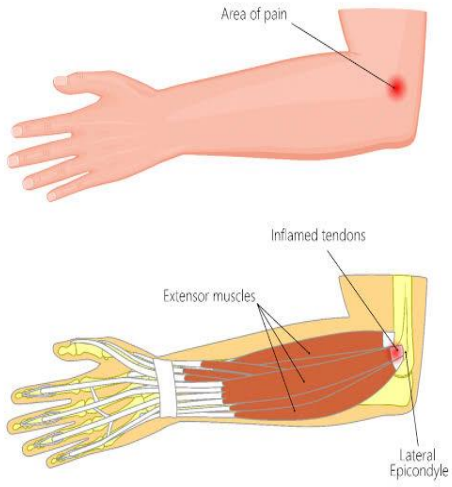
## 19. RADIAL ARTERY

The radial pulse can be felt by gently palpating the radial artery against the underlying muscle and bone.

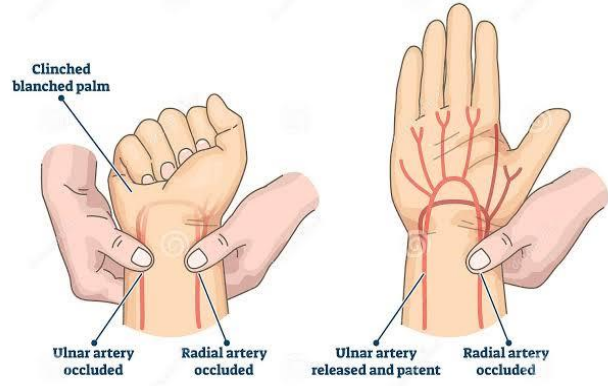
# VISUAL CLINICALS DEMONSTRATION OF UPPER LIMB



**TENNIS ELBOW  
(LATERAL EPICONDYLITIS)**



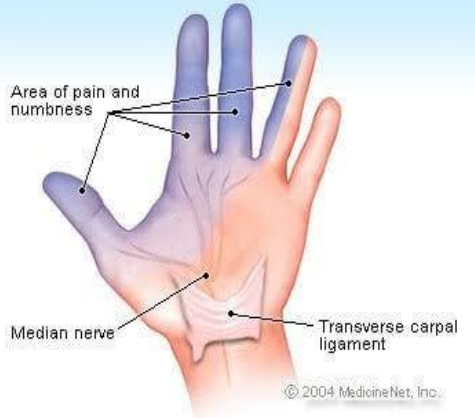
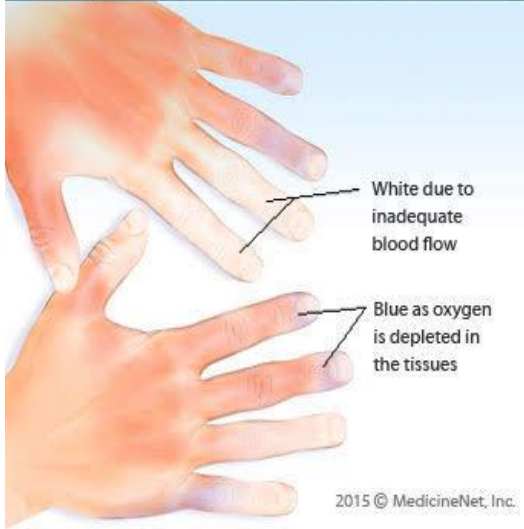**ALLENS TEST**



© dreamstime.com

ID 176109988 © VectorMine

**Raynaud's Phenomenom**



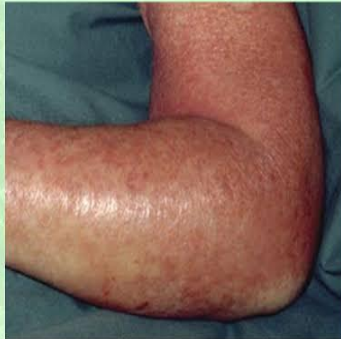
© 2004 MedicineNet, Inc.

**Carpal Tunnel Syndrome**

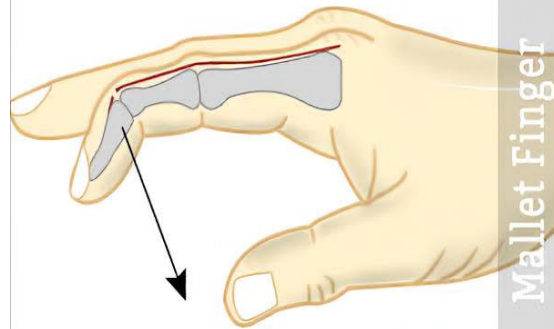


### Spontaneous Thrombosis of the Axillary Vein

Occasionally occurs after excessive and unaccustomed movements of the arm at the shoulder joint.



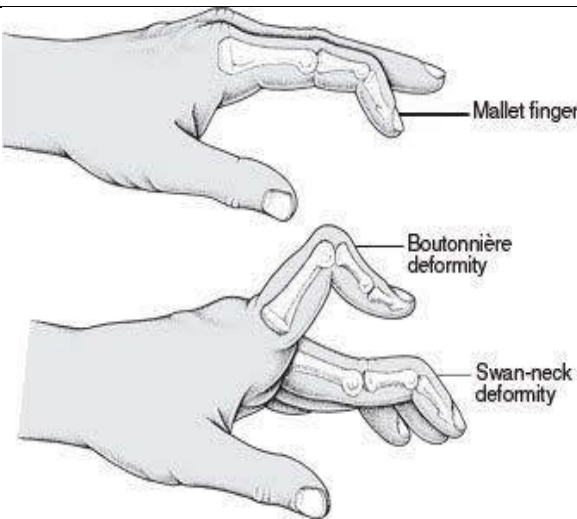
MEDICAL-ON-LINE/ALAMY



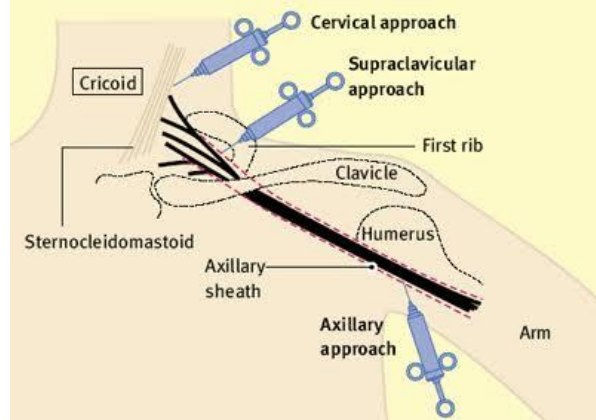
Mallet Finger

Mallet Finger / Baseball Finger

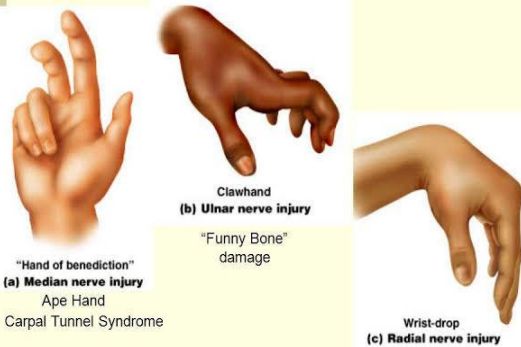
© www.medindia.net



### Surface anatomy of the brachial plexus emphasizing the approaches for brachial plexus block

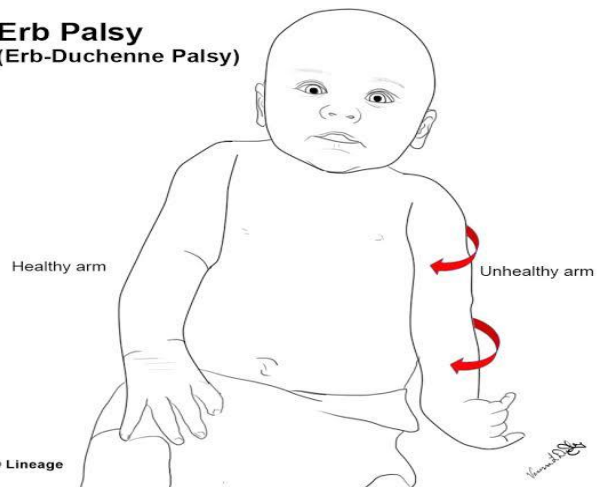


### Peripheral damage to the Brachial Plexus



Walters tip deformity seen in Erb's palsy

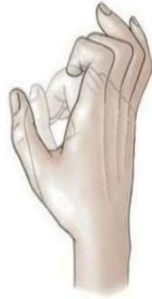### Erb Palsy (Erb-Duchenne Palsy)



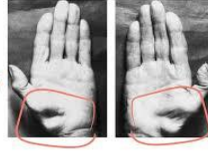
© Lineage

## KLUMPKE'S PALSY

- Named after augusta déjerine-klumpke, it is a variety of partial palsy of the lower roots of the brachial plexus.
- Results from a brachial plexus injury in which C8 and T1 nerves are injured.
- Affects, principally, the intrinsic muscles of the hand and the flexors of the wrist and fingers.
- The classic presentation of klumpke's palsy is the "claw hand" where the forearm is supinated and the wrist and fingers are hyperextended with flexion at interphalangeal and metatarso phalangeal joints.

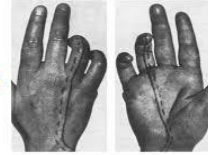

### Median Neuropathy



THUMB PAD ATROPHY, SO-CALLED "APE-HAND"

### Ulnar Neuropathy



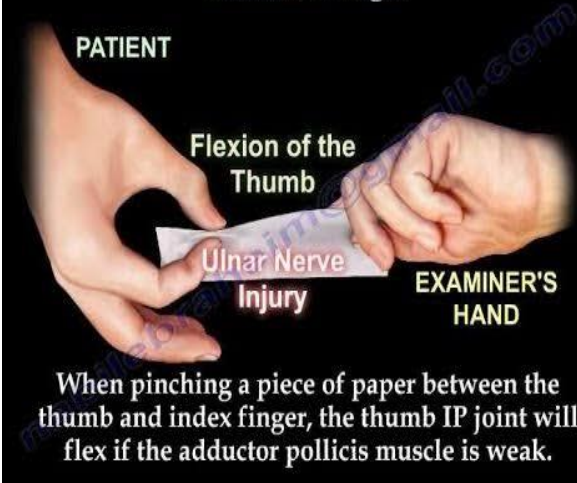POPE'S BLESSING, SO-CALLED "BENEDICTION SIGN" OR "ULNAR CLAW"

### Radial Neuropathy



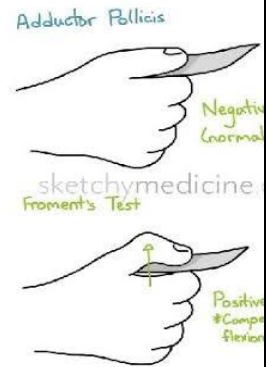
EXTENSOR MUSCLE WEAKNESS CAUSES WRIST DROP

## Froment's Sign



## Froment's sign

To perform the test, a patient is asked to hold an object, usually a flat object such as a piece of paper, between their **thumb** and index finger (pinch grip). The examiner then attempts to pull the object out of the subject's hands.<sup>[2]</sup>



Froment's sign : hyperflexion of IP jt of thumb while attempting a lateral pinch (indicates paralysis of adductor pollicis, 1st D1, with replacement of pinch function by FPL)

## TYPES OF CLAW HAND

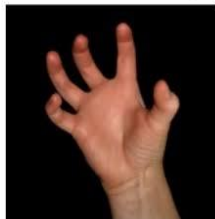### partial:

- Involving only ulnar 2 digits as in isolated ulnar nerve palsy



### Complete

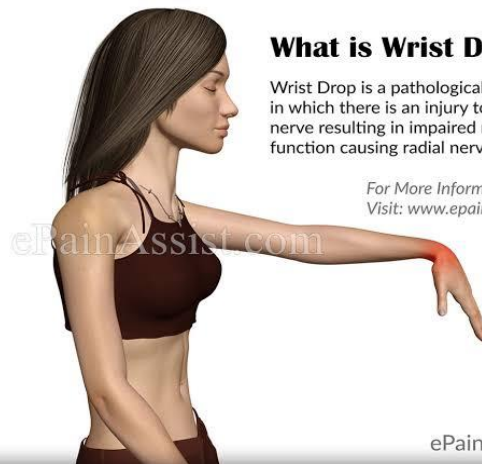
- Involving all digits and resulting form combined ulnar and median nerve palsy



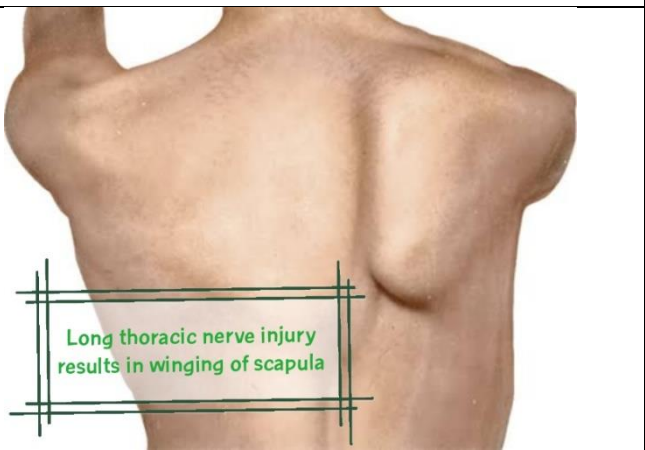
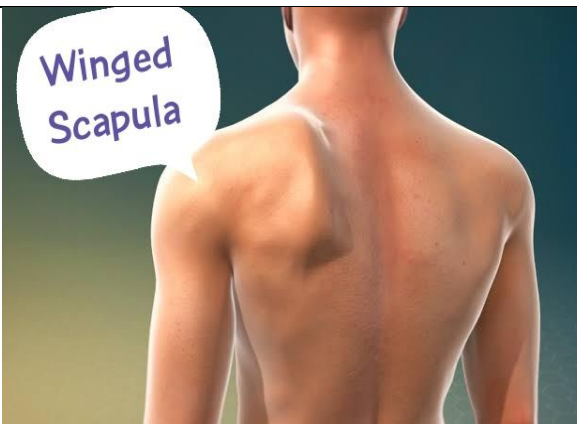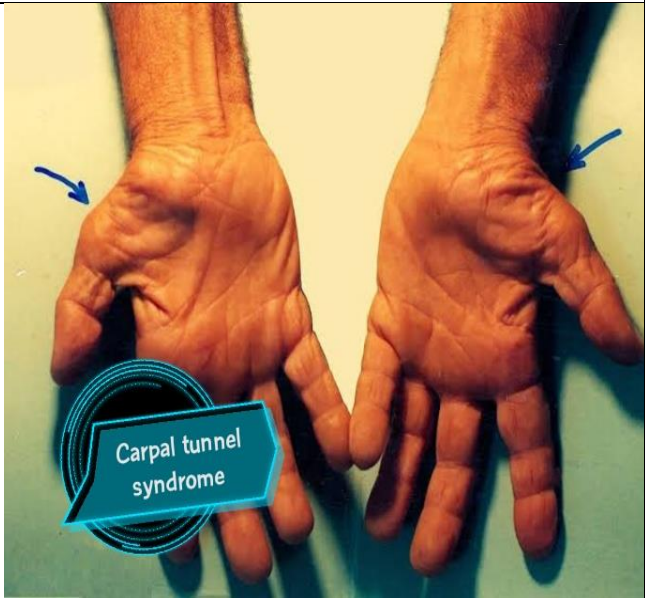
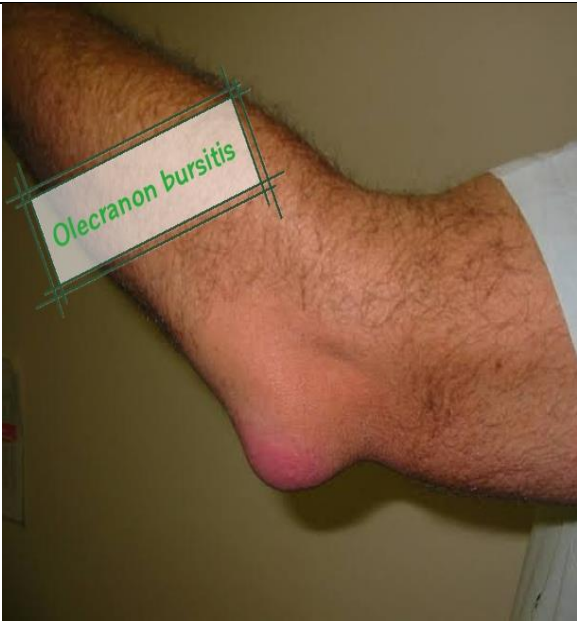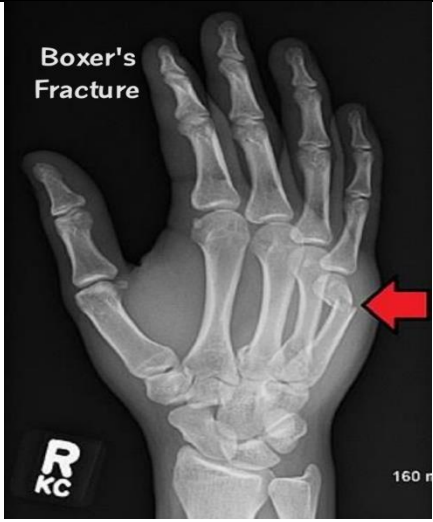## What is Wrist Drop?

Wrist Drop is a pathological condition in which there is an injury to the radial nerve resulting in impaired nerve function causing radial nerve palsy.

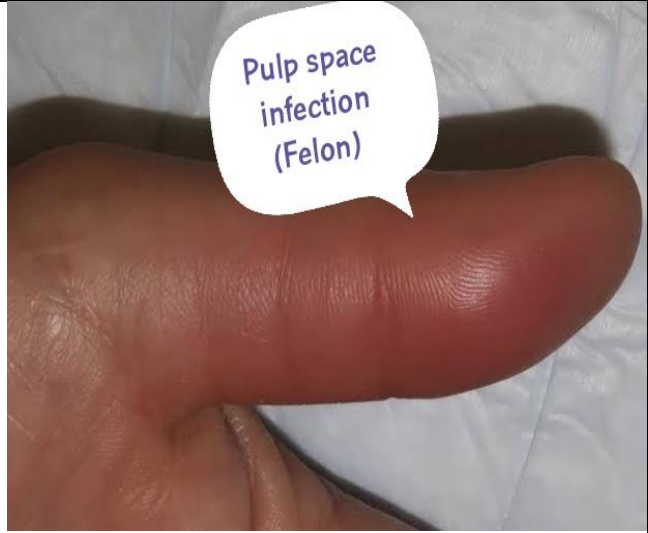
For More Information, Visit: [www.epainassist.com](http://www.epainassist.com)



ePainAssist.com







### MAMMOGRAPHY

**S.com**  
tacy

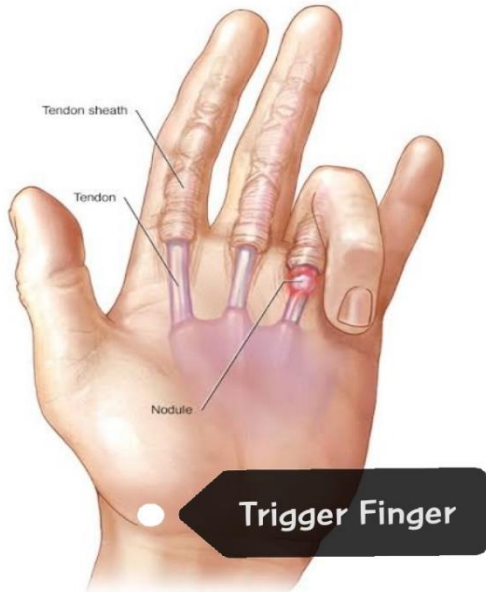
X-ray Source  
X-ray  
Compression Plates  
X-ray Detector

Normal mammogram	Benign cyst (not cancer)
Cancer	Calcium

A mammography exam, called a mammogram, aids in the early detection and diagnosis of breast diseases in women and men.


(A) (B) (C)

Volkmann's Ischemic Contracture



© MAYO FOUNDATION FOR MEDICAL EDUCATION AND RESEARCH. ALL RIGHTS RESERVED.

Typical Characteristic of Median nerve Injury is **Hand of Benediction**



Median nerve palsy



Normal

