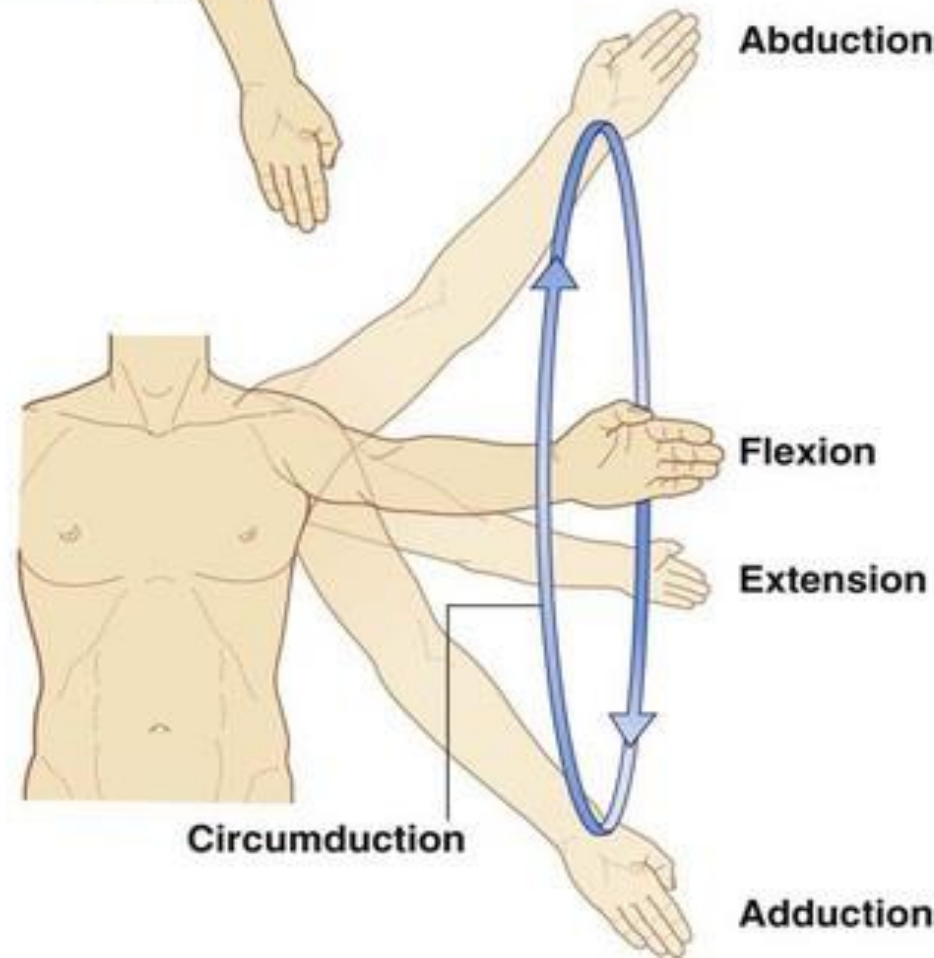
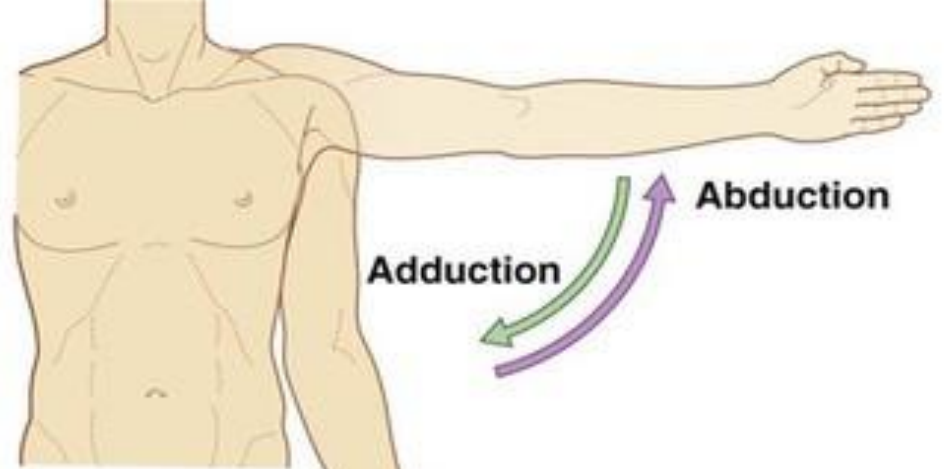
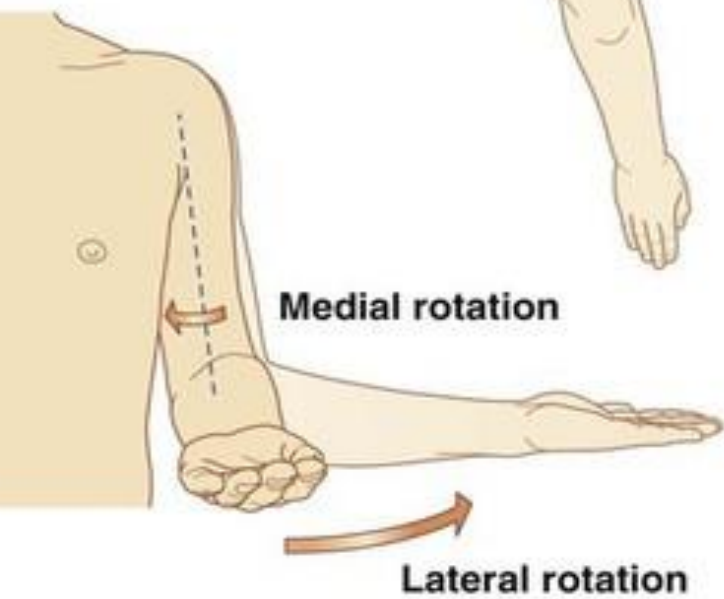
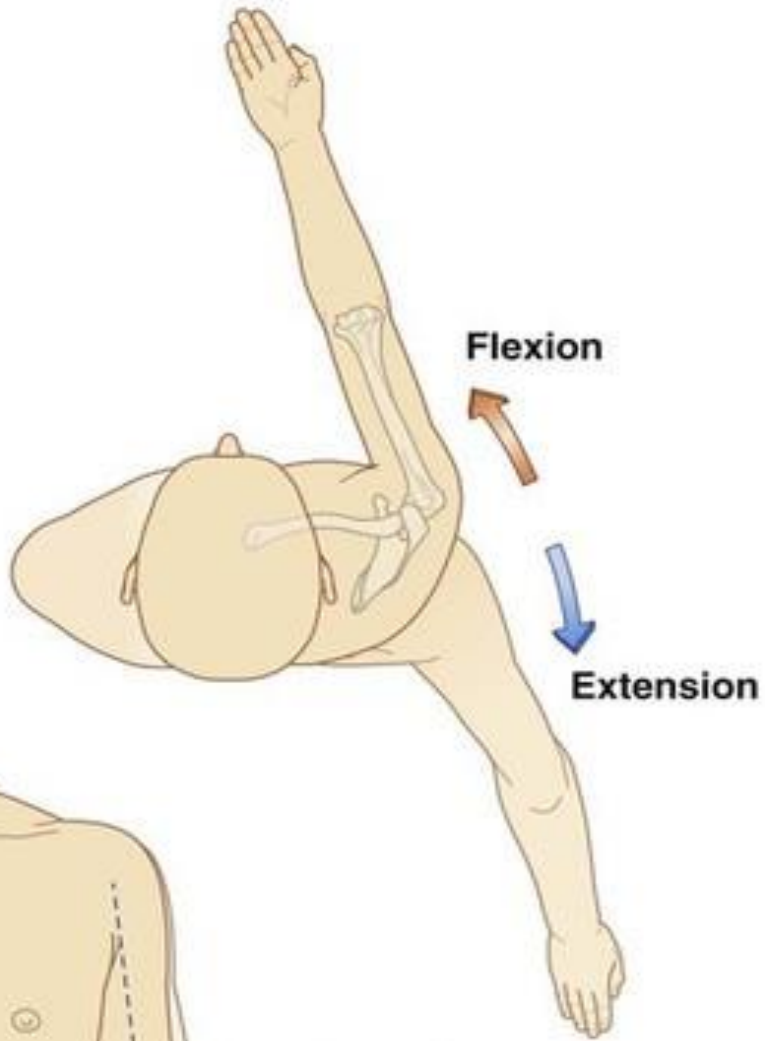


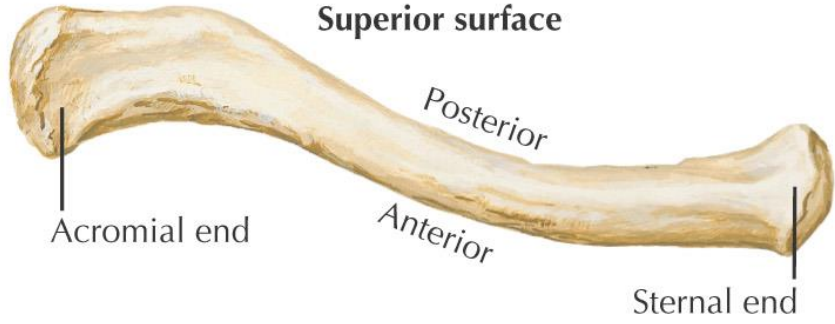
# Upper Limb Arm Region

By

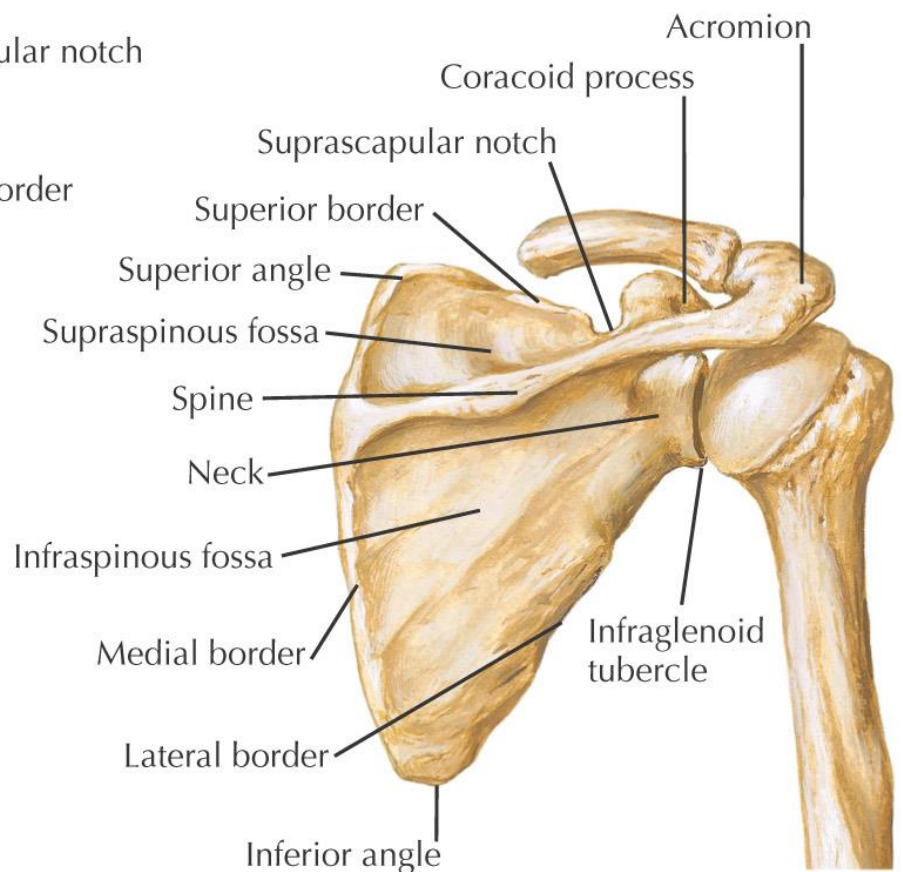
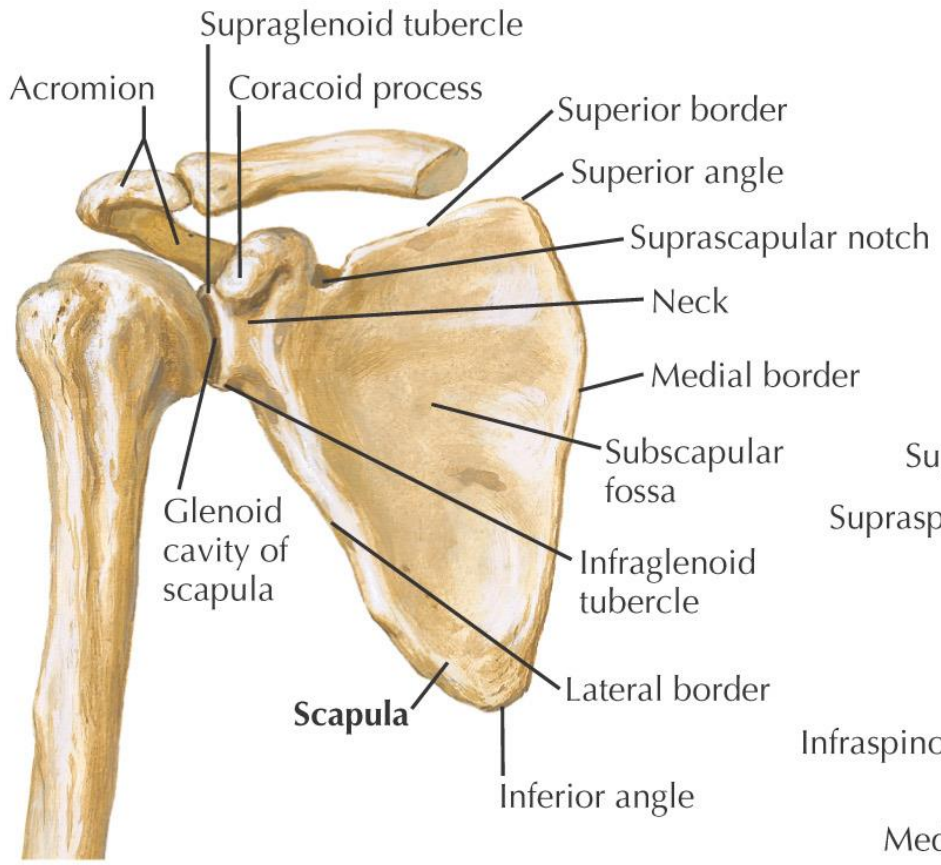
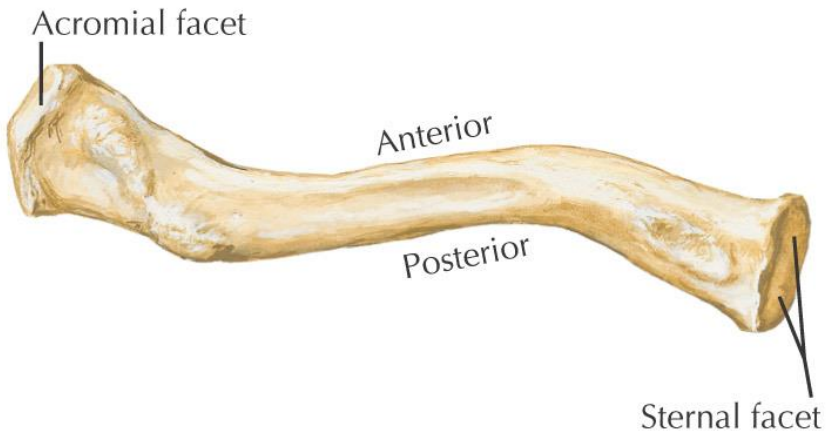
Dr Qaisar Zaman Afridi



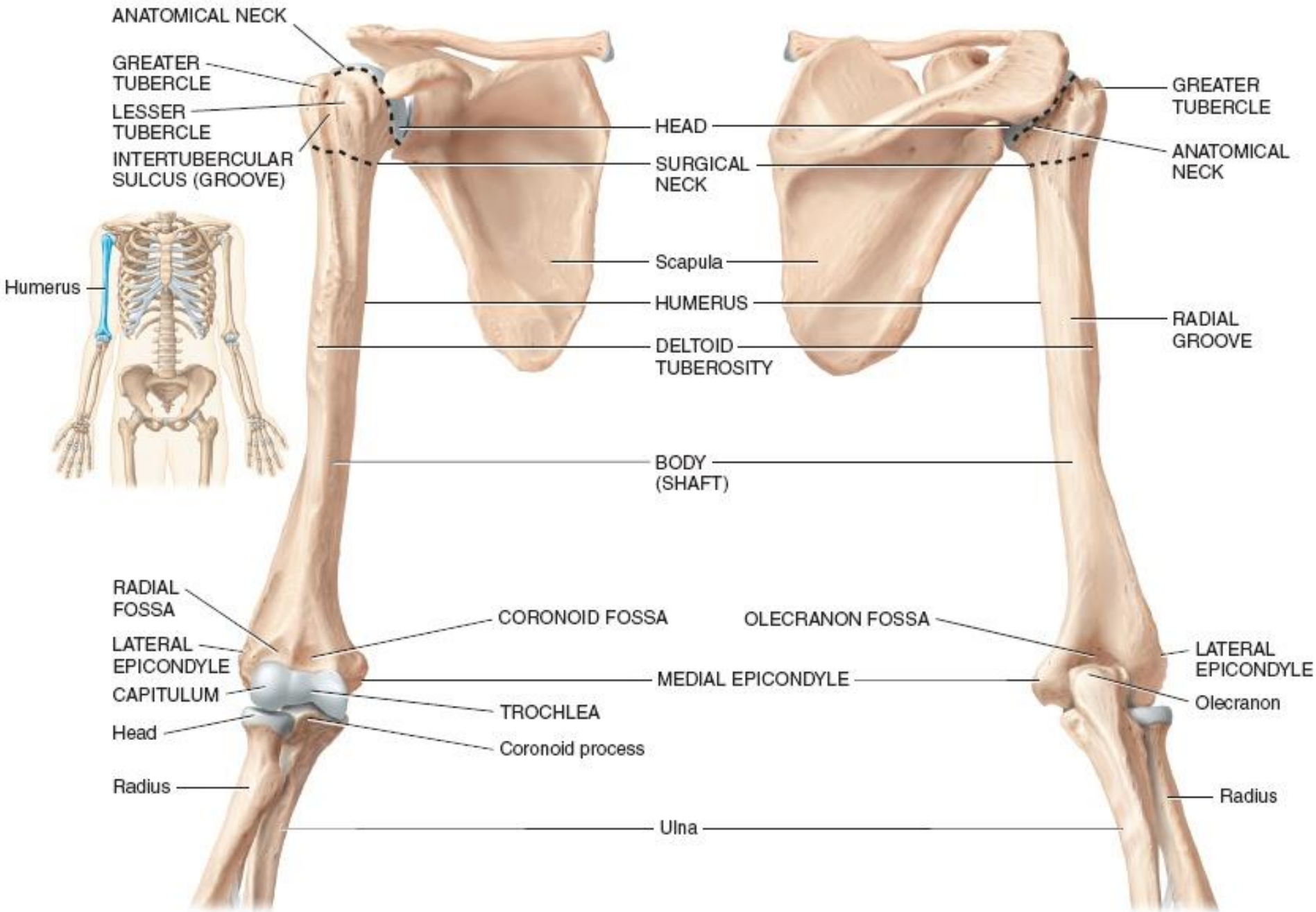
**Superior surface**



**Inferior surface**



*F. Netter M.D.*

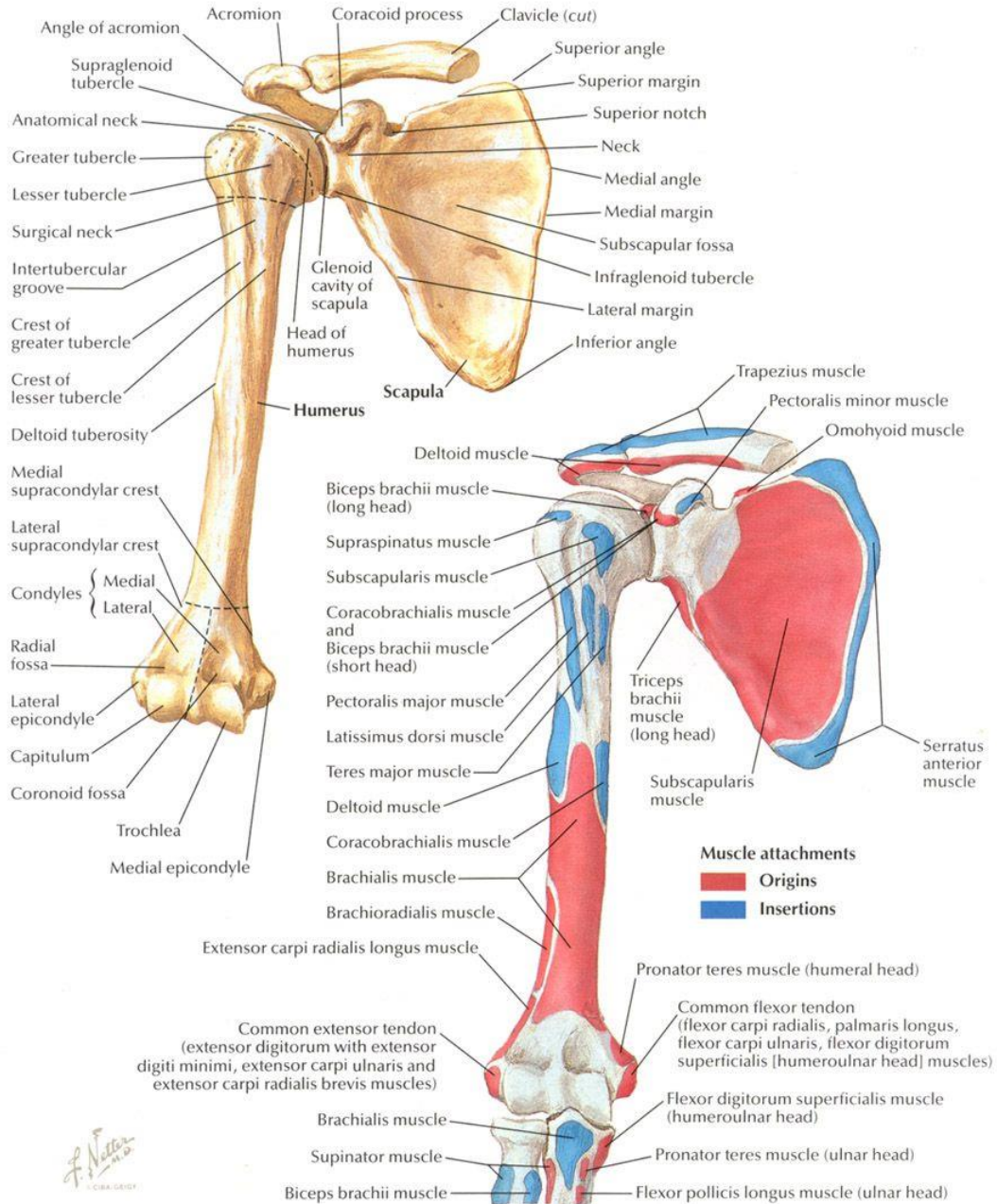


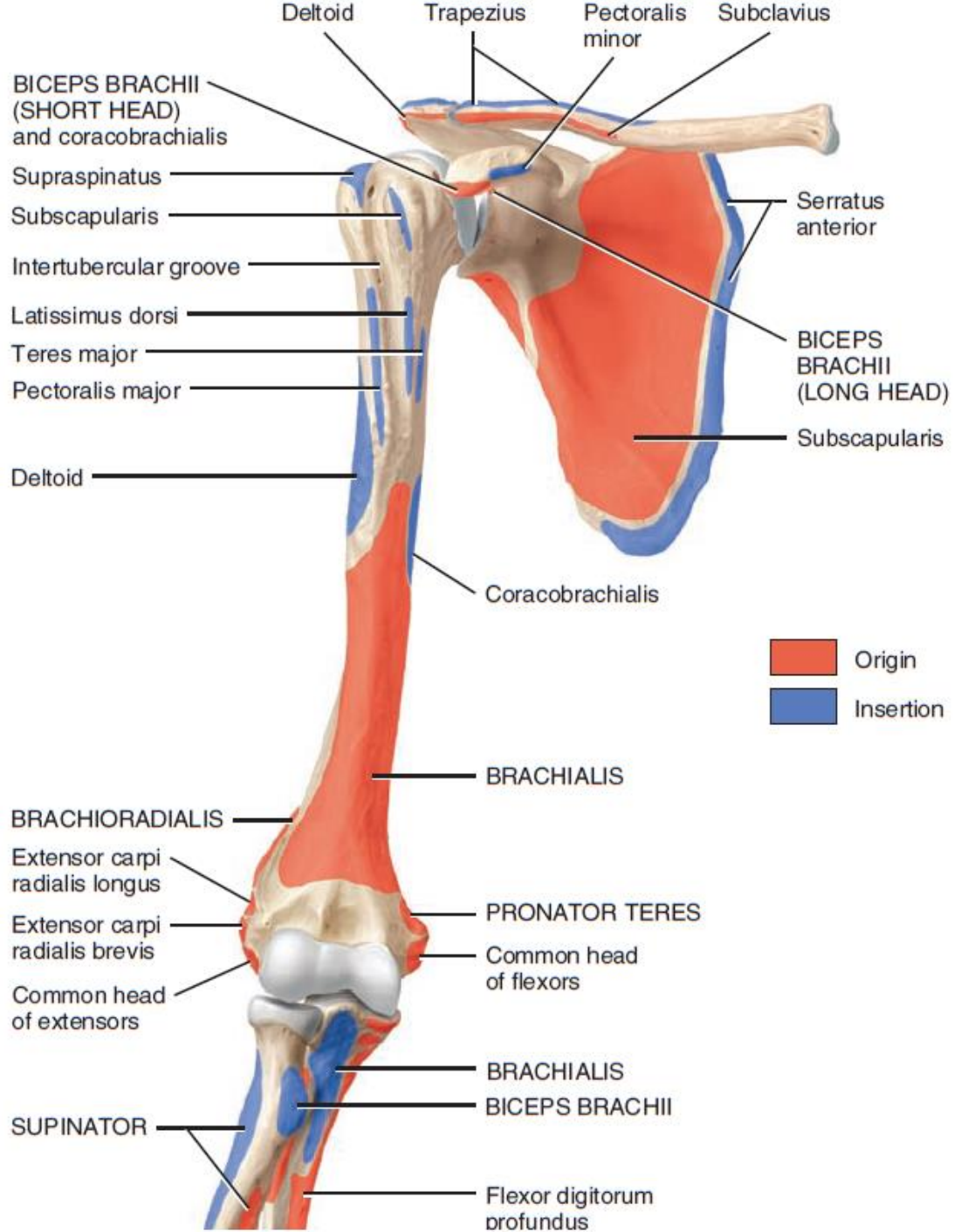
(a) Anterior view

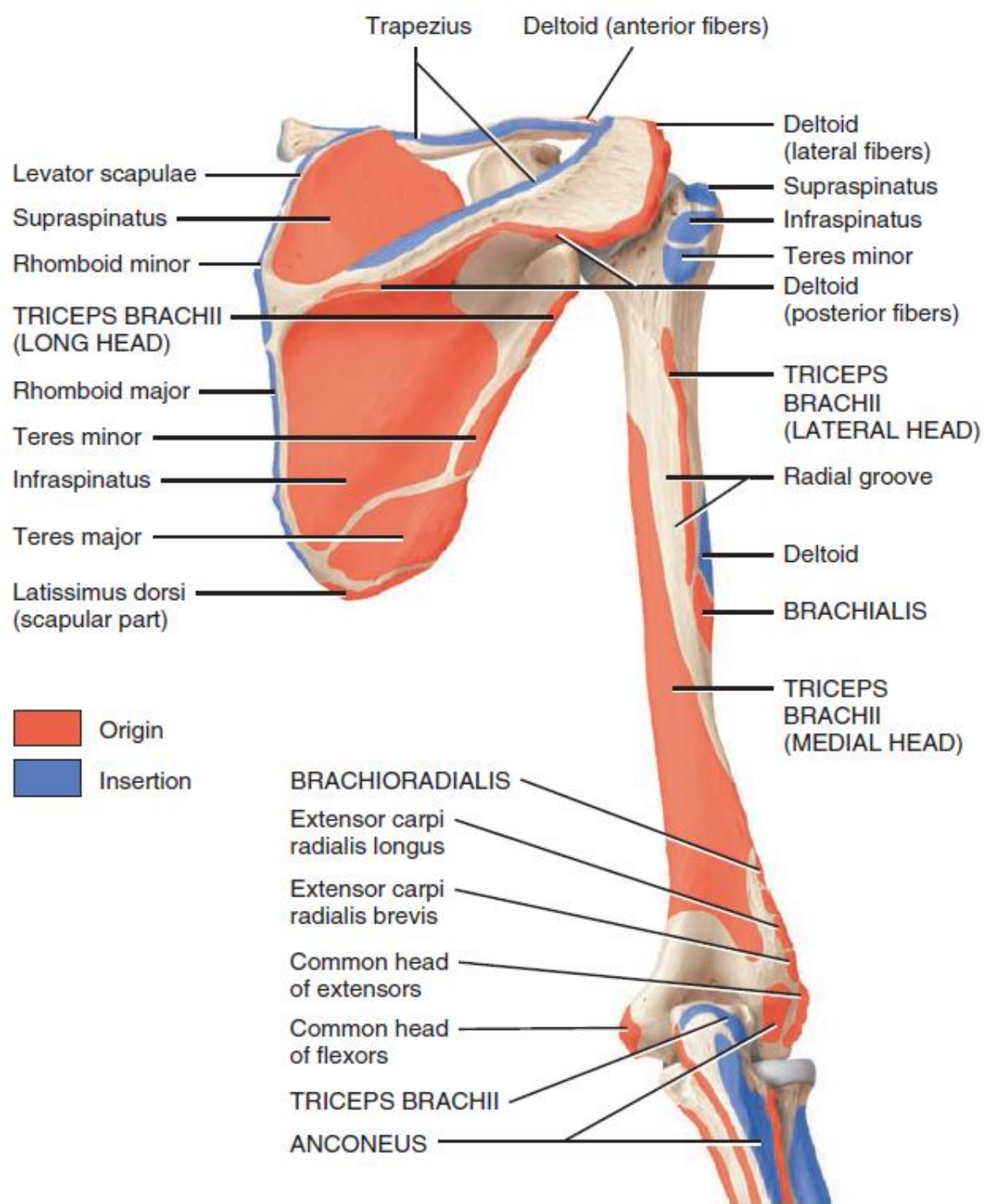
(b) Posterior view

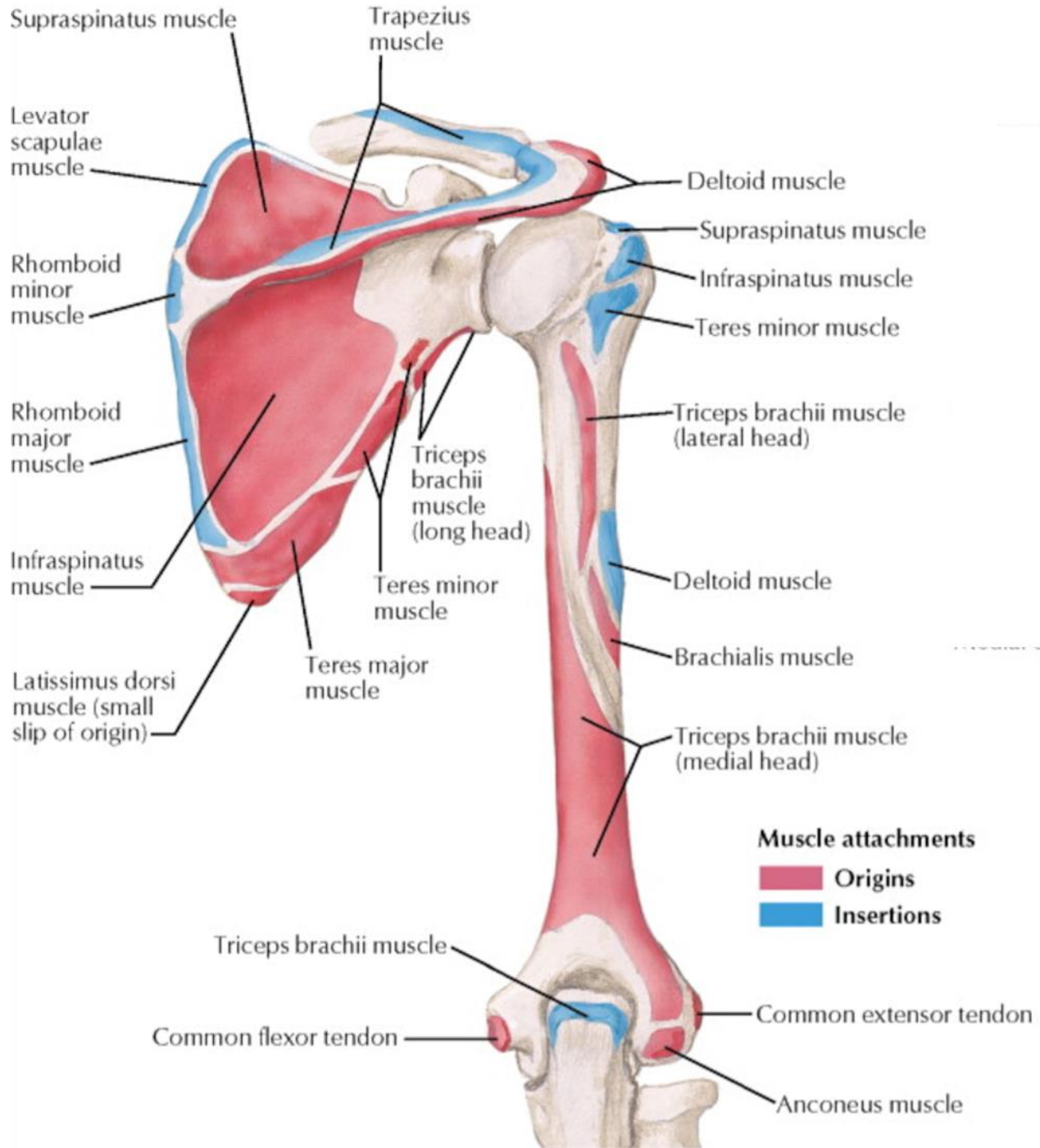
# Humerus and Scapula: Anterior Views

SEE ALSO PLATE 170

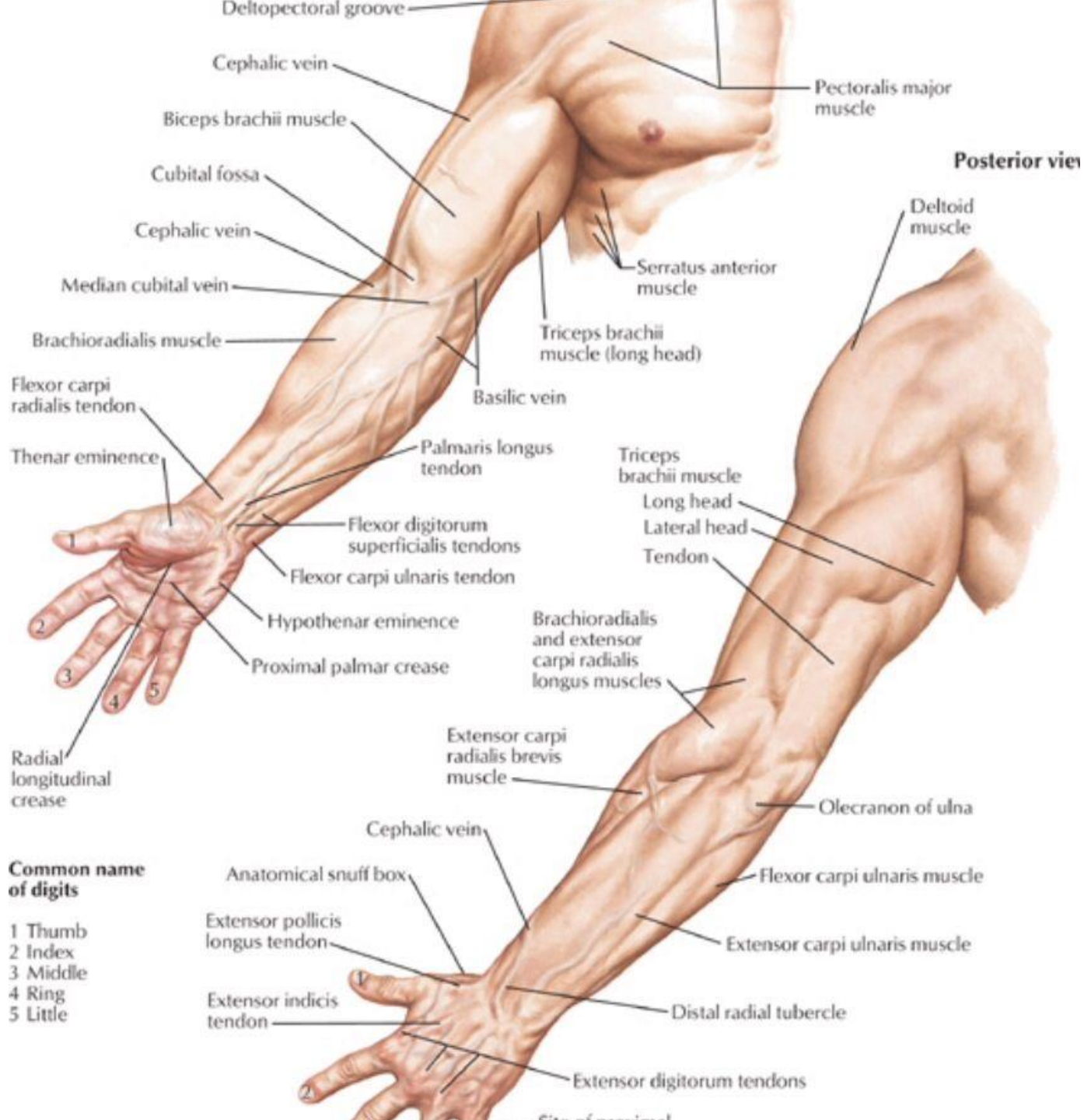


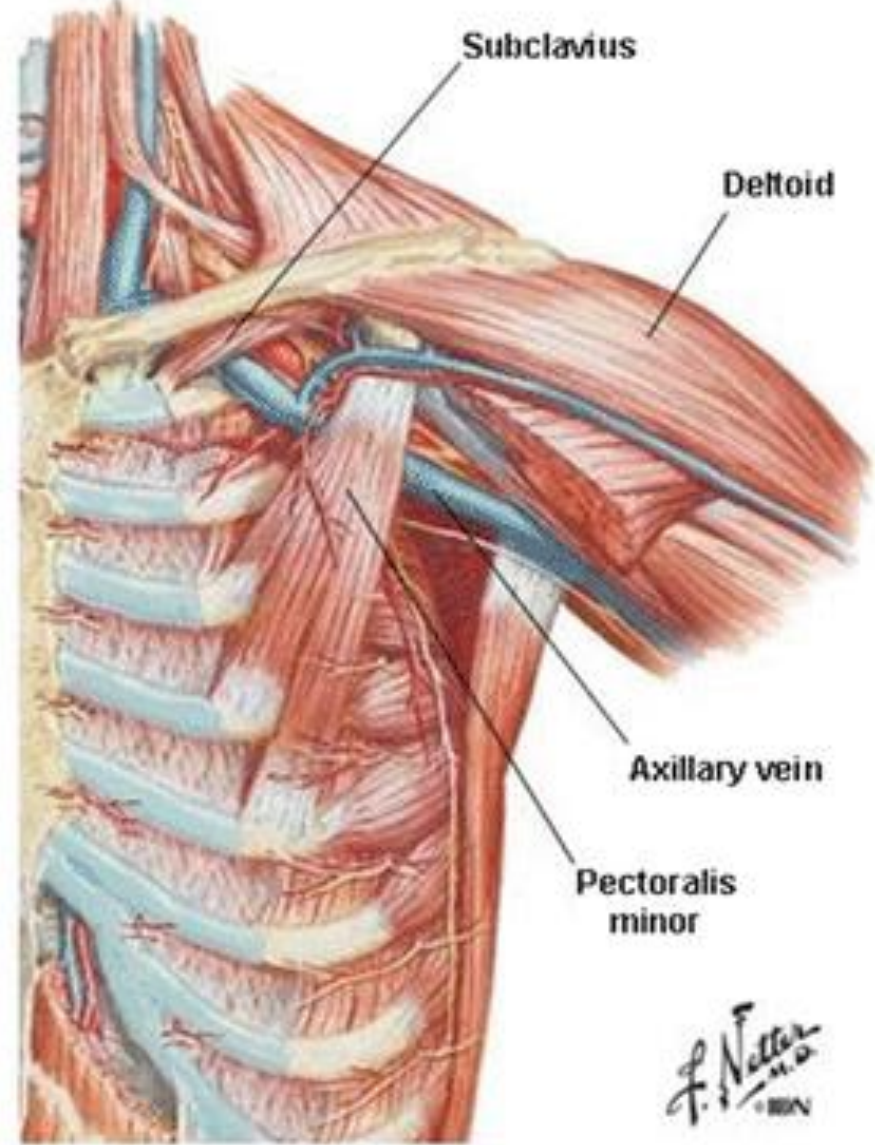
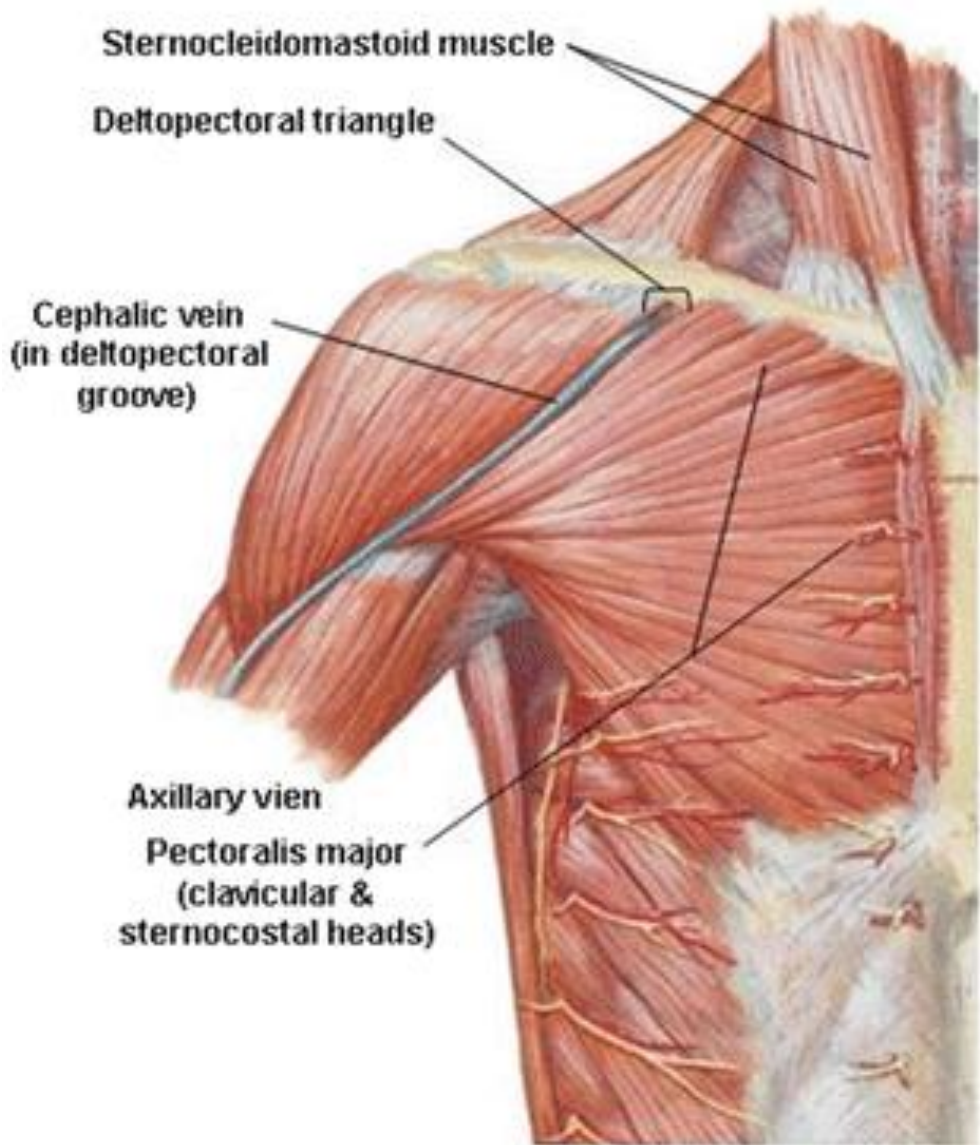


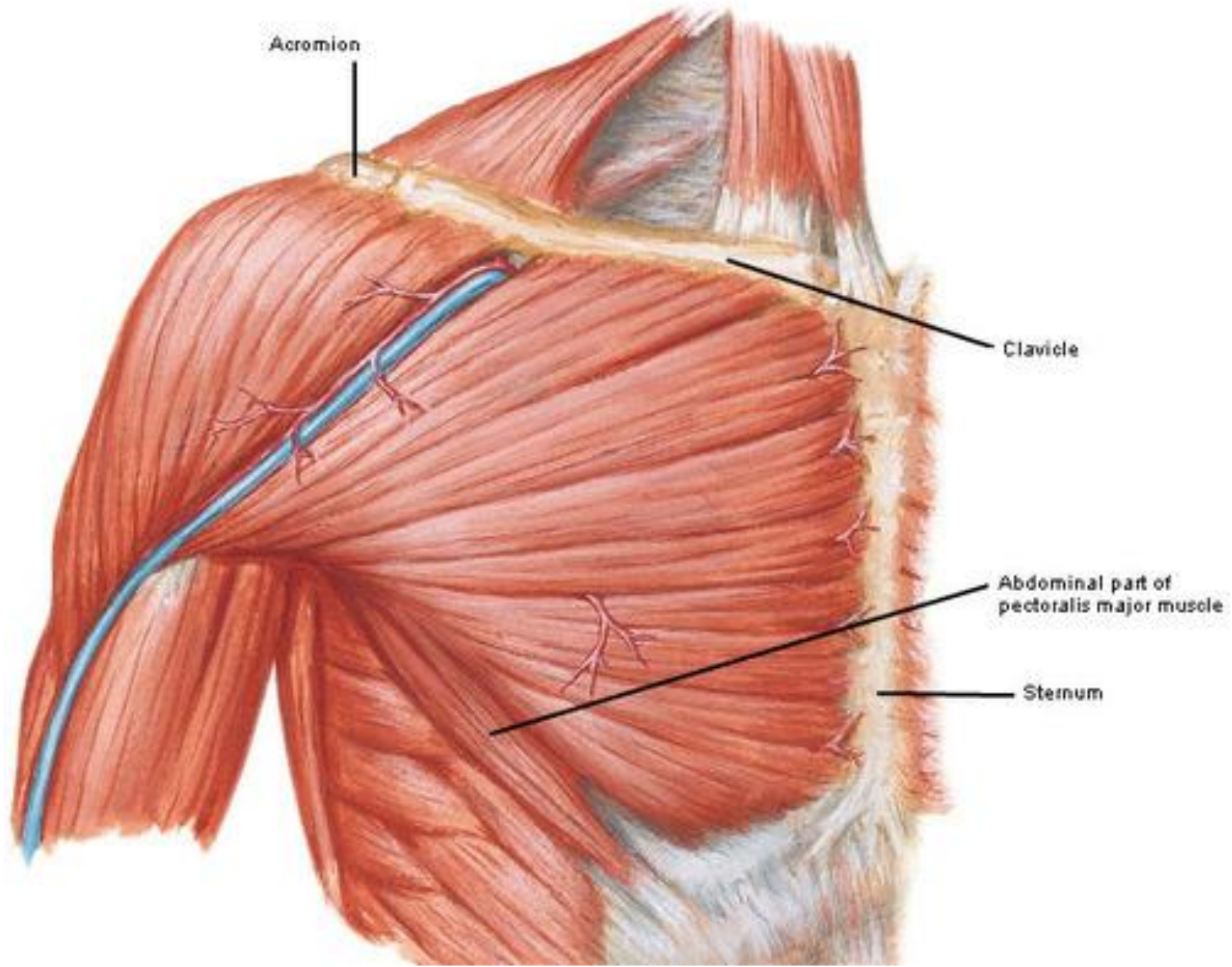


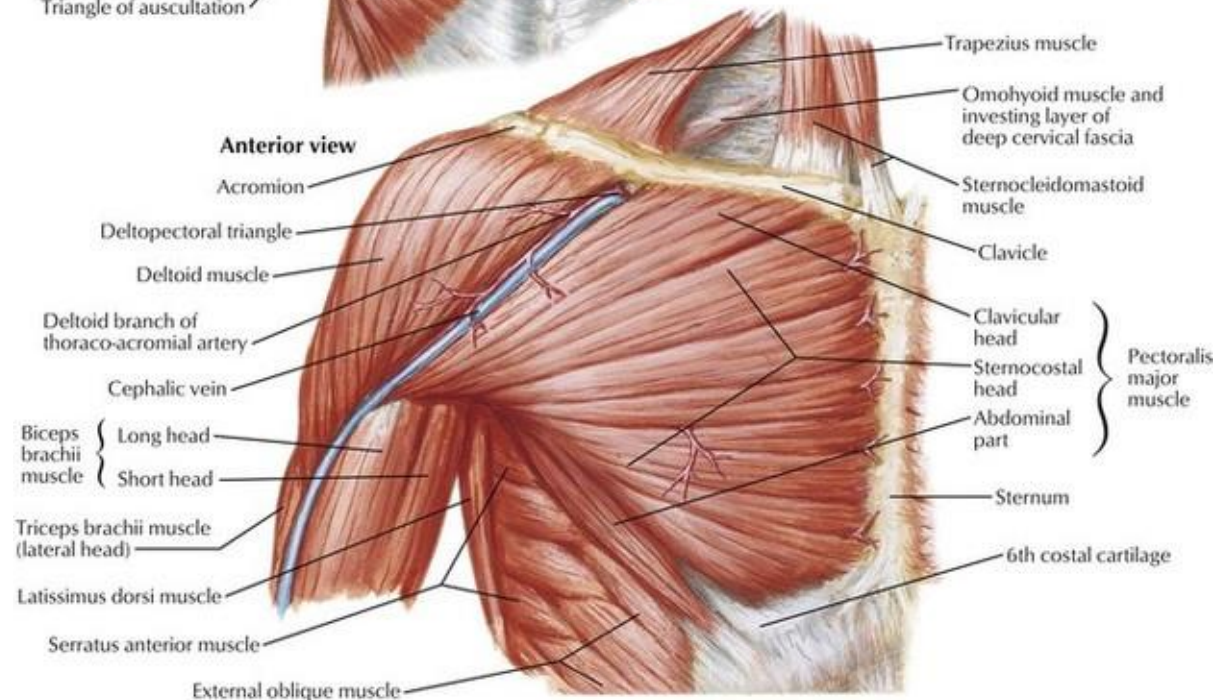
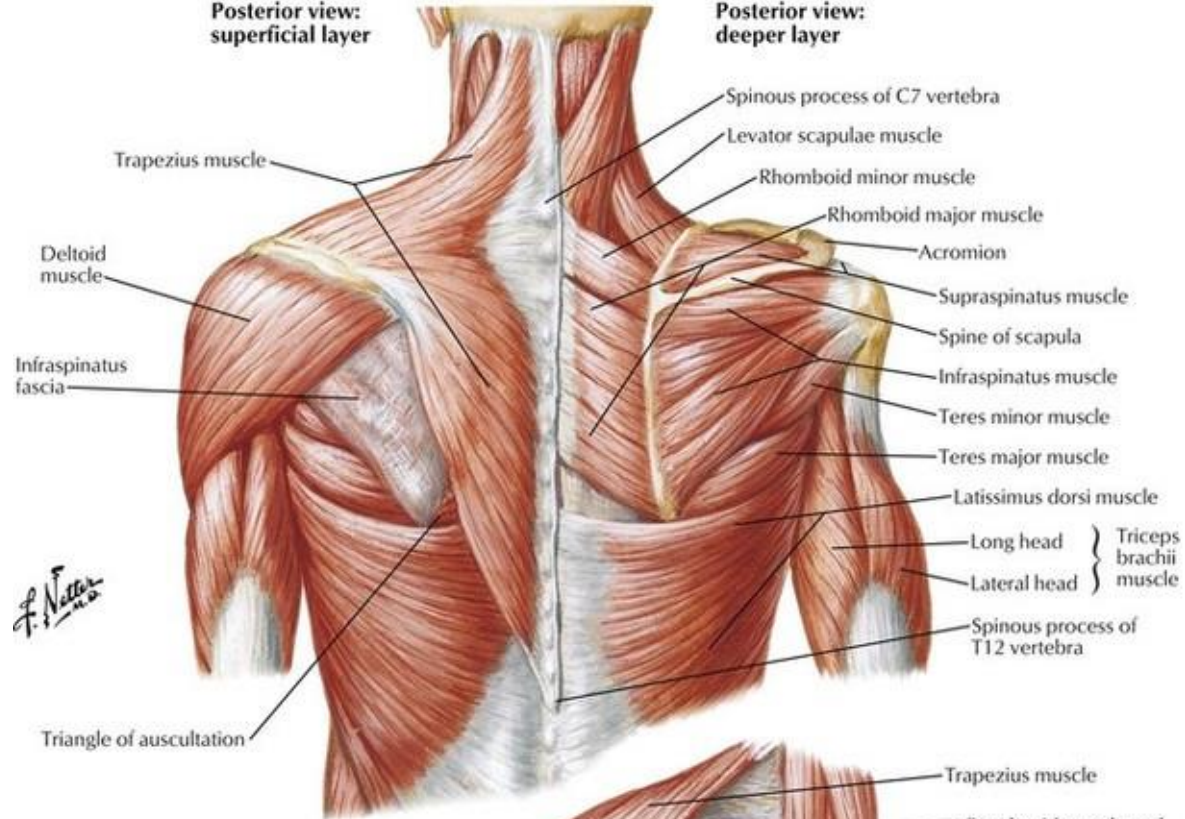






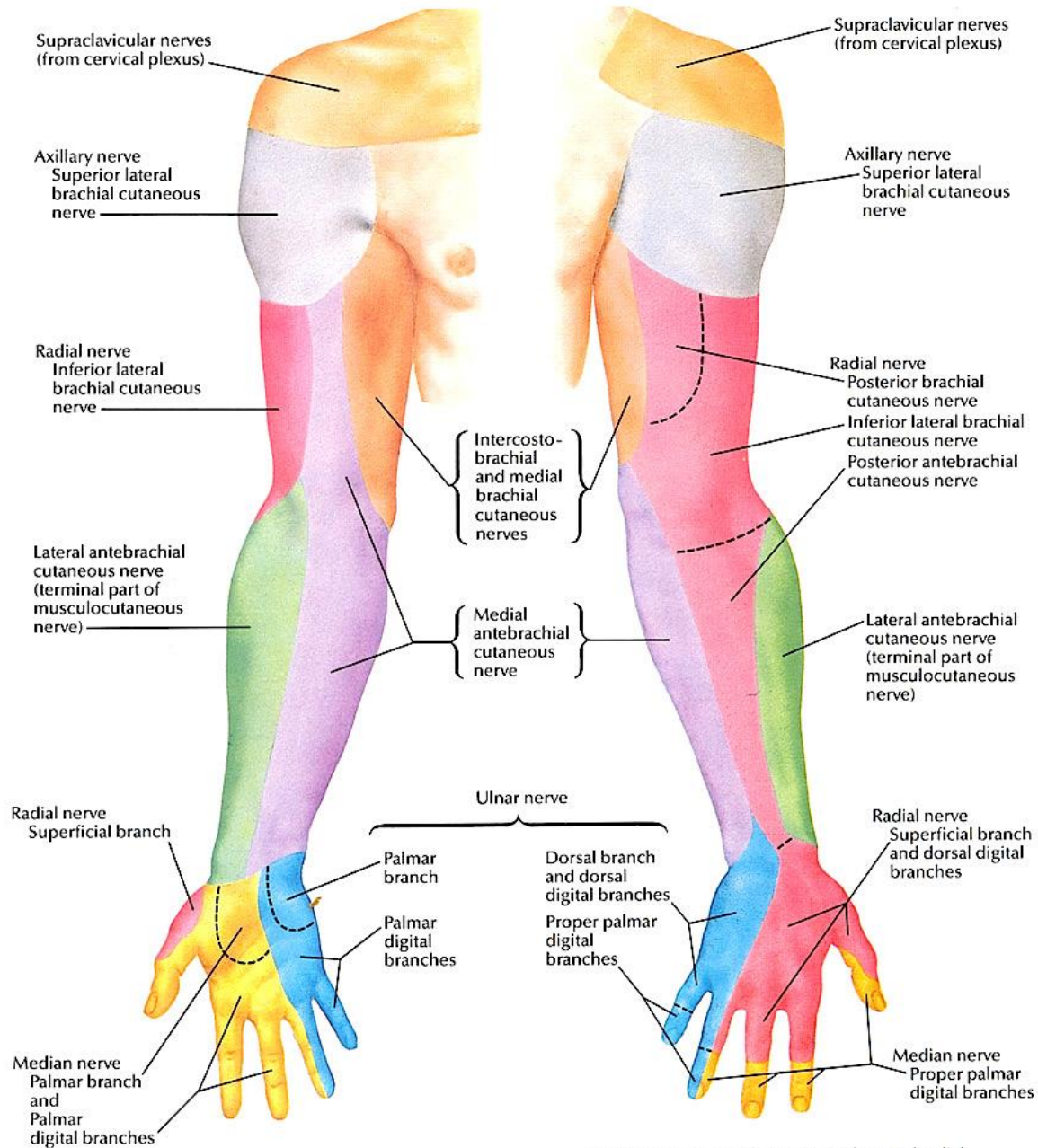




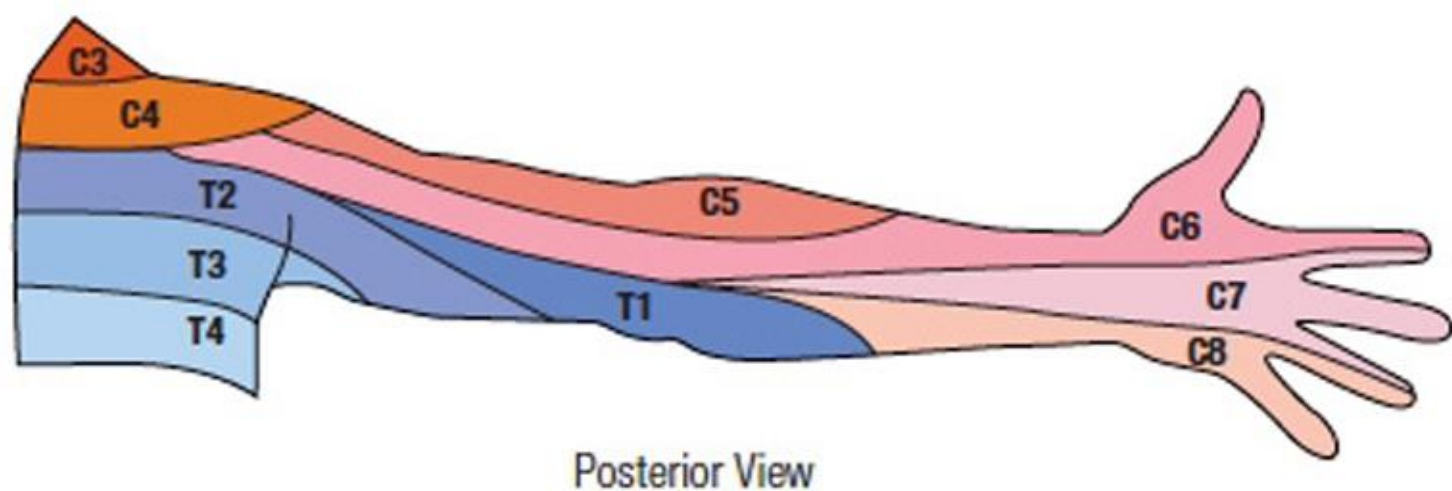
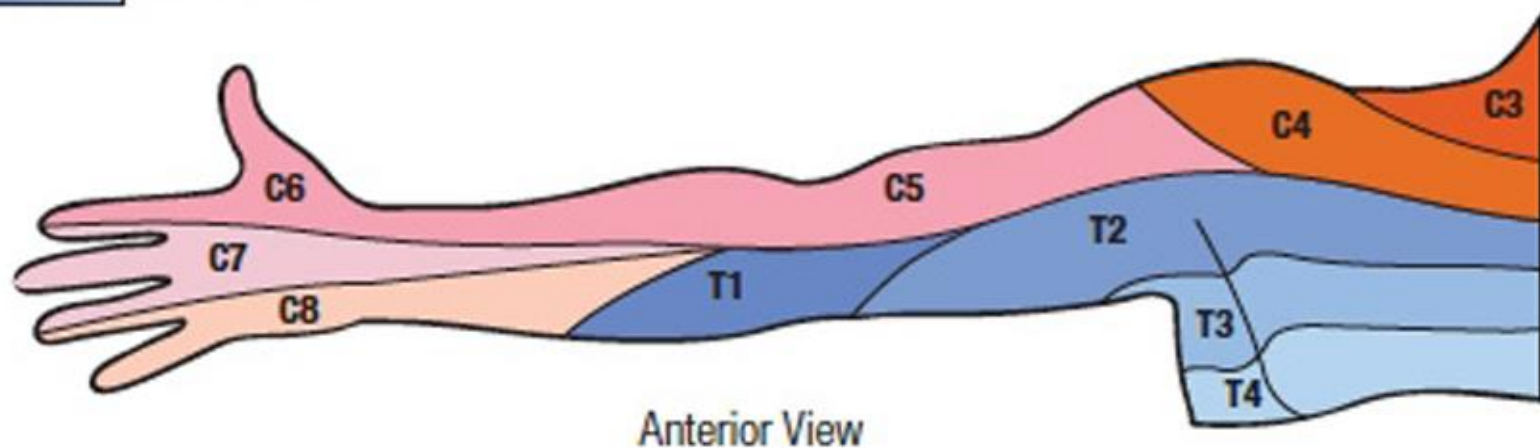
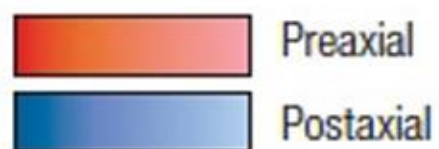

### Anterior (palmar) view

### Posterior (dorsal) view

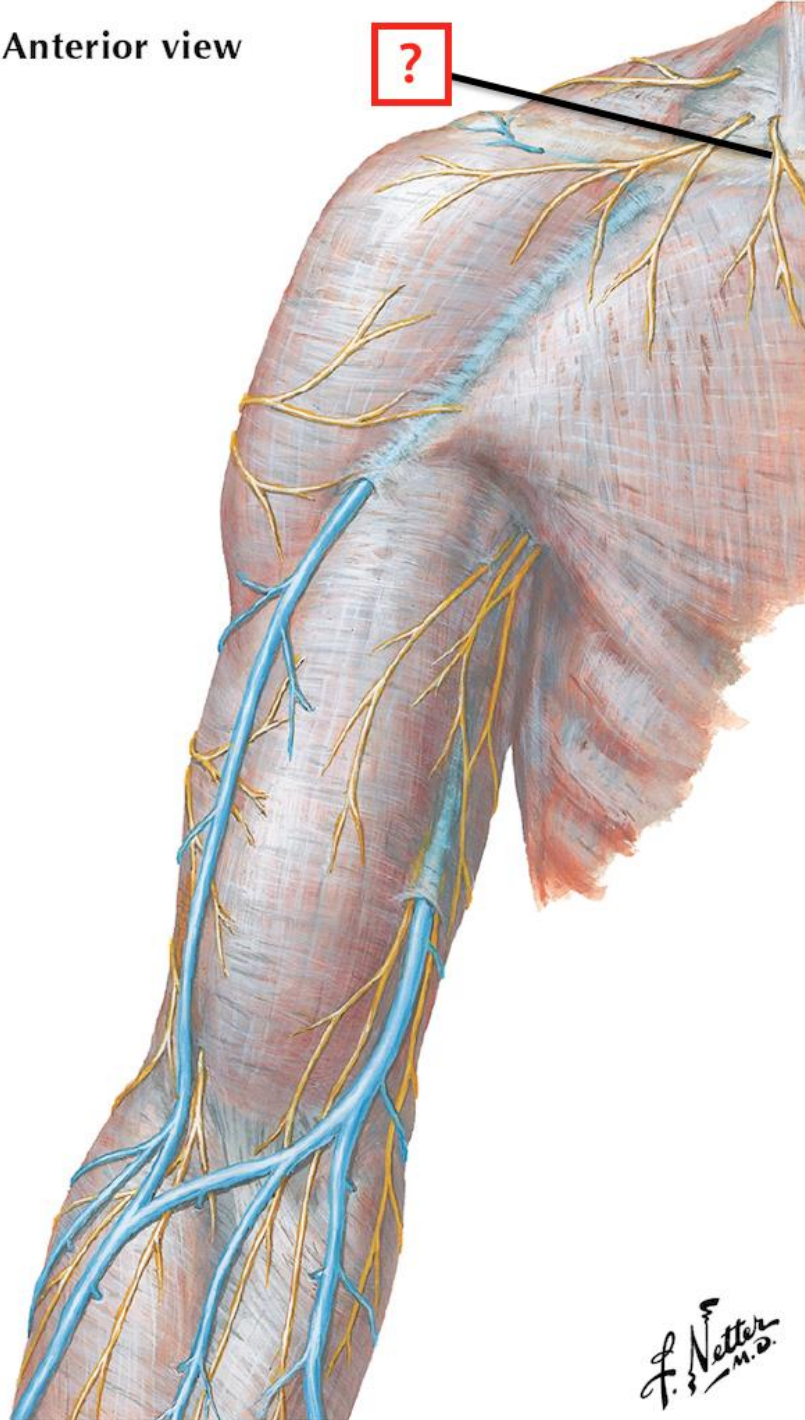


Note: division variable between ulnar and radial innervation on dorsum of hand and often aligns with middle of 3rd digit instead of 4th digit as shown

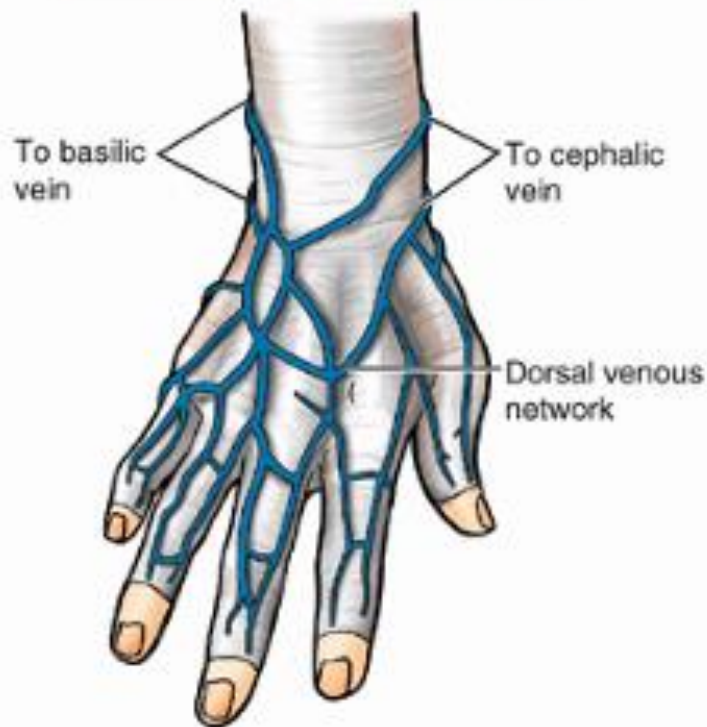
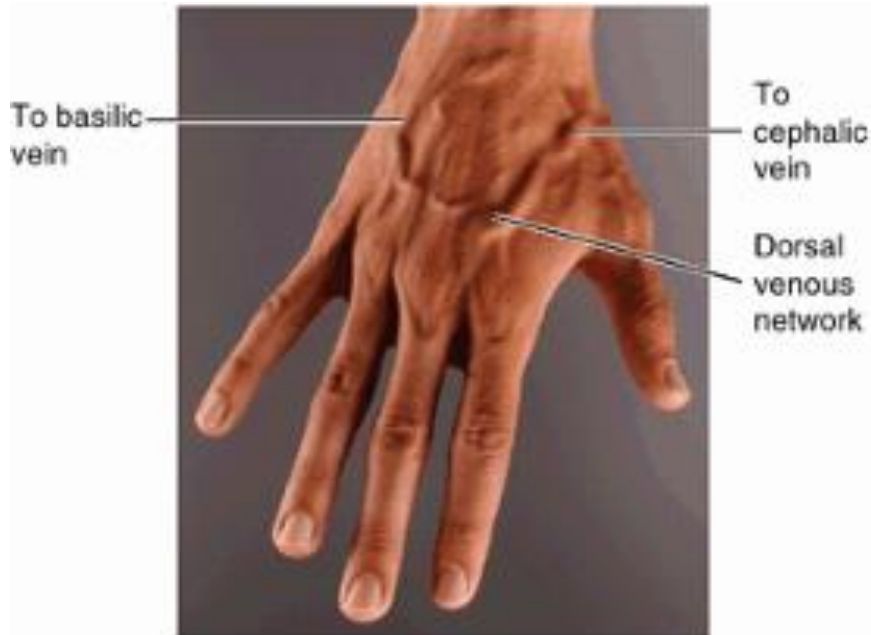

**Figure 2.** A map of dermatomal innervation of the shoulder and upper extremity.

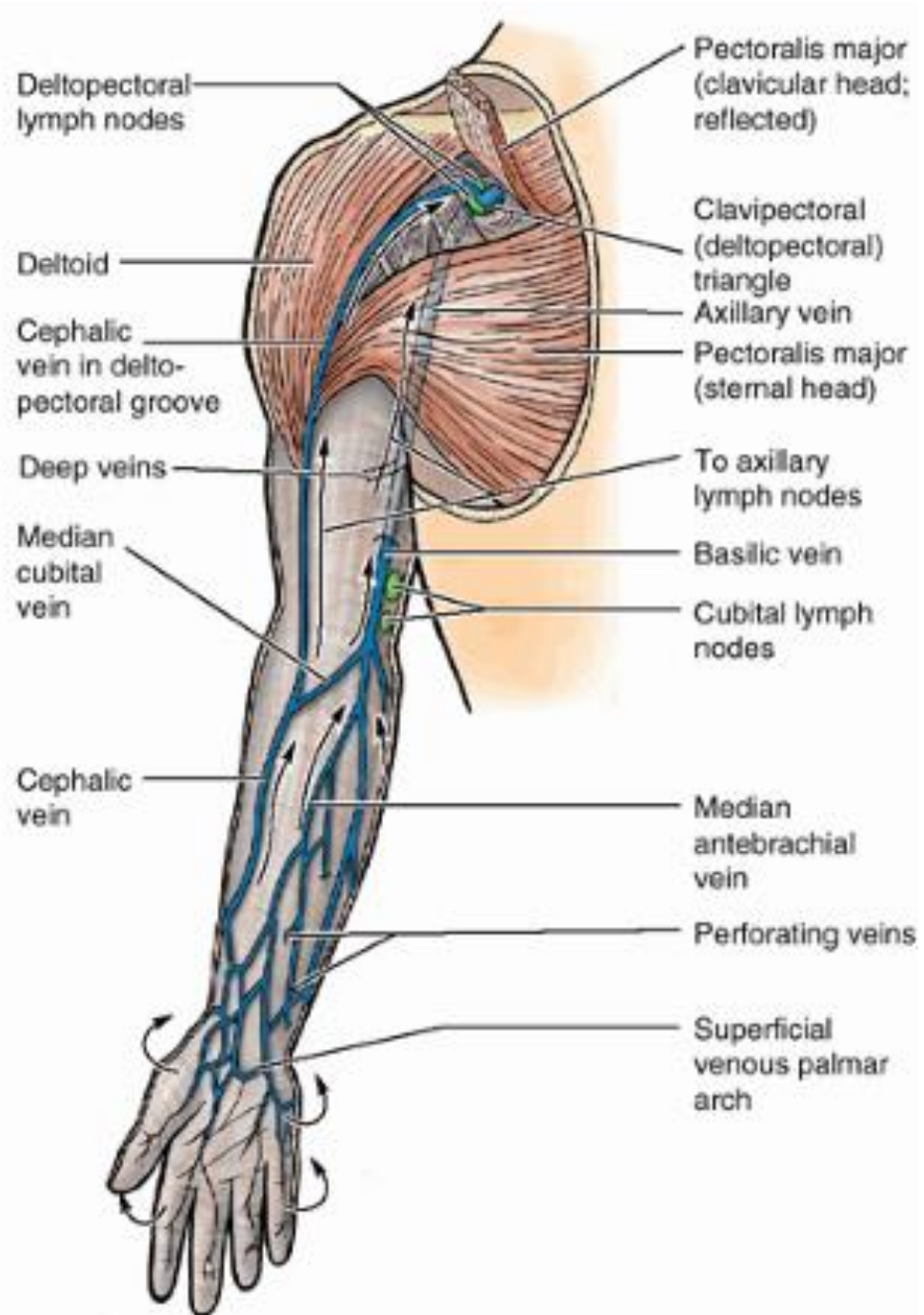
Anterior view



F. Netter  
M.D.

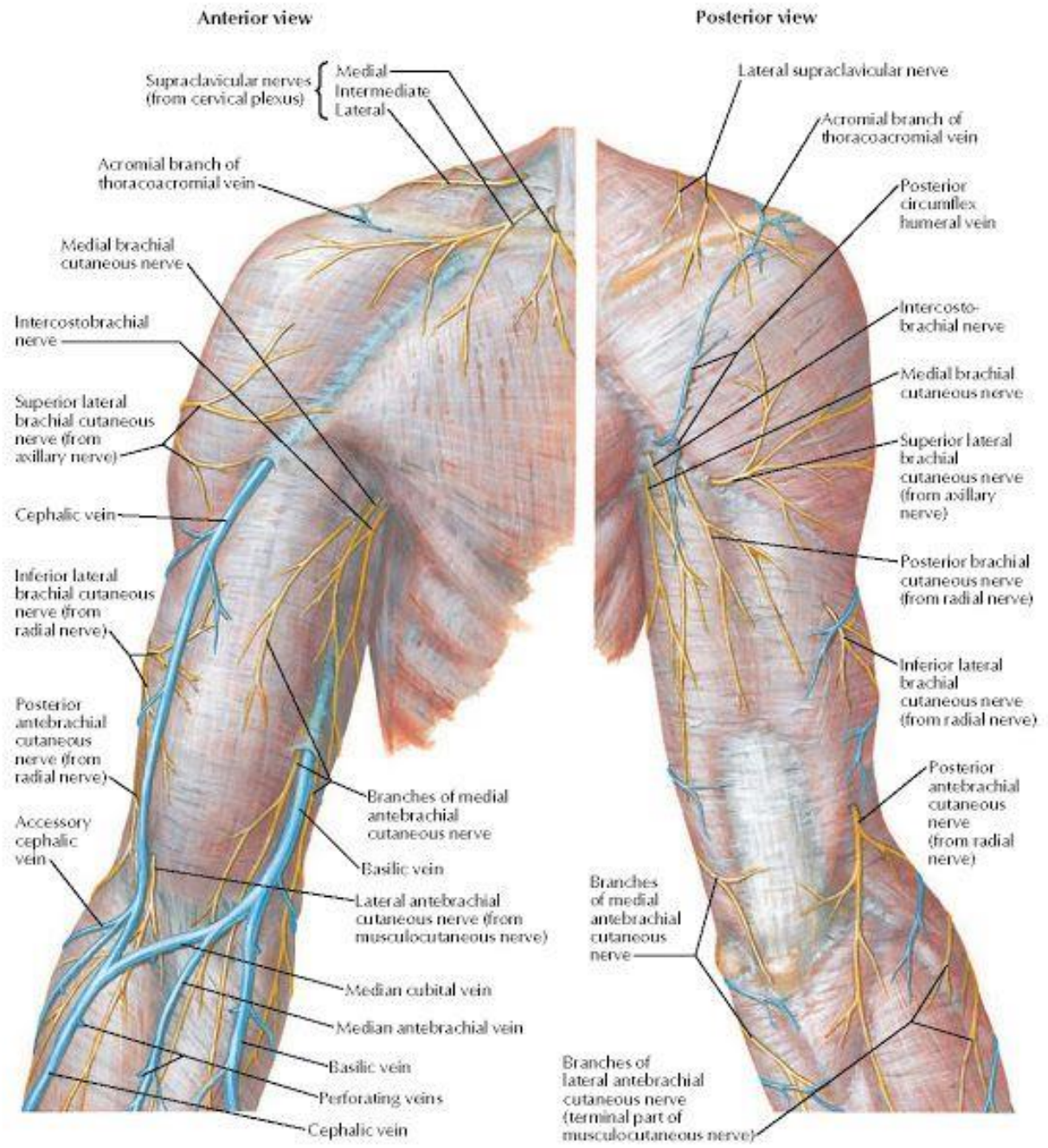


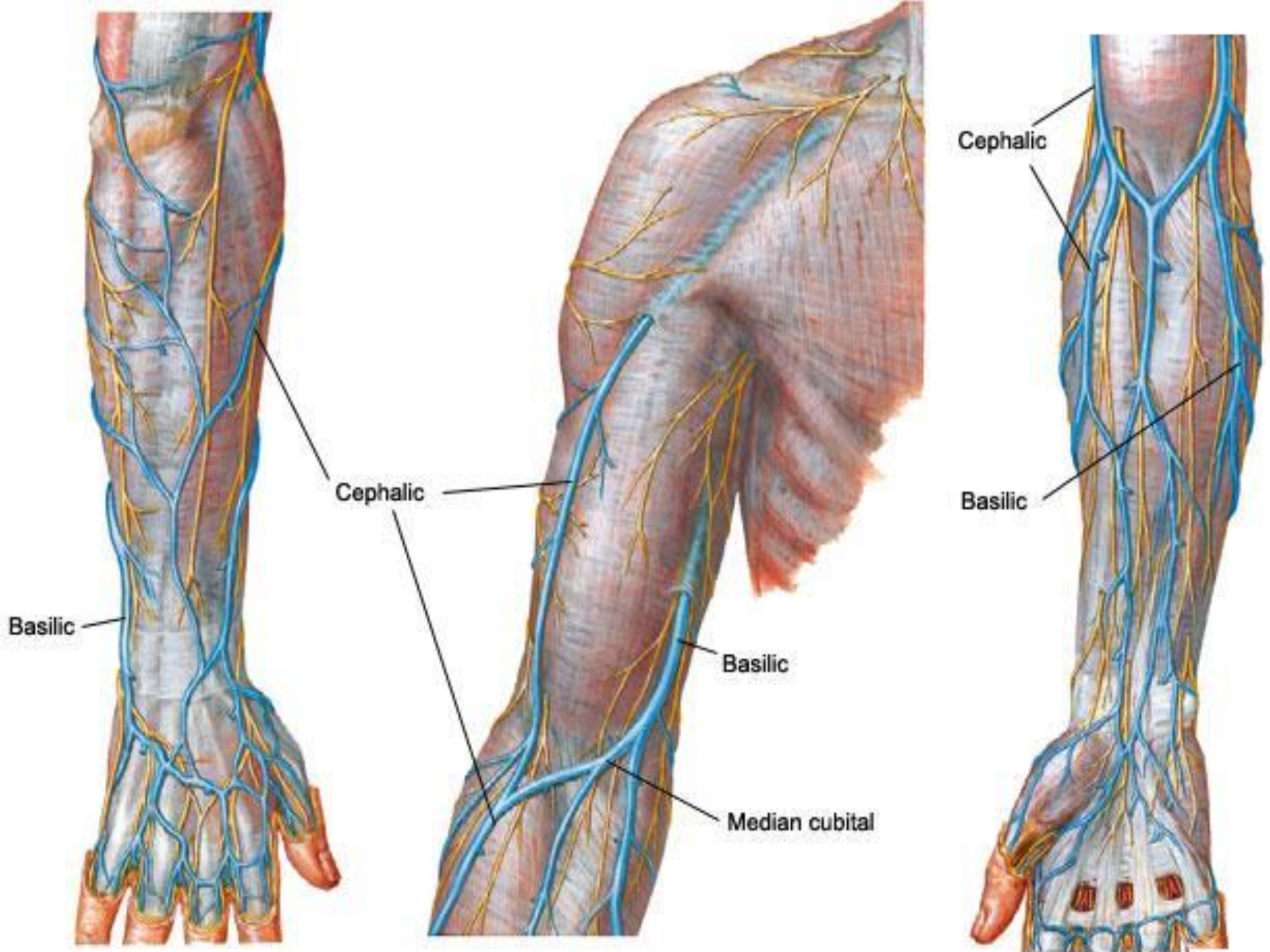
(A) Posterior (dorsal) views

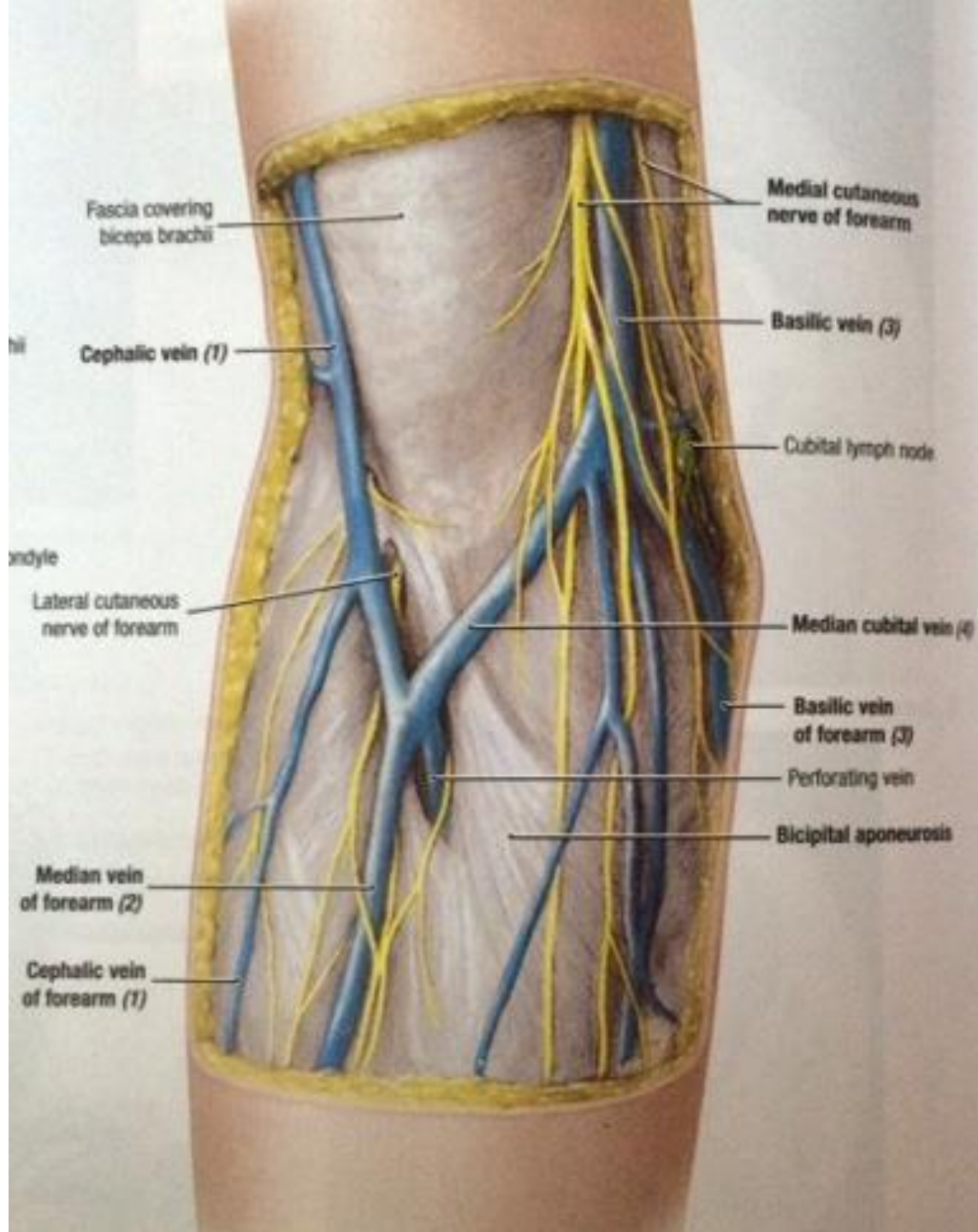


(B) Anterior (palmar) views



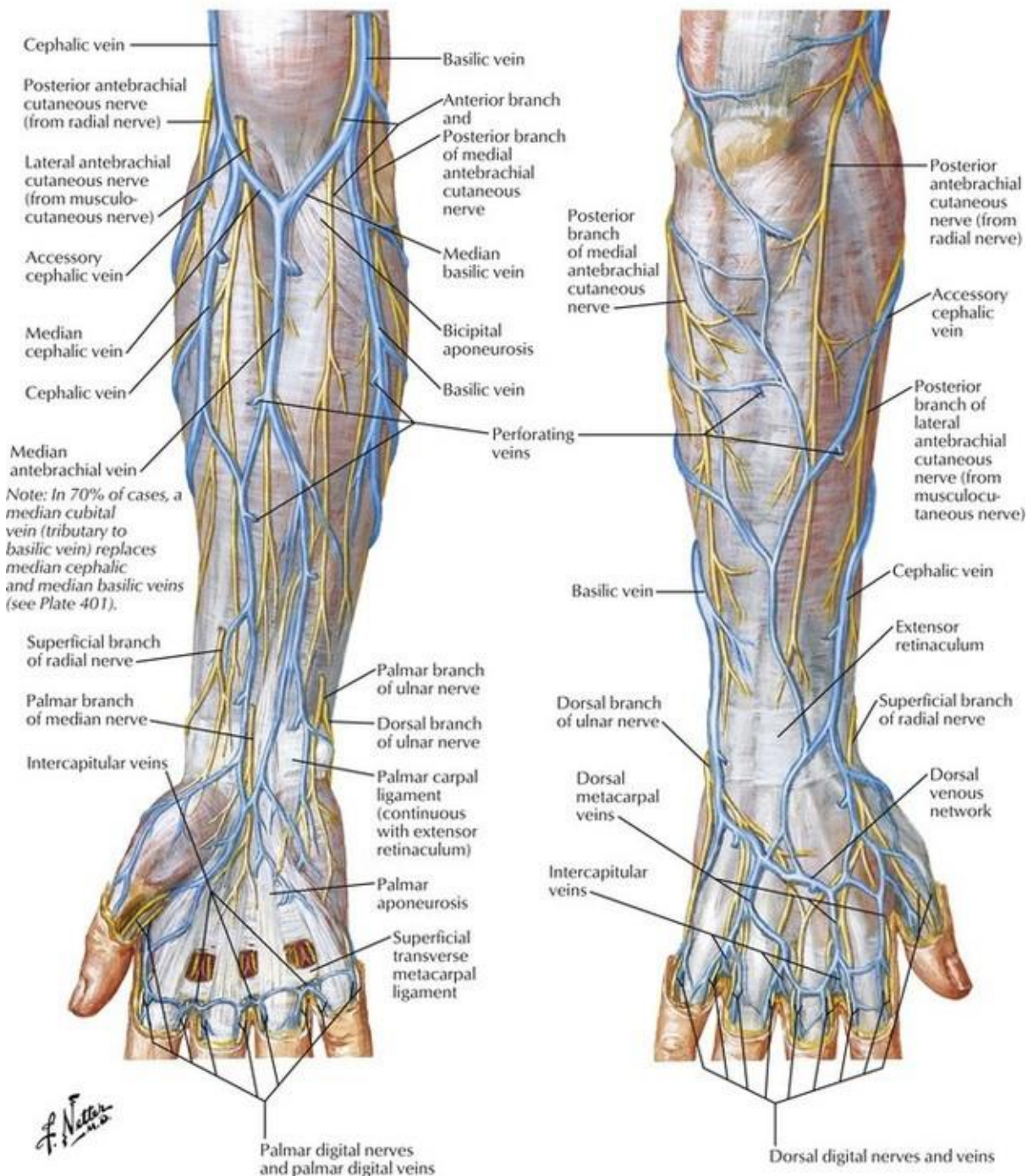


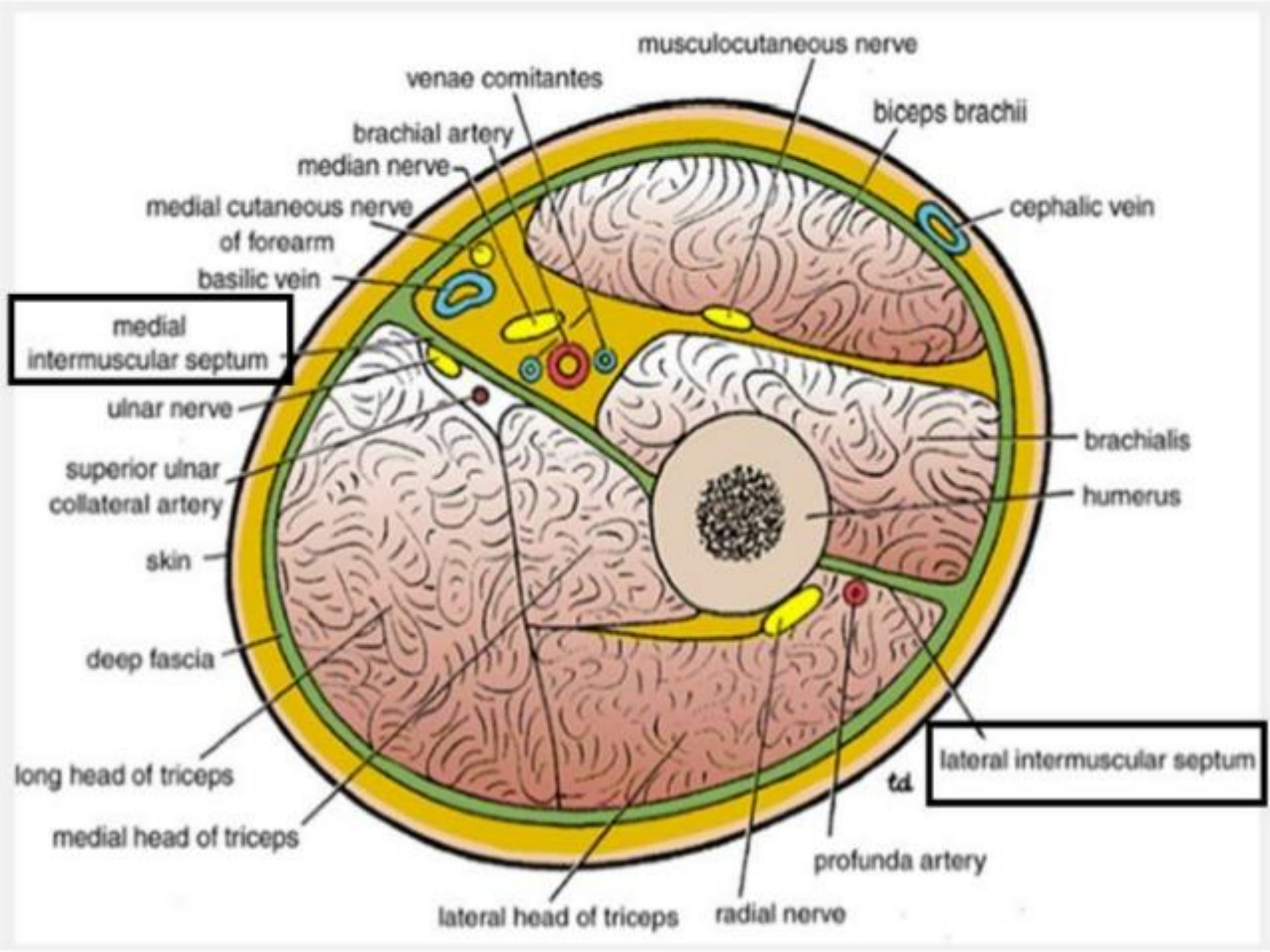


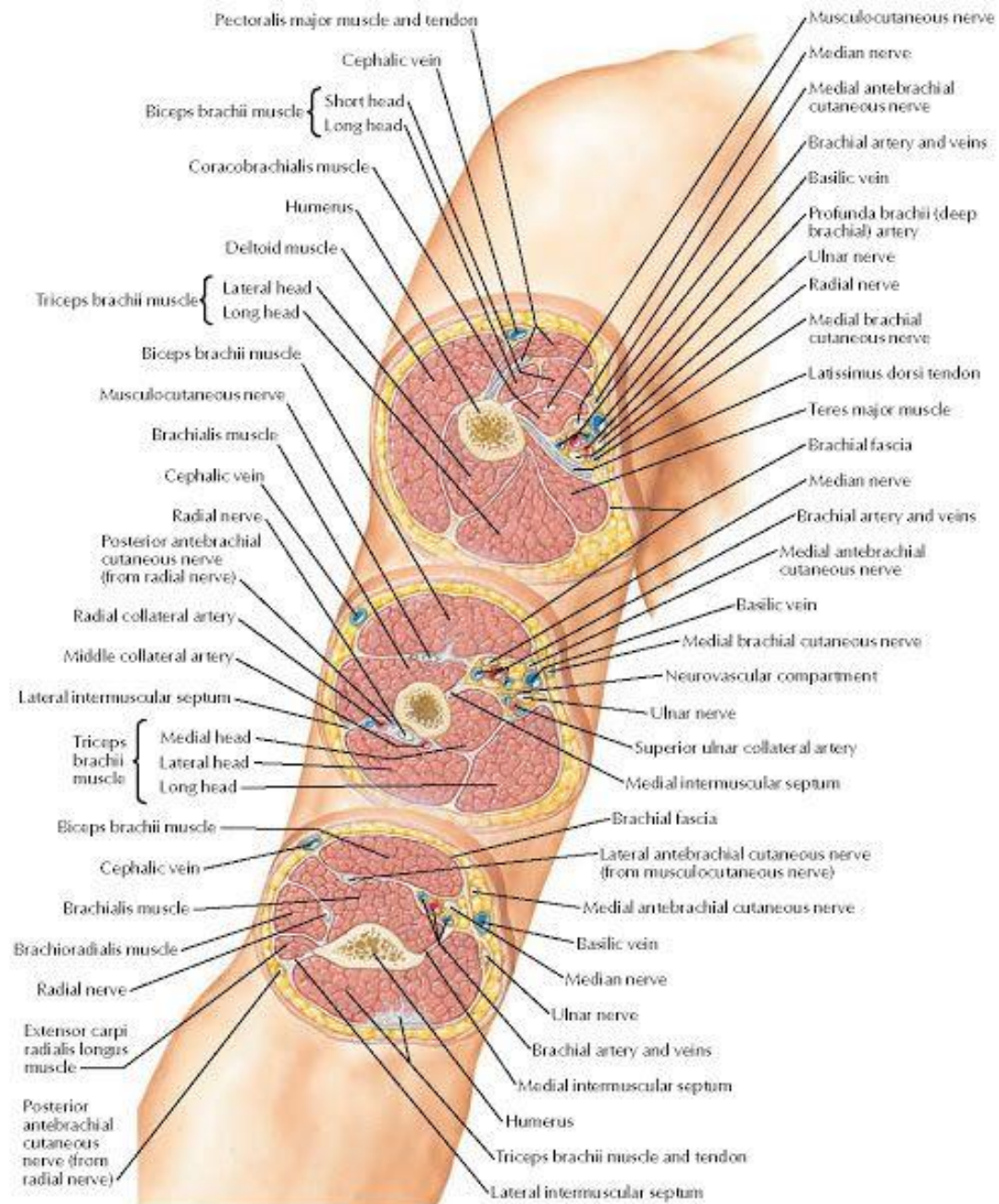


Anterior (palmar) view

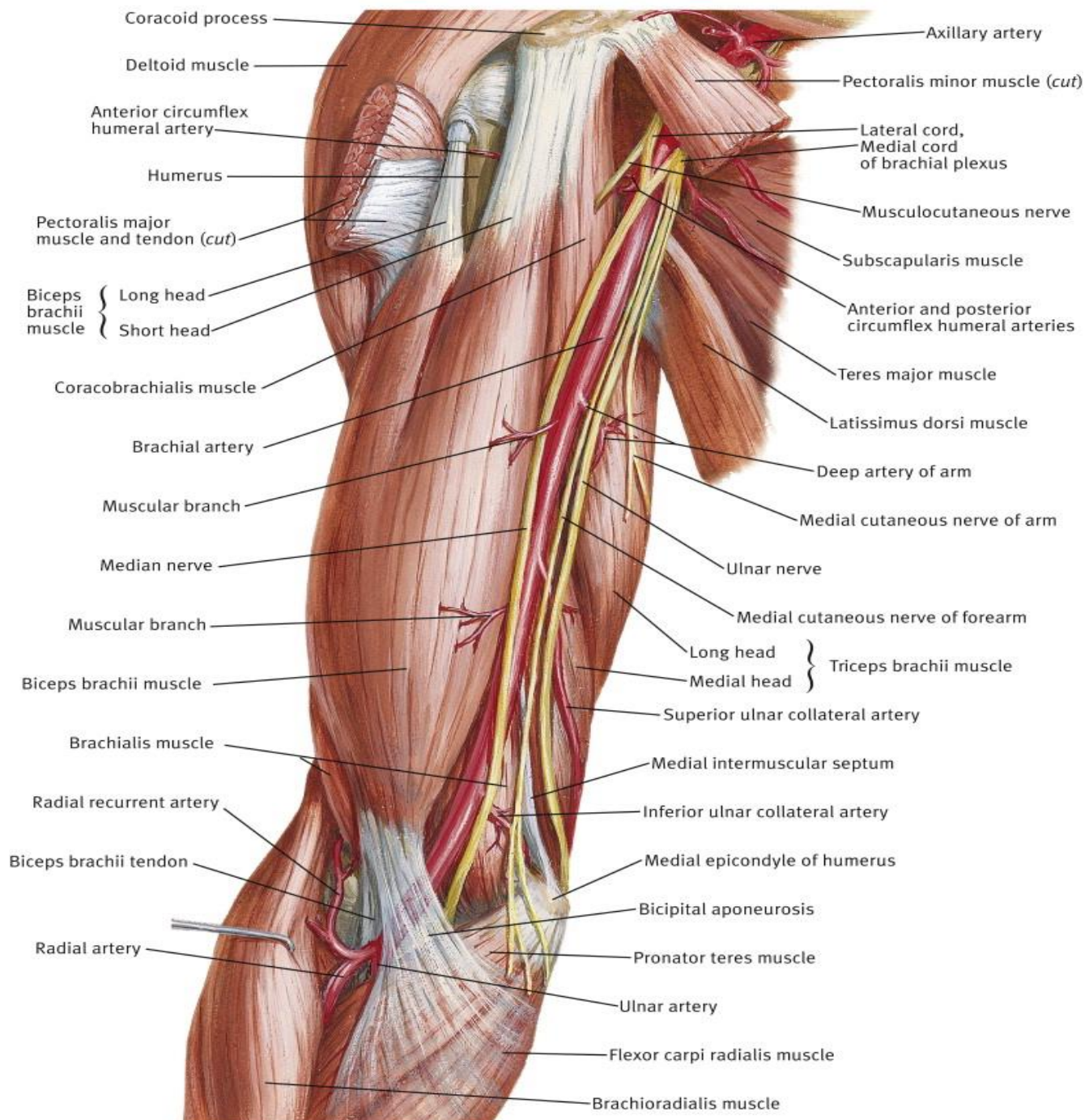
Posterior (dorsal) view







# Brachial Artery in situ



Anterior circumflex humeral artery

Long head  
Short head } Biceps brachii muscle

Brachial artery

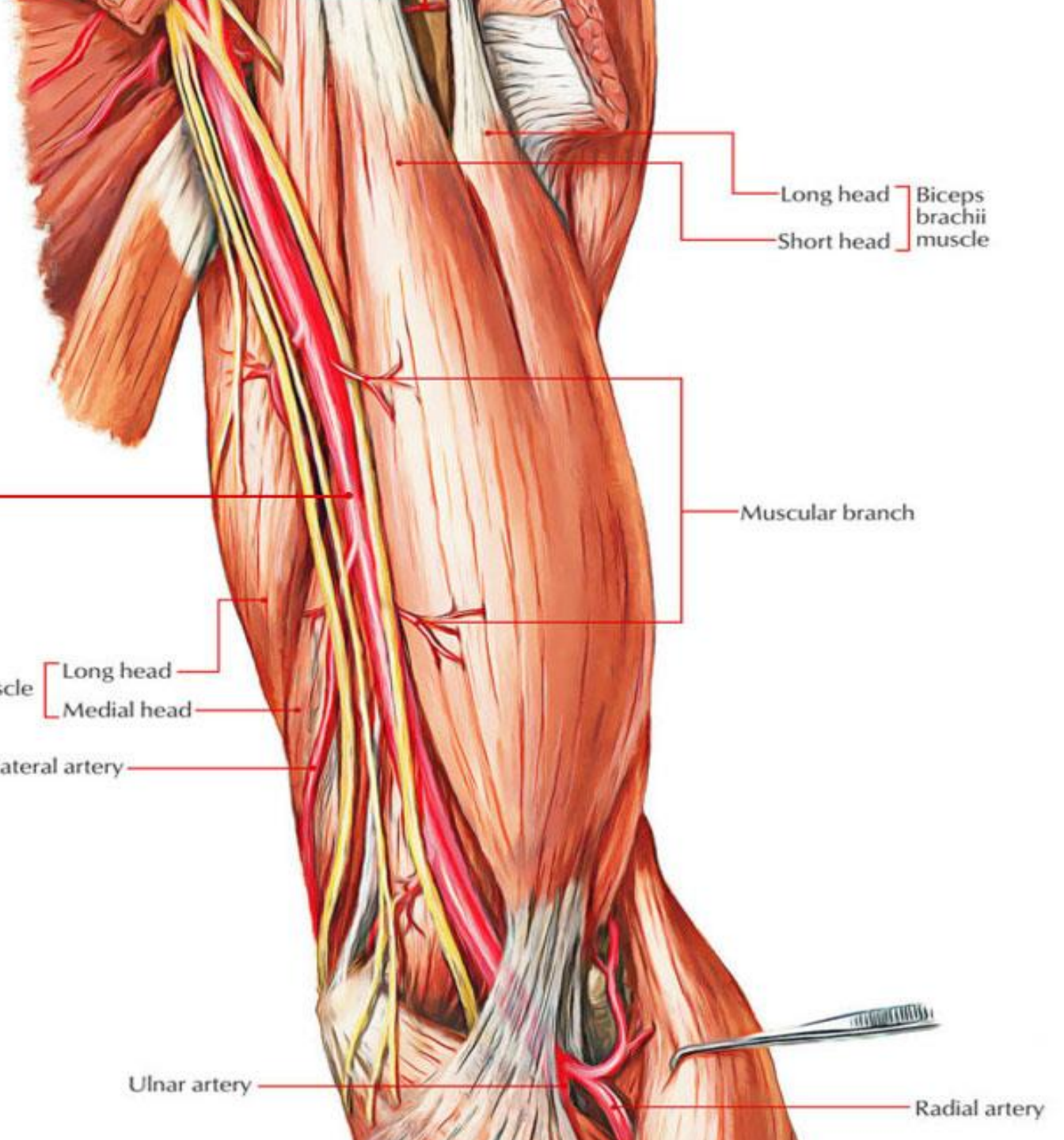
Muscular branch

Triceps brachii muscle  
Long head  
Medial head

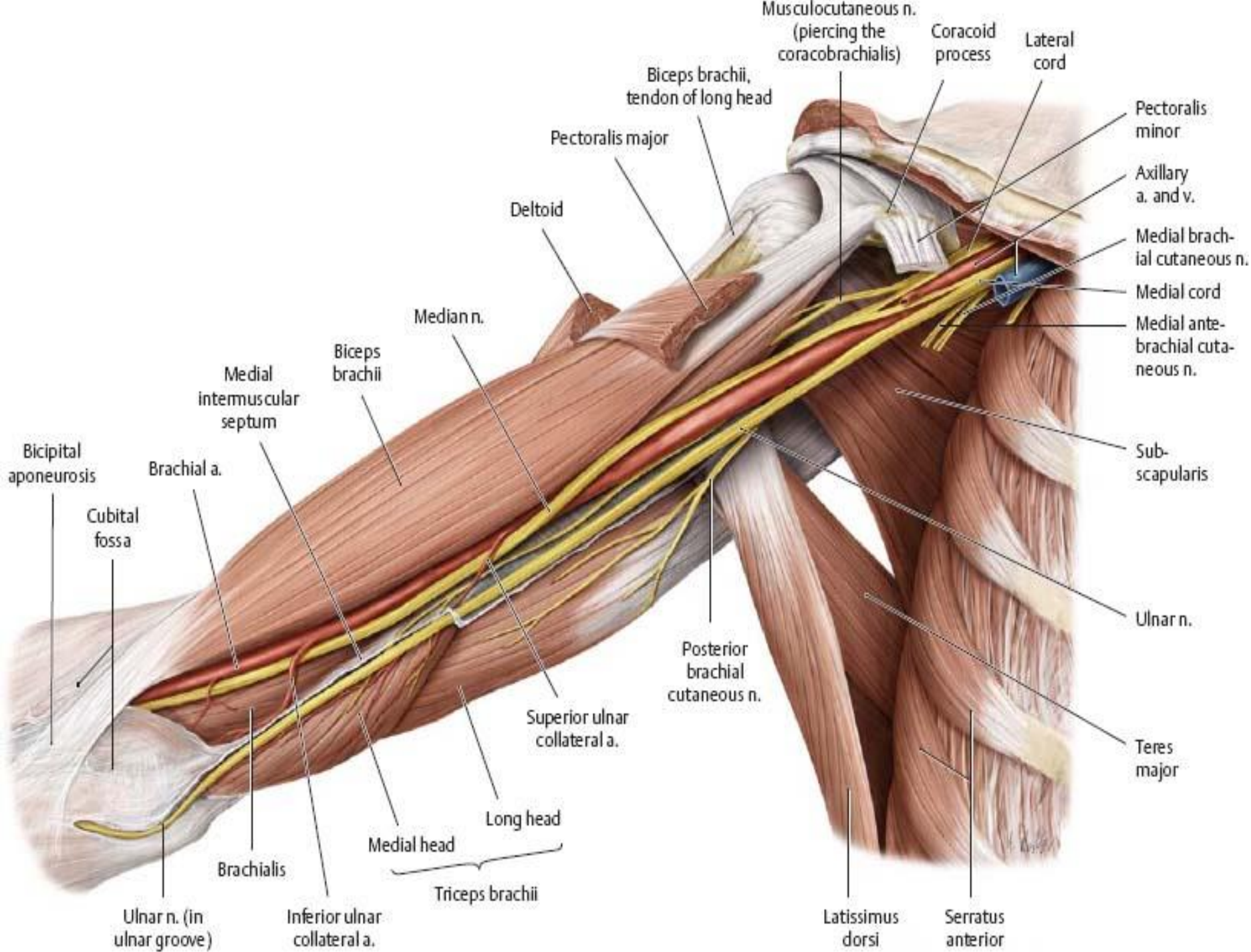
Superior ulnar collateral artery

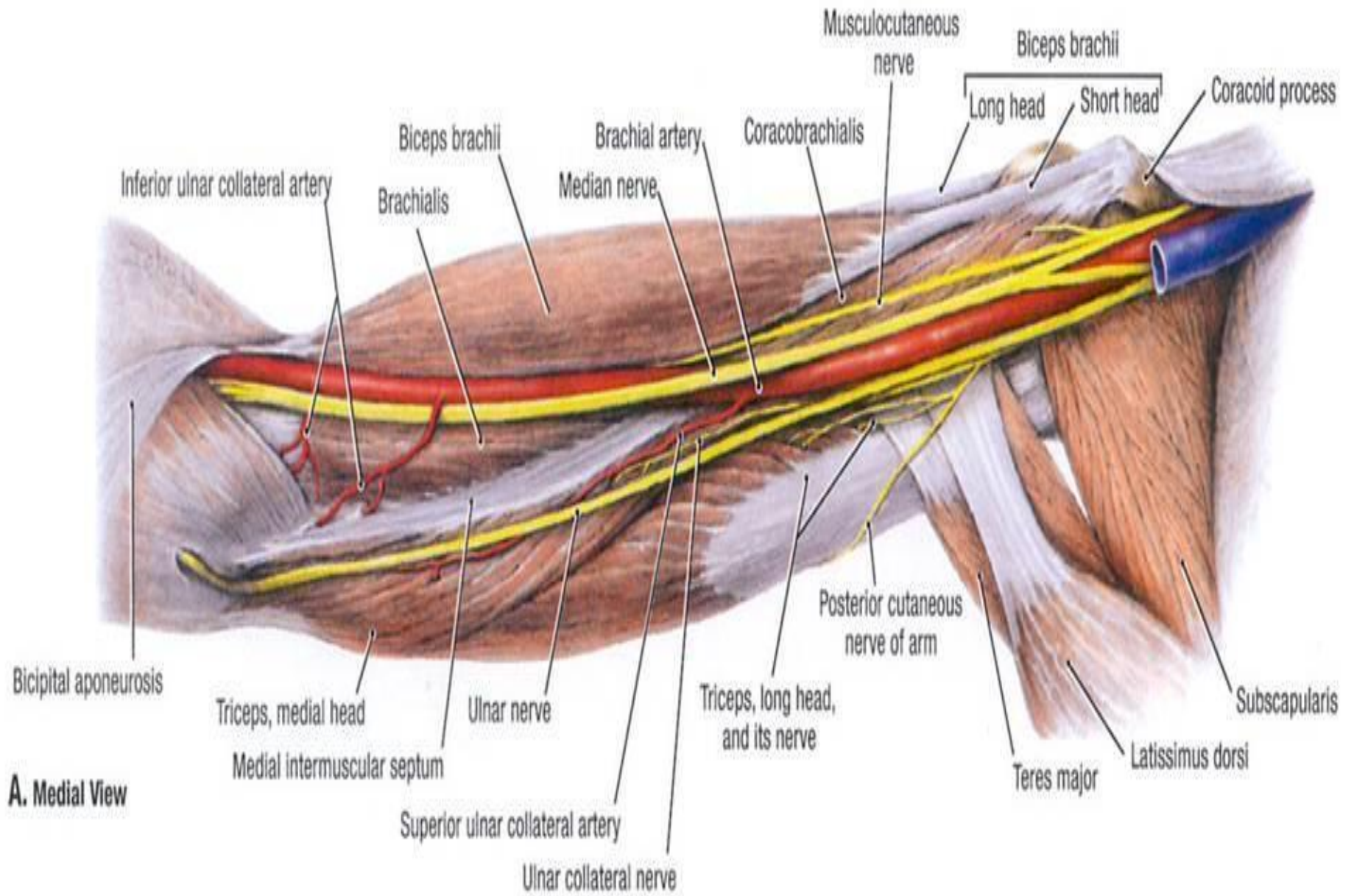
Ulnar artery

Radial artery

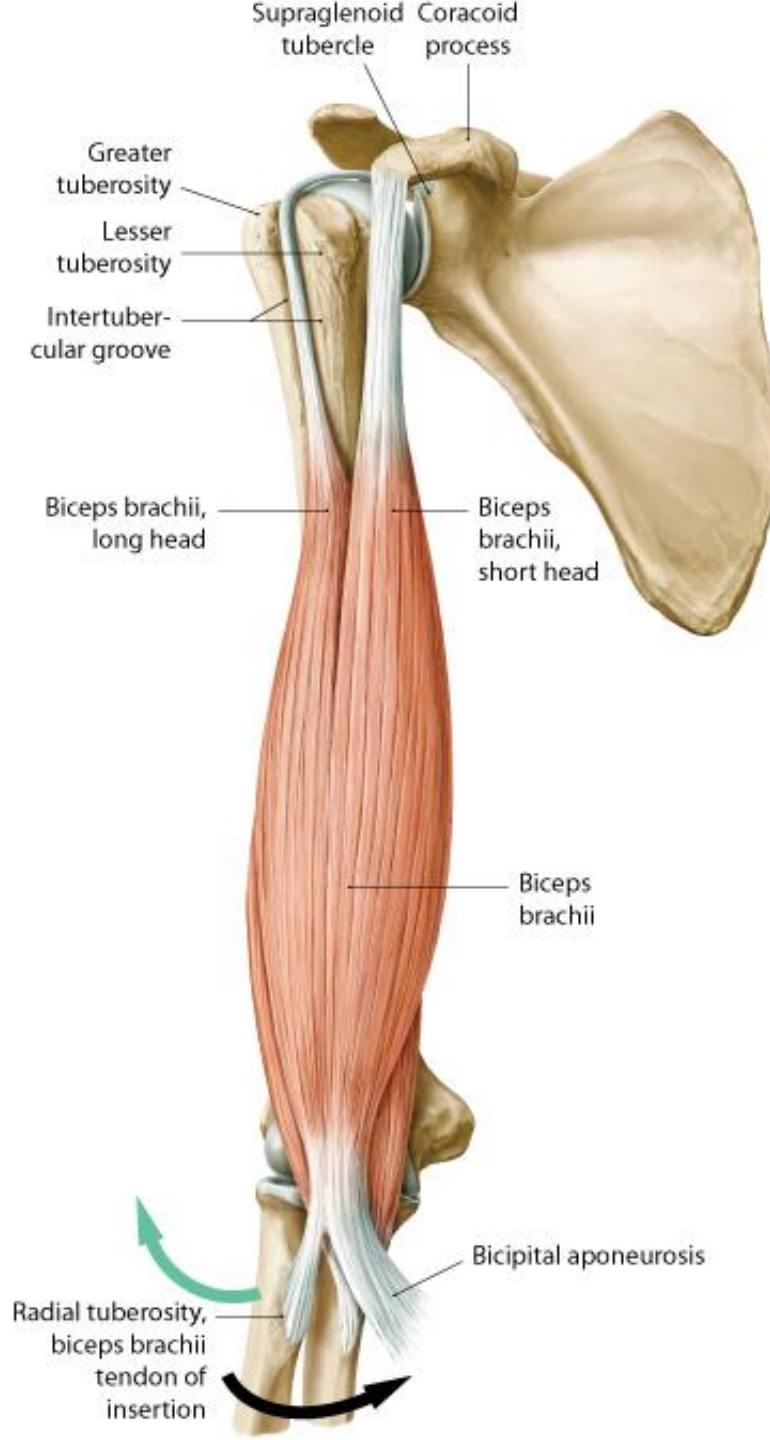


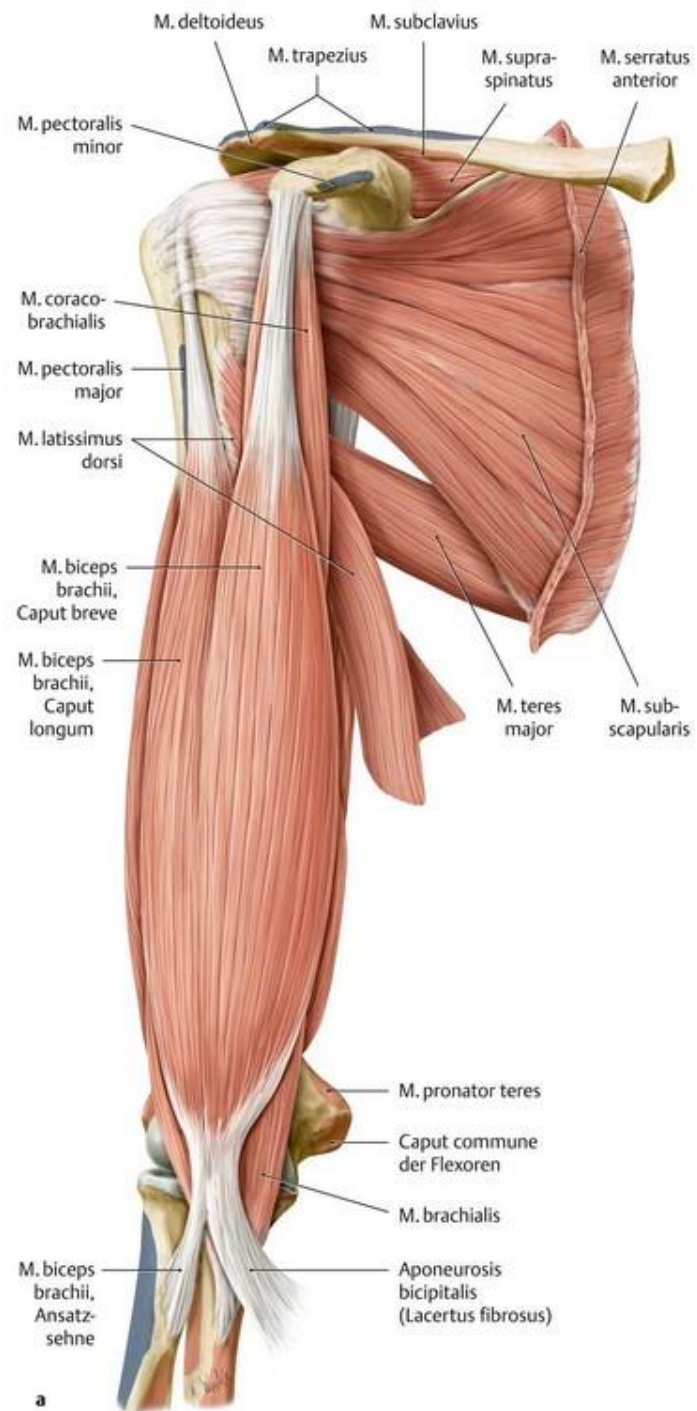




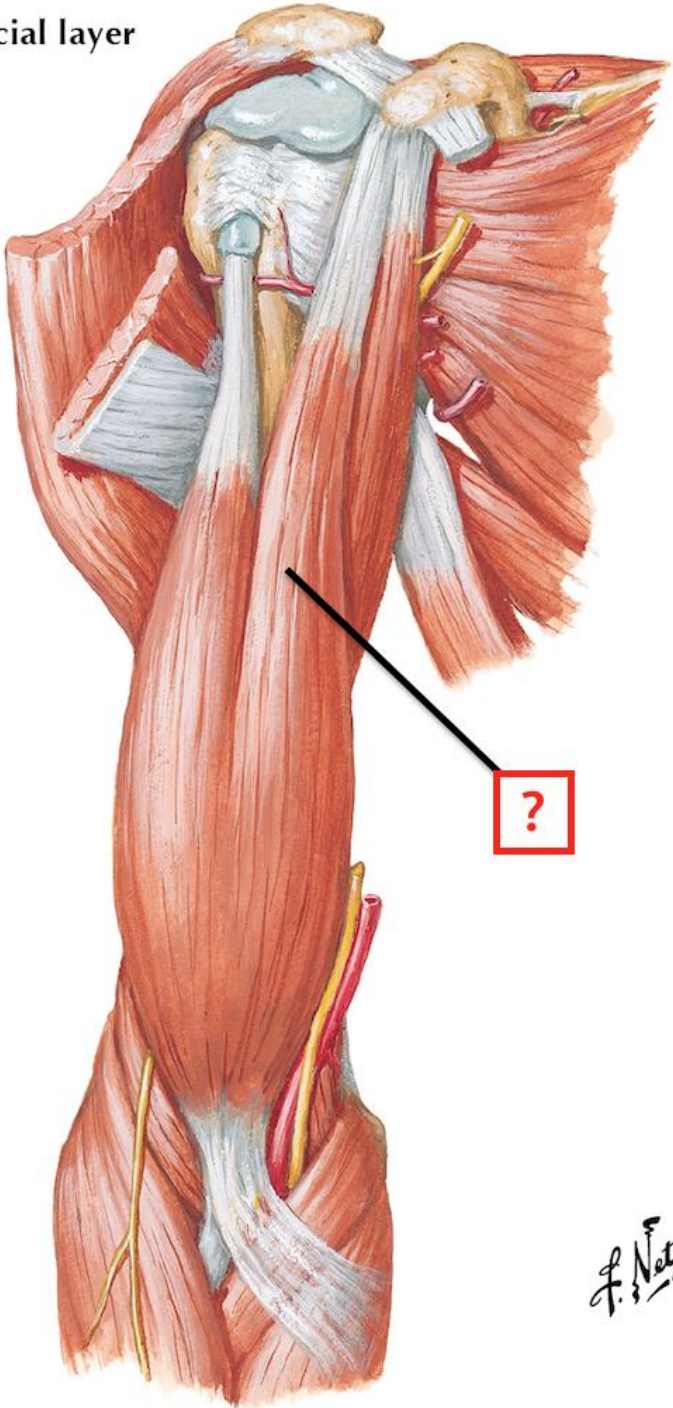


**A. Medial View**

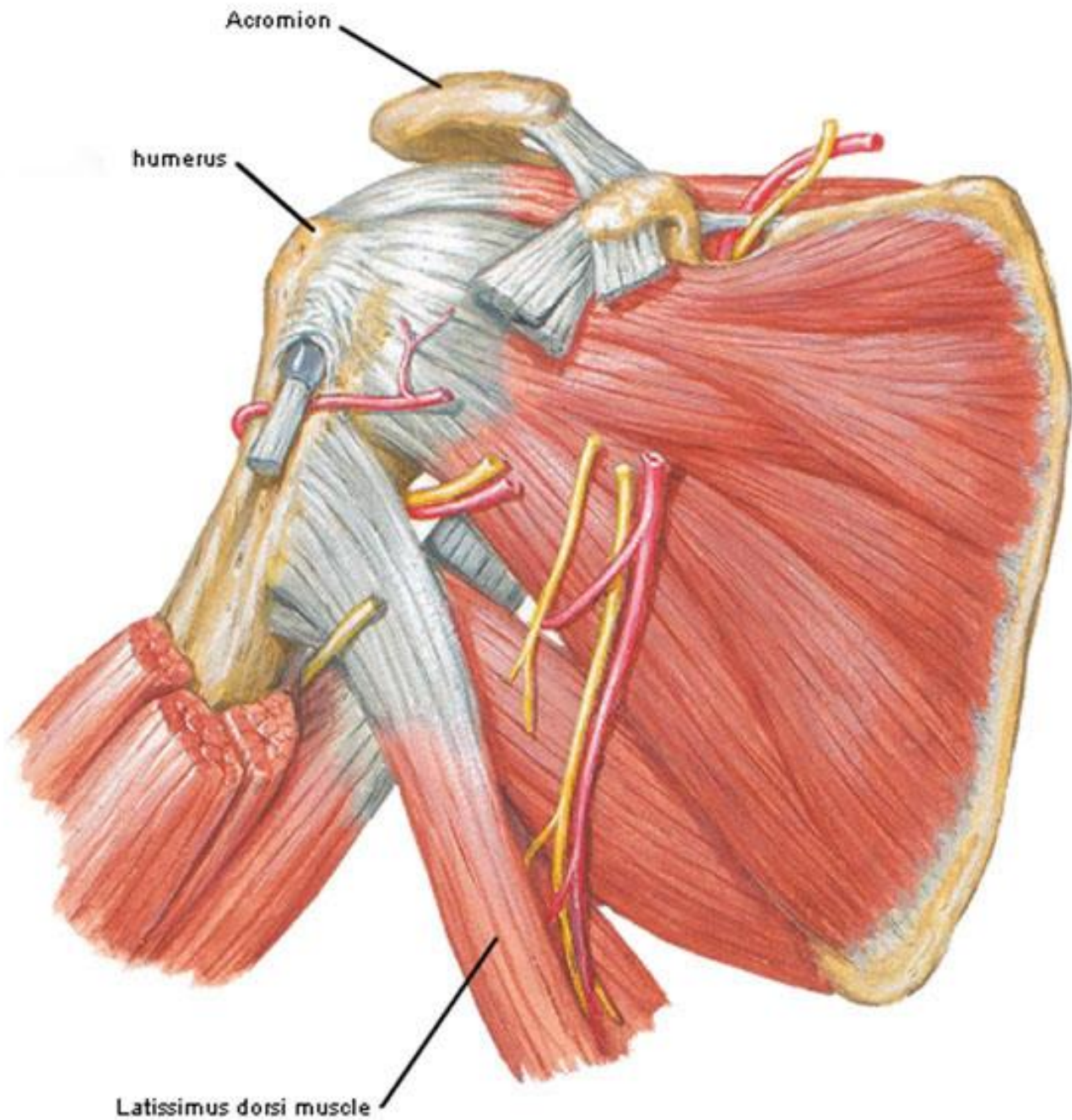


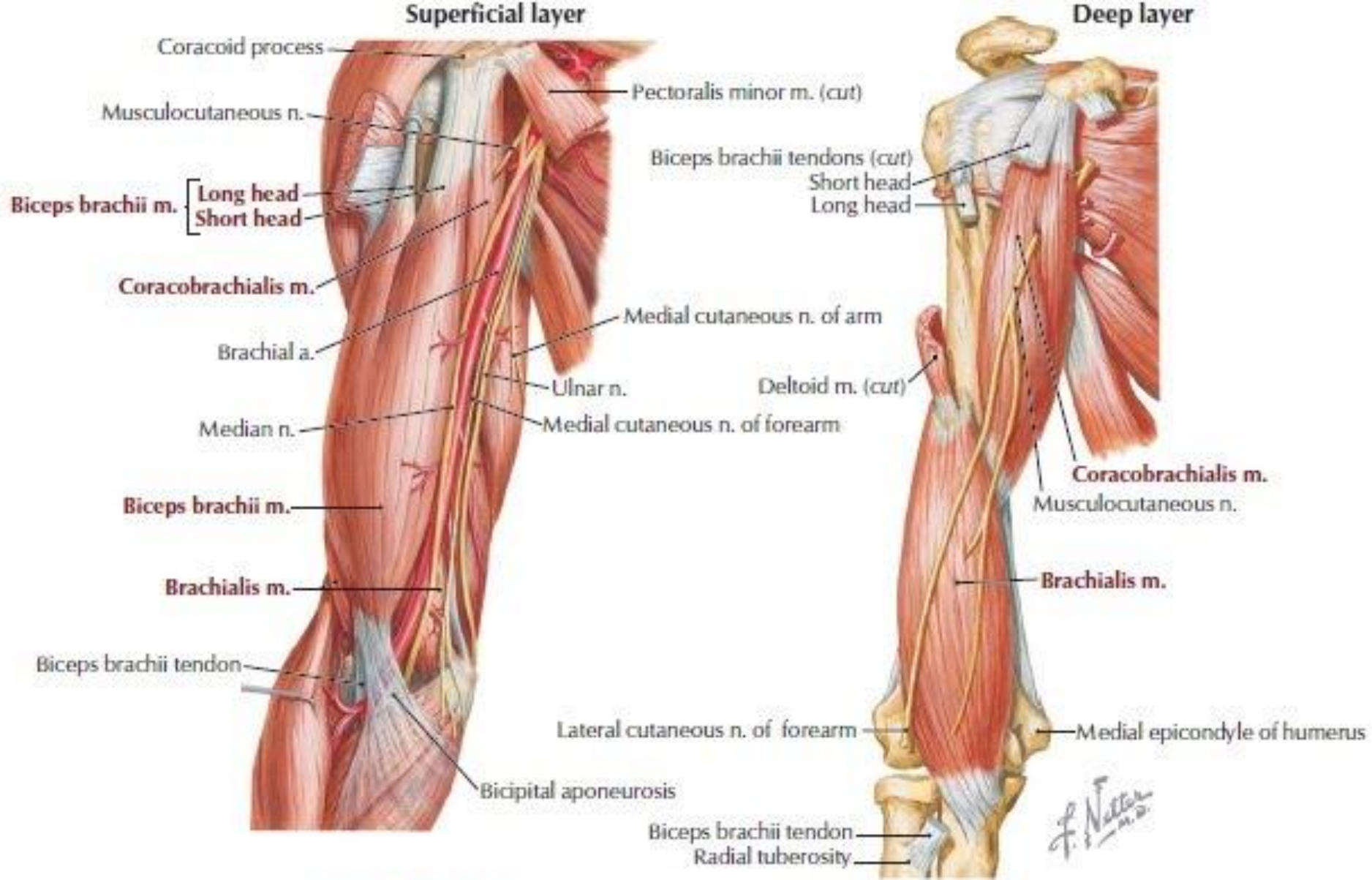


Superficial layer



F. Netter  
M.D.

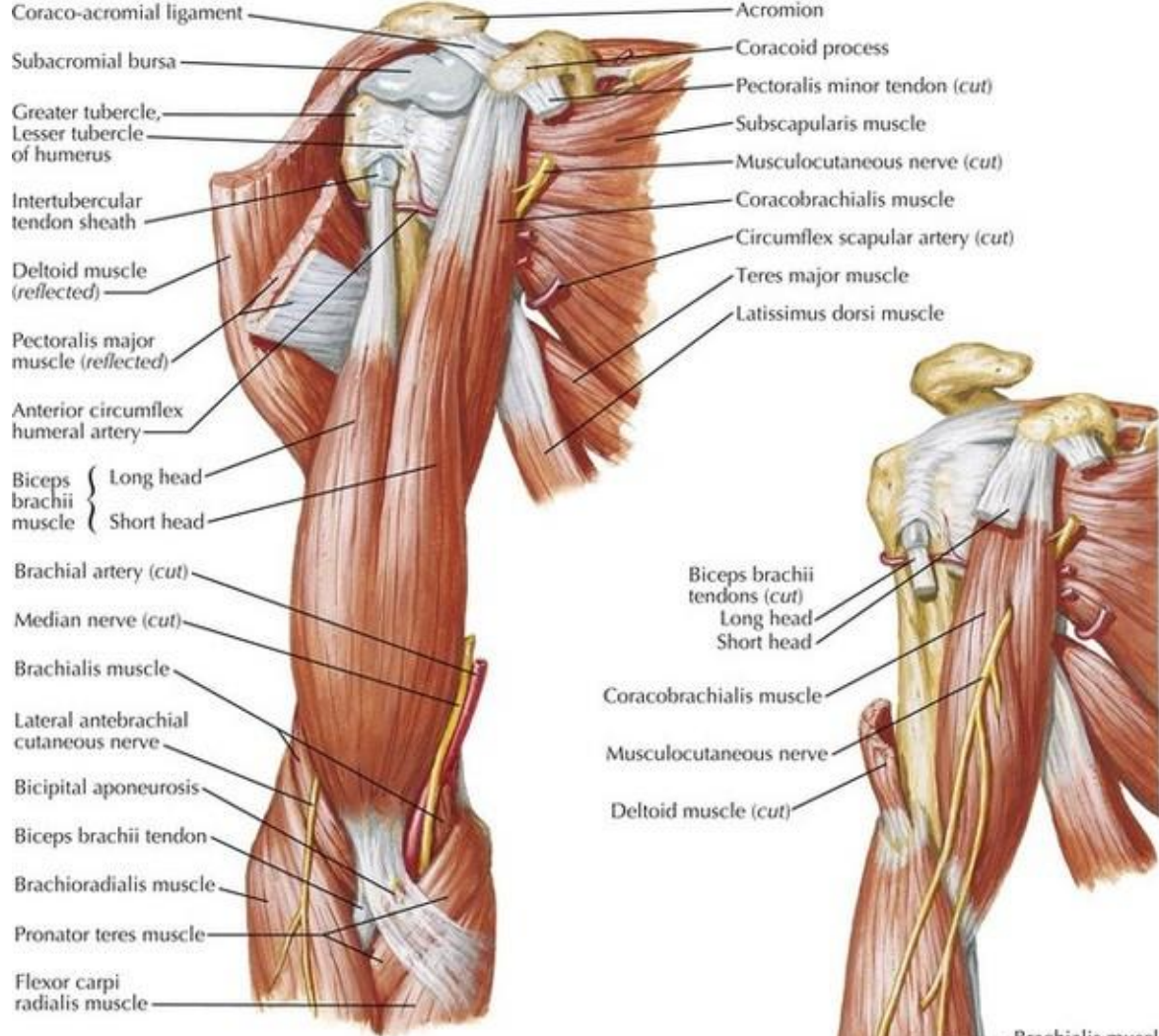




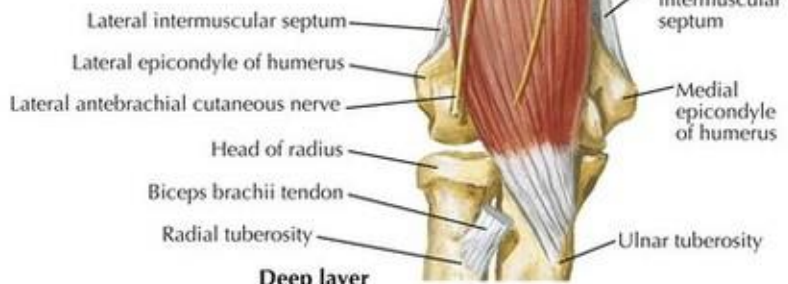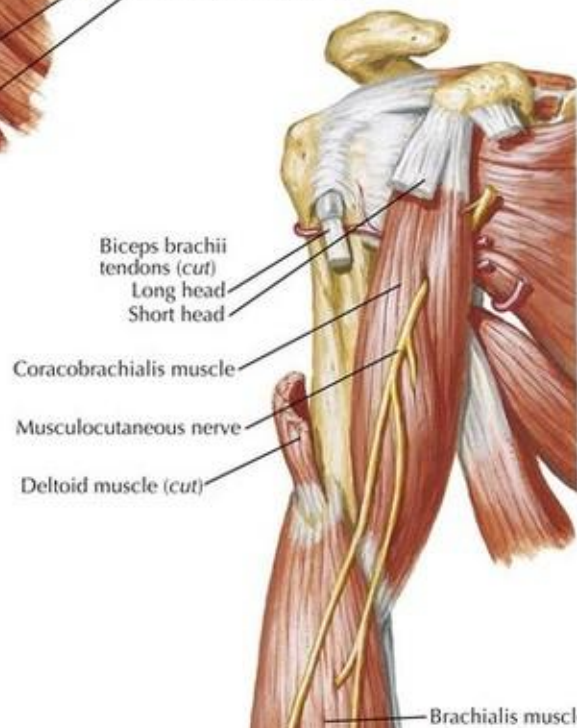**FIGURE 7-12** Anterior Compartment Arm Muscles and Nerves





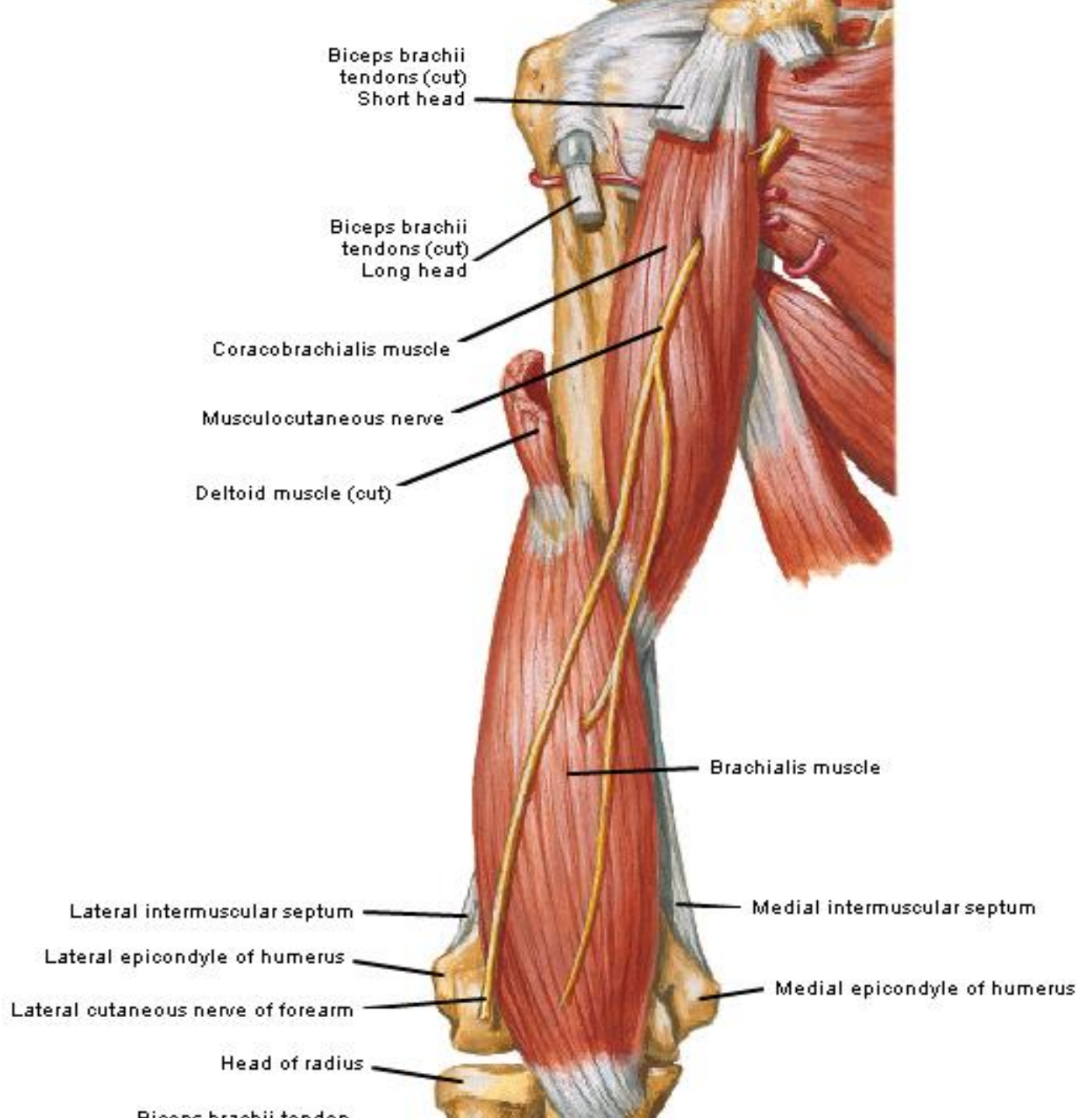


**Superficial layer**

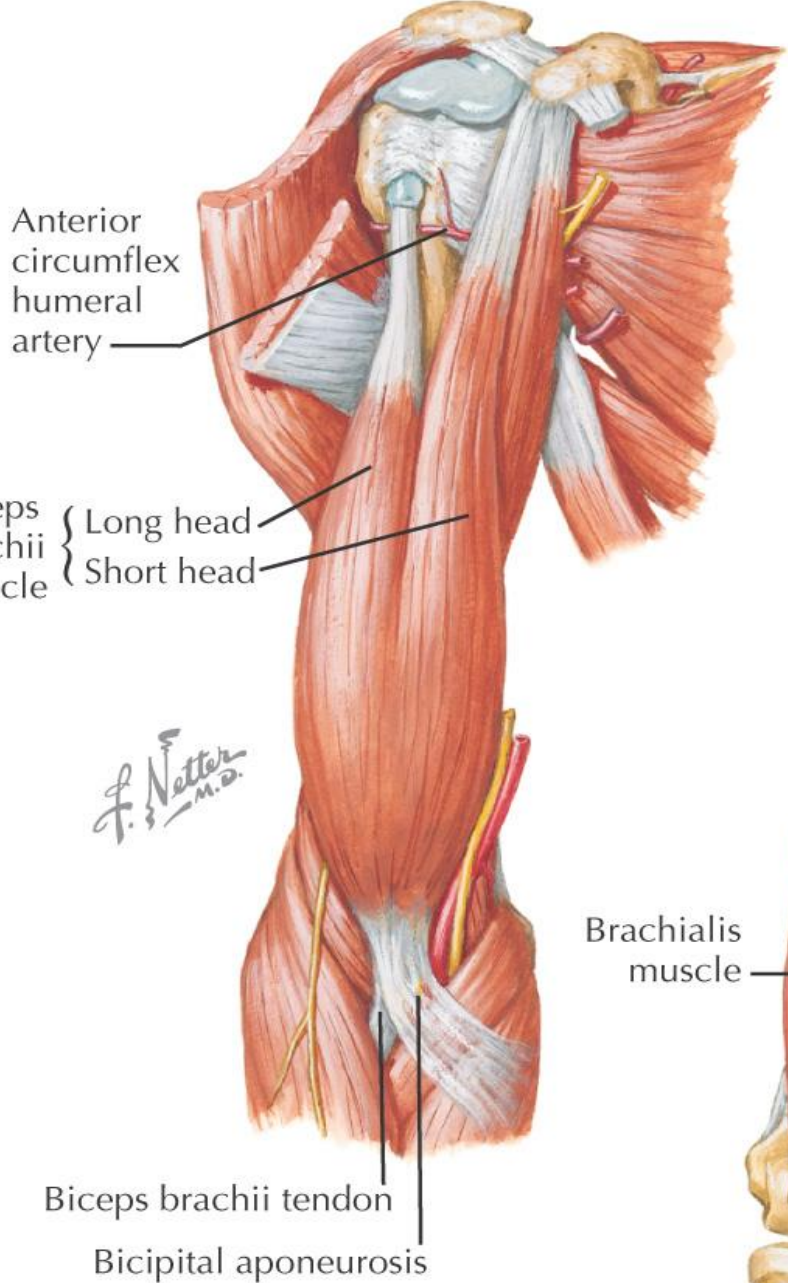


**Deep layer**

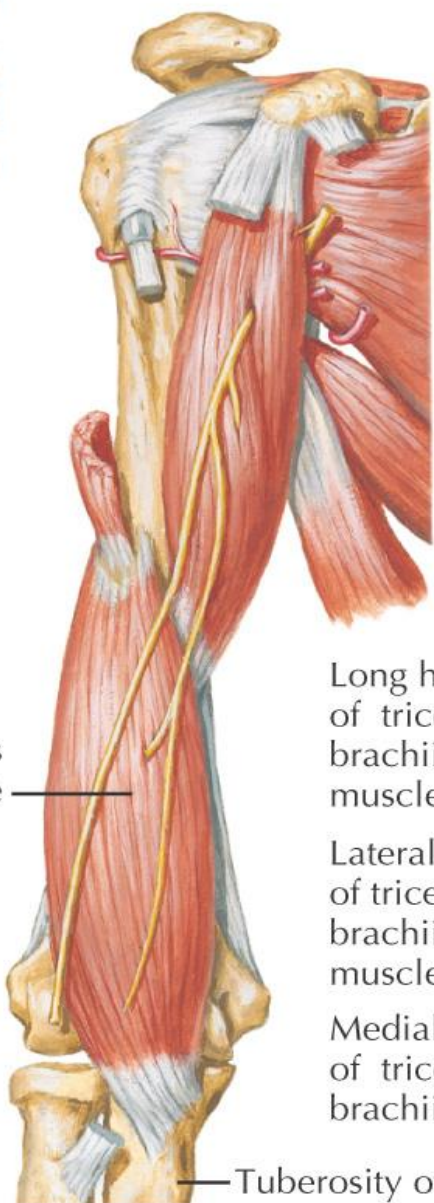
*F. Netter M.D.*



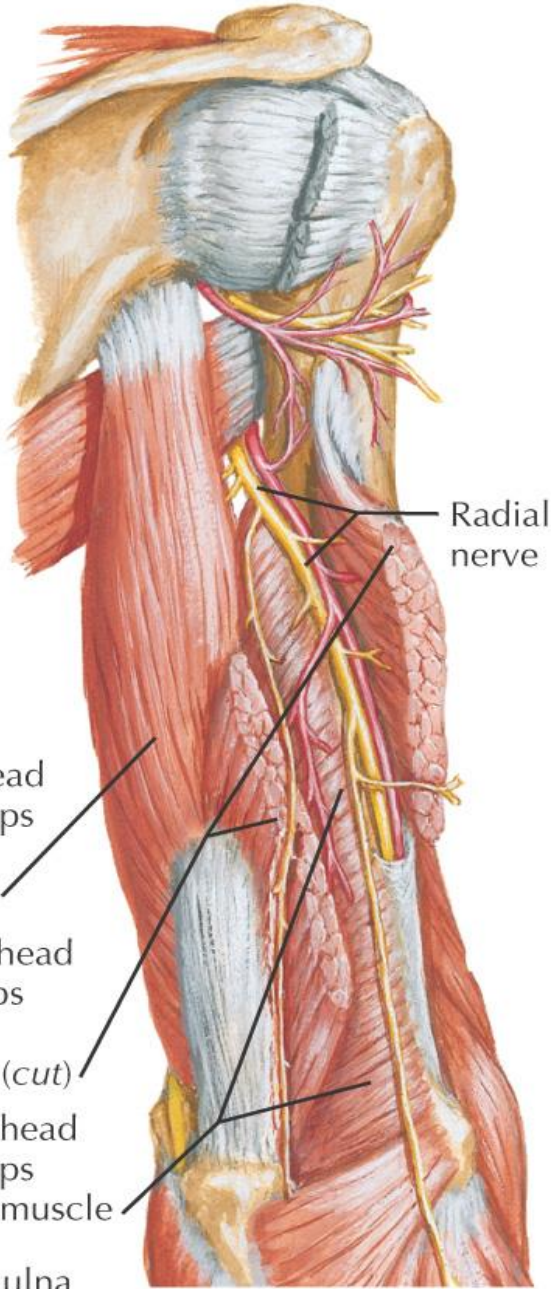
# Superficial layer

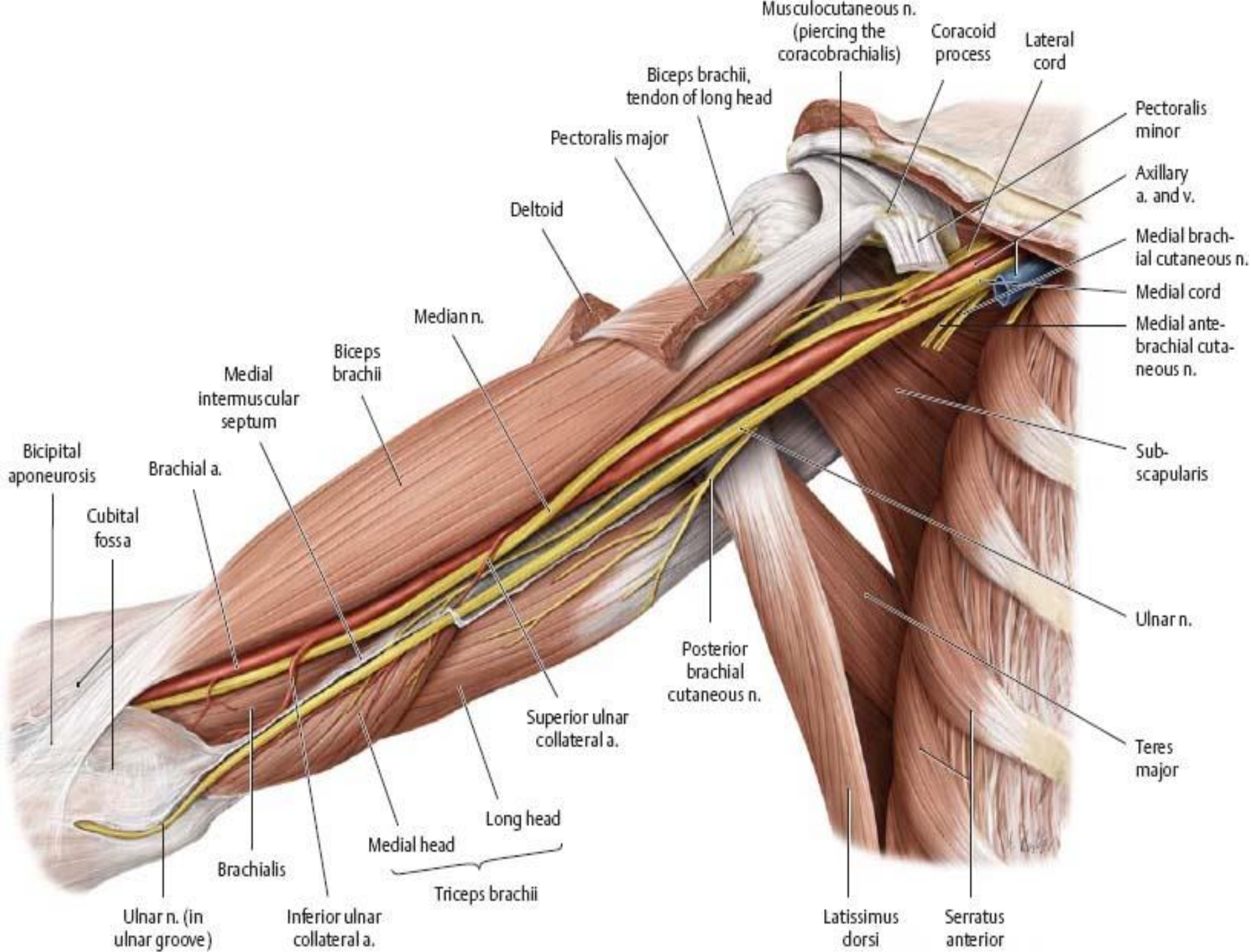


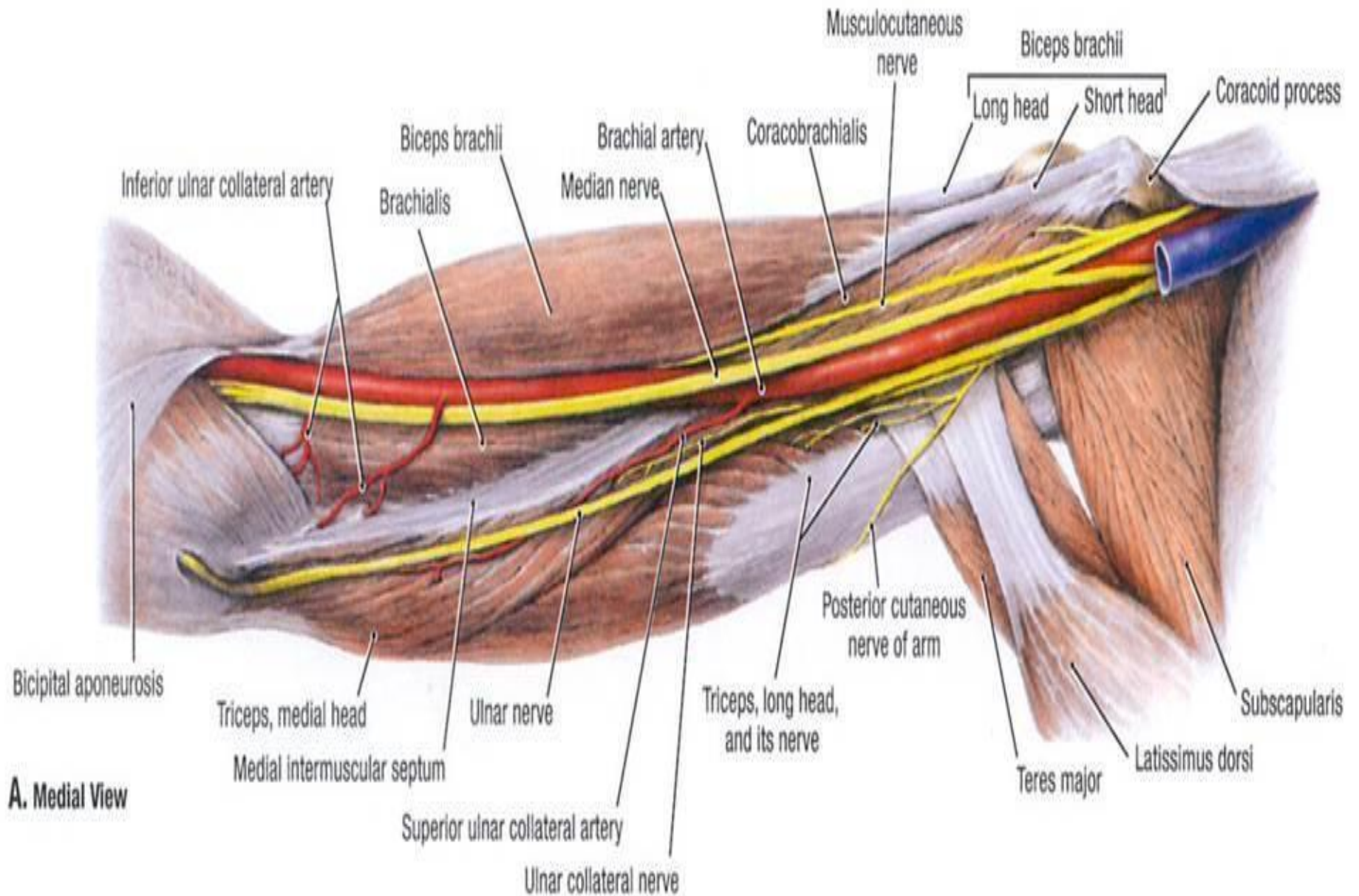
# Deep layer

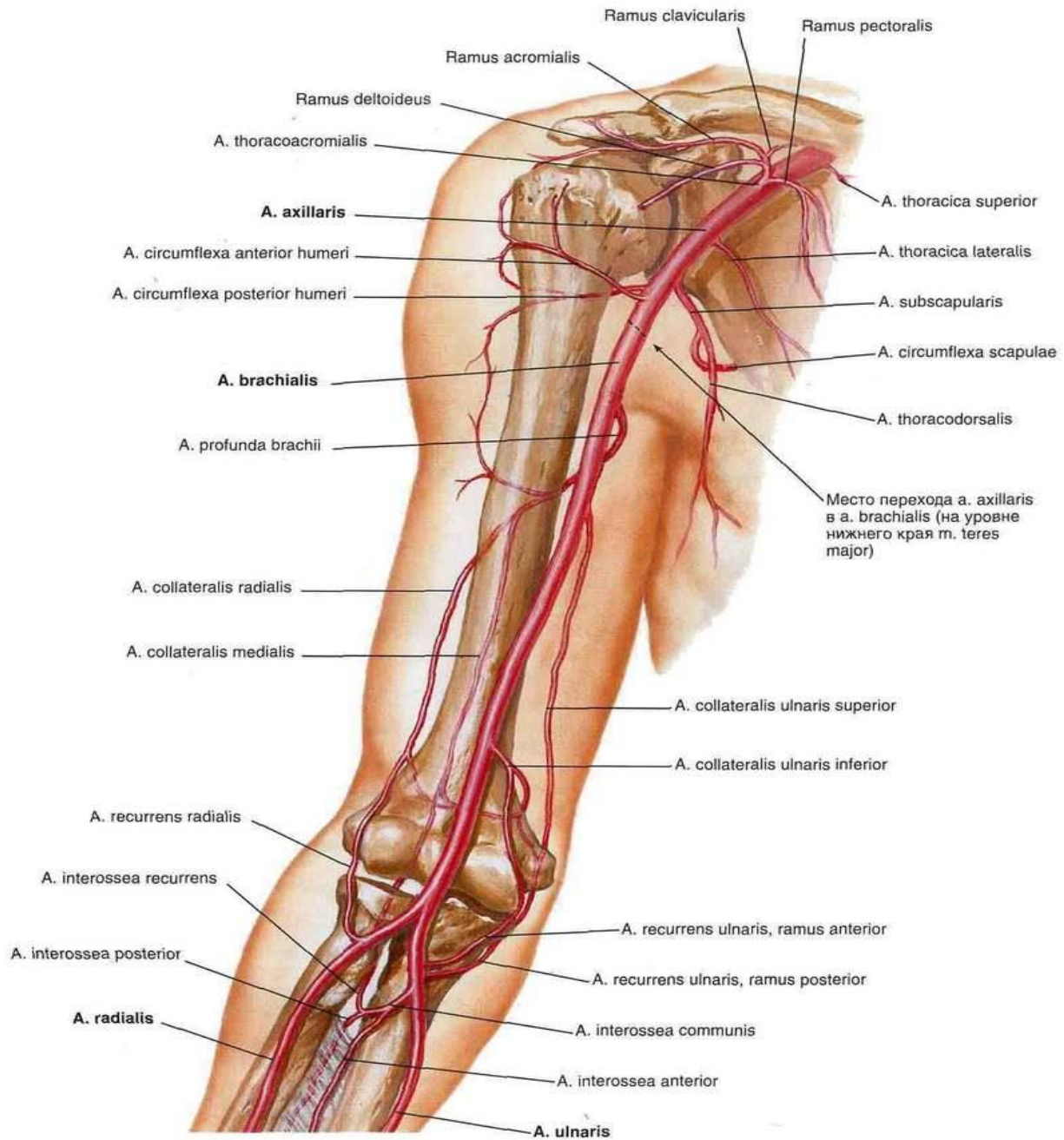


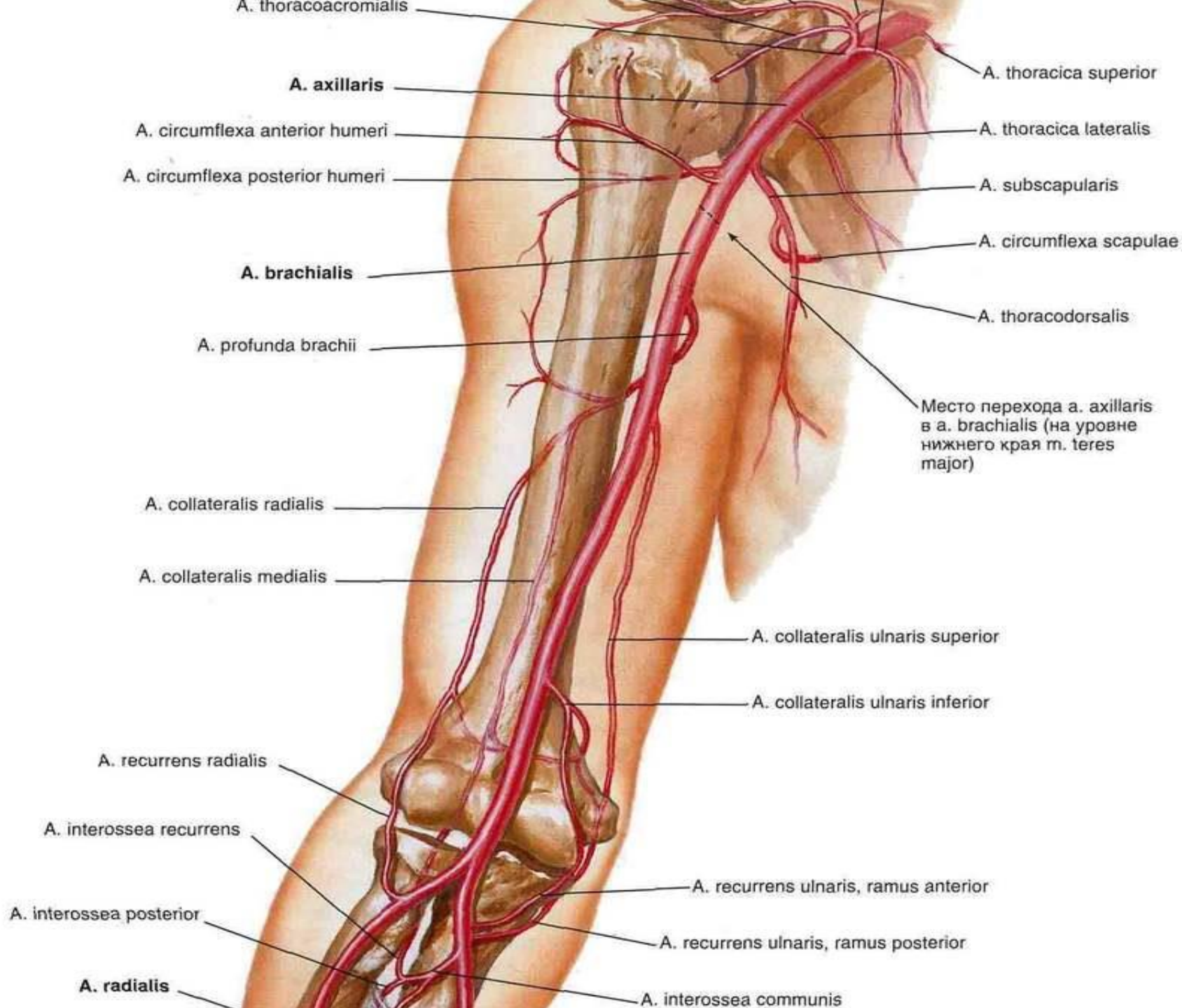
# Deep layer

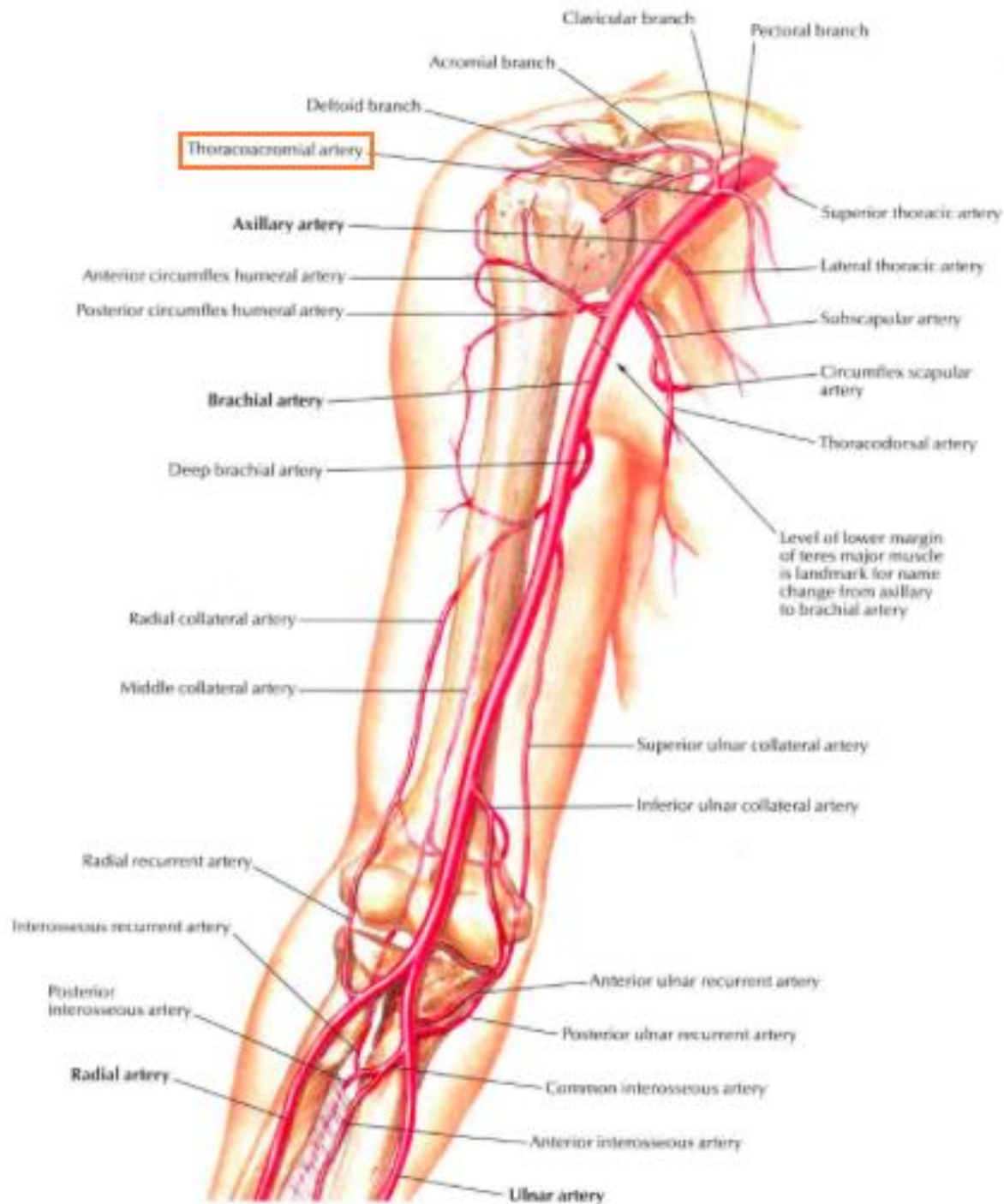




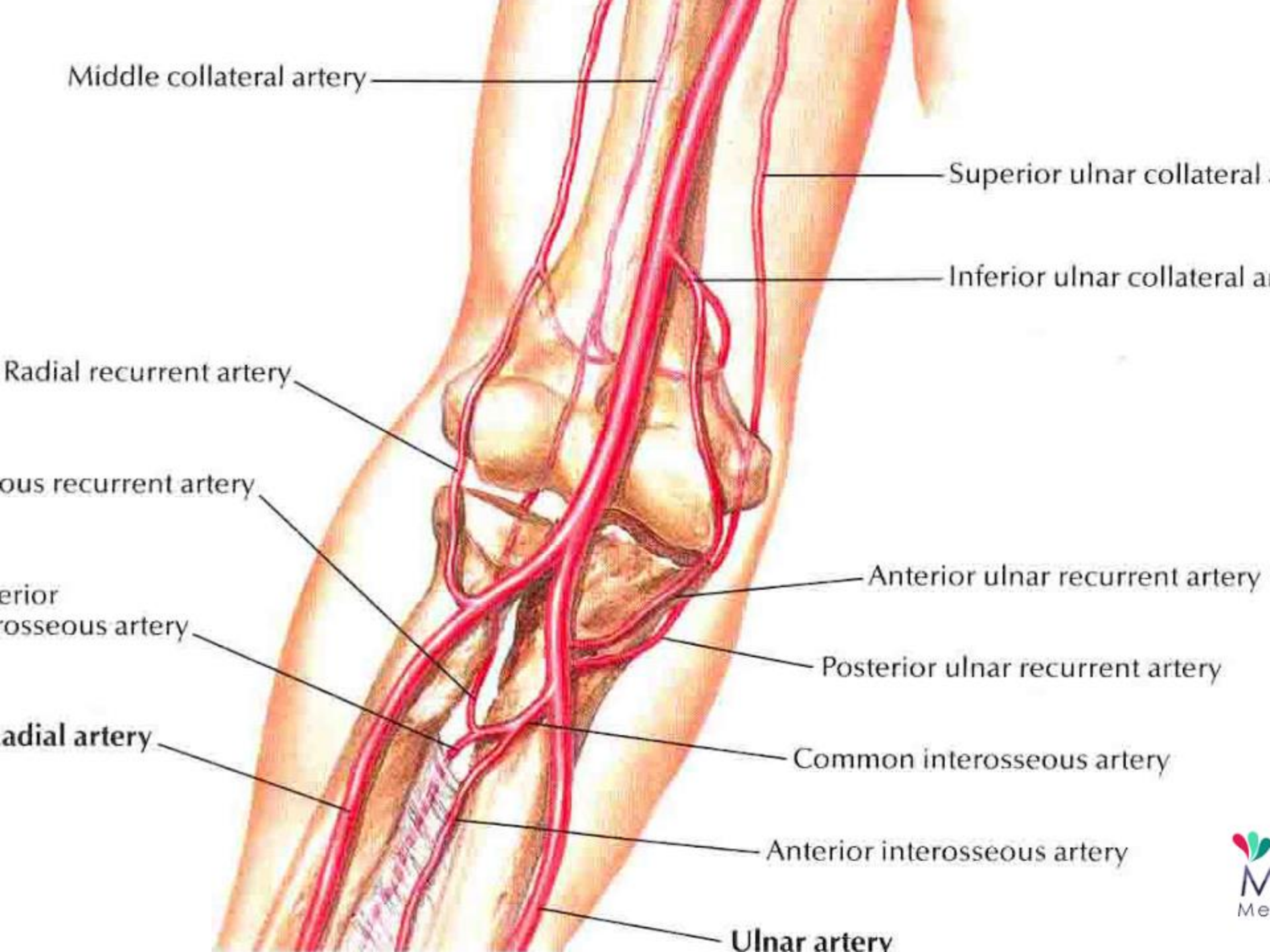












Middle collateral artery

Superior ulnar collateral

Inferior ulnar collateral a

Radial recurrent artery

ous recurrent artery

er  
osseous artery

Anterior ulnar recurrent artery

Posterior ulnar recurrent artery

radial artery

Common interosseous artery

Anterior interosseous artery

Ulnar artery

- ❑ Anastomosis occurs between branches of

- ❑ **Brachial, Radial and Ulnar arteries:**

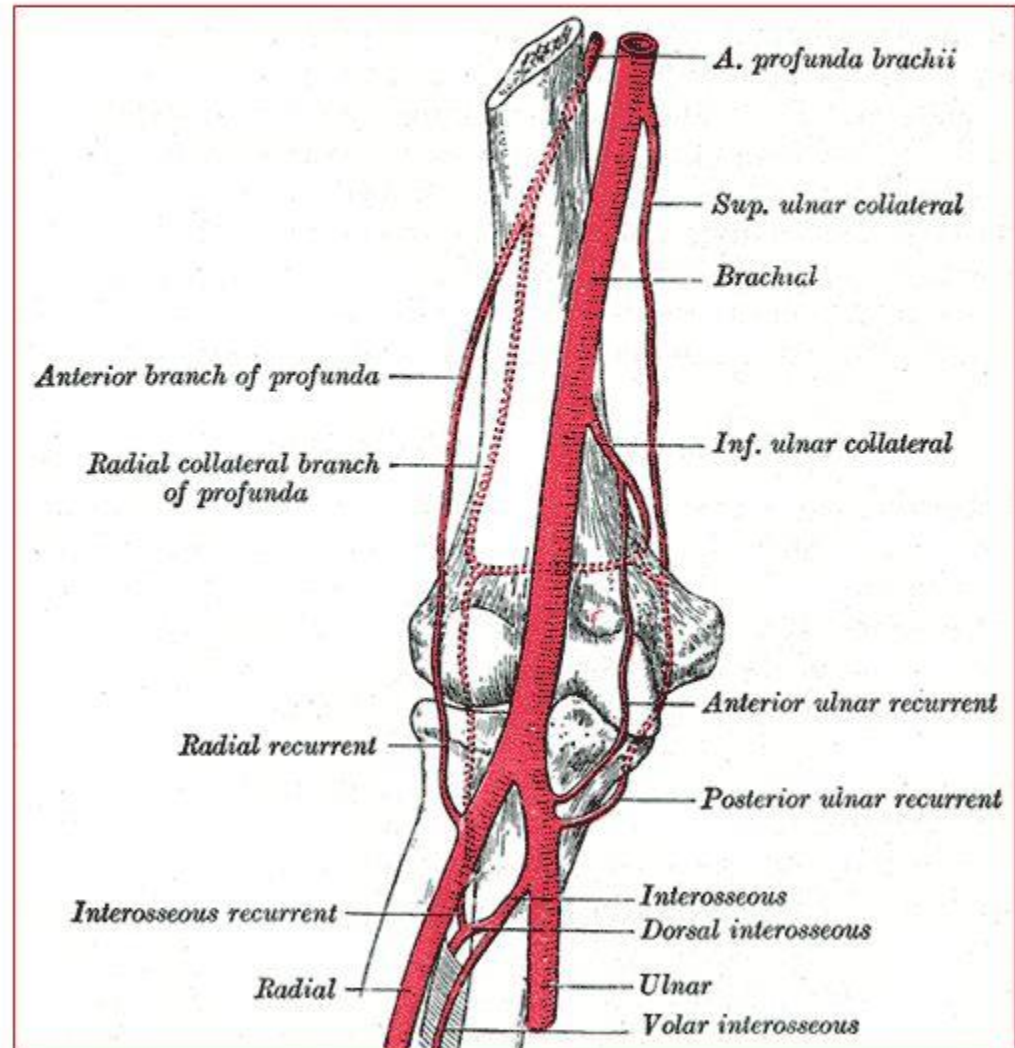
- **Branches from Brachial Artery:**

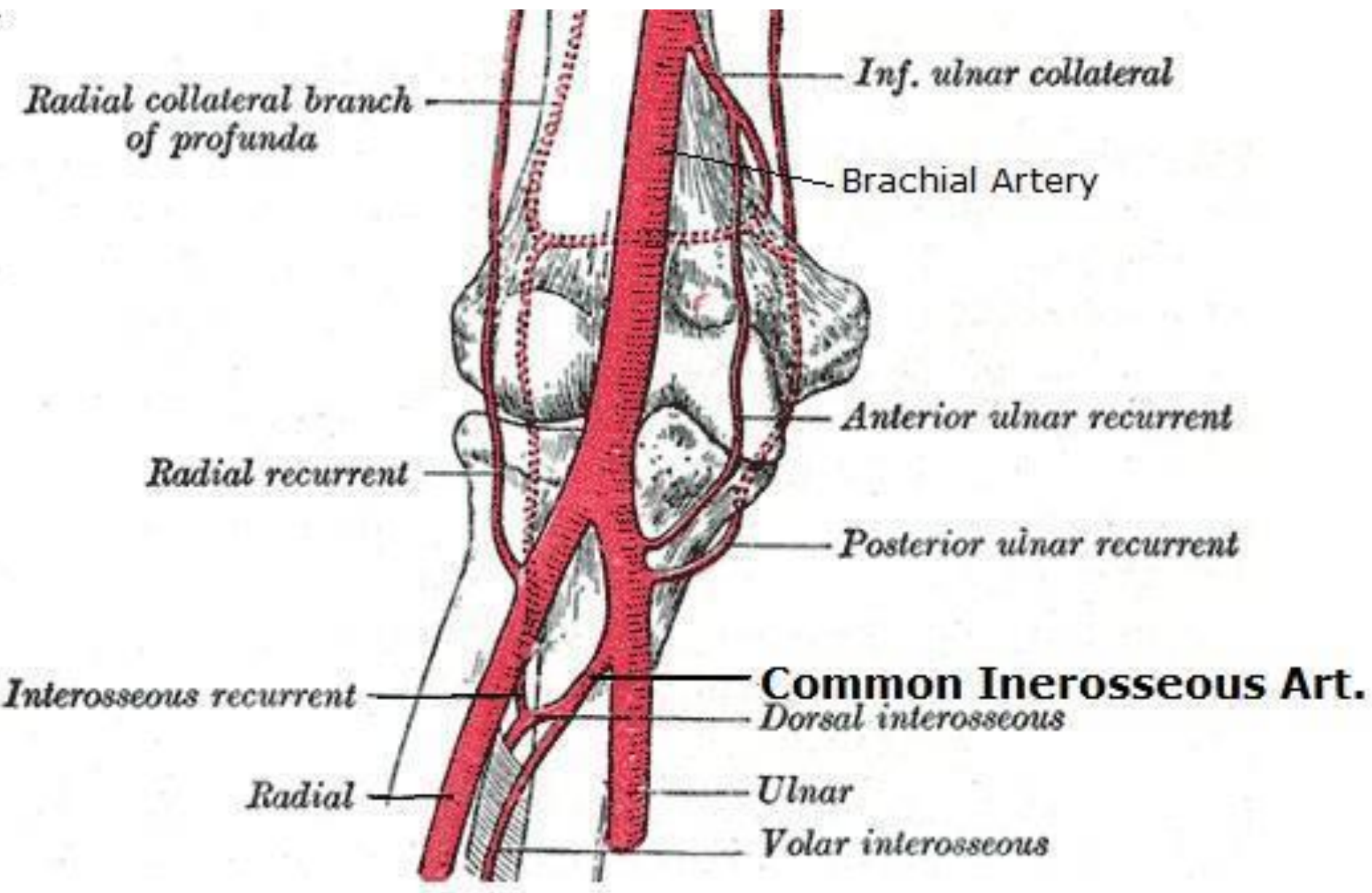
- Profunda Brachii artery
- Superior ulnar collateral artery
- Inferior ulnar collateral artery

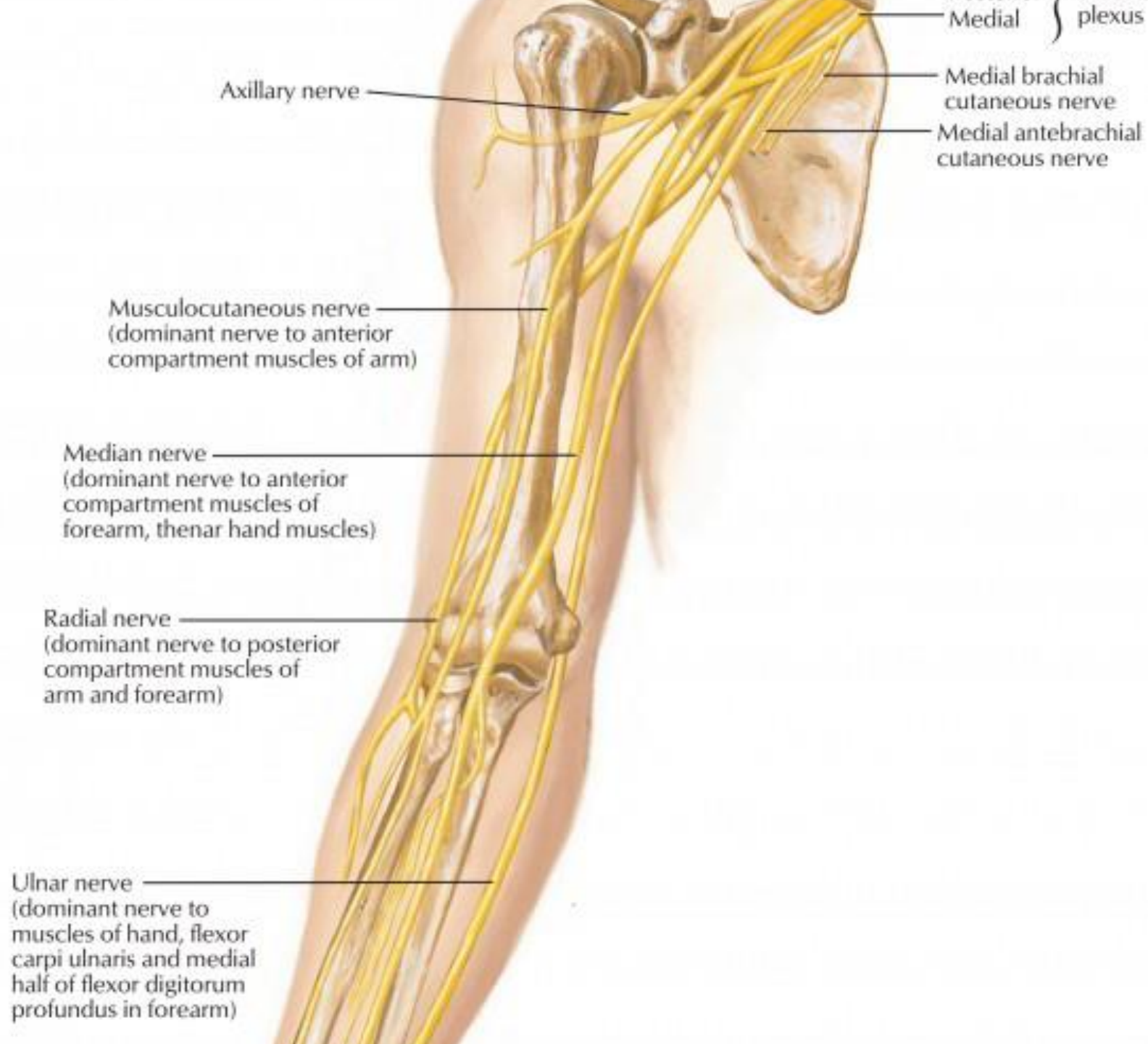
- **Branches from Ulnar and Radial Arteries:**

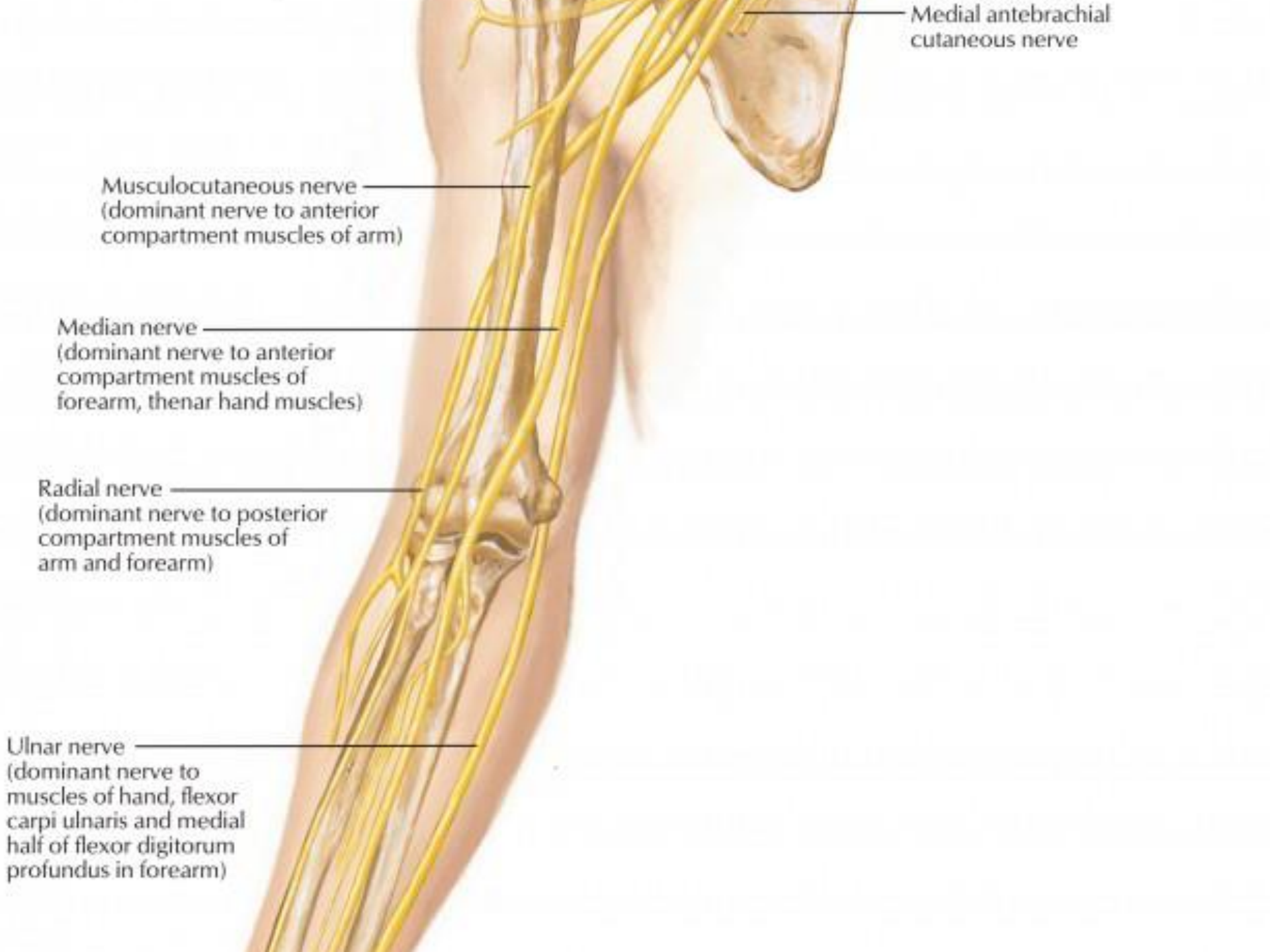
- Radial & ulnar recurrent arteries
- Posterior interosseous recurrent artery

## Anastomosis around elbow joint









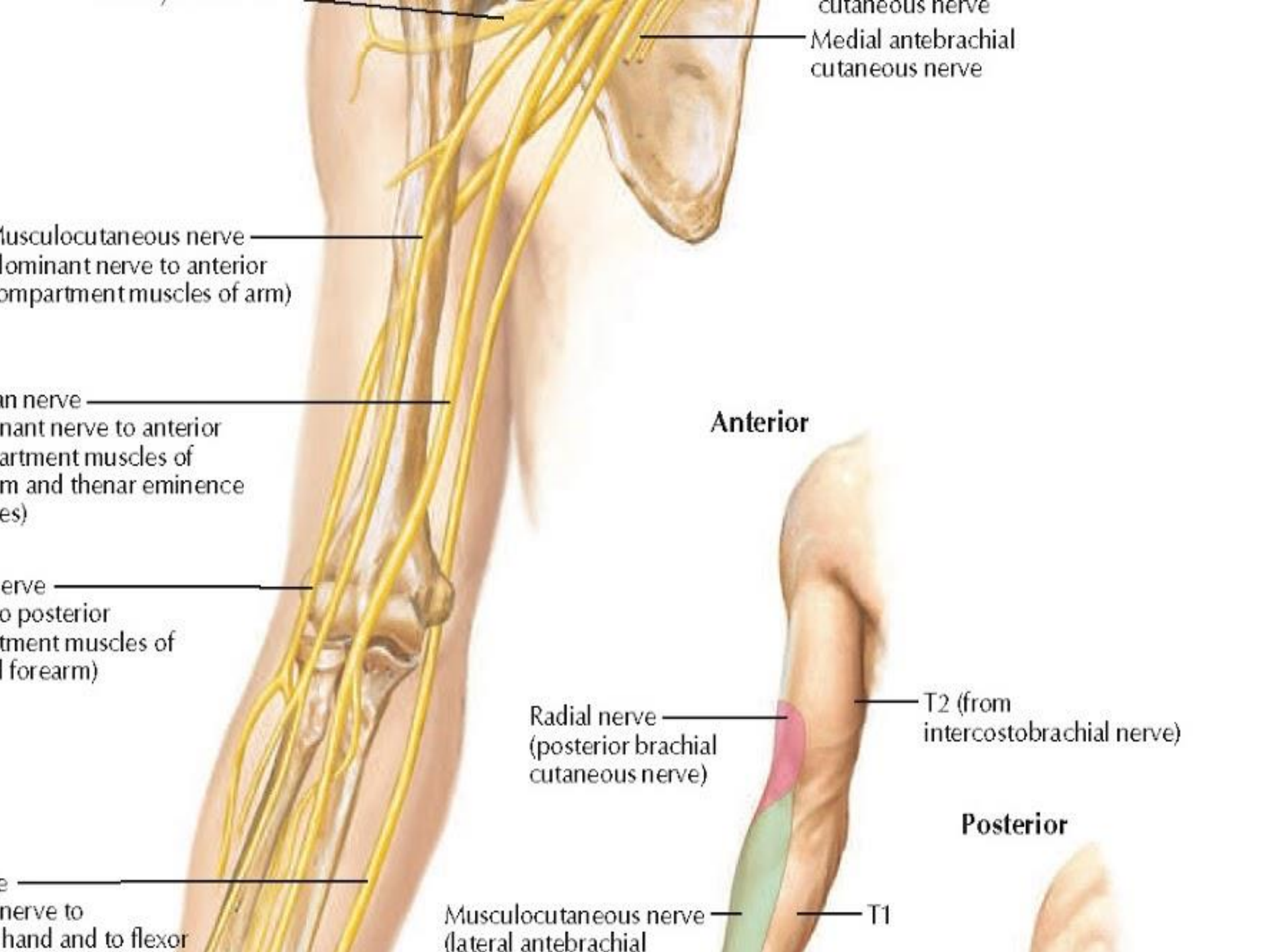
Medial antebrachial cutaneous nerve

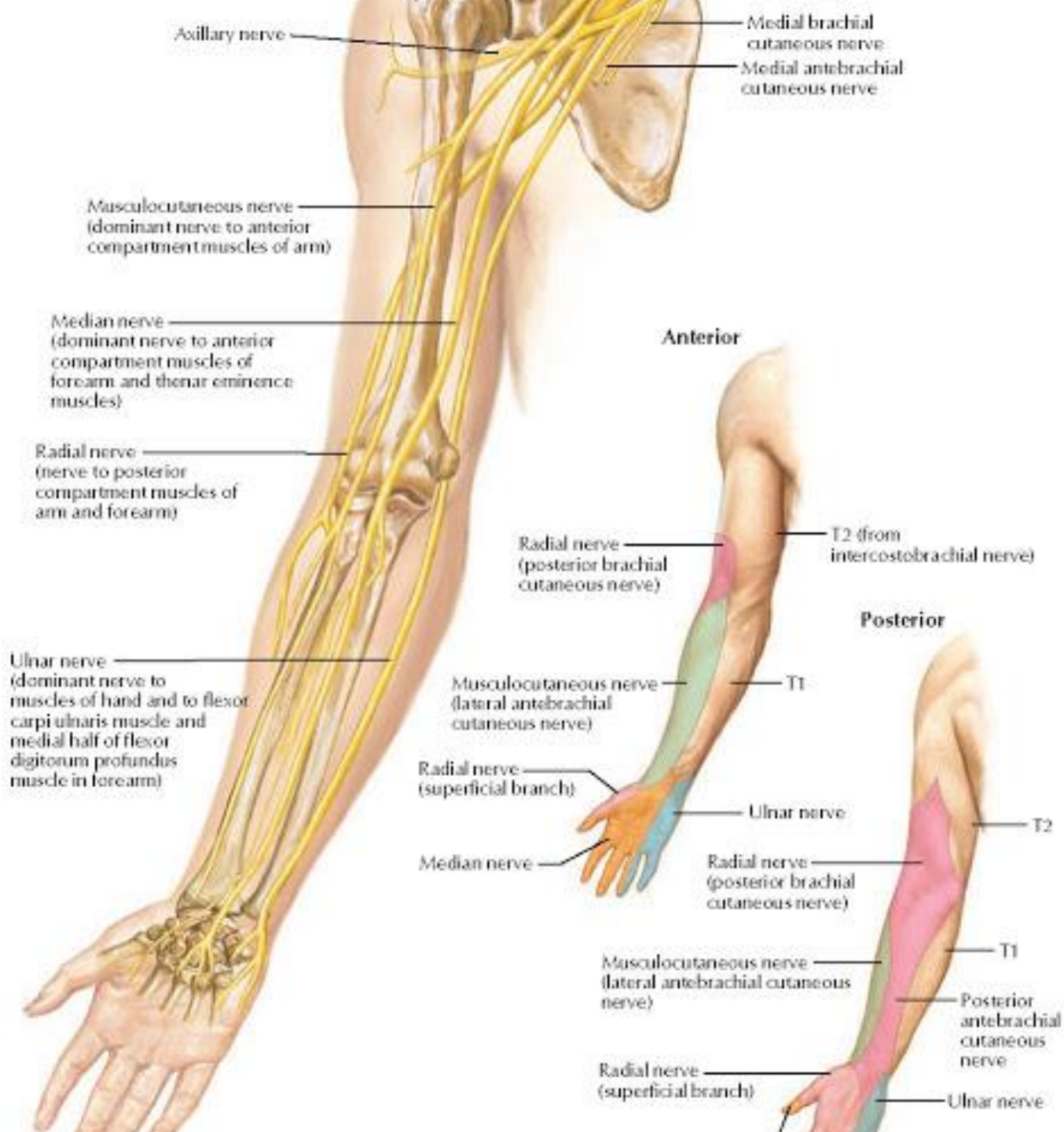
Musculocutaneous nerve  
(dominant nerve to anterior compartment muscles of arm)

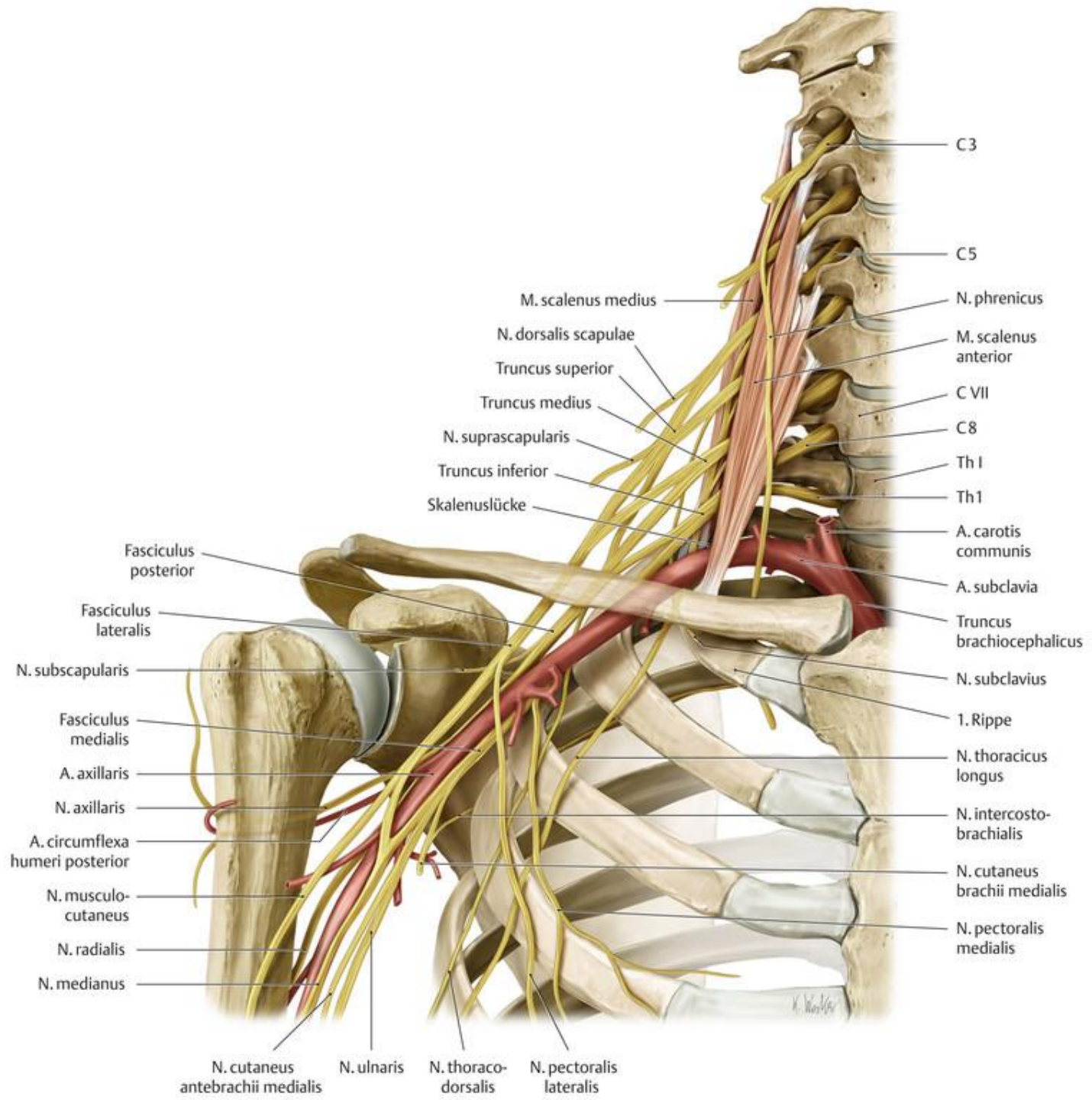
Median nerve  
(dominant nerve to anterior compartment muscles of forearm, thenar hand muscles)

Radial nerve  
(dominant nerve to posterior compartment muscles of arm and forearm)

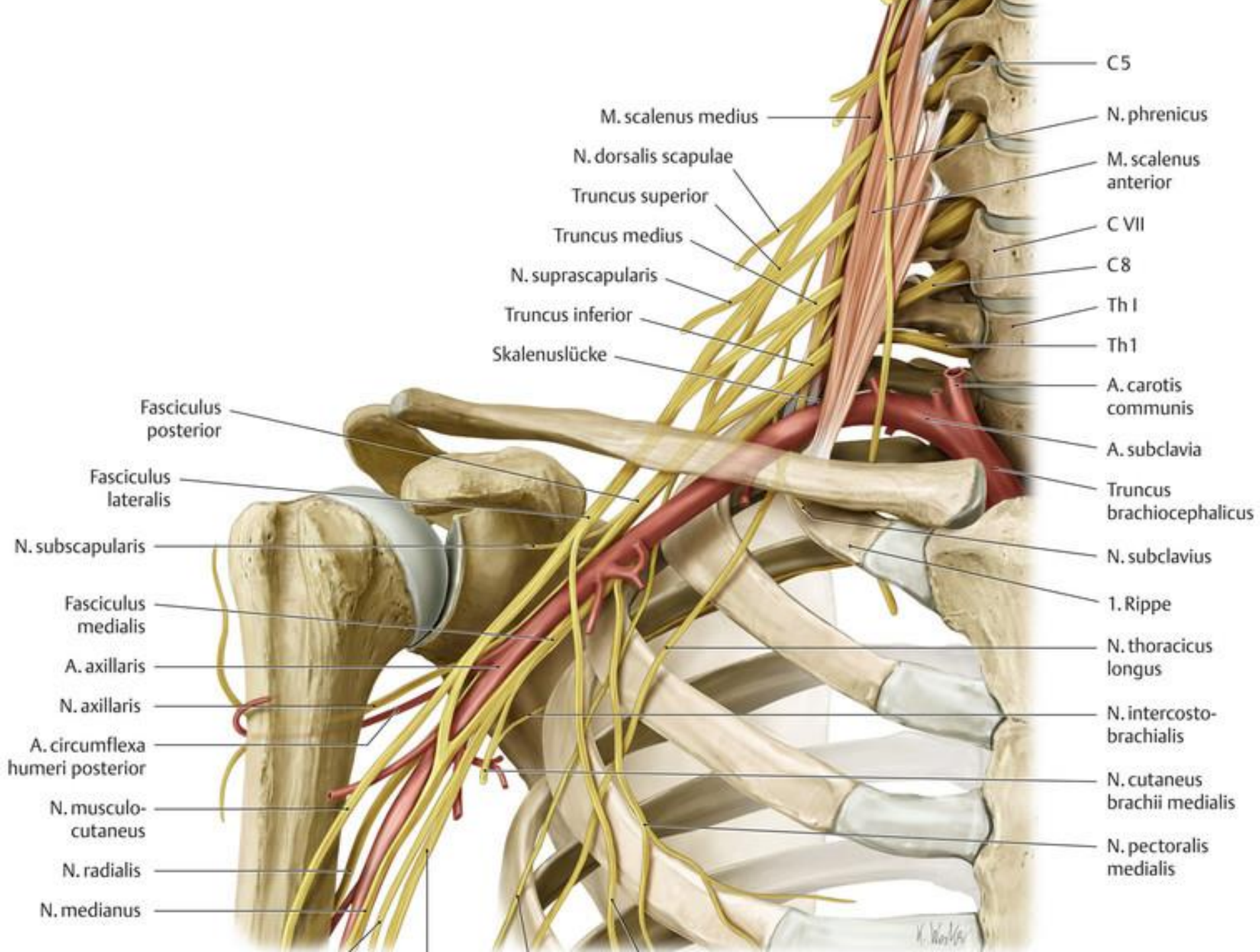
Ulnar nerve  
(dominant nerve to muscles of hand, flexor carpi ulnaris and medial half of flexor digitorum profundus in forearm)

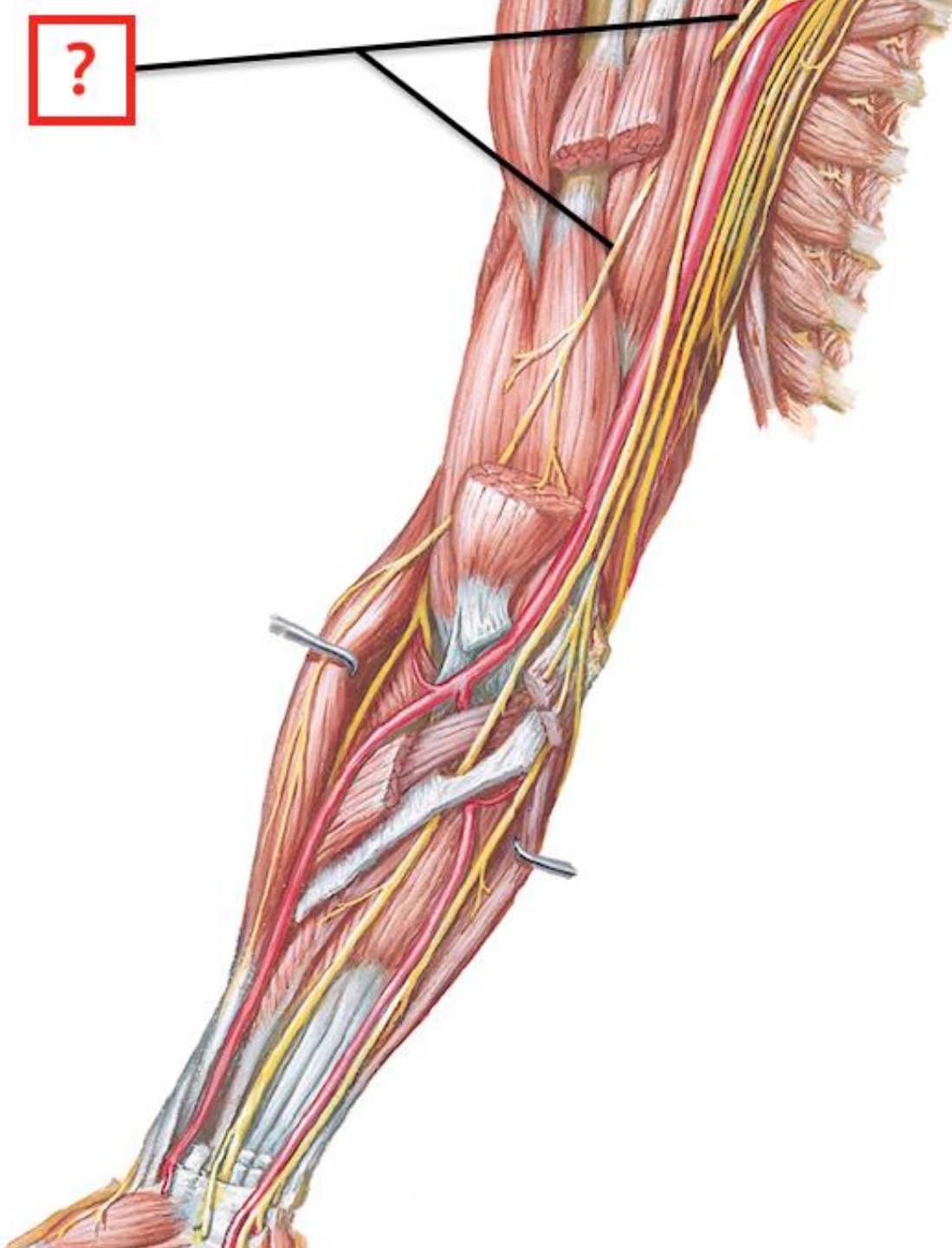


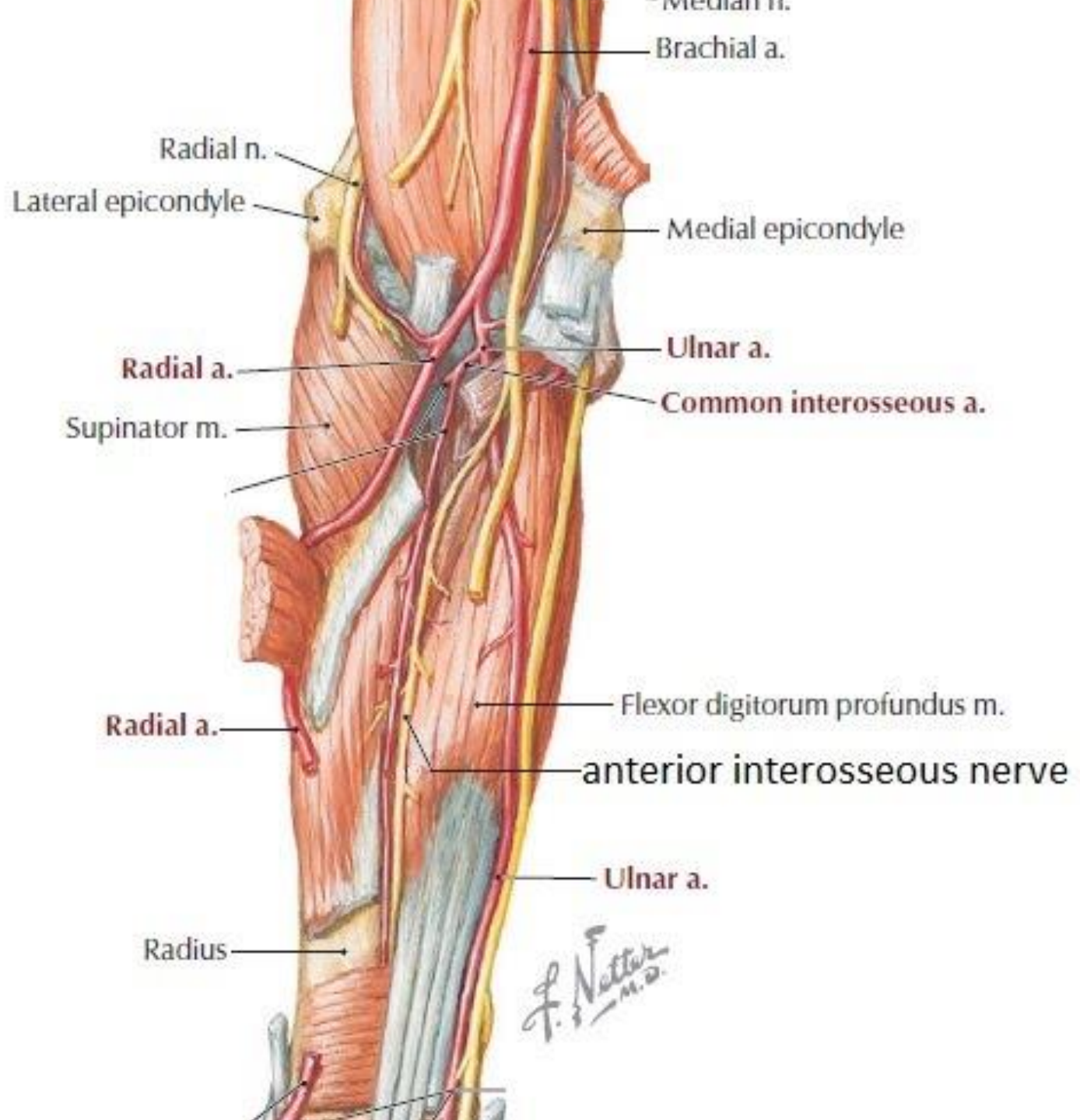


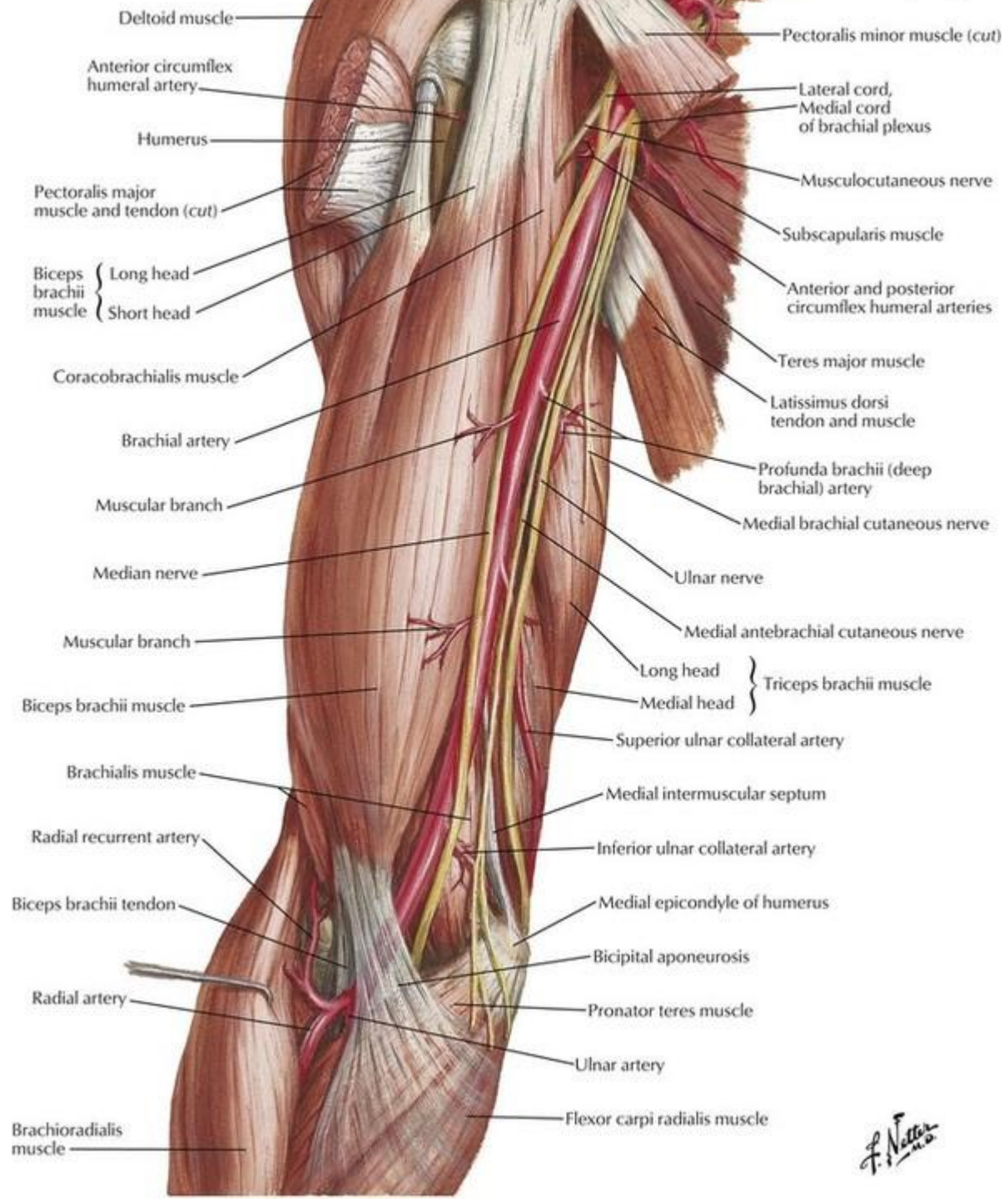




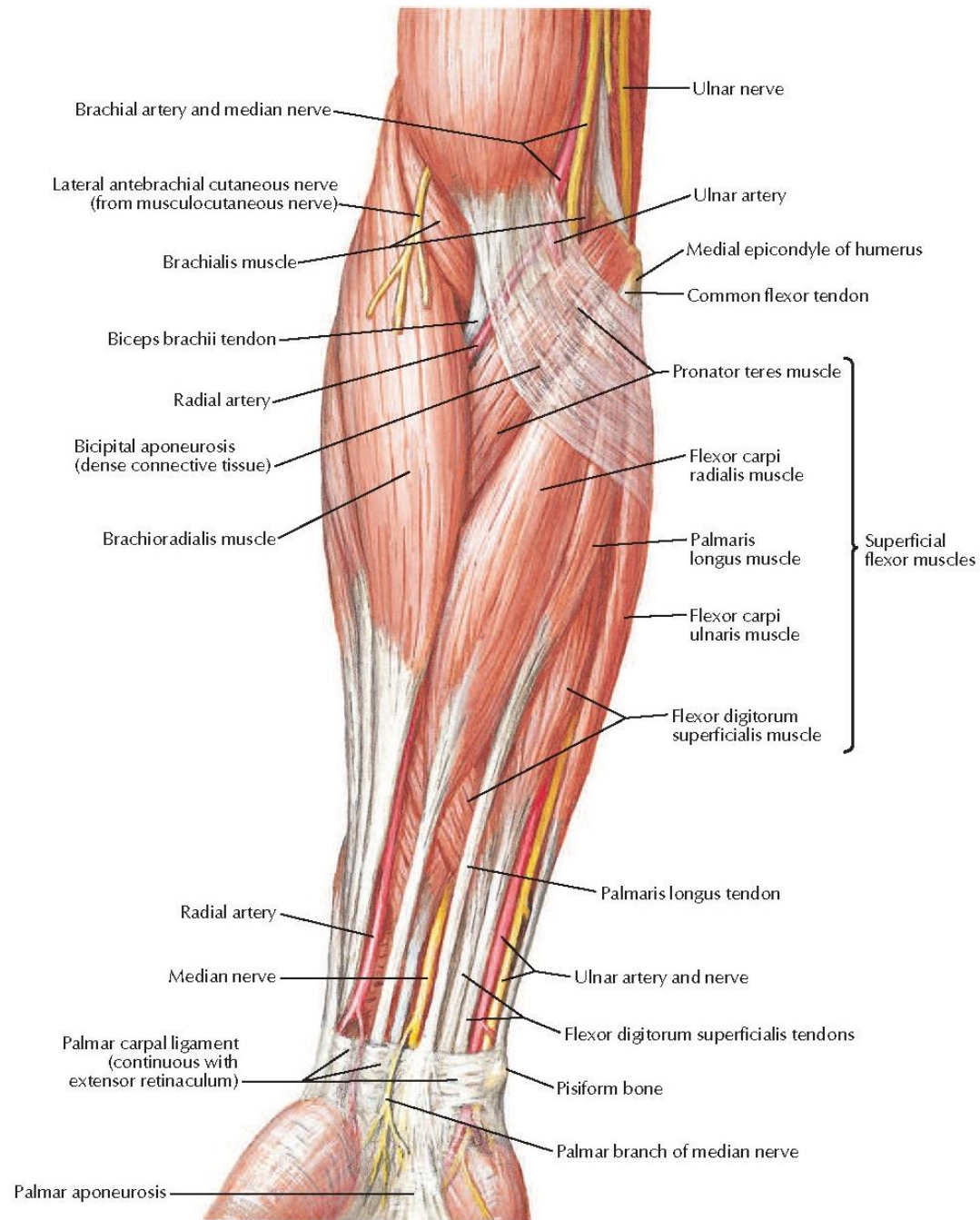


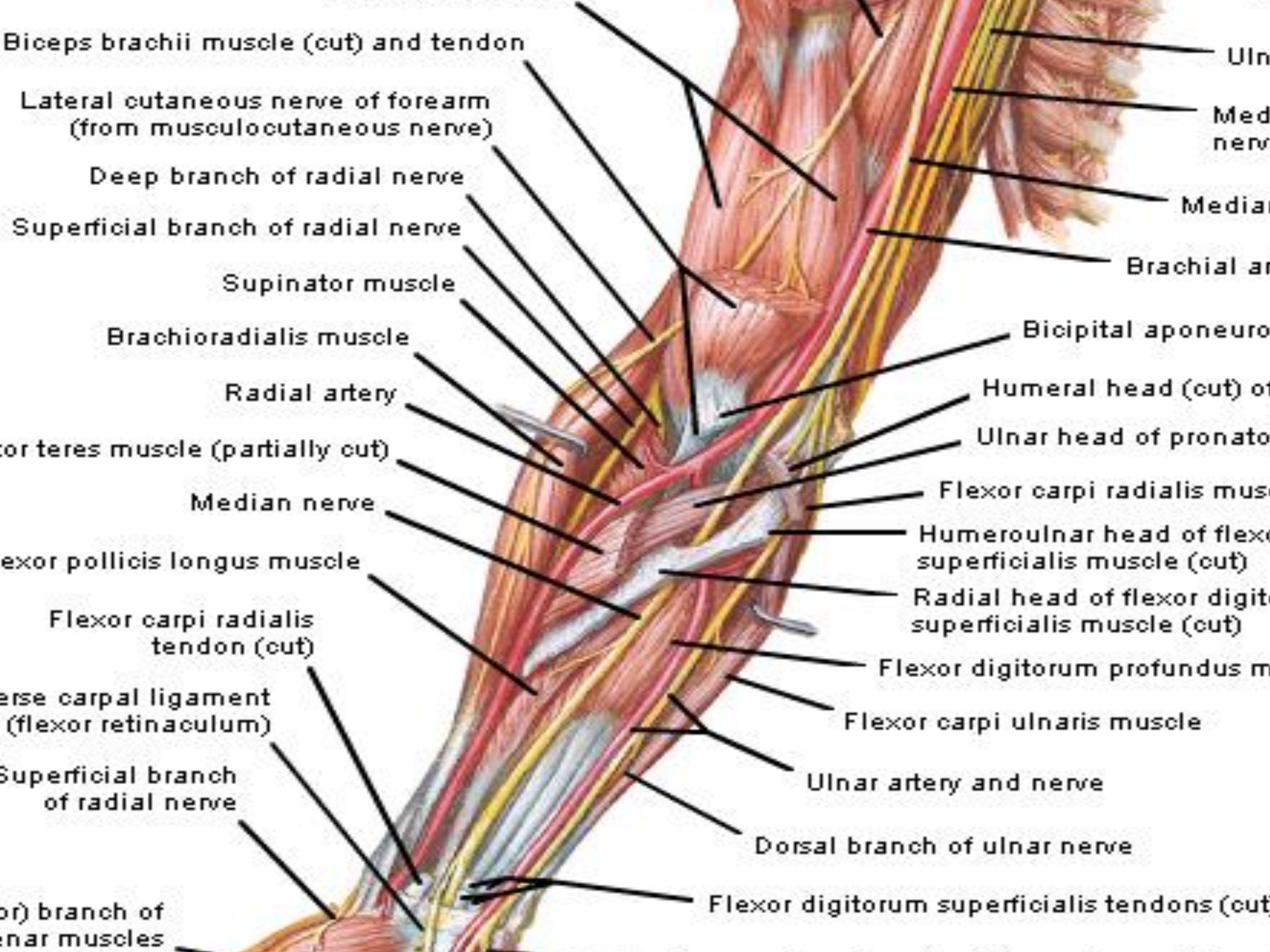






*F. Netter M.D.*





Biceps brachii muscle (cut) and tendon

Lateral cutaneous nerve of forearm  
(from musculocutaneous nerve)

Deep branch of radial nerve

Superficial branch of radial nerve

Supinator muscle

Brachioradialis muscle

Radial artery

Coracobrachialis muscle (partially cut)

Median nerve

Flexor pollicis longus muscle

Flexor carpi radialis  
tendon (cut)

Transverse carpal ligament  
(flexor retinaculum)

Superficial branch  
of radial nerve

Deep branch of  
ulnar muscles

Ulnar nerve

Medial nerve

Medial nerve

Brachial artery

Bicipital aponeurosis

Humeral head (cut) of  
pronator teres muscle

Ulnar head of pronator  
teres muscle

Flexor carpi radialis muscle

Humeroulnar head of flexor  
carpi radialis muscle (cut)

Radial head of flexor  
carpi radialis muscle (cut)

Flexor digitorum profundus muscle

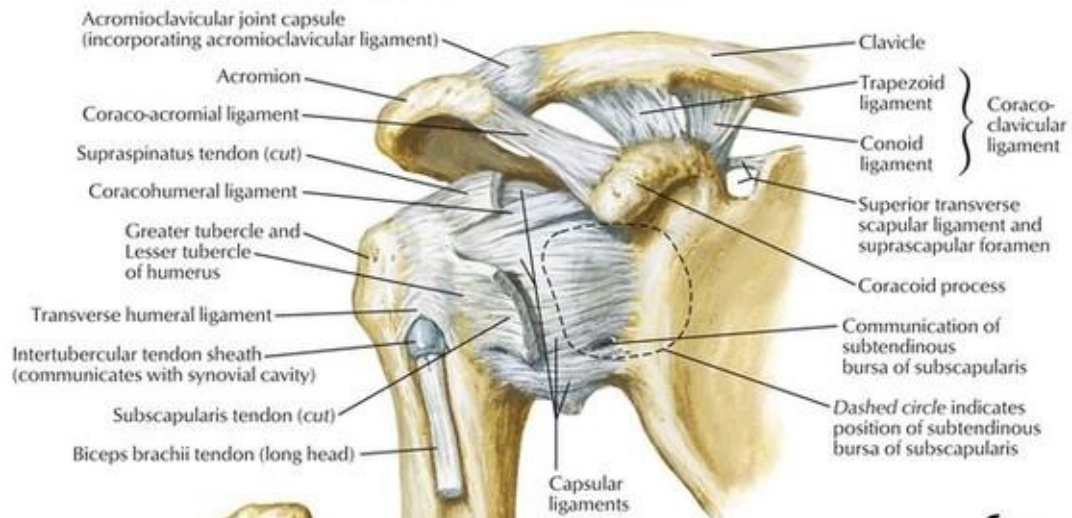
Flexor carpi ulnaris muscle

Ulnar artery and nerve

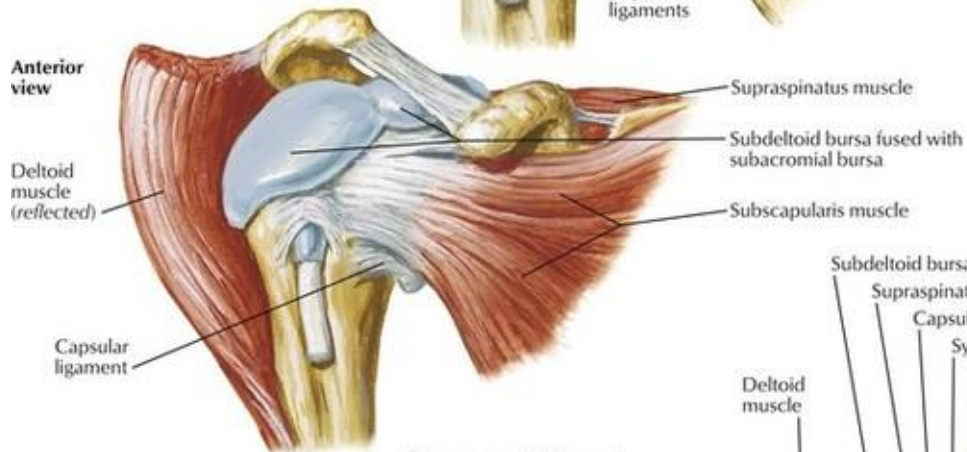
Dorsal branch of ulnar nerve

Flexor digitorum superficialis tendons (cut)

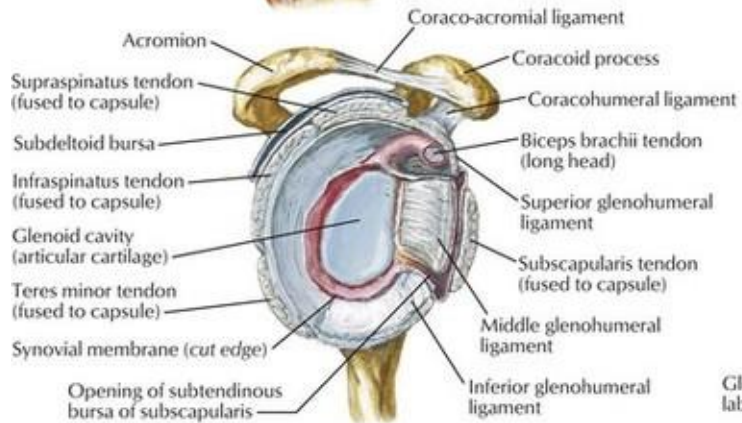
**Anterior view**



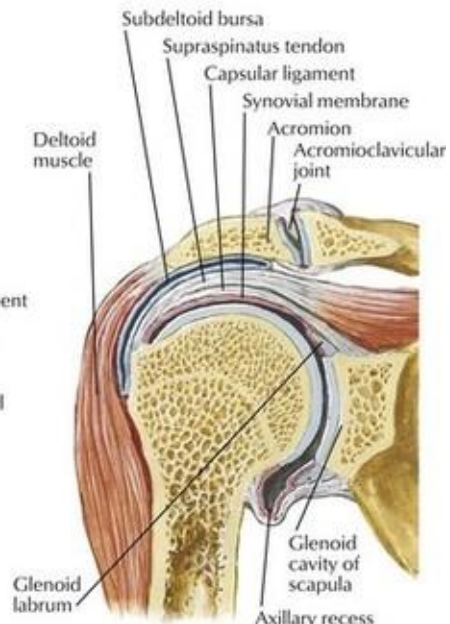
**Anterior view**



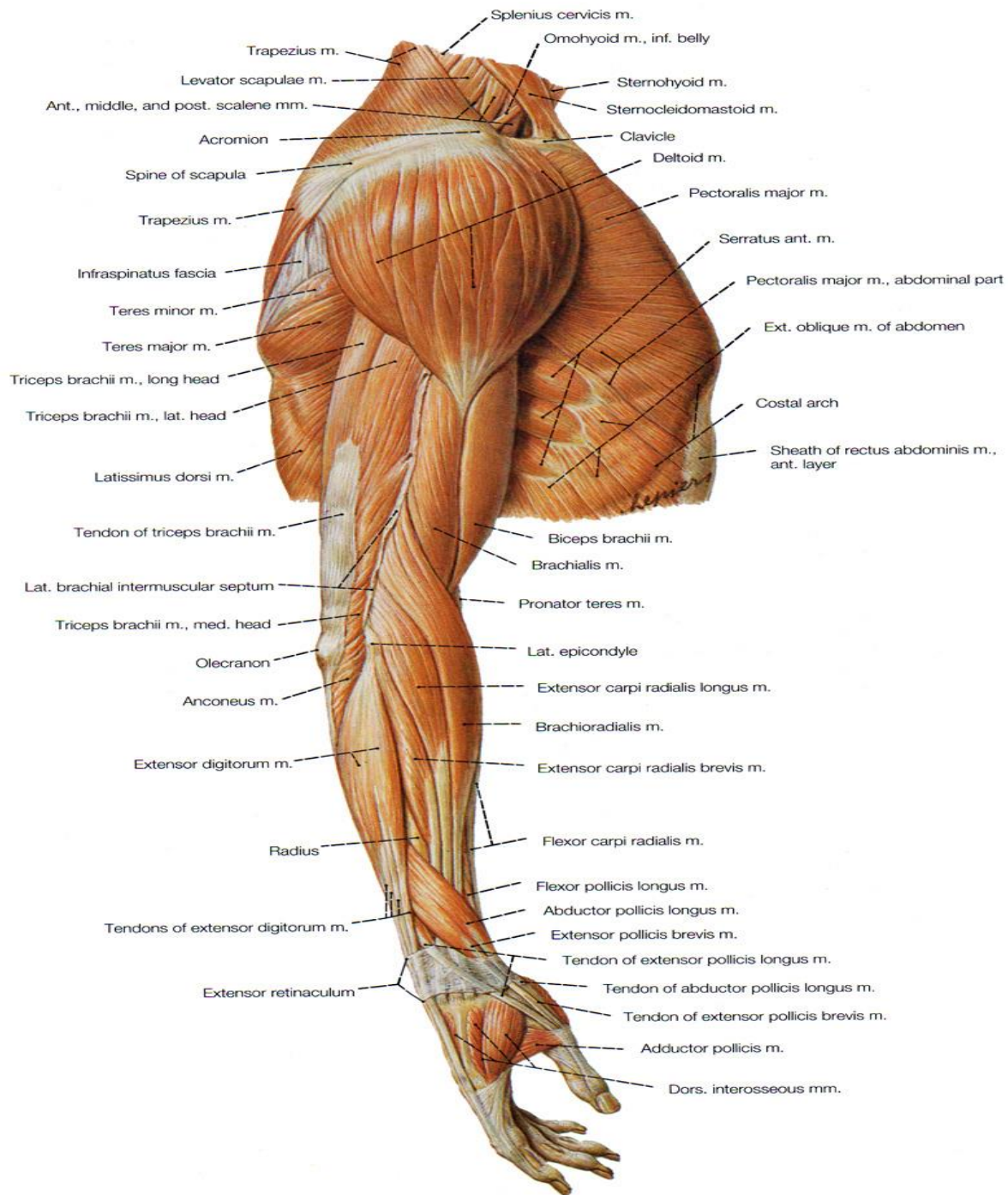
*F. Netter M.D.*



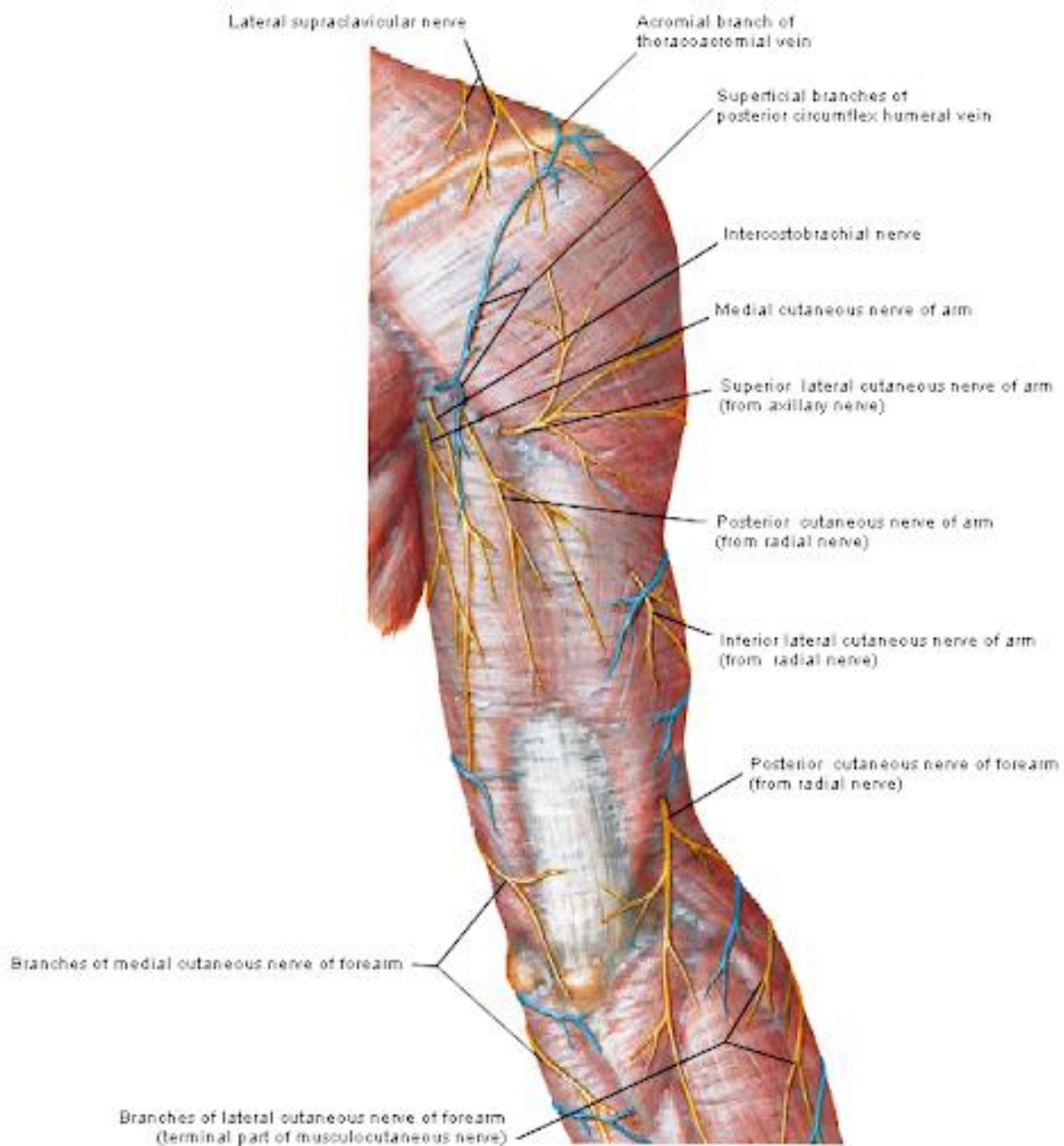
**Joint opened: lateral view**



**Coronal section through joint**







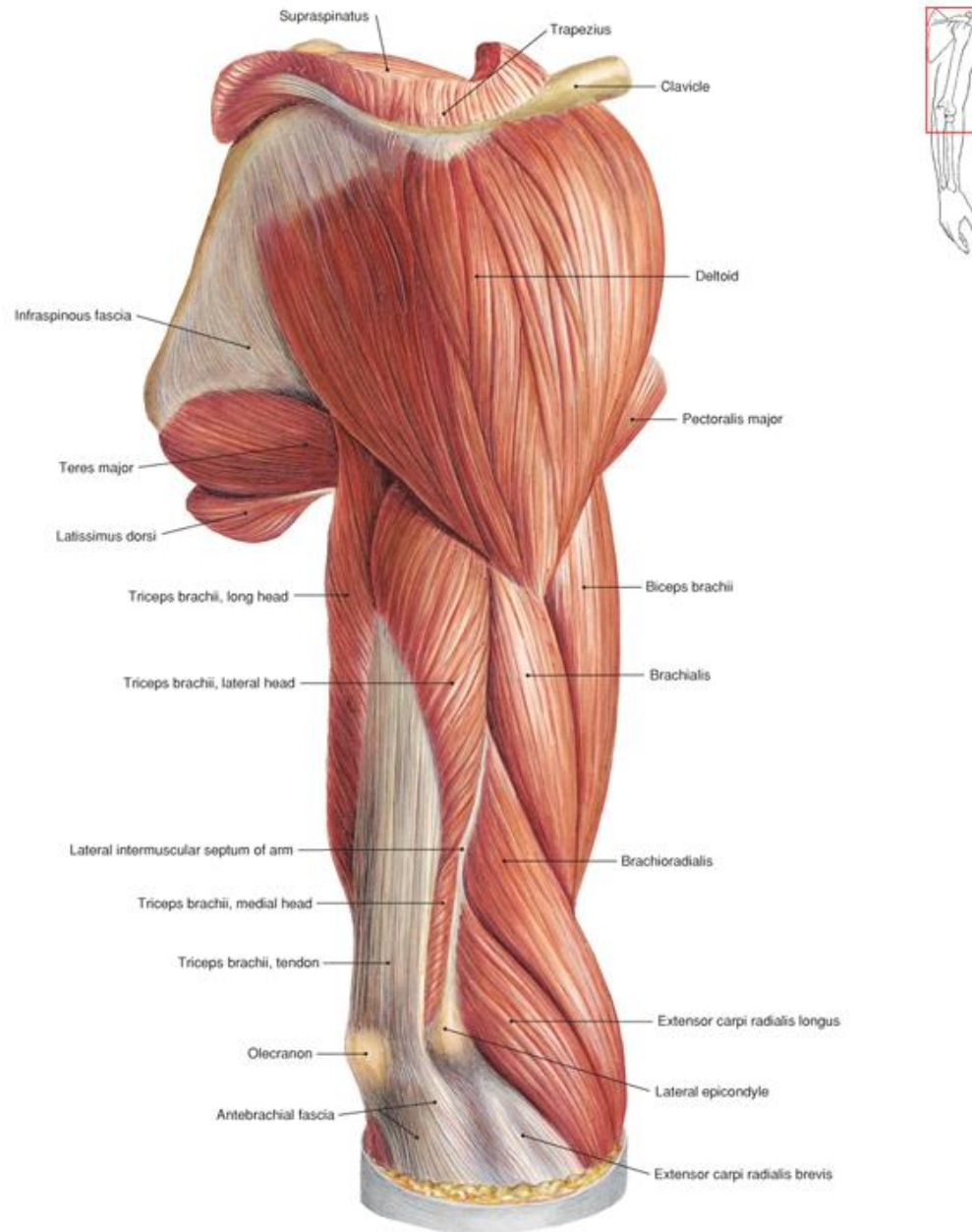
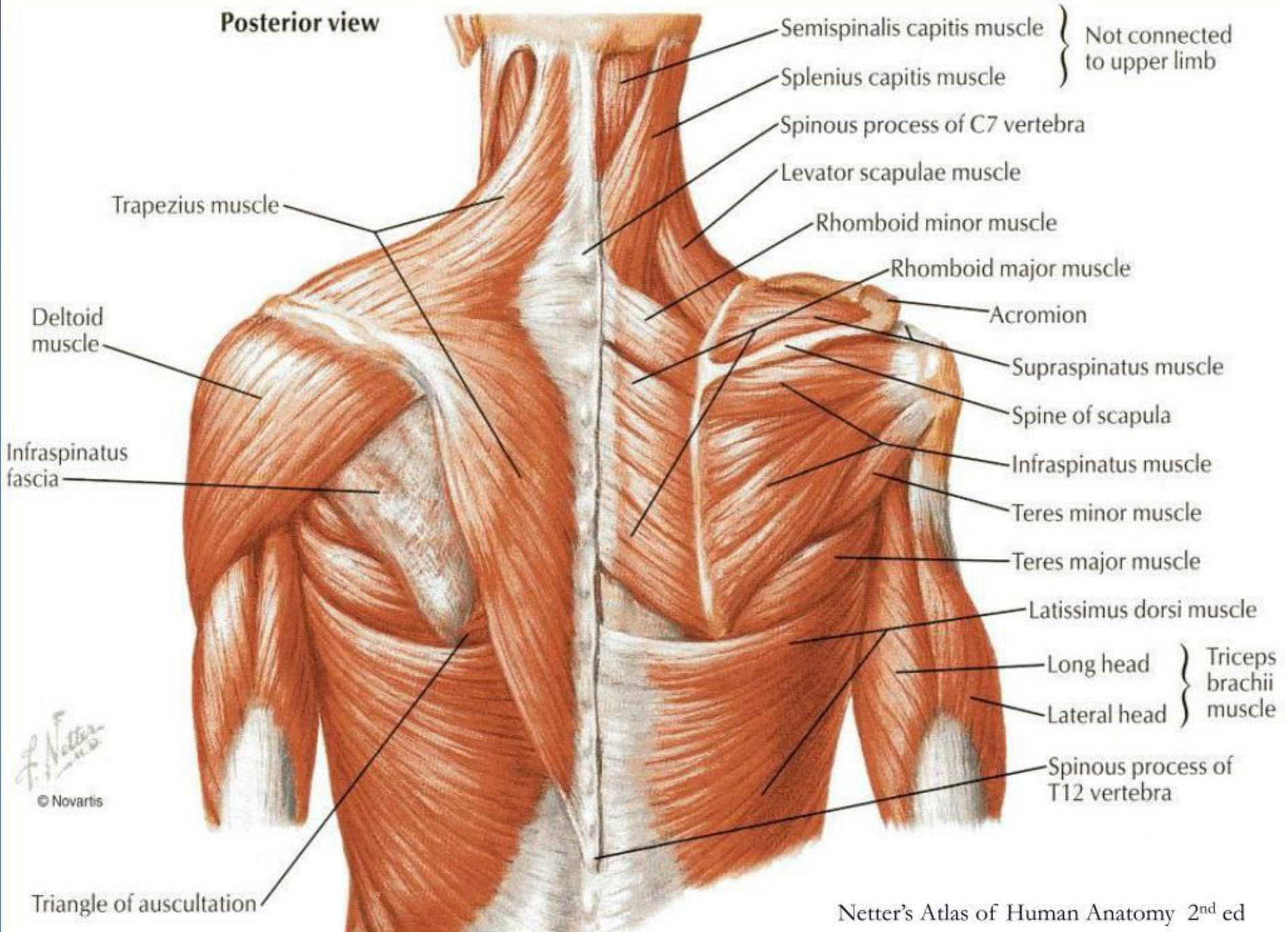
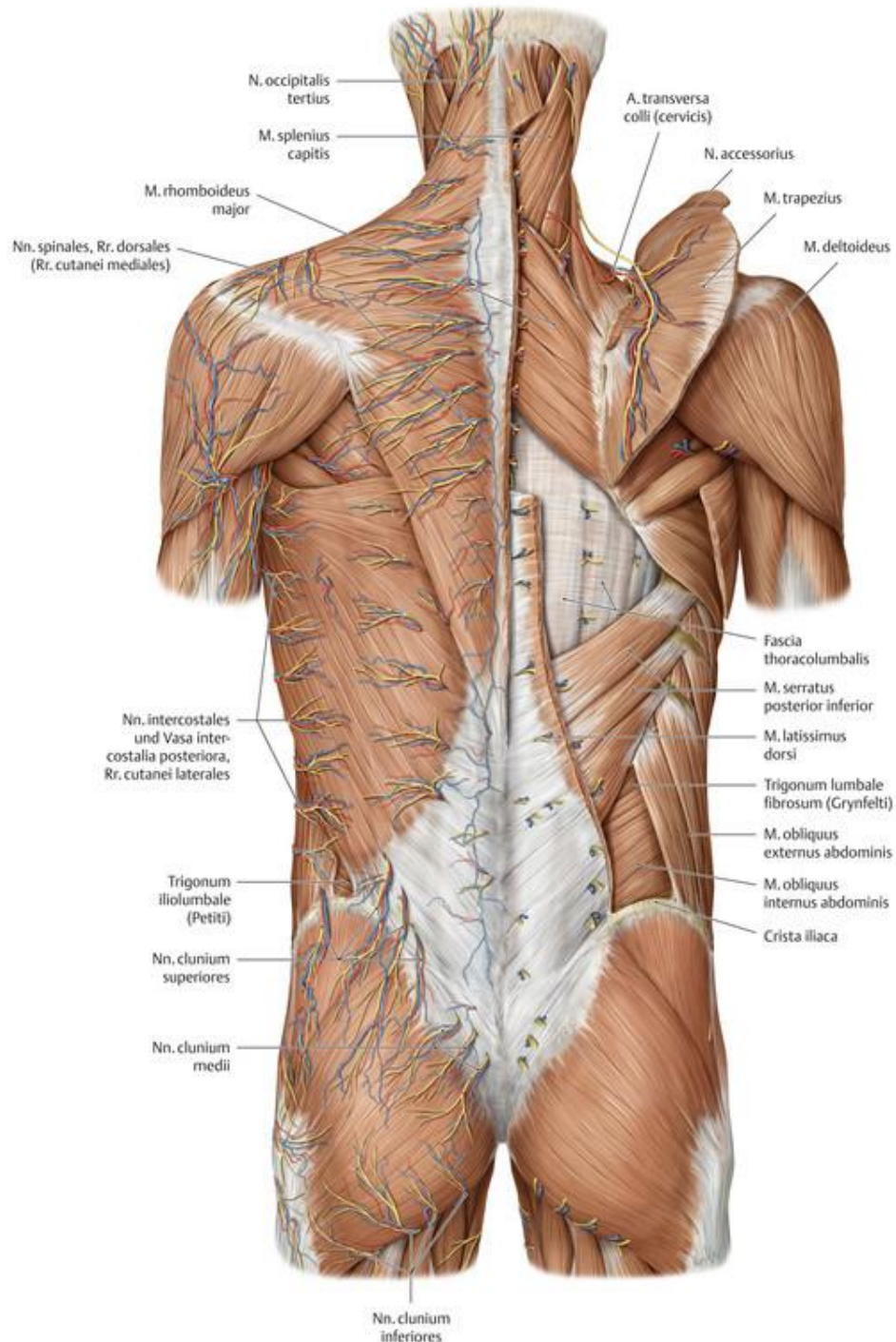


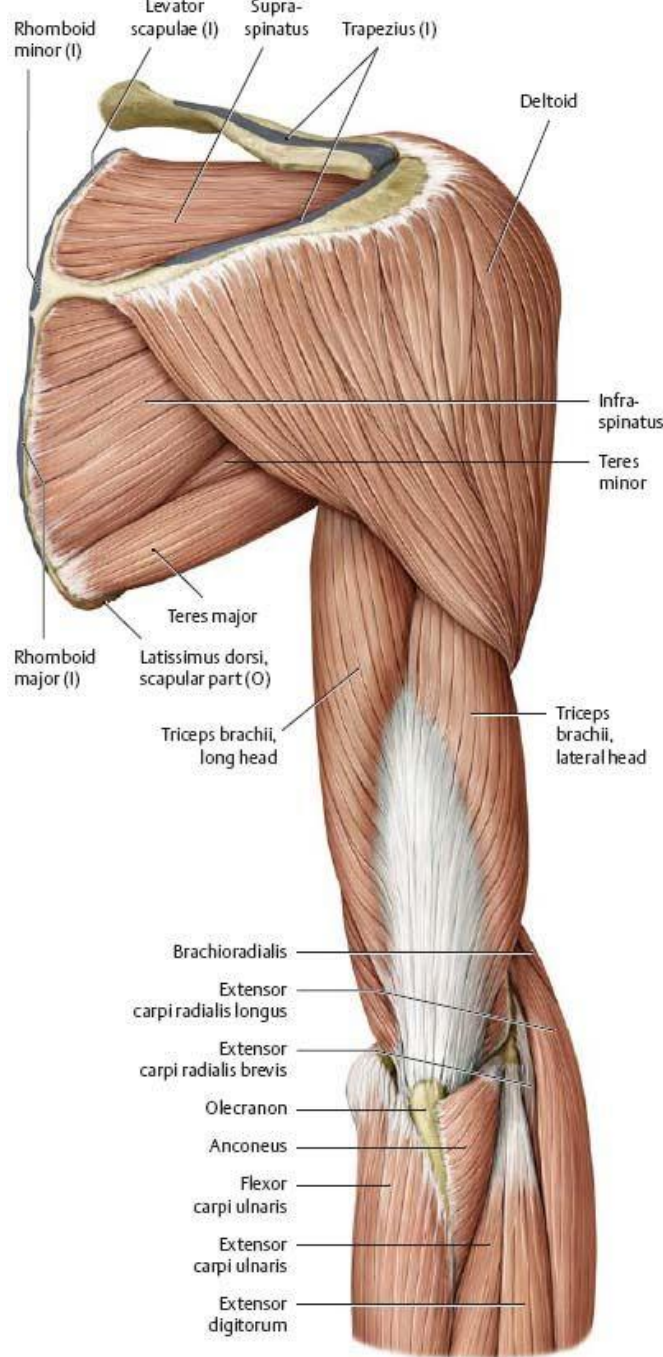
Fig. 345 Deltoid muscle.

Posterior view

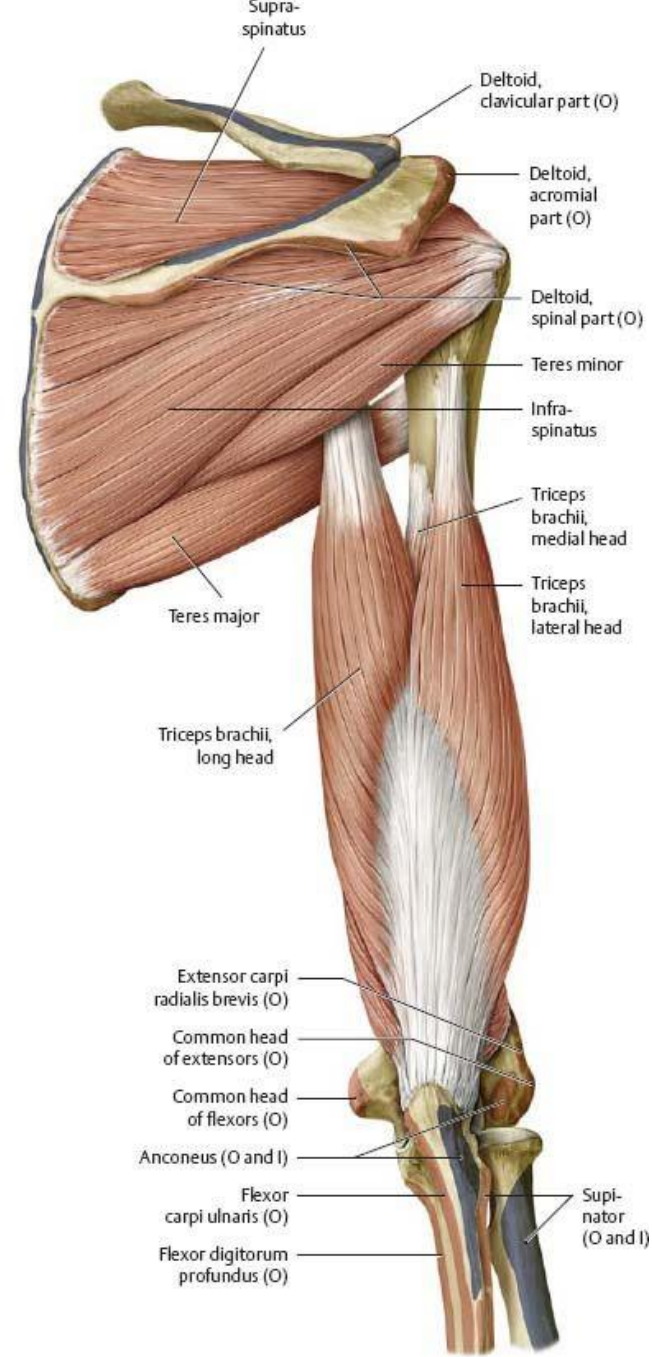


F. Netter M.D.  
© Novartis





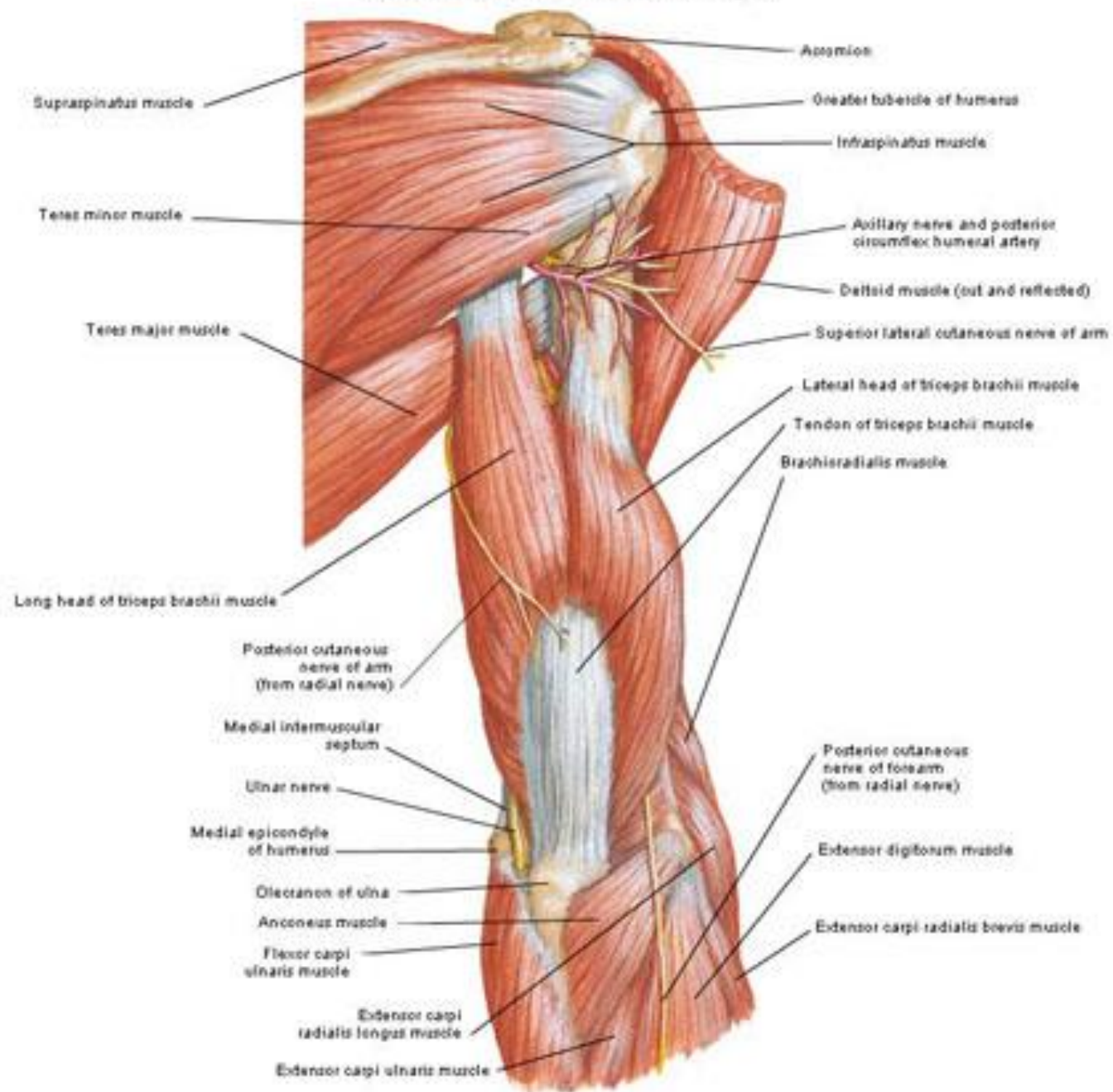
**A** Removed: Rhomboids major and minor, serratus anterior, and levator scapulae.

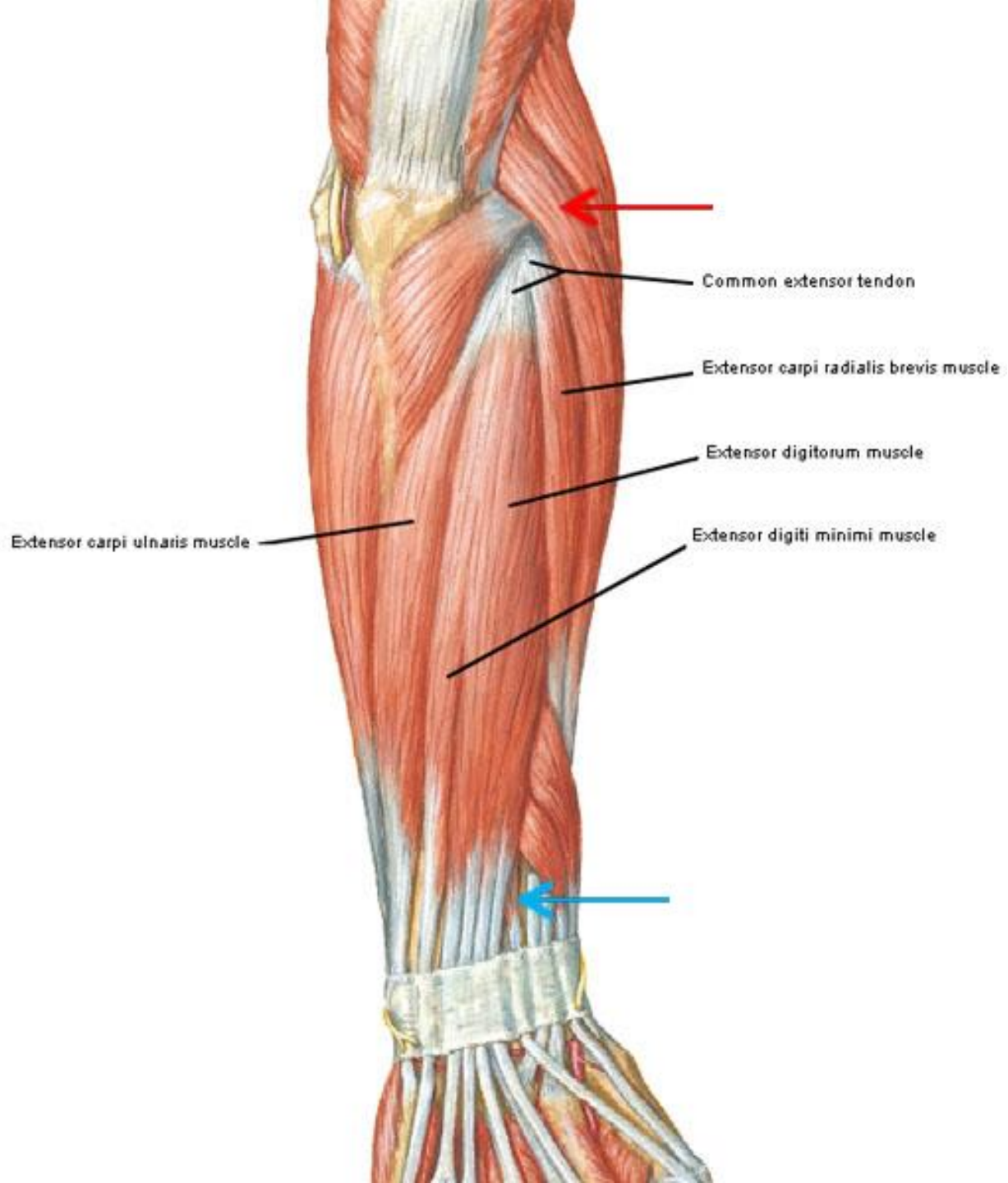


**B** Removed: Deltoid and forearm muscles.

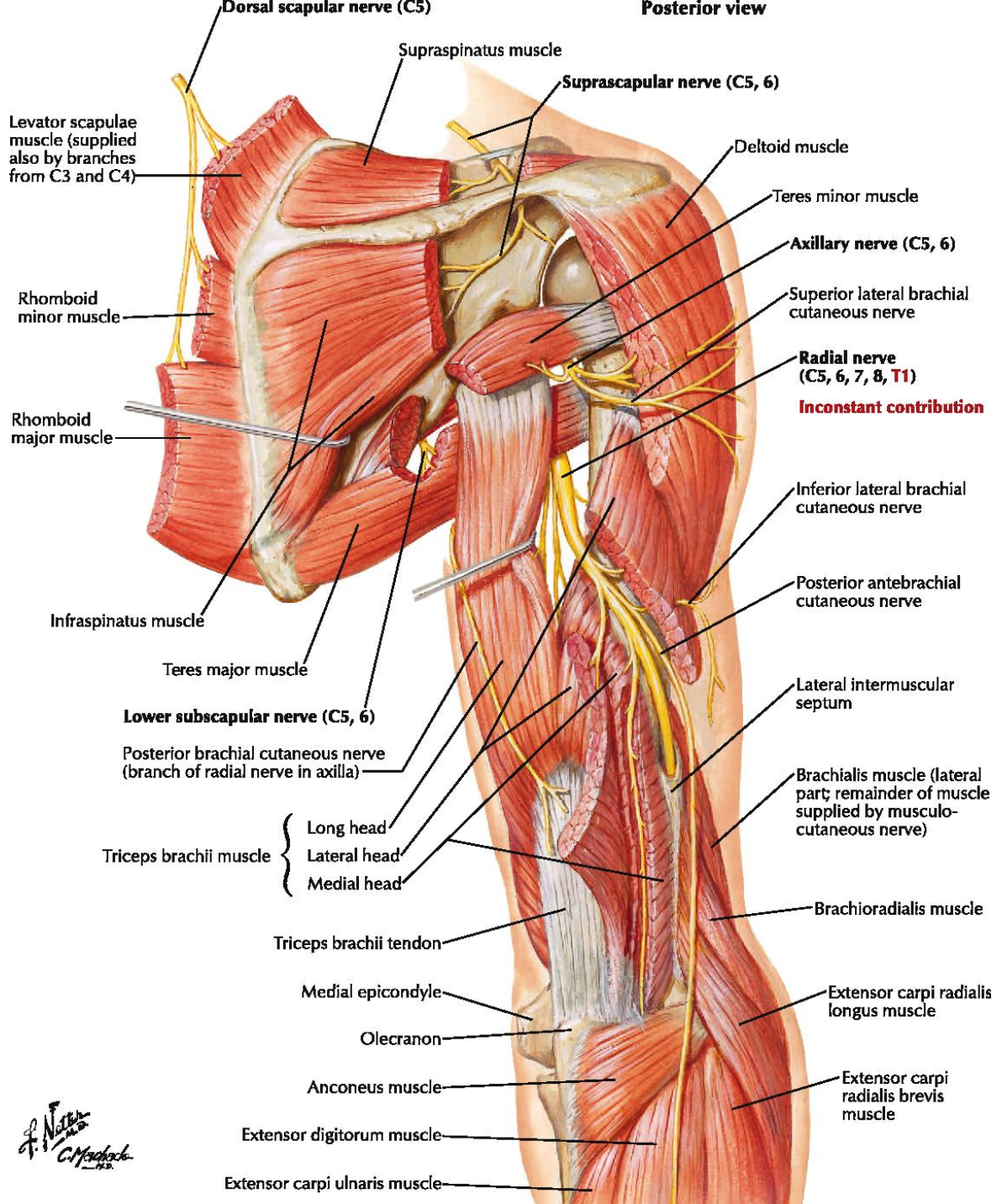
# Muscles of Arm

## Posterior View - Superficial layer



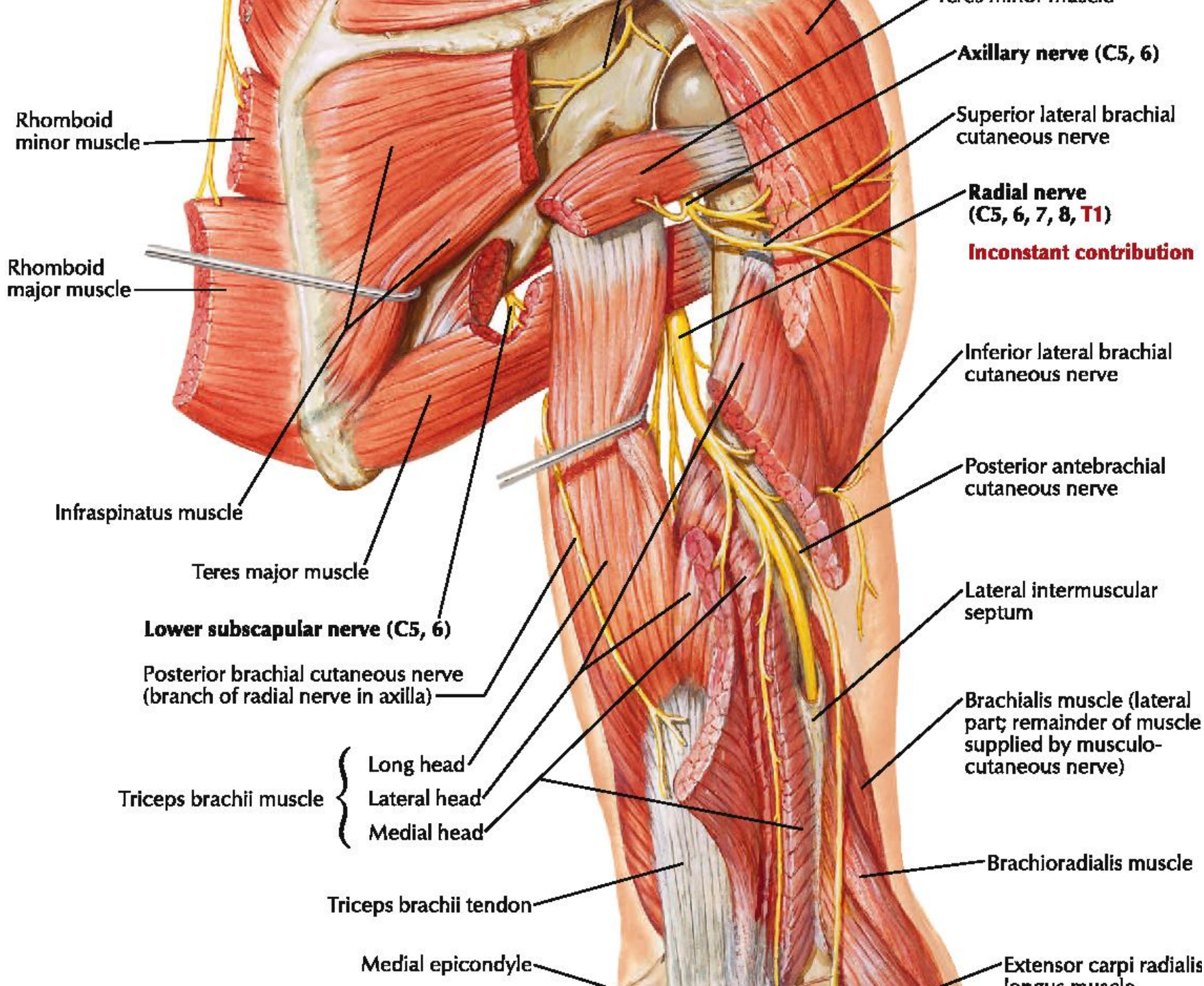


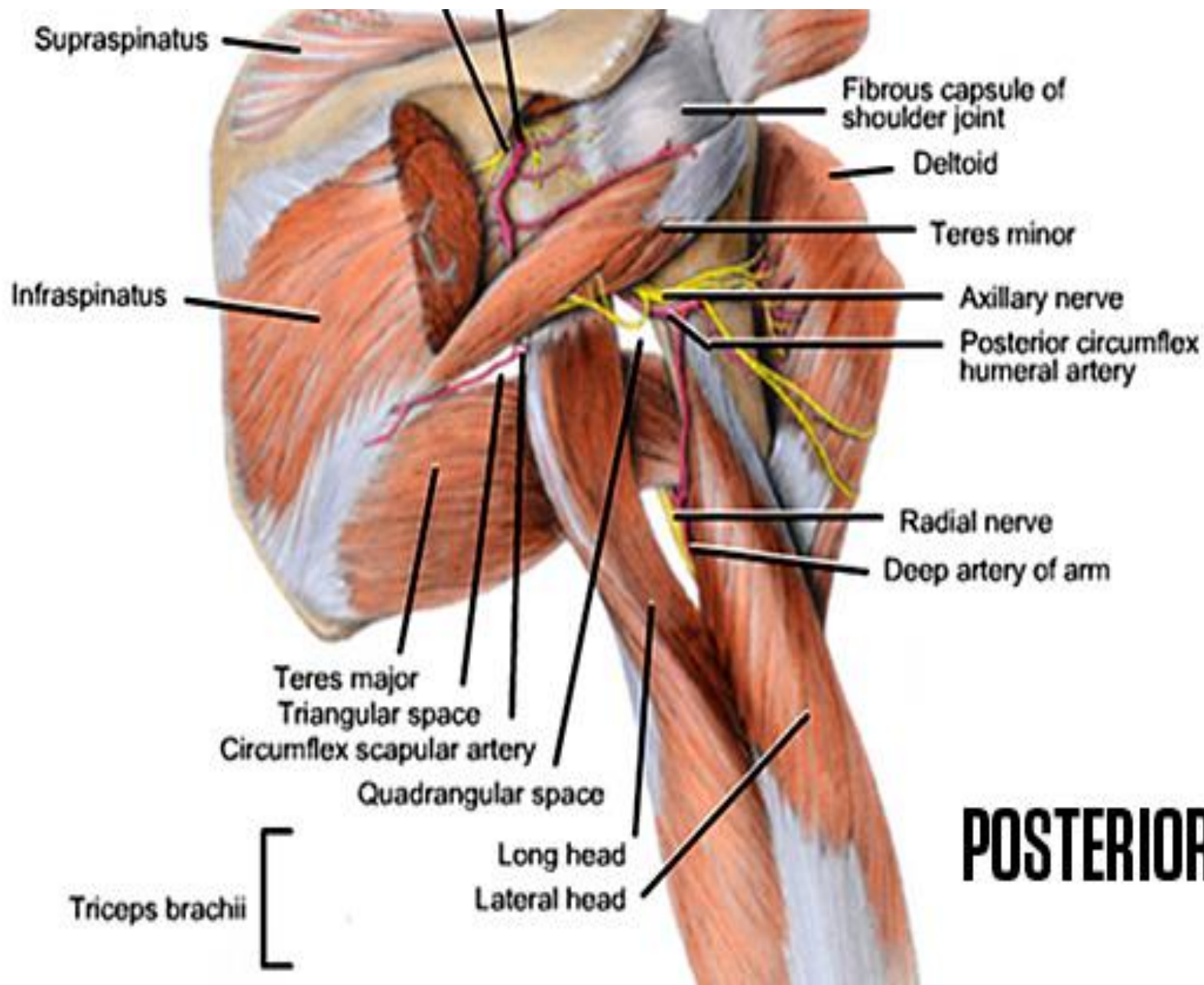
Posterior view



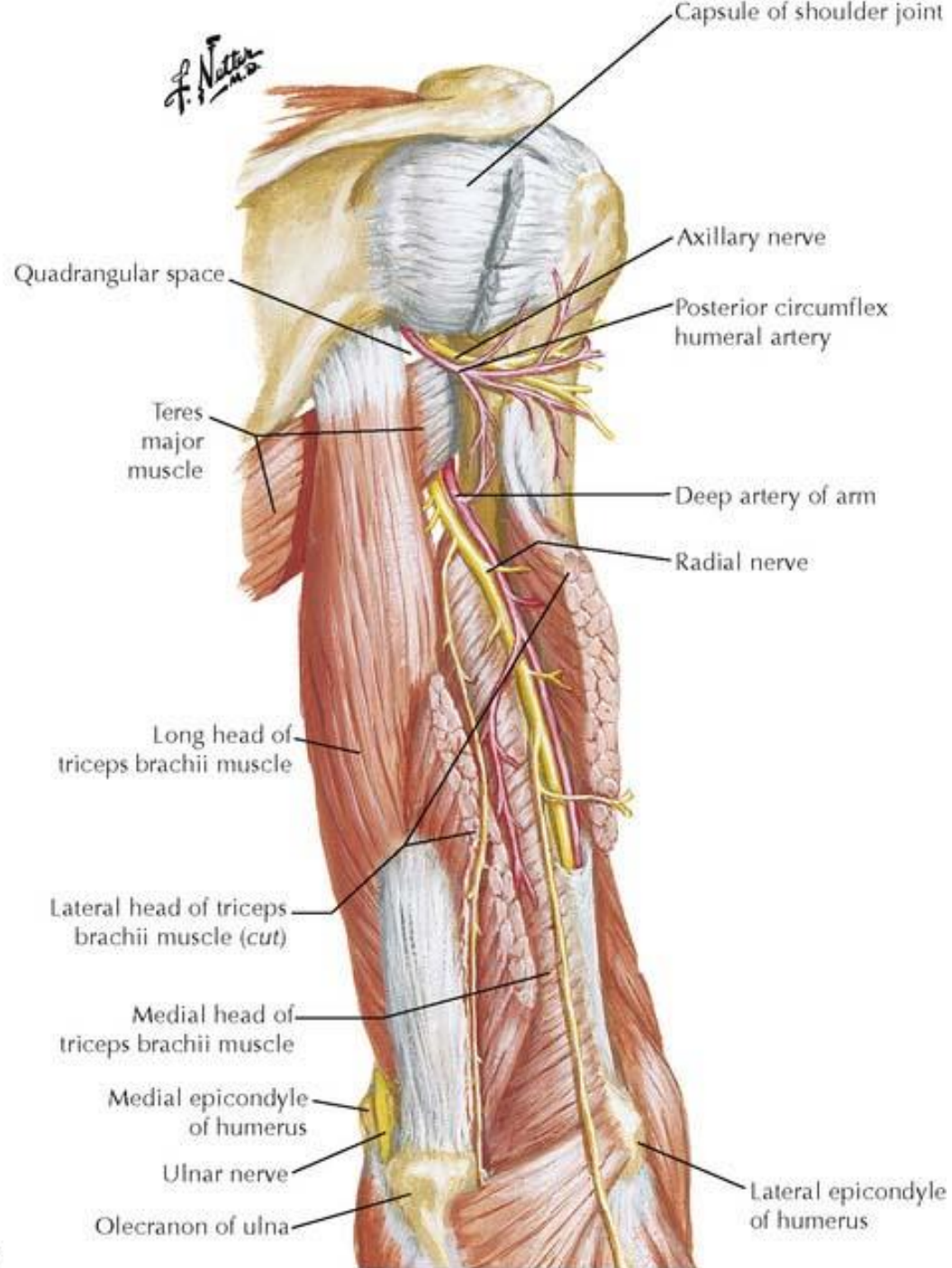
*F. Netter M.D.*  
*C. Madock*



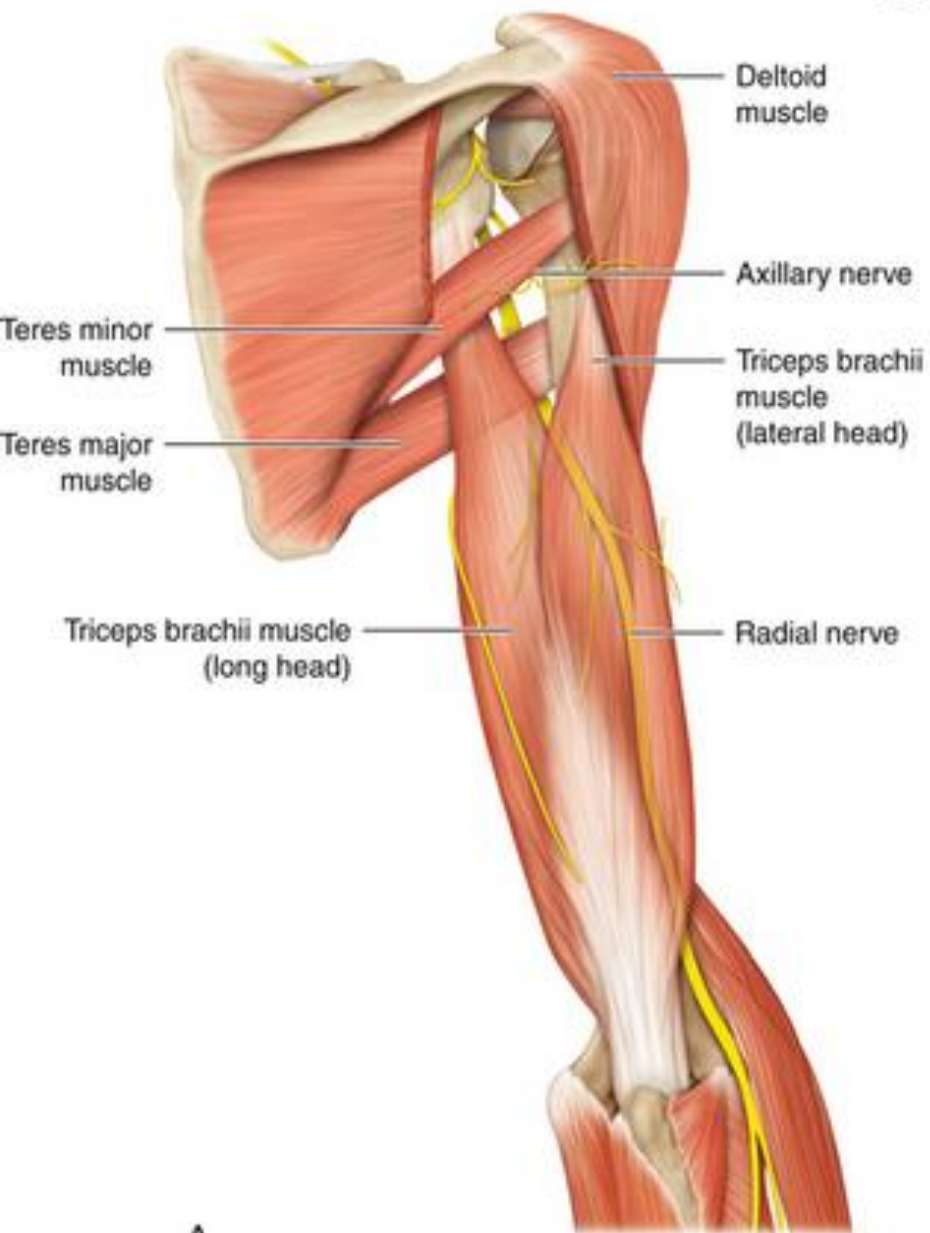




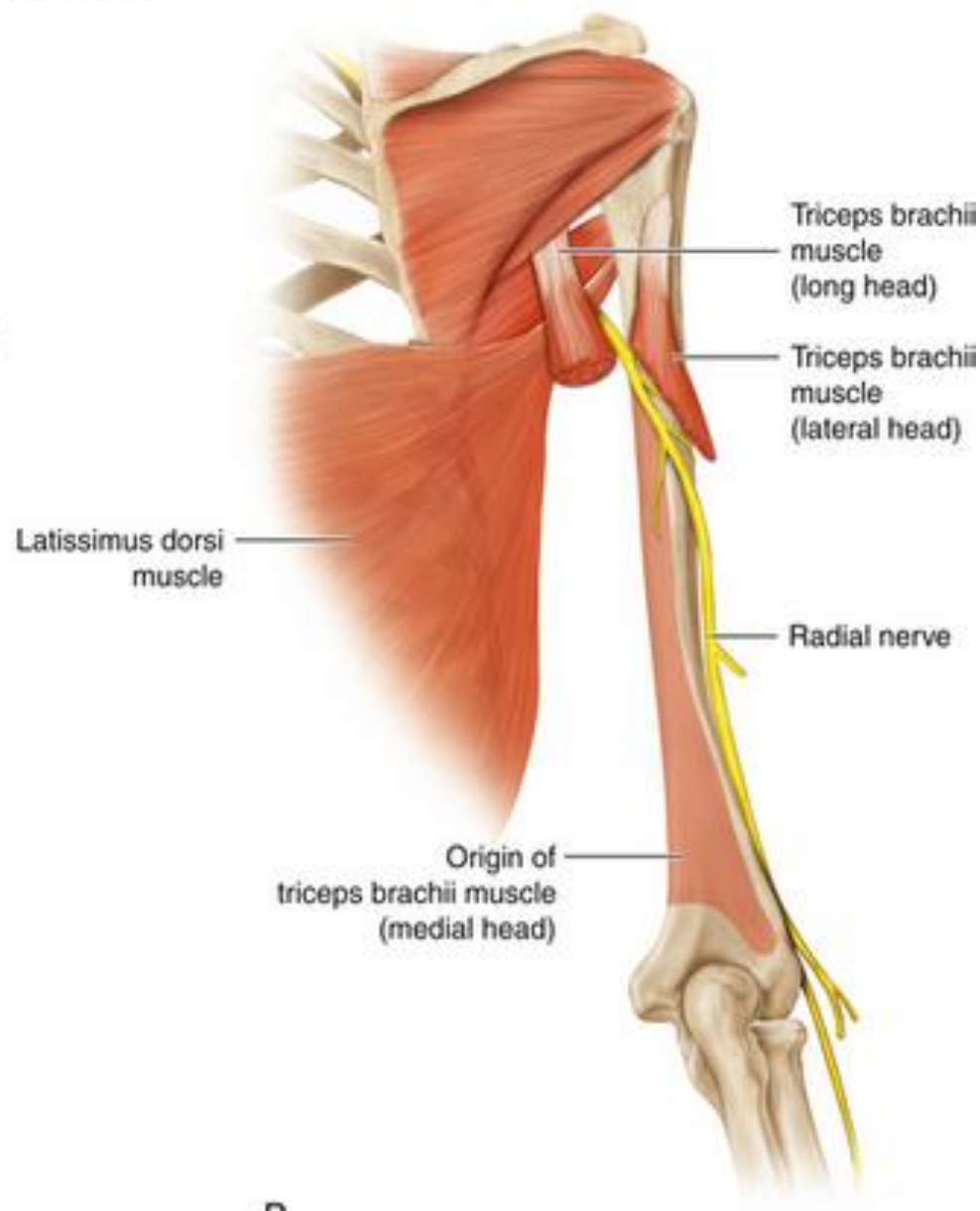
# POSTERIOR VIEW



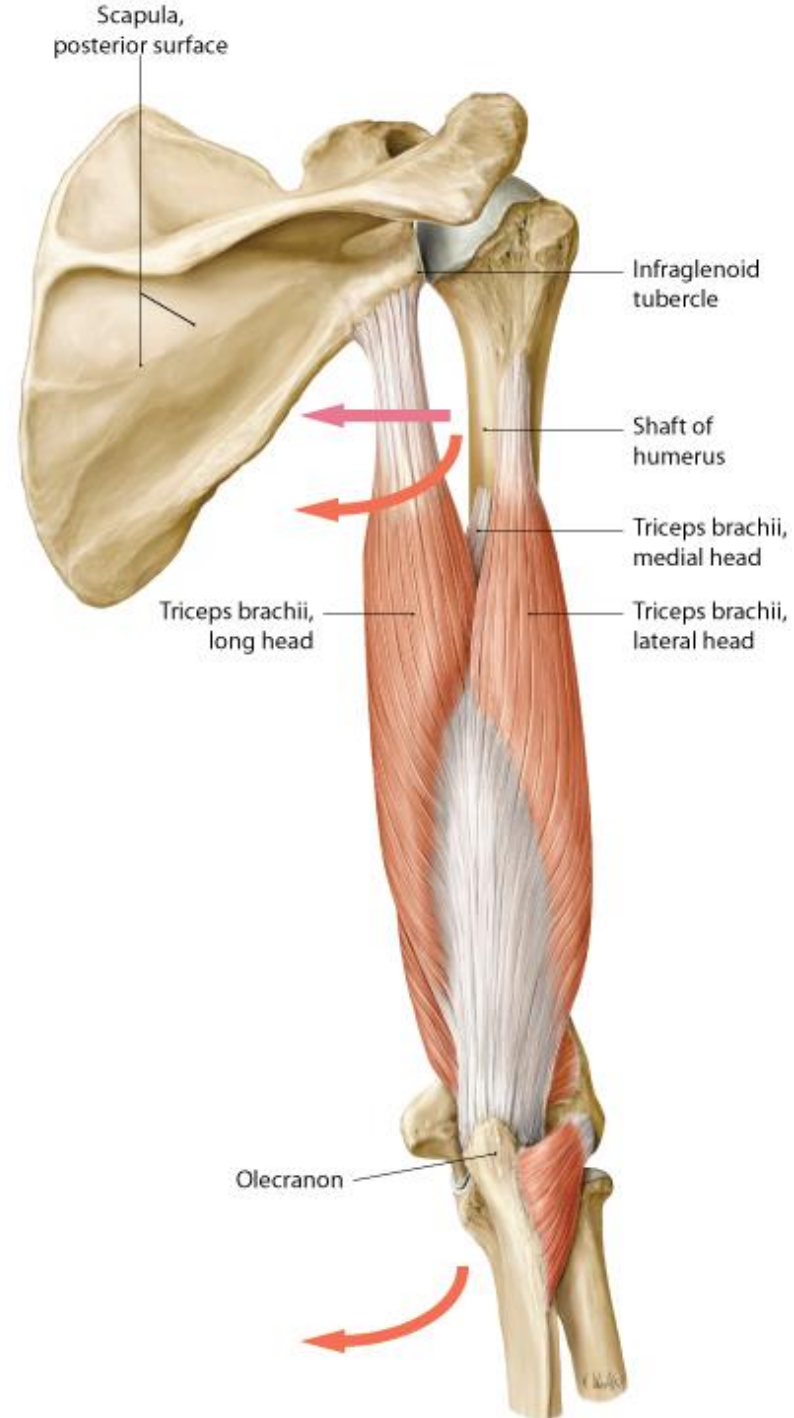
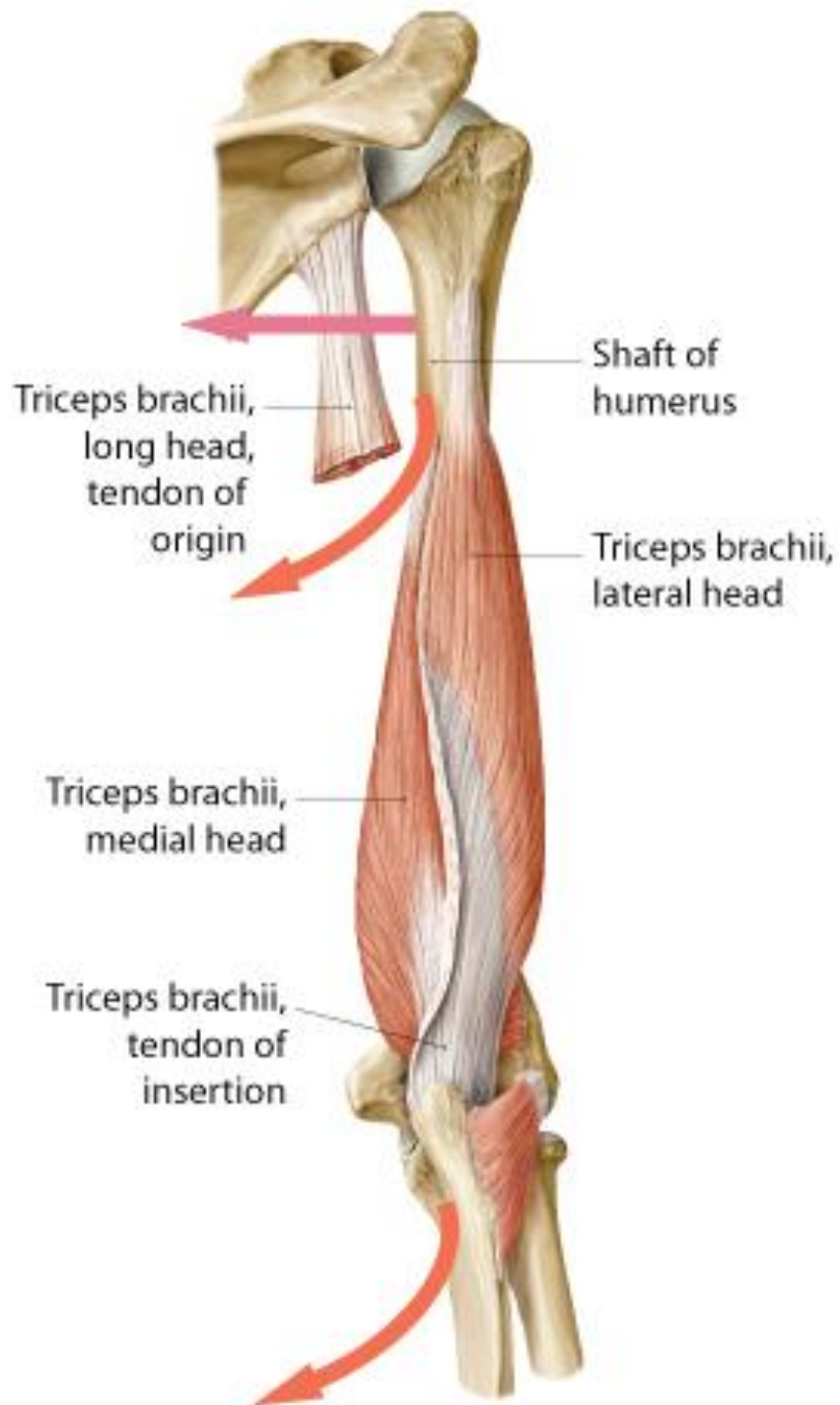
Posterior view



A



B

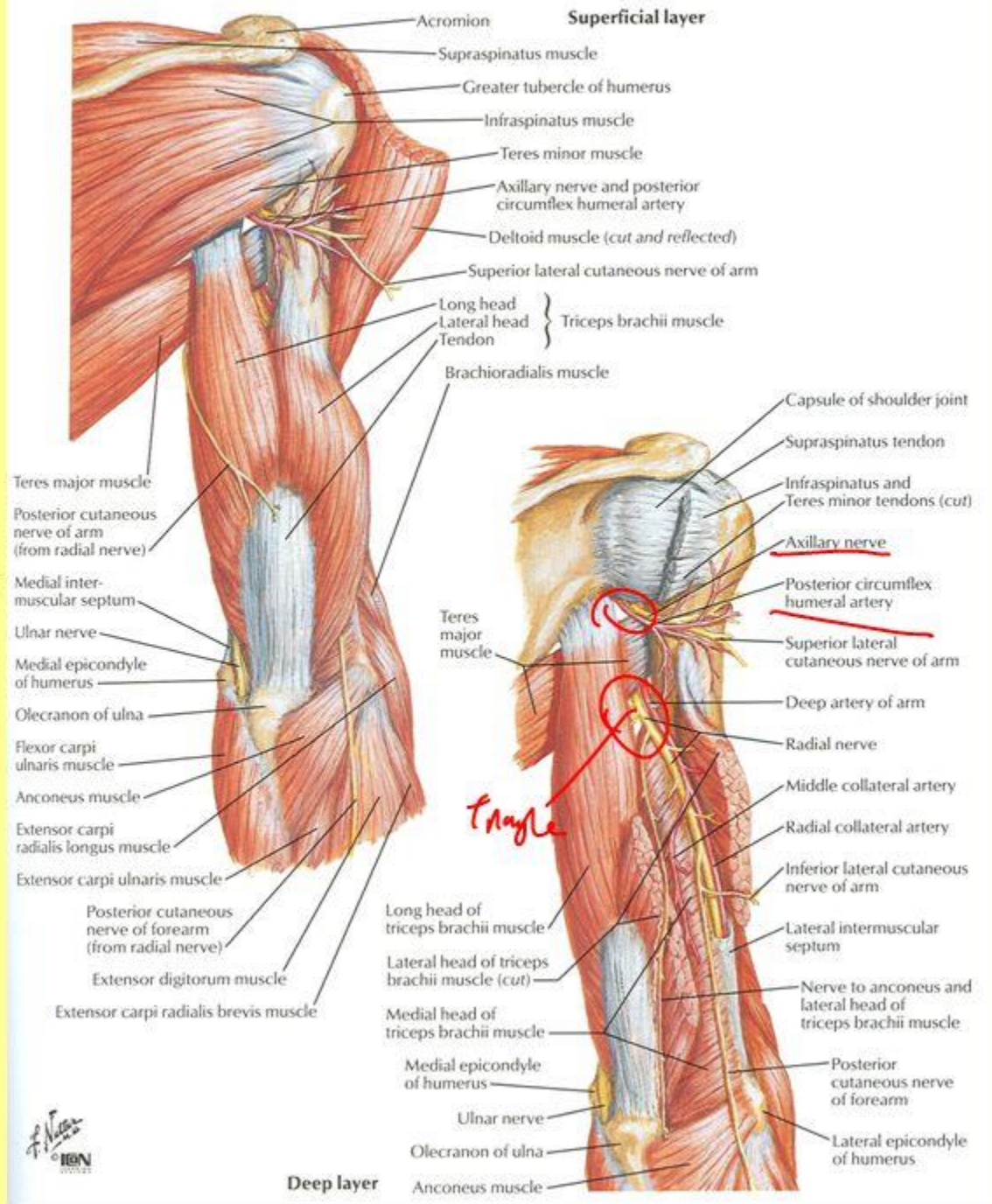


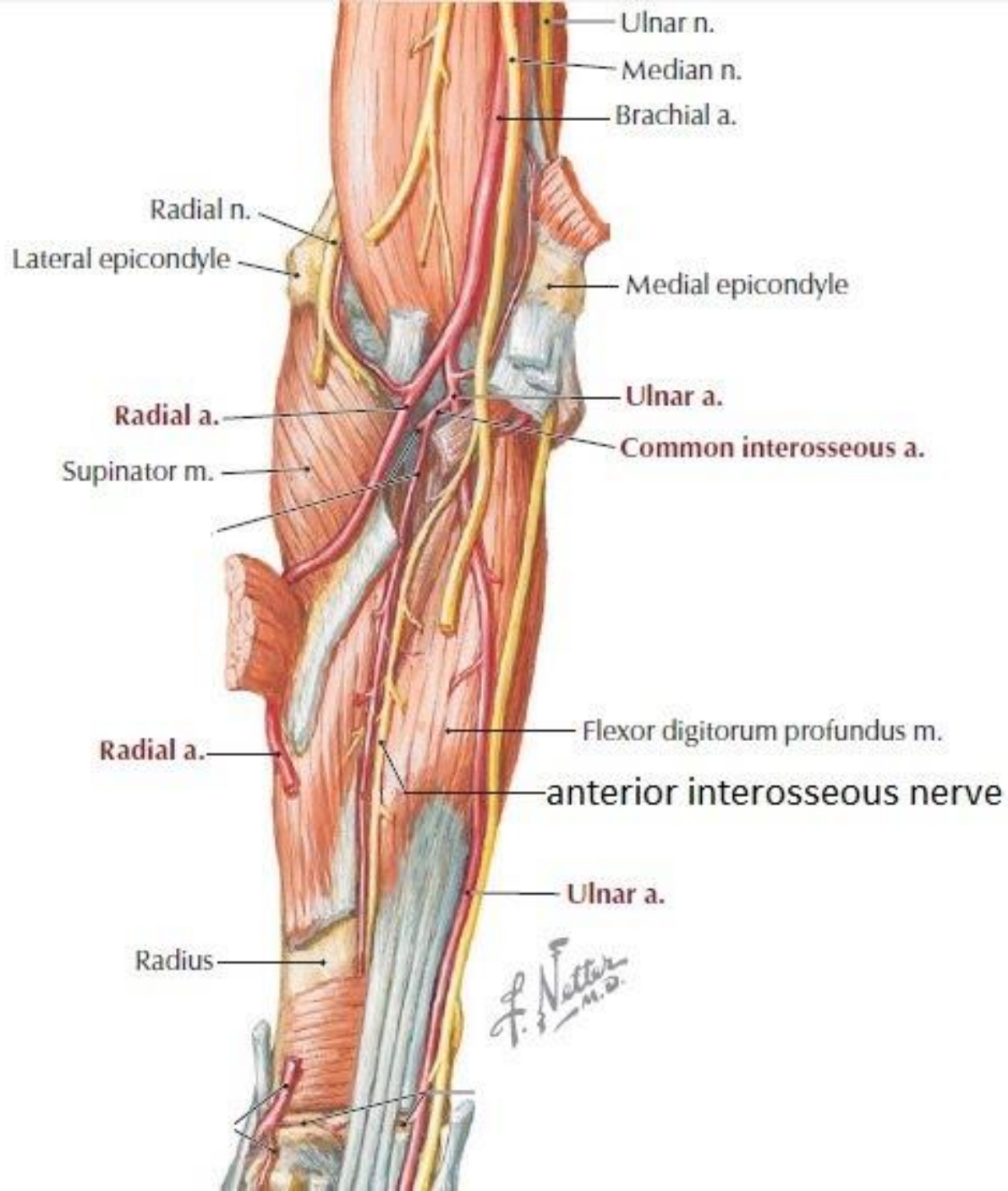
# Axillary spaces: \*

## Quadrangular space Triangular Spaces

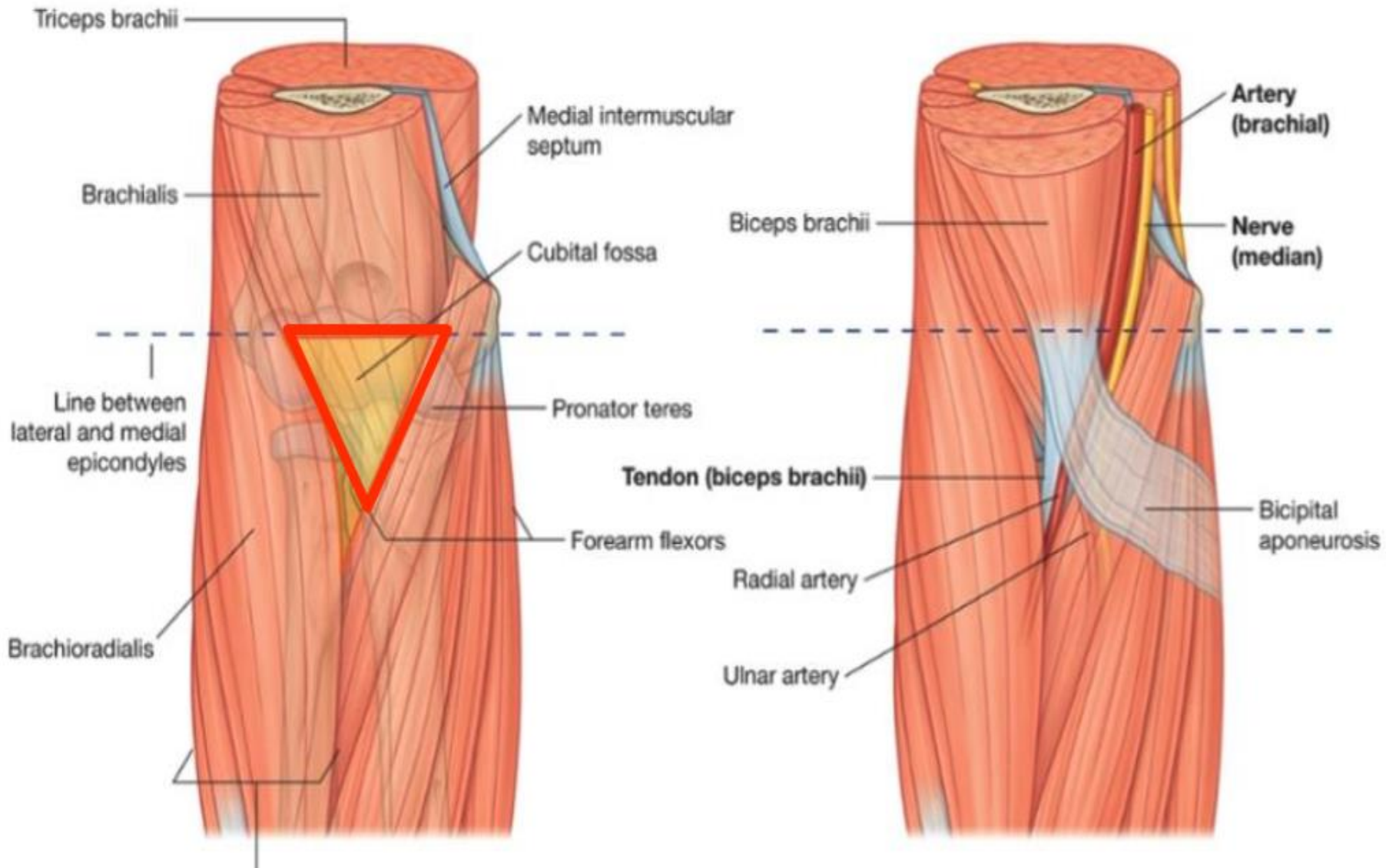
- 1- Teres Minor
- 2- Teres Major
- 3- Humerus
- 4- Long head of Triceps

Radial nerve is found deep in the posterior brachial region in radial groove of humerus accompanied by deep brachial A and V.





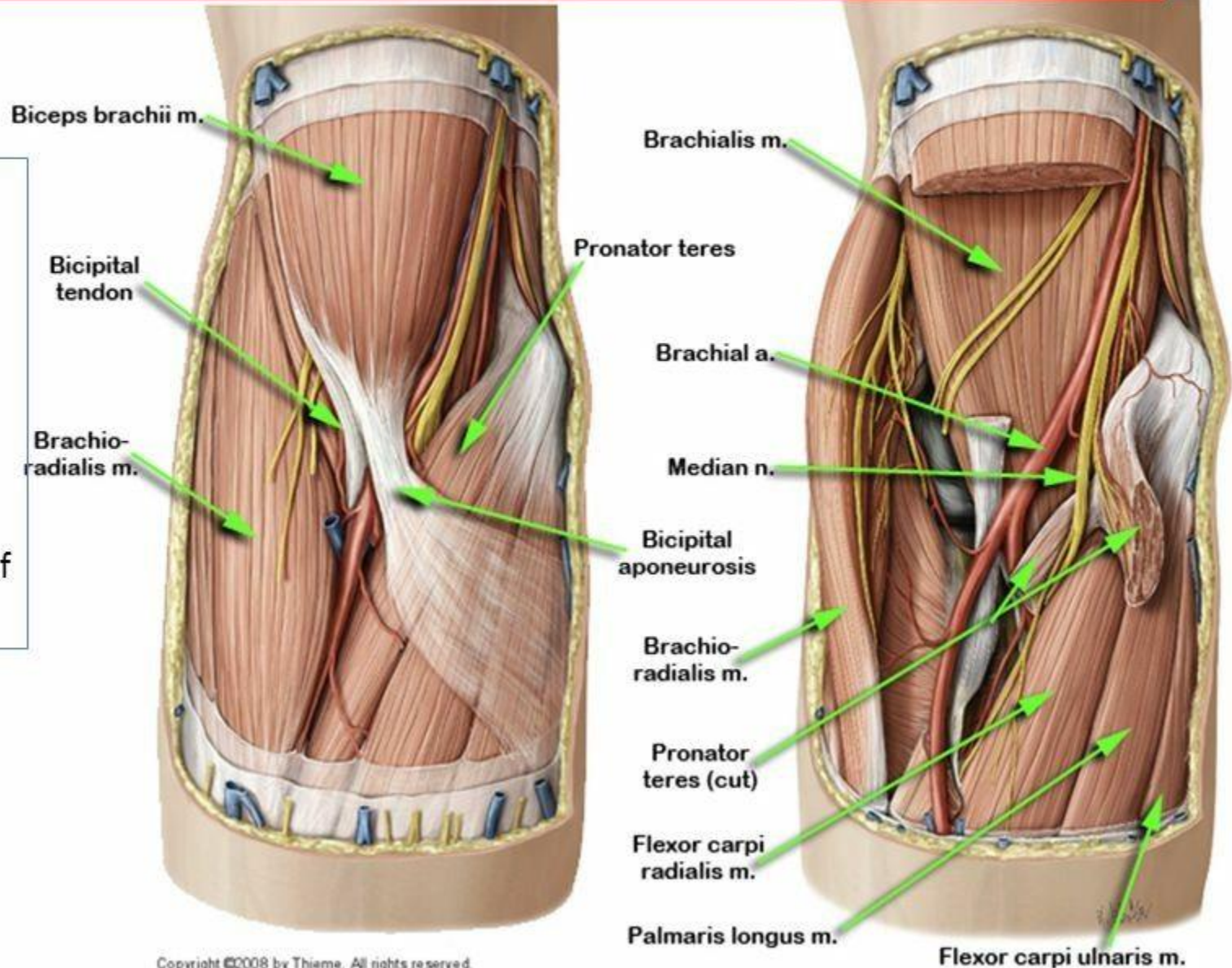
# Cubital fossa

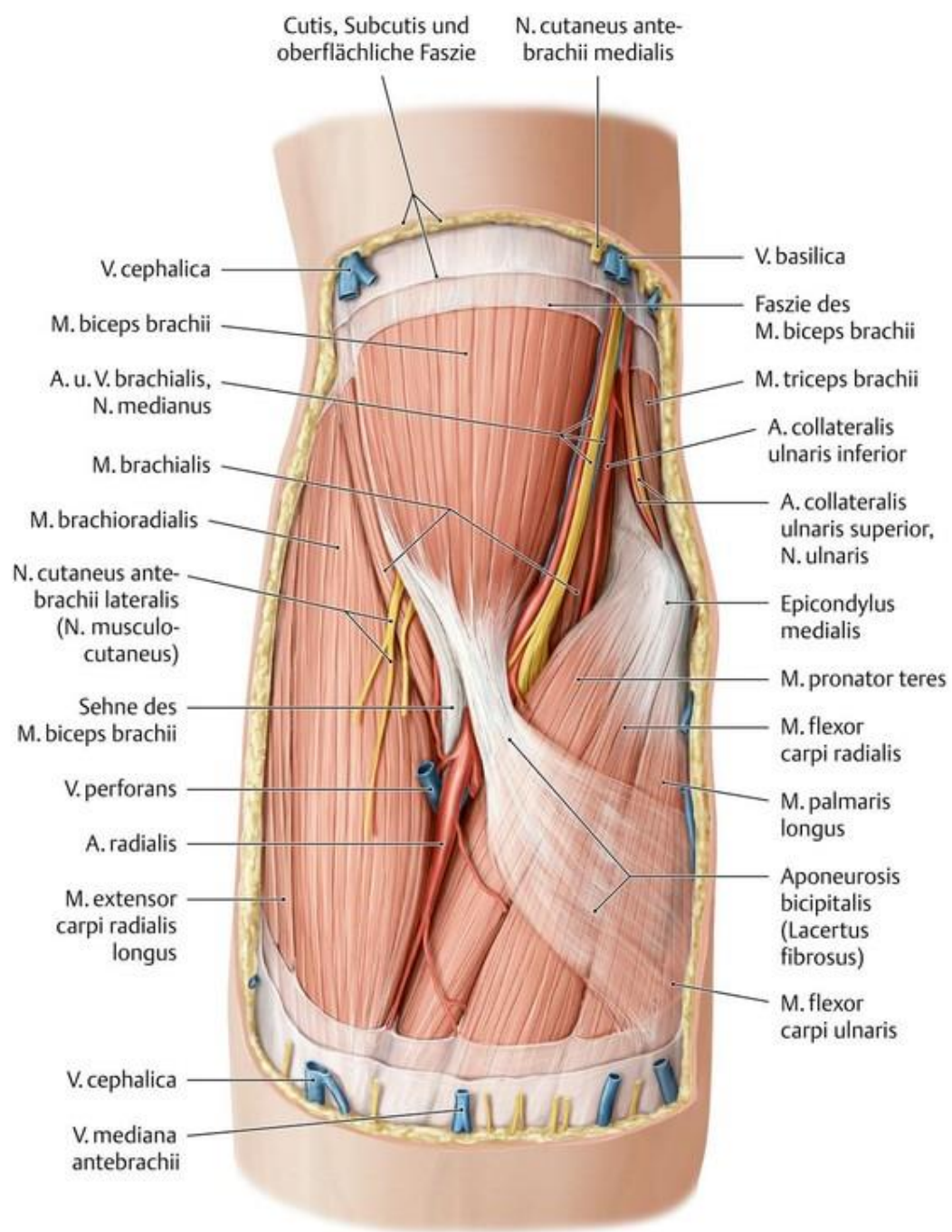


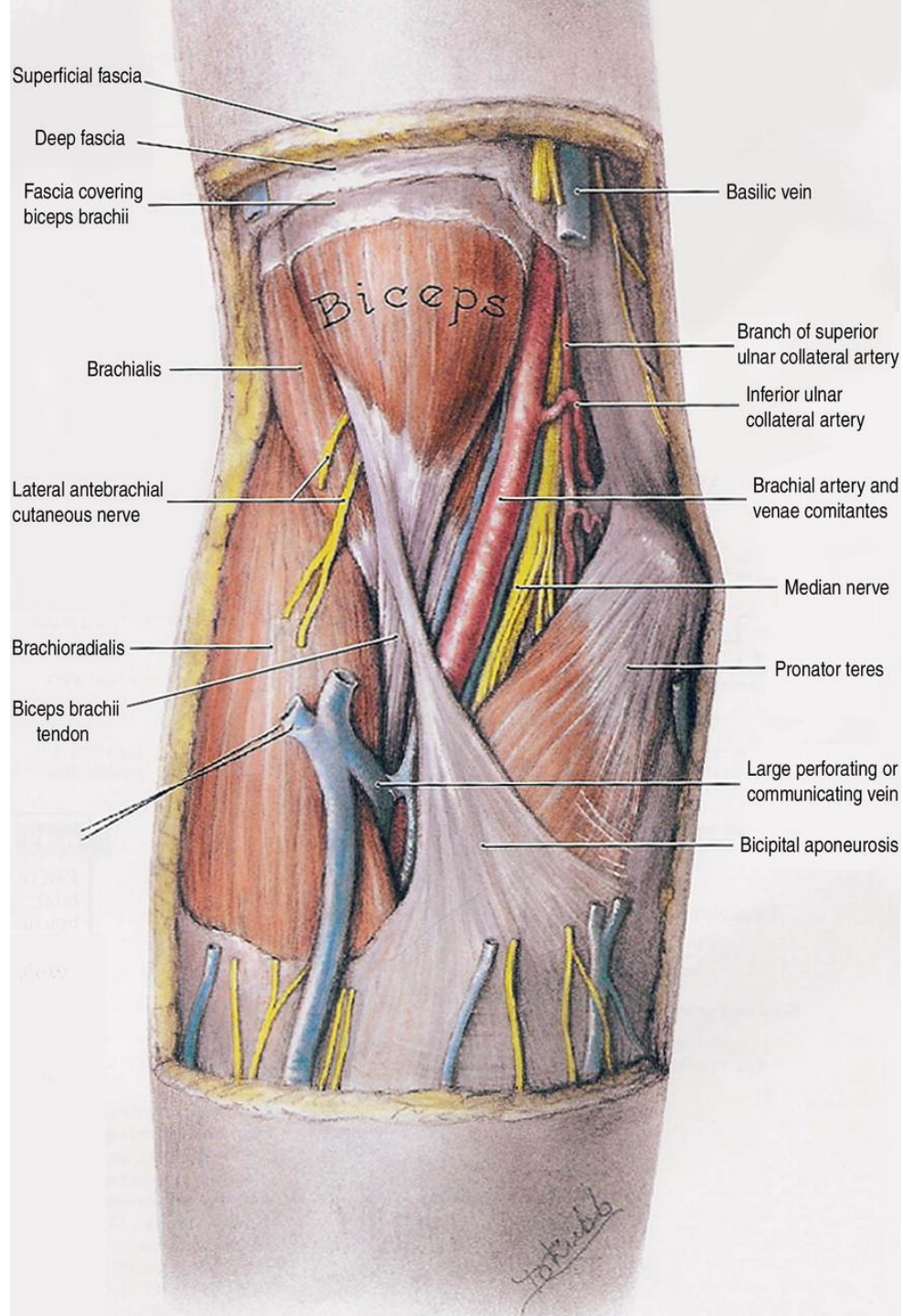


# Cubital Fossa

Identify the borders of the cubital fossa: **Brachioradialis m.** laterally, **Pronator teres** medially and **Brachialis** which forms the floor of the fossa.







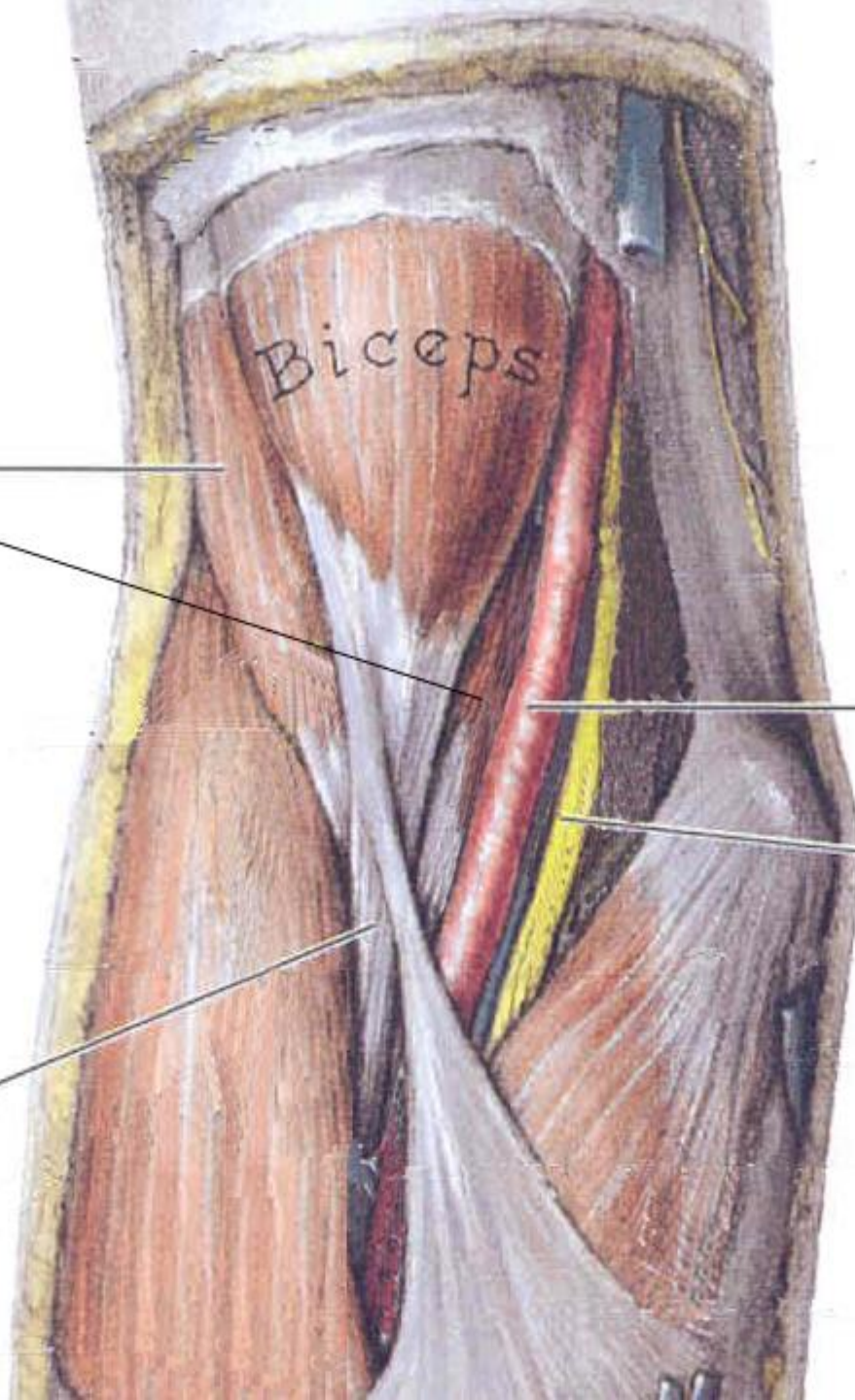
**Brachialis**

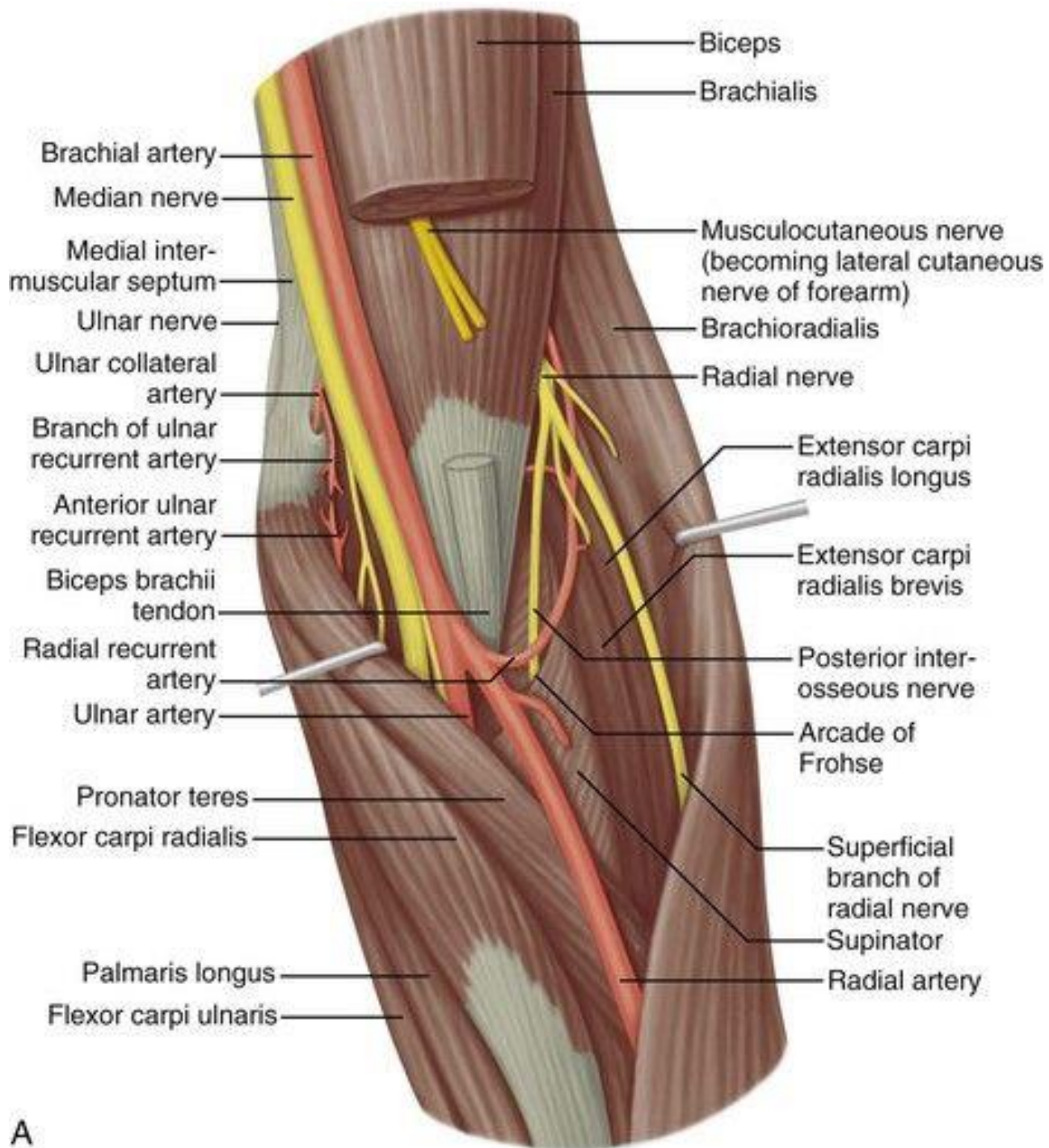
Biceps

**Brachial artery**

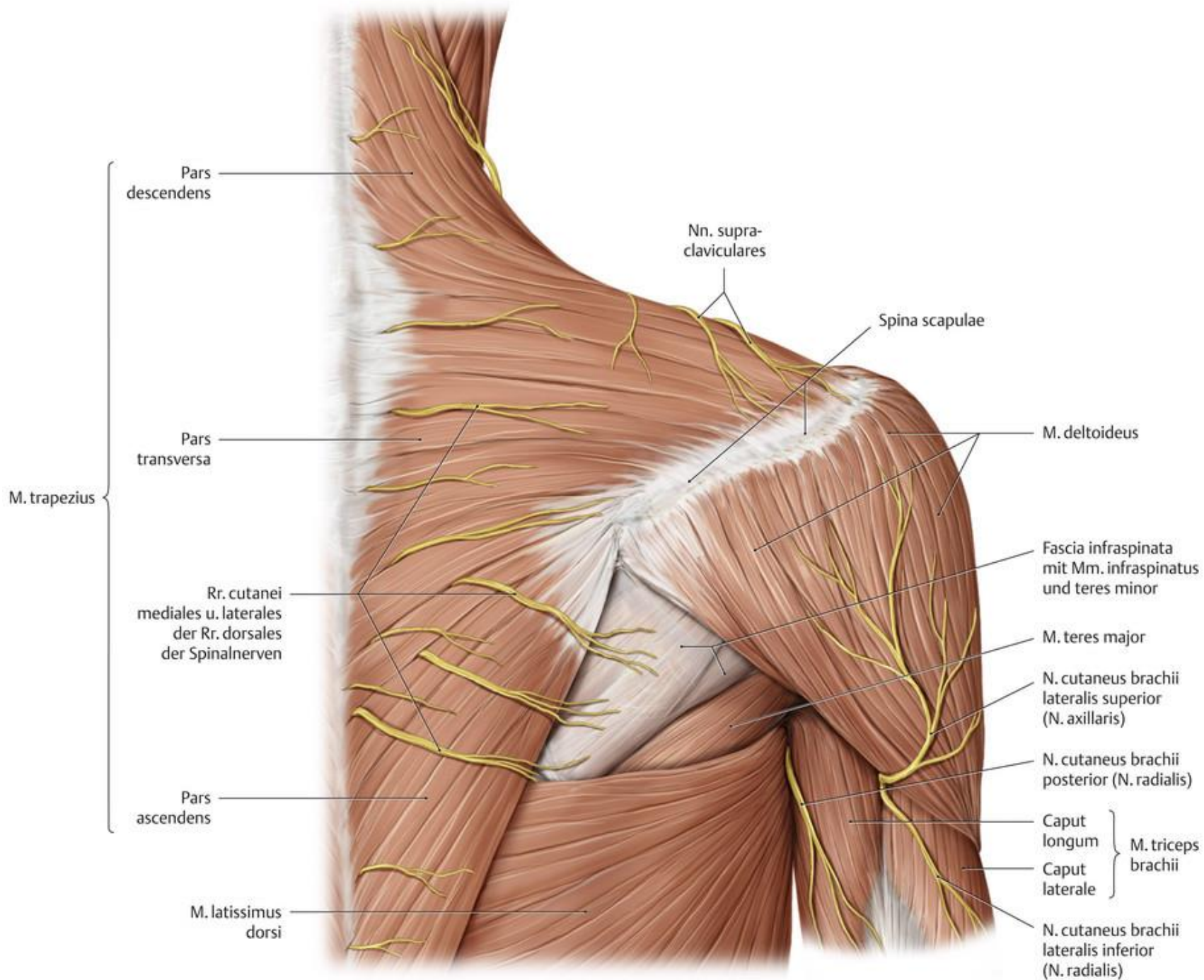
**Median nerve**

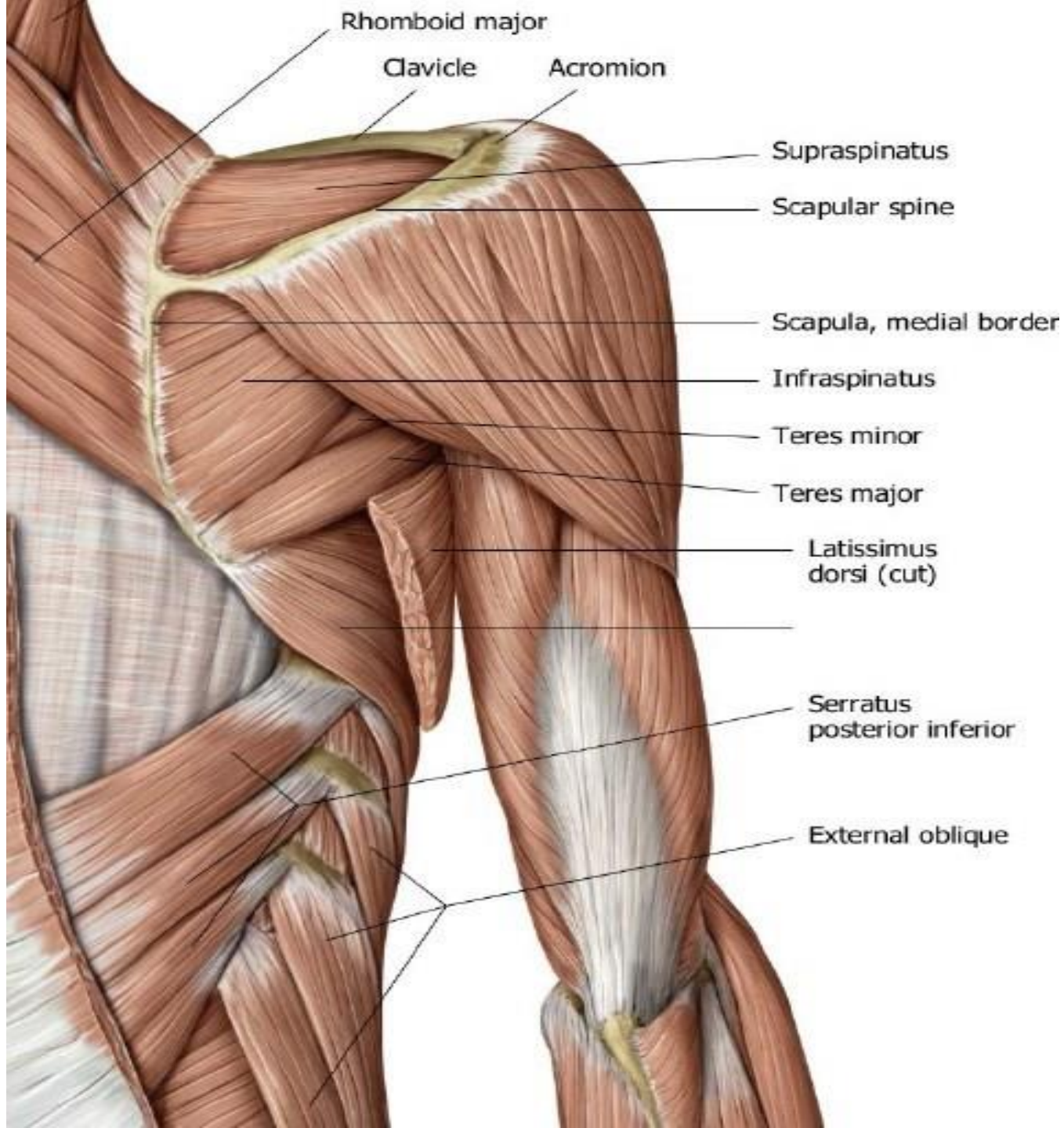
**Biceps brachii  
tendon**

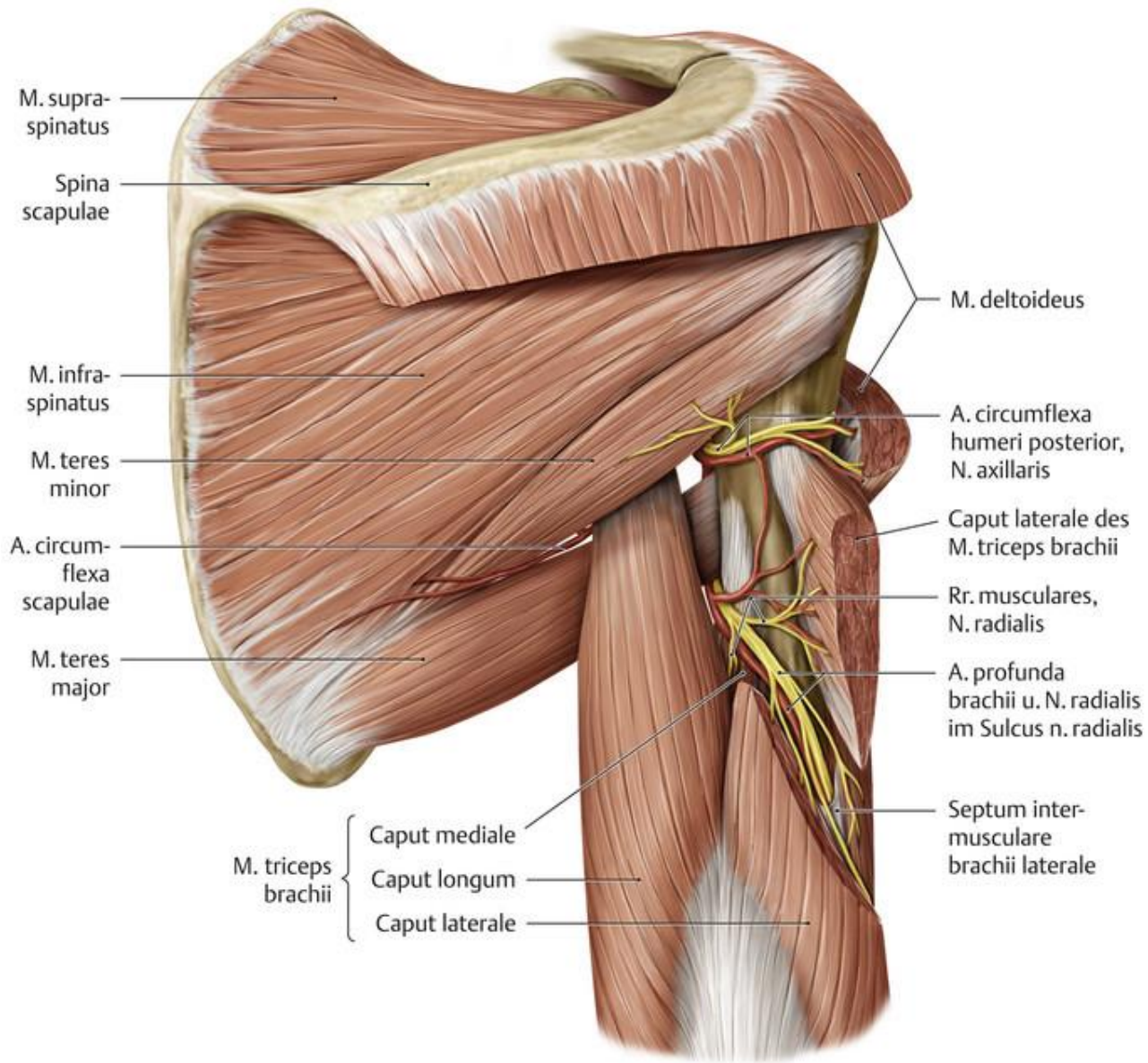




A









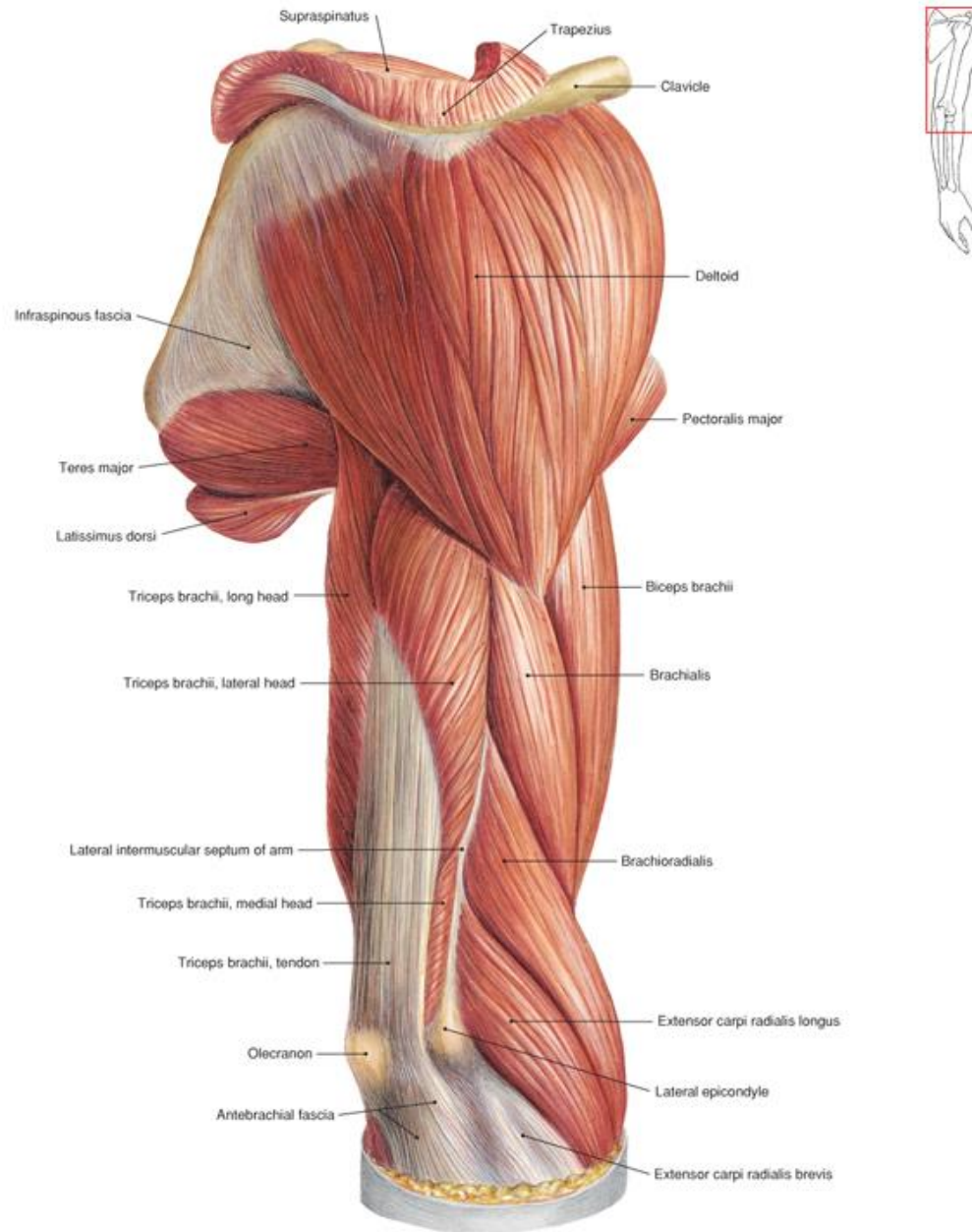
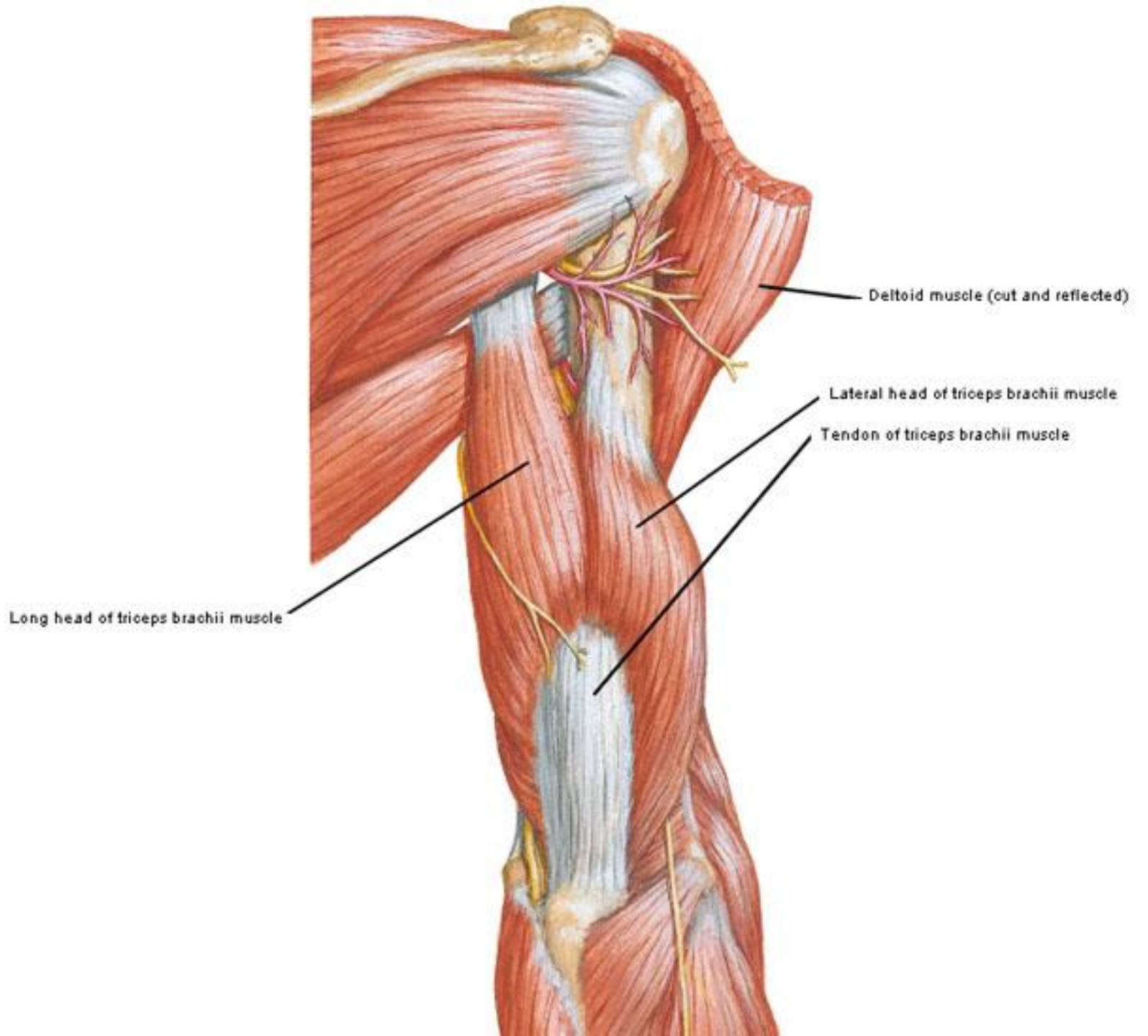
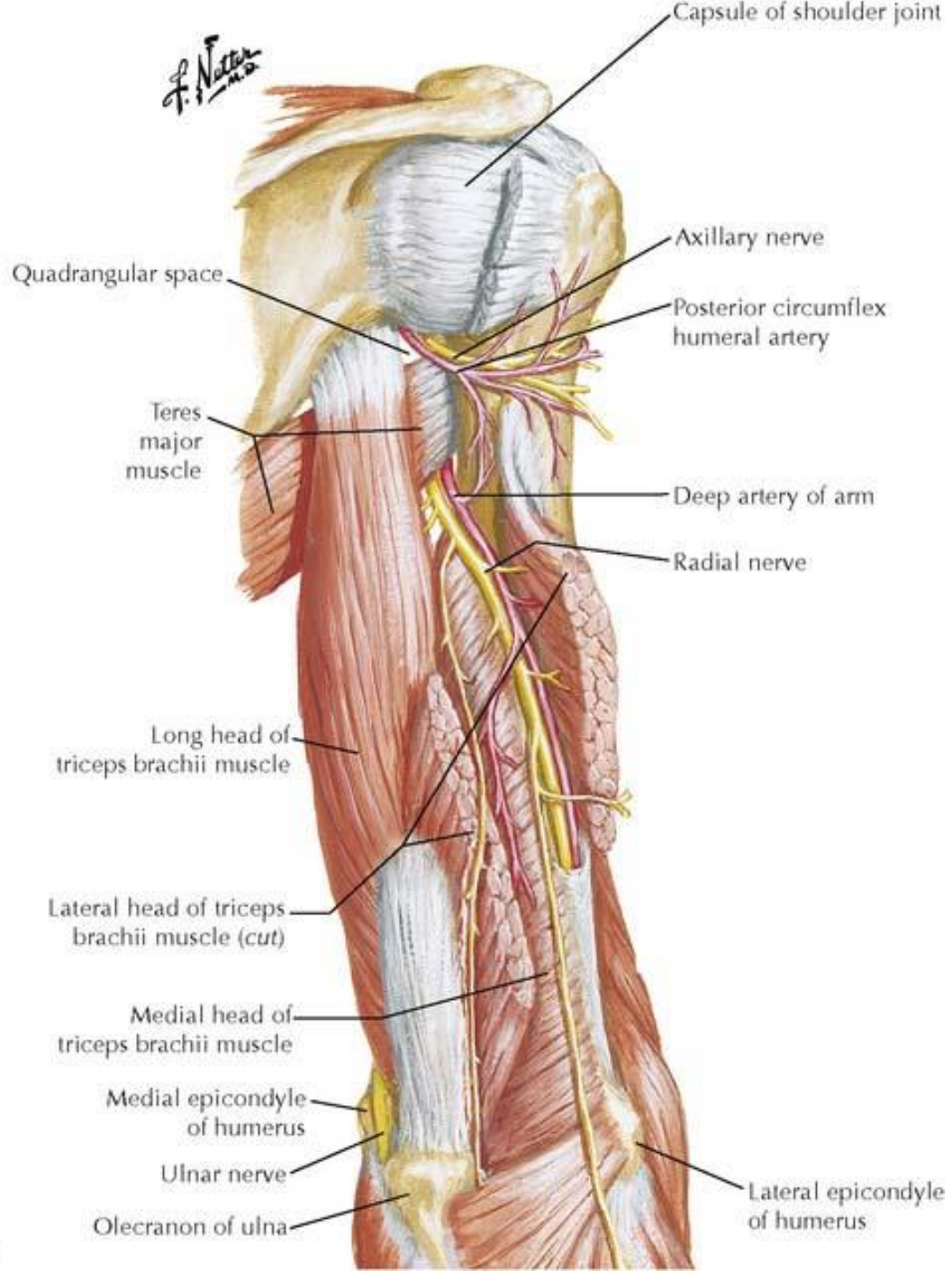


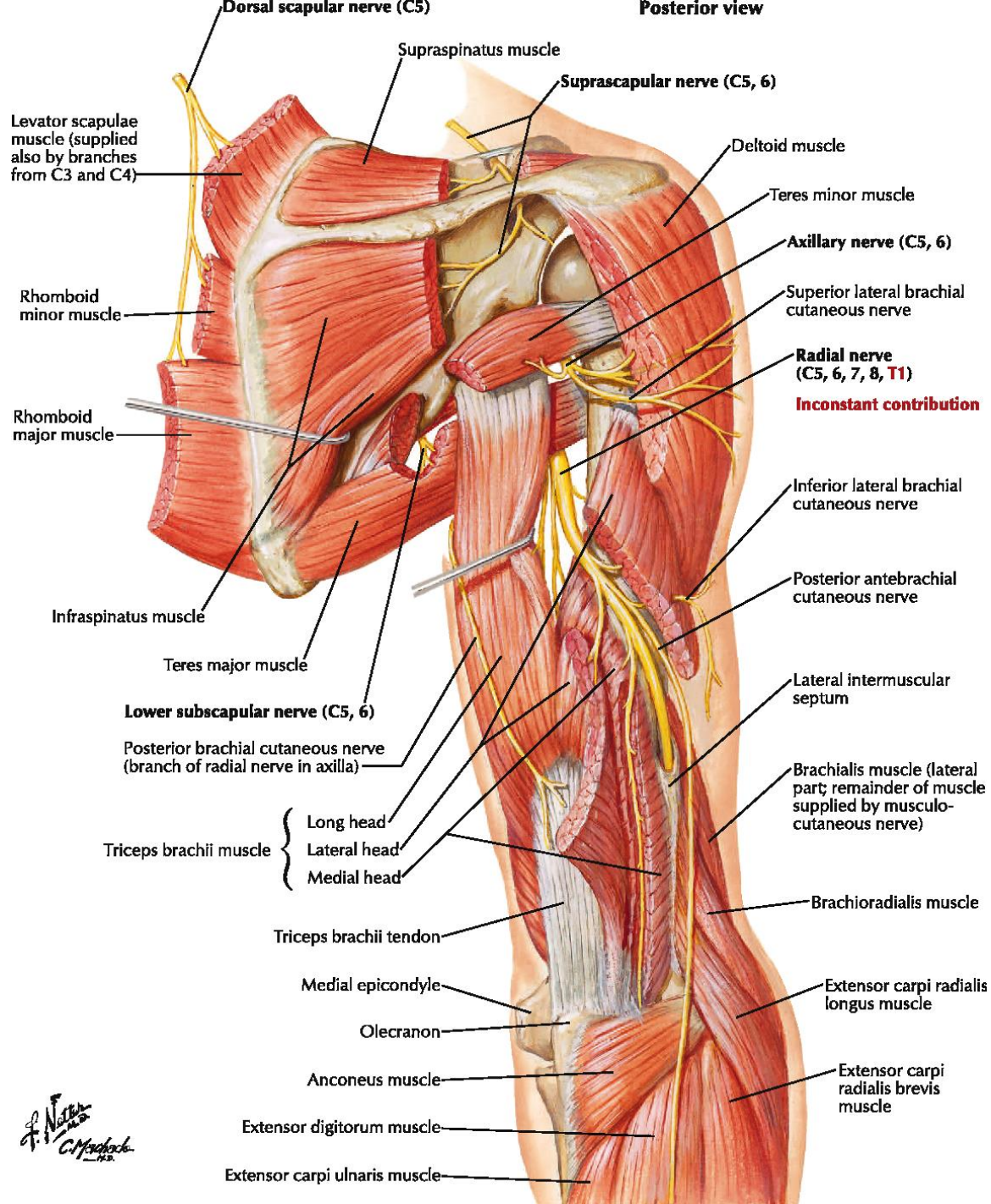
Fig. 345 Deltoid muscle.



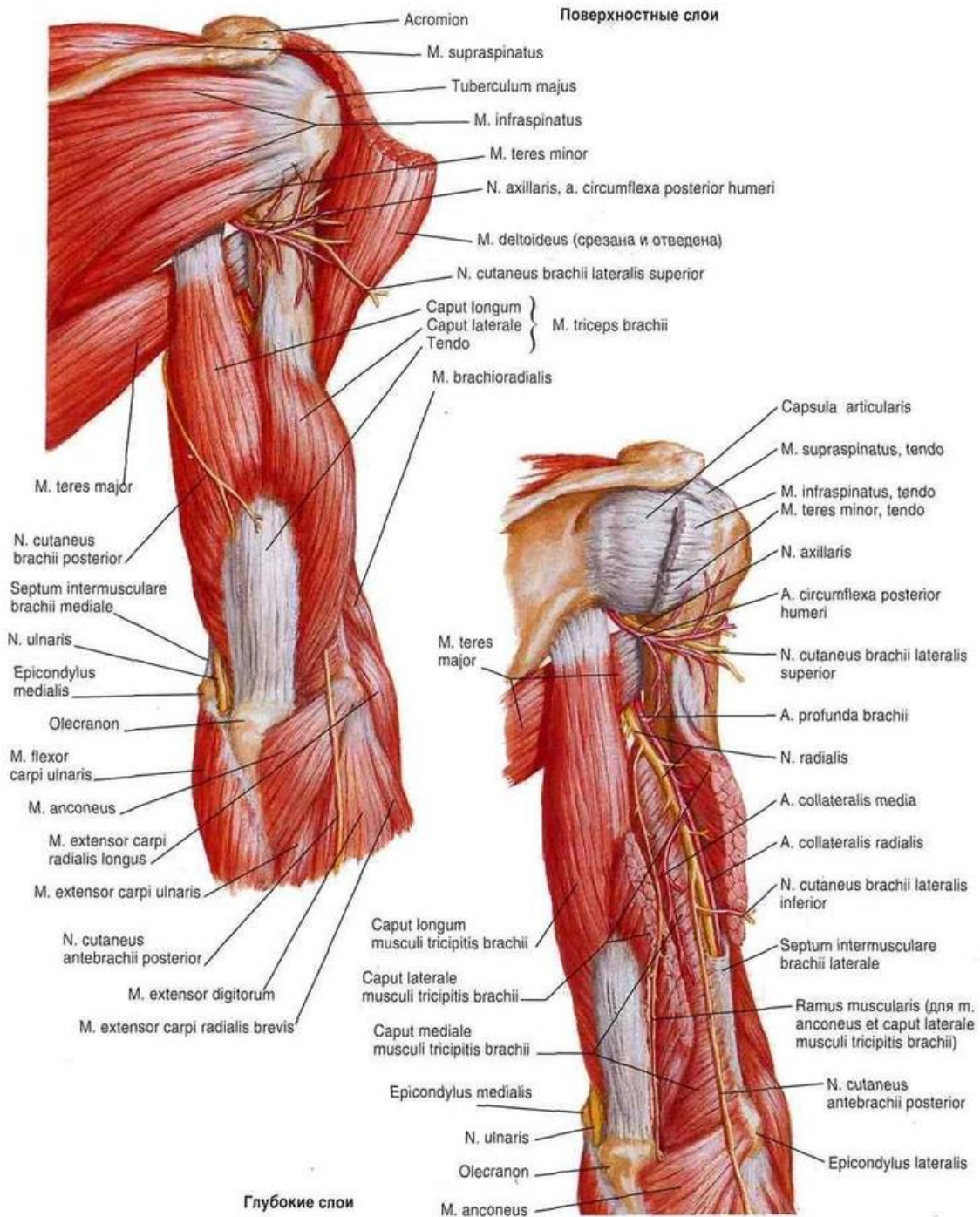


Deep layer

Posterior view



*A. Netter M.D.*  
*C. Mack*



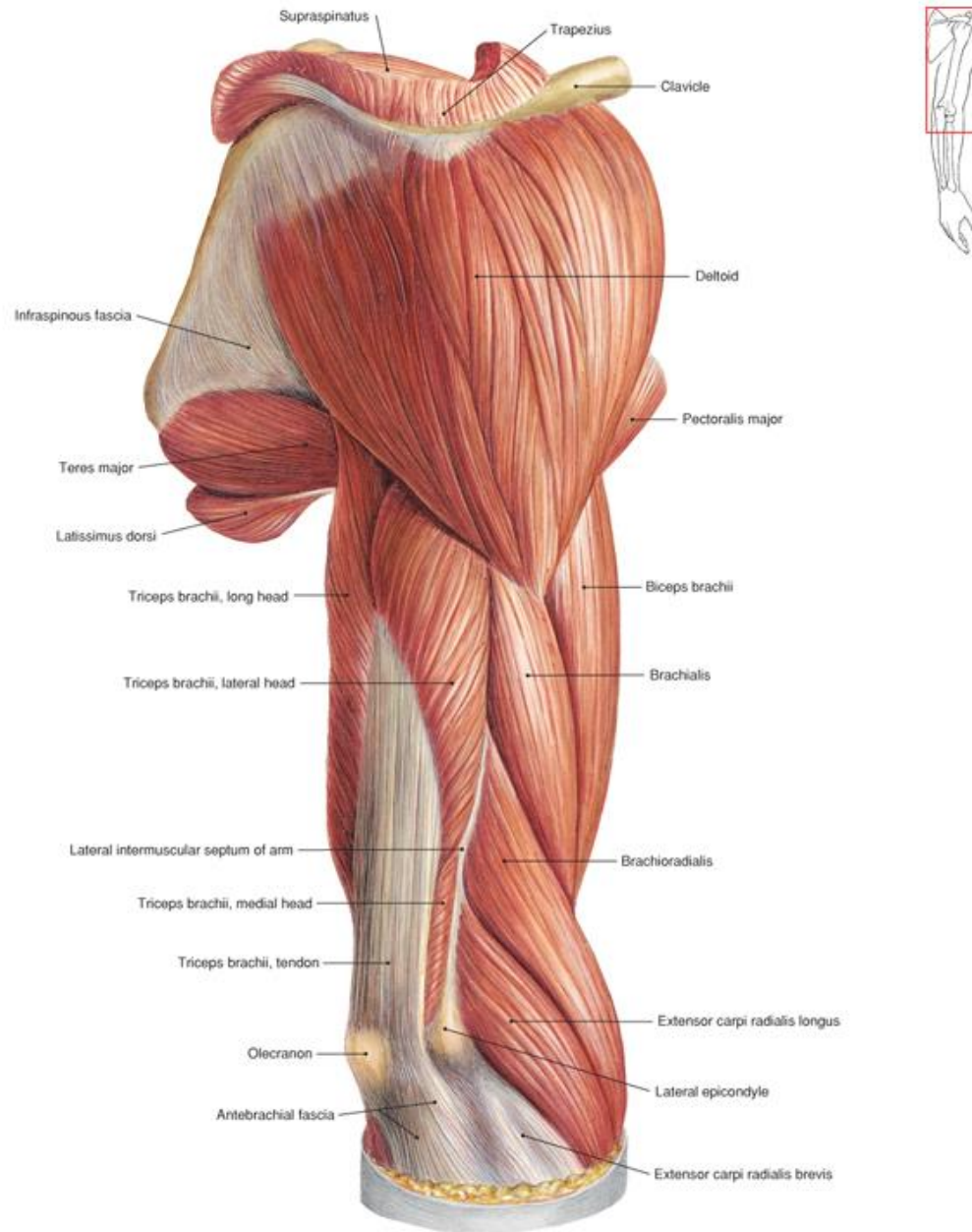
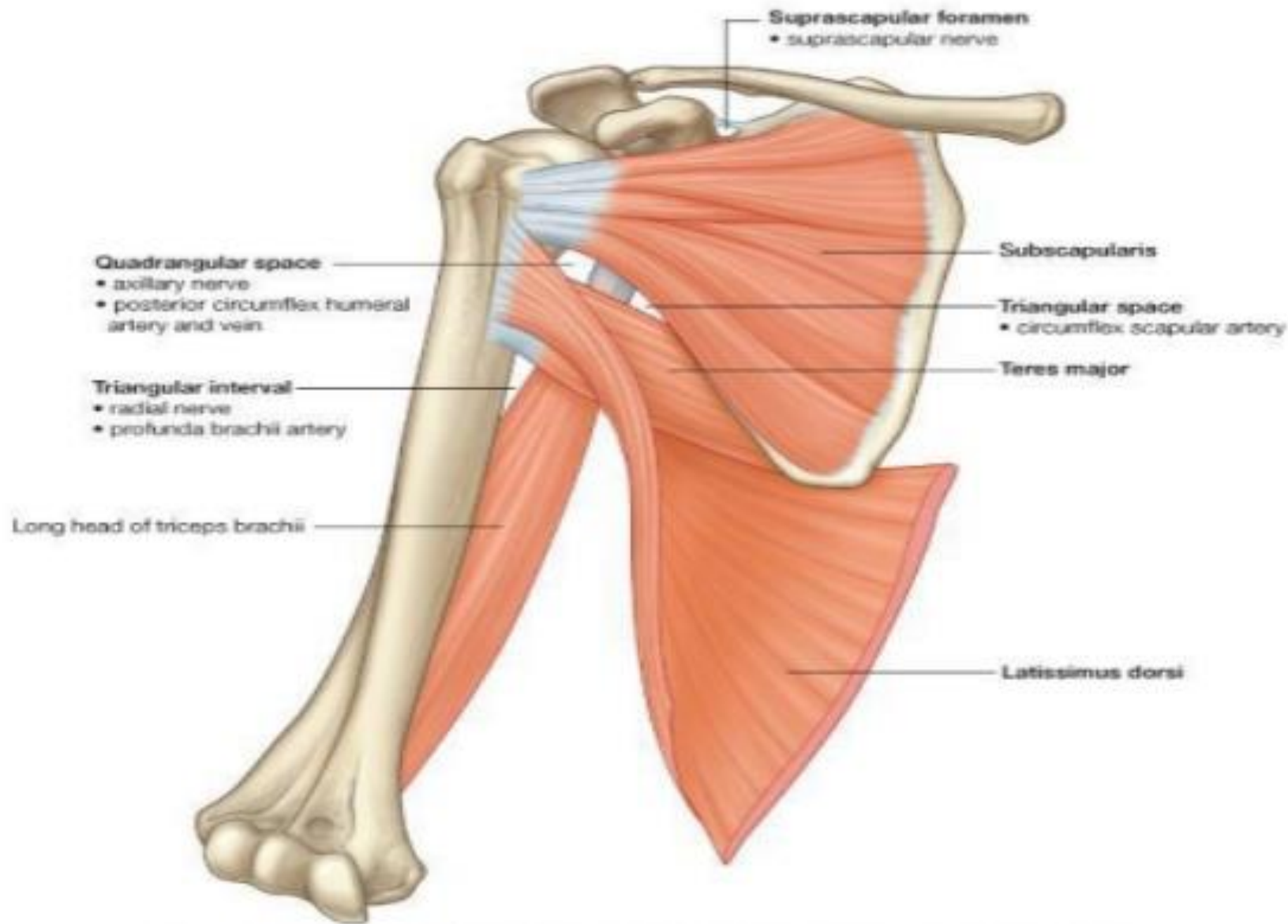
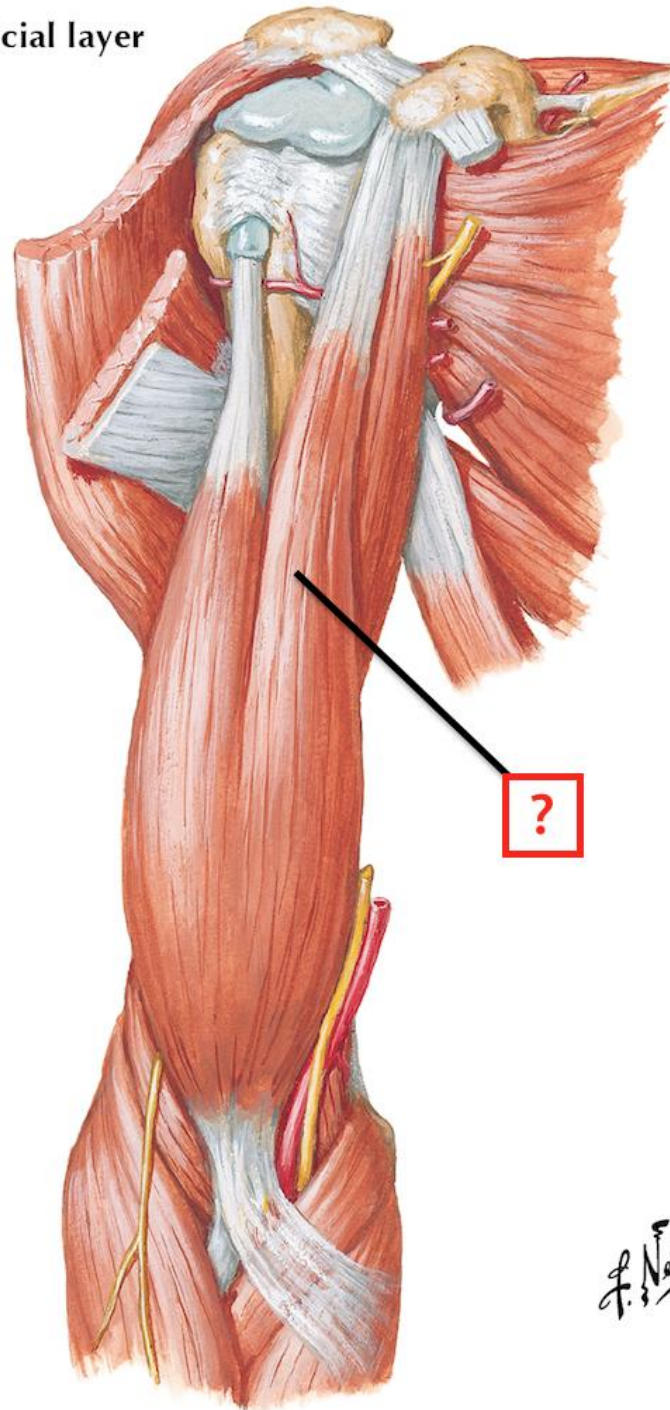


Fig. 345 Deltoid muscle.

# POSTERIOR WALL OF THE AXILLA

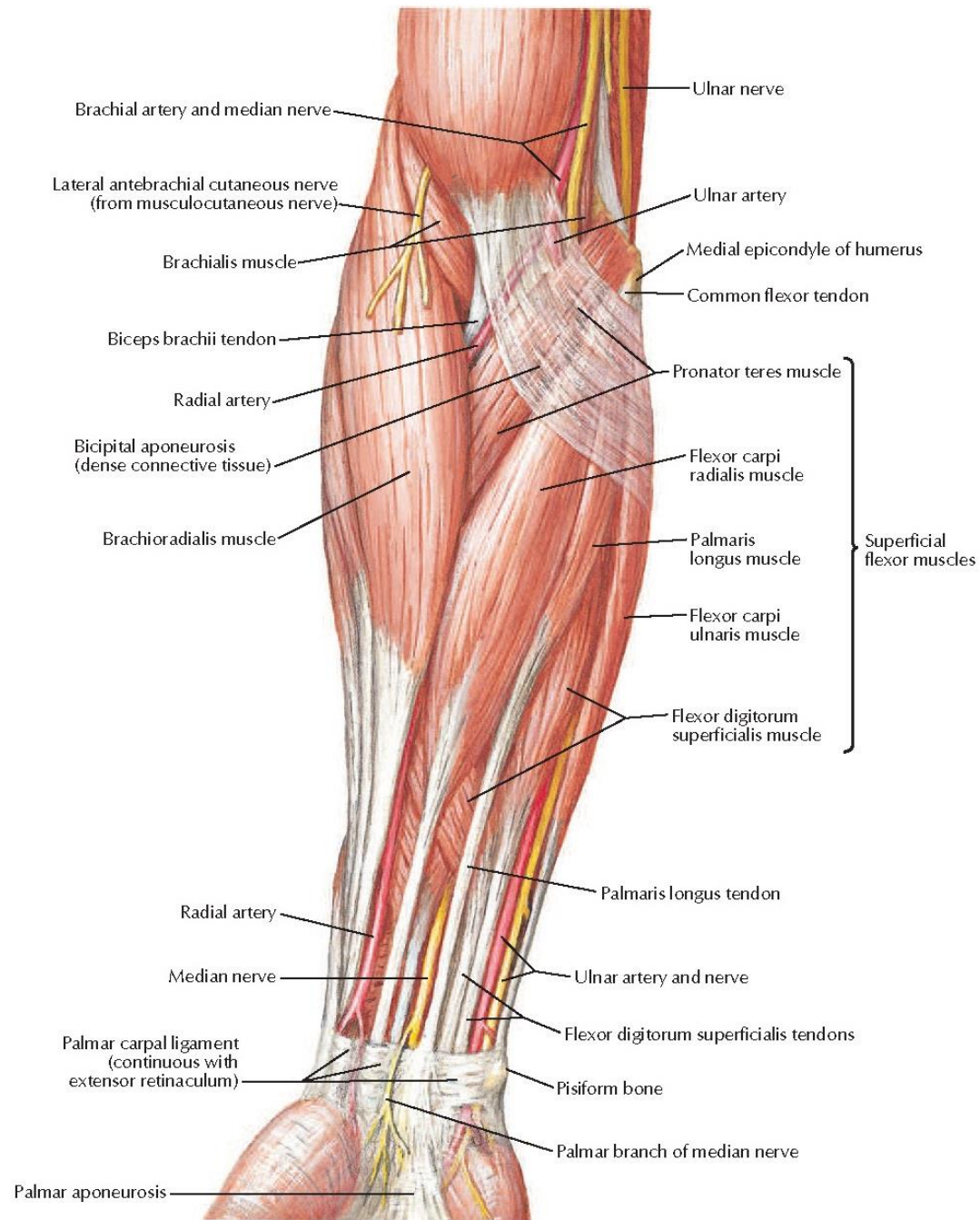


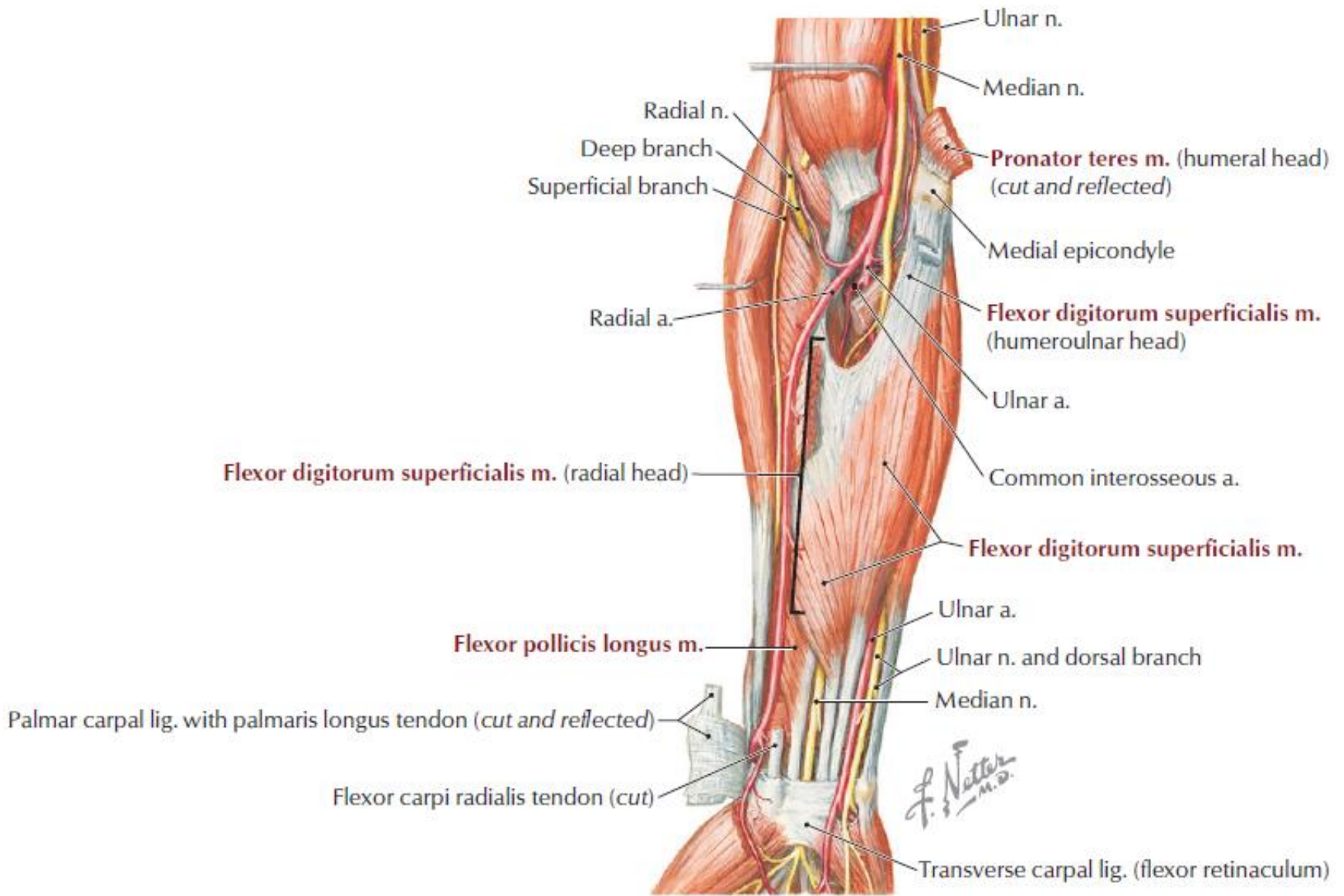
Superficial layer



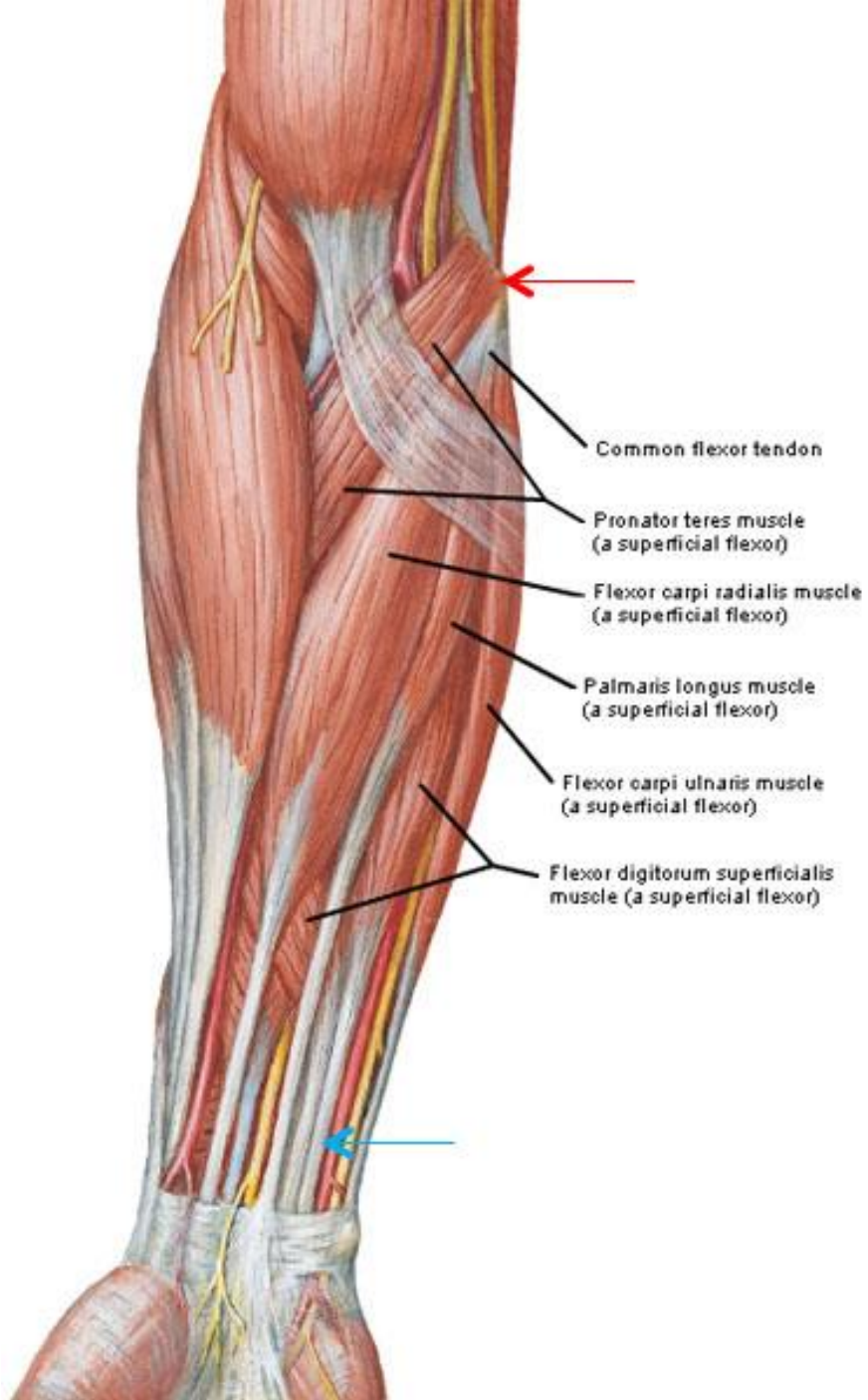
F. Netter  
M.D.

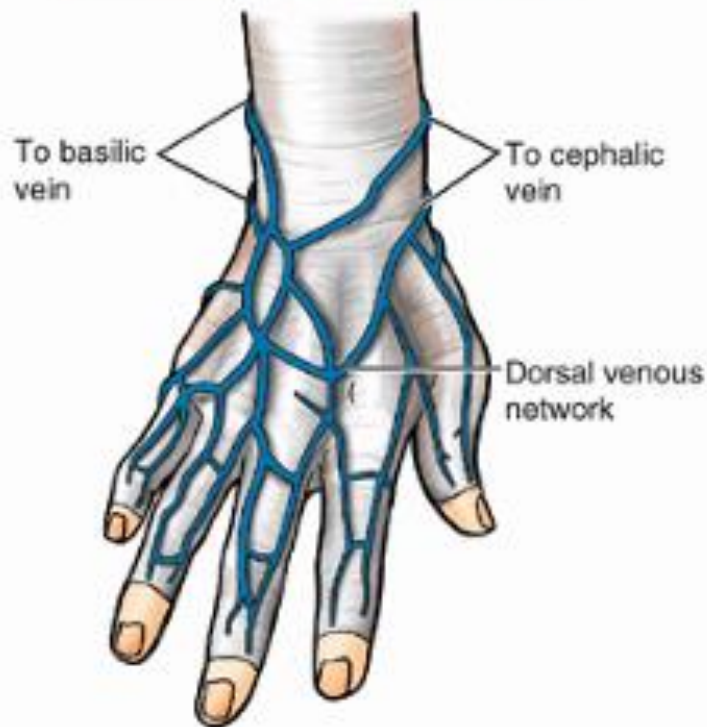




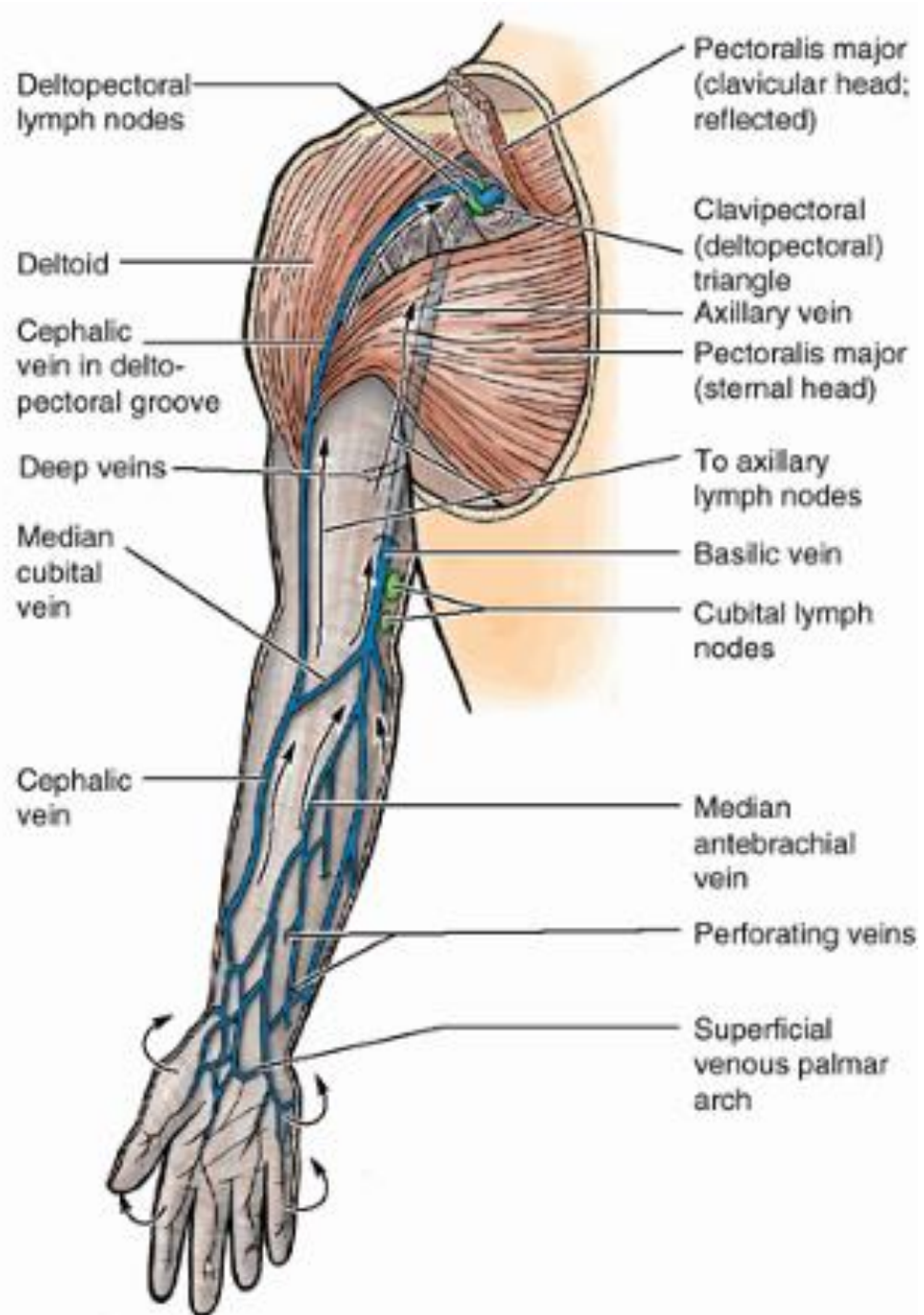


**FIGURE 7-19** Anterior Compartment Forearm Muscles and Nerves

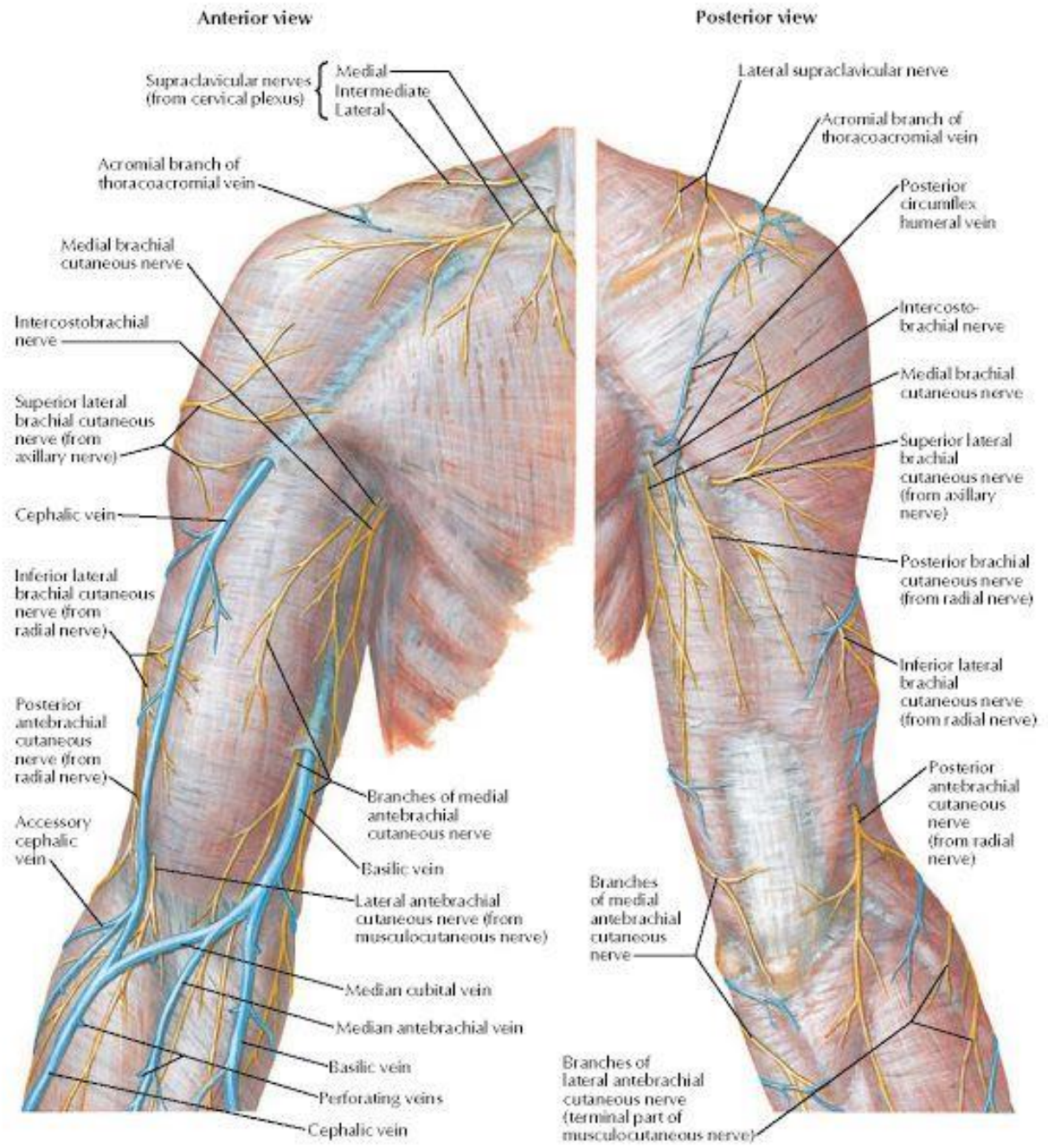


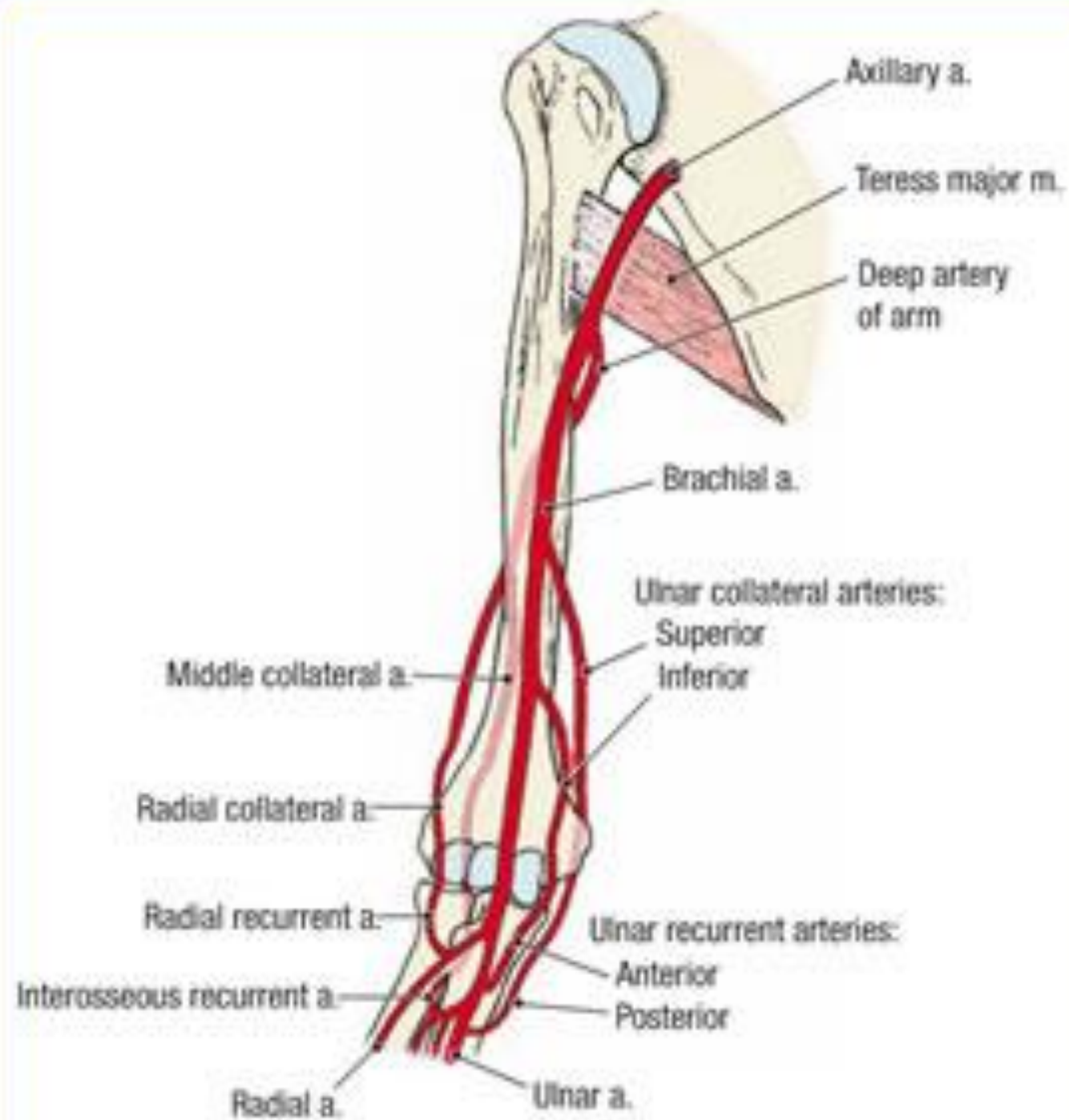


(A) Posterior (dorsal) views



(B) Anterior (palmar) views





- ❑ Anastomosis occurs between branches of

- ❑ **Brachial, Radial and Ulnar arteries:**

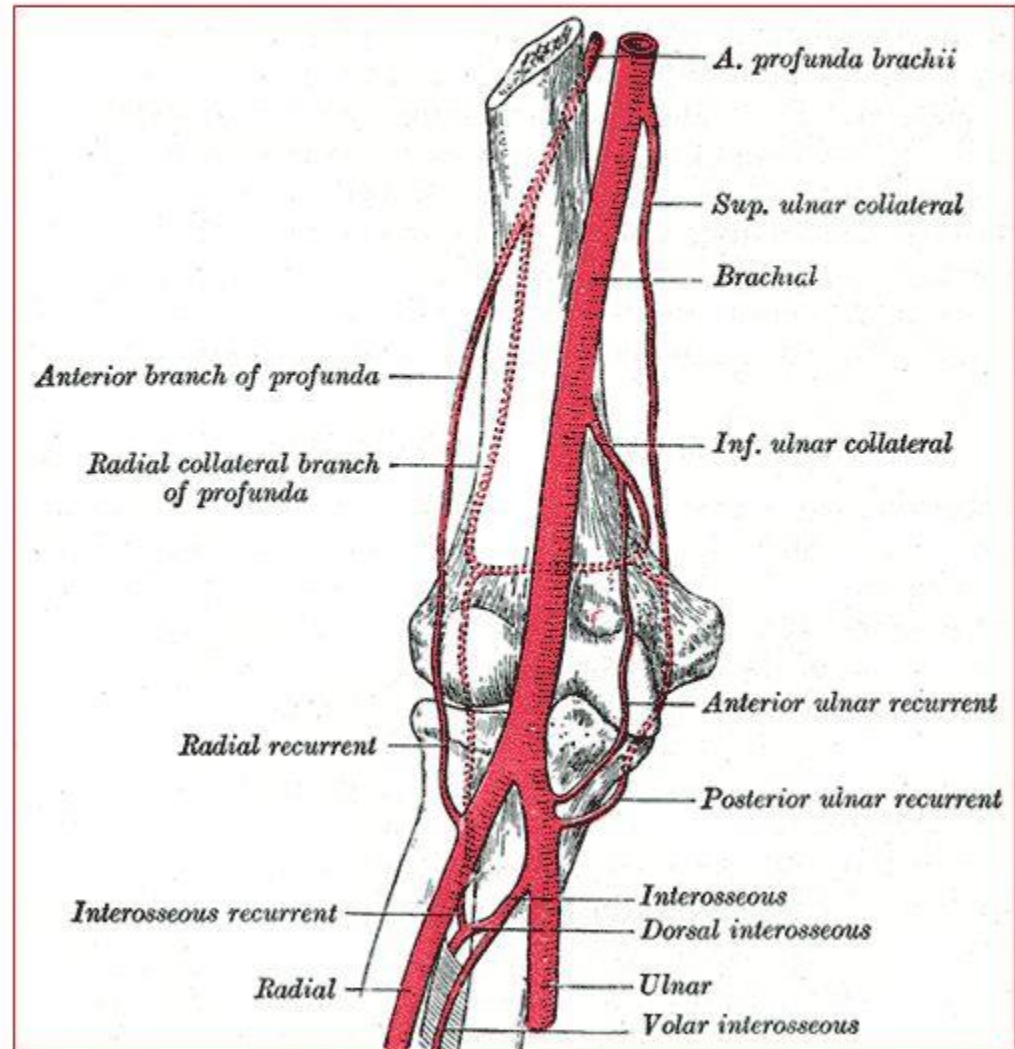
- **Branches from Brachial Artery:**

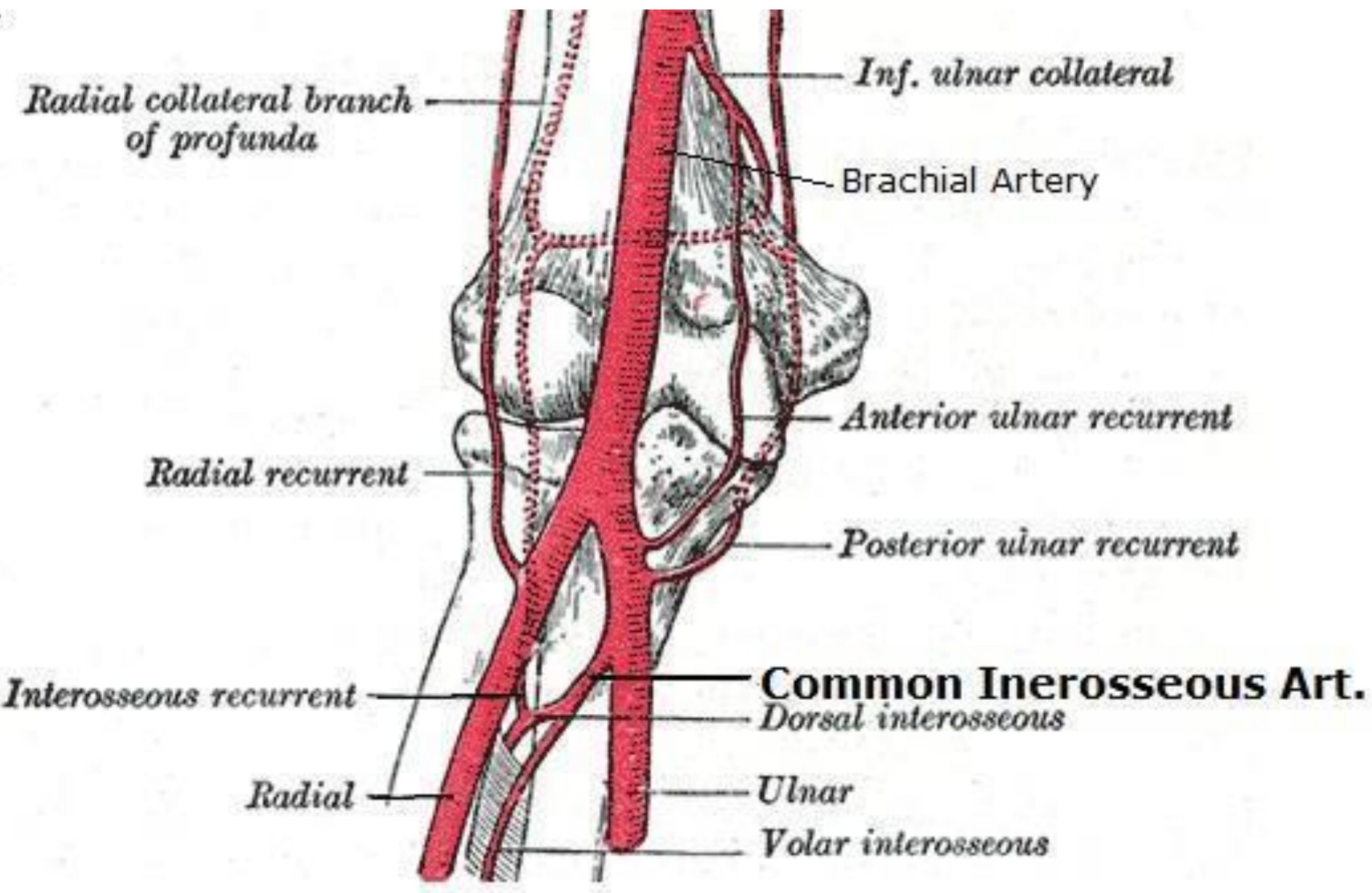
- Profunda Brachii artery
- Superior ulnar collateral artery
- Inferior ulnar collateral artery

- **Branches from Ulnar and Radial Arteries:**

- Radial & ulnar recurrent arteries
- Posterior interosseous recurrent artery

## Anastomosis around elbow joint

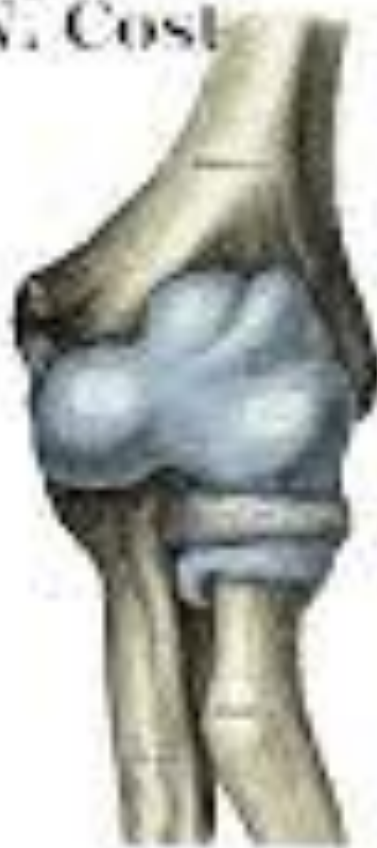

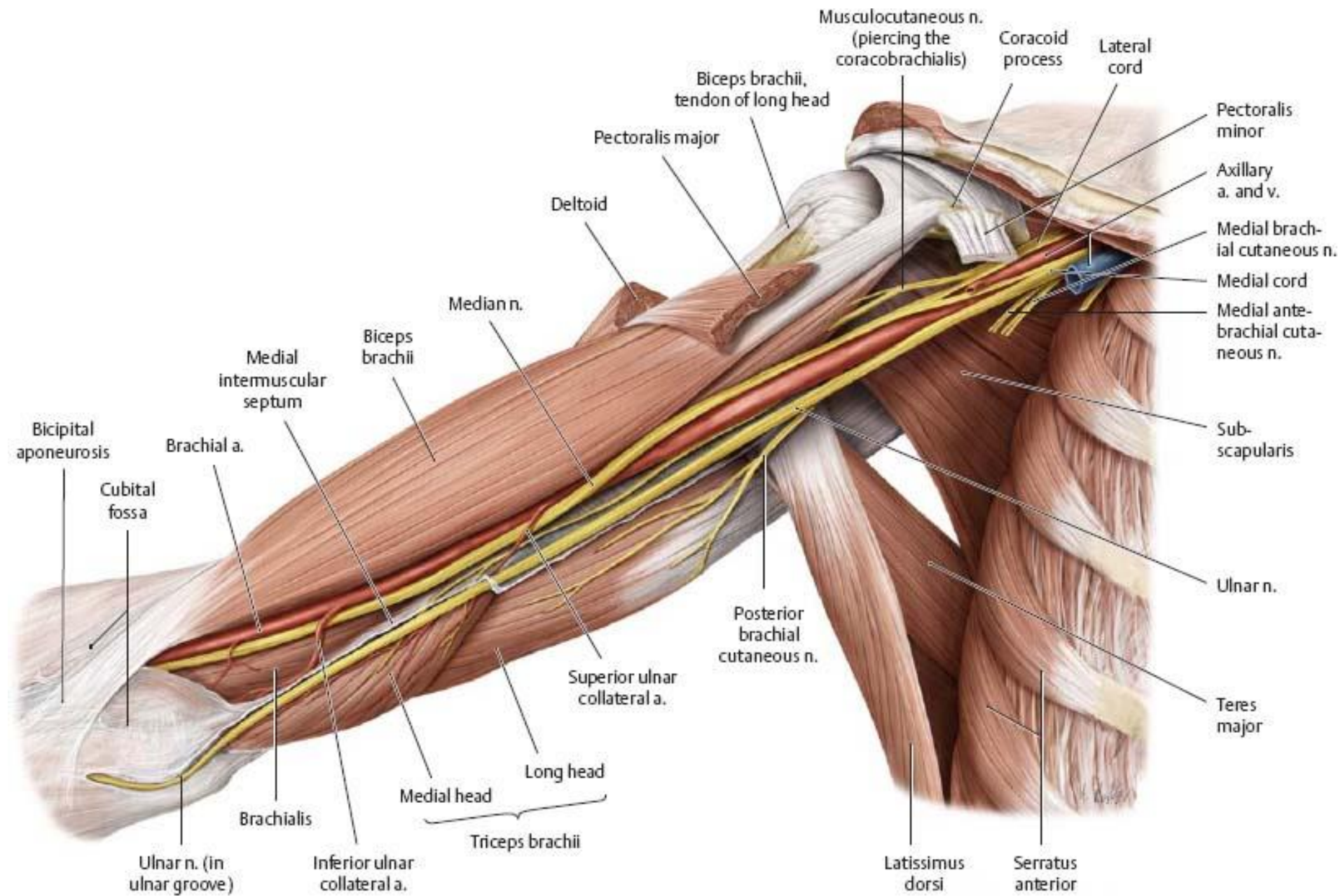


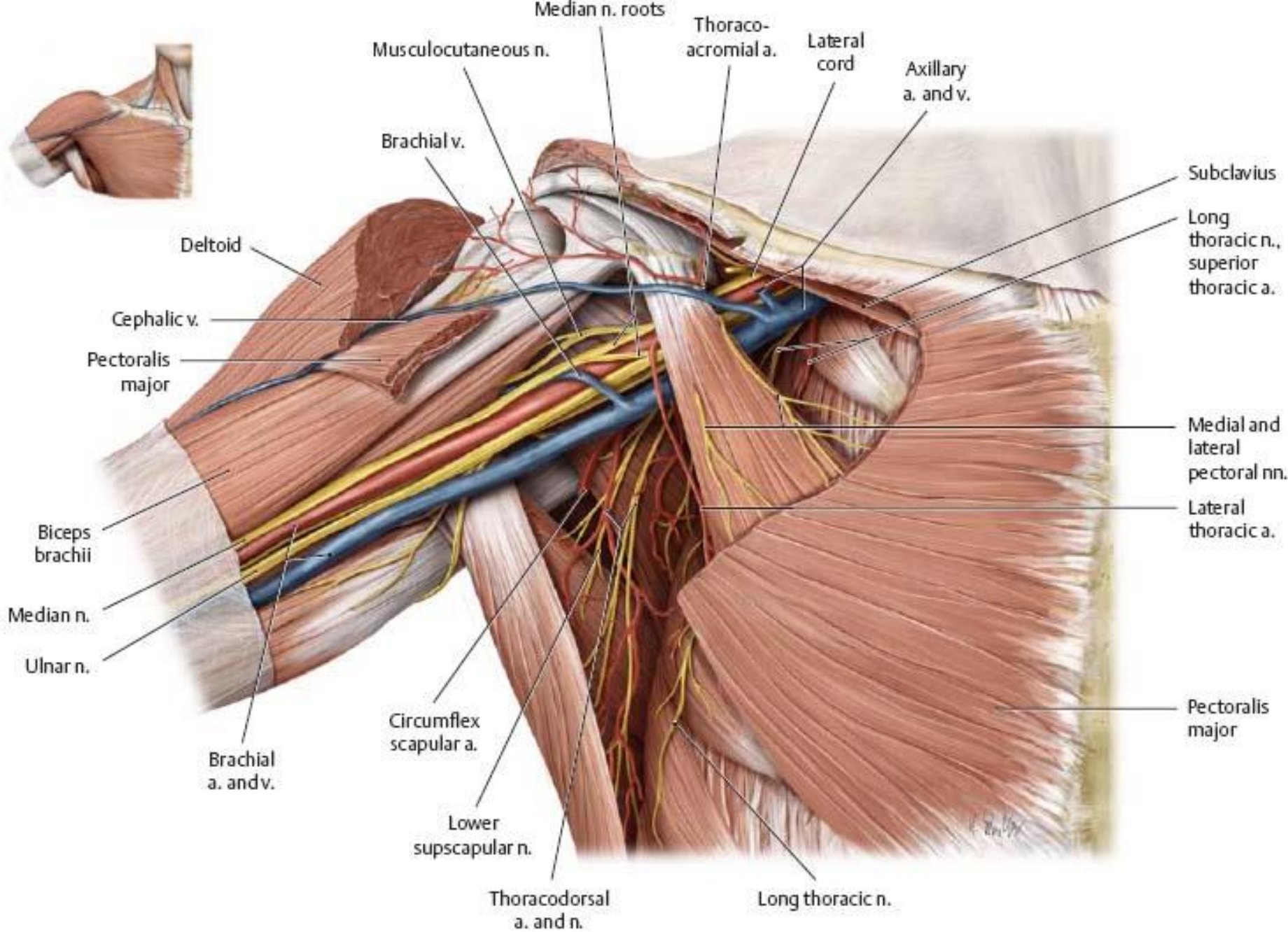


# Anatomy of the Elbow Region

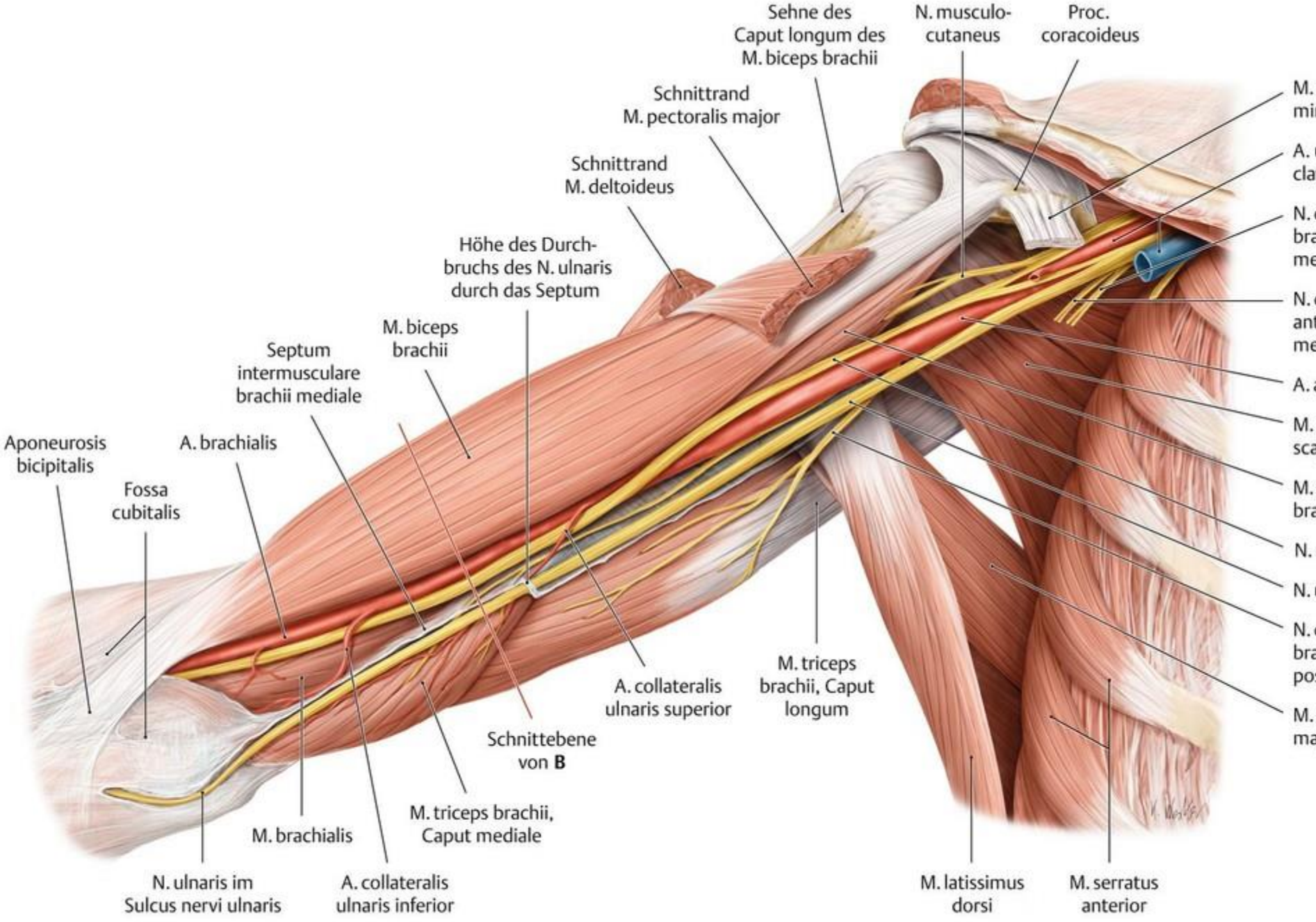
Ian N. Costello

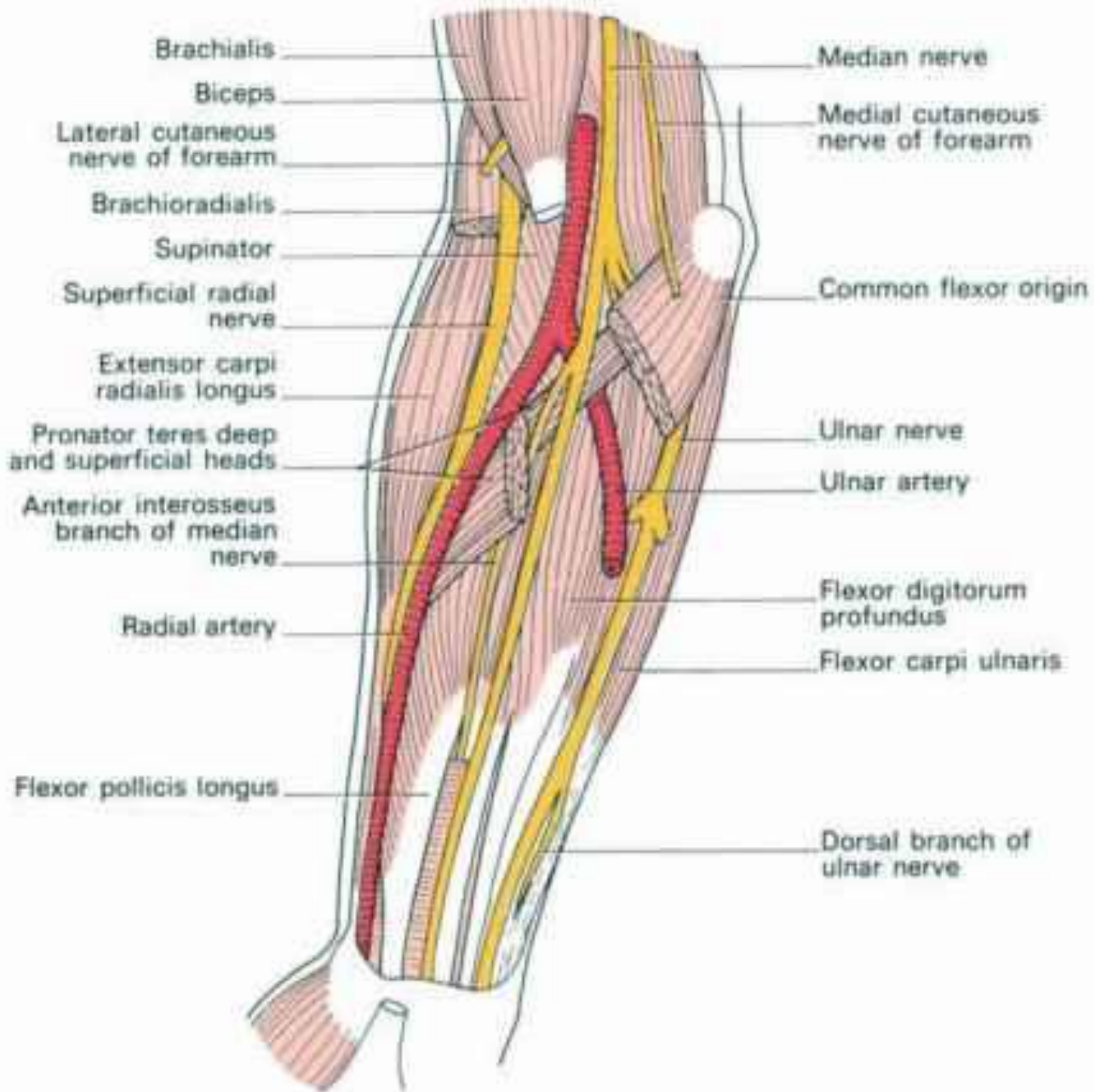




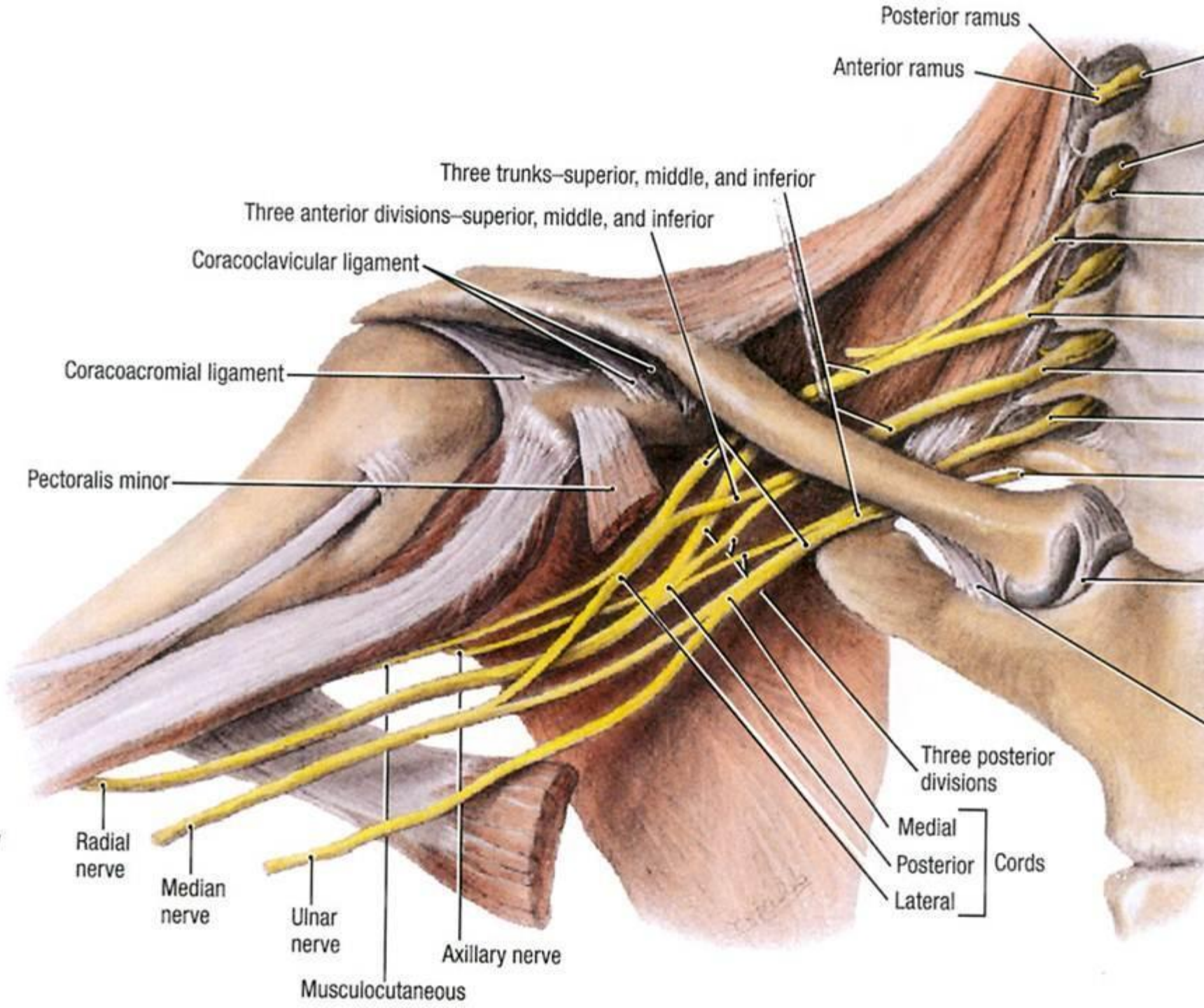


A Removed: Pectoralis major and clavicle.





**Anterior View**



Posterior ramus

Anterior ramus

Three trunks—superior, middle, and inferior

Three anterior divisions—superior, middle, and inferior

Coracoclavicular ligament

Coracoacromial ligament

Pectoralis minor

Radial nerve

Median nerve

Ulnar nerve

Axillary nerve

Musculocutaneous

Three posterior divisions

Medial

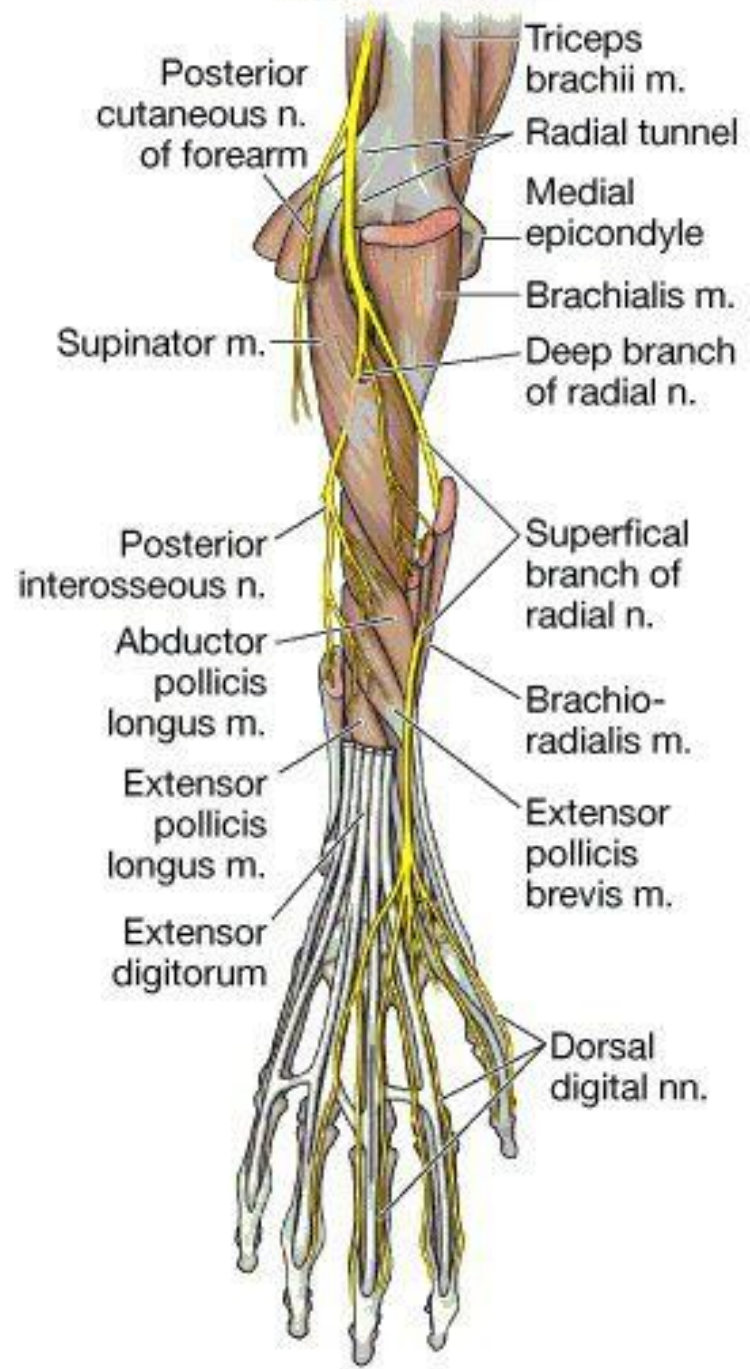
Posterior

Lateral

Cords



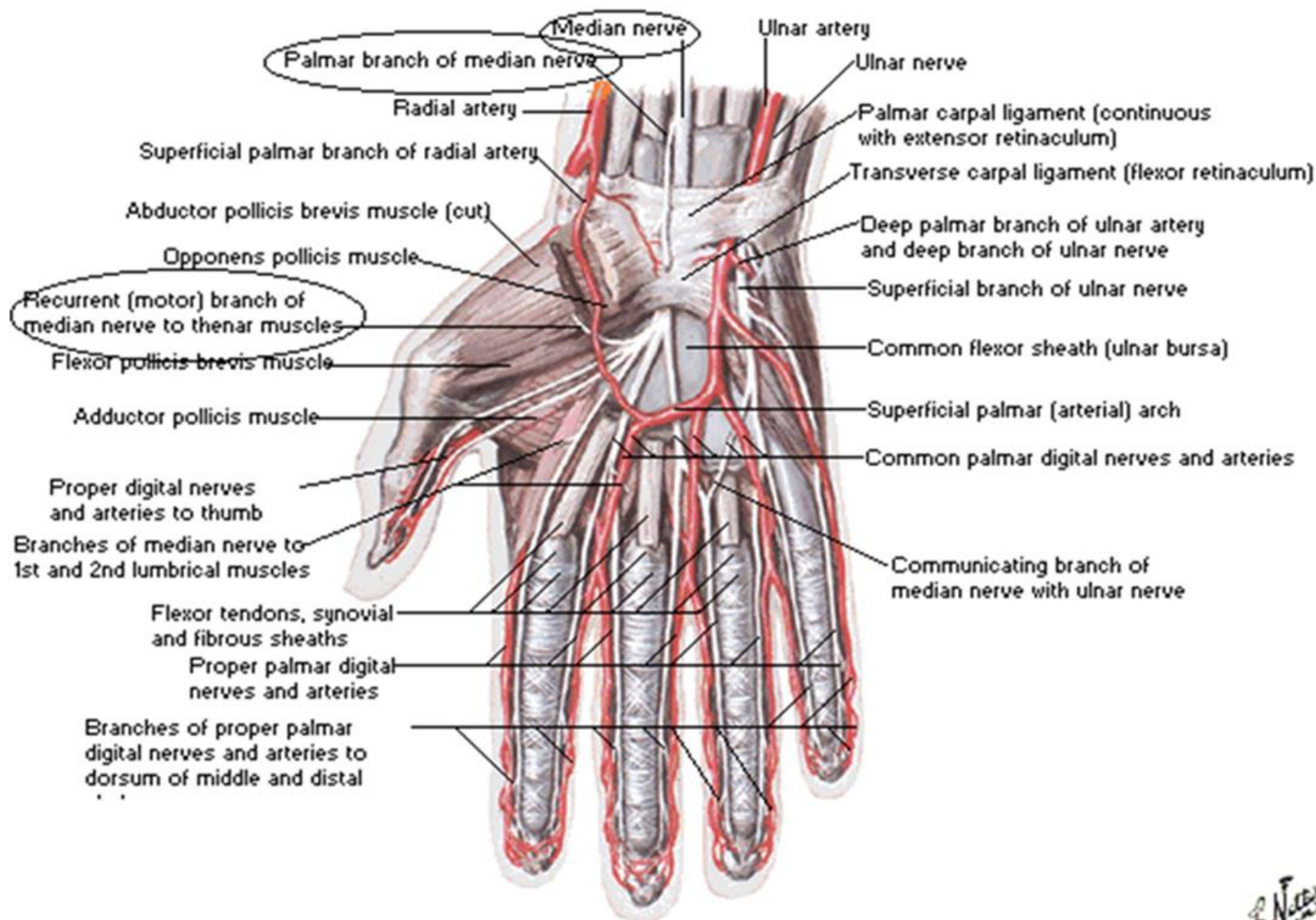
# RADIAL NERVE





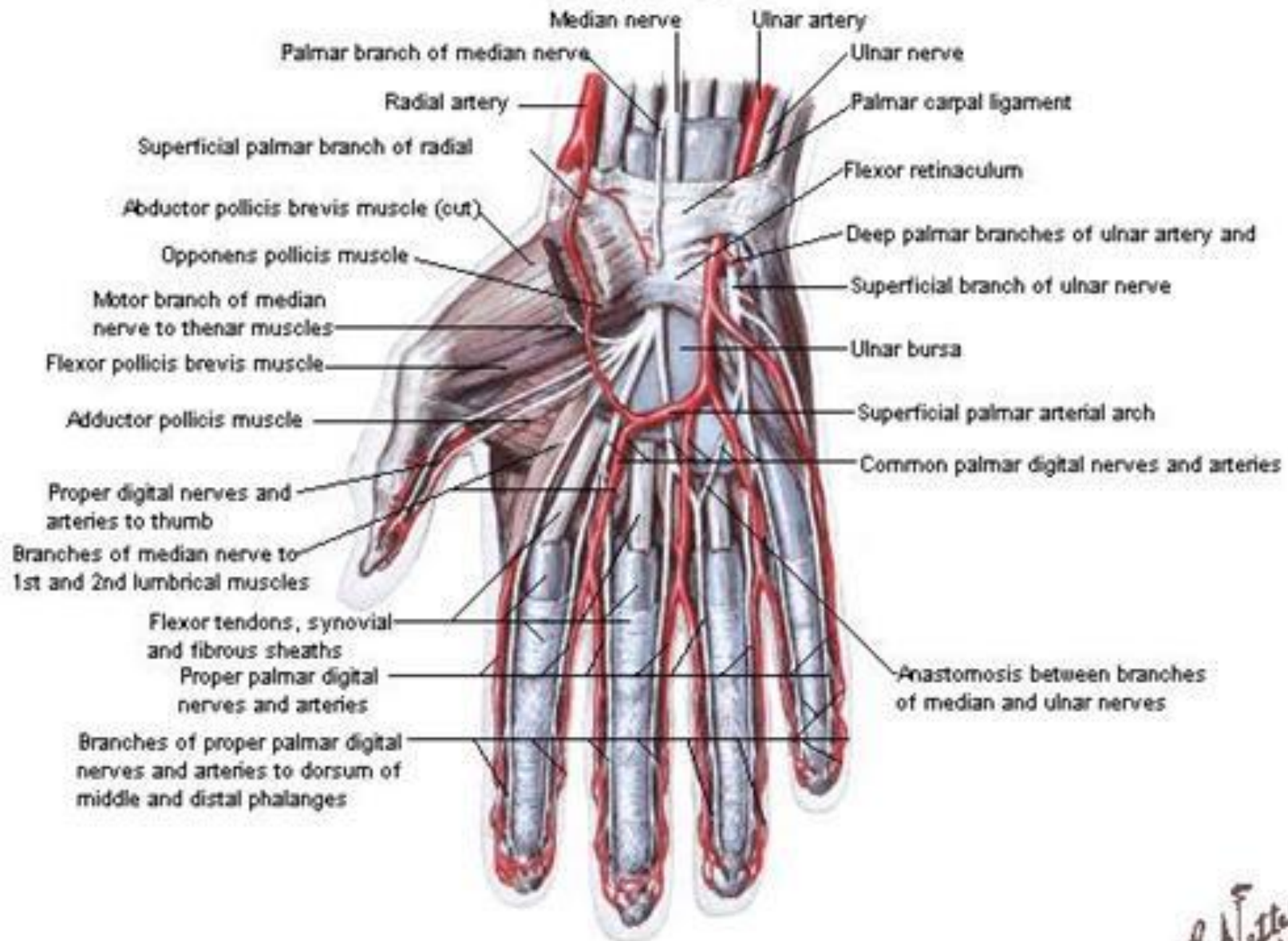
# Arteries and Nerves of Hand

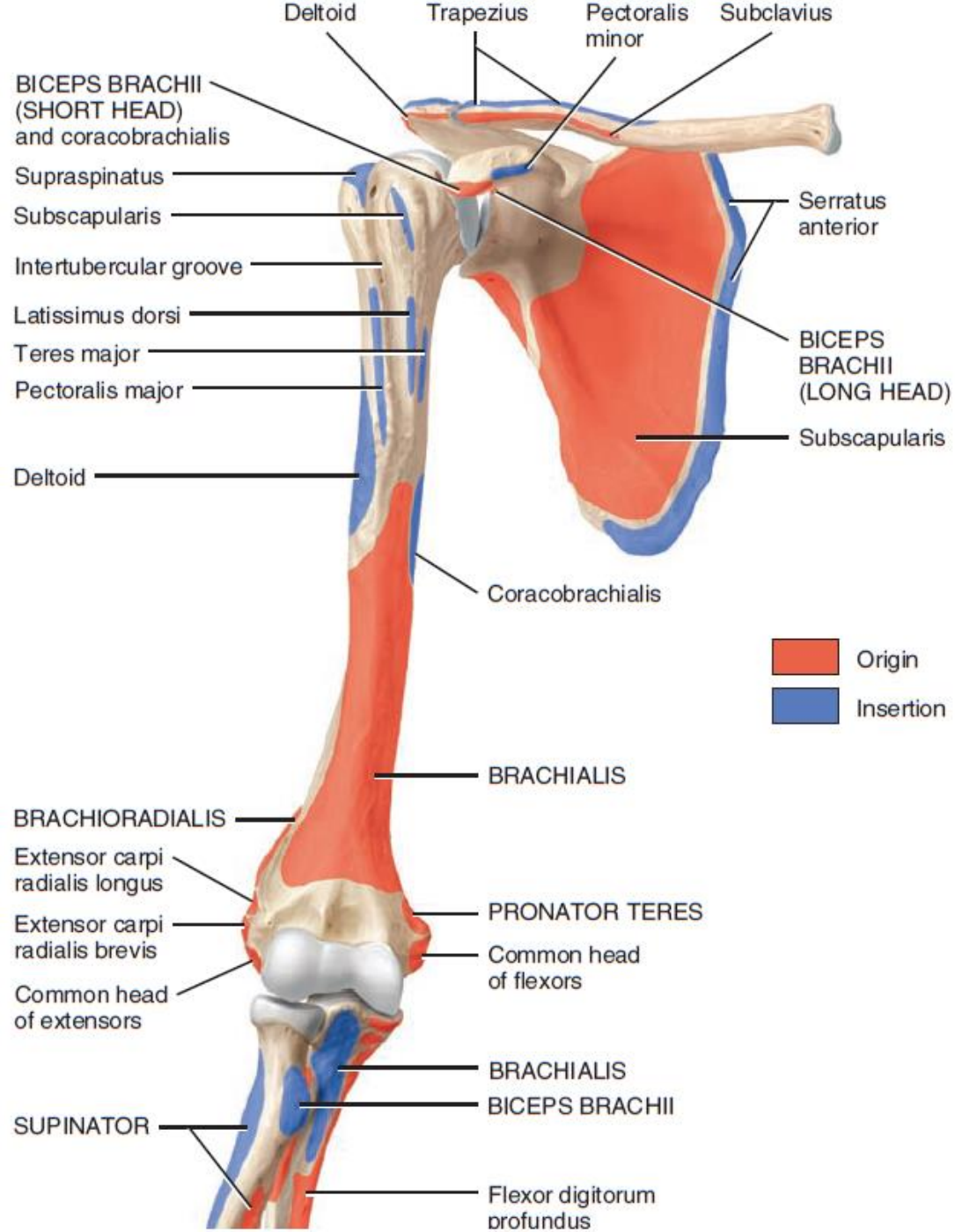
## Palmar View



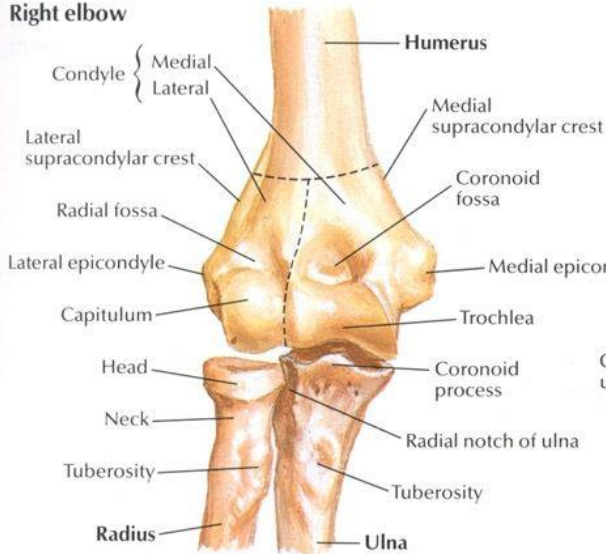
# Arteries and Nerves of Hand

## Palmar View

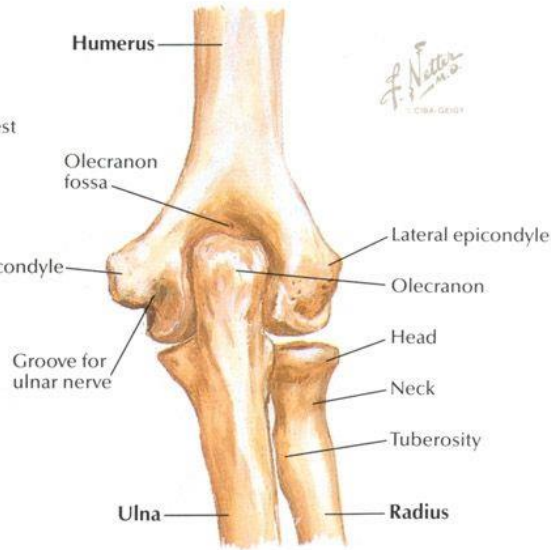




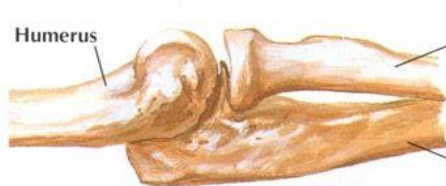**Right elbow**



**In extension: anterior view**



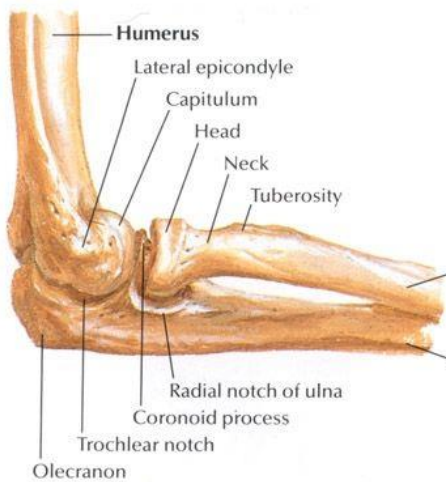
**In extension: posterior view**



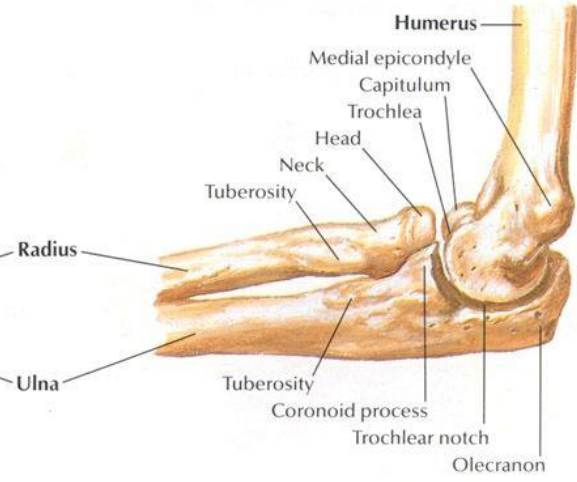
**In extension: lateral view**



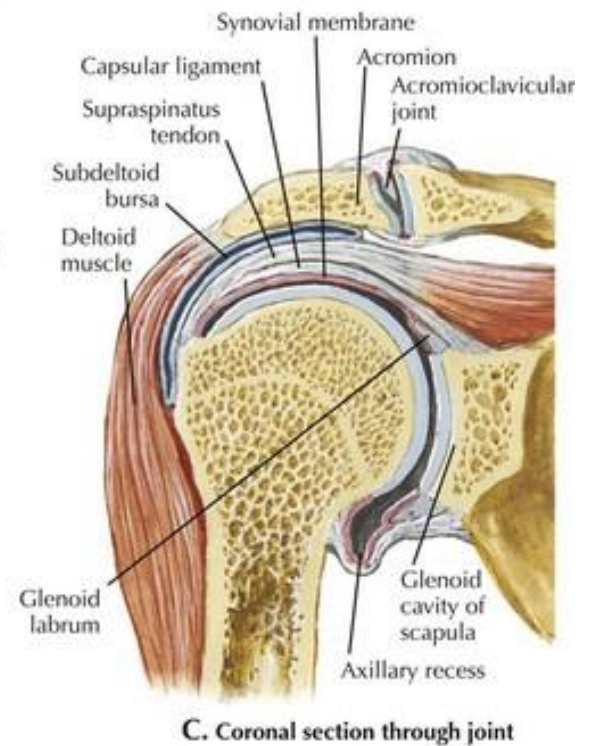
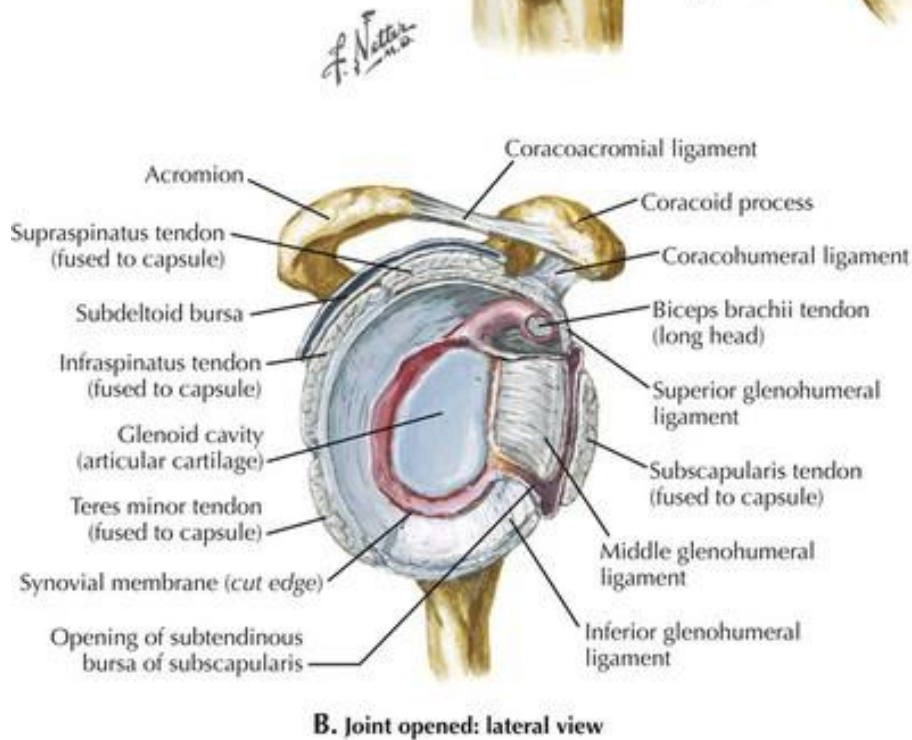
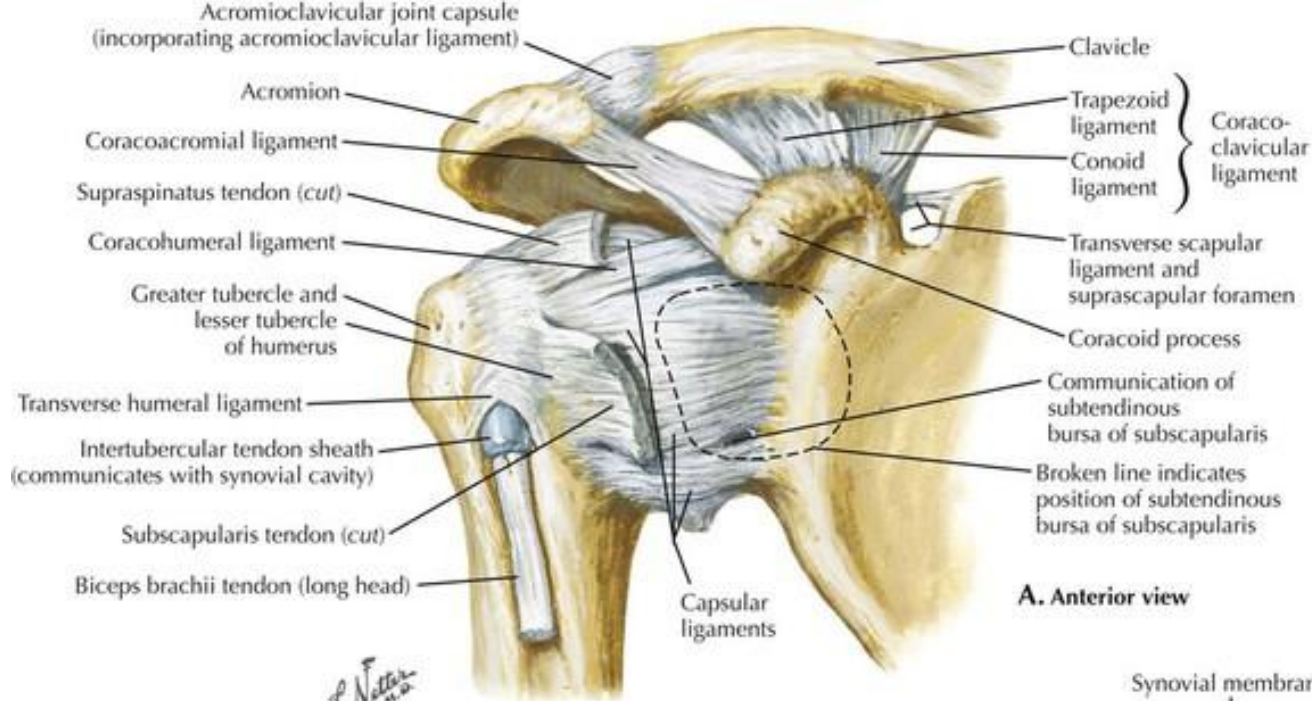
**In extension: medial view**

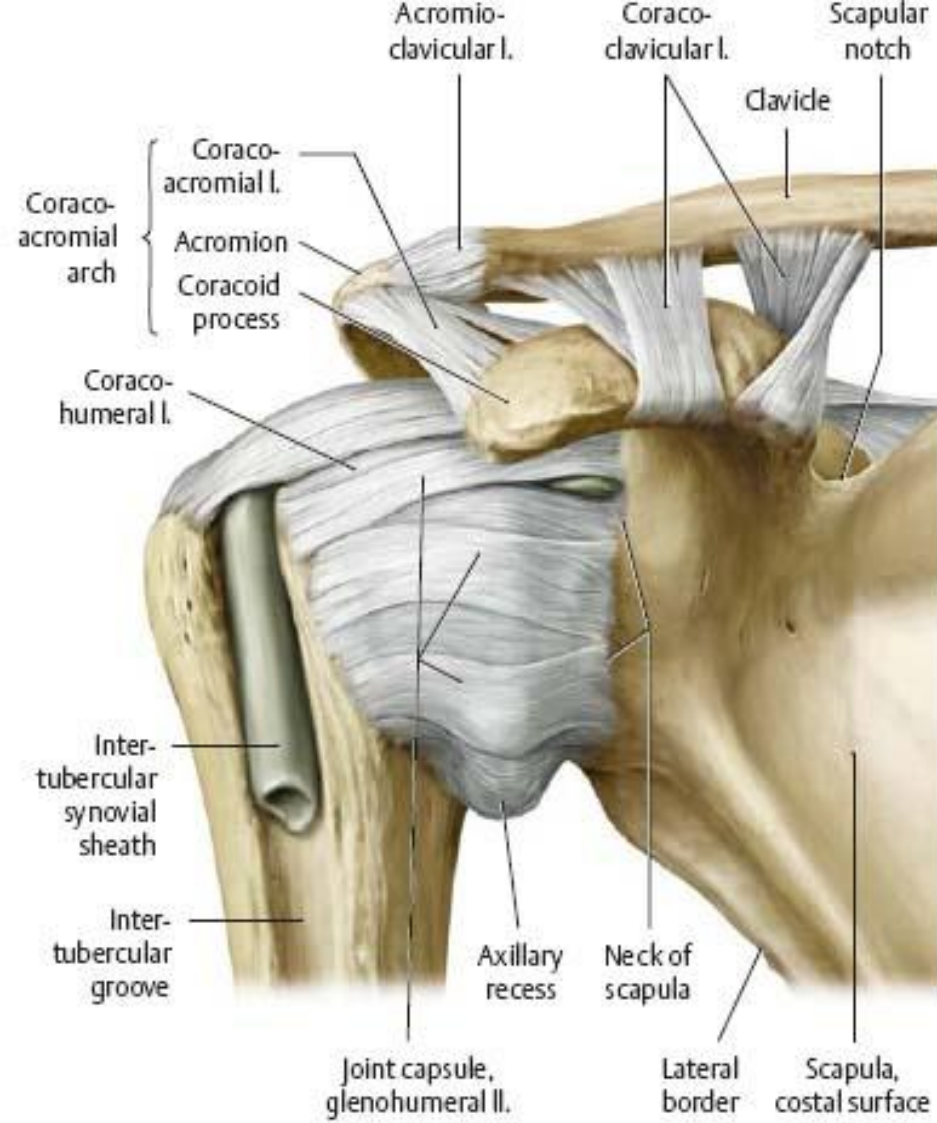


**In 90° flexion: lateral view**

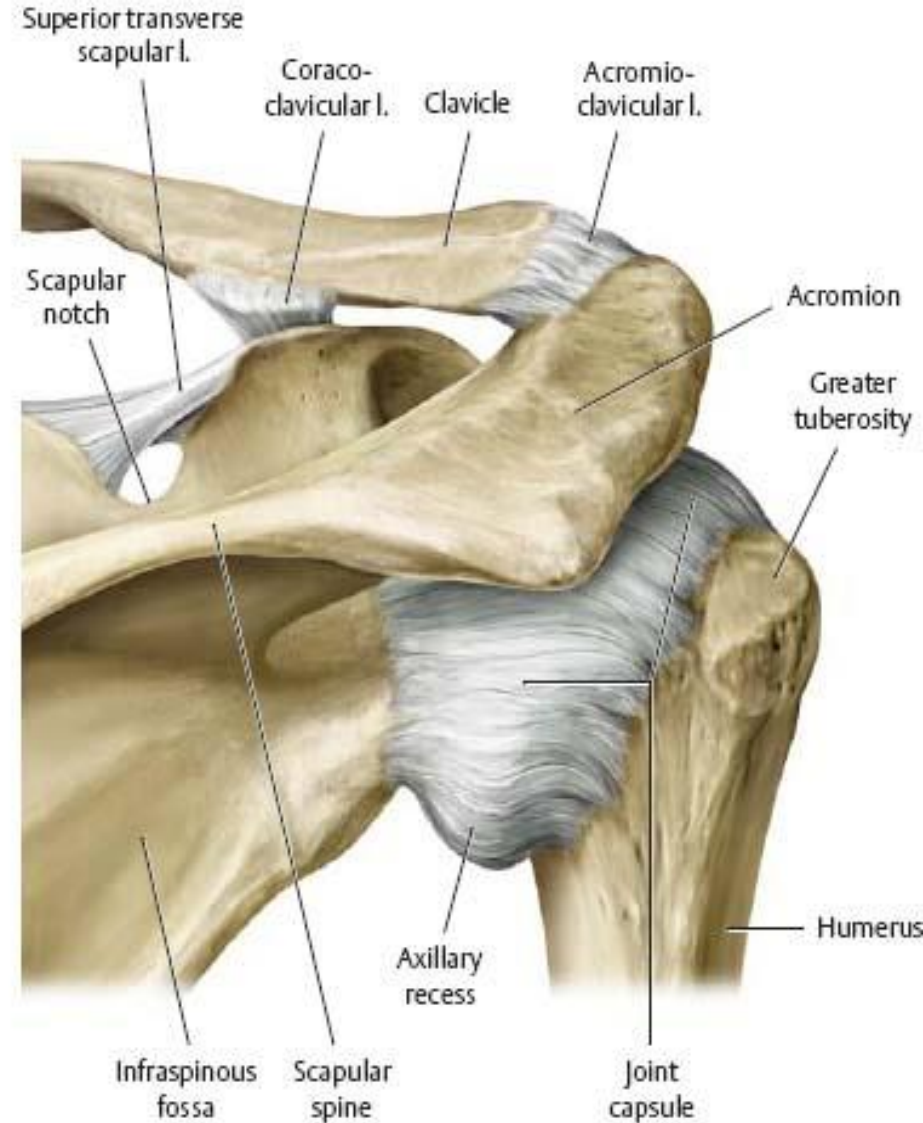


**In 90° flexion: medial view**

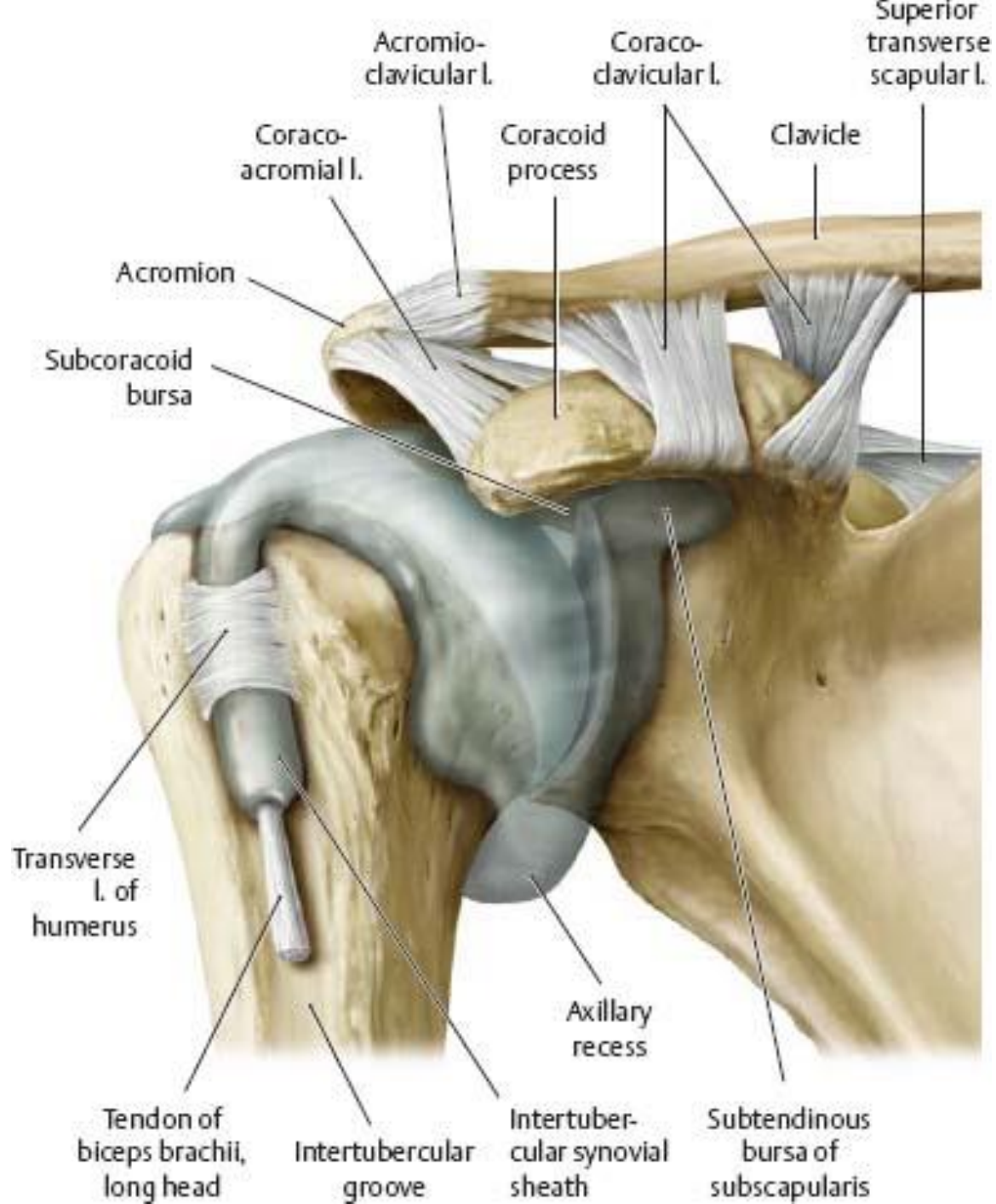




A Anterior view.

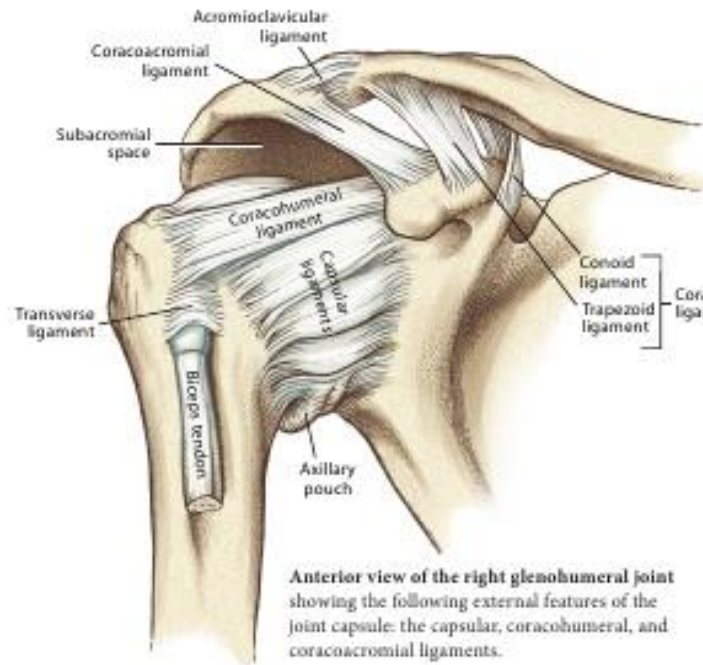


B Posterior view.

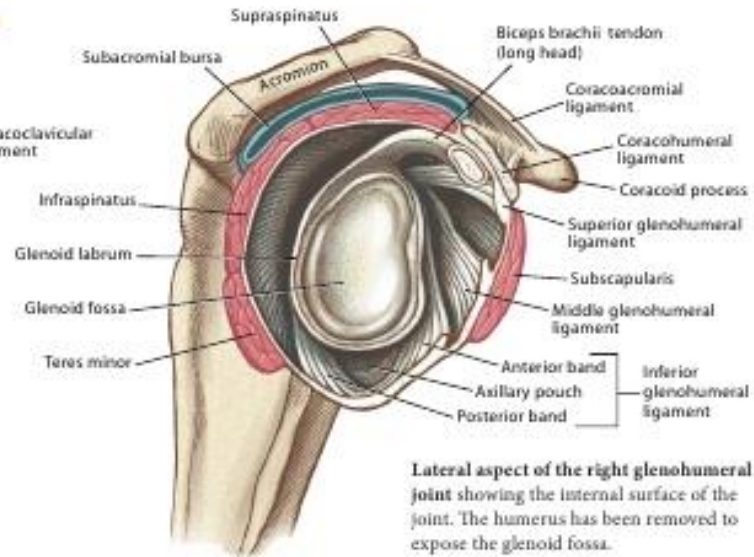


# The Glenohumeral Joint

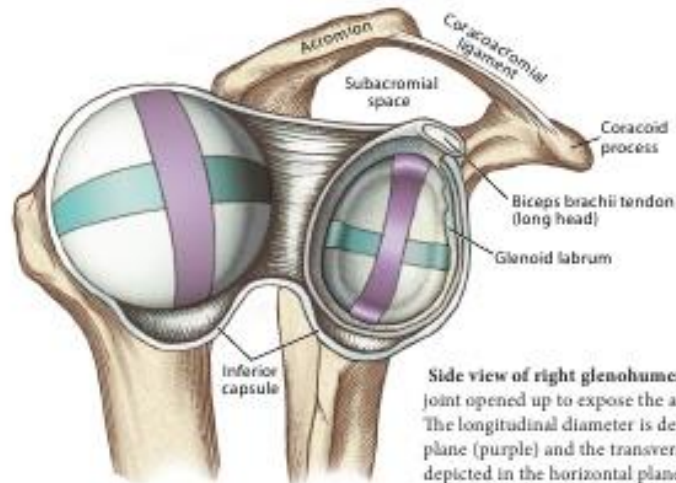
from *Kinesiology of the Musculoskeletal System, 2nd Edition*  
by Donald A. Neumann, © Elsevier Sciences



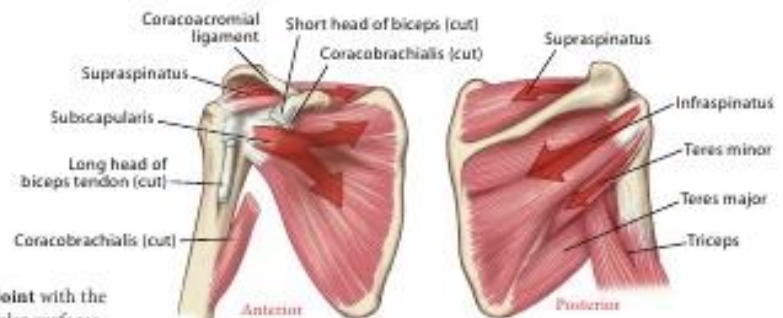
**Anterior view of the right glenohumeral joint** showing the following external features of the joint capsule: the capsular, coracohumeral, and coracoacromial ligaments.



**Lateral aspect of the right glenohumeral joint** showing the internal surface of the joint. The humerus has been removed to expose the glenoid fossa.

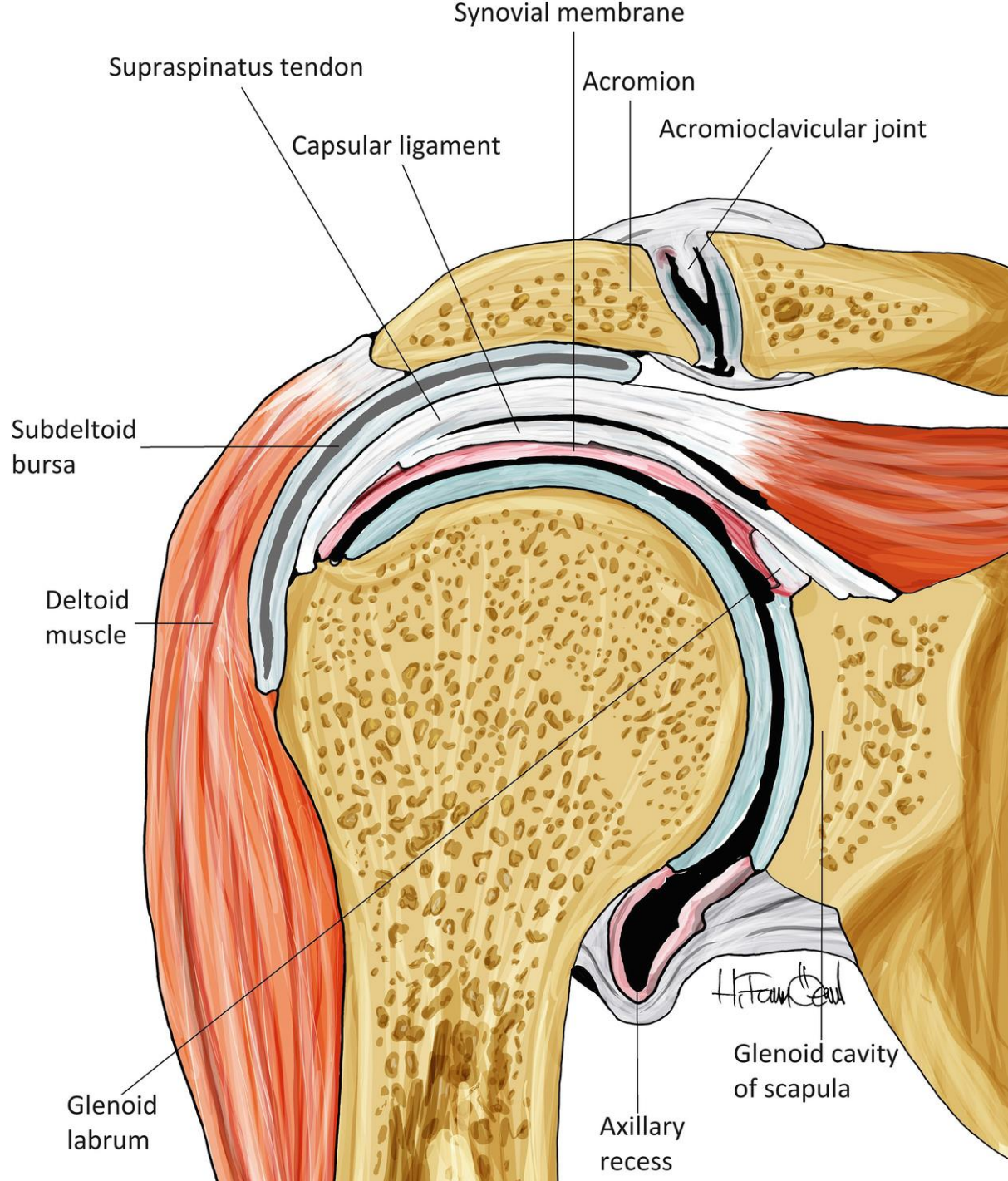


**Side view of right glenohumeral joint** with the joint opened up to expose the articular surfaces. The longitudinal diameter is depicted in the frontal plane (purple) and the transverse diameter is depicted in the horizontal plane (blue-green).



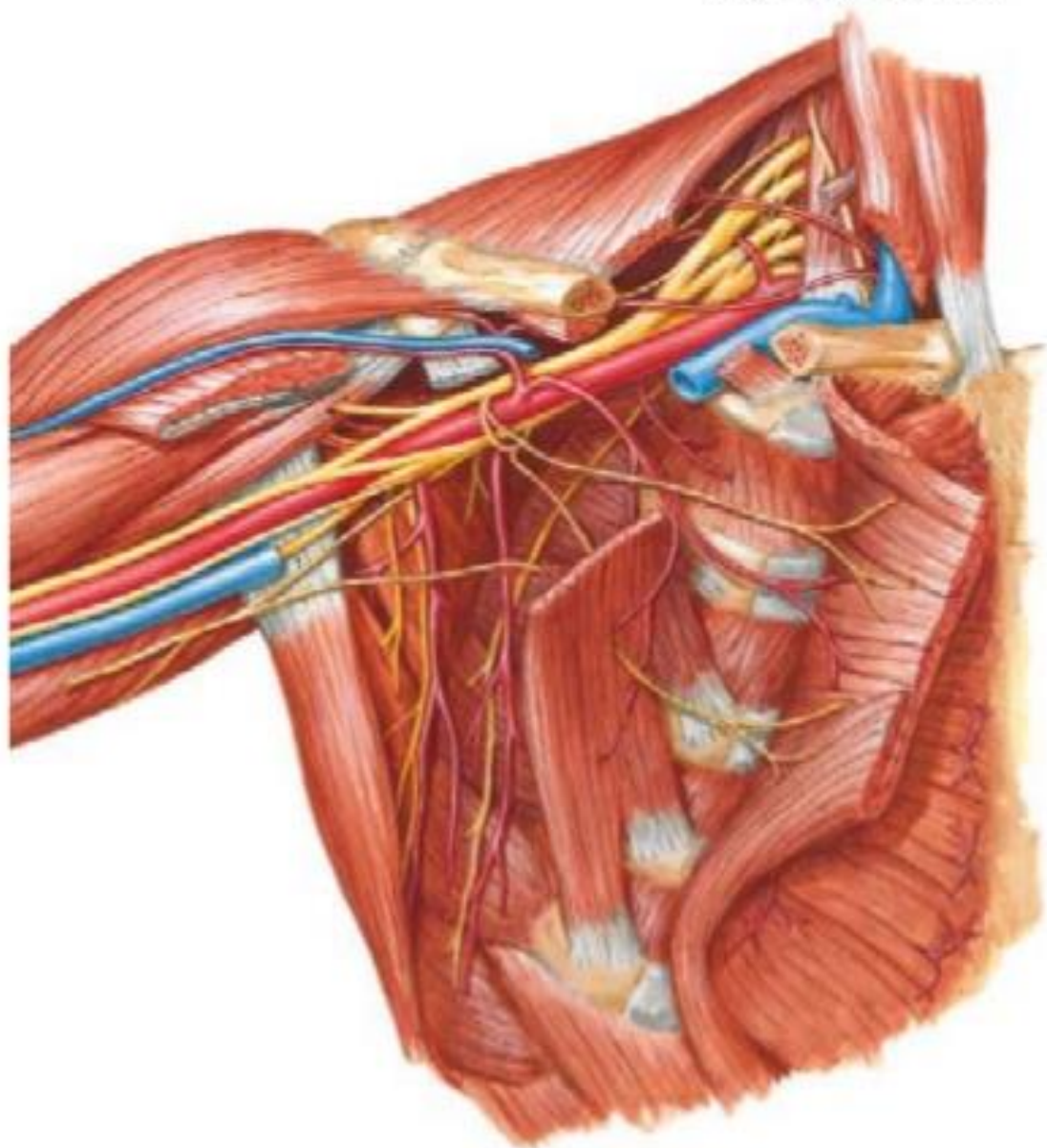
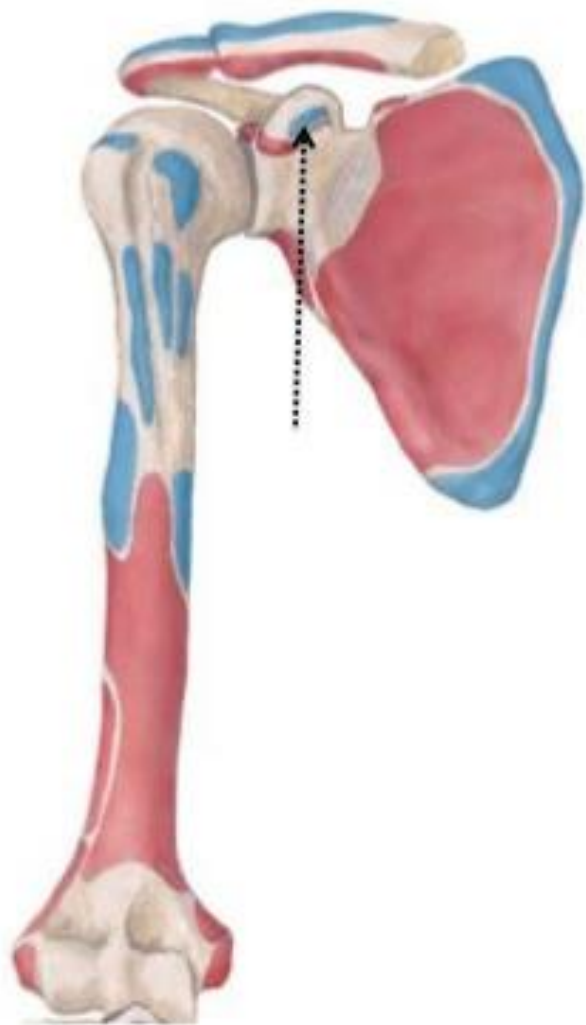**Anterior and posterior views of the right shoulder** showing the rotator cuff muscles blending into and reinforcing the glenohumeral joint capsule.



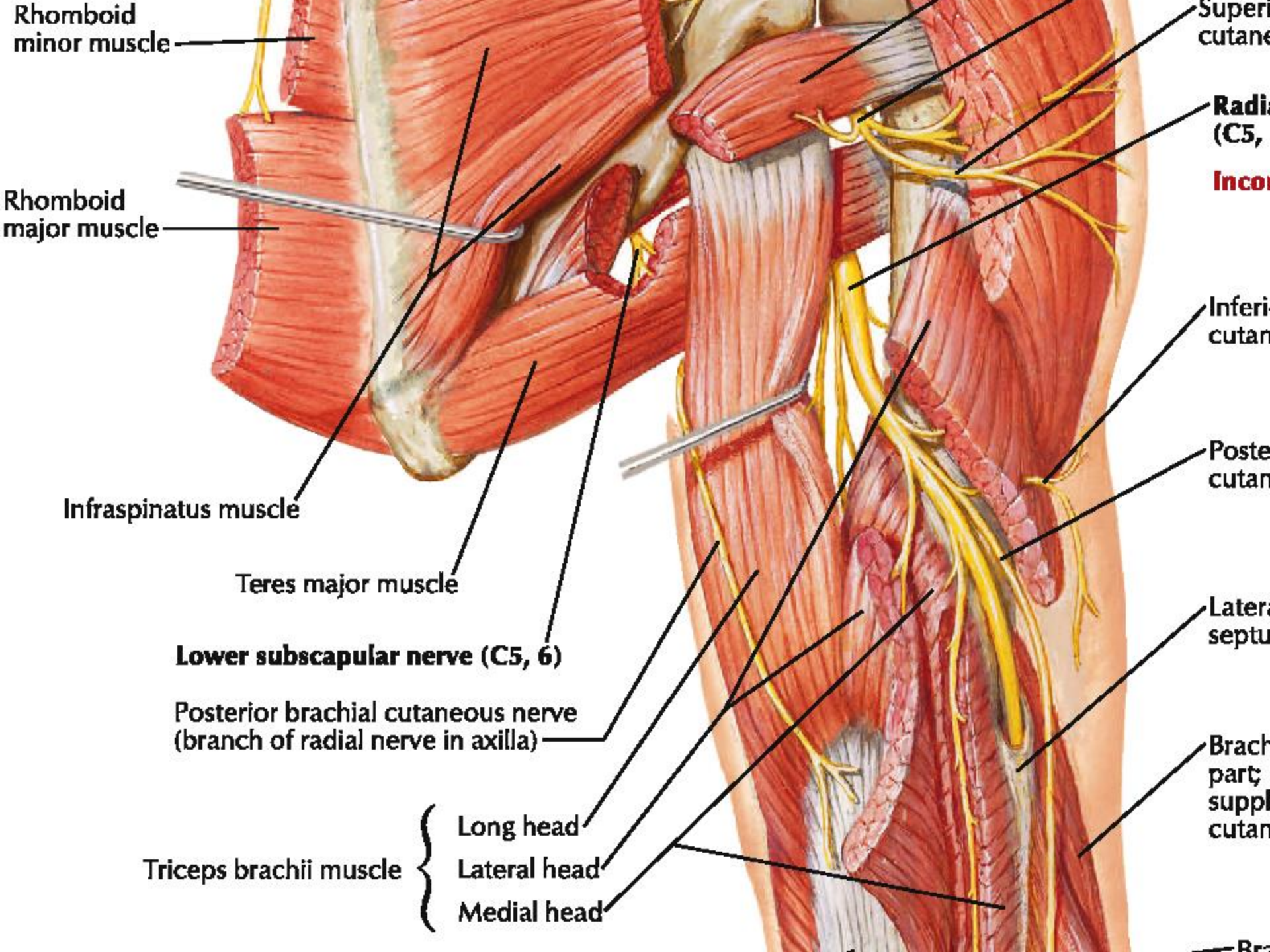


# M. Pectoral Menor

# INERVACION







Rhomboid minor muscle

Rhomboid major muscle

Infraspinatus muscle

Teres major muscle

Lower subscapular nerve (C5, 6)

Posterior brachial cutaneous nerve (branch of radial nerve in axilla)

Triceps brachii muscle

Long head

Lateral head

Medial head

Superficial cutaneous

Radial (C5, 6)  
Incomplete radial

Inferior cutaneous

Posterior cutaneous

Lateral septum

Brachial plexus (part supplying cutaneous)

Brachial plexus