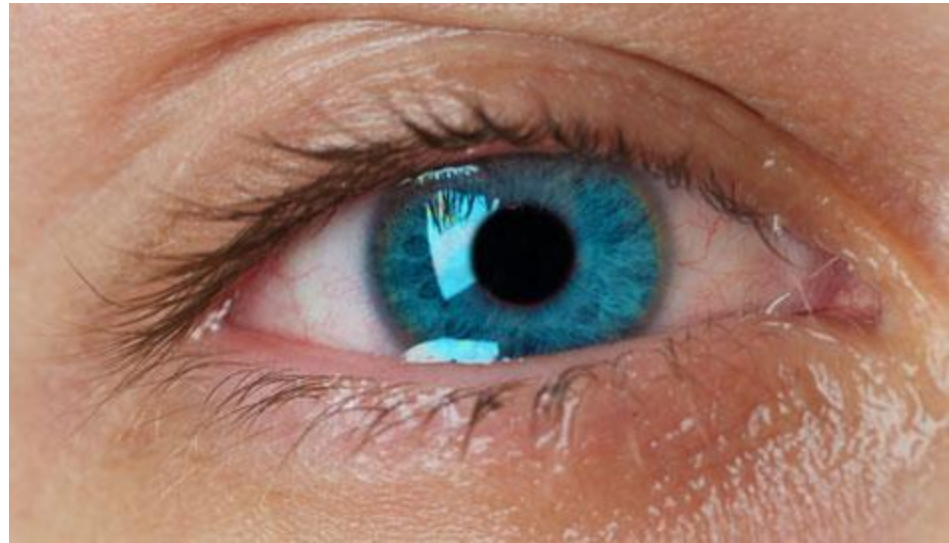


WATERY EYES



Dr. Irfan Ullah Khattak
Pediatric Ophthalmologist
HMC

EPIPHORA

- Watering that occurs secondary to abnormal excretory system



LACRIMATION

- Watering that occurs secondary excessive tear production in presence of normal excretory system



SECRETORY SYSTEM

- Lacrimal gland
 - Orbital part
 - Palpebral part
- Accesory lacrimal gland
 - Krause
 - wolfring



TEAR

- Smooth surface
- Nutrition
- Optical
- 3 layers
 - Mucin
 - Aquoues
 - Oil



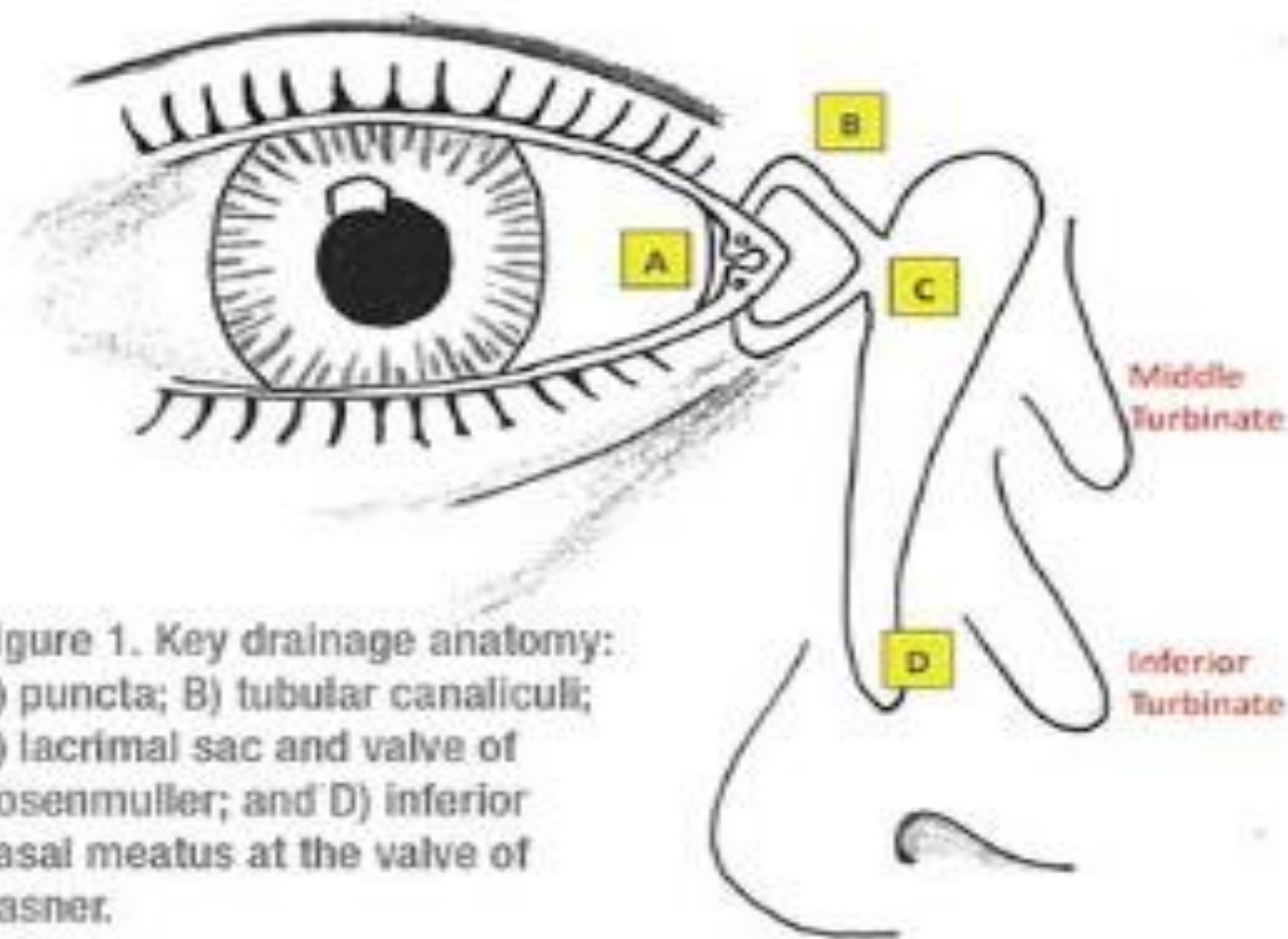
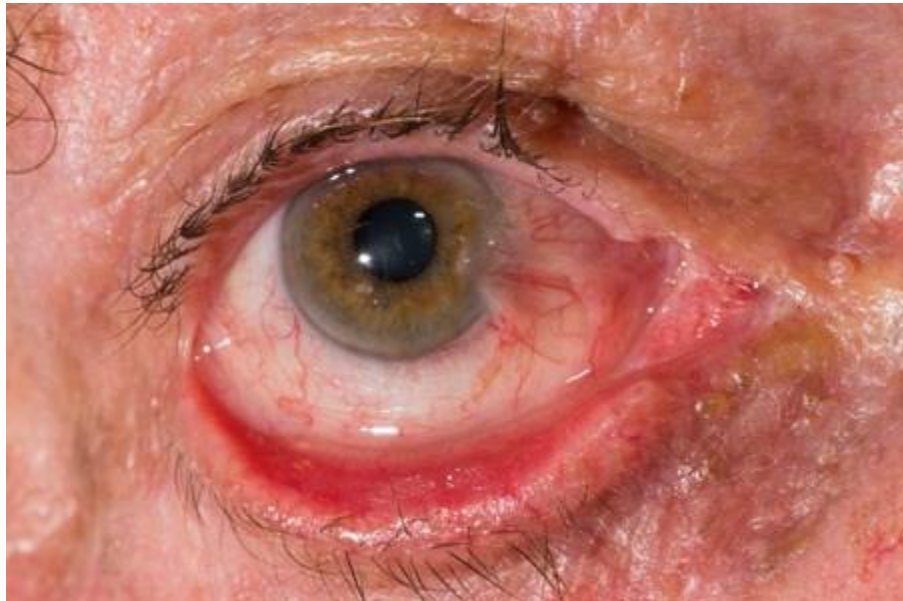

Figure 1. Key drainage anatomy:
A) puncta; B) tubular canaliculi;
C) lacrimal sac and valve of
Rosenmuller; and D) inferior
nasal meatus at the valve of
Hasner.



ECTROPION

- Senile
- Cicatricial
- Paralytic



PUNCTAL STENOSIS

- Aging
- Conjunctivitis
- Ectropion

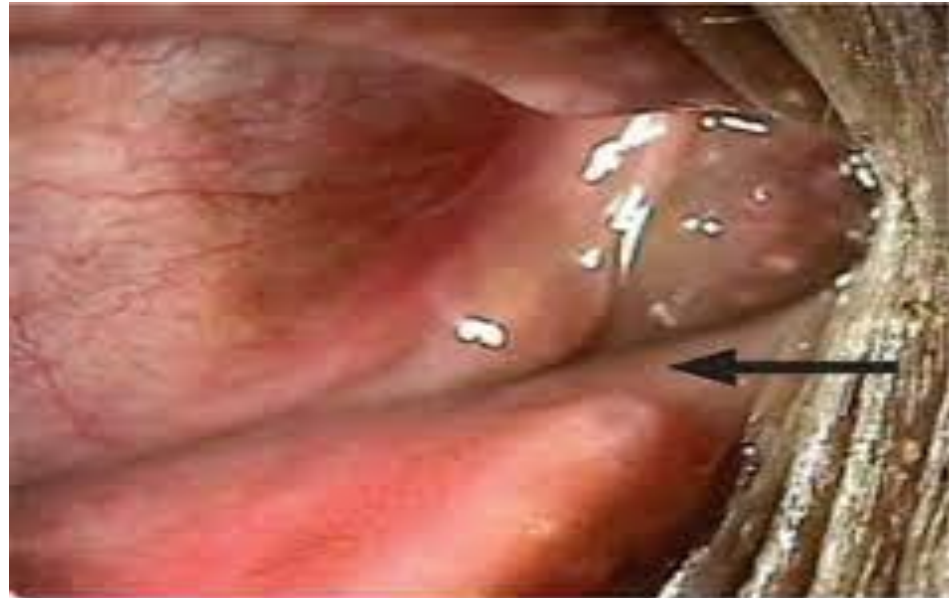
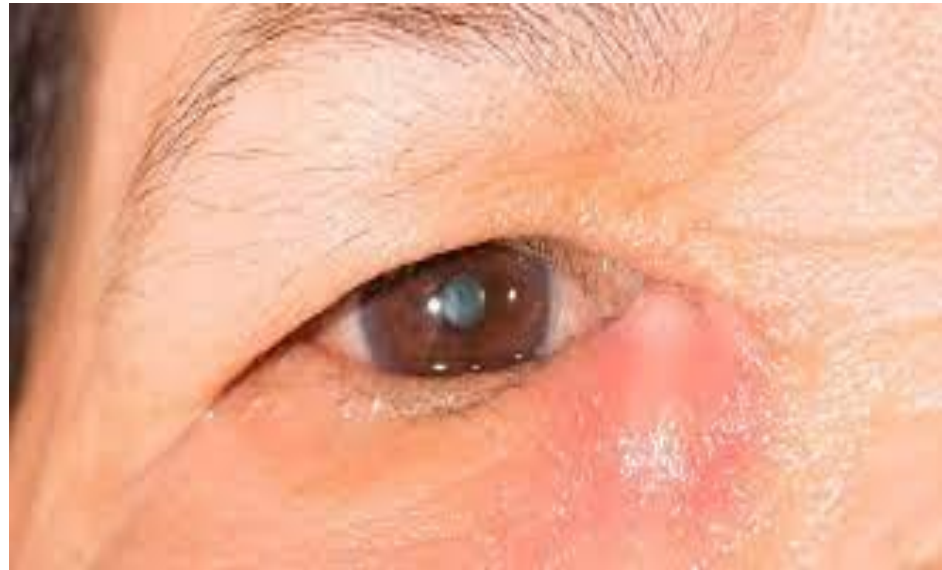
Figure 1: *involuntional punctal stenosis*



CHRONIC DACRYOCYSTITIS

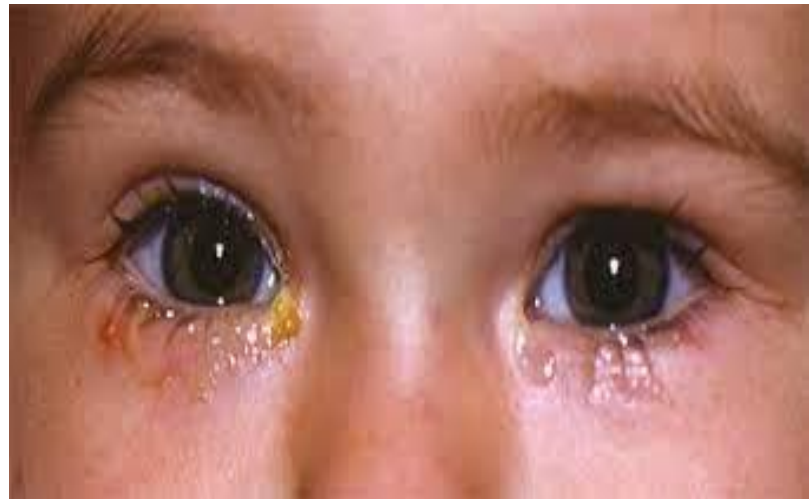- Blockage of nasolacrimal duct
- Treatment:
 - Antibiotics
 - DCR



CONGENITAL NASOLACRIMAL DUCT OBSTRUCTION

- Lacrimal massage
- Probing
- Balloon dilatation
- Closed intubation
- DCR

D/D: Cong Glaucoma



Lacrimation



EMOTIONAL STRESS

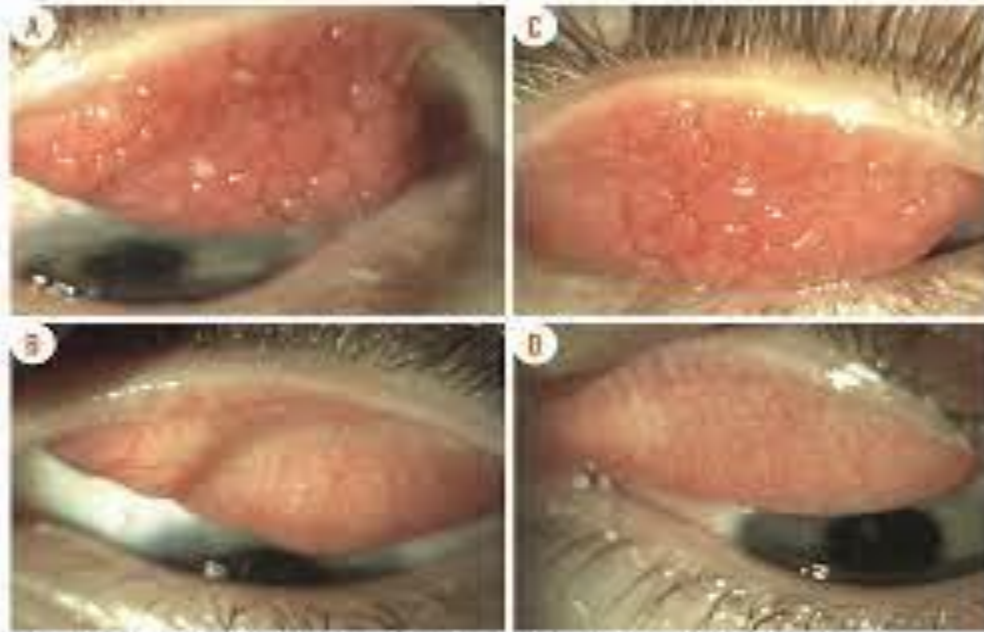


COMMON COLD



ALLERGIES

- Acute allergic reaction
- Vernal keratoconjunctivitis
- Atopic keratoconjunctivitis



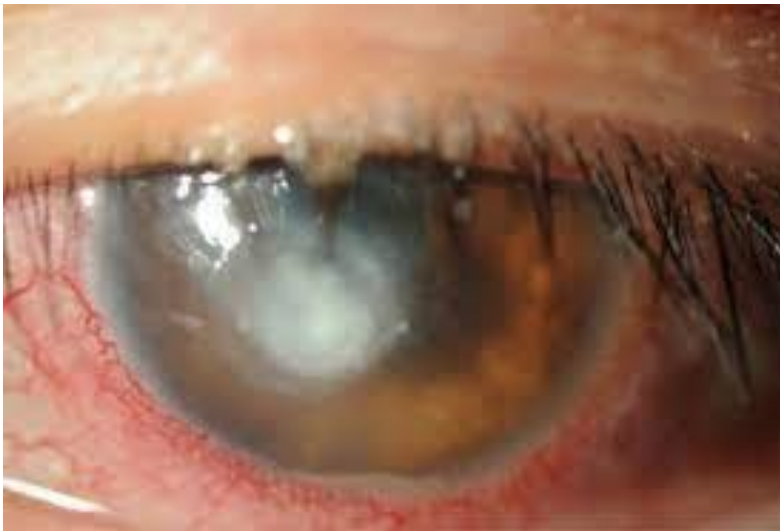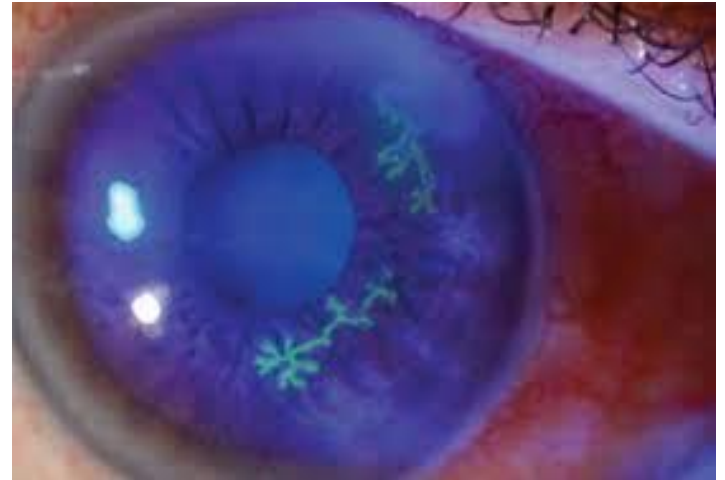Left eye before CsA (A) and after (B). Right eye before CsA (C) and after (D).

(Images courtesy of Andrea Leonard, MD)



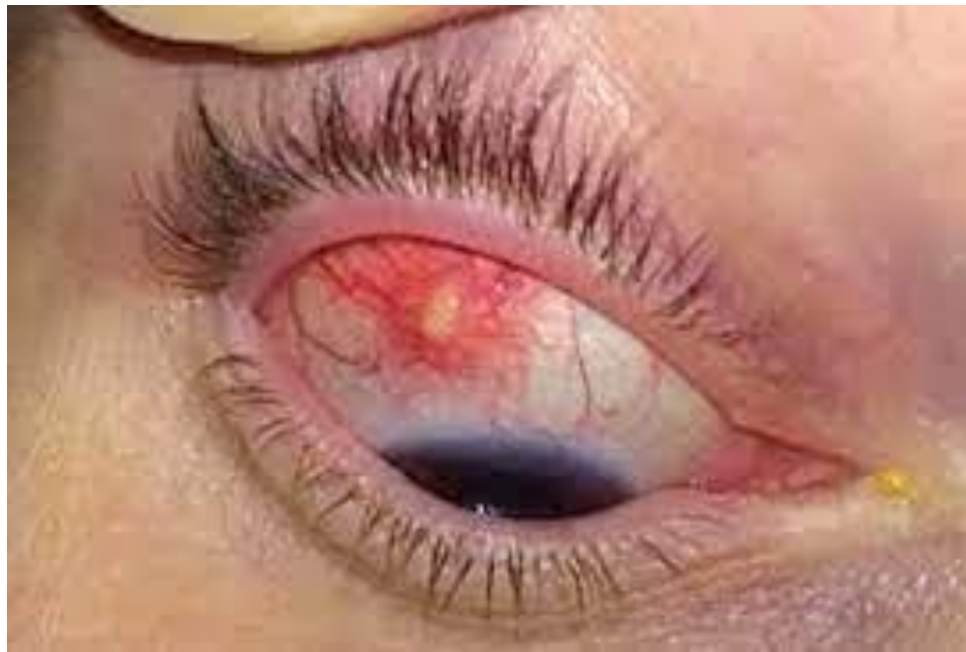INFECTIONS

- Bacterial keratitis
- Viral keratitis
- Fungal keratitis
- Conjunctivitis



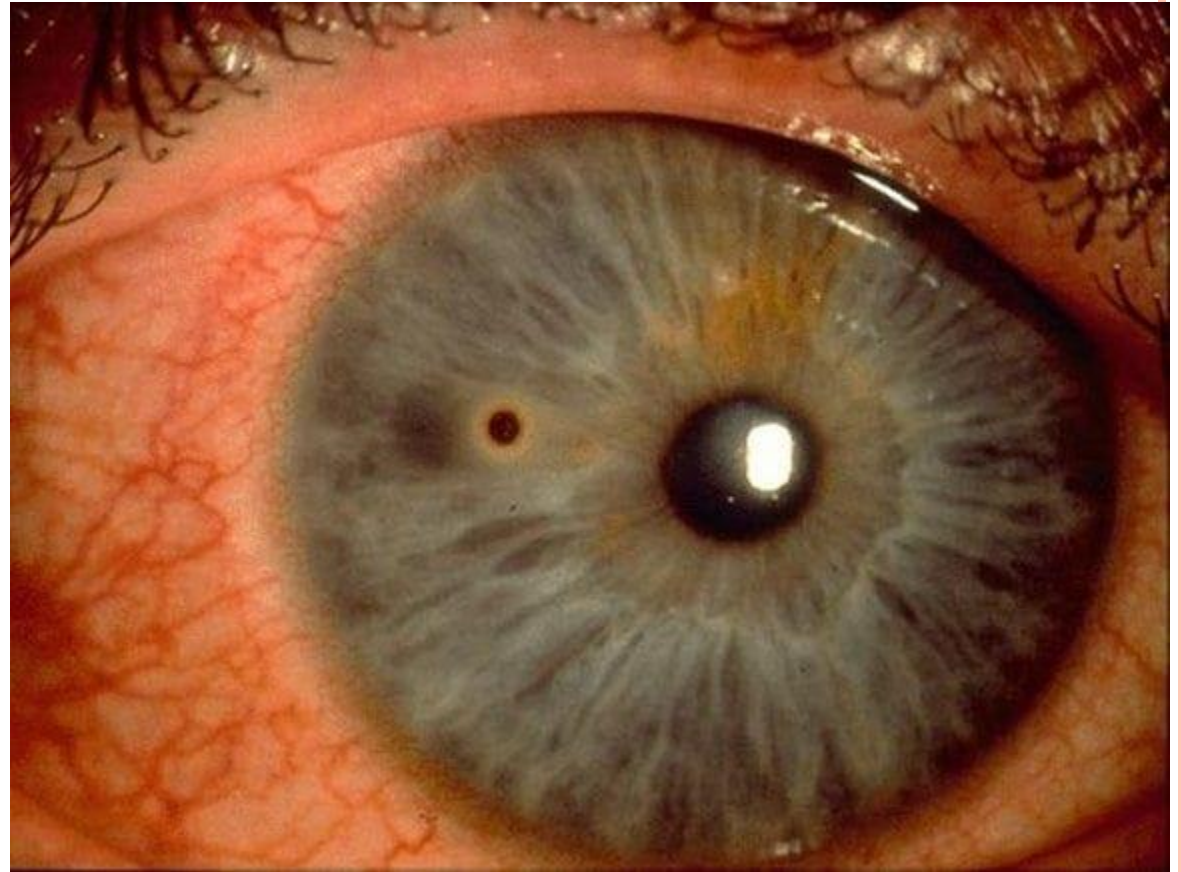
INFLAMMATION

- Scleritis
- Episcleritis
- Pinguaculitis
- Conjunctivitis



IRRITATION

- Foreign body
- Trichiasis
- Entropion
- Chemical injury



DRY EYES

- Reflex tearing
 - Keratoconjunctivitis sicca/Sjogren syndrome
 - SJS
 - Blepharitis





THANK

YOU!