



COMMON DIFFERENTIAL DIAGNOSIS OF RED EYE

CONJUNCTIVITIS VS ACUTE ANTERIOR UVIETIS VS ACUTE ANGLE CLOSURE
GLAUCOMA

00:03:37



VISION

CONJUNCTIVITIS

Good

ACUTE ANTERIOR
UVEITIS

Fair

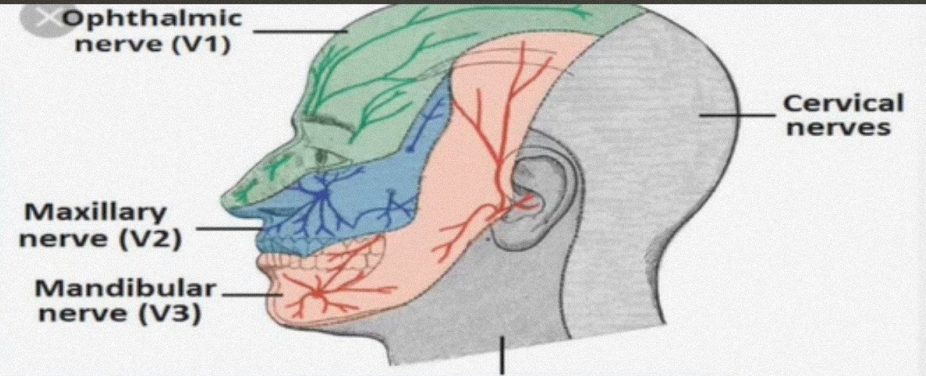
ACUTE ANGLE
CLOSURE
GLAUCOMA

Poor

00:03:53



PAIN



CONJUNCTIVITIS

ACUTE ANTERIOR
UVEITIS

ACUTE ANGLE
CLOSURE
GLAUCOMA

MILD

DISCOMFORT

MODERATE

Along the FIRST
division of the
trigeminal nerve

SEVERE

Along the entire
trigeminal nerve
area

00:04:54



SECRETIONS

CONJUNCTIVITIS	ACUTE ANTERIOR UVEITIS	ACUTE ANGLE CLOSURE GLAUCOMA
MUCOPURULENT / WATERY	WATERY	WATERY

00:05:59



PHOTOPHOBIA

CONJUNCTIVITIS	ACUTE ANTERIOR UVEITIS	ACUTE ANGLE CLOSURE GLAUCOMA
ABSENT	PRESENT	PRESENT

00:06:53



COLORED HALOES AROUND LIGHT

CONJUNCTIVITIS	ACUTE ANTERIOR UVEITIS	ACUTE ANGLE CLOSURE GLAUCOMA
-	-	+



00:07:16

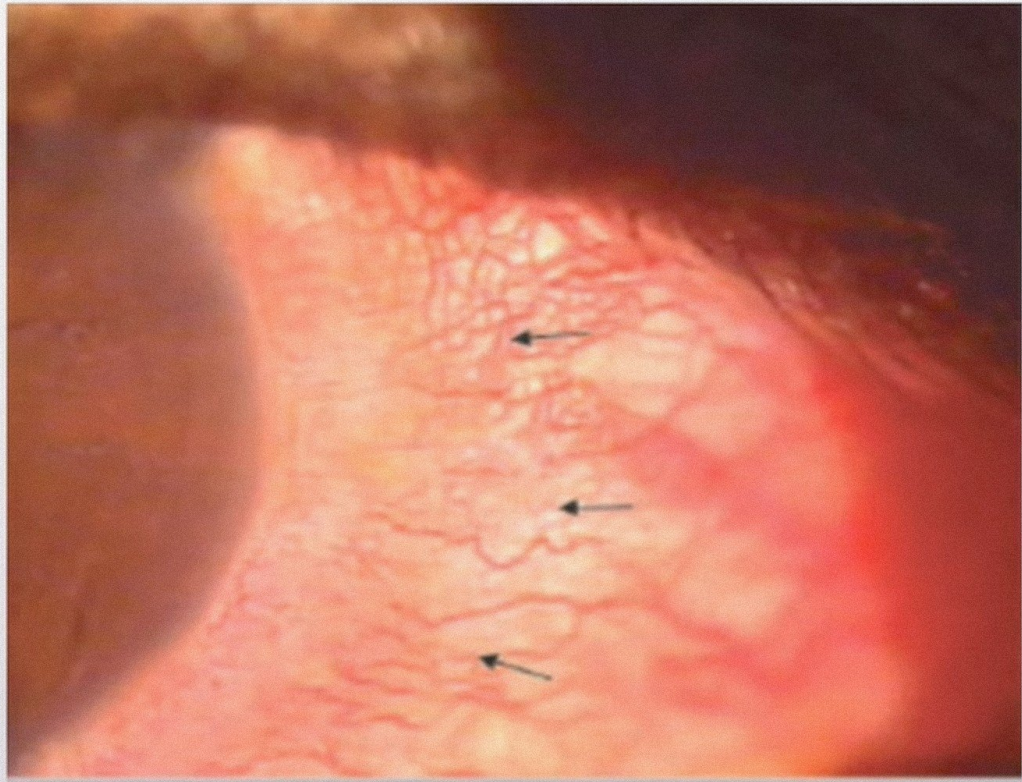
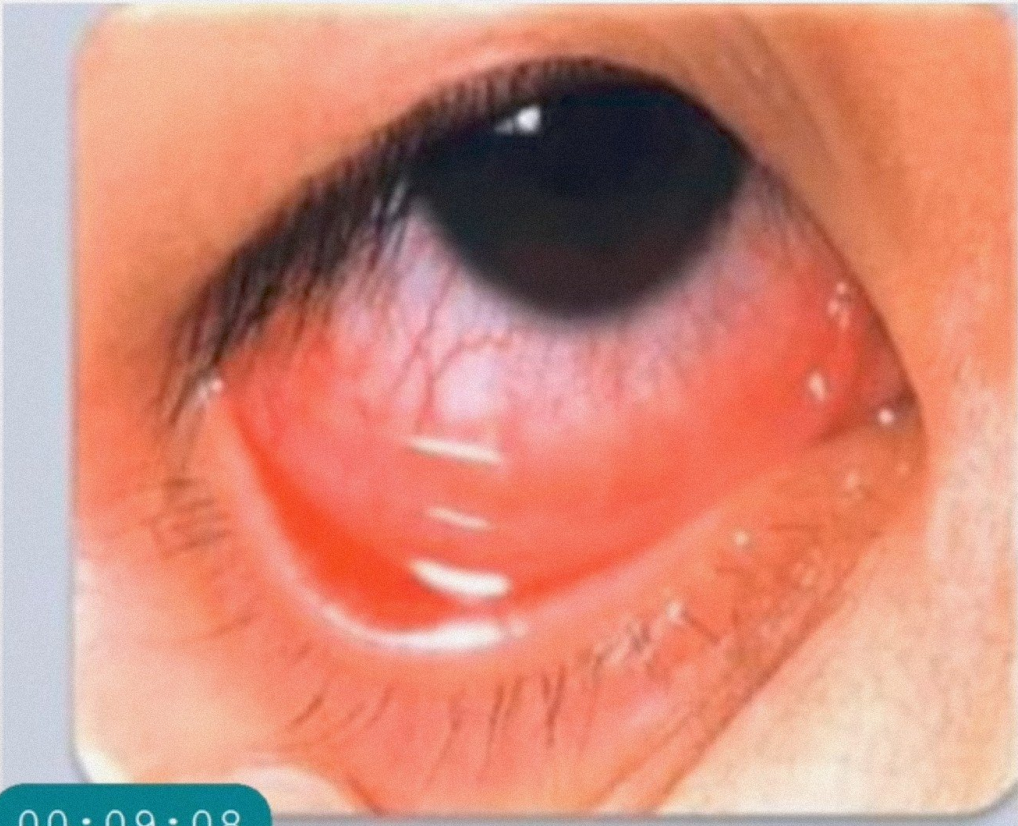


TYPE OF CONGESTION

CONJUNCTIVITIS	ACUTE ANTERIOR UVEITIS	ACUTE ANGLE CLOSURE GLAUCOMA
SUPERFICIAL	DEEP CILIARY(CCC)	DEEP CILIARY (CCC)

00:08:10





00:09:08



TYPES OF CONGESTION

Superficial congestion

- Maximum at fornix , fade towards limbus.
- COLOR :- **BRIGHT RED**
- VESSEL INVOLVED :- Superficial Vessels (Anterior and posterior)

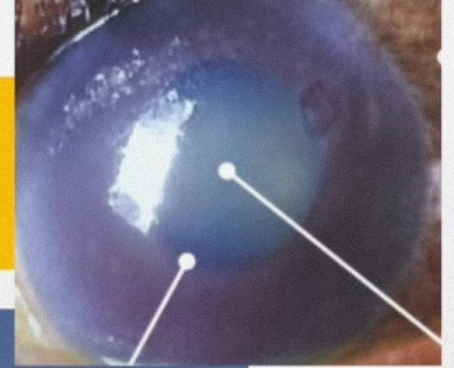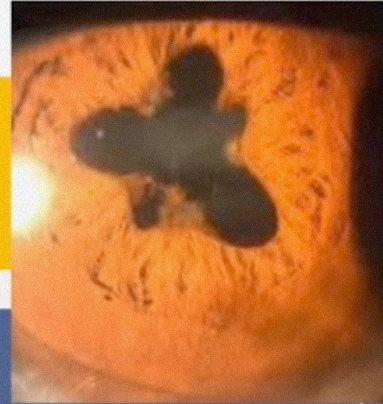
Deep ciliary congestion

- MAXIMUM at limbus, fades towards the fornix.
- COLOR :- **PINKISH HUE**
- VESSEL INVOLVED :- Deep Anterior Ciliary vessels

00:10:06



PUPIL



CONJUNCTIVITIS

ACUTE ANTERIOR
UVEITIS

ACUTE ANGLE
CLOSURE
GLAUCOMA

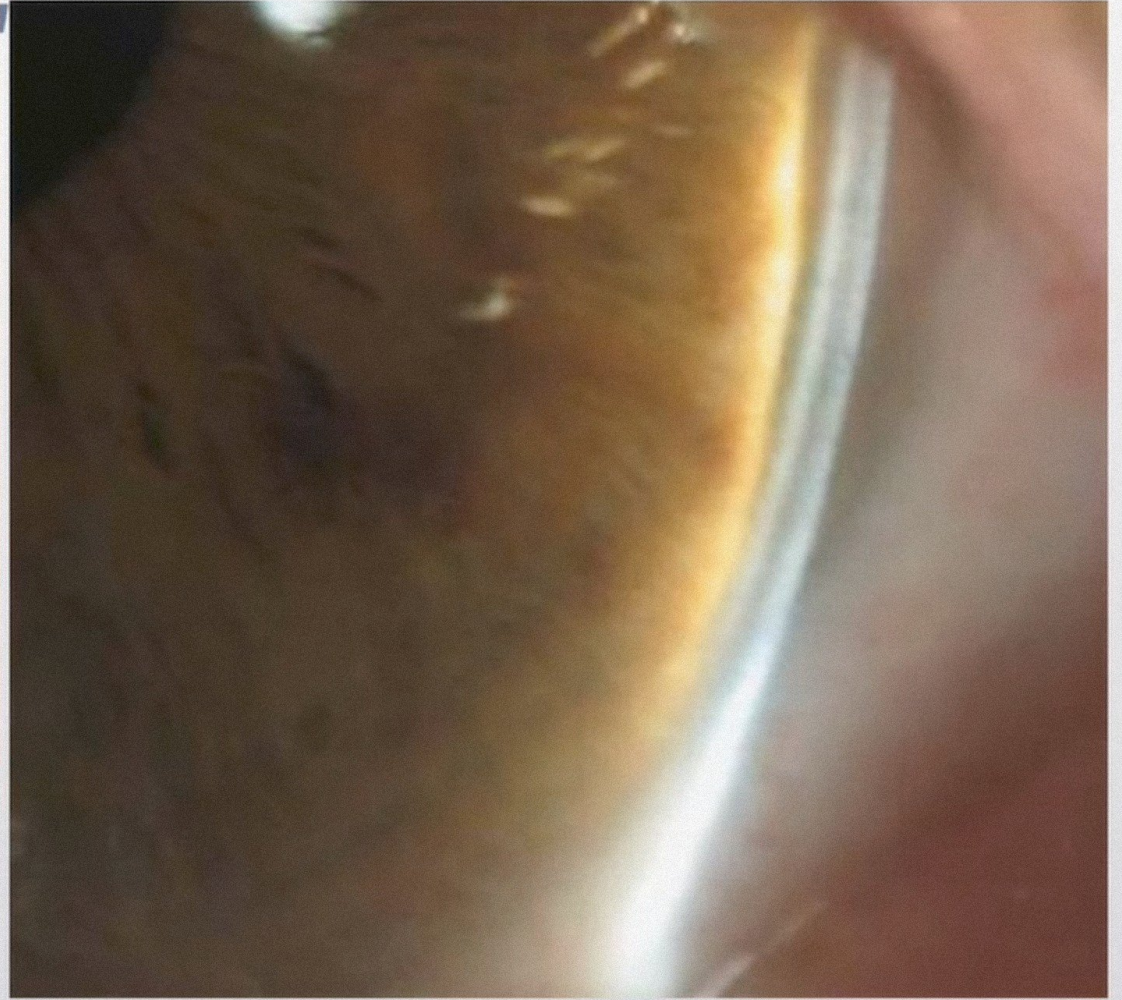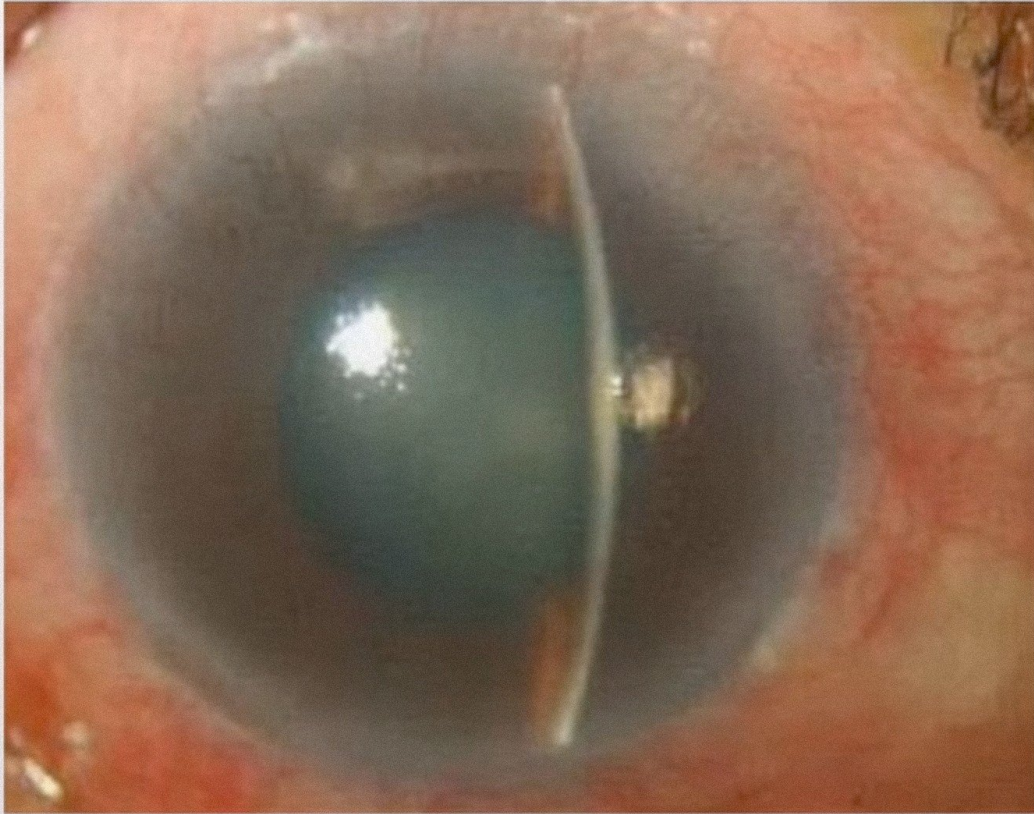
NORMAL

SMALL &
irregular

Large / Middilated
Vertically Oval

00:11:28



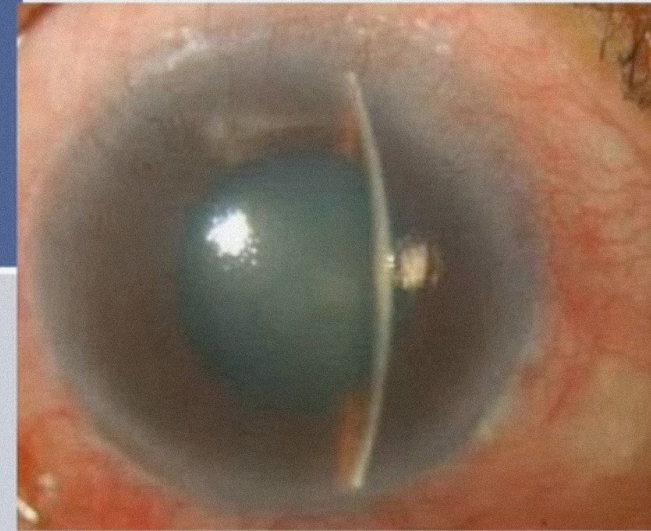


00:12:49



DEPTH OF THE ANTERIOR CHAMBER

CONJUNCTIVITIS	ACUTE ANTERIOR UVEITIS	ACUTE ANGLE CLOSURE GLAUCOMA
NORMAL	NORMAL	Shallow



00:13:16



TENDERNESS

CONJUNCTIVITIS

-

ACUTE ANTERIOR
UVEITIS

+

ACUTE ANGLE
CLOSURE
GLAUCOMA

++

00:13:45



INTRAOCULAR PRESSURE

CONJUNCTIVITIS

NORMAL

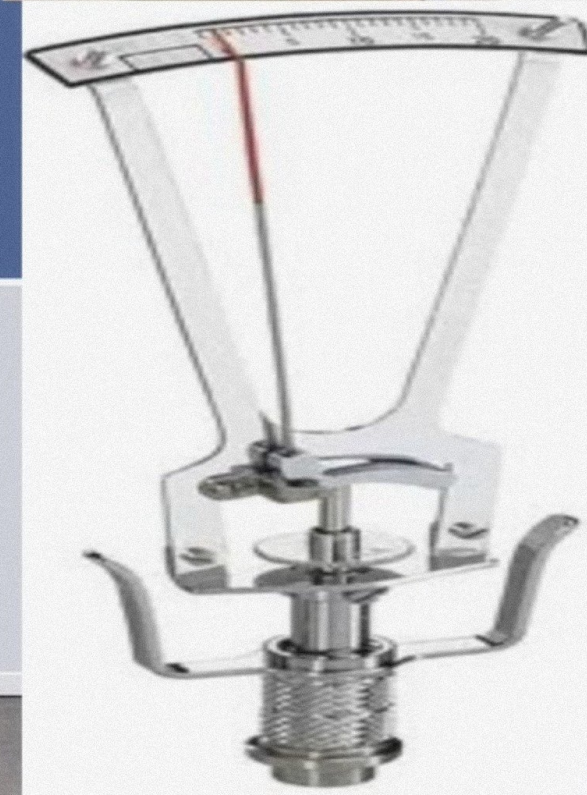

ACUTE
ANTERIOR
UVEITIS

*NORMAL/
RAISED/
LOW*

ACUTE ANGLE
CLOSURE
GLAUCOMA

RAISED

00:13:56



SYSTEMIC ASSOCIATIONS

CONJUNCTIVITIS	ACUTE ANTERIOR UVEITIS	ACUTE ANGLE CLOSURE GLAUCOMA
Absent	Referred pain	Prostration & Vomiting

00:15:12



TABLE 9.3 Differential Diagnosis of the Common Causes of a Red Eye

Clinical Features	Conjunctivitis	Acute Anterior Uveitis	Acute Angle-closure Glaucoma
Onset	Acute	Rapid, over a few days	Sudden
Vision	Good	Fair	Poor
Pain	Mild discomfort	Moderate in the eye and along the first division of the trigeminal nerve in iritis	Severe pain in the eye and entire trigeminal area
Secretion	Mucopurulent	Watery	Watery
Photophobia	Absent	Usually present	Usually absent
Coloured halos around lights	Absent	Usually absent	Commonly present
Conjunctival congestion	Superficial	Deep ciliary	Deep ciliary
Pupil	Normal	Small and irregular	Large and vertically oval
Tenderness	Absent	Present	Present
Depth of the anterior chamber	Normal	Normal	Shallow
Intraocular pressure	Normal	Usually normal but may be raised, sometimes low	Raised
Systemic symptoms	Absent	Referred pain	Prostration and occasional vomiting

00:15:25