

# 4 CLASSIFICATIONS OF HYPERTENSIVE RETINOPATHY

00:00:18



# MODIFIED SCHEIE CLASSIFICATION

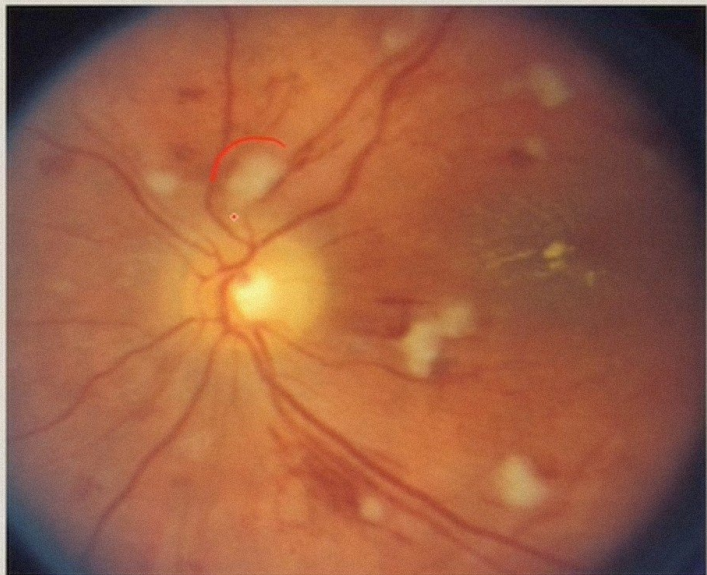
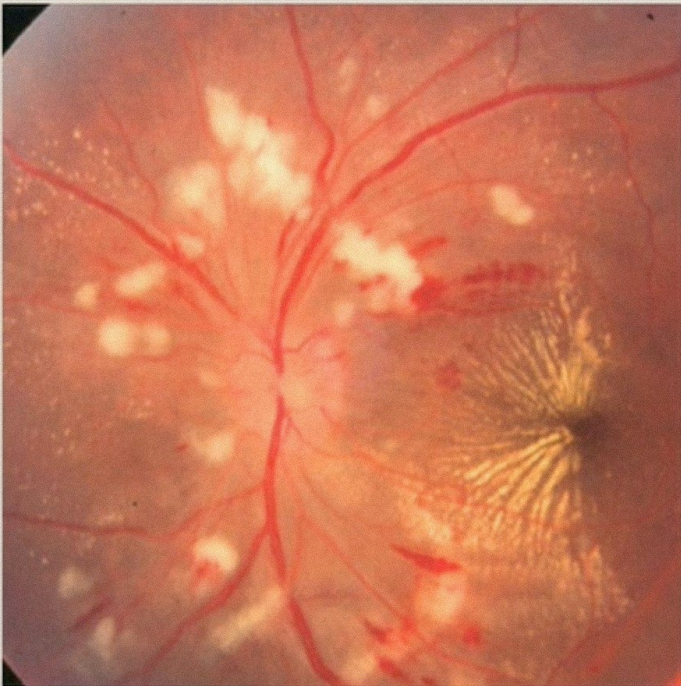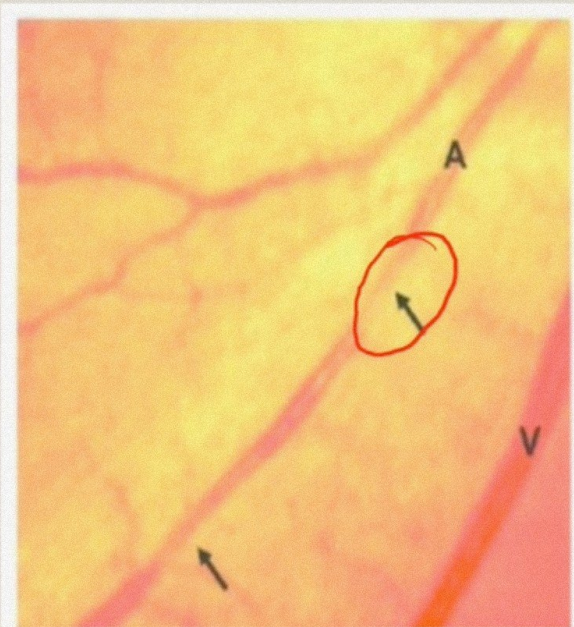
- **Grade 1:** Barely detectable arterial narrowing
- **Grade 2:** Obvious arterial narrowing with focal irregularities
- **Grade 3:** Grade 2 plus retinal haemorrhages, exudates, cotton wool spots,
- **Grade 4:** Grade 3 plus papilledema

00:00:45



ACUTE/  
MALIGNANT  
HYPERTENSION





00:02:10



# SCHEIE CLASSIFICATION

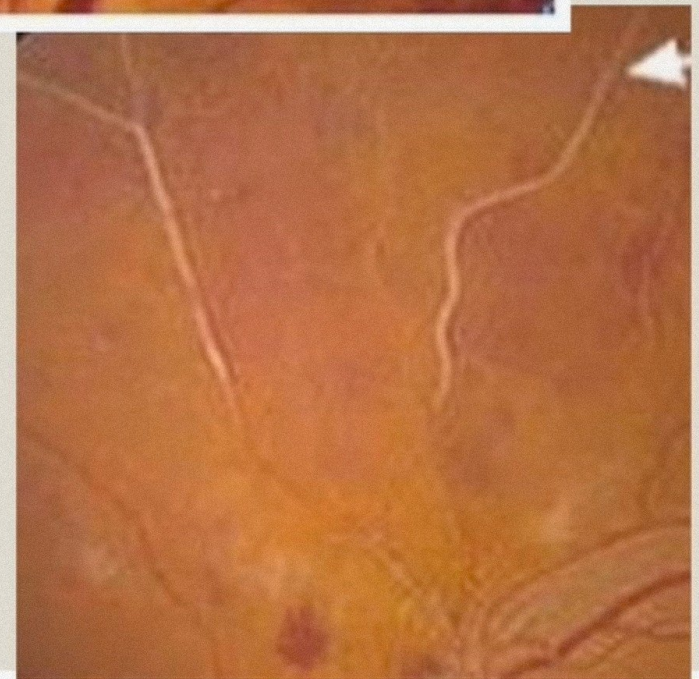
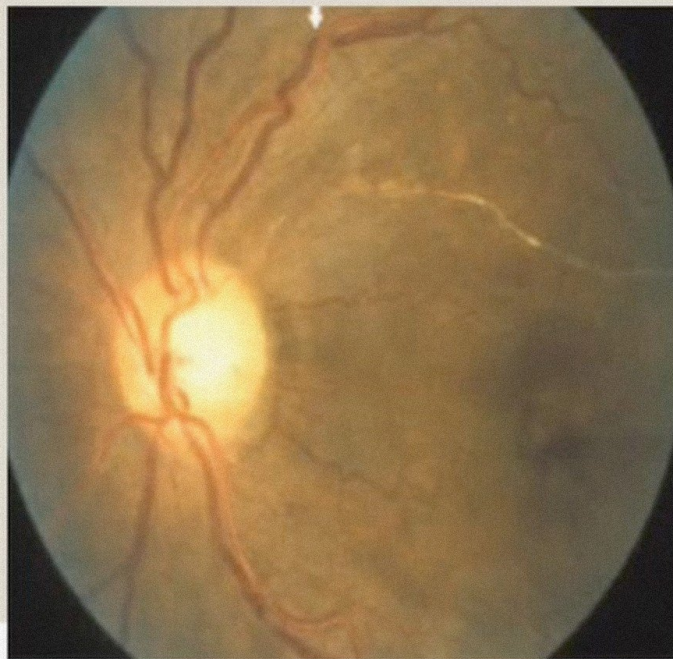
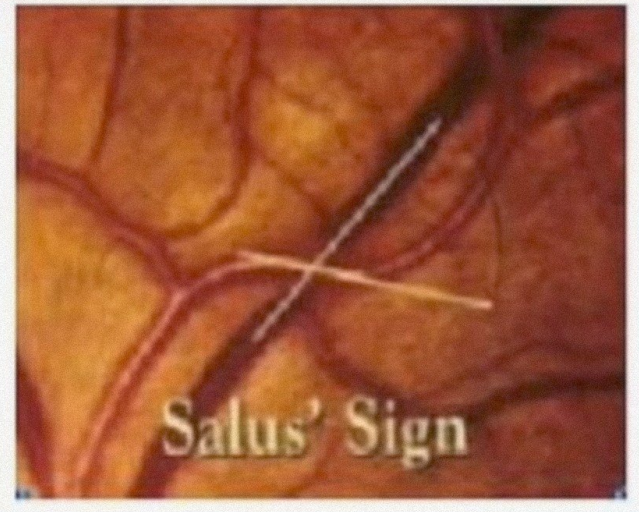

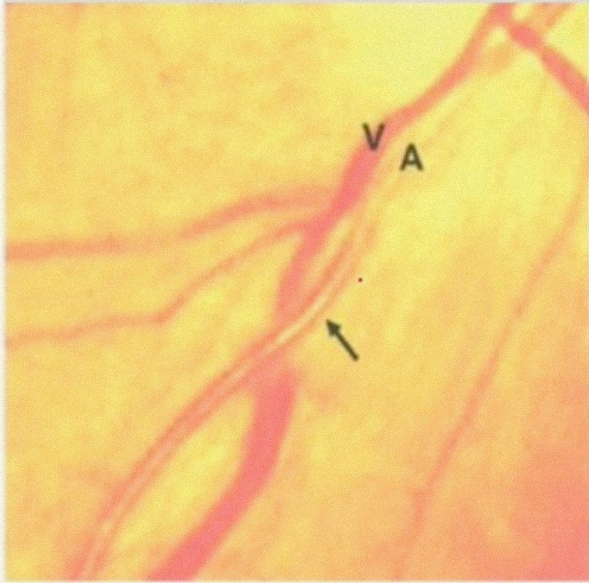
- **Stage 1:** widening of the arteriole light reflex
- **stage 2:** stage 1 + arteriovenous crossing sign
- **stage 3:** copper wiring of arterioles (copper coloured arteriole light reflex)
- **stage 4:** silver wiring of arterioles (silver coloured arteriole light reflex).

00:02:35



CHRONIC  
HYPERTENSION





00:04:22



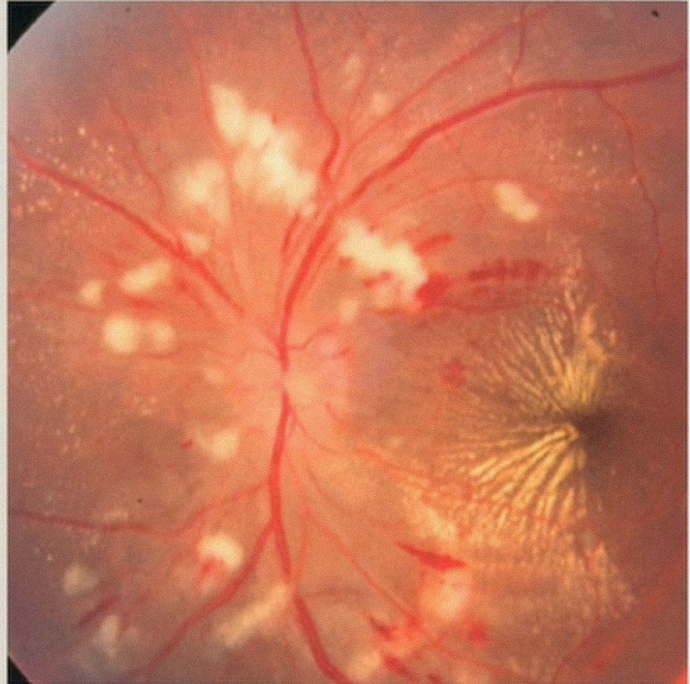
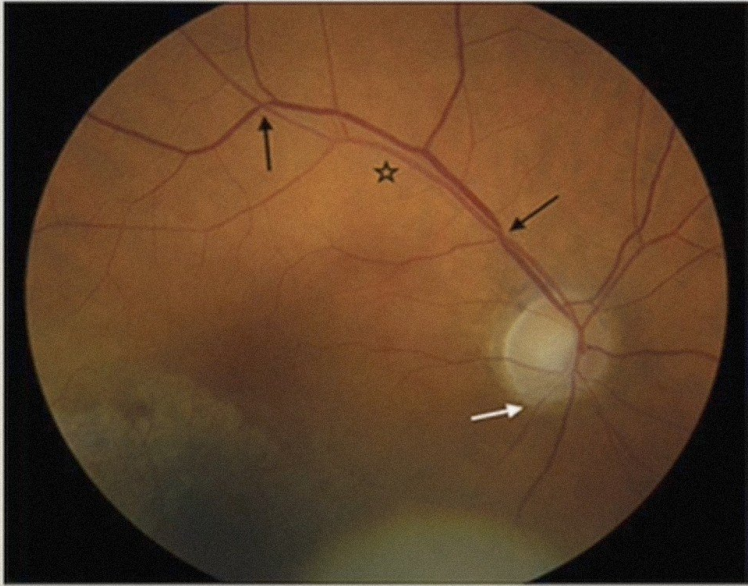
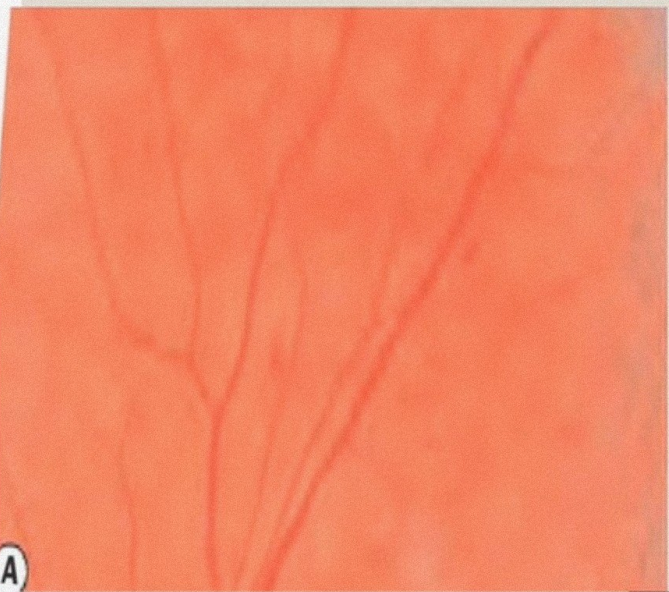
# KEITH-WAGNER-BARKER CLASSIFICATION

*Acute  
+  
Chronic  
H.*

- **GRADE 1:** Mild, generalized constriction of retinal arterioles
- **GRADE 2:** Definite focal narrowing of retinal arterioles + AV nicking, widening of arteriole reflex
- **GRADE 3:** Grade 2 + flame-shaped haemorrhages + cotton-wool spots + hard exudates
- **GRADE 4:** Severe Grade 3 retinopathy + papilledema

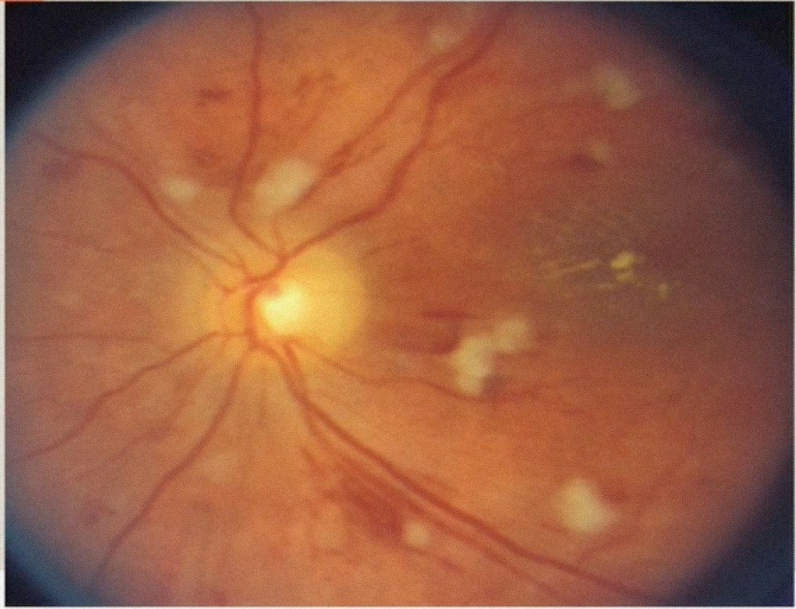
00:05:22 retinal oedema





A

00:06:34



# WONG AND MITCHELL ( 2004)

|            |   |
|------------|---|
| Mild       | One or more of the following signs: generalized arteriolar narrowing, focal arteriolar narrowing, AV nicking, arteriolar wall opacity (silver-wiring)       |
| Moderate   | Mild retinopathy with one or more of the following signs: retinal haemorrhages (blot, dot or flame-shaped), microaneurysms, cotton-wool spot, hard exudates |
| 00:07:21 d | Moderate retinopathy signs plus optic disk swelling; may be associated with visual loss   |





## Systemic associations

MILD

Weak associations with stroke, coronary heart disease and cardiovascular mortality

MODERATE

Strong association with stroke, congestive heart failure, renal dysfunction and cardiovascular mortality

SEVERE

Associated with mortality and renal failure

00:08:39

