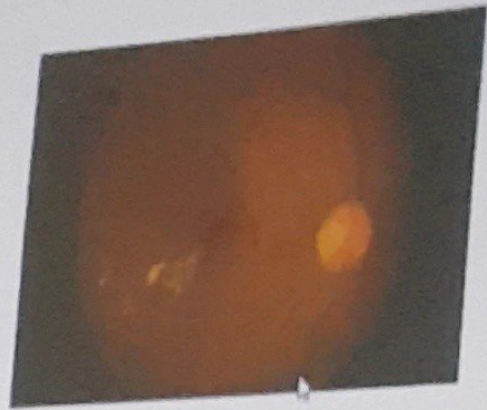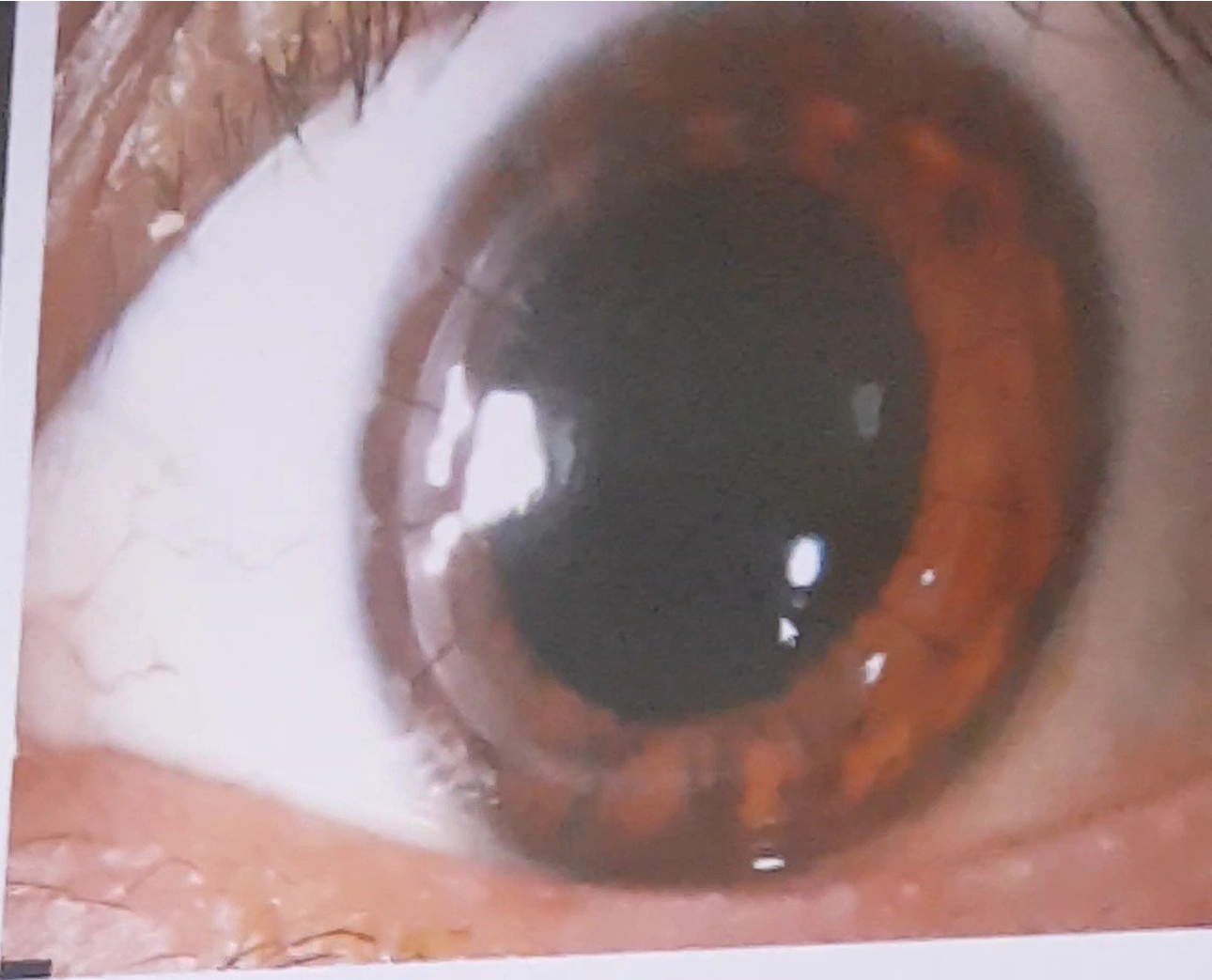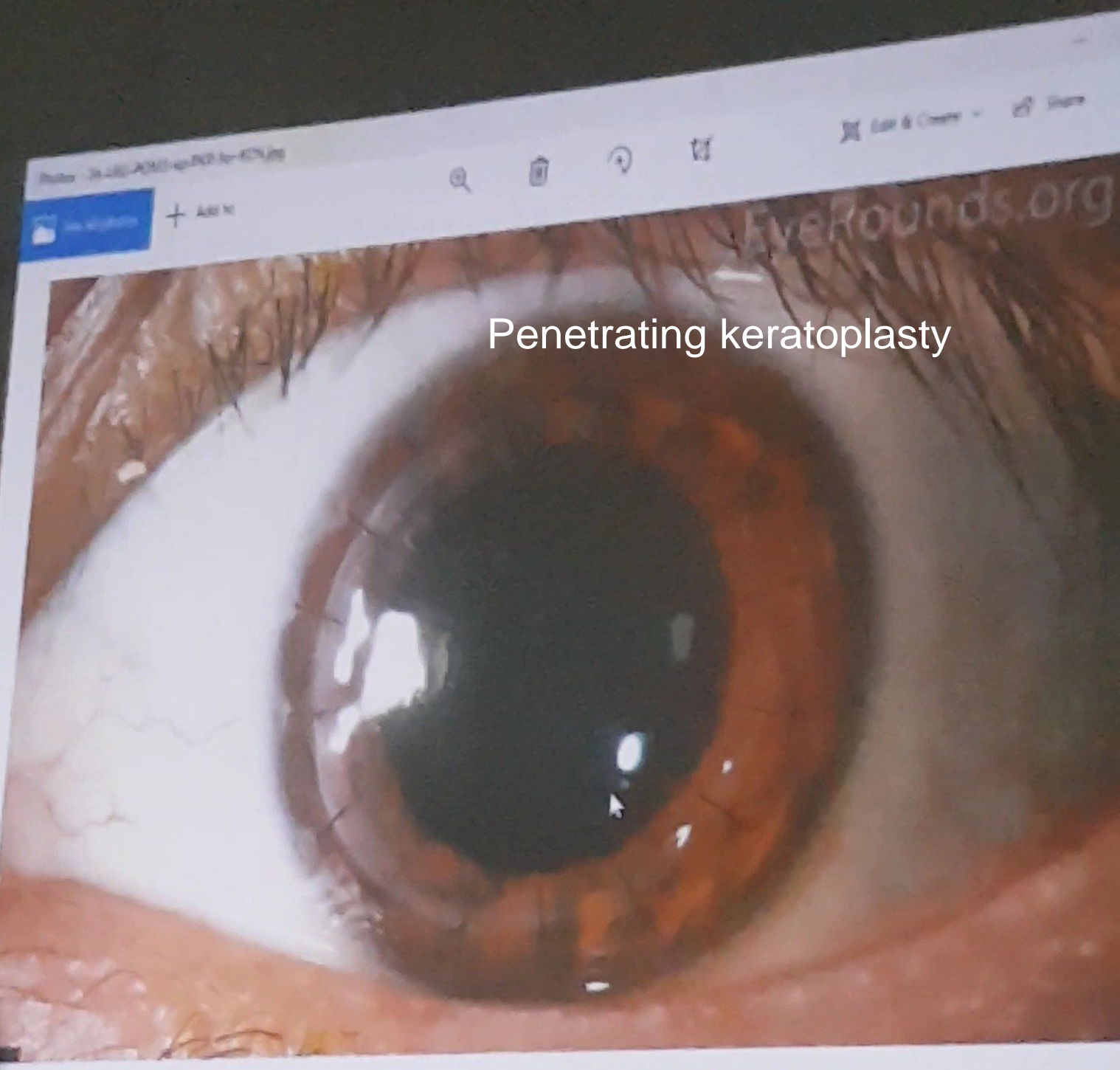




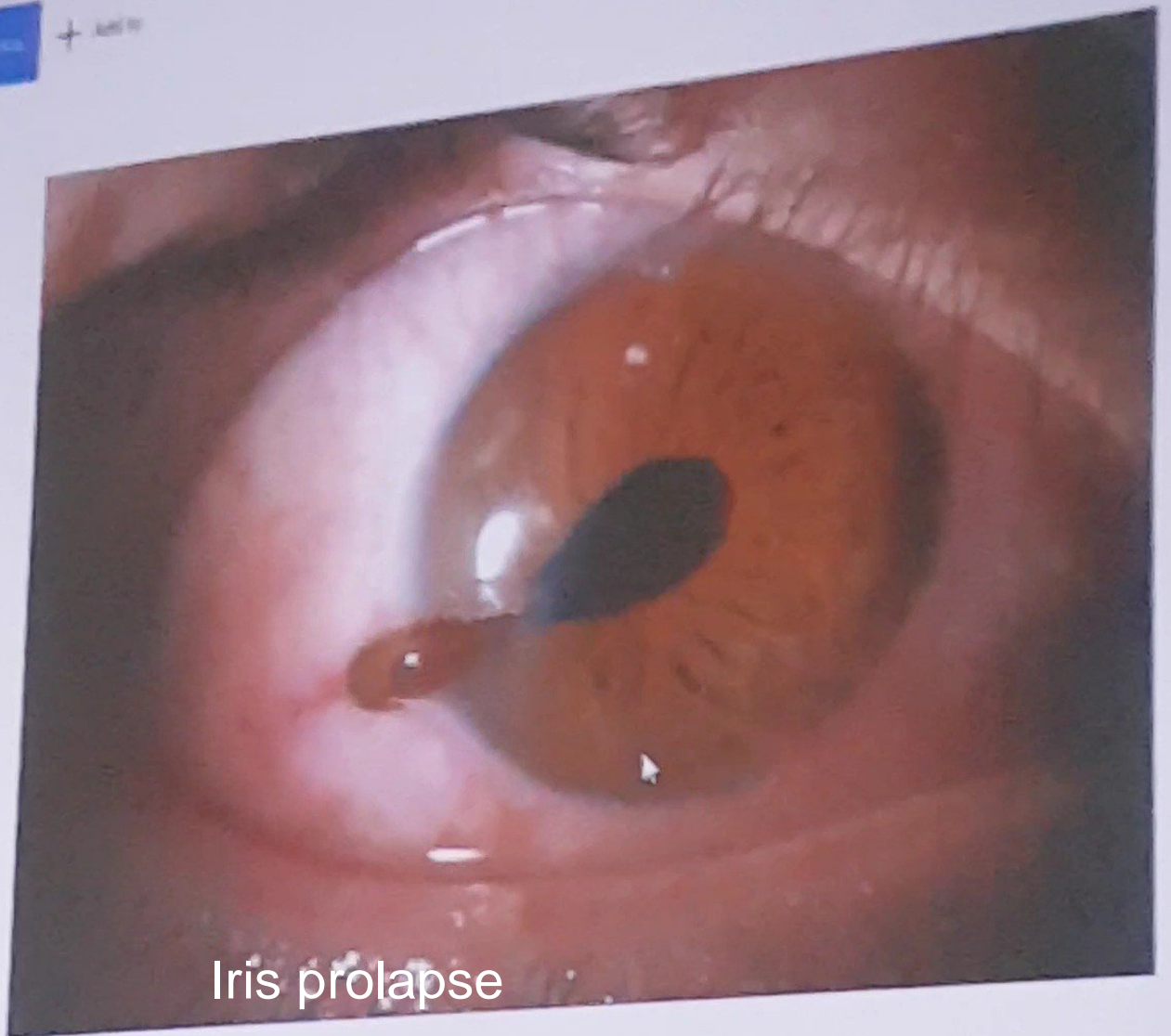Penetrating keratoplasty




Penetrating keratoplasty

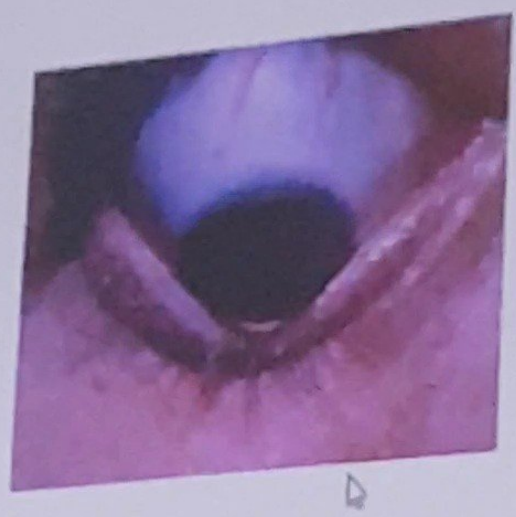
EyeRounds.org



Iris prolapse



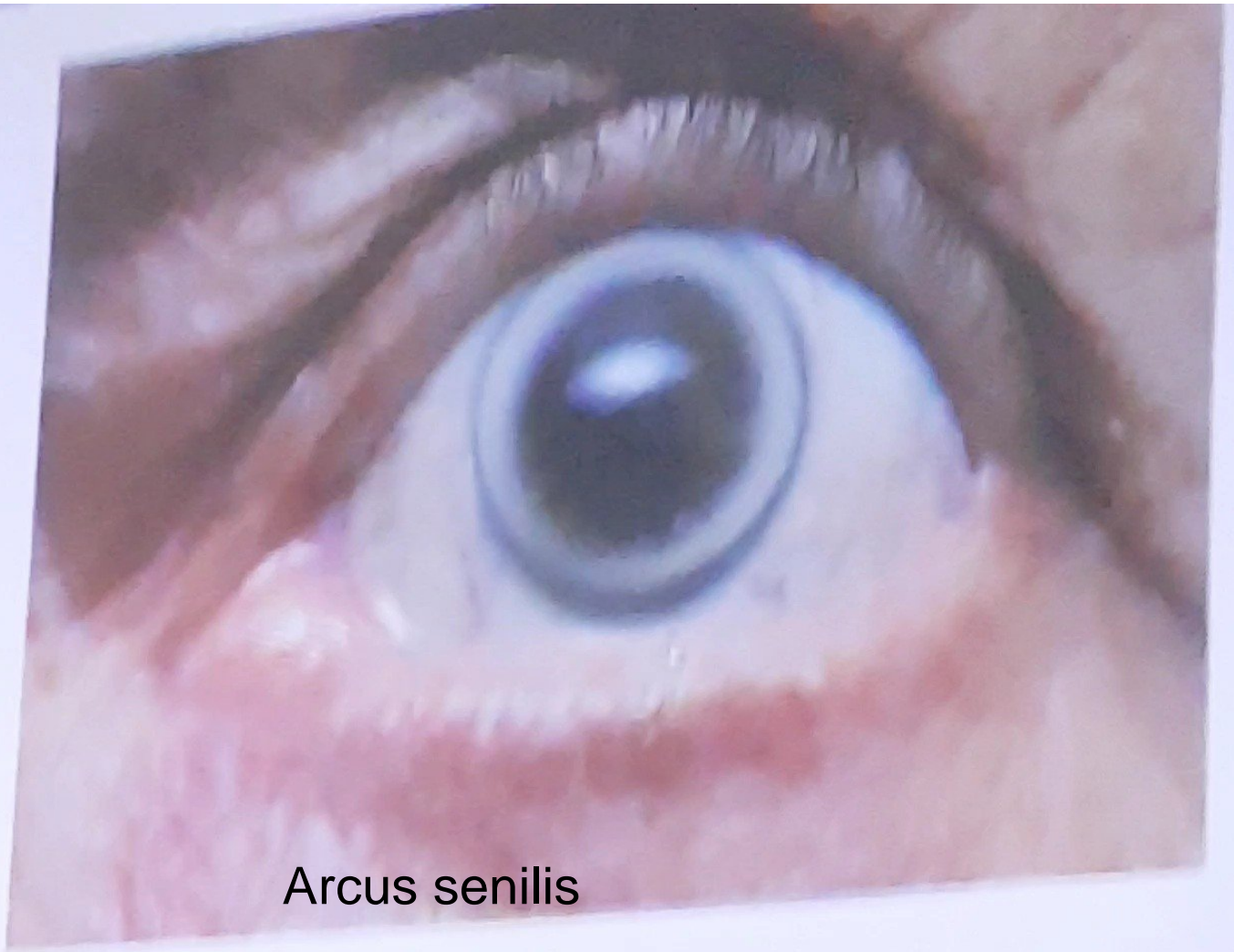Right exotropia



Keratoconus munson sign

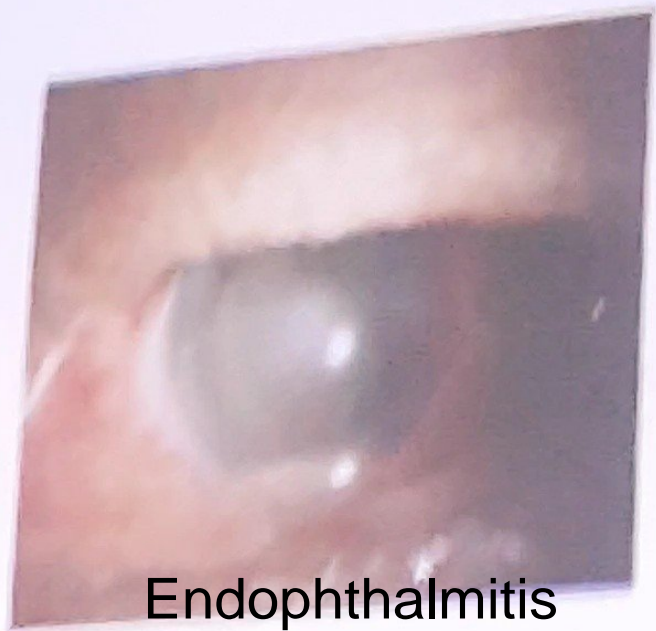

Left esotropia



Arcus senilis






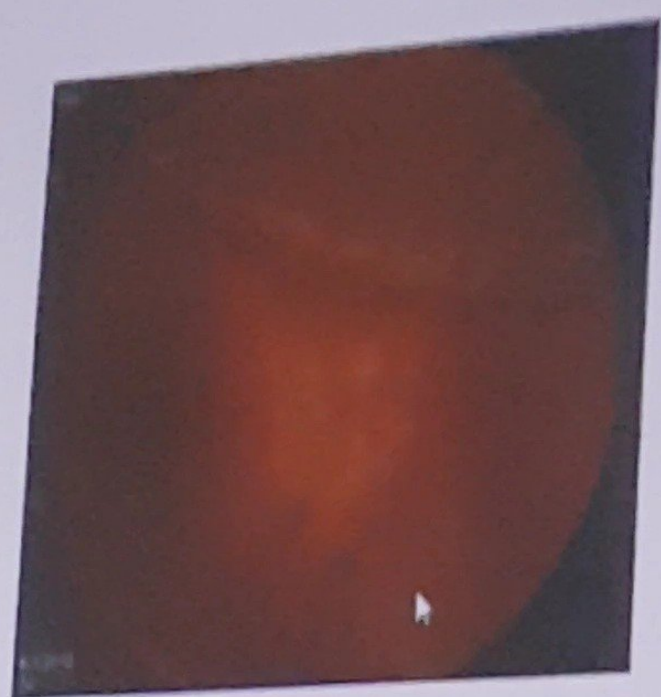
Endophthalmitis

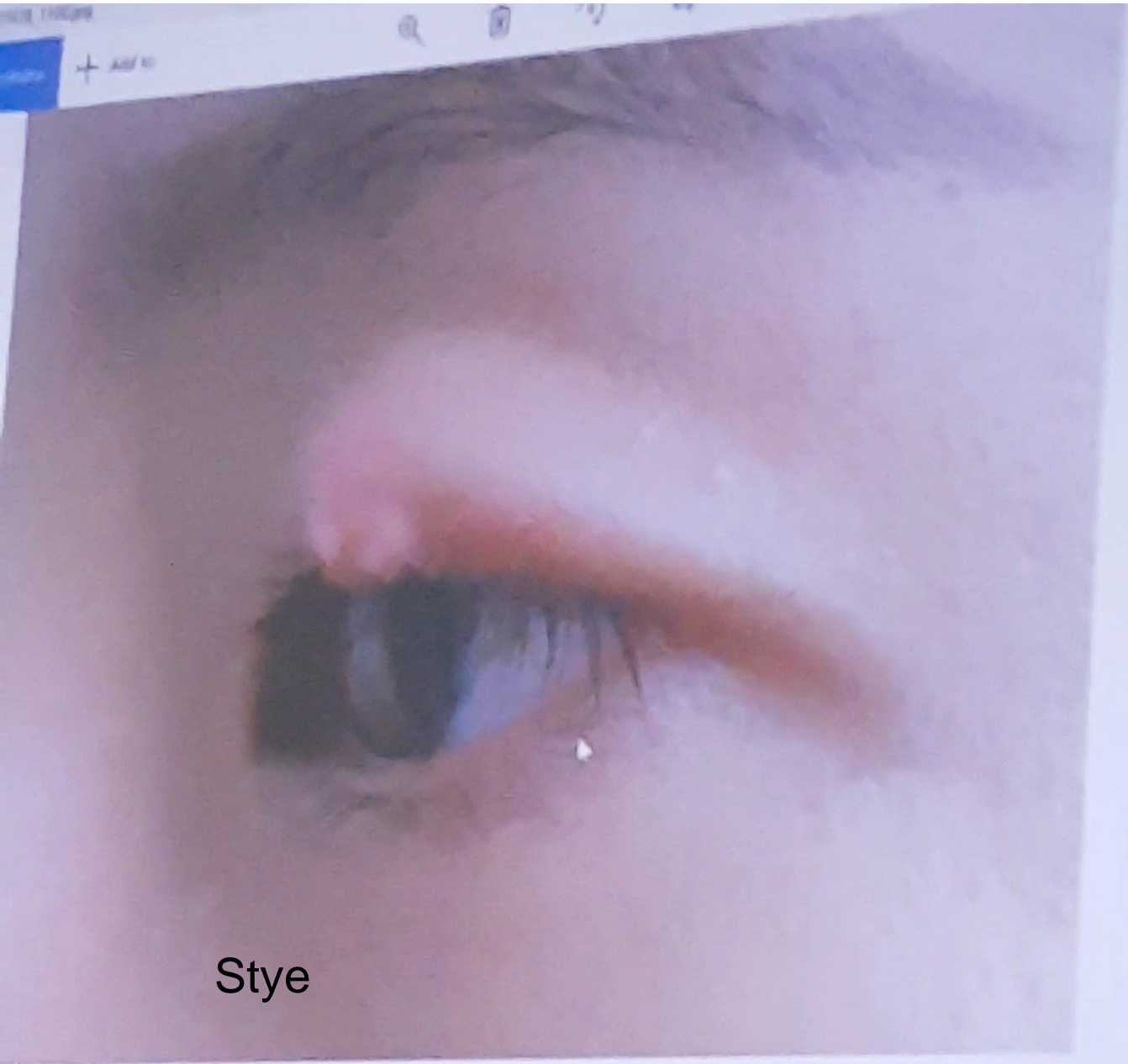Blank - 8/26/2023

Blank - 8/26/2023 + Add to



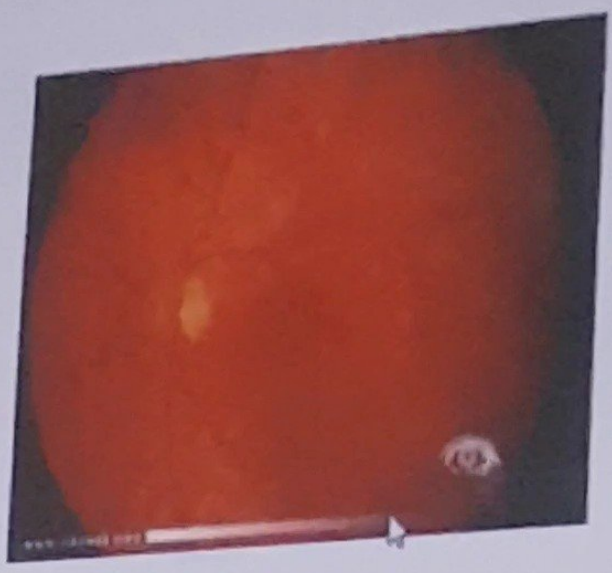Blank & Co. - Share

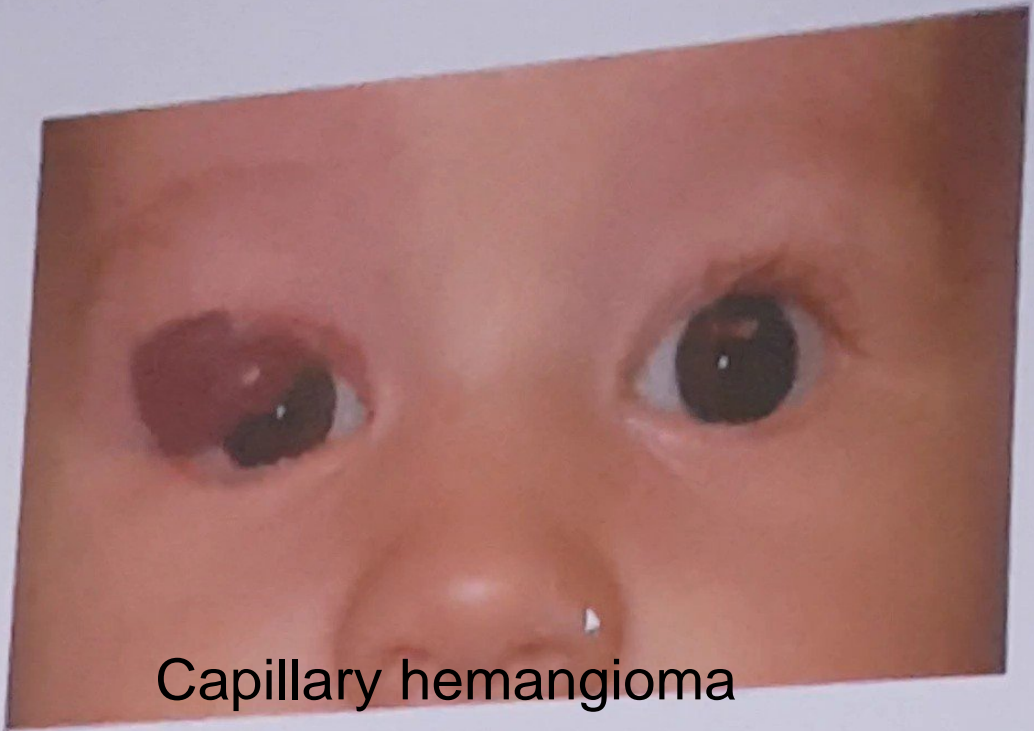



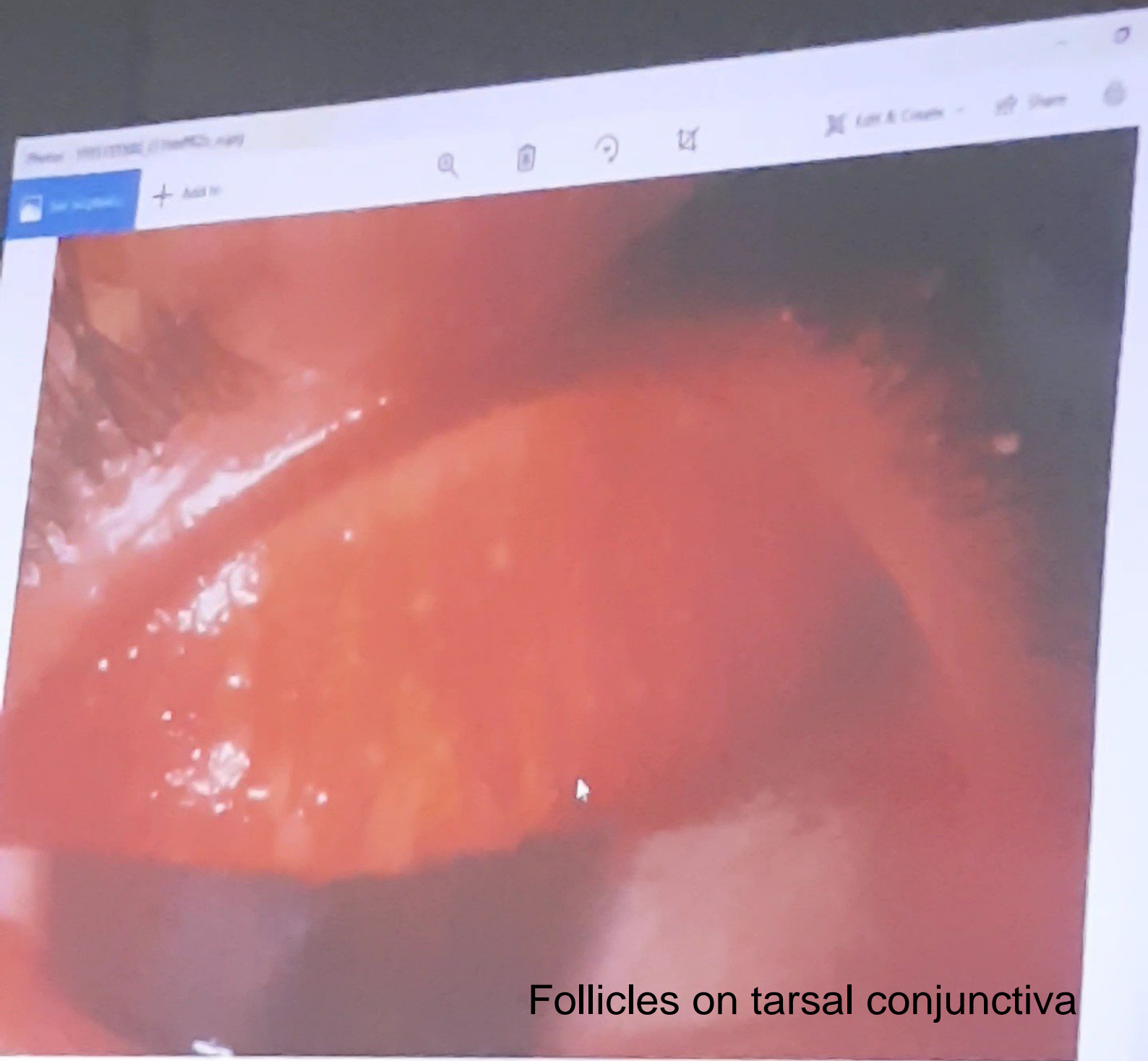Stye



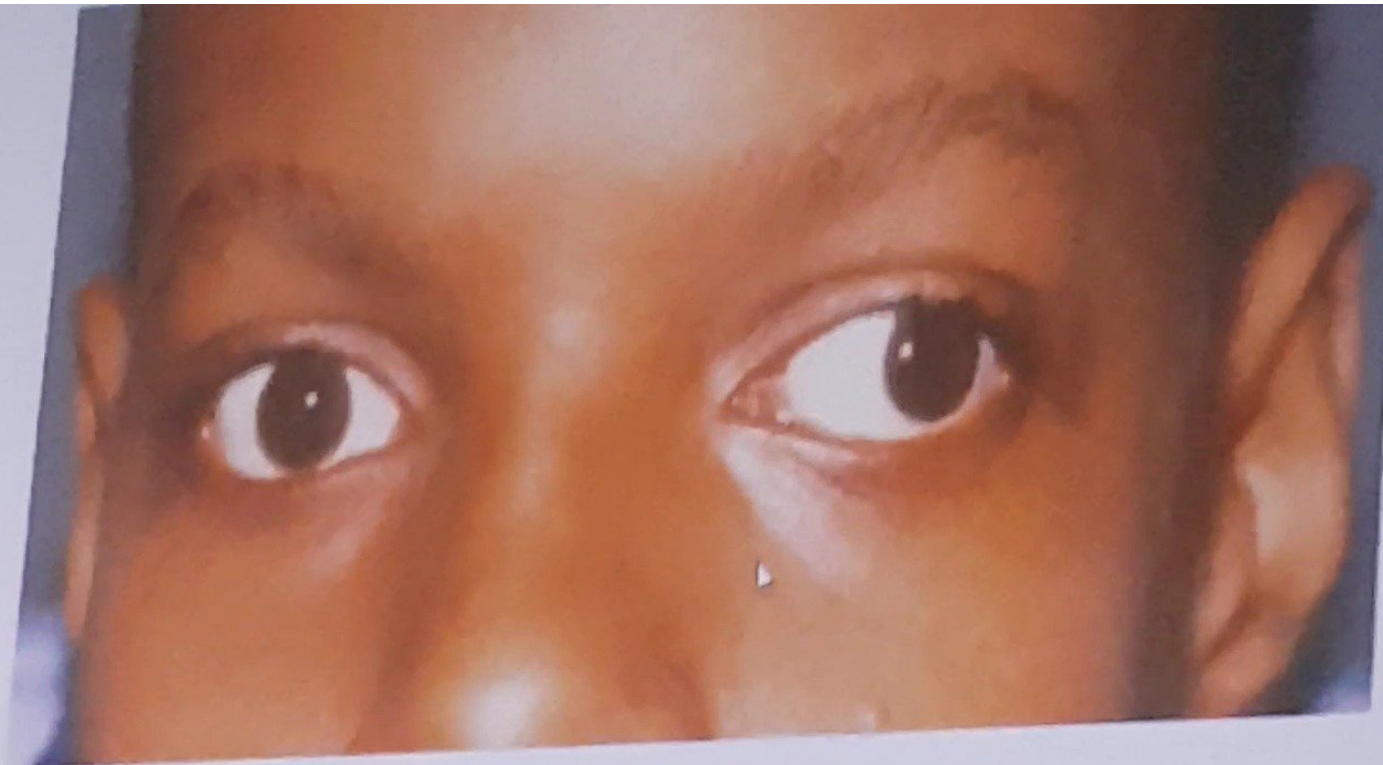



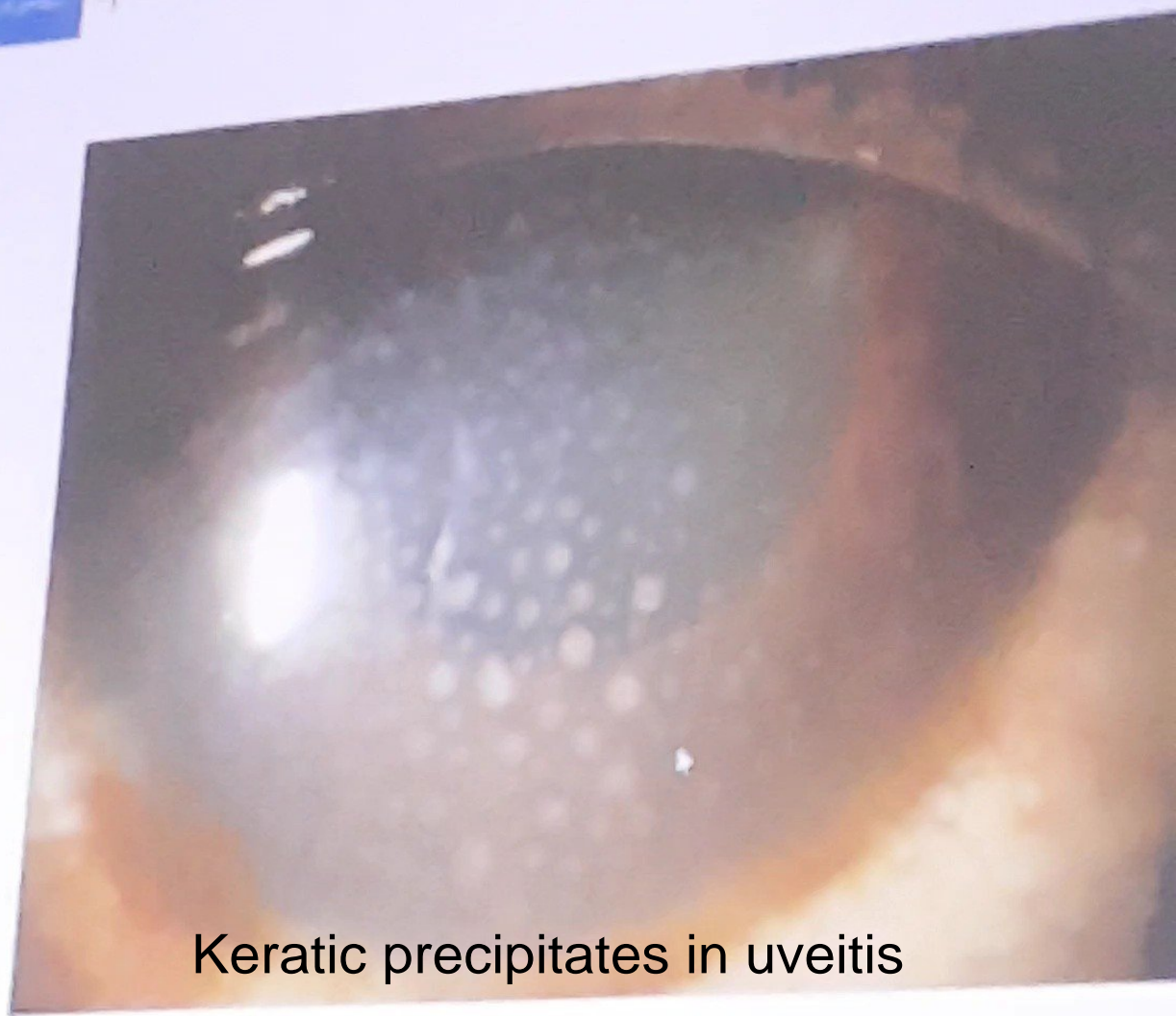
Capillary hemangioma



Follicles on tarsal conjunctiva

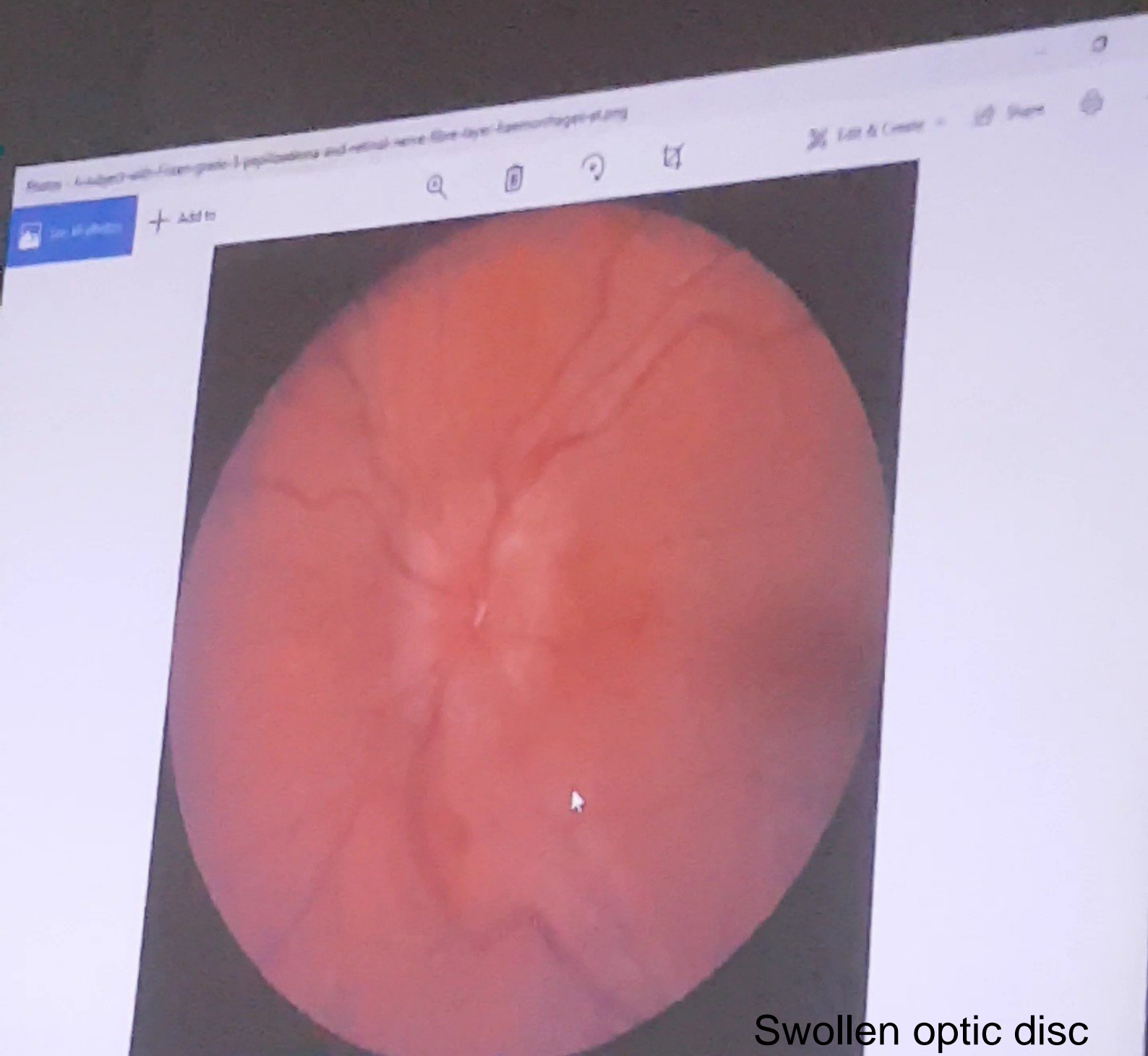


Left exotropia

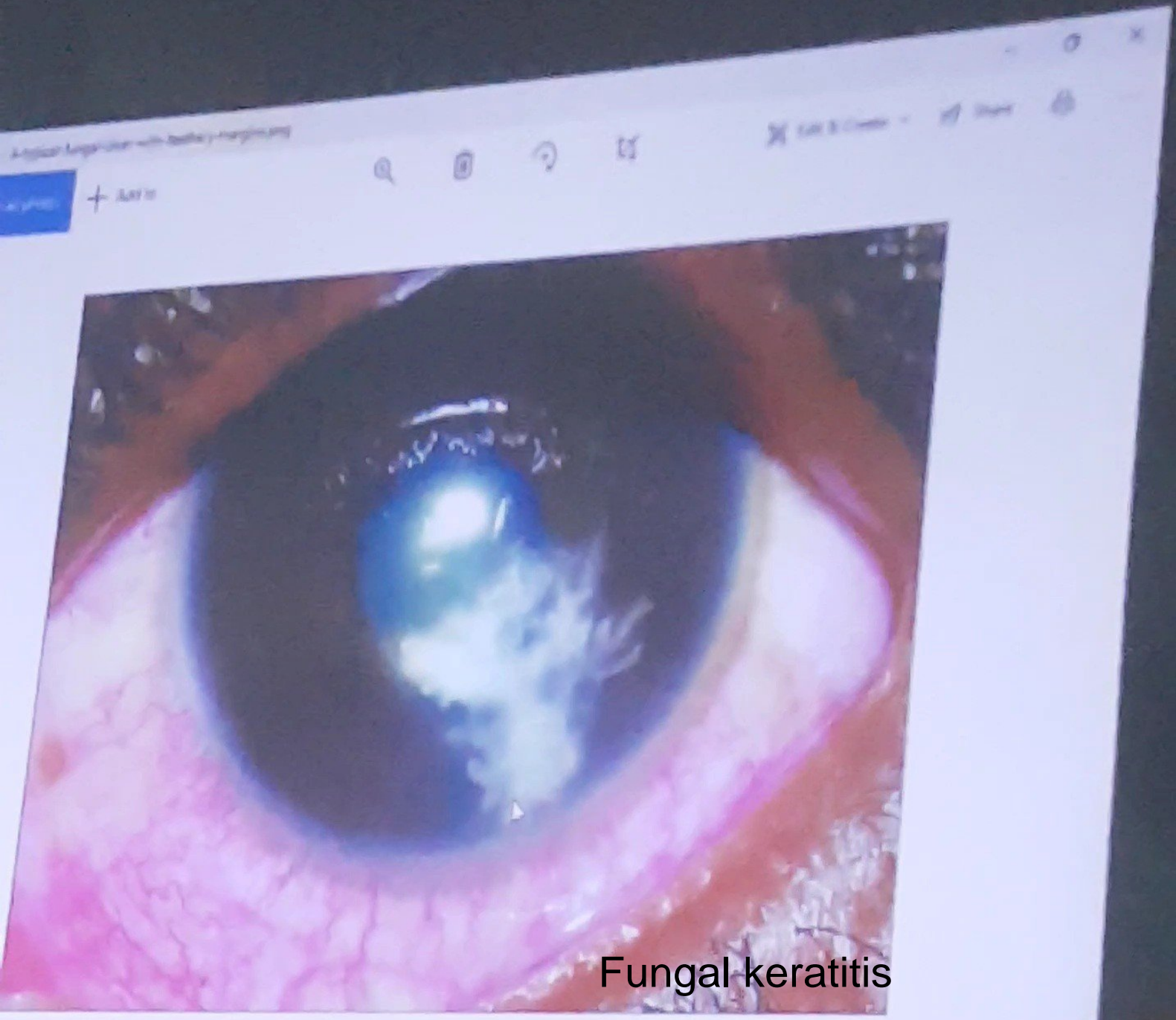

Keratic precipitates in uveitis





Swollen optic disc

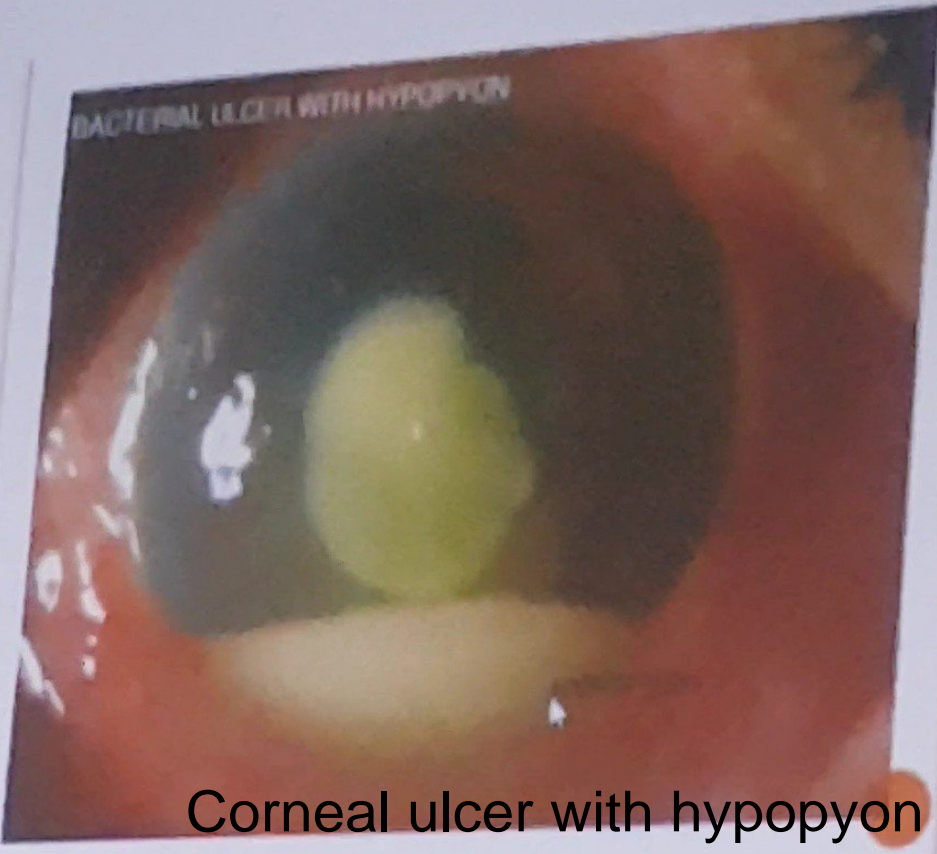


Fungal keratitis

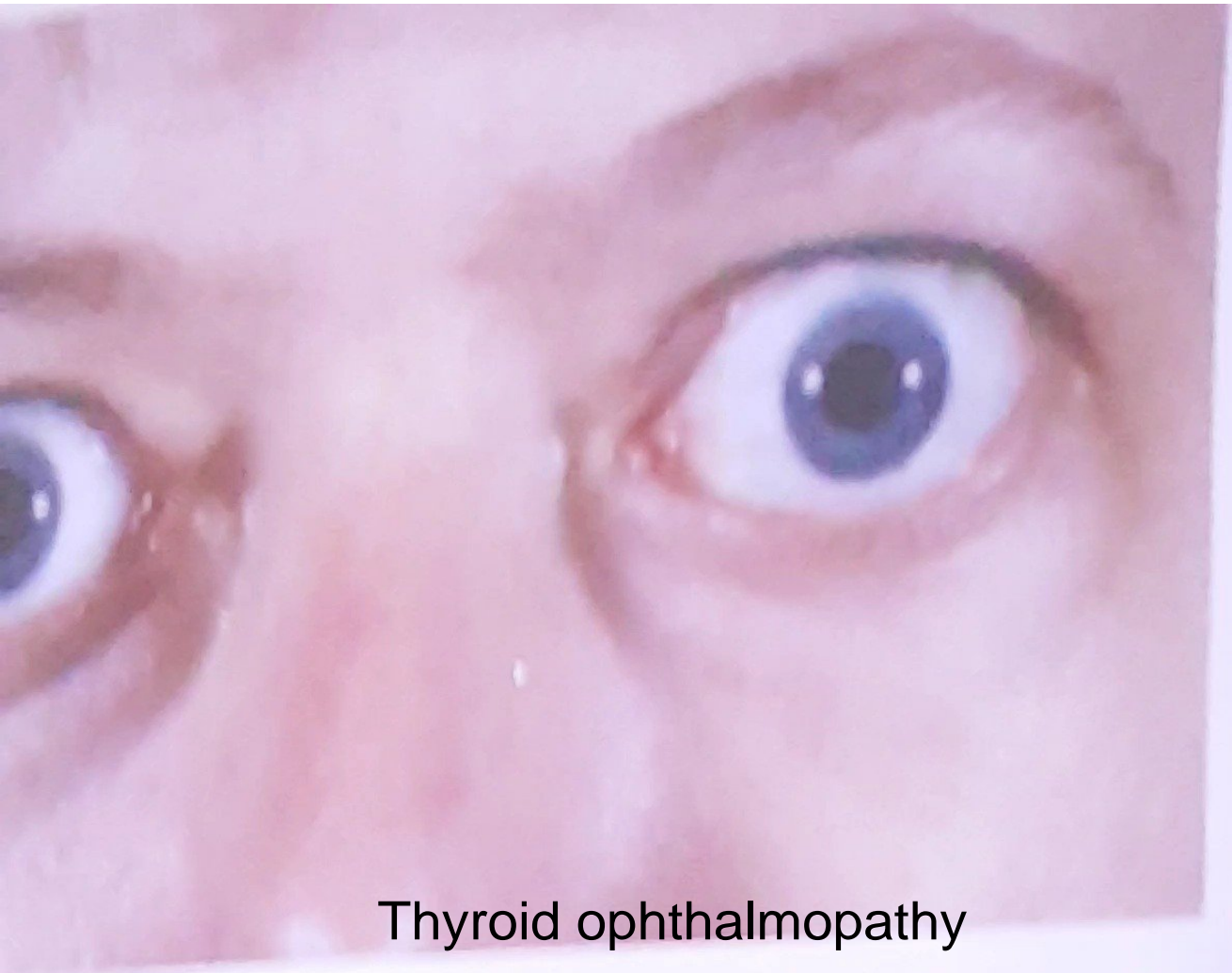

0 photos

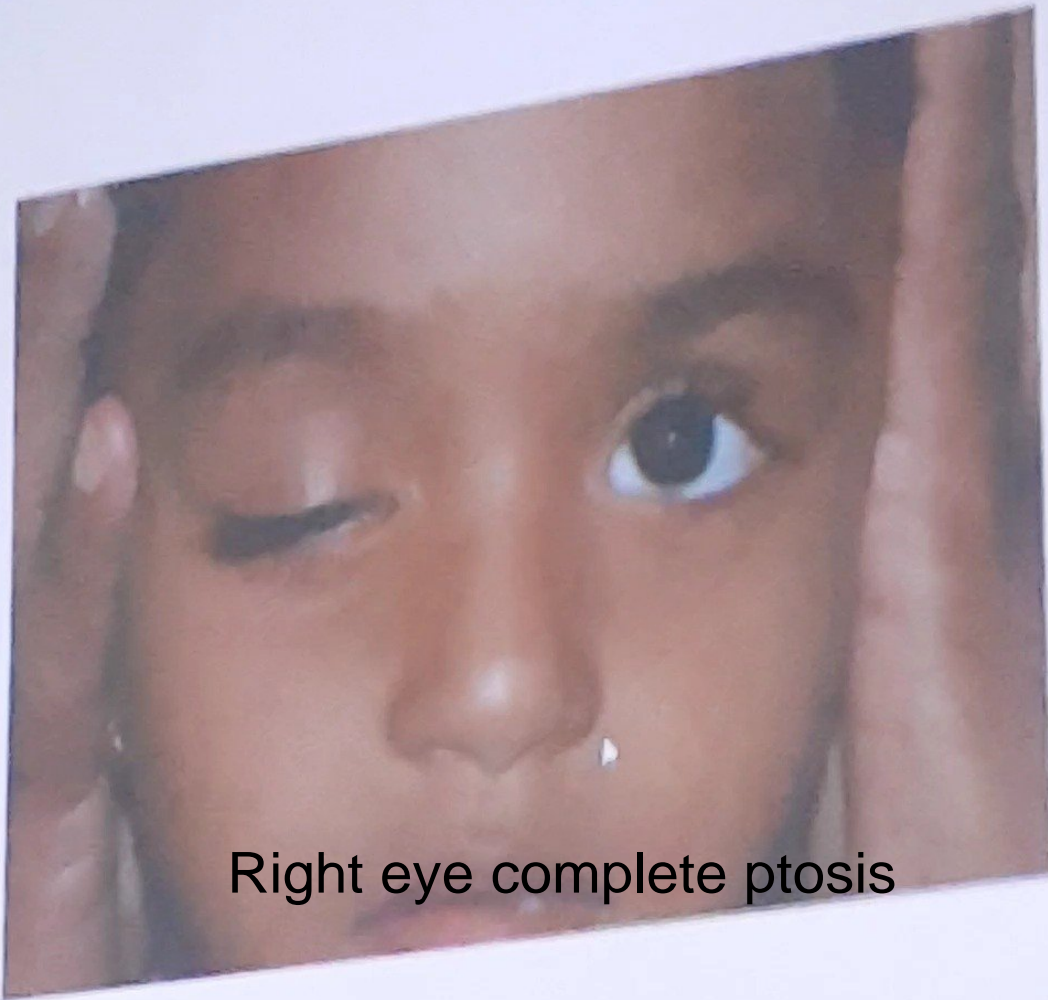+ Add



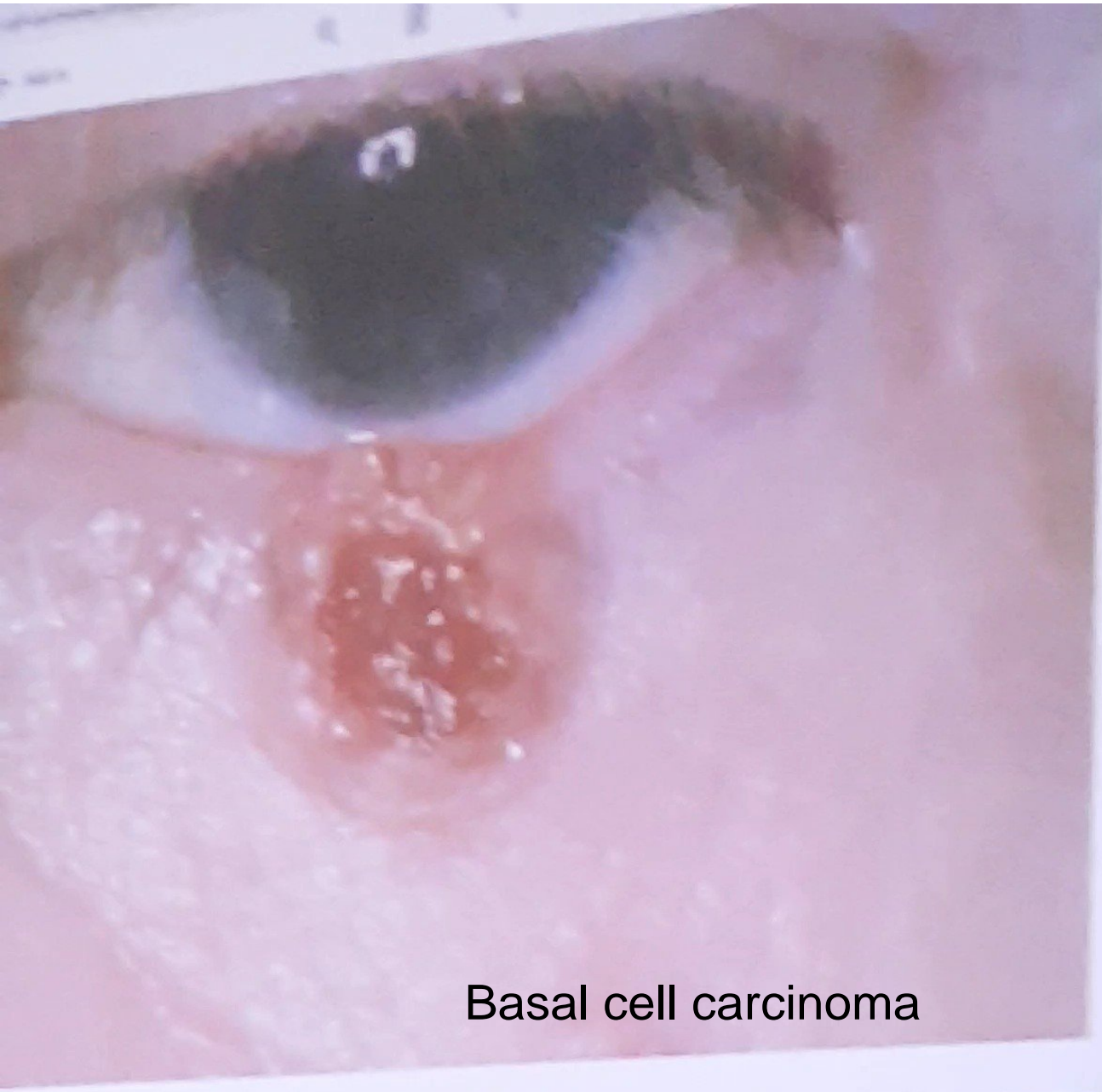
Corneal ulcer with hypopyon



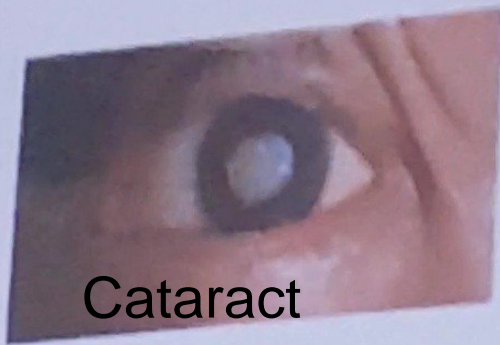
Thyroid ophthalmopathy



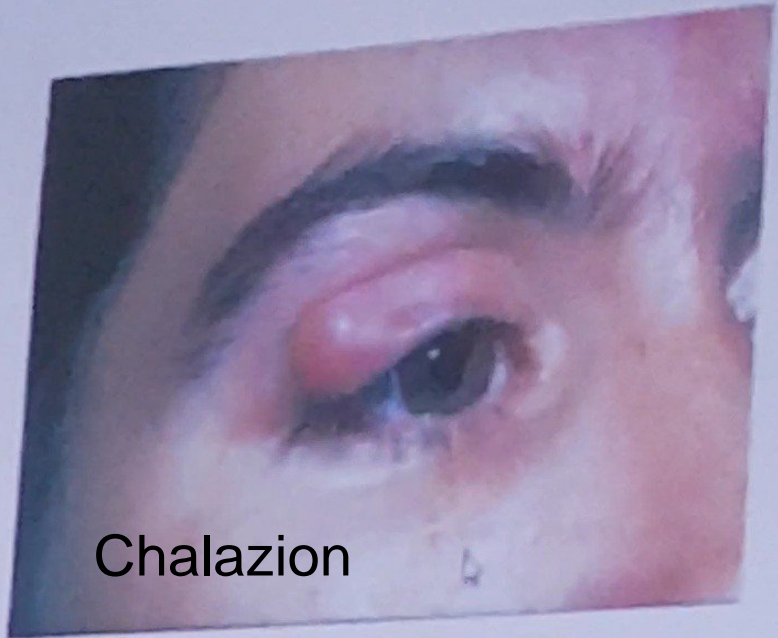
Right eye complete ptosis



Basal cell carcinoma

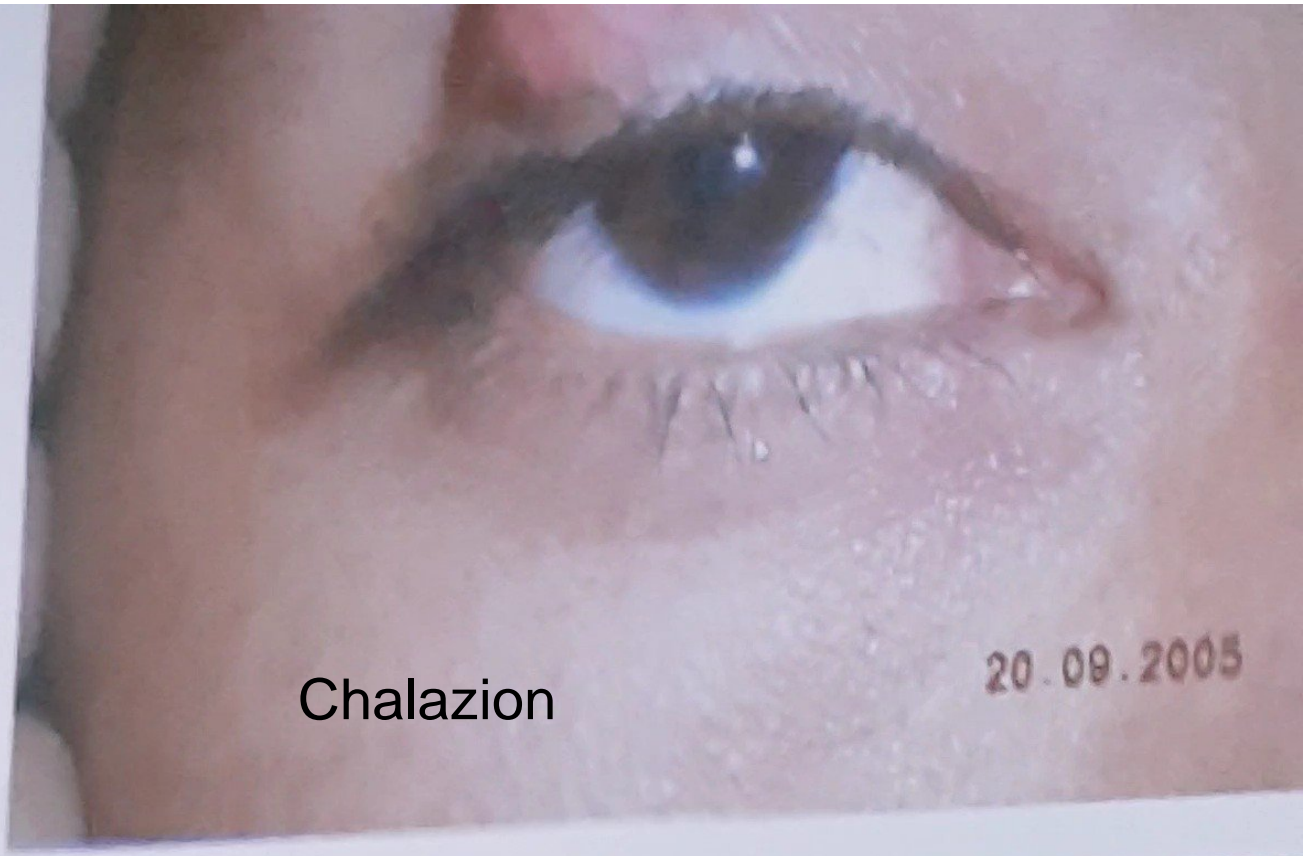


Cataract



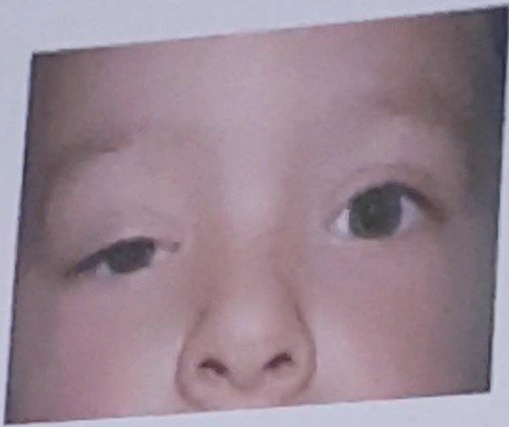
Chalazion



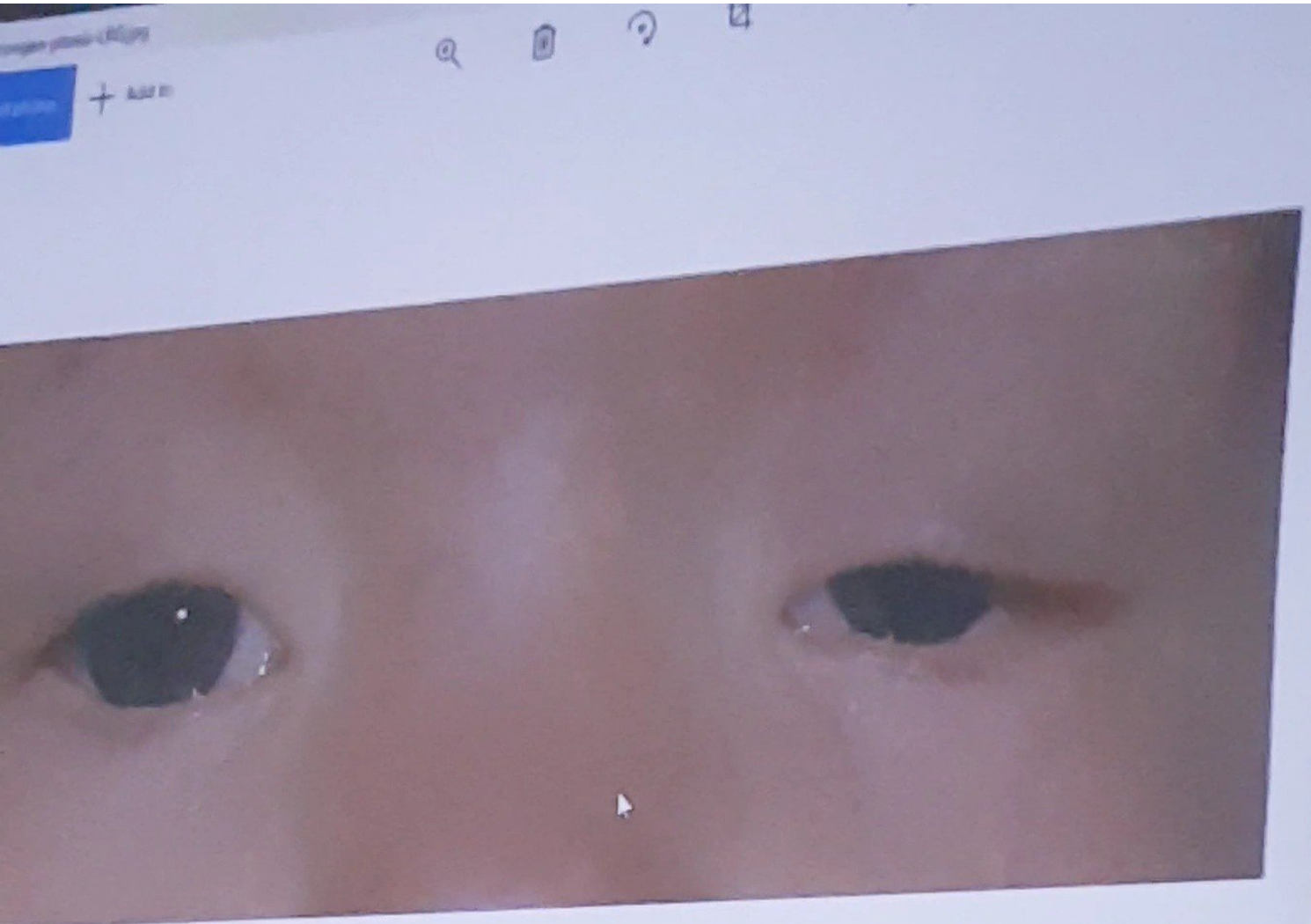


Chalazion

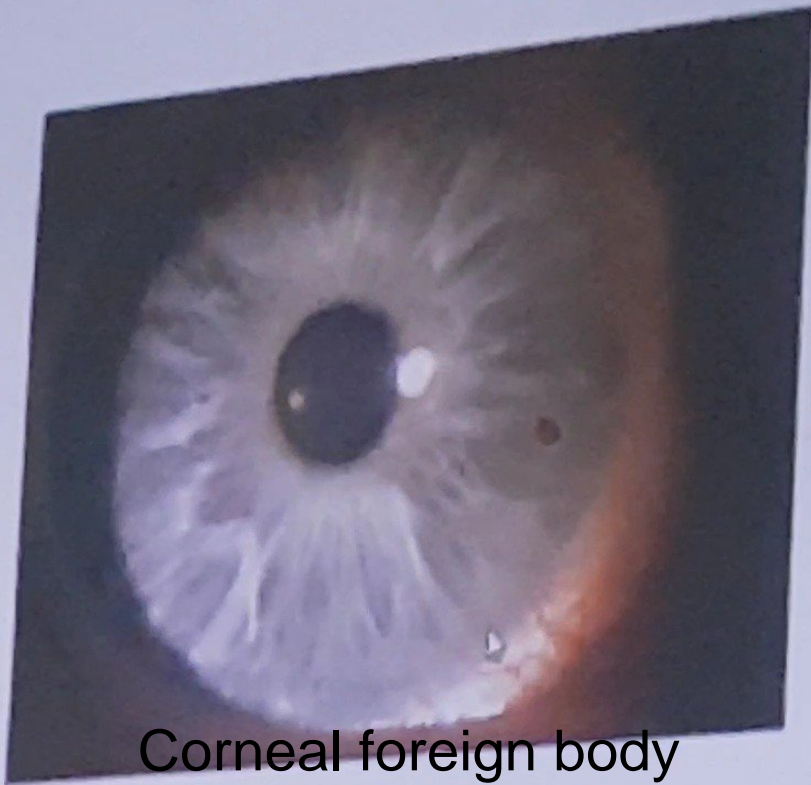20.09.2005



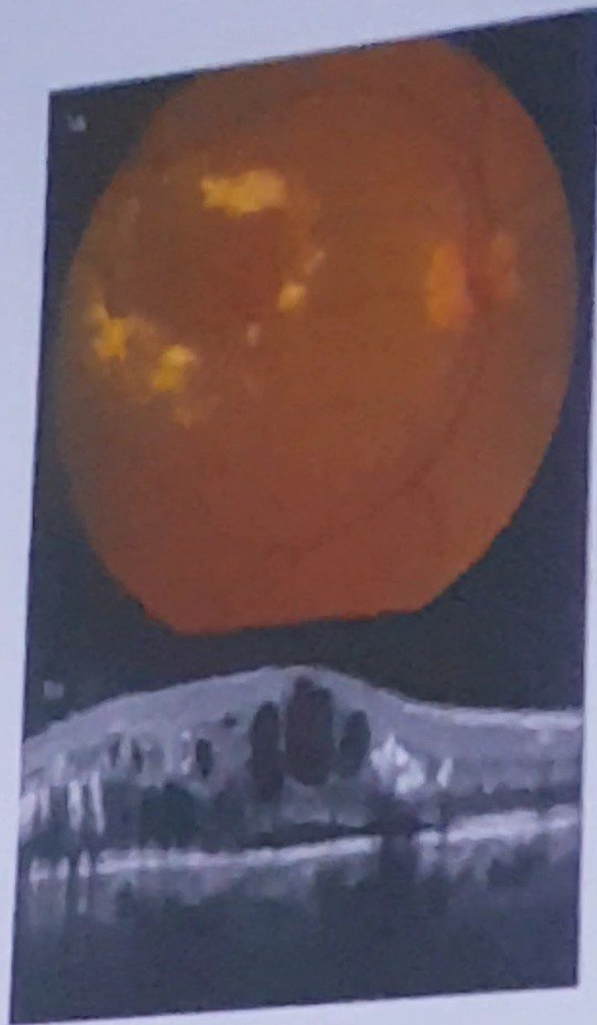Right eye partial ptosis



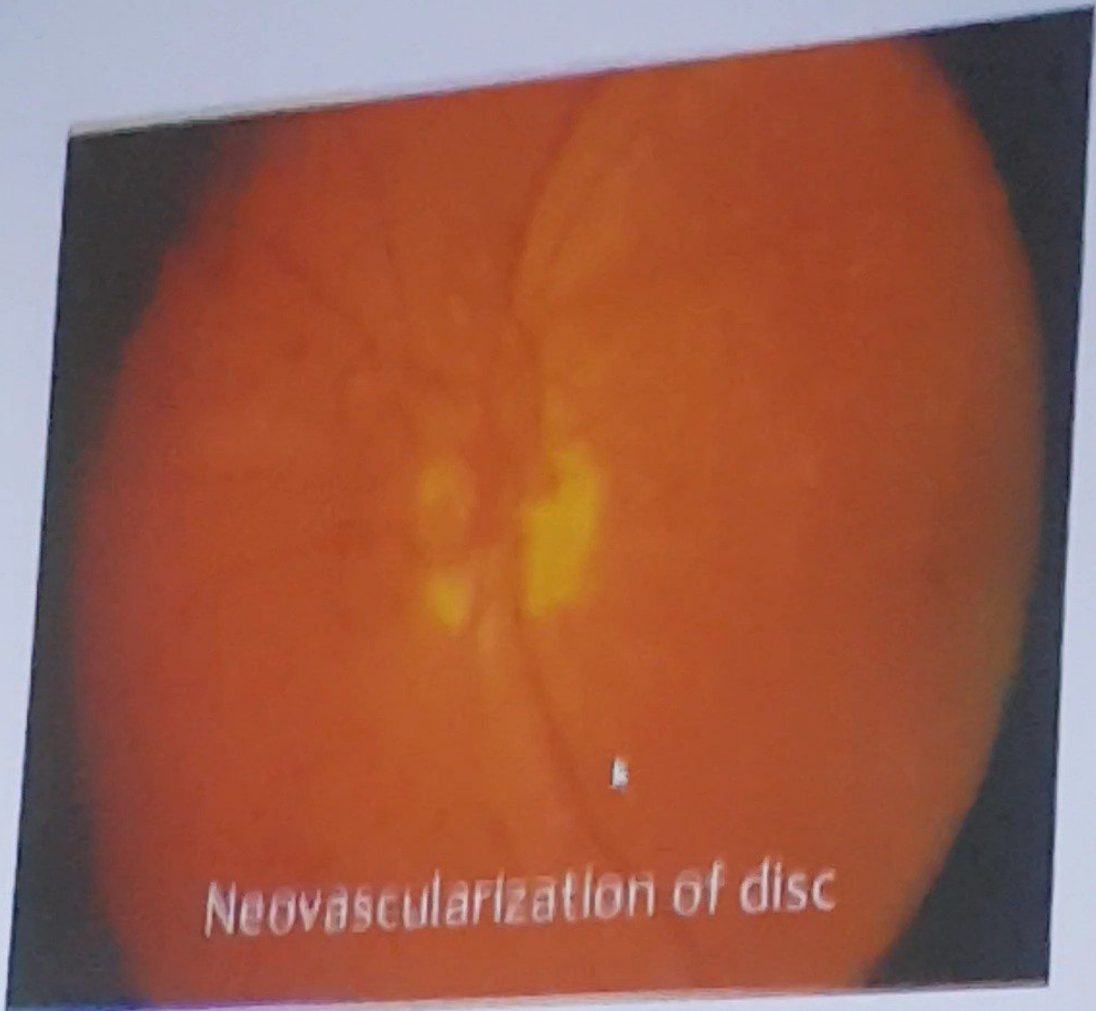Blepharophimosis syndrome



Corneal foreign body



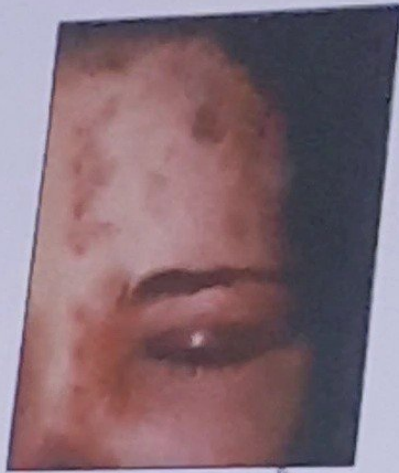
Diabetic macular edema  
with OCT



Neovascularization of disc

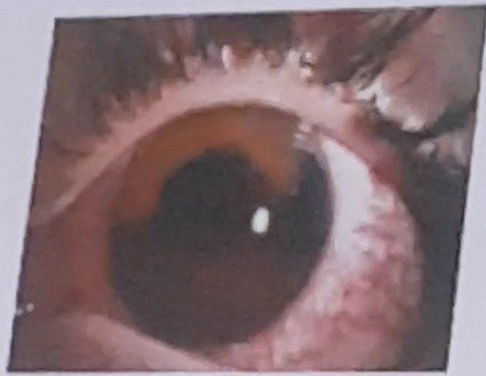

White pupil in left eye ( leukocoria)

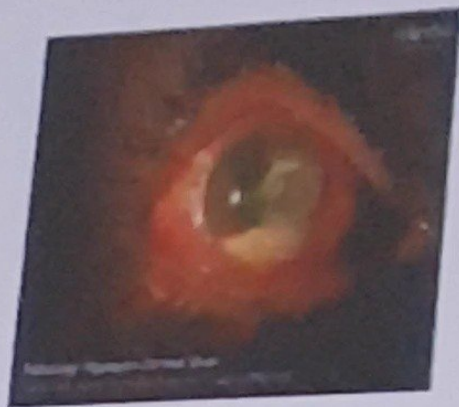

Herpes zoster ophthalmicus

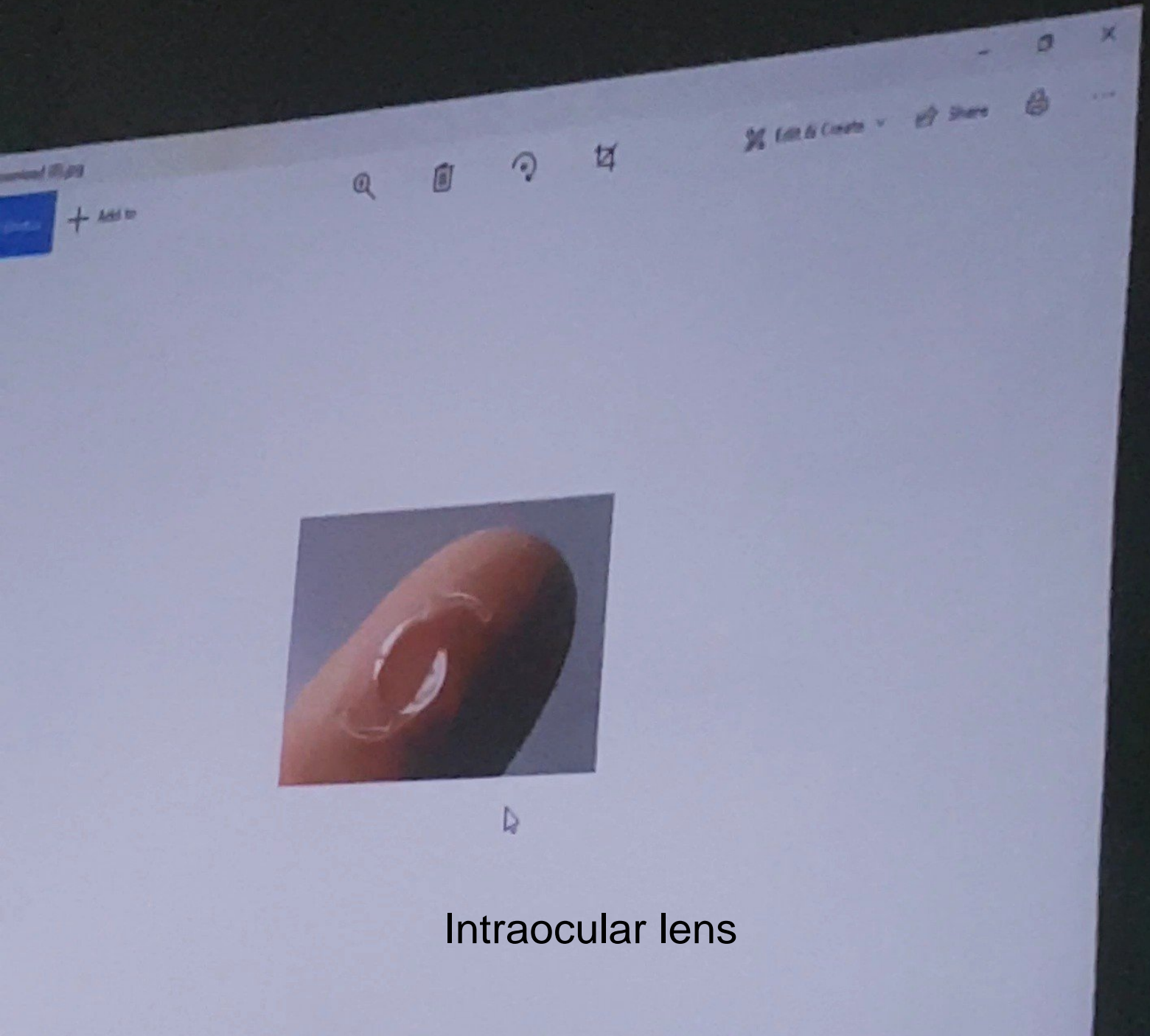




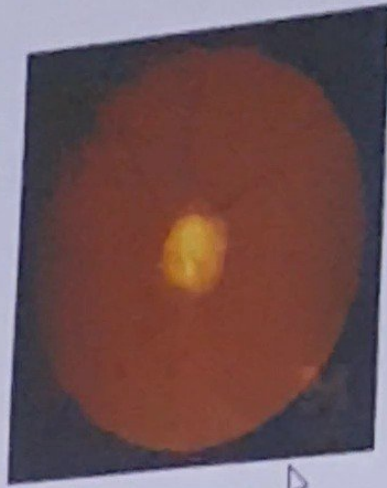Hyphaema



Corneal ulcer with hypopyon



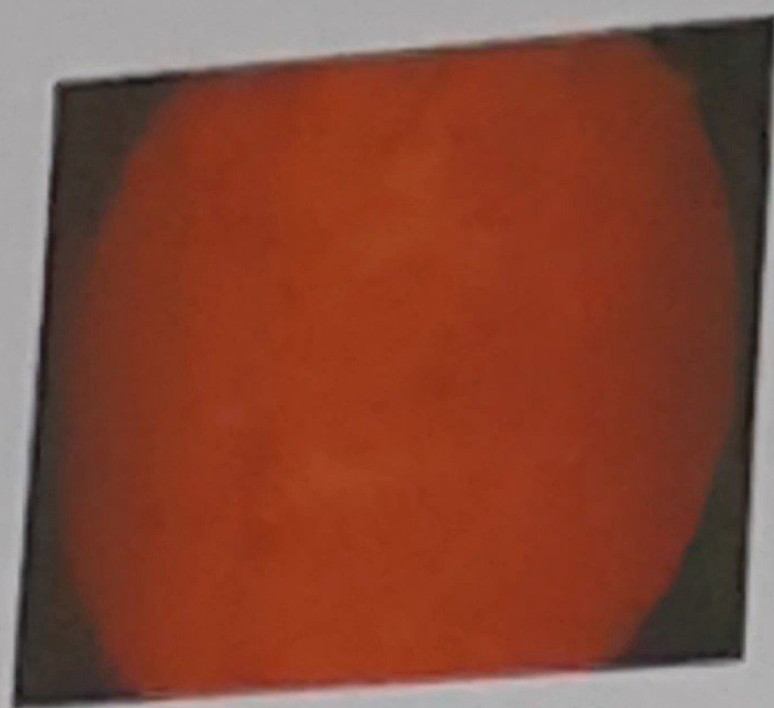Intraocular lens



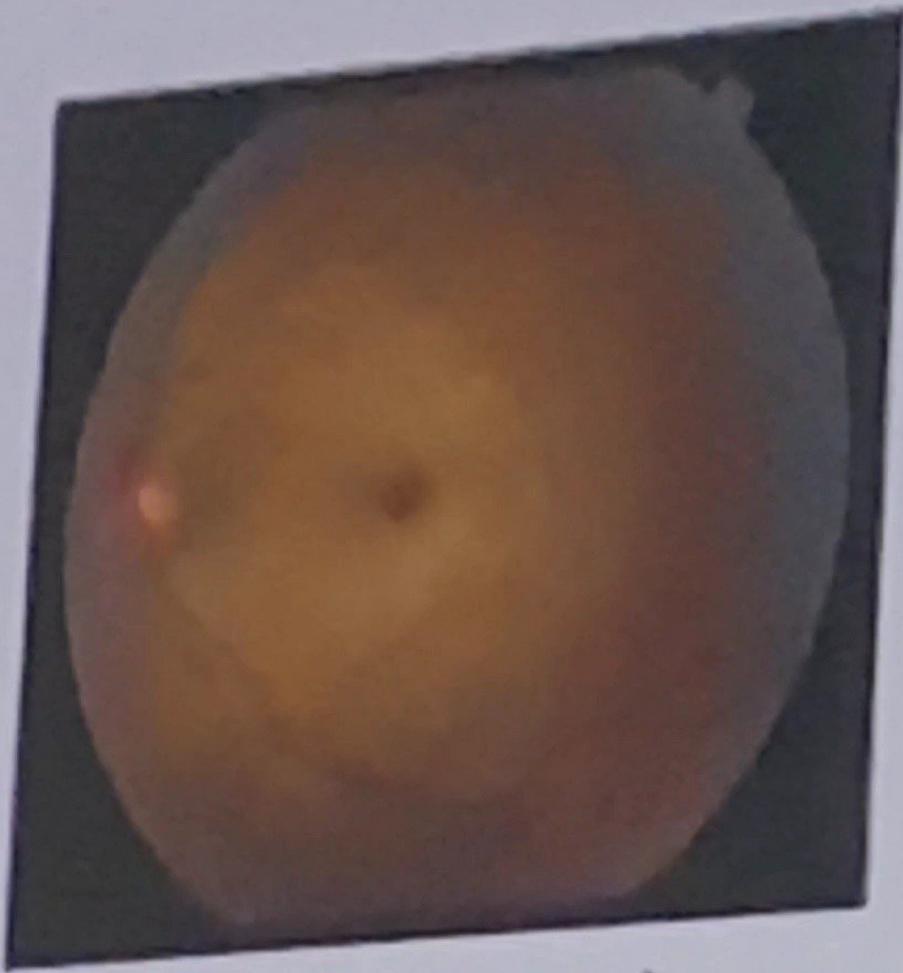

↑ 100%

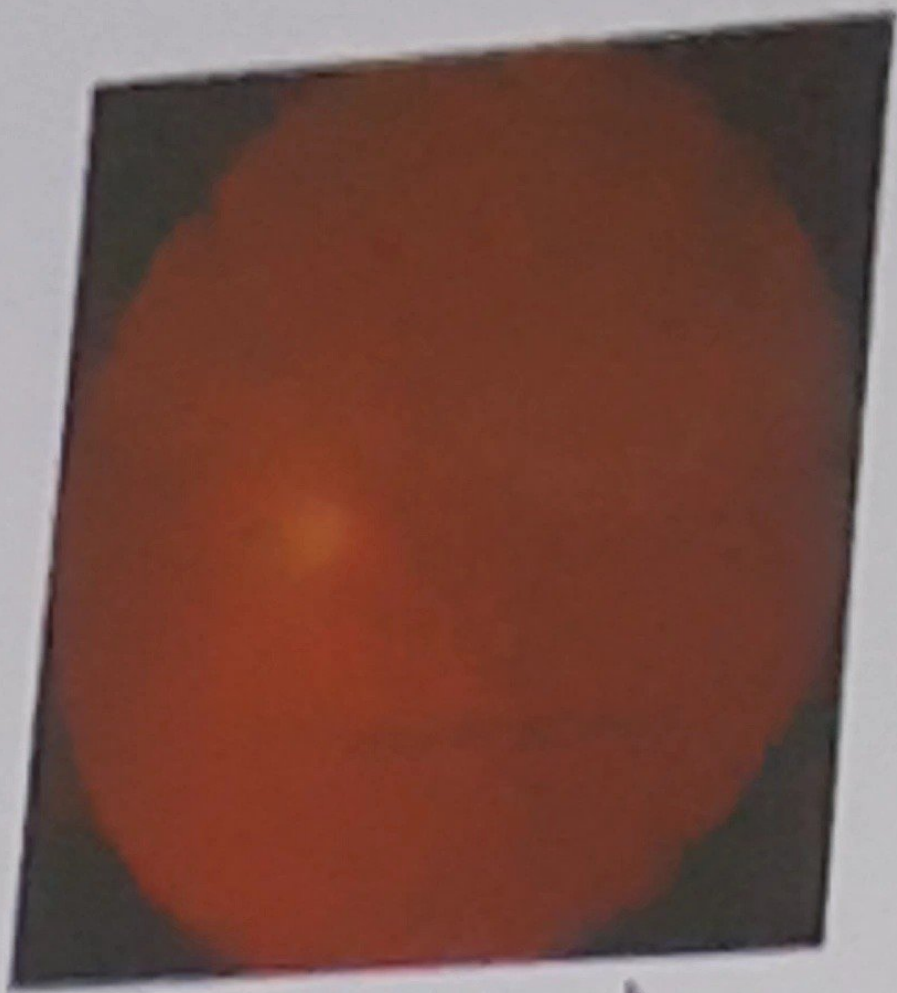



4

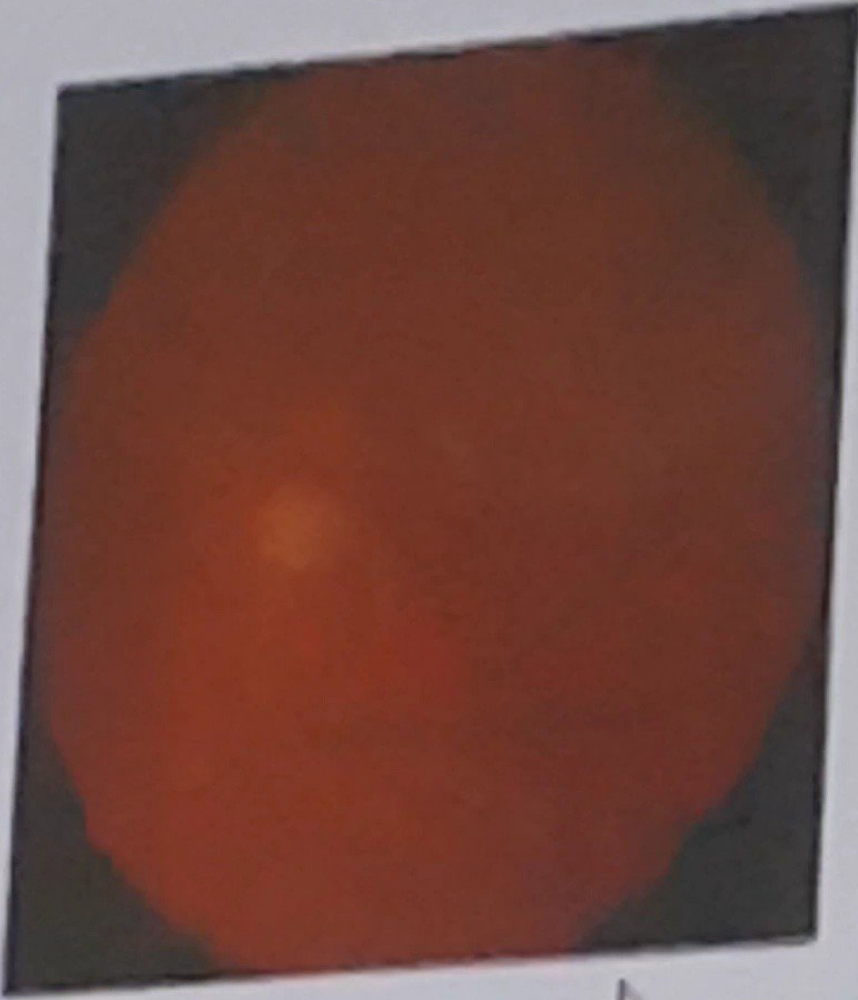

Central retinal artery  
occlusion with cherry red spot

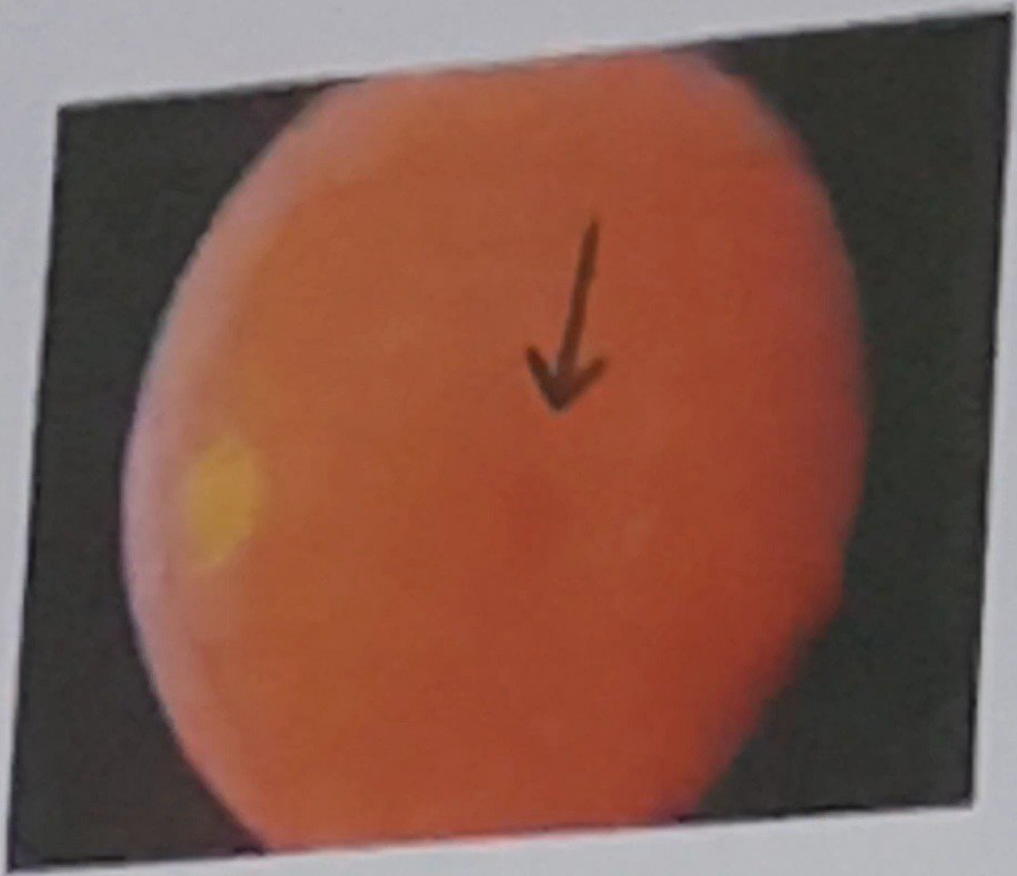

2

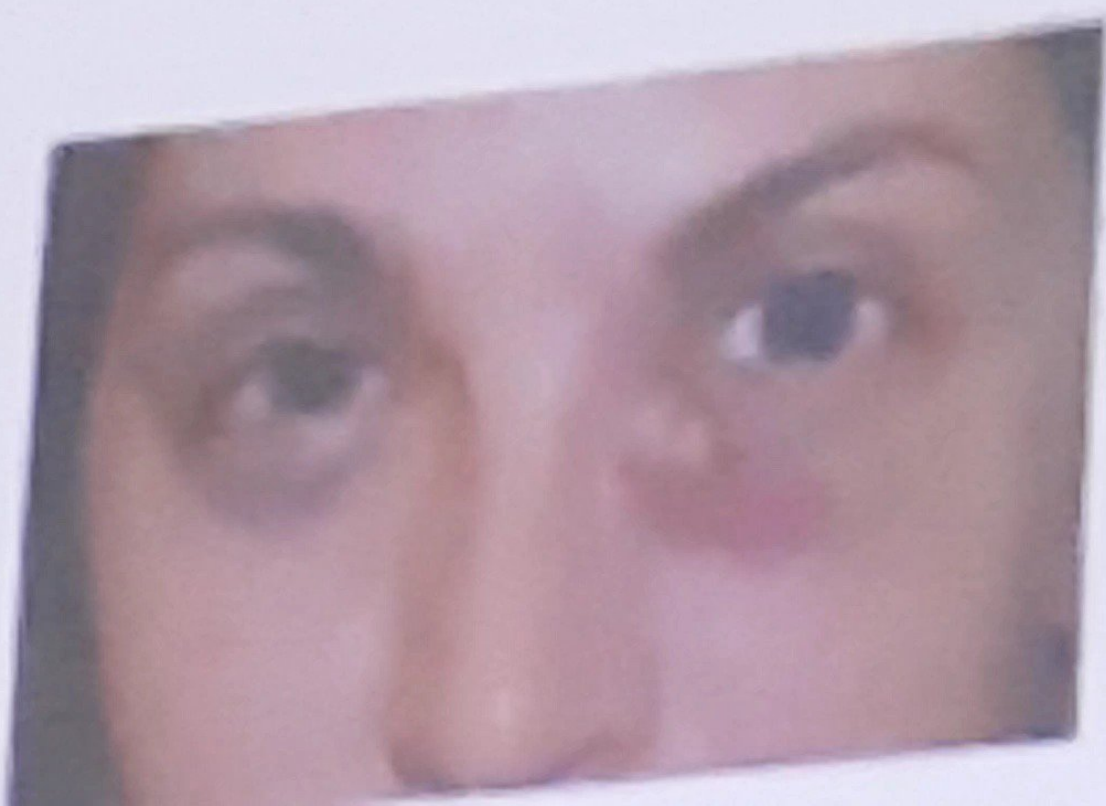




4



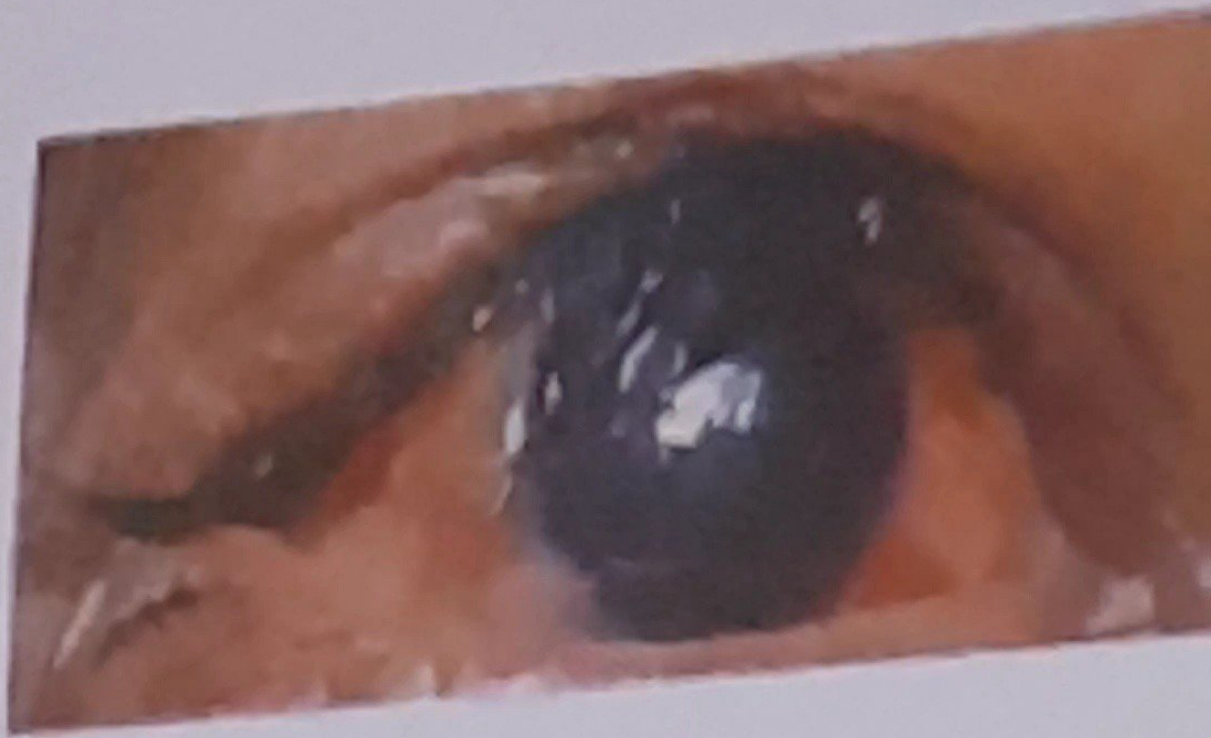4



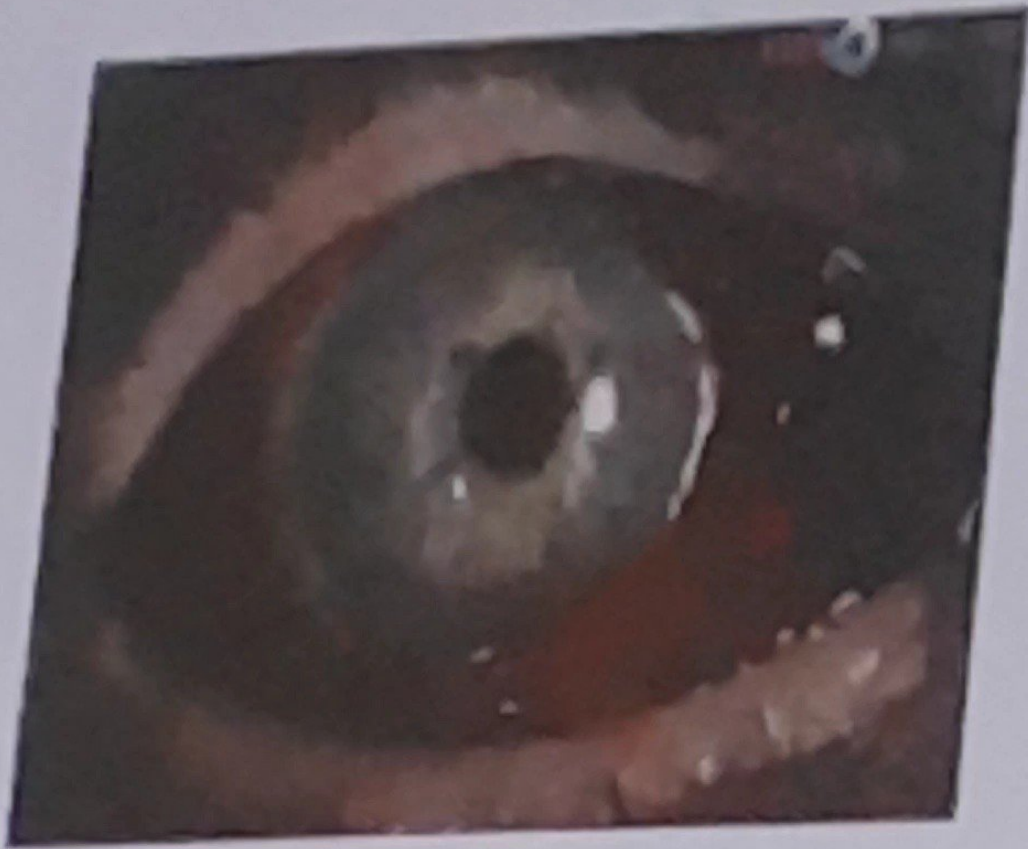
Acute  
dacryocystitis



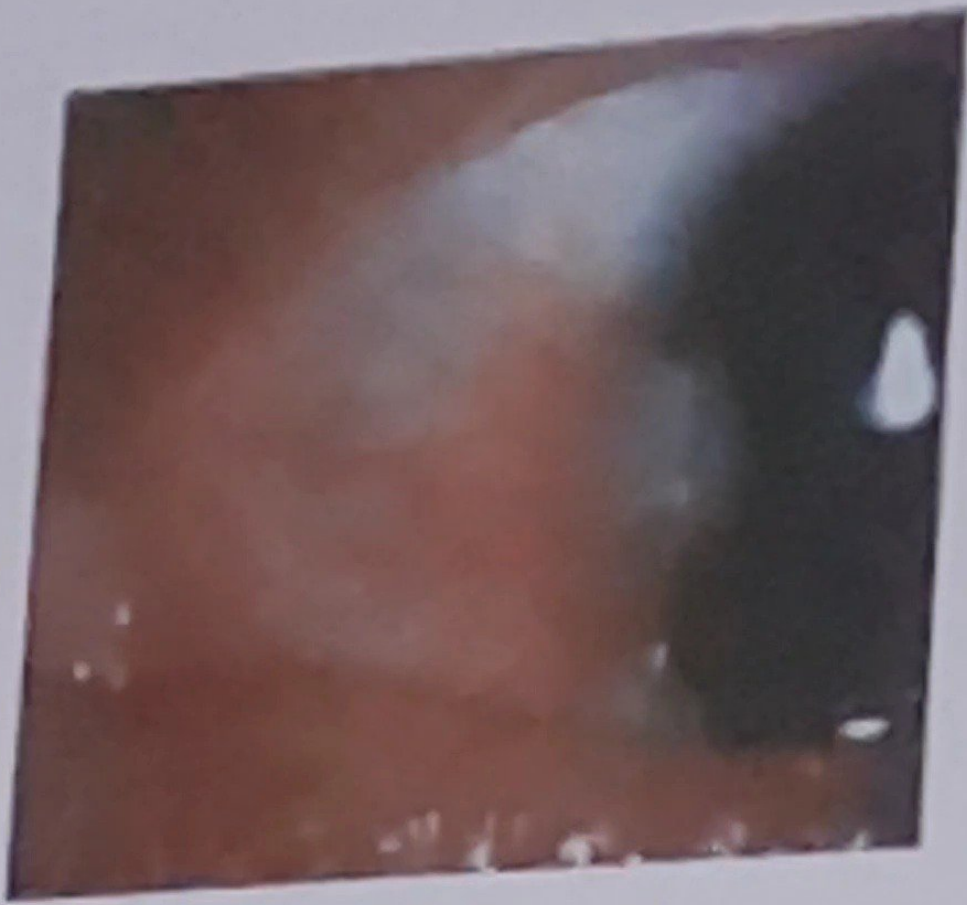
Acute dacryocystitis



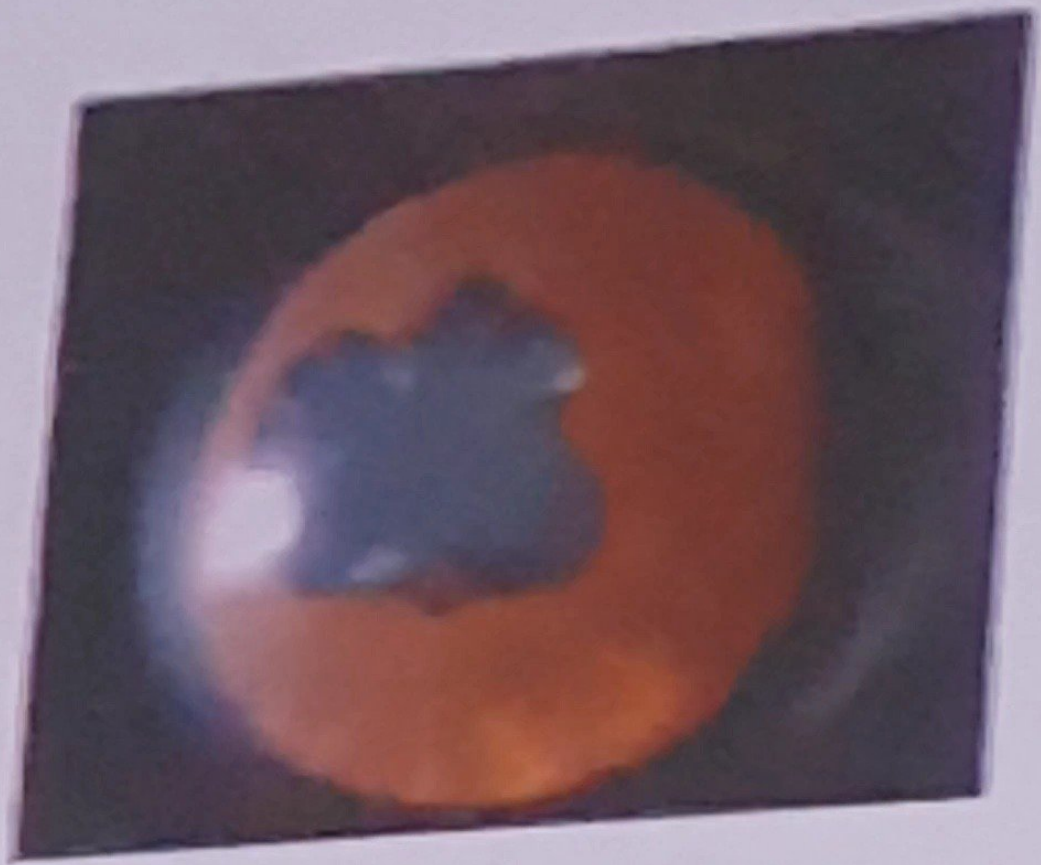Entropion of upper eyelid with  
trichiasis



Subconjunctival hemorrhage

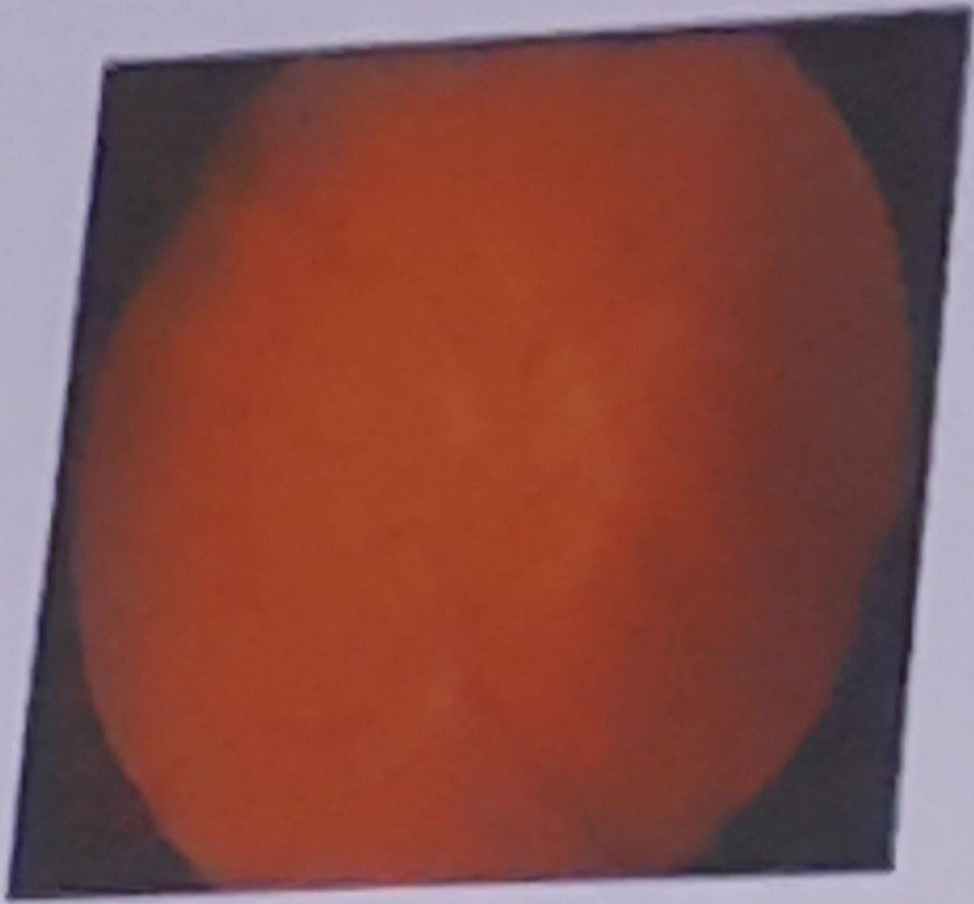

Pterygium




Posterior synechiae






4




Bilateral partial ptosis




Penetrating keratoplasty



White pupil in right eye



Refractive fully accomodative  
esotropia

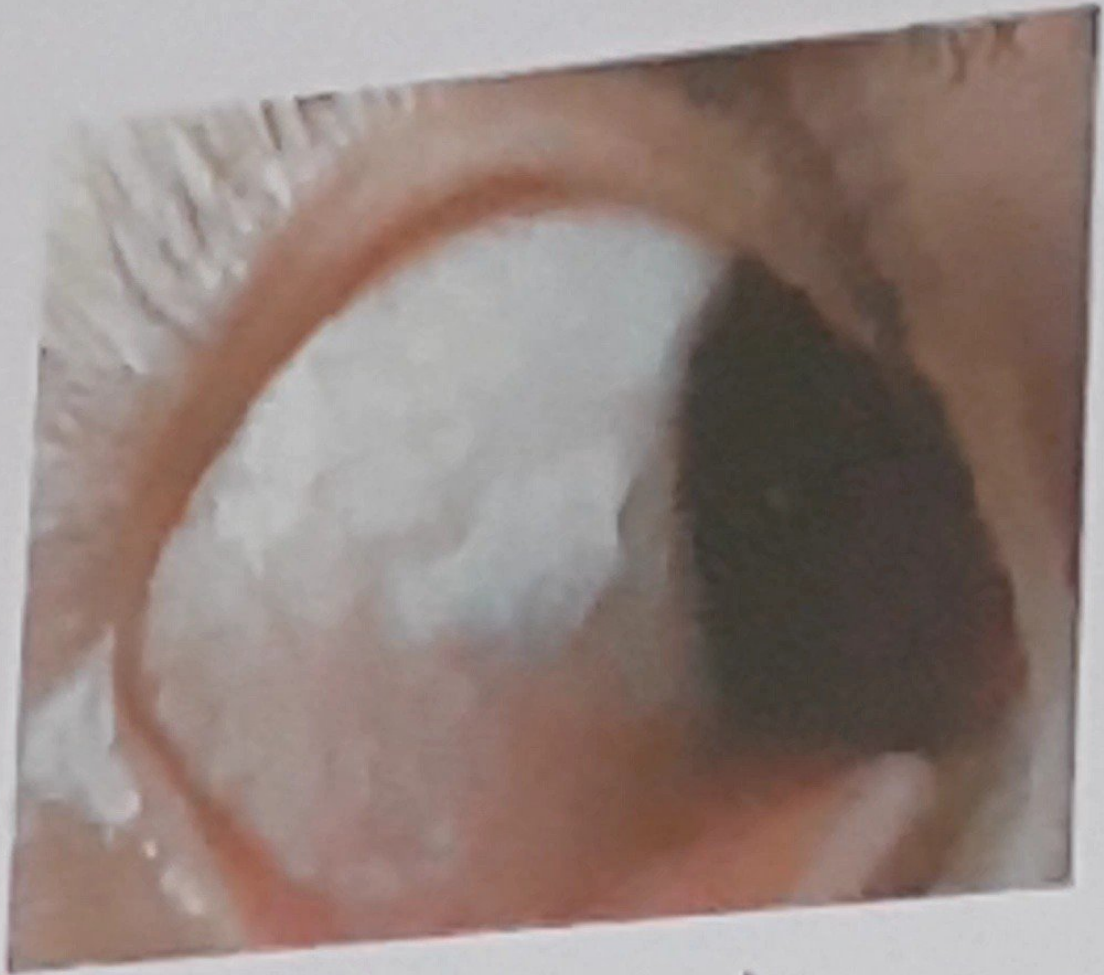


Blepharophimosis syndrome



Refractive fully accommodative  
esotropia

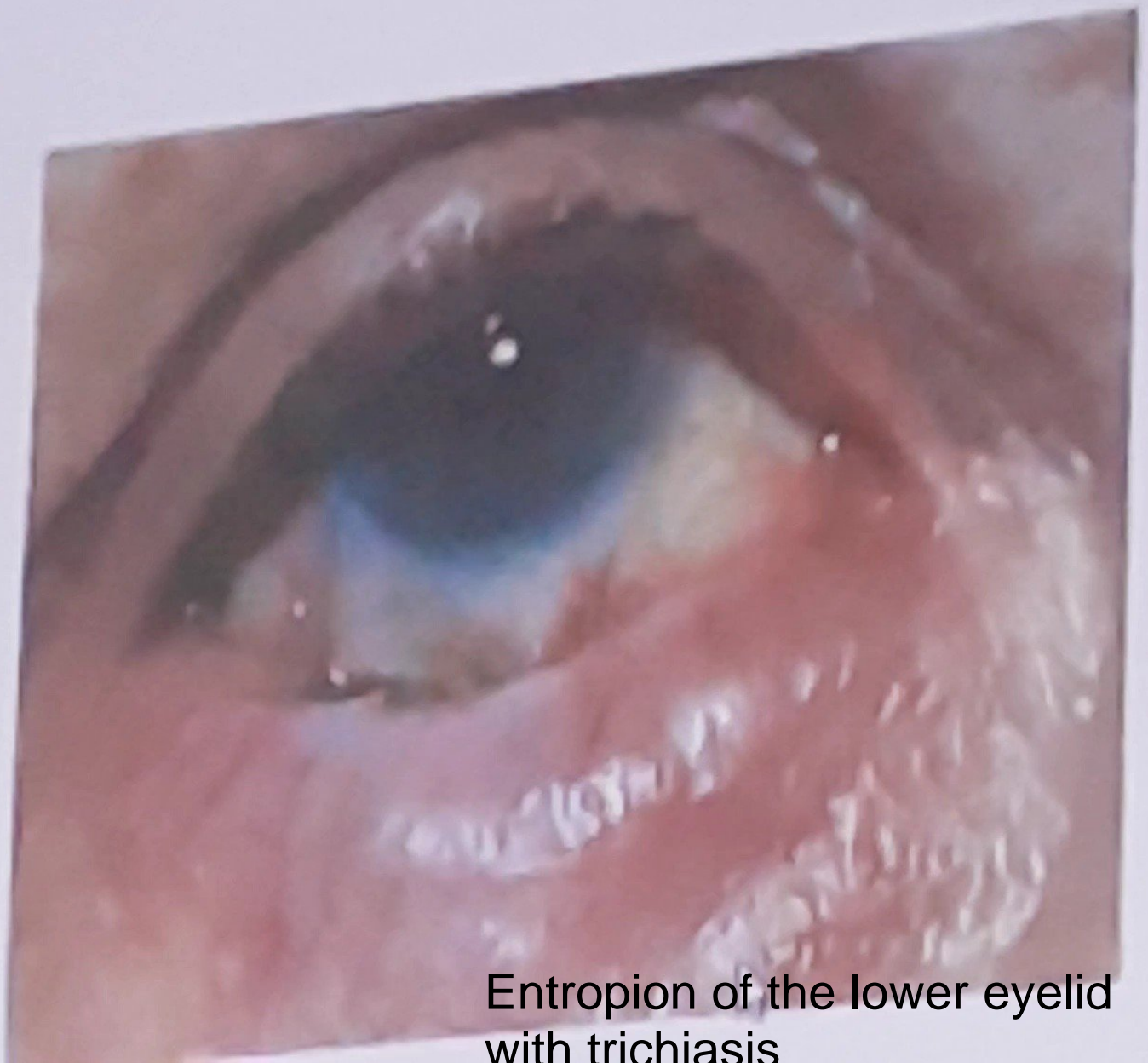
4



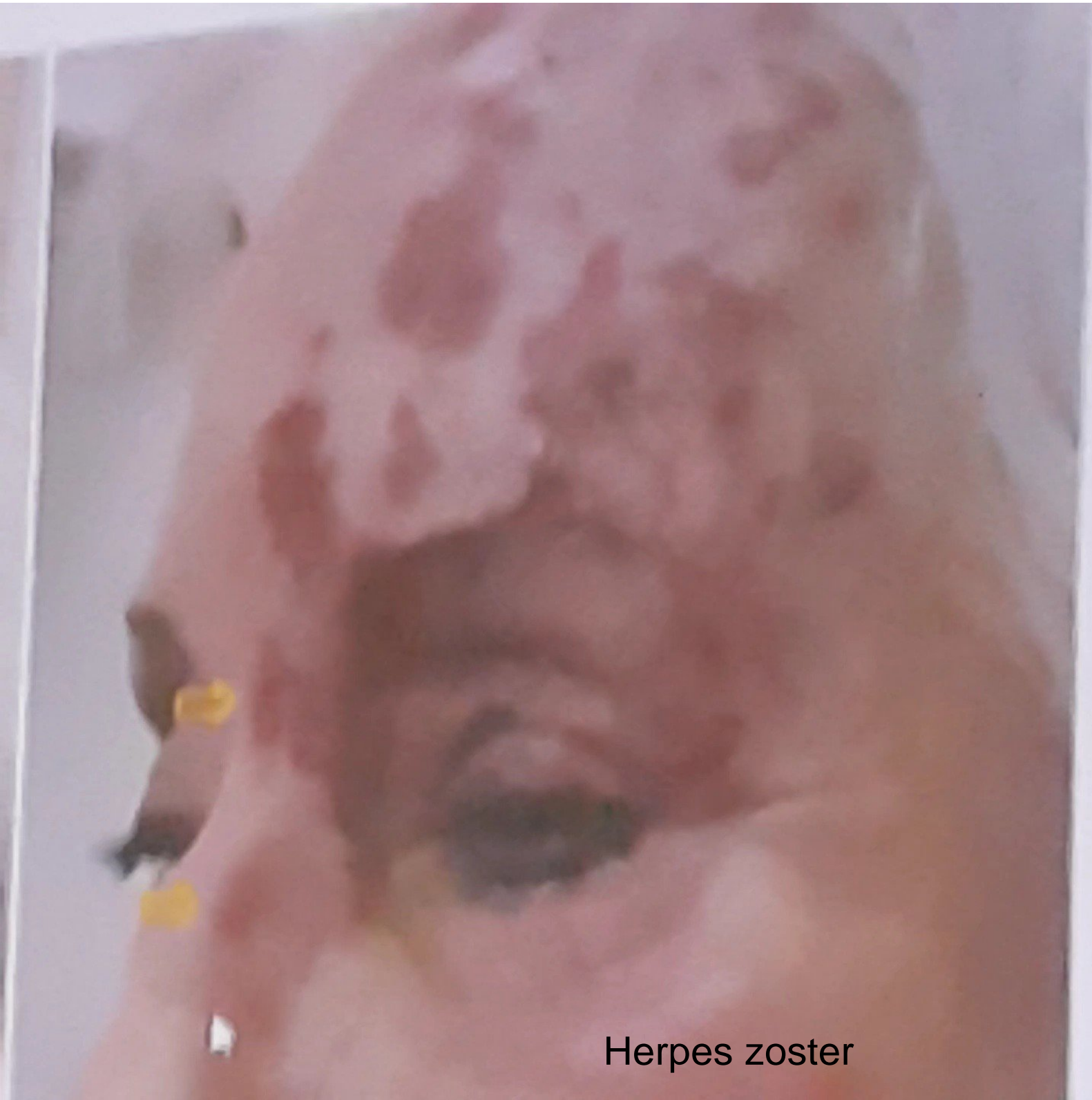Bitot spots



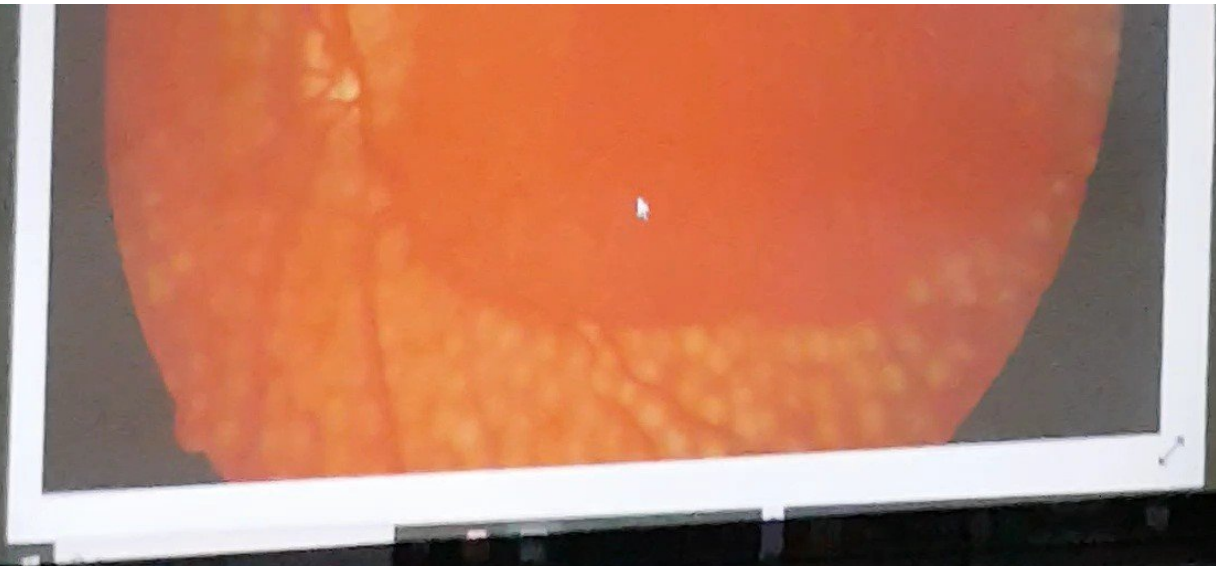




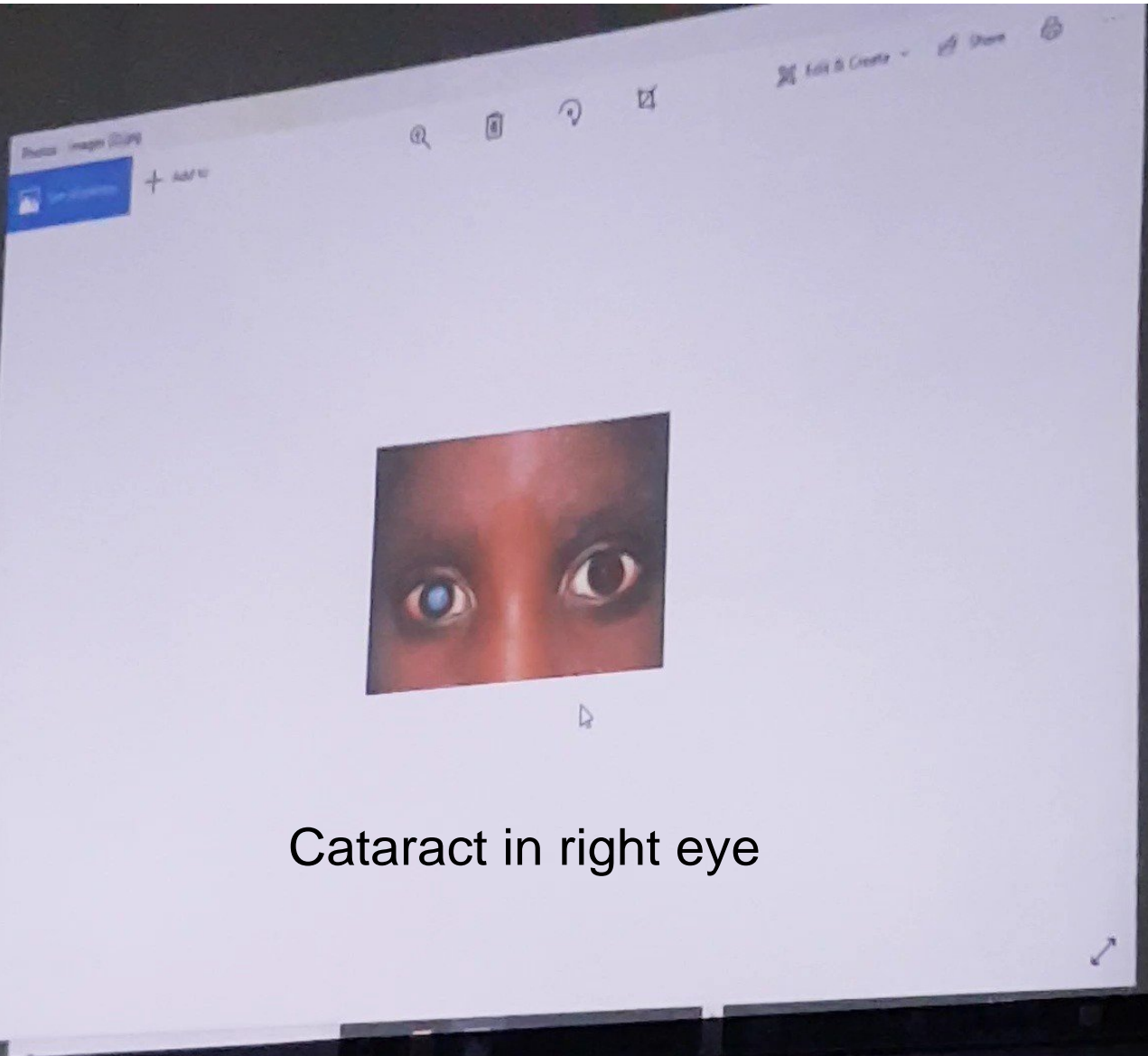
Entropion of the lower eyelid  
with trichiasis



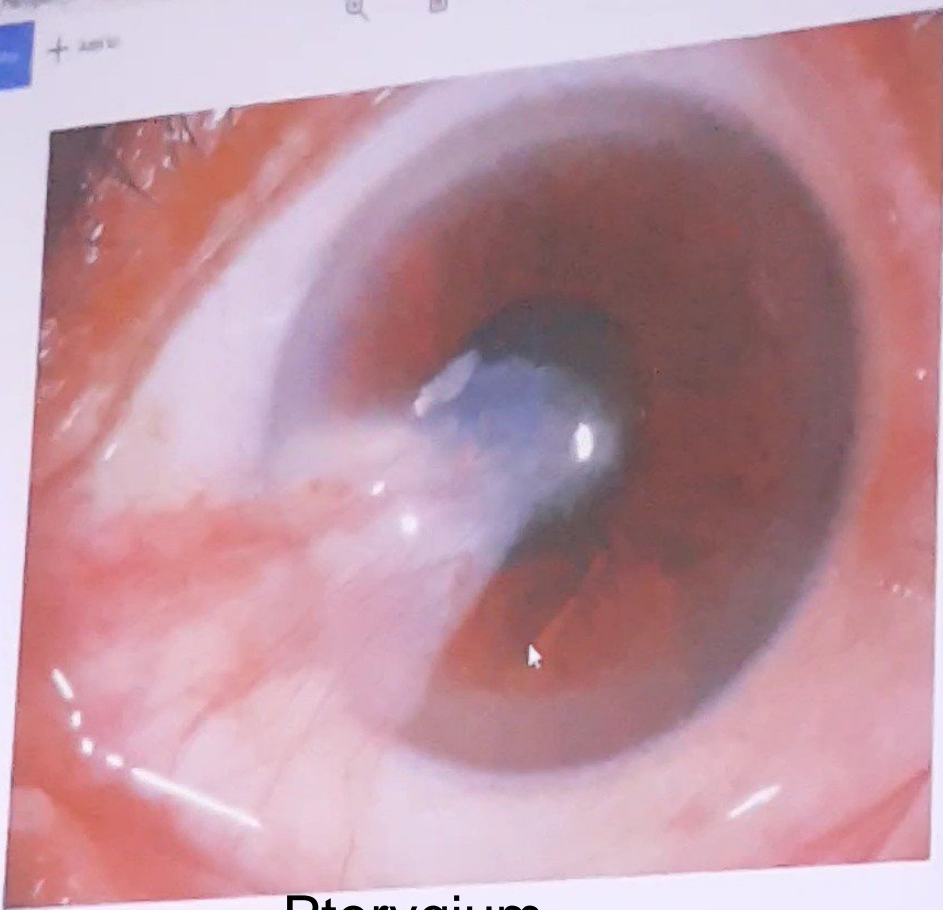
Herpes zoster



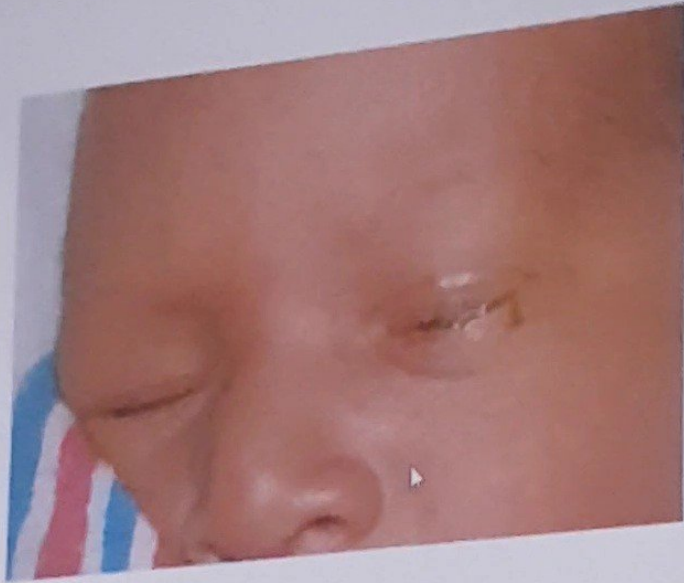Laser Photocoagulation of retina




Cataract in right eye

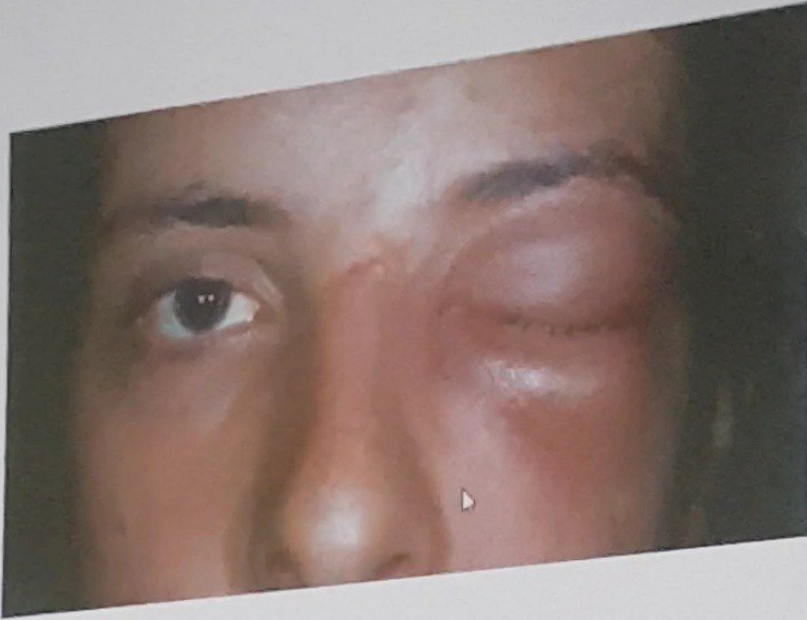

Pterygium



Ophthalmia neonatorum

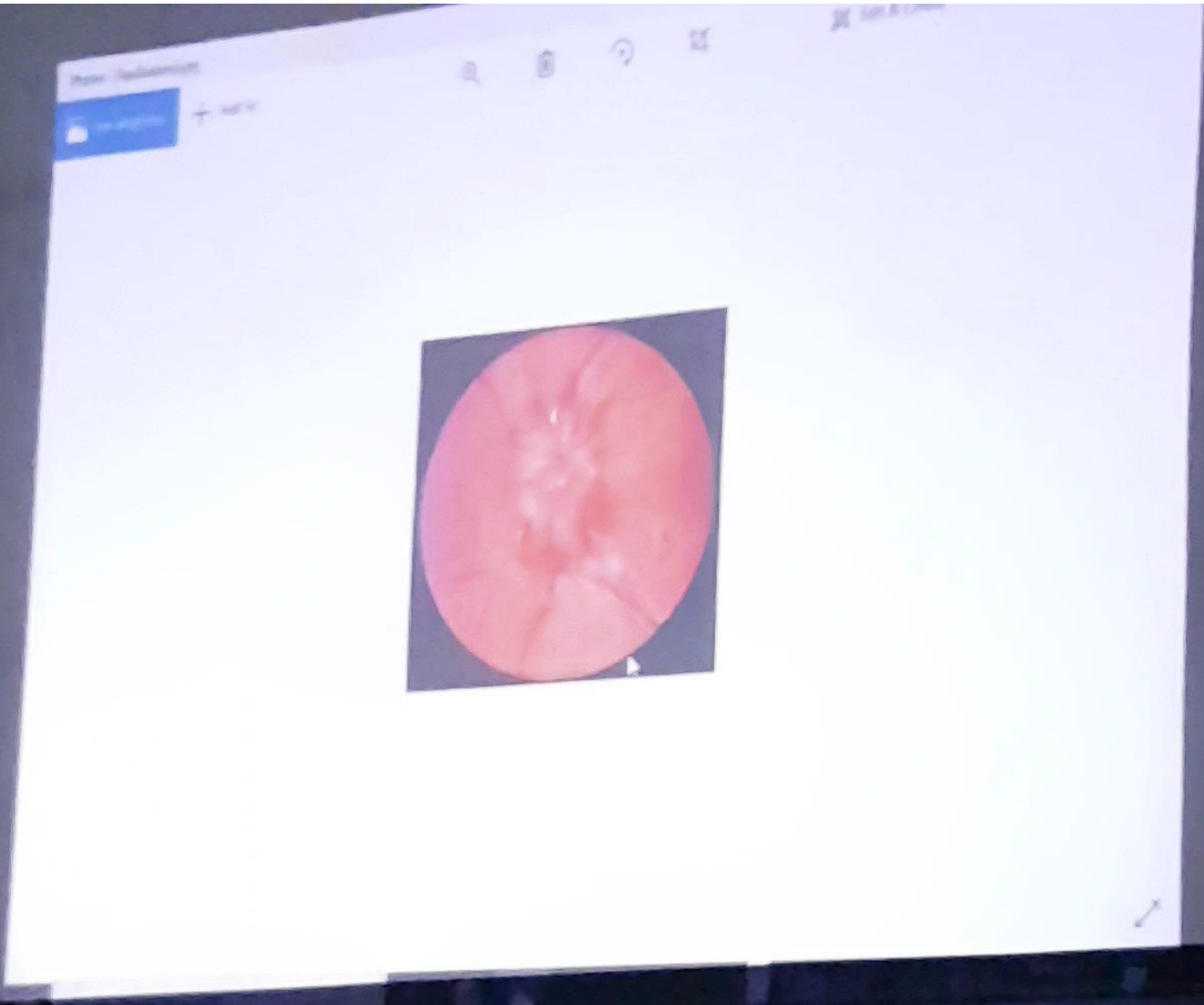


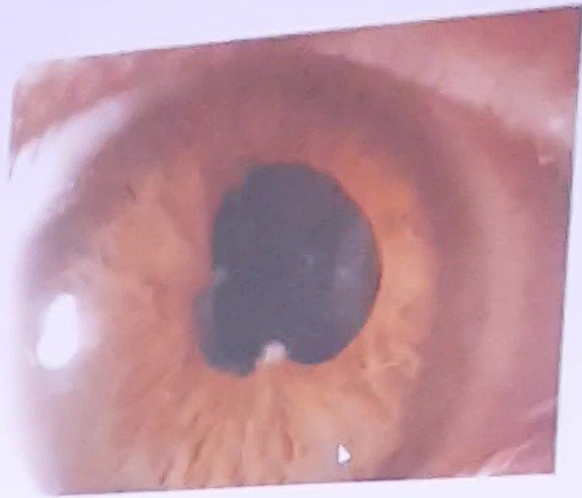

Orbital cellulitis

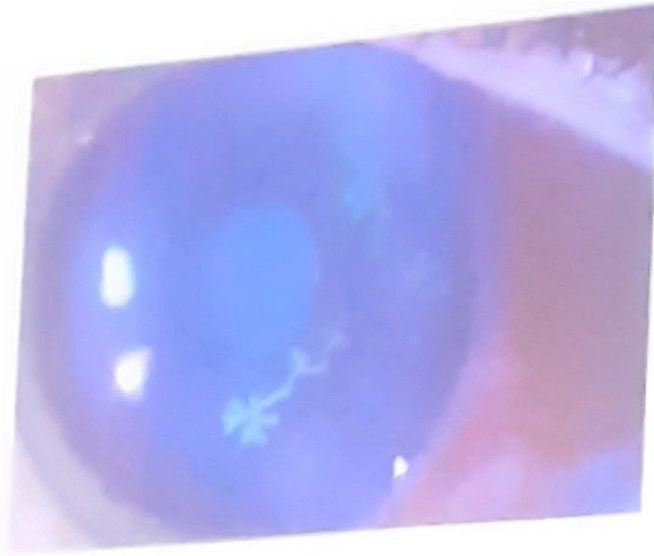




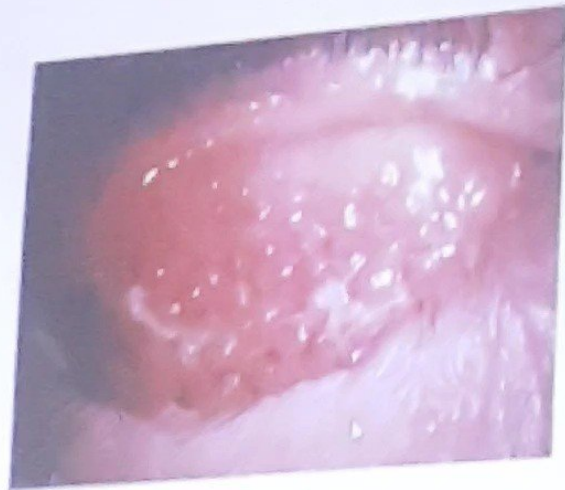



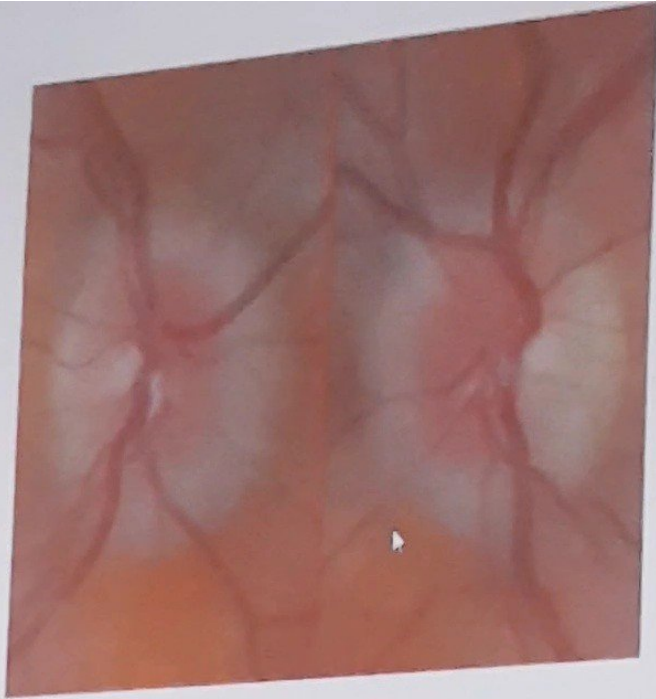Posterior synechiae



Dendritic ulcer

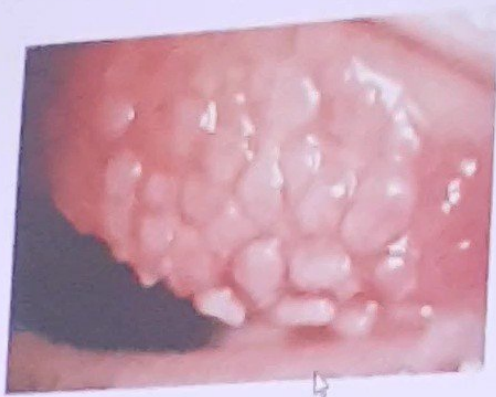

Papillae on tarsal conjunctiva in  
vernal keratoconjunctivitis



Bilateral swollen optic disc





Papillae on tarsal conjunctiva in VKC