

We're gonna talk about..

Optic nerve (II)
Nervus opticus

Scheme/Overview

Eye Anatomy

Visual field

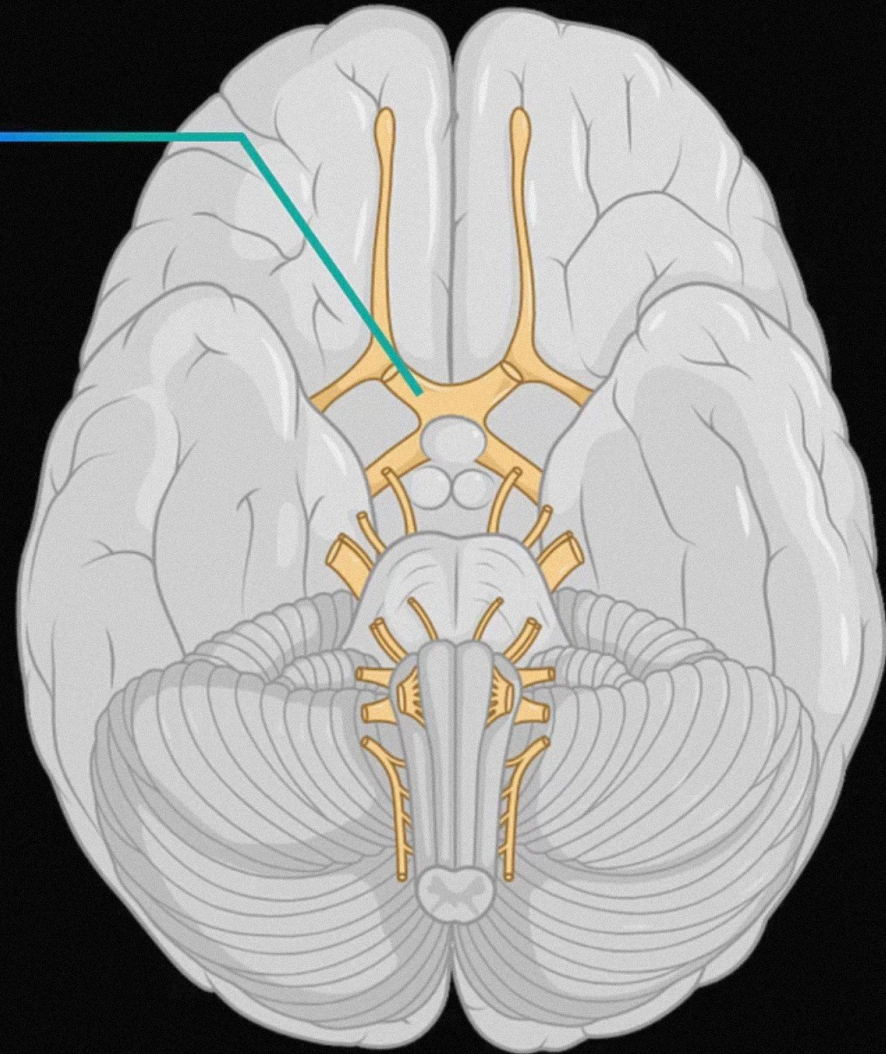
Course of the Visual Pathway

Visual Pathway Collaterals

Pupillary Light Reflex

Pathway of Convergence

Clinical Relevance

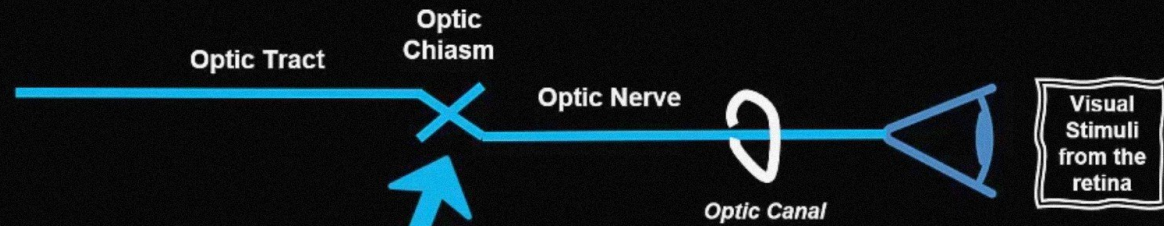


Optic nerve (II)

Nervus opticus

Scheme/Overview

The optic nerve carries visual information to the brain via the optic tract



Approx half of optic fibers cross the optic chiasm

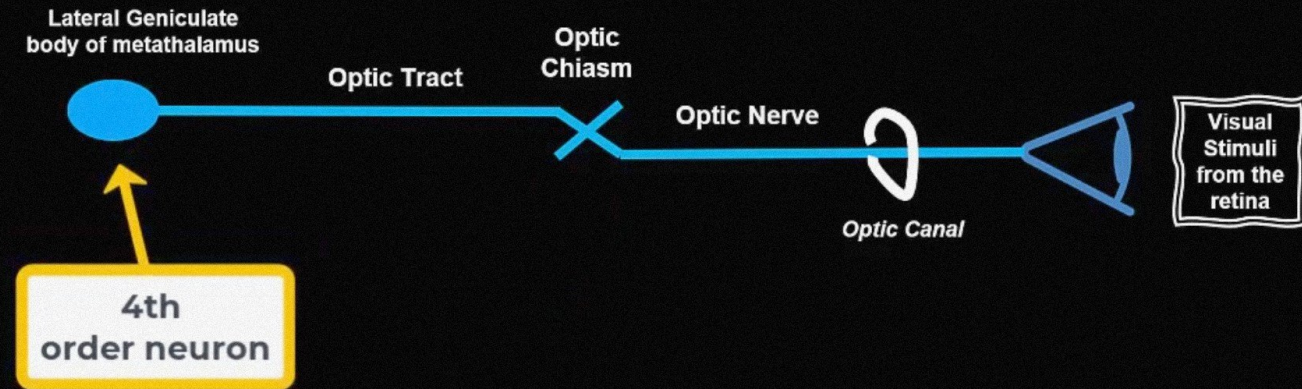


Optic nerve (II)

Nervus opticus

Scheme/Overview

The optic nerve carries visual information to the brain via the optic tract

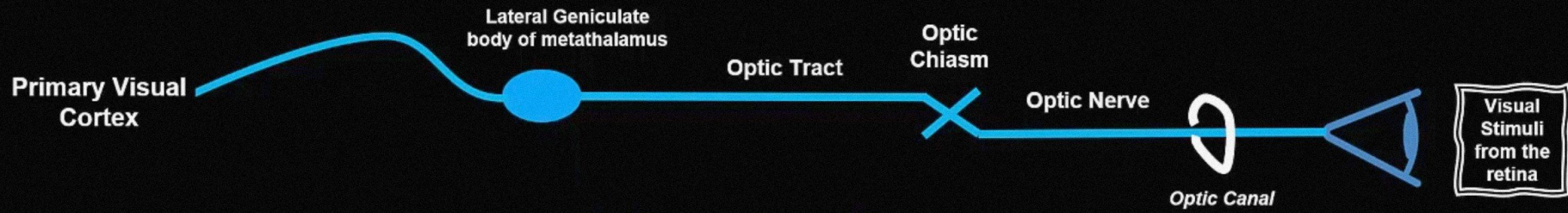


Optic nerve (II)

Nervus opticus

Scheme/Overview

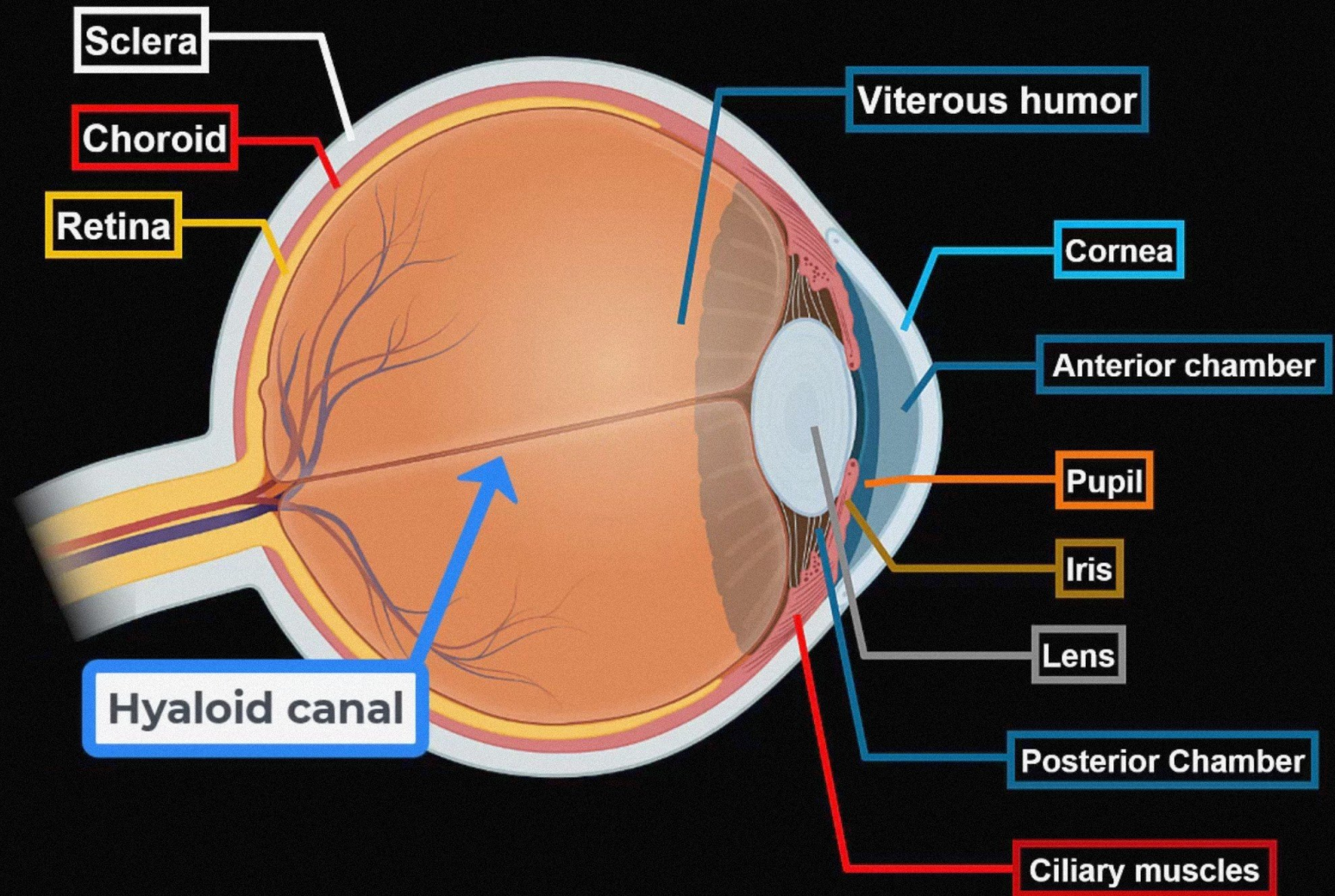
The optic nerve carries visual information to the brain via the optic tract



Optic nerve (II)

Nervus opticus

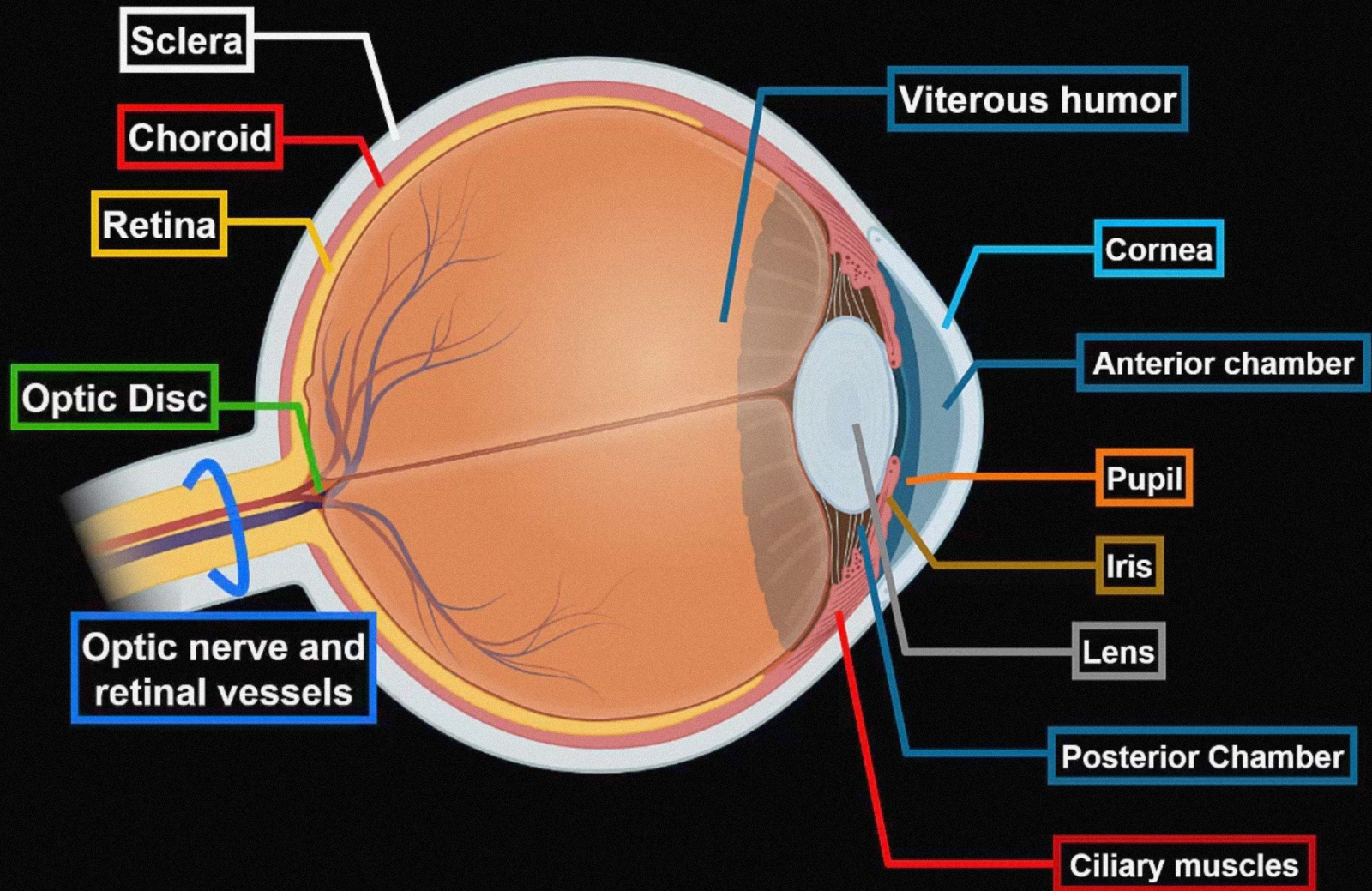
Eye Anatomy



Optic nerve (II)

Nervus opticus

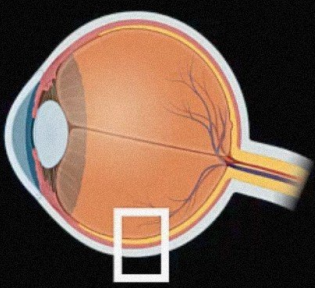
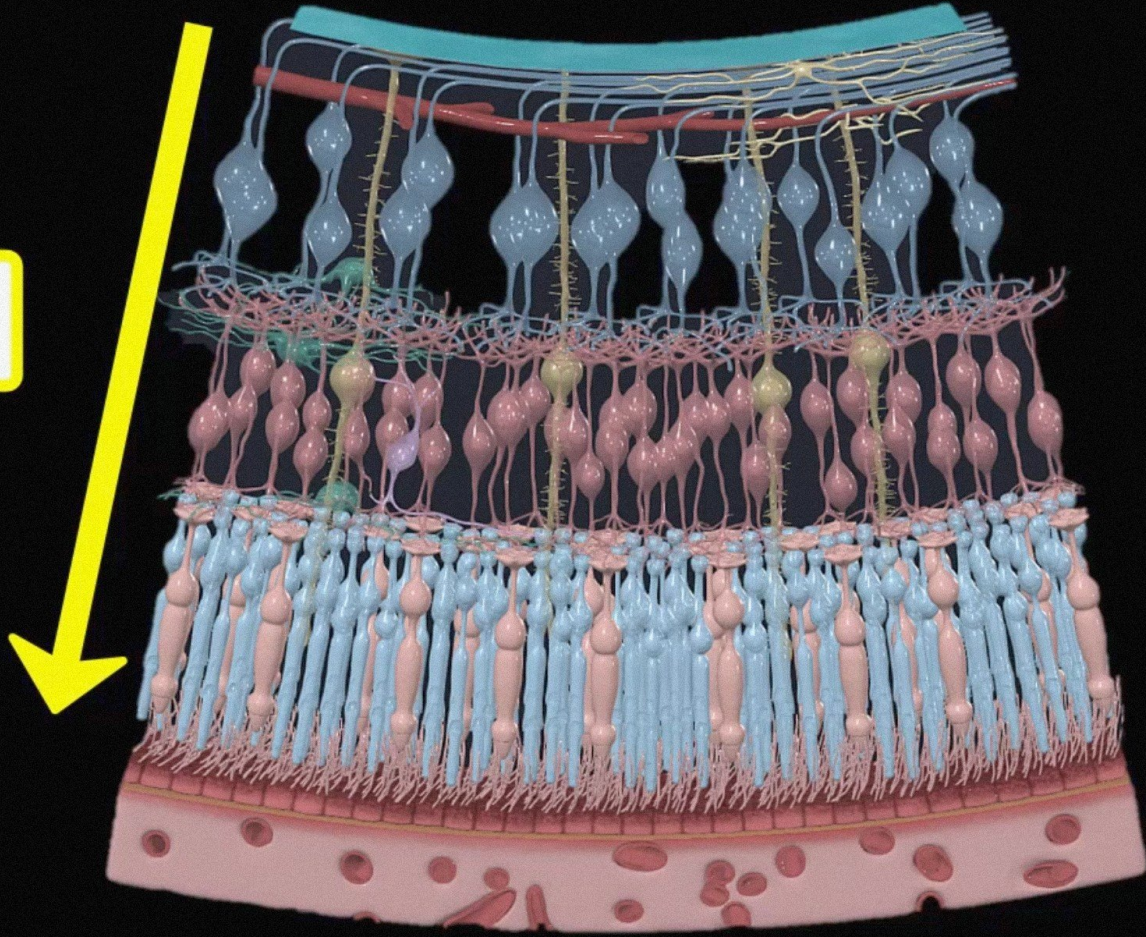
Eye Anatomy

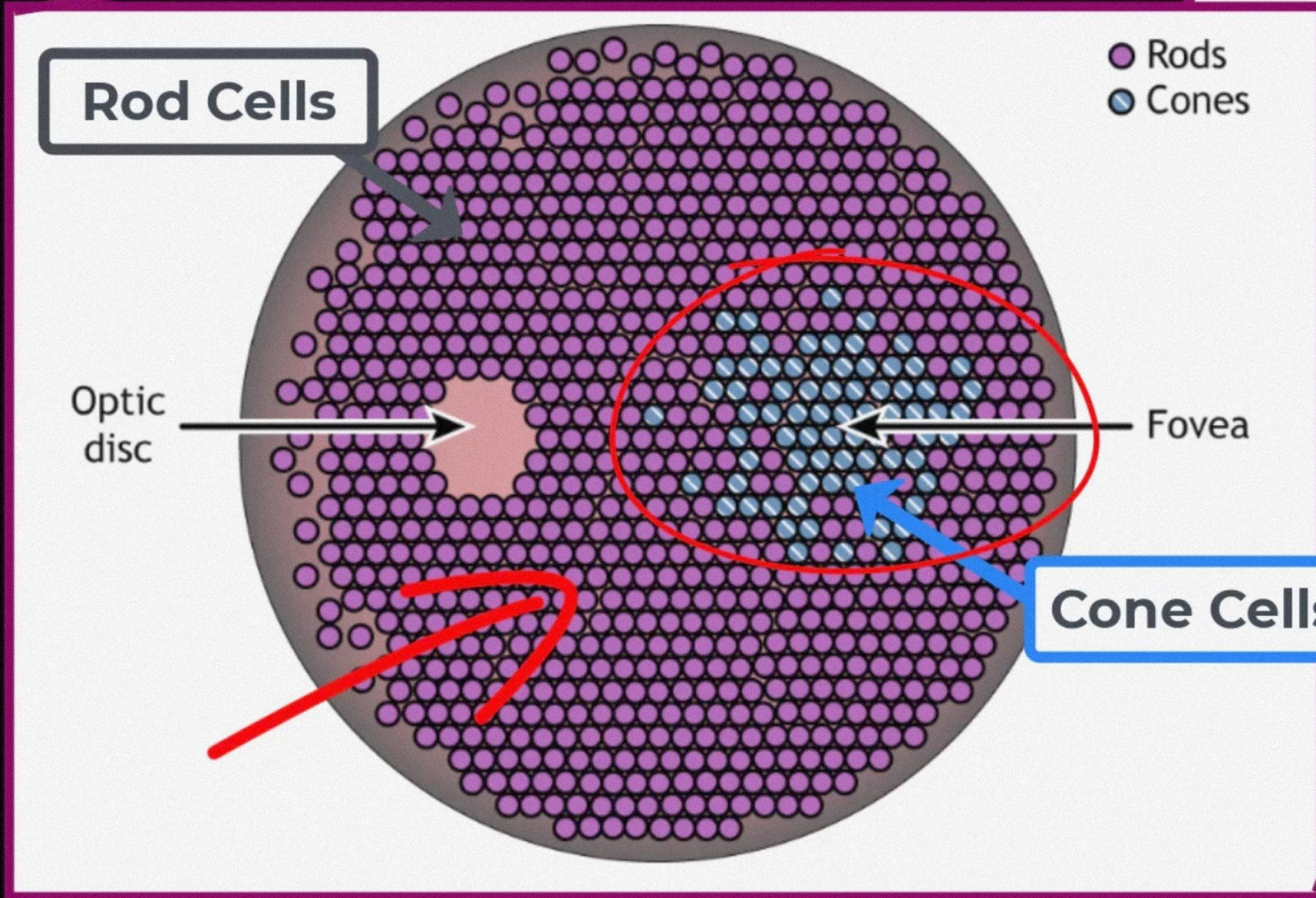
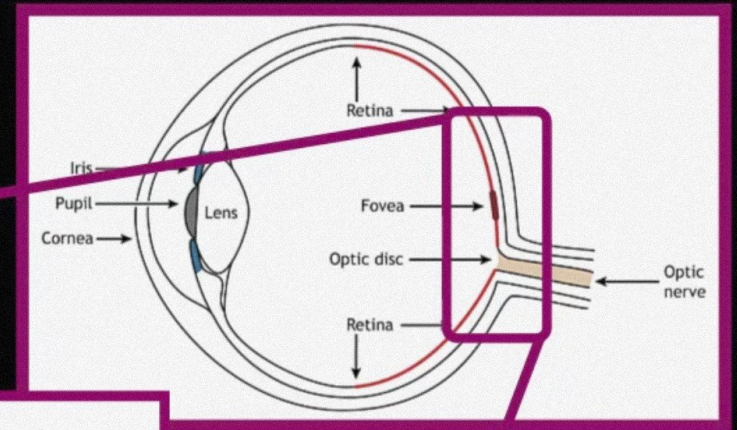
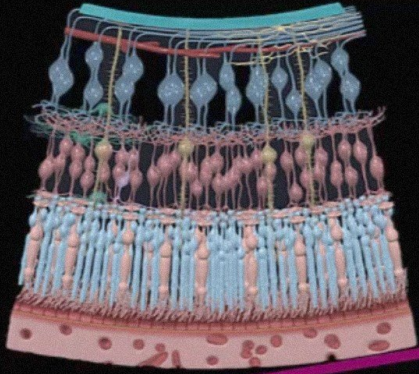


Optic nerve (II)
Nervus opticus

Eye Anatomy

Light

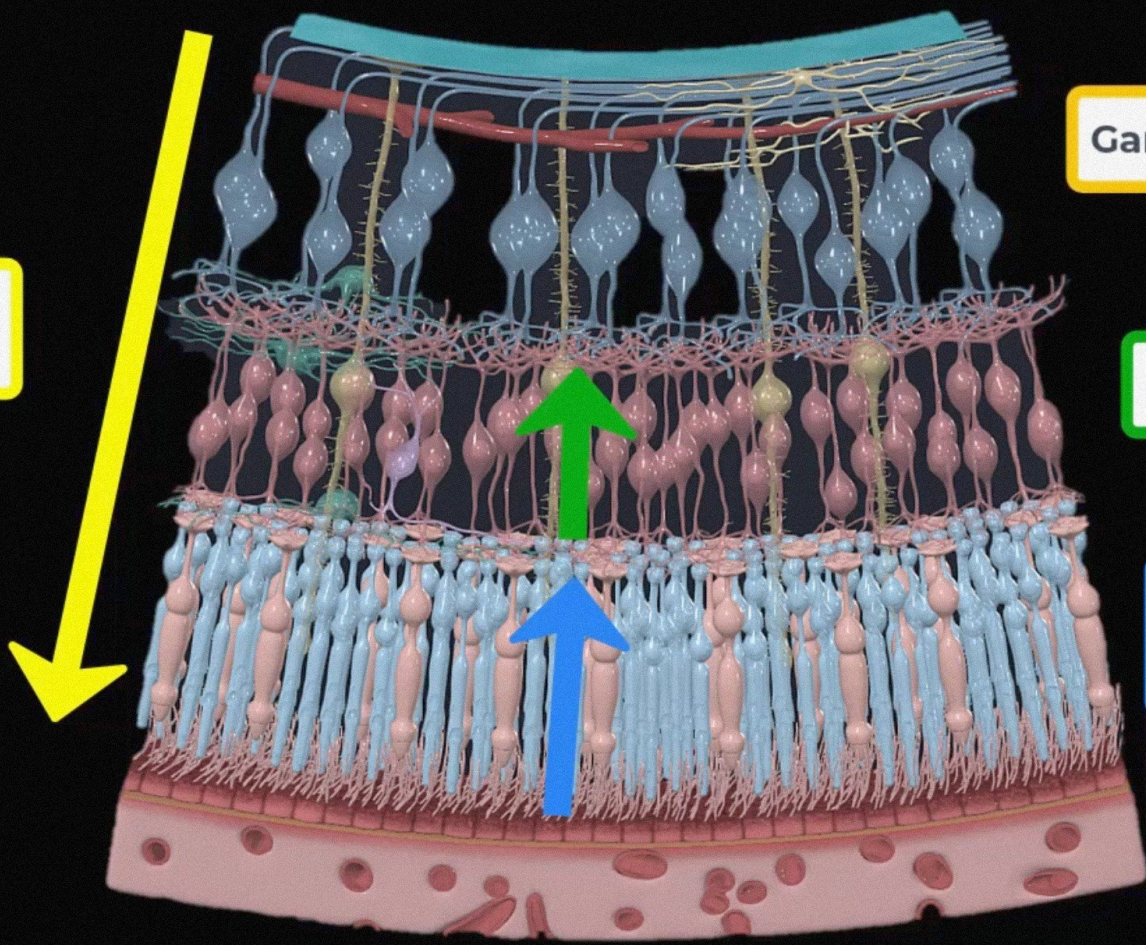




Optic nerve (II)
Nervus opticus

Eye Anatomy

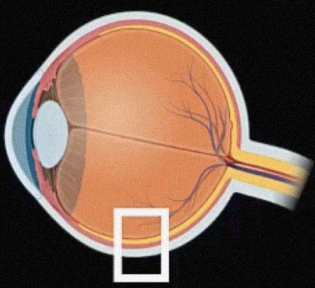
Light



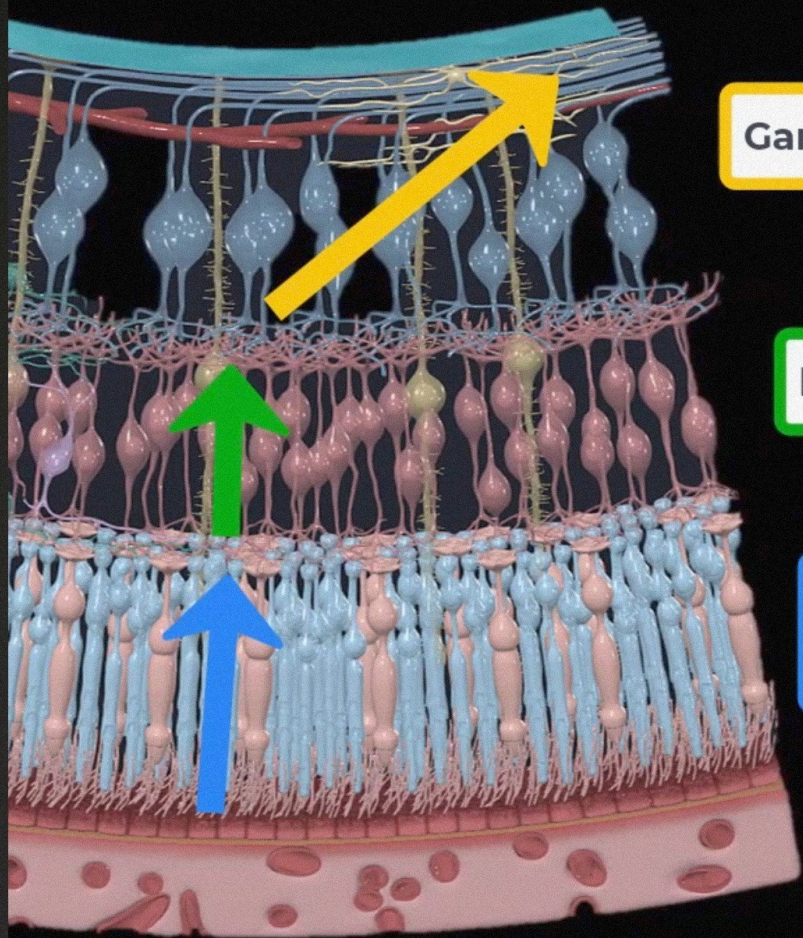
Ganglion cells

Bipolar cells

**Rods and
Cones**



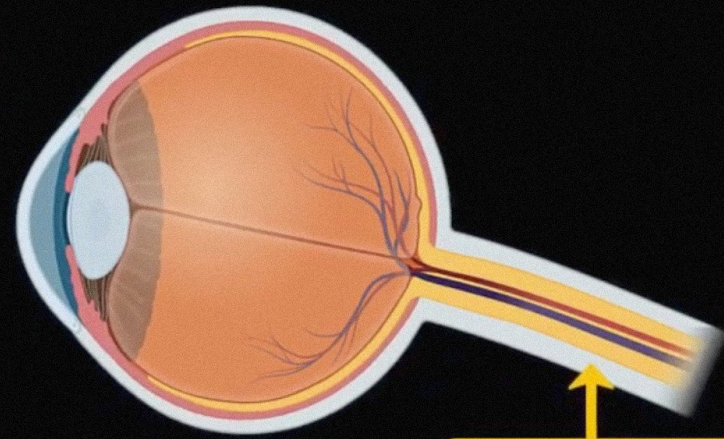
Eye Anatomy



Ganglion cells

Bipolar cells

Rods and
Cones



Optic Nerve



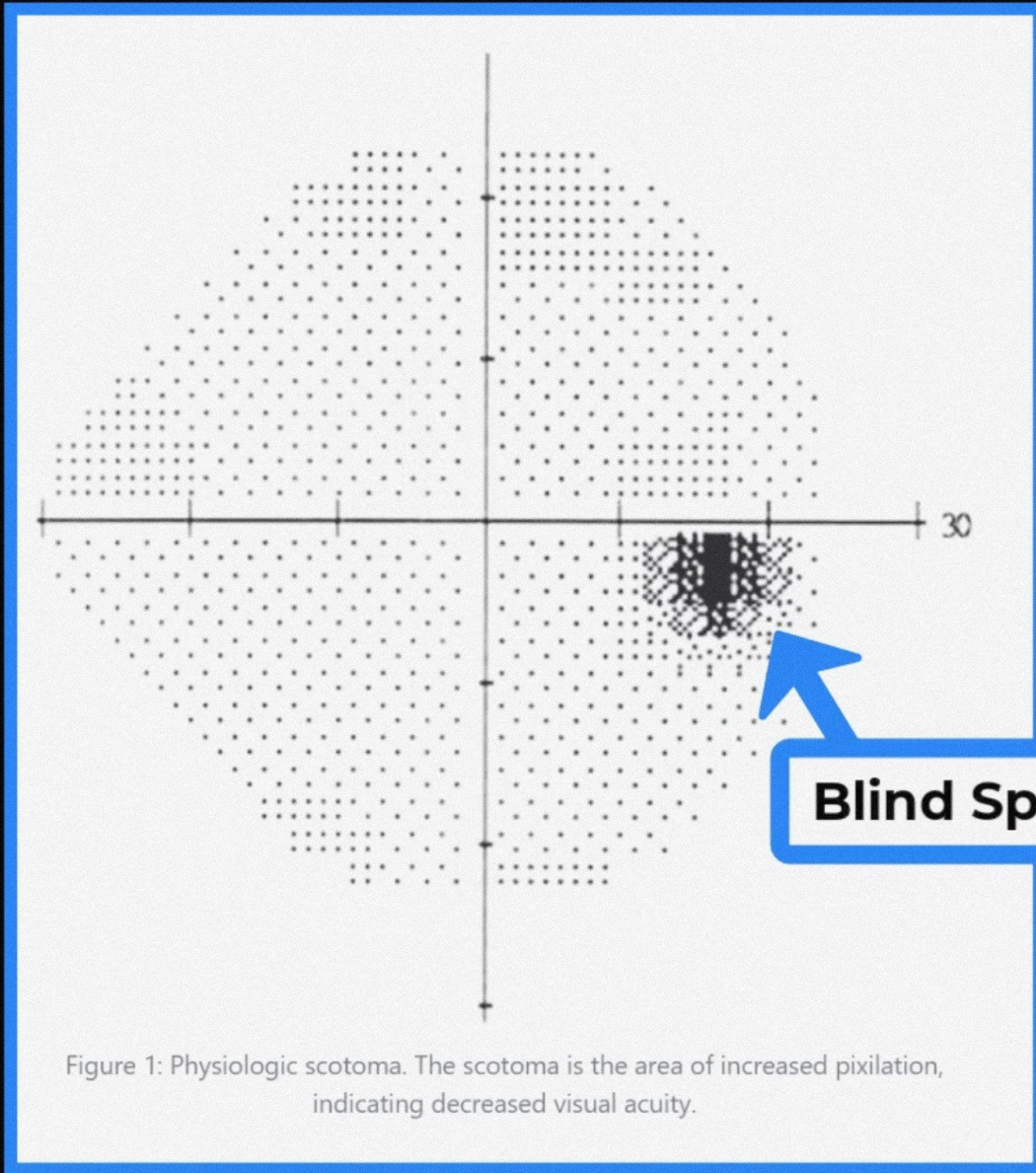
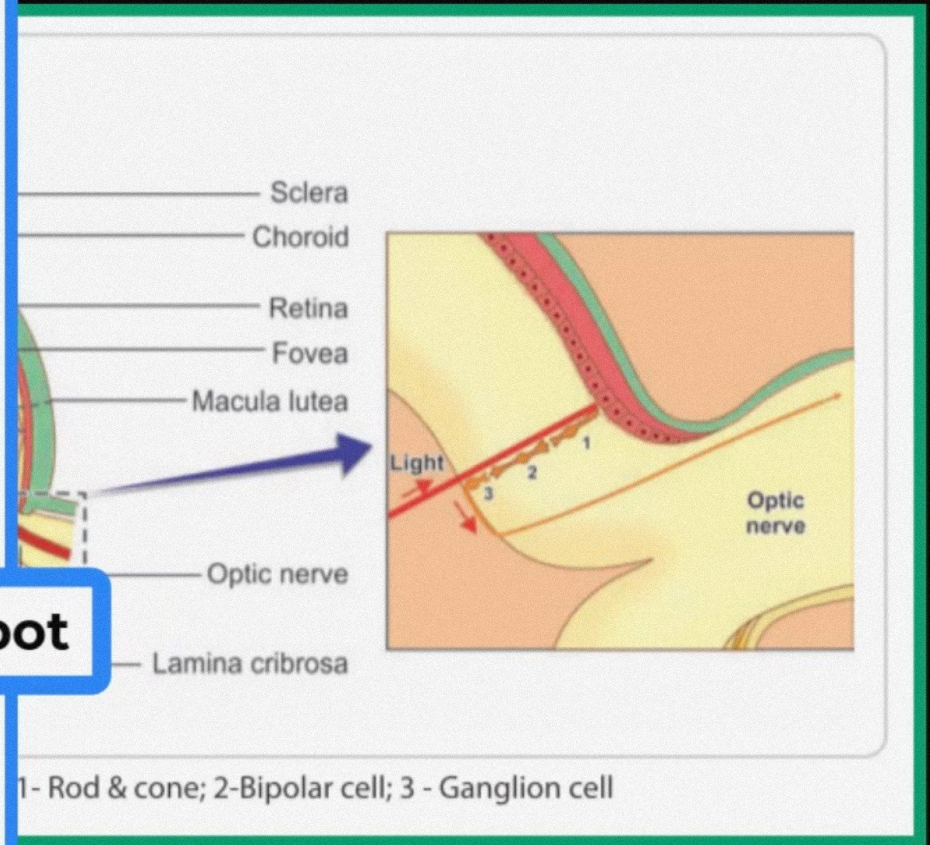


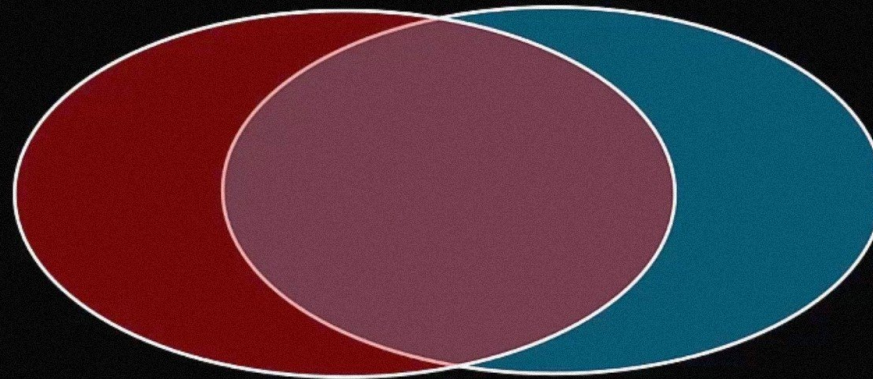
Figure 1: Physiologic scotoma. The scotoma is the area of increased pixilation, indicating decreased visual acuity.




Optic nerve (II)
Nervus opticus

Visual field

Visual field of left eye



Visual field of right eye




Optic nerve (II)
Nervus opticus

Visual field

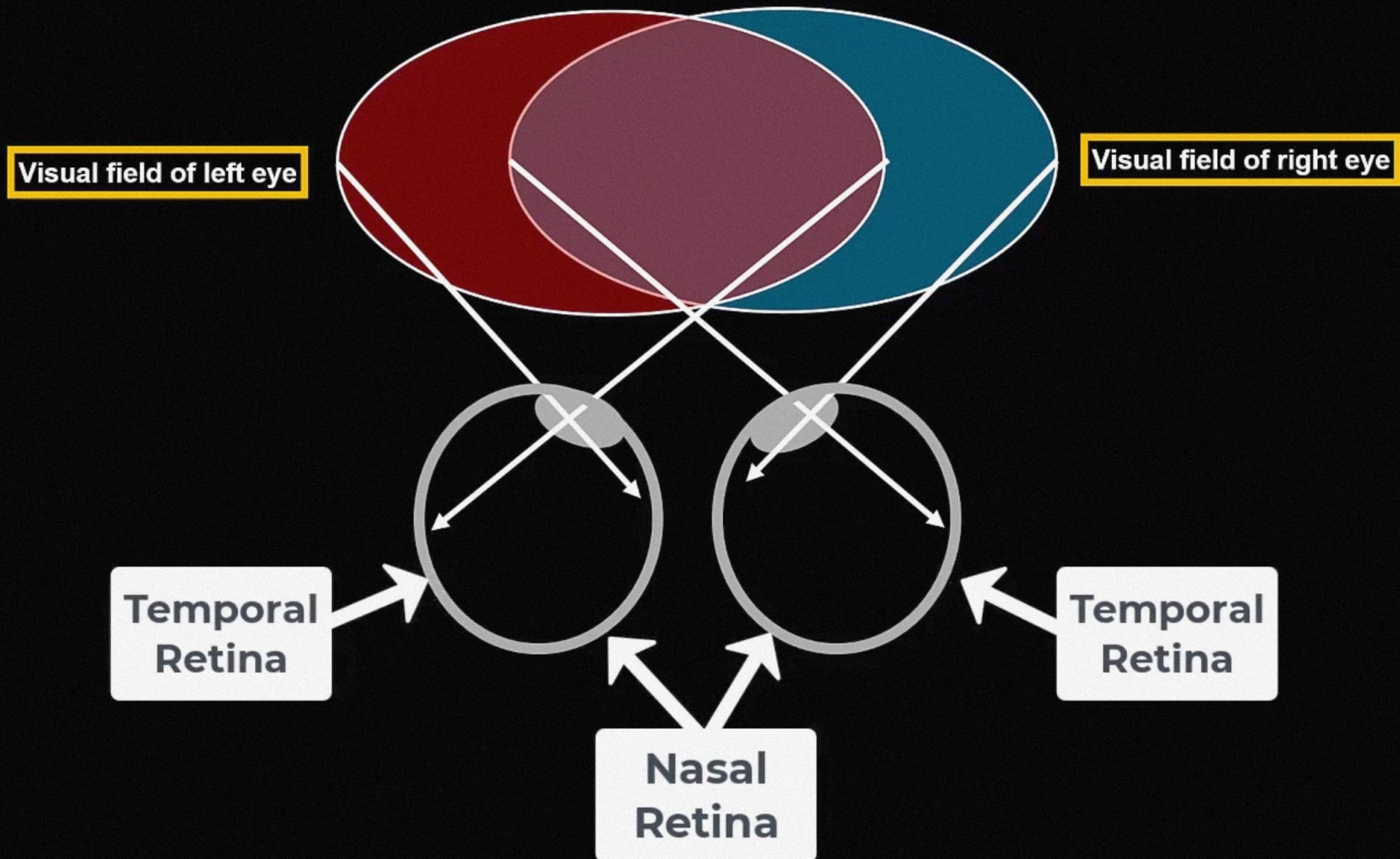
Visual field of left eye

Visual field of right eye



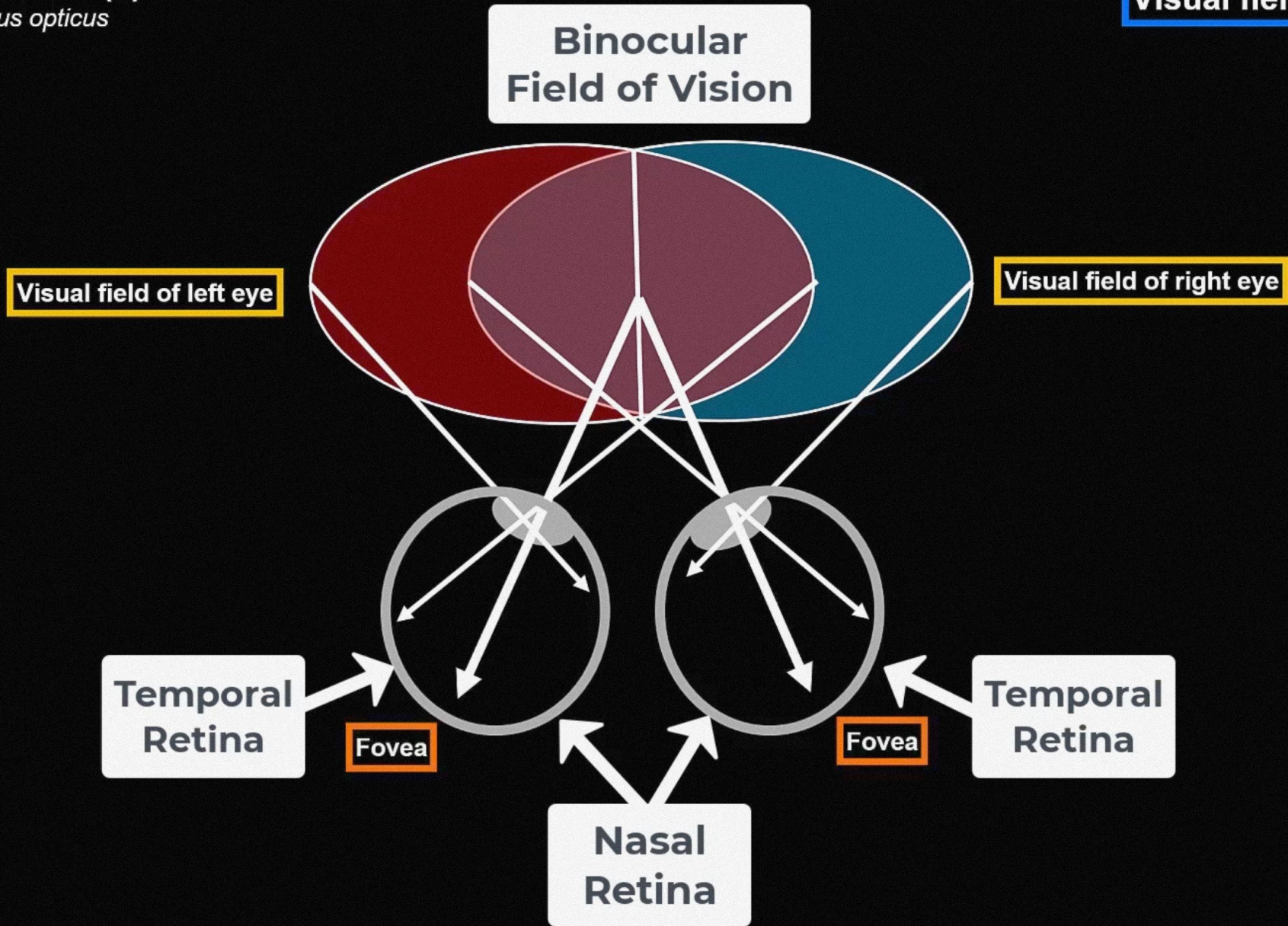
Optic nerve (II)
Nervus opticus

Visual field



Optic nerve (II)
Nervus opticus

Visual field

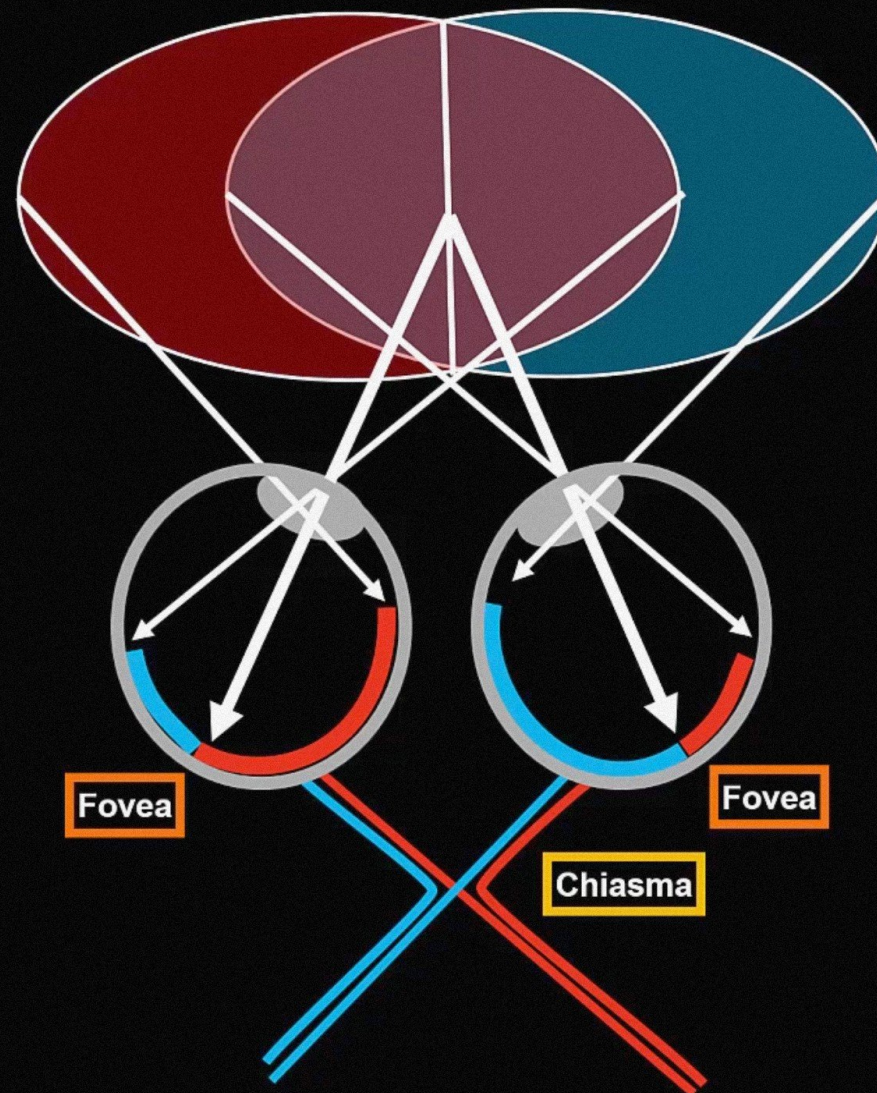


Optic nerve (II)
Nervus opticus

Visual field

Visual field of left eye

Visual field of right eye



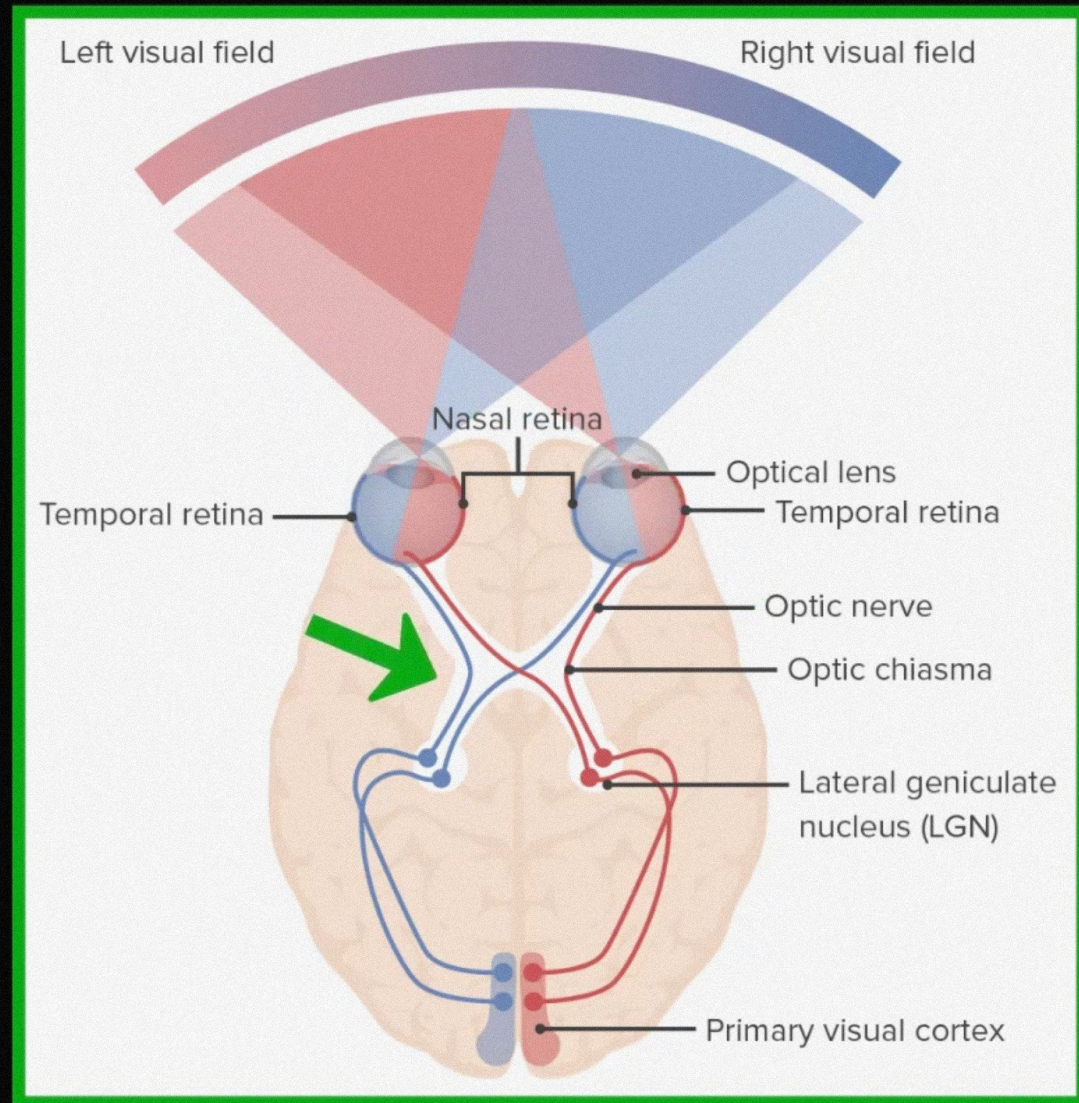
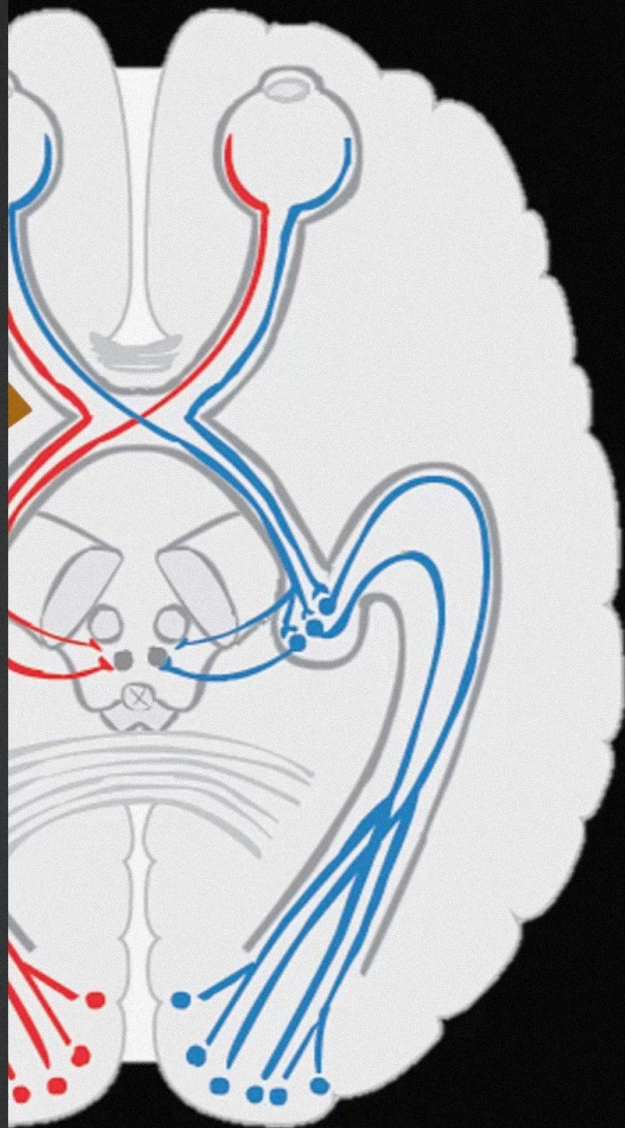
Fovea

Fovea

Chiasma

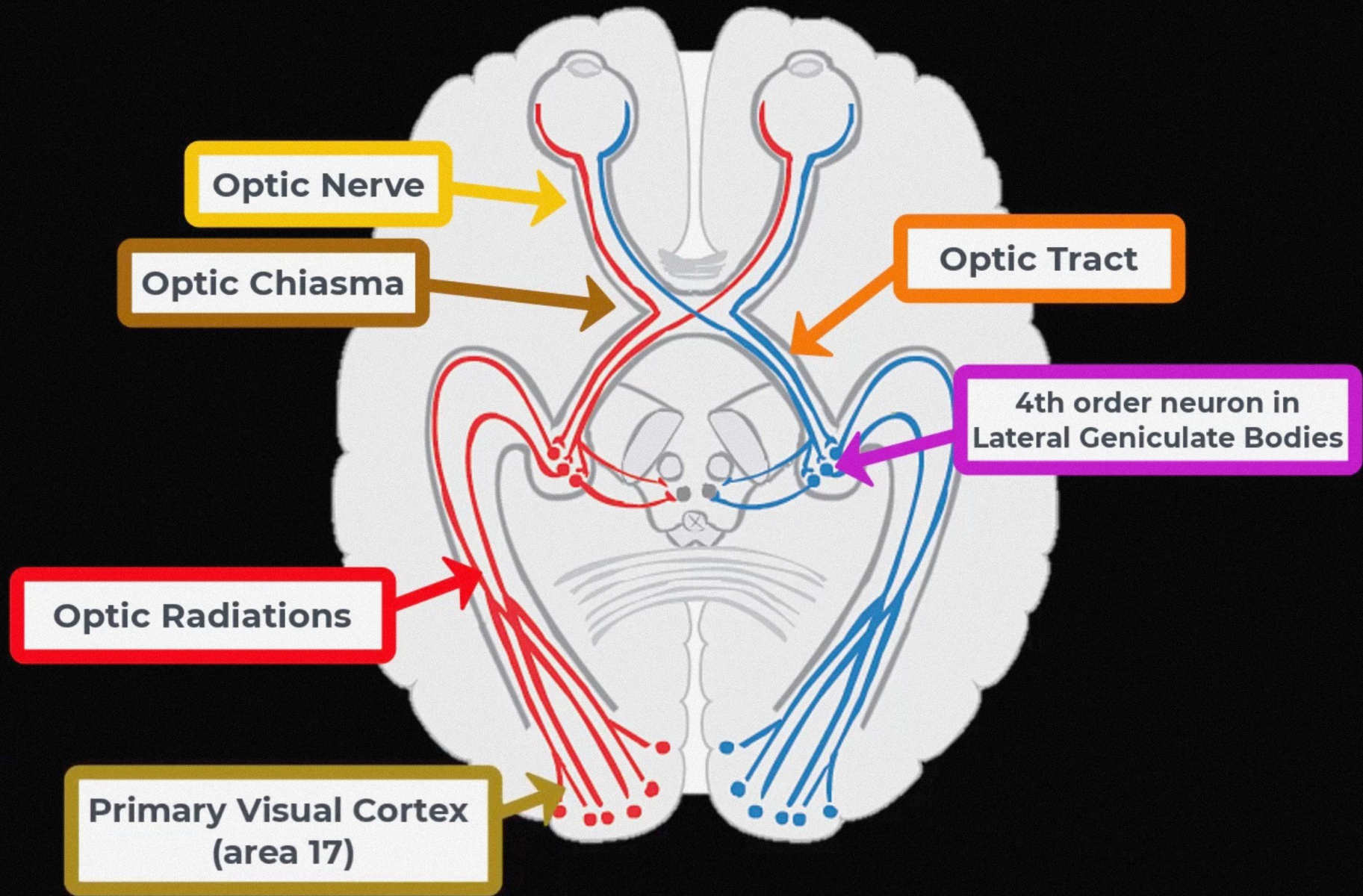


Course of the Visual Pathway



Optic nerve (II)
Nervus opticus

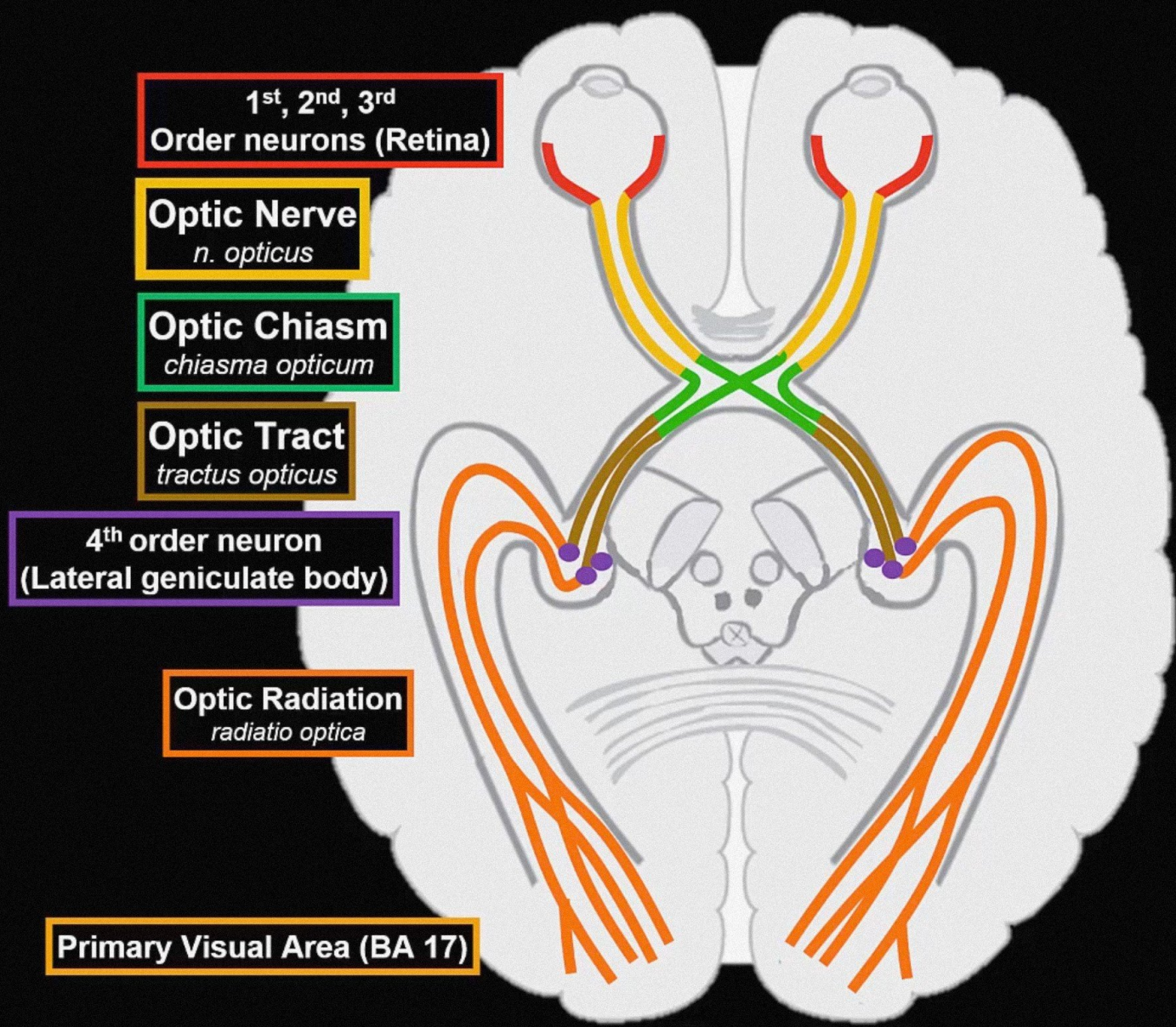
Course of the Visual Pathway



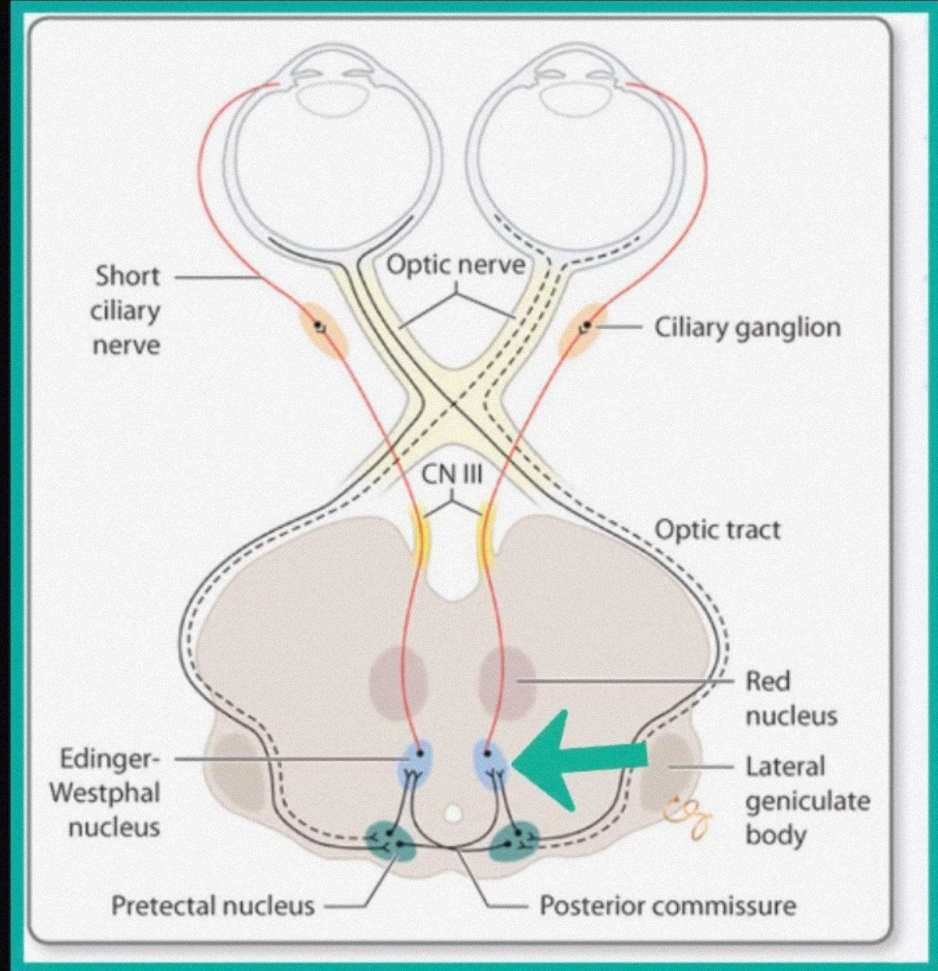
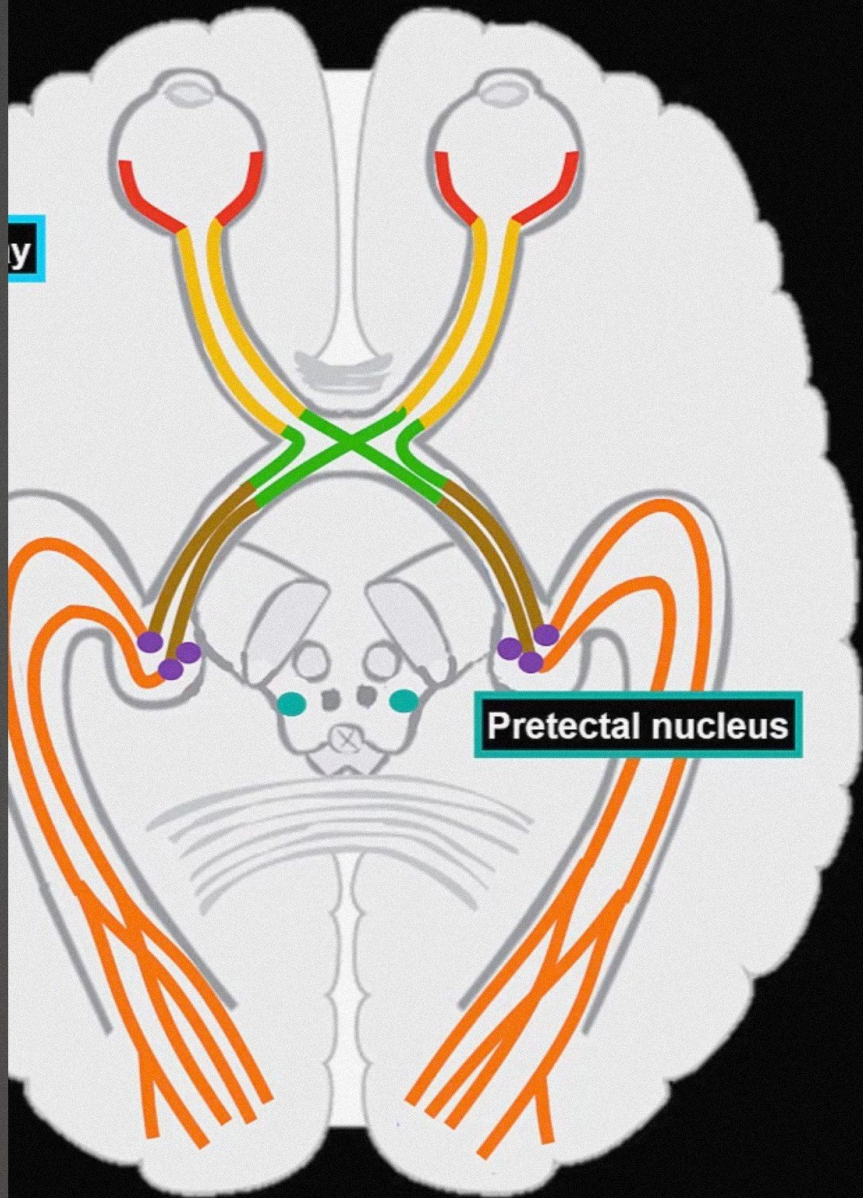
Optic nerve (II)

Nervus opticus

Course of the Visual Pathway

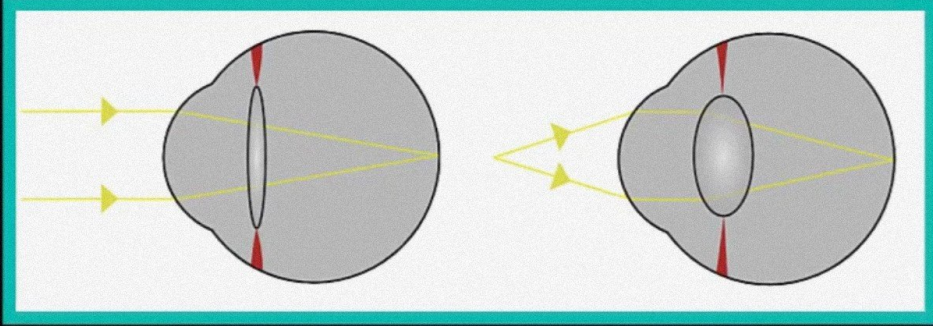


Visual Pathway Collaterals

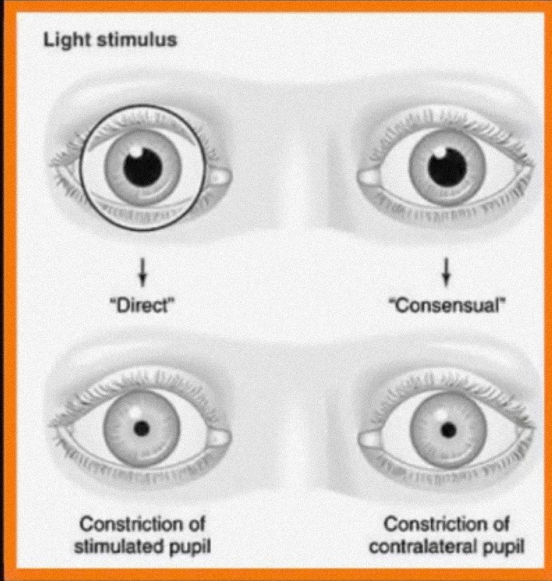


Visual Pathway Collaterals

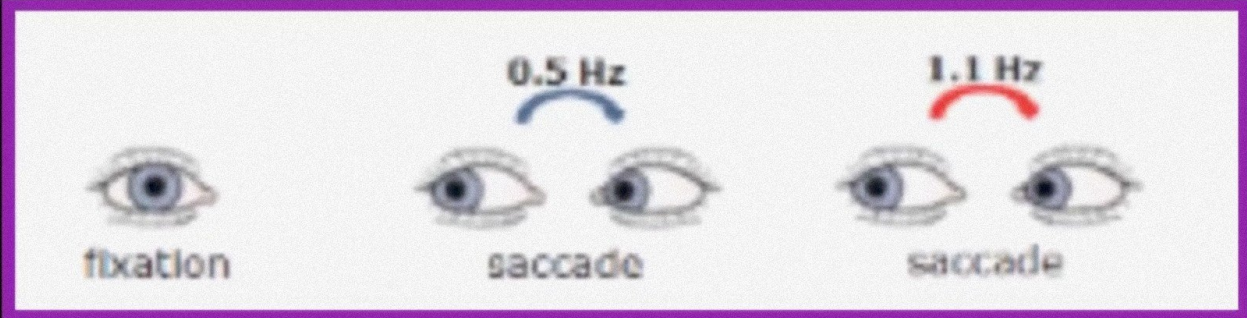
Accommodation Reflex



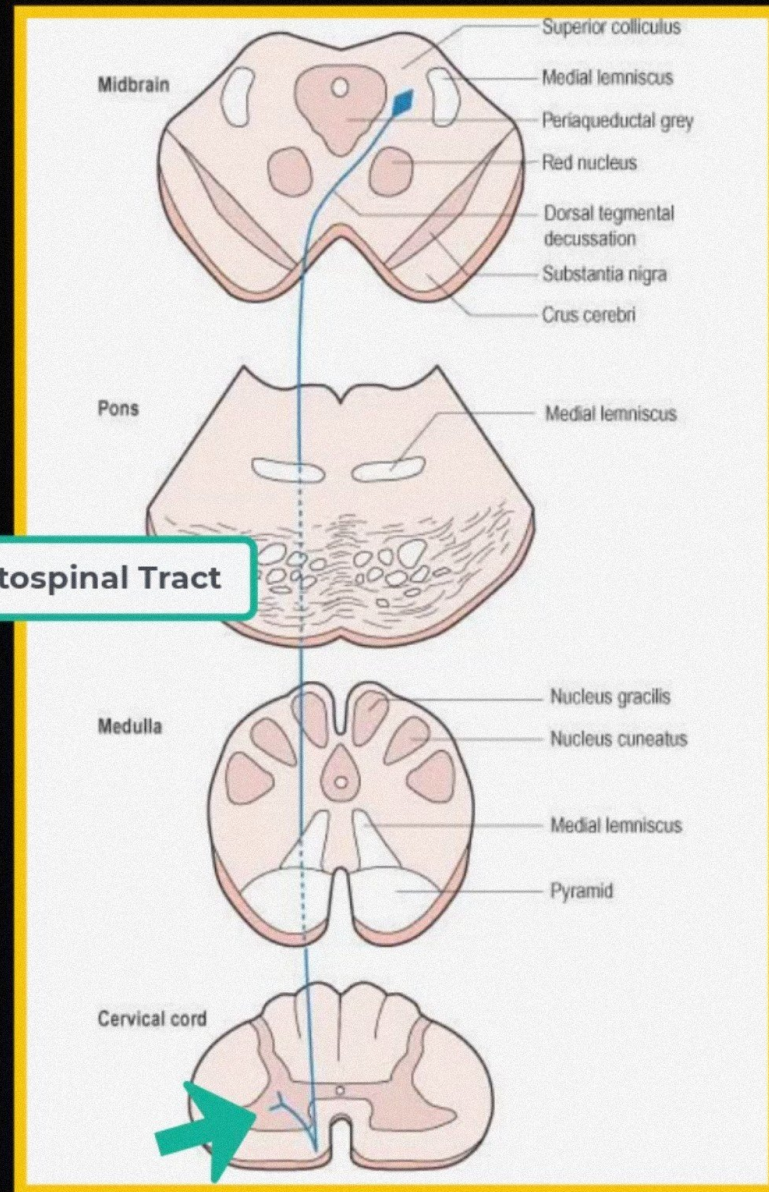
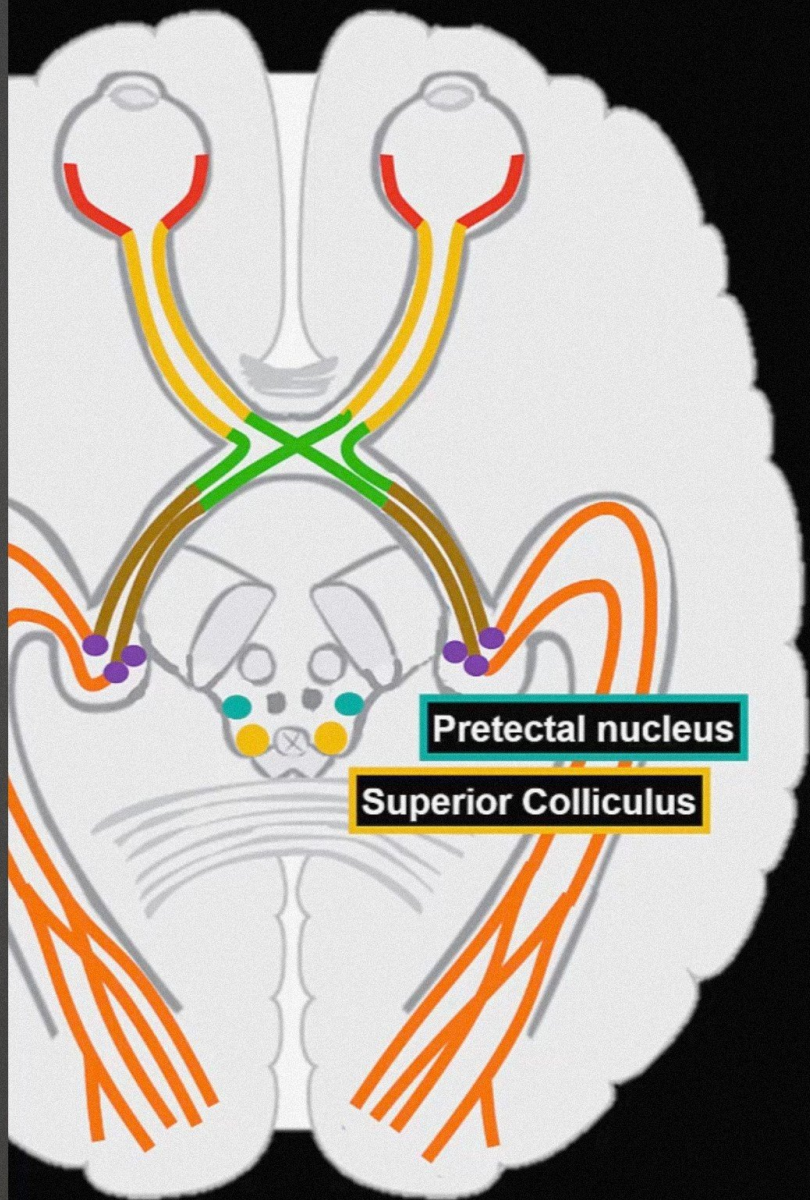
Direct and consensual light reflex



Saccadic eye movements



Visual Pathway Collaterals



Tectospinal Tract



Optic nerve (II)

Nervus opticus

Clinical Relevance

