

Gram Positive Cocci

Staphylococcus

- Cocci in clusters (grapes)
- Catalase ⊕
- Facultative anaerobes

S. aureus (Coagulase ⊕)

Features	Pathogenesis	Diseases	Treatment
<ul style="list-style-type: none"> • Small yellow colonies on blood agar • β-hemolytic • Ferments mannitol on mannitol salt agar <p>Reservoir</p> <ul style="list-style-type: none"> • Normal flora of nasal mucosa and skin <p>Transmission</p> <ul style="list-style-type: none"> • Hands, sneezing • Surgical wounds • Food: custard, potato salad, canned meats, ham 	<ul style="list-style-type: none"> • Protein A— inhibits opsonization (binds Fc component of IgG and prevents phagocytosis) • TSST-1— (Toxic shock syndrome toxin-1) superantigen binds MHC II • Coagulase— converts fibrinogen to fibrin clot (can hide out in blood clots) • α-toxin— cytolytic toxin that forms pores (hemolysis) • Exfolatins— (scalded skin syndrome/bullous impetigo) • Enterotoxins— (fast acting, heat stable) → food poisoning • Leukocidin— destroys leukocytes 	<p>Skin— (pathogenicity= exfoliatins/coagulase)</p> <ul style="list-style-type: none"> • Impetigo→Erythematous papules to bullae (blisters w/ clear fluid) • Scalded Skin Syndrome→Diffuse epidermal peeling (destroys keratinocyte attachments in stratum granulosum) • Abscess/mastitis→Subcutaneous tenderness, redness, swelling • Surgical infections→Fever w/ cellulitis <p>Systemic</p> <ul style="list-style-type: none"> • Toxic shock syndrome→ Fever, hypotension, scarlatiniform rash (particularly palms and soles, innumerable small red papules diffusely distributed), multiorgan failure • Infective endocarditis (acute) → 2nd MCC overall and MCC in IVDA) Fever, malaise, leukocytosis, heart murmur (tricuspid regurg) • Pneumonia→ Salmon colored sputum, rapid onset, high rate of necrosis, high fatality: **MC post-influenza (elderly; rapid 2-3 days), also associated with nosocomial, ventilator, IVDA, CGD, CF causes • Osteomyelitis (MCC)→ Bone pain, fever, redness, lytic bone lesions on imaging • Gastroenteritis→ (toxin <u>performed</u> in food) 2-6 hrs after ingestion: nausea, abdominal pain, vomiting, diarrhea (custard, potato salad, canned meats) 	<p>DOC</p> <ul style="list-style-type: none"> • Nafcillin • Oxacillin <p>MRSA</p> <ul style="list-style-type: none"> • Vancomycin <p>VRSA</p> <ul style="list-style-type: none"> • Quinupristin • Dalfopristin • Linezolid <p>Gastroenteritis is self limiting</p>

S. epidermidis (Coagulase ∅)

<ul style="list-style-type: none"> • γ-hemolytic • Novobiocin Sensitive • Urease ⊕ <p>Normal flora of skin</p>	<ul style="list-style-type: none"> • Biofilm producer (Makes antibiotic treatment largely ineffective, and implants must be removed) 	<ul style="list-style-type: none"> • Causes biofilms to grow on plastic devices placed within the body (IV catheters and medical prostheses) • Infective endocarditis→ MCC of patient with prosthetic valves 	<p>DOC</p> <ul style="list-style-type: none"> • Vancomycin + aminoglycoside <p>*Must remove or replace infected implant</p>
--	--	---	---

S. saprophyticus (Coagulase ∅)

<ul style="list-style-type: none"> • γ-hemolytic • Novobiocin Resistant <p>Normal flora of female genital tract</p>	<ul style="list-style-type: none"> • Adhesins (lactosamine structure) facilitate adherence to urothelium 	<ul style="list-style-type: none"> • Honeymoon cystitis→ UTI's in newly sexually active females when bacteria is displaced from the normal flora into the urethra • 2nd MCC UTI in females 17-27 (#1 E.Coli) 	<p>DOC</p> <ul style="list-style-type: none"> • Trimethoprim-sulfamethoxazole (TMP-SMX) • Quinolones
--	--	--	---

Streptococcus

- Cocci in chains
- Catalase ∅ and Coagulase ∅
- Facultative anaerobes

S. pyogenes (Group A)			
Features	Pathogenesis	Diseases	Treatment
<ul style="list-style-type: none"> • β-hemolytic • PYR ⊕ (pyrrolidonyl arylamidase) • Bacitracin Sensitive <p>Reservoir</p> <ul style="list-style-type: none"> • Human throat and skin <p>Transmission</p> <ul style="list-style-type: none"> • Direct contact • Respiratory droplets 	<ul style="list-style-type: none"> • M protein— <u>antiphagocytic</u> (M12 strains assoc. w/ acute glomerulonephritis) • Streptolysin O— immunogenic (creates antibodies, allows it to be assayed= ASO titer) • Streptolysin S—not immunogenic <p>Spreading Factors</p> <ul style="list-style-type: none"> • Streptokinase—breaks fibrin clot • Streptococcal DNase—liquefies pus • Hyaluronidase—hydrolyzes ground substance of connective tissue • Exotoxins A-C— pyrogenic/erythrogenic superantigens, cause fever and rash of scarlet fever 	<p>Acute suppurative infections:</p> <ul style="list-style-type: none"> • Pharyngitis→ Abrupt onset of sore throat, fever, malaise, headache, tonsillar abscesses, tender anterior cervical lymph nodes • Scarlet fever→ Pharyngitis followed by: <ul style="list-style-type: none"> ○ Blanching “<u>sandpaper rash</u>” (spares palms and soles, however desquamation of palms and soles is common) ○ <u>Strawberry tongue</u>, nausea/vomiting ○ Circumoral pallor (paleness around mouth) ○ Fever and rash mediated by <u>exotoxins</u> • Impetigo→ Pyogenic skin infection (<u>honey crusted lesions</u>) • Necrotizing fasciitis→ rapid, amputation, high mortality <p>Non-suppurative sequelae to infection:</p> <ul style="list-style-type: none"> • Rheumatic fever→ (Type 2 hypersensitivity) Antibodies to heart tissue 2 weeks post-pharyngitis (fever, joint inflammation, carditis, erythema marginatum, chorea) • Acute glomerulonephritis (M12 serotype)→ (Type 3 hypersensitivity) Post-pharyngitis; immune complexes bound to glomeruli (HT, pulmonary edema, <u>smoky urine</u>) 	<p>Diagnosis</p> <ul style="list-style-type: none"> • Rapid Strep test (ELISA-based) • ASO titer >200 is significant for RF <p>DOC</p> <ul style="list-style-type: none"> • Beta lactam drugs • (Macrolides for allergy) <p>Consider prophylactic antibiotics for 5 years post acute RF</p> <p>Jones criteria for RF</p> <p>Joints ♥(carditis) Nodules (subcutaneous) Erythema marginatum Sydenham Chorea</p>
S. agalactiae (Group B)			
<ul style="list-style-type: none"> • β-hemolytic • Hydrolyze hippurate • CAMP test ⊕ (arrowhead pattern hemolysis w/ S. aureus sphingomyelinase) • Bacitracin Resistant <p>Reservoir</p> <ul style="list-style-type: none"> • Vagina (Normal flora in 25% of women) and GI tract <p>Transmission</p> <ul style="list-style-type: none"> • Newborn infected at birth 	<ul style="list-style-type: none"> • Capsule—antiphagocytic • β-hemolysin • CAMP factor—enhances β-hemolysis 	<p>**MCC neonatal meningitis and septicemia**</p> <ol style="list-style-type: none"> 1. Group B strep 2. E. Coli 3. Listeria <p>Increased risk for women with prolonged labors after rupture of membranes</p>	<p>DOC</p> <ul style="list-style-type: none"> • Ampicillin + Aminoglycoside (or cephalosporin) • Prophylaxis during labor of infected women (intra partum)→ IV ampicillin or penicillin (clindamycin or erythro for allergies)

S. pneumoniae			
Features	Pathogenesis	Diseases	Treatment
<ul style="list-style-type: none"> Lancet shaped diplococci α-hemolytic (green ring) Optochin Sensitive Lysed by bile <p>Reservoir Upper respiratory tract</p> <p>Transmission Respiratory droplets</p>	<ul style="list-style-type: none"> Polysaccharide Capsule—major virulence factor IgA protease— colonizing factor→ aids in attachment to respiratory mucosa by cleaving immunoglobulins (also in: Neisseria, Haemophilus) Pneumolysin O—damages respiratory epithelium and inhibits respiratory burst/ classical complement fixation Teichoic acid <p>Predisposing Factors—Antecedent influenza/measles infection, COPD, CHF, Alcoholism, Asplenia</p>	<p>MCC Adult Meningitis→ Peptidoglycan and teichoic acids are highly inflammatory in CNS (CSF shows ↑WBCs, ↑protein, ↓glucose) Septicemia MCC death in Sickle cell children</p> <p>MCC Otitis media and sinusitis in children (can lead to cerebellar/temporal lobe abscesses)</p> <ol style="list-style-type: none"> Strep Pneumo H. Influenza Moraxella catarrhalis <p>MCC Typical pneumonia→ shaking chills, high fever, lobar consolidation, blood-tinged “rusty sputum” (due to pneumolysin O)</p> <p>MOPS= Meningitis, Otitis media, Pneumonia, Sinusitis</p> <p>Diagnosis</p> <ul style="list-style-type: none"> Quellung ⊕ reaction (swelling of capsule) Lattex particle agglutination (tests for capsular antigen) 	<p>DOC</p> <ul style="list-style-type: none"> Pneumonia: macrolides Meningitis: ceftriaxone Otitis media/sinusitis: amoxicillin + clavulanate (erythro for allergy) <p>Vaccine</p> <ul style="list-style-type: none"> Pediatric—Conjugated to diphtheria toxoid w/ 13 MC invasive serotypes Adult (>65 years)—Polysaccharide vaccine w/ 23 MC serotypes (for elderly, AIDs, asplenic, sickle cell)
Viridans Streptococci (S. Sanguis, S. mutans)			
<ul style="list-style-type: none"> α-hemolytic (green ring) Optochin Resistant <p>Reservoir</p> <ul style="list-style-type: none"> Normal flora in oropharynx <p>Transmission= endogenous</p>	<ul style="list-style-type: none"> Dextran (biofilm)— mediated adherence onto tooth enamel, damaged heart valve (fibrin-platelet aggregates), or each other (vegetation—provides protection from immune system) 	<ul style="list-style-type: none"> Dental Caries→ (mainly S. mutans) forms plaque via dextran Subacute Infective Endocarditis→ MCC overall (mainly S. sanguis) causing vegetations on damaged heart valves <p>Prophylactic antibiotics prior to dental work for those with damaged heart valve</p>	<p>DOC</p> <ul style="list-style-type: none"> Penicillin G + aminoglycosides
Enterococcus [Group D— E. faecalis, E. faecium, S. bovis (non-enterococcus)]			
<ul style="list-style-type: none"> PYR ⊕ Varied hemolysis (usually gamma: no hemolysis) Hydrolyze exculin in 40% bile and 6.5% NaCl (bile exculin agar turns black) (NOT strep bovis) <p>Reservoir</p> <ul style="list-style-type: none"> Colon, urethra <p>Transmission= endogenous</p>	<ul style="list-style-type: none"> Bile/ salt tolerance allows survival in bowel and gall bladder During medical procedures on GI/GU tract E. faecalis→ bloodstream→ previously damaged heart valves→ endocarditis 	<ul style="list-style-type: none"> UTI and biliary tract infections Infective (subacute) endocarditis → those with damaged heart valves during GI/GU procedures (often elderly) <p>Endocarditis with enterococcus is associated with GU procedure in the elderly</p> <p>If strep bovis is the causative agent of endocarditis there is a high association with underlying colon cancer or ulcerative colitis</p>	<p>All strains carry some drug resistance (no effective treatment for vanco resistant strains—D-ala D-ala → D-ala D-lac)</p> <p>Prophylactic use of penicillin+gentamycin in patients with damaged valves prior to GI/GU manipulations</p>

Gram Positive Rods

Spore-forming Bacillus (Aerobic)

B. anthracis			
Features	Pathogenesis	Diseases	Treatment
<ul style="list-style-type: none"> Large, boxcar-like rods Nonmotile Polypeptide capsule (poly-D-glutamate) Potential biowarfare agent <p>Reservoir</p> <ul style="list-style-type: none"> Animals, skin, soil <p>Transmission</p> <ul style="list-style-type: none"> Contact w/ infected animals or inhalation of spores 	<ul style="list-style-type: none"> Capsule—polypeptide (only human pathogen w/ polypeptide capsule) antiphagocytic <p>Anthrax toxin</p> <ul style="list-style-type: none"> Protective antigen— mediates entry of LF/EF into cells Lethal factor— kills cells Edema factor—adenylate cyclase (<u>calmodulin activated like pertussis adenylyate cyclase</u>) 	<ul style="list-style-type: none"> Cutaneous Anthrax→ Papule→ Malignant pustules→ <u>central necrosis (black eschar) with erythematous border</u> and <u>painful lymphadenopathy</u> Wool Sorter's disease (Pulmonary)→ Life threatening pneumonia: cough, fever, malaise, facial edema, cyanosis, shock with <u>mediastinal hemorrhagic lymphadenitis</u> Gastrointestinal anthrax→ rare, edema + blockage of GI tract, bloody diarrhea/vomiting, high mortality <p>Population at risk: postal workers, farmers, veterinarians</p>	<p>Diagnosis</p> <ul style="list-style-type: none"> Gram stain, serology, PCR <p>DOC</p> <ul style="list-style-type: none"> Ciprofloxacin or Doxycycline <p>Toxoid vaccine given to high risk occupations</p>

B. cereus			
<p>Reservoir= nature</p> <p>Transmission</p> <ul style="list-style-type: none"> Fried rice from Chinese buffet, meats/sauce 	<ul style="list-style-type: none"> Emetic toxin—preformed, fast (fried rice- 1-6 hrs) Diarrheal toxin—prod in vivo (meats/sauces- 18 hrs) ↑cAMP= watery diarrhea 	<ul style="list-style-type: none"> Gastroenteritis→ nonbloody, Emetic type (fried rice) similar to s. aureus. Diarrheal type (meats/sauces) similar to LT of ETEC. 	<p>Diagnosis</p> <ul style="list-style-type: none"> Clinical <p>Tx= self limiting</p>

Clostridium (Anaerobic)

C. tetani			
<ul style="list-style-type: none"> Produces Tetanus toxin <p>Reservoir= soil</p> <p>Transmission</p> <ul style="list-style-type: none"> Puncture wounds/trauma Contaminated w/ soil Requires low tissue O₂ 	<ul style="list-style-type: none"> Tetanospasmin—tetanus toxin produced by germination of spores in the tissues Toxin carried intra-axonally to CNS→ binds to ganglioside receptors→ Blocks release of inhibitory NT glycine/GABA at spinal synapses→ excitatory neurons unopposed= extreme muscle spasms 	<ul style="list-style-type: none"> Tetanus→ Risus sardonius (sardonic grin), Opisthotonus (hyperextension of back), Lock jaw/tingling (first sign), extreme muscle spasms <p>Tetanus prone wound</p> <ul style="list-style-type: none"> Blunt, burn, frostbite, w/ contaminants 1 cm deep and > 6 hrs old→ Vaccine (if >5yrs since last booster) + TIG (if vacc history unknown) <p>Not tetanus prone wound</p> <ul style="list-style-type: none"> Linear, 1 cm deep, no contaminants, < 6 hrs old → Vaccine if > 10 years since booster (or history unknown) 	<ul style="list-style-type: none"> TIG (tetanus immunoglobulin) to neutralize toxin plus metronidazole or penicillin Spasmolytic drugs (diazepam); debride; delay closure

C. botulinum

Features	Pathogenesis	Diseases	Treatment
<ul style="list-style-type: none"> • Produces Botulinum Toxin <p>Reservoir= soil/dust</p> <p>Transmission</p> <ul style="list-style-type: none"> • Food (canned vegetables, smoked fish, honey for infants) • Traumatic implantation 	<ul style="list-style-type: none"> • Spores survive in soil and dust; germinate in moist, warm, nutritious, but nonacidic and anaerobic conditions • Botulinum toxin (lysogenic phage encoded)—polypeptide neurotoxin (A-B types MC), heat labile • MOA—Absorbed by gut→ blood to peripheral nerve synapses→ Blocks release of ACh at neuromuscular junction→ flaccid paralysis 	<p>Forms of Botulism</p> <ul style="list-style-type: none"> • Adult—Preformed toxin ingested (alkaline vegetables—canned green beans, smoked fish); 1-2 day onset weakness, dizziness, blurred vision, flaccid paralysis, nausea, diarrhea, vomiting • Infant—Spores ingested (honey, dust), toxin produced in gut; constipation, “floppy baby” flaccid paralysis, diplopia, poor feeding, crying • Wound—Traumatic implantation of spores (IVDA) in vivo production of toxin; weakness, dizziness, flaccid paralysis (no GI symptoms) <p>Note: the flaccid paralysis is reversible</p>	<ul style="list-style-type: none"> • Respiratory support in all cases • Antitoxin for adults, hyperimmune human serum for infants • Antibiotics may worsen or prolong symptoms <p>Prevention</p> <ul style="list-style-type: none"> • Proper canning/heating of vegetables • No honey first year

C. perfringens

<ul style="list-style-type: none"> • Nonmotile • “Stormy fermentation” in milk media • Double zone of hemolysis <p>Reservoir= soil, colon</p> <p>Transmission</p> <p>Traumatic implantation</p> <p>Food (Reheated meat dishes)</p>	<ul style="list-style-type: none"> • Spores germinate in anaerobic conditions in tissue • Alpha toxin (phospholipase C)—(produced by vegetative cells) a lecithinase which disrupts membranes, cells, etc → massive hemolysis, tissue destruction (gamma toxin) • Nagler Reaction—(egg yolk agar) identifies alpha toxin using antitoxin on one side • Enterotoxin—produced in gut, disrupts ion transport; heat labile • 12 other toxins damage tissues 	<p>Gas gangrene (myonecrosis) mediated by alpha toxin→</p> <ul style="list-style-type: none"> • Contamination of wound w/ soil or feces • Acute/increasing pain at site • Tense tissue (edema, gas= crepitation) and exudate • Fever, tachycardia • Rapid, high mortality <p>Food poisoning→</p> <ul style="list-style-type: none"> • Reheated meat dishes; • Organism grows to high numbers (8-24hrs incubation) • Enterotoxin produced in gut • Self-limiting noninflammatory watery diarrhea 	<p>Gangrene:</p> <ul style="list-style-type: none"> • Debridement • delayed closure • Clindamycin+ penicillin • hyperbaric chamber • Prevent w/ extensive debridement+ penicillin <p>Food poisoning</p> <ul style="list-style-type: none"> • Self-limiting
---	--	--	--

C. difficile

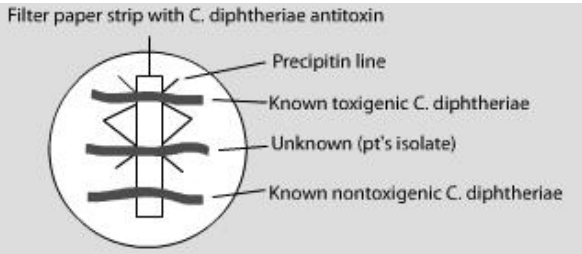
<p>Reservoir= colon/GI tract</p> <p>Transmission</p> <ul style="list-style-type: none"> • Endogenous • Long term broad spectrum antibiotic therapy 	<ul style="list-style-type: none"> • Toxin A—enterotoxin damaging mucosa leading to fluid increase; granulocyte attractant • Toxin B—cytotoxin: actin depolymerization and loss of cytoskeleton integrity 	<p>Antibiotic associated diarrhea, colitis, or pseudomembranous colitis (yellow plaques on colon; necrosis, exudates, fibrin, leukocytes)</p> <ul style="list-style-type: none"> • Clindamycin • Cephalosporins • Amoxicillin, Ampicillin <p>Caution in over-prescribing broad spectrum antibiotics (consider limited spectrum first)</p> <p>Check for C. diff toxin in stool</p>	<p>DOC</p> <ul style="list-style-type: none"> • Metronidazole • <u>Oral</u> Vancomycin (if no other drug available) • Discontinue antibiotic therapy <p>Isolate symptomatic nursing home patients; autoclave bed pans</p>
--	--	--	--

Non-spore forming

Listeria monocytogenes

Features	Pathogenesis	Diseases	Treatment
<ul style="list-style-type: none"> β-hemolytic Tumbling motility in broth; actin jet motility in cells Facultative intracellular parasite Cold growth <p>Reservoir</p> <ul style="list-style-type: none"> Animal GI tracts Plants, soil Unpasteurized milk products <p>Transmission</p> <ul style="list-style-type: none"> Vertical, trans-placental Food (deli meats, soft cheeses, coleslaw, hot dogs) 	<ul style="list-style-type: none"> Listeriolysin-O—β-hemolysin that facilitates rapid egress from phagosome to evade killing from lysosomal contents Actin filament formation—allows it to jet from cytoplasm to another cell Immune compromised predisposed to serious infection 	<p>Listeriosis (peaks in summer)</p> <ul style="list-style-type: none"> Healthy adults and children—asymptomatic or diarrhea Pregnant women—symptomatic carriage; fever/chills, can cross placenta in septicemia → <u>No deli meats (listeria)</u>, or changing cat litter (toxoplasma) <p>Neonatal disease</p> <ul style="list-style-type: none"> Early onset—(granulomatosis infantisepticum) transmission in utero w/ high mortality; disseminated granulomas w/ central necrosis Late onset—2-3 weeks after birth from fecal exposure; meningitis with septicemia <p>Immune compromised</p> <ul style="list-style-type: none"> Septicemia and meningitis (MC presentation of Listeria) Listeria meningitis—MCC meningitis in renal transplant patients and adults with cancer 	<p>Diagnosis</p> <ul style="list-style-type: none"> CSF wet mount shows tumbling motility <p>DOC</p> <ul style="list-style-type: none"> Ampicilin + gentamycin <p>(NOT covered by cephalosporins)</p> <p>Pregnant/immune compromised should not cold deli foods or change cat litter</p>

Corynebacterium diphtheriae

<ul style="list-style-type: none"> Aerobic, nonmotile Gray black colonies of club-shaped rods in V/L shapes (Chinese letter formation) Tellurite medium Granules (volutin) on Loeffler medium stain metachromically β-prophage genes can infect normal diphtheroid of another person <p>Reservoir</p> <ul style="list-style-type: none"> Throat/nasopharynx <p>Transmission</p> <ul style="list-style-type: none"> Bacteria/phage via respiratory droplets 	<ul style="list-style-type: none"> Diphtheria toxin (A-B component) lysogenic phage encoded—inhibits protein synthesis by adding ADP-ribose to eEF-2 (similar to pseudomonas) <p>Effects of toxin</p> <ul style="list-style-type: none"> Oropharynx → dirty gray pseudomembrae (dead cells, fibrin exudate, bacterial pigment) Lyrnx/trachea → obstruction Systemic → damage to nerves and heart (most likely cause of death)—do not scrape off! 	<p>Diphtheria</p> <ul style="list-style-type: none"> Sore throat w/ dirty gray pseudomembrane (bleeds easily) Bull neck (extremely swollen—potential respiratory obstruction) Recurrent laryngeal nerve palsy, lower limb polyneuritis Myocarditis, cardiac dysfunction (most likely cause of death) <p>Diagnosis</p> <p>New test → ELISA to test for toxin</p> <p>Elek test (old test) to document toxin production →</p> <ul style="list-style-type: none"> Toxin from toxin-producing strains diffuses away from growth Antitoxin diffuses away from strip of filter paper Precipitin lines form at zone of equivalence (= diphtheria) 	<p>DOC:</p> <ul style="list-style-type: none"> Erythromycin and antitoxin <p>Endocarditis</p> <ul style="list-style-type: none"> IV penicillin + aminoglycosides (for 4-6 weeks) <p>Vaccine: Toxoid vaccine (formaldehyde modified toxin part of DTaP, boosters at 10 yr intervals)</p>
--	--	---	---

Actinomyces israelii

Features	Pathogenesis	Diseases	Treatment
<ul style="list-style-type: none"> • Anaerobic • Branching rods <p>Reservoir= normal flora</p> <ul style="list-style-type: none"> • Gingival crevices • Female genital tract <p>Transmission= endogenous</p>	<ul style="list-style-type: none"> • Invasive growth in tissues with compromised oxygen supply 	Actinomycosis <ul style="list-style-type: none"> • Non-painful but very invasive (penetrating all tissues) • Tissue swelling→ draining abscesses (sinus tracts) w/ sulfur granules in exudate (hard yellow microcolonies; for diagnosis) • Cervicofacial (lumpy jaw)→ dental trauma or poor hygiene • CNS→ solitary brain abscess (Nocardia produces multiple foci) • Thoracic (aspiration w/ spread), Pelvic (from thoraci or IUDs), Abdominal (surgery or bowel trauma) 	<ul style="list-style-type: none"> • Gram ⊕ branching bacilli w/ sulfur granules = diagnostic <p>DOC</p> <ul style="list-style-type: none"> • Ampicillin or penicillin G, plus surgical drainage

Nocardia (N. asteroides, N. brasiliensis)

<ul style="list-style-type: none"> • Aerobic • Branching rods • Partially acid fast (some blue and some red on stain) 	<ul style="list-style-type: none"> • Predisposition in immune compromised (transplant patient) and cancer 	Cavitary bronchopulmonary nocardiosis (N. asteroides)→ <ul style="list-style-type: none"> • Cough, fever, dyspnea, localized or diffuse pneumonia w/ cavitation • May spread hematogenously to brain (abscesses- multiple foci) Cutaneous/Subcutaneous Nocardiosis (N. brasiliensis)→ <ul style="list-style-type: none"> • Traumatic implantation→ Cellulitis w/ swelling—draining subcutaneous abscesses w/ granules (mycetoma) 	<p>Diagnosis—sputum or pus culture</p> <p>DOC</p> <ul style="list-style-type: none"> • TMP-SMX or high dose sulfonamides
---	---	---	--

Mycobacterium

- **Obligate aerobe**, sensitive to UV
- **Acid fast** rods w/ waxy cell wall; ↑Lipid concentration (mycolic acid)
 - Resistance to desiccation (drying), chemicals (NaOH)

M. tuberculosis

Features	Pathogenesis	Diseases	Treatment
<ul style="list-style-type: none"> • Acid fast due to <u>mycolic acid</u> • Auramine-rhodamine stain (fluorescent green) • Slow growing on Lowenstein Jensen • Produces niacin • Produces heat sensitive catalase (∅ at 68.0°C) <p>Reservoir= Lungs Transmission= Respiratory droplets</p>	<ul style="list-style-type: none"> • Facultative intracellular organism • Sulfatides—inhibit phagosome-lysosome fusion • Cord factor (trehalose dimycolate)—serpentine growth in vitro, inhibits leukocyte migration (disrupts mitochondrial respiration and oxidative phosphorylation) • Tuberculin (surface protein) as well as mycolic acid—delayed hypersensitivity and cell-mediated immunity (CMI mediates granulomas and caseation) • Damage caused by immune system (cell-mediated) 	Primary pulmonary tuberculosis <ul style="list-style-type: none"> • Replication in naïve alveolar macrophages (kills macrophage until CMI is set up—Ghon focus- calcified tubercle in middle/lower lungs) • Macrophages transport bacilli to regional lymph node (Ghon complex) and most people heal without disease • Organisms walled off in Ghon complex remain viable unless treated <p>Latent phase (years)—become tuberculin ⊕</p> Reactivational tuberculosis (secondary) <ul style="list-style-type: none"> • Erosion of granulomas into airways (high O₂) later in life under conditions of ↓ T-cell immunity= mycobacterial replication/disease • Complex disease w/ potential of infecting any organ system • Dissemination→ seeds other organs (miliary TB)→ Vertebral column (Pott's disease); chronic meningitis (at base of brain); MC organ involved is kidney (sterile pyuria) PPD skin test (Mantoux)→ ⊕ zone of induration at 48-72 hrs if: <ul style="list-style-type: none"> ≥ 5mm in HIV+ or those w/ recent TB exposure ≥ 10mm in high risk (IVDA, poverty, immigrants) ≥ 15mm in low risk 	<p>Uncomplicated TB</p> <ul style="list-style-type: none"> • 2 months→ isoniazid+ rifampin + pyrazinamide • Next 4 months→ isoniazid + rifampin • Drug resistance add ethambutol (and/or streptomycin) <p>Prevention Family members take isoniazid (+rifampin) for 6 months</p> <p>**Must do PPD before starting anti-TNF therapy (Infliximab, adalimumab, etanercept- acts as receptor decoy)</p>

M. leprae

Features	Pathogenesis	Diseases	Treatment												
<ul style="list-style-type: none"> • Acid fast rods (seen in punch biopsy) • Obligate intracellular parasites (cannot be cultured in vitro) • Optimal growth at less than body temp • Phenolase ⊕ <p>Reservoir</p> <ul style="list-style-type: none"> • Mucosa, skin, nerves • Armadillos in Texas/Louisiana <p>Transmission</p> <ul style="list-style-type: none"> • Nasal discharge from untreated lepromatous leprosy patients 	<ul style="list-style-type: none"> • Obligate intracellular parasite • Cooler parts of body 	<p>Leprosy (Hansen's disease)</p> <table border="1"> <thead> <tr> <th>Tuberculoid</th> <th>Lepromatous</th> </tr> </thead> <tbody> <tr> <td>Strong CMI (TH1)</td> <td>Weak CMI (TH2)</td> </tr> <tr> <td>Lepromin test ⊕</td> <td>Lepromin test ∅</td> </tr> <tr> <td>Low number of organisms</td> <td>High number (foam cells filled)</td> </tr> <tr> <td>Damage due to CMI killing infected cells <ul style="list-style-type: none"> • Granulomas → nerve damage/enlargement • Sensation loss → burns/trauma </td> <td>Damage due to large number of intracellular organisms <ul style="list-style-type: none"> • Overgrowth in cells → nerve damage • Sensation loss → burns/trauma </td> </tr> <tr> <td>Symptoms <ul style="list-style-type: none"> • Fewer lesions; macular • Nerve enlargement • Paresthesia </td> <td>Symptoms <ul style="list-style-type: none"> • Numerous lesions; nodular • Loss of eyebrows • Destruction of nasal septum (saddle nose) • Leonine (lion-like) facies • Paresthesia </td> </tr> </tbody> </table>	Tuberculoid	Lepromatous	Strong CMI (TH1)	Weak CMI (TH2)	Lepromin test ⊕	Lepromin test ∅	Low number of organisms	High number (foam cells filled)	Damage due to CMI killing infected cells <ul style="list-style-type: none"> • Granulomas → nerve damage/enlargement • Sensation loss → burns/trauma 	Damage due to large number of intracellular organisms <ul style="list-style-type: none"> • Overgrowth in cells → nerve damage • Sensation loss → burns/trauma 	Symptoms <ul style="list-style-type: none"> • Fewer lesions; macular • Nerve enlargement • Paresthesia 	Symptoms <ul style="list-style-type: none"> • Numerous lesions; nodular • Loss of eyebrows • Destruction of nasal septum (saddle nose) • Leonine (lion-like) facies • Paresthesia 	<p>Diagnosis</p> <ul style="list-style-type: none"> • Punch biopsy or nasal scrapings → acid fast • Cannot be cultured <p>DOC</p> <ul style="list-style-type: none"> • Dapsone + rifampin (clofazimine added for lepromatous) <p>(Dapsone for close family contacts—can cause hemolysis in G6PD deficiency)</p>
Tuberculoid	Lepromatous														
Strong CMI (TH1)	Weak CMI (TH2)														
Lepromin test ⊕	Lepromin test ∅														
Low number of organisms	High number (foam cells filled)														
Damage due to CMI killing infected cells <ul style="list-style-type: none"> • Granulomas → nerve damage/enlargement • Sensation loss → burns/trauma 	Damage due to large number of intracellular organisms <ul style="list-style-type: none"> • Overgrowth in cells → nerve damage • Sensation loss → burns/trauma 														
Symptoms <ul style="list-style-type: none"> • Fewer lesions; macular • Nerve enlargement • Paresthesia 	Symptoms <ul style="list-style-type: none"> • Numerous lesions; nodular • Loss of eyebrows • Destruction of nasal septum (saddle nose) • Leonine (lion-like) facies • Paresthesia 														

Mycobacterium other than tuberculosis (MOTTs)

- Atypical mycobacteria commonly found in southeastern U.S.
- Noncontagious, found in surface waters, soil, cigarettes

Organism	Transmission	Disease/Presentation	Diagnosis	Treatment
M. avium-intracellulare (MAC)	Respiratory/ ingestion Reservoir- aerosolized water, dust, soil, cigarettes	Fevers, diarrhea, malabsorption/anorexia, bone marrow suppression Lung involvement resembles TB (fever, chills, etc) Seen in AIDS , cancer, chronic lung disease	Nonchromogen (no pigments) Blood culture— grows at 41°C	Clarithromycin, ethambutol, & rifampin Prophylaxis for AIDS patients at ≤50 CD4 with Azithromycin or Clarithromycin
M. kansasii		Resembles pulmonary tuberculosis Seen in AIDS , organ transplants, silicosis, hairy cell leukemia, chronic bronchitis, COPD	Photochromogen (pigment when exposed to light)	Rifampin , ethambutol, isoniazid, & pyridoxine for 12 months
M. scrofulaceum	Contaminated water sources	Painless solitary cervical lymph node in children (scrofula) with overlying bluish-purple color (Scrofula in adult most likely secondary TB)	Scotochromogen (pigment when exposed to dark)	Surgery
M. marinum	Abrasion to extremity in non-chlorinated water	Soft tissue infection → "fish tank granuloma" seen in tropical fish enthusiasts (purple papule)	Photochromogen	Clarithromycin + ethambutol

Gram Negative Cocci

Neisseria

- Kidney-bean shaped diplococci w/ flattened sides
- **Oxidase** ⊕ (test turns black)
- **Glucose** ⊕ fermentation

N. meningitidis (⊕ maltose fermentation)									
Features	Pathogenesis	Diseases	Treatment						
<ul style="list-style-type: none"> • Large capsule → latex particle agglutination • Chocolate agar growth (with 5% CO₂) • Ferments maltose <p>Reservoir</p> <ul style="list-style-type: none"> • Nasopharynx (5-10% carriers) <p>Transmission</p> <ul style="list-style-type: none"> • Respiratory droplets • Colonized individuals (dormitory setting, army recruits) 	<ul style="list-style-type: none"> • Oropharyngeal colonization; spreads to meninges via bloodstream • Polysaccharide capsule— (B strain MC but not immunogenic= no vaccine) • IgA1 protease— allows colonization in oropharynx • Endotoxin (LPS)— causes fever, septic shock, overproduction of outer membrane • Pili— help colonize and invade • C5-C9 deficiency predisposes to bacteremia (multiple recurrent N. meningitidis infections) 	<p>Meningitis and meningococemia (MCC children/young adults)</p> <ul style="list-style-type: none"> • Abrupt onset of <u>fever, chills</u>, malaise • Prostration (stretched in prone position; weakness) • <u>Stiff neck</u> (nuchal rigidity), vomiting, <u>photosensitivity</u> • Generalized petechial rash (including palms and soles) in later stages (NOT a good sign) <p>Fulminant cases → ecchymoses, DIC, shock, coma, death (Waterhouse-Friedrichsen syndrome—rapid hemorrhage into adrenal glands → adrenal insufficiency)</p> <p>Diagnosis</p> <ul style="list-style-type: none"> • Gram stain of CSF • PCR • Latex particle agglutination (identifies capsular antigen in CSF) 	<p>DOC children/adults</p> <ul style="list-style-type: none"> • Ceftriaxone • Cefotaxime • Prophylaxis of close contacts → rifampin (or ciprofloxacin) <p>DOC neonates</p> <ul style="list-style-type: none"> • Cefotaxime, ampicillin <p>Vaccine</p> <ul style="list-style-type: none"> • Capsular polysaccharide of strains Y, W-135, C, A • <u>No type B</u> (50% cases): not a good immunogen 						
N. gonorrhoeae (Ø maltose fermentation)									
<ul style="list-style-type: none"> • Diplococci in neutrophils • Thayer Martin medium (chocolate agar w/ VPN antibiotics to prevent normal flora growth) <p>Reservoir= Genital tract</p> <p>Transmission</p> <ul style="list-style-type: none"> • Sexual contact, birth • Sensitive to drying/cold 	<ul style="list-style-type: none"> • Pili (most important)— attachment to mucosal surfaces; inhibit phagocytosis; antigenic variation <p>Outer membrane proteins—</p> <ul style="list-style-type: none"> • OMP I (for serotyping) • Opa proteins (antigenic variation, adherence) • IgA protease (colonization) <p>Invades mucosal surfaces → inflammation and ↑ PMNs</p>	<p>Gonorrhea</p> <table border="1"> <tr> <td>Males → urethritis, proctitis, septic arthritis (knee MC)</td> <td>Complications</td> </tr> <tr> <td>Females → endocervicitis, PID, septic arthritis (knee MC) (more likely asymptomatic)</td> <td>Fallopian tube scarring (infertility, <u>ectopic pregnancy</u>), Fitz-Hugh-Curtis syndrome (Perihepatitis: RUQ tenderness)</td> </tr> <tr> <td>Infants → ophthalmia (at 2 days)</td> <td>Blindness if untreated</td> </tr> </table> <p>Sexually active patient with cloudy yellow green discharge</p> <p>Diagnosis</p> <ul style="list-style-type: none"> • Intracellular gram negative diplococci in PMNs from urethral smear • Culture on Thayer-Martin 	Males → urethritis, proctitis, septic arthritis (knee MC)	Complications	Females → endocervicitis, PID, septic arthritis (knee MC) (more likely asymptomatic)	Fallopian tube scarring (infertility, <u>ectopic pregnancy</u>), Fitz-Hugh-Curtis syndrome (Perihepatitis: RUQ tenderness)	Infants → ophthalmia (at 2 days)	Blindness if untreated	<p>DOC</p> <ul style="list-style-type: none"> • Ceftriaxone (and test for Chlamydia) <p>Prevention</p> <ul style="list-style-type: none"> • Adults—condoms • Neonatal ophthalmia—erythromycin ointment in eyes at birth (also protects against chlamydia)
		Males → urethritis, proctitis, septic arthritis (knee MC)	Complications						
		Females → endocervicitis, PID, septic arthritis (knee MC) (more likely asymptomatic)	Fallopian tube scarring (infertility, <u>ectopic pregnancy</u>), Fitz-Hugh-Curtis syndrome (Perihepatitis: RUQ tenderness)						
		Infants → ophthalmia (at 2 days)	Blindness if untreated						
<p>Moraxella catarrhalis (close relative of Neisseria)</p>		<p>DOC</p> <ul style="list-style-type: none"> • Amoxicillin + Clavulanate 							
<p>Reservoir= Normal flora</p> <ul style="list-style-type: none"> • Upper respiratory tract <p>Transmission</p> <ul style="list-style-type: none"> • Respiratory droplets 	<ul style="list-style-type: none"> • Endotoxin may play role in disease 								
		<ul style="list-style-type: none"> • Otitis media (3rd MCC) • Sinusitis (3rd MCC) • Bronchitis and bronchopneumonia in elderly w/ COPD 							

Gram Negative Rods

AEROBIC (Pseudomonas, Legionella, Francisella, Bordetella, Brucella)

Pseudomonas aeruginosa (Obligate aerobe)

Features	Pathogenesis	Diseases	Treatment
<ul style="list-style-type: none"> • Oxidase ⊕ • Motile, Non-lactose fermenter on MacConkey/EMB • Fluorescein and Pyocyanin (blue-green pigment on TSA agar) • Grape-like odor <p>Reservoir</p> <ul style="list-style-type: none"> • Ubiquitous in water <p>Transmission</p> <ul style="list-style-type: none"> • Water aerosols (dialysis equipment), raw veggies, flowers 	<ul style="list-style-type: none"> • Glycocalyx capsule/slime layer—allows formation of pulmonary microcolonies; antiphagocytic • Endotoxin (LPS)—causes inflammation in tissues and shock in septicemia • Exotoxin A—ADP ribosylation of eEF-2; inhibits protein synthesis (similar to diphtheria toxin) Primary target is liver 	<ul style="list-style-type: none"> • Healthy→ Hot tub folliculitis, otitis externa (swimmer's ear— malignant OE in diabetics), GI (loose stools), corneal infections (trauma, prolonged contact wear) • Diffuse bronchopneumonia in Neutropenic, CGD, burn patients [recurrent in <u>Cystic Fibrosis</u>—(↑slime-producing strains, biofilm)] • Sepsis→ Fever, shock, ± ecthyma gangrenosum in neutropenic patients (black, necrotic center w/ erythematous margins) • Cellulitis w/ blue green pus in Burn patients (GI tract colonization, skin, colonization of eschar, cellulitis, septicemia) • UTIs in catheterized patients • Osteomyelitis (Diabetics, nail through rubber footwear, IVDA) 	<p>Diagnosis</p> <ul style="list-style-type: none"> • Gram stain and culture <p>DOC</p> <ul style="list-style-type: none"> • Piperacillin + Tazobactam (pip-taz) • Aminoglycosides <p>Prevention</p> <ul style="list-style-type: none"> • Pasteurization/ disinfection of water-related equipment, hand washing • No flowers/ raw veggies in burn units

Legionella pneumophila (requires cysteine)

<ul style="list-style-type: none"> • Oxidase ⊕ • Weakly gram negative pleomorphic rods • Require cysteine & iron • Charcoal yeast extract <p>Reservoir</p> <ul style="list-style-type: none"> • WATER (rivers, streams, air-conditioners, produce mists) <p>Transmission</p> <ul style="list-style-type: none"> • Inspired aerosolized H₂O • NOT PERSON TO PERSON!! 	<ul style="list-style-type: none"> • Facultative intracellular pathogen (macrophages→ granulomas) • Endotoxin (LPS) <p>Predisposing factors</p> <ul style="list-style-type: none"> • Smokers > 55 yrs w/ high alcohol intake • Immunosuppressed patients 	<p>Legionnaires disease</p> <ul style="list-style-type: none"> • Atypical pneumonia (can consolidate however) • Mental confusion, diarrhea (however NO legionella in GI tract) • Causes hyponatremia • Associated w/ air conditioning systems • High mortality without treatment <p>Pontiac Fever</p> <p>Young person w/ pneumonitis</p> <p>Can go untreated</p> <p>Diagnosis→ DFA (direct fluorescent antibody) on biopsy, by silver stain</p> <p>Antigen can also be detected in urine</p>	<p>DOC</p> <ul style="list-style-type: none"> • Fluoroquinolones • Azithromycin • Erythromycin <p>(Add rifampin for immunocompromised)</p> <p>Prevention—routine decontamination of air-conditioner cooling tanks</p>
---	---	---	---

Francisella tularensis (requires cysteine)

<p>Reservoir= animals</p> <ul style="list-style-type: none"> • Rabbits, deer, rodents <p>Transmission</p> <ul style="list-style-type: none"> • Tick bite (dermacentor) • Skinning rabbits (implant or inspiring aerosol) • Undercooked meat 	<ul style="list-style-type: none"> • Facultative intracellular pathogen—localizes in reticuloendothelial cells (granulomatous response—type IV hypersensitivity) <p>Highest in Arkansas, Missouri</p> <p>Potential biowarfare agent as aerosol</p>	<p>Tularemia</p> <ul style="list-style-type: none"> • Ulceroglandular form→ Tick bite or traumatic implantation while skinning rabbits (ulcer with black base, fever, <u>regional lymph node enlargement and necrosis</u>) • Pneumonial form→ inhalation of aerosol from skinning rabbits • Typhoidal form→ ingestion of infected meat or contaminated water <p>*Rabbit hunter from Arkansas*</p>	<p>DOC</p> <ul style="list-style-type: none"> • Streptomycin • Doxycycline <p>Vaccine</p> <ul style="list-style-type: none"> • Live, attenuated for high risk (vets, forest ranger, hunter)
---	---	---	---

Brucella (<i>B. abortus</i> , <i>B. melitensis</i> , <i>B. suis</i>) (requires cysteine)											
Features	Pathogenesis	Diseases	Treatment								
<p>Reservoir= livestock</p> <ul style="list-style-type: none"> Cattle (<i>abortus</i>) Goats/sheep (<i>melitensis</i>) Pigs (<i>suis</i>) <p>Transmission</p> <ul style="list-style-type: none"> Unpasteurized dairy products—goat milk (recent travel to Mexico—<u>Cali and Texas</u> highest # cases) Direct contact with animal (<u>slaughterhouse</u>) 	<ul style="list-style-type: none"> Facultative intracellular pathogen—localizes in reticuloendothelial cells (granulomatous response with central necrosis) Endotoxin <p>Potential biowarfare agent</p>	<p>Brucellosis (undulant fever)→</p> <ul style="list-style-type: none"> Acute septicemias, fever 100- 104°F (often in evening) Profuse sweating, influenza-like, Arthralgias, anorexia, myalgia, back pain Hepatomegaly <p>Undulant form is milder (often result of incomplete treatment)</p> <p>Chronic form (more than one year w/ disease)</p> <ul style="list-style-type: none"> Usually <i>B. melitensis</i> in older veterinarians Cyclic bouts of depression, confusion, profuse sweating 	<p>DOC</p> <ul style="list-style-type: none"> Rifampin + Doxycycline (6 wks) <p>(children: cotrimoxazole instead of doxy)</p> <p>Prevention</p> <ul style="list-style-type: none"> Vaccinate cattle and high risk humans (vets, slaughterhouse workers, military) Pasteurize milk 								
Bordetella pertussis (cysteine NOT required)											
<ul style="list-style-type: none"> Encapsulated Bordet-Gengou medium (potato, blood and glycerol) <p>Reservoir</p> <ul style="list-style-type: none"> Vaccinated humans—(because vaccine is toxoid) Mucosal surface pathogen <p>Transmission</p> <ul style="list-style-type: none"> Respiratory droplets 	<p>Attachment (to nasopharyngeal ciliated epithelial cells)</p> <ul style="list-style-type: none"> Filamentous hemagglutinin—allows organism to bind Pertussis toxin aids in attachment <p>Toxins (damage respiratory epithelium)</p> <ul style="list-style-type: none"> Adenylate cyclase toxin—impairs leukocyte chemotaxis (inhibits phagocytosis; causes local edema→ similar to Anthrax edema factor toxin) Pertussis toxin—(A and B component, OM protein toxin) ADP-ribosylation of G_i interferes with transfer of signals from cell surface to intracellular mediator system= ↑cAMP <ul style="list-style-type: none"> Lymphocytosis promotion Islet-activation→ hypoglycemia Blocks immune effector cells Increased histamine sensitivity Tracheal cytotoxin—kills ciliated cells; interferes with ciliary action Endotoxin (LPS) 	<p>Pertussis (Whooping cough)</p> <p>Stages (duration)</p> <table border="1"> <tr> <td>Incubation (7-10 days)</td> <td>Very difficult to culture No symptoms</td> </tr> <tr> <td>Catarrhal (1-2 weeks)</td> <td>BEST chance of culture Runny nose, low-grade fevers, occasional cough, highly contagious</td> </tr> <tr> <td>Paroxysmal (2-4 weeks)</td> <td>Difficult to culture Fits of rapid forceful coughing followed by inspiratory gasps (whoops), vomiting often follows attacks Adults (persistent cough), children with immunization wearing off, and infants (cough w/ apnea spells) may not have typical whoop</td> </tr> <tr> <td>Convalescent (3-4 weeks)</td> <td>Cannot culture Infrequent/diminished attacks; secondary symptoms (pneumonia, seizures, encephalopathy)</td> </tr> </table> <p>Diagnosis</p> <ul style="list-style-type: none"> Regan-Lowe or Bordet-Gengou media during catarrhal stage (direct cough plates or nasopharyngeal cultures) Direct immunofluorescence (DFA) on nasopharyngeal smear PCR and serologic tests (ELISA) available 	Incubation (7-10 days)	Very difficult to culture No symptoms	Catarrhal (1-2 weeks)	BEST chance of culture Runny nose, low-grade fevers, occasional cough, highly contagious	Paroxysmal (2-4 weeks)	Difficult to culture Fits of rapid forceful coughing followed by inspiratory gasps (whoops), vomiting often follows attacks Adults (persistent cough), children with immunization wearing off, and infants (cough w/ apnea spells) may not have typical whoop	Convalescent (3-4 weeks)	Cannot culture Infrequent/diminished attacks; secondary symptoms (pneumonia, seizures, encephalopathy)	<p>Supportive care, hospitalization <6 months old</p> <p>DOC</p> <p>Erythromycin (14 days including all household contacts)</p> <p>Vaccine</p> <ul style="list-style-type: none"> DTaP (diphtheria, tetanus, acellular pertussis) Acellular pertussis= filamentous hemagglutinin + pertussis toxoid Immunity wanes 5-7 years Infants not protected by breast milk (IgA) bc mother's immunity has waned
Incubation (7-10 days)	Very difficult to culture No symptoms										
Catarrhal (1-2 weeks)	BEST chance of culture Runny nose, low-grade fevers, occasional cough, highly contagious										
Paroxysmal (2-4 weeks)	Difficult to culture Fits of rapid forceful coughing followed by inspiratory gasps (whoops), vomiting often follows attacks Adults (persistent cough), children with immunization wearing off, and infants (cough w/ apnea spells) may not have typical whoop										
Convalescent (3-4 weeks)	Cannot culture Infrequent/diminished attacks; secondary symptoms (pneumonia, seizures, encephalopathy)										

FACULTATIVE ANAEROBIC (rest of gram \emptyset except Bacteroides)

Curved/S-shaped Rods with Flagella

- Oxidase \oplus (test turns black)

Campylobacter jejuni

Features	Pathogenesis	Diseases	Treatment
<ul style="list-style-type: none"> • Curved rods with polar flagella (“gulls’ wings”) • Grows well at 42°C on Skirrow’s agar • Microaerophilic <p>Reservoir</p> <ul style="list-style-type: none"> • GI tract of humans, cattle, sheep, dogs, cats, poultry <p>Transmission</p> <ul style="list-style-type: none"> • Fecal-oral (MCC contaminated poultry), handling puppies 	<ul style="list-style-type: none"> • Low infectious dose (as few as 500) • Acid resistant • Invades/destroys mucosa of colon \rightarrow blood/pus in stool (inflammatory diarrhea) • Rarely causes septicemia 	<p>Gastroenteritis</p> <ul style="list-style-type: none"> • MCC infectious diarrhea in US • 10 or more stools/day, may be frankly bloody • Abdominal pain, fever, malaise, nausea, vomiting <p>Complications</p> <ul style="list-style-type: none"> • Guillain-Barre syndrome (GBS) \rightarrow (30% of GBS cases in US) <ul style="list-style-type: none"> ○ Ascending paralysis; weakness in hands/feet migrating to trunk ○ Serotype O:19, antigenic cross-reactivity between Campylobacter oligosaccharides and glycosphingolipids (gangliosides) on neural tissues (molecular mimicry) • Reactive arthritis (Reiter’s syndrome) 	<ul style="list-style-type: none"> • Supportive via fluid and electrolyte replacement • Generally self-limiting (3-5 days) <p>Severe/prolonged cases DOC</p> <ul style="list-style-type: none"> • Erythromycin • Ciprofloxacin

Helicobacter pylori

<ul style="list-style-type: none"> • Spiral bacilli w/ flagella • Urease \oplus • 37°C growth on Skirrow’s agar • Microaerophilic <p>Reservoir= humans Transmission= fecal-oral/ oral-oral</p>	<ul style="list-style-type: none"> • Motile • Urease— ammonium cloud neutralizes stomach acid, allowing survival in stomach acid • Mucinase— penetration of mucous layer (invades stomach lining: where pH is neutral) • Type I biotype (out of 2) produces vacuolating cytotoxin 	<ul style="list-style-type: none"> • Chronic gastritis and duodenal ulcers • Associated with several forms of stomach cancer (H. pylori is a type 1 carcinogen) <ul style="list-style-type: none"> ○ Gastric adenocarcinoma ○ Gastric MALT-oma ○ B-cell lymphoma <p>Diagnosis \rightarrow Biopsy w/ culture (gold standard); histology w/ giemsa or silver stain; also urea breath test (^{13}C-urea)</p>	<p>DOC= triple therapy</p> <ol style="list-style-type: none"> 1. Omeprazole 2. Amoxicillin 3. Clarithromycin <p>(PPI + 2 antibiotics)</p>
--	--	---	--

Vibrio Cholerae (V. parahaemolyticus, V. vulnificus)

<ul style="list-style-type: none"> • Curved rod w/ polar flagella • Growth on alkaline media Thiosulfate citrate bile salt sucrose (TCBS) • “Shooting star motility” • O1 biotypes—El Tor (MC) and Cholerae (classic) • O139 is more recent <p>Reservoir= colon and invertebrates (shellfish contaminated by water)</p> <p>Transmission= fecal-oral (hurricane, flood)</p>	<ul style="list-style-type: none"> • High infectious dose $>10^7$ (sensitive to stomach acid) • Motility, mucinase, and toxin coregulated pili (TCP) aid in attachment to intestinal mucosa • Cholera enterotoxin (cholerae)— similar to E. coli LT \rightarrow ADP ribosylation of Gs alpha activating adenylate cyclase \rightarrow \uparrow cAMP \rightarrow efflux of Cl⁻ and H₂O (ions leave cells, water follows) <p>Lysogenic phage encoded</p>	<p>Cholera</p> <ul style="list-style-type: none"> • Rice water diarrhea (specks of mucous) • Tremendous fluid loss (20L per day!) (ddx—ETEC is oxidase negative) <table border="1"> <thead> <tr> <th>V. parahaemolyticus</th> <th>V. Vulnificus</th> </tr> </thead> <tbody> <tr> <td>Consumption of undercooked/ raw seafood</td> <td>Swimming in brackish water, shucking oysters</td> </tr> <tr> <td>Gastroenteritis \rightarrow watery diarrhea with cramping and abdominal pain Cause of 25% food poisoning in Japan (3-day diarrhea)</td> <td>Cellulitis \rightarrow rapidly spreading; difficult to treat, may require amputation *Fisherman cuts themselves shucking oysters* (consumption could cause GE similar to V. parahaemolyticus)</td> </tr> <tr> <td>Self-limiting (Doxy if severe)</td> <td>DOC: Tetracyclines</td> </tr> </tbody> </table>	V. parahaemolyticus	V. Vulnificus	Consumption of undercooked/ raw seafood	Swimming in brackish water, shucking oysters	Gastroenteritis \rightarrow watery diarrhea with cramping and abdominal pain Cause of 25% food poisoning in Japan (3-day diarrhea)	Cellulitis \rightarrow rapidly spreading; difficult to treat, may require amputation *Fisherman cuts themselves shucking oysters* (consumption could cause GE similar to V. parahaemolyticus)	Self-limiting (Doxy if severe)	DOC: Tetracyclines	<ul style="list-style-type: none"> • Fluid and electrolyte replacement (IV) • Doxycycline or ciprofloxacin shorten disease and reduce carriage <p>Prevention= Proper sanitation</p> <p>Tetracyclines or third-generation cephalosporins for V. vulnificus cellulitis</p>
V. parahaemolyticus	V. Vulnificus										
Consumption of undercooked/ raw seafood	Swimming in brackish water, shucking oysters										
Gastroenteritis \rightarrow watery diarrhea with cramping and abdominal pain Cause of 25% food poisoning in Japan (3-day diarrhea)	Cellulitis \rightarrow rapidly spreading; difficult to treat, may require amputation *Fisherman cuts themselves shucking oysters* (consumption could cause GE similar to V. parahaemolyticus)										
Self-limiting (Doxy if severe)	DOC: Tetracyclines										

Enterobacteriae Family

- **Catalase** ⊕, **Oxidase** ∅
- Facultative anaerobic
- **Ferment glucose**
- Reduce nitrates to nitrites (UTIs—nitrites in urine)

Lactose fermenters turn **pink** on MacConkey Agar (vs. colorless)

Lactose fermenters	Non lactose fermenters (ShYPS)	
Citrobacter	Nonmotile (non-H ₂ S producers)	Motile (H ₂ S producers)
Enterobacter		
E. coli	Shigella	Proteus
Klebsiella	Yersinia	Salmonella

Lactose Fermenters

Escherichia coli

Colony Characteristics	Disease	Pathogenesis	Clinical Clues	Treatment
Colonies with iridescent green sheen on EMB Reservoir • Colon, may colonize vagina or urethra • Crops where human fecal fertilizer is used • EHEC strains: bovine feces Transmission • Endogenous • Fecal-oral • Maternal fecal flora • EHEC: raw beef, milk, apple juice from fallen apples	UTI (MCC)	Endogenous fecal flora contaminate; ascend Motility, adherence to uroepithelium—pili (pyelonephritis associated), X-adhesins, β-hemolytic (many)	Females > Males	TMP-SMX Fluoroquinolones
	Neonatal septicemia/ meningitis (2 nd MCC)	Maternal fecal flora contaminate during parturition Capsule—K1 serotype Endotoxin (LPS) causes shock, inflammation at BBB	Blood culture CSF culture	Ceftriaxone
	Septicemia (MCC gram neg sepsis)	Indwelling IV lines, cytotoxic drugs (damage intestinal mucosa; allow escape) Endotoxin (LPS, Lipid A)— Fever, hypertension	Blood culture	Fluoroquinolones
	E TEC (T raveler's diarrhea)	LT- heat labile → Stimulates adenylate cyclase (ADP ribosylation of Gs—similar to Cholera toxin) ST- heat stable toxin → Stimulates guanylate cyclase —capsule impedes phagocytosis; colonizing factor adhesins (CFAs) bind to intestine mucosa	Noninflammatory Bioassay, DNA probe	Rehydration (TMP-SMX may shorten symptoms)
	E PEC (P ediatric diarrhea)	2nd MCC infantile diarrhea (1 st is rotavirus) Adherence to M cells → rearrangement of actin; effacement of brush border microvilli	Noninflammatory; Babies in developing world	Fluoroquinolones
	E IEC (I nvasive diarrhea)	Inflammatory diarrhea similar to shigella (watery → bloody) Formation of actin jet trails; invades large bowel	Blood, pus, fever, abdominal pain	Fluoroquinolones
	E HEC (H amburger, bloody diarrhea)	O157:H7 strain most common; hamburger meat, petting zoos Inflammatory, noninvasive bloody diarrhea Verotoxin —Shigella-like toxins 1 and 2, ↓ protein synthesis by binding 60S ribosomal subunit (similar to shigella) Does not ferment sorbitol or contain glucuronidase	No fever or PMNs, Blood in stool, may progress to HUS in children (anemia, thrombocytopenia, acute renal failure)	NO antibiotics → ↑ risk of HUS (releases more toxin)
Others: EAEC (developing world—biofilm; EAST toxin); DAEC (infants to 5yrs—elongation of microvilli w/ bacteria in cell membrane)				

Klebsiella pneumoniae

Features	Pathogenesis	Diseases	Treatment
• Large polysaccharide capsule • Mucoid, lactose fermenting on MacConkey agar • “Viscous colonies” Reservoir= colon/Upper respiratory tract Transmission= endogenous	• Capsule—impedes phagocytosis • Endotoxin (LPS)—causes fever, inflammation and shock (septicemia)	Pneumonia (lobar) → • Seen in older males, chronic lung disease, alcoholism, diabetes • Frequent abscesses make treatment difficult; high fatality • Sputum thick and blood (currant jelly) NOT foul smelling UTIs (3rd MC) → Catheter-related (nosocomial) from fecal contamination Septicemia → Immunocompromised; bowel defects, IV line invasion (2 nd MCC gram neg sepsis)	Diagnosis—sputum culture or clean catch urine sample DOC • 3 rd gen cephalosporins • Fluoroquinolones Many resistant strains

Non-Lactose Fermenters

Nonmotile (Non-H₂S producers)

Shigella			
Features	Pathogenesis	Diseases	Treatment
<ul style="list-style-type: none"> Identified by serology w/ anti-O antibody in agglutination test <p>Reservoir</p> <ul style="list-style-type: none"> Human colon only <p>Transmission</p> <ul style="list-style-type: none"> Fecal-oral, person to person (Daycare) 	<ul style="list-style-type: none"> Endotoxin triggers inflammation Shigellae invade M cells (membrane ruffling and macropinocytosis) replicate in cytoplasm → polymerize actin jet trails laterally without going extracellular (produces very shallow ulcers—no invasion of blood vessels) Shiga toxin—Produced by <i>S. dysenteriae</i> (type 1— neurotoxic, cytotoxic, enterotoxic) A-B component toxin is internalized in human cells; inhibits protein synthesis by clipping 60s ribosomal subunit 	<p>Shigelosis/enterocolitis (most severe form= dysentery)</p> <ul style="list-style-type: none"> Low infectious dose (1-10 organisms; extremely acid resistant) 1-4 day incubation → organisms invade → bloody diarrhea Fever, lower abdominal cramps, tenesmus, starts as watery diarrhea then becomes bloody; invasive (shallow ulcers) but no septicemia Severity depends on age of patient and strain (usually 1-2 week duration) <ul style="list-style-type: none"> <i>S. sonnei</i> (MC in U.S.) <i>S. dysenteriae</i> (most severe disease) <i>S. flexneri</i> (associated with Reiter's syndrome) <i>S. boydii</i> <p>Diagnosis— isolation from stool during illness and culture on selective media</p>	<p>Mild cases—fluid and electrolyte replacement</p> <p>Severe cases— Fluoroquinolones NO ANTIDIARRHEALS</p> <p>Resistance by plasmid-encoded enzymes</p> <p>Prevent w/ proper sanitation</p>

Yersinia pestis			
<ul style="list-style-type: none"> Bipolar staining Facultative intracellular parasite Coagulase ⊕ <p>Reservoir</p> <ul style="list-style-type: none"> US desert southwest Rodents, prairie dogs <p>Transmission</p> <ul style="list-style-type: none"> Wild rodent flea bite (regurgitates stomach contents into humans) 	<ul style="list-style-type: none"> Coagulase (most important)—clots stomach content of flea and makes them hungry Endotoxin and exotoxin Envelope antigen (F-1)—inhibits phagocytosis Type III secretion system suppresses cytokine production and resists phagocytic killing 	<p>Bubonic plague</p> <ul style="list-style-type: none"> Flea bites infected animal and then later uninfected human Rapidly increasing fever Regional buboes (swollen lymph nodes) Conjunctivitis Leads to septicemia and death if untreated (DIC—turns black) <p>Pneumonic plague (potential biological warfare)</p> <ul style="list-style-type: none"> Highly contagious! Arises from septic pulmonary emboli in bubonic plague or inhalation of organisms from infected individual 	<p>Diagnosis:</p> <ul style="list-style-type: none"> No cultures—they are hazardous Serodiagnosis or direct immunofluorescence "Safety pin" staining (bipolar staining) <p>DOC</p> <ul style="list-style-type: none"> Aminoglycosides <p>Prevention</p> <ul style="list-style-type: none"> Killed vaccine (military)

Yersinia enterocolitica			
Features	Pathogenesis	Diseases	Treatment
<ul style="list-style-type: none"> Motile at 25°C (not 37) Cold growth <p>Reservoir= zoonotic</p> <p>Transmission</p> <ul style="list-style-type: none"> <u>Unpasteurized milk, pork, pet feces</u> Northern climates 	<ul style="list-style-type: none"> Enterotoxin, endotoxin Multiplies in the cold 	<p>Enterocolitis</p> <ul style="list-style-type: none"> Very young—febrile diarrhea (blood and pus) Adolescents—mimics appendicitis!!! (also <i>y. pseudotuberculosis</i>) Adults—enterocolitis with postinfective sequelae like reactive arthritis <p>Blood transfusion associated infections</p>	<p>Diagnosis</p> <ul style="list-style-type: none"> Stool culture, 25°C, cold enrichment <p>Supportive care</p> <ul style="list-style-type: none"> Fluoroquinolones for immunocompromised

Motile (H₂S producers)

Proteus (P. mirabilis, P. vulgaris)

Features	Pathogenesis	Diseases	Treatment
<ul style="list-style-type: none"> • “Swarming motility” on blood agar • Urease ⊕ Production <p>Reservoir</p> <ul style="list-style-type: none"> • Colon and environment (water and soil) <p>Transmission= Endogenous</p>	<ul style="list-style-type: none"> • Peritrichous flagella- motility (may aid entry into bladder) • Urease—raises uring pH to cause kidney stones (staghorn renal calculi) • Endotoxin—fever and shock when septicemia occurs 	<ul style="list-style-type: none"> • Urinary tract infections (4th MCC) • Kidney stones→ staghorn renal calculi (Ammonium magnesium phosphate) • Septicemia <p>Diagnosis—culture of blood or urine for lactose negative organisms with swarming motility; ↑ urine pH</p>	<p>DOC</p> <ul style="list-style-type: none"> • Fluoroquinolones • TMP-SMX • Remove stones <p>Prevention</p> <p>Remove urinary cath</p>

Salmonella enterica (subsp. typhi)

<ul style="list-style-type: none"> • Highly motile with the Vi capsule • Sensitive to acid • Facultative intracellular parasite <p>Reservoir</p> <ul style="list-style-type: none"> • Humans only <p>Transmission</p> <ul style="list-style-type: none"> • Fecal-oral (infection sets up in gall bladder) • ↓ Stomach acid or impairment of mononuclear cells (sickle cell) predisposes to infection 	<p>Ingested organism→ ileocecal infection→ M-cells → mesenteric lymph nodes→ blood</p> <p>Survives intracellularly and <u>replicates in macrophages</u>; resists macrophage killing due to:</p> <ul style="list-style-type: none"> • Decrease fusion of lysosomes with phagosomes • Defensins (proteins) allow it to withstand oxygen-dependent and independent killing • Vi capsular antigen—withstands complement-mediated killing 	<p>Typhoid fever</p> <ul style="list-style-type: none"> • Constipation first symptom (due to ileocecal infection) • At 1 week→ 80% ⊕ blood cultures, 25% rose spot rash on trunk • Liver and spleen infected→ ↑ bacteria in blood (septicemia/fever) • Biliary system infected→ organisms enter intestinal tract in bile • Fever, headache, abdominal pain • Alternating constipation and diarrhea <p>Complications if untreated</p> <ul style="list-style-type: none"> • Necrosis of Peyer patches→ perforation (local endotoxin) • Thrombophlebitis, cholecystitis, pneumonia, abscess, etc. <p>Diagnosis— organisms isolated from blood, bone marrow, urine, tissue from the rose spots</p>	<p>DOC</p> <ul style="list-style-type: none"> • Ceftriaxone • Fluoroquinolones <p>Prevention= sanitation</p> <p>3 Vaccines</p> <ul style="list-style-type: none"> • Parenteral polysaccharide capsular • Attenuated oral (strain 21- Ty21a) • Parenteral heat-killed (no longer used in US)
--	--	---	---

Salmonella enterica (subsp. enteritidis, typhimurium, choleraesuis, paratyphi, dublin)

<ul style="list-style-type: none"> • Serotyped with O, H, and Vi antigens—detected by agglutination: Widal test <p>Reservoir</p> <ul style="list-style-type: none"> • Enteric tracts of humans and domestic animals (chickens & turtles) <p>Transmission</p> <ul style="list-style-type: none"> • Raw chicken, eggs • Reptile pets (snakes, turtles) 	<ul style="list-style-type: none"> • High infectious dose— (>10⁵) Sensitive to stomach acid • Lowered stomach acidity (PPI's, antacids) increases risk • Endotoxin in cell wall • Invades mucosa in ileocecal region, invasive to lamina propria→ inflammation ↑ PG→ ↑ cAMP= loose diarrhea; shallow ulceration <p>MOA= inflammation (NO toxins)</p>	<p>Enterocolitis/gastroenteritis</p> <ul style="list-style-type: none"> • 2nd MC bacterial cause (1st Campylobacter) • 6-48 hr incubation→ nausea, vomiting; loose stools (occasionally bloody), fever, abdominal pain, myalgia, headache <p>Septicemia</p> <ul style="list-style-type: none"> • Choleraesuis, paratyphi, Dublin • Rare, only very young or elderly; 10% complicated w/ endocarditis <p>Osteomyelitis</p> <ul style="list-style-type: none"> • Salmonella is MCC causal agent in sickle cell disease <p>Diagnosis: culture on Hektoen agar (green agar that turns black)</p>	<p>Gastroenteritis</p> <ul style="list-style-type: none"> • Self-limiting, • NO ANTIBIOTICS (may prolong fecal excretion) <p>Invasive disease</p> <ul style="list-style-type: none"> • Ampicillin • Ceftriaxone • Fluoroquinolones • TMP-SMX
--	--	--	---

Haemophilus

- Pleomorphic rod (considered **coccobacillus**)
- **Requires growth factors X (hematin) and V (NAD)** for growth on blood agar
- **Satellite phenomenon** (with *S. aureus* on blood agar)
 - Pinpoint colonies (*S. aureus* secretes NAD and lysed blood releases hematin)
- **Chocolate agar** (provides both X and V factor)

Haemophilus influenzae

Features	Pathogenesis	Diseases	Treatment
<ul style="list-style-type: none"> • Encapsulated • 95% of invasive disease caused by capsular type b Reservoir <ul style="list-style-type: none"> • Human nasopharynx Transmission <ul style="list-style-type: none"> • Respiratory droplets • Shared toys <p>*Unvaccinated child*</p>	<ul style="list-style-type: none"> • Polysaccharide capsule (most important)—type b capsule is polyribitol phosphate • Attachment pili • IgA protease—colonizing factor • Latex particle agglutination screen for capsular antigen in CSF 	<p>Meningitis</p> <ul style="list-style-type: none"> • Epidemic in unvaccinated children ages 3 months (after maternal antibody wanes) to 2 years (before immune response is adequate) • <i>Before 1990</i>-- MCC meningitis in 1-5 yr old <p>Epiglottitis→ Unvaccinated toddlers—catcher's stance w/ drooling (dog sniffing position—drop heads to catch breath due to swelling of epiglottis)</p> <p><u>Nontypable strains</u> Otitis media/sinusitis→ 2nd MCC cause (also presents w/ conjunctivitis)</p> <p>Bronchitis→ exacerbations of acute bronchitis in smokers w/ COPD Pneumonia→ smoking history; rare in vaccinated children</p>	DOC <ul style="list-style-type: none"> • Ceftriaxone • Cefotaxime Rifampin= prophylaxis <p>Vaccine</p> <ul style="list-style-type: none"> • Conjugate capsular polysaccharide protein vaccine coupled to protein carrier (diphtheria toxoid) • Prevents <u>type b</u> • T-cell dependent • Not live; 2, 4, 6 months • Booster at 15 months

Haemophilus ducreyi

Reservoir <ul style="list-style-type: none"> • Human genitals Transmission <ul style="list-style-type: none"> • Sexual and direct contact 	No exotoxins	Chancroid <ul style="list-style-type: none"> • PAINFUL genital ulcer (syphilis is painless) • Often associated with unilateral swollen lymph node (can rupture releasing pus) <p>Painful chancroid= "you do cry with ducreyi"</p>	DOC <ul style="list-style-type: none"> • Azithromycin and/or Ceftriaxone • Ciprofloxacin
---	--------------	--	---

Gardnerella vaginalis

<ul style="list-style-type: none"> • Gram-variable rod (gram ⊕ that could become gram ∅ after culturing) Reservoir= normal flora <ul style="list-style-type: none"> • Vagina Transmission= endogenous <ul style="list-style-type: none"> • Flora gets disturbed (stress, menses, antibiotics, ↑ pH) 	<ul style="list-style-type: none"> • Polymicrobial infections • Works synergistically with other normal flora (<i>Lactobacillus</i>, <i>Mobiluncus</i>, <i>Bacteroides</i>, <i>Peptostreptococcus</i>) • ↑ pH associated with reduction of vaginal <i>Lactobacillus</i> 	Bacterial vaginosis Vaginal odor, thin, gray discharge <p>Diagnosis pH >4.5, Vaginal saline smear→ clue cells (vaginal epithelial cells that contain tiny pleomorphic gram negative bacilli within the cytoplasm) Whiff test: add KOH to sample→ "fishy" amine odor</p> <p>Other discharges</p> <ul style="list-style-type: none"> • Gonorrhea→ cloudy yellow-green, purulent • Chlamydia→ clear, white • Trichomonas→ frothy green w/ foul odor (strawberry cervix) • Candida→ cottage cheese (only one with decreased pH) 	DOC <ul style="list-style-type: none"> • Metronidazole • Clindamycin
---	--	--	---

Gram negative rods associated with Animal/Human bites

Pasteurella multocida			
Features	Pathogenesis	Diseases	Treatment
Reservoir <ul style="list-style-type: none"> Animal mouth; especially cats and dogs Requires cysteine Transmission <ul style="list-style-type: none"> Animal bite: particularly from cats 	<ul style="list-style-type: none"> Endotoxin Capsule Spreads rapidly within skin 	Cellulitis with lymphadenitis <ul style="list-style-type: none"> Wound infections, rapidly spreading (could spread to bone) Frequently polymicrobial infections Diagnosis—rarely cultured (prophylaxis is common) Other cysteine requiring bacteria: Francisella, Brucella, Legionella (Francis and Bruce play with Legos in the Pasture)	DOC <ul style="list-style-type: none"> Amoxicillin + Clavulanate (treatment and prophylaxis) Resistant to macrolides
Additional organisms			
Eikenella Corrodens	“Corrodes” agar; bleach like odor	Human bites or fist fight injuries→ Cellulitis	3 rd gen cephalosporins Fluoroquinolones
Capnocytophaga canimorsus	Filamentous rods	Dog bite wounds→ Cellulitis (overwhelming sepsis in asplenic pts)	3 rd gen cephalosporins Fluoroquinolones
Bartonella henselae	Immunocompromised (AIDS)	Cats/dog bits/ scratches “ cat scratch fever ” Bacillary Angiomatosis (AIDS) → raised purple/black splotches	Azithromycin Doxycycline
Bartonella quintana	Spread by lice	Trench fever (5 day fever with bone pain)	
HACEK group infections			
Haemophilus aphrophilus Actinobacillus actinomycetemcomitans Cardiobacterium hominis Eikenella corodens Kingella kingae	<ul style="list-style-type: none"> All part of normal flora 	<ul style="list-style-type: none"> 5-10% of infective endocarditis (subacute) MCC gram negative endocarditis in non-IV drug users (“non-culture endocarditis”) Diagnosis difficult→ mean diagnosis time of 3 months	3rd gen cephalosporins Fluoroquinolones

OBLIGATE ANAEROBIC

Bacteroides fragilis			
Features	Pathogenesis	Diseases	Treatment
<ul style="list-style-type: none"> ONLY gram negative obligate anaerobe Modified LPS with reduced activity Reservoir= normal flora <ul style="list-style-type: none"> Human colon Transmission= endogenous <ul style="list-style-type: none"> Bowel defects (cytotoxic drug use) Surgery or trauma 	<ul style="list-style-type: none"> Modified LPS (missing heptose and 2-keto-3 deoxyoctonate)= reduced endotoxin activity Capsule is antiphagocytic 	Septicemia (used to be MCC before prophylaxis during surgery) Peritonitis (mixed infection) Abdominal abscess → foul smelling Postpartum endometritis → foul smelling discharge with tender uterus Aspiration pneumonia with abscess and foul smelling sputum think anaerobic Diagnosis Anaerobes identified by biochemical tests and gas chromatography Other anaerobes: Prevotella, Fusobacterium, Peptostreptococcus	DOC <ul style="list-style-type: none"> Metronidazole Clindamycin Abscess should be surgically drained Antibiotic resistance common (7-10% clindamycin resistant) Prophylactic antibiotics for GI surgery

Spirochetes

Treponema pallidum (Thin spiral with axial filaments)

Features	Pathogenesis	Diseases	Treatment												
<ul style="list-style-type: none"> • Endoflagella- allow movement • Poor gram stain (but gram neg envelope) • Obligate pathogen; cannot culture <p>Reservoir= Humans</p> <ul style="list-style-type: none"> • Genital tract <p>Transmission</p> <ul style="list-style-type: none"> • Sexual or transplacental <p>False positive VRDL</p> <p>Viruses</p> <p>Drugs</p> <p>Rheumatic fever</p> <p>Lupus/Leprosy</p>	<ul style="list-style-type: none"> • NOT intracellular • Endarteritis (vasa vasorum destruction- aortic aneurysm) • Strong tendency to chronicity <p>Diagnosis</p> <ul style="list-style-type: none"> • Dark-field microscopy • Serology (2 types) <p>1. Nontreponemal (screening)—Ab binds to cardiolipin</p> <ul style="list-style-type: none"> • Cheap source of Ab usually from cow heart • VDRL, RPR, ART, ICE • Must confirm with FTA-ABS <p>2. Treponemal Ab (expensive)</p> <ul style="list-style-type: none"> • Ab binds to spirochetes • More specific, positive earlier, remain ⊕ for life • FTA-ABS (fluorescent treponemal antibody absorption); Most used (confirmatory) 	<p>Syphilis: Stages</p> <table border="1" style="width: 100%; border-collapse: collapse;"> <tr> <td style="width: 20%;">Primary</td> <td style="width: 50%;"> <ul style="list-style-type: none"> • PainLESS chancre on glans/vulva • Clean, indurated edge; contagious • Heals 3-6 weeks </td> <td style="width: 30%; text-align: center;">Dark field microscopy</td> </tr> <tr> <td>Secondary</td> <td> <ul style="list-style-type: none"> • Non-itchy, maculopapular, copper-colored rash on palms and soles (infectious) • Patchy alopecia (beard) • Condyloma lata (flat wart-like perianal/ mucous membrane lesions—highly infectious) </td> <td style="vertical-align: top;">Serology non specific and specific; both positive</td> </tr> <tr> <td>Tertiary</td> <td> <ul style="list-style-type: none"> • 3-15 years after after secondary; not infectious • Gummatous (soft tumor-like granulomas in skin (which can ulcerate), bone, liver, brain—gummas) • Neuro (<i>tabes dorsalis</i>, <i>Argyll Robertson pupils</i>) • Cardiovascular (“tree bark” aortic arch aneurysm) </td> <td style="vertical-align: top;">Specific serology tests (nonspecific may be negative)</td> </tr> <tr> <td>Congenital</td> <td> <ul style="list-style-type: none"> • During pregnancy or birth (symptoms in 1/3) • Still birth, keratitis, rash, fever, pneumonitis, pemphigous syphiliticus (bullae-palms/soles), hepatosplenomegaly, metaphyseal dystrophy • Untreated → CN VIII deafness, saddle nose, Higoumenaki’s sign (unilateral sternal clavicle enlargement), Hutchinson’s teeth (notched incisors), Saber shin (sharp anterior bowing) </td> <td style="vertical-align: top;">Serology should revert to negative within 3 months of birth if unaffected</td> </tr> </table>	Primary	<ul style="list-style-type: none"> • PainLESS chancre on glans/vulva • Clean, indurated edge; contagious • Heals 3-6 weeks 	Dark field microscopy	Secondary	<ul style="list-style-type: none"> • Non-itchy, maculopapular, copper-colored rash on palms and soles (infectious) • Patchy alopecia (beard) • Condyloma lata (flat wart-like perianal/ mucous membrane lesions—highly infectious) 	Serology non specific and specific; both positive	Tertiary	<ul style="list-style-type: none"> • 3-15 years after after secondary; not infectious • Gummatous (soft tumor-like granulomas in skin (which can ulcerate), bone, liver, brain—gummas) • Neuro (<i>tabes dorsalis</i>, <i>Argyll Robertson pupils</i>) • Cardiovascular (“tree bark” aortic arch aneurysm) 	Specific serology tests (nonspecific may be negative)	Congenital	<ul style="list-style-type: none"> • During pregnancy or birth (symptoms in 1/3) • Still birth, keratitis, rash, fever, pneumonitis, pemphigous syphiliticus (bullae-palms/soles), hepatosplenomegaly, metaphyseal dystrophy • Untreated → CN VIII deafness, saddle nose, Higoumenaki’s sign (unilateral sternal clavicle enlargement), Hutchinson’s teeth (notched incisors), Saber shin (sharp anterior bowing) 	Serology should revert to negative within 3 months of birth if unaffected	<p>DOC</p> <ul style="list-style-type: none"> • IM Penicillin G Benzathine (long acting— for 1° & 2°) • IV Penicillin G (for congenital & late) • Doxycycline <p>Jarisch-Herxheimer Reaction → Due to release of LPS from organism after it’s killed (shock in 1st 24 hrs of treatment: ↑temp, ↓BP, rigors, leucopenia)</p> <p>Benzathine penicillin given to contacts</p>
Primary	<ul style="list-style-type: none"> • PainLESS chancre on glans/vulva • Clean, indurated edge; contagious • Heals 3-6 weeks 	Dark field microscopy													
Secondary	<ul style="list-style-type: none"> • Non-itchy, maculopapular, copper-colored rash on palms and soles (infectious) • Patchy alopecia (beard) • Condyloma lata (flat wart-like perianal/ mucous membrane lesions—highly infectious) 	Serology non specific and specific; both positive													
Tertiary	<ul style="list-style-type: none"> • 3-15 years after after secondary; not infectious • Gummatous (soft tumor-like granulomas in skin (which can ulcerate), bone, liver, brain—gummas) • Neuro (<i>tabes dorsalis</i>, <i>Argyll Robertson pupils</i>) • Cardiovascular (“tree bark” aortic arch aneurysm) 	Specific serology tests (nonspecific may be negative)													
Congenital	<ul style="list-style-type: none"> • During pregnancy or birth (symptoms in 1/3) • Still birth, keratitis, rash, fever, pneumonitis, pemphigous syphiliticus (bullae-palms/soles), hepatosplenomegaly, metaphyseal dystrophy • Untreated → CN VIII deafness, saddle nose, Higoumenaki’s sign (unilateral sternal clavicle enlargement), Hutchinson’s teeth (notched incisors), Saber shin (sharp anterior bowing) 	Serology should revert to negative within 3 months of birth if unaffected													

Borrelia burgdorferi (Large spirochete)

<ul style="list-style-type: none"> • Microaerophilic <p>Reservoir</p> <ul style="list-style-type: none"> • White-footed mice • White-tailed deer <p>Transmission- ticks (Ixodes also carry Babesia, Ehrlichia)</p> <ul style="list-style-type: none"> • <i>I. scapularis</i> • <i>I. pacificus</i> 	<ul style="list-style-type: none"> • Invades skin and spreads via bloodstream to involve heart, joints, and CNS • Arthritis caused by immune complexes <p>Diagnosis</p> <ul style="list-style-type: none"> • Serodiagnosis (ELISA) • Western blot now test of choice 	<p>Lyme disease (#1 tick-borne disease in U.S.) → MC in northeast— spring</p> <table border="1" style="width: 100%; border-collapse: collapse;"> <tr> <td style="width: 40%;">1: Early localized (Days—Weeks)</td> <td style="width: 60%;"> <ul style="list-style-type: none"> • Target rash (aka bull’s eye, annular lesion, red w/ central clearing) Fatigue, fever, headache </td> </tr> <tr> <td>2: Early disseminated (Weeks—Months)</td> <td> <ul style="list-style-type: none"> • Hematogenous spread → Bilateral Bell’s Palsy, muscle and joint pain, swollen lymph nodes, secondary annular skin lesions, cardiac (AV block/myocarditis) </td> </tr> <tr> <td>3: Late persistent (Months—years)</td> <td> <ul style="list-style-type: none"> • Encephalitis, meningitis, extreme fatigue, conjunctivitis • Arthritis (MC in knees; immune complex-mediated) </td> </tr> </table> <p><i>Borrelia recurrentis</i> → recurrent fevers (from variable surface antigens) also tick vector</p>	1: Early localized (Days—Weeks)	<ul style="list-style-type: none"> • Target rash (aka bull’s eye, annular lesion, red w/ central clearing) Fatigue, fever, headache 	2: Early disseminated (Weeks—Months)	<ul style="list-style-type: none"> • Hematogenous spread → Bilateral Bell’s Palsy, muscle and joint pain, swollen lymph nodes, secondary annular skin lesions, cardiac (AV block/myocarditis) 	3: Late persistent (Months—years)	<ul style="list-style-type: none"> • Encephalitis, meningitis, extreme fatigue, conjunctivitis • Arthritis (MC in knees; immune complex-mediated) 	<p>DOC</p> <ul style="list-style-type: none"> • Doxycycline • Ceftriaxone (2°) • Amoxicillin (for children <8 and pregnant women) <p>Prevention—DEET; avoid tick bites</p>
1: Early localized (Days—Weeks)	<ul style="list-style-type: none"> • Target rash (aka bull’s eye, annular lesion, red w/ central clearing) Fatigue, fever, headache 								
2: Early disseminated (Weeks—Months)	<ul style="list-style-type: none"> • Hematogenous spread → Bilateral Bell’s Palsy, muscle and joint pain, swollen lymph nodes, secondary annular skin lesions, cardiac (AV block/myocarditis) 								
3: Late persistent (Months—years)	<ul style="list-style-type: none"> • Encephalitis, meningitis, extreme fatigue, conjunctivitis • Arthritis (MC in knees; immune complex-mediated) 								

Leptospira interrogans (Very thin with tight terminal hooks on both ends)

<ul style="list-style-type: none"> • Aerobic <p>Zoonotic (dogs, rats, livestock)</p> <p>Transmission</p> <ul style="list-style-type: none"> • Contact with animal urine in the water • Penetrates mucous membranes/ small breaks in skin • Jetskiers in Hawaii, Sewer workers 	<p>Leptospirosis (swamp fever, mud fever, swineherd’s disease)</p> <ul style="list-style-type: none"> • Influenza-like disease, high spiking temperatures, muscle aches (thighs/lower back) • Severe if not treated (Weil’s disease—hepatitis, jaundice, renal failure, organ hemorrhage, mental status changes, photophobia) <p>Diagnosis</p> <ul style="list-style-type: none"> • Serodiagnosis (agglutination test), Culture (blood, CSF, urine), • Darkfield NOT recommended 	<p>DOC</p> <ul style="list-style-type: none"> • Penicillin G • Doxycycline <p>Prevention: animal vaccination, rat control</p>
--	--	--

Unusual Bacteria

Obligate Intracellular Organisms (Chlamydia, Rickettsia, Anaplasma)

- Do not make sufficient ATP (must utilize host cell)

Chlamydia trachomatis (C. pneumoniae, C. psittaci)			
Features	Pathogenesis	Diseases	Treatment
<ul style="list-style-type: none"> NOT seen on gram stain; (peptidoglycan lacks muramic acid) Does not produce any ATP <p>Reservoir</p> <ul style="list-style-type: none"> Human genital tract; eyes <p>Transmission</p> <ul style="list-style-type: none"> Sexual contact, birth Trachoma by hand-to-eye contact and flies 	<ul style="list-style-type: none"> Infects nonciliated columnar or cuboidal epithelial cells of mucosal surfaces → granulomatous response, inflammation, damage Elementary body → (infective form) inactive, extracellular Reticulate body → (replicating form) active, <u>intracellular</u> 	<p>Sexually Transmitted Disease (Serotypes D-K)</p> <ul style="list-style-type: none"> MC bacterial STD in US (Overall: HPV, herpes) Nongonococcal urethritis, cervicitis, PID, inclusion conjunctivitis Inclusion conjunctivitis/pneumonia in neonates (staccato cough) <p>Complications → Sterility, <u>Reiter's syndrome</u>, <u>Fitz-Hugh Curtis</u></p> <p>Lymphogranuloma venereum (Serotypes L1,2,3)</p> <ul style="list-style-type: none"> Prevalent in Africa, Asia, South America Tertiary: rectal strictures, fistulas, <u>ulcers</u>, <u>swollen LN</u> → genital elephantiasis <p>Trachoma (Serotypes A-C)</p> <ul style="list-style-type: none"> Leading cause of preventable infectious blindness Follicular conjunctivitis → inturned eyelashes → corneal scarring 	<p>Diagnosis:</p> <ul style="list-style-type: none"> DNA probes (US) Cytoplasmic inclusions (reticulate bodies) on Giemsa <p>DOC</p> <ul style="list-style-type: none"> Doxycycline Azithromycin <p>Erythromycin (mothers at birth; drops for neonatal conjunctivitis)</p>
<p>C. pneumoniae</p> <p>TWAR strain— Person to person by respiratory route</p>	<ul style="list-style-type: none"> Intracellular growth; infects smooth muscle endothelial cells; coronary artery (atherosclerosis) 	<p>Walking pneumonia (2nd MCC)—(Atypical pneumonia)</p> <ul style="list-style-type: none"> Single lobe, bronchitis, scant sputum, dry cough/hoarseness Diagnosis= serology (complement fixation) 	<p>DOC</p> <ul style="list-style-type: none"> Doxycycline Macrolides
<p>C. psittaci</p> <p>Inhaled dried feces dust of birds, parrots, turkeys (US)</p>	<ul style="list-style-type: none"> Intracellular growth No glycogen in inclusion bodies 	<p>Psittacosis (ornithosis)—(Atypical pneumonia)</p> <p>Very contagious; cough initially absent</p> <p>Hepatitis; CNS and GI symptoms may be present</p>	<p>DOC</p> <ul style="list-style-type: none"> Doxycycline
Rickettsia rickettsii			
<ul style="list-style-type: none"> Aerobic, Gram ∅ bacilli (too small to stain) <p>Reservoir= zoonotic</p> <ul style="list-style-type: none"> Dogs, rabbits, rodents <p>Transmission</p> <ul style="list-style-type: none"> Demacantor ticks 	<ul style="list-style-type: none"> Invade endothelial cells lining capillaries → vasculitis in many organs (brain, liver, skin, lungs, kidney, and GI tract) Weil-Felix test ⊕ (Cross reaction of Rickettsia w/ Proteus vulgaris) 	<p>Rocky Mountain Spotted Fever →</p> <ul style="list-style-type: none"> Prevalent on East Coast (North Carolina area); 2-12 day incubation Headache, fever (102F), malaise, myalgias, toxicity, vomiting Maculopapular → petechial rash on ankles/wrists (w/ swelling) → spread to trunk, palms, soles, & face (centripetal rash) 	<p>Diagnosis</p> <ul style="list-style-type: none"> Clinical, start doxy before lab confirmation 4X ↑ titer is diagnostic <p>DOC= Doxycycline</p>
<p>Coxiella burnetti</p>	<p>Inhalation of endospores (feces, urine, placenta of slaughterhouses)</p>	<p>Q fever—interstitial pneumonia with NO rash; <u>Weil-Felix Negative</u></p>	
<p>R. prowazekii</p>	<p>Human louse → humans (war, prisons)</p>	<p>Epidemic Typhus → abrupt fever, headache, rash (no palms/soles), delirium</p>	
<p>R. typhi</p>	<p>Rats → Fleas → humans</p>	<p>Endemic Typhus → fever, headache, rash</p>	
<p>Orientia tsutsugamushi</p>	<p>Rodents → Mites → humans</p>	<p>Scrub Typhus → fever, headache, rash, muscle pain, cough → hemorrhaging</p>	
Anaplasma (formerly Ehrlichia; A. chaffeensis, A. phagocytophila)			
<ul style="list-style-type: none"> Gram ∅ bacilli <p>Reservoir= ticks/deer</p> <p>Transmission= ticks</p> <ul style="list-style-type: none"> Lone star (<i>chaffeensis</i>) Ixodes (<i>phagocytophila</i>) 	<p>Infects WBCs—</p> <p>Monocytic (<i>chaffeensis</i>)</p> <p>Granulocytic (<i>phagocytophilum</i>) → obligate bacterium of neutrophils</p> <p>*Borrelia co-infection common*</p>	<p>Anaplasmosis →</p> <ul style="list-style-type: none"> Similar to RMSF but without rash Leukopenia, low platelets, morulae (mulberry-like structures inside infected cells) <p>Diagnosis</p> <ul style="list-style-type: none"> Giemsa blood film, IFA, PCR 	<p>DOC</p> <ul style="list-style-type: none"> Doxycycline (begin before lab confirmation)

Mycoplasmas

- Missing peptidoglycan—No cell wall (**not seen on gram stain**)
- **Requires cholesterol** (plus nucleic acids) for in vitro culture → fried egg appearance (not seen in *M. pneumoniae*)

Mycoplasma pneumoniae			
Features	Pathogenesis	Diseases	Treatment
<ul style="list-style-type: none"> • Smallest extracellular bacteria • Sterols/cholesterol in membrane (but does not synthesize cholesterol) • Eaton's agar Reservoir <ul style="list-style-type: none"> • Human respiratory tract Transmission <ul style="list-style-type: none"> • Respiratory droplets • Close contact: military recruits, college dorms 	<ul style="list-style-type: none"> • Surface parasite (not invasive) • P1 Protein—attaches to respiratory epithelium • Inhibits ciliary action • Produces hydrogen peroxide, superoxide radicals, cytolytic enzymes (damage respiratory epithelium → necrosis, bad hacking cough) • Functions as superantigen—elicits production of IL-1, IL-6, and TNF-α (overwhelming immune response; inflammation) 	Walking pneumonia (MCC) (patients do not feel very sick) <ul style="list-style-type: none"> • MC atypical pneumonia in young adults • Dry hacking cough; pharyngitis, fever, otitis media • Also common in children and teens Diagnosis <ul style="list-style-type: none"> • Primarily clinical; PCR/nucleic acid probes • ELISA and immunofluorescence sensitive and specific • Mulberry-shaped colonies on sterol-containing media, 10 days • Positive cold agglutinins (IgM autoantibody to red cells) test is nonspecific and only positive in 65% of cases (however <u>this plus a clinical presentation has been an effective diagnostic tool</u>) 	DOC <ul style="list-style-type: none"> • Erythromycin (and other macrolides) • Tetracyclines Cephalosporins or penicillins do NOT work → (no cell wall!!!)
Ureaplasma urealyticum			
<ul style="list-style-type: none"> • Urease ⊕ 	<ul style="list-style-type: none"> • Becomes normal flora of sexually active adults • Seen in child= sexual abuse 	<ul style="list-style-type: none"> • Urethritis (yellow mucoid discharge) • Prostatitis • Renal calculi 	DOC <ul style="list-style-type: none"> • Erythromycin • Tetracycline

Quick Reference Chart

Encapsulated	Catalase ⊕	Oxidase ⊕	Urease ⊕	Obligate Aerobes	Culture media	
Strep (pneumo & GBS) Klebsiella Haemophilus Pseudomonas Neisseria Cryptococcus E. Coli Salmonella	Pseudomonas Listeria Aspergillus Candida E.coli Staph aureus Serratia	Campylobacter Pseudomonas Vibrio Helicobacter Legionella Neisseria (Enterobacteriae are negative)	Proteus Ureaplasma Nocardia Cryptococcus Helicobacter Epidermidis Saprophyticus Klebsiella	Nocardia Pseudomonas M. tuberculosis Bacillus anthracis Obligate Anaerobes Clostridium Bacteroides Actinomyces	Haemophilus Neisseria Bordetella C. diphtheriae M. tuberculosis Mycoplasma pneumo Legionella Fungi	Chocolate agar (factors V & X) Thayer Martin (VPN*) Bordet-Gengou Tellurite, Loeffler's media Lowenstein-Jensen Eaton's agar Buffered Charcoal Yeast Extract Sabouraud's agar
Some Killers Have Pretty Nice Capsules (Even Salmonella)	PLACESS for your Cat	Ox Can Pull Very Heavy Loads Nonstop	PUNCHES Kill	Aerobes—Nagging Pests Must Breathe Anaerobes—Can't Breathe Air	Special stains Giemsa → Chlamydia, Borrelia, Rickettsia, Trypanosomes, Plasmodium India ink → Cryptococcus neoformans Acid Fast → Mycobacterium, Nocardia (partial)	

*VPN= Vancomycin (kills gram positive), Polymyxin (kills gram neg except Neisseria), Nystatin (kills fungi)

Toxin comparisons

ADP ribosylation of eEF-2	Inactivate 60s ribosome subunit	ADP ribosylation of Gs (↑cAMP)	Act as adenylate cyclase
C. diphtheriae Pseudomonas	EHEC Shigella	ETEC (heat labile toxin) Vibrio Cholera	B. pertussis (adenylate cyclase toxin) B. anthracis (edema factor)

Cell Wall Synthesis Inhibitors

MOA	Bacteriocidal— D-ala D-ala analogs that bind and inactivate transpeptidase (PBP) Prevent <u>cross-linkage</u> of peptidoglycan chains (loss of cell rigidity→ cell death) Work best at period of maximal growth (log phase)		
Resistance	<ol style="list-style-type: none"> 1. Penicillinases (beta-lactamases) break lactam ring structure→ produced in periplasm of gram-negatives 2. Structural change in PBPs (MRSA) 3. Change in porin structure (Pseudomonas) 		
Penicillins		Cephalosporins	
Narrow Spectrum (penicillinase susceptible)	Neurosyphilis, Strep viridans, pneumo (Penicillin G) Strep pharyngitis (Penicillin V)	First generation	First —surgical prophylaxis (gram positive + Proteus, E.coli, Kebsiella)
<ul style="list-style-type: none"> • Penicillin G (IM or IV) • Penicillin V (oral) 	Safe in pregnancy	<ul style="list-style-type: none"> • Cephalexin (oral) • Cefazolin (IM or IV) 	Second — increased gram negative coverage including some anaerobes (<u>Cefuroxime</u> only one to enter CNS)
Narrow Spectrum (penicillinase resistant)	Mostly staphylococci (not MRSA)	Second generation	Third —gram positive/negative cocci, & many gram negative rods (all enter CNS except cefoperazone)
<ul style="list-style-type: none"> • Methicillin • Nafcillin • Oxacillin 	All penicillins are renally excreted except for oxacillin and nafcillin (excreted in bile) Methicillin can cause interstitial nephritis	<ul style="list-style-type: none"> • Cefoxitin • Cefotetan • Cefaclor • Cefamandole • Cefuroxime 	<ul style="list-style-type: none"> • <u>Ceftriaxone</u> (DOC Neisseria, strep pneumo meningitis, Salmonella, Haemophilus) • <u>Cefotaxime</u> (strep pneumo meningitis) • Cefoperazone & Ceftazidime (pseudomonas) • Ceftriaxone & Cefoperazone eliminated in bile
Broad Spectrum (penicillinase susceptible)	Mostly treat ear nose and throat infections	Third generation	Fourth —wider spectrum, resistant to most beta-lactamases, and enters the CNS
<ul style="list-style-type: none"> • Ampicillin (IV) • Amoxicillin 	<ul style="list-style-type: none"> • Streptococcus, H. influenza • Listeria (ampicillin+gentamycin) • Borrelia, H. pylori, ear infections (amoxicillin) 	<ul style="list-style-type: none"> • Cefotaxime • Ceftriaxone (IM) • Ceftazidime • Cefoperazone • Cefixime 	<u>Bacteria NOT COVERED by cephalosporins are LAME</u>
Extended Spectrum (penicillinase susceptible)	Increased activity against gram-negative rods including <u>pseudomonas</u>	Fourth generation	<ul style="list-style-type: none"> • Listeria • Atypicals (Chlamydia, Mycoplasma) • MRSA • Enterococci
<ul style="list-style-type: none"> • Ticarcillin • Piperacillin • Azlocillin 	Carbenicillin concentrates in urinary tract (for UTIs) Do not give ticarcillin to cardiac/hypertensive pts	<ul style="list-style-type: none"> • Cefepime (IV) 	Cefotetan and Cefoperazone have disulfiram-like effects
B-lactamase inhibitors		Carbapenems	
<ul style="list-style-type: none"> • Clavulanic Acid • Sulbactam • Tazobactam 	Irreversible inhibitors of beta-lactamase No antibacterial activity; used as fixed dose combination to widen spectrum <ul style="list-style-type: none"> • Amoxicillin + clavulanate • Ampicillin + sulbactam • Piperacillin + tazobactam (pseudomonas and bacteroides) 	<ul style="list-style-type: none"> • Imipenem • Meropenem • Ertapenem • Doripenem 	Important in-hospital agents for empiric use in severe life threatening infections (anaerobes, gram positive cocci and gram negative rods)—everything except MRSA <ul style="list-style-type: none"> • Imipenem given with cilastatin (inhibits renal dehydropeptidase & prevents toxic metabolite) • Cross allergenicity, CNS effects including seizures
Vancomycin		Monobactams	
MOA: binds at D-ala-D-ala muramyl pentapeptide (sterically hinders transglycosylation reactions involved in elongation of peptidoglycan chains— “blocks glycopeptide polymerization”)	<ul style="list-style-type: none"> • Drug of last resort • Used for MRSA, enterococci, & backup to metronidazole for C. difficile (oral only) • Resistance—terminal D-ala→ lactate • A/E: Ototoxicity, Nephrotoxicity, Red man syndrome (flushing red face, hypotension—histamine release) Reduce effects with antihistamine + slow infusion 	<ul style="list-style-type: none"> • Aztreonam 	Beta-lactamase resistant No gram ⊕ activity (Mainly active against gram negative rods) No cross allergenicity with penicillins (Specifically binds PBP-3)

Protein Synthesis Inhibitors

Bind 30s		Bind 50s		
Aminoglycosides <ul style="list-style-type: none"> Gentamycin Streptomycin Neomycin Tobramycin Kanamycin Amikacin 	Bactericidal— blocks formation of initiation complex (misreading of mRNA; also blocks translocation)	Chloramphenicol	Bacteriostatic— blocks peptidyl transferase ; inhibiting formation of a peptide bond	
	Treatment <ul style="list-style-type: none"> Severe gram negative rods; <u>cannot kill anaerobes</u> Synergistic with penicillins <u>Concentration dependent killing</u>— ↑ concentration kills more at a faster rate (single large dose) <u>Postantibiotic effect</u>—antibacterial activity persists beyond measurable drug (used once daily) Streptomycin—DOC bubonic plague & tularemia Neomycin- Hepatic coma to decrease coliform flora Gentamycin + Penicillin= DOC endocarditis Tobramycin—inhalation for pseudo in CF A/E <ul style="list-style-type: none"> Nephrotoxicity (especially with cephalosporins) Ototoxicity (especially with <u>loop diuretics</u>) Neuromuscular blockade (don't give to myasthenia gravis or with succinylcholine) Contraindicated in pregnancy Resistance: Transferase enzymes inactivate the drug by acetylation, phosphorylation or adenylation		Treatment of Salmonella, H. influenza, N. meningitides	A/E— <u>p450 inhibitor</u> , BM suppression, gray baby syndrome (pale, cyanosed; neonates lack glucuronidation)
Tetracyclines <ul style="list-style-type: none"> Tetracycline Doxycycline Minocycline Demeclocycline Tigecycline 	Bacteriostatic— blocks attachment of aminoacyl-tRNA to the acceptor site (inhibits AA incorporation)	Macrolides <ul style="list-style-type: none"> Azithromycin Clarithromycin Erythromycin Roxithromycin Telithromycin 	Bacteriostatic—Reversible binding to 23s of 50s subunit; inhibits aminoacyl translocation of peptidyl-tRNA	
	Treatment (doxycycline most used) <ul style="list-style-type: none"> Can be used in patients with renal failure (eliminated fecally) M. pneumoniae, H. pylori, Brucella, Vibrio Spirochetes (Borrelia; 2nd line for Treponema/Leptospirosis) Intracellular bacteria (Chlamydia, Rickettsia, Ehrlichia) <u>Minocycline</u>: concentrates in saliva/tears (meningitis carrier) <u>Demeclocycline</u> can be used in SIADH <u>Tigecycline</u>: used in complicated resistant skin infections A/E <ul style="list-style-type: none"> GI distress, photosensitivity Children—discoloration of teeth & bone growth inhibition Contraindicated in pregnancy Decreased absorption when taken with milk/antacids Resistance: Decreased uptake into cells or increased efflux out of the cell by plasmid-encoded transport pumps		Wide spectrum antibiotics <ul style="list-style-type: none"> Atypical pneumonias (Mycoplasma, Chlamydia, Legionella) Chlamydia, Campylobacter, H. pylori, Gram+ cocci (not MRSA) M avium (prophylaxis-azithro; treat-clarithro+ethambutol) Erythro drops: neonatal conjunctivitis (chlamydia/gonorrhea) A/E— <u>p450 inhibitors (especially erythromycin)</u> , prolongs QT interval, GI distress from stimulation of motilin receptors	Resistance: production of methyltransferases that alter drug binding sites, or active transport out of cells
	Clindamycin	Same MOA and resistance as macrolide <ul style="list-style-type: none"> Gram positive cocci including MRSA; backup for B. fragilis (anaerobic lung abscess) Concentrates in bone; clinical value in osteomyelitis A/E— <u>pseudomembranous colitis</u> 	Linezolid	Bactericidal— blocks formation of initiation complex (works at 23s subunit)
		Treatment of VRSA, VRE, and drug-resistant pneumococci		A/E—bone marrow suppression, thrombocytopenia; inhibits MAO increasing risk of serotonin syndrome
Streptogramins <ul style="list-style-type: none"> Quinupristin Dalfopristin 	Bacteriostatic—blocks the attachment of aminoacyl tRNA to acceptor site; stimulate dissociation from ternary complex	Streptogramins <ul style="list-style-type: none"> Quinupristin Dalfopristin 	Treatment- parenterally in severe infections caused by VRSA and VRE , as well as other drug resistant gram+ cocci	
	Resistance: Decreased uptake into cells or increased efflux out of the cell by plasmid-encoded transport pumps		A/E—nausea, diarrhea, myalgias, arthralgias, hepatotoxicity	

Nucleic Acid Synthesis Inhibitors

Inhibitors of Folic Acid Synthesis		Direct inhibitors of Nucleic Acid Synthesis	
Sulfonamides <ul style="list-style-type: none"> • Sulfamethoxazole • Sulfadoxine • Sulfasalazine • Sulfacetamide • Sulfadiazine • Mafenide 	Bacteriostatic—antimetabolites that competitively inhibit dihydropteroate synthase (structural analogs of PABA) Treatment: <ul style="list-style-type: none"> • Sulfasalazine—prodrug used in ulcerative colitis, Crohn's and rheumatoid arthritis (inhibits PGs and LTs) • Sulfacetamide—eyedrops for conjunctivitis • Silver Sulfadiazine—1% cream for burns A/E <ul style="list-style-type: none"> • Hypersensitivity reactions (Stevens Johnson), Phototoxicity • Kernicterus in neonates (↑ protein binding; avoid in 3rd trimester) • Hemolysis in G6PD deficiency 	Fluoroquinolones <ul style="list-style-type: none"> • Ciprofloxacin • Levofloxacin • Norfloxacin • Moxifloxacin 	Bactericidal— Inhibit topoisomerase II (DNA gyrase) and topoisomerase IV (responsible for separation of daughter cells during cell division) Treatment <ul style="list-style-type: none"> • TMP-SMX resistant UTIs • STDs/PID caused by chlamydia, gonorrhea • Skin, soft tissue, and bone infections (gram negative) • Diarrhea (Shigella, Salmonella, E. coli, Campylobacter) • Drug resistant pneumococci (levofloxacin) Iron/Calcium limit absorption (forms a chelate)—do not take with antacids Eliminated by kidney filtration/secretion A/E <ul style="list-style-type: none"> • Tendonitis, tendon rupture (inhibits elastin incorporation) • Phototoxicity, rashes, prolongs QT interval • CNS effects (insomnia, dizziness, headache, anxiety)—due to inhibition of GABA binding; glutamate overdrive • Contraindicated in pregnancy/children • CANNOT be used for anaerobes
Trimethoprim Pyrimethamine	Bacteriostatic—antimetabolites that inhibit dihydrofolate reductase Treatment→ Synergy with sulfonamides (↓ resistance) <ul style="list-style-type: none"> • Trimethoprim-sulfamethoxazole (TMP-SMX) DOC Nocardia, UTIs (S. sapro, E.coli, Proteus), P.jiroveci • Sulfadoxine+Pyrimethamine—DOC Toxoplasma, resistant malaria A/E <ul style="list-style-type: none"> • Megaloblastic anemia, leukopenia, granulocytopenia • Reversed by giving folinic acid 		

Antimycobacterial Drugs

Drug	Use	MOA and Resistance	Side Effects
Isoniazid	Tuberculosis Standard= 2 months: Isoniazid,	Prodrug requiring conversion by catalase→ inhibits mycolic acid synthesis Resistance: deletions in katG gene (encodes catalase)	Hepatitis (age/dose dependant) Peripheral Neuritis & sideroblastic anemia (must supplement with vitamin B6) SLE in slow acetylators
Rifampin	Rifampin, Ethambutol, Pyrazinamide 4 months: Isoniazid +	Inhibits DNA-dependent RNA polymerase (nucleic acid synthesis inhibitors)	Hepatitis Inducer of p450 (OC failure) Body secretions turn orange (metabolites in urine, sclera)
Ethambutol	Rifampin	Inhibits synthesis of arbingalactan (cell-wall component)	Dose-dependent retrobulbar neuritis Decreased red-green discrimination and visual acuity
Pyrazinamide	Prophylaxis— Isoniazid (+ rifampin if intolerant)	Decreased pH in the tubercle cavity	Hepatitis, phototoxicity Hyperuricemia (competes with uric acid secretion)
Streptomycin		Protein synthesis inhibition	Nephrotoxicity, Ototoxicity Vestibular dysfunction
Dapsone	Leprosy	Related to sulfonamides: inhibits DHT synthase	Hemolytic anemia in G6PD deficiency, Lepra reaction (Jarish Herxheimer)
Clofazimine	Lepra reaction from Dapsone	Binds to DNA and inhibits template function Produces cytotoxic free radicals that kill bacteria	Dye with a half life of 70 days; can cause reddish black skin

Microbial Genetics

Three different types of DNA found in a bacterial cell

1. **Bacterial chromosomal DNA**—one large circular DNA molecule (often multiple copies) organized into loops around a protein center → contain **essential genes**
2. **Plasmid DNA**—extrachromosomal genetic elements (circular DNA) for **nonessential genes** (fertility genes, antibiotic resistance, and exotoxins)
3. **Bacteriophage DNA**—stable pieces of bacteriophage DNA inserted into the bacterial chromosome → can enhance virulence (**lysogenic conversion**)

Rearrangement of DNA within a bacterium (can help stabilize)

Homologous Recombination

- Mechanism to incorporate short, linear pieces of DNA (exogenotes) into the bacterial chromosome—there is a **one-to-one exchange** of DNA
- **Requires recombinase A (recA)** and gene sequence homology

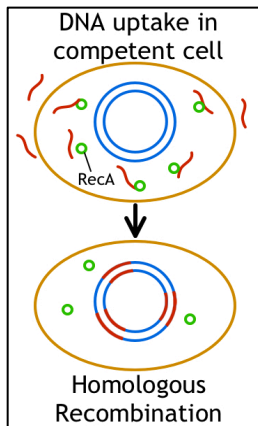
Site-Specific recombination

- Mechanism to combine circular pieces of DNA (plasmids, phage, transposons)
- Does not require homology and **no DNA is lost**
- **Requires restriction endonucleases**

Mechanisms of DNA exchange

Transformation

- Uptake of naked DNA from the environment by **competent cells**
- Introduced DNA is linear, homologous DNA which may be genetically diverse
- Incorporated and **stabilized by homologous recombination**



Bacteria that undergo natural transformation:

- **H. influenzae**
- **S. pneumoniae**
- **Bacillus** and **Neisseria**

Conjugation

Gene transfer from one bacteria to another with **direct cell-to-cell contact (sex pili)**

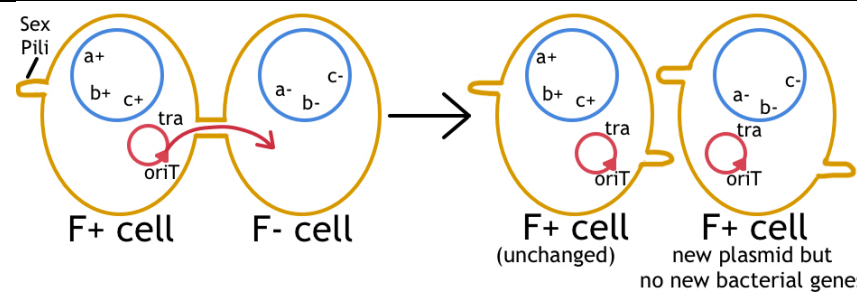
Donor (male) cells have fertility plasmids (F factors)

- The **tra region** encodes for sex pili, genes directing transfer, & stabilizing genes
- **oriT** (origin of transfer) initiates transfer where the single DNA strand break is made
- **Insertion sequences** are specific areas where the plasmid may integrate into the bacterial chromosome to create an **Hfr cell**
- Donor cells in which the fertility plasmid is in its free state are called **F+ cells**

Two types of crosses

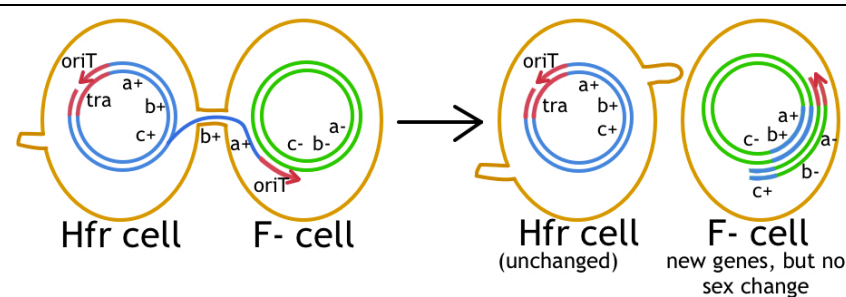
F+ cell → F- cell

- F factor free from chromosome
- Only a single strand transferred
- oriT transfers first
- **100%** of the plasmid crosses
- **F- becomes F+** but no new genes



Hfr cell → F- cell

- Only genes closest to oriT are transferred
- Must be **stabilized by homologous recombination**
- No "sex change" (tra is last and doesn't transfer)

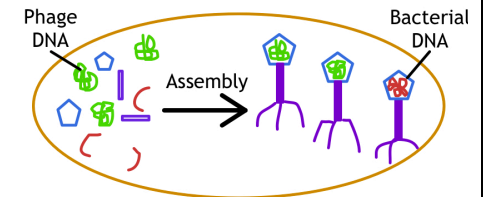


Transduction

Transfer of DNA by a **phage vector**

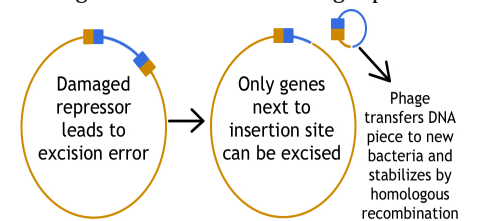
Generalized transduction

- Phage with a **lytic life cycle** (virulent phage or temperate phage) **mistakenly grabs a piece of bacterial DNA** during reassembly → infects other bacteria
- All genes have an equal chance of being transduced



Specialized transduction

- **Temperate phage** introduces its genomic DNA into bacterial DNA for excision later
- If **excision error** occurs, a piece of bacterial DNA can be carried along into the next generation of viruses
- Only **certain genes** because phages integrate at certain sites using repressors










DNA Viruses

Randall

“Her Po He Pa Par Ade”


- General rules (*exceptions*) → Icosahedral (*Pox= complex*)
 → dsDNA (*Hepadna= partial; Parvo= ssDNA*)
 → DNA replicates in nucleus (*Pox= cytoplasm*)

Enveloped					
	<p>Herpes</p> <ul style="list-style-type: none"> • Large dsDNA (linear) • <u>Envelope derived from nuclear membrane</u> • Virus assembly in nucleus (<i>others assemble in cytoplasm</i>) • Establishes latency 		<p>Pox</p> <ul style="list-style-type: none"> • Large dsDNA (linear) • <u>Replicates in cytoplasm</u> • Box shape, complex; NOT icosahedral 		<p>Hepadna</p> <ul style="list-style-type: none"> • Partial dsDNA (circular)
<p>① HSV-1 [Latent in trigeminal ganglia]</p> <ul style="list-style-type: none"> • Human mucosa → direct contact • Gingivostomatitis/ Herpes labialis (cold sores) vesicular blisters of mouth, lips • Esophagitis—punched out lesions • Keratoconjunctivitis (dendritic ulcers) • MCC sporadic encephalitis in U.S. (focal fronto-temporal lesions, necrotizing, high fatality) • Herpetic whitlow (dentists- vesicles on finger) <p>② HSV-2 [Latent in sacral nerve ganglia]</p> <ul style="list-style-type: none"> • Human mucosa → sexual contact • Painful genital vesicles, (encephalitis is mild) • Neonatal herpes (at birth; encephalitis) <p>③ VZV [Latent in dorsal root ganglia]</p> <ul style="list-style-type: none"> • Human mucosa → respiratory (also touch) • Chickenpox (fever, pharyngitis, asynchronous rash-macules, vesicles, scabs not same stage) • Shingles (Stress → reactivation of latent infection in 5th or 6th decade of life; pain & vesicles restricted to 1 dermatome (unilateral) <p>Tzanck smear—intranuclear Cowdry type A (All 3)</p>	<p>④ EBV [Latent in B-cells]</p> <ul style="list-style-type: none"> • Heterophile ⊕ mononucleosis (kissing disease; teens- fever, exudative sore throat, lymphadenopathy, splenomegaly) • Hairy oral leukoplakia (AIDS) • Malignancies (Burkitt lymphoma, Hodgkins, nasopharyngeal carcinoma) • Downey cells (atypical reactive T-cells) <p>⑤ CMV [Latent in mononuclear cells]</p> <ul style="list-style-type: none"> • MCC in utero infection U.S. (blueberry muffin baby- thrombocytopenia, MR, jaundice, pneumonitis, periventricular calcifications) • Heterophile neg mononucleosis • AIDS= retinitis + ulcerations of GI tract • Owl's eye inclusion bodies <p>⑥ HHV-6 [Transmitted by saliva]</p> <ul style="list-style-type: none"> • Roseola (infants— 3 day fever, seizures; lacy body rash <u>when fever breaks</u>) <p>⑧ HHV-8 [AIDS patients]</p> <ul style="list-style-type: none"> • Kaposi sarcoma (↑VEGF expression causes purple splotches) 	<p>Smallpox (Variola)</p> <ul style="list-style-type: none"> • Eradicated by live attenuated vaccine (Vaccinia) • Potential biological warfare agent • Upper respiratory infection → dissemination via lymphatics → viremia → tissues • Flu-like illness (2-4 days) followed by rash (begins in mouth → face arms, legs, hands, feet; covering entire body in 24 hrs) • Rash is synchronous (vesicles all in same stage of development) • Guarnieri bodies (intracytoplasmic) <p>Molluscum contagiosum</p> <ul style="list-style-type: none"> • Young adult—wrestling, swim team • Direct contact (sexual) or fomites • Replicates in dermis; Single/multiple benign umbilicated wart-like tumors • Molluscum bodies in central caseous material (eosinophilic cytoplasmic inclusion bodies) 	<p>Hepatitis B</p> <ul style="list-style-type: none"> • Acute or chronic hepatitis • Associations with cirrhosis, hepatocellular carcinoma • Serology: HBs, HBe, HBe • Possesses capacity to use reverse transcriptase (RNA dependent DNA polymerase) <p>HBsAg= currently infected HBsAb= provides immunity</p> <p>HBcAg= ⊕ acute & chronic HBcAb= IgM (acute) IgG (chronic); could be ⊕ during <u>window phase</u></p> <p>HBeAg= active proliferation; increased transmissibility HBeAb= low risk of transmissibility</p> <p>Dane particle= infectious HBV</p>		
Naked					
	<p>Papova (papilloma/polyoma)</p> <ul style="list-style-type: none"> • dsDNA (circular) 		<p>Parvo</p> <ul style="list-style-type: none"> • ssDNA (linear) • infects erythroid progenitor cells 		<p>Adeno</p> <ul style="list-style-type: none"> • dsDNA (linear) • Penton fibers toxic to cells • Virus is lytic in permissive cells
<p>Human Papilloma Virus (HPV)</p> <ul style="list-style-type: none"> • Direct contact, fomites • Genital warts (serotypes 6 & 11) • CIN, Cervical cancer (16, 18, 31, 33, 35) • E6 inhibits p53 • E7 inhibits Rb 	<p>Polyomaviridae (AIDS/transplant patients)</p> <ul style="list-style-type: none"> • BK virus (Bad Kidney) • JC virus (Junky Cerebrum: progressive multifocal leukoencephalopathy) 	<p>B19 (Erythrovirus)</p> <ul style="list-style-type: none"> • Child— erythema infectiosum, fifth's (flu → "slapped cheek" facial rash) • Adults—rash, stiff/swollen hands • Fetus—hydrops fetalis, abortion • Sick cell—aplastic crisis 	<ul style="list-style-type: none"> • Pneumonia (children, military recruits, college) • Pharyngoconjunctivitis (swimming pool; pink eye) • Epidemic keratoconjunctivitis (shipyard dust) • Acute hemorrhagic cystitis (young boys; hematuria) • Gastroenteritis (daycare; nonbloody diarrhea) 		

+ ssRNA Viruses

“Pi Ca To Fla Co”

- General rules (*exceptions*) → Icosahedral (*Corona= helical*)
 → Linear, Non-segmented
 → DNA replicates in cytoplasm; No virion-associated polymerase

Naked				Enveloped					
Pi	Picorna • Fecal-oral (<i>Rhino= resp</i>)	Ca	Calici	To	Toga	Fla	Flavi	 Co	Corona • Helical
Polio • Virus targets <u>anterior horn</u> motor neurons • Asymmetric paralysis (no sensory loss) • Progressive muscle atrophy (iron lung) • Vaccines [Live Sabin; Killed Salk (U.S.)] Echovirus • MCC acute fever in young • MCC aseptic meningitis (death= liver failure/myocarditis; summer months) Coxsackie A • Hand foot and mouth (A16; vesicular) • Herpangina (blisters) Coxsackie B • Bornhom disease (devil's grip) • Aseptic meningitis, severe in newborns • Myocarditis (MCC heart transplant) Rhinovirus • Acid-labile; Receptor= ICAM-1 • MCC common cold ; >100 serotypes Hepatitis A (Heparnavirus)	Norwalk virus (norovirus) • Fecal-oral, contaminated food/water • Cruise ships • Lose appetite → watery diarrhea • Children and adults (infants= rotavirus) <hr/> Hepevirus Hepatitis E • High mortality rate in pregnancy	Rubella (German measles) • 3 day measles • Truncal rash (Discrete, red maculopapular rash begins on face, progresses to torso); posterior auricular lymphadenopathy • Congenital rubella syndrome (crosses placenta/ breast milk—cataracts, PDA, deafness, MR) highest risk first 20 weeks gestation • Live, attenuated vaccine (MMR) <hr/> Alphaviruses (arboviruses) • Mosquito spread • East/West/Venezuelan equine encephalitis	Hepatitis C Arboviruses (mosquito spread) Hemorrhagic - <i>Aedes</i> mosquito (monkey host) • Dengue (breakbone fever; rash, muscle/joint pain; reinfection can cause hemorrhagic shock) • Yellow Fever (black vomit) with jaundice; damage to liver, kidney, heart, GI) Non-hemorrhagic - <i>Culex</i> mosquito (bird host) -Encephalitis • St. Louis Encephalitis • West Nile (can lead to muscle weakness and flaccid paralysis—damage to anterior horn motor neurons)	2 nd MCC common cold SARS (Severe acute respiratory syndrome) • <u>Bird/civet cat</u> reservoir • Atypical pneumonia • Fever > 100.4 • Flu-like, dry cough, progressive hypoxia • History of travel to China or Toronto • Patchy distribution of focal interstitial infiltrates					

Retroviridae (+ssRNA; enveloped; contain reverse transcriptase)			
Viruses	HIV genes/functions	HIV associated conditions	HIV labs/prophylaxis
HTLV (Human T-cell Leukemia Virus)—Oncovirus group • Adult T-cell Leukemia ; Japan, Caribbean • <u>C-type particle</u> (central, electron-dense nucleocapsid) HIV (Human Immunodeficiency Virus)—Lentivirus group • Diploid genome (2 copies of ssRNA) • Sexual contact, blood (needles), vertical transmission • Homosexual males, IVDA, sexually active adults • Infects <u>macrophages and T-cells</u> ; progresses to AIDS Progression followed by declining CD4 count -Early flu-like, generalized lymphadenopathy -Later progresses to AIDS-defining conditions -Homozygous CCR5 mutation= immune -Heterozygous CCR5 mutation= slow course	Gag genes • p24 (capsid protein; early marker) Pol genes • Reverse transcriptase • Integrase (DNA integration to host DNA) • Protease (cleaves viral polyprotein) Env genes • gp120 (binds CD4 & coreceptors CCR5:macrophages; CXCR4: T-cells) • gp41 (fusion to host cell) Regulatory genes • LTR (integration), Tat (transcription) Rev (transport), Nef (Virulence; when defective= won't progress to AIDS)	Early symptomatic period • Bacillary angiomatosis (disseminated bartonella) • Candidiasis, Hairy leukoplakia, Listeriosis • PID, Cervical dysplasia, Peripheral neuropathy AIDS associated conditions • Recurrent pneumonia (MCC death) <i>P. jiroveci</i> • Candidiasis of esophagus/upper airway, Coccidioidomycosis, Cryptococcosis, Histoplasmosis • Malignancies—Cervical carcinoma, Kaposi sarcoma, Burkitt's lymphoma (immunoblastic or primary CNS) • CMV, HSV, PML (JC virus), wasting due to TNF-α • Cryptosporidiosis, toxoplasmosis (brain lesions) • TB (>200 CD4), <i>M. avium</i> (<200), salmonella	Screening—ELISA Confirmation—Western blot Viral load—RT-PCR Newborns—PCR Early marker—p24 antigen Progression—CD4:CD8 ratio <i>P. jiroveci</i> < 200 CD4 Toxoplasma < 100 Histoplasma < 100 <i>M. avium</i> <50 CMV <50 Cryptococcus < 50

— ssRNA Viruses

- General rules (*exceptions*) → **ALL enveloped & helical**
- Linear (*Bunya/Arena/Delta= circular*)
 - ALL contain **RNA-dependent RNA polymerase**
 - DNA replicates in cytoplasm (*Orthomyxo= also nucleus*)

NON-segmented	Segmented
<p>Paramyxo</p> <ul style="list-style-type: none"> • Surface F protein (Fusion protein creates multinucleated giant cells) • HA (hemagglutinin) glycoprotein (Measles); HN glycoprotein (Mumps) 	<p>Orthomyxo (8 segments)</p> <ul style="list-style-type: none"> • HA & NA glycoproteins (used to serotype)
<p>Measles</p> <ul style="list-style-type: none"> • 3 C's → Cough, Coryza, Conjunctivitis • Koplik spots (blue/white spots with red base on buccal mucosa—white grains of sand in mouth) • Descending maculopapular rash (action of CTL on infected cells) ears down; presents last • Sequelae → Subacute sclerosing panencephalitis (Progressive CNS degeneration to death); Giant cell pneumonia (immunocompromised, rare; Warthin-Finkeldey cells) • Live attenuated vaccine (MMR—Measles, Mumps, Rubella) <p>Mumps</p> <ul style="list-style-type: none"> • Parotitis, Orchitis, Meningoencephalitis, Pancreatitis (Parotids & testes as big as POM-Poms) • Orchitis can cause sterility in males <p>Respiratory syncytial virus (RSV)</p> <ul style="list-style-type: none"> • Major cause of bronchiolitis in young (infants); pneumonia (Tx: Palivizumab; Ribavirin) <p>Parainfluenza</p> <ul style="list-style-type: none"> • Infants—Croup (seal-like barking cough); “steep sign” narrowing • Children/Adults—subglottal swelling, barking cough 	<p>Influenza</p> <ul style="list-style-type: none"> • Headache, malaise, fever, chills, myalgias, anorexia • Bronchiolitis, croup, otitis media, vomiting (younger children) • At risk for fatal bacterial superinfection (<i>S. Aureus pneumonia MC</i>; rapid 2-3 days) • Can lead to Reye syndrome (aspirin) or Guillain-Barre (also <i>c. jejuni</i>) <p>Influenza A (birds, pigs, humans); Influenza B (humans only)</p> <ul style="list-style-type: none"> • HA (hemagglutinin- promotes viral entry); • NA (neuraminidase- promotes progeny virion release) • Antigenic drift—(A and B) epidemics; mutations in HA and/or NA • Antigenic shift—(A only) pandemics; recombination/reassortment <p>Treatment</p> <ul style="list-style-type: none"> • Amantadine/rimantadine inhibit viral coating • Zanamivir/oseltamivir inhibit neuraminidase (prevent viral maturation and release) • Vaccines: Killed (2 strains A, 1 strain B); Live attenuated (intranasal for children < 5yrs)
<p>Rhabdo</p> <ul style="list-style-type: none"> • Bullet-shaped 	<p>Bunya (3 segments—one ambisense)</p> <p>Pseudocircular</p>
<p>Rabies</p> <ul style="list-style-type: none"> • Rabid animal bite/contact → U.S. (raccoons, bats, foxes, skunks); Worldwide (dogs) • Virus binds to peripheral nerves (nicotinic ACh receptor) • Travels via retrograde axoplasmic transport to DRG & spinal cord (then rapid to brain) • Flu-like → Hydrophobia, seizures, disorientation, hallucination → coma, death • Intracytoplasmic Negri bodies (eosinophilic inclusions) • Post exposure prophylaxis= Rabies Ig, 5 doses killed vaccine (day of, 3, 7, 14, 28) <p>Vesicular stomatitis (Flu-like in humans—handling livestock with foot & mouth disease)</p>	<p>California Encephalitis</p> <p>La Crosse Encephalitis</p> <ul style="list-style-type: none"> • Mosquito transmission (Minnesota area) → Viral encephalitis <p>Hantavirus</p> <ul style="list-style-type: none"> • Rat excrement/urine → Pulmonary syndrome • Cough, myalgia, pulmonary edema, hypotension; 50% fatal • Southwest U.S. (like <i>coccidiodes</i> & <i>Y. pestis</i>)
<p>Filo</p>	<p>Arena (2 segments—one ambisense)</p> <ul style="list-style-type: none"> • Circular
<p>Ebola virus (Bleeding from eyes; contact with blood transmission; high mortality)</p> <p>Marburg virus (Fatal Hemorrhagic fever)</p>	<p>Lymphocytic Choriomeningitis (South America—mouse excrement)</p> <p>Lassa Fever Virus (Africa—spread by mice; hemorrhagic fever)</p>
<p>Delta</p> <ul style="list-style-type: none"> • Circular 	<p>Reo (10-12 segments)</p> <ul style="list-style-type: none"> • ONLY double stranded RNA virus (not + or -); naked, icosahedral
<p>Hepatitis D</p> <ul style="list-style-type: none"> • Defected virus— requires Hepatitis B to “coat” Hep D for infection • Worse prognosis and chronic state more likely with superinfection (HBV carrier exposed to HDV) than with co-infection (HBV & HDV exposure at same time) 	<p>Rotavirus</p> <ul style="list-style-type: none"> • MCC diarrhea in infants—“Right Out The Anus” (day cares, kindergartens in winter months) • Villous destruction with atrophy (decreased absorption of Na⁺ and loss of K⁺) <p>Coltivirus</p> <ul style="list-style-type: none"> • Colorado tick fever—Fever with afebrile periods “saddleback fever” (Dermacantor tick)

Antivirals

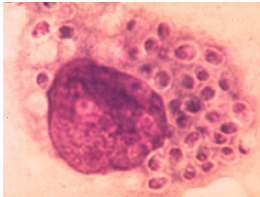
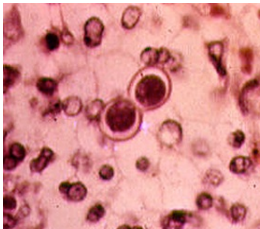
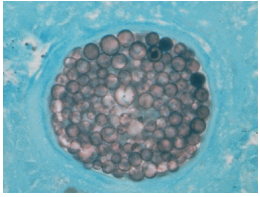
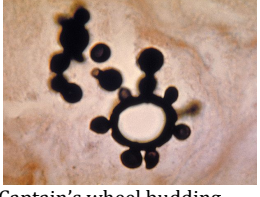
Drug	Mechanism	Uses	Side effects
Antitherpetics			
Acyclovir Valacyclovir (prodrug) Famciclovir	Inhibits Viral DNA polymerase by acting as a chain terminator (must be first phosphorylated by viral thymidine kinase & bioactivated by other kinases) Resistance= TK mutation/absence or change in DNA pol	HSV-1, HSV-2, VZV Reduces viral shedding; decreases acute neuritis but no effect on postherpetic shingles Famciclovir DOC VZV	Crystalluria (must stay hydrated) Neurotoxicity (agitation, confusion, seizures)
Ganciclovir Valganciclovir (prodrug)	Mechanism and resistance similar to acyclovir In CMV requires phosphotransferase for phosphorylation → inhibits DNA polymerase	CMV (2 nd line for HSV-1, HSV-2, VZV) Prophylaxis and treatment of CMV retinitis in AIDS & transplant patients	Hematotoxicity (leukopenia, thrombocytopenia) Mucositis (swallowing problems, GERD) Crystalluria
Foscarnet	Inhibits DNA/RNA polymerases & HIV reverse transcriptase Does not require phosphorylation	Same as ganciclovir Acyclovir resistant HSV-1/2	Nephrotoxicity , acute tubular necrosis, <u>electrolyte imbalance</u> (avoid pentamidine IV)
Cidofovir	Acyclic nucleoside phosphonate that selectively inhibits DNA polymerase; does not require phosphorylation	CMV retinitis (AIDS)—Intravenous Resistant HSV	Nephrotoxicity
Fomivirsen	Antisense oligonucleotide- Binds mRNA; inhibits protein synth	CMV retinitis (AIDS)—Intravitreal injection	
HIV Therapy			
Nucleoside RTi Zidovudine (AZT) Stavudine (D4T) Didanosine (DDI) Lamivudine (3TC) Zalcitabine (DDC)	Competitive inhibition of reverse transcriptase preventing the formation of dsDNA (interrupts elongation and impairs complementary DNA synthesis) Triphosphate is active form and requires phosphorylation by host enzymes	HAART therapy Prevents vertical transmission Used in pregnancy- 2 nd and 3 rd trimester Prophylaxis following needlestick injury (Zidovudine+ Lamivudine 1 month) Lamivudine active in Hep B	<ul style="list-style-type: none"> • Myelosuppression (Zidovudine greatest) • Peripheral Neuropathy (Didanosine, Zalcitabine, Stavudine, Zidovudine) • Pancreatitis (Didanosine) Lamivudine—Least toxic, some neutropenia
Non-nucleoside RTi Nevirapine Efavirenz Delavirdine	Directly binds and inhibits reverse transcriptase Does not require phosphorylation (Notice non-nucleosides have “vir” in the middle of the name)	Synergistically with NRTI in HAART therapy Prevents vertical transmission	NOT myelosuppressant Stevens Johnsons (Nevirapine) CNS dysfunction (Efavirenz)
Protease Inhibitors Squinavir Ritonavir Indinavir Nelfinavir	Inhibit protease—form immature non infectious viral particles (prevents development of new virus) Resistance= mutation of pol gene	Ritonavir inhibits CYP34A ; combined with other anti HIV drugs to give kinetic boost (especially Lopinavir)	GI upset, Hyperglycemia, hyperlipidemia, lipodystrophy (fat deposits causing atrophy and wasting) Pancreatitis with Ritonavir Kidney stones, hematuria (Indinavir—must stay hydrated)
Integrase inhibitor Raltegravir	Prevents integration of viral genome in host cell DNA (impairs mRNA transcription)	Added when resistance to HAART	Possible hypercholesterolemia; no other metabolic syndrome effects
Fusion Inhibitors Enfuvirtide Maraviroc	Enfuvirtide → Binds gp41 to inhibit fusion of HIV-1 onto CD4 T-cells (Added in when other drugs fail) Maraviroc (entry inhibitor) → Blocks CCR5, preventing gp120 association and subsequent viral entry		Injection site reaction
Other Antivirals			
Amantidine Rimantidine	Blocks attachment, penetration, & inhibits uncoating of Influenza A	Influenza prophylaxis May ↓ duration of flu symptoms 1-2 days Parkinson’s rescue drug; Chronic Hep C	Nervousness, insomnia, seizures in OD Atropine-like peripheral effects Livedo reticularis (purplish networking on skin)
Zanamivir (intranasal) Oseltamivir	Inhibit influenza neuraminidase, prevents release and maturation of progeny virus (Influenza A and B)	Influenza prophylaxis May ↓ duration of flu symptoms 2-3 days	
Ribavirin	Monophosphorylated form inhibits IMP dehydrogenase ; triphosphate inhibits RNA polymerase and end-capping	RSV , Hantavirus, Lassa Fever, adjunct to alpha-interferons for Hep C	Hematotoxic, upper airway irritation Teratogenic
Interferon-α	Activates host ribonuclease which degrades viral mRNA	HepB (+Lamivudine); HepC (+Ribavirin)	
Palivizimab	Monoclonal antibody—Blocks RSV protein F	RSV (when Ribavirin cannot be used)	

Fungi

Randall

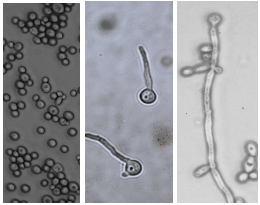
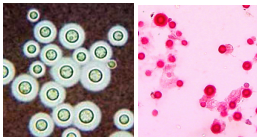
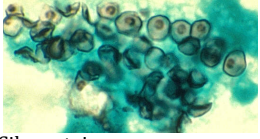
Systemic Mycoses

- **Dimorphic fungi** [mold in cold (25°C), yeast in the beast (37°C)]
- Most commonly present with pneumonia-like symptoms
- No person to person transmission
- Best diagnosis= biopsy; (also sputum culture on Sabouraud)

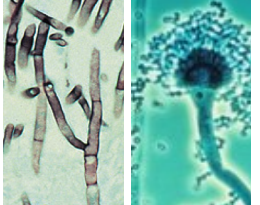



Histoplasma capsulatum				
Microscope	Features	Epidemiology	Diseases	Treatment
 <p>Yeast inside macrophage</p>	<p>Environmental form</p> <ul style="list-style-type: none"> • Hyphae with <u>microconidia</u> and tuberculate <u>macroconidia</u> <p>Tissue form</p> <ul style="list-style-type: none"> • Small, oval-budding yeast inside macrophages 	<ul style="list-style-type: none"> • Ohio and Mississippi River Valleys • Found in soil or dust enriched with bird/bat feces • <u>Spelunking, cleaning chicken coops</u> 	<p>Fungus flu (pneumonia)</p> <ul style="list-style-type: none"> • Asymptomatic or acute (self-resolving) • Hepatosplenomegaly may be present • Lesions tend to calcify as they heal • Increased relapse with T-cell immunosuppression • Disseminated in AIDS (mucocutaneous lesions) <p>Facultative intracellular parasite in RES (macrophages)</p>	<p>DOC</p> <ul style="list-style-type: none"> • Itraconazole • Amphotericin B (severe or pregnant)
Blastomyces dermatitidis				
 <p>Broad-based budding yeast</p>	<p>Environmental form</p> <ul style="list-style-type: none"> • Hyphae with small pear-shaped <u>conidia</u> <p>Tissue form</p> <ul style="list-style-type: none"> • Broad-based budding yeast • Double, refractile cell walls 	<ul style="list-style-type: none"> • Same as Histoplasma but extending north to great lakes, Ohio, Canada; and Southeast to Carolinas) • Soil or rotting wood (beaver dams) 	<p>Blastomycoses</p> <ul style="list-style-type: none"> • Acute and chronic pulmonary disease (pneumonia) • Less likely to self-resolve than Histoplasma/Coccidioides • Lesions do NOT calcify as they heal • Disseminated disease in immunocompromised (mostly affects skin; also bone marrow, CNS) <p>Broad-based budding yeast seen in sputum</p>	<p>DOC</p> <ul style="list-style-type: none"> • Itraconazole • Amphotericin B (severe or pregnant)
Coccidioides immitis				
 <p>Spherules with endospores</p>	<p>Environmental form</p> <ul style="list-style-type: none"> • Hyphae breaking up into barrel shaped <u>arthroconidia</u> <p>Tissue form</p> <ul style="list-style-type: none"> • Spherules with endospores 	<ul style="list-style-type: none"> • <u>Southwest US</u> (Arizona, New Mexico, southern Cal—San Joaquin Valley) • Arthroconidia inhaled from desert sand → spherules w/ endospores in tissue 	<p>Valley Fever</p> <ul style="list-style-type: none"> • Asymptomatic to self resolving pneumonia • Erythema nodosum (Desert bumps) and arthritis are good prognostic signs • Lesions tend to calcify as they heal • Dissemination in immunocompromised, AIDS, and 3rd trimester of pregnancy (meningitis, mucocutaneous) 	<p>DOC</p> <ul style="list-style-type: none"> • Fluconazole • Amphotericin B (severe or pregnant)
Paracoccidioides brasiliensis				
 <p>Captain's wheel budding</p>	<p>Environmental form</p> <ul style="list-style-type: none"> • Hyphae of variant forms <p>Tissue form</p> <ul style="list-style-type: none"> • Multiple-budding yeast with <u>captain's wheel</u> formation 	<ul style="list-style-type: none"> • <u>Latin America</u> • Soil fungus 	<p>Paracoccidioidomycosis</p> <ul style="list-style-type: none"> • Inhalation → mild pneumonia (can resemble TB) • Mucous membrane ulceration of the mouth and nose with spreading through the lymphatic system 	<p>DOC</p> <ul style="list-style-type: none"> • Ketoconazole • Amphotericin B (severe or pregnant)

Opportunistic Mycoses

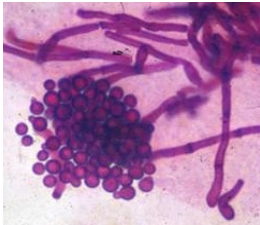

Yeast

Candida albicans				
Microscope	Features	Epidemiology	Diseases	Treatment
 <p>Yeast GermTube P-hyphae</p>	<ul style="list-style-type: none"> Oval yeast with single bud in mucous membranes Germ tubes in serum Forms pseudohyphae and true hyphae when invading tissues 	<ul style="list-style-type: none"> Part of the normal flora of skin, mucous membranes and GI tract Immunocompromised patients, IVDA, overuse of antibiotics 	<ul style="list-style-type: none"> Oral/esophageal thrush (neonates, AIDS, steroids, antibiotic overuse)—white patches easily scraped off Yeast vaginitis (↓pH; diabetic women, antibiotic overuse) Endocarditis (IVDA) Cutaneous infections (obesity, infants—diaper rash) <p>Nystatin—swish and swallow for oral thrush (topical for diaper rash or vaginitis)</p>	<p>DOC</p> <ul style="list-style-type: none"> Miconazole; Clotrimazole Nystatin Fluconazole, Amphotericin B (disseminated)
Cryptococcus neoformans				
 <p>India ink—capsular halos</p>	<ul style="list-style-type: none"> Urease ⊕ Monomorphic encapsulated yeast Mucicarmine stains capsule red 	<ul style="list-style-type: none"> Soil enriched with pigeon droppings Hodgkin/ AIDS patients Pidgeon breeders 	<p>Meningitis</p> <ul style="list-style-type: none"> Dominant meningitis in AIDS patients (begins in lungs; pneumonia-like symptoms→ soap bubble lesion in brain) Detect capsular antigen in CSF—latex agglutination India ink mount budding yeasts with “capsular halos” (misses 50%—only rules in) 	<p>DOC</p> <ul style="list-style-type: none"> Amphotericin B w/ flucytosine (min 10 weeks) then fluconazole
Pneumocystis jirovecii				
 <p>Silver stain</p>	<ul style="list-style-type: none"> Obligate extracellular parasite Silver stained cysts in tissues/alveolar fluid Foamy, honeycomb appearance on H&E stain 	<ul style="list-style-type: none"> Yeast inhaled AIDS patients, malnourished babies, premature neonates 	<p>Diffuse interstitial pneumonia in AIDS (CD4<200)</p> <ul style="list-style-type: none"> Fever, cough, SOB, non productive sputum Ground glass appearance on X-ray (patchy infiltrative) <p>Destruction of Type I pneumocytes= ↑ Type II pneumocytes; alveolar damage→ exudate leakage</p>	<p>DOC</p> <ul style="list-style-type: none"> TMP-SMX Clindamycin + Primaquine IV pentamidine Dapsone


Mold

Aspergillus fumigatus				
 <p>45° septate Conidiophore</p>	<ul style="list-style-type: none"> Monomorphic filamentous fungus (only exists as mold) Dichotomously branching Radiating chains of conidia Septate hyphae forming V-shaped acute 45° angles 	<ul style="list-style-type: none"> Compost pits, moldy marijuana Asthmatics, Cystic Fibrosis patients <p>*Some species produce aflatoxins associated with Hepatocellular Carcinoma</p>	<ul style="list-style-type: none"> Allergic bronchopulmonary aspergillosis (asthma, CF—growing in mucus plugs but not penetrating tissue) Type I HS; Eosinophilia, perihilar nodules, eventual bronchiectasis Fungus ball—free in preformed lung cavities (surgical removal to reduce coughing) “colonizing aspergillus” Invasive aspergillosis Severe neutropenia, CGD, CF (burn victims—cellulitis) Invades tissues causing infarcts/hemorrhage; Nasal colonization→ pneumonia or meningitis 	<p>DOC</p> <ul style="list-style-type: none"> Itraconazole Amphotericin B <p>DOC Invasive aspergillosis= Voriconazole ± Caspofungin</p>
Mucor, Rhizopus, Absidia—(Zygomycophyta)				
 <p>Nonseptate, broad angle</p>	<ul style="list-style-type: none"> Sporangiospores Nonseptate hyphae with broad 90° angles 	<ul style="list-style-type: none"> Soil—sporangiospores inhaled Ketoacidotic diabetic patients and leukemic patients at risk 	<p>Rhinocerebral infection</p> <ul style="list-style-type: none"> Facial pain/headache, paranasal swelling, black necrotic eschar on face, hemorrhagic exudates from nose/eyes, mental lethargy Can progress rapidly from sinuses (sphenoid to cavernous) into brain tissue (frontal lobe abscesses) Biopsy KOH of tissue—broad nonseptate hyphae at 90° angles 	<ul style="list-style-type: none"> Debride necrotic tissue (black pus) Immediately start Amphotericin B

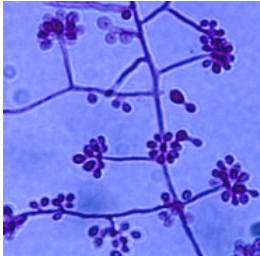
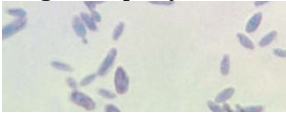

Superficial Infections

Malassezia furfur				
Microscope	Features	Epidemiology	Diseases	Treatment
 <p>Spaghetti/meatballs on KOH</p>	<ul style="list-style-type: none"> • Spaghetti and meatballs appearance on KOH mount of skin cells (yeast clusters & short curved septate hyphae) • Coppery fluorescence under Wood lamp (UV) 	<ul style="list-style-type: none"> • Moist, warm climates, sweating • Normal skin flora (lipophilic yeast) <p>Premature infants on lipid supplements → fungemia</p>	<p>Pityriasis (Tinea versicolor)</p> <ul style="list-style-type: none"> • Superficial infection of keratinized cells • Hypo- or hyperpigmented spots on the chest/back (blotchy suntan) 	<p>DOC</p> <ul style="list-style-type: none"> • Topical selenium sulfide

Cutaneous Infections

Dermatophytes (Microsporum, Trichophyton, Epidermophyton)				
 <p>Microsporum</p>	<ul style="list-style-type: none"> • Monomorphic filamentous fungi (mold form) • Mycosporum fluoresces a bright yellow-green under Wood lamp (UV) • KOH wet mount of nail or skin scrapings show arthroconidia and hyphae 	<ul style="list-style-type: none"> • Infect only skin, hair and/or nails—pruritic lesion w/ central clearing <p>Microsporum</p> <ul style="list-style-type: none"> • Skin & hair <p>Trichophyton</p> <ul style="list-style-type: none"> • Skin, hair, & nails <p>Epidermophyton</p> <ul style="list-style-type: none"> • Skin & nails 	<p>Tineas (ringworms)—itching MC symptom</p> <p>Tinea capitis (scalp)</p> <p>-favosa (permanent hair loss; very contagious)</p> <ul style="list-style-type: none"> -barbae (beard) -corporis (glabrous/hairless skin), -cruris (jock itch) -pedis (athlete's foot) -unguium (nails) <p><u>Highly</u> inflammatory = generally from <u>animals</u></p> <p><u>Little</u> inflammation = generally from <u>humans</u></p>	<p>DOC</p> <ul style="list-style-type: none"> • Miconazole; Clotrimazole • Tolnaftate; • Terbinafine • Oral imidazoles or griseofulvin w/infected hair <p>Keep areas dry</p>

Subcutaneous Infections

Sporothrix schenckii				
 <p>Hyphae with rosettes</p>	<p>Environmental form</p> <ul style="list-style-type: none"> • Hyphae with rosettes and sleeves of conidia <p>Tissue form</p> <ul style="list-style-type: none"> • Cigar-shaped yeast 	<ul style="list-style-type: none"> • Found on plant material (plum tree, rose thorns, wire/sphagnum moss) • Rose gardeners, alcoholics passing out in rose gardens 	<p>Sporotrichosis (rose gardener disease)</p> <ul style="list-style-type: none"> • Subcutaneous or lymphocutaneous lesions  <p>Pulmonary sporotrichosis (acute or chronic)</p> <ul style="list-style-type: none"> • Homeless urban alcoholics (alcoholic rose garden-sleeper disease) 	<p>DOC</p> <ul style="list-style-type: none"> • Itraconazole • Potassium iodide in milk (not for pulmonary)

Antifungals

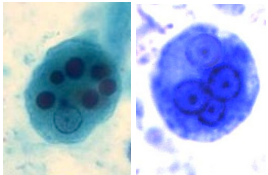
Drug	Mechanism	Clinical Use	Toxicity
Amphotericin B	Binds ergosterol; forms membrane pores that allow leakage of electrolytes "Polyene antifungal"	Serious systemic mycoses (disseminated) <ul style="list-style-type: none"> • Histoplasma • Blastomyces • Coccidioides • Candida • Cryptococcal meningitis (with or without flucytosine) <p>Administered via slow IV infusion (½ life > 2 weeks) Poorly penetrates CNS; safe in pregnancy</p>	<ul style="list-style-type: none"> • Fever, chills, malaise, hypotension during IV infusion (alleviated by NSAIDs) • Nephrotoxicity, arrhythmias, anemia, IV phlebitis, hypermagnesemia, hypokalemia • Hydration and liposomal amp B reduce nephrotoxicity • Flucytosine allows for synergism so not as much amp B needs to be used
Nystatin	Same as amphotericin B	Candida infections <ul style="list-style-type: none"> • Diaper rash or vaginal candidiasis (topical) • "Swish and swallow" for oral thrush (not absorbed in GI tract) 	Too toxic for systemic use (only use topical form)
-Azoles Ketoconazole Fluconazole Itraconazole Voriconazole Miconazole Clotrimazole Posaconazole	Inhibits 14-alpha demethylase (fungal CYP3A) which converts lanosterol to ergosterol Absorption (acidic environment) <ul style="list-style-type: none"> • Antacids ↓ ketoconazole • Food ↑ itraconazole 	Local and less serious systemic mycoses <ul style="list-style-type: none"> • Ketoconazole—DOC Paracoccidioides; dandruff (topical) • Fluconazole— DOC Candida, Coccidioides; Prophylaxis and suppression of Cryptococcal meningitis (penetrates CNS) • Itraconazole—DOC Blastomyces, Histoplasmosis, Sporothrichoses, Aspergillosis • Miconazole/Clotrimazole—topical (candida, dermatophytes) inexpensive, safe in pregnancy/breastfeeding • Posaconazole—for Mucor (Amp B more common treatment) 	<ul style="list-style-type: none"> • Testosterone synthesis inhibition (gynecomastia, ↓libido, hypoadrenalism: especially <u>ketoconazole</u>) • Ketoconazole biggest P450 inhibitor • ↑ Liver function tests <p>Oral forms not safe in pregnancy (teratogenic)</p>
Flucytosine	Needs to be converted into active 5-FU by cytosine deaminase → Inhibits thymidine synthase = ↓ thymidine, ↓ DNA and RNA biosynthesis	<ul style="list-style-type: none"> • Used in systemic fungal infections (esp. Cryptococcal meningitis in combo with amphotericin B) • Synergism reduces side effects of ampB (less ampB used); helps penetrate CNS • Resistance emerges rapidly if used alone 	<ul style="list-style-type: none"> • Bone marrow suppression • GI symptoms
Caspofungin Micafungin	Inhibits cell wall synthesis by inhibiting synthesis of β-glucan "fungal cell wall polysaccharide"	<ul style="list-style-type: none"> • Invasive aspergillosis (in combo with voriconazole) • Candida 	<ul style="list-style-type: none"> • GI upset • Flushing (histamine release)
Terbinafine	Inhibits squalene epoxidase Accumulates in stratum corneum	Dermatophytoses (especially onychomycosis —finger/toenail)	<ul style="list-style-type: none"> • GI distress, rash, headache • Abnormal LFTs, visual disturbances
Griseofulvin	Interferes with microtubule function ; disrupts mitosis (mitotic spindle). Deposits in keratin-containing tissues (stratum corneum)	Oral treatment of superficial infections Inhibits growth of dermatophytes (tinea, ringworm)	<ul style="list-style-type: none"> • Teratogenic, carcinogenic, confusion, headaches • P450 inducer (↑ warfarin metabolism) Disulfuram-like reaction

Parasites


Randall

PROTOZOA— GI infections

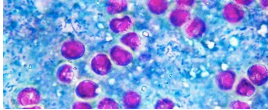
Entamoeba histolytica (amebae)

Findings	Form/Transmission	Diagnosis	Disease	Treatment
 <p>Trophozoite Cyst</p>	<ul style="list-style-type: none"> Cysts—water, fresh fruits and vegetables Fecal-oral transmission History of travel 	<ul style="list-style-type: none"> “Ova parasite stool study” (Trophozoites or cysts in stool) Serology—Nuclei have sharp central karyosome and fine chromatin “spokes” 	Amebiasis <ul style="list-style-type: none"> Dysentery (bloody diarrhea) Inverted flask shaped lesions in large intestine Lesions can extend to liver, lungs, brain, heart Liver abscess: “anchovy paste” exudate with RUQ pain 	DOC <ul style="list-style-type: none"> Metronidazole (for trophozoites) Followed by iodoquinol (for cyst form)

Giardia lamblia (flagellate)

 <p>Trophozoite Cyst</p>	<ul style="list-style-type: none"> Cysts—fecal (human, beaver, muskrat) Oral transmission—“Campers—water from a stream”, food, day care, ass to mouth sex (ATM) 	<ul style="list-style-type: none"> “Ova parasite stool study” (Trophozoites or cysts in stool) Fecal antigen test “Falling leaf motility” 	Giardiasis <ul style="list-style-type: none"> Ventral sucking disk attaches to lining of duodenal wall → inflammation decreases absorption at villi Fatty, foul-smelling diarrhea → malabsorption (duodenum, jejunum) 	DOC <ul style="list-style-type: none"> Metronidazole
---	--	---	---	--

Cryptosporidium parvum (apicomplexa)


 <p>Acid fast oocysts in stool</p>	<ul style="list-style-type: none"> Cysts—undercooked meat, water Not killed by chlorination 	<ul style="list-style-type: none"> Acid fast oocysts in stool Biopsy shows dots (cysts) in intestinal glands Intracellular multiplication in brush border 	Cryptosporidiosis <ul style="list-style-type: none"> Transient watery diarrhea in healthy Severe diarrhea in AIDS (immunocompromised) 	<ul style="list-style-type: none"> No treatment is 100% effective Prevent with filtration (Chlorination does NOT work) Nitrazoxanide for AIDS
--	---	---	---	--

Others (cause diarrhea in AIDS) (apicomplexa)

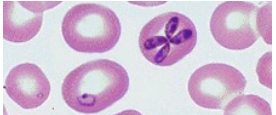
Isospora belli	<ul style="list-style-type: none"> Ingestion of oocysts Fecal-oral 	<ul style="list-style-type: none"> Acid fast elliptical oocysts in stool 	Transient diarrhea in AIDS (mimics giardiasis)	<ul style="list-style-type: none"> TMP-SMX
Cyclospora cayetanesis	<ul style="list-style-type: none"> Oocysts in water 	<ul style="list-style-type: none"> Acid-fast spherical oocysts in stool 	Severe diarrhea in AIDS (Self limiting in healthy)	<ul style="list-style-type: none"> TMP-SMX
Microsporidia	<ul style="list-style-type: none"> <u>Spores</u> ingested 	<ul style="list-style-type: none"> Gram ⊕, acid-fast spores in stool 	Persistent, debilitating diarrhea in AIDS (may become disseminated → neurologic, hepatitis)	<ul style="list-style-type: none"> None

PROTOZOA—Sexually transmitted

Trichomonas vaginalis (flagellate)

Findings	Form/Transmission	Diagnosis	Diseases	Treatment
 <p>Motile trichomonads</p>	<ul style="list-style-type: none"> One form= trophozoites Sexually transmitted 	<ul style="list-style-type: none"> Motile trophozoites in methylene blue wet mount Corkscrew motility 	Trichomoniasis <ul style="list-style-type: none"> Often asymptomatic Foul smelling, Frothy green vaginal discharge (increased vaginal pH) 	DOC <ul style="list-style-type: none"> Metronidazole

PROTOZOA—Hematologic infections

Babesia (apicomplexa)				
Findings	Form/Transmission	Diagnosis	Disease	Treatment
 Ring, maltese cross tetrad	<ul style="list-style-type: none"> Ixodes tick Co-infections with Borrelia Limited to US 	<ul style="list-style-type: none"> Giemsa stain Small ring form, Maltese cross, or tetrad in RBCs 	Babesiosis <ul style="list-style-type: none"> Malaria-like (mild) Fever, hemolytic anemia 	DOC <ul style="list-style-type: none"> Clindamycin + Quinine Atovaquone + Azithromycin

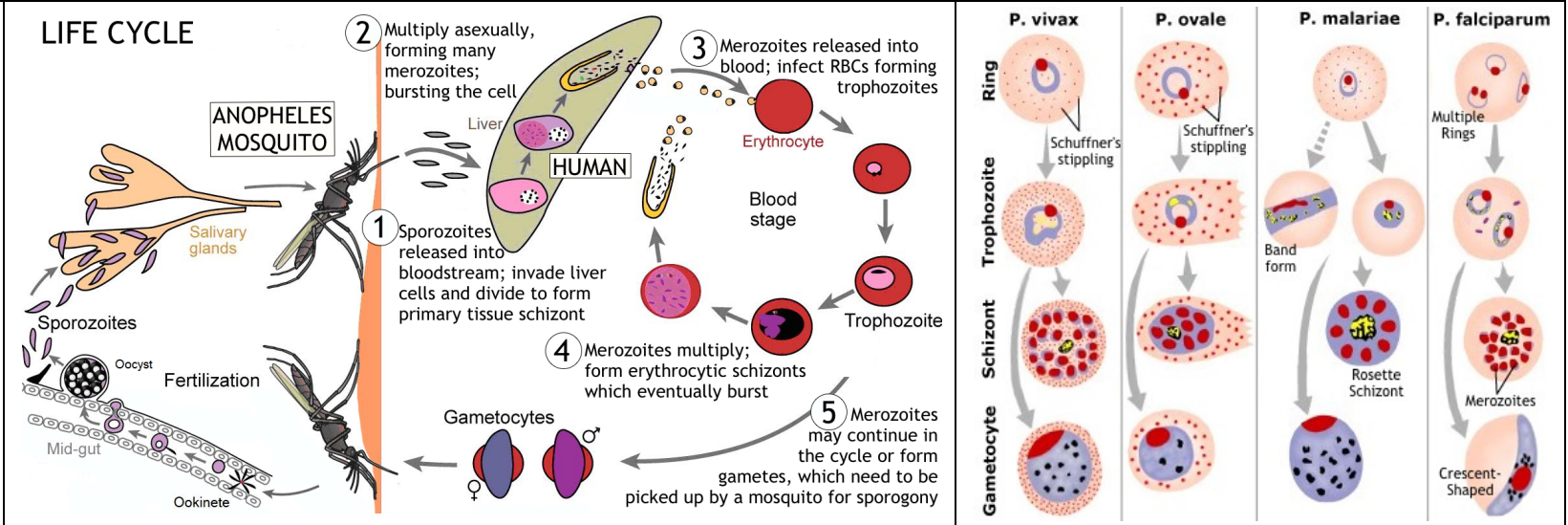
Plasmodium (P. vivax/ovale, P. malariae, P. falciparum) (apicomplexa)

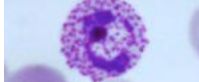
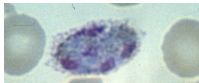
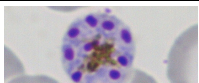
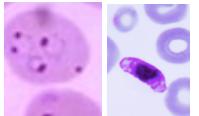
Two hosts

- Anopheles mosquito**
 - Sexual phase (sporogony)
- Vertebrates (humans)
 - Asexual phase in liver/RBCs (schizogony)

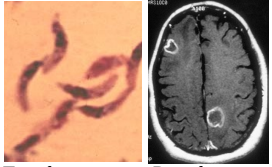

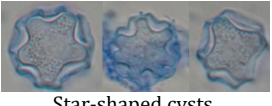
Symptoms

- Chills, fever-spike, malarial rigors**
- Occur when merozoites rupture RBCs (#4 in figure)

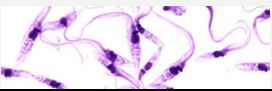

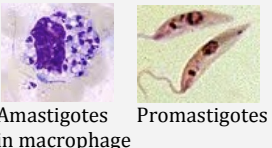


Species	Blood smear/ features	Disease	Liver stages	Treatment
P. vivax	 Ameboid trophozoite	Benign tertian <ul style="list-style-type: none"> 48 hour fever spikes (every 3rd day) 	Relapse due to persistent <u>hypnozoites</u> (dormant form in liver)	Chloroquine then primaquine
P. ovale	 Oval trophozoite	Benign tertian <ul style="list-style-type: none"> 48 hour fever spikes (every 3rd day) 	Relapse due to persistent <u>hypnozoites</u> (dormant form in liver)	Chloroquine then primaquine
P. malariae	 Rosette schizont	Quartan <ul style="list-style-type: none"> 72 hour fever spikes (every 4th day) Recrudescence 	No persistent form Recrudescence (symptoms reoccur) due to low level remaining in RBCs	Chloroquine
P. falciparum	 Multi-ring Gamete	Malignant tertian (most serious) <ul style="list-style-type: none"> Irregular fever spikes Causes cerebral malaria 	No persistent form Recrudescence (symptoms reoccur) due to low level remaining in RBCs	<u>Chloroquine resistance</u> a problem (use quinine sulfate + pyrimethamine-sulfadoxine)

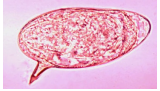


PROTOZOA— CNS infections

Toxoplasma gondii (apicomplexa)				
Findings	Form/Transmission	Diagnosis	Disease	Treatment
 <p>Trophozoites Ring lesions</p>	<ul style="list-style-type: none"> • Cat is essential definitive host • Raw pork MCC • Contact with cat feces • Most common protozoal infection in US 	<ul style="list-style-type: none"> • Serology • High IgM or rising IgM (acute infection) • Crescentric tachyzoites and necrosis 	<ul style="list-style-type: none"> • Healthy→ heterophile neg mononucleosis (flu-like illness with lymphadenopathy/fever) • Pregnant→ heterophile neg mononucleosis, can cross placenta (early: congenital infections— <u>chorioretinitis, hydrocephalus, intracerebral calcifications</u>; late: blindness in teens) • AIDS→ MCC focal CNS disease (ring-enhancing lesions) 	<p>DOC</p> <ul style="list-style-type: none"> • Primethamine + sulfadiazine (+ folinic acid) • Prophylaxis at CD4<100 for AIDS
Naegleria fowleri (free-living amoebae)				
 <p>Trophozoites in CSF</p>	<ul style="list-style-type: none"> • Swimming in warm fresh water • Enters cribriform plate 	<ul style="list-style-type: none"> • Motile trophozoites in CSF 	<p>Primary amebic meningoencephalitis (PAM)</p> <ul style="list-style-type: none"> • Severe prefrontal headache, <u>altered sense of smell</u>, nausea, high fever; often fatal 	<ul style="list-style-type: none"> • Amphotericin B (rarely successful)
Acanthamoeba (free-living amoebae)				
 <p>Star-shaped cysts</p>	<ul style="list-style-type: none"> • Contaminated contact lens solution 	<ul style="list-style-type: none"> • Star-shaped cysts on biopsy (not CSF) • Amoebic parasites in CSF 	<ul style="list-style-type: none"> • Keratitis • Granulomatous amebic encephalitis (immunocompromised) with focal neurological signs 	<ul style="list-style-type: none"> • Miconazole (keratitis)

PROTOZOA— Hemoflagellates

Trypanosoma				
Species	Transmission	Diagnosis	Disease	Treatment
T. cruzi 	<ul style="list-style-type: none"> • Reduviid bug (kissing bug, cone bug)—painless bite • Brazil, South America 	<ul style="list-style-type: none"> • Trypomastigote in blood films 	<p>Chagas disease</p> <ul style="list-style-type: none"> • Swelling around eye (Romaña sign), dilated cardiomyopathy, <u>megacolon, megaesophagus</u> 	<ul style="list-style-type: none"> • Nifurtimox • Benznidazole
T. brucei (gambiense, rhodesiense) 	<ul style="list-style-type: none"> • Tsetse fly (painful bite) 	<ul style="list-style-type: none"> • Trypomastigote in blood films, CSF 	<p>African Sleeping Sickness</p> <ul style="list-style-type: none"> • Enlarged lymph nodes, recurring fever (due to antigenic variation), somnolence, coma 	<ul style="list-style-type: none"> • Suramin (acute) • Melarsoprol (chronic/CNS involvement)
Leishmania				
L. donovani  <p>Amastigotes Promastigotes in macrophage</p>	<ul style="list-style-type: none"> • Sandfly bite (Phlebotomus) • Middle East, India, South America, North Africa 	<ul style="list-style-type: none"> • Amastigotes in macrophages in bone marrow, liver, spleen 	<p>Visceral Leishmaniasis (most severe) Hepatosplenomegaly, spiking fever, weight loss, fatigue, anemia, mucosal ulcers</p>	<p>Visceral</p> <ul style="list-style-type: none"> • Lipsomal Amp B <p>Cutaneous</p> <ul style="list-style-type: none"> • Sodium Stibogluconate
L. braziliensis		<ul style="list-style-type: none"> • Amastigotes in macrophages in cutaneous lesions 	<p>Mucocutaneous Leishmaniasis Extensive disfigurement of nasal septum, lips, and palate</p> <p>Cutaneous Leishmaniasis Oriental sore (local; open ulcerative lesion)</p>	
Leishmania (About 15 different species)				

Trematodes (flukes, flatworms) — Snails are 1st intermediate hosts



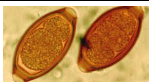



Ingestion					
Organism	Acquisition	Disease progression		Ova	Treatment
Clonorchis sinensis (chinese liver fluke)	<ul style="list-style-type: none"> • Raw fish • Southeast Asia 	<ul style="list-style-type: none"> • Biliary tract inflammation → pigmented gallstones • Assoc. with cholangiocarcinoma (MCC eastern world) 		Operculated Eggs	Praziquantel
Paragonimus westermani (lung fluke)	<ul style="list-style-type: none"> • Raw crab meat, crayfish 	<ul style="list-style-type: none"> • Mimics pulmonary TB • Lung inflammation & 2° bacterial infection; hemoptysis 			
Fasciola hepatica (sheep liver fluke)	<ul style="list-style-type: none"> • Aquatic plants (watercress) 	<ul style="list-style-type: none"> • Fever, nightsweats, malaise 			
Fasciolopsis buski (giant intestinal fluke)	<ul style="list-style-type: none"> • Aquatic plants (water chestnuts) 	<ul style="list-style-type: none"> • Diarrhea and abdominal pain 			
Skin penetration					
Schistosoma mansoni Schistosoma japonicum (Asia)	<ul style="list-style-type: none"> • Contact with water; • Skin penetration by cercariae (motile larva form) 	Intestinal schistosomiasis (TH2 mediated) <ul style="list-style-type: none"> • Skin penetration (itching) → mature in veins of mesentery • Eggs cause granulomas in liver (portal hypertension) 			Praziquantel
Schistosoma haematobium	<ul style="list-style-type: none"> • Contact with water • Skin penetration by cercariae • Egypt and Africa 	Vesicular schistosomiasis <ul style="list-style-type: none"> • Enter skin (itching) → mature in bladder veins (hematuria) • Chronic infection → high association with squamous cell carcinoma of the bladder 			
Non-human schistosomes (Trichobilharzia regenti)	<ul style="list-style-type: none"> • Contact with water • Skin penetration by cercariae • Great Lakes in U.S., birds 	Swimmer's itch <ul style="list-style-type: none"> • Penetrate skin → dermatitis (no further development) • Itching most intense at 2-3 days 		 Human: No ova	<ul style="list-style-type: none"> • Trimeprazine • Calamine • Sedatives

Cestodes (tapeworms)

Ingestion						
Organism	Acquisition	IH	DH	Disease progression	Diagnosis	Treatment
Taenia saginata (beef tapeworm)	Rare beef (containing cysticerci)	Cattle	Humans	Intestinal tapeworm (sm intestine) <ul style="list-style-type: none"> • Asymptomatic or vague abdominal pains 	Proglottids or eggs in feces	Praziquantel (surgery for some T. solium cysts)
Taenia solium (pork tapeworm)	Raw pork (containing cysticerci)	Swine	Humans	Intestinal tapeworm (same symptoms as saginata)	Proglottids or eggs in feces	
	Water, vegetation (contaminated with eggs)	Humans	—	Cysticercosis <ul style="list-style-type: none"> • Larvae develop in brain (brain cysts) "swiss cheese brain" eye, heart, lung → adult onset epilepsy, seizures • "Immigrant with new onset seizures" 	Biopsy	
Diphyllobothrium latum (fish tapeworm)	Raw pickled fish (with sparganum/larvae)	Crustacean → fish	Humans	Intestinal tapeworm <ul style="list-style-type: none"> • Competes for B12 in intestine (megaloblastic anemia) 	Proglottids or eggs in feces	
	Drinking pond water (contaminated by copepods carrying larvae)	Humans	—	Sparganosis <ul style="list-style-type: none"> • Larvae penetrate/encyst intestinal wall 	Biopsy	
Echinococcus granulosus	Ingestion of eggs from dog feces	Humans; Sheep	Herding dog	Hyatid cyst disease <ul style="list-style-type: none"> • Liver cysts with brood capsules (and/or lung cysts) 	Imaging; serology	Surgery; albendazole

Larvae develop in **Intermediate hosts** (IH)... Adult tapeworms develop in **Definitive hosts** (DH)... Cysticerci= encysted larvae found in Intermediate host

Nematodes (roundworms) [treatment usually –bendazoles (remember bendy worms)]

Ingestion—Eggs (larvae ingestion for Trichinella) Mnemonic—EAT				
Species	Acquisition	Disease	Diagnosis	Treatment
Enterobius vermicularis (MC helminth in U.S.)	<ul style="list-style-type: none"> Eggs ingested Also person to person 	Pinworms in large intestine <ul style="list-style-type: none"> Perianal itching Child scratches and gets eggs under nails 	<ul style="list-style-type: none"> Scotch tape test (sticky swab of perianal area) Ova have flattened side with larva inside 	Mebendazole; (treat entire family)
Ascaris lumbricoides (MC helminth worldwide)	<ul style="list-style-type: none"> Eggs ingested 	Ascariasis <ul style="list-style-type: none"> Egg→larva migrate through lung (cough) Mature in sm intestine (may obstruct) 	<ul style="list-style-type: none"> Bile stained, knobby eggs Adult roundworms up to a foot long 	Mebendazole; Surgery for migrations
Trichinella spiralis	<ul style="list-style-type: none"> Wild game meat Raw bacon Encysted larvae consumed 	Trichinosis <ul style="list-style-type: none"> Larvae encyst in muscle→ myalgia Fever, splinter hemorrhages, periorbital edema 	<ul style="list-style-type: none"> Muscle biopsy (cysts with larvae) Eosinophilia (Type I HS) 	Mebendazole (Severe: add steroids)
Toxocara canis (cati) (Dog & Cat Ascarids)	<ul style="list-style-type: none"> Eggs ingested Handling puppies Eating dirt in yard 	Visceral larva migrans <ul style="list-style-type: none"> Larva wander aimlessly until they die Cause inflammation 	<ul style="list-style-type: none"> Clinical findings and serology 	Mebendazole; Self-limiting
Trichuris trichiura	<ul style="list-style-type: none"> Eggs ingested 	Whipworm in cecum <ul style="list-style-type: none"> Appendicitis; rectal prolapse 	<ul style="list-style-type: none"> Barrel-shaped eggs with bipolar plugs in stools 	Albendazole
Skin penetration—Larvae Mnemonic—SAND				
Strongyloides stercoralis	<ul style="list-style-type: none"> Skin penetrated by filariform larva Autoinfection unless treated 	Threadworm strongyloidiasis <ul style="list-style-type: none"> Early—pneumonitis, abdominal pain, diarrhea Late—malabsorption, ulcers, bloody stool 	<ul style="list-style-type: none"> Larvae in stool Serology 	Ivermectin Thiabendazole
Ancylostoma braziliense Ancylostoma caninum (Dog & Cat hookworms)	<ul style="list-style-type: none"> Skin penetrated by filariform larva 	Cutaneous larva migrans <ul style="list-style-type: none"> Intense skin itching 	<ul style="list-style-type: none"> Presumptive diagnosis Larva cannot mature in humans 	Thiabendazole; Topical corticosteroids
Necator americanus (New World hookworm)	<ul style="list-style-type: none"> Bare feet penetrated by filariform larva 	Hookworm <ul style="list-style-type: none"> Bloodsucking intestine wall→ microcytic anemia Lung migration→ pneumonitis 	<ul style="list-style-type: none"> Fecal larvae- up to 13mm Ova- oval, transparent, 2-8 cell stage Occult blood possible 	Mebendazole (+ iron therapy)
Filarial Nematodes				
Wucheria bancrofti Brugia malayi, Brugia timori	<ul style="list-style-type: none"> Female mosquito 	<ul style="list-style-type: none"> Elephantiasis—Blockage of lymphatic vessels (takes a year for symptoms) 	Microfilariae in blood; Eosinophilia ; IgE-mediated degranulation of mast cells	Surgery, DEC+ivermectin
Loa Loa (African Eye worm)	<ul style="list-style-type: none"> Chrysops (Deer fly, horsefly, mangofly) 	<ul style="list-style-type: none"> Pruritis, calabar swellings (local swelling where worm travels; subcutaneous) Worm in conjunctiva 	<ul style="list-style-type: none"> Microfilariae in blood; Eosinophilia 	Surgery; DEC, ivermectin
Onchocerca volvulus	<ul style="list-style-type: none"> Female blackfly 	<ul style="list-style-type: none"> River blindness Itchy leopard rash (black skin nodules) 	<ul style="list-style-type: none"> Skin snips from calabar swellings 	Surgery; DEC, ivermectin
Dracunculus medinensis (Guinea worm, fiery serpent)	<ul style="list-style-type: none"> Drinking water with infected copepods 	<ul style="list-style-type: none"> Creeping eruptions, ulcerations, inflammation 	<ul style="list-style-type: none"> Increased IgE Worm eruption from skin 	Metronidazole; Slow worm removal w/stick

DEC= Diethylcarbamazine

Ectoparasites		
Pediculosis capitis (head lice)	• Head to head contact; prevalent in school children	• Permethrin 1% cream, Pyrethrin, Malathion, Lindane
Pediculosis pubis (crabs)	• Sexual contact (must also check for STDs)	
Scarcoptes scabiei (scabies)	• Burrows under skin (intense itching); interdigital webbing , feet, hands, trunk, elbows	• Permethrin 1% cream, Ivermectin, Lindane

Antimalarials

Drug	Mechanism	Clinical Use	Toxicity/Contraindications
Chloroquine	Erythrocytic shizontocide —Accumulates in food vacuole of parasite and prevents conversion of heme to hemozoin (heme accumulates= death)	P. vivax/ovale use chloroquine + primaquine P. falciparum/malariae use chloroquine alone Resistance= mutated transporter→ Drugs: Quinine + pyri/sulf > Mefloquine > Artemisinins	• Retinal damage • Itching (contraindicated in psoriasis) • Depression
Primaquine	Tissue schizontocide (Used with chloroquine)	For Plasmodium vivax/ovale (dormant in liver) Works against hypnozoites to prevent relapse	• Hemolysis in G6PD deficiency • Contraindicated in pregnancy
Chloroquine resistant cases			
Quinine	<u>First line</u> for chloroquine resistant P. falciparum		• Cinchonism (vertigo, tinnitus, flushing) • Blackwater fever (hemolysis in G6PD deficiency)
Pyrimethamine- Sulfadoxine	Used in combo with quinine for chloroquine resistant P. falciparum		• Hypersensitivity reaction
Mefloquine	Second line for resistance; prophylaxis in high risk areas Only take orally (20 day half life)		• Syncope, cardiac conduction defect, pneumonitis • Contraindicated in psychosis, seizures
Artemisinins (Artsunate, Arthemether)	Multi-drug resistance (obtained from Chinese herb)		• Generally well tolerated

Antiprotozoals

Drug	Clinical Use	Toxicity
Metronidazole	Accumulation of toxic metabolites (free radicals) which damage DNA • DOC: Giardia, Entamoeba, Trichomonas, Gardnerella, Anaerobes, H. Pylori (GET GAP on the Metro)	• Disulfuram-like reaction with alcohol • GI distress
Pyrimethamine-Sulfadoxine	Inhibits dihydrofolate reductase (interferes with THF/ DNA synthesis) • DOC: Toxoplasmosis • Prophylaxis at CD4<100 for AIDS	• Hypersensitivity reaction • Megaloblastic anemia
Trypanosomiasis		
Benznidazole	Produce T.cruzi-sensitive free radicals • DOC: Chagas disease (T. cruzi)	• Rash
Suramin	African sleeping sickness (T. brucei) Early (hemolytic) stages	• Adrenal damage • Uticarial rash
Melarsopral	African sleeping sickness (T. brucei) Late (CNS) stages	• Similar to arsenic poisoning Text
Nifurtimox	Backup (T. cruzi, T. brucei)	• GI & Neurological
Leishmaniasis		
Sodium Stibogluconate	Leishmaniasis (IV administration)	• Phlebotoxic • Pancreatitis

Trematodes/Cestodes

Drug	Mechanism
Praziquantel	• Increases calcium efflux

Nematodes

Drug	Mechanism
Mebendazole Albendazole	• Decrease glucose uptake & microtubular structure
Pyrantel Palmoate	• Spastic paralysis of worms

PARASITE HINTS

Findings	Organism
Cholangiocarcinoma	Clonorchis sinensis
Hemoptysis	Paragonimus westermani
Portal hypertension	Schistosoma mansoni
Hematuria, bladder cancer	Schistosoma haematobium
Brain cysts, seizures	Taenia solium
B12 deficiency	Diphyllobothrium latum
Liver cysts	Echinococcus granulosus
Perianal itching	Enterobius
Microcytic anemia	Necator, Ancylostoma